EADV CONGRESS
VIENNA
30 SEP - 3 OCT 2026

Abstract N°: 16

Pre-Clinical and Clinical Efficacy of an Oat-containing Lotion Demonstrated Increased Protein, Ceramide, Skin Resiliency and Speed of Healing the Skin Barrier

Brenda Edison*[1], Richard N. Besingi[1], Ramine Parsa[1], Akshat Thakore[1], Li Feng[1], Katherine Stephens[1], Wen-Hwa Li[1], Yuna Hu[2], Yali Qiu[2], Yuting Huang[2]

[1] Kenvue Brands LLC, Summit, United States

[2] JNTL consumer health (India) Pvt Ltd., a division of Kenvue, Mumbai, India

Introduction

Oat and concentrated components of oat (Avena sativa) have long been ingredients of choice for soothing and repairing skin. Filaggrin and loricrin are essential structural proteins involved in barrier integrity. A topical lotion containing three oat components was tested to determine skin resiliency and speed of healing.

Materials and Methods

Oat formulation was applied to reconstructed human epidermis and UV-irradiated human skin explants. Filaggrin and loricrin were assessed via immunofluorescence and image analysis. A 4-week clinical study was conducted with physical insult (25 D-Squame tape strips (TS)) after initial application of the test lotion and after 4 weeks of twice daily application. Transepidermal water loss was conducted before TS, after TS and 24 hours post-TS. TS were analyzed for changes in skin barrier lipids by shotgun lipidomics.

Results

Oat treatment significantly increased filaggrin (566%) and loricrin (194%) expression. In UV-damaged skin, oat preserved both proteins, mitigating UV-induced reductions. In a racially diverse study population (n=32), oat lotion showed significantly faster healing after 1 application at 24 hours versus untreated ($p=0.019$). After 4 weeks treatment and subsequent TS, the lotion demonstrated no significant difference in TEWL between PreTS and 24 hours ($p=0.193$), whereas untreated had significantly higher TEWL at 24 hours ($p=0.003$). Lipid analysis of TS showed a significant increase in the production of extra-long chain acyl ceramides compared to the baseline and control group.

Conclusions

Use of an oat-containing lotion showed increased production of skin barrier proteins, increased skin resiliency with faster healing and increased production of essential long chain ceramides.

Disclosures: This work was sponsored by Kenvue Brands LLC.
Author Disclosures: Authors were employees of Kenvue Brands LLC at the time of the research.

EA DV CONGRESS
VIENNA
30 SEP - 3 OCT 2026

Abstract N°: 60

Precision Punctures: The CO_2 Laser Pinhole Technique in Dermatology

Shady Ibrahim*[1]

[1] Al-Azhar University ,, Cairo, Egypt

Introduction

The pinhole technique using a carbon dioxide (CO_2) laser has emerged as a minimally invasive approach for the treatment of several dermatologic conditions. By delivering controlled micro-ablative punctures into the dermis, this method promotes dermal remodeling, lesion decompression, and transepidermal elimination while minimizing surrounding tissue damage. The use of low power and ultrashort pulse durations enhances precision and safety, making the technique suitable for multiple indications. To evaluate the clinical effectiveness and versatility of the CO_2 laser pinhole technique in the management of various dermatologic lesions, including papular acne scars, syringomas, calcifying acne lesions, fibrotic whithsh scars and resistant comedones.

Materials and Methods

A case series was conducted involving patients presenting with different dermatologic conditions treated using the pinhole technique with a CO_2 laser. The procedure utilized low energy settings with ultrashort pulse durations, creating multiple micro-punctures spaced across the lesion surface. The technique was applied to conditions including papular acne scars, syringomas, calcified acne nodules, fibrotic whitish scars and macrocomedones. Treatments were performed in one or more sessions depending on lesion type and response. Clinical improvement, safety, and patient satisfaction were evaluated during follow-up visits.

Results

The pinhole CO_2 laser technique demonstrated notable clinical improvement across multiple lesion types. Papular acne scars showed progressive flattening and textural improvement. Syringomas responded with gradual reduction in lesion prominence and improved cosmetic appearance. Calcifying acne lesions and macrocomedones were effectively decompressed and removed through targeted laser punctures. The procedure was well tolerated, with minimal downtime and a low incidence of adverse effects such as transient erythema or crusting.



A Case of Papular Acne Scar was treated with pinhole technique using surgical hand of CO2 laser

Conclusions

The CO_2 laser pinhole technique represents a precise, versatile, and minimally invasive therapeutic approach for a variety of dermatologic conditions. Using low power and ultrashort pulse durations allows targeted treatment with minimal collateral damage. This method may serve as an effective alternative or adjunct to conventional therapies for conditions such as papular acne scars, syringomas, calcifying acne lesions, fibrotic whitish scars and resistant comedones.

EA DV CONGRESS
VIENNA
30 SEP - 3 OCT 2026

Abstract N°: 108

Application of Supramolecular Hydrating Technology in Improving Sensitive Skin Condition —— A Prospective Randomized Controlled Clinical Study of 100 Cases

Li Ye*[1], Baiyu Li[2], Linshan Wu[1], Qilin Zhang[2], Xiaofeng He[3], Si Wen[1], Shuting Li[3], Rui Li[2], Zhen Yi[1], Yijie Zheng[2], Xuesong Xian[1], Bin Yang[1]

[1] Cosmetics Testing Center, Dermatology Hospital of Southern Medical University, NMPA Center for Innovation and Research in Regulatory Science, Translational Medicine Center, Dermatology Hospital of Southern Medical University, GuangZhou, China

[2] La Roche Posay, L'Oréal Dermatological Beauty, L'Oréal China, Shanghai, China

[3] Research and Innovation Center, L'Oréal China, Shanghai, China

Introduction

To compare the efficacy of supramolecular hydrating technology with traditional mesotherapy in improving facial dryness, dullness, laxity and redness in sensitive skin, clarify the skin repair characteristics and application value of supramolecular hydrating technology, and provide scientific experimental evidence for the selection of non-invasive repair regimens for sensitive skin.

Materials and Methods

This study was approved by the ethics committee (Approval No.: HZP-2025-013) and adopted a parallel-group controlled design. A total of 100 healthy Asian women aged 23–45 years with sensitive skin presenting facial dryness, dullness, and laxity were randomly assigned to a traditional mesotherapy group (n=50) or a supramolecular hydrating technology group (test product group, n=50). The mesotherapy group received one session of injectable sodium hyaluronate compound solution, with only growth factor applied postoperatively (no additional creams or emulsions). The test group used La Roche-Posay Supramolecular B5 Repairing Revitalizing Emulsion twice daily for 21 consecutive days. Objective parameters including stratum corneum hydration, transepidermal water loss, skin gloss, elasticity, firmness, red area percentage, and red zone a* value were measured at baseline (D0), day 3 (D3), and day 21 (D21) . Clinician visual assessment (redness, dryness, radiance) and subject questionnaires were also conducted.

Results

All 100 subjects completed follow-up, with no treatment-related adverse events (0% in both groups), confirming favorable safety for both interventions. At D0, stratum corneum hydration was comparable between groups. At D3, both groups showed significant increases from baseline ($P<0.001$), with higher levels in the mesotherapy group ($P<0.001$). At D21, hydration remained elevated in both groups ($P<0.001$, $P<0.05$), with the supramolecular group showing significantly higher values (57.36±12.45 vs 51.15±11.17, $P<0.05$). Skin gloss was similar at D0; both groups improved significantly at D3 and D21 ($P<0.001$), with the supramolecular group showing greater improvement at both time points (D3 $P<0.001$, D21 $P<0.05$). Skin elasticity (R2, Q1) improved significantly in both groups at D3 and D21 ($P<0.01$), with no intergroup differences ($P>0.05$). Skin firmness (F4) was comparable at D0. Both groups showed significant reductions at D3 ($P<0.001$), with greater changes in the mesotherapy group ($P<0.05$). At D21, values were similar between groups (3.49±0.68 vs 3.49±0.66), both significantly reduced from baseline ($P<0.001$). Red zone parameters (red area percentage, a* value) decreased in the mesotherapy group at D3 ($P<0.01$, $P<0.05$), with no change in the supramolecular group. At D21, these parameters decreased in the supramolecular group ($P<0.05$), while the mesotherapy group showed no further change. Clinician assessment at D21 showed the supramolecular group had better dryness scores and radiance improvement (both $P<0.05$).

Subject satisfaction rates for dryness and redness improvement reached 100% in the supramolecular group at D3 and D21, significantly higher than in the mesotherapy group ($P<0.05$, $P<0.01$), with no differences in other dimensions.

Conclusions

Supramolecular hydrating technology exhibits favorable safety in the repair of sensitive skin, and can effectively improve dryness, dullness and laxity of sensitive skin, with desirable improving effects on stratum corneum hydration, skin gloss, elasticity and firmness, as well as effectively relieving skin redness in the later stage. The skin repair effect of this technology is characterized by long-term stabilization and continuous improvement, especially outstanding in enhancing skin gloss. Long-term application can stably maintain skin hydration and improve skin dryness and redness. Compared with traditional mesotherapy, both achieve satisfactory clinical effects in improving skin elasticity and firmness. Supramolecular hydrating technology provides a safe and convenient non-invasive skin care regimen for sensitive skin.

EADV CONGRESS
VIENNA
30 SEP - 3 OCT 2026

Abstract N°: 114

An Oat-containing Glycerin Skin Protectant Ointment Shows Sustained Skin Resiliency and Offers Benefits Over a Petrolatum Ointment

Marena Marucci*[1], Brenda Edison[1], Richard N. Besingi[1], Ramine Parsa[1], Akshat Thakore[1], Felix De Dios[1], Eric Lazaro[1], Wen-Hwa Li[1], Yuna Hu[2], Yali Qiu[2], Inna Potrebko[1], Allison Barron[1]

[1] Kenvue Brands LLC, Summit, United States

[2] Kenvue Brands LLC, Shanghai, China

Introduction

Dry skin conditions are affected by deficiencies in Hyaluronic acid (HA) and Filaggrin degradation products pyrrolidone carboxylic acid (PCA) and urocanic acid (UCA), as major components of natural moisturizing factors (NMFs). A novel oat (Avena sativa) and glycerin containing ointment (Oat+Gly) was tested on dry skin providing healing benefits within the skin when compared to a standard petrolatum ointment (PET) which offers occlusion as primary benefit.

Objective 1: Determine improvement of an Oat-containing Glycerin Ointment on various endpoints including visual dryness, tactile surface roughness, and hydration measurements throughout treatment and regression periods

Objective 2: Demonstrate superiority of an Oat-containing Glycerin Ointment compared to petrolatum ointment both clinically and in consumer perception of aesthetics.

Materials and Methods

An oat-containing lotion (OCL) was applied to reconstructed human epidermis (RHE) and UV-irradiated human skin explants. HA was assessed via immunofluorescence and image analysis. PCA and UCA levels were quantified following protease K extraction. A 3-week regression clinical on dry legs (2 week treatment, 1 week regression/no treatment) was conducted comparing Oat+Gly to untreated and PET through clinical grading, instrumental measurements and digital photography.

Results

OCL significantly increased PCA and UCA levels in RHE by 125% and 43%, respectively, indicating enhanced filaggrin processing and NMF restoration. In skin explants, OCL fully preserved HA, mitigating UV-induced reduction. In vivo, Oat+Gly showed significant improvements in visual dryness, tactile roughness, and corneometer at all timepoints during treatment, and regression, compared to baseline ($p<0.05$); and throughout treatment and 5-7 days of regression compared to untreated ($p<0.05$). Oat+Gly showed significant improvement in moisture (corneometer) over PET at all timepoints during treatment and regression ($p<0.05$). Consumers preferred Oat+Gly to PET with superiority for non-greasy, fast absorption and feels more moisturized.

Conclusions

OCL demonstrated numerous preclinical benefits, while Oat+Gly showed clinical benefits for dry skin, outperforming a PET ointment, and demonstrating superior aesthetics.

Disclosures: This work was sponsored by Kenvue Brands LLC.
All authors were employees of Kenvue Brands LLC at the time of the research

EA DV CONGRESS
VIENNA
30 SEP - 3 OCT 2026

Abstract N°: 115

Beyond Efficacy: Pulse Duration is Crucial for Adverse Events in Pulsed-Dye Laser Therapy for Rosacea

Tingwei Liu*[1], Xiaoqi Meng[1], Yang Xu[1]

[1] The First Affiliated Hospital with Nanjing Medical University, Nanjing, China

Introduction
Pulsed dye laser (PDL) is widely recognized as an effective treatment for erythematotelangiectatic rosacea (ETR). However, the impact of pulse duration on both therapeutic efficacy and safety profiles remains insufficiently understood. Therefore, this study aimed to compare the efficacy, adverse effects, symptom improvement, and patient satisfaction associated with two pulse durations (6 and 10 ms) of PDL in the treatment of ETR.

Materials and Methods
This single-center, prospective, randomized controlled study enrolled 80 patients with ETR, who were randomly assigned to receive PDL treatment with either a 6 or 10 ms pulse duration. Treatment parameters included an energy density of 9–11 J/cm^2 and a 7 mm spot size. Baseline and Week 4 data collected comprised skin type, sex, age, and standardized facial photographs.Clinical efficacy was independently evaluated by three blinded dermatologists using the Clinical Erythema Assessment (CEA), telangiectasia scores, and the Rosacea Area and Severity Index (RASI). Objective vascular changes were quantified using ImageJ software to calculate the Relative Intensity of Redness (RIR) and the Percentage of Erythema Area (PEA).Adverse events were assessed via patient questionnaires on Days 3 and 7 post-treatment. At Week 4, sequelae, patient global assessment (PGA), erythema improvement scale, and symptom improvement scale were evaluated.

Results
Significant improvements over time were observed in both groups for CEA, RASI, RIR, and PEA (all $p < 0.001$). No significant time × pulse duration interactions were detected (all $p > 0.05$), indicating comparable efficacy between the two groups. Telangiectasia scores also showed no significant between-group differences ($p > 0.05$).However, adverse events on Day 3 were more frequent in the 6 ms group, with significantly higher incidences of edema ($p < 0.05$) and purpura ($p < 0.001$) compared with the 10 ms group. At Week 4, no significant differences were observed between groups in patient global assessment (PGA), erythema improvement scale, or symptom improvement scale (all $p > 0.05$).

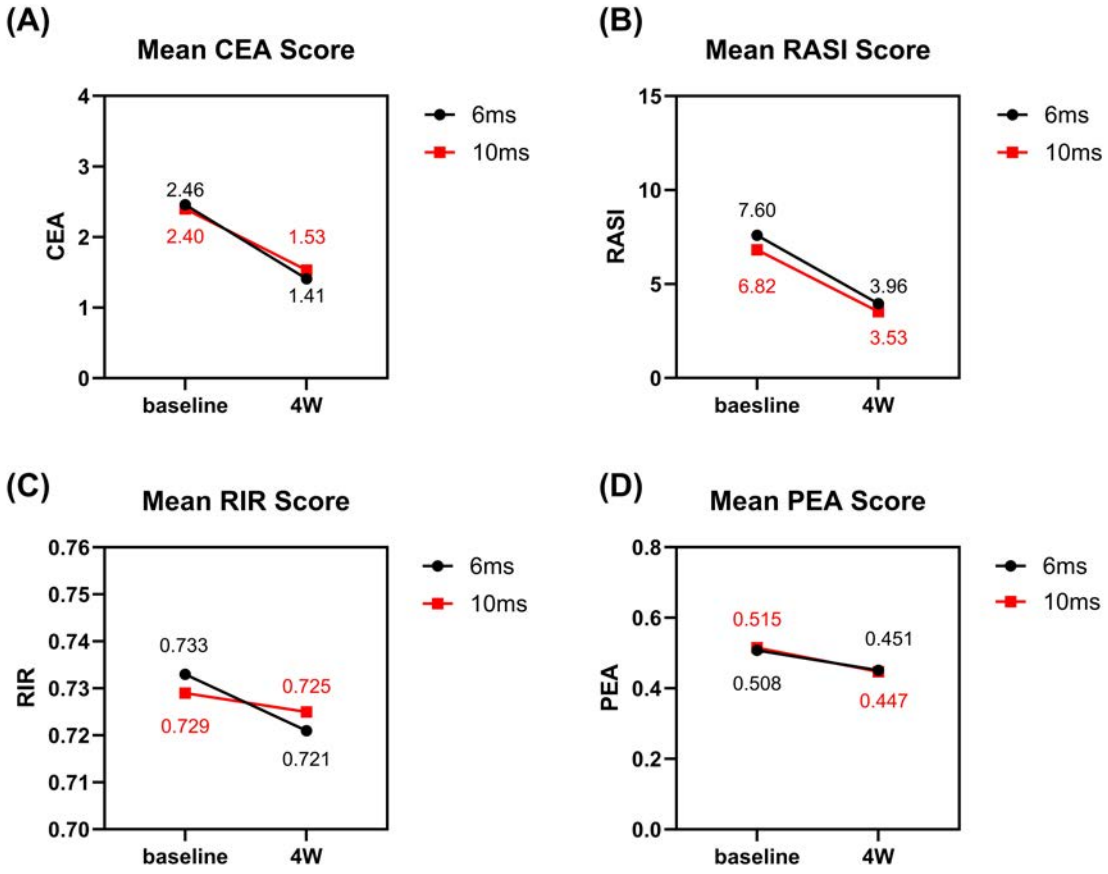

The following statistical charts illustrate the outcomes baseline and 4 weeks after treatment: elasticity values (A), Clinical Erythema Assessment (CEA) score (B), Rosacea Area and Severity Index (RASI) score (C), Relative Intensity of Redness (RIR) score (D), Percentage of Erythema Area (PEA) score. All the baseline and 4 weeks after treatment data showed no statistical significance.

Conclusions

Both 6 and 10 ms pulse duration PDL treatments are effective in reducing erythema in rosacea. However, the 10 ms pulse duration demonstrates a more favorable safety profile, with a lower incidence of adverse events and better patient acceptance. These findings suggest that a longer pulse duration may be preferable for optimizing the risk–benefit balance and improving overall patient experience in PDL therapy for rosacea.

EA DV CONGRESS
VIENNA
30 SEP - 3 OCT 2026

Abstract N°: 118

A case of granulomatous reaction to dermal injection of stem cell conditioned media

Chanhui Jang*[1], Hoseok Suh[1], Doorae Cha[1], Yongseuk Lee[1], Dowon Kim[1]

[1] Ulsan university hospital, Ulsan, Korea, Rep. of South

Introduction
Stem cell conditioned media containing exosomes have gained significant attention in dermatology for their potential in wound healing, skin rejuvenation, and hair regeneration. While these products are primarily approved for topical use, off-label use via intradermal injection has been increasingly performed in South Korea. Foreign body granuloma is an inflammatory response to exogenous materials within the dermis or subcutaneous tissue, typically presenting as erythematous indurated papules, nodules, or plaques. Histopathologically, it is characterized by granulomatous inflammation involving epithelioid histiocytes and multinucleated giant cells. To date, only a few cases of granulomatous reactions to the injection of conditioned media have been reported in the literature.

Case Presentation
A 51-year-old woman presented with multiple, grid-patterned, erythematous to flesh-colored papules on both cheeks and the chin. She had recently received intradermal injections of stem cell conditioned media containing exosomes to improve skin elasticity and wrinkles. Histopathology: Examination showed diffuse granulomatous inflammation with dense histiocytic infiltration surrounding basophilic foreign materials in the dermis. Immunohistochemistry: Staining was positive for CD68 and negative for cytokeratin. Based on the clinical history and pathological findings, the patient was diagnosed with a foreign body granuloma.

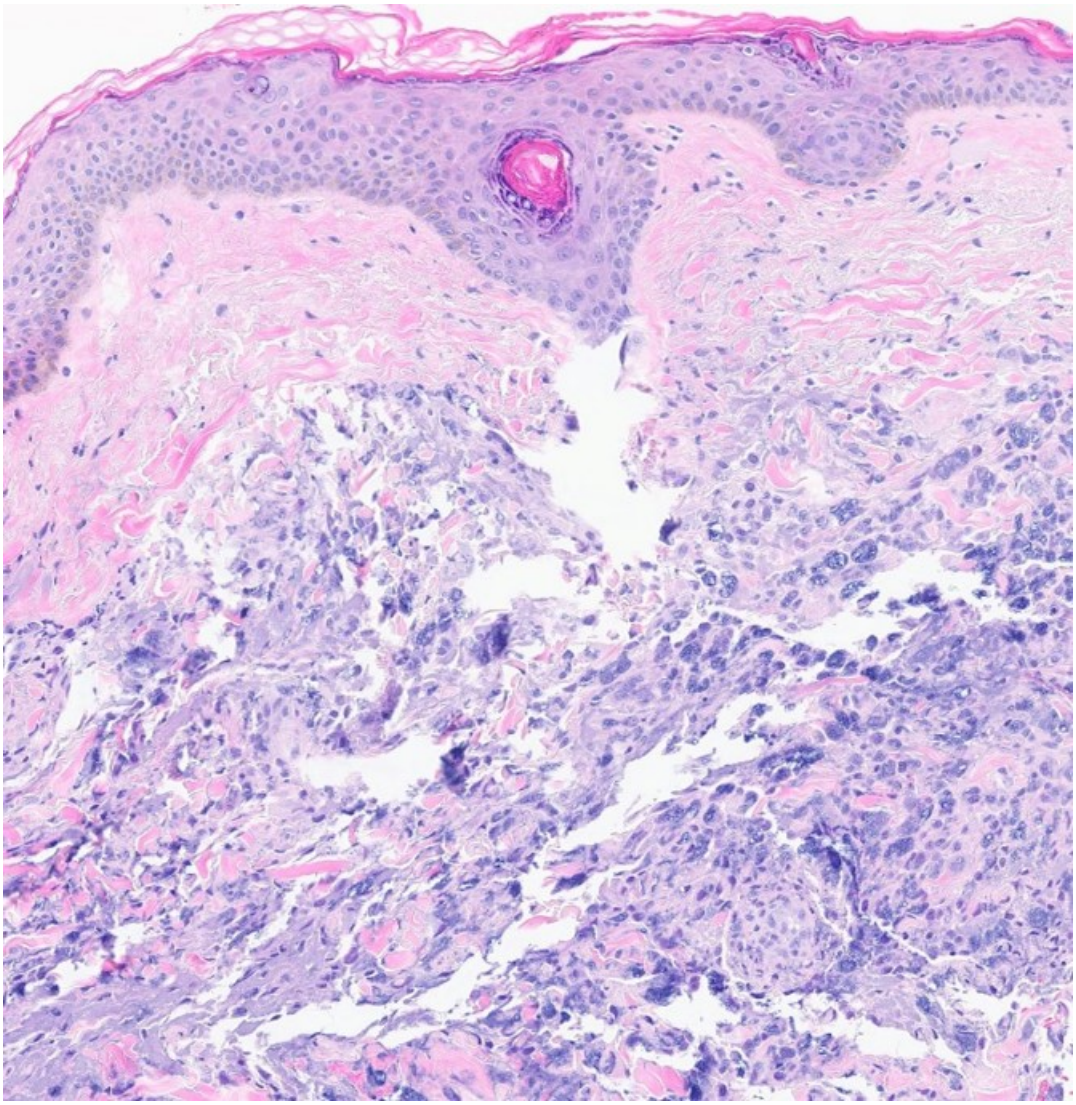

Conclusion

We report a rare case of foreign body granuloma following the intradermal injection of stem cell conditioned media. Although exosome-based therapies offer promising regenerative benefits, this case emphasizes the potential for adverse inflammatory reactions when non-injectable-grade products are administered via the intradermal route. Clinicians should be aware of these complications and exercise caution regarding off-label injection techniques

EADV CONGRESS
VIENNA
30 SEP - 3 OCT 2026

Abstract N°: 170

Synergistic Use Of Ultrasound Therapy And PLLA In Asingle Session For Facial Rejeuvenation , An Observational Study From Private Clinic.

Sahar Almahi Kabbashi Osman*[1, 2]

[1] Bright Clinics Company, Riyadh, Saudi Arabia

[2] Sudanese society of dermatology, Khartoum, Sudan

Introduction

The combined use of microfocused ultrasound(MFU) and poly-L-lactic acid (PLLA) in a single session offers a promising approach to address facial laxity and volume loss simultaneously. However, direct documentation of this protocol in routine clinical practice is limited .We report our observational experience with a standardized, same-day Ultherapy + PLLA protocol for facial rejuvenation.

Materials and Methods

DESIGN: Retrospective observational study. PATIENTS: 32 adults (June2024 - November 2025).• PROTOCOL: Ultherapy: 3.0 & 4.5 mm tranducers , ~120 shots .PLLA: 1 vial , 10 ml dilusion, fanning/Threading.
FOLLOW-UP: 3 and 6 months.
ASSESSMENTS: Photos, Laxity/Contour, Patient Satisfaction, Adverse events.

Results

32 adults underwent the treatement ,25 of them with mild to moderate laxity and 7 with severe laxity , 22 of them (68.8%) were very satisfied with the results, 6(19.8%) were satisfied and only 4(12.5%) showed neutral response.

Conclusions

Single session effective for mild-moderatelaxity.
Two sessions effective for severe laxity.
Safe, well-tolerated, no serious adverseevents.
Recommendations:
Evaluate longer-term outcomes (>12 months)to confirm durability of results.
• Patient counseling should highlight realisticexpectations based on laxity severity.
Limitations:
-Single-center, observational design.
-Small sample reduces statistical power.

EADV CONGRESS
VIENNA
30 SEP - 3 OCT 2026

Abstract N°: 176

Successful Treatment of Impending Skin Necrosis Due to Nasal Arterial Occlusion Following Multiple Hyaluronic Acid Filler Injections by a Non-Physician Injector

I Komang Harry Supradnyan*[1], Charles Kurnia Mahono[1], Ketut Suteja Wibawa[1], Ida Ayu Diah Purnama Sari[2]

[1] Dermatology Venereology and Aesthetic Department, Buleleng General Hospital, Faculty of Medicine, Ganesha University of Education, Singaraja, Bali, Indonesia

[2] Dermatology Venereology and Aesthetic Department, Faculty of Medicine, Ganesha University of Education, Singaraja, Bali, Indonesia

Introduction

Hyaluronic acid (HA) filler injections have become increasingly popular in Indonesia due to their ability to provide immediate aesthetic enhancement and restore facial proportions with minimal downtime. When performed by qualified medical professionals using standardized techniques and approved products, these procedures are generally safe with a low incidence of complications. However, the rapid expansion of aesthetic services driven by social media influence, inadequate regulatory enforcement, and lower-cost alternatives has led to a growing number of procedures being performed by untrained individuals, significantly increasing the risk of adverse events, including vascular complications.

Case Presentation

A 37-year-old woman presented with progressive pain, erythema, and multiple pustular lesions involving the nasal region, developing 48 hours after undergoing HA filler injections performed by a non-medical practitioner. Immediately following the procedure, the patient reported pain and mild numbness but was discharged without further evaluation. The injections were administered to the nasal and nasolabial regions. The patient had a history of similar procedures performed by the same injector 2 and 4 months earlier without complications.Over time, the symptoms worsened, characterized by increasing pain and progressive expansion of cutaneous lesions. The patient also reported receiving an additional injection of an unspecified “filler-dissolving” substance 24 hours after the initial procedure, with unknown composition and dosage.Physical examination revealed multiple pustules and areas of impending skin necrosis on an erythematous base across the nasal area, accompanied by delayed capillary refill suggestive of vascular compromise. Residual filler material was palpable in the nasolabial folds, nasal tip, and nasal dorsum.Prompt intervention was initiated with high-dose hyaluronidase (total of 1500 units), administered in three sessions until the filler material was no longer palpable and the patient’s pain significantly improved. Adjunctive therapy included oral cefixime, cetirizine (10 mg/day), methylprednisolone (16 mg/day), and aspirin (100 mg/day), along with topical mupirocin and normal saline compresses.The patient was closely monitored on a daily basis, with no evidence of clinical deterioration. Complete resolution of the lesions was achieved within 10 days, with only mild post-inflammatory hyperpigmentation remaining.

Conclusion

This case underscores the potentially severe consequences of HA filler injections performed by unqualified personnel. Early recognition of vascular compromise and immediate, aggressive management, particularly with timely administration of hyaluronidase, are essential to prevent irreversible tissue necrosis. Strengthening regulatory control and enhancing public awareness are crucial to minimizing such preventable complications.

POWERED BY M-ANAGE.COM

EA DV CONGRESS
VIENNA
30 SEP - 3 OCT 2026

Abstract N°: 196

Clinical Efficacy of a MultiBenefit SPF 80 Sunscreen with Antioxidant, AntiAging, and Oil Control Ingredientes: Skin Quality Improvements in a Broad Adult Population with Stratified Outcomes in Younger and Mature Skin

Debora Felix*[1], Isabelle Rennó[1], Lucas Porta[1], Cinthia Satake[1], Maria Carolina Semprini[1], Flavia Addor[2]

[1] Kenvue Brands LLC, São José dos Campos, Brazil

[2] MEDCIN - Skin Institute, Sao Paulo, Brazil

Introduction

Oily skin is highly prevalent in Brazil, yet there is limited scientific literature connecting oiliness, hydration balance and photoaging within photoprotection research. This gap reinforces the need for clinical and instrumental data supporting sunscreens aimed at improving skin quality across age groups. In this context, a prospective clinical study with broad phototype range conducted under normal daily UV exposure in Brazil evaluated the clinical and perceived efficacy an SPF 80 facial sunscreen containing a high concentration of anti-oxidant, anti-aging, and oil-control ingredients, applied twice daily for 56 days.

The primary objectives were to determine efficacy on aging signs and reduction in skin oil/shine, while assessing instrumental evidence of oiliness reduction, hydration and skin barrier maintenance. An exploratory objective was to examine whether efficacy differed by age group.

Materials and Methods

This was a single-arm clinical study in adults with oily skin and early-to-moderate facial aging according to dermatological assessment (N=73; 30–55 years; phototypes I–VI; multiethnic distribution: 45.2% White, 34.3% Brown, 20.5% Black). Participants applied the SPF 80 sunscreen twice daily (morning and midday) for 56 days. The product offers broad-spectrum UVB, UVA, long-UVA, and visible light protection, combined with a high concentration of anti-oxidant (Feverfew), anti-aging (Niacinamide and Neoglucosamine), and oil-control (SepicontrolTM) ingredients.

Clinical grading assessed pores, shine, texture/roughness, global wrinkles, fine lines, and firmness. Instrumental measurements included Sebumeter®, Corneometer®, Tewameter ® and Cutometer®. ColorFace® imaging evaluated shine reduction, and perceived efficacy was collected. Primary analyses compared Days 28 and 56 with baseline in age-stratified (30–44; 45–55) and combined groups using paired tests (α=5%).

Results

At baseline, both age groups showed high mean Sebumeter values (>170 µg/cm^2), confirming persistent oiliness regardless of age. Results showed a progressive and significant shine reduction: 19.8% at Day 28 and 28.7% at Day 56, consistent across age groups. Additional benefits were observed in several aging-related skin parameters, including global wrinkles, fine lines, texture/roughness, and firmness. ColorFace® imaging visually confirmed the reduction in shine. Instrumental assessments supported these findings: Sebumeter® measurements demonstrated reduced sebaceous secretion at both time points, while Corneometer® readings indicated preserved stratum corneum hydration throughout the 56-day period, showing that effective oil control was achieved without causing excessive skin dryness. Tewameter® results at Day 28 indicated that the skin barrier remained intact, and Cutometer® data showed 13.4% improved firmness at Day 56. Age-stratified analysis revealed a marked 23.7% improvement in skin firmness for younger participants, while the older group did not reach statistical significance, consistent with known biomechanical differences between younger and mature skin. Participant-reported outcomes aligned with clinical findings, noting reduced oiliness, less shine and visible improvements in texture

and aging signs with continued use.

Conclusions

In a Brazilian multiethnic population with oily skin, a SPF 80 facial sunscreen combining broad-spectrum photoprotection with high concentrations of anti-oxidant, anti-aging, and oil-control ingredients delivered significant improvements in shine/oiliness and visible aging parameters, while maintaining hydration and skin barrier integrity. Overall, findings demonstrate that a high-SPF, multi-benefit sunscreen with complete solar protection (UVB, UVA, long-UVA, VL) and targeted ingredients provides consistent benefits across adult life stages, reducing shine and oiliness and improving aging parameters, reinforcing its relevance for oily-skin phenotypes in high-UV environments.

Disclosures: This work was sponsored by Kenvue Brands LLC.

EA DV CONGRESS
VIENNA
30 SEP - 3 OCT 2026

Abstract N°: 258

Treatment of lips asymmetry in a patient with Ameloblastoma, with Hyaluronic Acid.

Georgios Palaiologos*[1]

[1] Private Surgery, Mytilini, Greece

Introduction

Ameloblastom is a benign epithelial tumor that constitutes about 14% of all jaw tumors and cysts. It has aggressive, destructive and unlimited growth potential, having the capacity for recurrence, malignant transformation and metastasis (in approximately 1% of cases). There is no differentiation according to sex. The global incidence of ameloblastoma is 0.5 cases/million people, with 10–15% of cases occurring in the pediatric population The methods of treatment consist of radical surgery (segmental resection) and conservative treatments (enucleation with bone curettage). Reconstruction with bone grafts or flaps may be necessary, but can lead to facial asymmetry and functional issues.

Case Presentation

A 35 years old woman presented to our clinic with a lip asymmetry.She had been diagnosed with Ameloblastoma and had underwent surgery treatment.As a consequence the anatomy of the area had been changed and the lips were asymmetrical.1 ml of Hyaluronic Acid was injected with a syringe, mostly in the lower lip.
There was great improvement and the patient was very satisfied



X-Ray image of the patient after the surgery

Conclusion

Hyaluronic Acid may be a very satisfactory option of correcting the asymmetry of the lips in patients with Ameloblastoma.

EA DV CONGRESS
VIENNA
30 SEP - 3 OCT 2026

Abstract N°: 262

From misdiagnosis to aesthetic restoration: two-stage management of multiple miliary osteoma cutis in skin of colour

Punit Saraogi*[1], Yash Shah[1]

[1] Everything Skin & Hair Medical & Aesthetic Dermatology Clinic, MUMBAI, India

Introduction

Background:Multiple miliary osteoma cutis (MMOC) is an underrecognized condition characterized by true dermal ossification and is frequently misdiagnosed as acne or other benign facial dermatoses, leading to prolonged ineffective treatments. This challenge is particularly significant in skin of colour, where interventions carry a higher risk of pigmentary and textural sequelae.
Objective:To highlight diagnostic pitfalls of MMOC in skin of colour and evaluate outcomes of a two-stage management strategy focused on optimizing aesthetic results.

Case Presentation

A 45-year-old female with Fitzpatrick skin type IV presented with multiple, asymptomatic, firm, skin-colored papules (2–3 mm) over the face for 8 years, previously treated as acne. Differential diagnoses included osteoma cutis, calcified milia, calcified cysts, and calcinosis cutis. Laboratory parameters were normal. High-frequency ultrasonography revealed hyperechoic dermal foci with posterior acoustic shadowing suggestive of ossified structures. The patient declined biopsy; a test extraction confirmed a bony core but healed with atrophic scarring and post-inflammatory hyperpigmentation (PIH). Following counselling, an informed decision was made to proceed with complete lesion extraction as stage one, followed by planned aesthetic rehabilitation. Lesions were removed using needle microincision and manual extraction under topical anesthesia, with healing by secondary intention. Stage two included alternating monthly sessions of microneedling radiofrequency combined with fractional ablative laser and pigment-targeting laser over 6 months.

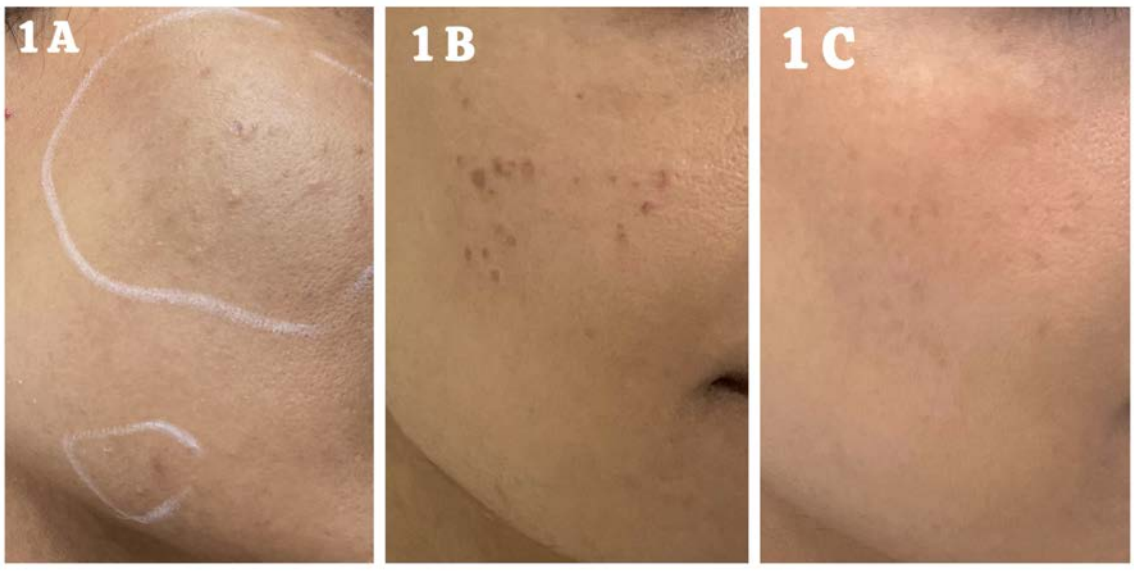

Figure 1: (A) Baseline presentation showing multiple firm papules over the face. (B) Three weeks post-extraction demonstrating post-inflammatory hyperpigmentation and early atrophic changes. (C) Six months following staged treatment showing significant improvement in pigmentation and skin texture.

Conclusion

Results:Complete clearance of nodules was achieved. Expected post-procedural PIH and mild atrophic changes were significantly improved following second-stage therapy. At 1-year follow-up, no recurrence was observed. There was a marked improvement in patient-reported quality of life and self-esteem.

Discussion:MMOC should be suspected in persistent, treatment-resistant facial papules, particularly when lesions are firm on palpation. Misdiagnosis as acne remains the most common clinical error. While histopathology is definitive, ultrasound and test extraction serve as useful adjuncts when biopsy is declined. Surgical extraction remains the cornerstone of treatment; however, in skin of colour, it predictably induces PIH and scarring. A structured two-stage approach—prioritizing lesion clearance followed by targeted pigment and collagen remodeling—effectively mitigates these sequelae and enhances aesthetic outcomes.

Conclusion:MMOC in skin of colour represents both a diagnostic and therapeutic challenge. A deliberate two-stage strategy combining extraction with subsequent laser-based rehabilitation enables effective disease clearance while optimizing aesthetic outcomes and patient satisfaction.

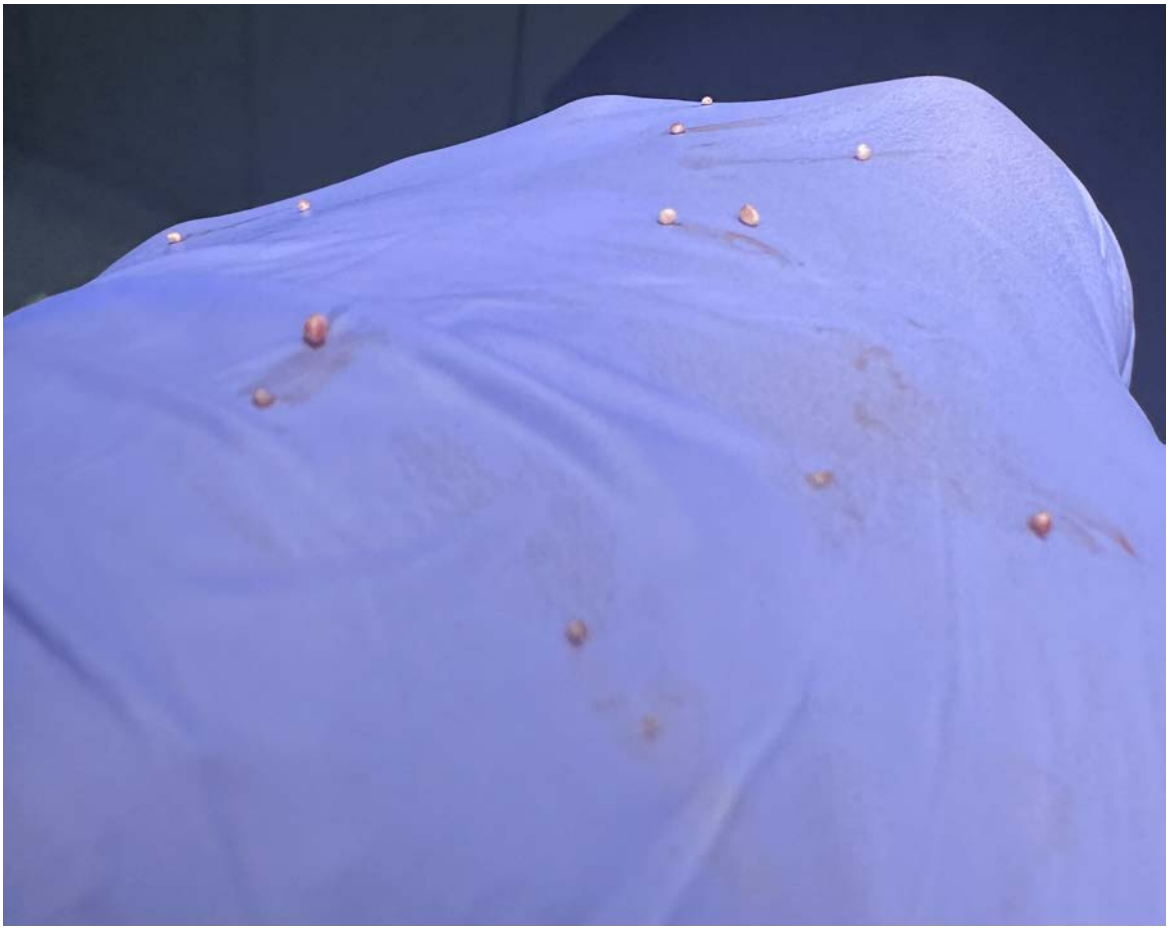

Extracted bony fragments following needle microincision and manual extrusion, consistent with osteoma cutis.

EADV CONGRESS
VIENNA
30 SEP - 3 OCT 2026

Abstract N°: 419

The Redness-Relieving Effect of a Cream Containing Centella Asiatica Leaf Extract, Panthenol, and Ceramide NP on Sensitive Facial Skin After a Single Application

Bohan Xu[1], Yinjuan Wang[1], Hong Fan*[1]

[1] Medical Affairs, Galderma China, Shanghai, China

Introduction
This study aimed to evaluate the redness-relieving effect of a cream containing centella asiatica leaf extract, panthenol, and ceramide NP after a single application in Asian subjects with sensitive skin through a human efficacy trial.

Materials and Methods
A total of 31 Asian female subjects aged 29-59 with sensitive skin and facial redness were enrolled. Subjects applied the test product once to the entire face. Assessments were conducted at baseline (D0T0) and at 30 minutes (D0T30min), 2 hours (D0T2h), 4 hours (D0T4h), and 8 hours (D0T8h) after application. Evaluation items included clinical assessment of overall facial redness visibility; subject self-assessment of redness visibility, heating sensation, and skin comfort (tightness and prickling sensation); and measurement of the chromaticity coordinate a* value in the facial redness area using Spectrophotometer™ CM700d. Statistical analysis was performed using the Wilcoxon signed-rank test, with $p < 0.05$ considered statistically significant.

Results
Compared to baseline, the clinical assessment scores for redness visibility were significantly reduced at 30 minutes, 2, 4, and 8 hours after product application ($p < 0.05$), with reduction rates of 9%, 34%, 43%, and 43%, respectively.
According to the subjects' self-assessment results, all indicators showed rapid and significant improvement. Redness visibility decreased by 25%, 47%, 65%, and 81% at 30 minutes, 2, 4, and 8 hours, respectively ($p < 0.001$). Heating sensation decreased by 31%, 52%, 68%, and 84% ($p < 0.001$). Skin comfort improved by 38%, 53%, 69%, and 83% ($p < 0.001$). The a* value decreased significantly at all time points compared to baseline ($p < 0.001$), with reductions of 5%, 10%, 12%, and 10%, respectively, reaching the maximum improvement at 4 hours.

Conclusions
The results of this trial indicate that this cream containing soothing and repairing composite active ingredients can rapidly and significantly improve facial redness in subjects with sensitive skin after a single application. The improving effect can be significantly perceived by subjects within 30 minutes and reaches and maintains its optimal effect within 4-8 hours. This effect has been consistently verified across three dimensions: clinical assessment, subject self-assessment, and instrumental measurement. Therefore, this product can serve as an effective option in the daily care of sensitive skin for quickly alleviating and durably improving facial redness and related discomfort symptoms.

EADV CONGRESS
VIENNA
30 SEP - 3 OCT 2026

Abstract N°: 446

Efficacy and safety of a one time medium depth peel for melasma and skin rejuvenation in skin of colour; A novel protocol based approach.

Amrit kaur amrit kaur*[1]

[1] Anticlock Clinic and Medispa, Chandigarh, India

Introduction
Melasma in skin of colour presents therapeutic challenges due to pigment instability and risk of irritation. while peels are commonly used, there is limited data on single session medium depth peels followed by structured, non hydroquinone based regimens for long term maintenance and skin rejuvenation in this population. The objective of this study is to evaluate the efficacy and safety of a medium depyh peel followed by a non steroidal non hydroquinone regimen for melasma and overall skin improvement in skin of colour.

Materials and Methods
22 patients (fitzpatrick skin type 4 and 5) underwent a one time medium depth peel. Post procedure, they were placed on a specific maintenance protocol including a non steroidal, non hydroquinone lightening cream, barrier repair moisturiser and sunscreen. follow ups were conducted over 12 months with tapering of the lightening cream based on individual response.

Results
Modified MASI (Melasma area severity index) scores improved by 80-90% within one month. VISIA analysis showed significant enhancements in skin texture, wrinkle score, and a 2-5 year reduction in skin age. No long term side effects were observed. The approach offered rejuvenation benefits beyond pigment correction.

Conclusions
A single medium depth peel with protocol based maintenance offers a safe, effient and time saving alternative for melasma and skin rejuvenation in skin of colour, reducing dependence on long term depigmenting agents.

EADV CONGRESS
VIENNA
30 SEP - 3 OCT 2026

Abstract N°: 480

CO2 Laser Vaporisation of Miescher Nevi: A 3- Year Retrospective Study.

Sidita Borici*[1, 2]

[1] Tiare' Dermatology Clinic, Tirana, Albania
[2] University of Medicine Tirana, Tirana, Albania

Introduction
Miescher nevi on the face are common acquired dermal melanocytic nevi that typically appear after puberty. While benign, they are often a cosmetic concern and a frequent presentation for removal at the dermatology practices. Surgical excision, though effective, carries risks of scarring. Co2 laser vaporization offers an almost scar-minimizing alternative, but the need for additional treatment sessions ia variable. Identifying the predictors of retreatment can improve patient selection and counceling. The aim of this study is to determine the proportion of patients requiring additional laser sessions after initial Co2 laser vaporization of Miescher nevi and to identify the associated factors.

Materials and Methods
Retrospective analysis of patients treated between November 2022 and November 2025 was performed. Patients above 18 years old, presenting to the dermatology clinic for mole check and removal of facial nevi for aesthetic reasons were included in the study. All lesions underwent pre-treatment dermoscopy to confirm the diagnosis of Miescher nevi (face) or Unna nevi (trunk). Patients with junctional nevi, Clark nevi or congenital nevi were excluded from the study. Co2 laser vaporisation was performed in a single session and patients were followed for 3-6 months. Additional laser sessions were performed when residual pigment or tissue was observed.

Results
Forty-seven patients (93 % females; 6 % males; mean age 36.4 years; range 22-58) and a total of 96 nevi (66 Miecher nevi, 30 Unna nevi) were included. Fitzpatrick skin type distribution was as follows: type I, 17 patients; type II ,15 patients, type III, 11 patients; type IV, 4 patients. After the initial Co2 laser, 23,4 % of patients required additional laser sessions to achieve complete clearance of facial nevi. Among 11 patients, 9 required 1-2 additional sessions while 2 required 3 sessions. No scarring or other complications were observed.

Conclusions
Fitzpatrick skin type I and the presence of multiple Miescher nevi are predictors of the need for retreatment after Co2 laser vaporisation. These simple clinical predictors can help guide preoperative counseling and optimize treatment planning.

EA DV CONGRESS
VIENNA
30 SEP - 3 OCT 2026

Abstract N°: 499

Early Recovery After Fractional CO_2 Laser: Barrier Repair Versus Corticosteroid in a Split-Face Study of Skin-of-Color Patients

Sonia Hanifati*[1], Selma Zein[2], Adhimukti Sampurna[1]

[1] Bamed Clinic, Jakarta, Indonesia

[2] Budhi Asih Hospital, Jakarta, Indonesia

Introduction

Fractional CO_2 laser induces controlled epidermal injury, leading to erythema and pain that determine early downtime and patient satisfaction. Post-procedural care traditionally relies on topical corticosteroids for inflammation control and prevention of post-inflammatory hyperpigmentation (PIH), particularly in skin of color. However, corticosteroids may delay wound healing when used beyond short durations. Barrier-repair strategies, which restore epidermal integrity and support skin homeostasis, may offer a mechanistically distinct approach. Evidence in skin-of-color populations remains limited. Thus, this study aims to compare the effects of a barrier-repair moisturizer versus a topical corticosteroid on erythema and pain following fractional CO_2 laser in an Indonesian skin-of-color population.

Materials and Methods

In this prospective split-face study, 12 participants with Fitzpatrick skin types III–V underwent full-face fractional CO_2 laser treatment. A barrier-repair moisturizer was applied to the right hemiface and a topical corticosteroid to the left. Erythema was quantified using VISIA "Red Areas" counts at baseline, immediately post-laser (D1), 24 hours (D2), 48 hours (D3), and day 7 (D7). Pain was assessed using a visual analog scale (VAS). Paired comparisons were analyzed using the Wilcoxon signed-rank test. The primary endpoint was change in erythema from D1 to D3.

Results

Absolute erythema counts did not differ significantly between treatments at any time point. However, the reduction in erythema from D1 to D3 was significantly greater on the barrier-repair side (median −10.5 vs 5.0, p=0.023). Pain decreased progressively in both groups, with a significantly greater cumulative reduction from D1 to D3 favoring the barrier-repair treatment (p=0.046), despite similar median changes at individual intervals. No statistically significant differences were observed at earlier (D1–D2) or later (D1–D7) time points, and clinical outcomes converged by day 7.

Table 1. Early erythema recovery following fractional CO_2 laser (paired analysis)

Time Interval	Barrier Repair (Right) ΔMedian	Corticosteroid (Left) ΔMedian	Z-value	p-value
D1–D2	−7.0	4.0	−0.97	0.328
D2–D3	−5.5	5.5	−1.65	0.099
D1–D3	**−10.5**	**5.0**	**−2.28**	**0.023**
D1–D7	−19.5	−13.5	−1.69	0.091

*Values represent median change (Δ) in VISIA "Red Areas" counts. Analysis performed using paired Wilcoxon signed-rank test.

Conclusions

While overall recovery after fractional CO_2 laser was comparable between treatments, barrier-repair cream demonstrated superior early resolution of erythema and pain within the first 48 hours. This early advantage may reflect enhanced restoration of epidermal barrier function rather than anti-inflammatory suppression alone. In skin-of-color populations, where minimizing downtime is critical, barrier-focused post-procedural care may represent a promising strategy without compromising overall outcomes.

EA DV CONGRESS
VIENNA
30 SEP - 3 OCT 2026

Abstract N°: 507

Low-Downtime Treatment of Acne Scars in Skin of Color Using 755-nm Picosecond Laser with 6-mm Diffractive Lens Array: A VISIA-Based Prospective Study

Sonia Hanifati*[1], Selma Zein[2], Teguh Manurung[1], Adhimukti Sampurna[1], Kentaro Oku[3]

[1] Bamed Clinic, Jakarta, Indonesia

[2] Budhi Asih Hospital, Jakarta, Indonesia

[3] Hills Grace Clinic, Yokohama, Japan

Introduction

Acne scarring remains a therapeutic challenge, particularly in skin of color, where ablative and fractional lasers are constrained by downtime and risk of post-inflammatory hyperpigmentation (PIH). Picosecond domain lasers enable collagen remodelling via photomechanical effects with minimal thermal injury, offering a potentially safer profile for higher Fitzpatrick skin types. However, objective evidence using standardized quantitative imaging remains limited. This study evaluated the efficacy, safety, and clinical practicality of a 755-nm picosecond alexandrite laser with a 6-mm diffractive lens array (DLA) at relatively high fluence using VISIA-based quantitative texture analysis under standardized imaging conditions, with particular attention to pigmentary safety in skin of color.

Materials and Methods

This prospective single-arm pilot study (November 2025–March 2026) included eleven adults (Fitzpatrick III–V; III: n=2, IV: n=7, V: n=2; mean age 30.5 ± 4.3 years; 3 females, 8 males) with stable atrophic acne scars. Sample size was comparable with prior picosecond laser pilot studies in this domain (n=7–24). Participants underwent two treatment sessions using a 755-nm picosecond alexandrite laser (PicoSure Pro, Cynosure; pulse duration 750 ps) with fractional DLA (6-mm spot, 0.6–1.06 J/cm^2, 2–3 passes, 20% overlap, 5 Hz) at 3-week intervals. This shortened interval was selected based on the non-ablative photomechanical mechanism of picosecond delivery, which induces minimal thermal injury and permits earlier re-treatment compared to ablative or fractional modalities. The endpoint was uniform erythema without epidermal ablation. Standardized VISIA imaging (Canfield Scientific) was performed under controlled positioning, fixed lighting, standardized facial masking, and closed-eye conditions to ensure reproducibility. VISIA texture counts were assessed at baseline and 4 weeks after the final treatment for frontal (primary), right, and left views. Paired t-tests and Cohen's d were used. Acne scar severity was assessed using *échelle d'évaluation clinique des cicatrices d'acné*(ECCA) grading scale, pain (VAS), PIH incidence, and downtime were recorded.

Results

Significant and consistent reductions in VISIA texture counts were observed across all facial views (18–23%). Frontal texture decreased from 2406.9 ± 739.7 to 1969.5 ± 713.3 (−18.2%; p< 0.001; d= 2.07). Right and left views showed reductions of −22.0% (p= 0.010; d= 0.96) and −23.3% (p= 0.006; d= 1.06), respectively. Two treatment sessions resulted in approximately 20% objective improvement in skin texture. Averaged ECCA scores from two blinded raters also significantly decreased after treatment (Wilcoxon signed-rank, p= 0.008), supporting clinical

acne scar improvement. No PIH was observed in any participant (0/11, 0%), including those with Fitzpatrick types IV and V, at the follow-up assessment. All subjects completed both sessions without withdrawal or adverse events requiring intervention. Downtime was minimal (<2 days of mild erythema), with low procedural pain (VAS 3–4).

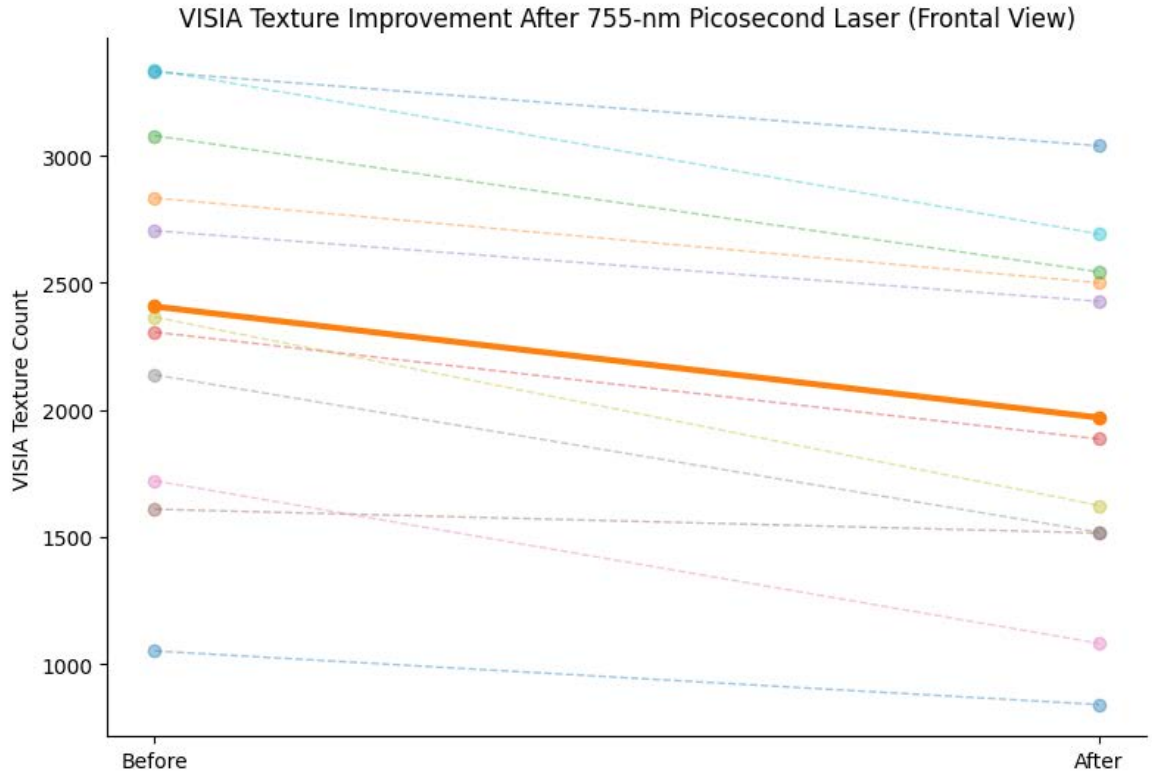

Figure 1. Individual changes in VISIA texture counts (frontal view) before and after treatment with a 755-nm picosecond laser using a 6-mm diffractive lens array. Dashed lines represent individual participants, while the solid line indicates the mean change. A consistent reduction in texture count was observed across most subjects, with an overall mean improvement of 18.2%.

Conclusions

A 755-nm picosecond laser with a 6-mm DLA at relatively high fluence provides consistent, clinically meaningful improvement in acne scar–related skin texture in skin of color, with minimal downtime and no PIH in this cohort. This approach represents a practical, low-downtime alternative to ablative and fractional laser modalities, particularly in patients at risk of pigmentary complications. Larger controlled studies are warranted.

EADV CONGRESS
VIENNA
30 SEP - 3 OCT 2026

Abstract N°: 530

Pigmented Purpuric Dermatosis Following Repeated Home-Use Intense Pulsed Light Epilation: A Clinical Case and Literature Review

Bengisu Meral Ketenci*[1], Ozge Karstarlı[2]

[1] konya city hospital, konya, Türkiye
[2] pamukkale university, denizli, Türkiye

Introduction

Pigmented purpuric dermatoses (PPD) are benign capillaritic disorders characterized by petechiae and purpura secondary to superficial dermal vascular injury. Although most cases are idiopathic, several triggering factors have been described, including medications, infections, venous hypertension, and mechanical or physical stimuli. Laser and light-based hair removal procedures are widely considered safe, with adverse effects typically limited to transient erythema and edema. Purpuric reactions after photoepilation have been rarely reported, and development of PPD following home-use intense pulsed light (IPL) devices has not been well documented. We present a case of PPD associated with repeated use of a home-use IPL device and briefly review relevant literature.

Case Presentation

A 21-year-old woman presented with asymptomatic purpuric lesions that had appeared 10 days prior to admission. She reported four sessions of full-body epilation using a home-use IPL device within the preceding two months. Dermatological examination revealed widespread, non-blanching purpuric macules and patches involving the trunk and both upper and lower extremities. There was no associated pruritus, pain, fever, arthralgia, or systemic symptoms. The patient had no history of chronic disease, recent infection, or medication and supplement use. Laboratory investigations, including complete blood count, coagulation profile, and inflammatory markers, were within normal limits. Histopathological examination of a punch biopsy demonstrated superficial perivascular lymphocytic infiltration with erythrocyte extravasation and hemosiderin deposition, without evidence of leukocytoclastic vasculitis. These findings were consistent with pigmented purpuric dermatosis. The patient was managed conservatively and showed gradual clinical improvement during follow-up.

Conclusion

Although laser and light-based hair removal procedures are generally considered safe, purpuric reactions have been rarely reported in the literature. In the present case, the absence of systemic disease, medication exposure, or coagulation abnormalities, together with the close temporal relationship between repeated home-use IPL applications and lesion onset, supports a possible causal association. The photothermal effect of IPL, which targets hemoglobin as a chromophore, may induce subclinical endothelial injury and capillary fragility, particularly when applied repeatedly over large body surface areas. Such vascular alterations may not only result in acute purpura but may also contribute to the development of chronic capillaritic dermatoses within the spectrum of pigmented purpuric dermatoses.Previous reports have primarily described purpura associated with clinic-based, medical-grade laser systems, while cases linked to home-use IPL devices remain extremely limited. This case highlights that over-the-counter cosmetic devices may also exert cumulative vascular effects capable of triggering capillaritic dermatoses.When evaluating unexplained purpuric eruptions, it is essential to obtain a detailed history of cosmetic procedures, including the frequency and extent of home-use device applications. This case underscores the importance of considering physical triggers in the differential diagnosis and contributes to improved patient counseling regarding potential adverse effects of repeated IPL exposure.

EADV CONGRESS
VIENNA
30 SEP - 3 OCT 2026

Abstract N°: 539

Oral Tranexamic Acid Pretreatment Before Repeat Intense Pulsed Light in IPL-Refractory Erythematotelangiectatic Rosacea With VISIA-Detected Pigment Signal: A Retrospective Cohort Study.

Miguel Montero[1], Sophie Edwards[1], Arif Aslam[1, 2], Faisal Ali*[1, 3, 4, 5]

[1] Discover laser, Burnley, United Kingdom
[2] Leeds & York Partnership NHS Foundation Trust, Leeds, United Kingdom
[3] Guys & Saint Thomas Nhs Foundation Trust, London, United Kingdom
[4] Mid Cheshire NHS Foundation Trust, Crewe, Northern Ireland
[5] University of Central Lancashire, Preston, United Kingdom

Introduction
A subset of patients with erythematotelangiectatic rosacea (ETR) show limited improvement after repeated intense pulsed light (IPL). In our practice, some of these patients also demonstrated subtle concurrent pigment signal on VISIA imaging.

Objectives: To evaluate outcomes of oral tranexamic acid (TXA) given before repeat IPL in patients with IPL-refractory ETR and VISIA-detected pigment signal.

Materials and Methods
We performed a retrospective cohort study of 46 patients with ETR at a UK laser clinic. Refractory disease was defined pragmatically as lack of significant response after three or more consecutive IPL treatments. All patients underwent baseline and follow-up VISIA imaging. Oral TXA 250 mg twice daily was given for a median of 8 weeks before further IPL. Subsequent IPL was delivered using the Lumenis M22 platform with 560-590 nm, 695 nm and vascular filters in a stacked multipass approach, with fluence starting at 14 J/cm^2 and adjusted according to skin type and clinical response.

Results
The cohort comprised 24 men and 22 women with median age 49 years. Fitzpatrick skin types were I-III. VISIA-detected pigment signal was present in 45/46 patients (98%) before TXA and was judged reduced in 43/46 (93%) after TXA. Following TXA and subsequent IPL, erythema improved in 42/46 patients (91%). The median number of post-TXA IPL sessions was 2. Among 37 patients who completed a satisfaction survey, 86% reported good-to-excellent satisfaction. No adverse events were recorded in this series.

Conclusions
In this retrospective real-world cohort, oral TXA followed by repeat IPL was associated with reduced VISIA-detected pigment signal and subsequent improvement in facial erythema in patients with IPL-refractory ETR. These findings support further prospective controlled study of this imaging-guided treatment sequence.

EADV CONGRESS
VIENNA
30 SEP - 3 OCT 2026

Abstract N°: 557

Intralesional botulinum toxin injection versus intralesional nano-fat injection in the treatment of hypertrophic scars and keloids.

Mohamed El-Khalawany*[1]

[1] Al-Azhar University, Cairo, Egypt

Introduction
Botulinum toxin has several beneficial mechanisms that improve hypertrophic scars (HTSs) including the reduction of muscle tension, modification of fibroblast activity and antipruritic effect. Autologous fat grafting has been introduced as the treatment of atrophic scars and contour deformity. It not only serves to improve contour and to fill areas of deficiencies, but increasingly there has been a focus on its ability to regenerate and remodel surrounding tissues. This study aimed to assess the role of intralesional botulinum toxin injection versus intralesional nano-fat injection in treatment of hypertrophic scars and keloids.

Materials and Methods
This prospective observational study was conducted on 40 patients suffering from hypertrophic scars or keloids. 20 patients treated with intralesional injection of botulinum toxin and 20 patients treated with intralesional injection of nano-fat.

Results
Age ranged from 8 to 60 years with a mean value (± SD) of 23.2 (± 11.79) years. Sex was male in 21 (52.5%) patients and female in 19 (47.5%) patients. Regarding lesion site, arm lesion was present in 10 (25%) patients, chest lesion was present in 3 (7.5%) patients, elbow lesion was present in 3 (7.5%) patients, face lesion was present in 4(10%) patients, forearm lesion was present in 3 (7.5%) patients, hand lesion was present in 7 (17.5%) patients, neck lesion was present in 6(15%) patients and shoulder lesion was present in 4 (10%) patients. In botulinum toxin treated patients VSS (vascularity, pliability, height of lesion and total) was significantly lower after one month, 3 months and 6 months than pretreatment (P value <0.05). In nano fat treated patients VSS (vascularity and pliability) was insignificantly different between pretreatment and after one month while was significantly lower after 3 months and 6 months than pretreatment (P value <0.05). In both groups Epidermal thickness and collagen thickness were significantly lower after treatment than pretreatment (P value <0.001). Elastic fibers thickness was significantly higher after treatment than pretreatment (P value <0.001).

Conclusions
Both botulinum toxin and nano fat injection are an easily mastered, day-care procedures for scar rejuvenation with minimal complications and good patient compliance. It improves the symptoms as well as the texture of all types of scars. Both are promising modalities in patients with keloid and hypertrophic scars.

EADV CONGRESS
VIENNA
30 SEP - 3 OCT 2026

Abstract N°: 564

Market Trends, Ingredient Characteristics, and Suspected Adverse Reactions of Cosmetics for Sensitive Skin in China: A Big-Data Analysis of Major E-commerce Platforms

Yu Li*[1]

[1] West china hospital of Sichuan university, Chengdu, China

Introduction
The global market for sensitive skin cosmetics is experiencing unprecedented growth. However, real-world evidence regarding product safety and consumer-reported adverse reactions remains limited, often overshadowed by commercial marketing. This study leverages advanced natural language processing (NLP) to systematically evaluate market trends, ingredient safety profiles, and suspected adverse reactions in a large-scale consumer cohort in China.

Materials and Methods
A comprehensive big-data analysis was conducted on cosmetics marketed for sensitive skin across major Chinese e-commerce platforms (2016–2021). We integrated data on sales volume, formulations, origins, and ingredient lists. A deep-learning model based on the Transformer architecture was developed to filter over 5 million consumer reviews, performing sentiment analysis and identifying keywords suggestive of cutaneous irritation or allergy (e.g., stinging, burning, erythema). Ingredient risk was quantified using the Environmental Working Group (EWG) scoring system. Spearman's rank correlation was applied to evaluate the relationship between formula complexity, risk ingredients, and reported adverse events.

Results
190 top-selling products from over 100 multinational brands were analyzed. Moisturizers, essences, and sunscreens were the most preferred categories. While domestic products held the largest market share, products from specific regions (e.g., France and South Korea) showed significantly higher suspected adverse reaction rates in this population. Crucially, the rate of suspected adverse reactions was not correlated with the total number of ingredients ($p > 0.05$), challenging the "minimalist formula is safer" myth. Instead, a significant positive correlation was found between the adverse reaction rate and both the absolute number and the proportion of "risk ingredients" ($r=0.146$ and $r=0.137$, respectively; $p < 0.05$). Thirteen specific ingredients, including certain chemical UV filters (e.g., Octocrylene) and formaldehyde-releasing preservatives (e.g., Diazolidinyl Urea), were identified as primary safety signals. Furthermore, fragrance-containing products were 25% more likely to be associated with high-allergy-ratio reports.

Conclusions
This study provides a robust real-world framework for cosmetic safety monitoring. Our data suggest that product safety is a multi-dimensional construct determined by qualitative ingredient risk rather than simple formula complexity. These findings offer critical insights for dermatologists in providing evidence-based skincare recommendations and for regulatory bodies in enhancing post-marketing surveillance.

EADV CONGRESS
VIENNA
30 SEP - 3 OCT 2026

Abstract N°: 581

Safety of combination of pulsed dye laser followed by intralesional triamcinolone acetonide and intralesional triamcinolone acetonide alone in the treatment of keloid – a study on 50 case

Sharmin Jahan*[1]

[1] Dhaka Medical College Hospital, Combined Military Hospital, Dhaka, Dhaka, Bangladesh

Introduction
Keloids are benign fibroproliferative lesions that extend beyond the original wound margins, often causing cosmetic disfigurement, discomfort, and psychosocial distress. Their high recurrence rates and resistance to conventional therapy make management challenging. Although various modalities such as surgery, corticosteroid injections, cryotherapy, radiotherapy, and laser treatments are available, no single method has shown consistent long-term superiority. The objective was to evaluate the safety and any associated side effects or complications of pulsed dye laser (PDL) followed by intralesional triamcinolone acetonide versus triamcinolone alone in keloid management.

Materials and Methods
This randomized comparative study enrolled 50 patients with clinically diagnosed keloids at the Department of Dermatology & Venereology, Combined Military Hospital, Dhaka. Patients were allocated into two groups (n = 25 each). Group A received PDL immediately followed by intralesional triamcinolone acetonide (40 mg/mL), while Group B received triamcinolone alone. Injections were delivered intradermally using a 30-gauge needle and 1 mL insulin syringe under aseptic conditions, with dosing adjusted according to clinical response. Outcomes were assessed at baseline and at 4, 8, and 12 weeks, focusing on safety, adverse effects, and clinical improvement.

Results
Both groups tolerated treatment well, with no serious adverse events. Combination therapy produced greater improvement than steroid alone, with earlier lesion softening and better overall response. The enhanced efficacy was attributed to PDL-induced edema, which may increase steroid penetration. For safety Profile- Telangiectasia was present at baseline in 9 patients (36%) in Group A and 10 patients (40%) in Group B. By the 12th week, no patients in Group A had telangiectasia, whereas in Group B, 3 patients (12%) still exhibited telangiectasia. No ulcerations were reported in either group at baseline or during follow-up. For pigmentation: At baseline, 13 patents (52%) in Group A and 12 patients (48%) in Group B had moderate pigmentation. By week 12, 21 patients (84%) in Group A and 19 patients (76%) in Group B showed no pigmentation. Skin Atrophy: No skin atrophy was noted in Group A throughout the study. In Group B, no atrophy was observed at baseline, but by week 12, 2 patients (8%) developed mild atrophy. Irritation: At baseline, 13 patients (52%) in Group A had moderate irritation, while 14 patients (56%) in Group B had mild irritation. By week 12, irritation had resolved in 23 patients (92%) in Group A and 21 patients (84%) in Group B.

Conclusions
Both methods were found to be individually safe. However, the combination of PDL and intralesional triamcinolone acetonide offers a safer approach that produces better clinical outcomes and quicker lesion softening compared to steroid injection alone, without added safety concerns.

POWERED BY M-ANAGE.COM

EA DV CONGRESS
VIENNA
30 SEP - 3 OCT 2026

Abstract N°: 607

Makeup with natural pigments from the BrazilianCerrado, offering multifunctional antioxidant and photoprotective action.

Joyce Guillen*[1], Claudineia Aparecida Sales de Oliveira Pinto[1], André Baby[1, 1], Maria Valeria Robles Velasco[1, 1]

[1] Faculty of Pharmaceutical Sciences USP, Faculty of Pharmaceutical Sciences USP, Faculty of Pharmaceutical Sciences USP, São Paulo, Brazil

Introduction

The Brazilian Cerrado covers approximately 22% of the national territory. It represents a rich plant biodiversity with a strategic reservoir of bioactive compounds with potential applications in the dermatological field, aiming to offer benefits such as antioxidant and photoprotective action, in addition to the conventional action of providingcolor and masking imperfections, making the formulation multifunctional. The concept of upcycling, which employs rawmaterials in the development of topical formulations has grown and is consistent with relevant environmental issues, as well as adding value to the final product.

Case Presentation

Objectives. To develop powder makeup formulations usingplant pigments from the repurposed species G. ulmifolia(bastard cedar) and C. fissilis (pink cedar), verifying theirantioxidant and photoprotective activity. Materials and Methods. Analyses were performed tocharacterize and quantify the antioxidant activity of bioactivecompounds from the species G. ulmifolia and C. fissilis(DPPH/ Trolox® equivalent method). The formulations weredeveloped as follows: Formulations (total 100%): Isolatedmutamba (38% w/w) (F1); isolated cedro-rosa (38% w/w) (F2) and mixture of mutamba (38%) and cedro-rosa (25%) (F3). Excipients: titanium dioxide, black clay, rice powder, hypoallergenic plant fragrance and Bertholletia excelsa seedextract (antioxidant). The formulations were subjected to theNormal Stability Test (NST) for 90 days, observing theirbehavior under the following storage conditions: refrigerator(4.0±2.0ºC), room temperature (22.0±2.0ºC) and oven(45±2.0ºC). The evaluations involved assessing: antioxidantactivity, and photoprotective activity (in vitro SPF, UVA/UVB ratio, and critical λ). Results and Discussion. The studied plants showed a high concentration of bioactive compounds, such as: phenoliccompounds, flavonoids, tannins, and saponins, with potentialapplications to protect the skin. The antioxidant activity of thespecies and formulations was proven, remaining acceptablein the NST (90 days/ room temperature) and superior in theformulations with isolated bastard ceder (F1), 375.30 µM/g, or associated with pink cedar (F3), 503.61 µM/g. In thephotoprotection assessment, after 90 days under theevaluated conditions (room temperature, oven, andrefrigerator), the in vitro SPF was greater than 39.0 (F1) atroom temperature and refrigerator, and the mixture of bothextracts (bastard and pink cedar/ F3) reached a minimum of40.0 in all three storage conditions. The minimum criticalwavelength (λ) was greater than 370 nm/ effective protectionagainst UVA and the UVA/UVB ratio above 0.7 (broadprotection against UVA and UVB radiation). The powdermakeup formulation without the extracts showed an in vitroSPF of 20.0, indicating effectiveness due to the extractd ofplants. The formulations studied indicated the effectivenessof bastard cedar extract, isolated or combined with pinkcedar extract, in combating oxidative stress and providingphotoprotection caused by exposure to UV radiation.

Conclusion

The use of the studied pigments obtained fromplant waste, bastard and pink cedar, proved effective in invitro antioxidant and photoprotective action with anti-UVA andUVB effects in powder makeup formulation, confirming themultifunctionality of the formulation, in addition to thedecorative effect and adding value to the product.

EADV CONGRESS
VIENNA
30 SEP - 3 OCT 2026

Abstract N°: 611

Fractional ablative CO2 laser to manage hypertrophic burn scars – a review of controlled clinical trials.

Daniel Worthington*[1], Bryony Marr[1], Adam Aslam-Baskeyfield[2]

[1] Torbay and South Devon NHS Trust, Torquay, United Kingdom
[2] Derriford Hospital, Plymouth, United Kingdom

Introduction
Hypertrophic scars are a potential thermal burn injury complication, which poses a challenge to clinicians and patients. Many factors contribute to the formation of hypertrophic scars, these can include the depth of tissue injury, prolonged healing, and wound complications. When hypertrophic scars occur, they can cause notable psychological, functional, and aesthetic issues, severely impacting a patient's quality of life. Current management strategies for hypertrophic scars are mainly conservative, however, surgical options do exist for incredibly problematic scars. Treatment with a fractional CO2 laser is a fairly new procedure for the management of hypertrophic scars. This review aims to determine whether this novel therapy improves hypertrophic scars' visual and histological appearance compared to a control group.

Materials and Methods
A literature review was conducted using a systematic approach of databases. A PICO-specific question was asked, and relevant papers were appraised using the CASP checklist. Final studies used only fractionated ablative CO2 laser treatment to manage to burn scars, and documented results using a scar scoring system, and histologically. Overall, three studies were found that met the inclusion criteria.

Results
A total of 53 patients were included in the results of the three studies. A combination of the Manchester Scar Scale (MSS), Vancouver Scar Scale (VSS), Patient and Observer Scar Assessment Scale (POSAS), and photography was used to measure the overall change of appearance of each of the scars used, relative to the control. All three studies showed a statistically significant improvement in scars that were treated with CO2 fractional laser ablation, compared to control groups. Tissue samples were also used in each of the three studies to assess histological change in response to treatment. Each of the studies demonstrated that treatment with a fractionated CO2 laser led to re-organisation and overall improvement in the underlying skin structure.

Conclusions
Overall, the results of the studies demonstrate that fractional CO2 laser therapy significantly improves both the visual and histological appearance of burn-induced hypertrophic scars. Further studies are indicated to assess the potential side effects of fractional CO2 laser therapy.

EA DV CONGRESS
VIENNA
30 SEP - 3 OCT 2026

Abstract N°: 640

Regenerative Injectable Therapies for Facial Rejuvenation: A Systematic Review and Meta-Analysis

Aida Kafai Golahmadi*[1], Theodora Mclauchlan[2], Jonathan Herron[3, 4]

[1] The Whittington Hospital, London, United Kingdom
[2] Imperial College London, School of Medicine, London, United Kingdom
[3] Barts Health NHS Trust, London, United Kingdom
[4] University of Greater Manchester,, Greatest Manchester, United Kingdom

Introduction

Regenerative injectable therapies for facial rejuvenation, including platelet-rich plasma (PRP), adipose-derived stem/stromal cell-based therapies (ADSCs), and exosomes, are increasingly used in aesthetic practice and are frequently promoted for wrinkle reduction, improved skin quality, and collagen stimulation. However, their clinical efficacy remains uncertain because published studies use highly variable preparation methods, injection protocols, comparators, and outcome measures. This systematic review and meta-analysis aimed to evaluate the efficacy and safety of injectable regenerative therapies for non-reconstructive facial rejuvenation, and to determine whether benefits are demonstrated across both overall aesthetic appearance and specific skin-quality domains.

Materials and Methods

A systematic review and meta-analysis was conducted according to PRISMA 2020 and a prospectively registered PROSPERO protocol. Studies of adults undergoing non-reconstructive facial regenerative injectable treatments for age-related facial skin changes were included. Searches were performed in PubMed/MEDLINE, Ovid MEDLINE, Cochrane CENTRAL, ClinicalTrials.gov, and Google Scholar from database inception to 21 January 2026. Interventions were grouped into three classes: blood-derived products (PRP and related preparations), ADSC/ADSC-derived therapies, and exosome-based therapies. Outcomes were grouped into clinically relevant domains, including global aesthetic improvement, wrinkle severity, pigmentation/luminance, skin texture/roughness, patient-reported outcomes, and structural or histologic measures. Where appropriate, controlled studies with extractable numerical data were pooled using random-effects meta-analysis and standardised mean differences (SMDs) with 95% confidence intervals. Risk of bias was assessed using RoB 2, ROBINS-I, and MINORS, and certainty of evidence was evaluated with GRADE.

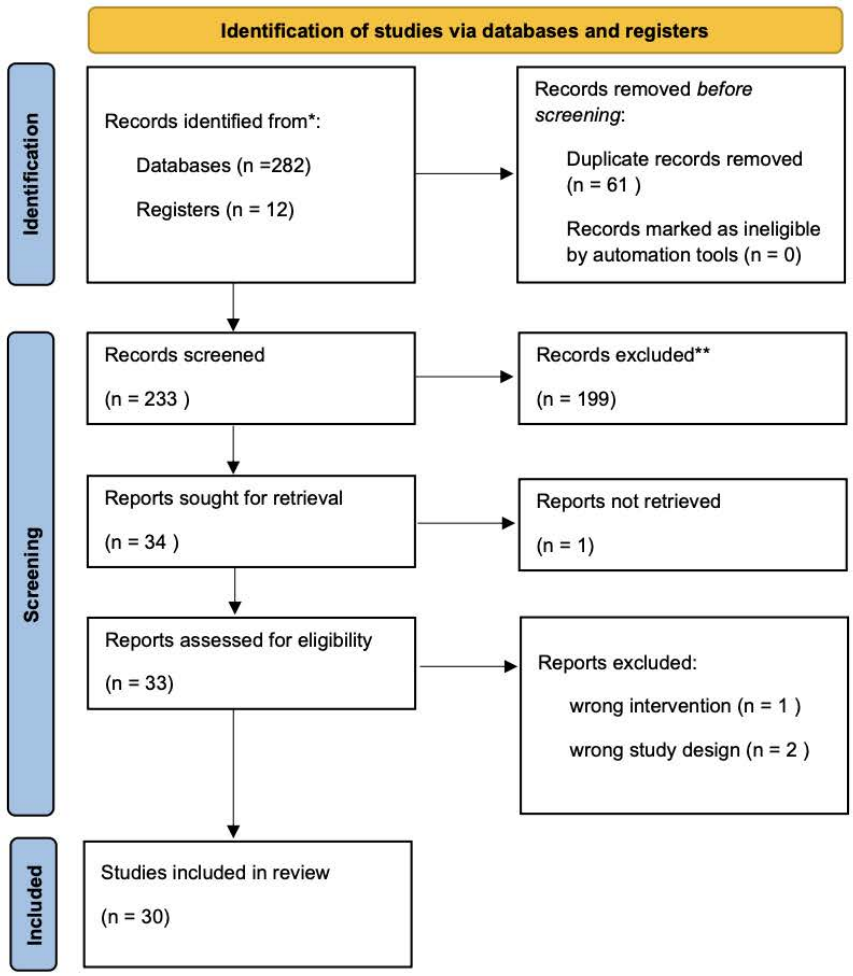

Source: Page MJ, et al. BMJ 2021;372:n71. doi: 10.1136/bmj.n71.

This work is licensed under CC BY 4.0. To view a copy of this license, visit https://creativecommons.org/licenses/by/4.0/

Figure 1. PIRSMA Flow Diagram

Results

Thirty studies involving 879 participants were included. The evidence base consisted of 8 randomised controlled trials, 7 non-randomised comparative studies, and 15 single-arm studies, with generally small sample sizes and predominantly female participants. Nineteen studies evaluated PRP or related blood-derived products, 9 evaluated ADSC or ADSC-derived therapies, and 2 evaluated exosome-based treatments. Only 5 placebo-, sham-, or no-treatment-controlled studies were sufficiently similar for primary meta-analysis. Regenerative injectable therapies demonstrated a statistically significant improvement in global aesthetic appearance versus control (SMD 1.11; 95% CI 0.07-2.16), with moderate heterogeneity. In contrast, no statistically significant pooled effects were observed for wrinkle severity, pigmentation/luminance, skin texture/roughness, patient-reported outcomes, or histologic/structural outcomes. Across studies, outcome reporting was heterogeneous and overall certainty of evidence was low to very low for most domains. Safety findings were generally reassuring: no serious adverse

events were reported, and adverse effects were limited to mild, self-limiting local reactions such as erythema, oedema, bruising, pain, burning, or transient swelling.

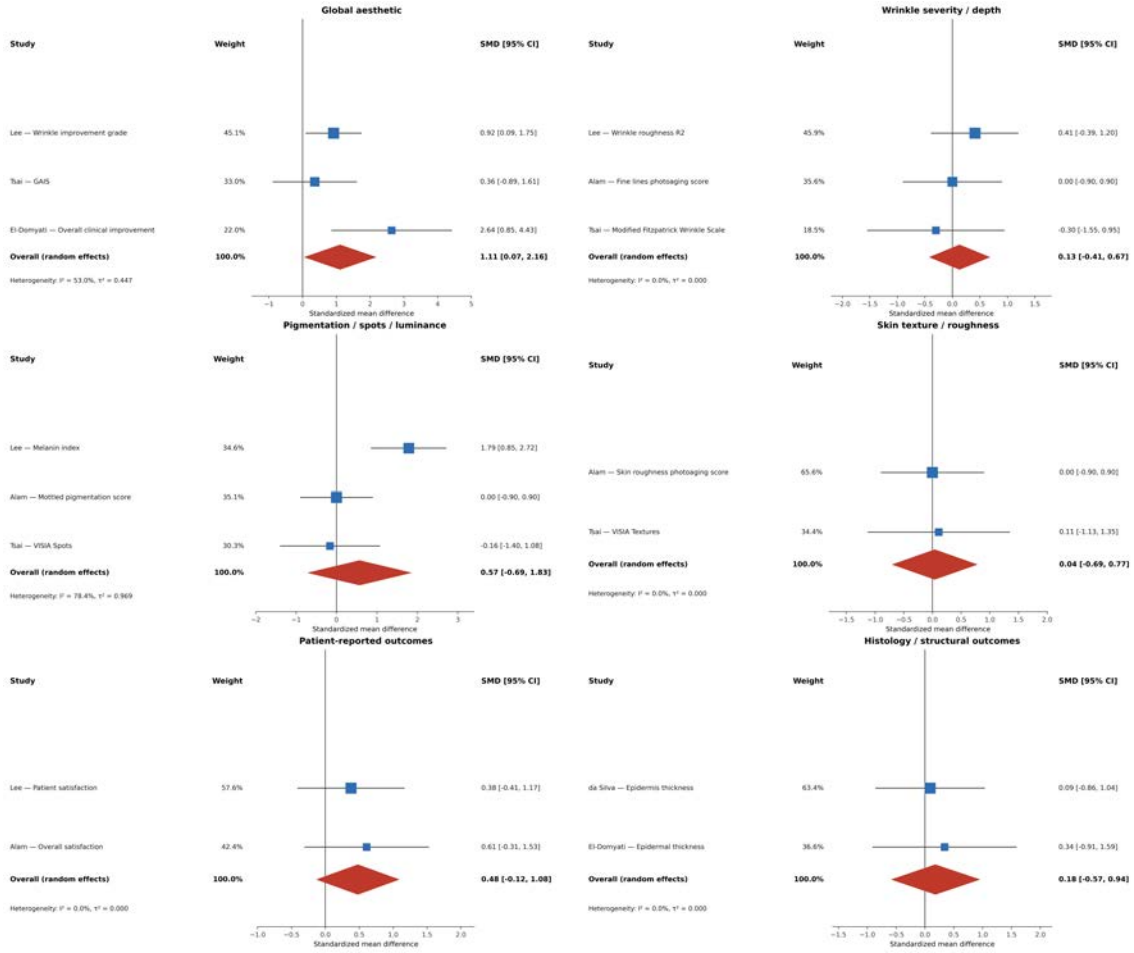

Figure 2. Combined Forest plots of pooled effects of regenerative therapies for facial rejuvenation across outcome domains, showing standardized mean differences (SMDs) with 95% confidence intervals (CIs) for regenerative therapies versus control across six outcome domains: (A) global aesthetic improvement, (B) wrinkle severity/depth, (C) pigmentation/spots/luminance, (D) skin texture/roughness, (E) patient-reported outcomes, and (F) histology/structural outcomes. Individual studies are represented by blue squares (weighted by inverse variance), with horizontal lines indicating 95% CIs. The pooled effect for each domain is shown as a red diamond (random-effects model), with width corresponding to the 95% CI. The vertical line at SMD = 0 represents no effect. Positive values favor regenerative therapies. Heterogeneity is reported using the I^2 statistic for each analysis.

Conclusions

Regenerative injectable therapies may improve overall facial aesthetic appearance, but current evidence does not support consistent, measurable benefits for specific ageing features such as wrinkles, pigmentation, texture, or histologic regeneration. On the basis of the available data, these treatments are better regarded as adjunctive options for general aesthetic enhancement rather than targeted corrective therapies. Their short-term safety profile appears favourable, but long-term efficacy and safety remain insufficiently defined. Higher-quality, adequately powered, standardised randomised controlled trials with longer follow-up are needed to establish true clinical benefit, durability, and comparative performance across regenerative modalities.

EADV CONGRESS
VIENNA
30 SEP - 3 OCT 2026

Abstract N°: 651

Efficacy of Low-Level Diode Laser Therapy in The Treatment of Oral Pemphigus VulgarisEfficacy of Low-Level Diode Laser Therapy in The Treatment of Oral Pemphigus Vulgaris

Hagar El Sayed Abdelghani Anter*[1], Olfat Shaker[1], Hesham Mahran[2, 2], Emad Tawfik[2], Hamada Hussein[2]

[1] Kasralainy school of medicine, Cairo University, Egypt, Cairo, Egypt

[2] Faculty of Physical Therapy, Cairo University, Cairo, Egypt

Introduction

Background: Pemphigus is a group of relatively chronic autoimmune disorders characterized by the formation of intraepithelial bullae in the skin and mucous membrane. Low-energy laser radiation has been found to have a stimulating effect on cells and is used to stimulate wound healing and treat ulcers.
Objective: This study aimed to assess the therapeutic efficacy of low-level laser therapy (LLLT) on oral pemphigus vulgaris patients.

Materials and Methods

Methods: Twenty-two patients diagnosed with oral pemphigus vulgaris were randomly assigned into two equal groups.The first group received low-level diode laser therapy at as 3 sessions per week for 4 weeks in addition to their systemic therapy while the second group received systemic therapy only. Tools of assessment used were wound and pain assessment, Pemphigus Oral Lesions Intensity Score (POLIS) and tissue level of (TNF alpha) as by ELISA. All measures were done before and after 4 weeks of treatment.

Results

Results: A statistically significant difference was found between the two groups regarding the percentage change of the ulcer length and the VAS score ($p<0.001$). Although the POLIS score and TNFα level decreased significantly in each group, there was no significant difference between the two groups (p-value≥0.05). A significant difference was found between both groups regarding physician global assessment scores while no significant difference regarding patient satisfaction scores although in the study group the patients were more satisfied.

Conclusions

Conclusion: Low level laser therapy can be considered an additive safe and effective therapy in treating oral pemphigus.

EA DV CONGRESS
VIENNA
30 SEP - 3 OCT 2026

Abstract N°: 659

Atypical Mycobacterial Infection Following Fractional Carbon Dioxide Laser Therapy for Burn Scars

Tugba Aydin*[1], Husnaa Ali[1, 2], Daniel Keith[1, 2], Christopher Wearn[2]

[1] Faculty of Health & Life Sciences, University of Bristol, Bristol, United Kingdom
[2] Bristol Laser Centre, North Bristol NHS Trust, Southmead Hospital, Bristol, United Kingdom

Introduction

Fractional CO_2 laser therapy is widely used in the management of hypertrophic burn scars, improving scar thickness, pliability, and functional outcomes. It is generally well tolerated, with expected adverse effects including transient erythema, oedema, and post-inflammatory pigmentary change. Infectious complications are uncommon and are typically caused by bacterial pathogens such as Staphylococcus aureus and Pseudomonas aeruginosa. Atypical mycobacterial infections following fractional CO_2 laser therapy are rarely reported. We present two cases of delayed-onset pustular eruptions following treatment, highlighting this important and under-recognised complication.

Case Presentation

We present two patients (A and B) who developed delayed-onset pustular eruptions following fractional CO_2 laser treatment for burn scars.

Patient A, a 43-year-old male with Fitzpatrick skin type II and 50% TBSA burns involving the face, upper limbs and trunk, had a background of immunosuppression, neutropenia, and chronic venous ulceration. Ten days following fractional CO_2 laser therapy for hypertrophic scar modulation, he developed a monomorphic pustular eruption confined strictly to laser-treated areas, with no systemic symptoms. Initial management with oral doxycycline, topical antiseptics, and corticosteroids resulted in minimal improvement over six weeks. Skin biopsy demonstrated acid-fast bacilli on staining, with negative fungal cultures. Findings were in keeping with an atypical mycobacterial infection. Partial clinical improvement was achieved with continued topical therapy.

Patient B, a 67-year-old male with Fitzpatrick skin type II and 17% TBSA burns affecting the anterior trunk, upper limbs and hands, had previously undergone fractional CO_2 laser therapy without complication. Following repeat treatment, he developed a similar delayed-onset, localised pustular eruption confined to treated areas. In view of the preceding case and treatment-resistant presentation, atypical mycobacterial infection was suspected. Skin biopsy confirmed Mycobacterium chelonae. He was managed with topical corticosteroids and antimicrobial washes, with gradual spontaneous resolution over several months without the need for systemic antibiotic therapy.Both cases demonstrated a consistent clinical pattern of delayed-onset, monomorphic pustular eruptions localised to laser-treated skin, with poor response to conventional antimicrobial therapy. These features, alongside confirmatory histology, support atypical mycobacterial infection as an important differential in post-laser complications.

Conclusion

These cases highlight atypical mycobacterial infection as a rare but important complication of fractional CO_2 laser therapy, presenting with delayed-onset treatment-resistant pustular eruptions confined to treated areas. Clinical courses may be variable, ranging from partial response to conservative therapy to spontaneous resolution without systemic antibiotics. Recognition of this characteristic pattern is essential, particularly in patients with poor response to standard antimicrobial treatment. A high index of suspicion should be maintained, and early biopsy

with microbiological investigation is crucial to facilitate timely diagnosis and guide appropriate management.

EA DV CONGRESS
VIENNA
30 SEP - 3 OCT 2026

Abstract N°: 663

Tattoos removal by QS Nd:YAG (1064 nm) laser

Islam Abuelkhair*[1]

[1] Cairo University, Cairo, Egypt

Introduction

Placement of tattoos has gained popularity , so has the number of people interested in their removal .
laser are the main devices used for tattoo removal. Qs NdYAG (1064 and 532), QS alexandrite (755), QS Ruby (694).
Light tissue interaction: photo mechanical, Photoacoustic damage breaks up the ink particles making them more available for macrophages phagocytosis and lymphatic system removal.
Chromophore :exogenous ink either in macrophage or extracullarly throughout the dermis.

Materials and Methods

Patients:
10 patients with diferent type and color of tattoos enrolled in this study.
all patients subjected to:
1- History taking :
- Allergy.
- Current medical condition.
- Medication like isotretinoin.
- History of scarring or keloid formation.
- Herpes simplex.
2-Assessment:
- Skin type.
- Type and color of tattoo.
- Photography.
- Test dose

laser type:
Q switched Yag laser(1064) which has these advantages:
- Deeper penetration.
- Suitable or dermal pigmented skin lesion.
- Safe in dark skin type.
- Suitable for black , blue and green tattoo.

Parameter:
Fluence: start by 1.0 up to 2.0j/cm2
Frequency: 2-5 HZ.
Repeated pass : 2-3.
Spot size: 5 mm
Treatment interval: 6 weeks.
Immediate endpoint: Immediate whitening and may be pinpoint bleeding.
Number of treatment sessions: 2-10 sessions

Case 1

Before



After



QS Nd:Yag (1064 nm) , 2 TX interval six weeks

Results

The least number of sessions for tattoo removal was observed in:

1- Fair skin

2- Black tattoo

3- Amateur tattoo

4- No scarring

Complicaion:

- Alteration of pigment PIH or hypopigmentation
- Allergic reaction as the dispersed ink particles can elicit a systemic response
- Textural changes and scarring
- Pruritus
- Incomplete response

Conclusions

- The Q- switched ND:YAG laser have been shown good efficacy to remove tattoos with a mild side effects and complicaion.
- significant whitinig observed after first session.
- professional tattoos are more resistant to treatment by laser.

Most common complication observed:

1-Textural changes

2- Incomplete clearance (the most important challenge)

EA DV CONGRESS
VIENNA
30 SEP - 3 OCT 2026

Abstract N°: 664

The Analgesic Effect of Forced Air Cooling during High-Intensity, High-Frequency, Parallel Ultrasound Beams Treatment

Shasha Zhao*[1], Yan Yan[1]

[1] Department of Dermatology, Plastic Surgery Hospital, Chinese Academy of Medical Sciences and Peking Union Medical College, Beijing, China

Introduction
The high-intensity parallel beam ultrasound device is clinically safe and effective for skin tightening. Mild to moderate pain during treatment is frequently reported, which may impact patient satisfaction and retention. Forced cold-air analgesia has proven helpful in alleviating pain and reducing severe adverse events during laser treatments. However, few studies have examined its efficacy and tolerability in the context of novel ultrasound device treatments. This study aims to evaluate the analgesic effects of forced air cooling during treatment with the novel ultrasound device. Additionally, we aimed to compare histological changes in porcine skin subjected to various energy settings and to evaluate whether the cooling method influences treatment efficacy in an animal study.

Materials and Methods
A prospective, randomized controlled trial involving twenty healthy participants was conducted to evaluate pain levels. A combination of forced air cooling and topical anesthetic was randomly applied to one side of the arm, while topical anesthetic monotherapy was applied to the other side. The same ultrasound device settings were used on both arms. Pain sensation was measured immediately after treatment using the visual analog scale. Additionally, three four-week-old Bama miniature pigs were selected as experimental subjects. The pigs' abdomens were treated under varying energy settings to assess the effect of forced-air cooling on treatment efficacy. Histological changes were examined immediately and six weeks post-treatment.

Results
A total of twenty participants were recruited. The mean age of the participants was 28.9 ± 4.2 years. Among all subjects, 85% (n = 17) were female. Six participants (30%) and fourteen (70%) had Fitzpatrick skin type III and IV, respectively. The mean VAS pain score was 6.58 ± 1.59 for the side treated with topical anesthesia alone. On the side treated with cold-air anesthesia and topical anesthesia, the mean pain score was 4.64 ± 1.62 (P□0.0001). Nine subjects (45%) reported significant improvement in pain perception in the area treated with topical anesthesia and forced air cooling. Five subjects reported faster pain relief following forced-air cooling. Transient erythema and edema were commonly observed on both sides. No serious adverse events were reported during this study.Mild erythema and edema were observed on the porcine skin in different areas immediately after treatment, with more pronounced effects in the high-energy group and more extensive erythema in the cooling group. Six weeks post-treatment, dermal thickness and collagen type I expression in the animal model increased significantly across all treatment groups using the ultrasound device compared with the control group. Furthermore, histological examination with Masson's trichrome staining revealed that the dermis was denser and thicker in all treated areas. No statistically significant differences were found between the cooling and no-cooling groups.

Conclusions
During the high-intensity parallel beam ultrasound treatment, forced air cooling effectively reduces the pain with minimal complications. Additionally, the temperature reduction at the skin’s surface does not affect collagen

remodeling. To sum up, the combination of forced air cooling and topical anesthesia is effective for pain relief during treatment with the novel ultrasound device.

EA DV CONGRESS
VIENNA
30 SEP - 3 OCT 2026

Abstract N°: 667

Clinical and histologic changes after 755-nm picosecond laser with a novel platinum focus lens array in the treatment of photo-aged skin

Shasha Zhao*[1], Yan Yan[1]

[1] Department of Dermatology, Plastic Surgery Hospital, Chinese Academy of Medical Sciences and Peking Union Medical College, Beijing, China

Introduction
The 755-nm picosecond laser with a diffractive lens array is effective in treating acne scars, photo-aging, and pigmented lesions. The laser device has undergone recent updates, including a new platinum focus lens array, which increases the maximum output energy to 300 mJ. This study aims to review and recognize the efficacy and safety profile of the new 755-nm picosecond laser device for skin lightening and rejuvenation. Additionally, we aimed to compare histological alterations in porcine skin under various settings of the new picosecond laser device.

Materials and Methods
A retrospective analysis was conducted on patients who received treatment with the updated 755-nm picosecond laser device. Standardized clinical photographs were taken prior to treatment and during follow-up assessments. A modified global aesthetic improvement scale was employed as the main evaluation indicator. Additionally, three four-week-old Bama miniature pigs were selected as experimental subjects. The abdomens of 4-week-old Bama miniature pigs were treated with the new laser device under different energy settings. Histological changes were examined using hematoxylin and eosin staining, Masson's Trichrome staining, and immunohistochemical techniques.

Results
A total of 10 female patients who received two consecutive treatment sessions at 1-month intervals were included in our analysis. The average age of the participants was 46.7 ± 11.47 years. The Fitzpatrick skin types were classified as type IV (90%) and V (10%). Treatment parameters were designed according to specific skin conditions. Notable improvements were observed, accompanied by minimal downtime and complications. One month following the second treatment, two blinded investigators assessed and scored the overall treatment outcome by a modified GAIS. Both investigators assigned ratings between 1 and 3, believing that over half of the patients demonstrated 'very much improved' of overall improvement. The common, prevalent adverse effects included mild to moderate pain, erythema, pruritus, and facial swelling. Adverse reactions were mainly transient and subsided within 7–10 days. No severe adverse reactions were reported.Erythema and petechial hemorrhage were observed on the porcine skin immediately following treatment with varying parameters, with more pronounced effects noted in the high-energy group. Vacuoles within the epidermis were identified across different fluence settings, accompanied by vascular damage, red blood cell extravasation, and infiltration of inflammatory cells in the superficial dermis. Six weeks after laser treatment, dermal thickness increased significantly across all energy settings. The expression of collagen type I proteins also increased post-treatment with the new device.

Conclusions
Our research confirms that the 755-nm picosecond laser with a new platinum focus lens array is safe for the Chinese race and achieves various treatment outcomes, including improved skin texture, better skin tone, and reduced pore size in a single treatment. The newly developed device effectively induces laser-induced optical

breakdown and initiates dermal remodeling. It represents a safe and effective therapeutic option for facial rejuvenation.

EA DV CONGRESS
VIENNA
30 SEP - 3 OCT 2026

Abstract N°: 675

Application of Thiamidol in Intense Pulsed Light (IPL) for Skin Brightening and Pigmentation Inhibition: A Split-Face Controlled Clinical Study

Li Ye*[1], Xi Fang[2], Kan Zhou[2], Linshan Wu[1], Zhen Yi[1], Si Wen[1], Xiaoyan Fu[1], Jinyin Liang[1], Hongling Zhu[1], Bin Yang[1]

[1] Cosmetics Testing Center, Dermatology Hospital of Southern Medical University, NMPA Center for Innovation and Research in Regulatory Science, Translational Medicine Center, Dermatology Hospital of Southern Medical University, GuangZhou, China

[2] Eucerin Germany, Beiersdorf Group, Shanghai, China

Introduction

Most photoelectric aesthetic procedures are associated with postoperative pigmentation and skin barrier repair problems. This study aims to verify a scientific comprehensive skin care method by evaluating the application of Thiamidol in preventing postoperative pigmentation after IPL photorejuvenation and the role of efficacious skin care products in integrated postoperative skin care after aesthetic procedures.

Materials and Methods

Forty healthy Asian women aged 25-55 years were enrolled, all meeting inclusion criteria including symmetrical facial spots, easy flushing and sensitivity. Subjects with pregnancy/lactation, recent aesthetic procedures or photosensitive skin diseases were excluded. A split-face self-controlled design was adopted: after IPL photorejuvenation, all subjects used a soothing repair cream on the entire face morning and evening. One randomly selected facial side was additionally applied with a whitening essence containing Thiamidol (intervention side), while the contralateral side was not (control side). During the trial, only unified facial cleanser and sunscreen were used, with strict sun protection and check-in records. Instrumental measurements, combined with clinical physicians' visual evaluation and subjects' self-assessment, were conducted at D0 (preoperative/postoperative), 20 minutes after the first use (T20min), and on the 3rd (D3), 14th (D14) and 28th (D28) days of use.

Results

All 40 subjects completed the trial, with no cases of skin discomfort , indicating that the two products were safe for postoperative use. Regarding the soothing repair cream, the postoperative stratum corneum hydration gradually increased from 58.14±14.07 before surgery to 69.85±10.09 at D28 ($P<0.001$**), maintaining skin moisture continuously with a clear moisturizing effect. Transepidermal water loss increased to 20.47±3.22 after surgery due to barrier damage, and then gradually decreased to 16.17±3.11 at D28 ($P<0.001$**), effectively repairing the skin barrier. Meanwhile, the proportion of red area decreased from 30.02±4.24 after surgery to 28.66±4.65 at D28 ($P=0.012$*), and the erythema a value decreased from 33.51±3.43 after surgery to 32.16±3.74 at D28 ($P=0.009$**), significantly relieving postoperative flushing with a prominent soothing effect. Regarding the whitening essence, there was no difference in melanin index between the two sides before surgery. The melanin index of the control side gradually increased after surgery (reaching 183.02±29.28 at D3, $P=0.002$**), showing a tanning tendency, while that of the intervention side remained stable throughout the trial (174.90±24.35 at D28, $P>0.05$), effectively preventing postoperative pigmentation. At D28, the proportion of hidden spot area on the intervention side decreased to 120.07±2.54 ($P=0.005$**), and the average optical density decreased to 124.15±15.99 ($P=0.021$), reducing potential melanin deposition in the underlying epidermis. In addition, the proportion of pigmented spot area (5.40±1.72 at D28) and average optical density (103.64±7.64 at D28) on the intervention side were both lower than those on the control side, and the ITA° value (31.58±5.14 at D28) was

significantly higher (P<0.001), showing prominent effects in spot lightening, whitening and skin brightening.

Conclusions

Efficacious skin care products with repair and soothing effects can efficiently moisturize, repair the skin barrier, and relieve flushing discomfort after IPL photorejuvenation, providing basic repair guarantee for the skin. The efficacious ingredient Thiamidol can not only lighten spots and whiten the skin, but also crucially prevent postoperative tanning and reduce hidden spots, improving skin color from the dual dimensions of "visible pigmented spots" and "potential melanin". Synergistic use can form a postoperative integrated care regimen of "basic repair + precise whitening", effectively avoiding the risk of pigmentation, prolonging the skin rejuvenation effect, and providing a practical option for clinical postoperative care.

EA DV CONGRESS
VIENNA
30 SEP - 3 OCT 2026

Abstract N°: 704

Exploration on Skin Safety and Skincare Efficacy of DC-Pure Liubai Extract Guided by Traditional Chinese Medicine Theory -A Comprehensive Evaluation Based on TCM Compatibility and Modern Pharmacology

Li Ye*[1], Heping Zheng[1], Bin Yang[1]

[1] Cosmetics Testing Center, Dermatology Hospital of Southern Medical University, NMPA Center for Innovation and Research in Regulatory Science, Translational Medicine Center, Dermatology Hospital of Southern Medical University, GuangZhou, China

Introduction
Guided by the TCM theories of treatment based on syndrome differentiation and holistic regulation, this study aimed to systematically evaluate the compatibility, skin safety and skincare efficacy of DC-Pure Liubai Extract, a blend of six traditional Chinese medicinal ingredients all named with the character “Bai” (meaning white). The research provides scientific support for the modernization and clinical translation of TCM in dermatological care, in line with China’s strategy for the innovative development of traditional Chinese medicine.

Materials and Methods
A comprehensive assessment integrating TCM theory and modern pharmacological verification was performed. The properties, meridian tropism and synergistic actions of the six herbal ingredients were analyzed according to TCM compatibility principles, alongside reviewing their historical topical applications. Safety and quality were examined in compliance with the Safety Technical Specifications for Cosmetics (2015 Edition), covering heavy metals, microorganisms and risk residues. Modern pharmacological evidence was summarized to clarify the active components and their anti-inflammatory, barrier-repairing and anti-allergic effects. Skin tolerance and sensitization risk were further evaluated using patch tests and safety criteria for topical TCM preparations.

Results
The formulation of DC-Pure Liubai Extract strictly follows the TCM compatibility principle of mutual reinforcement, presenting a scientific and synergistic ingredient combination. Dictamni Cortex (bitter, cold, acting on the spleen, stomach and bladder meridians), as the core component of the formula, exerts the effects of clearing heat, drying dampness, dispelling wind and detoxifying. Saururi Herba assists in clearing heat, draining dampness, reducing swelling and detoxification, enhancing the anti-inflammatory effect of the formula. Bletillae Rhizoma focuses on astringing hemostasis, reducing swelling and promoting granulation, which is mainly responsible for skin barrier repair. The other three “Bai” ingredients, namely Lilium Brownii, Chrysanthemum Parthenium and Nymphaea Alba, complement each other by nourishing yin and moistening dryness, dispelling wind-heat and clearing heat-cool blood, forming a balanced and synergistic effect of clearing heat, moistening dryness, detoxifying and repairing skin. Quality testing showed that the extract had stable physicochemical properties, and all safety indicators fully met the relevant standards: heavy metal contents, total bacterial count (< 1000 cfu/g), and residual amounts of hazardous substances (such as dioxane and phenol) were all lower than the limited standards, with no pesticide residues detected. Modern pharmacological studies confirmed that the core active components of the extract were highly consistent with its TCM efficacy: dictamnine from Dictamni Cortex achieved the effect of “dispelling wind and anti-allergy” by inhibiting histamine release; flavonoids from Saururi Herba exerted “clearing heat and reducing swelling” through regulating anti-inflammatory pathways; Bletillae polysaccharides realized “promoting granulation and repairing” by accelerating the proliferation of epithelial cells. The synergistic effect of these components can effectively improve skin barrier function and relieve skin sensitive inflammation. According to the skin safety evaluation data of external TCM preparations, the extract had no obvious sensitization risk and showed

good skin tolerance.

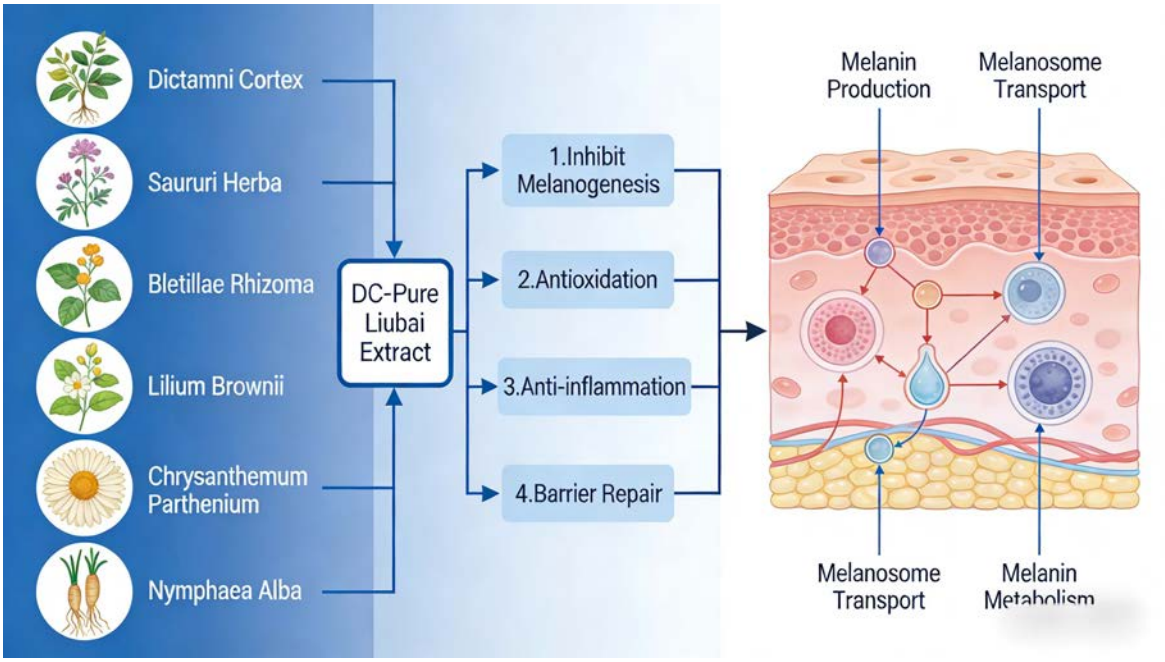

Conclusions

DC-Pure Liubai Extract presents rational TCM compatibility, reliable quality and high skin safety. Its efficacy aligns with the TCM concept of clearing heat and repairing skin lesions and is validated by modern pharmacology, showing good potential in sensitive skin care and barrier repair. This study serves as a practical model for TCM modernization and supports the medical application of plant-based dermatological products.

EA DV CONGRESS
VIENNA
30 SEP - 3 OCT 2026

Abstract N°: 705

Application of Dual-Probiotic Fermentation Combined with Liposome-Encapsulated Phenylethyl Resorcinol in Facial Whitening and Spot Fading -A Randomized Controlled Study of 66 Cases

Li Ye*[1], Yuge Yang[2], Yan Chen[2], Linshan Wu[1], Jinyin Liang[1], Xuesong Xian[1], Ye Zhong[2], Xiaoyan Fu[1], Zhen Yi[1], Bin Yang[1]

[1] Cosmetics Testing Center, Dermatology Hospital of Southern Medical University, NMPA Center for Innovation and Research in Regulatory Science, Translational Medicine Center, Dermatology Hospital of Southern Medical University, GuangZhou, China

[2] Shanghai Kans Biotechnology Co., Ltd, Shanghai Zhongyi Daily Chemical Co.,Ltd, Shanghai, China

Introduction

To investigate the efficacy of liposome-encapsulated phenylethyl resorcinol alone, as well as its combination with dual-probiotic fermentation (Tiracle Pro) technology, in improving facial pigmentation, enhancing skin brightness, reducing melanin content and relieving facial erythema. The characteristics and synergistic advantages of the two technical formulations were clarified, aiming to provide scientific evidence for the whitening management of pigmented and dull facial skin.

Materials and Methods

This ethically approved study adopted a randomized controlled design. A total of 66 healthy Asian subjects with facial pigmentation and dull skin were enrolled and randomly divided into three groups (n=22 each): blank control group, liposome-encapsulated phenylethyl resorcinol group, and dual-probiotic fermentation plus liposome-encapsulated phenylethyl resorcinol group. The two test groups applied corresponding topical formulations twice daily for 28 consecutive days, while the blank control group received no functional skincare products. Objective assessments including ITA°, melanin index, erythema index and skin gloss were measured at baseline (Day 0), Day 14 and Day 28 using CK MX18 and SkinGlossMeter instruments. Statistical analysis was performed using SPSS 25.0 with t-test for quantitative data; $P<0.05$ was considered statistically significant.

Results

All 66 subjects completed the study with no treatment-related adverse events, indicating favorable safety profiles of both test formulations. No significant intergroup differences were observed at baseline in ITA°, melanin index, erythema index or skin gloss ($P>0.05$). Both treatment groups showed significant improvements from baseline: at Day 14 and Day 28, ITA° and skin gloss were significantly increased ($P<0.001$), while melanin index and erythema index were significantly decreased ($P<0.05$, $P<0.001$) in both test groups, with significantly better effects than the control group ($P<0.05$). The combination group exhibited superior efficacy at Day 28, with higher ITA° (24.22±8.09), lower melanin index (198.95±53.70) and lower erythema index (293.36±63.10) compared with the single-agent liposome group. Skin gloss increased steadily in both treatment groups with no significant intergroup difference ($P>0.05$). In the control group, ITA° was significantly decreased and melanin index significantly increased at Day 14 and Day 28 ($P<0.05$), with no obvious changes in erythema index or skin gloss ($P>0.05$).

Conclusions

Both liposome-encapsulated phenylethyl resorcinol and its combination with dual-probiotic fermentation demonstrate excellent skin safety. They significantly elevate ITA°, reduce melanin and erythema indices, relieve dullness and redness, and enhance skin gloss, achieving effective whitening and spot-fading effects. The

synergistic combination further strengthens the magnitude and durability of whitening, spot fading and erythema soothing, providing a graded, safe and effective strategy for pigmented and dull skin with high practical value in clinical cosmetic dermatology.

EA DV CONGRESS
VIENNA
30 SEP - 3 OCT 2026

Abstract N°: 710

Comparative Study Of Foam Versus Liquid Sclerotherapy Standalone Or Combined With Diode LASER In Treatment Of Lower Limb Telangiectasias And Reticular Veins

Shereen Adel*[1], Walaa Ahmed[1], Mai Ashraf[1]

[1] Faculty of Medicine, Fayoum University, Department of Dermatology, Venereology and Andrology, Fayoum, Egypt

Introduction

Varicose veins are common disease affect 25–33% women and 10–20% men and still increasing. VVs are convoluted,expanded,and stretched veins of lower leg. It is described as tortuous dilated palpable veins,>3 mm in diameter. Telangiectasias&spider veins are tiny dilated veins,<1-mm located at superficial skin layers.Veins> telangiectasia, but still<3mm are reticular veins. If VVs are untreated, it may cause serious complications e.g edema,thrombophlebitis,external hemorrhage,lipodermatosclerosis,dermatitis,pigmentation, induration, and ulceration(Kumar et al., 2020).Different sclerosing solutions are used to treat VVs, like polidocanol(POL), sodium tetradecyl sulphate, hypertonic saline and corrosive sclerosants(Patel et al., 2021). There are 2 types of sclerotherapy, liquid and foam, foam sclerosants are by using a 3-way-stopcock (Tessari method) or 2-way connector (Tessari-DSS method),(Rabe et al., 2021). Laser and light sources are emerging options for management of small spider veins&telangiectasias which are <3 mm (Jindal et al., 2022).The aim of this work was to compare therapeutic effect of foam versus liquid sclerotherapy as standalone or combined with diode laser for treating lower limb telangiectasias and reticular veins CEAP1(Clinical-Etiology-Anatomy-Pathophysiology1).

Materials and Methods

This prospective-randomized-comparative study included 40 patients with lower limb telagiectasis and reticular veins(CEAP1). Categorized into 4 groups:A:10 patients treated with liquid sclerotherapy,B:10 patients treated with liquid sclerotherapy followed by Diode laser,C:10 patients treated with foam sclerotherapy andD:10 patients treated with foam sclerotherapy followed by diode laser. Polidocanol1% (Docavarico, Ethoxysclerol)® was the sclerosant agent and the WL of diode laser was 980 nm. 3sessions of liquid and foam sclarotherapy with 3 weeks interval followed by 2 sessions diode laser with 3 weeks interval in groups B&D. All patients were subjected to full history taking, general&dermatological examination to detect distribution of affected veins, shape and size of telangiectasias, measured by scaled lens. Duplex-US was done to all patients to exclude DVT and perforators incompetence. Photographic assessment was done before, after every session and after all sessions. In liquid sclerotherapy intravenous injection of the sclerosant (POL1%,10 ml/session) was performed slowly. Foam sclerotherapy was done by (Tessari method) for generation of sclerosant foam. Air is the gas component, ratio of liquid sclerosant to gas is 1+4 (1part liquid+4 parts air). Diode 980nm laser parameters were:1-15 pulse power, 15pulse width and 5 pulse frequency. Each patient and treating physician rated improvement on a scale from 1-4.

Results

We found a significant higher %of pain complain in group A and D (p=0.006) and a significant edema complaint highest in group D (p 0.07).There was a significant difference (p=0.043) between liquid and foam groups regarding patient satisfaction (fig.1,2) with higher satisfaction in foam groups. No significant difference (p>0.05) between foam and liquid groups regarding physician satisfaction. Highest mean cosmetic improvement score was observed in group D(66.5±4.5,p=0.010). There was no significant difference between study groups regarding side effects (p>0.05).There was a statistically significant positive correlation between cosmetic improvement and patient's and physician's satisfaction, also between edema improvement and size of VVs. There was a significant

negative correlation between cosmetic improvement and age, number of pregnancies and duration of lesions (p>0.05).

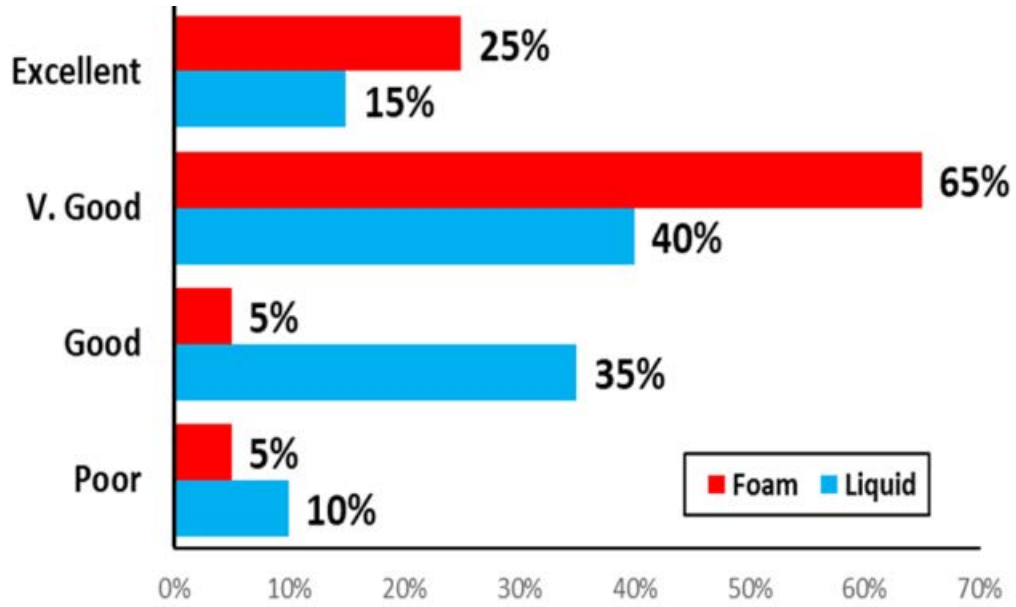

Fig.1: Comparison between liquid and foam sclerotherapy regarding patient's satisfaction.Fig.2: Comparison between study groups as regarding patient's satisfaction.

Conclusions

In conclusion injection sclerotherapy is safe efficient treatment for VVs and still corner stone of treatment, foam sclerotherapy has higher efficacy than liquid sclerotherapy with no significant difference as regarding side effects. Injection sclerotherapy followed by diode laser showed higher cosmetic improvement and patient satisfaction.

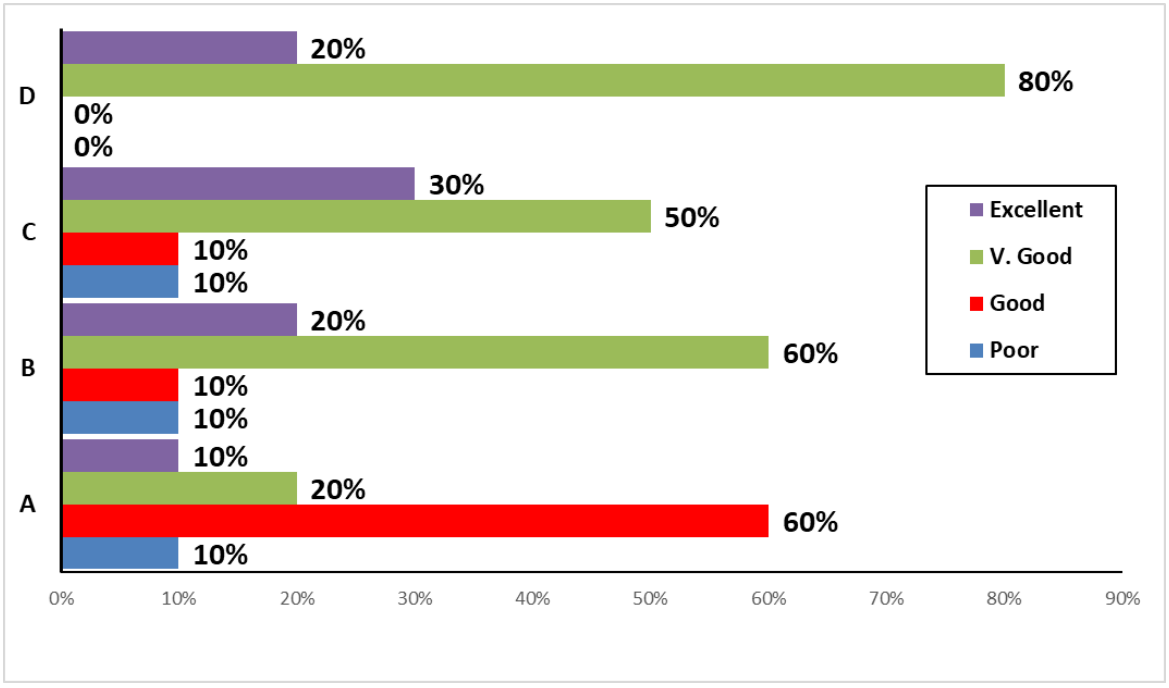

Fig.2: Comparison between study groups as regarding patient's satisfaction.

EA DV CONGRESS
VIENNA
30 SEP - 3 OCT 2026

Abstract N°: 735

Iatrogenic hypopigmentation after laser therapy of cryolipolysis-induced hyperpigmentation: A case report

Aleksandra Bukvić Šajinović*[1], Irena Komljenović[2], Milos Nisavic[1]

[1] Faculty of Medicine Novi Sad, University of Novi Sad, Novi Sad, Serbia

[2] Polyclinic Regena, Novi Sad, Serbia

Introduction

Laser procedures in dermatology are widely used in the management of cutaneous pigmentary disorders, however, pigment-related adverse effects remain an important clinical concern. Their efficacy depend on wavelength-specific tissue penetration and the photomechanical fragmentation of melanin. In heterogeneous pigmentary lesions, accurate assessment of pigment depth and distribution is essential, as inappropriate laser selection may lead to iatrogenic pigmentary complications with clinical and cosmetic consequences.

Case Presentation

A 44-year-old female patient with Fitzpatrick skin phototype III presented with well-demarcated, cryolipolysis applicator–shaped hyperpigmented macule on the abdomen measuring 15x8 cm in diameter, which developed after a cryolipolysis-associated frostbite-like injury 6 months ago. Clinically, the lesion showed heterogenous pigmentary pattern, with brown peripheral rim and brown-grayish central area.

A test spot was first performed on the hyperpigmented peripheral rim using a Q-switched KTP (532 nm) laser, and on the central area using a Q-switched Nd:YAG (1064 nm) laser. Both sites demonstrated an expected immediate laser endpoint response without adverse effects. According to these findings, a combined laser approach was initiated, with wavelength selection based on pigment depth: QS Nd:YAG for epidermal-dermal pigment and QS KTP for epidermal pigment.

In the first session, the QS Nd:YAG laser was applied to the central area (2 J/cm², 8 Hz, 8 mm spotsize, 8 passes), while the QS KTP laser was applied to the brown peripheral rim (1.2 J/cm², 2 Hz, 4 mm, single pass), targeting superficial epidermal pigment.

Clinical improvement was noted after the first session, with overall lightening of the lesion and a more pronounced response in the peripheral rim. A second session was performed after one month, with continuation of QS Nd:YAG treatment in central area and extension of QS KTP application to the central portion of the lesion, where residual brown pigment was still clinically evident, with no grayish hue.

Two days after the second treatment, the patient developed a laser-induced injury with blistering, followed by transient postinflammatory hypopigmentation in central area. Pimecrolimus 1% cream was initiated twice daily for 2 months, resulting in gradual improvement in pigmentation. At three-year follow-up, near-complete repigmentation (~95%) was observed.

Conclusion

This case highlights the risk of overtreatment in heterogeneous pigmentary lesions despite appropriate test spot responses. Thus, careful assessment of pigment distribution is essential to avoid iatrogenic complications. Topical calcineurin inhibitors may support repigmentation in laser-induced hypopigmentation.

EADV CONGRESS
VIENNA
30 SEP - 3 OCT 2026

Abstract N°: 762

Dermal safety profile of novel green tea extracts as anti-aging active ingredients in dermocosmetics

Milica Martinović*[1], Vanja Tadić[2], Ana Žugić[2], Marija Tasić Kostov[1], Ivana Nešić[1]

[1] Faculty of Medicine, Department of Pharmacy, Niš, Serbia

[2] Institute for Medicinal Plant Research "Dr.Josif Pančić", Department for Pharmaceutical Research and Development, Belgrade, Serbia

Introduction

Plant-derived active compounds have long played an important role in dermocosmetic research. Green tea (Camellia sinensis L.) stands out as a polyphenol-rich plant, frequently studied for its anti-aging, UV-protective, antioxidant, and anti-inflammatory properties. Traditional extraction methods often rely on volatile or toxic solvents, which has encouraged the development of more sustainable alternatives. Natural Deep Eutectic Solvents (NaDES), composed of natural metabolites like sugars and organic acids, have emerged as a biodegradable, non-toxic, and eco-friendly options. Recent in vitro studies have shown that NaDES-based extracts often show better acitivites than conventional ones, demonstrating significant inhibitory effects on skin-aging enzymes such as tyrosinase, hyaluronidase, and collagenase, as well as good antioxidant, anti-inflammatory and UV protective activity. The aim of this research was to assess the safety profile of green tea leaves extract prepared with a NaDES (tartaric acid and sorbitol).

Materials and Methods

The extracts were prepared by applying ultrasound-assisted extraction as green extraction method. Dried green tea leaves were mixed with previously prepared NaDES (tartaric acid + sorbitol), viscous, transparent liquid. The study was conducted in accordance with the Declaration of Helsinki and received ethical approval. A double-blind in vivo study was performed on 20 healthy volunteers (average age 25.85 ± 4.74 years). Using the Multi Probe Adapter System MPA® 9 (Courage + Khazaka), five biophysical parameters were monitored – EC (stratum corneum hydration), TEWL (transepidermal water loss), EI (erythema index), MI (melanin index) and pH. Safety was evaluated using a "patch test" method, where occlusion is applied to enhance the skin's exposure to the substances. Measurements were taken at baseline and 60 minutes after the removal of a 24-hour occlusion. Testing was conducted on multiple forearm sites - untreated control (UC), untreated control under occlusion (UCO) and test site (TS), which was treated with filter paper soaked in the extract and sealed with parafilm and adhesive tape.

Results

The results (Figure 1) showed statistically significant changes in almost all parameters at the UCO site, while parameters did not significantly change at UC, indicating that occlusion caused changes in skin parameters. At UCO, a statistically significant decrease in pH was observed, as well as an increase in TEWL (transepidermal water loss), EC (electrical capacitance), and EI (erythema index). However, on the test site, the 24-hour safety study revealed no adverse skin reactions. Results, expressed as mean values ± standard deviation, confirmed a favorable safety profile. Notably, there was no increase in TEWL or statistically significant elevation of the erythema index at the TS. Interestingly, the extract appeared to mitigate the irritation typically caused by the occlusion itself, suggesting that they are not only non-irritating substances but they may also possess anti-irritant properties. Later anti-irritation study with NaDES-based gels (hydroxyethyl cellulose gels loaded with 24% of NaDES extract) showed that application of NaDES-based gel significantly reduced induced irritation and improved skin barrier markers (TEWL, EI, and pH).

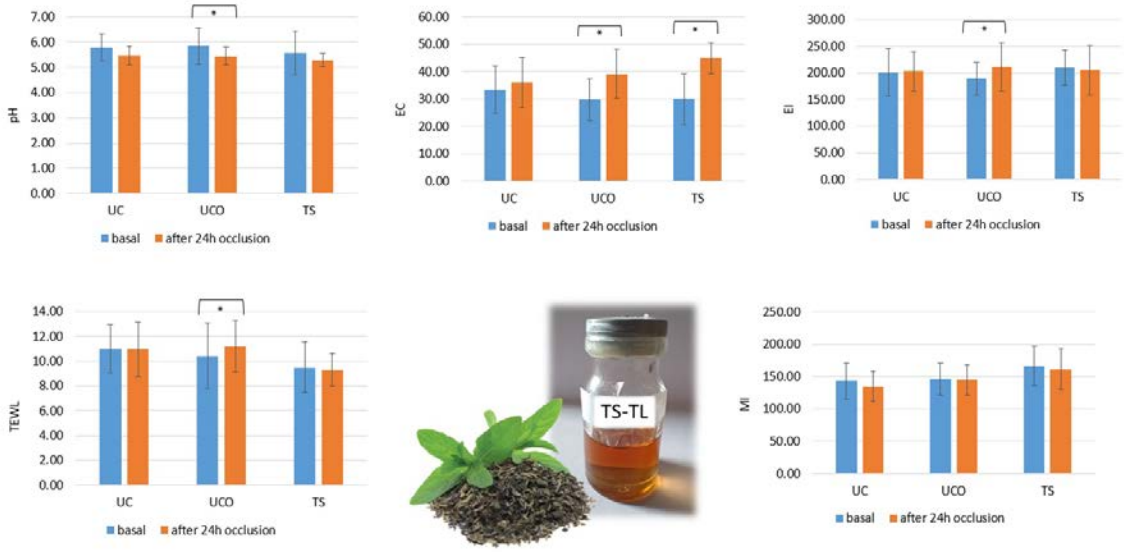

Figure 1. Results of in vivo safety study for determining the irritant potential of selected plant extract (TS-TL), untreated control (UC), and untreated control under occlusion (UCO) presented as mean ± standard deviation, while statistically significant differences are indicated by the symbol * ($p < 0.05$).

Conclusions

Green tea extracts obtained via NaDES are not only dermatologically safe but also exhibit significant anti-irritant properties. These "green" extracts offer a promising, sustainable alternative for formulating advanced dermocosmetics aimed at skin barrier repair and conditioning.

EA DV CONGRESS
VIENNA
30 SEP - 3 OCT 2026

Abstract N°: 769

Optimal Timing of Fractional Er:YAG Laser for Nevus Excision Scars: A Prospective Controlled Study Using Clinical and Ultrasonographic Assessment

Kadir Atacan Yıldız*[1], Seda Aladağ Kurt[2], Tugba Kevser Uzuncakmak[1]

[1] Istanbul University-Cerrahpasa, Cerrahpasa Medical Faculty, Dermatology and Venereology, Istanbul, Türkiye
[2] Istanbul University-Cerrahpasa, Cerrahpasa Medical Faculty, Radiology, Istanbul, Türkiye

Introduction
Scarring after nevus excision can lead to both esthetic dissatisfaction and functional impairment. Fractional ablative lasers are commonly used in scar management; however, the optimal timing for initiating treatment remains uncertain. This study aimed to investigate how different initiation times of fractional Er:YAG laser therapy influence scar outcomes, using both clinical scoring and ultrasonographic parameters.

Materials and Methods
In this prospective comparative study, 50 patients with post-excision scars located on trunk or extremities were enrolled. Participants were allocated into four groups: a control group (n=15), and three treatment groups in which laser therapy was initiated at suture removal (n=11), 1 month after suture removal (n=13), or 3 months after suture removal (n=11). Patients in the treatment arms underwent three sessions of fractional Er:YAG laser at monthly intervals. Evaluations were performed at baseline and at 6 months using the Vancouver Scar Scale (VSS) alongside ultrasonographic assessments. High-frequency ultrasound (10–14 MHz) was used for morphological evaluation, complemented by shear-wave elastography and superb microvascular imaging.

Results
Baseline demographic and clinical features, VSS scores, and elastographic measurements were comparable across all groups. At 6 months, total VSS scores showed a significant difference between groups (p=0.039). Lower scores were observed in patients treated at suture removal and at 1 month compared to both the control group and the 3-month group. The most favorable outcomes were seen in the 1-month group (mean VSS: 1.83 ± 0.94), followed by the suture removal group (2.09 ± 1.14), whereas higher scores were noted in the 3-month group (3.36 ± 1.96) and controls (3.33 ± 2.02). Within-group analyses revealed significant improvements in pliability, scar height, and total VSS scores in the early-treatment groups, while no significant changes were detected in the delayed-treatment or control groups. Ultrasonographic findings indicated a general decrease in tissue stiffness and vascularity over time, particularly in the early-treatment groups, although intergroup differences at 6 months were limited (Table 1).

Group	Total VSS Baseline	Total VSS 6 Months	Emean (kPa) Baseline	Emean (kPa) 6 Months	SMIvi Baseline	SMIvi 6 Months
Control	3.13 ± 0.74	3.33 ± 2.02	66.93 ± 35.62	25.66 ± 12.03	0.73 ± 1.06	0.07 ± 0.27
Laser at suture removal	3.27 ± 0.47	2.09 ± 1.14	69.77 ± 32.35	41.92 ± 18.28	0.48 ± 0.41	0.05 ± 0.18
Laser at 1 month	3.08 ± 0.28	1.83 ± 0.94	87.79 ± 35.13	37.32 ± 20.87	3.24 ± 6.06	0.00 ± 0.00
Laser at 3 months	3.18 ± 0.40	3.36 ± 1.96	42.13 ± 33.04	26.98 ± 22.74	0.84 ± 1.80	0.00 ± 0.00

Table 1. Clinical and ultrasonographic outcomes according to treatment timing. Data are presented as mean ± SD. Between-group p values at 6 months: Total VSS p=0.039; Emean p=0.106; SMIvi p=0.150. Emean: mean elasticity value; SMIvi: superb microvascular imaging vascular index.

Conclusions

Early initiation of Er:YAG laser therapy following nevus excision appears to enhance scar outcomes, with the best clinical results observed when treatment begins 1 month after suture removal. Delaying treatment until 3 months may lessen its effectiveness. These findings suggest that the early remodeling phase after surgery may represent the most advantageous window for laser-based scar modulation.

EA DV CONGRESS
VIENNA
30 SEP - 3 OCT 2026

Abstract N°: 803

A novel parameter for the clinical assessment of intrinsic aging and photoaging in vivo

Joachim W. Fluhr*[1], Georg Wiora[2], Razvigor Darlenski[3, 4]

[1] Charité Universitätsmedizin Berlin, Berlin, Germany
[2] Courage+Khazaka GmbH, Cologne, Germany
[3] Acibadem City Clinic Tokuda Hospital, Department of Dermatology & Venereology, Sofia, Bulgaria
[4] Medical Faculty, Trakia University, Department of Dermatology and Venereology, Stara Zagora, Bulgaria

Introduction
Non-invasive assessment of skin mechanical properties is widely used in dermatology to characterize age-related changes in skin function. Established suction-based parameters mainly describe skin deformation and immediate elastic recovery. However, delayed recoil, which is more closely related to dermal collagen function, is insufficiently reflected by standard readouts. We therefore investigated a novel parameter, Maximum Collagen Power (MCP), for the in vivo assessment of intrinsic aging and photoaging.Intrinsic aging and chronic ultraviolet exposure are major determinants of dermal structural change and contribute to reduced skin firmness and recoil. A parameter that more specifically reflects collagen-dependent resistance and recovery may improve the clinical interpretation of biomechanical measurements. In the present study, MCP was examined in relation to age, anatomical site, stratum corneum hydration, and UV-associated skin pigmentation.

Materials and Methods
Twenty healthy Caucasian subjects across different age groups were examined. Measurements were performed on the cheek and volar forearm using the Cutometer® MPA 580 in Mode 2. A gradual suction increase by 7,9 mbar per second to 450mbar was followed by a gradual pressure decrease with the same rate. MCP was derived by combining the deformation curve with the pressure curve to determine the point at which active tissue recoil starts during pressure release. Skin hydration and melanin index were measured to account for stratum corneum hydration and cumulative UV exposure at the test sites.

Results
MCP decreased significantly with increasing age, indicating reduced collagen-dependent recoil in older skin. In addition, lower MCP values were observed at sites with higher melanin index, consistent with the impact of chronic UV exposure. In contrast, stratum corneum hydration showed only a minor influence on MCP.

Conclusions
The present findings suggest that MCP captures clinically relevant changes in skin biomechanics associated with intrinsic aging and photoaging. In contrast to established suction-based parameters, MCP appears to reflect delayed recoil and may therefore provide additional information on dermal structural integrity. The observed reduction with age and at more UV-exposed sites supports its potential value for the in vivo characterization of aging skin. The limited influence of stratum corneum hydration further suggests that MCP is less affected by superficial hydration changes and may better reflect deeper tissue mechanics.MCP may improve the non-invasive clinical assessment of aging skin by capturing biomechanical changes related to intrinsic aging and chronic UV exposure.
This parameter may be useful for patient phenotyping and for monitoring treatment effects in studies targeting dermal structure and skin firmness.complement conventional biomechanical readouts in clinical and translational studies addressing dermal collagen function.

EADV CONGRESS
VIENNA
30 SEP - 3 OCT 2026

Abstract N°: 804

A CAPSULE CONTAINING HYALURONIC ACID AND PANTHENOL TO IMPROVED HEALING AND REPAIR OF AGED SKIN

Franck Juchaux*[1], Irène Troin[1], Checrallah James ODEIMI[2], Delphine Kerob[2], Anne-Laure Demessant-Flavigny[2], Chloé Delaunay[1], Frederique Labatut[1]

[1] L'Oréal R&I, Chevilly-Larue, France

[2] La Roche-Posay, Levallois-Perret, France

Introduction

During aging, the skin undergoes numerous changes affecting its structure and linked to an alteration of the hyalurosome, the set of mechanisms regulating the synthesis and signaling of hyaluronic acid (HA). Hyaluronic acid and its receptor CD44 regulate many biological processes (proliferation, migration, inflammation, etc.) [1-3], and a sudden loss of epidermal HA is considered as one of the first signs of skin senescence [4, 5]. But aging does not only alter the structure of the skin; it also affects its function, meaning its ability to repair and heal itself [6]. Regarding the wellknown role of HA in wound healing, we wanted to investigate whether reactivating the hyalurosome would allow the skin to regain its ability to repair itself effectively [7]. To do this, we used our new capsule containing hydrolyzed HA and panthenol. We have previously demonstrated that this capsule reactivates the hyalurosome and reverses age-related alterations, including epigenetic alterations. The current aim is now to demonstrate its ability to restore functional alterations. The objective of study was to demonstrate the efficacy of the capsule on wound closure in a human aged reconstructed skin.

Materials and Methods

Skin equivalents were reconstructed in vitro using cells from an aged donor. Skin models reconstructed with cells from a young donor were created in parallel as a control. A dermal-epidermal wound was created using a biopsy-punch (diameter 3 mm) and the tissues were topically treated or not (Control) with 0.4% Capsule HA :B5 for 3 days. Macroscopic assessment of the wound closure was performed. Histological and immunohistochemical analyses were performed to evaluate the quality of the reconstruction by measuring, in the injured area, epidermal thickness as well as the expression of HA and the phosphorylation of the histone g-H2AX, an epigenetic marker linked to cellular senescence.

Results

Results: model showed early deficits in epidermal reconstruction. Epidermal thickness in the injured area, as well as the amount of hyaluronic acid, were higher in younger tissues than in older tissues. Topical treatment with Capsule HA:B5 tested at 0.4% improved the quality of epidermal reconstruction. Epidermal thickness and the amount of hyaluronic acid in the injured area increased (+61% and +2000%, $p<0.0001$ respectively), while the phosphorylation of histone g-H2AX in the same area was significantly inhibited (-79%, $p<0.0001$).

Conclusions

These results highlight the interest to target the hyalurosome to restore the function of the skin, meaning its ability to repair, in using a caspule containing HA and Vitamin B5. This capsule has a repairing effect by promoting HA production and epidermal thickness in the injured area. The repair effect is even observed at an epigenetic level with the decrease in P-g-H2AX expression.

EADV CONGRESS
VIENNA
30 SEP - 3 OCT 2026

Abstract N°: 820

Focal 40% Trichloroacetic Acid Application for Post-Traumatic Nasal Scar in an Adolescent: A Case Report

Mohamed Gad*[1]

[1] Belqas General Hospital, Belqas, Egypt

Introduction
Post-traumatic facial scars, particularly on the nose, can cause significant cosmetic concern in adolescents. Effective, minimally invasive, and affordable treatment options are needed. Trichloroacetic acid (TCA) is commonly used for chemical reconstruction and scar remodeling.

Case Presentation
Materials and Methods:A 15-year-old patient presented with a post-traumatic scar on the nasal area. Treatment was performed using focal application of 40% TCA with a cotton-tipped applicator. Sessions were conducted every 3 weeks for a total of 10 sessions. Clinical improvement was assessed visually and through serial photographic documentation.

Results:Clinical improvement was evident after the second session. Progressive reduction in scar depth and visibility was observed throughout the treatment course. After 10 sessions, the patient showed marked improvement with excellent cosmetic outcome. The procedure was well tolerated, with no significant adverse effects.

Conclusion
Focal application of 40% TCA is a safe, effective, and low-cost modality for treating post-traumatic nasal scars in adolescents. It represents a practical option in resource-limited settings with favorable cosmetic results.

EA DV CONGRESS
VIENNA
30 SEP - 3 OCT 2026

Abstract N°: 836

Skin barrier recovery after aesthetic procedures in phototypes III-IV: a real-world comparative observational study of two post-procedure repair creams

Hayat El Moussati*[1], Chloé GOYET[2]

[1] Omorfia Medical Aesthetics Clinic, Lille, France
[2] ISISPHARMA, R&D Department, Lyon, France

Introduction
Medical aesthetic procedures induce a transient disruption of the stratum corneum integrity, characterised by increased transepidermal water loss (TEWL), erythema and patient discomfort. Post-procedure dermocosmetic care is now considered an integral component of the management protocol, yet evidence supporting specific formulations in phototypes III-V, a population at elevated risk of post-inflammatory hyperpigmentation, remains scarce. Moreover, treatment adherence, a critical yet underexplored determinant of real-world efficacy, is itself conditioned by product sensory acceptability. This study therefore aimed to simultaneously assess TEWL-based barrier recovery and patient-reported sensory experience with two post-procedure repair regimens in a predominantly phototype III-IV population.

Materials and Methods
This single-centre, observational, comparative study was conducted in routine practice. Patients undergoing superficial chemical peeling, non-ablative fractional laser, IPL, microneedling or micro-needling radiofrequency were assigned to one of two post-procedure repair regimens: Cream A, an *Onopordum acanthium*-based formulation, or Cream B, a madecassoside and vitamin B5 based balm, both applied as SPF version during the day and non-SPF at night. TEWL was measured with tewameter (TM Mobile) at four timepoints: before the procedure (t_{BP}), immediately after(t_{AP}), 20 min after first product application (t_{20}), and at day 7 (D7). Clinical assessment by the investigator was performed at t_{AP} and D7, rated on a 4-point scale. Patient-reported skin discomfort was assessed at t_{AP} and t_{20}. Additional patient-reported outcomes were collected via digital questionnaire at D3 and D7.

Results
43 patients were enrolled, including 63% with prior PIH history. Both regimens induced a significant and immediate TEWL reduction after first application (Cream A: -45.8%; Cream B: -39.7%, $p<0.001$ both) with no significant between-group difference. At D7, both groups showed substantial recovery versus post-procedure TEWL (Cream A: -55.8%; Cream B: -49.5%, $p<0.001$ both) with a more pronounced trend toward return to pre-procedure baseline in Cream A ($p=0.061$) than Cream B ($p=0.427$). Both products significantly reduced patient-reported discomfort at t_{20} versus t_{AP}, with complete absence of burning sensation and tingling reported by significantly more patients with Cream A than Cream B (81.8% vs 52.4% and 77.3% vs 47.6%, respectively, $p<0.05$). Cream A demonstrated superior sensory acceptability from D3 onwards, with significantly more favorable ratings for daily pleasantness of use as early as D3 (68% vs 33% fully agree, $p=0.026$), ease of daily use at D7 ($p=0.041$) and absence of shiny finish at D7 ($p<0.001$). Although conducted on a limited sample, Cream A consistently showed favorable outcomes across endpoints, achieving statistical significance on several sensory and patient-reported measures, suggesting that larger populations may consolidate these findings further.

Conclusions
In a real-world medical aesthetic practice setting with a predominantly phototype III-IV population, both post-

procedure repair regimens achieved equivalent and clinically meaningful barrier recovery, assessed through a comprehensive approach combining objective TEWL measurement, investigator-rated clinical signs and patient-reported outcomes. Beyond this equivalence, the *Onopordum acanthium*-based formulation demonstrated significantly superior sensory acceptability, observable from D3, which may support better treatment adherence, a key yet underexplored determinant of post-procedure healing outcomes. Consistent product use is particularly critical in phototype III-V patients, where adherence to the full repair protocol is essential to minimize post-inflammatory hyperpigmentation risk. These results highlight sensory profile as a clinically relevant dimension in post-procedure care selection and recovery evaluation, alongside objective barrier efficacy.

EADV CONGRESS
VIENNA
30 SEP - 3 OCT 2026

Abstract N°: 846

Application of Microemulsion Penetration-Enhancing Technology Combined with Peptide Anti-Wrinkle Matrix in Periorbital Rejuvenation -A Self Half-Face Controlled Study of 21 Cases

Li Ye*[1], Yan Pu[2], Ying Chen[2], Si Wen[1], Zhen Yi[1], Jie Chen[2], Shujing Peng[2], Hongling Zhu[1], Xiaoyan Fu[1], Linshan Wu[1], Bin Yang[1]

[1] Cosmetics Testing Center, Dermatology Hospital of Southern Medical University, NMPA Center for Innovation and Research in Regulatory Science, Translational Medicine Center, Dermatology Hospital of Southern Medical University, GuangZhou, China

[2] Guangdong Marubi Biotechnology Co., Ltd, Guangzhou, China

Introduction

To investigate the anti-aging efficacy of microemulsion penetration-enhancing technology combined with a precise peptide anti-wrinkle matrix in improving periorbital dynamic and static wrinkles, skin laxity and dark circles, and to compare its effectiveness and mildness with Fotona 4D treatment, so as to provide a safe and effective non-invasive strategy for periorbital rejuvenation with clinical evidence from human efficacy tests at the Dermatology Hospital of Southern Medical University.

Materials and Methods

This ethically approved study (Approval No.: IIT-2025-033) adopted a self-controlled half-face design. A total of 21 healthy Asian women aged 27–48 years with periorbital wrinkles (grade 3 or above) and skin laxity were enrolled. One randomly selected periorbital side was treated with a test formulation containing microemulsion penetration-enhancing technology (liquid crystal lamellar gel network based on EMULIUM KAPPA MB) and peptide anti-wrinkle matrix twice daily for 28 consecutive days (test side). The contralateral side received Fotona 4D treatment alone with no topical products (control side). Assessments were performed at baseline (Day 0), Day 14 and Day 28 using professional instruments including Primos-CR, CK MPA580, Antera3Dcs and CK MX18. Core indicators included wrinkle features (depth, number, volume), skin firmness (F4 value), roughness (Ra/Rq), canthal angle, eye bag volume, melanin index and stratum corneum hydration. Comprehensive evaluation was conducted by clinician visual assessment and subject self-assessment. Statistical analysis was performed using SPSS 25.0, with $P<0.05$ defined as statistically significant.

Results

All 21 subjects completed the study with no treatment-related adverse events, indicating excellent skin tolerability of the test formulation. No significant inter-side differences were observed at baseline ($P>0.05$). Both sides achieved significant anti-aging effects after intervention, and the test side showed superior performance in multiple parameters. Regarding wrinkle improvement, wrinkle number, length, area and volume were significantly reduced on both sides at Day 14 and Day 28 ($P<0.01$), with no significant inter-side difference ($P>0.05$). For skin firmness, the F4 value on the test side decreased significantly by 9.07% at Day 28 ($P<0.01$), while no significant change was found on the control side, with a highly significant difference between groups ($P<0.001$). Stratum corneum hydration on the test side increased by 86.60% and 81.37% at Day 14 and Day 28, respectively, both significantly higher than the control side ($P<0.01$). The melanin index on the test side decreased by 5.78% at Day 28 ($P<0.05$), whereas it increased by 8.28% on the control side, showing an extremely significant inter-side difference ($P<0.001$). Skin roughness (Ra/Rq) was significantly reduced on the test side at both time points ($P<0.01$), while no obvious improvement was observed on the control side. Both clinician and subject assessments showed continuous improvements in laxity, dark circles and skin smoothness on the test side. At Day 28, subjects'

subjective smoothness scores were significantly higher for the test side ($P<0.05$), and the acceptance rates for spreadability, absorbability and mildness reached 95.24%–100%.

Conclusions

The test formulation combining microemulsion penetration-enhancing technology and peptide anti-wrinkle matrix is safe, mild and non-irritating. It improves transdermal absorption of active ingredients via a liquid crystal delivery system and exerts synergistic effects through a multi-functional peptide matrix, achieving wrinkle smoothing, firmness enhancement, dark circle improvement and skin barrier repair. Compared with Fotona 4D, it shows superior performance in firmness, hydration and melanin reduction, with the additional advantages of non-invasiveness, convenience and no downtime. It provides a scientifically validated daily care solution for periorbital rejuvenation with high clinical application value.

EADV CONGRESS
VIENNA
30 SEP - 3 OCT 2026

Abstract N°: 870

World's First m-health Application for Improving Compliance in Laser Hair Removal: Development and Pilot Evaluation in a Resource-Limited Setting

Ayesha Siraj*[1], Muneeza Rizwan[1]

[1] Fazaia Post Graduate Medical Institute, Pakistan Air Force Hospital, Islamabad, Pakistan

Introduction
Laser hair removal is a widely performed dermatological procedure. In low- and middle-income countries, limited patient education and follow-up resources contribute to inconsistent adherence to treatment protocols and suboptimal outcomes, particularly in patients with skin of colour, where poor adherence increases the risk of hyperpigmentation, burns, and scarring. Digital health interventions may provide scalable and sustainable solutions, but evidence for their role in procedural dermatology is limited. This study evaluated the feasibility and usability of a purpose-designed m-health application for laser hair removal and its effectiveness in improving adherence to pre- and post-procedure instructions.

Materials and Methods
A prospective, parallel-group pilot study was conducted among 50 female patients undergoing facial laser hair removal. Participants were equally allocated to an intervention group (n = 25), using the m-health application "My Laser Care App", or a control group (n = 25), receiving standard care. The app provided educational content on lasers and hirsutism, structured pre- and post-procedure guidance, and automated reminders for care instructions and appointments. Usability was assessed using the System Usability Scale (SUS), an internationally validated tool and adherence with a 10-item internally validated compliance questionnaire (score range 0–40).

Results
The m-health application demonstrated excellent usability, reflected by a high mean System Usability Scale (SUS) score of 87.39 ± 10.41, indicating strong user acceptance and ease of use. Mean compliance scores were significantly higher in the application group than controls (34.7 ± 4.5 vs 24.2 ± 6.2), reflecting improved compliance to care instructions which was associated with fewer reported adverse effects and better treatment outcomes. Appointment attendance was higher among application users, reflecting better engagement with treatment schedules and follow-up care.

Conclusions
This preliminary pilot study demonstrates that a tailored m-health application for laser hair removal is practical, sustainable, user-friendly and effective in improving compliance. These findings support the potential role of digital health interventions in procedural dermatology and justify further evaluation in larger controlled studies.

EA DV CONGRESS
VIENNA
30 SEP - 3 OCT 2026

Abstract N°: 937

Early Career Outcomes in Laser Dermatology: Complications in Real-world Practice

Aleksandra Bukvić Šajinović*[1]

[1] Faculty of Medicine Novi Sad, University of Novi Sad, Novi Sad, Serbia

Introduction

Laser technologies represent a cornerstone of modern procedural dermatology, providing effective and minimally invasive treatments for various indications. Despite continuous technological advances and improved safety profiles, laser procedures remain operator-dependent and not risk-free. Complications may arise due to improper patient or parameter selection, patient-related factors and inadequate aftercare. Although uncommon, they may cause functional, aesthetic and psychological impact. Analysing complications and their management is essential to improve safety and optimise outcomes.

Materials and Methods

Observational analysis was conducted over 5 years. A total of 3098 laser procedures were performed across 34 indication groups. Multiple laser systems were used, including Nd:YAG, Er:YAG, Q-switched Nd:YAG and KTP lasers. Patients underwent clinical assessment and test spot prior to treatment, with laser parameters selected according to indication, lesion characteristics and skin phototype. Follow-up visits were conducted to evaluate treatment response. Laser-related complications were documented based on clinical findings during follow-up. Data regarding causative procedure, clinical presentation, follow-up and management strategies were recorded.

Results

Complications were observed in 6 out of 34 indication groups. In these 6 indication groups, 838 procedures were performed in total, among which 10 complications were recorded. The overall complication rate across all procedures was 0.32% (10/3,098; 95% Wilson CI 0.18–0.59%). Within the subgroup of indications in which complications were observed, the complication rate was 1.19% (10/838; 95% Wilson CI 0.65–2.18%). Complication rates for individual procedure groups were as follows: pigmented lesions removal 0.91% (1/110; 95% Wilson CI 0.16–4.96%); skin rejuvenation 0.49% (1/205; 95% Wilson CI 0.09–2.73%); vascular lesions removal 2.08% (3/144; 95% Wilson CI 0.71–5.95%); striae reduction 3.03% (1/33; 95% Wilson CI 0.54–15.76%); benign lesion removal 1.14% (1/88; 95% Wilson CI 0.20–6.16%); tattoo removal 1.16% (3/258; 95% Wilson CI 0.40–3.36%).

Personalised management was applied. Q-switched Nd:YAG and KTP treatment of post-cryolipolysis hyperpigmentation caused burns and hypopigmentation, resolving after topical calcineurin inhibitors within 2 months. Nd:YAG and Er:YAG rejuvenation combined with TCA CROSS for ice-pick scars caused burns, managed with Q-switched Nd:YAG and Er:YAG lasers within 1 year. Nd:YAG treatment of leg telangiectasias caused ulceration, managed with topical antibiotics and triple-combination therapy, leaving residual scarring and dermatofibroma after 6 months. Nd:YAG tretment of nasal telangiectasia caused scarring in 1 patient which improved with Er:YAG resurfacing within 4 months. However, same procedure caused persistent erythema in other patient and resolved with topical corticosteroids and calcineurin inhibitors after 5 months. Er:YAG treatment of striae and solar lentigines caused postinflammatory erythema and hyperpigmentation, resolving after Nd:YAG and QS Nd:YAG therapy within 6 months. Following Q-switched tattoo removal, 1 patient developed a keloid

improved with intralesional corticosteroids within 3 months, 1 developed burns with residual scarring and 1 developed an eschar-like wound with residual scarring.

Conclusions

Laser technologies are a cornerstone of modern procedural dermatology, providing effective and minimally invasive treatment options for various indications. Despite continuous technological advances and improved safety profiles, laser procedures remain operator-dependent and not devoid of risk. Complications may arise due to improper patient or parameter selection, patient factors, inadequate aftercare or combined procedures. Although uncommon, they may result in functional impairment, aesthetic concerns and psychological distress. Analysis of complications and their management is crucial for improving procedural safety and optimising patient care.

EADV CONGRESS
VIENNA
30 SEP - 3 OCT 2026

Abstract N°: 957

Lipid Signaling Dysregulation Underlies Recovery Dynamics Following Fractional CO2 Laser Injury: Insights from Integrated Lipidomics

Yan Tian[1], Congfen He[2], Jiaojiao Zhang[1], Yu Li[2], DongMei Yan[1], Rui Li*[3], Yijie Zheng[3]

[1] Department of Dermatology, Air Force Medical Center, PLA, Beijing, China
[2] Cosmetic Department□school of Light industry Science and Engineering,Bejing Tchnology and Business University, Beijing, China
[3] La Roche Posay, L'Oréal Dermatological Beauty, L'Oréal China, Shanghai, China

Introduction

Fractional CO2 laser (FCL) therapy is a cornerstone of dermatological remodeling, utilizing microscopic thermal zones to induce controlled epidermal and dermal disruption followed by rapid tissue regeneration.Emerging evidence suggests that lipid metabolites influence keratinocyte differentiation and inflammatory homeostasis through signaling pathways, including calcium-dependent mechanisms.

The objectives of this study were to:
Characterize the longitudinal shifts in the skin surface lipidome (SSL) following FCL injury.
Identify molecular "Lipidomic Recovery Signatures" (LRS) associated with barrier repair quality.
Elucidate the interaction between lipid dysregulation and the Lipid–Ca2+ signaling axis in epidermal regeneration.

Materials and Methods

Study Design: A randomized controlled trial involving 60 participants with atrophic acne scars.
Intervention: All subjects underwent 10,600 nm FCL surgery. Participants were randomized into Group A (panthenol-enriched balm) or Group B (Control; standard hospital preparation) for twice-daily applications over 28 days.
Clinical Assessments: Evaluated at D0, D1, D3, D7, D14, and D28. Parameters included stratum corneum hydration, TEWL, skin surface pH, melanin, and erythema indices, and multispectral imaging of pigment areas.
Lipidomic Profiling: SSL was collected from the malar region using adhesive patches and analyzed via a non-targeted UPLC-Q-TOF-MS system.
Bioinformatics: Differential lipids were screened using Orthogonal Partial Least Squares-Discriminant Analysis with criteria: VIP > 1, Fold Change (FC) > 2, and $p < 0.05$. Pathway enrichment (GO/KEGG) and target prediction (Swiss Target Prediction) were employed to map the signaling axis.

Results

1) Clinical Superiority of Panthenol Intervention
FCL surgery induced immediate barrier disruption, evidenced by a surge in TEWL and an alkaline shift in pH. Group A demonstrated significantly faster normalization of the acidic mantle by Day 1 ($p = 0.0399$) and Day 3 ($p = 0.0144$). This was followed by superior SCH recovery at Day 14 ($p < 0.01$) and Day 28 ($p < 0.05$).

2) Discovery of "Lipid Metabolic Dysregulation"
Non-targeted lipidomics revealed a non-linear reorganization of SSL post-laser. Untreated skin exhibited a "lipid metabolic dysregulation" phenomenon—a reactive, disorganized over-accumulation of specific lipids rather than a simple deficiency. Twenty-five key VIP lipids (VLCMs), including unsaturated fatty acids (UFAs) and specific triglycerides (TAGs), were identified as drivers of this inefficient metabolic response.

3) Defining the Lipidomic Recovery Signature
By refining the 25 VLCMs through multi-dimensional correlation with clinical parameters, we identified 6 critical barrier-function lipids (VLBFs) that constitute the LRS:
Pectenolone: Shows a significant positive correlation with erythema resolution and a negative correlation with TEWL.
Ceramides: Cer(d18:1/26:0) and Cer(d18:2/27:0) exhibit significant positive correlations with the Melanin Index.

4) The Lipid–Ca2+ Signaling Axis
Bioinformatic analysis (Figure 1) mapped the VLBFs to 34 unique protein targets:
Top Pathway: "Inflammatory mediator regulation of TRP channels" emerged as the top-ranked KEGG pathway, involving critical receptors TRPA1, TRPV1, and TRPV4.
Kinase Signaling: Targeted enrichment was observed in diacylglycerol (DAG)-dependent protein kinase C (PKC) activities and sphingolipid–calcium signaling.

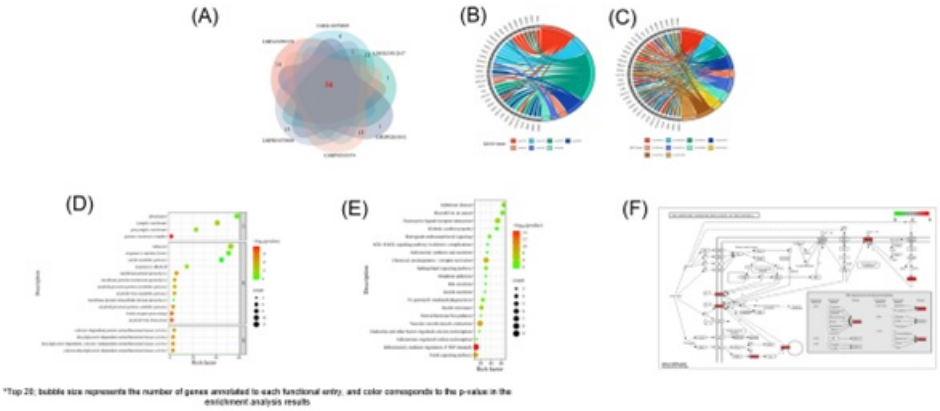

Figure 1: Bioinformatic characterization of the Lipid–Ca2+ axis and regulatory signaling pathways. (A) Venn Diagram showing the intersection of targets for 6 key lipids; (B) Chord Diagram of KEGG signaling pathways (top 7) corresponding to 34 targets; (C) Chord Diagram of GO terms (top 10) corresponding to 34 targets.□D□GO Enrichment Bubble Plot of 34 Targets Between Group A and Group B; (E) KEGG Enrichment Bubble Plot of 34 Targets Between Group A and Group B (F) Regulatory process of the "Inflammatory mediator regulation of TRP channels" signaling pathway.

Conclusions
We demonstrate that dysregulated lipids (UFAs and sphingolipids) drive a critical Lipid–Ca2+ axis through TRP channel modulation and DAG–PKC signaling. This axis acts as a molecular nexus connecting lipid matrix reorganization to post-procedural inflammatory responses. The identification of the LRS provides a novel framework for understanding barrier recovery and highlights the lipid–calcium interplay as a vital therapeutic target for optimizing skin regeneration in aesthetic medicine.

EADV CONGRESS
VIENNA
30 SEP - 3 OCT 2026

Abstract N°: 1023

Oral collagen supplementation improves skin ageing signs: results from a placebo-controlled study

Franck Juchaux[1], Claire DELOCHE[2], Corinne Chagnoleau[2], Natalia Kovylkina*[2], Lucie Guerin[1], CABERLOTTO ELISA[2]

[1] L'Oreal R&I, Chevilly-Larue, France
[2] Vichy Laboratoires, Levallois-Perret, France

Introduction

In recent years, oral collagen supplements have become a popular and trendy treatment in the world of skin health. It has been widely marketed to consumers for purported benefits in wrinkle reduction, skin-rejuvenation, skin-aging reversal, and skin plumping.

The aim of this investigation was to compare the benefit in 14 clinical skin ageing signs of an oral collagen complex or placebo supplementation after 3 months of intake.

Materials and Methods

112 Caucasian female subjects aged 45 to 65 years, with a BMI ≥20 and ≤ 30 kg/m^2, with a phototype I to III and a cheek skin firmness score ≥ 3 and ≤ 6 (on a 10 points scale) were included. Subjects were to be pre-menopausal with first symptoms of menopause or post-menopausal for 1 year to 10 years. Suitable subjects were randomized to receive either the collagen complex (54 volunteers) or the placebo (58 volunteers).

Visual clinical assessments were performed by a trained panel of 15 female experts with no vision problem on photos taken of the volunteers and using the Skin Ageing Atlas (volume 1 to 5) at baseline/month 0 and month 3. Assessed signs included 14 visible clinical markers of skin ageing comprising malar pigmentation, whole-face pigmentation, contrast of isolated pigmentary spot of the face, density of pigmentary spots, size of an isolated spot, corner of lips wrinkles, glabellar wrinkles, nasolabial fold, upper lip wrinkles, cheek folds, texture of the mouth contour, crows feet wrinkles, underneath the eye wrinkles and lower lip wrinkles.

The panel, by referencing to the atlas, determined on a continuous scale for each volunteer the grade that corresponds the best to the volunteer's characteristics.

Evaluations followed the sequential monadic mode and were blinded.

Results

According to the expert panel, collagen supplementation given for 3 months resulted in a visible and significant ($p<0.05$) decrease vs. placebo in malar pigmentation, corner of the lips wrinkles, glabellar wrinkles and upper lips wrinkles as well as in a reduced increase vs. Placebo of the whole-face pigmentation, contrast of isolated pigmentary spot of the face, density of pigmentary spots and texture of the mouth contour.

Conclusions

A 3-month oral supplementation with a natural complex of plant collagens compared to the placebo significantly improves skin ageing signs in women with visible skin ageing markers.

EADV Congress 2026, VIENNA
30 SEPTEMBER - 03 OCTOBER 2026
POWERED BY M-ANAGE.COM

EA DV CONGRESS
VIENNA
30 SEP - 3 OCT 2026

Abstract N°: 1157

beyound color: non-pigmentary applications of 1064 QS laser

Nermeen Bedair*[1], Mohamed Hegazy[2], Dina Azmy[1], Amal Sayed[3], Reem Abdelrahman[1], Bassant Gabr[4]

[1] Faculty of medicine, Capital University (formerly Helwan), Cairo, Egypt
[2] Military Medical Academy, Cairo, Egypt
[3] Kobry Elkobba Military hospital, Cairo, Egypt
[4] Faculty of medicine, Tanta University, Tanta, Egypt

Introduction

Introduction & Objectives:

Q-switched lasers are primarily considered the gold standard tool for removal of tattoos and certain pigmentary lesions. They have a unique laser-tissue interaction where their high power, nanoseconds pulses generate photomechanical expansion of tissues.

Post-acne erythema (PAE) refers to telangiectatic and erythematous lesions persisting after the inflammatory acne treatment. Although in some cases PAE improves over time, persisting erythema is not uncommon specifically in fair skinned individuals and it is cosmetically frustrating. To date, there's no gold standard treatment option and the treatment remains challenging with the pulsed dye laser being the most studied and most used laser in treating PAE

Onychomycosis, a chronic and often recalcitrant fungal infection of the nail unit, represents a significant global burden due to its high prevalence, risk of recurrence, and impact on quality of life. Traditional systemic and topical antifungal therapies are limited by prolonged treatment durations, variable efficacy, potential systemic toxicity and poor nail plate penetration.

The current two studies were designed to investigate the efficacy and safety of QS 1064 laser in treating PAE and onychomycosis and comparing it to other types of laser that were pulsed dye laser and long pulsed NDYAG respectively

Materials and Methods

Materials & Methods:

Eighteen patients with post acne erythema were subjected to 3 sessions with 2 weeks intervals composed of treating the right side of the face with pulsed dye laser and treating left side of the same patient with QS 1064 NDYAG laser then followed up for further 4 weeks. Investigator scores for erythema and texture were obtained for assessment and comparison

Meanwhile, a total of 22 patients with bilateral onychomycosis were recruited and the diagnosis was confirmed by culture on sabbaoroad agar after adding cycloheximide. Cultures were performed at baseline, weeks 8 and 20. The right-sided nails received long-pulsed Nd: YAG treatment, while the left-sided nails received Q-switched Nd: YAG laser therapy every two weeks for eight weeks. Clinical severity, dermoscopic features, mycological culture results, and patient-reported outcomes were assessed at baseline, week 8, and week 20.

Results
Results:

Patients with PAE:

Erythema scores between the studied sides: At the baseline, the mean erythema score on the PDL side was 3.94 ± 0.24 and on the QS side had a matching score of 3.94 ± 0.24, both scores decreased significantly at week 8 to 1.83 ± 1.15 and 1.11 ± 1.02 respectively ($p < 0.001$ and < 0.001 respectively)

The mean erythema scores on PDL and QS sides were improved by 53.70 ± 28.47% and 71.30 ± 26.69% respectively, with the QS side showing significantly better improvement ($p = 0.011$)

Texture scores between the sides studied: At the baseline, the mean erythema score on the PDL side was 3.44 ± 0.86 with a matching score on the QS side of 3.39 ± 0.85. Both scores showed significant reduction at week 8 to 2.28 ± 1.02 and 1.50 ± 0.86 respectively ($p < 0.001$ and < 0.001 respectively)

The mean texture scores on PDL and QS sides were improved by 34.72 ± 29.46 % and 57.87 ± 21.48 % respectively, with the QS side showing significantly better improvement ($p = 0.013$)

Patients with Onychomycosis:

The side treated with QS laser showed significantly more improvement ($p= 0.03$) with 16 patients shoing marked clinical omprovement than the side treated with long pulsed NDYAG with only 4 patients showing marked clinical improvement (more than 75% on a 5 points grading scale). However, both lasers were comparably effective in mycological improvement and changing the positive sultures into negative ($p = 0.289$). Self reported pain was significantly lower on the QS laser side ($p < 0.001$)

Conclusions
Conclusion: QS laser 1064 is effective in treating both post acne erythema and onychomycosis when compared to other types of laser.

EA DV CONGRESS
VIENNA
30 SEP - 3 OCT 2026

Abstract N°: 1191

Non-Damaging Thermal Conduction Combined with HSP47-Targeted Actives for Facial Skin Rejuvenation: A Prospective Clinical Evaluation

Li Ye*[1], Mingying Yu[2], Xian Xu[2], Zhanghao Li[2], Zhen Yi[1], Linshan Wu[1], Qinrun Lai[2], Dongcui Li[2], Hongling Zhu[1], Yuichi Sakanishi[3], Nobutaka Furuyama[4]

[1] Cosmetics Testing Center, Dermatology Hospital of Southern Medical University, NMPA Center for Innovation and Research in Regulatory Science, Translational Medicine Center, Dermatology Hospital of Southern Medical University, GuangZhou, China

[2] Research and Development, Hua An Tang Biotech Group Co., Ltd, Guangzhou, China

[3] HAT-Nihon Inemoto Joint Laboratory for Advanced Skin Science, Nihon Inemoto Co., Ltd., Tokyo, Japan

[4] Plastic surgery/Cosmetic surgery, Jiyugaoka Clinic., Tokyo, Japan

Introduction

Controlled thermal stimulation has been reported to enhance cutaneous microcirculation and facilitate transdermal delivery of bioactive compounds. This study aimed to evaluate the clinical efficacy of a non-damaging, thermal conduction–based delivery system incorporating HSP47-targeted actives for facial skin rejuvenation in adults with mild-to-moderate skin aging.

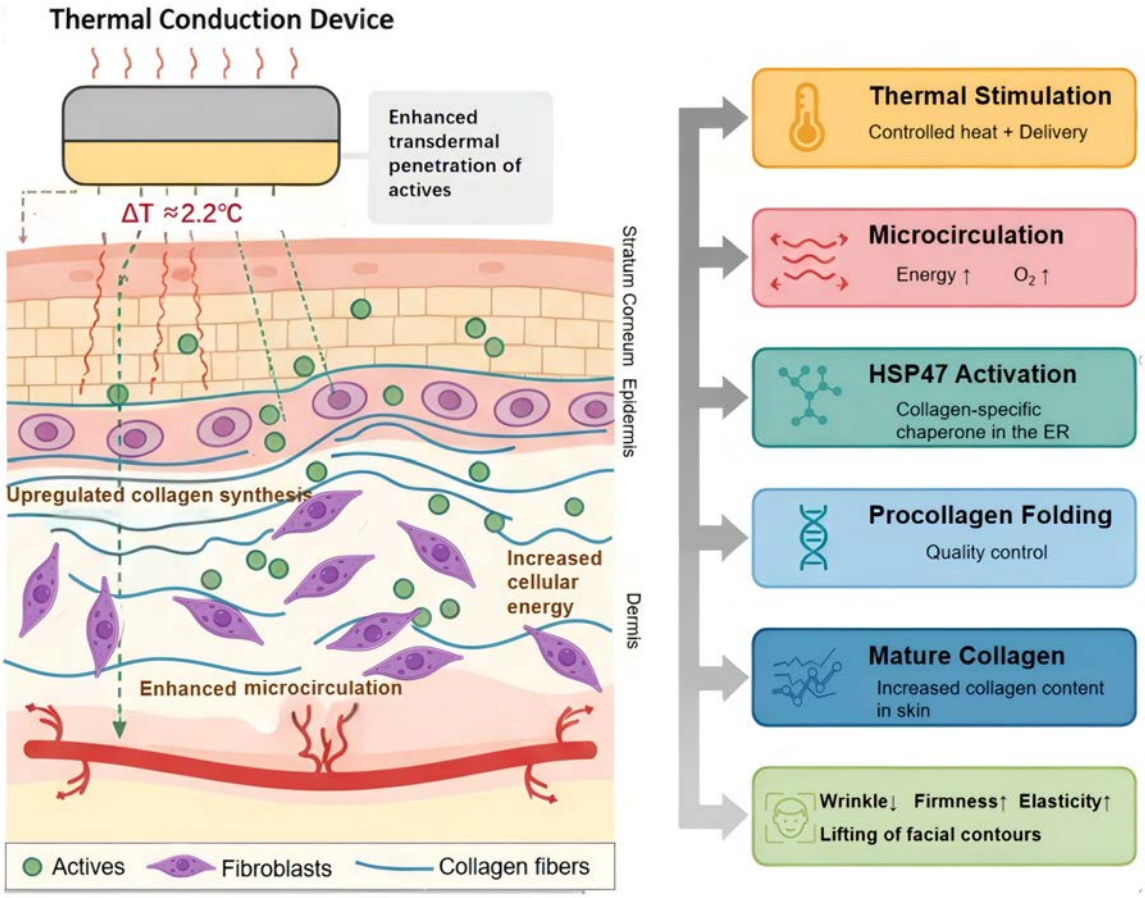

Materials and Methods

Thirty-one adult subjects were enrolled in a 5-week, single-center, prospective interventional study. The intervention involved low-level, controlled thermal stimulation designed to modulate the cutaneous microenvironment and enhance transdermal delivery of HSP47-targeted actives. Clinical efficacy was assessed using three-dimensional imaging (Antera 3D, VISIA, VECTRA) for facial contour and volumetric analysis, Cutometer measurements for skin elasticity, Corneometer CM825 and transepidermal water loss (TEWL) for stratum corneum hydration and barrier function, and infrared thermography (EvaTHERM) to evaluate skin surface temperature dynamics. Changes from baseline were analyzed using paired statistical tests ($p<0.05$).

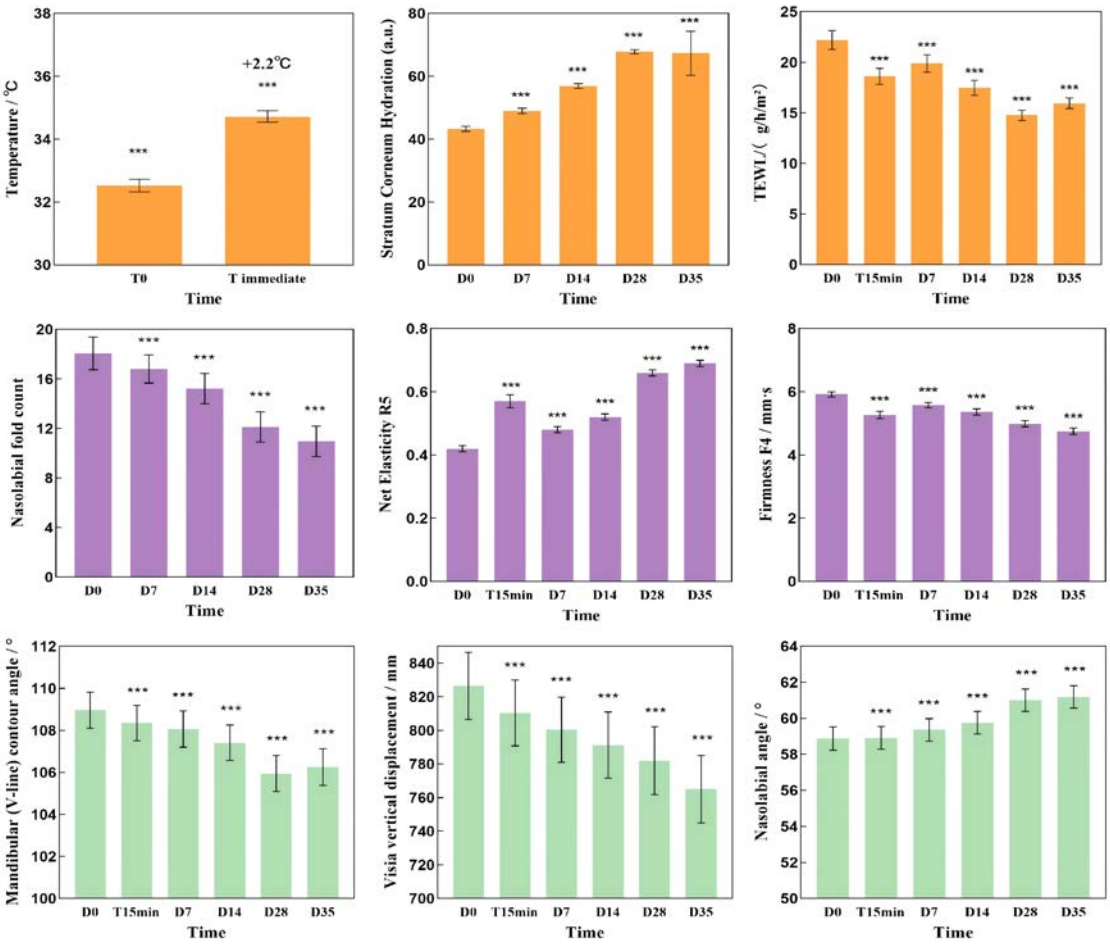

Results

After 5 weeks, significant and consistent improvements were observed across all endpoints ($p<0.05$). Three-dimensional imaging demonstrated enhanced lower-face contour, reduced perioral sagging, and improved jawline definition. Skin elasticity increased, accompanied by visible reductions in both dynamic wrinkles (forehead, crow's feet, glabellar lines) and static wrinkles (nasolabial folds, marionette lines), with pronounced improvements in periocular and glabellar regions. Stratum corneum hydration increased, while TEWL decreased, indicating improved barrier function. Volumetric analysis revealed increased malar fullness and reduced facial concavities. Infrared thermography showed a transient increase in skin surface temperature (2.2°C) and blood flow perfusion without evidence of tissue damage. The intervention was well tolerated, including in subjects with sensitive skin.

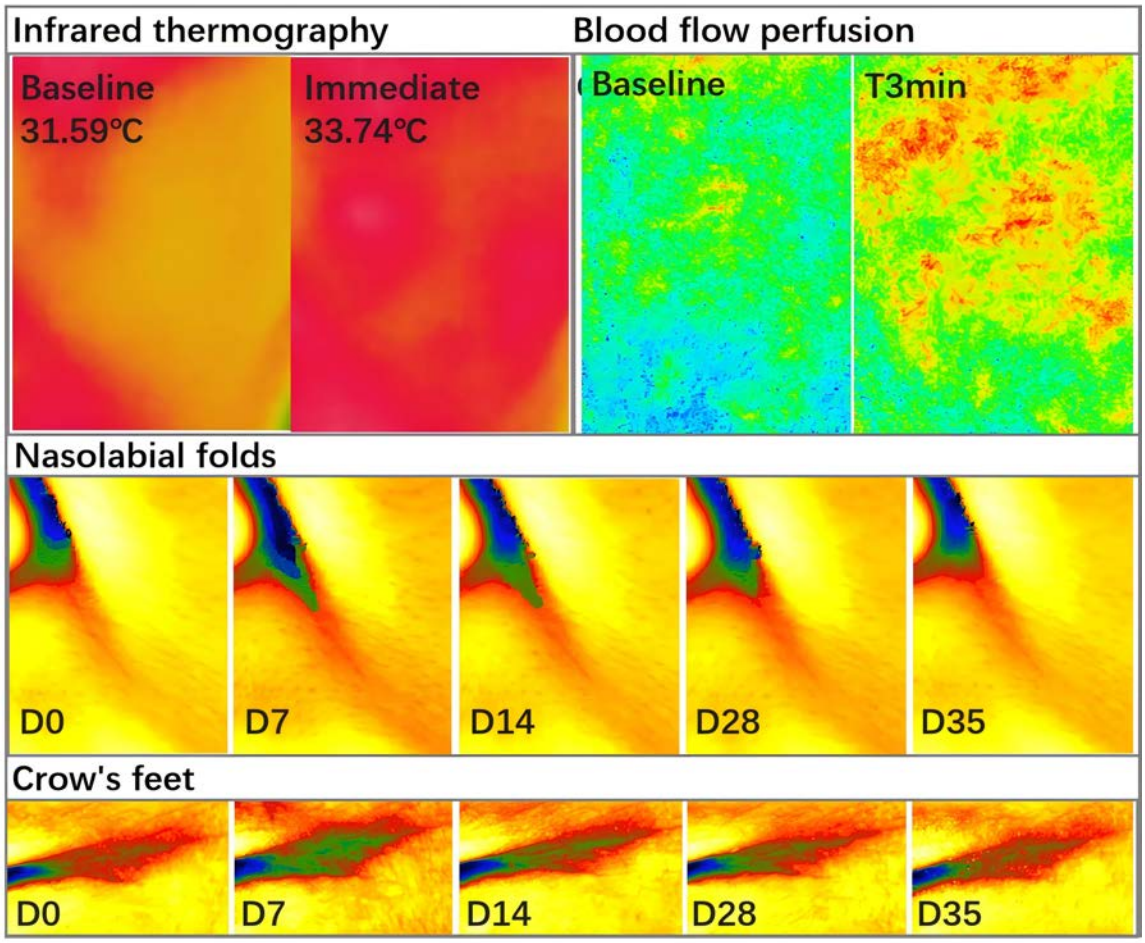

Conclusions

Non-damaging thermal conduction combined with HSP47-targeted actives was associated with improvements in multiple clinical parameters of facial rejuvenation, including skin elasticity, wrinkle appearance, hydration, and facial contour. These findings suggest that controlled thermal-assisted delivery may enhance the performance of dermal-targeting bioactives, potentially through improved transdermal transport and local bioavailability. This approach appears to be well tolerated and may represent a clinically relevant non-invasive modality for skin rejuvenation.

EA DV CONGRESS
VIENNA
30 SEP - 3 OCT 2026

Abstract N°: 1220

Misrepresentation of the Title 'Dermatologist' Among UK Aesthetic Practitioners: A Cross-sectional Analysis

Divas Mappa*[1], Sarika Grover[2], Bachun Cheema[3], Sochum Pandya[4], Julia Bahja[5], James Olding[6]

[1] Wrightington, Wigan and Leigh Hospital NHS Foundation Trust, Wigan, United Kingdom
[2] University Hospitals Coventry and Warwickshire NHS Trust, Coventry, United Kingdom
[3] Norfolk and Suffolk NHS Foundation Trust, Norwich, United Kingdom
[4] Birmingham Dental Hospital, Birmingham Community Healthcare NHS Trust, Birmingham, United Kingdom
[5] University Hospitals Bristol and Weston NHS Foundation Trust, Bristol, United Kingdom
[6] Interface Aesthetics, London, United Kingdom

Introduction

Background:
Professional titles used within aesthetic medicine strongly influence patient expectations and practitioner selection. In the United Kingdom, the title "dermatologist" denotes a physician listed on the General Medical Council (GMC) Specialist Register in Dermatology following completion of a Certificate of Completion of Training (CCT). However, the title itself is not legally protected and may be used by individuals without specialist dermatology accreditation.

Aim:
This study aimed to evaluate the extent of potential misrepresentation of the title "dermatologist" among medically qualified practitioners working in aesthetic medicine in the UK.

Materials and Methods

A cross-sectional analysis was conducted of practitioners listed on the British College of Aesthetic Medicine (BCAM) register. Dental surgeons were excluded. For each practitioner, GMC registration status and inclusion on the Specialist Register were verified. Associated public-facing websites and social media profiles were systematically reviewed for the use of the titles "dermatologist", "skin specialist", or "skincare expert", as well as claims of substantial dermatology training. Title misrepresentation was defined a priori as any public claim of "dermatologist" by a practitioner not listed on the GMC Specialist Register in Dermatology.

Results

Among 345 doctors identified, 196 (56.8%) were listed on a GMC Specialist Register in any specialty, while 134 (38.8%) were licensed non-specialists. Only 2 practitioners (0.6%) were registered dermatologists. Nineteen practitioners (5.5%) described themselves as dermatologists, of whom 17 (4.9%) lacked dermatology specialist registration. Additionally, 23 practitioners (6.7%) used the titles "skin specialist" or "skincare expert", and 51 (14.8%) referenced substantial dermatology training.

Conclusions

The findings highlight measurable title inflation within UK aesthetic practice. Ambiguous terminology such as "skin specialist" or "skincare expert" may contribute to patient misunderstanding, as these descriptors do not correspond to recognised medical qualifications. Strengthening advertising standards, improving regulatory

oversight, and considering formal protection of specialist titles may enhance transparency and promote patient safety within the aesthetic sector.

EA DV CONGRESS
VIENNA
30 SEP - 3 OCT 2026

Abstract N°: 1226

Oral JAK inhibitors for cosmetic injectable-associated granulomatous reactions: a case-based review of published reports

Mohammed shanshal[1], George Karanasios*[1]

[1] Imperial College Healthcare NHS Trust, London, United Kingdom

Introduction
Cosmetic injectables can trigger delayed inflammatory complications, including delayed-onset nodules, foreign-body granulomas, siliconomas, and related granulomatous reaction patterns that are diagnostically and therapeutically challenging. Conventional treatment commonly includes corticosteroids, antibiotics, hyaluronidase, minocycline, drainage, or intralesional therapy, but responses are inconsistent and relapse is not uncommon in refractory disease. Oral Janus kinase (JAK) inhibitors have recently emerged in scattered reports as off-label rescue options, but the published evidence remains fragmented. We reviewed the available case-based literature on oral JAK inhibitors for cosmetic injectable-associated granulomatous reactions.

Materials and Methods
We searched PubMed and Embase from inception to 1 April 2026, supplemented by backward reference screening, for published case reports and case series describing oral JAK inhibitors for cosmetic injectable-associated granulomatous reactions. After deduplication and screening, 9 publications were included. Data were extracted descriptively on trigger material, site, latency, diagnostic certainty, prior failed therapy, JAK regimen, and reported outcome. Because the evidence base consisted entirely of uncontrolled case-based reports, findings were synthesized narratively.

Results
Nine publications comprising 16 patients were included; all patients were women. The evidence base consisted of 2 case series and 7 individual case reports. Fifteen reactions involved the face and 1 involved the buttocks. Reported materials included hyaluronic acid, collagen, poly-L-lactic acid, silicone, and mixed mesotherapy products, although formulation detail was incomplete in several reports. Histologic confirmation was present in 6 of 16 patients (37.5%); the remainder were diagnosed clinically or with imaging or reflectance confocal microscopy support. Tofacitinib was the most frequently used JAK inhibitor, followed by abrocitinib, upadacitinib, and ruxolitinib; 1 mesotherapy case received sequential upadacitinib then tofacitinib because of cost. Most patients had already failed corticosteroid-based treatment, often with additional prior use of antibiotics, hyaluronidase, minocycline, drainage, or intralesional interventions. Reported latency ranged from 24 hours after mesotherapy to 25 years after filler placement, with most reactions developing within days to 3 months. Two informative outliers broadened this range: a silicone-associated reaction emerging 2 months after allogeneic haematopoietic stem-cell transplantation in a patient who had received filler 25 years earlier, and a facial foreign-body granuloma with an inferred latency of about 18 months. Across all 16 reported patients, authors described at least partial improvement after oral JAK inhibition. However, this should be interpreted as a directional signal only, because outcomes were qualitative, adjunctive therapies were common, and follow-up was short and uneven. Safety reporting was unsystematic, precluding meaningful safety conclusions.

Table. Evidence profile of published oral JAK inhibitor use in cosmetic injectable-associated granulomatous reactions

Domain	Key findings	Main caveat
Evidence base	9 publications, comprising 16 patients; 2 case series and 7 individual case reports; all patients were women	Entirely uncontrolled case-based evidence
Trigger materials / site	Reported materials included hyaluronic acid, collagen, poly-L-lactic acid, silicone, and mixed mesotherapy products; 15/16 reactions involved the face and 1/16 the buttocks	Formulation details were incomplete in several reports
Diagnostic certainty	Histologic confirmation in 6/16 (37.5%); remaining cases were diagnosed clinically or supported by imaging or reflectance confocal microscopy	Diagnostic certainty was heterogeneous, with no uniform case definition
Prior therapy / JAK exposure	Most patients had already failed corticosteroid-based treatment, often with additional prior use of antibiotics, hyaluronidase, minocycline, drainage, or intralesional therapy; tofacitinib was most frequently used, followed by abrocitinib, upadacitinib, and ruxolitinib	Concurrent or sequential adjunctive therapies were common, making the isolated contribution of JAK inhibition difficult to define
Latency / outcomes	Reported latency ranged from 24 hours after mesotherapy to 25 years after filler placement; most reactions developed within days to 3 months. Across all 16 patients, authors described at least partial improvement after oral JAK inhibition	Outcomes were qualitative, follow-up was short and uneven, and likely publication bias favours positive cases
Safety / interpretation	Most reports stated that no adverse events were observed during follow-up	Safety reporting was unsystematic, with no standardized monitoring or predefined adverse-event assessment; no meaningful safety conclusions can be drawn

Abbreviations: JAK, Janus kinase.

Conclusions

Published reports suggest a consistent directional signal for oral JAK inhibitors as an emerging off-label rescue option in selected refractory cosmetic injectable-associated granulomatous reactions. However, the current literature is limited to small uncontrolled case-based reports with substantial clinical, pathologic, and therapeutic heterogeneity and should be regarded as hypothesis-generating rather than practice-changing. Prospective multicentre registries with clearer diagnostic definitions, validated outcome measures, and standardized safety reporting are needed.

EADV CONGRESS
VIENNA
30 SEP - 3 OCT 2026

Abstract N°: 1243

Deciphering the Impact of Cellular Origin on Skin Diversity using in vitro approaches

sarah GIRARDEAU-HUBERT*[1], Rodrigo DE VECCHI[1]

[1] LOREAL, AULNAY-SOUS-BOIS, France

Introduction

For decades, dermatological research primarily focused on surface-level aspects/differences. However, skin diversity is rooted in complex biological systems/programs that govern structural integrity, regeneration, and aging. Building upon the identification of structural differences *ex vivo*, our research also evolved into a functional exploration of cellular heterogeneity and its impact on skin aging and regeneration using 3D reconstructed skin models/approaches.

Previous research established that darker and lighter skin types (from African and European descent) are intrinsically patterned. We previously demonstrated that skin types differed in their rete ridges pattern (dermal-epidermal junction - DEJ) and related protein expression in photoprotected skin, and that their keratinocytes follow specific differentiation and lipid metabolism programs -such as filaggrin processing- in *ex vivo* and *in vitro* models. These findings highlight that cellular origin is a primary driver of the skin phenotype in 3D reconstructed models [1].

Our most recent work shifts the focus to the pivotal role of fibroblast heterogeneity using*in vitro* 3D skin regeneration model [2]. By utilizing keratinocytes and fibroblasts from the same donor or combining different donors in 3D reconstructed skins, we demonstrated that the origin of papillary fibroblasts dictates the regenerative pace of the epidermis. We found that fibroblasts from lighter skin types significantly increased the commitment of keratinocytes to a differentiated state. In contrast, fibroblasts from darker skin types favor the maintenance of basal keratinocyte proliferation leading to a specific secretome, including KGF release, that shapes a unique dermal-epidermal crosstalk.

These intrinsic cellular and structural properties may lead to divergent aging trajectories. Our latest data revealed that the histological signs of aging - specifically the degradation of the collagen network [3] as well as the DEJ undularity - are significantly observed for both skin types on photoprotected skin. However, while lighter skin types showed an age-related increase in immature collagen fibers, darker skin types appeared to maintain a higher abundance of mature collagen fibers in older donors suggesting intrinsic extracellular matrix resilience, questioning the fibroblast functionality with aging for future work.

In conclusion, while the increasing complexity of global genetic admixture makes it challenging to model every skin type, these findings highlight a critical need for awareness of 3D *in vitro* model design. By acknowledging the influence of cell-intrinsic diversity on regeneration and aging, we can move toward inclusive studies by favoring a refined "question-led" approach to modeling. By selecting cell sources based on the specific biological function being studied -whether skin regeneration, barrier integrity, or aging- we can better anticipate variable responses and expand our knowledge of inclusive approaches to ultimately develop more accurate cutaneous treatments/innovations.

1. Girardeau-Hubert, S., et al., *Reconstructed Skin Models Revealed Unexpected Differences in Epidermal African*

and Caucasian Skin. Sci Rep, 2019. **9**(1): p. 7456.

2. Girardeau-Hubert, S., et al., *Exploring the Role of Fibroblast Heterogeneity from Different Skin Types in Epidermal Regeneration In Vitro.* J Invest Dermatol, 2026. **146**(3): p. 758-770 e7.
3. Salamito, M., et al., *Collagen diversity in human skin: Aging, wound healing, and disorders.* Matrix Biol, 2025. **140**: p. 133-153.

EADV CONGRESS
VIENNA
30 SEP - 3 OCT 2026

Abstract N°: 1265

Plant Stem Cell–Derived Bioactive Complex Enhances Mitochondrial Function and Attenuates Skin Aging: Mechanistic and Clinical Evaluation

Dongcui Li*[1], Li Ye[2], Yanxia Feng[1], Kathrin Nowak[3], Fred Zuelli[3], Si Wen[2], Linshan Wu[2], Lu Ren[1], Kangjin Zhang[1], Xuesong Xian[2], Zhiting Zhang[1], Yanhong Liu[1]

[1] Research and Development, Hua An Tang Biotech Group Co., Ltd, Guangzhou, China

[2] Cosmetics Testing Center, Dermatology Hospital of Southern Medical University, NMPA Center for Innovation and Research in Regulatory Science, Translational Medicine Center, Dermatology Hospital of Southern Medical University, GuangZhou, China

[3] Research and Development, Mibelle Biochemistry, Switzerland, Buchs, Swaziland

Introduction

Mitochondrial dysfunction is a key contributor to skin aging by impairing cellular energy metabolism and increasing oxidative stress, leading to progressive structural and functional deterioration of the skin. While most anti-aging approaches primarily target surface manifestations, strategies aimed at improving mitochondrial function may provide a more fundamental intervention. This study was designed to investigate the effects of a plant stem cell–derived bioactive complex on mitochondrial function and skin aging–related parameters, bridging mechanistic evaluation and clinical efficacy assessment from cellular mechanisms to in vivo outcomes.

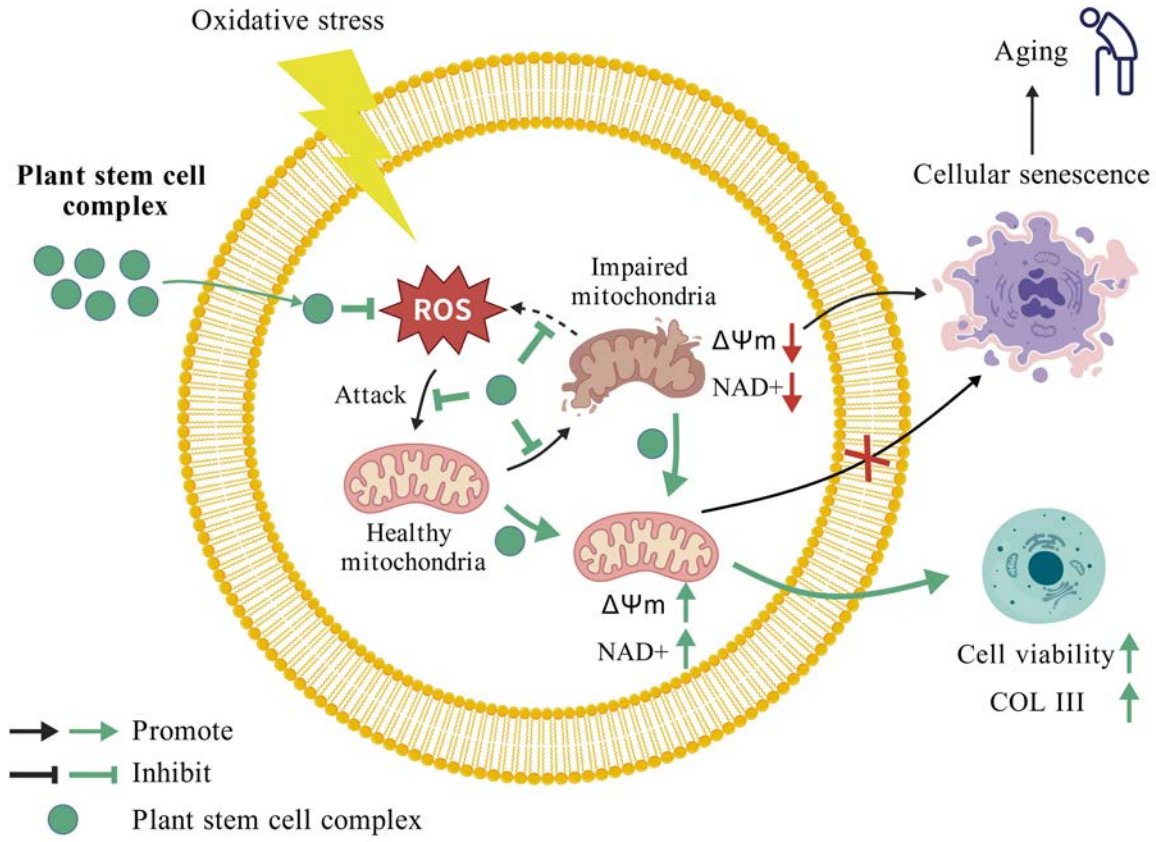

Materials and Methods

Antioxidant activity of the plant stem cell complex was evaluated using the DPPH radical scavenging assay. An in vitro UV-induced stress model in HaCaT keratinocytes was established to assess mitochondrial membrane potential (MMP). Type I collagen gene expression was quantified in dermal fibroblasts using quantitative real-time PCR (qPCR). A 28-day clinical study was conducted in 32 subjects using a topical formulation containing the complex. Clinical efficacy was assessed using instrumental measurements of skin aging–related parameters, including wrinkle severity and skin firmness, across multiple facial regions.

Results

The plant stem cell complex demonstrated significant free radical scavenging activity in the DPPH assay, indicating strong antioxidant capacity. In UV-stressed HaCaT cells, treatment resulted in a 571% increase in mitochondrial membrane potential ($P<0.001$), indicating improved mitochondrial function. In fibroblasts, collagen gene expression was significantly upregulated ($P<0.05$). Clinically, significant improvements in wrinkle parameters and skin firmness were observed after 28 days of treatment ($P<0.05$). Early improvements were detected as early as day 14, with progressive enhancement through day 28. Across eight anatomical facial regions (infraorbital, lateral canthal, buccal, nasolabial, oral commissure, glabellar, forehead horizontal, and frontal regions), consistent reductions in wrinkle severity were observed.

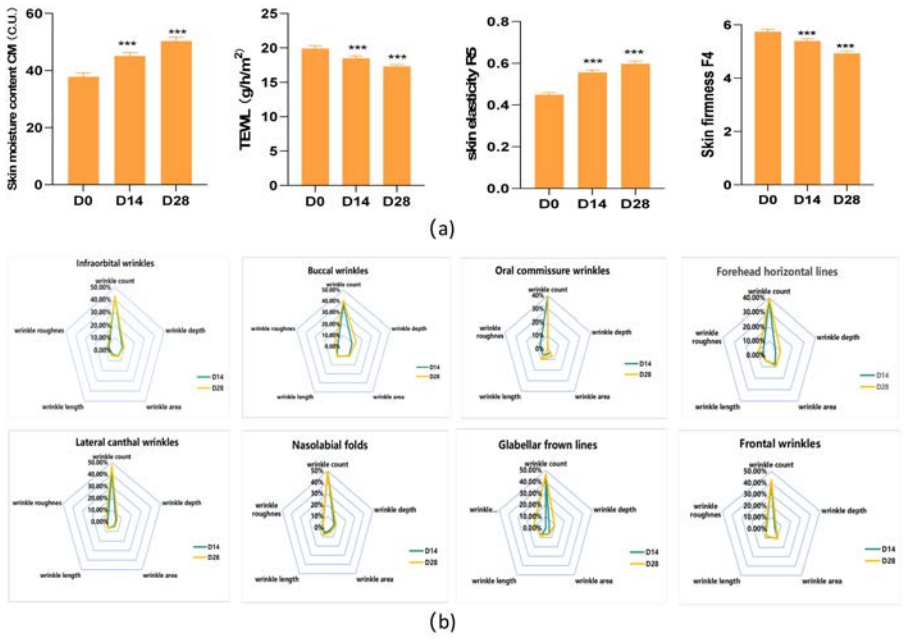

Conclusions

This study demonstrates that a plant stem cell–derived bioactive complex exerts antioxidant effects and improves mitochondrial function, as evidenced by enhanced mitochondrial membrane potential in vitro. These effects are associated with increased collagen gene expression and clinically observable improvements in wrinkle appearance and skin firmness. The findings suggest that targeting mitochondrial function may represent a mechanistically relevant approach for mitigating skin aging and improving skin quality. This mitochondria-associated strategy may provide a promising direction for future anti-aging interventions.

EA DV CONGRESS
VIENNA
30 SEP - 3 OCT 2026

Abstract N°: 1269

Efficacy of the combination of scar excision followed by fractional CO2 laser for facial scars.

Sudip Parajuli*[1], Upama Paudel[1]

[1] Department of Dermatology and Venereology , Maharajgunj Medical Campus , Institute of Medicine, Tribhuvan University, Kathmandu, Nepal

Introduction

Scars are among the most common reasons for consultations with Dermatologists. Despite improved surgical techniques and the use of recently developed energy-based devices, scarless healing remains difficult to achieve. The objectives of this study were to assess the efficacy of scar-reduction surgery combining scar excision followed by fractional CO_2 laser treatment, using the Manchester scar scale and satisfaction score.

Materials and Methods

This was a retrospective study of patients with scars who underwent scar revision surgery from 1st April 2018 through 1st March 2025 in the Department of Dermatology and Venereology …… and were referred to the author by other physicians for scar management. The study variables included age, sex, types of scars (physical trauma, burn, or chicken pox), Manchester Scar Scale at the time of presentation and after surgery and CO_2 laser, and satisfaction score. The patients who underwent excision for the scar and were unavailable at follow-up, patients with acne scars, patients unsuitable for primary excision, and patients who did not undergo fractional CO_2 laser post-surgery were excluded from the study.

The Manchester scar scale (MSS) score was used to assess the scar before and after the procedure. Manchester Scar Scale consists of the sum of the visual analogue scale (0-10) and scoring of different attributes of scar (color/matte vs shiny/contour/distortion/ texture). The satisfaction score was used to assess the scar at the last follow-up. It consists of quartile grading scores and is as follows: 0= no improvement (0-30%); 1=mild (31-50%); 2=moderate (51-70%); 3=good (71-90%); 4=excellent (> 90%).

Scars were excised with the incision line designed in a zigzag or geometric line just out of the scar tissue. The depth of the incision extended to the level of the subcutaneous tissue. Surgical margins were closed in two layers: dermis with absorbable suture 5-0, epidermis with non-absorbable cutaneous 5-0 interrupted suture. Dressing was done with normal saline every alternate day, and the suture was removed on the 7th day. Patients were called within 1 month (between 2 and 4 weeks after suture removal) for fractional CO2 laser treatment.

The study variables were entered into SPSS 25, and descriptive data analysis was done.

Results

There were nineteen patients who visited the department for consultation on the management of scars during the study period. Out of these nineteen patients, only 12 patients had undergone scar excision followed by fractional CO2 laser treatment during this period and were included in the study and analysis.

Out of these 12 patients, there were ten females and two males with ages ranging from 16 years to 36 years. Ten patients had traumatic scars due to physical trauma, one had a burn scar, and one had scars because of preceding chicken pox. Eight patients had scars on the forehead, two on the chin, and two on the glabella. The changes in

MSS were as follows: Patient 1: 22 to 4 at 4 months; Patient 2: 16 to 6 at 2 months; Patient 3: 14 to 7 at 2 months; Patient 4: 19 to 8 at 4 months; Patient 5: 19 to 6 at 2 months; Patient 6: 21 to 8 at 4 months; Patient 7: 22 to 7 at 12 months; Patients 8: 17 to 8 at one month; Patient 9: 20 to 8 at twelve months; Patient 10;18 to 10 at 24 months; Patient 11; 26 to 9 at 12 months; Patient 12; 15 to 5 at 12 months. MSS score of these patients at presentation ranged from 14 to 26, with a mean MSS score of 19.1 (+/- 3.4). The MSS score ranged from 5 to 10 with the mean value of 7.5 (+/- 1.3) after the procedure. The number of sessions of fractional CO2 ranged from one to nine. The time to follow-up ranged from two to twenty-four months. All the patients had a satisfaction score of 4.

Conclusions

Excision of scars followed by fractional CO2 laser may result in a better outcome of the scar on the face. However, a prospective study with a larger sample size and a control group will be required in the future to confirm this observation.

EA DV CONGRESS
VIENNA
30 SEP - 3 OCT 2026

Abstract N°: 1283

Nd:YAG Laser Hair Removal in the Treatment of Pilonidal Sinus: A Series of 23 Cases

Salma Kozmane*[1], Hanane Baybay[1], Ikrame Bejja[1], Saadia Boughaleb[1], Zakia Douhi[1], Meryem Soughi[1], Sara Elloudi[1], Fatimazahra Mernissi[1]

[1] Department of Dermatology, University Hospital Hassan II, Faculty of Medicine, Pharmacy and Dental Medicine, Sidi Mohamed Ben Abdellah University, fez, Morocco

Introduction
Pilonidal sinus is a chronic inflammatory disease of the intergluteal cleft that primarily affects young adults. It results from the penetration of hair into the intergluteal groove. The aim of this study was to evaluate the efficacy and tolerance of Nd laser hair removal in the management of pilonidal disease.

Materials and Methods
A retro-prospective study conducted between 2022 and 2025, including patients with pilonidal disease, whether operated or not. Patients were treated with an Nd laser (Fotona XP Dynamis, 1064 nm) using a 9 mm spot size. Parameters were adjusted according to phototype, hair thickness, and tolerance, with a fluence ranging from 10 to 25 J/cm² and a pulse duration of 0.6 to 1.6 milliseconds. A dynamic cooling system was used during sessions. Treatments were performed at intervals of 4 to 8 weeks for the first three to four sessions, then every 8 to 16 weeks until clinical remission and reduction of hair density, with an average of 3 sessions.

Results
Twenty-three patients were included, of whom 11 had undergone surgery. The mean age was 26 years, with a male predominance (61%). The main risk factors identified were intergluteal hypertrichosis (65%), prolonged sitting (56%), and passive smoking (43%). No short- or long-term complications related to laser hair removal were observed. Complete remission was achieved in 20 patients (87%), while three patients (13%) showed partial remission, with only one recurrence during one year of follow-up.

Conclusions
Pilonidal disease is closely associated with intergluteal hypertrichosis, which promotes hair penetration and retention. External Nd laser hair removal is an effective method for reducing hair density. Due to its wavelength of 1064 nm, it allows deep penetration and selective destruction of pigmented hair follicles through photothermolysis, thereby reducing one of the main triggering factors of the disease. Results reported in the literature show a high cure rate, good tolerance, and a low recurrence rate estimated at 9%, comparable to that observed in our series (13%). Another minimally invasive technique, sinus closure by endolaser (SiLaC), uses a fiber connected to a diode laser inserted into the fistulous tract; its thermal effect induces sinus closure. This technique also appears promising, with remission rates reported in the literature ranging from 75% to 94%, and recurrence rates varying between 8% and 25%.
In our study, Nd laser hair removal is an effective therapeutic option in the management of pilonidal sinus, with a low recurrence rate and good tolerance.

EA DV CONGRESS
VIENNA
30 SEP - 3 OCT 2026

Abstract N°: 1293

Application of Double-Layer Mask Structure–Induced Facial Microcompression to Enhance Skin Adhesion and Transdermal Permeation: A Clinical and Mechanistic Study with Real-Time Micropressure Sensing

Li Ye*[1], Dongcui Li[2], Lin Geng[2], Hongling Zhu[1], Dongqiu Chen[2], Yuchen Xin[2], Si Wen[1], Qingyang Wang[3], Ying Wu[3], Naisheng Jiang[3]

[1] Cosmetics Testing Center, Dermatology Hospital of Southern Medical University, NMPA Center for Innovation and Research in Regulatory Science, Translational Medicine Center, Dermatology Hospital of Southern Medical University, GuangZhou, China

[2] Research and Development, Hua An Tang Biotech Group Co., Ltd, Guangzhou, China

[3] School of Materials Science and Engineering, University of Science and Technology Beijing, Key Laboratory of Advanced Materials and Devices for Post-Moore Chips, Ministry of Education, Beijing, China

Introduction

Conventional facial masks often exhibit suboptimal skin adhesion and limited transdermal delivery efficiency. Existing strategies primarily rely on increasing formulation complexity or active ingredient concentration, which raises costs without fundamentally improving penetration. Mechanical modulation of the mask–skin interface represents an underexplored approach. This study aims to evaluate the effects of double-layer structure–induced facial microcompression on skin adhesion and transdermal permeation efficiency, and to elucidate its underlying mechanical contribution as an independent efficacy-enhancing parameter.

Materials and Methods

A controlled comparative study was conducted between a self-developed double-layer mask and a conventional single-layer mask. Finite element analysis (FEA) was used to simulate pressure distribution across facial regions. A flexible, custom-fabricated porous graphene-based pressure sensor (0–2 kPa) was employed to provide real-time, high-sensitivity, spatially resolved monitoring of facial microcompression dynamics during a 30-minute application. In vivo confocal Raman spectroscopy was used to quantify the penetration rate and depth of model active substances.

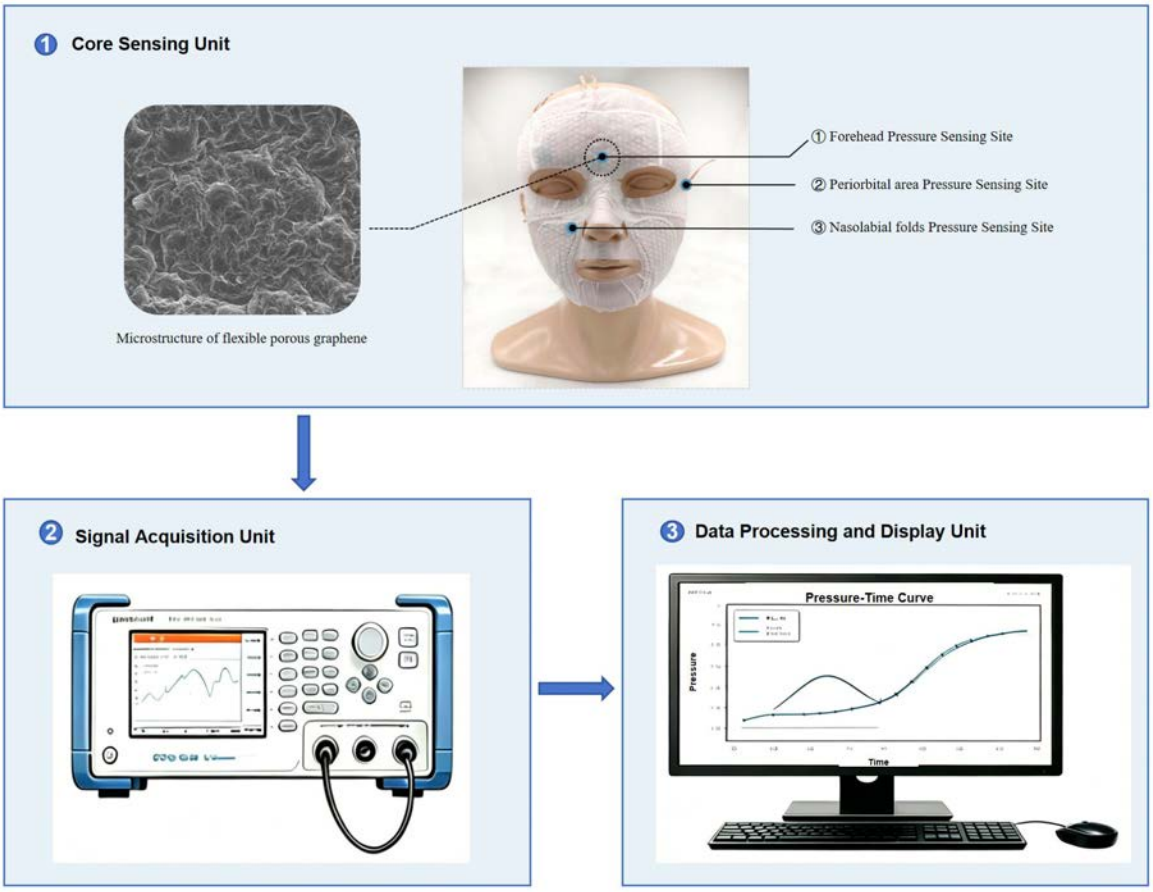

Results

Finite element analysis (FEA) demonstrated that the double-layer mask generated a more uniform and higher-intensity microcompression distribution, particularly in regions prone to poor contact, including the forehead, periorbital area, and nasolabial folds. Real-time micro-pressure sensor measurements showed an approximately 2-fold increase in pressure compared with the single-layer mask, along with improved temporal stability and reduced interfacial gaps, indicating enhanced skin adhesion. In vivo confocal Raman spectroscopy revealed that the double-layer mask achieved a relative penetration rate of 5.94% and a maximum penetration depth of 60 μm, with a sustained downward diffusion profile. These effects were achieved without increasing formulation complexity or active ingredient loading.

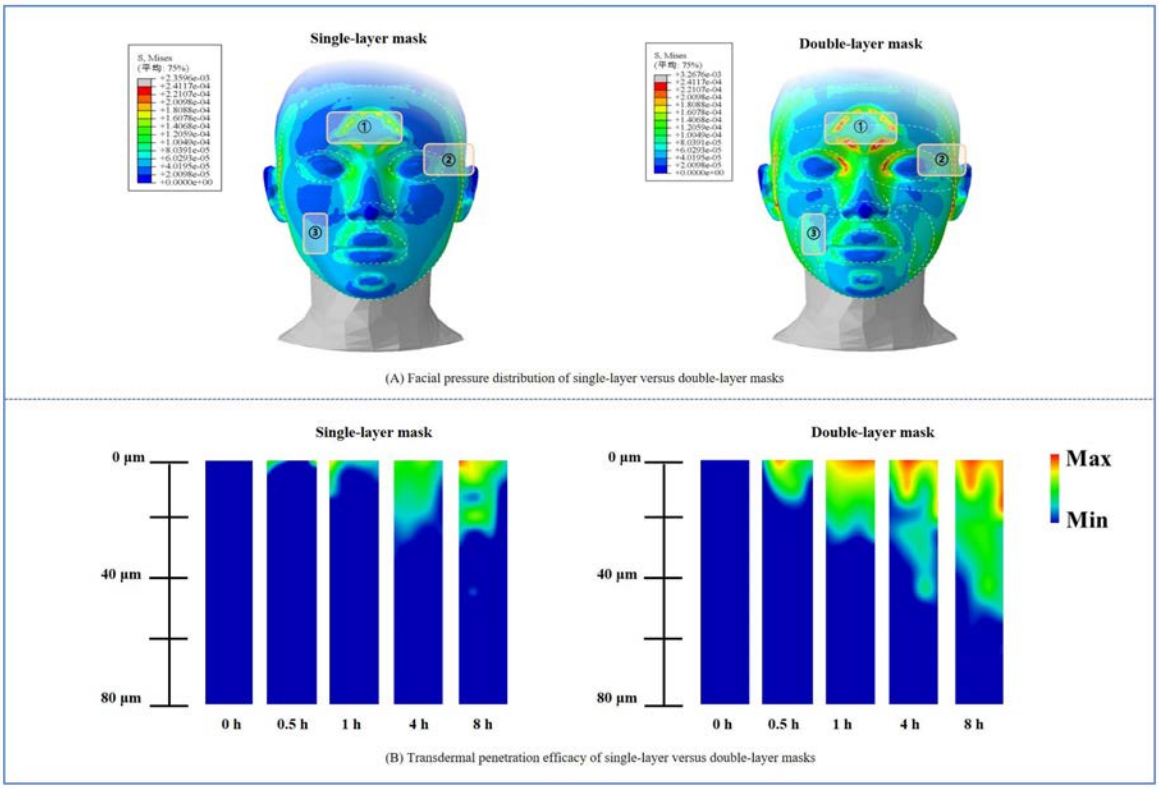

Conclusions

Facial microcompression is identified as an independent mechanical determinant of topical delivery efficiency. A double-layer mask structure modulates mask–skin interface pressure dynamics, thereby enhancing adhesion and facilitating transdermal permeation without altering formulation composition. These results highlight the relevance of mechanical interface regulation as a previously underappreciated parameter in cutaneous delivery, with potential implications for the design of advanced topical application systems.

EA DV CONGRESS
VIENNA
30 SEP - 3 OCT 2026

Abstract N°: 1297

A Novel Complex of Halophilic Fermentation-Derived Bioactives and Acetyl Hexapeptide-8 Ameliorates the Sensitivity-Aging Cycle: Mechanistic and Clinical Evidence

Li Ye*[1], Dongcui Li[2], Cairu Huang[2], Jinyin Liang[1], Lu Ren[2], Shuangyan Wang[2], Xiaoyan Fu[1], Yintao Lin[2], Mauricio Valerio-Santiago[3], Tomoko Oto[4]

[1] Cosmetics Testing Center, Dermatology Hospital of Southern Medical University, NMPA Center for Innovation and Research in Regulatory Science, Translational Medicine Center, Dermatology Hospital of Southern Medical University, GuangZhou, China

[2] Research and Development, Hua An Tang Biotech Group Co., Ltd, Guangzhou, China

[3] Lubrizol Life Science, Lipotec S.A.U., Barcelona, Spain, Barcelona, Spain

[4] Nihon Inemoto Co., Ltd, Tokyo, Japan

Introduction

Sensitive skin and aging are closely interconnected conditions that may mutually exacerbate barrier dysfunction and inflammatory reactivity. This study investigated the effects of a novel complex composed of halophilic fermentation-derived bioactives and acetyl hexapeptide-8 on molecular and clinical parameters associated with the sensitivity–aging cycle, aiming to restore epidermal homeostasis and attenuate inflammation-associated skin reactivity. Both mechanistic and clinical evaluations were conducted, with particular focus on Connexin 26 (Cx26), Nuclear Factor-κB (NF-κB), and chemokine CCL2 as representative markers of epidermal barrier function and inflammatory response.

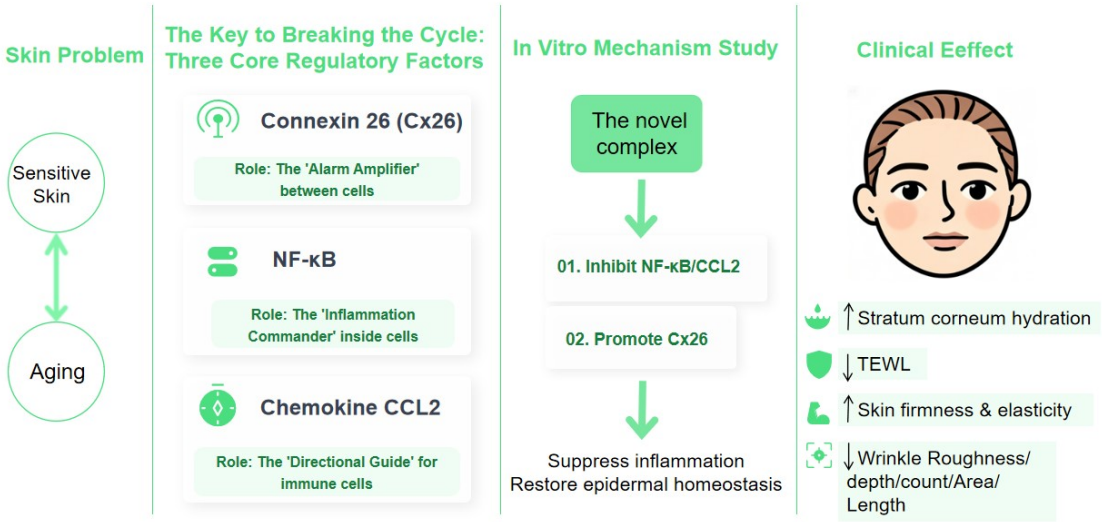

Materials and Methods

In vitro experiments were conducted in keratinocytes and macrophage-derived immune cells to evaluate

the effects of the complex on Cx26 and NF-κB gene expression, as well as CCL2 secretion. A randomized, single-center, open-label clinical study was conducted in 33 subjects with self-reported sensitive skin. The test formulation containing the complex was applied twice daily for 4 weeks. Clinical efficacy was assessed using instrumental measurements including stratum corneum hydration, transepidermal water loss, skin elasticity, firmness, and multi-site wrinkle analysis. Additional evaluations included blinded dermatologist assessment and subject self-assessment of sensitive skin symptoms.

Results

In vitro, the complex significantly increased Cx26 expression by 44% ($p<0.0001$), while reducing NF-κB expression by 39% ($p<0.001$) and CCL2 secretion by 73.1% ($p<0.01$), indicating coordinated modulation of epidermal barrier-associated and inflammatory-related markers. Clinically, significant time-dependent improvements were observed across all instrumental parameters after 4 weeks, including increased stratum corneum hydration and improved skin elasticity and firmness (all $p<0.001$). Multi-region wrinkle analysis demonstrated significant reductions in wrinkle depth, area, and length (all $p<0.001$), with the most pronounced effects observed in the periocular region. Blinded dermatologist assessment confirmed significant improvements in erythema, scaling, and overall skin reactivity. Subjective evaluation showed marked alleviation of dryness (64.9%), desquamation (68.0%), redness (57.5%), tightness (76.0%), stinging (86.9%), itching (86.3%), and burning (87.0%) (all $p<0.001$), with excellent tolerability and no reported adverse events.

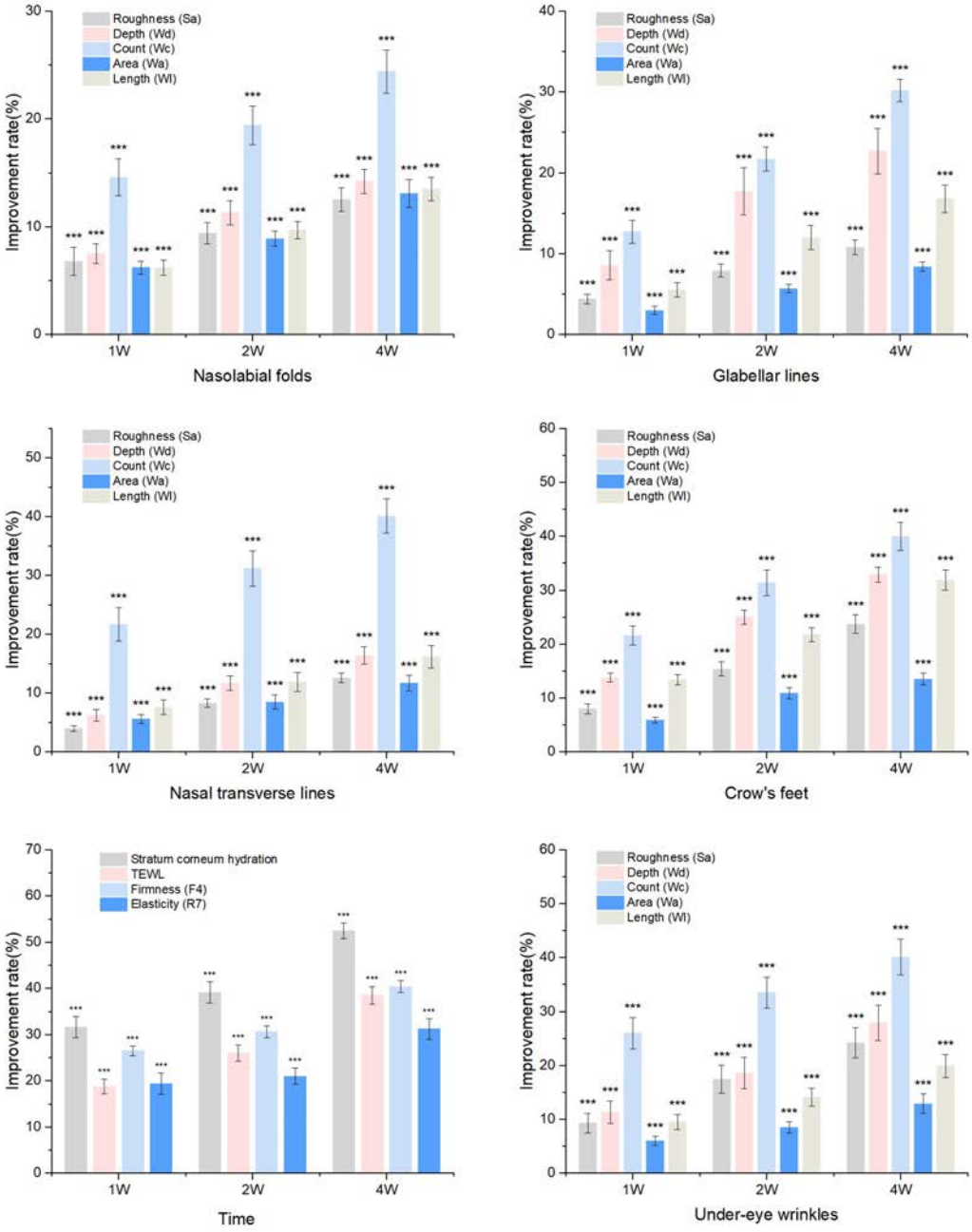

Conclusions

This study provides both mechanistic and clinical evidence that a halophilic fermentation-derived bioactive complex combined with acetyl hexapeptide-8 can beneficially modulate key markers associated with epidermal barrier function and inflammatory response in sensitive skin. The observed improvements in hydration, barrier integrity, inflammatory indicators, and clinical signs of aging support its potential utility in managing sensitive skin–associated aging phenotypes and further highlight the interplay between barrier dysfunction and inflammation-driven skin aging.

EADV CONGRESS
VIENNA
30 SEP - 3 OCT 2026

Abstract N°: 1304

Comparison of High-Dose versus Low-Dose Hyaluronidase in the Management of Vascular Complications Following Hyaluronic Acid Filler Injections: A Randomized Clinical Trial

Hamidreza Mahmoudi*[1], Maryam Daneshpazhouh[1], Mohadese Mousavimoghadam[1]

[1] Tehran University of Medical Sciences, Tehran, Iran

Introduction

Vascular occlusion following hyaluronic acid (HA) filler injection is a rare but potentially devastating aesthetic emergency. Hyaluronidase is considered the gold-standard treatment; however, there is no clear consensus regarding the optimal dosing strategy. This randomized controlled trial (RCT) aimed to directly compare the clinical efficacy of a low-dose pulsed hyaluronidase regimen (300 units) with a standard high-dose regimen (1500 units), with particular emphasis on clinical outcomes, sensory symptom improvement, and the relative importance of intervention timing in patients with HA filler–induced vascular complications.

Materials and Methods

In this single-center randomized controlled trial, 40 patients with HA filler–related vascular occlusion were randomized to receive either low-dose pulsed hyaluronidase (300 IU per session) or high-dose hyaluronidase (1500 IU per session), administered in two injections at 2-hour intervals. Clinical manifestations, capillary refill, sensory symptoms, and final outcomes were assessed at predefined time points up to 3 months. Outcomes were categorized as complete recovery, post-inflammatory hyperpigmentation, or scarring. Statistical analyses evaluated dose-related effects and the impact of time to intervention.

Results

Baseline characteristics and clinical presentations were comparable between groups. Although the high-dose regimen resulted in faster early capillary refill after the first injection, this advantage did not persist after cumulative dosing. Final clinical outcomes did not differ significantly between the low- and high-dose groups ($p > 0.05$). Both regimens led to significant improvement in pain, burning sensation, and paresthesia. Across all analyses, early initiation of hyaluronidase—particularly within 48 hours—was the strongest predictor of a favorable outcome and was independently associated with reduced scarring ($p < 0.05$), irrespective of dose.

Conclusions

Low-dose pulsed hyaluronidase achieves clinical outcomes comparable to those of a high-dose regimen in the treatment of HA filler–induced vascular occlusion. Treatment timing, rather than absolute dose, is the principal determinant of outcome. These findings support a shift toward early, targeted, and cumulative dosing strategies rather than routine escalation to high initial doses.

EADV CONGRESS
VIENNA
30 SEP - 3 OCT 2026

Abstract N°: 1305

Comparative Evaluation of Long-Pulsed Nd:YAG and Pulsed Dye Lasers in the Treatment of Venous Lake Lesions: A Prospective Clinical Study

Hamidreza Mahmoudi*[1], Maryam Daneshpazhouh[1]

[1] Tehran University of Medical Sciences, Tehran, Iran

Introduction
Venous lake are benign vascular malformations found mainly on the lips and face. Various treatment modalities have been proposed, with laser therapy emerging as an effective and minimally invasive option. This prospective observational study aimed to evaluate the efficacy and safety of different laser systems in managing venous lake.

Materials and Methods
A total of 23 patients with venous lake lesions were treated with PDL (n = 8) and Nd:YAG (n = 15) lasers. Data on patient demographics, lesion characteristics, treatment parameters, and outcomes were collected. Tow dermatologists evaluated treatment effectiveness by comparing pre- and post-treatment images, focusing on lesion size reduction and color improvement.

Results
The mean age of patients was 48.8 years (± 12.3), with a mean BMI of 25.8 (± 1.5). Patients averaged 2.35 treatment sessions over 8.2 months (± 4.9). Both lasers led to significant reductions in lesion size (58.3%) and color improvement (65.2%) ($P < 0.001$). A ≥75% size reduction was seen in 39.1% of patients, more commonly with Nd:YAG (53.3% vs. 12.5%, $P = 0.086$). Nd:YAG also achieved a ≥75% color improvement (60% vs. 0%, $P = 0.007$) and complete clearance in 17.4% of patients. Nd:YAG demonstrated a greater mean size reduction (0.68 vs. 0.40 cm; $P = 0.059$) and color improvement (0.75 vs. 0.46; $P = 0.007$). Outcomes were independent of age, sex, BMI, lesion size, and duration, while complete remission correlated with higher fluence ($P = 0.001$). Treatment was well tolerated, with only one case of scarring.

Conclusions
Lasers, particularly Nd:YAG systems, appear to be a safe and effective treatment for venous lake.

EA DV CONGRESS
VIENNA
30 SEP - 3 OCT 2026

Abstract N°: 1305

Tailored Trichloroacetic Acid, Pyruvic Acid, and Croton Oil Peel: A 14-Case Series Demonstrating Quantifiable Rejuvenation with Minimal Downtime

Christine Rachelle Prescendo Chaves*[1], Pedro Vargas[2], Letícia Bisch[3], Lucas H. R. da Silva[1], Michele Kreuz[4]

[1] Federal University of Rio Grande do Sul, Porto Alegre, Brazil

[2] Pontifical Catholic University of Rio Grande do Sul, Porto Alegre, Brazil

[3] Federal University of Health Sciences of Porto Alegre, Porto Alegre, Brazil

[4] Lutheran University of Brazil, Canoas, Brazil

Introduction

Dermal remodeling for acne scars, photoaging, and skin laxity usually requires high-cost or high-risk procedures. A tailored mix of trichloroacetic acid (TCA), pyruvic acid, and croton oil provides medium-depth resurfacing with adjustable penetration, favorable safety, and cost-effectiveness. This study aims to assess the therapeutic efficacy and safety of a tailored mix of TCA, pyruvic acid and croton oil.

Case Presentation

Case Series: Fourteen female patients (ages 29–77; Fitzpatrick I–III) underwent a single-session peel, customized by indication and skin type. All completed 30-day priming with retinoids and hydroquinone, discontinued 48 hours preprocedure. Antimicrobial and anti-herpetic prophylaxis was provided. Treatment: After degreasing and Jessner's solution, one of three protocols was selected: Heavy (TCA 35% + pyruvic 35% + croton oil 0.4%), Medium (TCA 35% + pyruvic 20% + croton oil 0.2%), or Light (TCA 20% + pyruvic 20% + croton oil 0.1%). Frosting intensity guided depth modulation. Results: Mean healing time was 6.2 ± 1.7 days. Across all regions, mean improvement scores (0–4 scale) were: firmness 3.4 ± 0.5, texture 3.2 ± 0.6, glow 3.1 ± 0.6, softness 3.0 ± 0.5, wrinkles 2.9 ± 0.7. Perioral and forehead regions showed the highest texture gains (3.4 and 3.3). All patients reported overall skin quality enhancement; three experienced mild, self-limited adverse events, with no bacterial or herpetic infections.



Before and after medium-depth ATA peel (TCA 35% + pyruvic acid 20% + croton oil 0.2%), showing improvement in pigmentation and skin texture.

Conclusion

Quantitative analysis confirms that individualized TCA–pyruvic–croton oil peels deliver substantial and predictable clinical improvements, approaching deep resurfacing results but with reduced risk and downtime. Depth modulation via frosting response enables precise targeting of diverse indications, positioning this as a versatile, high-value alternative in aesthetic dermatology.

EA DV CONGRESS
VIENNA
30 SEP - 3 OCT 2026

Abstract N°: 1323

Hidden Hazards Beneath: Delayed Hypersensitivity to Aesthetic Biomaterials: A Literature Review

Majd Abu Taleb*[1], Nesrine Ben Salah[1], Youssef Monia[1], Hichem Belhadjali[1], Jameleddine Zili[1]

[1] Dermatology Department, Fattouma Bourguiba University Hospital, Monastir, Tunisia

Introduction

Delayed cutaneous hypersensitivity to aesthetic biomaterials and implants underscores a complex immunologic interplay between exogenous substances and cutaneous defense mechanisms. Even materials traditionally considered biologically inert—such as dermal fillers, silicone prostheses, and dental implants—can trigger localized granulomatous reactions or systemic immune dysregulation through keratinocyte activation, antigen-presenting cell recruitment, and tissue-resident memory T-cell mobilization. Despite their growing clinical prevalence, the pathophysiology, risk stratification, and optimal management of these delayed reactions remain inadequately defined. This review synthesizes current evidence on the immunologic mechanisms, clinical phenotypes, predisposing factors, and therapeutic strategies associated with delayed hypersensitivity to aesthetic biomaterials, aiming to bridge mechanistic understanding with standardized clinical practice.

Materials and Methods

A comprehensive literature review was performed using PubMed, Scopus, and Web of Science. Fifty-four peer-reviewed studies—including clinical reports, immunopathological investigations, and biomaterials research—were analyzed. Keywords included “delayed hypersensitivity,” “cutaneous immune response,” “aesthetic biomaterials,” “dermal fillers,” “silicone implants,” and “immunomodulation.” Data were extracted on material types, clinical presentations, diagnostics, therapeutic strategies, and immunologic mechanisms.

Results

Delayed hypersensitivity reactions commonly present weeks to years after biomaterial implantation. Clinical features include indurated nodules, persistent erythema, edema, granulomatous inflammation, capsular contracture, and, rarely, systemic symptoms such as fever, arthralgia, or fatigue. Risk factors include female sex, age 30–60, atopic predisposition, autoimmune conditions, cumulative exposure to multiple biomaterials, and recent immune challenges. Diagnostic evaluation relies on clinical examination, imaging (ultrasound, MRI), histopathology, immunohistochemistry, and, in selected cases, lymphocyte transformation or patch testing. Management strategies range from topical or systemic corticosteroids, intralesional therapies, hyaluronidase for hyaluronic acid fillers, to surgical revision or explantation for refractory cases. Novel immunomodulatory biomaterials demonstrate reduced immunogenicity and improved integration.

Conclusions

Delayed hypersensitivity to aesthetic biomaterials demonstrates that biocompatibility is not a static property but a dynamic immunologic equilibrium shaped by host susceptibility, material composition, and procedural variables. Central to this pathogenesis are coordinated responses involving keratinocytes, antigen-presenting cells, tissue-resident memory T cells, and macrophage

polarization, which collectively dictate whether tissue adaptation or pathologic inflammation occurs. Clinically, these reactions remain underdiagnosed and require sustained diagnostic vigilance as aesthetic procedures proliferate. Management must be severity-stratified, ranging from targeted immunomodulatory therapy to definitive device removal, while proactive patient counseling and multidisciplinary coordination between dermatology, immunology, and surgical specialties are essential to mitigate risk and optimize outcomes. Looking forward, the development of bioengineered, immune-responsive biomaterials holds transformative potential to align aesthetic objectives with immunological safety. By establishing standardized diagnostic frameworks and evidence-based therapeutic algorithms, dermatologists can convert delayed hypersensitivity from a diagnostic challenge into a paradigm for precision aesthetic medicine, ultimately safeguarding patient welfare while guiding next-generation material innovation.

EADV CONGRESS
VIENNA
30 SEP - 3 OCT 2026

Abstract N°: 1357

Injectable Polydeoxyribonucleotide in Aesthetic Medicine: Clinical Evidence, Safety Profile, and Global Regulatory Landscape

Paidamoyo Chiota[1], Kholoud Mohamed Said Abdelaziz[2], Sheeda Jabeen[2], Mena Ayman Elgendy[3], Anuja Mali[4], Nancy Emmanuel*[5]

[1] Medical University of Łódź, Łódź, Poland

[2] Tbilisi State Medical University, Faculty of Medicine, Tbilisi, Georgia

[3] Misr University for Science and Technology, Giza, Egypt

[4] East European University, Tbilisi, Georgia

[5] Department of Dermatology, Hospital das Clínicas da Faculdade de Medicina da Universidade de São Paulo, São Paulo, Brazil

Introduction

Polydeoxyribonucleotide (PDRN) and Polynucleotides (PN) are bioactive, DNA-derived polymers increasingly utilized in regenerative aesthetic medicine. These compounds function primarily through the selective activation of the adenosine A2A receptor, a mechanism that modulates inflammatory responses, stimulates the metabolic activity of fibroblasts, and promotes therapeutic angiogenesis via the upregulation of vascular endothelial growth factor (VEGF). Furthermore, they provide essential nucleotides for DNA synthesis through the salvage pathway, particularly in damaged or hypoxic tissues. The objective of this study is to provide a comprehensive review and qualitative synthesis of the clinical efficacy, safety profile, and global regulatory status of injectable PDRN and PN in aesthetic medicine.

Materials and Methods

A systematic literature search was conducted across PubMed, Embase, and Web of Science using complex Boolean strings designed to capture the clinical and regulatory breadth of DNA-derived polymers. Keywords included "polydeoxyribonucleotide," "PDRN," "polynucleotide," and "PN," combined with "aesthetic medicine," "skin rejuvenation," and "injectable treatments." Records retrieved from PubMed, Embase, and Web of Science were manually screened for relevance, and 27 records were included in the final qualitative synthesis. This comprehensive review utilized a qualitative synthesis of evidence, with screening protocols focused on randomized controlled trials (RCTs), clinical studies, and official regulatory framework documents.

Results

Synthesis of clinical evidence reveals that PDRN and PN significantly improve skin quality, characterized by enhanced hydration, improved elasticity, and refined skin texture. In periorbital rejuvenation, injectable protocols have demonstrated high success in reducing tear-trough hollowing and crow’s feet through increased dermal thickness and elasticity. Dermal remodeling is consistently achieved through synergistic fibroblast activation and neocollagenesis, leading to long-term tissue revitalization. Injectable PDRN and PN preparations demonstrate a robust safety profile and high general tolerability. Adverse events are primarily restricted to transient local reactions such as mild edema, erythema, and site-specific pain. To date, no serious complications, such as

persistent nodules, hypersensitivity reactions, or vascular occlusive risks, have been reported when utilizing standardized aseptic techniques. The regulatory landscape is characterized by a distinction between "medical device" and "pharmaceutical/biologic" classifications. In major global markets such as South Korea, PDRN is typically classified as a pharmaceutical agent for tissue repair, whereas PN is designated as a medical device. In the European Union, PN-based products are often cleared via CE Marking as medical devices for skin revitalization. In the United States, while certain materials like PDO threads have Class II clearance, the regulatory pathway for injectable DNA-derived biologics remains more restricted under the FDA framework

Conclusions

Injectable PDRN and PN represent clinically viable modalities for aesthetic rejuvenation, providing objective improvements in dermal remodeling and skin quality with a minimal risk of adverse events. However, the current heterogeneity in international classifications underscores the urgent necessity of harmonizing regulatory standards to match the growing clinical evidence for their use in regenerative aesthetic medicine

EA DV CONGRESS
VIENNA
30 SEP - 3 OCT 2026

Abstract N°: 1362

Fractional CO2 Laser Therapy for the Young Face: A Comprehensive Review of Benefits and Clinical Indications for Prejuvenation

Sasha Jreije[1], Razan Hassan[1], Thaniya Rahumathulla[2], Merlyn Vellalar[3], Tala El Cheikh[4], Janadi Karawita[5], Nancy Emmanuel*[6]

[1] University of Balamand, Beirut, Lebanon

[2] Dr. Moopen's Medical College, Wayanad, Kerala, India

[3] Alte University, Tbilisi, Georgia

[4] Saint George University of Beirut, Beirut, Lebanon

[5] American MD Program, Tbilisi State Medical University, Tbilisi, Georgia

[6] Department of Dermatology, Hospital das Clínicas da Faculdade de Medicina da Universidade de São Paulo, São Paulo, Brazil

Introduction

Prejuvenation is defined as an active, preventative approach to anti-aging skincare, typically targeting patients aged 25–40. Rather than reactively correcting established rhytids and photodamage, younger generations are increasingly utilizing energy-based devices in their 20s and 30s to maintain a youthful appearance and prevent aging. Facial aging processes, including dermal thinning and volume loss, often initiate during this period. Consequently, a paradigm shift has occurred from aggressive, high-fluence traditional ablative resurfacing toward low-fluence, "micro-ablative" fractional protocols. The objective of this review is to evaluate the clinical indications and benefits of fractional carbon dioxide (CO2) laser for treating and maintaining skin texture, stimulating collagen, and delaying visible signs of aging in younger cohorts.

Materials and Methods

A comprehensive literature search was conducted across PubMed, Embase, and Web of Science up to April 2026 using terms such as fractional CO_2 laser, fractional carbon dioxide laser, ablative fractional laser, skin rejuvenation, photoaging, photodamage, wrinkles, skin texture, collagen remodeling, and acne scars. Eligible studies included clinical trials, observational studies, and review articles evaluating the use of fractional CO_2 laser in dermatologic and aesthetic indications, including skin rejuvenation, photoaging, acne scarring, and texture irregularities. Outcomes of interest included clinical efficacy, safety profiles, patient satisfaction, and histological changes such as collagen remodeling and neocollagenesis. Studies involving non-fractional laser modalities, animal or in vitro research, and non-English publications were excluded. Searches were limited to articles published between 2016 and 2026 yielding a total number of 1,212 articles (PubMed: 272; Embase: 813; Web of Science: 127).

Results

Clinical outcomes indicate that fractional CO2 laser therapy significantly improves skin uniformity, reduces pore size, and treats early atrophic rhytids, particularly in the periorbital and perioral regions. Furthermore, it is a primary modality for treating post-acne atrophic scars, specifically rolling and boxcar types, where it induces significant textural improvement and reduces scar severity scores. Histological analysis provides evidence of significant neocollagenesis and elastin

fiber reorganization. Objective studies show an intensity increase of 12.53% for Type I collagen and 0.4% for Type III collagen following treatment, suggesting the laser’s specific role in remodeling the structural framework of the skin. The mechanism involves the creation of micro-thermal zones (MTZs), which induce controlled dermal injury while sparing surrounding tissue, facilitating rapid re-epithelialization. Younger patients often demonstrate superior clinical responses for rejuvenation compared to older cohorts, potentially due to more efficient cellular renewal processes. While social downtime is minimal (typically 3–7 days), patients with darker skin phototypes (III–V) require customized low-fluence settings to mitigate the risk of reversible post-inflammatory hyperpigmentation.

Conclusions

Fractional CO2 laser therapy constitutes a primary therapeutic modality within the prejuvenation framework, providing an optimized efficacy-to-risk profile for early intervention. Current clinical evidence supports the implementation of low-fluence resurfacing protocols. We suggest a standardized regimen consisting of three sessions at monthly intervals repeated every 24 months, to promote sustained dermal remodeling and neocollagenesis. This approach maintains a favorable safety profile and minimal social downtime, highlighting the utility of proactive, tailored laser interventions to preserve cutaneous integrity and significantly postpone the clinical manifestation of senescent changes. Nonetheless, prospective longitudinal trials remain imperative to formalize standardized, evidence-based clinical frameworks for prejuvenation.

EA DV CONGRESS
VIENNA
30 SEP - 3 OCT 2026

Abstract N°: 1389

Picosecond Laser Combined with Different Concentrations of Platelet-Rich Plasma Injection in Treating Periorbital Hyperpigmentation

Ziqin Gan*[1], Ting Liu[1], Danyi Huang[1], Bo Zhang[1], Han Ma[1]

[1] The Fifth Affiliated Hospital of Sun Yat-sen University, Zhuhai, Guangdong, China

Introduction
Periorbital hyperpigmentation is a common dermatologic condition that imparts an appearance of fatigue and aging, thereby compromising facial aesthetics. Despite the availability of various therapeutic methods, its treating remains challenging. Both picosecond laser and platelet-rich plasma (PRP) have been demonstrated to improve periorbital hyperpigmentation; however, no study has investigated their combined application, nor has the effect of platelet concentration within PRP on therapeutic outcomes been explored. This study aims to compare the efficacy and safety of PRP injection combined with picosecond laser versus picosecond laser monotherapy in the treatment of periorbital hyperpigmentation, and to evaluate whether varying platelet concentrations in PRP injections influence treatment response.

Materials and Methods
Twenty patients with periorbital hyperpigmentation were randomly assigned to either the experimental group or the control group, receiving three sessions of platelet-rich plasma (PRP) injection combined with picosecond laser therapy or picosecond laser monotherapy, respectively. Within the experimental group, the left and right periorbital regions of each participant were randomly allocated to receive PRP injections with either a high or a low platelet concentration in a split-face design. Grayscale values of the hyperpigmented area, the standard deviation of pixel grayscale values within the region, Visual Analog Scale (VAS) scores, and Sadick tear through rating scale (TTRS) scores were assessed at baseline and four weeks after the final treatment session.

Results
At four weeks after the final treatment session, the experimental group demonstrated significant improvements from baseline in the grayscale values of the periorbital hyperpigmented area, the standard deviation of pixel grayscale values within the region, VAS scores, and TTRS scores. In contrast, the control group exhibited significant improvements only in the grayscale values of the hyperpigmented area and VAS scores. The median (interquartile range [IQR]) VAS scores in the experimental group decreased from 6.5 (6.0, 7.0) at baseline to 4.0 (3.0, 5.0) post-treatment, while those in the control group changed from 7.0 (5.0, 8.0) to 5.5 (3.0, 8.0). The median (IQR) grayscale values of the periorbital hyperpigmented area in the experimental group increased from 29 (24, 47) to 37 (32, 55), whereas those in the control group increased from 40 (24, 51) to 42 (28, 54). These results indicate a more favorable overall improvement in the experimental group. In the comparison between high-concentration and low-concentration PRP injections, a significant difference was observed solely in VAS scores: the median (IQR) VAS score in the high-concentration subgroup changed from 6.5 (6.0, 8.0) at baseline to 4.0 (4.0, 5.0) post-treatment, while that in the low-concentration subgroup changed from 6.0 (6.0, 7.0) to 4.0 (4.0, 5.0), suggesting superior efficacy of high-concentration PRP relative to low-concentration PRP.

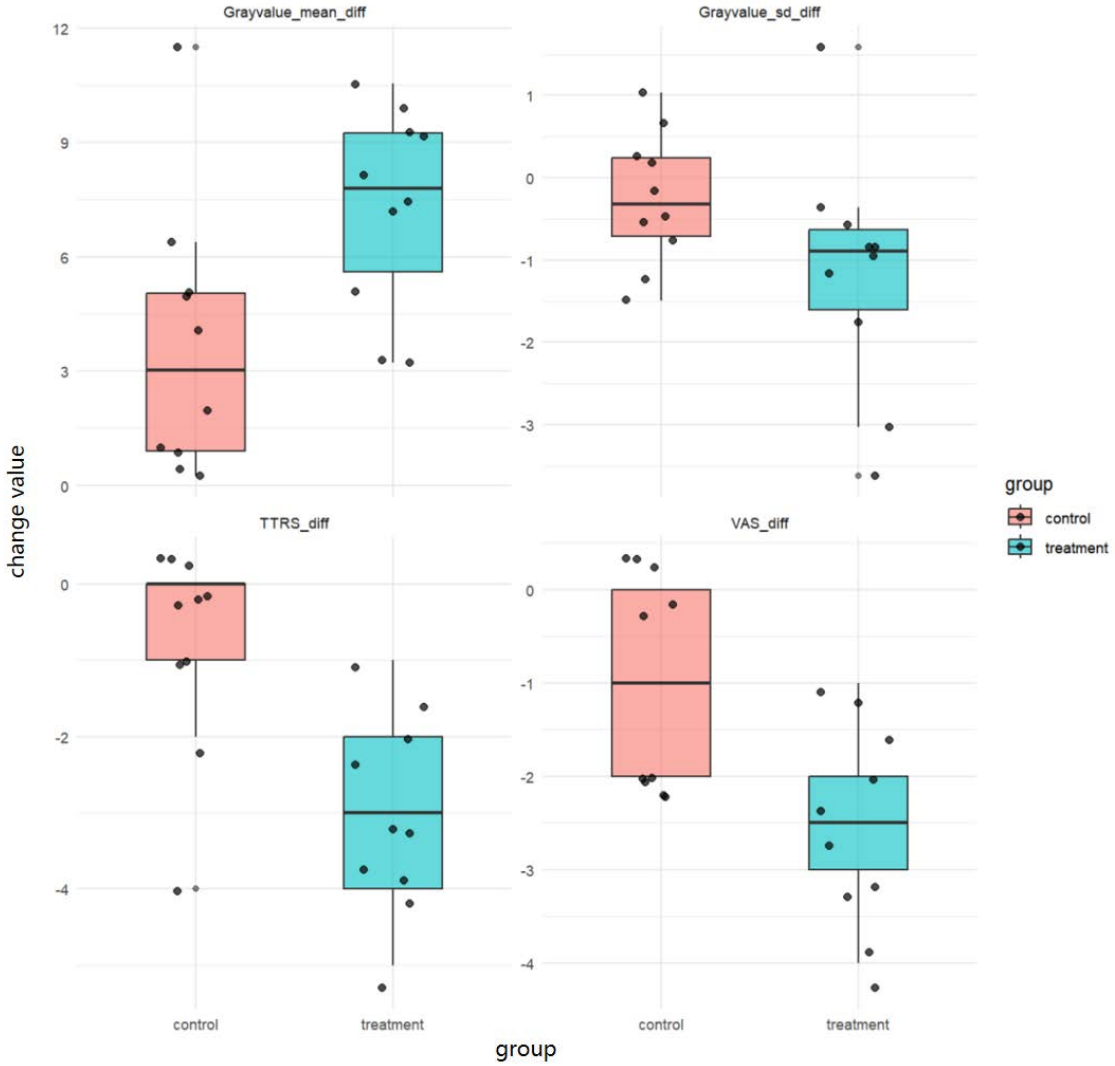

Post- to Pre-Treatment Changes in Outcomes: Experimental vs. Control Group

Conclusions

Platelet-rich plasma (PRP) injection combined with picosecond laser therapy is more effective than picosecond laser monotherapy in improving periorbital hyperpigmentation and significantly reduces the severity of tear trough deformity as well as the unevenness of pigment distribution. Furthermore, within a certain range of platelet concentrations, high-concentration PRP injection yields superior therapeutic efficacy compared to low-concentration PRP. This combined approach provides a novel therapeutic option for the clinical management of periorbital hyperpigmentation.

EA DV CONGRESS
VIENNA
30 SEP - 3 OCT 2026

Abstract N°: 1405

Targeting fundamental hallmarks of skin ageing: a multimodal approach with Proxylane, Ginkgo Biloba leaf extract and Niacinamide to restore aged-induced tissular alterations

Franck Juchaux[1], Ségolène de Menthiere[1], Jean-Thierry Simmonet[1], Natalia Kovylkina*[2], Lucie Guerin[1], Frederique Labatut[1]

[1] L'Oreal R&I, Chevilly-Larue, France

[2] Vichy Laboratoires, Levallois-Perret, France

Introduction

During ageing, the skin undergoes profound changes linked to a progressive decline of numerous biological processesalso called ageing hallmarks. Unlike the classical anti-ageing strategy which treats symptoms, the longevity strategy consists of treating root causes of ageing by targeting the hallmarks at a cellular level. However, to reset the ageing process in mature skin, acting on a single hallmark is insufficient. Therefore, a specific combination of active ingredients, referred to as Proxylane (PX, hydroxypropyl tetrahydropyrantriol), Niacinamide (B3), and a *Ginkgo biloba* leaf extract (GBL), was designed to target five essential hallmarks: cellular senescence, micro-inflammation, mitochondrial dysfunction, extracellular matrix changes and loss of proteostasis. This study assessed the interest to target several hallmarks and the efficacy of this triple combination (TC) in a longevity approach by measuring *in vitro* its capacity to reverse the aged skin phenotype.

Materials and Methods

Skin equivalents were reconstructed *in vitro* using cells from an aged donor. Skin models reconstructed with cells from a young donor served as control. Aged skin models were individually treated with TC for 28 days. Histological and immunohistochemical analyses measured epidermal thickness as well as the markers expression for senescence ($P16^{INK4A}$), autophagy (LC3B), DEJ (Collagen VII and Perlecan), and major structural proteins of skin (Collagen I, Elastin & Fibrillin). All conditions were performed in triplicate (n=3).

Results

Following treatment with TC, the aged skin phenotype showed similar characteristics than the control skin. Epidermal thickness significantly (+31.5%±7, $p<0.01$) increased and $P16^{INK4A}$-positive senescent cells were almost entirely eliminated (-96%±0.4, $p<0.001$) while the expression of autophagy marker LC3B was increased (+116%±16, $p<0,05$). The expression of the 2DEJ markers, Collagen VII and Perlecan, was significantly improved (+186%±20, $p<0.0001$ and +28%±5, $p<0.001$, respectively). Furthermore, the expression of the key structural proteins, Collagen I, Elastin, and Fibrillin was significantly enhanced (+19.6%± 3, $p<0.0001$; +60%± 4, $p<0.001$; and +24%±4, $p<0.001$, respectively).

Conclusions

The assay confirms the efficacy of the novel TC in a longevity approach. By targeting different ageing hallmarks, epidermal renewal was improved, senescent cells were eliminated, and cells regained their ability to manage proteostasis and to produce essential proteins within the dermal-epidermal junction and dermal extracellular

matrix.

EA DV CONGRESS
VIENNA
30 SEP - 3 OCT 2026

Abstract N°: 1407

Co-bonding technology: a benchmark for anti-ageing efficacy in epidermal and dermal rejuvenation

Franck Juchaux[1], Claire DELOCHE[2], Corinne Chagnoleau[2], Natalia Kovylkina*[2], Lucie Guerin[1], CABERLOTTO ELISA[2]

[1] L'Oreal R&I, Chevilly-Larue, France

[2] Vichy Laboratoires, Levallois-Perret, France

Introduction

Skin ageing is a complex biological process characterized by significant morphological alterations, including atrophy across all its compartments. These modifications are closely linked to the deterioration of various hallmarks of ageing, notably impacting the dermal extracellular matrix (ECM) and, more specifically, the integrity and functionality of collagen fibres. Previous research demonstrated that a unique combination of *Grifola frondosa* fruiting body extract (MTK), Rhamnose (RHA), and peptides (Palmitoyl Tripeptide-1 and Palmitoyl Tetrapeptide-7, M3K), leveraging a patented co-ponding technology, can effectively target different collagen families, leading to a notable improvement in 16 visible signs of ageing.
BAsed onthese findings, the present study aims to further evaluate the efficacy of this innovative combination by comparing its performance against well-established dermatological actives, namely retinol, retinoic acid, and vitamin C. To achieve this, an *in vitro* study was conducted using aged-reconstructed skin models, allowing for a comprehensive assessment of each treatment's ability to reverse the aged skin phenotype.

Materials and Methods

Skin equivalents were reconstructed *in vitro* using cells from an aged donor. Skin models reconstructed with cells from a young donor served as control. Aged skin models were individually treated with the actives for 28 days. Histological and immunohistochemical analyses measured epidermal thickness as well as the markers expression for Epidermal quality (Desmoglein 1), DEJ (Collagen IV), and major structural proteins of skin (Collagen I, V and VI). All conditions were performed in triplicate (n=3). The data were double-normalized by taking into account both the basal expression level in untreated aged skin and the expression level of untreated young skin, which represents 100% efficacy. The results were then distributed on a 6-point scoring scale from 0 to 5.

Results

The co-bonding technology demonstrated significant effects, leading to an increase in epidermal thickness, increase of epidermal cohesion and Hyaluronic acid, strengthening of the Dermo-Epidermal Junction (DEJ), and enhanced expression of dermal collagens. Globally, the effect of the co-bonding technology on epidermis (score 3.7) was on par with that of Retinol (score 3.9) but higher than that of retinoic acid (score 2.7) and vitamin C (score 2.8). Regarding the DEJ, the co-bonding effect (score 3.1) was slightly less pronounced than that of retinol (score 4.0) but on par with retinoic acid (score 3.5) and higher than that of vitamin C (score 2.7). At the dermal level, the co-bonding technology showed the best efficacy (score 4.2) compared to Retinol, Retinoic acid and vitamin C (scores 3.4, 3.1 and 2.8 respectively).

Conclusions

This study demonstrated the potent anti-ageing efficacy of the co-bonding technology. Comparative analysis revealed its performance to be on par with, and in some aspect's superior to, established derma-actives like Retinol, Retinoic Acid, and Vitamin C. These findings underscore co-bonding technology as a promising and well-tolerated novel solution for combating skin aging, warranting further *in vivo.* investigation.

EA DV CONGRESS
VIENNA
30 SEP - 3 OCT 2026

Abstract N°: 1436

Application of Combined Skin Imaging and Non-Invasive Detection in the Evaluation of Skin Rejuvenation Treatments

Xiang Wen*[1], Hua Dong[1]

[1] West China Hospital, Sichuan University, Sichuan, China

Introduction

Currently, the efficacy evaluation of skin rejuvenation treatment mainly relies on subjective scoring systems, lacking objective and reproducible quantitative indicators. The combination of skin imaging technology and non-invasive detection methods can provide quantitative evidence for therapeutic effect evaluation. This study aimed to explore the evaluation value of two-photon microscopy and high-frequency skin ultrasound in monopolar radiofrequency (RF) for facial rejuvenation.

Materials and Methods

A total of 22 subjects with facial wrinkles were enrolled, aged 30 to 50 years (inclusive), regardless of gender, and with scores ranging from 3 to 5 on the Fitzpatrick Wrinkle Classification Scale (FWCS). All subjects received one session of monopolar RF facial treatment. Assessments were performed at five time points: pre-treatment, immediately post-treatment, 1 month post-treatment, 3 months post-treatment, and 6 months post-treatment.

- **High-frequency ultrasound (Model A20, Mindray Medical)**: Detected at three standardized sites (see Figure 1) to evaluate changes in skin thickness (epidermis and dermis), skin elasticity, and skin viscosity.
- **Two-photon microscopy**: Employed to observe structural changes in skin fibrous tissue, measure epidermal thickness, and calculate the following parameters: autofluorescence (AF) intensity, second harmonic generation (SHG) intensity, dermal aging index [second harmonic generation to autofluorescence aging index of dermis (SAAID)], and the relative quantity ratio of elastic fibers to collagen fibers [elastin to collagen ratio (ELCOR)].

Figure 1 : Schematic diagram of measurement sites for ultrasound and two-photon microscopy

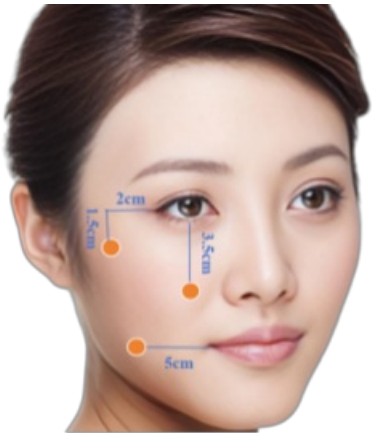

Figure 1 : Schematic diagram of measurement sites for ultrasound and two-photon microscopy

Results

1. **High-frequency ultrasound results**: Ultrasound results showed that at all detection sites, there were no significant differences in total skin thickness (epidermis + dermis), subcutaneous fat layer thickness, skin viscosity and subcutaneous fat layer viscosity immediately after treatment, at 1 month and 3 months post-treatment compared with baseline. The skin elasticity at Site 1 was significantly improved at 3 months after treatment; at Site 3, the elasticity of the subcutaneous fat layer, superficial fascia elasticity and superficial fascia viscosity increased notably at 3 months post-treatment.
2. **Two-photon microscopy results**: Two-photon microscopic observation revealed no significant changes in epidermal cell morphology after treatment. The morphology of elastic fibers and collagen fibers remained unchanged at 1 and 3 months post-treatment. The stratum corneum thickness decreased immediately after treatment. No significant differences in dermal epidermal junction index (DEJI) and epidermal thickness were observed at 3 months post-treatment. The signal intensities of two-photon excited fluorescence (TPEF) and SHG decreased immediately after operation. SHG intensity was lower than baseline at immediate, 1-month and 3-month follow-ups. At 3 months post-treatment, ELCOR was elevated while SAAID decreased compared with baseline. New TPEF signals were detected in some subjects at 3 months after treatment, which were speculated to be inflammatory cells or elastic fiber aggregates.

Conclusions

Skin ultrasound and two-photon microscopy present favorable feasibility in evaluating the efficacy of facial rejuvenation, with good consistency in epidermal examination. However, limited by the detection depth of two-photon microscopy (approximately 0.2 mm, only reaching the superficial dermis), it cannot effectively capture signals from the deep dermis and deeper fascial tissues, resulting in compromised overall detection performance. Further studies with enlarged sample size are required to fully verify its clinical evaluation value.

EADV CONGRESS
VIENNA
30 SEP - 3 OCT 2026

Abstract N°: 1477

Dermal Biostimulation Preceding Fractional Microneedling Radiofrequency for Atrophic Acne Scars: A Phased Multimodal Approach

Marcele Trindade[1], Leticia Azevedo[1], Emilia Ulerio[1], Bianca Fuser[1], Eduarda Gregório Arnaut Lima*[1]

[1] Policlínica Geral do Rio de Janeiro, Rio de Janeiro, Brazil

Introduction

Atrophic acne scars, remain a therapeutic challenge due to dermal collagen loss and limited spontaneous improvement. Available treatment modalities, including injectable biostimulators and energy-based devices, target different aspects of scar remodeling; however, the optimal sequencing of these approaches remains uncertain. Injectable poly-L-lactic acid (PLLA) and hyaluronic acid skin boosters may enhance dermal support prior to fractional microneedling radiofrequency (FMR) remodelling. The FMR acts by promoting neocollagenesis and dermal remodeling through controlled thermal injury. This case aimed to evaluate the clinical outcome of a phased multimodal approach combining injectable dermal biostimulation as a preparatory dermal conditioning step, followed by sequential FMR sessions in a patient with atrophic acne scars, evaluated using standardised clinical assessment tools.

Case Presentation

A 41-year-old patient presented with multiple punctate and boxcar-type post-acne scars on the malar and mandibular regions. A phased treatment regimen was initiated with injectable poly-L-lactic acid and a hyaluronic acid-based skin booster administered to the affected areas. One month later, the first of three FMR sessions was performed at a depth of 1.5 mm, followed by two additional sessions at one-month intervals. Clinical response was monitored using standardised photography, the Global Aesthetic Improvement Scale (GAIS), independently rated by two blinded dermatologists, and patient satisfaction assessed on a five-point Likert scale. One month after the injectable phase, softening of boxcar scars and mild volume improvement were observed, with GAIS rated as “improved” and patient satisfaction of 4/5. Progressive dermal remodeling and scar depth reduction were noted after the FMR sessions, reaching “very much improved” on GAIS at the final assessment, one month after the third session. Patient satisfaction improved to 5/5. No adverse effects beyond mild transient erythema and edema were reported.

Conclusion

This case demonstrated progressive clinical improvement in atrophic acne scars following a phased multimodal approach combining injectable dermal biostimulation followed by sequential FMR sessions. The sequential use of these modalities may offer complementary benefit by enhancing collagen and hydration scaffold before energy-based remodeling caused by the induced thermal injury. Clinical improvement was observed throughout treatment, with favorable tolerability and sustained results at five months. Further prospective studies are warranted to establish optimal interval duration and outcomes across diverse scar morphologies.

EA DV CONGRESS
VIENNA
30 SEP - 3 OCT 2026

Abstract N°: 1483

Ultrasound-Guided Procedures in Aesthetic Medicine: A Comprehensive Review of Vascular Mapping, Complication Management, and the Future of Precision Injections

Ekaterine Abashidze*[1], Sasha Jreije[2], Wele Parpelage Maleesha Sewmini[3], Maria Naaman[2], Christie Saad[2], Nicolas El Khoury[4], Nancy Emmanuel[5]

[1] Medical University of Łódź, Łódź, Poland

[2] University of Balamand, Beirut, Lebanon

[3] Tbilisi State Medical University, Faculty of Medicine, Tbilisi, Georgia

[4] Saint George University of Beirut, Beirut, Lebanon

[5] Department of Dermatology, Hospital das Clínicas da Faculdade de Medicina da Universidade de São Paulo, São Paulo, Brazil

Introduction

The global demand for minimally invasive aesthetic procedures has resulted in a significant increase in the administration of soft tissue fillers. While these treatments are generally considered safe, the absolute number of complications has risen, including catastrophic vascular adverse events such as skin necrosis and blindness. Traditionally, injections have been performed "blind," relying on surface landmarks and tactile feedback; however, significant individual anatomical variations in facial vasculature render this approach inherently risky. High-frequency ultrasound (US) has emerged as a transformative tool in dermatology, shifting the clinical paradigm from static anatomical assumptions to real-time, dynamic visualization of cutaneous and subcutaneous structures. This review evaluates the use of high-frequency ultrasound in enhancing procedural safety in aesthetic dermatology.

Materials and Methods

A systematic search was conducted using the query: ("ultrasound" OR "ultrasonography" OR "high-frequency ultrasound" OR "doppler ultrasound" OR "ultrasound-guided") AND ("dermal fillers" OR "soft tissue fillers" OR "facial fillers" OR "hyaluronic acid filler" OR "calcium hydroxylapatite" OR "poly-L-lactic acid" OR "cosmetic filler"). The review covered the date range 2010–2026 across PubMed (272 articles), Embase (411), and Web of Science (386), totaling 1,069 articles. Articles were uploaded to Rayyan for deduplication and selection. Screening was performed by two independent reviewers, with a third reviewer resolving conflicts. A final selection of 27 articles was chosen for this comprehensive review.

Results

Synthesized evidence identifies high-frequency ultrasound (US) as the imaging modality of choice for optimizing aesthetic safety and precision. By utilizing color Doppler, practitioners can perform pre-procedural vascular mapping to visualize the precise plane and course of major facial arteries, such as the angular and labial vessels, thereby mitigating the risk of intravascular emboli or extravascular compression in areas of unpredictable anatomical branching. Beyond vascular assessment, US serves to identify pre-existing materials. While hyaluronic acid appears as anechoic or hypoechoic deposits for example, calcium hydroxylapatite is characterized by hyperechoic deposits with posterior acoustic shadowing, and biostimulators like poly-L-lactic acid exhibit ill-

defined hypoechoic bands. This diagnostic capacity extends to detecting filler migration and evaluating tissue integration. In the management of adverse events, US-guided hyaluronidase delivery has emerged as the gold standard for reversing hyaluronic acid complications. This targeted approach facilitates rapid restoration of perfusion with significantly lower dosages (35–50 units) compared to high-dose blinded protocols. Furthermore, US distinguishes between inflammatory and non-inflammatory etiologies in late-onset nodules, often identifying misplaced material within the superficial musculoaponeurotic system (SMAS). The transition from diagnostic to interventional US additionally enables real-time visualization during high-risk procedures, such as non-surgical rhinoplasty, where simultaneous visualization of the cannula and dorsal nasal vessels minimizes ischemic risk. Moreover, US-guided structural augmentation of deep landmarks, including the pyriform space and anterior nasal spine, achieves superior aesthetic outcomes with minimal filler volumes. Consequently, the integration of high-frequency US represents a fundamental shift toward a new standard of care in aesthetic dermatology.

Conclusions

Advanced safety protocols now incorporate a three-step method: pre-procedural mapping, real-time guided delivery, and post-injection perfusion assessment to verify vascular patency. As the field evolves, ultrasound will become an essential diagnostic and interventional tool, ensuring patient safety and providing legal protection for medical professionals in the era of precision medicine.

EADV CONGRESS
VIENNA
30 SEP - 3 OCT 2026

Abstract N°: 1488

Beauty Centre Laser Resurfacing: When Rejuvenation Becomes Dermatological Harm

Ece Erbağcı*[1]

[1] Department of Dermatology and Venereology, Faculty of Medicine, Uşak University, Uşak, Türkiye, Uşak, Türkiye

Introduction

Energy-based cosmetic procedures are increasingly sought by patients with chronic dermatological diseases, sometimes outside medical supervision. Such interventions may cause severe adverse events and may also interfere with ongoing dermatological treatment. We report a case of severe infectious ulceration and permanent scarring after ablative facial laser resurfacing performed in a non-medical aesthetic setting in a patient receiving narrow-band ultraviolet B phototherapy for vitiligo.

Case Presentation

A 60-year-old woman followed for vitiligo was receiving narrow-band ultraviolet B phototherapy. During treatment, she underwent an ablative laser procedure on the forehead for rejuvenation at a beauty centre by non-medical personnel. The exact device and treatment parameters were not available, although the clinical history suggested carbon dioxide laser resurfacing. Shortly after the procedure, she developed painful ulcerated plaques with yellowish exudate and focal haemorrhagic crusts, sharply confined to the treated forehead area. Bacterial culture from the lesions yielded *Klebsiella pneumoniae*. Phototherapy to the face was discontinued, and subsequent sessions were continued with facial shielding. She was treated with oral amoxicillin/clavulanic acid twice daily and topical mupirocin for three weeks. The lesions healed with sharply demarcated, atrophic, deep scarring corresponding to the borders of the laser-treated area.

Conclusion

This case highlights a severe and preventable complication of laser resurfacing performed outside medical supervision. In addition to permanent aesthetic sequelae, the complication disrupted ongoing vitiligo treatment, as facial phototherapy could not be continued because of the risk of post-inflammatory dyspigmentation and further injury. Patients with chronic skin diseases may seek cosmetic procedures from non-physician providers even while under dermatological care. Dermatologists should proactively counsel patients about the risks of energy-based procedures, the importance of medically qualified operators, and the need to coordinate cosmetic interventions with ongoing treatment. This case also underscores the potential for permanent scarring, treatment interruption, and medicolegal consequences following inadequately supervised cosmetic procedures.

EA DV CONGRESS
VIENNA
30 SEP - 3 OCT 2026

Abstract N°: 1491

Is Facial Pain Lateralized? A Pragmatic Cohort Study of Side-Specific Pain Perception in Aesthetic Procedures

Abdullah Almeziny*[1]

[1] College of Medicine, Imam Mohammad Ibn Saud Islamic University, Riyadh, Saudi Arabia, Riyadah, Saudi Arabia

Introduction
Minimally invasive facial aesthetic procedures, including botulinum toxin and soft tissue fillers, are widely performed globally. Pain perception is a key determinant of patient satisfaction. Emerging evidence from neuroscience suggests lateralized pain perception, with increased sensitivity on the left side in right-handed individuals. While such differences have been reported in dentistry and ophthalmology, data on side-specific pain perception in aesthetic procedures remain limited and inconclusive.

Materials and Methods
A pragmatic cross-sectional cohort study was conducted including 326 patients undergoing bilateral facial aesthetic procedures. Eligible participants were adults receiving symmetrical treatment in comparable facial regions. Exclusion criteria included unilateral procedures, recent systemic analgesic use, and active inflammatory skin conditions.

Procedures included botulinum toxin, soft tissue fillers, combination treatments, energy-based devices, and regenerative therapies. Treatment side order was randomized. Pain was assessed using a visual analogue scale (VAS, 0–10) within 5 minutes post-procedure for each side separately.

Demographic, clinical, and procedural variables were collected, including age, sex, patient and clinician handedness, side treated first, prior procedures, prior surgeries, and menstrual status. Paired comparisons were performed using the Wilcoxon signed-rank test.

Results
The cohort was predominantly female (97.5%) and right-handed (93.6%). The most common procedures were botulinum toxin (43.3%) and fillers (25.5%).

Overall, **no clinically meaningful side-to-side difference in pain perception was observed**, with a mean difference of **0.22 on the VAS scale**, which was considered negligible. Median differences were zero across all subgroups, indicating no consistent lateralization effect.

Subgroup analysis identified statistically significant differences in right-handed patients (p=0.035) and patients with prior surgery (p=0.041). However, these differences remained **clinically negligible**, with minimal absolute change in pain scores.

No significant associations were observed with clinician handedness, procedure type, treatment order, or menstrual status. Across all procedures and patient groups, pain perception remained symmetrical.

Conclusions

Pain perception during aesthetic facial procedures appears **clinically symmetrical**, with no meaningful evidence of lateralized pain differences. Although minor statistical variations were observed in specific subgroups, these findings lack clinical relevance.

These results challenge assumptions derived from neurobiological models of pain lateralization and support a **uniform approach to procedural planning and patient counseling**. Future research should explore neurobiological mechanisms in controlled settings and assess whether specific procedures or patient populations demonstrate true lateralized pain responses.

EADV CONGRESS
VIENNA
30 SEP - 3 OCT 2026

Abstract N°: 1501

Picosecond Laser–Induced Skin Rejuvenation and Depigmentation: Integrated Immune and Structural Responses in a Porcine Model

Xinyi Li[1], Hao Wang[1], Xiang Weng*[1]

[1] Department of Dermatology, West China Hospital, Sichuan University, Chengdu, China

Introduction
Picosecond lasers are widely used for skin rejuvenation and hyperpigmentation, yet the biological basis of their clinical effects remains incompletely understood. This study aimed to characterize the inflammatory and immune responses, structural remodeling, and pigmentary changes following picosecond laser treatment.

Materials and Methods
Dual-wavelength picosecond laser irradiation (532/1064 nm) was applied to pigmented and non-pigmented skin in Bama miniature pigs. For rejuvenation, 1064 nm irradiation (6–10 mm, 0.2–1.4 J/cm^2) was used. For pigmentation treatment, 532 nm (3–4 mm, 0.4–1.0 J/cm^2) and 1064 nm (2–4 mm, 1.2–3.0 J/cm^2) were applied. Skin samples were collected immediately after treatment and at Days 3, 7, 14, and 30 post-irradiation. Hematoxylin–eosin staining was used to assess overall morphological changes. Multiplex immunohistochemistry was performed to evaluate macrophage subsets, cytokines, growth factors, barrier proteins, and melanocytic markers. Dermal matrix changes were assessed by Victoria blue staining, Picrosirius red staining, and three-dimensional collagen imaging. Transmission electron microscopy was used to examine melanosome ultrastructure. Fontana–Masson staining combined with CD163 immunofluorescence was used to evaluate macrophage-associated pigment removal, while tyrosinase was assessed by immunohistochemistry and Western blotting.

Results
An early but self-limited inflammatory response was observed after picosecond laser treatment, marked by increased IL-1β, IL-6, and TNF-α and enrichment of M1-like macrophages. As this response subsided, M2-like macrophages became predominant, together with a reparative microenvironment and increased expression of FGF2, TGF-β1, and GDF11. Over time, the skin showed progressive structural remodeling, including greater dermal thickness, increased elastic fiber content, and collagen reorganization, accompanied by a higher collagen I/III ratio and increased collagen fiber diameter. Filaggrin and claudins were also upregulated. For pigmentation, laser treatment induced melanosome disruption and a progressive reduction in epidermal melanin, which was greater after 532 nm treatment than after 1064 nm treatment. Melanin debris was found within dermal CD163$^+$ macrophages, supporting macrophage-associated pigment removal. Melanocytic markers were reduced, and tyrosinase expression remained suppressed.

Conclusions
Picosecond laser treatment induces coordinated immune and structural responses that contribute to skin rejuvenation and pigment clearance. A transient inflammatory phase is followed by a reparative macrophage response, associated with extracellular matrix remodeling, dermal thickening, and barrier improvement.

Depigmentation is associated with melanosome disruption, macrophage-associated pigment removal, and persistent suppression of melanogenesis. These findings provide mechanistic support for the clinical use of picosecond lasers in both rejuvenation and hyperpigmentation.

EA DV CONGRESS
VIENNA
30 SEP - 3 OCT 2026

Abstract N°: 1504

Traumatic Facial Asphalt Tattoo: Pigment Resolution with Sequential Q-switched Nd:YAG, Fractional CO_2 Laser, and Autologous Fat Grafting

Eduarda Gregório Arnaut Lima*[1], Eduardo Lima[1]

[1] Clínica Plenna Florianópolis, Universidade Federal de Santa Catarina, Florianópolis, Brazil

Introduction

Traumatic asphalt tattoos result from road accidents in which asphalt debris becomes forcibly embedded in the dermis, leading to persistent deep-dermal pigmentation, fibrosis, soft-tissue volume loss, and significant psychosocial impact. Conventional approaches, including dermabrasion, surgical excision, and cryosurgery, carry substantial risks of scarring and incomplete pigment clearance. While Q-switched neodymium-doped yttrium aluminium garnet (Nd:YAG) laser is recognised as a selective photothermolytic option for traumatic tattoos, structured multimodal protocols integrating sequential ablative and non-ablative laser modalities with interval modulation and reconstructive soft-tissue techniques remain poorly characterised in the literature. This case aims to describe the outcome of a stepwise dual-laser approach combined with autologous fat grafting, including detailed procedural documentation for the management of a complex deep-dermal traumatic tattoo.

Case Presentation

A 30-year-old woman presented 18 months following a motor vehicle accident with an extensive atrophic, sclerotic, dyschromic plaque with embedded asphalt particles and hyperpigmentation involving the temporal, zygomatic, and preauricular regions of the right hemiface, causing significant psychological distress. A twelve-session laser protocol was implemented (Table 1). Sessions one through four employed Q-switched Nd:YAG laser (1064 nm; 4–5 ns pulse duration; 10 Hz), initiating at a 6 mm spot size with 3 J/cm^2 fluence, with progressive escalation to a 4 mm spot size and 12 J/cm^2, targeting superficial pigment deposits. Fractional CO_2 laser (10,600 nm; 20 W; 600 µm spacing; 1600 µs pulse duration) was introduced in sessions five, six, seven, nine, and twelve to promote collagen remodelling, reduce fibrosis, and facilitate release of residual particles. Sessions eight, ten, and eleven returned to Q-switched Nd:YAG at a 3 mm spot size and 23 J/cm^2 fluence to address deeper dermal deposits. Sessions one to four were spaced at two-month intervals; subsequent sessions were extended to six-month intervals to minimise the risk of post-inflammatory hypopigmentation. At treatment completion, standardised photography documented complete pigment clearance and marked improvement in skin texture, with no treatment-induced adverse effects, scarring, or dyspigmentation. To address residual facial volume loss and contour asymmetry, autologous fat grafting was subsequently performed, with 110 mL of adipose tissue harvested via a 4 mm cannula, processed by decantation, and injected using 2.5 mm cannulas into the lateral right hemiface, with stable results at six months.

Laser treatment sessions

Session	Laser	Wavelength (nm)	Spot size(mm) / Spacing (µm)	Fluence (J/cm2) / Power (W)	Frequency (Hz) / Time (µs)
1	Q-switched Nd:YAG	1064 nm	6 mm	3 J/cm2	10 Hz
2	Q-switched Nd:YAG	1064 nm	6 mm	6 J/cm2	10 Hz
3	Q-switched Nd:YAG	1064 nm	4 mm	8 J/cm2	10 Hz
4	Q-switched Nd:YAG	1064 nm	4 mm	12 J/cm2	10 Hz
5	Fractional CO_2	10600 nm	600 µm	20 W	1600 µs
6	Fractional CO_2	10600 nm	600 µm	20 W	1600 µs
7	Fractional CO_2	10600 nm	600 µm	20 W	1600 µs
8	Q-switched Nd:YAG	1064 nm	3 mm	23 J/cm2	10 Hz
9	Fractional CO_2	10600 nm	600 µm	20 W	1600 µs
10	Q-switched Nd:YAG	1064 nm	3 mm	23 J/cm2	10 Hz
11	Q-switched Nd:YAG	1064 nm	3 mm	23 J/cm2	10 Hz
12	Fractional CO_2	10600 nm	600 µm	20 W	1600 µs

Table 1. Laser treatment sessions detailing modality, wavelength, spot size, spacing, fluence/power, and frequency/pulse duration across twelve sequential sessions. Abbreviations: Nd:YAG = neodymium-doped yttrium aluminium garnet; CO_2 = carbon dioxide; nm = nanometres; mm = millimetres; µm = micrometres; J/cm^2 = joules per square centimetre; W = watts; Hz = hertz; µs = microseconds; ns = nanoseconds.

Conclusion

This case illustrates the clinical outcome and tolerability of a scar-sparing, stepwise multimodal strategy, integrating sequential Q-switched Nd:YAG and fractional CO_2 lasers with staged treatment intervals and autologous fat grafting, for pigment clearance and aesthetic improvement of a severe deep-dermal traumatic facial asphalt tattoo. Progressive fluence escalation combined with strategic reduction in spot size allowed targeted treatment of superficial and deeper pigment deposits, while extended inter-session spacing in later stages was used to minimise the risk of post-inflammatory hypopigmentation. The adjunctive role of autologous fat grafting addressed volume loss and contour asymmetry, with possible additional regenerative effects. This integrated approach may represent a useful multimodal option for the treatment of complex traumatic tattoos and warrants prospective evaluation across varied tattoo depths, compositions, and skin phototypes.

EA DV CONGRESS
VIENNA
30 SEP - 3 OCT 2026

Abstract N°: 1534

Cutaneous sarcoidosis mimicking a reaction to fillers

Polina Ptashnikova*[1], Irina Smirnova[1], Evgenia Kulikova[1], Valeria Vasilieva[1], Tatiana Shmidt[1]

[1] Federal State Budgetary Educational Institution of Higher Professional Education “St. Petersburg State University”, St. Petersburg, Russian Federation, St. Petersburg, Russian Federation

Introduction

Cutaneous sarcoidosis holds a significant position among dermatoses affecting cosmetically sensitive areas, for which patients may seek consultation from a dermatologist or aesthetic practitioner. In certain instances, this condition can mimic a granulomatous reaction to filler injections (Frank K, et al., 2026).

Case Presentation

A 53-year-old female patient presented in March 2025 with significant malar edema and lesions in the cervical region. Upon dermatological examination, the cutaneous process was widespread, mimicking the clinical distribution of a granulomatous reaction to filler injections or poly-L-lactic acid (PLLA) in the upper face and neck. The facial lesions were symmetric, located in the malar region, and presented as palpable, deep-seated, mobile, and painless violaceous nodules with overlying telangiectasias. The neck involvement featured a linear arrangement of firm, mobile, painless nodules (approximately 1 cm in diameter), mimicking the correction of neck creases.

The patient categorically denied any history of filler injections. A skin biopsy was performed. Histopathological examination revealed an intact epidermis and multiple non-caseating epithelioid granulomas located in the deep dermis and subcutaneous tissue (Fig.1 a, b). The cellular composition of the granulomas included Langhans giant cells and histiocytes with sparse lymphocytic infiltration (Fig. 1 c), consistent with a diagnosis of cutaneous sarcoidosis. The patient was referred to a pulmonologist, chest CT was performed to rule out systemic involvement, revealing no pulmonary pathology or mediastinal lymphadenopathy. Following treatment with prednisolone (0.5 mg/kg), the lesions began to regress and reached near-complete resolution after three months.

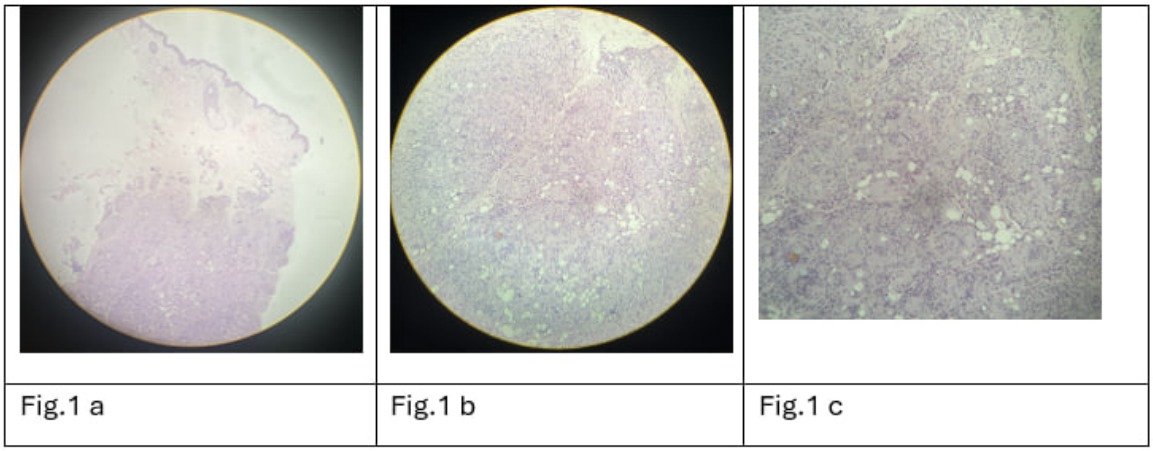

Fig.1 a	Fig.1 b	Fig.1 c

Histopathological examination, H&E.

Conclusion

Patients presenting with dermatoses in cosmetically sensitive areas may seek consultation from a wide range of specialists. Cutaneous sarcoidosis is a condition that necessitates a multidisciplinary approach and comprehensive diagnostics. Accurate diagnosis relies on identifying characteristic clinical and histopathological features, alongside imaging studies to evaluate for potential target organ involvement.

EADV CONGRESS
VIENNA
30 SEP - 3 OCT 2026

Abstract N°: 1601

Efficacy and Safety of OnabotulinumtoxinA for the Masseter Muscle: A Meta-analysis of Aesthetic and Functional Studies

Sema Okur*[1], Suat Morkuzu[1], Mehmet Aslan[2], Elif Ibis[3], Afshin Mosahebi[4]

[1] Istanbul University, Istanbul, Türkiye

[2] NHS, Istanbul, France

[3] Istanbul University-Cerrahpasa, Istanbul, Türkiye

[4] Royal Free Hospitals University College London, London, United Kingdom

Introduction

OnabotulinumtoxinA injection of the masseter is performed for both aesthetic indications (masseter muscle prominence; MMP) and functional indications (bruxism, sleep bruxism, masticatory muscle disorder), yet pooled efficacy and safety estimates from contemporary placebo-controlled randomized trials have not previously been reported.

Materials and Methods

Following PRISMA 2020 guideline, two reviewers independently searched PubMed/MEDLINE, Embase, and the Cochrane Central Register of Controlled Trials for double- or triple-blind randomized controlled trials of botulinum neurotoxin type A injection of the masseter in adults. Only original primary research was eligible; narrative and systematic reviews were excluded. Risk of bias was appraised with Cochrane RoB 2.

Results

Eleven primary randomized trials were included (1,030 adults; 8 aesthetic, 3 functional). Two pivotal aesthetic trials provided per-arm event data for quantitative pooling. In a Phase 2b trial (n=145), MMPS Grade ≤3 at Day 90 was achieved by 90.6% (48 U; 48/53), 91.3% (72 U; 42/46), and 21.7% (placebo; 10/46). In a Phase 3 multiregional trial (n=376; active 283, placebo 93), 51.2% versus 2.2% achieved ≥2-grade MMPS improvement (145/283 vs 2/93). The pooled odds ratio was 39.5 (95% CI 17.6–88.4), I^2=0%, P-heterogeneity=0.75. Mean lower-facial width fell by −5.24 mm versus −0.04 mm with placebo (P<.0001). Treatment-related adverse events occurred in 12.0% versus 3.2% (mastication disorder 3.5%); no serious treatment-related events were reported. In functional trials, masseter electromyographic amplitude and maximum bite force were significantly reduced by botulinum neurotoxin type A and recovered to baseline by 25–33 weeks.

Conclusions

Across pooled contemporary placebo-controlled randomized trials, onabotulinumtoxinA at a total dose of 72 U (36 U per side) produces a clinically meaningful and statistically robust improvement in masseter muscle prominence, with directionally consistent functional effects (reduced electromyographic activity and bite force) and a favourable, reversible safety profile. Adherence to a defined anatomical safe zone at least 1 cm posterior to the anterior border of the masseter, deep within the muscle belly, and beneath the line connecting the tragus and oral commissure minimises the principal risk of smile asymmetry from risorius diffusion.

EA DV CONGRESS
VIENNA
30 SEP - 3 OCT 2026

Abstract N°: 1638

Risk Stratification Before Energy-Based Device Procedures in Skin of Color: Beyond Fitzpatrick Type Alone

Hafiza Fathan Rasyid*[1]

[1] ONELIFE+ Integrated Health Center, South Jakarta, Indonesia

Introduction

Background:

Energy-based device (EBD) procedures are now widely used in skin of color for pigmentation, acne scarring, textural irregularities, and rejuvenation. Yet clinical risk in this population is often oversimplified through phototype-based categorization alone. While Fitzpatrick classification remains relevant, it does not fully account for the biologic and clinical variables that influence post-procedural inflammation, pigmentary sequelae, barrier recovery, and treatment tolerance. Current literature increasingly supports a more nuanced, patient-centered approach to procedural planning in skin of color.

Objective:

To propose an expanded risk-stratification framework for EBD procedures in skin of color that moves beyond phototype alone and incorporates additional determinants of procedural safety, recovery behavior, and outcome predictability.

Materials and Methods

Relevant literature on EBD applications in skin of color, post-inflammatory hyperpigmentation (PIH), and condition-specific procedural outcomes was reviewed and interpreted through a clinical risk-assessment lens. Particular emphasis was placed on variables that may modify inflammatory intensity, healing behavior, and pigment response before and after treatment.

Results

Reviewed evidence suggests that procedural risk in skin of color is determined by a multidimensional interaction between baseline phototype and other clinically relevant factors, including the treatment indication, degree of active or subclinical inflammation, epidermal barrier status, prior history of pigmentary reactivity, anatomic site, recent procedural exposure, and the magnitude of tissue response induced by the selected modality and settings. This broader framework offers a plausible explanation for why patients with similar phototypes may exhibit markedly different recovery patterns, treatment tolerance, and susceptibility to PIH despite undergoing comparable procedures. These observations support the need to reframe pre-procedural assessment from simple skin typing toward biologically informed risk prediction.

Conclusions

In skin of color, safer and more consistent EBD outcomes are unlikely to be achieved through phototype-based decision-making alone. A multidimensional risk-stratification model that integrates inflammatory state, barrier condition, indication-specific biology, and expected recovery dynamics may improve patient selection, counseling, procedural planning, and complication avoidance. Such an approach may also offer a more clinically meaningful framework for teaching, standardization, and future protocol development in aesthetic and procedural dermatology.

EADV CONGRESS
VIENNA
30 SEP - 3 OCT 2026

Abstract N°: 1689

Laser-induced skin microenvironment remodeling via exosomal CEBPA-mediated crosstalk between keratinocyte and fibroblast

Xiang Weng*[1]

[1] West China Hospital of Sichuan University, Chengdu, China

Introduction

Laser treatments are widely applied in aesthetic and clinical dermatology to promote skin rejuvenation by inducing controlled tissue disruption, activating repair processes involving keratinocyte proliferation, fibroblast migration, and extracellular matrix remodeling. However, the cellular specialization and intercellular communication mechanisms, particularly in the early stages following laser treatment, remain poorly understood.

Materials and Methods

Using single-cell RNA sequencing, we analyzed laser-treated and untreated skin, revealing significant differences in cell populations and functions.Cell-cell communication analysis uncovered a dynamic crosstalk between keratinocytes and fibroblasts.

Results

Keratinocytes and fibroblasts displayed the most prominent shifts in cell number and transcriptional diversity following laser exposure. In early-stage laser-induced skin remodeling, distinct keratinocyte subpopulations actively orchestrated skin repair, immune responses, and regenerative signaling.
Functional validation through co-culture revealed this crosstalk was mediated by exosomes derived from laser-treated keratinocytes, which were enriched with CEBPA. Mechanistically, these exosomes enhanced keratinocyte proliferation through YAP/TAZ activation, while concurrently suppressing fibroblast activity by upregulating IGFBP3 expression during the early phase of laser-induced skin remodeling.

Conclusions

Our findings provide new insights into how laser treatments modulate cellular behavior and intercellular signaling, emphasizing the therapeutic potential of exosome-based strategies for promoting skin regeneration and rejuvenation.

EA DV CONGRESS
VIENNA
30 SEP - 3 OCT 2026

Abstract N°: 1818

Microneedling combined with topical PLLA-HA for Skin Elasticity and Hydration: a Pilot Comparative Study

Victoria Arutinova*[1]

[1] Ilia State University, Total Charm Orbeliani Clinic, Tbilisi, Georgia

Introduction
Skin aging leads to reduced elasticity, hydration, and structural support, resulting in wrinkles and laxity. Microneedling, a minimally invasive technique, creates micro-injuries that trigger wound healing and dermal remodeling. It improves skin texture, fine lines, and overall quality, while also enhancing the transdermal delivery of topical agents. Hyaluronic acid (HA) hydrates the skin, while poly-L-lactic acid (PLLA) stimulates collagen production, promoting long-term skin improvement. Combining microneedling with PLLA+HA leverages these effects, with HA providing immediate hydration and PLLA supporting collagen remodeling. This pilot study evaluates the combined effects of microneedling and PLLA+HA on skin quality, hypothesizing that the combination will outperform microneedling alone in both biophysical and patient-reported outcomes.

Materials and Methods
This prospective pilot study was conducted at the Dermatology Department of Total Charm Orbeliani Clinic (Tbilisi, Georgia) over a 6-month period. Thirty healthy adults aged 22–50 years with low skin elasticity and hydration were enrolled to two treatment arms: microneedling alone or microneedling combined with topical PLLA+HA. Participants underwent 3 treatment sessions at 2-week intervals. Skin hydration, elasticity, and quality were assessed at baseline and at weeks 2, 4, 6, 8, and 12 using Corneometer® for hydration, Cutometer® (R2,R5,R7) for skin elasticity, and LifeViz® Mini Pro 3D imaging for skin quality. Patient-reported outcomes were the FACE-Q™ Satisfaction with Skin and FACE-Q™ Satisfaction with Outcome questionnaires and Global Aesthetic Improvement Scale (GAIS). Statistical analysis included the Mann–Whitney U test and linear mixed-effects models with multiplicity adjustment.

Results
A total of 30 participants were enrolled, with 15 in each treatment group. All participants completed the study through Week 12 with no discontinuations due to adverse events. At baseline, the microneedling-only group had higher elasticity values compared to the microneedling + PLLA+HA group. While the microneedling-only group showed an initial decrease in elasticity followed by gradual recovery, the microneedling + PLLA+HA group exhibited progressive improvements in all parameters, reaching significant changes by Week 12 ($p < 0.001$). The microneedling + PLLA+HA group also showed a significant increase in hydration (33.5%) compared to the microneedling-only group ($p < 0.001$). FACE-Q Satisfaction with Outcome scores improved significantly in the combination group at all timepoints ($p < 0.001$). In terms of GAIS, the microneedling + PLLA+HA group saw up to 100% of patients reporting improvements from Week 6, whereas the microneedling-only group had a higher percentage of patients classified as "unchanged" by Week 12. Significant improvements in wrinkles, pores, skin evenness, and oiliness were observed in the microneedling + PLLA+HA group. Both treatments were well tolerated, with mild transient erythema noted in one case in each group.

Conclusions

The combination of microneedling with topical PLLA+HA resulted in greater and more sustained improvements in skin hydration, elasticity, and overall skin quality compared to microneedling alone. This approach provided faster, more consistent results with longer-lasting improvements, particularly in skin hydration and elasticity. Given the exploratory design and small sample size, these results should be considered preliminary. Further studies with larger populations and extended follow-up are needed to confirm these findings and define the long-term clinical role and safety profile of this combination treatment approach.

EADV CONGRESS
VIENNA
30 SEP - 3 OCT 2026

Abstract N°: 1820

Reprogramming skin sensitivity: combining neurosensory modulation and high-tech systems to improve skin parameters after a single procedure

Karolina Lendzion*[1], Monika Pasikowska-Piwko[1], Agnieszka Pawlak[1], Renata Debowska[1], Katarzyna Rogiewicz[1], Irena Eris[1]

[1] Dr Irena Eris Centre for Science and Research, Piaseczno, Poland

Introduction

Sensitive, vascular, and irritation-prone skin is characterized by increased reactivity to external and internal stimuli, often associated with impaired barrier function and neurosensory dysregulation. There is a constant demand for the development of cosmetic treatments which improve skin condition and, at the same time, are well tolerated by reactive skin prone to redness. Cosmetic procedures which incorporate advanced technologies and active ingredients tailored to skin's needs can improve skin tolerance and reduce visible sensitivity symptoms as fast as after a single procedure.

The aim of this study was to evaluate the efficacy and tolerability of a professional cosmetic treatment dedicated to sensitive, vascular, and dehydrated skin, combining high-tech methods with bioactive formulations targeting neurosensory pathways and skin microbiota balance.

Materials and Methods

The treatment protocol included two alternative high-tech approaches: prebiotic cavitation combined with LED-assisted sonophoresis, or hydrabrasion followed by needleless mesotherapy. Treatment formulations were based on a combination of magnolol and honokiol (a patented synergistic complex acting on TRPV1 channels to reduce skin sensitivity and sensation of discomfort), *Agastache mexicana* extract (targeting the effects of psychological stress on the skin, including inhibition of NF-κB translocation to the cell nucleus), and a microbiota-balancing heptapeptide. Formulas have been enriched with multiple humectants, soothing properties. Lipids used in formulations include argan oil, ceramides and vitamin E- rich soy/sunflower oil complex. Skin parameters, including hydration, sebum levels, and erythema, were assessed instrumentally before and after a single treatment session. Skin sensitivity was evaluated using the SensiScale-10 questionnaire. Additionally, VISIA imaging analysis was performed to assess changes in skin texture, wrinkles, and red areas. Subjective evaluation of treatment satisfaction was also collected.

Results

A significant improvement was observed in skin hydration and lipid levels (+29%, and 15%, respectively), accompanied by a visible reduction in erythema after a single treatment. VISIA analysis demonstrated a decrease in skin unevenness (by 28%), wrinkle count (by 20%), and red areas (by 21%) in all participants. The mean SensiScale-10 score decreased from 25.3 to 7, which confirms that prop in objective sensitivity parameters correlate with subject's sensations. All participants declared willingness to undergo the treatment again, confirming high satisfaction and good tolerability.

Conclusions

The investigated procedure, combining advanced technologies with targeted active ingredients, demonstrated high efficacy in improving skin condition and reducing sensitivity in individuals with sensitive and vascular skin. The observed effects after a single treatment, along with excellent tolerability, support its potential as an effective intervention for demanding skin types.

EADV CONGRESS
VIENNA
30 SEP - 3 OCT 2026

Abstract N°: 1840

Clinical Efficacy of a Compound Chemical Peel Formulation Containing 30% Azelaic Acid and 20% Alpha-hydroxy Acid in the Treatment of Acne Induced Post-Inflammatory Hyperpigmentation

Fengmei He*[1, 2], aili Gao[1], Yumei Liu[1], Huilan Zhu[1], quan chen[1]

[1] Guangzhou Dermatology Hospital, Guangzhou, China
[2] GUANGZHOU MEDICAL UNIVERSITY, Guangzhou, China

Introduction

Post-inflammatory hyperpigmentation is one of the most common sequelae of acne vulgaris, significantly affecting patients' quality of life. Superficial chemical peeling involves the application of a peeling agent to the skin surface, leading to controlled destruction of the epidermis, thereby inducing skin regeneration and remodeling, which produces a therapeutic effect. Azelaic acid inhibits DNA synthesis and reduces tyrosinase activity, and is widely used in the treatment of various hyperpigmentation disorders. Alpha-hydroxy acids promote keratinocyte exfoliation and regeneration while enhancing the penetration of azelaic acid, exerting a synergistic effect that is highly effective in treating deep-seated hyperpigmentation. This study aims to investigate the clinical efficacy and safety of a compound chemical peel containing 30% azelaic acid and 20% alpha-hydroxy acid in the treatment of acne-induced post-inflammatory hyperpigmentation (PIH).

Materials and Methods

Twenty-five subjects with acne induced PIH received procedure with compound chemical peel containing azelaic acid and alpha-hydroxy acid at two-week intervals, for a total of two treatment sessions. Each session lasted six minutes, with the treatment endpoint defined as the appearance of erythema and a white frost. The VISIA® Complexion Analysis System (Canfield Scientific, Inc., Fairfield, NJ, USA). was used to assess skin erythema index and melanin index on the left side, midface, and right side. Non-invasive measurements were performed using a multiprobe system (Courage + Khazaka electronic GmbH, Cologne, Germany) at the initial visit and before each treatment session. Transepidermal water loss (TEWL) was measured on the forehead, nose, left cheek, right cheek, and chin, erythema and melanin indices in the facial hyperpigmented areas (with measurements taken at the same fixed points on each patient per session). Treatment-related adverse reactions were also recorded.

Results

After four weeks of treatment, TEWL values showed a decreasing trend across all measured sites, with significant reductions observed on the forehead, nose, and chin ($P < 0.05$), indicating enhanced skin barrier function. Nasal TEWL decreased from 34.91 ± 13.10 to 27.78 ± 9.83 ($t = 3.333$, $P = 0.003$), and chin TEWL decreased from 31.35 ± 7.96 to 27.32 ± 4.70 ($t = 2.476$, $P = 0.021$). Regarding skin physiological parameters measured by the CK system, the erythema index significantly decreased from 292.72 ± 95.37 to 254.97 ± 88.34 ($Z = -2.508$, $P = 0.012$), suggesting an attenuation of skin inflammation and telangiectasia. Similarly, the melanin index showed a significant reduction from 158.45 ± 135.27 to 126.91 ± 48.86 ($Z = -3.087$, $P = 0.002$), demonstrating an improvement in facial hyperpigmentation. However, although the VISIA-detected erythema index (with improvement rates of 5.84% on the left side, 5.73% on the midface, and 9.71% on the right side, respectively) and the melanin index on the left side and midface exhibited decreasing trends, these changes did not reach statistical significance ($P \geq 0.05$). In terms of safety, all patients experienced mild burning sensation and erythema during

treatment, with no adverse reactions such as facial edema or crusting observed after treatment.

Conclusions

Compound azelaic acid and alpha-hydroxy acid chemical peeling has a positive effect on skin barrier repair and erythema relief in patients with acne induced PIH, while its effect on improving hyperpigmentation is limited in the short term and may require a longer duration of intervention. A limitation of this study is that further improvement or recurrence of the condition after treatment discontinuation was not observed.

EADV CONGRESS
VIENNA
30 SEP - 3 OCT 2026

Abstract N°: 1867

Integrating Topical Biosimilar Collagen-III and Multi-Peptides with Two Minimally Invasive Aesthetic Procedures: A Clinical Assessment of Skin Quality Synergies

Chantal Sciuto*[1], Angela Capponi[2], Francesca Nicolucci[2], Ilaria Proietti[3], Eleonora Pizzamiglio[4], Nikola Barlokova[5], Andrea Dazzan[6]

[1] Studio Sciuto, Rome, Italy
[2] Studio Associato Medica, Latina, Italy
[3] Studio di Dermatologia Proietti, Latina, Italy
[4] SkinCeuticals, Milano, Italy
[5] SkinCeuticals, New York, United States
[6] Inmode, Rome, Italy

Introduction

Skin aging is primarily driven by the progressive degradation of the extracellular matrix (ECM), including loss of collagen and elastin fibers. This structural depletion reduces mechanical tension on fibroblasts, compromising their biosynthetic capacity and accelerating clinical signs of aging, such as laxity, wrinkles, and volume loss. Minimally invasive aesthetic procedures, such as energy-based devices and injectables, are commonly used to address these structural changes. However, optimizing post-procedural recovery and enhancing overall skin quality outcomes remains an unmet need. Targeted topical skincare used adjunctively with in-office procedures may help support tissue repair, improve recovery, and enhance clinical outcomes.

The objective of this case series was to evaluate the efficacy and safety of a topical serum formulated with 1.6% Recombinant Human Collagen-III (RHC-III), 0.5% Hyaluronic Acid, and a 3% Multi-Peptide complex when used as an adjunct to two distinct aesthetic procedures: Microneedling Radiofrequency (MNRF) and Calcium Hydroxyapatite (CaHA) injectable treatment.

Case Presentation

Two randomized, split-face clinical studies were conducted to evaluate the serum as an adjunct to aesthetic procedures. Study 1 (20 weeks) evaluated the serum in combination with two Microneedling RF sessions in 20 female subjects (aged 35–65, Fitzpatrick types II–IV) presenting with visible signs of photoaging. Study 2 (8 weeks) assessed the serum integrated with a single CaHA injectable treatment in 10 subjects (male and female, aged 30–60).

In both studies, subjects applied the serum twice daily with moisturizer, cleanser, and sunscreen. Clinical photography and clinical grading were performed at all timpoints. Primary endpoints included wrinkle severity and skin texture improvement. Secondary endpoints included Global Aesthetic Improvement Scare (GAIS) scores. Statistical significance was defined at $p<0.05$.

Across two distinct aesthetic procedures, the integrated protocol demonstrated procedure-specific synergistic benefits compared with standard treatment alone. In the Microneedling RF study, adjunctive serum use was associated with significantly accelerated post-procedural recovery, including reduced erythema and edema, together with improved lifting effects in the neck and jawline. In the CaHA study, the serum enhanced wrinkle

reduction by week 6 and supported sustained skin texture refinement throughout the study. In both models, improvements in GAIS and subject-perceived skin elasticity, firmness, and overall quality reinforced the broad skin quality benefits of the combined approach**.**

Conclusion

When used across both an energy-based procedure and an injectable treatment, this targeted RHC-III multi-peptide serum demonstrated distinct yet complementary clinical benefits, ranging from accelerated recovery to enhanced wrinkle correction and texture refinement. This cross-procedure efficacy highlights the serum's potential as a versatile adjunct for optimizing skin quality outcomes.

EADV CONGRESS
VIENNA
30 SEP - 3 OCT 2026

Abstract N°: 1945

Transient Reactive Cervical Lymphadenopathy Following PRP-Based Regenerative Procedures: A Two-Case Series

Mona Homayouni*[1], Zeinab Aryanian[2], Zinah Sharara[1], Mohammed Al Abadie[3], Parvaneh Hatami[4]

[1] Midlands medical academy. United Kingdom, London, United Kingdom

[2] Autoimmune Bullous Diseases Research Center, Razi Hospital ,Tehran University of Medical Sciences, Tehran, Iran, Department of Dermatology, Babol University of Medical Sciences, Babol, Iran, Tehran, Iran

[3] University of Wolverhampton, North Cumbria Integrated Care NHS Foundation Trust, United Kingdom., Wolverhampton, United Kingdom

[4] Autoimmune Bullous Diseases Research Center,Razi Hospital, Tehran University of Medical Sciences, Tehran, Iran, Tehran, Iran

Introduction

Platelet-rich plasma (PRP) procedures are increasingly utilised in aesthetic dermatology and hair restoration and are generally considered safe. Reactive cervical lymphadenopathy has rarely been reported following such interventions. We describe two patients who developed transient reactive cervical lymphadenopathy temporarily associated with PRP treatments.

Materials and Methods

This case series includes two patients who developed transient cervical lymphadenopathy following platelet-rich plasma (PRP)-based aesthetic procedures in an outpatient dermatology setting. Data were obtained retrospectively from clinical records, including procedural details, symptom onset, physical examination, laboratory investigations, ultrasound findings, and follow-up until complete resolution.

Results

A 33-year-old woman with androgenetic alopecia underwent scalp PRP using a double-spin centrifugation protocol with calcium chloride activation. Approximately 4–5 mL of PRP was administered via intradermal injections without microneedling. She developed painful unilateral occipital and cervical lymphadenopathy beginning on day 5–7 post-procedure, with pain preceding enlargement and reaching peak size within approximately 7 days. Ultrasound demonstrated three reactive cervical lymph nodes measuring up to 1.5 × 0.6 cm with preserved morphology. Complete blood count (CBC) was normal. No fever, flu-like symptoms, local infection, recent vaccination, or dental/ENT source was identified. The pain subsided after five days, and the lymphadenopathy resolved spontaneously within six weeks. One months later, a similar self-limiting episode occurred following a hair filler injection.

A 37-year-old woman developed painful bilateral cervical lymphadenopathy 4–5 days after facial platelet-rich plasma (PRP) combined with microneedling. PRP with microneedling was performed for the treatment of uneven skin tone and to improve skin texture. Ultrasound examination demonstrated two reactive cervical lymph nodes on the left and one on the right, measuring up to 2 × 0.8 cm. Complete blood count findings were normal, with no systemic symptoms or identifiable infectious source. The lymphadenopathy resolved spontaneously within approximately three to four weeks. Following a second PRP-only session performed six weeks later, the patient experienced recurrent cervical lymphadenopathy and self-administered azithromycin because of concern regarding recurrence; symptoms again resolved within three to four weeks.

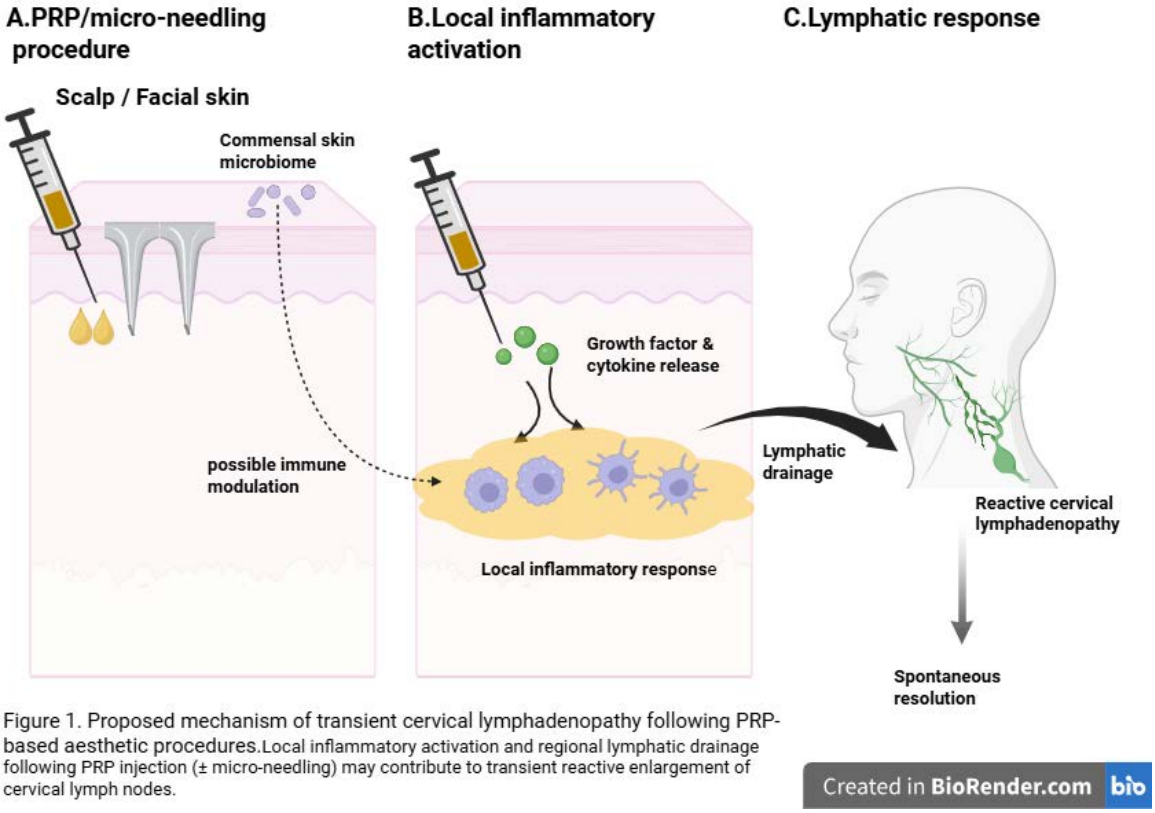

Figure 1. Proposed mechanism of transient cervical lymphadenopathy following PRP-based aesthetic procedures.Local inflammatory activation and regional lymphatic drainage following PRP injection (± micro-needling) may contribute to transient reactive enlargement of cervical lymph nodes.

PRP: platelet-rich plasma. Figure created using BioRender.com. Proposed mechanism shown for illustrative purposes only.

Conclusions

Clinicians performing PRP-based aesthetic procedures should be aware of transient cervical lymphadenopathy as a rare but benign and self-limiting adverse event. Appropriate clinical assessment and patient reassurance are essential to prevent over-investigation and overtreatment.

EADV CONGRESS
VIENNA
30 SEP - 3 OCT 2026

Abstract N°: 1989

Ex Vivo Evidence for Dual Collagen and Elastin Restoration and Dermal Rebuilding by a Topical Formulation in a Stretch Mark Skin Model

Gerald PEDRASSI[1], Georgina Logusso*[2], Ina Becker[1], Felipe Goñi[3], Adrian Garcia-Salvador[3]

[1] Global Pharmaceutical Development, Stada arzneimittel, Bad Vilbel, Germany

[2] Global product Development, STADA Arzneimittel GmbH, Sant Just Desvern, Barcelona, Spain

[3] Gaiker Technology Centre, Zamudio (Bizkaia), Spain

Introduction

Post-partum skin stretching results in complex dermal damage: simultaneous degradation of collagen (tensile strength) and elastin (elastic recoil), disorganization of the ECM architecture, and impaired cellular activity. An effective intervention should address all three levels. This study evaluated the efficacy of a specialized formulation containing a Centella asiatica complex, Vitamin E, and hydrolyzed elastin peptide in restoring these three dimensions of dermal integrity in an ex vivo model.

Materials and Methods

Human organotypic skin explant cultures (hOSEC) were exposed to a controlled daily stress protocol (UV radiation, 5 J/cm²) to simulate ECM degradation. Damaged explants were treated topically with the test formulation (2 mg/cm²/day, 8 applications over 10 days). Primary endpoints were: soluble collagen content (Sircol™ assay), elastin content (Fastin™ Elastin Assay), and cellular metabolic activity (resazurin reduction assay). Dermal architecture was assessed histomorphometrically via Masson's Trichrome (collagen fibre area) and Sirius Red staining under polarized light (Type I/III collagen maturation ratio).

Results

The test formulation demonstrated a triple action on the damaged ECM. First, it significantly counteracted the UV-induced metabolic decline, restoring cellular activity from day 7 onward ($p<0.05$). Second, it simultaneously and significantly restored both soluble collagen content (+82%) and elastin content (+82%) relative to the damaged control group ($p<0.05$ for both), directly addressing the dual protein loss characteristic of post-partum skin. Third, histomorphometric analysis confirmed a profound recovery of dermal architecture: collagen fibre area was restored by 86% ($p<0.05$), and the Type I/III collagen maturation ratio was fully recovered by 114% to levels statistically comparable to healthy skin ($p<0.05$).

Conclusions

This formulation, combining Centella asiatica, Vitamin E, and hydrolyzed elastin peptide, demonstrates a comprehensive triple action: protecting cellular resilience under stress, simultaneously restoring collagen and elastin levels, and rebuilding a healthy and organized dermal architecture. These findings confirm a multi-target mechanism, supporting its use as a cosmetic solution for the complex dermal repair required in post-partum and post-stretching situations.

EADV CONGRESS
VIENNA
30 SEP - 3 OCT 2026

Abstract N°: 2009

Large volume fat grafting is a procedure achievable under tumescent anesthesia ASDS

Paul Salmon*[1]

[1] Waikato Hospital Gate 2, Hamilton Central, New Zealand

Introduction

Large volume fat grafting has not been reliably demonstrated in the dermatology setting. Furthermore, the literature on this area presents the newcomer with a bewildering array of (expensive) devices with which to achieve this. The author will walk the attendee through the latest literature on large volume fat transfer. Which factors matter most? Is it donor site, extraction technique, graft handling, centrifugation parameters, extraction of stromal vascular fraction, preparation of stem cells, placement technique or preparation of the recipient site?

Materials and Methods

A prospective single cohort trial of large volume tumescent autologous fat transfer (TAFT) with 103 participants is presented using two different techniques of recipient site preparation. Outcomes included percentage of successfully grafted fat (%SGF) at 6 months and complications. Patient satisfaction was rated by post-operative questionaire at 6 months

Results

Data were processed using R 4.3.1. Two models were developed. The main model used a gamma distribution with log link to interrogate the %SGF was analysed by multivariate linear regression. All subjects were female, age range was 18-69. The mean %SGF was 82%. there were minimal complications and the technique was rated highly by participants.
Short video clips will demonstrate the key techniques and multiple examples of clinical outcomes

Conclusions

In summary, large volume TAFT offers a safe, effective, and well-tolerated method of large-volume grafting using autologous fat. The combination of careful patient selection, diligent pre-operative expansion, meticulous graft technique, and postoperative weight stability enables reproducible, natural-looking results without general anaesthesia or cellular manipulation.

EADV CONGRESS
VIENNA
30 SEP - 3 OCT 2026

Abstract N°: 2010

Large Volume Autologous Fat Transfer Entirely Under Tumescent Anaesthesia: Experience with 103 Patients over 7 years

Paul Salmon*[1]

[1] Waikato Hospital Gate 2, Hamilton Central, New Zealand

Introduction

Autologous fat transfer (AFT) provides a natural alternative to implants for breast augmentation. While most large-volume AFT is performed under general anaesthesia, experience with fully tumescent local anaesthesia is limited. This study evaluates the safety, efficacy, and volumetric outcomes of Breast Autologous Fat Transfer Entirely Under Tumescent Anaesthesia (BAFTEUTA) and examines the role of pre-expansion versus enrichment in graft survival.

Materials and Methods

In this prospective single-centre study, 87 patients (174 breasts) underwent large-volume AFT under local tumescent anaesthesia between 2018 and 2024. Pre-operative expansion used either rigid dome systems or negative-pressure wound-therapy (NPWT) dressings. Fat was harvested manually or mechanically, processed without centrifugation, and injected in multiple subcutaneous planes. Volumes were measured by 3-D imaging and water displacement. Outcomes included percentage of successfully grafted fat (%SGF), final increase in size at 6 months (%FIS), and complications

Results

No infections, haematomas, or systemic complications occurred. Five patients (6.25%) developed benign fat granulomas. Median graft survival was 82%. Dome expansion achieved higher mean %SGF (84.5% vs 79.5%) and %FIS (193% vs 158%) than NPWT, with strong correlation between expansion hours and %FIS ($r \approx 0.9$, $p < 0.001$). Smaller breasts and nulliparous women showed greater proportional gains. Mean satisfaction scores were 4.7–5.0 across domains.

Technique will be demonstrated through short video clips.

Conclusions

Large-volume breast fat transfer can be safely and reproducibly performed under tumescent anaesthesia. Pre-expansion—particularly with dome systems—is the most critical determinant of graft survival, enabling durable, natural results without stem-cell enrichment, general anaesthesia, or implants.

EA DV CONGRESS
VIENNA
30 SEP - 3 OCT 2026

Abstract N°: 2029

Binary Medical Laser

Nikolai Tankovich*[1]

[1] Paradigm Medical Corporation, San Diego, United States

Introduction

Over the last 30 years, laser technologies in medicine have predominantly used a single laser beam to irradiate tissues, occasionally in a sequential mode of radiation. Until recently, with the invention of the binary medical laser, there were no medical lasers on the market able to emit two or more laser beams simultaneously to irradiate a tissue target. This new simultaneous (or binary effect) of energy delivery to a treatment target, shows significant advantages in many medical fields compared with a single beam energy source. For example, simultaneous ultrasonic energy emission from multiple transducers is capable of destroying kidney stones whereas one beam cannot.

Case Presentation

Materials and Methods: The authors display a novel binary beam medical laser that can be defined as revolutionary in the medical technology market. Utilizing this, the authors present human skin histological results of the laser that is able to deliver two beam wavelengths of 1550 nm and 1927 nm simultaneously, and in any energy ratio between those two wavelengths. The laser is also able to deliver beams sequentially; in a separate, single mode as well. The study design compares four major groups of human skin histology irradiated with laser beams in the following modalities:

- Simultaneous beam delivery
- Sequential beam delivery
- Single beam delivery
- Control

A study was done on the low abdominal skin area prior to an abdominoplasty under general anesthesia with the written consent of the patient. Two powerful laser diodes of 1550 nm and 1927 nm directly placed into the laser handpiece emits light directly to the skin surface. The scanning surface of the laser is adjustable from 2 to 14 mm with changeable spacing in 0.5 mm increments in a range of 0.5/1.0/1.5/2.0 mm. Post abdominoplasty skin has been harvested for the histological investigation of each square. Sirius red + Hematoxylin staining was used to analyze collagen fibers and cells status in a regular and polarized light, while a histochemical Weigert method (Resorcinol-Fuchsin dyes staining) was used to highlight the elastic fibers in particular. Results demonstrated a significant difference in the depth of the laser radiation effect to the skin collagen and elastic fibers between simultaneous, sequential and single beam radiation.

Results: A single beam of laser radiation at 1550 nm penetrates into the skin up to 150-250 microns (contingent upon pulse energy of 35-45 mJ). A single beam of laser radiation of 1927 nm penetrates into the skin up to 50-90 microns (contingent upon pulse energy of 5-8 mJ). Sequential radiation of the skin with a 1550 nm beam followed by a 1927 nm beam penetrates up to 300-350 microns. Sequential radiation of the skin with a 1927 nm beam followed by a 1550 nm beam penetrates up to 300 microns. Simultaneous beam radiation of the skin with 1550

nm together with 1927 nm penetrates from 500 microns to 950 microns (almost 1 mm).

Conclusion

The Authors conclude that the binary effect of simultaneous beam radiation of the tissue has a deeper penetration, and a more significant thermal effect into the skin than a single beam or sequential beam radiation.

EA DV CONGRESS
VIENNA
30 SEP - 3 OCT 2026

Abstract N°: 2032

The dark side of red ink: a clinicopathological spectrum of adverse reactions

Polina Ptashnikova*[1], Irina Smirnova[1]

[1] Federal State Budgetary Educational Institution of Higher Professional Education "St. Petersburg State University", St. Petersburg, Russian Federation, St. Petersburg, Russian Federation

Introduction

The range and frequency of adverse reactions to tattoos are determined by a number of factors, one of which is the colour of the ink. Red tattoos, in particular, have received significant clinical attention (Manoj, Rohan et al., 2025). Red inks contain both organic and inorganic compounds, such as cinnabar, cadmium red, iron oxide, naphthol-AS pigment, quinacridone, and azo compounds (Dodig S et al., 2024). Organic azo compounds are chemically unstable and prone to photodegradation and thermal or enzymatic breakdown, leading to the formation of aromatic amines and other carcinogenic by-products (Kluger N, Cribier B, 2021).

Materials and Methods

We analysed the frequency and clinical patterns of reactions to red tattoos. We observed 16 patients with adverse reactions to tattoos of various colors. Among these, reactions to red ink were observed in 6 patients, 2 of them exhibited simultaneous reactions to both red and black pigments. In 10 patients, reactions developed exclusively to black pigment in the tattoos. Histological examination was performed in 15 patients.

Results

Patients with red tattoos exhibited a diverse spectrum of reactions: granulomatous (3/6), keratoacanthoma (1/6), allergic dermatitis (1/6), and pseudolymphoma following a tattoo removal attempt (1/6). In contrast, sarcoidal granulomatous reactions predominated in patients with black tattoos (10/10, $p=0.036$).

Sarcoidal granulomatous reactions presented as papular lesions within red tattoos (1/6), red and black tattoos (2/6), as well as in scars (1/6) and on normal skin (1/6). Systemic involvement of the lungs and intrathoracic lymph nodes was identified in 2 out of 6 patients with red tattoos, compared to 1 out of 10 patients with reactions to black pigment.

In one female patient, papular lesions emerged within a tattoo following Q-switched Nd:YAG laser removal. Histology and immunohistochemistry confirmed lichenoid-type T-cell lymphoid hyperplasia/pseudolymphoma; resolution was achieved following clobetasol therapy under occlusion.

In another patient (1/6) with a multicolored tattoo, a solitary nodule with a keratin-filled crater appeared two months after tattooing; biopsy revealed inflammation associated with red pigment, confirming a diagnosis of keratoacanthoma. Surgical excision was performed, with laser removal deferred due to the risk of releasing carcinogenic by-products during pigment photodegradation.

A third patient developed allergic dermatitis strictly localized to the red pigment.

Conclusions

Red tattoo pigment is the most common cause of keratoacanthomas and pseudoepithelial tumors (75%), as well as allergic reactions (up to 86%) (Kluger N, Cribier B, 2021; Rogowska P et al., 2021). Unlike stable black pigment, which predominantly causes granulomatous sarcoid reactions (10/16 cases), red pigment degrades under light/laser exposure, triggering a wide spectrum of adverse events: granulomatous reactions (3 cases), pseudolymphoma post-Nd:YAG laser treatment, keratoacanthoma, and allergic reactions (Sepehri M et al., 2017; Berros S et al., 2026). Our observations (3 granulomatous reactions to red pigment, 2 systemic sarcoidosis cases with scar and pulmonary involvement) highlight the need for pulmonary screening (van der Bent SAS et al., 2021). Furthermore, given the potential for neoplastic development, histological evaluation is frequently required. Finally, particular care should be taken when using photodestruction to remove red tattoos.

EADV CONGRESS
VIENNA
30 SEP - 3 OCT 2026

Abstract N°: 2056

Multimodal non-surgical management of deliberate self-harm scars: A single-center case series

Faiza Boukhobza[1], Hanane Baybay*[1], ikram bejja[1], Saadia Boughaleb[1], Zakia Douhi[1], Meryem Soughi[1], Sara Elloudi[1], Fatima zahra Mernissi[1]

[1] Dermatology departement HASSAN II University Hospital, FES, Morocco

Introduction
Deliberate self-harm (DSH) scars result from repeated self-inflicted injuries and carry significant emotional burden, social stigmatization, and impaired self-esteem. No standardized treatment protocol currently exists, making their management a major therapeutic challenge.

Materials and Methods
A single-center retrospective series included 11 adult female patients (age 21–38) presenting 46 DSH scars. All patients received systematic psychiatric follow-up throughout the treatment. Individualized protocols combined ablative and non-ablative lasers, TCA and phenol peels, intralesional corticosteroids, mesotherapy, botulinum toxin, cryotherapy, silicone sheeting, LED photobiomodulation, and topical depigmenting agents, over 3–7 sessions spaced 4–6 weeks apart. Outcomes were assessed using the Vancouver Scar Scale and serial digital photography.

Results
Among 46 scars, 14 were hypertrophic (30.4%), 21 mixed (45.6%), and 11 fibro-atrophic (23.9%). All patients presented significant emotional impact; psychiatric history was documented in 4 cases (36.4%) and undocumented in 7 (63.6%). Mean consultation delay was 58 months. Combined Er-YAG laser and strong TCA peels yielded the greatest overall improvement across all scar subtypes (78.2%). Hypertrophic lesions responded most favorably (68.7%), followed by mixed-type (38.1%) and fibro-atrophic scars (27.7%). Intralesional corticosteroids combined with ablative laser and cryotherapy effectively reduced hypertrophic bulk. Botulinum toxin was used as an adjunct in 36.4% of patients in movement-prone areas where mechanical tension delayed re-epithelialization. All patients received LED photobiomodulation.

After 6 sessions, 45.4% achieved good improvement. Prolonged consultation delay was associated with poorer outcomes. A camouflaging effect was noticed across all patients, by which treated lesions blended together and lost their recognizable DSH appearance. Interestingly, this effect was most pronounced in patients presenting multiple overlapping lesions on the same anatomical site, representing a central therapeutic goal given the profound social stigmatization associated with DSH scars. Side effects were transient and mild. Patients with controlled psychiatric conditions demonstrated better treatment adherence, with no significant difference across Fitzpatrick phototype.

Conclusions
Multimodal non-surgical protocols achieve meaningful clinical and aesthetic improvement in DSH scars, outperforming single-modality approaches. This study is among the few to address DSH scar management from a

truly comprehensive perspective, integrating procedural interventions, phase-adapted wound care, and active topical agents alongside systematic psychiatric follow-up. Psychiatric stability emerged as a key determinant of adherence and outcomes, reinforcing that dermatological and psychiatric care must be fully integrated to optimize results and restore quality of life.

EA DV CONGRESS
VIENNA
30 SEP - 3 OCT 2026

Abstract N°: 2142

Blindness after Platelet-Rich Plasma Injections: A Systematic Review of Reported Cases

Fahimeh Abdollahimajd*[1], Mandana Ebrahimzade[1], Shahriar Nazari[2], Mohammad Reza Pourani[3], Cristina Muñoz-Gonzalez[4], Maurizio Cavallini[5], Nabil Fakih-Gomez[6]

[1] Department of Dermatology, Shohada-e Tajrish Hospital, Shahid Beheshti University of Medical Sciences, Tehran, Iran

[2] Department of ENT and Head and Neck Surgery, BMI Hospital, Tehran, Iran

[3] Research Center of Artificial Intelligence in Health, Shohada-e Tajrish Hospital, Shahid Beheshti University of Medical Sciences Tehran, Iran, Tehran, Iran

[4] Private Practice. Facexpert Clinic and Academy, Torremolinos, Spain

[5] Agora Clinical Center, Milan, Italy

[6] Department of Facial Plastic & Cranio-Maxillo-Facial Surgery, Fakih Hospital, Khaizaran, Lebanon

Introduction

Platelet-rich plasma (PRP) is widely used in aesthetic dermatology and is generally considered safe due to its autologous nature. However, rare yet devastating vision-threatening complications have been reported following facial PRP injections. We aimed to systematically identify and analyze all reported cases of visual impairment following PRP injections and characterize their clinical patterns and potential risk factors.

Materials and Methods

A systematic literature search was conducted up to August 2025 in PubMed, Embase, and Scopus, supplemented by manual Google Scholar screening. Case reports describing visual impairment after PRP injection were included without language or date restrictions. Extracted data included patient demographics, treatment indication, injection site, onset and characteristics of visual loss, ophthalmologic findings, management, and outcomes.

Results

Seven publications reporting 10 cases of PRP-associated unilateral visual loss (2017–2025) were identified. All patients were female (22–64 years). PRP was administered for facial rejuvenation in 90% of cases, most frequently in the glabella (60%) and forehead (40%), while one case followed scalp PRP for alopecia. Vision loss occurred immediately and was painful in 90% of patients, with 80% presenting with no light perception. Fundoscopic findings consistently indicated retinal and choroidal ischemia suggestive of ophthalmic artery occlusion. Partial visual recovery occurred only in two patients with delayed or incomplete vision loss who received corticosteroid therapy. More than half of the procedures were performed by non-physicians or inadequately trained practitioners

Conclusions

Although rare, PRP injections can lead to irreversible blindness, most likely due to embolic ophthalmic artery occlusion. The predominance of cases in high-risk facial vascular zones and the frequent involvement of inadequately trained injectors highlight the urgent need for improved training, stricter credentialing, and adherence to safe injection techniques. Prevention and awareness are essential, as effective treatment options remain limited once vision loss occurs.

EADV Congress 2026, VIENNA
30 SEPTEMBER - 03 OCTOBER 2026
POWERED BY M-ANAGE.COM

EA DV CONGRESS
VIENNA
30 SEP - 3 OCT 2026

Abstract N°: 2143

Longitudinal multimodal split-face evaluation of calcium hydroxylapatite and poly-D, L-lactic acid biostimulation using ultrasound imaging and extracellular matrix genetic profiling: a pilot observational study

Assel Markabayeva*[1]

[1] Department of Aesthetic and Regenerative Medicine, AL Clinic of Plastic and Aesthetic Surgery, Almaty, Kazakhstan, Kazakhstan Society of Dermatologists, Cosmetologists and Leprologists, Kazakhstan, Almaty, Kazakhstan

Introduction

BACKGROUND

Objective longitudinal assessment of facial biostimulation remains limited despite increasing clinical use of collagen-stimulating injectables. Comparative remodeling dynamics between calcium hydroxylapatite and poly-D, L- lactic acid within the same patient have not been sufficiently characterized using multimodal imaging approaches.

Case Presentation

OBJECTIVES

To evaluate differential longitudinal tissue remodeling patterns following split-face administration of calcium hydroxylapatite and poly-D, L -lactic acid using serial high-frequency ultrasound imaging, standardized digital photography, blinded physician assessment, patient-reported outcomes, and exploratory extracellular matrix genetic profiling.

METHODS

A prospective split-face pilot observational study was conducted in an adult 40 y.o. male patient presenting with age-related facial soft tissue redistribution. The split-face design minimized interindividual variability in tissue remodeling response. Equal treatment volumes (4 mL per side) were administered using mechanism-specific injection techniques. Calcium hydroxylapatite was delivered along structural lifting vectors, whereas poly-D, L -lactic acid was distributed using diffuse subdermal fanning and cross-hatching techniques.

Serial ultrasound assessments were performed at baseline (T0), immediately post-procedure (T1), one month (T2), three months (T3), and six months (T4). Quantitative analysis included epidermal, dermal, subcutaneous, and total soft tissue thickness measurements, as well as mean tissue echogenicity assessment. Standardized FotoFinder digital imaging, patient satisfaction assessment, and blinded physician evaluation were additionally performed. Exploratory extracellular matrix genetic profiling included COL1A1 and MMP1 polymorphism assessment.

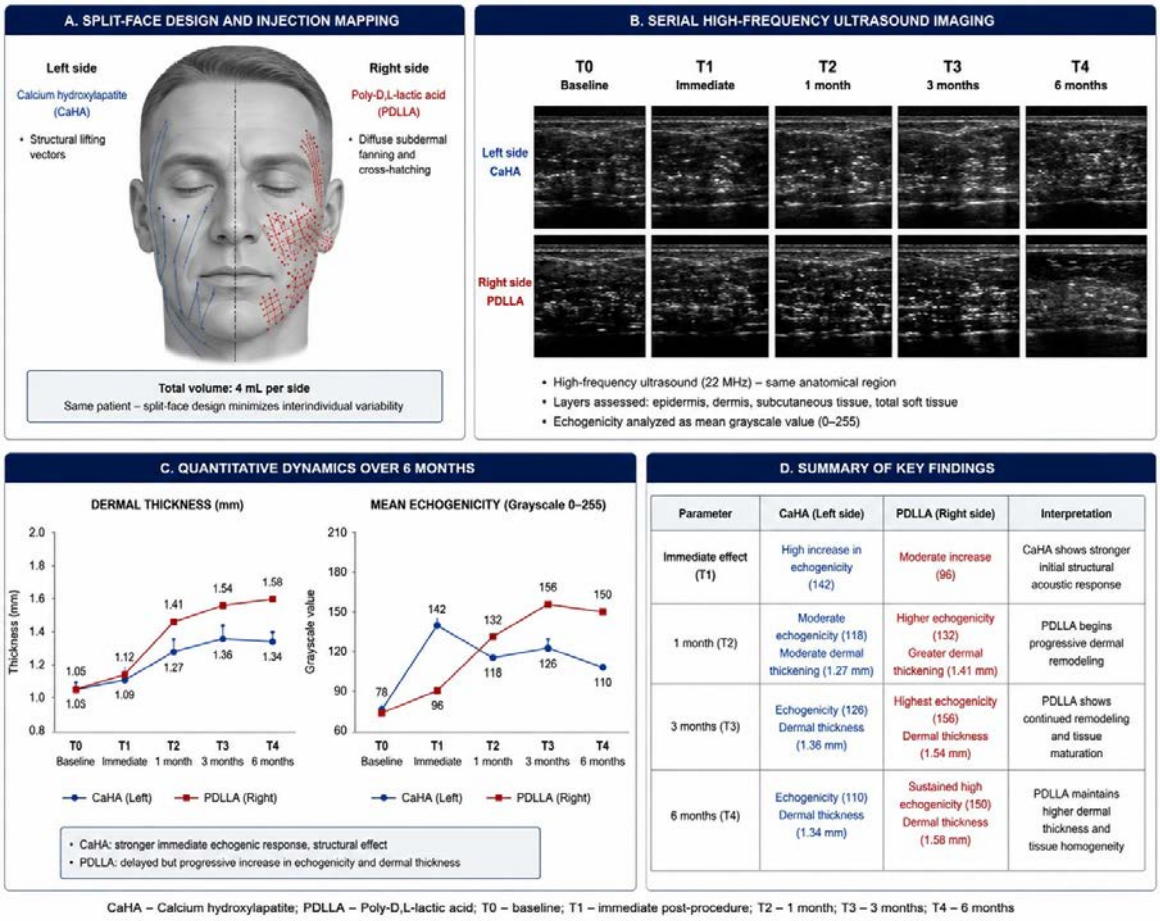

Longitudinal split-face multimodal assessment of calcium hydroxylapatite and poly-D,L-lactic acid biostimulation including standardized injection mapping, serial high-frequency ultrasound imaging, quantitative echogenicity analysis, and tissue remodeling dynamics from baseline to 6 months follow-up

Conclusion

CONCLUSIONS

Longitudinal multimodal split-face assessment demonstrated distinct structural and regenerative remodeling dynamics between calcium hydroxylapatite and poly-D,L-lactic acid within the same patient. Calcium hydroxylapatite demonstrated stronger immediate structural acoustic response, whereas poly-D, L -lactic acid demonstrated delayed but progressive diffuse dermal remodeling and tissue homogenization.

Integration of serial ultrasound imaging, standardized digital imaging, blinded evaluation, patient-reported outcomes, and exploratory extracellular matrix genetic profiling may provide a clinically relevant framework for individualized facial biostimulation assessment and future precision regenerative aesthetic strategies.

EA DV CONGRESS
VIENNA
30 SEP - 3 OCT 2026

Abstract N°: 2152

Advancing Scar Treatment: Argon Cold Atmospheric Plasma Promotes Rapid Regeneration and Remodeling in Chronic Post-Surgical ScarsIntroduction

Tercio Elyan Azevedo Martins*[1, 2], Zeisa Hohl[3], Shirley Silva[4], Rossana Vasconcelos[5]

[1] Paulista University, São Paulo, Brazil

[2] University of São Paulo, São Paulo, Brazil

[3] Hohl Medicina e Diagnóstico, Goiânia, Brazil

[4] Instituto Shirley Nogueira, Goiânia, Brazil

[5] Universidade de Santo Amaro, NOMINA Institute, São Paulo, Brazil

Introduction

Argon cold atmospheric plasma (ACAP) has emerged as a novel therapeutic modality for the management of cutaneous scars, including chronic post-surgical lesions. Its biological effects are mediated by the generation of reactive oxygen and nitrogen species (RONS), which modulate inflammation, cellular proliferation, and extracellular matrix remodeling.(1,2) ACAP has been shown to stimulate fibroblast activity, promote collagen reorganization, induce angiogenesis, and enhance tissue regeneration.(2,3) Additionally, its antimicrobial properties and ability to regulate redox signaling and growth factor expression contribute to an optimized microenvironment for wound healing. Recent evidence supports its safety and efficacy in chronic wound and scar management, with minimal adverse effects.(4,5) The aim of this study was to evaluate the efficacy and safety of ACAP in the treatment of chronic post-mammoplasty scars.

Case Presentation

A 57-year-old female patient (Fitzpatrick skin phototype III) with a 3-year chronic linear breast scar presenting erythema and residual hyperpigmentation was treated with CAP. Two sessions were performed, with application times ranging from 120 to 150 seconds per treated area. Clinical follow-up was conducted over 60 days using standardized photographic documentation and comparative clinical evaluation.

A marked improvement in scar appearance was observed, including approximately 50% reduction in erythema, improved skin texture, enhanced integration with surrounding tissue, and attenuation of hyperpigmentation. No adverse events were reported.

The observed effects can be explained by ACAP induced modulation of the tissue microenvironment. RONS reduce chronic inflammation by decreasing pro-inflammatory cytokines and regulating redox balance, favoring tissue repair [1,3]. ACAP also stimulates fibroblast proliferation and activity, promoting collagen remodeling and improved dermal structure [3]. Furthermore, ACAP induces angiogenesis and enhances tissue perfusion, essential for chronic scar repair [3,4]. Its antimicrobial action and ability to modulate cellular pathways, including growth factor expression, further support tissue regeneration [2,5].

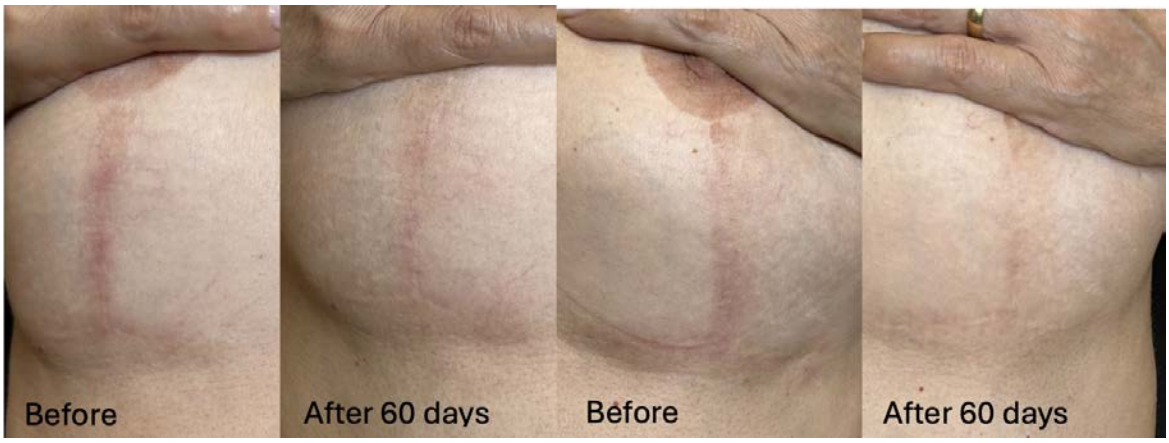

Before and after (60 days) treatment of a post-mammoplasty scar (3 years) treated with Atmospheric Cold Argon Plasma (ACAP).

Conclusion

ACAP is an effective, safe, and minimally invasive treatment for chronic post-mammoplasty scars, promoting significant clinical and aesthetic improvement. This technology represents a promising tool in regenerative dermatology, with potential for broader clinical applications and integration into advanced scar management protocols.

EA DV CONGRESS
VIENNA
30 SEP - 3 OCT 2026

Abstract N°: 2241

Efficacy and Tolerability of a Collagen-Boosting Serum Combined with Rejuvenating Procedures in Real-World Conditions

Flavia Addor*[1], Erika Fernandes[2], Izabella Martorelli[2], Natalia Kovylkina[3]

[1] Medcin Pesquisa, Osasco, Brazil

[2] L'Oréal Dermatological Beauty Brazil, Rio de Janeiro, Brazil

[3] L'Oréal Dermatological Beauty - Vichy Laboratories, Paris, France

Introduction

Skin ageing is associated with progressive structural and functional changes, including wrinkles, reduced firmness, irregular texture, and uneven skin tone. Minimally invasive procedures for collagen stimulation, such as ablative laser, radiofrequency microneedling, and microfocused ultrasound, are widely used to address these concerns. This study aimed to evaluate the efficacy and tolerability of a collagen-targeting topical serum combined with such procedures under real-world conditions.

Materials and Methods

Twelve patients (75% female), aged 25–56 years, with Fitzpatrick phototypes II–IV and signs of ageing classified according to Glogau grade II and/or III were included. Patients were allocated to one of three treatment groups (n=4 each) according to clinical needs: ablative laser, radiofrequency microneedling, or microfocused ultrasound. Participants met at least one of the following criteria: accelerated weight loss associated with GLP-1/GIP agonists, regular outdoor physical activity (≥3 times/week), or perimenopausal status. The study was conducted in accordance with ethical standards and approved by a local Ethics Committee (CAAE: 92683825.7.0000.0391, October 2025). Clinical assessment included a 10-point visual analogue scale evaluating wrinkles, radiance, texture, hydration, contour, elasticity, firmness, skin tone eveness, lower-face ptosis, and overall skin quality. Neck evaluation included folds, hydration, and firmness. Instrumental image analysis assessed wrinkles and skin age. Tolerability and patient-reported outcomes were also recorded. Patients applied a collagen-boosting serum containing a mix of *Grifola frondosa* (Maitake) extract, a peptide complex and Rhamnose: twice daily and neutral SPF 50 sunscreen once daily. Follow-up assessments were performed at 1 and 3 months.

Results

Progressive improvements were observed over time, with greater effects at 3 months, supporting a cumulative response. Early changes were already evident at 1 month, particularly in elasticity (+14.5%), firmness (+14.3%), and face contour (+4.2%), indicating initial dermal remodelling. These effects became more pronounced at 3 months, with elasticity reaching +22.4% and firmness +20.8%, consistent with ongoing collagen reorganisation. Face **c**ontour definition improved to +11.1% at 3 months, suggesting enhanced structural support and a lifting effect. Ptosis followed a progressive pattern, with improvements of +2.6% at 1 month and +5.1% at 3 months, indicating gradual tissue repositioning. Overall skin quality also improved over time, reaching +18.3% at 1 month and +28.2% at 3 months, alongside parallel gains in radiance, texture, and hydration. In the neck region, clinically meaningful improvements were observed, particularly in dermal-related parameters. Firmness improved progressively, reaching +4.0% at 1 month and

+8.0% at 3 months. Hydration showed a similar pattern, with gains of +15.6% and +19.5% at the respective timepoints, while folds were reduced by +2.7% and +4.0%, reinforcing the treatment effect in this anatomically challenging area. Instrumental analysis corroborated the clinical findings, demonstrating wrinkle reduction and an estimated decrease of 5 years in skin biological age after 3 months. Treatments were well tolerated, with no significant adverse events reported.

Conclusions

The combined use of collagen stimulation procedures and a collagen-boosting topical serum resulted in clinically relevant and progressive improvements in key dermal parameters, particularly elasticity, firmness, face contour, and ptosis, under real-world conditions. The sustained effects, together with favourable tolerability and positive patient-reported outcomes, support this combined approach as an effective strategy for enhancing skin quality and promoting collagen remodelling in both face and neck.

EADV CONGRESS
VIENNA
30 SEP - 3 OCT 2026

Abstract N°: 2249

Combined Laser and Infiltrative Therapy for Hypertrophic Scars and Keloids: A Case Series

Julia Castro Martín*[1], Antonio Martinez-Lopez[1], José Gallego García[1], Salvador Arias-Santiago[1]

[1] Hospital Universitario Virgen de las Nieves, Granada, Spain

Introduction

Hypertrophic scars and keloids are common dermatological conditions that remain difficult to treat. The emergence of light-based therapies has transformed their management, both as monotherapy and when combined with intralesional drug delivery. We report three cases of hypertrophic scars and keloids treated with various laser combinations alongside drug infiltration or delivery.

Case Presentation

Case 1: A 19-year-old male presented with a keloid on his right shoulder persisting for one year following epidermal cyst surgery. He underwent three sessions using KTP laser (9 J/cm^2, 8 mm spot, 10 ms pulse), Nd:YAG laser (100 J/cm^2, 8 mm spot, 12 ms pulse), and intralesional triamcinolone acetonide (40 mg/mL). Both lesion size and volume decreased.

Case 2: A 27-year-old female presented with a three-month history of three hypertrophic dorsal scars following melanoma surgery. She received two sessions of KTP laser (8.5 J/cm^2, 8 mm spot, 9 ms pulse) and Nd:YAG laser (80 J/cm^2, 8 mm spot, 10 ms pulse) combined with intralesional triamcinolone acetonide (40 mg/mL). Improvements in scar color and size were observed after two sessions.

Case 3: A 33-year-old female presented with a presternal keloid following epidermal cyst surgery. Treatment consisted of three sessions utilizing KTP laser (10 J/cm^2, 6 mm spot, 8 ms pulse), Nd:YAG laser (100 J/cm^2, 6 mm spot, 12 ms pulse), and fractional CO2 laser (72 mJ, 15% density) with triamcinolone acetonide delivery (40 mg/mL). Erythema and lesion volume were significantly reduced after three sessions.

Conclusion

Treating hypertrophic scars and keloids is complex and often yields poor results. However, combining KTP, Nd:YAG, and CO2 lasers with intralesional or delivered corticosteroids offers an effective and safe therapeutic option.

EA DV CONGRESS
VIENNA
30 SEP - 3 OCT 2026

Abstract N°: 2292

Sequential Monopolar/Bipolar Radiofrequency for Non-Invasive Body Contouring of the Upper Inner Arm: A Prospective Multi-Endpoint Clinical Study

Mukta Sachdev*[1], Narendra Kumar[2]

[1] Medical Director, MS Clinical Research Pvt. Ltd., HOD & Consultant, Dermatology, Manipal Hospital, Bangalore, India, Bengaluru, India

[2] Jeisys Med Inc, Seoul, Korea, Rep. of South

Introduction
Skin laxity of the upper inner arm is a prevalent and psychosocially impactful aesthetic concern, yet therapeutic options remain constrained — surgical brachioplasty carries a significant recovery burden, while non-invasive alternatives lack robust, clinical evidence. Radiofrequency (RF) energy induces collagen contraction and progressive neocollagenesis, offering a biologically plausible, non-invasive approach; however, its translation into objectively validated body-contouring outcomes remains incompletely characterised. This study addresses that evidence gap through a prospective, multi-dimensional clinical evaluation.

Objectives: To evaluate the clinical efficacy, biophysical skin response, safety, and patient-reported outcomes of a sequential monopolar/bipolar RF device for upper inner arm body contouring over three months.

Materials and Methods
Twenty-five healthy adult females (aged 25–60 years) with upper inner arm skin laxity grades 2–4 received a single RF treatment session and were assessed at baseline, immediate post-treatment, Day 30, and Day 90. Primary endpoints included dermatologist-rated skin firmness/laxity (1–5 scale), visual and tactile smoothness (0–9), and skin hydration (0–9). Secondary endpoints included the Global Aesthetic Improvement Scale (GAIS), objective skin elasticity via Cutometer MPA 580 (R2, R5, R7), an 8-parameter dermatological safety scale, subject self-assessment (10 domains), and satisfaction survey. The contralateral untreated arm served as an instrumental control.

Results
All 25 subjects completed the study (100% retention; zero protocol deviations). At Day 90, statistically significant improvements were observed across all primary endpoints: skin firmness/laxity −33.33% ($p<0.0001$), visual smoothness +22.58% ($p<0.0001$), tactile smoothness +29.73% ($p<0.0001$), and skin hydration +24.03% ($p<0.0001$). Improvements in surface smoothness were detectable as early as the immediate post-treatment visit, preceding the deeper collagen remodelling cascade. GAIS scores showed progressive physician-rated aesthetic improvement from Day 30 (mean: 2.84) to Day 90 (mean: 2.48; $p=0.0094$), approaching 'very much improved'. Gross skin elasticity (R2) increased significantly at all post-treatment time points ($p<0.0001$), with significant between-group differences versus the untreated arm, providing instrumental corroboration. Zero adverse events were recorded across all eight dermatological safety parameters. At Day 90, 100% of subjects agreed with all self-assessment domains and rated

satisfaction as 'very satisfied'.

Conclusions

A single session of sequential monopolar/bipolar RF delivered significant, durable, and instrumentally validated improvements in skin firmness, smoothness, hydration, and elasticity over three months, with an outstanding tolerability profile and exceptional patient-reported outcomes. This multi-endpoint evidence framework strengthens the case for RF-based body contouring as a clinically credible, patient-acceptable alternative to surgical intervention and supports its integration into evidence-based aesthetic dermatology practice.

EA DV CONGRESS
VIENNA
30 SEP - 3 OCT 2026

Abstract N°: 2386

An exploratory study evaluating the complementary Effects of Microneedling and Polyrevitalizing Serum: A Comprehensive Approach to Enhance Skin Structure and Quality.

Durand Nadège[1], Roxane Henry[2], Karima Bourougaa*[2]

[1] Laboratoires Filorga, Paris, France
[2] CP SKIN HEALTH, Paris, France

Introduction

Microneedling is a widely utilized, because minimally invasive, procedure in aesthetic dermatology for skin rejuvenation[1]. By creating controlled micro-injuries to trigger collagen induction, this technique is effective in treating wrinkles, fine lines, stretch marks, and acne scarring[2,3].

However, patient expectations have now evolved towards synergistic and multifaceted rejuvenation, with skin quality emerging as a fundamental clinical parameter[4,5,6]. Experts recommend periprocedural regimens to optimize recovery and aesthetic outcomes[7].

Our study aims to evaluate whether combining microneedling with a marketed topical polyrevitalizing serum provides superior skin quality through simultaneous dermal and surface action.

Materials and Methods

This IRB-approved, monocentric, single-blind, randomized 69-day exploratory study enrolled 17 female participants (15 completed, 41-55 y.o., phototypes II/III) with dull skin and loss of firmness.

Participants were divided into two groups: Group 1 (n=6) received microneedling (MN) only and applied a neutral moisturizer twice daily. Group 2 (n=11) received MN and applied the polyrevitalizing serum twice daily, starting 48h post-MN.

MN sessions occurred every 21 days, for a total of 3 treatments over 69 days, with a needle depth of 0.3-0.5 mm, speed 0.5-1.5 mm/sec, and 2-4 passes.

Skin quality (radiance, firmness, smoothness, tone homogeneity) and tonicity were clinically assessed by a dermatologist using 10-point scales. Standardized photographs were taken at baseline and end of study through the OBSERV520X® device. Safety was monitored via post-procedure skin checks. Participant satisfaction was recorded using the Global Aesthetic Improvement Scale (GAIS) at Day 69.

Results

After 69 days, the group 1(MN alone) did not show significant improvement in skin quality parameters. Skin tonicity parameter was significantly improved from D23 to D69, +24%* and +29%* respectively (*p<0.05).

However, the group 2 (combined treatment) showed significant improvements in skin quality parameters overtime until D69 :

- radiance: +39% (p<0.01),

- skin tone homogeneity: +24% ($p<0.05$),
- smoothness: +33% ($p<0.01$)
- firmness: +20% ($p<0.05$).

Tonicity was also improved by +24% ($p<0.05$).

Compared to microneedling alone, the combined therapy presents significantly superior clinical results in skin radiance (+39%, $p<0.05$) and smoothness (+33%, $p<0.01$). Non significant Improvements in skin tone homogeneity and firmness were also observed

In addition, while skin tonicity improved across the cohort, no statistical difference was observed between the two groups, suggesting that tonicity enhancement is driven by the mechanical action of microneedling.

High participant satisfaction was confirmed by the GAIS, with 100% of the group 2 (combined treatment) perceiving visible aesthetic improvements, vs. only 80% for the group 1 (MN alone). The protocol was proven safe, with excellent clinical tolerance and no adverse events reported.

Conclusions

This exploratory study shows that combining MN with a polyrevitalizing serum results in significant improvement in the different parameters assessed. Indeed, radiance, skin tone homogeneity, smoothness, and firmness and tonicity were significantly improved in the group receiving the combined treatment. While MN alone specifically drives tonicity improvement, the combination significantly amplifies skin radiance and smoothness parameters. Thus, this exploratory study underlines the potential of combining this serum with MN for comprehensive skin management and addressing patient expectations for multifaceted rejuvenation. Future research should confirm these observations on higher patient numbers and could investigate the combination of the polyrevitalizing serum with deeper MN for more specific conditions like acne scars.

EA DV CONGRESS
VIENNA
30 SEP - 3 OCT 2026

Abstract N°: 2394

Combined Efficacy of Calcium Hydroxyapatite Injections and a Topical Polyrevitalizing Serum on Skin Quality: An Exploratory Split-Face Analysis.

Ana SILVA GUERRA[1], Durand Nadège[2], Roxane Henry[3], Karima Bourougaa*[3]

[1] Clinica Ana Silva Guerra, Lisbon, Portugal

[2] Laboratoires Filorga, Paris, France

[3] CP SKIN HEALTH, Paris, France

Introduction

Injectables have surged by 44% since 2020, exceeding 15 million procedures in 2024. This growth is largely driven by regenerative fillers like Calcium Hydroxylapatite (CaHA) and Poly-L-Lactic Acid (PLLA), with an increase of 87.7% and 430.7%, respectively[1].

This reflects a shift toward an "aesthetic of health," where CaHA is crucial due to its role as a biostimulator, promoting cell proliferation, collagen and elastin synthesis, and stimulating angiogenesis[2]. Clinically, CaHA injections improve firmness, smoothness, tone, and radiance[3], fulfilling the modern desire for naturally rejuvenated skin.

However, achieving patient-perceived results often requires time and multi-session protocols spanning months, which may limit accessibility.

Therefore, integrating topical applications moving to tailored protocols could enhance and accelerate skin quality improvements.This study aims to assess benefits of applying a polyrevitalizing serum post-CaHA injection, evaluating whether the serum significantly enhances skin quality and patient satisfaction compared to CaHA injection alone.

Materials and Methods

A 12-week, monocentric, open-label, split-face, IRB approved study enrolled 20 subjects (30-50 years old, phototypes I-III) with skin laxity and a dull complexion.

On Day 0, all participants received a standardized subcutaneous injection of calcium hydroxylapatite (*Synthetic Calcium Hydroxyapatite microspheres (55.7%) in a cross-linked sodium hyaluronate gel, containing 0.3% (w/w) lidocaine HCl, 1.25mL syringe*).

Subjects then applied a marketed polyrevitalizing serum twice daily to one side of the face (treated) and a neutral cream to the contralateral side (control) for the study duration.

Clinical evaluations, performed every 4 weeks, assessed firmness, skin tone homogeneity, texture, radiance, tonicity, and hydration through clinical scoring. Standardized photography documented visual improvements.

Finally, patients completed a self-assessment questionnaire using the Global Aesthetic Improvement Scale (GAIS) for perceived satisfaction and efficacy.

Results

Over the 12-week study, both sides showed progressive and significant improvement of skin quality parameters (Table 1).

Also, significant differences were noticed between the two sides of the face on all the skin quality parameters. Indeed, compared to CaHA alone, the serum- treated side achieved an amplified and significant improvement in key skin quality parameters at 4 weeks to the end of the study.

In addition, the treated side was also significantly improved in tonicity (+40%,p<0.001) and moisture (+46%,p<0.001) after 12 weeks.

Standardized pictures confirmed those visible improvements.

Finally, patient-reported outcomes corroborated these findings: 90% of subjects reported overall satisfaction, and 95% noted a visible enhancement in their skin's "healthy look," all with an excellent safety profile.

Table 1: % improvement evaluated by clinical scoring compared to D0 (**p<0.01, ***p<0.001)

	4 weeks			8 weeks			12 weeks		
	CaHA alone	CaHA + Serum	% of improvement between groups	CaHA alone	CaHA + Serum	% of improvement between groups	CaHA alone	CaHA + Serum	% of improvement between groups
Radiance	+14%***	+28%***	+100%***	+18%**	+47%***	+161%***	+32***	+68%***	+112,5%***
Skin tone homogeneity	+9%**	+18%***	+100%***	+14%**	+42%***	+200%***	+19%**	+58%***	+205%***
Smoothness	+14%**	+28%***	+100%***	+20%***	+43%***	+115%***	+30%***	+58%***	+93%***
Firmness	+24%***	+39%**	+62,5%***	+36%***	+63%***	+75%***	+48%***	+86%***	+79%***

Table 1: % improvement evaluated by clinical scoring compared to D0 (**p<0.01, ***p<0.001)

Conclusions

This exploratory study showed a significant improvement in skin quality parameters—radiance, smoothness, firmness, and skin tone homogeneity—when a topical polyrevitalizing serum was integrated with a single Calcium Hydroxylapatite (CaHA) injection. In addition, enhanced tonicity and hydration were also observed.

The evolution profiles suggest the polyrevitalizing serum accelerates the achievement of these results. This confirms the complementary and dual-action 'biohacking' effect by bridging structural stimulation with intensive surface revitalization, to optimize aesthetic outcomes. Most importantly, this dual-action approach directly addresses the modern patient’s shift toward physiologically superior, natural outcomes where skin health and structural integrity are prioritized over simple correction. However, further research is needed to evaluate the long-term efficacy and the impact of multiple CaHA injections with this approach.

EA DV CONGRESS
VIENNA
30 SEP - 3 OCT 2026

Abstract N°: 2411

Beyond Wrinkle Reduction: An Exploratory Study of a Topical Regimen Combined with BoNT-A Injections for Facial Rejuvenation and Skin Quality improvement

Durand Nadège*[1], Roxane Henry[1], Karima Bourougaa[1]

[1] LABORATOIRES FILORGA, PARIS, France

Introduction

By targeting muscle relaxation, Botulinum toxin type A (BoNT-A) is the gold standard for treating dynamic facial wrinkles, mainly in the upper face (forehead, glabellar lines). In 2024, these injections represented 38.4% of non-surgical procedures1. Its effect is temporary, peaking at one month and lasting 3 to 4 months, requiring repeated injections2. Due to growing demand, we developed a dedicated anti-wrinkle range: a serum with a neuropeptidic complex for muscle relaxation, and a cream that remodels the dermal matrix by stimulating collagen, elastin, and hyaluronic acid3 The study's objective is to evaluate this two-step regimen combined with standard BoNT-A protocol.

Materials and Methods

Following IRB approval, a 6-month clinical study was conducted on 3 groups of 37 women each (35-65 years old, phototypes I-IV, 50% sensitive skin). Group 1 received one BoNT-A injection on forehead and glabella wrinkles (avg. 18 dose/unit per area) and applied a neutral cream twice daily. Group 2 applied the test two-step regimen (serum + cream) twice daily. Group 3 received the BoNT-A injection and applied the tested regimen. Evaluations were carried out at Baseline, Day 7, and Monthly (M1-M6) via dermatologist clinical scoring, global aesthetic improvement scale and self-assessment questionnaires. Adverse events were also monitored.

Results

Both Group 1 and Group 3 showed significant wrinkles improvement in BoNT-A-treated areas (forehead and glabella) as early as Day 7. This effect peaked at Month 3 for Group 1 (glabella: +31%***, forehead: +30%*$* and month 1 for Group 3 (glabella: +32%***, forehead: +36%*** (, then gradually declined over 6month study (***p<0.001). While efficacy on treated wrinkles (forehead and glabella) was similar, the adjunctive topical regimen (Group 3) showed significant superiority over Group 1 on untreated facial areas and overall skin quality. Indeed, compared to BoNT-A monotherapy (Group 1), the combined protocol (Group 3) showed statistically superior improvements (p<0.05) in untreated facial areas and skin quality parameters, with inter-group superiority emerging progressively (Table 1).

In Group 2, subjects showed continuous improvement in forehead and glabellar wrinkles from Month 1 to Month 6, reaching (+7%*** and +9%***, respectively, after 6 months, (***p<0.001). Interestingly, the routine's monotherapy efficacy on glabellar wrinkles represented 25.65% of BoNT-A's overall effectiveness. However, it outperformed the BoNT-A group in enhancing skin smoothness from Month 2 (+6%, p<0.01 vs. -2%, not significant for Group 1). Group 2 also shows gradually improved crow's feet, under-eye wrinkles, firmness , upper lip wrinkles and smoothness over the 6-month study.
Finally, both investigator-assessed GAIS and subject self-assessments confirmed greater aesthetic improvement and higher satisfaction with the topical regimen adjunct to BoNT-A injections: 92% of subjects felt this regimen prolonged the visibility of toxin effects on wrinkles, and 100% noted improved skin quality. No adverse events were reported.

Table 1: Percentages of significant improvement for Group 1 and Group 3 on non-injected areas

Parameter (area not treated by BoNT-A)	Time Point	Group 1	Group 3	Inter-group comparison (Group 3 vs Group 1)
Crow's Feet Wrinkles	Month 2	+2%**	+6% ***	+200% **
	Month 6	+3.1%***	+12.4% ***	+300%**
Skin Smoothness	Month 3 onwards	-2% (NS)	+12% **	+700%**
Skin Firmness	Month 4	+5% **	+11% ***	+120**
	Month 4	+7%***	+20%***	+185%***
	Month 6	+6% ***	+24% ***	+300%***
Under-Eye Wrinkles	Month 6	+6% ***	+13% ***	+116%**
Upper Lip Wrinkles	Month 6	+2% (NS)	+8% ***	+300%**

(**p<0.01, ***p<0.001)

Conclusions

BoNT-A effectively treats specific upper facial dynamic wrinkles, but often leaves other areas unaddressed. This study shows that adding a daily topical regimen (serum and anti-wrinkle cream) to BoNT-A injections successfully bridges this gap. The combined approach significantly reduces wrinkles in BoNT-A untreated areas (crow's feet, under-eye, upper lip) while providing overall skin quality enhancement, such as smoothness and firmness parameters. Both dermatologist and subject evaluations confirm this synergistic protocol maximizes aesthetic outcomes and yields superior patient satisfaction compared to BoNT-A alone.

EADV CONGRESS
VIENNA
30 SEP - 3 OCT 2026

Abstract N°: 2434

A Multicenter, Randomized, Evaluator-Blinded, Parallel-Group, Non-Inferiority Trial of a Novel Monopolar Radiofrequency Modality in the Treatment of Facial Wrinkles: Efficacy and Safety Analysis

Yimeng Wang*[1], XIN GUAN[1], Wenting Wu[1], Zixue Chen[2], Yucheng Huang[3], Hua Zhang[4], Yu Han[5], WENHUI WANG[1]

[1] Peking university third hospital, Beijing, China
[2] Zhengzhou Central Hospital Affiliated to Zhengzhou University, Zhenzhou, China
[3] The Fifth Clinical Medical College of Henan University of Chinese Medicine, Zhenzhou, China
[4] The Fifth Clinical Medical College of Henan University of Chinese Medicine, Beijing, China
[5] Peking University School and Hospital of Stomatology,, Beijing, China

Introduction
Radiofrequency (RF) is a minimally invasive modality for facial rejuvenation. This trial compared a novel monopolar RF (MRF) device to a standard device for reducing facial wrinkles.To evaluate the efficacy and safety of a novel MRF device for improving facial wrinkles

Materials and Methods
This multicenter, randomized, evaluator-blinded, parallel-controlled, non-inferiority clinical trial was conducted across four dermatology departments between June 2023 and April 2024. Participants (n=278) were enrolled and randomly assigned in a 1:1 ratio to the experimental or control group. Participants underwent a single facial treatment, with follow-up assessments at 7, 30, and 90 days post-treatment. The primary outcome was the Fitzpatrick Wrinkle and Elastosis Scale score 90 days post-treatment.

Results
The experimental group(n=120) demonstrated a significantly higher overall efficacy rate than the control group(n=119) (P=0.011). Non-inferiority was confirmed, with the experimental device demonstrating superior improvement in the periorbital area (83.3% vs. 70.0%, P=0.018) and nasolabial folds (84.2% vs. 64.7%, P=0.001). The investigator and participant Global Aesthetic Improvement Scale scores indicated significantly greater aesthetic improvements in the experimental group (P=0.006 and P<0.001, respectively). The experimental group reported higher immediate post-treatment pain scores than the control group (P=0.001); however, the overall satisfaction on day 90 was significantly higher in the experimental group (P=0.001). Adverse event rates were comparable, and no device malfunctions occurred.

Conclusions
The novel MRF device was effective in improving facial wrinkles, with superior efficacy in specific areas and higher patient satisfaction, supporting its clinical use.

EA DV CONGRESS
VIENNA
30 SEP - 3 OCT 2026

Abstract N°: 2453

Clinical and Biological Evaluation of a New Serum Integrating Micro-Growth Factor Technology: Significant Impact on Facial Volumization and Skin Architecture Restructuring

Durand Nadège*[1], Marwa El Hajoui[1], Coline Haxaire[2], Alexandra D'Arcangelis[2]

[1] LABORATOIRES FILORGA, PARIS, France
[2] CP SKIN HEALTH, PISCATAWAY, United States

Introduction

Skin aging is characterized by major structural alterations, including a compromised Dermo-Epidermal Junction (DEJ), a weakened extracellular matrix (ECM)1, and a loss of efficient cell-to-cell communication2. These changes lead to clinical signs such as sagging, loss of volume, and deep wrinkles. To address these changes, an innovative "Micro-Growth Factor" (MGF) complex was developed, including a biomimetic Fibroblast Growth Factor FGF peptide and additional peptides to improve ECM structure and skin elasticity. This work investigates the *ex vivo* and *in vivo* efficacy of an innovative topical serum incorporating this technology.

Materials and Methods

Active ingredients were first evaluated *in vitro* on cultured human fibroblasts to determine the optimal synergistic peptide ratio. Subsequently, *ex vivo* studies on human skin explants over 7 days quantified biomarkers for collagen (Collagen V, Lumican, pro-Collagen I) and elasticity (Elastin, MFAP4) via immunostaining and qRT-PCR. A robust 3-month clinical study, IRB-approved and under dermatological control, tested the investigational product on 32 subjects (40-60 years old, phototypes II-IV, various skin types including sensitive) presenting a lack of firmness. Evaluations included clinical scoring, bio-instrumentation (Cutometer) for firmness/elasticity, 3D AEVA for lower face ptosis and cheekbone volume, and self-assessment.

Results

In vitro testing of individual peptides and their combination, in fibroblast culture, showed asynergistic upregulation on the gene expression of COL4A1, elastin, and fibrillin-1, as well as the stimulation of procollagen 1 protein ($p<0.05$). Thus, this complex promotes DEJ integrity, ECM structure, and dermal restructuring . These results helped to identify the optimal ratio of the peptides to be used in the final serum formulation.

Ex vivo evaluation of the topical serum demonstrated a significant upregulation of the expression of Pro-Collagen I (+69%*), Collagen V (+101%*), Lumican (+67%*), and increased elastin fiber length (+121%*), (*$p<0.05$).

In vivo instrumental measurements using AEVA 3D showed a statistically significant decrease in crow's feet wrinkles count (-8.1%, $p<0.05$) after 84 days. Furthermore, the serum significantly increased cheekbone volume (+5.5%, $p<0.05$ at D28) and reduced the volume of lower face ptosis (-9.8%, $p<0.05$ at D56). Biomechanical assessments via Cutometer® showed that skin firmness (R0) significantly improved with a 15.1%, 11.0%, and 10.3% ($p<0.05$) decrease after 28, 56, and 84 days respectively. Similarly, skin elasticity (R2) significantly increased by 10.2%, 12.8%, and 10.7% ($p<0.05$) at the same time points. Clinical evaluations by the dermatologist supported the improvement observed on the instrumental data, revealing statistically significant increases in cutaneous smoothness (+28.9%*), firmness (+20.5%*), elasticity (+17.9%*), and cheek volume (+8.4%*) after 84 days of application (*$p<0.05$).

Finally, subjective assessments indicated high satisfaction, with 96.9% of the subjects agreeing their skin is less

saggy and 90.6% were satisfied with the results obtained.

Conclusions

Thanks to its optimal synergistic ratio, the developed Micro Growth Factor peptide complex, through its optimal synergistic ratio, effectively promotes skin integrity by upregulating key structural components of the DEJ and ECM, notably Collagen V and Lumican. These biological improvements translate into significant clinical benefits, providing lifting, volumizing, and firming benefits. This targeted peptide strategy offers a high-performance, non-invasive alternative or complementary strategy to significantly improve the architecture and firmness of aging skin.

EADV CONGRESS
VIENNA
30 SEP - 3 OCT 2026

Abstract N°: 2455

CO2 laser as an additive therapy for cutaneous symptoms of systemic amyloidosis associated with multiple myeloma - a case report

Krzysztof Kanabaj*[1], Aleksandra Dańczak-Pazdrowska[1]

[1] Department of Dermatology, Poznan University of Medical Sciences, Poznań, Poland

Introduction

Systemic amyloidosis (SA) remains a difficult-to-treat disease, especially in its primary form. The secondary form requires proper management of the underlying condition however, such therapy may be inefficient in treating skin symptoms.

Case Presentation

Herein we present a case of a 72-year-old woman, whose diagnosis of cutaneous amyloidosis led to the discovery of multiple myeloma (MM). The patient was initially diagnosed with colloid milium due to the clinical presentation - mildly pruritic, widespread, whitish papules located on the dorsal aspects of the hands, forehead and retroauricular area, but due to relatively benign symptoms of extrinsic aging and no history of chronic sun exposure or sunburns, a biopsy was taken, which revealed homogeneous eosinophilic amorphous masses of amyloid in the papillary dermis, which were positive on PAS and Congo red staining. Additional immunohistochemistry staining for cytokeratin was performed, in order to differentiate the lesions from colloid milium.

Due to concurrent paraproteinemia and monoclonal gammopathy, the patient was referred to a hematologist for further evaluation, who later confirmed the diagnosis of MM and the systemic form of light chain (AL) amyloidosis. The patient was treated with dexamethasone and lenalidomide, which turned out to be effective. However, during treatment the skin symptoms persisted with little to no improvement, with the appearance of bruising and skin atrophy as a side effect of systemic steroids.

Due to CA's recalcitrant nature, a surgical approach was taken with the use of an ablative surgical CO2 laser in ultrapulse mode. High energy (300 mJ) with short pulse duration (100 ms) settings were applied to minimize the thermal damage to surrounding tissues. The main consideration was the pain associated with the procedure, thus a twofold approach to anaesthesia was taken - a topical mixture of 5% lidocaine and 5% prilocaine under occlusion and, if a finger was operated on, the additional Oberst block.

Initially, the nondominant hand was operated on, which required 4 treatment sessions over the course of 4 months. Due to the significant improvement and no relapse of the symptoms, the dominant hand followed, which required 3 additional procedures.

Conclusion

In conclusion, the CO2 laser remains a viable option for the treatment of cutaneous symptoms of systemic amyloidosis with procedural pain and its relatively long duration being the main concerns.

EA DV CONGRESS
VIENNA
30 SEP - 3 OCT 2026

Abstract N°: 2456

Beyond Wrinkle Reduction: An Exploratory Study of a Topical Regimen Combined with BoNT-A Injections for Facial Rejuvenation and Skin Quality improvement

Durand Nadège*[1], Roxane Henry[1], Karima Bourougaa[2]

[1] LABORATOIRES FILORGA, PARIS, France

[2] CP SKIN HEALTH, PISCATAWAY, United States

Introduction

By targeting muscle relaxation, Botulinum toxin type A (BoNT-A) is the gold standard for treating dynamic facial wrinkles, mainly in the upper face (forehead, glabellar lines). In 2024, these injections represented 38.4% of non-surgical procedures1. Its effect is temporary, peaking at one month and lasting 3 to 4 months, requiring repeated injections2. Due to growing demand, we developed a dedicated anti-wrinkle range: a serum with a neuropeptidic complex for muscle relaxation, and a cream that remodels the dermal matrix by stimulating collagen, elastin, and hyaluronic acid3 The study's objective is to evaluate this two-step regimen combined with standard BoNT-A protocol.

Materials and Methods

Following IRB approval, a 6-month clinical study was conducted on 3 groups of 37 women each (35-65 years old, phototypes I-IV, 50% sensitive skin). Group 1 received one BoNT-A injection on forehead and glabella wrinkles (avg. 18 dose/unit per area) and applied a neutral cream twice daily. Group 2 applied the test two-step regimen (serum + cream) twice daily. Group 3 received the BoNT-A injection and applied the tested regimen. Evaluations were carried out at Baseline, Day 7, and Monthly (M1-M6) via dermatologist clinical scoring, global aesthetic improvement scale and self-assessment questionnaires. Adverse events were also monitored.

Results

Both Group 1 and Group 3 showed significant wrinkles improvement in BoNT-A-treated areas (forehead and glabella) as early as Day 7. This effect peaked at Month 3 for Group 1 (glabella: +31%***, forehead: +30%*$* and month 1 for Group 3 (glabella: +32%***, forehead: +36%*** (, then gradually declined over 6month study (***p<0.001). While efficacy on treated wrinkles (forehead and glabella) was similar, the adjunctive topical regimen (Group 3) showed significant superiority over Group 1 on untreated facial areas and overall skin quality. Indeed, compared to BoNT-A monotherapy (Group 1), the combined protocol (Group 3) showed statistically superior improvements (p<0.05) in untreated facial areas and skin quality parameters, with inter-group superiority emerging progressively (Table 1).

In Group 2, subjects showed continuous improvement in forehead and glabellar wrinkles from Month 1 to Month 6, reaching (+7%*** and +9%***, respectively, after 6 months, (***p<0.001). Interestingly, the routine's monotherapy efficacy on glabellar wrinkles represented 25.65% of BoNT-A's overall effectiveness. However, it outperformed the BoNT-A group in enhancing skin smoothness from Month 2 (+6%, p<0.01 vs. -2%, not significant for Group 1). Group 2 also shows gradually improved crow's feet, under-eye wrinkles, firmness , upper lip wrinkles and smoothness over the 6-month study.

Finally, both investigator-assessed GAIS and subject self-assessments confirmed greater aesthetic improvement and higher satisfaction with the topical regimen adjunct to BoNT-A injections: 92% of subjects felt this regimen

prolonged the visibility of toxin effects on wrinkles, and 100% noted improved skin quality. No adverse events were reported.

Table 1: Percentages of significant improvement for Group 1 and Group 3 on non-injected areas

Parameter (area not treated by BoNT-A)	Time Point	Group 1	Group 3	Inter-group comparison (Group 3 vs Group 1)
Crow's Feet Wrinkles	Month 2	+2%**	+6% ***	+200% **
	Month 6	+3.1%***	+12.4% ***	+300%**
Skin Smoothness	Month 3 onwards	-2% (NS)	+12% **	+700%**
Skin Firmness	Month 4	+5% **	+11% ***	+120**
	Month 4	+7%***	+20%***	+185%***
	Month 6	+6% ***	+24% ***	+300%***
Under-Eye Wrinkles	Month 6	+6% ***	+13% ***	+116%**
Upper Lip Wrinkles	Month 6	+2% (NS)	+8% ***	+300%**

(**p<0.01, ***p<0.001)

Conclusions

BoNT-A effectively treats specific upper facial dynamic wrinkles, but often leaves other areas unaddressed. This study shows that adding a daily topical regimen (serum and anti-wrinkle cream) to BoNT-A injections successfully bridges this gap. The combined approach significantly reduces wrinkles in BoNT-A untreated areas (crow's feet, under-eye, upper lip) while providing overall skin quality enhancement, such as smoothness and firmness parameters. Both dermatologist and subject evaluations confirm this synergistic protocol maximizes aesthetic outcomes and yields superior patient satisfaction compared to BoNT-A alone.

EA DV CONGRESS
VIENNA
30 SEP - 3 OCT 2026

Abstract N°: 2543

The social media skin: Cosmetic dermatology meets psychological health: A 30-Patient Case Series on the Biological Cost of the Social Media Aesthetic.

Farhat Khan*[1]

[1] Bansal hospital, bhopal, India

Introduction

In the era of Pinterest-perfect skin and AI-driven filters, the dermatology clinic has become the frontline for a new clinical phenomenon: Social Media Skin. Patients increasingly from younger demographics, are presenting with iatrogenic skin damage caused by complex, trending skincare routines and a psychological Filter Gap. This study investigates the intersection of cosmetic over-processing and Filter Dysmorphia, where the patient's clinical goal is a biologically impossible, poreless digital ideal

Materials and Methods

A 12-month prospective observational study was conducted on 30 patients (ages 11–32; 26 female, 4 male) presenting with new-onset inflammatory skin conditions linked to viral skincare trends. Criteria for inclusion included a self-reported multi-step routine (5 plus step skincare routine) and use of active ingredients (Retinoids, AHAs/BHAs) without medical supervision. Assessments included:

1. Clinical Grading: Documentation of skin barrier impairment (Perioral Dermatitis, Irritant Contact Dermatitis).
2. The Filter Gap Survey: A standardized questionnaire measuring the discrepancy between a patient's real-life appearance and their social media presence.
3. Ingredient Analysis: Audit of patient-provided product lists against clinical needs.

Results

The study identified three significant patterns defining the 2026 clinical landscape:

- The Sephora Kid Barrier Crisis:26% of the cohort (8/30) were under age 15, presenting with severe barrier disruption from high-potency anti-aging actives (Vitamin C & Retinol). In 100% of these cases, the primary source of product recommendation was a social media influencer.
- Barrier Burnout:53% (16/30) of patients presented with Perioral Dermatitis or Steroid-induced Rosacea secondary to over-exfoliation and slugging with incompatible comedogenic products.
- Filter Dysmorphia**:**83% (25/30) of patients expressed pathological dissatisfaction with normal skin features (pores, fine lines, texture), citing Glass Skin filters as their baseline for healthy skin.
- Iatrogenic Sensitization:20% (6/30) developed chronic hypersensitivity to previously tolerated ingredients, directly correlating with a thinned stratum corneum from chronic TikTok-trending peel solution.

Conclusions

Social Media Skin is a dual-diagnosis of physical barrier damage and psychological dysmorphia. In this 30-patient

series, the primary pathogen was not biological, but digital misinformation. We propose that dermatologists move toward a Minimalist & Mindful approach. This includes Skincare Fasting to repair the barrier and Visual Literacy counselling to bridge the Filter Gap. Clinicians must lead the shift from Glass Skin ideals back to Real Skin health to prevent a generation-wide epidemic of chronic skin sensitivity.

EA DV CONGRESS
VIENNA
30 SEP - 3 OCT 2026

Abstract N°: 2576

Management of Delayed-Onset Nodules Following Hyaluronic Acid Filler Injections: A Systematic Review

Samantha Bestavros*[1], Armaan Dhanoa[1], Yekta Ghane[2], Nicholas Chiang[1], Heather Zhao[1], Javad Ramezani[3, 4, 5], Aida Owlia[5, 6, 7, 8, 9]

[1] Temerty Faculty of Medicine, University of Toronto, Toronto, Canada

[2] School of Medicine, Tehran University of Medical Sciences, Tehran, Iran

[3] Department of Family Medicine, Simon Fraser University School of Medicine, Simon Fraser University, Surrey, Canada

[4] Department of Family Practice, University of British Columbia Faculty of Medicine, University of British Columbia, Vancouver, Canada

[5] Nava Medical Centre, Burnaby, Canada

[6] Division of Emergency Medicine, Temerty Faculty of Medicine, University of Toronto, Toronto, Canada

[7] Department of Emergency Medicine, Queen's University School of Medicine, Queen's University, Kingston, Canada

[8] Vancouver General Hospital, Vancouver, Canada

[9] Humber River Hospital, North York, Canada

Introduction

Hyaluronic acid (HA) filler injections are widely used as a safer alternative to permanent dermal fillers and surgical rejuvenation. Although HA naturally occurs in the skin's extracellular matrix, HA fillers have been linked to complications. Delayed-onset nodules (DONs), defined here as nodules, granulomas, or abscesses, may arise after triggering events, such as vaccination or systemic illness. Management of these DONs lacks consensus, as reported treatment strategies and clinical outcomes vary. This systematic review examines treatment approaches and outcomes for patients with DONs following HA filler and explores associations between potential triggering events and these complications.

Materials and Methods

Scopus, MEDLINE, and Embase were searched from inception to May 2025 per PRISMA guidelines. 120 studies reporting treatment outcomes for DONs following HA filler were identified, including 71 case reports, 27 case series, 6 cohort studies, 5 randomized controlled trials, 5 retrospective chart reviews, 4 narrative reviews with original cases, and 2 prospective pilot studies.

Results

We report on 272 patients, predominantly female (97.2%, n=175/180), with a mean age of 51.1 (range: 18-90) years. Mean time from HA filler injection to DON was 34.8 (range: 0.1-780) weeks. Of 329 DONs reported, 65.0% (n=214/329) were nodules, 24.0% (n=79/329) were granulomas, and 10.9% (n=36/329) were abscesses. Median time from reported triggers to DONs was 1.4 (range: 0-130) weeks. Commonly reported potential triggers included dental work (23.0%, n=14/61), COVID-19 vaccination (18.0%, n=11/61), and flu-like symptoms (9.8%, n=6/61). Mean treatment duration was 13.4 (range: 0.1-120) weeks. After treatment, 82.4% (n=224/272) of patients achieved complete response, 15.4% (n=42/272) achieved partial response, and 2.2% (n=6/272) had no

response. Complete response was defined as resolution with no permanent medical or cosmetic sequelae. Most patients received combination therapy (67.3%, n=183/272), while 32.7% (n=89/272) were managed with monotherapy. As many patients received multiple treatments, treatment instances were quantified to capture the frequency and effectiveness of each modality. Of 752 total treatment instances across all patients, intralesional therapies were the most employed (27.5%, n=207/752), resulting in complete response in 80.7% (n=167/207) of instances and partial response in 18.4% (n=38/207). Hyaluronidase was the primary intralesional agent (61.8%, n=128/207), yielding 83.6% (n=107/128) complete response. Systemic antibiotics were the second most frequently used therapy (24.2%, n=182/752), followed by surgical procedures (13.6%, n=102/752), systemic steroids (12.8%, n=96/752), systemic pharmacological agents (11.7%, n=88/752), conservative approaches (5.6%, n=42/752), topical treatments (3.6%, n=27/752), and energy-based therapies (1.1%, n=8/752). Notably, surgical intervention resulted in complete response in 89.2% (n=91/102) of instances, with a comparable rate for conservative management (88.1%, n=37/42). Incision and drainage (54.9%, n=56/102) and watchful waiting (47.6%, n=20/42) were the most common approaches within each category, respectively.

Conclusions

Treatment outcomes for HA filler-associated DONs were generally favourable, with most patients achieving complete response, though triggers such as dental work or vaccination may precipitate their development. Two or more treatment modalities, such as intralesional, systemic, or surgical therapies, were most frequently employed. Shared decision-making between clinicians and patients should inform treatment while considering severity, symptoms, and patient preferences. Our findings may help refine treatment strategies and support evidence-informed clinical guidelines for HA filler DONs. Future research is needed to better understand triggers and determine optimal standardized management. Limitations of this review include protocol heterogeneity, outcome variability, and potential reporting bias.

EADV CONGRESS
VIENNA
30 SEP - 3 OCT 2026

Abstract N°: 2583

Pulsed dye laser for rosacea-like erythematous facial plaques in biopsy-proven folliculotropic mycosis fungoides: a therapeutic challenge in an immunosuppressed renal transplant recipient

Byung Jin Kim*[1], Rosa Moran[2], Giles Dunnill[2], Daniel Keith[1]

[1] Bristol Laser Centre, Southmead Hospital, Bristol, United Kingdom

[2] Dermatology, Bristol Royal Infirmary, Bristol, United Kingdom

Introduction

Folliculotropic mycosis fungoides (FMF) is an uncommon clinicopathological variant of cutaneous T-cell lymphoma, with predilection for follicular structures and frequent head and neck involvement. FMF has a heterogeneous clinical presentation, including acneiform, papular, nodular and erythematous plaque-like lesions, and may mimic inflammatory dermatoses such as rosacea, contributing to diagnostic delay. Early-stage disease may be treated with topical therapies; however, these may be limited by site, tolerability and comorbidity. Pulsed dye laser (PDL) is established for treating erythema and telangiectasia in erythematotelangiectatic rosacea, but its role in MF-associated facial erythema has not been reported in the literature.

Case Presentation

A 49-year-old woman with Fitzpatrick type II skin had stage IB folliculotropic MF diagnosed 5 years previously. Her medical history included renal transplantation in 1998, with ongoing immunosuppression using tacrolimus and low-dose prednisolone. She developed persistent, well-demarcated, florid erythematous plaques involving the cheeks, chin, forehead and neck, with fixed telangiectasia, scale and poikilodermatous change. Episodic flushing was triggered by heat and other typical rosacea triggers, but there were no papules or pustules. The facial eruption was initially managed as rosacea and failed to respond to ivermectin cream, topical tacrolimus or a 3-month tetracycline course. A facial skin biopsy was supportive of FMF rather than rosacea. The appearance was distressing and socially limiting for the patient, with a Dermatology Life Quality Index score of 15.

Targeted 308-nm excimer laser had been considered as a treatment, but was avoided due to concerns about increased keratinocyte carcinoma risk in the context of ongoing immunosuppression following renal transplantation. She was receiving topical chlormethine, with limited benefit to the facial plaques. Given the rosacea-like morphology, including erythema and telangiectasia, a test area of PDL was undertaken to assess tolerability and early clinical response, aiming for a purpuric endpoint. The aim of treatment was reduction of erythema and telangiectasia where topical and oral rosacea treatments had failed and UV-based options were less attractive.

Conclusion

This case highlights biopsy-proven folliculotropic MF presenting with a rosacea-like erythematous and telangiectatic facial rash, associated with substantial psychosocial burden. In selected patients, particularly where immunosuppression limits ultraviolet-based therapy and clinical features overlap with erythematotelangiectatic rosacea, PDL may represent a pragmatic adjunctive skin-directed approach.

EA DV CONGRESS
VIENNA
30 SEP - 3 OCT 2026

Abstract N°: 2653

Reversing Signs of Hair Aging: Clinical Evidence of Gray Hair Pigmentation and Hair Quality Improvement

Layane Cavalcante[1], Lucia Holanda[1], Giulia Maciente[1], Mauricio Frazilho[1], Carla Favaro[1], Marisa Sacuragui[1], Carla Lopes[2], Ana Lúcia Pinheiro*[2], Mayara Ferreira[2], Viviane Albarici[2], Juliana Pinto[2]

[1] Mantecorp Skin Care, Hynova, São Paulo, Brazil

[2] Kosmoscience Group, Valinhos, Brazil

Introduction

Hair graying is one of the most prominent manifestations of aging, characterized by the progressive loss of hair pigmentation. It is often stated, as a general rule, that approximately 50% of individuals have 50% gray hair by the age of 50. This process is primarily associated with reduced melanin production, driven by melanocyte dysfunction and loss, and influenced by genetic, physiological, environmental, lifestyle, nutritional, and medical factors.

While it does not compromise physical health, the appearance of gray hair is often perceived as an early and visible sign of aging, with meaningful impacts on self-image, confidence, and overall psychological well-being. As a result, there is a growing consumer demand for effective, non-invasive cosmetic strategies capable of restoring a more youthful hair appearance. In response to this demand, the cosmetic and pharmaceutical industries have increasingly invested in multifunctional formulations designed not only to improve hair aesthetics but also to promote scalp health, which is for maintaining hair fiber quality and pigmentation.

This study aimed evaluate gray hair color recovery using image analysis, as well as improvements in hair health and quality based on perceived efficacy, following the use of SHAMPOO DC-021051-33 and LOTION DC-021052-06. Both formulations contain a combination of biotin, nanoencapsulated trichogenic auxin, and a blend of amino acids.

Materials and Methods

This study was approved by the Research Ethics Committee (CAAE 68991223.1.0000.5514). A total of 17 participants completed the study (mean age: 49 ± 7 years) after 90 days of home use of the products. For color recovery assessment, a region of interest (ROI) containing gray hair was defined according to each participant's anatomical characteristics. Color variation (C) within the ROI was quantified using color histogram analysis, where lower C values indicate reduced gray hair presence. Perceived efficacy was evaluated using a 5-point Likert scale. Attributes were considered validated when ≥70% of participants reported agreement.

Results

After 90 days of use, a significant reduction ($p < 0.05$) in gray hair color variation was observed, ranging from 13.7% to 20.4%, with 71% of the research participants showed recovery of gray hair coloration.

Perceived efficacy results further supported these findings, with all attributes related to hair health and quality achieving acceptance rates above 70% after both 45 and 90 days of home use. These outcomes highlight consistent improvements not only in hair pigmentation but also in overall hair condition. The Figure 1 summarizes the sensory evaluation results based on perceived efficacy.

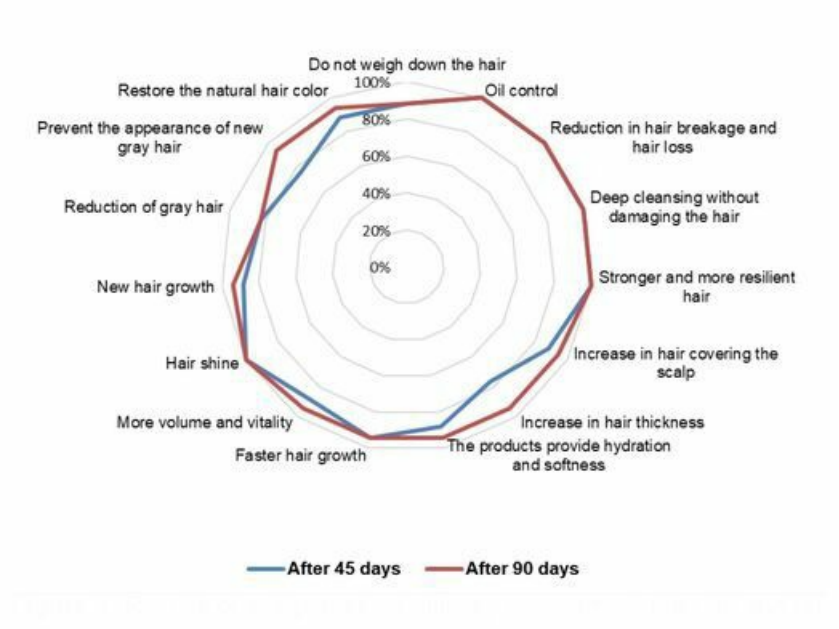

Figure 1. Results of self-perceived efficacy assessment after 45 and 90 days of use.

Conclusions

The combine use of SHAMPOO DC-021051-33 and LOTION DC-021052-06 for 90 days resulted in a significant improvement in gray hair appearance, as demonstrated by objective color recovery and high levels of perceived efficacy.

These findings indicate that the formulation effectively supports the restoration of hair pigmentation while enhancing overall hair health and quality, representing a promising non-invasive cosmetic approach for managing age-related hair changes.

EA DV CONGRESS
VIENNA
30 SEP - 3 OCT 2026

Abstract N°: 2654

Medical-grade lanolin vs. petrolatum: a comparative study on skin barrier repair and chapped lips.

Jean-Bernard ANTOINE[1], Clara ROUX[2], Chloé GOYET*[3]

[1] Stella, Mouscron, Belgium
[2] Dewavrin Cosmetics, Wasquehal, France
[3] ISISPHARMA, R&D Department, Lyon, France

Introduction

Lanolin is a natural, biomimetic waxy material obtained from sheep's wool. Medical-grade lanolin is especially valued for its lipid composition closely mirroring that of the human sebum. Unlike petrolatum, which acts solely as an impermeable occlusive, lanolin functions simultaneously as a semi-occlusive barrier agent, emollient, lipid replenisher, and indirect moisturizing agent capable of retaining over 200% of its weight in moisture within the skin while remaining breatheable. These multifaceted properties make it a compelling candidate for addressing compromised skin barriers in dermatological settings. The lips represent a particularly vulnerable site: thinner epidermis, absence of sebaceous glands, and constant environmental exposure render them highly susceptible to dryness and barrier disruption. Despite lanolin's well-established biomechanical properties, head-to-head clinical data comparing it to petrolatum on barrier function and repair remain scarce. This study aimed to compare medical-grade lanolin to petrolatum on barrier reinforcement, hydration, and repair, and to evaluate the efficacy of a 99.98% lanolin lip balm in subjects with compromised lips.

Materials and Methods

Two study phases were conducted. The first one consisted of a comparative instrumental assessment of lanolin *(Stellux AI-PF)* versus petrolatum (Vaseline™) on dry leg skin (22 women). Trans-epidermal water loss (TEWL, Tewameter® TM300) and cutaneous hydration rate (Corneometer® CM825) were measured at T6h, T8h, T24h, and T48h after first application on both treated zones and an untreated control zone. This was extended to compromised skin: following barrier disruption by a 0.5% SLS patch (D0-D1), both products were applied daily from D2, and TEWL was measured at D0, D1+3h, D4, D7, and D8 to assess repairing effect and barrier recovery. The second phase evaluated a lip balm formulated with 99.98% lanolin in 22 subjects with chapped, weakened lips, including 5 on isotretinoin, over 28 days of daily use. Repairing effect, cracked lips, hydration, and softness (0-10 scales) were scored at D0, D0Timm, D2, and D28, while subjects self-assessed discomfort and tightness at D0, D0Timm, and D2, and completed a satisfaction questionnaire at D28.

Results

Lanolin and petrolatum induced equivalent TEWL reductions on dry skin (-17% at T6h, -12% at T8h, -8% at T24h; $p<0.001$), with significant hydration improvements up to T48h for both. On irritated skin, lanolin outperformed petrolatum with a faster and greater TEWL reduction, showing superior barrier recovery as early as D4 and reaching -41% vs. -30% at D8 relative to post-irritation baseline (mean difference 2.76 ± 1.24 $g \cdot m^{-2} \cdot h^{-1}$, $p=0.0267$). Real-world application in subjects with chapped lips demonstrate that the product delivered rapid and sustained improvements across all endpoints. Repairing effect and crack reduction more than doubled by D2 and exceeded 115% improvement at D28, in 100% of subjects (all $p<0.0001$). Hydration and softness reached +142% and +144% at D28 respectively. Subjects reported near-complete resolution of discomfort and tightness from

D0Timm onward, with a 100% soothing effect at D2. The product was very well tolerated with no adverse events were reported.

Conclusions

Medical-grade lanolin demonstrates barrier reinforcement equivalent to petrolatum on intact dry skin, and superior repair on compromised skin. Formulated at 99.98% in a dedicated lip balm, it delivered rapid, sustained, and clinically significant improvements in lip repair, hydration, and comfort including in patients on isotretinoin. These findings position medical-grade lanolin as a high-performance, natural alternative to petrolatum for lip barrier repair, with direct relevance for dermatological practice.

EA DV CONGRESS
VIENNA
30 SEP - 3 OCT 2026

Abstract N°: 2705

Efficacy and Tolerability of a Multi-Weight Hyaluronic Acid Serum Following 1927 nm Fractional Thulium Laser Treatment for Skin Aging signs

Alexandre Filippo[1], Alessandro R do Nascimento[2], Renato Moura[2], Erika Fernandes[3], Izabella Mortorelli[3], Checrallah James ODEIMI[4], Caroline Lefloch[4], Linda Bourouf[4], Delphine Kerob*[4], Merete Haedersdal[5]

[1] Instituto de Dermatologia Prof. Rubem David Azula, Rio de Janeiro, Brazil

[2] Centre International de Développement Pharmaceutique (CIDP), Rio de Janeiro, Brazil

[3] L'Oréal Brasil, Rio de Janeiro, Brazil

[4] La Roche-Posay Laboratoire Dermatologique, Levallois-Perret, France

[5] Department of Dermatology D92, Bispebjerg Hospital, University of Copenhagen, Copenhagen, Denmark

Introduction

The 1927 nm Thulium laser is a fractional non-ablative laser that enables precise epidermal targeting while promoting cellular renewal, pigment reduction, and collagen stimulation. Despite its efficacy in skin rejuvenation, transient side effects such as erythema and dryness remain clinical challenges. Therefore, there is a clear need for post-procedure care to mitigate these effects, enhance skin barrier function, and improve patient outcomes over time. Hyaluronic acid (HA), essential for hydration and tissue repair, may optimize post-laser recovery. This study evaluated the efficacy and tolerability of a dermocosmetic serum (hereafter, DC serum)—containing four molecular weights of hyaluronic acid for multi-depth hydration, soothing vitamin B5, and reparative madecassoside—in improving clinical outcomes, including hydration and signs of aging, following non-ablative fractional Thulium laser treatment.

Materials and Methods

This monocentric, single-blinded study was conducted in Brazil under dermatological control. 99 female subjects (32–60 y.o) with mild to moderate facial aging and all phototypes underwent a 1927 nm non-ablative fractional Thulium laser procedure session (continuous wave, 350µs, 5W) and were randomized into two groups: control (laser alone, n=51) and treated (laser + DC serum, n=48). The tested DC serum was applied twice daily from Day 3 on the face, neck, and décolleté for 4 months / 112 days. All subjects used a repair balm for 3 days post-procedure and daily broad spectrum SPF50+ photoprotection. Clinical evaluation was performed by dermatologists using the Griffiths modified photoaging scale and Skin Aging Atlas (Bazin, Flament) to assess different aging signs parameters. Subjects self-assessments were also collected at the end of the study. Evaluations were conducted at baseline and throughout the study (D7, D28, D56, D84, D112).

Results

Baseline characteristics were comparable between the groups.

DC serum in adjunct to the laser treatment showed significantly enhanced skin radiance benefits *vs* baseline as early as Day 7 ($p<0.05$) and with continuous improvement over time ($p<0.001$; D112).

Overall skin appearance was significantly enhanced in the DC-treated group compared to the control group. Dermatological assessments at D112 showed markedly greater improvements, notably in forehead wrinkles (-21.0% *vs.* -10.0%), underneath eyes wrinkles (-25,3% vs. 0%) neck texture (-44.3% *vs.* -5.9%), and neck folds (-

30.8% *vs.* -5.4%).
Several skin aging parameters (including crow's feet wrinkles -15.1%, global fine lines -18.8%, radiance +36.2%, and skin texture +30.9%) showed earlier and/or sustained improvement in the treated group compared to the control group ($p<0.001$; D112) according to the dermatologist.
Subject self-assessments were consistent with clinical findings, showing improved scores across multiple parameters in the treated group, particularly for hydration +68.3%, radiance +76.2%, fine lines 64.8%, and skin softness +51.7% ($p<0.001$; D112) *versus* baseline.
Tolerance was evaluated as very good according to dermatologist at the end of the study D112

Conclusions

The addition of a DC serum containing hyaluronic acids to post-laser care significantly enhances skin repair and clinical outcomes following non-ablative fractional thulium laser. This approach visibly enhances skin aging signs and improves subject-reported benefits, supporting its use as an effective and highly tolerated adjunct to optimize laser treatment outcomes.

EA DV CONGRESS
VIENNA
30 SEP - 3 OCT 2026

Abstract N°: 2710

Efficacy of an anti-aging Serum in Enhancing Clinical Outcomes Following Hyaluronic Acid Injection, Microneedling, and Chemical Peeling: Results from a Randomized Split-Face Study

Elise Abric*[1], Floriane Desby Gayraud[1], Benoît Cadars[1], Marty Eloïse[1], Elodie VALIN[1], Elodie PRESTAT-MARQUIS[1]

[1] NAOS (Institut Esthederm), Aix-En-Provence, France

Introduction

The proteome is the set of proteins of a cell or tissue. Proteome impairement is a root cause of skin aging: protecting its integrity can slow down the aging process. With age, carbonylation irreversibly alters proteins' conformation leading to loss of functionality and premature aging signs. As proteins are the main component of the body after water and are involved in all biological mechanisms their preservation is key for cellular and skin longevity.

A serum containing a chaperone-like antioxidant patented active ingredient protecting proteome, demonstrated a preventive and long-lasting corrective efficacy on aging signs in a six-month comparative split face clinical study in 55 Caucasian women. Short term efficacy (2 weeks) across diverse skin types and ethnicites was confirmed in a 2-month clinical study in 120 subjects from 5 countries. Both studies showed short and long-term efficacy with cumulative benefits under application.

Aesthetic procedures help improve age-related changes, and using a well-tolerated serum that protects proteome can offer additional advantages. This study investigated the serum ability to intensify procedures' effects while being very well tolerated.

Materials and Methods

A 3-month split-face randomized clinical study was conducted in Brazil on 54 subjects aged 35 to 65 years with I to VI phototypes, presenting aging signs and undergoing a procedure: 15 received hyaluronic acid injections (nasolabial fold), 20 microneedling and 19 a peeling (Jessner's solution: 14% resorcinol, 14% salicylic acid, 14% lactic acid) on full face. The week following the procedure, subjects applied a repairing cream twice daily for 7 days. Then, they applied a light moisturizer on whole face and randomly the investigational serum on one half-face, twice a day for 84 days. Dermatologist assessed post-procedure efficacy and tolerance monthly. Subjects also completed a self-assessment questionnaire.

Results

The investigational serum was judged very well tolerated after 84 days of use. Clinical grading by dermatologist shows that the serum intensifies procedures' efficacy compared to procedure alone.

- In the pooled population (n=54), after 3 months, a statistically significant greater improvement was observed on the serum-treated side for radiance (-13% vs -9%)**, firmness (-16% vs -6%)***, density (-16% vs -5%)***, skin roughness (-20% vs -11%)***, and wrinkles (-8% vs -4%)*.
- Moreover, in each of the subgroups, added value was statistical in split face comparisons. In particular: the serum intensifies the targeted effects of microneedling: skin firmness and density were statistically significantly better improved on side treated with the serum as soon as after 1 month (respectively -25% vs -16% and -23% vs -15%)* and until 3 months (respectively -24% vs -14% and -22% vs -13%)**.

- After peeling, a statitistical significant difference was observed between sides, showing amplified efficacy on skin texture when using the serum after 3 months (-14% vs -1%)*.
- After hyaluronic acid injections, a statistically significant improvement in skin density at the nasolabial fold was observed on the serum-treated side compared to control (-23% vs -14%)* after 3 months. (*p<0.05, **p<0.01, ***p<0.001– Wilcoxon test).

Conclusions

This study results demonstrate that a proteome-targeting serum significantly enhances the efficacy of aesthetic procedures, such as hyaluronic acid injections, microneedling and peeling. When used post-procedure, the serum delivers additional and cumulative improvements in key signs of aging such as skin roughness, firmness, density and wrinkles, offering significant benefits compared to procedures alone. The serum was also very well tolerated across all subjects. These findings highlight the value of proteome preservation in optimizing and extending the aesthetic outcomes, supporting its use as a complementary strategy to improve skin quality and promote long-term skin longevity.

EA DV CONGRESS
VIENNA
30 SEP - 3 OCT 2026

Abstract N°: 2727

Efficacy of a Proteome-Targeting Serum on Aging Signs Across Multiple Ethnicities and Phototypes: A Multicenter, Real-World Dermatology Study

Elise Abric*[1], Floriane Desby Gayraud[1], Benoît Cadars[1], Marty Eloïse[1], Elodie VALIN[1], Elodie PRESTAT-MARQUIS[1]

[1] NAOS (Institut Esthederm), Aix-En-Provence, France

Introduction

The proteome is the set of proteins of a cell or tissue. Proteome impairement is the root cause of skin aging: with age, carbonylation irreversibly alters proteins' conformation resulting in loss of their functionalities and premature aging signs. Protecting its integrity can slow down the aging process. Because proteins are the main component of the body after water, their preservation is key for cellular and skin longevity.

A serum containing a chaperone-like antioxidant patented active ingredient protecting the proteome, demonstrated, in a six-months split face comparative monocentric clinical study (55 caucasian French women), a preventive and long lasting corrective efficacy on aging signs.

Wrinkles (crow's feet, underneath eye area, nasolabial fold), skin radiance, homogeneity (pigmented spot appearance and complexion homogeneity), firmness and density were explored on each half face: one treated with neutral cream, the other treated with both the neutral cream and the Proteome-targeting serum. From 8 weeks, all graded signs were significantly better improved on the side treated with serum. A cumulative effect was observed over 2 to 6 months without reaching a plateau.

A two-month, multicenter open study was launched to evaluate the efficacy and tolerance of the serum in a larger, more diverse multi-ethnic group of participants. The study aimed to assess both short- and long-term dermatologically graded effects (from two weeks to two months) of the serum under real-world conditions in dermatologists' private practices.

Materials and Methods

The study was conducted in 5 countries (Lithuania, United Arab Emirates, Canada, Ecuador, Kuwait) under the supervision of 26 dermatologists in 120 subjects from several ethnicities (Caucasian, Asian, Indian, Afro-American) with all face skin types and phototypes II to VI, aged from 27 to 68 years old. Subjects applied to full face the serum twice daily for 56 days. Dermatologists assessed tolerance and rated aging signs using a 10-point clinical scale (0–9) at D0, D14, D28 and D56. Evaluations included complexion homogeneity and luminosity, firmness, density, skin texture roughness, pigmented spots intensity, and wrinkles (face and eye contour). A well-being questionnaire was also completed by the subjects.

Results

Dermatologists' clinical scoring results showed a statistically significant improvement in each of the graded aging signs as soon as 2 weeks of use with increased and statistical improvement over 1 and 2 months of twice daily use (***$p<0.001$, Wilcoxon tests). Complexion homogeneity and luminosity grades reached respective improvement of +17% and +26% after 2 weeks of use to +48% and +58% after 2 months of use. Similarly, dermatologists found the skin firmer and denser by +16% and +15% after 2 weeks to +38% and +33% after 2 months, respectively. Skin texture roughness and wrinkles/fine lines grades at the eye contour level were also demonstrated to decrease by -11% and -7% at 2 weeks to -23% and -27% after 2 months, respectively. Even whole-face wrinkles grade showed a significant reduction of -23% after 2 months of use.

Pigmentation blemishes were finally statistically reduced as soon as after 2 weeks, with -8%** decrease that went on improving until 2 months (-28%)***. (**p<0.01, ***p<0.001– Wilcoxon test).

Conclusions

This study, conducted at a worldwide level, in dermatologists private practice and based on expert visual grading demonstrated that the use of a proteome-targeting serum can improve aging signs as early as after 2 weeks. A cumulative efficacy is observed up to 6 months witthout reaching a plateau, with sustained improvement observed across all parameters.

The serum shows global anti-aging efficacy, across all skin types and several ethnicities, with rapid and long-lasting effects, consistent with the biological mechanism of the patented technology protecting the proteome.

EA DV CONGRESS
VIENNA
30 SEP - 3 OCT 2026

Abstract N°: 2740

Multifunctional Tinted Sunscreen Combining Photoprotection, Visible Light Protection and Sustained Hydration: A Clinical and Instrumental Evaluation

Ingrid Alexandrino[1], Tatiana Rocha[1], Laura Fagundes[1], Nathalia Costa[1], Ramila Neves[1], Joziane Santos[1], Estela Brumatti[1], Vitor Seixas[1], mariana Lima[1], Bianca Melo[1], Felipe Mota Soares*[1], Matheus Mota Soares[1], Alcinea Balliana da Mota[1]

[1] ADCOS Group, Serra, Brazil

Introduction

The increasing complexity of light exposure, including ultraviolet (UV) radiation and visible light, has driven the development of multifunctional photoprotective strategies that extend beyond traditional sunscreens. Visible light has been associated with pigmentation disorders and photoaging, highlighting the need for tinted formulations capable of providing extended spectral protection while improving skin appearance. At the same time, adherence to daily photoprotection is strongly influenced by cosmetic attributes such as coverage, texture, and long-lasting wear. The incorporation of bioactive ingredients with hydrating and anti-aging properties may further enhance skin quality and user compliance. In this context, this study aimed to evaluate the efficacy, safety, and multifunctional performance of a high-coverage tinted sunscreen designed to deliver broad-spectrum protection, visible light protection and sustained hydration.

Materials and Methods

A comprehensive set of in vitro and clinical studies was conducted on a tinted facial sunscreen (SPF 60) formulated with multimolecular hyaluronic acid, niacinamide, and vitamin E. Safety was assessed through dermatological and ophthalmological evaluations, as well as comedogenic and acnegenic testing. Photoprotective efficacy was determined by in vivo SPF (ISO 24444) and UVA protection (ISO 24443), including critical wavelength assessment, and water resistance after 40 minutes of immersion. Protection against visible and blue light was evaluated using an in vitro spectrophotometric method. Skin hydration was measured by corneometry up to 12 hours after application, followed by product removal to assess persistence of effect. Additionally, a 28-day home-use study evaluated perceived efficacy and cosmetic performance through a structured questionnaire.

Results

The product demonstrated high photoprotective performance, with an SPF of 77.9, a UVA-PF of 20.8, and a critical wavelength of 381.0 nm, confirming broad-spectrum protection. Water resistance testing showed maintenance of protective efficacy after 40 minutes of immersion. In vitro analysis demonstrated protection against visible and blue light, with mean attenuation values of approximately 66% and 65%, respectively. Corneometry measurements showed a significant increase in skin hydration of up to 13.7% after 12 hours, indicating a persistent hydration effect on the stratum corneum, even after product removal, with 100% of participants showing improvement. The clinical perception study confirmed high cosmetic performance and user acceptance, including high coverage, immediate concealment of skin imperfections, and long-lasting wear. Additionally, the product did not accentuate expression lines and contributed to an improvement in the overall appearance of the skin, including improvements in the appearance of wrinkles. The formulation was well tolerated, with no evidence of comedogenic or acnegenic potential, and demonstrated a favorable dermatological and ophthalmological safety

profile.

Conclusions

This study demonstrates that the evaluated formulation provides combined photoprotective and functional skin benefits, including protection against visible light and sustained hydration. The persistence of hydration after product removal supports an effect extending beyond immediate surface action on the stratum corneum. Together with a favorable safety profile, these findings support its use as a multifunctional dermocosmetic approach for daily photoprotection.

EA DV CONGRESS
VIENNA
30 SEP - 3 OCT 2026

Abstract N°: 2762

Efficacy and safety of hyaluronic acid fillers for infraorbital hollowing: A systematic review and meta-analysis of randomized controlled trials

Laura Ghanem*[1], Ziad Hankach[2], Antonia Moubarak[1], Jacinthe Khater[1], Jana Mahdi[1], Elie Moukawam[2], Moussa Hojeij[2], Nina Rossa Haddad[1], Loubna Abboud[2], Ziad Sleiman[3]

[1] Faculty of Medical Sciences, Lebanese University, Beirut, Lebanon

[2] Faculty of Medical Sciences, Department of Plastic and Reconstructive Surgery, Lebanese University, Beirut, Lebanon

[3] Associate Professor and Head of the Department of Plastic and Reconstructive Surgery, Lebanese University, Beirut, Lebanon

Introduction

Infraorbital hollowing (IOH) causes a sunken, aged under-eye appearance. Dermal fillers are a popular minimally invasive treatment. This study assessed the efficacy and safety of hyaluronic acid (HA) for the treatment of IOH.

Materials and Methods

PubMed, Embase, and Cochrane were searched for RCTs following Cochrane and PRISMA guidelines. Eligible studies evaluated any type of HA filler in patients with IOH. Both pairwise and single-arm meta-analyses were conducted as data allowed. Data were pooled using an inverse-variance random-effects model with restricted maximum likelihood (REML), applying Hartung-Knapp-Sidik-Jonkman (HKSJ) correction when $\tau^2>0$ and >2 studies are included. Subgroup analyses by filler and injection type were done when applicable. Statistical analyses were performed using RStudio.

Results

Five RCTs with 875 patients (mean age 42.7 ± 17.8 years; 85.3% female) were analyzed. Two RCTs used a low–moderate G' HA filler, two used a high G' cross-linked HA filler, and one used a periocular-specific HA filler formulation. Investigator-assessed Global Aesthetic Improvement Scale (GAIS) at month 3 showed higher response with filler versus control (RR 14.31, 95% CI 1.03-198.13, p=0.049), and participant-assessed GAIS was also higher (RR 24.23, 95% CI 8.00-73.43, p<0.001). Modified Infraorbital Hollowing Assessment Scale (MIHAS) scores favored fillers (RR 5.22, 95% CI 3.11-8.76, p<0.001). Single-arm meta-analysis showed investigator-assessed GAIS of 87.8%, 88.9%, 84.0%, and 79.1%, and participant-assessed GAIS of 88.3%, 85.0%, 82.8%, and 78.1% at months 3, 6, 9, and 12, with needle injections showing higher responses than cannula (investigator: 97.3% vs 89%; participant: 95.2% vs 86.5% at month 3). Treatment-related TEAEs were 8.5% (95% CI 3.11-21.16).

Treatment-related adverse events occurred in 8.5% of participants (95% CI 3.1–21.2) and included infection or infestation, injection-site swelling, bruising, discoloration, erythema, pruritus, and mass effect. Infection or infestation was rare, with a non-significant trend toward higher occurrence in the HA group. Injection-site swelling was significantly increased following treatment, varying by filler

type and injection technique, with lower rates in periocular-specific formulations and with cannula use, and higher rates with structural/volumizing fillers and needle injections. Bruising and discoloration followed a similar pattern, being least frequent with periocular-specific formulations. Erythema occurred in around 45% of participants without clear inter-filler differences, while pruritus was uncommon, particularly with periocular-specific formulations. Mass effect affected approximately one-quarter of participants with variability across fillers. Implant-site swelling was the most common treatment-emergent adverse event (RR 12.90, 95% CI 2.56–67.07, p=0.002), higher with needle than cannula (RR 11.99 vs 6.26, p<0.001). Overall efficacy was comparable across fillers, while the periocular-specific formulation showed the most favorable safety profile.

Study	Design	Number of participants, n		Mean Age, years (SD)	Females n, (%)	Fitzpatrick Skin Type n, (%) (I- VI)	Intervention (Fillers Injection)	Mode of injection		Follow-up* (months)
		Filler injection, n	Control, n					Needle, Size	Cannula, Size	
Biesman 2024a†	Evaluator-blinded multicenter RCT	287	46	44.4 (11.67)	290 (87.1)	I-III: 228 (68.5) IV: 72 (21.6) V-VI: 33 (10)	Periocular-specific HA filler	NR	25/27 G	12
Biesman 2024b†	Evaluator-blinded multicenter RCT	97	53	43.3 (9.4)	125 (83.3)	I-III: 95 (63.3) IV-VI: 55 (36.7)	Low-moderate G′ HA filler	27 G, ½ inch	27 G, 40 mm	0.5
Fabi NCT0341 8545	Evaluator-blinded multicenter RCT	135	32	46 (33.3)	124 (91.9)	I-II: 46 (43.1) III-IV: 69 (51.1) V-VI: 20 (14.8)	High G′ cross-linked HA filler	32 G ½-inch	27 G 1½inch	3
NCT0377 7917	Evaluator-blinded multicenter RCT	43	22	46.4 (12.2)	55 (84.6)	I-III: 45 (69.2) IV-VI: 20 (30.8)	Low-moderate G′ HA filler	NA	27G	24
Yu 2026	Evaluator-blinded multicenter pilot RCT	120	40	33.8 (7.61)	152 (95)	NR	High G′ cross-linked HA filler	32 G ½ inch	NA	3

Table 1. Baseline characteristics of participants in the included studies evaluating fillers for infraorbital hollows. † To avoid confusion, since the same author published two distinct trials in the same year, we designated them as follows: Biesman 2024a refers to NCT04154930, and Biesman 2024b refers to NCT04594239. * The follow-up period was considered only until the primary comparison between treatment and no treatment (control group). Any subsequent delayed-treatment phases (e.g., control crossover or optional retreatment phases) were excluded from the analysis. Abbreviations: G: Gauge; HA: Hyaluronic Acid; I–VI: Fitzpatrick Skin Phototype Classification; mm: millimeters; n: number of participants; NA: not applicable; NCT: National Clinical Trial identifier; NR: Not Reported; RCT: Randomized Controlled Trial; SD: Standard Deviation.

Conclusions

This study shows that HA filler treatment for under-eye hollows provides high patient and investigator satisfaction and is generally safe.

EADV CONGRESS
VIENNA
30 SEP - 3 OCT 2026

Abstract N°: 2818

Platelet-Rich Plasma and Serum Sickness Disease: Uncovering a Rare Adverse Event of an Increasingly Popular Regenerative Therapy

Zuzanna Świerczewska*[1], Kinga Fabiańczyk[2], Marek Niedoszytko[3], Wioletta Baranska-Rybak[1]

[1] Department of Dermatology, Venereology and Allergology, Medical University of Gdańsk, Poland, Gdańsk, Poland

[2] Department of Allergology, Faculty of Medicine, Medical University of Gdansk, Gdańsk, Poland

[3] Department of Allergology, Medical University of Gdańsk, Poland, Gdańsk, Poland

Introduction

Platelet-rich plasma (PRP) therapy is increasingly used in regenerative and aesthetic medicine due to its anti-inflammatory and tissue-repair properties. As an autologous product, PRP is generally considered safe, with adverse effects usually limited to transient local reactions. Systemic immune-mediated complications remain exceptionally rare. We present a case of a patient who developed a systemic reaction following PRP administration.

Case Presentation

A 64-year-old woman with a history of hypertension and hyperlipidemia presented with generalized urticarial wheals, pruritus, facial edema, fever, nausea, myalgia, and arthralgia. Six days before symptom onset, she had undergone facial PRP mesotherapy performed by a beautician. The patient denied allergies and recent drug exposure. Laboratory investigations revealed leukocytosis, elevated C-reactive protein, erythrocyte sedimentation rate, aspartate aminotransferase, and anti-thyroglobulin antibodies, along with decreased complement C3/C4 levels. The autologous serum skin test was positive. Based on the clinical presentation, laboratory findings, and temporal relationship with PRP administration, serum sickness disease was diagnosed. Treatment with systemic corticosteroids and antihistamines resulted in complete symptom resolution.

Conclusion

Although PRP is derived from autologous blood, its immunogenic potential may be underestimated. Variability in preparation methods, leukocyte content, and platelet-derived cytokines may contribute to immune dysregulation in predisposed individuals. The presence of anti-thyroglobulin antibodies in our patient may indicate underlying autoimmune susceptibility. This case highlights the importance of recognizing rare systemic immune reactions associated with PRP therapy and underscores the need for further investigation into its immunomodulatory effects.

EADV CONGRESS
VIENNA
30 SEP - 3 OCT 2026

Abstract N°: 2823

Complementary Effects of a Dihydromyricetin-Based Epigenetically Active Serum Following Fractional Laser Treatment: Mechanistic Rationale and Clinical Case Series

Paula Pitta*[1], Firas Al-Niaimi[2], Julia Gallinger[1], Cassandra Falckenhayn[1]

[1] Beiersdorf AG, Hamburg, Germany

[2] St John's Institute of Dermatology, London, United Kingdom

Introduction

Fractional laser resurfacing is a well-established aesthetic procedure for skin rejuvenation, promoting controlled epidermal renewal and dermal extracellular matrix (ECM) remodelling. Transcriptomic studies demonstrate that fractional laser treatment modulates gene networks associated with collagen synthesis (including *COL1A1*, *COL3A1* and *COL5A1*), epidermal differentiation, and cellular renewal, resulting in sustained changes in skin biology beyond the immediate procedural period [1]. Increasing evidence indicates that epigenetic regulation, including DNA methylation dynamics and chromatin organization, plays a central role in maintaining these long-term rejuvenation profiles and skin homeostasis [2].

Dihydromyricetin (DHM), a naturally occurring flavonoid, has been identified as a bioactive compound with epigenetic and regenerative activity. Experimental studies show that DHM modulates DNA methylation patterns and transcriptional programs linked to epidermal differentiation (*FZD10*, *LYPD3*), cellular signaling (*PI4KB*), and ECM homeostasis, supporting its relevance as an adjunctive topical strategy in aesthetic skin rejuvenation [3–5].

Mechanistic and transcriptomic evidence reveals a biologically meaningful overlap between molecular pathways activated by fractional laser treatment and those modulated by DHM. While laser resurfacing primarily induces ECM-related gene expression, including collagen-associated pathways (*COL1A1*, *COL3A1, COL5A1*), DHM influences genes related to epidermal quality and wrinkle grade (*FZD10*, *LYPD3*, *PI4KB*). Importantly, overlapping targets such as *PLIN2*, *SPON2*, and *LPIN1*—genes involved in lipid metabolism and cell function—are modulated by both interventions [1,3,6,7]. This convergence supports complementary regulation of structural, metabolic, and epigenetically controlled pathways associated with sustained improvements in skin quality and appearance.

Case Presentation

As representative evidence, from clinical case series, **one patient with a lighter skin phototype (Fitzpatrick phototype 2)** treated with two sessions of fractional laser resurfacing followed by adjunctive use of a dihydromyricetin (DHM)-based topical serum was evaluated after 3 months. Dermatologist-led assessment between baseline and follow-up (**week 12**) demonstrated visible improvements in **global skin quality, glow, and skin texture/smoothness**.

The adjunctive topical regimen was well tolerated and easily integrated into post-procedure skincare, supporting its feasibility as a complementary strategy in aesthetic laser-based rejuvenation.



Figure 1. 3-months treatment with fractional laser and DHM-based topical serum.

Conclusion

The convergence of mechanistic, epigenetic, and clinical observations supports the use of a DHM-based serum as a biologically plausible adjunct to fractional laser procedures. By targeting overlapping molecular pathways involved in ECM remodelling, epidermal differentiation, lipid metabolism, and epigenetic regulation, this combined approach may help optimize and sustain aesthetic rejuvenation outcomes across different skin phototypes. Further controlled clinical studies are warranted to confirm synergistic effects and long-term benefits.

EADV CONGRESS
VIENNA
30 SEP - 3 OCT 2026

Abstract N°: 2867

Treatment of Xanthelasma Palpebrarum with Radiofrequency Ablation: Experience from a Tertiary Care Centre

Kirti Jangid *[1], Swagata Tambe[1], Gampi Ete[1]

[1] Seth VC Gandhi and MA Vora Municipal Hospital Rajawadi, Mumbai, India

Introduction

Xanthelasma palpebrarum (XP) is the most common type of xanthoma, presenting as soft, yellowish plaques over the eyelids. Although asymptomatic, these lesions are cosmetically distressing and may significantly affect quality of life. Various treatment modalities, including surgical excision, radiofrequency (RF) ablation, laser therapy, chemical cautery, and cryotherapy, have been employed; however, recurrence remains common. RF ablation is a minimally invasive, cost-effective modality that provides satisfactory cosmetic outcomes with minimal downtime. This study evaluates the efficacy and safety of RF ablation with wound suturing in the management of XP.

Materials and Methods

Nineteen patients with XP were enrolled in the study. The age range was 29–71 years, with a mean age of 47 years. The female-to-male ratio was 10:1. Associated comorbidities included diabetes mellitus (4 patients), hypertension (1 patient), hypothyroidism (2 patients), and hyperlipidaemia (5 patients). Three patients had undergone prior treatment and presented with recurrent lesions. Routine laboratory investigations were performed in all patients. Local anaesthesia using 2% lignocaine with adrenaline was administered before the procedure.

All patients underwent RF ablation using the standard technique. Lesions were ablated layer by layer until adequate clearance of the yellowish plaques was achieved, followed by wound suturing where required to facilitate optimal healing and cosmesis. Post-procedure, all patients received oral antibiotics and analgesics. Patients were followed up to assess healing, cosmetic outcome, complications, and recurrence.

Results

Most patients presented with lesions involving the upper eyelids. RF ablation was well tolerated in all patients.

Minor adverse effects included transient erythema, mild oedema, and superficial crusting, which resolved without sequelae. No significant bleeding, infection, persistent oedema, scarring, or post-inflammatory pigmentary alteration was observed. Cosmetic outcomes were satisfactory in most patients, with good lesion clearance and acceptable healing. No recurrence was observed during follow-up.

Conclusions

Comparison with Other Treatment Modalities

Study	Treatment Modality	Number of Patients	Recurrence Rate	Key Findings
Nahas TR et al. (2009)	70% trichloroacetic acid (TCA)	24	Higher in deeper lesions	Effective mainly for superficial lesions; risk of pigmentary changes, irritation, and multiple sittings required
Esmat SM et al. (2014)	CO_2 laser excision	20	Low recurrence	Precise lesion removal, Excellent haemostasis, but requires specialised equipment
Labandeira J et al. (2015)	Liquid nitrogen spray	4	Low recurrence	Transient hypopigmentation and oedema. Effective and well-tolerated with short freeze times

RF ablation with wound suturing is an effective, safe, and economical treatment modality for XP. It provides satisfactory cosmetic outcomes with minimal complications and downtime. The procedure is simple to perform, well tolerated by patients, and particularly useful for delicate periorbital lesions. Owing to its accessibility and cost-effectiveness, RF ablation remains a valuable therapeutic option, especially in resource-limited settings.

EADV CONGRESS
VIENNA
30 SEP - 3 OCT 2026

Abstract N°: 2908

Role of Ultrasound in the Diagnosis and Management of Dermal Filler Related Complications: A Systematic Review

Abdullatif Aldhafyan*[1]

[1] Imam Mohammad Ibn Saud Islamic University (IMSIU), Riyadh, Saudi Arabia

Introduction

Dermal filler complications are increasingly encountered in aesthetic dermatology, particularly with the rising global use of injectable fillers. Delayed inflammatory reactions, vascular compromise, nodules, edema, and filler migration may present with overlapping clinical features, making diagnosis and management difficult. Ultrasound has emerged as a valuable noninvasive tool that enables real-time visualization of filler location, tissue characteristics, vascular involvement, and treatment response. This systematic review evaluated the role of ultrasound in the diagnosis and management of dermal filler-related complications.

Materials and Methods

A systematic review was conducted in accordance with PRISMA 2020 guidelines. PubMed/MEDLINE, Scopus, and Web of Science were systematically searched from inception to 31 October 2025. Eligible studies included human subjects with dermal filler-related complications and reported the use of ultrasound for diagnosis or management. Data regarding study design, complication type, ultrasound findings, diagnostic utility, and ultrasound-guided interventions were extracted and synthesized narratively.

Results

A total of 8 studies were included following screening and eligibility assessment. Ultrasound demonstrated significant clinical value in identifying filler type, localization, depth, inflammatory changes, vascular involvement, and migration patterns. Common complications evaluated included delayed-onset nodules, vascular occlusion, edema, granulomatous reactions, and abscess formation. Several studies reported that ultrasound-guided management improved procedural precision and facilitated targeted hyaluronidase injection, aspiration, or drainage while minimizing unnecessary tissue trauma and excessive product dissolution. Doppler ultrasound was particularly useful in assessing vascular compromise and tissue perfusion. Despite heterogeneity among studies, ultrasound consistently improved diagnostic confidence and supported individualized treatment planning.

Conclusions

Ultrasound represents an important adjunctive tool in the evaluation and management of dermal filler-related complications. It improves diagnostic accuracy, enables targeted interventions, and may enhance treatment safety and clinical outcomes in aesthetic dermatology. Further prospective studies with standardized imaging protocols are needed to establish evidence-based recommendations for routine clinical practice.

EA DV CONGRESS
VIENNA
30 SEP - 3 OCT 2026

Abstract N°: 2918

Beyond Topicals: Non-Ablative Fractional Laser–Assisted Drug Delivery as a Novel Strategy for Alopecia Management

Michele Kreuz*[1], Christine Rachelle Prescendo Chaves[2], Mariana Vilhena Ferreira[3], Célia Petersen Vitello Kalil[4], Valéria Barreto Campos[5]

[1] Lutheran University of Brazil, Canoas, Brazil
[2] Federal University of Rio Grande do Sul, Porto Alegre, Brazil
[3] University of Vale do Sapucaí, Pouso Alegre, Brazil
[4] Pontifical Catholic University of Rio Grande do Sul, Porto Alegre, Brazil
[5] São Paulo State University, Botucatu, Brazil

Introduction
Alopecia, including androgenetic alopecia (AGA) and alopecia areata (AA), is a common condition affecting both men and women and significantly impairing quality of life. Conventional treatments are often limited by inadequate follicular drug penetration, delayed clinical response, and the potential for systemic side effects. Non-ablative fractional lasers (NAFLs) have emerged as a promising strategy to overcome these limitations by enhancing transdermal drug delivery while simultaneously promoting hair regrowth through biological stimulation. This study aimed to evaluate the efficacy of non-ablative fractional laser-assisted drug delivery (LADD) in improving treatment outcomes across different types of alopecia.

Materials and Methods
A narrative review of eight studies was conducted, including clinical trials, case series, and review articles investigating non-ablative fractional laser (NAFL) therapy in combination with topical or intradermal treatments. Additional evidence from studies on androgenetic alopecia (AGA) and alopecia areata (AA) was also included to support the analysis. The primary outcomes assessed were hair density, hair shaft diameter, time to regeneration, and treatment safety profiles.

Results
NAFL creates controlled microscopic thermal zones (MTZs), transiently disrupting the stratum corneum and thereby enhancing the delivery of therapeutic agents directly to the hair follicle and surrounding vasculature. Simultaneously, laser-induced microinjury promotes a regenerative microenvironment through increased cytokine release, angiogenesis, and activation of follicular stem cells, facilitating transition into the anagen phase. Its safety profile is supported by the lower degree of thermal damage and reduced incidence of adverse events compared with ablative fractional lasers while maintaining clinical efficacy.
Beyond the creation of microchannels for drug delivery, NAFL may also exert photobiomodulatory and regenerative effects by stimulating hair follicle stem cells and promoting re-entry into the anagen phase. Combination therapies consistently demonstrated superior outcomes compared with monotherapy, including increased hair shaft diameter, improved follicular density, and faster clinical response. Protocols combining NAFL with topical finasteride, minoxidil, corticosteroids, or growth factors resulted in clinically significant hair regrowth in both androgenetic alopecia (AGA) and alopecia areata (AA), including treatment-resistant cases.

However, the current evidence remains limited by small sample sizes, heterogeneity in treatment protocols and laser parameters, and variability in study methodologies.

Conclusions

LADD represents a transformative breakthrough in alopecia treatment by effectively overcoming the critical barrier of drug penetration into hair follicles. Its synergistic combination of enhanced therapeutic delivery and intrinsic follicular stimulation offers a promising strategy to improve treatment efficacy and optimize clinical outcomes in patients with alopecia.

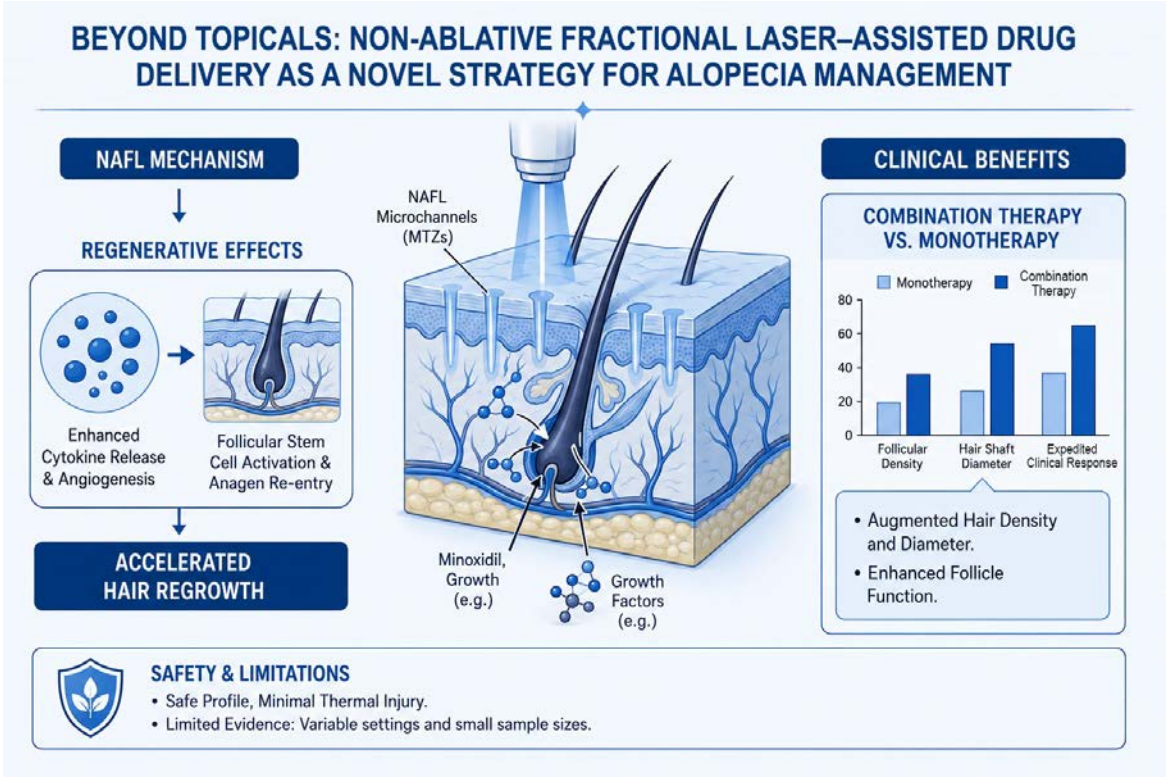

Graphic Abstract

EA DV CONGRESS
VIENNA
30 SEP - 3 OCT 2026

Abstract N°: 2980

Comparative Efficacy of Microneedling Combined With Platelet-Rich Fibrin Versus Platelet-Rich Plasma in Abdominal Striae Distensae: A Randomized Split-Abdomen Study

Fatma Badr Yosef Ibrahim Elkomy*[1]

[1] Al-Azhar university, Cairo, Egypt

Introduction
Striae distensae are a common cosmetic concern characterized by dermal connective tissue disruption and often associated with significant psychosocial impact. Despite the availability of multiple therapeutic modalities, achieving consistent clinical improvement remains challenging. Regenerative therapies combined with microneedling have recently gained increasing attention in aesthetic dermatology.

Objective: To compare the efficacy and safety of microneedling combined with autologous platelet-rich fibrin versus microneedling combined with autologous platelet-rich plasma in the treatment of abdominal striae distensae.

Materials and Methods
This randomized split-abdomen comparative study included 30 patients with bilateral abdominal striae distensae. Each abdominal side was randomly assigned to receive three monthly sessions of microneedling combined with either platelet-rich plasma or platelet-rich fibrin. Clinical evaluation was performed using the Davey score, Global Aesthetic Improvement Scale (GAIS), widest striae width measurement, blinded photographic assessment, and patient satisfaction scores. Histopathological evaluation was conducted using hematoxylin and eosin staining of punch biopsy specimens obtained before treatment and one month after the final session.

Results
Both treatment modalities demonstrated significant clinical improvement in abdominal striae distensae after therapy. Improvement was observed in the Davey score, striae width, GAIS grading, and patient satisfaction on both treated sides. Although the platelet-rich fibrin-treated side showed superior clinical trends in some patients, no statistically significant difference was detected between both modalities regarding overall clinical outcomes. Histopathological findings supported the observed clinical improvement in both groups. Platelet-rich fibrin also demonstrated practical advantages, including simplified preparation, lower cost, and absence of anticoagulant additives.

Conclusions
Microneedling combined with either platelet-rich fibrin or platelet-rich plasma is an effective and well-tolerated therapeutic approach for abdominal striae distensae. Platelet-rich fibrin may offer additional practical and regenerative advantages; however, no statistically significant superiority over platelet-rich plasma was demonstrated in overall clinical efficacy.

EADV CONGRESS
VIENNA
30 SEP - 3 OCT 2026

Abstract N°: 2981

Effectiveness of Iontophoresis with Topical Oxybutynin Versus Iontophoresis Alone in Primary Palmar Hyperhidrosis: A Randomized Split-Hand Comparative Study

Fatma Badr Yosef Ibrahim Elkomy*[1]

[1] Al-Azhar university, Cairo, Egypt

Introduction
Primary palmar hyperhidrosis is a distressing condition characterized by excessive sweating beyond physiological needs, significantly impairing quality of life, social interactions, and occupational performance. Iontophoresis is considered a well-established therapeutic option; however, optimizing its efficacy while maintaining tolerability remains an area of clinical interest.

Objective: To evaluate the efficacy and safety of iontophoresis combined with topical oxybutynin compared with iontophoresis alone in the treatment of primary palmar hyperhidrosis.

Materials and Methods
This randomized split-hand comparative study included 30 patients diagnosed with primary palmar hyperhidrosis between February 2025 and March 2026. Each patient received iontophoresis with topical oxybutynin 10% on one hand and iontophoresis alone on the contralateral hand. Clinical assessment was performed using the Hyperhidrosis Disease Severity Scale (HDSS) and iodine starch test before and after treatment.

Results
One month after therapy, both treatment modalities demonstrated significant clinical improvement. HDSS scores markedly decreased, with most patients achieving grades 1 or 2 post-treatment. On the oxybutynin-treated side, 56.7% of patients achieved HDSS grade 1 compared with 46.7% on the iontophoresis-only side. Iodine starch testing also showed highly significant improvement after treatment ($P < 0.001$), with 70% of patients exhibiting mild sweating severity post-therapy. However, no statistically significant difference was detected between both treatment approaches regarding overall HDSS improvement or recurrence during follow-up.

Conclusions
Iontophoresis is an effective, safe, and well-tolerated treatment modality for primary palmar hyperhidrosis. The addition of topical oxybutynin may provide early symptomatic improvement in some patients; however, it does not significantly influence long-term outcomes or recurrence rates.

EADV CONGRESS
VIENNA
30 SEP - 3 OCT 2026

Abstract N°: 2982

Prejuvenation Beyond Prevention: Can Epigenetic Modulation Delay Dermal Aging?

Fatma Badr Yosef Ibrahim Elkomy*[1]

[1] Al-Azhar university, Cairo, Egypt

Introduction

Aesthetic dermatology is undergoing a paradigm shift from reactive rejuvenation toward proactive preservation. Prejuvenation has emerged as a preventive strategy aimed at delaying visible aging before its onset. Beyond traditional preventive skincare, growing evidence suggests that targeting epigenetic mechanisms, cellular senescence, inflammaging, and extracellular matrix decline may redefine the concept of aging intervention.

Objective: To explore prejuvenation as a biologically driven strategy capable of delaying dermal aging through modulation of epigenetic pathways, preservation of collagen architecture, and early multimodal intervention.

Materials and Methods

This presentation reviews current evidence on molecular mechanisms involved in cutaneous aging including epigenetic alterations, telomere attrition, oxidative stress, glycation, and chronic inflammation and integrates these with contemporary prejuvenation strategies involving topical actives, neuromodulators, energy-based devices, regenerative approaches, and lifestyle optimization.

Results

Emerging evidence suggests that early intervention protocols may influence biological aging trajectories by reducing cumulative structural damage, preserving dermal integrity, and potentially delaying age-associated phenotypic changes. Personalized prejuvenation protocols integrating preventive dermatology with longevity science may offer a new framework in aesthetic medicine.

Conclusions

Prejuvenation is evolving from cosmetic prevention into a form of cutaneous longevity medicine. By integrating epigenetic science with evidence-based interventions, dermatologists may move beyond treating aging toward actively delaying its biological onset.

EA DV CONGRESS
VIENNA
30 SEP - 3 OCT 2026

Abstract N°: 3020

Perfect Blend: Optimizing Outcomes Through Combination Aesthetic Treatments-A Case-based Experience in Egyptian Patients

Sara Elhawary*[1]

[1] Vascuderm laser Center, Private aesthetic clinic, Cairo, Egypt

Introduction

To evaluate the effectiveness of combination-based aesthetic treatment protocols in optimizing cosmetic outcomes and patient satisfaction in Egyptian patients with skin of color.

Materials and Methods

A retrospective case series was conducted involving patients treated using customized multimodal aesthetic approaches according to individual clinical needs. Treatment combinations included Different combinations including Fractional Plasma and Diatermocontraction with dermal fillers or with skin boosters, and different types of laser-assisted scar management combined with subcision and injectable therapies. Clinical improvement was assessed through photographic evaluation, skin texture and contour improvement, scar appearance, downtime, and patient satisfaction.

Results

The presented cases demonstrated noticeable improvement in overall skin quality, texture, contour definition, and scar appearance following combination-based treatment protocols. The synergistic use of different modalities allowed comprehensive targeting of multiple aesthetic concerns with acceptable downtime and favorable safety profiles in skin of color patients. High levels of patient satisfaction and natural-looking outcomes were observed across all cases.

Conclusions

Combination aesthetic treatments offer synergistic benefits and enhanced clinical outcomes compared to single-modality approaches. Personalized multimodal protocols may provide effective and safe solutions for complex aesthetic concerns in skin of color populations while improving patient satisfaction and optimizing overall cosmetic results.

EA DV CONGRESS
VIENNA
30 SEP - 3 OCT 2026

Abstract N°: 3072

Combination of Zinc and Copper for Improved Tolerability and Reduced Downtime After Ablative and Non-Ablative Technologies: A Report of 6 Cases

Manuela Boleira*[1], Livia Pino[1], Mariana Veloso[2], Katia Vargas[2], Leonardo Cerqueira[3], Maria Luiza Chiganer[4], Andre Cherubim[2], Evilmara Pagani Bandeira[4], Fernanda Beltrao[4]

[1] Policlinica Geral do Rio de Janeiro, rio de janeiro, Brazil

[2] Private Practice, Sao Paulo, Brazil

[3] Private Practice, Feira de Santana, Brazil

[4] Private Practice, rio de janeiro, Brazil

Introduction

Fractional CO2 , Er:YAG, and Nd:YAG lasers are gold-standard treatments for acne scars, photoaging, and skin irregularities. However, their thermal effects—ranging from non-ablative fractional to fully ablative modes—often lead to complications. For non-ablative procedures, social downtime typically lasts 1.5 to 3.7 days; however, for ablative fractional lasers, re-epithelialization can take 7 to 14 days, with significant crusting and edema. Recent evidence suggests that topical formulations containing Copper (Cu) and Zinc (Zn) enhance wound management through anti-inflammatory and regenerative mechanisms, addressing the epidermal channels created by lasers that allow serum loss and bacterial entry. This report presents six clinical cases utilizing Cu-Zn formulations compared to a control, synthesized with current literature on mineral-based recovery.

Case Presentation

Seven patients were evaluated. One served as a control (no specific post-procedure formulation), while 6 applied a topical Cu-Zn combination twice daily.

Case 1 (Control): Female, 44, Er:YAG laserin the periocular region. Experienced intense burning and erythema for 3 days; redness and scaling persisted for 15 days.

Case 2: Female, 65, fractional ablative parameters. Presented with intense crusting and severe edema. Following Cu-Zn application and LED therapy, complete resolution was achieved in 5 days.

Case 3: Female, 35, phototype III, Er:YAG laser. Moderate erythema and mild desquamation. Edema resolved by day 3; desquamation cleared by day 5.

Case 4: Male, 49, acne scars. Achieved complete resolution of erythema, edema, and desquamation in 7 days.

Case 5: Female, 54, facial rejuvenation with CO2 laser. Severe immediate post-procedure edema. Complete recovery within 7 days.

Case 6: Female, 61, facial rejuvenation with CO2 laser. Significant immediate edema; resolved completely along with erythema and scaling in 12 days.

Case 7: Male, 44, Er:YAG laser for acne scars. Complete clinical recovery observed in only 2 days.

Conclusion

This case series provides robust evidence that Cu-Zn formulations significantly accelerate wound healing and improve tolerability. Comparing our findings with the Control Case (Case 1), where symptoms persisted for 15 days, the group demonstrated a reduction in downtime by more than 50% in most instances. This is particularly evident in Case 7, where recovery occurred in just 2 days, and Case 2, where severe ablative symptoms resolved in 5 days—significantly faster than the 7–14 days expected for standard re-epithelialization in ablative procedures.

These findings corroborate 2025 expert consensus guidelines, which emphasize that post-procedure topical care is integral of treatment to maintain moisture, reduce inflammation, and prevent infection. While literature suggests that probiotic-based creams can reduce erythema resolution to 14.3 days and edema to 9.3 days, our Cu-Zn protocol consistently outperformed these benchmarks, with most patients achieving complete resolution within 2 to 7 days. This clinical advantage is crucial for patient compliance and satisfaction, as the rapid closure of vaporized columns reduces trans-epidermal water loss (TEWL) and pain.

The clinical justification for this mineral-based approach is clear: fractional lasers compromise the epidermal barrier, increasing susceptibility to pathogens and irritants. Our results show that Cu-Zn formulations act as a biological shield, mitigating the 65% risk of irritant contact dermatitis observed in patients who do not follow adequate protocols. Furthermore, the mineral complex addressed the significant edema and crusting inherent to ablative modes more effectively than standard petrolatum-only protocols. By promoting faster tissue repair and reducing the inflammatory phase duration, the integration of Cu-Zn formulations emerges as a superior strategy to optimize clinical outcomes, minimize discomfort, and reduce social downtime after laser, establishing a new standard for post-laser recovery

EA DV CONGRESS
VIENNA
30 SEP - 3 OCT 2026

Abstract N°: 3089

Highlighting the Innovation of the Assessment Method: Ultrasonography as an Objective Measurement Tool in HIFU Treatment: A Two-Case Report.

Juliana Silva dos Santos*[1], Anna Paula Vaz de Oliveira Bomtempo[2], Patricia Cristina de Almeida[2]

[1] Universidade Metropolitana de Santos, Santos, Brazil

[2] Human Clinic, Department of Clinical, Cosmetic and Surgical Dermatology, São Paulo, Brazil

Introduction

High-intensity microfocused ultrasound (HIFU) is an established non-invasive technology for the treatment of skin laxity and rejuvenation, with a mechanism based on the delivery of focused ultrasonic energy at specific depths of the dermis and subdermal tissue, generating thermal coagulation points that induce collagen denaturation and subsequent neocollagenesis, resulting in progressive tissue remodeling and skin retraction. Dermatological ultrasonography enables objective and non-invasive measurement of skin layers, making it a valuable tool for pre-treatment planning and post-procedure evaluation.

Case Presentation

MATERIALS AND METHODS

Two patients underwent HIFU treatments with pre- and post-procedure ultrasonographic assessment. Case 1: a 42-year-old female patient treated with microfocused HIFU (Ultraformer III) in the abdominal region using 9 mm (1.0 J, 100 shots), 6 mm (1.0 J, 200 shots), and 4.5 mm (0.8 J, 200 shots) transducers. Ultrasonographic measurements of the SMAS, hypodermis, and dermis were obtained in five abdominal regions before and two weeks after the procedure. Case 2: a 43-year-old male patient who underwent combined micro- and macrofocused HIFU treatment (Ultraformer MPT + Volnewmer) for the full face including the submental region, with multiple transducers per area. Dermal and hypodermal thickness was measured in seven facial regions before and 15 days after the procedure.

Figure.

RESULTS

Case 1: SMAS thickness decreased in 4 of the 5 evaluated regions. Hypodermal thickness was reduced in three quadrants (upper left, upper right, and supraumbilical). Case 2: dermal thickness increased in all seven evaluated facial regions (range: +0.1 to +0.6 mm), while hypodermal thickness decreased at all sites (range: -0.4 to -1.2 mm), most notably in the inframalar, temporal, and jowl regions.

Table 1. Treatment parameters — Case 1 (Micro and macrofocused Ultraformer, abdomen)

Transducer	Energy	Shots
9 mm	1,0 J	100
6 mm	1,0 J	200
4,5 mm	0,8 J	200

Table 2. Pre- and post-procedure ultrasonographic measurements – Case 1

Region	SMAS pre	SMAS post	Hypo pre	Hypo post	Dermis pre	Dermis post
ULQ	0,9 mm	0,6 mm	7,1 mm	5,7 mm	2,1 mm	1,5 mm
LLQ	1,0 mm	0,9 mm	8,0 mm	8,3 mm	1,8 mm	1,7 mm
LRQ	0,9 mm	0,6 mm	8,6 mm	9,3 mm	1,6 mm	1,8 mm
URQ	0,7 mm	0,6 mm	7,9 mm	6,6 mm	1,7 mm	2,3 mm
Supraumbilical	0,8 mm	0,5 mm	9,8 mm	8,2 mm	1,5 mm	1,6 mm

Table 3. Treatment parameters — Case 2 (Ultraformer MPT, face)

Region	Transducer	Energy	Shots
Eyes	2 mm	0,2 J	200
Cheeks	4,5 mm	1,0 J	90
Cheeks	3 mm	0,8 J	70
Cheeks	2 mm	0,2 J	50
Jowl/Submental	4,5 mm	1,0 J	90
Jowl/Submental	3 mm	0,8 J	90

Table 4. Treatment parameters — Case 2 (Monopolar radiofrequency, face)

Region	Transducer	Energy	Shots	Mode
Eyes	0,25 cm^2	1,5 J	200	–
Lower third + submentum	3 cm^2	2,5–3,0 J	150	50% dynamic / 50% static

Table 5. Pre- and post-procedure ultrasonographic measurements — Case 2 (face)

Region	Dermis pre	Dermis post	Hypodermis pre	Hypodermis post
Jowl/Submental	0,7 mm	1,0 mm	1,9 mm	1,4 mm
Left cervical	0,9 mm	1,3 mm	1,7 mm	1,2 mm
Left inframalar	1,4 mm	1,6 mm	3,4 mm	2,2 mm
Left infraocular	1,2 mm	1,5 mm	1,9 mm	1,5 mm
Left temporal	1,1 mm	1,6 mm	2,4 mm	1,5 mm
Left eyebrow	0,8 mm	1,4 mm	0,5 mm	0,1 mm
Jowl	1,2 mm	1,3 mm	3,1 mm	1,9 mm

Abbreviations: ULQ: Upper Left Quadrant; LLQ: Lower Left Quadrant; LRQ: Lower Right Quadrant; URQ: Upper Right Quadrant; Hypo pre: hypodermal thickness before procedure; Hypo post: hypodermal

thickness after procedure.

Conclusion

The use of dermatological ultrasonography as a complementary assessment tool enabled objective structural analysis of the skin before and after treatment, contributing to more individualized HIFU protocols. In Case 1, the early reduction in SMAS (Superficial Musculo-Aponeurotic System) and hypodermal thickness in the abdominal region may reflect initial tissue contraction, consistent with the energy-dependent adipose remodeling described in body HIFU. In Case 2, dermal thickening associated with hypodermal reduction in all facial regions two weeks after treatment suggests initial collagen reorganization, although complete neocollagenesis extends over several months. Pre-procedure ultrasonographic assessment proved particularly relevant in the body context, where greater variability in tissue layer thickness directly influences transducer selection and treatment depth. Limitations include the small number of cases and the short follow-up period, restricting broader conclusions regarding the durability of results. Additionally, dermatological ultrasonography is an operator-dependent technique, subject to intra- and interobserver variability in image acquisition and delineation of tissue layers. Measurement accuracy depends on the examiner's experience, transducer angulation, pressure applied during the examination, and reproducibility of anatomical positioning between assessments. These factors may introduce bias in pre- and post-procedure comparisons, particularly in thin structures such as the dermis and SMAS. Rigorous standardization of the ultrasonographic acquisition protocol is therefore essential to minimize this variability and ensure the reliability of results in future studies.

Dermatological ultrasonography demonstrated early structural tissue changes following HIFU in both facial and body regions, supporting its use as an objective tool for treatment personalization and outcome monitoring. Prospective studies with larger cohorts are needed to validate these findings.

EADV CONGRESS
VIENNA
30 SEP - 3 OCT 2026

Abstract N°: 3103

Periorbital Rejuvenation of Dark Circles Through Structural Correction With Hyaluronic Acid Fillers

MARCELE TRINDADE DOS SANTOS[1], Mariana Santos Lopes Da Conceição*[1], Verônica Franco[1], Eduarda Gregório Arnaut Lima[1], Emilia Peralta Ulerio[1], Ana Amelia Bezerra Milfont[1], Bianca Fuser[1]

[1] Policlínica Geral do Rio de Janeiro, Rio De Janeiro, Brazil

Introduction
Periorbital dark circles (PDC) are a multifactorial condition encompassing vascular, pigmentary, and structural components, with mixed presentations predominating. Structural factors, such as tear trough deformity, malar volume loss, and orbital remodeling, generate infraorbital shadowing, amplifying the perception of hyperpigmentation. Current approaches favor global midface restoration over isolated tear trough filling, as malar support reduces infraorbital depth and may minimize the need for direct infraorbital treatment. Hyaluronic acid (HA) fillers are a key modality given their safety profile and rheological versatility. PDC carries a significant psychosocial burden, frequently impairing self-confidence and driving daily camouflage use.

Case Presentation
A 42-year-old woman presented with bilateral infraorbital hyperpigmentation associated with tear trough deformity and malar volume deficiency, progressively worsening over five years and aggravated by chronic sleep deprivation. Clinical examination revealed bluish-grey medial canthal discoloration with lateral brownish extension, consistent with a mixed structural-pigmentary subtype, alongside a prominent nasojugal groove and infraorbital shadowing accentuated by malar volume loss.

Treatment comprised two HA fillers with distinct rheological profiles: a higher-lifting-capacity product for deep supraperiosteal malar support (2.0 mL) and a softer formulation for infraorbital refinement (1.0 mL), administered using needle and cannula techniques. At 12 weeks, marked improvement in infraorbital contour and shadowing was observed. The patient reported high satisfaction and discontinued cosmetic camouflage use. No adverse events occurred.

Conclusion
Effective management of structural periorbital dark circles requires comprehensive assessment of the midface and tear trough complex to optimize aesthetic outcomes and minimize complications. Midface structural restoration with HA fillers may significantly improve infraorbital contour and patient satisfaction, while potentially reducing the need for isolated tear trough correction. This case highlights the central role of global structural assessment in treatment planning for periorbital dark circles.

EADV CONGRESS
VIENNA
30 SEP - 3 OCT 2026

Abstract N°: 3183

From Ring to Resolution: CO_2 Laser Circumcision as a Novel Therapeutic Approach for Circumferential Condyloma Acuminata

Rakesh Darla*[1]

[1] Serene skin & hair clinic, Guntur, India

Introduction

Genital warts caused by Human Papillomavirus (HPV) are among the most common sexually transmitted infections encountered in dermatology practice. Most cases respond well to topical agents or focal ablative procedures. However, when the entire preputial surface is involved in a circumferential pattern without any spared mucosa, management becomes particularly challenging. In such situations, topical therapies are difficult to apply safely, while conventional circumcision may risk inoculation of HPV-infected tissue at the surgical margin. We describe successful management of extensive circumferential condyloma acuminata using CO_2 laser circumcision in surgical ablative mode.

Case Presentation

A 38-year-old man presented with progressive, painless growths over the penis following unprotected sexual exposure. Examination revealed multiple acuminate papules involving the entire foreskin in a continuous circumferential pattern, without any clinically spared mucosal interval. A few similar papules were also present over the glans penis. The urethral meatus and perianal region were uninvolved. Dermoscopy demonstrated a mosaic vascular pattern with punctate vessels consistent with HPV-associated epithelial proliferation. HIV, VDRL, TPHA, hepatitis B, and hepatitis C serology were non-reactive.

Considering the extensive disease burden, we opted for CO_2 laser circumcision in continuous-wave surgical ablative mode. Under dorsal penile nerve block and ring block anesthesia, a circumferential incision line was marked on disease-free penile shaft skin proximal to the involved foreskin. The CO_2 laser was then used as a precise surgical scalpel to excise the entire HPV-infected foreskin in a single session. Residual warts over the glans penis were ablated using the same laser. Bleeding points were controlled with a defocused CO_2 beam, followed by placement of a few sutures and sterile dressing. Intraoperative blood loss was minimal.

Histopathology confirmed condyloma acuminata, showing koilocytic change, parakeratosis, and acanthosis. Healing was uneventful, with no infection, dehiscence, or residual wart tissue. By four weeks, complete healing with a satisfactory cosmetic outcome was achieved, and no recurrence was observed on follow-up.

Conclusion

Circumferential involvement of the foreskin by condyloma acuminata, without any spared mucosal tissue, represents an uncommon and therapeutically challenging presentation of genital HPV infection. In such cases, conventional treatment modalities including cryotherapy, trichloroacetic acid, and topical immunotherapy may be difficult

to administer safely and effectively because of the diffuse preputial involvement.
In our patient, CO_2 laser circumcision enabled complete excision of the HPV-infected tissue in a single session while simultaneously providing precise tissue dissection, effective hemostasis, and coagulation of the surgical margin. The photothermal effect of the laser may additionally help reduce residual viral burden at the cut edge, potentially lowering the risk of viral seeding associated with conventional circumcision. Furthermore, circumcision itself has been linked to reduced long-term HPV carriage and transmission.
Our experience suggests that CO_2 laser circumcision may serve not only as a surgical procedure, but also as a virologically sound therapeutic strategy for extensive or anatomically difficult genital warts. Greater awareness and further documentation of similar cases may help establish standardized laser-based approaches for such challenging presentations.

EA DV CONGRESS
VIENNA
30 SEP - 3 OCT 2026

Abstract N°: 3186

Effectiveness of a Topical Microbiome Containing Lactobacillus plantarum ATCC-8014 in Improving Wrinkle Index, Skin Hydration, and Ceramide Levels as an Anti-Aging Agent

Siti Aisha Nabila Ferina*[1], Thomas Utomo[2], Anis Irawan Anwar[3], Widya Widita[3]

[1] Dermatology, Venereology, and Aesthetic Department Faculty of Medicine Hasanuddin University, Makassar, Indonesia

[2] Dermatology, Venereology and Aesthetic Department Faculty Medicine Hasanuddin University, Makassar, Indonesia

[3] Dermatology, Venereology and Aesthetic Department Faculty Medicine of Hasanuddin University, Makassar, Indonesia

Introduction

Skin aging is a multifactorial process driven by oxidative stress and microbiome dysbiosis, leading to collagen degradation, impaired hydration, and reduced ceramide levels. *Lactobacillus plantarum* has emerged as a potential microbiome-based anti-aging agent targeting skin barrier function. This study investigates the combined effects of a topical microbiome-based formulation on both structural and barrier-related parameters of skin aging.

Materials and Methods

This randomized controlled clinical trial enrolled 36 subjects aged 30–60 years with moderate skin aging (Glogau II–III). Participants were allocated to receive either a topical *Lactobacillus plantarum* formulation or placebo for 12 weeks. Outcome measures included changes in wrinkle index, skin hydration, and ceramide levels. Wrinkle index was assessed using a skin analyzer, skin hydration using a corneometer, and ceramide levels quantified by enzyme-linked immunosorbent assay (ELISA). Assessments were performed at baseline and week 12. Within-group changes and between-group differences were analyzed using appropriate parametric or non-parametric tests based on data distribution, with statistical significance set at $p<0.05$.

Results

At week 12, the *Lactobacillus plantarum* group demonstrated a significantly greater reduction in wrinkle index compared with placebo (Δ3.9±2.23 vs 0.35±2.03; p=0.001). Skin hydration increased significantly in the treatment group and was higher than in the placebo group (Δ15.10±8.81 vs 9.06±8.15 AU; p=0.001). Ceramide levels increased in the treatment group (+15.38 ng/mL) but decreased in the placebo group (−9.57 ng/mL), with a significant between-group difference (p=0.003).

Conclusions

These findings suggest that *Lactobacillus plantarum* exerts anti-aging effects, potentially through mechanisms related to improved epidermal barrier function and lipid homeostasis. Topical *Lactobacillus plantarum* ATCC-8014 provides clinically meaningful improvements in both structural and functional parameters of skin aging, supporting targeted microbiome modulation as an effective and non-invasive anti-aging strategy, warranting further validation in larger and long-term

studies.

EADV CONGRESS
VIENNA
30 SEP - 3 OCT 2026

Abstract N°: 3196

RHINOPHYMA: EVALUATION OF QUALITY OF LIFE AND PATIENT SATISFACTION BEFORE AND AFTER CARBON DIOXIDE LASER TREATMENT

Joanna Adnan*[1], Matilda Sandström[1], Lisa Alenmyr[1]

[1] Department of Dermatology, Skåne University Hospital, Malmö, Sweden

Introduction
Rhinophyma is characterized by a progressive hypertrophy of the sebaceous glands and soft tissue of the nose. In advanced cases, it may be severely disfiguring and associated with considerable psychosocial impact. Treatment options include surgical techniques and ablative CO_2 laser. This prospective interventional study aimed to evaluate the impact of rhinophyma on quality of life and patient satisfaction before and after treatment with CO_2 laser.

Materials and Methods
A total of 40 patients with rhinophyma were included, consecutively. Quality of life and patient satisfaction were assessed using the dermatology life quality index (DLQI) and patient satisfaction, before treatment and 4-6 months after treatment. Long-term follow-up was performed after 5 years to evaluate patient satisfaction and risk of relapse.

Results
The severity of rhinophyma was graded as mild (n=10), moderate (n=13) and severe (n=17). 20% of the patients reported a DLQI score corresponding to a moderate effect on the patient´s life (6-10) and 15% had a value related to a very large effect on patient´s life (11-20). DLQI scores (mean±SEM) were significantly improved at the 4-6 months follow-up compared with baseline (5.58±0.74 versus 1.46±0.40, $p<0.001$). 98% of the patients would recommend the treatment to others and 90% were satisfied or very satisfied with the result. Surgical results were graded by two independent physicians as excellent in 44% and good in 56%. At the long-term follow-up, high patient satisfaction was sustained and over 50% of the patients did not experience any signs of rhinophyma. 45% reported a mild relapse which did not motivate additional treatment. Only two patients received retreatment with CO_2 laser for moderate relapses.

Conclusions
Patients experienced improved quality of life after treatment and reported very high treatment satisfaction. The results were greatly sustained during long-term follow-up. Our data support that ablative CO_2 laser is an effective treatment option for rhinophyma, with short healing time, precise sculpturing with minimal scarring and high long-term patient satisfaction. Based on our findings, we suggest that DLQI can be a useful primary assessment tool as it is easy to use and well established in clinical practice.

EA DV CONGRESS
VIENNA
30 SEP - 3 OCT 2026

Abstract N°: 3199

Digital Beauty Filters, AI-Generated Facial Ideals, and Psychodermatologic Burden in Cosmetic Dermatology: A Scoping Review

Zeynep Gayhan*[1], Mohd Faizan Siddiqui[2]

[1] Bezmialem Vakif University Faculty of Medicine, Istanbul, Türkiye
[2] International Medical Faculty, Osh State University, Osh, Kyrgyzstan

Introduction
The growing use of augmented reality filters and AI-based image editing across social media platforms has changed what many patients expect from cosmetic dermatology. Rather than bringing in photographs of celebrities or public figures, patients now frequently arrive with edited images of themselves, processed by algorithms whose outputs no clinical procedure can reliably replicate. This shift has given rise to presentations described in the literature as Snapchat dysmorphia and, more recently, algorithmic dysmorphia, characterized by body image distortion, unrealistic outcome expectations, and in some patients, features consistent with body dysmorphic disorder. This scoping review aimed to synthesize current evidence on the psychodermatologic burden of digital image manipulation and AI-generated beauty exposure in cosmetic dermatology settings.

Materials and Methods
A scoping review was conducted in accordance with PRISMA-ScR guidelines. Systematic searches were performed across MEDLINE, Embase, PsycINFO, Scopus, Web of Science, and CINAHL from January 2015 to March 2025. Three search domains were applied: digital exposure (AR and AI filter use, selfie editing, videoconferencing appearance), psychological phenotype (BDD, body image dissatisfaction, appearance anxiety, social comparison), and clinical outcome (cosmetic procedure intent, BDD screening, expectation-outcome discrepancy). Following deduplication, title and abstract screening, and full-text eligibility assessment, 24 studies were included in the final synthesis, comprising systematic reviews, experimental studies, cross-sectional surveys, and clinical reviews.

Results
Included studies covered literature representing more than 20,000 participant observations across experimental and survey-based designs. Greater engagement with filtered beauty content was consistently associated with higher body dissatisfaction and increased interest in cosmetic procedures. Randomized experimental evidence showed that exposure to manipulated peer images was associated with worsening body image in adolescent girls; selfie editing extent predicted facial dissatisfaction in a dose-dependent pattern replicated across independent samples, and habitual appearance comparison tendencies amplified susceptibility. A systematic review of 43 experiments (N = 8,637) confirmed that idealized social media imagery increases body dissatisfaction across sexes, with social comparison as the primary mediating mechanism.

24.4% of individuals had probable Body Dysmorphic Disorder (BDD), rising from 19% in light social media users to 29% in those spending 4–7 hours a day on image-focused platforms. Due to altered virtual self-perception, many patients sought cosmetic consultations for periocular and perioral fillers and neuromodulators. Over time, AI beauty filters raised posting confidence but decreased self-esteem and mental health. Cosmetic dermatologists see 9% of patients with BDD, compared to 2% in the general population, and up to 75% of affected patients

remain mentally unsatisfied after cosmetic operations.

Conclusions

AI-enhanced and digitally manipulated beauty ideals appear to be shifting patient expectations in cosmetic dermatology toward standards that procedures cannot realistically achieve. Algorithmic dysmorphia is not yet a validated clinical diagnosis; it is more accurately understood as the most recent expression of a filter- and selfie-mediated appearance dissatisfaction continuum documented progressively in the dermatologic literature. These findings highlight the importance of incorporating validated screening tools, including the BDDQ-Dermatology Version, alongside realistic expectation counseling and psychiatric or psychological referral where indicated, into routine aesthetic practice. Prospective clinical research examining filter and AI image exposure in cosmetic consultation settings remains a clear research priority.

EA DV CONGRESS
VIENNA
30 SEP - 3 OCT 2026

Abstract N°: 3218

LC-OCT Evidence of Skin Remodeling following Poly-L-Lactic Acid Treatment

Chiara Battilotti*[1], Concetta Potenza[2], Stefania Guida[3], Ilaria Proietti[2]

[1] Dermatology Clinic, Department of Clinical and Cardiovascular Sciences, Sapienza University of Rome, Rome, Italy
[2] Department of Medical and Surgical Sciences and Biotechnologies, Division of Dermatology "Daniele Innocenzi", University of Rome "La Sapienza", Polo Pontino, Terracina (LT), Italy
[3] Dermatology Clinic, IRCCS San Raffaele Scientific Institute, Università Vita Salute San Raffaele, Milan, Italy

Introduction

Poly-L-lactic acid (PLLA) is a biodegradable collagen-stimulating injectable increasingly used in aesthetic dermatology for facial rejuvenation and the correction of age-related volume loss. Unlike conventional fillers, which mainly provide immediate volumetric replacement, PLLA induces gradual tissue remodeling through fibroblast activation, extracellular matrix deposition, and neocollagenesis, leading to progressive improvement in skin firmness, texture, and structural support. Over the last years, PLLA has gained increasing interest not only for volumetric restoration but also for its regenerative properties and its ability to improve overall skin quality. Nevertheless, despite its widespread clinical use, objective in vivo evaluation of treatment-induced skin remodeling remains limited, and most assessments still rely primarily on clinical photography and subjective aesthetic evaluation. Line-field confocal optical coherence tomography (LC-OCT) is an emerging non-invasive imaging technique that enables real-time visualization of skin microarchitecture with near-histological resolution. By combining vertical and horizontal imaging modalities, LC-OCT allows detailed assessment of epidermal and superficial dermal structures, including dermo-epidermal junction morphology and collagen organization. In this context, LC-OCT may represent a promising tool for the in vivo assessment of structural skin changes induced by collagen-stimulating injectables. We report clinical and LC-OCT findings following PLLA treatment for facial aging in a patient showing significant clinical response after a single treatment session.

Case Presentation

A 49-year-old woman presented with facial aging characterized by midface volume loss and reduced skin firmness. Her medical history was notable for long-standing alopecia universalis of approximately 20 years' duration. The patient underwent a single treatment session with PLLA for midface rejuvenation. Clinical assessment and LC-OCT imaging of the treated cheek area were performed at baseline and after 6 months of follow-up. At clinical evaluation, progressive improvement in midface contour, cheek projection, skin texture, and overall skin quality was observed at follow-up. LC-OCT imaging demonstrated relevant modifications in both epidermal and dermal architecture (Figure 1). No nodules, granulomatous reactions, vascular complications, prolonged edema, or inflammatory adverse events were observed during follow-up. Interestingly, unexpected hair regrowth was also observed during follow-up, despite injections being limited to the midface region. Clinical examination and trichoscopy demonstrated the appearance of newly emerging vellus and early terminal hairs in the parietal scalp region.

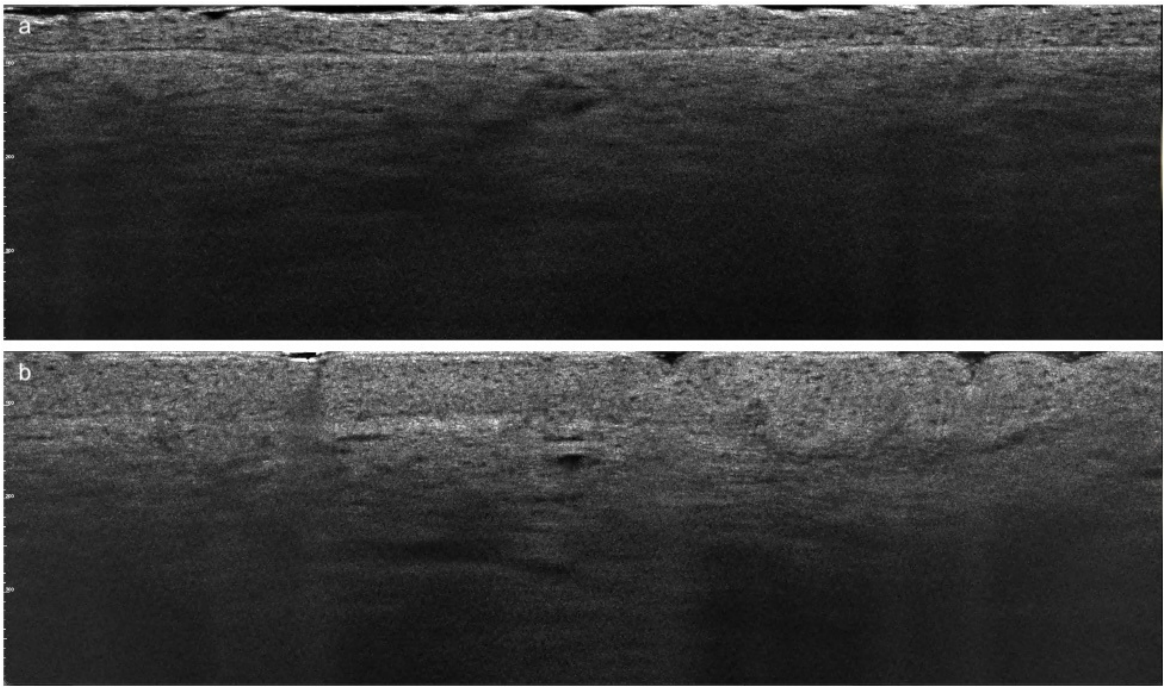

Compared with baseline (a), follow-up images revealed increased epidermal thickness and restoration of a more undulated dermo-epidermal junction. In the superficial dermis, LC-OCT showed increased reflectivity associated with a denser and more organized fibrillar collagen pattern, suggestive of extracellular matrix remodeling and neocollagenesis (b).

Conclusion

This case highlights the potential role of LC-OCT as a non-invasive imaging tool for the in vivo assessment of skin remodeling following PLLA treatment in aesthetic dermatology. Clinical improvement after PLLA treatment was associated with combined epidermal and dermal structural modifications detectable by LC-OCT, including increased epidermal thickness, restoration of dermo-epidermal junction architecture, and dermal collagen reorganization. Moreover, the unexpected observation of hair regrowth in a patient with long-standing alopecia universalis raises questions regarding possible interactions between PLLA-induced tissue remodeling, inflammatory pathways, and hair follicle biology. Although further studies involving larger patient cohorts and longer follow-up are necessary, LC-OCT may represent a promising tool for objective monitoring of regenerative aesthetic treatments and their biological effects in vivo.

EADV CONGRESS
VIENNA
30 SEP - 3 OCT 2026

Abstract N°: 3252

Sleep and Mood as Lifestyle Determinants of Skin Longevity: A Longitudinal Digital Phenotyping Study

Tim Sonntag[1], Paula Pitta*[1], Amine Masmoudi[1], Laura Wenderoth[1], Sven Clemann[1], Sören Jaspers[1]

[1] Beiersdorf AG, Hamburg, Germany

Introduction

Lifestyle and psychosocial factors are increasingly recognized as relevant contributors to skin aging within the framework of longevity [1,2]. Digital health applications enable longitudinal tracking of real-world lifestyle parameters, offering novel opportunities to investigate their association with visible skin aging signs [1]. The Skinly ecosystem comprises a dedicated Skinly device and a companion mobile application. The device is used for daily skin measurements via an integrated camera and moisture sensor, while the mobile app enables self-tracking of lifestyle features, including sleep and mood. Accordingly, mood tracking is an adherence-dependent feature available only to users with high and sustained engagement [1].

Objectives:
To investigate the association between sleep pattern and mood quality with skin aging, assessed by forehead wrinkle scores, across different age groups using longitudinal real-world digital tracking data.

Materials and Methods

This retrospective observational analysis included 1501 German participants using the Skinly device who met predefined tracking adherence criteria.

For mood analysis, 808 participants with at least 80 days of mood tracking were included. Days were classified into high-stress and low-stress based on mood quality scores. For each participant, ratios of high-stress and low-stress days were calculated. Within each age group, the 20% of participants with the highest ratio of high-stress days constituted the high-stress cohort, while the 20% with the highest ratio of low-stress days formed the low-stress cohort, with no overlap between groups.

For sleep analysis, 693 participants with at least 100 days of sleep tracking were included. Days were categorized as very good or very bad sleep days based on sleep quality scores. Within each age group, the top 15% of participants with the highest ratios of very bad sleep days were compared to the top 15% with the highest ratios of very good sleep days.

Forehead wrinkle scores were extracted for all selected participants. Data were visualized using boxplots (whiskers defined as 5th–95th percentiles; outliers removed for visualization). Normality was assessed using the Shapiro–Wilk test, followed by intra-age group comparisons using the Mann–Whitney U test.

Results

Mood:
In the 40–49-year age group, participants with low stress exhibited a median forehead wrinkle score of 62.0 AU (n = 151), compared to 67.0 AU in the high-stress cohort (n = 152), indicating a statistically significant difference.

In participants aged ≥50 years, median wrinkle scores were 67.0 AU for low-stress participants (n = 252) and 72.0 AU for high-stress participants (n = 253). Notably, the median wrinkle score of highly stressed participants aged 40–49 years was comparable to that of low-stress participants aged ≥50 years, suggesting an association between sustained psychological stress and increased wrinkle severity [2].

Sleep:
In the 40–49-year age group, good sleepers showed a median wrinkle score of 63.5 AU (n = 134), while bad sleepers showed 67.2 AU (n = 134), without reaching statistical significance. In contrast, among participants aged ≥50 years, good sleepers had a median wrinkle score of 66.0 AU (n = 213), compared to 70.0 AU in bad sleepers (n = 212), representing a statistically significant difference, consistent with previous evidence linking chronic sleep impairment to skin aging [3].

Conclusions

Long-term digital tracking of mood and sleep quality revealed significant associations with forehead wrinkle severity, particularly in older age groups. Sustained psychological stress and poor sleep quality were associated with higher wrinkle scores, highlighting the relevance of lifestyle and psychosocial factors in skin aging. These findings demonstrate the value of longitudinal digital phenotyping for generating dermatologically relevant real-world evidence and support lifestyle-oriented approaches in skin aging and longevity research.

EA DV CONGRESS
VIENNA
30 SEP - 3 OCT 2026

Abstract N°: 3260

Successful use of pulsed dye laser to treat urticaria pigmentosa of the face

Kate Dear*[1, 2], Stephanie Weston[3]

[1] Perth Children's Hospital, Perth, Australia
[2] Chelsea and Westminster Hospital, London, United Kingdom
[3] Subi Derm, Perth, Australia

Introduction

Urticaria pigmentosa is the most common form of cutaneous mastocytosis and is characterised by brown to erythematous macules or papules triggered by mast cell inflammation of the skin. Management is directed at symptom control with antihistamines, trigger avoidance and photoprotection playing a central role. Treatment for persistent cosmetically troubling lesions remain limited. Reports of laser therapy in urticaria pigmentosa are scarce, with most published cases describing pigment targeting lasers for pigmented lesions and only limited evidence for vascular laser treatment for telangiectatic change.

Case Presentation

We present the case of a 62-year-old woman with longstanding urticaria pigmentosa successfully treated with pulsed dye laser (PDL) of the facial lesions.

The patient was diagnosed with urticaria pigmentosa approximately twenty years ago, with progression to more widespread lesions in recent years. Examination revealed widespread brown and erythematous papules particularly prominent on the thighs, buttocks and upper arms. There were significant telangiectatic macules on the cheeks, nose and glabella regions of the face. Lesions were pruritic and became more pronounced and erythematous following exercise. Previous treatment included regular antihistamines, sun protection and Narrow Band UVB phototherapy. Due to an elevated mast cell tryptase, a bone marrow aspirate was performed which was negative.

PDL (595nm) was first trialled on this patient six years ago as a test patch to two telangiectatic macules on the right side of the face. However, she was lost to follow up. She represented four years later with significant facial erythema and bothersome ongoing facial telangiectasia. Topical brimonidine (Mirvaso) had only been partially successful. Between August 2024 and October 2025, she underwent seven treatments of PDL to the full face, including the cheeks, chin and glabella regions (Candela V Beam Perfecta, 595nm wavelength) using spot size of 7mm, pulse width of 1.5ms-6ms and energy of 7.25 – 9.0J, with cryogen cooling. There were no local or systemic adverse effects from the treatments, apart from expected purpura and erythema. The patient reports improvement in facial erythema and that her face is now less reactive.

There is a paucity of literature regarding the use of lasers for urticaria pigmentosa limited to a small number of case reports and small case series. Reported laser modalities include Q-switched Nd:Yag (532nm) lasers, used mainly for cosmetically bothersome pigmented lesions in urticaria pigmentosa. In contrast, vascular devices such as pulsed dye laser, and intense pulsed light have been reported primarily in telangiectatic mastocytosis phenotypes, including telangiectasia macularis eruptive perstans and systemic mastocytosis with cutaneous vascular involvement. The majority of reports focus on improvement in appearance, while data on symptoms benefit, durability and recurrence remain sparse.

Conclusion

Our case adds to this limited literature by suggesting that serial 595nm pulsed dye laser may be a safe and effective option for prominent facial erythema and telangiectatic lesions in longstanding urticaria pigmentosa.

EADV CONGRESS
VIENNA
30 SEP - 3 OCT 2026

Abstract N°: 3340

Demonstrating the Efficacy of Low Levels of Retinol Versus Other Vitamin A Derivatives and Other Retinol Alternatives

Arthur Pellegrino[1], Kalen Leone*[2], Claudia Linstone[1], Maeve Crane[1], Thierry Oddos[3]

[1] RoC Skincare, New York, United States

[2] RoC Skincare, Paris, France

[3] Science-TO-Skin, Paris, France

Introduction

Retinoic acid is the gold standard in dermatology for reversing signs of skin aging. However, retinoic acid has the potential for instability and irritation. To overcome this, derivatives of vitamin A and alternatives have been developed. It is logical to believe that the molecule with the least conversion steps to retinoic acid would provide more significant anti-aging benefits. However, since overall product efficacy depends on molecular stability, delivery mechanisms, and formulation synergy, skin explant and in vivo studies were selected as the most representative test methods to demonstrate product behavior on skin: study results highlight that with the right formula matrix, topical formulas with retinol can outperform topical formulas with retinal and other retinol alternatives.

Materials and Methods

- Protein level analysis of retinol versus alternatives in skin explants
- Patch test of retinol formulations versus control
- Clinical studies of retinol formulation for efficacy and tolerance

Results

- In the explant study, 0.07% retinol was the only ingredient that had a positive effect on the CRABP2 at Day 2, with an increase of 30%. On Day 5, retinol was equivalent to 0.2% hydroxypinacolone retinoate and superior to the other tested ingredients. When tested for Filaggrin expression, Retinol was superior to 0.2% hydroxypinacolone retinoate, 0.2% retinyl palmitate, and 0.25% bakuchiol ester.
- When tested under occlusion and compared to untreated control, formulations containing 0.110% and 0.055% retinol showed erythema was not elevated and visual dryness was better.
- When tested in vivo, in two separate clinical studies, a retinol formulation containing 0.015% retinol was shown to be efficacious for wrinkle reduction and very well tolerated.

Conclusions

The combination of retinol + DHMC has better efficacy than retinol alone in clinical testing and better biological

activity than either retinol or retinol alone in ex-vivo testing. When well formulated, retinol at low levels is proven to be efficacious without compromising tolerance.

EA DV CONGRESS
VIENNA
30 SEP - 3 OCT 2026

Abstract N°: 3410

Three simple steps to treat suborbital and midface areas by fillers

Fatima-zahra Belgnaoui*[1]

[1] university mohamed VI of sciences of health, Rabat, Morocco

Introduction

Materials and Methods

Infraorbital hollowing usually associated with tear trough depression is frequently observed in aged persons but also in younger people. Anatomical basics of this are lack of bone supports, atrophy and descent of infraorbital and malar fat pads and/or ligaments elongation.
Beeing one of the most challenging procedure in medical esthetic, the aim of this lecture is to present an easy, safe and reproducible technic

Results

We developped a technic combining the treatment of both suborbital and zygomatic areas anddivided in 3 steps:
- step 1: to start by zygomatic deep boluses in order to create pilars with lift up of the midface tissus. This lead to repositionning of superficial fat compartments and better horizontalization of the zygomatic cutaneous ligaments and orbicularis retaining ligaments. By this, prezygomatic space and deep fat compartments becomes more easy to inject in the appropriate depth.
- Step 2: done by canula from the inferior and lateral mid cheek to treat mid-cheek groove until the medial part of the suborbital holloweness.
- Step 3: also with horizontal deep injection done by canula from the latero-inferior part of the holloweness. This last step gives an optimization of the infraorbital treatment and helps also to reduce lateral opening of the orbital rim by lateral fanning
This technic has multiple advantages:
* more vascular safety, because of the predominance of use of canula and the optimal choice of the entry points locations
* Less risk of hematoma
* Less risk of tyndall effect
* Satisfying results in both young and older patient with also an improvement of their dark circles and their midface curves and volumes

Conclusions

this technic using 3 simple steps to treat suborbital abnormalities and midface area in the same time is an easy technic that could encourage many beginners colleagues to start treating this indication and could also simplify the procedure for more advanced ones

EA DV CONGRESS
VIENNA
30 SEP - 3 OCT 2026

Abstract N°: 3444

Glass Skin or Barrier Breakdown? Evaluating the Quality and Safety of Viral Korean Skincare Routines on TikTok

Maria Lúcia Paysano*[1], Barbara Antonia Dups Talah[2], Maria Carolina Elias[3], Michele Kreuz[4]

[1] Instituto de Dermatologia Professor Rubem David Azulay - Santa Casa da Misericórdia do Rio de Janeiro, Rio de Janeiro, Brazil

[2] Pontifical Catholic University of Paraná, Curitiba, Brazil

[3] University of Miami Miller School of Medicine Dr. Phillip Frost Department of Dermatology & Cutaneous Surgery, Miami, United States

[4] Lutheran University of Brazil, Canoas, Brazil

Introduction

Korean skincare routines promoting "glass skin" have gained massive popularity on TikTok, reaching millions of users with little regulatory oversight. The dermatologic accuracy and safety of this content remain largely unevaluated. This study aimed to assess the accuracy and dermatologic safety of viral Korean skincare and "glass skin" content on TikTok, evaluating information on skin barrier health, irritation risk, contact dermatitis, acne-prone skin cautions, sun protection, and excessive use of active ingredients, as well as overall video quality and reliability.

Materials and Methods

A cross-sectional content analysis was conducted on TikTok videos related to viral Korean skincare and "glass skin" routines. Searches were performed in May 2026 using a neutral account with no prior engagement history to minimize algorithmic bias. Five predefined search terms were used: "Glass Skin," "Korean Glass Skin," "Korean Skincare," "KBeauty Skincare," and "Korean Skincare Routine." The top 10 videos per search term were screened, yielding 50 initial videos. Duplicates, non-English videos, and non-skincare content were excluded, resulting in a final sample of 38 videos.

For each video, extracted variables included engagement metrics, creator type, presence of commercial content, promoted skincare practices, and dermatologic claims. Videos were systematically assessed for key safety disclosures, including mention of skin barrier health, irritation risk, allergic or irritant contact dermatitis, acne-prone or sensitive skin cautions, sun protection, over-exfoliation risk, and recommendation to seek dermatologic care. Misleading claims were recorded, including promises of instant results, pore closure, acne cure, and promotion of excessive active ingredient combinations without safety guidance.

Video quality was assessed using the Global Quality Scale (GQS), a widely used 5-point tool ranging from poor (1) to excellent (5) quality. Content reliability was evaluated using the modified DISCERN (mDISCERN), a 5-item instrument assessing clarity of aims, citation of sources, balanced information, reference to additional sources, and acknowledgment of uncertainty. Both instruments were independently applied by two reviewers; discordant scores were resolved by consensus. Descriptive statistics were used to summarize content patterns, safety disclosures, and quality categories.

Results

The 38 included videos were created predominantly by non-physician influencers (81.6%), followed by beauty brands (10.5%) and other beauty content creators (7.9%). No videos were produced by dermatologists. Glass skin/glow was the predominant claim (81.6%), followed by hydration (42.1%) and instant results (34.2%). Essences/serums (57.9%) and barrier repair products (50.0%) were the most promoted practices. Safety disclosures were rare: only 2.6% mentioned irritation risk, 5.3% addressed sun protection, and no video recommended dermatologic consultation or mentioned contact dermatitis risk. At least one misleading claim was identified in 94.7% of videos, most commonly ignoring skin type (84.2%), promoting excessive active ingredient combinations (44.7%), and promising instant results (31.6%). Mean GQS score was 1.13 (±0.47), with 94.7% rated as low quality. Mean mDISCERN score was 0.84 (±0.97); 100% of videos were classified as unreliable or less reliable, and no video cited external sources or references.

Variable	n (%)
CREATOR TYPE	
Non-physician influencer	31 (81.6%)
Beauty brand / company	4 (10.5%)
Beauty content page	3 (7.9%)
Dermatologist	0 (0%)
Sponsored / commercial content	9 (23.7%)
DERMATOLOGIC SAFETY DISCLOSURES	
Mentioned irritation risk	1 (2.6%)
Mentioned contact dermatitis risk	0 (0%)
Addressed sun protection	2 (5.3%)
Mentioned over-exfoliation risk	1 (2.6%)
Addressed skin type considerations	6 (15.8%)
Recommended dermatologist consultation	0 (0%)
VIDEO QUALITY - GLOBAL QUALITY SCALE (GQS, 1-5)	
Mean score (+-SD)	1.13 +- 0.47
Low quality (score 1-2)	36 (94.7%)
Moderate quality (score 3)	2 (5.3%)
High quality (score 4-5)	0 (0%)
CONTENT RELIABILITY - MODIFIED DISCERN (MDISCERN, 0-5)	
Mean score (+-SD)	0.84 +- 0.97
Unreliable or less reliable (score 0-2)	38 (100%)
Cited external sources or references	0 (0%)

GQS = Global Quality Scale; mDISCERN = modified DISCERN instrument.

Initial sample: 50 videos; 12 duplicates excluded; final sample: 38 videos.

Table 1. Content quality and dermatologic safety of TikTok videos on Korean skincare and "glass skin" routines (n = 38)

Conclusions

Viral Korean skincare and "glass skin" content on TikTok is predominantly created by non-physician influencers

and critically lacks dermatologic safety guidance. Misleading claims are nearly universal, and video quality and reliability are strikingly low regardless of engagement metrics. These findings highlight the importance of dermatologist involvement in digital health communication, reinforcing the need for evidence-based guidance on viral skincare trends that may carry dermatologic risks

EADV CONGRESS
VIENNA
30 SEP - 3 OCT 2026

Abstract N°: 3444

Improved skin recovery after fractional laser Erbium:YAG 2490 nm: a split-face evaluation of sucralfate topical use

Valeria Barreto Campos[1], Camila Gouvea Facure*[1], Carolina Lourenço dos Santos Landini Freitas[1], Carolina Siqueira Varotto Martins[1], EDUARDA LUISA ROCHA CORTI[1]

[1] Faculdade de Medicina de Jundiaí - FMJ, jundiai, Brazil

Introduction

The Erbium:YAG 2490 nm laser represents one of the most used fractional ablative technologies in contemporary aesthetic dermatology for skin rejuvenation, promoting epidermal renewal and dermal remodeling through the induction of controlled thermal microzones. Its mechanism of action is related to the selective vaporization of tissue water, resulting in stimulation of neocollagenesis, reorganization of dermal fibers and progressive improvement of skin architecture. Clinically, it is associated with the reduction of fine wrinkles, improvement of skin texture and elasticity, attenuation of dyschromia and overall restoration of skin quality.

Despite the high clinical efficacy, the post-procedure period remains associated with transient inflammatory changes, such as erythema, edema, burning sensation and temporary impairment of the skin barrier, making relevant strategies aimed at optimizing tissue repair. In this context, sucralfat has aroused interest due to its healing, anti-inflammatory and cytoprotective properties, related to the stimulation of epithelial regeneration, local inflammatory modulation and favoring re-epithelialization.

Split-face comparative models are a valuable methodological tool in dermatology, as they allow intra-individual analysis between different therapeutic approaches, minimizing biases related to the patient's own characteristics, such as age, phototype and environmental exposures.This report describes the clinical evolution of a patient undergoing Erbium:YAG 2490 nm laser for facial rejuvenation, comparing the use of topical sucralfate in a hemiface to the patient's usual care in the contralateral hemiface.

Case Presentation

Female patient, 75 years old, Brazilian, phototype II of Fitzpatrick Classification, clear eyes, submitted to a single session of Erbium laser:YAG 2490 nm throughout the face for the purpose of skin rejuvenation.

A comparative split-face protocol was adopted, in which a hemiface received pre-procedure preparation with topical sucralfate, also maintained during the post-laser period, while the contralateral hemiface remained only with the patient's usual skin care routine, without the use of a specific repair agent. The clinical evaluation was performed through standardized photographic documentation on the day of the procedure (D0), after five days (D5), 14 days (D14) and 30 days (D30). Parameters related to skin recovery were analyzed, including erythema intensity, residual inflammatory aspect, skin texture, overall skin quality and attenuation of fine wrinkles.

Global clinical improvement was observed in both hemifaces, compatible with the expected effects of fractional ablative laser on facial rejuvenation. There was improvement in skin texture, smoothing of fine wrinkles and global improvement in skin quality, associated with the stimulation of dermal remodeling and neocollagenesis. However, the hemiface treated with sucralfat showed a more favorable evolution, characterized by lower intensity of residual erythema, faster recovery of the skin barrier and better overall clinical appearance in serial evaluations, especially in D5 and D14, in addition to greater comfort.

Conclusion

Topical sucralfate used as an adjuvant during pre-treatment preparation and post-laser recovery after Erbium:YAG 2490 nm treatment demonstrated potential benefits in modulating the inflammatory response and accelerating skin repair in a

split-face comparative model. In addition to the expected facial rejuvenation effects, earlier clinical recovery, reduced residual erythema, and improved overall skin quality were observed on the treated hemiface throughout follow-up. These findings suggest that sucralfate may represent a promising strategy for optimizing peri- and post-procedural care in fractional ablative technologies.

EA DV CONGRESS
VIENNA
30 SEP - 3 OCT 2026

Abstract N°: 3447

High-Frequency Ultrasound for Hyaluronic Acid Filler Complications: Pattern Recognition and a Practical Diagnostic Algorithm from 160 Cases

Maria Lúcia Paysano*[1], Estevão Vargas[1], Luara Boson[1]

[1] Instituto de Dermatologia Professor Rubem David Azulay - Santa Casa da Misericórdia do Rio de Janeiro, Rio de Janeiro, Brazil

Introduction
Hyaluronic acid (HA) filler complications may present with overlapping clinical features despite requiring different management strategies. High-frequency dermatologic ultrasound enables real-time assessment of filler depth, echogenicity, morphology, perifiller reaction, fluid collections, and vascular activity using color Doppler. This study aimed to identify reproducible ultrasound patterns of HA filler-related complications and develop a practical imaging-based diagnostic algorithm.

Materials and Methods
This study was conducted within an ongoing dermatologic ultrasound program comprising over 1,000 facial mapping examinations. From this cohort, 160 patients evaluated for suspected HA filler-related complications between 2023 and 2026 were included. All examinations were performed using high-frequency ultrasound with color Doppler and a 22 MHz linear probe (GE Logiq E). Assessed parameters included filler echogenicity, depth, morphology, perifiller reaction, fluid collections, and Doppler vascularity. The initial clinical impression was compared with sonographic findings. Cases were categorized as PIDS (Persistent Intermittent Delayed Swelling), non-inflammatory nodule, inflammatory nodule, infection-suggestive pattern, sterile collection, Tyndall effect, xanthelasma-like deposit, or vascular compromise. A pattern-recognition algorithm was developed based on recurring imaging features.

Results
Eight sonographic patterns were identified, each corresponding to a specific complication category and management pathway. PIDS was the most frequent pattern, characterized by anechoic residual HA deposits with hyperechogenicity of the adjacent subcutaneous tissue, supporting conservative management. Nodular complications were the second most frequent category, showing variable echogenicity from anechoic to hypoechoic. Color Doppler helped differentiate inflammatory from non-inflammatory nodules by demonstrating increased peripheral vascularity in the former.
The most clinically relevant distinction was between inflammatory nodules and infection-suggestive patterns, which may be clinically indistinguishable. Inflammatory nodules showed moderate peripheral Doppler vascularity with well-defined borders, whereas infection-suggestive patterns were characterized by multiple small fluid collections with peripheral vascularization at the injection sites — a finding more consistent with mycobacterial infection or sterile collection (the latter confirmed by negative culture and mild adjacent inflammatory signs). Vascular compromise was the least frequent category; Doppler confirmed reduced or absent arterial flow and monitored perfusion restoration after hyaluronidase. Overall, ultrasound frequently refined the initial clinical impression, influencing treatment decisions and preventing inappropriate interventions.

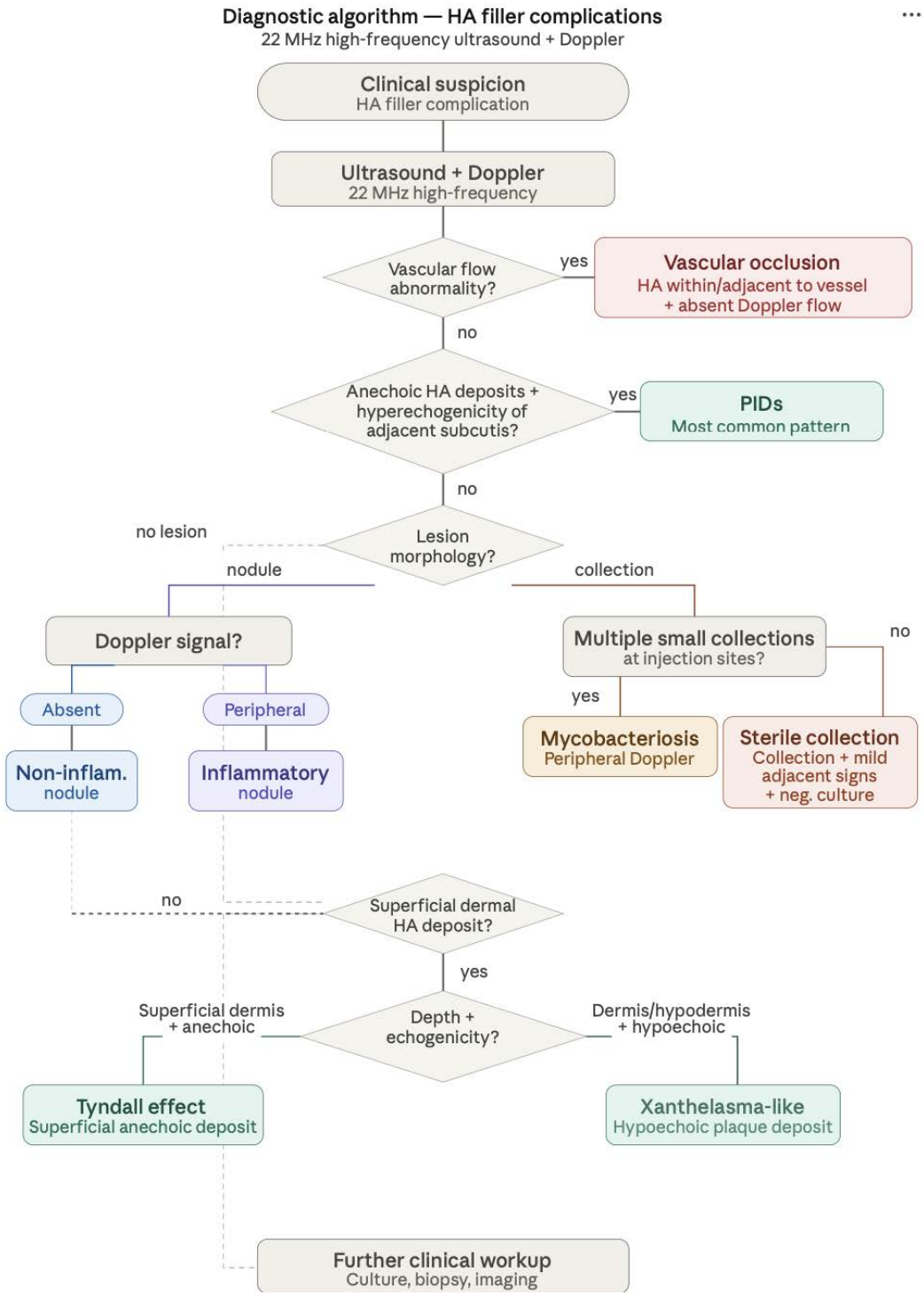

Figure 1. Diagnostic Flowchart for Ultrasonographic Classification of Hyaluronic Acid Filler Complications

Conclusions

High-frequency dermatologic ultrasound enables objective differentiation of clinically overlapping HA filler complications. PIDS, the most frequent pattern, was reliably identified by residual anechoic HA deposits with perifocal inflammatory edema. A pattern-recognition algorithm based on echogenicity, depth, morphology, perifiller reaction, and Doppler vascularity may support targeted diagnosis and reduce inappropriate interventions. These real-world findings support integrating dermatologic ultrasound into routine assessment of filler-related complications. Multicenter prospective studies are warranted to validate the proposed algorithm.

EADV CONGRESS
VIENNA
30 SEP - 3 OCT 2026

Abstract N°: 3460

Bilateral gram-negative facial abscesses after polynucleotide injections

Mohammed shanshal[1], Emily Moon*[1], Radhika Bali[1], Sumbel Khan[1]

[1] Imperial College Healthcare NHS Trust, London, United Kingdom

Introduction

Polynucleotide injections are increasingly used as injectable skin boosters in aesthetic practice, but severe infectious complications remain poorly characterised. Expected early post-injection swelling may obscure evolving infection, particularly when inflammation is bilateral or initially resembles a treatment reaction. We report bilateral culture-confirmed gram-negative facial abscesses after facial polynucleotide injections and highlight the diagnostic and antimicrobial implications.

Case Presentation

A 57-year-old otherwise healthy woman, with no diabetes or immunosuppression, developed bilateral cheek erythema and oedema within 24 hours of facial polynucleotide injections. Initial management reflected presumed post-procedural cellulitis with gram-positive cover. Over the following five days, pain and swelling progressed, inflammatory markers rose, and bilateral tender fluctuant cheek masses developed. Ultrasound on post-injection day 6 demonstrated complex subcutaneous collections in both cheeks with surrounding cellulitis. Aspirate microscopy showed numerous leukocytes and gram-negative bacilli, prompting hospital admission, intravenous antimicrobial therapy and urgent incision and drainage. Operative cultures grew ***Enterobacter cloacae*** **complex** and ***Klebsiella variicola***; mycobacterial cultures were negative. The patient improved after source control and culture-directed antimicrobial therapy, with clinical resolution and normalisation of inflammatory markers before discharge. A targeted literature search did not identify a prior published culture-confirmed gram-negative facial abscess after polynucleotide injection.

Conclusion

This case highlights a severe infectious complication after polynucleotide injections that initially mimicked expected post-injection inflammation. Progressive pain, fluctuance, bilateral enlargement, rising inflammatory markers and poor response to usual gram-positive cover are important warning features that justify early ultrasound and aspiration for microscopy and culture. The recovery of *Enterobacter cloacae* complex and *Klebsiella variicola* from operative cultures supports an atypical post-procedural gram-negative infection rather than routine community-acquired cellulitis. As polynucleotide injections become more widely used, clinicians need a low threshold for microbiological sampling, timely drainage and culture-directed antimicrobial therapy when post-cosmetic-injection inflammation follows an atypical or progressive course.

EADV CONGRESS
VIENNA
30 SEP - 3 OCT 2026

Abstract N°: 3477

Treatment of a Port Wine Stain in a South Asian Infant using the 595nm Pulsed Dye Laser

Evangelia Vetsiou[1, 2], Saqib Bashir*[1, 2]

[1] Dermatology Department, King's College Hospital NHS Foundation Trust, London, United Kingdom
[2] Skin 55 Clinic, London, United Kingdom

Case Presentation

A 3.5-month-old South Asian infant presented with a port-wine stain involving the midline forehead, nasal dorsum, upper lip, and left cheek. Developmental milestones were age-appropriate, and no systemic abnormalities were identified. Due to the lesion's distribution, Sturge–Weber syndrome was excluded based on a normal neurological examination and brain MRI, which showed no leptomeningeal or vascular anomalies. Ophthalmologic monitoring was initiated because of eyelid involvement and the increased risk of glaucoma.

Clinical evaluation confirmed a flat, erythematous capillary malformation consistent with a port-wine stain. He had Fitzpatrick skin type IV. In accordance with evidence supporting early intervention, treatment with a 595-nm pulsed dye laser was initiated. Nine treatment sessions were conducted at two-week intervals. Parameters included a 10 mm spot size, fluence of 7–7.5 J/cm^2, and a pulse duration of 1.5 ms, with dynamic cooling employed. These settings were selected to optimize vascular targeting and minimize adverse effects. The two-week interval allowed for sufficient recovery and monitoring of therapeutic response. The treatment was well tolerated, with transient purpura as the only reported side effect. No topical anaesthesia was used and the patient was fully awake, held in his parent’s arms. Appropriate eye protection was provided. Progressive lightening of the lesion was observed, resulting in near-complete resolution after the ninth session. 6 moths after the final treatment, there was no relapse, and the parents report that facial flusing, during crying, in the area of the port wine stain, was markedly reduced.

Conclusion

Port-wine stains are capillary malformations that may darken and develop hypertrophy if untreated. Early pulsed dye laser therapy targets superficial, immature vessels, leading to improved clearance compared to delayed intervention. Recent evidence supports early, high-frequency treatment protocols. Infants treated before six months of age experience greater lesion lightening, require fewer sessions, and have a lower risk of hypertrophy. Early intervention is also linked to improved long-term outcomes and higher parental satisfaction. Shorter treatment intervals during infancy may further enhance results and reduce long-term cosmetic and psychosocial sequelae (1).

This case illustrates the safety and efficacy of early, high-frequency pulsed dye laser therapy. Near-complete clearance was sustained at three-month follow-up, with no recurrence or late adverse effects observed. Continued follow-up is planned to evaluate the durability of the response. Early referral and intervention are critical to optimizing outcomes in this patient population.

EA DV CONGRESS
VIENNA
30 SEP - 3 OCT 2026

Abstract N°: 3504

Knowledge, Attitudes, and Perceptions of Dermatologists and Residents Toward Exosome-Based Therapies: A Cross-Sectional Survey

Taige Cao*[1]

[1] Sengkang General Hospital, Singapore, Singapore

Introduction
Exosomes and other extracellular vesicles (EVs) have rapidly emerged as a frontier in aesthetic and therapeutic dermatology, with growing applications in skin rejuvenation, scar remodeling, and alopecia. However, the field remains constrained by regulatory uncertainty, lack of standardization, and limited high-level clinical evidence. Despite increasing commercial availability and patient curiosity, little is known about how practicing dermatologists and residents understand and approach this technology. This study assessed the knowledge, attitudes, and perceptions (KAP) of dermatologists and residents regarding exosome-based therapies.

Materials and Methods
A cross-sectional survey was administered to dermatologists and dermatology residents. The instrument comprised 15 structured multiple-choice items covering three domains: Knowledge (K1–K10) on EV nomenclature, characterization markers, regulatory status, clinical evidence, dosing standardization, and barriers to adoption; Attitudes (A1–A2) toward regulation and clinical incorporation; and Perceptions (P1–P3) of safety, efficacy, and patient demand. Twenty participants contributed responses, with 13–17 responses per item. Frequencies and percentages were computed for each option.

Results
Knowledge: Respondents demonstrated mixed proficiency. Most correctly identified that "exosomes" should not be used as a generic term for all EVs (75%), recognized fractional laser/microneedling adjuvant studies as the strongest aesthetic evidence (93.3%), identified the Florida stem-cell clinic infections as the trigger for the FDA safety communication (73.3%), recalled improved scar scores in the 2020 CO_2 + hASC-Exos RCT (94.1%), identified BRE-AD01/BxC-I17e as the Phase 1 atopic dermatitis program (66.7%), characterized current alopecia evidence as promising with ongoing RCTs (87.5%), and recognized that abundant Phase III evidence is *not* a barrier to adoption (78.6%). However, key gaps were evident: only 30.8% identified CD9/CD63/CD81 as the standard EV characterization markers (61.5% incorrectly chose CK5/6/AE1/AE3), and 73.3% incorrectly believed FDA-approved exosome products exist for skin indications. Only 41.2% correctly recognized that EV dosing is not standardized.

Attitudes: No respondent was strongly supportive or strongly opposed to current regulation; 60% were neutral awaiting further guidance and 40% supported flexible clinician-directed use. Regarding clinical incorporation, 31.3% were strongly supportive and eager to adopt, 50% supportive pending more trials, 12.5% neutral, and 6.3% opposed.

Perceptions: On safety, 40% felt exosomes may pose unknown risks due to limited human data, 33.3% were unsure due to lack of training, and 26.7% considered them safe only if regulated; none viewed them as broadly safe or unsafe. On efficacy, 40% perceived moderate effectiveness pending research, 40% were unsure, and 20% viewed them as minimally effective; none endorsed high efficacy. Patient demand was perceived as low to minimal by 75% (43.8% minimal, 31.3% low, 25% moderate), with no respondent reporting high or very high demand.

Conclusions

Dermatologists and residents demonstrate a working knowledge of exosome clinical evidence and regulatory landmarks but harbor important misconceptions, particularly regarding FDA approval status, EV characterization markers, and dosing standardization. Attitudes are cautiously optimistic, with the majority supporting incorporation contingent on stronger trial data, while perceptions of safety and efficacy remain tempered by uncertainty and limited training exposure. Patient-driven demand appears modest in this cohort. These findings highlight the need for targeted educational initiatives, standardized terminology and dosing frameworks, and clearer regulatory communication to support evidence-based integration of exosome therapies into dermatology practice.

EADV CONGRESS
VIENNA
30 SEP - 3 OCT 2026

Abstract N°: 3559

Evaluation of Cardiac Implantable Electronic Device Integrity During Focused Ultrasound-Based Facial Tissue Tightening: A Prospective Observational Study

Nitina Yeesibsean*[1], Thanaporn Utrachon[2], Theerachai Thammathiwat[3], Nattakorn Songsirisuk[4]

[1] Division of Dermatology, Department of Medicine, Faculty of Medicine, Naresuan University, Muang Phitsanulok, Thailand

[2] Department of Medicine, Phichit Medical Education Center, Faculty of Medicine, Naresuan University, Phichit, Thailand

[3] Division of Nephrology, Department of Medicine, Faculty of Medicine, Naresuan University, Muang Phitsanulok, Thailand

[4] Division of Cardiology, Department of Medicine, Faculty of Medicine, Naresuan University, Muang Phitsanulok, Thailand

Introduction

Although focused ultrasound (FU) is a popular modality for noninvasive facial tissue tightening. The use of focused ultrasound for facial rejuvenation in patients with cardiac implantable electronic devices (CIEDs) raises concerns regarding possible electromagnetic interference (EMI) and thermal injury. This prospective observational study evaluated the safety of FU exposure in individuals with CIEDs.

Materials and Methods

Fourteen patients with CIEDs underwent FU-based facial tissue tightening using a within-subject pre-post comparison design. The cohort consisted of 9 pacemaker recipients (64%), 3 patients with implantable cardioverter-defibrillators (21%), and 2 with cardiac resynchronization therapy-defibrillators (15%). Each participant received 1,090 FU-treatment lines (total 15,260 FU-lines throughout the study) at 2-7 MHz and 0.1-1 J. Electrograms were continuously monitored before, during, and immediately after treatment to detect arrhythmias or EMI events. All CIEDs were interrogated post-procedure to assess functional integrity. Paired comparisons between the preprocedural and intraprocedural periods were analyzed using the exact McNemar test, with an additional one-sided analysis to evaluate increased intraprocedural risk.

Results

No device-detected events occurred during FU exposure. Eight participants (57.1%) had recorded events in the preprocedural period, whereas six (42.9%) had no events in either phase. Although a statistical difference was observed between periods ($p = 0.0078$), this finding likely reflects the shorter intraprocedural monitoring window. The one-sided analysis showed no increase in intraprocedural events ($p = 1.000$). No device malfunction or electrical reset was detected.

Conclusions

FU-based facial tissue tightening appears safe and is not contraindicated in patients with CIEDs. Nonetheless, avoiding direct energy delivery toward implanted devices is recommended to reduce theoretical mechanical or thermal risks.

EA DV CONGRESS
VIENNA
30 SEP - 3 OCT 2026

Abstract N°: 3585

Longitudinal Ultrasonographic Evaluation of Morphologic, Elastographic, Vascular, and Adaptive Muscle Changes Following AbobotulinumtoxinA Injection in Bruxism-Associated Masseter Hypertrophy

Pelin Koçyiğit[1], Merve Alızada*[1], Fatma Zehra Keleş[1], Sıla Şahin[1], Evren Ustuner[2]

[1] Ankara Üniversitesi Tıp Fakültesi Hastaneleri, Department of Dermatology, Ankara University Faculty of Medicine, ankara, Türkiye

[2] Ankara Üniversitesi Tıp Fakültesi Hastaneleri, Department of Radiology, Ankara University Faculty of Medicine, ankara, Türkiye

Introduction

Bruxism-associated masseter hypertrophy is characterized by chronic masticatory muscle hyperactivity and facial contour alteration. Although botulinum toxin type A (BoNT-A) is an established minimally invasive treatment, its longitudinal effects on muscular morphology and function remain incompletely understood. This study aimed to evaluate morphologic, biomechanical, vascular, and adaptive muscular changes following abobotulinumtoxinA treatment using multimodal ultrasonography.

Materials and Methods

This prospective longitudinal study included 10 treatment-naïve male patients with probable sleep bruxism and clinically confirmed bilateral masseter hypertrophy. All patients underwent bilateral masseter injections with 80 U abobotulinumtoxinA, while the left temporalis muscle additionally received 20 U. Standardized grayscale ultrasonography, shear-wave elastography (SWE), and superb microvascular imaging (SMI) were performed at baseline and at 1-, 3-, and 6-month follow-up visits. Bilateral masseter muscle thickness, elasticity, vascularity scores, ultrasonographic muscle patterns, and temporalis muscle thicknesses were longitudinally analyzed.

Results

A significant reduction in left masseter muscle thickness was observed at 3 months compared with baseline (12.84±2.81 mm vs. 10.92±2.88 mm, p=0.041), corresponding to approximately 15% volumetric reduction. Although right masseter thinning did not reach statistical significance, a parallel reduction trend was observed. SWE measurements demonstrated dynamic but non-significant temporal alterations bilaterally, with early decreases in stiffness followed by partial recovery, suggesting reversible biomechanical remodeling rather than permanent fibrotic transformation. SMI vascularity scores similarly showed non-significant yet biologically relevant reductions in intramuscular vascular signal during follow-up, particularly within the first 3 months, supporting possible BoNT-A–related microvascular remodeling. All patients initially demonstrated a Type 2 ultrasonographic muscle pattern; however, transient conversion to Type 1 was observed in nearly half of the cohort during early follow-up, with complete return to baseline appearance at 6 months, indicating reversible echotextural adaptation. Notably, bilateral temporalis muscle thickening developed during follow-up despite unilateral temporalis injection, with significant increase in right temporalis thickness at 3 months (p=0.012), suggesting compensatory masticatory muscle adaptation.

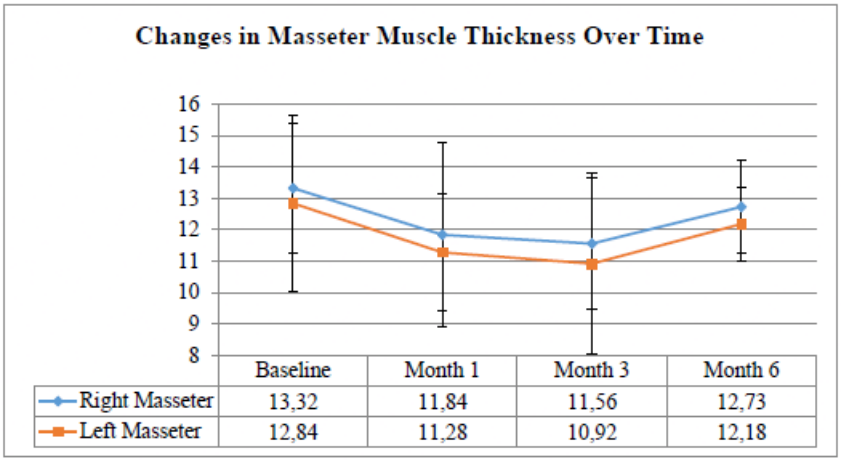

Figure 2B.

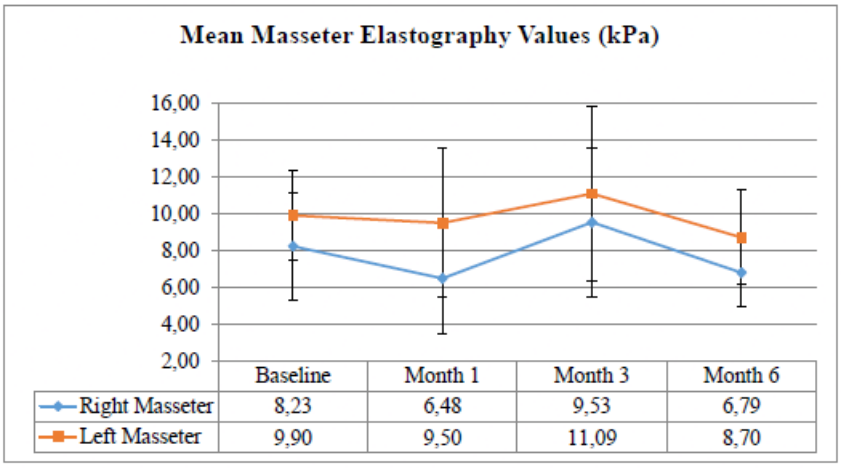

Figure 2A. Longitudinal changes in bilateral masseter muscle thickness (mm)
Figure 2B. Longitudinal changes in bilateral masseter elastography values (kPa)

Conclusions

BoNT-A treatment in bruxism-associated masseter hypertrophy induces complex and dynamic muscular remodeling extending beyond simple muscle thinning. Multimodal ultrasonography demonstrated time-dependent morphologic, echotextural, elastographic, vascular, and compensatory muscular changes following treatment, highlighting the value of combined grayscale ultrasonography, SWE, and SMI for longitudinal monitoring. The observed transient muscle pattern alterations and bilateral temporalis adaptation suggest that BoNT-A–related remodeling may involve reversible microstructural and functional reorganization of the masticatory musculature. These findings provide novel insight into the adaptive response of masticatory muscles after BoNT-A therapy and support the clinical utility of advanced ultrasonographic assessment in treatment monitoring and future protocol optimization.

EA DV CONGRESS
VIENNA
30 SEP - 3 OCT 2026

Abstract N°: 3628

Real-World Evaluation of a Dihydromyricetin-Based Topical Serum Used as Adjunctive and Monotherapy Care in Aesthetic Dermatology Among Latin American Patients

Oscar Candia[1], Natacha Quezada[2], Claudia Piper[3], Verónica Catalan[4], Francisca Daza[5], Franco Gemigniani[6], Daniela Alfaro-Sepúlveda[4], Julia Gallinger[7], Paula Pitta*[7]

[1] Beiersdorf Chile, Santiago, Chile
[2] Dermaline, Santiago, Chile
[3] Clínica Estoril, Santiago, Chile
[4] Clínica Dermédica, Santiago, Chile
[5] Clínica Opia, Santiago, Chile
[6] Clínica Klein, Santiago, Chile
[7] Beiersdorf AG, Hamburg, Germany

Introduction

Aesthetic dermatologic treatments, including fractional laser resurfacing, microneedling, chemical peels, and botulinum toxin injections, are widely used to improve clinical signs of skin aging through controlled epidermal and dermal remodelling. Adjunctive topical skincare is essential to optimize outcomes by supporting skin integrity, ensuring continuity between procedures, and reinforcing daily maintenance strategies [1,2]. Additionally, well-tolerated regimens may improve patient adherence and perception of results, which are critical determinants of long-term success [3].

Cutaneous aging results from cumulative intrinsic and extrinsic stressors that induce persistent alterations in gene expression. Epigenetic mechanisms, particularly DNA methylation modifications, are recognized as key drivers of these changes [4–6]. Targeting epigenetic pathways therefore represents a biologically relevant strategy to improve skin quality and resilience, particularly in combination with aesthetic procedures.

Materials and Methods

This multicentre, prospective, observational study was conducted across five dermatology clinics in Chile. Fifty adults (25–70 years) were assigned to four procedural groups (chemical peel, fractional CO_2 laser, microneedling, or botulinum toxin), all followed by Epicellin Serum®, or to a monotherapy control group.

Participants applied the dihydromyricetin (DHM)-based serum twice daily for 8 weeks, in combination with standardized skincare including gentle cleansing and daily SPF 50 photoprotection.

Assessments were performed at baseline, week 4, and week 8. Objective skin quality was evaluated using imaging equipment and expressed as percentile scores relative to age- and phototype-matched reference populations. Statistical analyses were performed using non-parametric tests (Wilcoxon signed-rank and Kruskal–Wallis), with significance set at $p < 0.05$.

Results

All participants completed the study with full adherence. Over the 8-week period, improvements were observed

across key parameters reflecting skin quality and aging. The most pronounced relative changes were observed for wrinkles (+32%), brown spots (+48%), and UV spots (+25%), indicating improvements in both structural and pigmentation-related components of skin aging.

Within-group analyses showed a statistically significant improvement in UV spot scores in the botulinum toxin group ($p = 0.049$). Improvements in wrinkle-related parameters were consistently observed across treatment groups, although they did not reach statistical significance.

The proportion of participants demonstrating improvement varied across parameters, with higher response rates observed for wrinkle-related features in both monotherapy and procedure-combined groups. No statistically significant differences were detected between treatment modalities ($p > 0.05$).

No clinically relevant adverse events were reported. Tolerability was rated as excellent, with high patient satisfaction and 100% treatment adherence.

Conclusions

In this multicentre real-world study, a DHM-based serum demonstrated excellent tolerability and was associated with improvements in parameters related to skin quality, pigmentation, and wrinkles.

Used both as monotherapy and as adjunctive care, the serum may support optimization of outcomes following aesthetic dermatologic procedures while facilitating integration into daily skincare routines. These findings support the role of epigenetically active topical formulations as a complementary strategy in aesthetic dermatology and warrant further controlled studies.

EADV CONGRESS
VIENNA
30 SEP - 3 OCT 2026

Abstract N°: 3664

Efficacy of a Dihydromyricetin-based serum on facial and neck signs of skin aging across all fitzpatrick skin phototypes: an 8-week clinical study

Paula Pitta*[1], Katja Warnke[1], Elke Grönniger[1], Julia Gallinger[1]

[1] Beiersdorf AG, Hamburg, Germany

Introduction

Altered DNA methylation patterns have emerged as a key mechanism in understanding the phenotypic changes associated with human aging, including fine lines, wrinkles, and reduced skin elasticity. [1] Previous studies have demonstrated that Dihydromyricetin (DHM) reverses age-dependent DNA methylation, effectively reducing the biological age of skin cells by restoring their youthful epigenetic patterns. [2] This active ingredient, with its unique mode of action, offers an innovative approach for anti-aging dermocosmetics. A novel serum was developed incorporating DHM as its core technology, enriched with hyaluronic acid, glycine saponin and glycyrrhetinic acid. Recognizing the distinct aging characteristics of darker skin tones, a clinical study was conducted in Brazil to evaluate the efficacy of the formulation in addressing signs of aging across all Fitzpatrick skin phototypes and diverse ethnicities.

Materials and Methods

An 8-week, single-center, blinded, non-comparative study was conducted to evaluate the performance of the formulation using clinical assessments (expert grading), subjective measures (self-assessment including quality of life), and instrumental evaluations (imaging and ultrasound). A total of 60 volunteers (Fitzpatrick phototypes I–IV: n=40; V–VI: n=20), aged 29–70 years and presenting signs of skin aging, were enrolled according to inclusion criteria. Participants applied the serum twice daily to the face and neck in combination with basic sunscreen SPF 50. Evaluations were performed at baseline, week 4, and week 8.

Results

Instrumental analysis demonstrated a statistically significant reduction in the coefficient of visibility of wrinkles after 4 and 8 weeks of application, with 86.4% of participants showing improvement at the 8-week time point. Dermal density assessed an increase in signal intensity of 10.4% at 8 weeks, suggesting enhanced dermal structure and architecture.

Expert clinical grading indicated significant improvements ($p < 0.05$) in global facial wrinkles (visual), skin texture, elasticity, and firmness (tactile), neck elasticity, radiance/luminosity (visual), and horizontal neck wrinkles after both 4 and 8 weeks compared to baseline.

Subjective perception assessments at 8 weeks showed that 100% of participants considered the product ideal for their skin type and tone, with 93.3% rating it as the best anti-wrinkle product they had used. Additionally, a 79.2% improvement in overall quality of life scores was reported.

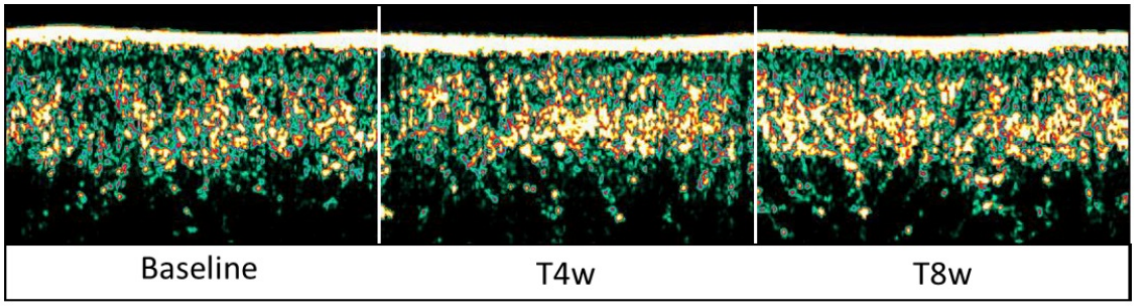

Figure 1. Ultrasound-assessed dermal density improvement at weeks 4 and 8 (representative case).

Conclusions

The serum formulation demonstrated significant clinical, instrumental, and subjective improvements in key signs of aging on both the face and neck. These findings underscore the efficacy of the DHM-based serum across all skin phototypes, including darker skin tones and —an underrepresented population in dermatologic research—highlighting its potential as a promising and inclusive approach to supporting skin longevity.

EA DV CONGRESS
VIENNA
30 SEP - 3 OCT 2026

Abstract N°: 3666

An Assessment of Recombinant Collagen Liquid Combined with Microneedling for Facial Skin Rejuvenation

Danyi Huang[1], ChunYiu Leung[1], Huiling Li[1], Jun Zhao[1], Ruifen Liu[1], Yiming Lin[1], Han Ma*[1]

[1] Department of Dermatology, The Fifth Affiliated Hospital, Sun Yat-sen University, Zhuhai, Guangdong Province, 519000 China, Zhuhai, Guangdong Province, China

Introduction

To investigate the efficacy and safety of recombinant collagen liquid dressing combined with microneedling therapy in improving facial skin aging.

Materials and Methods

Twenty patients with facial skin aging were enrolled as subjects. Specifically, each subject received three sessions of recombinant collagen liquid dressing combined with microneedling therapy, with an interval of approximately one month between sessions. Data from the CBS multispectral facial imaging system, Wrinkle Severity Rating Scale (WSRS) scores, and Global Aesthetic Improvement Scale (GAIS) scores were compared before and after treatment, and the occurrence of adverse reactions was also recorded.

Results

Skin analysis via the multispectral facial imaging system showed that most of the assessed skin parameters—including pigmentation, pore count, skin smoothness, wrinkles, red areas, and brown areas—were significantly improved after treatment compared with baseline, with statistically significant differences ($P < 0.05$). Additionally, according to the investigators' assessment, WSRS scores were generally improved after treatment compared with baseline, and the difference was statistically significant ($P < 0.05$). For GAIS scores, 8 cases (40%) achieved significant improvement, 7 cases (35%) achieved moderate improvement, and 5 cases (25%) achieved mild improvement. Furthermore, all 20 patients reported satisfaction with the treatment, and a high proportion (100%) rated the outcome as "very satisfied".

Table 1 Comparison of data on pigmentation, smoothness, deep wrinkles, fine lines, and red areas before and after treatment

Indicators	VISIT 1	VISIT 2	VISIT 3	VISIT 4	Z value*	P value
Superficial pigmentation (mm^2)	309.8300	227.335000	213.3300	196.1000	-3.920	<0.001
Skin smoothness	74.63%	78.73%	79.56%	80.85%	-3.920	<0.001
Deep wrinkles	247.460000	217.205000	206.275000	199.955000	-3.920	<0.001
Fine lines	15.230000	10.025000	7.780000	6.925000	-3.920	<0.001
Red areas (mm^2)	785.465000	627.895000	584.345000	530.995000	-3.920	<0.001

Note: Data do not conform to a normal distribution; values in the table are medians.

*The Wilcoxon signed-rank test was used to analyze differences between VISIT 1 and VISIT 4.

Table 2 Comparison of data on pore count, shallow wrinkles, and brown areas before and after treatment

Indicators	VISIT 1	VISIT 2	VISIT 3	VISIT 4	Mean difference*	P value
Pore count	1892.35±200.27	1669.35±187.27	1557.45±179.26	1473.05±167.32	419.3±80.851	<0.001
Shallow wrinkles	111.30±14.00	88.43±10.92	83.02±10.93	79.82±10.54	31.474±7.470	0.003
Brown areas (mm^2)	949.26±70.74	876.76±59.81	830.75±57.92	792.28±55.04	156.981±24.504	<0.001

Note: Data conform to a normal distribution; values in the table are presented as mean ± standard deviation ($\bar{x} \pm s$) and meet the assumptions of normality and sphericity.

*Repeated-measures analysis of variance was used to analyze differences among VISIT 1 to VISIT 4, with Bonferroni correction for multiple comparisons.

Table 3 Comparison of WSRS Scores Before and After Treatment

WSRS Grade	VISIT 1	VISIT 4	Z value*	P value
Grade 1	0	3	-4.001	<0.001
Grade 2	2	17		
Grade 3	18	0		
Total	20	20		

Note: Assessed by independent physicians. *The Wilcoxon signed-rank test was used for statistical analysis.

Conclusions

Recombinant collagen liquid dressing combined with microneedling therapy can effectively improve facial skin aging, with a favorable safety profile.

EA DV CONGRESS
VIENNA
30 SEP - 3 OCT 2026

Abstract N°: 3668

A Systematic Review, Meta-Analysis and Meta-Regression of Randomised Controlled Trials on the Efficacy of Oral Collagen Supplementation for Skin Aging

Emiliano Arantes*[1], Gustavo Reis[2], Ana Paula Lima[3], Klivia Finzer[1], Gabriela Stutz[4]

[1] Clínica Menu, Rio verde, Brazil

[2] Faculdade de Medicina da UFMG, Belo Horizonte, Brazil

[3] Faculdade de Medicina da Universidade de Rio Verde, Rio verde, Brazil

[4] Hospital Federal dos Servidores do Estado do Rio de Janeiro, Niterói, Brazil

Introduction

Despite growing consumer demand, the clinical evidence supporting oral collagen supplementation for skin aging remains fragmented by methodological heterogeneity and potential industry influence. We performed a systematic review and meta-analysis of randomised controlled trials (RCTs) to quantify the effect of oral collagen on skin elasticity, hydration, and wrinkles, and to investigate whether mean participant age modulates treatment response via meta-regression.

Materials and Methods

PubMed, Embase and Cochrane were searched from inception through February 2026. Eligible studies were double-blind RCTs comparing oral collagen (any source, form, or dose) versus placebo in adults with at least one quantitative skin outcome at ≥4 weeks. Two independent reviewers conducted screening and data extraction. Effect sizes were expressed as standardized mean differences (SMD) with 95% confidence intervals (CI), pooled using random-effects models with restricted maximum likelihood (REML). Statistical heterogeneity was assessed via I^2 and Cochran's Q. Meta-regression with mean participant age as a continuous moderator was conducted for elasticity and hydration.

Results

Twenty-three RCTs met inclusion criteria. At 12 weeks, oral collagen significantly improved skin elasticity (SMD 0.53, 95% CI 0.23–0.83; P<0.001) and hydration (SMD 0.42, 95% CI 0.18–0.65; P<0.001). Wrinkle reduction also favored oral collagen (SMD 0.64, 95% CI 0.26 – 1.03; P<0.001). Substantial between-study heterogeneity was observed for all outcomes. Meta-regression identified no statistically significant association between mean participant age and treatment effect magnitude for either elasticity or hydration, suggesting age does not linearly explain the observed variance in effect sizes.

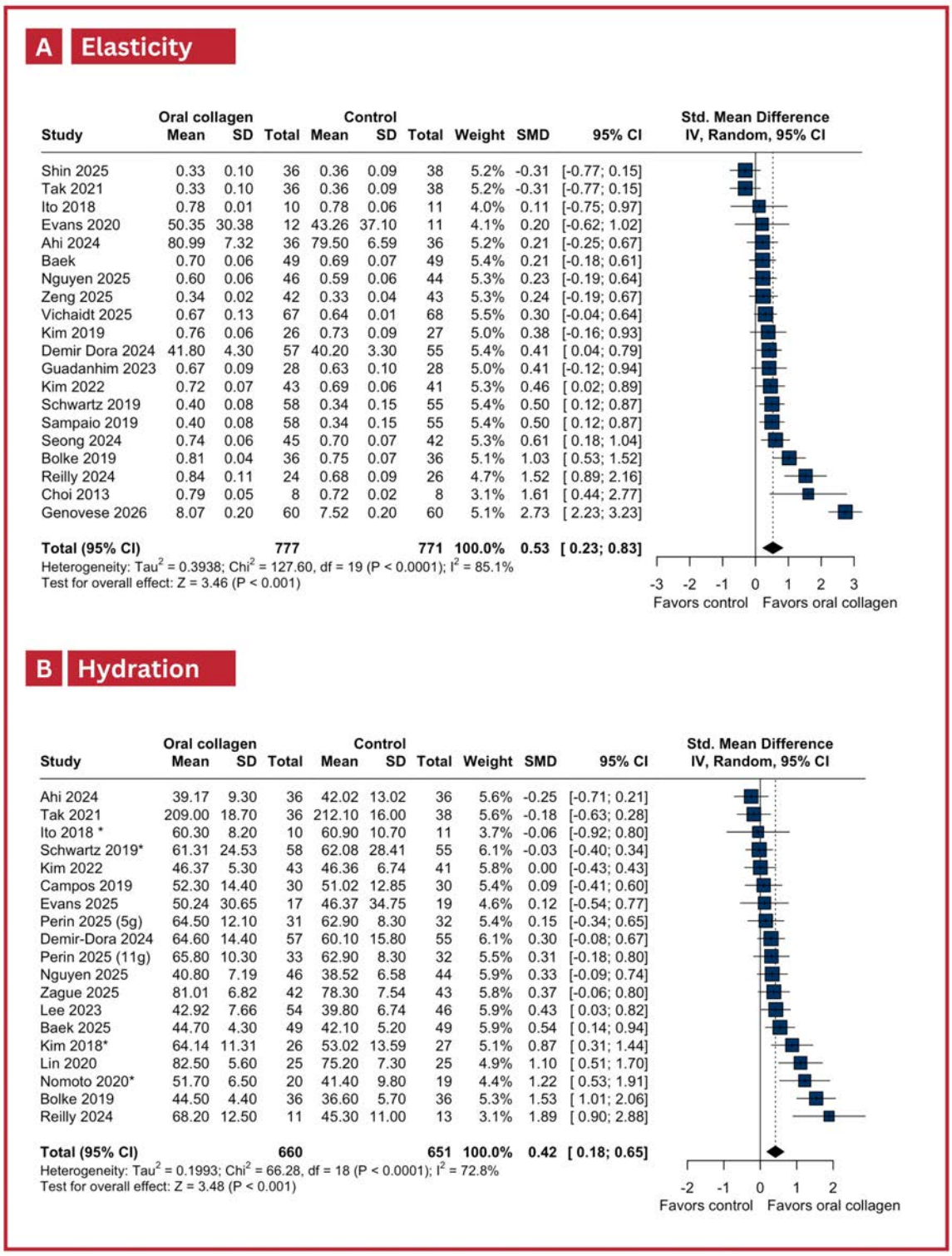

Forest plots of the effect of oral collagen supplementation versus control on skin elasticity (Panel A) and skin hydration (Panel B). The diamond represents the pooled standardized mean difference (SMD) with 95% confidence interval using a random-effects inverse-variance model. Positive SMD values favor oral collagen supplementation. Heterogeneity was assessed using the I^2 statistic and Cochran's Q test. CI = confidence interval; SMD = standardized mean difference; SD = standard deviation; IV = inverse variance.

Conclusions

Oral collagen supplementation produces statistically significant and clinically directional improvements in skin elasticity and hydration in RCTs, with consistent effects on wrinkles. The persistence of high heterogeneity unexplained by participant age points to collagen source, molecular weight, and co-formulation as candidate effect modifiers warranting investigation in future individual participant data analyses.

EADV Congress 2026, VIENNA
30 SEPTEMBER - 03 OCTOBER 2026
POWERED BY M-ANAGE.COM

EADV CONGRESS
VIENNA
30 SEP - 3 OCT 2026

Abstract N°: 3674

Protection against UV and pollution-induced oxidative stress with a vitamin-infused active sunscreen

Hendrik Mießner[1], Paula Pitta*[1], Philip Drescher[1], Anette Bürger[1], Julia Gallinger[1], Katja Warnke[1]

[1] Beiersdorf AG, Hamburg, Germany

Introduction

Ultraviolet (UV) radiation and environmental pollutants are major extrinsic contributors to oxidative stress in skin, leading to barrier disruption, inflammation and accelerated skin aging through excessive generation of reactive oxygen species (ROS). [1] Importantly, combined exposure to UV radiation and pollutants results in amplified oxidative stress, as UV light can photoactivate pollutant-associated compounds and enhance radical formation via redox and photocatalytic mechanisms. Beyond erythema-based sun protection, the ability of sunscreen formulations to counteract UV- and pollution-induced oxidative pathways is increasingly recognized as a relevant dimension of photoprotection. [2] For this, Electron Spin Resonance (ESR) spectroscopy enables direct, quantitative assessment of antioxidative activity and radical-scavenging capacity.

Materials and Methods

The antioxidative activity of an active sunscreen formulation with sodium ascorbyl phosphate, tocopherol and licochalcone A was investigated by ESR spectroscopy using stable nitroxide radical probes. The decrease in ESR signal over time (immediate, 24h, 48h) was used to quantify free radical scavenging capacity, reaction kinetics and overall antioxidative power of the formulation. Measurements were performed for the active formulation in comparison with its corresponding vehicle control.

To assess protective performance under environmental stress, a further experimental setup included (i) baseline conditions, (ii) simulated UV exposure, and (iii) combined exposure to UV radiation and environmental pollution. Using an ex vivo surrogate for human skin, products were applied at 2 mg/cm² and incubated prior to exposure to simulated solar radiation (UVB 280–320 nm; UVA 320–400 nm). Cigarette smoke was used as a standardized model for urban airborne pollution. Radical formation and persistence were monitored in the presence or absence of the tested formulations.

Results

The active sunscreen formulation exhibited high antioxidative activity, characterized by a pronounced reduction of stable radical levels compared with the vehicle formulation. ESR signal decay analysis showed faster radical neutralization kinetics for the active formulation, indicating effective interruption of photo-oxidative reactions at all timepoints.

Under simulated UV exposure, radical persistence was substantially lower in samples treated with the active sunscreen formulation, demonstrating efficient control of UV-induced oxidative processes. Combined pollution and UV exposure resulted in a pronounced increase in radical formation in untreated and vehicle-treated samples, confirming the synergistic pro-oxidative interaction between pollutants and UV radiation. In contrast, treatment with the active sunscreen formulation significantly reduced pollution-amplified radical levels (by 38.5%) and maintained strong antioxidative performance under combined stress conditions.

Conclusions

These findings demonstrate that the active sunscreen formulation provides effective antioxidative protection against UV-induced and pollution-enhanced oxidative stress. The ability to mitigate radical amplification under combined environmental challenges highlights the relevance of incorporating antioxidative activity into modern photoprotection strategies. ESR-based evaluation of radical-scavenging capacity offers a mechanistically meaningful complement to conventional sunscreen efficacy assessment and supports claims related to protection from oxidative stress and environmental aggressors.

EA DV CONGRESS
VIENNA
30 SEP - 3 OCT 2026

Abstract N°: 3684

Revisiting the Skin Health and Beauty Pyramid: An Adapted Aging Framework Integrating Epigenetic Modifications as a Primary Hallmark

Lilia Guadanhim*[1], Paula Pitta[2]

[1] UNIFESP, Sao Paulo, Brazil

[2] Beiersdorf AG, Hamburg, Germany

Introduction

The Skin Health and Beauty Pyramid was initially proposed as a hierarchical framework to structure dermatological and dermocosmetic interventions, organizing skin care strategies into fundamental protection, transformational renewal, and optimization through stimulation. Early models emphasized photoprotection and antioxidant defense as core elements, while subsequent adaptations incorporated regenerative and reparative approaches. However, advances in aging research have demonstrated that visible skin aging reflects underlying molecular alterations that precede and drive tissue dysfunction.

The hallmarks of aging - classified as primary (damage drivers), antagonistic (initially protective but later harmful), and integrative (systemic frailty contributors), provide a framework for understanding molecular aging and guiding targeted interventions [1,2]. Genetic factors account for less than 25% to skin aging, underscoring the predominant role of epigenetic and post-translational regulation. [3]

Extrinsic factors act through mechanisms that mirror and amplify core hallmarks of aging, particularly mitochondrial dysfunction, genomic instability, epigenetic alterations, and cellular senescence. Thus, extrinsic aging not only accelerates the aging phenotype but also mechanistically intertwines with intrinsic aging through shared biological hallmarks.[3]

Materials and Methods

This work aims to propose a biologically driven adaptation of the Skin Health and Beauty Pyramid that incorporates the hallmarks of skin aging, such as epigenetic alterations.

This work integrates previously published pyramid models [4,5] with current insights from aging biology, including the updated classification of aging hallmarks. Aging mechanisms are organized into primary, antagonistic, and integrative hallmarks.

Epigenetic dysregulation—encompassing DNA methylation changes, histone modifications, and chromatin remodeling—is positioned as an upstream driver influencing genomic instability, telomere attrition, loss of proteostasis, impaired macroautophagy, and altered cellular stress responses.

These interconnected pathways are recognized as central determinants of skin aging and loss of tissue resilience.

Results

In the adapted pyramid, epigenetic alterations form the foundational base, representing a primary hallmark that modulates cellular identity, adaptive capacity and long-term skin homeostasis [1]. The base layer expandes beyond classical UV protection and antioxidant defense to include interventions targeting epigenetic regulation and cellular maintenance mechanisms. This hierarchical organization reflects the causal relationship between molecular aging processes and clinical skin aging phenotypes.

This model supports a shift from symptomatic approaches, that only mask aging signs, toward interventions that modulate the biological pathways driving aging, ultimately preserving skin health and extending skin longevity [6].



Figure 1: Adapted proposed pyramid.

Conclusions

Positioning the hallmarks of aging, including epigenetic alterations, within the Skin Health and Beauty Pyramid provides a more mechanistic and biologically coherent framework for understanding skin aging. This updated model supports a paradigm shift toward preventive, mechanism-oriented dermatological strategies that address upstream drivers of aging rather than solely downstream clinical manifestations.

EADV CONGRESS
VIENNA
30 SEP - 3 OCT 2026

Abstract N°: 3731

Synergistic Effects of A Topical Scalp and Hair Formula in Mitigating Hair Loss: A 12-Week Clinical Evaluation

Florante Ricarte*[1], Brenda Stiles[1], Claudia Roseler[1], Kat Burki[1]

[1] Kat Burki Skincare Inc., Greenwich, United States

Introduction

Rice bran derivatives from *Oryza sativa* are natural ingredients commonly found in hair and cosmetic products and were used for centuries before its mechanism of action was determined. Current day study data for rice bran shows promise of promoting hair growth, given its ability to increase expression of growth factors and molecular signals associated with maintaining anagen phase, decreasing inflammation, inhibiting 5α-reductase, and promoting melanogenesis.

Likewise, a study on the effect of tripeptide-copper complexes on human hair growth provided strong*in vitro* evidence that they may stimulate hair growth by increasing the proliferation of dermal papilla cells, and by preventing their apoptosis.

Plant stem cell-derived extracts have also shown potential as a promising treatment for hair morphogenesis and regeneration through noninvasive delivery.

Given the limited availability of noninvasive procedures for hair loss, studies exploring new treatment options combining synergistic ingredients in topical form are both needed and important.

The primary purpose of this study was to evaluate the treatment effect of a topical scalp and hair treatment product after 84 days of treatment.

Materials and Methods

Under conditions of the study, a total of 30 male and female subjects in good health and in the age range of 30-60 years of age, reporting problems related to hair loss, completed the study.

Eligible subjects were enrolled in the study on the basis of the subject inclusion/exclusion criteria. Assessments included hair density analysis by blue light scanner and a combing test for number of fallen hairs. Following baseline assessments, the subject had standardized imaging.

Subjects were given the test product with use instructions as directed by the Sponsor and scheduled to return to the testfacility 84 days (12 weeks) post-treatment. At the D84 visit, all procedures/measurements carried out at baseline were then repeated. Subjects were also asked to complete a self-assessment questionnaire.

Results

Data analysis of assessment values after use of the test product for 84 days, comparing with baseline values showed:

- Significantly increased hair density by 8.8 ± 1.5%

- Significantly reduced hair loss by 31.9 ± 15.3%

The efficacy of the treatment was also subjectively evaluated by a use test (self-assessment questionnaire), answered by each of the subjects. Results showed an overall acceptance average of 83%. Specifically, positive evaluations (overall acceptance ≥ 80 %) were obtained for all evaluated parameters.

Conclusions

This study confirms that a topical formulation combining rice bran derivatives, tripeptide-copper complexes, and plant stem cell extracts effectively mitigates hair loss and improves hair density over 12 weeks. The 8.8% increase in density and 31.9% reduction in shedding provide clinical evidence for the synergistic role of these ingredients in maintaining the anagen phase and protecting dermal papilla cells. High subject satisfaction further supports its viability as a non-invasive, multi-modal intervention for hair regeneration.

EA DV CONGRESS
VIENNA
30 SEP - 3 OCT 2026

Abstract N°: 3733

Beyond Moisture and Plump: A Translational Approach to Skin Rejuvenation Through Biostimulatory Effects of a Novel Cosmetic Formulation Associating Multi-molecular Weight Hyaluronic Acids and Biotechnological PDRN.

Valentin Parat[1], Franck Juchaux[1], Charlotte Boissard[2], Katherine BUTCHER[3], Wissem ZEKRI[3], Sabrine Bensosmane[1], Charlotte Tacheau[2], sophie Coic[2], lais lima[2], Elisabeth Bouhadana*[3]

[1] L'Oreal Paris, L'Oreal R&I, Aulnay sous bois, France

[2] L'Oreal Paris, Chevilly larue, France

[3] L'Oreal Paris, L'Oreal Paris, clichy, France

Introduction

Hyaluronic acid (HA) is a gold standard in aesthetic dermatology for its ability to restore hydration and fill finelines & wrinkles. Aesthetic procedures are currently shifting from fillers towards skin boosters that promote skin transformation. In this context, Polydeoxyribonucleotides (PDRN) are rapidly emerging as potent bioactive agents to rejuvenate skin, potentiating HA's effects.

Thanks to biotech advances, cosmetic science is now able to produce made to measure actives to boost formulations, such as low MW HA and bio-synthetic PDRN that not only hydrate but also transform skin quality.

This work aims to evaluate the rejuvenating performance of a novel HA-PDRN association through a multi-level assessment. It investigates the potential synergy of these compounds in vitro to understand the biostimulatory impact on the dermal matrix, while concurrently validating their clinical benefits on cell renewal and wrinkle reduction to provide a comprehensive view of skin transformation.

Materials and Methods

In vitro: Firstly, the molecular and cellular impact of the HA-PDRN combination was investigated using reconstructed skin equivalents from an aged donor. Skin models were topically treated or not (control) with the following actives, alone or in combination (high MW HA / low MW HA/ Acetylated HA +/- PDRN) for 8 days to check the potential synergy of HA and PDRN as the expression of CD44 might be increased by both PDRN A2A stimulation and low MW HA. A second control was created in parallel using reconstructed skin from a young donor. Histological and immunohistochemical analyses measured the expression of HA receptor CD44 and markers of the DEJ (Collagen IV), dermal ECM (Collagen I / Elastin / Fibrillin-1) and epidermis (Desmoglein-1).

In vivo cell turnover evaluation: The impact of the HA-PDRN combination in a topical serum was evaluated using the Dansyl Chloride technique on 32 women (aged 33-65). After a 1-week washout and a 2-week pre-treatment with the serum on one forearm, fluorescent dye patches were applied to both forearms for 24h. Following patch removal, dye disappearance (turnover rate) was monitored for 3 weeks using Wood's lamp on both forearms. Results were statistically compared (treated vs untreated) to evaluate turnover acceleration, a predictive indicator of its rejuvenation properties.

Cosmetoclinical Efficacy: A 56-day clinical study was conducted on 59 women (aged 34–59, all skin types, including 86% sensitive skin). The serum was applied twice daily. Dermatological assessments were performed at baseline, immediately after the first application, and days 14, 28 and 56. Clinical grading was performed using the

modified 10-point Griffiths scale for skin quality (radiance, evenness, smoothness, firmness, elasticity), and the Skin Aging Atlas (Vol. 2)1 for structural signs, including wrinkles. Self-assessment questionnaires completed the study.

[1]*Bazin R, Flament F. Skin Aging Atlas. Vol. 2. Editions Med'Com; 2010*

Results

In vitro results show that after topical treatment with the HA-PDRN combination, the overall structure of aged skin is improved. The epidermis is thicker, the expression of CD44, the HA receptor, is increased, as is the expression of enzymes involved in the integrity of the DEJ and the quality of the dermal ECM. The skin regains a youthful phenotype.

The serum significantly accelerated epidermal renewal compared to the untreated site ($p=0.0007$), showing a faster cell turnover (21.5 days vs. 23.0 days), predictive of a rejuvenating effect of the serum and confirming the effect observed in vitro on epidermal thickening.

Clinical evaluation under dermatological control showed statistical improvement on forehead, crow's feet and nasolabial wrinkles from week 2 onward, confirming further the anti-aging benefits highlighted in the in vitro study.

Conclusions

This work clearly demonstrates, from vitro to vivo, the benefit of biotech HA-PDRN combination in a cosmetic serum for skin rejuvenation from moisture and plump to skin quality.

EADV CONGRESS
VIENNA
30 SEP - 3 OCT 2026

Abstract N°: 3745

Clinical Evaluation of a Topical Serum Combining Copper Peptides and Coenzyme Q10: Impact on Photodamage and Cutaneous Aging

Florante Ricarte*[1], Brenda Stiles[1], Claudia Roseler[1], Kat Burki[1]

[1] Kat Burki Skincare Inc., Greenwich, United States

Introduction

The integration of regenerative signaling molecules and potent antioxidants in cosmetic formulation is a key contributor for mitigating the signs of skin photoaging. This study evaluated the efficacy of a serum formulation combining copper peptides and Coenzyme Q10 over a 6-week period.

Copper peptides are established mediators of tissue remodeling, demonstrated in *in vivo* and *in vitro* models to enhance wound epithelialization, stimulate growth factor production, and upregulate antioxidant enzyme activity. Concurrently, CoQ10 serves a dual role as a critical component of mitochondrial energy metabolism and a lipophilic antioxidant. Its high tolerability across diverse skin types makes it a versatile agent for protecting against cellular-level damage and improving cutaneous senescence.

The primary objective of this research was to utilize quantifiable bioinstrumental assessments to evaluate changes in the skin's mechanical properties, barrier function, and visual appearance. By focusing on objective data, this study aims to validate the synergistic impact of these actives on skin health and regeneration.

Materials and Methods

In this study, 33 female subjects of all skin types underwent a 6-week treatment regimen with the test formula. Individuals of any race, in the age range of 35-60 years of age and in good health, having visible fine lines and wrinkles in the forehead and mouth areas, hyperpigmentation/age spots, uneven skin tone/redness or dullness were eligible to participate.

Potential subjects reported to the facility a minimum of 5 days prior to the start of the study and were then enrolled in the study on the basis of the subject inclusion/exclusion criteria. Enrolled subjects received a neutral soap to use for washing their face during the washout period and study period.

Following the washout period subjects returned to the facility for baseline measurements. Subjects equilibrated by remaining quietly seated for a minimum of 30 minutes in a temperature/humidity controlled room prior to close-up facialphotography and bioinstrumental assessments.

Subjects were given the formula with use instructions as directed by the Sponsor and scheduled to return to the testfacility 6 weeks post-treatment. The formula was self-applied by the subjects following the manufacturer instructions. Subjects were instructed to discontinue use if signs of irritation appeared.

At the 6 week timepoint, all procedures/measurements carried out at baseline were then repeated.

Treatment effect was assessed through statistical analysis of quantitative Cutometer data measuring skin firmness, elasticity, skin barrier function, and texture; chromometer data for brightness and redness. Clinical photography was used to evaluate fine lines and wrinkles in forehead and mouth areas, hyperpigmentation/age spots, UV damage, skin radiance and tone.

Results

Efficacy results showed the following results after 6 weeks of treatment, compared with baseline values:

- Statistically significant improvement in skin brightness, for the vast majority of subjects.
- Statistically significant improvement in skin radiance and tone.
- Statistically significant improvement in appearance of fine lines and wrinkles in the forehead and mouth area, for the majority of subjects.
- There were non-statistically significant improvements in skin redness, elasticity, firmness and UV spots.

Conclusions

This study demonstrates that a topical serum combining copper peptides and CoQ10 significantly improves key visual indicators of cutaneous aging. Over 6 weeks, subjects showed statistically significant enhancements in skin brightness, radiance, and tone, alongside a reduction in the appearance of fine lines. While mechanical changes in elasticity and firmness remained non-significant within this timeframe, the observed improvements in global radiance and wrinkle depth suggest that the synergistic antioxidant and metabolic support of these actives effectively revitalizes the skin's overall appearance.

EA DV CONGRESS
VIENNA
30 SEP - 3 OCT 2026

Abstract N°: 3813

Microneedle-Assisted Delivery of Exosomal miRNA for Targeted Skin Rejuvenation: A Narrative Review

Janadi Karawita*[1], Andrea Anna Beji[2], Suhana Sumayya Sudheer[2], Sri Pawan Ganesh[2], Aalif Kader Mohaideen[2]

[1] American MD Program, Tbilisi State Medical University, Tbilisi, Georgia

[2] Faculty of Medicine, Ivane Javakhishvili Tbilisi State University, Tbilisi, Georgia

Introduction

Exosomal microRNAs (miRNAs) are increasingly recognized as key mediators of cutaneous regeneration, with potential roles in collagen remodeling, fibroblast activation, inflammation control, and protection against photoaging. Yet their therapeutic use in skin rejuvenation is constrained by limited epidermal penetration, cargo instability, and inconsistent tissue targeting. Microneedle-based delivery offers a minimally invasive strategy to bypass the stratum corneum and deposit biologically active vesicles directly into the viable epidermis and dermis. This review evaluates the emerging rationale and evidence for microneedle-assisted delivery of exosomal miRNAs as a targeted approach to skin rejuvenation.

Materials and Methods

A narrative review was conducted using 75 peer-reviewed studies published between 2013 and 2026, covering exosomes and extracellular vesicles in skin aging, miRNA-mediated regenerative mechanisms, microneedle-assisted transdermal delivery, and integrated exosome–microneedle platforms. Findings were synthesized across four domains: biological mechanisms, delivery advantages, rejuvenation-relevant outcomes, and translational limitations.

Results

The reviewed evidence suggests that exosomal miRNAs may influence several processes central to skin rejuvenation, including dermal fibroblast proliferation, extracellular matrix preservation, collagen I/III synthesis, oxidative stress reduction, and modulation of inflammatory and senescence-associated pathways. Specific studies highlighted miRNA-dependent regulation of macrophage polarization, angiogenic signaling, matrix metalloproteinase activity, and UV-induced damage responses.

Microneedle systems emerged as a promising delivery solution by enabling localized, controlled, and potentially sustained release of exosomes or miRNA-enriched vesicles within skin tissue. Preclinical exosome–microneedle constructs demonstrated enhanced regenerative activity in models of senile wounds, endothelial senescence, scar remodeling, and photoaging-associated damage. Human studies remain limited, but clinically adjacent evidence, including combined microneedling and exosome approaches for facial aging and pigmentary disorders, supports the translational plausibility of this strategy.

Despite rapid progress, the field remains heterogeneous. Exosome source, isolation methods, miRNA cargo characterization, microneedle material, dosing, and outcome measures vary considerably across studies. Direct clinical evidence specifically evaluating microneedle-delivered exosomal miRNA for aesthetic skin rejuvenation is still lacking.

Conclusions

Microneedle-assisted exosomal miRNA delivery represents a biologically compelling and technologically innovative platform for targeted skin rejuvenation. By pairing regenerative vesicle cargo with barrier-bypassing delivery, this approach may address key limitations of conventional topical or injectable regenerative therapies. However, standardized formulation methods, reproducible miRNA profiling, dermatology-specific outcome measures, and controlled human trials are needed before clinical adoption.

EA DV CONGRESS
VIENNA
30 SEP - 3 OCT 2026

Abstract N°: 3907

Comparative Efficacy of Topical treatment with Macrocystis Pyrifera Ferment -Containing Lotion Versus Hyaluronic Acid Mesotherapy in Facial Rejuvenation: A Clinical Study

Suyu Wang[1], xiaomin zhao*[1], Lisa DiNatale[2, 3], Uma Santhanam[3], yan zhong[1], Justin He[1], Claude Saliou[3]

[1] Estee Lauder Companies Innovation R&D (China) Co., Ltd, Shanghai, China

[2] La Mer Max Huber Research Laboratories, New York, United States

[3] Research & Development, The Estee Lauder Companies, New York, United States

Introduction

Mesotherapy, also referred to as "skin hydra-glow," has gained increasing popularity in China, particularly hyaluronic acid (HA)-based mesotherapy. This procedure is primarily used to address skin dullness, dehydration, and rough texture, while also providing mild-to-moderate rejuvenating effects, including improvement in fine lines, wrinkles, and skin elasticity. A notable advantage of HA mesotherapy is its rapid onset of action, with visible effects potentially occurring immediately or within several days after treatment. However, the duration of efficacy is generally limited because non- or minimally crosslinked HA is rapidly degraded in vivo.

Topical skincare products, particularly treatment lotions, may confer a similar range of cosmetic benefits without the need for invasive procedures. Therefore, a split-face comparative study was designed and conducted to evaluate whether the magnitude of clinical improvement achieved with topical treatment is comparable to that of HA mesotherapy.

Materials and Methods

A randomized, controlled, evaluator-blinded split-face clinical trial was conducted on 35 eligible subjects, aged from 40 to 64 years. All subjects received a single session of a hyaluronic acid mesotherapy procedure (1ml, 12mg HA, Bloomage Biotech, China) on one side of face according to the pre-defined randomization table, and *Macrocystis pyrifera* ferment (MPF)-containing treatment lotion was applied on the other side of face twice daily for 35 days. In addition, a standard moisturizer was applied on full face throughout the study. Both instrument and clinical assessments were performed. Clinical grading included grading on skin texture and skin tone related attributes, forehead fine lines and wrinkles and under-eye fine lines. Instruments encompassed stratum corneum hydration measurement by Corneometer, skin barrier function measurement by Tewameter, skin topography measurement by Visoscan and skin gloss analysis by Glossymeter at baseline, D5, D21, D35.

Results

For instrumental assessment, a significant improvement in hydration, skin barrier, skin gloss and skin roughness was observed both in mesotherapy side and treatment lotion side from D5 to D35 when compared with baseline. There was no significant difference in hydration improvement between the two groups at D21, and treatment lotion side showed greater hydration improvement at D35. Regarding barrier improvement, there was no significant difference between the two groups at D5 and D21, while treatment lotion demonstrated statistical superiority versus mesotherapy at D35. Glossymeter analysis results revealed mesotherapy showed greater improvement at D5 and D21, while demonstrating non-inferior efficacy at D35. Additionally, no difference in skin roughness improvement of the groups was found throughout the study period.

For clinical grading, skin texture, appearance of pores, forehead fine lines and wrinkles, under-eye fine lines and skin tone related attributes including sallowness, radiance, skin tone evenness, translucency were notably enhanced in the treatment lotion side compared to baseline and no significant differences was observed compared to mesotherapy at D21 and D35.

Conclusions

In conclusion, this MPF-containing treatment lotion is a highly effective skin care product in skin hydration, barrier, skin tone and skin texture, showing comparable and in some parameters superior skin rejuvenation efficacy versus a single-session hyaluronic acid mesotherapy.

EADV CONGRESS
VIENNA
30 SEP - 3 OCT 2026

Abstract N°: 3909

Impact of Non-Dermatologist Injectors on Scarring Alopecia after Cosmetic Filler-Related Vascular Events

Sabah Iqbal*[1], Harleen Multani[2], Jonique Depina[3], Kashika Bharol[4], Nicole Werpachowski[5], Julia Vinagolu-Baur[6], Kelly Frasier[7], Raman Madan[7]

[1] Rowan-Virtua School of Osteopathic Medicine, Stratford, NJ, United States
[2] Meharry Medical College School of Medicine, Nashville, TN, United States
[3] Kansas City University College of Osteopathic Medicine, Kansas City, MO, United States
[4] University of Massachusetts T.H. Chan School of Medicine, Worcester, MA, United States
[5] Lenox Hill Hospital, Northwell Health, New York, NY, United States
[6] Norton College of Medicine, SUNY Upstate Medical University, Syracuse, NY, United States
[7] Northwell, New Hyde Park, NY, United States

Introduction
Cosmetic filler–associated vascular compromise is an infrequent but high-morbidity complication with underrecognized consequences for hair-bearing scalp tissue, including permanent scarring alopecia. As injectable aesthetic procedures increasingly expand outside dermatology practices, variability in anatomic training, complication preparedness, and ischemia management has emerged as a determinant of long-term dermatologic outcomes.

Materials and Methods
An integrative review of published filler-related vascular events involving the scalp and adjacent vascular territories was conducted using clinical case reports, case series, medicolegal analyses, and dermatopathologic studies. Variables assessed included injector specialty, filler type and injection plane, latency to ischemia recognition, availability and timing of hyaluronidase administration, escalation of care, and resulting alopecia pattern and severity.

Results
Delayed recognition of vascular compromise and prolonged ischemia were consistently associated with irreversible follicular unit loss, perifollicular fibrosis, and cicatricial alopecia. Hair follicle stem cell susceptibility to ischemic injury, combined with limited collateral scalp perfusion, contributed to poor regenerative capacity following vascular insult. Non-dermatologist injector involvement was more frequently associated with delayed escalation of care, incomplete reversal protocols, and reduced access to dermatology-directed salvage interventions. Once established, filler-induced scarring alopecia demonstrated limited responsiveness to medical therapy and restricted candidacy for surgical restoration.

Conclusions
Cosmetic filler–associated scarring alopecia represents a preventable yet permanent complication linked to ischemic injury and variability in injector preparedness. Permanent alopecia following cosmetic vascular events

necessitates standardized injector education, mandatory ischemia-response protocols, and clearly defined procedural oversight to prevent avoidable follicular destruction and enduring aesthetic morbidity associated with injectable practices.

EA DV CONGRESS
VIENNA
30 SEP - 3 OCT 2026

Abstract N°: 3911

Quantitative Measurement of Cosmetic Product Use in Korean Adults: Real-World Exposure Data for Risk Assessment

Mi Soo Choi*[1], Dong Ho Kim[1], Eunyoung Lee[2], Kyoung-Ae Kong[3], Kyu Bong Kim[4], Il Yong Park[5], Hak Rim Kim[6], Byung Cheol Park[1], Myung Hwa Kim[1]

[1] Department of Dermatology, College of Medicine, Dankook University, Cheonan, Korea, Rep. of South
[2] IEC Korea, Seoul, Korea, Rep. of South
[3] College of Medicine, Ehwa University, Seoul, Korea, Rep. of South
[4] College of Pharmacy, Dankook University, Cheonan, Korea, Rep. of South
[5] Department of Biomedical Engineering, College of Medicine, Dankook University, Cheonan, Korea, Dem. People's Rep. of
[6] Department of Pharmacology, College of Medicine, Dankook University,, Cheonan, Korea, Rep. of South

Introduction
Cosmetic usage patterns vary across countries due to differences in climate, sociocultural context, and lifestyle, leading to variability in exposure factors such as usage amount and frequency. Therefore, risk assessment of cosmetic ingredients requires country-specific, real-world exposure data.

Materials and Methods
In this study, nationwide quantitative measurements of cosmetic product use were conducted among Korean adults to generate representative exposure factors for risk assessment. To capture a broad range of product categories, the study was conducted in two phases with different product groups. A total of 1,141 participants (423 males and 718 females) were enrolled, including 563 participants in the first phase (June 2025) and 578 participants in the second phase (January–February 2026).

Results
In the first phase, product use was directly measured for skin toner, facial lotion, sunscreen, sunscreen spray, body cleanser, shampoo, hair conditioner, spray-type deodorant, wet wipes (simulated), and liquid hand soap (simulated). Mean daily usage amounts (g/day) were; skin toner (1.519), facial lotion (0.906), sunscreen (0.424), sunscreen spray (1.076), spray-type deodorant (0.835), body cleanser (4.469), shampoo (4.575), hair conditioner (3.151), liquid hand soap (3.800), and wet wipes (0.812). In the second phase, product use was directly measured for facial cream, body lotion/cream, hand cream, cleansing products (lotion, cream, and oil), foam cleanser, lip products, and hair styling products. Mean daily usage amounts (g/day) were; facial cream (1.03), body lotion/cream (4.05), hand cream (0.72), cleansing lotion (1.92), cleansing cream (0.98), cleansing oil (1.24), foam cleanser (0.98), lip products (0.03), hair gel (1.47), hair wax (0.38), and hair spray (0.84).

Conclusions
These findings provide robust, population-based real-world exposure data derived from direct measurement of cosmetic product use across a wide range of product categories in Korean adults. The generated exposure factors can support more accurate and representative risk assessment of cosmetic ingredients.

This research was supported by a grant (25202MFDS003) from Ministry of Food and Drug Safety in 2026.

EADV Congress 2026, VIENNA
30 SEPTEMBER - 03 OCTOBER 2026
POWERED BY M-ANAGE.COM

EADV CONGRESS
VIENNA
30 SEP - 3 OCT 2026

Abstract N°: 3923

Efficacy and Safety of a Novel Monopolar Radiofrequency Device for Periorbital and Cheek Wrinkles: A Multicenter, Randomized, Single-Blind, Noninferiority Trial

Hye Sung Han*[1], Sun Young Choi[1], Youngin Lee[2], Ju Hee Lee[2], Kang Su Kim[3], Chong Hyun Won[3]

[1] Chung-Ang University Gwangmyeong Hospital, Gyeonggi-do, Korea, Rep. of South

[2] Yonsei University College of Medicine, Seoul, Korea, Rep. of South

[3] Asan Medical Center, University of Ulsan College of Medicine, Seoul, Korea, Rep. of South

Introduction

Monopolar radiofrequency (RF) devices are widely used for noninvasive facial rejuvenation. This study evaluated the efficacy and safety of a novel monopolar RF device compared with a commercially available monopolar RF system for improving periorbital and cheek wrinkles. The objective of this study was to determine whether the investigational RF device is noninferior to the reference RF system in adults with mild-to-moderate facial wrinkles.

Materials and Methods

In this multicenter, randomized, single-blind, split-face noninferiority trial, 80 participants received treatment with the investigational RF device on one side of the face and the reference RF system on the contralateral side. Primary endpoints included investigator-assessed changes in Crow's Feet Grading Scale (CFGS) and Cheek Line Grading Scale (CLGS) scores at weeks 4 and 16. Secondary endpoints included ≥1-point improvement rates, Global Aesthetic Improvement Scale scores, procedural pain assessed using a visual analog scale, and safety outcomes.

Results

Seventy-nine participants completed the study. Both devices demonstrated significant improvements in CFGS and CLGS scores from baseline at weeks 4 and 16 (all $p<0.001$), confirming noninferiority of the investigational device. Responder rates and Global Aesthetic Improvement Scale scores were comparable between groups. Procedural pain scores were significantly lower with the investigational device ($p=0.018$). All adverse events were mild and transient without serious device-related complications.

Conclusions

The novel monopolar RF device demonstrated wrinkle improvement noninferior to that of the reference RF system, with reduced procedural discomfort and a favorable safety profile. These findings support its potential as a safe and effective option for noninvasive facial rejuvenation.

EADV CONGRESS
VIENNA
30 SEP - 3 OCT 2026

Abstract N°: 3952

CO2 Laser Surgical Handpiece for XanthelasmaPalpebrarum: An Added Aesthetic Benefit on EyelidPuffiness

Fatma Badr Yosef Ibrahim Elkomy*[1]

[1] Al-Azhar university, Cairo, Egypt

Introduction

Xanthelasma palpebrarum is the most common cutaneous xanthoma affecting the eyelids and represents a therapeutic challenge because of cosmetic concerns, recurrence risk, and the delicate anatomy of the periorbital area. Carbon dioxide (CO2) laser is an established therapeutic option; however, its potential additional aesthetic benefits on periocular skin laxity and eyelid puffiness remain underreported.

Objective
To demonstrate the efficacy of a CO2 laser surgical handpiece in treating eyelid xanthelasma while simultaneously improving eyelid puffiness and periocular appearance.

Materials and Methods

A patient presenting with bilateral eyelid xanthelasma associated with marked eyelid puffiness underwent a single treatment session using a surgical handpiece of ablative CO2 laser. Lesions were carefully ablated layer by layer with preservation of surrounding tissue integrity. Clinical evaluation and standardized photographic assessment were performed before and after treatment. Healing time was approximately two weeks.

Results

Complete clearance of xanthelasma lesions was achieved with excellent cosmetic outcome and no significant complications. In addition to lesion removal, marked improvement in eyelid puffiness and periocular skin tightening was observed post-treatment, resulting in noticeable overall rejuvenation of the periorbital area. No recurrence was observed during a two-month follow-up period. Patient satisfaction was high.

Conclusions

The surgical handpiece of CO2 laser may provide a dual therapeutic and aesthetic benefit in patients with eyelid xanthelasma by achieving effective lesion clearance together with improvement of eyelid puffiness and periocular appearance. This minimally invasive approach may represent a valuable option for selected patients seeking both therapeutic and cosmetic enhancement.

EA DV CONGRESS
VIENNA
30 SEP - 3 OCT 2026

Abstract N°: 4073

Safety and Efficacy of 1470 nm Diode Laser for Skin Laxity and Neck Sagging in Darker Skin Phototypes: A Prospective Clinical Study in Indian Patients

Anurag Tiwari*[1]

[1] Center for skin Diseases & Laser Treatments, Bhopal, India

Introduction
Treatment of facial skin laxity and sagging neck in darker skin phototypes remains challenging because of the higher risk of post-inflammatory hyperpigmentation (PIH), prolonged erythema, and delayed recovery associated with many resurfacing lasers and energy-based devices.The 1470 nm diode laser, characterized by selective water absorption and controlled dermal thermal injury, promotes collagen remodeling and neocollagenesis while minimizing epidermal damage. This mechanism enables effective tissue tightening and dermal rejuvenation with reduced downtime and lower risk of pigmentary complications. The device has shown promise in improving facial skin laxity, jawline definition, neck sagging, acne scars, and overall skin texture.However, limited clinical data exist regarding the safety and efficacy of 1470 nm laser treatment in Indian patients with darker skin phototypes. This study aimed to evaluate the clinical outcomes, tolerability, and safety profile of 1470 nm diode laser treatment for facial skin laxity and cervical sagging in Fitzpatrick skin types IV and V.

Materials and Methods
A prospective observational clinical study was conducted on 25 Indian patients with Fitzpatrick skin phototypes IV and V presenting with mild to moderate facial skin laxity, jawline blunting, neck sagging, acne scars, and textural irregularities. Patients with active cutaneous infections, recent isotretinoin use, keloidal tendency, pregnancy, connective tissue disorders, or photosensitivity disorders were excluded.All patients underwent treatment using a 1470 nm diode laser system with treatment parameters individualized according to skin type, anatomical area, and severity of laxity. Single Session was performed and patient evaluated post procedure at one week and 8 weeks. Standardized clinical photography was obtained at baseline and during follow-up visits under identical lighting and positioning conditions.Clinical efficacy was assessed using Physician Global Assessment (PGA), quartile improvement grading, and patient satisfaction scores. Particular emphasis was placed on improvement in skin firmness, jawline definition, cervical contour, skin texture, and scar appearance. Safety assessment included monitoring for erythema, edema, PIH, hypopigmentation, scarring, infection, and duration of post-procedure downtime. Patients were followed up after each session and for 3 months after completion of treatment.

Results
All 25 patients completed the study protocol. Progressive clinical improvement in facial skin tightening and reduction in neck laxity was observed over successive treatment sessions. Most patients demonstrated moderate to marked improvement in skin firmness, jawline definition, and cervical contour at final evaluation. Improvement in overall skin texture, superficial acne scars, and pore size was also noted.Patient satisfaction scores were high, with most participants reporting visible improvement in facial rejuvenation and skin tightening with acceptable downtime. The treatment was generally well tolerated. Transient erythema and mild edema were the most common immediate adverse effects and resolved spontaneously within a few days. No cases of permanent dyspigmentation, hypertrophic scarring, infection, or significant long-term adverse effects were observed.

Conclusions

The 1470 nm diode laser appears to be a safe and effective modality for the treatment of facial skin laxity and neck sagging in darker skin phototypes. Its ability to induce controlled dermal remodeling with minimal epidermal disruption results in clinically significant skin tightening and rejuvenation with a low incidence of pigmentary complications in Indian skin.The treatment demonstrated favorable outcomes in improving skin firmness, jawline definition, neck contour, and overall skin quality while maintaining minimal downtime and an excellent safety profile. The 1470 nm laser may therefore represent a valuable non-surgical rejuvenation option for patients with Fitzpatrick skin types IV–V.

EADV CONGRESS
VIENNA
30 SEP - 3 OCT 2026

Abstract N°: 4160

How Dermatologic Interventions Optimize Surgical Facial Rejuvenation: A Comprehensive Review

Laurentia Fidella Averina Setia Santoso[1], Marie Line Chedid[2], Sarah Rafehi[3], San Khasraw Mohammed Mohammed[4], Charbel Saad[5], Gregory Nicolas[6], Juan Pablo Menendez[6], Nancy Emmanuel*[7]

[1] Faculty of Medicine, Universitas Padjadjaran, Sumedang, Indonesia

[2] Medical University of Łódź, Łódź, Poland

[3] University of Balamand, Beirut, Lebanon

[4] Sulaymaniyah General Directorate of Health, Slemani, Iraq

[5] Department of Plastic and Reconstructive Surgery, Johns Hopkins University School of Medicine, Baltimore, Maryland, United States

[6] Department of Plastic and Reconstructive Surgery, Hospital das Clínicas of the Faculdade de Medicina da Universidade de São Paulo, São Paulo, Brazil

[7] Department of Dermatology, Hospital das Clínicas da Faculdade de Medicina da Universidade de São Paulo, São Paulo, Brazil

Introduction

Isolated surgical rhytidectomy remains the gold standard for structural repositioning and the correction of facial ptosis. However, these procedures are inherently limited as they do not address qualitative skin changes such as solar elastosis, dyschromia, and fine static rhytids. Comprehensive facial rejuvenation requires a multi-layered approach that simultaneously targets structural descent, subcutaneous volume depletion, and epidermal/dermal surface irregularities. This review establishes the clinical rationale for combining surgical lifting with non-surgical interventions commonly used in cosmetic dermatology to achieve optimal aesthetic outcomes and increased patient satisfaction.

Materials and Methods

This is a comprehensive literature review focusing on clinical trials, retrospective analyses, and meta-analyses evaluating the safety and efficacy of combined facial rejuvenation. The modalities investigated include surgical lifting (rhytidectomy, blepharoplasty, brow lift) performed concomitantly with energy-based devices (fractional carbon dioxide laser, erbium:YAG laser, microfocused ultrasound), chemical interventions (trichloroacetic acid and phenol peels), and injectables (botulinum toxin, hyaluronic acid fillers, and autologous fat grafting). Analysed data include laser settings (fluence, frequency, passes), chemical concentrations, and volumes for fat grafting and fillers.

Results

Fractional carbon dioxide laser resurfacing is safe over undermined skin flaps when utilizing conservative energy settings (e.g., 20 mJ, 500 microthermal zones/cm² for four passes). In contrast, non-elevated areas such as the perioral and nasal regions can tolerate higher energy (40–125 mJ) and total ablation modes. Erbium:YAG laser settings typically range from 20 to 25 J with 80–100 µm of ablation, but depth is restricted to <50–100 µm over undermined flaps to preserve microvasculature. Preoperative skin preparation often involves topical tretinoin and 4%

hydroquinone for 4 to 6 weeks to minimize post-inflammatory hyperpigmentation. Chemical interventions remain highly effective; a standard circumoral phenol peel formula utilizes 3 mL phenol (USP), 2 mL sterile water, 8 drops of liquid soap, and 3 mL croton oil, applied either the day of or the day following surgery. Regional neck skin can be treated with 25% trichloroacetic acid for 2 minutes to achieve a light frost prior to laser application. Surgical lifting combined with 1064 nm laser-assisted lipolysis is performed at 12W and 40 Hz, delivering an average of 5,050 Joules, with a clinical endpoint of a 38–40°C skin surface temperature. Microfocused ultrasound typically requires 700 to 1,000 lines (average 780) to target the deeper musculoaponeurotic system before superficial laser resurfacing. Injectable synergy is achieved through hyaluronic acid (30 mg/mL) or autologous fat grafting. Common fat volumes include 3 cc for the lips and nasolabial folds and 2 cc for the malar regions. Combining platelet-rich plasma with autologous fat in a 5:1 ratio has been utilized to enhance graft survival. For specific post-surgical complications like parotid fistulas, botulinum toxin A (100 U diluted with 2.0 mL saline) has been successfully administered via 20 superficial microinjections.

Conclusions

Optimal facial rejuvenation is best achieved through a multi-layered, synergistic strategy that addresses the complex physiopathology of the aging face. Success depends on strictly adhering to reduced energy parameters over undermined flaps and utilizing rigorous preoperative skin conditioning. Combining surgical repositioning with energy-based devices and injectables maximizes aesthetic outcomes while streamlining recovery. This multimodal approach is safe when performed by experienced practitioners using appropriate clinical parameters and is strongly recommended for patients seeking comprehensive rejuvenation

EA DV CONGRESS
VIENNA
30 SEP - 3 OCT 2026

Abstract N°: 4161

Clinical Impact of Topical- Safflower Glucoside on Skin Barrier Strength and Ceramide Levels: A Double-blinded 4-Week Randomized Controlled Trial

Hequn Wang*[1], Mohammedali Sajun[1], Stephen lynch[1], Liliana Xavier[1], Stephanie Morris[1], Nicole Burkhard[1], Xue Lucia Liu[1]

[1] L'Oréal USA Research Center, Clark, United States

Introduction

Ceramides are fundamental to stratum corneum integrity, yet clinical evidence of topical ingredients increasing *in vivo* ceramide levels is limited. Safflower glucoside is a novel ingredient intended to improve barrier function by enhancing the levels of ceramides. This study aimed to evaluate the clinical efficacy of safflower glucoside at 0.1% and 0.5% concentrations on skin hydration, trans-epidermal water loss (TEWL), and molecular changes in ceramide content.

Materials and Methods

This 4-week, mono-centric study involved 84 women (ages 18–65) characterized by dry and sensitive skin, including a subgroup(N=42) with a personal or family history of atopic dermatitis. Following a 2-week washout period, subjects applied a simple standard emulsion containing either a 0.1% or 0.5% safflower glucoside to a designated inner forearm twice daily. The contralateral forearm remained untreated. Clinical and instrumental evaluations were performed at baseline, Week 2, and Week 4. Assessments included dermatologist grading of tactile roughness and flakiness (0–9 scale), corneometer for hydration, and vapometer for TEWL. Confocal Raman microscopy was utilized to quantify total ceramide levels and water content within the stratum corneum.

Results

Both 0.1% and 0.5% SP094 concentrations resulted in significant clinical and instrumental improvements compared to baseline and untreated sites ($p < 0.05$). Within 2 weeks, we observed significant reduction in skin dryness (12.7%, $p<0.001$) and tactile roughness (13.1%, $p<0.001$) for 0.1% group compared to untreated control.

In addition, confocal Raman spectroscopy confirmed the mode of action of the technology combination in the formulations. By Week 4, total ceramide content increased by 15.5% and 18.1% for the 0.1% and the 0.5% groups compare to baseline ($p < 0.05$), respectively. Both concentrations significantly . Stratum corneum water content also improved significantly by the end of the study. statistical difference in total ceramide content was observed between the 0.1% and 0.5% formulations.

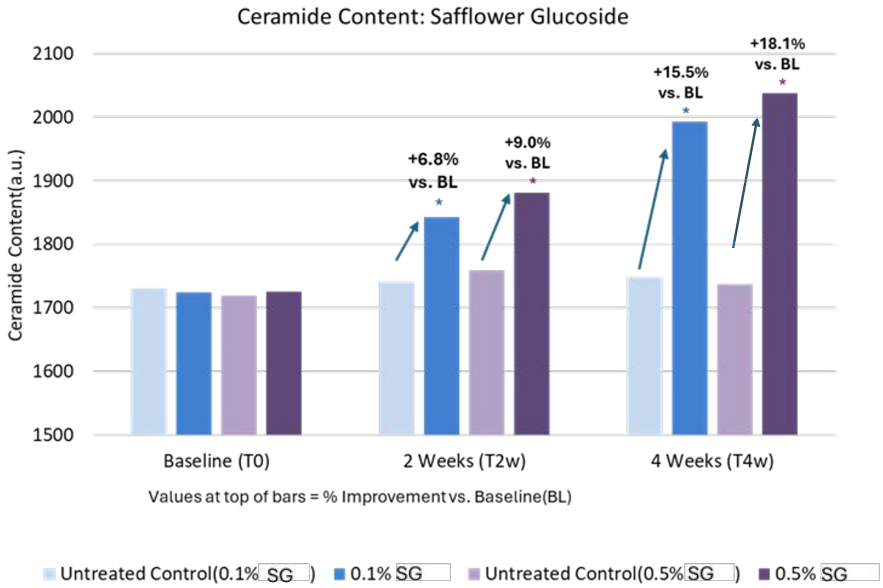

Figure 1: Total ceramide content (a.u.) at different timepoints. Both active concentrations (0.1% and 0.5% Safflower Glucoside(SG)) significantly increased ceramide levels compared to baseline and untreated control areas at Weeks 2 and 4 ($p < 0.05$). Percentages indicate improvement relative to baseline.

Conclusions

Topical formulation with safflower glucoside significantly increases the total ceramide levels measured by confocal Raman spectroscopy, with improvement on skin barrier function and hydration, leading to significant clinical improvement on skin texture and appearance of dry sensitive skin. These findings suggest safflower glucoside is a potent candidate for skincare formulations targeting barrier dysfunction and skin dryness.

EA DV CONGRESS
VIENNA
30 SEP - 3 OCT 2026

Abstract N°: 4210

Artificial intelligence driven facial imaging aging assessment

□ □*[1], LI MA[1], FaBing Shen[2]

[1] Binzhou Polytechnic University, Suzhou NMTBIOTECH Co.,Ltd., Binzhou,ShangDong, China

[2] Shanghai Meice Information Technology Co.Ltd., shanghai, China

Introduction

Grounded in the 2022 "Human Skin Aging Evaluation Standards," this study leverages artificial intelligence to address the limitations of conventional facial aging assessment methods — including skin feature analysis, biomarker profiling, and smartphone-based photography. The goal is to develop an efficient, accurate, non-invasive, and scalable facial aging evaluation framework that reduces dependence on complex equipment, simplifies data acquisition, and raises the level of automation.

Materials and Methods

1. A deep learning model was trained on 2D facial images captured from multiple angles (−40°, +40°) under varied lighting conditions. Convolutional Neural Networks (CNNs) were applied to extract complex facial features — texture, color, and structural geometry — enabling detection of key aging indicators such as wrinkles, pigmentation, and surface patterns. Correlation analysis and feature selection were used to derive a composite aging index.

   To improve cross-ethnic adaptability, separate classification models were built for White, Black, East Asian, and South Asian populations. The face was partitioned into seven anatomical regions (including forehead, crow's feet, and nasolabial folds), each assessed on a nine-level wrinkle grading scale. Regional segmentation was integrated to mitigate overfitting and strengthen generalization.

   Annotation efficiency was enhanced through inference-assisted labeling. Semi-supervised training, transfer learning, and fine-tuning were applied to accommodate data distribution shifts. Independent validation datasets were used to confirm grading performance and quantify aging severity.

Results

1. Analysis of millions of images confirmed that wrinkle rating curves align with age progression trends — for example, the inter-glabelar crease yielded a correlation coefficient of −0.96. The average grading error of the wrinkle detection model was below 1.5 levels, with strong agreement against manual evaluation. Rating curves for wrinkles and pigmentation across facial regions were consistent with established aging patterns, validating the methodology.

   The model demonstrated high accuracy and robustness across diverse ethnic groups and challenging imaging conditions, including partial occlusion and uneven illumination. Compared to traditional approaches, this system reduces equipment dependency, lowers invasiveness, and decreases the volume of manually annotated data required.

Conclusions

This facial aging assessment model integrates region-specific aging features into a unified, quantifiable index, providing reliable data support for clinical research and anti-aging applications. It represents a practical, scalable tool with broad relevance across dermatology, cosmetic science, and medical research — and meaningful step forward in applying AI to aging biology.

EA DV CONGRESS
VIENNA
30 SEP - 3 OCT 2026

Abstract N°: 4221

High-Frequency Dermatological Ultrasound for Pre-Procedural Facial Mapping: The PRECISE Protocol for Vascular Risk Assessment

Patrícia Cristina de Almeida[1], Janaína Johnsson[1], Nayra Regina Pereira Dantas[1], Sheeda Jabeen[2], Nancy Emmanuel*[3], Ivan Rollemberg[1]

[1] Human Clinic, Department of Clinical, Cosmetic and Surgical Dermatology, São Paulo, Brazil

[2] Tbilisi State Medical University, Faculty of Medicine, Tbilisi, Georgia

[3] Department of Dermatology, Hospital das Clínicas da Faculdade de Medicina da Universidade de São Paulo, São Paulo, Brazil

Introduction

The increasing demand for minimally invasive facial aesthetic procedures has been paralleled by a rising incidence of vascular complications, including skin necrosis and irreversible blindness. Significant inter-individual variability in facial vascular anatomy limits the reliability of safety strategies based solely on classical anatomical landmarks. High-frequency dermatological ultrasound (HFUS) offers real-time visualization of subcutaneous vascular structures, enabling individualized pre-procedural risk assessment. This study presents the PRECISE (Procedural Real-time Echography for Cosmetic Injection Safety and Efficacy) Protocol, a systematized approach for vascular mapping of critical facial risk areas.

Materials and Methods

A comprehensive literature review was conducted on facial vascular anatomy, ultrasound applications in aesthetic medicine, and prevention of filler-related complications. Based on anatomical evidence and clinical expertise, the PRECISE Protocol was developed, prioritizing four high-risk facial regions: (1) Lips and Chin: Facial, superior/inferior labial, and mental arteries; (2) Nasal Region: Dorsal nasal, angular, and lateral nasal arteries; (3) Ocular Region: Supratrochlear, supraorbital, and infraorbital arteries; and (4) Temples: Superficial temporal artery. The protocol employs HFUS for real-time vessel identification, depth measurement, and the mapping of anastomotic pathways between the internal and external carotid systems

Results

In the lips and chin, the protocol navigates the extreme depth variability of the facial artery, which resides in subdermal (13%), subcutaneous (29%), or muscular (24%) planes, to mitigate filler-induced ischemia. The nasal region remains a critical focus as it accounts for 40% of vision-threatening events, primarily because the dorsal nasal and angular arteries serve as pivotal anastomotic bridges between the external and internal carotid systems. Similarly, in the ocular region, cutaneous involvement of the ophthalmic angiosome is statistically linked to a significantly higher risk of vision loss (39% vs. 0.8%, $P < 0.00001$) and stroke (8% vs. 0.8%, $P = 0.0085$), necessitating precise depth measurement to avoid retrograde embolic events. In the temples, the superficial temporal artery can lie as shallowly as 1.15 mm from the skin surface, making real-time visualization essential for safe volumization. Clinical validation further underscores these risks, revealing that 84.2% of individuals possess complex anastomoses across both superficial and deep layers, while only 57.9% have a single connection point, and females exhibit a 54.3% rate of facial artery asymmetry. Ultimately, by identifying these anatomical variations, the protocol prevents catastrophic retrograde filler passage into the ophthalmic circulation and facilitates

immediate, ultrasound-guided hyaluronidase delivery in the event of an occlusion.

Conclusions

The PRECISE Protocol provides a necessary evolution in aesthetic medicine, replacing anatomical assumptions with evidence-based visualization. Pre-procedural vascular mapping significantly reduces the incidence of skin necrosis and permanent blindness while improving predictability. Adopting standardized imaging protocols is no longer optional but essential for modern, safety-first clinical practice.

EA DV CONGRESS
VIENNA
30 SEP - 3 OCT 2026

Abstract N°: 4299

Scrotal Pumping: Recognizing the cutaneous and systemic complications of an underreported practice

Andrew Williams*[1, 2], Kyle Mueller[1, 3], John Trinidad[1]

[1] Massachusetts General Brigham, Boston, United States
[2] SUNY Upstate Medical University, Syracuse, United States
[3] Jacobs School of Medicine and Biomedical Sciences, Buffalo, United States

Introduction

Scrotal pumping, or self-injection of foreign substances such as air, saline, or oils into the scrotum, was first reported in 1952.[1] This practice is a form of body modification typically used for sexual arousal and/or aesthetic purposes. Current literature focuses primarily on penile or penile-and-scrotal injections for augmentation with complications including cosmetic dissatisfaction, penile necrosis, and lymphedema.[2] Isolated scrotal pumping has been rarely reported, and the potential medical complications remain poorly characterized. We sought to descriptively characterize these complications and their reported outcomes in a narrative review of the literature.

Materials and Methods

A literature search was performed on PubMed, Google Scholar, Embase, Cochrane, and Web of Science using combinations of search strings such as “scrotal injection,” “scrotal inflation,” “scrotal infusion,” “scrotal pumping,” “self-injection,” and “scrotum.” Over 500 articles were screened. Articles were included only if they described cases of self-injection directly into the scrotum with subsequent clinical outcomes. Cases involving penile injection, medical supervision, suspected but unconfirmed scrotal pumping, or for which we could not access a full report were excluded. Age, substance, volume, time to presentation, dermatologic and systemic complications, management, and outcomes were collated. Associations between substance type and dermatologic complications were analyzed using fisher exact tests and significance level of $p < 0.05$. To contextualize these findings, we explored the activity of online community platforms Reddit and Google Trends related to scrotal pumping practices by searching the terms “scrotal pumping,” “scrotal inflation,” “scrotal saline,” “ball ballooning,” “saline balls,” “scrotal infusion,” “saline scrotum,” and “scrotal saline infusion.”

Results

Ten total articles were included from over the past 75 years. Among these, the median age was 46.5 (range 21-52). The injected substance in 5 of 10 (50%) cases was saline; 3 of 10 (30%) reported oil: mineral oil, olive oil, or silicone; and 2 of 10 (20%) reported injection of air. Time to presentation was provided in 7 (70%) cases, with a median of 1.5 days, though 2 cases described more than a year to presentation. Cellulitis occured in 6 (60%) and Fournier’s gangrene in 2 (20%) cases. Systemic complications occurred in 5 (50%) cases, including sepsis, lipoid pneumonia, respiratory arrest, and diffuse subcutaneous emphysema, with death. The most common management was antibiotic administration, used in 7 (70%) cases. Surgical treatment was used in 3 (30%) cases, with 2 (20%) requiring reconstructive surgery. 1 (10%) case described a patient found post-mortem. Fisher exact tests demonstrated a significant association between saline injection and cellulitis ($p = 0.0476$), as well as oil injection and granuloma formation ($p=0.0083$). 7 (70%) of these cases were published in the last 30 years. An activity scan of two subreddits, r/salineinflation and r/ballpumping, showed 5,900 weekly visitors with 79 weekly

contributions and 5,600 weekly visitors with 215 weekly contributions, respectively. Google trends showed oscillating activity over the past 10 years (Figure 1).

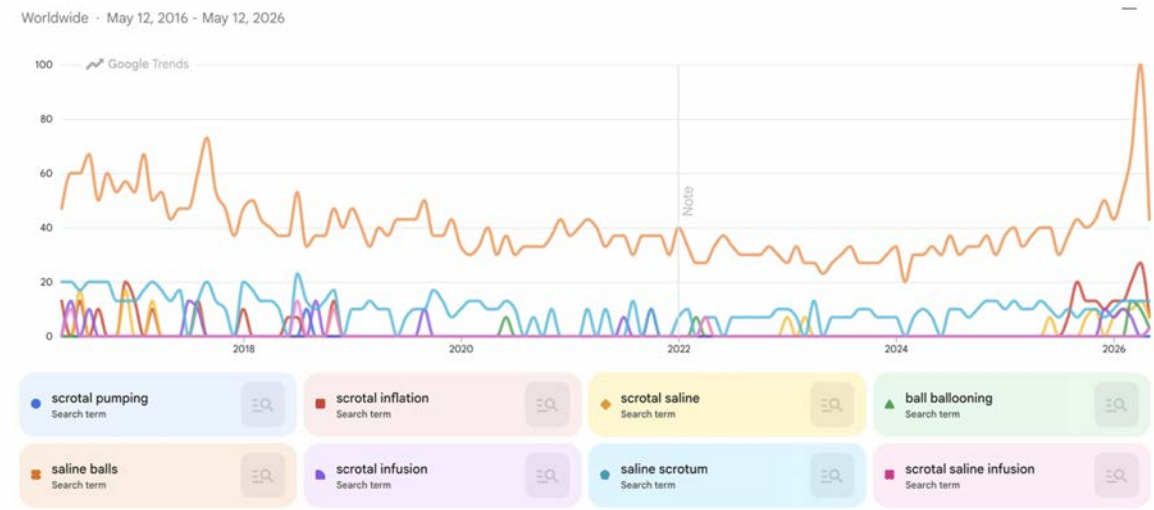

Figure 1. Google trends analysis showing the number of times the terms “scrotal pumping,” “scrotal inflation,” “scrotal saline,” “ball ballooning,” “saline balls,” “scrotal infusion,” “saline scrotum,” and “scrotal saline infusion” were searched on Google since May 12, 2016.

Conclusions

From a small pool of evidence, scrotal injections demonstrate a unique potential for harmful and potentially lethal complications. Recognizing the cases where patients initially omitted performing scrotal pumping[3], this practice may have low rates of clinical presentation and be underreported. Notably, our digital scan revealed thousands of users and consistent weekly engagement on online forums dedicated to scrotal pumping, suggesting a greater prevalence than reflected in the medical literature. This may be due to stigma, patient hesitancy, and gaps in clinical recognition, and emphasizes the need for dermatologists to be aware of these practices and their potential complications.

EADV CONGRESS
VIENNA
30 SEP - 3 OCT 2026

Abstract N°: 4307

Comparative Study: PRP + Fractional CO2 Laser vs. Fractional CO2 Laser Alone for Acne Scars

Shraddha Ingole*[1]

[1] Viveka Hospital, Nagpur, India

Introduction

Atrophic acne scars cause significant psychological distress and present clinical treatment challenges. Fractional Carbon Dioxide (CO2) laser resurfacing represents the gold standard for skin remodeling but carries risks of prolonged erythema and post-inflammatory hyperpigmentation (PIH). Platelet-Rich Plasma (PRP) accelerates tissue healing and enhances collagen synthesis through autologous growth factors.

Materials and Methods

The objective of this study was to evaluate and compare the clinical efficacy, safety profile, and patient satisfaction of combination therapy (Fractional CO2 laser plus autologous PRP) versus Fractional CO2 laser monotherapy using a split-face study model. This was a prospective, randomized, evaluator-blinded, split-face clinical trial involving 30 patients with moderate-to-severe atrophic acne scars (rolling, boxcar, and icepick). The right side of the face received Fractional CO2 laser resurfacing followed immediately by topical and intradermal PRP application, while the left side received Fractional CO2 laser resurfacing monotherapy. Three treatment sessions were performed exactly 4 weeks apart. Standardized digital photography, the Goodman and Baron quantitative scale, and patient-reported visual analogue scales (VAS) were used for evaluation. Follow-up assessments were conducted at 1, 3, and 6 months post-final treatment.

Results

The right side treated with combination therapy showed a significantly higher reduction in scar depth compared to the left side treated with laser monotherapy. Combined therapy yielded superior improvement in texture, skin elasticity, and rolling scar types. Furthermore, the right side demonstrated reduced crusting time and faster epithelialization, whereas the left side exhibited prolonged erythema, higher pain scores, and an elevated incidence of PIH. Patient-reported satisfaction scores were significantly higher for the right side.

Conclusions

Combining Platelet-Rich Plasma with Fractional C02 laser resurfacing synergistically improves atrophic acne scar outcomes. This combination shortens post-procedure recovery times and lowers adverse effect rates compared to Fractional CO2 laser monotherapy

EADV CONGRESS
VIENNA
30 SEP - 3 OCT 2026

Abstract N°: 4324

Effectiveness and Safety of Modified Partitioned Small-incision Excision Surgery vesus Microneedles Radiofrequency Therapy for Axillary Omhidrosis: A Prospective Study

Yujing Huang*[1], Chengcheng Shen[1], Ping He[1], Tao Cai[1], Aijun Chen[1], Na Tan[1]

[1] The First Affiliated Hospital of Chongqing Medical University, Chongqing, China

Introduction
Axillary osmidrosis is an unpleasant disorder characterized by odor elimination. It is caused by the coordination between abnormal increasing activity of apocrine glands and local homing bacteria. Nowadays, effective treatments of axillary osmidrosis pursued are not only for permanent effect but for the safe solution. This study aimed to compare the efficacy and safety of microneedles radiofrequency therapy versus modified partitioned small-incision excision surgery for moderate-to-severe cases.

Materials and Methods
In this single-center, randomized, controlled, and prospective study, a total of 60 subjects (Park-Shin grades 2-3) were recruited. All the subjects had the same grading on both the left and right sides, and were randomly assigned microneedles radiofrequency therapy for one side and modified partitioned small-incision excision surgery for another side. Primary outcome is 6-months self-reported VAS score(0-10, 0 for no improvement at all) and secondary outcomes include effective rate derived from investigator-reported Park-Shin grade and patient satisfaction. Baseline characteristics including sex, age ,and etc were recorded. Any side-effects during the study, including pain, erythema, post-treatment hyperpigmentation, scar and any other unexpected results were recorded with duration and quartile grading scaled. Histopathology to assessing sweat gland fibrosis and density was done before treatment and at the end of the study period.

Results
Self-reported VAS score of modified partitioned small-incision excision surgery side (3.5) is lower than microneedles radiofrequency side (4.9) ($p<0.05$), indicating higher effective rate in surgery. Patient satisfaction confirmed no significant difference (79.7% vs. 76.8%, p=0.791). But microneedles radiofrequency therapy demonstrated significantly fewer complications.

Conclusions
Modified partitioned small-incision excision surgery achieved higher effective rates to microneedles radiofrequency therapy but with more complications, reduced scarring, and quicker recovery. These findings support both microneedles radiofrequency therapy for one side and modified partitioned small-incision excision surgery as safe alternative for axillary bromhidrosis.

EA DV CONGRESS
VIENNA
30 SEP - 3 OCT 2026

Abstract N°: 4342

ARTIFICIAL INTELLIGENCE IN DERMATOLOGICAL DIAGNOSTICS AND AESTHETIC PROCEDURE PLANNING : A REVIEW OF CURRENT TECHNOLOGIES

Wiktoria Szablewska*[1], Miłosz Lewandowski[2, 3], Martyna Sławińska[2, 3]

[1] Dermatological Students Scientific Association, Department of Dermatology, Venerology and Allergology, Faculty of Medicine, Medical University of Gdansk, Gdańsk, Poland

[2] Department of Dermatology, Venerology and Allergology, Faculty of Medicine, Medical University of Gdansk, Gdańsk, Poland

[3] Department of Dermatology, Venerology and Allergology, University Clinical Centre in Gdansk, Gdańsk, Poland

Introduction

Artificial intelligence (AI) is transforming dermatological practice by shifting from subjective assessments to objective medical standards in both clinical diagnosis and aesthetic planning. Traditional methods, particularly in aesthetic medicine, have long relied on clinical scales prone to inter-observer variability and personal biases. This work explores how AI addresses these challenges through standardized data and predictive modeling.

Materials and Methods

This review analyzes the performance of deep learning architectures, specifically Convolutional Neural Networks (CNNs) for lesion classification, and the emerging multimodal foundation model, PanDerm, which integrates over 2 million images across four imaging modalities. It also examines the international consensus on objective aesthetic indices (SQI, FAI) and the application of Generative Adversarial Networks (GANs) for simulating surgical outcomes in procedures such as rhinoplasty and facelifts.

Results

In diagnostics, CNNs have demonstrated accuracies comparable to or exceeding experienced dermatologists in identifying melanoma, with models like PanDerm outperforming clinicians by 10.2% in early-stage detection. In aesthetic medicine, the implementation of the Skin Quality Index (SQI) and Facial Aesthetic Index (FAI) provides a reproducible framework for evaluating skin health and facial harmony, effectively preventing overcorrection. Furthermore, generative AI tools such as DALL-E 2 and Midjourney can produce hyper-realistic simulations of surgical results, although they currently exhibit biases favoring lighter skin tones and younger demographics.

Conclusions

AI serves as a potent supplementary tool that enhances diagnostic precision and personalizes treatment planning. However, successful clinical integration requires addressing significant obstacles, including algorithmic biases across diverse skin phototypes and the need for transparency via Explainable AI (XAI). Ultimately, AI must be ethically integrated to augment the doctor-patient relationship rather than supplanting the clinician’s irreplaceable judgment.

EADV CONGRESS
VIENNA
30 SEP - 3 OCT 2026

Abstract N°: 4440

Fractional Ablative CO_2 Laser Versus Screw Threads for Post-Traumatic Atrophic Linear Scars: A Prospective Randomized Clinical Study

Sherihan Allam*[1]

[1] Dermatology Department, Mansoura University, Mansoura, Egypt

Introduction
Post-traumatic atrophic linear scars may result in significant aesthetic and psychosocial impairment and remain therapeutically challenging. Fractional ablative CO_2 laser promotes dermal remodeling and collagen stimulation, improving scar texture and dyspigmentation. Screw threads represent a minimally invasive regenerative modality that may enhance tissue support and collagen production with minimal downtime.

Materials and Methods
This prospective randomized clinical study included 42 patients with post-traumatic atrophic linear scars, divided equally into two groups. Group A (n=21) was treated with fractional ablative CO_2 laser, while Group B (n=21) received screw thread treatment. Scar assessment before and after treatment was performed using the Modified Manchester Scar Scale. Clinical improvement was evaluated using a quartile grading scale, while pain intensity was assessed using the Visual Analogue Scale (VAS).

Results
Both treatment modalities demonstrated significant clinical improvement in scar appearance after treatment. Significant improvement was observed regarding scar shine and distortion in both groups. No statistically significant difference was detected between the two groups regarding overall clinical efficacy, patient satisfaction, or total Modified Manchester Scar Scale scores. Patient satisfaction was slightly higher in the screw thread group without statistical significance. Both modalities were well tolerated.

Conclusions
Fractional ablative CO_2 laser and screw threads are effective and safe treatment options for post-traumatic atrophic linear scars, demonstrating comparable clinical outcomes and high patient satisfaction. Screw threads may represent a promising minimally invasive alternative for scar remodeling and aesthetic improvement, particularly in patients with darker skin phototypes where laser-associated post-inflammatory pigmentary changes may be a concern.

EA DV CONGRESS
VIENNA
30 SEP - 3 OCT 2026

Abstract N°: 4441

Antioxidant Boosters Synergistically Enhance Vitamin C Protection Against Oxidative Damage and Collagen Degradation in Human Skin

Ludmila Prudkin*[1], Adrià Ribes[1], Anthony Brown[1], Carolina Escardó[1], Monica Foyaca[1]

[1] Innovation & Development, ISDIN S.A., Barcelona, Spain

Introduction

Oxidative stress profoundly impacts human skin, triggering cellular dysfunction and accelerating premature aging. Environmental aggressors lead to the excessive production of reactive oxygen species, resulting in severe oxidative damage, such as protein carbonylation, and the structural degradation of the extracellular matrix, prominently marked by the loss of collagen. While topical antioxidants like Vitamin C are widely recognized to mitigate these detrimental oxidative effects, L-ascorbic acid is challenging due to its propensity for oxidation and limited penetration across the stratum corneum. Maximizing its efficacy remains a priority. This study evaluates the synergistic protective efficacy of a Vitamin C complex (L-ascorbic acid, 3-O-ethyl-L-ascorbic acid and Ascorbyl Tetraisopalmitate) combined with three specific booster agents (Hinokitiol, Levulinic Acid and Tocopherol) against oxidative stress in human skin explants.

Materials and Methods

Ex vivo human skin explants were topically treated with the vitamin C complex alone or in combination with the 3 boosters. After 3 hours, samples were exposed to UVA radiation (6 J/cm^2) to induce oxidative stress, followed immediately by a second treatment. Levels of oxidative damage (protein carbonylation) within epidermis and dermis was determined at 3h, and levels of dermal collagen III 24 hours after exposure.

Results

The addition of boosters to vitamin C increased antioxidant capacity across all skin compartments. This effect was especially pronounced in the epidermis where efficacy was 7× higher in epidermis while showing a 17% net protective efficacy increase in dermis. Protection against dermal collagen loss was doubled (Table 1).

Evaluated Biomarker	Skin Compartment	3 Vitamin C vs. control	3 Vitamin C + 3 Boosters vs control
Protein Carbonylation (Oxidative Damage)	**Epidermis**	15%	99%
	Dermis	63%	80%
Structural Degradation	**Collagen III**	58%	104%

Table 1. Synergistic improvement of vitamin C efficacy by antioxidant boosters in human skin.

Conclusions

These results demonstrate that the antioxidant efficacy of a combination of L-ascorbic acid, 3-O-ethyl-L-ascorbic acid, and ascorbyl tetraisopalmitate can be synergistically enhanced by co-formulation with hinokitiol, levulinic acid, and tocopherol, likely due to improved stability and enhanced penetration across the epidermis.

EA DV CONGRESS
VIENNA
30 SEP - 3 OCT 2026

Abstract N°: 4486

Treatment of severe actinic damage including field cancerisation and SCC in situ, with 1940nm laser and CO2 laser

Evangelia Vetsiou*[1, 2], Saqib Bashir[1, 2]

[1] Dermatology Department, King's College Hospital NHS Foundation Trust, London, United Kingdom
[2] Skin 55 Clinic, London, United Kingdom

Introduction

Actinic keratoses (AK) and Bowen disease are forms of keratinocyte dysplasia with the potential to progress to invasive squamous cell carcinoma. Standard treatments include cryotherapy, topical 5-fluorouracil, imiquimod, photodynamic therapy (PDT), curettage, and surgery. Laser-based treatments may benefit field cancerisation and cosmetically sensitive areas, though supporting evidence is variable. One study found that a fractional 1927 nm thulium laser reduced facial AK count by 86.6% at 6 months; reviews indicate that fully ablative CO_2/Er: YAG lasers may be more effective than fractional lasers, but require longer healing. For Bowen disease, fractional CO_2 laser-assisted PDT has shown favourable clearance and safety, and combination treatments appear more effective than laser monotherapy.

Materials and Methods

Objective: To evaluate outcomes of 1940 nm fractional laser with our without adjunct CO_2 laser for AK, field cancerisation and Bowen's disease in routine clinical practice.

Methods: This retrospective anonymised case series included patients treated between May 2025 and April 2026.
Inclusion criteria were clinically or biopsy proven diagnosed AK or Bowen's disease treated with an energy-based device.
Exclusion criteria included suspected invasive SCC requiring excision
Treated sites were the scalp, face, pre-/post-/auricular area, and extremities, using the non-ablative fractional laser 1940 nm and CO_2 laser.

Laser settings: The 1940 nm fractional laser was typically used at 10–12 mJ 30–40% coverage, and a depth of 190–200 µm, with 3–4 passes, adjusted for site and lesion thickness. Repeated treatments were used for the scalp or face in all patients. The CO_2 laser was reserved for thicker lesions or seborrhoeic/keratotic components, with settings of 50–84 mJ in focused or ablative modes.

Results

Results:

Seven patients were included (5 male, 2 female; age range 66–89 years). Most patients were treated for actinic keratoses and field cancerisation, with one mixed AK/Bowen disease case.

Treatment sites included the scalp (n=4), cheeks/nose (n=2), forehead/temples (n=1), upper lip (n=1), and neck (n=1). The 1940 nm fractional laser alone was used in four patients, while three received adjunctive CO_2 laser for thicker or keratotic lesions.

Excellent clinical improvement or clearance was observed in 6/7 patients. Clearance or near-clearance was documented between 3 weeks and 12 months of follow-up. One mixed AK/Bowen disease case involving the forehead, temples and nose achieved complete clearance at 12 months following four passes of 1940 nm laser without topical anaesthesia. Persistent small foci of disease occurred in two patients, including a residual thicker neck lesion managed with focal 5-fluorouracil (Efudix) and one isolated keratotic scalp lesion treated with cryotherapy.

Several patients reported treatment to be less painful than PDT. No significant adverse events, scarring, or pigmentary complications were documented. Minor expected effects, including erythema, inflammation, crusting, and tenderness, were noted

Histology: Post-treatment biopsies were not needed to confirm clearance.

Conclusions

Conclusion: Fractional 1940 nm and CO_2 lasers appear to be effective and well-tolerated options for actinic keratoses, field cancerisation and Bowen disease. Clinical improvement was observed across scalp and facial sites with favourable tolerability and minimal adverse effects. Existing evidence supports high clearance rates with fractional lasers and improved efficacy with CO_2-based and combination approaches (e.g. laser-assisted PDT), indicating a growing role for energy-based, field-directed therapies as practical non-surgical treatments for keratinocyte dysplasia. One common clinical challenge is the treatment of large areas of the face and scalp in a single session, without the pain typical of photodynamic therapy or prolonged treatments with topical therapy.

EA DV CONGRESS
VIENNA
30 SEP - 3 OCT 2026

Abstract N°: 4519

Skin longevity in aesthetic dermatology: cellular senescence as an emerging target in photoaging

Allen Becker*[1], Manuela Attianesi de Freitas Rocha[2], Maria Luiza Corrêa Sebba[1], Julia Dionisio Lima[3], Renata da Gama Cruz Luz[1], Giovana Bueno Fernandes[1], Caroline Teruszkin Wiedermann[1], Ana Beatriz Gomes Cordovil[1]

[1] Universidade Estácio de Sá, Rio de Janeiro, Brazil

[2] Faculdade São Leopoldo Mandic, São Paulo, Brazil

[3] Universidade do Oeste Paulista, São Paulo, Brazil

Introduction

Photoaging is a major concern in aesthetic dermatology and results primarily from chronicultraviolet radiation exposure, leading to oxidative stress, extracellular matrix degradation and premature skin aging. Recent evidence suggests that cellular senescence may play an important role in this process through persistent inflammatory signaling and impaired tissue repair. Senescent cells remain metabolically active and develop a pro-inflammatory secretory phenotype that contributes to tissue dysfunction and progression of skin aging. In this context, the concept of skin longevity has emerged as a biologically oriented approach focused on prevention and modulation of aging mechanisms rather than exclusively on cosmetic correction. This review aims to evaluate the role of cellular senescence in photoaging and discuss senescence-targeted strategies as emerging approaches for prevention and treatment in aesthetic dermatology.

Materials and Methods

A narrative review was conducted using scientific literature indexed in PubMed, Scopus andGoogle Scholar. The search included the terms “photoaging”, “cellular senescence”, “skin aging”, “senescence-associated secretory phenotype”, “oxidative stress”, “senolytics”, “senomorphics” and “aesthetic dermatology”. Articles addressing molecular mechanisms of photoaging, senescent cells in skin aging and emerging therapeutic strategies targeting senescence were selected.

Results

Photoaging results from cumulative molecular damage induced mainly by chronic ultravioletradiation exposure, leading to oxidative stress, DNA damage, mitochondrial dysfunction, inflammatory signaling and extracellular matrix degradation. Increased expression of matrix metalloproteinases contributes to collagen fragmentation, dermal thinning, loss of elasticity and dyschromia (Fisher et al., 2002; Gilchrest, 2013). Cellular senescence appears to amplify these alterations through the senescence-associated secretory phenotype (SASP), characterized bythe release of pro-inflammatory cytokines, growth factors and matrix-degrading enzymes that sustain chronic low-grade inflammation and tissue dysfunction. Senescent dermal fibroblasts, mitochondrial dysfunction and impaired extracellular matrix homeostasis contribute to reduced regenerative capacity and progression of skin aging (Campisi, 2013; Hernandez-Segura et al., 2018; López-Otín et al., 2013). Emerging approaches such as photoprotection, antioxidants, retinoids, regenerative procedures, energy-based devices and senescence-modulating therapies may represent a shift from purely corrective aesthetic interventions toward biologically oriented skin aging management. However, senolytic and senomorphic therapies remain investigational in dermatology and require further clinical validation (Campisi, 2013; Gilchrest, 2013).

Conclusions

Cellular senescence is an important mechanism in photoaging and may represent a promising target in aesthetic dermatology. Understanding its role may support a broader model of skin longevity, focused not only on visible correction but also on prevention and biological modulation of skin aging. Although senescence-targeted therapies are still emerging, this field may contribute to the future of aesthetic dermatology by integrating molecular science, regenerative strategies and personalized prevention.

EADV CONGRESS
VIENNA
30 SEP - 3 OCT 2026

Abstract N°: 4525

4-Point Cannula technique for Lip filler injection

Shery Labib*[1]

[1] The Klinic - Medical center, cairo, Egypt

Materials and Methods

As reported that cannulas are much more safe regarding intravascular injection & vascular occlusion. In addition it is less painful as it has less entry points than injection with a needle, subsequently less traumatizing to tissues with reduced incidence of bruising and swelling.

Before the procedure, patient's requirement should be clear, either she wants lip contouring or she wants more volume in her lips. In addition, patients should be educated that this will differ in type to be injected, more volume might be accompanied with more edema as well.

A full medical history specially intake of medications as aspirin, NSAIDS, Vit E supplements. Inform the patients that Edema and swelling will occur & will subside in 3-5 days up to 7 days. Inform the patients with post procedure instructions; avoid sun exposure, hot weather, excessive sweating, sauna, jaccuzi , vigorous exercise for a week after the injection. Topical anaesthesia is used to decrease pain at entry points.
Photos are taken before/after the procedure with a written consent.
After sterilizing the lower part of the face, Lip is divided into 4 parts (2 upper parts & 2 lower parts). Entry points are done with needle For 25G cannula, it has 23G needle. 25 G cannula is more safe and much easier for filler injection than 27G cannula.

Entry points are at middle of vermilion border in each part (so it is easy to move with cannula at both medial and lateral without need of extra entry points). Injections are performed in a superficial plane. This is often guided by the cannula is being visible beneath the skin. Injections are micro-bolus at 5 lip tubercles (medial) & retrograde towards oral commissures (lateral)

After the procedures, ice packs for cooling are applied which help minimize edema. The patient is asked if she experience any severe pain. Syringe batch/lot number label is given to the patient for her reference. Topical antibiotic and systemic antihistamines are often prescribed. Systemic antibiotic are prescribed in some cases (Zithromycin 500 mg for 3 days).

Side effects that might occur are the same as with any other techniques of injection. The pain at needle entry point was bearable for all patients. Mild Bleeding occurred at some needle entry points, pressure was applied till bleeding stops. In addition to edema on lip borders (vermillion border) which usually subsides with ice packs.

This technique is not recommended for patients who want to change in her lip shape. It is best for contouring or volumizing same shape.

The patients are very satisfied with the results with a minimal experienced pain. They seek to have their filler injected using cannulas for other face areas as well.