EADV CONGRESS
VIENNA
30 SEP - 3 OCT 2026

Abstract N°: 478

Irritant contact dermatitis secondary to accidental spillage in a case of paraquat poisoning.

Sivasankari m*[1], Manoj Madakshira[1], Preema Sinha[2]

[1] Command Hospital Eastern Command, Kolkata, India

[2] Apollo hospital, newdelhi, India

Introduction

Paraquat is an easily available herbicide in India. Cases of poisoning with paraquat have been reported in India with various systemic involvement. However, cutaneous involvement in paraquat poisoning is infrequently reported. We report a case of irritant contact dermatitis due to accidental contact with the poison.

Case Presentation

A 38-year-old female presented with history of intentional ingestion of around 15 ml of liquid form of paraquat at home which was followed by one episode of spontaneous vomiting soon after the ingestion. There was no history of abdominal pain, loose stools, fever or fits. She was immediately managed conservatively in a nearby hospital with intravenous fluids and H2 blockers. She was brought to our emergency care unit around ten hours after the ingestion. She was conscious and well-oriented with normal vital signs. All the investigations including complete hemogram, renal and liver function tests were within normal. She was treated with H2 blockers and parenteral methylprednisolone. On the second day she developed multiple red-coloured lesions with slight itching over the limbs and trunk. Dermatological examination revealed multiple discrete to coalescing ecchymotic lesions in a retiform pattern seen over the abdomen, inner aspect of forearms and thighs [Figure 1]. Mucosae were normal. Patient denied any direct contact with the poison. However, she recollected that there was a spillage of the vomitus and gastric lavage on her clothes, which she was wearing till the time she reached our hospital. Histopathological examination of the ecchymotic lesions revealed features of irritant contact dermatitis [Figure 2]. The patient was managed with topical emollients and topical steroids with the lesions resolving well [Figure 3]. The patient is on regular follow up for any further pulmonary or renal involvement.Paraquat is a non-selective contact weedicide with its active ingredient as dimethyl-4,4′-bipyridinium. In India, paraquat a herbicide is available as 24% solution over the counter. It is highly toxic to humans and has a significantly high case fatality ratio.The poisoning due to paraquat has been due to accidental ingestion, inhalation or due to intentional self-harm. However, cases of paraquat poisoning have been reported due to accidental direct contact of skin with the poison in children, coffee plantation workers and farmers who spray the herbicide. Paraquat causes oxidative stress and the release of toxic reactive oxygen species, which is the main cause of damage to the organs. The percutaneous absorption is higher in case of contact with undiluted poison (20 % concentration). The poison is readily absorbed through damaged skin and can lead to erythema, blisters, skin necrosis and ulcerative lesions. It usually doesn’t affect intact skin, but prolonged direct contact with the poison on an intact skin can lead to skin lesions. Case reports have shown that percutaneous absorption of the poison can cause systemic involvement and can be fatal.

Conclusion

In our case, there was no spill of the poison during ingestion. However, the wet clothes which had the ingested poison, which she immediately vomited and the contents of the poison in the gastric lavage over the intact skin for a prolonged time would have caused the contact dermatitis. Despite the prolonged skin contact, her systemic involvement was very mild, and she recovered fully. It is essential to highlight the secondary accidental route of exposure to the poison in our case. It emphasizes the importance of removing the contaminated clothing as early as possible and irrigating the areas in contact. This would reduce the rate of the poison's percutaneous absorption

and the rare chances of fatality occurring secondary to the skin absorption. Clinicians need to be sensitized to suspect occupational causes when they come across such unusual lesions.

EA CONGRESS DV
VIENNA
30 SEP - 3 OCT 2026

Abstract N°: 517

Efficacy of cyclosporine in parthenium dermatitis: A prospective study on treatment outcomes and cytokine analysis

Rhea Ahuja*[1], Kaushal Verma[2], Neetu Bhari[2], Alpana Sharma[2]

[1] UNSW sydney, Sydney, Australia

[2] All india Institute of Medical sciences, New Delhi, New Delhi, India

Introduction

Parthenium dermatitis is a chronic relapsing allergic contact dermatitis caused by Parthenium hysterophorus, presenting therapeutic challenges. Cyclosporine, a calcineurin inhibitor with rapid anti-inflammatory effects, may be useful for short-term disease control.

Materials and Methods

This prospective, open-label study aimed to evaluate the effectiveness and safety of cyclosporine in parthenium dermatitis and correlate treatment response with inflammatory cytokine levels. Fifty patch test–positive patients were enrolled and treated with cyclosporine (2.5 mg/kg/day) for up to 12 weeks. Clinical severity scores (CSS) and adverse effects were monitored. Serum cytokines (TNF-α, IL-6, IL-17, IL-10) were assessed pre- and post-treatment in 27 patients. Patients were followed monthly for three months post-treatment to assess relapse.

Results

Of 48 patients who were evaluated, 35 (72.9%) achieved complete remission (CSS = 0), and 7 (14.6%) showed significant improvement. IL-6 levels decreased significantly post-treatment (p = 0.0003), while TNF-α and IL-17 showed a non-significant decline. IL-10 levels remained unchanged. Relapse occurred in 69% of patients within a mean of 2.9 weeks after treatment cessation.

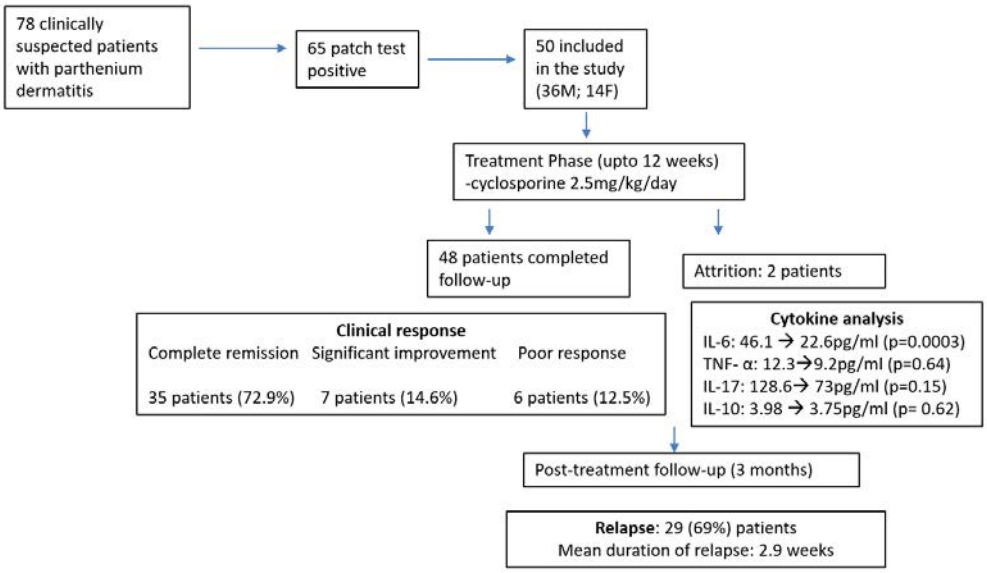

Conclusions

Cyclosporine is an effective short-term therapy for parthenium dermatitis, but relapse is frequent after abrupt withdrawal. Tapering or transitioning to steroid-sparing agents may enhance long-term control. Reduction in IL-6 highlights its role in disease pathogenesis and response to immunosuppression.

EADV CONGRESS
VIENNA
30 SEP - 3 OCT 2026

Abstract N°: 553

Increasing Epoxy Resin Sensitisation with High Occupational Relevance: A 30-Year Retrospective Study from a Tertiary Referral Centre

Esen Özkaya[1], Omer Mangir*[1], Yasemin Erdem[1]

[1] İstanbul University, İstanbul Faculty of Medicine, Department of Dermatology and Venereology, Istanbul, Türkiye

Introduction
Epoxy resins are potent contact allergens widely used in industry and strongly associated with occupational allergic contact dermatitis (ACD) because of their high sensitisation potential and frequent airborne or direct skin exposure. However, data remain limited. This study aimed to evaluate the frequency, clinical relevance, and associated demographic and occupational factors of epoxy resin-induced ACD over a 30-year period.

Materials and Methods
This study analysed data from 2733 patients consecutively patch tested with epoxy resin between 1996 and 2025. Epoxy resin was tested as diglycidyl ether of bisphenol A (DGEBA) 1% pet. as part of the European baseline series. 133 patients were additionally patch tested with epoxy hardeners and reactive diluents. Clinical and occupational relevance, exposure sources, localisation of dermatitis, and co-sensitisations with other allergens were retrospectively assessed.

Results
The prevalence of sensitisation to epoxy resin was 0.95% (26/2733). A slight male predominance was observed (female:male = 1:1.6), with a mean age of 34.7 years. Clinical relevance was confirmed in 96.2% of cases. Most reactions were occupationally related (88.5%), predominantly affecting workers in shipyards, the textile industry, aircraft maintenance, jewellery production, and industrial painting. Non-occupational relevance was rare (11.5%) and mainly related to hobby-related exposures. An airborne pattern, particularly facial involvement, was frequent, with facial dermatitis significantly more common in epoxy-positive patients than in epoxy-negative patients ($p<0.001$). Fourteen patients (53.8%) showed isolated positive reactions to epoxy resin, while concomitant patch test reactions were observed in 5 patients to 4,4'-diaminodiphenylmethane (n=2), triethylenetetramine (n=1), diethylenetriamine (n=1), cresyl glycidylether (n=1), and hexamethylene tetramine (n=1). Sensitisation was detected by DGEBA in all patients with epoxy-related ACD.

Conclusions
Epoxy resin allergy shows an increasing prevalence, and is predominantly associated with occupational ACD, highlighting the need for appropriate patch testing and effective preventive strategies in exposed occupations.

EA DV CONGRESS
VIENNA
30 SEP - 3 OCT 2026

Abstract N°: 656

Validity of Using Detailed, Specific Prompts in ChatGPT for Allergen Avoidance Recommendation in Common Contact Allergen

Supakit Kiewprasert*[1], Papatwarin Suesat[1], Thanida Kamolphasukchuen[1], Pawit Phadungsaksawasdi[1]

[1] Chulabhorn International College of Medicine, Phathum Thani, Thailand

Introduction
Allergic contact dermatitis (ACD) imposes a significant clinical burden, where optimal management depends on precise allergen avoidance. Yet, converting patch test results into practical, individualized product recommendations remains a persistent challenge in dermatologic care. Large language models, particularly ChatGPT, represent a transformative opportunity to deliver scalable, patient-centered guidance; however, their clinical reliability remains uncertain. This study investigates whether detailed, structured prompting can optimize the validity of AI-generated allergen avoidance recommendations, positioning ChatGPT as a potential adjunct in precision dermatology.

Materials and Methods
This study included the ten most prevalent contact allergens in Thailand, based on Boonchai et al. (2008), with five common sources selected for each allergen. A structured and specific prompt was developed to instruct ChatGPT to generate five product recommendations appropriate for patients allergic to each allergen, ensuring clarity and consistency across all queries. Responses were generated using GPT-4 (ChatGPT Plus) in September 2023. To minimize contextual bias, each query was conducted in a new chat session. A total of 50 queries were performed, representing 10 allergens and 5 sources per allergen. Responses that did not specify a product model or brand were classified as unresponsive. All responses were independently evaluated by a dermatologist. Validity was categorized as valid (absence of the specified allergen), invalid (presence of the allergen), unknown (insufficient ingredient information), or unresponsive (no specific product identified). Product ingredients were verified using manufacturer websites, safety data sheets, and established online databases. Data were collected and analyzed using Microsoft Excel. The proportion of each validity category was calculated relative to the total number of product recommendations to determine overall accuracy.

Results
A total of 250 product recommendations were generated and systematically evaluated. The overall validity of ChatGPT-generated responses was 82.0% (205/250), with 3.2% (8/250) classified as invalid, 6.8% (17/250) as unknown, and 8.0% (20/250) as unresponsive. At the allergen level, complete validity (100%) was observed for fragrance mix and colophony. High validity rates were also demonstrated for potassium dichromate (92%), neomycin sulfate (92%), balsam of Peru (88%), cobalt chloride (80%), parabens mix (80%), and budesonide (80%). In comparison, lower validity was identified for phenylenediamine (64%) and nickel sulfate (44%), with greater proportions of unknown and unresponsive responses. When analyzed by product category, the highest validity was observed in cosmetics and personal care products (92.26%), followed by cleaning products (90.0%), pharmaceuticals (86.0%), and paint and varnish (60.0%). In contrast, validity was low in jewelry (6.67%) and absent in leather products (0%), where a high proportion of unknown responses was observed.

Conclusions
This study demonstrates that ChatGPT achieves a high overall validity (82.0%) in generating allergen avoidance product recommendations when guided by structured and specific prompts. The model performed particularly

well in cosmetics and personal care products, as well as in several common allergens, while lower validity was observed in certain allergen groups and product categories with limited ingredient transparency. These findings highlight the potential of ChatGPT as a supportive tool in allergen avoidance counseling, particularly in enhancing efficiency and accessibility of patient education. However, variability in performance and the presence of invalid and uncertain responses underscore the need for cautious use and clinical verification. Further research is warranted to improve generalizability, explore a broader range of allergens and product types, and evaluate consistency across different prompt designs and AI models.

EA DV CONGRESS
VIENNA
30 SEP - 3 OCT 2026

Abstract N°: 714

Contact Allergy to Nail Cosmetics: A Scoping Review

Azhar Ahmed[1], Mohammed Alahmadi*[2], Sara Alghamdi[3], Sarah Almohammdi[4], Mohammed Alharbi[2], Ghaida Alharbi[5], Haifa k. Alqahtani[6], Zahra Abuayfah[5]

[1] Department of Dermatology, King Faisal Specialist Hospital and Research Center, Medina, Saudi Arabia
[2] Department of Dermatology, King Fahad General Hospital, Medina, Saudi Arabia
[3] Department of Dermatology, King Fahad Hospital, Al-Baha, Saudi Arabia
[4] Department of Dermatology, King Salman bin Abdulaziz Medical City, Medina, Saudi Arabia
[5] College of Medicine, Taibah University, Medina, Saudi Arabia
[6] College of Medicine, King Saud University, Riyadh, Saudi Arabia

Introduction
The rising use of artificial nails, gel manicures, and adhesives has increased exposure to methacrylates and acrylates, known causes of allergic skin reactions. However, the available research is heterogeneous and methodologically diverse. This scoping review synthesizes current evidence on nail cosmetic allergies, focusing on exposure patterns, diagnostic approaches, culprit allergens, and clinical presentations.

Materials and Methods
This scoping review was conducted following the methodological framework developed by Arksey and O'Malley and refined by Levac et al, and is reported in accordance with the Preferred Reporting Items for Systematic Reviews and Meta-Analyses extension for Scoping Reviews (PRISMA-ScR) guidelines.A review protocol was developed by the research team before initiation. A comprehensive search was conducted across seven electronic databases: PubMed, Scopus, Web of Science, Wiley Online Library, MEDLINE, EBSCO, and Google Scholar. The search strategies combined terms related to nail cosmetics and contact dermatitis using database-specific syntax and Boolean operators

Tables and figures were created using a descriptive summary of the extracted data. The main aim of this study was to outline the current data about study parameters, exposure trends, diagnostic techniques, allergen identification, and significant clinical symptoms.

Results
The comprehensive database search yielded 987 records across a variety of databases, including Scopus, PubMed, Web of Science, Wiley Online Library, MEDLINE, EBSCO, and Google Scholar. The final scoping review included 39 studies after screening and applying the established eligibility criteria. The study selection process is summarized in the PRISMA flow diagram (Figure 1).

Both consumers and nail technicians were identified as key exposed populations. Patch testing was the main diagnostic tool. Acrylates, especially hydroxyethyl methacrylate (HEMA) and other methacrylate derivatives, were the predominant allergens. Dermatitis most commonly involves the hands, fingers, and periungual areas, with frequent spread to the face, eyelids, and neck. Allergic contact dermatitis from nail cosmetics is a growing concern, driven primarily by acrylate sensitization. Most reports describe cases but do not provide detailed data.

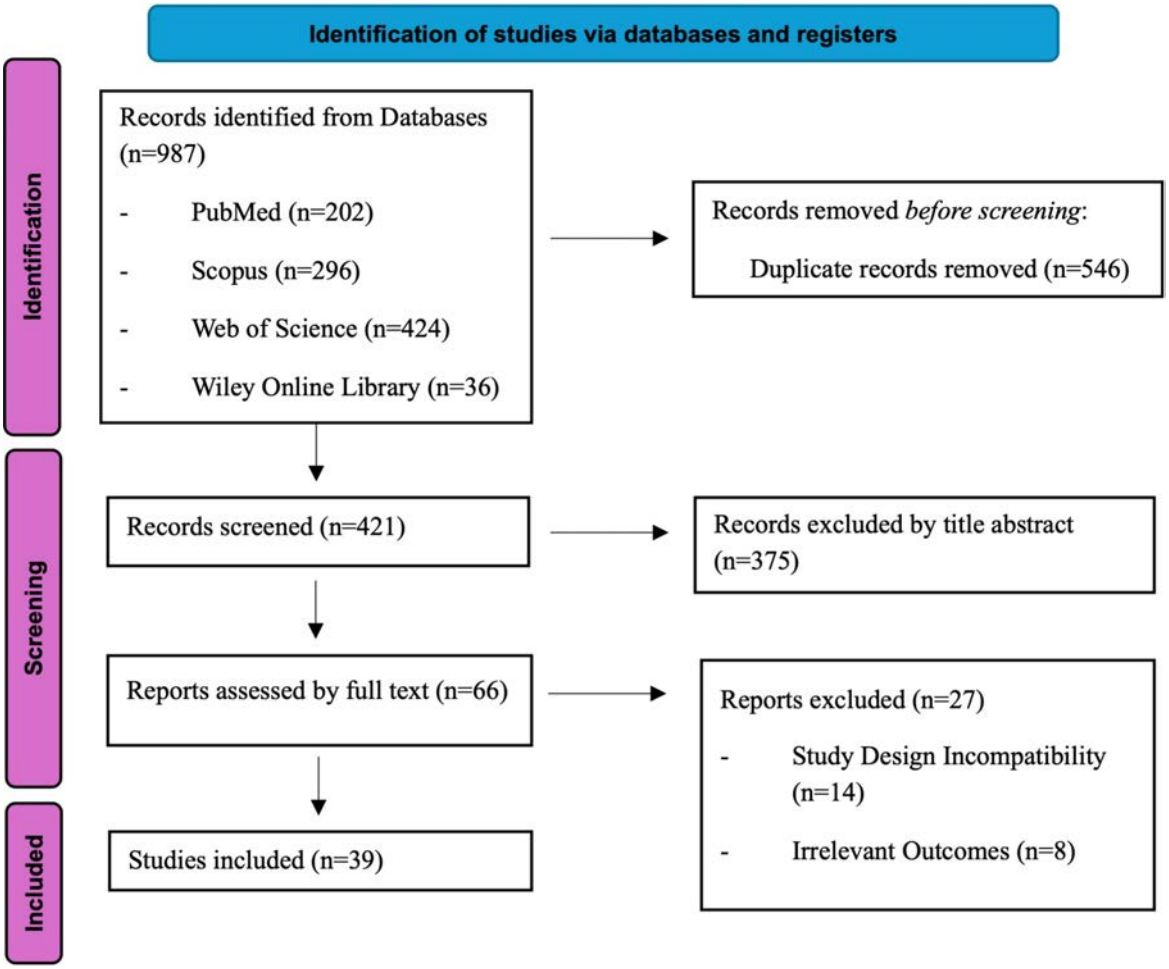

Figure 1: PRISMA Flowchart

Conclusions

This scoping review summarizes the available evidence on contact allergens in nail cosmetics. Cases of allergic contact dermatitis caused by these products are increasing among both consumers and professionals. Nail technicians are at higher risk due to more frequent exposure. Acrylate compounds, particularly HEMA and other methacrylates, are the primary allergens found in nail cosmetics. The hands, fingers, and periungual areas are the most common sites of symptom manifestation; however, dermatitis can also occur on the face and eyelids, most likely due to indirect allergen transfer. Few large-scale epidemiological studies have been conducted in this area; consequently, many available data come from case reports and small observational studies. Additional research is needed on the incidence of nail cosmetic allergies, the impact of novel cosmetic compounds, and the effectiveness of preventive measures for both professionals and consumers, particularly given the increasing number of reported cases.The findings of this review underscore the importance of strengthening prevention measures to reduce allergen exposure and raising awareness among healthcare professionals and nail industry workers about the hazards associated with nail cosmetics.

EA DV CONGRESS
VIENNA
30 SEP - 3 OCT 2026

Abstract N°: 742

OCCUPATIONAL CONTACT DERMATITIS IN AUTOMOBILE MECHANICS IN PORT HARCOURT CITY, NIGERIA: PREVALENCE AND RISK FACTORS

Ichechiek Ujile*[1]

[1] Dermatology unit, Department of Internal Medicine, University of Port harcourt Teaching Hospital, Port Harcourt, Nigeria

Introduction
Occupational Contact dermatitis is common among automobile mechanics, with reported prevalence rates ranging from 4.6% to 80%. They are caused by a wide range of exposures to industrial chemicals used in the motor vehicle repair industry. These include heavy metals contained in brake fluids, detergents, oils, lubricants, paints, gasoline, solvents, adhesives, and particulates from sanding, glass fibre, burn injury, and exposure to ultraviolet radiation.

Materials and Methods
This was a descriptive cross-sectional study involving 94 male participants recruited between December 2024 and March 2025 from a cluster of two major automobile mechanics in Ikoku and Elekahia mechanic villages in Port Harcourt City, selected using simple random sampling.The study participants were actively involved in various aspects of automobile repair.

Results
All respondents in this study were male. Most participants were within the age range of 30–39 years (63.83%). In terms of educational attainment, over half (53.19%) had only primary education, while 20.21% had secondary education, and 26.60% had attained tertiary education.Occupational distribution showed that most participants were auto mechanics (48.90%). Others included panel beaters (16.00%), car air conditioning technicians (9.60%), painters (8.50%), auto electricians (6.40%), auto transmission engineers (6.40%), and blacksmiths (4.30%). In this study, prevalence of contact dermatitis was 6.4%.Common dermatological conditions among participants included thermal injuries (59.60%), onychodystrophy (44.70%), dyschromia (21.00%), vesicles (4.00%), and scales (2.00%). The overall prevalence of eruptive lesions was 6.40%, with most occurring on the upper limbs. Specifically, 5.30% of participants reported on the arm or forearm, 4.30% on the dorsum of the hand, 4.30% on the palmar surface, and 2.10% on the medial surface of the lower limbs.Among the irritants, 83% of the individuals were exposed to gasoline. Regarding knowledge of personal protective equipment (PPE), 72.30% of participants had heard of PPE. However, only 29.41% of those were able to correctly identify PPE as items worn to protect oneself from occupational hazards.Patch testing showed positive responses in four study participants, the allergens identified are p-ter butylphenolformaldehyde resin, parthenolide, ethylenediamine dihydrochloride, mercapto-benzothiazole, colophony, cobalt chloride, sodium orothiosulphate, lanolin alcohol,p-phenylenediamine, thiuram mix, quaternium-15, bacitracin, carba mix, neomycin sulphate and methyl(chloro) isothiazolinone.

Conclusions
In this study, the prevalence of contact dermatitis was 6.4%, the high exposure to gasoline(petrol) was 83%, and infrequent use of personal protective equipment (68.75%) are consistent with those of previous studies, highlighting similar trends in occupational exposure and dermatological outcomes.

EADV CONGRESS
VIENNA
30 SEP - 3 OCT 2026

Abstract N°: 812

Yellow-orange palmoplantar keratoderma: consider carotenoderma

Eya Bouzaien*[1], Anissa Zaouak[1], Houda Hammami[1]

[1] Dermatology Department, Habib Thameur Teaching Hospital, Tunis, Tunisia

Introduction

Carotenoderma is a benign condition characterized by yellow-orange skin discoloration due to carotene deposition within the epidermis. It is most commonly related to excessive dietary intake of carotenoids but may also occur in certain metabolic conditions. We report an unusual case of carotenodermia presenting as yellow-orange palmoplantar keratoderma (PPK) in the context of prolonged daily consumption of turmeric.

Case Presentation

A 40-year-old man, with no past medical history and no medication use, presented with a progressive yellow-orange discoloration of the palms and soles evolving over several weeks. Dermatological examination revealed a well-demarcated, homogeneous palmoplantar keratoderma with slightly infiltrated borders. The patient reported no associated symptoms, including pruritus, pain, dark urine, or pale stools. Physical examination showed skin involvement limited to the hands and feet, with no scleral or mucosal discoloration, thereby excluding jaundice. Laboratory investigations, including liver enzymes, thyroid function tests, and serum albumin, were within normal limits. Histopathological examination demonstrated hyperkeratosis without dermal inflammatory infiltrate. Detailed dietary history revealed prolonged daily intake of turmeric, consumed as a glass of turmeric-infused water. A diagnosis of diet-induced carotenoderma presenting as palmoplantar keratoderma was established. Reduction of carotenoid intake led to clinical improvement.
Carotenoderma results from the accumulation of carotenoids in the stratum corneum, explaining its predilection for areas with a thick epidermis such as the palms and soles. While most cases are related to excessive dietary intake, it may also be associated with metabolic disorders such as hypothyroidism and diabetes mellitus, even in the absence of increased carotenoid consumption. Diagnosis relies primarily on a thorough dietary history, assessing the type, quantity, and duration of carotenoid intake. The characteristic yellow-orange pigmentation typically spares the sclera and mucous membranes and may appear more pronounced under artificial lighting. Management consists of reducing carotenoid intake, leading to gradual resolution of skin discoloration. The exact mechanisms underlying this regression remain incompletely understood. Patient reassurance is essential given the benign and reversible nature of the condition.

Conclusion

Carotenoderma is a benign and reversible cause of yellow-orange skin discoloration that should be recognized to avoid unnecessary investigations.

EADV CONGRESS
VIENNA
30 SEP - 3 OCT 2026

Abstract N°: 1183

Clinical Characteristics and Treatment Outcomes of Perioral Dermatitis: A Retrospective Analysis Using the PODSI Score

Sera Yücesoy[1], Güllü Gencebay[2], Ömer Cacına*[1], Melisa Özay[2]

[1] Istanbul University-Cerrahpaşa, Istanbul, Türkiye

[2] Bezmialem University, Istanbul, Türkiye

Introduction

Perioral Dermatitis is a common inflammatory facial dermatosis characterised by erythematous papules, papulopustules, and fine scaling involving the perioral region. It affects predominantly young women and may be due to topical corticosteroid usage, cosmetic product exposure, epidermal barrier dysfunction, and microbial factors. Despite being defined as a common clinical entity, comprehensive real-world data with demographic characteristics, comorbid conditions, triggering factors, and objective severity scoring remain limited. The Perioral Dermatitis Severity Index offers a standardized method for quantifying disease activity based on erythema, papules, and scaling, yet its application in routine practice with treatment outcome is underreported.

Materials and Methods

This retrospective observational study included 34 patients with clinically confirmed Perioral Dermatitis who had complete baseline and follow-up documentation available. Demographic variables, age at diagnosis, disease duration, comorbid dermatologic conditions, and reported triggering factors were extracted from standardized clinical records. Disease severity was quantified using Perioral Dermatitis Severity Index, a validated scoring system grading erythema, papules, scaling with a total interval of 0-9, both before and after treatment. Treatment outcome was evaluated using post-treatment PODSI scores. Statistical analyses included the Wilcoxon signed rank test for pre and post-treatment comparisons, Spearman correlation for continuous associations, Mann-Whitney U test for group comparisons, and multivariable linear regression to identify independent predictors of post-treatment severity.

Results

The mean patient age was 26.7 years, with a median disease duration of 5.5 weeks. Female patients constituted 85.3% of the cohort. The most prevalent comorbid dermatologic conditions were seborrheic dermatitis and rosacea (each 20.6%), followed by tinea infection (8.8%), chronic urticaria (5.9%) and acne vulgaris (2.9%). Topical corticosteroid exposure was the most commonly reported trigger (32.4%). Treatment regimens varied widely: topical metronidazole monotherapy was used in 20.6% of patients, topical erythromycin in 14.7%, and topical calcineurin inhibitors alone in 14.7%. Combination therapies were frequently given, with topical metronidazole plus systemic antibiotics being the most common approach (23.5%), followed by topical calcineurin inhibitors combined with systemic antibiotics (14.7%). Mean baseline Perioral Dermatitis Severity Index score declined significantly from 5.68 to 1.97 following treatment, with statistically significant improvement observed across all three individual components erythema, papules, and scaling. No significant associations were identified between Perioral Dermatitis Severity Index scores and age, sex, disease duration, comorbid conditions, or triggering factors. On multivariable linear regression analysis, baseline Perioral Dermatitis Severity Index score was the only independent predictor of post-treatment severity, while age and disease duration did not reach significance.

Conclusions

Clinically meaningful improvement in Perioral Dermatitis Severity Index scores was achieved across all treatment groups, independent of patient demographics, comorbid dermatoses, or reported triggers. Baseline disease severity emerged as the primary determinant of short term therapeutic outcome, highlighting the importance of early assessment in guiding treatment decisions. These findings support the routine use of Perioral Dermatitis Severity Index as a reliable clinical monitoring tool. Prospective studies with larger cohorts are warranted to further define predictors of treatment response and to compare the efficacy of specific regimens.

EA DV CONGRESS
VIENNA
30 SEP - 3 OCT 2026

Abstract N°: 1326

Sting's Silent Legacy: Delayed Cutaneous Hypersensitivity Post-Jellyfish Envenomation: A Review

Majd Abu Taleb*[1], Nesrine Ben Salah[1], Youssef Monia[1], Hichem Belhadjali[1], Jameleddine Zili[1]

[1] Dermatology Department, Fattouma Bourguiba University Hospital, Monastir, Tunisia

Introduction
Jellyfish envenomation represents a frequent marine injury, classically associated with acute, self-limiting cutaneous reactions mediated by direct toxin delivery via nematocyst discharge. However, a distinct subset of patients develops delayed hypersensitivity reactions emerging days to months after initial exposure a phenomenon that remains critically underrecognized in both emergency and dermatologic practice. These delayed manifestations exhibit remarkable clinical and histopathological heterogeneity, reflecting complex, immune-mediated pathways that extend well beyond acute envenomation toxicity. Despite growing case documentation, the underlying immunopathogenesis, diagnostic frameworks, and evidence-based management strategies remain fragmented across the literature. This review synthesizes current evidence on the pathophysiology, clinical phenotypes, histopathological patterns, and therapeutic approaches to delayed cutaneous reactions following jellyfish stings, aiming to establish a standardized diagnostic and clinical management roadmap for dermatologists managing marine-related skin injuries.

Materials and Methods
A comprehensive literature review was conducted across PubMed, Scopus, Web of Science, and Google Scholar, using terms including “jellyfish sting,” “delayed skin reaction,” “Cnidarian hypersensitivity,” and “granulomatous dermatitis.” Thirty-nine English and French clinical reports were analyzed for patient characteristics, implicated species, lesion morphology, histopathological findings, treatments, and outcomes. Data were synthesized descriptively due to heterogeneity across studies.

Results
Delayed reactions most commonly present as pruritic eczematous or papulovesicular eruptions aligned along sting marks, often evolving into chronic or recurrent dermatitis. Less frequent presentations include lichenoid, granulomatous, pustular lesions, panniculitis, or vasculitis-like eruptions. Histopathology reveals dermal lymphohistiocytic infiltrates, spongiosis, occasional eosinophils, and granuloma formation, consistent with type IV hypersensitivity to retained nematocyst components. Therapeutic strategies are largely empirical, including topical corticosteroids, calcineurin inhibitors, systemic corticosteroids for severe disease, and supportive measures. Intralesional corticosteroids or adjunctive physical therapies have been reported for recalcitrant lesions. Persistent antigenic stimulation can lead to “cutaneous memory” reactions, with lesions recurring at previously affected sites.

Conclusions

Delayed cutaneous hypersensitivity following jellyfish envenomation exemplifies a complex immunologic cascade driven by the interplay of residual venom toxins, persistent nematocyst structural proteins, and host immune activation. Type IV T-cell–mediated pathways, chronic antigen

persistence, and localized tissue-resident memory responses collectively underpin lesion recurrence and prolonged inflammation. Given the marked clinical and histopathological heterogeneity of these reactions, diagnosis remains predominantly clinical but critically benefits from targeted skin biopsy in atypical, refractory, or diagnostically uncertain cases to exclude mimics and guide targeted therapy. Current management is empirical, relying on individualized topical or systemic anti-inflammatory regimens and structured dermatologic follow-up to monitor evolution and prevent relapse. To advance care beyond reactive strategies, the dermatology community must prioritize the development of standardized diagnostic criteria, elucidate the molecular immunopathogenesis of delayed envenomation responses, and conduct comparative trials of therapeutic interventions. By integrating marine toxicology with precision dermatology, delayed jellyfish-induced dermatoses can be transformed from an underrecognized clinical pitfall into a model for immune-mediated cutaneous disease management, ultimately improving patient outcomes and informing evidence-based guidelines for marine-related skin injuries.

EA DV CONGRESS
VIENNA
30 SEP - 3 OCT 2026

Abstract N°: 1385

Topical Antifungals as Emerging Allergens: A Cross-Sectional Study of Allergic Contact Dermatitis in Eastern India

Pranomita Sahoo*[1], Chinmoy Raj[1], Nithya Satish[2], Chakravarthi R Srinivas[2]

[1] Kalinga Institute of Medical Sciences, bhubaneswar, India

[2] Ranga's Centre of Dermatology, Coimbatore, India

Introduction

Chronic recurrent dermatophytosis has emerged as a mounting dermatological challenge in the Indian subcontinent, characterized by persistent pruritus, therapeutic failures, and significant impairment of quality of life. Driven by widespread availability of over-the-counter (OTC) preparations, patients frequently self-medicate with topicals containing antifungals, corticosteroids, antibiotics, and anesthetics, often for prolonged and indiscriminate duration. Repeated and sustained cutaneous exposure to these formulations predisposes susceptible individuals to contact sensitization, directed not only against pharmacologically active ingredients but also against excipients and preservatives inherent to the preparation. The resultant allergic contact dermatitis (ACD) superimposed on an already recalcitrant dermatophytic infection substantially complicates clinical management, perpetuating a cycle of worsening inflammation. This study was undertaken to characterize the spectrum of contact sensitization to both active antifungal and excipient in formulations among patients with long-standing dermatophytosis.

Materials and Methods

This ethics-approved cross-sectional study included patients above 18 years of age who have used multiple topical antifungals and over-the-counter (OTC) drugs and remained symptomatic after adequate treatment. Analytical-grade antifungal antigens (1% in white petrolatum) were prepared from pharmaceutical-grade compounds. Patch testing was performed using Finn chambers with antifungal antigens, extended Indian Standard Series (ISS) preservatives, and patients' own topical preparations applied 'as is', read and interpreted per ICDRG guidelines. Statistical analysis employed IBM SPSS v26.0, with Mann–Whitney U test for group comparisons.



One percent preparation of the antigen prepared with analytical grade chemical which was triturated with white petroleum jelly and loaded into 5ml syringe

Results

Of 124 patients (mean age 33.56 ± 11.66 years; 62M:62F), patch test positivity was recorded in 49 patients (39.5%). Sensitization correlated significantly with duration of topical antifungal use (mean 12.65 vs. 10.85 months in positive vs. negative groups; p = 0.035), with no significant association observed for age, sex, disease duration, or atopic status. Multiple-allergen sensitization was present in 51% of positive patients. Among 109 total positive reactions, 34 (31.2%) were elicited by analytical-grade antifungals. Fragrance mix was the most prevalent allergen (16 patients, 12.9%), followed by benzyl alcohol and *'as is'* preparations (9.67% each). Luliconazole emerged as the leading antifungal allergen (5.64%), consistent with its dominant market share. Notably, eberconazole sensitization was identified in 6 patients (4.83%) with no prior documented reports of ACD. Fluconazole, a systemic triazole rarely implicated in topical ACD, sensitized 5 patients (4.03%), and terbinafine positivity in 4 patients (3.22%) raises concern for systemic contact dermatitis in those receiving oral therapy. Critically, 116 patients (93.54%) reported prior exposure to one or more topical antifungal preparations, and among those who tested positive, 28 patients (57.14%) demonstrated positivity to at least one allergen directly correlating with their documented topical exposure.

Conclusions

This study demonstrates a high and likely underdiagnosed prevalence of ACD to topical antifungals in patients with chronic dermatophytosis. Hence, we recommend patch test screening with antifungal series in all patients whose symptoms worsen while on treatment or continue following adequate treatment. Individualized allergen-guided management may substantially improve outcomes in this challenging cohort.

EADV CONGRESS
VIENNA
30 SEP - 3 OCT 2026

Abstract N°: 1470

Fixed drug eruption due to etoricoxib confirmed by lesional patch testing

ÁLVARO GONZÁLEZ GONZÁLEZ[1], JOSE JAIME GODAY BUJÁN*[1], JESÚS DEL POZO LOSADA[1]

[1] COMPLEJO HOSPITALARIO UNIVERSITARIO DE A CORUÑA, A CORUÑA, Spain

Introduction

Fixed drug eruption (FDE) is a prototypical type IVc delayed hypersensitivity reaction mediated by cytotoxic CD8+ T cells, characterized by site-specific recurrence of lesions upon re-exposure to the offending drug. This phenomenon is driven by the persistence of epidermal resident memory T cells (Trm) within previously affected skin, which enables rapid and localized reactivation. While the diagnosis is often clinical, identification of the causative agent may be challenging in patients exposed to multiple medications. Lesional patch testing has emerged as a pathophysiologically grounded diagnostic tool, potentially increasing sensitivity by targeting Trm-enriched sites. However, published data on FDE induced by selective cyclooxygenase-2 inhibitors, particularly etoricoxib, remain scarce, and diagnostic approaches are not fully standardized.

Case Presentation

A middle-aged patient presented with recurrent episodes of sharply demarcated erythematous-violaceous plaques involving the trunk and proximal extremities. Lesions consistently recurred at identical anatomical locations within hours following the intake of anti-inflammatory medication and resolved spontaneously over several days, leaving residual hyperpigmentation. This pattern was highly suggestive of fixed drug eruption.

The patient reported intermittent use of multiple nonsteroidal anti-inflammatory drugs, precluding reliable identification of the culprit agent based on clinical history alone. In this context, targeted lesional patch testing was performed on previously affected hyperpigmented skin using etoricoxib 8,4% (2,3 g) in petrolatum.

A clearly positive reaction was observed at 48 and 96 hours, characterized by localized erythema and infiltration strictly confined to the application site. No reaction was detected on non-lesional skin. The lesional restriction of the response supports a localized immunological memory phenomenon consistent with FDE.

Based on the temporal relationship, lesion reproducibility, and site-specific patch test positivity, a diagnosis of etoricoxib-induced fixed drug eruption was established. Drug withdrawal resulted in complete clinical remission, with no recurrences during follow-up.

Conclusion

FDE induced by selective cyclooxygenase-2 inhibitors is infrequently reported in the literature, with only a limited number of cases involving etoricoxib. Available evidence suggests that lesional patch testing may provide higher diagnostic sensitivity than conventional approaches, although results can vary depending on drug concentration and testing site. In this context, our case reinforces previous observations while further supporting the use of etoricoxib 8,4% (2,3g) in petrolatum as a practical and clinically relevant approach for diagnostic confirmation.

Moreover, the strict confinement of the reaction to previously affected skin highlights the role of resident memory T cells and provides clinically relevant evidence of site-specific immune imprinting. Incorporating this approach into routine clinical practice may improve diagnostic accuracy, reduce the need for drug provocation tests, and allow safe, targeted drug avoidance

EADV Congress 2026, VIENNA
30 SEPTEMBER - 03 OCTOBER 2026
POWERED BY M-ANAGE.COM

EA DV CONGRESS
VIENNA
30 SEP - 3 OCT 2026

Abstract N°: 1561

Artificial Intelligence-Based Evaluation of Patch Test Reactions: A Retrospective Study

Dilayda Kayapınar*[1], zafer turkoglu[1]

[1] University of Health Sciences,Istanbul, Department of Dermatology, Basaksehir Cam and Sakura City Hospital, Istanbul, Türkiye

Introduction

The clinical evaluation of patch test reactions remains subjective, with significant inter-observer variability. This study aims to develop and validate a high-precision, automated diagnostic system using state-of-the-art (SOTA) deep learning architectures to standardize the grading of allergic contact dermatitis (ACD) reactions from smartphone images.

Materials and Methods

A retrospective dataset of high-resolution clinical images was collected from **200 patients** at the Basaksehir Cam and Sakura City Hospital. All images were captured using **iPhone smartphones** under standard clinical lighting. A total of 6,000 individual patch chambers (European Baseline Series) were annotated via **Roboflow** based on the gold standard physical examination findings.

We implemented a **Dual-Path Model Architecture**:

1. **Path A (Detection-Based):** Utilized one-stage detectors (YOLOv11, RT-DETRv2) for simultaneous localization and classification to ensure real-time efficiency.
2. **Path B (Crop-Based):** Employed a hierarchical approach where detected patches were cropped and re-classified using specialized backbones (EfficientNet-B7 and Vision Transformers) to capture fine-grained textural features like vesiculation and infiltration.

Results

- **High-Precision Localization:** Our two-stage dual-path pipeline achieved near-perfect patch chamber detection with an **mAP@0.5 of 0.9939** (using YOLOv11s).
- **Optimal Classification:** The combination of YOLOv11s (localization) and EfficientNet-B0 (classification) delivered a robust **Macro F1-score of 0.831**, effectively grading reactions (- to +++) while isolating irritant responses.
- **Single-Pass Efficiency:** An alternative single-pass model (YOLOv10n) achieved a highly competitive**F1-score of 0.837**, offering a low-latency solution ideal for real-time mobile applications.

Conclusions

- **Fully Automated Localization:** Unlike the manual image tiling used by the **Mayo Clinic** or the manual bounding boxes in **Vezakis et al.**, our YOLO-based pipeline achieves fully automated, near-perfect chamber detection (mAP 0.99).

- **Robust Generalizability:** By utilizing a large cohort of 200 patients (~6,000 chambers), our CNN models overcome the dataset limitations seen in earlier foundational studies like **Stanford** (77 patients), proving high reliability across diverse cases.
- **Context-Aware Grading:** We confirmed that AI, much like dermatologists, requires surrounding healthy skin for accurate color contrast (erythema vs. dye), addressing the morphological challenges highlighted by **Vezakis et al.**
- **Teledermatology Ready:** Achieving expert-level F1-scores using standard iPhone images validates the "at-home diagnosis" vision proposed by **Stanford** and the democratization goals of the **Mayo Clinic**, without needing specialized medical cameras.

EADV CONGRESS
VIENNA
30 SEP - 3 OCT 2026

Abstract N°: 1633

Red Ink, Severe Complications: From Chronic Tattoo Dye Contact Allergy to Pyoderma Gangrenosum

Alexandra Starica*[1], Ioana Pescaru[2]

[1] Elias Emergency Hospital, Dermaexpert, Bucharest, Romania
[2] Dermaexpert, Bucharest, Romania

Introduction

The increasing popularity of tattoos has been accompanied by a rise in tattoo-related complications encountered in dermatologic practice. Among these, inflammatory reactions to tattoo pigments represent a heterogeneous group of disorders that may pose important diagnostic and therapeutic challenges. Red tattoo pigments are particularly associated with delayed hypersensitivity reactions and may induce a wide spectrum of clinical manifestations, including hyperkeratotic papules, nodules, plaques, ulceration, and chronic eczematous changes. The latency between tattoo placement and symptom onset can range from several weeks to years, which may complicate recognition of the causal relationship. In rare situations, persistent inflammatory reactions and repeated local trauma may trigger severe neutrophilic dermatoses through pathergic mechanisms.

Case Presentation

A 38-year-old man presented to our dermatology department seeking laser removal of a tattoo located on the right lower leg. The tattoo had been performed seven months earlier. Within several weeks after tattooing, the patient noticed the gradual appearance of intensely pruritic hyperkeratotic papules and nodules confined predominantly to the red-pigmented areas of the tattoo. Small ulcerations also developed adjacent to the tattooed skin. His medical history was otherwise unremarkable. Previous treatment with topical corticosteroids had failed to produce clinical improvement.

Given the persistent and symptomatic nature of the lesions, surgical excision of the affected tattooed area followed by skin grafting was performed. Postoperative healing proved difficult, and approximately eight weeks later the patient returned with multiple painful ulcerations involving both upper and lower extremities.

Based on the clinical evolution and morphology of the lesions, pyoderma gangrenosum secondary to a pathergic phenomenon triggered by severe allergic contact dermatitis to red tattoo pigment was suspected.

Systemic treatment with oral prednisone at a dose of 1 mg/kg/day, gradually tapered over time, together with local wound care, resulted in progressive healing of the ulcerations within four weeks.

Conclusion

Inflammatory reactions to red tattoo pigments remain among the most frequent adverse events associated with tattoos and may present with highly variable clinical patterns. Although most reactions remain localized, severe complications may occasionally occur. Awareness of this rare but significant complication is important, particularly in patients presenting with ulcerative lesions and impaired wound healing after interventions involving tattooed skin. Early recognition and prompt immunosuppressive treatment may substantially improve clinical outcomes.

POWERED BY M-ANAGE.COM

EADV CONGRESS
VIENNA
30 SEP - 3 OCT 2026

Abstract N°: 1649

Eczema restricted to the hands– etiologies and response to treatments

Mona Eid[1], ASSAF HANDELSMAN[2], Judith Nevet[1], Emily Avitan-Hersh*[1]

[1] Rambam Health Care Campus, Technion Israel Institute of Technology, Haifa, Israel
[2] Tel Aviv Medical Center, Rambam Health Care Campus, Tel Aviv, Israel

Introduction
Hand eczema (HE) is a common dermatological disorder that affects approximately 14.5% of the general population. The principal etiologies include irritant contact dermatitis, allergic contact dermatitis, and atopic dermatitis (AD). The main morphologies are hyperkeratotic, dyshidrotic and fingertip dermatitis. Data on allergen distribution, anatomical patterns and treatment response in real-world clinical cohorts remain limited. The aim of this study is to characterize the clinical features, patch test results , and treatment response of patients with HE.

Materials and Methods
We conducted a retrospective observational study including 442 patients diagnosed with *hand-limited eczema*. Demographic characteristics, disease duration, atopy, occupational exposure, anatomical distribution, patch test results, and treatment response were analyzed.

Results
A total of 442 patients with HE were included. The mean age was 37.4 years, and 66.1% were women. Fingers and palmar involvement predominated, and frequent recurrences were common. AD was present in 14.7% of patients, while 27.8% had atopic background. Patients with AD developed HE at a significantly younger age. Patch testing was positive in 63.2% of patients, with clinically relevant reactions in 57.2%. Women were more likely to have positive results, while AD patients were less likely. Nickel, acrylates, fragrance mix, Kathon CG, palladium, and chromium were the most common allergens. Allergen distribution differed by gender and anatomical location. Response to topical steroids was low with 36% achieving clear or almost clear, while 67% of patients treated with topical PUVA achieved response. Across treatment modalities, a substantial proportion of patients failed to achieve adequate disease control, including 22.6–34.5% remaining severely affected after therapy.

Conclusions
HE in this cohort was characterized by female predominance, frequent contact sensitization, and suboptimal treatment response. Patch testing demonstrated high diagnostic yield and should be routinely performed in patients with HE. Our findings highlight the need for improved treatment strategies for patients with HE.

EA DV CONGRESS
VIENNA
30 SEP - 3 OCT 2026

Abstract N°: 1854

Airborne Allergic Contact Dermatitis in a Printing House Worker: The Role of Indoor Occupational Allergens

Lana Lomidze*[1], Magda Gogilidze[1], Natia Khutsishvili[1], Tatia Khatchapuridze[1], Ekaterine Beraia[1]

[1] Kani Clinic, Tbilisi, Georgia

Introduction

Occupational exposures are not always readily apparent, and in enclosed working environments, clinically significant allergens may remain unrecognized despite prolonged exposure. Airborne allergic contact dermatitis (AACD) poses a considerable diagnostic challenge, particularly when indoor exposure patterns mimic more common inflammatory dermatoses.

Case Presentation

A 46-year-old man developed rapidly progressive facial dermatitis within 2-3 weeks of starting work in a printing house. He reported erythema, fine scaling, mild edema, intense pruritus, and a burning sensation strictly confined to exposed facial areas. A distinct occupational pattern emerged, as symptoms consistently worsened during working days and improved over weekends.

His daily tasks involved handling freshly printed materials and sorting old books, resulting in continuous exposure to printing inks, adhesives, pigments, and substantial amounts of paper dust in a poorly ventilated environment. No facial protective equipment was used. His medical history was notable only for dust-related allergic rhinitis.

Clinical examination demonstrated diffuse erythema predominantly affecting the cheeks and periorbital regions, accompanied by mild edema and fine eczematous scaling. Eyelid involvement and sparing of covered areas strongly suggested an airborne pattern of exposure. Dermoscopy revealed a diffuse erythematous background with ill-defined margins, fine linear and irregular vessels, and superficial whitish scaling, without follicular plugging or other specific diagnostic structures.

Laboratory evaluation showed mildly elevated total IgE levels and slight eosinophilia, while CRP and ESR remained within normal limits. Allergological testing identified sensitization to Alternaria alternata, consistent with exposure to mold-contaminated books and indoor dust. Sensitization to house dust mites was considered clinically relevant only for respiratory symptoms and insufficient to explain the cutaneous findings.

Although patch testing was unavailable, the diagnosis of occupational AACD was established based on the characteristic distribution of lesions, the clear temporal relationship with workplace exposure, supportive dermoscopic and immunological findings, and the clinical response to treatment. Differential diagnoses, including irritant contact dermatitis, atopic dermatitis, seborrheic dermatitis, rosacea, and photocontact dermatitis, were excluded based on clinical and dermoscopic criteria.

The patient received a short course of intramuscular dexamethasone combined with a non-sedating antihistamine and topical therapy, including a gentle cleanser, barrier-repair moisturizer, and topical corticosteroid. At the 7-day teledermatology follow-up, marked clinical improvement was observed, with significant reduction in erythema, edema, pruritus, and burning sensation, and no development of new lesions.

Conclusion

This case emphasizes that indoor occupational environments, even in the absence of obvious chemical exposure, may harbor clinically significant airborne allergens. The combination of facial distribution, eyelid involvement, and work-related fluctuation of symptoms should prompt early consideration of AACD. In the absence of patch testing, careful clinicopathological correlation remains essential for diagnosis. Early recognition and intervention are critical to preventing chronic disease and ensuring favorable outcomes.

EA DV CONGRESS
VIENNA
30 SEP - 3 OCT 2026

Abstract N°: 1911

Dermatological Presentations and Clinical Progression of Paederus Dermatitis: A Prospective Cross-Sectional Study from a General Hospital

Waritsara Piyanonpong*[1]

[1] King Narai Hospital, Lopburi, Thailand

Introduction
Paederus dermatitis is a form of irritant contact dermatitis caused by exposure to rove beetles. Due to its variable clinical presentations, it may resemble other dermatologic conditions, leading to diagnostic confusion and treatment delays. This study aimed to describe the dermatological findings, clinical progression, and management of Paederus dermatitis in a general hospital setting.

Materials and Methods
A prospective cross-sectional study was conducted including patients diagnosed with Paederus dermatitis at a general hospital between May 1, 2025, and March 31, 2026, which was the peak seasonal period. Demographic data, exposure history, clinical features, timing of symptom onset, treatment, and outcomes were collected and analyzed using descriptive statistics.

Results
A total of 17 patients were included. The majority of the patients (88.24%) did not recall prior exposure to rove beetles. Symptoms most commonly developed on awakening (52.94%). Dermatological findings and associated symptoms were often multiple in a single patient. The most frequent dermatological manifestations were linear lesions, and erythematous lesions with gray centers (41.17% each), followed by kissing lesions (29.41%). These were predominantly accompany by itching (76.45%) and burning sensation (58.82%). The median duration from symptom onset to first hospital visit was 2 days (range 1–7 days). Initial misdiagnoses included herpes zoster, allergic contact dermatitis, cellulitis, and non-specific rash. Most patients (64.71%) required only one visit to receive a definitive diagnosis. The median time to diagnosis by a dermatologist was 3 days (IQR 2–4). Topical corticosteroids were the most commonly prescribed treatment (64.71% initially; 100% after dermatology consultation). Post-inflammatory hyperpigmentation was observed in a small proportion of patients (5.88%).

Conclusions
Paederus dermatitis presents with characteristic but variable clinical features, with linear lesions and erythematous lesions with grey centers being the most common, occuring more frequently than the classic kissing lesions. Misdiagnosis may still occur at the initial hospital visit. Early recognition and appropriate treatment, particularly with topical corticosteroids, lead to favorable outcomes. Increased awareness of its diverse clinical presentations may help reduce diagnostic delays.

EA DV CONGRESS
VIENNA
30 SEP - 3 OCT 2026

Abstract N°: 1948

Atopic dermatitis-derived polygenic risk score is a stronger predictor of hand eczema than a hand eczema-derived score and shows additive effects with wet work exposure

Weixin Zhou*[1, 2], Peter van der Most[2], Harold Snieder[2], Laura Loman[1], Marie-Louise Schuttelaar[1]

[1] Department of Dermatology, University of Groningen, University Medical Center Groningen, Groningen, Netherlands

[2] Department of Epidemiology, University of Groningen, University Medical Center Groningen, Groningen, Netherlands

Introduction

Hand eczema (HE) is a multifactorial disease determined by environmental factors, including wet exposure, and genetic susceptibility. Previous genetic studies have shown substantial genetic overlap between HE and atopic dermatitis (AD). We aimed to compare HE- and AD-derived polygenic risk scores (PRSs) for predicting HE and to determine whether genetic susceptibility and wet exposure interact or contribute independently to HE risk.

Materials and Methods

We used questionnaire-derived and genotype data from a Dutch population-based cohort and biobank. HE was defined as self-reported lifetime HE, and AD as self-reported physician-diagnosed AD. Wet exposure was assessed using daily duration of wet contact and glove use, and frequency of handwashing in occupational and non-occupational settings. The HE PRS was derived from genome-wide association study (GWAS) summary statistics from an earlier genotyped subset (batch 1) and was evaluated in an independent genotyped subset (batch 2). The AD PRS was derived from the largest external AD GWAS and was analyzed in both batch 1 and batch 2 dataset. We first compared both scores in batch 2 (n=9,779; 1,694 cases and 8,085 controls) to assess their relative performance for HE. The AD PRS was subsequently evaluated in the combined batch 1-2 dataset (n=44,718; 7,626 cases and 37,092 controls) to increase statistical power. Logistic regression adjusted for age, sex, ancestry principal components, and genotyping chip, where applicable, tested main effects and multiplicative PRS × wet-exposure interactions. In batch 2, self-reported AD history was additionally included in a sensitivity analysis.

Results

In batch 2, both PRSs were associated with HE, but the AD PRS showed a stronger effect than the HE PRS (OR 1.27, 95% CI 1.21-1.34, $P = 1.21\times10^{-19}$ vs OR 1.14, 95% CI 1.07-1.21, $P = 7.7\times10^{5}$). Correlation between the two scores was low ($r = 0.143$, $P < 2.2\times10^{-16}$). In a joint model, both scores remained significant, and the AD PRS retained the stronger association (OR 1.26, $P < 2.2\times10^{-16}$ vs OR 1.09, $P = 0.006$). Occupational, non-occupational and overall wet exposure were each independently associated with HE, but no significant PRS × wet-exposure interaction was detected. After adjustment for self-reported AD history, the AD PRS remained associated with HE (OR 1.21, $P = 2.53\times10^{-6}$). The AD PRS was subsequently evaluated in the combined dataset where it remained strongly associated with HE (OR 1.32, $P < 2.2\times10^{-16}$), while wet exposure showed consistent independent effects without evidence of interaction. In descriptive analyses, HE prevalence across AD PRS tertiles increased from 12.1%, 15.4% and 19.9% in participants without occupational wet exposure to 18.9%, 22.5% and 30.0% in exposed participants. Similar increasing trends were observed for non-occupational and overall wet exposure, indicating

cumulative effects of genetic susceptibility and environmental exposure.

Conclusions

AD-derived PRS was a stronger predictor of HE than an internally derived HE PRS. Genetic susceptibility and wet exposure contributed independently and additively to HE risk, with no evidence of effect modification. Individuals with both a high AD PRS and wet exposure had the highest prevalence of HE, supporting the potential value of genetic risk stratification for identifying high-risk groups in prevention-focused and wet-work settings.

EA DV CONGRESS
VIENNA
30 SEP - 3 OCT 2026

Abstract N°: 2552

Contact allergy amongst Healthcare Professionals in Singapore: a single-center retrospective study of patch test data from 2004 to 2021

Kim Yao Ong*[1], Shi Yu Derek Lim[1], Yung Hian Leow[1], Anthony Teik-Jin Goon[1], Tricia Yi Rui Chong[1], Suzanne Cheng[1]

[1] National Skin Centre, Singapore, Singapore

Introduction
Allergic contact dermatitis amongst healthcare professionals is underrecognised and underdiagnosed. We aimed to identify the frequency and relevance of contact allergy amongst healthcare professionals undergoing patch testing at the National Skin Centre, Singapore.

Materials and Methods
We retrospectively analysed patch test results of patients in healthcare-related professions who underwent patch testing to contact allergens from 2004 to 2021. Readings were performed on days 3 and 7. Descriptive analysis was performed for all variables.

Results
Three-hundred and thirty-two patients were included, with mean (SD) age of 35.0 (14.4) years. Most were female (80.4%) and of Chinese ethnicity (63.9%). 69 (20.8%) had atopic dermatitis. Commonest professions were nurses (43.4%), allied health (20.5%) and support staff (13.6%). Commonest sites involved were hands (37.7%), fingers (26.2%) and face (22.9%). 50 patients (76.9%) had contact allergy to one allergen, 15 (23.1%) had contact allergy to multiple allergens. One had contact allergy to five different allergens.

There were 409 positive reactions from 145 patients (43.7%) to 68 of the 684 allergens (9.9%) tested against Commonest allergens to test positive were nickel(II)sulfate hexahydrate (64/269, 23.8%), *Myroxylon pereirae* (19/269, 7.1%) and p-Phenylenediamine (14/268, 5.2%).

Sixty-five patients (19.6%) accounted for 89 reactions (21.8%) to 25 allergens (36.8%) deemed clinically relevant, most commonly nickel(II)sulfate hexahydrate (41/89, 46.1%), p-Phenylenediamine (8/89, 9.0%) and colophonium (5/89, 5.6%). Sixty-six patients (19.9%) had occupationally associated contact dermatitis, of which four were allergic contact dermatitis. There were 34 (8.3%) late positive reactions from 25 allergens, of which 16 (18.0%) from seven allergens were clinically relevant.

Conclusions
Contact dermatitis is not uncommon amongst healthcare professionals. Although most cases of occupationally associated contact dermatitis were irritant in nature, patch testing is still essential to differentiate between irritant and allergic reactions. Evaluation and improvement of workplace practices can help minimise associated morbidity and days taken off work.

EA DV CONGRESS
VIENNA
30 SEP - 3 OCT 2026

Abstract N°: 2553

Contact allergy amongst dental professionals in Singapore: a single-center retrospective study of patch test data from 2004 to 2021

Kim Yao Ong*[1], Shi Yu Derek Lim[1], Yung Hian Leow[1], Anthony Teik-Jin Goon[1], Tricia Yi Rui Chong[1], Suzanne Cheng[1]

[1] National Skin Centre, Singapore, Singapore

Introduction
Allergic contact dermatitis amongst dental professionals is underrecognised and underdiagnosed. We aimed to identify the frequency and clinical relevance of contact allergy amongst dental professionals undergoing patch testing at the National Skin Centre, Singapore.

Materials and Methods
We retrospectively analysed patch test results of patients in dental-related professions who underwent patch testing to contact allergens from 2004 to 2021. Readings were performed on days 3 and 7. Descriptive analysis was performed for all variables.

Results
Thirty-two patients were included, with mean (SD) age of 35.5 (14.1) years. Majority were female and of Chinese ethnicity (25/32, 78.1% for both). Five (15.6%) had atopic dermatitis. There were 14 (43.8%) dentists, nine (28.1%) dental assistants and nine (28.1%) other dental-related professionals. Commonest sites involved were hands (10/32, 31.3%), face (9/32, 28.1%) and fingers (6/32, 18.8%). Thirteen (40.6%) had contact allergy to one allergen, five (15.6%) had contact allergy to multiple allergens. One had contact allergy to seven different allergens. Eight had occupationally associated contact dermatitis, all of which were irritant contact dermatitis.

There were 41 positive tests from 18 patients (56.3%) to 14 of the 176 allergens (7.0%) tested against. Commonest allergens to test positive were nickel(II)sulfate hexahydrate (14/50, 28.0%), goldsodiumthiosulfate (4/24, 16.7%), fragrance mix and potassium dichromate (4/50, 8.0% for both).

Eight patients (25.0%) accounted for eight reactions (19.5%) deemed clinically relevant to four allergens (28.6%) – four to nickel(II)sulfate hexahydrate, two to goldsodiumthiosulfate, one each to lanolin alcohol and lyral. There were four clinically relevant late positive reactions to three allergens – two to goldsodiumthiosulfate, one each to lanolin alcohol and lyral.

Conclusions
Contact dermatitis is not uncommon amongst dental professionals. Occupationally associated contact dermatitis were irritant in nature and careful evaluation can help to minimise unnecessary patch testing. Improvement of workplace practices may reduce associated morbidity and days taken off work. When patch testing is performed, Day 7 readings are essential for diagnosis, due to significant proportion of clinically relevant, late positive reactions.

EADV CONGRESS
VIENNA
30 SEP - 3 OCT 2026

Abstract N°: 2554

Periorbital contact dermatitis in Singapore: a single-center retrospective study of patch test data from 2004 to 2021

Kim Yao Ong*[1], Shi Yu Derek Lim[1], Yung Hian Leow[1], Anthony Teik-Jin Goon[1], Tricia Yi Rui Chong[1], Suzanne Cheng[1]

[1] National Skin Centre, Singapore, Singapore

Introduction
Periorbital contact dermatitis is uncommon. We aimed to identify the frequency and clinical relevance of periorbital contact allergy among patients undergoing patch testing at the National Skin Centre, Singapore.

Materials and Methods
We retrospectively analysed patch test results of all patients with periorbital dermatitis who underwent patch testing with one or more of eight contact allergens from the in-house periorbital series from 2004 to 2021. Readings were performed on days 3 and 7. Descriptive analysis was performed for all variables.

Results
Two-hundred and seventy patients were included, with mean (SD) age of 42.9 (17.5) years. Majority were female (222, 82.2%) of Chinese ethnicity (229, 84.8%), with no history of atopic dermatitis (212, 78.5%). Three cases were occupationally related irritant contact dermatitis. Half (50.7%) had dermatitis at multiple sites. Apart from periorbital involvement, commonest sites were face (31.9%), neck (9.3%) and lips (6.3%); one had generalised disease.

Thirty-six positive reactions to four of eight allergens were identified from 23 patients (8.5%) - thimerosal (19/23, 82.6%), phenylmercuric acetate (2/23, 8.7%), chloramphenicol and toluenesulfonamide formaldehyde resin (1/23, 4.5% each). All patients had contact allergy to a single allergen. Three patients (37.5%) accounted for nine reactions (25.0%) deemed clinically relevant to thimerosal (7/9, 77.8%), chloramphenicol and phenylmercuric acetate (1/9, 11.1% each). Of seven late positive reactions, four were clinically relevant (44.4%); all were to thimerosal.

Conclusions
Allergic contact sensitisation in periorbital dermatitis predominantly affects females, possibly reflecting increased cosmetics use. Specific periorbital dermatitis series is useful to identify clinically relevant allergens such as thimerosal, phenylmercuric acetate and chloramphenicol. Day 7 readings are essential, given substantial proportion of clinically relevant late positive reactions.

EA DV CONGRESS
VIENNA
30 SEP - 3 OCT 2026

Abstract N°: 2685

Occupational hand eczema patterns and allergen exposure profiles in healthcare workers: a comparison of surgical and internal medicine settings

Zeynep Keskinkaya[1], Tuğçe Karaman*[1], Omer Mangir[2], Esen Özkaya[3]

[1] Çanakkale Onsekiz Mart University Faculty of Medicine, Department of Dermatology and Venereology, Çanakkale, Türkiye

[2] Arnavutköy State Hospital, Clinic of Dermatology and Venereology, Istanbul, Türkiye

[3] Istanbul University, Istanbul Faculty of Medicine, Department of Dermatology and Venereology, Istanbul, Türkiye

Introduction

Healthcare workers are at substantial risk of developing occupational hand eczema. Exposure to contact allergens and irritants is thought to vary according to specialty. This study aimed to determine the prevalence of hand eczema, associated risk factors and patterns of contact allergen exposure among healthcare workers in surgical and internal medicine departments.

Materials and Methods

This prospective, cross-sectional, single-center study was conducted at a tertiary healthcare center between March and April 2026 using face-to-face interviews. Sociodemographic characteristics and risk factors related to hand eczema were recorded. Occupational medical products and domestic/personal care products were evaluated for preservative and fragrance allergens based on their ingredient labeling. A history of hand eczema within the past year was obtained. Participants with active hand eczema were further assessed in terms of morphology, localization and severity, the latter using the Hand Eczema Severity Index (HECSI).

Results

A total of 250 participants (mean age: 32.3 ± 6.7 years; female:male ratio: 1.4:1; atopic skin: 34.8%) were included. Healthcare workers from surgical (n=125) and internal medicine (n=125) departments were comparable in terms of age, sex and the presence of atopic skin. Overall, 42.8% of participants reported a history of hand eczema within the past year, while current hand eczema was detected in 45.6%. The most common morphology was erythemato-squamous (n=107) and the dorsum of the hands was the most frequently affected site (n=79). Among patients with hand eczema, the mean HECSI score was 10.4 ± 7.2 and 41.2% had moderate-to-severe disease. Healthcare workers in surgical departments had significantly higher rates of current hand eczema (55.2% vs. 36%) and a history of hand eczema within the past year (51.2% vs. 34.4%) compared to those in internal medicine departments ($p<0.05$). Healthcare workers with current hand eczema had significantly higher rates of atopic skin (44.7% vs. 26.5%), ≥2 hours/day of wet work (34.2% vs. 20.6%) and ≥2 hours/day of glove use (62.3% vs. 44.9%) than those without current hand eczema ($p<0.05$). In contrast, ≥2 hours/day of domestic wet work and glove use did not differ significantly between these two groups. Healthcare workers in surgical departments also had higher rates of ≥2 hours/day of wet work (40% vs. 13.6%) and glove use (73.6% vs. 32%) ($p<0.05$). The main occupational sources of allergen exposure were hospital/operating room soaps, latex/nitrile gloves, disinfectants, medical adhesives, systemic/topical medications and ultrasound gel. The most common allergens included surfactants such as cocamidopropyl betaine (n=249), preservatives such as methylchloroisothiazolinone/methylisothiazolinone (n=247) and rubber-related allergens (n=243), predominantly

in the occupational setting. Fragrances such as linalool (n=156) and limonene (n=153) were also identified as significant allergens, mainly associated with domestic/personal care products. Exposure to benzyl alcohol, the Contact Allergen of the Year 2026, was identified in 21.6% of participants, exclusively through domestic/personal care products.

Conclusions

Considering the prominent contribution of constitutional and occupational factors to hand eczema, it is not surprising that healthcare workers in surgical departments exhibit a higher disease burden, given the greater frequency of these risk factors in this group. The wide range of allergen groups, particularly in the occupational setting, further underscores the need for targeted preventive strategies.

EADV CONGRESS
VIENNA
30 SEP - 3 OCT 2026

Abstract N°: 2717

Glossed over: the increasing importance of ultraviolet-cured gel nail polish in allergic contact dermatitis

Aalia Syed*[1], Brandon Tan[1], Dédée Murrell[1]

[1] Faculty of Medicine, University of New South Wales, Sydney, NSW, Australia, Department of Dermatology, St. George Hospital, Sydney, NSW, Australia, Sydney, Australia

Introduction

Allergic contact dermatitis (ACD) is a rare, but increasingly recognised complication of gel nail polish (GNP) use. Hydroxypropyl methacrylate (HPMA) is a potent sensitiser capable of inducing type IV hypersensitivity reactions, particularly due to incomplete curing, which results in inadequate polymerisation and residual monomer exposure. We report a case of rapid-onset, extensive ACD following a single at-home use of HPMA-containing GNP in a 46-year-old woman with pre-existing palmar dyshidrotic eczema.

Case Presentation

The patient developed an acute, multifocal vesiculopapular eruption involving the hands, lips, face and neck within 24 hours of at-home GNP use. Prodromal periungual burning occurred six hours post-application, prompting removal of the product, followed by the onset of widespread vesicles and erythematous papules, severe pruritus and paraesthesia. There were no alternative identifiable exposures. Her history was notable for chronic palmar dyshidrotic eczema and nickel contact allergy.

Examination demonstrated a multifocal eczematous eruption over the dorsal hands, neck, postauricular, forehead and perioral skin. Vital signs were normal. Laboratory findings revealed mild eosinophilia (0.81 $\times 10^9$/L) and a mildly elevated C-reactive protein (7 mg/L). A diagnosis of methacrylate-induced ACD was made based on temporal association with GNP use and known HPMA exposure. Management was considered and involved oral prednisone 25mg daily, cetirizine 10mg twice daily, and daily wet dressings with mometasone furoate 0.1%, tapered over two weeks. Marked clinical improvement was observed at six weeks post-treatment.

These findings are consistent with existing literature, including a 2022 systematic review of 62 cases of GNP-induced ACD, in which HPMA was the most commonly implicated allergen (90.7%). The sensitisation rate of HPMA is 1% amongst methacrylate-exposed populations. There has been a growing number of occupational and non-occupational cases of methacrylate-induced ACD, corresponding with the trend towards affordable and convenient do-it-yourself (DIY) beauty.

Conclusion

This case highlights the potential for severe, rapid-onset ACD following a single use of at-home GNP, underscoring the need for greater consumer awareness and stricter regulation of DIY methacrylate-containing nail products.

EADV CONGRESS
VIENNA
30 SEP - 3 OCT 2026

Abstract N°: 2831

Unilateral facial dermatitis induced by topical nepafenac mimicking infectious folliculitis

Alberto Sticchi*[1], Alessandra Grazia Condorelli[1], Vito Di Lernia[1]

[1] Dermatology Unit, Arcispedale Santa Maria Nuova, Azienda USL-IRCCS di Reggio Emilia, Reggio Emilia, Italy

Introduction

Topical ophthalmic medications may induce localized facial dermatitis with clinical and histopathological features overlapping infectious, inflammatory and neoplastic skin disorders, leading to significant diagnostic challenges. We report a case of unilateral facial dermatitis associated with topical nepafenac mimicking an infectious folliculitis-like process.

Case Presentation

A 62-year-old man presented with a rapidly enlarging, asymptomatic keratotic plaque on the right malar region extending to the medial canthus. Dermoscopy showed compact yellowish scales, peripheral erythema and scattered yellowish ovoid structures. Differential diagnoses included impetigo, dermatophytosis, cutaneous leishmaniasis, squamous cell carcinoma and discoid lupus erythematosus.

Histopathology revealed a dense folliculocentric lymphogranulocytic infiltrate rich in eosinophils with epidermal spongiosis and serocrusts, suggestive of an infectious folliculitis-like process. Periodic acid–Schiff staining, microbiological cultures and polymerase chain reaction for *Leishmania*were all negative. Empirical azithromycin therapy produced no clinical improvement.

Because of the discrepancy between histopathological findings, microbiological investigations and clinical evolution, the patient’s history was reassessed in detail. Only upon further questioning did he specify that topical nepafenac 0.3%, initially reported among his regular medications, had been administered exclusively to the right eye for two months before lesion onset. The unilateral distribution and proximity to the treated eye raised suspicion of a drug-induced dermatitis. Following discontinuation of nepafenac, the lesion rapidly improved and completely resolved with emollients and photoprotection alone.

Conclusion

This case highlights nepafenac-induced facial dermatitis as a diagnostic pitfall capable of clinically and histologically mimicking infectious disease. Careful reassessment of drug exposure and clinicopathological correlation remain essential in unilateral facial eruptions, particularly when microbiological investigations are negative and clinical evolution is atypical.

EADV CONGRESS
VIENNA
30 SEP - 3 OCT 2026

Abstract N°: 2920

Are Products Marketed for "Sensitive Skin" Less Likely to Contain Contact Allergens? A Cross-Sectional Analysis of Facial Skincare Products on Amazon UK

Dhanya Kuladeva*[1], Katherine Farquhar[1]

[1] NHS Greater Glasgow and Clyde, Glasgow, United Kingdom

Introduction
Sensitive skin is a common consumer concern, and products marketed as "sensitive" or "hypoallergenic" are widely promoted as safer options. However, studies suggest these products may still contain recognised contact allergens associated with allergic contact dermatitis. Online marketplaces are now a major route for skincare purchasing, and search results can strongly influence consumer choice. We aimed to evaluate whether facial moisturisers and cleansers marketed for sensitive skin on a major online retailer (Amazon) are less likely to contain recognised contact allergens.

Materials and Methods
A cross-sectional analysis of facial skincare products available on Amazon UK was performed. Searches were conducted using predefined terms representing four categories: sensitive-skin moisturisers, standard moisturisers, sensitive-skin cleansers, and standard cleansers. Searches were conducted in an incognito browser session and filtered by "best sellers" to reduce the influence of sponsored listings.

Products were screened using predefined inclusion and exclusion criteria. Eligible products were facial moisturisers or cleansers available on Amazon UK with ingredient lists reported using International Nomenclature of Cosmetic Ingredients (INCI). Products containing ultraviolet filters (SPF), duplicate formulations, size variants, multipacks, and products without accessible ingredient lists were excluded.

A target of 25 products per category (n = 100) was included. Products appearing under sensitive-skin search terms were classified as sensitive-skin products, reflecting those most likely encountered by consumers searching for sensitive skincare.

The primary outcome was the proportion of products containing at least one predefined contact allergen based on allergens in the British Society of Cutaneous Allergy (BSCA) facial series, supplemented by EU-labelled fragrance allergens and selected botanical ingredients. Secondary outcomes included ingredient count, fragrance presence, accuracy of fragrance-free claims, and availability of ingredient lists online. Proportions were compared using χ^2 tests.

Results
A total of 100 products were analysed (25 per category). Recognised contact allergens were present in 72–84% of products across categories. Among moisturisers, 18/25 (72%) sensitive-skin products and 19/25 (76%) standard products contained at least one allergen (χ^2 = 0.11, p = 0.74). Among cleansers, 21/25 (84%) sensitive-skin and 21/25 (84%) standard cleansers contained at least one allergen (χ^2 = 0.00, p = 1.00). Products marketed for sensitive skin were no less likely to contain recognised contact allergens than standard formulations.

After deduplication by brand and product name, 63 unique products were identified. Of these, 41/63 (65%) carried a sensitive-skin claim, yet 32/41 (78%) contained at least one recognised allergen and 15/41 (37%)

contained more than one allergen. Fragrance was present in 13/41 (32%).

Among unique products, 39/63 (62%) claimed to be fragrance-free; however, 10/39 (26%) contained fragrance or fragrance allergens. The mean ingredient count was 29.1 per product (median 25; IQR 21–34). Ingredient lists were available directly on Amazon pages for 38/63 (60%) products, while 25/63 (40%) required consultation of manufacturer websites.

Limitations include restriction to Amazon UK best-sellers, cross-sectional design, allergen identification based on ingredient presence rather than concentrations, lack of clinical correlation, and regulatory variations limiting generalisability.

Conclusions

Products marketed for sensitive skin frequently contained recognised contact allergens and were not less likely to contain allergenic ingredients than standard products. Marketing claims such as “sensitive skin” or “fragrance-free” did not consistently correspond to reduced allergen exposure. Greater ingredient transparency may help clinicians guide patients with sensitive skin or allergic contact dermatitis when selecting over-the-counter skincare.

EADV CONGRESS
VIENNA
30 SEP - 3 OCT 2026

Abstract N°: 2961

Sevestre-Jacquet Post-erosive syphilitic dermatitis: A poorly recognized Peristomal Skin Complication

Hiba Essolaymany*[1], Hanane Baybay[1]

[1] CHU HASSAN II, FES, Morocco

Introduction

Sevestre-Jacquet Posterosive Syphilitic Dermatitis (SPSD) is a rare condition, mainly reported in the diaper area. It is thought to be a manifestation of chronic irritant contact dermatitis that develops as a result of prolonged exposure to liquid stool and/or urine. We describe an uncommon peristomal presentation of SPSD in four adult patients and adress the various therapeutic options.

Materials and Methods

This retrospective descriptive study included four patients presenting with SPSD. Data were collected from patient files, including demographic characteristics, underlying condition requiring stoma formation, type and duration of stoma (colostomy, ileostomy, or urostomy), clinical presentation of the dermatitis and associated symptoms. Diagnostic evaluation was primarily clinical. When necessary, additional investigations such as microbiological swabs or skin biopsy were performed to exclude differential diagnoses.

Results

Four patients (3 men, 1 woman) with a mean age of 70 years, were referred to our dermatology department for skin lesions around surgical stoma. Three patients had urostomy for bladder carcinoma and one patient had colostomy after surgical treatment of bowel cancer. The mean interval between stoma creation and the onset of the skin condition was one year. The patients reported itching (50%), burning (25%) and pain (25%). Skin examination showed several 3 to 7mm moist flat gray-white warty like papulo-nodules of firm consistency distributed around the stomal orifice. Most of the lesions were showing central erosions. Concomitant Candida Albicans infection was identified in two patients. Dermoscopy showed central erythematous area (100%) withpolymorphic vascular pattern (100%), peripheral macerated white rim (100%), milky-red structureless areas(75%), white streaks (50%), white circles (25%), and rosettes (25%). The therapeutic modalities used in our patients were Zinc oxide cream, topical corticosteroids, antifungal creams, alginate dressings to absorb moisture and silver nitrate application to promote lesion flattening. Our patients also underwent a protocol using LED light therapy with eosin 2%. Complete resolution was noted after a mean time of two weeks in all patients.

Conclusions

SPSD, represents a severe form of chronic irritant contact dermatitis resulting from prolonged contact with feces, urine or both. It was historically named for its resemblance to syphilitic lesions and was classically considered as a form of diaper dermatitis, but has also been reported in other areas of chronic moisture, as it can arise in adults

with urinary and/or fecal incontinence or as a consequence of stomy leakage. This condition most commonly occurs around urostomies, although it has been documented around fecal stomas as well. The classic clinical presentation of SPSD includes multiple moist and shiny gray-white dome-shaped papulo-nodules of 2 to 10 mm in diameter. Histopathological examination reveals psoriasiform hyperplasia, papillomatosis, acanthosis, with hyperparakeratosis. Treatment interventions revolve around obtaining a secure ostomy seal to avoid leaks, and to maintain dry peristomal skin, and using proper fitting pouch with an antireflex mechanism . Cleansing the peristomal skin with just water is most appropriate to limitate exposure to chemicals that could cause sensitization. Thoroughly drying the peristomal skin and allowing brief periods of air exposure prior to application of the pouching system are manditory. Other practical, and individualized methods derived from each physician's experience have been described, such as acetic acid soaks applied during each pouch changing. Topical olive oil is also routinely used by several practitioners because of its ability to provide direct skin protection. In our experience, we used a protocol using LED light therapy with eosin 2% given its antibacterial and drying effect, safety profile, availability, and low cost, but also its photodynamic properties when combining it with a light source.

EADV CONGRESS
VIENNA
30 SEP - 3 OCT 2026

Abstract N°: 3006

Foot Eczema Related to Shoe Adhesives: A Report of four Cases

Nouhaila Amrani*[1], Lahouel Ines[1], yosra soua[1], hichem Belhadjali[1], Jameleddine Zili[1]

[1] Dermatology Department, CHU Fattouma Bourguiba Monastir, Monastir, Tunisia

Introduction

Foot eczema is a frequent reason for dermatologic consultation and is often multifactorial. Allergic contact dermatitis (ACD) to footwear components is well recognized; however, sensitization to shoe adhesives remains underappreciated. p-tert-Butylphenol (PTBP), a phenolic compound used in the production of p-tert-butylphenol-formaldehyde resins (PTBPFR), is a known contact allergen primarily reported in occupational settings. Non-occupational exposure through everyday footwear is likely underdiagnosed.

Case Presentation

We report four female patients aged 20, 50, 57 and 60 years who presented with chronic foot eczema of variable morphology and severity. Clinical manifestations included vesiculobullous plantar lesions developing after the use of new orthopedic insoles, hyperkeratotic fissured palmoplantar eczema resistant to topical therapy and requiring systemic methotrexate, and chronic dorsal eczematous plaques with poor response to conventional treatment in two cases. In one case, associated dermato-tillomania contributed to lesion persistence. Histopathology, when performed, confirmed eczematous dermatitis. Patch testing revealed positive reactions to PTBP in three patients and colophonium in one patient. Subsequent analysis identified the presence of these allergens in shoe or insole adhesives. All patients showed significant clinical improvement following targeted allergen avoidance combined with appropriate dermatological management.

Conclusion

Shoe adhesives contain a complex mixture of potential sensitizers, including phenol-formaldehyde resins such as p-tert-butylphenol (PTBP) derivatives and natural resins such as colophonium. PTBP, used in p-tert-butylphenol-formaldehyde resins, is a well-established contact allergen, mainly reported in occupational settings such as shoemaking and the leather industry. However, non-occupational exposure through everyday footwear remains underrecognized. Sensitization rates in patch-tested populations range between 1–2%, suggesting that clinically relevant cases may be underestimated. Colophonium, a natural resin derived from pine trees, is another frequent allergen in adhesives and shoe components. It is widely used for its adhesive and tackifying properties and is a well-known cause of contact dermatitis, with sensitization rates varying between 1–5% in European patch test series. Unlike PTBP, colophonium allergy is more commonly identified in the general population, yet its implication in footwear dermatitis may be overlooked if not specifically investigated. Our cases illustrate the clinical variability of adhesive-related ACD, ranging from acute vesiculobullous plantar eczema to chronic hyperkeratotic and treatment-resistant forms. Persistent or refractory foot eczema should prompt consideration of ongoing allergen exposure, particularly to shoe adhesives. These observations underscore the importance of comprehensive patch testing in patients with chronic, atypical, or recalcitrant foot eczema

EADV CONGRESS
VIENNA
30 SEP - 3 OCT 2026

Abstract N°: 3264

Reining in the Cold: Equestrian Perniosis as an Occupational Hazard

Sana Mariam Sankey*[1], Prarthana Desai[1], Manju Paul[1]

[1] Royal Stoke university hospital, Stoke on Trent, United Kingdom

Introduction

Perniosis (chilblains) is an inflammatory cold-induced vascular disorder resulting from prolonged exposure to non-freezing cold and damp conditions. It commonly affects acral sites such as the fingers, toes, ears, and nose, presenting with painful or pruritic erythematous to violaceous lesions. Although typically associated with cold climates and underlying connective tissue disease, occupational and sport-related perniosis remains underrecognized. Equestrian athletes are exposed to prolonged cold, wind, and moisture during outdoor riding, often compounded by immobility of the extremities and tight-fitting riding equipment. We present a rare case of equestrian perniosis in a competitive rider, highlighting the diagnostic challenges, contributory environmental factors, and the importance of early recognition in preventing chronic symptoms and tissue injury.

Case Presentation

A 32-year-old female equestrian presented with a two-year history of recurrent, painful erythematous thigh lesions occurring during winter months. Lesions progressed to superficial ulceration and resolved over 5–6 weeks. She regularly rode horses twice weekly and wore tight-fitting riding apparel.

Previous investigations, including skin biopsy and serological testing for connective tissue disease, were unremarkable. She had minimal response to multiple courses of antibiotics and topical therapies and was empirically treated for Lyme disease without improvement.

Clinical examination revealed post-inflammatory hyperpigmentation of both thighs. Patient photographs showed erythematous, targetoid and ulcerated plaques. Repeat skin biopsy demonstrated features consistent with chilblains/perniosis, confirmed at the skin inflammatory multidisciplinary team meeting. In the context of cold exposure and pressure from riding equipment, a diagnosis of equestrian perniosis was made.

Conclusion

Equestrian perniosis results from cold-induced vasoconstriction exacerbated by local pressure from riding clothing and equipment. Lesions typically affect the thighs and may mimic vasculitis, infection, or connective tissue disease, leading to delayed diagnosis and unnecessary investigations. Diagnosis is primarily clinical, supported by histopathology in atypical cases. Most cases are self-limiting and respond to conservative measures, including thermal protection and avoidance of cold exposure. Pharmacological treatment such as nifedipine may be considered for persistent or severe disease.This case highlights equestrian perniosis as an important differential diagnosis in recurrent cold-induced thigh lesions and underscores the importance of a detailed occupational history.

EADV CONGRESS
VIENNA
30 SEP - 3 OCT 2026

Abstract N°: 3303

Allergic contact dermatitis to ethylhexylglycerin in a periocular cosmetic: a clinically relevant but easily overlooked sensitizer

Marco Sousa *[1], Ines Lobo[1]

[1] Unidade Local Saúde Santo António, Porto, Portugal

Introduction

Ethylhexylglycerin is an alkyl glyceryl ether increasingly used in cosmetic products for its skin-conditioning, emollient and antimicrobial-enhancing properties. Although generally considered a low-risk ingredient, it has been increasingly recognized as a clinically relevant cosmetic sensitizer, particularly in leave-on facial products. Because it is not universally included in baseline patch test series, sensitization may be missed unless the patient's own products and selected ingredients are tested.

Case Presentation

A 60-year-old woman was referred for suspected cosmetic-induced allergic contact dermatitis after developing erythema and oedema of the periocular area a few days after starting a new anti-ageing eye-contour/facial cosmetic containing sun protection filters. Pruritus was absent or minimal. The clinical distribution and temporal relationship with product application raised suspicion of allergic contact dermatitis to a cosmetic ingredient. Patch testing was initially performed with the Portuguese baseline series, the patient's own cosmetic tested "as is", and selected allergens from cosmetic and sunscreen series chosen according to the product composition. Positive reactions were observed to the suspected cosmetic tested "as is" and to ethylhexylglycerin, an ingredient present in the product. Additional positive reactions were found to nickel, fragrance mix I, fragrance mix II, hydroxyisohexyl 3-cyclohexene carboxaldehyde and a textile dye mix; however, these were not considered to explain the current periocular eruption. Subsequently, extended patch testing with the cosmetic and sunscreen series was performed and was negative, except for the previously identified positive reactions to the patient's own cosmetic and ethylhexylglycerin. Based on the exposure history, anatomical correlation and concordant positive patch test reactions, a diagnosis of allergic contact dermatitis to ethylhexylglycerin with current clinical relevance was established. The patient was advised to avoid ethylhexylglycerin-containing cosmetics and to carefully review ingredient labels, particularly in leave-on facial products, eye-area cosmetics and sunscreens.

Conclusion

This case highlights the importance of testing both the patient's own cosmetic product and selected ingredients guided by its composition in suspected facial cosmetic dermatitis. Ethylhexylglycerin is present in a wide range of personal care products and may be found in products perceived as suitable for sensitive skin. Facial and periocular dermatitis is consistent with previous reports, in which leave-on facial cosmetics were among the main culprit products. Concomitant positive reactions to common allergens may occur, but clinical relevance should be interpreted according to exposure, distribution and temporal relationship. Ethylhexylglycerin should be considered in patients with periocular or facial dermatitis temporally related to cosmetic use. Targeted patch testing based on the patient's own products is essential to identify clinically relevant cosmetic allergens and to provide effective avoidance advice.

EADV Congress 2026, VIENNA
30 SEPTEMBER - 03 OCTOBER 2026
POWERED BY M-ANAGE.COM

EA DV CONGRESS
VIENNA
30 SEP - 3 OCT 2026

Abstract N°: 3424

Epidemiological Profile of Occupational Dermatoses in Brazil

Dâmmarys Nascimento*[1], Paula Rebello[1], Adriana Raposo[1]

[1] Fundação Hospitalar de Dermatologia Tropical e Venereologia 'Alfredo da Matta', Manaus, Brazil

Introduction

Occupational dermatoses (OD) comprise an important group of work-related health conditions, characterized by alterations affecting the skin, mucous membranes, and/or skin appendages, triggered, aggravated, or perpetuated by factors present in the occupational environment. OD result from the interaction between individual characteristics (such as race, sex, age, and comorbidities) and exposure to physical agents (heat, cold, and radiation), chemical agents (organic and inorganic substances), mechanical agents (pressure, friction, and vibration), and biological agents (microorganisms), with the skin representing the main interface between workers and the occupational environment. In addition to their clinical relevance, occupational dermatoses exert a significant socioeconomic impact, leading to work absenteeism, reduced productivity, and impaired quality of life. Therefore, early recognition of these conditions, combined with effective preventive measures and adequate reporting systems, is essential to strengthen surveillance and control strategies.

Materials and Methods

An observational, descriptive, retrospective epidemiological study was conducted using secondary data obtained from the Informatics Department of the Brazilian Unified Health System (DATASUS/SINAN), covering the period from 2015 to 2025. Collected data were organized into a database and submitted to descriptive statistical analysis using JAMOVI software.

Results

A total of 5.385 cases of occupational dermatoses were reported between 2015 and 2025. Of these, 2.436 notifications (45.2%) occurred among individuals aged 20–39 years, while 2.324 cases (43.1%) were observed in the 40–59-year age group. Regarding sex distribution, 2.861 cases (53.1%) occurred in males and 2.523 (46.9%) in females. Concerning lesion location, the hands were the most frequently affected site, accounting for 1.863 cases (34.6%). Among diagnostic categories, dermatitis and eczema (ICD L20–L30) predominated, comprising 2.229 cases (41.7%) of all notifications. Regarding educational level, 2.086 patients (38.7%) had incomplete secondary education or lower. In terms of self-reported race/color, 2.173 individuals (40.3%) identified as mixed-race (“pardo”). From an occupational perspective, 1.704 workers (31.6%) required sick leave, while 1.182 (22.0%) had documented effective days away from work.

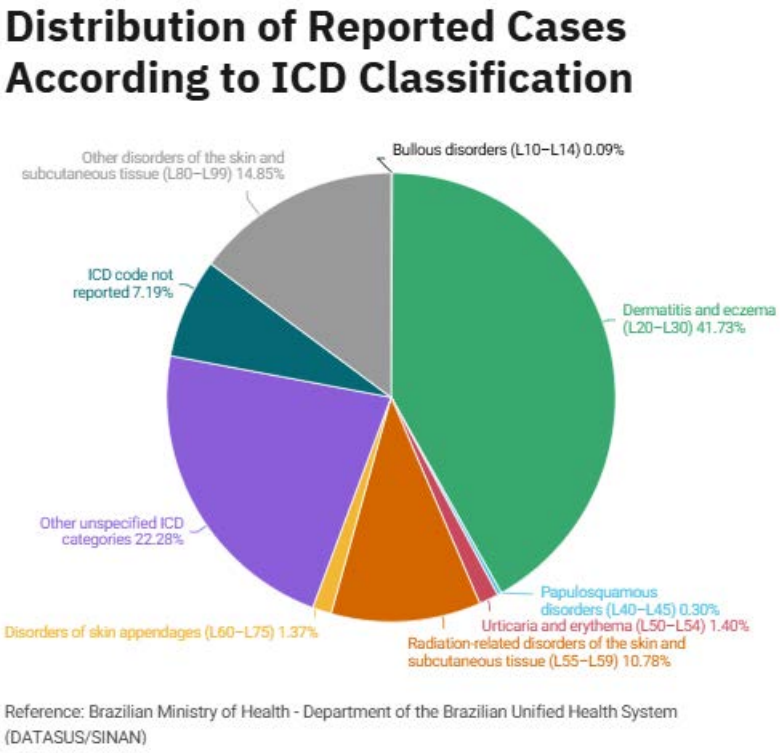

Conclusions

Occupational dermatoses represent a significant public health issue in Brazil, predominantly affecting economically active individuals and directly impairing work capacity and quality of life. The predominance of dermatitis and eczema, as well as the major involvement of the hands, reinforces the central role of occupational exposure to irritants and sensitizing agents. The association with lower educational attainment highlights the influence of social determinants on the distribution of these diseases. In this context, strengthening preventive strategies, health education initiatives, and the appropriate use of personal protective equipment is essential, alongside improvements in surveillance and reporting systems.

EA DV CONGRESS
VIENNA
30 SEP - 3 OCT 2026

Abstract N°: 3436

Vulvar Dermatitis Associated With Prolonged Activewear Compression in the Era of Athleisure and Performance Fabrics

Haily Fritts*[1], Kaylahn Jones[2], Mary Claire Swaim[3], Kristina Mueller[4], Kiley McKerrow[5], Kelly Frasier[6], Pooja Shah[6]

[1] Idaho College of Osteopathic Medicine, Meridian, United States
[2] Kansas City University College of Osteopathic Medicine, Kansas City, United States
[3] NYIT College of Osteopathic Medicine, Jonesboro, United States
[4] Philadelphia College of Osteopathic Medicine, Philadelphia, United States
[5] A.T. Still University Kirksville College of Osteopathic Medicine, Kirksville, United States
[6] Northwell, New Hyde Park, United States

Introduction
Athleisure culture has blurred the line between workout wear and everyday clothing, yet the dermatologic effects of prolonged activewear use on vulvar skin remain poorly characterized. Tight compression garments composed of synthetic moisture-wicking fabrics are increasingly worn continuously beyond exercise settings, including during prolonged sitting, commuting, studying, sleeping, and occupational activities. Sustained occlusion, friction, humidity, heat retention, and mechanical compression across highly sensitive vulvar tissue may contribute to a unique pattern of barrier injury and chronic inflammation. Despite widespread consumer adoption of leggings, shapewear, biker shorts, and performance fabrics, vulvar dermatology literature has minimally addressed the intersection of textile engineering, athleisure behaviors, and vulvar cutaneous health. Contemporary behavioral trends including all-day activewear wear, wellness branding, social media-driven fitness aesthetics, and “hot girl walk” culture may represent underrecognized contributors to chronic vulvar irritation patterns amongst adolescents and young adult women.

Materials and Methods
Biomechanical and microenvironmental effects of chronic activewear occlusion are examined through the lens of barrier physiology, frictional injury, altered microbial ecology, sweat accumulation, and prolonged textile-skin interaction. Particular attention is given to synthetic fiber composition, prolonged compression exposure, repetitive moisture trapping, and diagnostic overlap with infectious, allergic, and primary inflammatory vulvar disorders.

Results
Clinical observations and reports analyzed throughout this comprehensive review suggest associations with irritant contact dermatitis, intertrigo, folliculitis, microbiome disruption, sweat retention–associated inflammation, and exacerbation of underlying vulvar dermatoses.

Conclusions
Greater recognition of athleisure-associated vulvar dermatitis may improve diagnostic accuracy, reduce delays in management, and expand dermatologic understanding of how modern lifestyle behaviors and performance textile

technologies influence vulvar skin disease.

EADV CONGRESS
VIENNA
30 SEP - 3 OCT 2026

Abstract N°: 3466

Keratin-based Hair Treatments: An Extended Analysis of Safety Practices and Product Ingredients

Rania Abdusamad*[1], Nadia Kirmani*[1], Golara Honari[2]

[1] Stanford School of Medicine, Palo Alto, United States
[2] Stanford Department of Dermatology, Redwood City, United States

Introduction
Keratin-based hair treatments are widely-marketed hair straightening practices primarily targeting women. Despite their widespread popularity, several of the products used to produce these results contain or release formaldehyde, a chemical linked to eye, skin and lung irritation. This exposure risk affects hair technicians, many of whom report occupational safety practices inconsistent with current Occupational Safety and Health Administration (OSHA) recommendations.

Materials and Methods
We conducted a cross-sectional study investigating hair salon practices across all 9 districts of a major metropolitan area. A mystery caller format was adopted to identify real-world behavior, with calls following a scripted, 6-question survey format. All analyses were run on R (version 4.5.2), with significance set at alpha<0.05.

Results
Of 275 responding hair salons, 64% offered keratin-based hair treatments, including keratin hair straightening and Brazilian-style treatment. 38% of these salons additionally endorsed products containing formaldehyde, and nearly 17% were unaware of whether their products contained it. 81% of hair salons had ventilation practices, but only 18% reported active ventilation. The use of protective equipment was additionally inconsistent, with 68% of offering salons reporting nonuse of goggles or masks, a potential violation of current OSHA guidelines. Notably, 22% of salons reported accounts of irritation, with the majority endorsing eye irritation. Neither treatment availability nor formaldehyde status were influenced by the median income of included districts, suggesting widespread exposure risk. Further characterization of commonly-used products demonstrated substantial use of formaldehyde-releasing compounds, including glyoxylic acid and glyoxyloyl carbocysteine, as well as EU-banned reproductive toxins, such as Methylisothiazolinone and Methylchloroisothiazolinone.

Conclusions
This study emphasizes a substantial gap in the awareness and safety practices related to keratin-based treatments. Given the predominantly female labor force in this industry, these findings raise concerns about persistent gender-based vulnerabilities in occupational safety.

EADV CONGRESS
VIENNA
30 SEP - 3 OCT 2026

Abstract N°: 3576

Idiopathic Aquagenic Syringeal Acrokeratoderma Presenting With Transient Palmar Changes After Water Exposure

Ece Güçsav*[1], Beyza Çolpan[1], Isil Inanir[1]

[1] Celal Bayar University, Manisa, Türkiye

Introduction

Aquagenic syringeal acrokeratoderma (ASA) is a rare, transient palmoplantar dermatosis characterized by the rapid development of edematous papules and plaques accompanied by marked palmar wrinkling after water exposure. It has been reported in association with cystic fibrosis, hyperhidrosis, and certain medications; however, idiopathic cases are less common. Recognizing this condition is important to avoid unnecessary investigations and to initiate appropriate management.

Case Presentation

A 29-year-old woman presented with intermittent itching, a feeling of tightness, rash, and wrinkling of the hands since 2021. She reported that her symptoms typically occurred after more than 2–3 minutes of water exposure or sweating and resolved spontaneously. She had no comorbidities, and her personal and family history was unremarkable. Dermatological examination was normal at baseline. Routine laboratory tests were within normal limits.

During the water immersion test, edematous, pale papules and plaques became evident, particularly on the palmar surfaces of both hands, within 5 minutes of water exposure. Based on these findings, ASA was considered as the leading diagnosis. A detailed drug history did not reveal any potential triggering agent. The patient was evaluated for cystic fibrosis; no clinical features were suggestive of the disease. The sweat chloride level was 25 mmol/L, and cystic fibrosis was excluded.

In the absence of any identifiable secondary cause, a diagnosis of idiopathic ASA was made. Treatment was initiated with topical aluminum chloride hexahydrate (15–20%) applied once daily for the first 3 days, followed by every other day application. In addition, a topical corticosteroid containing diflorasone diacetate was prescribed once daily. The patient was followed up, and a marked improvement in symptoms was observed.

Conclusion

The pathogenesis of ASA is thought to involve increased water retention in the stratum corneum and functional abnormalities of eccrine sweat glands. Although it is most commonly associated with cystic fibrosis, it has also been linked to certain medications, particularly nonsteroidal anti-inflammatory drugs. Nevertheless, idiopathic cases are being increasingly recognized.

The differential diagnosis includes hereditary papulotranslucent acrokeratoderma, aquagenic urticaria, and changes related to hyperhidrosis. The water immersion test is a simple and effective diagnostic tool. Treatment options include topical aluminum salts, anticholinergic agents, and botulinum toxin in resistant cases.
Idiopathic ASA should be considered in patients presenting with transient palmar changes triggered by water exposure. A careful history, exclusion of cystic fibrosis, and the water immersion test are key elements for

diagnosis. Topical therapies can provide effective symptomatic relief.

EADV CONGRESS
VIENNA
30 SEP - 3 OCT 2026

Abstract N°: 3586

Allergic Contact Dermatitis Caused by Fencing Equipment: A Case Report

Dzhemile Dervish*[1], Vera Traykova[1], Malena Gergovska[1], Jana Kazandjieva[1]

[1] Group Dermatology and Venerology Practice, EuroDerma Clinic, Sofia, Bulgaria

Introduction

Allergic contact dermatitis is an increasingly recognized inflammatory dermatosis associated with exposure to allergens present in occupational and recreational environments, including sports equipment. Athletes represent a specific risk group due to repeated exposure to metals, textile dyes, adhesives, synthetic materials, and friction-enhanced skin penetration during intensive physical activity. Fencing equipment contains numerous potential sensitizers, particularly nickel, cobalt, chromium, and textile dyes, which may induce cutaneous hypersensitivity reactions in predisposed individuals. The coexistence of atopic dermatitis may further impair epidermal barrier function and facilitate allergen sensitization. We present a pediatric case of allergic contact dermatitis associated with fencing equipment exposure, confirmed by patch testing.

Case Presentation

We report the case of an 11-year-old boy presenting with acute erythema, edema, and intense pruritus involving the face and hands. The patient had been practicing fencing for six months prior to symptom onset. Cutaneous manifestations appeared immediately after participation in a competition during which newly replaced fencing equipment was used, suggesting a direct relationship between allergen exposure and symptom development.

Past medical history was significant for atopic dermatitis. Dermatological examination revealed pronounced erythema and edema of the face, predominantly affecting the cheeks and eyelids, while the forehead, nose, and perioral region were relatively spared. On the right hand, erythematosquamous lesions with focal erosions were observed on the palm and interdigital spaces, corresponding to areas of direct contact with the fencing glove and weapon grip.

Epicutaneous patch testing demonstrated positive reactions to nickel, cobalt, and textile dyes at 48 hours, with persistent positivity at the 72-hour reading. Further analysis of the fencing equipment identified these allergens in multiple components regularly used by the patient. The stainless steel mesh of the fencing mask, as well as the blade and guard, represented potential sources of nickel and cobalt exposure. In addition, the internal lining of the mask and the fencing gloves contained synthetic textiles, foam materials, fastening elements, and dyed fabrics capable of releasing textile dyes and metallic particles during prolonged use. The repetitive mechanical friction, occlusion, perspiration, and increased local heat associated with intensive physical activity likely promoted epidermal barrier disruption and enhanced percutaneous absorption of allergens, contributing to the development of allergic contact dermatitis.

Reports in the dermatological literature have described allergic contact dermatitis associated with sports equipment, most frequently linked to metals and textile dyes, particularly in individuals with pre-existing barrier dysfunction such as atopic dermatitis.

Conclusion

The initiation of a new sporting activity may expose children and adolescents to previously unrecognized allergens present within specialized athletic equipment. This case highlights the importance of detailed exposure history, targeted patch testing, and increased clinical awareness of sports-related contact dermatoses. Early recognition of allergenic sources is essential for adequate management, prevention of recurrent disease, and continuation of sports activity with appropriate modifications.

EADV CONGRESS
VIENNA
30 SEP - 3 OCT 2026

Abstract N°: 3601

Erythroderma Caused by Caustic Soda Exposure During Homemade Soap Production: A Case Report

Sarah Leite*[1], Leticia Scaramussa[2], Larissa Souza[3]

[1] Instituto IMS - Hospital da Gamboa, Rio de Janeiro, Brazil

[2] Universidade Unigranrio Afya, Rio de Janeiro, Brazil

[3] Hospital Federal de Bonsucesso, Rio de Janeiro, Brazil

Introduction

Erythroderma is a rare and potentially fatal condition characterized by diffuse erythema and scaling affecting more than 90% of the body surface area. It can result from cutaneous or systemic diseases, such as contact dermatitis, psoriasis, and drug hypersensitivity reactions. The estimated incidence rate is 1 to 2 cases per 100,000 adults, and it is more frequent in men and in individuals between 40 and 60 years of age. It is characterized by erythematous scaly or crusted plaques that coalesce and may affect almost the entire skin surface, potentially progressing to white or yellow scales, shiny and thin skin, and other associated symptoms such as pruritus, edema, and fever. Although it is a clinical diagnosis, laboratory and histopathological examinations help confirm the diagnosis and identify the underlying cause. Treatment requires identification of the etiology, inpatient management, and measures including adequate wound care, corticosteroids, antibiotics, and symptomatic therapy.

Case Presentation

A 67-year-old hypertensive woman presented to the emergency department with lesions that began on her hands approximately 35 days earlier after handling caustic soda while making homemade soap with used cooking oil. She reported pruritus followed by burning pain, erythema, and scaling. Physical examination revealed erythematous scaly plaques over the entire body and lower limb edema. She progressed with fever and exfoliative erythroderma including the face, along with lamellar desquamation of the palms and soles. A skin biopsy was performed, and histopathology revealed irregular acanthosis, parakeratosis with a small crust in the stratum corneum, spongiosis associated with marked edema of the papillary dermis, and a perivascular inflammatory infiltrate composed of lymphocytes and neutrophils with occasional eosinophils in the superficial and mid dermis, consistent with exfoliative erythroderma. Treatment was initiated with intravenous methylprednisolone at 1 mg/kg/day for 7 days, in addition to symptomatic therapy for fever and pruritus and skin moisturization with petrolatum. From the time of admission, the patient was withdrawn from exposure to the irritant agent, and a drug-related etiology was ruled out through detailed medical history. The patient achieved complete resolution within 25 days and showed no recurrence during outpatient follow-up.

Conclusion

Caustic soda, or sodium hydroxide, is a highly corrosive chemical most commonly used in industrial settings and occasionally in domestic environments for cleaning purposes. The patient inadvertently handled, without gloves, a homemade soap recipe widely shared on the internet containing used cooking oil, water, caustic soda, alcohol, and fragrances. This substance can cause poisoning, allergic reactions, burns, and may even be fatal. Although contact dermatitis caused by caustic soda exposure is relatively common, its exact incidence is not well documented in the medical literature, as cases are generally grouped under broader categories of chemical injuries or occupational dermatoses. The pathophysiology may involve increased expression of adhesion molecules in epithelial cells, leading to increased dermal inflammation and epidermal proliferation, resulting in intense exfoliation and chronicity in cases of re-exposure. In our case, the acute clinical presentation and medical history supported the diagnosis of erythroderma secondary to contact dermatitis caused by caustic soda. Early recognition, withdrawal of the offending agent, corticosteroid therapy, and supportive care were essential for a favorable outcome, considering that erythroderma carries a mortality rate ranging from 18% to 64%. This report highlights the importance of detailed history taking and preventive education regarding the safe handling of caustic soda, especially in non-industrial environments.

EADV CONGRESS
VIENNA
30 SEP - 3 OCT 2026

Abstract N°: 3626

Contact allergy amongst hairdressers: a single-center retrospective study of patch test data from 2004 to 2021

Shi Yu Derek Lim*[1], Yung Hian Leow[1], Anthony Teik-Jin Goon[1], Tricia Yi Rui Chong[1], Suzanne Wei Na Cheng[1]

[1] National Skin Centre, Singapore, Singapore

Introduction
Hairdressers are at risk of occupational dermatitis, including allergic contact dermatitis, due to the nature of their work. We aim to identify the frequency and relevance of contact allergy amongst hairdressers undergoing patch testing at our tertiary dermatological referral centre.

Materials and Methods
We retrospectively analyzed patch test results of hairdressers who underwent patch testing to contact allergens from 2004 to 2021. Readings were performed on days 3 and 7. Descriptive analysis was performed for all variables.

Results
Thirty-five hairdressers were included, with a mean (SD) age of 43.3 (14.3) years. 27 (77.1%) were female, and the majority (30, 85.7%) were of Chinese ethnicity. 8 (22.9%) had a history of atopic dermatitis. The commonest sites involved were the hands (23, 65.7%), fingers (18, 51.4%) and palms (9, 25.7%). 34 (97.1%) patients had contact allergy to at least one allergen.

Among allergens which were tested on five patients or more, the highest frequencies of contact allergy were to p-phenylenediamine (18 of 34, 52.9%), nickel(II)sulfate hexahydrate (9 of 34, 26.5%), gold(I)sodium thiosulfate dihydrate (1 of 5, 20.0%), followed by ammonium persulfate and captan (each 4 of 25, 16.0%). p-chloro-m-cresol and zinc pyrithione were positive in only one patient each and deemed to be of past or present relevance. Otherwise, the top allergens of past or present relevance were nickel(II)sulfate hexahydrate (8 of 9, 88.9%), p-phenylenediamine (12 of 18, 66.7%), ammonium thioglycolate (2 of 3, 66.7%), and colophonium (2 of 3, 66.7%). The top allergens deemed occupationally relevant were zinc pyrithione (1 of 1, 100%), ammonium thioglycolate (2 of 3, 66.7%), followed by p-phenylenediamine (11 of 18, 61.1%).

Conclusions
Allergic contact dermatitis is common among hairdressers. Patch testing is essential for diagnosis to guide safe workplace practices. The limitations of this study include its single-center design, retrospective nature, and missing data especially with regard to relevance of positive reactions.

EA DV CONGRESS
VIENNA
30 SEP - 3 OCT 2026

Abstract N°: 3768

Contact dermatitis induced by Nigella sativa oil: caution with traditional herbal remedies

Ouissal Hormi*[1], Salma Moujahid[1], Khadija Imam[1], Nour Haddar[1], Souha Denna[1], Nassiba Zerrouki[1], Nada Zizi[1]

[1] Department of Dermatology, Venereology and Allergology, Mohammed VI University Hospital Center, Oujda, oujda, Morocco

Introduction

Traditional herbal medicine remains widely used worldwide, particularly in North African and Middle Eastern populations, where *Nigella sativa* (black seed) is commonly applied for its presumed anti-inflammatory, analgesic and healing properties. Although generally perceived as a safe natural remedy, topical use of *Nigella sativa* may expose patients to irritant or allergic cutaneous adverse reactions related to its bioactive compounds, including thymoquinone and essential oils. Reports of contact dermatitis induced by *Nigella sativa* remain rare and probably underdiagnosed because patients frequently omit mentioning the use of traditional remedies during medical consultations.

Case Presentation

A 54-year-old woman with no personal or familial history of atopy or previous contact allergy consulted for the sudden onset of intensely pruritic skin lesions localized to the right knee. Symptoms appeared a few hours after repeated topical application of *Nigella sativa* oil used for chronic osteoarthritic pain. Dermatological examination revealed a well-demarcated erythematous and oedematous plaque associated with burning sensations and multiple vesiculobullous lesions strictly confined to the application site. No mucosal involvement or systemic symptoms were observed.

The patient denied the use of any topical medications, cosmetics or other potentially sensitizing substances before lesion onset. Routine biological investigations were unremarkable. Based on the suggestive temporal relationship, the characteristic distribution of lesions and the absence of alternative etiologies, the diagnosis of acute contact dermatitis induced by *Nigella sativa* oil was retained, with irritant dermatitis considered the most likely mechanism.

Immediate discontinuation of the oil, combined with topical corticosteroids and local skin care, led to progressive clinical improvement with complete regression of lesions within 10 days without residual scarring.

Although *Nigella sativa* is widely regarded as beneficial in traditional medicine, several experimental studies have demonstrated that some of its constituents may exert cytotoxic, irritant or sensitizing effects on the skin. This observation underlines the growing need for clinicians to actively inquire about the use of herbal and traditional products when evaluating acute dermatitis, particularly in regions where self-medication with natural remedies is common.

Conclusion

This case highlights that *Nigella sativa* oil, despite its widespread traditional use and reputation as a harmless natural product, may induce acute contact dermatitis. Awareness of potential adverse cutaneous reactions associated with herbal remedies is essential for early diagnosis, appropriate management and patient education. Systematic investigation of traditional medicine exposure should be integrated into routine allergological and dermatological assessment.

EA DV CONGRESS
VIENNA
30 SEP - 3 OCT 2026

Abstract N°: 4076

Footwear-associated allergic contact dermatitis: a single-center retrospective study of patch test data from 2004 to 2021

Shi Yu Derek Lim*[1], Yung Hian Leow[1], Anthony Teik-Jin Goon[1], Tricia Yi Rui Chong[1], Suzanne Wei Na Cheng[1]

[1] National Skin Centre, Singapore, Singapore

Introduction
A variety of allergens present in footwear can be responsible for causing allergic contact dermatitis (ACD). The incidence of footwear-associated ACD differs widely across studied populations. We aim to identify the frequency and relevance of footwear-associated ACD amongst patients undergoing patch testing at our tertiary dermatological referral centre.

Materials and Methods
We retrospectively analyzed patch test results of patients with suspected footwear-associated ACD who underwent patch testing to contact allergens from 2004 to 2021. Readings were performed on days 3 and 7. Descriptive analysis was performed for all variables.

Results
196 patients were included, with a mean (SD) age of 38.0 (19.2) years. 91 (46.4%) were male, and the majority (148, 75.5%) were of Chinese ethnicity. 38 (19.4%) had atopic dermatitis. The commonest sites involved were the feet (148, 75.5%), soles (67, 34.2%) and toes (65, 33.2%).

70 (35.7%) had contact allergy to one or more allergens. Table 1 shows the relative frequencies of positive reactions, clinically relevant reactions and contact allergy attributed to footwear.

Among allergens which were tested on five patients or more, the highest frequencies of contact allergy were to nickel(II)sulfate hexahydrate (24 of 167, 14.4%), potassium dichromate (19 of 167, 11.4%), and fragrance mix 1 (13 of 167, 7.8%). The allergens with the highest frequencies of clinically relevant contact allergy were nickel(II)sulfate hexahydrate (13 of 167, 7.8%), colophonium (8 of 165, 4.8%), potassium dichromate (7 of 167, 4.2%), and 4-tert-butylphenolformaldehyde resin (4 of 167, 2.4%). Of the 36 positive patch test reactions, nine (25%) were attributed to footwear. In addition, five (2.6%) patients tested positive to their own footwear. Six (3.0%) patients had occupationally-related dermatitis. Females were more likely to have contact allergy than males (44% vs 26%, p = 0.01). The presence of atopic dermatitis was not associated with contact allergy (32% vs 37%, p = 0.55).

Table 1: Allergens ranked by relative frequency (%) of positive reactions, represented as a total proportion of all patients undergoing to testing to the specific allergen

Allergen	Number Tested	Contact Allergy, n (%)	Late Positive Reactions, n (%)	Past or Present Relevance, n (%)	Contact Allergy Attributed to Footwear, n (%)
Leather	167	19 (11.4)	3 (15.8)	7 (4.2)	3 (15.8)
Potassium dichromate, 0.5%	167	19 (11.4)	3 (15.8)	7 (4.2)	3 (15.8)
Metals	241	27 (11.2)	4 (14.8)	13 (5.4)	0 (0)
Nickel(II)sulfate hexahydrate, 5.0%	167	24 (14.4)	4 (16.7)	13 (7.8)	0 (0)
Cobalt(II)chloride hexahydrate, 1.0%	36	2 (5.6)	0 (0)	0 (0)	0 (0)
Gold(I)sodium thiosulfate dihydrate, 2.0%	38	1 (2.6)	0 (0)	0 (0)	0 (0)
Adhesives	543	20 (3.7)	4 (20)	12 (2.2)	4 (20)
Colophonium, 20.0%	165	12 (7.3)	2 (16.7)	8 (4.8)	0 (0)
4-tert-Butylphenolformaldehyde resin, 1.0%	167	6 (3.6)	2 (33.3)	4 (2.4)	4 (66.7)
2-Hydroxyethyl methacrylate, 2.0%	44	1 (2.3)	0 (0)	(0)	(0)
Epoxy resin, 1.0%	167	1 (0.6)	0 (0)	(0)	(0)
Fragrances	932	30 (3.2)	0 (0)	3 (0.3)	0 (0)
Fragrance Mix 1, 8.0%	167	13 (7.8)	0 (0)	3 (1.8)	0 (0)
Myroxylon pereirae, 25.0%	167	9 (5.4)	0 (0)	0 (0)	0 (0)
Cinnamyl alcohol, 2.0%	19	1 (5.3)	0 (0)	0 (0)	0 (0)
Eugenol, 2.0%	55	1 (1.8)	0 (0)	0 (0)	0 (0)
Hydroxyisohexyl 3-cyclohexene carboxaldehyde, 5.0%	131	2 (1.5)	0 (0)	0 (0)	0 (0)
2-n-Octyl-4-isothiazolin-3-one, 0.1%	142	2 (1.4)	0 (0)	0 (0)	0 (0)
Fragrance Mix 2 , 14.0%	84	1 (1.2)	0 (0)	0 (0)	0 (0)
Sesquiterpene lactone mix, 0.1%	167	1 (0.6)	0 (0)	0 (0)	0 (0)
Rubber	919	16 (1.7)	3 (18.8)	3 (0.3)	3 (18.8)
Tetramethylthiuram monosulfide, 1.0%	1	1 (100)	0 (0)	0 (0)	0 (0)
Thiuram mix, 1.0%	167	6 (3.6)	2 (33.3)	1 (0.6)	1 (16.7)
Carba mix, 3.0%	149	5 (3.4)	0 (0)	0 (0)	0 (0)
Black rubber mix, 0.6%	153	1 (0.7)	1 (100)	1 (0.7)	1 (100)
Diaminodiphenylmethane, 0.5%	150	1 (0.7)	0 (0)	1 (0.7)	1 (100)
N,N´-Diphenylthiourea, 1.0%	149	1 (0.7)	0 (0)	0 (0)	0 (0)
2,2,4-Trimethyl-1,2-dihydroquinoline, 1.0%	150	1 (0.7)	0 (0)	0 (0)	0 (0)
Medicaments	667	11 (1.6)	0 (0)	0 (0)	0 (0)
Lanolin alcohol, 30.0%	167	5 (3)	0 (0)	0 (0)	0 (0)
Neomycin sulfate, 20.0%	167	4 (2.4)	0 (0)	0 (0)	0 (0)
Budesonide, 0.01%	166	1 (0.6)	0 (0)	0 (0)	0 (0)
Quinoline mix, 6.0%	167	1 (0.6)	0 (0)	0 (0)	0 (0)
Preservatives and Biocides	639	9 (1.4)	1 (11.1)	0 (0)	0 (0)
Sodium-2-pyridinethiol-1-oxide, 0.1% aq	3	1 (33.3)	0 (0)	0 (0)	0 (0)
t-Butylhydroquinone, 1.0%	3	1 (33.3)	0 (0)	0 (0)	0 (0)
Dimethyl fumarate, 0.1%	62	1 (1.6)	1 (100)	0 (0)	0 (0)
Methyldibromo glutaronitrile, 0.5%	131	2 (1.5)	0 (0)	0 (0)	0 (0)
Paraben mix, 16.0%	165	2 (1.2)	0 (0)	0 (0)	0 (0)
Glutaral, 0.2%	136	1 (0.7)	0 (0)	0 (0)	0 (0)
Formaldehyde, 1.0% aq	139	1 (0.7)	0 (0)	0 (0)	0 (0)
Dyes	306	4 (1.3)	0 (0)	3 (1)	1 (25)
Disperse Orange 3, 1.0%	139	2 (1.4)	0 (0)	1 (0.7)	1 (50)
p-Phenylenediamine, 1.0%	167	2 (1.2)	0 (0)	2 (1.2)	0 (0)

Note: Allergens in petrolatum, except where indicated otherwise. Late reactions refer to patch test reactions that only became positive on the Day 7 reading. Relevance was classified into four categories: (i) Present: the allergen is causing the current dermatitis. (ii) Past: the allergen had caused dermatitis in the past but not currently. (iii) Exposed: the allergen had been encountered by the patient previously, but the patient did not develop dermatitis then. (iv) Unknown: no known exposure. Only categories (i) and (ii) were deemed relevant.

Conclusions

Adhesives, rubber-related and leather-related allergens were the most common culprit allergens. Patch testing to the patient's own footwear is useful, as there may be instances where patch testing to standard allergens may return negative. The limitations of this study include its single-center design, retrospective nature, and missing data with regard to relevance of positive reactions.

EA DV CONGRESS
VIENNA
30 SEP - 3 OCT 2026

Abstract N°: 4112

Evaluation of Effectiveness and Safety of Oral Tofacitinib in Patients with Parthenium Dermatitis: A Prospective Interventional Open-Label Study

Vanshika Arora*[1], Shreya Gowda[1], Kaushal Verma[1]

[1] All India Institute of Medical Sciences, New Delhi, New Delhi, India

Introduction

Airborne contact dermatitis is a chronic inflammatory dermatosis caused by airborne allergens, most commonly *Parthenium hysterophorus* in India, accounting for nearly 40% of contact dermatitis clinic cases. Management remains challenging due to the ubiquitous presence of the allergen and the relapsing nature of the disease. Although corticosteroids and conventional immunosuppressants are effective, their long-term use is limited by adverse effects and the need for regular monitoring.

Parthenium dermatitis is predominantly mediated through Th1- and Th17-driven immune pathways involving JAK–STAT signalling. Tofacitinib, an oral pan-JAK inhibitor, suppresses multiple pro-inflammatory cytokines implicated in disease pathogenesis.

Materials and Methods

This single-center, prospective, open-label interventional study was conducted at a tertiary care center in India. Fifty-three adults with parthenium dermatitis confirmed by a positive patch test and a Parthenium Dermatitis Severity Score (PDSS) ≥10 were enrolled.

Patients received oral tofacitinib at a dose of 5 mg twice daily for 12 weeks or until complete remission, whichever earlier. Additionally, topical clobetasol propionate 0.05% and oral levocetirizine 5 mg were given for symptomatic control.

They were followed up monthly with a comprehensive clinical assessment, including calculation of PDSS, patient and physician global assessments using VAS scores and side effects. Laboratory monitoring (CBC, LFT, and fasting lipid profile) was performed at 4 weeks, and at the end of therapy. After discontinuation of therapy, patients were followed monthly for an additional 3 months to identify relapse or any delayed adverse effects. Relapse was defined as an increase in PDSS to ≥50% of the baseline value, and these patients were managed with standard treatment (oral corticosteroids and conventional immunosuppressants). Primary outcome was change in PDSS from baseline to end of treatment, while the secondary outcomes included adverse events and relapse rate.

Changes in PDSS and VAS scores from baseline to follow-up visits were compared using the Wilcoxon signed-rank test (p-value <0.05 considered significant).

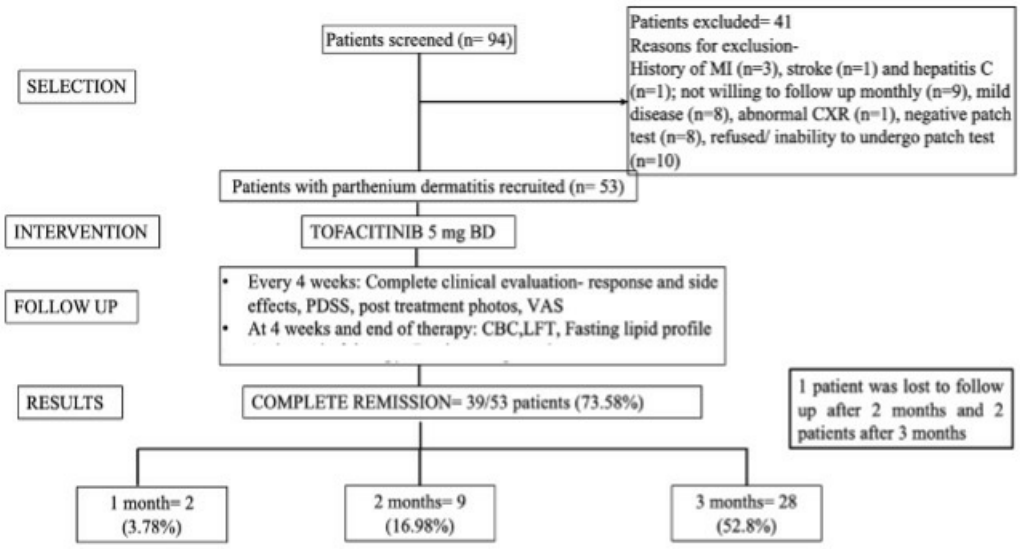

Flowchart showing recruitment of patients in the study

Results

Among the 53 included patients, 39 were males and 14 females, with a mean age of 50.8 ± 7.8 years. Disease duration ranged from 2 to 35 years (mean 9.72 ± 8.03 years).

Treatment resulted in a marked reduction in disease severity, with mean PDSS decreasing from 41.64 ± 10.69 at baseline to 2.09 ± 3.60 at the end of therapy (94.98% reduction). Overall response was excellent (>75% improvement) in 51 patients (96.2%) and good (50%-75% improvement) in 2 patients (3.8%), with no poor responders.

Complete remission (PDSS = 0) was achieved in 2 patients (3.8%) at 1 month, 9 (17.0%) at 2 months, and 28 (52.8%) at 3 months, while 39 patients (73.6%) achieved remission at some point during therapy. Both patient- and physician-reported VAS scores showed significant improvement.

A total of 11 adverse events occurred in 10 patients, all mild and not requiring treatment discontinuation. Hyperlipidaemia was the most common adverse effect, observed in 4 patients (8%).

Among the 50 patients completing the 3-month post-treatment follow-up, 10 (20%) relapsed after discontinuing tofacitinib. Most relapses (80%) occurred within the first month, while the remaining occurred within 2 months.

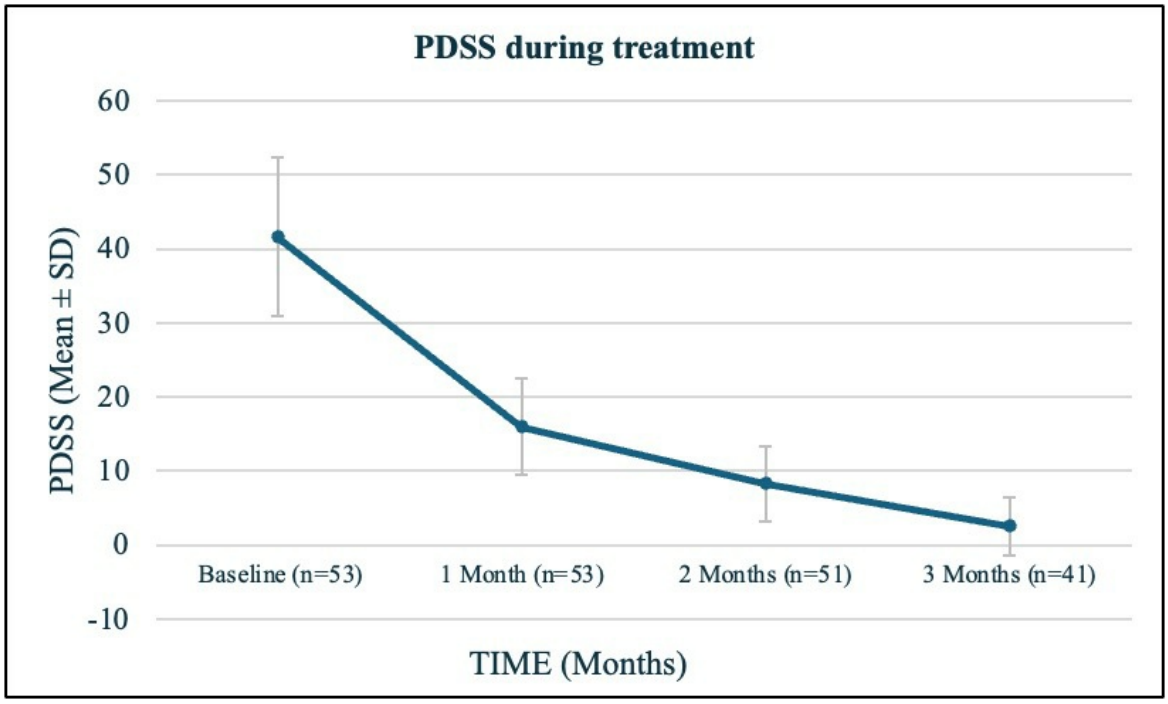

Change in mean Parthenium Dermatitis Severity Scores (PDSS) during treatment

Conclusions

This study demonstrates that tofacitinib is an effective, safe and rapidly acting treatment for parthenium dermatitis. The relapse rate was lower than that reported with conventional therapies, suggesting relatively durable disease control. Adverse effects were mild and infrequent.

Importantly, this is the first prospective study evaluating tofacitinib in a comparatively larger cohort of patients with parthenium dermatitis. Limitations include the small sample size, absence of a comparator arm, and short follow-up duration.

EADV CONGRESS
VIENNA
30 SEP - 3 OCT 2026

Abstract N°: 4149

p-phenylenediamine (PPD) sensitization is often accompanied by allergies to other chemicals, and this makes PPD-induced contact dermatitis complex and difficult to control.

Ying Zou*[1], Yue Wu[1], Chengwen Fei[1]

[1] Shanghai Skin Disease Hospital, Shanghai, China

Introduction
p-phenylenediamine (PPD) sensitization is often accompanied by allergies to other chemicals, and this makes PPD-induced contact dermatitis complex and difficult to control. The study aimed to investigate the pattern of contact sensitization in PPD-sensitized and PPD-non-sensitized populations and to evaluate the cross-reactions and co-sensitizations characteristics of PPD in China.

Materials and Methods
The sociodemographic and clinical data of patients who underwent PPD patch testing between 2018 and 2023 were analyzed. The frequency and strength of PPD sensitization and cross-reactions or co-sensitizations with other chemicals were assessed.

Results
Out of 4760 patients who underwent PPD patch testing, 210 (4.41%) presented with positive reactions. Up to 96.67% PPD-sensitized individuals exhibited cross-reactions or co-sensitizations to one or more allergens. Co-sensitization to PPD was more likely to occur in patients younger than 60 years or in women. Patients with extremely strong PPD reactions showed significantly more frequent cross-reactions to textile dye mix.

Conclusions
The observed pattern of cross-reactions and co-sensitizations suggests that avoidance of only PPD may not be sufficient to protect against all associated allergic reactions. Moreover, patch testing may prove highly valuable for detecting cross-reactions and co-sensitizations and long-term dermatitis treatment in patients who are suspected of being allergic to PPD.

EADV CONGRESS
VIENNA
30 SEP - 3 OCT 2026

Abstract N°: 4156

Feasibility of self-application of multiple patch test chambers to support reduced-visit patch testing pathways: a simulated study

Weijia Yi*[1]

[1] Department of Dermatology, John Hunter Hospital, New South Wales, Australia

Introduction
Routine patch testing requires multiple in-person visits, posing logistical barriers for patients living in rural or remote areas. A reduced-visit model incorporating home application may improve access but depends on reliable chamber placement by individuals without healthcare training.

Materials and Methods
In a single-centre exploratory feasibility study, 19 adults (≥18 years) with no prior patch test experience or healthcare training received standardised instruction (handout, demonstration video, reference photograph, and opportunity for questions). Participants then applied six empty patch test chambers to a "dummy" back without investigator presence. Placement was assessed against pre-specified criteria: order, orientation, flat adhesion, spacing, and marking. Participants recorded confidence before and after education and rated ease of application using 0–10 numerical rating scales.

Results
Nineteen participants (14 women, 5 men; mean age 47 years [range 19–72]) completed the task. Overall correct application meeting all criteria occurred in 18/19 participants (94.7%; exact 95% CI 74.0–99.9). Correct order, flat adhesion, spacing, and marking were achieved by all participants; one participant placed a single chamber upside down (orientation error). Mean confidence increased from 3.5/10 pre-education to 9.5/10 post-education; mean ease-of-application rating was 9.6/10.

Conclusions
Following brief education, laypersons accurately and confidently applied multiple patch test chambers in a simulated setting, supporting feasibility of home application as a component of reduced-visit patch testing pathways for allergic contact dermatitis. Prospective evaluation in real-world home conditions is required, including delayed application, 48-hour adhesion, and photo-verification workflows.

EADV CONGRESS
VIENNA
30 SEP - 3 OCT 2026

Abstract N°: 4470

Sports-Related Dermatoses in Athletes: Prevalence and Risk Factors in a Cross-Sectional Study of 378 Athletes

Hajar Dahmani*[1], Ouiame El Jouari[1], Salim Gallouj[1]

[1] University Hospital Center Mohammed VI of Tangier, Tangier, Morocco

Introduction
Sports-related dermatoses are common yet underrecognized conditions that may impair athletes' comfort, performance and quality of life. Their prevalence, clinical spectrum and associated risk factors remain insufficiently explored in heterogeneous athletic populations. Therefore, this study aimed to evaluate the prevalence, clinical patterns and major risk factors associated with sports-related dermatoses among athletes.

Materials and Methods
A cross-sectional study was conducted between May and September 2025 among 378 athletes in the northern region of Morocco. Data were collected using a structured questionnaire evaluating demographic characteristics, sports practices, environmental exposures, preventive measures and dermatological manifestations. Statistical analyses included chi-square tests and multivariate logistic regression.

Results
Among participants, 42.1% reported sports-related dermatoses, while 73% experienced post-exercise cutaneous symptoms. The most frequent dermatoses were ingrown toenails (56.1%), interdigital intertrigo (41.8%) and tinea pedis (34.7%). Significant associations were observed between dermatoses and type of sport (p=0.04), training frequency (p=0.002), training duration (p=0.015), environmental exposure (p=0.0119) and lack of protective equipment (p=0.043). Multivariate analysis identified insufficient protective equipment use (OR=3.2; 95% CI: 2.1–4.9), environmental exposure (OR=2.8; 95% CI: 1.9–4.1) and aquatic sports (OR=2.5; 95% CI: 1.6–3.9) as major independent risk factors. Use of sunscreen and protective products was associated with lower prevalence of cutaneous symptoms (p=0.0327).

Conclusions
Sports-related dermatoses are highly prevalent and strongly associated with environmental exposure, training intensity and inadequate preventive measures. Improved awareness, targeted prevention strategies and early dermatologic management may significantly reduce the burden of cutaneous disorders among athletes.

EA DV CONGRESS
VIENNA
30 SEP - 3 OCT 2026

Abstract N°: 4488

Dermatological Risks of Social Media–Influenced Cosmetic Use: A Narrative Review

Natalia Avelar E Lima*[1], Rossana Vasconcelos[1]

[1] University of Santo Amaro (UNISA), São Paulo, Brazil

Introduction

The global beauty and personal care market generated approximately USD 571.1 billion in 2023, driven by social media and digital marketing strategies that transformed cosmetic consumption, fostering excessive product use and frequent replacement based on digital influencer recommendations. Such content, often lacking scientific evidence, promotes extensive skincare and haircare routines with overlapping irritating or allergenic substances. Increasing cases of cosmetic acne, contact dermatitis, and photoallergic reactions have been associated with cosmetic use without medical supervision. Fragrances, preservatives, and colorants are major sensitizing agents identified in recent analyses. Additionally, p-phenylenediamine (PPD), widely used in hair dyes, has been linked to persistent allergic and irritative scalp reactions. Digital influence further encourages repetitive consumption without considering skin type or product compatibility. These practices may impair the skin barrier, promote chronic inflammation, and perpetuate dermatological disorders. Understanding these effects is essential for clinical management and educational strategies promoting rational cosmetic use. Thus, this study aimed to analyze recent evidence regarding dermatological risks associated with excessive and unsupervised cosmetic use influenced by social media, emphasizing skin, hair, and dermatoses.

Materials and Methods

A narrative review was conducted using articles published between December 2021 and September 2025, prioritizing systematic reviews and observational studies. The descriptors “Cosmetics,” “Contact Dermatitis,” “Peer Influence,” “Social Media,” “Skin,” and “Adverse Effects” (DeCS/MeSH) were combined with AND and OR in PubMed, SciELO, and Web of Science. English-language publications addressing cutaneous and hair-related adverse events associated with cosmetic use were included, whereas case reports, in vitro studies, and reviews without clinical data were excluded. Selection was based on title, abstract, and full-text screening, followed by qualitative analysis of relevant findings.

Results

Recent evidence indicates that frequent and unsupervised cosmetic use is associated with a high prevalence of cutaneous adverse events, as shown in Table 1. A pooled prevalence of 41.1% of adverse events was reported among regular cosmetic users. Fragrances and preservatives were major sensitizing agents, with sensitization rates of 6.81% and 3.64% for Fragrance Mix I and II, respectively. On the scalp, PPD and related amines remain major allergens in hair dyes, with risks of cross-reactivity and prolonged sensitization. Occlusive cosmetics and creams containing silicones and oils have also been associated with cosmetic acne and perioral dermatitis, especially when combined with topical corticosteroids. Photoallergic and phototoxic reactions related to sunscreens and ultraviolet-sensitive fragrances, such as benzophenone-3, have also been reported, in addition to contact urticaria caused by preservatives and perfumes. The overlapping use of products containing multiple irritating active ingredients may result in epidermal barrier dysfunction and cumulative irritant dermatitis. Recent studies indicate that patients still trust dermatologists more than digital influencers, reinforcing the specialist’s role in disseminating evidence-based information.

Table 1. Main adverse reactions related to cosmetic use according to recent reviews (2021–2025)

Type of Cosmetic	Predominant Adverse Reaction	Reported Frequency / Prevalence (Studied Population)	Reference
Cosmetics in general (daily use / skincare)	Irritation, pruritus, erythema, allergic and irritant contact dermatitis	41.1% among regular cosmetic users (general population, multicenter meta-analysis)	Kumari S et al., 2024
Fragrances (e.g., Fragrance Mix I and II)	Allergic contact dermatitis	6.81% (Mix I) and 3.64% (Mix II) among patients with contact dermatitis (Europe)	Botvid S et al., 2024
Hair dyes (p-phenylenediamine, amines)	Contact dermatitis, cross-reactions, prolonged sensitization	6.8% self-reported cutaneous reactions among hair dye users (general population, Netherlands)	Tsimpidakis A et al., 2024; Rosenberg FM et al., 2024
Occlusive facial creams, silicones, and oils	Cosmetic acne, perioral dermatitis, exacerbation by topical corticosteroids	No consolidated prevalence (causal association observed in young adults)	Searle T et al., 2021; Tolaymat L et al., 2023
Sunscreens / photosensitizing fragrances	Photoallergic and phototoxic reactions, contact urticaria	6.4% with photoallergy and 5.7% sensitivity to UV chemicals (pediatric cohort)	Mahajan VK et al., 2024; Gabros S et al., 2023
Cosmetics with multiple irritating active ingredients	Epidermal barrier dysfunction, cumulative irritant dermatitis	No consolidated prevalence (experimental and observational studies)	Alyahya RS et al., 2025; Pîrvulescu L-E et al., 2025
Digital beauty content (social media)	Encouragement of indiscriminate use; behavioral influence and aesthetic perception	Cross-sectional observational study with social media users (n≈2,000)	Bal ZI et al., 2025; Ünal S et al., 2025

Conclusions

Indiscriminate cosmetic use amplified by digital influence significantly increases the risk of irritative, allergic, and acneiform dermatoses, as well as adverse scalp reactions. Educational interventions led by dermatologists are essential to promote rational cosmetic use and early identification of adverse reactions. Healthcare professionals and regulatory agencies must engage in digital education and dissemination of evidence-based content to mitigate risks associated with cosmetic self-medication.

POWERED BY M-ANAGE.COM