EADV CONGRESS
VIENNA
30 SEP - 3 OCT 2026

Abstract N°: 24

When “Atopic Dermatitis” Blisters: Herpetiform Pemphigus Revealed as a Diagnostic Pitfall

Sofiia Tymchuk*[1]

[1] Saint-Petersburg State University, Saint-Petersburg, Russian Federation

Introduction

Herpetiform Pemphigus is a rare clinical variant of Pemphigus characterized by intensely pruritic polymorphic eruptions with vesicles or bullae and histological features of eosinophil-rich subcorneal acantholysis. The disease is associated with autoantibodies targeting desmosomal proteins and may clinically resemble inflammatory dermatoses. Patients with long-standing Atopic Dermatitis frequently present with chronic pruritic and polymorphic skin lesions, which may obscure the early manifestations of autoimmune blistering disorders.The aim of this study is to present a clinical case of herpetiform pemphigus initially mimicking an exacerbation of atopic dermatitis and to emphasize an important diagnostic pitfall in patients with chronic inflammatory dermatoses.

Case Presentation

A 27-year-old male presented with generalized pruritus and widespread inflammatory skin lesions. The patient reported a lifelong history of chronic pruritic dermatitis consistent with atopic dermatitis, previously diagnosed as eczema or neurodermatitis. Family history was positive for atopic dermatitis in the patient’s mother.Initial clinical assessment suggested an exacerbation of atopic dermatitis, and appropriate therapy was initiated with partial improvement.However, the patient subsequently developed new vesicular and bullous lesions accompanied by severe pruritus. The lesions were located on the trunk and extremities, raising suspicion of an autoimmune blistering dermatosis.Histopathological examination demonstrated a large subcorneal blister containing numerous eosinophils and occasional acantholytic cells. The underlying dermis showed moderate lymphohistiocytic infiltration with eosinophilic exocytosis into the epidermis. These findings were consistent with herpetiform pemphigus.The patient was hospitalized, systemic therapy was initiated, and significant clinical improvement was observed.

Conclusion

Herpetiform pemphigus may clinically mimic an exacerbation of atopic dermatitis, particularly in patients with long-standing pruritic dermatoses.The sudden appearance of vesicles or bullae in such patients should prompt reconsideration of the diagnosis and early histopathological examination.Recognition of this diagnostic pitfall is essential for the timely identification of autoimmune blistering diseases and appropriate patient management.

EADV CONGRESS
VIENNA
30 SEP - 3 OCT 2026

Abstract N°: 60

Bilateral Lupus Panniculitis at SARS-CoV-2 Vaccination Sites Mimicking Granulomatous Dermatoses

Thais Barros Felippe Jabour*[1], Artur Antonio Duarte[1], Kaique Arriel[1]

[1] University of Santo Amaro, São Paulo, Brazil

Introduction

Lupus panniculitis is a rare form of chronic cutaneous lupus characterized by inflammation of the subcutaneous adipose tissue, often presenting as indurated plaques that may later develop surface erythema, scaling, and secondary atrophy. Its pathogenesis involves genetic susceptibility, type I interferon signaling, lymphocyte activation, and inflammatory cytokines. Although uncommon, cutaneous lupus has occasionally been reported after immunogenic stimuli in predisposed individuals.

Case Presentation

A 30-year-old woman presented with a two-year history of an erythematous, painful, pruritic plaque on the right upper arm, which had appeared two weeks after SARS-CoV-2 vaccination. One year later, she developed a similar lesion on the contralateral arm, corresponding to the site of the second vaccine dose. She denied fever, weight loss, or other systemic symptoms. Physical examination revealed bilateral erythematous, scaly, infiltrated plaques involving the deltoid regions and extending into the subcutaneous tissue. The main differential diagnoses included lupus panniculitis, cutaneous tuberculosis, and sarcoidosis. Incisional biopsies were obtained from both lesions. Histopathological examination showed vacuolar degeneration of the basal layer, thickening of the basement membrane, and deep perivascular and periadnexal lymphocytic infiltrates. The subcutaneous tissue exhibited lobular panniculitis with hyaline degeneration of adipocytes, fat necrosis, and lymphocytic aggregates. One specimen also showed a verrucous epidermal pattern. Special stains for infectious agents were negative. The findings were consistent with lupus panniculitis associated with chronic cutaneous lupus. Laboratory evaluation showed normal blood count and inflammatory markers, negative serologies, non-reactive antinuclear and extractable nuclear antigen antibodies, indeterminate anti-RNP, normal C3, and mildly reduced C4. Urinalysis disclosed mild proteinuria. Chest radiography was normal. There were no criteria for systemic lupus erythematosus. Treatment with methotrexate 15 mg weekly, folic acid, and topical corticosteroid under occlusion led to progressive improvement in pain, pruritus, and infiltration, with subsequent lesion stabilization and residual mild atrophic depression.

Conclusion

This case highlights an unusual localized presentation of lupus panniculitis in the deltoid region, clinically simulating granulomatous dermatoses and requiring careful clinicopathological correlation. The bilateral topography and temporal relationship with vaccination suggest a possible immunological trigger in a susceptible individual, although causality cannot be established. Early recognition of this rare presentation is important to guide appropriate investigation and treatment.

EADV CONGRESS
VIENNA
30 SEP - 3 OCT 2026

Abstract N°: 78

Amicrobial Pustulosis of the Folds Transitioning to Metastatic Crohn’s Disease A Diagnostic and Therapeutic Challenge

salah eddin awawde*[1], Tasnime Bouaziz[1], Issam TABLIT[1], Lemya Mezdour[1], Saliha Takheroubt[1], Asma Haciane[1], Samira Zobiri[1]

[1] Mustapha University Hospital Center, Dermatology and venereology, Sidi M'Hamed - alger, Algeria

Introduction

Amicrobial Pustulosis of the Folds (APF) is a rare neutrophilic dermatosis characterized by sterile pustules affecting major skin folds. Metastatic Crohn’s Disease (MCD) is an uncommon extraintestinal manifestation defined by granulomatous cutaneous lesions separated from the GI tract by normal skin. Cutaneous manifestations, such as deep genital ulcerations, can precede GI symptoms by several years, making early diagnosis incredibly challenging. We report a complex case of a patient initially treated for APF who progressively developed severe mucocutaneous lesions revealing an underlying metastatic Crohn’s disease.

Case Presentation

A 38-year-old female presented in 2019 with intense genital pruritus and oozing papules extending to the trunk. In 2022, she was diagnosed with APF based on axillary and inguinal sterile pustules and compatible histology. She proved refractory to multiple therapies (corticosteroids, colchicine, cyclosporine). Despite a partial response to dapsone, severe relapses led to the initiation of infliximab in March 2025. By late 2025, she was admitted with severe cachexia (BMI 16.4 kg/m^2) and a spectacular clinical flare. Dermatological examination revealed widespread ichthyosiform scaling, persistent sterile axillary pustules, and a purulent 3-cm scalp tumor. Crucially, the ano-genital examination showed profound infiltration, pseudo-marisques, and bilateral "knife-cut" linear ulcers. Mucosal involvement included fetid otitis externa, severe dry eyes, macrocheilia, and macroglossia.

Extensive investigations were conducted to assess for active gastrointestinal Crohn's. Colonoscopy (December 2025) and upper endoscopy (February 2026) were strictly normal. Perineal MRI showed no anomalies; however, fecal calprotectin was mildly elevated at 164 µg/g. Histopathology of the genital "knife-cut" ulcers and the scalp tumor revealed non-specific inflammation without visualizing non-caseating granulomas. Despite normal endoscopies and non-specific biopsies, the highly pathognomonic clinical presentation (linear genital ulcers, macrocheilia, pseudo-marisques) led the multidisciplinary team to diagnose severe cutaneous metastatic Crohn’s disease. The patient received IV methylprednisolone (1 mg/kg/day) and metronidazole, followed by an induction with adalimumab (160 mg) combined with azathioprine in February 2026. This led to rapid drying of auricular lesions and a marked reduction in genital infiltration.

Conclusion

This case highlights a deceptive and challenging clinical overlap. The patient's initial presentation fit APF, but the development of deep linear ulcers and macrocheilia strongly indicated MCD. Cutaneous Crohn's can be the inaugural symptom of the disease, preceding digestive involvement by months or years. The absence of granulomas on a biopsy does not exclude the diagnosis when the clinical signs are pathognomonic. The striking mucocutaneous severity justified an aggressive "top-down" therapeutic approach with anti-TNF alpha and immunosuppressant combotherapy, despite the absence of luminal disease. Close clinical follow-up is imperative, as this patient remains at a very high risk for future gastrointestinal involvement.

EA DV CONGRESS
VIENNA
30 SEP - 3 OCT 2026

Abstract N°: 81

Paraneoplastic Pemphigus Occurring 16 Years After Remission of Pemphigus Vulgaris Recurrence or New

salah eddin awawde*[1], Lemya Mezdour[1], Issam TABLIT[1], Saliha Takheroubt[1], Asma Haciane[1], Samira Zobiri[1]

[1] Mustapha University Hospital Center, Dermatology and venereology, Sidi M'Hamed - alger, Algeria

Introduction

Pemphigus vulgaris is a chronic autoimmune bullous dermat osis characterized clinically by bolllous lésions et histologically by acantholysis of the skin and mucous membranes. In contrast, paraneoplastic pemphigus is a rarer and more severe variant, typically associated with under lying malignancies and characterized by extensive mucosal involvement and resistance to treatement . This case raises a critical clinical question: does a late-stage recurrence of bullous symptoms represent a secondary para neoplastic manifestation of a new malignancy, or is it a distinct autoimmune entity triggered by a change in the patient's immune landscape?

Case Presentation

We report the case of a 49-year-old woman with a medic al history of severe PV diagnosed in 2009. She is in complete clinical remission since 2016 by treatment with systemic corticosteroids and azathioprine. However, in January 2025, she was diagnosed with invasive ductal carci noma of the right breast (pT1cN1a) and underwent a tumorectomy followed by a chemotherapy protocol (3AC-3T). Four days after her fifth cycle, the patient presented with rapid-onset labial bullae that evolved into extens ive oral erosions, involving the palate, buccal mucosa, and tongue. These lesions were accompanied by severe odynophagia and dysphagia. Diagnostic confirmation of paraneoplastic pemphigus was obtain ed through labial biopsy, direct immunofluorescence (DIF), and ELISA testing, which revealed a broad spectrum of autoanti bodies including Dsg1, Dsg3, BP230, envoplakin, and collagen VII.

Upon exam ination, the patient also displayed hyperpigmented scarring on the trunk from her 2009 episode, and her Pemphigus Disease Area Index (PDAI) was recorded at 12.

The emergence of paraneoplastic pemphigus 16 years after an initial episode of PV is exceptional and invites several pathogenic hypotheses.

First, it is possible that the initial PV in 2009 was actually an early, low-grade manifestation of a paraneoplastic process that preceded the clinical detection of the breast carcinoma by over a decade. Literature suggests that PNP can precede tumor disco very in approximately one-third of cases, indicating that certain autoimmune manifestations may act as long-term precur sors to malignancy. This hypothesis is supported by the extreme rarity of two distinct types of pemphigus coexisting in the same patient.

Secondly, these could be two separate entities: a classic PV in 2009 followed by a de novo PNP in 2025. This theory is supported by the long clinical interval, the specific onset of breast cancer, and the multi-specific antibody profile (notably anti-envoplakin).

Furthermore, the PNP may have been triggered by the 3AC-3T chemotherapy and the overall immunological stress associated with the malignancy. This environment likely disrupted immune tolerance, leading to the reactivatio n of autoreactive lymphocytes and the phenomenon of "epitope spreading," where the immune system begins targetin g new antigens like the plakin family.

Conclusion

This case presents a unique immunological crossroads: a patient with quiescent Pemphigus Vulgaris for 16 years develops Paraneoplastic Pemphigus immediately following breast cancer chemotherapy.

Two hypotheses emerge: either the 2009 PV was an unrecognized early paraneoplastic manifestation preceding tumor detection by over a decade, or chemotherapy and malignancy triggered true epitope spreading—transforming stable PV into aggressive PNP with plakin antibodies.

The detection of anti-envoplakin confirms PNP, not simple relapse. This underscores a critical lesson: history of PV does not exclude PNP. When bullous disease recurs with malignancy, aggressive investigation is mandatory. Treatment must target both autoimmune eruption and underlying neoplasm, as PNP carries high mortality. The immune system's evolution over 16 years reminds us that autoimmune history is never truly closed.

EADV CONGRESS
VIENNA
30 SEP - 3 OCT 2026

Abstract N°: 121

12-month effect of semaglutide on psoriatic lesions in obese patients suffering from diabetes mellitus type 2- a open labeled interventional follow-up study

Jelena Petkovic- Dabic*[1]

[1] University Clinical Center of Republic of Srpska, Faculty of medicine Banja Luka, Banja Luka, Bosnia and Herzegovina

Introduction

Psoriasis is considered an inflammatory multisystemic disease that, in addition to the skin, can also affect the joints, in the form of the development of psoriatic arthritis, and numerous other organs in the form of the so-called comorbid diseases, such as metabolic syndrome, diabetes, cardiovascular diseases and depression. It has been proven that patients with psoriasis have a higher frequency of Diabetes mellitus type 2 (T2DM) compared to the general population. Observational data indicate a more aggressive (severe) course of T2DM too and a higher prevalence and risk of micro- and macro-vascular complications among patients compared to those without psoriasis.

Materials and Methods

After we are demonstrating semaglutide's effects on PASI scores during 12 weeks of treatment [Petkovic at al, 2025.], a open labeled interventional follow-up study was conducted involving five obese patients with psoriasis and T2DM over 12 months of therapy. The objective of this Follow Up study was to investigate the effect of a GLP-1 receptor agonist semaglutide therapy on pro-inflammatory factors in the serum and the severity of the clinical picture of psoriasis in obese patients with type 2 diabetes mellitus (T2DM) on chronic metformin therapy. After initial period of 12 weeks, five of total number treated patients with semaglutide (n = 15) were followed-up during 12 months along with standard metformin antidiabetic therapy.

Results

The results demonstrated that the severity of the clinical picture of psoriasis, determined by the Psoriasis Area and Severity Index (PASI) score, was significantly better after the administration of semaglutide. Also, the quality of life in the group of patients who received the drug, measured by the Dermatology Life Quality Index (DLQI), improved significantly after 12 months.

Conclusions

Our 12-month follow-up study demonstrates that long-term treatment with semaglutide, in addition to standard antidiabetic therapy, leads to a significant and sustained clinical improvement in patients with moderate-to-severe plaque psoriasis and comorbid type 2 diabetes and obesity. These results suggest that GLP-1 receptor agonists like semaglutide represent a promising therapeutic strategy for a "dermometabolic" approach to psoriasis.

EA DV CONGRESS
VIENNA
30 SEP - 3 OCT 2026

Abstract N°: 128

Hypogammaglobulinemia, Late-Onset Neutropenia and Infection After Rituximab in Pemphigus, with Divergent Desmoglein Antibody and Immunoglobulin Kinetics: A Retrospective Cohort Study

Ece Gokyayla[1], Mert Bardak*[1], Hakan Kocer[1], Nezahat Mizrakli[1], Idil Unal[1], İlgen Ertam[1], Isil Karaarslan[1], Nilay Duman[1], Ayda Acar[2]

[1] Ege University Hospital Department of Dermatology and Venereology, Izmır, Türkiye

[2] Private practice, Izmir, Türkiye

Introduction

Pemphigus is a rare autoimmune blistering disease treated first-line with rituximab. Reduction of B lymphocytes lowers pathogenic desmoglein antibodies but may also suppress the synthesis of protective immunoglobulin, leading to hypogammaglobulinemia, and late-onset neutropenia is another uncommon adverse effect, both of which may increase infection risk. Most safety data derive from lymphoma, rheumatoid arthritis and vasculitis cohorts. In pemphigus, where cycles are repeated less often, the frequency of hypogammaglobulinemia and late-onset neutropenia, the baseline markers of risk, and whether desmoglein antibody titers and total immunoglobulin fall together have not been defined; we therefore conducted a single-center retrospective cohort study of pemphigus patients treated with rituximab to assess hypogammaglobulinemia, late-onset neutropenia and infection during rituximab treatment, the baseline predictors of hypogammaglobulinemia, and whether desmoglein antibody titers and total immunoglobulin fall together.

Materials and Methods

Single-center retrospective cohort study of 97 patients given rituximab for pemphigus between January 2015 and June 2026. IgG, IgA and IgM levels, absolute neutrophil count, desmoglein antibody titers and the methylprednisolone dose were recorded before each cycle and at months 3 and 6. Hypogammaglobulinemia was defined as an IgG level below 700 mg/dL at any measurement after rituximab, the pretreatment value being used only as a predictor, and severe hypogammaglobulinemia as a level below 400 mg/dL. Late-onset neutropenia was defined as a neutrophil count below 1.5x10^3/uL at least four weeks after the last infusion. Patients receiving intravenous immunoglobulin were excluded, leaving 69 (Figure 1).

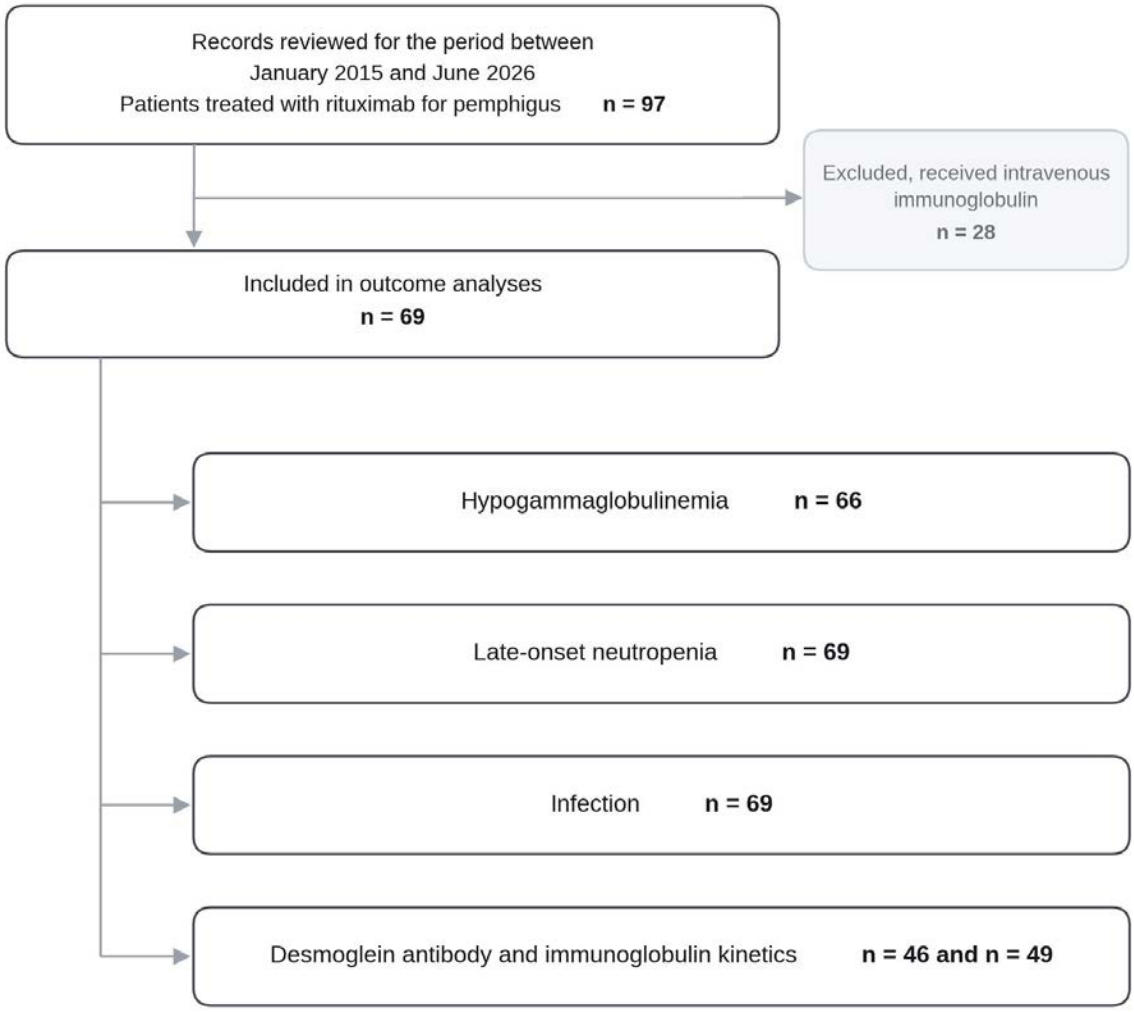

Flow of the patients through the study.

Results

Of the 97 patients, 60 were women and 37 men, the mean age was 59.1 years, 87 had pemphigus vulgaris and 10 foliaceus, and the median number of cycles was 1 (1-6). Post-treatment IgG could be assessed in 66 patients. Hypogammaglobulinemia occurred in 12 patients (18%, 95% CI 11-29), the lowest value was 497 mg/dL and no patient developed severe hypogammaglobulinemia (Figure 2A). Among the 51 patients whose baseline IgG was 700 mg/dL or above, 5 (10%) developed new-onset hypogammaglobulinemia and baseline IgG discriminated them comparably (AUC 0.83 vs 0.90). The cumulative number of cycles was not associated with IgG levels (rho=-0.11, p=0.37). Median age was higher and median baseline IgG and IgM were lower in patients who developed hypogammaglobulinemia, whereas baseline IgA was similar. Areas under the curve were 0.90 for IgG (cut-off 800 mg/dL), 0.83 for IgM (60 mg/dL) and 0.71 for age (60 years). Baseline IgG and IgM retained significance after false discovery rate correction. Late-onset neutropenia was not detected in any of the 97 patients and the lowest count was 1.68x10^3/uL. Infection occurred in 5/69 patients (7%) and severe infection in 2/69 (3%), both pneumonia and one with hypogammaglobulinemia. Infection occurred in 3/12 patients with hypogammaglobulinemia (25%) and in 2/54 without (4%), a risk difference of 21 percentage points (exact odds ratio 8.2, 95% CI 0.8-111.7). Six months after induction, desmoglein 1 and desmoglein 3 antibody titers had fallen to 16% and 19% of baseline whereas IgG and IgA remained at 97%, with the most pronounced decline seen in IgM (83%, Figure 2B). In the 41 patients with both measurements the ratio to baseline was lower for desmoglein antibodies than for total immunoglobulin ($p<0.001$), and this ratio was unrelated to hypogammaglobulinemia and to the IgG ratio.

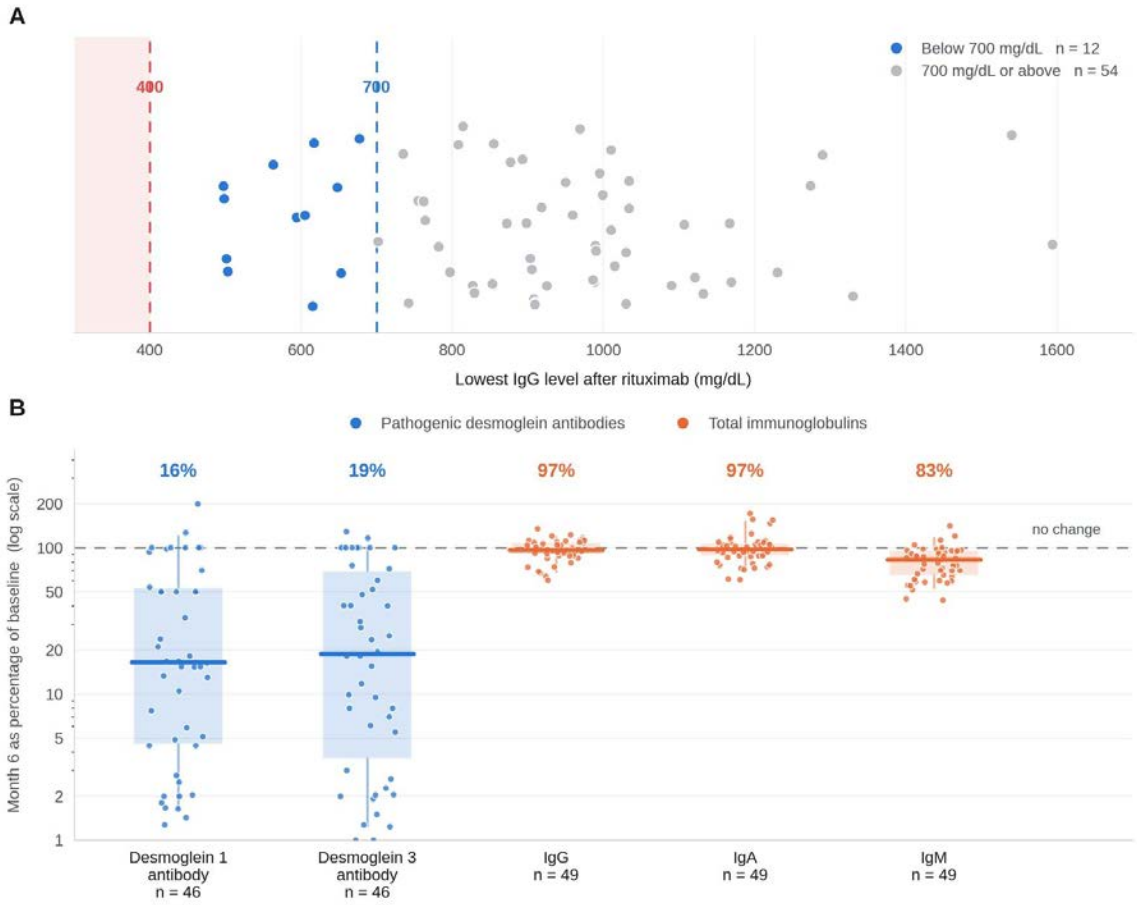

A, lowest IgG level after rituximab in each patient. B, month 6 desmoglein antibody titers and total immunoglobulin levels as a percentage of baseline.

Conclusion

Hypogammaglobulinemia remained mild, severe hypogammaglobulinemia and late-onset neutropenia were not observed and severe infection was rare. The fall in desmoglein antibodies was not accompanied by a fall in total immunoglobulin, so the two are not interchangeable measures. Advanced age and low baseline IgG and IgM levels emerged as candidate markers of risk, which supports measuring immunoglobulin levels before treatment.

EA DV CONGRESS
VIENNA
30 SEP - 3 OCT 2026

Abstract N°: 151

Effect of Early Omalizumab Initiation on Autoimmune Comorbidities in Chronic Urticaria: A Retrospective Cohort Study Using the TriNetX Database

Yi-Hsuan Shen*[1], Yu-Chen Huang[1, 2, 3]

[1] Department of Dermatology, Wan Fang Hospital, Taipei Medical University, Taipei, Taiwan
[2] Department of Dermatology, School of Medicine, College of Medicine, Taipei Medical University, Taipei, Taiwan
[3] Research Center of Big Data and Meta-analysis, Wan Fang Hospital, Taipei Medical University, Taipei, Taiwan

Introduction

A growing body of evidence indicates the presence of a substantial autoimmune component in chronic urticaria (CU) pathogenesis. Omalizumab, an anti-IgE monoclonal antibody, can effectively treat CU by suppressing mast cell degranulation and modulating immune responses. Omalizumab has been proposed to reduce IgE autoantibodies to tissue factor and thyroglobulin, prompting us to examine whether early omalizumab use may lower the risk of autoimmune thyroid disease (ATD) and other autoimmune conditions.

Materials and Methods

This retrospective cohort study, conducted in December 2025, utilized data from the TriNetX Global Collaborative Network. Patients with CU were identified using the ICD-10-CM code L50.8. Omalizumab use was defined as having received at least two prescriptions. The outcomes included systemic lupus erythematosus (SLE) (ICD-10-CM: M32), Sjögren's syndrome (ICD-10-CM: M35.0), rheumatoid arthritis (RA) (ICD-10-CM: M05, and M06), and ATD (ICD-10-CM: E06.3, E05.0, E05.00, and E05.01). Patients were grouped by omalizumab initiation: early (<1 year) or late (≥1 year) after CU diagnosis. Subgroup analyses were included those with the initiation of systemic corticosteroids, cyclosporine, or dupilumab, and those absence of these treatments. Propensity score matching was performed at a 1:1 ratio to balance baseline characteristics including baseline demographics, lifestyle factors, comorbidities, medication use, and laboratory parameters between groups.

Results

After propensity score matching, the overall CU cohort used to evaluate the risk of ATD included 1,967 patients in both the early and late omalizumab initiation groups. In the early initiation group, the mean age was 37.8 years, with 79.5% women and 66.2% identifying as White. Compared with the late initiation group, patients with CU receiving early omalizumab initiation had a significantly lower risk of ATD (HR: 0.482, 95% CI: 0.289–0.804). Conversely, Cox regression analyses showed no significant differences in the risks of RA, Sjögren's syndrome, or SLE between the two groups (HR: 0.637, 95% CI: 0.370–1.096; HR: 0.919, 95% CI: 0.554–1.523; and HR: 0.572, 95% CI: 0.280–1.168, respectively; Table 1). Among patients receiving systemic corticosteroids, cyclosporine, or dupilumab, as well as those not receiving these treatments, the analyses showed either no significant differences between early and late initiation or fewer than 10 outcome events, precluding detailed presentation of the results. The results of sensitivity analyses were consistent when limited to patients with ≥2 CU diagnoses or ≥3 omalizumab records, and early versus late magnesium oxide initiation showed similar autoimmune disease risk.

Table 1. Comparison of autoimmune disease risk between early and late omalizumab initiation.

	Early initiation in overall patients with CU	Late initiation in overall patients with CU		Early initiation in patients receiving systemic corticosteroids, CSA, or dupilumab	Late initiation in patients receiving systemic corticosteroids, CSA, or dupilumab	
Outcome	Total eligible patients (No. of outcomes, 1–15 years)	Total eligible patients (No. of outcomes, 1–15 years)	Hazard ratio (95% CI)	Total eligible patients (No. of outcomes, 1–15 years)	Total eligible patients (No. of outcomes, 1–15 years)	Hazard ratio (95% CI)
ATD	**1,851 (19)**	**1,847 (75)**	**0.482 (0.289, 0.804)**	976 (16)	968 (42)	0.658 (0.366, 1.182)
RA	1,926 (18)	1,912 (53)	0.637 (0.370, 1.096)	1,019 (13)	1,012 (28)	0.768 (0.394, 1.498)
Sjögren's syndrome	1,922 (23)	1,920 (51)	0.919 (0.554, 1.523)	-[a]	-[a]	-[a]
SLE	1,936 (10)	1,925 (33)	0.572 (0.280, 1.168)	1,032 (11)	1,021 (17)	1.087 (0.505, 2.340)

CU: chronic urticaria, CSA: cyclosporine, ATD: autoimmune thyroid disease, RA: rheumatoid arthritis, SLE: systemic lupus erythematosus

[a] According to TriNetX's enhanced privacy policy, counts between 1 and 9 are masked and displayed as blank. Statistical analysis was not feasible because fewer than 10 outcome events were recorded.

Comparison of autoimmune disease risk between early and late omalizumab initiation

Conclusions

Our study suggests early omalizumab use may lower ATD risk, warranting future studies to clarify mechanisms and long-term benefits of early therapy.

EADV CONGRESS
VIENNA
30 SEP - 3 OCT 2026

Abstract N°: 183

Improvement of Cutaneous Manifestations in Patients with SLE Treated with Anifrolumab in the ASTER Real-World Study: 12-Month Interim Analysis

François Chasset*[1], Marta Mosca[2], Julia Weinmann-Menke[3, 4], Ioannis Parodis[5, 6], Zahir Amoura[7], Mark Matsos[8], Lyra Agustin[9], Parisa Karimi[10], Jonatan Natman[11], Ayobami Olojo[9]

[1] Dermatology and Allergology Department, Faculty of Medicine, Tenon Hospital, and INSERM U1135, CIMI, Sorbonne University, Paris, France

[2] Department of Clinical and Experimental Medicine, University of Pisa, Pisa, Italy

[3] Department of Nephrology and Rheumatology, Center of Immunotherapy, Medical Center of the Johannes Gutenberg University, Mainz, Germany

[4] Department of Nephrology, University Hospital Heidelberg, Heidelberg, Germany

[5] Karolinska Institutet, Karolinska University Hospital, Solna, Sweden

[6] Örebro University, Örebro, Sweden

[7] French National Reference Centre for Systemic Lupus Erythematosus, Pitié-Salpêtrière Hospital, Paris, France

[8] McMaster University Medical Center, Hamilton, Ontario, Canada

[9] BioPharmaceuticals Medical, AstraZeneca, Cambridge, United Kingdom

[10] BioPharmaceuticals Medical, AstraZeneca, Gaithersburg, Maryland, United States

[11] BioPharmaceuticals Medical, AstraZeneca, Gothenburg, Sweden

Introduction

Systemic lupus erythematosus (SLE) affects multiple organ systems, with up to 80% of patients experiencing cutaneous manifestations. Anifrolumab, a monoclonal antibody inhibiting type 1 interferon signaling, is approved in moderate to severe SLE, and can improve disease activity across multiple organs, particularly in the mucocutaneous domain. Here, we characterize the effect of anifrolumab on cutaneous SLE manifestations from the real-world ASTER study.

Materials and Methods

ASTER (NCT05637112) is an ongoing, multinational, observational study assessing the effectiveness of anifrolumab in SLE patients in routine clinical practice. Adults were enrolled during routine visits prior to anifrolumab initiation (IV 300 mg once every 4 weeks) alongside standard therapy (including antimalarials, glucocorticoids, immunosuppressants, and/or biologics). Patients in the 12-month (M) interim analysis had either completed their 12M visit or had ≥12M in the study, from first anifrolumab infusion to the data cut-off date. CLASI-Activity (CLASI-A) scores were evaluated at the pretreatment visit and at 3, 6, 9, and 12M of follow-up. Here, we present data for all patients with an assessment at 12M, and in the subgroup of patients with CLASI-A ≥10 (moderate to severe disease activity) at the pretreatment visit.

Results

Of the 255 patients included in this 12M interim analysis (overall cohort, irrespective of cutaneous involvement), 59 (23.1%) had CLASI-A ≥10 at the pretreatment visit (CLASI-A ≥10 subgroup). Pretreatment demographics and clinical characteristics were broadly similar between the CLASI-A ≥10 subgroup and the overall cohort: mean age was 44.3 and 45.0 years, and 91.5% and 89.8% of patients were female, respectively. Median time from SLE diagnosis to first anifrolumab infusion was 12.3 years and 12.2 years in the CLASI-A ≥10 subgroup and overall cohort. Median pretreatment CLASI-A score in the CLASI-A ≥10 subgroup was 14.0 (interquartile range [IQR]

11.0–20.0) vs 4.0 (1.0–9.0) in the overall cohort. Pretreatment, 22.0% of patients in the CLASI-A ≥10 subgroup had CLASI-A scores of 21–70, vs 5.1% in the overall cohort. In the CLASI-A ≥10 subgroup, median (IQR) CLASI-A score decreased following anifrolumab treatment (3M: 3.5 [2.0–6.0], n=54; 12M: 1.0 [0.0–2.5], n=47); reductions in CLASI-A score were also seen in the overall cohort (3M: 1.0 [0.0–3.0], n=225; 12M: 0.0 [0.0–2.0], n=189). In the CLASI-A ≥10 subgroup, 79.6% of patients had a CLASI-A-50 response at 3M, increasing to 95.7% by 12M (**Figure**). A CLASI-A-70 response was achieved by 59.3% at 3M and 89.4% at 12M. Among patients in the CLASI-A ≥10 subgroup with available data at 3M and ≥1 follow-up visit, 76.5% (39/51) of patients attained CLASI-50 response at 3M and sustained it to their next non-missing study visit. The proportion of patients with a CLASI-A score of 0–1 or 0–3 also increased over time with anifrolumab treatment in both the CLASI-A ≥10 subgroup and in the overall cohort (**Figure**). In the CLASI-A ≥10 subgroup, 50.0% and 80.9% of patients had CLASI-A scores of 0–3 by 3M and 12M, respectively, whereas in the overall cohort, CLASI-A 0–3 was achieved in 78.7% and 87.8% at 3M and 12M. In the CLASI-A ≥10 subgroup, 24.1% patients achieved CLASI-A 0–1 at 3M and 55.3% by 12M. Achievement of CLASI-A 0–1 was 56.9% at 3M and 71.4% at 12M in the overall cohort.

Figure: Proportion of patients achieving CLASI-A-50 or CLASI-A-70 responses, or CLASI-A scores of 0–3 or 0–1 over time with anifrolumab in the 12-month interim analysis of the real-world ASTER study

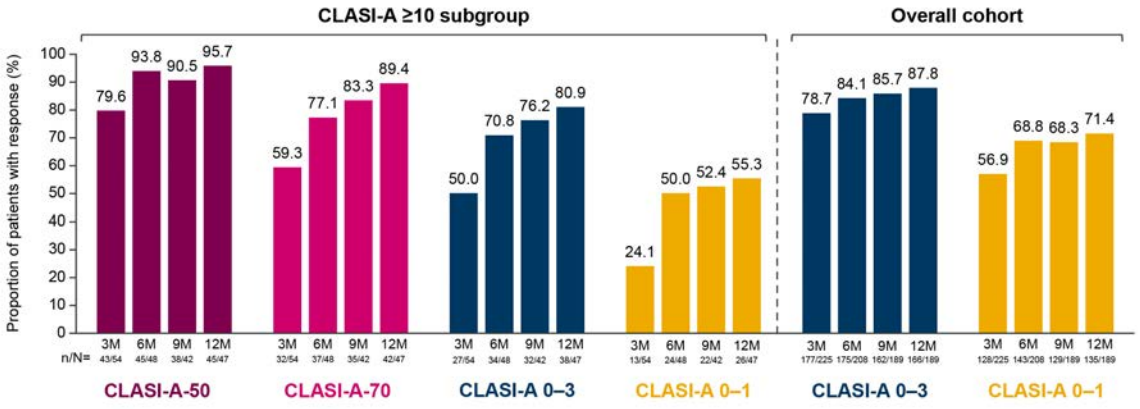

The overall cohort represents all patients that had either completed their 12-month study visit or had ≥12 months in the study, from first anifrolumab infusion to the data cut-off date. The CLASI-A ≥10 subgroup includes patients with available CLASI-A data and a CLASI-A score of ≥10 at the pretreatment visit.
CLASI-A-50 response: ≥50% reduction in CLASI-A score from the pretreatment visit; CLASI-A-70 response: ≥70% reduction in CLASI-A from the pretreatment visit.
Statistical testing was not performed; results are descriptive only. No imputation of missing values was performed; only patients with non-missing CLASI-A scores at the respective time point were included in this complete-case analysis.
CLASI-A, Cutaneous Lupus Erythematosus Disease Area and Severity Index-Activity; M, month of follow-up visit; n, number of patients with a response; N, total number of patients with available data.

Conclusions

Meaningful cutaneous improvements were seen as early as the first study visit (3M) in SLE patients treated with anifrolumab in routine practice, even in those with moderate to high cutaneous disease activity prior to anifrolumab initiation. The majority of patients, regardless of pretreatment CLASI-A score, achieved stringent thresholds of response (ie, CLASI-A 0–1) by the second visit (6M). Our data support further investigation of anifrolumab in patients with cutaneous lupus erythematosus in the ongoing phase 3 LAVENDER study (NCT06015737).

Study and medical writing support funding: AstraZeneca

EA DV CONGRESS
VIENNA
30 SEP - 3 OCT 2026

Abstract N°: 190

Stapokibart for Treatment of Immune Checkpoint Inhibitor-induced Bullous Pemphigoid

Min Zou*[1], Wei Li[1]

[1] West China Hospital, Sichuan University, Chengdu, China

Introduction

Bullous pemphigoid (BP) is the most common subepidermal autoimmune blistering disease, with escalating incidence in the aging population. As a rare immune-related adverse event, immune checkpoint inhibitor-induced BP (ICI-BP) represents a particularly challenging subtype that frequently requires systemic corticosteroids and interruption of ICI therapy for cancer. Type 2 inflammatory pathways are pivotal in BP pathogenesis, leading to FDA approval of dupilumab, an IL-4Rα antagonist, for adult BP in 2025. Stapokibart, another humanized monoclonal antibody targeting IL-4Rα currently utilized for inflammatory diseases including atopic dermatitis and seasonal allergic rhinitis, offers a promising therapeutic alternative. We report, to our knowledge, the first case of ICI-BP successfully managed with stapokibart.

Case Presentation

A 68-year-old man diagnosed with lung adenocarcinoma over a year ago had been receiving the programmed death-1 (PD-1) inhibitor sintilimab. Ten months ago, after 2 months of sintilimab therapy, he developed erythema and papules with pruritus on the feet that gradually generalized. He was previously treated with topical and systemic corticosteroids, achieving partial remission that relapsed upon discontinuation. Over the preceding month, his disease worsened with newly-emerged blisters and intolerable pruritus, prompting referral to our department.

Physical examination revealed scattered erythema, vesicles, hemorrhagic bullae, and erosions, with a visual analogue scale (VAS) pruritus score of 8, and the hands were prominently involved. Histopathology of a left arm biopsy showed subepidermal blisters, liquefaction degeneration of the basal layer, and a dermal infiltrate of lymphocytes and eosinophils. Direct immunofluorescence demonstrated linear deposition of IgG and C3 in the basement membrane zone, while indirect immunofluorescence using rat bladder as substrate was negative. Laboratory studies demonstrated markedly elevated total IgE (7,600 IU/mL; reference: <165) and positive anti-BP180 antibodies (185.62 AU/mL; reference: <20, chemiluminescence assay), with negative anti-BP230, anti-desmoglein 1 and 3 antibodies. These findings, in conjunction with his clinical history, supported a diagnosis of ICI-BP.

ICI therapy was discontinued. We initiated treatment with oral prednisone 40 mg/d, minocycline hydrochloride 100 mg/d, and topical glucocorticoids. After two weeks, improvement was minimal (BPDAI decreased from 34 to 30), the pruritus score remained at 8, and the patient reported adverse effects, including dizziness from prednisone. We obtained consent and administered stapokibart 600 mg as an initial dose, followed by 300 mg every two weeks, while reducing prednisone to 30 mg/d. Under this regimen, the patient's BPDAI and VAS score progressively declined, antibody titers decreased correspondingly, with glucocorticoid dose successfully tapered. Steroid-related adverse effects diminished, and no stapokibart-associated adverse events were reported.

At week 8 of stapokibart therapy, the BPDAI decreased to 7, and anti-BP180 antibodies became negative. We therefore reduced prednisone to 10 mg/d and adjusted stapokibart to 300 mg every 4 weeks. By week 24 of stapokibart treatment, the cutaneous lesions had nearly cleared, with only mild pruritus. Both stapokibart and

glucocorticoids were discontinued. During the follow-up, the patient shows no signs of BP recurrence.



Figure 1. Changes in cutaneous lesions of the patient during stapokibart treatment: A, Week 0; B, After 12-week treatment; C, After 24-week treatment.

Conclusion

To our knowledge, no reports have described stapokibart use in ICI-BP, and even published experience in classical BP is virtually absent. ICI-BP differs clinically from classical BP, is complex to manage, and often requires systemic glucocorticoids. This case illustrates the therapeutic potential and safety of stapokibart in ICI-BP and the capacity to facilitate rapid steroid tapering, with prospective studies warranted to further evaluate.

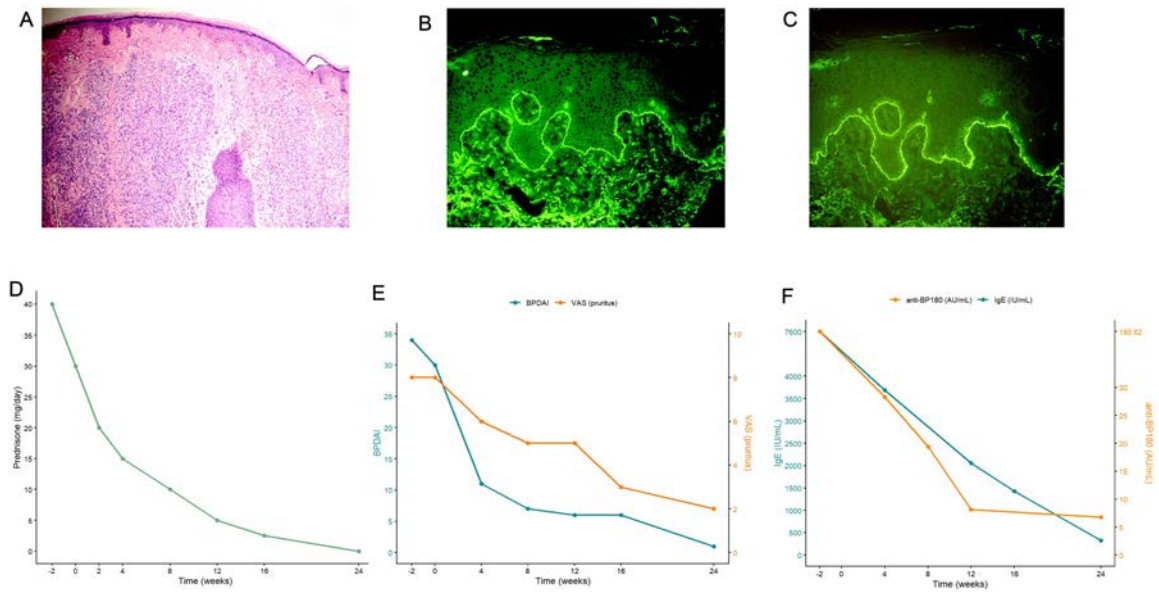

Figure 2. A, Histopathology examination exhibits irregular epidermal hyperplasia, liquefaction and degeneration of partial basal layer, and infiltration of a small number of lymphocytes, eosinophils, and neutrophils in the superficial dermis (hematoxylin and eosin staining, ×100); B and C, Linear IgG and C3 deposition in basal membrane zone in direct immunofluorescence (×200); D, Dose changes of glucocorticoids in the patient; E, Changes in BPDAI (bullous pemphigoid disease area index) and VAS (visual analogue scale) of pruritus scores; F, Changes in anti-BP180 antibodies and total IgE titers.

EADV Congress 2026, VIENNA
30 SEPTEMBER - 03 OCTOBER 2026
POWERED BY M-ANAGE.COM

EA DV CONGRESS
VIENNA
30 SEP - 3 OCT 2026

Abstract N°: 191

A Rare Case of Inverse Psoriasis and Psoriatic Arthritis in a Patient with Antisynthetase Syndrome

Fan Xu*[1], Xiao-Yong Man[1]

[1] Department of Dermatology, Second Affiliated Hospital, Zhejiang University School of Medicine, hangzhou, China

Introduction

Antisynthetase syndrome (ASS) is a rare autoimmune disorder serologically characterised by the presence of anti-tRNA synthetase (ARS) antibodies and clinically manifests as interstitial lung disease (ILD), myositis, arthritis, fever, Raynaud phenomenon and mechanic's hands. ASS is thought to result from a breakdown of immune tolerance, resulting in self-reactivity of the immune system. Psoriasis is a chronic systemic inflammatory disease affecting not only the skin but also various tissues and organs including joints, gut, eye, and metabolic and cardiovascular systems. Here, we present a rare case involving the development of psoriasis- initially scalp psoriasis, followed by inverse psoriasis and psoriatic arthritis (PsA) in a patient with ASS.

Case Presentation

A 44-year-old female was admitted to our department with a 2-year history of erythematous scaly plaques on the scalp and a 2-week history of erythematous lesions in the flexural areas accompanied by joint pain.
Six years earlier, she was diagnosed with ASS (anti-EJ +++, anti-Ro-52 +++, along with ILD). Over the course of her illness, she received various treatments in response to changes in her condition and was currently being treated with oral methylprednisolone (16 mg QD) and nintedanib (100 mg BID). Two years ago, she developed erythematous scaly plaques on the scalp, without similar lesions elsewhere on the body. Dermoscopic examination revealed features consistent with scalp psoriasis. Topical treatment with calcipotriol and halometasone resulted in partial improvement of the lesions. Two weeks before admission, she developed symmetric, mildly thickened, smooth erythematous plaques in the flexural areas, including the neck, antecubital fossae, axillae, inframammary folds, vulva, and perianal area. Concurrently, she experienced pain in the left knee, heel, and left index finger joint, without noticeable joint swelling or deformity.
Laboratory tests: CRP 12 mg/L, CK-MB 31 U/L, ANA 1:80 (++), anti-EJ +++, anti-Ro-52 +++, anti-SS-A +++, anti-SS-B ++, and RF, anti-CCP, ANCA, and HLA-B27 were negative. Skin biopsy of lesions in the antecubital fossae showed mild hyperkeratosis and perivascular lymphocytic infiltration in the dermis. MRI of the left knee showed mild soft tissue edema and minimal joint effusion. The patient was additionally treated with oral tofacitinib (5 mg BID), and two weeks later, the flexural erythema and joint pain had significantly improved.
Results: The patient was diagnosed with ASS, scalp psoriasis, inverse psoriasis, and PsA. She was additionally treated with oral tofacitinib (5 mg BID), resulting in significant improvement of scalp and flexural lesions, as well as joint pain within two weeks.

Conclusion

The overlapping of psoriasis and connective tissue diseases has been occasionally reported. However, coexistence of psoriasis (especially inverse psoriasis and PsA) and ASS is extremely rare. In addition to the genetic background, shared pathogenesis including pDC, type I interferon, and IL-23/Th17 axis, may contribute to the development of both psoriasis and ASS. Furthermore, in this case, the addition of the JAK inhibitor tofacitinib to baseline treatment with corticosteroids and nintedanib appeared to be effective.

EADV CONGRESS
VIENNA
30 SEP - 3 OCT 2026

Abstract N°: 203

Impact of Rituximab Timing on Long-Term Outcomes in Pemphigus: A Real-World Propensity-Matched Study

Khalaf Kridin*[1], Ralf Ludwig[2]

[1] Galilee Medical Center, Nahariya, Israel, Nahariya, Israel

[2] University of Lubeck, Lubeck, Germany, Lübeck, Germany

Introduction

Rituximab has transformed the management of pemphigus; however, the optimal timing of initiation relative to disease onset remains uncertain. In the current study, we sought to compare long-term outcomes among patients with pemphigus receiving early rituximab (within 1 year of diagnosis) versus late rituximab (≥1 year after diagnosis).

Materials and Methods

We conducted a retrospective cohort study using the TriNetX Global Collaborative Network. Adult patients with pemphigus treated with rituximab were identified and propensity score–matched 1:1 based on demographic characteristics, comorbidities, and prior immunosuppressive exposure. Primary outcomes included mortality, corticosteroid-related complications (type-2 diabetes mellitus, hypertension, osteoporosis), infectious and thromboembolic events, relapse, and systemic corticosteroid dependence. Hazard ratios (HRs) were estimated using Cox regression.

Results

A total of 1,172 patients were included (586 early; 586 late). Early rituximab was associated with significantly reduced risks of type-2 diabetes mellitus (6.2% vs 18.8%; HR 0.44, 95% CI 0.30–0.65), osteoporosis (3.3% vs 12.8%; HR 0.40, 95% CI 0.24–0.66), and hypertension (13.1% vs 31.6%; HR 0.58, 95% CI 0.43–0.76). Mortality and infectious complications were numerically lower with early treatment but did not reach statistical significance. Early rituximab was associated with sustained reductions in relapse and corticosteroid dependence at ≥2 years (relapse: 47.3% vs 85.2%; HR 0.80; corticosteroid use: 37.5% vs 86.0%; HR 0.56), ≥3 years (HR 0.77 and 0.55, respectively), and ≥5 years (HR 0.73 and 0.51, respectively).

Conclusions

Early initiation of rituximab in pemphigus is associated with reduced corticosteroid-related complications, lower relapse rates, and decreased long-term corticosteroid dependence compared with delayed treatment, supporting early B-cell depletion as a strategy to optimize long-term outcomes.

EADV CONGRESS
VIENNA
30 SEP - 3 OCT 2026

Abstract N°: 204

Integrated Proteomic Analysis Reveals IL-12B as a Negative Regulator of Disease Activity in Pemphigus Vulgaris

Yale Liu*[1], Shiran Kang[1], Yumin Xia[1]

[1] the Second Affiliated Hospital of Xi'an Jiaotong University, Xi'an, China

Introduction

Pemphigus vulgaris (PV) is an autoimmune blistering disease driven by IgG autoantibodies against desmoglein-3 (Dsg3) and desmoglein-1 (Dsg1). While humoral immunity is central, broader inflammatory networks critically influence disease activity and outcomes. Current clinical indices, such as the Pemphigus Disease Area Index (PDAI), and conventional biomarkers, including anti-Dsg titers, incompletely reflect immunologic activity or predict therapeutic response.

Here, we applied the Olink Target 96 Inflammation panel to profile serum inflammatory proteins in PV patients and healthy controls. We aimed to identify differentially expressed proteins, evaluate their associations with disease severity, autoantibody levels, and treatment response, and define molecular endotypes within PV. These findings may improve biomarker discovery and provide insights into disease mechanisms and precision therapeutic strategies.

Materials and Methods

Serum from 50 PV patients and 50 age- and sex-matched healthy controls was analyzed using the Olink Target 96 Inflammation panel. Differential protein expression was assessed with limma, and correlations with disease severity (PDAI) and anti-DSG1/DSG3 antibody titers were performed. Key candidates were validated by ELISA and immunohistochemistry (IHC), including longitudinal analyses following therapy. In vitro assays examined the impact of IL-12B on T cell polarization.

Results

Eleven proteins were significantly upregulated in PV (log2FC >1), including TNFSF14, AXIN1, IL-8, SIRT2, OSM, ST1A1, CASP-8, CXCL11, EN-RAGE, TGF-α, and STAMBP, reflecting neutrophil chemokine activity, TNF superfamily signaling, and epithelial stress pathways. IL-12B was uniquely downregulated (log2FC <−1) and inversely correlated with PDAI and anti-DSG1 titers. ELISA and IHC confirmed reduced IL-12B in active lesions, with levels rising after clinical remission. Mechanistically, IL-12B promoted Th1 responses while suppressing Th17 polarization in vitro, suggesting its deficiency skews PV immunity toward Th17-driven pathology.

Conclusions

PV exhibits a coordinated inflammatory proteomic signature; however, IL-12B uniquely functions as a negative biomarker of disease activity and a counter-regulatory cytokine. These findings highlight defective IL-12 axis signaling as a mechanistic driver of Th17-mediated pathology and support IL-12B as a candidate for both biomarker development and therapeutic intervention.

EADV CONGRESS
VIENNA
30 SEP - 3 OCT 2026

Abstract N°: 205

Resident memory T cells are the dominant cellular source of IL-13 in bullous pemphigoid

Yale Liu*[1], Shiran Kang[1], Yumin Xia[1]

[1] the Second Affiliated Hospital of Xi'an Jiaotong University, Xi'an, China

Introduction
Bullous pemphigoid (BP) is a prototypic autoimmune blistering disorder driven by type 2 inflammation, in which interleukin (IL)-13 plays a central pathogenic role. Although multiple immune cells have been proposed as sources of IL-13, their variability across patients suggests the existence of a more stable, tissue-resident contributor. Tissue-resident memory T (Trm) cells are long-lived lymphocytes that persist in barrier tissues and orchestrate chronic inflammation. We hypothesized that Trm cells represent a dominant source of IL-13 in BP lesions.

Materials and Methods
We performed an integrated analysis of public datasets and previously generated single-cell RNA sequencing (scRNA-seq) data comprising 30 skin samples (BP, pemphigus vulgaris, atopic dermatitis, psoriasis, and healthy controls), supplemented with newly generated BP and healthy samples. Immune cell populations were re-annotated with preservation of Trm identity, defined as $CD3^{+}CCR7^{-}CD69^{+}ITGAE^{+}$ cells. Type 2 immune activity was quantified using UCell scoring based on curated gene signatures. Multiplex immunofluorescence was conducted to validate IL-4 and IL-13 expression at the protein level. Cell–cell communication was inferred using CellChat to evaluate IL-4/IL-13 signaling networks.

Results
Trm cells were consistently identified across all skin conditions but exhibited a markedly enhanced type 2 signature specifically in BP lesions, comparable to atopic dermatitis and largely absent in psoriasis and pemphigus vulgaris. Protein-level validation demonstrated that IL-13 expression was predominantly localized to Trm cells in BP skin, whereas IL-4 expression was relatively weak. $IL\text{-}13^{+}$ Trm cells were enriched at sites of tissue injury, including the dermal–epidermal junction. CellChat analysis revealed that Trm cells were the principal source of IL-13 signaling, with preferential interaction toward IL13RA1-expressing migratory dendritic cells (migDCs). Spatial co-localization of $IL\text{-}13^{+}$ Trm cells and $LAMP3^{+}$ migDCs further supported a functional interaction axis.

Conclusions
Our findings identify Trm cells as the dominant and previously underappreciated source of IL-13 in BP lesions, refining the cellular basis of type 2 inflammation in this disease. The Trm–IL-13–migDC axis provides mechanistic insight into BP pathogenesis and may explain the clinical efficacy of IL-4/IL-13–targeted therapies. Targeting Trm cell persistence or cytokine production may represent a promising strategy for durable disease control and relapse prevention in BP.

EADV CONGRESS
VIENNA
30 SEP - 3 OCT 2026

Abstract N°: 239

Oesophageal mucous membrane pemphigoid across the diagnostic spectrum: from progressive stricture to haemorrhagic shock

Vanessa Tey*[1]

[1] National University Hospital, Singapore, Singapore

Introduction

Mucous membranepemphigoid (MMP) involving the oesophagus can cause stricture, bleeding and major nutritional compromise. We report two elderly women with severe oesophageal disease at opposite ends of the clinical spectrum, illustrating delayed seronegative scarring disease and acute haemorrhagic presentation.

Case Presentation

Case 1 was a 75-year-old woman with recurrent oral ulceration since 2020/2021. Oral biopsy showed subepithelial blistering mucositis with linear IgG/C3 at the epithelial basement membrane zone. Routine BP180/BP230, desmoglein 1/3 and indirect immunofluorescence were repeatedly negative, although prior NaCl-split skin testing detected roof-binding circulating IgA autoantibodies. She later developed acute dysphagia, diffuse friable ulcerative oesophagitis with stricture, and 16-kg weight loss. Extensive infective and malignancy work-up was negative, supporting presumptive seronegative MMP with severe oesophageal involvement. Multiple steroid-sparing agents were limited by intolerance or toxicity, necessitating pulsed intravenous cyclophosphamide. Case 2 was a 75-year-old woman who presented with a tense blistering eruption without obvious mucosal disease, then developed haematemesis, melena, haemodynamic shock and severe anaemia. Endoscopy demonstrated multiple large oesophageal bullae with active bleeding. Direct immunofluorescence showed linear IgG/C3 with an n-serrated pattern; split-skin indirect immunofluorescence showed an epidermal pattern; immunoblot detected circulating IgG against the C-terminal BP180 fragment, confirming MMP. Escalation to prednisolone 1 mg/kg and rituximab produced marked cutaneous improvement and no recurrent gastrointestinal bleeding.

Conclusion

Oesophageal MMP may present insidiously with strictures and weight loss or catastrophically with upper gastrointestinal haemorrhage, even when routine serology is negative or mucosal signs are initially absent. Early endoscopy, careful exclusion of mimics, and prompt systemic therapy are essential to reduce morbidity.

EA DV CONGRESS
VIENNA
30 SEP - 3 OCT 2026

Abstract N°: 249

Clinical And Immunological Profiles of Immune Checkpoint Inhibitor–Related Bullous Pemphigoid: A Cohort Study from Register Database

Min Zou*[1], Xun Feng[1], Jishu Li[1], Wei Li[1]

[1] West China Hospital, Sichuan University, Chengdu, China

Introduction

Bullous pemphigoid (BP) is the most prevalent autoimmune subepidermal blistering disease, and immune checkpoint inhibitor–associated BP (ICI-BP) has emerged as a clinically challenging subset owing to the coexistence of active malignancy and complex immunomodulatory effects of checkpoint blockade. Although prior case series have suggested that ICI-BP may differ from classic BP in certain features, comparative data on clinical presentation, immunological dynamics, therapeutic management, and prognosis remain scarce. This study aimed to systematically characterise ICI-BP relative to BP occurring in the context of malignancy without ICI exposure and to classic BP, with particular focus on dynamic antibody changes and treatment response.

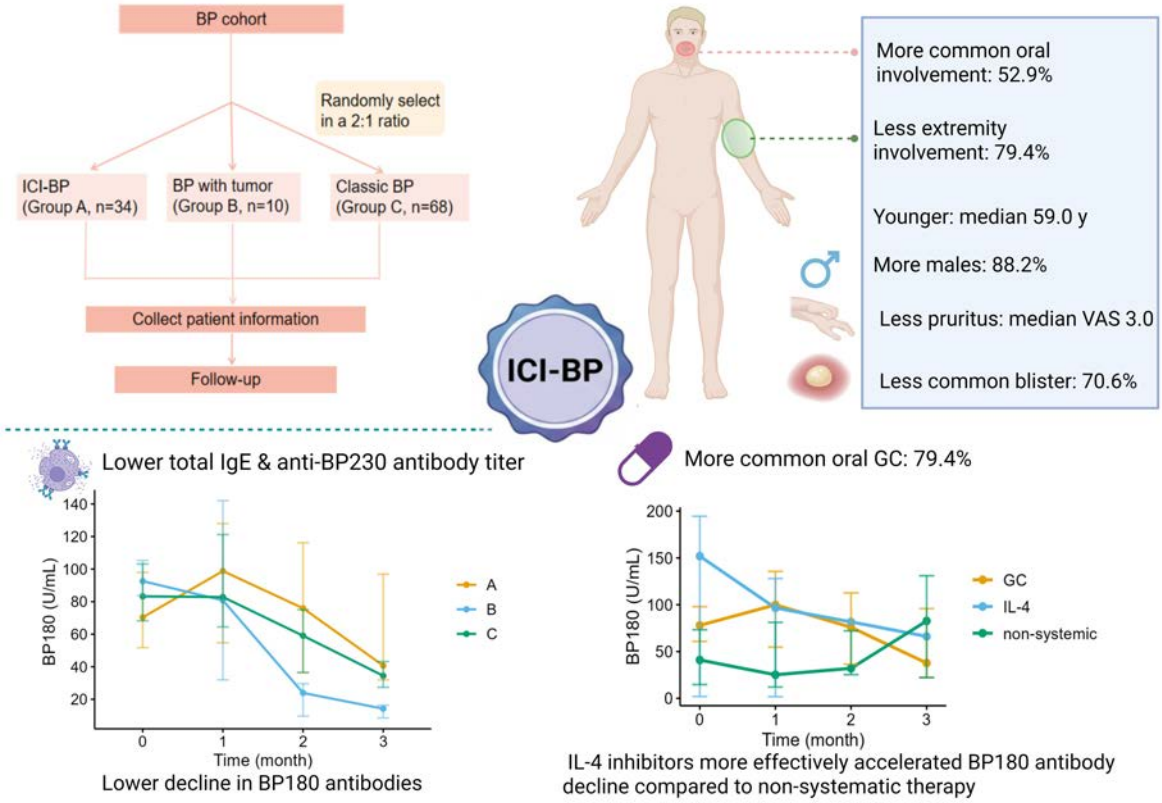

Graphical abstract

Materials and Methods

This retrospective, single-centre cohort study enrolled consecutive patients with BP from the Autoimmune Bullous Disease Registry of West China Hospital between January 2019 and July 2025. Patients were stratified into three groups: Group A (ICI-BP, n = 34), Group B (BP with concomitant malignancy but no ICI exposure, n = 10), and Group C (classic BP, n = 68; randomly sampled at a 2:1 ratio to Group A). Diagnosis was established by clinical

features, histopathology, direct immunofluorescence, and serology (anti-BP180/BP230 ELISA or chemiluminescent immunoassay). Baseline demographics, clinical and laboratory parameters, and treatment modalities were recorded. Short-term (3-month) outcomes—including anti-BP180 titres, Bullous Pemphigoid Disease Area Index (BPDAI), and glucocorticoid dose—were analysed using generalised linear mixed models (GLMM). Long-term overall survival and oncological outcomes were also assessed.

Results

The median follow-up was 24.5 months (IQR 10.8–50.0). All ICI-BP cases were induced by PD-1 inhibitors, most frequently sintilimab (29.4%), with a median latency of 12.0 months. Group A presented at a significantly younger age (median 59.0 years; P < 0.001) with a marked male predominance (88.2%; P = 0.003). Clinically, ICI-BP featured more frequent oral involvement (52.9%; P = 0.024), fewer classic blisters (70.6%; P = 0.016), more non-specific papules/plaques (38.2%; P = 0.026), and lower pruritus VAS scores (median 3.0; P < 0.001). Immunologically, peripheral eosinophil counts, total IgE, and anti-BP230 titres were all significantly lower in Group A than in Group C (P < 0.05), while anti-BP180 titres did not differ at baseline. GLMM analysis revealed a transient, non-significant rise in anti-BP180 reactivity during the first two months in ICI-BP, and the subsequent decline was slower compared with the other groups. Systemic glucocorticoids were required more frequently in Group A (79.4%; P = 0.036), whereas topical corticosteroids and minocycline were used significantly less often. Among ICI-BP patients, IL-4 inhibitors (dupilumab or stapokibart) demonstrated a significantly more rapid decline in anti-BP180 antibody titres compared with non-systemic therapy (P = 0.040). Tumour remission rates were comparable between Groups A and B (32.4% vs. 30.0%; P > 0.999), as was overall mortality across all three groups. However, patients in Group A who died did so significantly earlier than those in Group C (median 6.5 vs. 30.0 months; P = 0.048).

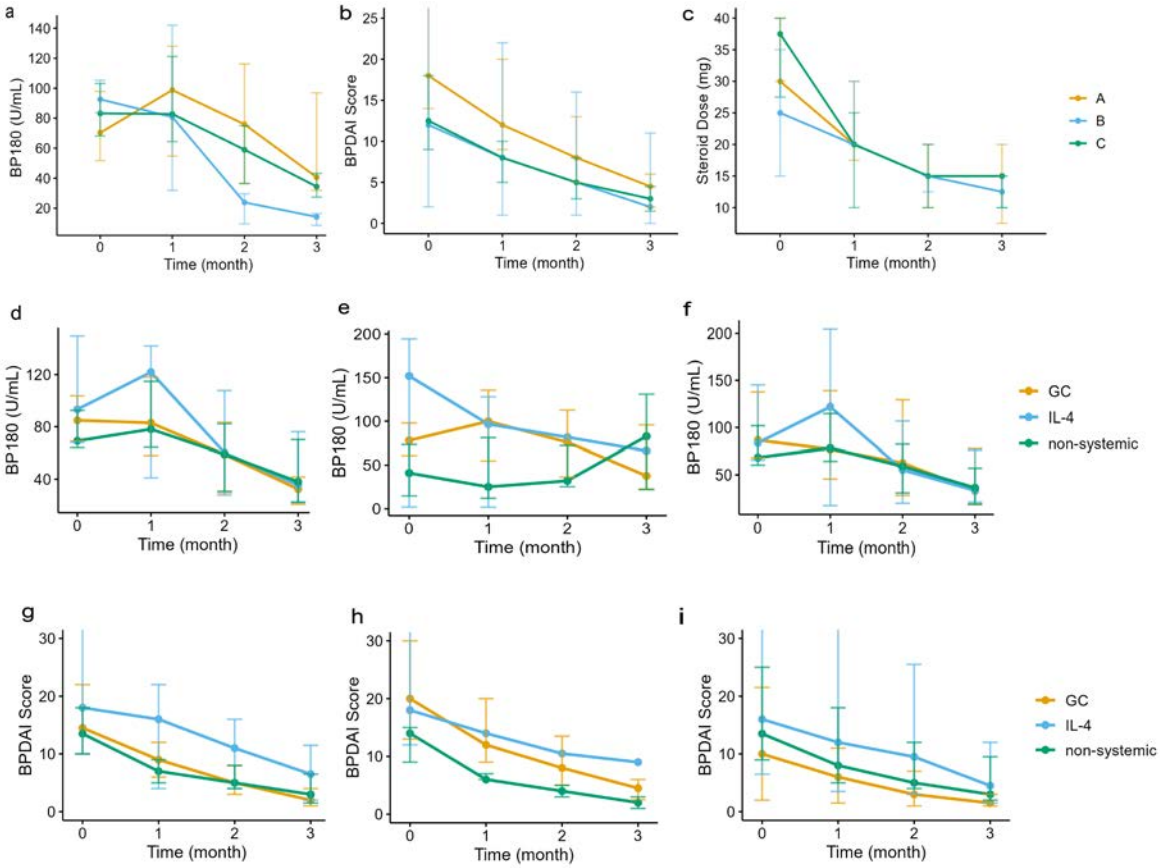

Short follow-up (3 months) data of patients (a-c), changes in anti-BP180 antibodies, BPDAI scores, and corticosteroid dose of overall patients; (d-f) changes in anti-BP180 antibodies among the overall, Group A, and Group C patients with different therapies; (g-i) changes in BPDAI scores among the overall, Group A, and Group C patients with different therapies.

Conclusions

ICI-BP is clinically and immunologically distinct from non-ICI BP, presenting at a younger age with male

predominance, greater oral involvement, atypical morphology, lower eosinophil counts, reduced IgE and anti-BP230 levels, and a slower anti-BP180 antibody decline. A transient early rise in anti-BP180 reactivity may reflect epitope spreading. ICI-BP more frequently necessitates systemic glucocorticoids, while IL-4 inhibitors show superior efficacy in accelerating antibody decline. These findings support individualised diagnostic and therapeutic strategies for ICI-BP patients.

EA DV CONGRESS
VIENNA
30 SEP - 3 OCT 2026

Abstract N°: 269

Efficacy and safety of abdakibart (ABD), a humanized high affinity and potency IgG4 anti-IL-1β agent for treatment of moderate to severe hidradenitis suppurativa at Week 16; IHS4 subgroup and lesion type ANdT results of the Phase 2 placebo-controlled LOTUS Trial

Martina L. Porter*[1], Alexa B. Kimball[1], Mittie Doyle[2], Leanne Gasink[2], Falk G. Bechara[3], Afsaneh Alavi[4], Lisa Goldberg[2], Youyi Shu[2], John W. Frew[5]

[1] Harvard Medical School, Cambridge, United States
[2] Avalo Therapeutics, Wayne, United States
[3] Universitätsklinikum St. Josef-Hospital, Bochum, Germany
[4] Mayo Clinic, Rochester, United States
[5] Liverpool Hospital, Sydney, Australia

Introduction

Hidradenitis suppurativa (HS) is a chronic inflammatory disease of the pilosebaceous unit characterized by formation of abscesses (A), nodules (N), and tunnels (dT) in intertriginous areas. Both the Hidradenitis Suppurativa Clinical Response (HiSCR) and International HS Severity Score (IHS4) assess disease severity and are used in clinical trials. Changes from baseline and/or proportions of subjects with significant improvement in IHS4 and ANdT (A+N+dT) are proposed as more inclusive tools due to greater emphasis ontunnel assessment. Anti-cytokine agents (e.g., anti-TNFα, IL17A/F [biologics]) are often prescribed after failed antibiotic therapy, but few demonstrate 40% of subjects achieving 75% improvement from baseline in IHS4 at Week 16. New, novel therapies are still needed. IL-1β is a key upstream inducer for TNFα and IL-17. We present the efficacy and safety results from the LOTUS trial, a double-blind Phase 2, placebo-controlled trial focusing on the changes from baseline in IHS4 scores, achievement of IHS4-55/75/90 and changes in ANdT, A, N, and dT over the 16-week trial period.

Materials and Methods

The LOTUS trial compared 2 dosing regimens of ABD (600 mg loading dose, followed by 300 mg every 4 weeks [Q4W], or 300 mg loading dose, followed by 150 mg every 2 weeks [Q2W]) to placebo [PBO] (1:1:1 randomization) in subjects with moderate-severe HS. Eligible subjects: ≥18 years old, symptoms of HS ≥6 months, Hurley Stage II/III, total AN count ≥5, and presence of HS in ≥2 distinct anatomical areas. Subjects with and without biologics experience were eligible. The primary endpoint was the proportion of subjects achieving HiSCR75 at Week 16 (≥ 75% reduction in total AN count; no increase in abscess/dT count relative to baseline). Subjects who received systemic rescue therapy before Week 16, or discontinued study treatment due to adverse events or lack of efficacy were treated as non-responders. Subjects with missing data were imputed as non-responders. Primary endpoint analysis compared both ABD groups to placebo using a closed testing procedure controlling overall Type 1 error at 0.05 significance level (2-sided). Key secondary endpoints included change from baseline in IHS4 and dT. Proportions of IHS4-55/75/90 responders at Week 16 were pre-specified secondary endpoints; changes in A, N, dT and combined ANdT measurements were performed post-hoc with nominal p values provided. Subjects were followed for safety through Week 20.

Results

A total of 253 subjects were enrolled. 86% of subjects completed study treatment. Baseline characteristics were generally balanced, though more subjects in ABD cohorts were female, biologics experienced with baseline dT counts >1 compared to placebo. A greater proportion of subjects in the combined (ABD: 42.5%; placebo: 25.6%; p=0.004; 16.1% vs 6.0%, p= 0.009 at Week 4) and individual ABD groups achieved the primary endpoint of HiSCR75 versus placebo at Week 16. By Week 2, ABD treated subjects demonstrated significantly greater mean change from baseline in IHS4 (PBO: -3.0; Q2W: -5.7; Q4W: -6.9 [p=0.018]) and dT (PBO: 0; Q2W: -0.8 [p=0.018]; Q4W: -0.7 [p=0.025]) and a greater mean change in N for Q4W group by Week 4 (PBO: -2.0; Q4W: -5.4; p=0.0). No significant changes from baseline in A between groups were detected. At Week 16, a significantly higher proportion of ABD treated subjects achieved IHS4-55, IHS4-75 (Figure) and changes in ANdT, with the Q4W cohort significantly separating in IHS4-55/75 from placebo within 4 weeks of treatment (IHS4-55:37.0% vs 20.5%[p=0.025]; IHS4-75:24.7% vs 9.6% [p=0.012]); proportions of IHS4-90 responders trended to significance in the Q2W group. Rates of treatment-emergent adverse events (AE) were similar between ABD and placebo with no unexpected safety findings.

Conclusion

In the LOTUS Trial, rapid (≤2-4 weeks) and significant improvements in IHS-4, IHS4-55/75 and 90, N, dT and ANdT were achieved with ABD compared to placebo with an acceptable safety profile.

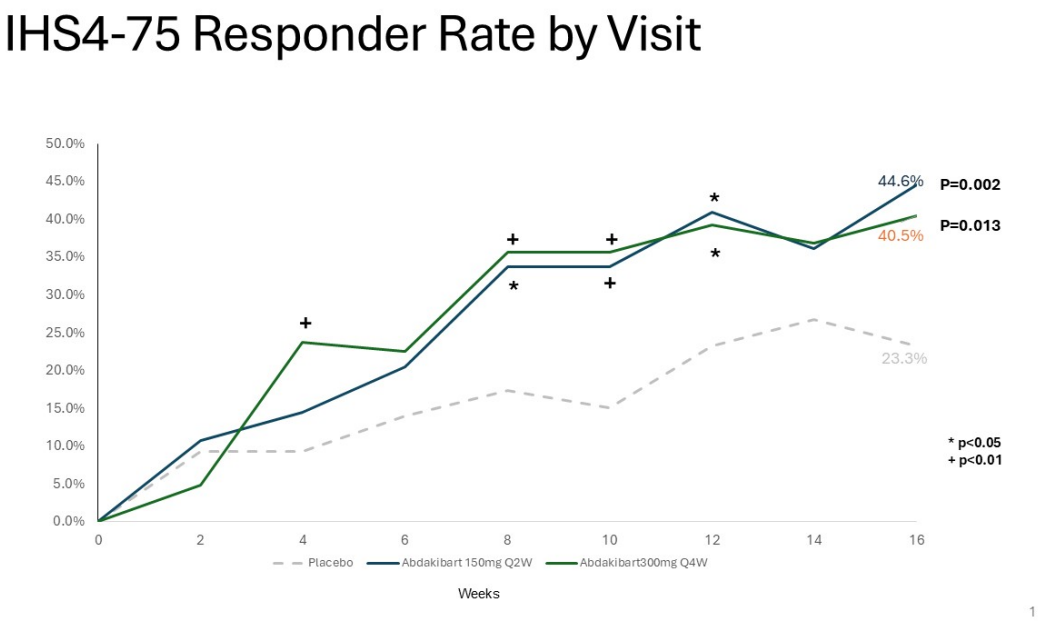

EA DV CONGRESS
VIENNA
30 SEP - 3 OCT 2026

Abstract N°: 296

Facial proliferative pyoderma gangrenosum mimicking infectious dermatoses

Xueyi Huang*[1], Jia Liao[1]

[1] Department of Dermatology, Zhongshan Second People's Hospital, Zhongshan, China

Introduction

This case describes a rare facial proliferative pyoderma gangrenosum (PG) in a 67-year-old male presenting with painful ulcers and nodules. Initially misdiagnosed as a mycobacterial infection, the lesions progressed despite empirical antimicrobial therapy. Diagnosis was confirmed after excluding infection via histopathology and negative cultures. Treatment with oral prednisone led to rapid remission within three days. This case highlights that rapidly progressive facial lesions unresponsive to antibiotics should raise suspicion for proliferative PG.

Case Presentation

A 67-year-old male presented with a 1-month history of painful facial pustules, nodules, and ulcers (Figure 1A). Physical examination revealed infiltrative erythema, pustular nodules, and brown crusts involving the left cheek, perinasal area, upper lip, and auricle. Initial differential diagnoses included cutaneous tuberculosis, nontuberculous mycobacterial infection, and deep fungal infection. Comprehensive workup—encompassing T-SPOT.TB, purified protein derivative testing, Xpert MTB/RIF assay, secretion cultures, and targeted metagenomic sequencing (covering 376 pathogens)—yielded negative results. Routine laboratory studies, including complete blood count, rheumatological evaluation, and immunodeficiency screening, showed no abnormalities; however, mild elevations of C-reactive protein (CRP) and erythrocyte sedimentation rate (ESR) were noted. Histopathology of a skin biopsy demonstrated suppurative granulomatous inflammation. Based on the clinical–pathological correlation, empirical anti-nontuberculous mycobacteria treatment (clarithromycin, rifampicin, moxifloxacin) was initiated. (clarithromycin, rifampicin, moxifloxacin) was initiated. However, the lesions rapidly progressed within 1 week (Figure 1B). Repeat biopsies and bronchoalveolar lavage cultures (bacteria, fungi, mycobacteria) with sequencing again yielded negative results. After excluding infection, a diagnosis of proliferative pyoderma gangrenosum (PG) was established. Oral prednisone (40 mg/day) was started, leading to marked regression within 3 days (Figure 1C). One month later, cribriform atrophic scars were observed, and prednisone tapering combined with colchicine was prescribed(Figure 1D).

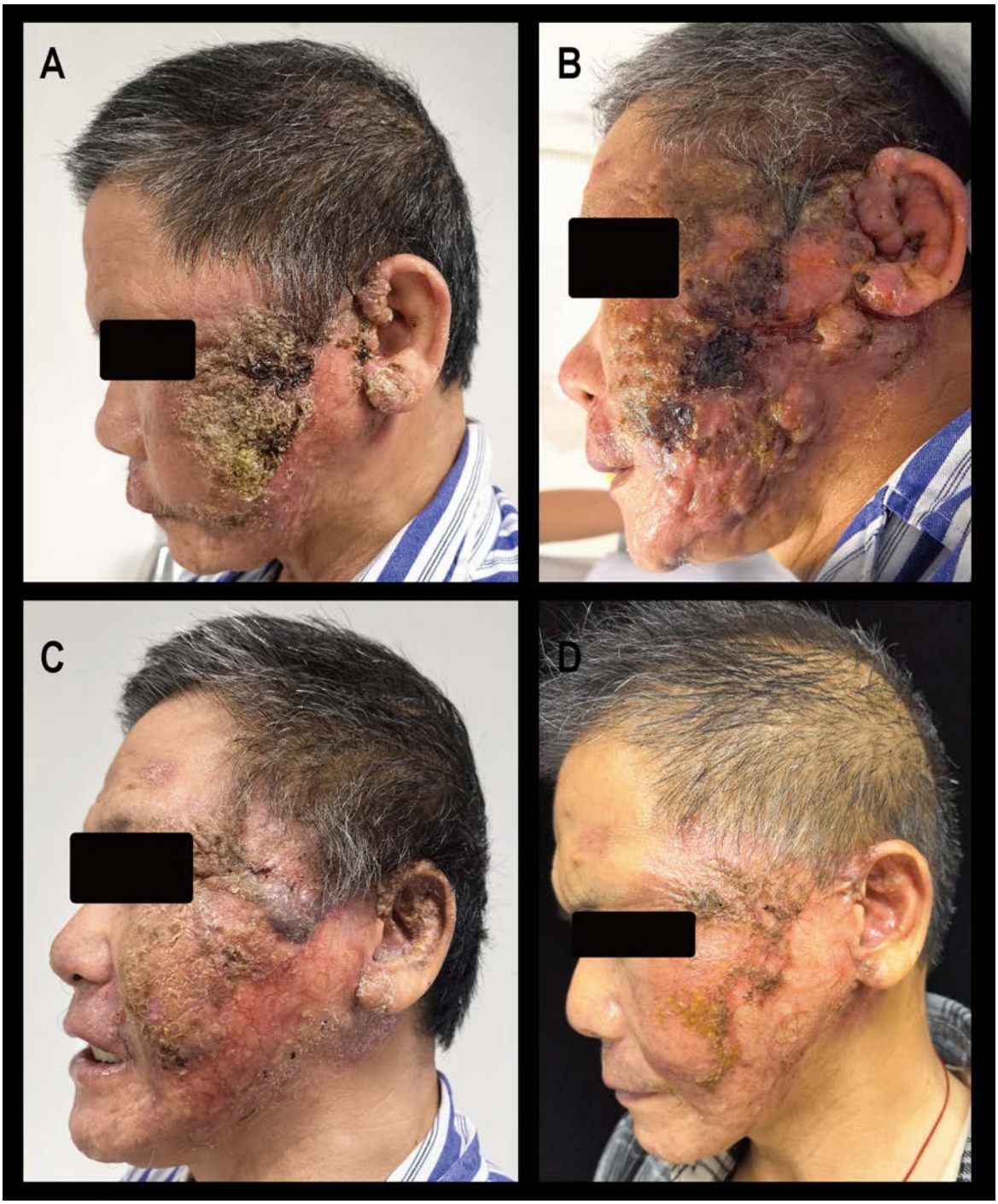

Conclusion

PG is a rare noninfectious neutrophilic dermatosis characterized by recurrent painful necrotic ulcers. Four subtypes are recognized: ulcerative (accounting for ~85%), pustular, bullous, and proliferative. The proliferative variant, also known as superficial granulomatous pyoderma, usually affects the lower extremities and trunk, while facial involvement is uncommon and prone to misdiagnosis. Shavit et al. reported five cases of proliferative PG on the face, suggesting that this subtype may be confined to the skin, rarely associated with systemic disease, and generally exhibits a favorable therapeutic response. Our case underscores the importance of considering proliferative PG in patients with rapidly progressive facial lesions unresponsive to antimicrobial therapy.

EADV CONGRESS
VIENNA
30 SEP - 3 OCT 2026

Abstract N°: 299

A Case of Pemphigus Herpetiformis Diagnosed by Tzanck Smear: Are The Acantholytic Cells Different from Pemphigus Vulgaris?

Hasan Emre İlgenli*[1], Selami Aykut Temiz[1], İlkay Özer[1]

[1] Necmettin Erbakan University Faculty of Medicine Dermatology Department, Konya, Türkiye

Introduction

Pemphigus herpetiformis is a rare variant of pemphigus that exhibits immunopathological features of pemphigus vulgaris and clinically resembles dermatitis herpetiformis (1). Clinical features typically include itchy, clustered vesicles or papules, urticarial plaques, and erythematous lesions, often herpetiform or ring-shaped. The Tzanck test is used in the preliminary diagnosis of many skin diseases, especially vesiculbullous diseases (2,3). We would like to share a previously unreported finding that we detected in acantholytic cells in the Tzanck smear of our 28-week pregnant patient who presented to our clinic.

Case Presentation

A 28-week pregnant patient presented to our clinic with a bullous rash of purulent discharge, itching, in the breasts, behind the ears, and on the neck, which had been present for one week. The patient had no known illnesses, allergies, or history of medication use, but stated that she had experienced a similar condition in the same area four years prior. Dermatological examination revealed intermammarian and submammarian lesions with impetiginized,serous discharge, and scattered eroded bullae and vesicles, as well as one eroded bullae behind the ear and one on the neck(Figure 1). Samples were taken from the intermammarian bullae for the Tzanck test and examined. This examination showed rosette formation, scattered eosinophils, scattered neutrophils, numerous tadpole cells, and a small number of acantholytic cells(Figure 2).Low-dose medication was recommended. Systemic corticosteroid treatment was initiated.

Conclusion

Pemphigus herpetiformis is a variant of pemphigus vulgaris, an autoimmune bullous disease, and is clinically similar to dermatitis herpetiformis. In this disease, while numerous tadpole cells and a small number of acantholytic cells are observed in the Tzanck test, acantholytic cells may be missed, so immunofluorescence examination should be performed in conjunction with cytology to approach the diagnosis(4).In Tzanck smear examinations performed in patients with pemphigus herpetiformis, it has been observed that acantholytic cells have a higher cytoplasm ratio and their nuclei are flatter and more peripherally located, unlike classical acantholytic cells. In classical pemphigus vulgaris, antibodies (anti-Dsg3) break the bonds between cells (acantholysis). Since the cells cannot adhere to each other, the cytoskeleton collapses around the nucleus. This condition causes the cell to shrink, become rounded, and the cytoplasm to concentrate around the nucleus (perinuclear halo), making the nucleus appear narrower. In pemphigus herpetiformis, in addition to widespread edema, there is also disruption of intercellular connections. This condition, also known as spongiosis, refers to the infiltration of fluid into and between epidermal cells. The cells undergo acantholysis before or during rupture and heal (intracellular edema occurs). Therefore, acantholytic cells in pemphigus herpetiformis may appear to have larger cytoplasm because they are filled with fluid, compared to the "shrunken" cells in pemphigus vulgaris.

EA DV CONGRESS
VIENNA
30 SEP - 3 OCT 2026

Abstract N°: 334

Atypical Presentation of Mat-Like and Disseminated Telangiectasias in Systemic Sclerosis: A Case Report

Imene Mahiou*[1], Samira Zobiri[1]

[1] mustapha bacha hospital center, algiers, Algeria

Introduction
Telangiectasias in systemic sclerosis SSc are typically punctate erythematous lesions affecting the face, lips, and hands. More rarely, confluent and extensive “mat-like” telangiectasias have been described, suggesting a distinct vascular phenotype.

Case Presentation
A 26-year-old woman with a history of acute rheumatic fever presented with progressive, asymptomatic erythematous macules blanching on diascopy, ranging from a few millimeters to 2 cm. Lesions predominated on the face, extending to the trunk, forearms, and dorsal hands. Raynaud’s phenomenon preceded the eruption. Examination showed puffy fingers, digital pulp scars, and skin thickening of the hands extending to the forearms. Dermoscopy revealed fine branching vessels arranged in confluent mat-like areas. Nailfold capillaroscopy demonstrated a scleroderma pattern with giant capillaries, avascular areas, and pericapillary edema. Antinuclear antibodies were positive (1:1000) with anti-RNP and anti-fibrillarin specificity. Histology showed dilated superficial dermal capillaries without inflammation or vasculitis; direct immunofluorescence was negative. Systemic screening was unremarkable. The diagnosis of SSc was established with a score of 21 according to the 2013 ACR/EULAR criteria.

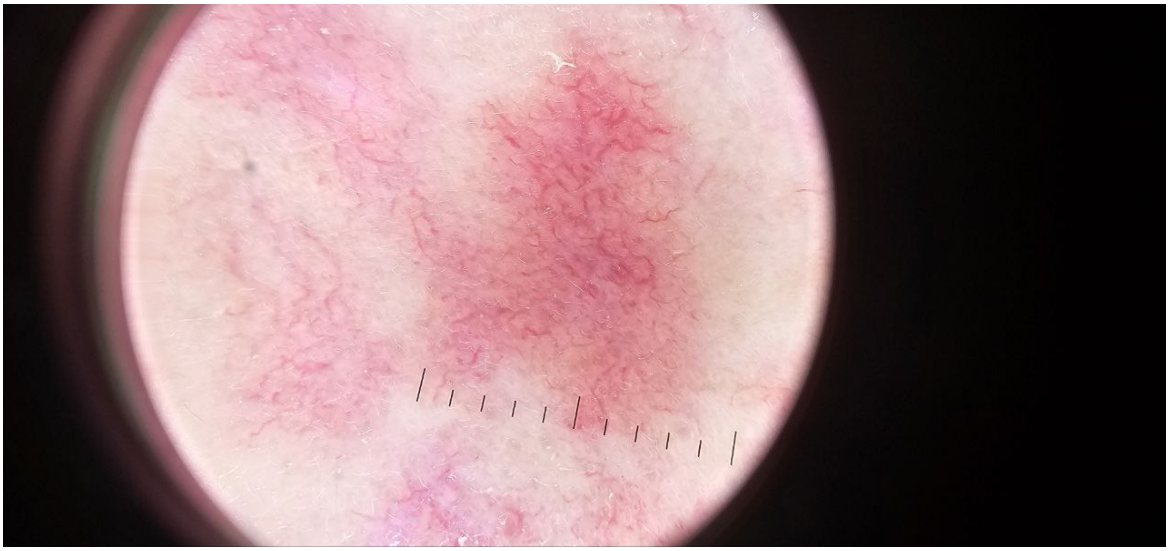

fine arborizing linear vessels on an erythematous background on dermoscopy

Conclusion
In SSc, telangiectasias reflect chronic microangiopathy driven by endothelial injury, capillary rarefaction, and maladaptive vascular remodeling. The extensive mat-like pattern observed here exceeds the usual punctate morphology and suggests organized superficial vascular reconstitution rather than isolated ectasia. Dermoscopic and capillaroscopic findings support a continuum between deep microvascular destruction and compensatory but

ineffective angiogenesis. Similarities with hereditary hemorrhagic telangiectasia raise the hypothesis of shared dysregulation of the TGF-β pathway, central to endothelial integrity and extracellular matrix homeostasis. In SSc, paradoxical pro-angiogenic signaling (notably VEGF overexpression) coexists with defective vascular repair, leading to persistent ectatic networks. Importantly, cohort studies have linked telangiectasia burden with pulmonary arterial hypertension, suggesting that diffuse mat-like lesions may signal global microvascular vulnerability. Despite normal initial screening, sustained cardiopulmonary surveillance is warranted.

EA DV CONGRESS
VIENNA
30 SEP - 3 OCT 2026

Abstract N°: 347

Pyodermatitis Vegetans in Two Psychoactive Substance Users: Distinct Clinical Presentations with Drug Exposure as a Common Link

Laisa Goulart Saviatto Picasky*[1], Eduarda Dos Reis Vial[1], Angelica Seidel[1], Amanda Pereira[1, 2], Gabriella Funchal[1, 2], Bárbara Hartung Lovato[1]

[1] Santa Tereza Sanitary Dermatology Hospital, São Pedro de Alcântara, Brazil
[2] Ufsc, Florianópolis, Brazil

Introduction

Pyodermatitis vegetans (PDV) and pyostomatitis vegetans (PSV) are rare inflammatory mucocutaneous disorders characterized by pustular and vegetating lesions affecting the skin and oral mucosa. They are considered part of a clinicopathological spectrum and are classically associated with inflammatory bowel disease (IBD), particularly ulcerative colitis. However, PDV/PSV may pose a diagnostic challenge due to their rarity and overlap with infectious, inflammatory, and autoimmune conditions. Histopathological findings typically include epidermal hyperplasia and intraepithelial collections of neutrophils and eosinophils, while direct immunofluorescence may show variable findings. Although strongly associated with IBD, reports describing PDV/PSV in the context of psychoactive substance use remain scarce. Here, we report two male patients with histopathological findings consistent with PDV and granular IgG deposits along the basement membrane zone on direct immunofluorescence, both with a history of cocaine use and without endoscopic evidence of IBD, presenting with distinct clinical manifestations.

Case Presentation

Two male patients presented with chronic, progressive vegetating lesions and no gastrointestinal symptoms. The first patient, a 50-year-old man with a long history of cocaine use, developed an initial lesion on the right nasal ala that evolved over one year to involve the nasolabial region and oral cavity, including the hard palate, with extensive septal perforation (Figure 1A). The second patient, a 47-year-old male with a history of hypertension and prior ischemic stroke possibly related to cocaine use, presented with a chronic vegetating ulcer affecting the distal left foot, extending from the second to fifth toes with interdigital involvement and friable, partially necrotic tissue (Figure 1B).

In both cases, extensive infectious workup — including bacterial, fungal, mycobacterial, and parasitic studies — was negative, and upper and lower gastrointestinal endoscopy showed no evidence of IBD. Histopathological examination revealed features consistent with PDV, including epidermal hyperplasia and dense inflammatory infiltrates, and direct immunofluorescence demonstrated granular IgG deposits along the basement membrane zone (Figures 1C and 1D).

A temporal relationship between substance use and disease course was observed. The first patient showed marked clinical improvement after two months of complete abstinence. The second patient demonstrated improvement during periods of abstinence, with recurrent exacerbations during relapse. He is currently receiving oral corticosteroids and cyclosporine, with partial response.

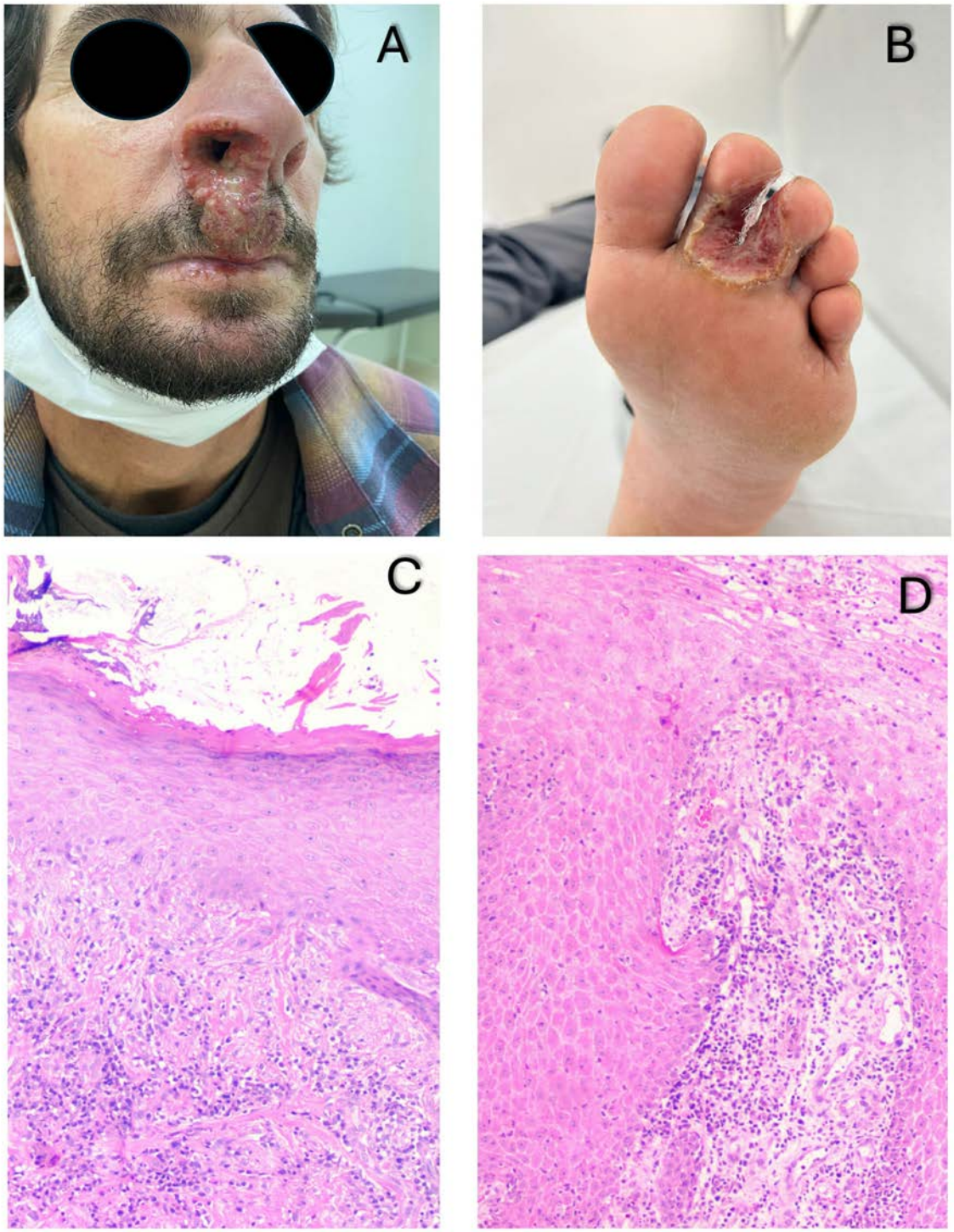

Figure 1: A.Clinical presentation of patient 1 showing vegetating lesion involving nasal ala and nasolabial region; B. Clinical presentation of patient 2 showing vegetating ulcer with interdigital involvement of the left foot ; C and D: Histopathological findings of patient 1 (C) and 2 (D) demonstrating epidermal hyperplasia and inflammatory infiltrate with features consistent with PDV.

Conclusion

These cases illustrate atypical presentations of PDV in the absence of IBD and raise the possibility of an association with cocaine use. The temporal relationship observed — with improvement during abstinence and worsening upon relapse — suggests a potential role for cocaine as a contributing or exacerbating factor. Given the limited evidence currently available, further studies are needed to better understand this relationship.

References:

- Chrcanovic BR, et al. Pyodermatitis-pyostomatitis vegetans: a case report and systematic review focusing on oral involvement. *Oral Surg Oral Med Oral Pathol Oral Radiol*. 2024. doi:10.1007/s10006-024-01234-1
- Clark LG, et al. Pyostomatitis vegetans (PSV)-pyodermatitis vegetans (PDV): A clinicopathologic study of 7 cases at a tertiary referral center. *J Am Acad Dermatol*. 2016;75(3):578–584. doi:10.1016/j.jaad.2016.03.047
- Fabregat-Pratdepadua M, et al. Vegetative lesions associated with inhaled cocaine use. *Clin Exp Dermatol*. 2022. doi:10.1111/ced.15221

EA DV CONGRESS
VIENNA
30 SEP - 3 OCT 2026

Abstract N°: 378

Racial and Ethnic Disparities in Outcomes Among Patients with Autoimmune Inflammatory Blistering Diseases: A Propensity-Matched Analysis of a Large Real-World Database

Soumya Somani*[1], Umer Nadir[2], Stanislav Tolkachjov[1, 2]

[1] Department of Dermatology, University of Texas Southwestern Medical Center, Dallas, Texas, United States
[2] Division of Dermatology, Baylor University Medical Center, Dallas, Texas, United States

Introduction
Autoimmune blistering diseases (AIBDs) represent a heterogeneous group of rare, potentially life-threatening dermatoses driven by pathogenic autoantibodies against structural skin proteins, resulting in significant morbidity. Racial and ethnic disparities in AIBD-associated outcomes remain understudied. This study leverages real-world electronic health record (EHR) data to characterize outcome differences across racial and ethnic groups.

Materials and Methods
Using the TriNetX Global Collaborative Network (171 predominantly U.S.-based healthcare organizations), we identified patients with any AIBD diagnosis (encompassing pemphigus vulgaris, pemphigus foliaceus, bullous pemphigoid, cicatricial pemphigoid, dermatitis herpetiformis, and acquired epidermolysis bullosa) across four groups: White (n = 36,924), Black or African American (n = 5,054), Asian (n = 4,827), and Hispanic or Latino (n = 2,437). The date of first AIBD diagnosis served as the index event. Propensity score matching (PSM) balanced cohorts for pairwise comparisons (White vs. Black: n = 4,520/group; White vs. Asian: n = 4,344/group; White vs. Hispanic: n = 2,394/group) on pre-index comorbidities (endocrine/metabolic disease, health service utilization) and medication exposures (dermatologic agents, hormones, antimicrobials, immunologic agents, antineoplastics). Outcomes occurring after the index event included incidence of non-melanoma skin cancer, general malignancy, skin/soft tissue infection (e.g. impetigo, cellulitis, cutaneous abscess), mental health diagnoses (depression and anxiety), hospitalization, and all-cause mortality. Risk and Kaplan-Meier survival analyses were performed after PSM.

Results
Skin cancer risk was markedly higher in White patients across all comparisons: RR 9.28 vs. Asian ($p<0.001$), RR 10.65 vs. Black ($p<0.001$), and RR 4.53 vs. Hispanic ($p<0.001$). General malignancy was significantly higher in White vs. Asian patients (RR 2.33, $p=0.001$) but did not differ in other comparisons. Skin/soft tissue infection rates did not differ significantly across any comparison. Mental health diagnoses were more prevalent in White patients vs. Asian (RR 1.95, $p<0.001$), Black (RR 1.14, $p=0.036$), and Hispanic patients (RR 1.19, $p=0.035$). White patients had significantly higher hospitalization risk than Asian (RR 2.23, $p<0.001$) and Hispanic patients (RR 1.26, $p=0.003$); Black patients had both higher hospitalization risk than White patients (RR 0.85 favoring Black, $p=0.001$) and a significantly greater mean number of hospitalizations (mean 2.67 vs. 2.09, $p=0.007$). For all-cause mortality, White patients had significantly higher risk than Hispanic patients (RR 2.04, $p<0.001$; HR 1.90, $p<0.001$) and Black patients (RR 1.11, $p=0.021$); Asian patients had higher all-cause mortality than White patients (RR 0.68, $p<0.001$; HR 0.64, $p<0.001$).

Outcome	Comparison	White Risk	Comparator Risk	RR (95% CI)	p	HR (95% CI)	p
Skin Cancer	White vs. Asian	0.056	0.006	9.28 (6.20–13.88)	**<0.001**	—	—
	White vs. Black	0.052	0.005	10.65 (6.89–16.48)	**<0.001**	—	—
	White vs. Hispanic	0.059	0.013	4.53 (3.08–6.67)	**<0.001**	—	—
General Malignancy	White vs. Asian	0.012	0.005	2.33 (1.42–3.84)	**0.001**	—	—
	White vs. Black	0.014	0.011	1.27 (0.88–1.83)	0.209	—	—
	White vs. Hispanic	0.011	0.006	1.79 (0.94–3.44)	0.075	—	—
Skin Infection	White vs. Asian	0.087	0.098	0.89 (0.77–1.02)	0.101	—	—
	White vs. Black	0.098	0.108	0.91 (0.80–1.04)	0.164	—	—
	White vs. Hispanic	0.088	0.086	1.02 (0.84–1.24)	0.816	—	—
Mental Health	White vs. Asian	0.143	0.073	1.95 (1.69–2.24)	**<0.001**	—	—
	White vs. Black	0.143	0.126	1.14 (1.01–1.28)	**0.036**	—	—
	White vs. Hispanic	0.146	0.123	1.19 (1.01–1.39)	**0.035**	—	—
Hospitalization	White vs. Asian	0.157	0.070	2.23 (1.95–2.56)	**<0.001**	2.21 (1.92–2.56)	**<0.001**
	White vs. Black	0.173	0.204	0.85 (0.77–0.93)	**0.001**	0.83 (0.74–0.92)	**<0.001**
	White vs. Hispanic	0.158	0.125	1.26 (1.08–1.47)	**0.003**	1.18 (1.00–1.39)	**0.047**
All-Cause Mortality	White vs. Asian	0.177	0.262	0.68 (0.62–0.73)	**<0.001**	0.64 (0.58–0.70)	**<0.001**
	White vs. Black	0.189	0.170	1.11 (1.02–1.21)	**0.021**	1.08 (0.98–1.19)	0.138
	White vs. Hispanic	0.173	0.085	2.04 (1.74–2.39)	**<0.001**	1.90 (1.60–2.24)	**<0.001**

Table 1. Propensity-matched risk and survival analysis across racial/ethnic comparisons in AIBD patients. RR = Risk Ratio; HR = Hazard Ratio; CI = Confidence Interval. Bold p-values indicate statistical significance ($p<0.05$). All outcomes used incident analyses. Data source: TriNetX Global Collaborative Network

Conclusions

These findings provide the first large-scale, propensity-matched evidence that racial and ethnic background is associated with distinct outcome profiles in AIBD patients. Recognizing these disparities is clinically important: differences in skin cancer risk, malignancy, mental health diagnoses, hospitalization, and mortality suggest that a uniform approach to AIBD management may inadequately serve patients across racial and ethnic groups, and that individualized, equity-conscious care pathways warrant consideration. As a preliminary exploratory study, this work establishes a quantitative foundation for future investigations to build upon, including prospective studies examining disease severity, treatment patterns, and healthcare access by race and ethnicity, as well as the development of risk-stratified surveillance and screening protocols. Ultimately, these data make a case for embedding race and ethnicity as standard variables in AIBD clinical registries and research frameworks, so that the field can move toward a more complete and equitable understanding of this disease.

EA DV CONGRESS
VIENNA
30 SEP - 3 OCT 2026

Abstract N°: 436

A Rare Case of Pemphigus Herpetiformis Highlighting Clinicopathological and Immunological Features

Abhishek Wilson Pallippattu*[1], Anu Gunavardhan[1], Periasamy Balasubramaniam[1]

[1] Wrexham Maelor Hospital, Wrexham, United Kingdom

Introduction
Pemphigus herpetiformis (PH) is a rare autoimmune bullous disorder that combines the clinical features of dermatitis herpetiformis with the immunologic characteristics of pemphigus. We report a case highlighting the correlation between clinical, histopathological, and immunological findings.

Case Presentation
A 39-year-old female presented with a 3-month history of pruritic dermatosis involving the scalp, trunk, and extremities. Cutaneous examination revealed scaly scalp lesions and annular erythematous plaques with grouped vesicles, bullae, and papules, accompanied by severe pruritus. Widespread excoriations and hypopigmented patches from prior lesions were noted. Previous treatment with topical mometasone and tacrolimus was ineffective. There was no relevant personal or family history. Histopathological examination of a skin biopsy demonstrated an intraepidermal blister containing eosinophils and neutrophils. Adjacent epidermis showed spongiosis with lymphocytic and eosinophilic exocytosis. The dermis exhibited perivascular and interstitial inflammatory infiltrates rich in eosinophils, lymphocytes, and histiocytes. Direct immunofluorescence revealed intercellular deposition of IgG and C3 within the epidermis. Serology confirmed pemphigus antibodies, with mild peripheral eosinophilia (0.5×10^9/L). Routine laboratory investigations were otherwise unremarkable. Based on the clinical presentation resembling dermatitis herpetiformis, characteristic histopathology, and confirmatory immunopathology, a diagnosis of PH was established. The patient was treated with oral prednisone (0.5 mg/kg/day, tapered) in combination with dapsone (50 mg/day), resulting in initial clinical improvement.
Pemphigus herpetiformis (PH) is an uncommon variant of pemphigus. As far back as 1955, Floden and Gentele described certain clinical features they dubbed “acantholytic dermatitis herpetiformis”, and the diagnostic criteria for this entity were proposed by Jablonska et al. in 1975. Since then, around 100 cases had been reported in the literature. Mean age at onset is 65 years (range 30–80 years). Skin lesions are usually similar to dermatitis herpetiformis, including erythematous, vesicular, bullous, or papular lesions, often in a grouped pattern and with severe pruritus. Peripheral eosinophilia is found in 40% of cases on average. PH differs histologically from classic pemphigus because of the presence of spongiosis and microabscesses in the mid or subcorneal epidermis, mostly without acantholysis, which, if present, emerges only later in the disease process. Inflammatory cell infiltration, predominantly eosinophils (20%), neutrophils (20%), or both (60%), is also a feature. Given the histopathologic diversity, the diagnosis of PH should be based on immunopathology. Direct immunofluorescence on perilesional skin samples shows IgG and C3 deposition around the cell surfaces of keratinocytes in the upper epidermis. The target autoantigen is usually desmoglein 1 (or less frequently desmoglein 3). The treatment of choice for PH is dapsone, at a dose of between 100 and 300mg/day. It can be used in monotherapy, but should ideally be combined with steroids and/or systemic immunosuppressants which includes azathioprine and cyclophosphamide. Prognosis is generally favourable, although progression to classic pemphigus may occur.

Conclusion
This case emphasizes the importance of recognizing PH as a differential diagnosis in pruritic bullous disorders with features suggestive of dermatitis herpetiformis, ensuring accurate diagnosis and appropriate management.

EADV CONGRESS
VIENNA
30 SEP - 3 OCT 2026

Abstract N°: 456

Necrotic Purpura at the Crossroads of Hepatitis C and B-Cell Lymphoma: A Manifestation of Mixed Cryoglobulinemia

Wissal Souhail*[1, 2], Layla Bendaoud[1, 2], Meryam Aboudourib[1, 2], Ouafa Hocar[1, 2], Said Amal[1, 2]

[1] Dermatology Department, Arrazi Hospital, Mohammed VI University Hospital, Marrakech, Marrakech, Morocco
[2] Biosciences Research Laboratory, FMPM, Cadi Ayyad University, Marrakech, Marrakech, Morocco

Introduction

Chronic hepatitis C virus infection represents a model of persistent antigenic stimulation, leading to extrahepatic manifestations predominantly characterized by mixed cryoglobulinemia. This small-vessel immune complex-mediated vasculitis may range from mild cutaneous forms to severe necrotic involvement. At the same time, chronic virus-induced B-cell dysregulation promotes the emergence of lymphoid proliferations, which may progress to diffuse large B-cell lymphoma, suggesting a pathophysiological continuum linking viral infection, autoimmunity, and oncogenesis.We report a case of necrotic purpura revealing mixed cryoglobulinemia in a patient with hepatitis C and B-cell lymphoma, illustrating the close interplay between chronic infection, immune dysregulation, and lymphoproliferative transformation.

Case Presentation

A 72-year-old woman, followed for stage IV diffuse large B-cell non-Hodgkin lymphoma and treated with R-CHOP, with associated hepatitis C infection, was admitted for necrotic purpura complicated by bilateral cutaneous necrosis of the legs (12 × 5 cm), along with nodular lesions of the shoulder suggestive of secondary involvement.Skin biopsy showed leukocytoclastic vasculitis. Laboratory investigations revealed an inflammatory syndrome (CRP 70 mg/L, elevated erythrocyte sedimentation rate) associated with neutropenia (absolute neutrophil count: 600/mm^3). Immunological work-up demonstrated type II mixed cryoglobulinemia (monoclonal IgM associated with polyclonal IgG).The diagnosis of necrotic purpura secondary to mixed cryoglobulinemia was retained. Systemic corticosteroid therapy (1 mg/kg/day), combined with necrosectomy, local wound care with directed healing, and LED sessions twice weekly, led to clinical improvement with reduction of tissue loss, allowing planning for skin grafting.
Hepatitis C induces chronic antigenic stimulation responsible for prolonged B-cell activation. This activation promotes the production of monoclonal immunoglobulins, most often IgM with rheumatoid factor activity, capable of forming immune complexes with IgG. The resulting mixed cryoglobulinemia is characterized by precipitation of these complexes at low temperature, their deposition in small vessels, and complement activation, leading to leukocytoclastic vasculitis.

Conclusion

This case illustrates a severe form of mixed cryoglobulinemia occurring in the dual setting of hepatitis C and diffuse large B-cell non-Hodgkin lymphoma, revealed by extensive necrotic purpura. It highlights the importance of considering this diagnosis in any severe cutaneous vasculitis and of favoring a comprehensive management approach targeting both the immunological process and the underlying disease.

EADV CONGRESS
VIENNA
30 SEP - 3 OCT 2026

Abstract N°: 457

Acute Acral Purpura Revealing an Autoimmune Triad: Dermatomyositis Sine Dermatitis–Systemic Lupus Erythematosus Overlap with Evans Syndrome

Wissal Souhail*[1, 2], Layla Bendaoud[1, 2], Meryam Aboudourib[1, 2], Ouafa Hocar[1, 2], Said Amal[1, 2]

[1] Dermatology Department, Arrazi Hospital, Mohammed VI University Hospital, Marrakech, Marrakech, Morocco
[2] Biosciences Research Laboratory, FMPM, Cadi Ayyad University, Marrakech, Marrakech, Morocco

Introduction

Dermatomyositis is an autoimmune inflammatory myopathy characterized by proximal muscle involvement and, classically, specific cutaneous manifestations. However, certain atypical forms, particularly dermatomyositis sine dermatitis, may occur in the absence of skin lesions, making the diagnosis more challenging.Dermatomyositis may occur as part of overlap syndromes with other autoimmune diseases, particularly systemic lupus erythematosus, reflecting systemic immune dysregulation. Its association with Evans syndrome remains exceptional but indicates more severe and complex autoimmunity.In this context, unusual manifestations such as acute acral purpura may represent a misleading presenting feature. We therefore report a case revealing dermatomyositis–lupus overlap associated with Evans syndrome.

Case Presentation

A 22-year-old woman with no notable past medical history was admitted for acral purpura evolving over one month, associated with severe disabling myalgia and progressive dyspnea. Clinical examination revealed photosensitivity and a malar rash. Dermoscopy showed an inverse strawberry pattern.Laboratory investigations revealed cytopenia with severe hemolytic anemia (Hb 6.2 g/dL), thrombocytopenia (46,000/mm^3), and lymphopenia (460/mm^3). There was marked hepatocellular injury (ALT 23 times the upper limit of normal, AST 43 times the upper limit of normal), as well as a major elevation in CPK levels (156 times the upper limit of normal). A CRP/ESR dissociation was noted (CRP 3 mg/L, ESR 70 mm/h). Viral serologies for hepatitis B and C, EBV, CMV, and parvovirus B19 were negative.Because of dyspnea, CT pulmonary angiography was performed and showed acute pulmonary edema, probably of cardiogenic origin. The patient was admitted to the intensive care unit for management of multiorgan involvement.Immunological investigations revealed homogeneous antinuclear antibodies, high anti-native DNA antibody levels (300 IU), as well as myositis-specific autoantibodies (anti-Mi-2, anti-TIF1-γ, and anti-Ku), with normal complement levels.The diagnosis of overlap between dermatomyositis sine dermatitis and systemic lupus erythematosus, complicated by Evans syndrome, was retained. The outcome was unfavorable, marked by acute multiorgan failure leading to death.

Conclusion

This case illustrates a severe form of overlap between dermatomyositis sine dermatitis and systemic lupus erythematosus, complicated by Evans syndrome and revealed by acute acral purpura. It highlights the central role of immune microangiopathy and lymphocytic hyperactivation in the severity of these complex forms.

EA DV CONGRESS
VIENNA
30 SEP - 3 OCT 2026

Abstract N°: 462

Bullous Pemphigoid Associated with Thymoma: An Atypical Case Report

Luana de Brito[1], Maria Eduarda Cesar Garcez*[2], GABRIELA ALENCAR[2], Ingrid Teixeira[2], Ernesto Zambrano[2], Ana VARGAS[1], Alexandre Gripp[2], David Souza[2]

[1] Universidade do Estado do Rio de Janeiro, Rio de Janeiro, Brazil
[2] Universidade do Estado do Rio de Janeiro - UERJ, Rio de Janeiro, Brazil

Introduction

Bullous pemphigoid (BP) is the most common subepidermal autoimmune blistering disorder, predominantly affecting elderly individuals, especially those over 70 years of age. It is characterized by the production of IgG autoantibodies directed against basement membrane zone antigens, primarily BP180 and BP230, leading to the formation of tense subepidermal blisters on an erythematous or urticarial base, accompanied by intense pruritus. BP is classically associated with triggering factors such as viral infections and the use of certain medications. Thymoma, in contrast, is a rare epithelial tumor of the thymus, recognized for its association with various autoimmune diseases, attributed to the production of autoreactive T lymphocytes. Reports describing an association between thymoma and BP are scarce. Hypereosinophilia, observed in both conditions, has been proposed as a possible shared pathophysiological mechanism, although this relationship remains incompletely understood.

The present study aims to report a case of this rare association, contributing to its recognition and reinforcing the importance of investigating underlying malignancy in patients with BP, particularly in atypical presentations.

Case Presentation

An 80-year-old male patient with a history of diabetes mellitus and dyslipidemia was diagnosed with BP, confirmed by skin biopsy demonstrating a unilocular subepidermal blister with predominantly fibrinous content, neutrophils, and eosinophils. The dermis showed a dense eosinophil-rich inflammatory infiltrate, erythrocyte extravasation, and spongiosis in the adjacent epidermis, findings consistent with bullous pemphigoid.

He had been receiving prednisone 60 mg/day combined with azathioprine 100 mg/day for approximately 15 days, with continued progression of cutaneous lesions. Dermatological examination revealed tense blisters containing serous fluid, widely distributed over the upper limbs, abdomen, back, and inguinal and perineal regions, without mucosal involvement.

Due to treatment refractoriness, the patient required hospital admission for investigation of a possible paraneoplastic syndrome and initiation of corticosteroid pulse therapy.

Computed tomography scans revealed a solid-cystic expansile lesion in the anterior mediastinum, with well-defined margins and regular contours, with imaging features suggestive of thymoma.

A course of intravenous methylprednisolone was administered for three consecutive days; however, clinical deterioration ensued. The use of rituximab was considered but subsequently contraindicated due to the presence of hypogammaglobulinemia.

Additionally, in a multidisciplinary decision with the thoracic surgery team, surgical resection of the tumor was proposed as a potential strategy to aid in disease control. However, during the preoperative period, the patient developed septic shock of cutaneous origin and an acute ischemic cardiac event, ultimately progressing to death.

Conclusion

A literature review conducted via PubMed identified only three previously reported cases describing the association between bullous pemphigoid and thymoma, underscoring the rarity of this correlation.

Thymomas are well known to be associated with autoimmune phenomena, likely resulting from defects in central immune tolerance and the release of autoreactive T lymphocytes. Although classically linked to myasthenia gravis, their association with autoimmune dermatoses remains uncommon. In this context, the identification of a thymic lesion in a patient with refractory BP supports a possible pathophysiological interaction between these conditions.

This report contributes to expanding the recognition of this rare association and emphasizes the importance of investigating underlying malignancies in cases of BP with atypical presentation, refractory course, or unfavorable evolution. It also highlights the relevance of a multidisciplinary approach, given the potential impact of thymoma diagnosis on therapeutic decision-making and patient prognosis.

EADV CONGRESS
VIENNA
30 SEP - 3 OCT 2026

Abstract N°: 473

MCT1-Mediated hnRNPC Lactylation Promotes Fibrosis in Systemic Sclerosis Dermal Fibroblasts

Ruixuan Zhu*[1], Rong Xiao[1], Zixin Pi[1], Licong Liu[1], Yaqian Shi[1], Ke Chai[1]

[1] Department of Dermatology, Second Xiangya Hospital of Central South University, Changsha, China

Introduction
Systemic sclerosis (SSc) is a chronic and fatal autoimmune skin disease. Progressive fibrosis is its main pathological feature, but the exact mechanisms remain unclear. Recent studies have shown that protein lactylation is involved in multiple tissue fibrotic processes; however, its role in the pathogenesis of SSc has not been established.

Materials and Methods
We collected plasma samples from SSc patients and healthy individuals. Using proteomic profiling and protein lactylation sequencing, we analyzed proteomic and lactylation changes in skin tissues from both groups to identify critical lactylation sites. The identified site was then knocked down to evaluate its impact on fibrosis. Transcriptome sequencing was performed to examine downstream pathways affected by this modification, followed by further validation. In addition, mouse models of skin fibrosis and pulmonary fibrosis were used to verify the functional pathway.

Results
Compared with healthy individuals, SSc patients exhibited elevated plasma lactate levels and upregulation of the lactate transporter MCT1 in lesional skin. A high-lactate environment induced fibroblast protein lactylation and promoted fibroblast activation. Lactylation sequencing revealed a global increase in lactylation modifications in patient lesions, with hnRNPC-K157 and hnRNPC-K176 showing the most prominent lactylation. Knockdown of the lactylation site on hnRNPC followed by transcriptome sequencing indicated that hnRNPC-K157/K176 lactylation led to alternative splicing of the ubiquitin ligase TRIM24, resulting in decreased TRIM24 expression. Immunoprecipitation assays further confirmed that TRIM24 suppresses fibrosis by mediating ubiquitination and inhibition of the TGF-β/Smad pathway.

Conclusions
MCT1-mediated hnRNPC lactylation in SSc fibroblasts regulates alternative splicing to downregulate TRIM24 expression, thereby impairing TRIM24-mediated ubiquitination of the TGF-β/SMAD pathway and promoting fibrosis.

EADV CONGRESS
VIENNA
30 SEP - 3 OCT 2026

Abstract N°: 477

Scleredema Diabeticorum with joint involvement with response to high dose methotrexate in a 40 year old Filipino patient: A Case Report

Ma Christina Carmela Ozaeta*[1], Bernardita Policarpio[1]

[1] University of Santo Tomas Hospital, Manila, Philippines

Introduction

Scleredema is a connective tissue disease that is characterized by woody, non-pitting induration on the neck, shoulders, and trunk that typically follows a febrile infection, or is associated with underlying conditions such as diabetes mellitus or paraproteinemia. Treatment primarily targets the underlying condition, and with variable treatment response.

Case Presentation

This is a case of a forty year-old male who presented with a 2-year history of painless, indurated plaques on the nape and upper back with new onset type 2 diabetes mellitus. He had no history of upper respiratory tract infection. Histopathology showed thickened dermis due to enlarged collagen bundles with mucinosis. Phototherapy was initially recommended, but patient opted to observe since it was not causing significant physical impairment at that time. He was given oral hypoglycemic medications however despite treatment for 5 months, he experienced sudden and progressive limitation of range of motion in his left shoulder. He was started on high dose methotrexate of 25mg/ week with significant improvement on his joint mobility after one month.

Conclusion

Although scleredema is generally a benign disease, it may be progressive, debilitating and can have restriction of range of motion, thus early recognition, follow up and treatment options are crucial to prevent complications.

EA DV CONGRESS
VIENNA
30 SEP - 3 OCT 2026

Abstract N°: 496

Epidermolysis bullosa acquisita occurring in a patient with myasthenia gravis

Masahiro Kamata*[1], Fumi Hama[1], Kotaro Hayashi[1], Yoshiki Okada[1], Ayu Watanabe[1], Thalita Bastos[1], Yayoi Tada[1]

[1] Teikyo University School of Medicine, Tokyo, Japan

Introduction

Epidermolysis bullosa acquisita (EBA) is a rare autoimmune subepidermal blistering disease caused by autoantibodies against type VII collagen. EBA has been reported in association with several autoimmune diseases, including inflammatory bowel disease and systemic lupus erythematosus; however, its coexistence with myasthenia gravis (MG), an antibody-mediated autoimmune disorder affecting the neuromuscular junction, has not been reported to date.

Case Presentation

A man in his 60s with a history of MG, treated with oral prednisolone and tacrolimus, presented with pruritic erythema and tense blisters on the trunk and extremities. Prednisolone had initially been administered at 30 mg/day and gradually tapered to 7 mg/day, at which point the skin lesions developed. Approximately two months before presentation, pruritic erythema appeared, followed by the development of tense blisters one week prior to referral. Laboratory tests were negative for anti-desmoglein 1, anti-desmoglein 3, and anti-BP180 antibodies. Histopathological examination revealed a subepidermal blister with inflammatory cell infiltration in the upper dermis. Direct immunofluorescence demonstrated linear deposition of IgG along the basement membrane zone. Indirect immunofluorescence using salt-split skin showed IgG deposition on the dermal side. Based on these findings, a diagnosis of EBA was established. Treatment with systemic prednisolone at 60 mg/day resulted in marked improvement of the skin lesions.

Conclusion

This case represents, to our knowledge, the first reported coexistence of EBA and MG. The development of EBA during tapering of prednisolone from 30 mg/day to 7 mg/day, together with clinical improvement following escalation to 60 mg/day, suggests a dose-dependent effect of systemic corticosteroids on disease expression. The occurrence of EBA despite ongoing immunosuppressive therapy further indicates that autoimmune responses against type VII collagen may arise even under partial immunosuppression. These findings suggest a shared background of immune dysregulation and highlight the need for further accumulation of cases to clarify the immunological relationship between these two conditions.

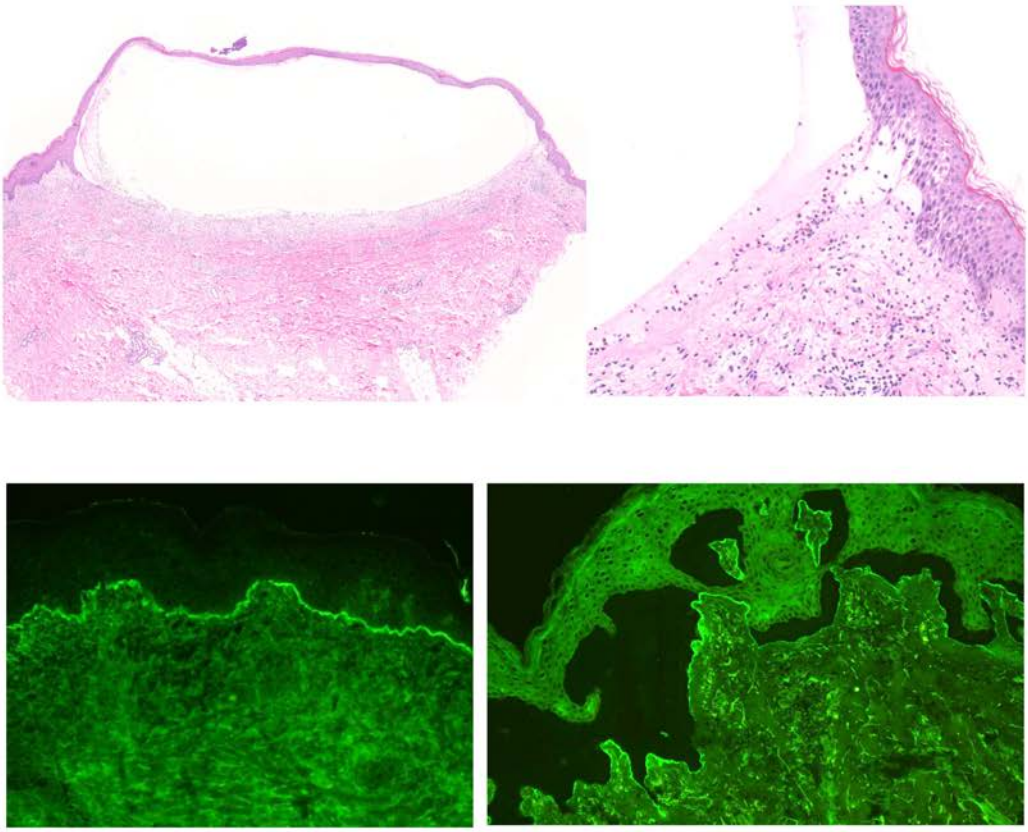

Histopathological and immunofluorescence findings showing subepidermal blister formation, linear IgG deposition along the basement membrane zone, and dermal-side reactivity on salt-split skin.

EADV CONGRESS
VIENNA
30 SEP - 3 OCT 2026

Abstract N°: 550

Epigenetic Dysregulation in Autoimmune Skin Diseases: Functional Analysis of ADGRA2, DUSP22, and FAAP20

Young-Min Han*[1], Jua Lee[1], Mi Kyung Park[2, 3], Hye-Jin Ahn[1]

[1] Department of Dermatology, Kyung Hee University College of Medicine, Kyung Hee University Hospital, Seoul, Korea, Rep. of South

[2] Department of Cancer Biomedical Science, Graduate School of Cancer Science and Policy, National Cancer Center, Goyang, Korea, Rep. of South

[3] Department of Biomedical Science, Hwasung Medi-Science University, Hwaseong, Korea, Rep. of South

Introduction
Epigenetic alterations, particularly aberrant DNA methylation, are emerging as key regulators in autoimmune skin disorders. This study aimed to identify disease-specific DNA methylation signatures in autoimmune skin diseases, and to functionally validate the role of differentially methylated genes in modulating apoptosis using disease-model cell lines.

Materials and Methods
Genome-wide DNA methylation analysis was performed on patients with vitiligo, alopecia areata (AA), and healthy controls, followed by differential analysis. Based on these results, ADGRA2 (GPR124) was identified as the candidate gene for AA, while DUSP22 and FAAP20 were selected as candidate genes for vitiligo. To investigate the functional significance of these genes, siRNA-mediated knockdown experiments were conducted. After gene knockdown, cells were subjected to oxidative stress using hydrogen peroxide, and the following assays were conducted to assess the effects: cell viability was measured by MTT assay, apoptosis was evaluated via FACS analysis, and the expression of pro-apoptotic genes was examined using qPCR.

Results
Knockdown of ADGRA2 resulted in a significant increase in the expression of pro-apoptotic genes indicating an enhancement of apoptotic processes. Similarly, silencing of DUSP22 and FAAP20 led to upregulation of apoptotic gene expression, reduced cell viability, and increased apoptotic cell populations when cells were exposed to oxidative stress conditions. These findings collectively suggest that disease-specific epigenetic silencing of these target genes sensitizes skin cells to apoptosis.

Conclusions
These findings highlight novel epigenetic mechanisms underlying autoimmune skin diseases and suggest potential therapeutic targets for intervention.

EA DV CONGRESS
VIENNA
30 SEP - 3 OCT 2026

Abstract N°: 605

Patients with Lupus erythematosus at the Female Department of the Clinic of Dermatology and Venereology, University Clinical Center – five-year experience

Dubravka Zivanovic*[1], Antonio Popesku[2], Marija Malinic[3], Jelena Vukovic[3], Vesna Reljic[1]

[1] Faculty of Medicine, University of Belgrade, Belgrade, Serbia, Clinic of Dermatology and Venereology, University Clinical Center of Serbia, Belgrade, Serbia

[2] Faculty of Medicine, University of Belgrade, Belgrade, Serbia, Belgrade, Serbia

[3] Clinic of Dermatology and Venereology, University Clinical Center of Serbia, Belgrade, Serbia

Introduction

Lupus erythematosus is a group of multisystem autoimmune diseases characterized by a breakdown of tolerance. The disease has a broad spectrum of clinical presentations and can manifest as an exclusively cutaneous form or as systemic lupus erythematosus. The course of the disease is characterized by alternating remissions and exacerbations.

The Aim: The aim of our study was the analysis of patients with lupus erythematosus at the 1st Female department of the Clinic for Dermatovenerology of the University Clinical Center of Serbia for five years, from 2020-2024.

Material and Methods: A cross-sectional retrospective study was conducted that included 98 female patients treated at the 1st Female Department of the Clinic for Dermatovenerology of the University Clinical Center of Serbia in the period from 2020 to 2024. Data were collected and analyzed from medical information systems and medical records. Statistical analysis was performed using the IBM SPSS Statistics (Statistical Package for Social Sciences) 24. Numerical variables were shown as median and range. The difference was considered statistically significant ($p \leq 0.05$) and very statistically significant ($p \leq 0.01$).

Results: The median age of patients was 59 years (ranging from 21-86 years). Cutaneous lupus erythematosus (CLE) was recorded in 74 (75.5%) and systemic lupus erythematosus (SLE) in 24 (24.5%) of patients ($p<0.001$). Of patients with CLE, discoid lupus erythematosus was the most frequent, in 50% of patients. Subacute cutaneous lupus erythematosus (SCLE) was recorded in 18% of patients, two of them with TEN- like (toxic epidermal necrolysis) SCLE. Associated autoimmune diseases were recorded in 36 (36.7%), autoimmune thyroid gland disease being the most common (15.4%). In 42 (42.9%) patients, changes in the complete blood count were recorded, interestingly, more often in patients with CLE compared to SLE ($p=0.05$). Antinuclear antibodies were elevated in 55 (56.1%) of patients. Decreased complement components were significantly more common in SLE (81.5%) compared to CLE (18.5%), $p<0.001$. The most common complications were fever (18.6%), non-erosive arthritis (10%), and retinopathy caused by the use of antimalarials (5.2%). In patients with SLE, severe Lupus nephritis (class IV) was recorded in 2, neuropsychiatric lupus in 2 (manifesting either as psychosis or seizures), lupus- related pleuritis and pericarditis in 2 patients.

Case Presentation

NA

Conclusion

We have confirmed that discoid lupus erythematosus was the most common form of the disease. We also confirmed the presence of autoimmune thyroiditis as the most common associated disease. We showed an elevated ANA titer, hematological and immunological disorders as the most frequently met criteria for the diagnosis of systemic lupus erythematosus.

EADV CONGRESS
VIENNA
30 SEP - 3 OCT 2026

Abstract N°: 606

Paraneoplastic Dermatomyositis Associated with Metastatic Breast Adenocarcinoma: A Case Report.

Nikol Kosturkova*[1], Mina Suleva[1], Miroslava Mihova[1], Elena Petrova[1, 1], Ivan Botev[1], Lyubomir Dourmishev[1]

[1] Medical University Sofia, Department of Dermatology and Venerology, Sofia, Bulgaria

Introduction

Dermatomyositis (DM) is an idiopathic inflammatory autoimmune disorder characterized by distinctive cutaneous manifestations and variable degrees of muscle involvement. In up to 40% of adult patients, DM is associated with an underlying malignancy and may present as a paraneoplastic syndrome, most commonly linked to breast, lung, or ovarian cancer. The recognition of paraneoplastic dermatomyositis is of critical importance, as cutaneous and muscular symptoms may precede, coincide with, or follow the diagnosis of malignancy.We report a case of paraneoplastic dermatomyositis with clinical, laboratory, and histopathological features in a patient with metastatic breast adenocarcinoma, highlighting the importance of early diagnosis and multidisciplinary management.

Case Presentation

Materials and Methods:

A 58-year-old female patient was admitted to our dermatology clinic with a several-month history of progressive cutaneous eruption, pruritus, and proximal muscle weakness. The skin lesions first appeared in September 2024 and were temporally associated with swelling of a right axillary lymph node. Histopathological examination of the lymph node revealed metastasis from a poorly differentiated breast adenocarcinoma. The patient underwent three cycles of ribociclib and letrozole therapy . Her past medical history included bronchial asthma, arterial hypertension, and Hashimoto thyroiditis.Dermatological examination revealed a heliotrope erythema with periorbital edema, symmetrically distributed erythematous plaques on the trunk and extremities, and disseminated erythematous papules on the forearms. Gottron’s papules were present on the dorsal aspects of the hands, accompanied by periungual erythema and capillary telangiectasias.

Results:

Laboratory investigations demonstrated elevated serum creatine phosphokinase (CPK) and CK-MB levels, supporting active muscle involvement. Electromyography, revealed findings consistent with myogenic muscle damage affecting selected muscle groups. Histopathological examination of a lesional skin biopsy showed an intact epidermis with vacuolar degeneration of basal keratinocytes, dilated vessels within the superficial and mid dermis, and a mild perivascular and diffuse lymphocytic inflammatory infiltrate, consistent with an autoimmune connective tissue process. Notably, the absence of epidermal atrophy and follicular involvement argued against cutaneous lupus erythematosus. Based on the constellation of clinical, laboratory, and histopathological findings, a diagnosis of paraneoplastic dermatomyositis was established. The patient was treated with systemic methylprednisolone at a dose of 60 mg daily in combination with topical clobetasol propionate and emollients, leading to partial clinical improvement of both cutaneous and muscular symptoms.

Discussion:

Paraneoplastic dermatomyositis remains a diagnostic challenge due to its heterogeneous presentation and overlap with other dermatological and autoimmune conditions. The presence of hallmark features such as heliotrope rash, Gottron’s papules, periungual telangiectasias, and proximal muscle weakness should prompt thorough evaluation for an underlying malignancy, particularly in adult patients.

Conclusion

This case underscores the importance of early recognition of dermatomyositis as a potential paraneoplastic entity and highlights the need for a multidisciplinary approach involving dermatologists, oncologists, and neurologists. Timely diagnosis and appropriate management of the underlying malignancy may significantly impact disease course and overall prognosis.

EA DV CONGRESS
VIENNA
30 SEP - 3 OCT 2026

Abstract N°: 613

Association Between the RCLASI Score and Immunological Activity in Cutaneous Lupus: A Prospective Analytical Study

Wissal Souhail*[1, 2], Maryem Aboudourib[1, 2], Layla Bendaoud[1, 2], Ouafa Hocar[1, 2], Said Amal[1, 2]

[1] Dermatology Department, Arrazi Hospital, Mohammed VI University Hospital, Marrakech, Marrakech, Morocco
[2] Biosciences Research Laboratory, FMPM, Cadi Ayyad University, Marrakech, Marrakech, Morocco

Introduction
Cutaneous lupus is a common manifestation of lupus erythematosus and may occur either in isolation or in association with systemic involvement. The RCLASI (Revised Cutaneous Lupus Erythematosus Disease Area and Severity Index) is a validated tool for assessing cutaneous disease activity. However, the relationship between cutaneous severity, biological activity, and systemic lupus activity remains incompletely defined. The aim of this study was to analyze the association between the RCLASI score and the biological and systemic markers of lupus activity.

Materials and Methods
This was a prospective, observational, analytical study including 70 patients with clinically and histologically confirmed cutaneous lupus. The RCLASI score, biological parameters (anti-dsDNA antibodies, complement C3/C4), and the 2019 EULAR/ACR systemic score were analyzed. Composite biological activity was defined by anti-dsDNA positivity and/or hypocomplementemia. Statistical analyses were performed using IBM SPSS Statistics and Python, including descriptive analyses, nonparametric group comparisons, quartile-based analyses, and ROC curve analyses. Statistical significance was set at $p < 0.05$.

Results
The study population comprised 70 patients, with a mean age of 43.3 ± 15.3 years, and a marked female predominance, with a male-to-female ratio of 0.11.The clinical forms of cutaneous lupus were dominated by discoid lupus (44.3%), followed by acute cutaneous lupus (25.7%), subacute cutaneous lupus (18.6%), lupus panniculitis (10%), and tumid lupus (1.4%).Overall, the RCLASI score reflected moderate cutaneous disease activity. Composite biological activity, defined by anti-dsDNA positivity and/or hypocomplementemia, was observed in 55% of patients, while significant systemic activity (EULAR score > 10) was found in approximately 30% of the cohort.The RCLASI score was significantly associated with biological and systemic markers of lupus activity. It showed a moderate positive correlation with the EULAR score ($\rho = 0.65$; $p < 0.001$) and with anti-dsDNA antibody positivity ($\rho = 0.47$; $p = 0.002$), as well as a significant inverse correlation with complement levels ($\rho = -0.57$; $p < 0.001$).Quartile analysis of the RCLASI score showed a progressive increase in the frequency of composite biological activity and systemic activity across the higher quartiles, suggesting a dose-response relationship between cutaneous severity and lupus activity.The ROC curve analysis of the RCLASI score for identifying composite biological activity showed an area under the curve (AUC) of 0.68, indicating moderate discriminative ability. The optimal threshold, determined by the Youden index, was approximately 14, with a sensitivity of 61% and a specificity of 88%.In comparative analysis, the RCLASI score was significantly higher in patients with hypocomplementemia (Mann-Whitney test, $p < 0.001$). Similarly, the RCLASI score differed significantly according to the clinical subtype of cutaneous lupus (Kruskal-Wallis test, $p < 0.05$), with higher values observed in acute and subacute forms compared with discoid forms.

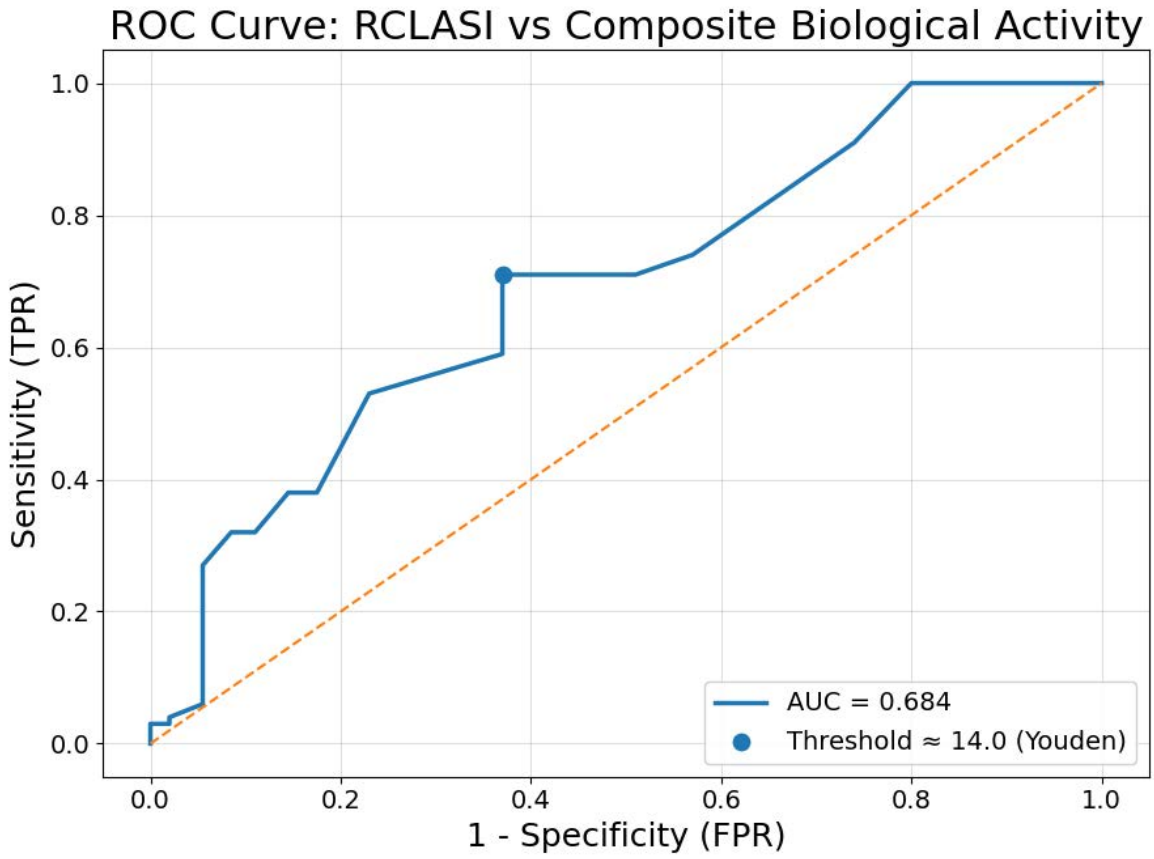

ROC curve : RCLASI vs composite biological activity

Conclusions

Our results suggest that the RCLASI score, beyond its role in dermatological assessment, could serve as an indirect indicator of the biological and systemic activity of lupus. Its integration into clinical practice could help identify patients requiring closer biological and systemic monitoring. Multicenter longitudinal studies are needed to confirm these findings and to further clarify the predictive value of the RCLASI.

EA DV CONGRESS
VIENNA
30 SEP - 3 OCT 2026

Abstract N°: 638

A 13-year diagnostic delay in atypical discoid lupus erythematosus mimicking seborrheic dermatitis

Mariangeles Jofre*[1]

[1] Private Institution, Autonomous City of Buenos Aires, Argentina

Introduction
Discoid lupus erythematosus (DLE) is a chronic cutaneous lupus subtype with variable clinical presentations. Atypical forms may mimic common inflammatory dermatoses, leading to delayed diagnosis and prolonged exposure to ineffective treatments.

Case Presentation
A 36-year-old patient presented with a 13-year history of persistent facial dermatosis characterized by recurrent flares and partial remissions, with occasional extension to the chest. Previous treatments included topical corticosteroids, calcineurin inhibitors, antifungals, and prolonged courses of tetracyclines, all with minimal or transient improvement.Physical examination revealed multiple well-demarcated erythematous plaques measuring 1–2 cm in diameter, with fine superficial scaling, symmetrically distributed on both cheeks and less prominently on the forehead. Some lesions showed coalescence with relative central clearing.A presumptive diagnosis of refractory seborrheic dermatitis led to initiation of oral isotretinoin (20 mg/day), with poor clinical response after three months. Further evaluation was performed.Laboratory tests showed normal hematologic and metabolic parameters. Autoimmune serology revealed antinuclear antibodies at a titer of 1:320 with a dense fine speckled pattern, while anti-double-stranded DNA, anti-Ro, anti-La, and anti-Sm antibodies were negative. Complement levels were within low-normal range.Histopathological examination demonstrated epidermal atrophy with flattening of rete ridges, hyperkeratosis with focal parakeratosis, follicular plugging with infundibular dilation, and focal vacuolar degeneration of the basal layer. The dermis showed a dense band-like lymphohistiocytic infiltrate with focal lichenoid features, fibrosis, and dilated capillaries. Periodic acid–Schiff staining was negative.Based on clinicopathological correlation, a diagnosis of atypical discoid lupus erythematosus was established. Isotretinoin was discontinued, and hydroxychloroquine (200 mg/day) was initiated after ophthalmologic clearance. Systemic involvement was excluded.At two-month follow-up, the patient showed marked clinical improvement, with significant reduction in lesion number and size, leaving only minimal residual erythema and scaling.



First physical exam

Conclusion

This case highlights the diagnostic challenge of atypical DLE and emphasizes the importance of early skin biopsy in chronic, treatment-refractory dermatoses. Delayed diagnosis may lead to prolonged disease burden and unnecessary treatments. Clinicopathological correlation and interdisciplinary management are essential for accurate diagnosis and optimal outcomes.



Last physical exam

EA DV CONGRESS
VIENNA
30 SEP - 3 OCT 2026

Abstract N°: 639

Pemphigus Herpetiformis: A Rare Variant within the Pemphigus Spectrum

Mikołaj Łanocha*[1], Anna Tekielak[1], Szymon Leonik[1], Beata Bergler-Czop[1]

[1] Department of Dermatology, School of Medicine in Katowice, Medical University of Silesia, Katowice, Poland

Introduction

Pemphigus herpetiformis is a rare variant of pemphigus characterized by a combination of clinical features resembling dermatitis herpetiformis and immunopathological findings typical of pemphigus. The disease presents with erythematous lesions with grouped, tense vesicles and pustules arranged in a herpetiform or annular pattern, accompanied by intense pruritus. Histopathologically, it is distinguished by eosinophilic spongiosis and subcorneal pustules composed of eosinophils and neutrophils, with minimal or absent acantholysis. Immunologically, it is defined by the presence of IgG autoantibodies directed against keratinocyte cell surface antigens, most commonly desmoglein 1. Pemphigus herpetiformis is considered by many authors to represent a clinical variant within the pemphigus spectrum, sharing immunological mechanisms with pemphigus foliaceus and pemphigus vulgaris. The disease course is often more benign compared to classical forms of pemphigus; however, its polymorphic clinical presentation may lead to diagnostic challenges. The aim of this study was to present a rare case of pemphigus herpetiformis, emphasizing its clinical, histopathological, and immunological features, as well as highlighting diagnostic difficulties and therapeutic management.

Case Presentation

We report the case of a 69-year-old male with a 3-year history of blistering disease. Clinical examination revealed disseminated erythematous, erosive, and crusted lesions with peripheral vesicles and pustules, predominantly on the trunk and buttocks. Annular vesiculopustular lesions and erosions with crusting were also noted on the face, including the lips, while other mucous membranes remained unaffected. Histopathological examination demonstrated subcorneal pustules containing numerous eosinophils and neutrophils, accompanied by spongiosis and superficial perivascular inflammatory infiltrates composed mainly of eosinophils. Acantholysis was absent. Direct immunofluorescence (DIF) revealed intercellular IgG deposition within the epidermis. Indirect immunofluorescence showed a significant increase in circulating pemphigus autoantibody titers (up to 1:3200). Based on the combination of clinical, histopathological, and immunological findings, a diagnosis of pemphigus herpetiformis was established. The patient had a history of multiple hospitalizations due to disease exacerbations and had previously been treated with systemic corticosteroids, dapsone, and antibiotics. Dapsone therapy was discontinued due to the development of anemia. During the current hospitalization, the patient received intravenous methylprednisolone, followed by oral prednisone in combination with topical corticosteroids. Under this therapeutic regimen, partial clinical improvement was observed, including a reduction in inflammatory activity, decreased formation of new vesiculopustular lesions, and gradual re-epithelialization of erosions.

Conclusion

Pemphigus herpetiformis remains a diagnostically challenging entity due to its heterogeneous clinical and histopathological presentation and its resemblance to other vesiculobullous and inflammatory dermatoses. This case highlights the crucial role of integrating clinical features with immunopathological findings, particularly direct and indirect immunofluorescence, as histopathology alone may be inconclusive, especially in the absence of acantholysis. Pemphigus herpetiformis is increasingly regarded as a clinical variant within the pemphigus spectrum. In the presented case, the involvement of the lips suggests a closer relationship to pemphigus vulgaris Systemic corticosteroids remain the cornerstone of therapy, with additional agents such as dapsone offering

therapeutic benefit in selected patients. The chronic and relapsing nature of the disease necessitates long-term follow-up and individualized treatment strategies. Early recognition and appropriate management are crucial to control disease activity, alleviate symptoms, and prevent complications.

EADV CONGRESS
VIENNA
30 SEP - 3 OCT 2026

Abstract N°: 643

Faster disease control and corticosteroid sparing with short-course stapokibart in moderate-to-severe bullous pemphigoid: a prospective study

Yue Zhu*[1], Jinbo Chen[1]

[1] Department of Dermatology, Traditional Chinese and Western Medicine Hospital of Wuhan, Tongji Medical College, Huazhong University of Science and Technology, Wuhan, China

Introduction
Moderate-to-severe bullous pemphigoid (BP) is commonly treated with systemic corticosteroids plus immunosuppressants such as mycophenolate mofetil (MMF), but both carry important risks, especially in older patients with multiple comorbidities. As previously reported biologic strategies in BP have mostly relied on maintenance treatment, we evaluated short-course stapokibart as an acute-phase corticosteroid-sparing strategy.

Materials and Methods
This single-center prospective non-randomized controlled study included 40 patients with confirmed BP and BPDAI ≥20. Patients who had received biologics, immunosuppressants, intravenous immunoglobulin, or related treatments within the previous 6 months were excluded. Twenty-four patients received stapokibart plus systemic corticosteroids, consisting of a 600 mg loading dose followed by 300 mg every 2 weeks for a total of 6 injections over 8 weeks. Sixteen patients received MMF plus systemic corticosteroids. Main outcomes were time to disease control and cumulative oral corticosteroid exposure. Additional outcomes included Week-24 BPDAI and pruritus numerical rating scale (NRS), the proportion achieving prednisone ≤10 mg/day at Week 24, and adverse events (AEs) and relapse during follow-up.

Results
Baseline age, sex, body weight, and corticosteroid dose were comparable between groups. Patients treated with stapokibart achieved disease control earlier than those treated with MMF, with a median time to disease control of 3.0 (1.0–5.0) days versus 6.5 (4.75–9.25) days (log-rank P=0.001). Cumulative oral corticosteroid exposure was lower in the stapokibart group than in the MMF group [3010.0 (2721.2–3736.2) mg vs 3745.0 (3399.4–4716.2) mg, P=0.019]. At Week 24, BPDAI was lower in the stapokibart group [4.0 (1.8–6.0) vs 7.0 (6.0–8.0), P<0.001]. Pruritus NRS at Week 24 was numerically lower [0.0 (0.0–1.0) vs 0.5 (0.0–1.0)], and a higher proportion achieved prednisone ≤10 mg/day at Week 24 (62.5% vs 31.2%); however, these differences were not statistically significant. Rates of AEs and relapse were lower in the stapokibart group than in the MMF group (0 vs 25.0%, P=0.020; 4.2% vs 31.3%, P=0.029, respectively).

Conclusions
Short-course stapokibart was associated with faster disease control, lower corticosteroid exposure, and lower disease activity than MMF in moderate-to-severe BP, and may represent a feasible acute-phase corticosteroid-sparing strategy.

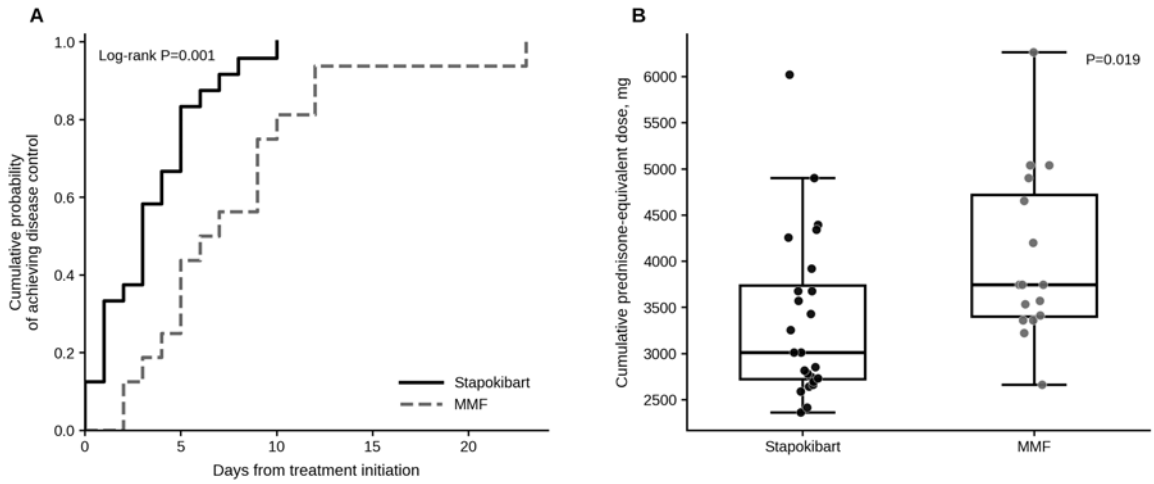

Figure. Clinical outcomes in patients with moderate-to-severe bullous pemphigoid treated with short-course stapokibart plus systemic corticosteroids or MMF plus systemic corticosteroids. (A) Time to disease control was shorter in the stapokibart group than in the MMF group. (B) Cumulative oral corticosteroid exposure through Week 24 was lower in the stapokibart group than in the MMF group. Boxes indicate median and interquartile range; whiskers indicate range; points indicate individual patients.

EADV Congress 2026, VIENNA
30 SEPTEMBER - 03 OCTOBER 2026
POWERED BY M-ANAGE.COM

EA DV CONGRESS
VIENNA
30 SEP - 3 OCT 2026

Abstract N°: 657

Rowell Syndrome: A Rare Clinical Entity With Atypical Features

Aslıhan Akkaya*[1], Beyza Çolpan[2], Peyker Temiz[3], Cemal Bilaç[1]

[1] Manisa Celal Bayar University Faculty of Medicine, Department of Dermatology, MANİSA, Türkiye
[2] Manisa Celal Bayar University Faculty of Medicine, Department of Dermatology, İZMİR, Türkiye
[3] Manisa Celal Bayar University Faculty of Medicine, Department of Pathology, MANİSA, Türkiye

Introduction

Rowell syndrome (RS) is a rare clinical entity characterized by erythema multiforme (EM)-like cutaneous lesions arising in the context of lupus erythematosus (LE),accompanied by distinct immunological findings.Its true incidence remains undetermined.Diagnostic criteria were revised by Zeitouni et al. in 2000; however,whether RS represents an independent entity or a variant within the lupus spectrum remains debated. Due to the morphological heterogeneity of EM-like lesions, RS may overlap with subacute cutaneous LE,bullous LE,urticarial vasculitis, and Stevens-Johnson syndrome,necessitating a thorough differential diagnostic approach. Given its rarity and ongoing diagnostic controversy, each newly reported case contributes to a deeper understanding of its clinicopathological and immunological spectrum. Herein,we report a case of extensive cutaneous and mucosal RS developing in an SLE patient receiving rituximab (RTX),with emphasis on its atypical clinical features and temporal association with biologic therapy.

Case Presentation

A 32-year-old female with SLE and celiac disease presented with a two-week history of pruritic erythematous lesions. Examination revealed target lesion morphology on the face, malar-mandibular region, trunk, and extremities; targetoid plaques on bilateral palmoplantar surfaces; and buccal mucosal erosion.The patient was under treatment with subcutaneous methotrexate (MTX; 15 mg/week) and RTX for SLE, and the onset of lesions approximately 10 days after the second RTX infusion suggested a clinically significant temporal relationship. Laboratory findings revealed anemia (10.5 g/dL), leukocytosis, thrombocytosis,elevated erythrocyte sedimentation rate and CRP; renal and hepatic function tests and electrolytes were within normal limits. An infectious serology panel including HIV,syphilis,viral hepatitis,EBV,CMV,and Parvovirus was negative. ANA was positive (speckled pattern, 1/100),with positivity for Anti-SSA/Ro,Anti-SSB/La and Ro-52; Anti-dsDNA and RF were negative; C3 and C4 levels were decreased; and 24-hour urine protein was 200 mg/day. Neurolupus workup was unremarkable. A punch biopsy obtained from an elbow lesion under differential diagnoses of subacute cutaneous lupus erythematosus, EM, granuloma annulare, urticarial vasculitis, and RS demonstrated subepidermal edema,focal blister formation,and mixed inflammatory cell infiltration in the dermis; direct immunofluorescence (DIF) was negative; findings were reported as consistent with EM. In light of the clinical, serological,and histopathological findings, the patient fulfilled the diagnostic criteria proposed by Zeitouni et al. and was diagnosed with RS (SLE + EM overlap).Treatment was initiated with intravenous methylprednisolone (60 mg/day), oral hydroxychloroquine (2×200 mg/day), subcutaneous MTX (15 mg/week), and topical clobetasol. Following an 18-day inpatient course with progressive lesion resolution,the patient was discharged on oral methylprednisolone (48 mg/day) and enrolled in routine follow-up.

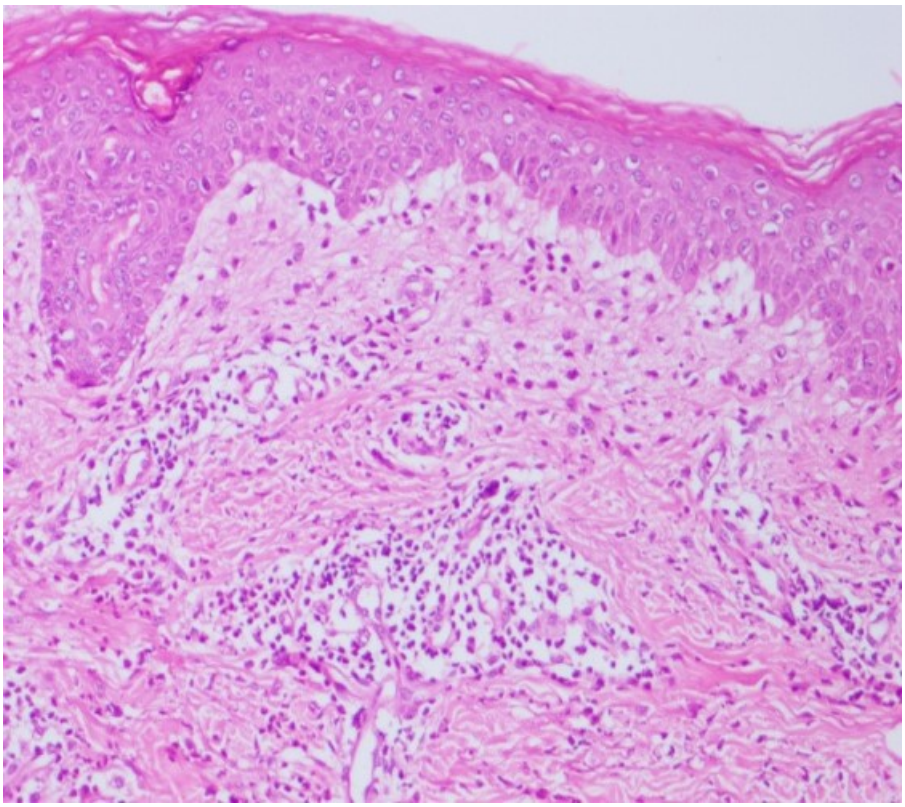

Figure 1. Basal vacuolization beneath the intact epidermis, papillary dermal edema, and perivascular chronic inflammatory cell infiltration.

Conclusion

Two points distinguish this case in the literature.First,while most RS cases are reported on a DLE background with acral-predominant lesions,our case arose on an SLE background with widespread involvement of the trunk,extremities,and malar region, alongside oral mucosal erosion suggesting RS phenotype may extend beyond classical descriptions,and that reliance on acral distribution may delay diagnosis. Second,and previously undocumented,lesions emerged 10 days after the second RTX infusion,with infectious triggers and new medications excluded.RTX-induced B-lymphocyte depletion may impair CD8+ T-cell regulation through regulatory B-cell loss,while concomitant type I interferon upregulation may accelerate anti-Ro/SSA-mediated keratinocyte injury,precipitating RS. This temporal association implicates RTX as a potential trigger,highlighting that RS should be considered in the differential diagnosis of unexpected cutaneous eruptions in lupus patients on biologic therapy.

EA DV CONGRESS
VIENNA
30 SEP - 3 OCT 2026

Abstract N°: 662

Comparison of intralesional triamcinolone acetate treatment and platelet rich plasma treatment in patients diagnosed with alopecia areata

Ramazan Ülker[1], İlknur Yorğun Özdemir*[1], Hatice Uce Ozkol[1], Sena Uçan[1]

[1] Van Yüzüncü Yıl Üniversitesi Faculty of Medicine, Dermatology, Van, Türkiye

Introduction
Alopecia areata is a common chronic autoimmune disease that causes non-scarring hair loss, affecting approximately 2% of the general population. Various local and systemic treatments are available for Alopecia areata. Recently, Platelet-Rich Plasma (PRP) therapy has become more widely used in treatment. In our study, we aimed to evaluate the effectiveness of intralesional triamcinolone acetonide (ILCS) and PRP treatment in alopecia areata patients and to compare the effectiveness of the two methods.

Case Presentation
Our study included alopecia areata patients who applied to the Dermatology Polyclinic between March 27, 2024 and March 27, 2025. The age range of our patients was 18-65 years, and they were patients who had not previously received treatment for alopecia areata diagnosis. We divided the patients into 2 groups. The first group received 3 sessions of PRP treatment every 4 weeks. The second group received 3 sessions of ILKS treatment every 4 weeks. The scalp of the two groups was photographed at first, 3 months and 6 months, and the severity of alopecia tool (SALT) was calculated and statistically compared. The effect of age, gender, disease duration and family history on treatment response was investigated and compared.
Our study included a total of 60 patients, 41 (68.33%) of whom were male and 19 (31.66%) female, who were diagnosed with alopecia areata.The patients' age was calculated as 27.97±7.36 years. The duration of the disease was 5±7.11 months. The baseline, 3rd month and 6th month SALT scores of patients who received PRP treatment were 6.03±0.89, 2.53±2.01 and0.93±1.72, respectively. A significant decrease was observed in the SALT scores at baseline, 3rd month and 6th month in patients who received PRP treatment ($p<0.001$). The baseline, 3rd month and6th month SALT scores of patients who received ILCS treatment were 6.07±0.78, 2.60±2.07 and 1.27±2.03, respectively. In patients receiving ILCS treatment,A significant decrease was detected in SALT scores at baseline, 3 months, and 6 months ($p<0.001$). When comparing SALT score changes between baseline and 3 months ($p=0.951$), baseline and 6 months ($p=0.576$), and 3 months and 6 months ($p=0.568$) between the two groups, no statistically significant difference was found. No significant difference was found between age, gender, disease duration, and family history and the treatment process. PRP treatment was evaluated as follows:4 (13.33%) patients had no response, 7 (23.33%) patients had a partial response, 7 (23.33%) patients had a good response, and 12 (40%) patients had a very good response. At the end of the 6th month,when re-evaluated, 2 (6.66%) patients showed no response, 2 (6.66%) patients showed partial response, 3 (10%) patients showed good response, and 23 (76.66%) patients showed very good response. In 30 patients receiving ILCS therapy, at the 3rd month treatment rate, 5 (16.66%) patients showed no response, 8 (26.66%) patients showed detailed response, 7 (23.33%) patients showed good response, and 10 (33.33%) patients showed very good response. At the end of the 6th month,when re-evaluated, 3 (10%) patients showed no response, 3 (10%) patients showed partial response, 4 (13.33%) patients showed good response, and 20 (66.66%) patients showed very good response.

Conclusion
There was no difference between the two groups. Although there was no statistically significant difference, it was observed that the decrease in SALT scores of patients in the PRP groups was faster or higher than in the ILCS

groups.

EA DV CONGRESS
VIENNA
30 SEP - 3 OCT 2026

Abstract N°: 664

BCMA-Targeted T-Cell Engager Therapy Induces Rapid and Durable Remission in Refractory Pemphigus

Moritz Ronicke*[1], Tobias Rothe[2], Fabian Müller[3], Carola Berking[1], Georg Schett[2], Ricardo Grieshaber-Bouyer[2], Michael Sticherling[1]

[1] Department of Dermatology, Uniklinikum Erlangen, Friedrich-Alexander University Erlangen-Nürnberg, Erlangen, Germany
[2] Department of Rheumatology, Uniklinikum Erlangen, Friedrich-Alexander University Erlangen-Nürnberg, Erlangen, Germany
[3] Department of Hematooncology, Uniklinikum Erlangen, Friedrich-Alexander University Erlangen-Nürnberg, Erlangen, Germany

Introduction

Pemphigus is a potentially life-threatening autoimmune blistering disease driven by pathogenic autoantibodies against the desmosomal proteins, desmoglein 1 and 3. While the anti-CD20 antibody rituximab is the current standard of care, a proportion of patients do not respond to rituximab or experiences a short-term relapse. In those, persisting autoreactive B-cell clones despite rituximab therapy indicate incomplete depletion. Therefore, strategies for refractory disease are needed.

Teclistamab, a bispecific T-cell engager directed against CD3 and B-cell maturation antigen (BCMA), effectively depletes B-cells and plasma cells through T-cell engagement in various organs. It is approved for multiple myeloma, but has recently also shown efficacy in immune-mediated diseases. We report its first use in pemphigus.

Case Presentation

Two multi-drug resistant pemphigus patients were treated with teclistamab. Both were refractory to rituximab and had received mycophenolate mofetil as their last therapy, discontinued three weeks prior to teclistamab to allow T-cell recovery. Teclistamab was administered subcutaneously in a step-up scheme (day 1: 0.06 mg/kg; day 3: 0.3 mg/kg; day 5: 1.5 mg/kg), followed by one maintenance dose of 1.5 mg/kg 12–14 days after the final step-up dose.

Teclistamab rapidly depleted circulating $CD19^+$ B-cells in both patients. Complete depletion of serum free light chains within three weeks indicated successful ablation of the plasma cell compartment. Desmoglein antibodies decreased concordantly, with seroconversion within eight weeks. Both patients achieved a Pemphigus Disease Area Index-activity subscore (PDAI-A) of zero within weeks. Intermittent hoarseness and dysphagia in patient #2, indicating laryngeal and esophageal involvement, resolved entirely.

Both patients experienced grade 1 cytokine release syndrome after the second dose, resolving promptly under treatment with tocilizumab and paracetamol, respectively. No neurotoxicity was observed. Patient #1 experienced transient grade 3 neutropenia lasting one day and resolving without further intervention. Both patients developed transient hypogammaglobulinemia requiring intravenous immunoglobulin substitution and moderate upper respiratory tract infections. B-cells repopulated after 17 and 21 weeks of aplasia, displaying a naïve phenotype consistent with deep

immune reset. Free light chains reappeared around weeks 32 and 36, respectively. Both patients remain relapse- and treatment-free at 48+ weeks of follow-up.

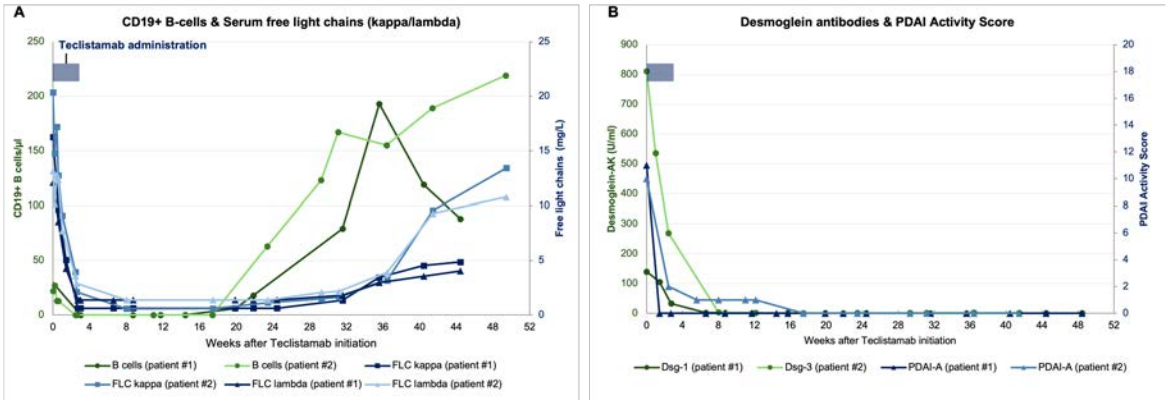

Teclistamab induced rapid depletion of B-cells and free light chains (Panel A) and seroconversion of desmoglein antibodies with decline of PDAI-A to zero (Panel B) in both patients.

Conclusion

Teclistamab induced rapid seroconversion and complete clinical remission in two patients with rituximab-refractory pemphigus, with durable treatment-free remission. It utilizes T-cell-mediated cytotoxicity as a more potent effector mechanism compared to rituximab, which utilizes antibody dependent cytotoxicity and complement activation. Further, the direct elimination of (long-lived) plasma cells via targeting BCMA, which are inaccessible to anti-CD20 therapy, may explain the rapid response to teclistamab. Adverse effects were manageable with close monitoring. These results support teclistamab as a promising therapy for refractory pemphigus and warrant evaluation in larger cohorts.

EADV CONGRESS
VIENNA
30 SEP - 3 OCT 2026

Abstract N°: 698

Repigmentation Induced by Reverse Koebner Phenomenon Following Dermabrasion by using the surgical handpiece of Fractional CO_2 Laser in vitiligo Patients

Ahmed Farouk Tamer Abdallah*[1]

[1] kafr Elsheikh General Hospital, Kafr El sheikh, Egypt

Introduction
Vitiligo is a chronic depigmenting disorder with variable therapeutic responses. Koebner phenomenon is a skin condition that is named after Heinrich Koebner in 1876 .The concept of the reverse Koebner phenomenon, where repigmentation occurs following controlled skin injury, has gained interest as a potential therapeutic mechanism. Fractional CO_2 laser has been proposed as a modality to stimulate melanocyte migration and proliferation. This study aims to evaluate the efficacy of dermabrasion by using the surgical handpiece of fractional CO_2 laser in inducing repigmentation in patients with active and stable vitiligo.

Materials and Methods
This study included a large cohort of patients with clinically diagnosed vitiligo, including both active and stable cases. All patients underwent treatment with dermabrasion by using the surgical handpiece of fractional CO_2 laser sessions at monthly intervals. we selected vitiligo patients exhibiting a positive Koebner response who were resistant to conventional therapies . Dermabrasion by using the surgical handpiece of Fractional CO2 Laser , directed from the center of the vilitignous patches outward , maintaining 2 mm margin from the edges. Sessions were repeated every 4 weeks with consistent technique. Clinical evaluation and photographic documentation were performed at baseline and during follow-up visits. The degree of repigmentation and response to therapy were assessed throughout the treatment period.

Results
Most patients demonstrated a favorable response to dermabrasion by using the surgical handpiece of fractional CO_2 laser sessions , with visible repigmentation observed from the first session. Progressive improvement was noted with subsequent sessions.Peripheral Repigmentation was observed in nearly all cases leading to reduction in lesion size . Both active and stable vitiligo cases responded to treatment, supporting the role of laser-induced micro-injury in triggering melanocyte activation and migration consistent with the reverse Koebner phenomenon.

Conclusions
Dermabrasion by using the surgical handpiece of Fractional CO_2 laser may induce a Reverse Koebner Phenomenon which appears to be an effective and safe therapeutic option for inducing repigmentation in vitiligo patients. The early onset of response and sustained improvement highlight its potential role as a valuable adjunct in vitiligo management. Further controlled studies are recommended to validate these findings.

EADV CONGRESS
VIENNA
30 SEP - 3 OCT 2026

Abstract N°: 723

Overlap syndrome of cutaneous lupus erythematosus and lichen planus: a diagnostic and therapeutic challenge in a 62-year-old patient

Iris Sarai Guevara Suazo*[1]

[1] Universidad Nacional Autónoma de Honduras, Distrito Central, Honduras

Introduction

The coexistence of cutaneous lupus erythematosus (CLE) and lichen planus (LP) in a single patient, known as CLE-LP overlap syndrome, is an extremely rare entity. Diagnostic frameworks, such as Jicha's criteria (2021), distinguish between "classic" and "possible" forms based on serological markers. This case explores the diagnostic journey of a patient where clinical and histological findings strongly suggest an overlap despite negative serology.

Case Presentation

A 62-year-old female, fron Honduras, Central America presented with a one-year history of a progressive dermatosis characterized by pruritic, violaceous plaques localized on the forehead, bilateral malar regions, nose, and upper back. Physical examination revealed well-defined erythematous-violaceous plaques with slight central atrophy.An incisional skin biopsy showed orthokeratotic hyperkeratosis, irregular acanthosis, and vacuolar degeneration of the basal layer with Max-Joseph spaces and colloid bodies. A dense band-like lymphohistiocytic infiltrate with plasma cells was identified in the papillary and mid-dermis. Importantly, immunological workup revealed negative antinuclear antibodies (ANA <1:80), and the patient showed no systemic manifestations, allowing for the exclusion of systemic lupus erythematosus (SLE) at the time of diagnosis.

Conclusion

Discussion: CLE-LP overlap syndrome represents a unique clinical intersection. As proposed by Camisa et al. and Jicha, the absence of positive ANA titers places this case within the "possible" overlap category or a strictly cutaneous manifestation. This seronegativity is a crucial prognostic factor, as it suggests a lower immediate risk of systemic involvement, although the 5-10% risk of future conversion to SLE reported in the literature warrants long-term surveillance. Management focused on high-potency topical corticosteroids and photoprotection, with favorable initial response. Conclusions: This case highlights that a negative ANA result does not rule out CLE-LP overlap syndrome when clinico-pathological correlation is strong. It underscores the necessity of using multi-parameter diagnostic algorithms to differentiate strictly cutaneous overlap from systemic disease, ensuring appropriate therapeutic management and specialized follow-up.

EADV CONGRESS
VIENNA
30 SEP - 3 OCT 2026

Abstract N°: 738

Tumid lupus erythematosus: Clinicopathological, immunological and therapeutic features in a retrospective study of 73 patients

Xavier Bosch-Amate*[1], Daniel Barquero-Orias[2], Laura Serra-Garcia[1], Priscila Giavedoni[1], Daniel Morgado Carrasco[1], José M. Mascaró Jr.[1]

[1] Department of Dermatology, Hospital Clínic de Barcelona, Barcelona, Spain

[2] Department of Dermatology, Caja Costarricense del Seguro Social, San José, Costa Rica

Introduction

Tumid lupus erythematosus (TLE) is a subtype of cutaneous lupus erythematosus (CLE). Although it was described decades ago, comprehensive studies remain scarce. It is currently classified as an independent form within the group of intermittent CLE, but further research is needed to better define its position within the lupus erythematosus spectrum. The aim of this study was to characterize the demographic, clinical, immunological, and histopathological features of TLE, and to evaluate the efficacy and safety of therapeutic approaches.

Materials and Methods

A retrospective study of patients with TLE treated at a Spanish tertiary care hospital between 2007 and 2024 was conducted.

Results

Seventy-three patients with TLE were included (median age at diagnosis, 43.3 years [IQR, 34.2–49.3]; 47 women, 64.4%). Systemic lupus erythematosus coexisted in 12 patients (16.4%), and 22 (30.1%) also presented another CLE subtype. Regarding autoantibodies, ANA were positive in 53 patients (74.6%), and anti–smooth muscle antibodies in 38 (44.7%). Histology showed preserved epidermis, perivascular and periadnexal lymphocytic infiltrates, and abundant mucin deposition. $CD123^{+}$ plasmacytoid dendritic cells were detected in 21 biopsies (31.3%). Prednisone (87%) and anifrolumab (100%) achieved the highest remission rates, while antimalarials showed a mean response rate of 52%. Among immunosuppressants, mycophenolate demonstrated the best results (75%). Overall, 60 patients (82.2%) achieved complete remission.

Conclusions

TLE is a distinct subtype of CLE characterized by minimal epidermal damage and prominent mucin deposition. Coexistence with SLE and other CLE variants was relatively frequent in our cohort. Prednisone, mycophenolate, and hydroxychloroquine showed the highest response rates, while anifrolumab may represent a valuable alternative in refractory cases.

EADV CONGRESS
VIENNA
30 SEP - 3 OCT 2026

Abstract N°: 751

The therapeutic challenge of a post COVID-19 recalcitrant Bullous Pemphigoid case

Vasiliki Karathanasi*[1], Eleni-Nefeli Kolokotsa[1], Maria Fountoulaki[1], Chariklia Kouvidou[2]

[1] Dermatology Department, General Hospital of Athens Evaggelismos, Athens, Greece
[2] Pathology Department, General Hospital of Athens Evaggelismos, Athens, Greece

Introduction

Bullous Pemphigoid (BP) represents an autoimmune blistering skin disease characterized clinically by severe itching and tense bullae developed on urticarial erythematous plaques. Almost half of the cases are classified as idiopathic and the rest are attributed to variable factors including infections.Since the onset of the SARS-CoV-2 pandemic it has been noted that the COVID-19 infection may cause immunological dysregulation through abnormal cytokines release and T-cells activation, so leading to increased autoimmune diseases including BP.

Case Presentation

A 61 one year old male was presented at our Dermatological Department on the 31/01/2025 due to persistent blistering itching rash of 5 months duration which had developed 4 days post COVID-19 infection. Clinically, a diffuse severe exanthema was observed consisting of tense enlarged bullae based on erythematous plaques located on the head, trunk, upper and lower limps accompanied by severe itching which had greatly compromised the quality of the patient's life. At first the patient had been administered local and systematic corticosteroid regimens with partial response by a private Dermatologist and subsequently he was referred to our Special Department of Autoimmune Bullous Diseases of our Hospital, where the laboratory further testing confirmed the BP diagnosis without unrevealing other significant pathological findings. Despite the reinforcement of the corticosteroid treatment alongside with antihistamines the disease showed a chronic recalcitrant progress with frequent relapses which led to the off-label use of omalizumab with a satisfactory response over a few months. In February of 2026 the patient was hospitalized due to severe flare up of the disease which was resistant to increased systematic corticosteroid treatment (1 mg/kg) and he was managed with rituximab (1 g i.v.). The clinical course was further complicated by atrial fibrillation and Staphylococcus aureus bacteremia. Thereafter, the patient demonstrated rapid recession of the skin disease and exited the hospital in the March of 2026 with the decision of a therapeutic "bridge" establishment with dupilumab taking into consideration the cardiac disease. The patient has been under dupilumab treatment for almost 2 months with a steady clinical improvement.

Conclusion

The present clinical case highlights the potential correlation between COVID-19 infection and the development of persistent BP caused by the abnormal activation of various immunological mechanisms triggered by SARS-CoV-2. Thus, the "aggressive" phenotypic variant of BP demands a flexible therapeutic approach including off-label treatments and the involvement of the adequate medical specialties if necessary.

EADV CONGRESS
VIENNA
30 SEP - 3 OCT 2026

Abstract N°: 756

A Case Report: Multiple Nodular Cutaneous Amyloidosis Lesions in a 27-Year-Old Female with Sjögren's Syndrome

Olha Mykhailychenko*[1], Ganna Nesterenko[1]

[1] LLC "EuroDerm", Kyiv, Ukraine

Introduction

Sjögren's syndrome is a chronic systemic autoimmune disease primarily affecting exocrine glands, particularly salivary and lacrimal glands, but may also be associated with a broad spectrum of extraglandular manifestations, including cutaneous involvement. Primary localized cutaneous nodular amyloidosis (PLCA) is a rare form of cutaneous amyloidosis characterized by amyloid deposits derived from immunoglobulin light chains within the dermis, in the absence of systemic amyloidosis. Although uncommon, PLCA has been described in association with Sjögren's syndrome, with some studies suggesting a prevalence of up to 25% among patients with nodular amyloidosis. The recognition of this clinical association is essential due to the potential risk of systemic progression and underlying lymphoproliferative disorders.

Case Presentation

A 27-year-old woman was referred to our clinic in 2023 with a chief complaint of multiple painless nodules that gradually increased in size and number (up to 4) over the last 3 years on the anterior abdominal wall. Physical examination revealed several firm, dome-shaped, waxy nodules measuring 1–4 cm on the anterior abdominal wall. A few months before the visit in our clinic, the patient was diagnosed with Sjögren's syndrome and was prescribed further examination and appropriate treatment. It is important to note that the solitary nodule on the anterior abdominal wall had appeared prior to the diagnosis of Sjögren's syndrome (in 2021). Laboratory abnormalities included: elevated erythrocyte sedimentation rate (Westergren method) 40 mm/hour; polyclonal increase in gamma globulin; and strongly positive antinuclear, anti-Ro (SS-A) and anti-La (SS-B) antibodies. Immunoelectrophoresis of the serum and concentrated urine showed strongly positive monoclonal immunoglobulins and light chains. Histopathological analysis of a skin biopsy demonstrated homogeneous, amorphous deposits in the dermis staining positively with Congo red, confirming the diagnosis of PLCA. Immunohistochemical analysis showed a κ to λ ratio of immunoglobulin-positive plasma cells of approximately 10:1, suggesting clonality, confirming the diagnosis of primary localized cutaneous nodular amyloidosis. The patient was managed by a rheumatologist with systemic therapy including hydroxychloroquine and methylprednisolone for Sjögren's syndrome. Dermatologic treatment consisted of two intralesional injections of triamcinolone acetonide administered into the lesions.



Conclusion

PLCA is believed to arise from localized plasma cell dyscrasia with overproduction of immunoglobulin light chains that deposit as amyloid in the dermis. In patients with Sjögren's syndrome, chronic immune activation may further promote this process. Although PLCA is typically confined to the skin, the presence of monoclonal plasma cells warrants regular monitoring for potential progression to systemic amyloidosis or a lymphoproliferative disorder, particularly in autoimmune contexts such as Sjögren's syndrome. Recent literature emphasizes the importance of early identification, histopathologic confirmation, and interdisciplinary follow-up in these patients.

This case highlights a rare but clinically significant association between PLCA and Sjögren's syndrome in a young female patient. Awareness of such manifestations is essential for both dermatologists and rheumatologists. Timely diagnosis through biopsy, immunohistochemistry, and exclusion of systemic involvement represent critical steps for optimal management and prognosis.



POWERED BY M-ANAGE.COM

EADV CONGRESS
VIENNA
30 SEP - 3 OCT 2026

Abstract N°: 783

Predictors of Relapse After the Third Rituximab Dose in Pemphigus Vulgaris: A Real-World Study

Kerem Balan*[1], Furkan Aydin[1], Leyla Huseynova Terzi[1], Basak Yalici Armagan[1], Neslihan Akdogan[1], Sibel Dogan Gunaydin[1], Sibel Ersoy Evans[1], Duygu Gulseren[1]

[1] Hacettepe University, Department of Dermatology and Venereology, Ankara, Türkiye

Introduction

Pemphigus vulgaris is a rare and severe autoimmune blistering disease caused by pathogenic autoantibodies directed against desmoglein 1 and/or desmoglein 3, two desmosomal adhesion proteins primarily found in the skin and superficial mucosal surfaces. Although uncommon, pemphigus vulgaris markedly impairs patients' quality of life and imposes a substantial economic burden on the healthcare system. Therefore, achieving clinical remission and improving quality of life should be major goals in the treatment of pemphigus. In recent years, rituximab, an anti-CD20 monoclonal antibody targeting the CD20 molecule, has been recommended as a first-line treatment for moderate-to-severe pemphigus in many treatment guidelines. Although several studies have evaluated predictors of relapse in patients receiving rituximab, there is still insufficient evidence regarding relapse risk after the third dose of rituximab, particularly with respect to markers that may predict this risk. This study aimed to evaluate clinical and laboratory markers that may predict relapse after the third dose of rituximab in patients with pemphigus vulgaris.

Materials and Methods

This retrospective descriptive study included 31 patients with pemphigus vulgaris who received a third dose of rituximab at the Department of Dermatology and Venereology, Hacettepe University, between January 2015 and July 2025. Patients were divided into two groups according to whether relapse developed or not. Clinical parameters, including disease duration, age at onset, and previous treatments, as well as laboratory parameters, including leukocyte count, C-reactive protein (CRP), erythrocyte sedimentation rate (ESR), neutrophil-to-lymphocyte ratio (NLR), and desmoglein 1 and 3 levels, were evaluated before treatment, at month 3, and during relapse.

Results

In the relapse group, a lower leukocyte count before the third dose of rituximab was found to be statistically significant ($p=0.04$). According to ROC analysis, the optimal leukocyte cut-off value for predicting relapse was 6,840/μL, with a sensitivity of 93.4% and a specificity of 50%. In Kaplan–Meier analysis, a leukocyte count below this threshold was associated with a significantly increased risk of relapse ($p=0.003$). Receiving any immunosuppressive treatment before rituximab did not increase the risk of relapse ($p=0.259$). No significant association was found between relapse and the other evaluated parameters.

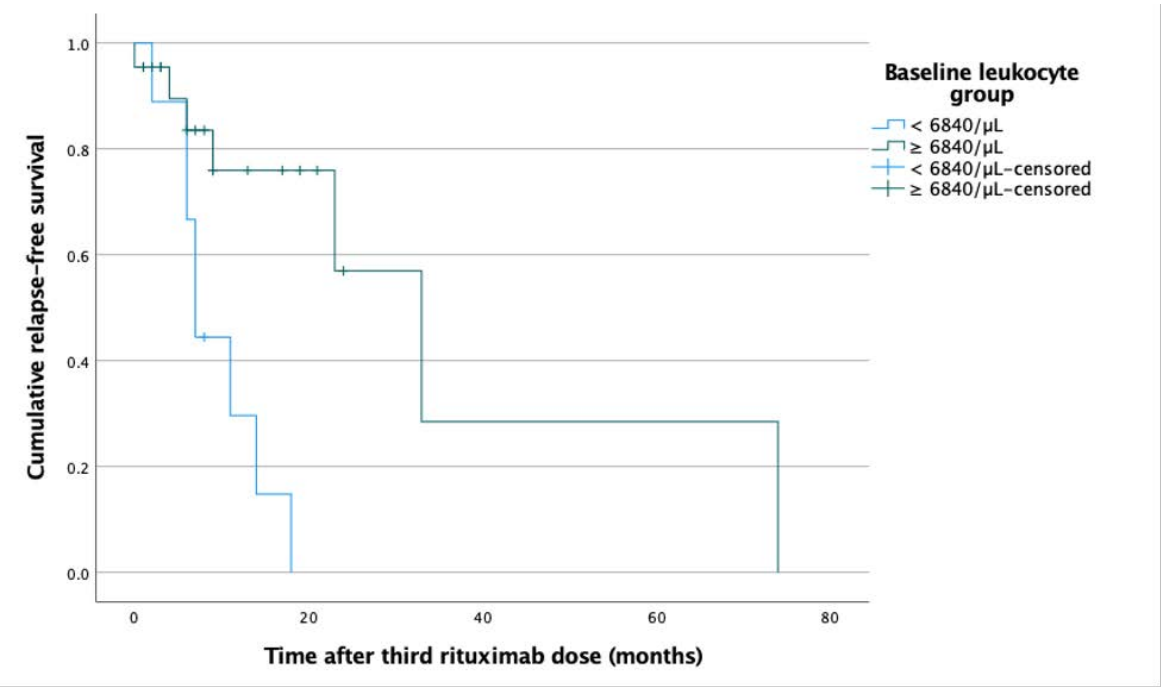

Figure 1. Kaplan–Meier analysis of relapse-free survival after the third rituximab dose

Conclusions

A low leukocyte count before the third dose of rituximab may be a potential predictor of relapse in patients with pemphigus vulgaris. One limitation of the study is that all included patients underwent laboratory testing while receiving oral corticosteroid treatment. Since oral corticosteroids are known to affect complete blood count parameters, such as causing neutrophilia, lymphopenia, and leukocytosis, and may also suppress ESR and CRP because of their anti-inflammatory effects, these factors should be considered when interpreting the findings. Nevertheless, this finding may support closer monitoring of patients at risk and the development of individualized treatment plans.

EADV CONGRESS
VIENNA
30 SEP - 3 OCT 2026

Abstract N°: 819

Assessing ST18 gene polymorphisms (rs17315309, rs2304365) in Israeli patients with Pemphigus vulgaris

Wisal Sawaed[1], Yasmin Yosif[1], Khalaf Kridin*[1]

[1] Galilee Medical Center, Nahariya, Israel, Nahariya, Israel

Introduction
Pemphigus vulgaris (PV) is a severe autoimmune blistering disease caused by autoantibodies against desmoglein (DSG) 3 and/or 1, leading to loss of keratinocyte adhesion. Genetic factors, particularly polymorphisms in the ST18 gene, have been implicated in PV susceptibility in a population-dependent manner. This study aimed to investigate the association between ST18 polymorphisms (rs17315309 A/G and rs2304365 C/T), disease susceptibility, antibody levels, and ethnic background in PV patients.

Materials and Methods
Thirteen PV patients and eight healthy donors were included. Serum anti-DSG1 and DSG3 levels were measured by ELISA. ST18 polymorphisms were genotyped using PCR and Sanger sequencing. Genotype and allele frequencies were compared between groups, and associations with antibody levels, ethnicity, and clinical features were evaluated.

Results
Allele analysis of rs2304365 showed a higher frequency of the C allele in PV patients compared to controls (80.7% vs. 50%, p=0.036), although genotype distribution did not reach statistical significance (p=0.07). No significant differences were observed for rs17315309 between PV patients and controls (p=0.19).A strong association was found between the rs17315309 genotype and ethnicity: all Arab patients carried the AG genotype, whereas all Jewish patients had the AA genotype (p<0.001), indicating a population-specific effect. No significant association with ethnicity was observed for rs2304365 (p=0.24).No association was detected between ST18 polymorphisms and antibody positivity. However, T-allele carriers at rs2304365 (CT+TT) showed a trend toward higher DSG3 levels than CC homozygotes. For rs17315309, DSG3 levels were similar across genotypes, whereas AA carriers had higher DSG1 levels than GA carriers.No significant association was found between ST18 polymorphisms and clinical phenotype.

Conclusions
ST18 polymorphisms demonstrate population-dependent patterns in PV. rs17315309 is strongly associated with ethnicity rather than disease susceptibility, while rs2304365 may be linked to immunoserological features of the disease. These findings emphasize the importance of considering ethnic background in genetic studies of PV.

EADV CONGRESS
VIENNA
30 SEP - 3 OCT 2026

Abstract N°: 822

Exploring the role of type-2 inflammation in the pathogenesis of pemphigoid diseases

Wisal Sawaed[1], Nora Abu Romi[1], Khalaf Kridin*[1]

[1] Galilee Medical Center, Nahariya, Israel, Nahariya, Israel

Introduction
Pemphigoid diseases (PD), including bullous pemphigoid (BP) and mucous membrane pemphigoid (MMP), are autoimmune blistering disorders caused by autoantibody-mediated disruption of the dermal-epidermal junction. Standard treatment relies heavily on corticosteroids, which carry significant toxicity and high relapse rates. Increasing evidence implicates type 2 cytokines—particularly interleukin-4 (IL-4) and interleukin-13 (IL-13)—as key drivers of BP and MMP pathogenesis by promoting Th2 polarization, eosinophil recruitment, autoantibody production, and epithelial damage. However, their relative contributions and the therapeutic potential of selectively targeting this axis remain incompletely defined. This study aimed to elucidate the contribution of the IL-4/IL-13 axis to BP and MMP pathogenesis through serum cytokine profiling and in vitro keratinocyte stimulation.

Materials and Methods
Serum samples from healthy donors (HD, n=5; mean age 32), BP patients (n=16; mean age 76), and MMP patients (n=17; mean age 60) were analyzed via ELISA. HaCaT keratinocytes were stimulated with either patient sera or recombinant cytokines. Subsequent gene expression was assessed using RT-qPCR, and cytoskeletal changes were evaluated via actin quantification.

Results
Serum analysis revealed significantly elevated IL-13 levels in MMP patients compared to HD, whereas IL-8 was increased in BP sera. In vitro, stimulating keratinocytes with either recombinant IL-13 or MMP sera upregulated IL-13Rα1 and IL-6 expression, while IL-4Rα levels remained unchanged. IL-8 and CCL17 expressions varied without significant consistency. Following IL-4Rα blockade with dupilumab, IL-13Rα1 expression significantly decreased in treated keratinocytes compared to untreated controls, though IL-4Rα, IL-6, IL-8, and CCL17 expressions remained largely unaffected. Morphologically, BP and MMP sera induced irregular cytoskeletal patterns and prominent actin filament thickening compared to the uniform organization seen with HD sera. Notably, dupilumab treatment restored a more defined filament organization and increased actin intensity across all conditions.

Conclusions
Collectively, these findings confirm the active involvement of the IL-4/IL-13 axis in driving epithelial dysregulation in pemphigoid diseases. The ability of IL-4Rα blockade to modulate receptor expression and restore cytoskeletal integrity further underscores this pathway as a promising therapeutic target.

EA DV CONGRESS
VIENNA
30 SEP - 3 OCT 2026

Abstract N°: 838

Global Disease Burden among Patients with Vitiligo or Lichen Sclerosus: A Psychometric Evaluation of the Patient-Reported Impact of Dermatological Diseases (PRIDD) Measure

Caroline Stuhlmann[1], Allison Fitzgerald[2], Anna Loeffler*[3], Rachael Pattinson[2], Neuza da Silva[1], Jennifer Austin[4], Christine Bundy[2], Matthias Augustin[1]

[1] University Medical Center Hamburg-Eppendorf, Hamburg, Germany

[2] School of Dentistry - Cardiff University, Cardiff, United Kingdom

[3] Institute for Health Services Research in Dermatology and Nursing (IVDP), University Medical Center Hamburg-Eppendorf (UKE), Hamburg, Germany

[4] International Alliance of Dermatology Patient Organizations, Ottawa, Canada

Introduction

Vitiligo and lichen sclerosus (LS) are chronic skin diseases that both present with depigmentation of the skin, though lesions of LS additionally involve skin texture changes, itching, and pain. Another important distinction between these conditions is that prevalence rates of vitiligo are higher (0.4-1%) than for LS (0.1-0.3%), which is considered a rare condition. Understanding the impact of these diseases from a patient perspective is essential to addressing patient concerns and providing adequate health care. Following COnsensus-based Standards for the selection of health Measurement INstruments (COSMIN) criteria, we developed the Patient-Reported Impact of Dermatological Diseases (PRIDD) and found that it is a valid and reliable tool for all skin conditions but has yet to be evaluated for specific disease groups. The present study examined measurement properties of PRIDD among patients with vitiligo or LS.

Materials and Methods

Two global online surveys were administrated (approximately 6-week interval between Survey 1 and 2) in 17 different languages. Adults with a self-reported skin condition were recruited through patient organizations and social media. Participants provided sociodemographic and clinical information, completed the PRIDD questionnaire (16 items assessing physical, life responsibilities, psychological and social impact domains), as well as measures of quality of life, health status, depressive and anxiety symptoms. Additionally for Survey 2, participants reported their Global Perceived Effect (GPE) which measured global rating of change of the impact of the dermatological condition after 6 weeks. Psychometric analyses examined internal consistency, test re-test reliability, measurement error, criterion and construct validity, responsiveness, and interpretability of the PRIDD including a distribution-based minimally important change (MIC). Data were analyzed among 264 patients with vitiligo (77% female, 44 ± 14 years, N at Survey 2 = 79) and 481 patients with LS (98% female, 54 ± 14 years, N at Survey 2 = 196).

Results

Using Survey 1 data, PRIDD had high internal consistency for vitiligo and LS, each with a Cronbach's alpha of 0.93. Criterion validity was demonstrated through strong associations between PRIDD and DLQI for vitiligo and LS, ρ = .81 and .78, respectively. Construct validity (convergent and discriminative validity) was confirmed for both disease groups: 19 out of 25 hypotheses (76%) were met for vitiligo, and 23 out of 25 hypotheses (92%) for LS. PRIDD scores from Survey 1 and 2 were significantly correlated for vitiligo and LS (ICC = .83, .89, respectively), demonstrating good test re-test reliability. Although responsiveness was not tested for vitiligo due to small sample size, responsiveness for LS was ascertained. There were significant differences in the change of PRIDD total scores by GPE ($F(2, 193) = 11.75$, $p < 0.001$, $\eta p2 = 0.11$), specifically for those who rated their disease as

"improved" compared to "stable" or "worse." Floor and ceiling effects were not present for either diagnosis group. Regarding MIC, a change of ≥ -3.59 points for vitiligo and ≥ -3.25 points for LS in the PRIDD total score could be interpreted as a clinically significant improvement.

Conclusions

Psychometric performance of PRIDD demonstrated that it is a reliable and valid dermatology-specific measure for assessing impact of vitiligo or LS on patients' lives. Findings for patients with vitiligo and LS were similar to that of the original sample which included participants with any skin condition. Though responsiveness could not be addressed for vitiligo, PRIDD was able to detect meaningful changes for both vitiligo and LS, demonstrating clinical utility in patient care and clinical trials.

Table. Summary of Psychometric Evaluation of PRIDD Measure for Patients with Vitiligo or Lichen Sclerosus

COSMIN Requirement		LS		Vitiligo	
		Result	Rating	Result	Rating
VALIDITY					
Criterion validity	High correlation (≥ 0.70) with gold-standard PROM	Correlation between PRIDD and DLQI total score ρ = 0.78.	+	Correlation between PRIDD and DLQI total score ρ = 0.81.	+
Construct validity	75% of hypotheses for convergent and discriminant validity met	17 of 19 (89.5%) hypotheses were met for convergent validity; 6 of 6 (100%) hypotheses were met for discriminative validity. In total, 23 of 25 hypotheses for construct validity were met (92%).	+	15 of 19 (78.9%) hypotheses were met for convergent validity; 4/6 (67%) for discriminative validity. In total, 19 of 25 hypotheses for construct validity were met (76%)	+
RELIABILITY					
Internal consistency	Cronbach's α ≥ 0.70	α = 0.93 (total score)	+	α = 0.93 (total score)	+
Test-retest reliability	ICC or weighted κ ≥ 0.70	ICC = 0.886 (total score)	+	ICC = 0.832 (total score)	+
Measurement error	SDC or LoA < MIC	LoA (-0.45) < MIC (3.25)	+	LoA (-0.65) < MIC (3.59)	+
RESPONSIVENESS					
Responsiveness	The result is in accordance with the hypothesis	Responsiveness was ascertained as there was a statistically significant difference in PRIDD total change scores across the three GPE groups [$F_{(2, 193)}$ = 11.75, $p < 0.001$, η_p^2 = 0.11]. The post-hoc pairwise comparisons confirmed that the differences were statistically significant for "improved" compared with "worse" or "stable". Differences between "worse" and "stable" were not significant.	+	Not tested because of small sample size	N/A
INTERPRETABILITY					
Floor and ceiling effects	Considered present when > 15% of patients achieved the minimum or maximum possible score	1.5% of participants with minimum score and 0.0% of participants with maximum score for PRIDD total at Survey 1.	+	1.1% of participants with minimum score and 0.0% of participants with maximum score for PRIDD total at Survey 1.	+
Distribution-based MIC (anchor-based MIC could not be determined)	N/A	3.25	N/A	3.59	N/A

Note. COSMIN = COnsensus-based Standards for the selection of health Measurement INstruments, LS = lichen sclerosus, PROM = patient-reported outcomes measure, PRIDD = Patient-Reported Impact of Dermatological Diseases, DLQI = Dermatology Life Quality Index, ICC = intraclass correlation coefficient, SDC = smallest detectable change, LoA = limits of agreement, MIC = minimally important change, N/A= not applicable or not able to be determined.

EADV CONGRESS
VIENNA
30 SEP - 3 OCT 2026

Abstract N°: 885

Increased risk of cutaneous lupus erythematosus flare during the late menopausal transition: a retrospective study of 64 women

Quentin Allibert[1], Alexandre Teboul[1], François Chasset*[1]

[1] Sorbonne Université, Faculté de médecine, AP-HP, Service de Dermatologie et Allergologie, Hôpital Tenon, F75020 Paris, France, Paris, France

Introduction

Sex hormones are considered to play a major role in lupus pathogenesis. Although some data suggest that systemic lupus erythematosus (SLE) is associated with decreased disease activity and reduced magnitude of flares after menopause, data on cutaneous lupus erythematosus (CLE) remain scarce. Compared with SLE, CLE is characterized by a lower female-to-male ratio (3-4/1 vs 8-9/1) and a higher age at onset. The objectives of this study were (1) to assess whether the menopausal transition impacts CLE activity and (2) whether CLE activity decreases after menopause. In a cohort of consecutive CLE patients seen between January 2021 and July 2023, women aged ≥45 years were included. Men and women aged < 45 years were excluded. Participants completed a standardized questionnaire focusing on the date of the final menstrual period (FMP), age at menstrual irregularity, climacteric symptoms, and use of menopausal hormone therapy. CLE subtypes, associated SLE, and CLE treatments were extracted from electronic medical records. Follow-up was divided into predefined one-year windows relative to the FMP: perimenopause (Year −2 [Y−2] and Year −1 [Y−1]), and early postmenopause (Year +1 [Y+1]). In the absence of systematic longitudinal activity scores for all patients, intensification in CLE treatment were used as a pragmatic proxy for CLE flares. The primary analysis used mixed-effects logistic regression with a random intercept for patients (GLMM, binomial logit) to account for repeated measures and unbalanced follow-up. Results are reported as adjusted probabilities and odds ratios with 95% confidence intervals, using the reference year at age 40 as the comparator. Overall, among 263 CLE patients, 64 women were included. Median age at CLE onset was 35 years (IQR, 29–43), and median age at last follow-up was 55 years (IQR, 50–62). Most patients were diagnosed with CLE before menopause (58/64, 91%). At last follow-up, 49 patients (77%) were postmenopausal, with a median age at menopause of 50 years (IQR, 45–51), and climacteric symptoms were reported by 40 of them (82%). Chronic CLE was the most frequent subtype (90%), and 48% fulfilled SLE classification criteria (Table 1). Treatment intensification was significantly more frequent at Y−1 (OR, 3.07; 95% CI, 1.11–8.47; Supplementary Table 1), with 45% intensification compared with 24% at reference (Figure 1). Moreover, no significant reduction in treatment intensification was observed at last follow-up compared with the reference period (OR, 1.71; 95% CI, 0.67–4.40).

Conclusion

Overall, we found a significant increase in CLE flares during late perimenopause in the year preceding the FMP. This finding is consistent with a previous clinical study that lacked longitudinal follow-up and statistical analysis. It has been suggested that hormonal imbalance preceding menopause may account for these flares. Moreover, the absence of a decreased flare rate at last follow-up suggests that CLE activity usually persists after menopause. This aligns with the LUMINA cohort, showing that menopause in SLE is associated only with a reduction in renal flares. Limitations include the retrospective design, potential recall bias, and the absence of longitudinal CLASI-A scoring and sex hormone measurements. Further prospective studies are needed to confirm these results.

EA DV CONGRESS
VIENNA
30 SEP - 3 OCT 2026

Abstract N°: 893

Reliability and validity of a novel, internationally developed 5-point composite investigator global assessment scale for epidermolysis bullosa acquisita

Aalia Syed*[1], Sera Sarsam[1], Aikaterini Patsatsi[2], Baoqi Yang[3], Kossara Drenovska[4], Angelo Valerio Marzano[5], Snejina Vassileva[4], Emiliano Antiga[6], Maryam Daneshpazhouh[7], Soner Uzun[8], Anisa Mosam[9], Avital Baniel[10], Eli Sprecher[10], Nisha Suyien Chandran[11], Donna A. Culton[12], Dipankar De[13], Dario Didona[14], Ncoza Dlova[15], Pascal Joly[16], Johannes S. Kern[17], Yen Loo Lim[18], Hamidreza Mahmoudi[7], Aimee Payne[19], Marwah Saleh[20], Elia Valeva[4], Jun Yamagami[21], Boaz Shulruf[22], Dédée Murrell[1]

[1] Faculty of Medicine, University of New South Wales, Sydney, NSW, Australia, Department of Dermatology, St. George Hospital, Sydney, NSW, Australia, Sydney, Australia

[2] Second Department of Dermatology, School of Medicine, Papageorgiou Hospital, Aristotle University, Thessaloniki, Greece, Thessaloniki, Greece

[3] Shandong Provincial Hospital for Skin Diseases, Shandong First Medical University, Shandong, China, Shandong, China

[4] Department of Dermatology and Venereology, Medical University – Sofia, University Hospital "Alexandrovska", Sofia, Bulgaria, Sofia, Bulgaria

[5] Dermatology Unit, Fondazione IRCCS Ca 'Granda Ospedale Maggiore Policlinico, Milan, Italy, Department of Pathophysiology and Transplantation, Università degli Studi Di Milano, Milan, Italy, Milan, Italy

[6] Section Dermatology, Department of Health Sciences, University of Florence, Florence, Italy, Florence, Italy

[7] Department of Dermatology, Tehran University of Medical Sciences, Tehran, Iran, Tehran, Iran

[8] Department of Dermatology and Venereology, Akdeniz University Faculty of Medicine, Antalya, Turkey, Antalya, Türkiye

[9] Department of Dermatology, Nelson R Mandela School of Medicine, University of Kwazulu-Natal, South Africa, Inkosi Albert Luthuli Central Hospital, Cato Manor, Durban, South Africa, Durban, South Africa

[10] Division of Dermatology, Tel Aviv Soura sky Medical Center, Tel Aviv, Israel, Tel Aviv, Israel

[11] Division of Dermatology, Department of Medicine, National University Hospital, Singapore, Singapore, Singapore, Singapore

[12] Department of Dermatology, University of North Carolina at Chapel Hill, Chapel Hill, North Carolina, USA, North Caroline, United States

[13] Department of Dermatology, Venereology and Leprology, Postgraduate Institute of Medical Education and Research, Chandigarh, India, Chandigarh, India

[14] Department of Dermatology and Allergology, Philipps-Universität Marburg, Marburg, Germany, Marburg, Germany

[15] Department of Dermatology, Nelson R Mandela School of Medicine, University of Kwazulu-Natal, South Africa, Durban, South Africa

[16] Department of Dermatology, Rouen University Hospital, INSERM 1234, Normandie University, Rouen, France, Rouen, France

[17] The School of Translational Medicine, Monash University and Alfred Health, Melbourne, VIC, Australia, Melbourne, Australia

[18] National Skin Centre, Singapore, Singapore, Yong Loo Lin School of Medicine, Lee Kong Chian School of Medicine, Duke-NUS, Singapore, Singapore, Singapore, Singapore

[19] Department of Dermatology, Vagelos College of Physicians and Surgeons, Columbia University, New York, New York, USA, New York, United States

[20] Department of Dermatology, Faculty of Medicine, Cairo University, Cairo, Egypt, Cairo, Egypt

[21] Department of Dermatology, Tokyo Women's Medical University, Tokyo, Japan, Tokyo, Japan

[22] Faculty of Medicine, University of New South Wales, Sydney, NSW, Australia, Sydney, Australia

Introduction

Epidermolysis bullosa acquisita (EBA) is a rare autoimmune blistering disease for which no validated Investigator Global Assessment (IGA) scale for severity assessment exists. The absence of an IGA, which is the Food and Drug Administration's (FDA's) preferred outcome measure, is significant as it hinders reliable disease assessment, treatment evaluation and clinical trial development. This study aimed to develop and validate a 5-point composite IGA scale for EBA (EBA-IGA) and assess the scale against existing scoring instruments; the EB Disease Activity and Scarring Index (EBDASI) and the EBA Disease Area Index (EBADAI). We hypothesised that the EBA-IGA would demonstrate excellent interrater reliability, intrarater reliability, and strong convergent validity with existing severity instruments.

Materials and Methods

Content and face validity of the EBA-IGA were established through international dermatologist and patient surveys. A multi-centre, image-based validation study was conducted using an initial de-identified photo set of 35 EBA patients independently scored by 24 international dermatologists with expertise in blistering diseases using the four instruments. Four weeks later, a second de-identified photo set, comprising 20 new EBA patients and 10 repeat EBA patients, was distributed to assess for intrarater reliability. Interrater and intrarater reliability were statistically assessed using the intraclass correlation coefficients (ICC), and convergent construct validity was assessed using Pearson's correlation coefficient (r). ICCs greater than 0.9 were considered excellent.

Results

The EBA-IGA sections for skin activity and damage are demonstrated in Figure 1. For interrater reliability, the ICCs for overall scores were: EBA-IGA 0.979, EBDASI 0.969 and EBADAI 0.962. For intrarater reliability, the ICCs for overall scores were: EBA-IGA 0.931, EBDASI 0.890 and EBADAI 0.891. The EBA-IGA demonstrated a very strong positive correlation with the EBADAI ($r = 0.829$, $p<0.001$) and a strong positive correlation with the EBDASI ($r = 0.755$, $p<0.001$). The EBADAI was very strongly positively correlated with the EBDASI ($r = 0.837$, $p<0.001$).

	Morphological Descriptors
0 – Clear	No active blisters or erosions.
1 – Almost clear	≤3 small* blisters/erosions in two or less anatomical areas.
2 – Mild	10 or less scattered small* and/or medium**-sized blisters/erosions in one or more anatomical areas. AND/OR One large*** blister/erosion in one anatomical area.
3 – Moderate	Between 11 and 24 scattered small* and/or medium**-sized blisters/erosions in one or more anatomical areas. 5 or less large blisters/erosions may be present. AND/OR Between 2 and 5 large*** blisters/erosions in one or more anatomical areas. AND/OR One large confluent area of blisters/erosions across two anatomical areas.
4 – Severe	≥25 small* and/or medium**-sized blisters/erosions in one or more anatomical areas. Large*** blisters/erosions may be present in any number. AND/OR Multiple large*** blisters/erosions (>5) in one or more anatomical areas. AND/OR One large confluent area of blisters/erosions in three or more anatomical areas

Small: <0.5cm in diameter
Medium: 0.5cm-1.5cm in diameter
***Large**: >1.5cm in diameter

	Damage Lesion = Post-inflammatory hyperpigmentation/hypopigmentation, erythema from resolving lesion, scarring and milia
0 – Clear	No skin damage lesions.
1 – Almost clear	≤3 small* skin damage lesions in two or less anatomical areas
2 – Mild	10 or less scattered small* and/or medium**-sized skin damage lesions in one or more anatomical areas. AND/OR One large*** skin damage lesion in one anatomical area.
3 – Moderate	Between 11 and 24 scattered small* and/or medium**-sized skin damage lesions in one or more anatomical areas. 5 or less skin damage lesions may be present. AND/OR Between 2 and 5 large*** skin damage lesions in one or more anatomical areas. AND/OR A large confluent area of damage in two anatomical areas.
4 – Severe	≥25 small* and/or medium**-sized skin damage lesions in one or more anatomical areas. Large*** skin damage lesions may be present in any number. AND/OR >5 large*** skin damage lesions in one or more anatomical areas. AND/OR One large confluent area of damage in three or more anatomical areas

Small: <0.5cm in diameter
Medium: 0.5cm-1.5cm in diameter
***Large**: >1.5cm in diameter

Figure 1: Section I of the IGA for EBA, assessing skin activity (left) and section III of the IGA for EBA, assessing skin damage (right).

Conclusions

The EBA-IGA demonstrated excellent interrater and intrarater reliability, as well as strong-to-very-strong convergent validity, indicating its utility in FDA-compliant clinical trials. Together, the EBA-IGA, EBDASI and EBADAI are complementary instruments for harmonising disease assessment in clinical practice and trial settings.

EA DV CONGRESS
VIENNA
30 SEP - 3 OCT 2026

Abstract N°: 910

Bullous Pemphigoid at Skin Graft and Donor Sites Following Burn Injury: A Case Report

Aneela Anwar*[1], Mary Laing[1], Mary-Catherine Walsh[1], ElKhansaa Elsamani[1]

[1] University hospital Galway, Ireland, Dermatology, Dublin, Ireland

Introduction

Bullous pemphigoid is an autoimmune subepidermal blistering disorder that may be triggered by trauma, burns, or surgical procedures. We report a case of bullous pemphigoid occurring at both donor and recipient skin graft sites following a burn injury in an elderly patient. Diagnosis was confirmed by histopathology and direct immunofluorescence demonstrating linear deposition of IgG and C3 along the basement membrane zone. The patient showed a favorable response to systemic corticosteroids and immunosuppressive therapy with complete healing of the graft site.

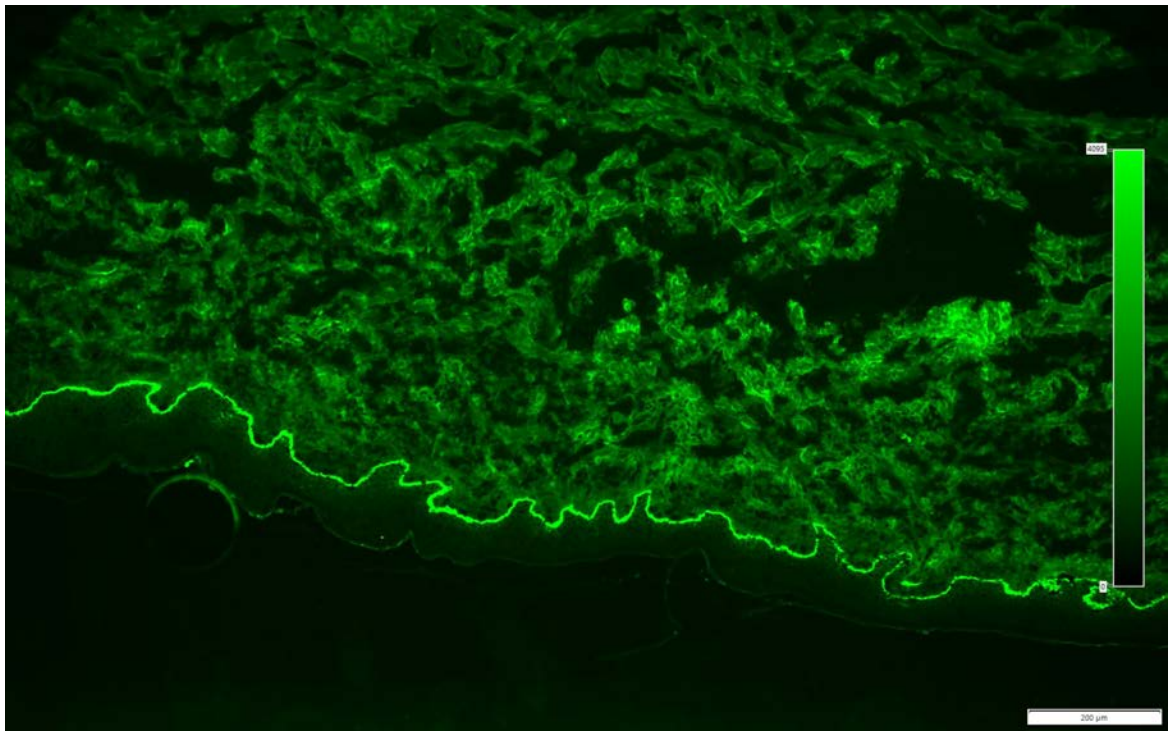

Direct immunofluorescence demonstrating linear C3 deposition along the basement membrane zone.

Case Presentation

An 85-year-old male was reviewed as an inpatient dermatology consultation on 26 May 2025. He had sustained a burn injury to the right posterior lower leg in February 2025, for which he underwent debridement and split-thickness skin grafting in the same month. The graft, harvested from the right lateral thigh, had remained non-healing with persistent overgranulation tissue. The recipient site had similarly failed to epithelialize.According to collateral history from his wife, silver-based dressings had been applied, following which blistering developed over the lower leg.On examination, there was a well-demarcated, erythematous, rectangular, moist plaque over the lateral thigh donor site, with thickened borders and areas of crusting. A single intact bulla was noted at the lateral margin of the wound, with additional blisters present over the right groin. The recipient site on the posterior lower

leg appeared pink to erythematous with overlying yellow crusting, without evidence of active discharge.Initial differential diagnoses included an irritant bullous reaction to silver dressings, bullous pemphigoid, and pyoderma gangrenosum. Skin biopsies were obtained from a fresh blister, perilesional skin, and the edge of the donor site.Histopathological examination demonstrated subepidermal blister formation, while direct immunofluorescence revealed linear deposition of IgG and C3 along the basement membrane zone, consistent with bullous pemphigoid. Circulating bullous pemphigoid antibodies were negative on two separate occasions.The patient was commenced on systemic prednisolone, with subsequent addition of mycophenolate mofetil, nicotinamide, and minocycline. Local wound care included daily potassium permanganate soaks and application of barrier film (Cavilon).Within one month, there was marked clinical improvement, with cessation of new blister formation and progressive healing of both donor and recipient sites. Prednisolone was gradually tapered, while the dose of mycophenolate mofetil was escalated. During the course of treatment, the donor site developed a secondary infection requiring antibiotic therapy.At three-month follow-up, tapering of mycophenolate mofetil was initiated, with the patient currently maintained on 250 mg once daily. The graft site had completely healed, and the donor site demonstrated near-complete re-epithelialization with only a small residual central erosion.

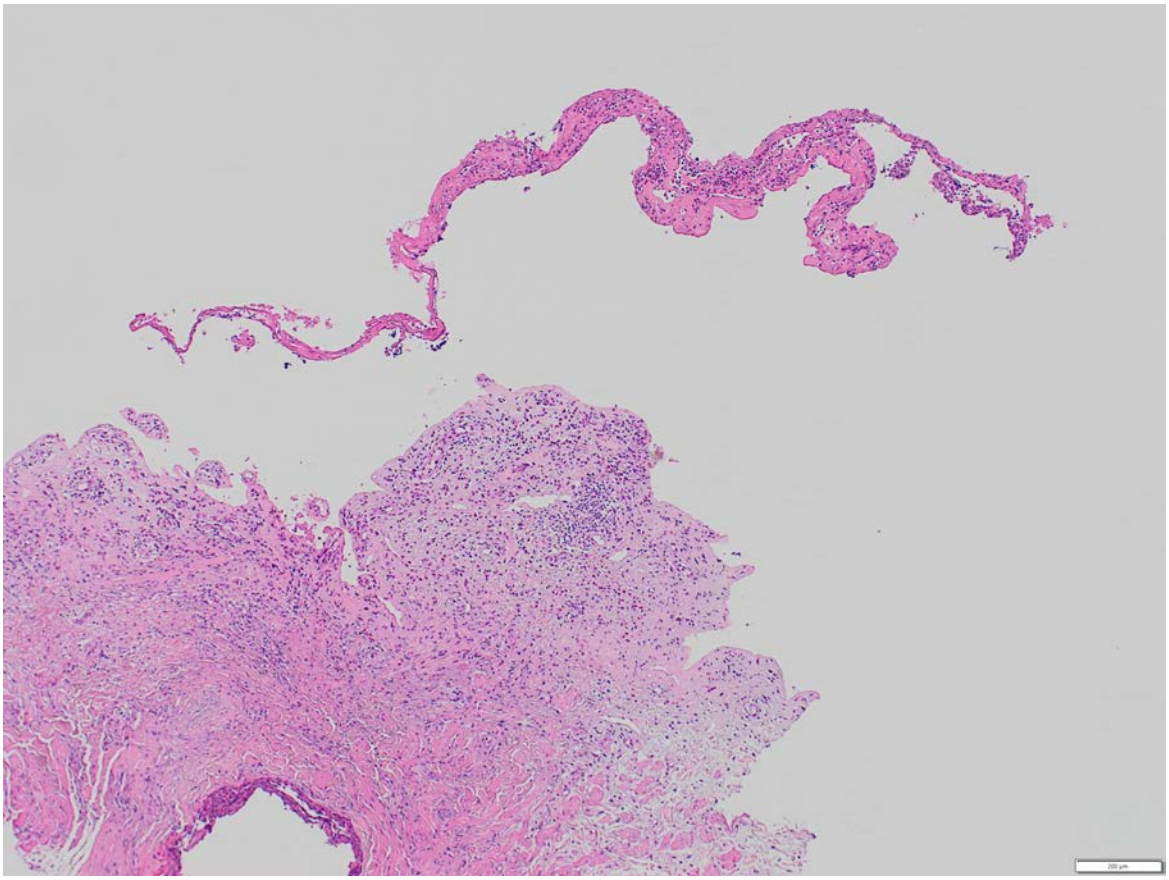

Histopathology (H&E stain) showing subepidermal blister formation consistent with bullous pemphigoid.

Conclusion

In our case, the involvement of both donor and recipient graft sites further reinforces the role of trauma as a precipitating factor and suggests a broader local susceptibility to antigen exposure following burn injury and grafting.

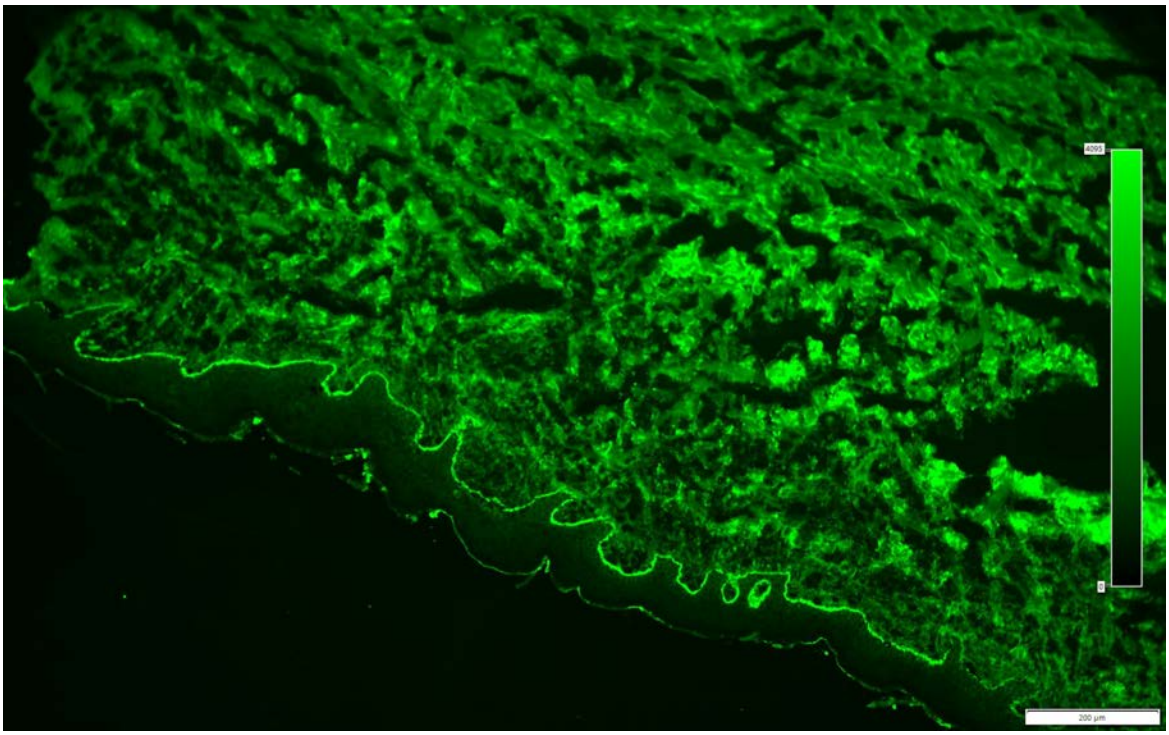

Direct immunofluorescence demonstrating linear IgG deposition along the basement membrane zone.

EADV CONGRESS
VIENNA
30 SEP - 3 OCT 2026

Abstract N°: 948

Cutaneous Manifestations as a Marker of Disease Progression in Neoplastic Disease

Luis Daniel Pérez Cáceres*[1], Camila Triana Moreno[2], María Ariza[2], Gabriela Fuentes Navarrete[1], Carolina Ivette Cortes Correa[1], Elkin PEÑARANDA[1]

[1] Fundación Universitaria Sanitas, Bogotá, Colombia

[2] Clínica los Nogales, Bogota, Colombia

Introduction

Dermatomyositis (DM) is an autoimmune inflammatory myopathy characterized by proximal muscle weakness and distinctive cutaneous findings such as Gottron's papules and heliotrope erythema. In adults, it may present as a paraneoplastic syndrome, with an association with malignancy of 20–30%. The risk is higher between 45 and 75 years of age and remains elevated up to five years after diagnosis. Autoantibodies such as anti–TIF1-γ and anti–NXP2, together with advanced age and dysphagia, are predictors of underlying neoplasia.

Case Presentation

Two cases of paraneoplastic DM with different oncologic contexts are presented. Clinical, biochemical, electromyographic findings and autoantibody profiles were analyzed. The diagnosis was established through clinicopathologic correlation.

Case 1

A 40-year-old man with a history of metastatic colorectal carcinoma to the liver who developed persistent erythematous-violaceous skin lesions initially attributed to chemotherapy toxicity with capecitabine. On physical examination, heliotrope erythema, Gottron's papules and sign, shawl sign, and periungual changes compatible with Samitz sign were observed. Studies showed elevation of creatine phosphokinase (CPK 653), antinuclear antibodies (1:1280, fine granular pattern), and electromyography compatible with inflammatory myopathy.

Case 2

A 60-year-old woman with stage IVb serous ovarian carcinoma with metastases to the peritoneum, retroperitoneum, rectum, and central nervous system, who consulted for progressive proximal muscle weakness and appearance of cutaneous lesions. On physical examination, heliotrope sign, Gottron's papules, holster sign, and periungual capillary alterations were present. Studies showed positive ANA (1:640), elevation of CPK and aldolase, and electromyography compatible with inflammatory myopathy. Autoantibodies were positive for anti–PM/Scl75, without anti–TIF1-γ or anti–NXP2. The evolution was unfavorable, with death approximately seven months after dermatologic evaluation after requesting euthanasia in the context of progression of metastatic disease.

Conclusion

Paraneoplastic DM should be considered a clinical marker of underlying malignancy, especially in patients older than 40 years. Its cutaneous manifestations may precede or mimic therapeutic toxicity, generating diagnostic delays. Comprehensive evaluation allows risk stratification; inparticular, anti–TIF1-γ positivity requires an active

search for neoplasia. Prognosis is mainly determined by tumor evolution, with oncologic control being the axis of management.

EADV CONGRESS
VIENNA
30 SEP - 3 OCT 2026

Abstract N°: 951

Refractory Linear IgA Bullous Dermatosis with DIF-confirmed Intercellular IgG Deposition and Serum Antibodies to Dsg3 and Dsc1–3

Satoko Shimizu*[1], Ken Muramatsu[2], Takashi Seo[1], Satsuki Naruse[1], Miho Maruo[1], Norito Ishii[3], Hiroshi Koga[3]

[1] Department of Dermatology, Sapporo City General Hospital, Sapporo, Japan
[2] Department of Dermatology, Hokkaido University, Sapporo, Japan
[3] Department of Dermatology, Kurume University, Kurume, Japan

Introduction

Blistering disease cases that demonstrate antibodies related to linear IgA bullous dermatosis (LABD) together with intercellular epidermal antibodies are rare. Most previously reported cases predominantly present with intraepidermal blisters and have been described as IgA pemphigus or LABD overlap syndromes; however, LABD cases with intercellular IgG deposition and multiple anti-intercellular antibodies have seldom been reported. We report a rare case that exhibited multiple intercellular antibodies while clinically and histopathologically presenting with subepidermal blisters and a refractory course.

Case Presentation

A man in his 50s presented with a one-year history of recurrent annular erythema and blisters affecting the trunk, extremities, and scalp. The blisters were up to 1 cm in diameter, and there was no mucosal involvement. Past medical history included gastroesophageal reflux disease; there were no notable medications or history of ulcerative colitis or malignancy. Histopathology of skin biopsies showed subepidermal blistering with eosinophilic and neutrophilic infiltration. Direct immunofluorescence (DIF) revealed the linear deposition of IgG and IgA at the basement membrane zone, accompanied by intercellular IgG deposition within the lower epidermis. Indirect immunofluorescence (IIF) on rat bladder was negative, while IIF using 1 M NaCl-split skin showed IgA reactivity on the epidermal side. Immunoblotting identified IgA antibodies against LAD-1 (120 kDa) and LABD97 (97 kDa). ELISA/CLEIA revealed IgG anti-Dsg3 antibodies, IgA anti-Dsc2 antibodies, and IgG/IgA anti-Dsc1 and anti-Dsc3 antibodies. Extensive malignancy screening was negative. Prednisolone (PSL) monotherapy was ineffective. Dapsone initially improved the skin lesions but was discontinued due to methemoglobinemia and hemolytic anemia. Subsequent treatments, including steroid pulse therapy, two cycles of intravenous immunoglobulin, rituximab, colchicine, azathioprine, and sulfasalazine, failed to maintain remission during PSL tapering. The introduction of mycophenolate mofetil in combination with PSL and sulfasalazine has led to gradual improvement, although complete disease control has not yet been achieved.

Conclusion

This case met the diagnostic criteria for LABD while simultaneously harboring multiple intercellular autoantibodies against Dsg3 and Dsc1–3. Unlike most previously reported overlap cases presenting with intraepidermal blisters, this patient maintained a subepidermal blistering phenotype. The pathogenesis may involve initial autoimmunity targeting the basement membrane zone leading to tissue damage and subsequent epitope spreading, resulting in a complex autoantibody profile. The in vivo deposition of these antibodies in intercellular spaces suggests their potential role in disease pathogenesis, beyond their mere presence in serum. This rare case highlights the complexity of overlapping blistering diseases and the associated therapeutic challenges.

POWERED BY M-ANAGE.COM

EA DV CONGRESS
VIENNA
30 SEP - 3 OCT 2026

Abstract N°: 1017

Diffuse Systemic Sclerosis with Cardiopulmonary Involvement Treated with Methotrexate: A Case Report

Christina Putri Wijaya*[1], I Putu Paramananda[2], I Komang Harry Supradnyan[3]

[1] Ganesha Hospital Gianyar, Gianyar, Bali, Indonesia

[2] Ganesha University of Education, Singaraja, Bali, Indonesia

[3] Buleleng General Hospital, Ganesha University of Education, Singaraja, Bali, Indonesia

Introduction

Systemic sclerosis (SSc) is a rare autoimmune connective tissue disease characterized by immune dysregulation, vasculopathy, and progressive fibrosis affecting the skin and internal organs. The disease predominantly affects women and typically presents in middle age. The pathogenesis involves complex interactions between endothelial injury, immune activation, and fibroblast dysregulation leading to excessive extracellular matrix deposition. Among systemic manifestations, cardiopulmonary involvement, particularly interstitial lung disease (ILD) and cardiac dysfunction, is a major determinant of morbidity and mortality. Early identification of organ involvement is crucial, as prognosis worsens significantly in patients with pulmonary fibrosis and cardiac complications.

Case Presentation

A 54-year-old female presented with progressive dyspnea, fatigue, and functional limitation, accompanied by long-standing skin changes since 2017. The patient reported gradual skin tightening initially affecting the hands and feet, later spreading to the face and trunk, associated with stiffness, decreased mobility, and difficulty opening the mouth. Dermatological examination revealed generalized skin induration with a “salt-and-pepper” pattern of hypo- and hyperpigmentation, puffy fingers, and microstomia. Palpation demonstrated woody skin consistency with reduced elasticity involving the extremities, trunk, and facial region. Systemic evaluation revealed respiratory distress with bilateral pulmonary infiltrates on chest imaging suggestive of interstitial lung disease. Echocardiography demonstrated mild mitral regurgitation due to annular dilation, along with features consistent with congestive heart failure. Based on the 2013 ACR/EULAR classification criteria, the patient fulfilled the diagnostic threshold for diffuse cutaneous systemic sclerosis with multisystem involvement. The patient was treated with methotrexate 5 mg every 12 hours, administered three times weekly (total 15 mg/week), combined with folic acid 5 mg weekly and topical corticosteroids, alongside comprehensive cardiopulmonary management including diuretics, bronchodilators, and corticosteroids. Diffuse cutaneous systemic sclerosis is associated with rapid progression and early visceral involvement, contributing to poorer outcomes. Cutaneous fibrosis remains a hallmark feature, often accompanied by musculoskeletal limitation and functional impairment. Methotrexate is widely used for cutaneous manifestations of SSc due to its immunomodulatory and anti-fibrotic properties. Mechanistically, methotrexate inhibits dihydrofolate reductase, disrupting DNA synthesis in rapidly proliferating cells, while also increasing extracellular adenosine levels, resulting in anti-inflammatory effects. Clinical studies have demonstrated its efficacy in reducing skin thickening and improving functional status without significant additional organ toxicity. Expected outcomes of therapy include decreased skin induration, improved joint mobility, and stabilization of disease progression, although its effect on internal organ involvement remains limited. In this case, the patient showed a favorable response with improved skin flexibility, reduced stiffness, and better functional capacity, along with stabilization of cardiopulmonary symptoms during follow-up.

Conclusion

This case highlights the importance of early recognition of diffuse systemic sclerosis with multisystem involvement, particularly cardiopulmonary complications that significantly impact prognosis. Methotrexate at a

weekly dose of 15 mg demonstrated a good clinical response in improving cutaneous manifestations and functional outcomes. A multidisciplinary approach remains essential to optimize management and improve overall prognosis in patients with systemic sclerosis.

EA DV CONGRESS
VIENNA
30 SEP - 3 OCT 2026

Abstract N°: 1025

Progesterone Rebels: Unraveling Diagnostic Pitfalls in Two Autoimmune Cyclic Dermatitis Cases

Majd Abu Taleb*[1], Nesrine Ben Salah[1], Youssef Monia[1], Seif Ben Hammouda[2], Khadija Mansour[3], Hichem Belhadjali[1], karim Aouem[3], Jameleddine Zili[1]

[1] Dermatology Department, Fattouma Bourguiba University Hospital, Monastir, Tunisia
[2] Anatomopathology Department, Fattouma Bourguiba University Hospital, Monastir, Tunisia
[3] Clinical Pharmacology Department, Fattouma Bourguiba University Hospital, Monastir, Tunisia

Introduction

Autoimmune progesterone dermatitis (APD), more accurately referred to as progestogen hypersensitivity, is a rare condition characterized by cyclic cutaneous eruptions related to progesterone fluctuations during the menstrual cycle. Symptoms typically occur during the luteal phase and reflect loss of immunologic tolerance to endogenous progesterone, sometimes following sensitization to exogenous progestins. Its marked clinical polymorphism and the absence of standardized diagnostic criteria frequently delay recognition. We report two illustrative cases confirmed by pharmacologic testing and complementary investigations, highlighting the diagnostic challenges and therapeutic implications of this uncommon disorder.

Case Presentation

The first patient, a 40-year-old woman, presented with a generalized pruritic maculopapular eruption occurring 15 days after administration of a progestin-based contraceptive injection, initially suggestive of a drug-induced exanthem. After treatment discontinuation, she developed recurrent papulo-violaceous plaques and fixed urticarial lesions involving approximately 30% of the body surface area. Lesions appeared three days before menstruation and resolved spontaneously four days after its completion, demonstrating clear luteal-phase periodicity. Laboratory investigations were unremarkable. Skin biopsy revealed a nonspecific chronic dermal inflammatory infiltrate, and direct immunofluorescence was negative. Intradermal progesterone testing showed positive immediate and delayed reactions. Treatment with combined oral contraceptives resulted in complete and sustained remission.

The second patient, a 38-year-old woman with no relevant medical history, developed an acute pruritic maculopapular eruption associated with urticarial lesions on the trunk and limbs three weeks after initiation of a progestin-only contraceptive. Histopathologic examination demonstrated a perivascular lymphocytic infiltrate, and direct immunofluorescence findings were negative. Re-exposure to the progestin reproduced the eruption, supporting the diagnosis. Despite definitive discontinuation of the contraceptive, cyclic premenstrual flares persisted, with exacerbations associated with stress and fatigue.

Conclusion

Progestogen hypersensitivity represents a clinically heterogeneous immunologic disorder encompassing both IgE-mediated and T-cell–driven pathways, frequently initiated by sensitization to exogenous progestins. Diagnosis remains predominantly clinical, anchored by the characteristic triad of recurrent premenstrual eruptions, symptom exacerbation following progesterone exposure, and resolution with ovulation suppression. While intradermal testing provides adjunctive support,

its incomplete standardization reinforces the primacy of clinical acumen. Given the substantial risk of prolonged diagnostic delay, dermatologists must maintain a high index of suspicion for this condition in women presenting with cyclic premenstrual dermatoses, particularly following exogenous progestin exposure. Early recognition not only shortens diagnostic odysseys but directly enables targeted hormonal modulation via combined oral contraceptives or GnRH analogs, which consistently achieve robust symptom control. These findings position dermatology at the critical intersection of cutaneous, immunologic, and endocrine medicine, advocating for prompt clinical diagnosis over reliance on unvalidated laboratory assays. Systematic integration of this diagnostic framework will streamline management pathways, optimize therapeutic precision, and substantially improve quality of life for affected patients.

EADV CONGRESS
VIENNA
30 SEP - 3 OCT 2026

Abstract N°: 1026

Knowledge and referral practices regarding oral health in patients with cutaneous and systemic lupus erythematosus: a survey among dermatologists and rheumatologists

Irene Alonso Rodríguez*[1], María Castellanos Gonzalez[1], Alejandra Méndez Valdés[1], Sara De Benito Mendieta[1], José María Añíbarro Vega[1], Lucía Martínez Rozas[1], Marta Andreu Barasoain[1], Jose Luis López Estebaránz[1]

[1] Hospital Universitario Fundación Alcorcón, Alcorcón, Madrid, Spain

Introduction
Systemic and cutaneous lupus erythematosus (LE) are multisystem autoimmune diseases with well-known mucocutaneous manifestations. However, oral and dental involvement remains under-recognized, despite increasing evidence of a higher prevalence of periodontal disease and a potential bidirectional relationship with disease activity. This study aimed to evaluate the knowledge and clinical practices of dermatologists and rheumatologists regarding oral health in patients with LE.

Materials and Methods
Cross-sectional observational study based on an anonymous survey distributed to dermatologists and rheumatologists. The questionnaire included demographics, experience, awareness of oral involvement, oral examination practices, referral to dental care, and consideration of treatment-related oral effects. Descriptive analysis was performed.

Results
A total of 134 physicians participated (88.1% dermatologists, 11.9% rheumatologists); 50% had >15 years of experience and 23% reported expertise in autoimmune diseases.Oral mucosa was examined routinely by 43%, while only 12.7% systematically assessed dentition; 64.9% never evaluated dental status.Knowledge of increased dental pathology in LE was limited: 61.9% were uncertain and only 9.7% reported clear awareness.Regarding referral, 43.3% had never recommended dental evaluation and only 5% did so systematically. Recommendations were mostly non-standardized and symptom-driven.Additionally, 70.9% did not consider the impact of immunosuppressive treatments on oral health.

Conclusions
There is a significant gap between current evidence and clinical practice regarding oral health in LE. Limited knowledge is associated with low rates of dental examination and referral, and treatment-related oral effects are frequently overlooked. These findings highlight the need for improved education and a multidisciplinary approach integrating dental care into routine management.

EA DV CONGRESS
VIENNA
30 SEP - 3 OCT 2026

Abstract N°: 1027

JAK Inhibitors in Refractory Mucous Membrane Pemphigoid: A Systematic Review of Emerging Evidence

Alessandra Rallo*[1], Antonio Di Guardo[1, 1], Federica Trovato[2], Dario Didona[1], Biagio Didona[1], Feliciana Mariotti[1], Giovanni Di Zenzo[1]

[1] IDI - Istituto Dermopatico dell'Immacolata, Roma, Italy
[2] "Sapienza" University Of Rome, Rome, Italy

Introduction

Mucous Membrane Pemphigoid (MMP) is a rare chronic autoimmune subepithelial blistering disorder characterized by autoantibody-mediated damage to the basement membrane, leading to progressive inflammation and fibrosis of mucosal surfaces. It mainly affects the conjunctiva, oral cavity, and upper aerodigestive tract, causing irreversible scarring and severe complications such as blindness or airway stenosis. Current treatments include corticosteroids, immunosuppressants, and biologics (e.g., rituximab), but are often limited by inefficacy, relapse, or toxicity. The JAK/STAT pathway plays a key role in cytokine signaling and immune regulation, and is implicated in autoimmune blistering diseases through modulation of Th1, Th2, and Th17 responses [1,4].

Materials and Methods

A systematic search of PubMed, Scopus, and Web of Science was performed to identify studies reporting the use of JAK inhibitors in MMP. Eligible studies included case reports and case series describing clinical outcomes. Data on patient characteristics, prior treatments, type of JAK inhibitor, and clinical response were extracted.

Results

Evidence is limited to case reports of refractory MMP. Tofacitinib showed efficacy in severe ocular and multisite disease, inducing rapid and sustained control of inflammation and preventing fibrosis progression after failure of multiple therapies [1,4]. Relapse after discontinuation and improvement after reintroduction suggest a direct effect [1]. Baricitinib demonstrated similar benefits in multisystem MMP, improving inflammation and enabling steroid tapering [3], and stabilizing advanced ocular disease [2]. JAK inhibitors appear to provide rapid control, especially in high-risk ocular involvement.Mechanistically, cytokines involved in MMP (IL-6, IL-4, IL-13, IL-17, IFN-γ) signal through JAK pathways, contributing to inflammation and fibrosis [1,4]. JAK inhibition targets multiple pathways simultaneously, offering broader immunomodulation than conventional therapies. Reported cases showed good tolerability, although known risks include infections, cytopenias, lipid alterations, and thromboembolism [1,4].(Table 1)

Author (Year)	Age/Sex	MMP Involvement	Prior Treatments	JAK Inhibitor	Outcome	Notes
Sarny et al. (2018)	43/M	Ocular	Methotrexate, cyclophosphamide, MMF, rituximab, IVIG	Baricitinib 4 mg/day	Marked clinical improvement; disease stabilization	Temporary neutropenia → brief interruption
James et al. (2021) – Case 1	79/F	Ocular	Methotrexate, MMF, rituximab, cyclophosphamide, IVIG	Tofacitinib 11 mg/day	Rapid and sustained control of conjunctival inflammation	Maintained remission over months
James et al. (2021) – Case 2	70/M	Ocular, oral, nasal	Topical therapy, methotrexate, MMF, cyclophosphamide, rituximab	Tofacitinib 11 mg/day + MMF	Resolution of inflammation and mucosal lesions	Relapse after withdrawal, improved after reintroduction
Burningham et al. (2022)	69/F	Ocular, oral, esophageal	Steroids, MTX, IVIG, rituximab, MMF, cyclophosphamide	Baricitinib 2 mg/day + MTX	Significant improvement; steroid taper; near remission	Long-term disease control

Table 1. Overview of reported cases of mucous membrane pemphigoid treated with Janus kinase (JAK) inhibitors, highlighting disease involvement, previous therapeutic failures, treatment regimens, and clinical responses.

Conclusions

Current evidence, although limited, suggests that JAK inhibitors may represent an effective therapeutic option in refractory MMP, particularly in severe and multisystem disease. However, data are restricted to anecdotal reports, and no controlled studies are available. Larger prospective studies are needed to define efficacy, safety, and positioning within treatment algorithms.

EA CONGRESS
VIENNA
30 SEP - 3 OCT 2026

Abstract N°: 1053

Topical roflumilast for localized Brunsting-Perry Pemphigoid: A case report with literature review

Victor Estenssoro-Alvarez*[1], Yasmine Yesli[2], Annie Belisle[3], Melissa Saber[1], Alexandre Lemieux[4]

[1] Université de Montréal, Division of Dermatology, Department of Medicine, Centre Hospitalier de l'Université de Montréal, Montréal, Canada

[2] Université de Montréal, Faculty of Medicine, Montreal, Canada

[3] Université de Montréal, Division of Pathology, Department of Medicine, Centre Hospitalier de l'Université de Montréal, Montreal, Canada

[4] Université de Montréal, Division of Dermatology, Department of Medicine, Hôpital du Sacré-Cœur de Montréal, Montreal, Canada

Introduction

Brunsting-Perry pemphigoid (BPP) is a rare, localized cutaneous variant of mucous membrane pemphigoid characterized by recurrent subepidermal bullae, predominantly on the scalp and neck, which typically result in cicatricial scarring. Due to its localized nature and clinical overlap with inflammatory or neoplastic conditions, BPP is often misdiagnosed or diagnosed late. Management is currently non-standardized, relying on case-specific systemic or topical therapies. A review of 15 BPP cases from the last decade confirms a mean age of approximately 63 years and a predilection for the scalp (Table 1).Mucosal involvement was reported in 4 of 15 cases (27%), most often affecting the oral mucosa, and was generally mild and non-dominant relative to cutaneous disease. Diagnostic delays are common, with BPP frequently mistaken for cicatricial alopecia or squamous cell carcinoma. Treatment remains heterogeneous, involving topical corticosteroids, dapsone, doxycycline, and occasionally targeted therapies like dupilumab. While methotrexate is an effective steroid-sparing agent, its use is often limited in elderly patients by poor tolerability.

Article (year)	Age (years)/Sex	Location	Histology; DIF	Treatment	Response
Reis Gavazzoni et al. (2018)	45/F	Scalp, face, ears, extremities (hands, knees)	Subepidermal blister; IgG/IgA at BMZ	Colchicine + topical corticosteroids	Partial clinical improvement
Reis Gavazzoni et al. (2018)	62/F	Scalp, oral mucosa	Subepidermal blister; linear IgG/C3 at BMZ	Dapsone + systemic and topical corticosteroids	Marked clinical improvement
Chandan et al. (2018)	45/F	Scalp	Subepidermal blister; linear IgG/IgA/C3, BP180 Ab ↑	Doxycycline + topical corticosteroids	Marked clinical improvement with residual scarring
Eichhoff (2019)	76/F	Scalp	Subepidermal blister; DIF not available	Surgical excision (initially managed as SCC)	Healed scar; retrospective BPP diagnosis
Zhou et al. (2020)	63/M	Scalp, oral mucosa	Subepidermal blister; linear IgG/C3	Systemic + topical corticosteroids	Disease controlled with residual scarring
Henry et al. (2020)	46/M	Face, neck	Subepidermal blister; linear IgG/C3	Dapsone	Marked clinical improvement (1-year follow-up)
Bosch-Amate et al. (2020)	73/F	Scalp, oral/genital mucosa	Subepidermal blister; linear IgG/C3; BP180-NC16a (+)	Systemic corticosteroids + dapsone	Remission; subsequent frontal fibrosing alopecia
Raef and Elmariah (2021)	63/F	Scalp, oral mucosa	Subepidermal blister; linear C3; BP180 Ab mildly ↑	Dupilumab	Marked clinical improvement following multiple treatment failures
Blum and Sigmon (2021)	71/M	Scalp, neck	Subepidermal blister; linear IgG/C3	Dupilumab	Near-complete remission; mild residual pruritus/bullae
Michalska-Jakubus et al. (2022)	36/F	Face, neck	Subepidermal blister; linear IgG/IgA/C3	Systemic corticosteroids + dapsone	Complete healing with residual scarring; dapsone dose adjusted due to methemoglobinemia
Kakurai et al. (2023)	79/F	Scalp	Subepidermal blister; linear C3; BP180 Ab ↑	Topical corticosteroids	Marked clinical improvement with residual atrophic scarring
Lennartz et al. (2024)	80/M	Scalp, face (nose)	Subepidermal blister; linear C3; BP180 Ab low titer ↑	Topical and systemic corticosteroids + dapsone	Complete healing (6 weeks)
Niknezhad et al. (2024)	75/M	Scalp	Subepidermal blister; linear IgG/C3	Systemic + topical corticosteroids	Marked clinical improvement (3 weeks)
Kohut et al. (2025)	68/F	Scalp	Subepidermal blister; linear C3c/IgM at BMZ	Intralesional + topical corticosteroids	Disease controlled with stabilization of cicatricial alopecia
Chen et al. (2025)	61/F	Scalp	Subepidermal blister; linear IgG/C3	Systemic and topical corticosteroids + doxycycline	Disease controlled; relapse during doxycycline taper

Table 1: Clinical characteristics, treatments, and outcomes of Brunsting-Perry pemphigoid cases reported over the last decade. Cases published between 2016 and 2026 with available clinicopathologic, treatment, and outcome data. Abbreviations: BPP, Brunsting-Perry pemphigoid; F, Female; M, Male; DIF, direct immunofluorescence; BMZ, basement membrane zone; BP180 Ab,

antibodies against bullous pemphigoid antigen 180; SCC, squamous cell carcinoma.

Case Presentation

An 89-year-old male presented with a several-month history of recurrent, tense bullae and erosions on the scalp and face that healed with scarring. Histopathology revealed a subepidermal blister with eosinophilic infiltrate, and direct immunofluorescence (DIF) showed linear IgG and C3 deposition, confirming BPP. After partial response to doxycycline and intolerance to dapsone and methotrexate, the patient was started on topical roflumilast 0.3% cream. He achieved complete clinical clearance within four weeks and has remained disease-free on monotherapy without adverse effects (Figure 1A and 1B).

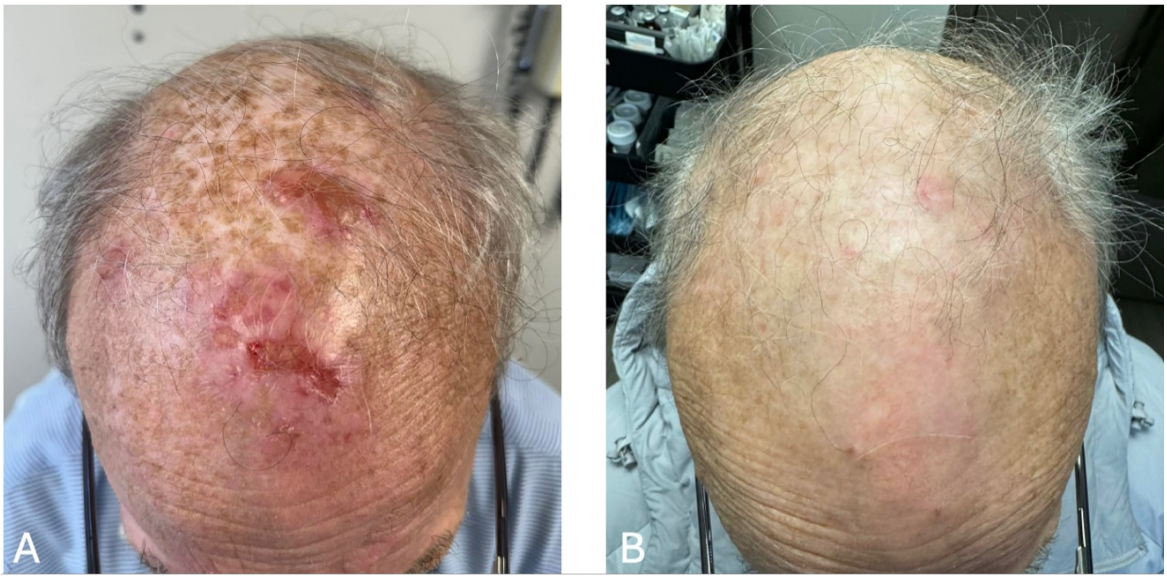

Figure 1: Brunsting-Perry pemphigoid on the scalp. (A) Erosive and crusted erythematous plaques on the scalp with a tense bulla and early cicatricial changes at baseline. (B) Complete resolution after topical roflumilast 0.3% with mild cicatricial changes

Conclusion

This report identifies topical roflumilast as a novel, effective, and well-tolerated treatment for localized BPP. Given the risks associated with systemic immunosuppression in older populations, topical phosphodiesterase-4 inhibitors may offer a valuable alternative in the BPP treatment algorithm, though further evaluation is required.

EA DV CONGRESS
VIENNA
30 SEP - 3 OCT 2026

Abstract N°: 1064

A Simple Disease Activity Score Identifies a Targetable Th2-Driven Inflammatory Endotype in Bullous Pemphigoid

Zhiqiang Cao*[1], shuzhen kong[1], Jianqiao Ye[1], Weihong Hu[1], Yanyan Zhu[1], Yueran Tao[1], Delu Che[1], Baobao Yuan[1], Yanhong Gui[1], Ulrike Raap[2], Bin Peng[1], Songmei Geng[1]

[1] The Second Affiliated Hospital of Xi'an Jiaotong University, Xi'an, China

[2] Carl von Ossietzky University Oldenburg, Oldenburg, Germany

Introduction

Bullous pemphigoid (BP) exhibits significant clinical heterogeneity, yet the molecular drivers underlying these distinct phenotypes remain poorly understood, hindering the development of precision medicine approaches. Although several proteomic studies have demonstrated profound molecular dysregulation in BP, none have correlated clinical phenotypes with molecular endotypes in a clinically translatable manner. Here, for identifying clinical markers that reflect specific molecular endotypes, we correlate clinical phenotypes, defined by the Bullous Pemphigoid Disease Area Index (BPDAI), with molecular endotypes using serum proteomic profiling.

Materials and Methods

This cohort study enrolled 143 hospitalized patients with BP at a tertiary centre between January 2024 and June 2025. Patients were stratified into inflammatory BP (I-BP; BPDAI urticaria/erythema subscore ≥5) and pauci-inflammatory BP (PI-BP; subscore <5) based on the first quartile of the subscore. Clinical features, laboratory parameters, histopathological findings, and treatment outcomes were compared. Serum proteomic profiling (Olink Target 96 Inflammation) was performed in a representative subset (n=37).

Results

Among 143 patients (mean age 73.9 years; 58.7% male), 108 (75.5%) were classified as I-BP and 35 (24.5%) as PI-BP. Compared to PI-BP, I-BP patients were younger, had more severe pruritus, and exhibited significantly elevated peripheral eosinophil counts (0.6 vs 0.2 $\times 10^9$/L; P=0.001) and serum IL-5 levels (52.5 vs 3.9 pg/mL; P=0.007). Histopathological examination revealed a distinct landscape: the I-BP subtype showed a significantly denser eosinophil-rich infiltrate (37.0 vs. 5.0 per high-power field; P=0.007), whereas the periblister neutrophil count was similar between the two subtypes. Patients with I-BP showed a higher tendency to receive targeted therapy (79.3% vs. 50.0%; P = 0.010) and had a longer median length of hospital stay (8 vs. 7 days; P = 0.029). Multivariate linear regression analysis, adjusting for age, sex, and baseline severity, confirmed that the severity of the urticaria/erythema subscore was an independent predictor of prolonged hospitalization. Proteomic analysis identified eight differentially expressed proteins. IL-13, thymic stromal lymphopoietin (TSLP), oncostatin M (OSM), and MCP-4 were upregulated in I-BP compared with PI-BP and showed moderate positive correlation with the urticaria/erythema subscore (P<0.05) but not with the erosions/blisters subscore. IL-13 demonstrated the highest diagnostic accuracy for the I-BP endotype (AUC=0.87). Functional enrichment analysis confirmed differential activation of type 2 inflammation and the JAK-STAT signaling pathway in the I-BP group.

Conclusions

The BPDAI urticaria/erythema subscore serves as a reliable clinical surrogate for a Th2-driven molecular endotype in BP. The identification of a specific Th2-ligand/JAK-STAT-signaling circuit in the inflammatory phenotype supports a stratified treatment approach, suggesting that patients with a high inflammatory burden may benefit from targeted type 2 immunotherapies or JAK inhibitors, which warrants further prospective validation.

EA DV CONGRESS
VIENNA
30 SEP - 3 OCT 2026

Abstract N°: 1120

Cross-Lingual Clinical Communication in Behçet Syndrome: Evaluating LargeLanguage Models

Ahmet Uğur Atilan*[1], Niyazi Çetin[2]

[1] Pamukkal Medicine e University Faculty of Medicine, Department of Dermatology, Denizli, Türkiye
[2] Pamukkale University Faculty of Medicine, Department of Dermatology, Denizli, Türkiye

Introduction
Despite rapid clinical adoption, the performance of large language models (LLMs) inmultilingual, patient-facing consultations remains insufficiently characterised, particularly inrare diseases. Behçet syndrome illustrates this gap due to its variable course, risk of severecomplications, and impact on quality of life, all requiring both clinical accuracy andempathetic communication. The condition disproportionately affects individuals of Turkish, Middle Eastern, and East Asian descent, many of whom are linguistic or culturalminorities in Western healthcare settings. These factors make Behçet syndrome aninstructive model for evaluating LLMs in multilingual consultations.

Materials and Methods
We benchmarked five LLMs: ChatGPT-4 (Turbo), Claude 4 (Sonnet), Gemini 2.5 (Flash), DeepSeek V3, and Kimi K1.5, using standardized zero-shot first-consultation scenarios in English and Turkish. Each scenario simulated a clinician explaining a new diagnosis, with expected responses of 300–400 words. Models were accessed via official web interfaces under default settings.Outputs were assessed across ten criteria: word count, readability (Flesch and Ateşman indices), understandability (PEMAT-P), medical accuracy, and clinical focus (percentage scores). Five additional domains, content coverage, actionability, empathy, quality-of-life framing, and preparedness for acute complications, were rated on a 5-point Likert scale. Two clinicians independently evaluated all responses; disagreements were resolved by consensus or third review. Inter-rater reliability was excellent ($\kappa = 0.893$, 95% CI: 0.63–1.00).

Results
Models showed both shared limitations and domain-specific variability. English responses were ~60% longer than Turkish, suggesting conservative generation in lower-resource languages. Despite this, understandability remained high, while readability was moderate and consistent across languages (Flesch 55.4 ± 6.77; Ateşman 53.46 ± 6.72).Clinical focus and medical accuracy were high across models, except for an error in Kimi's Turkish output referencing a non-existent drug class. Kimi performed poorly overall in Turkish but relatively well in English empathy and quality-of-life framing, indicating likely English-centric training bias.Preparedness for acute complications and quality-of-life framing were consistently weak across models, suggesting underrepresentation of these domains in training data. DeepSeek performed best in Turkish across coverage, empathy, and actionability, while Gemini and Claude showed stronger actionability in Turkish than in English. Gemini achieved the highest empathy scores in English, likely reflecting advantages in coherence and contextual fluency.

Conclusions
All models demonstrated limitations in providing sufficient clinical depth for complex, long-term disease management and showed domain-specific weaknesses. Human-led communication remains essential in such contexts. Differences in performance likely reflectvariations in model architecture and training data, highlighting areas for refinement. Although limited by a single prompt set, five models, and two languages, these findings provide preliminary insights into multilingual benchmarking and model optimization for patient-facing use.

EA DV CONGRESS
VIENNA
30 SEP - 3 OCT 2026

Abstract N°: 1145

Massive Vulvar Edema Following Vaginal Delivery in a Patient with Autoimmune Hepatic Cholangitis

Nour El Houda Samari*[1], Ouiame El Jouari[1], Sabrina Oujdi[1], Salim Gallouj[1]

[1] Dermatology Department, Mohammed VI University Hospital, Faculty of Medicine and Pharmacy, Abdelmalek Essaâdi University, Tangier, Morocco

Introduction

Massive postpartum vulvar edema is a rare and alarming presentation that can mimic infectious cellulitis, necrotizing fasciitis, deep venous thrombosis, or other obstetric emergencies, often leading to urgent dermatologic consultation. While preeclampsia, diabetes, tocolysis, and capillary leak syndromes are known causes, its link with chronic autoimmune liver disease has rarely been described. As dermatologists are frequently the first to evaluate acute vulvar swelling and to look for systemic causes, awareness of this presentation is important. We report, to our knowledge, the first case highlighting severe hypoalbuminemia related to autoimmune cholangitis as an under-recognized mechanism of massive postpartum vulvar edema.

Case Presentation

A 28-year-old primigravida followed for autoimmune hepatic cholangitis under long-term immunosuppressive therapy delivered vaginally at term without obstetric complications. On the first postpartum day, she developed rapidly progressive massive bilateral vulvar edema predominantly involving the labia majora, accompanied by significant ascites. There was no fever, erythema, necrosis, severe localized pain, or clinical signs suggestive of infection or thromboembolic disease. Blood pressure monitoring and absence of proteinuria ruled out preeclampsia, and Doppler ultrasound excluded deep venous thrombosis. Infectious workup was negative.

Laboratory evaluation revealed profound hypoalbuminemia at 20 g/L, providing a clear physiopathological explanation for the dramatic fluid shift through reduced plasma oncotic pressure and extravasation into lax vulvar subcutaneous tissues, the same mechanism likely responsible for the associated ascites. Dermatologic differentials including infectious cellulitis, necrotizing fasciitis, angioedema, vulvar hematoma, and lymphatic obstruction were systematically excluded.

Conservative management was initiated, combining intravenous human albumin infusions, oral loop diuretics, serrapeptase, mannitol-soaked compresses, and local ice application, while avoiding invasive surgical drainage. The clinical course was favorable, with substantial regression of the edema within days and complete resolution of both vulvar swelling and ascites within one week.



Massive bilateral vulvar edema on postpartum day 1, predominantly involving the labia majora, without erythema, necrosis, or signs of infection

Conclusion

This case shows that severe hypoalbuminemia related to autoimmune liver disease can cause extreme postpartum vulvar edema, a presentation that dermatologists may be the first to see. Recognizing this mechanism is important to avoid misdiagnosis as infection or vascular compromise, to prevent unnecessary surgery, and to guide appropriate conservative treatment. This report broadens the dermatologic differential of acute vulvar swelling and highlights the need for systemic evaluation in sudden, dramatic genital edema, particularly in patients with chronic hepatic, renal, or autoimmune conditions.

EADV CONGRESS
VIENNA
30 SEP - 3 OCT 2026

Abstract N°: 1147

Reversing Systemic Sclerosis: A Case of Autoimmune/Inflammatory Syndrome Induced by Adjuvants (ASIA) Following Silicone Implant Rupture

Beatriz Soto Cala*[1], Sofia Restrepo-Samper[1, 2], Claudia Gonzalez-Diaz[3], Daniel Perdomo-Pachon[1], Juan-Guillermo Chalela[2]

[1] Private Practice at Dermatology Clinic, Bogota, Colombia

[2] Dermatology Professor, Hospital Militar Nueva Granada, Bogota, Colombia

[3] Private Practice at Radiology Clinic, Bogota, Colombia

Introduction

Autoimmune/Inflammatory Syndrome Induced by Adjuvants (ASIA) encompasses a spectrum of immune-mediated conditions triggered by chronic exposure to adjuvant substances such as aluminum, vaccine components, and, notably, silicone. While silicone-induced autoimmunity is recognized, cases demonstrating a complete clinical and serological reversal of systemic sclerosis upon removal of the trigger remain rare and highly instructive for the scientific community.

Case Presentation

We report the case of a 68-year-old woman with a 20-year history of silicone breast augmentation, who underwent implant rupture and reimplantation three years prior to symptom onset. She presented with Raynaud's phenomenon, cutaneous calcinosis and sicca symptoms, culminating in a diagnosis of limited cutaneous systemic sclerosis. The patient also exhibited cognitive impairment and depressive symptoms.

Laboratory investigations confirmed the presence of anti-centromere antibodies and elevated acute-phase reactants. Nailfold capillaroscopy demonstrated an early scleroderma pattern. Imaging and subsequent histopathological examination confirmed silicone migration to axillary lymph nodes (siliconomas).

The patient underwent total capsulectomy, removal, and excision of the silicone-laden lymph nodes. Post-operatively, she experienced a dramatic resolution in systemic, cutaneous, and neuropsychiatric symptoms, and her autoimmune profile normalized (seroconversion to negative antibodies). This complete remission following the removal of the adjuvant confirmed the diagnosis of ASIA syndrome.

Conclusion

This case highlights the broad clinical spectrum of ASIA syndrome,a potential reversible trigger of systemic sclerosis. It underscores the importance of clinical suspicion in patients with unexplained autoimmune manifestations and a history of adjuvant exposure. Early multidisciplinary evaluation and individualized therapeutic strategies can lead to complete disease remission, challenging the typically progressive nature of systemic sclerosis.

EA DV CONGRESS
VIENNA
30 SEP - 3 OCT 2026

Abstract N°: 1152

Acquired Hemophilia A in an Elderly Patient: Case Report and Evidence-Based Review

Sarah Ramos Acedo*[1], Mariana Ferrari[2], Raisa Resende[3], Lívia Sabia[4]

[1] University Nove de Julho, São Paulo, Brazil
[2] Pontifical Catholic University of Campinas (PUCCampinas), Campinas, Brazil
[3] University of Marília (FAMEMA), Marília, Brazil
[4] University of Taubaté (UNITAU), Taubaté, Brazil

Introduction

Acquired hemophilia A (AHA) is a rare autoimmune coagulopathy caused by autoantibodies against factor VIII. Unlike the hereditary form, it affects both sexes and typically presents in elderly patients or in individuals with autoimmune diseases, malignancies, or those using immunosuppressive drugs. It commonly presents with extensive hematomas, soft tissue bleeding, and occasionally hemarthroses. The diagnosis is based on an isolated prolonged aPTT, reduced factor VIII levels, and detection of inhibitors.

Case Presentation

Male patient, 65 years old, with no prior history of coagulopathy, presented with spontaneous ecchymoses on the left arm, which resolved spontaneously. Approximately five months later, the patient developed multiple hemarthroses involving the heel, knee, and hand, as well as enanthema of the bilateral buccal mucosa.

Laboratory tests revealed a prolonged activated partial thromboplastin time (aPTT), corresponding to 2.8 times the reference value, reduced factor VIII levels (4.5%), and the presence of an inhibitor against factor VIII, consistent with the diagnosis of Acquired Hemophilia A.

Treatment was initiated with Prednisone 40 mg/day orally for four days, followed by pulse therapy with Methylprednisolone 160 mg intravenously in weekly cycles for four weeks. Significant clinical improvement was observed after the third cycle.

As immunobiological reinforcement, a single dose of Rituximab was given, with a favorable response and stabilization of the clinical condition.

Acquired hemophilia is a rare autoimmune condition characterized by the development of autoantibodies (inhibitors) against coagulation factor VIII, resulting in spontaneous bleeding, prolonged aPTT, and reduced plasma levels of factor VIII. Unlike hereditary forms, this condition may arise in individuals without a personal or family history of bleeding disorders, as observed in this case.

The most common clinical manifestations include hematomas, ecchymoses, muscular and joint bleeding, as well as mucosal involvement. The patient initially presented with spontaneous ecchymosis and later progressed to multiple hemarthroses and enanthema, reflecting disease severity and progression.

The diagnosis was confirmed by isolated prolongation of aPTT (2.8 times the reference value), reduced factor VIII levels (4.5%), and the presence of a specific inhibitor against factor VIII, in accordance with international guidelines. Treatment is based on two main pillars: control of bleeding and eradication of the inhibitor. In this case, a stepwise immunosuppressive approach was adopted, initially with oral prednisone followed by pulse therapy with methylprednisolone, achieving significant clinical response after the third cycle. As consolidation therapy, rituximab, an anti-CD20 immunobiological agent, was used, resulting in good clinical and laboratory

stabilization.

This therapeutic regimen is consistent with current recommendations for refractory cases or those with partial response to corticosteroid monotherapy, demonstrating the effectiveness of combined immunosuppressive strategies in progressive stages of the disease.

Conclusion

Acquired hemophilia A (AHA) should be considered in patients with unexplained bleeding and isolated prolonged aPTT. Sequential treatment with corticosteroids and Rituximab has proven effective. Early diagnosis and multidisciplinary management are crucial to prevent complications and ensure favorable outcomes.

EADV CONGRESS
VIENNA
30 SEP - 3 OCT 2026

Abstract N°: 1181

Discoid lupus erythematosus of the eyelids

Dimitrina Guleva*[1], Dafina Antonova[2], Valentina Broshtilova[1], Stefka Neycheva[3], Presian Genchovski[2], Vessel Kantardjiev[1]

[1] Dep. of Dermatology, Military Medical Academy- Sofia, Sofia, Bulgaria
[2] Dep. of Ophthalmology, Military Medical Academy-Sofia, Sofia, Bulgaria
[3] Dep. of Rheumatology, Militaray Medical Academy- Sofia, Sofia, Bulgaria

Introduction

Discoid lupus erythematosus (DLE) is a chronic autoimmune disease of the connective tissue which usually involves the sun-exposed areas (scalp, face, upper part of the trunk and upper extremities). Rarely, the eyelid could be affected and the most common clinical presentation is blepharitis, especially if the eyelid is the first affected of the disease. The diagnosis is a challenge and usually it takes months to years to be established the correct diagnosis and to be prevented the further complications.

Case Presentation

A 44-years-old male presented with 1-year history of redness, progressive thickness, itching and burning sensation of the lower eyelid of the both eyes. He was treated before for an allergic blepharitis but the symptoms continued to worsen. Over time, it got worsd and referred to our Dermatological department from the ophthalmologists. On the lower eyelids of both eyes (mostly the left one) were noticed erythematous infiltrated plaques with central atrophy, yellowish scaling and lack of eyelashes of the affected areas. No other ocular involvements were observed. Laboratory examinations were within normal ranges. ANA, anti-SSA, anti-SSB, anti-dsDNA and anti-Sm antibodies were negative. Protein in urine was in normal ranges as well. The histology showed epidermal atrophy, vacuole degeneration of the basal cell with apoptotic keratinocytes and periadnexal lymphocytic infiltration in the superficial and deep dermis. Mucin is present as well. DLE was confirmed. The patient was treated with low dose systemic steroid, topical steroid and hydroxychloroquine 400mg/ daily for 2 weeks and then reduced to 200 mg/daily for another 8 months. Un improvement was noticed but there were still a slight erythema and infiltration. We decided to include off label antifrolumab for DLE to prevent the complications as entropium, ectropium, visual and psycho-emotional impairment.

Conclusion

Eyelid discoid lupus erythematosus is very challenging diagnosis. It could be under suspicions if the lesion is refractory to therapy or scarring is presented. Therapy could be a game changer preventing the complications. A long term follow-up is needed for new discoid lesion or systemic involvement. In recalcitrant cases it could be discussed a biological therapy with type I interferon receptor antagonist as antifrolumab.

EA DV CONGRESS
VIENNA
30 SEP - 3 OCT 2026

Abstract N°: 1184

Refractory Linear IgA Bullous Dermatosis Successfully Managed with Tofacitinib: A Challenging Therapeutic Course

Andrea Isabel Rodriguez-Sanna*[1], Manuel Sánchez-Díaz[1], Carmen García-Moronta[1], Francisco Javier León Pérez[1], Pablo Díaz-Calvillo[1], Salvador Arias-Santiago[1]

[1] Hospital Universitario Virgen de las Nieves, Granada, Spain

Introduction

Linear IgA bullous dermatosis (LABD) is a rare subepidermal autoimmune blistering disease characterized by linear deposition of IgA along the basement membrane zone. It is mediated by IgA autoantibodies targeting structural proteins of the dermoepidermal junction, leading to neutrophil-driven tissue injury. Clinically, LABD presents with pruritic vesicles and tense bullae, often arranged in annular patterns, with possible mucosal involvement.

First-line therapy consists of dapsone, which usually provides rapid disease control; however, a subset of patients develops refractory disease requiring systemic corticosteroids, immunosuppressants, intravenous immunoglobulin (IVIG), or biologic therapies. Emerging evidence suggests a potential role for Janus kinase (JAK) inhibitors in autoimmune bullous diseases, although data in LABD remain limited.

Case Presentation

We report the case of a middle-aged patient who developed a chronic pruritic blistering eruption in 2017, initially presenting with widespread vesicles and tense bullae without mucosal involvement. Histopathology revealed a subepidermal blister with neutrophilic infiltrate, and direct immunofluorescence demonstrated linear IgA deposition, consistent with LABD after diagnostic reassessment.

The disease followed a relapsing-remitting course with progressive refractoriness. Initial partial response to systemic corticosteroids and dapsone was observed; however, multiple flares occurred despite dose escalation. Over subsequent years, the patient required repeated therapeutic escalation, including colchicine, azathioprine, mycophenolate mofetil, methotrexate, and doxycycline, all yielding incomplete or transient responses.

Due to persistent disease activity and corticosteroid dependence, advanced therapies were initiated. Rituximab and IVIG led to partial improvement but failed to achieve sustained remission. The clinical course was further complicated by treatment-related adverse effects, including iatrogenic Cushing syndrome and opportunistic infection with visceral leishmaniasis.

More recently, anti-TNF therapy with adalimumab resulted in initial clinical improvement followed by loss of efficacy and gastrointestinal intolerance. Given the refractory nature of the disease, off-label treatment with tofacitinib was initiated, leading to clinical improvement with reduction in lesion burden.

Conclusion

Although LABD is generally considered a benign disease with a favorable prognosis and limited recurrences, this case highlights that a subset of patients may develop severe, treatment-refractory disease requiring multiple lines

of therapy. Management in these cases is particularly challenging due to corticosteroid dependence, repeated treatment failures, and complications related to prolonged immunosuppression, requiring careful balancing of disease control against cumulative toxicity and infection risk.

Given the overlap in inflammatory mechanisms with other autoimmune bullous diseases, where activation of the JAK/STAT pathway has been demonstrated, JAK inhibitors may represent a promising therapeutic option. In this patient, tofacitinib achieved clinical improvement after failure or intolerance to multiple therapies, supporting its potential role as a strategy in highly refractory LABD. Further studies are needed to better define its efficacy and safety in this setting.

EADV CONGRESS
VIENNA
30 SEP - 3 OCT 2026

Abstract N°: 1235

New-Onset Psoriasis in a Bullous Pemphigoid Patient Successfully Treated with Long-Term Omalizumab: A Rare Comorbidity

Leyla Aghayeva*[1], BURHAN ENGIN[1]

[1] Istanbul Cerrahpaşa, Fatih, Türkiye

Introduction

Bullous Pemphigoid (BP) is the most common autoimmune blistering disorder, characterized by subepidermal blisters and IgE-mediated pathogenesis. Omalizumab, an anti-IgE monoclonal antibody, has emerged as an effective therapeutic option in treatment-refractory BP. Psoriasis is a chronic immune-mediated inflammatory skin disease affecting approximately 2-3% of the general population. The co-occurrence of BP and psoriasis is uncommon, and the development of new-onset psoriasis during omalizumab therapy has rarely been reported in the literature. Here, we present a case of new-onset psoriasis developing in a BP patient under long-term omalizumab therapy with sustained disease control.

Case Presentation

A 73-year-old male patient with no known systemic disease or family history was diagnosed with Bullous Pemphigoid and has been followed for 4 years. Omalizumab therapy was initiated and has been continued with significant and sustained efficacy, achieving complete control of bullous lesions. No additional systemic immunosuppressive therapy was required. Within the last 6 months, the patient developed erythematous, scaly plaques localized exclusively to both elbows, with no involvement of other body regions. The lesions were clinically evaluated as Psoriasis Vulgaris. Topical corticosteroids were initiated for the psoriatic lesions. No skin biopsy was performed as the clinical presentation was characteristic.

Conclusion

This case highlights the rare co-occurrence of Bullous Pemphigoid and Psoriasis Vulgaris. Omalizumab demonstrated sustained efficacy in controlling BP over 4 years without any need for additional systemic immunosuppressive therapy. The development of localized psoriatic lesions during this period is considered an independent comorbidity rather than a treatment-related adverse event, reflecting the complex immune dysregulation underlying autoimmune skin disorders. This case underscores the importance of careful dermatological follow-up in BP patients, as new inflammatory skin conditions may emerge independently of ongoing biologic therapy.

EADV CONGRESS
VIENNA
30 SEP - 3 OCT 2026

Abstract N°: 1256

A Pathogenic TVM–Treg Imbalance Underlies the Immunologic Interplay Between Atopic Dermatitis and Alopecia Areata

Joon Seok*[1], Hyun Joo Lee[1], Ayeon Choi[1], Eo Jin Kim[1], Se In Jung[1], Su-Young Kim[1], Beom Joon Kim[1]

[1] Department of Dermatology, Chung-Ang University Hospital, Chung-Ang University College of Medicine, Seoul, Korea, Rep. of South

Introduction

Alopecia areata (AA) is a T cell–mediated autoimmune disease with a predominantly $CD8^+$ T cell-skewed immune profile, whereas atopic dermatitis (AD) is characterized by Th2-dominant inflammation, particularly in the acute phase. Despite these distinct immune milieus, AA and AD are frequently observed as comorbid conditions with each other. Virtual memory T (T_{VM}) cells are known to undergo IL-4–driven expansion and serve as precursors of pathogenic $CD8^+$ T cells in AA. We therefore hypothesized that IL-4 in AD may promote T_{VM} cell expansion, thereby enlarging the pool of pathogenic precursor cells and contributing to AA exacerbation.

Materials and Methods

AA was induced in C3H/HeJ mice using an adoptive transfer model. AD-like dermatitis was induced with house dust mite concurrently with AA. Disease severity was assessed over 12 weeks by measuring ear thickness, followed by immunohistochemistry and flow cytometric analysis.

Results

In the co-induction model, ear thickness was increased compared to AD-only mice. In addition, the proportion of T_{VM} cells was expanded compared to AD-only mice. Furthermore, the co-induction model showed a reduction in regulatory T (T_{reg}) cell frequency along with decreased expression of CTLA-4 and ICOS, suggesting a potential impairment of immunoregulatory function.

Conclusions

These findings support a bidirectional immunologic interaction between AA and AD, in which AD may potentiate pathogenic AA-associated $CD8^+$ T-cell responses through T_{VM}-cell expansion, while AA may aggravate AD by impairing T_{reg} cell-mediated immune regulation.

EADV CONGRESS
VIENNA
30 SEP - 3 OCT 2026

Abstract N°: 1259

Mechanical-metabolic crosstalk through the YAP1-PPARγ axis drives fibroblast activation in skin fibrosis

Yiming Qin*[1], Xiao Yan Lyu[1]

[1] Sichuan University, chengdu, China

Introduction

Localized scleroderma (LS) is a chronic fibrosing skin disease characterized by persistent fibroblast activation and progressive tissue stiffening. While both altered tissue mechanics and metabolic reprogramming contribute to fibrosis, the mechanisms linking matrix stiffening to fibroblast state transitions remain unclear. We therefore aimed to define fibroblast state changes during LS progression, elucidate the mechanistic interplay between mechanical signalling and metabolic reprogramming, and assess a locally deliverable therapeutic strategy targeting this pathway.

Materials and Methods

Public single-cell RNA-seq datasets were integrated with skin biopsy samples from 10 patients with LS and 5 healthy controls to characterize fibroblast subpopulations and associated mechano-metabolic programmes. Key mechanistic findings were validated in human dermal fibroblasts using siRNA-mediated perturbation, in vitro functional assays, and bulk RNA sequencing. For translational assessment, a sustained-release verteporfin (VP)-loaded PLGA microneedle platform was developed and tested in a bleomycin-induced murine model of LS-like skin fibrosis.

Results

A lipogenic fibroblast subpopulation was progressively depleted during LS progression, accompanied by loss of lipogenic identity and transition towards a profibrotic state. Mechanistically, pathological matrix stiffening activated YAP1, which suppressed PPARγ-driven lipogenic programmes and promoted profibrotic fibroblast reprogramming. Pharmacological inhibition with VP restored PPARγ signalling through two complementary mechanisms. In vivo, the VP@PLGA microneedle platform achieved sustained intradermal delivery and significantly improved fibrotic features, including dermal thickening and collagen deposition.

Conclusions

These findings identify a clinically relevant mechano-metabolic axis in LS in which matrix stiffening drives YAP1 activation, loss of PPARγ-dependent lipogenic fibroblast identity, and progression to fibrosis. Local restoration of PPARγ activity using VP, delivered through a sustained-release microneedle system, represents a promising mechanism-based therapeutic strategy for skin fibrosis.

POWERED BY M-ANAGE.COM

EADV CONGRESS
VIENNA
30 SEP - 3 OCT 2026

Abstract N°: 1264

Bronze skin and Raynaud's phenomenon: a rare overlap of hereditary haemochromatosis and systemic sclerosis

Cindy Denisse Leyva De Los Rios*[1], Jesus Sebastian Rodriguez Gutierrez[1], Juan Daniel Osorio Barboza[1]

[1] Hospital Civil de Culiacan, Culiacan, Mexico

Introduction

Hereditary haemochromatosis (HH) and systemic sclerosis (SSc) are two distinct conditions that, when concurrent, create a diagnostically challenging overlap with prominent cutaneous manifestations. HH type 1 is the most common autosomal recessive iron overload disorder in European-descent populations, with a C282Y homozygote prevalence of 0.23–0.40% and H63D allele frequencies of 13–22%; the compound heterozygous genotype C282Y/H63D confers low but clinically relevant penetrance, with up to 10% of carriers developing significant iron overload. SSc is a rare systemic fibro-inflammatory disorder (global prevalence: 38–341 per million) characterized by vasculopathy, autoimmunity, and fibrosis; its cardinal dermatological features include Raynaud's phenomenon, sclerodactyly, and an active nailfold capillaroscopy pattern with megacapillaries and microhemorrhages. When both coexist, the cutaneous phenotype is particularly complex: diffuse bronze hyperpigmentation—the hallmark of iron deposition—may accompany Raynaud's phenomenon and esophageal dysmotility, demanding systematic dermatological evaluation. Excess iron promotes reactive oxygen species generation that may amplify SSc-associated vascular injury and fibrosis. Co-occurrence of ACR/EULAR 2013-confirmed SSc with genetically verified HH remains exceedingly rare. We report a case identified and led by the dermatology department, underscoring its pivotal role in diagnosing complex systemic overlaps.

Case Presentation

A 29-year-old male presented to the dermatology department with a 6-month history of episodic violaceous-bluish acral discoloration triggered by cold, with paresthesias consistent with Raynaud's phenomenon. Medical history included severe gastroesophageal reflux disease of 5 years managed with proton pump inhibitors, complicated by laryngospasm and dysphonia one year prior, suggestive of esophageal dysmotility. Dermatological examination revealed diffuse homogeneous bronze-toned hyperpigmentation without sclerodactyly. This triad prompted a dermatology-initiated autoimmune workup: a comprehensive autoantibody panel and thyroid function tests were requested; ANA returned positive at titer 1:1280 with a homogeneous pattern. Nailfold capillaroscopy revealed an active scleroderma pattern with megacapillaries and microhemorrhages. These findings fulfilled ACR/EULAR 2013 criteria, establishing limited SSc (CREST syndrome). To assess systemic involvement, transthoracic echocardiogram and abdominal ultrasound were obtained: the echocardiogram showed a hyperreflective pericardium suggestive of pericarditis; the ultrasound revealed diffuse increased hepatic echogenicity, raising concern for iron deposition. Combined with bronze hyperpigmentation, this prompted iron studies: ferritin 1,020 ng/mL (repeat 1,373 ng/mL); transferrin saturation 81.74% (reference <45%); serum iron 231 µg/dL (reference 60–170 µg/dL). Given the severity of iron overload, a liver biopsy was performed for HFE mutational analysis, confirming C282Y heterozygous and H63D homozygous genotype, establishing concurrent hereditary haemochromatosis. Multidisciplinary follow-up by dermatology, rheumatology and hematology was initiated.

Conclusion

This case highlights dermatology’s central role in recognizing rare overlapping systemic conditions. The co-occurrence of Raynaud’s phenomenon and bronze hyperpigmentation should alert the dermatologist to concurrent autoimmune and metabolic disease. Iron overload-driven reactive oxygen species may act synergistically with SSc vasculopathy and fibrosis. Despite the low-penetrance nature of C282Y/H63D, a biochemically severe phenotype was observed, underscoring the relevance of genetic modifiers. Dermatology outpatient settings are a critical entry point for multisystem diseases, and thorough evaluation of cutaneous signs can lead to life-changing diagnoses.

EADV CONGRESS
VIENNA
30 SEP - 3 OCT 2026

Abstract N°: 1272

Management of topical steroid therapy in male patients with Lichen Sclerosus after circumcision

Luca Mastorino*[1], Lorenzo Pessina[1], Simone Ribero[1], Pietro Quaglino[1]

[1] University of Turin, department of medical sciences, Turin, Italy

Introduction

Lichen Sclerosus et Atrophicus (LSA) is a chronic inflammatory dermatosis of multifactorial aetiology, mainly affecting the genital area in both sexes and at any age. First-line therapy involves topical corticosteroids, while surgery, particularly circumcision in males, is reserved for non-responders or phimosis cases. Some patients show persistent disease post-surgery. The study aims to compare the effectiveness of circumcision versus topical corticosteroids in improving QoL in men with LSA, assess postoperative recurrence risk.

Materials and Methods

A retrospective study of consecutive male patients with histological or clinical genital LSA were undergone. We collected clinical, anamnestic, and therapeutic data, including pre- and post-circumcision topical treatments. The DLQI questionnaire assessed quality of life according to treatment type.

Results

Fifty-five males were analysed; 40% underwent circumcision. Of these, 83% used topical steroids before surgery and 68% resumed afterward (Steroid-Free Survival: 19 months). Resumption correlated with prior treatment (p=0.043). QoL improved after circumcision and worsened with active therapy or phimosis (p=0.002; p=0.006)

Conclusions

Circumcision improves QoL, especially in phimosis, though relapses are frequent. Topical therapies are commonly employed but do not appear to significantly impact QoL. The results underline that LSA management should be personalized, combining medical and surgical approaches based on severity and patient response.

EADV CONGRESS
VIENNA
30 SEP - 3 OCT 2026

Abstract N°: 1307

LOW-TEMPERATURE ARGON PLASMA IN COMBINATION THERAPY FOR NON-SEGMENTAL VITILIGO

Nader Ouaili*[1], konstfntin lomonosov[2]

[1] Sechenov First Moscow State Medical University(Sechenov University), Moscow, Russian Federation

[2] Sechenov First Moscow State Medical University (Sechenov University), Moscow, Russian Federation

Introduction

Narrowband UVB therapy at 311 nm is a first-line treatment for non-segmental vitiligo; however, repigmentation is slow, and some patients demonstrate an insufficient early response. Data on the use of low-temperature argon plasma in combination with phototherapy for non-segmental vitiligo are virtually nonexistent, while the complementary mechanisms of both modalities justify their combination.

Materials and Methods

Aim of the study. To evaluate the efficacy and safety of the combined use of low-temperature argon plasma and UVB-311 nm compared with UVB-311 nm monotherapy in patients with non-segmental vitiligo, based on changes in the VASI and quality of life (VitiQoL) over 4 and 8 weeks, and 1 month after completion of treatment.
Methods. Adult patients with non-segmental vitiligo with depigmented lesions assessed by the VASI were included in this prospective, non-randomized, controlled comparative study.Patients with segmental and mixed forms of vitiligo, pregnant women, individuals with photodermatoses, a history of systemic immunosuppressants, and skin cancer were excluded. Patients in the study group received treatment of lesions with the Plasmoran (Russian plasma-arc surgical unit) device followed by a UVB-311 nm session, while the comparison group received UVB-311 nm monotherapy.Treatment was administered three times a week for 8 weeks.Assessments were performed at baseline, after 4 and 8 weeks, and 1 month after completion of therapy.

Results

Sixty patients were included; all completed the follow-up. In the main group, the median VASI score decreased from 3.8 to 2.3 points by week 8 (a 39.5% decrease), and in the comparison group, from 4.1 to 3.1 points (24.4%); the difference between groups was 0.5 points [95% C1 0.04-0.96], p = 0.03.After 1 month, the difference remained (2.1 versus 2.9 points, p = 0.04). According to VitiQoL, the median score at week 8 was 30.5 versus 35.0 points (p = 0.04), and after 1 month, 28.0 versus 33.5 points (p = 0.03). The advantage of the combination regimen was significant for non-acral locations and disease durations of less than 5 years. Adverse events were reported in 7 of 28 patients in the study group and 5 of 32 in the comparison group; all were transient and resolved spontaneously.

Conclusions

The combination of low-temperature argon plasma with 311 nm UVB therapy provides a statistically significantly greater reduction in VASI and improvement in quality of life compared to monotherapy.

EA DV CONGRESS
VIENNA
30 SEP - 3 OCT 2026

Abstract N°: 1341

Drug-Induced Fibrosing Alopecia in a Pattern Distribution triggered by immune checkpoint inhibitor Nivolumab-Relatlimab: A Case Report

Amanda Periquito*[1, 2], ÚRSULA DE ALBUQUERQUE[3], VIVIANE TORTELLI[4], GABRIELA FINGER[2], LUDMILA PORFIRIO[2]

[1] POLICLÍNICA GERAL DO RIO DE JANEIRO, INSTITUTO NACIONAL DO CÂNCER - INCA, Rio de Janeiro, Brazil
[2] INSTITUTO NACIONAL DO CANCER - INCA, Rio de Janeiro, Brazil
[3] HOSPITAL DA GAMBOA, Rio de Janeiro, Brazil
[4] HOSPITAL CENTRAL DO EXÉRCITO, Rio de Janeiro, Brazil

Introduction

Fibrosing alopecia in a pattern distribution (FAPD) is considered clinical variant of lichen planopilaris (LPP), characterized by a distribution pattern resembling androgenetic alopecia (AGA), but with histopathological features consistent with lymphocytic scarring alopecia. This condition predominantly affects postmenopausal women, although cases have also been described in premenopausal women and men.

Clinically, FAPD presents with progressive hair thinning involving the frontal, centroparietal and vertex regions, mimicking AGA; however, it is often accompanied by inflammatory signs, including perifollicular erythema, scaling, and occasionally pruritus or localized discomfort. Trichoscopic findings typically include loss of follicular openings, perifollicular hyperpigmentation, and fibrosis, warranting histopathological confirmation. Scalp biopsy usually reveals a perifollicular lymphocytic inflammatory infiltrate and destruction of follicular architecture, consistent with cicatricial alopecia.

Nivolumab, an anti–programmed death-1 (PD-1) antibody, and relatlimab, an anti–lymphocyte activation gene-3 (LAG-3) antibody, are immune checkpoint inhibitors indicated for the treatment of metastatic or unresectable melanoma. Although cutaneous immune-related adverse events are well recognized, alopecia associated with this combination therapy is rare and remains poorly characterized in literature.



Progressive hair thinning affecting the frontoparietal region.

Case Presentation

A 56-year-old woman with a medical history of systemic arterial hypertension, hypothyroidism, and type 2 diabetes mellitus was diagnosed with nodular melanoma of the right calcaneus, with a Breslow thickness of 5 mm. Sentinel lymph node biopsy was positive, and the disease was staged as IIIC (T4b N2c M0). The patient underwent treatment with nivolumab and relatlimab, achieving no evidence of viable neoplastic tissue after one year of therapy.

During treatment, the patient developed achromic macules suggestive of vitiligo, along with progressive hair thinning affecting the frontoparietal and vertex regions and eyebrow involvement, without associated pruritus or trichodynia. Trichoscopic examination demonstrated absence of follicular openings, peripilar casts, hair shaft breakage and reduced vellus hair density. Histopathological analysis of two scalp biopsy specimens revealed findings consistent with fibrosing alopecia in a pattern distribution.

Topical 5% minoxidil therapy was initiated. Notably, following discontinuation of nivolumab and relatlimab, the patient exhibited partial hair regrowth, an unexpected finding in the context of scarring alopecia.



Absence of follicular openings, peripilar casts.

Conclusion

Nivolumab has been associated with immune-related adverse events, including alopecia, in approximately 1–2% of patients, likely as a consequence of immune system activation. Although the precise pathophysiological mechanisms remain unclear, immune dysregulation may trigger an autoimmune response targeting hair follicles.

Most reported cases of alopecia associated with nivolumab involve alopecia areata, a non-scarring form of hair loss. In contrast, scarring alopecia in this context has not been previously well documented. Hair loss typically develops within the first year of treatment, consistent with the timeline observed in the present case.

Clinical trials evaluating the combination of nivolumab and relatlimab have reported pruritus, rash, and vitiligo as the most common cutaneous adverse events, whereas alopecia is infrequently described. Furthermore, the partial reversal of alopecia following treatment discontinuation is not a characteristic feature of cicatricial alopecia, suggesting a potentially unique or overlapping pathogenic mechanism.

This case raises the possibility of a causal relationship between immune checkpoint inhibition and the development of FAPD-like scarring alopecia, underscoring the importance of dermatological monitoring in patients receiving these therapies. Further studies are needed to elucidate the underlying mechanisms and clinical behavior of this rare adverse event.

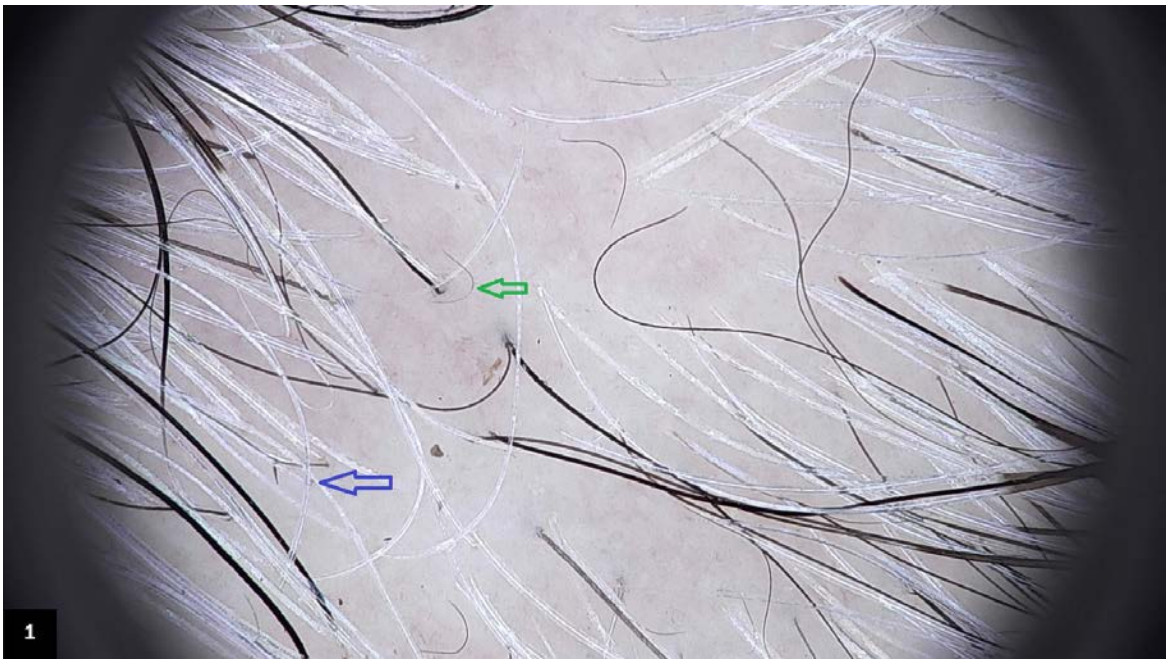

Hair shaft breakage and reduced vellus hair density.

EA DV CONGRESS
VIENNA
30 SEP - 3 OCT 2026

Abstract N°: 1343

Successful Treatment of Refractory Pyoderma Gangrenosum with Vunakizumab: A Case Report

Ying Qiu*[1], Yaru Wang[1], Yumei Wang[2]

[1] Jining No.1 People's Hospital, jining, China

[2] Jining Rencheng District Jincheng Subdistrict (Zhonghe) Community Health Service Center, jining, China

Introduction

Pyoderma gangrenosum (PG) is a rare neutrophil-driven autoimmune disease causing severe skin ulcers, primarily in adults aged 40–60 years. Its pathogenesis involves excessive neutrophil activation, T cell clonal proliferation, Th1/Th17 imbalance, and reduced regulatory T cells. PG is difficult to treat and often associated with systemic diseases. Rapid-acting immunosuppressants (e.g., glucocorticoids, cyclosporine) are first-line but long-term use increases adverse event risk. This study aims to explore therapies for refractory PG (RPG) to: control cutaneous inflammation and pain, halt lesion progression; promote ulcer healing and improve quality of life; increase response rates while minimizing adverse events of traditional immunosuppressants.

Case Presentation

A 74-year-old female patient (70 kg) with RPG presented with multiple painful ulcers on both lower extremities that had persisted for one year. One year prior to admission, she developed multiple erythematous lesions on both lower extremities without identifiable precipitating factors; these lesions rapidly progressed into ulcers associated with severe pain. Over time, the ulcerative lesions gradually worsened.

Dermatological examination: Multiple deep-seated ulcers were observed on both lower extremities, with a small amount of yellowish exudate on the ulcer bases. Violaceous borders were noted around the ulcers, along with marked spontaneous pain and tenderness.

Skin histopathological examination: Diffuse inflammatory infiltration, predominantly composed of neutrophils, was observed in the dermis and subcutaneous fat layer, accompanied by tissue necrosis and ulceration (Figure 1). After excluding infection, vasculitis, neoplasms, and other diseases, the diagnosis of pyoderma gangrenosum (PG) was confirmed.

Clinical course: Initial treatment consisted of methylprednisolone 24 mg once daily. One month later, the skin lesions improved, but the patient developed hypertension and hyperglycemia. The methylprednisolone dose was then reduced to 10 mg once daily, which resulted in ulcer enlargement and increased pain. Cyclosporine 200 mg once daily was added, leading to stabilization and regression of the skin lesions. Forty-five days later, the patient developed acute renal failure, thrombocytopenia, and anemia, and was admitted for symptomatic management. The trough concentration of cyclosporine was 211 ng/mL; therefore, cyclosporine was discontinued, and symptomatic treatment continued. The patient was discharged after 12 days. Following discharge, the patient continued on cyclosporine 75 mg once daily and methylprednisolone 24 mg once daily. Over the next month, the ulcers persisted with intractable severe pain.

Vunakizumab, a humanized anti-IL-17A monoclonal antibody, was then added at a dose of 240 mg subcutaneously at weeks 0, 2, and 4. After administration, the patient reported a subjective reduction in exudate and improvement in pain. The maintenance regimen was subsequently adjusted to 240 mg subcutaneously once monthly. Significant improvement in skin lesions was observed at 12 weeks of treatment, and the ulcers were

nearly healed with only local scars remaining at 24 weeks.
results:Treatment with an individualized regimen of Vunakizumab plus low-dose glucocorticoids and low-dose cyclosporine resulted in pain relief and gradual healing of the cutaneous ulcers. No severe adverse events, including serious infections or hepatorenal injury, occurred during the entire treatment course, demonstrating a favorable safety profile.

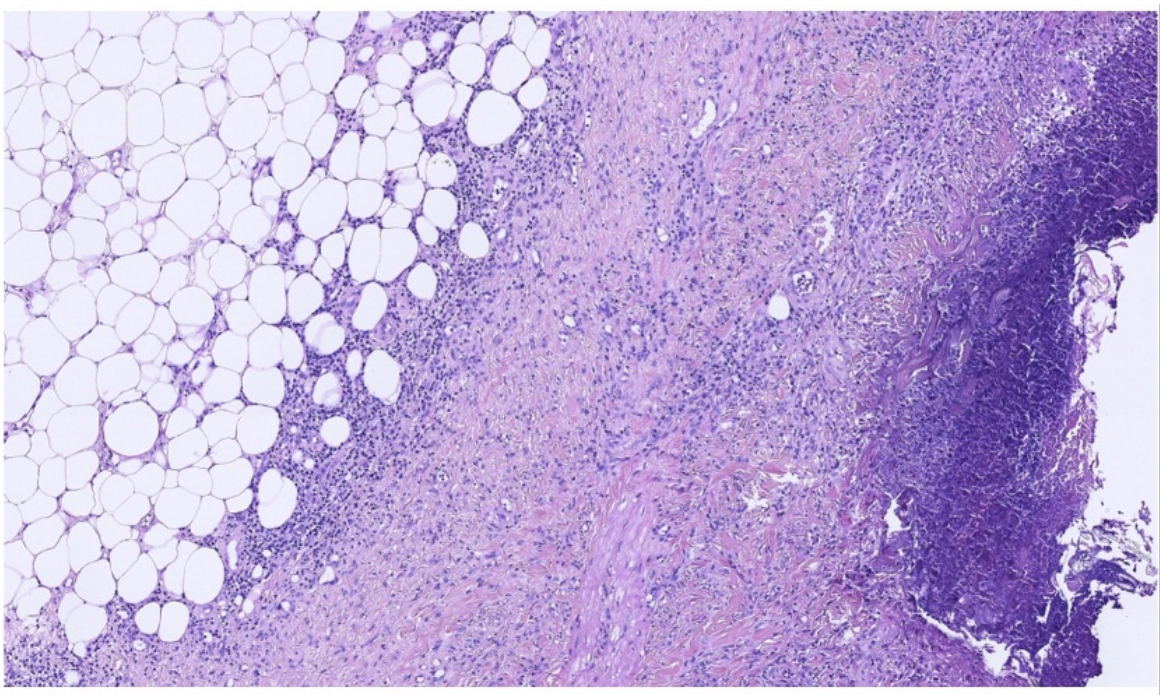

Figure 1. Diffuse neutrophilic infiltration in the dermis and subcutaneous fat layer, with associated tissue necrosis and ulceration.

Conclusion

The combination of Vunakizumab with low-dose glucocorticoids and low-dose cyclosporine reduces tissue damage and ulcer formation, providing a new therapeutic direction and insight for the clinical management of RPG.

EA DV CONGRESS
VIENNA
30 SEP - 3 OCT 2026

Abstract N°: 1348

From Skin to Systemic: Tumid Lupus Erythematosus as a Harbinger of Seropositive Systemic Lupus Erythematosus

Merna Shohdy*[1], Catherine Tawfik[2], Kevin Mai[2], Sabiha Uddin[2], Charles Gropper[2], Paul Chu[3], Cindy Hoffman[2]

[1] City University of New York, New York, United States

[2] Saint Barnabas Hospital, New York, United States

[3] Bridge Dermatopathology, Tarrytown, United States

Introduction

Tumid lupus erythematosus (TLE) is a rare subtype of chronic cutaneous lupus characterized by erythematous, edematous plaques, dermal mucin deposition, and minimal epidermal change. It is traditionally regarded as a skin-limited entity with absent scarring, negative or low-titer autoantibodies, and minimal risk of systemic involvement. However, the clinical and serologic features that may predict progression to systemic lupus erythematosus (SLE) remain poorly defined, and reported cases of transition are limited.

Case Presentation

A 42-year-old woman with a history of Hodgkin's lymphoma in sustained remission and a family history of SLE in two first-degree relatives presented with a rapidly progressive, intensely pruritic eruption involving the face, scalp, ears, neck, chest, and bilateral upper extremities. Physical examination revealed violaceous, flat-topped plaques in a malar distribution with diffuse alopecia. Punch biopsy demonstrated perivascular lymphocytic infiltrates with abundant dermal mucin deposition and no significant interface change, consistent with TLE (Figure 1). Despite treatment with topical triamcinolone and low-dose prednisone, the patient demonstrated a rapidly progressive eruption with limited response to therapy, followed by the stepwise development of fatigue, diffuse alopecia, inflammatory arthralgias, and cytopenias, in the absence of initial major organ involvement. Laboratory evaluation revealed anemia, leukopenia, and elevated inflammatory markers. Serologic testing demonstrated highly specific autoantibodies, including anti-Smith, anti-U1 RNP, and anti-histone antibodies, with equivocal anti–double-stranded DNA. Notably, complement levels were elevated rather than consumed, and renal function remained preserved. The constellation of findings fulfilled the 2019 ACR/EULAR classification criteria for SLE. Hydroxychloroquine was initiated with gradual improvement, and multidisciplinary follow-up with dermatology, rheumatology, and oncology was established given her prior malignancy.

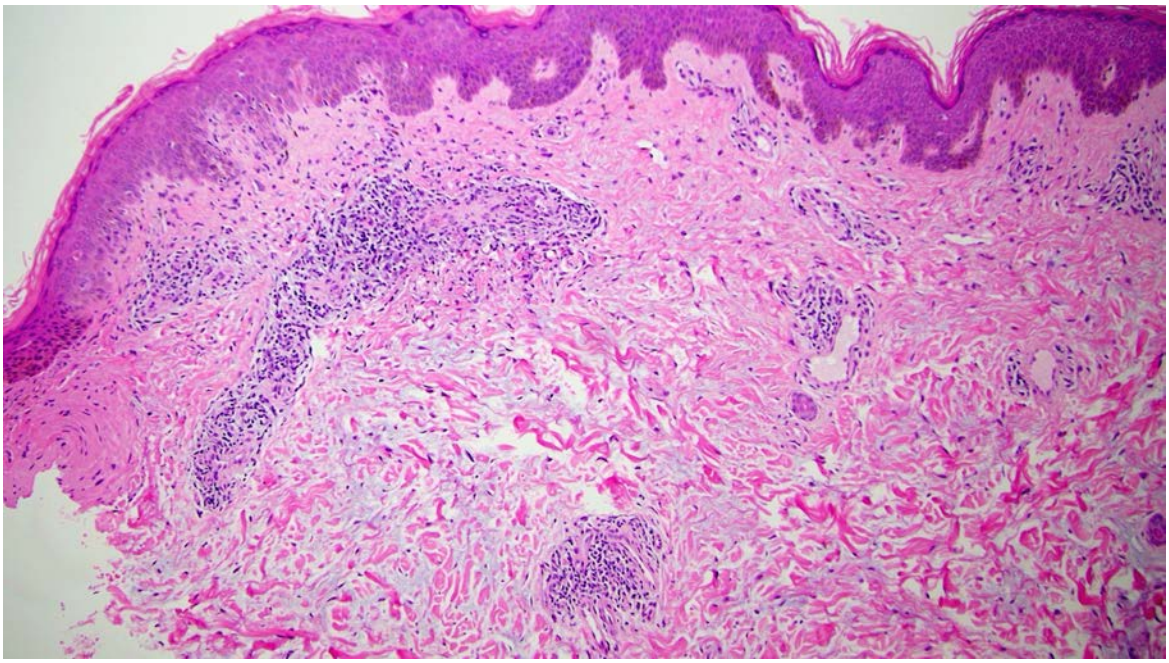

Figure 1: Classic tumid lupus histology showing perivascular/periadnexal lymphocytes embedded in a mucin-rich dermis.

Conclusion

This case highlights an uncommon progression from biopsy-confirmed TLE to seropositive SLE and challenges the conventional characterization of TLE as a strictly skin-limited disease. The evolution of constitutional symptoms, cytopenias, and lupus-specific autoantibodies, including anti-Smith antibodies, a highly specific marker of systemic disease, served as early indicators of systemic transition. Notably, the presence of elevated complement levels, rather than the expected consumption seen in active SLE, represents an atypical serologic finding that may reflect a distinct immunologic state during early disease evolution. In addition, the patient's history of Hodgkin lymphoma introduces the possibility of underlying immune dysregulation or paraneoplastic phenomena contributing to disease progression, further complicating the traditional distinction between cutaneous and systemic lupus. Together, these features suggest that a subset of patients with TLE, particularly those with rapidly progressive disease, atypical serologic profiles, or complex oncologic histories, may be at higher risk for progression than previously recognized. This case underscores the importance of early and repeated systemic evaluation, including comprehensive serologic assessment, in patients with TLE who demonstrate clinical progression, and highlights the need for further investigation into predictors of systemic transition within this population.

EADV CONGRESS
VIENNA
30 SEP - 3 OCT 2026

Abstract N°: 1356

Metabolic syndrome in cutaneous lupus erythematosus: Prevalence and associated factors in a cross-sectional study.

María del Pilar Arévalo-Bermúdez*[1], Sabela Paradela De la Morena[1], Rosa María Fernández Torres[1], Vanesa Balboa Barreiro[1], Nuria Maria Villamarin Bello[1], Eduardo Fonseca[1]

[1] Complexo Hospitalario Universitario A Coruña, A Coruña, Spain

Introduction
Cutaneous lupus erythematosus (CLE) is characterized by a chronic inflammatory state that may predispose patients to systemic comorbidities. Metabolic syndrome (MetS) is a major determinant of atherosclerotic cardiovascular risk and type 2 diabetes mellitus; however, its prevalence across CLE subtypes remains insufficientl characterized. This study aimed to determine the prevalence of MetS and its associated factors in a cohort of patients with CLE.

Materials and Methods
We conducted a cross-sectional of predominantly Caucasian patients (n=260) with CLE followed at a tertiary dermatology center from April 2013 to August 2016. The sample size was calculated assuming α=0.05 and precision ± 6.5%. MetS was defined according to the National Cholesterol Education Program Adult Treatment Panel-III (NCEP ATP III, 2001) criteria. Anthropometric, clinical, laboratory, and immunological variables were analyzed using univariate and multivariate logistic regression models to identify factors associated with metabolic syndrome.

Results
The mean age of the cohort was 48.5 ± 14.4 years, and 70.4% of patients were women. MetS was present in 32.7% of patients. The most frequent components were arterial hypertension (61.5%), abdominal obesity (46.9%), and low HDL cholesterol (40.6%). No significant differences in MetS prevalence were observed according to sex or CLE subtype ($p > 0.05$). Interestingly, patients with exclusively cutaneous involvement showed a trend toward higher MetS prevalence (34.7%) compared to those with concomitant systemic lupus (22.7%). In multivariate analysis, factors independently associated with MetS were higher body mass index (OR 1.43; IC95% 1.10-1.84; $p < 0.05$) and, notably, lupus anticoagulant positivity (OR 9.78; IC95% 1.09-87.45; $p < 0.05$). Other factors associated in univariate analysis included age, waist-to-hip ratio, Charlson comorbidity index, hyperuricemia, and elevated erythrocyte sedimentation rate.

Conclusions
MetS was present in nearly one-third of patients with CLE, a prevalence higher than that typically reported in the general population. Higher BMI and lupus anticoagulant positivity were the main independent factors associated with its presence. Although we observed a strong statistical

association between MetS and lupus anticoagulant positivity, which could suggest a shared pathogenic pathway involving endothelial damage and inflammation, this finding should be interpreted with caution due to the small size of the subgroup with this serological profile and the fact that it is based on a single cross-sectional determination. Prospective studies are required to assess whether this association persists over time with confirmed persistent positivity. These findings highlight the importance of systematic metabolic screening and weight management in all patients with CLE, regardless of the severity of cutaneous or systemic involvement.

EA DV CONGRESS
VIENNA
30 SEP - 3 OCT 2026

Abstract N°: 1391

Persistent non-pitting facial oedema as an initial presentation of systemic lupus erythematosus: lupus profundus mimicking subcutaneous panniculitis-like T-cell lymphoma

Meghna Shetty*[1], Qamar Razali[1], Shekhar KC[1], Purvi Mathur[1]

[1] Queen Elizabeth Hospital, London, United Kingdom

Introduction

Persistent non- pitting facial oedema is an uncommon presentation with a wide differential, including Morbihan's disease, Idiopathic facial lymphoedema, scleromyxoedema and connective tissue disease related panniculitis. Distinguishing lupus profundus from subcutaneous panniculitis-like T-cell lymphoma (SPTCL) can be challenging due to overlapping clinical and histological features possibly representing a continuum.

Case Presentation

Case discussion

A 21 year old female presented with a one year history of progressive, non-pitting facial oedema. This initially affected the periocular region and subsequently resolved with a short course of oral prednisolone. The swelling recurred a few months later in the summer, persisting despite a short course of oral prednisolone and progressed to affect the entire midface. The facial swelling was significant enough to obscure her vision.

She later developed fatigue, patchy alopecia affecting the scalp and intermittent joint pains and swelling affecting her finger joints. Examination showed indurated mid facial oedema with periocular swelling, patchy scarring alopecia with follicular plugging, and multiple tender subcutaneous nodules and indurated plaques affecting the left arm, chest and back. Systemic examination was normal.

Blood tests demonstrated a positive antinuclear antibody (1:640) with anti-Ro52(TRIM21) and anti-SM/RNP positivity, elevated immunoglobulin G with persistent leukopenia and neutropenia. Double-stranded DNA and complement levels were normal. A diagnosis of systemic lupus erythematosus with predominantly cutaneous involvement was made following review by the rheumatology team.

Initial skin biopsy findings were non-specific. Repeat biopsies from new nodules showed a predominantly lobular panniculitis and mild perivascular lymphohistiocytic infiltrate, mucin deposition, fat necrosis with mononuclear cell infiltrate, and lymphocytic rimming. Immunophenotyping demonstrated a CD8-positive T-cell population with cytotoxic marker expression, raising concern for SPTCL. A small percentage of reactive CD20 positive cells were seen. However, T-cell receptor gene rearrangement was polyclonal.

A diagnosis of lupus profundus was made. She showed excellent response to oral prednisolone 30 mg weaning dose but relapsed on withdrawal despite hydroxychloroquine 200 mg twice daily. Subcutaneous methotrexate was introduced and increased to 15 mg weekly, with good improvement in both skin and joint symptoms, allowing successful steroid withdrawal.

Discussion

This case highlights the difficulty in distinguishing lupus profundus from SPTCL, as both can demonstrate lobular panniculitis and cytotoxic T-cell infiltrates. In this case, autoimmune serology, polyclonal T-cell receptor studies

and clinical course favoured lupus profundus.

The initial biopsy was non-diagnostic, reflecting the limitations of superficial sampling. Repeat biopsy was key in reaching a diagnosis. Clinical response to immunosuppressive treatment further supported an inflammatory rather than lymphoproliferative process. Close clinical monitoring is warranted given the potential for overlap.

Conclusion

Persistent non-pitting facial oedema may be an early or atypical feature of lupus profundus and can clinicopathologically overlap with SPTCL. This case highlights the importance of repeat biopsy, multidisciplinary assessment and clinicopathological correlation when histology is inconclusive.

EADV CONGRESS
VIENNA
30 SEP - 3 OCT 2026

Abstract N°: 1417

Successful treatment of psoriasis and rheumatoid arthritis with baricitinib: a case report

Carol Estefania Marquez Maldonado*[1], Dolores Maribel Arellano Vivero[1], Lucia Achell Nava[1], Angel Ortegon Blanco[1], Analy Gomez-Picos[1]

[1] Centro Medico Nacional 20 de Noviembre, Ciudad de México, Mexico

Introduction

Psoriasis and rheumatoid arthritis (RA) are chronic immune-mediated inflammatory diseases with distinct clinical manifestations but overlapping pathogenic pathways, particularly involving cytokine signaling through the Janus kinase–signal transducer and activator of transcription (JAK–STAT) pathway. Therapeutic strategies targeting shared mechanisms may offer benefits in patients with coexisting conditions.



Figure. 1. Clinical presentation. (A–C) Multiple confluent erythematous hyperkeratotic plaques with scale on the dorsum of the hands, elbows, knees, palms, and soles.

Case Presentation

A 65-year-old woman with a 40-year history of rheumatoid arthritis, previously treated with abatacept and methotrexate, developed a 2-year history of progressive palmoplantar psoriasis. Clinical examination revealed well-demarcated erythematous hyperkeratotic plaques affecting the palms, soles, and extensor surfaces (Figure 1). Due to inadequate disease control and coexistence of both conditions, abatacept was discontinued and baricitinib 4 mg daily was initiated.

The patient demonstrated rapid clinical improvement, achieving a Psoriasis Area and Severity Index (PASI) 80 response at 2 months and complete clearance (PASI 100) at 4 months (Figure 2). Concomitant improvement in joint symptoms was also observed. Treatment was well tolerated, with good adherence and no reported adverse events.

Psoriasis and RA share key inflammatory mediators, including tumor necrosis factor-α, interleukin-6, and interleukin-17, which signal through the JAK–STAT pathway. Inhibition of this pathway represents a rational therapeutic approach in patients with overlapping immune-mediated diseases. In this case, switching from a T-cell co-stimulation modulator to a JAK inhibitor allowed effective targeting of downstream cytokine signaling, resulting in significant clinical improvement in both cutaneous and articular manifestations.



Figure. 2. Clinical response. (A–C) Complete clearance of previously affected areas following treatment with baricitinib.

Conclusion

Baricitinib may represent an effective dual-target therapeutic option in patients with concomitant psoriasis and rheumatoid arthritis by modulating shared inflammatory pathways. This case highlights the potential of JAK inhibitors as a unified treatment strategy in overlapping immune-mediated conditions.

EA DV CONGRESS
VIENNA
30 SEP - 3 OCT 2026

Abstract N°: 1434

Who Recognized the Zebra? The Critical Role of Dermatologists in Autoimmune Blistering Disease Diagnosis and Care

Marney White*[1], Marc Yale[2], Mary Tomayko[3]

[1] Yale School of Public Health, Yale School of Medicine, New Haven, United States
[2] International Pemphigus & Pemphigoid Foundation, Roseville, CA, United States
[3] Yale School of Medicine, New Haven, United States

Introduction

Autoimmune blistering diseases are a group of severe, chronic skin disorders requiring immunosuppressive treatments. Left misdiagnosed or improperly treated, patients are at risk of severe complications including death. Previous research had reported that patients with AIBD frequently experience a delay to diagnosis and often report multiple misdiagnoses prior to initiating appropriate treatment. Diagnostic errors and delays result in prolonged pain and unsuitable treatments with iatrogenic effects.

Materials and Methods

Here we report data from National Organization for Rare Disorders (NORD) and US Food and Drug Administration (FDA) IAmRare ® Program's Natural History Study of Autoimmune Blistering Disease patients, co-sponsored by the International Pemphigus and Pemphigoid Foundation. This longitudinal registry collects information about diagnosis, symptoms and disease course, treatment access and history, and quality of life and psychosocial outcomes. Our goal was to characterize the pathways through which AIBDs are diagnosed and treated.

Results

Participants were 197 patients with AIBD who volunteered to participate in the longitudinal natural history study. The majority (45.2%, n=89) had PV, 28.4% (n=56) had MMP, 18.8% (n=37) had BP, 5.1% (n=10) had PF, and the remaining had a different AIBD.

Most participants (61.3%) sought treatment within 3 months of experiencing the first symptom. The majority (58.1%) saw 3 or more healthcare providers before obtaining their AIBD diagnosis; 44.4% reported receiving a misdiagnosis. Participants were most likely to first visit a dermatologist (26.7%), GP/internist (24.1%), or dentist (22.5%). Participants were most likely to have been accurately diagnosed by a dermatologist (58.5% of cases). When restricted to participants whose blisters first appeared in the mouth (n=94), dermatologists were still the most likely to diagnose (43.6% of cases), followed by oral surgeons (16.0%), oral pathologists (13.8%), and periodontists (11.7%).

Conclusions

Dermatologists play a critical role in diagnosing AIBD and in providing appropriate treatment.

EADV Congress 2026, VIENNA
30 SEPTEMBER - 03 OCTOBER 2026
POWERED BY M-ANAGE.COM

EADV CONGRESS
VIENNA
30 SEP - 3 OCT 2026

Abstract N°: 1439

From Refractory Disease to Remission: Anifrolumab in Severe Discoid Lupus and Lupus Panniculitis

Teresa López Bernal*[1], BEATRIZ VICTORIA VAN INGEN ARTEAGA[1]

[1] Hospital Universitario Infanta Cristina, Parla, Madrid, Spain

Introduction

Discoid lupus erythematosus (DLE) and lupus panniculitis (lupus profundus) are chronic cutaneous manifestations of lupus erythematosus that may lead to significant morbidity and scarring. Although first-line management includes antimalarials and conventional systemic therapies, a proportion of patients remain refractory. Anifrolumab, a monoclonal antibody targeting the type I interferon receptor, has demonstrated efficacy in systemic lupus erythematosus and is emerging as a potential option for difficult-to-treat cutaneous disease.

Case Presentation

A 47-year-old woman with systemic lupus erythematosus predominantly affecting the skin presented with severe discoid lupus erythematosus associated with lupus panniculitis and hypocomplementemia. Her treatment included hydroxychloroquine (200 mg daily), acitretin (25 mg daily), belimumab (from December 2021 to June 2025), low-dose aspirin, as well as topical corticosteroids and immunomodulators. She had also required multiple courses of systemic prednisone. In May 2025, she experienced a significant flare of cutaneous lesions predominantly involving the upper trunk, which she associated with heat exposure and stress. She denied mucosal involvement, asthenia, arthralgias, or urinary symptoms. Given the lack of response, belimumab was discontinued and anifrolumab was initiated in July 2025, while maintaining acitretin and starting prednisone 30 mg daily, which was tapered and discontinued by the end of August 2025. By September 2025, the patient showed a marked clinical improvement, with complete resolution of active lesions and only residual cicatricial changes. In January 2026, acitretin was discontinued, with sustained remission maintained to date under anifrolumab therapy.

Conclusion

This case illustrates the successful use of anifrolumab in a patient with refractory cutaneous lupus, including severe discoid lupus erythematosus and lupus panniculitis, who had failed multiple systemic therapies such as acitretin and belimumab. Targeting the type I interferon pathway may represent an effective therapeutic strategy in recalcitrant cutaneous lupus, supporting the need for further studies to define its role in this subset of patients.

EADV CONGRESS
VIENNA
30 SEP - 3 OCT 2026

Abstract N°: 1459

Excellent Response of Treatment-Refractory Rare Cutaneous Lupus Erythematosus Variants (Degos and Kikuchi-like) to Anifrolumab

Marina Selva del Río*[1], Ignasi Rodríguez-Pintó[2], Maria Cecilia Garbarino[2], Priscila Giavedoni[1, 3], José Manuel Mascaró[1, 3, 4]

[1] Department of Dermatology, Hospital Clínic de Barcelona, Barcelona, Spain
[2] Department of Autoinmune Disease, Hospital Clínic de Barcelona, Barcelona, Spain
[3] IDIBAPS, Barcelona, Spain
[4] University of Barcelona, Barcelona, Spain

Introduction

Cutaneous lupus erythematosus (CLE) encompasses a heterogeneous spectrum of clinical phenotypes. In addition to classic subtypes, rare CLE variants such as pseudo-Degos and Kikuchi-like inflammatory pattern (KLIP) have been described. These presentations should not be regarded as distinct entities, but rather as part of the broad clinical spectrum of CLE; however, their recognition and treatment remain challenging in clinical practice. Anifrolumab, a monoclonal antibody targeting the type I interferon receptor, has demonstrated high efficacy both in systemic lupus erythematosus (SLE) and CLE, though data in these rare CLE variants remain limited.

Case Presentation

A case series of three female patients with SLE and rare CLE manifestations was analyzed.

Patient 1 had a diagnosis of SLE with acute CLE at disease onset and, 19 years later, developed highly refractory pseudo-Degos extensive lesions.

Patient 2 had SLE presenting with Evans syndrome and lupus nephritis with no initial cutaneous involvement; during disease evolution she developed discoid CLE, chilblain lupus, and pseudo-Degos lesions.

Patient 3 had SLE requiring intensive care unit admission at diagnosis due to myopericarditis and developed, five years later, cutaneous lesions clinically suggestive of subacute CLE, with histopathological findings consistent with KLIP.

All patients had previously exhibited inadequate response to multiple therapies. Following confirmation of a positive type I interferon signature, anifrolumab was initiated at a dose of 300 mg every 4 weeks for their cutaneous disease.

Patient 1 received anifrolumab as monotherapy. Patient 2 was treated with anifrolumab in combination with mycophenolate mofetil, hydroxychloroquine, mepacrine, while Patient 3 received anifrolumab in combination with mepacrine.

In Patient 1, a marked clinical response was observed within 3 months, with subsequent negativization of the interferon signature. After 22 months of sustained stability, the dosing interval was progressively extended, and the patient is currently receiving treatment every 6 weeks with maintained disease control. Patient 2 has recently initiated treatment and is already showing significant clinical improvement, assessment of the interferon signature is not yet available due to the short follow-up. Patient 3, despite persistent positivity of the interferon signature,

achieved complete resolution of her cutaneous lesions after 5 months of therapy and remains on monthly dosing.

Anifrolumab was well tolerated in all cases, with no significant adverse events observed during follow-up.

Patient No.	Age,y/ Gender/ Ethnicity	Diagnosis	Clinical presentation	Previous treatments
1	44/F/ Caucasian	Pseudo-Degos	Papules with a central porcelain white atrophy area surrounded by a peripheral rim of erythema on the upper limbs, hands and face	Hydroxychloroquine, mycophenolate, mepacrine, prednisone methotrexate, belimumab, baricitinib
2	24/F/ African	Pseudo-Degos	Papules with a central porcelain white atrophy area surrounded by a peripheral rim of erythema on the dorsum and palms of hands, face	Hydroxychloroquine, mepacrine, mycophenolate, methotrexate, prednisone tacrolimus, belimumab
3	37/F/ Asian	KLIP	Erythematous annular plaques and macules on upper limbs and thighs. Papulosquamous psoriasiform lesions on the hands, fingers and face	Hydroxychloroquine, prednisone, mepacrine

Conclusion

Atypical variants of CLE, including pseudo-Degos and KLIP patterns, represent diagnostically challenging and potentially refractory presentations. Our findings suggest that anifrolumab may be an effective therapeutic option in these rare manifestations, supporting the role of type I interferon blockade in their pathogenesis. Further studies are warranted to confirm these observations.

EA DV CONGRESS
VIENNA
30 SEP - 3 OCT 2026

Abstract N°: 1487

Isotopic response : Autoimmune bullous disorders on scarred skin

Keepa Manandhar*[1], Shreya Gowda[1], Neha Taneja[1], Sudheer Arava[1], Somesh Gupta[1]

[1] All India Institute of Medical Sciences, New Delhi, India

Introduction

Pemphigus vulgaris (PV) and bullous pemphigoid (BP) are common autoimmune bullous disorders, driven by autoantibodies targeting desmogleins and hemidesmosomal proteins, respectively. Emerging evidence supports a bidirectional relationship between autoimmune bullous disorders and cutaneous scarring. Surgical scars and keloids may act as immunocompromised districts with localised microenvironment of immune dysregulation, predisposing to site specific de novo blistering. This phenomenon aligns with Wolf's isotopic response, wherein a distinct dermatosis arises at the site of previously altered skin. Despite its clinical relevance, this association remains underrecognized, with few documented cases in literature.

Case Presentation

Case 1: A 48-year old male developed pustules over a long-standing presternal keloid, progressing to vesicles, crusted erosions and plaques, with spread to the surrounding chest and upper back over 1-2 months. Histopathology revealed a suprabasal cleft with acantholytic cells and a characteristic “row of tombstones” appearance, with underlying keloidal collagen. Direct immunofluorescence (DIF) demonstrated intercellular IgG deposition in a fishnet pattern, consistent with pemphigus vulgaris.

Case 2: A 58-year old female presented with tense bullae on an urticarial base localized to a saphenous vein harvest scar, four weeks following coronary artery bypass grafting, with subsequent limited generalization. Histopathology showed a subepidermal blister with an eosinophil-rich inflammatory infiltrate. DIF demonstrated linear IgG and C3 deposition along the basement membrane zone, confirming bullous pemphigoid.

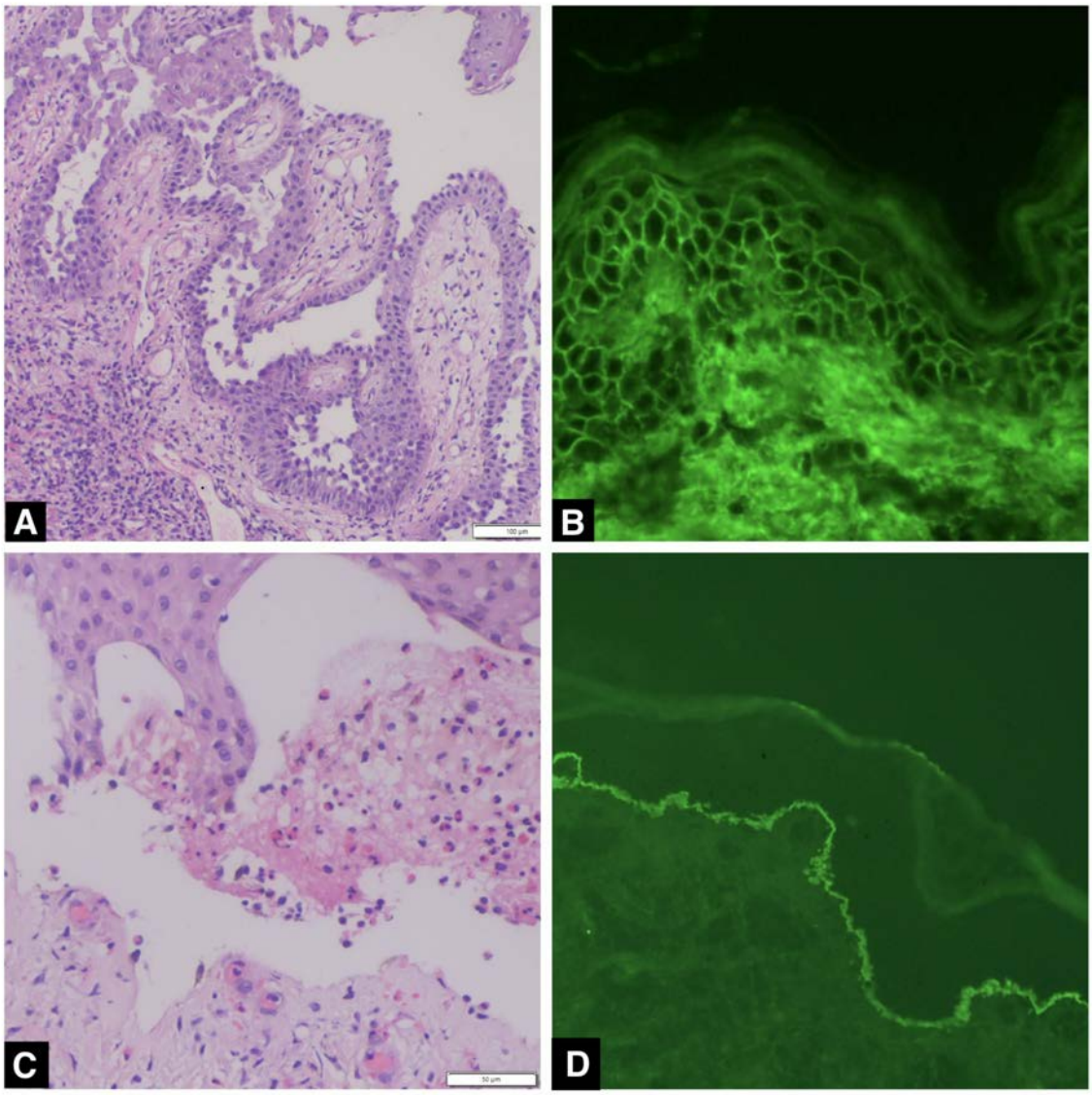

(A) Case 1: Haematoxylin and eosin (H&E) stain showing a suprabasal cleft with acantholytic keratinocytes and " row of tombstone" pattern (B) Case 1: DIF demonstrating intercellular IgG deposition in a fishnet pattern within the epidermis, consistent with pemphigus vulgaris (C) Case 2: H&E stain showing a subepidermal blister with an eosinophil-rich inflammatory infiltrate (D) Case 2: DIF demonstrating linear IgG and C3 deposition along the basement membrane zone, consistent with bullous pemphigoid

Conclusion

Surgical scars and keloids may represent localized microenvironments of immune dysregulation, predisposing to autoimmune blistering disorders. Injury induced alterations in basement membrane architecture and keratinocyte adhesion may expose sequestered autoantigens, while wound healing associated immune activation enhances antigen presentation. These mechanisms support the concept of an immunocompromised district and may underlie Wolf's isotopic phenomenon, wherein a new dermatosis arises at the site of previously altered skin. Such presentations may mimic infection or scar related changes, leading to diagnostic delay. Recognition of this entity, with confirmation by histopathology and DIF, is essential for accurate diagnosis and timely management. These cases expand the spectrum of isotopic responses involving autoimmune bullous disorders.

EA DV CONGRESS
VIENNA
30 SEP - 3 OCT 2026

Abstract N°: 1507

NEUTROPHILIC DERMATOSIS OF THE HANDS: A LOCALIZED VARIANTE OF SWEET SYNDROME

Erika Zúñiga Ramírez*[1], Valerie Dafne Alcantara Ramirez[1], Salvador Gutierrez[1], Cinthya Karina Gutiérrez[1], Diana Valeria Guerrero Hernández[1], Gabriela Rigel[1]

[1] Althiora Medical Center, Department of Dermatology, San Cristóbal de las Casas, Mexico

Introduction

Sweet's syndrome (SS), also known as acute febrile neutrophilic dermatosis, is an inflammatory disease characterized by the infiltration of neutrophils in the dermis. There is an atypical variant known as acral Sweet's syndrome, or neutrophilic dermatosis of the dorsal hands (NDDH), with only about 100 cases reported in the literature to date. We present a rare case of a bullous variant of Sweet's syndrome localized to the acral region.

Case Presentation

A 63-year-old man presented with multiple tense bullae of 5 cm in diameter with serosanguineous and purulent content, surrounded by an erythematous-violaceous border; associated with edema, pain, and difficulty mobilizing both hands. He denied recent drug use, contact with corrosive substances, or a history of recent infection. Key laboratory findings included a leukocyte count of 11.8 × 10^3/µL and a glycated hemoglobin of 10.2%. A skin biopsy was performed for diagnostic confirmation. Histopathological examination revealed an epidermis with moderate acanthosis and a dense infiltrate in the reticular dermis composed predominantly of neutrophils, with few eosinophils and prominent extravasation of erythrocytes. Based on the clinicopathological correlation, a diagnosis of Sweet's syndrome localized to the hands was established. Treatment was initiated with oral corticosteroids (prednisone 1 mg/kg/day). Three weeks after starting treatment, the dermatosis showed significant improvement, with the absence of bullae and a substantial decrease in symptoms**.**

Conclusion

Sweet's syndrome, or acute febrile neutrophilic dermatosis, is a prototypical neutrophilic dermatosis. Acral Sweet's syndrome is accepted as an atypical localized variant of SS. Its pathophysiology is complex; it is believed that a hypersensitivity reaction to a triggering antigen (bacterial, viral, or tumor) promotes the disease, mediated by inflammatory cytokines, resulting in the infiltration of neutrophils activated by IL-1. The presence of IL-1, IL-2, and IFN-γ, with the absence of IL-4, suggests an important role for TH1 cells. Similar to classic Sweet's syndrome, acral sweet's syndrome is classified as classical, malignancy-associated, or drug-induced.[7] Clinically, there is involvement of the dorsum of the hands, and in some cases, it affects the lateral and palmar aspects. It is characterized by the abrupt appearance of symmetrically distributed erythematous plaques or bullae, and occasionally pustules, associated with edema, pain, and difficulty with mobilization. The diagnostic criteria are the same as for SS; laboratory findings include leukocytosis, neutrophilia (not always present in variant acral), and elevated acute-phase reactants. Histopathology plays a crucial role in establishing the diagnosis; classically, a perivascular infiltrate is found in the dermis, composed of neutrophils, occasionally lymphocytes, histiocytes, and eosinophils, as well as extravasation of erythrocytes and leukocytoclasis. In contrast to classic SS, the incidence of fever is much lower in acral sweet's syndrome, and it is not always accompanied by neutrophilia or systemic symptoms. The differential diagnosis primarily includes mycotic or bacterial infections, arthropod bites or acrodermatitis continua of Hallopeau. The treatment of choice is systemic corticosteroids, which leads to rapid remission of cutaneous and

systemic manifestations. The prognosis is good when the disease is limited to the skin; the lesions typically resolve without leaving scars.

Sweet's syndrome localized to the hands is a rare and infrequently described variant. Its etiology is multifactorial, and the specific cause is not always determined. It usually follows a favorable course with treatment if diagnosed promptly. This case highlights the importance of considering Sweet's syndrome within the differential diagnoses of bullous dermatoses, especially in patients with underlying systemic conditions.

EA DV CONGRESS
VIENNA
30 SEP - 3 OCT 2026

Abstract N°: 1541

Diagnostic value of the complement fixation test in pemphigoid diseases and association with IgG1/IgG4 subclass profiles

Zixian Liang*[1], Marije van der Molen[1], Jeffrey Damman[2], Jeroen Bremer[1], Joost Meijer[1], Gilles Diercks[1]

[1] University Medical Center Groningen, Groningen, Netherlands
[2] Erasmus Medical Center Rotterdam, Rotterdam, Netherlands

Introduction

Activation of the complement system contributes to blister formation in pemphigoid diseases. In routine diagnostics, complement involvement is mainly assessed by C3c deposition in skin by direct immunofluorescence, while the additional value of serum autoantibody-induced complement activation remains unclear. The complement fixation test (CFT) detects circulating IgG autoantibodies on salt-split human skin that are capable of binding complement. Since complement activation may depend on both antibody presence and antibody subclass, CFT may provide functional information beyond routine indirect immunofluorescence on salt-split skin (IIF SSS). This study aimed to evaluate the additional diagnostic value of CFT in suspected pemphigoid diseases and to explore its relationship with routine serological findings, clinical phenotype, and IgG subclass expression.

Materials and Methods

This prospective study included serum samples from patients with suspected pemphigoid diseases tested for routine diagnostics between January and December 2023. All samples underwent IIF SSS for IgG and CFT. For CFT, patient serum was incubated on salt-split human skin, followed by fresh human serum as a complement source and fluorescent anti-C3 antibody to detect C3 deposition at the basement membrane zone. IIF SSS-IgG-positive samples were grouped as CFT-positive (CFT(+) group) or CFT-negative (CFT(-) group). Associations with routine serological findings and clinical phenotype, including bullous lesions, were explored. For IgG subclass analysis, samples with strong IIF SSS-IgG intensity were further stained for IgG1 and IgG4 to minimize the confounding effect of total IgG intensity.

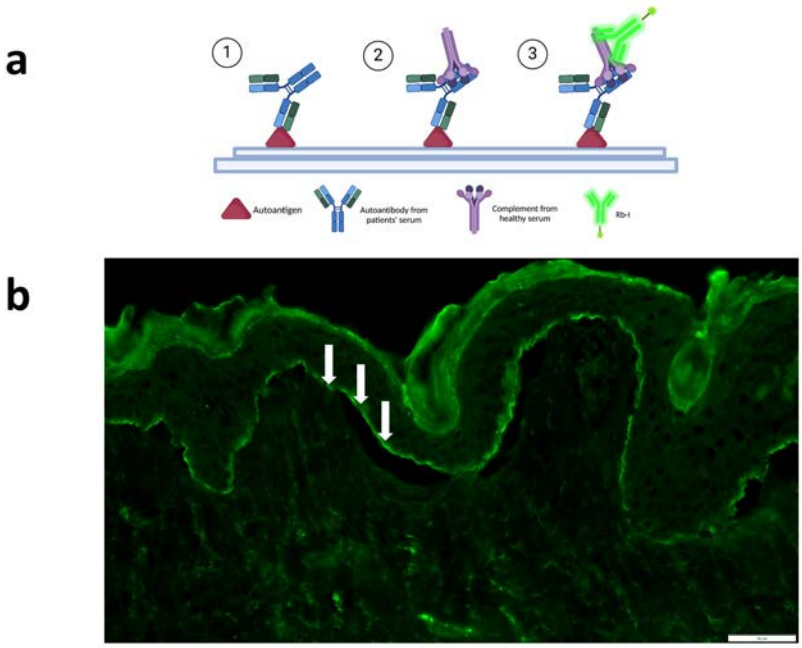

Figure. Principle and representative image of the complement fixation test (CFT). (a) Patient serum was incubated on salt-split human skin to allow autoantibodies to bind the basement membrane zone, followed by fresh human serum as complement source and fluorescent anti-C3 antibody to detect complement deposition. (b) Representative CFT-positive staining showing linear C3 deposition along the basement membrane zone (original magnification ×200; scale bar = 50 μm).

Results

A total of 806 consecutive serum samples were analyzed, including 446 female patients (55.3%) and 360 male patients (44.7%). IIF SSS-IgG was positive in 21.1% (170/806), while CFT was positive in 8.9% (72/806). Among IIF SSS-IgG-positive samples, 41.8% (71/170) were CFT-positive and 58.2% (99/170) were CFT-negative. Age and sex distributions were similar. One CFT-positive/IIF SSS-IgG-negative sample was excluded due to uncertain interpretation.

CFT positivity was associated with stronger serological and clinical findings. IIF SSS-IgG intensity was higher in CFT(+) than CFT(-) samples ($P < 0.0001$), with high-intensity staining (2+, 3+) in 85.9% (61/71). BP180 and BP230 ELISA titers were also higher in CFT(+) samples (BP180: 88.6 ± 49.3 vs. 39.8 ± 31.2, $P < 0.0001$; BP230: 81.9 ± 64.5 vs. 40.9 ± 25.2, $P = 0.0007$). Bullous lesions were more frequent in CFT(+) than CFT(-) samples (60.6%, 43/71 vs. 29.9%, 29/99; $P < 0.0001$).

For subclass analysis, 113 high-IgG sera were included: 61 CFT-positive and 52 CFT-negative. CFT(+) sera most commonly showed both IgG1 and IgG4 positivity (59.0%, 36/61), whereas CFT(-) sera predominantly showed IgG4-only positivity (65.4%, 34/52). Strong IgG1 intensity (2+, 3+) was more frequent in CFT(+) than CFT(-) sera (57.4%, 35/61 vs. 1.9%, 1/52, $P < 0.0001$), while IgG4 intensity did not differ significantly.

Conclusions

CFT detects complement-fixing circulating autoantibodies in sera from patients with suspected pemphigoid diseases, but adds limited value to routine IIF SSS diagnostics, as almost all CFT-positive samples were already IIF SSS-IgG-positive. However, CFT positivity was associated with stronger IIF SSS-IgG staining, higher BP180 and BP230 ELISA titers, and bullous lesions, suggesting that CFT reflects a more active complement-fixing antibody profile. Subclass analysis further showed that complement fixation was strongly associated with IgG1 expression and IgG1 staining intensity, but not with IgG4 intensity. Thus, while CFT may not substantially improve routine serological diagnostics, it may help characterize complement-activating antibody profiles and support future studies on complement-mediated disease activity and complement-targeted therapies.

EADV Congress 2026, VIENNA
30 SEPTEMBER - 03 OCTOBER 2026
POWERED BY M-ANAGE.COM

EA DV CONGRESS
VIENNA
30 SEP - 3 OCT 2026

Abstract N°: 1563

Dupilumab as a Steroid-Sparing Therapy in Treatment-Refractory Junctional Epidermolysis Bullosa: A Case Report

Leyla Aghayeva*[1], Tugba Kevser Uzuncakmak[1], Zeynep Altan Ferhatoğlu[1]

[1] Istanbul Cerrahpaşa, Fatih, Türkiye

Introduction

Junctional Epidermolysis Bullosa (JEB) is a rare, inherited mechanobullous disorder caused by mutations in genes encoding basement membrane proteins. LAMB3 gene mutations are among the most commonly identified genetic causes, leading to impaired laminin-332 function and subsequent skin fragility. Management of severe JEB remains challenging, as no curative treatment exists. Prolonged systemic corticosteroid use is associated with significant morbidity. Dupilumab, an IL-4/IL-13 receptor antagonist approved for atopic dermatitis, has recently emerged as a potential therapeutic option in inflammatory skin conditions.

Materials and Methods

We report a 46-year-old female patient with a clinical diagnosis of JEB confirmed by NGS panel revealing a homozygous LAMB3 variant (NM_000228.3): c.-37-2A>G, classified as a variant of uncertain significance (VUS) located in the 5'UTR splice-site acceptor region. The patient had been on systemic prednisolone since 2019, developing Cushingoid features. Previous treatments including azathioprine (discontinued due to neutropenia), mycophenolate mofetil, and dapsone had failed. Dupilumab 300 mg was initiated in August 2025.

Results

At 4 months following dupilumab initiation, significant clinical improvement was observed. Widespread bullous and erosive lesions on the back, inguinal, and genital regions showed marked regression. Systemic corticosteroid therapy was successfully discontinued. The patient reported a substantial improvement in quality of life.

Conclusions

This case suggests that dupilumab may represent an effective and steroid-sparing therapeutic option in patients with treatment-refractory Junctional Epidermolysis Bullosa. Further studies are warranted to establish its role in the management of JEB.

EADV CONGRESS
VIENNA
30 SEP - 3 OCT 2026

Abstract N°: 1622

Refractory Pediatric Linear IgA Bullous Dermatosis Successfully Treated with Omalizumab: A Case Report

Selen Taner Akbay*[1], Nurinnisa Kızılay[1], Arbil Açıkalın[2], Tümay Özgür[3]

[1] Hatay Mustafa Kemal University Tayfur Ata Sökmen Medical Faculty, Dermatology Department, Hatay, Türkiye
[2] Çukurova University, Faculty of Medicine, Department of Pathology, Adana, Türkiye
[3] Hatay Mustafa Kemal University Tayfur Ata Sökmen Medical Faculty, Pathology Department, Hatay, Türkiye

Introduction

Linear IgA bullous dermatosis (LABD) is a rare autoimmune subepidermal blistering disorder of childhood characterized by linear IgA deposition along the basement membrane zone. Dapsone is considered first-line therapy; however, treatment may be limited by hematologic adverse effects. We report a pediatric patient with refractory LABD complicated by dapsone-induced hemolytic anemia who achieved complete remission with omalizumab.

Case Presentation

A 12-year-old girl presented with a 5-day history of widespread tense bullae and erosions predominantly involving the extremities, accompanied by oral mucosal involvement. Initial clinical evaluation suggested erythema multiforme major. Laboratory investigations revealed leukocytosis, elevated C-reactive protein, positive antistreptolysin O titers, and progressive peripheral eosinophilia. Viral and bacterial studies were negative. During hospitalization, lesions evolved into annular vesiculobullous plaques with a characteristic “string of pearls/crown of jewels” appearance, raising suspicion for LABD. Histopathologic examination demonstrated subepidermal blister formation with neutrophil- and eosinophil-rich inflammatory infiltrates, while direct immunofluorescence confirmed linear IgA deposition along the basement membrane zone.

Following confirmation of normal glucose-6-phosphate dehydrogenase activity, dapsone therapy was initiated and gradually escalated with close hematologic monitoring. Initial clinical improvement was observed; however, after dose escalation to 125 mg/day, the patient developed hemolytic anemia characterized by decreased hemoglobin, indirect hyperbilirubinemia, elevated lactate dehydrogenase, reticulocytosis, and fragmented erythrocytes on peripheral smear despite a negative direct Coombs test. Reduction of the dapsone dose failed to achieve disease control, and new vesiculobullous lesions continued to develop. Because of persistent disease activity, eosinophilia, and dose-limiting dapsone toxicity, omalizumab 300 mg every 4 weeks was added as adjunctive therapy. No adverse effects were observed. Approximately 70% clinical regression was achieved by the second month, and complete remission was obtained by the fourth month of treatment.

Conclusion

This case highlights the diagnostic challenges of pediatric LABD, particularly when the initial presentation mimics erythema multiforme major or other inflammatory vesiculobullous diseases. It also demonstrates that significant dapsone-induced hemolysis may occur despite normal G6PD activity, emphasizing the importance of close hematologic monitoring during treatment. The marked clinical response achieved with omalizumab suggests that anti-IgE therapy may represent a safe and effective adjunctive option in selected refractory pediatric LABD cases, especially in patients with eosinophilic predominance or intolerance to dapsone. Further studies are needed to

clarify the role of omalizumab in treatment algorithms for childhood LABD.

EADV CONGRESS
VIENNA
30 SEP - 3 OCT 2026

Abstract N°: 1634

Nodular cutaneous lupus mucinosis in a systemic lupus erythematosus patient

Mengjie Zhao*[1]

[1] Zhongnan Hospital of Wuhan University, Wuhan, China

Introduction

Nodular cutaneous lupus mucinosis (NCLM), also known as papulonodular mucinosis, is a rare disease which cause is not yet known. Rongioletti et al. had reported an incidence rate of 1.5% in patients with lupus erythematosus. Although there is no evidence confirming that NCLM in SLE patients is associated with a higher risk of organ involvement or disease activity, in practice, clinicians should take attention to involvement of the kidneys and joints. NCLM is common in middle-aged men, and characterized by mucin deposition in the dermal interstitium. Rashes predominantly involve the face, chest, back and upper limbs, manifesting as scaly or erythematous papules and nodules ranging from mung-bean to jujube-sized accompanied by itchy or pain. Scales, central atrophy or discoid lesions may present in some patients. For treatment, 97.4% patients respond effectively with systemic medications, including glucocorticos-teroids, hydroxychloroquine, and immunosuppressants. Systemic glucocorticosteroids are the most common therapy, followed by oral hydroxychloroquine. Symptoms, lesions and laboratory tests often improved within 3 months.

Case Presentation

A 44-year-old male presented to the dermatology department with facial edema for one year and a rash for two months. One year ago, he experienced bilateral eyelid and nasal wing edema with significant hair loss without any obvious trigger. Two months ago, the left facial edema worsened, and there was patchy erythema around the nose, which aggravated after sun exposure. And then, a large number of redness raised symmetrical papules and nodules presented on both forearms, back, and behind both ears, with no significant skin temperature elevated, and he experienced slight pain in the upper limb joints. Two days later, the skin lesions color changed to skin or white. Systemic examination showed no positive signs. Dermatological examination revealed edema in the forehead, eyelids, and around the nose, with scattered purplish-red spots. There were numerous white or skin-colored soft nodules symmetrically distributed on both forearms, behind both ears, and on the upper trunk. Sparse hair was noted on the occipital area. Abnormal examination results included a positive antinuclear antibody (ANA) test with a titer of 1:320 and a granular nuclear pattern. Additionally, antibodies to nRNP/Sm and Sm were positive. Leukocyte count was reduced at 3.47×10^9/L (normal: 4-10×10^9/L). Chest CT, Ultrasound and Echocardiogram were no specific abnormalities. According to the 2019 EULAR/ACR classification criteria for systemic lupus erythematosus (SLE)，the patient's cumulative score exceeds 10, confirming the diagnosis of SLE. However, the symmetric, soft, skin or white nodules observed in this patient are not typical cutaneous manifestations of SLE. Pathological examination of the skin biopsies from the forehead (Figure 1d) and left forearm (Figure 1e) revealed concordant findings: hyperkeratosis and follicular plugging, and the epidermis is atrophic and rather flattened. Chronic inflammatory cell including lymphocytes, and plasma cells infiltrate in the perivascular and periadnexal tissue. Meanwhile, marked mucin deposition in the dermis (Figure 1d inset) (Figure 1e inset). Based on the clinical features and histopathologic findings, a diagnosis of nodular cutaneous lupus mucinosis was proposed. At the 1-month follow-up, the lesions were partial remission with prednisone 30mg and hydroxychloroquine 200mg.

Conclusion

In summary, NCLM is a rare clinical disease and its pathogenesis is unknown, but it is necessary that dermatologists recognize the disease early in clinical practice. Therefore, for patients with typical symptoms of NCLM, whether SLE-related evidence or not, dermatologists should be timely associated and pay attention to SLE.

EA DV CONGRESS
VIENNA
30 SEP - 3 OCT 2026

Abstract N°: 1662

Refractory Erythema Elevatum Diutinum Associated with Mixed Cryoglobulinemia and Systemic Red Flags: A Clinical Challenge

Julio Alberto Arias Diaz*[1], Elkin PEÑARANDA[1], Paula Ramos Chaparro[2]

[1] Fundacion Universitaria Sanitas, Bogota DC, Colombia

[2] Universidad de la Sabana, Bogota DC, Colombia

Introduction

Erythema elevatum diutinum (EED) is an extremely rare, chronic variant of leukocytoclastic vasculitis (LCV).(1,2) Its pathogenesis is characterized by the deposition of immune complexes within the postcapillary venules, which triggers complement activation and subsequent neutrophil infiltration.(1)(3) While the exact etiology remains unknown, EED is frequently recognized as a cutaneous marker for various systemic conditions, including autoimmune disorders, chronic infections, and hematologic malignancies.(1)

Case Presentation

A 67-year-old male with type 2 diabetes mellitus (DM2), a history of cryoglobulinemic vasculitis, moderate smoking, and frequent alcohol use presented with a complex dermatological progression. In 2021, the patient developed pruritic papular lesions on the arms and trunk. By 2022, the eruption became generalized, and a skin biopsy revealed leukocytoclastic vasculitis. He was treated with methotrexate in 2023, achieving only a partial response.

By 2024, the clinical picture worsened with the evolution of painful purpuric and ecchymotic lesions, pruritus, ocular redness, and a 6 kg weight loss. Laboratory studies at this time showed positive cryoglobulins, an erythrocyte sedimentation rate (ESR) of 44 mm/h, and C-reactive protein (CRP) of 12 mg/L, while viral and autoimmune panels were negative. In 2025, lesions progressed to ulceration on the elbows and knees, accompanied by recurrent oral ulcers and neurological symptoms. Physical examination revealed highly characteristic EED findings: a symmetric periarticular distribution of papulonodular morphology and plaques with variable consistency.

Further investigations included a Doppler ultrasound, which identified superficial venous thrombosis and inguinal adenomegalies. A chest X-ray revealed a calcified pulmonary granuloma. Electrophysiology confirmed sensory axonal polyneuropathy.

Histopathological findings: Microscopic examination of the specimens revealed a dense perivascular infiltrate composed of polymorphonuclear leukocytes and lymphocytes within the dermis, accompanied by prominent leukocytoclasia (nuclear dusting);Additional findings included erythrocyte extravasation and endothelial edema; Sections corresponding to clinical ulceration showed reactive epidermal changes, a fibrinoid base, and capillary proliferation associated with a lymphoplasmacytic infiltrate; These findings are diagnostic and consistent with Erythema Elevatum Diutinum (EED).

Conclusion

Discussion

The clinical course suggests mixed cryoglobulinemia (type II/III) as the primary etiological driver, where immune

complex deposition and complement activation lead to persistent vascular damage.(1)(5) The presence of inguinal adenomegalies serves as a "red flag" for potential lymphoproliferative disease, necessitating ongoing vigilance for non-Hodgkin’s lymphoma or other malignancies often associated with EED.(1,2) Furthermore, the suspicion of an underlying monoclonal gammopathy remains high, with protein electrophoresis and immunofixation studies currently pending.(2)(6)

The calcified pulmonary granuloma suggests prior tuberculosis exposure, a known infectious trigger for EED.(1)(4) Comorbidities also play a significant role: DM2 contributes to chronic inflammation and vascular damage, while smoking and alcohol use further exacerbate endothelial dysfunction.(5) This case highlights the refractory nature of EED when driven by a persistent immune complex-mediated process.

Conclusion EED serves as a critical marker for significant systemic disease. This case underscores the importance of identifying underlying etiologies, such as mixed cryoglobulinemia or occult malignancy, particularly in patients with systemic symptoms and refractory skin lesions. A comprehensive hematologic evaluation is mandatory in such clinical scenarios to address the potentially life-threatening causes of this dermatosis.

EADV CONGRESS
VIENNA
30 SEP - 3 OCT 2026

Abstract N°: 1693

Real-world outcomes of stapokibart-based combination therapy in bullous pemphigoid: a single-center retrospective cohort

Sihang Wang*[1], Yagang Zuo[1]

[1] Peking union medical college hospital, Beijing, China

Introduction
Bullous pemphigoid (BP) mainly affects older adults, and prolonged systemic corticosteroid use is often limited by toxicity. Evidence for stapokibart, an anti-IL-4 receptor alpha antibody, in BP remains limited.

Materials and Methods
We retrospectively reviewed consecutive adults with BP who initiated stapokibart between October 2024 and October 2025 and had at least 4 months of follow-up. Stapokibart was administered as a 600 mg loading dose followed by 300 mg every 2 weeks. Outcomes included time to disease control, time to Bullous Pemphigoid Disease Area Index (BPDAI) activity score of 0, complete remission (CR) on minimal therapy, adverse events, and longitudinal changes in BPDAI activity, pruritus numeric rating scale (NRS), anti-BP180 titres, eosinophil counts, and corticosteroid exposure.

Results
Twelve patients were included, with a median age of 77.5 years and a median follow-up of 216.5 days. All received concomitant tripterygium glycosides, and 7/12 (58.3%) also received oral corticosteroids at stapokibart initiation. All patients achieved disease control, with a median time of 14.5 days, and 11/12 (91.7%) did so within 4 weeks. BPDAI activity score of 0 was reached in all patients, with a median time of 65.5 days. Seven patients (58.3%) achieved CR on minimal therapy, with a median time of 176.0 days among responders. BPDAI activity, pruritus NRS, eosinophil counts, anti-BP180 titres, and prednisone doses all decreased during follow-up. Among the 7 corticosteroid-treated patients, median prednisone dose decreased from 30.0 mg/day at baseline to 20.0 mg/day at month 2 and 10.0 mg/day at month 4. One patient reported transient fatigue and later developed herpes zoster. No treatment discontinuations occurred.

Conclusions
In this retrospective cohort, stapokibart-based combination therapy was associated with rapid disease control and short-term clinical improvement in BP. Because all patients received concomitant background therapy, these findings should be interpreted as descriptive real-world evidence.

EADV CONGRESS
VIENNA
30 SEP - 3 OCT 2026

Abstract N°: 1697

A Qualitative Study to Support the Content Validity of the Cutaneous Lupus Activity Investigator's Global Assessment—Revised (CLA-IGA-R): Clinician Perspectives

Joseph F. Merola[1], Weihong Yang[2], Jason Randall[3], Feng Zeng*[2]

[1] Department of Dermatology and Department of Medicine, Division of Rheumatology, UT Southwestern Medical Center, O'Donnell School of Public Health, Dallas, United States

[2] Biogen, Cambridge, United States

[3] Clinical Outcomes Solutions, Folkestone, United Kingdom

Introduction

The Cutaneous Lupus Activity Investigator's Global Assessment—Revised (CLA-IGA-R) is an emerging clinician-reported outcome measure of the severity of cutaneous lupus erythematosus (CLE) disease activity, consisting of three items ('Erythema', 'Other morphologic characteristics' [edema, scale, and secondary change], and 'Follicular activity'). This qualitative study aimed to assess whether CLA-IGA-R captures the primary skin-related signs of CLE activity, and to confirm that its three items are understandable and appropriate for evaluating key signs in CLE.

Materials and Methods

Thirteen clinicians (8 dermatologists; 5 rheumatologists) took part in semi-structured interviews via Zoom; transcripts were coded and subjected to thematic analysis by two independent researchers.

Results

All clinicians had at least 10 years' experience treating CLE, with 61.5% having more than 20 years' experience. Only dermatologists were asked to describe CLE signs (concept elicitation). Seven skin-related lupus signs were described by all dermatologists, all of which are captured within the CLA-IGA-R items: erythema (red/pink/purple skin), scale (dry/scaly skin), edema/infiltration (swollen skin/areas), erosion (open wounds), crusting (after open wounds), vesicles (blisters), and follicular activity. Every CLA-IGA-R item was clear for all clinicians; dermatologists and rheumatologists found it simple to complete and that it captured frequently occurring CLE signs deemed important to patients. In addition, all clinicians stated that the recall periods and response options were suitable and clear.

Conclusions

This study supports the content validity of CLA-IGA-R for future use by clinicians, as the tool was well understood, clinically relevant, and reflected clinicians' experience in treating CLE. In the next phase, its psychometric properties will be evaluated.

EADV CONGRESS
VIENNA
30 SEP - 3 OCT 2026

Abstract N°: 1699

Correlation Between CLASI and CLA-IGA-R Among Patients With CLE in a Multi-Center Cross-Sectional Study in the US

Scott A. Elman[1], Benjamin F. Chong[2], S. Sam Lim[3], David Fivenson[4], Joseph F. Merola[5], Weihong Yang[6], Feng Zeng[6], Qianyun Li[6], Fariba Mirzaei*[6]

[1] Dr. Phillip Frost Department of Dermatology and Cutaneous Surgery, University of Miami Miller School of Medicine, Miami, United States

[2] Department of Dermatology, UT Southwestern Medical Center, Dallas, United States

[3] Emory University School of Medicine, Department of Medicine, Division of Rheumatology, Atlanta, United States

[4] Fivenson Dermatology, Ann Arbor, United States

[5] Department of Dermatology and Department of Medicine, Division of Rheumatology, UT Southwestern Medical Center and O'Donnell School of Public Health, Dallas, United States

[6] Biogen, Cambridge, United States

Introduction

Cutaneous lupus erythematosus (CLE) is an autoimmune disease with varying skin manifestations. The CLE Disease Area and Severity Index (CLASI) measures disease activity (CLASI-A; 0–70) and damage (CLASI-D; 0–56) in the most affected lesion per area. Cutaneous Lupus Activity Investigator's Global Assessment—Revised (CLA-IGA-R) is a novel global assessment tool that evaluates disease activity across all lesions, scoring erythema (0–4), other morphologic characteristics (OMC; 0–4), and follicular activity (0–1). The correlation between these two measures of CLE disease activity is unknown.

Materials and Methods

This observational cross-sectional study included adults with confirmed CLE from four US clinics. Disease severity (CLASI-A; CLA-IGA-R) was assessed at a single visit. Polyserial correlations with two-sided, unadjusted P-values were calculated to evaluate associations between CLASI-A and CLA-IGA-R.

Results

Participants (N=122) were predominantly female (86.1%) and African American (73.0%). Participant distribution by CLASI-A score was 44.3% CLASI-A=0, 37.7% CLASI-A=1–9, and 18% CLASI-A>9. Using the CLA-IGA-R, ~50% presented as clear and ~32% presented as almost-clear to mild for erythema or OMC; smaller proportions of participants had moderate or severe erythema (15.6%) or OMC (8.2%). Strong direct correlations were observed between CLASI-A Erythema and CLA-IGA-R Erythema scores ($r = 0.780$, $P<0.001$) and CLASI Scale/Hypertrophy and CLA-IGA-R OMC scores ($r = 0.742$; $P<0.001$).

Conclusions

This is the first study to compare CLE disease activity using CLA-IGA-R with CLASI-A in a real-world setting, demonstrating direct correlation. It is limited by differences in scale structure and smaller numbers in severe disease, with future work in a longitudinal setting needed to corroborate the findings.

EADV CONGRESS
VIENNA
30 SEP - 3 OCT 2026

Abstract N°: 1754

Long-term outcomes and biomarker trajectories of dupilumab for bullouspemphigoid: a 104-week extended follow-up case series

Saori Takamura*[1], Tomoo Fukuda[1]

[1] Saitama Medical Center, Saitama Medical University, Kawagoe, Japan

Introduction
Dupilumab was approved in 2025 as the first targeted biologic for bullous pemphigoid (BP), yet evidence guiding long-term treatment decisions remains sparse. Real-world data beyond 52 weeks are limited, and no study has reported treatment continuation patterns, drug holiday outcomes, or comparative biomarker kinetics over 2 years. The optimal treatment duration, feasibility of drug holidays, and the role of biomarkers in guiding these decisions remain clinically pressing but unanswered questions. We evaluated 104-week clinical outcomes and serial trajectories of TARC/CCL17 and anti-BP180-NC16A antibodies in 18 BP patients, extending our previously reported 52-week cohort.

Materials and Methods
This single-centre retrospective case series included 18 consecutive BP patients (median age 78 years; 9 males, 9 females) treated with dupilumab (600 mg loading then 300 mg subcutaneously every 2 weeks). Building on our previously reported 52-week cohort (Acta Derm Venereol 2025;105:adv43999), follow-up was extended to 104 weeks. Baseline BPDAI was 46.0 (median, range 24–78). Patients were stratified by prior/background therapy: systemic-corticosteroid–refractory or relapsing during corticosteroid tapering (n=8), and minocycline/topical-corticosteroid–resistant (n=10). Clinical response was assessed by BPDAI. Serum TARC/CCL17 and anti-BP180-NC16A antibodies were monitored serially during active treatment and drug-free intervals. Treatment status at week 104 was classified as continuation, drug holiday, discontinuation, or interruption. Newly analysed outcomes included systemic corticosteroid-sparing rates, drug holiday durability, and biomarker dynamics around relapse.

Results
In the previously reported 52-week data, complete remission was achieved in 16/18 (90.9%), baseline TARC correlated with BPDAI (r=0.5376, p=0.0317), and anti-BP180 normalised in only 6/18 (33.3%) despite clinical control. During extended follow-up, at week 104, 9 patients (50.0%) were continuing dupilumab, of whom 3 had restarted after relapse during a prior drug-free interval (including the 2 relapsers originally reported at median 23.3 weeks). Five patients (27.8%) remained on drug holiday and maintained complete clinical remission for up to 2 years after cessation without documented relapse. One patient (5.6%), previously a partial responder, was reclassified and discontinued at week 28 for insufficient response. Three patients (16.7%) interrupted treatment for non-disease-related reasons. Among the 8 patients on concomitant systemic corticosteroids at baseline, 25.0% (2/8) achieved systemic corticosteroid-free status by week 104; the remainder continued at reduced doses. Serial biomarker analysis revealed divergent kinetics. TARC/CCL17 declined in parallel with BPDAI improvement and normalised before or concurrent with clinical remission, serving as a real-time indicator of disease activity. Anti-BP180-NC16A dynamics were heterogeneous, with delayed or incomplete normalisation in a subset despite sustained clinical control. Among the 3 relapsers after cessation, TARC elevation consistently preceded clinical recurrence, whereas anti-BP180 changes were temporally inconsistent. No new serious adverse events were observed.

Conclusions

Dupilumab provides durable disease control in BP over 104 weeks in real-world practice. Notably, 27.8% of patients maintained complete remission during drug holiday for up to 2 years, demonstrating that sustained treatment-free remission is achievable. TARC/CCL17 showed superior responsiveness as a real-time disease activity biomarker compared with anti-BP180, both during treatment and at relapse. These findings support the feasibility of drug holiday strategies in dupilumab-treated BP and underscore the potential of TARC-guided monitoring to inform discontinuation and retreatment decisions.

Figure. Treatment Timeline of 18 Patients with Bullous Pemphigoid Treated with Dupilumab

A 104-week real-world case series (Swimmer Plot)

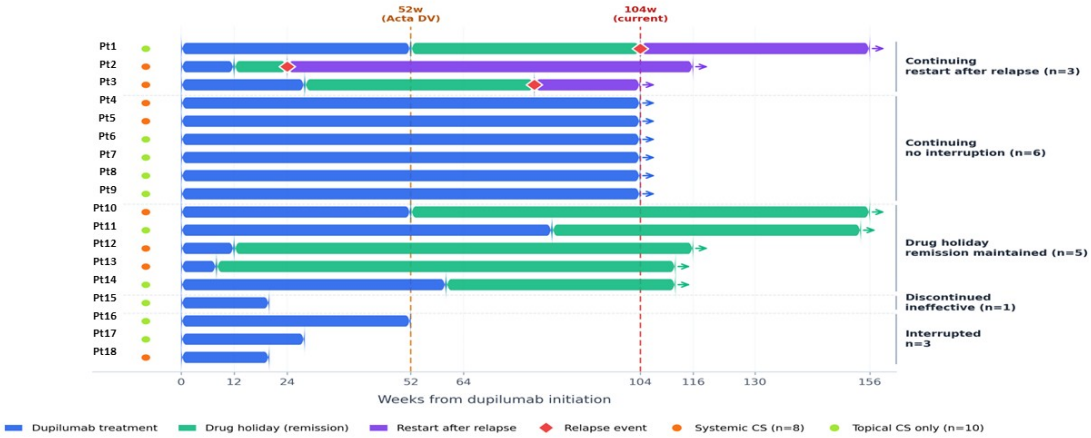

Figure legend. Swimmer plot showing individual treatment trajectories of 18 consecutive patients with bullous pemphigoid treated with dupilumab (300 mg every 2 weeks), grouped by treatment status at week 104. Blue bars denote active dupilumab treatment; green bars denote drug holiday with sustained remission; purple bars denote restart after relapse. Red diamonds mark relapse events. Arrows indicate ongoing observation beyond the snapshot. Reference lines mark the 52-week Acta DV endpoint and the 104-week current analysis endpoint. Notably, all 5 patients on drug holiday maintained complete remission for up to 2 years after dupilumab cessation.

EA DV CONGRESS
VIENNA
30 SEP - 3 OCT 2026

Abstract N°: 1761

Real-World Efficacy of Ivarmacitinib for Eyebrow and Eyelash Alopecia in Patients with Alopecia Areata

Xingyu Chen*[1]

[1] Qingdao Municipal Hospital, Qingdao, China

Introduction

Alopecia areata (AA) is a common chronic tissue-specific autoimmune disease. Ivarmacitinib,a selective oral Janus kinase 1 (JAK1) inhibitor, , was recently approved as a systemic therapy for severe AA. While clinical trials have shown its superiority over placebo in terms of scalp hair regrowth (assessed by the Severity of Alopecia Tool [SALT]), no real-world studies have specifically evaluated its effect on eyebrow and eyelash alopecia in adult patients with severe AA. Objective was to evaluate the real-world efficacy and safety of Ivarmacitinib for the treatment of eyebrow and eyelash alopecia in adult patients with alopecia areata.

Materials and Methods

A retrospective analysis was performed on the clinical data of five adult patients with severe alopecia areata who received Ivarmacitinib treatment at our hospital from November 2025 to March 2026. The Severity of Alopecia Tool (SALT), Alopecia Areata Severity and Morbidity Index (ASAMI), and Dermatology Life Quality Index (DLQI) were compared before treatment and at 4, 8, 12, and 16 weeks after treatment. The Clinician-Reported Outcome (ClinRO) scale was used to quantify the degree of eyebrow and eyelash loss and treatment response. Adverse events during the treatment period were recorded.

Compared with baseline, the SALT score decreased by 2.2%, 26.7%, 60.5%, and 68.7% at weeks 4, 8, 12, and 16 after treatment, respectively; the ASAMI improved by 2.1%, 26.8%, 49.6%, and 77.3%, respectively; and the DLQI improved by 7.3%, 8.9%, 30.2%, and 40.6%, respectively. The Clinician-Reported Outcome (ClinRO) scale showed improvements in eyebrow and eyelash loss of 6.5%, 36.8%, 50.3%, and 66.7% at the corresponding time points.

	Week 4	Week 8	Week 12	Week 16
SALT score reduction from baseline	2.2%	26.7%	60.5%	68.7%
Change in ASAMI from baseline	2.1%	26.8%	49.6%	77.3%
Change in DLQI from baseline	7.3%	8.9%	30.2%	40.6%
Change in eyebrow and eyelash ClinRO from baseline	6.5%	36.8%	50.3%	66.7%

Table 1. Percentage change from baseline for each observed indicator

Results

All patients exhibited progressive, time-dependent improvements in both eyebrow and scalp hair parameters. Notably, eyebrow regrowth was generally superior to scalp regrowth.

Conclusions

In adult patients with alopecia areata, Ivarmacitinib demonstrates superior efficacy in treating eyebrow and eyelash alopecia compared with scalp alopecia, along with a favorable safety profile.

EADV CONGRESS
VIENNA
30 SEP - 3 OCT 2026

Abstract N°: 1765

Pemphigus Herpetiformis: A Case Report

raouia Roumili*[1], Dali osmane Rima[1], mira chikhaoui[2], Baya Moussaoui[2], sahel houria[2]

[1] Dermatologie, C.H.U Lamine Debaghine, bab elouad, Algeria
[2] C.H.U Lamine Debaghine, BAB ELOUAD, Algeria

Introduction

Pemphigus herpetiformis (PH) is a rare clinical entity within the spectrum of autoimmune pemphigus. It combines a clinical presentation suggestive of dermatitis herpetiformis with the immunopathological features of pemphigus. We report a case of PH that posed a diagnostic challenge, highlighting the critical importance of correlating clinical, histological, and immunological findings.

Case Presentation

A 53-year-old woman with a medical history of hypertension and asthma presented with a four-year history of a diffuse, pruritic vesiculobullous eruption. Physical examination revealed urticarial plaques with vesicular borders arranged in a herpetiform pattern, involving the face, scalp, trunk, and limbs. Nikolsky's sign was negative, and no mucosal involvement was observed. Laboratory investigations revealed peripheral blood hypereosinophilia at 1,500/mm^3 (03N)three times the upper limit of normal.

Histopathological examination showed spongiosis with pseudo-acantholysis. The dermis exhibited a predominantly lymphohistiocytic inflammatory infiltrate. Direct immunofluorescence demonstrated intercellular deposits of IgG and C3 in the lower layers of the epidermis.Based on these findings, the diagnosis of pemphigus herpetiformis was established. The patient was treated with oral corticosteroids (0.5 mg/kg/day) combined with dapsone (50 mg/day), leading to a favorable clinical outcome.

Conclusion

Pemphigus herpetiformis represents a rare and atypical variant of pemphigus, characterized by a discrepancy between its clinical presentation and its immunopathological features. It predominantly affects middle-aged women and typically presents with pruritic herpetiform lesions, with an almost constant absence of mucosal involvement.
Our patient shared these general characteristics but also exhibited several atypical features. Marked facial involvement and prominent scalp lesions, which are rarely predominant in PH, constituted unusual findings. Peripheral blood eosinophilia, although reported in some cases, remains uncommon and may reflect the intensity of the inflammatory process, correlating with the eosinophilic spongiosis observed histologically.
The chronic course over four years prior to diagnostic confirmation underscores the diagnostic difficulty of this entity; the favorable response to combined moderate-dose corticosteroids and dapsone supports published data indicating the high therapeutic sensitivity of PH to this regimen.

This case highlights the importance of clinico-immunological correlation in the diagnosis of autoimmune bullous dermatoses and emphasizes that pemphigus herpetiformis should be considered in any acquired pruritic vesicular

eruption with a herpetiform pattern.

EA DV CONGRESS
VIENNA
30 SEP - 3 OCT 2026

Abstract N°: 1768

Isolated Lupus Panniculitis: A Case Report

raouia Roumili*[1], Dali osmane Rima[1], tinhinane benbrahim[1], mira chikhaoui[1], yasmine namaoui[2], nassima djennane[2], sahel houria[1]

[1] Department of Dermatology, Lamine Debaghine University Hospital, bab elouad, Algeria
[2] Department of Pathology, Lamine Debaghine University Hospital, bab elouad, Algeria

Introduction

Lupus panniculitis (LP), also known as lupus profundus, is a rare manifestation of lupus erythematosus, accounting for approximately 1–3% of cases. We report a case of isolated lupus panniculitis without systemic involvement.

Case Presentation

A 47-year-old woman with a medical history of hypothyroidism and primary biliary cholangitis presented with an 18-year history of nodules involving both lower limbs, evolving in the context of preserved general health.

Dermatological examination revealed multiple subcutaneous nodules and plaques, several centimeters in diameter, with partially erythematous overlying skin. The lesions were firm, mobile, and tender on palpation. They were located on the legs, left forearm, and right arm. Extracutaneous examination was unremarkable.

Laboratory investigations were within normal limits except for positive antinuclear antibodies (ANA) at a titer of 1:1000, as well as positive anti-Smith and anti-mitochondrial M2 antibodies.

Histopathological examination of a deep skin biopsy demonstrated lobular panniculitis with a predominantly lymphocytic inflammatory infiltrate and no evidence of vasculitis.

Clinicopathological correlation supported the diagnosis of lupus panniculitis. The patient was treated with oral prednisone at a dose of 0.5 mg/kg/day combined with hydroxychloroquine. After six months, lesions regressed, leaving residual hyperpigmented scars.

Conclusion

Lupus panniculitis is an uncommon variant of lupus erythematosus that predominantly affects middle-aged women. Clinically, it presents with deep, firm, and often painful nodules, classically involving the face, proximal upper arms, trunk, buttocks, and thighs, frequently progressing to atrophic scarring.
Lower limb involvement, as observed in our patient, is atypical. Diagnosis may be challenging when lesions are isolated and unaccompanied by clinical or biological features of systemic lupus erythematosus, making histopathological evaluation essential.
Histologically, LP is characterized by lobular or mixed lymphocytic panniculitis, sometimes associated with hyaline fat necrosis.
Early treatment is recommended and is primarily based on antimalarial agents, with or without adjunctive local or systemic corticosteroid therapy.

Conclusion: Lupus panniculitis is a rare and sometimes isolated entity requiring precise histological diagnosis. Early initiation of antimalarial therapy, potentially combined with corticosteroids, may reduce the risk of permanent scarring.

Lupus panniculitis is a rare and sometimes isolated entity requiring precise histological diagnosis. Early initiation of antimalarial therapy, potentially combined with corticosteroids, may reduce the risk of permanent scarring.

EADV CONGRESS
VIENNA
30 SEP - 3 OCT 2026

Abstract N°: 1774

Efficacy and Safety of Vunakizumab in the Treatment of Moderate-to-Severe Plaque Psoriasis in Patients with High Body Weight

Yuan Li[1], Hongxia Yan[1], Dongmei Shi*[1]

[1] Jining Medical University, Jining First People's Hospital, Jining, China

Introduction
High body weight may affect the efficacy of biologic agents, and data on vunakizumab in this specific population are limited. Objective was to evaluate the efficacy and safety of vunakizumab in patients with moderate-to-severe plaque psoriasis who weigh ≥80 kg or have a BMI ≥28 kg/m^2.

Materials and Methods
Six patients with high body weight (5 male, 1 female) were included, with a mean age of 39.5 years, mean weight of 89.8 kg, mean BMI of 28.5 kg/m^2, and mean baseline PASI score of 12.97. Five patients completed at least 8 weeks of treatment (including 4 who completed 12 weeks) and were included in the efficacy analysis. Patients received standard vunakizumab therapy. PASI 75/90/100 response rates, sPGA 0/1 response rates, and safety were assessed.

Results
Among the 5 evaluable patients, both PASI 75 and PASI 90 response rates were 100% (5/5). The PASI 100 response rate was 80% (4/5; 3 patients achieved PASI 100 at Week 12, and 1 patient achieved PASI 100 at Week 8). The sPGA 0/1 response rate was 100% (5/5). Among the 4 patients who completed 12 weeks, all achieved PASI 75 by Week 4; the remaining evaluable patient achieved PASI 75 by Week 8. No adverse events were reported among the 6 patients, and there were no treatment discontinuations.

Conclusions
In this cohort of patients with high body weight, vunakizumab demonstrated rapid onset of action (most patients achieved PASI 75 by Week 4) and a high rate of complete skin clearance (PASI 100 in 80%). No adverse events were observed. These preliminary findings suggest favorable efficacy and safety of vunakizumab in patients with high body weight, though validation in larger studies is warranted.

EA DV CONGRESS
VIENNA
30 SEP - 3 OCT 2026

Abstract N°: 1777

Longitudinal changes in BPDAI domains during biologic therapy in bullous pemphigoid: pruritus parallels disease activity

Ruggero Cascio Ingurgio*[1, 2], Angela Alfano[1, 2], Aalia Syed[3, 4], Luigi Gargiulo[1, 2], Alessandra Narcisi[1, 2], Antonio Costanzo[1, 2], Dédée Murrell[3, 4]

[1] Dermatology Unit, IRCCS Humanitas Research Hospital, Rozzano (Milan), Italy
[2] Department of Biomedical Sciences, Humanitas University, Pieve Emanuele (Milan), Italy
[3] Faculty of Medicine, University of New South Wales, Sydney, Australia
[4] Department of Dermatology, St George Hospital, Sydney, Australia

Introduction

Biologic therapies targeting type 2 inflammation are increasingly used in bullous pemphigoid, but the relationship between pruritus and specific disease domains remains unclear. The Bullous Pemphigoid Disease Area Index allows separate assessment of activity, damage, and pruritus, yet the clinical significance of pruritus as a disease domain remains to be clarified.

Materials and Methods

We performed a retrospective dual-center study of 25 patients with bullous pemphigoid treated with dupilumab, omalizumab, or tralokinumab in routine clinical practice. Bullous Pemphigoid Disease Area Index activity, damage, and pruritus were recorded at baseline and at weeks 16, 32, and 52 when available. Follow-up data were available for 25, 22, and 16 patients at weeks 16, 32, and 52, respectively. Longitudinal changes were analyzed using the Wilcoxon signed-rank test, and associations between score improvements were assessed using Spearman correlation.

Results

received omalizumab and one tralokinumab. Biologic therapy was associated with rapid and sustained improvement in disease activity and pruritus across all timepoints. Median Bullous Pemphigoid Disease Area Index activity decreased from 20 at baseline to 4 at week 16, 0.5 at week 32, and 0 at week 52 (all $p \leq 0.0001$). Pruritus also improved, decreasing from 20 to 6, 4.5, and 0, respectively ($p=0.001$, $p<0.001$, and $p=0.0002$). In contrast, damage showed a slower and less pronounced reduction, becoming significant only at weeks 32 and 52.
A ≥50% improvement in activity was observed in 72%, 77.3%, and 81.3% of patients at weeks 16, 32, and 52, respectively, while corresponding pruritus response rates were 56.0%, 72.7%, and 75.0%. Improvement in pruritus correlated significantly with improvement in activity at week 16 (rho=0.46, $p=0.021$), week 32 (rho=0.62, $p=0.003$), and week 52 (rho=0.58, $p=0.020$), whereas no significant correlation was observed with damage.
Systemic corticosteroid exposure decreased over time, with median prednisone-equivalent dose declining from 10 mg/day at baseline to 0 mg/day at weeks 16, 32, and 52 (all $p \leq 0.001$). The proportion of patients discontinuing corticosteroids increased from 52.0% at week 16 to 72.7% at week 32 and 81.3% at week 52.

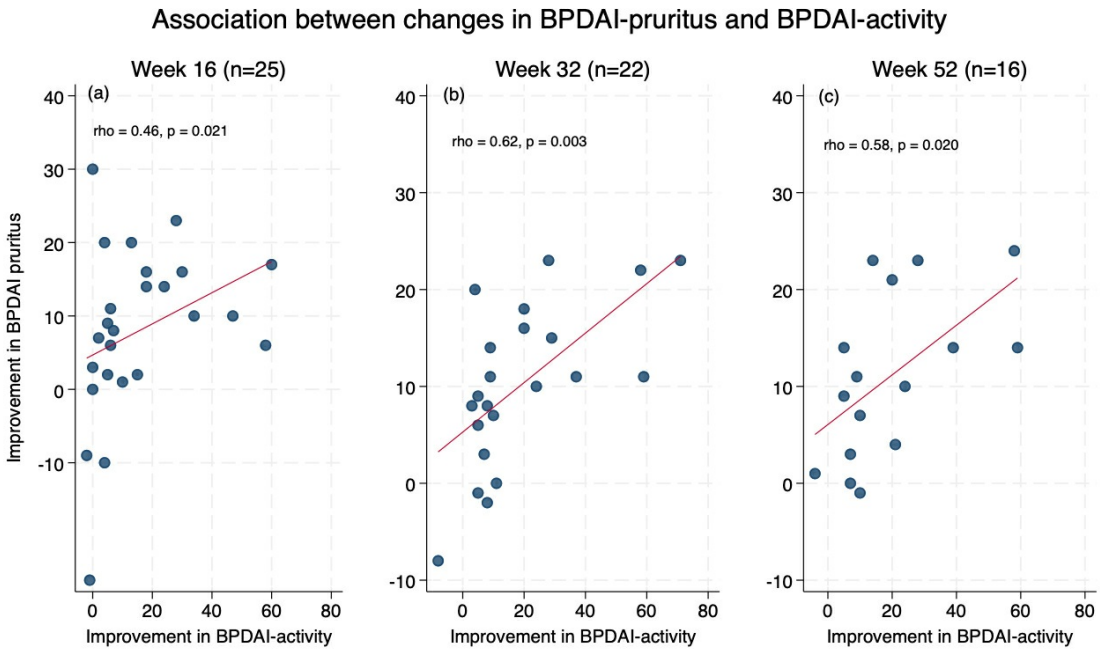

Conclusions

During biologic therapy for bullous pemphigoid, pruritus behaves as a dynamic domain closely linked to inflammatory disease activity rather than residual damage. These findings support domain-based assessment and suggest that pruritus is a clinically meaningful outcome for monitoring treatment response.

EADV CONGRESS
VIENNA
30 SEP - 3 OCT 2026

Abstract N°: 1787

Efficacy and safety of topical Methotrexate 0.5% gel versus topical Tacrolimus 0.1%ointment in treatment of non segmental vitiligo

Ahmed Kadah*[1]

[1] assistant professor, cairo, Egypt

Introduction

Vitiligo is the most common depigmenting skin disorder (0.5–1%).
The most frequent type, non-segmental vitiligo, presents as well-defined milky-white macules of variable size and distribution and may be associated with sensorineural deafness, uveitis, and thyroiditis. It is classified into segmental and non-segmental types; non-segmental vitiligo includes acrofacial, mucosal, generalized, universal, and mixed forms.
It is a multifactorial disorder caused by the loss of functional melanocytes through genetic, autoimmune, oxidative stress, inflammatory, and detachment mechanisms, involving both innate and adaptive immunity.
Methotrexate (MTX), a folic acid antagonist, has antiproliferative and immunomodulatory effects: it decreases TNF-α–producing T cells, increases IL-10–producing T cells, suppresses B cells, and inhibits IL-6 and reactive oxygen species. Topical MTX shows no significant hepatotoxic or hematologic adverse effects compared with systemic MTX.
Topical calcineurin inhibitors (e.g., tacrolimus) inhibit CD8+ T-cell activation, proliferation, and cytokine production, and directly stimulate melanocyte proliferation, migration, and function.

Conclusion

Further studies with larger sample sizes are required to determine the simplest and most effective treatment modality for clinical use.

EADV CONGRESS
VIENNA
30 SEP - 3 OCT 2026

Abstract N°: 1836

Tirzepatide-Induced Bullous Pemphigoid: A Case Report

Jon Fulgencio Barbarin*[1], Elena Porres López[1], José Luis Alejo Fernández Baillo[1], Pablo Luis Ortiz-Romero[1], Paula Hernández Madrid[1]

[1] Hospital universitario 12 de Octubre, Madrid, Spain

Introduction

Bullous pemphigoid is a subepidermal autoimmune blistering disorder characterized by tense blisters and intense pruritus. It is mediated by autoantibodies against hemidesmosomal proteins BP180 and BP230 at the dermoepidermal junction. Several medications have been implicated as triggering factors, including dipeptidyl peptidase-4 inhibitors and, more recently, glucagon-like peptide-1 (GLP-1) receptor agonists. Tirzepatide is a novel dual GLP-1 and glucose-dependent insulinotropic polypeptide (GIP) receptor agonist increasingly used for type 2 diabetes and weight management. However, its potential to induce autoimmune cutaneous reactions remains poorly characterized.

Case Presentation

We report the case of a 64-year-old male with a history of arterial hypertension and stable multiple sclerosis who presented with a two-week history of pruritic skin lesions affecting the trunk and extremities. Notably, tirzepatide therapy had been initiated two weeks prior for weight management. Physical examination revealed erythematous, infiltrated plaques with multiple tense, serous-filled blisters arranged in an annular pattern Histopathological examination demonstrated a subepidermal blister with inflammatory infiltrate. Direct immunofluorescence showed linear deposition of IgG and C3 along the basement membrane zone, and indirect immunofluorescence was positive for circulating anti-basement membrane antibodies, confirming the diagnosis of bullous pemphigoid. Tirzepatide was discontinued, and treatment with oral prednisone (initial dose 30 mg/day, tapered) and topical clobetasol was initiated. At three-month follow-up, the patient showed complete clinical resolution.

Conclusion

This case suggests a potential association between tirzepatide and the development of bullous pemphigoid. Although GLP-1 receptor agonists have been increasingly linked to autoimmune blistering diseases, reports involving tirzepatide remain scarce. Clinicians should be aware of this possible adverse effect, particularly given the expanding use of these agents. Early recognition and prompt drug withdrawal are essential to improve outcomes. Further studies are needed to clarify the underlying mechanisms and identify patients at increased risk for this rare but clinically significant complication.

EA DV CONGRESS
VIENNA
30 SEP - 3 OCT 2026

Abstract N°: 1851

Low-dose rituximab in juvenile pemphigus vulgaris: a case series

Yiqian Peng*[1], Yue Zhu[1], Jinbo Chen[1]

[1] Traditional Chinese and Western Medicine Hospital of Wuhan, Tongji Medical College, Huazhong University of Science and Technology, Wuhan, China

Introduction
Pemphigus vulgaris (PV) in children and adolescents is rare. Rituximab (RTX), an anti-CD20 monoclonal antibody, has become a cornerstone of treatment in refractory or moderate-to-severe PV. However, dosing strategies in pediatric populations remain poorly defined, with most evidence extrapolated from adult cohorts. We report three cases of juvenile PV successfully managed with low-dose RTX in combination with corticosteroids.

Materials & Methods:

We present a case series of three pediatric and adolescent patients with confirmed PV treated at our department between 2022 and 2025. Diagnosis was established by clinical presentation, serum dsg1/3 levels (normal 20U/mL), and histopathology with direct immunofluorescence where applicable. All patients received RTX alongside systemic corticosteroids, with cotrimoxazole prophylaxis against pneumocystis jirovecii pneumonia. Disease activity was assessed using the Pemphigus Disease Area Index (PDAI).

Case Presentation
Case 1. A 10-year-old girl presented with a 3-month history of painless oral mucosal erosions. PDAI was 9, and the level of dsg3 was 126.38 U/mL at admission. She received two infusions of RTX 200 mg, 2 weeks apart, combined with prednisolone 25mg/day. Oral lesions resolved within weeks, and she was maintained on tapering prednisolone. At the two-year follow-up, PDAI was 0 and prednisolone had been reduced to 10 mg/week.

Case 2. A 14-year-old girl presented with severe, generalised PV involving both skin and mucosae. PDAI was 75 and the level of dsg1 and dsg3 were 191.44 and 237.68 U/mL, respectively. She received two infusions of RTX 500 mg, two weeks apart, combined with prednisolone 50 mg/day. PDAI declined from 75 to 47 during hospitalisation. At the seven-month follow-up, PDAI was 7, dsg1 and dsg3 fell to 1.65 U/mL and 12.94 U/mL, respectively, and the patient remained on prednisone 15 mg/day.

Case 3. A 15-year-old boy with a 2-year history of skin and mucosal erosions, previously refractory to high-dose prednisolone 93 mg/day, cyclosporine, and intravenous immunoglobulins, was referred to our department. He received two infusions of RTX 500 mg, two weeks apart, and achieved sustained remission with prednisolone tapered to 17.5 mg/day. Residual scalp lesions prompted a second 500 mg RTX twelve months later, with subsequent remission. After two years, self-discontinuation of all medications led to relapse within six weeks, necessitating a third 500 mg RTX with prednisolone 20 mg/day. At the eight-month follow-up, PDAI was 6, dsg1 and dsg3 had declined to 31.98 and 1.35 U/mL, and the patient remained on prednisolone 15 mg/day.

Across all three cases, RTX was well tolerated. Adverse events included one episode of infusion-related fever, resolving with antipyretics and one incidental oral candidiasis managed with topical antifungals. No serious infections or haematological complications were observed.

Conclusion

Low-dose RTX (400–1000 mg per cycle) combined with prednisolone demonstrates favourable efficacy and safety in juvenile PV, including in treatment-refractory cases, and repeated cycles can be administered safely upon relapse. Although adolescent dosing remains unstandardised, recent guidelines recommend 375 mg/m² weekly for four weeks as a reference regimen; our experience suggests that lower fixed doses may achieve comparable disease control while potentially reducing the immunosuppressive burden. Prospective studies are needed to define optimal dosing regimens and retreatment thresholds in this population.

EA DV CONGRESS
VIENNA
30 SEP - 3 OCT 2026

Abstract N°: 1863

Sudden Onset of Bullous Pemphigoid in a 100-year-old Filipino Female

Michaela Gabrielle Guieb*[1], Patricia Guieb[1]

[1] Dra. Patricia Geluz-Guieb Derma Clinic, Cavite, Philippines

Introduction

Bullous pemphigoid (BP) is the most common autoimmune subepidermal blistering disease of the elderly, predominantly affecting individuals aged 60 years and older. It is characterized by autoantibodies directed against hemidesmosomal proteins, particularly BP180 (BPAG2), leading to dermoepidermal separation. Occurrence in extreme old age, especially among centenarians, is exceptionally rare. This age group presents distinct clinical challenges due to physiologic decline, comorbidities, polypharmacy, and increased susceptibility to adverse drug reactions, necessitating careful therapeutic decision-making.

Case Presentation

A 100-year-old Filipino female presented with a one-week history of intensely pruritic vesicles and tense bullae arising on an erythematous base over the trunk, upper and lower extremities, and palms. The lesions progressed rapidly, with no mucosal involvement noted. Dermatologic examination revealed multiple intact and ruptured bullae, some with crusting and surrounding erythema. There were no systemic symptoms reported. Histopathologic examination of a lesional skin biopsy demonstrated a subepidermal blister with a dense inflammatory infiltrate rich in eosinophils. Serologic evaluation showed positivity for BP180 (BPAG2) autoantibodies, confirming the diagnosis of bullous pemphigoid. Complete blood count revealed eosinophilia at 16%, further supporting the diagnosis.

Given the patient's advanced age and increased risk for systemic complications, a conservative and steroid-sparing regimen was initiated. Treatment consisted of topical betamethasone valerate 0.01% cream applied twice daily then tapered to once daily to affected areas, oral doxycycline 100 mg twice daily for its anti-inflammatory properties, and oral bilastine 20 mg daily as needed for symptomatic relief of pruritus. Occasional low-dose oral prednisone (5 mg) was administered for disease flares. Over a three-month period, this regimen resulted in marked reduction of pruritus and complete resolution of bullous lesions. The patient tolerated therapy well, with no reported adverse effects. However, recurrence of bullae was observed after initial resolution, with intermittent development of new lesions during follow-up, necessitating continued maintenance therapy and close monitoring.

Conclusion

This case highlights the exceptional rarity of bullous pemphigoid presenting at the extreme threshold of human longevity. It reinforces that autoimmune blistering diseases may still manifest even at a century of life. In this population, management requires a balance between therapeutic efficacy and safety. Conservative, steroid-sparing regimens may achieve symptom control while minimizing the risks associated with systemic immunosuppression. Nevertheless, sustained disease remission remains difficult to achieve, underscoring the persistent therapeutic challenge in managing bullous pemphigoid in centenarian patients.

EADV CONGRESS
VIENNA
30 SEP - 3 OCT 2026

Abstract N°: 1891

When Purpura Speaks: A Cutaneous Gateway to Cryoglobulinemia and B-Cell Proliferation

Sarah Zemrani*[1], Christina Tarabay[1], Florine Hodique[1], Stephane Dalle[1]

[1] Department of Dermatology, Lyon Sud Hospital, Hospices Civils de Lyon, Lyon, France, LYON, France

Introduction

Cutaneous leukocytoclastic vasculitis may be the first manifestation of systemic diseases, including autoimmune disorders and lymphoproliferative conditions. Type II cryoglobulinemia is classically associated with immune complex vasculitis and may reveal an underlying B-cell clonal disorder.

Case Presentation

A woman presented with a one-year history of recurrent infiltrated purpura of the lower limbs. Skin biopsy confirmed leukocytoclastic vasculitis. Initial investigations showed negative viral serologies and the presence of a monoclonal IgM kappa component associated with type II cryoglobulinemia, hypocomplementemia, and inflammatory syndrome.
Over time, the clinical picture evolved with extension of purpura, onset of Raynaud phenomenon, and sicca symptoms. Minor salivary gland biopsy revealed lymphocytic sialadenitis (Chisholm score 4), supporting the diagnosis of Sjögren's syndrome. Concomitantly, immunological workup identified a monoclonal B-cell population, raising suspicion of an indolent B-cell lymphoproliferative disorder.

The disease course was marked by systemic involvement, including renal impairment with proteinuria and hematuria. Kidney biopsy demonstrated membranoproliferative glomerulonephritis with immune complex deposits (IgM, IgG, C3) and light chain restriction, consistent with cryoglobulinemic vasculitis.
Cutaneously, the patient exhibited persistent purpuric lesions of the lower limbs, associated with intermittent flares. Laboratory findings confirmed active disease with persistent cryoglobulinemia, elevated rheumatoid factor activity, and marked complement consumption.

The overall presentation led to the diagnosis of type II cryoglobulinemic vasculitis secondary to Sjögren's syndrome, associated with an underlying indolent B-cell lymphoproliferation. Treatment with rituximab was initiated, resulting in partial biological improvement.

Conclusion

This case highlights the importance of considering cryoglobulinemic vasculitis in chronic or recurrent purpura, particularly when associated with hypocomplementemia and monoclonal gammopathy. The association with Sjögren's syndrome and B-cell lymphoproliferation underscores the need for a comprehensive systemic evaluation. Early recognition is essential to guide targeted therapy and prevent organ involvement.

POWERED BY M-ANAGE.COM

EADV CONGRESS
VIENNA
30 SEP - 3 OCT 2026

Abstract N°: 1891

Diagnosis and management of anti-p200 pemphigoid: Perspectives of international dermatologists with expertise in immunobullous diseases

Michael Kasperkiewicz[1], Joy Xu*[1], Mishek Thapa[1], Donna A. Culton[2], Philip Curman[3], Takashi Hashimoto[4], Joost Meijer[5], Aikaterini Patsatsi[6], Mary Tomayko[7], Julia Lehman[8], Enno Schmidt[9]

[1] David Geffen School of Medicine, Los Angeles, United States
[2] University of North Carolina, Chapel Hill, United States
[3] Karolinska Institutet, Stockholm, Sweden
[4] Osaka City University Graduate School of Medicine, Osaka, Japan
[5] UMCG Center of Expertise for Blistering Diseases, Groningen, Netherlands
[6] Aristotle University School of Medicine, Thessaloniki, Greece
[7] Yale University School of Medicine, New Haven, United States
[8] Mayo Clinic, Rochester, United States
[9] University of Lübeck, Lübeck, Germany

Introduction

Anti-p200 pemphigoid is a rare autoimmune blistering disorder which clinically mimics bullous pemphigoid (BP), the most common immunobullous disease, while displaying a unique immunological profile, with laminin β4 and laminin γ1 (subunits of the dermal 200-kDa protein) being the relevant target antigens.1-3 In contrast to BP,4,5 the current diagnostic and therapeutic approaches for anti-p200 pemphigoid among immunobullous experts are poorly characterized.

Materials and Methods

From November 2025 to March 2026, we surveyed anti-p200 pemphigoid-related practice trends of international dermatologists specializing in immunobullous diseases. Of 124 invited experts, 78 (63%) responded and were included (Table 1). Participants were members of the Autoimmune Blistering Diseases Task Force of the European Academy of Dermatology and Venereology (EADV) (n=40; "EADV group") and the US-based immunobulloUSconsortium (n=38; "US group"), with a few dermatologists from the US group, who all practice in the US, also being partly involved in the EADV Task Force (not included in the latter).

Results

Regarding diagnosis, the vast majority prioritized clinical assessment (90%), histopathology (83%), and ruling out both BP by enzyme-linked immunosorbent assay (ELISA) BP180/BP230 testing (79%) and epidermolysis bullosa acquisita by ELISA or indirect immunofluorescence (IIF)-biochip collagen VII testing (69%). Specific anti-p200 pemphigoid autoantigen detection by immunoblotting, IIF-biochip, and ELISA was overall reported in only 7-21%, 21%, and 5%, respectively. Direct immunofluorescence (DIF; regular and serration pattern analysis) and immunoblotting for p200/laminin γ1 were significantly more commonly used by the EADV group compared to the US group (Figure 1).

Specific autoantigen detection methods were performed at respondents' own institute/hospital/university (51%), within own country but outside the workplace (40%), outside the US (US colleagues only; 13%), and outside Europe (European colleagues only; 7%). Overall, 62% considered anti-p200 pemphigoid a diagnosis of exclusion, 67% reported diagnostic difficulties, and 78% identified a need for diagnostic improvement.

Considering therapy of mild disease, super potent topical corticosteroids on lesions only (79%) was the overall most preferred treatment. Prednisone/prednisolone at an initial dose of <0.5 mg/kg and adjuvant dapsone were significantly more commonly used by the EADV group compared to the US group (Figure 1).

For moderate disease, prednisone/prednisolone at an initial dose of 0.5 mg/kg (66%) was overall most preferred. Super potent topical corticosteroids on whole body except the face and adjuvant dapsone were significantly more commonly used by the EADV group (Figure 1).

For severe or treatment-refractory disease, prednisone/prednisolone at an initial dose of >0.5 mg/kg (69%) and adjuvant rituximab (69%) were overall most preferred. Super potent topical corticosteroids on whole body except the face and adjuvant azathioprine were significantly more commonly used by the EADV group (Figure 1). Compared to BP, respondents perceived treatment response in anti-p200 pemphigoid as better (24%), similar (43%), or worse (33%).

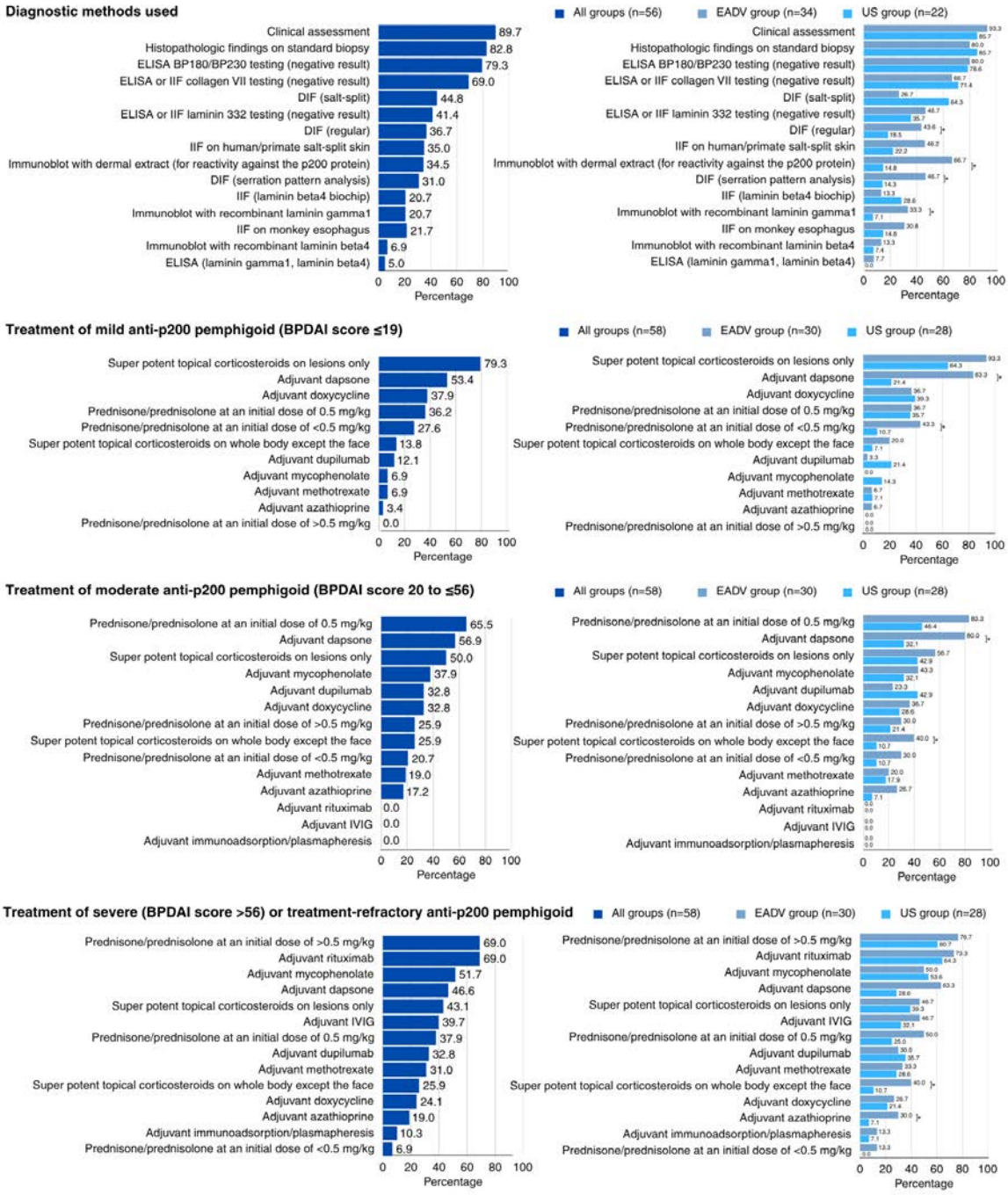

Figure 1. Results of international immunobullous experts who diagnosed and/or treated patients with anti-p200 pemphigoid. BPDAI, bullous pemphigoid disease area index; DIF, direct immunofluorescence; EADV, European Academy of Dermatology and Venereology; ELISA, enzyme-linked immunosorbent assay; IIF, indirect immunofluorescence; IVIG, intravenous immunoglobulin *p < 0.05

Conclusions

This cross-sectional study revealed partly regionally different opinions, practice patterns, and gaps regarding the diagnosis/treatment of anti-p200 pemphigoid. Notably, most experts diagnosed by excluding other pemphigoid diseases rather than testing for disease-specific autoantibodies. We highlight the need for better diagnostic test availability/accessibility, particularly in the US, and standardized consensus guidelines to ensure optimized management of this likely underrecognized immunobullous disease.

Table 1. Survey respondent characteristics (n=78).

Respondent characteristics	Outcome
Sex, n (%)	
Male	43 (55%)
Female	35 (45%)
Age, years	
Median (range)	50 (42, 60)
Prefer not to report, n (%)	8 (13%)
Race/ethnicity, n (%)	
White	58 (74%)
Black/African American	1 (1.3%)
Asian	16 (21%)
Hispanic/Latino	0 (0%)
American Indian/Alaskan Native	0 (0%)
Prefer not to answer	2 (2.6%)
Others	1 (1.3%)
Workplace, n (%)*	
Private practice	7 (9%)
Academic center	75 (96%)
Other	1 (1.3%)
Years of work experience as dermatologist, years median (range)	
Years	15 (7, 30)
Prefer not to report	3 (5%)
Has diagnosed anti-p200 pemphigoid, n (%)	
Yes, n (%)	56 (72%)
No, n (%)	22 (28%)
Has treated anti-p200 pemphigoid, n (%)	
Yes, n (%)	58 (74%)
No, n (%)	20 (26%)

*Percentages are based on all respondents (N = 78) for this "select all" item, thus totals may exceed 100%

Table 1. Survey respondent characteristics (n=78).

EA DV CONGRESS
VIENNA
30 SEP - 3 OCT 2026

Abstract N°: 1897

Cemiplimab induced bullous pemphigoid: a rare clinical case involving skin and mucosa

Lidiya Todorova*[1, 2], Teodor Aleksiev[1]

[1] Medical University Plovdiv, Plovdiv, Bulgaria
[2] Follica: Hair & Scalp Clinic, Plovdiv, Bulgaria

Introduction

Bullous pemphigoid (BP) is an autoimmune subepidermal blistering disease caused by IgG autoantibodies and activated T lymphocytes targeting the epidermal basement membrane, specifically the protein BP180 (Type XVII collagen) and, less frequently, BP230. Clinically, BP presents as tense bullae that rupture and form oozing erosions covered with crusts. Various drugs, vaccines, infections, and physical factors can induce BP. Recently, cancer immunotherapies have been associated with its onset. The relationship between BP and malignancies remains controversial, and some authors recommend oncological screening only in select cases.
We present a case of severe BP induced by cemiplimab, an immunotherapeutic agent used for metastatic squamous cell carcinoma treatment.

Case Presentation

Sixty-five year old patient presented to the clinic of Dermatology and Venereology with symptoms for 8 months, which started with a prodromal itch and scabs behind the ears. Four months later, the patient reported the appearance of bullae filled with clear fluid and blood, which after rupturing formed hemorrhagic crusts. Lesions in the oral mucosa appeared a couple of days before hospitalization. The patient was prescribed methylprednisolone in ambulatory care for 15 days after and their condition improved. The symptoms however returned after stopping the medication.

The patient has been diagnosed with metastatic squamous cell carcinoma of the peritoneum 3 months before the skin symptoms appeared for which she was treated with cemiplimab every 3 weeks for 10 therapies. Other concomitant conditions include: Hashimoto thyroiditis and diabetes type 2.

The dermatological examination showed tense bullae of different sizes filled with serous or hemorrhagic fluid and erosions with yellow or hemorrhagic crusts affecting the face, neck, décolleté, trunk upper and lower limbs accompanied by excoriations. A single bulla was observed on the lower lip and erosions covered with a fibrinous deposits in the oral mucosa. On the legs there were also hyperpigmented macules.

Routine blood laboratory tests showed deviations only in TSH 9.77 [ranges 0.35-5.1 mU/L]. Biopsy and DIF were performed and they confirmed the diagnosis of bullous pemphigoid.

Cemiplimab was discontinued systemic steroid therapy was applied the patient received Dexamthasone 8 mg intramuscularly/daily for 9 days; Allergosan 10mg/ml intramuscularly/daily for 10 days; Helides 40mg per orally daily for 9 days. By the end of the hospital stay the dermatological condition showed regression. The patient was

transferred to endocrinology clinic for revision of the hormonal therapy and then to oncology clinic for revision of the chemotherapy due to risk of BP induction of continued.

Conclusion

We herein describe a rare instance of bullous pemphigoid (BP) induced by cemiplimab in a patient receiving cemiplimab treatment for metastatic cSCC. By far, there are two articles in the literature discussing cemiplimab induced BP, and our case report presents the third one. Further research is required to elucidate the pathogenesis, identify prognostic indicators, and develop optimal therapeutic strategies for patients with immune checkpoint inhibitor–associated bullous pemphigoid.

EA DV CONGRESS
VIENNA
30 SEP - 3 OCT 2026

Abstract N°: 1901

Disseminated Extragenital Lichen Sclerosus Masquerading as Chronic Pigmented Dermatitis: A Prolonged Clinicopathological Diagnostic Delay

João Henrique Aurich*[1], Ana Lígia Scotti Alérico[1], Julia Carneiro da Cunha[1], Sandra e Dinato[1], Aline Falci[1], José de Almeida[1]

[1] UNILUS, Fundação Lusíada, Santos, Brazil

Introduction

Lichen sclerosus is a chronic inflammatory disorder that predominantly affects the anogenital region. Purely extragenital involvement is uncommon and may be underrecognized, particularly when early lesions are clinically atypical and histopathological findings are subtle. Disseminated forms without genital disease are rare and may lead to prolonged diagnostic delay.

Case Presentation

A three-year history of slowly progressive asymptomatic cutaneous lesions was noted in a 55-year-old woman. The eruption began on the lower limbs as hyperpigmented macules and plaques with mild scaling, gradually extending to the inguinal folds, back, and anterior chest. She denied pruritus, pain, mucosal symptoms, constitutional complaints, weight loss, fever, or other systemic manifestations. There was no history of autoimmune disease, previous immunosuppressive therapy, chronic medication use, or relevant family history.

During follow-up at outside institutions, several skin biopsies were performed without diagnostic definition. Initial histopathological reports described chronic dermatitis with pigment incontinence, mild acanthosis, focal spongiosis, and superficial perivascular lymphomononuclear infiltrate, without cytologic atypia or evidence of malignancy. Additional immunohistochemical studies demonstrated a mixed reactive lymphoid phenotype (CD3+, CD4+, CD5+, CD7+, CD8+, CD20+), arguing against cutaneous lymphoproliferative disease. Because of the persistent dyschromic plaques and repeated nondiagnostic pathology, the clinical course remained unresolved for years.

At our evaluation, lesions had evolved into multiple well-demarcated atrophic hypopigmented plaques with a parchment-like wrinkled surface and discretely hyperpigmented borders, involving the lower extremities, inguinal region, anterior trunk, and back. Residual depressed hyperpigmented macules were also present, corresponding to earlier lesions. No genital, oral, scalp, or nail involvement was identified.

Comprehensive clinicopathological reassessment and slide review demonstrated subtle epidermal atrophy, focal basal damage with pigment incontinence, a lichenoid inflammatory infiltrate separated from the epidermis, and superficial dermal collagen sclerosis entrapping the inflammatory band. These findings, integrated with the characteristic atrophic plaques on examination, established the diagnosis of disseminated purely extragenital Lichen sclerosus.

Therapy with narrowband UVB phototherapy twice weekly was maintained, with 35 sessions completed at reassessment. Intermittent topical Clobetasol propionate was prescribed for inflammatory flares, andTacrolimus was introduced as a steroid-sparing alternative. Systemic therapy was considered but deferred given the favorable early response. Follow-up demonstrated stabilization of disease activity and progressive lightening of lesions.

Conclusion

Extragenital Lichen sclerosus may occur in isolation and lacks the symptoms that frequently drive diagnosis in genital disease. In this patient, the initial presentation with hyperpigmented scaly plaques and histological pigment incontinence favored alternative diagnoses such as chronic pigmented dermatitis or interface dermatoses, delaying recognition. Repeated nondiagnostic biopsies likely reflected sampling during an early inflammatory phase before the emergence of overt sclerosis, a known pitfall in lichen sclerosus pathology.

This case is noteworthy because of the disseminated distribution, absence of genital involvement, three-year clinicopathological delay despite multiple biopsies, and misleading initial pathology reports. It underscores the importance of repeated clinical reassessment, close clinicopathological correlation, and expert histological review when persistent dyschromic or atrophic plaques remain unexplained. It also highlights narrowband UVB phototherapy as a valuable non-systemic option for extensive extragenital disease, particularly when topical therapy alone is insufficient or impractical.

EADV CONGRESS
VIENNA
30 SEP - 3 OCT 2026

Abstract N°: 1909

First-in-Class Anti-IL-7R x IL-4R Bispecific Antibody with Quadruple-Pathway Blockade: A Differentiated Strategy for the Treatment of Inflammatory Diseases

Wenwen Dai[1], Weikang Hou[1], Haichao Zhao[1], Xin Song[1], Hongyan Li[1], Xiaodong Liu[2], Yafeng Zhang[1], Mingjiu Chen*[1]

[1] Biosion, Inc., Nanjing, Jiangsu, China, Nanjing, China

[2] Biosion USA, Inc., Newark, DE, USA., Newark, United States

Introduction

Inflammatory diseases are driven by complex cytokine networks (Soumelis et al., 2002). Despite the success of current biologics and small-molecule inhibitors, significant unmet medical needs remain: 30-40% of atopic dermatitis (AD) patients fail to achieve clear skin (Paller et al., 2021). For alopecia areata (AA), current systemic JAK inhibitors require continuous dosing and carry systemic safety warnings (Gilhar et al., 2019). Similarly, vitiligo patients face a relapse rate of approximately 40% within a year of stopping treatment (Ezzedine et al., 2015). Mechanistically, IL-4 and IL-13 signal through IL-4Rα to drive barrier breakdown, while TSLP signals via the TSLPR/IL-7Rα heterodimer to initiate the inflammatory cascade and induce itch (Ziegler et al., 2013). Crucially, IL-7/IL-7Rα provides the obligate survival signal for Th2 Tissue-Resident Memory T cells (TRMs) in AD and autoreactive CD8+ TRMs in AA and vitiligo (Adachi et al., 2015; Boniface et al., 2018). Thus, single-pathway inhibition is insufficient to achieve durable remission.

We developed BSI-532, a first-in-class, Fc-silenced, half-life extended bispecific antibody simultaneously targeting IL-7R and IL-4R for a "vertical blockade"—simultaneously neutralizing upstream alarmins (TSLP), downstream effectors (IL-4, IL-13), and memory survival signals (IL-7). The objective of this study was to evaluate its preclinical binding, functional neutralization and synergistic efficacy.

Materials and Methods

Binding affinities to IL-7R and IL-4R were determined via surface plasmon resonance (SPR). Functional neutralization was evaluated through cell proliferation and STAT phosphorylation assays following ligand induction. Synergistic effects were assessed using primary T cells and also human peripheral blood mononuclear cells (PBMCs) stimulated with multi-cytokine combinations, measuring downstream cell proliferation and cytokine release.

Results

BSI-532 demonstrated simultaneous high-affinity binding to human IL-7R (K_D = 1.88 nM) and human IL-4R (K_D = 0.86 nM). It maintained single-target inhibitory activity and achieved potent quadruple blockade, effectively neutralizing IL-7, TSLP and IL-4, IL-13 signaling. In IL-7/IL-4 co-induced functional assays, BSI-532 achieved striking synergy, yielding 98% and 97% maximum inhibition of $CD4^+$ and $CD8^+$T cell proliferation, respectively. This significantly outperformed the monotherapy equivalents of Bempikibart (IL-7R antagonist, 75% and 82%) and Dupilumab (IL-4R antagonist 66% and 54%). Crucially, it simultaneously suppressed both the Th2 (CCL-17 release) and the Th1 inflammatory axes (IFNγ release). This broad immune modulation is essential for driving chronic disease states. BSI-532 utilized an engineered LALA YTE Fc to abrogate effector functions and extend half-life, and it maintained excellent biophysical stability and developability under accelerated thermal stress, indicating low developability risk.

Conclusions

BSI-532 differentiates itself through a multi-layer quadruple blockade that "shuts down" both innate and adaptive inflammatory signals. By addressing the limitations of single-pathway inhibition and directly "starving" the pathogenic TRMs that cause chronic relapse, this unique mechanism of action offers a compelling rationale for achieving durable, long-term remission and support its further development, with an IND submission anticipated in H1 2027.

EA DV CONGRESS
VIENNA
30 SEP - 3 OCT 2026

Abstract N°: 1914

Enoxaparin Injection-Site- Triggered Pemphigoid Gestationis: A RareAtypical Presentation and Proposed Isomorphic Mechanism.

Nada Alghamdi*[1], Yasmeen Alwaheed[2]

[1] saudi commission for health specialties, Eastern Province, Saudi Arabia

[2] Ministry of Health, Saudi Arabia, Eastern Province, Saudi Arabia

Introduction

Pemphigoid gestationis (PG), formerly known as herpes gestationis, is a rare, pregnancy-associated autoimmune subepidermal bullous disease. With an estimated incidence of approximately 1 in 50,000 pregnancies, it primarily occurs during the second or third trimester. The pathogenesis involves IgG1 autoantibodies targeting the NC16A domain of bullous pemphigoid antigen 180 (BP180), a protein essential for epidermal-dermal adhesion. Classically, PG presents with intense pruritus and an eruption starting in the periumbilical region in 90% of cases before spreading centrifugally. Diagnosis is confirmed via direct immunofluorescence (DIF), which reveals linear C3 deposits along the basement membrane zone (BMZ) in nearly 100% of cases. While various drugs have been linked to bullous pemphigoid (BP), the site-specific triggering of PG by low-molecular-weight heparins (LMWH) like enoxaparin is virtually undocumented. This case explores the Koebner (isomorphic) phenomenon—where lesions arise at sites of trauma—as a potential mechanism for PG initiation.

Case Presentation

A 39-year-old female (G4P3) at 24 weeks gestation presented with a two-week history of pruritic bullae exclusively at sites where she self-administered prophylactic enoxaparin injections. The patient had started enoxaparin two months prior and injected daily into alternating thighs. Upon developing tense bullae and intense pruritus at these sites, she was initially treated with fusidic acid and betamethasone without success. After relocating injections to her upper arms, new bullae appeared at the new sites within 72 hours, suggesting a reproducible, site-dependent pattern.

Examination revealed confluent, edematous plaques with eroded and intact tense bullae on the thighs, tiny vesicles on the left wrist, and excoriation marks on the forearms and abdomen. Histopathology showed subepidermal blistering with neutrophils and eosinophils, while DIF demonstrated linear C3 deposits along the BMZ, confirming a diagnosis of PG. Following the discontinuation of enoxaparin and the initiation of a prednisolone taper (50 mg daily) and topical mometasone furoate, the patient's condition improved significantly. Targetoid plaques—an atypical morphological variant of PG—briefly appeared on the forearms and abdomen during follow-up before resolution.

Conclusion

This rare case of enoxaparin injection-site-triggered PG challenges the classical periumbilical diagnostic paradigm. The strict localization and rapid replication of bullae at new injection sites suggest that the Koebner phenomenon, driven by mechanical trauma and local pharmacological inflammation, acted as the isomorphic trigger for disease onset in an immunologically primed patient. Establishing an autoimmune diagnosis via DIF was critical to distinguish this presentation from enoxaparin-induced bullous hemorrhagic dermatosis or fixed drug eruptions.

Because PG is associated with increased risks of preterm birth and small-for-gestational-age infants, early recognition of atypical, non-periumbilical presentations is vital for optimizing maternal and fetal outcomes. Clinicians should maintain a high index of suspicion for PG in pregnant patients with bullous eruptions at injection sites.

EADV CONGRESS
VIENNA
30 SEP - 3 OCT 2026

Abstract N°: 1922

Long-term Real-World Effectiveness and Safety of Topical Ruxolitinib With or Without Phototherapy in Patients With Non-Segmental Vitiligo

Jose Luis Lopez-Estebaranz*[1], Alejandra Méndez Valdés[1], JAVIER MARTIN ALCALDE[1], Sara de Benito Mendieta[1], Lucía Martínez Rozas[1], Jose Maria Añibarro Vega[1], Marta López-Pando[1]

[1] Hospital Universitario Fundacion Alcorcon, DermoMedic Center, Madrid, Spain

Introduction
Vitiligo is a chronic autoimmune disorder affecting 0.2–1.5% of the population and associated with substantial psychosocial burden. Topical ruxolitinib, a selective JAK1/2 inhibitor, has recently expanded therapeutic options for non-segmental vitiligo. However, real-world evidence on long-term outcomes and on combination strategies with phototherapy remains scarce.
Objective: To describe baseline characteristics, long-term effectiveness (VASI, PGA), and safety of ruxolitinib cream in patients with vitiligo treated in routine clinical practice, including those receiving concomitant phototherapy.

Materials and Methods
A retrospective observational study was conducted in two dermatology centers including consecutive patients who initiated ruxolitinib cream between 2024 and 2025. Demographics, phototype, disease stability, body surface area (BSA), lesion distribution, vitamin D levels, and concomitant therapies were collected. Effectiveness was assessed using F-VASI, T-VASI, and PGA at weeks 12, 24, and 56. Safety outcomes were recorded throughout follow-up. Concomitant phototherapy included excimer light, narrowband UVB (NB-UVB), or heliotherapy.

Results
: Sixty-six patients were included (65% female; median age 48 years). Phototypes were II 9%, III 35%, IV 30%, and not evaluated 26%. Disease was stable in 52%, and genital involvement was present in 27%. Median BSA was 6%. Concomitant phototherapy was used in 47% of patients (excimer 19.7%, NB-UVB 13.6%, heliotherapy 13.6%). Vitamin D deficiency was identified in 40%.

Effectiveness: • **Week 12:** F-VASI50 72%, F-VASI75 44%; T-VASI50 56.5%, T-VASI75 30.4%. •**Week 24:** F-VASI50 83%, F-VASI75 61%; T-VASI50 70%, T-VASI75 40%. • **Week 56:** F-VASI50 71%, F-VASI75 57%; T-VASI50 57%, T-VASI75 43%.

Patients receiving ruxolitinib plus phototherapy showed faster and more pronounced repigmentation, particularly in facial areas, compared with those on monotherapy.
Safety: Adverse events occurred in 9% of patients, were mild (mainly acne and pruritus), and did not lead to treatment discontinuation.

Conclusions
In this real-world cohort with at least one year of follow-up, topical ruxolitinib demonstrated high and sustained

repigmentation rates with an excellent safety profile. Combination therapy with excimer light or NB-UVB was associated with accelerated and enhanced clinical responses. These findings support ruxolitinib cream as a central component of long-term vitiligo management and highlight the added value of integrating targeted therapy with phototherapy in routine practice

EA DV CONGRESS
VIENNA
30 SEP - 3 OCT 2026

Abstract N°: 1935

Behind a scratching lesion: an unexpected diagnosis of lichen striatus

Sihame Alaoui*[1], Kenza Benothmane[1], Najoua Ammar[1], Syrine Hamada[1], Nadia Ismaili[1], Laila Benzekri[1], Mariam Meziane[1]

[1] Ibn Sina University Hospital, Rabat, Morocco

Introduction

The Koebner phenomenon refers to the development of typical lesions of a dermatosis on previously unaffected skin following trauma. While it is well described in inflammatory dermatoses such as psoriasis and lichen planus, its role in lichen striatus is rarely reported. Lichen striatus is an acquired inflammatory dermatosis characterized by a linear eruption following Blaschko's lines, likely related to an immune response targeting mosaic keratinocyte clones.



Linear erythematous to violaceous papular lesions with scaling and crusting on the left cheek, arranged in a linear distribution corresponding to the site of prior trauma.

Case Presentation

A 33-year-old woman with no significant medical history presented with a lesion on the left cheek evolving over 5 months, initially considered a scratching lesion and unsuccessfully treated with topical corticosteroids and antibiotics.

Clinical examination revealed a linear pruritic hyperpigmented lesion on an erythematous-violaceous background, covered with whitish scales, following the site of the initial trauma.

Dermoscopy showed an erythematous background, whitish scaling, peppering, follicular keratotic plugs, and shiny white structures.

Histopathological examination demonstrated hyperkeratosis, basal layer alterations, a superficial dermal lymphocytic infiltrate, and numerous melanophages. Additional investigations were negative.

The overall findings supported the diagnosis of lichen striatus, likely triggered by a Koebner phenomenon.

Treatment with systemic corticosteroids combined with topical tacrolimus, photoprotection, and adjuvant therapies led to progressive improvement over 3 months.

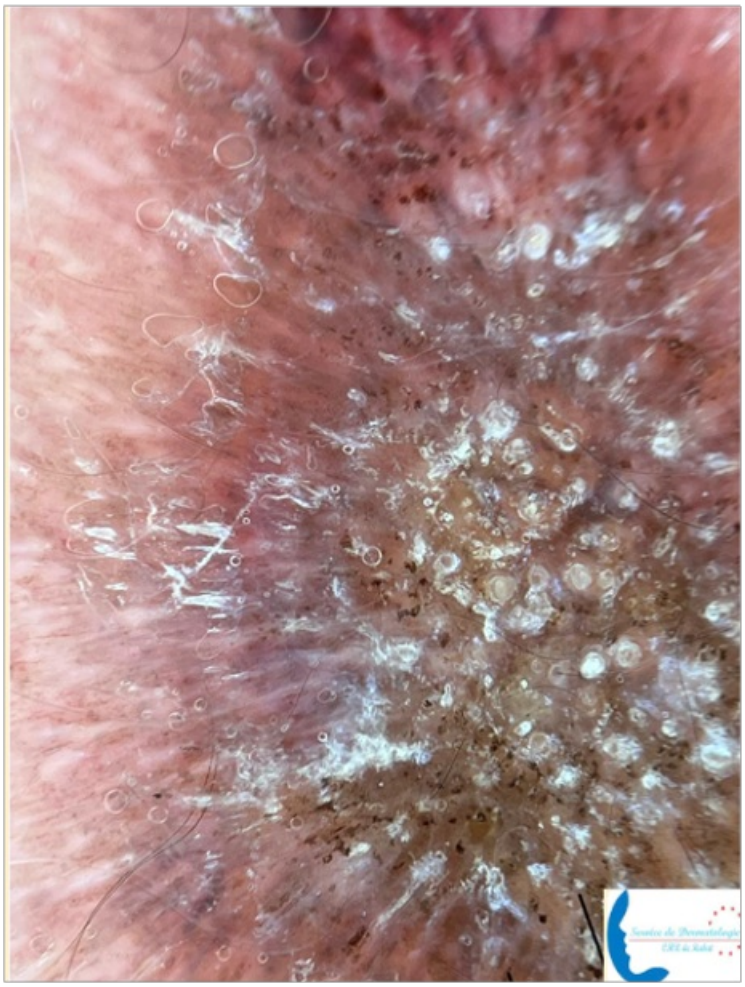

Dermoscopy showing an erythematous background with diffuse whitish scaling, brown-grey peppering, follicular keratotic plugs, and multiple shiny white structures.

Conclusion

This case illustrates an unusual presentation of lichen striatus revealed by cutaneous trauma, suggesting a Koebner phenomenon. It highlights the importance of considering this diagnosis in persistent linear lesions and

emphasizes the role of clinicodermoscopic and histopathological correlation to avoid misdiagnosis and guide appropriate management.

EADV CONGRESS
VIENNA
30 SEP - 3 OCT 2026

Abstract N°: 1939

TOPICAL RUXOLITINIB IN NON-SEGMENTAL VITILIGO: REAL-WORLD OUTCOMES IN TERTIARY HOSPITAL SETTING

Iñigo Sánchez Benítez*[1], Iker Narvaez[1], Barbara Lada[1], Ane Lobato[1], Isabel Gainza[1], Rosa María Izu[1]

[1] HOSPITAL UNIVERSITARIO DE BASURTO, Bilbao, Spain

Introduction
Non-segmental vitiligo is an autoimmune dermatosis driven by the IFN-γ/JAK-STAT signaling pathway. Topical ruxolitinib, a selective JAK1/2 inhibitor, has demonstrated efficacy in clinical trials; however, validation in real-world clinical practice remains essential. The aim of this study is to describe the preliminary effectiveness and safety of ruxolitinib cream in patients with vitiligo.

Materials and Methods
A retrospective descriptive study was conducted including patients with vitiligo treated with ruxolitinib 1.5% cream in the Dermatology outpatient clinics of a tertiary care hospital. Demographic and clinical variables, prior treatments, disease type and extent were collected. Treatment response was assessed using BSA, VASI, and F-VASI at baseline and at 6 months. Repigmentation patterns and adverse events were also recorded.

Results
A total of 45 patients were included, showing a balanced sex distribution and a wide range of ages and phototypes. Most patients had received prior therapies, including topical corticosteroids, calcineurin inhibitors, and phototherapy. Preliminary analysis demonstrates clinical improvement in a substantial proportion of cases, particularly in facial involvement, with a reduction in F-VASI at 6 months. Repigmentation patterns were predominantly follicular and marginal. Treatment was well tolerated, with mild local adverse effects and no relevant systemic events.

Conclusions
Preliminary real-world data support the use of topical ruxolitinib as an effective and safe targeted therapy for vitiligo, with particularly favorable outcomes in facial involvement. Final analysis will better define the magnitude of response and predictive factors.

EADV CONGRESS
VIENNA
30 SEP - 3 OCT 2026

Abstract N°: 1946

From Skin to Bone: A Case of Pediatric Deep Morphea with Musculotendinous Involvement

Ouissal Laadime*[1], Bendaoud Layla[1], nouhaila Bourht[1], kenza allali[1], Mariem Aboudourib[1], ouafa hocar[1], Amal Said[1]

[1] Department of Dermatology and Venereology, Arrazi Hospital, Mohammed VI University Hospital Center, Marrakech, Morocco

Introduction

Deep morphea is a rare form of localized scleroderma in children, affecting the deep dermis, the aponeurosis, and sometimes the muscle. It leads to significant musculoskeletal deformities and can present diagnostic and therapeutic challenges.

Case Presentation

We report the case of a 6-year-old child with no significant medical history, referred for a right equinus foot and limb length discrepancy. According to the parents, the first lesions appeared at the time of walking. Clinical examination revealed a hardened sclerotic-atrophic plaque on the outer surface of the right thigh, associated with orthopedic deformities but no other visible skin lesions. Biopsies of the skin, aponeurosis, and muscle showed dense and extensive fibrosis with hyalinization, loss of normal architecture, and a minimal lymphoplasmacytic inflammatory infiltrate, without signs of malignancy. Lower limb MRI confirmed moderate muscle hypotrophy with early fatty infiltration, without mass or collection, as well as a valgus deformity of the right femoral neck with anterior orientation of the femoral head. A signal abnormality in the metaphyseal-epiphyseal region of the lower end of the left femur was noted on STIR hyperintensity and T1 hypointensity, suggesting bone edema adjacent to the cutaneous-muscular involvement, raising the possibility of reactive bone involvement associated with deep morphea. Given the functional progression and musculoskeletal impact, the child was treated with systemic corticosteroids and methotrexate, along with orthopedic follow-up.

Conclusion

This case illustrates the need for early suspicion of deep morphea in any child presenting with a sclerotic-atrophic plaque associated with musculoskeletal deformity. Diagnostic confirmation relies on clinical, histological, and radiological correlation. A multidisciplinary approach and early immunosuppressive treatment are essential to limit disease progression and prevent severe functional complications.

EADV CONGRESS
VIENNA
30 SEP - 3 OCT 2026

Abstract N°: 1947

Adult-Onset Purpura Revealing Cryoglobulinemia Secondary to Early Rhupus Syndrome: A Case Report

Ouissal Laadime*[1], Bendaoud Layla[1], houda azour[1], Mariem Aboudourib[1], ouafa hocar[1], Amal Said[1]

[1] Department of Dermatology and Venereology, Arrazi Hospital, Mohammed VI University Hospital Center, Marrakech, Morocco

Introduction

Adult-onset vascular purpura is a common reason for consultation and may represent the first clinical manifestation of an underlying systemic disease. Among its etiologies, cryoglobulinemia occupies a particular place due to its strong association with autoimmune disorders. Rhupus syndrome, a rare overlap condition combining features of systemic lupus erythematosus (SLE) and rheumatoid arthritis (RA), is an uncommon entity. Its association with cryoglobulinemia has only exceptionally been reported. We describe a case in which vascular purpura was the inaugural manifestation of cryoglobulinemia secondary to early rhupus syndrome.

Case Presentation

A 61-year-old woman with no significant past medical history was hospitalized for vascular purpura associated with inflammatory arthralgia. Skin biopsy revealed leukocytoclastic vasculitis, and direct immunofluorescence showed IgA deposits, consistent with IgA vasculitis. Immunological investigations demonstrated positive cryoglobulinemia (typing pending), polyclonal hypergammaglobulinemia, positive antinuclear antibodies, positive anti-Sm antibodies, and positive anti-cyclic citrullinated peptide (anti-CCP) antibodies. The patient was treated with colchicine at a dose of 1 mg/day, resulting in marked improvement of purpuric lesions, and was subsequently referred to the internal medicine department for further management of cryoglobulinemia.

Conclusion

This case highlights that adult-onset vascular purpura may reveal cryoglobulinemia secondary to rhupus syndrome. It demonstrates that this rare overlap condition can initially present with vascular complications before classical lupic or articular manifestations become evident. Systematic screening for underlying autoimmune diseases should be performed in cases of vascular purpura associated with positive cryoglobulinemia, including rare overlap syndromes such as rhupus.

EA DV CONGRESS
VIENNA
30 SEP - 3 OCT 2026

Abstract N°: 1964

Rare association of genital vitiligo and hypothyroidism in a child with DiGeorge syndrome

Sihame Alaoui*[1], Syrine Hamada[1], Najoua Ammar[1], Nadia Ismaili[1], Mariam Meziane[1], Laila Benzekri[1]

[1] Ibn Sina University Hospital, Rabat, Morocco

Introduction

DiGeorge syndrome (22q11.2 deletion) is a genetic disorder characterized by immune dysregulation, predisposing to autoimmune diseases. Thyroid disorders are among the most frequently reported manifestations, whereas cutaneous autoimmune conditions such as vitiligo remain uncommon. Their association in pediatric patients is rarely described.

Case Presentation

A 6-year-old girl with a known history of DiGeorge syndrome and hypothyroidism under replacement therapy presented with localized depigmentation of the genital area.

Clinical examination revealed well-defined achromic macules without infiltration or associated inflammatory signs. No other cutaneous lesions or mucosal involvement were observed. The general condition was preserved.

In the context of immune dysregulation related to DiGeorge syndrome and associated thyroid disease, a diagnosis of localized genital vitiligo was established.



Well-demarcated achromic patches involving the genital and anal regions, with erythema.

Conclusion

This case highlights a rare association of genital vitiligo and hypothyroidism in a child with DiGeorge syndrome. It underscores the importance of screening for cutaneous autoimmune manifestations in this context to ensure early diagnosis and appropriate management.

EADV CONGRESS
VIENNA
30 SEP - 3 OCT 2026

Abstract N°: 2012

Deep Cutaneous Lupus in Childhood: A Rare Entity with ClinicopathologicalDiagnostic Challenges

Luis Daniel Pérez Cáceres*[1], Monica Paola Novoa Candia[2], gabriella gonzález franco[1]

[1] Fundación Universitaria Sanitas, Bogotá, Colombia

[2] E.S.E. Centro Dermatológico Federico Lleras Acosta, BOGOTA, Colombia

Introduction

Lupus erythematosus profundus (LEP) is an uncommon variant of chronic cutaneous lupus that affects the subcutaneous tissue. It has been described in association with discoid lupus, although it may also occur in isolation or, less frequently, as a manifestation associated with systemic lupus erythematosus. Clinically, LEP presents as recurrent, indurated subcutaneous plaques or nodules, with a predilection for the proximal extremities, face, and scalp, and may result in permanent lipoatrophy. In adults, it accounts for 1–3% of cutaneous lupus cases and predominantly affects women between 20 and 60 years of age. In contrast it is extremely rare in the pediatric population. In a 22-year retrospective review, only 10 pediatric patients with LEP were identified. We present the case of an 11-year-old boy with a three-month history of facial and scalp lesions, in whom LEP was confirmed without association with systemic lupus erythematosus.

Materials and Methods

An 11-year-old, with no relevant medical history, presented with a three-month history of localized occipital alopecia and progressively enlarging multifocal infiltrated facial lesions. Physical examination revealed erythematous-violaceous nodules on the left nasolabial fold, nasal dorsum, and right cheek, along with an indurated infiltrated alopecic plaque measuring 2 × 2.5 cm in occipital region. A small, mobile, non-tender cervical lymph node was palpated, with no other significant findings on examination.

Given the suspicion of LEP, with subcutaneous panniculitis-like T-cell lymphoma as a differential diagnosis, biopsies of the cheek and scalp lesions were performed. Histopathological examination showed an epidermis without interface activity, with hyperkeratosis and follicular plugging, and a mononuclear lymphohistiocytic infiltrate forming nodular aggregates accompanied by plasma cells. At the subcutaneous level, lobular panniculitis associated with a granulomatous process was observed. Additionally, follicular destruction, basement membrane thickening (PAS), and interstitial mucin deposition (Alcian blue) were identified, findings collectively suggestive of LEP.

Further workup revealed low-titer positive antinuclear antibodies (ANA, 1:80), with negative extractable nuclear antigens and lupus-specific antibodies. Complement levels were normal, and no systemic involvement was documented. Treatment was initiated with hydroxychloroquine (5 mg/kg/day) and tapering prednisolone, resulting in significant clinical improvement at 45 days.

Results

Cutaneous lupus may progress to systemic disease (0–42% in adults and 0–31% in pediatric patients), thus requiring ongoing clinical and laboratory monitoring, with higher risk in patients presenting with more diagnostic criteria. Initial evaluation includes complete blood count, acute phase reactants, creatinine, urinalysis, and immunological profile including ANA, ENA, anti-dsDNA, and complement levels.

The main differential diagnosis is subcutaneous panniculitis-like T-cell lymphoma, an entity associated with higher

morbidity and mortality. Clinically, LEP more frequently involves the face and scalp and usually lacks systemic symptoms, whereas lymphoma predominantly affects the extremities and is associated with fever and cytopenia. Histologically, the presence of mucin, plasma cells, and B-cell aggregates favor LEP, while lymphocytic atypia, erythrophagocytosis, and atypical CD8+ lymphocytes suggest lymphoma.

Antimalarials, particularly hydroxychloroquine, are the first-line treatment; systemic corticosteroids are reserved for short-term use in severe disease. Immunosuppressive agents may be considered in refractory cases.

Conclusions

Early recognition of LEP and its appropriate differentiation from panniculitis-like lymphoma are essential to avoid diagnostic delays, optimize therapeutic management, and improve prognosis, which differs significantly between these two entities.

EA DV CONGRESS
VIENNA
30 SEP - 3 OCT 2026

Abstract N°: 2015

Extensive Vitiligo Triggered by Alpha-Interferon in a Patient with Chronic Hepatitis C: A Case Report

Maria Eduarda Cesar Garcez*[1], Julia Cascardo Géo de Siqueira[1], Amanda Quintaes[1], Luna Azulay-Abulafia[1]

[1] Pedro Ernesto University Hospital (HUPE), State University of Rio de Janeiro (UERJ), Rio de Janeiro, Brazil

Introduction

Chronic hepatitis C virus (HCV) infection may be associated with extrahepatic manifestations, including cutaneous involvement. In addition to the disease itself, alpha-interferon, historically used in HCV treatment, has been linked to dermatological and immune-mediated adverse events. Among these, interferon-induced vitiligo is considered rare and has been reported as a presumed autoimmune mechanism involving activation of cytotoxic lymphocytes and induction of autoantibodies against melanocytes. The literature also indicates that lesions may persist even after discontinuation of antiviral therapy. We report a striking case of extensive vitiligo triggered after alpha-interferon therapy for chronic hepatitis C, highlighting its rarity, persistent progression, and therapeutic implications.

Case Presentation

A 60-year-old man with chronic HCV infection diagnosed in 1994 underwent initial treatment shortly after diagnosis, without therapeutic response. In 2005, he underwent a second treatment attempt with alpha-interferon, again without virological success. One month after treatment initiation, he developed hypochromic lesions that progressed to achromic patches on the right upper limb, followed by involvement of the face, especially the frontal region, left upper limb, anterior chest, back, abdomen, lower limbs, and genital area. Over the years, the lesions progressively increased in extent. In 2010, he underwent phototherapy, the only dermatological treatment performed, without effective response, followed by loss to follow-up. In 2016, he received a new HCV treatment with Sofosbuvir, Daclatasvir, and Ribavirin, achieving virological response; however, the cutaneous lesions continued to progress. He is currently under follow-up in the hospital's Dermatology and Hepatology Departments of the hospital.

On follow-up examination, the patient presented with extensive vitiligo involving more than 80% of the body surface area. The chronology, with lesion onset after alpha-interferon initiation and subsequent progression, supported the diagnosis of extensive vitiligo triggered by alpha-interferon used in chronic hepatitis C treatment. The literature describes vitiligo associated with interferon in HCV patients as uncommon but well documented, with onset occurring weeks to months after treatment initiation; in the largest case series identified, comprising eight patients, the interval ranged from one week to three months. Persistent achromic macules after discontinuation of therapy have also been reported.

A diagnosis of extensive vitiligo probably induced by alpha-interferon was established based on the temporal relationship between drug exposure and lesion onset, as well as the subsequent progressive dissemination of depigmentation. Given the marked extent of involvement and the absence of response to prior phototherapy, depigmentation of the remaining preserved areas with phenolic agents or cryotherapy was considered a plausible therapeutic option. The patient remains under specialised follow-up.

Conclusion

This case illustrates an extensive presentation of vitiligo probably induced by alpha-interferon in the setting of chronic hepatitis C, with persistent progression even after subsequent HCV therapies and no response to phototherapy. The literature reinforces that, although rare, this association should be recognised, particularly in the presence of a clear temporal relationship between interferon initiation and lesion onset, as well as the

possibility of prolonged persistence of cutaneous manifestations. In this case, the magnitude of involvement makes depigmentation of the residual preserved areas with phenolic agents or cryotherapy a plausible therapeutic alternative, while maintaining specialised follow-up. This report underscores the importance of dermatological surveillance in patients exposed to interferon and adds to the documentation of severe autoimmune cutaneous manifestations related to its use.

EADV CONGRESS
VIENNA
30 SEP - 3 OCT 2026

Abstract N°: 2029

Description of cutaneous and systemic sarcoidosis in Spain, a retrospective study

Alfonso Gotor-Rivera*[1], Carmen Romero Ferreiro[2], María Carpy[1], Julian Acosta-Hernández[1], José Alejo Fernández-Baillo[1], José Luis Rodríguez Peralto[1], Virginia Velasco-Tamariz[1]

[1] Hospital Universitario 12 De Octubre, Madrid, Spain

[2] Universidad Francisco de Vitoria, Pozuelo de Alarcón, Spain

Introduction

Sarcoidosis is a multisystem granulomatous disease commonly involving the lungs, lymph nodes, eyes and skin; although virtually any organ may be involved. Though it has been reported to affect all ethnicities, ages and both sexes, typically shows a bimodal age distribution (25-35 and 45-55 years) with a slight female predominance. Cutaneous involvement is reported in 20-35% of patients with systemic sarcoidosis, and often is the initial manifestation of the disease.

Cutaneous sarcoidosis is classically divided into specific and non-specific lesions based on histopathology. Specific lesions demonstrate non-caseating, "naked", granulomas, and clinically may present as maculopapular exanthema, chronic plaques, subcutaneous nodules, scar sarcoidosis, lupus pernio or other descriptions. Non-specific lesions exhibit a reactive inflammatory pattern, such as erythema nodosum, erythema multiforme, calcifications or prurigo.

Materials and Methods

We conducted a retrospective observational single-center study of cases diagnosed with sarcoidosis. We identified patients with a histopathological diagnosis of "sarcoid granuloma" or sarcoidosis" in any organ between January 2010 to September 2025. Of 842 cases retrieved, only 157 were included in the study after exclusion of patients with insufficient follow-up, alternative diagnosis or non-confirmed sarcoidosis. Cases with a sarcoid granulomatous foreign body reaction pattern were also excluded. A retrospective review of medical records was conducted to retrieve demographic data, comorbidities, clinical features, laboratory finding, diagnostic workup and treatments.

Results

Age at diagnosis range from 13 to 81 years, with a mean of 50.18 years. There was a slight male predominance (60.96%) in the global cohort, and the largest proportion of patients (28.03%) were in their sixth decade of life.

Cutaneous involvement was present in 47 (29.94%) of patients, of whom 35 (74.47%) also had systemic disease. In cases with both systemic and cutaneous involvement the most common presentation was simultaneous (40%), followed by systemic onset (34.29%). Mean time to systemic involvement after cutaneous onset was 0.58 (0.98) years. Duration of skin lesion range from 1 to 120 months, with a mean of 25.25 (24.40) months. Most frequent morphologies were maculopapular eruptions and plaques (42.55% each). Non-specific lesions were observed in eight patients, predominantly erythema nodosum (87.50%), with one case of prurigo.

Systemic involvement was identified in 145 patients (92.36%), of whom 24.14% had associated cutaneous sarcoidosis. Pulmonary involvement was the most frequent manifestation (143 cases), followed by lymph node

and joint involvement.

All patients underwent chest radiography and routine laboratory testing, with blood count, liver and renal function, and C-reactive protein. Mean serum angiotensin-converting enzyme level was 82.31 (68.99) U/L, mean calcium was 10.16 (4.80) mg/dL and mean vitamin D level was 21.90 (12.94) ng/mL. Screening for latent tuberculous infection was performed in 79.62% of patients, with a positivity rate of 13.60%. Urinalysis was available in 80.13%, pulmonary function test in 87.16% and chest computed tomography in 92.36%. Cardiological evaluation (including EKG) was performed in 79.62% of patients, dermatological assessment in 43.31%, ophthalmological evaluation in 41.1%, neurologic assessment in 21.02% and otorhinolaryngological evaluation in 10.83%.

No specific cutaneous phenotype, laboratory parameter or treatment modality was associated with the development of systemic sarcoidosis. Absence of treatment for systemic sarcoidosis (RR 1.56; p=0.037), involvement of multiple organs (RR 1.72; p=0.020) and treatment with methotrexate (RR 1.59, p=0.001) was associated with developing cutaneous sarcoidosis.

Conclusions

This single-centre retrospective study of biopsy-confirmed sarcoidosis highlights the clinical spectrum of cutaneous and systemic disease.

EA DV CONGRESS
VIENNA
30 SEP - 3 OCT 2026

Abstract N°: 2055

Comparative Safety and Steroid-Sparing Efficacy of Dupilumab Versus Traditional Immunosuppressants in Bullous Pemphigoid: A Retrospective Cohort Study

Khalaf Kridin*[1], Ralf Ludwig[2]

[1] Galilee Medical Center, Nahariya, Israel, Nahariya, Israel

[2] University of Lubeck, Lubeck, Germany, Lübeck, Germany

Introduction

The management of bullous pemphigoid (BP) traditionally relies on long-term systemic corticosteroids, necessitating effective and safe steroid-sparing agents to minimize adverse effects. While dupilumab has emerged as a promising targeted therapy, large-scale comparative data remains limited. We aimed to evaluate the safety, efficacy, and steroid-sparing potential of dupilumab compared to methotrexate (MTX), mycophenolate mofetil (MMF), and azathioprine (AZA) in a real-world BP population

Materials and Methods

We conducted a retrospective cohort study utilizing the TriNetX global health research network After matching for baseline characteristics, we analyzed three distinct cohorts of BP patients initiating dupilumab versus MTX (N=1,086 per group) , dupilumab versus MMF (N=1,372 per group), and dupilumab versus AZA (N=660 per group). The primary outcomes were the 3-year risk of mortality and systemic complications Secondary outcomes included the risk of disease relapse and the use of systemic corticosteroids at one and two years post-initiation.

Results

Baseline characteristics were well-balanced, with a mean patient age ranging from 72.2 to 73.6 years across cohorts. Over the 3-year follow-up, dupilumab was associated with a significantly reduced risk of herpes zoster (1.3% vs. 3.3%; HR 0.53; P=0.049) and osteoporosis (2.8% vs. 6.5%; HR 0.63; P=0.047) compared to MTX. Against MMF, dupilumab showed significantly lower risks of herpes zoster (1.6% vs. 4.2%; HR 0.50; P=0.005) and myocardial infarction (3.2% vs. 6.4%; HR 0.65; P=0.021). Compared to AZA, dupilumab significantly reduced the risk of incident type 2 diabetes mellitus (24.0% vs. 33.4%; HR 0.73; P=0.002). Mortality rates were not significantly different across groups, though they trended lower for dupilumab versus AZA (10.4% vs. 19.8%; HR 0.76; P=0.076). Crucially, dupilumab significantly reduced the need for systemic corticosteroids after one year compared to MTX (12.0% vs. 35.8%; HR 0.68; P<0.001) and MMF (13.1% vs. 31.3%; HR 0.79; P=0.013). This steroid-sparing effect persisted at year two against both MTX (4.6% vs. 25.5%; HR 0.67; P=0.012) and MMF (5.02% vs. 22.0%; HR 0.75; P=0.038). Corticosteroid use did not significantly differ between dupilumab and AZA Relapse rates remained statistically similar between dupilumab and all comparators across all observed time points.

Conclusions

Dupilumab provides superior, sustained steroid-sparing benefits compared to MTX and MMF, without a significant difference in relapse rates. Additionally, dupilumab offers a robust safety advantage by significantly reducing the risk of severe systemic and metabolic complications, supporting its use as a highly effective steroid-sparing agent in BP management.

EADV CONGRESS
VIENNA
30 SEP - 3 OCT 2026

Abstract N°: 2062

Atypical manifestation of cutaneous borreliosis mimicking the holster sign in a patient with dermatomyositis – a case report.

Maria Zasadzińska[1], Natalia Dąbrowska[1], Aleksandra Anderson[1], Malgorzata Maj*[1], Marta Kurzeja[1], Joanna Czuwara[1], Lidia Rudnicka[1]

[1] Department of Dermatology, Medical University of Warsaw, Warsaw, Poland

Introduction

Dermatomyositis (DM) is an autoimmune inflammatory myopathy characterized by proximal muscle weakness and typical cutaneous manifestations, including the "holster sign" – violaceous erythema on the lateral thighs. Due to its heterogenic clinical picture, it may be misdiagnosed with various dermatoses, especially in immunocompromised patients. Herein, we present a case of atypical cutaneous borreliosis mimicking the holster sign in a patient with established dermatomyositis.

Case Presentation

A 71-year-old female patient with anti-Mi-2 positive dermatomyositis was admitted for evaluation of disease activity. The patient was treated with alternating doses of prednisone and hydroxychloroquine.

Upon physical examination, violet erythema on the skin over the metacarpophalangeal and proximal and distal interphalangeal joints and erythematous lesions on the skin of the upper chest were observed. Additionally, the patient reported a pruritic, progressively enlarging, 10–12 cm erythematous-infiltrating lesion on the right lateral thigh of 6 months' duration. The initial clinical observation led to the lesion being identified as the "holster sign". However, when asked for detailed medical history, the patient reported a tick bite at the same site of the lesion was reported.

The videodermoscopy of the lesion revealed polymorphic vessels (dotted and comma-like vessels) on erythematous background. The line-field confocal optical coherence tomography (LC-OCT) imaging in vertical, horizontal, and 3D modes showed perivascular infiltration of small hyper-reflective cells corresponding to inflammatory cells. Additionally, a lesional skin biopsy was performed. Histopathologic examination revealed a perivascular inflammatory infiltrate, diffusely distributed around eccrine glands and between collagen fibers, along with dilated superficial blood and lymphatic vessels with endothelial cell edema and bands of degenerating collagen.

Based on these findings, borreliosis was suspected. Serological testing revealed negative IgM and positive IgG on ELISA, confirmed by Western blot. The patient was treated with doxycycline 200 mg daily, with the regression of the disease.

Conclusion

In the presented case, an atypical manifestation of borreliosis was mimicking the classical holster sign in patient with dermatomyositis. A comprehensive history along with histopathological findings of a predominantly superficial perivascular and peri-eccrine lymphocytic infiltrate with dilated superficial vessels and collagen degeneration, contrasting with the usual vacuolar interface dermatitis of DM, supported the diagnosis of

cutaneous borreliosis. The clinical suspicion of borreliosis confirmed with histopathological and serological examintation prevented unnecessary escalation of immunosuppressive therapy of DM. Careful reassessment of persistent or atypical skin lesions, supported by histopathology and serology, is essential to avoid misdiagnosis and ensure appropriate treatment.

EA DV CONGRESS
VIENNA
30 SEP - 3 OCT 2026

Abstract N°: 2080

Neumann-type pemphigus vegetans mimicking squamous cell carcinoma in a patient with pemphigus vulgaris

Monaly da Silva Ribeiro*[1, 2], Mariana Menezes de Mauro[1, 3], Carminia Zelmy Rivas Ulunque[1, 4], Bruna Patrícia Ifanger[1, 5], Luísa Scaravelli Mario[1, 6], Ricardo Tadeu Villa[1], Gustavo Bedin[1]

[1] Advanced Dermatology Institute, São Paulo, Brazil
[2] Faculdade São Leopoldo Mandic, Campinas, Brazil
[3] Universidade São Francisco, Bragança Paulista, Brazil
[4] Universidad Mayor de San Simón, Cochabamba, Bolivia
[5] Universidade Antônio Carlos, Juiz de Fora, Brazil
[6] Universidade Comunitária da Região de Chapecó, Chapecó, Brazil

Introduction
Pemphigus vegetans is a rare variant of pemphigus vulgaris, representing 1–2% of cases, characterized by vegetating, verrucous, or papillomatous plaques originating from vesiculobullous lesions. It preferentially affects intertriginous areas, but can also involve non-flexural sites, such as the scalp. The Neumann subtype has a more persistent and aggressive course, frequently beginning as classic pemphigus vulgaris with subsequent phenotypic transition to vegetating lesions. Its clinical presentation can mimic proliferative and neoplastic conditions, especially squamous cell carcinoma, representing a significant diagnostic challenge, particularly in immunosuppressed patients.

Neumann-type pemphigus vegetans mimicking squamous cell carcinoma in a patient with pemphigus vulgaris

Introduction:

Pemphigus vegetans is a rare variant of pemphigus vulgaris, representing 1–2% of cases, characterized by vegetating, verrucous, or papillomatous plaques originating from vesiculobullous lesions. It preferentially affects intertriginous areas, but can also involve non-flexural sites, such as the scalp. The Neumann subtype has a more persistent and aggressive course, frequently beginning as classic pemphigus vulgaris with subsequent phenotypic transition to vegetating lesions. Its clinical presentation can mimic proliferative and neoplastic conditions, especially squamous cell carcinoma, representing a significant diagnostic challenge, particularly in immunosuppressed patients.

Case Presentation

A 62-year-old male patient, with a previous diagnosis of pemphigus vulgaris confirmed by two biopsies showing suprabasal cleavage and acantholysis, presented a new suspicious lesion in the frontal region of the scalp during the gradual withdrawal of systemic corticosteroids. The patient's medical history included hypertension, dyslipidemia, atrial fibrillation, and long-term smoking. The initial disease affected the oral mucosa and scalp, with a significant response to high-dose corticosteroid therapy. A new lesion presented as an exophytic, verrucous, and hyperkeratotic plaque with extensive scaling and patterns consistent with squamous cell carcinoma. Dermatoscopic evaluation revealed nonspecific patterns, without criteria to exclude truly malignant neoplasms, maintaining a high diagnostic suspicion of squamous cell carcinoma. Given this scenario, an excisional biopsy was performed for diagnostic clarification. Histopathological analysis revealed marked epidermal hyperplasia with papillomatosis, hyperkeratosis, and focal parakeratosis, associated with the presence of multiple suprabasal clefts containing acantholytic cells. Involvement of the follicular infundibulum and a dense lymphoplasmacytic dermal inflammatory infiltrate with eosinophils were also observed. No signs of dysplasia or malignancy were identified. The results confirmed the diagnosis of pemphigus vegetans, Neumann subtype. After diagnostic confirmation, the patient continued follow-up with a gradual reduction in the dose of corticosteroids, paying attention to therapeutic intensification, including rituximab, according to clinical evolution.

Neumann-type pemphigus vegetans mimicking squamous cell carcinoma in a patient with pemphigus vulgaris

Case Presentation:

A 62-year-old male patient, with a previous diagnosis of pemphigus vulgaris confirmed by two biopsies showing suprabasal cleavage and acantholysis, presented a new suspicious lesion in the frontal region of the scalp during the gradual withdrawal of systemic corticosteroids. The patient's medical history included hypertension, dyslipidemia, atrial fibrillation, and long-term smoking. The initial disease affected the oral mucosa and scalp, with a significant response to high-dose corticosteroid therapy. A new lesion presented as an exophytic, verrucous, and hyperkeratotic plaque with extensive scaling and patterns consistent with squamous cell carcinoma. Dermatoscopic evaluation revealed nonspecific patterns, without criteria to exclude truly malignant neoplasms, maintaining a high diagnostic suspicion of squamous cell carcinoma. Given this scenario, an excisional biopsy was performed for diagnostic clarification. Histopathological analysis revealed marked epidermal hyperplasia with papillomatosis, hyperkeratosis, and focal parakeratosis, associated with the presence of multiple suprabasal clefts containing acantholytic cells. Involvement of the follicular infundibulum and a dense lymphoplasmacytic dermal inflammatory infiltrate with eosinophils were also observed. No signs of dysplasia or malignancy were identified. The results confirmed the diagnosis of pemphigus vegetans, Neumann subtype. After diagnostic confirmation, the patient continued follow-up with a gradual reduction in the dose of corticosteroids, paying attention to therapeutic intensification, including rituximab, according to clinical evolution.

Conclusion

This is a phenotypic transition from pemphigus vulgaris to Neumann-type pemphigus vegetans, with a clinical presentation that mimics squamous cell carcinoma. The occurrence of an isolated vegetating lesion in a non-intertriginous area, especially in a patient with oncological risk factors, significantly increases the diagnostic challenge. The absence of clinical and dermatoscopic findings capable of excluding malignancy reinforces the central role of histopathological evaluation. Early recognition of this variant is essential, considering its more aggressive course. This report reinforces the need for vigilance during the gradual reduction of corticosteroid doses and a high degree of suspicion for pemphigus variants in the presence of atypical proliferative lesions in the context of autoimmune bullous diseases.

Neumann-type pemphigus vegetans mimicking squamous cell carcinoma in a patient with pemphigus vulgaris

Conclusion:

This is a phenotypic transition from pemphigus vulgaris to Neumann-type pemphigus vegetans, with a clinical presentation that mimics squamous cell carcinoma. The occurrence of an isolated vegetating lesion in a non-intertriginous area, especially in a patient with oncological risk factors, significantly increases the diagnostic challenge. The absence of clinical and dermatoscopic findings capable of excluding malignancy reinforces the central role of histopathological evaluation. Early recognition of this variant is essential, considering its more aggressive course. This report reinforces the need for vigilance during the gradual reduction of corticosteroid doses and a high degree of suspicion for pemphigus variants in the presence of atypical proliferative lesions in the context of autoimmune bullous diseases.

EA DV CONGRESS
VIENNA
30 SEP - 3 OCT 2026

Abstract N°: 2123

Prevalence of Skin Cancer and Vitamin D Levels in a Cohort of Patients With Vitiligo: A Tertiary Center Experience

Gemma Maria Jumilla Martinez*[1], Diana Patricia Ruiz Genao[1], Sara de Benito Mendieta[1], Irene Alonso Rodríguez[1], José María Añíbarro Vega[1], Lucía Martínez Rozas[1], José Luis López Estebaranz[1]

[1] University Hospital Alcorcon Foundation, Madrid, Spain

Introduction
Vitiligo is an autoimmune disease characterized by melanocyte destruction. A potential protective role against skin cancer has been proposed, mediated by enhanced immune surveillance. Conversely, routine photoprotection in these patients may reduce vitamin D (VitD) levels, whose immunomodulatory role could also be involved in disease pathogenesis. However, the relationship between VitD and cutaneous carcinogenesis is complex, as ultraviolet exposure is both the main oncologic risk factor and the primary source of VitD, which exerts antitumoral molecular effects, including DNA repair, and regulation of proliferation, differentiation, and apoptosis.

The aim of this study was to analyze the prevalence of skin cancer in patients with vitiligo and its correlation with VitD levels.

Materials and Methods
We conducted a single-center, observational, retrospective, cross-sectional study including 1,059 patients with vitiligo (54.5% women; median age, 55.05 years [range, 7–111]). A subgroup with available VitD measurements (n = 228; 21.5%) was analyzed. The prevalence of skin cancer and its association with clinical variables and VitD levels were assessed.

Results
The overall prevalence of invasive skin cancer was 3.5% (n = 37), with basal cell carcinoma being the most frequent (2.5%), followed by squamous cell carcinoma (1.0%) and melanoma (0.4%). Actinic keratosis prevalence was 3.9%.

Skin cancer was significantly associated with older age (82.0 vs 54.08 years; $p < .001$) and showed a non-significant association with male sex (3.7% vs 3.3%; $p = .819$).

Among patients with VitD measurements, 75.9% had low levels, with no differences by sex or age. A higher proportion of cutaneous neoplasms was observed in patients with low VitD levels (66.7%) compared with normal levels (33.3%), although this was not statistically significant Pearson χ^2 test, $p = .490$).

Conclusions
Our results are consistent with previous literature reporting a low prevalence of skin cancer in patients with vitiligo, supporting a possible protective role of immune surveillance. Although lower VitD levels were more frequently observed in patients with cutaneous neoplasms, this association was not statistically significant. Further

prospective studies are warranted to better clarify the role of VitD in skin carcinogenesis in patients with vitiligo.

EADV CONGRESS
VIENNA
30 SEP - 3 OCT 2026

Abstract N°: 2145

Toxic epidermal necrolysis-like subacute cutaneous lupus erythematosus: rapid and complete response to anifrolumab.

Iolanda Prats Caelles*[1], Abraham Santa Cruz Martin[2], Mª Tatiana Cobo Ibáñez[3], Silvia Salinas-Moreno[1], Alberto Sáez Vicente[1], Noelia Garcia Muñoz[1]

[1] Infanta Sofia University Hospital, Pº Europa s/n, San Sebastian de los Reyes, Spain
[2] Infanta Sofia University Hospital, Pª Europa s/n, San Sebastian de los Reyes, Spain
[3] Infanta Sofía University Hospital, Pº Europa s/n, San Sebastian de los Reyes, Spain

Introduction

Toxic epidermal necrolysis-like subacute cutaneous lupus erythematosus (TEN-like SCLE) is a rare and severe variant of cutaneous lupus, characterized by extensive epidermal necrosis and blistering. Differentiating TEN-like SCLE from classic TEN is essential due to differences in management and prognosis. Recent advances highlight the central role of type I interferon in lupus pathogenesis, positioning anifrolumab—a monoclonal antibody targeting the IFN-α receptor—as a promising therapeutic option for refractory cutaneous lupus.

Case Presentation

A 73-year-old woman with a family history of systemic lupus erythematosus presented with annular lesions on the trunk, suggestive of SCLE. Initial biopsy and serology (anti-La+, ANA 1/80) confirmed the diagnosis. The lesions remitted with oral corticosteroids. One month later, new cutaneous lesions appeared, clinically and histologically compatible with TEN-like SCLE. Laboratory findings included positive anti-Ro (Ro52+) and anti-La antibodies, with no evidence of systemic lupus activity or mucosal involvement. A second biopsy revealed epidermal necrosis without lupus-specific features, and direct immunofluorescence was negative. Extensive neoplasia screening was performed due to paraneoplastic suspicion.

Given the lack of cutaneous response to hydroxychloroquine and systemic corticosteroids, anifrolumab was initiated (300 mg intravenously every 4 weeks), without additional immunosuppressive agents. Clinical improvement was rapid and marked, although the cutaneous lesions did not fully resolve after the first infusion; subsequent infusions led to complete clearance, with no adverse effects or recurrence. This outcome mirrors recent real-world evidence, where anifrolumab has demonstrated rapid efficacy across multiple CLE subtypes, even in patients previously refractory to conventional therapies



Extensive involvement of the back with confluent erythematous lesions, areas of superficial necrosis, and exfoliation, with greater involvement in sun-exposed areas

Conclusion

Anifrolumab represents a paradigm shift in the management of severe cutaneous lupus variants, including TEN-like SCLE. Its rapid and sustained efficacy, favorable safety profile, and independence from corticosteroids or conventional immunosuppressants make it an ideal option for patients with refractory or severe disease. Early recognition and targeted therapy with anifrolumab can lead to complete remission and improved quality of life. This case underscores the importance of considering anifrolumab as first-line therapy in TEN-like SCLE, supported by growing real-world evidence.

EADV CONGRESS
VIENNA
30 SEP - 3 OCT 2026

Abstract N°: 2148

A case of rituximab-associated regrowth of scalp, eyebrow, and eyelash hair in anti-transcriptional intermediary factor 1-γ (anti-TIF1-γ) and Ro52 antibody-positive dermatomyositis (DM)

Ocean Chan*[1], Joanna Hawkins[2], Harshita Ryali[3], Katherine Finucane[3], Charankumal Singh[3]

[1] Bristol Medical School, University of Bristol, Bristol, United Kingdom

[2] Epsom and St Helier University Hospitals, London, United Kingdom

[3] Dermatology, Southmead Hospital, North Bristol Trust, Bristol, United Kingdom

Introduction

DM is a rare autoimmune condition that causes chronic muscle inflammation and a distinctive skin rash. Cutaneous manifestations, such as diffuse non-scarring alopecia and madarosis, are frequently associated with DM. One of the significant psychosocial burdens in DM is refractory alopecia, while there is scattered documentation of treatment-responsive hair outcomes. Although myositis and classic cutaneous features can often be stabilised with conventional systemic agents, alopecia can be highly recalcitrant. A rare case of a patient with a background of anti-TIF1-γ and Ro52 antibody-positive DM, present with profound multi-site hair regrowth that is temporally associated with rituximab (RTX) induction, following inadequate hair response to standard therapies, is illustrated in this case report.

Case Presentation

A 59-year-old female attended dermatology with presentation of severe erythroderma, proximal muscle weakness, and dysphagia. Subsequent immunological screening shows positive antinuclear antibodies with anti-TIF1-γ and anti-Ro52 antibodies, which confirms the diagnosis of DM. Occult neoplasm has been consistently negative over three years via extensive malignancy screenings, including serial whole-body positron emission tomography-computed tomography scans. Meanwhile, the patient developed progressive, severe non-scarring alopecia manifesting as profound diffuse scalp thinning, with the temporal scalp being the most pronounced. The patient nearly lost all of her eyebrows, eyelashes, axillary, and leg hair. The initial management consists of oral prednisolone and subcutaneous methotrexate, which is titrated to 25 mg weekly. Her systemic and classic cutaneous symptoms are partially controlled with the combination of the above regimen, topical corticosteroids, namely clobetasol propionate and betamethasone valerate, and liberal emollient usage. Yet, her alopecia continued to progress. Her hair density was not improved with the administration of an acute infusion of intravenous immunoglobulin for a systemic disease flare. She experienced a complete cessation of hair shedding following the first RTX induction cycle, which was subsequently maintained on a six-monthly dosing schedule. Progressive and striking multi-site hair regrowth was observed over the ensuing 12 months. Her scalp hair density improved from an estimated 50% loss at its worst to approximately 85% of her pre-morbid baseline. The visually obvious scalp exposure was completely resolved, barring a minor residual area of right-temporal thinning. There is marked thickening of her eyebrows and significant visual recovery of her eyelashes from prior total loss. This profound trichologic improvement occurred simultaneously with the stabilisation of her other cutaneous manifestations and overall systemic disease control, including improved proximal muscle strength (Manual Muscle Testing-8 increased from 126/150 to 143/150).

Conclusion

This case demonstrates that severe, refractory alopecia and madarosis in DM can be highly resistant to standard immunomodulators, namely methotrexate and intravenous immunoglobulin. Targeted B-cell depletion with RTX resulted in remarkable multi-site hair regrowth, as evidenced in this anti-TIF1-γ and Ro52-positive case. This case also highlights RTX's potential efficacy as a therapeutic option for recalcitrant alopecia in DM, thereby showcasing the role of B-cell-mediated pathways in the pathogenesis of DM-associated hair loss. Future research can focus on evaluating the RTX's efficacy in DM patients with profound alopecia systematically. Patient perspective: "I was very scared before I knew the diagnosis. Once I was diagnosed, the treatment was very effective, and it was amazing. My hair is noticeably thicker and still improving."

EADV CONGRESS
VIENNA
30 SEP - 3 OCT 2026

Abstract N°: 2169

Discoid Lupus Erythematosus Involving Scalp and Beard Area in a Phototype V Patient: Diagnostic and Therapeutic Challenges

Ana Raimundo*[1], Hudson Rezende[1], João Henrique Aurich[1], Letícia Ferreira de Hybi Cerqueira[1], Nara Cristina Tasso Almeida Carvalho[2]

[1] Centro Universitário CESMAC – Maceió, AL, Maceio, Brazil

[2] Centro Universitário de Araraquara (UNIARA) – Araraquara, SP, Araraquara, Brazil

Introduction

Discoid lupus erythematosus (DLE) is a chronic inflammatory dermatosis that predominantly affects photoexposed areas of the head and neck and may lead to scarring alopecia. DLE is more prevalent and often more severe in patients with darker phototypes, with higher risk of disfiguring sequelae. Although scalp involvement is well recognized, involvement of the beard area is less commonly reported and may pose diagnostic challenges, particularly in atypical presentations or in cases with limited treatment options.

Case Presentation

A 53-year-old Brazilian male with phototype V presented with erythematous, scaly plaques on the scalp associated with burning and stinging sensations. Clinical examination revealed inflammatory lesions consistent with cicatricial alopecia. Trichoscopy demonstrated perifollicular scaling, follicular keratotic plugs, and white structureless areas, features suggestive of discoid lupus erythematosus. During follow-up, a new lesion developed in the right beard area, adjacent to the sideburn, measuring approximately 1.5 cm, with similar clinical and trichoscopic characteristics.

The patient had contraindication to hydroxychloroquine and developed leukopenia during methotrexate therapy, limiting standard systemic treatment options. Given these restrictions, dapsone was initiated, leading to stabilization of both scalp and beard lesions, symptom improvement, and no evidence of further progression.

Conclusion

This case highlights an uncommon presentation of DLE involving the beard area in a patient with darker phototype. DLE may act as an imitator and atypical localization can delay its diagnosis, particularly when there is low clinical suspicion. It underscores the clinical relevance of recognizing this condition in the beard area, in these patients in whom the disease may be more severe and cosmetically impactful. Trichoscopy plays a key role in early diagnosis, especially in unusual locations. Therapeutic management may be challenging when first-line systemic agents are contraindicated or not tolerated. In such scenarios, dapsone may represent a valuable alternative in selected cases, contributing to disease stabilization and prevention of irreversible scarring.

EADV CONGRESS
VIENNA
30 SEP - 3 OCT 2026

Abstract N°: 2173

Koebner Phenomenon in Vitiligo Induced by Lip Licking Dermatitis

Ana Raimundo*[1], Hudson Rezende[1], João Henrique Aurich[1], Antonio Moraes Madeira Quindos[2], Juliana Santos Rodrigues[1]

[1] Centro Universitário Lusíada (UNILUS) – Santos, SP, Santos, Brazil
[2] Universidade de Taubaté (UNITAU), Taubaté, Brazil

Introduction

The Koebner phenomenon describes the appearance of lesions of a pre-existing dermatosis at sites of cutaneous injury. Although well recognized in conditions such as vitiligo and psoriasis, its triggers may be subtle and easily overlooked, particularly when related to repetitive or behavioral trauma.

Case Presentation

Disease control had been stable for a prolonged period. Under treatment with topical tacrolimus and regular phototherapy, a 17-year-old patient with acrofacial vitiligo had achieved satisfactory repigmentation, including the perioral area. A change in this pattern became evident over the course of a few months. Pruritus of the lips was followed by erythema and progressive depigmentation surrounding the mouth, creating a sharply demarcated achromic halo that contrasted with the previously repigmented skin. This shift led to frustration and interruption of treatment. Examination revealed xerosis, scaling, and superficial fissures of the lips, consistent with irritant cheilitis. The distribution of depigmentation, however, suggested more than disease progression alone. It was only after further questioning that a recently acquired habit came to light: frequent lip licking. The combination of irritant contact dermatitis and repetitive mechanical exposure to saliva provided a plausible explanation for localized trauma. In this context, the perioral depigmentation was interpreted as koebnerization of vitiligo triggered by lip licking dermatitis. Management included behavioral guidance, psychological support, and a short course of topical corticosteroids, followed by reintroduction of tacrolimus. Clinical improvement was observed, with stabilization of the lesions and partial repigmentation.

Conclusion

This case highlights how seemingly minor and repetitive behaviors may act as relevant triggers of koebnerization, particularly in patients with vitiligo. Lip licking dermatitis, often regarded as a benign and self-limited condition, may represent a sufficient stimulus for disease activation in predisposed individuals. Beyond its dermatological aspects, this presentation underscores the importance of a broader clinical perspective, integrating behavioral and psychological factors into patient evaluation. Early recognition of such triggers may prevent misinterpretation as disease progression and allow timely, targeted intervention.

EADV CONGRESS
VIENNA
30 SEP - 3 OCT 2026

Abstract N°: 2174

From Tinea Capitis to Lichenoid Process: The Diagnostic Challenge of Post-Kerion Evolution

KHALDI HANANE FADOUA*[1], HACHEMI NIHED[1], Mahi Ilhem[1], BOUAYED GHIZLENE[1], DAHMANI Boumediene[1], Benhamed Nardjes[1]

[1] Department of Dermatology and Venereology, CHU Tlemcen, Tlemcen, Algeria

Introduction

The sequential occurrence of two distinct dermatoses at the same anatomical site represents one of the most intriguing phenomena in contemporary dermatology. This clinical progression illustrates the complexity of cutaneous immune interactions. Rather than a coincidental finding, the emergence of lichen planus on a previously healed lesion defines the Wolf's isotopic response. We report a rare case of scalp lichen planus succeeding an inflammatory tinea capitis (Kerion).

Case Presentation

A 13-year-old male presented with a Celsus kerion of the scalp, initially characterized by a suppurative inflammatory plaque. Trichoscopy revealed pustules, scales, crusts, an erythematous background, broken hairs, and comma hairs. A therapeutic strategy combining systemic antifungal treatment (itraconazole) and a brief course of oral corticosteroids led to symptomatic resolution. However, the clinical course was marked by a persistent alopecic plaque, where semiological remodeling revealed a secondary lichenoid process. Dermoscopic examination showed crystalline Wickham striae, an erythemato-violaceous background, and a peripheral circinate vascular network, highly suggestive of lichen planus. Histopathological confirmation revealed interface dermatitis with epidermal acanthosis, vacuolization of basal keratinocytes, and a dense band-like lymphohistiocytic infiltrate. This shift from infectious alopecia to an autoimmune inflammatory pathology was managed with intralesional corticosteroid therapy, inducing follicular regeneration by day 15 and confirming the reversibility of the process prior to the stage of atrophic fibrosis .Historically confused with the Koebner isomorphic phenomenon, the concept of isotopic response, introduced by Wolf in 1995, defines the emergence of a new dermatosis at the site of a previously healed, unrelated affection. While herpes zoster remains the classic trigger, this spectrum now extends to fungal and bacterial insults. This suggests that local vascular and neuro-immunological remodeling creates a *locus minoris resistentiae* in genetically predisposed individuals. Such alterations in the cutaneous microenvironment can induce inflammatory hyperreactivity, favoring lichenoid or granulomatous processes. Although the nosological distinction between Wolf and Koebner remains a theoretical challenge due to pathogenic overlap, our case is noteworthy for its rarity: it constitutes, to our knowledge, the first description of follicular lichen planus occurring on inflammatory tinea capitis.

Conclusion

This observation highlights the phenotypic shift from infectious alopecia to autoimmune pathology and establishes trichoscopy as a pivotal tool in pathological diagnosis and dermatological follow-up. Finally, this transition underscores a nosological "gray zone" between the Koebner and Wolf phenomena, emphasizing the need for larger studies to further characterize these complex interactions.

POWERED BY M-ANAGE.COM

EA DV CONGRESS
VIENNA
30 SEP - 3 OCT 2026

Abstract N°: 2179

Enpatoran, a Toll-Like Receptor 7/8 Inhibitor, in Skin Manifestations of Cutaneous Lupus Erythematosus or Systemic Lupus Erythematosus: Pooled Safety Data from the Phase 2 WILLOW Trial

Eric F Morand[1], Victoria P. Werth*[2], Richard Furie[3], Sanjeev Roy[4], Ruth Fernandez-Ruiz[5], Summer G. Goodson[5], Hans Gühring[6], Genevieve Jehl[7], David R. Pearson[8]

[1] Centre for Inflammatory Diseases, Monash University, Melbourne, Australia

[2] Department of Dermatology, Perelman School of Medicine, University of Pennsylvania and Philadelphia, Philadelphia, United States

[3] Division of Rheumatology, Northwell Health, Great Neck, New York, United States

[4] Ares Trading SA, Eysins, Switzerland, an affiliate of Merck KGaA, Eysins, Switzerland

[5] EMD Serono Research & Development Institute, Inc., Billerica, MA, USA, an affiliate of Merck KGaA, Billerica, United States

[6] Merck Healthcare KGaA, Darmstadt, Germany

[7] Merck Sante S.A.S., an affiliate of Merck KGaA, Lyon, France

[8] Department of Dermatology, University of Minnesota, Minneapolis, United States

Introduction

Cutaneous manifestations of lupus, occurring either in isolation as cutaneous lupus erythematosus (CLE) or as part of systemic lupus erythematosus (SLE), are common, however, approved therapies specifically targeting their underlying pathogenic mechanisms are currently lacking. Toll-like receptors (TLR) 7/8 are key upstream drivers of the interferon (IFN) pathway and neutrophil, myeloid cell and B cell activation. Enpatoran is a novel, first-in-class, highly selective, oral TLR7/8 inhibitor. In a Phase 2 randomised, double-blind, placebo-controlled study (WILLOW [NCT05162586]), enpatoran reduced disease activity in participants with cutaneous manifestations of CLE/SLE (Cohort A) or moderate-to-severe SLE (Cohort B), with high rates of CLASI-50/CLASI-70 responses, and was well tolerated. We report pooled safety and tolerability in the subgroup of participants with cutaneous manifestations in Cohorts A and B.

Materials and Methods

The WILLOW study includes two cohorts: Cohort A (patients with CLASI-A ≥ 8; SLE or CLE and BILAG-2004 1B, C, D); and Cohort B (patients with SLE of moderate to high disease activity BILAG 2004 ≥1A/2B, and hybrid SELENA-SLEDAI ≥6 and/or CLASI-A ≥8)[1-3]. Both cohort participants were randomised to placebo or enpatoran (25, 50, or 100 mg twice daily)[1-3]. Safety of enpatoran was evaluated from Day 1 to the end of safety follow-up at Week 26, according to the pre-defined secondary endpoints of treatment-emergent adverse events (TEAEs), treatment-emergent serious adverse events (SAEs), adverse events of special interest (AESIs), abnormal (grade 3) laboratory values, and clinically important increases in QT interval corrected using Fridericia's Formula (QTcF). Cutaneous manifestations of lupus were defined as CLASI-A ≥8 at screening and baseline.

Results

Safety data from 265 participants with cutaneous manifestations were included. The incidence of treatment-related TEAEs was marginally higher with enpatoran versus placebo, but did not increase with increasing

enpatoran dose (Table 1). One treatment-related SAE was reported (herpes zoster infection in the enpatoran 100 mg BID group). No TEAEs led to death in any treatment group. The most frequently reported treatment-related TEAEs were infections and infestations, gastrointestinal disorders, and investigations and were more often reported with enpatoran than placebo (Table 1). Three (3.8%) participants reported ≥1 AESI, all in the enpatoran 100 mg BID group. Decreased lymphocyte count was more common with placebo (n=4; 5.9%) than enpatoran 25 mg BID (n=1; 1.9%), 50 mg BID (n=2; 3.1%) or 100 mg BID (n=2; 2.5%). No clinically relevant between-group differences were observed in other laboratory parameters, vital signs, or electrocardiogram findings including QTcF.

Table 1. Pooled safety data from WILLOW Cohorts A and B for participants with CLE/SLE and cutaneous manifestations[a]

Adverse event category, n (%)	Placebo BID N=68	Enpatoran 25 mg BID N=53	Enpatoran 50 mg BID N=64	Enpatoran 100 mg BID N=80
Any TEAE	37 (54.4)	34 (64.2)	37 (57.8)	55 (68.8)
Related TEAE	11 (16.2)	15 (28.3)	17 (26.6)	21 (26.3)
Leading to permanent discontinuation	3 (4.4)	1 (1.9)	3 (4.7)	4 (5.0)
Leading to death	0 (0.0)	0 (0.0)	0 (0.0)	0 (0.0)
Any SAE[b]	1 (1.5)	3 (5.7)	2 (3.1)	1 (1.3)
Related SAE	0 (0.0)	0 (0.0)	0 (0.0)	1 (1.3)
Any AESI[c]	0 (0.0)	0 (0.0)	0 (0.0)	3 (3.8)[d]
Frequent related TEAEs by SOC[e]				
Infections and infestations	3 (4.4)	6 (11.3)	8 (12.5)	8 (10.0)
Gastrointestinal disorders	2 (2.9)	3 (5.7)	5 (7.8)	6 (7.5)
Investigations	5 (7.4)	5 (9.4)	3 (4.7)	6 (7.5)

Adverse events were coded using the Medical Dictionary for Regulatory Activities (MedDRA®) Version 27.0 (Cohort A) and Version 27.1 (Cohort B).
[a]Defined as CLASI-A ≥8 at screening and baseline; [b]Adverse reactions that results in death, are life-threatening, require hospitalization or prolongation of existing hospitalization, result in persistent or significant disability or incapacity, or result in birth defects; [c]Adverse events considered to be of special interest were severe infections (grade ≥3), seizure (any grade), clinically significant cardiac arrythmia or serotonin syndrome; [d]Bradyarrythmia (n=1); tachycardia (n=1); herpes zoster grade ≥3 (n=1); [e]≥5% in any treatment group.
AESI, adverse event of special interest; BID, twice daily; CLASI-A, Cutaneous Lupus Disease Area and Severity Index-Activity; SAE, treatment-emergent serious adverse event; SOC, system organ class; TEAE, treatment-emergent adverse event.

Conclusions

Enpatoran was well tolerated across all doses in participants with cutaneous manifestations of lupus at baseline in the WILLOW study, consistent with the overall study population and other previous studies of enpatoran, with no new safety concerns identified.

References:

1. Morand EF et.al. presented at SLEuro 2026. Abstract S1:04
2. Morand EF, et al. The Lancet Rheumatology 2026 [In press]
3. Morand EF, et al. The Lancet 2026 [In press]

EA DV CONGRESS
VIENNA
30 SEP - 3 OCT 2026

Abstract N°: 2183

Bullous Pemphigoid in an Elderly Patient with Alzheimer's Disease: Therapeutic Challenges and Delirium Associated with Polypharmacy - A Case Report

Rafaela Del Piccolo Campos[1], Mariana Garcia[2], Simone Diniz[3], Diogo Pazzini Bomfim*[4], Eduarda Martins[5], Pietra Diniz Pereira[6], Julia Laluce Cardoso[7]

[1] Universidade de Santo Amaro, São Paulo, Brazil
[2] Universidade Católica de Brasília, Brasília, Brazil
[3] Centro Universitário FMABC, São Paulo, Brazil
[4] Faculdade de Medicina de Marília, Marília, Brazil
[5] Pontifícia Universidade Católica de Campinas, Campinas, Brazil
[6] Faculdade de Ciências Médicas de São José dos Campos - Humanitas, São José dos Campos, Brazil
[7] Instituto Lauro de Souza Lima, Bauru, Brazil

Introduction

Bullous pemphigoid (BP) is an autoimmune subepidermal blistering disease that predominantly affects the elderly population and is characterized by tense blisters and intense pruritus (1,2). Advanced age and comorbidities are important predictors of poor prognosis, particularly in patients with neurological disorders such as Alzheimer's disease (AD), which have been associated with increased disease burden and complexity of management (3,4).

Management in elderly patients is often challenging due to reduced tolerance to systemic therapies and increased susceptibility to adverse drug reactions. Drug-induced Delirium is highly prevalent in this population and represents a significant clinical concern, particularly in the context of polypharmacy (5).

In this context, we report the case of an 87-year-old patient with advanced Alzheimer's disease who developed bullous pemphigoid with a recurrent and difficult-to-control course, complicated by polypharmacy and the occurrence of Delirium. This case highlights the therapeutic challenges of managing bullous pemphigoid in cognitively impaired elderly patients.

Case Presentation

Patient N.D.P., an 87-year-old female with advanced Alzheimer’s disease and multiple chronic comorbidities, presented in early August 2025 with pruritic bullous lesions disseminated across the body, representing the initial clinical manifestation of the condition.

Initially, treatment with levocetirizine was instituted for 7 days in association with emollient therapy, without complete resolution of the lesions. In late August 2025, due to persistence and progression of symptoms, systemic corticosteroid therapy was initiated with prednisone 40 mg daily for 7 days, followed by tapering to 20 mg daily for an additional 14 days. Concomitantly, levocetirizine 5 mg nightly and cephalexin 1 g/day for 7 days were administered, given the suspicion of secondary bacterial infection

The patient exhibited recurrent disease activity requiring multiple therapeutic adjustments, including additional antihistamines, topical therapy, and repeated courses of systemic corticosteroids. Management also included the continuous use of emollients and ketoconazole shampoo for concomitant seborrheic dermatitis. During the disease course, the patient developed an episode of delirium, possibly secondary to an adverse drug reaction in the context of cognitive frailty.

The clinical course was marked by persistent and relapsing activity, and a diagnosis of bullous pemphigoid was ultimately established. Management was particularly challenging due to severe cognitive impairment, which compromised treatment adherence and understanding. Additional aggravating factors included frequent excoriations secondary to intense pruritus, increased lesion recurrence, and urinary incontinence, contributing to persistently moist skin areas and a higher risk of local complications.

Conclusion

PB is a chronic disease, with spontaneous exacerbations and remissions, and consequently, with repercussions on

quality of life that require individualized therapeutic plans. (4,5) Advanced age and comorbidities are associated with worse outcomes and increased therapeutic complexity (3).

Bullous pemphigoid in elderly patients with severe neurocognitive impairment represents a therapeutic challenge. Cognitive decline, functional dependence, comorbidities and polifarmacy may compromise treatment adherence and self- care, contributing to disease persistence and complications.

EA DV CONGRESS
VIENNA
30 SEP - 3 OCT 2026

Abstract N°: 2190

Efgartigimod PH20 Subcutaneous in Adults With Systemic Sclerosis: Design of a Phase 2, Randomized, Double-Blinded, Placebo-Controlled, Parallel-Group Study (eSScape)

Dinesh Khanna[1], Francesco Del Galdo[2, 3], Christopher P. Denton[4], Oliver Distler[5], Masataka Kuwana[6], Despoina Papadopoulou[7], Bas Van Der Woning[7], Agna Neto[7], Piotr Zabrocki[7], Erica Falkenbach*[7], Marco Matucci-Cerinic[8, 9]

[1] University of Michigan Scleroderma Program, Ann Arbor, Michigan, United States
[2] Leeds Institute of Rheumatic and Musculoskeletal Medicine, University of Leeds, Leeds, United Kingdom
[3] NIHR Leeds Biomedical Research Centre, Leeds Teaching Hospitals NHS Trust, Leeds, United Kingdom
[4] UCL Centre for Rheumatology, Division of Medicine, University College London, London, United Kingdom
[5] University Hospital Zurich, University of Zurich, Zurich, Switzerland
[6] Nippon Medical School Graduate School of Medicine, Tokyo, Japan
[7] argenx, Ghent, Belgium
[8] Unit of Immunology, Rheumatology, Allergy and Rare Diseases, IRCCS San Raffaele Hospital, Milan, Italy
[9] Vita Salute San Raffaele University, Milan, Italy

Introduction
Systemic sclerosis (SSc) is a rare, chronic, systemic autoimmune rheumatic disease marked by inflammation, progressive skin and internal organ fibrosis, and severe vasculopathy. Emerging data highlight the active role of immunoglobulin G1 (IgG1) autoantibodies in SSc pathophysiology, with increasing evidence showing associations between specific autoantibodies, disease subtype, disease course, and manifestations. There is currently no disease-modifying treatment for SSc and an unmet need for more effective and targeted therapies remains. Efgartigimod is a human IgG1-derived Fc fragment engineered for increased affinity to neonatal Fc receptor (FcRn) compared with endogenous IgG and is uniquely composed of only the part of the IgG antibody that binds FcRn. It shows efficacy in several IgG-driven autoimmune diseases. In a topoisomerase I–immunized mouse model of SSc, a murine efgartigimod homologue was well tolerated and reduced skin thickening, lung fibrosis, GI transit delay, and levels of profibrotic cytokines, as well as downregulated fibrosis- and inflammation-related genes in the skin. Findings highlight the potential of FcRn blockade to simultaneously target the autoimmune, inflammatory, and fibrotic features of SSc. The eSScape study (NCT06655155) aims to establish proof-of-concept of subcutaneous (SC) efgartigimod PH20 in patients with SSc.

Materials and Methods
In this phase 2, randomized, double-blinded, placebo-controlled, parallel-arm study, approximately 81 adults (age ≥18 years) with SSc will be randomized 2:1 to receive weekly administrations of efgartigimod or placebo PH20 SC (coformulated with recombinant human hyaluronidase PH20).. Participants may be on permitted concurrent background medication, as determined by the investigator, and will be stratified by disease duration at baseline (<18 or ≥18 months after the first non-Raynaud's phenomenon manifestation) and anti-RNA polymerase III positivity. Interstitial lung disease (ILD) status will be considered during enrolment. The number of participants with no ILD will be limited to 50% of the study population. The study includes a screening period of up to 4 weeks, 48-week treatment, and 56-day safety follow-up period. Key inclusion criteria are SSc classification as per 2013 American College of Rheumatology (ACR)/European League Against Rheumatism (EULAR) criteria, antinuclear antibody seropositivity, Health Assessment Questionnaire-Disability Index (HAQ-DI) score of ≥0.5 or Patient Global Assessment (PGA) score of ≥3, modified Rodnan Skin Score (mRSS) score of ≥15–≤35, and local mRSS of 1 or less in ≥1 injection site. Participants will be either anti–RNA polymerase III–negative with disease onset (since

the first non-Raynaud's phenomenon manifestation) <5 years, or anti–RNA polymerase III–positive with disease onset <2 years before screening. Exclusion criteria include isolated anticentromere antibody seropositivity, significant pulmonary arterial hypertension, or any condition that would put participants at undue risk.

Results

Primary endpoint is the change from baseline in mRSS at Week 24. Secondary endpoints include change from baseline in mRSS (Week 48), HAQ-DI, PGA, and Clinician's Global Assessment (Weeks 24 and 48); the proportion of participants who improved in ≥2 or ≥3 of the 5 core items of the revised Composite Response Index in Systemic Sclerosis (CRISS)-25; and the annualized rate of Forced Vital Capacity decline in those with ILD. Incidence/severity of treatment-emergent adverse events (AEs), serious AEs, and AEs leading to discontinuation, along with pharmacokinetics, pharmacodynamics, and immunogenicity parameters will also be assessed.

Conclusions

This phase 2 study will evaluate efgartigimod PH20 SC as a potential treatment for patients with SSc. Emerging data showing a causal role of autoantibodies in SSc and the favorable preclinical effects of FcRn blockade on autoimmune, inflammatory, and fibrotic pathways provide strong biological rationale for this clinical investigation.

EADV CONGRESS
VIENNA
30 SEP - 3 OCT 2026

Abstract N°: 2191

LC-OCT for cutaneous lupus erythematosus: characterization across disease subtypes and differentiation from rosacea

Daniele Traini*[1], Gerardo Palmisano[1], Rebecca Ventura[2], Maria Vittoria Cannizzaro[1], Clara De Simone[1], Pierluigi Rizzuti[2], Viviana Antonella Pacucci[2], Pier Giacomo Cerasuolo[2], Cesare Gavotti[2], Giacomo Caldarola[1], Mariano Suppa[3], Alessandro Di Stefani[1], Maria Antonietta D'Agostino[2], Ketty Peris[1]

[1] Dermatology, Catholic University Of The Sacred Heart, Rome, Italy, Policlinico Universitario Agostino Gemelli, Rome, Italy, Rome, Italy

[2] Rheumathology, Catholic University Of The Sacred Heart, Rome, Italy, Rome, Italy

[3] Université libre de Bruxelles, Bruxelles, Belgium

Introduction

Cutaneous lupus erythematosus (CLE) encompasses a heterogeneous group of autoimmune skin manifestations that often overlap clinically with other inflammatory dermatoses, particularly rosacea. While histopathology remains the gold standard, its invasiveness limits routine and longitudinal use. Line-field confocal optical coherence tomography (LC-OCT) is an emerging non-invasive imaging modality capable of providing real-time, near-histological resolution of skin architecture. The objective of this study was to characterize LC-OCT features across different CLE subtypes and assess its utility in distinguishing CLE from rosacea.

Materials and Methods

In this cross-sectional observational study, 45 patients (30 CLE: 16 acute, 5 subacute, 9 chronic; 15 rosacea) underwent LC-OCT imaging of active lesions. Images were independently evaluated using predefined criteria reflecting histopathological features. Frequencies of imaging findings were analyzed across subtypes, and an exploratory comparison between acute CLE (ACLE) malar rash and rosacea was performed.

Results

LC-OCT identified key histopathological correlates of CLE in vivo. Interface dermatitis features (including dermoepidermal junction disruption, basal cell vacuolization, and band-like inflammatory infiltrate) were highly prevalent in ACLE and SCLE, while chronic CLE was characterized by epidermal atrophy, hyperkeratosis, fibrosis, and adnexal destruction. In contrast, rosacea exhibited a vascular and folliculocentric pattern with frequent peri-adnexal inflammation and Demodex infestation, without interface changes. Interobserver agreement was substantial to excellent for most criteria.

In the ACLE versus rosacea comparison, interface dermatitis features like band-like DEJ infiltrate, DEJ disruption, basal vacuolization, and apoptotic bodies were associated with ACLE. Conversely, rosacea exhibited a vascular-folliculocentric profile with peri-infundibular infiltrates and Demodex mites.

Conclusions

LC-OCT enables non-invasive visualization of disease-specific microarchitectural patterns in CLE, reflecting both

inflammatory and chronic remodeling changes. It shows promise as a “virtual biopsy” tool, particularly in differentiating ACLE from rosacea, and may support diagnosis, staging, and treatment monitoring in clinical practice.

EADV CONGRESS
VIENNA
30 SEP - 3 OCT 2026

Abstract N°: 2195

Chronic Recurrent Periorbital Swelling and Eye Dryness as an Initial Presentation of Autoimmune Connective Tissue Disease, Most Likely Primary Sjögren Syndrome

Shaher Al Kaabi*[1], Zeyana Al Bahri[2], Moawiya Al Hinai[2]

[1] Oman Medical Specialty Board (OMSB), Muscat, Oman

[2] Al Khuwair Health Center, Ministry Of Health, Muscat, Oman

Introduction

Primary Sjögren syndrome is a multisystem autoimmune connective tissue disease (CTD) affecting the lacrimal and salivary glands and classically presenting with ocular and oral sicca. Diagnosis may be challenging because of clinical and serological overlap with other CTDs, particularly systemic lupus erythematosus (SLE), rheumatoid arthritis, systemic sclerosis, and dermatomyositis. Cutaneous or systemic manifestations may precede sicca symptoms, making dermatologists key contributors to early recognition. We report a 39-year-old woman with chronic recurrent bilateral erythematous-violaceous periorbital swelling and ocular dryness as an unusual initial presentation of autoimmune CTD, most suggestive of primary Sjögren syndrome.

Case Presentation

A previously healthy 39-year-old woman presented with an 8-month history of recurrent bilateral periorbital swelling, erythema, and ocular dryness. The swelling was non-pruritic and non-tender, with no eczema, lip swelling, dyspnea, or identifiable triggers. Symptoms partially improved with systemic corticosteroids but recurred after discontinuation. She denied fever, oral dryness, photosensitivity, arthralgia, myalgia, dry cough, or other skin lesions. Family history was positive for SLE. Examination showed bilateral erythematous-violaceous periorbital swelling with mild crusting, more marked on the left. Ophthalmology revealed bilateral superficial punctate keratitis, vitritis, weak retinal blood flow with peripheral sclerosis, scattered retinal hemorrhages, and pale retinas, consistent with retinal ischemia and bilateral ocular dryness. Orbital CT showed moderate left preseptal swelling with a bulky enhancing lacrimal gland; the extraocular muscles, globe, and optic nerve were unremarkable. Patch testing showed weak nickel positivity, but the clinical pattern was not typical of allergic contact dermatitis. Inflammatory markers, complement levels, renal/liver function, thyroid function, creatine kinase, coagulation profile, antiphospholipid screen, urinalysis, anti-dsDNA, rheumatoid factor, infectious screening, and myositis panel were negative or normal, except for moderate anti-Ro52 positivity. Complete blood count showed microcytic hypochromic anemia. Extractable nuclear antigen testing showed moderate anti-SSA/Ro and weak anti-SSB positivity, with weak anti-ribosomal P and anti-nucleosome antibodies. Immunoglobulins showed mildly elevated IgG with normal IgG4. Left cheek punch biopsy showed subtle vacuolar interface dermatitis, occasional dyskeratotic keratinocytes, pigment incontinence, mild-to-moderate mixed perifollicular inflammation, and increased dermal mucin. No vasculitis, granuloma, atypical lymphoid infiltrate, amyloid, or fungal elements were identified. Histopathology favored CTD.

Conclusion

Chronic recurrent periorbital swelling with ocular dryness may be an uncommon first manifestation of

autoimmune CTD and should not be attributed solely to allergic contact dermatitis, angioedema, infection, or idiopathic orbital inflammation. In this patient, relapsing steroid-responsive periorbital inflammation, lacrimal gland enlargement, keratitis with ocular dryness, retinal ischemic changes, anti-SSA/Ro and anti-SSB positivity, mild IgG elevation, and CTD-type interface dermatitis with dermal mucin support an autoimmune process, most likely primary Sjögren syndrome. Although SLE remains a differential diagnosis given family history and weak anti-ribosomal P and anti-nucleosome positivity, negative anti-dsDNA, normal complement levels, negative antiphospholipid screen, absence of systemic lupus features, and prominent ocular/lacrimal involvement favor primary Sjögren syndrome. This case highlights the need to consider Sjögren syndrome in unexplained recurrent periorbital inflammation with ocular dryness, even without dry mouth, and supports multidisciplinary follow-up with objective sicca assessment to classify the disease and monitor for systemic evolution.

EADV CONGRESS
VIENNA
30 SEP - 3 OCT 2026

Abstract N°: 2202

Extensive Pemphigus Foliaceus with Complete Long-Term Remission after Rituximab

Elena Sánchez Romero*[1], Eloy Rodríguez Díaz[1], Susana García Mallo[2], Elías Alejandro Albarrán Coria[1], Teresa González de las Heras[1], Claudia Alvargonzález Fernández[1], Juan Manuel Calzada González[3], Lucía Palacio Aller[1]

[1] Hospital Universitario de Cabueñes, Department of Dermatology, Gijón, Spain
[2] Hospital General Universitario Reina Sofía, Department of Dermatology, Murcia, Spain
[3] Hospital Universitario de Cabueñes, Department of Pathology, Gijón, Spain

Introduction

Pemphigus foliaceus (PF) is a rare autoimmune blistering disorder characterized by superficial epidermal blistering caused by autoantibodies directed against desmoglein-1. Clinically, the disease usually manifests with superficial erosions, crusted plaques and erythematous scaly lesions involving seborrheic areas; however, generalized and erythrodermic presentations may occur in severe cases and can mimic other inflammatory or exfoliative dermatoses, leading to diagnostic delay.

Case Presentation

A 59-year-old man with no relevant past medical history was referred to the Dermatology Department because of a several-month history of intensely pruritic skin lesions initially located on the trunk, with subsequent progressive dissemination to almost the entire body surface. The patient had received multiple topical and systemic treatments, including antibiotics and corticosteroids, without clinical improvement, showing progressive worsening of the cutaneous involvement.

Physical examination revealed widespread erythematous-edematous plaques with erosive areas alternating with crusted and desquamative lesions over a diffuse congestive erythematous background. The lesions involved nearly the entire cutaneous surface, while the mucous membranes remained unaffected. No systemic symptoms were reported.

A skin biopsy was performed from one of the active lesions. Histopathological examination demonstrated an intraepidermal vesicle with acantholytic changes and a predominantly perivascular mononuclear inflammatory infiltrate with scattered eosinophils within the superficial dermis. Direct immunofluorescence studies revealed intercellular epidermal deposits of IgG, C1q, C3 and C4, supporting the diagnosis of pemphigus foliaceus.

Laboratory tests revealed positive anti-desmoglein 1 antibodies, with a value of 3, while anti-desmoglein 3 antibodies were negative. Additional work-up, including chest radiography and abdominal ultrasound, showed no significant pathological findings.

Based on the clinical, histopathological and immunopathological findings, treatment with oral prednisone at a dose of 1 mg/kg/day associated with topical corticosteroids was initiated. Despite treatment, the patient showed insufficient clinical response, with persistence of extensive inflammatory and erosive lesions. Therefore, rituximab therapy was started following a rheumatoid arthritis protocol consisting of 1,000 mg administered on day 1 and repeated two weeks later.

Following rituximab administration, the patient experienced a slow but progressive clinical improvement, with gradual resolution of the erosive and crusted lesions. Complete clinical remission was ultimately achieved and has

been maintained for three years to date with low-dose oral prednisone as maintenance therapy, without significant relapses.

Conclusion

This case illustrates an extensive and severe presentation of pemphigus foliaceus refractory to conventional corticosteroid therapy. It also highlights the usefulness of rituximab as an effective therapeutic option capable of inducing sustained long-term remission in difficult-to-treat cases. Early recognition and prompt initiation of targeted immunomodulatory therapy may improve prognosis and reduce disease-related morbidity in patients with severe generalized pemphigus foliaceus.

EADV CONGRESS
VIENNA
30 SEP - 3 OCT 2026

Abstract N°: 2213

Diagnostic challenges in mixed-phenotype epidermolysis bullosa acquisita: the role of salt-split skin immunofluorescence in a resource-limited setting

Botirbek Ernazarov*[1], Khasan Nasimov[1], Sherzod Khonkhodjaev[1], Akram Rakhmatov[1]

[1] Republican Specialized Scientific-Practical Medical Center of Dermatovenereology and Cosmetology, Tashkent, Uzbekistan

Introduction

Epidermolysis bullosa acquisita (EBA) is a rare autoimmune subepidermal blistering disease driven by autoantibodies against type VII collagen. Marked clinical heterogeneity — mechanobullous, inflammatory bullous pemphigoid (BP)-like, mucous membrane pemphigoid (MMP)-like and mixed phenotypes — often leads to misdiagnosis and refractory disease. Confirmation typically requires anti-type VII collagen ELISA, indirect immunofluorescence on salt-split skin or immunoelectron microscopy, none routinely available in many low- and middle-income regions. Salt-split skin direct immunofluorescence (ssDIF) of perilesional skin is a technically accessible adjunct that localises immune deposits to the dermal ("floor") or epidermal ("roof") side of the artificial blister, providing useful discrimination among subepidermal autoimmune blistering diseases. We report a diagnostically challenging mixed-phenotype EBA case in which ssDIF, implemented for the first time at our centre, was decisive.

Case Presentation

A 58-year-old woman presented in April 2026 with an 8-year history (onset 2018) of recurrent erosions and blistering involving the trunk, extremities, oral mucosa and acral areas. She had been diagnosed with BP in September 2025 and treated with oral corticosteroid 0.5 mg/kg/day with insufficient response; subsequent dapsone 50 mg/day (October–November 2025) was discontinued due to severe haemolytic anaemia (Hb 60 g/L). Examination revealed widespread erosive-ulcerative lesions on an erythematous background, atrophic and normotrophic scars studded with milia, and erosions in healing on the palms, soles and dorsa of hands and feet. Painful oral erosions, dysphagia, dysphonia and a cicatricial change at the medial canthus of the right eye indicated mucosal involvement with scarring. Nikolsky sign was negative.

Histopathology showed a subepidermal blister with a predominantly neutrophilic infiltrate and scattered eosinophils. DIF revealed linear IgG and C3 along the basement membrane zone (IgA, IgM negative). Anti-desmoglein 1/3 ELISA was within normal limits. ssDIF on 1M NaCl-split perilesional skin demonstrated linear IgG and C3 deposition exclusively on the dermal ("floor") side of the artificial split, strongly supporting a diagnosis consistent with mixed mechanobullous, BP-like inflammatory and mucosal-phenotype EBA.

Therapy was switched to oral corticosteroid 17.5 mg/day, mycophenolate mofetil 3 g/day and colchicine 2 mg/day, with two plasmapheresis sessions and a topical corticosteroid, under gastric, electrolyte and vitamin cover. After about four months disease activity stabilised: mucosal erosions re-epithelialised, dysphagia and dysphonia improved (residual cicatricial changes persisted), cutaneous lesions entered the healing phase and only sporadic new blisters appeared. Hb normalised to 104 g/L.



A. Milia and atrophic scarring



B. Inflammatory BP-like blistering



C. Esophageal erosions and scarring



D. Pharyngeal and epiglottic erosions with scarring

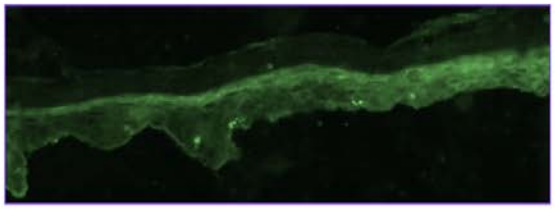

E. ssDIF IgG: epidermal side

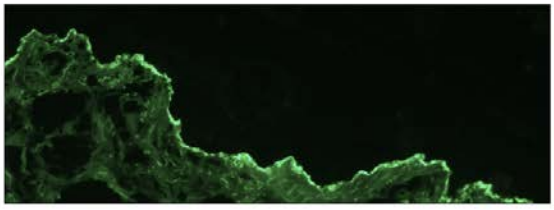

F. ssDIF IgG: dermal side (floor pattern)

Mixed-phenotype epidermolysis bullosa acquisita. Clinical images demonstrate mechanobullous lesions with milia and scarring on the extensor forearms (A), inflammatory BP-like blistering on the distal upper arm (B), and mucosal involvement with erosions and cicatricial changes of the esophagus (C), pharynx and epiglottis (D). Salt-split skin direct immunofluorescence shows absence of IgG deposition on the epidermal side (E) and linear IgG deposition on the dermal side of the artificial split ("floor" pattern) (F).

Conclusion

The mixed phenotype, refractoriness to corticosteroid monotherapy and dapsone-related haemolytic anaemia are recognised pitfalls in EBA. With anti-type VII collagen serology, indirect immunofluorescence and immunoelectron microscopy unavailable, ssDIF provided critical diagnostic discrimination among subepidermal autoimmune blistering diseases. Dermal-side binding combined with mechanobullous distribution, milia, scarring and mucosal involvement fulfilled current criteria for probable EBA and informed combined immunosuppression and apheresis. Dermal binding may also occur in anti-laminin-332 MMP and rare epidermal-binding EBA variants, so integrated clinico-immunopathological correlation, not ssDIF alone, supported the diagnosis.

This case illustrates the diagnostic challenge of mixed-phenotype EBA and the important role of ssDIF as an

accessible discriminative tool in resource-limited settings, where targeted reclassification enabled effective combination therapy and disease stabilisation. ssDIF should be considered an important accessible component of the work-up of refractory subepidermal blistering disease where advanced serology is unavailable.

EA DV CONGRESS
VIENNA
30 SEP - 3 OCT 2026

Abstract N°: 2231

Efficacy and patient characteristics of ritlecitinib in non-responders (SALT score >20) and responders (SALT score ≤20) at Month 36 in patients with alopecia areata from the ALLEGRO clinical trial program

Arash Mostaghimi*[1], Amy Paller[2], Manabu Ohyama[3], Cheng Zhou[4], Michela Starace[5, 6], Christos Tziotzios[7], Dalia Wajsbrot[8], Robert Wolk[8], Alexandre Lejeune[9], Helen Tran[10]

[1] Harvard Medical School, Boston, United States
[2] Northwestern University Feinberg School of Medicine, Chicago, United States
[3] Department of Dermatology, Kyorin University School of Medicine, Tokyo, Japan
[4] Department of Dermatology, Peking University People's Hospital, Beijing, China
[5] Dermatology Unit, IRCCS Azienda Ospedaliero-Universitaria di Bologna, Bologna, Italy
[6] Department of Medical and Surgical Sciences, Alma Mater Studiorum University of Bologna, Bologna, Italy
[7] St John's Institute of Dermatology, Guys and St Thomas' Hospital, London, United Kingdom
[8] Pfizer Inc, Groton, United States
[9] Pfizer Inc, Paris, France
[10] Pfizer Inc, New York, United States

Introduction
Ritlecitinib is an oral, selective, JAK3/TEC family kinase inhibitor approved to treat patients aged ≥12 years with severe alopecia areata (AA). Ritlecitinib 50 mg once daily was shown to be efficacious up to 3 years in patients from the ALLEGRO phase 2/3 study (NCT03732807) who rolled over to the phase 3, open-label ALLEGRO-LT (NCT04006457) study. At Month 36, 71/109 patients (65.1%) receiving ritlecitinib 50 mg achieved Severity of Alopecia Tool (SALT) score ≤20 response (≤20% scalp hair loss). Data on the efficacy of ritlecitinib, including scalp and non-scalp manifestations of AA, in patients who did not achieve the SALT score ≤20 response threshold are limited. We evaluated efficacy results, including scalp and non-scalp manifestations, in patients who did not achieve SALT score ≤20 at Month 36.

Materials and Methods
Overall, 109 adolescent (n=13) and adult (n=96) patients with AA and ≥50% scalp hair loss who received once daily ritlecitinib 50 mg in ALLEGRO-2b/3, rolled over to ALLEGRO-LT (continued 50 mg daily), and had SALT data at Month 36, were included. Outcomes included the proportion of patients with SALT score ≤20 response over time, Eyebrow/Eyelash assessment (EBA/ELA) response and Patient Global Impression of Change (PGI-C) response (defined as 'moderately improved' or 'greatly improved') in patients who had and had not achieved SALT score ≤20 at Month 36. Datacut was June 25, 2024.

Results
Month-36-responders (n=71; 65%) had a SALT score ≤20 at Month 36. Non-responders (n=38; 35%) had a SALT score >20 at Month 36. At baseline, non-responders had longer current AA episodes (3.4 vs 1.9 years, median) and time since diagnosis (7.6 vs 6.1 years, median) than responders. A lower proportion were female (47.4% vs 69.0%). Non-responders had higher SALT scores at baseline than responders (mean [SD]: 93.6 [11.5] vs 87.3 [16.2]). A higher proportion of non-responders had abnormal eyebrows and eyelashes at baseline than responders. Of the non-responders at Month 36, 18.4% had achieved SALT score ≤20 at some point prior. Among

those with abnormal EBA/ELA at baseline, 43.5%/52.4% of non-responders had EBA/ELA response at Month 36. Of non-responders, 26.3% reported a PGI-C response at Month 36, suggesting participants perceived improvement despite not reaching SALT score ≤20. All values given as observed.

Conclusions

Overall, baseline characteristics of Month 36 non-responders and responders were consistent with previous responder analyses. Non-responders were more likely to be male, have longer disease and episode duration, higher SALT score at baseline, and have abnormal EBA/ELA scores at baseline. In patients considered Month-36-non-responders based on SALT score >20, intermittent improvements in SALT score and non-scalp assessments were observed in some patients at earlier time points.

EADV CONGRESS
VIENNA
30 SEP - 3 OCT 2026

Abstract N°: 2237

Exploring fingernail involvement in alopecia areata and efficacy of ritlecitinib: a post-hoc analysis in patients from the ALLEGRO trials

Brett King*[1], Crystal Aguh[2], Ying Luo[3], Kazutoshi Harada[4], Leila Asfour[5], Vivien Hébert[6], Dalia Wajsbrot[7], Helen Tran[8], Alanna Chaudhry[8], Robert Wolk[7], Alexandre Lejeune[9]

[1] Dermatology Physicians of Connecticut-Fairfield, Fairfield, United States
[2] Department of Dermatology, Johns Hopkins School of Medicine, Baltimore, United States
[3] Dermatology Hospital, Southern Medical University, No. 2 Yuexiu District, Guangzhou, China
[4] Department of Dermatology, Tokyo Medical University, Tokyo, Japan
[5] Chelsea and Westminster NHS Foundation Trust, London, United Kingdom
[6] Department of Dermatology, CHU Rouen and INSERM U1234, Normandie University, Rouen, France
[7] Pfizer Inc, Groton, United States
[8] Pfizer Inc, New York, United States
[9] Pfizer Inc, Paris, France

Introduction
Ritlecitinib is an oral, selective, JAK3/TEC family kinase inhibitor approved to treat patients aged ≥12 years with severe alopecia areata (AA). Nail involvement is a recognized manifestation of AA with nail changes reported in 7–84% (on average, 22%) of patients with AA, and more frequent with more severe AA.This *post hoc* analysis assessed fingernail involvement, its association with disease and patient characteristics, and its response to ritlecitinib in patients with AA from the ALLEGRO-2b/3 (NCT03732807, ≥50% scalp hair loss at baseline) and ALLEGRO-LT (NCT04006457, *de* novo patients, ≥25% scalp hair loss at baseline) studies.

Materials and Methods
Baseline characteristics were assessed in all patients in ALLEGRO-2b/3 (N1=684) and *de novo* patients in ALLEGRO-LT (N1=437). Efficacy was assessed in patients from ALLEGRO-2b/3 (n=82) who received ritlecitinib 50-mg (no loading dose), and *de novo* patients in ALLEGRO-LT (n=164) who received ritlecitinib 50-mg with a 4-week 200-mg daily loading dose. All values are given as observed. Patients with <10 fingernails, or with missing values for fingernails assessed, both at baseline, were excluded.

Results
In ALLEGRO-2b/3 and ALLEGRO-LT, 41.6% and 37.5% of patients, respectively, had ≥1 fingernail affected at baseline. Mean numbers of affected fingernails were higher in adolescents than adults (ALLEGRO-2b/3: 4.2 vs 2.9; ALLEGRO-LT: 3.1 vs 2.4). A greater proportion of male than female patients had fingernail involvement (46.7% vs 38.4% in ALLEGRO-2b/3; 45.2% vs 33.2% in ALLEGRO-LT). Patients with higher baseline SALT score had a higher mean number of affected fingernails (ALLEGRO-2b/3: SALT 50 to <95: 2.1; SALT 95-100: 3.7; ALLEGRO-LT: SALT 25 to <50: 1.6; SALT 50 to <95: 2.3; SALT 95-100: 3.1). Fingernail involvement was also higher with baseline eyebrow or eyelash involvement. Among those patients with ≥1 fingernail affected at baseline, the proportion with all fingernails affected decreased from 51.2% to 17.2% at Month 36-38 in patients who received ritlecitinib 50 mg in ALLEGRO-2b/3 (N=82), and from 43.3% to 12.5% in *de novo* patients in ALLEGRO-LT (N=164).

Conclusions

Fingernail involvement was not uncommon in this cohort; 41.6% and 37.5% of patients in the two studies had ≥1 fingernail affected at baseline. Fingernail involvement was more common with more severe AA disease, as indicated by SALT score and eyebrow/eyelash involvement, and decreased over time with ritlecitinib treatment.

EA DV CONGRESS
VIENNA
30 SEP - 3 OCT 2026

Abstract N°: 2255

Clinical, diagnostic and therapeutic implications of scalp involvement in patients with cutaneous lupus

Miguel Limeres de la Rosa*[1], José Gallego García[1], Daniel Muñoz Barba[1], Salvador Arias-Santiago[1], Manuel Sanchez-Diaz[1]

[1] Hospital Universitario Virgen de las Nieves, Granada, Spain

Introduction
Cutaneous lupus (CL) is a chronic inflammatory disease of autoimmune origin, which may present in isolation or in association with systemic lupus erythematosus and other autoimmune diseases. Scalp involvement is common, with an estimated prevalence of between 10% and 60% of patients, and manifests as a broad clinical spectrum ranging from acute, reversible forms to chronic lesions with scarring potential. This involvement carries significant morbidity, particularly due to the risk of irreversible scarring alopecia, which justifies an early and aggressive diagnostic and therapeutic approach.

Materials and Methods
Prospective study of patients with CL treated in a unit specialising in cutaneous autoimmune diseases at a tertiary care hospital. All patients treated for CL over a two-year period were included, along with clinical variables, reasons for referral, proposed treatments and clinical efficacy.

Results
The study included 49 patients with CL (45 women, 4 men) with a mean age of 52.84 years (SD = 17.16). The most common subtype of CL was discoid lupus, accounting for 44.9%, followed by subacute lupus at 32.65%. They had a mean baseline CLASI-A score of 7.85 (SD = 9.77). 61.22% had scalp involvement and, of these, 20% had a diagnosis other than CL at baseline (alopecia areata, androgenetic alopecia, tinea capitis, seborrhoeic dermatitis, psoriasis and non-specific pruritus). Patients with scalp involvement presented with lower use of antimalarials ($p = 0.01$), showing no differences in regard to other treatments. These were also patients with more severe presentations (CLASI-A 11.56 vs 5.48, $p = 0.05$; CLASI-D 15 vs 13, $p = 0.03$). CLASI-A decreased over the course of follow-up, with a more marked reduction in patients without scalp involvement (5.58 at baseline vs 1.32 after 9 months) than in those who did present lesions in this location (13.79 at baseline vs 4.07 after 9 months), which was statistically significant ($p = 0.02$). In terms of laboratory findings, they presented lower levels of hypocomplementaemia (0% vs 73.33%, $p=0.01$) and anti-RO antibodies (26.32% vs 53.33%, $p = 0.08$).

Conclusions
Patients with scalp involvement are more likely to receive inadequate treatment relative to the severity of their CL. This site of involvement increases diagnostic complexity by broadening the differential diagnosis and is associated with a poorer response to treatment, highlighting the need for an earlier and more targeted approach.

EA DV CONGRESS
VIENNA
30 SEP - 3 OCT 2026

Abstract N°: 2261

When pruritus uncovers the unexpected: bullous pemphigoid arising in hereditary epidermolysis bullosa

NOUSSAIBA CHEMLAL[1], Boumediene Dahmani[1], Kamila Bouchenak khelladi[1], Adil Zerrouk*[1]

[1] Department of Dermatology, CHU Tlemcen, Aboubakr Belkaid, Faculty of Medicine, Tlemcen, Dermatology Association of the Wilaya of Tlemcen (ADWIT), TLEMCEN, Algeria

Introduction

Bullous pemphigoid is the most common autoimmune bullous dermatosis in the elderly, mediated by autoantibodies directed against BP180 and BP230 antigens of the dermoepidermal junction.

Epidermolysis bullosa, particularly in its hereditary forms, is characterized by chronic skin fragility secondary to structural alteration of this junction.

The association between bullous pemphigoid and epidermolysis bullosa (whether acquired or hereditary) remains exceptional and raises pathophysiological questions, particularly regarding the role of chronic dermoepidermal junction alteration in exposing antigenic epitopes and triggering an autoimmune response.

Case Presentation

We report the case of an 81-year-old man with a medical history of stroke, epilepsy, benign prostatic hyperplasia, and deep vein thrombosis.

Since childhood, the patient had presented with congenital skin fragility, with blister formation induced by minimal trauma. These blisters, containing clear or hemorrhagic fluid, developed on erythematous skin, were non-pruritic, and had a diffuse distribution with acral predominance. The course resulted in residual atrophic hypopigmented lesions, particularly on the dorsum of the hands.

A diagnosis of hereditary epidermolysis bullosa had been established.

At the age of 81, the patient was referred for worsening of blistering lesions associated with the recent onset of intense generalized pruritus. This exacerbation followed a major emotional stress related to the death of his spouse.

Clinical examination revealed numerous blisters, erosions, and crusts on an erythematous background, diffusely distributed over the trunk, back, and upper and lower limbs.

Atrophic hypopigmented scars were also noted on the dorsum of the hands and feet.

A skin biopsy was performed, showing a dermoepidermal separation associated with an inflammatory infiltrate rich in eosinophils.

Based on clinical and histological findings, the diagnosis of bullous pemphigoid arising in the setting of hereditary epidermolysis bullosa was established.

Treatment with methotrexate at a dose of 10 mg per week was initiated, with a favorable outcome marked by significant regression of pruritus and blistering lesions.

DISCUSSION

The association between bullous pemphigoid and epidermolysis bullosa is rare but has been described in the literature, including both acquired and hereditary forms.

The pathophysiological hypothesis is based on chronic alteration of the dermoepidermal junction in epidermolysis bullosa, promoting exposure of normally hidden antigens (BP180, BP230), leading to a breakdown of immune tolerance and the production of autoantibodies. This mechanism is comparable to the Epitope spreading phenomenon.

Clinically, the onset of intense pruritus in a patient with hereditary epidermolysis bullosa should raise suspicion of an associated autoimmune complication.

The very long delay between EB and the onset of bullous pemphigoid, exceeding several decades in our case, has also been reported in the literature. This supports the hypothesis of a progressive immune sensitisation process secondary to chronic alteration of the dermo-epidermal junction.

Histological examination shows a sub-epidermal split, often accompanied by an inflammatory infiltrate predominantly composed of eosinophils.

Management is based on standard treatments for bullous pemphigoid. Methotrexate represents an interesting alternative in elderly patients, particularly in cases of contra-indication to systemic cortico-steroids.

Conclusion

This case illustrates a rare association between bullous pemphigoid and epidermolysis bullosa, highlighting the importance of investigating for an autoimmune dermatosis in the presence of any clinical change particularly the onset of pruritus in these patients, which should be considered a major warning sign suggestive of the development of an associated autoimmune bullous disease, especially bullous pemphigoid.

Early diagnosis allows appropriate management and improves functional prognosis.

EA DV CONGRESS
VIENNA
30 SEP - 3 OCT 2026

Abstract N°: 2277

Pemphigus Vegetans of the Nose: A Rare and Misleading Localization

Seddiki Meriem*[1], Taibi Lynda[1], Omar Atawna[1], Imene Mahiou[1], Samira Zobiri[1]

[1] Mustapha University Hospital Center, Algiers, Algeria

Introduction

Pemphigus vegetans is a rare variant of pemphigus vulgaris, an autoimmune blistering disorder. It is characterized by vegetative, papillomatous lesions that typically involve intertriginous areas. We report an unusual case with predominant nasal involvement.

Materials and Methods

A 50-year-old male with no significant past medical history presented in 2019 with painful oral erosions leading to impaired oral intake. Fifteen days later, he developed vegetative lesions on the nose associated with whitish discharge and lacrimation, along with bullous lesions on the thigh and dysphonia (hoarseness).

Histopathological examination of biopsies from the nasal lesion and thigh revealed intraepidermal blistering with acantholysis. Direct immunofluorescence and ELISA demonstrated elevated anti-desmoglein 3 antibodies (552 U/mL), confirming the diagnosis of pemphigus vegetans.

The patient was initially treated with systemic corticosteroids (0.5 mg/kg/day) with limited clinical response. Clinical examination revealed vegetative plaques on the nose and axillae, extensive oral erosions, and significant mucosal involvement, including nasal, oropharyngeal, and conjunctival involvement with ectropion and purulent conjunctivitis. An otorhinolaryngology evaluation was performed to rule out an associated malignancy and was unremarkable.

Given the severity of the disease, characterized by extensive multi-mucosal involvement, rituximab therapy was initiated according to current therapeutic recommendations.

Results

Pemphigus vegetans accounts for approximately 1–5% of pemphigus vulgaris cases. It is characterized by papillomatous vegetative plaques, typically involving intertriginous areas and mucous membranes, particularly the oral cavity. Nasal involvement is extremely rare and may represent a diagnostic challenge.

These lesions may mimic chronic infections or neoplastic conditions, especially squamous cell carcinoma, potentially delaying diagnosis. Several cases have been initially misdiagnosed as infectious or tumoral processes prior to histological confirmation.

Diagnosis relies on histopathological findings of intraepidermal acantholysis with epithelial hyperplasia and immunological evidence of autoantibodies directed against desmoglein 3. Pemphigus vegetans may be associated with internal malignancies or drug exposure, particularly captopril. In our case, malignancy workup was negative, and no triggering medication was identified.

While systemic corticosteroids are a mainstay of treatment, current guidelines support the early use of rituximab in moderate-to-severe pemphigus, particularly in cases with extensive mucosal involvement, as observed in our patient.

Conclusions

This case highlights an unusual presentation of pemphigus vegetans with predominant nasal involvement. It underscores the importance of considering this diagnosis in atypical vegetative nasal lesions and supports early escalation to rituximab in severe, multi-mucosal disease.

EA DV CONGRESS
VIENNA
30 SEP - 3 OCT 2026

Abstract N°: 2278

Role of Rituximab in the Management of Refractory Epidermolysis Bullosa Acquisita

Seddiki Meriem*[1], Taibi Lynda[1], Hiba Attig[1], Imene Mahiou[1], Samira Zobiri[1]

[1] Mustapha University Hospital Center, Algiers, Algeria

Introduction

Epidermolysis bullosa acquisita (EBA) is a rare autoimmune blistering disorder, and refractory forms to conventional therapies represent a major therapeutic challenge. Rituximab has emerged as a promising off-label therapeutic option in such cases.

Materials and Methods

A 50-year-old man with no significant past medical history presented with severe EBA evolving over 2 years. The initial involvement affected the scalp and oral mucosa, followed by extension to the entire integument. The clinical course was marked by severe esophageal involvement, trauma-induced blistering, milia formation, and nail dystrophy.The diagnosis was based on a suggestive clinical presentation, supported by histopathological findings and positive direct immunofluorescence. Serological testing by ELISA detected circulating anti–type VII collagen antibodies, confirming the diagnosis of EBA.Systemic corticosteroids resulted in partial improvement but led to corticosteroid dependence. The addition of dapsone and cyclosporine provided only transient benefit.Despite these treatments, the disease progressed with persistent dysphagia and esophageal strictures requiring repeated dilations. Intravenous immunoglobulins (2 g/kg/month for 6 cycles) were initiated, yielding only partial efficacy, with ongoing blister formation, painful oral erosions, persistent dysphagia, and a disease activity score of EBDASI = 26. Given this refractory course, rituximab was initiated at a dose of 1 g. At 3 months post-treatment, a significant clinical improvement was observed, with a reduction in the number of daily blisters, decreased frequency of flares, and drying of lesions with early re-epithelialization of previous erosions. Additionally, dysphagia improved, esophageal strictures regressed, and the need for dilations decreased. The EBDASI score improved to 13.

Results

Refractory forms of EBA, particularly those with mucosal and cicatricial involvement, represent a major therapeutic challenge. Rituximab targets CD20+ B lymphocytes, reducing the production of pathogenic autoantibodies, including anti–type VII collagen antibodies.In our patient, rituximab led to a reduction in blister formation and significant improvement in esophageal involvement. However, complete remission was not achieved.This partial response is consistent with the literature, which reports variable efficacy of rituximab in EBA, ranging from complete to partial or delayed responses. This variability may be related to disease chronicity, the level of circulating autoantibodies, and the presence of irreversible tissue damage.Nevertheless, even partial improvement is clinically meaningful, allowing better disease control and potential corticosteroid sparing, thereby supporting the use of rituximab in multi-refractory cases. Long-term follow-up is essential to assess delayed responses and optimize treatment strategies.

Conclusions

Rituximab is a valuable therapeutic option in refractory EBA. It can significantly reduce disease activity and

improve functional outcomes.

EA DV CONGRESS
VIENNA
30 SEP - 3 OCT 2026

Abstract N°: 2286

HDM3017-1, a Potent and Selective STAT6 Degrader for the Treatment of Autoimmune and Inflammatory Diseases

Shulun Chen*[1], Mengting Zhao[1], Ke Chen[1], Chaodong Xiong[1], Wei Sun[1], Jiabo Xu[1], Xinxin Jin[1], Zhiping Zhang[1], Yiming Cao[1], Xin Xu[1], Dongzhou Liu[1]

[1] Global R&D Center, Huadong Medicine, Hangzhou, China

Introduction

STAT6, the master transcription factor of the IL-4/IL-13 signaling axis, orchestrates Th2-driven inflammation in allergic disorders. The clinical success of dupilumab, an approved injectable monoclonal antibody that blocks IL-4/IL-13 signaling for multiple atopic diseases, such as AD and asthma, further validates STAT6 as a promising therapeutic target. Targeting STAT6 itself has remained challenging with conventional small molecules due to its reliance on complex protein–protein and protein–DNA interactions. Notably, STAT6 degraders offer a novel approach by selectively degrading the entire protein, enabling more sustained and potent pathway suppression.

Materials and Methods

Here we report the development of HDM3017-1, a novel orally administered degrader exhibiting exceptional potency and selectivity for STAT6. Its biological functions were evaluated in vitro in human primary immune and tissue cells relevant to allergic disease pathogenesis, and proteomic analysis was also performed to identify the target selectivity of HDM3017-1. In vivo characterization was performed across multiple preclinical species to confirm pharmacokinetic profiles, STAT6 degradation activity and PK/PD relationships. The efficacy of HDM3017-1 was further assessed in a MC903-induced atopic dermatitis model and a HDM-induced asthma model.

Results

Through systematic molecular design and rigorous drug-likeness screening, we identified HDM3017-1 as a promising therapeutic candidate. This compound achieved complete STAT6 degradation in human PBMCs across tested concentrations and fully blocked IL-4/13-induced CCL17 expression in these cells with a picomolar IC_{50}. Meanwhile, HDM3017-1 demonstrated high selectivity for STAT6 degradation in the human PBMC proteome at $100\times DC_{90}$, with no degradation of other STAT family members and no significant off-target degradation detected. In vivo animal studies, HDM3017-1 displayed favorable pharmacokinetic profiles across multiple species. In the MC903-induced atopic dermatitis mouse model, HDM3017-1 attenuated skin inflammation via dose-dependent manner, accompanied by robust STAT6 degradation in the spleen and markedly reduced total serum IgE levels. Additionally, it exhibited favorable efficacy in an asthma animal model. Notably, HDM3017-1 achieved complete STAT6 degradation in PBMCs from monkey whole blood at extremely low doses.

Conclusions

These findings confirm HDM3017-1 as a promising STAT6 degrader candidate for the treatment of autoimmune and inflammatory diseases, including atopic dermatitis and asthma. Supported by its potent STAT6 degradation activity as well as the anti-inflammatory activity, and favorable drug developability, HDM3017-1 is in the process

of proceeding to IND-enabling development.

EA DV CONGRESS
VIENNA
30 SEP - 3 OCT 2026

Abstract N°: 2306

Linear IgA Bullous Dermatosis Revealing Lymph NodeTuberculosis: A Case Report

Wijdane tebbaai*[1], bendaoud leyla[1], aboudourib meriem[1], hocar ouafa[1], amal said[1]

[1] Department of Dermatology, Arrazi Hospital, Mohammed VI University Hospital, Marrakech Research Laboratory in Biosciences, Marrakech, Morocco

Introduction

Linear IgA bullous dermatosis (LABD) is a rare autoimmune subepidermal blistering disease characterized by neutrophilpredominant bullae. It may be idiopathic, drug-induced, or associated with inflammatory, infectious, or neoplastic
diseases. Lymph node tuberculosis is the most common extrapulmonary form of tuberculosis, often with a subacute and misleading clinical course. The association between LABD and tuberculosis is exceptional and deserves recognition, as cutaneous manifestations may constitute a revealing sign of an underlying systemic infection.

Case Presentation

We report the case of a 23-year-old woman with no relevant medical history, admitted for a generalized vesiculobullous dermatosis evolving over three months in a context of low-grade fever, intense pruritus, and impaired general condition.Dermatological examination revealed diffuse erythematous annular and polycyclic plaques involving the trunk, face, and all four limbs, surmounted by tense bullae, vesicles, pustules, and post-bullous erosions, with a negative Nikolsky sign. Mucosal involvement was absent. Clinical examination also revealed a firm, fixed, non-tender right submandibular lymph node measuring approximately 4 cm.Skin biopsy showed a subepidermal blister containing abundant neutrophils without acantholysis or keratinocyte necrosis. The dermis demonstrated a polymorphous perivascular inflammatory infiltrate with a predominance of neutrophils and eosinophils. Direct immunofluorescence was negative on two occasions (IgA, IgG, IgM, C3, C1q). Overall clinicopathological correlation was consistent with linear IgA bullous dermatosis (LABD). Cervico-thoraco-abdominopelvic CT scan revealed necrotic right cervical lymphadenopathy without other lesions. Lymph node biopsy showed epithelioid and giant-cell granulomatous inflammation with caseous necrosis, consistent with lymph node tuberculosis. Extension workup was negative, confirming isolated tuberculous lymphadenitis.The patient was treated with dapsone and standard antituberculous therapy, with good clinical evolution.

Linear IgA bullous dermatosis is a rare autoimmune blistering disease with an estimated incidence of 0.2–2.3 cases per million inhabitants per year. It is histologically characterized by a neutrophil-predominant subepidermal blister and mediated by IgA autoantibodies directed mainly against BP180/LAD-1.The originality of this case lies in its association with isolated lymph node tuberculosis. Although rarely reported, associations between LABD and tuberculosis have been described, suggesting a possible parainfectious relationship.
Several hypotheses may explain this association. First, chronic antigenic stimulation induced by tuberculosis may lead to a breakdown of immune tolerance and promote the development of IgA autoantibodies targeting basement membrane components. Second, the systemic inflammatory state associated with tuberculosis may enhance neutrophil-mediated cutaneous responses characteristic of LABD. Finally, bystander activation of autoreactive lymphocyte clones in the context of chronic infection may contribute to the persistence of autoimmunity.



Conclusion

Linear IgA bullous dermatosis may represent a misleading cutaneous presentation revealing an underlying systemic disease such as lymph node tuberculosis. Beyond dermatological diagnosis, LABD should be considered an entity with multiple e6tiologies, including idiopathic, drug-induced, infectious, inflammatory, and neoplastic causes, requiring a rigorous and systematic e6ological investigation. A multidisciplinary approach based on clinico-histological correlation and targeted exploration of associated signs, notably lymph node biopsy in cases of persistent lymphadenopathy, is essential to avoid diagnostic delay and initiate appropriate etiological management.

EADV CONGRESS
VIENNA
30 SEP - 3 OCT 2026

Abstract N°: 2308

Lupus erythematosus tumidus : Unexpected and misleading presentation

Hiba Essolaymany*[1], Meryem Soughi[1]

[1] CHU HASSAN II, FES, Morocco

Introduction

There is no doubt about lupus erythematosus tumidus (LET) being a separate entity due to its characteristic clinical and histological features. LET with isolated eyelid involvement is extremely rare, which makes diagnosis difficult and often leads to delayed or inappropriate treatment. Our case heightened our suspicion regarding this unique clinical presentation, and increased awareness of its association with positive SSA antibodies and Sjogren syndrome.

Case Presentation

Forty years-old female with no past medical history was referred to us, complaining of persistent asymptomatic bilateral periorbital erythema that appeared 8months prior to admission. She reported positive history of photosensitivity with exacerbation of lesions by sun exposure with mild xerostomia. She denied any other systemic symptoms. Physical examination showed bilateral, symmetrical peri-orbital erythema that extended to both cheeks with mild swelling with a raccoon-eye appearance.The surface wasn't scaly nor atrophic and the lesions were infiltrative and had firm consistency in palpation. No follicular plugging was observed on dermoscopy. Laboratory investigations were all within normal limits besides anti-Ro SSA positivity. Our patient underwent skin biopsy and the diagnosis of LE tumidus (LET) was confirmed based on clinical and histopathological findings although direct immunofluorescence did not reveal a lupus band. She was treated with hydroxychloroquine and prednisolone with excellent outcome following 4 weeks of therapy without residual scarring or dyspigmentation.

Conclusion

CLE encompasses a broad range of clinical manifestations. Clinically, when the erythema is associated with marked edema, it represents a rarer manifestation of CLE in its tumidus form. LET is a less common subtype that falls under the rubric of chronic cutaneous lupus erythematosus (CCLE). However, some autors consider it a separate entity, as it has so many characteristic and distinct features.

LET is characterized by indurated, succulent, urticaria-like, single or multiple plaques with a bright reddish or violaceous, smooth surface on sun-exposed areas. The swollen appearance of LET lesions and the absence of clinically visible epidermal involvement are the most important features of this subtype. Scaling, follicular plugging, atrophy, or residual scarring of Discoid LE (DLE) are absent. Provocative phototesting has been crucial in defining LET as the most photosensitive variant of CLE. The prognosis is generally favorable. Furthermore, once a lesion has developed, it persists in the same location, However, it can also display long-term remission with the use of sunscreens, with no scarring or dyspigmentation. Association with systemic disease seems to be very rare in patients with LET. In our case, there was no evidence of systemic involvement or progression to systemic LE even though our patient had positive SSA antibodies.

Although rare, periorbital edema may be the sole manifestation of CLE. The rates of occurrence of eyelid edema and erythema as a primary manifestation of LE is uncommon, with only a handful of related case reports. Laboratory immunologic findings of patients presenting CLE in this isolated periorbital localisation revealed primarily negative results, except anti-SSA/SSB positivity that occurred at a higher rate of around 50% as in our patient. An understanding of factors associated with these autoantibodies might elucidate the possible pathomechanism. In deed, a positive association between photosensitivity and anti-SSA reactivity had been demonstrated.
Management of LET patients with periorbital presentation mainly comprised antimalarial agents and steroids. Strict and consistent photoprotection is mandatory.

EADV CONGRESS
VIENNA
30 SEP - 3 OCT 2026

Abstract N°: 2348

Connective Tissue Diseases in the Elderly: Epidemiological, Clinical, and Immunological Profile of Six Cases

raouia Roumili*[1], Dali osmane Rima[1], tinhinane benbrahim[1], fella laissaoui[1], Lydia iberraken[1], Maroua sakhri[1], mira chikhaoui[1], Baya Moussaoui[2], sahel houria[1]

[1] Department of Dermatology, Lamine Debaghine University Hospital, bab elouad, Algeria
[2] Department of Pathology, Lamine Debaghine University Hospital, bab elouad, Algeria

Introduction

Connective tissue diseases (CTDs) are systemic autoimmune disorders well described in young adults. Their presentation in the elderly is often atypical. Diagnosis is frequently delayed or overlooked due to comorbidities and non-specific clinical features.

Through six observations, we describe the epidemiological, clinical, immunological, and outcome characteristics of CTDs in elderly patients, with the aim of improving their diagnosis and management.

Materials and Methods

We collected all patients aged ≥65 years hospitalized for CTDs in the Dermatology Department of CHU Bab El Oued between September 2023 and December 2025.

The diagnosis of systemic lupus erythematosus (SLE) and Sjögren's syndrome (SS) was based on ACR/EULAR criteria, while dermatomyositis (DM) was diagnosed according to the Bohan and Peter criteria.

Results

Six patients were included (five women and one man). The mean age was 70.5 years (range: 65–75 years).

Diagnoses were as follows: 2 cases of SLE, 2 cases of DM, 1 overlap case (DM–SLE), and 1 case of SS. The delay between symptom onset and diagnosis ranged from 3 weeks to 5 years.

Cutaneous manifestations were the presenting feature in all cases, including photosensitivity (erythema in photo-exposed areas), malar rash, extensive maculopapular eruptions, heliotrope rash, Gottron's papules, discoid lupus lesions with scarring alopecia, and dermo-hypodermal nodules.

The most frequent extracutaneous manifestations were predominant proximal muscle involvement, associated with gastrointestinal symptoms (epigastric pain and dysphagia) (3 cases), and respiratory involvement (resting dyspnea) (2 cases). General deterioration with fever and anorexia was observed in 2 cases (SLE and DM–SLE).

Pancytopenia with a positive Coombs test was found in both SLE cases. Antinuclear antibodies (ANA) were positive in all patients, and anti-Mi-2α antibodies were detected in one overlap case (SLE/DM).

Five patients received corticosteroid therapy (SLE and DM), combined with methotrexate in one patient (SLE) and intravenous immunoglobulins in another (DM–SLE).

Two patients died: one from fulminant DM associated with SLE, and the other from acute adrenal insufficiency

complicating SLE after abrupt self-discontinuation of corticosteroids. Favorable outcomes were observed in the remaining patients.

Conclusions

The World Health Organization defines the elderly population as individuals aged 65 years and older. Aging is associated with immune dysregulation known as immunosenescence. Physiological autoimmunity is more common in healthy elderly individuals, in contrast to the relative rarity of connective tissue diseases in this population.

CTDs in the elderly exhibit distinct features compared to early-onset forms. In our series, diagnostic delay reached up to 5 years, as reported in the literature. General symptoms, particularly overall deterioration, anorexia, and gastrointestinal disturbances, were frequent and sometimes inaugural, consistent with previous studies highlighting the predominance of systemic manifestations in elderly patients.

Proximal muscle involvement was constant in DM cases and sometimes severe, with dysphagia and dyspnea, in agreement with literature describing more severe and potentially fulminant late-onset forms. Immunologically, ANA positivity was constant. The presence of anti-Mi-2α antibodies in the overlap SLE/DM case represents a rare but reported situation in elderly patients.

Overall, outcomes under corticosteroids and immunosuppressive therapy were favorable; however, one death occurred after corticosteroid discontinuation despite initial improvement, highlighting therapeutic fragility and the risk of adverse outcomes in this population.

Our observations confirm that CTDs in the elderly are characterized by atypical presentations, marked systemic involvement, and the need for early, continuous, and individualized management.

EA DV CONGRESS
VIENNA
30 SEP - 3 OCT 2026

Abstract N°: 2363

Correlations Between CLE Disease Severity and Quality of Life in a US Multi-Center Real-World Cross-Sectional Study

Ben Chong[1], Scott A. Elman[2], david fivenson[3], Joseph F. Merola[4], Weihong Yang[5], Catherine Mak[5], Qianyun Li[5], Fariba Mirzaei*[5]

[1] Department of Dermatology, UT Southwestern Medical Center, Dallas, United States

[2] Dr. Phillip Frost Department of Dermatology and Cutaneous Surgery, University of Miami Miller School of Medicine, Miami, United States

[3] Fivenson Dermatology, Ann Arbor, United States

[4] Department of Dermatology and Department of Medicine, Division of Rheumatology, UT Southwestern Medical Center, O'Donnell School of Public Health, Dallas, United States

[5] Biogen, Cambridge, United States

Introduction

Cutaneous lupus erythematosus (CLE) is a serious and chronic autoimmune disease primarily affecting the skin causing a range of potentially disfiguring skin manifestations that vary in severity and presentation. CLE has a negative impact on patients' physical and mental health, significantly diminishing overall quality of life (QoL). This multicenter, cross-sectional, registry-based observational study evaluated patients with CLE in real-world clinical settings. The objective of this analysis was to examine the relationship between disease severity and QoL using disease specific QoL instruments.

Materials and Methods

Adults with clinically confirmed CLE from four US dermatology and rheumatology clinics (August 2023–April 2024) were consecutively enrolled. Demographics, clinical history, and disease severity data were collected during a single study visit and/or from medical records. At the study visit, patients were asked to complete two disease-specific QoL questionnaires: 1) CLEQoL: A 37-item CLE-specific questionnaire evaluating five domains (symptoms, emotions, functioning, photosensitivity/alopecia, and body image/cosmetic effects) on a 0–100 scale, with higher scores indicating worse QoL; 2) Dermatology Life Quality Index (DLQI): A 10-item dermatology-specific questionnaire assessing six domains (symptoms/feelings, daily activities, leisure, work/school, personal relationships, and treatment); total scores range from 0 (no impairment) to 30 (maximum impairment). CLE severity was assessed using the Cutaneous Lupus Activity Investigator's Global Assessment-Revised (CLA-IGA-R) and CLE Disease Area and Severity Index (CLASI). Correlations between QoL scales and disease severity were evaluated using Pearson's, Spearman's, or Polyserial correlations, depending on assessment distributions. Correlations were tested for statistical significance; two-sided, unadjusted p-values were provided.

Results

Among 120 participants with a complete valid CLEQoL questionnaire, the median score was 43.0 (Q1, Q3: 25.0, 63.0). The lowest median scores (i.e., less impact) were in the 'functioning' domain (24.0 [Q1, Q3: 4.0, 44.0]), and the highest (i.e., higher impact) in the 'photosensitivity and alopecia' domain (67.0 [Q1, Q3: 42.0, 92.0]). Among 121 participants with a complete DLQI, the median score was 5.0 (Q1, Q3: 1.0, 12.0), though substantial variability was observed. The lowest impact from skin disease (i.e., lower score) was in the 'treatment subscale' (0.0 [Q1, Q3: 0.0, 0.0]) and the highest impact in the 'symptoms and feelings' subscale (2.0 [Q1, Q3: 1.0, 4.0]). Most participants had no or mild disease activity (median CLASI-A: 1.0 [Q1, Q3: 0.0, 6.0]), with over half scoring clear or almost clear for erythema or other morphological characteristics (OMC) per CLA-IGA-R. Significant but low correlations were

observed between CLEQoL and DLQI total scores and disease severity (correlation coefficients: 0.185–0.337; all unadjusted p-values <0.05) **(Table 1)**. CLA-IGA-R erythema, CLA-IGA-R OMC, and CLASI-A total score correlated with CLEQoL and DLQI total scores. CLASI-D showed low correlations with CLEQoL and DLQI. A linear trend between worse QoL and disease severity was observed across most domains for CLEQoL and DLQI. For CLEQoL, the strongest associations were in the 'symptom' and 'emotion' domains, while 'photosensitivity and alopecia' and 'body image' domains were weaker but presented higher scores that did not vary much across severity categories. For DLQI, stronger associations were observed in the 'symptoms and feelings' domain, followed by 'daily activities' and 'work and school', whereas 'personal relationships' had the lowest association.

Disease Severity Measure	CLEQoL Total Score		DLQI Total Score	
	Correlation	p-value	Correlation	p-value
CLA-IGA-R Erythema score[a]	0.300	0.001	0.313	<0.001
CLA-IGA-R OMC score[a]	0.329	<0.001	0.317	<0.001
CLASI-A total score[b]	0.270	0.003	0.337	<0.001
CLASI-A Erythema[b]	0.247	0.007	0.316	<0.001
CLASI-A Scale/Hypertrophy[b]	0.234	0.010	0.257	0.004
CLASI-D total score[b]	0.194	0.034	0.185	0.042

[a]**Polyserial correlation**
[b]**Spearman correlation**

Table 1. Correlation Between Disease Specific QoL Scales and CLE Severity (CLA-IGA-R and CLASI)

Conclusions

Overall, a low but significant correlation was observed between the two disease-specific QoL questionnaires total scores (CLEQoL and DLQI) and disease severity (CLA-IGA-R and CLASI). Higher disease severity scores were associated with worse QoL outcomes, reflected by higher median CLEQoL and DLQI total and domain scores.

EA DV CONGRESS
VIENNA
30 SEP - 3 OCT 2026

Abstract N°: 2368

When treatment strikes back: Plaque morphea following radiation for breast carcinoma

zineb selka*[1]

[1] CHU Docteur Tidjani Damardji, Mansourah, Algeria

Introduction

Morphea (from the Greek *morphe*: form), also referred to as **"localized scleroderma"** as opposed to systemic sclerosis encompasses various dermatological manifestations.

These manifestations share the common characteristic of being (or having been) indurated (sclerosis), reflecting a fibrosis of the dermis and sometimes the underlying tissues, occurring without a known cause.

Case Presentation

The patient is a 72-year-old female (M.M.) with a history of left breast adenocarcinoma diagnosed in 2011. She underwent a mastectomy with axillary lymph node dissection that same year. The patient completed chemotherapy and radiotherapy sessions, which concluded in 2012. Her breast cancer is currently in remission.

In April 2025, she presented with a well-defined, erythematous, sclerotic induration measuring approximately 20 cm along its major axis. This was located on the left hemithorax, specifically within the previous radiation field. Additionally, an oval sclerotic plaque measuring approximately 20 cm along its major axis was noted on the tibial aspect of the right leg.

She was started on systemic corticosteroid therapy (methylprednisolone) at a dosage of 0.5 mg/kg/day, combined with methotrexate at 20 mg per week, and topical treatment (clobetasol propionate).

The patient remains on methotrexate (20 mg/week) and topical treatment. A favorable progression of her morphea is noted, characterized by a softening of the sclerosis, resulting in residual post-inflammatory hyperpigmentation.

Radiation-induced morphea (RIM) is a rare and frequently underdiagnosed complication of radiotherapy, as it is often confused with chronic radiation dermatitis (sclerotic radiodermatitis). The distinction between the two is established through histological examination.

Radiation-induced morphea can appear after a latency period ranging from 1 to 12 years following the completion of radiotherapy. It is not correlated with the delivered radiation dose. The plaques may manifest at the irradiation site or even at distant sites.

There is currently no therapeutic consensus; however, the use of systemic treatment (phototherapy, methotrexate, corticosteroids, or immunoglobulins) appears more effective than topical treatment with dermocorticoids alone. The best clinical responses are observed with the combination of methotrexate and phototherapy.

Conclusion

Radiation-induced morphea is a rare and often unrecognized complication. It can occur after a variable latency

period, sometimes appearing several years after irradiation; furthermore, lesions can manifest even at a distance from the initial irradiation site.

To date, no therapeutic consensus exists, and the most common treatment modalities include simple clinical observation, the use of topicals (particularly steroid-based), and surgical excision

EADV CONGRESS
VIENNA
30 SEP - 3 OCT 2026

Abstract N°: 2382

Prurigo-like pemphigoid : A diagnostic pitfall

Kawtar Diaa*[1]

[1] CHU IBN SINA Rabat, Rabat, Morocco

Introduction
Bullous pemphigoid is the most common autoimmune bullous disease in the elderly, characterized by antibodies targeting hemidesmosomal proteins. It typically presents with tense subepidermal bullae on erythematous skin, often associated with pruritus. Some atypical forms manifest as highly pruritic papulo-nodular lesions mimicking nodular prurigo or chronic eczema, sometimes without initially visible bullae, which can mislead the diagnosis. We report the case of a patient with a prurigo-like form.

Case Presentation
A 100-year-old woman with no significant medical history presented with a generalized highly pruritic eruption evolving for 4 years. Clinical examination revealed a phototype II patient, afebrile, in good general condition, with multiple erythematous-violaceous papulo-nodules (some excoriated), eczematous plaques involving the back, trunk, abdomen, upper and lower limbs, occipital region, and scalp, as well as hypertrophic scaly plaques with excoriations on the buttocks and legs. The face was spared, with no palmoplantar or mucosal involvement. Laboratory tests were normal, with no eosinophilia. Skin biopsy showed a hyperplastic epidermis with subepidermal detachment; the superficial loose fibrous dermis contained a moderate polymorphic perivascular inflammatory infiltrate composed of lymphocytes and eosinophils. Direct immunofluorescence was positive, and indirect immunofluorescence revealed anti-BP180 and anti-BP230 antibodies. The diagnosis of prurigo-like bullous pemphigoid was established. The patient was treated with topical clobetasol propionate associated with oral doxycycline 200 mg/day, with excellent evolution.

Conclusion
Discussion:
Bullous pemphigoid is an autoimmune bullous dermatosis characterized by antibodies against BP180 and BP230 antigens of the basement membrane. Up to 20% of patients may initially present a non-bullous phase with non-specific eczematous, urticarial, nodular, lichenoid, or vesicular lesions.
The prurigo-like form is rare, clinically characterized by excoriated pruritic papulo-nodules and hyperkeratotic nodules simulating nodular prurigo, but with the histological and immunological profile of bullous pemphigoid. Histopathological findings of nodular pemphigoid combine features close to nodular prurigo (orthokeratotic hyperkeratosis, focal parakeratosis, irregular epidermal hyperplasia) with those of bullous pemphigoid (prominent eosinophilic spongiosis and subepidermal detachment). These findings justify performing direct and indirect immunofluorescence to detect autoantibodies.
Published treatment data are limited; therapeutic options include systemic corticosteroids, azathioprine, dapsone, intravenous immunoglobulins, and minocycline. However, topical corticosteroids remain the treatment of choice, especially in very elderly patients, to limit systemic corticosteroid side effects.

Conclusion:
This case illustrates a rare and atypical form of prurigo-like bullous pemphigoid, posing a diagnostic and therapeutic challenge in the elderly. Skin biopsy with direct immunofluorescence should be systematic in any

chronic resistant pruritus or papulo-nodular eruption in the elderly, even in the absence of bullous lesions.

EA DV CONGRESS
VIENNA
30 SEP - 3 OCT 2026

Abstract N°: 2385

Efficacy of Ivarmacitinib for Mild-to-Severe Alopecia Areata: A Case Series

jin wu*[1]

[1] The Second Hospital & Clinical Medical School , Lanzhou University, Lanzhou, China

Introduction

Alopecia areata (AA) is a common chronic immune-mediated inflammatory non-scarring hair loss disorder. The JAK-STAT signaling pathway plays a critical role in AA pathogenesis, and a growing number of JAK inhibitors have been developed for its clinical management. Ivarmacitinib, a highly selective JAK1 inhibitor, has been approved by the NMPA for adult patients with severe AA. However, real-world evidence on its efficacy across the spectrum of mild-to-severe AA remains scarce.

Case Presentation

Objective

This study aimed to evaluate the real-world efficacy and safety of ivarmacitinib in patients with alopecia areata.

Methods

A total of 10 AA patients with varying disease severity receiving oral ivarmacitinib 4 mg once daily (QD) were enrolled. The primary efficacy endpoint was the percentage improvement in SALT score from baseline at 3 months, calculated as: (Baseline SALT score − Post-treatment SALT score) / Baseline SALT score × 100%. Safety outcomes were assessed by monitoring and recording all adverse events (AEs) during treatment.

Conclusion

Results and Conclusions

Of the 10 patients, 6 had severe AA, 3 had moderate AA, and 1 had mild AA. After 3 months of ivarmacitinib therapy, 6 patients achieved ≥30% improvement in SALT score. Subgroup analysis showed that 50% (3/6) of severe AA patients and 75% (3/4) of mild-to-moderate AA patients attained over 30% SALT score improvement.

Among the 4 patients with suboptimal initial response, 2 underwent dose escalation to 8 mg daily. Their SALT scores declined markedly after dose adjustment and continued to decrease with ongoing treatment; notably, one patient achieved a SALT score of 0. No adverse events were reported in any participant during the entire treatment period.

Ivarmacitinib yields meaningful improvements in hair loss and promotes hair regrowth after 3 months of treatment in both mild-to-moderate and severe AA patients, with a higher rate of satisfactory response observed in the mild-to-moderate subgroup. Dose escalation can achieve rapid therapeutic benefits in patients with an initially poor response. Larger real-world cohorts are warranted to further validate the efficacy and safety profile of ivarmacitinib, especially in mild-to-moderate AA populations.

SALT Score Data of Patients

Patient	Treatment duration(M)	SALT score			SALT score reduction	SALT score improvement percentage
		Baseline	3-month	Final follow-up		
case_1	8	28%	3%	0	25%	89%
case_2	7	82%	75%	30.50%	7%	9%
case_3	7	91%	91%	64.50%	0%	0%
case_4	7	7%	3%	1%	4%	57%
case_5	4	86%	75%	58%	11%	13%
case_6	5	70%	49%	86%	21%	30%
case_7	7	92%	56%	34%	36%	39%
case_8	4	28%	17%	7%	11%	39%
case_9	3	44.50%	32%		13%	28%
case_10	3	54%	36%		18%	33%

EADV Congress 2026, VIENNA
30 SEPTEMBER - 03 OCTOBER 2026
POWERED BY M-ANAGE.COM

EADV CONGRESS
VIENNA
30 SEP - 3 OCT 2026

Abstract N°: 2398

Risk of pemphigus among hypertensive patients who take ACE inhibitors

Ajay Pandey*[1], Grace Hemingway[1], Shari Lipner[2]

[1] AU/UGA Medical Partnership, Athens, United States

[2] Department of Dermatology, Weill Cornell Medicine, New York, United States

Introduction

ACE inhibitors including lisinopril and enalapril remain mainstays in hypertension management, a condition which affects approximately 48% of Americans. While case reports and series have suggested pemphigus is a rare side effect of ACE inhibitor use, large-scale case-control studies validating that association are missing. Thus, we assessed for potential associations between ACE inhibitor use and pemphigus diagnosis using a retrospective cohort design.

Materials and Methods

The TriNetX Research Network was queried for adult (≥18-years) patients with at least two diagnoses of essential hypertension (ICD-10: I10) with vs. without ACE inhibitor use, 2006-2016. Index date was defined as date of ACE inhibitor initiation or date of second hypertension diagnosis for the control group. Patients with a prior diagnosis of pemphigus (ICD: L10) or pemphigoid (ICD-10: L12) prior to index date were excluded. Cohorts were propensity score matched by age, sex, race, and ethnicity. Relative risk of pemphigus diagnosis ≥1-day following index date were calculated.

Results

After matching, 5005750 hypertensive patients with ACE inhibitors were matched with an equal number of hypertensive patients without ACE inhibitor use. ACE inhibitor use was associated with increased risk of pemphigus (0.031% vs. 0.021%, RR: 1.45, 95%CI: 1.34-1.57). In subgroup analysis, benazepril, captopril, enalapril, lisinopril, and quinapril were associated with increased risk of pemphigus.

Conclusions

While the absolute risk of developing pemphigus among hypertensive patients who use ACE inhibitors is low, our study confirms increased relative risk compared to patients who do not use ACE inhibitors. Patients should be counseled about this rare adverse side effect, and future work should evaluate ideal treatment strategies for patients who develop pemphigus on ACE inhibitors.

EADV CONGRESS
VIENNA
30 SEP - 3 OCT 2026

Abstract N°: 2442

Bullous pemphigoid after kidney transplantation: insights into allograft-related immune dysregulation and dupilumab as a targeted therapy

Victoria Martínez Sernández*[1, 2], Gonzalo Peón Currás[1, 2], Sandra Martínez Fernández[1, 2], Verónica Andreina Barcia Odor[3], Guillermo López González[1, 2], Emma Romeo Iglesias[1, 2], Francisco Javier Domínguez Cid[1, 2], Laura Salgado Boquete[1, 2]

[1] Department of Dermatology, Pontevedra University Hospital, Pontevedra, Spain
[2] DIPO Research Group, Galicia Sur Health Research Institute (IIS Galicia Sur), SERGAS-UVIGO, Pontevedra, Spain
[3] Diaverum Vilagarcía de Arousa, Vilagarcía de Arousa, Spain

Introduction

Bullous pemphigoid (BP) is the most common autoimmune blistering disease. Its occurrence in kidney transplant recipients is rare and poorly characterized, posing both diagnostic and therapeutic challenges.

Case Presentation

We report a 48-year-old man with a history of MPO-ANCA vasculitis who underwent kidney transplantation in 2022. His course was complicated by chronic antibody-mediated rejection and BK virus nephropathy, leading to progressive graft dysfunction and end-stage renal disease requiring hemodialysis. In the context of progressive reduction of immunosuppression to control viral replication and enable future retransplantation, he developed tense blisters involving the skin and oral mucosa five weeks after tacrolimus tapering. BP was confirmed by histology, direct immunofluorescence, and positive anti-BP180 antibodies.
The disease initially responded to high-dose systemic corticosteroids but followed a steroid-dependent course. Given the need to minimize immunosuppression, dupilumab was initiated, leading to rapid clinical control, absence of new lesions at two months, and progressive corticosteroid tapering. Anti-BP180 levels decreased but remained detectable. During further tacrolimus reduction, the patient developed graft intolerance syndrome requiring transient intensification of immunosuppression. Concomitantly, mild, self-limited blistering recurred at sites of mechanical trauma, together with a slight increase in anti-BP180 levels. Ongoing graft-related immune activity prompted consideration of graft embolization.

Conclusion

A review of 31 published cases of BP after kidney transplantation revealed a distinct clinical profile compared to classical BP, closely mirroring our patient. These cases showed a younger age at onset (median 42 years), frequent mucosal involvement (39%), and a high prevalence of graft dysfunction (77%) and dialysis (68%) at diagnosis. Immunosuppression changes preceded disease onset in a substantial proportion of patients. Most patients were treated with systemic corticosteroids and conventional immunosuppressive agents, and graft nephrectomy was required in 39% of cases to achieve disease control. Importantly, to the best of our knowledge, our case represents the first reported use of dupilumab in this setting.
These findings support a multifactorial pathogenesis in which allograft-related immune dysregulation plays a central role. Chronic antigenic stimulation from the failing graft, together with shifts in immunosuppression, may promote loss of immune tolerance and trigger autoantibody production. From a therapeutic perspective,

management is particularly challenging, as conventional immunosuppressive strategies may be contraindicated due to infection risk, viral reactivation, or graft-related complications. In this setting, dupilumab represents a particularly attractive steroid-sparing option, as it selectively targets Th2-driven inflammation without increasing global immunosuppression or compromising antiviral immunity. In contrast to conventional agents, it does not require dose adjustment in renal impairment, is not nephrotoxic, and has a favorable safety profile supported by real-world data.

Sustained clinical control with dupilumab despite persistent autoantibody positivity suggests a predominant effect on the inflammatory effector phase in this setting. However, ongoing graft-related immune activation may sustain low-grade disease activity, highlighting the potential need to eliminate the underlying antigenic stimulus to achieve complete remission.

EA DV CONGRESS
VIENNA
30 SEP - 3 OCT 2026

Abstract N°: 2458

Extensive Crusted Scalp Lesions in an Adolescent: A Diagnostic Challenge

Karine Domingues Tavares*[1], Luiz Rei[1], Raphael Pereira[1], Rafaela Lopes[1], David Souza[1], Paula Figueiredo de Marsillac[1], Juan Piñeiro-Maceira[1], Alexandre Gripp[1]

[1] Universidade Estadual do Rio de Janeiro - Hospital Pedro Ernesto, Rio de Janeiro, Brazil

Introduction

Crusted scalp lesions frequently represent a diagnostic challenge for dermatologists. Among the various cutaneous manifestations, those affecting the cephalic region are particularly notable due to their potential stigmatizing impact on patients. We present a remarkable case of crusted scalp lesions in a 13-year-old patient, with a history of multiple ineffective therapeutic approaches and an unexpected diagnostic outcome.

Case Presentation

A 13-year-old male from Sumidouro presented with a 9-month history of erosive occipital lesions progressing to diffuse exudative and crusted plaques involving the entire scalp. Five months later, flaccid blisters developed on the trunk and limbs, evolving rapidly into erosions and leaving residual post-inflammatory hyperpigmentation. Physical examination revealed painful bilateral submandibular lymphadenopathy without mucosal involvement. Previous treatments with systemic antibiotics and terbinafine showed no clinical response. The patient also developed significant depressive symptoms, including school abandonment.

Initial differential diagnoses included crusted scabies, kerion celsi, and Pveg. Due to social vulnerability and disease severity, hospital admission was indicated for diagnostic investigation and multidisciplinary care. Direct mycological examination and fungal culture were negative. Histopathology demonstrated focal superficial acantholysis associated with acanthosis and papillomatosis, favoring pemphigus vegetans. Direct immunofluorescence revealed intercellular IgG deposition throughout the epidermis, confirming the diagnosis. The patient was classified as Neumann-type Pveg because of the initial bullous presentation followed by erosive and vegetating lesions. Treatment with prednisone (0.5 mg/kg/day) associated with topical clobetasol propionate 0.05% resulted in complete clinical response after approximately 45 days. Azathioprine was subsequently introduced during corticosteroid tapering. The patient remains stable, without new lesions.

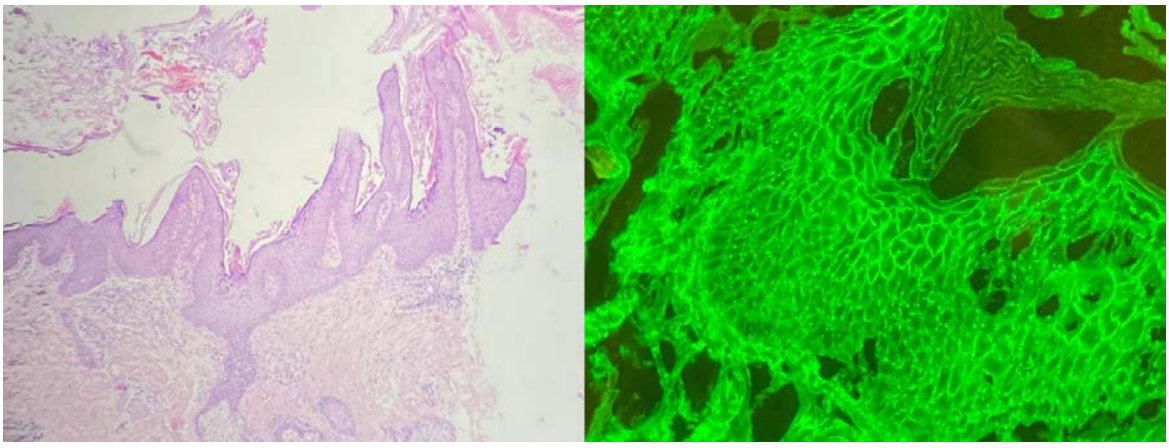

Figure 1. H&E histopathology showing hyperkeratosis, marked acanthosis, and papillomatosis, with small foci of acantholysis in the granular layer, findings suggestive of a pemphigus spectrum disorder, particularly the vegetative form. | Figure 2. Direct immunofluorescence showing intercellular IgG deposition within the epidermis.

Conclusion

Pveg is a rare variant of pemphigus vulgaris, accounting for 1–2% of cases. Predominant scalp involvement in Neumann-type Pveg appears to be exceptionally uncommon. Histopathology and direct immunofluorescence are essential for diagnosis, especially in atypical presentations mimicking infectious dermatoses. Early recognition and prompt immunosuppressive treatment may lead to complete remission. In the present case, systemic corticosteroids combined with topical therapy were chosen due to the extensive scalp involvement. The patient achieved complete clinical remission, remaining free of new lesions for 8 months, with marked improvement in quality of life, return to school activities, and ongoing psychological follow-up.

EA DV CONGRESS
VIENNA
30 SEP - 3 OCT 2026

Abstract N°: 2463

Simultaneous Morphea and Atrophoderma of Pasini and Pierini: Distinct Entities or a Disease Spectrum? A Case Report

Ana Lígia Scotti Alérico*[1], Sandra e Dinato[1], Paulo Ricardo Criado[1], João Henrique Aurich[1, 1], Ingrid Palloma Vieira de Melo[1]

[1] Centro Universitário Lusíada - UNILUS, Santos, Brazil

Introduction

Localized scleroderma (morphea) and Idiopathic Atrophoderma of Pasini and Pierini (AIPP) are dermatoses involving the dermis and extracellular matrix, with partially overlapping clinical and histopathological features. Morphea is characterized by an autoimmune inflammatory and fibrosing process, whereas AIPP typically presents with non-indurated atrophic plaques and minimal or absent inflammation. The relationship between these entities remains controversial, with some authors suggesting that AIPP may represent a superficial or late-stage variant within the morphea spectrum. This case aims to contribute to a better clinical, histopathological, and therapeutic understanding of these conditions.

Case Presentation

We report the case of a 72-year-old white female presenting with multiple asymptomatic skin lesions. Dermatological examination revealed brownish plaques distributed over the shoulders, inframammary regions, lateral and posterior trunk, and thighs. Some lesions exhibited hypopigmented centers and atrophic features without induration. Additionally, a plaque with a hardened hypopigmented center was identified on the left hip, suggesting a sclerotic component compatible with morphea.

The coexistence of indurated and non-indurated atrophic lesions raised the differential diagnosis between morphea and AIPP, as well as the possibility of overlap within the same disease spectrum.

Biopsies of the brownish lesions revealed a rectified epidermis with a mild perivascular lymphocytic infiltrate, without histopathological features of sclerosis, findings suggestive of AIPP. In contrast, biopsies of the lesions with hypopigmented centers and atrophic features demonstrated a rectified epidermis, collagen hyalinization throughout the dermis, and a mild perivascular lymphocytic infiltrate, findings commonly observed in morphea.

Initial treatment with methotrexate was initiated but discontinued after one month because of gastrointestinal intolerance. Topical clobetasol therapy was maintained, resulting in mild improvement in pigmentation. Subsequently, oral vitamin E (400 mg twice daily for 90 days) was prescribed, leading to stabilization of the lesions. No significant progression was observed during follow-up, although the patient reported subjective hardening in some affected areas.

Conclusion

This case highlights the simultaneous presence of clinical and histopathological features suggestive of both morphea and AIPP in the same patient, supporting the hypothesis that these conditions may represent different manifestations within a disease spectrum rather than entirely distinct entities. Detailed clinical and histopathological evaluation remains essential for accurate diagnosis and appropriate management. Further studies are needed to clarify the pathophysiological relationship between morphea and AIPP and to establish more effective therapeutic approaches.

EADV Congress 2026, VIENNA
30 SEPTEMBER - 03 OCTOBER 2026
POWERED BY M-ANAGE.COM

EA DV CONGRESS
VIENNA
30 SEP - 3 OCT 2026

Abstract N°: 2488

IMMUNE CHECKPOINT INHIBITOR- INDUCED SUBACUTE CUTANEOUS LUPUS ERYTHEMATOSUS WITH MUCOSAL INVOLVEMENT: A DIAGNOSTIC CHALLENGE

Ederson Lopes de Oliveira*[1], Roberto Bueno Filho[2]

[1] University of São Paulo, Ribeirão Preto, Brazil

[2] Ribeirão Preto Medical School, University of São Paulo, Ribeirão Preto, Brazil

Introduction

Pembrolizumab, a humanized monoclonal antibody targeting programmed cell death protein-1 (PD-1), has become an important therapeutic option for several malignancies, including non-small cell lung carcinoma (NSCLC)[1-6]. By enhancing T-cell-mediated antitumor immunity, immune checkpoint inhibitors may also trigger immune-related adverse events, particularly autoimmune cutaneous disorders. Subacute cutaneous lupus erythematosus (SCLE) is an uncommon but increasingly recognized adverse event associated with PD-1/PD-L1 inhibitors[7-14]. We report a case of pembrolizumab-induced SCLE in a patient with NSCLC, initially raising concern for paraneoplastic pemphigus (PNP) due to oral mucosal involvement.

Case Presentation

A 72-year-old white, non-smoking woman was diagnosed in 2018 with lung adenocarcinoma and underwent left upper lobectomy, including resection of pulmonary segments, pleura, and mediastinal lymph nodes. Histopathological and immunohistochemical analyses demonstrated adenocarcinoma with predominantly lepidic pattern (~90%) and focal invasive acinar component (~10%), consistent with NSCLC.

The patient received three sequential treatment regimens composed of 3 cycles each: 1) pemetrexed, carboplatin, and pembrolizumab; 2) pemetrexed and pembrolizumab; 3) pembrolizumab monotherapy. Intervals between regimens ranged from 15 to 22 days, with 21-day intervals between cycles.

Two weeks after initiation of the first regimen, the patient developed erythematous scaly plaques on the anterior chest, arms, forearms, and malar region (Figure 1A). Partial improvement was observed after systemic corticosteroid therapy. However, eight weeks after pembrolizumab initiation, recurrence and worsening of lesions occurred in the same locations (Figure 1B).

After 27 weeks of pembrolizumab exposure, the eruption became extensive, involving the upper back and posterior upper limbs, with annular plaques, marked erythema and scaling, in addition to new lesions on the thighs and dorsal hands. Painful labial mucosal ulcerations with crusting were also observed (Figures 1C–1D).

Laboratory investigation revealed: ANA positive (1:320), mixed homogeneous and fine speckled nuclear pattern with positive metaphase plate; anti-single-stranded DNA 70.0 U/mL (<20.0 U/mL); anti-Ro/SSA 240 U/mL (<7.0 U/mL); anti-La/SSB <7.0 U/mL; anti-Sm<7.0 U/mL; and complement C_3 within normal range (128 mg/dL).

Histopathological examination demonstrated focal parakeratosis, vacuolar interface dermatitis, and superficial perivascular and lichenoid chronic inflammatory infiltrate (Figure 1E).

Indirect immunofluorescence (IIF) studies showed:(A) weak positivity for IgG in keratinocyte nuclei on normal skin substrate;(B) perinuclear IgG positivity on salt-split skin substrate;(C) weak IgG positivity on rat bladder epithelium (Figure 1F).

Considering the clinical presentation, histopathological findings, autoantibody profile, and temporal relationship with pembrolizumab therapy, a diagnosis of pembrolizumab-induced SCLE was established. Treatment with hydroxychloroquine 400 mg/day and strict photoprotection resulted in progressive clinical improvement (Figure 1G).

Conclusion

Pembrolizumab-induced SCLE is a rare immune-related adverse event that should be recognized promptly, particularly in patients presenting with annular or photodistributed scaly eruptions during PD-1 inhibitor therapy[8-9,15-16]. In this case, oral mucosal involvement and weak positivity on rat bladder substrate initially raised suspicion for PNP, highlighting the diagnostic challenge of immune-mediated dermatoses associated with cancer immunotherapy.

Correlation between clinical findings, histopathology, serological profile, and immunofluorescence studies was essential for accurate diagnosis. As the use of immune checkpoint inhibitors continues to expand, awareness of atypical autoimmune cutaneous toxicities becomes increasingly important for early diagnosis and appropriate management[8-9,15-16].

EADV CONGRESS
VIENNA
30 SEP - 3 OCT 2026

Abstract N°: 2491

Topical sodium thiosulfate as a promising treatment for calcinosis cutis in dermatomyositis

Amanda Quintaes*[1], Julia Cascardo Géo de Siqueira[1], Raphael Pereira[1], Maria Eduarda Cesar Garcez[1], Ana VARGAS[1], Luna Azulay-Abulafia[1]

[1] Department of Dermatology, Universidade do Estado do Rio de Janeiro (UERJ), Rio de Janeiro, Brazil, Rio de Janeiro, Brazil

Introduction

Calcinosis cutis is a challenging complication characterized by ectopic calcium deposition in the skin and subcutaneous tissue, frequently associated with autoimmune connective tissue diseases such as dermatomyositis and systemic sclerosis. Clinically, calcinosis cutis may lead to pain, tissue rigidity, ulceration, recurrent inflammation, and significant impairment in quality of life, while therapeutic options remain limited and inconsistently effective. Sodium thiosulfate has emerged as a promising treatment because of its calcium-chelating, antioxidant, and solubilizing properties, with potential benefit in reducing ectopic calcium deposits. Topical formulations are particularly attractive because they provide a noninvasive and generally well-tolerated therapeutic approach for localized disease.In a case series of six patients with digital calcinosis cutis, topical sodium thiosulfate was described as a reliable treatment option, with meaningful clinical improvement in painful and functionally limiting lesions. Likewise, a case series and systematic review evaluating topical sodium thiosulfate/sodium metabisulfite identified complete response in 20% of patients and partial response in 58%, supporting its role as a promising therapeutic alternative. Given the lack of standardized therapies, additional reports are valuable to expand real-world evidence regarding efficacy and tolerability. Herein, we present a case of dermatomyositis-associated calcinosis cutis successfully managed with topical sodium thiosulfate 25%.

Case Presentation

A 35-year-old woman with dermatomyositis diagnosed in 2023 (symptom onset in 2021) was followed at a tertiary dermatology clinic. Disease manifestations included photosensitivity, Gottron papules, shawl sign, V-sign, digital ischemia, myopathic findings on electromyography, and previous interstitial lung abnormalities. She also had autoimmune thyroiditis. Cutaneous examination revealed an extensive hyperpigmented scleroatrophic plaque on the right gluteal region extending to the lumbar area, in addition to smaller similar plaques on the lower limbs. Multiple firm subcutaneous nodules were palpable at the periphery of the plaques and on the upper limbs. Soft-tissue ultrasonography demonstrated grouped calcifications forming plaques within the subcutaneous tissue, some adjacent to the dermis, with posterior acoustic shadowing, dermal thickening, increased Doppler flow, and adjacent panniculitis. A skin biopsy later confirmed dystrophic calcification consistent with calcinosis cutis. Previous treatments included methotrexate, hydroxychloroquine, colchicine, alendronate, and aluminum hydroxide, with partial response. Due to persistent symptomatic calcinosis, topical sodium thiosulfate was prescribed initially at 20% and later increased to 25% in petrolatum twice daily. During follow-up, the patient reported marked improvement in plaque rigidity and significant reduction of gluteal pain while sitting, resulting in better daily functioning. Hyperpigmentation showed minimal change, but progressive softening of calcified plaques was clinically evident. No relevant adverse effects were reported.

Conclusion

Calcinosis cutis remains a refractory manifestation of dermatomyositis, with limited therapeutic options In this case, topical sodium thiosulfate 25% was associated with reduced plaque rigidity and marked improvement in pain while sitting, providing meaningful functional benefit despite minimal residual hyperpigmentation. Previous reports have shown that topical sodium thiosulfate may reduce pain, soften lesions, and induce partial or complete responses with few adverse effects. Our case expands this evidence by demonstrating benefit in extensive plaque-type calcinosis of the gluteal and lower limb regions, supporting topical sodium thiosulfate as a safe, accessible, and promising adjunctive therapy. Further prospective studies are necessary.

EA DV CONGRESS
VIENNA
30 SEP - 3 OCT 2026

Abstract N°: 2525

Toxic epidermal necrolysis-like lupus erythematosus treated with anifrolumab, a case report

Juan Aramberri Araiz *[1], Pedro José Fernández Esparcia[1], Jon Ignacio Uriarte[1], Miguel Centeno Pons[1], Ana Barquín Ruiz[1], Montserrat Fernández Guarino[1]

[1] Hospital Universitario Ramón Y Cajal, Madrid, Spain

Introduction

Toxic epidermal necrolysis (TEN)-like eruptions are rare and severe manifestations of systemic lupus erythematosus (SLE), characterized by widespread epidermal detachment mimicking drug-induced TEN. Unlike classical TEN, TEN-like lupus is thought to result from immune complex deposition and type I interferon pathway dysregulation. Treatment typically relies on high-dose corticosteroids and immunosuppressive therapies, with variable outcomes. Anifrolumab, a monoclonal antibody targeting the type I interferon receptor, has shown efficacy in cutaneous SLE, but its role in TEN-like lupus remains unclear. We report a case of TEN-like SLE successfully treated with anifrolumab.

Case Presentation

In January 2026, a 77-year-old woman was admitted with a 3-day history of pruritic cutaneous lesions on the trunk, face, and extremities. Examination revealed dusky erythematous plaques with erosions and a positive Nikolsky sign. Stevens–Johnson syndrome/toxic epidermal necrolysis (SJS/TEN) secondary to recently administered antibiotics was initially suspected, given a similar episode in November 2025 with biopsy findings consistent with SJS/TEN, which resolved after drug withdrawal and intravenous corticosteroids. Her only relevant history was pulmonary thromboembolism in 2025. Intravenous methylprednisolone pulses were started. Due to progression, ciclosporin A and intravenous immunoglobulins were added after 8 days. Repeat skin biopsy was again consistent with SJS/TEN; however, direct immunofluorescence showed granular C3 deposition along the dermoepidermal junction. Autoimmune testing revealed high-titer antinuclear antibodies (1:1280) and positive anti–double-stranded DNA antibodies. Laboratory tests showed pancytopenia and elevated C-reactive protein. These findings, together with the subacute course, photodistribution, and absence of mucosal involvement, supported a diagnosis of TEN-like systemic lupus erythematosus. Hydroxychloroquine and anifrolumab were initiated, resulting in rapid improvement within 3 days and complete resolution in 2 weeks. Cyclosporin and intravenous immunoglobulins were discontinued, and the patient remained on hydroxychloroquine and anifrolumab 300 mg every 4 weeks without further flares.

Conclusion

TEN-like lupus is a rare, severe variant of lupus erythematosus within the spectrum of acute syndrome of apoptotic pan-epidermolysis and may represent the first manifestation of disease. Differentiation from Stevens–Johnson syndrome/toxic epidermal necrolysis (SJS/TEN) is challenging, particularly in polymedicated patients. Clinical clues supporting TEN-like lupus include a subacute course, photodistribution, absence of a clear drug trigger, and limited mucosal involvement. Differential diagnoses include Drug Reaction with Eosinophilia and Systemic Symptoms, early Acute Generalized Exanthematous Pustulosis, and extensive fixed drug eruption. Infectious triggers should also be excluded. Histopathology usually shows extensive keratinocyte necrosis with interface dermatitis and epidermal detachment, although findings may overlap with SJS/TEN and classical lupus features can be absent. In these cases, direct immunofluorescence demonstrating immunoglobulin and/or

complement deposition supports the diagnosis. Management includes withdrawal of suspected triggering drugs and immunosuppressive therapy, although responses are variable. In our patient, progression despite standard treatments, together with clinical and laboratory findings consistent with systemic lupus erythematosus, prompted initiation of anifrolumab, leading to complete resolution. Specialized wound care, including non-adherent dressings, infection prevention, and fluid-electrolyte management, together with multidisciplinary support, were also essential for recovery. This case highlights anifrolumab as a potential fast-acting option in severe refractory TEN-like lupus, although further evidence is needed.

EADV CONGRESS
VIENNA
30 SEP - 3 OCT 2026

Abstract N°: 2530

Quality of Life in Bullous Pemphigoid: A Systematic Review of Patient Reported Outcomes

Marie Line Chedid*[1], Ibrahim El Awar[1], Aleksandra Małolepsza[2], Agnieszka Zebrowska[2]

[1] Medical University of Łódź, Łódź, Poland

[2] Department of Dermatology and Venereology, Medical University of Lodz, Lodz, Poland

Introduction

Bullous pemphigoid (BP) is the most common autoimmune subepidermal blistering disease, primarily affecting elderly individuals and associated with significant morbidity. Beyond cutaneous manifestations, BP imposes a substantial burden on health-related quality of life (HRQoL), largely driven by persistent pruritus and functional impairment. This study aimed to systematically evaluate the impact of BP on quality of life (QoL) and its clinical correlates.

Materials and Methods

A systematic search of PubMed, Scopus, and Embase was conducted up to April 2026. Observational and interventional studies assessing QoL in patients with BP were included. A total of 777 records were screened using Rayyan after duplicate removal. Study selection was performed independently by two reviewers in a blinded manner, with disagreements resolved by a third reviewer. Extracted data included study characteristics, patient demographics, comorbidities, treatment details, QoL outcomes, and adverse events.

Results

A total of 48 studies were included. The mean age of patients ranged from 49 to 79 years and frequently presented with multiple comorbidities. Pruritus emerged as the primary determinant of QoL impairment, significantly affecting sleep and daily functioning. QoL was most commonly assessed using the Dermatology Life Quality Index (DLQI), with mean scores ranging from 9.4 to 11.6, indicating a moderate to severe impact. Disease-specific instruments demonstrated greater sensitivity to functional limitations. Treatment was associated with significant improvements in QoL, with targeted therapies such as dupilumab showing marked reductions in DLQI scores. The relationship between disease severity and QoL was variable, with subjective symptoms showing a stronger correlation than objective severity indices.

Conclusions

Bullous pemphigoid significantly impairs quality of life, primarily through persistent pruritus and functional decline. These findings highlight the need for patient-centered management strategies and targeted therapies aimed at improving both clinical outcomes and overall well-being.

EA DV CONGRESS
VIENNA
30 SEP - 3 OCT 2026

Abstract N°: 2546

Chronic cutaneous Lupus Erythematosus (discoid) associated with ustekinumab therapy in a patient with severe plaque psoriasis

Claudio Lelis Souza[1], Julia Coffler*[2], Ana Laura Ritter[1], Guilherme Gonçalves Nascimento[3], Ana Clara Freitas[1], Mônica Linhares Sachett[3]

[1] unifenas, alfenas, Brazil

[2] EMESCAM, Vitória, Brazil

[3] FMABC, Santo Andre, Brazil

Introduction

Psoriasis Vulgaris is a chronic inflammatory dermatosis characterized by thick plaque lesions affecting different body areas. Globally, Psoriasis affects approximately 2–3% of the population and is associated with a substantial psychological and financial burden, consequently impairing patients' quality of life. Advances in the understanding of Psoriasis pathogenesis have enabled the development of new therapeutic approaches, and biologic agents currently have well-established recommendations and international guidelines, being indicated for patients who are nonresponsive or intolerant to conventional systemic therapies. However, paradoxical autoimmune manifestations may occur during treatment. With the introduction of new therapies into the market, reports of drugs potentially inducing Lupus Erythematosus have emerged. Chronic cutaneous Lupus Erythematosus induced by ustekinumab is an uncommon adverse event and represents a therapeutic challenge, particularly in patients with limited treatment options and previous drug intolerance.

Case Presentation

A 40-year-old female patient with a 9-year history of severe Psoriasis Vulgaris presented with disseminated erythematous-desquamative plaques affecting the scalp, trunk, and limbs, with a PASI score of 25. She developed therapeutic failure after two years of methotrexate use, associated with drug-induced hepatotoxicity. Acitretin and cyclosporine were contraindicated due to childbearing potential and residence in a tuberculosis-endemic area, respectively. Given the severity of the condition and the impossibility of using conventional therapies, treatment with ustekinumab 45 mg was initiated, resulting in an excellent clinical response maintained for six years. However, after this period, the patient developed infiltrated atrophic lesions in the malar region and nasal dorsum, in a butterfly-shaped distribution, and biopsy confirmed the diagnosis of chronic cutaneous Lupus Erythematosus, probably induced by the biologic agent. Treatment with hydroxychloroquine was initiated; however, the patient developed severe drug eruption with target lesions and mucosal involvement, requiring discontinuation of the medication and initiation of systemic corticosteroid therapy with prednisone, which resulted in worsening of the previously controlled psoriasis. Due to the need to discontinue ustekinumab, therapeutic substitution with secukinumab was chosen, using an induction regimen followed by continuous maintenance therapy. Tuberculosis screening showed a nonreactive QuantiFERON-TB Gold test and a normal chest radiograph, ruling out active infection.

Conclusion

This case reports a rare complication: chronic cutaneous Lupus Erythematosus induced by ustekinumab, a therapy initiated after previous therapeutic failure and inability to use conventional drugs. Furthermore, it highlights the complexity of managing severe Psoriasis in patients with contraindications and adverse reactions to multiple therapies, emphasizing the importance of early recognition of potential complications to enable appropriate therapeutic adjustments. In addition, it reinforces the relevance of documenting and analyzing case reports

related to adverse events associated with novel biologic therapies. In this context, switching to anti-IL-17 therapy proved to be a viable and effective alternative, underscoring the importance of individualized therapeutic strategies in the management of complex autoimmune dermatological diseases.

EA DV CONGRESS
VIENNA
30 SEP - 3 OCT 2026

Abstract N°: 2564

Generalized SCLE with Atypical Clinical Presentation

Mariya Razlozhka*[1], Inna Popova[1], Toma Tomov[1], Krasimir Yanev[1], Grisha Mateev[1]

[1] Medical University- Sofia, University Hospital "Alexandrovska", Department of Dermatology and Venerology, Sofia, Bulgaria

Introduction

Subacute Cutaneous Lupus Erythematosus is a disease characterized by a clinical presentation of erythematous, scaly, annular or papulosquamous shaped lesions often located on the sun-exposed areas of the skin - the face, shoulders, arms and upper chest and back. Patients are typically highly photosensitive. Some common causes and risk factors are UV exposure, genetic predisposition and the condition could also be drug-induced.

We present the case of a 61-year-old patient with a skin rash affecting the skin of the whole body. Therash is characterized by multiple polycyclic annular erythematous plaques with trailing scale. The patient stated that the onset of the rash was on the skin of his chest about 3 months before coming to the clinic and following a seaside vacation he went to. He also reported that he has been treated with both local and systemic antimycotics since then, worsening the rash significantly. He shared that the rash was accompanied by a significant pruritus and skin tenderness.



Day 1

Case Presentation

After being admitted to the clinic a detailed anamnesis was obtained and a series of diagnosticprocedures was done. A biopsy for histological examination, direct imunoflourence, routine laboratory blood and immunologic tests were done. An initial diagnosis of cutaneous lupus erythematosus was suspected based on the photo-distributed onset of the eruption and its significant worsening following the antifungal therapy, while pemphigoid and psoriasis were included as differential diagnosis.

The results showed a histological picture of slightly flattened dermo-epidermal junction, vacuolar degeneration of a part of the basal keratinocytes, sparse lichenoid lymphocytic infiltrate at the same zone. Histopathological findings were consistent with cutaneous lupus erythematosus. The performed direct immunofluorescence was negative and not of diagnostic character. The immunologic tests were of highly positive values for Anti-SS-A, positive value for Anti-Ro 52, Anti-SS-B and lightly positive for Anti-PM-Scl 100, supportive the diagnosis of SCLE.

The patient was treated with systemic methylprednisolone 40 mg daily, ceftriaxone 2 g daily and adjunctive emollient therapy. Throughout the treatment period the patients' condition improved significantly and he was discharged with substantial improvement both to the skin condition and to the perceived accompanying symptoms he stated at arrival.



Day 1

Conclusion

This case highlights an atypical generalized presentation of SCLE mimicking inflammatory and infectious dermatoses. Early clinicopathological correlation and immunological testing are essential for accurate diagnosis and timely initiation of

appropriate therapy. The case also underlines the potential aggravating role of inappropriate empiric treatment.

EADV CONGRESS
VIENNA
30 SEP - 3 OCT 2026

Abstract N°: 2565

vPsoriasis or ichthyosis? About two clinical cases raising a diagnostic challenge

tinhinane benbrahim*[1]

[1] CHU Bab El Oued, ALGIERS, Algeria

Introduction
The differential diagnosis between psoriasis and hereditary ichthyoses may be challenging, particularly in children, due to overlapping clinical presentations. These observations illustrate this diagnostic pitfall and highlight the importance of histopathology and genetic context.

Case Presentation
The first observation concerns a 3-year-old child born to consanguineous parents, presenting since the age of 3 months with erythematous-squamous lesions initially localized to the legs, later extending to the thighs and trunk. In the absence of response to topical treatments, the condition progressed to dry desquamative erythroderma. Treatment with acitretin (Soriatane®) led to an initial improvement followed by relapse after discontinuation, without complete remission, and secondary development of scaly axillary lesions. A skin biopsy was subsequently performed and was consistent with ichthyosis. Genetic testing is currently ongoing.

The second observation concerns a 13-year-old child born to third-degree consanguineous parents, with a family history of collodion baby. Since birth, the patient had presented with diffuse erythematous-squamous lesions. An initial skin biopsy favored psoriasis, and treatment with cyclosporine was initiated without improvement. Due to lesion extension and the appearance of a clinical pattern typical of ichthyosis, a second biopsy was performed, leading to revision of the diagnosis in favor of ichthyosis. The clinical course was marked by the occurrence of paraplegia followed by fatal cardiomyopathy, suggestive of syndromic ichthyosis, although genetic confirmation was not obtained.

Discussion

These observations highlight the difficulty of differentiating psoriasis from ichthyosis, particularly in the setting of consanguinity and neonatal or early-onset disease. Certain forms of ichthyosis may mimic psoriasis both clinically and histologically. Clinicopathological discordance, lack of response to immunosuppressive therapy, and atypical evolution should prompt reconsideration of the diagnosis and lead to repeated biopsies and genetic investigations.

Conclusion
In any diffuse erythematous-squamous dermatosis with early onset, especially in cases of consanguinity or positive family history, ichthyosis should be systematically considered. A multidisciplinary approach involving dermatology, pathology, and genetics is essential to avoid diagnostic and therapeutic errors.

POWERED BY M-ANAGE.COM

EADV CONGRESS
VIENNA
30 SEP - 3 OCT 2026

Abstract N°: 2571

"Livedo Racemosa and Cutaneous Ulceration as the Presenting Manifestations of Systemic Lupus Erythematosus: A Case-Based Review"

Ana Barquín Ruiz*[1], Juan Aramberri Araiz[1], Jon Uriarte Terán[1], Miguel Centeno Pons[1], Pedro José Fernández Esparcia[1], Asunción Ballester Martínez[1]

[1] Hospital Universitario Ramón y Cajal, Madrid, Spain

Introduction

Systemic Lupus Erythematosus (SLE) is a chronic, multisystemic autoimmune disorder characterized by the production of autoantibodies and immune complex deposition, leading to widespread inflammatory damage. Cutaneous involvement is a hallmark of the disease, often serving as the primary diagnostic clue. Within the spectrum of vascular skin manifestations, livedo racemosa (LR) represents a critical clinical finding that must be meticulously distinguished from the more common and often benign livedo reticularis.

While livedo reticularis consists of a fine, complete, and reversible cyanotic network typically triggered by cold, livedo racemosa presents as a persistent, violaceous, and irregular "broken-branch" pattern with open segments. Pathophysiologically, LR reflects a significant impairment of blood flow in the medium-sized arteries of the dermis and subcutis [1]. This pattern is not merely a localized skin condition but a cutaneous marker of a systemic prothrombotic state. It is highly specific for Antiphospholipid Syndrome (APS), a condition defined by recurrent thrombosis and the presence of antiphospholipid antibodies, which can occur as a primary disorder or secondary to SLE. The recognition of LR is of paramount importance, as it has been strongly correlated with a higher risk of systemic involvement, particularly cerebrovascular disease and renal microangiopathy [1,2]

Case Presentation

A 20-year-old female with no relevant medical history presented to the emergency department with a one-month history of pain, pruritus, and bruising in the lower extremities, accompanied by nocturnal paresthesia. The patient reported a history of Raynaud’s phenomenon and symmetric arthralgia in the interphalangeal joints. Physical examination revealed extensive livedo racemosa extending from the lower limbs to the buttocks and the dorsum of the hands, along with painful perimalleolar ulcers covered by hematic crusts.

Laboratory investigations showed significant hypocomplementemia (C3 and C4 consumption) and a positive immunological profile, including ANA (1:1280), anti-dsDNA, and positivity for beta 2 -glycoprotein I and anticardiolipin antibodies. A skin biopsy from a pale area of the livedo revealed an organized focal thrombus within a medium-sized vessel, without evidence of leukocytoclastic vasculitis. Following the development of mucositis, fever, and asthenia, a diagnosis of SLE associated with secondary APS was established according to international classification criteria [4].

Conclusion

Livedo racemosa is a "red flag" for prothrombotic states and should prompt an immediate investigation for APS and SLE. The histopathological finding of non-inflammatory thrombosis is characteristic of APS-related cutaneous involvement [2] .Early recognition of this

dermatological pattern is essential for initiating appropriate therapy, such as hydroxychloroquine and antiaggregation, to prevent major thrombotic events and manage systemic inflammation [3]. This case underscores the role of the skin as a sentinel organ in complex autoimmune disorders.

EA DV CONGRESS
VIENNA
30 SEP - 3 OCT 2026

Abstract N°: 2574

Prognostic Factors in Pediatric Alopecia Areata: Clinical, Environmental, and Therapeutic Determinants in a Cohort of 73 Patients

Ouissal Laadime*[1], Bendaoud Layla[1], Mariem Aboudourib[1], ouafa hocar[1], Amal Said[1]

[1] Department of Dermatology and Venereology, Arrazi Hospital, Mohammed VI University Hospital Center, Marrakech, Morocco

Introduction
Alopecia areata (AA) is an autoimmune disorder with an unpredictable course, ranging from spontaneous regrowth to severe forms such as alopecia totalis or universalis. Identifying prognostic factors is essential for risk stratification and therapeutic decision-making.

Materials and Methods
We conducted a retrospective, analytical, and longitudinal study (2012–2025) including 73 children with AA and ≥12 months follow-up. Statistical analysis was performed using SPSS ($p<0.05$).

Results
Seventy-three children were included (mean age 9.5±3.6 years) with female predominance (68.5%). Disease onset occurred mainly between 4–10 years (65%), with early onset (<3 years) in 12%. Family history was found in 12.3%, while autoimmune diseases were uncommon (5.5%). Clinically, extensive forms predominated: alopecia universalis (34.2%), localized (32.9%), multifocal (17.8%), diffuse (11%), and ophiasis (4.1%) ($p<0.001$), with more than two-thirds presenting non-limited disease. Nail involvement was observed in 19.2% ($p=0.01$). Eyebrow, eyelash, and body hair involvement occurred in 50.7%, 39.7%, and 32.9%, respectively ($p<0.001$), indicating frequent extension beyond the scalp. Disease duration before consultation ranged from 7 days to 10 years, with most patients presenting within the first year ($p=0.004$). Spontaneous regrowth before treatment was rare (5.3%, $p<0.001$). Stressful events and infections preceded onset in 13.7% and 8.2% of cases, respectively. Autoimmune workup was negative in 92.1% of tested patients, with only 7.9% showing positive autoantibodies ($p<0.001$). Nutritional deficiencies were found in 32.9%, mainly iron deficiency anemia (16.4%) and vitamin D deficiency (11%) ($p=0.002$). According to SALT classification, severe forms predominated: 42.5% had SALT 5, 23.3% SALT 1, 24.7% SALT 2, and 9.6% SALT 3 ($p<0.001$). Treatments were heterogeneous and often combined: minoxidil (68.5%), oral corticosteroid mini-pulses (47.9%), topical corticosteroids (45.2%), methylprednisolone pulses (32.9%), and immunosuppressants (12.3%). Clinical outcomes were globally favorable: complete regrowth occurred in 40.5%, partial regrowth in 43.2%, and no regrowth in 16.2% ($p<0.001$). At last follow-up, 51.4% remained on treatment. Among those who discontinued, 30% had no relapse, while 15.7% relapsed within 2 months to 1 year. SALT score improved significantly over time: at 3 months, 62% had SALT >40% and 18% <20%; at 6 months, 45% achieved SALT ≤20% and 27% complete regrowth; at 1 year, 53% achieved SALT=0 and 75% SALT ≤20% ($p<0.001$).

Conclusions
This study highlights several prognostic factors in pediatric alopecia areata. Favorable outcomes were associated with localized forms, absence of appendage involvement, spontaneous regrowth, and negative immunological workup. Conversely, severe forms (particularly SALT 5), nail involvement, appendage involvement, autoimmune comorbidities, and nutritional deficiencies were associated with poorer prognosis and higher risk of persistence or relapse. Early clinical and

biological assessment is essential to identify high-risk patients and tailor therapeutic strategies accordingly.

EADV CONGRESS
VIENNA
30 SEP - 3 OCT 2026

Abstract N°: 2575

Epidemiological, Clinical, and Outcome Profile of Pediatric IgA Vasculitis: A Series of 48 Patients

Ouissal Laadime*[1], Bendaoud Layla[1], Mariem Aboudourib[1], ouafa hocar[1], Amal Said[1]

[1] Department of Dermatology and Venereology, Arrazi Hospital, Mohammed VI University Hospital Center, Marrakech, Morocco

Introduction
IgA vasculitis (Henoch–Schönlein purpura) is the most common vasculitis in children, characterized by palpable purpura with joint, gastrointestinal, and renal involvement. Although usually benign, complications—especially renal—may affect prognosis. This study aimed to describe clinical, biological, and outcome features in hospitalized children.

Materials and Methods
Retrospective descriptive and analytical study (January 2021–December 2025) including children aged 0–15 years hospitalized for purpura. Post-traumatic cases and incomplete records were excluded.

Results
Forty-eight children were included (mean age 9.2 years) with slight female predominance (54%). All presented vascular purpura, predominantly involving lower limbs and buttocks (92%), mainly petechial/infiltrated (87%), with edema in 10 cases and hemorrhagic bullae in 3. Fever was noted in 10 patients, and recent infection—mainly upper respiratory—was reported in 28.

Gastrointestinal involvement occurred in 67%, mainly abdominal pain, with vomiting (9 cases) or bleeding (7 cases). Intussusception was diagnosed in 4 cases. Articular involvement was observed in 62%, mainly ankles and knees.

Renal involvement occurred in 33%, including microscopic hematuria (10 cases), proteinuria <1 g/24 h (6 cases) and ≥1 g/24 h (3 cases). Two patients developed nephritic syndrome and two nephrotic syndrome, with transient renal failure in 3 cases. Orchitis was observed in one patient.

Skin biopsy (12 cases) showed leukocytoclastic vasculitis with IgA deposits. Renal biopsy (5 cases) revealed IgA nephropathy, including proliferative forms with crescents and one rapidly progressive extracapillary glomerulonephritis.

Laboratory findings showed normal platelet counts (except one ITP case), leukocytosis, and variable CRP (median ~30 mg/L). Immunological tests were mostly normal. Abdominal ultrasound was normal in 29 cases, with abnormalities or intussusception in others.

Treatment was mainly symptomatic (analgesics/NSAIDs). Corticosteroids were used in 21 cases (severe digestive or renal forms). Two patients received IV immunoglobulins and two immunosuppressants. ACE inhibitors were prescribed in 7 cases.

Mean hospital stay was 6.5 days. Outcome was favorable in 96%, with resolution of symptoms. Complications included persistent renal involvement (2 cases), intussusception (4), cutaneous infection (1), and orchitis (1). No ICU admission or death occurred. Two children had persistent renal abnormalities at follow-up.

Conclusions

IgA vasculitis showed typical cutaneous, digestive, and articular involvement. Renal manifestations, present in one-third of cases, ranged from mild to severe and justify long-term monitoring. Despite this, short-term prognosis was favorable in most patients.

EADV CONGRESS
VIENNA
30 SEP - 3 OCT 2026

Abstract N°: 2595

Macrophage Activation Syndrome in a Child with Vesiculobullous Juvenile Dermatomyositis: A Diagnostic Odyssey

Keshav Yadav*[1], Prashant Verma[1]

[1] Vardhman Mahavir Medical College and Safdarjung Hospital, New Delhi, India

Introduction
Introduction

Macrophage Activation Syndrome (MAS) is a severe, life-threatening systemic hyperinflammatory syndrome associated with autoimmune diseases, including juvenile dermatomyositis (JDM). Although rare in JDM, MAS can significantly impact patient outcomes. This case report describes an unusual case of MAS in a child with Atypical JDM, highlighting the challenges in diagnosis and management.

Case Presentation
Case Synopsis

A 16-year-old girl presented with a 6-month history of joint pain and generalized weakness. She was initially treated with Etoricoxib from outside. Later on developed oral, ocular, and genital mucosal erosions, along with poikilodermatous skin changes, raising suspicion of Stevens-Johnson syndrome (SJS). Despite discontinuation of the medication, her symptoms worsened, including increased myalgia, arthralgia, proximal muscle weakness, and neck drop. Physical examination revealed poikiloderma vasculare atrophicans, heliotrope rash, Gottron's papules and sign, and vesiculobullous lesions over poikilodermatous macules. Dermoscopy revealed reticulate hyperpigmentation, white structureless atrophic areas and background erythema and telangiectasias. Nail fold capillaroscopy showed ragged cuticle (Samitz sign), capillary dropouts, irregular capillary network and prominent sup-papillary plexus. Laboratory findings showed elevated muscle enzymes (CK, CK-MB, AST, LDH), positive antinuclear antibody (ANA) with a speckled pattern and positive Anti U1 RNP antibody. Her serological tumor markers like CA 125, beta-HCG were also mildly increased, but No abnormality was detected on ultrasonography. Electromyography reported low amplitude, short duration of muscle action potential with polyphasic waves, early recruitment and spontaneous fibrillations. Muscle MRI also reported diffuse symmetric feathery edema with hyperintense signals over proximal. Diagnosis of JDM (poikilodermatous and vesiculobullous variant) was made and was then started on systemic steroids. Subsequently, she developed increased muscle weakness, tenderness, sudden-onset dyspnea and chest pain. Investigations for cardiac and thromboembolic events were unremarkable, except for elevated NT-proBNP and D-dimer levels. Significantly increased serum ferritin, triglycerides, and AST levels led to the diagnosis of MAS complicating JDM. Treatment with pulse methylprednisolone, fresh frozen plasma, Rituximab with lymphoma protocol and subsequent dexamethasone and enoxaparin resulted in significant clinical improvement within a couple of months.

Conclusion
Discussion & Conclusion

This case underscores the diagnostic challenges in distinguishing between severe cutaneous drug reactions like

Stevens-Johnson syndrome and acute manifestations of JDM. The presence of vesiculobullous lesions in JDM is uncommon and can mimic other dermatological conditions. Clinicians should maintain a high index of suspicion for MAS in patients with JDM presenting with systemic deterioration, as early and aggressive immunosuppressive therapy is essential for improving prognosis.

EADV CONGRESS
VIENNA
30 SEP - 3 OCT 2026

Abstract N°: 2606

A cross-sectional observational study to correlate serum C3 and C4 levels with oral palatal ulcer and disease activity index in SLE patients in a tertiary care hospital

Rohan Barua*[1]

[1] IPGME&R and SSKM HOSPITAL Kolkata, Kolkata, India

Introduction
SLE is a heterogeneous autoimmune disorder with complement activation playing a key role in pathogenesis of immune mediated tissue injury. Though palatal ulcer is a common manifestation occuring in around 51% of SLE patients, not much is known about it's association with serological markers or systemic involvement.
The objective of my study being correlation of serum C3 and C4 levels with oral palatal ulcer and SLE disease activity in patients.

Materials and Methods
A total of 80 SLE patients (diagnosed as per American College of Rheumatology revised criteria) during 9 months period were included after taking informed consent.
Proper history taking, cutaneous including oral mucosa examination and assessment of SLE disease activity were performed with Systemic Lupus Erythematosus Disease Activity Index(SLEDAI) 2K. SLEDAI 2K was graded as: 1-5 (mild), 6-10 (moderate), 11-20 (severe) and >=20 (very severe activity). Based on disease progression (among cutaneous findings), photosensitivity was determined as early symptoms, malar rash as metaphase symptoms and palatal ulcer as late symptoms.
Blood samples were collected for serum C3 and C4 level estimation and collected data was analysed.

Results
Based on clinical findings and titres of serum markers, complement C3 and C4 levels in SLE patients with oral ulcer were markedly reduced ($p<0.05$) whereas those with photosensitivity and malar rash showed no significant reduction. Significant linear and negative correlation was also observed between serum complement levels and SLE disease activity using Pearsons correlation coefficient ($r= -0.707$ for C3 and $r= -0.423$ for C4). Also it was observed that presence of oral palatal ulcer correlated with particular titre of complement levels (C3: 0.3-0.5 g/l in 67% patients and C4: 0.06-0.08 g/l in 59% patients).

Conclusions
Study results showed C3 and C4 levels were negatively correlated with presence of palatal ulcer and presence of palatal ulcer correlated with particular titre of complement levels. Oral palatal ulcers in SLE are not merely mucocutaneous findings but serve as potential marker of active immunological disease. The study results indicate different inflammatory and complement pathways play an important role in both pathogenesis and clinical manifestations of SLE, additionally complement level estimation can serve as valuable marker in monitoring disease activity.

EA DV CONGRESS
VIENNA
30 SEP - 3 OCT 2026

Abstract N°: 2618

Quality of Life and Psychosocial Burden in Mucous Membrane Pemphigoid

Marney White*[1], Marc Yale[2], Mary Tomayko[3]

[1] Yale School of Public Health, Yale School of Medicine, New Haven, United States
[2] International Pemphigus & Pemphigoid Foundation, Roseville, CA, United States
[3] Yale School of Medicine, New Haven, United States

Introduction

Mucous membrane pemphigoid (MMP), a rare autoimmune blistering disease of the mucous membranes, may be associated with mental health burden. Studies of patients with autoimmune blistering diseases more broadly have documented significant psychosocial burden and quality of life impairment. To date few studies have reported the psychological and social consequences of MMP specifically. This study sought to characterize psychosocial outcomes of a relatively large sample (n=123) of people living with MMP.

Materials and Methods

Participants were recruited with the help of the International Pemphigoid and Pemphigus Foundation via social media, direct email, and newsletters. Participants completed an anonymous online questionnaire battery measuring demographics, disease course, and validated instruments of depressive symptomatology, social support, quality of life (QOL), illness perceptions (a patient's understanding of their disease including whether they believe treatment can help control their disease), and illness invalidation (when a patient feels that their illness or symptoms are misunderstood or minimized by their social or medical network).

Sample items from the assessment battery
Cognitive illness perceptions: higher scores denote strong beliefs that disease is not manageable and severely impacts life · How much does your illness affect your life? (*no affect at all* to *severely affects my life*) · How much control do you feel you have over your illness? (*extreme amount of control* to *absolutely no control*) · How much do you think your treatment can help your illness? (*extremely helpful* to *not at all*)
Invalidation: higher scores denote greater feelings of invalidation My family or significant person… · makes me feel like I am an exaggerator (*never* to *very often*) · finds it odd that I can do much more on some days than on other days (*never* to *very often*) · understands the consequences of my health problems or illness (*never* to *very often*)

Results

Participants reported disease-specific and general quality of life impairments. The majority (67%) reported at least *mild* depression. More than 1 in 4 (28.2%) reported *moderate* to *severe* depression. Beliefs about illness – especially cognitive illness perceptions (e.g., that treatment cannot help control their disease) – were associated with depression and impaired QOL. Participants living with MMP reported high levels of invalidation from their primary support networks and lower perceived social support than community norms.

Conclusions

Quality of psychological functioning and strength of social support were strongly associated, suggesting that interventions designed to garner and boost social support would be helpful. Illness invalidation was significantly associated with lower social support and QOL; when patients feel that their symptoms are dismissed or otherwise not believed, this contributes to a worsened psychiatric profile. Illness beliefs were also associated with QOL variables, with particular cognitive beliefs being most strongly associated with poor QOL. Together these results suggest that cognitive-behavioral therapy might be especially beneficial in this patient group.

EA DV CONGRESS
VIENNA
30 SEP - 3 OCT 2026

Abstract N°: 2624

INTRALESIONAL RITUXIMAB FOR REFRACTORY ORAL MUCOSAL PEMPHIGUS VULGARIS: A PROSPECTIVE PILOT CASE SERIES WITH IMMUNOLOGICAL PROFILING

Júlia Opolski Nunes Da Silva[1], Adriana Vieira[1], Aline Turatti[1], Ana Ferreira Roselino[1], Roberto Bueno Filho*[1]

[1] Division of Dermatology, Internal Clinic Department, Ribeirão Preto Medical School, University of São Paulo, Ribeirão Preto, Brazil, Ribeirão Preto, Brazil

Introduction

Pemphigus vulgaris (PV) is a severe autoimmune blistering disease in which oral mucosal lesions are frequently refractory to systemic immunosuppressive therapy **[1]**. Systemic rituximab (RTX), an anti-CD20 monoclonal antibody, has demonstrated superior efficacy in moderate-to-severe PV **[2]**; however, high cost, systemic adverse effects, and the need for specialized infusion facilities limit broader applicability. Intralesional RTX has been explored in limited case series of refractory oral and scalp PV, demonstrating local healing with systemic B-cell depletion **[1,3]**. A randomized trial showed comparable efficacy between intralesional RTX and triamcinolone in resistant PV lesions, with no significant adverse events **[4]**.

Materials and Methods

A prospective pilot case series enrolled two adults with biopsy-confirmed PV and refractory oral mucosal involvement, defined as failure to respond to at least two concurrent systemic immunosuppressants. Three lesions per patient were treated with intralesional RTX (5 mg/cm^2) at Day 0 (D0) and Day 15 (D15) as an outpatient procedure. Lesion area (cm^2) was measured serially at D0, D15, and D30 with ImageJ Software (version 1.52K, NIH, USA). Immunological evaluation included anti-desmoglein (Dsg) 1 and 3 ELISA, indirect (IIF) and direct (DIF) immunofluorescence, serum immunoglobulins, and peripheral B-cell counts (CD19/CD20) at D0 and D30. Systemic therapy was maintained unchanged throughout.

Results

Clinical Results

Six lesions were treated (three each patient). Mean lesion area decreased from 0.34 cm^2 at D0 to 0.15 cm^2 at D15 (−55.9%), with partial regression to 0.18 cm^2 at D30. Patient 1 showed total area reduction from 1.57 to 0.64 cm^2 at D15 (−59.2%) [Figure 1]; all three lesions remained smaller than baseline at D30 (0.72 cm^2). Patient 2 showed reduction from 0.47 to 0.26 cm^2 at D15 (−44.7%), with fluctuation at D30 (0.37 cm^2) driven by one lesion exceeding baseline (Table 1). No local or systemic adverse events were recorded.

Laboratory Results

Patient 1 showed marked B-cell depletion at D15: CD20 fell from 395 to 15.4 cells/μL; CD19 from 400 to 40 cells/μL. At D30, IIF converted from positive to negative and anti-Dsg1 declined from 36 to 12.1 U/mL (from positive to negative); anti-Dsg3 remained elevated (201.3 to 225.5 U/mL). Patient 2 presented with baseline B-cell depletion consistent with prior systemic RTX (CD20: 4; CD19: 7 cells/μL). Even though baseline levels were already low, a further decline to even lower levels was observed after the intralesional RTX applications (CD20: 1.32; CD19:

1.38 cells/µL). Anti-Dsg3 rose from 0.4 to 22.2 U/mL (remaining negative); anti-Dsg1 remained below the positivity threshold (Table 2).

Table 1: Lesion area (cm²) per patient and at D0, D15, and D30.

Patient	Lesion	D0	D15	D30
Patient 1		**Area (cm²)**	**Area (cm²)**	**Area (cm²)**
	Lesion 1	1.00	0.48	0.63
	Lesion 2	0.35	0.13	0.07
	Lesion 3	0.22	0.03	0.02
Patient 1 – Total		**1.57**	**0.64 (−59.2%)**	**0.72 (−54.1%)**
Patient 2		**Area (cm²)**	**Area (cm²)**	**Area (cm²)**
	Lesion 1	0.13	0.04	0.25
	Lesion 2	0.15	0.05	0.03
	Lesion 3	0.19	0.17	0.09
Patient 2 – Total		**0.47**	**0.26 (−44.7%)**	**0.37 (−21.3%)**
Overall Mean		**0.34**	**0.15 (−55.9%)**	**0.18 (−47.1%)**

Percentages in parentheses represent change from baseline.

Table 2. Immunological parameters at D0 and D30.

Parameter	D0	D30	Units
PATIENT 1			
CD20	395	15.4	cells/µL
CD19	400	40	cells/µL
IIF	Positive	Negative	—
DIF – oral Tzanck Smear	Positive	NP	—
Anti-Dsg1 ELISA	36.0	12.1	U/mL
Anti-Dsg3 ELISA	201.3	225.5	U/mL
IgG	1430	1320	mg/dL
PATIENT 2			
CD20	4	1.32	cells/µL
CD19	7	1.38	cells/µL
IIF	Negative	Negative	—
DIF – oral Tzanck Smear	Positive	NP	—
Anti-Dsg1 ELISA	2.0	5.9	U/mL
Anti-Dsg3 ELISA	0.4	22.2	U/mL
IgG	549	413	mg/dL

***IIF**: Indirect Immunofluorescence; **DIF**: Direct Immunofluorescence; **ELISA**: Enzyme-Linked Immunosorbent Assay; **NP**: not performed at this timepoint;*
Normal reference ranges:
IgG: 770–1510 mg/dL;
anti-Dsg1: <18 U/mL (negative), 18-36 (indeterminate), ≥36 (positive);
anti-Dsg3: <19 U/mL (negative), 19-37 (indeterminate), ≥37 (positive);
CD19/CD20: 110–618 cells/µL.

Conclusions

Intralesional RTX produced clinically meaningful lesion reduction in refractory oral PV, with confirmed systemic B-cell depletion via local administration, consistent with prior reports **[1,2]**. Partial discordance between immunological markers and clinical response suggests that local tissue mechanisms contribute to mucosal healing beyond circulating antibody levels. The favorable safety profile parallels observations with intralesional corticosteroids **[3]**. These findings support intralesional RTX as a targeted, steroid-sparing strategy in localized refractory oral PV, especially in localized refractory cases. Nonetheless, larger prospective studies are warranted to define optimal protocols and long-term outcomes.

EA DV CONGRESS
VIENNA
30 SEP - 3 OCT 2026

Abstract N°: 2630

Dermatitis herpetiformis in an adolescent: an extensive paediatric presentation

oumaima berradi*[1], narjess errachdy[1], najwa ammar[1], syrine hamada[1], nadia ismaili[1], laila benzekri[1], meriame meziane[1]

[1] chu avicenne rabat, rabat, Morocco

Introduction

Dermatitis herpetiformis is a chronic autoimmune blistering disease associated with gluten-sensitive enteropathy. It is uncommon in children and adolescents and may be difficult to recognise because of its polymorphic, pruritic and excoriated vesiculobullous presentation. We report an extensive paediatric case confirmed by histopathological and immunopathological examination.

Case Presentation

A 14-year-old adolescent with a history of childhood asthma, treated with inhaled salbutamol on demand, presented with a 10-day history of a rapidly progressive, intensely pruritic vesiculobullous eruption. There was no recent drug intake, no recent infectious prodrome and no known personal or family history of autoimmune blistering disease. The eruption initially involved the perioral region and subsequently extended to the neck, trunk, back, hands and feet.

Initial laboratory tests showed leukocytosis with neutrophilia and mild eosinophilia, while C-reactive protein was negative. Clinical examination revealed a polymorphic eruption composed of grouped vesicles, tense bullae, post-bullous erosions, crusts and multiple excoriations on an erythematous background. Lesions involved the perioral and cervical areas, anterior trunk, back, hands and feet, with marked pruritus. There was no obvious oral or genital mucosal involvement.

The main differential diagnoses included dermatitis herpetiformis, linear IgA bullous dermatosis, bullous impetigo and other autoimmune subepidermal blistering diseases. Histopathological examination showed a subepidermal blister associated with neutrophilic microabscesses in the dermal papillae. Direct immunofluorescence demonstrated granular IgA deposits in the papillary dermis, confirming the diagnosis of dermatitis herpetiformis. Screening for gluten-sensitive enteropathy was initiated. A gluten-free diet was recommended, and dapsone was considered after appropriate baseline evaluation.



Clinical presentation of dermatitis herpetiformis in an adolescent. Extensive pruritic vesiculobullous eruption with grouped vesicles, tense bullae, post-bullous erosions, crusts and excoriations involving the perioral area, neck, anterior trunk and hand.

Conclusion

This case highlights an uncommon extensive paediatric presentation of dermatitis herpetiformis. In children and adolescents, this diagnosis should be considered in the presence of an intensely pruritic polymorphic vesiculobullous eruption, even when the distribution is atypical. Histopathological examination and direct immunofluorescence are essential for confirmation. Early recognition allows appropriate treatment and screening for associated gluten-sensitive enteropathy.

EADV CONGRESS
VIENNA
30 SEP - 3 OCT 2026

Abstract N°: 2651

Long-term Outcomes of Rituximab Treatment in Bullous Pemphigoid

Iakov Shimanovich*[1], Nina Schumacher[1], Evelyn Gaffal[1], Christoph Hammers[1, 2]

[1] University of Lübeck, Lübeck, Germany

[2] Novartis AG, Basel, Switzerland

Introduction

Bullous pemphigoid (BP) is the most common autoimmune blistering disease whose management can be challenging. Our aim was to assess the long-term efficacy of rituximab in this disease.

Materials and Methods

We conducted a retrospective study of 22 patients with severe and/or treatment-refractory BP treated with rituximab and observed over an average period of 66 months.

Results

The rate of complete remission (CR) on minimal immunosuppressive therapy or off therapy after the first rituximab cycle was 63%, increasing to 77% with additional cycles. All but one of the remaining patients achieved a near CR (minimal disease status). The rate of complete serological remission as measured by BP180 NC16A ELISA after the first rituximab cycle was 32%, increasing to 45% with further cycles. In the remaining patients the levels of anti-BP180 NC16A autoantibodies were significantly reduced. The recurrence rate after CR induced by the first rituximab cycle was 43%. In all relapses after CR retreatment with rituximab led to renewed CR. The average duration of CR increased from 16 months after the first rituximab cycle to 22 months after subsequent cycles. The rate of severe bacterial infections after rituximab therapy was 0.013 infections/person-month as opposed to 0.055 infections/person-month under conventional immunosuppression prior to rituximab.

Conclusions

Rituximab is a valuable management option for patients with severe and/or refractory BP. Relapses are common, but are well amenable to renewed rituximab treatment. In addition, both quality and duration of rituximab-induced remissions increases with repeated rounds of therapy. The likelihood of severe bacterial infections after rituximab treatment is significantly lower than under conventional immunosuppression.

EA DV CONGRESS
VIENNA
30 SEP - 3 OCT 2026

Abstract N°: 2684

Lichenoid and Interface Dermatitis Rapidly Cleared with Nemolizumab: A Case Report

BRANDON TIBBITTS*[1]

[1] Demos Dermatology, West Springfield, United States

Introduction

Lichen planus is an idiopathic, pruritic inflammatory skin disorder. The pathogenesis is thought to be due to direct and T-cell mediated auto-immune damage to basal keratinocytes that may be idiopathic, virally mediated or medication induced. Severe and often refractory itch is a common complaint in this condition. No expert consensus has been derived for treatment of this difficult to treat condition.

Nemolizumab, a monoclonal antibody targeting IL-31RA, has been approved as indicated for the treatment of atopic dermatitis and prurigo nodularis, with demonstrated efficacy in treating such conditions as well as offering rapid and significant itch relief.

Gene expression profiling has demonstrated that lichen planus lesions express higher mRNA levels of IFN-γ, respectively.

The end physiological target in lichen planus is the keratinocyte. IFN-γ is the predominant cytokine contributing to the apoptosis of keratinocytes through both cell mediated and cytotoxic response mechanisms. IFN-γ is primarily produced by CD8+ and CXCL13+ CD8+ cells in lichen planus. Blockade of keratinocytic IL-31RA with downstream inhibition of JAK2/STAT1 signaling shuts down major histocompatibility complex (MHC) class I upregulation in the epidermis leading to prevention of CD8+ and CXCL13+ lymphoid infiltrate in lichen planus, conferring to a novel approach to treatment.

The secondary blockade of IL-31RA on the sensory neuron may also promote rapid and significant itch relief to the patient, thereby decreasing morbidity.

Case Presentation

A 66-year-old female phototype II patient with a history of degenerative disc disease, inactive nephrolithiasis, bipolar disorder type II, generalized anxiety disorder, major depressive disorder, agoraphobia, chronic obstructive pulmonary disease, tobacco use, sleep apnea and family history of melanoma was diagnosed with biopsy proven lichenoid and interface dermatitis on the upper and lower extremities. Failed therapies included hydrocortisone 2.5% ointment, clobetasol ointment 0.05%, ceramide-based moisturizer cream, betamethasone dipropionate augmented ointment 0.05%, and tacrolimus ointment 0.1%.

The patient was started on nemolizumab 60mg SC injection single dose followed by nemolizumab 30mg SC injection every four weeks thereafter. She was seen at three weeks follow up and reported zero itch after starting her first injection 60mg SC injection of nemolizumab. On follow up, she had full clearance of her lichenoid and interface dermatitis on both her upper and lower extremities. She did not report any adverse events. She had discontinued topicals as they were no longer needed. The patient was directed to continue nemolizumab 30mg every four weeks following initial injection with close follow up.

Conclusion

The rapid clearance of lesions along with complete itch relief after initial 60mg SC injection of nemolizumab suggests that anti IL-31 therapy may be a safe and viable treatment option for lichen planus and lichenoid and interface dermatitis.

However, large multi-centered, randomized and double blinded controlled trials may be required for further validation.

EA DV CONGRESS
VIENNA
30 SEP - 3 OCT 2026

Abstract N°: 2710

Lichen Sclerosus in a 13-year-old girl associated with vitiligo and autoimmune thyroiditis.

Armine Adilkhanyan*[1], Tatevik Harutyunyan[1], Inga Mkhitaryan[1]

[1] Arabkir Joint Medical Center, ICAH, Yerevan, Armenia

Introduction

Lichen sclerosus (LS) is a chronic inflammatory disease of the skin and mucosa, cause significant pruritus, pain, and scarring. It commonly develops in the anogenital region, but can affect any area. LS presents more frequently in females with two peak ages of presentation: prepubertal girls and postmenopausal women.

The pathogenesis of LS is unknown. Autoimmune factors have been investigated and association with one or more other autoimmune diseases such as autoimmune thyroiditis, vitiligo, alopecia areata, pernicious anemia and celiac disease were reported. Genetic, hormonal, environmental, and infectious factors have also been implicated as possible causes of this disease.

A diagnosis of LS is based on clinical signs, specific dermoscopic features and histopathological results. Early recognition and prompt management of the disorder is crucial in preventing long-lasting complications.

Case Presentation

A 13-year-old girl presented with a history of pruriginous whitish sclerotic and scaly lesions on different parts of body, which had appeared 2 years ago as depigmented macules, which were diagnosed as a vitiligo. The lesions had gradually increased in number and size, also changed in their appearance. Physical examination revealed multiple sclerotic and atrophic, shiny, some of them slightly scaly, wrinkled hypopigmented patches on the posterior side of neck, shoulder, lumbar region and gluteal fold, wrists, ankles and knees. She had also depigmented macules on her upper eyelids. The genital region was not affected. There were no other complaints.

Laboratory investigations, including a complete blood count, serum glucose level, renal and liver tests, CRP, ANA, ds DNA were within normal range. Thyroid function investigation revealed Anti-TPO antibodies elevated 313IU/ml (N-<26 IU/ml), TSH, Anti-TG antibodies were normal. Abdominal ultrasound examination was without pathology. A skin biopsy of a patch on her knee was performed. Histopathological examination showed the epidermal hyperorthokeratosis, atrophy, spongiosis, moderate acanthosis and single follicular plugs. There was collagen fibers homogenization in the papillary dermis, with a moderate fibrosis and edema in the lower layers. The moderate lichenoid lymphoplasmacytic infiltrate and dilated vessels around the skin appendages were revealed. The skin appendages were not affected.

Conclusion

We report a case of a 13-years-old girl with extragenital LS, which is associated with palpebral vitiligo and autoimmune thyroiditis. The diagnosis was made on the basis of clinical presentation, dermoscopy, and histology results. The topical treatment with ultrapotent corticosteroids and calcineurin inhibitor tacrolimus was prescribed. The correct diagnosis of LS is essential in order to implement a regular follow-up and possible complications prevention such as scarring, disfigurement, or squamous cell carcinoma in case of genital LS.

EADV Congress 2026, VIENNA
30 SEPTEMBER - 03 OCTOBER 2026
POWERED BY M-ANAGE.COM

EA DV CONGRESS
VIENNA
30 SEP - 3 OCT 2026

Abstract N°: 2729

When the Scalpel Worsens the Wound: Diagnostic and Therapeutic Challenges of Post-Cesarean Pyoderma Gangrenosum

Hiba Et-Taghy*[1], Sihame Alaoui[1], ikram lahmouch[1], Narjess Errachdy[1], Najoua Ammar[1], Syrine Hamada[1], Meriem Meziane[1], Nadia Ismaili[1], Laila Benzekri[1]

[1] Department of Dermatology, CHU Ibn Sina, Rabat, Morocco

Introduction

Pyoderma gangrenosum (PG) is a rare neutrophilic dermatosis characterized by rapidly progressive, sterile cutaneous ulcerations with pathergy. Although 50-70% of cases are associated with systemic inflammatory or hematologic disorders, gravid-puerperal PG occurring on cesarean scars represents an exceptional trigger, with approximately 40 cases reported in the literature. These lesions frequently mimic surgical site infections, leading to diagnostic delay and inappropriate surgical interventions. This case illustrates the clinico-pathologic features and management principles of postpartum PG.

Case Presentation

A 31-year-old woman (G1P1) without medical history was hospitalized for suspected endometritis following cesarean delivery. On postoperative day 6, fever (39°C) and a pustule at the scar edge rapidly progressed to a painful 3×5 cm ulceration with erythematous-vegetative base, fibrinous exudate, and elevated violaceous undermined border (Fig1). Broad-spectrum antibiotics proved ineffective. Laboratory findings revealed marked inflammation (CRP 327.9 mg/L), hypochromic microcytic anemia (Hb 10.6 g/dL), and neutrophilic leukocytosis (31,000/mm^3, 84% neutrophils). Thoraco-abdominopelvic CT was normal; all cultures (wound, vaginal, blood) were sterile. Edge biopsy confirmed PG with dense dermal neutrophilic infiltrate without vasculitis. Systemic corticosteroids (prednisone 0.5 mg/kg/day) induced rapid clinical and biological improvement within one month (Fig2), consistent with pathergy triggered by cesarean trauma in the gestational pro-inflammatory context.



Figure 1: Clinical presentation of Pyoderma gangrenosum ; a 3×5 cm ulceration with an erythematous, vegetative surface covered by fibrinous exudate, bordered by an elevated violaceous inflammatory rim.

Conclusion

Post-cesarean pyoderma gangrenosum represents a critical diagnostic challenge due to its clinical resemblance to necrotizing surgical site infection. This case underscores that rapidly progressive, sterile, antibiotic-unresponsive postoperative wounds require urgent dermatologic evaluation to exclude PG. Surgical debridement must be strictly avoided due to pathergy risk. Early systemic immunosuppression remains the cornerstone of therapy, emphasizing the need for interdisciplinary awareness between obstetricians, surgeons, and dermatologists.



Figure 2 : Clinical improvement at one-month follow-up

EA DV CONGRESS
VIENNA
30 SEP - 3 OCT 2026

Abstract N°: 2733

Design of Phase 3, Randomised, Double-Blind, Placebo-Controlled Parallel Studies to Evaluate the Efficacy and Safety of Enpatoran in Active Cutaneous Manifestations of Lupus With or Without Systemic Disease (ELOWEN-1 and ELOWEN-2)

Eric F. Morand[1], J. Michelle Kahlenberg[2], Benjamin F. Chong[3], Edward Vital[4], Joseph F. Merola*[5], Jörg Wenzel[6], Sanjeev Roy[7], Ruth Fernandez-Ruiz[8], Summer G. Goodson[8], Hans Gühring[9], Evridiki Sgouroudi[9], Lena Klopp-Schulze[9], Genevieve Jehl[9], Victoria P. Werth[10]

[1] Centre for Inflammatory Diseases, Monash University, Melbourne, Australia

[2] Departments of Internal Medicine and Dermatology, University of Michigan, Ann Arbor, United States

[3] Department of Dermatology, University of Texas Southwestern Medical Center, Texas, United States

[4] Leeds Institute of Rheumatic and Musculoskeletal Medicine, University of Leeds, Leeds, United Kingdom

[5] Department of Dermatology and Department of Medicine, Division of Rheumatology, UT Southwestern Medical Center and O'Donnell School of Public Health, Dallas, United States

[6] Department of Dermatology, University Hospital of Bonn, Bonn, Germany

[7] Ares Trading SA, Eysins, Switzerland, an affiliate of Merck KGaA, Eysins, Switzerland

[8] EMD Serono Research & Development Institute, Inc., Billerica, MA, USA, an affiliate of Merck KGaA, Billerica, United States

[9] Merck Healthcare KGaA, Darmstadt, Germany

[10] Department of Dermatology, Perelman School of Medicine, University of Pennsylvania, Pennsylvania and Philadelphia VAMC, Philadelphia, United States

Introduction

There are no FDA-approved therapies specifically targeting cutaneous disease in lupus, which occur in isolation (cutaneous lupus erythematosus [CLE]) or as a manifestation of systemic lupus erythematosus (SLE). As a result, many patients with refractory cutaneous lupus lack effective, approved options, making this a significant area of unmet need. Toll-like receptors (TLR)7/8 are key upstream drivers of type I interferon (IFN) pathway activation and myeloid- and B-cell activation. Enpatoran is a novel, first-in-class, highly selective, oral TLR7/8 inhibitor. In a Phase 2, 24-week, randomised, double-blind, placebo-controlled, dose-finding basket study (WILLOW [NCT05162586]), enpatoran provided clinically meaningful improvements in patients with cutaneous and systemic lupus disease activity, including Cutaneous Lupus Disease Area and Severity Index-Activity (CLASI-A) scores, CLASI-50/70 response rates, and suppression of IFN gene signatures; and was well tolerated. Results from the WILLOW study warrant further evaluation of enpatoran in participants with cutaneous manifestations of lupus, with or without systemic disease, supporting the initiation of Phase 3 trials (ELOWEN-1 [NCT07332481] and ELOWEN-2 [NCT07355218]).

Materials and Methods

In a phase 3, randomised, double-blind, placebo-controlled study (one of two replicate, parallel studies) the efficacy and safety of enpatoran will be investigated in adults with SLE or CLE, and cutaneous manifestations (CLASI-A ≥8) of discoid lupus erythematosus, or subacute CLE (with/without systemic disease), or acute CLE (with systemic disease). Participants will be randomised 1:1 to placebo or 50 mg enpatoran BID for 24 weeks alongside standard of care (with corticosteroid taper from Weeks 2–12), followed by a 4-week safety follow-up

(Figure 1). Randomisation will be stratified by factors including region, systemic disease severity (none/mild or moderate/severe [BILAG ≥1A/2B]) and cutaneous disease severity (CLASI-A 8–9 or ≥10).

Results

The primary objective will be to demonstrate the efficacy of enpatoran for reducing cutaneous disease activity by achieving CLASI-70 response at Week 24; secondary endpoints include BICLA response at Week 24 in the subpopulation of participants with moderate to severe SLE to assess efficacy across all affected organs, CLASI score of ≤3 at Week 24, CLASI-50 response at Weeks 4 and 24; and safety and tolerability from Day 1 to week 24 in the overall population (Figure 1).

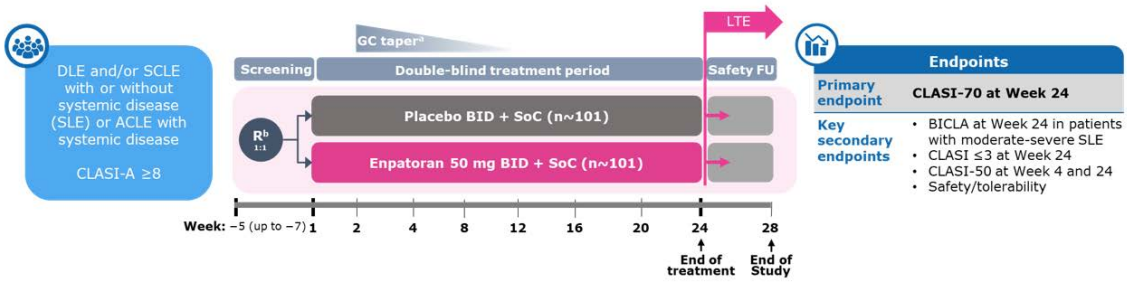

[a]GC must be tapered from Week 2 to Week 12. Tapering to 5 mg/day prednisone equivalent by Week 12 is mandatory (as clinically tolerated); tapering to 2.5 mg/day prednisone equivalent is recommended but not required. Prior to Week 2 and after Week 12 no GC changes are permitted; [b]Randomization will be stratified by region, systemic disease activity (none/mild or moderate/severe [BILAG ≥1A/2B]) and cutaneous disease severity (CLASI-A 8–9 or ≥10)

ACLE, acute cutaneous lupus erythematosus; BICLA, British Isles Lupus Assessment Group-based Composite Lupus Assessment; BID, twice daily; BILAG, British Isles Lupus Assessment Group; CLASI(-A), Cutaneous Lupus Erythematosus Disease Area and Severity Index(-Activity); CLE, cutaneous lupus erythematosus; DLE, discoid lupus erythematosus; FU, follow-up; GC, glucocorticoid; LTE, long-term extension; R, randomization; SoC, standard of care; SCLE, subacute cutaneous lupus erythematosus; SLE, systemic lupus erythematosus

Figure 1: Phase 3 study design and primary/key secondary endpoints

Conclusions

This novel phase 3 trial design aims to benefit a broader group of participants than conventional CLE or SLE trials, by evaluating enpatoran in participants with cutaneous manifestations of lupus with or without systemic disease. This approach has the potential to transform the lupus treatment paradigm for cutaneous manifestations of the disease, whilst also addressing underlying lupus pathophysiology upstream of IFN.

EA DV CONGRESS
VIENNA
30 SEP - 3 OCT 2026

Abstract N°: 2738

Improvement in Active Cutaneous Manifestations of Lupus with Enpatoran in Participants with Cutaneous Lupus Erythematosus or Systemic Lupus Erythematosus: A Pooled Post-Hoc Exploratory Analysis of the Phase 2 Willow Study

Eric F. Morand[1], Victoria P. Werth*[2], Richard A. Furie[3], Sanjeev Roy[4], Ruth Fernandez-Ruiz[5], Summer G. Goodson[5], Genevieve Jehl[6], David R. Pearson[7]

[1] Centre for Inflammatory Diseases, Monash University, Melbourne, Australia

[2] Department of Dermatology, Perelman School of Medicine, University of Pennsylvania and Philadelphia, Philadelphia, United States

[3] Division of Rheumatology, Northwell Health, Great Neck, New York, United States

[4] Ares Trading SA, Eysins, Switzerland, an affiliate of Merck KGaA, Eysins, Switzerland

[5] EMD Serono Research & Development Institute, Inc., Billerica, MA, USA, an affiliate of Merck KGaA, Billerica, United States

[6] Merck Sante S.A.S., an affiliate of Merck KgaA, Lyon, France

[7] Department of Dermatology, University of Minnesota, Minneapolis, United States

Introduction

Cutaneous manifestations of lupus impact physical and mental wellbeing; they can occur in isolation (in cutaneous lupus erythematosus [CLE]) but are also common features of systemic lupus erythematosus (SLE). There are currently no approved therapies specific for cutaneous disease in lupus and management is challenging due to inadequate responses to treatment across disease subtypes. Overexpression of type I interferon (IFN) and IFN-induced gene products in the skin has been implicated in lupus pathogenesis, and preclinical data suggest that cutaneous IFN activation may trigger autoantibody production and systemic inflammation. Toll-like receptors 7 and 8 (TLR7/8) are upstream drivers of the IFN pathway and neutrophil, myeloid cell and B-cell activation, and play key roles in innate and adaptive immune responses that lead to inflammation in lupus.[1,2] Enpatoran is a novel, first-in-class, selective, oral TLR7/8 inhibitor[3]. In WILLOW, a phase 2, 24-week, randomised, double-blind, placebo-controlled basket study (NCT05162586), enpatoran was well tolerated and resulted in clinically meaningful improvements in cutaneous and systemic manifestations of lupus, as well as robust IFN gene signature inhibition.[4,5] Based on these findings, the current study aims to compare improvement of cutaneous manifestations of lupus with enpatoran in participants with CLE only vs cutaneous manifestations of SLE.

Materials and Methods

This was a pooled, post-hoc, exploratory analysis of the phase 2 WILLOW study, including data from all participants with active cutaneous manifestations (Cutaneous Lupus Erythematosus Disease Area and Severity Index-Activity [CLASI-A] ≥8 at screening and baseline) of CLE or SLE. Participants were randomised to receive enpatoran (25 mg twice daily [BID], 50 mg BID or 100 mg BID) or placebo BID for 24 weeks, plus standard of care therapy. Endpoints included percentage change from baseline in CLASI-A total score, CLASI-50/70 response rates (≥50%/70% improvement from baseline) and exploratory definitions of low cutaneous disease activity/remission (CLASI-A total score 0 or 1 or ≤3, Cutaneous Lupus Activity Investigator's Global Assessment (CLA-IGA) score 0 or 1, or the combination of CLASI-A 0 or 1 and CLA-IGA 0 or 1, all at Week 24.

Results

Overall, 262 participants with cutaneous manifestations of lupus were included; 58 with CLE only (64% female; mean [standard deviation (SD)] age, 49 [11] years) and 204 with SLE (94% female; mean [SD] age, 42 [12] years). At Week 24, CLASI-A total score was improved with enpatoran vs placebo both in participants with CLE and SLE; least squares mean difference versus placebo was up to 46.0% and up to 29.2%, respectively. At Week 24, CLASI-50/70 response rates and the proportions of patients attaining exploratory definitions of low cutaneous disease activity or remission were higher with enpatoran vs placebo in participants with CLE or SLE with active cutaneous manifestations (Table 1).

Table 1. Cutaneous disease activity outcomes at Week 24 in participants with CLE or SLE with cutaneous manifestations in the WILLOW trial

	Placebo BID	Enpatoran 25 mg BID	Enpatoran 50 mg BID	Enpatoran 100 mg BID
CLE only	**N=14**	**N=14**	**N=15**	**N=15**
SLE with cutaneous manifestations	**N=53**	**N=38**	**N=48**	**N=65**
CLASI-50 response[a]				
CLE, n (%)	3 (21.4)	12 (85.7)	9 (60.0)	12 (80.0)
OR (95% CI) vs placebo[b]		22.0 (3.1–157.3)	5.5 (1.1–28.4)	14.7 (2.4–88.5)
SLE, n (%)	22 (41.5)	25 (65.8)	39 (81.3)	51 (78.5)
OR (95% CI) vs placebo[b]		2.7 (1.1–6.4)	6.1 (2.5–15.1)	5.1 (2.3–11.5)
CLASI-70 response[a]				
CLE, n (%)	2 (14.3)	9 (64.3)	7 (46.7)	10 (66.7)
OR (95% CI) vs placebo[b]		10.8 (1.7–68.9)	5.3 (0.9–32.0)	12.0 (1.9–75.7)
SLE, n (%)	15 (28.3)	19 (50.0)	29 (60.4)	35 (53.8)
OR (95% CI) vs placebo[b]		2.5 (1.1–6.1)	3.9 (1.7–8.9)	3.0 (1.4–6.4)
CLASI-A total score 0 or 1, n (%)				
CLE	1 (7.1)	3 (21.4)	3 (20.0)	5 (33.3)
SLE	10 (18.9)	11 (28.9)	16 (33.3)	18 (27.7)
CLASI-A total score ≤3, n (%)				
CLE	2 (14.3)	8 (57.1)	6 (40.0)	9 (60.0)
SLE	16 (30.2)	19 (50.0)	29 (60.4)	36 (55.4)
CLA-IGA score of 0 or 1, n (%)				
CLE	3 (21.4)	6 (42.9)	6 (40.0)	6 (42.9)
SLE	18 (34.0)	18 (47.4)	25 (52.1)	42 (67.7)
CLASI-A total score 0 or 1 and CLA-IGA score 0 or 1, n (%)				
CLE	1 (7.1)	3 (21.4)	3 (20.0)	3 (20.0)
SLE	8 (15.1)	10 (26.3)	14 (29.2)	18 (27.7)

[a]CLASI-50/70 response defined as ≥50%/70% improvement from baseline in CLASI-A total score; [b]OR and 95% CI based on logistic model for binary data, with treatment group as a categorical variable.
BID, twice daily; CI, confidence interval; CLA-IGA, Cutaneous Lupus Activity Investigator's Global Assessment; CLASI, Cutaneous Lupus Erythematosus Disease Area and Severity Index; CLASI-A, CLASI-Activity; CLE, cutaneous lupus erythematosus; OR, odds ratio; SLE, systemic lupus erythematosus.

Conclusions

Enpatoran provided clinically meaningful improvements in cutaneous disease activity in participants with CLE and SLE, underscoring shared pathogenic mechanisms. These data warrant further evaluation of enpatoran and the initiation of the phase 3 trials (ELOWEN-1 [NCT07332481] and ELOWEN-2 [NCT07355218]) in participants with active cutaneous manifestations of lupus with or without systemic disease.[6]

References:

1. Fetter T, et al. *Front Med (Lausanne).* 2022;9:915828.
2. Bender AT, et al. *Immunohorizons*. 2020;4:93–107.
3. Witte T, et al. *Lupus Sci Med*. 2025 Oct 23;12(2): e001705.
4. Morand EF, et al. *The Lancet Rheumatology* 2026 [In press];
5. Morand EF, et al. *The Lancet 2026* [In press].
6. Morand EF, et al. PO:11:286, *Lupus Science & Medicine*. 2026;13.

EADV Congress 2026, VIENNA
30 SEPTEMBER - 03 OCTOBER 2026
POWERED BY M-ANAGE.COM

EA DV CONGRESS
VIENNA
30 SEP - 3 OCT 2026

Abstract N°: 2746

Dermatomyositis Mortality by Myositis-Specific Autoantibodies: A Systematic Review and Meta-analysis

Adam Bai[1], Ryan S. Q. Geng*[2], Mutian Ding[3], Vinesh Rao[4], Shireen Dumont[5], Ernest Choy[6], Vincent Piguet[5]

[1] Faculty of Medicine, University of Ottawa, Ottawa, Canada
[2] Division of Dermatology, Department of Medicine, University of Toronto, Toronto, Canada
[3] Temerty Faculty of Medicine, University of Toronto, Toronto, Canada
[4] Faculty of Medicine and Dentistry, University of Alberta, Edmonton, Canada
[5] Division of Dermatology, Department of Medicine, Women's College Hospital, Toronto, Canada
[6] Division of Infection and Immunity, Cardiff University, Cardiff, United Kingdom

Introduction
Dermatomyositis is an idiopathic inflammatory myopathy characterized by muscular weakness and cutaneous findings. The identification of myositis-specific autoantibodies (MSAs) has redefined the management of dermatomyositis by refining diagnosis, guiding therapy, and improving prognostic assessment according to autoantibody-specific clinical phenotype. However, mortality outcomes across MSAs in dermatomyositis remain unclear. This systematic review and meta-analysis aims to quantify mortality outcomes in dermatomyositis, stratified by disease-specific autoantibodies.

Materials and Methods
MEDLINE and Embase were searched using specific keywords. Articles were independently screened by 2 reviewers for articles reporting on MSA mortality outcomes, including TIF-1γ, Mi-2, MDA-5, NXP-2, and SAE. Methodological quality was assessed using the PROBAST approach, while evidence certainty was assessed using the GRADE approach. Meta-analyses were conducted using a restricted maximum likelihood random-effects model to estimate pooled mortality prevalence with 95% confidence intervals (CI).

Results
A total of 158 articles comprising 15,033 patients were included in the analysis, with 138/158 low-risk studies, and 20/158 medium-risk studies. There were 94.5% (14213/15033) patients with anti-MDA5 with mean age 51.0 years and 63.6% (7519/11825) females. Mean mortality was 29% (CI: 27-32%; n=14,213) [high-certainty], with 46.2% (6570/14213) patients receiving systemic therapy during mean follow-up duration of 20.6 months. The most common reported causes of mortality included respiratory failure (RF; 51.0%, 1146/2248) and respiratory infection (9.6%, 216/2248). Within the anti-MDA5 positive cohort, 65.3% (9283/14213) had concurrent interstitial lung disease (ILD), with mean mortality of 32% (CI: 29-34%; n=9,283) [high-certainty] despite 45.7% (4245/9283) patients receiving systemic therapy during mean follow-up duration of 19.1 months.

There were 1.9% (283/15033) patients with anti-TIF1-γ with mean age 59.5 years and 69.2% (54/78) females. Mean mortality was 30% (CI: 18-43%; n=283) [moderate-certainty], with 16.3% (46/283) patients receiving systemic therapy during mean follow-up duration of 50.2 months. The most common reported causes of mortality included malignancy (58.3%, 28/48) and RF (14.6%, 7/48).

There were 1.6% (241/15033) patients with anti-NXP2 with mean age 32.4 years and 67.7% (67/99) females. Mean mortality was 15% (CI: 11-20%; n=241) [moderate-certainty], with 53.9% (130/241) patients receiving systemic therapy during mean follow-up duration of 39.3 months. The most common reported causes of mortality included

gastrointestinal perforation (20.0%, 5/25) and RF (16.0%, 4/25).

There were 1.0% (143/15033) patients with anti-SAE with mean age 55.3 years and 77.5% (93/120) females. Mean mortality was 12% (CI: 7-19%; n=143) [moderate-certainty], with 83.2% (119/143) patients receiving systemic therapy during mean follow-up duration of 44.6 months. The most common reported causes of mortality included malignancy (47.4%, 9/19) and respiratory infection (21.1%, 4/19).

There were 1.0% (156/15033) patients with anti-Mi-2 with mean age 49.2 years and 66.7% (46/69) females. Mean mortality was 7% (CI: 1-16%; n=156) [moderate-certainty], with 45.5% (71/156) patients receiving systemic therapy during mean follow-up duration of 41.2 months. The most common reported causes of mortality included malignancy (28.6%, 2/7) and RF (28.6%, 2/7).

Conclusions

Screening for MSAs in suspected dermatomyositis provides important prognostic information. Anti-MDA5, particularly when associated with ILD, was associated with the highest mortality. The mortality observed in anti-TIF1-γ dermatomyositis may appear lower than expected given its strong association with malignancy, which may reflect improved cancer treatment or insuffient follow-up duration.

EADV CONGRESS
VIENNA
30 SEP - 3 OCT 2026

Abstract N°: 2749

Buschke scleredema associated with autoimmune and metabolic overlap syndrome: diagnostic and therapeutic challenges

Alícia Mendes*[1], Angela Mendes[1], Cassiano Gomes[1], Karem Silva[1], Maria Fernanda Addor[1], Eduarda Rodriguez[1], Leonardo Ribeiro[1], José Victor Martinez[1]

[1] Pontifícia Universidade Católica de São Paulo- campus Sorocaba, Sorocaba, Brazil

Introduction

Scleredema of Buschke is a rare sclerosing dermatosis of the connective tissue, characterized by cutaneous thickening resulting from the dermal deposition of mucopolysaccharides and increased collagen. Classically, it is associated with diabetes mellitus, preceding infections, and monoclonal gammopathies. Clinically, it manifests as diffuse cutaneous induration, predominantly in the posterior cervical region, shoulders, and upper back, which can lead to significant functional limitation. Diagnosis is based on clinicopathological correlation, with histopathology being fundamental for differentiation from other sclerodermiform dermatoses, especially systemic sclerosis. We report a case of Scleredema of Buschke in a patient with significant overlap of autoimmune and metabolic diseases, highlighting the diagnostic and therapeutic challenges of the condition.

Case Presentation

A 44-year-old female patient presented with type 1 diabetes mellitus with chronic complications, systemic arterial hypertension, Hashimoto's thyroiditis with hypothyroidism, Sjögren's syndrome, celiac disease, autoimmune panniculitis, vitiligo, systemic sclerosis, megaloblastic anemia, epilepsy, and recurrent urinary tract infections, in a context of polypharmacy. She reported a two-year progression of progressive cutaneous induration on the upper back, shoulders, and face, associated with local pain and a sensation of stiffness. Upon dermatological examination, hardened skin thickening was observed in the referred regions, with an inability to pinch the skin (negative pinch test), and no distal involvement.

A skin biopsy was performed in the shoulder region, revealing dermal thickening due to increased collagen bundles associated with interstitial mucopolysaccharide deposition, compatible with Scleredema of Buschke. Following diagnostic confirmation, UVA-1 phototherapy was initiated. However, due to high clinical complexity and low treatment tolerance, the decision was made for multidisciplinary outpatient follow-up and conservative management.

Conclusion

Scleredema of Buschke remains a rare and potentially underdiagnosed condition, particularly in patients with concomitant autoimmune diseases and sclerodermiform cutaneous manifestations. This case highlights the relevance of histopathological investigation in the differential diagnosis of sclerosing dermatoses, especially in scenarios of clinical overlap with systemic sclerosis. Furthermore, it evidences the therapeutic challenges imposed by high clinical complexity, polypharmacy, and limited tolerance to available treatments. Considering the rarity of the presented association, this report contributes to expanding the clinical recognition of Scleredema of Buschke and reinforces the need for individualized and multidisciplinary approaches for these patients.

EADV Congress 2026, VIENNA
30 SEPTEMBER - 03 OCTOBER 2026
POWERED BY M-ANAGE.COM

EADV CONGRESS
VIENNA
30 SEP - 3 OCT 2026

Abstract N°: 2796

Atypical Non-Bullous Pemphigoid Revealing Hepatocellular Carcinoma in an 80-Year-Old Man: A Paraneoplastic Phenomenon?

Fatima Zahra Sassine*[1], Chourouq Mustapha Eid[1], Meria Saci[2], Michele Sanchez[2]

[1] Ibn Sina University Hospital, Dermatology Derpartment, Rabat, Morocco

[2] Hopital Henri Duffaut, Dermatology Department, Avignon, France

Introduction

Bullous pemphigoid (BP) is the most common autoimmune subepidermal blistering disease, predominantly affecting the elderly. Up to 20% of patients present with atypical non-bullous variants, including eczematous, prurigo-like, or urticarial lesions, leading to significant diagnostic delay. The association between BP and internal malignancy remains controversial. A meta-analysis found no association with overall cancer, though a possible link with hematologic malignancies was observed. We report a case of atypical non-bullous pemphigoid with acral and auricular involvement, revealing an underlying hepatocellular carcinoma (HCC) on cirrhosis.

Case Presentation

An 80-year-old man with a history of hypertension and cardiac arrhythmia, both under treatment, was admitted for extensive crusted lesions of the limbs with prominent involvement of the hands, feet, and ears, associated with severe pruritus and eczematiform plaques. Notably, no tense bullae were observed. The clinical presentation of the hands resembled desquamation rather than blistering, and the overall picture was suggestive of prurigo.

Skin biopsy with direct immunofluorescence (DIF) revealed linear deposits of IgG and C3 along the basement membrane zone. Indirect immunofluorescence (IIF) was positive, confirming the diagnosis of bullous pemphigoid despite the absence of typical bullae.

During hospitalization, laboratory workup revealed hepatocellular insufficiency with features consistent with cirrhosis. CT and MRI of the abdomen identified a hepatic tumor consistent with hepatocellular carcinoma.

This case illustrates two noteworthy aspects of BP: its atypical non-bullous presentation and its potential association with occult malignancy.

Non-bullous pemphigoid accounts for over 20% of BP cases and presents with heterogeneous pruritic lesions including papules, nodules, eczematous plaques, or excoriations. The mean diagnostic delay is 22–29 months. DIF and IIF remain essential for diagnosis, as histopathology is often nonspecific in non-bullous variants. The acral distribution involving hands, feet, and ears in our patient is unusual and may mimic prurigo nodularis or chronic eczema.

The relationship between BP and malignancy is debated. A systematic review and meta-analysis of eight studies found no significant association with overall cancer. Conversely, a Japanese study of 1,113 BP patients reported a 5.8% malignancy rate, significantly exceeding age-matched controls. The main pathogenic hypothesis suggests that antibodies directed against tumor-associated antigens may cross-react with BP180 and BP230 at the basement membrane zone. HCC is known to

generate a broad repertoire of autoantibodies against tumor-associated antigens, which could theoretically trigger such cross-reactivity. A case of BP associated with sitagliptin use in a patient with liver cirrhosis and rapidly progressive HCC has been reported, though the respective roles of the drug and the tumor were difficult to disentangle.

The temporal relationship in our patient, with BP as the presenting manifestation leading to the discovery of HCC, raises the possibility of a paraneoplastic phenomenon. Oncological screening has been recommended in early-onset BP, refractory BP, and in patients with clinical features suggestive of underlying neoplasia.

Conclusion

This case highlights the importance of recognizing non-bullous pemphigoid variants and performing a thorough systemic workup, including hepatic assessment, in elderly patients with atypical BP. The discovery of HCC in this clinical context supports the recommendation for oncological screening in selected BP patients.

EADV CONGRESS
VIENNA
30 SEP - 3 OCT 2026

Abstract N°: 2820

Anifrolumab in Challenging Cutaneous Lupus: Clinical Experience in Patients Without Systemic Disease

Sofia Haselgruber*[1], Daniel Muñoz Barba[1], Francisco Javier León Pérez[1], Andrea Isabel Rodriguez-Sanna[1], Manuel Sanchez-Diaz[1]

[1] Dermatology Department. Hospital Universitario Virgen de las Nieves., Granada, Spain

Introduction
Anifrolumab is a monoclonal antibody targeting the type I interferon receptor subunit 1, currently approved for the treatment of moderate-to-severe systemic lupus erythematosus (SLE). Increasing evidence supports its efficacy in cutaneous lupus erythematosus (CLE), with or without associated systemic disease. We present a case series of female patients with CLE without SLE criteria who were treated with anifrolumab in special clinical scenarios.

Case Presentation
We report four female patients with CLE treated with anifrolumab under special circumstances. Clinical data, treatment efficacy assessed by the Cutaneous Lupus Erythematosus Disease Area and Severity Index (CLASI), and safety outcomes were collected. The cases included: extensive discoid lupus involving the scalp, a multirefractory discoid lupus, severe photosensitivity, and one case of facial lupus panniculitis in the context of latent tuberculosis infection (positive IGRA). All patients showed a marked reduction in CLASI activity scores within 6 months of treatment initiation. Treatment was generally well tolerated; mild adverse events included headache in one patient and myalgia in another. Dose optimization was achieved in selected cases after sustained clinical remission.

Conclusion
In our experience, anifrolumab appears to be an effective and well-tolerated option for CLE in patients without SLE, including challenging and refractory cases. Clinical improvement was rapid, often evident from the first infusions, and maintained over time. These findings support the potential role of anifrolumab in selected CLE patients, even in complex scenarios such as latent tuberculosis infection, scalp involvement, panniculitis, or severe photosensitivity.

EA DV CONGRESS
VIENNA
30 SEP - 3 OCT 2026

Abstract N°: 2846

Wolf's Phenomenon Triggered by Anthrax: A Case Report

Meriem Harrouchi*[1], Anissa Zaouak[1], Houda Hammami[1]

[1] Department of Dermatology, Habib Thamer Hospital, tunis, Tunisia

Introduction

Wolf's isotopic response is a rare dermatological phenomenon first described by Ronni Wolf in 1995, defined as the development of a new, unrelated skin disorder at the exact site of a previously healed skin disease. The most commonly reported trigger is herpes zoster, although other infectious and inflammatory conditions have also been implicated. We report a unique case of Wolf's isotopic response in a patient with linear IgA bullous dermatosis (LABD), in whom bullous lesions recurred exclusively at the healed site of a surgically treated anthrax.

Case Presentation

A 58-year-old female patient presented to our dermatology department with a subepidermal bullous eruption. Histopathological examination revealed subepidermal blistering associated with a dermal infiltrate composed predominantly of neutrophils and occasional eosinophils. Direct immunofluorescence (DIF) demonstrated fine, linear deposits of IgA and C3 along the dermal-epidermal junction (DEJ), establishing the diagnosis of linear IgA bullous dermatosis (LABD). The patient was initiated on systemic corticosteroid therapy and achieved complete clinical remission after four months of treatment.

During the follow-up period, while in full remission, the patient developed an anthrax on her back, which required surgical management by the general surgery department. One month postoperatively, at a routine dermatological follow-up visit, new bullous lesions were incidentally discovered. Remarkably, the eruption was strictly confined to the previously healed surgical site of the anthrax, with no involvement of surrounding healthy skin or other body areas. The patient reported no systemic symptoms, and her general condition remained.

The patient was once again treated with oral corticosteroid therapy and achieved complete clinical remission.

This case fulfills the three cardinal criteria for Wolf's isotopic response: a documented and fully healed primary skin disease (anthrax), the subsequent development of a distinct dermatosis (LABD), and strict topographic confinement of the new lesion to the previously affected site.

The pathophysiological mechanism in this case likely involves the profound local tissue remodeling induced by the anthrax which may have disrupted the integrity of the dermal-epidermal junction, exposing LABD-associated autoantigens (primarily BP180/type XVII collagen) to circulating IgA autoantibodies.

The pre-existing dysregulation of the humoral immune response in LABD patients may further predispose the locally altered skin to targeted autoimmune attack.

Differential diagnoses considered included a Koebner phenomenon which would require active LABD rather than complete remission, a bullous drug reaction to the perioperative antibiotherapy, and a local infectious bullous complication. These were excluded based on the clinical context, the confirmed remission status prior to the anthrax episode and the sterile nature of the new blisters.

This case highlights the importance of prolonged dermatological surveillance of previously diseased skin areas in

patients with autoimmune bullous disorders, even during periods of apparent complete remission.

Conclusion

We report a rare case of Wolf's isotopic response triggered by anthrax in a patient with LABD, in which a healed anthrax site induced a localized recurrence of linear IgA bullous dermatosis despite complete remission. This case expands the spectrum of triggers and dermatoses associated with Wolf’s phenomenon.

EADV CONGRESS
VIENNA
30 SEP - 3 OCT 2026

Abstract N°: 2862

Refractory Superficial Erythema Annulare Centrifugum Successfully Treated With Tofacitinib: A 20-Year Chronic Case

Claudio Lelis Souza[1], Ana Laura Ritter[1], Mônica Linhares Sachett*[2], Guilherme Gonçalves Nascimento[2], Ana Clara Freitas[1]

[1] unifenas, alfenas, Brazil

[2] FMABC, Santo Andre, Brazil

Introduction

Erytema annulare centrifugum (EAC) is a rare, benign, inflammatory dermatosis characterized by annular erythematous lesions with centrifugal growth and trailing scale. The superficial variant typically presents with fine collarette desquamation and may follow a chronic, relapsing course. Although EAC is often self-limited or controlled with topical therapies and treatment of underlying triggers, a subset of patients exhibits persistent, treatment-resistant disease. Evidence regarding systemic immunomodulatory options in refractory EAC remains scarce.

Case Presentation

A 51-year-old white female entrepreneur reported a more than 20-year history of recurrent cutaneous lesions that appeared predominantly during warm seasons, with partial improvement and disappearance in winter. Dermatological examination revealed multiple annular erythematous patches with centrifugal expansion, fine collarette scale at the inner margin, and a surrounding hypopigmented halo, predominantly on the trunk and proximal extremities. A skin biopsy demonstrated a mild superficial perivascular lymphohistiocytic infiltrate with subtle basal spongiosis and focal parakeratosis. The histopathological diagnosis of superficial erythema annulare centrifugum was favored, with negative PAS staining for fungal organisms, reinforcing the clinical impression and excluding dermatophytosis. Initial treatment with topical corticosteroid (mometasone cream) combined with oral prednisone 40 mg/day produced no sustained clinical benefit. Subsequent systemic therapies included dapsone 100 mg/day, which had to be discontinued due to methemoglobinemia, followed by methotrexate 20 mg/week for two months without significant response. A 60-day course of griseofulvin 500 mg/day was also ineffective. Given the chronic, refractory nature of the disease, tofacitinib 10 mg/day was initiated, leading to marked improvement and near-complete resolution of lesions, with significant impact on quality of life and no severe adverse effects observed during follow-up.

Conclusion

This case illustrates a rare, long-standing superficial EAC with poor response to conventional therapies, successfully controlled with tofacitinib. Janus kinase inhibition may represent a promising off-label option in refractory EAC, especially in chronic, debilitating cases where standard treatments fail. Prospective studies are needed to better define efficacy, safety and optimal dosing of JAK inhibitors in this setting.

EA DV CONGRESS
VIENNA
30 SEP - 3 OCT 2026

Abstract N°: 2881

Dermatological and immunological characterization of patients with confirmed dermatomyositis diagnosis attended at high-complexity centers

Gabriella Gonzalez*[1], Carolina Ivette Cortes Correa[1], Elkin PEÑARANDA[1], daniel perez[1], Maria Palacios[1]

[1] Fundacion Universitaria Sanitas, Bogota, Colombia

Introduction

Introduction: Dermatomyositis (DM) is a rare autoimmune inflammatory myopathy with distinctive cutaneous manifestations of diagnostic and prognostic value. Data on the dermatological and immunological profile of DM in Latin America remain scarce. This study aimed to describe the sociodemographic, clinical, dermatological and immunological characteristics of patients with confirmed DM diagnosis attended at two high-complexity centers in Colombia between 2015 and 2025.

Materials and Methods

Methods: Observational, descriptive, cross-sectional, retrospective study. Patients older than 15 years with confirmed diagnosis according to Bohan and Peter or EULAR/ACR criteria were included. Qualitative variables were expressed as frequencies and percentages, and quantitative variables as medians with interquartile ranges (IQR). An exploratory bivariate analysis was performed across clinical subtypes.

Results

Results: A total of 114 patients were included, with a median age of 56 years (IQR 45-65) and female predominance (67.5%). The classic subtype was the most frequent (65.8%), followed by amyopathic (15.8%), paraneoplastic (9.6%) and hypomyopathic (8.8%). Systemic involvement was present in 57.0% of patients, pulmonary in 19.3% and gastrointestinal in 7.9%. The most frequent cutaneous findings were Gottron papules (72.8%), heliotrope erythema (64.9%), shawl sign (44.7%), V-sign (41.2%), holster sign (23.7%), mechanic hands (11.4%) and cutaneous ulcers (7.0%), with significant differences across subtypes (Table 1). Electromyography was abnormal in 97.3% of the classic subtype. Baseline CPK was significantly higher in the classic subtype (median 1543 U/l) compared to the amyopathic subtype (69 U/l; $p<0.0001$). The autoantibody co-occurrence profile is shown in Figure 1. The most frequent autoantibodies were ANA (64.0%), anti-Mi2 (18.4%), anti-Ro52 (17.5%), anti-Jo1 (13.2%) and anti-TIF1 gamma (13.2%). Anti-TIF1 gamma was significantly more frequent in the paraneoplastic subtype (63.6% versus 4-20%; $p<0.0001$), as were cutaneous ulcers (27.3%; $p=0.04$). Malignancy was documented in 11.4% of patients, almost exclusively in the paraneoplastic subtype (90.9%); the most frequent types were gastrointestinal (33.3%) and gynecological (25.0%). Hospitalization was required in 45.6% of cases. Overall mortality was 21.9%, significantly higher in the paraneoplastic subtype (54.5%; $p=0.04$), with malignancy (32%) and interstitial lung disease (24%) as the leading causes of death.

Conclusions

Conclusions: This study represents the first detailed characterization of the cutaneous and immunological profile of DM in Colombia. Cutaneous ulcers and anti-TIF1 gamma positivity identify patients at highest risk of occult malignancy and death, positioning the dermatologist as a central actor in risk stratification and the early detection of potentially life-threatening systemic complications.

Table 1. Key clinical features by dermatomyositis subtype (n=114)

Variable	Total (n=114)	Classic (n=75)	Hypomyopathic (n=10)	Amyopathic (n=18)	Paraneoplastic (n=11)	p-value
Gottron papules	72.8%	69.3%	70.0%	83.3%	81.8%	0.582
Heliotrope erythema	64.9%	62.7%	60.0%	72.2%	72.7%	0.804
Shawl sign	44.7%	45.3%	60.0%	33.3%	45.5%	0.593
Cutaneous ulcers	7.0%	4.0%	10.0%	5.6%	27.3%	**0.043**
V-sign	41.2%	37.3%	50.0%	33.3%	72.7%	0.124
Baseline CPK (U/l)*	228	1543	150	69	228	**<0.0001**
Malignancy	11.4%	1.3%	0.0%	11.1%	90.9%	**<0.0001**
Hospitalization	45.6%	53.3%	20.0%	16.7%	63.6%	**0.007**
Mortality	21.9%	18.7%	10.0%	22.2%	54.5%	**0.043**
Cause of death: malignancy (n=25)	32.0%	0.0%	0.0%	50.0%	100.0%	**0.004**

*Medians reported. CPK: creatine phosphokinase.

EADV Congress 2026, VIENNA
30 SEPTEMBER - 03 OCTOBER 2026
POWERED BY M-ANAGE.COM

EADV CONGRESS
VIENNA
30 SEP - 3 OCT 2026

Abstract N°: 2907

Clinical and Serological Predictors of Relapse Following Rituximab in Pemphigus Vulgaris: A Systematic Review and Meta-analysis

Abdullatif Aldhafyan*[1]

[1] Imam Mohammad Ibn Saud Islamic University (IMSIU), Riyadh, Saudi Arabia

Introduction
Despite the effectiveness of rituximab in pemphigus vulgaris, relapse remains a major obstacle to sustained disease control and long-term remission. Identifying factors associated with recurrence may improve risk stratification, optimize follow-up, and support risk-adapted maintenance strategies.

Materials and Methods
A systematic review and meta-analysis were conducted according to PRISMA 2020 guidelines. PubMed/MEDLINE, Web of Science, and the Cochrane Library were searched through November 2025. Studies reporting relapse following rituximab therapy in pemphigus vulgaris were included. A random-effects model was used to estimate the pooled relapse proportion, while clinical, serological, and immunological predictors were synthesized narratively.

Results
Seven studies involving 390 patients were included. The pooled relapse proportion was 0.47 (95% CI: 0.14–0.82), with substantial heterogeneity ($I^2 = 96.5\%$). Higher baseline disease activity, persistent or rising anti-desmoglein antibody levels, and early B-cell repopulation were frequently associated with increased relapse risk. In contrast, maintenance or preemptive rituximab strategies were associated with more sustained remission and delayed recurrence across several cohorts.

Conclusions
Relapse following rituximab therapy remains frequent and appears to result from the combined interaction of disease severity, serological activity, rituximab treatment strategy, and immune reconstitution. Integrated clinical and immunological assessment may help identify patients at higher risk of recurrence and support more personalized monitoring and maintenance-based therapeutic approaches.

EA DV CONGRESS
VIENNA
30 SEP - 3 OCT 2026

Abstract N°: 2925

Multiple Autoimmune Syndrome exclusively involving dermatological autoimmune diseases

assia zenagui*[1], I Mahi[1], B dahmani[1]

[1] CHU Dr Tidjani Damerdji of Tlemcen, Faculty of Medicine, Tlemcen, Algeria

Introduction

Multiple Autoimmune Syndrome (MAS) is defined by the coexistence of at least three distinct autoimmune diseases in a single patient. In patients with MAS, the presence of at least one dermatological manifestation most commonly Vitiligo or Alopecia areata is frequently observed, reflecting an underlying immunological cascade.

Case Presentation

A 45-year-old woman with a past medical history of patchy alopecia areata and vitiligo evolving for 10 years. Her family history was notable for autoimmune thyroiditis in her mother and sister, vitiligo in her sister and grandfather, and breast cancer in three sisters.

Clinical examination revealed multiple depigmented macules, a band-like recession of the frontotemporal hairline, lateral eyebrow loss, and generalized body hair involvement. Trichoscopic evaluation of the eyebrows showed hair regrowth in different directions, supporting the diagnosis of Frontal fibrosing alopecia.

Additionally, a well-demarcated alopecic plaque with erythematous and focally atrophic areas was observed. Histopathological examination of a skin biopsy favored a diagnosis of Lichen planopilaris.

Discussion :

This case illustrates an exceptional form of Multiple Autoimmune Syndrome (MAS) extending beyond traditional classifications, characterized by the rare coexistence of four major cutaneous autoimmune disorders: Vitiligo, Alopecia areata, Frontal fibrosing alopecia, and Lichen planopilaris. This unique association reflects a state of intense cutaneous polyautoimmunity, in which the breakdown of immune privilege—both follicular and melanocytic—appears to represent a shared pathogenic denominator.

Under conditions of oxidative stress, upregulation of major histocompatibility complex (MHC) molecules promotes an immune cascade mediated by CD8+ T lymphocytes and interferon-γ (IFN-γ), leading to targeted tissue-specific destruction depending on the affected structure: the bulge region in (LPP/AFF), the hair bulb in alopecia areata, and melanocytes in vitiligo.

The complexity of this phenotype highlights the need for thorough systemic screening for associated autoimmune conditions and supports the therapeutic interest of targeting shared immunological pathways, particularly the JAK/STAT axis, in order to restore lost immune tolerance.

Conclusion

This exceptional case represents a spectrum of autoimmunity combining Vitiligo, Alopecia areata, Frontal fibrosing alopecia, and Lichen planopilaris. This clustering supports a shared pathogenic mechanism characterized by breakdown of immune privilege with activation of the IFN-γ/JAK-STAT pathway.

It underscores the need for increased diagnostic vigilance in light of the immunological continuum between hair follicles and melanocytes.. Finally, this rare phenotype supports the rationale for broad targeted therapies aiming to restore global immune tolerance.

EA DV CONGRESS
VIENNA
30 SEP - 3 OCT 2026

Abstract N°: 2936

Real-World Effectiveness and Safety of Ritlecitinib in Moderate-to-Severe Alopecia Areata: A Tertiary Referral Center Cohort

Julia Castro Martín*[1], Manuel Sanchez-Diaz[1], Daniel Muñoz Barba[1], Salvador Arias-Santiago[1]

[1] Hospital Universitario Virgen de las Nieves, Granada, Spain

Introduction
Ritlecitinib, a selective JAK3 inhibitor, has demonstrated efficacy in moderate-to-severe Alopecia areata in clinical trials, but real-world evidence remains limited.

Objectives: To describe the clinical profile of patients treated with ritlecitinib, evaluate effectiveness at 3 and 6 months (scalp and adnexal involvement), explore factors associated with 6-month response, and assess safety.

Materials and Methods
Single-center descriptive study conducted at a tertiary hospital including patients with alopecia areata who initiated ritlecitinib between 2024 and 2025 and had at least one follow-up visit. Clinical variables, comorbidities, prior systemic therapies, laboratory values, and adverse events were collected. In patients with ≥6 months follow-up, effectiveness was defined as SALT ≤20 and/or SALT50 (≥50% reduction from baseline) at 3 and 6 months. Given the limited sample size, analyses were considered exploratory and restricted to bivariate comparisons.

Results
Fifteen patients were included (67% women). Clinical phenotypes were patchy (40%), ophiasis (27%), totalis (13%), and universalis (20%). Median baseline SALT score was 50 [40–86.5]. Eyebrow involvement was present in 7/15 (46.7%) and eyelash involvement in 5/15 (33.3%). Six patients (40%) were JAK-naïve and nine (60%) had prior JAK exposure (Baricitinib 7/9, Tofacitinib 4/9; two both).

At 3 months (n=13), 4/13 (31%) achieved SALT ≤20 and 2/13 (15%) achieved SALT50. At 6 months (n=9), 4/9 (44.4%) achieved SALT ≤20 and 3/9 (33.3%) achieved SALT50; a trend toward SALT improvement versus baseline was observed (p=0.058). Eyebrow density improved by ≥1 point in 4/9 (44.4%) and eyelash density in 2/9 (22.2%).

Patients achieving SALT ≤20 at 6 months had longer disease duration, lower baseline SALT, higher baseline ESR, and less prior JAK exposure, although without statistical significance (p>0.10).

No serious infections, herpes zoster, or thrombotic events were observed. Mild respiratory infection occurred in 1/15 (6.7%), acneiform eruption/folliculitis in 3/15 (20%), and gastrointestinal symptoms in 1/15 (6.7%), leading to treatment discontinuation.

Conclusions
In routine clinical practice, ritlecitinib was used in moderate-to-severe alopecia areata patients with substantial prior treatment burden, showing clinically meaningful responses at 6 months and a favorable safety profile.

Exploratory analyses suggested better outcomes in patients with lower baseline severity, higher ESR, and less prior JAK exposure. These findings require confirmation in larger cohorts with longer follow-up.

EADV CONGRESS
VIENNA
30 SEP - 3 OCT 2026

Abstract N°: 2937

Demographic and Conceptual Disparities in Systemic Lupus Erythematosus: A Comparative Analysis from Riyadh, Saudi Arabia

Abdullatif Aldhafyan*[1]

[1] Imam Mohammad Ibn Saud Islamic University (IMSIU), Riyadh, Saudi Arabia

Introduction

Systemic lupus erythematosus (SLE) is a chronic multisystem autoimmune disease associated with significant morbidity and delayed diagnosis. Limited public understanding of SLE may contribute to misconceptions, delayed healthcare seeking, and reduced disease recognition. This study aimed to evaluate public awareness, conceptual understanding, and demographic disparities related to SLE among the general population in Riyadh, Saudi Arabia.

Materials and Methods

A cross-sectional study was conducted using a validated electronic questionnaire distributed among adults in Riyadh, Saudi Arabia, between October 2024 and January 2025. The survey assessed demographic characteristics, awareness of SLE manifestations and complications, understanding of disease mechanisms, and attitudes toward diagnosis and treatment. Statistical analyses were performed to evaluate associations between demographic variables and awareness levels, with statistical significance set at $P < 0.05$.

Results

A total of 646 participants were included. Approximately two-thirds of participants had previously heard of SLE; however, substantial misconceptions regarding its autoimmune nature, multisystem involvement, and complications were identified. Awareness levels differed significantly according to sex, healthcare-related background, and previous SLE diagnosis. Female participants and individuals with healthcare-related experience demonstrated higher levels of awareness and conceptual understanding. Social media and online platforms represented the primary sources of information. Despite moderate general familiarity with SLE, detailed clinical understanding remained limited across multiple domains.

Conclusions

Considerable gaps in public understanding of SLE remain present despite moderate general awareness of the disease. Persistent misconceptions and demographic disparities highlight the need for targeted educational strategies and broader public health initiatives aimed at improving disease recognition and encouraging earlier healthcare engagement.

EADV CONGRESS
VIENNA
30 SEP - 3 OCT 2026

Abstract N°: 2964

A Case of Pemphigoid Gestationis Managed Without Systemic Therapy

Gizem Özer*[1], Banu Yaman[2], İdil Ünal[1]

[1] Department of Dermatology, Ege University Faculty of Medicine, İzmir, Türkiye
[2] Department of Pathology, Ege University Faculty of Medicine, İzmir, Türkiye

Introduction

Pemphigoid gestationis is a rare autoimmune blistering dermatosis of pregnancy that typically presents during the second or third trimester with severe pruritus and polymorphic vesiculobullous eruptions. Management may be challenging because treatment options are limited during pregnancy and systemic corticosteroid exposure may be undesirable in selected patients. We present a case of pemphigoid gestationis successfully controlled with intensive topical therapy without the need for systemic corticosteroids.

Case Presentation

A 27-year-old multigravid woman at 26 weeks of gestation presented with intensely pruritic erythematous plaques and vesiculobullous lesions that initially developed on the abdomen and subsequently spread to the upper and lower extremities. Previous treatment with topical corticosteroids and oral antihistamines had failed to provide adequate clinical improvement.

Dermatological examination revealed annular erythematous plaques with grouped vesiculobullous lesions in a "string of pearls" configuration accompanied by focal erosions. Mucosal involvement was absent, and fetal ultrasonography demonstrated no abnormalities.

Histopathological examination of a punch biopsy showed a subepidermal blister with eosinophil-rich inflammatory infiltrates and perivascular lymphocytic infiltration. Direct immunofluorescence demonstrated linear C3 deposition along the dermoepidermal junction, while IgG, IgA, IgM, C1q, and fibrinogen were negative, confirming the diagnosis of pemphigoid gestationis.

Considering the patient's pregnancy and the aim of avoiding systemic corticosteroid exposure, intensive topical treatment with betamethasone valerate cream, wet dressings containing 2% boric acid, and oral cetirizine was initiated. Marked clinical improvement was achieved without systemic therapy, and no recurrence was observed during follow-up.

Conclusion

This case highlights that intensive and appropriately administered topical therapy may achieve effective disease control in selected patients with pemphigoid gestationis, potentially avoiding the need for systemic corticosteroid treatment during pregnancy. Early recognition and clinicopathological confirmation are essential for prompt management and favorable maternal and fetal outcomes.

EADV CONGRESS
VIENNA
30 SEP - 3 OCT 2026

Abstract N°: 2971

Adult-Onset Linear Discoid Lupus Erythematosus: A Rare Clinical Presentation

Luiza Soares Berenbaum*[1], FELIPE AGUINAGA[1], David Rubem Azulay[1], Julia Cazelli Passos Ricardo[1], Karime Menezes[1], Anna Maira Massad Conte[1], Fernando Belles[1]

[1] Professor Rubem David Azulay Institute of Dermatology, Rio de Janeiro, Brazil

Introduction

Linear discoid lupus erythematosus (LDLE) is an uncommon variant of chronic cutaneous lupus erythematosus, characterized by erythematous plaques distributed linearly along the lines of Blaschko. While its onset is predominantly observed in childhood, adult-onset cases are rare. This case report aims to describe an adult patient diagnosed with LDLE. A comprehensive literature review was conducted for this case, highlighting that LDLE in adults is rare and poorly documented, with a limited number of cases described to date.

Case Presentation

A 41-year-old woman with no relevant medical history, presented with a six-month history of asymptomatic, hyperpigmented plaque arranged linearly across the right frontal region. An initial biopsy had previously yielded a diagnosis of lichenoid actinic keratosis, and the patient had undergone topical treatment with 5% 5-fluorouracil cream, without clinical improvement. Upon referral to our dermatology service, the initial diagnosis was reevaluated, and a histopathological reassessment was requested. The revised analysis revealed thickening of the dermoepidermal basal membrane and vacuolar interface dermatitis with follicular involvement. Correlating these histopathological findings with the linear distribution of the lesions and the absence of systemic symptoms, a diagnosis of LDLE was established. Treatment was initiated with hydroxychloroquine (400 mg/day) and topical 0.1% tacrolimus ointment, alongside strict photoprotection measures.

Conclusion

Lupus erythematosus encompasses a broad spectrum of autoimmune disorders with diverse cutaneous and systemic manifestations. LDLE is a particularly rare cutaneous subtype, most commonly seen in pediatric patients. This case reinforces the need to consider LDLE in the differential diagnosis of linear dermatoses, even among adult patients, to facilitate accurate diagnosis and effective treatment.

EADV CONGRESS
VIENNA
30 SEP - 3 OCT 2026

Abstract N°: 2977

Chilblain Lupus with nail and cutaneous involvement – a case report

Catherine Castelo Branco*[1], Luciana Pantaleão[2], Livia Pino[1], Paula Dadalti-Granja[1]

[1] Fluminense Federal University, Antonio Pedro University Hospital, Department of Dermatology, Niterói, Rio de Janeiro, Brazil
[2] Fluminense Federal University, Antonio Pedro University Hospital, Department of Pathology, Niterói, Rio de Janeiro, Brazil

Introduction
Chilblain lupus (CL) is a rare subtype of chronic cutaneous lupus erythematosus that may occur sporadically or in familial forms. It is characterized by painful or pruritic erythematous-violaceous papules, plaques, or nodules affecting mainly acral regions, especially fingers and toes and less frequently the nose and ears [1–4]. Cold exposure is a common triggering or exacerbating factor, due to abnormal vascular response, in addition to the endothelial damage associated with autoantibodies [3]. CL may occur alone or in association with systemic lupus erythematosus (SLE), affecting up to 20% of SLE patients [4].

Case Presentation
A 46-year-old female smoker with SLE diagnosed in 2017 presented ANA 1:160 (homogeneous nucleolar pattern), associated with polyarthralgia, alopecia, photosensitive lesions, malar rash, leukopenia, and pancytopenia. In 2021, she developed painful and pruritic erythematous-violaceous papules on the palms, soles, heels, and distal digits, progressing to nail dystrophy. Lesions persisted even in warm climates.

Laboratory tests were negative for anti-Ro, anti-La, anti-Sm, and anti-dsDNA antibodies, with normal complement levels. A skin biopsy of a lesion on the right palm was performed to exclude differential diagnoses such as vasculitis and revealed hyperkeratosis, edema, extravasated erythrocytes, superficial band-like inflammatory infiltrate, rare perieccrine lymphocytes, and dermal mucin deposition demonstrated by Alcian blue staining, confirming CL, based on the clinical and histopathological findings.

The patient had been receiving hydroxychloroquine 400 mg/day since 2017. Methotrexate, used from 2021 to 2023, was discontinued because of persistent transaminase elevation. Mycophenolate mofetil 2 g/day was initiated in 2024. High-potency topical corticosteroids and clobetasol nail lacquer resulted in partial improvement only.

Conclusion
CL may present as a sporadic condition or as a familial autosomal dominant disorder associated with TREX1 mutations [5]. Patients who develop CL in association with systemic diseases such as systemic lupus erythematosus (SLE) may be more likely to experience persistence of lesions beyond the colder seasons [6], as in this case.

Diagnosis is mainly clinical, while histopathology is useful in atypical cases to exclude vasculitis and other differential diagnoses. Typical findings include perivascular lymphocytic infiltrate, interface dermatitis, and dermal mucin deposition. Direct immunofluorescence may reveal deposits of immunoglobulins and complement at the dermoepidermal junction [4].

Treatment includes protection from cold exposure, smoking cessation, topical corticosteroids or calcineurin inhibitors, and nifedipine. Evidence regarding therapeutic efficacy remains limited. Hydroxychloroquine may be less effective in CL than in SLE [7]. Mycophenolate mofetil and methotrexate may be beneficial in refractory cases [8,9].

This case highlights the chronic and relapsing course of CL despite multiple systemic therapies. In some patients, there appears to be a correlation between lupus activity and CL flares, whereas in others this association is not observed, highlighting the need for further studies to better elucidate this relationship [4].

EADV CONGRESS
VIENNA
30 SEP - 3 OCT 2026

Abstract N°: 2982

Rituximab combined with jak inhibitors in the rapid improvement of refractory bullous pemphigoid: four cases

Lin Sun*[1], Fei Wang[2]

[1] School of Medicine, Southeast University, Department of Dermatology, Zhong Da Hospital of Southeast University, Nanjing, China

[2] Department of Dermatology, Zhong Da Hospital of Southeast University, Nanjing, China

Introduction

Bullous pemphigoid (BP) is the most common autoimmune subepidermal blistering disease. In recent years, biological agents targeting BP pathogenic antibodies and the Th2 axis have gradually been applied in clinical practice. Specific binding to the CD-20 antigen to deplete B cells and reduce the production of autoantibodies, and JAK inhibitors that act on JAK kinases and STAT signaling to participate in the regulation of immune inflammation. This study analyses the clinical efficacy of rituximab(RTX) combined with JAK inhibitors in the treatment of 4 patients with refractory bullous pemphigoid.

Case Presentation

A 61y female patient presented with erythema, blisters, and itching all over the body for 2 years. She was treated with steroid 40 to 60 mg/d in combination with methotrexate. During reducing the dosage the lesions reoccurred. Due to severe adverse effect of glaucoma and RTX 200mg was started intravenously. 3 weeks after RTX, the patient did not notice any new erythema, nonetheless extreme itching persisted. At 8 weeks after RTX, JAK inhibitors 100mg qd was adjusted to 100mg bid (3d later) rapidly relieved pruritus same day, allowing steroid discontinuation. JAK inhibitors 100mg bid continued for 6 months with no adverse effects.

A 52y woman presented with pruritus and erythema for over 2 months along with blisters and erosion for past 3 days. Initial treatment with steroid 40 to 100mg/d, minocycline, and RTX 500mg twice resulted in general remission of erythema and blisters, but the pruritus continued. Nevertheless the lesions recurred when steroid was reduced to 60mg daily. Subsequently, oral jak inhibitors of 100mg qd was administered to the patient at 4 weeks after RTX. On the same day there was improvement by more than 70%. After 2 months of JAK inhibitors, steroid reduced to 12mg/d with ongoing tapering; no adverse effects at 3-month follow-up.

A 56y male patient presented with generalized erythema and pruritus for over 2 months, and blisters for 23 days. The patient was treated with 40-120 mg/d of steroids, minocycline, and RTX 500 mg twice daily. Two weeks after RTX, erythema decreased but 30 blisters/day and severe pruritus persisted, with generalized annular edematous erythema confirming refractory BP. Therefore, jak inhibitors 200 mg once daily was added to the treatment 2 weeks after RTX. Within 2 days, the pruritus improved by more than 70%, and the blisters decreased within 4 days. Follow-up for 1 month showed that the steroid was reduced to 32 mg/d, and the jak inhibitors was reduced to 100 mg once daily.

A 55y female patient presented with generalized recurrent erythema and blisters with pruritus for 3 years,

recurrence for 20 days. The patient had a 3-year history and received RTX 500 mg twice intravenously 21 months ago. The erythema and blisters subsided, but the pruritus was significant, and steroid was gradually reduced to 16 mg/day. The erythema and blisters recurred 20d ago, and the pruritus was severe. Considering history of rheumatoid arthritis and osteoporosis, methylprednisolone 40 mg once daily and upadacitinib 15 mg once nightly were administered. Within 2 days, the blisters significantly decreased, and the pruritus was significantly relieved. Follow-up for 1 month showed that the steroid was reduced to 20 mg/day, and oral upadacitinib was discontinued.

Conclusion

When RTX is combined with JAK inhibitors, it can not only target B cells and eliminate autoantibodies, but also include the mechanism of targeting type II inflammatory pathways. This makes its therapeutic effect more extensive than using RTX alone. Moreover, RTX is to reduce the dosage of steroid and alleviate adverse reactions. Since RTX has a slow onset effect and is highly dependent on hormones, while using JAK inhibitors to quickly relieve pruritus can help patients control the inflammatory response more quickly. So far, there have been no reports of combined use of the two drugs. This regimen holds significant clinical value for rapid refractory BP control.

EA DV CONGRESS
VIENNA
30 SEP - 3 OCT 2026

Abstract N°: 2992

REAL-WORLD EXPERIENCE WITH ANIFROLUMAB IN REFRACTORY DERMATOMYOSITIS: RAPID CLINICAL RESPONSE IN A THREE-PATIENT CASE SERIES

Ainhoa Roca Martiartu*[1, 1], Emilio Del Río Pena[1], Belén Argüello Marcos[1], Ignacio Serrano Aguilar[1], Javier Vilela Martín[1], Ana Pareja Martínez[1], Eva Chavarría Mur[1], Cristina Mauleón Fernández[1], María Ángeles Martín Díaz[1]

[1] Hospital Infanta Leonor, MADRID, Spain

Introduction

Dermatomyositis (DM) is a heterogeneous autoimmune disease characterized by cutaneous and systemic manifestations in which type I interferon pathway activation plays a central pathogenic role. Management of refractory DM remains challenging, particularly in patients with persistent cutaneous activity despite multiple immunosuppressive therapies. Anifrolumab, a monoclonal antibody targeting the type I interferon receptor subunit 1, has shown efficacy in interferon-driven diseases and is emerging as a potential therapeutic option in DM.

Case Presentation

We report three patients with refractory DM treated with anifrolumab in real-world clinical practice.

Case 1: A 78-year-old woman with anti-SAE-positive DM and cutaneous, muscular, and interstitial lung involvement had persistent disease despite methotrexate, mycophenolate mofetil, prednisone, and hydroxychloroquine. Anifrolumab 300 mg IV every 4 weeks was initiated in February 2025 with baseline CDASI-A 32. Rapid improvement was observed after the first infusion (CDASI-A 16 at week 4), achieving complete cutaneous remission by May 2025 (CDASI-A 0). Treatment interruption due to jejunal diverticulitis was followed by a severe cutaneous-muscular flare refractory to intravenous immunoglobulins. Reintroduction of anifrolumab in October 2025, combined with methylprednisolone pulses for pulmonary progression, resulted in marked clinical improvement (CDASI-A 3 in December 2025).

Case 2: A 54-year-old woman with anti-TIF1-positive amyopathic DM presented severe refractory cutaneous disease despite corticosteroids, methotrexate, intravenous immunoglobulins, mycophenolate mofetil, tofacitinib, and hydroxychloroquine. Anifrolumab was initiated in December 2024, leading to complete clinical remission after the third infusion. Disease control was maintained with progressive extension of infusion intervals to every 7 weeks.

Case 3: A 61-year-old man with anti-TIF1γ-positive paraneoplastic DM associated with stage IV esophageal adenocarcinoma had severe persistent cutaneous involvement (baseline CDASI 65) despite prednisone, chemotherapy, and intravenous immunoglobulins. Following initiation of anifrolumab in November 2025, rapid and substantial improvement was documented, with CDASI decreasing to 30 after 2 weeks and to 18 after 8 weeks.

Conclusion

In this real-world series, anifrolumab was associated with rapid and clinically meaningful improvement in refractory DM across distinct clinical phenotypes, including amyopathic and paraneoplastic disease. Notably, all patients experienced early cutaneous responses after failure of multiple prior therapies. Our findings support the growing evidence implicating the type I interferon pathway in DM pathogenesis and suggest that anifrolumab may represent an effective therapeutic strategy in difficult-to-treat cases. Larger prospective studies are

warranted to further define its efficacy, safety profile, and optimal positioning in the treatment algorithm for DM.

EADV CONGRESS
VIENNA
30 SEP - 3 OCT 2026

Abstract N°: 3010

Not Just Winter Chilblains : A Case of Cutaneous Lupus in a 4 year old

sanae mizab*[1], Meryem Soughi[1], salma kozman[1], Saadia Boughaleb[1], ikram bejja[1], Zakia Douhi[1], Sara Elloudi[1], Hanane Baybay[1], Fatima Zohra Mernissi[1]

[1] Department of Dermatology, University Hospital Hassan II, Faculty of Medicine, Pharmacy and Dental Medicine, Sidi Mohamed Ben Abdellah University, fes, Morocco

Introduction

Pediatric cutaneous lupus remains uncommon and diagnostically challenging due to its polymorphic presentation and overlap with vascular or inflammatory dermatoses. Chilblain lupus erythematosus (CHLE) is a rare chronic variant of cutaneous lupus characterized by acral inflammatory lesions clinically resembling perniosis. It may occur as an isolated cutaneous form or in association with systemic lupus erythematosus (SLE).

Case Presentation

A 4-year-old boy with no personal or familiar history was admitted for evaluation of painful erythematous lesions affecting the face and fingers that started at the age of 1 persistant beyond winter period and worsened 2weeks ago. Dermatological examination revealed a malar rash in which dermoscopy showed: erythematous background, hairpin and serpentine vessels, follicular keratotic plugs and pseudo-strawberry pattern on the nasal surface. Acral findings included erosive pulpitis involving fingers and toes, with lesions in different stages of healing.
Additionally, multiple erythematous-violaceous plaques were noted on the dorsal aspects of the hands and feet: involving all digits, sparing the joints, non-tender with preserved warmth. Further lesions included: bilateral erythematous scaly papules on the arms and ear lobules over a dyschromic background and erythematous palmoplantar keratoderma with fissures at the heels. Nailfold capillaroscopy revealed the presence of megacapillaries and avascular areas.
Acute and subacute cutaneous lupus erythematosus were considered in association with chilblain lupus, given the persistence of chilblain lesions outside the winter season, leading to the initiation of an immunological assessment. Antinuclear antibodies with a speckled pattern were positive, along with anti-SSA, anti-SSB, anti-Sm, and anti-Sm/RNP antibodies No systemic manifestations were identified on further evaluation.
The patient was treated with photoprotection, antimalarial therapy, and topical corticosteroids, resulting in a favorable clinical response

Conclusion

This case highlights a rare presentation of suspected pediatric lupus with chilblain-like acral involvement.
CHLE is frequently misdiagnosed due to its clinical similarity with idiopathic chilblains and other acral dermatoses . Dermoscopy may therefore play an essential role in early suspicion of lupus in pediatric patients.

EA DV CONGRESS
VIENNA
30 SEP - 3 OCT 2026

Abstract N°: 3050

Serration pattern analysis in direct immunofluorescence microscopy for pemphigoid diseases: results from the prospective multicenter study 'maximization and optimization of serration pattern analysis in routine diagnostics for pemphigoid diseases' (MAXISPA)

Nina van Beek[1], Joost Meijer*[2], Zixian Liang[2], Marije van der Molen[2], Ingeborg Atefi[3], Emiliano Antiga[4], Marzia Caproni[4], Jeffrey Damman[5], Kossara Drenovska[6], Claudia Günther[7], Matthias Goebeler[8], Michael Horn[9], Outi Lindgren[10], PARTHENA MELTZANIDOU[11], Aikaterini Patsatsi[11], Kaisa Tasanen-Maatta[10], Snejina Vassileva[6], Giovanni Di Zenzo[12], Barbara Horvath[2], Enno Schmidt[13], Gilles Diercks[14]

[1] Department of Dermatology. Allergology and Venerology, University of Luebeck, Department of Dermatology. Allergology and Venerology, University Hospital Schleswig-Holstein, Campus Luebeck, Luebeck, Germany

[2] Department of Dermatology, UMCG Center for Blistering Diseases Groningen, ERN SKIN , University Medical Center Groningen, University of Groningen, Groningen, Netherlands

[3] Department of Dermatology. Allergology and Venerology, University Hospital Schleswig-Holstein, Campus Luebeck, Luebeck, Germany

[4] Section of Dermatology, Department of Health Sciences, University of Florence, Florence, Italy

[5] Department of Pathology, Erasmus Medical Center Rotterdam, Rotterdam, Netherlands

[6] Department of Dermatology and Venereology, Medical University - Sofia, Sofia, Bulgaria

[7] Department of Dermatology, University Hospital, Eberhard Karls Universität Tübingen, Department of Dermatology, University Hospital, Technische Universität (TU) Dresden, Dresden Germany, Tübingen, Germany

[8] Department of Dermatology, Venereology and Allergology, University Hospital Würzburg, Würzburg, Germany

[9] University Institute of Clinical Chemistry and Center of Laboratory Medicine, Inselspital, Bern, Switzerland

[10] Department of Dermatology and Medical Research Center Oulu, Oulu University Hospital and University of Oulu, Oulu, Finland

[11] 2nd University Dermatology Department, Aristotle University School of Medicine, Papageorgiou General Hospital, Thessaloniki, Greece

[12] Molecular and Cell Biology Laboratory, IDI-IRCCS, Rome, Italy

[13] Department of Dermatology. Allergology and Venerology, University of Luebeck, Luebeck Institute of Experimental Dermatology (LIED), University of Luebeck, Luebeck, Germany

[14] Department of Dermatology, UMCG Center for Blistering Diseases Groningen, ERN SKIN , University Medical Center Groningen, University of Groningen, Department of Pathology and Medical Biology, University Medical Center Groningen, Groningen, Netherlands

Introduction

To distinguish the autoimmune bullous disease epidermolysis bullosa acquisita (EBA) from other pemphigoid diseases (PD), clinical presentation alone is not sufficient and circulating autoantibodies occur only in 40-60% of patients, often leading to missed diagnosis. The characteristic linear u-serration pattern observed by direct immunofluorescence microscopy (DIF) associated with reactivity to type VII collagen is pathognomonic for EBA. In this prospective multicenter study, we evaluated the diagnostic accuracy of serration pattern analysis for PD and specifically to detect EBA in 11 European dermatology centers between 2021-2026.

Materials and Methods

Centers first evaluated DIF serration patterns according to their routine diagnostic procedures and, subsequently, sent the evaluated slides as well as unstained slides to the main study centers (Groningen and Lübeck) for blinded second observation and validation. Samples were divided in 2 batches; the first containing 50 samples from routine diagnostics of all patterns, the second only samples with u-serrated or undetermined patterns. After the second observer's assessment, all discrepant samples were reevaluated in a blinded manner by both second observers for quality control.

Results

In total, 337 samples were analyzed and validated (n=293 first batch, n=44 second batch). In the first batch representing routine diagnostics, 293 samples were included showing 77.9% (n=229) of n-serrated, 3.1% (n=9) of u-serrated, and 19.0% (n=56) of undetermined patterns. Rated by second observer 220 (75.1%) n-serrated, 7 (2.4%) u-serrated and 66 (22.5%) undetermined patterns were registered reflecting previously published frequencies. Considering both, first and second batches, a total of 16 samples with u-serrated pattern, 230 samples with n-serrated pattern and 91 with undetermined pattern were identified by first observers. Identification of n-serrated and u-serrated patterns showed a high conformity (Cohens kappa 0.93) in assessment between first and second observers, irrespective of slide thickness, staining method or transport medium used in the individual study centers. Three samples with an u-serrated pattern and 45 n-serrated patterns were not confirmed by second evaluation due to weak or faded staining intensity/reduced quality of samples after sample shipments. On the other hand, 51 out of 91 undetermined patterns were reclassified as n-serrated when using the additional unstained slides.

Conclusions

In conclusion, the MAXISPA study provides validation of recognizability of n-serrated and u-serrated patterns in routine diagnostics for PD across European dermatologic laboratories. When a pattern can be identified, n-serrated and u-serrated patterns can be distinguished with high conformity between observers (Cohen kappa 0.93). Proportions of identification of linear n-serrated, u-serrated and undetermined patterns were similar across centers and literature. When no pattern can be identified, we suggest a re-evaluation on additional cuts.

EA DV CONGRESS
VIENNA
30 SEP - 3 OCT 2026

Abstract N°: 3056

Identifying Molecular and Immune Profiles of Morphea and Lichen Sclerosis (LS): Towards novel targeted therapy

Yasamin Kalantari*[1], Katharina Meier[1], Alexander Nast[1], Sonja Molin[1], Sonja Leson[1], Maria Kinberger[1], Luz Maria Cano Rochin[1], Franz Joachim Hilke[1], Kamran Ghoreschi[1]

[1] Department of Dermatology, Venerology and Allergology, Charité – Universitätsmedizin Berlin, Berlin, Germany

Introduction

Morphea (localized scleroderma) and lichen sclerosus (LS) are chronic inflammatory skin diseases with overlapping clinical and histopathological features. Emerging evidence suggests involvement of Type 1, Type 2, and Type 3 immune responses contributing to T-cell–mediated inflammation and fibrosis. Current therapies mainly include corticosteroids, immunosuppressives, and UV-A phototherapy, while targeted treatments remain limited due to incomplete understanding the mechanisms. This study aimed to characterize the immune landscape of morphea and LS by analyzing T-helper cell subsets, cytokine profiles, and related signaling pathways.

Materials and Methods

Peripheral blood mononuclear cells (PBMCs), serum, and tissue samples were collected from patients with morphea and LS. T-cell subsets within the memory $CD4^+$ T-cell ($CD3^+CD4^+CD45RA^-$) were defined according to chemokine receptor expression: Th1 ($CXCR3^+CCR6^-$), Th2 ($CCR4^+CCR6^-$), Th17 ($CCR4^+CCR6^+$), and Th17.1 ($CXCR3^+CCR6^+$). Regulatory T cells ($CD4^+CD25^+CD127$low) and follicular helper T-cells (Tfh1, Tfh2, Tfh17, Tfh17.1) were analyzed by CXCR5 co-expression. FFPE lesional skin biopsies underwent immunohistochemistry staining for CD3, CD4, CD8, pSTAT1, pSTAT2, pSTAT3, pSTAT4, pSTAT5, and pSTAT6, as well as qPCR for IL-1A, IL-1B, IL-4, IL-10, IL-12, IL-13, IL-17, IL-21, IL-22, IL-23, IL-24, IL-31, IFN-γ, TGF-β, MMP-1, ACTA2, and S100A4.

Results

A total of 57 patients (35 morphea, 16 LS, 6 morphea-LS overlap) and 27 healthy controls were analyzed. Flow cytometry demonstrated distinct T-helper cell patterns across disease phenotypes. Inflammatory morphea lesions showed higher Th1 cell frequencies compared with sclerotic lesions and healthy controls, whereas sclerotic morphea lesions demonstrated increased Th2 levels compared with inflammatory lesions and controls, reaching statistical significance versus healthy controls ($p = 0.03$). In patients with LS, Th1 and Tfh1 responses predominated over Th2 and Tfh2 populations ($p = 0.0002$ and $p = 0.0001$, respectively). A similar, though less pronounced, Th1/Tfh1 predominance was also observed in inflammatory morphea lesions ($p = 0.050$ and $p = 0.0035$, respectively). Previous systemic treatment in morphea patients was associated with lower Th1 frequencies compared with untreated patients. In contrast, Th17 and Th17.1 populations showed only minor alterations across disease groups.

qPCR analysis of lesional tissue supported the presence of a mixed inflammatory milieu and partially mirrored the immune signatures observed in peripheral blood. Morphea lesions demonstrated significantly increased expression of IL-1B ($p = 0.0389$), IL-10 ($p = 0.0117$), IL-22 ($p = 0.0101$), and MMP-1 ($p = 0.0310$) compared with healthy controls. In addition, increased expression trends were observed for IFN-γ, IL-4, IL-13, IL-17, IL-21, IL-23, and IL-31, suggesting concurrent activation of Th1-, Th2-, and Th17-associated inflammatory pathways. LS lesions

similarly demonstrated elevated expression of several inflammatory and profibrotic mediators, including IL-13, IL-17, IL-21, IL-23, TGF-β, and S100A4, although without statistical significance.

Immunohistochemistry further confirmed significant dermal T-cell infiltration in both morphea ($p = 0.0064$) and LS ($p = 0.0393$) compared with healthy controls. Increased expression of pSTAT3, pSTAT4, and pSTAT6 was additionally observed in diseased tissue, supporting activation of Th17-, Th1-, and Th2-associated signaling pathways within lesional skin.

Conclusions

Morphea and LS demonstrate complex and partially overlapping Type 1-, Type 2-, and Type 3-associated immune signatures in peripheral blood and lesional skin. Distinct Th1- and Th2-dominant patterns were associated with inflammatory and sclerotic disease phenotypes, respectively, while additional Th17-related pathways contributed to tissue inflammation. This integrated cellular and molecular characterization may help to identify disease-specific inflammatory patterns and provide a rationale for future targeted therapies.

EA DV CONGRESS
VIENNA
30 SEP - 3 OCT 2026

Abstract N°: 3096

When hyperpigmentation is not melasma — lichen planus pigmentosus in clinical practice

Aleksandra Frątczak*[1], Kamil Kania[2], Martyna Biadasiewcz[2], Beata Bergler-Czop[2], Bartosz Miziołek[1]

[1] Department of Dermatology, School of Medicine in Katowice, Medical University of Silesia, Katowice, Poland
[2] Students' Scientific Association at the Department of Dermatology, School of Medicine in Katowice, Medical University of Silesia, Katowice, Poland

Introduction

Lichen planus pigmentosus (LPP) is a rare variant of lichen planus characterized by interface dermatitis with predominant basal layer damage and dermal pigment incontinence. The etiopathogenesis remains incompletely understood; however, current evidence supports an immune-mediated mechanism resembling classical lichen planus. T-cell–mediated cytotoxicity directed against basal keratinocytes and secondary melanocyte injury lead to disruption of the dermo-epidermal junction and pigment incontinence. Melanin moved into the dermis is phagocytosed by dermal macrophages, forming melanophages responsible for persistent gray-brown hyperpigmentation. Potential triggering factors include ultraviolet radiation, contact allergens, and individual susceptibility, although their exact role remains unconfirmed. The aim of this report is to present a case of extensive LPP and highlight its clinicopathological features and therapeutic approach.

Case Presentation

We report a case of a 77-year-old male patient with a 1-year history of progressive cutaneous hyperpigmentation, initially involving the upper back and extending to the axillary regions, groin, hips, and left knee. Clinical examination, dermoscopy, and histopathological analysis of a skin biopsy were performed to confirm the diagnosis of lichen planus pigmentosus. The patient was treated with systemic acitretin (25 mg once daily), topical mometasone furoate once daily, emollients, and strict photoprotection. Regular laboratory monitoring was implemented, and follow-up was planned in 3 months.Histopathological evaluation confirmed interface dermatitis with pigment incontinence, consistent
with LPP. Following initiation of therapy, disease stabilization was observed, with no further progression of hyperpigmentation. The treatment was well tolerated, with no clinically relevant adverse effects reported during follow-up. The patient remained under clinical and laboratory surveillance.

Conclusion

LPP should be considered in the differential diagnosis of chronic, progressive hyperpigmented dermatoses, particularly in cases lacking pruritus or classical lichen planus morphology. Definitive diagnosis relies on clinicopathological correlation supported by dermoscopic and histopathological findings. LPP is a chronic disease affecting the junction between the epidermis and the dermis, in which the key issue is not the pigmentation itself, but a persistent, minimally symptomatic inflammatory process that damages the basal layer of the epidermis, leading to irreversible migration of pigment into the dermis. Treatment aims to suppress disease activity and stabilize the process, rather than to rapidly remove hyperpigmentation, which often persists despite control of the inflammation.

EA DV CONGRESS
VIENNA
30 SEP - 3 OCT 2026

Abstract N°: 3097

Therapeutic Challenges in Pemphigus Vulgaris. A Case Study of Multimorbidity and Treatment Limitations

Aleksandra Frątczak*[1], Martyna Biadasiewcz[2], Anna Mandecka[2], Wiktor Kruczek[2, 3], Bartosz Miziołek[1], Beata Bergler-Czop[1]

[1] Department of Dermatology, School of Medicine in Katowice, Medical University of Silesia, Katowice, Poland
[2] Students' Scientific Association at the Department of Dermatology, School of Medicine in Katowice, Medical University of Silesia, Katowice, Poland
[3] Doctoral School, Medical University of Silesia, Katowice, Poland

Introduction
Pemphigus vulgaris (PV) is a chronic condition that is characterised by the formation of blisters on the skin and mucous membranes. This autoimmune condition is driven by autoantibodies that target the proteins desmoglein 1 and 3. The primary therapeutic objective is to achieve clinical remission whilst minimising the adverse effects of long-term glucocorticoid (GKS) therapy. However, the presence of comorbidities and treatment-related complications frequently poses significant challenges. The objective of this study is to present the therapeutic difficulties encountered in a 69-year-old male patient with PV, highlighting how clinical complications and contraindications can severely limit standard treatment options.

Case Presentation
A retrospective analysis was conducted on a clinical case of a 69-year-old male patient with a long-standing history of pemphigus vulgaris and multiple comorbidities. A comprehensive data set was meticulously compiled from a variety of sources, including hospital records, laboratory tests (comprising hemoglobin and CRP levels), histopathological reports, and imaging studies (CT and RTG). The clinical progression of the condition was meticulously monitored through a series of dermatological examinations and the utilisation of photodocumentation, which facilitated a comparative analysis of disease activity over time. The progression of the disease was characterised by recurrent exacerbations and an inadequate
response to conventional corticosteroid-sparing medications. In an effort to mitigate the GCS dose, attempts were made to introduce adjunctive therapy. Nevertheless, these endeavours encountered impediments due to the emergence of adverse effects and contraindications. In particular, dapsone was discontinued due to the onset of anaemia (Hb ~10.4 g/dL), while azathioprine was contraindicated due to the detection of nodular and fibrotic changes in the lungs during computed tomography. Further complications, including a 10-kg weight loss and recurrent bacterial infections, necessitated extensive diagnostic testing to rule out cancer. The patient is currently undergoing evaluation to determine eligibility for biological therapy involving the administration of rituximab.

Conclusion
This case demonstrates that managing pemphigus vulgaris in patients with significant comorbidities requires a highly individualised approach. The emergence of treatment-related complications, including dapsone-induced anaemia, and the presence of pre-existing conditions such as pulmonary fibrosis, can impose significant limitations on the available therapeutic options. The findings emphasise the necessity for early consideration of alternative therapies and biological agents when conventional steroid-sparing drugs are contraindicated, underscoring the complexity of balancing

disease control with patient safety.

EADV CONGRESS
VIENNA
30 SEP - 3 OCT 2026

Abstract N°: 3110

Pemphigus foliaceus masquerading as chronic eczema: a 10-year diagnostic delay associated with spongiotic histopathology

Milena Neves Sampaio*[1], Lara Lopes[2], Alesso Sartorelli[3], Raimunda Sampaio[1]

[1] University of Brasília, University Hospital of Brasília, BRASILIA, Brazil

[2] University of Brasília, University Hospital of Brasília, Brasília, Brazil

[3] São Paulo State University, Botucatu, Brazil

Introduction

Pemphigus foliaceus (PF) classically presents with superficial blisters and erosions resulting from subcorneal acantholysis. However, atypical presentations may mimic chronic eczematous dermatoses, creating important diagnostic pitfalls. We report a case of PF with a decade-long diagnostic delay due to a persistently spongiotic clinical and histopathological phenotype preceding overt blister formation.

Case Presentation

A 25-year-old woman presented with a 10-year history of recurrent pruritic erythematous and scaly lesions primarily affecting the anterior chest. Disease onset occurred at approximately 15 years of age. Over the following decade, the condition exhibited a chronic-relapsing course with exacerbations frequently associated with emotional stress. During this period, there was no history of blistering.

Initial histopathological examination demonstrated a spongiotic dermatitis pattern characterized by acanthosis, hyperkeratosis, parakeratosis, eosinophilic infiltrate, and mild spongiosis, favoring the diagnosis of eczema. Multiple therapeutic approaches were attempted over the years. Antifungal therapies were ineffective, whereas systemic corticosteroids consistently induced rapid and complete remission within seven days, followed by early relapse after tapering or discontinuation. Topical corticosteroids provided only transient improvement.

After approximately 10 years of persistent relapsing disease, the clinical phenotype evolved with the development of serous blisters and painful erosions. Repeat biopsy revealed a subcorneal bulla containing serofibrinous material and acantholytic keratinocytes, associated with mild residual spongiosis in the adjacent epidermis. Direct immunofluorescence demonstrated weak intercellular C3 deposition (+/3+) with negative IgG. The negative IgG finding was interpreted in the context of chronic intermittent corticosteroid exposure. Based on clinicopathological correlation, a diagnosis of PF was established. Retrospectively, the prolonged eczematous phase was recognized as a pre-acantholytic or spongiotic stage of the same autoimmune blistering disease.

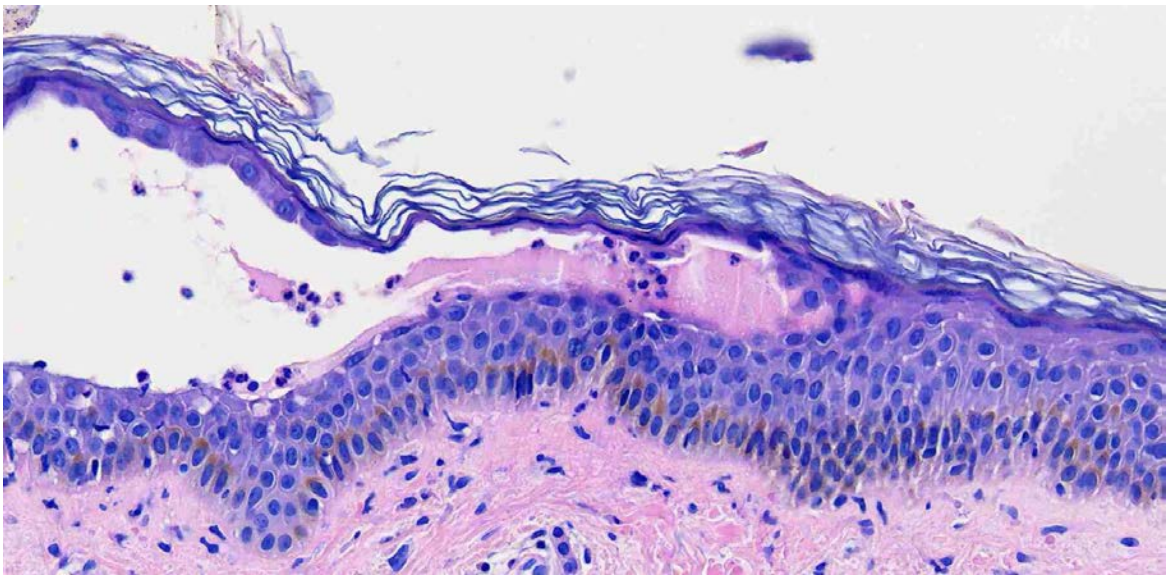

Histopathological examination of a bullous lesion demonstrating a subcorneal blister with acantholytic keratinocytes and superficial epidermal acantholysis, supporting the diagnosis of pemphigus foliaceus (H&E).

Conclusion

Pemphigus foliaceus may masquerade for years as a purely eczematous phenotype both clinically and histologically, resulting in substantial diagnostic delay. This case highlights that spongiosis, particularly when accompanied by eosinophils, does not exclude autoimmune blistering disease and may precede overt acantholysis. Chronic relapsing “eczema” demonstrating marked corticosteroid responsiveness with rapid recurrence after withdrawal should prompt consideration of PF. Early repeat biopsy and clinicopathological correlation remain essential, particularly when immunological findings are subtle or influenced by prior treatment.

EADV CONGRESS
VIENNA
30 SEP - 3 OCT 2026

Abstract N°: 3180

Association between vitiligo and diabetes mellitus: a Bayesian meta-analysis of over two million patients

Ana Paula Lima*[1], vinicius oliveira[2], Ariadne Silva[3], Maria Cecilia Tartuce[4], Luciana Vilela[2], Emiliano Arantes[5], Nanja van Geel[6], Reinhart Speeckaert[6]

[1] University of Rio Verde, Rio verde, Brazil
[2] Federal University of Goias, Goiania, Brazil
[3] Evangelical University of Goias, Anapolis, Brazil
[4] Clínica MCNS, Rio Verde, Brazil
[5] Clínica Menu, Rio verde, Brazil
[6] Department of Dermatology, Ghent University Hospital, Ghent, Belgium

Introduction
Vitiligo frequently coexists with other autoimmune conditions, including thyroid disorders, alopecia areata, and diabetes mellitus (DM). Previous meta-analyses have confirmed this association using frequentist methods, but none have applied Bayesian approaches capable of providing direct probability statements about the magnitude of the effect. Because the available studies are few and heterogeneous, a Bayesian random-effects meta-analysis is particularly suitable, as it allows assessment not only of the average association, but also of the certainty of this estimate and its expected variability across populations or future studies.

Materials and Methods
We conducted a Bayesian random-effects meta-analysis to estimate the association between vitiligo and DM, with a pre-specified subgroup analysis for type 1 DM (T1DM). PubMed, Embase, and the Cochrane Library were searched from inception through March 2026 for case-control, cohort, or cross-sectional studies reporting the prevalence of DM among vitiligo patients compared with non-vitiligo controls. Mendelian randomization studies were excluded. The primary measure of association was the odds ratio (OR). Log-transformed ORs and their standard errors were derived from reported effect estimates and 95% confidence intervals. Bayesian random-effects models were fitted using the bayesmeta R package with vague priors for both the overall effect (μ: normal, mean 0, SD 2.7) and between-study heterogeneity (τ: half-normal, scale 1.0). Posterior results are reported as medians with 95% credible intervals (CrIs). To make the findings clinically interpretable, we estimated how likely the association was to exceed several increasing effect sizes (OR > 1, 1.5, 2.0, and 3.0), and we assessed how much the estimated association might vary across different populations or future studies. Sensitivity analyses were performed to check whether the results changed when different assumptions were made about how much studies differ from each other (τ values of 0.5 and 1.5).

Results
Seven studies (2,056,190 participants: 173,363 vitiligo patients, 1,882,827 controls) were included in the all-type DM analysis. The pooled OR was 1.79 (95% CrI 1.05–3.21), with τ = 0.50 (95% CrI 0.13–1.06) and a 95% prediction interval of 0.48–7.30. The posterior probability of a positive association (OR >1) was 98.5%, of a moderate association (OR >1.5) 74.1%, of a strong association (OR >2.0) 32.3%, and of a very strong association (OR >3.0) 4.3%. Under the posterior predictive distribution, the probability that a new study would show a positive

association (OR >1) was 85.3%, and a strong association (OR >2.0) 39.9%. Sensitivity analyses varying the τ prior yielded consistent results: OR 1.76 (95% CrI 1.08–2.93) with scale = 0.5 and OR 1.80 (95% CrI 1.03–3.32) with scale = 1.5.

In the T1DM subgroup, 4 studies yielded a pooled OR of 4.52 (95% CrI 1.71–11.13), with τ = 0.68 (95% CrI 0.22–1.49) and a 95% prediction interval of 0.60–31.23. Posterior probabilities were 99.4% for OR >1, 98.1% for OR >1.5, 95.5% for OR >2.0, and 84.3% for OR >3.0. The predictive probability that a new study would show a positive association (OR >1) was 94.5%, and a strong association (OR >2.0) 84.3%. Sensitivity analyses were robust: OR 4.70 (95% CrI 2.24–9.44) with scale = 0.5 and OR 4.43 (95% CrI 1.46–12.29) with scale = 1.5.

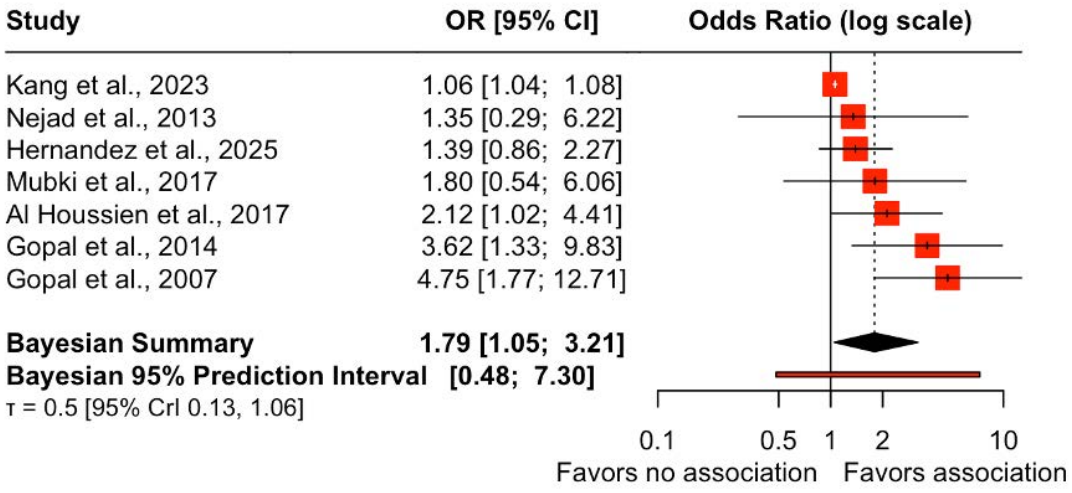

Figure 1. Bayesian random-effects forest plot for the association between vitiligo and diabetes mellitus (mixed types). The diamond represents the pooled odds ratio with 95% credible interval, and the red bar represents the 95% prediction interval. τ = between-study heterogeneity standard deviation; CrI = credible interval.

Conclusions

In this Bayesian meta-analysis of over two million participants, vitiligo was associated with DM, with a posterior probability of 98.5% for any positive association. This association was substantially stronger for T1DM, with a four-fold increase in odds and a 95.5% posterior probability that the true OR exceeds 2.0. These findings support screening vitiligo patients for DM, particularly T1DM.

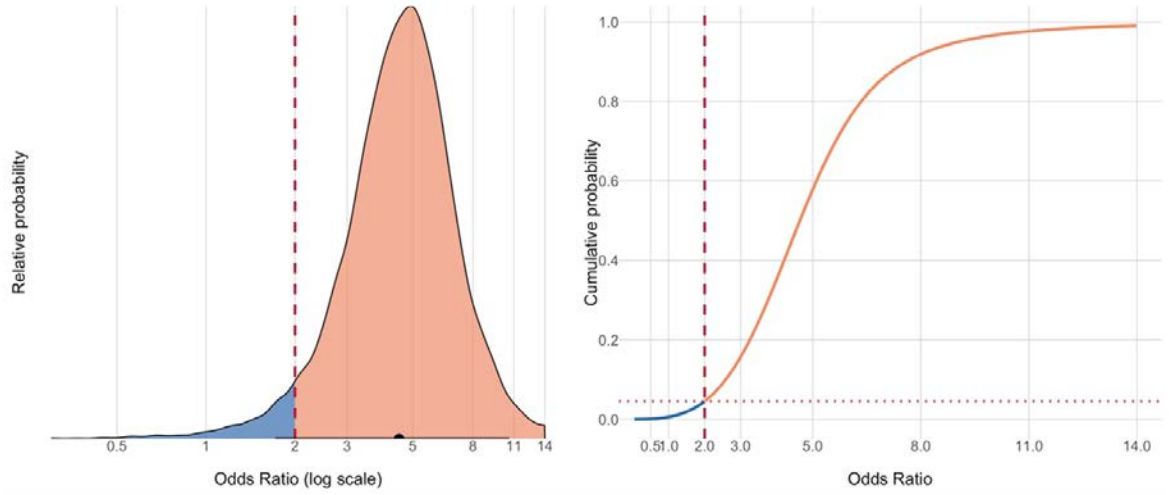

Figure 2. Left panel. Distribution of plausible odds ratios for the association between vitiligo and type 1 diabetes mellitus. The shaded areas represent the probability that the true odds ratio lies below (blue) or above (salmon) a clinically relevant threshold of OR = 2 (vertical dashed line). The salmon colored area indicates that 95.5% of the total probability lies above OR = 2, consistent with a high likelihood of a strong association. Right panel. Cumulative probability that the true odds ratio is less than or equal to a given value. The dashed vertical line marks the clinically relevant threshold of OR = 2. At this threshold, only a small proportion of the probability lies below the line, indicating a high probability that the true association exceeds OR = 2.

EA DV CONGRESS
VIENNA
30 SEP - 3 OCT 2026

Abstract N°: 3182

Impact of Bullous Pemphigoid on Patient and Caregiver Quality of Life: A Prospective Study

Chen He*[1], Ellie Choi[2, 3], May Liau[2], Nisha Suyien Chandran[2, 3]

[1] National University Hospital, Singapore, Singapore
[2] Division of Dermatology, Department of Medicine, National University Hospital, Singapore, Singapore
[3] Yong Loo Lin School of Medicine, National University of Singapore, Singapore, Singapore

Introduction

Bullous pemphigoid (BP) is a chronic, relapsing disease predominantly affecting older adults and cause painful, disfiguring blisters that impair quality of life (QoL) and burden caregivers. Despite therapeutic advances, patient QoL remains profoundly impacted and caregiver burden is underexplored. This study evaluated patient-reported QoL in BP patients and quantified caregiver burden using validated psychometric instruments.

Materials and Methods

This prospective, single-centre study recruited dermatologist-confirmed BP patients and their caregivers at the National University Hospital. Patients completed the Patient-Reported Impact of Dermatological Diseases (PRIDD), a multidimensional measure of disease impact, while caregivers completed the Family Dermatology Life Quality Index (FDLQI). Disease severity was assessed using body surface area (BSA) involvement. Clinical data were obtained from medical records, and associations with QoL outcomes were analysed using Spearman correlations.

Results

A total of 57 patient–caregiver dyads were included. Median patient age was 77 years (IQR 72–83). Overall disease activity was low, with mean BSA involvement of 1.78% (median 0%) for erythema/urticated plaques and 1.03% (median 0.50%) for blisters/erosions. Correspondingly, overall patient-reported burden was within the mild impact range, with a median PRIDD total score of 20.4 (IQR 17.5–23.2).

Correlations between clinical characteristics, PRIDD domains, and caregiver burden are summarised in a Spearman correlation heat map (Figure 1). Greater BSA involvement was significantly associated with worse patient-reported QoL (erythema: $\rho=0.323$, $p=0.014$; blisters: $\rho=0.277$, $p=0.037$), driven primarily by the physical domain (erythema BSA: $\rho = 0.361$, $p = 0.006$; blister/erosion BSA: $\rho = 0.344$, $p = 0.009$). Older age at diagnosis correlated with increased overall disease impact ($\rho = 0.329$, $p = 0.012$), particularly in social participation ($\rho = 0.294$, $p = 0.027$) and life responsibilities ($\rho = 0.366$, $p = 0.005$). Patient QoL was moderately correlated with caregiver burden ($\rho=0.425$, $p<0.001$), with the strongest association observed in the social participation domain ($\rho = 0.562$, $p < 0.001$), followed by life responsibilities domain ($\rho = 0.380$, $p = 0.004$).



	Age	Disease Duration	BP 180	BP 230	BSA erythema	BSA blisters	Total PRIDD	Physical	Psychological	Life Responsibilities	Social	FDLQI total
Age	—											
Disease Duration	-0.155	—										
BP 180	-0.107	-0.342	—									
BP 230	0.112	-0.321	0.519	—								
BSA erythema	0.168	0.04	-0.206	-0.329	—							
BSA blisters	0.121	0.06	-0.342	-0.269	0.741	—						
Total PRIDD	0.329	-0.2	-0.046	-0.137	0.323	0.277	—					
Physical	0.243	-0.094	-0.021	-0.117	0.361	0.344	0.7	—				
Psychological	0.068	-0.226	-0.071	-0.148	0.219	0.138	0.694	0.315	—			
Life Responsibilities	0.366	-0.14	0.049	-0.072	0.194	0.158	0.812	0.351	0.52	—		
Social	0.294	-0.208	0.097	-0.01	0.183	0.181	0.715	0.329	0.305	0.609	—	
FDLQI total	0.262	-0.167	-0.039	-0.017	0.236	0.238	0.425	0.203	0.286	0.38	0.562	—

Figure 1. Spearman correlation heat map of associations between clinical severity, patient-reported disease impact (PRIDD), and caregiver burden (FDLQI) in bullous pemphigoid. Greater colour intensity represents stronger correlation coefficients. BSA, body surface area involvement.

Conclusions

These findings suggest that even in clinically mild BP, measurable patient QoL impairment remains and is closely aligned with caregiver burden. Caregiver burden correlated most strongly with patient social participation and life responsibility impacts than with physical or psychological impacts. Routine assessment of QoL domains and targeted interventions addressing social participation and functional dependence may improve holistic care in BP.

EADV CONGRESS
VIENNA
30 SEP - 3 OCT 2026

Abstract N°: 3194

Progression of Cutaneous Lupus Erythematosusto Systemic Lupus Erythematosus: A Nationwide Cohort Study in Korea

Seon Young Song*[1], Jiyeong Kim[2, 3], Yu-Mi Kim[4, 5], Joo Yeon Ko[1, 6]

[1] Department of Dermatology, Hanyang University Medical Center, Seoul, Korea, Rep. of South

[2] Department of Pre-Medicine, College of Medicine, Hanyang University, Seoul, Korea, Rep. of South

[3] Biostatistics Laboratory and Medical Research Collaborating Center, Hanyang University, Seoul, Korea, Rep. of South

[4] Department of Preventive Medicine, College of Medicine, Hanyang University, Seoul, Korea, Rep. of South

[5] Graduate School of Public Health, Hanyang University, Seoul, Korea, Rep. of South

[6] Department of Dermatology, College of Medicine, Hanyang University, Seoul, Korea, Rep. of South

Introduction

Cutaneous lupus erythematosus (CLE) is an LE-specific cutaneous manifestation that can occur in isolation or with systemic lupus erythematosus (SLE). While several studies have investigated the progression of CLE to SLE, large-scale epidemiological data in Asian countries remain limited. Therefore, this study aimed to evaluate the progression of CLE to SLE in the Korean population.

Materials and Methods

Using a nationwide cohort from the Korean National Health Insurance Service-National Health Information Database from 2005 to 2020, we identified CLE patients using International Classification of Diseases (ICD)-10 code L93. For patients without SLE, diagnosis was validated through ancillary testing or specific prescriptions. Concurrent cases were defined as those receiving both CLE and SLE diagnoses within a 6-month window. Cumulative incidence estimates and time-to-event analyses were employed to evaluate the progression to SLE.

Results

Of the 32,337 patients identified with CLE, 16.6% (n = 5,367) presented with concomitant SLE. After excluding those with pre-existing or concurrent conditions, the overall progression rate to SLE was 2.0% (563/27,533). Subtype-specific analysis revealed that SCLE had the highest progression frequency (3.3%), followed by other localized LE (2.3%) and DLE (2.0%). The mean (SD) progression time from CLE to SLE was 3.2 (3.0) years. The cumulative incidence of SLE following a CLE diagnosis was 8.4% at 1 year, 11.4% at 5 years, and 13.0% at 10 years. Systemic progression risk varied significantly by clinical subtype (log-rank test, $p < .001$); notably, SCLE was associated with an approximately twofold higher risk of progression to SLE compared to DLE. Multivariable Cox models further confirmed that SCLE carried a significantly higher hazard of progression compared to DLE (adjusted hazard ratio, 1.95; 95% CI, 1.79–2.11).

Conclusions

This nationwide longitudinal study provides real-world evidence on CLE progression in an Asian population. Although the overall risk of systemic progression of CLE is relatively low, the majority of progression events occur

within the first five years of diagnosis, with SCLE conferring the highest risk. These results underscore the necessity of a risk-stratified follow-up strategy that prioritizes systemic assessment, particularly during the critical initial five-year period to optimize clinical counseling and patient management.

EA CONGRESS
VIENNA
30 SEP - 3 OCT 2026

Abstract N°: 3197

Autoantibody-mediated mechanisms in the pathogenesis of adverse pregnancy outcomes in Pemphigoid gestationis

Sophie von Fritsch*[1], Asmahan Khodr El Oueyk[2], Lewis Renshall[3], Katja Bieber[2], Michael Gembicki[4], Natalie Gross[2], Gocht Andreas[5], Artem Vorobyev[6], Evelyn Gaffal[7], Paul Brownbill[3], Ralf Ludwig[8]

[1] Department of Dermatology, University Medical Centre of the State of Schleswig-Holstein (UKSH), Campus Lübeck, Lübeck, Germany, Lübeck Institute of Experimental Dermatology, University of Lübeck, Lübeck, Germany, Lübeck, Germany

[2] Lübeck Institute of Experimental Dermatology, University of Lübeck, Lübeck, Germany, Lübeck, Germany

[3] Maternal & Fetal Health Research Centre, Division of Developmental Biology & Medicine, School of Medical Sciences, Faculty of Biology, Medicine and Health, University of Manchester, Manchester, United Kingdom, St Mary's Hospital, Manchester University Hospital NHS Foundation Trust, Manchester Academic Health Science Centre, Manchester, United Kingdom, Manchester, United Kingdom

[4] Department of Gynaecology and Obstetrics, University Medical Centre of the State of Schleswig-Holstein (UKSH), Campus Lübeck, Lübeck, Germany, Lübeck, Germany

[5] Institute of Pathology, University Medical Centre of the State of Schleswig-Holstein (UKSH), Campus Lübeck, Lübeck, Germany, Lübeck, Germany

[6] Department of Dermatology and Allergology, University Hospital Gießen and Marburg GmbH, Marburg, Germany, Marburg, Germany

[7] Department of Dermatology, University Medical Centre of the State of Schleswig-Holstein (UKSH), Campus Lübeck, Lübeck, Germany, Lübeck, Germany

[8] Lübeck Institute of Experimental Dermatology, University of Lübeck, Lübeck, Germany, Department of Dermatology, University Medical Centre of the State of Schleswig-Holstein (UKSH), Campus Lübeck, Lübeck, Germany, Lübeck, Germany

Introduction

Pemphigoid gestationis (PG) is a rare autoimmune blistering disease of pregnancy or the postpartum period and is clinically characterized by severe pruritus and vesiculobullous lesions. The condition is associated with an increased risk of adverse pregnancy outcomes (APOs), although the underlying pathogenic mechanisms remain incompletely understood. Central to disease pathogenesis is a loss of immunological tolerance to the hemidesmosomal protein BP180 (collagen XVII), with autoantibodies predominantly directed against the NC16A domain. Importantly, BP180 is expressed not only in the skin but also in placental tissues, including amniotic epithelial cells and cytotrophoblasts within chorionic villi, and patient-derived autoantibodies have been shown to bind to these structures.

Materials and Methods

Histopathological and immunofluorescence examination of placentae from PG patients and cryosection-based assays were performed. To further investigate potential pathogenic mechanisms, an ex vivo placental explant model was established.

Results

Histopathological examination of placental tissue from PG patients revealed morphological alterations including inflammation, hypoplasia and split formation. In placental explant cultures, exposure to anti-BP180 IgG was associated with altered inflammatory responses, including a trend toward increased interleukin-8 (IL-8) secretion. In addition, cryosection-based assays demonstrated split formation at the basement membrane zone of chorionic villi following incubation with anti-BP180 NC16A antibodies compared with control conditions, supporting a direct pathogenic effect on placental basement membranes. Future studies will extend these observations by employing cultures of amniotic epithelial cells and cytotrophoblasts to evaluate the effects of anti-BP180 NC16A autoantibodies on inflammatory mediator release and gene expression profiles.

Conclusions

Collectively, these findings provide further insight into the contribution of anti-BP180 NC16A autoantibodies to placental injury and their potential role in mediating APOs in PG. A more comprehensive understanding of these mechanisms is essential for improving maternal and fetal outcomes and may have broader implications for other autoantibody-mediated pregnancy disorders.

EA DV CONGRESS
VIENNA
30 SEP - 3 OCT 2026

Abstract N°: 3212

Severe radiotherapy-induced bullous pemphigoid with response to two doses of anti-CD20 therapy

Harold Farit Arenas Torrado*[1], Miguel Angel Nieto Bayona[1], Hector Perez[1], Juan Orjuela Morales[2]

[1] Universidad Nacional de Colombia, Bogotá, Colombia
[2] Universidad del Rosario, Bogotá, Colombia

Introduction

Bullous pemphigoid (BP) is an immune-mediated subepidermal vesiculobullous disease characterized by tense blisters on erythematous skin. Its prevalence has been reported from 1.46 to 47.9 cases per 100,000 persons, with a global incidence of 0.82 cases per 100,000 person-years.

Case Presentation

We present the case of a 51-year-old woman with a history of right plantar melanoma, stage IIIC, surgically treated in 2011, which subsequently relapsed locoregionally with a lymph node conglomerate in the right thigh involved by melanoma. Given that this was not surgically resectable, she required adjuvant radiotherapy, completed in March 2023, as well as immunotherapy with pembrolizumab, for a total of 15 completed cycles.
In December 2024, the patient presented with a two-week history of tense blisters beginning on the right lower limb and subsequently spreading to the rest of the body. A diagnosis of severe BP was established with a Bullous Pemphigoid Disease Area Index (BPDAI) score of 75 points and involvement of approximately 80% of the total body surface area, initially attributed to anti-PD-1 therapy. She required intensive care unit admission with corticosteroid pulses and azathioprine; however, she developed superinfection, bacteremia, and subsequent septic shock requiring antibiotic treatment. Given the lack of response to initial management, five cycles of plasmapheresis were performed with partial and transient response. She was ultimately considered a candidate for anti-CD20 therapy (rituximab) once the infectious process was controlled, receiving 1g on day 0 and a second dose on day 14, with satisfactory response. She was discharged on azathioprine and returned for follow-up three months later with near-complete clinical remission; however, new lesions persisted limited to the previously irradiated area, raising suspicion of radiotherapy-induced BP. A biopsy was performed, revealing a subepidermal blister over a dermis with radiation-induced changes, confirming the diagnosis. Given the adequate response, the third dose of rituximab — indicated at six months — was deferred, and one year later the patient presents only occasional lesions localized to the irradiated site, managed with topical corticosteroids. Due to the severity of the initial presentation, the immune checkpoint inhibitor was not restarted.

The main pathophysiological mechanism of BP is the formation of autoantibodies (predominantly IgG and IgE) against the basement membrane zone antigens BP180 and BP230, triggering complement activation and internalization of BP180, resulting in dermoepidermal separation. Several BP triggers have been described, including neurological conditions such as stroke, Parkinson's disease, and multiple sclerosis; medications such as dipeptidyl peptidase IV inhibitors (particularly vildagliptin and linagliptin), immune checkpoint inhibitors (anti-PD1, anti-PDL1, and anti-CTLA4), and loop diuretics, among others. Radiotherapy is a recognized triggering factor, although infrequent; the proposed mechanism is that ionizing radiation induces keratinocyte apoptosis with subsequent exposure of BP180/BP230 antigens, facilitating their recognition by the immune system and antibody formation. Most reported cases have been observed in breast cancer patients.

Conclusion

Our case represents a severe case of radiotherapy-induced BP, in which prior exposure to anti-PD1 is believed to have exacerbated the clinical presentation. Several cases of radiotherapy-induced BP treated with conventional therapy have been reported; however, to our knowledge, this is the first patient with severe radiotherapy-induced BP to show a satisfactory outcome following rituximab treatment, which is considered a therapeutic option in severe BP induced by immune checkpoint inhibitors by the National Comprehensive Cancer Network.

EA DV CONGRESS
VIENNA
30 SEP - 3 OCT 2026

Abstract N°: 3249

Mitochondria derived from human umbilical cord mesenchymal stem cells rescue vitiligo melancytes senescence by enhancing mitochondria function

Zhe Jian*[1], Zeqian Wang[1]

[1] Department of Dermatology, Xijing Hospital, Fourth Military Medical University, Xi'an, China

Introduction

Vitiligo is a depigmentary disorder caused by progressive melanocyte loss, involving oxidative stress, immune dysfunction, and melanocyte defects. Melanocyte senescence is a key pathological driver: sustained oxidative stress induces irreversible senescence leading to depigmentation, making it a promising therapeutic target. Mitochondrial dysfunction is an early hallmark of senescent melanocytes. Mesenchymal stem cell-derived mitochondrial transplantation is a novel organelle-targeted therapy, but whether human umbilical cord mesenchymal stem cell-derived mitochondria (hUMSC-Mito) can rescue senescent melanocytes in vitiligo remains unclear. The GABA-glutamate axis maintains mitochondrial homeostasis and regulates cellular senescence, yet its role in hUMSC-Mito-mediated protection is unknown. We established oxidative stress-induced melanocyte senescence and vitiligo mouse models to explore the therapeutic effect and mechanism of hUMSC-Mito.

Materials and Methods

hUMSC-Mito was extracted from hUMSCs by differential centrifugation and characterized by TEM, particle size analysis, Western blot, and JC-1 staining. A vitiligo mouse model was established by B16F10 injection combined with Treg depletion. Mice were randomly assigned to model, hUMSC, hUMSC-Mito, GABA, and GAD inhibitor groups, with tail vein administration. Tail depigmentation was monitored, and skin, blood, and spleen were collected. *In vitro*, H_2O_2-induced senescent PIG1 cells were treated with hUMSC-Mito, GABA, or DL-Allylglycine. Senescence was evaluated by SA-β-gal staining, ROS detection, γ-H2AX, Western blot, and qRT-PCR. Mitochondrial transfer was observed via co-culture and isolated mitochondria systems using fluorescent labeling, confocal imaging, and SEM. Untargeted metabolomics identified differential metabolites. ELISA and HPLC measured GABA, glutamate, and GAD activity. Serum from vitiligo patients and healthy controls was analyzed by HPLC. ROC and Spearman correlation assessed diagnostic value. GAD expression in lesional skin was detected by immunofluorescence.

Results

First, clinical and transcriptomic analyses confirmed melanocyte senescence as a core pathological feature of vitiligo. Senescence genes and SASP factors were upregulated in lesional skin, and p16 expression increased in perilesional areas. Next, in vitiligo mice, hUMSC-Mito treatment effectively reversed depigmentation, suppressed $CD8^+$ T cell infiltration, and rebalanced the Treg/$CD8^+$ ratio, achieving lesion repair through dual regulation of cellular senescence and immune homeostasis. In vitro, hUMSC-Mito entered damaged melanocytes via tunneling nanotubes or direct internalization. It reduced SA-β-gal positivity, ROS burst, and DNA damage, while downregulating p53/p21/p16 and SASP. The treatment also restored mitochondrial ATP production and membrane potential, thereby reversing mitochondrial dysfunction. Mechanistically, untargeted metabolomics identified the GABA-glutamate pathway as a key target of hUMSC-Mito, with GABA showing the most significant upregulation and enhanced GAD activity. Critically, GAD inhibition abolished hUMSC-Mito's anti-senescence

effects, while exogenous GABA recapitulated them. Clinical validation showed serum GABA was decreased in vitiligo patients, negatively correlated with disease severity, and GAD was downregulated in lesional skin, confirming GABA synthesis deficiency as an intrinsic vitiligo feature and the GABA axis as a potential diagnostic biomarker and therapeutic target.

Conclusions

hUMSC-Mito rescues senescent melanocytes in vitiligo by entering cells through tunneling nanotubes and endocytosis. Mechanistically, its therapeutic effect is mediated by activating the GABA-glutamate axis via upregulating GAD-dependent GABA synthesis. This activation repairs mitochondrial dysfunction and inhibits melanocyte senescence. This study identifies a novel mitochondria-GABA regulatory axis, providing a targeted therapeutic strategy for vitiligo.

EADV CONGRESS
VIENNA
30 SEP - 3 OCT 2026

Abstract N°: 3257

Atypical Localized Papular Eruption as a Cutaneous Manifestation of Adult-onset Still's Disease During Canakinumab Therapy: a Case Report

Merve Markal Bay*[1], Fadime Kilinc[1]

[1] Department of Dermatology and Venereology, Ankara Bilkent City Hospital, Ankara, Türkiye

Introduction

Adult-onset Still's disease (AOSD) is a systemic autoinflammatory disorder classically characterized by quotidian fever, arthritis, systemic inflammation and an evanescent, salmon-pink, non-pruritic eruption. Atypical persistent cutaneous lesions may occur and can be diagnostically challenging, particularly in patients receiving biologic therapy.

Case Presentation

A 31-year-old woman with a 7-year history of AOSD, controlled for the last 5 years with canakinumab, presented with a 2-month history of intermittently appearing erythematous papular lesions on the right inframammary area. During the last 15 days, similar erythematous papules developed over the right clavicular region extending toward the neck. The lesions were non-pruritic. Her previous AOSD-related eruption at diagnosis had consisted of transient, non-pruritic, salmon-pink eruptions on the extremities accompanying intermittent fever, which had resolved after systemic treatment. At the current presentation, fever and arthritis were absent; however, she reported a recent urinary tract infection preceding the eruption. Antinuclear antibody and extractable nuclear antigen panel were negative.

Considering atypical AOSD-related cutaneous involvement, atypical unilateral pigmented purpuric dermatosis and purpuric contact dermatitis, a skin biopsy was performed. Medium/high-potency topical corticosteroid and barrier cream were initiated, without significant clinical benefit. Histopathology revealed single and grouped dyskeratotic keratinocytes extending up to the cornified layer, with a perivascular lymphohistiocytic inflammatory infiltrate in the dermis accompanied by scattered polymorphonuclear leukocytes. These findings were interpreted as compatible with cutaneous involvement of AOSD. During follow-up, the patient developed an arthritis flare. After multidisciplinary evaluation with rheumatology, systemic corticosteroid therapy was initiated.

Conclusion

This case highlights that AOSD may present with atypical localized papular eruptions even in patients with long-standing disease controlled with IL-1β inhibition. Infectious triggers may precede cutaneous and systemic reactivation. In patients with a history of AOSD, persistent or atypically localized papular lesions should prompt consideration of disease activity, and histopathologic assessment may provide important diagnostic support.

EADV CONGRESS
VIENNA
30 SEP - 3 OCT 2026

Abstract N°: 3270

Systemic sclerosis and cutaneous lupus erythematosus overlap

Ofeliya Kercheva*[1], Mina Saleva-Stateva[1], Miroslava Mihova[1], Elena Petrova[1], Valeria Mateeva[1], Lyubomir Dourmishev[1]

[1] University Hospital "Alexandrovska", Medical University - Sofia, Sofia, Bulgaria, Sofia, Bulgaria

Introduction
Systemic sclerosis (SSc) and cutaneous lupus erythematosus (CLE) are chronic autoimmune connective tissue diseases with distinct clinical and histopathological profiles. Although they may share overlapping features, their coexistence as an overlap syndrome is rare and poses significant diagnostic and therapeutic challenges.
The objective of this report is to present an uncommon case of systemic sclerosis-cutaneous lupus erythematosus overlap in a patient with severe vasculopathic complications despite biologic therapy and to underscore the importance of thorough clinicopathological correlation and multidisciplinary management.

Case Presentation
We report a 49-year-old woman with a long history of progressive systemic sclerosis, complicated by severe digital vasculopathy and multiple amputations of the fingers of the upper extremities. The patient was under long-term treatment and follow-up including biologic therapy with Tocilizumab for systemic sclerosis. She was admitted to our department for diagnostic clarification of newly observed inflammatory skin lesions.
Dermatological examination revealed, erythematous macules and papules confluent into plaques involving the periocular and perioral regions as well as the nasolabial folds of face. On the trunk and upper extremities, erythematous-livid, lichenified macules and papules were observed. The hands showed advanced sclerodactyly, digital contractures, and post-amputation stumps of several fingers, reflecting severe longstanding vasculopathy on the background of systemic sclerosis.
Laboratory investigations demonstrated positive antinuclear antibodies (ANA 1:160) and strongly positive anti-SSA antibodies. Histopathological examination revealed features consistent with lupus erythematosus. Topical treatment with calcineurin inhibitors and corticosteroids, together with strict photoprotection, resulted in clinical improvement of the skin lesions.

Conclusion
Our case confirms the rarity and diagnostic challenge of systemic sclerosis-cutaneous lupus erythematosus overlap, particularly in a patient with long-standing, biologic-treated SSc and severe vasculopathic damage. The coexistence of these disorders underscores the need for thorough clinicopathological correlation to achieve an accurate diagnosis and to guide appropriate, multidisciplinary management.

EA DV CONGRESS
VIENNA
30 SEP - 3 OCT 2026

Abstract N°: 3313

Optimising Management in Cutaneous Lupus Erythematosus: Current Evidence, Emerging Therapeutic Targets, and Proposal of a Randomised Controlled Trial

Sahar Shams*[1]

[1] Cardiff University, Cardiff, United Kingdom

Introduction

Background:

Cutaneous lupus erythematosus (CLE) comprises a heterogeneous group of autoimmune dermatoses characterised by variable clinical phenotypes, serological profiles, and therapeutic responses. Despite advances in systemic and targeted therapies, no universally accepted international guideline currently exists for CLE diagnosis and management, and many therapies remain off-label. Existing recommendations, including the S2K, British Association of Dermatologists (BAD), and EULAR guidelines, differ in therapeutic sequencing and monitoring strategies, contributing to variability in clinical practice across Europe. High-quality comparative evidence guiding optimal management, particularly in refractory CLE, remains limited.

Objectives:

To evaluate current and emerging therapeutic strategies for CLE through a systematic literature review, compare major international management guidelines, and propose a pragmatic randomised controlled trial (RCT) framework addressing current therapeutic uncertainties.

Materials and Methods

A systematic literature review was conducted using PubMed, MEDLINE, EMBASE, and the Cochrane Library, supplemented by manual bibliography searches without date restrictions. Eligible studies included adult populations reporting clinical, histopathological, serological, or treatment outcome data across CLE subtypes. Study designs included randomised controlled trials, cohort studies, case-control studies, and systematic reviews.

The S2K, BAD, and EULAR guidelines were systematically compared. Summary tables were created by extracting and categorising recommendations relating to first-line, second-line, and refractory disease therapies, systemic treatment escalation, monitoring strategies, and supportive interventions. Comparative analysis identified areas of consensus, variation, and gaps in standardisation. Data extraction used a standardised template capturing study design, subtype classification, interventions, and outcomes.

Results

CLE management remains largely subtype- and severity-dependent, with substantial reliance on expert consensus due to limited comparative trial data. Photoprotection and smoking cessation are universally recommended baseline interventions. Topical corticosteroids and calcineurin inhibitors remain first-line therapies for localised disease. Hydroxychloroquine remains the cornerstone systemic therapy; however, variable response rates and partial refractoriness are frequently reported. Refractory disease often requires escalation to systemic immunosuppressive agents including methotrexate, mycophenolate mofetil, and azathioprine. Emerging biologic therapies targeting type I interferon pathways and B-cell activity demonstrate promising early efficacy, although

long-term comparative data remain limited.

Comparative analysis demonstrated broad agreement between guidelines regarding foundational management, but notable differences in escalation pathways, monitoring recommendations, and positioning of second-line agents. To address current therapeutic uncertainties, a multicentre pragmatic parallel-group RCT framework is proposed comparing hydroxychloroquine with methotrexate in CLE without systemic involvement refractory to topical therapy. The primary endpoint would assess treatment response using improvement in CLASI score.

Conclusions

Current CLE management follows a predominantly stepwise and empiric approach combining conventional and emerging therapies according to disease subtype and severity. However, the evidence base remains limited by heterogeneous study designs, inconsistent outcome measures, and a lack of high-quality head-to-head comparative trials. Standardised multicentre RCTs are required to optimise evidence-based management strategies and support development of unified international CLE management guidelines.

EA DV CONGRESS
VIENNA
30 SEP - 3 OCT 2026

Abstract N°: 3332

Cutaneous Lupus Erythematosus Management Across Europe: Comparative Guideline Analysis and Proposal of a Pragmatic Randomised Controlled Trial

Sahar Shams*[1]

[1] Cardiff University, Cardiff, United Kingdom

Introduction

Background

Cutaneous lupus erythematosus (CLE) comprises a heterogeneous group of autoimmune dermatoses characterised by variable clinical phenotypes, serological profiles, and therapeutic responses. Despite advances in systemic and targeted therapies, no universally accepted international guideline currently exists for CLE diagnosis and management, and many therapies remain off-label. Existing recommendations, including the S2K, British Association of Dermatologists (BAD), and EULAR guidelines, differ in therapeutic sequencing and monitoring strategies, contributing to variability in clinical practice across Europe. High-quality comparative evidence guiding optimal management, particularly in refractory CLE, remains limited.

Objectives

To evaluate current and emerging therapeutic strategies for CLE through a systematic literature review, compare major international management guidelines, and propose a pragmatic randomised controlled trial (RCT) framework addressing current therapeutic uncertainties.

Materials and Methods

A systematic literature review was conducted using PubMed, MEDLINE, EMBASE, and the Cochrane Library, supplemented by manual bibliography searches without date restrictions. Eligible studies included adult populations reporting clinical, histopathological, serological, or treatment outcome data across CLE subtypes. Study designs included randomised controlled trials, cohort studies, case-control studies, and systematic reviews.

The S2K, BAD, and EULAR guidelines were systematically compared. Summary tables were created by extracting and categorising recommendations relating to first-line, second-line, and refractory disease therapies, systemic treatment escalation, monitoring strategies, and supportive interventions. Comparative analysis identified areas of consensus, variation, and gaps in standardisation. Data extraction used a standardised template capturing study design, subtype classification, interventions, and outcomes.

Results

CLE management remains largely subtype- and severity-dependent, with substantial reliance on expert consensus due to limited comparative trial data. Photoprotection and smoking cessation are universally recommended baseline interventions. Topical corticosteroids and calcineurin inhibitors remain first-line therapies for localised disease. Hydroxychloroquine remains the cornerstone systemic therapy; however, variable response rates and partial refractoriness are frequently reported. Refractory disease often requires escalation to systemic immunosuppressive agents including methotrexate, mycophenolate mofetil, and azathioprine. Emerging biologic

therapies targeting type I interferon pathways and B-cell activity demonstrate promising early efficacy, although long-term comparative data remain limited.

Comparative analysis identified important inconsistencies in therapeutic sequencing, monitoring recommendations, and positioning of second-line agents across major international guidelines, highlighting the need for harmonised evidence-based management strategies. To address current therapeutic uncertainties, a multicentre pragmatic parallel-group RCT framework is proposed comparing hydroxychloroquine with methotrexate in CLE without systemic involvement refractory to topical therapy. The primary endpoint would assess treatment response using improvement in CLASI score.

Conclusions

Current CLE management follows a predominantly stepwise and empiric approach combining conventional and emerging therapies according to disease subtype and severity. However, the evidence base remains limited by heterogeneous study designs, inconsistent outcome measures, and a lack of high-quality head-to-head comparative trials. These findings support urgent development of standardised multicentre RCTs to inform unified international CLE management guidelines.

EADV CONGRESS
VIENNA
30 SEP - 3 OCT 2026

Abstract N°: 3344

Atypical Pediatric Dermatitis Herpetiformis Mimicking Scabies: The Diagnostic Value of Digital Pulp Petechiae

Maria Eugênia Dumont Adams Prudente Corrêa*[1], Fernanda Birraque Saleme[1], Luisa Homem de Mello Maciel Campilongo[1], Thais Uemura[1], João Alberti[1], Carlos D Apparecida Santos Machado Filho[1]

[1] Faculdade de Medicina do ABC, Santo André, Brazil

Introduction

Dermatitis Herpetiformis (DH) is the specific cutaneous manifestation of Celiac Disease, characterized by intensely pruritic polymorphic eruptions, classically involving extensor surfaces. Histopathological findings include subepidermal vesicles with neutrophilic microabscesses in the dermal papillae, while direct immunofluorescence reveals granular IgA deposition along the basement membrane zone. Acral petechiae, particularly involving the palms, soles, and digital pulps, have been described as an uncommon but distinctive manifestation in pediatric cases and may represent an important diagnostic clue.

Case Presentation

A 9-year-old girl presented with an eight-month history of intensely pruritic erythematous urticarial plaques involving the face, trunk, and extremities, associated with excoriations. Due to a history of poor hygiene and inadequate sanitation conditions, an initial diagnosis of scabies was considered, and the patient underwent multiple topical and systemic treatments without improvement.

Ongoing symptoms and the subsequent appearance of vesicles and petechiae involving the digital pulps prompted reconsideration of the diagnosis. Skin biopsy and serologic testing were performed. Anti-endomysial and anti-tissue transglutaminase antibodies were positive. Direct immunofluorescence demonstrated granular IgA and C3 deposition along the basement membrane zone, confirming DH.

Treatment with dapsone and a gluten-free diet was initiated, leading to rapid symptom control and progressive resolution of skin lesions.

Pediatric DH may present with atypical clinical features, contributing to diagnostic delay, especially in settings where infectious dermatoses are initially suspected. Digital pulp petechiae are a subtle but characteristic finding that may be overlooked, particularly when classic papulovesicular lesions are absent or sparse. Recognition of this sign can support earlier investigation for DH and associated celiac disease, avoiding prolonged morbidity and unnecessary treatments.

Conclusion

This case highlights digital pulp petechiae as a valuable clinical clue in pediatric DH and reinforces the importance of including DH in the differential diagnosis of chronic pruritic eruptions unresponsive to conventional therapies. Early recognition of atypical signs, combined with clinicopathological correlation, is essential for timely diagnosis and appropriate management.

POWERED BY M-ANAGE.COM

EADV CONGRESS
VIENNA
30 SEP - 3 OCT 2026

Abstract N°: 3358

Pemphigus erythematosus: a case report

Ane Lobato-Izagirre*[1], Jurvist Rodríguez Blandon[1], Iker Narvaez Gonzalo[1], Leopoldo Domper Fernández[1], Gonzalo Irigoyen Miró[1], Rosa Mª Izu Belloso[1]

[1] Basurto University Hospital, Bilbao, Spain

Introduction

Pemphigus erythematosus or Senear-Usher syndrome, is a rare autoimmune bullous skin disorder with clinical, histopathological and immunological features overlapping those of pemphigus foliaceus and cutaneous lupus erythematosus. Clinically, it is characterized by erythematous scaly plaques with crusting localized to photoexposed and seborrheic areas, while mucosal involvement is uncommon.

Case Presentation

A 45-year-old woman presented to the dermatology department with erythematous scaly plaques on the forehead and cheeks, together with hyperkeratotic plaques and crusts on the scalp. Nikolsky sign was positive. Histopathological examination revealed subcorneal acantholysis, while direct immunofluorescence demonstrated intercellular deposits of IgG and C3. Serological testing showed negative antinuclear antibodies (ANA), positive anti-desmoglein 1 antibodies, and negative anti-desmoglein 3 antibodies. Based on the clinical, histopathological, and immunological findings, a diagnosis of pemphigus erythematosus was established. Treatment with systemic corticosteroids and methotrexate resulted in significant clinical improvement.

Conclusion

Pemphigus erythematosus represents an overlap entity between pemphigus foliaceus and cutaneous lupus erythematosus. Diagnosis may be challenging and should be considered in persistent photoexposed facial dermatoses. Histopathological and immunological evaluation are essential for accurate diagnosis and appropriate management.

EA DV CONGRESS
VIENNA
30 SEP - 3 OCT 2026

Abstract N°: 3361

Juvenile dermatomyositis in American skin of color patients: a cohort study

Michelle Colbert*[1], Nessa Aghazadeh Mohandesi[1], Sindhuja Sominidi Damodaran[1]

[1] Mayo Clinic, Rochester, United States

Introduction

Juvenile dermatomyositis (JDM), defined by symptom onset prior to 18 years old, is a rare autoimmune myositis with characteristic cutaneous and systemic manifestations. JDM is highly associated with cutaneous calcinosis and is less associated with malignancy compared to adult DM. There are few JDM cohort studies focused on skin of color (SOC), but an association between Black race and poor outcomes, including calcinosis, has been observed in several of these studies. Outcomes for non-Black SOC patients are not as well studied. This descriptive retrospective cohort study adds to the literature by describing the outcomes of a cohort of 7 SOC patients with JDM

Materials and Methods

Patients evaluated between 1/2000 to 8/2025 were identified using an institutional data exploration and retrieval tool. Text-based criteria for the search were 'juvenile dermatomyositis' and 'non-White race'. SOC was defined as Black, East Asian, South/Southeast Asian, nonwhite Hispanic/Latino, Native American, Pacific Islander, or 2+ races. Data was obtained via retrospective chart review. An online calculator was used to classify patients according to EULAR/ACR criteria based on their initial workup. Due to the consultative nature of most cases, the number of follow-up years was not recorded.

Patient	Race	Gender	Age at diagnosis	Antibody Profile	Cutaneous manifestations	Systemic manifestations	Other clinical information	Treatments trialed	EULAR/ACR Score
1	B	F	4	ANA, CCP, MDA-5, RF	None	Arthritis, myopathy	Overlap syndrome-rheumatoid arthritis	MTX, prednisone	9.8
2	B	M	5	Negative	Calcinosis leading to neuropathy, Gottron papules, Gottron's sign, ragged cuticles	Myopathy	In remission at time of study	IVIG, MTX, prednisone	12.8
3	B	F	11	MDA-5, SSA	Calcinosis leading to contractures and amputations, cutaneous ulcerations, Gottron papules, nailfold capillary ectasias	Arthritis, dysphagia, interstitial lung disease, myopathy	Overlap syndrome-antiphospholipid syndrome, rheumatoid arthritis	Abatacept, hydroxychloroquine, IVIG, MTX, mycophenolate, prednisone, rituximab, tofacitinib	10.2
4	B	F	16	Ku, RNP, Smith	Gottron papules, heliotrope rash, nailfold capillary ectasias	Dysphagia, myopathy	No symptoms of systemic sclerosis given anti-Ku Abs	Azathioprine, IVIG, MTX, prednisone	8.2
5	2+	F	8	ANA, NXP-2	Calcinosis leading to contractures, Gottron papules, heliotrope rash	Arthritis, dysphagia	Flare after streptococcal pharyngitis, flare after COVID-19 infection	Colchicine, cyclophosphamide, etanercept, hydroxychloroquine, IVIG, MTX, mycophenolate, prednisone, rituximab, tofacitinib	6.8
6	SA	F	12	N/A	N/A	Myopathy	Overlap syndrome-autoimmune neutropenia. JDM in remission at time of study.	Topical corticosteroids	3.1
7	SEA	F	5	Negative	Gottron papules, heliotrope rash	Restrictive cardiomyopathy	Deceased due to complications of cardiac transplant	None	3.1

Table 1. Patient demographics, autoantibody profiles, cutaneous/systemic manifestations, treatments trialed, and EULAR scoring. B= Black, SA = South Asian, SEA = Southeast Asian, 2+ = two or more

races.

Results

Our search yielded a total of 7 patients (Table 1). The median age of onset was 8.7 years old (range: 4-16). The majority of patients were female (7 of 8, 86%). Four (57%) patients were Black, 2 (29%) were South or Southeast Asian, and 1 (14%) identified as 2+ races. One patient was deceased at the time of the study due to complications of a heart transplant in the setting of restrictive cardiomyopathy.

Antibody profiles were tested for 6 of 7 patients. Two (33%) patients had negative autoantibody testing, including the patient with restrictive cardiomyopathy. Of these, one was diagnosed via muscle biopsy and the other was diagnosed clinically with supportive skin biopsy findings. The DM-specific antibodies identified in this study were NXP-2, MDA-5, and Ku, and will be categorized as such moving forward. Nonspecific autoantibodies observed in this study were will be defined as ANA, CCP, Ku, RF, RNP, Smith, and SS-A. Of the DM-specific autoantibodies, MDA-5 and ANA were each observed twice (frequency = 18% each) and were the most common autoantibodies represented in the cohort. CCP, Ku, NXP-2, RF, RNP, Smith, and SS-A were each observed once (frequency = 9% each).

Three of 7 patients (43%) had calcinosis and all developed calcinosis-associated complications including contractures, ulceration, or neuropathy. One patient with extensive calcinosis cutis did have NXP-2 autoantibodies. Gottron sign/Gottron papules and myopathy were observed in 5 (71%) of patients each. Heliotrope rash and ragged cuticles/nailfold capillary ectasias were each observed in 3 patients (43%). One (17%) patient had interstitial lung disease and 3 (43%) had dysphagia. Two (29%) patients were amyopathic.

Three of 7 patients (43%) had an overlap syndrome with either antiphospholipid syndrome, rheumatoid arthritis, or autoimmune neutropenia. Five of 7 patients (41%) received systemic therapy at some point in their treatment course. The average number of immunosuppressive treatments trialed was 5.4 (range: 0-10) (Figure 1). The average EULAR/ACR score was 7.7 (range: 3.1-12.8).

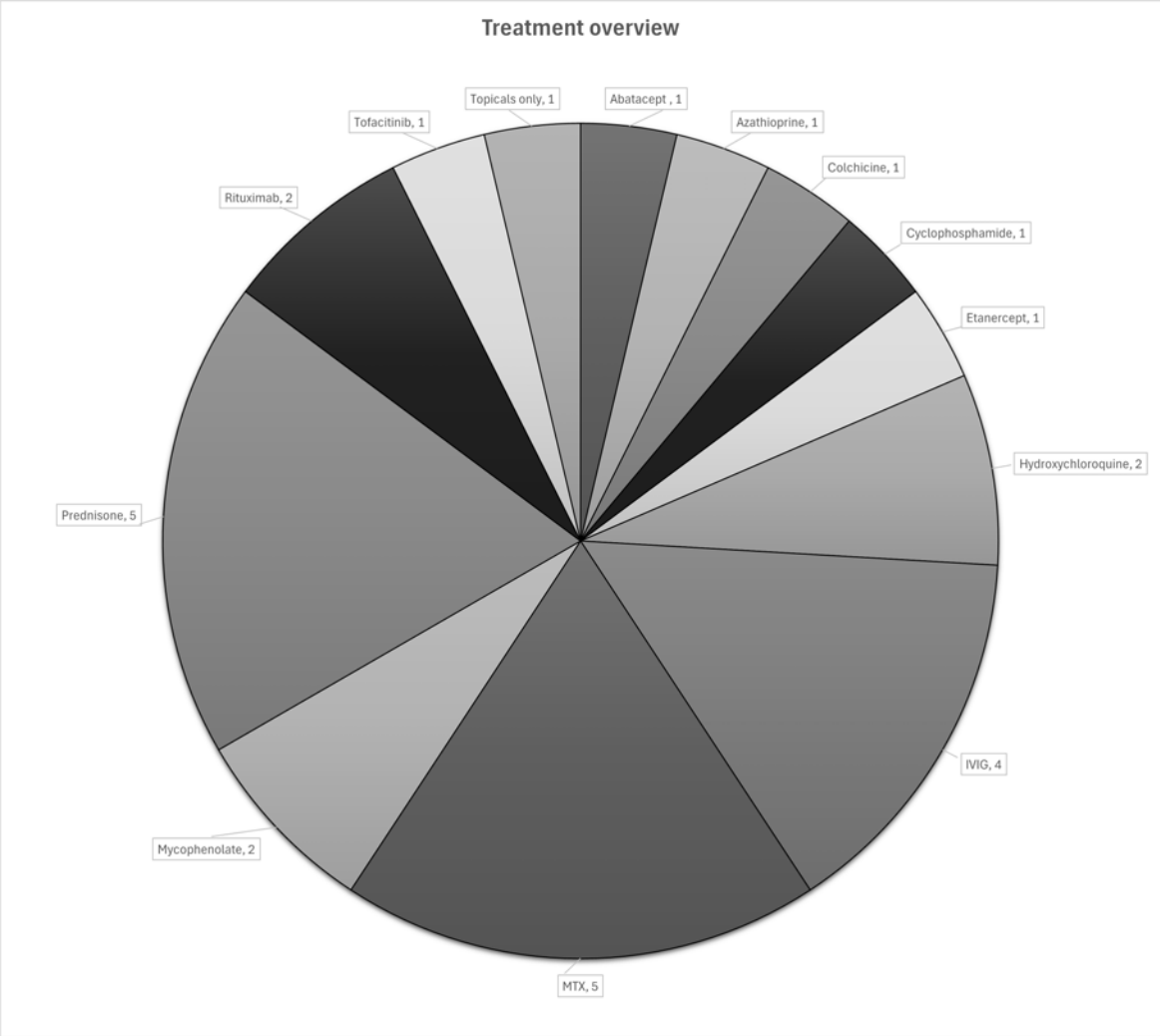

Figure 1. Graphical representation of the treatments prescribed to JDM patients in the cohort (medication name, # of patients prescribed the medication at some point during treatment). IVIG = intravenous immunoglobulin, MTX =methotrexate.

Conclusions

There are few case series describing JDM in SOC patients. MDA-5 and ANA were the commonest autoantibodies. All cases of calcinosis were associated with severe sequelae in keeping with prior observations. RA was the most prevalent overlap syndrome. Limitations include sample size, lack of male patients, lack of standardized scoring systems such as PhGA at the time of consultation, underrepresentation of non-Black patients of color and East Asian patients, and follow up data availability. Future cohort studies can further delineate whether all SOC patients face an increased risk of poorer outcomes or if the observation is limited to Black patients.

EADV CONGRESS
VIENNA
30 SEP - 3 OCT 2026

Abstract N°: 3366

Pemphigus Herpetiformis: Clinicopathological Profile, Immunological Features, and Therapeutic Outcomes in a 15-Year Retrospective Study

Ines Atoui*[1], Litaiem Noureddine[1], Soumaya Gara[1], Meriem Jones[1], Faten Zeglaoui[1], rammeh soumaya[1]

[1] Dermatology department -Charles Nicolle Hospital, Tunis, Tunisia

Introduction

Pemphigus herpetiformis is a rare autoimmune blistering disorder, characterized by pruritic herpetiform lesions and variable clinicopathological features. Diagnosis relies on the correlation of clinical, histological, and immunological findings.

Case Presentation

Materiels and methods

This is a retrospective descriptive study including all cases of pemphigus herpetiformis diagnosed in our department between 2010 and 2025.

Results

Eight patients were enrolled in the study, six of whom were female, with a mean age of 37.75 years. The mean delay before consultation was 8.5 months. Clinically, all patients presented with pruritic erythematous plaques surmounted by vesiculobullous lesions in a herpetiform arrangement, associated with post-bullous erosions. Oral mucosal involvement was observed in two cases, while the Nikolsky sign was positive in two patients. Histopathological examination showed acantholysis in six cases and an eosinophil-rich dermal infiltrate in five cases. The cleavage level was subcorneal in seven cases and suprabasal in one case. Direct immunofluorescence revealed intercellular IgG and C3 deposits in a fishnet pattern in seven patients. ELISA testing demonstrated positivity for anti-desmoglein 1 antibodies in all cases, whereas anti-desmoglein 3 antibodies were detected in only one patient. Systemic corticosteroid therapy at a dose of 1–1.5 mg/kg/day was administered to all patients, leading to lesion healing within a mean period of 21 days. Adjunctive therapy with methotrexate (7.5 mg/week) was required in one case, while another patient received azathioprine 100 mg/day, both with favorable outcomes. Relapse occurred in two patients after a mean follow-up of 13 months.

Conclusion

Pemphigus herpetiformis is a rare autoimmune blistering disease with a polymorphous and pruritic presentation that may delay diagnosis. This series highlights its predominance in young women and its characteristic clinicopathological and immunological profile, notably anti-desmoglein 1 positivity with typical intercellular IgG deposition. Systemic corticosteroids provided rapid and effective disease control in most patients, while immunosuppressants were reserved for selected cases. Although prognosis was generally favorable, the occurrence of relapses supports the need for long-term follow-up.

EA DV CONGRESS
VIENNA
30 SEP - 3 OCT 2026

Abstract N°: 3387

Therapeutic Adherence in Patients with Pemphigus: Clinical, Socioeconomic, and Psychosocial Determinants

MOHAMED HOUBAYELI*[1], layla bendaoud[1], Nouhaila Bourht[2], Mariem Aboudourib[1], Ouafa Hocar[1], Amal Said[1]

[1] Mohammed VI University Hospital of Marrakech, Bioscience and Health Laboratory, Department of Dermatology Venerology, marrakech, Morocco

[2] Mohammed VI University Hospital of Marrakech, Bioscience and Health Laboratory, Department of Dermatology Venerology, Mohammed VI University Hospital of Marrakech, Bioscience and Health Laboratory, Department of Dermatology Venerology, Marrakech, Morocco, Mohammed VI University Hospital of Marrakech, Bioscience and Health Laboratory, Department of Dermatology Venerology, Marrakech, Morocco, marrakech, Morocco

Introduction
Pemphigus is a chronic autoimmune blistering disease requiring long-term treatment with systemic corticosteroids, immunosuppressants, or biologic therapies. Poor adherence may compromise disease control and increase relapse risk. This study aimed to evaluate therapeutic adherence and identify determinants of non-adherence among pemphigus patients followed at our tertiary center.

Materials and Methods
A cross-sectional analytical study was conducted including 123 patients with pemphigus at the Dermatology Department of Mohammed VI University Hospital, Marrakech. Adherence was assessed using a composite approach including a visual analog scale (VAS), missed treatment days, and behaviors inspired by the Morisky Medication Adherence Scale. Patients with VAS ≥80%, ≤2 missed treatment days/month, and no frequent non-adherent behaviors were considered adherent. Univariate and multivariate logistic regression analyses were performed.

Results
The mean patient age was 55 years, with female predominance (67%). Pemphigus vulgaris represented 82% of cases, and 23% had severe disease (PDAI >45). The overall non-adherence rate was 46%.

Non-adherence was significantly associated with rural residence, low educational level, treatment complexity (≥3 daily doses), adverse effects, polypharmacy, severe disease, corticosteroid fear, and financial difficulties. In multivariate analysis, treatment complexity, financial constraints, corticosteroid fear, severe disease, and polypharmacy remained independent predictors of non-adherence. Conversely, rituximab use and strong trust in healthcare providers were associated with better adherence.

Conclusions
Therapeutic adherence in pemphigus remains insufficient in our context. Non-adherence is driven by therapeutic, socioeconomic, and psychosocial factors. A multidimensional strategy combining therapeutic education, treatment simplification, and psychosocial support may improve adherence and disease outcomes.

EADV CONGRESS
VIENNA
30 SEP - 3 OCT 2026

Abstract N°: 3392

When autoimmunity spreads: Pemphigus Vulgaris meets Dermatomyositis

Rafael Santos*[1], João Fernandes[1], Manuel Costa[1], Rúben Costa[1], Patrícia Gomes[1], Bárbara Granja[1], Filomena Azevedo[1], Maria Cruz[1]

[1] Unidade Local de Saúde de São João, Department of Dermatology and Venereology, Porto, Portugal

Introduction
Patients with pemphigus vulgaris (PV) have an increased risk of developing other autoimmune diseases. However, the association with dermatomyositis (DM) remains poorly documented. We report a rare case of long-standing PV with subsequent development of classic seronegative DM.

Case Presentation
A 79-year-old woman with biopsy-confirmed PV diagnosed 9 years prior, in partial remission on topical corticosteroids alone for the past 4 years, presented to the emergency department with asthenia, proximal lower limb weakness, and new-onset skin rash. Physical examination revealed shawl sign, V-sign, holster sign, and scalp erythema, without Gottron papules or heliotrope rash. Laboratory findings showed markedly elevated muscle enzymes. Magnetic resonance imaging and electromyography were suggestive of inflammatory myopathy. Muscle biopsy (performed after one month of corticosteroid therapy) demonstrated changes consistent with inflammatory myopathy, without a definitive histological pattern. Myositis-specific antibody panel was negative. Chest computed tomography showed no interstitial lung disease. Malignancy screening was unremarkable. Treatment with prednisolone 60 mg/day and azathioprine was initiated, with favorable response.

Conclusion
We report a rare case of coexisting Pemphigus Vulgaris and classic seronegative Dermatomyositis with significant muscle involvement. While large epidemiological studies do not identify DM among the most frequent autoimmune comorbidities of PV, isolated overlap cases have been described, predominantly in amyopathic forms. This case highlights the importance of monitoring for new autoimmune manifestations in patients with established autoimmune disease. Epitope Spreading may underlie this association through diversification of the immune response toward novel autoantigens.

EADV CONGRESS
VIENNA
30 SEP - 3 OCT 2026

Abstract N°: 3399

Refractory high-risk mucous membrane pemphigoid treated with Telitacicept

Xun Feng*[1], Wei Li[1]

[1] West China Hospital of Sichuan University, Chengdu, China

Introduction

Mucous membrane pemphigoid (MMP) is a chronic autoimmune subepithelial blistering disorder predominantly affecting mucosal surfaces and often associated with significant morbidity, particularly in high-risk cases with ocular, laryngeal, or oesophageal involvement. Management of refractory MMP remains challenging, as many patients require prolonged systemic corticosteroids and multiple immunosuppressive agents. Telitacicept, a dual inhibitor of B-lymphocyte stimulator (BLyS) and a proliferation-inducing ligand (APRIL), has shown potential in other autoantibody-mediated diseases, but its use in MMP has not been reported.

Case Presentation

A 59-year-old man presented with a 3-month history of painful gingival erythema, swelling, and bleeding, accompanied by nasal erosions. Histopathology showed subepithelial mucosal inflammation, and direct immunofluorescence demonstrated linear IgG and partial C3 deposition along the basement membrane zone. Gastro-oesophageal endoscopy also revealed oesophageal involvement. Serological testing showed a complex autoantibody profile, including IgG reactivity to type VII collagen NC1 and BP180, with weaker additional reactivity to laminin 332, supporting the diagnosis of high-risk MMP.

The disease course was prolonged and refractory over approximately 16 months despite sequential treatment with systemic corticosteroids, ciclosporin, mycophenolate mofetil, minocycline, and thalidomide. Disease activity remained steroid-dependent, and thalidomide was discontinued because of peripheral neuropathy. In September 2025, conjunctival involvement developed, indicating progression to high-risk disease. Telitacicept was then initiated at 160 mg subcutaneously once weekly in combination with prednisone 15 mg daily. Following treatment, the patient showed progressive and sustained clinical improvement. The Mucous Membrane Pemphigoid Disease Area Index (MMPDAI) decreased from 11 at baseline to 8.25 at 4 weeks, 5 at 8 weeks, and 2 at 12 weeks. Complete clinical remission (MMPDAI 0) was achieved at 16 weeks, with resolution of oral, nasal, and ocular lesions. Prednisone was tapered to 10 mg daily by 3 months, and no relapse or major adverse events were observed during follow-up.

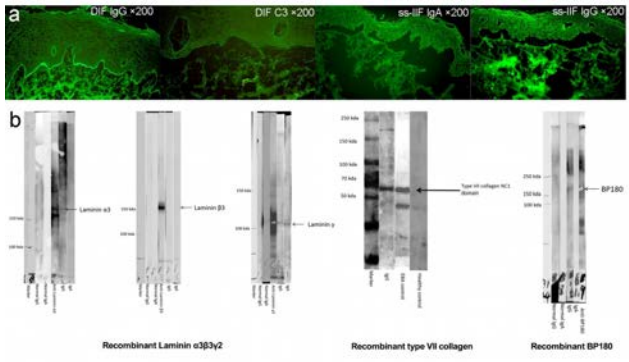

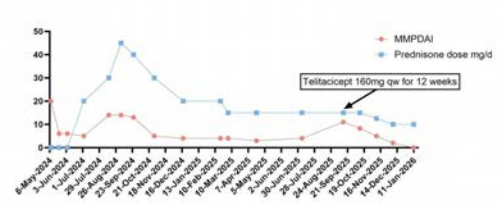

Week	CD4 T cell count	CD8 T cell count	B cell count	IgG mg/L	IgA mg/L	IgM mg/L
0	516	364	53	781	216	188
12	360	266	12	618	94	99
16	467	349	16	656	95	97

Conclusion

This case suggests that telitacicept may be a promising therapeutic option for selected patients with refractory high-risk MMP. Dual BLyS/APRIL inhibition may provide benefit in mucosal-dominant autoimmune blistering disease by suppressing pathogenic humoral immunity beyond conventional immunosuppressive approaches. Further studies are needed to clarify the efficacy and safety of telitacicept in MMP.

EADV CONGRESS
VIENNA
30 SEP - 3 OCT 2026

Abstract N°: 3411

Localised bullous pemphigoid of the neck triggered by chronic mechanical

Ibrahim El Awar*[1], Aleksandra Małolepsza[1], Katarzyna Juczyńska[1], Agnieszka Żebrowska[1]

[1] Medical University of Łódź, Łódź, Poland

Introduction
Bullous pemphigoid (BP) is the most common autoimmune subepidermal blistering disease, characterized by autoantibodies directed against the hemidesmosomal antigens BP180 and BP230. The classical phenotype is a generalized, intensely pruritic eruption of tense bullae in elderly patients. Localized BP is a far less recognized variant in which lesions remain confined to a single anatomical site, frequently following a local trigger, surgery, radiotherapy, thermal or UV injury, or chronic mechanical irritation, that is thought to expose basement membrane zone (BMZ) antigens and initiate an autoimmune response. Diagnosis is often delayed because circulating antibodies may be undetectable, leaving direct immunofluorescence (DIF) of perilesional skin as the cornerstone of confirmation.

Case Presentation
A 76-year-old woman presented with a two-month history of pruritic blistering lesions strictly confined to the left side of the neck. The eruption had developed insidiously at a site of repeated frictional trauma from a metal necklace and had failed to heal under symptomatic care. Examination revealed extensive erosions with residual blister roofs and marginal crusting, together with a few intact tense bullae; pruritus was marked. Inspection of the oral cavity showed minor erythematous changes on the soft palate, attributed to denture friction, with no frank erosions. No lesions were present elsewhere on the skin and there was no nasal, ocular or genital involvement. A punch biopsy of perilesional skin was performed under ethyl chloride anesthesia for DIF. An indirect immunofluorescence (IIF) panel using monkey esophagus and salt-split human skin substrates, together with a multiparametric ELISA against BP180, BP230, desmoglein 1, desmoglein 3, envoplakin and type VII collagen, was simultaneously requested. Both circulating antibody assays returned entirely negative results. On the other hand, DIF, , demonstrated linear deposits of IgG (++) and complement C3 (++) along the BMZ, confirming the diagnosis of localized BP. Topical corticosteroid therapy with a high-potency agent applied once to twice daily, supplemented by a non-sedating second-generation H1 antihistamine for pruritus, achieved progressive re-epithelialization and clinical remission within weeks.

Conclusion
This case illustrates two diagnostic challenges of localized BP. First, the eruption may convincingly mimic an irritant or contact dermatitis at the site of mechanical trauma, particularly when the trigger is as mundane as a piece of jewelry; the persistence of tense, well-roofed blisters in an elderly patient should prompt suspicion regardless of distribution. Second, seronegativity does not exclude BP. In localized disease the antigenic stimulus is geographically restricted and the resulting humoral response is often below the detection threshold of IIF and ELISA, even on salt-split skin. DIF of perilesional skin therefore remains the diagnostic gold standard and should be obtained whenever the clinical picture is suggestive, irrespective of serology. The proposed mechanism that local trauma unmasks BMZ antigens and primes a focal autoimmune reaction, is supported by the consistent association of localized BP with surgery, radiotherapy, burns, lymphedema and, as here, sustained frictional injury. Recognition matters: localized BP carries a more favorable prognosis than the generalized form, frequently responds to potent topical corticosteroids alone, and rarely requires the systemicimmunosuppression that drives much of the morbidity of classical BP. Awareness of trauma-induced, serology-negative BP is therefore essential to

avoid both under-diagnosis and unnecessary over- treatment.

EADV CONGRESS
VIENNA
30 SEP - 3 OCT 2026

Abstract N°: 3414

RITUXIMAB IN PEMPHIGUS VULGARIS AND FOLIACEUS: REAL-WORLD EVIDENCE FROM A BRAZILIAN TERTIARY CENTRE

Júlia Opolski Nunes Da Silva*[1], AMANDA ZANLUCHI[1], Aline Turatti[1], Ana Ferreira Roselino[1], Roberto Bueno Filho[1]

[1] Division of Dermatology, Internal Clinic Department, Ribeirão Preto Medical School, University of São Paulo, Ribeirão Preto, Brazil, Ribeirão Preto, Brazil

Introduction

Pemphigus vulgaris (PV) and pemphigus foliaceus (PF) are potentially life-threatening autoimmune bullous diseases. The RITUX 3 trial established rituximab (RTX) as first-line therapy for moderate-to-severe PV, achieving 89% complete remission (CR) off-therapy.1 However, real-world data from Latin American, where high disease burden, distinct comorbidity profiles, and biosimilar use shape clinical outcomes remain scarce.2

In this study we evaluate the efficacy and safety of RTX in a real-world cohort of pemphigus patients treated at a tertiary referral centre, comparing outcomes between the rheumatoid arthritis (RA) protocol and the lymphoma protocol (LY), and exploring predictors of single-cycle CR.

Materials and Methods

Retrospective cohort study of 71 consecutive patients with confirmed PV or PF treated with RTX. Two protocols were used: RA protocol (2x1000mg, 15 days apart; n=12) and LY protocol (4x375 mg/m^2, weekly; n=51). Remission and relapse definitions followed the 2008 International Pemphigus Consensus.3

Primary outcome: CR off-therapy after the 1º cycle. Secondary outcomes: CR with minimal therapy, systemic corticosteroid (SCS) dose reduction, complete steroid withdrawal, relapse rate, and adverse events. Study approved by local ethics committee; reported following STROBE guidelines.4

Results

The cohort included 71 patients (52.1% female; mean age 49.8 ± 15.2 years; PV 69%, PF 31%; 83.1% LY protocol). High baseline comorbidity burden was observed: dyslipidaemia (42.3%), obesity (40.8%), hypertension (29.6%), and diabetes mellitus (28.2%). All patients had received prior immunosuppressants, including azathioprine (54.0%), pulse dexamethasone with or without cyclophosphamide (58.7%; median 6 cycles), and dapsone (28.6%).

After the first cycle, CR off-therapy was achieved in 54.9% patients; any CR (off or with minimal therapy) in 67.6%. Median prednisone dose was significantly reduced 2 months after RTX (median -31.9%). Complete SCS withdrawal in 6 months occurred in 63.4%. Relapse occurred in (41.7%) patients who achieved CR.

The RA protocol showed numerically higher CR off-therapy (75.0% vs. 50.8%) and any CR (91.7% vs. 62.7%), with greater steroid reduction in 2 months (-46.5% vs. -29.0% mg/day) and complete withdrawal rates in 6 months (83.3% vs. 59.3%). Relapse rates were similar (33.3% vs. 37.3%). Adverse events occurred in 12.7% patients; infusion reactions in 4.2%. Deaths occurred in 5.6% patients, none directly attributable to rituximab. All results are described in Table 1.

Table 1. Clinical characteristics, comorbidities, and treatment outcomes of pemphigus patients treated with rituximab: comparative analysis by subtype (PF vs PV) and dosing protocol (RA vs lymphoma protocol)

Parameter	Overall (n = 71)	Pemphigus Foliaceus (n = 22)	Pemphigus Vulgaris (n = 49)	p-value (PF vs PV)	RA Protocol (n = 12)	Lymphoma Protocol (n = 59)	p-value (RA vs Lymphoma)
I. DEMOGRAPHIC CHARACTERISTICS							
Age (years) [mean ± SD]	49.8 ± 15.2	45.5 ± 16.8	51.8 ± 14.2	0.107	58.4 ± 15.5	48.1 ± 14.7	**0.031***
Female sex, n (%)	37 (52.1%)	8 (36.4%)	29 (59.2%)	0.122	7 (58.3%)	30 (50.8%)	0.756
BMI (kg/m²) [mean ± SD]	29.5 ± 6.0	30.6 ± 6.7	28.9 ± 5.6	0.311	29.2 ± 7.6	29.5 ± 5.8	0.928
Pemphigus subtype, n (%)	PF: 22 (31.0%) PV: 49 (69.0%)	—	—	—	PF: 4 (33.3%) PV: 8 (66.7%)	PF: 18 (30.5%) PV: 41 (69.5%)	1.000
Protocol used, n (%)	RA: 12 (16.9%) Lymphoma: 59 (83.1%)	RA: 4 (18.2%) Lymphoma: 18 (81.8%)	RA: 8 (16.3%) Lymphoma: 41 (83.7%)	1.000	—	—	—
Disease duration (months)[a] *Median (IQR) · [Min – Max] · Mann-Whitney U*	4 (3 – 12) *[0 – 135]*	6 (4 – 25) *[0 – 135]*	4 (2 – 11) *[0 – 35]*	**0.046***	3.5 (2.0 – 11.5) *[1 – 135]*	4 (3 – 12) *[0 – 39]*	0.859
Time from diagnosis to RTX initiation (months)[a] *Median (IQR) · [Min – Max] · Mann-Whitney U*	42 (10 – 95) *[0 – 354]*	87 (8 – 132) *[1 – 354]*	42 (10 – 78) *[0 – 228]*	0.171	61 (15 – 170) *[3 – 354]*	42 (10 – 83) *[0 – 236]*	0.189
II. BASELINE COMORBIDITIES							
Hypertension, n (%)	21 (29.6%)	8 (36.4%)	13 (26.5%)	0.414	4 (33.3%)	17 (28.8%)	0.740
Diabetes mellitus, n (%)	20 (28.2%)	8 (36.4%)	12 (24.5%)	0.394	7 (58.3%)	13 (22.0%)	**0.029***
Dyslipidaemia, n (%)	30 (42.3%)	10 (45.5%)	20 (40.8%)	0.797	5 (41.7%)	25 (42.4%)	1.000
Obesity, n (%)	29 (40.8%)	8 (36.4%)	21 (42.9%)	0.795	4 (33.3%)	25 (42.4%)	0.750
Hypothyroidism, n (%)	5 (7.0%)	3 (13.6%)	2 (4.1%)	0.169	1 (8.3%)	4 (6.8%)	1.000
Other autoimmune diseases, n (%)	6 (8.5%)	4 (18.2%)	2 (4.1%)	*0.070†*	2 (16.7%)	4 (6.8%)	0.266
III. CORTICOSTEROID ADVERSE EFFECTS (PRE-RTX)							
Cushing syndrome, n (%)	11 (15.5%)	6 (27.3%)	5 (10.2%)	*0.084†*	2 (16.7%)	9 (15.3%)	1.000
LTBI, n (%)	14 (19.7%)	4 (18.2%)	10 (20.4%)	1.000	1 (8.3%)	13 (22.0%)	0.437
HBV (Anti-HBc positive), n (%)[b]	7/63 (11.1%)	1/20 (5.0%)	6/43 (14.0%)	0.415	2/9 (22.2%)	5/54 (9.3%)	0.260
Hyperglycaemia from CS, n (%)	16 (22.5%)	4 (18.2%)	12 (24.5%)	0.760	6 (50.0%)	10 (16.9%)	**0.022***
Hypertension from CS, n (%)	13 (18.3%)	3 (13.6%)	10 (20.4%)	0.741	4 (33.3%)	9 (15.3%)	0.213
Osteoporosis / Osteopenia, n (%)	11 (15.5%)	4 (18.2%)	7 (14.3%)	0.729	3 (25.0%)	8 (13.6%)	0.382
Cataract, n (%)	10 (14.1%)	0 (0.0%)	10 (20.4%)	**0.025***	2 (16.7%)	8 (13.6%)	0.673
IV. RITUXIMAB TREATMENT							
RTX cycles, n (%)	—	—	—	—	—	—	—

Parameter	Overall (n = 71)	Pemphigus Foliaceus (n = 22)	Pemphigus Vulgaris (n = 49)	p-value (PF vs PV)	RA Protocol (n = 12)	Lymphoma Protocol (n = 59)	p-value (RA vs Lymphoma)
1 cycle	37 (52.1%)	14 (63.6%)	23 (46.9%)	0.211	8 (66.7%)	29 (49.2%)	0.349
2 cycles	19 (26.8%)	5 (22.7%)	14 (28.6%)	0.774	4 (33.3%)	15 (25.4%)	0.722
≥3 cycles	15 (21.1%)	3 (13.6%)	12 (24.5%)	0.363	0 (0.0%)	15 (25.4%)	*0.058†*
V. CLINICAL OUTCOMES							
Complete remission off-therapy, n (%)	39 (54.9%)	12 (54.5%)	27 (55.1%)	1.000	9 (75.0%)	30 (50.8%)	0.203
Complete remission on minimal therapy, n (%)	9 (12.7%)	2 (9.1%)	7 (14.3%)	0.711	2 (16.7%)	7 (11.9%)	0.643
Partial remission off-therapy, n (%)	1 (1.4%)	1 (4.5%)	0 (0.0%)	0.310	1 (8.3%)	0 (0.0%)	0.169
Partial remission on minimal therapy, n (%)	16 (22.5%)	5 (22.7%)	11 (22.4%)	1.000	0 (0.0%)	16 (27.1%)	*0.056†*
No remission[c], n (%)	6 (8.5%)	2 (9.1%)	4 (8.2%)	1.000	0 (0.0%)	6 (10.2%)	0.581
Relapse, n (%)	26 (36.6%)	8 (36.4%)	18 (36.7%)	1.000	4 (33.3%)	22 (37.3%)	1.000
CS dose reduction at 2 months (%)[d] [mean ± SD]	31.9 ± 26.9	26.5 ± 29.8	34.1 ± 25.7	0.301	46.5 ± 24.6	29.0 ± 26.6	**0.049***
Complete CS withdrawal at 6 months, n (%)	45 (63.4%)	15 (68.2%)	30 (61.2%)	0.607	10 (83.3%)	35 (59.3%)	0.189
VI. SAFETY							
Any adverse event, n (%)	9 (12.7%)	2 (9.1%)	7 (14.3%)	0.711	2 (16.7%)	7 (11.9%)	0.643
Infusion reaction, n (%)	3 (4.2%)	2 (9.1%)	1 (2.0%)	0.225	0 (0.0%)	3 (5.1%)	1.000
Hypogammaglobulinaemia, n (%)	14 (19.7%)	4 (18.2%)	10 (20.4%)	1.000	3 (25.0%)	11 (18.6%)	0.693
Loss to follow-up, n (%)	14 (19.7%)	6 (27.3%)	8 (16.3%)	0.339	2 (16.7%)	12 (20.3%)	1.000
Death, n (%)	4 (5.6%)	2 (9.1%)	2 (4.1%)	0.583	0 (0.0%)	4 (6.8%)	1.000

Abbreviations: *BMI = body mass index; CR = complete remission; CS = corticosteroid; IQR = interquartile range; LTBI = latent tuberculosis infection; PF = pemphigus foliaceus; PR = partial remission; PV = pemphigus vulgaris; RA = rheumatoid arthritis protocol (rituximab 1g IV × 2, 15 days apart); RTX = rituximab; SD = standard deviation. Lymphoma protocol = rituximab 375 mg/m² IV × 4, weekly.*

Statistical methods: *Continuous variables with normal distribution (Shapiro-Wilk p > 0.05; n ≤ 50): independent samples t-test (Welch correction when Levene test indicated unequal variances); presented as mean ± SD. Non-normally distributed continuous variables: Mann-Whitney U test; presented as median (IQR). Categorical variables: Fisher's exact test (expected counts < 5 in any cell) or Pearson chi-square; presented as n (%). Normality assessed by Shapiro-Wilk test (age p = 0.477; BMI p = 0.960; CS reduction p = 0.642). All tests were two-tailed; α = 0.05.*

[a] Disease duration: 6 missing values (all from the PV subgroup); analysis based on n = 65 patients.

[b] HBV (Anti-HBc): assessed in 63 of 71 patients (8 with unavailable result reported as "—"); denominator reflects tested patients per subgroup (PF: n=20; PV: n=43; RA: n=9; Lymphoma: n=54).

[c] No remission: patients with no complete or partial remission (off-therapy or on minimal therapy) after the first RTX cycle.

[d] CS dose reduction at 2 months: expressed as percentage reduction from baseline (higher values = greater reduction); calculated on 66 patients with available data.

[e] RTX cycle distribution: 1 cycle = 37 (52.1%); 2 cycles = 19 (26.8%); 3 cycles = 14 (19.7%); 4 cycles = 1 (1.4%). By subtype — PF: 14/5/3/0; PV: 23/14/11/1. By protocol — RA: 8/4/0/0; Lymphoma: 29/15/14/1.

** p < 0.05 (statistically significant, bold red). † 0.05 ≤ p < 0.10 (statistical trend, italic blue).*

Source: Primary data — Department of Dermatology, Hospital das Clínicas, FMRP-USP, Ribeirão Preto, Brazil (2021–2025). n = 71 patients.

Conclusions

In this real-world Brazilian cohort, RTX achieved CR off-therapy in 54.9% of pemphigus patients after a single cycle and enabled complete SCS withdrawal in 63.4%, confirming its steroid-sparing role. RTX was equally effective in PV and PF (CR off-therapy 55.1% vs 54.5%), but PF patients accumulated greater prior SCS toxicity, highlighting the need for earlier rituximab introduction in this subtype.

Our findings are consistent with previously real-world cohorts and observational studies reporting CR rates ranging from approximately 58-83% and relapse rates between 24-65%.5–8 Similar to prior studies, earlier RTX use appeared associated with improved outcomes and reduced corticosteroid exposure.5–8

The RA protocol showed a significantly greater SCS reduction at 2 months (46.5% vs 29.0%) and consistent numerical superiority across CR and steroid-sparing endpoints, with fewer cycles required, though selection bias (older, more comorbid patients assigned to RA protocol) precludes definitive efficacy conclusions.

Hypogammaglobulinaemia (19.7%) and the long median time to rituximab initiation (42 months) underscore the need for systematic immunoglobulin monitoring and earlier RTX access in Brazilian tertiary centres. These findings strengthen the role of RTX as a key disease-modifying therapy in pemphigus management and support broader implementation of standardized RTX-based treatment protocols in referral centers.

EADV CONGRESS
VIENNA
30 SEP - 3 OCT 2026

Abstract N°: 3441

Annular plaques with central scarring and necrotising granulomas on histopathological examination: The exception to the rule

Juan Jose Garcia Alfonso*[1], Marcial Álvarez Salafranca[1], Andrés Ederra Galé[1], Marco Cilleruelo Fouz[1], Beatriz Clemente Hernández[1], Zita Álvarez Bobillo[1], Paula Martínez Soler[1], Yolanda Gilaberte Calzada[1]

[1] Hospital Universitario Miguel Servet, Zaragoza, Spain

Introduction

Cutaneous sarcoidosis is a highly heterogeneous manifestation of a multisystem granulomatous disorder and may represent the initial clue to systemic disease. Histologically, sarcoidosis is classically associated with non-necrotizing granulomas; however, atypical presentations with necrotizing granulomatous inflammation have been described, creating significant diagnostic uncertainty and frequently prompting investigation for infectious or vasculitic causes. Awareness of this uncommon presentation is essential to avoid diagnostic delay.

Case Presentation

We report the case of a 61-year-old man, a former worker in the vitrification industry, with no relevant medical history, who presented with a three-year history of progressive cutaneous lesions involving the supralabial, left preauricular, and pectoral regions, associated with asthenia. Clinical examination showed annular and arcuate infiltrated plaques with central scarring.

Repeated skin biopsies demonstrated granulomatous dermatitis with focal necrotizing granulomas composed of epithelioid histiocytes and multinucleated giant cells. Histochemical stains for acid-fast bacilli and fungi were negative, and extensive microbiological evaluation—including direct examination, culture, and PCR—repeatedly failed to identify an infectious pathogen. Given the presence of necrosis, the initial differential diagnosis included lupus vulgaris, atypical mycobacterial infection, deep fungal infection, granulomatosis with polyangiitis, and other granulomatous inflammatory disorders.

Laboratory workup showed normal angiotensin-converting enzyme levels and mildly elevated soluble interleukin-2 receptor (649 U/mL; normal ≤623). Thoracic CT revealed small pulmonary nodules and partially calcified mediastinal lymphadenopathy. PET-CT demonstrated moderate hypermetabolic uptake in bilateral axillary and inguinal lymph nodes without significant pulmonary parenchymal activity. Pulmonary function testing showed no major functional impairment.

Considering the exclusion of infectious causes, compatible systemic findings, and clinicopathological correlation, a diagnosis of systemic sarcoidosis with atypical necrotizing cutaneous involvement was established. Treatment with prednisone (0.5 mg/kg/day) and hydroxychloroquine resulted in progressive improvement of both cutaneous lesions and systemic symptoms.

Conclusion

Although sarcoidosis is classically defined by non-necrotizing granulomas, necrotizing granulomatous histology does not exclude the diagnosis. Cutaneous sarcoidosis may rarely mimic chronic infectious granulomatous dermatoses or systemic vasculitis, representing an important diagnostic pitfall. This case highlights the importance of repeated microbiological exclusion, multidisciplinary clinicopathological correlation, and systemic evaluation when assessing necrotizing granulomatous skin lesions.

EADV Congress 2026, VIENNA
30 SEPTEMBER - 03 OCTOBER 2026
POWERED BY M-ANAGE.COM

EA DV CONGRESS
VIENNA
30 SEP - 3 OCT 2026

Abstract N°: 3442

Levamisole-induced vasculitis presenting as extensive ulceronecrotic lesions with crack cocaine use

Bianca Miyazawa*[1], Barbara Messias Pereira[1], Joao Marcos de Souza[1], Jéssica Pagan Faria[1], Rogerio Kondo[1], Cássio Moreira[1], Mariana Collete[1]

[1] State University of Londrina, Londrina, Brazil

Introduction

Crack/ cocaine use representes a major public health issue in Brazil, one of the world's largest consumer markets for these substances. Ilicit drugs are frequently adulterated wit levamisole, na antihelminthic agent with immunomodulatory Properties capable os triggering neutrophil-mediated autoimmunity. Recente studies suggest that levamisole induces aberrant formation of neutrophil extracellular traps (NETs). leading to ANCA production, complement activation, vascular inflammation, thrombotic vasculopathy, and tissue necrosis. We report a severe case of levamisole-induced vasculitis in a young patient with substance use disorder, highlighting the diagnostic, therapeutic, and social challenges involved in management.

Case Presentation

A 24-year-old homeless man with chronic crack cocaine and cannabis use was referred to a tertiary hospital with a three-month history of extensive, extremely painful ulceronecrotic lesions on both lower limbs. Initially attributed to trauma with secondary infection, the patient underwent recurrent hospitalizations for broad-spectrum antibiotics without improvement. Due to progressive tissue necrosis, two surgical debridements were performed, also with poor response.

On admission, he was febrile and presented extensive bilateral necrotic ulcerations. Laboratory tests revealed anemia, markedly elevated inflammatory markers, and positive ANCA serology. Dermatological evaluation initially raised the hypothesis of pyoderma gangrenosum. Skin biopsy demonstrated neutrophilic vasculitis with fibrinoid necrosis of the vascular wall and intense fibrin deposition. Combined with the history of crack cocaine use, these findings supported the diagnosis of levamisole-induced vasculitis.

Systemic corticosteroid therapy (methylprednisolone at a prednisone-equivalent dose of 1 mg/kg/day), targeted antibiotics for culture-confirmed secondary bacterial infection, and intensive wound care were initiated. After approximately 20 days, significant improvement was observed, with granulation tissue formation and reduction in ulcer depth.

Management was severely impacted by social vulnerability, substance dependence, and poor adherence to treatment. In January 2025, the patient was discharged with outpatient follow-up but failed to attend scheduled visits. In July 2025, he returned with severe recurrence associated with continued crack cocaine use. On readmission, he presented deeper ulcers, infection, and bone exposure. Magnetic resonance imaging confirmed extensive osteomyelitis. Despite reintroduction of corticosteroids and broad-spectrum antibiotics, extensive osteonecrosis required transtibial amputation. The patient subsequently agreed to referral to a rehabilitation center.

Conclusion

Levamisole-induced vasculitis should bem considered in the differential diagnosis of painful ulceronecrotic lesions in patient whit substance (crack/cocaine) use disorder, particularly in the presence of ANCA serology. This imune-mediated condition involves innate and adaptative imune responses especially neutrophil activation. Treatment is based on discontiuation of crack/cocaine use, supportive care, and immunosuppressive therapy in severe cases. This case highlights the destructive potentital of this entity and reinforces the importance of multidisciplinar management addressing both substance dependence and social vulnerability.

EA DV CONGRESS
VIENNA
30 SEP - 3 OCT 2026

Abstract N°: 3446

scalp amicrobial pustulosis associated with systemic lupus erythematous

ZINEB ABDELJEBBAR[1], feriel Amri[1], meriem tabka[1], salma nefzi[1], ines Nacer[2], smahen souissi[1], morad mokni*[1]

[1] Department of Dermatology, La Rabta Hospital, tunis, Tunisia
[2] Department of internal medecine La Rabta Hospital, tunis, Tunisia

Introduction
Amicrobial pustulosis(AP) of intertriginous areas is a rare neutrophilic dermatosis characterised by sterile pustules, follicular or non-follicular, resulting from neutrophilic infiltration. It typically affects skin folds but may rarely involve or extend to the scalp, often with a chronic and relapsing course. This dermatosis is frequently associated with autoimmune diseases, particularly systemic lupus erythematosus (SLE).

Case Presentation
Case 1 A 40-year-old woman with SLE and stage V lupus nephropathy, treated with mycophenolate mofetil and systemic corticosteroids, presented with a two-month history of chronic scalp pruritus. Dermatological examination revealed a crusted, scaly scalp with oozing areas. Trichoscopy showed follicular and non-follicular pustules on an erythematous background with psoriasiform scales. Secondary impetiginisation was initially suspected and treated with amoxicillin–clavulanic acid for seven days. Fifteen days later, lesions had worsened, becoming more inflamed and painful, with the appearance of erythematous erosive plaques bordered by pustules in retroauricular, inter- and inframammary, and pubic folds. Laboratory tests revealed a moderate inflammatory syndrome without leukocytosis, and bacterial cultures were negative. Skin biopsy demonstrated a spongiform intraepidermal pustule, acanthosis, and parakeratosis, with the dermis exhibiting a neutrophilic infiltrate, confirming the diagnosis of amicrobial pustulosis of folds in the context of SLE. Acitretin (25 mg/day) was initiated without significant improvement; subsequent treatment with dapsone (100 mg/day) resulted in rapid lesion resolution.
Case 2 A 44-year-old woman with SLE and Sjögren's sd, under hydroxychloroquine, also had colonic Crohn's disease with fissured intergluteal intertrigo and autoimmune thyroiditis. She initially developed a scaly scalp, treated as scalp psoriasis with topical corticosteroid shampoo. Over time, alopecia developed alongside worsening squamous lesions and secondary impetiginisation. Examination revealed an erosive, alopecic, malodorous scalp plaque covered with thick yellow-green scales, oozing pus, and multiple pustules of variable size, extending from the frontal hairline to the lambdoid suture. The remainder of the skin was spared. Trichoscopy showed diffuse scalp erythema with scattered pustules and yellowish scales. Skin biopsy demonstrated spongiosis, acanthosis, and parakeratosis. Direct immunofluorescence was positive, showing moderate granular and linear IgM deposition at the dermoepidermal junction. Clinical and immunopathological findings supported the diagnosis of scalp amicrobial pustulosis. Treatment with topical care (petrolatum, fusidic acid ointment, antiseptic shampoo) combined with systemic corticosteroids (prednisone 30 mg/day) resulted in near-complete resolution of scalp lesions.

Conclusion
Amicrobial pustulosis belongs to the spectrum of neutrophilic dermatoses and is characterised by sterile neutrophilic infiltration. In both cases, the coexistence of SLE with sterile erosive pustular scalp lesions allowed the diagnosis of AP. This association is increasingly reported in the literature, suggesting a pathophysiological link. The second case also illustrates the association with Crohn's disease, reinforcing the hypothesis of a shared neutrophilic mechanism. Diagnosis relies on the integration of clinical, histological, and microbiological data to

exclude infection. Management remains challenging due to disease rarity and the absence of consensus, with treatments including systemic corticosteroids, dapsone, colchicine, immunosuppressants, and biologics showing variable efficacy.

AP is a rare and atypical manifestation of neutrophilic dermatoses, potentially associated with SLE and, less commonly, other autoimmune disorders such as Crohn’s disease. These two cases underscore the importance of considering this diagnosis in patients presenting with sterile pustular scalp lesions, particularly in an autoimmune context.

EADV CONGRESS
VIENNA
30 SEP - 3 OCT 2026

Abstract N°: 3458

Low-dose D-penicillamine in recurrent localized scleroderma: an effective and underused approach

Eduardo Lacaz Martins[1], Camila Simão Teixeira de Andrade de Andrade[1], Guilherme Gonçalves Nascimento*[1]

[1] Intituto da Pele da Faculdade de Medicina do ABC - FMABC, Santo André, Brazil

Introduction

Localized scleroderma (morphea) is a chronic inflammatory and fibrosing disorder characterized by excessive collagen deposition in the skin and subcutaneous tissues, often leading to cosmetic and functional impairment. Although methotrexate combined with systemic corticosteroids is currently considered first-line therapy for active disease, treatment of recurrent or refractory cases remains challenging, particularly in patients with prior therapeutic failure or contraindications to immunosuppressive regimens. D-penicillamine, a collagen cross-linking inhibitor historically used in sclerosing disorders, has progressively fallen out of favor due to concerns regarding dose-dependent toxicity. However, lower-dose regimens may still represent a valuable therapeutic alternative in selected patients, potentially offering clinical benefit with a more favorable safety profile.

Case Presentation

Localized scleroderma (morphea) is a chronic fibrosing disorder with a variable course and risk of recurrence. While methotrexate is considered first-line therapy, alternative treatments may be relevant in selected patients.
A 56-year-old woman (phototype III) presented with hyperpigmented, indurated, sclerodermiform plaques on the right lateral hip extending to the gluteal region. Skin biopsy confirmed cutaneous scleroderma, and systemic involvement was excluded through laboratory evaluation. The patient had a history of two previous episodes at ages 19 and 32, both treated with D-penicillamine, achieving complete remission with residual hyperpigmentation. Given the recurrence and prior favorable response, low-dose D-penicillamine (Trolovol® once daily) was initiated. Progressive clinical improvement was observed, with softening of the lesions and no clinical or laboratory adverse effects during follow-up.
D-penicillamine inhibits collagen cross-linking but is underused due to dose-related toxicity. This case highlights that lower dosing regimens may offer a favorable balance between efficacy and safety. Revisiting older therapies with optimized dosing may represent a valuable strategy in recurrent localized scleroderma.

Conclusion

- Localized scleroderma can recur after prolonged remission
- D-penicillamine remains a therapeutic option in selected patients
- Low-dose regimens may improve safety without compromising efficacy
- Optimization of older therapies is relevant in modern practice

EADV CONGRESS
VIENNA
30 SEP - 3 OCT 2026

Abstract N°: 3472

Atypical Site-Refractory Pemphigus Vulgaris: Persistent Nasal Pyramid Involvement in a Young Adult under Conventional Immunosuppression

Mihaela Mănăilă*[1], Gabriela Turcu[1], Ana-Maria Țuțu[1], Dan Mircioi[1], Razvan-Theodor Andrei[2], Dana-Gabriela Ionescu[2], Andra Dinu[1], Andra-Daniela Miu[1], Kimberley Noel Pallourios[2]

[1] "Carol Davila" University of Medicine and Pharmacy, Colentina Clinical Hospital, Bucharest, Romania

[2] Colentina Clinical Hospital, Bucharest, Romania

Introduction

Pemphigus is defined as a group of life-threatening blistering disorders characterized by acantholysis that results in the formation of intraepithelial blisters in the mucous membranes and skin. Pemphigus vulgaris (PV) is a rare autoimmune disease that typically affects older adults. We report a case of PV in a 20-year-old patient characterized by a dramatic onset at an unusually young age.

Case Presentation

A 20-year-old overweight male patient presented to the Dermatology Department with confluent, papillomatous, vegetating, grey-violaceous plaques, anamnesticly preceded by blisters and erosions, located in intertriginous areas, with a 2-month history, along with oral cavity erosions and disseminated erythematous, erosive, impetiginized plaques involving the trunk, limbs, and perioronasal region. The differential diagnoses considered for this patient included pyodermatitis pyostomastitis vegetans, Hailey-Hailey disease, pyoderma vegetans, paraneoplastic pemphigus, epidermolysis bullosa acquisita, and pemphigus vulgaris.

In the Dermatology Department two skin biopsies were obtained for histopathological examination and direct immunofluorescence that confirmed pemphigus vulgaris. A CT scan of the thorax, abdomen, and pelvis was carried out to exclude the paraneoplastic etiology. Immunosuppressive therapy with systemic corticosteroid and Mycophenolate mofetil, subsequently switched to Azathioprine was followed by complete remission.

After 8 months since the first presentation, it was noted the appearance of erosions covered by hemorrhagic crusts and pustules on an erythematous background limited at the level of the nasal apex and nostrils. Given the newly developed lesions, several diagnostic possibilities were considered, including herpetic infection, folliculitis, impetigo, steroid-induced acne rosacea, and relapse of pemphigus vulgaris. The patient received topical treatment with antibiotics (fusidic acid, clindamycin, metronidazole), topical ivermectin, topical acyclovir, and high-potency topical steroids, but without improvement so a biopsy was performed. Histopathological examination confirmed the diagnosis of pemphigus vulgaris.

Conclusion

To our knowledge, such a pattern of relapse confined to a single anatomical site, the level of nasal pyramid, has not been previously reported in the literature, as a refractory pemphigus vulgaris typically involves persistence or recurrence across all the initially affected areas or oral involvement.

POWERED BY M-ANAGE.COM

EADV CONGRESS
VIENNA
30 SEP - 3 OCT 2026

Abstract N°: 3497

Lichen planus presenting with generalized erythroderma in an adult patient

Darko Manchevski*[1], Mina Saleva-Stateva[1], Miroslava Mihova[1], Elena Petrova[1], Valeria Mateeva[1], Lyubomir Dourmishev[1]

[1] University Hospital "Alexandrovska", Medical University - Sofia, Sofia, Bulgaria, Sofia, Bulgaria

Introduction

Lichen planus (LP) is a chronic inflammatory dermatosis characterized by a T-cell–mediated immune response targeting basal keratinocytes. It affects both skin and mucous membranes and typically presents with violaceous, polygonal papules and plaques. In rare cases, LP may present with extensive involvement, including erythroderma.
The aim of this report is to present a severe generalized form of lichen planus with mucocutaneous involvement.

Case Presentation

A 59-year-old female patient was admitted with an acute exacerbation of a long-standing dermatological condition (approximately 10 years duration). She presented with generalized erythematous-squamous lesions, intense pruritus, and involvement of the oral mucosa. The lesions were distributed over the trunk and extremities with a tendency to coalesce, leading to a near-erythrodermic presentation.
No relevant drug history or associated systemic diseases were reported.
Laboratory investigations were largely within normal limits, with mild inflammatory activity. Histopathological examination demonstrated a lichenoid interface dermatitis. Direct immunofluorescence (DIF) revealed linear deposition of IgG and C3 along the basement membrane zone. These findings supported the diagnosis of lichen planus. Systemic corticosteroid therapy (dexamethasone 4 mg daily) and topical high-potency corticosteroid (clobetasol propionate cream) were initiated, resulting in significant clinical improvement.

Conclusion

Lichen planus may rarely present with generalized erythroderma, posing a diagnostic challenge. Histopathology and direct immunofluorescence remain essential for confirming the diagnosis. Early recognition and appropriate systemic therapy are crucial for achieving disease control.

EADV CONGRESS
VIENNA
30 SEP - 3 OCT 2026

Abstract N°: 3533

Coexistence of facial multiple miliary osteoma cutis in two case of FFA (A rare Association)

Negin Safdarian*[1]

[1] Behsima Dermatology Specialized Centre, Tehran, Iran

Introduction

Frontal Fibrosing Alopecia is a lymphocytic scarring alopecia increasingly recognized worldwide, particularly among postmenopausal women. Beyond hair loss, facial papules and cutaneous changes are frequently observed, reflecting the complex inflammatory and fibrotic nature of the disease. Multiple Miliary Osteoma Cutis is a rare disorder characterized by the presence of ectopic bone formation within the dermis, most commonly affecting the face. The coexistence of FFA and MMOC has rarely been described and may suggest overlapping pathogenic pathways .This can highlight the relationship between chronic follicular inflammation and ectopic ossification.

Case Presentation

Two middle-aged women presented with prominent facial papules .
Case 1 ; 56 years with progressive frontotemporal hairline recession accompanied by partial eyebrow loss and multiple asymptomatic, skin-colored papules involving the cheeks and forehead. Trichoscopic examination demonstrated perifollicular erythema and scaling consistent with FFA. Histopathological evaluation of scalp biopsies confirmed lymphocytic cicatricial alopecia compatible with FFA .Additional biopsy of facial papules revealed mature lamellar bone formation within the dermis, confirming MMOC.
Case2;58 years with no frontotemporal recession and prominent firm facial papules.
Neither patient had metabolic abnormalities related to calcium or phosphate homeostasis, and there was no history of acne vulgaris, trauma, or inflammatory dermatoses traditionally associated with secondary osteoma cutis.
Both patients treated with extraction of hard particles and then tretinoin cream and pimecrolimus cream and systemic treatment for FFA treatment.

Conclusion

These cases highlight a possible association between FFA and MMOC and suggest that osteoma cutis may represent an underrecognized cause of treatment resistance facial papules in some patients with FFA. Chronic inflammation and fibrosis may contribute to ectopic ossification .

EADV CONGRESS
VIENNA
30 SEP - 3 OCT 2026

Abstract N°: 3534

Pemphigus Vegetans of Hallopeau: A Case Report

Hosam Alazaiza*[1], Safa Djebbas[1], kaghouche lilia[1], Amel Gherfi[1], esma bouhila[1], khadidja bouarroudj[1], Tarek Mansoul[1], RIADH BOUSSAID[1], Ahmed Samaouel Chehad[1]

[1] Department of Dermatology constantine, constantine, Algeria

Introduction

Pemphigus vegetans (Hallopeau type) is a rare variant of autoimmune bullous dermatosis, characterized by an indolent clinical course, the initial presence of flat pustules, and subsequent vegetative transformation. We report a new case of this rare clinical entity

Case Presentation

A 60-year-old female with a history of type 2 diabetes, hypertension, and thyroidectomy presented with an 8-month history of erosive and vegetative lesions.
Clinical examination revealed flaccid pustules with milky content surrounding vegetative plaques in flexural areas and on the trunk, associated with oral mucosal erosions, a positive Nikolsky sign, and pruritus. Histopathological analysis demonstrated suprabasal acantholysis with a papillomatous epidermal surface and intraepidermal neutrophilic microabscesses, while ELISA confirmed anti-desmoglein 1 and 3 antibodies.
A diagnosis of Hallopeau-type pemphigus vegetans was established, and the patient was initiated on rituximab combined with systemic corticosteroids (prednisone 1 mg/kg/day).
Pemphigus vegetans is a rare variant representing less than 2% of pemphigus cases, traditionally subdivided into the Neumann and Hallopeau types. While both forms present as ulcerated, papillomatous plaques in intertriginous areas, the Hallopeau subtype is distinguished by a pustular onset rather than bullae, typically following a more indolent course with a more favorable prognosis.
Although immunological findings overlap with pemphigus vulgaris, the distinctive papillomatous architecture remains a diagnostic hallmark of the vegetative variants

Conclusion

Hallopeau-type pemphigus vegetans represents a rare clinical entity. A high index of suspicion is required when encountering acquired bullous diseases where initial pustules evolve into vegetative plaques

EA DV CONGRESS
VIENNA
30 SEP - 3 OCT 2026

Abstract N°: 3546

Laser-Based Management of Acne Scarring in Systemic Lupus Erythematosus Under Severe Immunosuppression

Ana-Maria Toma*[1], Mara Mădălina Mihai[1]

[1] Elias Emergency University Hospital- Department of Oncologic Dermatology, Bucharest, Romania

Introduction
Ablative and fractional laser procedures are often approached with caution in patients with systemic lupus erythematosus (SLE), given concerns regarding photosensitivity, impaired wound healing, infection risk, and potential disease exacerbation. While the available evidence remains limited, published reports and reviews suggest that laser-based interventions—including CO_2 resurfacing and ablative fractional photothermolysis—may be feasible in selected lupus patients with stable disease. We present a complex, severely immunosuppressed SLE case in which fractional CO_2 laser was used for the management of post-acne scarring following control of steroid-exacerbated acne.

Case Presentation
We report the case of a young female patient diagnosed with systemic lupus erythematosus complicated by proliferative lupus nephritis, who experienced a severe and relapsing disease course requiring multiple lines of therapy. Disease control required multiple immunosuppressive strategies over time, including prolonged systemic corticosteroid therapy, mycophenolate mofetil, ciclosporin, belimumab, and ultimately B-cell–depleting therapy with rituximab, under which complete systemic and renal remission was achieved.
During ongoing immunosuppressive treatment, the patient underwent dermatologic evaluation for juvenile acne exacerbated by long-term corticosteroid exposure. Inflammatory acne lesions were successfully controlled with topical therapy; however, clinically significant post-acne scarring persisted. Given the patient's history of severe immunosuppression and lupus-associated photosensitivity, procedural intervention for scar management required careful consideration. Following interdisciplinary discussion and rheumatologic approval, serial sessions of fractional CO_2 laser were performed for the treatment of acne scarring, using progressively increased parameters. Fractional CO_2 laser treatment was associated with a favorable clinical response and an unexpectedly rapid healing course. Cutaneous recovery occurred noticeably faster than typically anticipated for comparable procedures in routine practice, despite the patient's background of profound immunosuppression and known lupus-associated photosensitivity. No peri-procedural infectious complications, delayed wound healing, or systemic disease exacerbation were observed throughout the treatment period. Systemic remission remained stable during dermatologic intervention.

Conclusion
This complex SLE case demonstrates that, even in the setting of severe and prolonged immunosuppression, fractional CO_2 laser therapy may be well tolerated and associated with accelerated cutaneous healing when systemic disease activity is adequately controlled. The unexpectedly rapid recovery observed in this patient adds to the limited existing literature and supports the concept that, with careful patient selection and close multidisciplinary coordination, CO_2 laser procedures may represent a feasible therapeutic option in selected high-risk autoimmune patients.

EADV Congress 2026, VIENNA
30 SEPTEMBER - 03 OCTOBER 2026
POWERED BY M-ANAGE.COM

EADV CONGRESS
VIENNA
30 SEP - 3 OCT 2026

Abstract N°: 3546

Redefining "Early Remission" In Autoimmune Blistering Diseases: A Critical Review Of Cd20-Targeted Therapy Milestones.

Randa Abdelhamid*[1], Krish Lightwala[1], Zeel Lightwala[1]

[1] Belarusian state medical university, Minsk, Belarus

Introduction
Rituximab is effective in pemphigus and other autoimmune blistering diseases, yet no consensus exists on the definition of "early remission." The prevailing assumption holds that complete B-cell depletion is necessary for symptom control. However, accumulating evidence demonstrates that patients can achieve complete symptom resolution despite persistent detectable B cells. This review aims to determine the specific conditions under which incomplete B-cell depletion corresponds to complete clinical tolerance.

Materials and Methods
A systematic analysis was performed on 14 prospective trials and 8 cohort studies from 2018 to 2025, encompassing 1,247 patients treated with CD20-targeted therapy (rituximab or ofatumumab). Disease activity was assessed using PDAI and ABSIS scores, while B-cell subsets including $CD19^+$ total B cells, $CD27^+$ memory B cells, and $CD38^+$ plasmablasts were evaluated at weeks 4, 12, and 24 post-infusion. Random forest modeling and SHAP analysis were applied to identify predictors of disease flare versus sustained remission. "Incomplete B-cell depletion" was strictly defined as >5 $CD19^+$ cells/μL or detectable skin-homing B-cell clones by flow cytometry.

Results
Among patients achieving complete clinical remission by week 12, 31% exhibited persistent B cells. These individuals maintained remission for a median duration of 14 months (95% CI, 11–18), which was comparable to fully depleted patients ($p=0.34$). Three independent predictors of tolerance despite incomplete depletion were identified: a >70% reduction in double-positive $CD27^+CD38^+$ B cells (AUC 0.91), undetectable anti-desmoglein 3/1 by ELISA (odds ratio 7.2, 95% CI 4.1–12.6), and normalization of $CD1d^+CD5^+$ regulatory B cells to >2% of total B cells. Redefining early remission at week 8 as PDAI ≤3 or ABSIS ≤5, combined with either absolute B cells <10/μL or a >70% reduction in double-positive $CD27^+CD38^+$ cells, improved the predictive accuracy for 12-month relapse avoidance from 0.66 to 0.89 ($p<0.001$).

Conclusions
Complete clinical tolerance in autoimmune blistering diseases does not require absolute B-cell depletion. Functional silencing of memory and plasmablast subsets, rather than numerical elimination, represents the key immunologic mechanism. A practical clinical milestone is proposed: the CD20-Tolerance Remission Index (CD20-TRI), defined by clinical score ≤3/≤5 plus either low B-cell count or >70% reduction in pathogenic double-positive B cells. When TRI criteria are met, therapy de-escalation can be safely pursued despite persistent B cells, shifting the therapeutic paradigm from "deplete to treat" to "modulate to tolerate."

EA DV CONGRESS
VIENNA
30 SEP - 3 OCT 2026

Abstract N°: 3547

Prognostic factors associated with cutaneous remission in dermatomyositis: a French multicenter retrospective study

Ariane Le Clainche Compagnie*[1], Alexandre Teboul[2], helene traineau[2], Quentin Beytout[3], Emmanuelle DIAZ[2], Chloé Grolleau[4], Charles Cassius[4], Vincent Descamps[5], CAROLINE FAUCON[5], didier bessis[6], Yves Allenbach[7], EDOUARD BEGON[8], Benjamin Terrier[1], Diane Kottler[9], Baptiste Hervier[4], François Chasset[2], Nicolas Dupin[1]

[1] Hopital Cochin Port Royal, Paris, France
[2] Hopital Tenon, Paris, France
[3] Hopital Henri Mondor, Créteil, France
[4] Hopital Saint Louis, Paris, France
[5] Hopital Bichat, Paris, France
[6] University Hospital Montpellier, montpellier, France
[7] Hopital Pitié Salpétrière, Paris, France
[8] Hopital de Brive La gaillarde, Brive la Gaillarde, France
[9] Hopital de Caen, caen, France

Introduction
Dermatomyositis (DM) is a chronic inflammatory myopathy with constant cutaneous involvement, a major determinant of disease burden and quality of life. Its management remains poorly standardized in skin-predominant, cancer-free patients. Hydroxychloroquine (HCQ) is widely used as first-line therapy despite limited evidence. In a recent meta-analysis, HCQ showed low efficacy as monotherapy or with topical treatments (complete response 22%) and frequent cutaneous adverse events (AEs 21%), leading to discontinuation in 25% of cases. However, real-world data in early DM remain scarce. We aimed to identify clinical, biological, and therapeutic predictors of cutaneous complete remission (CCR) within the first year, study the evolution of disease activity through CDASI (Cutaneous Dermatomyositis Disease Area and Severity Index) scores over time and reassess HCQ effectiveness and safety in a nationwide real-world cohort.

Materials and Methods
We conducted a retrospective multicenter cohort including adult DM patients diagnosed between 2015 and 2023. Patients with malignancy or severe systemic involvement (symptomatic or rapidly progressive interstitial lung disease, severe swallowing or gastrointestinal disorders, or cardiac involvement) were excluded. Primary endpoint was CCR at 12 months, defined as CDASI <5. Secondary endpoints included CDASI evolution and partial cutaneous response (PCR), defined as ≥75% improvement or ≥ 5-point CDASI decrease. Time-to-event analyses used Cox models with time-dependent covariates. Longitudinal CDASI changes were assessed using linear mixed-effects models.

Results
102 patients were included (70% female; median age 52.5 years), including 60% classic DM, 31% clinically amyopathic DM (CADM), and 9% hypomyopathic DM (HDM). Median baseline CDASI was 18 (range 6–38), with 48% moderate-to-severe disease, defined as CDASI score > 14.

CCR was achieved in 59% (n=60) at 12 months, with most improvement within the first 3 months. In multivariable

analysis **(Table 1)**, Gottron's papules were associated with lower CCR (HR 0.41; p=0.01), whereas moderate-to-severe baseline CDASI predicted higher CCR (HR 2.76; p=0.01) reflecting probably greater treatment intensification. No systemic treatment was independently significantly associated with CCR. For PCR, anti-TIF1γ antibodies were associated with lower response (HR 0.38; p=0.03), while moderate-to-severe CDASI (HR 2.62; p=0.01) and intravenous immunoglobulin (IVIg) (HR 3.38; p<0.01) were associated with higher response rates.

In longitudinal analysis**,** IVIg exposure was associated with a greater decrease in CDASI from baseline (β −4.64; 95% CI −8.44 to −0.85; p=0.016). Glucocorticoids (β −2.33; 95% CI −4.73 to 0.07; p=0.057) and methotrexate (β −1.01; 95% CI −3.12 to 1.10; p=0.35) were not significantly associated with additional changes in CDASI over time. In contrast, HCQ exposure was associated with a smaller decrease in CDASI, indicating less improvement or worsening (β 2.78; 95% CI 0.08 to 5.47; p=0.044).

Among 57 HCQ-treated patients, CADM (p=0.03) and anti-TIF1γ antibodies (p=0.02) were more frequent. Cutaneous AEs occurred in 35% (mostly mild), and worsening in 16%. It leads to treatment discontinuation in 10% of cases.

Table 1: Univariate and multivariate Cox analysis for CCR (time-dependant)

	HR	IC 2.5%	IC 97.5%	p-value
Univariate analysis				
Age at diagnosis	1.01	0.99	1.02	0.34
Female	0.91	0.52	1.57	0.73
Muscular involvement	1.69	0.99	2.89	0.06
CDASI baseline moderate-severe	1.72	0.45	3.49	0.13
Anti-TIF1 γ	**0.44**	**0.2**	**0.97**	**0.04**
Hydroxychloroquine	**0.56**	**0.33**	**0.97**	**0.04**
Methotrexate	1.13	0.68	1.89	0.64
Glucocorticoids	1.66	0.91	3.02	0.1
IVIG	1.35	0.64	2.87	0.43
Multivariate analysis				
Gottron's papules	**0.41**	**0.21**	**0.82**	**0.01**
Muscular involvement	1.47	0.72	3.00	0.29
CDASI baseline moderate-severe	**2.76**	**1.25**	**6.07**	**0.01**
Anti TIF1 γ	0.43	0.16	1.16	0.1
Hydroxychloroquine	0.57	0.27	1.2	0.14
Glucocorticoids	0.7	0.29	1.2	0.43

Conclusions

In this nationwide cohort of skin-predominant DM, nearly 60% achieved CCR within one year, with early improvement. Clinical phenotype and baseline severity were key determinants of outcome. IVIg was consistently associated with improved cutaneous response and disease activity, whereas HCQ was not associated with improved outcomes, showed limited impact on disease trajectories and was associated to cutaneous AEs.

These findings are consistent with meta-analytic data suggesting limited efficacy and frequent toxicity of HCQ and support cautious use of HCQ in DM, with individualized assessment of its risk–benefit ratio. Larger, prospective studies are warranted to confirm these associations.

EADV CONGRESS
VIENNA
30 SEP - 3 OCT 2026

Abstract N°: 3560

When two dermatoses collide: lichen planus pemphigoides as an overlap syndrome

fatima zahrae EL Abidi*[1], Meryem Soughi[1], IKRAME BEJJA[1], Saadia Boughaleb[1], Zakia Douhi[1], Sara Elloudi[1], Hanane Baybay[1], Fatima Zohra Mernissi[1]

[1] dermatology departement, FEZ, Morocco

Introduction

Lichen planus pemphigoides (LPP) is a rare autoimmune subepidermal blistering disease that combines clinical features of lichen planus and bullous pemphigoid. Because it may initially mimic bullous pemphigoid, diagnosis relies on careful clinicopathological and immunopathological correlation.

Case Presentation

We report the case of a 37-year-old woman with no significant past medical history who presented with a 2-month history of a generalized, intensely pruritic bullous eruption. Clinical examination revealed multiple tense bullae involving the limbs, trunk, and back. Some blisters arose on erythematous skin, whereas others developed on erythematous-violaceous plaques. In addition, polygonal violaceous scaly plaques were noted on the back and on the flexor aspects of both wrists, suggesting lichen planus. Urticarial lesions were also present. Nikolsky sign was negative, with no mucosal involvement, atrophic scarring, or milia. Histopathological examination of a violaceous plaque and a tense bulla showed subepidermal clefting associated with lichenoid interface dermatitis. Direct immunofluorescence demonstrated linear IgG and C3 deposition along the dermo-epidermal junction, with negative IgA and IgM, supporting the diagnosis of Lichen Planus Pemphigoides. The patient was treated with oral corticosteroids (1 mg/kg/day), resulting in marked clinical improvement. Dapsone (150 mg/day) was subsequently introduced as a

Conclusion

This case underscores Lichen Planus Pemphigoides as an uncommon yet important differential diagnosis in patients presenting with a bullous pemphigoid-like eruption. Early recognition of its characteristic clinical and immunopathological features is essential to prevent misdiagnosis and to ensure timely and appropriate therapeutic management.

EADV CONGRESS
VIENNA
30 SEP - 3 OCT 2026

Abstract N°: 3573

Dual Labeling in Direct Immunofluorescence: An Immunopathological Signature of Paraneoplastic Pemphigus Revealing Occult Prostate Carcinoma

Douae Jayat*[1], Sara Elloudi[1], IKRAME BEJJA[1], Saadia Boughaleb[1], Zakia Douhi[1], Meryem Soughi[1], Hanane Baybay[1], Fatima Zohra Mernissi[1]

[1] Department of Dermatology, Hassan II University Hospital, Fes, Morocco

Introduction

Paraneoplastic pemphigus (PNP) is a rare and severe autoimmune bullous dermatosis characterized by marked clinical and immunological polymorphism. It is strongly associated with underlying neoplasia and has a poor prognosis. Diagnosis relies on a combination of clinical, histopathological, and immunopathological findings. Direct immunofluorescence (DIF) plays a central role, and the presence of a double deposit both between keratinocytes and at the dermo-epidermal junction is a highly suggestive diagnostic sign.

Case Presentation

We report the case of a 96-year-old patient with a history of Parkinson's disease, hospitalized for extensive bullous dermatosis that had been progressing for several weeks. Initially, he presented with tense bullae, urticarial plaques, and no mucosal involvement, suggestive of bullous pemphigoid. A skin biopsy with histopathological examination and direct immunofluorescence (DIF) was performed. During the clinical course, the patient developed severe involvement of the oral mucosa, polymorphic lesions (tense and flaccid bullae, extensive erosions), and extension to 45% of his body surface area. Histopathology showed interface dermatitis with basal vacuolar alterations and focal subepidermal cleavage. DIF revealed a dual deposition of IgG and C3 both at the dermo-epidermal junction and between keratinocytes. The ELISA showed only isolated positivity for anti-BP180 antibodies. This immunopathological profile prompted a complete neoplastic workup. A cervico-thoraco-abdomino-pelvic CT scan revealed a heterogeneous prostate with iliac lymphadenopathy, and the PSA level was elevated at 12 ng/mL, suggestive of prostate carcinoma.

Conclusion

This case highlights the importance of clinical evolution in diagnostic reassessment and the need for rigorous immunopathological analysis for any atypical or polymorphic bullous dermatosis in order not to miss an underlying silent neoplasm.

EA DV CONGRESS
VIENNA
30 SEP - 3 OCT 2026

Abstract N°: 3573

Efficacy and Safety of Ivarmacitinib in Adult and Pediatric Patients with Alopecia Areata: A Real-World Analysis

Wen jun Zheng*[1]

[1] The First Affiliated Hospital of Guangxi Medical University, Nanning, China

Introduction

Alopecia areata is a T-cell-mediated autoimmune hair disorder. Ivarmacitinib, a novel and highly selective JAK1 inhibitor, has been approved for moderate to severe adult alopecia areata. This study aims to evaluate the real-world efficacy and safety of ivarmacitinib in adult and pediatric patients with alopecia areata.

Materials and Methods

This study enrolled adult and pediatric patients with alopecia areata. All participants received oral ivarmacitinib 4 mg once daily. Efficacy was assessed via SALT score at baseline and weeks 4, 8, 12, 16, and 24, with adverse events monitored.

Results

Between June 23, 2025 and January 5, 2026, 19 patients were screened, 9 of whom were pediatric patients. The mean duration of the current episode of alopecia areata was 3.9 years. Overall, 68.4% of the patients had severe disease as reflected by a SALT score ≥50; 47.4% receive at least one previous therapy for alopecia areata This interim analysis demonstrated that after 12 weeks of ivarmacitinib treatment, 8 out of 19 patients achieved a reduction of over 50% in SALT score from baseline. Notably, 3 patients (including 1 pediatric patient) attained a SALT score of 0. The mean SALT score at baseline, week 4 and week 12 were 41, 26, 11, respectively, demonstrating sustainable hair regrowth (Fig 1). No adverse events were reported during treatment in all patients.

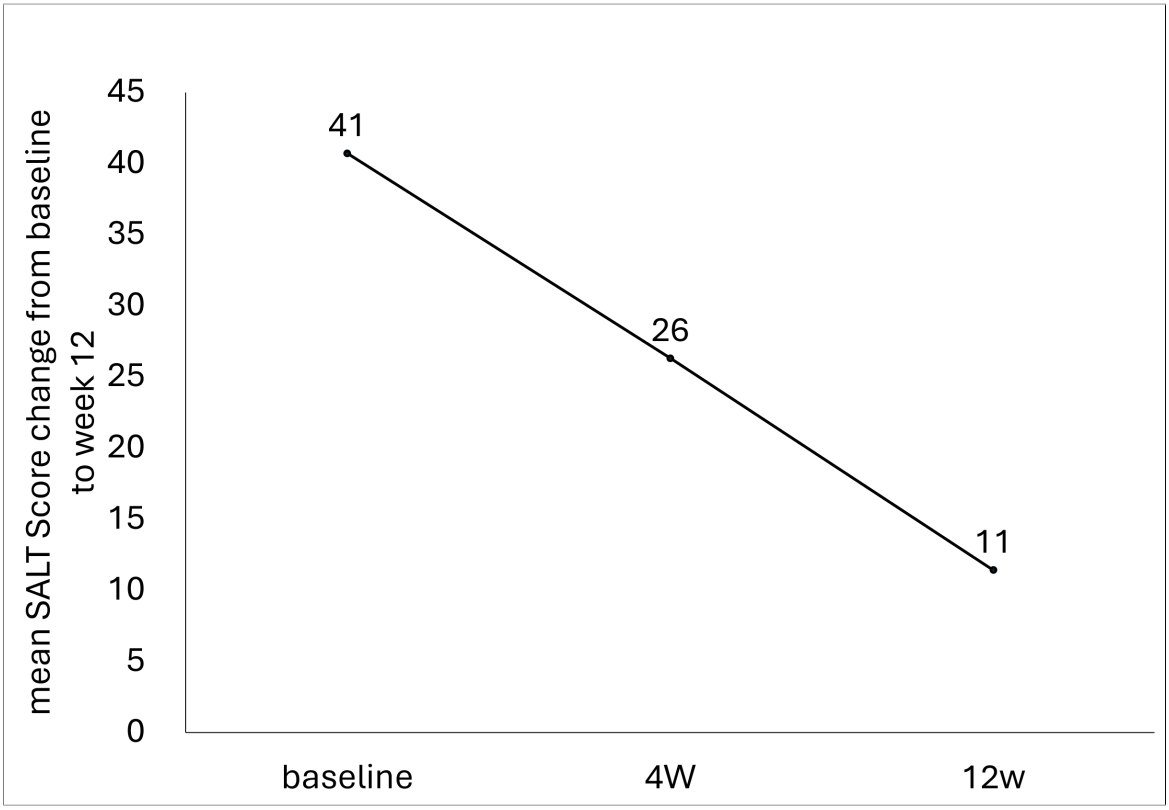

Figure 1. The mean SALT score change through week 12

Conclusions

Ivarmacitinib demonstrated significant efficacy and a favorable safety profile in both adult and pediatric patients. The study is currently ongoing with continued follow-up and enrollment to gather longer-term data.

EADV CONGRESS
VIENNA
30 SEP - 3 OCT 2026

Abstract N°: 3585

Nodular Cutaneous Amyloidosis in a Patient with Sjögren Syndrome and Severe Axonal Neuropathy: Clinicopathological Insights from a Rare Presentation

Guilherme Gonçalves Nascimento*[1], Mônica Linhares Sachett[1], Paulo Ricardo Criado[1], Carlos D Apparecida Santos Machado Filho[1]

[1] Intituto da Pele da Faculdade de Medicina do ABC - FMABC, Santo André, Brazil

Introduction

Nodular primary cutaneous amyloidosis (NPCA) is a rare localized form of amyloid deposition confined to the skin, often manifesting as asymptomatic nodules on the lower extremities. It may associate with chronic inflammatory and autoimmune disorders such as Sjögren syndrome and rheumatoid arthritis, and can herald or overlap with systemic amyloidosis. Accurate distinction from sclerotic dermatoses relies on histopathology and Congo red staining.

Case Presentation

A 66-year-old female was referred for investigation of asymptomatic nodular lesions on the lower limbs evolving over 10 years, progressively increasing in size and number. She reported progressive “stocking” hypoesthesia with toe anesthesia since adulthood, and had Sjögren syndrome, rheumatoid arthritis, severe chronic axonal sensori-motor neuropathy, Raynaud syndrome, hypertension, prediabetes, hypothyroidism and dyslipidemia. Dermatologic examination showed firm nodules on both legs. ANA was positive with high-titer centromeric nuclear pattern; renal and hepatic tests were normal. Initial biopsy of the right ankle revealed dense dermal collagen sclerosis extending to the hypodermis with lymphoplasmacytic infiltrate; Congo red was negative and kappa/lambda immunostaining was non-contributory, raising suspicion for nodular amyloidosis versus systemic sclerosis. A subsequent multi-site biopsy (pre-tibial and interscapular skin) demonstrated dermal and subcutaneous deposits of eosinophilic, hyaline, amorphous material, with positive Congo red staining confirming cutaneous amyloidosis in both sites. The pre-tibial sample also showed focal fibroblastic proliferation and heterotopic ossification, while the interscapular lesion was reported as cutaneous amyloidosis.

Conclusion

This case illustrates NPCA in a complex autoimmune and neuropathic background, initially mimicking sclerosing connective tissue disease. Repeat targeted biopsies with Congo red were crucial to establish the diagnosis and to guide systemic work-up, reinforcing the importance of clinicopathological correlation in nodular leg lesions associated with Sjögren syndrome.

EADV CONGRESS
VIENNA
30 SEP - 3 OCT 2026

Abstract N°: 3588

UNEXPECTED REMISSION? POTENTIAL EFFECT OF IMATINIB ON EPIDERMOLYSIS BULLOSA ACQUISITA IN A PATIENT TREATED FOR CHRONIC MYELOID LEUKEMIA

Inasse El Biyaali*[1], Meryem Soughi[1], IKRAME BEJJA[1], Saadia Boughaleb[1], Zakia Douhi[1], Sara Elloudi[1], Hanane Baybay[1], Fatima Zohra Mernissi[1]

[1] Hassan II University Hospital Fes, Fes, Morocco

Introduction

Epidermolysis bullosa acquisita is a rare autoimmune disease, characterized by the synthesis of anti-collagen VII autoantibodies. The antigen-antibody binding elicits a complex inflammatory response, which culminates in the loss of dermo-epidermal adhesion of the skin and/or mucous membranes. Skin fragility with bullae, erosions, and milia in areas of trauma characterizes the disease. Standard therapy includes systemic and/or topical glucocorticoids with colchicine or dapsone, but the outcome is sometimes unsatisfactory. Imatinib is a tyrosine kinase inhibitor acts through a competitive inhibition at the ATP binding site and selectively blocks the BCR ABL oncoprotein, ckit and PDFGR, making it have an anti-inflammatory and anti-proliferative properties.

We report a special case of acquired epidermolysis bullosa accidentally treated with imatinib, never seen before in literature.

Case Presentation

A 39-year-old woman with a history of chronic myeloid leukemia treated with imatinib for 1 month presented with a 2 week history of multiple newly developed tense bullae with clear and hemorrhagic content, erosions and some target like lesions, resting over normal skin, mainly in acral regions, the trunk and axillary and pubic areas, with an erosive cheilitis and one small erosin on the inner surface of the lower lip. The patient was otherwise healthy, without any other disorders . Biopsy results showed a subepidermal blister, and direct immunofluorescence results revealed linear deposition of immunoglobulin (Ig) G and C3 antibodies along the basement membrane zone.

The patient was seen 3 months later, with complete remission and the appearance of milia on the trunk, the patient received a diagnosis of EBA already controlled by imatinib.

Conclusion

This case highlights the emerging possible treatment of imatinib in epidermolysis bullosa acquisita.

EADV CONGRESS
VIENNA
30 SEP - 3 OCT 2026

Abstract N°: 3610

Extradigital glomus tumor in a patient with neurofibromatosis type 1: a diagnostic challenge in an atypical location.

Cristian Saul Gonzalez Flores*[1], Oscar Gulliermo Aguirre Felix[1], Alisi Lucila Lopez Marquez[1]

[1] Secretaría de La Defensa Nacional, Ciudad de México, Mexico

Introduction

Glomus tumors are mesenchymal neoplasms derived from modified smooth muscle cells of the glomus body, a specialized thermoregulatory structure. Although their classic presentation is subungual, extradigital variants represent a diagnostic challenge due to their nonspecific clinical presentation and frequent misdiagnosis as other soft tissue tumors. The association with neurofibromatosis type 1 (NF1) is uncommon but increasingly recognized because of shared molecular alterations involving the Ras-MAPK pathway.

Case Presentation

A 47-year-old active-duty military man with a family history of café-au-lait macules in his mother, brother, and daughter presented with a dermatosis involving the left arm and left thigh. Physical examination revealed four painful subcutaneous nodules ranging from 0.5 to 1.5 cm in diameter, soft, mobile, and partially violaceous. Multiple hyperpigmented macules and axillary and inguinal freckling consistent with NF1 were also identified.

The lesions first appeared in 2022 as asymptomatic millimetric nodules on the upper extremities, later increasing in size and becoming painful. The patient was evaluated by Internal Medicine, Endocrinology, and Genetics, where a clinical diagnosis of neurofibromatosis type 1 was established. He was subsequently referred to Dermatology with a presumptive diagnosis of neurofibromas.

Ultrasound examination demonstrated well-defined ovoid lesions; one lesion showed central Doppler vascularity and linear reflective streaks parallel to the skin surface, findings suggestive of the “vascular stalk” sign described in extradigital glomus tumors.

Histopathological examination revealed a well-circumscribed vascular proliferation involving the reticular dermis and subcutaneous tissue, composed of round cells with basophilic nuclei and pale eosinophilic cytoplasm surrounding dilated vascular channels without significant atypia. Immunohistochemistry demonstrated positivity for smooth muscle actin and focal CD34 expression, confirming the diagnosis of glomus tumor.

Conclusion

Extradigital glomus tumors should be considered in the differential diagnosis of painful nodules in patients with neurofibromatosis type 1, particularly in atypical locations and prolonged clinical courses. Definitive diagnosis requires clinicopathological and immunohistochemical correlation. This case reinforces the association between both entities and highlights the importance of maintaining a high index of suspicion to avoid diagnostic delay.

EADV CONGRESS
VIENNA
30 SEP - 3 OCT 2026

Abstract N°: 3618

Linear IgA bullous dermatosis in association with vitiligo

Maria Magdalena Kirilova*[1], Slavian Tumnev[1], Elia Vuleva[1], Dimitrina Serafimova[1], Snejina Vassileva[1], Kossara Drenovksa[1]

[1] Department of Dermatology and Venereology, Medical University - Sofia, Sofia, Bulgaria, Sofia, Bulgaria

Introduction

Linear IgA bullous dermatosis (LABD) and vitiligo are two autoimmune disorders that target the skin and mucosa through distinct pathological mechanisms. Linear IgA dermatosis is a rare subepidermal blistering disease mediated by IgA antibodies, which attack the basement membrane zone antigens and form linear deposits at the dermo-epidermal junction on direct immunofluorescence. Vitiligo affects pigment-producing melanocytes through autoreactive CD8+ T cells. It has frequently been reported in association with other autoimmune bullous diseases (AIBD) such as dermatitis herpetiformis (DH) and occasionally bullous pemphigoid or pemphigus vulgaris while its co-existence with LABD is exceptional.

Case Presentation

An 82-year-old man presented with a pruritic disseminated eruption of erythematous plaques with peripheral annular vesiculation showing “string of pearls” sign on the trunk and extremities of two-week duration. During the dermatological exam, it became evident that the patient was also suffering from long-lasting vitiligo presenting with symmetrical hypopigmented macules on the forearms and hands. Some of the vesiculobullous lesions were confined to the hypopigmented macules.

Routine laboratory work-up including full blood count, blood sugar, comprehensive metabolic panel, and coagulation, revealed only elevated D-dimer of 4.05 ug/mL, correlating most likely to the current inflammatory process. Histology from a vesicular lesion showed a subepidermal bulla with an eosinophilic infiltrate suggestive of subepidermal bullous dermatosis. Direct immunofluorescence on perilesional skin demonstrated linear deposits of IgA(++) along the basement membrane confirming LABD. Initial treatment with systemic dexamethasone 8mg/24hr and topical clobetasol propionate twice daily along with dapsone 50mg/day lead to rapid improvement, with no new lesions within two-week follow-up.

Conclusion

The reported case of LABD in an elderly patient with another preexisting autoimmune disease - vitiligo is extremely rare with very limited observations of similar associations. Among the AIBD that may coexist with vitiligo, DH is the most frequent one while LABD has been reported only in isolated cases of Vogt-Koyanagi-Harada disease where vitiligo is part of the clinical presentation of the latter. The reported association may be coincidental but a probable common pathogenetic mechanism may be related to genetic predisposition, oxidative stress or environmental factors.

EA DV CONGRESS
VIENNA
30 SEP - 3 OCT 2026

Abstract N°: 3626

Localized Sclerodermiform Breast Sclerosis : An Unusual Presentation

Rehab Bellout*[1], Salim Gallouj[1], Ouiame El Jouari[1]

[1] Dermatology Department, University Hospital Center Mohammed VI, Tangier, Morocco

Introduction
Sclerodermiform skin disorders constitute a heterogeneous group of fibrosing cutaneous conditions characterized by dermal induration and sclerosis, clinically resembling morphea (localized scleroderma) or systemic sclerosis. In most cases, these sclerodermiform reactions are secondary to identifiable triggers such as radiotherapy, medications, trauma, chronic infection, or paraneoplastic processes.

Rarely, clinicians encounter localized sclerotic lesions that fulfill both clinical and histopathological criteria of scleroderma-like conditions but remain unexplained after thorough etiological investigation. These idiopathic or unclassified sclerodermiform presentations challenge current nosological classifications and raise diagnostic as well as therapeutic dilemmas.

We report a rare case of idiopathic localized sclerodermiform skin sclerosis of the breast with favorable response to topical calcipotriol–betamethasone therapy.

Case Presentation
A 62-year-old woman with a medical history of total thyroidectomy on hormone replacement therapy and mechanical heart valve replacement performed 10 years earlier, treated with long-term acenocoumarol, presented with a progressively enlarging pigmented and indurated plaque of the left breast evolving over three months.

There was no history of trauma, radiotherapy, infection, recent travel, drug exposure known to induce fibrosis, or similar familial cases.

Physical examination revealed a poorly demarcated, sclerotic, hyperpigmented plaque measuring approximately 7 cm in its greatest diameter, involving the two inner quadrants of the left breast. The contralateral breast was unremarkable. Dermoscopic examination showed irregular areas of hyperpigmentation on a focally erythematous background.

Routine laboratory investigations, including complete blood count, metabolic panel, thyroid function tests, fasting glucose, and serum protein electrophoresis, were within normal limits. Serological testing for Borrelia burgdorferi was negative.

Histopathological examination revealed an atrophic epidermis with mild orthokeratotic hyperkeratosis. The dermis showed fibro-edematous changes with thickened collagen bundles predominantly affecting the mid-dermis, associated with a mild perivascular mononuclear inflammatory infiltrate. Adnexal structures were preserved, and no evidence of mutilating fibrosis was observed, supporting the diagnosis of an early to intermediate sclerodermiform process.

Conclusion

This case highlights a rare presentation of idiopathic localized sclerodermiform skin sclerosis of the breast, characterized by limited fibro-inflammatory dermal changes without identifiable systemic or local triggers. Recognition of this entity is essential to avoid unnecessary extensive investigations or systemic immunosuppression. Early topical treatment with calcipotriol–betamethasone may represent an effective and safe therapeutic option, warranting further investigation in similar cases.

EADV CONGRESS
VIENNA
30 SEP - 3 OCT 2026

Abstract N°: 3627

Bullous lupus erythematosus : two cases

Mohammad Azouagh*[1], Mariem Tabka[1], Soumaya Gara[2], Feryel Amri[1], Rihab Sayari[3], Lilia Laadhar[3], Mourad Mokni[1], Faten Zeglaoui[2], Maryam Kallel Sellami[3]

[1] Dermatology department, La Rabta Hospital, Tunis, Tunisia
[2] Dermatology department, Charles Nicolle Hospital, Tunis, Tunisia
[3] Immunology department, La Rabta Hospital, Tunis, Tunisia

Introduction

Bullous lupus erythematosus (BLE) is a rare autoimmune blistering manifestation of systemic lupus erythematosus (SLE), characterised by subepidermal blistering that may closely mimic other autoimmune bullous dermatoses. Although classically associated with autoantibodies against type VII collagen, atypical immunological profiles have been increasingly reported, including dual antigen positivity or complete seronegativity. This serological heterogeneity highlights the diagnostic complexity of BLE and the need for refined immunopathological evaluation. We report two contrasting cases illustrating these diagnostic challenges.

Case Presentation

Case 1

A 59-year-old woman with SLE complicated by neuropsychiatric involvement presented with a vesiculobullous eruption initially localised to photo-exposed areas, subsequently extending to covered skin. Painful erosions of the oral mucosa (lower lip and buccal mucosa) were also noted.

Histopathological examination revealed a subepidermal blister with a lymphocytic infiltrate. Direct immunofluorescence demonstrated linear IgG and C3 deposition along the dermo–epidermal junction. Indirect immunofluorescence on salt-split skin showed combined epidermal and dermal binding.

Detection of anti–type VII collagen antibodies using transfected cells expressing the NC1 domain confirmed the diagnosis of bullous lupus erythematosus. Interestingly, ELISA for BP180 NC16A was also positive, an unusual finding in this context.

Case 2

A 40-year-old woman with SLE and lupus nephritis presented with a two-week history of widespread vesiculobullous eruption predominantly affecting the face and flexural areas, healing with residual dyspigmentation without scarring. Oral mucosal erosions covered by fibrinous exudate were present.

Histology showed a subepidermal blister associated with a mixed lymphocytic and neutrophilic infiltrate. Direct immunofluorescence revealed linear deposition of IgG, IgA, IgM, and C3 along the dermo–epidermal junction.

Indirect immunofluorescence on salt-split skin demonstrated dermal (floor) binding. Testing using transfected cells expressing type VII collagen was negative, consistent with a seronegative form of bullous lupus erythematosus. ELISA for BP180 was also negative.

Conclusion

Bullous lupus erythematosus does not correlate with SLE disease activity or severity; however, it is frequently associated with systemic involvement, most commonly renal (approximately 50%) and haematological (45%), and less frequently neuropsychiatric (7%), according to recent literature.

Anti-BP180 antibodies, detected in 0–25% of BLE cases, may reflect several pathogenetic mechanisms. Epitope spreading represents a plausible explanation for their presence. In cases associated with neuropsychiatric lupus, chronic central nervous system inflammation may expose neuronal isoforms of BP180, triggering circulating autoantibody production, as reported in other neurological conditions without clinical bullous pemphigoid. Additionally, chronic cutaneous inflammation in SLE may expose epidermal BP180, promoting autoantibody generation.

Seronegative forms account for approximately 30% of BLE cases, while anti–type VII collagen antibodies are detected in 67–69% of patients. This seronegativity may reflect alternative antigenic targets, including the NC2 domain or the triple-helical region of type VII collagen, as suggested in recent studies. It is also possible that low or transient autoantibody titres escape detection using conventional assays.

The immunological heterogeneity of bullous lupus erythematosus reflects a complex and dynamic autoimmune response. The coexistence of multiple antigenic targets or complete seronegativity poses significant diagnostic challenges, underscoring the need for comprehensive and multimodal immunopathological evaluation.

EADV CONGRESS
VIENNA
30 SEP - 3 OCT 2026

Abstract N°: 3632

Alterations of the oral microbiota in pemphigus vulgaris: novel diagnostic opportunities

Anna Pira[1], Feliciana Mariotti[1], Mauro Truglio[2], Giulia Pascolini[3], Jo Linda Maria Sinagra[3], Tiziano Tonanzi[3], Biagio Didona[3], Enea Gino Di Domenico[2], Giovanni Di Zenzo*[1]

[1] Istituto Dermopatico dell'Immacolata (IDI)-IRCCS, Rome, Italy

[2] Microbiology and Virology, San Gallicano Dermatological Institute, Rome, Italy

[3] Rare Diseases Center, Istituto Dermopatico dell'Immacolata (IDI)-IRCCS, Rome, Italy

Introduction

Pemphigoid (PE) and pemphigus vulgaris (PV) are autoimmune blistering diseases characterized by autoantibodies directed against different structural components of the skin and mucous membranes and by the formation of subepithelial and intraepithelial blisters, respectively. When oral involvement is the only clinical manifestation, differential diagnosis may be challenging. Oral PV is often associated with a characteristic fetor that is usually absent in PE, but its biological basis remains unclear. Because mucosal damage may reshape local microbial communities, disease-specific oral microbiota profiles may contribute to this feature. This study investigated whether oral PV and PE spectrum disorders are associated with distinct oral microbial profiles and whether specific bacterial signatures are linked to the characteristic fetor observed in PV patients.

Materials and Methods

A total of 20 PV patients with oral involvement, 19 PE patients with or without oral lesions, and 20 healthy donors (HD) were enrolled. Oral microbiota samples were collected by oral swab and analyzed through sequencing of the V1–V3 hypervariable regions of bacterial 16S rRNA.

Results

Alpha diversity analysis showed that the three groups (PE, PV, and HD) had comparable overall diversity (Shannon index) and evenness (Pielou index). By contrast, species richness and phylogenetic diversity, measured by Chao1 and Faith's PD, progressively declined from HD to PV and PE, indicating a selective reduction in oral microbial complexity.

The Jaccard index, based on microbial presence/absence, showed significant differences between HD and PE ($p = 0.0015$) and between PV and PE ($p = 0.0015$), whereas HD and PV differed only marginally ($p = 0.0379$). These findings indicate that PE is associated with a distinct oral microbial community composition, mainly driven by the loss or acquisition of low-abundance taxa rather than by major shifts in dominant species.

LEfSe analysis identified discriminant microbial taxa in HD and PV patients, whereas no enriched taxa were detected in the PE group in comparison with HD. This lack of biomarkers in PE is consistent with the reduced microbial richness and phylogenetic diversity observed. Conversely, compared with both HD and PE patients, the PV group showed enrichment of several bacterial genera potentially associated with oral inflammation and halitosis, including *Fusobacterium, Porphyromonas, Leptotrichia, Capnocytophaga, Aggregatibacter, Allisonella,* and *Peptostreptococcus.* These bacteria may exert a direct pathogenic role or provide ecological support for pathogenic species.

The enrichment of predominantly anaerobic genera associated with volatile sulfur compounds suggests that the characteristic fetor of PV may result from underlying mucosal barrier damage, leading to the formation of anaerobic niches (intraepidermal blisters) that favor colonization by anaerobic, odor-producing bacteria.

Conclusions

Oral PV and PE spectrum disorders display distinct microbial signatures despite partially preserved global diversity metrics. In PV, enrichment of anaerobic and inflammation-associated taxa provides a plausible microbial basis of the characteristic oral fetor and identifies candidate biomarkers for future diagnostic validation. These findings support further studies integrating microbiota profiling and volatile metabolite analysis that may lead to the development of a rapid, non-invasive diagnostic assay, potentially useful in cases with negative direct and indirect immunofluorescence and/or negative ELISA results, as well as for guiding molecular diagnostic investigations.

EA DV CONGRESS
VIENNA
30 SEP - 3 OCT 2026

Abstract N°: 3637

Erosive oral lichen planus in a paediatric patient with circulating autoantibodies

Mohammad Azouagh*[1], Mariem Tabka[1], Feryel Amri[1], Asmahane Souissi[1], Rihab Sayari[2], Lilia Laadhar[2], Mourad Mokni[1], Maryam Kallel Sellami[2]

[1] Dermatology department, La Rabta Hospital, Tunis, Tunisia
[2] Immunology department, La Rabta Hospital, Tunis, Tunisia

Introduction

Erosive oral lichen planus (EOLP) is an uncommon entity in the paediatric population. Its diagnosis may be challenging due to clinical and immunological overlap with autoimmune blistering diseases (AIBDs), particularly mucous membrane pemphigoid and pemphigus vulgaris. We report a paediatric case of histologically confirmed EOLP associated with circulating autoantibodies typically observed in AIBDs.

Case Presentation

A 14-year-old adolescent with no significant past medical history presented with recurrent oral erosions evolving over a two-year period, causing significant pain and functional impairment. Clinical examination revealed a reticular whitish lichenoid network on the buccal mucosa associated with erosive gingivitis. Cutaneous and extra-oral mucosal examination was unremarkable.

Histopathological analysis demonstrated acanthotic, hyperkeratotic and hypergranular epithelium with a dense band-like lymphocytic infiltrate obscuring the dermo-epidermal junction, saw-tooth rete ridges, and Civatte bodies, without evidence of subepithelial clefting, consistent with EOLP. Direct immunofluorescence was negative, thereby excluding mucous membrane pemphigoid.

Enzyme-linked immunosorbent assay (ELISA) revealed circulating anti-BP180, anti-BP230, and anti-desmoglein 1 and 3 autoantibodies. In light of the clinico-pathological correlation and negative direct immunofluorescence findings, a diagnosis of EOLP was retained. Viral serologies, including hepatitis B and C, were negative. The patient was treated with intralesional corticosteroid injections (triamcinolone acetonide), resulting in marked clinical improvement.

Conclusion

EOLP is exceedingly rare in children. In the present case, no classical triggering factors, such as medications, dental materials, or viral infections, were identified. The originality of this observation lies in the presence of multiple circulating autoantibodies typically associated with AIBDs. This finding may be explained by the exposure of cryptic antigens leading to a non-specific humoral immune response.

The absence of linear deposits on direct immunofluorescence, together with consistent clinical and histopathological features, allowed exclusion of mucous membrane pemphigoid and pemphigus vulgaris, supporting the diagnosis of EOLP.

This case highlights the need for cautious interpretation of serological findings in erosive oral lichen planus, particularly in paediatric patients, in order to avoid misdiagnosis of autoimmune blistering diseases.

EADV Congress 2026, VIENNA
30 SEPTEMBER - 03 OCTOBER 2026
POWERED BY M-ANAGE.COM

EA DV CONGRESS
VIENNA
30 SEP - 3 OCT 2026

Abstract N°: 3642

Pemphigus vulgaris and antiphospholipid syndrome – a possible immunological overlap

Ralitsa Kompanska*[1], Kamelia Kukova[1], Dimitrina Serafimova[1], Elia Valeva[1], Snejina Vassileva[1], Kossara Drenovska[1]

[1] Department of Dermatology and Venereology, Medical University – Sofia, Sofia, Bulgaria, Sofia, Bulgaria

Introduction

Pemphigus vulgaris (PV) is a rare autoimmune blistering disease mediated by autoantibodies against desmosomal adhesion proteins, leading to mucocutaneous blistering and erosions. Pemphigus patients, particularly with severe or long-standing disease, may have a higher risk of developing venous thrombosis. Antiphospholipid syndrome (APS) is a systemic autoimmune disorder characterized by recurrent arterial and venous thrombosis associated with antiphospholipid (aPL) antibodies. The coexistence of PV and APS is an extremely rare autoimmune overlap which poses substantial diagnostic and therapeutic challenges, particularly due to the increased thrombotic risk, long-term immunosuppressive treatment, and potential corticosteroid-related complications.

Case Presentation

We report a 37-year-old woman with clinically, histopathologically and immunologically confirmed severe muco-cutaneous PV of 6 months duration that was initially treated with high dose systemic corticosteroids and adjuvants. The patient's medical history was notable also for concomitant APS diagnosed 10 years before without current therapy. At observation, solitary bullous lesions on the scalp progressively evolving into painful erosions as well as solitary oral lesions were observed. In the course of treatment the patient complained of severe arthralgia, myalgia and fatigue limiting her daily activities. Later she developed significant corticosteroid-related complications, including osteonecrotic bone infarctions of the femoral bones, recurrent joint effusions, steroid-induced glaucoma and finally deep vein thrombophlebitis of the lower extremities.

Routine laboratory investigations revealed mild leukocytosis, elevated inflammatory markers and urinary abnormalities including clinically insignificant hematuria and proteinuria. Coagulation status demontrated significantly prolonged INR and activated partial thromboplastin time (aPTT), consistent with the patient's underlying APS and anticogulant therapy. aPL antibodies were not detectable. Histopathological examination, direct immunofluorescence and immunoserological tests have been confirmative for PV. Magnetic resonance imaging demonstrated necrosis of the right hip joint and femoral head. Due to the above-mentioned complications and poor disease control, rituximab therapy was initiated in the course of tapering of the systemic corticosteroid. This, together acenocoumarol and topical corticosteroids resulted in marked clinical response.

Conclusion

PV and APL are both related to a higher thrombotic risk.

Their association, although rare, may be driven by underlying, shared autoimmune mechanisms that generate aPLs, such as IgM or IgG anticardiolipin antibodies, leading to thrombosis.

Some evidence suggests that elevated antiphospholipid antibodies can occur in autoimmune blistering diseases, but they do not always manifest as full-blown anti-phospholipid syndrome. Additionally, t he combination of chronic autoimmune inflammation, thrombotic predisposition, and prolonged immunosuppressive therapy may result in severe systemic complications and increased morbidity. Therefore, close monitoring for vascular, thromboembolic events is recommended for patients with

extensive pemphigus. Treatments such as rituximab, which targets CD20+ B-cells, have been used in cases of co-existing conditions to address both the autoimmune blistering and potential underlying, systemic autoimmunity.
Early recognition of this overlap syndrome and a multidisciplinary approach are essential for optimal disease control and prevention of long-term complications.

EADV CONGRESS
VIENNA
30 SEP - 3 OCT 2026

Abstract N°: 3643

Pemphigus foliaceus mimicking seborrheic dermatitis and subacutecutaneous lupus erythematosus: a diagnostic odyssey resolved byrepeat biopsy

Raul Cartagena Rossi*[1], Mariana Menezes de Mauro[2], Grace Lugnani Lopes Oliveira[3], Rosangela Ramirez Taborda[4], Diogo Pazzini Bomfim[5], Julia Laluce Cardoso[6]

[1] Universidade de Taubaté, Taubaté, Brazil
[2] Universidade São Francisco, Universidade Paranaenese Unipar, Universidade Positivo, Bragança Paulista, Brazil
[3] Universidade Paranaenese Unipar, PARANA, Brazil
[4] Universidade Positivo, Curitiba, Brazil
[5] Universidade Federal de São Paulo, São Paulo, Brazil
[6] Instituto Lauro de Souza Lima, Bauru, Brazil

Introduction

Pemphigus foliaceus (PF) is an autoimmune blistering disorder mediated by IgG autoantibodies against desmoglein-1, resulting in acantholysis within the superficial layers of the epidermis. In its early stages, PF may mimic seborrheic dermatitis or — when lesions are photodistributed with facial involvement — subacute cutaneous lupus erythematosus (SCLE), leading to diagnostic delay and inappropriate treatment.



Figure 1. Close-up of the face demonstrating erythematous patches and superficial erosions with crusting over the malar cheeks and nasolabial folds, in a butterfly-like distribution reminiscent of pemphigus erythematosus (Senear-Usher syndrome), a clinical variant of pemphigus foliaceus.

Case Presentation

A 44-year-old previously healthy woman presented in August 2025 with pruritic erythematous-scaly papules and macules on the trunk and gluteal region, initially interpreted as an allergic reaction. She was treated with

prednisolone 40 mg/day without satisfactory response. Seborrhoeic-psoriasiform facial lesions subsequently appeared on the malar region with photosensitivity, raising the hypothesis of SCLE. Skin biopsy showed spongiotic dermatitis without interface dermatitis or acantholysis. Laboratory workup revealed negative ANA, anti-dsDNA, anti-Sm, anti-Ro and anti-La antibodies with normal complement levels, excluding systemic autoimmune disease. Given the clinico-laboratory discordance, systemic corticosteroid was withdrawn. Following discontinuation, the patient worsened significantly, developing flaccid blisters, widespread erosions on the trunk, buttocks and limbs, and a positive Nikolsky sign. Dermatological examination revealed erythematous-scaly lesions in seborrhoeic areas, eczematous plaques, grouped microvesicles, and a Koebner pattern. Repeat skin biopsy demonstrated superficial intraepidermal acantholysis with subcorneal cleavage and an eosinophil-rich inflammatory infiltrate, confirming pemphigus foliaceus. Treatment was initiated with deflazacort 1.2 mg/kg/day, with marked improvement within three weeks. As a secondary complication, the patient developed recurrent furunculosis due to staphylococcal hypercolonisation, managed with topical mupirocin for decolonisation and oral cefalexin for abscesses, with good response.



Figure 2. Posterior trunk showing widespread erythematous-to-violaceous patches, crusted erosions, and postinflammatory hyperpigmentation distributed over the upper back and interscapular region, consistent with the characteristic seborrheic distribution of pemphigus foliaceus.

Conclusion

PF may present atypically in its early stages or under corticosteroid use, closely mimicking seborrheic dermatites or SCLE. The absence of autoantibodies, interface dermatitis and mucin deposits argues against lupus. Corticosteroid withdrawal was decisive in allowing full clinical expression and definitive diagnosis. This case highlights the importance of clinico-pathological correlation and repeat biopsy when initial findings are non-specific.

EA DV CONGRESS
VIENNA
30 SEP - 3 OCT 2026

Abstract N°: 3648

Refractory ocular mucous membrane pemphigoid treated with rituximab and intravenous immunoglobulin

Ezgi Arslan Yavuz*[1], Azat Onur Arcan[1], Ezgi Aktaş[1]

[1] Prof. Dr. Cemil Taşcıoğlu City Hospital, Department of dermatology and venerology, Istanbul, Türkiye

Introduction

Mucous membrane pemphigoid (MMP) is a chronic autoimmune subepidermal blistering disease predominantly affecting mucosal surfaces and may lead to progressive scarring. Ocular involvement represents one of the most severe forms of the disease and can result in symblepharon, entropion, trichiasis, corneal damage, and visual loss. Diagnosis may be challenging in patients with isolated ocular involvement, as histopathological and immunopathological findings can occasionally be nonspecific or negative. Herein, we present a diagnostically challenging case of refractory ocular MMP with negative immunopathological findings that responded successfully to rituximab and intravenous immunoglobulin therapy.

Case Presentation

A 64-year-old man with a history of gout was referred for evaluation of persistent ocular complaints. He had been followed by ophthalmology for nearly two years because of bilateral burning, stinging, dryness, recurrent conjunctivitis episodes, and bilateral entropion. During this period, he underwent two separate entropion operations, however recurrence developed after both procedures and symptoms persisted.

Due to progressive ocular inflammation and persistent symptoms,a conjunctival biopsy was performed in July 2025.. Histopathological examination revealed diffuse polymorphic lymphoid infiltration without definitive subepithelial cleft formation.Upon referral to our clinic, repeat conjunctival biopsy specimens for histopathological and direct immunofluorescence examinations were obtained; however, due to existing conjunctival scarring and the risk of aggravating cicatricial changes, tissue sampling had to be performed in a limited manner. Histopatholohic examination demonstrated nonspesific findings and direct immunofluorescence examination was negative for immunoreactant deposition.. Despite negative immunopathological findings, the overall clinical findings were considered compatible with ocular mucous membrane pemphigoid.

The patient was initially treated with methylprednisolone 80 mg/day and mycophenolate mofetil 2 g/day. During follow-up, partial clinical improvement was observed, with mild regression of conjunctival inflammation and ocular findings. However, mycophenolate mofetil was discontinued because of severe elevation of liver transaminases. Following discontinuation of mycophenolate mofetil, liver enzyme levels returned to the normal range. Considering the persistence of severe ophthalmologic findings despite treatment, therapy was escalated to intravenous rituximab and intravenous immunoglobulin. Rituximab was administered as two infusions of 1000 mg given two weeks apart, together with intravenous immunoglobulin at a total dose of 2 g/kg.

Following combination therapy, significant clinical improvement was observed. Burning, dryness, and irritation symptoms decreased markedly, and recurrent conjunctivitis episodes became less frequent during follow-up. In addition, regression of conjunctival inflammation was noted on ophthalmologic examination.

Conclusion

This case highlights the diagnostic challenges of ocular MMP, particularly in patients with nonspecific histopathological findings and negative direct immunofluorescence results. Recurrent conjunctivitis accompanied by relapsing entropion should raise suspicion for ocular MMP even in the absence of confirmatory immunopathological findings. Rituximab combined with intravenous immunoglobulin may represent an effective therapeutic option in refractory ocular disease.

EA DV CONGRESS
VIENNA
30 SEP - 3 OCT 2026

Abstract N°: 3652

Paediatric IgA pemphigus : a rare case and literature review

Mohammad Azouagh*[1], Mariem Tabka[1], Feryel Amri[1], Chaima Nasri[1], Asmahane Souissi[1], Rihab Sayari[2], Lilia Laadhar[2], Mourad Mokni[1], Maryam Kallel Sellami[2]

[1] Dermatology department, La Rabta Hospital, Tunis, Tunisia
[2] Immunology department, La Rabta Hospital, Tunis, Tunisia

Introduction

Intercellular IgA dermatoses comprise a heterogeneous group of autoimmune blistering diseases characterised by interkeratinocyte IgA deposition directed against various keratinocyte surface antigens. Paediatric forms remain exceedingly rare. We report a case in an adolescent, highlighting the variability of immunopathological patterns within this entity.

Case Presentation

A 13-year-old girl with no relevant medical history and no recent drug exposure presented with an acute-onset, generalised, pruritic vesiculobullous eruption. Lesions initially involved the lower limbs, with subsequent centrifugal extension to the entire integument.

Clinical examination revealed vesiculobullous lesions containing clear to turbid fluid, associated with crusted erosions, symmetrically distributed and occasionally arranged in a rosette-like pattern. No mucosal involvement was observed.

Histopathological examination of a blister showed superficial acantholysis associated with a dermal inflammatory infiltrate rich in neutrophils and eosinophils.

Direct immunofluorescence demonstrated intercellular IgA deposition within the epidermis, associated with linear IgG deposition along the dermo–epidermal junction.

Serological investigations by ELISA were negative for desmoglein 1 and 3, envoplakin, type VII collagen, and BP180/BP230 antigens. In view of the clinico-pathological and immunological correlation, a diagnosis of intercellular IgA dermatosis, consistent with superficial IgA pemphigus, was established.

Treatment with systemic corticosteroids (prednisolone 0.5 mg/kg/day) combined with dapsone (2 mg/kg/day) resulted in complete remission within one month, allowing progressive tapering of corticosteroids. No relapse was observed after four months of follow-up.

Conclusion

To date, only 11 paediatric cases of IgA pemphigus have been reported, with a median age of 7 years (range 11 months–11 years) and a slight female predominance (sex ratio F/M = 1.2).

Clinically, lesions most often resemble those observed in linear IgA dermatosis or bullous impetigo. Mucosal

involvement has been reported in a minority of cases. Both subcorneal (7 cases) and intraepidermal (4 cases) variants have been described; our patient corresponds to the intraepidermal subtype.

In our case, direct immunofluorescence demonstrated, in addition to intercellular IgA deposition, linear IgG deposits along the dermo–epidermal junction, a finding less frequently reported but already described in the literature. Indeed, among published cases, three patients exhibited junctional IgA and/or IgG deposition, either linear (two cases) or granular (one case).

When performed, ELISA analyses have identified antibodies directed against desmocollins (1 case), desmoglein 3 (1 case), and a triple positivity for desmoglein 3, desmocollin 1, and desmoplakins (1 case), while other patients showed negative serology or were not investigated.

Negative desmoglein ELISA in our case does not exclude the diagnosis. This may reflect the limited sensitivity of conventional assays, which are primarily designed to detect IgG autoantibodies rather than IgA, or involvement of alternative targets such as desmocollins, which were not assessed in this patient.

Dapsone remains the mainstay of therapy in most reported cases.

This case highlights the importance of comprehensive immunological assessment in autoimmune blistering diseases. Precise identification of target antigens and recognition of immunopathological variability may contribute to improved characterisation of intercellular IgA dermatoses.

EA DV CONGRESS
VIENNA
30 SEP - 3 OCT 2026

Abstract N°: 3660

EGL-003 First in human study: An IL-2 Mutein inducing potent and selective amplification of Treg with preferential activation of effector/memory skin homing Tregs

Aurélie Auguste*[1], Anupama Karnam[1], Caroline Janot-Sardet[1], Erica Russo[1], Marco Pretti[1], Nedra Chriti[1], Sébastien Lemoine[1], Bernard Vanhove[1], Elsa Lheriteau[1], Cindy Orvain[1], Thiziri Nait Achour[1], Rebecca Tanzi[1], Sofia Giacosa[1], jonathan back[1], Dirk Palla[2], Kenji Hashimoto[1]

[1] Egle Therapeutics, Paris, France

[2] Parexel International GmbH, Berlin, Germany

Introduction

Regulatory T cells (Tregs) play a critical role in maintaining immune homeostasis by suppressing excessive immune responses and defects in Treg function have been linked to autoimmune and inflammatory diseases such as atopic dermatitis (AD). EGL-003 is a novel IL-2 mutein Fc-fusion protein with potent and selective Treg-expanding activity, with the potential to restore immune homeostasis.
This first-in-human study aims to evaluate the safety, tolerability, pharmacokinetics (PK), pharmacodynamics (PD) of EGL-003 (EU CT n° 2025-521658-40-00). The study includes a single ascending dose (SAD) phase in healthy volunteers, which will be followed by a multiple ascending dose (MAD) phase in patients with AD.

Materials and Methods

In the SAD, a total of 24 subjects were enrolled. Participants were healthy male and female volunteers aged 18–55 years. Subjects received a single subcutaneous injection at one of four ascending doses of EGL-003. Safety assessments included the number of treatment-related adverse events (TRAEs) as well as evaluations of vital signs, clinical laboratory tests, electrocardiograms (ECGs), and injection site reactions (ISRs). PK and PD were assessed until day 56. PD analyses included deep immunophenotyping of peripheral blood to evaluate Treg IL-2 signaling, activation, expansion, and expression of tissue-homing markers as well as cytokines analysis.

Results

EGL-003 was safe and well tolerated. The most frequent TRAEs were mild ISRs, which were self-limited.Cmax was dose proportional and no anti-drug antibodies were detected.

EGL-003 produced a rapid, robust, and dose-dependent PD activity that was highly selective for Tregs. Treatment resulted in strong IL-2 signaling in Tregs, along with marked activation. Robust upregulation of key Treg markers, including FOXP3, CD25, CTLA-4, ICOS, as well as enhanced proliferation (Ki67) and a dose-dependent rise in serum IL-10 levels, were observed.

This heightened activation translated into a substantial expansion of the Treg population over time and total Treg elevation was sustained through Day 28.

Importantly, EGL-003 preferentially amplified and activated effector/memory Tregs expressing skin homing markers.

Conclusions

EGL-003 demonstrates a favorable safety profile and induces potent, selective Treg activation with sustained expansion. Notably, EGL-003 preferentially activates effector/memory Tregs with a skin-homing profile. These findings support testing EGL-003 in a multiple ascending dose

EADV CONGRESS
VIENNA
30 SEP - 3 OCT 2026

Abstract N°: 3667

Vildagliptin-induced bullous Pemphigoid

Mohammad Azouagh*[1], Mariem Tabka[1], Feryel Amri[1], Aida Khadhar[2], Asmahane Souissi[1], Rihab Sayari[3], Lilia Laadhar[3], ines chelly[2], Mourad Mokni[1], Maryam Kallel Sellami[3]

[1] Dermatology department, La Rabta Hospital, Tunis, Tunisia
[2] Anatomopathology department, La Rabta Hospital, Tunis, Tunisia
[3] Immunology department, La Rabta Hospital, Tunis, Tunisia

Introduction

Drug-induced bullous pemphigoid (BP) represents an increasingly recognised model of iatrogenic autoimmunity. Among implicated agents, dipeptidyl peptidase-4 inhibitors (DPP-4i, gliptins), particularly vildagliptin, are most frequently associated. Despite this well-established link, clinical and immunological presentations remain heterogeneous and incompletely characterised. We report a clinico-immunological case illustrating this entity.

Case Presentation

A 66-year-old woman with a history of hypertension treated with a calcium channel blocker and type 2 diabetes mellitus managed with vildagliptin (introduced 18 months earlier) presented with a one-month history of a pruritic vesiculobullous eruption.

Clinical examination revealed tense, clear-fluid bullae arising on an erythematous urticarial base, involving the face, neck, trunk, and limbs, with occasional rosette-like configurations. Prominent mucosal involvement affected the oral, genital, and anal mucosae.

Histopathological examination demonstrated a subepidermal blister associated with a dermal lymphocytic and eosinophilic infiltrate. Direct immunofluorescence revealed strong linear IgG deposits along the dermo–epidermal junction, with moderate IgA and C3 deposition. Indirect immunofluorescence on salt-split skin showed a dual binding pattern.

Serological testing demonstrated strongly positive anti-BP180 NC16A antibodies (+++), with associated anti-BP230 positivity. Autoantibodies against type VII collagen (NC1), β4 integrin subunit, p200 protein, and laminin 332 were negative.

Withdrawal of vildagliptin, replaced by insulin therapy, combined with topical corticosteroids and low-dose systemic corticosteroids (0.5 mg/kg/day), led to complete resolution within one month. Corticosteroids were rapidly tapered, with no relapse observed after 10 months of follow-up.

Conclusion

Systematic reviews indicate that drug-induced BP tends to occur in relatively younger patients and is more frequently associated with mucosal involvement compared with idiopathic forms. These cases generally show favourable outcomes following drug withdrawal, often requiring only low-dose corticosteroid therapy, consistent

with our observation.

Meta-analyses have demonstrated that exposure to gliptins increases the risk of BP approximately threefold, with vildagliptin conferring a particularly high risk, estimated to be 3.4 times greater than that associated with other agents in this class.

The underlying pathophysiology remains incompletely understood. One proposed mechanism involves DPP-4 inhibition leading to altered plasmin activity, resulting in abnormal cleavage of haemidesmosomal proteins and subsequent induction of autoantibodies targeting BP180.

Additionally, observational studies have reported that gliptin-induced BP accounts for 15–27% of BP cases, often characterised by more frequent cephalic involvement and a more extensive initial presentation, followed by rapid improvement after drug discontinuation, as observed in our patient.

Gliptin-induced bullous pemphigoid represents a distinctive form of iatrogenic autoimmunity with frequently atypical clinical features. Early recognition of the offending drug is essential, as its withdrawal is associated with a favourable and often rapid clinical outcome.

EADV CONGRESS
VIENNA
30 SEP - 3 OCT 2026

Abstract N°: 3673

Pediatric Subcorneal Pustular Dermatosis Triggered by Mycobacterium abscessus: A Rare Association and Literature Review

Azzam Al Marbouai*[1]

[1] Sultan Qaboos University Hospital, Oman Medical Specialty Board, muscat, Oman

Introduction

Subcorneal pustular dermatosis (SPD), first described by Sneddon and Wilkinson in 1956, is a rare chronic relapsing neutrophilic dermatosis characterized by the development of sterile, flaccid, subcorneal pustules predominantly affecting the trunk and flexural areas[1]. The pathogenic mechanism is still unclear[2]. This condition affects middle-aged and elderly individuals, with female predominance, and pediatric cases are exceptionally uncommon [2]. Pediatric SPD is exceptionally rare, with only a few dozen cases reported worldwide to date, posing significant challenges for diagnosis and management in this age group. We describe SPD in an immunocompromised child with recurrent disease flares associated with *Mycobacterium abscessus* infection an unreported association. A link between SPD and non-tuberculous mycobacterial infections is suggested in this case, emphasizing the importance of early detection and targeted therapy. A successful treatment with systemic antibiotics provides new insights into the management of SPD in immunocompromised pediatric patients.

Case Presentation

A 6-year-old girl with interferon-gamma receptor II deficiency, post–bone marrow transplant complicated by graft rejection, was hospitalized multiple times due to recurrent non-tuberculous mycobacterial (NTM) infections.
In late 2020, she was diagnosed with *Mycobacterium fortuitum* lymphadenitis and improved with systemic antibiotics and anti-mycobacterium therapy. In November 2023, due to poor compliance with medication, she developed disseminated *Mycobacterium abscessus* infection with generalized lymphadenopathy and osteomyelitis. Concurrently, she presented with a diffuse pustular eruption over her trunk and extremities, which resolved within a week of systemic anti- mycobacterium treatment.
In August 2024, she was admitted again with suspected progression of disseminated NTM infection, presenting with lymphadenopathy, splenomegaly, and an asymptomatic skin eruption. The lesions symmetrically involved the intertriginous areas, trunk, and extremities, sparing the mucosa. They consisted of multiple coalescing flaccid pustules over an erythematous base. A lymph node biopsy was positive for *Mycobacterium abscessus*; lesions resolved with systemic anti-mycobacterium treatment. In November 2024, the patient was admitted with recurrence of a similar cutaneous presentation (Figure 1,2). Given the recurrence and complexity of the case, multiple differential diagnoses were considered, warranting further histopathological and microbiological evaluation.

Punch biopsies from the trunk revealed subcorneal pustules filled with neutrophils, consistent with subcorneal pustular dermatosis (SPD) (Figure 3), while tissue culture showed no growth. Notably, each recurrence of her SPD coincided with a flare of her NTM infection. Blood cultures identified *Mycobacterium abscessus*, which was exclusively sensitive to amikacin. Upon initiation of amikacin therapy, the patient demonstrated a dramatic clinical response, with significant resolution of both systemic and cutaneous manifestations.

Conclusion

This case expands the spectrum of infectious triggers associated with pediatric subcorneal pustular dermatosis by identifying disseminated non-tuberculous mycobacterial infection as a novel precipitating factor. In contrast to adult SPD, which more often follows an autonomous relapsing course and is commonly associated with plasma cell dyscrasias, pediatric SPD appears more frequently driven by infections and immune dysregulation. The close temporal relationship between systemic mycobacterial flares and cutaneous disease activity, supported by characteristic histopathology and rapid response to targeted antimicrobial therapy, suggests a reactive immune-mediated process rather than primary skin infection. Early recognition of this association and thorough systemic evaluation are essential, as prompt treatment of the underlying trigger can result in favorable outcomes even in complex immunocompromised pediatric settings.

EADV CONGRESS
VIENNA
30 SEP - 3 OCT 2026

Abstract N°: 3690

Efficacy of botulinum toxin in perniosis

Ignacio Hernandez Aragues*[1], Alba Navarro Bielsa[2], Marcial Álvarez Salafranca[1], Itziar Muelas Rives[1], Beatriz Clemente Hernández[1], Tamara Gracia Cazaña[1], Yolanda Gilaberte Calzada[1]

[1] Hospital Universitario Miguel Servet, Zaragoza, Spain
[2] Hospital San Pedro, Logroño, Spain

Introduction

Perniosis (chilblains) is a localized inflammatory vascular disorder triggered by cold exposure. While many cases respond to conservative measures, a subset of patients remains refractory to first-line therapies, including potent topical corticosteroids and systemic calcium channel blockers like nifedipine. Given the vasodilatory and neuromodulatory effects of Botulinum Toxin Type A (BTX-A), it has emerged as a potential therapeutic alternative, similar to its application in Raynaud's phenomenon. Recently, the use of Botulinum Toxin Type A (BTX-A) has been extrapolated from protocols for Raynaud's Phenomenon. The rationale lies in its ability to inhibit the release of acetylcholine from pre-ganglionic sympathetic nerves and, crucially, to downregulate alpha-2-adrenergic receptors and inhibit the release of nociceptive neuropeptides like Substance P and Calcitonin Gene-Related Peptide (CGRP). This dual action reduces both cold-induced vasospasm and neurogenic inflammation.
This study evaluates the efficacy and safety of BTX-A in patients with chronic, treatment-resistant perniosis.

Materials and Methods

We conducted a retrospective study of 5 adult patients (4 females, 1 male; mean age 51.4 years, range 42–59) diagnosed with refractory perniosis. All patients had previously failed treatment with potent topical corticosteroids and intensive emollient therapy; three patients had also shown poor response or intolerance to oral nifedipine.

The intervention consisted of injecting Onabotulinum toxin A using a technique adapted from digital vasospastic protocols. A dose of **5 IU** was administered at each lateral aspect of the base of each affected digit (totaling 10 IU per finger). Clinical efficacy was assessed at baseline and at a 3-month follow-up using the **Dermatology Life Quality Index (DLQI)**, the **Visual Analogue Scale (VAS)** for pain/burning sensations, and a standardized clinical evaluation of erythema, violaceous tone, and edema.

Results

At the 3-month evaluation, all five patients demonstrated significant clinical and symptomatic improvement.

- **Pain & Sensations:** The mean VAS score decreased from **7.6 (±1.2)** at baseline to **1.4 (±0.8)** post-treatment.
- **Quality of Life:** Mean DLQI scores improved from **15.2 (±3.4)** to **3.8 (±1.5)**, reflecting a substantial reduction in the disease's impact on daily activities.
- **Clinical Appearance:** A marked reduction in the erythematous-violaceous hue and digital edema was observed in 100% of the cohort.

The procedure was well-tolerated. Notably, there were no reported instances of intrinsic muscle weakness,

specifically regarding the **thumb pinch strength**, nor were any other systemic or local adverse effects recorded during the follow-up period.

Conclusions

Botulinum Toxin Type A appears to be a safe and highly effective "off-label" intervention for patients suffering from refractory perniosis. By targeting the underlying vasospasm and inflammatory cycle, BTX-A provides sustained symptomatic relief and clinical clearance where conventional therapies fail. The 10 IU per finger dose (split laterally) appears sufficient to achieve clinical remission without compromising motor function. Given the lack of standardized treatments for refractory cases, BTX-A represents a promising second- or third-line intervention that warrants further investigation in larger prospective trials. L

EA DV CONGRESS
VIENNA
30 SEP - 3 OCT 2026

Abstract N°: 3697

Chin and Auricular Involvement as a Possible Diagnostic Clue in Comedonal Chronic Discoid Lupus Erythematosus

Gaia Bellesi*[1], Ingrid Šutić Udović[1, 2], Lucija Marcelić[1, 2], Vilma Grbas Kranjčević[1, 2], Katarina Dujmovic-Hasanbegovic[1, 2], Sandra Peternel[1, 2]

[1] Clinical Hospital Center Rijeka, Rijeka, Croatia

[2] Faculty of Medicine, University of Rijeka, Rijeka, Croatia

Introduction

Comedonal chronic discoid lupus erythematosus (CDLE) is a rare variant of cutaneous lupus erythematosus characterized by acneiform lesions, comedones, cysts, and follicular plugging, frequently resulting in delayed diagnosis. Due to its clinical and histopathological overlap with acne vulgaris, hidradenitis suppurativa, milia en plaque, epidermal cysts, and folliculotropic mycosis fungoides (FMF), recognition remains challenging. We present three female patients with comedonal CDLE sharing a strikingly similar distribution involving the chin and auricular/retroauricular regions, suggesting a possible predilection pattern and clinically valuable diagnostic sign.

Case Presentation

Patient 1, a 35-year-old woman, presented with persistent comedones and atrophic scarring on the lateral chin and both peri-/retroauricular regions. Histopathology demonstrated markedly dilated keratin-filled follicles with perifollicular CD3+/CD4+ lymphocytic infiltrates and numerous CD123+ cells, favoring comedonal CDLE over FMF. During follow-up, lesions recurred on the chin, retroauricular areas, glabella, cheek, and intermammary region despite treatment with hydroxychloroquine, methotrexate, isotretinoine, azathioprine, doxycycline, intralesional triamcinolone.

Patient 2, a 56-year-old woman with hypothyroidism, developed recurrent milia-like lesions on the lateral chin and both auricles over several years. Lesions temporarily regressed following electrocautery but relapsed repeatedly. Clinical examination showed grouped yellowish milia and comedones around an atrophic scar on the chin, as well as milia and comedones involving the auricular conchae and preauricular skin. Comedonal CDLE was confirmed with biopsy and direct immunofluorescence and the patient started on intralesional triamcinolone therapy.

Patient 3, a 57-year-old woman with Crohn disease, hypertension, glaucoma, and hypothyroidism, had a 10-year history of retroauricular lesions preceding involvement of the chin and cheeks. Examination revealed erythematous infiltrated plaques with numerous comedones on the retroauricular areas, chin, and cheeks. Histopathology showed hyperkeratosis, vacuolar degeneration of basal keratinocytes, basement membrane thickening, follicular plugging, dermal mucin deposition, and papillary dermal fibrosis. Direct immunofluorescence demonstrated granular-to-band-like deposits of IgG, IgA, IgM, and C3 along the basement membrane zone, confirming discoid lupus erythematosus and excluding FMF. The patient refused proposed systemic treatment and was lost at follow up.

Conclusion

Comedonal CDLE is an uncommon and frequently underrecognized variant of cutaneous lupus erythematosus that may mimic multiple follicular and acneiform disorders, particularly FMF. In all three patients, lesions consistently involved the lateral chin and auricular/retroauricular regions, with auricular involvement preceding chin lesions in

one case. This recurrent distribution pattern may represent a characteristic predilection site and potentially a clinically useful sign of comedonal CDLE. Awareness of this characteristic localization pattern, together with clinicopathological and immunopathological correlation, may facilitate earlier recognition of comedonal CDLE, reduce diagnostic delay, and help prevent irreversible scarring and disfiguring sequelae.

EA DV CONGRESS
VIENNA
30 SEP - 3 OCT 2026

Abstract N°: 3698

Upadacitinib in Adults and Adolescents With Severe Alopecia Areata: Efficacy and Safety Results from Week 52 of the UP-AA1 and UP-AA2 Phase 3 Clinical Trials

Arash Mostaghimi*[1], Melinda Gooderham[2, 3, 4], Charles Lynde[5, 6, 7], Rodney Sinclair[8, 9], Brett King[10], Maria Hordinksy[11], Lidia Rudnicka[12], Emma Guttman-Yassky[13], Diamant Thaçi[14], Ignasi Figueras-Nart[15], Marni Wiseman[16, 17], Ramona Vladea[18], Sebastian Meerwein[19], Ahmed M Soliman[18], Xianwei Bu[18], Chenyang Duan[18], Tianshuang Wu[18], Henrique Teixeira[18], Andreas Lazar[19], Thierry Passeron[20, 21]

[1] Department of Dermatology, Brigham and Women's Hospital, Boston, MA, United States
[2] SKiN Centre for Dermatology, Probity Medical Research, Peterborough, ON, Canada
[3] Probity Medical Research, Peterborough, ON, Canada
[4] Department of Medicine, Queen's University, Kingston, ON, Canada
[5] Division of Dermatology, Temerty Faculty of Medicine, University of Toronto, Toronto, ON, Canada
[6] The Lynde Institute for Dermatology & Lynderm Research Inc., Markham, ON, Canada
[7] Probity Medical Research Inc., Markham, ON, Canada
[8] Department of Medicine, University of Melbourne, Melbourne, Victoria, Australia
[9] Sinclair Dermatology, Melbourne, Victoria, Australia
[10] Dermatology Physicians of Connecticut, Fairfield, CT, United States
[11] Department of Dermatology, University of Minnesota Medical School, Minneapolis, MN, United States
[12] Department of Dermatology, Medical University of Warsaw, Warsaw, Poland
[13] Department of Dermatology and the Laboratory for Inflammatory Skin Diseases, Icahn School of Medicine at Mount Sinai, New York, NY, United States
[14] Institute and Comprehensive Center for Inflammation Medicine, University of Lübeck, Lübeck, Germany
[15] Bellvitge Hospital, University of Barcelona, Barcelona, Spain
[16] Section of Dermatology, Department of Medicine, University of Manitoba, Winnipeg, MB, Canada
[17] SKiNWISE Dermatology, Winnipeg, MB, Canada
[18] AbbVie Inc., North Chicago, IL, United States
[19] AbbVie Deutschland GmbH & Co. KG, Ludwigshafen, Germany
[20] INSERM U 1065, Centre Méditerranéen de Médecine Moléculaire (C3M), Côte d'Azur University, Nice, France
[21] Department of Dermatology, Centre Hospitalier Universitaire de Nice, Côte d'Azur University, Nice, France

Introduction

Alopecia areata (AA), a chronic, systemic immune-mediated disease, is characterized by non-scarring hair loss. In period A of the ongoing phase 3 clinical trial program (UP-AA; NCT06012240) investigating upadacitinib (UPA) for the treatment of severe AA in adults and adolescents, UPA demonstrated higher efficacy than placebo (PBO) and no new safety signals following 24 weeks of treatment. Here, we report the efficacy and safety of UPA through 52 weeks of treatment.

Materials and Methods

Patients aged 12-63 years with severe AA (Severity of Alopecia Tool [SALT] score ≥50) were randomized 2:2:1 to UPA 15 mg (UPA15), UPA 30 mg (UPA30), or PBO once daily for 24 weeks (period A; double-blinded) and a 28-

week blinded extension treatment period (period B) in 2 parallel replicate studies (UP-AA1 and UP-AA2). Patients initially randomized to PBO who achieved SALT score ≤20 at week 24 remained on PBO in period B; those with a SALT score >20 at week 24 were re-randomized 1:1 to one of 2 blinded treatment groups: UPA15 or UPA30. Patients originally randomized to UPA15 or UPA30 continued the same treatment in period B. At week 40, patients achieving <30% improvement in SALT score were assigned open-label UPA30; those without any improvement in SALT score were discontinued. Multiple efficacy endpoints related to improvements in measures of extent of hair loss and health-related quality of life (HRQoL) were assessed through week 52. Safety was assessed by adverse event (AE) monitoring (reported as events/100 patient-years [PYs]), laboratory tests, and vital signs.

Results

A total of 1399 patients (UP-AA1, n=676; UP-AA2, n=723) were enrolled in the trials. Demographics and baseline characteristics were well balanced, with mean [SD] SALT scores (83.9[18.9]) and mean [SD] episode duration in years (3.1[2.2]) across all groups. At week 52, for patients randomized to UPA15 and UPA30 at baseline, 59.3% and 63.8%, respectively (UP-AA1) and 55.0% and 63.3%, respectively (UP-AA2) achieved SALT score ≤20. Furthermore, 28.5% and 26.6% of patients on UPA15 and 35.8% and 37.0% on UPA30 in UP-AA1 and UP-AA2, respectively, achieved the stringent endpoint of SALT score 0 at week 52. Efficacy across measures of SALT, clinician-reported outcomes for eyebrows and eyelashes, and HRQoL continued to improve in period B (Table 1). As reported in period A, response rates for most key endpoints in adolescents were numerically higher than in adults in period B. At week 52, in adolescent patients randomized to UPA15 (UP-AA1, n=25; UP-AA2, n=23) and UPA30 (UP-AA1, n=26; UP-AA2, n=21) at baseline, 76.0% and 88.5%, respectively (UP-AA1) and 60.9% and 85.7%, respectively (UP-AA2) achieved SALT score ≤20; 40.0% and 65.4%, respectively (UP-AA1) and 34.8% and 52.4%, respectively (UP-AA2) achieved SALT score 0. For patients on UPA who achieved SALT score ≤20 at week 24, >90% maintained the response at week 52 across both doses and studies. The safety profile of both doses of UPA through week 52 was consistent with that observed at week 24 and in approved indications (Table 2). Across both studies, the most commonly reported treatment-emergent AEs (≥5/100PYs in any UPA group) included upper respiratory tract infection, acne, nasopharyngitis, blood creatine phosphokinase increase, folliculitis, oral herpes, influenza, and headache. One event each of adjudicated venous thromboembolism, adjudicated major adverse cardiovascular events, and breast cancer were reported. No deaths were reported.

Table 1. Achievement of Key Efficacy Endpoints at Week 52[a,b]

	UP-AA1		UP-AA2	
	UPA 15 mg[c] N = 270	UPA 30 mg[c] N = 271	UPA 15 mg[c] N = 289	UPA 30 mg[c] N = 289
SALT score ≤ 20, n (%)	160 (59.3)	173 (63.8)	159 (55.0)	183 (63.3)
SALT score ≤ 10, n (%)	140 (51.9)	150 (55.4)	141 (48.8)	163 (56.4)
SALT score 0, n (%)	77 (28.5)	97 (35.8)	77 (26.6)	107 (37.0)
ClinRO for eyebrow hair loss score of 0 or 1 with a ≥2-point improvement from BL[d], n/N (%)	101/170 (59.4)	119/178 (66.9)	98/192 (51.0)	137/197 (69.5)
ClinRO for eyelash hair loss score of 0 or 1 with a ≥2-point improvement from BL[d], n/N (%)	84/151 (55.6)	103/145 (71.0)	85/166 (51.2)	109/158 (69.0)
Change from BL in Skindex-16 AA Emotions Domain scores, LS Mean (SE)	-32.3 (2.1)	-37.5 (2.0)	-32.3 (1.9)	-35.2 (1.9)
Change from BL in Skindex-16 AA Functioning Domain scores, LS Mean (SE)	-22.7 (1.8)	-26.1 (1.8)	-23.8 (1.7)	-25.1 (1.7)

[a]The list of endpoints is not comprehensive. The complete list will be included in a future peer reviewed publication. [b]Missing data and intercurrent events were handled using the NRI approach for binary endpoints and the RTB-MI approach for continuous endpoints. [c]Patients reported here are those who continued on the same dose of UPA through 52 weeks. [d]Among patients with score ≥ 2 at baseline. SALT score ≤ 20 is defined as less than or equal to 20% scalp hair loss. SALT score ≤ 10 is defined as less than or equal to 10% scalp hair loss. SALT score 0 is defined as 0% scalp hair loss. The ClinRO for eyebrow hair loss is comprised of the following response options: 0 = The eyebrows have full coverage and no areas of hair loss; 1 = There are minimal gaps in eyebrow hair and distribution is even; 2 = There are significant gaps in eyebrow hair or distribution is not even; 3 = No notable eyebrows. The ClinRO for eyelash hair loss is comprised of the following response options: 0 = The

eyelashes form a continuous line along the eyelids on both eyes; 1 = There are minimal gaps and the eyelashes are evenly spaced along the eyelids on both eyes; 2 = There are significant gaps along the eyelids or the eyelashes are not evenly spaced along the eyelids; 3 = No notable eyelashes. AA, alopecia areata; BL, baseline; ClinRO, clinician-reported outcome; LS, least square; NRI, nonresponder imputation; RTB-MI, return-to-baseline incorporating multiple imputation; SALT, Severity of Alopecia Tool; SE, standard error; UPA, upadacitinib.

Conclusions

At week 52 of the phase 3 UP-AA clinical trial program, both UPA15 and UPA30 led to clinical improvements in hair regrowth and HRQoL in substantial proportions of patients and showed maintenance of a positive benefit/risk profile in adults and adolescents with severe AA. The safety profile for UPA in AA was generally consistent with that reported in approved indications; no new safety signals were identified.

Table 2. Patients With Treatment-Emergent Adverse Events Through Week 52

	UP-AA1		UP-AA2	
TEAE, Events (E/100PY)	**Any UPA 15 mg (N = 331) (PYs = 273.8)**	**Any UPA 30 mg (N = 393) (PYs = 297.3)**	**Any UPA 15 mg (N = 355) (PYs = 286.8)**	**Any UPA 30 mg (N = 421) (PYs = 319.4)**
Any TEAE	741 (270.6)	948 (318.9)	948 (330.5)	2007 (315.2)
SAEs	11 (4.0)	25 (8.4)	10 (3.5)	11 (3.4)
AEs leading to discontinuation of study drug	7 (2.6)	11 (3.7)	4 (1.4)	9 (2.8)
Deaths	0	0	0	0
AESIs				
Serious infections	2 (0.7)	2 (0.7)	4 (1.4)	4 (1.3)
Opportunistic infection excluding TB and herpes zoster	0	0	0	0
Active tuberculosis	0	0	0	0
Herpes zoster	5 (1.8)	9 (3.0)	13 (4.5)	16 (5.0)
Malignancy	1 (0.4)[a]	0	0	0
Hepatic disorder	15 (5.5)	45 (15.1)	22 (7.7)	17 (5.3)
Adjudicated GI perforations	0	0	0	0
Anemia	9 (3.3)	10 (3.4)	3 (1.0)	5 (1.6)
Neutropenia	11 (4.0)	18 (6.1)	11 (3.8)	25 (7.8)
Lymphopenia	3 (1.1)	6 (2.0)	2 (0.7)	6 (1.9)
Renal Dysfunction	0	0	0	0
Elevated CPK	39 (14.2)	48 (16.1)	23 (8.0)	38 (11.9)
Adjudicated MACE	0	0	0	1 (0.3)[b]
Adjudicated VTE	0	0	1 (0.3)[c]	0
Bone Fractures	4 (1.5)	5 (1.7)	8 (2.8)	2 (0.6)
Retinal Detachment	2 (0.7)[d]	0	0	0
Serious Hypersensitivity Reactions	0	0	0	0

[a]One patient with pre-existing nodules on mammogram reported breast cancer in the UPA 15 mg group in UP-AA1 after approximately 4 months in the study. [b]One patient with several risk factors reported ischemic stroke on UPA 30 mg in UP-AA2. [c]One patient with multiple risk factors reported VTE on UPA 15 mg in UP-AA2. [d]Both events occurred in one adult patient who experienced retinal detachment with a concurrent TEAE of retinal tear approximately 5 months after starting the study drug. AE, adverse event; AESI, adverse event of special interest; CPK, creatine phosphokinase; GI, gastrointestinal; MACE, major adverse cardiovascular event; SAE, serious adverse event; TB, tuberculosis; TEAE, treatment-emergent adverse event; UPA, upadacitinib; VTE, venous thromboembolic event.

EADV CONGRESS
VIENNA
30 SEP - 3 OCT 2026

Abstract N°: 3704

Unusual Upper Limb Localization of Atrophoderma of Pasini and Pierini

imane denni*[1], Saadia Boughaleb[1], ikram bejja[1], Zakia Douhi[1], Meryem Soughi[1], Sara Elloudi[1], Hanane Baybay[1], Fatima Zohra Mernissi[1]

[1] Department of Dermatology, Hospital Hassan II University, FES, Morocco

Introduction

Atrophoderma of Pasini and Pierini is a rare dermatosis considered by many authors to be a superficial variant of morphea. It is characterized by hyperpigmented, slightly depressed plaques without significant induration or sclerosis. The condition mainly affects adolescents and young adults and most commonly involves the trunk. We report a rare case of upper limb involvement in an adolescent patient.

Case Presentation

A teenage patient with no significant medical history presented with an asymptomatic hyperpigmented lesion of the right arm evolving progressively over six months. Dermatological examination revealed a single well-demarcated brownish atrophic patch measuring approximately 8 cm on the lateral aspect of the right arm, without induration or inflammatory signs. Dermoscopy showed an irregularly distributed prominent pigment network with focal wavy patterns, associated with regular perifollicular white areas and preserved hairs.

Histopathological examination revealed mild dermal thinning, subtle collagen alteration, and a discrete perivascular inflammatory infiltrate without marked sclerosis, supporting the diagnosis of Atrophoderma of Pasini and Pierini. Routine laboratory investigations were unremarkable and no systemic involvement was detected. The patient was treated with topical corticosteroids with favorable evolution.

Conclusion

Atrophoderma of Pasini and Pierini is a rare benign condition that should be considered in adolescents presenting with asymptomatic hyperpigmented atrophic plaques. Histopathological examination remains essential to confirm the diagnosis and exclude other sclerosing or malignant disorders. Our case highlights an uncommon upper limb localization and emphasizes the importance of clinicopathological correlation.

EA DV CONGRESS
VIENNA
30 SEP - 3 OCT 2026

Abstract N°: 3705

Pediatric Subcorneal Pustular Dermatosis Triggered by Mycobacterium abscessus: A Rare Association and Literature Review

Azzam Al Marbouai*[1]

[1] Sultan Qaboos University Hospital, Al Seeb, Oman

Introduction

Subcorneal pustular dermatosis (SPD), first described by Sneddon and Wilkinson in 1956, is a rare chronic relapsing neutrophilic dermatosis characterized by the development of sterile, flaccid, subcorneal pustules predominantly affecting the trunk and flexural areas. The pathogenic mechanism is still unclear . This condition affects middle-aged and elderly individuals, with female predominance, and pediatric cases are exceptionally uncommon. Pediatric SPD is exceptionally rare, with only a few dozen cases reported worldwide to date, posing significant challenges for diagnosis and management in this age group. We describe SPD in an immunocompromised child with recurrent disease flares associated with *Mycobacterium abscessus* infection _an unreported association. A link between SPD and non-tuberculous mycobacterial infections is suggested in this case, emphasizing the importance of early detection and targeted therapy. A successful treatment with systemic antibiotics provides new insights into the management of SPD in immunocompromised pediatric patients.

Case Presentation

A 6-year-old girl with interferon-gamma receptor II deficiency, post–bone marrow transplant complicated by graft rejection, was hospitalized multiple times due to recurrent non-tuberculous mycobacterial (NTM) infections. In late 2020, she was diagnosed with *Mycobacterium fortuitum* lymphadenitis and improved with systemic antibiotics and anti-mycobacterium therapy. In November 2023, due to poor compliance with medication, she developed disseminated *Mycobacterium abscessus* infection with generalized lymphadenopathy and osteomyelitis. Concurrently, she presented with a diffuse pustular eruption over her trunk and extremities, which resolved within a week of systemic anti- mycobacterium treatment. In August 2024, she was admitted again with suspected progression of disseminated NTM infection, presenting with lymphadenopathy, splenomegaly, and an asymptomatic skin eruption. The lesions symmetrically involved the intertriginous areas, trunk, and extremities, sparing the mucosa. They consisted of multiple coalescing flaccid pustules over an erythematous base. A lymph node biopsy was positive for *Mycobacterium abscessus*; lesions resolved with systemic anti-mycobacterium treatment. In November 2024, the patient was admitted with recurrence of a similar cutaneous presentation (Figure 1,2). Given the recurrence and complexity of the case, multiple differential diagnoses were considered, warranting further histopathological and microbiological evaluation. Punch biopsies from the trunk revealed subcorneal pustules filled with neutrophils, consistent with subcorneal pustular dermatosis (SPD) (Figure 3), while tissue culture showed no growth. Notably, each recurrence of her SPD coincided with a flare of her NTM infection. Blood cultures identified *Mycobacterium abscessus*, which was exclusively sensitive to amikacin. Upon initiation of amikacin therapy, the patient demonstrated a dramatic clinical response, with significant resolution of both systemic and cutaneous manifestations.

Conclusion

This case expands the spectrum of infectious triggers associated with pediatric subcorneal pustular dermatosis by

identifying disseminated non-tuberculous mycobacterial infection as a novel precipitating factor. In contrast to adult SPD, which more often follows an autonomous relapsing course and is commonly associated with plasma cell dyscrasias, pediatric SPD appears more frequently driven by infections and immune dysregulation. The close temporal relationship between systemic mycobacterial flares and cutaneous disease activity, supported by characteristic histopathology and rapid response to targeted antimicrobial therapy, suggests a reactive immune-mediated process rather than primary skin infection. Early recognition of this association and thorough systemic evaluation are essential, as prompt treatment of the underlying trigger can result in favorable outcomes even in complex immunocompromised pediatric settings.

EADV CONGRESS
VIENNA
30 SEP - 3 OCT 2026

Abstract N°: 3729

Anetoderma revealing systemic lupus erythematosus

Amira Laribi*[1], Meriem Tabka[1], Feryel Amri[1], Asmahane Souissi[1]

[1] Rabta Hospital of Tunis, Tunis, Tunisia

Introduction

Anetoderma is a rare dermatosis characterized by focal loss of dermal elastic fibers, resulting in localized atrophic and flaccid skin lesions. Its association with autoimmune diseases, particularly systemic lupus erythematosus, has been well documented in the literature. We report a case of anetoderma revealing systemic lupus erythematosus in a child.

Case Presentation

A 12-year-old girl with no significant past medical history presented with the progressive appearance, over several months, of white atrophic macules located on the face, trunk, and upper
limbs.
Physical examination revealed well-demarcated, round plaques, slightly erythematous, with a wrinkled surface and a characteristic herniation phenomenon, located on the face, the left arm, and the trunk. Medical history indicated that the lesions had appeared spontaneously on
previously healthy skin. The patient also reported photosensitivity and inflammatory arthralgia.
Histopathological examination of a cutaneous macule, using orcein staining, demonstrated a marked reduction of the dermal elastic fiber network, consistent with primary anetoderma, which was therefore retained as the diagnosis.
The initial etiological workup, including HIV and syphilis serology as well as thyroid function tests, showed no abnormalities. Immunological investigations revealed positive antinuclear antibodies with a speckled pattern (1:800), strongly positive anti–double-stranded DNA antibodies, positive anti-extractable nuclear antigen antibodies, and weakly positive anti–β2 glycoprotein I IgG antibodies, with negative anti–β2 glycoprotein I IgM and anticardiolipin IgGand IgM antibodies. The diagnosis of anetoderma associated with systemic lupus erythematosus
was retained.

Conclusion

We report a case of anetoderma occurring in a child, highlighting the association of this condition with autoimmune diseases, particularly systemic lupus erythematosus. Several studies suggest that dermal microthrombotic events, promoted by immunological or prothrombotic
abnormalities, may induce local ischemia leading to degeneration of elastic fibers. In our observation, the diagnosis of lupus was established following the investigation of anetodermic lesions, emphasizing the potential role of anetoderma as a revealing manifestation of an underlying systemic disease.

This case highlights the importance of performing a systematic immunological workup in any
patient presenting with anetoderma in order to allow early detection of associated autoimmune
diseases, particularly systemic lupus erythematosus.

EADV CONGRESS
VIENNA
30 SEP - 3 OCT 2026

Abstract N°: 3732

Generalized Cutaneous Lichen Planus Following COVID-19 Vaccination

Nikola Skevov*[1], Slavyan Tamnev[1], Elia Valeva[1], Dimitrina Serafimova[1], Kossara Drenovska[1], Snejina Vassileva[1]

[1] Department of Dermatology and Venereology, Medical University - Sofia, Bulgaria, Sofia, Bulgaria

Introduction

Lichen planus (LP) is a chronic immune-mediated inflammatory dermatosis with unknown etiology affecting the skin and its adnexa, and/or mucosal surfaces. Several clinical variants of LP exist based on lesion morphology and localization, of which LP pigmentosus (LPP) is the less frequently reported. It often affects middle-aged adults with darker skin phototype and presents with irregularly shaped, dark brown-grey patches on sun exposed areas. Potential triggering factors include sun exposure, chemical trauma, and viral infections, namely hepatitis C virus infection. Increasing evidence suggests a possible association between COVID-19 vaccination and the onset or exacerbation of lichenoid dermatoses, including various forms of LP. We observed a case of generalized pigmented LP developing after COVID-19 vaccination.

Case Presentation

A 72-year-old Caucasian man of type IV phototype presented with a 4-year history of progressive asymptomatic darkening of the face, neck and skin folds that appeared shortly after administration of the third COVID-19 vaccine (Moderna) dose.

A comprehensive clinical, laboratory, histopathological and immunofluorescence (IF) evaluation was performed to establish the diagnosis and guide therapy.

Dermatological examination revealed large but well-demarcated dark-brown and grayish hyperpigmented macules on the skin of the forehead, cheeks, nasolabial

and perioral areas, the chin and submental crease. Similar smaller hyperpigmented macules and papules coalescing into plaques were symmetrically distributed on the volar wrists, axillae, groins, and medial lower legs. Mucous membranes were unaffected. Laboratory investigations showed elevated erythrocyte sedimentation rate and mildly increased fasting glucose, with otherwise unremarkable routine parameters and a negative hepatitis serology. Histopathology demonstrated findings consistent with lichen planus. Direct IF from a wrist lesion showed fine granular IgM deposition along the dermo-epidermal junction with occasional cytoid bodies, compatible with LP/lichenoid dermatitis, while direct IF from a neck lesion was negative. Owing to the coexistence of lesions on sun-exposed and non-sun exposed flexural areas, the diagnosis of generalized LPP with features of its inverse variant, known as LPP inversus (LPPI), was retained. Systemic treatment with low-dose dexamethasone and antihistamines therapy combined with strict photoprotection, topical clobetasol propionate, tacrolimus and emollients led to noticeable fading of the facial hyperpigmentation within 3-months.

Conclusion

LPPI is a rare subvariant of LPP, with only a few cases reported in the medical literature. The unique flexural pattern of skin involvement and clinical features, coupled with the lichenoid histology, are distinctive and separate it from other similar entities, such as LP actinicus and erythema dyschromicum perstans/ashy dermatosis. The concurrence of LPP and LPPI has been described in oncology patients, and in association with HCV infection. In our patient there was a strong temporal relationship of both conditions with COVID-19 vaccination, thus supporting the growing evidence that vaccination may act as a trigger in predisposed individuals. Recognition of this potential association is important for timely diagnosis, appropriate management and patient counseling.

EA DV CONGRESS
VIENNA
30 SEP - 3 OCT 2026

Abstract N°: 3738

Intralesional rituximab versus triamcinolone for recalcitrant scalp pemphigus vulgaris

Elia Valeva*[1], Slavyan Tamnev[1], Snejina Vassileva[1], Kossara Drenovska[1]

[1] Department of Dermatology and Venereology, Medical University - Sofia, Sofia, Bulgaria

Introduction

Pemphigus vulgaris (PV) is a chronic autoimmune blistering disease, characterized by painful mucocutaneous erosions due to loss of keratinocyte adhesion caused by circulating autoantibodies against desmosomal proteins. Although rituximab has become an established first line therapeutic option for PV, clinically significant subset of patients develops lesions on anatomically challenging areas that remain recalcitrant to conventional systemic therapy, particularly the scalp, nose and oral mucosa, often associated with delayed healing and poor drug penetration. Scalp involvement in PV is especially problematic as erosions may be extensive, chronic, refractory to treatment and carrying a substantial impact on patients' quality of life. Intralesional triamcinolone acetonide is a well-established option for localized, treatment-resistant PV lesions, with reports documenting complete clinical remission following targeted injection. More recently, intralesional rituximab has emerged as a targeted salvage approach for refractory pemphigus, with published experience including recalcitrant oral and scalp lesions. We present our experience with intralesional rituximab versus intralesional triamcinolone acetonide for recalcitrant scalp PV.

Case Presentation

A 58-year-old Caucasian man with a 10-year history of histologically and immunologically confirmed PV experienced mild relapses over the years while on maintenance corticosteroid therapy. Despite the clinical remission of the widespread erosions achieved after a rituximab cycle consisting of two intravenous infusions of 1000mg each, administered two weeks apart, solitary erosions persisted on the scalp and the left ala nasi, refractory to any kind of topical and systemic therapy. Therefore, we decided to attempt intralesional rituximab injections into the recalcitrant erosions and to compare it with intralesional triamcinolone acetonide. With this aim, we chose similarly looking contralateral erosions, two on the left temporal zone measuring 3x3 cm each, and one on the right temporal scalp, 10x6 cm, to be injected with rituximab and triamcinolone, respectively. Two ml of rituximab 10mg/ml on the left and 2ml of triamcinolone 10mg/ml on the right were applied intradermally in the respective lesions. A second session of the procedure was performed within a month.

One month following the second session, we observed almost complete epithelization with mild postinflammatory erythema of the left erosions injected with rituximab, whereas partial epithelialization with dry adherent scales was present in the triamcinolone-injected erosion.

Conclusion

Intralesional triamcinolone is an established treatment option for localized, therapy-resistant PV lesions. In our case despite the prior failure of the systemic therapy, intralesional rituximab resulted in complete healing of the recalcitrant scalp lesions, compared to intralesional triamcinolone which achieved only partial epithelization, making it a well-tolerated, and cost-effective treatment option. However comparative evidence directly evaluating intralesional rituximab against intralesional triamcinolone in scalp-predominant, refractory PV remains limited to small studies and case reports, therefore further research is required.

EADV Congress 2026, VIENNA
30 SEPTEMBER - 03 OCTOBER 2026
POWERED BY M-ANAGE.COM

EA DV CONGRESS
VIENNA
30 SEP - 3 OCT 2026

Abstract N°: 3748

Long-Term Disease-Free Survival and Relapse Predictor After First-Line Rituximab Therapy in Pemphigus: A Real-World Cohort Study

Echreiva Mohammed Sidi El Moctar*[1], Hanane Baybay[1], IKRAME BEJJA[1], Saadia Boughaleb[1], Zakia Douhi[1], Meryem Soughi[1], Sara Elloudi[1], Fatima Zohra Mernissi[1]

[1] Hassan II university hospital, FEZ, Morocco

Introduction

Rituximab (RTX) has transformed pemphigus management, showing superior efficacy to corticosteroid-based regimens in randomized trials. However, long-term real-world data on disease-free survival, sustained complete remission off therapy (CRoff), relapse predictors, and safety remain limited. Identifying factors associated with relapse is essential to optimize long-term disease control and therapeutic strategies.

Materials and Methods

We conducted a retrospective cohort study including all patients with pemphigus managed between 2014 and 2026. Patients who received first-line RTX combined with low-dose, short-duration corticosteroids, as well as those treated with prednisone-based regimens as first-line therapy, were included.
Efficacy analyses focused on the RTX group, while safety was compared between both groups. Patients were eligible if RTX was used as initial
therapy; those previously treated with prednisone combined with other immunosuppressants were excluded. Data were collected from medical
records.
DFS was defined as the time from disease control to first relapse or last follow-up. Kaplan–Meier analysis was used to estimate relapse-free
survival, with disease control as time zero and relapse, last evaluation, or study end as endpoints. Potential predictors of relapse, particularly
mucosal involvement, were assessed using Kaplan–Meier analysis and univariate Cox regression. Median follow-up was 7 years.

Results

Results
A total of 236 patients were included: 86 received first-line RTX with low-dose corticosteroids, and 150 received prednisone-based regimens.
In the RTX group, mean age was 57.1 ± 11.2 years, and 67.4% were female. Pemphigus vulgaris was the most common subtype (66.3%), followed
by pemphigus foliaceus (16.3%), vegetans (9.3%), and seborrheic (8.1%). Mucosal involvement was present in 76.7% of patients, with oral
involvement ≥30% in 34.1%.
Median disease duration before RTX was 8 months, and the median IKEDA score was 8 (IQR 7–9). Severe disease was observed in 70% of
patients. Most patients received the rheumatoid arthritis protocol (92.4%), while 19.8% received the lymphoma protocol. Maintenance RTX was
administered in 84.9%, with infusions at months 6, 12, and 18 in 81.6%, 60.0%, and 39.2% of cases, respectively.
Kaplan–Meier analysis showed sustained disease control, with relapse-free survival rates of approximately 90% at

12 months, 80% at 36 months,
and 45–50% at 60 months. Median DFS was 61 months (95% CI: 53.8–68.2). Overall, 84.4% of patients achieved CR off therapy; among them,
50.0% maintained remission for 36–60 months.
Oral mucosal involvement ≥30% was significantly associated with a higher risk of relapse (log-rank p = 0.004), with an approximately threefold
increase in risk (HR ≈ 3.0).
RTX showed a favorable safety profile, with adverse events in 16% of patients, mainly infections (9.3%) and hypersensitivity reactions (5.8%). In
contrast, prednisone-based regimens were associated with adverse events in 34% of cases, most commonly diabetes (18.3%) and metabolic
complications (11.1%).

Conclusions

RTX provides sustained long-term disease control in pemphigus, with a median DFS of 61 months and high relapse-free survival
during the first three years. A substantial proportion of patients achieve prolonged CR off therapy. Oral mucosal involvement ≥30% is a significant
predictor of relapse. RTX also demonstrates a more favorable safety profile than prednisone-based regimens, supporting its use as first-line
therapy.

EADV CONGRESS
VIENNA
30 SEP - 3 OCT 2026

Abstract N°: 3761

Diagnostic Challenges in Gliptin-Induced Bullous Pemphigoid: A CaseReport Requiring Triple Immunopathological Verification

Magdalena Antoszewska*[1], Robert Dubel[1]

[1] Department of Dermatology, Venereology and Allergology, Medical University of Gdańsk, Gdańsk, Poland

Introduction

Bullous pemphigoid (BP) is the most common autoimmune subepidermal bullous disease, primarily affecting the elderly population. It typically presents with widespread bullous lesions and intense pruritus. Among the triggering factors for BP, the use of systemic medications - particularly dipeptidyl peptidase-4 inhibitors (gliptins) - and internal malignancies are well-recognized. Diagnosis is established based on clinical presentation, histopathological findings, and, most crucially, positive direct immunofluorescence (DIF) microscopy. However, the diagnostic process can often be challenging.

Case Presentation

We present the case of a 75-year-old male patient with gliptin-induced bullous pemphigoid. The patient, who was being treated for type 2 diabetes, presented with generalized bullous eruptions and severe itching. Despite a strong clinical suspicion, the initial diagnostic workup was inconclusive. To confirm the diagnosis, the skin biopsy for DIF had to be repeated three times. While the first two biopsies failed to show immunoreactants, the third attempt finally revealed the characteristic linear fluorescence along the epidermal basement membrane zone (BMZ). This definitive finding allowed for the final diagnosis of bullous pemphigoid and subsequent clinical management, including the discontinuation of the triggering agent.

Conclusion

This case underscores that clinical suspicion must take precedence over initial negative laboratory results in the diagnosis of bullous pemphigoid. It is critically important to repeat skin biopsies for DIF if the first results are inconclusive. Persistent diagnostic verification is essential to confirm drug-induced variants and to ensure the timely discontinuation of triggering agents like gliptins.

EADV CONGRESS
VIENNA
30 SEP - 3 OCT 2026

Abstract N°: 3782

Generalized Morphea with Linear Involvement and Multiple Dermatofibromas: A Rare Diagnostic Overlap

Pedro Barbosa*[1], Maria Isaac[1], Corina Busso[1]

[1] Hospital Universitario Austral, Pilar, Buenos Aires, Argentina

Introduction
Morphea is a localized sclerosing disorder that may involve the skin, subcutaneous tissue, fascia, and, less frequently, deeper structures. Generalized and linear forms can coexist and may lead to atrophy, asymmetry, pain, and important functional limitation. Multiple dermatofibromas have rarely been described in association with immune-mediated or altered connective tissue disorders. Their occurrence within areas affected by morphea may raise diagnostic difficulties, particularly with nodular morphea and other sclerodermiform conditions.

Case Presentation
A 41-year-old woman with a long-standing diagnosis of generalized morphea with linear involvement of the limbs was followed for progressive sclerosis, deep tissue atrophy, and multiple firm nodular lesions arising mainly within areas of affected skin. Despite previous treatment with systemic corticosteroids, methotrexate for two years, and phototherapy, she continued to present persistent indurated and atrophic plaques with incipient functional symptoms. Her medical history included atypical fibroxanthoma in early adulthood and partial oophorectomy for an adnexal tumor.

On physical examination, she presented erythematous-brown, atrophic and indurated plaques involving the trunk and all four limbs, with lower-limb asymmetry and areas of deep tissue atrophy. Multiple brown, firm-elastic nodules were observed mainly on the limbs, especially over areas of morphea.

During follow-up, she developed pain and mild functional limitation of the right upper limb, together with an active erythematous linear plaque on the right arm and forearm. A skin biopsy from this area showed panniculitis associated with atrophy of underlying structures. Several biopsies of nodular lesions performed over time showed findings consistent with dermatofibromas. A biopsy from an atrophic plaque revealed lamellar fibrosis with horizontally arranged fine collagen bundles at the dermal-hypodermal interface.
Laboratory studies, including antinuclear antibodies and extractable nuclear antigen antibodies, were negative. Magnetic resonance imaging of both thighs showed focal thinning and irregularity of the skin and subcutaneous tissue, without muscle or bone involvement.

In 2026, the patient developed three new painful nodules and reported increased induration of the right forearm. High-frequency ultrasound of one lesion showed a 6.2 × 5.6 × 3.2 mm hypoechoic dermal-hypodermal lesion, without Doppler flow or involvement of deep planes, suggestive of dermatofibroma. New biopsies were performed and histopathological results are pending. The case was reassessed to define further therapeutic management and to consider genetic evaluation for sclerodermiform syndromes.

Conclusion
This case describes the coexistence of generalized and linear morphea with multiple dermatofibromas arising mainly in affected skin. The case was clinically challenging because some nodular lesions could mimic nodular morphea or other sclerosing disorders. Repeated biopsy, imaging studies, and long-term clinicopathological

correlation were useful to assess lesion depth, exclude deeper involvement, and guide management. This association should be considered when multiple firm nodules develop in patients with complex morphea phenotypes.

EA DV CONGRESS
VIENNA
30 SEP - 3 OCT 2026

Abstract N°: 3835

PeriorbitalHemiatrophy: A Rare Manifestation of Lupus Tumidus.

Kenza Bouketta*[1], Tarek Mansoul[1], Riad Boussaid[1], Ahmed Samaouel Chehad[1]

[1] Department of dermatology, Ibn Badis hospital center., Constantine, Algeria

Introduction

Lupus tumidus is a rare subtype of chronic cutaneous lupus erythematosus (CCLE), typically characterized by erythematous, edematous, urticarial-like plaques on sun-exposed areas. Unlike discoid lupus erythematosus, lupus tumidus classically spares epidermal structures and does not result in scarring or atrophy. We report an atypical case of periorbital lupus tumidus with secondary atrophic evolution, a rarely described presentation.

Case Presentation

A 27-year-old previously healthy man presented with progressive left periorbital atrophy evolving over 18 months. Clinical examination revealed a 5 cm infiltrated erythematous plaque centered by cutaneous atrophy in the right periorbital region, associated with eyelid edema. Two additional similar plaques were observed on the contralateral periorbital area and over the left zygomatic region.Lesions developed in a context of marked photosensitivity. Laboratory investigations showed positive antinuclearantibodies (ANA) and anti-Ro52 antibodies. Other laboratory findings were within normal limits. Skin biopsy demonstrated:Epidermalatrophy perivascular and peri-adnexal lymphocyt icinfiltrate with prominent dermal mucin deposition. Based on clinical, immunological, and histopathological findings, the diagnosis of lupus tumidus was established. The patient was initially treated with hydroxychloroquine (400 mg/day), which was discontinued due to intolerance. Methotrexate (15 mg/week) was subsequently introduced, resulting in marked improvement of inflammatory infiltration, with residual atrophy.



Image1: infiltrated erythematous plaque centered by cutaneous atrophy in the right periorbital region.

Conclusion

Lupus tumidus typically presents as non-scarring, edematous, urticarial-like plaques on photo-exposed areas. Diagnosis may be delayed due to clinical overlap with other dermatoses. Periorbital involvement is exceptionally reported, particularly in the tumidus subtype. Histologically, lupus tumidus ischaracterized by dermal lymphocytic infiltrates with abundant mucin and minimal epidermal changes, distinguishing it from discoid lupus erythematosus. Although scarring and atrophy are classically absent, isolated cases of secondary atrophy—similar to our observation—have been described. Antimalarials remain first-line therapy, while methotrexate is an effective alternative in refractory or intolerant patients. Our patient showed significant clinical improvement under methotrexate therapy.

We report an exceptional case of periorbital lupus tumidus distinguished by its unusual localization and secondary atrophic evolution, expanding the clinical spectrum of this rare entity.

EA DV CONGRESS
VIENNA
30 SEP - 3 OCT 2026

Abstract N°: 3839

Clinical and Inflammatory Predictors of Severe Disease Activity in Geriatric Bullous Pemphigoid: A Multicentre Retrospective Cohort Study

Selen Taner Akbay*[1], ezgi tan[1], nazlı totik[2], mustafa tosun[3], mustafa esen[4], Mustafa Altaş[4], özge zorlu[5], hülya albayrak[5], sema aytekin[5], Arzu Kılıç[6], pelin hızlı[6], selen gezmen[7], necip enis kaya[8], emine çölgeçen[8], bahadır aslancan[9], gülhan güler[10], gonca bayar[10], tubanur çetinarslan[11], aylin türel ermertcan[11], gökhan çınar[12], meryem temel[12], berna solak[13], selami aykut temiz[14], munise daye[14], özge sevil karstarlı bakay[12], derya nur ünsal[13], serkan yazıcı[15], emel bülbül başkan[15], fatma etgü[16], burak burç[16], fatma aslı hapa[17], seval tekel[17], asena çiğdem doğramacı[1], ümit türsen[7]

[1] Hatay Mustafa Kemal University, Tayfur Ata Sökmen Faculty of Medicine, Department of Dermatology, Hatay, Türkiye
[2] Hatay Mustafa Kemal University, Tayfur Ata Sökmen Faculty of Medicine, Department of Biostatistics, Hatay, Türkiye
[3] Sivas Cumhuriyet University,Faculty of Medicine, Department of Dermatology, sivas, Türkiye
[4] Dicle University, Faculty of Medicine, Department of Dermatology, diyarbakır, Türkiye
[5] Tekirdağ Namık Kemal University, Faculty of Medicine, Department of Dermatology, tekirdağ, Türkiye
[6] Balıkesir University, Faculty of Medicine, Department of Dermatology, balıkesir, Türkiye
[7] Mersin University, Faculty of Medicine, Department of Dermatology, mersin, Türkiye
[8] Yozgat Bozok University, Faculty of Medicine, Department of Dermatology, Yozgat, Türkiye
[9] Department of Dermatology, Şanlıurfa Training and Research Hospital, Şanlıurfa, Türkiye, şanlıurfa, Türkiye
[10] Faculty of Medicine, Afyonkarahisar Health Sciences University, Afyonkarahisar, Türkiye, afyonkarahisar, Türkiye
[11] Manisa Celal Bayar University, Faculty of Medicine, Department of Dermatology, manisa, Türkiye
[12] Pamukkale University, Department of Dermatology, Faculty of Medicine, denizli, Türkiye
[13] Sakarya University, Faculty of Medicine, Department of Dermatology, sakarya, Türkiye
[14] necmettin erbakan university, Faculty of Medicine, Department of Dermatology, konya, Türkiye
[15] bursa uludağ University, Faculty of Medicine, Department of Dermatology, bursa, Türkiye
[16] Department of Dermatology, Faculty of Medicine, Ordu University, Ordu, Türkiye, ordu, Türkiye
[17] izmir buca seyfi demirsoy research and training hospital, Department of Dermatology, izmir, Türkiye

Introduction

Bullous pemphigoid (BP) predominantly affects older adults and carries substantial morbidity; BPDAI cut-offs enable severity stratification, and inflammatory blood markers are increasingly studied as practical correlates of activity. We compared etiologic and clinical features of geriatric BP with inflammatory biomarkers and sought predictors of severe disease.

Materials and Methods

This retrospective multicentre chart review included patients aged ≥65 years with biopsy and/or direct immunofluorescence-confirmed BP diagnosed between 2015 and 2025; patients aged <65 years, those without histopathological/DIF confirmation, and those with incomplete required records were excluded. Prespecified subgroup analyses used BPDAI categories (mild/moderate/severe), with severe BPDAI as the positive state for ROC

and logistic models. Variables were summarized with distribution-appropriate descriptive statistics. Group comparisons used Student's t-test or Mann–Whitney U test, one-way ANOVA or Kruskal–Wallis test with Scheffé/Bonferroni post hoc correction, Pearson's chi-square or Fisher's exact tests, Spearman correlation, ROC analysis with Index-of-Union-derived cut-offs, and uni/multivariable logistic regression.

Results

The cohort comprised 797 patients (median age 77.0 years, IQR 71.0–83.0; 58.8% female); 82.3% had at least one comorbidity. BPDAI severity data were available for 705 patients (216 mild, 316 moderate, 173 severe). Age and disease duration were not correlated with BPDAI or ABSIS (all $p>0.05$), whereas nursing-home residence was associated with lower BPDAI than home residence (23.0 vs 30.5, $p=0.028$). ABSIS increased stepwise across BPDAI strata (12.0 vs 30.0 vs 56.0; all pairwise $p<0.001$). Inflammatory variables also differed across severity categories, including WBC (8.54 vs 9.27 vs 9.34; $p=0.001$), platelets (252.0 vs 257.0 vs 277.0; $p=0.013$), the reported neutrophil parameter (5.64 vs 6.35 vs 6.57; $p=0.002$), CRP (4.10 vs 6.32 vs 7.08; $p=0.002$), ESR (22.0 vs 21.0 vs 19.0; $p=0.018$), and procalcitonin (0.03 vs 0.05 vs 0.17; $p<0.001$); SIRI was not significant ($p=0.074$). Severe BP showed more erosions, urticaria and pruritus, and these remained independent predictors in multivariable analysis: erosion OR 3.779 (95% CI 2.374–6.016; $p<0.001$), pruritus OR 3.393 (95% CI 1.549–7.432; $p=0.002$), and urticaria OR 1.616 (95% CI 1.061–2.462; $p=0.025$). Diabetes mellitus, DPP-4 inhibitor use and clopidogrel were associated with severe BP only in univariate analyses; clopidogrel remained borderline after adjustment [OR 2.316 (95% CI 0.973–5.513); $p=0.058$]. ROC analysis showed procalcitonin had the best discrimination for severe BPDAI [AUC 0.733 (95% CI 0.636–0.830), $p<0.001$; cut-off 0.105; sensitivity 72.7%; specificity 62.8%], whereas SII showed only weak discrimination [AUC 0.555 (95% CI 0.504–0.607), $p=0.046$]. The final model had modest explanatory power (Nagelkerke $R^2=0.192$) with good fit (Hosmer–Lemeshow $p=0.971$).

Conclusions

In geriatric BP, severe disease was more strongly defined by an erosive, pruritic, urticarial phenotype than by large standalone biomarker effects. Among laboratory variables, procalcitonin was the most informative discriminator, while composite inflammatory indices added limited value. Retrospective design, variable-specific missing data, and likely inter-centre management heterogeneity should temper inference. These findings support combining bedside morphology with selected inflammatory biomarkers for risk stratification in older adults.

EA DV CONGRESS
VIENNA
30 SEP - 3 OCT 2026

Abstract N°: 3859

Dermatomyositis in the elderly: a case report

fella laissaoui*[1], Houria Sahel[1]

[1] Department of Dermatology, Bab El Oued University Hospital, Algiers, Algiers, Algeria

Introduction

Dermatomyositis (DM) is a rare inflammatory myopathy, more severe in elderly patients, characterized by significant muscle involvement, systemic complications, and increased mortality risk. Its immunological profile and the potential risk of underlying malignancy require thorough clinical and laboratory evaluation. We report a case.

Materials and Methods

A 70-year-old female patient with a history of type 2 diabetes and hypertension presented with definite dermatomyositis according to the Bohan and Peter criteria.

On examination, she had lilac-colored eyelid edema and Gottron's papules over the metacarpophalangeal and interphalangeal joints. Proximal muscle weakness of the shoulder and pelvic girdles was observed, with positive "chair" and "comb" signs.

Laboratory tests revealed creatine phosphokinase (CPK) levels elevated 15-fold, hepatic cytolysis at 4-fold the normal range, and high-sensitivity troponin at 400 ng/L with a stable kinetic. Immunologic testing showed positive ANA at 1:1000, anti-Ro52 positivity, and anti-Mi-2 positivity.

Cardiac MRI showed no abnormalities, and coronary angiography revealed no significant stenosis, except for infiltration of the right coronary arteries.

The patient was initially treated with corticosteroids at 1 mg/kg/day without satisfactory response, requiring an increase to 1.5 mg/kg/day combined with methotrexate 15 mg/week, resulting in notable clinical and laboratory improvement.

Results

Dermatomyositis (DM) is a rare inflammatory myopathy whose incidence increases with age. In elderly patients, it often presents more severely, with marked muscle involvement, higher risk of systemic complications, and increased mortality. Muscle enzymes can rise substantially, sometimes leading to rhabdomyolysis, reflecting extensive muscle damage. Early management is therefore essential to prevent complications, particularly renal.

Cardiac involvement, although documented, is heterogeneous: an isolated and stable troponin elevation may reflect skeletal muscle involvement rather than myocarditis, highlighting the need for complete cardiologic evaluation before drawing conclusions.

The immunologic profile plays a key role in classification and prognosis; for instance, anti-Mi-2 antibodies are associated with "classic" DM, which responds well to treatment and has a favorable prognosis, even in elderly patients.

Finally, adult-onset DM in the elderly is strongly associated with an increased risk of underlying malignancy, independent of the autoimmune profile, requiring rigorous and prolonged oncologic screening.

Thus, DM in elderly patients represents a distinct entity, requiring an integrated approach combining clinical, laboratory, and immunologic data.

Conclusions

Dermatomyositis in the elderly constitutes a distinct entity necessitating an integrated management approach. Early intervention, cardiologic monitoring, and prolonged cancer screening are essential to improve prognosis and prevent complications.

EA DV CONGRESS
VIENNA
30 SEP - 3 OCT 2026

Abstract N°: 3863

Health-Related Social Needs in Pemphigus: Burden, Patterns, and Associations with Self-Reported Health Status and Emergency Department Utilization

Justin Baroukhian*[1], Rosy Zel[1], Kristina Seiffert-Sinha[1], Animesh Sinha[1]

[1] Jacobs School of Medicine & Biomedical Sciences, Department of Dermatology, Buffalo, United States

Introduction

Social determinants of health (SDoH), the conditions in which people are born, grow, live, work, and age, account for an estimated 50% or more of health outcomes. Health-related social needs (HRSNs) are the actionable, individual-level manifestations of adverse SDoH, and their cumulative burden has been linked to worse self-rated health, greater emergency department (ED) reliance, and higher comorbidity in general population studies. Research characterizing HRSNs in autoimmune and rare diseases has been sparse, and in pemphigus specifically, entirely absent. This is particularly consequential as effective management of the disease demands timely specialist access, prolonged immunosuppressive regimens, and close longitudinal follow-up, while its unpredictable course and substantial psychosocial burden further compound patients' vulnerability to social adversity.

Materials and Methods

We conducted a cross-sectional survey of US based pemphigus patients using the previously validated Accountable Health Communities HRSN Screening Tool. The presence or absence of unmet HRSNs across each of thirteen domains was assessed (living situation, food, transportation, gas/utility, safety, financial strain, employment, family/community support, education, physical activity, substance use, mental health, disabilities), and a score representing composite HRSN burden (0–13) was calculated per respondent. Composite HRSN burden scores were then used to classify respondents as having either a low (<4) or high (≥4) burden of unmet HRSNs, based on previously reported thresholds. Primary outcomes were self-rated health status (fair/poor vs. good/very good/excellent) and high ED dependence (≥2 visits/12 months). Unadjusted and multivariable logistic regression models were fit, along with continuous-exposure models to assess dose-response.

Results

Respondents (n=162) were predominantly female (75.9%) and had pemphigus vulgaris (87.0%); mean age was 54.4±15.6 years. The cohort was relatively advantaged by socioeconomic measures: 69.8% had college-level education or higher and 53.1% reported household income ≥$75,000. Nevertheless, HRSNs were pervasive: 97.5% reported at least one unmet need, 40.1% met criteria for a high cumulative burden of unmet needs (score ≥4), and mean burden was 3.8±2.6 unmet HRSNs. Mental health was the most frequent domain (80.5%), followed by physical activity limitation (72.0%), and disabilities (32.9%). Fair/poor health was reported by 42/162 respondents (25.9%). High-burden respondents had more than triple the absolute prevalence of fair/poor health compared with low-burden respondents (44.6% vs 13.4%; risk difference 31.2%, 95% CI 11.6–48.7). RR was 3.33 (95% CI 1.88–5.91) and OR was 5.21 (95% CI 2.43–11.15); the association remained significant after adjustment (aOR 4.63, 95% CI 1.75–12.27; p=0.0020). Each one additional unmet HRSN domain increased adjusted odds of fair/poor health by 55% (aOR 1.55, 95% CI 1.27–1.90; p=1.944e-05). High ED dependence occurred in 20.0% (13/65) of the high-burden group versus 9.4% (9/96) of the low-burden group (OR 2.42, 95% CI 0.97–6.04; p=0.059). Continuous models showed increased odds per additional unmet HRSN domain (OR 1.23, 95% CI 1.05–1.43;

p=0.010), though this attenuated after adjustment (OR 1.11, 95% CI 0.88–1.41; p=0.39).

Conclusions

Pemphigus patients demonstrate a striking and previously unmeasured burden of unmet HRSNs, with nearly universal exposure and 40% meeting high-burden criteria, despite disproportionately high educational attainment, income, and engagement with specialty advocacy group networks among our sample. Cumulative HRSN burden was significantly, independently, and dose-dependently associated with poorer self-rated health. Integrating validated multidimensional HRSN screening into dermatologic practice may identify high-risk patients for targeted social support, and represents a critical, currently absent component of comprehensive care for autoimmune blistering diseases.

EA DV CONGRESS
VIENNA
30 SEP - 3 OCT 2026

Abstract N°: 3906

EMERGING TARGETED THERAPIES IN CUTANEOUS LUPUS ERYTHEMATOSUS: A SCOPING REVIEW OF EVIDENCE FROM 2014 TO 2026

Paola Estefania Falla Rivera*[1], Carolina Ivette Cortes Correa[2], Maria Palacios[1]

[1] Fundación Universitaria Sanitas, Bogotá, Colombia

[2] Hospital Universitario De La Samaritana E S E, Bogotá, Colombia

Introduction

Cutaneous lupus erythematosus (CLE) is a heterogeneous autoimmune disease associated with significant morbidity, including scarring, dyspigmentation, alopecia, pain, and impaired quality of life. Current treatment strategies rely mainly on corticosteroids, calcineurin inhibitors, antimalarials, and conventional immunosuppressants; however, many patients remain refractory to therapy. Advances in the understanding of CLE pathogenesis have identified novel therapeutic targets, particularly the type I interferon pathway, plasmacytoid dendritic cells, and intracellular signaling kinases. **Objectives:** To identify and synthesize the available evidence regarding emerging therapies investigated for CLE between 2014 and 2026.

Materials and Methods

A scoping review was conducted including studies published between 2014 and 2026 evaluating emerging therapies for CLE. Randomized clinical trials, pilot studies, observational studies, case series, systematic reviews, and translational studies were included. Data regarding mechanisms of action, CLE subtype, study design, and level of evidence were extracted and narratively synthesized.

Results

Fifty studies were included, identifying eleven emerging therapeutic categories. Therapies targeting the type I interferon pathway demonstrated the most advanced clinical development. Anti-BDCA2 agents, including litifilimab and VIB7734, showed reduction of interferon-driven inflammation and clinical improvement in chronic and subacute CLE. Litifilimab advanced from phase 2 evaluation to ongoing phase 2/3 studies. Anifrolumab, targeting IFNAR1, demonstrated rapid and sustained responses in refractory CLE and is currently under phase 3 investigation.

Increasing evidence also supports kinase inhibition strategies. Deucravacitinib, a selective TYK2 inhibitor, demonstrated favorable responses in discoid, subacute, tumid, and refractory CLE across multiple reports and small case series. Additional JAK inhibitors, including tofacitinib and topical ruxolitinib, also showed promising results in refractory disease.

Belimumab remains the biologic therapy supported by the largest observational evidence base, with substantial CLASI improvement reported in refractory CLE cohorts. Traditional immunomodulatory agents such as thalidomide and lenalidomide continue to demonstrate efficacy in severe refractory disease, although their safety profile limits broader use.

Preliminary evidence was also identified for fumaric acid esters, topical SYK inhibition, and topical nicotinamide.

Conclusions

The therapeutic landscape of CLE is rapidly evolving toward targeted immunologic therapies. Agents directed against the type I interferon pathway and TYK2 signaling currently represent the most promising strategies and may redefine CLE management in the coming years. Nevertheless, major unmet needs persist, including the absence of approved CLE-specific therapies, limited randomized controlled trial data, heterogeneous outcome measures, and underrepresentation of ethnically diverse populations in clinical studies.

EA DV CONGRESS
VIENNA
30 SEP - 3 OCT 2026

Abstract N°: 3942

Clinical Features of Localized Scleroderma in Patients of the Uzbek Population

Shahnoza Mavlyanova*[1], Bekzod Parpiyev[1]

[1] Republican Specialized Scientific and Practical Medical Center of Dermatovenereology and Cosmetology of the Ministry of Health of the Republic of Uzbekistan, Tashkent, Uzbekistan

Introduction
Scleroderma belongs to the group of collagen diseases characterized primarily by the induration of connective tissue followed by fibrosis and atrophy of either localized or diffuse nature. The clinical course of scleroderma is chronic and is accompanied by disturbances in cellular immunity, microcirculation, and increased collagen production.

Objective of the study: To evaluate the clinical course of localized scleroderma lesions in patients of the Uzbek population.

Materials and Methods
A total of 56 patients with localized scleroderma aged 6 to 32 years were examined. Among them, 34 were female and 22 were male. All patients underwent clinical, biochemical, histological, and statistical examinations.

Results
Among the 56 patients, 24 (42.8%) were aged 6–12 years, 18 (32.1%) were 13–18 years old, and 14 (25%) were 19–32 years old. According to the clinical form, plaque-type scleroderma was diagnosed in 38 (67.8%) patients, while linear scleroderma was observed in 18 (32.1%) patients. Considering gender characteristics, plaque-type scleroderma was more commonly diagnosed in males — 21 (55.3%), whereas linear scleroderma was more frequently observed in females — 16 (88.8%).

Clinical observations demonstrated various stages of localized scleroderma lesions, including erythema, sclerosis, atrophy, and their combinations. In 30 patients (53.6%), lesions at different developmental stages (erythema + atrophy + sclerosis) were noted; 17 patients (30.4%) had the sclerosis stage, while 9 patients (16.1%) presented with erythema + sclerosis. Depending on the disease stage, patients complained of itching, skin tightness, and decreased skin sensitivity within the lesions.

Lesions were predominantly localized on the scalp, extremities, and trunk. In 27 patients (48.2%), lesions were located only on the scalp; in 12 patients (21.4%) on the trunk; in 14 patients (25%) on the upper extremities; and in 3 patients (5.6%) on the lower extremities.

Among concomitant diseases, endocrinopathies (thyroid disorders) were detected in 32 patients (57.1%), anemia in 8 patients (14.3%), and hepatitis in 5 patients (8.9%). Along with the clinical manifestations of localized scleroderma, serological parameters were analyzed. Rheumatoid factor analysis in 6 examined patients showed negative results. Analysis of ASLO levels in the blood serum demonstrated elevated values in patients with plaque-type localized scleroderma up to 229.4 ± 10.4 IU/mL compared to the normal value of up to 200 IU/mL. In patients with linear localized scleroderma, ASLO levels increased to 278.1 ± 47.1 IU/mL ($P < 0.05$), exceeding the normal

value by 1.4 times (P < 0.05).



Foto: A-B - plaque-type localized scleroderma, C-D – linear scleroderma.

Conclusions

Among the examined patients, children and individuals of working age predominated, while the incidence decreased with increasing age. The disease was predominantly observed in females (3.5 times more often than in males). Among the clinical forms, multiple plaque-type localized scleroderma at different stages of development was most frequently diagnosed, mainly in males at the stages of sclerosis and atrophy, whereas females more

commonly presented with the linear form, which resulted in increased erythema and induration indices.

EADV CONGRESS
VIENNA
30 SEP - 3 OCT 2026

Abstract N°: 3961

Early-onset Parrey Romberg

Dali osmane Rima*[1]

[1] Hospital Mouhamed Lamine Debagine, Alger, Algeria

Introduction

Parry–Romberg syndrome (PRS) is a rare disorder characterized by progressive hemifacial atrophy, typically beginning in early childhood. We report a case of early-onset Parry–Romberg syndrome in a young patient.

Materials and Methods

Case Report: A 6-year-old boy, born to fourth-degree consanguineous parents, had presented since the age of 2 years with a right preauricular hyperpigmented plaque associated with progressive hemifacial atrophy and alopecia of the right lower eyelid eyelashes. Neurological examination was normal. Mild bilateral sensorineural hearing loss was noted. Laboratory investigations revealed positive antinuclear antibodies (ANA) at a titer of 1:1000, strongly positive anti-M2 antibodies, and weakly positive anti-gp210 antibodies, with normal liver function tests. Brain MRI is ongoing. The patient was started on systemic corticosteroid therapy at 1 mg/kg/day combined with methotrexate 10 mg/week.

Results

Discussion: PRS classically begins during childhood or adolescence, most commonly between 5 and 15 years of age. Very early onset, before the age of 3 years, remains exceptional. PRS is thought to represent a vasculitic process leading to ischemic atrophy of deep cutaneous and subcutaneous tissues. Associations with other autoimmune disorders—including primary biliary cholangitis, Sjögren's syndrome, autoimmune hemolytic anemia, and systemic lupus erythematosus—have been reported. The positive immunological findings in our patient support this hypothesis. Familial cases described in the literature, as well as parental consanguinity among affected individuals, suggest the possible involvement of a hereditary or degenerative factor underlying the atrophic process. This hypothesis is considered in our patient given the consanguinity. Hearing loss in PRS is rare, and its mechanism remains unclear. Two main hypotheses may be proposed: first, a genetic origin related to mutations in the GJB2 gene, particularly in the setting of consanguinity; second, hearing loss may represent a secondary complication of progressive hemifacial atrophy. Current recommendations advocate performing brain MRI regardless of the presence of neurological symptoms. Therapeutic management of pediatric PRS is not standardized; however, the combination of systemic corticosteroids and methotrexate is currently considered the reference regimen in active and progressive forms.

Conclusions

Parry–Romberg syndrome is a rare disease of uncertain etiology. It frequently begins in early childhood, exceptionally before the age of 3 years. It may coexist with other disorders, highlighting the importance of multidisciplinary management.

EADV CONGRESS
VIENNA
30 SEP - 3 OCT 2026

Abstract N°: 3983

High-therapeutic-index fluticasone propionate as adjunctive therapy in moderate bullous pemphigoid treated with oral prednisone: a randomized pilot study

Yue Zhu*[1], Jinbo Chen[1]

[1] Department of Dermatology, Traditional Chinese and Western Medicine Hospital of Wuhan, Tongji Medical College, Huazhong University of Science and Technology, Wuhan, China

Introduction

Current guidelines recommend superpotent topical corticosteroids as first-line treatment for mild-to-moderate bullous pemphigoid (BP), with systemic corticosteroids as an alternative. Although clobetasol propionate regimens have been optimized, prolonged superpotent use over large body surface areas may cause cutaneous atrophy, secondary infection and HPA-axis suppression, particularly when combined with systemic corticosteroids. Whether adjunctive topical potency can be de-escalated in moderate BP treated with oral prednisone remains unclear. We evaluated adjunctive fluticasone propionate, a high-therapeutic-index topical corticosteroid of lower potency than clobetasol propionate, in this setting.

Materials and Methods

This single-centre, prospective, randomized, open-label pilot study enrolled 20 adults with newly diagnosed moderate BP, defined as a Bullous Pemphigoid Disease Area Index (BPDAI) score of 20–56. Patients with mild/localized BP, severe BP requiring immediate treatment intensification, or exposure within 12 weeks to BP-active corticosteroid, biologic, anti-inflammatory or immunosuppressive treatment were excluded. Patients were randomized 1:1 to adjunctive 0.02% clobetasol propionate cream or 0.05% fluticasone propionate cream. Both groups received oral prednisone at approximately 0.5 mg/kg/day as systemic background therapy and followed the identical 12-week topical taper: 30 g/day (Weeks 0 - 3), 15 g/day (Weeks 4 - 5), 15 g every other day (Weeks 6 - 7), 15 g twice weekly (Weeks 8 - 9), and 15 g once weekly (Weeks 10 - 11). Primary endpoints were time to disease control and Day-14 disease control, defined as cessation of new lesions with beginning healing of established lesions. Secondary endpoints included Week-24 BPDAI and itch numerical rating scale (NRS), Week-24 prednisone ≤10 mg/day, cumulative oral prednisone exposure through Week 24, cumulative topical corticosteroid use during the 12-week topical taper and adverse events.

Results

Ten patients were assigned to each group. Baseline characteristics and oral prednisone dose were broadly balanced. Median time to disease control was 9.0 (7.2–12.5) days with clobetasol versus 8.5 (5.2–13.5) days with fluticasone (P=0.794). Day-14 disease control occurred in 9/10 (90.0%) versus 7/10 (70.0%) patients (P=0.582). At Week 24, prednisone ≤10 mg/day was achieved in 6/10 (60.0%) versus 5/10 (50.0%) patients. Cumulative oral prednisone exposure through Week 24 was 2898.0 (2502.5–3412.5) mg versus 2940.0 (2537.5–3596.3) mg (P=0.762), and cumulative topical corticosteroid use during the 12-week taper was 1245.0 (825.0–1365.0) g versus 1245.0 (825.0–1260.0) g (P=0.727). BPDAI and itch NRS scores improved descriptively in both groups up to Week 24 (Figure 1). Five adverse events were recorded in each group. Local cutaneous events were uncommon, with folliculitis in the clobetasol group and fungal infection in the fluticasone group. No clear safety imbalance was observed.

Conclusions

In this randomized pilot study of moderate BP treated with oral prednisone, adjunctive fluticasone propionate showed no clear signal of delayed early disease control, increased oral prednisone exposure, lower Week-24 steroid-tapering success, or poorer short-term safety compared with adjunctive clobetasol propionate. Despite identical gram-based topical application, fluticasone propionate represents a lower-potency, high-therapeutic-index adjunct and may reduce potency-adjusted topical corticosteroid exposure. These preliminary findings support larger, adequately powered trials, including non-inferiority designs, to evaluate topical potency de-escalation in selected patients with moderate BP.

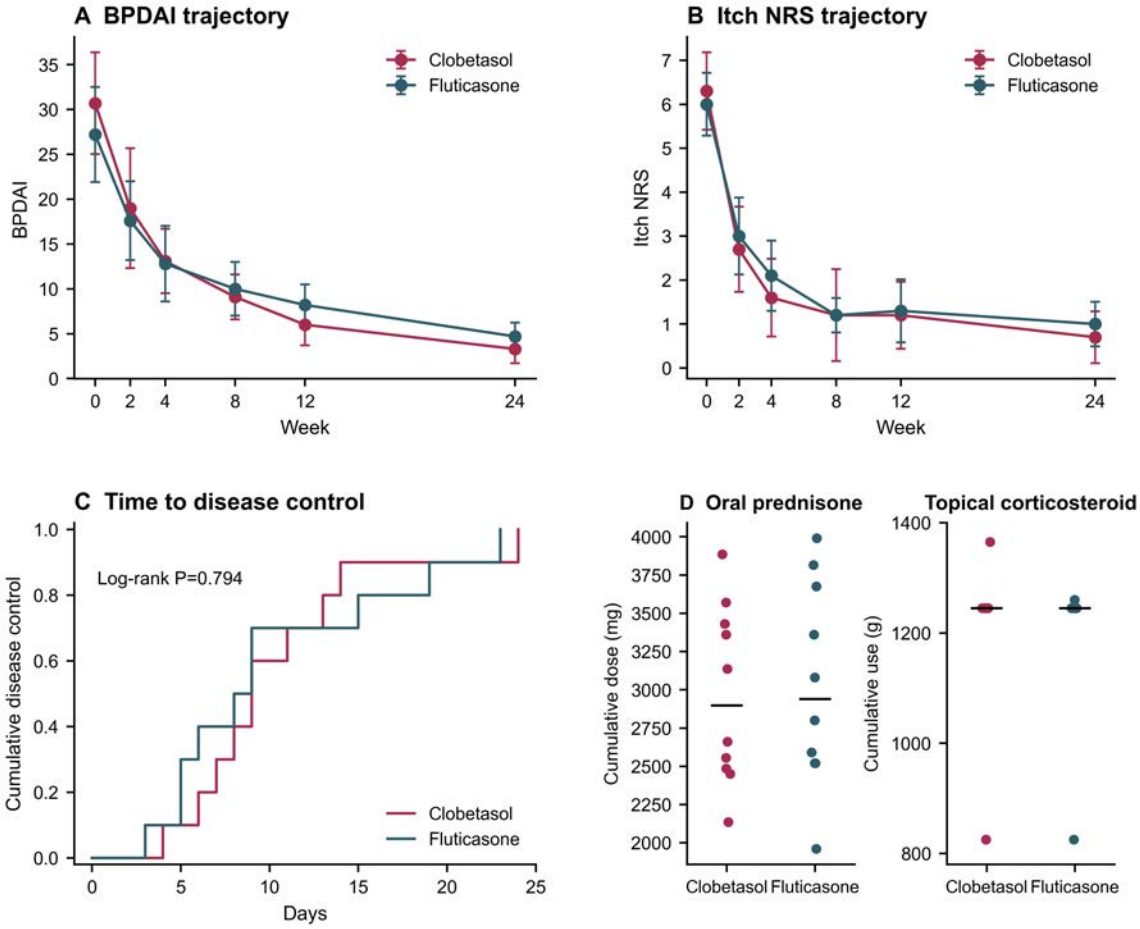

A. BPDAI trajectory through Week 24. B. Itch NRS trajectory through Week 24. Data in A and B are shown as mean with 95% confidence intervals. C. Cumulative disease control curves; groups were compared using the log-rank test. D. Cumulative oral prednisone exposure through Week 24 and cumulative topical corticosteroid use during the 12-week topical taper. Dots represent individual patients, and horizontal bars indicate medians. Clobetasol and fluticasone refer to the adjunctive clobetasol propionate and fluticasone propionate groups, respectively. BPDAI, Bullous Pemphigoid Disease Area Index; NRS, numerical rating scale.

EADV CONGRESS
VIENNA
30 SEP - 3 OCT 2026

Abstract N°: 4004

Local Immune Memory in Cutaneous Lupus Erythematosus: A Possible Role for Tissue-Resident Memory T Cells

Esra Tastan*[1], Lidia Sacchelli[1, 2], Federico Bardazzi[2], Michelangelo La Placa[1, 2]

[1] Department of Medical and Surgical Sciences, Alma Mater Studiorum – University of Bologna, Bologna, Italy

[2] Dermatology Unit, IRCCS Azienda Ospedaliero-Universitaria di Bologna, Policlinico S. Orsola Malpighi, Bologna, Italy

Introduction
Cutaneous lupus erythematosus is a chronic autoimmune skin disease characterized by recurrent lesions. Although its immunopathogenesis has been increasingly studied, the mechanisms responsible for lesion persistence and recurrence are still not fully understood. Tissue-resident memory T cells are a non-recirculating subset of T cells that remain in peripheral tissues for prolonged periods and have been linked to several inflammatory skin diseases, including psoriasis, dermatomyositis, and systemic sclerosis. Their persistence in the skin raises the possibility that they may also contribute to local immune memory in cutaneous lupus erythematosus. This study aims to explore the possible role of tissue-resident memory T cells in local immune memory, lesion persistence, and recurrence in cutaneous lupus erythematosus.

Materials and Methods
A narrative literature review was conducted using PubMed and Google Scholar. The review focused mainly on recent peer-reviewed articles together with key earlier studies relevant to the topic. Articles addressing cutaneous lupus erythematosus, tissue-resident memory T cells, and related evidence from inflammatory skin diseases were reviewed. Keywords included “cutaneous lupus erythematosus”, “tissue-resident memory T cells”, “disease recurrence”, and “disease persistence”.

Results
Available studies showed that tissue-resident memory T cells are increased in the lesional skin of cutaneous lupus erythematosus compared with healthy skin. Their increase was not clearly associated with disease severity, which may suggest a closer relation to persistence than to severity alone. Some studies also suggested that type I interferon may promote TRM-related features in CLE. In psoriasis, TRM have been recognized as important contributors to lesion recurrence, often in the same skin sites. This observation may be relevant when considering their possible role in CLE.

Conclusions
These findings suggest that tissue-resident memory T cells may contribute to lesion persistence and recurrence in cutaneous lupus erythematosus and may also play a role in local immune memory. Since the evidence in CLE is still limited, further studies are needed to better define their role and to understand whether this may also be relevant for future treatment approaches in cutaneous lupus.

EA DV CONGRESS
VIENNA
30 SEP - 3 OCT 2026

Abstract N°: 4056

Systemic JAK inhibitors in cutaneous lupus erythematosus: a phenotype-stratified systematic review

Mohammed shanshal[1], George Bethimoutis[1], George Karanasios[1], Sukhmunni Johal*[2]

[1] Imperial College Healthcare NHS Trust, London, United Kingdom
[2] Imperial College London, London, United Kingdom

Introduction
Cutaneous lupus erythematosus (CLE) comprises clinically and biologically heterogeneous inflammatory, scarring, panniculitic, bullous, alopecic and chilblain phenotypes. Type I interferon activation and downstream JAK-STAT signalling provide a strong mechanistic rationale for systemic JAK inhibition, but available evidence spans skin-primary trials, systemic SLE studies and lower-certainty phenotype-specific reports. We aimed to determine where credible cutaneous signals exist when evidence is separated by phenotype, endpoint and study design.

Materials and Methods
PubMed, Embase and CENTRAL were searched from inception to 30 August 2026. Eligible reports evaluated systemic conventional JAK1/2/3 inhibitors in CLE, lupus-related cutaneous phenotypes or SLE with extractable mucocutaneous outcomes. Two reviewers independently screened studies and extracted data. Risk of bias was assessed using design-appropriate tools. Evidence was synthesised descriptively because heterogeneity in phenotype, agent, comparator, endpoint and follow-up precluded a clinically meaningful meta-analysis. The review was registered in PROSPERO (CRD420261373587).

Results
Fifty reports representing 45 independent studies were included: 6 randomised, 7 nonrandomised and 32 case-based studies. The phase 2 filgotinib CLE trial did not meet its primary week 12 CLASI-A endpoint, with least-squares mean change of -8.7 versus -5.5 with placebo. In pooled BRAVE data, CLASI-50 rates were similar with placebo, baricitinib 2 mg and baricitinib 4 mg at 58%, 56% and 57%, respectively. SLEek showed exploratory CLASI-50 signals with upadacitinib 30 mg with or without elsubrutinib in very small CLASI-active subgroups. A 5-patient lupus erythematosus panniculitis crossover pilot showed at least 20% RCLASI-A improvement in 2/3 baricitinib-first versus 0/2 placebo-first patients at week 12.

More dermatologically direct uncontrolled evidence suggested phenotype-dependent activity. Open-label tofacitinib in mucocutaneous SLE produced CLASI partial response in 73% at week 8 and 82% at week 24, whereas a 5-patient DLE pilot showed heterogeneous responses, including one nonresponder. Selected case reports strengthened attribution through dose-response relationships, withdrawal and restart, objective skin scores or lesional molecular concordance. However, persistent DLE, refractory panniculitis or chilblain disease and loss of durability after initial response were also documented.

Conclusions
Current evidence does not establish a systemic JAK-inhibitor class effect in CLE. Instead, it supports phenotype-specific hypotheses and prioritises skin-primary trials enriched for active inflammatory disease. Future studies

should prespecify CLE subtype, separate reversible inflammatory activity from established damage, use validated cutaneous endpoints and treat interferon biomarkers as pharmacodynamic measures rather than surrogate efficacy endpoints.

EADV CONGRESS
VIENNA
30 SEP - 3 OCT 2026

Abstract N°: 4087

Clinical Burden, Mortality and Epidemiology of Bullous Pemphigoid: A Real-World, UK Population-Based Cohort Study

Philip J. Hampton[1], Emma Benton[2], Lisa Sutour[3], Danielle L. Isaman[3], Anastasia Petrova[4], Ellen Hubbuck[5], Leah Fisher[5], Aron Buxton[5], Wenzhen Ge[6], Marine Payan*[7]

[1] Royal Victoria Infirmary, Newcastle upon Tyne, United Kingdom
[2] St John's Institute of Dermatology, London, United Kingdom
[3] Sanofi, Cambridge, MA, United States
[4] Sanofi, Reading, United Kingdom
[5] Human Data Sciences, Cardiff, United Kingdom
[6] Regeneron Pharmaceuticals, Inc, Tarrytown,NY, United States
[7] Sanofi, Amsterdam, Netherlands

Introduction
Bullous pemphigoid (BP) is a rare, predominantly autoimmune subepidermal blistering disorder primarily affecting elderly individuals with multiple comorbidities. BP is associated with substantial healthcare burden and increased mortality. Oral corticosteroids are a common treatment used for BP but have been linked to higher mortality rates in the BP population. While increasing global incidence rates of BP have been reported, evidence on its epidemiology and associated outcomes in the UK remains limited. This study investigated the epidemiology, patient demographics and real-world clinical outcomes of BP in a large UK population-based cohort.

Materials and Methods
This retrospective cohort study used Clinical Practice Research Datalink (CPRD) Aurum data linked to Hospital Episode Statistics (HES), Index of Multiple Deprivation (IMD), and Death Registration datasets. Patients with BP were selected between 2014–2018, with index date defined as the first recorded BP diagnosis. BP patients were 1:2 matched to non-BP controls on index year, age, gender, ethnicity, IMD and select comorbidities (congestive heart failure, chronic pulmonary disease, diabetes mellitus, moderate-to-severe renal disease). Follow-up extended from index date to the earliest of death, last practice data collection date, or HES scheme end date or 31st December 2019. Baseline characteristics at index date were summarized using descriptive statistics. Rate ratios and 95% confidence intervals were calculated for mortality rates. Crude incidence and event rates per 100 person-years were assessed during follow-up. Annual BP prevalence from 2012–2022 was calculated by dividing the number of prevalent BP patients by the total registered population for each calendar year. Annual BP incidence was calculated by dividing the number of newly diagnosed BP patients by the total person-years at risk for each calendar year.

Results
A total of 4,196 patients with BP were matched to 8,392 non-BP controls. The mean age of BP patients was 79 years (standard deviation [SD] 12.3) and 52.8% were female. At baseline, BP patients had significantly higher use of topical steroids, emollients, and oral corticosteroids compared with non-BP patients (Table 1). Atopic and respiratory conditions (e.g., atopic dermatitis, asthma, chronic obstructive pulmonary disease) were significantly

more prevalent among BP patients. During follow-up, BP patients had significantly higher mortality rates than controls (rate ratio [RR]: 1.9; 95% CI: 1.8–2.0, p<0.001) and higher rates of fractures (RR: 1.3; 95% CI: 1.2–1.5, p<0.001). For both incident and recurrent events, BP cases demonstrated significantly higher rates for the majority of clinical outcomes, particularly skin infections and cataracts. Higher rates were also observed for obesity, pulmonary embolism, confusion, psychosis and depression in BP patients compared with non-BP patients (Figures 1 and 2). BP prevalence ranged from 2.97 per 10,000 person-years in 2012 to 4.23 per 10,000 person-years in 2022. Incidence rose from 0.52 per 10,000 person-years in 2012 to a peak of 0.69 per 10,000 person-years in 2019, then remained consistent at 0.63 per 10,000 person-years in 2022.

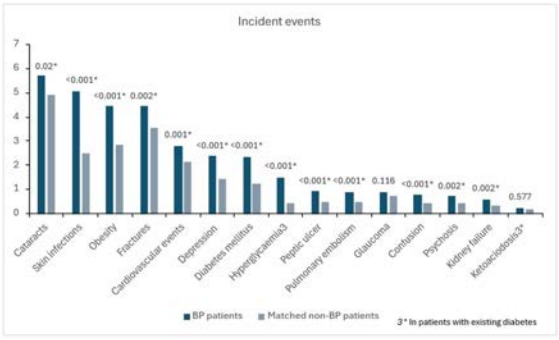

Figure 1. The rate of clinical outcomes for BP patients and propensity score-matched non-BP patients for incident events. *notes significant differences between BP patients and matched non-BP patients.

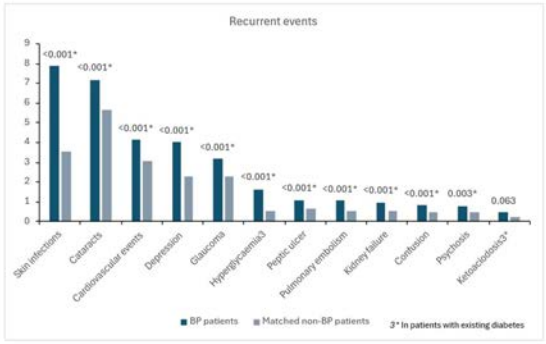

Figure 2. The rate of clinical outcomes for BP patients and propensity score-matched non-BP patients for all recurrent events. *notes significant differences between BP patients and matched non-BP patients.

Table 1. Baseline demographic and clinical characteristics of BP patients and propensity score-matched non-BP patients.

Characteristic	BP Patients N=4,196	Non-BP Patients N=8,392[1]	p-value
Age			
Mean (SD)	79.2 (12.3)	79.6 (11.5)	0.081
Median (LQ-UQ)	82.0 (73.0-88.0)	82.0 (74.0-88.0)	
Gender; Number (%)			
Male	1,981 (47.2%)	3,913 (46.6%)	0.549
Female	2,215 (52.8%)	4,479 (53.4%)	
Prescribed treatments; Number (%)			
Topical steroids	2,846 (67.8%)	1,092 (13.0%)	<0.001
Oral corticosteroids	1,851 (44.1%)	681 (8.1%)	<0.001
Emollients	2,623 (62.5%)	1,599 (19.1%)	<0.001
Tetracycline antibiotics	759 (18.1%)	390 (4.7%)	<0.001
Other antibiotics (dapsone)	20 (0.5%)	0 (0.0%)	<0.001
Immunosuppressants (azathioprine/mycophenolate mofetil)	83 (2.0%)	16 (0.2%)	<0.001
Biologics (rituximab, omalizumab)	<5	5 (0.1%)	>0.999
Intravenous immunoglobulin	5 (0.1%)	<5	0.169
Comorbidity; Number (%)			
Osteopenia	238 (5.7%)	433 (5.2%)	0.244
Osteoporosis	721 (17.2%)	1,139 (13.6%)	<0.001
Type 2 diabetes	1,038 (24.7%)	1,948 (23.2%)	0.061
Hypertension	3,025 (72.1%)	5,610 (66.9%)	<0.001
Hyperlipidaemia	1,256 (29.9%)	2,227 (26.5%)	<0.001
Skin infection	1,697 (40.4%)	1,964 (23.4%)	<0.001
Dementia	723 (17.2%)	856 (10.2%)	<0.001
Depression	554 (13.2%)	844 (10.1%)	<0.001
Psychosis	92 (2.2%)	114 (1.4%)	<0.001
Atopic dermatitis	513 (12.2%)	696 (8.3%)	<0.001
Chronic Spontaneous Urticaria	63 (1.5%)	42 (0.5%)	<0.001
EoE	178 (4.2%)	273 (3.3%)	0.006
Prurigo nodularis	53 (1.3%)	20 (0.2%)	<0.001
CRSwNP	95 (2.3%)	74 (0.9%)	<0.001
Asthma	1,013 (24.1%)	1,782 (21.2%)	<0.001
COPD	741 (17.7%)	1,317 (15.7%)	0.005

A two-step matching approach was employed. First, BP patients were directly matched 1:4 to controls on age, sex, ethnicity, and Index of Multiple Deprivation (IMD). Within this direct-matched cohort, propensity score matching was then applied to achieve 1:2 matching, incorporating the demographic variables (to preserve existing balance) plus comorbidities identified through a data-driven approach. Comorbidities included in the propensity score model were select Charlson Comorbidity Index conditions with standardized mean difference >0.1 in the direct-matched cohort: congestive heart failure, chronic pulmonary disease, diabetes mellitus, and moderate-to-severe renal disease

Table 2. The mortality rate each year for BP patients and propensity score-matched non-BP patients.

Mortality	Rate per 100 person years[2]		Rate ratio (95% CI)	p-value
	BP patients	Non-BP patients		
Y1	22.24	8.21	2.71 (2.44-3.01)	<0.001
Y2	15.20	9.05	1.68 (1.47-1.92)	<0.001
Y3	13.81	9.13	1.51 (1.28-1.79)	<0.001
Y1-3	16.71	8.01	2.09 (1.94-2.25)	<0.001
Total	15.30	8.08	1.89 (1.77-2.02)	<0.001

[1] Crude incidence and event rates per 100 person-years were assessed within each follow-up interval, with total representing all available follow-up.

Conclusions

Patients with BP had a substantially higher burden of type 2 inflammatory diseases at baseline and faced significantly higher risks of mortality, fractures, infections, cardiovascular events, neuropsychiatric conditions compared to matched non-BP patients. These real-world findings indicate that BP patients experience substantial systemic disease burden beyond its dermatological manifestations, emphasizing the need for comprehensive clinical management and consideration of treatment-related risks in relation to clinical outcomes.

EADV CONGRESS
VIENNA
30 SEP - 3 OCT 2026

Abstract N°: 4089

Nebaprubart in Linear IgA Dermatosis: Rapid Disease Control and Sustained Remission in an Open-Label Phase Ib Proof-of-Concept Study

Pascal Joly*[1], Cezary Kowalewski[2], Katarzyna Woźniak[2], Małgorzata Zajda[3], Louis Boon[4], Peter Simons[4], Aleksandra Cegiel[4], Tomasz Grabowski[4], Anna Łosińska[4], Dawid Łyżwa[4]

[1] Dermatology Department, Rouen university Hospital, INSERM 1234, Normandie University, Rouen, France
[2] National Medical Institute of the Ministry of the Interior and Administration, Warsaw, Poland
[3] MTZ Clinical Research powered by Pratia, Warsaw, Poland
[4] Warsaw, Poland

Introduction

Linear IgA Dermatosis (LAD) is a rare autoimmune blistering disease driven by IgA autoantibodies deposited linearly at the basement membrane, leading to neutrophil-dominant inflammation, subepidermal blistering, pruritus, and painful erosions. There is no approved therapy, and treatment relies on non-specific, off-label, anti-inflammatory, and immunosuppressive agents - most commonly dapsone, with potentially severe side effects.

Nebaprubart is a first-in-class humanized **anti-CD89 monoclonal antibody** designed to inhibit IgA-CD89-mediated inflammation and reduce immune-complex size. Nebaprubart received an **Orphan Drug Designation from the European Commission for treatment of LAD** in 2022.

Materials and Methods

In an ongoing **phase Ib, prospective, multicenter, open-label, clinical trial**, 2 patients with LAD received intravenous nebaprubart 10 mg/kg every 4 weeks. Primary objectives were safety and tolerability, with secondary objectives including pharmacokinetics, immunogenicity, pharmacodynamics, early efficacy, disease activity, quality of life, histologic assessment, and durability of effect.

Prior to this patient cohort, full Phase I evaluation in healthy volunteers showed a favorable safety and tolerability profile, predictable pharmacokinetics, no anti-drug antibody formation, and pharmacodynamic evidence of target engagement.

The trial was approved by the Medical Research Agency's Chief Bioethics Committee for Clinical Trials, Poland.

Results

Two male patients aged 39 and 41 y/o with a LAD not fully controlled despite a treatment with dapsone at dose of 50 mg/day were included. They presented with urticarial lesions, blisters with a BPDAI (TAS) score of 11 and 7 respectively, and a mild/moderate pruritus.

Reduction of pruritus was observed within 3 days of first dosing at Day 28, both patients had **complete response with a BPDAI (TAS)** activity score of 0 and were able to stop dapsone. Response after dapsone withdrawal was sustained: one patient maintained complete response (no active lesions and no pruritus) at Day 56 and Day 141 (End of Study). The second patient had a mild pruritus at Day 56 and achieved complete response again at Day 141.

Overall, **clinical remission was maintained after dapsone withdrawal up to end of the study**in the two patients (Day 141).

A total of 7 Treatment-Emergent Adverse Event (TEAEs) were reported in Subject A and 4 TEAEs in Subject B, with an identical number of possibly drug-related TEAEs observed in each subject (n=3). **Drug-related events were predominantly mild** and no imbalance between subjects was identified. Several adverse events, including pruritus and skin lesions, occurred prior to first administration of nebaprubart and were considered expected following tapering of Standard of Care (SoC) to subtherapeutic doses. Musculoskeletal events (myalgia and arthralgia) were reported in both subjects and are listed as possibly IMP-related. Other events included headache, eye haemorrhage, toothache, and gingival swelling, with no apparent pattern suggestive of an IMP-related safety signal.

Overall, no unexpected adverse events or clinically meaningful safety concerns were identifiedbased on the available data. At the time of this abstract editing and after a 4 months follow-up, both patients remain in complete remission.

Treatment outcomes for Patient A

Outcome	*Baseline*	*Day 28*	*Day 56*	*Day 141 (EoS)*
BPDAI TAS	11 (mild)	0 (CR)	0 (CR)	0 (CR)
BPDAI pruritus	17 (moderate)	5 (minimal to no pruritus)	0 (no pruritus)	0 (no pruritus)
EQ-5D-5L (self-assessment, 0-100)	70	80	50	80

Abbreviations: CR = complete remission, N/A = not applicable, BPDAI TAS = Bullous Pemphigoid Disease Area Index Total Activity Score, EQ-5D-5L = EuroQol 5-Dimension 5-Level questionnaire

Lesion improvement visualization for Patient B



Treatment outcomes for Patient A and lesion improvement visualization for Patient B

Conclusions

These interim findings support CD89 blockade with **nebaprubart** as a targeted therapeutic approach in LAD, with **rapid onset of activity, successful withdrawal of chronic dapsone treatment, and durable clinical remission in the first treated patients**. The results support continued clinical evaluation of nebaprubart in LAD and other IgA-driven diseases.

EA DV CONGRESS
VIENNA
30 SEP - 3 OCT 2026

Abstract N°: 4143

Racial and Ethnic Representation and Reporting in Bullous Pemphigoid Clinical Trials: a Systematic Review

Brendan Amoyaw*[1], Sana Gupta[2], Junseok Ham[3], Geeta Yadav[4]

[1] University of British Columbia, Vancouver, Canada
[2] University of Ottawa, Ottawa, Canada
[3] University of Manitoba, Winnipeg, Canada
[4] University of Toronto, Toronto, Canada

Introduction

Bullous pemphigoid (BP) is an autoimmune skin condition, characterized by tense bullae and intense pruritus. Dermatologic research has historically underrepresented minorities, limiting understanding of disease manifestation and treatment outcomes among non-White patients. Since BP may have variable clinical burden and sequelae based on skin tone, evaluating ethnoracial diversity in clinical trials is essential to determine the generalizability of BP-related evidence. This systematic review evaluates racial and ethnic representation and reporting practices in BP clinical trials.

Materials and Methods

Following PRISMA guidelines, PubMed and ClinicalTrials.gov were searched in December 2025 using keywords related to "bullous pemphigoid" and "randomized controlled trial." English-language RCTs were eligible, with no publication date or participant age restrictions. Two reviewers independently screened results in duplicate with disagreements resolved via consensus. Racial and ethnic data was extracted using terminology from the United States Food and Drug Administration. Any mention of participant race or ethnicity was considered evidence of reporting, regardless of quantitative breakdowns. Following methods from Charrow et al., RCTs were considered non-diverse if non-White participants comprised under 20% of the cohort. Per Cochrane ROB 2.0, 34 trials (85.0%) had a moderate risk of bias and 6 (15.0%) low.

Results

Of 231 results identified, 40 unique RCTs comprising 2442 participants (58.9% female, mean age: 75.41 years) were included. Most trials spanned multiple countries, with 28.2% conducted in France (n=11/40). Of 40 trials, 10 (25.0%) reported participant race and ethnicity. Three (30.0%) were conducted exclusively in the USA, and the majority were industry-funded (60.0%, n=6/10). RCTs published after 2020 (36.8%, n=7/19) were not more likely to report race or ethnicity than those published earlier (14.3%, n=3/21) (Fisher exact, p=0.15). Methods of race and ethnicity ascertainment (i.e. investigator-assessed versus patient-reported) were not specified. Across trials reporting race or ethnicity, White participants comprised over three-quarters of all patients. 52 (8.1%) participants were classified as "Other". Ethnically, 1.1% (n=7/622) identified as Hispanic or Latino. Three trials (30%) met Charrow et. al's diversity criteria, where greater than 20% of participants were non-White. No RCTs incorporated skin-type assessments, such as Fitzpatrick phototypes. Furthermore, none reported efficacy or safety outcomes by race or ethnicity.

Table 1. Summary of patient and trial characteristics.

Patient characteristics (n = 2442)	**N (%)**
Age (y), mean (n = 564)	75.41
Sex, female (n = 1334)	786 (58.9)
Ethnicity (n = 622)	
Hispanic or Latino	7 (1.1)
Not Hispanic or Latino	615 (98.9)
Race (n = 640)	
White	498 (77.8)
Black or African American	12 (1.9)
Asian	77 (12.0)
American Indian/Alaskan Native	1 (0.2)
Native Hawaiian/other Pacific Islander	0 (0.0)
Other	52 (8.1)
Study characteristics (n = 40)	**N (%)**
Published after 2020	19 (47.5)
RCT phase (n = 26)	
1	2 (7.7)
2	13 (50.0)
3	8 (30.8)
4	3 (11.5)
Blinding (n = 38)	
Single-blind	27 (71.1)
Double-blind	1 (2.6)
Open-label	10 (26.3)
Funding source (n = 37)	
Academic	15 (40.5)
Industry	16 (43.2)
Government	5 (13.5)
No funding	1 (2.7)
Location (n = 39)	
France	11 (28.2)
United States of America	5 (12.8)
Japan	4 (10.3)
Germany	2 (5.1)
Switzerland	2 (5.1)
Austria	1 (2.6)
China	1 (2.6)
Egypt	1 (2.6)
India	1 (2.6)
Taiwan	1 (2.6)

Abbreviations: RCT: randomized controlled trial

Conclusions

This review highlights persistent gaps in the reporting of race and ethnicity among BP RCTs. One-quarter of trials reported racial or ethnic data with none describing ascertainment methods, restricting comprehensive assessments of study populations and external validity. Most reporting trials were industry-funded, suggesting regulatory or sponsor influence in data collection and emphasis on demographic transparency. The emergence of novel therapies has catalyzed BP clinical trial activity, with 12 trials recruiting or active on ClinicalTrials.gov as of February 2026. This ongoing research underscores that temporal distance cannot excuse inadequate diversity reporting—the problem persists in contemporary studies. Limitations include restriction to English-language trials, and reliance on FDA-defined classifications, which may aggregate phenotypically or genetically heterogeneous populations under broad labels. Enforcing inclusive recruitment and standardized, transparent reporting practices is necessary to ensure that the evidence guiding BP care is generalizable to the full spectrum of affected patients.

EADV CONGRESS
VIENNA
30 SEP - 3 OCT 2026

Abstract N°: 4166

Epidemiology of autoimmune bullous diseases in Finland 2000-2024

Emilia Veikkolainen[1], Outi Varpuluoma*[1], Jari Jokelainen[1], Laura Huilaja[1], Kaisa Tasanen[1]

[1] University of Oulu, Oulu University Hospital, Oulu, Finland

Introduction

Autoimmune bullous dermatoses (AIBD) include pemphigus and pemphigoid groups, and dermatitis herpetiformis (DH). The aim of this national retrospective registry study was to investigate the epidemiology of all AIBD in Finland and analyze the trend of incidence. We included all patients over 16 years of age who were diagnosed with an AIBD in Finland between 2000-2024. Data was collected from the Finnish Care Register for Health Care using specific ICD-10 codes.

Materials and Methods

We included all patients over 16 years of age who were diagnosed with an AIBD in Finland between 2000-2024. Data was collected from the Finnish Care Register for Health Care using specific ICD-10 codes.

Results

A total of 7940 patients met our inclusion criteria. More than half of the cases (73.6 %) were diagnosed with pemphigoid diseases, 20.9 % with DH and only about 5.5% had pemphigus diseases. There was a female predominance in all other AIBD except in DH and pemphigus foliaceus (PF), the female to male ratio varying from 1.04 to 1.65. The largest patient groups were bullous pemphigoid (BP) with 66.9% (n=5315), DH with 20.9% (n=1662), mucous membrane pemphigoid with 3.8% (n=302), pemphigus vulgaris with 2.1% (n=168) and PF with 2.5% (n=196) of all included patients. We calculated crude incidence of each disease in 5-year periods. The incidences of PV, PF and BP continued to rise until 2020, after which their incidence began to decrease. The incidence of DH was steadily declining during the study period. MMP and pemphigus erythematosus also had a slightly decreasing incidence. For the other AIBD the incidence remained constant. BP had the highest incidence being 58 cases/million/year during 2020-2024

Conclusions

All AIBD are rare or extremely rare in Finland. BP was by far the most common AIBD. Interestingly, we found a recent decline in the incidence of BP; further research is needed to understand the reasons behind this observation. Pemphigus diseases and other pemphigoid diseases excluding BP are very rare, and there were no changes in their incidence during the study period, although the small number of cases limits the interpretation of the results

EADV CONGRESS
VIENNA
30 SEP - 3 OCT 2026

Abstract N°: 4186

A retrospective review of anti-p200 pemphigoid in Singapore

Yen Loo Lim*[1], Derek Lim[1]

[1] National Skin Centre, Singapore, Singapore

Introduction
Anti-p200 pemphigoid is a rare autoimmune subepidermal blistering disease characterized by autoantibodies against laminin β4 and laminin γ1. While most reported cases originate from Europe and Japan, this series represents a cohort from Southeast Asia, specifically Singapore.

Materials and Methods
We retrospectively analysed clinical presentations, histopathological, immunological data and treatment of 22 patients diagnosed with anti-p200 pemphigoid between 2006 and 2022. Diagnosis was confirmed by immunoblotting against the p200/laminin γ1 antigen, supplemented by direct and indirect immunofluorescence, ELISA, and clinicopathological correlation.

Results
Of the 22 patients, 16 (73%) were of Chinese ethnicity, 4 (18%) Malay, and 2 (9%) Indian. Ages ranged from 28 to 82 years, with a male predominance. Cutaneous blistering was the predominant presentation, seen in 20 patients (91%). Additional mucosal involvement (oral or genital) was documented in 6 patients (27%), underscoring phenotypic variability. Initial misdiagnosis occurred in 15 patients (68%), most commonly as bullous pemphigoid, epidermolysis bullosa acquisita (EBA), or mucous membrane pemphigoid (MMP). Immunoblotting was pivotal in refining diagnoses, especially in cases with atypical histology or overlapping features. Multiple antibody reactivity was observed in 5 patients (23%), involving combinations with BP180, laminin-332, or LAD-1. One case showed lichen planus–like lesions preceding blistering. Coexistent psoriasis (including pustular psoriasis) was observed in 2 patients (9%). Corticosteroids remained the mainstay of treatment, often combined with dapsone, azathioprine, mycophenolate mofetil and methotrexate. One patient with more recalcitrant disease was treated with IVIg and rituximab.

Conclusions
This Singapore cohort underscores the heterogeneity of anti-p200 pemphigoid, with unique presentations affecting the face, acral palms and soles a swell as mucosal involvement. Detection of antibodies to other target antigens other than p200 is common and probably reflects the phenomenon of epitope spreading and emphasizes the importance of clinicopathological correlation for accurate diagnosis. Immunoblotting proved essential in distinguishing p200 pemphigoid from other autoimmune subepidermal blistering diseases.

EADV CONGRESS
VIENNA
30 SEP - 3 OCT 2026

Abstract N°: 4189

Epitope distribution and diagnostic performance of target antigens in autoimmune bullous diseases: a systematic review

Xun Feng*[1], Wei Li[1]

[1] West China Hospital of Sichuan University, Chengdu, China

Introduction
Autoimmune bullous diseases (AIBDs) are a heterogeneous group of autoantibody-mediated disorders targeting structural proteins involved in epidermal adhesion and dermal–epidermal junction integrity. Although commercial serological assays mainly focus on immunodominant antigens or domains, such as Dsg1, Dsg3, BP180 NC16A, and BP230, atypical or serologically ambiguous cases may involve broader antigenic and epitope profiles. This systematic review aimed to summarize the epitope distribution and diagnostic performance of AIBD-related target antigens and to clarify the evidence supporting multi-antigen and multi-epitope serological testing.

Materials and Methods
A systematic literature search was conducted in PubMed, Embase, Web of Science, and CNKI according to PRISMA principles. Studies were eligible if they reported target antigens, antigenic domains, epitope localization, immunological detection methods, antibody positivity, specificity, or clinical correlations in AIBDs. Data were extracted regarding disease subtype, target antigen, epitope/domain, assay platform, antibody positivity, specificity, and clinical relevance. Because of substantial heterogeneity in study populations, antigen preparations, assay platforms, thresholds, and reporting methods, a structured stratified synthesis rather than a formal meta-analysis was performed. Methodological quality was assessed using QUADAS-2.

Results
Sixty-one studies were included. The available evidence showed that AIBD-related autoantibody responses are characterized by multi-antigen and multi-domain immune recognition (Table 1). In pemphigus, Dsg1 and Dsg3 remained the principal diagnostic antigens, with extracellular domains contributing differently to disease-specific antibody profiles. In paraneoplastic pemphigus, envoplakin, periplakin, desmoplakin, and desmocollins provided additional diagnostic value. In bullous pemphigoid, BP180 NC16A was the most extensively studied immunodominant region and showed relatively high diagnostic performance in ELISA-based assays; however, non-NC16A regions of BP180 and BP230, particularly the C-terminal domain, also showed diagnostic relevance. In epidermolysis bullosa acquisita, type VII collagen NC1 demonstrated consistently high serological positivity and specificity, whereas NC2 alone appeared less sensitive. In anti-p200 pemphigoid and mucous membrane pemphigoid, antibody responses were more heterogeneous and involved multiple basement membrane zone antigens, including laminin γ1, laminin 332, integrin α6β4, BP180, BP230, and type VII collagen. Across disease groups, diagnostic performance varied according to antigenic domain and detection platform, indicating that single-antigen assays may be insufficient for complete serological classification in diagnostically challenging AIBDs.

Table 1 Comprehensive serological positive rate results of different epitopes and detection methods

Antigen	Domain	Detection method	Research number	Case number	Positive rate range	Weighted positive	Specificity range(%)

		method	number	number	rate range (%)	positive rate (%)	range(%)
Dsg1	extracellular domain	ELISA/CLIA	4	119	75.0-100.0	91.6	94-100
	full length	ELISA/CLIA	1	50	96.0	96.0	99.1
	extracellular domain	BIOCHIP	1	66	80.3	80.3	NA*
Dsg3	extracellular domain	ELISA/CLIA	7	916	0-100	58.3	85-100
	full length	ELISA/CLIA	1	71	100	100	99.6
	extracellular domain	IB	2	27	77.5-100	81.5	100
	full length	IB	1	5	40	40	NA
	extracellular domain	BIOCHIP	1	66	83.3	83.3	NA
Desmoplakin	carboxyl terminal	IB	1	6	50	50	100
	full length	IB	2	106	18.75-100	27.4	100
Dsc1	extracellular domain	BIOCHIP	1	333	3	3	98.8
Dsc2	extracellular domain	BIOCHIP	1	333	0.3	0.3	100
Dsc3	extracellular domain	BIOCHIP	1	333	1.2	1.2	100
	extracellular domain	ELISA/CLIA	1	226	2.9-60.7	24.8	100
Envoplakin	amino terminal	ELISA/CLIA	2	288	36.9-81.7	58.7	88-98
	carboxyl terminal	ELISA/CLIA	1	130	52.3-75.4	63.8	92-96
	carboxyl terminal	IB	1	6	100	100	100
Periplakin	amino terminal	IB	1	11	82	82	NA*
	carboxyl terminal	IB	2	17	64-100	76.5	100
	Mid	IB	1	11	73	73	NA
	full length	IB	1	5	80	80	NA
	amino terminal	ELISA/CLIA	1	195	55.4-64.6	61.0	66-78
	carboxyl terminal	ELISA/CLIA	1	130	18.5-44.6	31.5	96-98
BP180	NC16A	ELISA/CLIA	15	1196	0-100	65.8	96-100
	Non-NC16A	ELISA/CLIA	3	816	3.3-96	36.6	100
	full length	ELISA/CLIA	1	22	99.3	99.3	100
	NC16A	IB	5	308	28.6-86.3	47.7	100
	Non-NC16A	IB	9	1504	0-100	34.4	100

	full length	IB	5	422	18-72	48.6	100
	NC16A	BIOCHIP	2	47	79.3-83.3	80.9	NA*
BP230	carboxyl terminal	ELISA/CLIA	5	321	53.3-93.5	74.1	98.5-100
	amino terminal	ELISA/CLIA	1	105	21.9-51.6	40.0	100
	Mid	ELISA/CLIA	1	105	31.7-46.9	41.0	100
	full length	ELISA/CLIA	2	240	55.9-59.0	57.5	NA
	carboxyl terminal	IB	2	145	90.6-92.7	91.7	100
	amino terminal	IB	1	105	19.5-81.8	57.1	100
	Mid	IB	1	105	46.3-71.9	61.9	100
	full length	IB	2	202	43.0-52.9	48.0	NA
	carboxyl terminal	BIOCHIP	2	47	24.1-39.0	29.8	NA
Type VII collagen	NC1	ELISA/CLIA	4	268	82.2-100	89.9	98.6-100
	NC1+NC2	ELISA/CLIA	4	189	79.2-94	88.4	93.3-100
	full length	ELISA/CLIA	1	101	80.2	80.2	93.8
	NC1	IB	2	157	37.5-100	82.8	100
	NC2	IB	1	41	22	22	NA*
	full length	IB	2	125	87.1-91.7	88	100
	NC1	BIOCHIP	1	101	89.1	89.1	100
Laminin γ1	Carboxyl terminal	ELISA/CLIA	1	35	69	69	98.7
	Carboxyl terminal	IB	3	75	84-90	86.7	100
	Non-carboxyl terminal	IB	1	125	4-16	8.8	NA*
	full length	IB	1	60	80-90	85	100
Laminin β4	full length	IB	1	60	100	100	100

Conclusions

AIBD-related autoantibody responses are characterized by immunodominant core regions, domain-specific heterogeneity, and overlap across disease spectra. Current evidence supports the value of integrating multiple antigens and epitopes to improve serological classification, particularly in atypical or serologically ambiguous cases. Further multicentre studies using standardized antigen preparations, assay thresholds, and well-annotated clinical cohorts are needed to validate high-specificity biomarkers and clarify the relationship between epitope-specific immune responses and clinical phenotypes.

EADV CONGRESS
VIENNA
30 SEP - 3 OCT 2026

Abstract N°: 4220

Clinical and immunohistochemical profile of Vitiligo Vulgaris: A hospital-based case control study

Anishka Gopinath*[1]

[1] yenepoya medical college, mangalore, karnataka, india, mangalore, India

Introduction
In vitiligo vulgaris, reliable tissue biomarkers of immune activity are lacking. We aimed to define the clinical profile of vitiligo vulgaris and to compare lesional skin expression of CD1a, CD3, and CD4 with healthy control skin, while relating these to clinical and histopathological activity.

Materials and Methods
In this prospective case-control study, 26 adults with vitiligo vulgaris and 13 healthy controls underwent 4-mm skin biopsy. We recorded clinical features (including the Vitiligo Disease Activity Score, VIDA) and histopathology from lesional biopsies. Formalin-fixed sections were immunostained for CD1a, CD3, and CD4, and positive cells in epidermis/dermis were quantified in five high-power fields (cells/5 HPF).

Results
Among cases, 16/26 (61.5%) were clinically unstable (active) by VIDA, whereas only 4/26 (15.4%) had an unstable histopathological score. Mean lesional counts were CD1a 22.6±12.5, CD3 31.7±19.7, CD4 17.8±9.2 cells/5HPF. Compared to controls, CD3 was markedly higher in vitiligo lesions (31.7±19.7 vs 10.4±8.3 cells/5HPF; mean difference 21.3; p=0.001). By contrast, CD1a (22.6±12.5 vs 16.3±8.8; p=0.114) and CD4 (17.8±9.2 vs 11.9±8.9; p=0.067) did not differ significantly. None of the markers showed a significant association with VIDA category or histopathological activity.

Conclusions
Vitiligo vulgaris showed a clear lesional T-cell signature: CD3—but not CD1a or CD4—distinguished affected skin from healthy skin. This supports the concept that vitiligo is driven by T-cell–mediated autoimmunity, and suggests that CD3 could serve as a useful lesional immune readout. In this cohort, however, CD1a and CD4 were not robust standalone markers of disease activity.

EADV CONGRESS
VIENNA
30 SEP - 3 OCT 2026

Abstract N°: 4325

Unmasking the Mimicker: Trichoscopic and Histopathological Profiling of Alopecia Areata Incognita and the Therapeutic Potential of Tofacitinib

Rashmi Kumar Swamy*[1]

[1] Dr.Dixit Cosmetic Dermatology Clinic, Bangalore Medical College and Research Institute, Bengaluru, India

Introduction
Alopecia Areata Incognita (AAI) is an underrecognized diffuse variant of alopecia areata that commonly presents as sudden extensive hair shedding, often mimicking chronic telogen effluvium and diffuse androgenetic alopecia. In the absence of classical patches, patients are frequently misdiagnosed and subjected to prolonged ineffective treatments and unnecessary procedures. This study highlights the clinical, trichoscopic, and histopathological profile of AAI in patients presenting with extensive diffuse hair loss unresponsive to conventional therapy, while also evaluating the therapeutic response to oral tofacitinib.

Materials and Methods
Sixty patients presenting with extensive diffuse non-scarring alopecia and poor response to prior treatments were evaluated between January 2024 and April 2026. All patients underwent detailed clinical assessment, trichoscopy, and scalp biopsy. Trichoscopic findings included coiled hairs, black dots, yellow dots, short regrowing hairs, and follicular miniaturization. Histopathological examination assessed perifollicular and peribulbar lymphocytic infiltrate, increased telogen follicles, follicular miniaturization, pigment casts, and eosinophilic infiltration. Confirmed cases were initiated on oral tofacitinib following routine laboratory investigations

Results
Coiled hairs and black dots were observed in 88% of patients, while yellow dots were seen in 82%. Histopathology confirmed AAI in 56 out of 60 patients, with predominant findings of dense peribulbar lymphocytic infiltrate, increased telogen-to-anagen ratio, follicular miniaturization, perifollicular inflammation, and pigment casts. Eosinophilic infiltrates were noted in a subset of biopsies. Patients treated with oral tofacitinib demonstrated marked reduction in hair shedding with significant regrowth or stabilization within 8–12 weeks. No major adverse effects were encountered during follow-up.

Conclusions
AAI should be strongly considered in patients with extensive diffuse non-scarring hair loss unresponsive to standard therapies. Early diagnosis through combined trichoscopy and histopathological evaluation is crucial in differentiating AAI from other diffuse alopecias and avoiding unnecessary interventions. Oral tofacitinib demonstrated favorable clinical response with good tolerability, supporting its role as a promising therapeutic option in this frequently overlooked entity.

EADV CONGRESS
VIENNA
30 SEP - 3 OCT 2026

Abstract N°: 4464

Anti-laminin 332 mucous membrane pemphigoid: predominant cutaneous involvement and immunopathological heterogeneity

Mohammad Azouagh*[1], Mariem Tabka[1], Soumaya Gara[2], Feryel Amri[1], Rihab Sayari[3], Lilia Laadhar[3], Houda Hammami[4], Faten Zeglaoui[2], Mourad Mokni[1], Maryam Kallel Sellami[3]

[1] Dermatology department, La Rabta Hospital, Tunis, Tunisia
[2] Dermatology department, Charles Nicolle Hospital, Tunis, Tunisia
[3] Immunology department, La Rabta Hospital, Tunis, Tunisia
[4] Dermatology department, Lahbib Thameur Hospital, Tunis, Tunisia

Introduction

Anti-laminin 332 mucous membrane pemphigoid (MMP) is a rare autoimmune blistering disorder characterised by autoantibodies directed against laminin 332, a key glycoprotein of the lamina densa within the dermo–epidermal junction. Its recognition as a distinct entity has emerged relatively recently, owing to advances in immunopathological techniques. An association with malignancy has been reported in several series, conferring particular diagnostic relevance. We report the first Tunisian case series of anti-laminin 332 MMP and describe its epidemiological, clinical, and immunopathological features.

Materials and Methods

We conducted a retrospective case series including patients diagnosed with anti-laminin 332 MMP across three dermatology departments between 2018 and 2025.

Diagnosis was established based on:

- a compatible clinical presentation of an autoimmune blistering disease;
- direct immunofluorescence demonstrating linear IgG and/or C3 deposition along the dermo–epidermal junction;
- detection of anti-laminin 332 autoantibodies by indirect immunofluorescence using transfected cells (Biochip Laminin 332, Dermal Binder Mosaic 1, EUROIMMUN), with exclusion of other dermal-binding antigens.

Results

Seven patients were included (4 men, 3 women), with a median age of 49 years [5–80]. No patient had a known history of malignancy or neurological disease at diagnosis.

Two drug-associated cases were identified: one paediatric case occurring after exposure to amoxicillin–clavulanic acid, with onset seven days after discontinuation, and one adult case associated with recent exposure (two weeks) to hydroxyzine, levomepromazine, and heroin.

Cutaneous involvement was constant and often initial, mimicking bullous pemphigoid. Lesions predominantly affected the face and/or neck (7 cases), trunk (6 cases), and extremities (5 cases), consisting of tense bullae and post-bullous erosions. Nail involvement was observed in one case and scalp involvement in two cases.

Mucosal involvement was also constant, invariably affecting the oral mucosa. Additional involvement included genital mucosa (2 cases), ocular mucosa (2 cases), and upper aerodigestive tract (1 case).

Histopathology revealed a subepidermal blister in all cases.

Direct immunofluorescence demonstrated linear IgG and C3 deposition along the dermo–epidermal junction in all patients, with associated IgA deposits in four cases.

Indirect immunofluorescence on salt-split skin showed dermal binding in four cases, a dual binding pattern in two cases, and was negative in one case.

Anti-BP180 ELISA was positive in two patients.

Conclusions

This series highlights the clinical and immunopathological heterogeneity of anti-laminin 332 mucous membrane pemphigoid. Notable features include a relatively young age at onset, including a paediatric case, and a constant, predominant cutaneous involvement. The absence of associated malignancy in our cohort should be interpreted with caution given the lack of systematic screening.

The diversity of immunological profiles underscores the importance of comprehensive immunopathological assessment in the diagnostic work-up. The presence of multiple antigenic targets may reflect epitope spreading mechanisms.

EA DV CONGRESS
VIENNA
30 SEP - 3 OCT 2026

Abstract N°: 4472

Anti-p200 (anti–laminin γ1/laminin β4) pemphigoid: epidemiological, clinical and immunopathological features from a Tunisian case series

Mohammad Azouagh*[1], Mariem Tabka[1], Soumaya Gara[2], Feryel Amri[1], Rihab Sayari[3], Lilia Laadhar[3], Houda Hammami[4], Faten Zeglaoui[2], Mourad Mokni[1], Maryam Kallel Sellami[3]

[1] Dermatology department, La Rabta Hospital, Tunis, Tunisia
[2] Dermatology department, Charles Nicolle Hospital, Tunis, Tunisia
[3] Immunology department, La Rabta Hospital, Tunis, Tunisia
[4] Dermatology department, Lahbib Thameur Hospital, Tunis, Tunisia

Introduction

Anti-p200 pemphigoid, also known as anti–laminin γ1 pemphigoid, is a rare autoimmune subepidermal blistering disorder characterised by autoantibodies targeting a 200-kDa protein, identified as (laminin γ1/ laminin β4 subunit), within the dermo–epidermal junction. Its polymorphic clinical presentation, often mimicking other autoimmune blistering diseases, makes diagnosis challenging and reliant on specialised immunopathological techniques.

We report the first Tunisian case series of anti-p200 pemphigoid and describe its epidemiological, clinical, and immunopathological characteristics.

Materials and Methods

We conducted a retrospective case series including patients diagnosed with anti-p200 pemphigoid across three dermatology departments between 2018 and 2025.

Diagnosis was established based on:

- a compatible clinical presentation of an autoimmune blistering disease;
- direct immunofluorescence demonstrating linear IgG and/or C3 deposition along the dermo–epidermal junction;
- indirect immunofluorescence on salt-split skin demonstrating dermal binding;
- detection of autoantibodies against laminin β4 subunit, using indirect immunofluorescence on transfected cells (Dermal Binder Mosaic 1, EUROIMMUN).

Results

Four patients were included. The median age at diagnosis was 79 years [65–98], with a male predominance (3 men, 1 woman).

No history of neuropsychiatric disease, malignancy, or psoriasis was reported. No chronic medication use was identified, including drugs known to trigger autoimmune blistering diseases such as gliptins.

Pruritus was constant and represented the initial symptom in all patients. Cutaneous lesions were present on the limbs in all cases, with consistent involvement of flexural and acral sites. A predilection for friction-prone and

trauma-exposed areas was observed in three cases. The trunk and cephalic region (head and/or neck) were involved in three cases each, while external genital involvement was noted in two patients.

Mucosal involvement was present in three cases, affecting the oral mucosa (2 cases), genital mucosa (2 cases), and upper aerodigestive tract (1 case). One patient exhibited multi-mucosal involvement.

Blisters arose on normal-appearing skin in all cases, without urticarial plaques. All patients had generalised disease, which was multibullous in three cases and paucibullous in one. No milia were observed during healing.

Histopathology demonstrated subepidermal blistering with a dermal inflammatory infiltrate that was predominantly eosinophilic in all cases, associated with lymphocytic (3 cases) and/or neutrophilic components (2 cases), highlighting a variable cellular profile.

Direct immunofluorescence revealed linear IgG and C3 deposition along the basement membrane zone in all cases, with additional IgA (3 cases) and IgM (1 case) deposits.

Indirect immunofluorescence on salt-split skin showed dermal binding in two cases and a dual binding pattern in two cases.

ELISA detected anti-BP180 antibodies in two patients and anti-BP230 antibodies in one patient. In addition to anti–laminin γ1 reactivity, one patient demonstrated low-level reactivity against laminin 332.

Conclusions

In our series, the median age at onset was higher than that typically reported in the literature (79 vs 65). Unlike previous studies describing an association with psoriasis in up to 30% of cases, no such association was identified. No gliptin-induced cases were observed.

Clinically, the constant acral involvement was consistent with published data. The relatively high frequency of mucosal involvement (three-quarters of cases) highlights the importance of systematic mucosal examination, as this feature may be under-recognised in anti-p200 pemphigoid.

Histologically, the predominance of eosinophilic and lymphocytic infiltrates contrasts with the neutrophil-predominant pattern more commonly described.

EADV CONGRESS
VIENNA
30 SEP - 3 OCT 2026

Abstract N°: 4493

International Consensus on Terminology and Definitions of Disease Activity Signs in Vitiligo: Results from the ACTIVE Project Topic 1

Lise Vanden Broucke*[1], Nanja van Geel[1], Reinhart Speeckaert[1], Albert Wolkerstorfer[2]

[1] University of Ghent, Ghent University Hospital, Gent, Belgium

[2] Netherlands Institute For Pigment Disorders, Amsterdam, Netherlands

Introduction

Given the unpredictable course of the disease in vitiligo patients, adequate assessment of disease activity in vitiligo is important for therapeutic decision-making, prognostic evaluation, and clinical trial design. Although clinical signs are recognized indicators of disease activity, their use remains limited by heterogeneous terminology and lack of standardized definitions.

Materials and Methods

Topic 1 of the ACTIVE project aimed to establish international consensus-based terminology and definitions for visible clinical signs of disease activity in vitiligo patients. A structured international eDelphi process was conducted according to CREDES recommendations and consisted of a preparatory item-reduction survey, two eDelphi rounds and a final online conclusive meeting. Thirty-eight vitiligo experts from five continents participated through the Vitiligo Task Force network, while five VIPOC patient representatives attended the final meeting as observers. Consensus was predefined as ≥70% agreement, <15% disagreement, and absence of major opposing arguments.

Results

Consensus was achieved for the terminology and definitions of all four disease activity signs. Final consensus terms included ‘confetti-like depigmentation(s)’ (88% agreement), ‘ill-defined borders’ (72%), ‘Koebner phenomenon’ (100%), and ‘inflammatory vitiligo’ (91%). Consensus was also reached on the Vitiligo European Task Force classification of the Koebner phenomenon. The clinical relevance and degree of association to disease activity of ‘inflammatory vitiligo’ still needs to be defined.

Conclusions

This study provides the first internationally consensus-based terminology and definitions for clinical disease activity signs in vitiligo. By creating a shared framework for recognizing and describing these signs, this topic of the ACTIVE project aims to improve consistency in clinical practice and research and to enhance comparability across vitiligo studies and therapeutic trials.