EA DV CONGRESS
VIENNA
30 SEP - 3 OCT 2026

Abstract N°: 21

A Solitary Pink Facial Nodule: An Unusual Diagnosis - Angiolymphoid Hyperplasia with Eosinophilia

Şeyma Nur Erol*[1], Ecenur Koyuncu[2], Selda Pelin Kartal[1]

[1] Ankara Etlik City Hospital, Department of Dermatology and Venereology, Ankara, Türkiye
[2] Ankara Etlik City Hospital, Department of Pathology, Ankara, Türkiye

Introduction
Angiolymphoid hyperplasia with eosinophilia (ALHE) is a rare benign vasoproliferative disorder characterized by solitary or multiple firm, pink-to-red papules and nodules with a predilection for the face, scalp, and periauricular region, most commonly affecting women in their third to fourth decades. Despite its rarity, this distinct clinical profile can enable the clinician to suspect the diagnosis prior to histopathological confirmation. Pink nodular lesions of the face, however, represent a broad diagnostic challenge encompassing both benign and malignant entities. Dermoscopy is a valuable non-invasive tool that may provide supportive diagnostic clues; yet reports specifically describing dermoscopic features of ALHE remain scarce in the literature.

Case Presentation
A 27-year-old woman presented with a slowly enlarging, firm, well-circumscribed pink nodule with a shiny and slightly lobulated surface (8×11 mm) on the left temporal region near the hairline, accompanied by a palpable subcutaneous extension evolving over four months. No pain, pruritus, or bleeding was reported. Prior evaluations by neurosurgery and rheumatology were unremarkable, and ultrasonography excluded vasculitis. Dermoscopy revealed a milky-pink background with whitish cloud-like structureless areas and preserved hair follicles. A 4-mm punch biopsy demonstrated thick-walled vascular channels lined by prominent epithelioid endothelial cells with a dense lymphoeosinophilic infiltrate, confirming ALHE. Given the subcutaneous component, Kimura disease was considered; however, cervical ultrasonography showed no lymphadenopathy, peripheral eosinophilia was absent, and renal function tests and urinalysis were within normal limits. The patient was referred for surgical excision.

Only a limited number of studies have described the dermoscopic features of ALHE. Padilla-España et al. were first to report dermoscopic findings in a single lesion from their 7-case series, describing a lacunar pattern resembling hemangioma. Rodríguez-Lomba et al. subsequently described a polymorphous vascular pattern composed of dotted and linear irregular vessels over a light pink background in two cases. Kalantri and Khopkar further characterized a polymorphic vascular pattern including red dots and globules, linear regular and irregular vessels, reticular vessels on a pink-white background, and white shiny structures. Akay et al. reported red clods with dotted vessels, subtle white lines, and pink structureless areas in two histopathologically confirmed cases, along with a literature review. Most recently, Chauhan et al. described the dermoscopic spectrum in the largest reported series of six patients with skin of colour. In our case, dermoscopy demonstrated a milky-pink background with whitish cloud-like structureless areas and preserved hair follicles — findings that partially overlap with previously described features, and likely reflect variability related to lesion depth and individual vascular density.

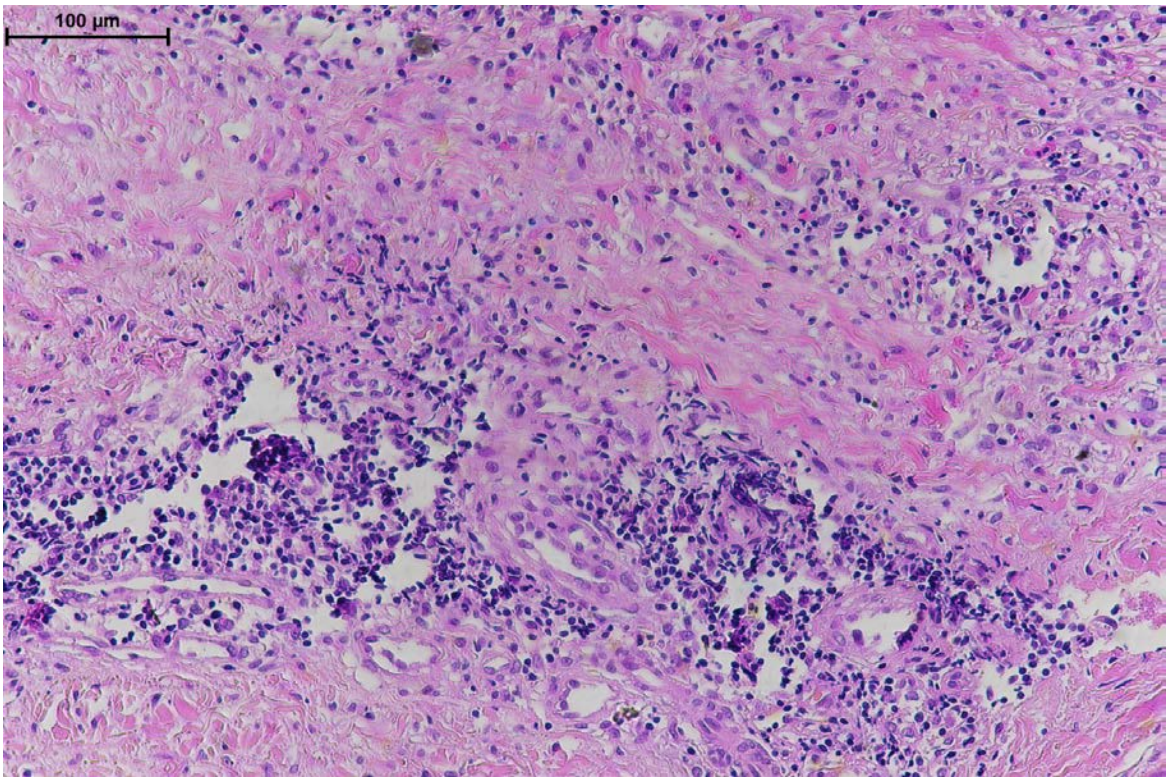

H&E sections demonstrate numerous thick-walled vessels with swollen endothelial cells and dense lymphocytic and eosinophilic infiltration in the surrounding stroma (H&E ×200).

Conclusion

ALHE should be considered when evaluating a solitary firm pink nodule on the face, scalp, or especially the periauricular region of a young woman, given its recognizable clinical picture. As pink facial lesions pose a broad diagnostic challenge, dermoscopy may help guide timely biopsy decisions. Given the still limited and heterogeneous dermoscopic descriptions of ALHE in the literature, further reports are needed to better define its dermoscopic spectrum.

EADV CONGRESS
VIENNA
30 SEP - 3 OCT 2026

Abstract N°: 48

Deep Kaposiform Hemangioendothelioma Without Cutaneous Lesions Mimicking Malignant Bone Disease: A Diagnostic Challenge in Pediatric Vascular Tumors

Aleksandra Osińska*[1], Szymon Pochwatka[1], Klaudia Marchewka[1], Karolina Wyżkiewicz[1], Jakub Szczepański[1], Andrzej Materniak[2]

[1] Student Scientific Society at the Department of Pediatric Radiology, Medical University of Lublin, Lublin, Poland
[2] Medical University of Lublin, Lublin, Poland

Introduction

Kaposiform hemangioendothelioma (KHE) is a rare, locally aggressive vascular tumor typically managed within the spectrum of complex vascular anomalies in dermatology. It most commonly involves the skin and deep soft tissues and may be associated with Kasabach–Merritt phenomenon. Purely osseous presentation without visible skin lesions is exceptionally rare and may obscure recognition of this vascular entity.

Case Presentation

A 5-year-old boy presented with progressive limp and persistent hip pain, without cutaneous vascular lesions, erythema, or swelling. Initial radiologic findings suggested inflammatory or malignant bone pathology. Empirical antibiotic therapy failed.Pelvic MRI revealed lytic and mixed lesions of the left iliac bone and proximal femur. Core biopsy was nondiagnostic. Open biopsy demonstrated spindle-cell vascular proliferation forming slit-like channels and glomeruloid structures. Immunohistochemistry confirmed endothelial differentiation (CD31+, CD34+) and excluded infantile hemangioma (GLUT1−), establishing the diagnosis of deep kaposiform hemangioendothelioma.There was no evidence of Kasabach–Merritt phenomenon. Systemic therapy with sirolimus combined with corticosteroids led to rapid symptom resolution and radiologic stabilization.

Conclusion

KHE is part of the spectrum of rare pediatric vascular tumors encountered in dermatologic practice. When occurring without cutaneous involvement, diagnosis may be delayed, and lesions may be mistaken for malignancy or chronic osteomyelitis. Histopathology and immunohistochemistry are crucial to distinguish KHE from other vascular proliferations and bone tumors. Increasing evidence supports sirolimus as an effective targeted therapy in complex vascular anomalies.This case underscores that KHE should be considered in the differential diagnosis of atypical deep or musculoskeletal lesions in children, even in the absence of skin findings. Dermatologic expertise in vascular tumors and access to appropriate histopathologic evaluation are essential for accurate diagnosis and optimal management.

EA DV CONGRESS
VIENNA
30 SEP - 3 OCT 2026

Abstract N°: 105

From Livedo Reticularis to Multisystem Involvement: A Case of Persistent Livedoid Dermatosis

Filipe Monteiro*[1], Inês Pereira Amaral[1], Joana Vieitez Frade[1], Inês Tribolet de Abreu[1], Gustavo Silva[1], Ivânia Soares[1], Sonia Fernandes[1], Joana Antunes[1]

[1] Unidade Local de Saúde Santa Maria, Lisboa, Portugal

Introduction

Livedoid dermatoses encompass a spectrum of cutaneous disorders characterized by vascular involvement, reflecting underlying thrombotic, inflammatory, or mixed pathogenic processes. These conditions often present with a range of clinical manifestations, from reticular erythema to ulceration and nodular lesions, making early recognition challenging. Distinguishing livedoid vasculopathy from other vascular dermatoses can be particularly difficult, especially in cases with prolonged evolution, systemic symptoms, or histopathologic findings that vary over time. The overlap of clinical and microscopic features between thrombotic and inflammatory mechanisms further complicates diagnosis, emphasizing the need for a careful integration of clinical history, laboratory evaluation, and sequential histopathology. Understanding this heterogeneity is essential not only for accurate diagnosis but also for guiding individualized therapeutic strategies and anticipating potential systemic involvement.

Case Presentation

We report the case of a 78-year-old woman with a history of hypertension, chronic venous insufficiency, and prior breast cancer, who presented with a chronic, progressive cutaneous disorder. The initial lesions, first noted in 2012, consisted of erythematoviolaceous papules and edema affecting the feet and lower legs. By 2019, she developed punctate, star-shaped ulcers on the dorsum of the feet and additional erythematoviolaceous papules on the thighs. Over time, the livedoid pattern extended from the lower limbs to the upper limbs and trunk, ultimately forming a disseminated livedo racemosa, accompanied by subcutaneous nodules on the thighs and recurrent ulcerations. Electromyography revealed a concomitant sensory-motor polyneuropathy.Laboratory evaluation demonstrated a low-titer positive ANA (1:160) with no other autoimmune markers, negative antiphospholipid antibodies, and no evidence of systemic vasculitis. Thrombophilia testing identified a heterozygous PAI-1 4G variant and reduced protein S levels. Multiple skin biopsies revealed fibrin deposition within vessel walls, episodes of mixed panniculitis, and lymphocytic vasculitis of small vessels, reflecting a combination of thrombotic and inflammatory mechanisms.The patient received multiple therapeutic interventions, including systemic corticosteroids, pentoxifylline, antiplatelet therapy, anticoagulation, intravenous immunoglobulin, and hyperbaric oxygen therapy, but clinical improvement was limited.

Conclusion

Based on the patient’s prolonged clinical course, progressive cutaneous manifestations, histopathologic features, and comprehensive etiologic evaluation, the primary differential diagnoses included livedoid vasculopathy and lymphocytic thrombophilic arteritis. The presence of recurrent ulcerations with stellate borders, widespread livedo racemosa, fibrin deposition in vessel walls, and mixed episodes of paniculitis with lymphocytic vasculitis pointed toward a predominantly thrombotic microvascular process rather than a primary inflammatory arteritis. In contrast, lymphocytic thrombophilic arteritis is typically characterized by chronic lymphocytic infiltration of small- to medium-caliber vessels with minimal thrombotic involvement and often presents with more limited cutaneous findings. The identification of a heterozygous PAI-1 4G mutation further supports a thrombotic predisposition, reinforcing the diagnosis of livedoid vasculopathy in this patient.This case illustrates the diagnostic challenges

inherent to chronic livedoid dermatoses, particularly in long-standing, multifocal presentations with overlapping inflammatory and thrombotic histopathologic features. It underscores the essential role of integrating clinical evolution, histopathology, and underlying prothrombotic risk factors in establishing an accurate diagnosis.

EADV CONGRESS
VIENNA
30 SEP - 3 OCT 2026

Abstract N°: 166

When “chronic urticaria” is not urticaria: hypocomplementemic urticarial vasculitis unveiling systemic lupus erythematosus with renal involvement

Gloria Fernández Robles[1], Ilse Marilú Delgado Wences*[1], Livier Sainz Bravo[1], Ma. Virgilia Soto Abraham[1], Jennifer Topacio Tapia Baez[1], Dalia Ibarra Morales[1], luis miguel moreno-lópez[1], VALERIA LYZZETE DIAZ MOLINA[1]

[1] Hospital General de México "Dr. Eduardo Liceaga", Ciudad de México, Mexico

Introduction

Urticarial vasculitis (UV) is a small-vessel leukocytoclastic vasculitis characterized by urticarial lesions persisting for more than 24 hours. Hypocomplementemic urticarial vasculitis (HUV) is strongly associated with systemic disease, particularly systemic lupus erythematosus (SLE), and may precede its diagnosis. Early recognition is critical, as hypocomplementemia is linked to more severe systemic involvement, including renal disease.

Case Presentation

A 41-year-old woman presented without active dermatosis but reported a 10-year history of recurrent generalized urticarial lesions lasting more than 24 hours, associated with pain, myalgia, and arthralgia. Episodes resolved with short courses of low-dose prednisone.

Laboratory evaluation revealed positive circulating immune complexes, ANA 1:80 (fine speckled pattern), and marked hypocomplementemia (C3: 20.9 mg/dL; C4: 2.15 mg/dL), raising suspicion of urticarial vasculitis.

Within 24 hours, she developed persistent pruritic urticarial plaques that progressed to a disseminated dermatosis involving photoexposed areas, along with malar erythema. Repeat laboratory tests showed renal impairment (GFR: 29 mL/min), anemia, and thrombocytopenia, suggesting systemic involvement.

Skin biopsy confirmed leukocytoclastic vasculitis, and direct immunofluorescence demonstrated IgM deposition along vessel walls. Renal biopsy revealed immune complex–mediated endocapillary proliferative glomerulonephritis with advanced global sclerosis, consistent with lupus nephritis.

These findings supported the diagnosis of hypocomplementemic urticarial vasculitis secondary to systemic lupus erythematosus.

Conclusion

Hypocomplementemic urticarial vasculitis should be recognized as a potential early manifestation of systemic lupus erythematosus. Persistent urticarial lesions lasting more than 24 hours warrant prompt biopsy and complement evaluation.

This case underscores the critical role of dermatologists in identifying early cutaneous signs of systemic disease. Delayed recognition may lead to advanced organ involvement, as illustrated by severe renal impairment at presentation. Early diagnosis enables timely multidisciplinary management and may improve outcomes.

EA DV CONGRESS
VIENNA
30 SEP - 3 OCT 2026

Abstract N°: 204

Granulomatosis with polyangiitis mimicking malignancy: breast mass with pyoderma gangrenosum-like ulceration in a male patient

Hayrunnisa Arslan*[1], Tubanur Cetinarslan[1], Atakan Eren[1], Peyker Temiz[2], Aylin Türel Ermertcan[1]

[1] Manisa Celal Bayar University Faculty of Medicine, Department of Dermatology, Manisa, Türkiye
[2] Manisa Celal Bayar University Faculty of Medicine, Department of Pathology, Manisa, Türkiye

Introduction

Granulomatosis with polyangiitis (GPA) is a necrotizing small- to medium-vessel vasculitis within the spectrum of ANCA-associated vasculitides. Diagnosis relies on the integration of clinical phenotype, physical examination, imaging findings, serology—particularly PR3/c-ANCA—and, when feasible, histopathological confirmation from involved tissues. Cutaneous involvement is common; however, pyoderma gangrenosum-like ulceration with violaceous borders represents an uncommon presentation that may lead to diagnostic delay and inappropriate management. Breast involvement is exceedingly rare and may closely mimic malignancy both clinically and radiologically, necessitating tissue biopsy for definitive diagnosis, particularly in male patients.

Case Presentation

A 57-year-old man with a history of hypertension and diabetes mellitus presented with a 5-month history of a progressively enlarging ulcer on the right upper extremity. Physical examination revealed a large ulcer with violaceous undermined borders extending to the forearm. Based on clinical findings, pyoderma gangrenosum, squamous cell carcinoma, and vasculitis were considered in the differential diagnosis, and an excisional biopsy was performed. The patient also reported a longstanding retroareolar breast mass, which was categorized as BI-RADS 4C on mammography; therefore, a tru-cut biopsy was obtained to exclude malignancy. Histopathological examination of both the breast lesion and the cutaneous ulcer consistently demonstrated features of leukocytoclastic vasculitis, including fibrinoid necrosis and perivascular erythrocyte extravasation. Serological analysis revealed c-ANCA positivity. Magnetic resonance imaging of the right upper extremity excluded osteomyelitis. Initial thoracic imaging showed mediastinal and hilar lymphadenopathy; follow-up high-resolution computed tomography revealed new pulmonary nodules and consolidations consistent with early-stage granulomatosis with polyangiitis.Renal evaluation revealed albuminuria (237 mg/24 h) without evidence of active glomerulonephritis. Electromyography findings were consistent with sensorimotor polyneuropathy, clinically correlating with wrist drop. Upper respiratory tract examination was unremarkable. Treatment with systemic corticosteroids and intravenous immunoglobulin led to marked regression of both the ulcer and breast lesion, as well as improvement in inflammatory markers. During corticosteroid tapering, recurrence of the breast mass and constitutional symptoms occurred. Mycophenolate mofetil was initiated in the context of pulmonary involvement and to reduce long-term corticosteroid exposure. Following mycophenolate mofetil therapy, sustained clinical improvement was achieved, with complete healing of the ulcer and regression of the breast lesion.

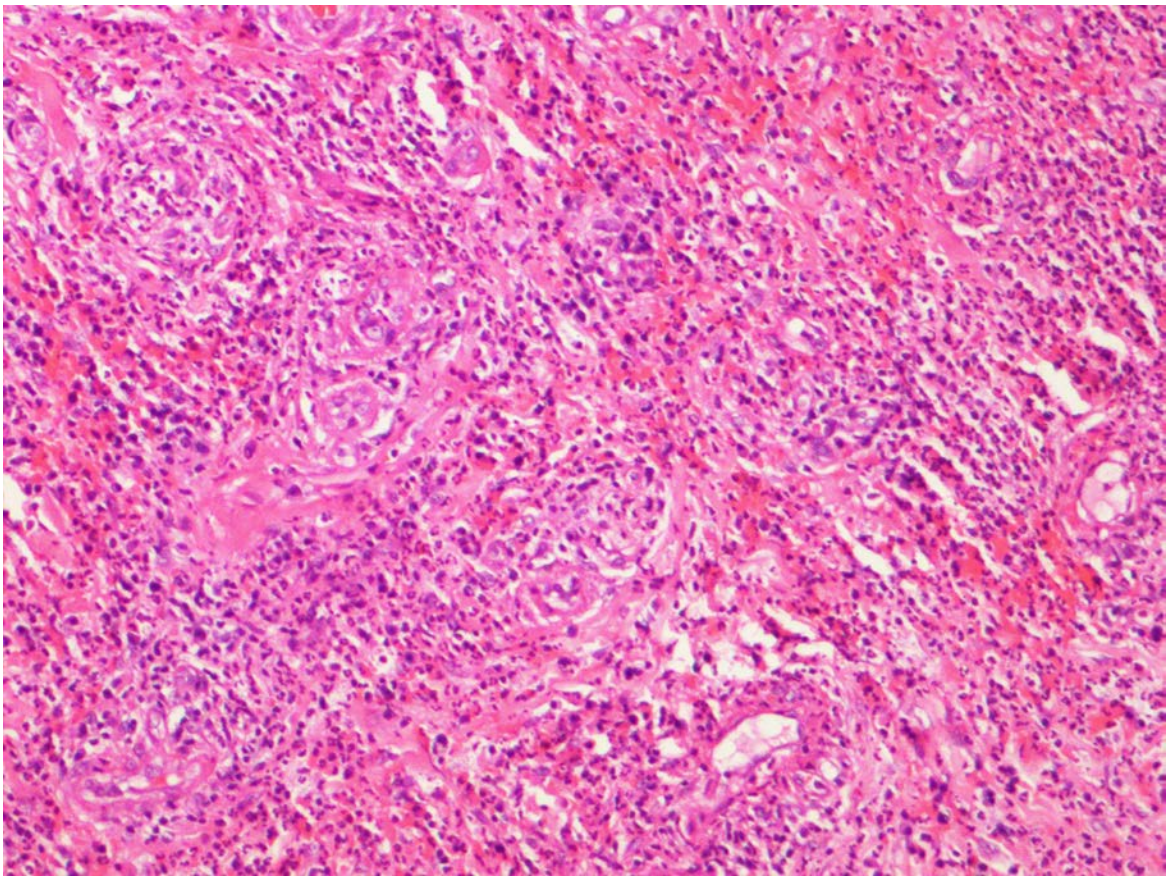

The vessel walls show infiltration by polymorphonuclear leukocytes, with associated fibrinoid necrosis and perivascular erythrocyte extravasation.

Conclusion

Breast involvement in GPA is exceedingly rare, with most reported cases occurring in female patients and presenting as a suspicious mass mimicking malignancy, often requiring histopathological confirmation. Male breast involvement is exceptionally uncommon and may further complicate the diagnosis. Cutaneous manifestations are frequent and encompass a broad spectrum of lesions; among them, pyoderma gangrenosum-like ulcerations represent a rare presentation that may be misdiagnosed as infection or primary neutrophilic dermatosis. The coexistence of a breast mass and PG-like ulceration, as in our case, constitutes an unusual and diagnostically challenging presentation. This case represents, to the best of our knowledge, the first reported male patient with GPA presenting with both a breast mass and PG-like ulceration, highlighting the importance of correlating multisite histopathology with serological findings. Overall, these findings underscore that ANCA-associated vasculitis should be considered in cases of PG-like ulceration at atypical sites and in the presence of multi-organ involvement, in order to avoid diagnostic delay and enable timely initiation of appropriate immunosuppressive therapy.

EA DV CONGRESS
VIENNA
30 SEP - 3 OCT 2026

Abstract N°: 226

Diffuse Dermal Angiomatosis of the Breast

almeghari widad*[1], Saliha Takheroubt[1], Samira Zobiri[1]

[1] CHU MUSTAPHA, Alger, Algeria

Introduction

Diffuse dermal angiomatosis of the breast (DDAB) is a variant of diffuse dermal angiomatosis (DDA) that primarily affects women aged 40-60 years and is commonly associated with macromastia, obesity, smoking , and vasculopathic disorders. DDAB is considered a distinct entity within the spectrum of reactive cutaneous angiomatoses.



Clinical examination revealed fine telangiectasias involving both breasts, predominantly in the lower quadrants.

Case Presentation

A 50-year-old woman presented with bilateral vascularlesions of the breasts that had been evolving for twoyears. Apart from obesity (body mass index: 38.6), hermedical history was othrerwise unremarkable.Clinical examination revealed fine telangiectasiasinvolving both breasts, predominantly in the lowerquadrants. Dermoscopic examination showed a reticulatedvascular network with of linear and grid-like structurescorresponding to dermal capillary proliferation. The vesselsdisplayed a violaceous to dark-redcoloration, reflectingblood extravasation andincreased dermal vascularization.A deep skin biopsy revealed diffuse proliferation ofdermal vessels and endothelial cells between collagenbundles, with uniform positivity on Immunoperoxidasestaining for CD31 and CD34, characteristic vascularmarkers of diffuse dermal angiomatosis.The diagnosis of diffuse dermal angiomatosis of thebreast (DDAB) was therefore established.Additional investigations, including a thoracic CT scanand Doppler ultrasound of the supra-aortic trunks,revealed no underlying vascular abnormalities.The patient was advised to reduce her body weight. Inaddition, breast reduction surgery was discussed, and aconsultation with a breast surgeon was arranged.

DDAB typically affects middle-aged women, the clinical presentation of diffuse dermal angiomatosis is variable

and may include erythematous or violaceous macules, indurated plaques, and occasionally ulcerated lesions.Most cases are described on the lower limbs and are often associated with trauma or ischemic mechanisms. This condition is linked to underlying chronic or focal hypoxemia resulting from various etiologies.
Histologically, a benign extravascular endothelial proliferation expressing CD31 and CD34 is observed between dermal collagen fibers.
Currently, there is no standardized treatment for DDAB.Several therapeutic approaches have been proposed, including revascularization procedures, weight reduction, smoking cessation, systemic corticosteroids, and isotretinoin. More recently, breast reduction surgery has been suggested , as it may eliminate the principal causal factor of DDAB, namely the weight of large, pendulous breast tissue, which leads to vascular compression, torsion, and ultimately tissue hypoxia.



Dermoscopic examination showed a reticulated vascular network with of linear and grid-like structures corresponding to dermal capillary proliferation.

Conclusion

We report a case of diffuse dermal angiomatosis involving the breast. This rare condition belongs to the spectrum of reactive cutaneous angiomatoses. Patients often present with multiple comorbidities. Careful clinical evaluation of vascular status , along with counseling regarding weight reduction and smoking cessation is essential, as appropriate management aimed at reducing tissue hypoxia may provide therapeutic benefit.



Clinical examination revealed fine telangiectasias involving both breasts, predominantly in the lower quadrants.

EA DV CONGRESS
VIENNA
30 SEP - 3 OCT 2026

Abstract N°: 353

Topical sirolimus 0.1% for cutaneous microcystic lymphatic malformations in children and adults (TOPICAL trial): a multicenter phase 2, within-person, randomized, double-blind, vehicle-controlled clinical trial

Sophie Leducq*[1], Le Vilain-Abraham Floriane[2], Juliette Mazereeuw-Hautier[3], Sébastien Barbarot[4], didier bessis[5], Isabelle Quéré[5], Olivia Boccara[6], BERTILLE BONNIAUD[7], Pierre Vabres[7], Anne-Claire Bursztejn[8], Christine Chiaverini[9], Stéphanie Mallet[10], Anne Dompmartin[11], Laurent Guibaud[12], Annouk Bisdorff[13], Christine Labreze[14], Catherine Droitcourt[15], Alice Phan[12], Patrice Plantin[16], Helene Bourgoin[1], Sandy Vrignaud[17], Marie-Sara Agier[18], Valérie Gissot[2], Caille Agnes[2], Annabel Maruani[1]

[1] University Hospital of Tours, Tours, France
[2] Clinical Investigation Center, INSERM 1415, University Hospital of Tours, Tours, France
[3] University Hospital of Toulouse, Toulouse, France
[4] University Hospital of Nantes, Nantes, France
[5] University Hospital of Montpellier, Montpellier, France
[6] University Hospital Necker-Enfants Malades, Paris, France
[7] University Hospital of Dijon, Dijon, France
[8] University Hospital of Nancy, Nancy, France
[9] University Hospital of Nice, Nice, France
[10] University Hospital of Marseille, Marseille, France
[11] University Hospital of Caen, Caen, France
[12] University Hospital of Lyon, Lyon, France
[13] Lariboisière Hospital, APHP, Paris, France
[14] University Hospital of Bordeaux, Bordeaux, France
[15] University Hospital of Rennes, Rennes, France
[16] Hospital of Quimper, Quimper, France
[17] University Hospital of Angers, Angers, France
[18] Regional Pharmacovigilance Center of Tours, University Hospital of Tours, Tours, France

Introduction
Cutaneous microcystic lymphatic malformations (CMLMs) are rare conditions in children and adults with no approved treatment. The objective of this clinical trial was to evaluate the efficacy and safety of a 12-week application of 0.1% topical sirolimus versus topical vehicle for cutaneous microcystic lymphatic malformations (CMLMs).

Materials and Methods
This investigator- and patient-blinded, multicenter, randomized controlled phase 2 trial (NCT03972592), using a within-person design, included children and adults aged >= 6 years. The CMLM was divided into two equal areas separated by a 2-cm–wide area. Each area was randomly allocated to receive 0.1% topical sirolimus or topical vehicle, applied by a nurse, once daily for 12 weeks. At the end of the 12-week period, the patient/parent treated the whole area of CMLM with 0.1% topical sirolimus on the remaining lesions, for eight more weeks. The primary outcome was the improvement of the CMLM in the area treated with topical sirolimus compared to the area treated with topical vehicle using a 6-point Physician Global Assessment (PGA) score at week 12. Secondary outcomes included safety and efficacy on oozing, bleeding, erythema, and thickness.

Results

Fifty-three patients were analysed. The median age was 15.0 [IQR 11-24] years; 50.9% (n=27) were male. The malformation was mainly located on the trunk (47.2%, n=25). The results showed a significant reduction in PGA in sirolimus area (mean PGA score 2.02±1.01) compared to vehicle area (2.57±1.14) (mean difference -0.55 [95% CI -0.86; -0.23], p=0.0009). Physician efficacy assessments were significant for bleeding, erythema and thickness. Thirty-five patients (66%) patients experienced 142 adverse events (AEs): 41 local AEs and 101 general AEs. Of the 142 AEs, 41 were probably associated with sirolimus treatment and none were serious AEs, and all were expected with sirolimus treatment. Local AEs were mainly bleeding, burning and pruritus. At week 12, the sirolimus dosage was undetectable for 42 patients (82.4%) (not performed for 2 patients).

Conclusions

In children and adults with CMLM, this study demonstrated the efficacy of a 12-week application of 0.1% topical sirolimus compared to topical vehicle, assessed by the PGA score. These findings broaden the therapeutic arsenal for superficial lymphatic malformations, for which systemic treatments are often burdensome. However, the optimal long-term management for this chronic condition remains to be defined.

EADV CONGRESS
VIENNA
30 SEP - 3 OCT 2026

Abstract N°: 397

Cutaneous vasculitis as the first clinical manifestation of HIV infection: a case report

Marcel Alex Soares dos Santos*[1], Vitória Toyama[1], Stefani Ferreira[1], José Alexandre Mendonça[2]

[1] São Leopoldo Mandic Faculty of Campinas, Campinas, Brazil
[2] Pontifícia Universidade Católica de Campinas, Campinas, Brazil

Introduction

Vasculitis associated with human immunodeficiency virus (HIV) infection is a rare condition, reported in less than 1% of infected patients. It results from vascular inflammation induced directly or indirectly by the virus and may affect small-, medium-, or large-caliber vessels. With the advent of antiretroviral therapy (ART), its incidence has further decreased, being more commonly observed in untreated individuals.
We report a case in which the diagnosis of HIV infection was established following the investigation of cutaneous vasculitis.

Case Presentation

A 39-year-old male presented with a lesion on the dorsum of the right foot for 15 days, with progressive worsening. He sought care at an emergency department on the fifth day of symptoms and was prescribed antibiotics for 10 days, with no improvement. He subsequently developed similar lesions on the left foot 5 days prior to presentation. Dermatological examination revealed purpura, ulcers, ruptured blisters, and serous discharge on the dorsum of both feet, more pronounced on the right side.
Histopathological examination demonstrated leukocytoclastic vasculitis associated with septal panniculitis. During laboratory investigation, HIV infection was diagnosed, with a CD4+ T-cell count of 534 cells/mm^3 and a viral load of 48,000 copies/mm^3.
Antiretroviral therapy with tenofovir and lamivudine was initiated, along with oral corticosteroids, leading to complete resolution of the condition after one month.

Conclusion

The pathophysiology of HIV-associated vasculitis is not fully understood and may involve direct viral damage to the vascular wall, immune complex deposition, and dysregulated immune activation. Clinical manifestations are heterogeneous and depend on the size of the affected vessels, occurring at any stage of infection.
Cutaneous involvement most commonly affects small vessels, presenting as palpable purpura, predominantly on the lower extremities, and may progress to ulceration, blistering, or necrosis.
Management includes control of HIV infection with ART and, in selected cases, the use of immunosuppressive agents. These should be used with caution due to the increased risk of opportunistic infections and are generally indicated in patients with CD4+ counts above 200 cells/mm^3 and low viral activity.
Although rare, HIV-associated vasculitis represents an important clinical manifestation with a variable spectrum of severity. Early recognition of cutaneous findings may be crucial for the diagnosis of underlying systemic diseases such as HIV infection. This case highlights the essential role of the dermatologist in diagnostic investigation and appropriate management, contributing to improved patient prognosis and survival.

EA DV CONGRESS
VIENNA
30 SEP - 3 OCT 2026

Abstract N°: 423

Adult-onset tufted angioma managed with pulsed dye laser and itraconazole: a multimodal therapeutic approach

Hannah Lois Co*[1], Krisha Lim[1], Mia Katrina Gervasio[1]

[1] University of the Philippines- Philippine General Hospital, Manila, Philippines

Introduction

Tufted angioma is a rare benign vascular tumor that typically presents in infancy or early childhood. Adult-onset disease is uncommon and may pose diagnostic and therapeutic challenges, particularly when lesions are progressive, painful and unresponsive to empiric treatment. Because standardized treatment recommendations are lacking, management is often individualized. Repurposing existing systemic agents may expand treatment options in difficult adult cases. We describe an adult-onset tufted angioma managed with combined pulsed dye laser and repurposed itraconazole, highlighting the potential value of a multimodal strategy in symptomatic, treatment-resistant disease.

Case Presentation

A 65 year old male presented with a one-year history of a solitary, slowly progressive, well-defined, erythematous-to-violaceous abdominal plaque with clustered papules and marked localized pain. The lesion had initially been managed as other conditions and showed no meaningful improvement with topical antibiotics, topical corticosteroid combinations or antiviral therapy, aside from transient partial pain relief. Histopathologic examination, supported by ERG and D2-40 immunostaining, demonstrated discrete dermal vascular lobules in a cannonball-like distribution with crescentic peripheral spaces, consistent with tufted angioma. Clinical, dermoscopic, laboratory and imaging assessment was performed to refine the diagnosis, exclude major mimickers, assess for associated coagulopathy including Kasabach-Merritt phenomenon and establish treatment safety. A multimodal strategy was selected to address both superficial lesional vasculature and deeper biologic activity, including repurposing itraconazole as systemic antiangiogenic therapy. Oral itraconazole was administered at 200 mg twice daily for five months. In parallel, six sessions of pulsed dye laser were performed using a 585-nm wavelength, 7-mm spot size, single-pulse delivery, fluence of 10-10.5 J/cm2 and morphology-adjusted pulse durations, with shorter pulses applied to papular areas and longer pulses to the surrounding plaque, using transient purpura as the clinical endpoint. Early response included fading of erythema, reduction in papule prominence and marked pain reduction during the first month. With continued itraconazole and completion of six laser sessions, improvement became more substantial. The patient ultimately reported complete pain resolution and no longer required oral analgesics. Sleep and daily activities normalized, while serial follow-up showed continued softening and flattening of papular components, decreased vascular prominence and overall plaque lightening. No major treatment-limiting adverse events were observed.

Figure 1. Treatment timeline and clinical response in adult-onset tufted angioma

Five months of itraconazole and six pulsed dye laser sessions resulted in complete pain resolution.

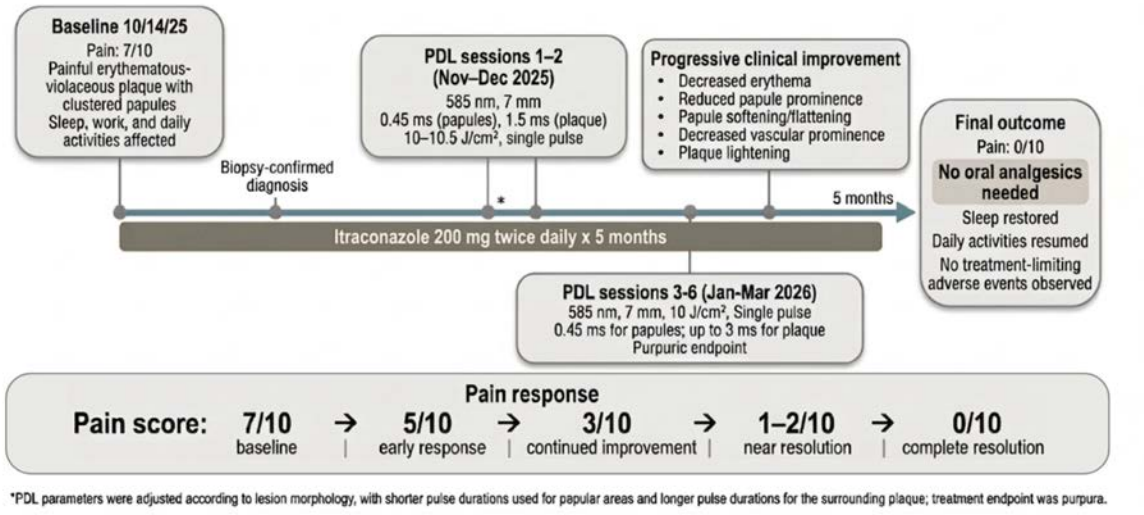

*PDL parameters were adjusted according to lesion morphology, with shorter pulse durations used for papular areas and longer pulse durations for the surrounding plaque; treatment endpoint was purpura.

Treatment timeline and clinical response in adult-onset tufted angioma. Five months of oral itraconazole at 200 mg twice daily and six pulsed dye laser sessions were associated with progressive morphologic improvement, marked pain reduction, and eventual complete pain resolution without further oral analgesic use.

Conclusion

This case highlights that adult-onset tufted angioma may present as a chronic vascular plaque that is easily mistaken for other entities and may remain unresolved without biopsy. In symptomatic adult disease, multimodal treatment may be preferable to observation alone. The combination of pulsed dye laser and repurposed itraconazole was associated with progressive morphologic improvement and complete pain resolution with discontinuation of oral analgesics. This approach may represent a practical option for selected adults with treatment-resistant tufted angioma and supports further study of multimodal therapy incorporating drug repurposing in uncommon adult presentations.

EA DV CONGRESS
VIENNA
30 SEP - 3 OCT 2026

Abstract N°: 513

Case of portwine stain in Sturge-Weber syndrome

Makhliyokhon Zokhidova*[1]

[1] Republican Specialized center of Dermatovenerology and Cosmetology, Tashkent, Uzbekistan

Introduction

Sturge-Weber syndrome (SWS) is a rare vascular disorder characterized by the association of a facial birthmark called a port-wine birthmark, abnormal blood vessels in the brain, and eye abnormalities such as glaucoma. Sturge-Weber syndrome is characterized by the presence of a nevus on the skin of the face ("Portwinestain", PWS) or a red wine stain located on the face, usually on one side, as a result of early embryonic vascular malformation. Port wine stain (or, as this disease is popularly called,Flaming nevus) is a violation of the development of small blood vessels. As a result of the pathological expansion of capillaries, an irregularly shaped spot appears on the human skin, the color of which varies from light pink to purple, burgundy and purple. Most often, the flaming nevus is located on the skin of the face and neck, but in some cases it can be localized on other parts of the body. As a person grows up, the wine stain increases in size. This pathology is congenital and develops in about 0.3% of cases. In most cases, wine stains are a congenital defect. They are present in the baby immediately after its birth and increase in size in proportion to the further growth of the child. An important feature of age spots is the-absence of spontaneous regression — they are formed for life and, as a rule, have a negative impact on the psychological state of a person.

Case Presentation

We present the case of portwine stain in Sturge-Weber syndrome in 40 years old patient woman. The patient has been ill since birth and has never received treatment. No pathology was found by the neurological and ocular organs. We analyzed the effectiveness of the PDL 595 nm laser in the treatment of this patient with spots on the skin of the face and neck. Spots of various sizes with clear borders of bright red color, spots in most cases merge and form large foci. According to the patients, these spots have existed since birth. There are no subjective feelings. Pathomorphological studies were carried out and the diagnosis was confirmed: Port wine stain. After the diagnosis was confirmed, laser treatment was recommended according to the standards of dermatovenerology. Patient has received complex treatment in combination with a pulsed dye laser (PDL) with a wavelength of 595 nm every 3-4 weeks, the course oftreatment averaged 10 sessions. Treatment of capillary malformation was carried out on pulsed dye laser installations. After laser treatment with a 595 nm pulsed laser, a significant decrease in the size of the vascular spot was noted by 81% ($P>0.01$). The patient was more concerned about the presence of pathology in the area of the hand. 2 months after the 1st session of laser coagulation on a 595 nm device (7mm - 1.5 ms - 10-11 J/cm2), a significant improvement was noted. When using a pulsed laser on a 595 nmdye to correct "wine stains", a short pulse is set, which leads to rupture of blood vessels and the formation of purpura. This effect is an important indicator of the effectiveness of treatment. The flashes cannot be superimposed on each other; the best option is to place them close to each other.





The result of treatment of portwine stain in Sturge-Weber syndrome using PDL 595 nm laser. Before and after

Conclusion

The 595 nm pulsed dye laser is still the "gold standard" in the treatment of "Portwine stains".However, with the help of this device, in rare cases it is possible to completely coagulate all the vessels,and in 20% of cases there is complete resistance to treatment.

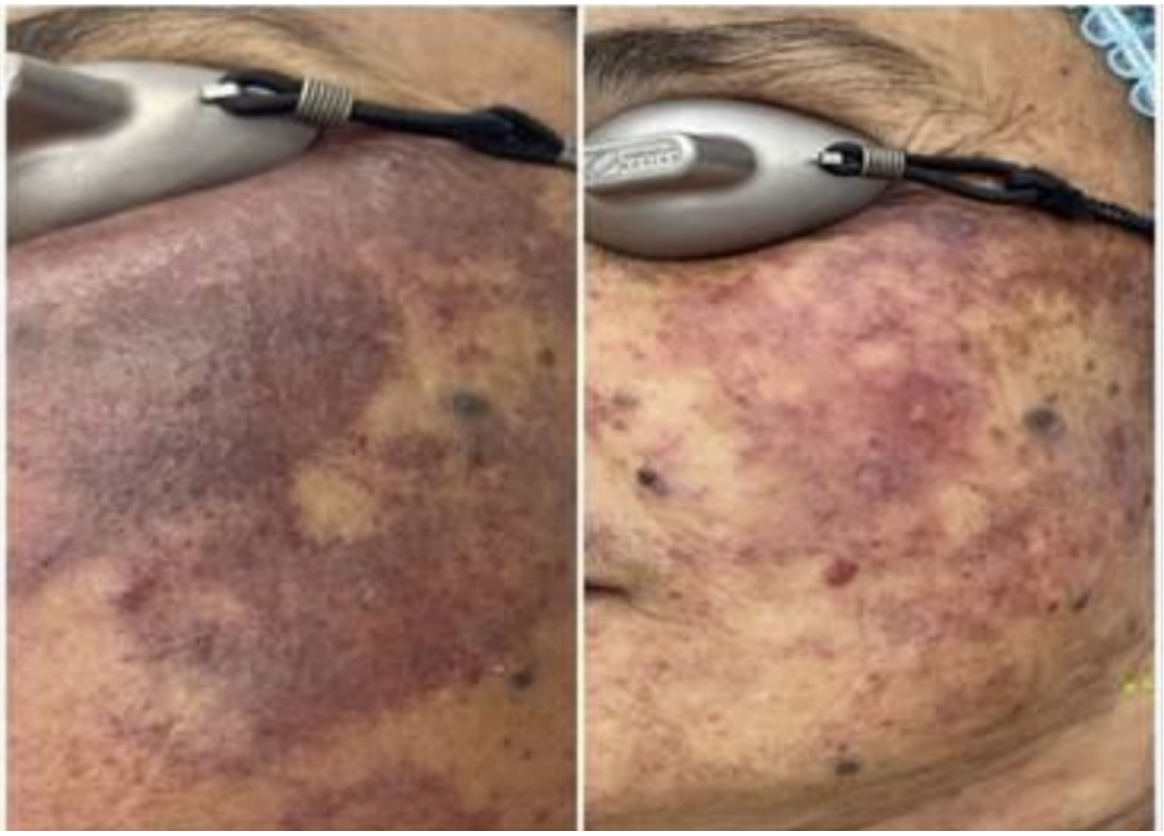

EA DV CONGRESS
VIENNA
30 SEP - 3 OCT 2026

Abstract N°: 562

A Case of Verrucous Venous Malformation and Challenges Associated with Treatment

Yasmeen Al Sadek*[1], emmanuel odega[1], Sarah Bufton[1], Rabia Sarfraz[2]

[1] University Hospitals of Derby and Burton, Derby, United Kingdom
[2] University Hospitals of Northamptanshire, Northampton, United Kingdom

Introduction

Verrucous Venous Malformation (VVM) is a rare congenital vascular malformation presenting as blue-red papules, plaques or nodules, that typically evolve into verrucous and hyperkeratotic lesions over time. Histopathology shows dilated capillaries and veins within the deep dermis, with occasional extension into the subcutaneous tissue. VVM commonly affects the lower extremities and presents at birth or early childhood. The condition is progressive, increases in size with age, and has a high recurrence rate if not completely excised.

Case Presentation

We present a 20-year-old female with congenital vascular lesions on the left leg. She had no significant medical or family history. The lesions were stable in childhood but enlarged after puberty, becoming painful, crusted, and prone to bleeding with minimal trauma. This led to significant anxiety and impaired sleep, exercise, and daily activities.Initial management was conservative, including emollients and analgesia (co-codamol and nortriptyline). Due to worsening symptoms, the patient reconsidered procedural options.

Examination revealed multiple pigmented, hyperkeratotic, exophytic, inflamed, and tender plaques and nodules measuring approximately 10 × 10 cm over the anterior thigh and knee. Angiokeratoma circumscriptum neviforme (ACN) was initially suspected. However, histopathology showed epidermal hyperkeratosis and acanthosis with dilated thin-walled vessels extending into the reticular dermis and subcutis, consistent with verrucous vascular malformation (VVM). Immunohistochemistry demonstrated positive WT-1 and GLUT-1 staining, supporting VVM and excluding ACN. MRI confirmed subcutaneous involvement without deeper extension.

Following multidisciplinary discussion, staged curettage and cautery were performed initially, with surgical excision presented as an option for refractory disease. Two plaques were treated but rapidly recurred within two months. Given lesion size, multifocality, symptom burden, and recurrence, staged surgical excision was recommended. Single-stage excision was avoided due to the need for a large graft and risk of poor cosmesis. A staged approach was undertaken, beginning with conservative excision of the lower lesion across the knee, preserving surrounding tissue and closing with absorbable sutures.The first stage of surgical excision was completed in November 2025. Further surgical intervention will depend on healing and response.

Pictures before and after curettage and cautery are available. We are also awaiting pictures following excision of the lesions via surgery; these will be obtained by end of April 2025.



Multiple plaques and nodules overlying the left lower anterior thigh and knee, arranged in a linear fashion. The marked arrow highlights the upper lateral lesion that was to be excised by double curettage and cautery.

Conclusion

VVM is a rare condition that can significantly impair quality of life. In severe cases, it may be disfiguring and lead to painful contractures that limit activities of daily living. Surgical excision remains the gold-standard treatment with low rates of recurrence, but carries notable morbidity, particularly in extensive disease. Emerging systemic therapies such as sirolimus may offer less-invasive alternatives with improved cosmetic outcomes, and may help prevent progression of complex lesions; however, further research is required to establish long-term effectiveness and recurrence risk. This case highlights the diagnostic challenge of distinguishing VVM from ACN, and reinforces the importance of early histopathological and immunohistochemical assessment to guide appropriate management and set realistic expectations for patients and families. It also illustrates the substantial functional and psychosocial consequences of VVM in our patient. Timely diagnosis enables appropriate intervention, optimises patient counselling and has the potential to transform long-term quality of life.

EADV CONGRESS
VIENNA
30 SEP - 3 OCT 2026

Abstract N°: 598

Adult Henoch–Schönlein Purpura mimicking urticarial vasculitis: diagnostic challenges in a chronic relapsing case

Diego Gallego García*[1], David Moyano Bueno[1], Daniel Robles Murcia[1], Pedro José Ezomo Gervilla[1], José Molina Espinosa[1], Ricardo Ruiz Villaverde[1]

[1] Hospital Universitario Clínico San Cecilio, Granada, Spain

Introduction

Henoch–Schönlein purpura (HSP) is a small-vessel vasculitis typically seen in childhood, but less common in adults, in whom it may present a more atypical and treatment-resistant course. Evidence on the management of refractory cases is limited and based on small case series, with no well-defined therapeutic consensus. We present a case of adult HSP with persistent cutaneous and gastrointestinal involvement.
A retrospective analysis was performed through review of the medical history, laboratory studies, and histopathological and direct immunofluorescence (DIF) findings obtained during follow-up.

Case Presentation

A 50-year-old woman with a history of hypertension, dyslipidemia, obesity, and endometriosis presented, since 2019, recurrent flares of palpable purpura on the extremities, later spreading to the abdomen and face. She reported colicky abdominal pain and arthralgias, without hematuria. The first biopsy showed leukocytoclastic vasculitis and, in 2021, DIF demonstrated vascular deposits of IgA and C3 consistent with HSP. Laboratory tests showed preserved renal function, negative autoimmunity, and normal IgA levels.
During the course, she developed multiple relapses with urticarial lesions, raising diagnostic uncertainty with urticarial vasculitis, later confirmed histologically in 2023 with negative DIF.
She received multiple systemic treatments with insufficient response or poor tolerance, including corticosteroids, azathioprine, dapsone, methotrexate, mycophenolate, cyclosporine, rituximab, intravenous immunoglobulins, omalizumab, and tofacitinib. In 2025, after a new biopsy consistent with IgA vasculitis, treatment with anakinra plus mycophenolate was started, achieving progressive cutaneous control and partial gastrointestinal improvement. Currently, the patient remains asymptomatic, with residual hyperpigmentation and no active flares.

Conclusion

Adult HSP may follow a chronic and refractory course, representing a diagnostic and therapeutic challenge, especially when variable histological patterns coexist. Long-term follow-up and clinical and histological reassessment are essential.

EA DV CONGRESS
VIENNA
30 SEP - 3 OCT 2026

Abstract N°: 634

A Case of Poikilodermatous Plaque-Like Haemangioma Initially Masked by Senile Dermatitis

Mun Leng Lee*[1], Alan Evans[1], John Foerster[1]

[1] NHS Tayside, Dundee, United Kingdom

Introduction

Poikilodermatous plaque-like haemangioma (PPLH) is a recently described, rare benign vascular proliferation. We report a case of an elderly male presenting with a persistent, erythematous plaque on the posterior left thigh, which on biopsy demonstrated features consistent with PPLH. This case adds to the limited clinical literature on this entity and highlights PPLH as a differential diagnosis in elderly patients presenting with a solitary erythematous plaque on the lower limb.



Solitary, large, persistent, non-tender erythematous scaly atrophic plaque (10x11 cm) on the posterior left thigh

Case Presentation

Poikilodermatous plaque-like haemangioma (PPLH) is a distinct, acquired vascular proliferation described only recently. It characteristically presents as a solitary erythematous or violaceous atrophic plaque, most commonly affecting the lower extremities of elderly males. PPLH follows an indolent, benign course and is generally resistant to treatment, supporting its classification as a true haemangioma rather than as a reactive vascular lesion. Histopathologically, it is defined by a reproducible band-like proliferation of blood vessels resembling post

capillary venules within the superficial dermis, often accompanied by poikilodermatous epidermal changes.

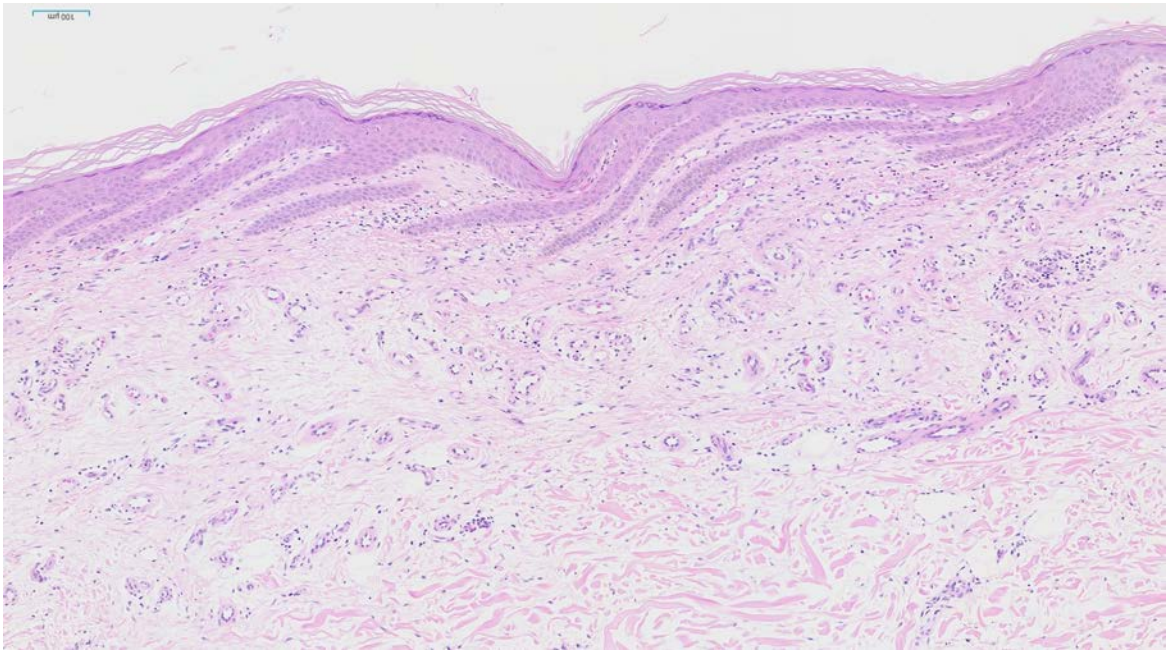

The biopsy showed a superficial dermal band-like proliferation of blood vessels resembling post-capillary venules without a Grenz zone

Conclusion

We report a case of an elderly man initially treated for widespread senile dermatitis. After resolution of the dermatitis, a persistent solitary erythematous plaque on the posterior aspect of his left thigh was unmasked, subsequently diagnosed by biopsy as PPLH. This case highlights PPLH as an important differential diagnosis for clinically similar conditions, including cutaneous T-cell lymphoma (CTCL).

EA DV CONGRESS
VIENNA
30 SEP - 3 OCT 2026

Abstract N°: 758

Topical Application of Oral Sirolimus Solution for Microcystic Lymphatic Malformation: A Case Report

Yusuf Can Erkoc*[1], BURHAN ENGIN[1]

[1] Department of Dermatology, Faculty of Medicine, İstanbul University-Cerrahpaşa, Istanbul, Türkiye

Introduction

Microcystic lymphatic malformation (MLM), also known as lymphangioma circumscriptum, is a congenital vascular anomaly resulting from impaired lymphatic vessel formation during embryogenesis. It typically presents at birth or in early childhood as grouped translucent vesicles with a “frog egg” appearance and hyperkeratotic papules filled with lymphatic fluid, commonly on the neck, shoulders, and trunk. Although benign, MRI is recommended to evaluate deep tissue involvement. Treatment options include surgical excision, cryotherapy, laser therapy, sclerotherapy, and pharmacological agents. However, recurrence rates remain high. Sirolimus, an mTOR inhibitor, has shown promise in managing vascular anomalies by inhibiting endothelial cell proliferation and lymphangiogenesis. Topical application offers a localized approach with fewer systemic adverse effects. We present an 18-year-old male with MLM successfully treated with topical oral sirolimus suspension.

Case Presentation

An 18-year-old male presented with multiple skin-colored papules on the left neck and shoulder. His chief concern was that the lesions prevented him from passing a professional physical examination. Dermatological examination revealed multiple grouped papules measuring less than 1 cm (Figure 1A). A prior biopsy had confirmed MLM. MRI showed no deep tissue invasion. The patient requested a non-scarring approach, as cryotherapy and surgical excision would leave scars incompatible with his professional requirements. Since commercial topical sirolimus was unavailable locally, oral sirolimus suspension (1 mg/mL) was applied topically. Baseline laboratory evaluation including liver and renal function tests, fasting glucose, electrolytes, thyroid function, urinalysis, and complete blood count were all normal. Treatment was initiated twice daily. However, significant erythema and burning consistent with contact dermatitis developed within the first week (Figure 1B), necessitating temporary discontinuation. After one week of mometasone furoate ointment, sirolimus was resumed once daily. At one month, considerable lesion regression was observed (Figure 1C). Serum sirolimus level was 0.1 µg/L (therapeutic range: 4–20 µg/L), confirming negligible systemic absorption. Treatment continued through six months. At the six-month assessment, all parameters remained normal, blood sirolimus was 0.11 µg/L, and the lesions were significantly flattened (Figure 1D).

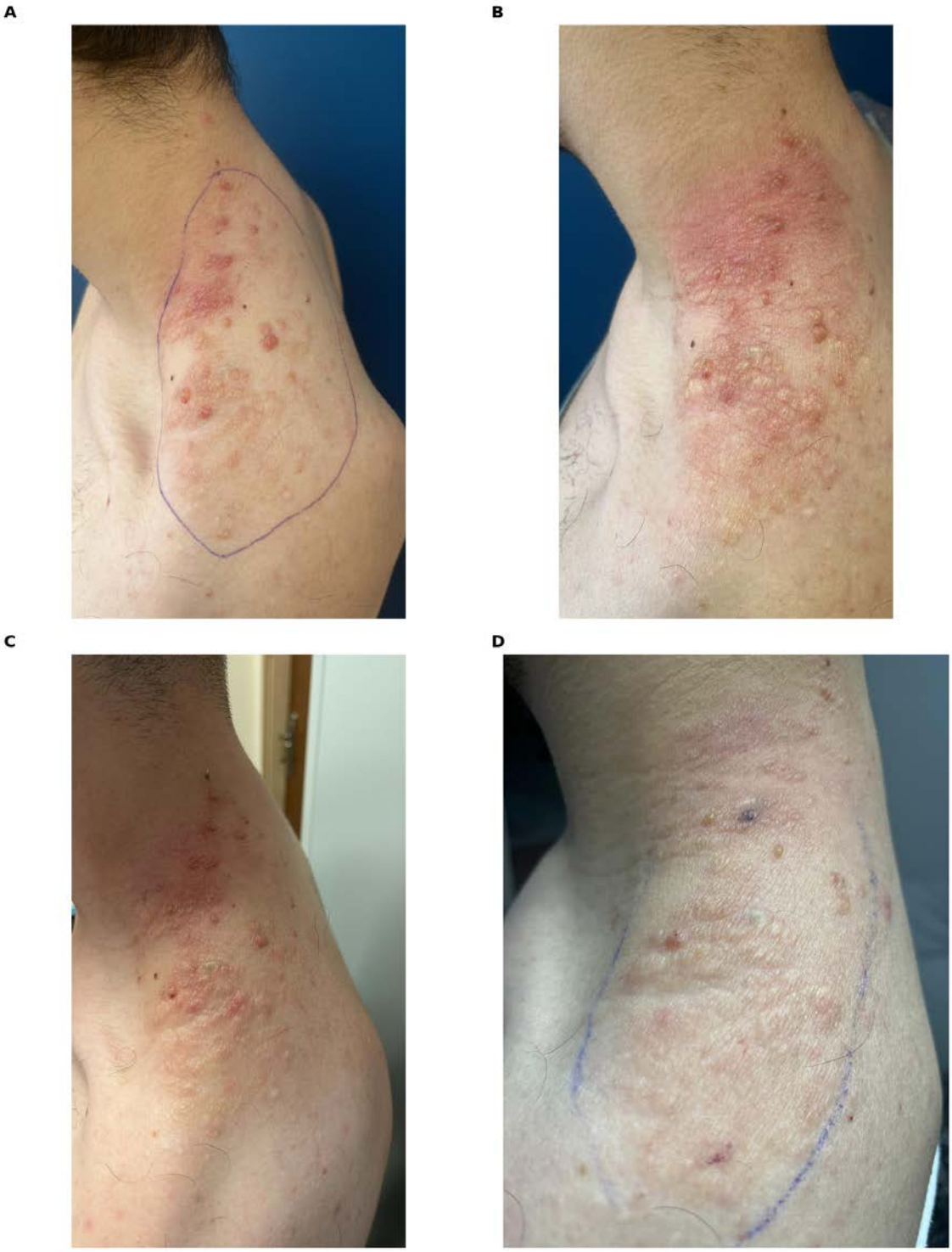

Figure 1. Clinical photographs of microcystic lymphatic malformation on the left neck and shoulder region. (A) Baseline: multiple skin-colored papules less than 1 cm in diameter on the left neck and shoulder (demarcated area). (B) Week 1: contact dermatitis with erythema and edema following twice-daily topical sirolimus application. (C) Month 1: considerable regression of lesions after dose reduction to once daily. (D) Month 6: significant flattening of lesions with sustained improvement.

Conclusion

This case demonstrates the efficacy and safety of off-label topical oral sirolimus suspension for MLM. Sirolimus suppresses mTOR signaling involved in cell growth, angiogenesis, and lymphatic vessel formation, making it a rational agent for lymphatic malformations. Topical administration provides a favorable safety profile with negligible systemic absorption, as confirmed by consistently subtherapeutic serum levels. The contact dermatitis with twice-daily application resolved upon dose reduction to once daily, highlighting the importance of frequency optimization. Sustained improvement at six months supports topical sirolimus as a viable option for MLM,

particularly for patients requiring non-scarring alternatives. Where commercial formulations are unavailable, oral sirolimus suspension applied topically represents a practical option. Further controlled trials are warranted to establish optimal dosing and long-term outcomes.

EADV CONGRESS
VIENNA
30 SEP - 3 OCT 2026

Abstract N°: 873

Beyond the Skin Surface: Decision Pathways in Vascular Laser Therapy

Ahmed Ibrahim Mohamed Nagaty*[1]

[1] Beni-Suif Specialized Hospital, Beni-Suif, Egypt

Introduction

This lecture aims to enhance clinicians' ability to select the optimal vascular laser across diverse conditions. It offers practical guidance on tailoring wavelength, pulse duration, and cooling strategies to specific vascular lesions, thereby maximizing efficacy while ensuring patient safety. Vascular lasers have transformed dermatologic practice, providing precise and effective treatment for port-wine stains, vascular tumors, scars, and leg veins. Advances in selective photothermolysis, pulse duration modulation, and epidermal cooling have improved both safety and outcomes, yet clinical decision-making remains complex.

Materials and Methods

A review of current evidence, clinical guidelines, and case-based experience highlights the principles of wavelength penetration (KTP, PDL, Nd:YAG), pulse duration matching to vessel size, and epidermal cooling. Applications across pediatric lesions, vascular tumors, scar erythema, and leg veins are clarified through case-based discussion.

Results

PDL is most effective for superficial vascular lesions and scars, KTP provides optimal outcomes for fine telangiectasias, and Nd:YAG is superior for deeper vessels and leg veins. Sequential PDL+Nd:YAG enhances results in resistant cases. Early intervention in pediatric lesions and vascular tumors improves clearance and long-term cosmetic outcomes.

Conclusions

Individualized vascular laser protocols tailored to lesion depth, vessel size, and patient profile optimize therapeutic outcomes. Mastery of wavelength selection, pulse duration adjustment, and cooling strategies ensures both safety and efficacy, effectively translating evidence into improved clinical results across diverse vascular lesions.

EA DV CONGRESS
VIENNA
30 SEP - 3 OCT 2026

Abstract N°: 962

Lymphatic malformation with overgrowth of the Foot: A Diagnostic Challenge in a Patient with Lifelong Disease Burden

Krista Yordanova*[1], Seda Aykanat[1], Roman Saternus[1], Thomas Vogt[1]

[1] Department of Dermatology, Saarland University, Homburg/Saar, Germany, Saarland, Germany

Introduction

Introduction: Lymphatic malformations with overgrowth are rare benign vascular anomalies characterized by abnormal development of lymphatic vessels. They may occur as isolated lesions or as part of a syndromic disorder. Cutaneous lymphatic malformations show large clinical heterogeneity and can be challenging to classify, typically requiring reference to the ISSVA classification system. Many vascular malformations associated with segmental overgrowth are caused by somatic mutations in the *PIK3CA*-related overgrowth spectrum, a group of disorders driven by dysregulation of the *PI3K/AKT/mTOR* pathway. These conditions are commonly associated with asymmetric, segmental overgrowth and combined vascular malformations, often affecting the lower extremities. Differentiation from other overgrowth syndromes, such as Proteus syndrome, is essential and relies on clinical, radiological, and genetic findings. The heterogeneous clinical presentation may complicate diagnosis, often leading to delayed recognition and treatment. Although benign, lymphatic malformations can significantly impair quality of life. This case highlights diagnostic challenges and underscores the importance of a multidisciplinary, targeted therapeutic approach.

Case Presentation

Case Report: A 25-year-old patient presented to our dermatology department with a lifelong history of progressive skin changes affecting the left foot, associated with severe pain, recurrent inflammation, and impaired mobility. Asymmetry between both feet had been present since birth; suspected Proteus syndrome had previously been genetically excluded. In recent years, recurrent infections required repeated antibiotic treatments. Clinically, the lesion progressed from discoloration to exophytic growth with fluid discharge. Prior interdisciplinary evaluations, including orthopedic and vascular surgery consultations and magnetic resonance imaging, excluded an arteriovenous malformation. A previous biopsy showed reactive epidermal hyperplasia and lymphatic stasis without a definitive diagnosis. Based on the clinical presentation, a diagnosis of lymphatic malformation with segmental overgrowth was established, and treatment was initiated. Initial therapy consisted of CO_2 laser application and surgical debulking. Histopathological examination revealed multiple ectatic vascular channels, partly filled with erythrocytes, without atypia or invasive growth. Immunohistochemical staining showed positivity for podoplanin, supporting lymphatic endothelial differentiation. Postoperatively, wound healing was favourable, with marked flattening of the lesion. Further staged treatment of the remaining affected forefoot under general anaesthesia is planned.

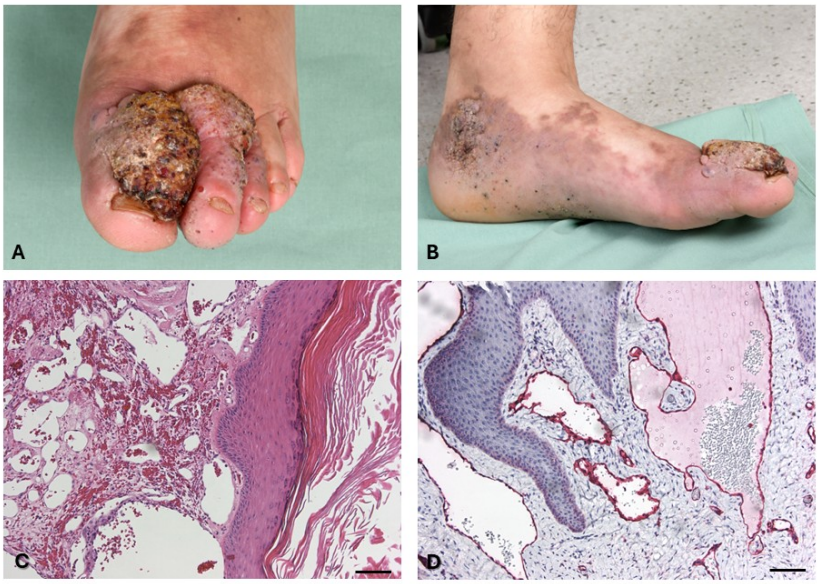

Figure 1: (A,B) Clinical photographs of the patient demonstrating cutaneous discoloration and exophytic growth on the leg. (C) Hematoxylin and eosin (H&E) staining of a skin biopsy from the lesion demonstrating multiple ectatic vascular structures, partly filled with erythrocytes, without atypia or invasive growth, as well as reactive epidermal hyperplasia. (D) Podoplanin staining is positive in endothelial cells, confirming the diagnosis. Scale bars: (C, D) 100 µm.

Conclusion

Discussion: This case illustrates the substantial physical and psychological burden of an undiagnosed lymphatic malformation with overgrowth. Despite its benign nature, the condition can severely impair mobility and quality of life. Lymphatic malformations may mimic other vascular or inflammatory conditions, contributing to diagnostic delay despite extensive evaluation. Histopathology remains essential for definitive diagnosis. Such presentations may be associated with somatic mutations within the *PIK3CA*-related overgrowth spectrum. Therapeutic options include surgical excision or debulking, laser therapy, and in selected cases sclerotherapy; however, complete removal is often challenging due to the infiltrative growth pattern. Targeted systemic therapies such as mTOR inhibitors have shown promising results in complex lesions. Therefore, treatment is frequently individualized and may require a staged, interdisciplinary approach.

Conclusion: Delayed diagnosis of lymphatic malformations with overgrowth can result in significant morbidity and reduced quality of life. Early recognition and interdisciplinary management are crucial. Targeted interventions such as surgical debulking, laser therapy, or medical treatment can significantly improve symptoms and patient well-being.

EA DV CONGRESS
VIENNA
30 SEP - 3 OCT 2026

Abstract N°: 968

Successful treatment of cryoglobulinemic Vasculitis with Upadacitinib

Inga Hansen-Abeck*[1], Finn Abeck[1], Julika Heilberger[1], Nina Booken[1], Stefan Schneider[1]

[1] Department of Dermatology and Venereology, University Medical Center Hamburg-Eppendorf, Hamburg, Germany

Introduction

Cryoglobulins are immunoglobulins that precipitate below 37°C and are classified according to Brouet into type I (monoclonal) and mixed types II/III (immune complex–mediated). While type I is associated with occlusive vasculopathy, mixed cryoglobulinaemia typically causes small-vessel vasculitis with manifestations such as palpable purpura, ulcers, and systemic involvement. Therapeutic strategies depend on the underlying disease and severity, but evidence-based guidelines remain limited.

Case Presentation

We report an 80-year-old woman with type III cryoglobulinaemic vasculitis in the setting of long-standing rheumatoid arthritis (RA). She initially presented with painful bilateral lower leg ulcers. Histology showed small-vessel vasculitis with C3 and fibrinogen deposition, and mixed cryoglobulins (polyclonal IgM/IgG) were detected. Other causes including viral hepatitis and ANCA-associated vasculitis were excluded. High-dose corticosteroid pulses induced complete ulcer healing within six months.

Due to refractory RA activity under tocilizumab, therapy was switched to abatacept. In 2025, the patient developed recurrent ulcerations complicated by a soft tissue abscess requiring surgical and antibiotic treatment. Discontinuation of abatacept led to worsening vasculitis. Despite corticosteroid pulses and prophylactic anticoagulation, the disease course remained refractory.

Given limited therapeutic options due to prior hepatotoxicity and infection susceptibility, treatment was switched to the JAK1 inhibitor upadacitinib. Under therapy with upadacitinib (15 mg daily), low-dose prednisolone, and tinzaparin, rapid clinical improvement was observed. Near-complete ulcer healing occurred within 12 weeks, with full pain resolution after eight weeks. RA disease activity was simultaneously well controlled.

Conclusion

Management of type III cryoglobulinaemic vasculitis typically targets autoimmune B-cell activity, using glucocorticosteroids and, in severe cases, rituximab or cyclophosphamide. In this patient, these options were contraindicated. JAK inhibition represents a novel therapeutic approach, supported by emerging evidence in systemic vasculitides. The rapid clinical response suggests a modulatory effect on immune complex–mediated vascular inflammation.

This case demonstrates successful treatment of refractory cryoglobulinaemic vasculitis with upadacitinib, achieving both ulcer healing and RA control. JAK inhibitors may represent a promising alternative in patients with limited treatment options. Further studies are warranted to evaluate their efficacy and safety in cryoglobulinaemic vasculitis.

EADV Congress 2026, VIENNA
30 SEPTEMBER - 03 OCTOBER 2026
POWERED BY M-ANAGE.COM

EADV CONGRESS
VIENNA
30 SEP - 3 OCT 2026

Abstract N°: 1007

Intravascular Papillary Endothelial Hyperplasia Presenting as a Penile Ulcer: A Diagnostic Pitfall

Aastha Choudhary*[1], Rachita Misri[1]

[1] Pt. Madan Mohan Malviya Hospital, Delhi, India

Introduction

Intravascular papillary endothelial hyperplasia (IPEH), or Masson's tumor, is a benign vascular proliferation that typically arises within blood vessels, often in association with thrombus formation. It is most commonly seen in the head, neck, and extremities, while genital involvement is exceptionally rare. Because of its clinical appearance, IPEH can easily be mistaken for sexually transmitted infections or even malignancy, especially when presenting as a chronic genital ulcer.

Case Presentation

A 20-year-old sexually active male presented with a painless ulcer over the dorsal penile shaft of one-month duration, which had not responded to prior empirical antibiotic therapy. There was no history of trauma, high-risk exposure, or systemic symptoms. On examination, a well-defined, indurated, crusted lesion measuring approximately 1.5 × 1 cm with a necrotic base was noted, without regional lymphadenopathy.

Serological investigations for syphilis, HIV, and herpes simplex virus were negative. In view of the persistent nature of the lesion, a punch biopsy was performed. Notably, the procedure was associated with profuse bleeding, which raised suspicion of an underlying vascular process.

Histopathological examination revealed dilated vascular channels containing intraluminal papillary proliferations with hyalinized cores lined by bland endothelial cells, without atypia or mitotic activity, findings consistent with IPEH. The lesion was subsequently excised completely with clear margins. The postoperative course was uneventful, and no recurrence was observed at six-month follow-up

Conclusion

Although rare, IPEH should be considered in the differential diagnosis of chronic penile ulcers, particularly when routine investigations are inconclusive and the lesion shows unusual bleeding during biopsy. Recognition of this entity is important, as it closely mimics more common infectious and malignant conditions but requires only simple surgical excision for cure. Early diagnosis helps avoid unnecessary treatments and ensures appropriate management.

EA DV CONGRESS
VIENNA
30 SEP - 3 OCT 2026

Abstract N°: 1103

Topical sirolimus for lingual lymphatic malformations: A pilot individually randomized stepped-wedge trial

Antoine Marchand[1], Jules Pereira Macedo[2], Joly Aline[3], Sophie Leducq[4], Olivia Boccara[5], Nicolas Leboulanger[6], Hélène Aubert Wastiaux[7], Ludovic Martin[8], Valérie Gissot[9], Marie-Sara Agier[10], Annouk Bisdorff[11], Bruno Giraudeau[12], Shoshana Greenberger[13], laurence Boon[14], Catherine Mc Cuaig[15], Caille Agnes[16], Annabel Maruani*[17]

[1] University Hospital of Orleans, Orleans, France
[2] University of Tours, INSERM U1246-SPHERE, Tours, France & INSERM CIC1415, Tours, France
[3] CHRU Tours, Department of maxillo-facial and plastic surgery, MAGEC-Tours Reference Center for Vascular Anomalies, Tours, France
[4] University of Tours, INSERM U1246-SPHERE, CHRU Tours, Department of Dermatology, Pediatric Dermatology Unit, MAGEC-Tours Reference Center for Vascular Anomalies, On behalf of the Research Groupe of the French Society for Pediatric Dermatology, Tours, France
[5] AP-HP Centre, "Paris Cité University, Necker-Enfants Malades Hospital", Department of Dermatology and Reference Center for Genodermatoses and Rare Skin Diseases (MAGEC), Paris Centre University, Imagine Institute, Paris, France
[6] TÊTECOU – rare malformations of the head, neck, and teeth, Department of Pediatric Otolaryngology and Cervicofacial Surgery, Reference center for rare ENT malformations, Paris, France
[7] Nantes University Hospital, Nantes, France
[8] PXE Referral Centre Angers University Hospital, Angers, France
[9] University Hospital of Tours, MAGEC-Tours Reference Center for Vascular Anomalies, Tours, France
[10] University Hospital of Tours, Tours, France
[11] Lariboisière hospital, Paris, France, Neuroradiology Department, Paris, France
[12] University of Tours, INSERM U1246-SPHERE, Tours, France & INSERM CIC1415, CHU de Tours, Tours, France
[13] Pediatric Dermatology Unit, Edmond and Lily Safra Children's Hospital, Sheba Medical Center, Ramat Gan, Israel and The Gray Faculty of Medical and Health Sciences, Tel aviv, Israel
[14] Vascular Malformations Center of the Saint-Luc University Clinics,, Bruxelles, Belgium
[15] CHUSJ - Research Center, Sainte-Justine University Hospital Center University Hospital Center for Mothers and Children, montreal, Canada
[16] University of Tours, INSERM U1246-SPHERE, Tours, France & INSERM CIC1415, CHRU Tours, Tours, France
[17] University of Tours, Inserm 1246-SPHERE, Center of Reference for vascular anomalies MAGEC-Tours, CHU Tours, Department of dermatology, Unit of Pediatric dermatology, Tours, France

Introduction

Microcystic lingual lymphatic malformations (CLMs) are rare congenital vascular anomalies associated with aesthetic and functional burden. Therapeutic options remain limited. Although systemic sirolimus may reduce lesion severity, its use is constrained by adverse effects (AEs). Evidence supporting topical sirolimus for mucosal LMs is scarce.
The objectove of this study was to evaluate the efficacy and safety of 1% topical sirolimus oral solution in children and adults with lingual CLMs.

Materials and Methods

This Institutional randomized, open-label, multicenter, individual stepped-wedge trial was conducted over 24

weeks (Clinicaltrials.gov: NCT24435875). Twelve participants aged ≥ 5 years were randomly assigned (1:1:1:1) to four sequences corresponding to treatment initiation at weeks 0, 4, 8, or 12. The intervention consisted of once-daily application of 1 mg/mL sirolimus oral solution. The primary outcome was independent photographic physician's global assessment (PGA) after 12 weeks of treatment. Secondary outcomes included investigator-assessed PGA, patient-reported symptoms, lesion volume, quality of life, AEs, and plasma sirolimus concentrations.

Results

No significant treatment effect was observed for independent photographic PGA after 12 weeks (estimated treatment effect −0.53; 95% CI −1.45 to 0.39; p = 0.256). Investigator-assessed PGA improved significantly (−2.10; 95% CI −3.33 to −0.87; p=0.001). Bleeding was significantly reduced (−3.16; 95% CI −5.43 to −0.89; p=0.007), and patient-reported global evolution improved (+4.86; 95% CI 0.32 to 9.39; p=0.036). Median lesion volume decreased from 8.2 cm^3 at baseline to 1.7 cm^3 at week 24. No serious AEs occurred. Systemic exposure was minimal (mean plasma concentration 0.3 ± 0.7 ng/mL), with a maximum level of 2.7 ng/mL.

Conclusions

Topical sirolimus oral solution appears safe and feasible for the management of lingual CLMs. However, the variable and potentially insufficient duration of treatment exposure may have limited the detection of maximal therapeutic effects, and longer studies are warranted.

EA DV CONGRESS
VIENNA
30 SEP - 3 OCT 2026

Abstract N°: 1115

Unusual association of two rare diseases in a 24 years old girl: acquired cutaneous lymphangiomas and giant intra-abdominal lipoma.

Filomena Mandato*[1], Arianna Lamberti[2], Margherita Vannucchi[3], Maria Ricci[4], Pasquale Moio[5]

[1] Section of Dermatology , ASREM Azienda Sanitaria Regione Molise, Campobasso, Italy
[2] Section of Dermatology; Department of Medical, Surgical and Neurological Science, University of Siena, Siena, Italy
[3] Section of Pathology; Department of Medical Biotechnology, University of Siena, Siena, Italy
[4] Nuclear medicine Unit, ASREM Azienda Sanitaria Regione Molise, Campobasso, Italy
[5] Section of Internal Medicine, ASREM Azienda Sanitaria Regione Molise, Campobasso, Italy

Introduction

Lymphangiomas are uncommon, benign malformations of the lymphatic system as they represent 4% of all vascular tumors.They can occur anywhere on the skin and mucous membranes. Lymphangiomas can be categorized as deep or superficial based on the depth and size of the abnormal lymphatic vessels or as congenital or acquired. Acquired lymphangioma, which is also referred to in the literature as lymphangiectasia, is most often found in the axilla, inguinal, and genital areas and there is often coexisting lymphedema.
Primary intra-abdominal lipomas are rare cause of a large benign intra-abdominal mass limited to case reports in the literature. We report a case of concomitance of these two rare benign tumors, both asymptomatic, in a 24-years old girl.



Dermoscopy of acquired cutaneous lymphangiomas of the back.

Case Presentation

A 24 year old girl , whose past medical history was unremarkable, presented painless, nonitchy plaques, consisting of vescicles , resembling frog spawn with the same tone of the skin, clear or reddish containg serum or serohematic fluid, on the lower back. A dark red plaque resembling hemangioma was also present on her left buttock . All these lesions appeared six years earlier and gradually acquired their current size. On genital examination, the girl presented bilaterally swollen labia with multiple papular or vescicular lesions similar to genital warts . Dermoscopy revealed multiple white-yellowish lacunae, surrounded by pale septa and including variable amounts of blood (image 1,3). In some lacunae the blood was accumulated in the lowest part (hypopyon sign). The patients also reported swelling of her legs of some months duration, expecially before her menstrual period. The acquired lymphangiomas diagnosis was suggested by the clinical practice and dermoscopy examination that allowed to rule out the most differential diagnoses. Biopsy specimens (punch 4 mm diameter) of all three different morphologically lesions (lower back, buttock, vulva) were performed. Histological analysis revealed dilated lymphatic vessels, some containing lymph, erythtocytes or inflammatory cells, both in the papillary dermis, and in the reticular dermis. In the vulvar specimen hyperkeratosis and acanthosis were seen. Also the

immunohistochemistry with CD31 was performed. Blood cell counts and biochemistry were within normal limits. Abdominal ultrasound rivealed a not well demarcated intra-abdominal mass mildly hyperechogenic. An abdominal contrast-enhanced CT scan , demonstrated a large mass (maximum axial dimensions of about 17,5 cm) in the epi-mesogastric region, not well circumscribed, characterized by hyperdensity of adipose tissue, with internal solid foci, some with pseudo-nodular morphology and some with an elongated appearance, which show contrast enhancement (image 2). This mass appeared to compress and displace the adjacent intestinal regions (ascending and transverse colon, jejunal and duodenal loops); it was closely related to the stomach, pancreas, right kidney and retroperitoneal vascular structures, encompassing the superior mesenteric artery and vein, up to the spleno-mesenteric-portal confluence, without signs of compression. Given the rarity of intra-abdominal lesions and possibility of a malignant process, the patient was discussed in a surgical oncology multidisciplinary meeting. An ultrasound-guided core needle biopsy was performed to rule out liposarcoma: no malignant cells were seen. No metabolically active disease was demonstrated on FDG 18 PET. Long-term surveillance was reccommended by the surgeons .



Tc scan image of the giant intra-abdominal lipoma.

Conclusion

Cutaneous lymphangiomas are rare benign tumors of lymphatic vessel; also primary intra-abdominal lipomas are rare cause of giant intra-abdominal mass limited to case reports in the literature. In our case acquired asymptomatic lymphangiomas associated to mild lymphedema of the legs led to investigate and discover the asymptomatic intra-abdominal giant lipoma.



Dermoscopy of vulvar lymphangiomas.

EADV CONGRESS
VIENNA
30 SEP - 3 OCT 2026

Abstract N°: 1165

Life-threatening Kaposiform Hemangioendothelioma with Kasabach–Merritt Phenomenon in an Infant: Diagnostic and Therapeutic Challenges with Sirolimus-based Management

Swetalina Pradhan*[1], Rishav Sanghai[1]

[1] All India Institute of Medical Sciences Patna, Patna, India

Introduction

Kaposiform hemangioendothelioma (KHE), is a rare, locally aggressive vascular neoplasm that predominantly affects infants and young children. It typically presents as an ill-defined cutaneous lesion with infiltrative growth, frequently extending into deeper soft tissues. Though extremities are most common sites, KHE may also arise in the head and neck region, trunk, and less commonly in the retroperitoneal or thoracic cavity. KMP is a life-threatening consumptive coagulopathy caused by intralesional platelet trapping within the tumour. It is characterized by severe thrombocytopenia, hypofibrinogenemia, microangiopathic haemolytic anaemia. It occurs in association with certain aggressive tumours like KHE and Tufted angioma. The reported mortality rate of KHE complicated by KMP approaches 30%, with deaths largely attributable to local invasion with compression of vital structures or complications arising from KMP. Here we are presenting such a case which proved to be a diagnostic and therapeutic challenge, and was eventually managed with oral Prednisolone in combination with Sirolimus.

Case Presentation

A 2-month-old male infant of body weight 5 kg presented with a single, well-defined erythematous-to-dusky, firm, tender, partially blanchable, warm, indurated plaque without any bruit or thrill of size 22 × 9 cm over the anterolateral abdominal wall approaching the midline and extending posteriorly to the back up to the flank crossing the paraspinal line. It was noticed at birth and suddenly progressed associated with severe pain resulting in irritability, excessive crying and refusal to feed. There was associated with severe thrombocytopenia (platelet count= 8,000/microlitre) and hypofibrinogenemia(70mg/dL). The patient was clinically diagnosed with KMP secondary to either KHE or Tufted angioma. KMP was treated with oral corticosteroids 1.5 mg/kg along with Sirolimus (dose ranging from 0.4 mg/m^2 of body surface area(BSA) BD to 0.8 mg/m^2 BSA BD) along with fresh frozen plasma (FFP), random donor platelets (RDP), packed red blood cells (PRBC) transfusion. Histopathology from the erythematous indurated plaque revealed a dermal-based tumour composed of sheets and nodules of spindle cells arranged in short fascicles forming slit-like vascular spaces, with a characteristic glomeruloid pattern. Tumour cells showed mild nuclear pleomorphism with hyperchromatic spindle nuclei, inconspicuous nucleoli, and moderate eosinophilic cytoplasm. Extravasated red blood cells and a mixed inflammatory infiltrate were present. Immunohistochemistry demonstrated strong diffuse positivity for FLI-1, and CD34 in endothelial cells, with CD31 negativity. The Ki-67 proliferation index was 3–5%. Overall features were consistent with KHE. (Figure 2 a and 2b). Complete clinical regression of the lesion with normalization of platelet counts and coagulation parameters was observed in 3 months.



Figure 1 a

Figure 1 b

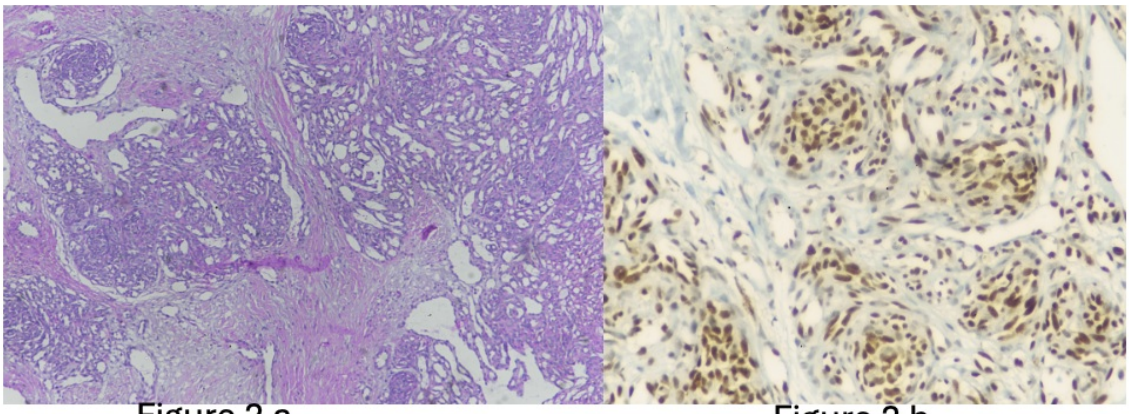

Figure 2 a

Figure 2 b

Figure 1 a:Clinical Image of the infant demonstrating an indurated bright red plaque with bosselated appearance and nodules in the anterolateral abdominal wall (at baseline), Figure 1b:complete resolution of the plaque and indurated mass after 3 months of treatment , Figure 2a:Histopathological micrograph demonstrating characteristic glomeruloid pattern of vascular channels with slit like spaces (10x), Figure 2b:Immunohistochemistry showing diffuse strong CD34 positivity highlighting endothelial cells (40x)

Conclusion

Kaposi hemangioendothelioma (KHE) should be suspected in infants with rapidly enlarging vascular lesions associated with severe thrombocytopenia and coagulopathy, as early recognition of Kasabach–Merritt phenomenon is critical to reduce mortality. Kasabach–Merritt phenomenon represents a life-threatening consumptive coagulopathy due to intralesional platelet trapping, and requires urgent multidisciplinary management including correction of coagulopathy and close monitoring for bleeding complications. Sirolimus-based therapy, in combination with systemic corticosteroids, is an effective and increasingly preferred treatment strategy for KHE with KMP, especially in cases refractory to steroids or where rapid clinical control is required.

EADV CONGRESS
VIENNA
30 SEP - 3 OCT 2026

Abstract N°: 1247

Facial Unilateral Nevoid Telangiectasia: a case report and diagnostic considerations

Cecilia Tejero García*[1, 2], Carmen Cánovas Seva[1, 2], Brais Chao Maseda[1, 2], Pedro Vieites Pérez[1, 2], Carlos Aliste Santos[3], Ángeles Flórez[1, 2, 4], Elena Rosón López[1, 2]

[1] Dermatology Department, Complejo Hospitalario Universitario de Santiago de Compostela, Santiago de Compostela, Spain

[2] Translational Research in Dermatological Diseases, Health Research Institute of Santiago de Compostela (IDIS), Santiago de Compostela, Spain

[3] Pathology Department, Hospital Clínico Universitario de Santiago de Compostela, Santiago de Compostela, Spain

[4] Faculty of Medicine and Dentistry, University of Santiago de Compostela, Santiago de Compostela, Spain

Introduction

Segmental facial telangiectatic lesions constitute an unusual clinical finding that may pose a diagnostic challenge, often requiring integration of clinical, dermoscopic and histopathologic findings for accurate diagnosis.

Case Presentation

A 41-year-old man presented with a progressively enlarging facial lesion of 2 years' duration. Examination revealed a linear erythematoviolaceous macular lesion extending from the left frontal hairline across the forehead, to the ipsilateral medial canthus, left nasal sidewall, and ala. The distribution predominantly followed the ophthalmic territory of the trigeminal nerve (V1). Dermoscopy showed fine telangiectatic vessels. The leading differential diagnoses were unilateral nevoid telangiectasia (UNT) and angioma serpiginosum, although dermoscopic identification of fine telangiectatic vessels supported the diagnosis of UNT. Histopathology showed mild ectasia of small-caliber dermal vessels without atypia or significant wall thickening, supporting the diagnosis of UNT. Complete blood count, thyroid and liver function tests, hepatitis B and C serologies, serum estrogen levels, follicle-stimulating hormone, luteinizing hormone, 17β-estradiol, testosterone, and dehydroepiandrosterone sulfate were all within normal limits. Twenty-four-hour urinary catecholamines and 5-hydroxyindoleacetic acid were likewise normal.

Conclusion

UNT is a rare dermatosis that is more often acquired and predominantly affects female patients. It is characterized by unilateral telangiectatic macules distributed along dermatomes or along Blaschko lines. Dermoscopic examination is particularly useful to distinguish UNT from angioma serpiginosum, which shows multiple small, well-demarcated, round-to-oval red lagoons rather than thin telangiectatic vessels. Although UNT has been associated with hyperestrogenic states, thyroid dysfunction, viral hepatitis (VHB and VHC), liver cirrhosis and carcinoid syndrome, it may also arise in otherwise healthy individuals, as in our case. In this setting, a localized mosaic predisposition, possibly coupled with angiogenic pathways involving VEGF, has been proposed. Pulsed-dye laser therapy has shown favourable outcomes, and our patient was referred to an external centre for this treatment option. This case emphasizes that UNT should be considered in the differential diagnosis of segmental telangiectatic lesions and underscores that its pathogenesis remains unexplained in patients without an

identifiable associated condition.

EADV CONGRESS
VIENNA
30 SEP - 3 OCT 2026

Abstract N°: 1327

Pseudo-Kaposi Sarcoma Mimicking Kaposi Sarcoma: A Diagnostic Pitfall with Distinctive Dermoscopic Clues

Simge Ünal[1], Saadet Miray Ayyildiz*[1]

[1] Usak University Faculty of Medicine, Usak, Türkiye

Introduction

Pseudo-Kaposi sarcoma (acroangiodermatitis) is a benign vascular proliferation that may mimic Kaposi sarcoma both clinically and histopathologically, often associated with chronic venous hypertension.

The aim of this study is to present a clinically and dermoscopically distinctive case of pseudo-Kaposi sarcoma and to highlight key features that aid in its differential diagnosis.

Case Presentation

A 63-year-old male presented with a 4-year history of a lesion located on the medial aspect of the left tibia, associated with occasional pain but no pruritus. Dermatological examination revealed an erythematous–violaceous plaque. Varicose veins were observed on the affected lower extremity, suggesting underlying venous insufficiency, although no formal diagnosis had been established. Dermoscopic evaluation showed regularly distributed dotted vessels on a violaceous background, accompanied by yellow scales and white structureless areas. A skin biopsy was performed for histopathological and immunohistochemical analysis.

Histopathological examination demonstrated dermal vascular proliferation with increased small vessels and erythrocyte extravasation, without cellular atypia. Immunohistochemical staining revealed CD34 positivity, while HHV-8, PAS, Congo red, crystal violet, and CK5/6 were negative. These findings excluded Kaposi sarcoma and other mimickers such as cutaneous amyloidosis. The patient showed partial clinical improvement with topical corticosteroid therapy.

Conclusion

Pseudo-Kaposi sarcoma should be considered in chronic violaceous plaques of the lower extremities, particularly in the presence of varicose veins or other signs of venous insufficiency. Dermoscopic features and HHV-8 negativity are critical for accurate diagnosis and to avoid unnecessary oncologic interventions.

EA DV CONGRESS
VIENNA
30 SEP - 3 OCT 2026

Abstract N°: 1331

Adult recognition of reticular infantile haemangioma with minimal or arrested growth on the heel

Mohammed shanshal*[1], Emily Moon[1], Georgios Kallikas[1]

[1] Imperial College Healthcare NHS Trust, London, United Kingdom

Introduction

Infantile haemangioma with minimal or arrested growth is an under-recognised infantile haemangioma subtype that may present as a predominantly flat, telangiectatic or reticular vascular patch with little postnatal proliferation. Subtle lesions may persist into adulthood and remain clinically unclassified, particularly at acral sites and when routine histopathology lacks a classic lobular capillary proliferation.

Case Presentation

A 22-year-old woman presented with a longstanding asymptomatic vascular patch on the posterolateral heel, reported by family to have been present since infancy and stable over time. Examination showed a faint brown–violaceous telangiectatic patch with a reticular configuration, without nodularity or palpable subcutaneous component. Punch biopsy demonstrated a predominantly fibrosed/sclerotic dermis containing sparse small-calibre vascular profiles, without a discrete lobular capillary proliferation. GLUT1 immunohistochemistry highlighted endothelial staining within scattered dermal vascular profiles. Taken together, the congenital history, stable reticular acral morphology, non-proliferative histological appearance and GLUT1 positivity supported a diagnosis of reticular-type infantile haemangioma with minimal or arrested growth.

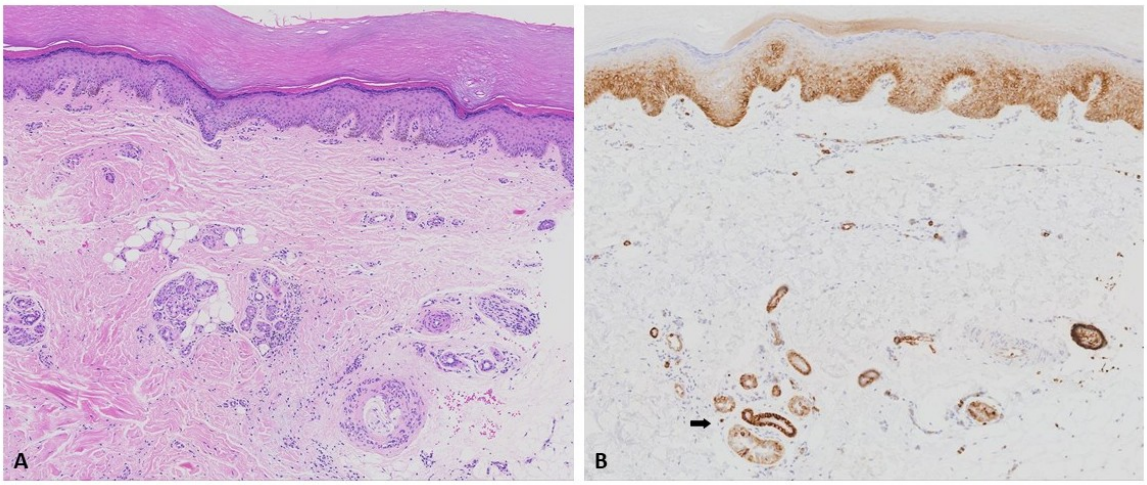

Figure 1. Histological support for reticular infantile haemangioma with minimal or arrested growth. (A) Haematoxylin and eosin section showing a predominantly fibrosed/sclerotic dermis with sparse small-calibre vascular profiles and no discrete lobular capillary proliferation. (B) GLUT1 immunohistochemistry showing endothelial staining within scattered dermal vascular profiles, supporting infantile haemangioma lineage in the appropriate clinicopathological context.

Conclusion

This case highlights adult recognition of reticular infantile haemangioma with minimal or arrested growth as a subtle acral lesion of the heel. Its diagnostic value lies in showing that infantile haemangioma-spectrum lesions

may persist into adulthood with minimal clinical bulk and non-classic routine histology. In longstanding or predominantly fibrosed lesions, GLUT1 immunohistochemistry can support infantile haemangioma lineage when interpreted alongside the congenital history and reticular vascular morphology.

EA DV CONGRESS
VIENNA
30 SEP - 3 OCT 2026

Abstract N°: 1375

The MTHFR-Homocysteine-Folate Axis across the Livedo Spectrum:A Retrospective Cohort Study of Livedo Reticularis, Livedo Racemosa, and Livedoid Vasculopathy

Soyun Cho*[1], Soomin Park[2]

[1] Seoul Metropolitan Government-Seoul National University Boramae Medical Center, Seoul National University College of Medicine, Seoul, Korea, Rep. of South

[2] Seoul Metropolitan Government-Seoul National University Boramae medical Center, Seoul National University College of Medicine, Seoul National University Hospital, Seoul, Korea, Rep. of South

Introduction

Livedo reticularis (LR), livedo racemosa (LRa), and livedoid vasculopathy (LV) are a spectrum of disorders involving the cutaneous microcirculation, ranging from functional flow disturbance to endothelial injury and microthrombosis. Although these conditions frequently overlap in clinical practice, biomarkers that help delineate their relationships remain unclear. We set out to compare LR/LRa and LV in a Korean cohort and to evaluate whether the MTHFR C677T-homocysteine-folate axis provides clinically informative stratification across the livedo spectrum.

Materials and Methods

We retrospectively reviewed 152 patients from a single-center in Korea, including 89 patients with LR/LRa and 63 patients with LV. Data were collected on demographics (age, sex, age at onset), clinical features (including seasonal aggravation), and laboratory parameters (homocysteine, folate, vitamin B6, vitamin B12, lipoprotein(a), and prothrombin time), along with MTHFR C677T genotype when available. Continuous variables were compared with the Mann-Whitney U or Kruskal-Wallis tests, and categorical variables with the Fisher exact or chi-square tests. Hyperhomocysteinemia was defined as homocysteine >15 μmol/L. Receiver operative characteristic (ROC) analysis was used to derive and optimal folate cutoff for predicting hyperhomocysteinemia.

Results

LR/LRa and LV did not differ significantly in sex, age, onset age, homocysteine, folate, vitamin B6, vitamin B12, lipoprotein(a), or prothrombin time. Seasonal aggravation differed markedly, with summer worsening in 53/62 (85.5%) evaluable patients with LV versus 3/82 (3.7%) with LR/LRa, whereas winter worsening was seen in 1/62 (1.6%) and 54/82 (65.9%), respectively ($P<.001$). Among all patients with available genotyping, TT homozygotes had significantly higher homocysteine and lower folate than CC or CT carriers (both $p\leq.002$). Folate predicted hyperhomocysteinemia with an area under the curve (AUC) of 0.749; the Youden-optimal cutoff was 5.8 ng/mL, with sensitivity of 77.8% and specificity of 89.1%.

Conclusions

LR/LRa and LV are not clearly separated by routine laboratory parameters. Alongside the diagnostic classification, assessment of the MTHFR–homocysteine–folate axis, particularly folate levels, may provide a clinically meaningful assessment across the livedo spectrum.

EADV Congress 2026, VIENNA
30 SEPTEMBER - 03 OCTOBER 2026
POWERED BY M-ANAGE.COM

EA DV CONGRESS
VIENNA
30 SEP - 3 OCT 2026

Abstract N°: 1439

Acceptability, Tolerance, and Severity Change After Treatment of Infant Congenital Lymphedema

Isabelle Luchsinger[1], Marion Peradon*[2], Nataliia Zhovta[1], Olivia Boccara[3], Stephane Vignes[4], Yanir Choubane[2], Sophie Leducq[2], Lisa Weibel[1], Caille Agnes[2], Annabel Maruani[2]

[1] Apotheke Kinderspital Zürich, Zürich, Switzerland
[2] Centre Hosp Régional Universitaire Tours, Tours, France
[3] Hôpital Necker-Enfants Malades, Paris, France
[4] Hôpital Cognacq Jay, Paris, France

Introduction

Rationale

Congenital primary lymphedema (CPLE), with onset in the first year of life, is a rare condition which treatment relies on physical therapies (compression garments, short-stretch bandaging, lymphatic drainage). However optimal timing remains unclear because of limited data and concerns about gait development.

Objectives

To assess acceptability, tolerance, and change in disease severity in children with CPLE treated within the first two years of life.

Materials and Methods

Methods

This retrospective multicenter observational study in France and Switzerland included children with CPLE diagnosed before 1 year of age. Parents rated acceptability (0–10), tolerance, and perceived change in disease severity (–10 to +10). Pre- and post- 2-year-old severity was assessed with Physician Global Assessment (PGA, 0–5) on photographs and compared between early treated (< 2 years) and non-early treated children.



Results

Results

Fifty-six children were included (30 males, 53.6%). Lower limbs were involved in 54 cases (96.4%), bilaterally in 44/54 (81.5%). Karyotyping (n = 24, 42.9%) identified monosomy X in 3 cases. NGS (n = 29, 51.8%) detected germinal pathogenic variants in 18 patients (62.1%), most frequently *FLT4* (n = 11). Acceptability of early physical therapy averaged 7.6 ± 2.2, with time spent on care as the main limiting factor (3.4 ± 3.8 h/week). Tolerance was excellent, with six mild adverse events. Parent-reported change in disease severity was +7.2 ± 3.1. Mean PGA scores improved from 3.4 ± 0.8 to 2.0 ± 0.8 (ΔPGA –1.4) in early treated children and from 3.3 ± 0.8 to 2.0 ± 0.7 (ΔPGA –1.2) in non-early treated children, with no significant difference (p = 0.464). Age at independent walking did not differ between early and non-early treated children.

Conclusions

Conclusion

Initiating physical therapy within the first two years of life, before independent walking, appears safe, well-accepted and well-perceived by parents and does not impair gait development.

EADV CONGRESS
VIENNA
30 SEP - 3 OCT 2026

Abstract N°: 1479

A RARE CUTANEOUS DİSORDER, UNILATERAL NEVOID TELENGIECTASIA

FATMA SAHIN*[1], TUĞBA KEVSER UZUNCAKMAK[1]

[1] Cerrahpaşa Faculty of Medicine, Istanbul University-Cerrahpaşa,, ISTANBUL, Türkiye

Introduction
Unilateral nevoid telangiectasia (UNT) is a rare, benign cutaneous vascular anomaly characterized by multiple superficial dermal telangiectasias distributed unilaterally, often following a dermatomal or Blaschkoid pattern. It can be congenital or acquired; the acquired form is more common in women and has been associated with hyperestrogenic states such as pregnancy, oral contraceptive use, chronic liver disease, and endocrine disorders. Estrogen is thought to contribute to its pathogenesis by promoting angiogenesis; however, UNT may also occur in individuals without detectable hormonal abnormalities.

In addition, a possible neurocutaneous association has been suggested in some cases. Histopathologically, UNT is characterized by dilated superficial dermal vessels with minimal perivascular inflammation. Diagnosis is primarily clinical and can be supported by dermoscopy, which typically demonstrates a non-melanocytic vascular pattern consisting of tortuous and dilated capillaries. Differential diagnosis includes capillary hemangioma, angioma serpiginosum, and nevus flammeus.

Case Presentation
A 54-year-old female patient presented to our clinic with a 4–5 year history of progressively increasing petechial eruptions on an erythematous background localized to the left side of the neck. The patient reported no associated symptoms such as pruritus, burning, or pain. Her medical history was significant for ankylosing spondylitis and hypothyroidism. She was using analgesics as needed and levothyroxine

Dermoscopy of the lesions revealed punctate vascular structures on an erythematous background. The lesions blanched with diascopy.

A 4-mm punch biopsy demonstrated orthokeratosis in the epidermis and prominent telangiectasia in the upper dermis, along with solar elastosis and mild perivascular infiltration of lymphocytes and histiocytes.

Immunohistochemical analysis showed that the infiltrating lymphocytes were CD3(+). CD4, CD8, CD2, and CD7 exhibited weak staining due to technical reasons, while most lymphocytes stained with CD5. CD68 highlighted accompanying histiocytes.

The histopathological findings were consistent with superficial perivascular dermatitis characterized by prominent telangiectatic vessels in the upper dermis, and were morphologically compatible with unilateral nevoid telangiectasia.

Conclusion
UNT is a rare but clinically relevant vascular disorder that should be considered in the differential diagnosis of unilateral telangiectatic lesions. Diagnosis relies on careful clinical evaluation supported by histopathological findings. Hormonal assessment should be considered, although the condition may also occur in otherwise healthy

individuals without hyperestrogenism. Increased awareness of this entity is important to avoid misdiagnosis and unnecessary interventions. Further studies are needed to better clarify its etiopathogenesis and potential systemic associations.

EADV CONGRESS
VIENNA
30 SEP - 3 OCT 2026

Abstract N°: 1561

Lymphocytic thrombophilic arteritis presenting with ulceration: a mimicker of livedoid vasculopathy and cutaneous polyarteritis nodosa

Ceren Kabak*[1], Sedef Sahin[1], Cuyan Demirkesen[2]

[1] Acıbadem Mehmet Ali Aydınlar University, Department of Dermatology, Istanbul, Türkiye
[2] Acıbadem Mehmet Ali Aydınlar University, Department of Pathology, Istanbul, Türkiye

Introduction

Lymphocytic thrombophilic arteritis (LTA), also known as macular lymphocytic arteritis, is a rare cutaneous lymphocytic vasculitis characterized by an indolent clinical course and distinctive histopathological findings. It is frequently underrecognized and may be misdiagnosed as other thrombotic or vasculitic disorders, particularly livedoid vasculopathy and cutaneous polyarteritis nodosa, leading to inappropriate management.

Case Presentation

We report a 29-year-old female presenting with a three-year history of recurrent, asymptomatic ulcerations on the lower extremities. The lesions were exacerbated by prolonged immobilization, such as long-haul flights, and periods of psychological stress. She had previously been diagnosed with livedoid vasculopathy at another center and treated with rivaroxaban without clinical improvement.

On dermatological examination, irregular ulcerations with surrounding livedoid discoloration were observed. Laboratory tests, including autoimmune and coagulation panels, were unremarkable. Given the atypical clinical course and treatment resistance, a deep punch biopsy was performed. Histopathological examination revealed a lymphocytic infiltrate targeting the walls of small- to medium-sized arteries at the dermal–subcutaneous junction, accompanied by luminal fibrin deposition forming a characteristic “fibrin ring.” These findings supported the diagnosis of LTA as a form of lymphocytic arteritis.

The patient was treated with low-dose aspirin and topical clobetasol propionate. During a 9-month follow-up period, complete clinical resolution was achieved, with no development of new ulcerations. In addition, lifestyle modifications aimed at reducing immobility were recommended.

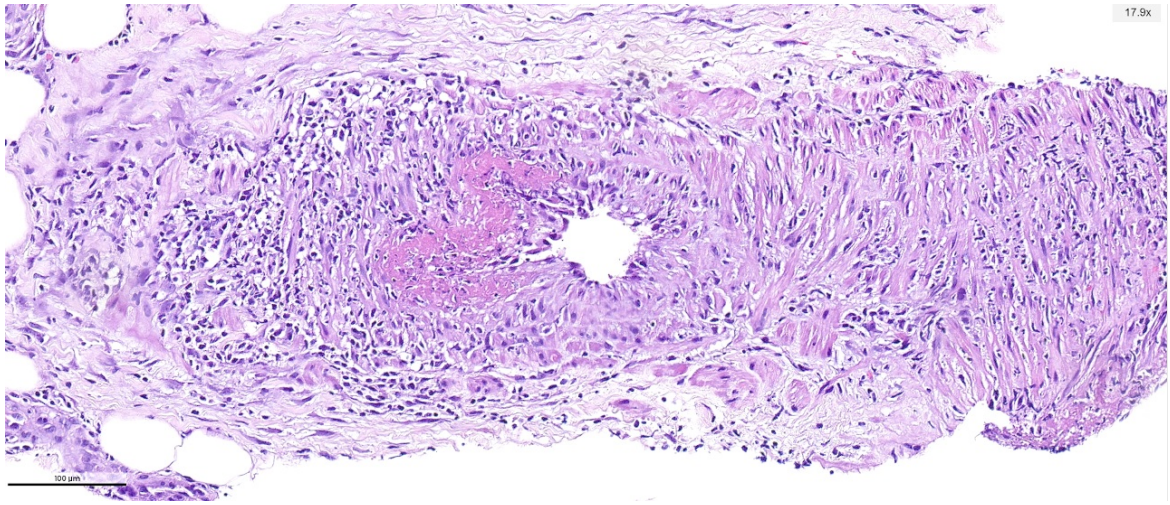

Conclusion

This case highlights an uncommon ulcerative presentation of LTA and higlights its potential to mimic both livedoid vasculopathy and cutaneous polyarteritis nodosa. Recognition of key histopathological features, particularly lymphocytic arteritis and fibrin ring formation, is essential for accurate diagnosis. Differentiating LTA from these entities is crucial, as livedoid vasculopathy represents a thrombotic vasculopathy and cutaneous polyarteritis nodosa a neutrophilic vasculitis, whereas LTA constitutes a distinct lymphocytic vasculitis, with important therapeutic implications. Increased awareness of this entity may help prevent misdiagnosis and unnecessary aggressive treatments.

EADV CONGRESS
VIENNA
30 SEP - 3 OCT 2026

Abstract N°: 1639

Cutaneous Polyarteritis Nodosa Presenting with Retiform Purpura Mimicking Infectious Vasculopathy: A Diagnostic Challenge

Tuğçe Kılıç Ballı*[1], ELİF BANU YILDIRAN[1], CEM LEBLEBİCİ[2], AYŞE ESRA KOKU AKSU[1]

[1] University of Health Sciences, Istanbul Training and Research Hospital, Dermatology Department, ISTANBUL, Türkiye

[2] University of Health Sciences, Istanbul Training and Research Hospital, Pathology Department, ISTANBUL, Türkiye

Introduction

Background: Cutaneous polyarteritis nodosa (cPAN) is a rare necrotizing vasculitis of small- to medium-sized arteries confined to the skin. Its presentation may mimic life-threatening infectious or thrombotic conditions, particularly when retiform purpura is present.

Case Presentation

Case Presentation: A 35-year-old male presented with a 12-day history of painful purpuric lesions, ulcerations, and fever, initially arising in the axillary region and rapidly disseminating. Dermatological examination revealed widespread retiform purpura with central necrosis and starburst-like extensions, accompanied by tender subcutaneous nodules. Laboratory investigations showed markedly elevated inflammatory markers, leukocytosis, and thrombocytosis, while procalcitonin was negative. Infectious vasculopathy was initially suspected; however, the patient showed no response to broad-spectrum antibiotics, and extensive microbiological and serological investigations including ricketsiya species were unremarkable.

Due to persistent inflammation, doxycycline was initiated, resulting in a marked reduction in inflammatory markers. Clinical improvement with doxycycline, despite negative infectious workup, likely reflects its anti-inflammatory effect rather than evidence of infection. Histopathology initially demonstrated leukocytoclastic vasculitis with fibrinoid necrosis and PAS-positive intraluminal material, raising suspicion for cryoglobulinemia. Although cryoglobulin and cryofibrinogen were initially positive, repeat testing at 12 weeks was negative, excluding the diagnosis. A second biopsy revealed necrotizing vasculitis of medium-sized vessels with associated septal panniculitis. In the absence of systemic involvement and after exclusion of alternative etiologies, a diagnosis of cPAN was established.

Conclusion

Retiform purpura represents a diagnostic challenge requiring prompt exclusion of infectious causes. cPAN should be considered in patients with painful nodules and characteristic starburst-patterned purpura. Transient cryoglobulin positivity may be misleading; therefore, clinicopathological correlation is essential for accurate diagnosis and management.

EADV CONGRESS
VIENNA
30 SEP - 3 OCT 2026

Abstract N°: 1693

Kaposi Sarcoma: beyond the usual clinical spectrum

Brais Chao Maseda*[1, 2, 3], Carmen Cánovas Seva[1, 2, 3], Cecilia Tejero García[1, 2, 3], Pedro Vieites Pérez[1, 2, 3], Carlos Aliste Santos[3, 4], Jose Manuel Suárez Peñaranda[3, 4], Lorena Martínez Leborans[1, 2, 3], Ángeles Flórez[1, 2, 3]

[1] Department of Dermatology, Hospital Universitario de Santiago de Compostela, Santiago de Compostela, Spain., Santiago de Compostela, Spain
[2] Translational research in dermatological diseases, Health Research Institute of Santiago de Compostela, IDIS., Santiago de Compostela, Spain
[3] Faculty of Medicine and Dentistry, University of Santiago de Compostela, Santiago de Compostela, Spain
[4] Department of Pathology, Hospital Universitario de Santiago de Compostela, Santiago de Compostela, Spain

Introduction
Kaposi sarcoma (KS) is a vascular tumour associated with HHV-8 infection and encompasses several clinical variants, including classic, endemic, iatrogenic and HIV-related forms. In addition, a fifth variant has been recently described in HIV-negative men who have sex with men (MSM), typically following an indolent cutaneous course. While these entities show distinct epidemiological and clinical patterns, atypical presentations may occur, even in the absence of recognised risk factors (1–3).

Case Presentation
Case 1: A 54-year-old man, with a history of dyslipidemia, presented with a progressively enlarging bleeding lesion on the right buttock. After surgical excision, histopathology confirmed KS. Further history revealed MSM and previous syphilis. HIV serologies were negative, thoracoabdominopelvic computed tomography (CT) was unremarkable, and no new cutaneous or mucosal lesions developed during follow-up.
Case 2: A 60-year-old man with hypertension, diabetes and dyslipidemia presented with a left popliteal mass. After surgical excision, histopathology confirmed KS. HIV serology was negative and no underlying immunosuppression was detected. He denied high-risk sexual behaviour, including MSM. Despite initial negative staging and the absence of recognised epidemiological risk factors, the patient developed multiple distant skin lesions during close follow-up
Discussion:
These cases illustrate the spectrum of non-HIV KS. The first case shows KS in an HIV-negative MSM, an increasingly recognized group. These patients are usually younger and tend to have a milder, slower course, mostly affecting the skin, with rare involvement of mucosal or internal organs, although unusual presentations can occur (1–3). The second case shows how a lesion that initially appears to be limited can later evolve into multifocal cutaneous disease, despite reassuring initial staging, and highlights that KS may also occur in relatively young individuals without identifiable risk factors (2,3).
As mucosal involvement in HIV-negative KS is uncommon but clinically relevant, staging should include careful examination of visible mucosae, especially oral and genital sites, while further investigations should be individualized according to symptoms, extent and evolution rather than fixed invasive protocols (2,4).
Management varies considerably and should be adapted to the extent of disease, the patient's symptoms and their clinical course. In practice, systemic therapy is generally reserved for cases that are progressive, symptomatic, or show mucosal, nodal, or visceral involvement (2).

Conclusion
HIV-negative Kaposi sarcoma should be kept in mind when evaluating atypical vascular lesions. Despite their

typically indolent behaviour, these presentations may still show unexpected progression, even in HIV-negative MSM and in cases that initially appear localised.

Bibiliography:

1. *Htet KZ, Bahrani E, Leslie KS. Updates on Kaposi sarcoma. Clin Dermatol. 2026;44(1):67-77.*
2. *Esser S, Schöfer H, Hoffmann C, Claßen J, Kreuter A, Leiter U, et al. S1 guidelines for the Kaposi sarcoma. J Dtsch Dermatol Ges. 2022;20(6):892-904.*
3. *Denis D, Seta V, Régnier-Rosencher E, Kramkimel N, Chanal J, Avril MF, et al. A fifth subtype of Kaposi's sarcoma, classic Kaposi's sarcoma in men who have sex with men: a cohort study in Paris. J Eur Acad Dermatol Venereol. 2018;32(8):1377-84.*
4. *Brambilla L, Maronese CA, Bortoluzzi P, Barberi F, Tourlaki A. Mucosal Kaposi's sarcoma in HIV-negative patients: a large case series from a single, tertiary referral center in Italy. Int J Dermatol. 2021;60(9):1120-5.*

EA DV CONGRESS
VIENNA
30 SEP - 3 OCT 2026

Abstract N°: 1722

Adult presentation of a Complex Cervicofacial Mixed Vascular Malformation Driven by a Novel Somatic KRAS Mutation

Manuel Bernardo Rodrigues Costa*[1], Rafael Baptista Santos[1], Rúben Nogueira Costa[1], Patrícia Moreira Gomes[1], Sofia Pedrosa[2], Patrícia Amoedo[1], Gilberto Rosa[1, 3], Alberto Mota[1, 3, 4], Filomena Azevedo[1]

[1] Department of Dermatology and Venereology, Unidade Local de Saúde do São João, Porto, Portugal
[2] Department of Pathology, Unidade Local de Saúde do São João, Porto, Portugal
[3] Departamento de Medicina, Faculdade de Medicina da Universidade do Porto, Porto, Portugal
[4] RISE-Health, Faculdade de Medicina, Universidade do Porto, Porto, Portugal

Introduction
Vascular malformations are structural anomalies of blood vessels, typically congenital and resulting from errors in vascular development. Most are driven by somatic mutations affecting the PI3K/AKT/mTOR pathway, while alterations in the RAS/MAPK pathway are less common. Among these, mutations in KRAS are rare but have been increasingly reported in mosaic vascular anomalies, particularly high-flow lesions such as arteriovenous malformations.

Case Presentation
A 47-year-old male presented with a congenital vascular lesion involving the left cervicofacial and supraclavicular regions. His past medical history included inguinal hernia repair and dyslipidemia, with no relevant family history.

Since birth, the patient exhibited a brownish-vinous patch extending from the left upper thoracic region to the lower face in a segmental distribution. Over the past 2–3 years, this evolved with the development of erythematous macules, telangiectasias, and multiple nodules, showing slow growth and variation with position and temperature.

Physical examination revealed a homogeneous brownish-vinous lesion over the left lateral neck and hemiface, with superimposed polymorphic papules, elastic subcutaneous nodules, and visible ectatic venous trajectories, without palpable thrill.

Doppler ultrasound and CT angiography demonstrated extensive collateral vascular circulation in the subcutaneous tissues from the left auricular region to the supraclavicular area. No thoracic vascular obstruction, deep extension, mediastinal masses, lymphadenopathy, or pulmonary abnormalities were identified. Cervical MRI showed hypertrophy of the left common and external carotid arteries, with numerous predominantly superficial high-flow vessels in the left hemiface and hemineck. Ectasia of the left internal and external jugular veins suggested arteriovenous shunting.

Histopathological examination of a punch biopsy revealed fibroadipose tissue containing a mixture of capillary, venous, and focal arterial-type vessels, some ectatic and tortuous, without cytological atypia. Genetic analysis identified a somatic KRAS mutation (c.35G>A; p.(Gly12Asp)) in affected skin, absent in blood, which, to our knowledge, has not previously been reported in mosaic vascular anomalies.. The patient is currently under multidisciplinary follow-up, with conservative management due to clinical stability



Clinical presentation

Conclusion

This case describes a complex mixed vascular malformation (capillary–venous–arterial) associated with a novel somatic KRAS mutation, diagnosed in adulthood despite lifelong lesions. The findings expands the molecular and phenotypic spectrum of RAS/MAPK-driven vascular malformations and supports the role of molecular diagnostics in guiding classification and emerging targeted therapies.

EADV CONGRESS
VIENNA
30 SEP - 3 OCT 2026

Abstract N°: 1791

An intriguing case of "twin trouble": Rare association of neurocutaneous syndrome with congenital hamartomatous malformation

Rohan Barua*[1]

[1] IPGME&R and SSKM HOSPITAL Kolkata, Kolkata, India

Introduction

Neurocutaneous syndromes or phakomatoses are a diverse group of multisystem disorder affecting the skin and central nervous system commonly presenting in childhood and adolescent. Here I present a rare case of neurocutaneous syndrome associated with congenital hamartomatous malformation in an adolescent female.

Case Presentation

A 17 year old female presented with raised, skin coloured, nodular plaques over the scalp and face. Parents gave history of hairless, yellowish plaque present over scalp since birth which increased in size with spread over face during puberty. Detailed history revealed, the girl had mental retardation and recurrent episodes of seizures since childhood.

On cutaneous examination, multiple, skin coloured, firm, well demarcated nodular plaques having numerous folds with characteristic "sulci-gyri" appearance were present over scalp and face.

Dermoscopy revealed perifollicular yellowish brown globules (with central crater and peripheral striations) in lobular pattern. Histopathology showed hyperkeratosis, marked papillomatosis and sebaceous gland proliferation in dermis. MRI brain revealed right sided cerebral and cerebellar atrophy with extensive cortical dysplasia.

A correlation diagnosis of cerebriform variant of nevus sebaceous associated with Schimmelpenning Feuerstein Mims syndrome was made.

Conclusion

Nevus sebaceous of Jadassohn is a congenital hamartomatous malformation of pilosebaceous follicular units. Cerebriform type is a rare morphological variant. It may be associated with Schimmelpenning syndrome (as in our case) characterized by disseminated nevus sebaceous along with abnormalities of central nervous, skeletal, occular or cardiovascular system.

Trichoblastoma followed by syringocystadenoma papilliferum are the two most common bening tumors which develop secondarily in nevus sebaceous, while very rarely (<1% cases) BCC can develop.

Our case is unique with respect to multiplicity of lesions, pattern of distribution and most importantly it's association with epidermal nevus syndrome, Schimmelpenning syndrome. Only 12 cases of cerebriform variant of nevus sebaceous being reported till 2025.

I am presenting this case due to it's rarity and to highlight the importance of careful evaluation to look for multiorgan involvement and also proper follow up for early diagnosis of secondary changes in these patients.

EADV CONGRESS
VIENNA
30 SEP - 3 OCT 2026

Abstract N°: 1889

The Hands Remember: Delayed Puffy Hand Syndrome After Intravenous Drug Use

Sarah Zemrani*[1], christina tarabay[1], Emmanuel Ribereau Gayon[1], Stephane dalle[1]

[1] Department of Dermatology, Lyon Sud Hospital, Hospices Civils de Lyon, Lyon, France, LYON, France

Introduction
Puffy hand syndrome is a delayed complication of intravenous drug use, characterized by chronic or recurrent edema of the hands. Its presentation may mimic inflammatory, vascular, or connective tissue diseases, leading to diagnostic confusion.

Case Presentation
A middle-aged man with no significant medical history presented with a chronic acrosyndrome evolving since 2020, characterized by recurrent bilateral hand edema. Episodes occurred weekly, lasted two to three days, and resolved spontaneously. The swelling was sometimes associated with mild pruritus and progressive functional discomfort.

On examination, there was diffuse thickening and edema of the dorsal aspects of the fingers, with mild erythema over the proximal interphalangeal joints. There were no papules, no sclerosis, no Raynaud phenomenon, and periungual capillaroscopy was normal. A positive prayer sign was noted.
The patient also reported inflammatory arthralgia of the hands and feet, as well as recent weight loss and digestive symptoms under investigation.

Laboratory workup showed no specific autoimmune abnormalities. Histopathological examination revealed dermo-hypodermal vascular dilation without inflammatory infiltrate, mucin deposition, or fibrosis, excluding connective tissue disease or infiltrative dermatosis.

A key element of the history was prior intravenous drug use (3-MMC) between 2015 and 2017, with injections in both forearms and hands.

The combination of chronic recurrent hand edema, absence of specific histological or immunological findings, and history of intravenous drug use led to the diagnosis of puffy hand syndrome.

Conclusion
Puffy hand syndrome should be considered in patients presenting with chronic or recurrent hand edema, especially with a history of intravenous drug use, even years after exposure. Recognition of this entity is essential to avoid misdiagnosis and unnecessary investigations.

EADV CONGRESS
VIENNA
30 SEP - 3 OCT 2026

Abstract N°: 2003

Anti-VEGF–Induced Necrotic Angiodermatitis (Martorell-like Ulcer) in a Patient Treated with Atezolizumab–Bevacizumab

Soukaina El Mellouki*[1], Laila Alami[1], meryem khalidi[1], Rachid FRIKH[1], Hjira Naoufal[1]

[1] Mohammed V Military Training Hospital, Rabat, Morocco

Introduction

Necrotic angiodermatitis (Martorell ulcer) is a rare ischemic dermatosis classically associated with hypertensive microangiopathy. However, anti-angiogenic therapies such as Bevacizumab may induce similar microvascular changes. The increasing use of combined oncologic regimens, including immune checkpoint inhibitors like Atezolizumab, complicates the diagnostic approach to atypical leg ulcers.

Case Presentation

We report the case of an 85-year-old woman with hepatitis C–related cirrhosis and hepatocellular carcinoma treated with atezolizumab–bevacizumab, who developed multiple rapidly progressive and extremely painful lower limb ulcers. A comprehensive evaluation including clinical examination, laboratory tests, vascular imaging, microbiological studies, and histopathological analysis was performed

Cutaneous examination revealed multiple small (0.5–1.5 cm), well-circumscribed, round to oval ulcers with fibrinonecrotic bases, involving both lower legs and the dorsum of the right foot. Lesions were at different stages of evolution, with erythematous to violaceous borders in recent ulcers and post-inflammatory hyperpigmentation in older ones. Pain was marked and disproportionate to lesion size.

Laboratory investigations showed a mild inflammatory response without metabolic abnormalities. Doppler ultrasonography demonstrated chronic venous insufficiency but excluded deep vein thrombosis and significant peripheral arterial disease. Microbiological cultures were negative.

Histopathological examination revealed epidermal hyperplasia with ulceration and a dermal inflammatory infiltrate associated with characteristic microvascular changes, including hyalinized and thickened vessel walls, endothelial proliferation, and luminal narrowing, without evidence of vasculitis or calcification. Direct immunofluorescence was negative. These findings were consistent with necrotic angiodermatitis.

Conclusion

This case highlights anti-VEGF therapy as a potential cause of Martorell-like ischemic ulcers. The association with Atezolizumab may further complicate the clinical picture by mimicking inflammatory dermatoses such as pyoderma gangrenosum. Accurate diagnosis relies on clinicopathologic correlation and exclusion of mimickers. Early recognition is essential, as management differs significantly and requires multidisciplinary coordination.

EADV CONGRESS
VIENNA
30 SEP - 3 OCT 2026

Abstract N°: 2099

Pulsed dye laser for cutaneous collagenous vasculopathy: a report of two cases highlighting clinical diversity and symptomatic relief

Theophile Dugast*[1], Ewa Hainaut[1]

[1] CHU de Poitiers, Poitiers, France

Introduction

Cutaneous collagenous vasculopathy (CCV) is a rare, acquired cutaneous microangiopathy characterized by the progressive development of extensive telangiectasias. While often considered a primary cosmetic concern, its clinical spectrum can vary from asymptomatic presentations to cases associated with systemic autoimmune diseases or significant neuropathic pain. We describe two cases of CCV highlighting the efficacy of pulsed dye laser (PDL) for both aesthetic and symptomatic management.

Case Presentation

Two female patients presented with long-standing, progressive telangiectasias affecting thelimbs and trunk.

The first patient was a female patient in her 50s presented with a 2-year history of extensive telangiectasias that began on the dorsal feet and progressed upward to the thighs and thorax. The lesions were associated with daily dysesthesia, described as stinging, burning, and crushing sensations. Extensive investigations, including venous and arterial Doppler, electromyogram, brain and spinal MRI, and sudoscan, were all within normal limits. Histopathological examination revealed numerous telangiectasias in the superficial dermis with thickened vessel walls, emphasized by PAS staining. Immunohistochemistry showed strong marking for anti-collagen IV in the walls of dermal and hypodermal capillaries, confirming the diagnosis of CCV. She received three sessions of PDL (fluence: 5.5 to 7.0 J/cm^2, pulse duration: 0.5 ms, spot size: 10 mm). Following the first session, the patient experienced transient painful edema and blistering on the tibial crests lasting 7 to 10 days. However, upon healing, she reported a marked improvement in both the erythema and the nocturnal neuropathic pain. After 3 sessions, a complete clearance was observed.

The second patient was a female patient with a 15-year history of cutaneous lupus, rheumatoid arthritis, and Sjögren's syndrome presented with widespread telangiectatic patches. The lesions were predominantly located on the lower limbs, inner thighs, and arms, appearing concurrently with erythematous macules on the trunk. Histopathology revealed ectatic dermal capillaries with thickened, collagenous, PAS-positive walls, confirming CCV. After two sessions of PDL on the forearms (fluences: 6.5–8.0 J/cm^2 ; pulse durations: 2–6 ms; spot size: 10 mm), a significant clearing was observed on all treated areas, leading to near-complete regression of the vascular lesions. Multiplex laser (PDL combined with Nd:YAG) was also evaluated but appeared slightly less effective than PDL alone. The treatment was well-tolerated, with only transient purpura and a slight, temporary hypopigmentation noted after the use of shorter pulse durations.

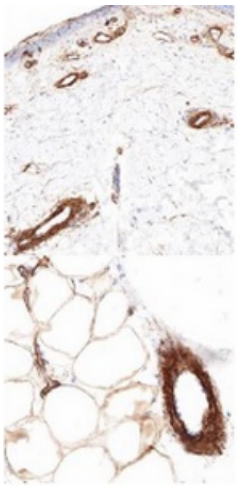

Fig 1. Patient 1. Telangiectasia of papillary dermal capillaries with thickening of the vessel wall and positive immunohistochemical staining for collagen IV.

Conclusion

These cases illustrate that CCV can manifest with varying clinical associations, including neuropathic components that mimic small-fiber neuropathy. Despite the severity of the symptoms, the number of treatment sessions required to achieve complete regression is surprisingly low. PDL represents a highly effective first-line treatment, offering substantial benefits for both the visible microangiopathy and the associated sensory symptoms. Further research is needed to understand the underlying mechanisms of pain relief following vascular laser therapy in CCV patients.

EADV CONGRESS
VIENNA
30 SEP - 3 OCT 2026

Abstract N°: 2244

Moon terrain thighs : a double disaster

Anupam Das*[1]

[1] KPC Medical College and Hospital, KOLKATA, India

Introduction

Papillomatosis cutis lymphostatica is a rare condition which is associated with chronic lymphedema caused by hereditary lymphedema or damage to the lymphatics. Its pathophysiology involves injury where damaged lymphatic vessels cause impaired drainage along with subsequent lymphedema.

Case Presentation

A 43 year old man presented with complaints of raised cutaneous lesions which developed over his amputation stump for a duration of 4 months . The patient had a history of a road traffic accident 2 years back following which he underwent a below knee amputation . Since then he had been using a plastic prosthesis . On examination , multiple skin coloured papules were present which coalesced to form plaques over the amputation stump . Clinically tuberculosis verrucosa cutis , chromoblastomycosis and papillomatosis cutis lymphostatica were considered as differentials . Histopathology revealed hyperkeratosis , verrucoid acanthosis and papillomatosis of the epidermis . Dilated lymphatic vessels were seen in the upper dermis . Mycobacterial , bacterial as well as fungal cultures were negative . Special stains used did not reveal any organism . Other routine investigations were within normal limits . D2-40 staining confirmed lymphatic pathogenesis, and a diagnosis of papillomatosis cutis lymphostatica was done. The patient was advised to use compression stockings along with external compression to increase lymphatic outflow . He was also advised to change the prosthesis . One month after this an improvement was noted and the patient was counselled to continue the same.

Conclusion

Papillomatosis cutis lymphostatica presents as verrucous plaques over the lower limb and can occur over an amputation stump. The treatment is directed towards various etiological factors. Compression therapy plays an important part in the management and prevents further progression while improving lymphatic drainage .

EA DV CONGRESS
VIENNA
30 SEP - 3 OCT 2026

Abstract N°: 2250

Successful treatment of Multiple Glomovenous Malformation using combined PDL and Nd:YAG Laser: A Case series

Hagar Ahmed Elgezeri*[1], Polly Stevenson[2], Daniel James Keith[2]

[1] Cairo University, Faculty of medicine, Alkasr Alainy, Cairo, Egypt

[2] North Bristol NHS Trust, Bristol Laser Centre, Bristol, United Kingdom

Introduction

Glomuvenous malformations [GVMs] are rare benign vascular neoplasms that may present at birth or appear later in life. Typically due to an abnormal growth of blood vessels with accumulation of glomus cells. Although GVMs may be sporadic, they have been linked to a glomulin gene defect and can be present at birth or appear later in life. They present as pink, red or blue localised or segmental nodules or coalescing plaques that may be associated with pain. Patients usually receive treatment for aesthetic reasons or to relieve the pain and improve functionally. Current treatment modalities depend on location and size of GVMs. They include surgery, scleropathy or laser. In the case of multiple or large GVMs, treatment options are challenging, as surgery may be impractical and leading to scarring. Other treatment options have side effects such as skin ulceration and hyperpigmentation.

We present 2 cases of glomangiomatosis treated with combined 585-nm PDL and 1064-nm Nd:YAG laser achieving an excellent clinical outcome with resolution of the pain associated with the lesions.

Case Presentation

A 29 year old woman presented to dermatology outpatients with a more than 10 year history of multiple blueish/purple lesions on her arms, legs and trunk. She described no family history. The Lesions were very tender and interfered with her work as a primary school teacher as they were causing pain when cuddling or picking up young children. Multiple glomuvenous malformations were suspected and a punch biopsy was taken for confirmation. Histology revealed dilated vessels and a prominent population of glomus cells consistent with a glomangioma.

We treated her with 1 session of long-pulsed Nd:YAG laser alone (1064nm, 10ms pulse width, 60-100J/cm^2fluence, 7mmspot) and 5 sessions of combined Pulsed Dye Laser (585nm, 0.5-10ms pulse width, 7-8J/cm^2fluence) and Long-pulsed Nd:YAG laser (1064nm, 15-20ms pulse width, 30-60J/cm^2 fluence) using Multiplex settings and a 10mm spot. She achieved complete or partial remission of all lesions and resolution of her painful symptoms.

We also describe a second patient, a 34 year old woman with history of glomangiomas since childhood and positive family history of multiple glomovenous malformation. The patient experienced acceleration in her lesions and described them as painful limiting movement. She received multiple previous excisions of her lesions. However, rapid recurrence occurred around the scar following surgery. Histology following her excision was consistent with GVMS.

We treated her with 4 sessions of combined Pulsed Dye Laser (585nm, 0.5ms pulse width, 7.0-8.0J/cm^2 fluence) and Long-pulsed Nd:YAG (1064 nm, 15ms pulse width, 40-60J/cm^2 fluence) using Multiplex settings and a 10mm spot. She experienced softening and flattening of her lesions, resolution of pain with no clinical recurrence at her follow up 6 months after her final treatment.

Conclusion

Treatment of GVMs, especially when multiple or extensive, is challenging with a high recurrence rate and is associated with several side effects. With surgery being impractical in the multiple variant, laser as an approach can be a promising treatment option. The dual administration of PDL and Nd:YAG laser can target different depths improving the likelihood of a better outcome while reducing the possible side

effects of Nd:YAG such as ulceration and scarring. Although PDL is superficial and can only help flatten superficial lesions and relieve pain, PDL increases the absorption of Nd:YAG allowing the use of lower fluencies thus reducing the possible side effect and allow a better outcome with thicker lesions which may be more challenging to treat. We present a case study of safe, effective and well tolerated combined PDL/Nd:YAG laser treatment for multiple GVM.

EADV CONGRESS
VIENNA
30 SEP - 3 OCT 2026

Abstract N°: 2255

A Rare Case of Reticular Erythematous Mucinosis Masquerading as a Vascular Dermatosis

Bouchra Idrissi Rhenimi*[1], Fadwa El Aissoug[1], Geraldine Titeca[1]

[1] Clinique notre dame de grace - gosselies, Gosselies, Belgium

Introduction

Reticular erythematous mucinosis (REM) is a rare primary cutaneous mucinosis characterized by persistent erythematous papules and plaques, usually involving the midline chest or back. Clinical presentation may mimic vascular dermatoses, connective tissue diseases, or inflammatory eruptions, making diagnosis challenging. We report a rare telangiectatic presentation of REM in a 57-year-old man.

Case Presentation

A 57-year-old man presented with a chronic asymptomatic eruption of the upper back evolving over several years. Clinical examination revealed diffuse erythematous maculo-papular and telangiectatic lesions forming confluent vascular-like patches on the scapular region. Dermoscopy demonstrated a diffuse erythematous background with irregular telangiectatic vessels and scattered reddish papules.

A punch biopsy was performed. Histopathological examination showed a superficial and deep dermal inflammatory infiltrate with predominantly perivascular and perisudoral distribution extending focally into the interstitium. The infiltrate consisted mainly of lymphohistiocytic cells without significant neutrophilic or eosinophilic component. Alcian blue staining highlighted discrete intradermal mucin deposits. Immunohistochemistry revealed predominance of CD3-positive T lymphocytes with balanced CD4/CD8 expression, rare CD20-positive B lymphocytes, and scattered CD138-positive plasma cells.

Clinicopathological correlation supported the diagnosis of reticular erythematous mucinosis. Cutaneous borreliosis was considered as a differential diagnosis but was regarded as unlikely based on the clinicopathological findings.



Erythematous telangiectatic macules and papules coalescing into vascular-like plaques on the upper back

Conclusion

This case illustrates a rare telangiectatic presentation of reticular erythematous mucinosis clinically mimicking a vascular dermatosis. Histopathological examination associated with mucin staining was essential for establishing the diagnosis. Recognition of atypical clinical presentations of REM may help prevent diagnostic delay and inappropriate management.



Dermoscopy showing a diffuse erythematous background with irregular linear telangiectatic vessels and scattered reddish structureless areas.

EADV CONGRESS
VIENNA
30 SEP - 3 OCT 2026

Abstract N°: 2265

Disseminated Classic Kaposi Disease with Probable Visceral Involvement in an HIV-Negative 89-Year-Old Woman

Maryam Benssied*[1], YOUSSEF ZEMMEZ[1], JAWAD EL AZHARI[1], MOHAMED EL AMRAOUI[1], RACHID FRIKH[1], NAOUFAL HJIRA[1]

[1] Department of Dermatology, Military Hospital of Instruction Mohammed V, RABAT, Morocco

Introduction

Classic Kaposi disease is an HHV-8-associated angioproliferative disorder predominantly affecting elderly patients. Although usually limited to the skin, disseminated forms with visceral involvement may occur and represent therapeutic challenges in frail geriatric patients.

Case Presentation

An 89-year-old HIV-negative woman presented with a two-month history of progressively spreading violaceous lesions of the lower limbs.

Dermatological examination revealed multiple bilateral angiomatous lesions consisting of macules, papules, plaques and infiltrated nodules involving the legs and feet, associated with bilateral lower-limb edema. Plantar involvement and violaceous macular lesions of the left palm were also observed.

Histopathological examination of a skin biopsy demonstrated a dermal vascular and spindle-cell proliferation with red blood cell extravasation. Immunohistochemistry showed positive HHV-8 nuclear staining, confirming classic Kaposi disease.

Thoraco-abdomino-pelvic CT scan revealed peribronchovascular pulmonary micronodules with septal thickening, multiple hypodense splenic nodules and a hepatic nodular lesion, suggestive of probable visceral involvement. Histological confirmation of visceral lesions was not performed due to the patient’s advanced age and frailty.

Laboratory investigations showed isolated aregenerative anemia (Hb 10 g/dL). Hematological assessment did not support myelodysplastic syndrome. During hospitalization, the patient was also treated for *Moraxella catarrhalis* bronchopulmonary infection with favorable evolution.

Following multidisciplinary assessment, systemic treatment with weekly low-dose paclitaxel was initiated.

Conclusion

This case illustrates an uncommon disseminated presentation of classic Kaposi disease with probable visceral involvement in a very elderly HIV-negative patient. Comprehensive staging assessment and multidisciplinary management remain essential in advanced presentations of classic Kaposi disease.

EADV CONGRESS
VIENNA
30 SEP - 3 OCT 2026

Abstract N°: 2358

The devil behind a devastated face

Anupam Das*[1]

[1] KPC Medical College and Hospital, KOLKATA, India

Introduction

Vascular neoplasms are one of the most difficult entities to manage, on account of their variable clinical presentations and unpredictable behaviour. Dabska tumor, or papillary intralymphatic angioendothelioma, is a rare low-grade angiosarcoma characterised by the presence of anastomosing vascular channels and papillary projections. While usually not metastasizing, they can have a locally invasive potential.

Case Presentation

A 50-year-old male presented with a conspicuous swelling over the left cheek, present for the preceding two years. Multiple biopsies by otorhinolaryngology (ENT) surgeon could not help in arriving at a definitive diagnosis. Magnetic resonance imaging revealed maxillary and ethmoidal sinusitis, for which the patient underwent functional endoscopic sinus surgery. However, gradually the swelling worsened, extending to the right cheek and eventually involving the entire face. Cutaneous examination revealed multiple ulcerated and disfigured plaques distributed over the facial and cervical region. A repeat biopsy of the left cheek skin revealed an unusual papillary endovascular proliferation of atypical endothelial cells. Immunohistochemistry was positive for CD 31 and CD 34 and negative for HHV-8 and MIB-1. The proliferative index was 15–20%. Final impression was consistent with papillary intralymphatic angioendothelioma (Dabska tumor).Repeat MRI confirmed the extension of the lesions, and the patient was started on chemotherapy (vinblastine, methotrexate and propranolol.)



Multiple ulcerated and atrophic plaques over face and neck along with eye involvement, producing a devastated look

Conclusion

Dabska tumor is a rare vascular neoplasm with variable clinical presentations. This case highlights the diagnostic complexity and underlines the importance of histopathological evaluation in persistent atypical facial swellings. Timely recognition and multidisciplinary management are key to favorable outcomes, and avoiding unnecessary delay in management.

EA DV CONGRESS
VIENNA
30 SEP - 3 OCT 2026

Abstract N°: 2384

Papillomatous complications of lymphedema: clinical features and associated factors

Ilhame Jegoual*[1], Layla Bendaoud[1], Mariem Aboudourib[1], Ouafa Hocar[1], Said Amal[1]

[1] Dermatology Department, Arrazi Hospital, Mohammed VI University Hospital, Biosciences Research Laboratory, FMPM, Cadi Ayyad University, Marrakesh, Morocco

Introduction
Papillomatous complications of lymphedema represent a late and severe manifestation of chronic lymphatic insufficiency, reflecting cutaneous changes secondary to prolonged lymphatic stasis, which may progress to advanced stages such as elephantiasis nostras verrucosa. Despite their significant functional and aesthetic impact, these forms remain insufficiently described, highlighting the need for better clinical and etiological characterization.

Materials and Methods
We conducted a prospective descriptive study over a 2-year period from 2024 to 2026, aiming to describe the profile of patients presenting with papillomatous complications of lymphedema managed in the Dermatology Department of Mohammed VI University Hospital in Marrakech, and to identify associated risk factors and comorbidities.

Results
Our study included 11 patients with papillomatous lesions complicating lymphedema, with a mean age of 64 years and a male predominance (62.5%). Most patients had metabolic comorbidities, including diabetes or prediabetes (75%) and obesity (mean BMI: 33.4 kg/m^2). Hypertension was present in 50% of cases and chronic venous insufficiency in 37.5%.

The mean duration of lymphedema was 7.5 years, with a predominance of advanced stages: 62.5% were classified as stage II and 37.5% as stage III according to the International Society of Lymphology classification. Episodes of erysipelas were reported in 87.5% of cases, including 25% with multiple recurrences.

Clinically, papillomatosis was severe (score ≥2) in 62.5% of cases. Hyperkeratosis was constant, frequently associated with erythema and oozing (62.5%), whereas fissures and pain were less common (25%). Etiological investigations performed in all patients did not reveal any specific cause, particularly no neoplastic origin.

Management mainly relied on antibiotic therapy in cases of superinfection (75%), sometimes combined with surgical debridement of papillomatous lesions. Lymphedema management remained suboptimal, with poor adherence to lymphatic drainage and compression therapy.

Conclusions
Papillomatous complications of lymphedema reflect a chronic, insufficiently controlled disease course, promoted by comorbidities and recurrent infections. They highlight the importance of early and appropriate management of lymphedema to prevent progression to severe forms such as elephantiasis nostras verrucosa.

EADV Congress 2026, VIENNA
30 SEPTEMBER - 03 OCTOBER 2026
POWERED BY M-ANAGE.COM

EADV CONGRESS
VIENNA
30 SEP - 3 OCT 2026

Abstract N°: 2419

CLAPO Syndrome: A Severe Case Revealed Prenatally and Treated With Alpelisib and Sclerotherapy

Naia Oillarburu*[1], Olivia Boccara[2], Juliette Mazereeuw-Hautier[1], Yohan Gallois[3], Laurent Guibaud[4], Maella Severino-Freire[1]

[1] Larrey Hospital, University Hospital of Toulouse, Toulouse, France
[2] Necker-Enfants Malades Hospital, AP-HP University Hospital, Paris, France
[3] Children's Hospital, Toulouse University Hospital, Toulouse, France
[4] Hospital Femme Mère Enfant, Lyon University Hospital, Bron, France

Introduction

CLAPO syndrome is a rare *PIK3CA*-related overgrowth spectrum (PROS) disorder with 28 cases reported to date. It is characterized by a congenital lower-lip capillary malformation, face/neck lymphatic malformations, facial and/or limbs asymmetry, and partial/generalized overgrowth. We report an exceptionally severe case with prenatal diagnosis, treated with alpelisib and sclerotherapy.

Case Presentation

Second-trimester ultrasonography revealed a massive bilateral cervicofacial cystic lymphatic malformation. Prenatal maternal sirolimus treatment was ineffective, with progressive lesion growth and poor tolerance, including severe hypertriglyceridaemia.
At birth, the newborn had mild respiratory difficulties. Clinical and MR exam revealed characteristic CLAPO features, including lower-lip capillary malformation and extensive cervicofacial mixed macrocystic and mainly microcystic lymphatic malformation. Endoscopy showed diffuse infiltration of the tongue base and pharynx, leading to airway compromise. Initial drainage of macrocysts led to acute respiratory failure, requiring tracheostomy.

Systemic corticosteroids and sirolimus (0.2 mg/kg/day) were initiated at birth. After confirmation of a pathogenic *PIK3CA* mutation at one month of age, alpelisib (20 mg/day) was introduced. The clinical course was complicated by recurrent infections. At two months, sirolimus and corticosteroids were discontinued due to lack of efficacy and to reduce immunosuppression, while alpelisib was continued as monotherapy. Subsequent sclerotherapy with bleomycin and doxycycline resulted in a slow but progressive clinical improvement, allowing successful decannulation and recovery of spontaneous breathing. The patient was transferred to a rehabilitation unit and subsequently discharged home after six months of hospitalization. At the 4-month post-sclerotherapy evaluation, efficacy remained sustained, with no increase in cyst size and no recurrence of respiratory difficulties. Long-term functional prognosis and treatment safety remain uncertain.



Findings at 2 months before sclerotherapy, immediately after sclerotherapy, and at 4-month follow-up.

Conclusion

Most cases of CLAPO syndrome are mild to moderate postnatally diagnosed condition (mean age: 8 years) and generally do not require systemic treatment. Our case is exceptional due to its prenatal presentation and severity. Sirolimus has shown partial efficacy in several congenital lymphatic malformations reported in the literature, but it was ineffective in our patient. Alpelisib, a selective *PIK3CA* inhibitor, has demonstrated promising results, including reductions in lesion size and symptom improvement. We report a severe CLAPO case showing improvement with combined alpelisib and sclerotherapy; however, its long-term efficacy and safety remain to be determined.

EADV CONGRESS
VIENNA
30 SEP - 3 OCT 2026

Abstract N°: 2423

Beyond the Shins: Extensive Schamberg's Disease With Atypical Distribution in a 62-Year-Old Woman

Fatima Zahra Sassine[1], Chourouq Mustapha Eid*[1], Meria Saci[2], Michele Sanchez[2]

[1] Ibn Sina University Hospital, Dermatology Derpartment, Rabat, Morocco

[2] Hopital Henri Duffaut, Dermatology Department, Avignon, France

Introduction

Pigmented purpuric dermatoses (PPDs) are a group of chronic benign capillaropathies characterized by petechiae, purpura, and hemosiderin deposition. Schamberg's disease, the most common variant, typically presents as asymptomatic orange-brown macules with "cayenne pepper" petechiae on the lower extremities. The pathogenesis involves a cell-mediated immune mechanism with perivascular CD4+ T-lymphocyte infiltration and upregulation of adhesion molecules (LFA-1, ICAM-1) on endothelial cells, leading to capillary damage and erythrocyte extravasation. Venous hypertension, capillary fragility, and gravitational dependency are recognized contributing factors. We report a case of extensive Schamberg's disease in a patient with multiple vascular and metabolic comorbidities.

Case Presentation

A 62-year-old woman with type 2 diabetes mellitus, arterial hypertension, and overweight consulted for a progressive eruption of the lower extremities evolving over several years with a gradual increase in lesion number. The lesions were mostly asymptomatic. Dermatological examination revealed bilateral erythematous macules and papules with fine scaling distributed over the dorsal feet, legs, and distal thighs. Lesions were confluent in some areas with a linear arrangement noted in places. Varicosities and varicose vein clusters consistent with CVI were observed. Dermoscopy showed an erythematous background, fine white scales, and coppery-brown pigmentation, features characteristic of PPD. Based on the clinical presentation and dermoscopic findings, a diagnosis of extensive Schamberg's disease was established. Laboratory workup including complete blood count and coagulation studies was normal, excluding coagulopathy. Management included oral ascorbic acid supplementation to support capillary integrity, compression therapy to address underlying venous hypertension, weight loss counseling, and referral to a vascular specialist for evaluation and management of varicose veins. The combination of ascorbic acid and rutoside has demonstrated complete clearance in up to 71% of patients in a retrospective series, with early treatment associated with better outcomes. Compression therapy is recommended as a cornerstone of CVI management and directly targets the venous hypertension contributing to capillary damage. The patient was scheduled for regular follow-up, given that extensive or treatment-resistant PPD warrants long-term monitoring and potential biopsy to exclude purpuric mycosis fungoides, which can mimic PPD clinically and has been documented to arise from longstanding PPD in rare cases

Conclusion

This case illustrates an extensive presentation of Schamberg's disease driven by the convergence of multiple vascular and metabolic comorbidities, CVI, diabetes mellitus, hypertension, and obesity, all contributing to capillary fragility and venous hypertension in the lower extremities. The diagnosis was established clinically and dermoscopically without the need for biopsy in this typical

presentation. A multimodal therapeutic approach combining capillary-protective supplementation, compression therapy, vascular referral, and lifestyle modifications offers the most comprehensive management strategy. Long-term follow-up is warranted to monitor treatment response, detect recurrence, and exclude the rare but important possibility of evolution toward mycosis fungoides in extensive presentations.

EADV CONGRESS
VIENNA
30 SEP - 3 OCT 2026

Abstract N°: 2518

A CUTANEOUS VASCULITIS REVEALING A UTERO-OVARIAN NEOPLASIA

TEMA SIDI YACOUB*[1], Allim Asmaa[1], AMEL KHELIL[1]

[1] University Hospital Center of Oran, Department of Dermatology, ORAN, Algeria

Introduction

Paraneoplastic cutaneous vasculitis (PCV) is a rare entity observed primarily in myelodysplastic syndromes and rarely in solid tumors [1]. The tumor process is a triggering factor, but the vasculitis tends to become autonomous thereafter [2]. We report a case of vasculitis revealing an Utero-ovarian cancer in an elderly patient.

Materials and Methods

A 60-year-old woman, followed since 2022 for recurrent dependent purpura, was hospitalized at our level in 2025. Clinical examination revealed purpuro-necrotic and ulcerated lesions of the legs associated with marked asthenia and anorexia.

There was a biological inflammatory syndrome, neutrophilic leukocytosis, and microcytic hypochromic anemia (hemoglobin 11 g/dL). Renal and hepatic function tests were normal, and serological tests (hepatitis B, C, and HIV) were negative. Immunological testing (ANA, ANCA, rheumatoid factor) was negative. A skin biopsy showed necrotizing leukocytoclastic vasculitis. The patient was being treated with corticosteroids (25 mg/day) and colchicine (1 mg/day).

The initial course was favorable, but the patient subsequently developed inflammatory arthralgia, a distended abdomen painful to palpation, constipation, metrorrhagia, and a relapse of her cutaneous vasculitis in her legs. A thoraco-abdomino-pelvic CT scan revealed a malignant utero-ovarian tissue process with peritoneal carcinomatosis. The patient died suddenly from multiple organ failure before being referred to oncology.

Results

VCP represents 2 to 5% of all types of vasculitis and occurs in approximately 1 in 1800 hematological malignancies and 1 in 80,800 solid tumors [3]. Lung (non-small cell), prostate, colon, breast, and kidney cancers are the tumors most frequently associated with vasculitis.[4].

The clinical picture is very polymorphic: vascular purpura or ecchymotic plaques, nodular, vesiculo-bullous lesions, ulcerations or even skin necrosis [1].Several types can be encountered, the most frequent being leukocytoclastic vasculitis, vasculitis of the polyarteritis nodosa type, or those similar to Henoch-Schönlein purpura.[5]

The etiopathogenic mechanisms underlying cutaneous venous thrombosis (CVT) are related either to hypersensitivity of cutaneous vessels to antigens or cytokines produced by neoplastic cells, iatrogenic causes, or causes of an intercurrent infectious factor.[5]; ForIn our observation, the neoplasm was unrecognized and no chemotherapy was initiated.

Conclusions

Chronic or persistent vasculitis that responds poorly to usually effective treatment, particularly in elderly patients,

should be evaluated taking into account the possibility of a paraneoplastic syndrome and necessitates investigation for malignancy (hematological disorders or solid cancer).

EA DV CONGRESS
VIENNA
30 SEP - 3 OCT 2026

Abstract N°: 2712

Giant facial port wine stain with macroglossia without systemic manifestations

Dr. Smriti Venkatesh*[1], Dr. Meghana Phiske[1], Dr. Shylaja Someshwar[1, 2]

[1] Mgm Institute of Health Sciences, Panvel, India
[2] Kasturba Medical College, Mangaluru, India

Introduction

Port-wine stain (PWS) or Nevus flammeus is a congenital capillary malformation with a 0.3–0.5% prevalence, being second most common congenital vascular malformation observed in infancy. Most isolated lesions harbour somatic (mosaic) GNAQ mutations, in affected skin. Sex distribution is approximately equal among males and females.

PWS is predominantly located in the facial and cervical regions, occasionally on limbs and trunk. Colour of PWS can range from pale pink to red to purple, with varying degrees of hypertrophy of overlying soft tissue. PWS does not regress spontaneously, but if left untreated it may darken and thicken with age. It is of three types: pink , purple and nodular thickening type. PWS may show uneven surface, cobblestone-like nodules (10-30% in some studies), and progressive soft tissue expansion with age. PWS on face can cause gingival hypertrophy, lip hypertrophy, mucosal/gingival staining, malocclusion, gingivitis, facial asymmetry, maxillary and mandibular hypertrophy. Facial PWS can occur alone or as part of vascular syndromes, including Sturge–Weber syndrome (SWS), Klippel–Trenaunay syndrome (KTS), phakomatosis pigmentovascularis (PPV), and Proteus syndrome.

Macroglossia is rare in isolated PWS. Significant tongue enlargement is described in rare case reports of Sturge Weber Syndrome. Macroglossia with PWS should prompt evaluation for other syndromes (e.g., Beckwith-Wiedemann) rather than isolated PWS. True incidence of these changes in isolated PWS without syndromic association remains unclear.

Dermoscopy of PWS shows homogeneous red coloration, red lagoons and linear vessels and absence of white scar-like areas. Histopathology reveals dilated capillaries and postcapillary venules in papillary and reticular dermis. Normal endothelial lining, no proliferation and reduced perivascular nerve fibers. Treatment includes pulsed dye laser, Nd:YAG laser for hypertrophic lesions, fractional resurfacing and surgical excision for nodular PWS.

Case Presentation

A 37/M, with unremarkable developmental history, presented with a single, large, well-defined, dusky red, patch involving bilateral lower half of cheeks with extension over ears, both lips, chin anterior aspect of neck and upper half of chest. Hypertrophy of lower lip, macroglossia with deep fissure in midline of tongue was noted, along diffuse erythema over hard palate, extending to soft palate with lower lip hypertrophy. There was bilateral submandibular lymphadenopathy. Lesions had gradually increased in size. He had no systemic manifestations.

Dermoscopy from cheek lesion showed point globular vessels and linear blood vessels (corresponding to superficial pattern). Dermoscopy from chest lesion shows globular vessels, linear blood vessels and reticular blood vessels (deep pattern). Ultrasonography of abdomen and pelvis revealed bilateral non-obstructive renal calculi and right mildly complex renal cortical cyst at mid pole. MRI brain showed mild mucosal thickening involving left maxillary and ethmoid sinuses. Ophthalmologic evaluation was normal. Based on clinic-dermoscopic and investigative findings, diagnosis of giant facial PWS was made with macroglossia and without systemic involvement.

Conclusion

Facial PWS can be disfiguring, hence early detection, investigations and multidisciplinary management are required.

EA DV CONGRESS
VIENNA
30 SEP - 3 OCT 2026

Abstract N°: 2879

Angiolymphoid Hyperplasia with Eosinophilia Presenting with Extensive Upper Extremity Involvement: A Rare Case Report

Ferdi Öztürk[1], Yüsra Barali*[1], Şaduman Balaban Adım[2], Hayriye Saricaoglu[1]

[1] Bursa Uludag University,Faculty of Medicine,Department of Dermatology and Venereology,Türkiye, Bursa, Türkiye

[2] Bursa Uludag University,Faculty of Medicine,Department of Surgical Pathology,Türkiye, Bursa, Türkiye

Introduction

Angiolymphoid hyperplasia with eosinophilia (ALHE) is a rare benign vascular proliferative disorder characterized clinically by erythematous to violaceous papules and nodules. Histopathologically, it is defined by the proliferation of small- to medium-sized vessels lined by characteristic epithelioid endothelial cells with a hobnail-like appearance, accompanied by a dense inflammatory infiltrate rich in lymphocytes and eosinophils.Although approximately 85% of cases are located in the head and neck region, lesions may rarely occur on the trunk, extremities, and genital area. Extracutaneous involvement affecting the orbit, oral mucosa, parotid gland, colon, and bone has also been reported. Cases showing diffuse involvement along an entire extremity, as in the present case, are exceedingly rare in the literature. Establishing a diagnosis of ALHE in atypical locations requires a high index of clinical suspicion and careful immunohistochemical confirmation in order to exclude malignant mimickers such as Kaposi sarcoma and angiosarcoma. Herein, we present a rare case of ALHE involving the left axilla and extending along the arm and forearm.

Case Presentation

A 19-year-old female patient presented to our clinic in August 2025 with pruritic lesions on the left upper extremity that had been present for approximately five months. She had previously been evaluated at another center and had received doxycycline treatment; however, no specific diagnosis had been established, and no clinical improvement was observed. Her past medical history was unremarkable.Dermatological examination revealed a total of 18 papulonodular lesions on the left upper extremity. The lesions were distributed as follows: two in the left axilla, thirteen on the upper arm, and three on the forearm.Morphologically, the lesions appeared as dome-shaped papules and nodules with a prominent erythematous center and a pink peripheral zone, measuring approximately 1–2 cm in diameter. All lesions were associated with marked pruritus.Routine laboratory tests were within normal limits, and peripheral eosinophilia was not detected, with an eosinophil count of 0.23 and a percentage of 3.2%.Two 3-mm punch skin biopsies were performed for histopathological examination in the context of the differential diagnoses of molluscum contagiosum, Kaposi sarcoma, cutaneous epithelioid angiomatous nodules, multiple disseminated pyogenic granulomas, and pseudolymphoma.Immunohistochemical examination demonstrated positivity for CD31 and CD34. Hemosiderin deposition was observed in the upper dermis. These findings were considered consistent with angiolymphoid hyperplasia with eosinophilia.Due to molluscum contagiosum being among the initial clinical differential diagnoses, topical keratolytic treatment was initiated in August 2025. After one month of treatment, approximately 30% regression of the lesions was observed. Following the development of new lesions in September 2025, treatment was switched to cryotherapy. After three sessions of cryotherapy, near-complete regression was achieved, with only a single persistent papule remaining on the dorsal aspect of the upper arm.

Conclusion

This case demonstrates that rare and extensive extremity-localized forms of ALHE may pose diagnostic challenges and

may mimic malignant vascular tumors. In atypical locations, a high index of clinical suspicion, histopathological confirmation, and immunohistochemical evaluation are critical for accurate diagnosis. In addition, cryotherapy may represent a low-cost, easily applicable treatment option with favorable cosmetic outcomes in patients with a large lesion burden. This case supports the potential value of cryotherapy in the management of multifocal ALHE.

EADV CONGRESS
VIENNA
30 SEP - 3 OCT 2026

Abstract N°: 3001

Efficacy and Tolerability of Atenolol vs. Propranolol in Treating Infantile Hemangiomas

Dorra Medhaffar*[1], Noureddine Litaiem[1], Gara Soumaya[1], Jones Mariem[1], Zeglaoui Faten[1]

[1] Charles Nicolle Hospital, Tunis, Tunisia

Introduction

Infantile hemangiomas (IHs) are the most common childhood benign vascular tumour with an estimated prevalence of 5% to 10% . Most IHs regress spontaneously without treatment . However, 10–15% may cause complications, and early intervention is required when lesions are life- or function-threatening. Propranolol, a nonselective β1/β2 blocker, is first-line for complex IHs but can cause adverse events ; atenolol, a cardioselective β1-blocker with minimal β2 activity, may offer a safer profile, though pediatric data remain limited.The objective of this study was to compare the efficacy and tolerability of propranolol versus atenolol in the treatment of IHs.

Materials and Methods

We conducted a retrospective study (2020–2025) comparing oral atenolol with propranolol for IHs requiring systemic therapy. Inclusion criteria were infants >1 month with function- or appearance-threatening, or ulcerated IHs. Non-inclusion: >2 IHs, disseminated hemangiomatosis, or β-blocker contraindications. Exclusion: prior systemic β-blocker or <1 month of therapy. Propranolol was escalated to 3 mg/kg/day in two doses; atenolol to 1 mg/kg/day once daily. Patients were evaluated at baseline and 1, 3, 6, 9, and 12 months with clinical and photographic assessments. Responses were categorized as complete, major partial (>50%), partial (<50%), or no response. Adverse events (AEs) were recorded. Efficacy and tolerance comparisons used the Mann–Whitney U test ($p<0.05$).

Results

Thirty-seven patients were included (26 females, 11 males ; mean age at treatment initiation was 6.46 months). Localization was predominantly nasal tip and cheek/parotid (each 21.6%); most IHs were localized (97.3%) and mixed (54.1%). Propranolol was given to 29 patients (78.4%) and atenolol to 8 (21.6%). The total duration of treatment ranged from 1 to 24 months, with a mean of 7.81 ± 5.43 months . At 3 months, response distribution differed significantly ($p=0.041$): atenolol—7/8 major partial, 1 partial; propranolol—1 complete, 9 major partial, 9 partial, 5 no response. No significant differences appeared at months 1, 6, or 9; month-12 analysis was not performed because no responses were recorded in the atenolol group . Relapse within 3 months post-withdrawal occurred in 2 propranolol patients (5.4%). The mean duration of follow-up was 12.3 ± 13.1 months . AEs occurred in 8 patients (21.6%): sleep disturbance (10.8%), digestive disorders (8.1%), bronchospasm (5.4%), hypoglycemia (2.7%). AE rates were 24.1% (propranolol) vs 12.5% (atenolol), not significant ($p=0.479$).

Conclusions

Our findings suggest that atenolol is as effective as propranolol for the treatment of IHs, with a trend toward faster improvement at 3 months. The lower, though not statistically significant, rate of adverse events supports its favorable tolerability. Once-daily dosing may also represent a practical advantage for adherence in infants.

EADV Congress 2026, VIENNA
30 SEPTEMBER - 03 OCTOBER 2026
POWERED BY M-ANAGE.COM

EA DV CONGRESS
VIENNA
30 SEP - 3 OCT 2026

Abstract N°: 3065

Eosinophilic angiolymphoid hyperplasia treated with radiotherapy: an effective therapeutic option

Sofia Torres-Figueroa*[1], Hector Perez-Cely[1]

[1] Universidad Nacional de Colombia, Bogota, Colombia

Introduction

Angiolymphoid hyperplasia with eosinophilia (ALHE), also known as epithelioid hemangioma, is a rare benign vasoproliferative disorder characterized by cutaneous vascular proliferation lined by epithelioid endothelial cells and an inflammatory infiltrate rich in lymphocytes and eosinophils. Although benign, ALHE may show progressive growth, local recurrence, pain, bleeding, or suppuration, and its management remains challenging because no universally effective standard treatment has been established.



Figure 1: Angiolymphoid hyperplasia with eosinophilia before (A) and after radiotherapy management (B).

Case Presentation

A 74-year-old woman presented with a 3-year history of progressively enlarging, painful, suppurative lesions in the right retroauricular region. Physical examination showed multiple violaceous nodules coalescing into an infiltrated

plaque of approximately 8 cm, with serosanguineous drainage. Skin biopsy revealed dermal infiltration by pleomorphic oval and elongated cells with scant cytoplasm, small nucleoli, occasional mitoses, and an edematous fibrovascular stroma with lymphocytes, plasma cells, and eosinophils. Immunohistochemistry was negative for EMA, progesterone receptor, CD34, STAT6, smooth muscle actin, desmin, ALK, S-100, and AE1/AE3; CD68 highlighted abundant histiocytes, leukocyte common antigen highlighted the lymphoid infiltrate, and Ki-67 showed low proliferative activity. These findings supported the diagnosis of ALHE.

The patient received intralesional triamcinolone 10 mg/mL, approximately 2 mL per session, for 4 months without improvement, followed by intralesional bleomycin 2 IU/cm² for 3 months without clinical response. Dapsone 90 mg orally once daily and clobetasol 0.05% cream once daily achieved disease stabilization and partial pain relief, but the lesion persisted and continued to affect quality of life. Surgical excision was considered; however, due to the lesion size, location, and expected morbidity, an interdisciplinary team decided to defer surgery. The patient subsequently received radiotherapy using three-dimensional conformal radiotherapy and volumetric modulated arc therapy, completing 33 sessions for a total dose of 66 Gy, administered as 2 Gy per session. After treatment, she reported approximately 80% improvement, with resolution of pain and suppuration, absence of further growth, and persistent clinical control. She continues dapsone to reduce the risk of relapse.



Figure 1: Angiolymphoid hyperplasia with eosinophilia before (A) and after radiotherapy management (B).

Conclusion

This case highlights radiotherapy as a potentially effective therapeutic option for refractory ALHE when surgical excision is not feasible because of lesion size, anatomical location, or patient-related risk. In this patient, radiotherapy achieved meaningful symptomatic and clinical improvement after failure of intralesional, topical, and systemic therapies.

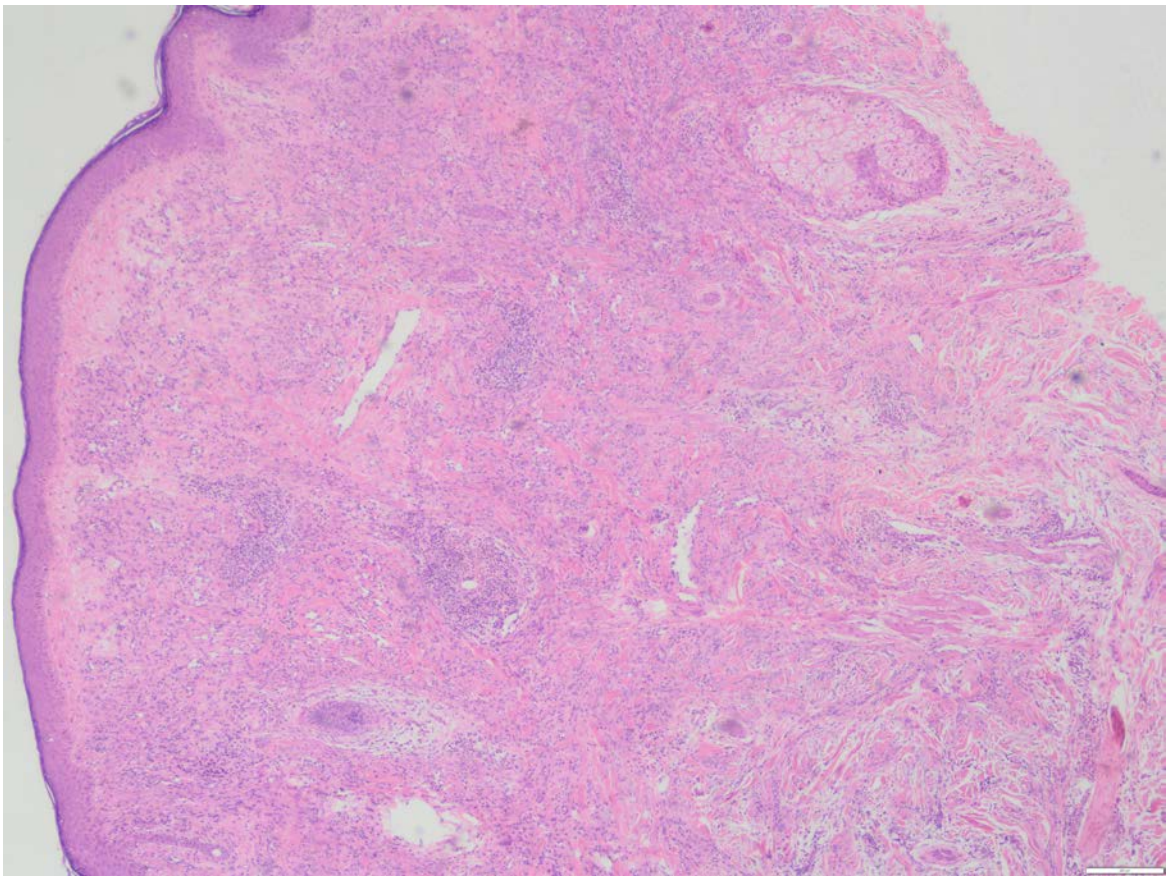

Histopathology showing dermal infiltration of skin with cells containing scant cytoplasm, pleomorphic, oval, angular nuclei, some elongated, with small nucleoli and occasional mitoses (A, H&E, 4X)

EA DV CONGRESS
VIENNA
30 SEP - 3 OCT 2026

Abstract N°: 3145

Determinants of Quality of Life Impairment in Facial Port-Wine Stain: A Cross-Sectional Study Using Skindex-29

Hira Khalil*[1]

[1] Department of Dermatology, Lahore Medical and Dental College, Lahore, Pakistan, Wah international hospital, The aesthetic clinic, Islamabad, Pakistan

Introduction

Facial port-wine stains (PWS) are visible congenital vascular malformations associated with substantial psychosocial burden. However, determinants of quality of life (QoL) impairment in affected individuals remain insufficiently characterized.

This study aimed is to assess QoL impairment in patients with facial PWS using Skindex-29 and to identify clinical factors associated with increased disease burden.

Materials and Methods

In this cross-sectional study, 69 patients aged ≥13 years with facial PWS were evaluated. QoL was measured using the Skindex-29 questionnaire across three domains: symptoms, emotions, and functioning. Demographic and clinical variables, including lesion size and color, were analyzed for their association with QoL scores.

Results

Facial PWS was associated with a moderate overall impairment in quality of life (QoL) with the greatest impact observed in the emotional domain (25.7±7.8), followed by functioning (21.0±11.3) and symptoms (8.2±6.7). Larger lesion size was significantly associated with worse emotional ($p=0.04$) and symptom scores ($p=0.003$). Increased lesion depth, reflected by darker color, correlated with greater symptom burden ($p=0.01$). No significant sex-based differences were observed.

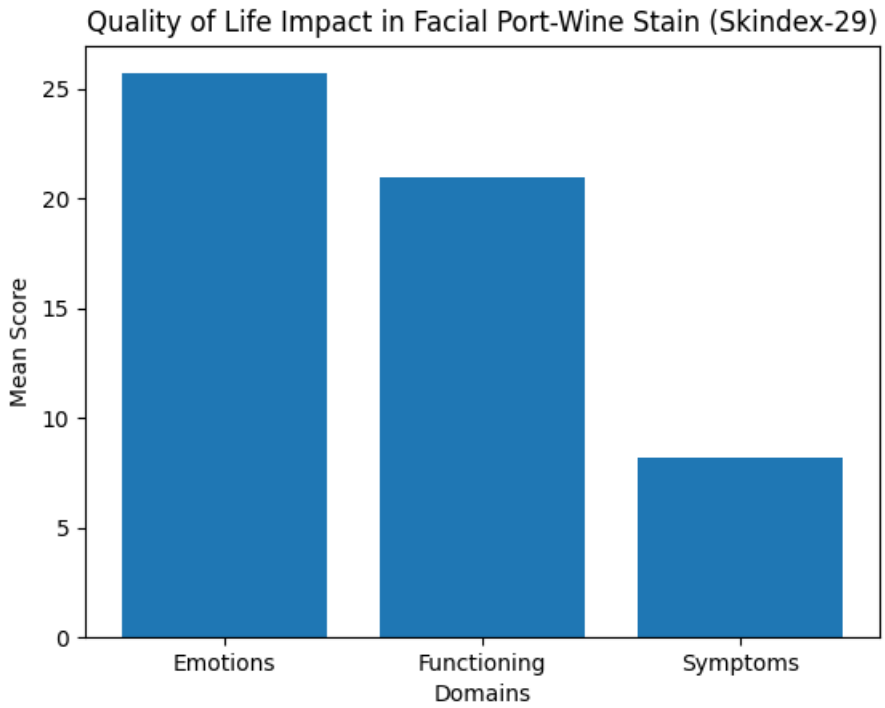

Figure: Mean Skindex-29 domain scores demonstrating greatest impairment in emotional well-being, followed by functioning and symptoms in patients with facial port-wine stain.

Conclusions

Facial PWS exerts a measurable and clinically relevant impact on
quality of life, predominantly affecting emotional well-being. Disease extent and lesion characteristics are key determinants of patient burden. These findings underscore the importance of early intervention and a holistic management approach incorporating psychosocial support

EA DV CONGRESS
VIENNA
30 SEP - 3 OCT 2026

Abstract N°: 3150

Penoscrotal Elephantiasis nostras verrucosa: A case report

Carla Siqueira*[1], Nurimar Fernandes[2]

[1] Postgraduate Course in Dermatology, Department of Dermatology – Hospital Universitário Clementino Fraga Filho – Federal University of Rio de Janeiro, Rio de Janeiro, Brazil
[2] Associate Professor, Department of Dermatology – Hospital Universitário Clementino Fraga Filho – Federal University of Rio de Janeiro, Rio de Janeiro, Brazil

Introduction

Elephantiasis nostras verrucosa (ENV) is a rare and progressive condition resulting from chronic non-filarial lymphedema, characterized by dermal fibrosis and exuberant cutaneous changes include hyperkeratosis, papillomatosis, and verrucous lesions.

The lower limbs are the most commonly affected sites, especially in patients with obesity, chronic venous insufficiency, and recurrent erysipelas or cellulitis. However, atypical presentations involving the external genitalia, abdomen, upper limbs, ears, and face may occur and are usually associated with significant functional morbidity and psychosocial impact. Penoscrotal involvement is a rare manifestation, with few cases reported in the literature.

We report a case of extensive ENV involving the lower limbs and penoscrotal region in an obese patient.

Case Presentation

A 51-year-old man with hypertension and grade 2 obesity, originally from the countryside of São Paulo, presented with a 16-year history of progressive and chronic enlargement of the lower limbs, later evolving to severe penoscrotal lymphedema. He reported recurrent episodes of erysipelas/cellulitis over several years.

Physical examination revealed non-pitting edema of the lower limbs associated with diffuse skin thickening, hyperkeratosis, papillomatosis, and confluent verrucous lesions. Marked penoscrotal involvement with significant local volumetric enlargement was also observed.

The patient denied exposure to filariasis or travel to endemic areas. There was no history of congestive heart failure, malignancy, or surgery related to lymphatic obstruction.

Based on the clinical history, chronic course and characteristic dermatological findings, a clinical diagnosis of ENV with penoscrotal involvement was established.

Conclusion

ENV is a rare and progressive disorder caused by chronic non-filarial lymphedema. The term nostras was introduced by Aldo Castellani in 1934 to distinguish lymphedema occurring in temperate regions from filarial disease. Although initially described as a consequence of recurrent bacterial infections, ENV is currently associated with several causes of chronic lymphatic obstruction, including obesity, malignancy, trauma, surgery, and lymphangioma.

The pathogenesis involves persistent lymphatic dysfunction, leading to accumulation of protein-rich fluid in the dermis and subcutaneous tissue. This process induces chronic inflammation, fibroblast proliferation, fibrosis, and progressive cutaneous changes. Obesity and recurrent erysipelas/cellulitis are important factors contributing to lymphatic damage and worsening fibrosis.

Clinically, ENV presents with non-pitting edema, skin thickening, hyperkeratosis, papillomatosis, and verrucous lesions. Although the lower limbs are most frequently affected, penoscrotal involvement is uncommon and may cause severe functional impairment and reduced quality of life.

Diagnosis is mainly clinical, although histopathology may help exclude differential diagnoses such as filariasis and cutaneous malignancies, particularly squamous cell carcinoma and angiosarcoma associated with chronic lymphedema.

Management remains challenging, with conservative measures including weight reduction, compression therapy, lymphatic drainage, and prevention of recurrent infections constituting the mainstay of treatment. Retinoids and surgical intervention may be considered in selected cases, although recurrence is common.

ENV is a rare and debilitating complication of chronic non-filarial lymphedema. Penoscrotal involvement represents an unusual and potentially disfiguring presentation that requires a high degree of clinical suspicion for early diagnosis.

This case highlights the important role of obesity and chronic lymphatic stasis in the pathogenesis of ENV and the therapeutic challenges associated with this condition. Early recognition and a multidisciplinary approach are essential to minimize disease progression, reduction morbidity, and improvement patients' quality of life.

EA DV CONGRESS
VIENNA
30 SEP - 3 OCT 2026

Abstract N°: 3191

Beyond livedoid vasculopathy: Adult-onset DADA2-associated vasculitis with recurrent leg ulcers and mononeuritis multiplex diagnosed by sural nerve biopsy

Alicia Kwan Su Huey*[1], Farida Aliyu[2], Qasim Akram[3], David Gosal[2]

[1] Manchester University NHS Foundation Trust, Greater Manchester, United Kingdom
[2] Salford Royal NHS Foundation Trust, Greater Manchester, United Kingdom
[3] Stockport NHS Foundation Trust, Stockport, United Kingdom

Introduction

Deficiency of adenosine deaminase 2 (DADA2) is a rare but treatable autosomal recessive monogenic vasculitis with marked phenotypic heterogeneity. Clinically apparent adult-onset disease is only occasionally reported and may overlap with acquired systemic vasculitis, livedoid vasculopathy and chronic venous disease.

Case Presentation

A 34-year-old woman developed recurrent painful lower-leg ulcers after her third pregnancy, with livedoid change, post-inflammatory hyperpigmentation, progressive paraesthesia and severe neuropathic pain. Initial dermatology assessment favoured livedoid vasculopathy. Incisional ulcer biopsy demonstrated fibrosis, vascular/stasis-related change and haemosiderin deposition, without active vasculitis or specific vascular occlusion. Lower-limb arterial Dopplers were normal. Serial vasculitic, autoimmune and thrombotic screens were repeatedly negative apart from persistent polyclonal IgG elevation. Partial superficial ulcer improvement with dressings, topical steroid therapy and a short pentoxifylline trial, together with radiologically confirmed venous incompetence and pelvic congestion, reinforced competing livedoid and venous explanations. However, the extra-cutaneous picture continued to evolve. Dermatology later considered systemic ANCA-negative vasculitis with lower-leg ulceration complicated by venous disease. Neurophysiology demonstrated mild asymmetrical sensory neuropathy, with possible sensory neuronopathy. Sural nerve biopsy subsequently confirmed peripheral nerve vasculitis, and neurology diagnosed small-vessel vasculitis presenting as mononeuritis multiplex with associated recurrent leg ulceration. Genetic testing identified a homozygous pathogenic ADA2 variant, c.139G>A; p.Gly47Arg, establishing adult-presenting DADA2. She later deteriorated despite rituximab and was escalated to adalimumab.

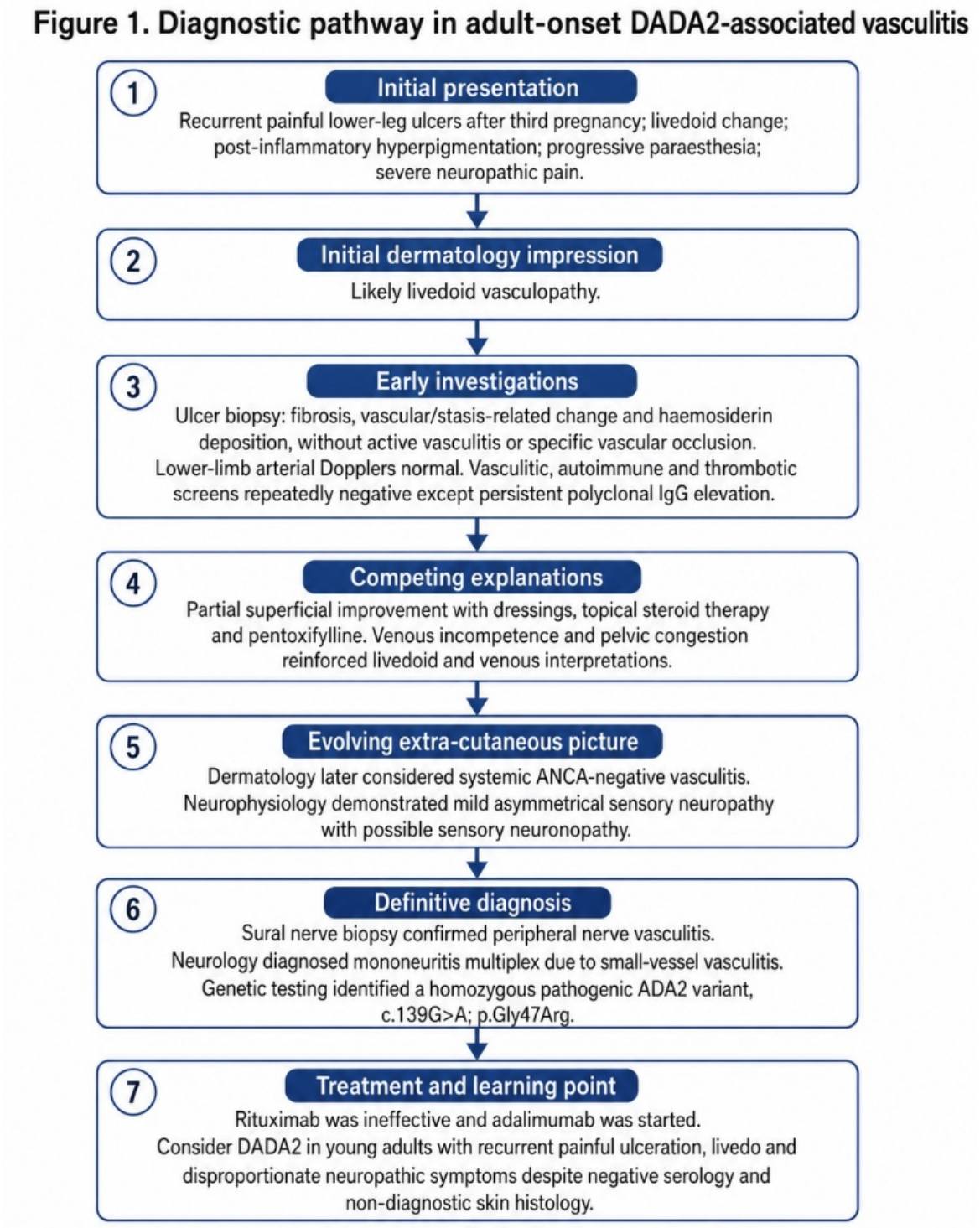

Figure 1. Timeline showing recurrent leg ulceration after the third pregnancy, initial livedoid vasculopathy diagnosis, non-diagnostic skin biopsy and negative serology, neurophysiology demonstrating sensory-predominant axonal neuropathy, sural nerve biopsy confirming peripheral nerve vasculitis, genetic confirmation of a homozygous pathogenic ADA2 variant, rituximab failure, and subsequent adalimumab initiation.

Conclusion

This case highlights an important dermatological diagnostic pitfall: monogenic vasculitis may present through skin disease yet be obscured by genuine venous pathology, negative serology and non-diagnostic ulcer histology. The instructive feature is the diagnostic sequence: skin-first disease, livedoid change and ulceration, repeated negative blood work, venous confounding, falsely reassuring skin biopsy, evolving neuropathic symptoms and finally sural nerve biopsy revealing vasculitic neuropathy. DADA2-associated vasculitis should be considered in young adults with recurrent painful ulceration, livedo and disproportionate neuropathic symptoms despite negative serology. When the clinicopathological picture does not fit common acquired vasculitides or venous disease, deeper tissue

biopsy and genetic testing should be pursued.

EADV CONGRESS
VIENNA
30 SEP - 3 OCT 2026

Abstract N°: 3294

Propylthiouracil-induced ANCA-associated vasculitis presenting as large tense bulla and extensive cutaneous necrosis: a case report

Weijia Yi*[1]

[1] Department of Dermatology, John Hunter Hospital, New South Wales, Australia

Introduction

Propylthiouracil (PTU) is a well-recognised cause of drug-induced antineutrophil cytoplasmic antibody (ANCA)-associated vasculitis (AAV), with ANCA seroconversion reported in 20–64% of treated patients. Cutaneous involvement includes typically purpura, retiform vascular change, or necrotising ulceration and is the predominant manifestation in drug-induced AAV. This contrasts to idiopathic ANCA vasculitis which more frequently involves renal and pulmonary systems. Antibody specificity in PTU-induced AAV is predominantly anti-myeloperoxidase (MPO); dual MPO and proteinase-3 (PR3) positivity is unusual and has been associated with more florid disease expression. Cessation of the offending drug with or without corticosteroids is typically curative in cutaneous-limited disease.

Case Presentation

We report a 63-year-old female with hyperthyroidism on long-term PTU who presented with an asymptomatic retiform vascular macule of the left inferior ankle that rapidly evolved into a large tense haemorrhagic 12cm × 8cm bulla, then subsequently a necrotic ulcer with satellite lesions on the left thigh and right ankle. Initial presentation to a regional centre led to treatment as cellulitis, with several weeks of diagnostic delay before specialist review. Autoimmune evaluation demonstrated strongly positive ANCA at 1:1280 (cANCA), with markedly elevated PR3 (137 IU/mL) and MPO (10 IU/mL), representing an unusual dual-positive pattern. Positron emission tomography confirmed cutaneous-only disease. Skin biopsy demonstrated a dermal neutrophilic infiltrate with small thrombi and neovascularisation consistent with leukocytoclastic vasculitis. PTU was ceased and prednisolone commenced, resulting in progressive wound healing and a gradual decline of PR3 to 6 IU/mL over four months.

Conclusion

This case illustrates the potential for PTU-induced AAV to manifest as a tense bulla alongside severe cutaneous necrosis, causing significant morbidity before diagnosis, particularly when presenting to non-dermatological services and regional or rural centres. It highlights the utility of PR3 titre as a disease activity biomarker throughout the treatment course, and the importance of a coordinated approach across dermatology, rheumatology, and endocrinology when antithyroid drug cessation necessitates alternative thyroid disease management.

EA DV CONGRESS
VIENNA
30 SEP - 3 OCT 2026

Abstract N°: 3380

Erythema Elevatum Diutinum with Granulomatous Features Mimicking Granuloma Annulare: A Diagnostic Challenge

Javier Soro Miranda*[1], Jose Asensio Gomez[1], Jose Gonzalez Fernandez[1], Paula Soto Revuelta[1], Lydia Corbalan Escortell[1], Karol Nicole Sabas Ortega[1], Isabel Escanilla Royo[1], Marta Fernandez Sancho[1], Mariano Ara Martin[1], Mar Garcia Garcia[1]

[1] IASS Aragon, Zaragoza, Spain

Introduction

Erythema elevatum diutinum (EED) is a rare chronic leukocytoclastic vasculitis characterized by symmetrical erythematous, violaceous, or yellowish papules and plaques predominantly involving extensor surfaces. Histopathological findings may evolve from neutrophilic leukocytoclastic vasculitis in early lesions to fibrosis and granulomatous inflammation in chronic stages, potentially leading to diagnostic difficulties. EED has been associated with infections, autoimmune diseases, inflammatory disorders, hematologic abnormalities, monoclonal gammopathies, and solid organ malignancies, particularly IgA-related dyscrasias. We present a case of EED with clinical and histopathological features initially suggestive of granuloma annulare.

Materials and Methods

A case-based literature review was performed following the evaluation of a patient diagnosed with EED in our department. Clinical, laboratory, and histopathological findings were collected and analyzed. A narrative review of the literature was conducted using PubMed and major dermatology reference texts, including reviews and case reports focused on the epidemiology, clinicopathological features, associated diseases, differential diagnosis, and therapeutic management of EED.

Case Presentation

A 67-year-old man presented with symmetrical circinate erythematous-purpuric plaques on the dorsal hands and cheeks evolving over four months. His medical history included obesity, dyslipidemia, hypertension, and obstructive sleep apnea. Initial clinical suspicion was granuloma annulare. Laboratory studies revealed fasting hyperglycemia and mild IgA elevation.

Histopathological examination of a punch biopsy from the dorsum of the hand demonstrated epidermal acanthosis with mild orthokeratotic hyperkeratosis and a dermal perivascular mixed inflammatory infiltrate composed of neutrophils with leukocytoclasia, lymphohistiocytic aggregates, multinucleated giant cells, and focal fibrinoid necrosis of vessel walls. PAS, Grocott, and Ziehl–Neelsen stains were negative. Clinicopathological correlation established the diagnosis of EED.

The patient experienced partial improvement with topical clobetasol and remained clinically stable without new lesions. Systemic treatment with dapsone was proposed but declined by the patient. Hematologic assessment excluded monoclonal gammopathy despite elevated IgA levels.

Literature review confirmed that EED may be associated with hematologic disorders, including monoclonal gammopathies and IgA paraproteinemia, as well as infectious diseases such as hepatitis B virus, HIV, and human herpesvirus 6 infection. Reported inflammatory and autoimmune associations include inflammatory bowel disease, celiac disease, rheumatoid arthritis, systemic lupus erythematosus, and relapsing polychondritis. Associations with

solid malignancies, including prostate carcinoma and testicular lymphoma, have also been described.

Conclusion

EED is an uncommon chronic leukocytoclastic vasculitis with variable clinical and histopathological manifestations that may mimic granulomatous dermatoses such as granuloma annulare or sarcoidosis. Recognition of characteristic lesion distribution and careful clinicopathological correlation are essential for accurate diagnosis, especially in late-stage lesions with granulomatous features. Given its broad spectrum of associated infectious, inflammatory, autoimmune, hematologic, and neoplastic conditions, appropriate systemic evaluation and follow-up are recommended. Dapsone remains the first-line therapy, although localized mild disease may respond to topical corticosteroids.

EADV CONGRESS
VIENNA
30 SEP - 3 OCT 2026

Abstract N°: 3382

Iatrogenic Nasal Pseudoaneurysm Mimicking Cutaneous Neoplasia

Ricardo Moreno-Borque*[1], Carmen Quijano-Gil[1], Jesús Miguel Oviedo-Escobar[1], Elena Lozano-Martínez[1], Alfredo García-Mares[1], Ana Sirgado-Martínez[1], Khrystyna Krasnovska-Zayets[1]

[1] Hospital Universitario Clínico San Carlos, Madrid, Spain

Introduction

Introduction

Pseudoaneurysm is an uncommon vascular complication secondary to trauma or iatrogenic procedures. Although it has been described after dermatologic surgery, its occurrence following a skin biopsy on the nasal tip is exceptionally rare and may clinically mimic rapidly growing tumors or infectious processes. Early recognition is essential to avoid diagnostic delay and inappropriate management.



Case Presentation

Case Presentation

An 80-year-old man presented with a rapidly enlarging papulo-nodular lesion on the nasal tip. One month earlier, a punch biopsy had been performed on the same site, with histopathological diagnosis of actinic keratosis. Clinical examination revealed a violaceous, soft, dome-shaped nodular lesion located exactly at the biopsy site, with progressive growth over several weeks.

Given the rapid enlargement and vascular appearance of the lesion, Doppler ultrasonography was performed. Imaging demonstrated a well-circumscribed encapsulated vascular lesion with turbulent bidirectional blood flow (“ying-yang” pattern), highly suggestive of pseudoaneurysm.

Complete surgical excision was subsequently performed. Histopathological examination confirmed the diagnosis of pseudoaneurysm, showing a vascular cavity communicating with the arterial lumen and surrounded by organizing thrombotic material and fibrous tissue.

The postoperative course was uneventful, with complete resolution and no recurrence during follow-up.

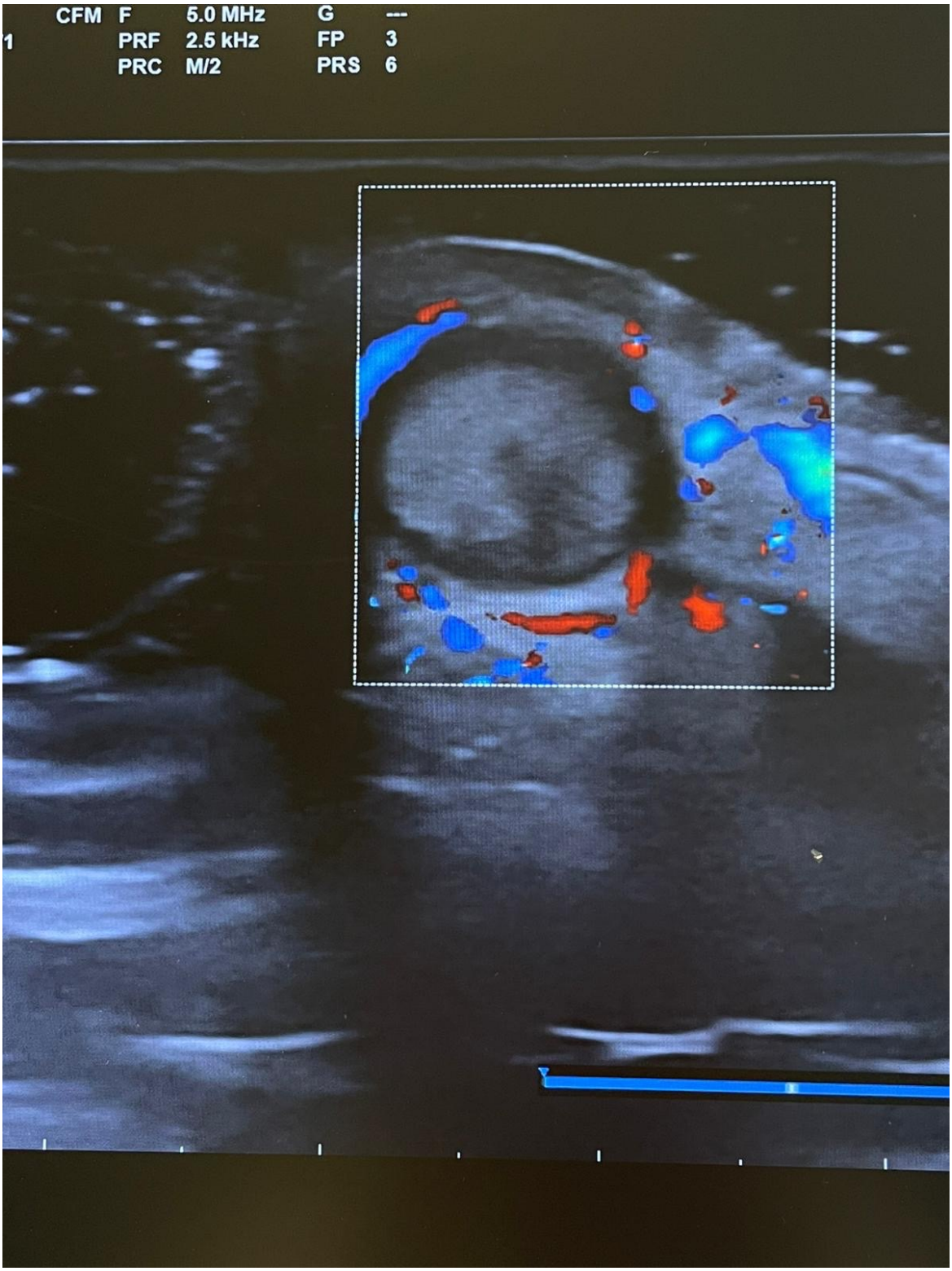

Conclusion

Conclusion

Pseudoaneurysm should be considered in the differential diagnosis of rapidly growing nodular lesions arising after dermatologic procedures or local trauma, particularly in highly vascularized facial areas such as the nose. Although

uncommon, this complication is probably underrecognized in dermatologic practice. Doppler ultrasonography represents a crucial, non-invasive diagnostic tool, allowing prompt confirmation of the diagnosis and appropriate therapeutic planning. Awareness of this entity may help prevent unnecessary procedures and diagnostic errors.



EADV CONGRESS
VIENNA
30 SEP - 3 OCT 2026

Abstract N°: 3486

Eruptive Angiokeratoma: A Case Report

Nisa Nur Cengiz*[1], Gizem Özge Öztürk Aktaş[1], Selcen Kundak[1], Meltem Türkmen[1]

[1] İzmir City Hospital, İzmir, Türkiye

Introduction

Angiokeratomas are well-demarcated vascular lesions histopathologically characterized by superficial vascular ectasia accompanied by hyperkeratosis. Five distinct clinical variants have been identified. With the exception of angiokeratoma circumscriptum, which is regarded as a capillary-lymphatic or capillary malformation, angiokeratomas arise from ectatic dilatation of pre-existing vessels within the papillary dermis.(1) We report a case of eruptive angiokeratomas in a previously healthy 35-year-old woman

Case Presentation

A 35-year-old female presented to the dermatology outpatient clinic with a 1-month history of asymptomatic skin lesions over her left hand, with rapid progression in the number and size of the lesions. The patient had no significant past medical history and denied fever, accompanying systemic symptoms, or preceding physical trauma. A dermatologic examination revealed multiple sharply demarcated, hyperkeratotic, and dark blue, dark violaceous or black nodules of varying sizes. The lesions were distributed over the palmar and dorsal aspects of the left hand. The size of the lesions ranged from 1×1 mm to a maximum size of 1 × 1 cm in diameter. Laboratory investigations, including complete blood count, liver and renal function tests, coagulation parameters, and serology, were normal. An excisional biopsy was performed. Histopathological examination findings were consistent with angiokeratoma. Immunohistochemical staining demonstrated positivity for CD31 in the endothelial cells, confirming the vascular nature of the lesion. All lesions resolved spontaneously within 2 months without treatment.

Conclusion

Angiokeratomas are histopathologically distinct vascular lesions that most frequently present as solitary lesions(2,3) The exact pathogenesis of angiokeratoma has not yet been fully elucidated.(2) Angiokeratomas most commonly present as small, hyperkeratotic black papules localized to the lower extremities, although they may occur at any anatomical site.(1) Most recognized types of angiokeratomas are persistent lesions with little tendency for spontaneous regression.(2,3) In the present case, multiple localized angiokeratomas developed rapidly over a short period on the patient’s left hand in the absence of an identifiable triggering factor, and all lesions resolved spontaneously without treatment.

REFERENCES
1.Bolognia J.L., Schaffer J.V., Cerroni . Dermatology. 5th ed. Elsevier; 2024. Vascular neoplasms and neoplastic-like proliferations.
2.Al Shidhani, S. A., Al Ali, A., Al-Azri, A. R., & Al-Hosni, F. (2022). Localized eruptive acquired multiple angiokeratomas with spontaneous resolution in a healthy child. *JAAD Case Reports*, *28*, 90-93.
3.Schliep S., Kiesewetter F., Simon M., Grupp C., Heinzerling L. Drug-induceddilemma: angiokeratomas and decreased renal function. Am J Med. 2014;127(7):598–600. doi: 10.1016/j.amjmed.2014.03.034.

EADV CONGRESS
VIENNA
30 SEP - 3 OCT 2026

Abstract N°: 3544

PERIPHERAL PIGMENT NETWORK AROUND CHERRY ANGIOMAS IN ADDISON'S DISEASE: ENDOCRINE-RELATED DIFFFUSE HYPERPIGMENTATION MODIFY THE DERMOSCOPIC APPEARANCE OF TYPICAL VASCULAR LESIONS

Miłosz Lewandowski[1, 2], Aleksandra Kujach*[1, 2], Magdalena Lange[1, 2], Martyna Sławińska[1, 2]

[1] Department of Dermatology, Venereology and Allergology, Faculty of Medicine, Medical University of Gdansk, Gdańsk, Poland

[2] Department of Dermatology, Venereology and Allergology, University Clinical Centre in Gdańsk, Gdańsk, Poland

Introduction

Cherry angiomas are common benign vascular proliferations that classically present dermoscopically as well-demarcated red, reddish-blue or violaceous lacunae, often with whitish septa or a milky-white veil. A peripheral pigment network is not regarded as a typical dermoscopic feature of cherry angiomas. To our knowledge, this finding has been described only once in the literature, in a study focused on dermoscopy of non-melanocytic and pink tumors among 128 brown skin patients, where a peripheral pigment network was observed in 2 cherry angiomas.

Case Presentation

We present the case of a 39-year-old woman with long-standing Addison's disease, hypothyroidism, premature ovarian insufficiency, and a history of cutaneous mastocytosis, which regressed spontaneously around puberty. Before developing Addison's disease, she had Fitzpatrick skin phototype II; subsequently, she developed diffuse skin hyperpigmentation, related to increased POMC-derived melanocortin peptides, including ACTH and MSH, resulting in melanocortin receptor activation and enhanced eumelanin synthesis. Total-body dermoscopic examination revealed numerous cherry angiomas with the characteristic pattern of well-demarcated red lacunae and regular peripheral pigment network. No dermoscopic features concerning for cutaneous malignancy were observed.

Conclusion

To our knowledge, peripheral pigment network around cherry angiomas has not previously been reported in Addison's disease. The case suggests that endocrine-related hyperpigmentation may modify the dermoscopic appearance of typical vascular lesions.

EADV CONGRESS
VIENNA
30 SEP - 3 OCT 2026

Abstract N°: 3604

Digital ischemia secondary to Steal Syndrome

Hicham Mokhtari*[1], malek ben slimane[1], Fadwa El Aoufir[1], Mohamed Abderraouf Dhaoui[1]

[1] Department of Dermatology, Military Hospital of Tunis, Tunis, Tunisia

Introduction

Steal syndrome (SS) is secondary to the creation of an arteriovenous shunt in hemodialysis patients. Although easy to diagnose, this relatively common complication remains little known among dermatologists. We report a case of ischemia of the left hand in a young adult associated with SS.

Case Presentation

A 40-year-old man presented with painful acrosyndrome of the left hand that had been developing for two days. Ten years earlier, he had undergone a kidney transplant for undetermined nephropathy with maintenance of a left brachiocephalic arteriovenous fistula post-transplant. Dermatological examination revealed erythematous-purple macules predominantly on the palmar surfaces of the left fingers. No ulceration or necrosis was observed. No motor or sensory deficits were noted. Radial and ulnar pulses were present. The clinical signs were located only on the side of the AVF and improved when the fistula was compressed. Arterial Doppler ultrasound showed a non-functional humeral-cephalic AVF with partial thrombosis in the distal third of the humeral artery and a large thrombus in the post-anastomotic vein protruding into the arterial lumen. A diagnosis of SS was made and the patient was referred for vascular surgery.

Conclusion

VV corresponds to a diversion of blood flow to the detriment of the distal part of the limb following the creation of vascular access in hemodialysis patients. In 30% of cases, ischemic manifestations may occur late in the creation of the fistula, as in the case of our patient. Several risk factors are implicated in the development of VV: diabetes, female gender, and tobacco use. The presence of a proximal fistula, as in our patient, is another major risk factor. The clinical picture is that of limb ischemia with coldness, mottling, paresthesia, loss of pulses, and sometimes sensory-motor deficit. Later on, amyotrophy, ulceration, or distal gangrene may develop. Treatment is typically surgical and conservative in order to resolve ischemic symptoms while preserving vascular access. The technique usually proposed is DRILL, which consists of creating a venous bypass between the proximal artery and the distal artery at the AVF anastomosis.

Steal syndrome is a complication to be suspected in chronic hemodialysis patients with an arteriovenous fistula as vascular access. Early diagnosis is crucial in order to not delay surgical revascularization.

EA DV CONGRESS
VIENNA
30 SEP - 3 OCT 2026

Abstract N°: 3621

Juvenile gangrenous vasculitis of the scrotum

Hicham Mokhtari*[1], malek ben slimane[1], Fadwa El Aoufir[1], Mohamed Abderraouf Dhaoui[1]

[1] Department of Dermatology, Military Hospital of Tunis, Tunis, Tunisia

Introduction

Juvenile gangrenous vasculitis of the scrotum (JGVS) is a rare and distinct entity belonging to the wide group of scrotal ulcers. It follows a typical disease course with well-defined characteristics. We present a case of this extremely rare disease affecting a young male.

Case Presentation

A previously healthy 25-year-old male presented with a sudden onset of painful scrotal ulcers, preceded by 4 days of fever, odynophagia and lethargy. He denied any sexual risk behaviors, local trauma, insect bites as well as previous genital or oral ulcers. Physical examination revealed two well-defined necrotic ulcers with erythematous and raised borders located in each hemiscrotum ranging from 0.6 to 1.5 cm in diameter. There was no palpable connection to the testicle or epididymis. Oral examination showed enlarged inflamed tonsils. Laboratory findings revealed leukocytosis with neutrophilia and elevated C-reactive protein. Immunological studies and evaluation of sexually transmitted diseases yielded negative results. Histopathological assessment of scrotal ulcers showed a perivascular inflammatory infiltrate in the dermis, composed primarily of neutrophils, and fibrinoid necrosis of small vessels. Microbiological examination of the skin biopsy revealed negative findings. Altogether, these findings were compatible with JGVS and the patient was started on a short course of oral prednisolone (0.5 mg/kg/day), progressively tapered over the next 3 weeks, with atrophic scarring occurring withing 3 weeks of treatment.

Conclusion

Exclusively affecting juvenile males, JGVS is characterized by the abrupt onset of painful necrotic scrotal ulcers following usually a recent upper respiratory infection which correlates with our patient. Complementary tests (immunological, microbiological and serological studies) are typically negative. The main histopathological features are epidermal necrosis, dermal infiltrate with neutrophil predominance and fibrinoid necrosis of small vessels such as seen in our case. Although the etiology of JGVS is still unclear, Caputto et al. have proposed that this vasculitis may be a localized variant of pyoderma gangrenosum due to clinicopathologic similarities. Chen et al. have hypothesized that JGVS may be the male counterpart of Lipschütz ulcer in light of the clinical and prognosis overlap between these two diseases. JGVS has a self-limited benign course with complete resolution without relapse. No consensus exists regarding the therapeutic management of JGVS but a few approaches have yielded satisfactory results such as short cycle of systemic steroids, surgical debridement and broad-spectrum antibiotics.

This case depicted a typical presentation of JGVS, an extremely rare disease with well-defined clinicopathological characteristics that should be considered in the differential diagnosis of genital ulcers in men.

EADV Congress 2026, VIENNA
30 SEPTEMBER - 03 OCTOBER 2026
POWERED BY M-ANAGE.COM

EADV CONGRESS
VIENNA
30 SEP - 3 OCT 2026

Abstract N°: 3653

Multifocal acquired elastotic hemangioma: an uncommon clinical presentation with dermoscopic and histopathologic correlation

Wanessa Rolando Roselli*[1], Reinaldo Tovo Filho[1], Marcela Cestari[1], Amanda Cochlar[1], Rodrigo Scabora[1], Silmara Cestari[1]

[1] Hospital Sírio-Libanês-Bela Vista, São Paulo, Brazil

Introduction

Acquired elastotic hemangioma is a rare benign vascular neoplasm associated with chronic sun exposure, usually presenting as a solitary lesion on photoexposed skin. Since its first description, few cases have been reported, and its dermoscopic features remain poorly characterized. Unusual presentations may clinically resemble malignant vascular tumors, creating diagnostic challenges. This report describes an uncommon multifocal presentation of acquired elastotic hemangioma, presents its dermoscopic findings and emphasizes the relevance of clinicopathological correlation for accurate diagnosis.

Case Presentation

A 58-year-old woman presented with a four-year history of asymptomatic erythematous macules initially located on the right arm(Figure 1), with progressive involvement of the left shoulder and arm. Lesions showed increased erythema after heat exposure and were restricted to photoexposed areas. Dermoscopic examination demonstrated a homogeneous erythematous background with linear irregular and serpiginous vessels arranged in a delicate vascular network, without well-defined lacunae(Figure 1).

Histopathologic examination revealed a band-like proliferation of small capillary vessels within the superficial dermis arranged parallel to the epidermis, associated with marked solar elastosis and hobnail endothelial cells (Figure 2).Immunohistochemical analysis demonstrated positivity for CD31, CD34, and D2-40, supporting the diagnosis of acquired elastotic hemangioma.

Conclusion

This case highlights an unusual multifocal presentation of acquired elastotic hemangioma, expanding the recognized clinical spectrum of the disease. Its vascular appearance and atypical distribution may mimic malignant vascular neoplasms, potentially leading to diagnostic uncertainty. Recognition of characteristic dermoscopic findings and correlation with histopathologic and immunohistochemical features are essential for establishing an accurate diagnosis, avoiding misdiagnosis, and preventing unnecessary aggressive management.

EADV CONGRESS
VIENNA
30 SEP - 3 OCT 2026

Abstract N°: 3846

Severe PHACE Syndrome Associated With Extensive Segmental Infantile Hemangioma Successfully Treated With Early Propranolol Therapy

Elaine Shizue Novalo-Goto*[1], Giovanna Guimarães Soares[1], Lucia Mioko Ito[1], Cristina Marta Maria Laczynski[1], Carlos D´Apparecida Santos Machado Filho[1]

[1] FMABC University Center, Santo André, Brazil

Introduction

PHACE syndrome is a rare neurocutaneous condition characterized by large segmental infantile hemangiomas associated with structural abnormalities involving the central nervous system, cardiovascular system, and eyes. Early diagnosis is essential, as affected infants may develop significant functional impairment and potentially life-threatening complications.

Case Presentation

A 2-month-old female infant presented with rapidly progressive erythematous-violaceous lesions involving the right side of the face and neck, first noticed two weeks after birth. Dermatological examination revealed extensive segmental hemangiomas affecting the scalp, malar, preauricular, cervical, periocular, and supralabial regions, with additional involvement of the oral mucosa, including the right hemipalate. A smaller erythematous-violaceous plaque was also observed on the left lower limb.

The lesions rapidly increased in size and became associated with dysphagia, ulceration, recurrent bleeding, and symptomatic anemia. Due to the extensive distribution and functional impairment, the patient underwent multidisciplinary evaluation. Imaging studies demonstrated patent foramen ovale, cerebellar asymmetry with right-sided hypoplasia, enlargement of cerebrospinal fluid spaces, dysmorphic fourth ventricle, right ocular proptosis, right parotid enlargement, hepatic hemangioma, and right periorbital edema, supporting the diagnosis of PHACE syndrome.

Treatment with oral propranolol (1 mg/kg/day) combined with topical timolol was initiated during hospitalization under cardiologic monitoring. After seven months of therapy, the patient showed marked clinical improvement, with significant regression of the hemangiomas, reduction of bleeding episodes, improvement of dysphagia, and better tolerance of breastfeeding.

Conclusion

This case highlights the importance of early recognition of PHACE syndrome in infants presenting with extensive segmental hemangiomas. Functional impairment and multisystem involvement require prompt multidisciplinary assessment and early therapeutic intervention. Early treatment with propranolol may lead to substantial clinical improvement and help prevent severe complications.

EADV CONGRESS
VIENNA
30 SEP - 3 OCT 2026

Abstract N°: 4194

Ultrasonographic monitoring of subcutaneous tissue changes during complete decongestive therapy in breast cancer-related lymphedema: a prospective pilot study

Hsiang Chi Chang*[1], Yi Chun Fang[2]

[1] Taipei Hospital, Ministry of Health and Welfare, National yang ming chiao tung university, Taipei, Taiwan
[2] Taipei Hospital, Ministry of Health and Welfare, Taipei, Taiwan

Introduction

Breast cancer-related lymphedema (BCRL) is a chronic condition involving progressive subcutaneous tissue fibrosis and fluid accumulation, with significant dermatological and functional consequences. Complete decongestive therapy (CDT) is the gold-standard treatment, yet objective monitoring tools beyond water displacement volumetry (WDV) and circumferential measurement (CM) remain underutilised. High-frequency ultrasonography offers real-time, non-invasive assessment of subcutaneous tissue thickness and echogenicity, but its correlation with standard clinical measures during CDT has not been fully established.

To evaluate the efficacy of CDT on limb swelling and upper extremity function in BCRL patients, and to assess the concurrent validity of ultrasonographic subcutaneous tissue measurement against WDV and CM as outcome monitoring tools.

Materials and Methods

This prospective, single-centre pilot study enrolled five women with clinically diagnosed BCRL (ISL stages I–II). All participants received eight CDT sessions over four weeks (2 sessions/week), delivered by a certified lymphedema therapist, comprising manual lymphatic drainage, multilayer compression bandaging, skin care, and decongestive exercise. Outcomes were assessed at each session and at one-month follow-up: (1) limb volume by WDV; (2) total arm circumference by sequential CM every 2 cm from the web space to the axillary fold, converted to volume using the truncated-cone formula; (3) high-frequency ultrasonography (8–15 MHz linear probe, four-quadrant measurements at the upper arm and forearm); (4) upper extremity function by the Disabilities of the Arm, Shoulder and Hand questionnaire (DASH); and (5) psychological impact by the Beck Depression Inventory (BDI) and a lymphedema-specific quality-of-life questionnaire. Statistical analysis included paired t-tests and Pearson correlation coefficients.

Results

Following eight CDT sessions, mean total arm circumference decreased from 663.1 ± 124.4 cm to 626.9 ± 89.4 cm (mean reduction −36.2 cm, −4.9%), and mean WDV decreased from 3,470 ± 802 mL to 3,288 ± 762 mL (mean reduction −182 mL, −5.4%). DASH scores improved in three of five participants (mean pre-CDT 27.7; mean post-CDT 21.6). Ultrasonographic subcutaneous tissue thickness showed progressive reduction across sessions and demonstrated concordance with changes in both CM and WDV. BDI scores varied widely across participants (range 0–41), highlighting the heterogeneous psychological burden of BCRL.

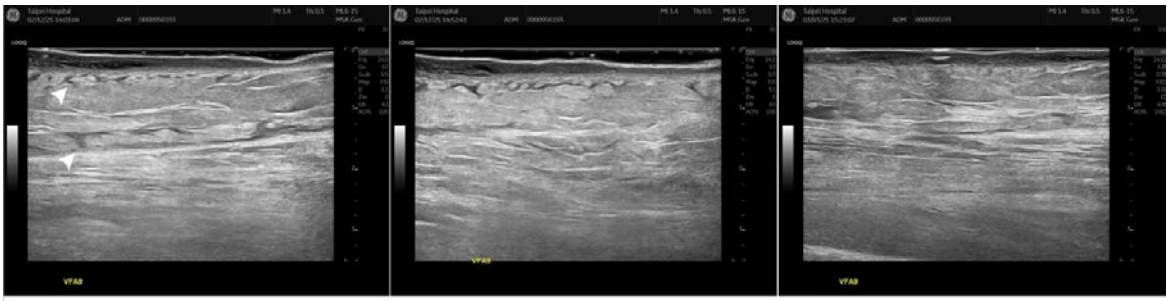

Serial ultrasound imaging of upper-extremity lymphedema. (A) Baseline longitudinal ultrasound image demonstrating diffuse subcutaneous edema with hypoechoic fluid clefts within the subcutaneous tissue (arrowheads) and cobblestone appearance superficial to the deep fascia. (B) Follow-up examination showing partial resolution of subcutaneous fluid accumulation and decreased tissue heterogeneity. (C) Late follow-up image demonstrating near-complete resolution of subcutaneous edema with restoration of normal fibrillar echotexture.

Conclusions

CDT produced measurable reductions in limb swelling and improved upper extremity function in BCRL patients. High-frequency ultrasonography appears to be a promising real-time adjunct monitoring tool, showing concordance with established volumetric and circumferential measures. Its ability to visualise subcutaneous structural changes may support more individualised treatment decisions, particularly relevant in dermatological and oncology-rehabilitation practice. Larger controlled studies are warranted to confirm these preliminary findings.