EA CONGRESS
VIENNA
30 SEP - 3 OCT 2026

Abstract N°: 1

Efficacy and Safety of Oturkibart in Adults with Prurigo Nodularis: 52-Week Results from a Phase 3 Trial

Jianzhong Zhang*[1], Yan Zhao[1], Cheng Zhou[1], Jiwan Qiu[2], Junfang Xu[3], LIMING WU[4], Yun Wang[5], Aihua Wei[6], Dehou Yu[7], Zixue Chen[8], Juan Su[9], Ying Li[10], Litao Zhang[11], Qin Xiaoming[12], Min Zhu[13], Hengguang Zhao[14], Jianjian Zhu[15], Furen Zhang[16], Qingchun Diao[17], XIAOHUA WANG[18], Yanling Li[19], Fuqiu Li[20], Shuping Guo[21], Zhouwei Wu[22], Xiaohua Tao[23], Shasha Fan[23], Songmei Geng[24], Mao Lin[25], Xiumin Yang[26], Lixia Zhang[27], Danhong Jiao[28], Xiguang Liu[29], Tongxiang Zeng[30], Guan Jiang[31], Huiming Zeng[32], Ruoyu Li[33], XIAOHONG ZHU[34], Xinghua Gao[35], Huiping WANG[36], Sen Yang[37], Yuling Shi[38], Yangfeng Ding[38], Wenlin Yang[39], Guang Xiang[40], XiaoJing Kang[41], Xianwei Wu[42], Guoqiang Zhang[43], Rixin Chen[44], Zudong Meng[45], Shanshan Li[46], Xianwei Cao[47], Jingfa Lu[48], Wei Qin[49], Jianping Zhang[50], Niu Xiang[51], Xueyuan Yang[52], Shifa Zhang[53], Hui TANG[54], Zu'an Guo[55], Hongfang Han[56], Bin Qu[57], Tao Lu[58], Liang xiong'an[59], Yong Jiang[60], Yi Zhao[61], Kaiming Ji[62], Xiaoyong Man[63], Xianjin Chen[64], Ting Wang[2], Yi Wang[2], Tao Chen[2], Zhuoya Li[2], Liuli Bai[2], Zenong Wu[2], Yang Lu[3], Chun Li[3], Cui Chen[3], Si Y[3], Lijun Shen[3], Kaile Zhou[3], Hanyan Wu[3], Jiahui Wang[3], Xiaochan Feng[3]

[1] Peking University People's Hospital, Beijing, China
[2] Qyuns Therapeutics Co., Ltd., Taizhou, China
[3] Hangzhou Zhongmei Huadong Pharmaceutical Co., Ltd., Hangzhou, China
[4] Affiliated Hangzhou First People's Hospital, School of Medicine, Westlake University, Hangzhou, China
[5] Taiyuan Central Hospital of Shanxi Medical University, Taiyuan, China
[6] Beijing Tongren Hospital, Capital Medical University, Beijing, China
[7] Affiliated Hospital of Guizhou Medical University, Guiyang, China
[8] Zhengzhou Central Hospital Affiliated to Zhengzhou University, Zhengzhou, China
[9] Xiangya Hospital of Central South University, Changsha, China
[10] Qilu Hospital of Shandong University, Jinan, China
[11] Tianjin Academy of Traditional Chinese Medicine Affiliated Hospital, Tianjin, China
[12] The Second Affiliated Hospital of Wannan Medical College, Wuhu, China
[13] Ruikang Hospital Affiliated to Guangxi University of Chinese Medicine, Nanning, China
[14] The Second Affiliated Hospital of Chongqing Medical University, Chongqing, China
[15] The First People's Hospital of Changde, Changde, China
[16] Shandong Provincial Hospital for Skin Diseases, Jinan, China
[17] The First Affiliated Hospital of Chongqing University of Chinese Medicine, Chongqing, China
[18] Dermatology Hospital of Southern Medical University, Guangzhou, China
[19] The Second Hospital of Hebei Medical University, Shijiazhuang, China
[20] The Second Norman Bethune Hospital of Jilin University, Changchun, China
[21] First Hospital of Shanxi Medical University, Taiyuan, China
[22] Shanghai General Hospital, Shanghai, China
[23] Zhejiang Provincial People's Hospital, Hangzhou, China
[24] The Second Affiliated Hospital of Xi'an Jiaotong University, Xi'an, China
[25] West China Hospital of Sichuan University, Chengdu, China
[26] Beijing Aerospace Center Hospital, Beijing, China

[27] Sichuan Academy of Medical Sciences & Sichuan Provincial People's Hospital, Chengdu, China
[28] Sanmenxia Central Hospital, Sanmenxia, China
[29] Heilongjiang Provincial Hospital, Harbin, China
[30] Jingzhou Central Hospital, Jingzhou, China
[31] The Affiliated Hospital of Xuzhou Medical University, Xuzhou, China
[32] Hainan Fifth People's Hospital, Haikou, China
[33] Peking University First Hospital, Beijing, China
[34] Wuxi Second People's Hospital, Wuxi, China
[35] The First Hospital of China Medical University, Shenyang, China
[36] Tianjin Medical University General Hospital, Tianjin, China
[37] The First Affiliated Hospital of Baotou Medical College, Baotou, China
[38] Shanghai Skin Disease Hospital, Shanghai, China
[39] The Second Affiliated Hospital of Guangzhou Medical University, Guangzhou, China
[40] Chongqing Three Gorges Medical College, Chongqing, China
[41] People's Hospital of Xinjiang Uygur Autonomous Region, Urumqi, China
[42] Gansu Provincial Hospital, Lanzhou, China
[43] The First Hospital of Hebei Medical University, Shijiazhuang, China
[44] Nanyang First People's Hospital, Nanyang, China
[45] Shiyan People's Hospital (Affiliated to Hubei University of Medicine), Shiyan, China
[46] The First Bethune Hospital of Jilin University, Changchun, China
[47] The First Affiliated Hospital of Nanchang University, Nanchang, China
[48] First Affiliated Hospital of Gannan Medical University, Ganzhou, China
[49] Jiangmen Central Hospital, Jiangmen, China
[50] The Second Affiliated Hospital of Jiaxing University, Jiaxing, China
[51] The First Affiliated Hospital of Fujian Medical University, Fuzhou, China
[52] Hospital for Skin Diseases, Institute of Dermatology, Chinese Academy of Medical Sciences and Peking Union Medical College, Nanjing, China
[53] Northeast International Hospital, Shenyang, China
[54] Huashan Hospital of Fudan University, Shanghai, China
[55] The People’s Hospital of Hezhou, Hezhou, China
[56] The First Affiliated Hospital of Bengbu Medical University, Bengbu, China
[57] Shulan (Hangzhou) Hospital, Hangzhou, China
[58] The First Affiliated Hospital of Shantou University Medical College, Shantou, China
[59] The First Affiliated Hospital of Hainan Medical University, Haikou, China
[60] The Second Hospital of Tianjin Medical University, Tianjin, China
[61] Beijing Tsinghua Changgung Hospital, Beijing, China
[62] The Second Affiliated Hospital of Xiamen Medical College, Xiamen, China
[63] The Second Affiliated Hospital of Zhejiang University School of Medicine, Hangzhou, China
[64] Yantai Yuhuangding Hospital, Yantai, China

Introduction

Prurigo nodularis (PN) is a chronic, recurrent disease characterized by intensely pruritic and hyperkeratotic nodules. Oturkibart (R&D code: QX005N), a novel humanized anti-IL-4Rα IgG4 monoclonal antibody, has demonstrated clinically meaningful improvements in itch and skin lesions in adults with PN through Week 24 (findings to be presented soon as an e-poster at EADV 2026). Here, we report the first long-term open-label extension (OLE) data for an IL-4Rα inhibitor in PN, evaluating the efficacy and safety of oturkibart through Week 52 in a phase 3 OLE period to address this evidence gap.

Materials and Methods

Adults (18-75 years) with PN, who had an inadequate response or intolerance to topical corticosteroids (TCS), a

weekly average Worst Itch Numeric Rating Scale (WI-NRS) score ≥7, and an Investigator's Global Assessment for PN-Stage (IGA PN-S) ≥3 were randomized 1:1 to receive oturkibart 450 mg every 2 weeks (Q2W) or placebo for 24 weeks. This was followed by a 28-week OLE period, during which all patients received oturkibart 450 mg Q2W through Week 52, and a final 8-week follow-up. The primary endpoint was the proportion of participants achieving a ≥4-point reduction from baseline in the weekly average WI-NRS at Week 24. The key secondary endpoint was the proportion of participants with an IGA PN-S score 0/1 at Week 24. Other secondary endpoints included the proportion of patients achieving an Investigator's Global Assessment for PN-Activity (IGA PN-A) score 0/1, changes in Dermatology Life Quality Index (DLQI) and Hospital Anxiety and Depression Scale (HADS) scores, the use of rescue therapy. In addition, post-hoc analyses were performed on the proportion with a weekly average WI-NRS score ≤2, and the proportion with a weekly average WI-NRS score ≤1. For the OLE period, analyses were based on observed data, with no imputation for missing values. The safety of oturkibart was also evaluated.

Results

A total of 206 participants received oturkibart and 206 received placebo. Baseline demographics and disease characteristics were well balanced in two groups. At Week 52, responses were maintained among patients initially randomized to oturkibart (itch response, 95.5%(95% confidence interval [CI]: 91.24%, 98.02%); IGA PN-S 0/1, 66.9%(95% CI: 59.36%, 73.78%);IGA PN-A 0/1, 68.0%(95% CI: 60.54%, 74.84%)). Among patients who crossed over from placebo at Week 24, responses at Week 52 were substantially improved and similar to those achieved by patients initially randomized to oturkibart (itch response, 90.6%(95% CI: 85.39%, 94.43%);IGA PN-S 0/1, 49.2% (95% CI: 41.68%, 56.69%); IGA PN-A 0/1, 49.7%(95% CI: 42.22%, 57.24%)). Similar improvements in DLQI and HADS from Week 24 to Week 52 were reported in both groups (DLQI: oturkibart/oturkibart, -12.4; placebo/oturkibart, -11.1; HADS: oturkibart/oturkibart, -6.4; placebo/oturkibart, -5.3). Rescue therapy was used in 2.1% of the oturkibart/oturkibart group and 13.3% of the placebo/oturkibart group. Additionally, post-hoc analysis results showed: at Week 52, among patients initially randomized to the oturkibart, the proportion achieving a weekly average WI-NRS score ≤2 was 76.7%, and the proportion achieving a weekly average WI-NRS score ≤1 was 55.1%. The trends in the above endpoint for patients who crossed over from placebo were consistent with those in the oturkibart/oturkibart group. oturkibart was generally well tolerated during the extension period, with few grade ≥3 treatment-emergent adverse events (AEs) or serious AEs (oturkibart/oturkibart, 6.8% and 3.7%; placebo/oturkibart, 5.3% and 3.7%, respectively).

Conclusion

Oturkibart 450 mg Q2W for 52 weeks was well tolerated and demonstrated clear long-term efficacy in adult patients with PN, providing sustained and stable clinical benefits, including improvements in itch and skin lesions, as well as improvements in patients' quality of life and anxiety/depression.

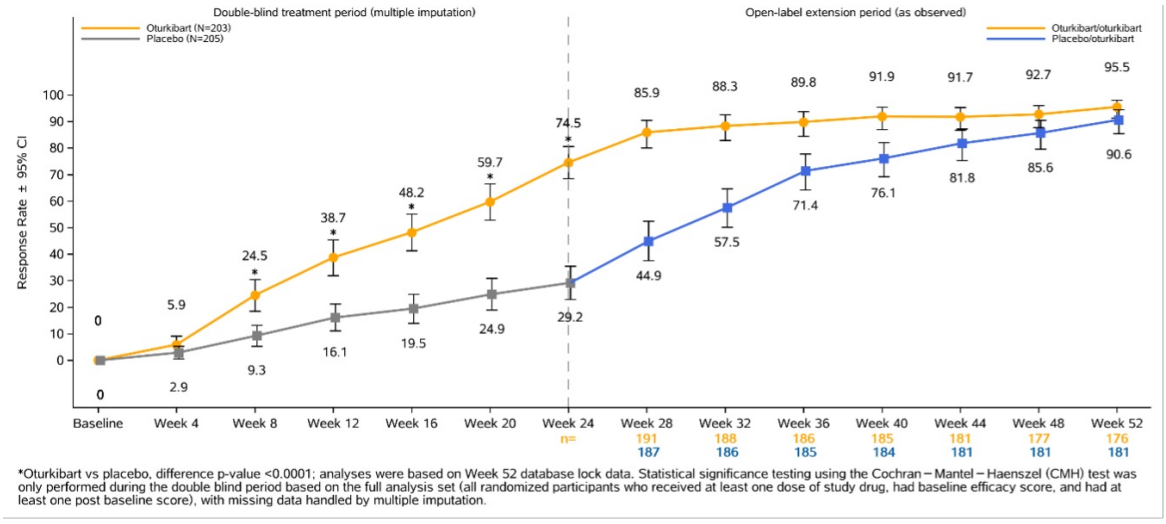

Proportion of patients achieving a WI-NRS improvement of ≥4 points from baseline.

EA DV CONGRESS
VIENNA
30 SEP - 3 OCT 2026

Abstract N°: 76

Koebner Phenomenon Traumatic in Erythema Multiforme Major A Rare Finding Documented

salah eddin awawde*[1], Widad Sellami[1], Taibi Lynda[1], Samira Zobiri[1]

[1] Mustapha University Hospital Center, Dermatology and venereology, Sidi M'Hamed - alger, Algeria

Introduction

Erythema Multiforme (EM) is an acute, self-limiting mucocutaneous hypersensitivity reaction, most commonly triggered by infections (predominantly Herpes Simplex Virus - HSV) or medications. The standard clinical presentation involves a generalized symmetric eruption of typical target lesions. The Koebner phenomenon, defined as the development of typical skin lesions at the site of preceding trauma in an otherwise healthy area, is commonly observed in psoriasis, lichen planus, and vitiligo. Its occurrence within Erythema Multiforme, particularly the severe Major variant (EMM), which involves significant mucosal involvement, is an exceptionally rare and poorly documented finding. We report a unique case of a young male presenting with Erythema Multiforme Major where traumatic injury distinctly localized the isomorphic response, confirmed as a true Koebner phenomenon.

Case Presentation

A 25-year-old male , no medical history, presented with an 8-day history of cutaneous eruption and bilateral conjunctivitis. His history revealed a flu-like syndrome one week prior, treated with NSAID (frequently used) and AMOX-CLAV (taken for the first time). Two days before the eruption, the patient experienced a symptomatic cold sore (HSV labialis).The dermatological eruption evolved sequentially from erythematous papules to vesicular-centered lesions, stabilizing as classic target lesions.Crucially, physical examination revealed not only a generalized distribution but also a A distinct pericannular arrangement of typical target lesions was observed on the right forearm, sustained one day before the generalized eruption. Bilateral conjunctivitis and oral mucosal involvement were confirmed. The patient was in good general condition and afebrile. Based on the preceding HSV infection, the recent drug intake, the pathognomonic target lesions, and severe mucosal involvement, a clinical diagnosis of Erythema Multiforme Major with an isomorphic Koebner response was established.

The patient was managed with a conservative yet intensive regimen to address the primary triggers and alleviate severe symptoms. The therapeutic protocol included: Antiviral Therapy: Oral Aciclovir 2 g/day for 10 days to treat the HSV trigger and potentially reduce EM duration. Systemic Anti-inflammatory: Oral Prednisone 0.5 mg/kg/day for 5 days. Topical Care: Mouthwash containing corticosteroids, antifungal agents, and antiseptics.

The patient’s condition evolved favorably and rapidly. Within 10 days, all skin lesions showed significant regression, including those in the traumatized areas. Oral and ocular mucosal involvement resolved without sequelae. No new lesions were reported during the intensive 10-day follow-up.

Conclusion

This case offers a striking visual narrative of the "iatrogenic" Koebner phenomenon. While we traditionally expect the isomorphic response to follow accidental injuries like scratches, here it was distinctly mapped by medical intervention. The localization of Erythema Multiforme Major (EMM) lesions specifically around cannula insertion sites on the dorsal hand and within the venous trajectory of the antecubital fossa (pli du coude) transforms a systemic immune event into a localized clinical map.This "non-linear" Koebner response highlights that the "locus

of least resistance" is not merely caused by surface trauma, but by the deeper, localized inflammatory stress of catheterization and venous access. It serves as a profound reminder for clinicians that in the acute phase of a hypersensitivity reaction, every point of skin breakage—even those performed for therapeutic benefit—can become a focal point for the eruption.By documenting this, we emphasize that the Koebner phenomenon in EMM is a versatile "mimic" of trauma, regardless of whether that trauma is accidental or medical. Recognizing this link is vital for accurate diagnosis and reminds us that the skin's immune memory is as sensitive to the needle as it is to the thorn.

EADV CONGRESS
VIENNA
30 SEP - 3 OCT 2026

Abstract N°: 159

The recognition of occupational dermatoses: protocol for a national certification-based 10 year study in Portugal

Ana Brasileiro*[1, 2], Maria João Paiva Lopes[1, 2]

[1] NOVA Medical School | Faculdade de Ciências Médicas da Universidade Nova de Lisboa, Lisbon, Portugal, Lisbon, Portugal

[2] Dermatology Department, ULS S. José, Lisbon, Portugal

Introduction
Occupational skin diseases (OSD), particularly occupational contact dermatitis, are among the most common work-related conditions in Europe. Despite their significant clinical and socioeconomic impact, national epidemiological data remain scarce in several countries, including Portugal. Understanding patterns of recognition, certification, and occupational exposures is essential to inform prevention strategies and improve occupational disease surveillance systems.
We aim to describe the epidemiology, occupational distribution, and certification patterns of occupational dermatoses in Portugal over a ten-year period using nationwide certification data.

Materials and Methods
This study is designed as a retrospective observational analysis of occupational dermatoses notified and certified by the Portuguese Department for Protection against Professional Risks (DPRP) between 2015 and 2024. Pseudonymized administrative and clinical certification records will be analysed. Variables to be collected include demographic characteristics, occupational sector, clinical diagnosis, reported causal exposures, certification outcomes, and timelines from notification to final recognition. Descriptive statistics will be used to characterize the burden and distribution of occupational dermatoses, while temporal trend analyses will explore changes over the study period, including potential variations associated with the COVID-19 pandemic and intensified hygiene practices. Where available, sector-specific patterns and exposure profiles will also be examined.

Results
This study will provide the first national overview of certified occupational dermatoses in Portugal, identifying high-risk occupational sectors, characterizing diagnostic patterns, and describing certification pathways within the national occupational disease recognition system.

Conclusions
By generating the first comprehensive national dataset on occupational dermatoses, this project aims to strengthen the epidemiological basis for occupational skin disease surveillance in Portugal and to inform targeted prevention strategies, improved referral pathways, and future research in occupational dermatology.

EADV CONGRESS
VIENNA
30 SEP - 3 OCT 2026

Abstract N°: 315

Hypertrophic Earlobe Scarring After Piercing: Reconstruction Following Nickel-Induced Allergic Contact Dermatitis

Raluca Ghete*[1], Giulia Mora[2], Nicholas Kormos[1]

[1] Freya Medical Clinic, Floresti, Romania

[2] Iuliu Haţieganu University of Medicine and Pharmacy, Dermatology, Cluj-Napoca, Romania

Introduction

Allergic contact dermatitis (ACD) is a frequent dermatological condition, with nickel as a common trigger. Over time, prolonged exposure may lead to locally severe complications and pose diagnostic challenges in distinguishing reactive hypertrophic scars from true keloids.

Case Presentation

We present the case of a 35-year-old woman with previously suspected chronic prurigo who presented with multiple pruritic, antihistamine-resistant leg ulcerations. After she underwent improper ear piercing at age 14, due to an unrecognized nickel allergy, she developed ACD. The subsequent eczema, infection, and chronic inflammation led to bilateral earlobe lesions that became nodular, fibrotic, and indurated. Moreover, underlying dermatitis artefacta was identified as the cause of the leg ulcerations and a contributing factor to the chronic earlobe scarring. The management was distinctive, with surgical intervention deemed as appropriate considering the chronicity and psychological background. Healing was uneventful, with complete recovery and no recurrence.

Conclusion

To the best of our knowledge, this is among the few reports of hypertrophic earlobe scarring caused by the coexistence of nickel-induced dermatitis, chronic inflammation, and dermatitis artefacta. We therefore present and address this case in order to raise awareness.

EA DV CONGRESS
VIENNA
30 SEP - 3 OCT 2026

Abstract N°: 339

"ZOSTERIFORM CUTANEOUS LEPIDOPTERISM INDUCED BY SATURNIA PYRI CATERPILLAR: A RARE DERMATOLOGICAL MIMIC"

Karthi Kishore*[1], Siva Senapathi[1]

[1] MILITARY HOSPITAL SHILLONG, SHILLONG, India

Introduction

Lepidopterism refers to a spectrum of clinical manifestation involving the skin seen in individuals who encounter larval or adult form of various species of moths and butterflies. Among the various species of insects seen worldwide, around 12 species are responsible for causing contact dermatitis in humans.1,2 Among insects, caterpillars are found to be notorious in causing severe cutaneous allergic response when brought in contact with the skin. We report a rare clinical presentation of lepidopterism following contact with peacock moth caterpillar (Saturnia pyria),where the skin lesion mimics zosteriform dermatoses.

Case Presentation

A 45 yr old male presented with complaints of painful itchy red raised lesions over the left neck and left upper chest of 3 days duration. He gave no history of fever or recent travel. However, he gave history of contact with an insect over his neck while gardening 5 days ago. (Figure 1) On dermatological examination, there were multiple well defined grouped vesicles filled with clear fluid which was distributed over the left side of neck and left upper chest, mimicking a dermatomal distribution along the territory of C3-T2 dermatomes.(Figure 2) Tzanck smear was done on the fluid obtained from one of the vesicle which did not show any findings suggestive of herpes zoster infection. PCR for herpes done on the vesicle fluid was negative. The patient was diagnosed as a case of caterpillar dermatitis or lepidopterism mimicking a herpes zoster infection due to the morphological pattern. The patient was managed with topical steroids and oral antihistamines to which he responded well.



Figure 1 : Insect specimen brought by the patient to the hospital Figure 2: Multiple well defined grouped vesicles filled with clear fluid distributed over the left side of neck (A) and left upper chest (B), mimicking a dermatomal distribution along the territory of C3-T2 dermatomes.

Conclusion

Lepidopterism or caterpillar dermatitis is a contact dermatitis caused by exposure to venomous spines of various caterpillar species. Usually the clinical presentation is varied ranging from urticarial wheals, papules to anaphylaxis.3 In our case the culprit insect was Peacock moth caterpillar(Saturnia pyri) identified from the insect specimen brought in by the patient, which is characterized by a black body with prominent spiny protrusions and scattered blue tubercles giving it a vibrant appearance.(Figure 1) The species is native to Europe and can be found in India due to captive breeding. It is found that the caterpillar may secrete certain biogenic amines such as gamma aminobutyric acid and phenolic compounds which may cause severe cutaneous response.4 In our patient the morphological presentation of cutaneous reaction with a zosteriform presentation makes the diagnosis unique and challenging. Hence this case report helps to highlight the need to consider lepidopterism as one of the differential diagnosis while dealing with cases of zosteriform dermatoses. This case also adds on to the sparse literature available on the various clinical presentation of caterpillar dermatitis.

EADV CONGRESS
VIENNA
30 SEP - 3 OCT 2026

Abstract N°: 441

Molecular-Genetic and Immunobiological Determinants of Disease Severity and Clinical Heterogeneity in Rosacea

Saida Agzamkhodjaeva*[1]

[1] Tashkent State medical university, Tashkent, Uzbekistan

Introduction
Rosacea is a chronic inflammatory dermatosis characterized by significant clinical heterogeneity and an incompletely understood pathogenesis. Although genetic predisposition and innate immune dysregulation are increasingly recognized, clinically applicable molecular predictors of disease severity remain limited.

Materials and Methods
A case–control study included 135 patients with rosacea and 40 healthy controls. Clinical assessment was performed using standardized subtype classification and severity grading. Genotyping targeted polymorphisms involved in hemostasis and folate metabolism, including ITGB3 (rs5918), PAI-1, and MTHFR (C677T, A1298C). Immunological and biochemical parameters were evaluated, including systemic inflammatory indices (NLR, PLR, SII). Correlation analysis and multivariate modeling were applied.

Results
Significant associations were identified between genetic polymorphisms and rosacea risk and severity. The ITGB3 (rs5918) polymorphism was associated with an increased risk of rosacea ($p=0.04$; OR=9.1), as well as PAI-1 ($p=0.03$; OR=7.5), supporting the role of platelet-mediated hemostatic mechanisms in disease pathogenesis. Polymorphisms of folate metabolism genes were also implicated: the MTHFR A1298C variant was associated with increased risk of rosacea (OR=1.3) and severe papulopustular subtype (OR=2.9), while the likelihood of papulopustular lesions increased up to 14-fold ($p<0.05$). The MTHFR C677T genotype increased disease risk by 9.5-fold ($p<0.05$). Immunobiological analysis revealed significant elevation of systemic inflammatory indices (NLR, PLR, SII) ($p<0.05$), indicating activation of innate immune pathways and correlating with disease severity.An integrative predictive model combining genetic, immunological, and biochemical markers demonstrated high diagnostic performance, with sensitivity of 88%, specificity of 85%, and explained variance of 71.3%.

Conclusions
Genetic polymorphisms in hemostasis (ITGB3, PAI-1) and folate metabolism (MTHFR), together with activation of innate immunity, contribute significantly to disease severity and clinical heterogeneity in rosacea. The identification of strong associations (OR up to 9.1) and the development of a high-performance predictive model highlight the potential of integrated molecular and immunological biomarkers for risk stratification and personalized management. These findings provide important translational insights linking molecular mechanisms to clinically relevant outcomes in rosacea.

EA DV CONGRESS
VIENNA
30 SEP - 3 OCT 2026

Abstract N°: 546

Clinical Outcomes of Gentamicin Therapy in Dystrophic Epidermolysis Bullosa: A Case-Based Literature Review

Caroline Teruszkin Wiedermann*[1], Jessica Lima[1], Valentina Badaro[1], Omar Lupi[1], Yuliana Oros Sucari[1]

[1] Policlica Geral do Rio de Janeiro, Rio de Janeiro, Brazil

Introduction

Epidermolysis bullosa (EB) comprises a group of inherited disorders characterized by skin fragility and blister formation resulting from mutations in proteins essential for dermoepidermal adhesion. Dystrophic EB (DEB), particularly its recessive form (RDEB), is caused by mutations in the COL7A1 gene, leading to defective type VII collagen and impaired anchoring fibrils. Clinically, severe forms are associated with chronic wounds, scarring, pseudosyndactyly, mucosal involvement, and increased risk of cutaneous squamous cell carcinoma. Current therapeutic options remain limited and largely supportive. Gentamicin has emerged as a potential disease-modifying therapy due to its ability to induce translational readthrough of nonsense mutations, restoring partial production of functional collagen VII. This study aims to analyze published cases of EB treated with gentamicin and identify patterns in clinical response and therapeutic outcomes.

Materials and Methods

A case-based literature review was conducted, including studies published between 2020 and 2026, retrieved from the PubMed and SciELO databases, in English, Portuguese, and Spanish. Patients with severe generalized dystrophic epidermolysis bullosa treated with gentamicin were included. Extracted variables comprised age, sex, EB subtype, genetic mutation, route of administration (topical or intravenous), treatment duration, methods used to assess response (including immunofluorescence, quality of life scales, and pain scores), collagen VII expression before and after treatment, clinical improvement, adverse effects, and follow-up duration. Data from four studies were compiled into a comparative table to identify trends in therapeutic response and safety outcomes.

Author	year	EB type	Gene	Genre	Age	Over topical	For how long was it used (weeks)	Method of evaluation used to register the improvement of the skin	ISCORE B	Did it help? (yes/ no)	collagen VII before	collagen VII after	COL7A1 before	COL7A1after	Plectin before	Plectin after	Side effects	Follow up (weeks)
Katarzyna Osipowicz, Piotr Wychowanski, Paweł Nieckuła, Sara Shamsa, Katarzyna Wertheim-Tysarowska, Katarzyna Wozniak, Cezary Kowalewski	2020	severe generalized dystrophic epidermolysis bullosa (RDEB)	COL7A1	F	16	topical	4	immunofluorescence for collagen VII quantification		yes	Not reported (qualitative increase)	Not reported (qualitative increase)					None	Not mentioned
Katarzyna Osipowicz, Piotr Wychowanski, Paweł Nieckuła, Sara Shamsa, Katarzyna Wertheim-Tysarowska, Katarzyna Wozniak, Cezary Kowalewski	2020	severe generalized dystrophic epidermolysis bullosa (RDEB)	COL7A1	F	18	topical	4	immunofluorescence for collagen VII quantification		yes	Not reported (qualitative increase)	Not reported (qualitative increase)					None	Not mentioned
Katarzyna Osipowicz, Piotr Wychowanski, Paweł Nieckuła, Sara Shamsa, Katarzyna Wertheim-Tysarowska, Katarzyna Wozniak, Cezary Kowalewski	2020	severe generalized dystrophic epidermolysis bullosa (RDEB)	COL7A1	F	28	topical	4	immunofluorescence for collagen VII quantification		yes	Not reported (qualitative increase)	Not reported (qualitative increase)					None	Not mentioned
Katarzyna Osipowicz, Piotr Wychowanski, Paweł Nieckuła, Sara Shamsa, Katarzyna Wertheim-Tysarowska, Katarzyna Wozniak, Cezary Kowalewski	2020	severe generalized dystrophic epidermolysis bullosa (RDEB)	COL7A1	F	42	topical	4	immunofluorescence for collagen VII quantification		yes	Not reported (qualitative increase)	Not reported (qualitative increase)					None	Not mentioned
David T Woodley, Michelle Hao, Andrew Kwong , Brandon Levian , Jon Cogan , Yingqing Hou , Daniel Mouallasi , Elana Kleinman, Kate Zheng , Claire Chung , Gene Kim , David Peng , Mei Chen	2024	severe generalized dystrophic epidermolysis bullosa (RDEB)	COL7A1	M	19	IV	12	immunofluorescence for collagen VII quantification Skindex-16 quality of life (QoL) Wong -Baker FACES Pain Rating Scale		Yes	not detected	45%					None	24
David T Woodley, Michelle Hao, Andrew Kwong , Brandon Levian , Jon Cogan , Yingqing Hou , Daniel Mouallasi , Elana Kleinman, Kate Zheng , Claire Chung , Gene Kim , David Peng , Mei Chen	2024	severe generalized dystrophic epidermolysis bullosa (RDEB)	COL7A1	F	28	IV	12	immunofluorescence for collagen VII quantification Skindex-16 quality of life (QoL) Wong -Baker FACES Pain Rating Scale		yes	5%	90%					None	24
David T Woodley, Michelle Hao, Andrew Kwong , Brandon Levian , Jon Cogan , Yingqing Hou , Daniel Mouallasi , Elana Kleinman, Kate Zheng , Claire Chung , Gene Kim , David Peng , Mei Chen	2024	severe generalized dystrophic epidermolysis bullosa (RDEB)	COL7A1	F	18	IV	12	immunofluorescence for collagen VII quantification Skindex-16 quality of life (QoL) Wong -Baker FACES Pain Rating Scale		Yes	50%	125%					None	24
Lucía Martínez-Santamaría, Rocío Maseda,María del Carmen de Arriba	2022	Epidermolysis bullosa simplex with muscular dystrophy	PLEC1	F	30	IV	2	immunofluorescence for plectin evaluation EuroQoL-5D-3L		Yes					0%	30%	None	12
Mahajan, Rahul; Manjunath, Seema; Madakshira, Manoj G; Das, Dipankar; Handa, Sanjeev; Chatterjee, Debajyoti1; Radotra, Bishan D.	2022	severe generalized dystrophic epidermolysis bullosa (RDEB)	COL7A1	M	8	topical	12	Immunofluorescence for COL7A1 evaluation	78.6	yes			1239	3407			none	12
Mahajan, Rahul; Manjunath, Seema; Madakshira, Manoj G; Da, Dipankar; Handa, Sanjeev; Chatterjee, Debajyoti1; Radotra, Bishan D.	2022	severe generalized dystrophic epidermolysis bullosa (RDEB)	COL7A1	F	1	topical	12	Immunofluorescence for COL7A1 evaluation	16	yes			241	1012			none	12
Mahajan, Rahul; Manjunath, Seema; Madakshira, Manoj G; Da, Dipankar; Handa, Sanjeev; Chatterjee, Debajyoti1; Radotra, Bishan D.	2022	severe generalized dystrophic epidermolysis bullosa (RDEB)	COL7A1	F	1	topical	12	Immunofluorescence for COL7A1 evaluation	42	Yes			1322	4800			none	12
Mahajan, Rahul; Manjunath, Seema; Madakshira, Manoj G; Da, Dipankar; Handa, Sanjeev; Chatterjee, Debajyoti1; Radotra, Bishan D.	2022	severe generalized dystrophic epidermolysis bullosa (RDEB)	COL7A1	M	1. 5	topical	12	Immunofluorescence for COL7A1 evaluation	50	Yes			1126	1262			none	12
Mahajan, Rahul; Manjunath, Seema; Madakshira, Manoj G; Da, Dipankar; Handa, Sanjeev; Chatterjee, Debajyoti1; Radotra, Bishan D.	2022	severe generalized dystrophic epidermolysis bullosa (RDEB)	COL7A1	M	7	topical	12	Immunofluorescence for COL7A1 evaluation	72	Yes			620	987			none	12
Mahajan, Rahul; Manjunath, Seema; Madakshira, Manoj G; Da, Dipankar; Handa, Sanjeev; Chatterjee, Debajyoti1; Radotra, Bishan D.	2022	severe generalized dystrophic epidermolysis bullosa (RDEB)	COL7A1	F	1	topical	12	Immunofluorescence for COL7A1 evaluation	54	Yes			2544	3100			none	12
Mahajan, Rahul; Manjunath, Seema; Madakshira, Manoj G; Da, Dipankar; Handa, Sanjeev; Chatterjee, Debajyoti1; Radotra, Bishan D.	2022	severe generalized dystrophic epidermolysis bullosa (RDEB)	COL7A1	M	1	topical	12	Immunofluorescence for COL7A1 evaluation	16	Yes			140	1046			none	12
Mahajan, Rahul; Manjunath, Seema; Madakshira, Manoj G; Da, Dipankar; Handa, Sanjeev; Chatterjee, Debajyoti1; Radotra, Bishan D.	2022	severe generalized dystrophic epidermolysis bullosa (RDEB)	COL7A1	F	14	topical	12	Immunofluorescence for COL7A1 evaluation	54	Yes			2542	2932			none	12

Table 1. Clinical, genetic, and therapeutic characteristics of patients with epidermolysis bullosa treated with gentamicin, including route of administration, treatment duration, collagen VII expression, and clinical outcomes.

Results

Across the analyzed cases, gentamicin therapy was consistently associated with increased expression of type VII collagen and corresponding clinical improvement, including enhanced wound healing and reduction of mucocutaneous lesions. These findings support its mechanism of action as a readthrough agent that partially restores protein synthesis in patients with nonsense mutations in COL7A1. Both topical and intravenous routes demonstrated therapeutic benefit, although with different clinical profiles. Topical administration was predominantly associated with localized improvement, particularly in oral and cutaneous lesions, reflecting its direct action on treated areas. In contrast, intravenous administration was associated with more systemic effects. Despite these promising findings, variability in treatment response was observed, likely influenced by mutation type, disease severity, and differences in treatment protocols. Additionally, methodological heterogeneity across studies, such as variation in biopsy sites, outcome measures, and duration of therapy, limits direct comparability. Importantly, no significant adverse effects were reported across the included studies, suggesting a favorable short-term safety profile. Some studies also demonstrated maintenance of collagen VII expression after treatment discontinuation, although without evidence of progressive improvement over time.

Conclusions

Gentamicin appears to be a promising therapeutic strategy for patients with dystrophic epidermolysis bullosa, particularly those with nonsense mutations in COL7A1. The available evidence demonstrates increased collagen VII expression and associated clinical improvement, regardless of the route of administration. The absence of significant adverse effects supports its short-term safety. However, further large-scale and controlled studies are needed to establish standardized treatment protocols and confirm long-term efficacy.

EADV CONGRESS
VIENNA
30 SEP - 3 OCT 2026

Abstract N°: 565

Topical Triclosan Exposure Rewires Skin Lipid Metabolism and Provokes Cutaneous Immune Activation

Yi Jin*[1], Xin Luo[1], Ruifang Wu[1], Siying Li[1]

[1] The Second Xiangya Hospital of Central South University, Changsha, China

Introduction
Triclosan (TCS) is a synthetic antimicrobial widely incorporated into personal care products and dermatological formulations. Although its cutaneous toxicity has been previously reported, the metabolic and immunological consequences of dermal TCS exposure remain insufficiently defined.

Materials and Methods
Here, we integrated transcriptomics and untargeted metabolomics to systematically evaluate the effects of TCS on skin homeostasis.

Results
Repeated dermal exposure induced erythema, epidermal thickening, and scaling in mice, accompanied by pronounced infiltration of neutrophils and macrophages. Multi-omics profiling revealed that TCS activated inflammatory pathways, including include NF-κB, IL-17, and cytokine–cytokine receptor interaction pathway, and upregulated the expression of Il6, Il1b, and Tnf. Concurrently, TCS disrupted sphingolipid metabolism and the biosynthesis of unsaturated fatty acids, resulting in elevated levels of sphinganine-1-phosphate, glucosylsphingosine, adrenic acid, and related lipid intermediates. Correlation analyses demonstrated strong positive associations between TCS-induced lipid perturbations, pro-inflammatory cytokine expression, and immune-cell infiltration.

Conclusions
Collectively, these findings indicate that dermal TCS exposure reprograms skin lipid metabolism and triggers inflammatory activation. This study establishes a mechanistic link between antimicrobial exposure, lipid metabolic remodeling, and cutaneous inflammation, highlighting the potential risks of TCS-containing products—particularly for individuals with pre-existing barrier impairment.

EADV CONGRESS
VIENNA
30 SEP - 3 OCT 2026

Abstract N°: 650

Allergic contact dermatitis of the scalp: analysis of patch test results

Emina Kasumagic-Halilovic*[1], Nermina Ovčina-Kurtović[1], Amra Hujic-Colic[1], Sladjana Samardzic[1], Sabina Omic[1]

[1] University Clinical Center Sarajevo, Sarajevo, Bosnia and Herzegovina

Introduction
Allergic scalp contact dermatitis (ASCD) is a delayed type of hypersensitivity from contact with a specific allergen to which the patients has developed a specific sensitivity. Allergic contact dermatitis is less frequent on the scalp than at other anatomical sites; it is underdiagnosed due to overlapping dermatoses and remains understudied. Epicutaneous patch tests are tools used in the identification of the etiological agents of allergic contact dermatitis. It is a scientific method of investigation, with internationally defined rules and well-established foundations. The function of the patch test is to produce, in a controlled manner, the elicitation phase of ACD, and thus determine the etiological agent of this dermatitis. The aim of the study was to evaluate the results of patch testing with standard series of contact allergen in patients suspected to have ASCD.

Materials and Methods
This was a descriptive case study carried out at the Department of Dermatology in a tertiary care centre. 119 cases of scalp contact dermatitis were included in the study. Test substances were applied on the upper part of the patient's back, on clinically uninvolved and untreated skin. The patch test was removed and reaction were evaluated after 48 h and 72 h. The grading of negative (-) to positive (+ to ++++) patch test was done in accordance with the International Contact Dermatitis Research Group.

Results
Among the 119 cases, 88 patients were female (73.9 %) and 31 were male (26.1 %). The age of participants spanned 17 to 73 years. The commonest age group affected was 41-50 years. The most common positive reactions were recorded to nickel sulphate 24 (20.2%), cobalt chloride 20 (16.8 %), fragrance mix 18 (15.1%), balsam of Peru 14 (11.8%), carba mix 8 (6.7%) and paraphenylenediamine 6 (5.0%). Females were more likely to show a positive response to two or more allergens. Scalp itching or burning were reported as the most common symptom.

Conclusions
Scalp ACD predominantly affects middle-aged women. Our results suggest that nickel sulphate and cobalt a along with fragrances, balsam of Peru, were the predominant allergens responsible for the induction of ASCD. Patch tests are essential for the diagnosis of contact sensitisation. Our findings may help clinicians identify potential allergens responsible for scalp dermatitis and provide guidance on allergen selection for patch testing. These findings are crucial in the treatment, long term management, and education of patients with ASCD.

EADV CONGRESS
VIENNA
30 SEP - 3 OCT 2026

Abstract N°: 654

Common Cosmetic Allergens in Skincare Products Labeled for Sensitive Skin Available in Thailand

Supakit Kiewprasert*[1, 2], Papatwarin Suesat[1, 2], Phunisa Kunvutthidee[1, 2], Torntan Tirakunwichcha[2], Pawit Phadungsaksawasdi[2]

[1] Faculty of Medicine Thammasat University, Phathum Thani, Thailand
[2] Chulabhorn International College of Medicine, Phathum Thani, Thailand

Introduction
The increasing use of cosmetic products has led to greater exposure to potential contact allergens, contributing to the rising burden of allergic contact dermatitis. Fragrances and preservatives remain the most common triggers. Although products labeled for "sensitive skin" are widely marketed to minimize irritation, this claim lacks clear regulatory definition. Data on the prevalence of allergens in such products in Thailand are limited, warranting further investigation.

Materials and Methods
A cross-sectional study was conducted between April and November 2023 to evaluate contact allergens in skincare products labeled for sensitive skin available in Thailand. Products were collected from major retail stores and online platforms. Eligible products included those labeled for sensitive skin across various categories. Ingredient information was obtained from product labels and official sources. All products were screened for known allergens based on U.S. FDA cosmetic allergen lists and the EU Cosmetic Regulation (Annex III). The primary outcome was the prevalence of contact allergens, analyzed using descriptive statistics.

Results
Following the data collection process, a total of 130 products were collected. Most of the products were leave on products (60%) and 40% were rinse off products. Cleansers were the most common type of skincare products found (40%). Followed by moisturizer (28%), serum (19%), toner (8%), sunscreen (3%) and oil (2%). Most of the products were made from North America (35%). Europe was the second most common (30%), followed by Asia (31%) with 14% were from Thailand. Products from Australia were the least found (3%).Eleven out of the forty-seven allergens werefound in products of this study. Eight were fragrance allergens and three were preservative allergens.Allergens were more found in leave on products than wash off products. Seventy percent of the product contained at least one allergen. Most of the allergens found were products from Europe (45.2%). France was the most common (22.6%) followed by United Kingdom (9.4%), Russia (7.5%), Spain (3.8%) and Germany (1.9%). Asia was in the second place (26.5%) (South Korea (18.9%), Singapore (3.8%) and Thailand (3.8%)), followed by North America (20.8%) (Canada (1.9%) and United states of America (18.9%) and Australia (7.5%) respectively.For the Fragrance allergensOut of 26 reference fragrance allergens, 8 were found in 26 skincare products designed for sensitiveskin. Twenty percent of these products contained at least one of these allergens, with 11% having two or more, and 9% containing only one. The prevalence of each allergen ranged from 0.8% to 10%, with Linalool and Limonene being the most common. Each was found in 10% of the products. Geraniol was found in 5.3% of the products, Citronellol in 4.6%, Benzyl alcohol in 3.8%, Hexyl cinnamaldehyde and Citral in 2.3%, and Farnesol in less than 1%.For the Preservative allergens Out of 10 reference preservative allergens, 3 were found in 3 products designed for sensitive skin.These allergens were Diazolidinyl urea, Dimethylol-dimethyl hydantoin, and Imidazolidinyl urea, each detected in 0.8% of the products.

Conclusions

Skincare products labeled for sensitive skin frequently contain contact allergens, with fragrance allergens being the most predominant. These findings highlight that “sensitive skin” labeling does not necessarily guarantee the absence of allergenic ingredients and may pose a risk to susceptible individuals. Careful evaluation of product ingredients and avoidance of known allergens remain essential. Establishing clearer regulatory standards for such labeling could provide significant benefits for both clinicians and consumers.

EADV CONGRESS
VIENNA
30 SEP - 3 OCT 2026

Abstract N°: 959

Prevalence and Cross-Reactions of Hair Dye Allergens:An 18-Year Experience from the Patch Test Clinic of Andreas Syggros Hospital, Athens, Greece

Antonios Tsimpidakis*[1], Katerina Tsaoutou[1], Electra Nicolaidou[1], Dimitrios Rigopoulos[1], Alexander Stratigos[1], Stamatis Gregoriou[1]

[1] National & Kapodistrian University of Athens, First Department of Dermatology, Andreas Sygros Hospital, Athens, Greece

Introduction
Allergic contact dermatitis (ACD) related to hair dyes is a common problem affecting both consumers and professionals.The main allergens are aromatic amines, such as para-phenylenediamine (PPD) and toluene-2,5-diamine (TDA), which may exhibit cross-reactivity with chemically related compounds.
Objective
To analyze patch test results in patients with hair dye-related allergic contact dermatitis, focusing on the prevalence of sensitization to hair dye allergens, cross-reactions and potential occupational differences

Materials and Methods
A retrospective study of 666 patients who underwent patch testing between 2005–2023 at the Patch Test Clinic of Andreas Syggros Hospital was conducted.All patients were tested with the European Baseline Series and the Extended Hairdresser Series.Results were evaluated according to ICDRG/ESCD criteria.Odds ratios (ORs) for co-sensitization were calculated using logistic regression, adjusted for age and sex.

N=666	Total (N=666)	Hairdressers (N=241)	Customers (N=425)	p-value
Gender				<0.001
Male	66 (9.9)	49 (20.3)	17 (4.0)	
Female	600 (90.1)	192 (79.7)	408 (96.0)	
Age (years)				<0.001
Mean	37.6	32.2	40.7	
Median	35.5	28	41	
Standard Deviation	15.6	13.0	16.1	
Atopy History				0.661
No	435 (65.3)	160 (66.4)	275 (64.7)	
Yes	231 (34.7)	81 (33.6)	150 (35.3)	
Anatomical Site				<0.001
Hands	195 (30.3)	151 (62.9))	44 (10.9)	
Face/Scalp	317 (49.3)	32 (13.3)	285 (70.7)	
Elsewhere	12 (1.9)	6 (2.5)	6 (1.5)	
> 1 sites	119 (18.5)	51 (21.3)	68 (16.9)	

Patients Characteristics

Results

Overall, 82.4% of patients showed a reaction to at least one allergen, with a median of three positive reactions.PPD was the most common allergen (47.9%), followed by TDA (35.9%) and nickel (41.1%).Significant co-sensitization was observed between PPD and several chemically related compounds, including m-aminophenol, p-aminophenol, benzocaine, textile dyes, hydroquinone, and pyrogallol ($p < 0.001$). Similar associations were also identified for TDA.Hairdressers were younger (mean age 32.2 vs 40.7 years, $p < 0.001$) and predominantly presented with hand dermatitis (62.9%). Patients reacting to multiple hair dye components had a significantly increased likelihood of PPD sensitization.Co-sensitization between PPD and cocamidopropyl betaine likely reflects co-exposure via cosmetic products rather than true structural cross-reactivity.

Allergen	n (%)
PPD	319 (47.9)
Nickel	274 (41.1)
TDA (Toluenediamine)	239 (35.9)
Aminophenol 4	150 (22.5)
Aminophenol 3	94 (14.1)
Thiomersal	89 (13.4)
Fragrance mix	80 (12.0)
Textile	67 (10.1)
Cobalt	61 (9.2)
Cocamidopropyl betaine	55 (8.3)
Balsam of Peru	54 (8.1)
Black rubber	42 (6.3)
Benzocaine	34 (5.1)
Hydroquinone	30 (4.5)
Thiuram mix	29 (4.35)
Potassium	26 (3.90)
Formaldehyde	25 (3.75)
Kathon	22 (3.3)

Most common allergens is our sample, in frequency order

Conclusions

PPD and TDA remain the primary sensitizers in hair dye–related allergic contact dermatitis, showing strong cross-reactivity with aminophenols, benzocaine, and textile dyes.The use of the extended Hairdresser patch test series is essential for accurate diagnosis, as 7% of patients sensitized to para-amino compounds would have remained undiagnosed if only PPD had been tested.Occupational exposure and polysensitization highlight the need for safer formulations and preventive strategies in the use of hair dyes.

Allergen	TDA association (OR, 95% CI, p)	PPD association (OR, 95% CI, p)
PPD	35.83 (21.16–60.67), <0.001	—
TDA	—	35.00 (21.10–60.40), <0.001
p-Aminophenol (Aminophenol_4)	37.81 (20.45–69.88), <0.001	52.00 (20.90–130.00), <0.001
m-Aminophenol (Aminorhenol_3)	58.71 (21.06–163.62), <0.001	132.00 (18.00–959.00), <0.001
Hydroquinone	43.17 (5.79–321.88), <0.001	<0.001
Resorcinol	2.92 (0.51–16.84), p = 0.23	1.85 (0.30–10.50), p = 0.48
Pyrogallol	14.83 (1.87–117.81), p = 0.011	<0.001
Cainemix (Benzocaine / PABA-esters)	54.97 (7.43–406.76), <0.001	33.50 (4.50–247.00), 0.001
Textile dyes (disperse/azo)	7.57 (4.11–13.95), <0.001	43 (10.4 – 177), <0.001
Ammonium persulfate	1.84 (1.19–2.84), 0.006	3.25 (2-5.2), <0.001
Cocamidopropyl betaine	3.43 (1.89–6.24), <0.001	2.75 (1.5-5.1),<0.001

Hair dye related allergens and co-sensitazation to PPD and TDA

EADV Congress 2026, VIENNA
30 SEPTEMBER - 03 OCTOBER 2026
POWERED BY M-ANAGE.COM

EADV CONGRESS
VIENNA
30 SEP - 3 OCT 2026

Abstract N°: 1043

Allergic Contact Dermatitis to Benzisothiazolinone Induced by Swimming Goggles: An Underrecognized Source in Children

Ines Lahouel*[1], Mounira Ben Yahia[1], Syrine Ben Hadj Hassen[1], Hichem hba[1], monia youssef[1], jameleddine zili[1]

[1] Fattouma Bourguiba Hospital, Monastir, Tunisia

Introduction

A significant increase in the prevalence of contact allergy to benzisothiazolinone (BIT) has been observed in recent years, related to its growing use as a preservative in cosmetic, household, and industrial products. However, non-cosmetic sources of exposure often remain underrecognized. We report a case of allergic contact dermatitis (ACD) to BIT secondary to the use of swimming goggles in a child.

Case Presentation

A 10-year-old boy, a competitive swimmer, presented with periocular erythematous-vesicular lesions evolving over one month. The gradual onset of the lesions coincided with frequent use of swimming goggles during training and competitions. Clinical examination revealed well-demarcated eczema strictly confined to the periocular region, corresponding exactly to the areas of contact with the goggle seals.

Allergological assessment was performed using patch tests with the European baseline series and a rubber series (Chemotechnique©). Readings at Day 2 and Day 3 showed a positive reaction to benzisothiazolinone (++/++). Additional analysis of the goggle materials confirmed the presence of BIT. Clinical relevance was established based on chronological and topographical correlation, as well as identification of the allergen in the suspected item. A diagnosis of BIT-induced ACD was therefore retained.

Treatment with topical corticosteroids combined with allergen avoidance, through replacement of the goggles with a BIT-free model, led to complete resolution of the lesions.

Conclusion

This case highlights swimming goggles as a rare and underestimated source of allergic contact dermatitis in children. These devices may contain various potential allergens, including rubber components, silicone, or preservatives such as BIT. The periocular region, characterized by thin and fragile skin, is particularly vulnerable to contact dermatitis, especially with repeated exposure, occlusion, and contact with chlorinated water.

In cases of persistent periocular dermatitis in swimmers, patch testing including rubber and preservative series is essential to identify the causative allergen.

EADV CONGRESS
VIENNA
30 SEP - 3 OCT 2026

Abstract N°: 1110

A case of type III hereditary angioedema with a MYOF variant of uncertain significance successfully treated with omalizumab

Qiying Zhang*[1], Xuefeng Fu[1], Hui Sun[2], Kaili Chen[1], Lvjun Zhang[1], Meiyan Wang[1]

[1] Jinhua Municipal Central Hospital, Jinhua, China
[2] Huzhou Central Hospital, Jinhua, China

Introduction

Hereditary angioedema (HAE) is a rare disorder characterized by recurrent subcutaneous or submucosal edema. Type III HAE (normal C1 inhibitor) is extremely rare and often underdiagnosed. MYOF gene mutations have been linked to HAE type 7. We report a case with a MYOF variant of uncertain significance (VUS) who responded dramatically to omalizumab.

Case Presentation

A 76-year-old woman presented with a three-year history of episodic angioedema affecting the face, lips, tongue, and periorbital region. Attacks typically began at night, lasted 2-3 days, and were accompanied by abdominal pain and chest pain. She had previously consulted multiple departments: emergency medicine (for unexplained abdominal/chest pain with normal cardiac enzymes, troponin, and CT scans), pain clinic (normal inflammatory markers, tumor markers, and bone metabolism), dermatology (transient improvement with antihistamines and dexamethasone), and stomatology (normal complement C3, C4, total IgE, immunoglobulins, and allergen tests). C4 and C1 esterase inhibitor levels and function were repeatedly normal.

Due to high clinical suspicion, whole-exome sequencing was performed and identified a heterozygous missense variant in the MYOF gene: c.5786C>T (p.Ala1929Val). This variant is classified as a VUS and is associated with HAE type 7 (MIM:619366). Her parents were deceased, and her daughter declined genetic testing; no family history of angioedema was reported.

Treatment with omalizumab (300 mg subcutaneously every 4 weeks) was initiated. Complete resolution of all angioedema episodes, including facial, lip, tongue, periorbital, and abdominal symptoms, was achieved. After 6 months, the dosing interval was successfully extended to 12 weeks without any relapse during 12 months of follow-up.

This case highlights several important points. First, type III HAE should be suspected in patients with recurrent angioedema without urticaria, even when C4 and C1-INH are normal and genetic testing yields a VUS. Second, to our knowledge, this is a rare report of omalizumab as an effective treatment for HAE associated with a MYOF variant. Third, it emphasizes the diagnostic odyssey often faced by HAE patients, who may present with atypical symptoms like abdominal and chest pain for years before diagnosis.

Conclusion

Clinicians should maintain a high index of suspicion for type III HAE in elderly patients with recurrent, unexplained angioedema. Genetic testing may identify VUS in MYOF that can support the diagnosis. Omalizumab may be a

valuable treatment option for such cases.

Abstract N°: 1152

Atopic dermatitis and distress- an inquiry study

Saly Abdelhadi[1], Mikael Holst[2], Louise Lönndahl*[1]

[1] Unit of Dermatology and Venereology, Department of Medicine, Solna, Karolinska Institutet, Department of Dermatology, Karolinska University Hospital, Stockholm, Sweden
[2] Pediatric Endocrinology Unit, Department of Woman and Child Health, Astrid Lindgren Children's Hospital, Karolinska Institutet, Stockholm, Sweden

Introduction
Atopic dermatitis (AD) is a chronic inflammatory skin disease associated with substantial pruritus and a high psychosocial burden. Psychological stress is generally recognised as a trigger of disease exacerbation, yet its relationship to clinical disease expression and pruritus characteristics remains insufficiently investigated.This study aimed to systematically investigate the prevalence and impact of stress, anxiety and depression in a large AD population, and to examine their associations with disease severity and pruritus.

Materials and Methods
Adult patients with AD (n=3,395 invited) were recruited from specialised dermatology care. Participants completed an anonymous online questionnaire developed from patient focus groups and refined with a patient organisation. Validated instruments were used to assess quality of life (DLQI), chronic stress (KEDS), perceived stress (PSS), and anxiety/depression (HADS). Disease extent was assessed using a modified PO-SCORAD, and pruritus intensity and characteristics were evaluated.

Results
A total of 609 patients (17.9%) responded. Over half of the patient population reported current stress, anxiety, depression or exhaustion (50.3%), and 55.7% had previously sought medical care for these conditions. Stress was identified as the most important exacerbating factor, with 82.5% reporting stress-induced worsening of eczema and 85.1% reporting stress-aggravated pruritus.Significant correlations were observed between disease severity (PO-SCORAD) and quality of life, as well as with chronic stress, anxiety and depression. Notably, chronic stress showed a stronger association with disease severity than perceived stress.Pruritus was highly prevalent (72.5%), typically of moderate intensity (median NRS 3), and frequently described as both superficial and deep. Importantly, 85.1% of patients reported stress-related exacerbation of itch, emphasizing the strong link between psychological stress and symptom expression in patients with atopic dermatitis.

Conclusions
Psychological stress and psychiatric comorbidity are highly prevalent and closely linked to both disease severity and pruritus in AD. This study highlights chronic stress as a particularly relevant factor and provides detailed patient-reported data on itch characteristics in relation to stress.These findings support the need for integrated, multidisciplinary management strategies in AD, incorporating systematic assessment and treatment of psychological factors.

EA DV CONGRESS
VIENNA
30 SEP - 3 OCT 2026

Abstract N°: 1278

Gut-Derived Metabolites, Intestinal Barrier Dysfunction, and Food Sensitization in Adult Atopic Dermatitis

Leszek Blicharz*[1], Emilia Samborowska[2], Radosław Zagożdżon[3], Joanna Czuwara[1], Michał Zaremba[1], Michał Dadlez[2], Zbigniew Samochocki[1], Malgorzata Olszewska[1], Lidia Rudnicka[1]

[1] Department of Dermatology, Medical University of Warsaw, Warsaw, Poland

[2] Mass Spectrometry Laboratory, Institute of Biochemistry and Biophysics, Polish Academy of Sciences, Warsaw, Poland

[3] Laboratory of Cellular and Genetic Therapies, Medical University of Warsaw, Warsaw, Poland

Introduction

Gut microbiome dysbiosis has been implicated in metabolic disturbances, intestinal barrier dysfunction, and immune dysregulation, which may contribute to food sensitization and the exacerbation of atopic dermatitis. This study aimed to evaluate the relationship between food sensitization, disease severity, and biomarkers of the gut–skin axis in adults with atopic dermatitis.

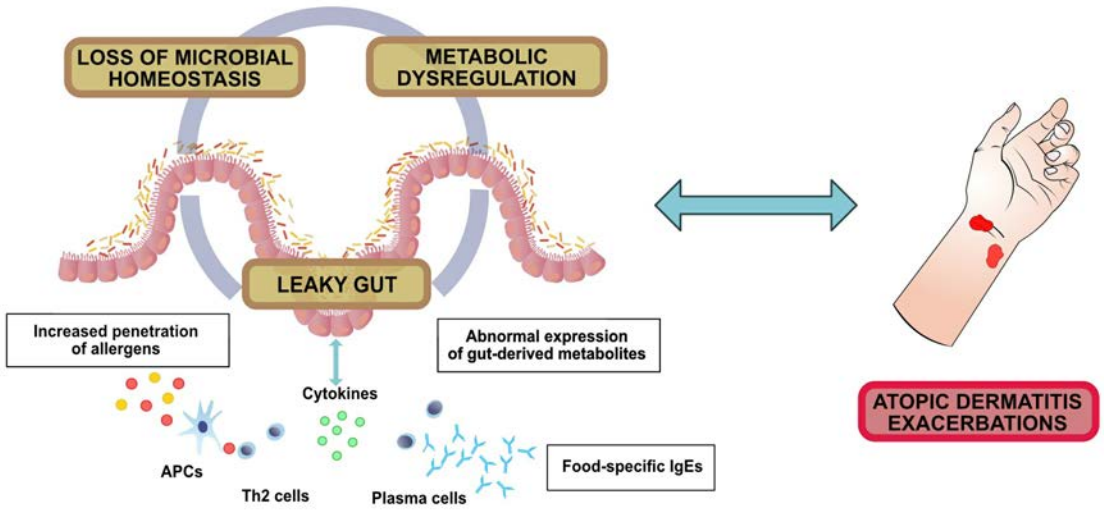

Schematic representation of the gut–skin axis in atopic dermatitis: microbial dysbiosis and metabolic dysregulation contribute to intestinal barrier impairment ('leaky gut'), promoting allergen translocation, immune activation, and subsequent exacerbation of cutaneous inflammation.

Materials and Methods

In this cross-sectional study, 50 adult patients with atopic dermatitis and 25 healthy controls were enrolled. Disease severity was assessed using EASI and SCORAD indices. Serum levels of total IgE, food-specific IgEs, gut-derived metabolites, and intestinal permeability biomarkers were measured using immunoturbidimetry, Polycheck, liquid chromatography–mass spectrometry, ELISA and Luminex immunoassays. Associations between biomarkers and clinical parameters were analyzed.

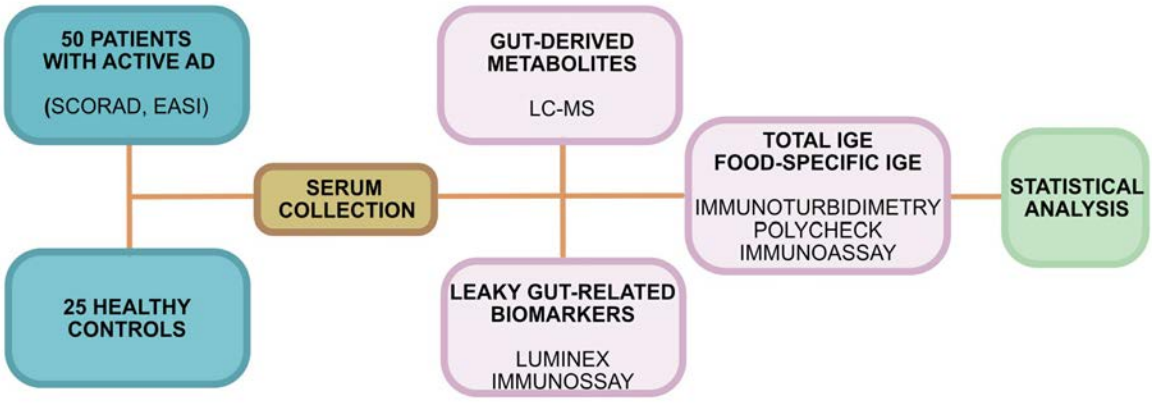

Study design overview: a cross-sectional comparison of adults with active atopic dermatitis and healthy controls, integrating clinical severity assessment with serum analysis of gut-derived metabolites, intestinal permeability biomarkers, and IgE profiles.

Results

Food sensitization was significantly more prevalent in patients with atopic dermatitis compared to controls and was associated with increased disease severity, as reflected by higher EASI and SCORAD scores and a greater number of positive food-specific IgEs. Patients with atopic dermatitis exhibited elevated levels of caproic acid, glycerophosphocholine, Reg3A, I-FABP, IL-10, and IL-22, alongside reduced trimethylamine concentrations. Greater disease severity and higher IgE levels were associated with lower concentrations of short-chain fatty acids, including caproic and isocaproic acids, and higher levels of indoxyl and intestinal permeability markers (LBP, syndecan-4, Reg3A, IL-10, IL-22). Indoxyl and leaky gut biomarkers correlated positively with disease activity, while short-chain fatty acids showed inverse relationships with severity and sensitization. Additionally, leaky gut-related biomarkers were positively associated with C6 short-chain fatty acids and negatively with indoxyl.

Conclusions

These findings support a link between food sensitization, gut-derived metabolites, and intestinal barrier dysfunction in atopic dermatitis. Alterations in short-chain fatty acids and indoxyl may contribute to immune dysregulation and increased disease severity. Dietary strategies, including increased fiber intake and moderated protein consumption, may help modulate these pathways and reduce food sensitization risk. However, the cross-sectional design limits causal interpretation, and prospective studies are needed to confirm these relationships and their therapeutic implications.

EADV CONGRESS
VIENNA
30 SEP - 3 OCT 2026

Abstract N°: 1280

From Plate to Pattern: A Striking Case of Shiitake-Induced Flagellate Dermatitis

Madalina Moraru*[1], Roxana Dumitrescu[1], Simona Georgescu[2]

[1] Clinical Hospital of Tropical and Infectious Diseases Dr. Victor Babeș, Bucharest, Romania

[2] Clinical Hospital of Tropical and Infectious Diseases Dr. Victor Babeș, Carol Davila University of Medicine and Pharmacy, Bucharest, Romania

Introduction

Flagellate dermatitis is a distinctive eruption characterized by linear, whip-like erythematous streaks, most commonly linked to drugs such as bleomycin, but also to systemic diseases. A less recognized cause is ingestion of raw or undercooked shiitake mushrooms (*Lentinula edodes*), due to a toxic or delayed hypersensitivity reaction to lentinan. Limited awareness may lead to misdiagnosis. **Objectives:**
To highlight the clinical and anamnestic hallmarks of shiitake-induced flagellate dermatitis, emphasize the diagnostic role of dietary history, and improve recognition to avoid unnecessary investigations.

Materials and Methods

We present the case of 56-year-old male, with no significant personal or family medical history, who presented to the dermatology emergency department with an acute-onset, intensely pruritic eruption. The cutaneous manifestations developed 24–48 hours following the ingestion of insufficiently cooked shiitake mushrooms. Dermatological examination revealed multiple linear, erythematous, flagellate streaks distributed over the trunk and proximal extremities, in the absence of mucosal involvement or systemic symptoms. No recent drug exposure or infectious triggers were identified. In the context of a highly suggestive clinical morphology and a relevant dietary history, a diagnosis of shiitake-induced flagellate dermatitis was established, without indication for further laboratory or histopathological investigations. Symptomatic therapy with topical corticosteroids and oral antihistamines was initiated.

Results

Rapid improvement was observed, with resolution of pruritus and lesions within days, without sequelae. No recurrence occurred after avoidance of shiitake consumption.

Conclusions

Shiitake-induced flagellate dermatitis represents a distinctive clinicodermatological entity whose recognition relies predominantly on the integration of characteristic morphological features with targeted anamnesis. Heightened clinician awareness is essential to accurately differentiate this condition from other etiologies of flagellate dermatitis, thereby minimizing diagnostic uncertainty and preventing unnecessary laboratory or histopathological investigations. Prompt identification facilitates appropriate symptomatic management and reinforces the value of detailed dietary history as a key diagnostic tool in dermatological practice.

EA DV CONGRESS
VIENNA
30 SEP - 3 OCT 2026

Abstract N°: 1324

Wearable Shadows: Delayed Hypersensitivity to Transdermal and Smart Devices: A Systematic Review

Majd Abu Taleb*[1], Nesrine Ben Salah[1], Youssef Monia[1], Hichem Belhadjali[1], Jameleddine Zili[1]

[1] Dermatology Department, Fattouma Bourguiba University Hospital, Monastir, Tunisia

Introduction
The rapid expansion of wearable and transdermal medical devices for personalized health monitoring has introduced new dermatologic challenges at the interface of technology and skin biology. Prolonged cutaneous contact with these devices; composed of acrylates, metals, adhesives, and pigments can trigger delayed hypersensitivity reactions, including irritant and allergic contact dermatitis, modulated by individual susceptibility factors such as barrier integrity, atopic predisposition, and prior sensitization. Despite their growing clinical prevalence, the pathophysiology, diagnostic criteria, and evidence-based management strategies for device-induced cutaneous reactions remain fragmented. This review synthesizes synthesize current evidence on pathophysiology, clinical features, diagnostics, management, and preventive strategies for delayed cutaneous reactions induced by wearable devices.

Materials and Methods
A systematic literature review was conducted (PubMed, Scopus, Web of Science; 1995–2024). Keywords included "wearable medical devices," "contact dermatitis," and "patch testing." Studies included clinical reports, trials, mechanistic studies, and reviews. Data were extracted on epidemiology, clinical manifestations, diagnostic approaches, treatment, and prevention.

Results
Delayed reactions are multifactorial: irritant contact dermatitis results from keratinocyte injury and barrier disruption, whereas allergic contact dermatitis is T-cell-mediated type IV hypersensitivity to haptens. Clinically, patients present with sharply demarcated eczematous, vesicular, or lichénified plaques under adhesive components, often pruritic with chronic lichenification or post-inflammatory hyperpigmentation. High-risk populations, such as children and diabetic patients using glucose monitors or insulin pumps, show sensitization rates up to 70%, primarily to acrylates and colophane. Patch testing is the diagnostic gold standard, though composite materials and chemical instability may produce false negatives. Management includes device removal or substitution with hypoallergenic alternatives, topical corticosteroids, calcineurin inhibitors, systemic therapy for severe cases, patient education, and regular dermatologic follow-up. Emerging prophylactic strategies, including N-acetylcysteine–lysine–enriched hydrogels, show potential for modulating early sensitization pathways.

Conclusions
Wearable device induced cutaneous reactions exemplify a dynamic triad of material chemistry, environmental modifiers (occlusion, friction, heat, moisture), and host susceptibility (atopy, barrier dysfunction, prior sensitization) that collectively drive delayed hypersensitivity pathogenesis. The diagnostic complexity introduced by novel composite materials and proprietary device formulations

necessitates heightened clinical vigilance and systematic allergen identification through patch testing and material safety data review. Management must be personalized and multidisciplinary, integrating targeted anti-inflammatory therapy, strategic device modification or substitution, and proactive patient education on skin-barrier protection. Critically, the rising frequency of these reactions demands standardized diagnostic protocols and preventive frameworks; such as pre-deployment biocompatibility screening and post-marketing dermatovigilance to mitigate sensitization risk and ensure long-term device tolerability. By championing evidence-based algorithms and fostering collaboration between dermatology, biomedical engineering, and regulatory science, our specialty can transform device-related dermatitis from an emerging adverse event into a model for precision prevention in digital health. This translational approach not only safeguards patient adherence to essential monitoring technologies but also positions dermatology as a key steward of safe innovation in personalized medicine.

EADV CONGRESS
VIENNA
30 SEP - 3 OCT 2026

Abstract N°: 1349

Acute Generalized Exanthematous Pustulosis–like Reaction in VEXAS Syndrome

Hami Kork*[1], Alican Karakoç[2], Sinem Nihal Esatoğlu[2], Muazzez Cigdem Oba[1]

[1] İstanbul University-Cerrahpaşa, Cerrahpaşa Medical Faculty, Department of Dermatology, İstanbul, Türkiye
[2] İstanbul University-Cerrahpasa, Cerrahpaşa Medical Faculty, Department of Rheumatology, İstanbul, Türkiye

Introduction

VEXAS syndrome is an adult-onset autoinflammatory disorder driven by somatic mutations in the ubiquitin-like modifier activating enzyme 1 (UBA1) gene in the myeloid lineage, presenting with systemic inflammation, hematologic abnormalities, and frequently cutaneous involvement. The latter are highly heterogeneous and include conditions like vasculitis or neutrophilic dermatoses. We report a case of VEXAS syndrome presenting with acute generalized exanthematous pustulosis (AGEP)-like eruption, followed by the development of macrophage activation syndrome (MAS), requiring intensive immunosuppressive therapy.

Case Presentation

A 69-year-old man was referred to the rheumatology clinic due to elevated acute phase reactants, normochromic normocytic anemia and joint pain. ^{18}F-FDG PET/CT demonstrated findings consistent with large-vessel vasculitis. Colonoscopy was compatible with inflammatory bowel disease. Subcutaneous tocilizumab and high dose corticosteroid was subsequently initiated. During corticosteroid tapering, the patient developed lesions consistent with Sweet syndrome and a pathogenic UBA1 gene mutation (Met41Leu) confirmed the diagnosis of VEXAS syndrome, and treatment was switched to intravenous tocilizumab.

While the patient was in remission under tocilizumab and 5 mg prednisolone therapy for 1 year, Sweet syndrome lesions relapsed following influenza vaccination. Partial improvement was achieved with moderate-dose corticosteroids; however, despite ongoing tocilizumab therapy, tapering of corticosteroids over 2 weeks resulted in a progressive and widespread cutaneous eruption requiring hospitalization. The lesions appeared as AGEP-like pustular eruptions, predominantly involving the scalp and trunk, and subsequently coalesced into extensive erosions. Histopathological examination demonstrated subcorneal pustules with neutrophilic infiltration. Pulse methylprednisolone (1 g) and intravenous cyclosporine were initiated. On the second day of treatment, anemia and thrombocytopenia worsened, liver enzymes increased, and hyperferritinemia with hypofibrinogenemia developed; cyclosporine was discontinued.

With a diagnosis of macrophage activation syndrome (MAS), intravenous immunoglobulin and anakinra (500 mg/day) were initiated, and pulse methylprednisolone (1 g) completed for a total of 5 days.After MAS was controlled within a week, tapering of corticosteroids led to the development of painful acral pustular lesions and targetoid lesions on the extremities. Pulse methylprednisolone (1 g). therapy was re-administered, and anakinra was continued, with very gradual corticosteroid tapering.

After approximately two months of hospitalization, the patient demonstrated significant clinical improvement. The patient is relapse-free under 10 mg prednisolone therapy, and iv tocilizumab since 4 months.

Conclusion

VEXAS syndrome is characterized by acquired somatic mutations leading to dysregulated immunity. This results in an exaggerated and uncontrolled inflammatory response when exposed to potential triggers. In our case, vaccination appeared to act as a triggering factor, leading to Sweet syndrome lesions. AGEP-like lesions despite the absence of a drug culprit might also have been triggered with vaccination However, given the lack of a clear temporal association with vaccination, we considered AGEP-like lesions a part of the neutrophilic skin lesions of the Met41Leu variant of VEXAS syndrome.

VEXAS syndrome may present with AGEP-like cutaneous eruption. Such lesions may represent part of the dermatological spectrum of VEXAS syndrome, and their recognition is crucial to avoid misdiagnosis and delay in appropriate treatment.

EADV CONGRESS
VIENNA
30 SEP - 3 OCT 2026

Abstract N°: 1535

Hereditary Angioedema with Normal C1 Inhibitor Due to an F12 Variant: The First Case Report in the Slavic Population Describing a Slovenian Family

Irena Dezelak*[1, 2], Matija Rijavec[2], Mihaela Zidarn[1, 2]

[1] Faculty of Medicine, University of Ljubljana, Ljubljana, Slovenia

[2] University Clinic of Respiratory and Allergic Diseases Golnik, Golnik, Slovenia

Introduction

Hereditary angioedema with normal C1 inhibitor (HAE-nC1INH) is a rare, genetically heterogeneous condition characterized by recurrent bradykinin-mediated angioedema. Among its subtypes, HAE-FXII is caused by pathogenic variants in the *F12* gene and predominantly affects women, with disease expression frequently triggered or exacerbated by estrogen exposure. Diagnosis is challenging due to clinical overlap with other conditions and the absence of C1-INH abnormalities on routine laboratory testing. We report the first Slovenian family with genetically confirmed HAE-FXII and, to our knowledge, the first published case from a Slavic population.

Case Presentation

The index patient was a 62-year-old male with a long-standing history of recurrent angioedema, chronic gastrointestinal symptoms including abdominal pain, bloating and diarrhoea, and recurrent urticaria. Standard complement studies showed normal C1-INH levels and function. Clinical exome sequencing identified the pathogenic *F12* variant NM_000505.4:c.983C>G, p.(Thr328Arg), confirming the diagnosis of HAE-FXII. Multiple courses of danazol were prescribed without clinical benefit, while on-demand icatibant was effective for acute swelling episodes. Following the index patient's diagnosis, targeted Sanger sequencing confirmed the same pathogenic variant in his daughter. She presented with predominantly gastrointestinal symptoms including chronic abdominal bloating since childhood, worsening from puberty onward. During a brief trial of estrogen-containing oral contraceptives, she developed severe abdominal distension, syncope, vomiting, and free abdominal fluid on ultrasound, consistent with an acute HAE abdominal attack. Visible angioedema occurred only rarely throughout her life. On-demand C1 esterase inhibitor concentrate was recommended given the possibility of future pregnancy. The two affected family members demonstrated marked intrafamilial phenotypic variability despite carrying the same pathogenic variant, with differences in predominant symptom type, attack frequency, and severity.

Conclusion

This report expands the known geographic distribution of HAE-FXII to the Slavic population. It illustrates the considerable clinical variability of this condition, including atypical presentations with predominantly gastrointestinal symptoms and the significant influence of sex and hormonal factors on disease expression. Both individuals presented with features suggestive of coexisting conditions, highlighting the diagnostic challenge of recognizing HAE in patients with complex, overlapping symptom presentations. This case demonstrates the value of genetic testing in patients with complex clinical presentations whose symptoms are not adequately explained by existing diagnoses. Genetic testing should be considered in patients with recurrent angioedema and/or unexplained gastrointestinal symptoms despite normal C1-INH levels, and family screening is warranted once a

pathogenic variant is identified.

EADV CONGRESS
VIENNA
30 SEP - 3 OCT 2026

Abstract N°: 1727

Successful Remibrutinib Treatment in Chronic Spontaneous Urticaria Refractory to Cyclosporin and High-Dose Omalizumab: A Case Report

Abhishek De*[1], Bidisha Sarkar[2], Disha Chakraborty[3], Emek Kocatürk Göncü[4], Ivan Cherrez-Ojeda[5]

[1] Dermatology, Calcutta National Medical College, Dermatology, Wizderm Hair and Skin Specialty Clinic, Kolkata, India

[2] Clinical Research Associate, Wizderm Skin and Hair Specialty Clinic, Kolkata, India

[3] Dermatology, Mayo Clinic, Rochester, Rochester, United States

[4] Charité - Universitätsmedizin Berlin, Institute of Allergology, Fraunhofer Institute for Translational Medicine and Pharmacology ITMP, Allergology and Immunology, Berlin, Germany

[5] Charité - Universitätsmedizin Berlin, Institute of Allergology, Fraunhofer Institute for Translational Medicine and Pharmacology ITMP, Allergology and Immunology, Berlin, Germany, Espiritu Santo University, Samborondon Ecuador, Respiralab Research Group, Guayaquil, Berlin, Germany

Introduction

Chronic spontaneous urticaria (CSU) with type IIb autoimmune endotype is often associated with higher disease activity, lower total IgE, positive autoreactivity markers, and suboptimal response to standard therapies, including omalizumab. Bruton tyrosine kinase inhibition represents a mechanistically relevant therapeutic approach in such patients, given its role in FcεRI- and B-cell receptor–mediated signaling. We report the clinical course of a young woman with refractory CSU who demonstrated meaningful improvement after initiation of remibrutinib.

Case Presentation

A 28-year-old female patient had CSU for 4 years before presentation. She had previously received multiple second-generation H1-antihistamines, including up-dosing up to fourfold in accordance with Indian and international guideline recommendations, with inadequate disease control. She had also been treated with cyclosporine and methotrexate, both producing only limited clinical benefit. Standard evaluation identified a type IIb endotype CSU phenotype. The patient had accompanying symptomatic dermographism. Omalizumab was initiated at 300 mg subcutaneously every 4 weeks; however, because of inadequate response, the dose was escalated to 300 mg every 2 weeks. After 9 months of omalizumab therapy with persistent disease activity, remibrutinib was commenced.

In the 4 weeks preceding remibrutinib, UAS7 remained high and fluctuating, with weekly values of 38, 30, 39, and 24. At remibrutinib initiation, UAS7 was 10.

Thereafter, disease activity remained low, with UAS7 values of 7 at week 4, 4 at week 8, and 3 at week 12. This corresponded to an 87.5% reduction from the immediate pre-treatment week −1 value and a 92.3% reduction from the highest pre-treatment value. UCT improved from 2 at baseline to 11, 14, and 15 at weeks 4, 8, and 12, respectively, indicating transition from uncontrolled disease to near-complete control. Quality-of-life indices showed parallel improvement: CU-Q2oL decreased from 55 at baseline to 18 at week 4, 7 at week 8, and 9 at week 12, while DLQI improved from 16 to 1, 2, and 1 at the corresponding visits. No disease worsening was observed during the 12-week follow-up period. Patient tolerated the medication well, there was no adverse event noted during the period of follow up.

Conclusion

This case demonstrates rapid and sustained improvement with remibrutinib in a patient with difficult-to-treat CSU refractory to high-dose antihistamines, cyclosporine, methotrexate, and intensified omalizumab. The marked reduction in UAS7, restoration of disease control, and substantial improvement in quality of life support the potential utility of BTK inhibition in autoimmune-endotype CSU, particularly in patients with inadequate response to anti-IgE therapy. Larger real-world datasets are warranted to better define predictors of response, durability, and positioning of remibrutinib in refractory CSU treatment algorithms.

EADV CONGRESS
VIENNA
30 SEP - 3 OCT 2026

Abstract N°: 1758

“Cow’s Milk Protein Allergy: Unresolved Questions and Future Research Directions”

Prof. Bhuvnesh G. Shah[1], keya sheth*[2]

[1] Government Medical college, Surat, Skin Care Institute,Surat, surat, India
[2] Skin Care Institute, surat, India

Introduction

Milk is considered to be a good source of nutrients.Milk allergy is one of the most common allergies in children worldwide.It can trigger a series of allergic reactions. Around 2-3 % of children worldwide have milk protein allergies. Milk allergy is often mistaken as a single entity, but in reality it is driven by different proteins, which have different nature and behave differently causing different patterns of allergies.

Aim: To understand milk proteins and its behavior.

Materials and Methods

Material: Cow milk samples.

Results

Milk proteins are mainly classified into 2 groups:

1. Casein (= 75-80%)

Subtypes:

1.as1 casein

2.as2 casein

3.Beta casein

4. Kapa casein

1. Whey (=20-25%)

1.Beta lactoglobulin(most abundant)

2.Alpha lactoglobulin

3.Serum albumin

4. Immunoglobulins
5. Lactoferrin.

Characteristic features:

Caseins form the solid portion when the milk curdles(curd, paneer, cheese).

It is heat stable, resistant to heating and boiling.

Caseins are often digested slowly.

While whey remains in the liquid after milk curdles.

They are heat sensitive, degrade upon heating and cooking.

But they are digested fast.

Allergic potential Casein vs whey:

CASEIN is the most common cause of allergies.

as1 casein is responsible for most allergies.

Casein allergy may be presented as hives, eczema,swelling.

Gastrointestinal symptoms like diarrhoea, vomiting, abdominal pain.

Respiratory symptoms like cough, wheezing.

In severe cases it can even lead to anaphylaxis.

Casein allergies are often persistent and long lasting, especially in children.

Symptoms occur even after eating baked or processed milk products.

Whey, particularly Beta lactoglobulin, can also trigger allergies.

It is not found in human milk, so often considered foreign by the immune system.

It usually causes mild to moderate symptoms like hives and itching. Respiratory and gastrointestinal symptoms are less common.

Some may tolerate heated or processed dairy products better because of partial denaturation.

Allergies may be triggered with whey protein supplements.

Casein allergy is more common than whey allergy. Few people may be allergic to both casein and whey.

Conclusions

This topic is clinically important to understand the milk proteins and its nature so as to provide proper diagnosis, dietary planning and create public awareness regarding milk allergy. There remains a considerable scope for research to improve the understanding, the diagnosis and targeted treatment for milk protein allergies in the world.

EADV CONGRESS
VIENNA
30 SEP - 3 OCT 2026

Abstract N°: 1793

Cutaneous Presentation of Acute Graft-versus-Host Disease after Allogeneic Bone Marrow Transplantation in a Child with Acute Myeloid Leukemia

Ilhame Jegoual*[1], Layla Bendaoud[1], Mariem Aboudourib[1], Said Amal[1], Ouafa hocar[1]

[1] Dermatology Department, Arrazi Hospital, Mohammed VI University Hospital, Biosciences Research Laboratory, FMPM, Cadi Ayyad University, Marrakesh, Morocco

Introduction

Acute graft-versus-host disease (aGVHD) is a frequent and potentially severe complication following allogeneic bone marrow transplantation, occurring early after transplantation. Cutaneous involvement, often the initial manifestation, is a key element in the diagnosis, although its clinical presentation may be polymorphic and may mimic other post-transplant complications. Diagnosis relies on a careful clinicopathological correlation. We report a case of cutaneous aGVHD in a child with acute myeloid leukemia.

Case Presentation

We report the case of an 11-year-old patient followed in hematology for acute myeloid leukemia evolving over two years with relapse, currently at day 33 following allogeneic bone marrow transplantation. The patient was receiving prophylactic treatment with valacyclovir 500 mg/day, fluconazole 200 mg/day, and ursodeoxycholic acid 400 mg/day for four weeks, as well as cyclosporine 100 mg/day initiated five days prior to symptom onset.

The clinical course was marked by the development of a non-pruritic morbilliform erythematous rash involving 51% of the body surface area, associated with perioral, retroauricular, and axillary desquamation, as well as whitish macules on the buccal mucosa. This presentation was accompanied by diarrhea, without other associated symptoms.

Laboratory investigations revealed pancytopenia, while other parameters were within normal limits. Skin biopsy was non-specific. Treatment with prednisone at a dose of 1 mg/kg/day, combined with topical corticosteroids and emollients, was initiated.

Clinical evolution was favorable, with resolution of erythema followed by diffuse desquamation and the development of post-inflammatory dyschromia characterized by hyperpigmented and hypopigmented macules.

Conclusion

Cutaneous acute graft-versus-host disease presents with variable clinical features and poses diagnostic challenges, particularly in distinguishing it from other post-transplant conditions. Early diagnosis and prompt management allow for favorable outcomes.

EA DV CONGRESS
VIENNA
30 SEP - 3 OCT 2026

Abstract N°: 1822

Clinical Response, Predictors of Discontinuation, Changes in Health-Economic Burden, and Concomitant Treatment Patterns in Chinese Patients with Moderate-to-Severe Atopic Dermatitis Treated with Dupilumab: A Prospective Real-World Study

Xinyun Tang*[1], Wanyi Qin[2], Lanyan Jin[3], Tingting Chen[4], Sijie Zhou[3], YONGHONG LU[3], Peimei Zhou[4]

[1] Chengdu Medical College, Chengdu Second People's Hospital, chengdu, China

[2] Leshan Traditional Chinese Medicine Hospital, Leshan, China

[3] Chengdu Second People's Hospital, chengdu, China

[4] The Eighth Affiliated Hospital, Sun Yat-sen University, Shenzhen, China

Introduction

Atopic dermatitis (AD) is a common chronic inflammatory skin disease that severely affects quality of life. Dupilumab has shown good efficacy and acceptable safety in clinical trials and real-world settings for AD treatment. In China, however, AD patients have unique genetic backgrounds, environmental exposures, and healthcare settings. Current prospective real-world study data in the Chinese population are limited, particularly regarding medication retention, efficacy and discontinuation predictors, and health-economic burden. Therefore, we conducted a single-center, prospective observational study to systematically evaluate the performance of dupilumab in the real-world Chinese environment.

Materials and Methods

A single-center, prospective observational study included 237 patients (≥12 years) with moderate-to-severe AD treated with dupilumab at our Hospital (May 2022–October 2023). Patients were followed at baseline and at 1, 4, 8, and 12 months. Primary assessments included SCORAD, DLQI/CDLQI, PP-NRS, ADCT, POEM scores, concomitant drug use, treatment-related economic burden, medication retention rate, and adverse events (AEs). Multivariable logistic and Cox regression were used to analyze factors predicting efficacy and drug discontinuation.

Results

Dupilumab significantly improved SCORAD, DLQI/CDLQI, PP-NRS, ADCT, and POEM scores at 1 month (all $p < 0.001$) with sustained efficacy at 12 months. The use of concomitant medications, hospitalization costs, and absenteeism all significantly decreased over time. Antihistamine use was linked to achieving SCORAD50 at 1 month, while Traditional Chinese Medicine (TCM) use was linked to SCORAD75 at 4 months. Moisturizer use significantly improved itch relief at 1 year. The 1-year medication retention rate was 57.4%, and BMI classification was associated with an increased risk of drug discontinuation. The incidence of AEs was 9.28%, and conjunctivitis was the most common.

Conclusions

In the real-world Chinese population, dupilumab significantly improves clinical symptoms and quality of life in moderate-to-severe AD, with good safety and health-economic benefits. Antihistamines, TCM, and moisturizer use

were associated with improved efficacy, while BMI was an important predictor of overall medication retention.

EADV CONGRESS
VIENNA
30 SEP - 3 OCT 2026

Abstract N°: 1940

Analysis of test performance and documentation quality of patch testing patient's own material: Results of the 317b-research project

Swen Malte John*[1], Antje Alberts[1], Katja Dicke[1], Lara Obermeyer[1], Christoph Skudlik[1], Richard Brans[1]

[1] Institute for Interdisciplinary Dermatological Prevention and Rehabilitation (iDerm) at the Osnabrück University, Department of Dermatology, Environmental Medicine and Health Theory, Institute for Health Research and Education, Osnabrück University, Lower Saxony Institute of Occupational Dermatology (NIB), Osnabrueck, Germany

Introduction
Due to the steadily declining availability of commercial patch test substances, the diagnosis of contact allergies using patient's own material is becoming increasingly more important. Transparent documentation and established test methods according to guidelines are imperative in order to obtain meaningful results. The present study evaluated the quality of the documentation and performance of patch tests using patient's own material in patients with suspected occupational dermatitis.

Materials and Methods
As part of the FB 317b research project, funded by the German Social Accident Insurance, protocols of patch tests commissioned by the statutory accident insurance bodies and carried out in patients with suspected occupational dermatitis throughout Germany between 2013 and 2025 were evaluated based on (inter)national guidelines as well as the German Social Accident Insurance's test sheet for patch testing workplace materials.

Results
Data of 14,955 patch tests with patient's own materials performed in 2,137 patients were included. Gloves were most commonly tested (36.9%). The test concentration was specified in 88.7%, the application vehicle in 75.6%, and the pH in 43.0% of cases where this information was relevant. In 73.3% of the 14,955 tests, the material tested was adequately documented. Among the 613 positive test reactions to patient's own materials, 211 (34.4%) were suspected false-positive due to unsuitable test methods. 352 (57.4%) of the positive test reactions to patient's compound products were sufficiently clarified by identifying the ingredients and demonstrating corresponding reactivity to them in commercial test trays and 24 (3.9%) by separately patch testing the individual ingredients of complex mixtures.

Conclusions
This is the first study of its kind to examine patch testing using patient's own material in cases of suspected occupational dermatitis in a whole country. The results reveal quality deficits both in the documentation and in the performance of patch tests with patient's own material. They demonstrate a pressing need for further training of dermatologists to ensure patch test with patient's own material are conducted and documented in accordance with guidelines and, consequently, that patients receive appropriate diagnostics and care.

EA DV CONGRESS
VIENNA
30 SEP - 3 OCT 2026

Abstract N°: 2068

EVALUATION OF THE RELATIONSHIP BETWEEN SERUM LIPOXIN A4 AND RESOLVIN E1 LEVELS AND DISEASE ACTIVITY IN PATIENTS WITH CHRONIC SPONTANEOUS URTICARIA

Beyza Nur Yetim*[1], Arzu Kılıç[1], Mehmet Orbay Soğucak[2], Özgür Baykan[2]

[1] Balikesir University Dermatology and Venereology Department, Balikesir, Türkiye

[2] Balikesir University Medical Biochemistry Department, Balikesir, Türkiye

Introduction

Chronic Spontaneous Urticaria (CSU) is a chronic inflammatory dermatosis characterized by pruritic wheals and angioedema episodes that significantly impair quality of life. Although CSU is currently considered both an autoallergic and autoimmune disease, the incomplete elucidation of the underlying mechanisms limits the development of novel biomarkers capable of predicting disease severity and personalized treatment options. Recent studies have established that inflammation does not resolve passively; instead, it is actively terminated by "Specialized Pro-resolving Mediators". Lipoxin A4 (LxA4) and Resolvin E1 (RvE1), members of this family, have been implicated in the pathogenesis of chronic inflammatory diseases such as asthma, atopic dermatitis and rheumatoid arthritis; however, their roles in the pathogenesis of CSU and inflammatory resolution have not yet been explored. This study aimed to investigate the relationship between serum LxA4 and RvE1 levels and disease activity in patients with CSU, and to evaluate their potential role as a biomarker and a therapeutic target.

Materials and Methods

This prospective cross-sectional study enrolled 55 CSU patients and 35 healthy controls. Patients treated with omalizumab in the preceding 3 months, or with systemic corticosteroids or immunosuppressive agents in the preceding 1 month, were excluded from the study. Disease activity was assessed using the Urticaria Activity Score-7 (UAS-7). Serum LxA4 and RvE1 levels were measured by ELISA; the Systemic Immune-Inflammation Index (SII), Systemic Inflammation Response Index (SIRI), and Platelet-to-Lymphocyte Ratio (PLR) were calculated from complete blood count parameters. C-reactive protein (CRP) levels and body mass index (BMI) values of participants were recorded, and their relationship with disease severity was evaluated. Data were analyzed statistically; $p<0.05$ was considered statistically significant.

Results

Severe disease was observed more frequently in patients with higher BMI ($p<0.05$). No significant difference was detected between the patient and control groups in terms of serum LxA4 and RvE1 levels ($p>0.05$). A significant negative correlation was found between the disease severity and serum RvE1 levels ($p<0.05$). In ROC analysis performed to distinguish severe disease from mild-moderate disease, the area under the curve (AUC) value for RvE1 was 0.661 (%95 CI: 0.518–0.805; $p=0.041$); an AUC value above 0.5 indicates discrimination beyond chance, while the upper bound of the confidence interval (0.805) suggests that RvE1 may potentially achieve an acceptable level of discriminative ability. SII, SIRI, and PLR values were significantly higher in the patient group compared to the control group ($p<0.05$). No significant association was found between serum RvE1 and LxA4 levels and SII, SIRI, PLR, or CRP ($p>0.05$).

Conclusions

The negative correlation between serum RvE1 levels and disease severity suggests that this specialized pro-resolving mediator, which plays a role in the resolution phase of inflammation, may be involved in the pathogenesis of CSU, and that lower serum RvE1 levels may be associated with increased clinical severity. Elevated SII, SIRI, PLR, CRP, and BMI in CSU patients confirm the presence of substantial systemic inflammatory burden. The lack of correlation between systemic inflammatory markers and serum RvE1 levels suggests that RvE1 may be associated with disease-specific inflammatory mechanisms rather than serving as a general inflammatory marker in the pathogenesis of CSU. To our knowledge, this study is the first to evaluate serum RvE1 and LxA4 levels in adult patients with CSU, demonstrating that RvE1 may serve as a biomarker for predicting disease course and as a potential therapeutic target for personalized treatment strategies.

EA DV CONGRESS
VIENNA
30 SEP - 3 OCT 2026

Abstract N°: 2094

Sensitization Profiles to Inhalant and Food Allergens in Patients from Huzhou, Northern Zhejiang Province, China: Insights from Repeated Serum-Specific IgE Testing in a Humid Subtropical Region

Hui Sun*[1], Wei Shen[1], Qiying Zhang[2], Shun-Li Tang[1], Yuan Wu[1], Hua-Jie Zhong[1], Qiang Yan[1]

[1] Huzhou Central Hospital, Huzhou, China

[2] Jinhua Municipal Central Hospital, Jinhua, China

Introduction

Allergic skin diseases such as atopic dermatitis and chronic urticaria are frequently associated with IgE-mediated sensitization and represent a major burden in dermatology. Allergen sensitization profiles show significant regional differences driven by climate and environment. Huzhou, located in northern Zhejiang Province, China, has a humid subtropical climate with high humidity that promotes year-round proliferation of house dust mites.

Although atopic diseases are rising in eastern China, specific sensitization data for the Huzhou region are limited. Most studies focus on large cities, leaving a knowledge gap for local dermatological practice. This retrospective study aimed to characterize sensitization patterns to common inhalant and food allergens in Huzhou patients using repeated serum-specific IgE (sIgE) testing and to discuss implications for managing allergic skin diseases.

Materials and Methods

We retrospectively analyzed serum-specific IgE (sIgE) test results (project code 3006772) from multiple detections in patients from Huzhou, northern Zhejiang Province, China. The panel covered numerous inhalant allergens (house dust mite mix, cat dander, dog dander, house dust, mold mix, tree pollen mix, mugwort, ragweed, hop) and food allergens (cow's milk, beef, shrimp, crab, lobster/scallop, egg white, peanut, etc.). Positivity was defined as ≥0.35 kU/L. Total IgE (reference <87 IU/mL) was measured concurrently. Sensitization frequency, peak values, recurrence, and co-sensitization patterns were summarized.

Results

Total IgE was repeatedly elevated (mostly 50–300 IU/mL, with multiple peaks >2000 IU/mL), indicating strong atopy in this cohort.

House dust mite mix was the dominant inhalant sensitizer with multiple strong positives (peaks up to 266.65 kU/L). Cat dander (peaks 117.81 kU/L) and dog dander (peaks 43.51 kU/L) also showed recurrent sensitization. House dust was positive in several tests (peaks 12.27 kU/L). Occasional positives occurred for cockroach, molds, tree pollen, mugwort, ragweed, and hop.

Cow's milk was the leading food sensitizer (peaks 31.53 kU/L), followed by beef (peaks 4.64 kU/L). Seafood (shrimp peaks 16.38 kU/L, crab 6.7 kU/L, lobster/scallop 9.78 kU/L) showed occasional moderate positivity. Most other foods (egg white, peanut, soybean, mutton, fish) remained negative (<0.35 kU/L). Poly-sensitization involving house dust mite with pet dander or milk/beef was common.

Conclusions

In Huzhou patients, house dust mite sensitization predominates the inhalant profile, consistent with the humid subtropical climate. Cow’s milk and beef are the main food sensitizers, with variable seafood positivity. Persistently elevated total IgE reflects pronounced atopy. These findings emphasize the need for region-specific management in dermatology, including rigorous dust mite avoidance, pet exposure control, and dietary counseling. Component-resolved diagnostics and mite-specific immunotherapy should be prioritized to improve outcomes in allergic skin diseases.

EA DV CONGRESS
VIENNA
30 SEP - 3 OCT 2026

Abstract N°: 2094

Atypical Erythromelalgia Following Alphachloralose Poisoning

Salma Kozmane*[1], Zakia Douhi[1], Hafsa Laouni[1], Ikrame Bejja[1], Saadia Boughaleb[1], Meryem Soughi[1], Sara Elloudi[1], Hanane Baybay[1], Fatimazahra Mernissi[1]

[1] Department of Dermatology, University Hospital Hassan II, Faculty of Medicine, Pharmacy and Dental Medicine, Sidi Mohamed Ben Abdellah University, fez, Morocco

Introduction

Erythromelalgia (EM) is a rare acrosyndrome, characterized by episodes of erythema, increased temperature, and burning pain, which most commonly affects distal extremities and may appear secondary to the use of specific medications or substances that influence vascular or neuronal function. We report a case of erythromelalgia induced by alphachloralose intoxication. To the best of our knowledge, this association has not been previously reported.

Case Presentation

It is a 16-year-old female patient with no previous medical history, who was hospitalized in the intensive care unit for alphachloralose poisoning, with suicidal intent. Upon awakening, the patient reported paroxysmal, burning pain in her left lower extremity, triggered by heat. This pain made walking difficult, prompting her to repeatedly place her foot in a bucket of cold water to relieve her symptoms. The patient reported no associated systemic symptoms, and there was no similar history in her family. Clinical examination revealed a circular, hot, and painful, swollen, purplish-red plaque on the left foot. Given this clinical presentation, we considered erythromelalgia secondary to alphachloralose ingestion, bacterial dermohypodermitis, and deep vein thrombosis. Laboratory tests were ordered, including a complete blood count with blood smear, protein electrophoresis, erythrocyte sedimentation rate, antinuclear antibodies, cryoglobulinemia, fasting blood glucose, thyroid-stimulating hormone, and liver function tests. The arterial and venous lower extremity doppler showed no abnormalities. A neurology consultation was also requested. Based on the characteristic symptoms that appeared a week after ingestion of alphachloralose, particularly the paroxysmal pain and burning sensation reported by the patient, and after ruling out other differential diagnoses and primary causes of erythromelalgia, we concluded that secondary erythromelalgia induced by alphachloralose intoxication was retained. The patient was started on gabapentin 300 mg tablets, once daily for 5 days, then twice daily for 3 months, with psychiatric follow-up. The patient was seen again one month later and reported an improvement in tingling, the disappearance of the burning sensation, and motor deficit.

Conclusion

Erythromelalgia can be bilateral and symmetrical, but it can also be unilateral, as in our case. It is thought to result from a combination of nervous and vascular dysfunction. Nociceptive C and A-delta fibers become hyperexcitable, releasing neuropeptides like substance P, which induce inflammation and vasodilation. A variety of drugs and toxins have been previously linked to the development of secondary erythromelalgia, such as cyclosporine, rosuvastatin, and simvastatin. Alphachloralose is frequently used in Morocco as a rodenticide in agriculture and domestic settings. It is easily accessible in grocery stores. It is a centrally acting sedative-hypnotic and neurotoxic agent that potentiates GABAergic inhibition and suppresses excitatory neurotransmission, leading to profound

central nervous system depression. No cases of erythromelalgia have been reported.

The association between alphachloralose and erythromelalgia may be explained by a combination of peripheral nerve sensitization and microvascular dysregulation. Neurotoxic effects on C fibers could have induced neurogenic inflammation, while autonomic dysfunction may have altered microcirculatory perfusion, resulting in the characteristic burning pain, redness, and warmth.

In the absence of any identified primary or secondary cause of erythromelalgia in our patient, a toxic etiology related to alphachloralose exposure appears plausible. Further reports and studies are needed to confirm this relationship and better understand the underlying mechanisms.

EA DV CONGRESS
VIENNA
30 SEP - 3 OCT 2026

Abstract N°: 2177

Diagnostic Delay in Mastocytosis Despite Frequent Symptoms: A Cross-sectional Cohort Study

Ethan Bendayan*[1], Raquel Lazarowitz[1], Aliyah King[2], Joaquim Cohen[1], Catherine Zhu[3], Moshe Ben-Shoshan[4], Barbara Miedzybrodzki[3], Michael Fein[5], Elena Netchiporouk[3, 6]

[1] Faculty of Medicine, McGill University, Montreal, Canada

[2] Faculty of Medicine, University of Ottawa, Ottawa, Canada

[3] Division of Dermatology, McGill University Health Centre, Montreal, Canada

[4] Division of Pediatric Allergy and Clinical Immunology, Department of Pediatrics, McGill University Health Centre, Montreal, Canada

[5] Department of Allergy and Clinical Immunology, McGill University Health Centre, Montreal, Canada

[6] Division of Experimental Medicine, Department of Medicine, McGill University, Montreal, Canada

Introduction

Mastocytosis is a rare clonal mast cell neoplasm with cutaneous (CM) and/or systemic (SM) involvement. Diagnostic delay has been described in SM, but remains poorly characterised in cutaneous-predominant populations, in which dermatologists are often the first clinicians to recognise disease. Identifying clinical features associated with delayed recognition is essential to improving timely diagnosis in dermatologic practice. We aimed to evaluate diagnostic delay and its clinical correlates in a cutaneous-enriched mastocytosis cohort, and to characterise the spectrum and frequency of associated symptoms.

Materials and Methods

We analysed patients enrolled in our prospective registry (2015–2026) with mastocytosis diagnosed according to World Health Organization criteria. Diagnostic delay was defined as age at diagnosis minus self-reported age at symptom onset. Symptom frequency was captured using ordinal categories (daily, weekly, monthly, yearly). Continuous variables are reported as medians with interquartile ranges (IQRs) and categorical variables as counts and percentages. Diagnostic delay was compared across clinical subgroups using the Wilcoxon rank-sum test, and logistic regression assessed whether greater symptom burden was associated with delay exceeding the cohort median.

Results

Sixty patients were included (60.0% female; 81.7% White; 86.7% with cutaneous involvement; 38.3% meeting SM criteria; 48.3% with pediatric-onset disease). Dermatologists established the diagnosis in 80.0% of cases. Median age at symptom onset was 19.5 years (IQR, 0.75–35.0) and at diagnosis 30.0 years (IQR, 1.75–45.5), corresponding to a median diagnostic delay of 2.0 years (IQR, 0.38–7.0). Patients consulted a median of two physicians before diagnosis (range, 1–20), and 45.0% reported prior misdiagnosis. Delay was significantly longer in previously misdiagnosed patients (5.0 vs 1.0 years; $p<0.01$) and in those with SM versus CM alone (5.0 vs 1.0 years; $p=0.04$). Symptom burden was substantial: 93.3% reported ≥1 symptom and 85.0% reported ≥2, with pruritus (70.0%), flushing (66.7%), brain fog (66.7%), urticaria (61.7%), fatigue (60.0%), and musculoskeletal pain (60.0%) most frequent. Daily symptoms were common among affected patients, including flushing (42.5%), fatigue (72.2%), and brain fog (45.0%). Each additional symptom was associated with greater odds of delay exceeding 2 years (OR 1.19; 95% CI 1.06–1.34; $p<0.01$).

Conclusions

Despite frequent, predominantly cutaneous manifestations, diagnostic delay in mastocytosis remains common and

is paradoxically greater in patients with higher symptom burden and prior misdiagnosis. Rather than reflecting absent clinical clues, delayed recognition appears to stem from difficulty synthesising numerous nonspecific, mediator-related complaints, which may be mistakenly attributed to functional or unrelated disorders when considered in isolation. For dermatologists, persistent pruritus, flushing, or urticaria accompanied by neurocognitive, gastrointestinal, or cardiopulmonary symptoms—particularly in the setting of compatible cutaneous lesions—should prompt consideration of mastocytosis as a unifying diagnosis. Greater awareness of this clustered symptom pattern may shorten the diagnostic pathway and improve patient care.

EADV CONGRESS
VIENNA
30 SEP - 3 OCT 2026

Abstract N°: 2312

Real-life retrospective study of advanced systemic therapies in patients with chronic hand eczema: patient profile, drug effectiveness and safety.

David Pesqué*[1], Francisco Navarro-Triviño[2], Marta Bertolín-Colilla[1], Esther Serra-Baldrich[3], Vicente Expósito-Serrano[4], Miguel Antonio Lasheras-Pérez[5], Mercedes Rodriguez-Serna[5], Gemma Melé-Ninot[6], Tatiana Sanz-Sánchez[7], Trinidad Montero-Vílchez[8], Fátima Tous-Romero[9], Mónica Munera-Campos[10], José M Carrascosa[10], Fernando Gallardo[1], Ramon Pujol[1], Ana Giménez-Arnau[1], Juan Francisco Silvestre-Salvador[11]

[1] Hospital Del Mar, Barcelona, Spain
[2] Hospital Universitario Clínico San Cecilio, Granada, Spain
[3] Hospital de Sant Pau, Barcelona, Spain
[4] Hospital Parc Taulí De Sabadell, Sabadell, Spain
[5] Hospital Universitario La Fe, Valencia, Spain
[6] Hospital Universitari Sagrat Cor, Barcelona, Spain
[7] Hospital Infanta Sofía, San Sebastián de los Reyes, Spain
[8] Hospital Universitario Virgen de las Nieves, Granada, Spain
[9] Hospital 12 de Octubre, Madrid, Spain
[10] Hospital Germans Trias I Pujol, Badalona, Spain
[11] Hospital General Universitari Doctor Balmis, Alicante, Spain

Introduction
Chronic hand eczema (CHE) is a prevalent, heterogeneous and impairing condition with limited real-life data on advanced systemic therapies. This study aims to describe patient profiles and evaluate effectiveness and safety of advanced systemic therapies used in patients with moderate-to-severe CHE

Materials and Methods
Multicenter retrospective cohort study of adults with CHE who were treated off-label with advanced systemic agents between January 2022 and June 2025. Demographic, disease and treatment characteristics were obtained retrospectively, as well as IGA-CHE and DLQI scores at weeks 0, 4 and 12 for all treatments.

Results
103 patients were treated with 112 therapies, including dupilumab (n=65), tralokinumab (n=16), upadacitinib (n=13), abrocitinib (n=13) and baricitinib (n=5). IGA-CHE achievement at weeks 4 and 12 was between 29.2%-69.2% and 56.9-84.6%, respectively. DLQI reduction was seen among all drugs. At week 12, at least 60% of patients had reached a DLQI≤5 across all treatments. Drug discontinuation due to drug failure occurred in 6 patients (9 therapies). Adverse effects were observed in 16 patients (15.5%), but only resulted in drug discontinuation in 4 patients.

Conclusions
Daily-practice data may support the favorable effectiveness and safety of advanced systemic options for patients with moderate-to-severe CHE.

EA DV CONGRESS
VIENNA
30 SEP - 3 OCT 2026

Abstract N°: 2587

Multidisciplinary Immunodermatology Clinics: A Scoping Review of Structural Models, Clinical Outcomes, and Measures of Utility

Anna Riminchan*[1], Meghna Varambally[2], Shun Chi Ryan Lo[1], Chaocheng Liu[1]

[1] The University of British Columbia, Faculty of Medicine, Vancouver, Canada

[2] Schulich School of Medicine and Dentistry, Western University, London, Canada

Introduction

Inflammatory skin conditions such as atopic dermatitis, contact dermatitis, and urticaria, are often managed across medical specialties. Multidisciplinary clinics integrating dermatology and immunology/allergy are a promising model for holistic care of complex patients. Understanding of their structure, workflow, or impact remains limited in the current literature. In this scoping review, we aim to identify and describe multidisciplinary clinic models integrating dermatology with allergy/immunology services and to evaluate their reported clinical outcomes and measures of utility.

Materials and Methods

A scoping review was conducted by following SPICE framework and PRISMA ScR guidelines. MEDLINE, CINAHL, Embase, and Scopus were searched through March 2026 with a structured grey literature search. Studies describing a clinic or service model integrating dermatology and immunology/allergy were included. Two reviewers independently screened and extracted data.

Results

Fifteen sources were included, representing programs in 7 countries. Fourteen programs that reported location were all situated in tertiary hospitals. The most common structural model was a co-located concurrent or sequential specialist consultation (12/15; 80%). One clinic employed a hybrid committee-based model. Annual patient volumes in these programs ranged from 20-169 patients. Refractory, moderate-to-severe, or difficult-to-treat atopic dermatitis (AD) was the primary clinical condition treated in 73.3% of programs. The remaining programs addressed contact dermatitis, contact or atopic dermatitis, autoinflammatory conditions, and life-threatening adverse drug reactions. In addition to the dermatologist and allergist/immunologist, the multidisciplinary team included nurses in 5 studies, psychologists/psychiatrists in 5 studies, dietitians/nutritionists in 5 studies, clinical pharmacists in 3 studies, and other allied healthcare professionals. Active patient and caregiver engagement was mentioned as formally embedded in the care model in 5 programs through mechanisms such as shared decision-making, participation in care plan development, patient-reported outcome measures, and patient education. The most reported diagnostic services were patch testing (40%), skin prick testing (33%), psychological support (33%), nutritional counselling (27%), patient and family education (27%), and oral food challenges (20%). Four clinics, all treating patients with AD, reported validated quantitative outcomes such as EASI, ADQ, DLQI, and SCORAD. All 4 studies demonstrated significant improvements in these outcomes compared to baseline measurements. Notably, in one study, mean EASI decreased by 91.52% by the 7th follow-up visit, while another study showed that 77% of children achieved ≥75% reduction in disease activity on the SAEASI and/or minimal quality of life impact on the CDLQI at 6 months. Clinically meaningful improvements were shown in the Children's Dermatology Life Quality Index (CDLQI) in 2 programs, the Patient-Oriented Eczema

Measure (POEM) in 1 program, and the Child Health Questionnaire (CHQ-PF50) in 1 program. Of the three studies measuring patient satisfaction, all identified high patient satisfaction. Billing and reimbursement challenges were reported by two studies as being barriers to this model's implementation. Despite this, 7 out of 15 programs reported operating as permanent services, while only one was described as a pilot program.

Conclusions

Multidisciplinary immunodermatology clinics demonstrate consistent improvements in disease severity, quality of life, and patient satisfaction, particularly in difficult-to-treat atopic dermatitis. However, outcomes lack direct comparison to patients seen by each specialist separately. The confinement of multidisciplinary clinics to tertiary centers also represents a gap in access to community-based integrated care and financial barriers to implementation highlight the need for reimbursement reform to support equitable access to these collaborative services.

EADV CONGRESS
VIENNA
30 SEP - 3 OCT 2026

Abstract N°: 2601

Atypical shiitake flagellate dermatitis mimicking pityriasis rubra pilaris and viral or hypersensitivity exanthem

Monika Stradczuk-Mazurek*[1], Kacper Pawlik[1], Irena Walecka-Herniczek[1]

[1] National Medical Institute of the Ministry of the Interior and Administration, Department of Dermatology, Warsaw, Poland

Introduction

Shiitake flagellate dermatitis is a toxic dermal reaction that typically appears within 24 hours to several days after ingestion of raw or undercooked shiitake mushrooms (Lentinula edodes). First described in East Asian countries, it is being reported increasingly worldwide in parallel with the growing culinary use of shiitake mushrooms.
Clinically, the eruption usually presents as pruritic papules arranged in a characteristic linear, flagellate pattern resembling whiplash marks, most commonly involving the trunk and extremities. Diagnosis is primarily clinical and is based on the distinctive morphology of the eruption together with a specific patient history. We present an atypical case of shiitake flagellate dermatitis requiring differentiation from viral or hypersensitivity exanthem and pityriasis rubra pilaris.

Case Presentation

A 49-year-old man was admitted from the emergency department with a rapidly progressive papular eruption. The eruption began as small erythematous papules on the right forearm and progressed over the next 2 days to involve the scalp, trunk, and limbs. On examination, the lesions consisted of multiple, predominantly perifollicular papules, some arranged linearly over the thighs, back, and abdomen. Additional findings included a confluent erythematous plaque on the right lower leg and erythematous macules on the palms. No mucosal involvement was observed. The patient denied pruritus, fever, recent infective symptoms, arthralgia, myalgia, muscle weakness, and mechanical irritation of the skin that could explain a Koebner phenomenon. He also denied exposure to new medications, supplements, or cosmetic products. Further inquiry revealed a recent trip during which arthropod bites could not be ruled out, as well as ingestion of mushroom ramen approximately 2 days before the onset of the eruption, after which he experienced weakness and flushing. Because of the rapid progression of the eruption and its clinical resemblance to a hypersensitivity reaction, he was initially treated in the emergency department with a single 16-mg dose of oral dexamethasone, with partial improvement in erythema. Laboratory investigations demonstrated elevated C-reactive protein, monocytosis, and eosinophilia. Active CMV, EBV, and parvovirus B19 infections, as well as latent syphilis, were excluded. Imaging studies were unremarkable. In view of the heterogeneous clinical presentation, early pityriasis rubra pilaris and hypersensitivity or viral exanthem were initially considered, prompting skin biopsy. Given the history of mushroom ramen ingestion and the partially flagellate arrangement of the lesions, shiitake dermatitis was also included in the differential diagnosis. The patient was treated with intravenous dexamethasone, acyclovir, and cefuroxime together with topical 0.1% mometasone, resulting in rapid regression of lesions during hospitalization, followed by complete resolution during outpatient follow-up. Histopathological findings were consistent with the diagnosis of shiitake flagellate dermatitis, showing focal epidermal spongiosis and papillary dermal oedema, accompanied by perivascular and interstitial lymphocytic infiltrates with admixed eosinophils and focal lymphocyte exocytosis into the epidermis.

Conclusion

This case highlights shiitake dermatitis as an uncommon toxic dermal reaction that should be considered in the differential diagnosis of flagellate erythema. In the described patient, the diagnosis was particularly challenging because the linear

arrangement of papules was only partial and accompanied by disseminated perifollicular papules and palmar lesions, necessitating consideration of pityriasis rubra pilaris and a hypersensitivity or viral exanthem. Recognition of atypical presentations of shiitake flagellate dermatitis is essential to avoid unnecessary antiviral or antimicrobial treatment, given that the condition is self-limiting and responds to symptomatic therapy alone.

EA DV CONGRESS
VIENNA
30 SEP - 3 OCT 2026

Abstract N°: 2632

Comparative risk of incident systemic rheumatic disease across anti-obesity treatments in adults with obesity

Fatemeh Gorzin[1], Henning Olbrich[1], Jens Humrich[1], Diamant Thaçi[1], Jens Marquardt[1], Philip Curman[2], Bieber Katja[1], Lina Jegodzinski[1], Gabriela Riemekasten[1], Evelyn Gaffal[1], Walter Raasch[1], Hatim Kerniss[3], Svenja Meyhoefer[1], Ralf Ludwig*[1]

[1] Universität zu Lübeck, Lübeck, Germany

[2] Karolinska University Hospital, Solna, Sweden

[3] University Hospital Frankfurt, Frankfurt/Main, Germany

Introduction

Obesity has been associated with an increased risk of several systemic rheumatic diseases (SRDs), raising the possibility that anti-obesity interventions may reduce SRD risk. Bariatric surgery and pharmacologic therapies, including glucagon-like peptide-1 receptor agonists (GLP-1RAs) and tirzepatide, are widely used for weight management, but their comparative associations with incident SRD are unclear. We compared incident SRD risk across anti-obesity treatment strategies in adults with obesity.

Materials and Methods

We conducted a real-world retrospective cohort study using TriNetX. Adults with obesity receiving GLP-1RAs, tirzepatide, other anti-obesity medications, or bariatric surgery were identified. Incident SRD was defined as a composite of rheumatoid arthritis or systemic connective tissue disorders because event counts for individual SRDs were low. Propensity score matching balanced baseline characteristics. Hazard ratios (HRs) and 95% confidence intervals (CIs) were estimated in primary and sensitivity analyses, including model triangulation with multivariable Cox proportional hazards models and analyses stratified by sex or ancestry.

Results

In contextual analyses, obesity was associated with increased incident SRD compared with non-obese controls. For the comparative analysis relating to the risk of incident SRD, 30,134 to 102,963 patients were included in each arm depending on the comparators selected. Compared with other pharmacologic weight-loss therapies, both GLP-1RAs (HR 0.83, 95%-CI 0.75-0.91) and tirzepatide (HR 0.79, 95%-CI 0.63-0.98) were associated with lower SRD incidence in the primary analysis, with consistent findings across sensitivity analyses. Direct comparison showed no significant difference between tirzepatide and GLP-1RAs. Associations were more pronounced in women than in men, while ancestry-stratified analyses were limited by low event counts. Compared with bariatric surgery, no significant overall difference in SRD risk was observed for either GLP-1RAs or tirzepatide. Bariatric surgery also was not associated with a significant difference in SRD risk compared with other pharmacologic weight-loss therapies.

Conclusions

In adults with obesity, incretin-based pharmacotherapies were associated with a reduced risk of incident SRD compared with other pharmacologic weight-loss treatments, while showing no significant overall difference

compared with bariatric surgery. Whether these associations reflect weight loss alone or additional anti-inflammatory effects requires further study.

EA DV CONGRESS
VIENNA
30 SEP - 3 OCT 2026

Abstract N°: 2643

Biphasic cutaneous hypersensitivity to exogenous progesterone during assisted reproduction: a dual-route diagnostic challenge

Jose María Camino-Salvador*[1], Isabel Zapata-Martínez[2], Javier Torres Marcos[2], Alicia Martínez Fernández[2], Consuelo Sánchez Herreros[2], Clara Chiloeches Fernández[2], Esther De Eusebio-Murillo[2], María Antonia Pastor-Nieto[2]

[1] Dermatology Department. Hospital Universitario Puerta de Hierro - Majadahonda, Madrid, Spain

[2] Dermatology Department. Hospital Universitario Guadalajara, Guadalajara, Spain

Introduction

Progesterone is essential for implantation and early pregnancy maintenance, and exogenous progesterone is routinely used for luteal support in assisted reproductive technologies. Progesterone hypersensitivity is an uncommon immune-mediated disorder triggered by endogenous progesterone fluctuations or exogenous progestogens. Diagnostic criteria include a temporal relationship with luteal progesterone rise or progesterone administration, improvement after ovulation suppression or withdrawal, and recurrence after challenge when feasible. Its phenotype is heterogeneous, ranging from urticaria, angioedema and anaphylaxis to eczematous, erythema multiforme-like and fixed drug eruption-like reactions. Assisted reproduction creates a distinctive diagnostic scenario, as high-dose progesterone exposure, multiple routes and early pregnancy may coexist, limiting provocation testing and requiring coordinated dermatology-gynaecology decision-making.

Case Presentation

A 36-year-old woman with premature ovarian insufficiency undergoing her second in vitro fertilisation/intracytoplasmic sperm injection cycle presented with a 3-week progressive eruption during luteal support with intramuscular progesterone 100 mg daily. She first developed painful burning plaques at injection sites 6–12 hours after each dose. After embryo transfer, intramuscular progesterone was stopped because of local reactions and replaced with vaginal progesterone 400 mg every 12 hours. Twelve hours after the latest vaginal dose, she developed abrupt generalisation with intense pruritus, facial swelling and pharyngeal discomfort, without chest tightness or gastrointestinal symptoms.

Physical examination showed two simultaneous morphologies. Well-demarcated annular erythematous-violaceous scaly plaques were present on previous injection sites, resembling fixed drug eruption. In parallel, confluent non-evanescent erythematous-oedematous urticarial plaques involved the trunk and proximal limbs, with mucosal sparing. Gynaecological examination was normal and urine pregnancy test was positive.

Laboratory tests showed elevated C-reactive protein (17.1; reference <5) and increased total IgE (193 IU/mL; reference 0–120), without leukocytosis or peripheral eosinophilia. Skin biopsy demonstrated superficial perivascular and interstitial lymphocytic dermatitis with scattered eosinophils, focal interface/vacuolar change, no cytological atypia and no neutrophilic infiltrate (Figure 1). The temporal sequence, topographic recurrence at injection sites, systemic flare after route switching, compatible histology, improvement after withdrawal and a Naranjo score of 9 supported probable exogenous progesterone hypersensitivity. Progesterone challenge was not performed because pregnancy was ongoing.

After gynaecological assessment, exogenous progesterone was discontinued in all forms, as no further luteal support was considered necessary. Treatment consisted of a high-potency topical corticosteroid, oral cetirizine and close monitoring. Pruritus improved progressively; the urticarial component resolved within 48 hours,

whereas fixed drug eruption-like plaques cleared within 10 days, leaving post-inflammatory hyperpigmentation. At 3-month follow-up, pregnancy was progressing favourably and no further episodes had occurred.

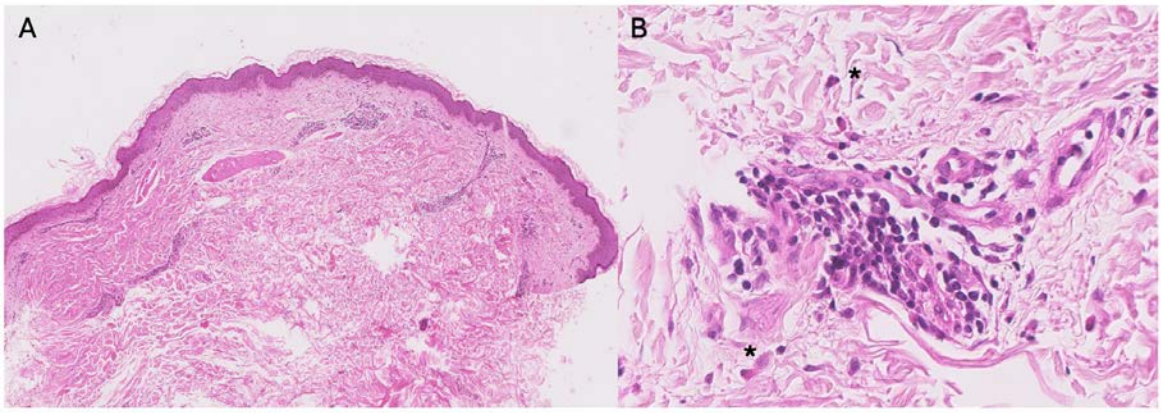

Figure 1. Skin biopsy showing superficial perivascular and interstitial lymphocytic dermatitis with scattered eosinophils and focal interface/vacuolar change, without cytological atypia or neutrophilic infiltrate (H&E).

Conclusion

This case illustrates an unusual biphasic presentation of exogenous progesterone hypersensitivity during assisted reproduction, with delayed fixed drug eruption-like plaques at injection sites followed by an immediate urticarial/angioedema-like flare after vaginal administration. Recognition of this dual pattern is clinically relevant because it may be mistaken for nonspecific injection-site reaction or unrelated drug eruption. In assisted reproduction, temporally related polymorphic eruptions should prompt consideration of progesterone hypersensitivity and early multidisciplinary management.

EA DV CONGRESS
VIENNA
30 SEP - 3 OCT 2026

Abstract N°: 2672

Glyoxylic Acid Hair Straightening and the Skin–Kidney Continuum: Calcium Oxalate–Mediated Acute Tubular Necrosis

Majd Abu Taleb*[1], Nesrine Ben Salah[1], Raiss Houda[1], Youssef Monia[1], Hichem Belhadjali[1], Jameleddine Zili[1]

[1] Dermatology Department, Fattouma Bourguiba University Hospital, Monastir, Tunisia

Introduction
Glyoxylic acid–based "formaldehyde-free" hair straighteners are increasingly used globally. While cutaneous toxicity is documented, systemic nephrotoxicity remains underrecognized. We delineate the clinicopathological spectrum of acute kidney injury (AKI) associated with toxic contact dermatitis following glyoxylic acid exposure, emphasizing the skin–kidney continuum.

Materials and Methods
Retrospective analysis of three young women admitted (2023–2025) for AKI within 48 hours of glyoxylic acid–based hair straightening. Inclusion required temporal association, exclusion of alternative AKI etiologies, and histopathological confirmation of both dermatitis and renal injury. Clinical, biochemical, histologic, and therapeutic data were systematically reviewed.

Results
Three young women (median age 25 years; range 22–27) presented 24–48 hours post-procedure with refractory nausea, lumbar pain, and oliguria. Dermatologic examination revealed well-demarcated erythematous, scaly plaques confined to the scalp vertex. Skin biopsy demonstrated spongiotic and interface dermatitis with necrotic keratinocytes and a superficial perivascular lymphocytic infiltrate, consistent with severe toxic contact dermatitis. Renal function was profoundly impaired: median serum creatinine 310 µmol/L (IQR 275–355), eGFR <20 mL/min/1.73m^2. Urinalysis consistently showed active sediment with dysmorphic erythrocytes, pyuria, and abundant birefringent envelope-shaped calcium oxalate crystals under polarized light. Renal biopsy confirmed diffuse tubular calcium oxalate deposition with focal crystal-induced rupture, acute tubular necrosis, and interstitial edema, sparing glomeruli. Comprehensive workup excluded nephrotoxic drugs, autoimmune nephritis, and primary hyperoxaluria. All patients received aggressive IV crystalloid hydration (3 L/day) and IV methylprednisolone (1 mg/kg/day). Cutaneous lesions resolved within 5 days; renal function normalized by day 12 (median creatinine 72 µmol/L). At 6-month follow-up, all maintained stable eGFR (>90 mL/min/1.73m^2) without proteinuria, underscoring the reversible nature of oxalate-mediated tubular injury when promptly recognized.

Conclusions
Glyoxylic acid–based straighteners exemplify a deceptive cosmetic paradigm: “formaldehyde-free” labeling masks a dual-pathway toxicity where scalp barrier disruption precedes systemic oxalate surge and tubular crystallization. The dermatitis in our series functioned not merely as a local reaction, but as a clinical sentinel of transdermal absorption and impending nephrotoxicity. This skin–kidney continuum demands a diagnostic paradigm shift:

dermatologists must recognize early cutaneous warning signs as triggers for immediate renal workup, while nephrologists should routinely query recent cosmetic exposures in unexplained AKI. Future frameworks should mandate standardized labeling of metabolic byproducts, integrate targeted patch-testing for glyoxylic acid formulations, and establish cross-specialty toxicovigilance networks. Until regulatory oversight aligns with cosmetic chemistry, clinical vigilance remains the most effective barrier against iatrogenic cosmetic nephropathy.

EA DV CONGRESS
VIENNA
30 SEP - 3 OCT 2026

Abstract N°: 2675

Unexpected Reaction to RSV Vaccine in a Patient with Known Ketorolac Trometamol Allergy: A Case Highlighting the Importance of Excipient Awareness

Bruna Marques Bilia*[1], Sandra e Dinato[1], Paulo Ricardo Criado[1], João Henrique Aurich[1], Ana Raimundo[1]

[1] Centro Universitário Lusíada (UNILUS), Santos, Brazil

Introduction

Vaccine excipients are substances added to the active ingredient to ensure formulation stability. The respiratory syncytial virus (RSV) vaccine Abrysvo and the COVID-19 vaccine Comirnaty, both produced by Pfizer, contain tromethamine, which is used as a buffering agent. This excipient is also present in the formulation of other medications, such as ketorolac trometamol, a nonsteroidal anti-inflammatory drug. Although hypersensitivity reactions to anti-inflammatory drugs are well documented, there is still limited consistent evidence in the literature concerning reactions specifically related to excipients.

Case Presentation

A 30-year-old female patient, at 31 weeks and 5 days of gestation, with a history of hypersensitivity to nonsteroidal anti-inflammatory drugs (NSAIDs), two previous episodes of angioedema following oral administration of ketorolac trometamol, received the recombinant respiratory syncytial virus (RSV) vaccine produced by Pfizer (Abrysvo). Twelve hours after the vaccine administration, a local hematoma developed, associated with an erythematous plaque located below the injection site. After 24 hours, the patient developed an urticarial plaque accompanied by pruritus and localized pain. Over the subsequent five days, there was a progressive increase in the extension and itch.

The patient was taking a multivitamin and had not used any other medications before or after vaccination. There was no history suggestive of viral illness or insect bites during this period. Cold compresses were applied, resulting in partial relief of pruritus. A gradual reduction in pruritus, pain, and lesion size was observed over a 45-day period. No systemic or obstetric complications were identified.

Importantly, the patient reported a similar delayed cutaneous reaction following administration of a COVID-19 vaccine developed by Pfizer three years earlier.

Causality assessment using the Naranjo Algorithm yielded a total score of 8, classifying the event as a probable adverse drug reaction.

Question	Yes	No	Do Not Know	Score
1. Are there previous conclusive reports on this reaction?	+1	0	0	0
2. Did the adverse event appear after the suspected drug was administered?	+2	-1	0	2
3. Did the adverse event improve when the drug was discontinued or a specific antagonist was administered?	+1	0	0	1
4. Did the adverse event reappear when the drug was readministered?	+2	-1	0	2
5. Are there alternative causes that could on their own have caused the reaction?	-1	+2	0	2
6. Did the reaction reappear when a placebo was given?	-1	+1	0	0
7. Was the drug detected in blood or other fluids in concentrations known to be toxic?	+1	0	0	0
8. Was the reaction more severe when the dose was increased or less severe when the dose was decreased?	+1	0	0	0
9. Did the patient have a similar reaction to the same or similar drugs in any previous exposure?	+1	0	0	1
10. Was the adverse event confirmed by any objective evidence?	+1	0	0	0
			Total Score:	**8**

Conclusion

This case highlights the potential role of vaccine excipients, particularly tromethamine, in hypersensitivity reactions in patients with a prior history of allergy to ketorolac tromethamine. The recurrence of a similar skin reaction after exposure to two different vaccines containing the same excipient strengthens the hypothesis of a causal association.

EADV CONGRESS
VIENNA
30 SEP - 3 OCT 2026

Abstract N°: 2676

Acute Generalized Exanthematous Pustulosis in Childhood and Pancreatitis: A Rare but Possible Systemic Involvement – A Case Report

Manal Kettam*[1], Maryem Aboudourib[1], Layla Bendaoud[1], Ouafa Hocar[1], Said Amal[1]

[1] Dermatology and venereology departement, University Hospital Center Mohammed VI,, Marrakesh, Morocco

Introduction

Acute Generalized Exanthematous Pustulosis (AGEP) is a rare and potentially severe dermatosis characterized by an acute, generalized pustular eruption, frequently accompanied by systemic manifestations. Although AGEP is classically associated with a favorable outcome, it may, in certain cases, reflect underlying systemic involvement. In children, the diagnosis of AGEP may be more challenging due to clinical variability and the difficulty in distinguishing mild from severe forms.

Case Presentation

A 6-year-old boy with a history of tonsillectomy one year earlier presented with generalized erythematous lesions surmounted by pustules evolving over two days. The eruption was preceded by an episode of pharyngitis for which he had been treated with amoxicillin, along with antiemetic therapy and paracetamol, initiated 48 hours prior to the onset of the rash. The clinical course occurred in a febrile context with deterioration of general condition.

Dermatological examination revealed numerous non-follicular pustules distributed over the entire body, sparing the face, arising on an erythematous background, with a granular-appearing erythema over the trunk. Abdominal examination disclosed epigastric tenderness. The remainder of the physical examination showed bilateral subcentimetric cervical lymphadenopathy.

Laboratory investigations demonstrated leukocytosis with neutrophil predominance, eosinophilia, elevated inflammatory markers, and serum lipase levels elevated to 3.2 times the upper limit of normal. Abdominal computed tomography revealed stage A acute pancreatitis without detectable obstruction.

Skin biopsy showed an acanthotic epidermis with minimal spongiosis, predominantly orthokeratosis with focal parakeratosis, subcorneal pustules, and altered neutrophils, consistent primarily with the morphological features of AGEP.

All non-essential medications were discontinued, and the case was reported to the pharmacovigilance center. The patient was treated with topical corticosteroids and received appropriate medical management for acute pancreatitis.

Conclusion

Pediatric AGEP may be accompanied by rare systemic complications such as acute pancreatitis. Although this association is uncommon, it requires multidisciplinary management and careful follow-up. Further research is needed to better understand the pathophysiological mechanisms underlying this association and to optimize therapeutic strategies.

EA DV CONGRESS
VIENNA
30 SEP - 3 OCT 2026

Abstract N°: 2678

Delayed Cutaneous Reactions Following Rhizostoma pulmo Envenomation: A Polymorphic Immune-Mediated Spectrum

Majd Abu Taleb*[1], Nesrine Ben Salah[1], Raiss Houda[1], Youssef Monia[1], Hichem Belhadjali[1], Jameleddine Zili[1]

[1] Dermatology Department, Fattouma Bourguiba University Hospital, Monastir, Tunisia

Introduction
Jellyfish envenomation by *Rhizostoma pulmo* is endemic across Mediterranean coastlines, typically provoking immediate nociceptive and urticarial reactions driven by direct cytotoxicity and histamine release. Delayed hypersensitivity responses remain exceptionally rare and poorly characterized, frequently mimicking primary inflammatory dermatoses. We delineate the polymorphic spectrum of delayed immune-mediated cutaneous reactions following *R. pulmo* stings, emphasizing clinicopathological correlation and therapeutic implications.

Materials and Methods
Retrospective analysis of four patients developing delayed cutaneous manifestations 36–96 hours after documented *R. pulmo* envenomation (2022–2025). Inclusion required strict temporal association, exclusion of drug-induced, infectious, or systemic autoimmune etiologies, and histopathological confirmation where feasible. Clinical phenotypes, laboratory parameters, histological findings, therapeutic interventions, and follow-up outcomes were systematically evaluated.

Results
The cohort comprised two pediatric (6 and 10 years) and two adult female patients (24 and 25 years). Delayed cutaneous onset ranged from 36 to 96 hours post-envenomation. Phenotypic-histopathological correlation revealed: (1) ALEP at 36 hours, showing sterile subcorneal pustules with neutrophilic microabscesses and mild spongiosis; resolved in 4 days with potent topical corticosteroids. (2) Facial angioedema-eczematous dermatitis at 48 hours, exhibiting eosinophilic spongiosis and marked dermal edema; responded to a 5-day tapering course of oral prednisone (0.5 mg/kg/day). (3) Lichenoid eruption on the dorsal wrist at 72 hours, histologically confirming interface dermatitis with Civatte bodies and a band-like CD8+ lymphocytic infiltrate; complete resolution after 10 days of mid-potency topical therapy. (4) Purpuric acral lesions in a 10-year-old at 96 hours, demonstrating leukocytoclastic vasculitis with prominent eosinophilic perivascular infiltration and fibrinoid necrosis; peripheral eosinophilia reached 12%. Clinical resolution was achieved after 14 days of systemic corticosteroids (1 mg/kg/day). Comprehensive workup excluded drug-induced, infectious, or systemic autoimmune triggers in all cases. During a median follow-up of 12 months (range 6–18), no recurrences, post-inflammatory sequelae, or systemic immune dysregulation were documented. Uniform corticosteroid responsiveness across phenotypes supports a shared delayed hypersensitivity spectrum modulated by venom-derived antigenic stimulation.

Conclusions
Rhizostoma pulmo envenomation can trigger a diverse array of delayed, immune-mediated cutaneous reactions,

ranging from pustular and eczematous eruptions to lichenoid and vasculitic phenotypes. The temporal latency, histopathological hallmarks, eosinophilic infiltration, and corticosteroid responsiveness strongly implicate a type IV hypersensitivity or immune-complex-mediated pathogenesis. Recognition of this polymorphic spectrum is critical to prevent diagnostic misclassification, avoid unnecessary systemic workups, and initiate targeted anti-inflammatory therapy. Dermatologists and coastal emergency providers should incorporate delayed envenomation syndromes into their differential diagnostic framework, and standardized prospective registries are warranted to elucidate long-term immunological sequelae and refine management algorithms.

EADV CONGRESS
VIENNA
30 SEP - 3 OCT 2026

Abstract N°: 2869

Acute localized exanthematous pustulosis: a prospective case series highlighting a facial-predominant presentation and diagnostic challenges

aouzal mohamed amine*[1], chaouche mohammed[1], mhaimer soukaina[1], ikram zouine[1], Nassma AIT ABDELALI[1], Fatima Zahra El Alaoui El Abidi[1], Fatima Zahra Hagag[1], Mortaji Zineb[1], sokaina chhiti[1], radia chakiri[1]

[1] Faculty of Medicine and Pharmacy of Agadir, Ibn Zohr University, Agadir, Morocco, Mohammed VI University Hospital Center of Agadir, agadir, Morocco

Introduction
Acute localized exanthematous pustulosis (ALEP) is a rare and recently identified variant of acute generalized exanthematous pustulosis (AGEP), characterized by sterile pustular eruptions confined to limited areas. Unlike the generalized form, ALEP may lack systemic features, leading to frequent misdiagnosis, particularly as infectious dermatoses, and inappropriate therapeutic management.
Objectives:
To describe the clinical, dermoscopic, etiological, and histopathological features of ALEP and to emphasize its diagnostic challenges in routine dermatological practice.

Materials and Methods
We conducted a prospective descriptive case series including five patients presenting with acute localized pustular eruptions. Clinical data collected included demographic characteristics, medical history, suspected drug exposure, latency period, lesion distribution, and associated symptoms. Dermoscopic examination was systematically performed in all patients. Histopathological analysis was carried out in all cases. Therapeutic management, drug withdrawal, and clinical outcomes were recorded.

Results
Five female patients were included, with a mean age of 32.8 years (range: 23–45). Lesions predominantly involved the face (4/5, 80%), presenting as localized eruptions of non-follicular pustules on an erythematous background. No patient developed fever or systemic involvement, supporting the localized nature of the condition.
Dermoscopy consistently revealed an erythematous background with multiple non-follicular pustules showing a characteristic milky-white content (5/5, 100%). Additional dermoscopic features included whitish scaling and yellowish crusts in two cases (2/5, 40%), as well as keratin plugs in two cases (2/5, 40%)
Histopathological examination consistently revealed a characteristic AGEP-like pattern, with subcorneal and intraepidermal pustules (5/5, 100%) associated with marked spongiosis (5/5, 100%). The dermis showed a predominantly neutrophilic inflammatory infiltrate (5/5, 100%), often arranged in a perivascular distribution, with occasional eosinophils (1/5, 20%). Focal keratinocyte necrosis was observed in 3 cases (60%), along with basal vacuolar alteration in 2 cases (2/5, 40%). Papillary dermal edema was noted in some patients, further supporting an acute inflammatory process. These findings were consistent with a pustular drug eruption within the spectrum of AGEP.
All cases were reported to the pharmacovigilance system, and drug exposure was identified in all patients (5/5, 100%), with pharmacovigilance assessment supporting a drug-induced etiology. Antibiotics were the most frequently implicated (4/5, 80%), particularly amoxicillin–clavulanic acid (2/5, 40%), followed by doxycycline and metronidazole (one case each). In one case (20%), ALEP occurred following exposure to a combination drug, with paracetamol suspected among its components. The latency period ranged from 1 to 8 days.
All patients underwent prompt withdrawal of the suspected drug (5/5, 100%) and were treated with topical

corticosteroids. No systemic corticosteroids were required. Complete clinical resolution was achieved within 4–10 days in all cases (5/5, 100%), with no recurrence observed during follow-up.

Conclusions

Acute localized exanthematous pustulosis is an uncommon drug-induced pustular eruption that should be recognized as part of the AGEP spectrum. Its predominantly facial presentation and absence of systemic symptoms may lead to diagnostic confusion, particularly with infectious dermatoses, resulting in unnecessary antibiotic use. Dermoscopy appears to be a valuable adjunctive tool, highlighting characteristic non-follicular milky-white pustules on an erythematous background. Early recognition and prompt drug withdrawal are essential for optimal management.

EA DV CONGRESS
VIENNA
30 SEP - 3 OCT 2026

Abstract N°: 2879

Omalizumab response predictors in chronic spontaneous urticaria – a systematic review

Adalia-Cristiana Iancu*[1, 2], Shatha Al Aqarbeh[3], Tamara Hossein[4], Heli Butala[5], Marwan Kobtan[6]

[1] Carol Davila University of Medicine and Pharmacy, Bucharest, Romania
[2] Victor Babes University of Medicine and Pharmacy, Timisoara, Romania
[3] Near East University, Nicosia, Cyprus
[4] University of Medicine and Pharmacy of Craiova, Craiova, Romania
[5] Lake Erie College of Osteopathic Medicine, Erie, PA, United States
[6] Cairo University Hospitals Kasr Al Ainy, Cairo, Egypt

Introduction

Omalizumab, an anti-immunoglobulin E (IgE) antibody, has emerged as an effective therapy for antihistamine-refractory chronic spontaneous urticaria (CSU), significantly improving disease control and quality of life. However, a substantial proportion of patients show partial or no response and patient characteristics associated with different response rates to omalizumab are not yet fully understood. Studies suggest that time to response may vary across patient subgroup phenotypes and highlight the need for reliable outcome predictors in order to further guide personalized treatment strategies. This review aims to synthesize current evidence on clinically applicable predictors of omalizumab response in CSU.

Materials and Methods

A comprehensive systematic review was conducted by searching public access registers, such as PubMed, Web of Science and Scopus, for articles published within the last ten years. Inclusion criteria were original studies identifying predictive factors of omalizumab response in patients with CSU that have already tried the highest dose of antihistamines with little to no effect, with UAS7>16 for 6 months. In all included studies, baseline biomarkers were assessed before receiving omalizumab 300 mg subcutaneously every four weeks and response rates were followed throughout a 12 week follow-up period through UAS7 and UCT scores. Studies that did not assess baseline biomarkers and did not follow patients for at least 12 weeks were excluded. Patients were categorized into responders, for whom UAS7≤6 was achieved either early by week 4 or late by week 12, and non-responders, who failed to achieve UAS7≤6 by week 12 and had persistently low UCT (<12). Data on baseline standard laboratory parameters, biomarkers and clinical features were extracted and results were qualitatively analyzed.

Results

In total, eight original studies were reviewed, encompassing 1551 patients. Across multiple studies, consistent evidence indicates that higher baseline total IgE levels were associated with a favorable response to omalizumab, while low IgE levels (<40-60 IU/mL) predicted poor or non-response. In a larger cohort of 307 patients, atopy was identified as a protective factor (OR = 0.299, 95% CI: 0.1040.858, p=0.025), suggesting its potential use as a predictor of treatment response. One other study found that atopic status correlated to an early response to

omalizumab (33% ER, 41% LR, 9% NR, p<0.05). Novel biomarkers associated with treatment response that have shown a predictive value included inflammatory indices such as systemic immune-inflammation index (SII) (OR 1.002, p=0.036), systemic inflammation response index (SIRI) (OR 4.334, p=0.002), elevated circulating Gal-9+ eosinophils (53.3% vs. 20%, p <0 .05) and dynamic IgE changes, with the week 4/baseline IgE ratio identified as a robust predictor of treatment response. Clinical factors associated with reduced treatment response included inducible urticaria (p = 0.021) and angioedema (OR = 3.309, 95% CI: 1.044–10.487, p=0.042). Markers of autoimmune type IIb CSU, such as positive thyroid autoantibodies (TPOAb, p=0.0209), low complement levels (C3, p=0.12, C4, p=0.0013), basopenia (p=0.0004) and eosinopenia (p<0.0001) and positive autologous serum skin test (ASST, p=0.011), were also associated with poor treatment response.

Conclusions

Baseline total IgE remains the most practical and reliable biomarker for predicting omalizumab response in CSU. Emerging biomarkers such as SII, SIRI, Gal-9+ eosinophils, autoimmune markers and atopy show promising predictive value for treatment outcomes, but require further validation. The integration of these parameters into routine assessment may support a more personalized therapeutic approach, optimizing treatment selection. Further multicentric and multiethnic validation is warranted to further refine patient stratification.

EA DV CONGRESS
VIENNA
30 SEP - 3 OCT 2026

Abstract N°: 2911

Allergic Contact Cheilitis to Gold Associated with an Orthodontic Retainer and Oral Jewelry Exposure

José Ramos*[1], Cláudia Brazão[2], Vasco Macias[3]

[1] Hospital Garcia de Orta - ULS Almada-Seixal, Almada, Portugal
[2] Hospital Garcia de Orta, ULS Almada-Seixal, Almada, Portugal
[3] Hospital Lusíadas de Lisboa, Lisboa, Portugal

Introduction

Allergic contact cheilitis is an important and frequently underrecognized cause of chronic lip dermatitis, often requiring detailed exposure history and extended patch testing for diagnosis.

Case Presentation

A 26-year-old woman with a past medical history relevant for allergic rhinitis was referred for patch testing due to a one-and-a-half-year history of chronic, treatment resistant cheilitis. Initially limited to the vermilion border, the eruption progressively worsened, with subsequent involvement of the entire lips and perioral skin. Previous prick testing and patch testing with the European baseline series were negative.

Clinical history revealed several potential triggers. Symptoms began shortly after the application of gel nail polish, which was later discontinued with only partial improvement. She had a fixed metallic and acrylic orthodontic retainer and used gold jewelry. Oral hygiene products remained unchanged, and no mouthwashes were used.

Examination showed dermatitis restricted to the lips and perioral area in an atopic patient. Patch testing was performed according to International Contact Dermatitis Research Group recommendations. Cosmetic series testing was negative, whereas the dental screening series revealed strong positive reaction to gold (+++) and a mild reaction to mercury (+).

Following identification of these positive reactions, the patient was questioned in detail. She described having the habit of regularly placing the gold necklace that she used in her mouth, and also the patient confirmed, after discussion with her dentist, that the orthodontic retainer contained gold. She subsequently reported marked improvement after its removal and avoidance of oral contact with gold jewelry. Therefore, a diagnosis of allergic contact cheilitis to gold was established.

Conclusion

This case highlights gold as an uncommon but clinically relevant allergen in chronic cheilitis, particularly in the context of prolonged mucosal exposure to dental materials and oral habits. It also underscores the importance of targeted dental series patch testing in patients with recalcitrant lip dermatitis and initially negative baseline series testing.

EADV CONGRESS
VIENNA
30 SEP - 3 OCT 2026

Abstract N°: 3049

Mucocutaneous rash induced by methotrexate: distinguishing toxicity from hypersensitivity

Salma Moujahid*[1], Ouissal Hormi[1], Nassiba Zerrouki[1], Nada Zizi[1]

[1] Department of Dermatology, Venereology and Allergology, Mohammed VI University Hospital, Oujda, Morocco

Introduction

Methotrexate (MTX) is a competitive inhibitor of dihydrofolate reductase, widely used in the treatment of gestational trophoblastic tumors (GTT) and various autoimmune diseases. Although generally well tolerated, it may cause rare but potentially severe adverse effects, particularly mucocutaneous involvement that may herald severe systemic toxicity, especially myelosuppression [5,6]. These manifestations can mimic drug hypersensitivity reactions, making differential diagnosis essential for appropriate management. We report a case of MTX-induced mucocutaneous toxicity revealing pancytopenia in a patient followed for GTT.

Case Presentation

We report the case of a 36-year-old woman with no significant past medical history, followed for a low-risk gestational trophoblastic tumor (GTT). She initially presented with first-trimester metrorrhagia in the setting of an unmonitored pregnancy. Obstetric ultrasound revealed a “honeycomb” appearance, and the β-hCG level was markedly elevated at 1,800,000 IU/L. Ultrasound-guided suction evacuation with histopathological examination confirmed a complete hydatidiform mole. Following secondary stagnation of β-hCG levels, the diagnosis of GTT was established. Staging investigations revealed uterine involvement with a pulmonary nodule, classifying the patient as low risk (FIGO score = 5), thus indicating single-agent chemotherapy with MTX.

The patient received intramuscular methotrexate at a dose of 1 mg/kg (60 mg) every other day, for a total dose of 240 mg over 8 days, combined with folic acid 10 mg every other day. Six days after treatment initiation, she developed ulcerative and erosive cutaneous and mucosal lesions involving the oral and genital mucosa, associated with lesions on the back, arms, and buttocks, causing significant pain and difficulty with eating and speaking. Histological examination showed focally ulcerated epidermis with dermoepidermal cleavage, moderate spongiosis, and focal keratinocyte necrosis, associated with a lymphoplasmacytic inflammatory infiltrate containing a few eosinophils and neutrophils. Laboratory investigations revealed pancytopenia: hemoglobin 10 g/dL, neutrophils 710/mm^3, platelets 55,000/mm^3, and white blood cells 1,570/mm^3.

In view of these findings, the diagnosis of MTX-induced mucocutaneous toxicity was established. Treatment was immediately discontinued, while folic acid supplementation and symptomatic management were maintained. The outcome was favorable, with regression of the lesions and gradual normalization of blood counts. At one month, only post-inflammatory hyperpigmentation persisted, with no recurrence.

Conclusion

Methotrexate-induced mucocutaneous toxicity is a rare but potentially severe complication that may reveal profound myelosuppression. It can mimic drug hypersensitivity reactions, making differential diagnosis essential. This case highlights the importance of early recognition of these warning signs, close monitoring, and appropriate management in order to prevent serious complications while optimizing the treatment of gestational trophoblastic tumors.

EA DV CONGRESS
VIENNA
30 SEP - 3 OCT 2026

Abstract N°: 3209

A rare cause of acetic acid-induced severe anaphylaxis after alcohol intake

Damian Kostner*[1], Lisbeth Dadak[1], Christine Bangert[1]

[1] Medizinische Universität Wien, Wien, Austria

Introduction

Alcohol-associated anaphylaxis is rare and diagnostically challenging. Adverse reactions to alcoholic beverages are common, but most often attributed to ethanol intolerance, histamine, sulfites, or underlying food allergies, while true IgE-mediated hypersensitivity to ethanol is exceedingly rare. Acetic acid is the major metabolite of ethanol and a ubiquitous component of fermented products. While it is generally considered non-immunogenic, hypersensitivity reactions to acetic acid have been occasionally reported. As a small molecule, it is inherently absent from standard allergologic workups designed for protein allergens, rendering conventional diagnostics inadequate and potentially contributing to underdiagnosis.

Case Presentation

A 30-year-old woman presented with two episodes of rapid-onset anaphylaxis within minutes after ingestion of a rosé wine spritzer and beer, respectively. The first episode was characterized by facial flushing, angioedema, generalized urticaria, dyspnea, and hypotension (80/60 mmHg), requiring intramuscular epinephrine, systemic corticosteroids, and antihistamines, followed by emergency department monitoring. A second episode occurred three weeks later after two sips of beer, with similar symptoms, again requiring epinephrine.

Extensive allergologic evaluation revealed a negative skin prick testing for standard food and inhalant allergens, as well as negative prick-to-prick testing for diverse alcoholic beverages such as beer, wine, whiskey and vodka. Specific IgE for common food and environmental allergens including peach lipid transfer protein, wheat omega-5 gliadin and grapes was also negative. Further laboratory testing demonstrated mildly elevated total IgE (133 kU/L), normal baseline tryptase (5 mcg/L), elevated eosinophilic cationic protein (70 mcg/L), and normal diamine oxidase levels. In contrast, prick-to-prick testing to multiple vinegar preparations (e.g. apple cider vinegar, wine vinegar, and pure vinegar essence (20% acetic acid)) showed reproducible strong positive reactions, while a healthy control person tested negative (Table 1). On follow-up visits, the patient further reported reproducible flushing after intake of vinegar-based salad dressing and alcohol-containing mouthwash exposure. After strict avoidance of vinegar and alcohol, no further reactions occurred. Due to the previously experienced severe anaphylactic reactions, the patient currently declined oral challenge testing with alcoholic beverages and vinegar.

Test category	Test performed	Result
Skin prick testing – nutritive allergens	Egg, milk, codfish, soybean, peanut, celery, wheat flour	Negative
	Apple, tomato (prick-to-prick)	Negative
Skin prick testing – inhalant allergens	House dust mite, storage mite (flour mite), cat dander	Negative
	Alternaria, *Cladosporium*	Negative
	Birch, plantain, grasses, rye, mugwort, ragweed, ash, *Ficus benjamina*	Negative
Skin prick testing – alcoholic beverages	Beer, wine, whiskey, vodka, herbal liqueur	Negative
Prick-to-prick testing – vinegars	Apple cider vinegar (5% acetic acid)	**Positive**
	Balsamic vinegar (6% acetic acid)	**Positive**
	Table vinegar (5% acetic acid)	**Positive**
	Apple-wine vinegar (7.5% acetic acid)	**Positive**
	Wine vinegar (~6-7% acetic acid)	**Positive**
	Rice vinegar (~4-5% acetic acid)	**Positive**
	Vinegar essence (20% acetic acid)	**Positive**
	Vinegar essence dilution 1:10, 1:1000	Negative
Control testing	Vinegar (all) prick-to-prick in healthy control	**Negative**
Total IgE	Serum total IgE	Mildly elevated (133 kIU/L)
Specific IgE (RAST)	Wheat (incl. omega-5 gliadin), grape, tomato, mustard, onion, peach LTP, alpha-gal, pollens	Negative
Mast cell marker	Baseline serum tryptase (post-event only)	Normal
Eosinophilic markers	Peripheral eosinophil count	Mildly elevated (0.6 G/L)
	Eosinophilic cationic protein (ECP)	Elevated (70.9 µg/L)
Histamine metabolism	Serum diamine oxidase (DAO)	Normal

Table 1. LTP, lipid transfer protein; RAST, radioallergosorbent test; ECP, eosinophilic cationic protein; DAO, diamine oxidase. Vinegar essence dilutions 1:10 and 1:1000 correspond to approximately 2% and 0.02% acetic acid, respectively. Bold results indicate clinically significant findings.

Conclusion

This case highlights a rare mechanism of alcohol-associated anaphylaxis. The consistent clinical history, reproducible prick-to-prick reactivity across multiple vinegar preparations, and absence of sensitization to common allergens suggest hypersensitivity to acetic acid or a vinegar-specific component. Standard assays for specific IgE do not include low-molecular-weight compounds such as acetic acid, precluding conventional antibody-based confirmation. It is tempting to speculate that acetic acid acquires immunogenicity via a hapten-like mechanism through binding to endogenous carrier proteins.

The case carries important practical implications. As acetic acid is ubiquitous in fermented beverages, condiments, and preservatives, sensitized individuals face an inadvertent exposure risk well beyond obvious triggers, necessitating thorough dietary counseling. Importantly, standard allergologic workup is inherently ill-suited to detect such sensitization, as commercial skin prick extracts and specific IgE panels do not include acetic acid and will return false-negative results, even in truly sensitized individuals. Prick-to-prick testing with native vinegar

preparations therefore represents a critical and accessible diagnostic step in patients with unexplained reactions to alcohol or fermented foods.

Further research employing in-vitro models and conjugate-specific immunoassays is needed to elucidate the underlying immunologic mechanism.

EA DV CONGRESS
VIENNA
30 SEP - 3 OCT 2026

Abstract N°: 3282

Barzolvolimab Treatment Leads to Substantial Improvement in Patient-Reported Outcomes and Demonstrates Corresponding Benefits in Quality of Life in Chronic Inducible Urticaria

Martin Metz[1, 2], Ana Maria Giménez-Arnau*[3], Nazreen Hussen[4], Jurate Staikūnienė-Kozonis[5], Tomas Slomskis[6], Jonny Peter[7], Bradley Bloom[8], Lan Duan[8], Philip Golden[8], Haolan Lu[8], Armend Lokku[8], Jonathan Bernstein[9]

[1] Institute of Allergology, Charité-Universitätsmedizin Berlin, corporate member of Freie Universitäts Berlin and Humboldt-Universitäts zu Berlin, Berlin, Germany

[2] Fraunhofer Institute for Translational Medicine and Pharmacology ITMP, Immunology and Allergology,, Berlin, Germany

[3] Department of Dermatology, Hospital del Mar Research Institute, Universitat Pompeu Fabra, Barcelona, Spain

[4] WorthWhile Clinical Trials, Gauteng, South Africa

[5] CD8 Clinic, Kaunas, Lithuania

[6] Center of Allergy Diagnosis and Treatment, Vilnius, Lithuania

[7] Division of Allergy and Clinical Immunology, University of Cape Town, and Allergy and Immunology Unit, University of Cape Town Lung Institute, Cape Town, South Africa

[8] Celldex Therapeutics, Inc., Hampton, New Jersey, United States

[9] University of Cincinnati College of Medicine and Advanced Allergy Group/Bernstein Clinical Research Center, Cincinnati, Ohio, United States

Introduction

Mast cells are central effector cells in chronic urticaria and play a role in chronic inducible urticaria (CIndU) pathophysiology. Barzolvolimab, a humanized mAb that inhibits SCF–mediated KIT activation, depletes skin mast cells in patients with CIndU. We previously reported that barzolvolimab significantly improved complete response rates (negative provocation tests) and demonstrated a >3-fold increase vs placebo in the likelihood of achieving DLQI 0/1 (no effect of disease) on quality of life (QoL) in cold urticaria (ColdU) and symptomatic dermographism (SD) (NCT05405660). Here, we characterize whether benefits in QoL are reflected in relief of key symptoms of urticaria as reported in daily diaries.

Materials and Methods

In this Phase 2, double-blind, placebo-controlled study, participants with ColdU and SD were randomized to receive subcutaneous barzolvolimab (150 mg Q4W or 300 mg Q8W) or placebo for 20 weeks, followed by a 24-week follow-up period. An analysis of covariance was conducted to determine treatment effects on the change from baseline at Week 20 of weekly average numeric rating scale(s) (NRS) of worst itch (WI-NRS), worst hives (WH-NRS), worst burning (WB-NRS), and worst pain (WP-NRS) across both CIndU subtypes. Pairwise correlation analyses were performed between changes from baseline to Week 20 in Dermatology Life Quality Index (DLQI) and weekly average WI-NRS, WH-NRS, WB-NRS, and WP-NRS using Pearson correlation coefficients.

Results

ColdU: A total of 96 participants (150 mg Q4W: n=32; 300 mg Q8W: n=32; Placebo: n=32) with baselines of WI-NRS (range: 3.62-4.88), WH-NRS (range: 3.49-4.49), WB-NRS (range: 3.08-4.68), and WP-NRS (range: 2.79-4.32)

received at least one dose of barzolvolimab. There was a significant improvement in mean change from baseline at Week 20 in WI-NRS, WH-NRS, WB-NRS, and WP-NRS (least squares [LS] means range: −1.34 to −2.02) for both barzolvolimab treatment groups compared with the placebo group (all $P<0.05$). Correlation coefficients for change from baseline in WI-NRS, WH-NRS, WB-NRS, and WP-NRS and change from baseline in DLQI scores ranged from 0.522 to 0.699 (all $P<0.05$), indicating a positive correlation between these endpoints.

SD: A total of 97 participants (150 mg Q4W: n=33; 300 mg Q8W: n=33; placebo: n=31) with baselines of WI-NRS (range: 5.08- 5.76), WH-NRS (range: 3.88-5.31), WB-NRS (range: 3.73-4.65), and WP-NRS (range: 2.98-4.07) received at least one dose of barzolvolimab, suggesting that itch was the most prominent component and pain was the least prominent component of urticaria at baseline. There was significant improvement in LS mean change from baseline at Week 20 in WI-NRS, WH-NRS, and WB-NRS (range: −1.43 to −2.10) for both barzolvolimab treatment groups compared with the placebo group (all $P<0.05$), while the treatment difference for WP-NRS did not achieve statistical significance. Correlation coefficients for improvements in WI-NRS, WH-NRS, and WB-NRS and change in DLQI scores ranged from 0.443 to 0.697 (all $P<0.05$), indicating a positive correlation between these endpoints. The correlation coefficient for change from baseline in WP-NRS and change from baseline in DLQI score was 0.383 ($P=0.0536$). The strongest correlations were between change from baseline WI-NRS and DLQI.

Conclusions

Patients with ColdU and SD experience a variety of symptoms including itch, hives, burning and pain. Barzolvolimab improved symptoms experienced by patients with CIndU in their daily lives, with symptom improvement showing moderate to strong association with better QoL. Benefits were apparent for itch, hives, burning and pain for patients with ColdU and for itch, hives, and burning for patients with SD. A Phase 3 study of barzolvolimab (NCT07266402) in ColdU and SD is currently recruiting patients.

EA DV CONGRESS
VIENNA
30 SEP - 3 OCT 2026

Abstract N°: 3297

Immune activation triggers in delayed inflammatory reactions to hyaluronic acid fillers: is the filler truly a bystander?

Ana Beatriz Gomes Cordovil*[1], Julia Dionisio Lima[2], Maria Luiza Corrêa Sebba[1], Allen Becker[1], Caroline Teruszkin Wiedermann[1], Maria Eduarda da Silva Cunha Pinheiro[1], Renata da Gama Cruz Luz[1], Giovana Bueno Fernandes[1], Manuela Attianesi de Freitas Rocha[3], Alice Klajman Agostino[1], Clara Brito Hegedüs[1], Maria Esperança Figueira de Mello Altberg[1], Sofia Rase Chaves[1], Laura Kale Machado Pereira do Amaral Daher[1]

[1] Universidade Estácio de Sá, Rio de Janeiro, Brazil

[2] Universidade do Oeste Paulista, São Paulo, Brazil

[3] Faculdade São Leopoldo Mandic, São Paulo, Brazil

Introduction
Delayed inflammatory reactions (DIRs) to hyaluronic acid (HA) fillers are increasingly recognized in aesthetic dermatology. While traditionally attributed to filler-related properties, these events are frequently preceded by systemic immune activation, suggesting a paradigm shift toward host-driven mechanisms. This study investigates whether HA fillers function primarily as passive substrates within an immune-primed microenvironment rather than as direct triggers of inflammation.

Materials and Methods
A narrative literature review was conducted using PubMed, Embase, and Scopus, including studies published between 2014 and 2024. The search strategy employed predefined combinations of keywords (e.g., 'hyaluronic acid fillers,' 'delayed inflammatory reactions,' 'immune activation,' 'vaccination,' 'biofilm,' and 'Toll-like receptors') using Boolean operators. Sixteen studies meeting the predefined inclusion criteria were selected from the retrieved literature. Included publications comprised clinical reports, case series, and mechanistic studies describing temporal associations between systemic immune activation and inflammatory responses at filler sites. Studies lacking clear temporal correlation or mechanistic relevance were excluded. A qualitative synthesis of the evidence was performed.

Results
A consistent temporal association was identified between DIRs and systemic immune activation events, including viral infections, vaccinations, and inflammatory stimuli such as dental procedures. These findings support a recurrent pattern in which systemic immune activation is followed by localized inflammatory responses at previously treated filler sites. Mechanistically, this process involves innate immune activation, with macrophage recruitment, T-cell activation, and pro-inflammatory cytokine release. Low-molecular-weight HA fragments may contribute to amplification of this response through interaction with pattern recognition receptors, particularly TLR2 and TLR4, within a previously primed tissue niche. Subclinical biofilms likely act as chronic immunological cofactors by exacerbating the inflammatory cascade rather than acting as its primary initiator. Despite these interactions, HA demonstrates low intrinsic immunogenicity, reinforcing its role as a biologically permissive substrate rather than a primary antigenic trigger. Additionally, variations in cross-linking technologies and rheological properties may influence tissue persistence, with more hygroscopic and degradation-resistant fillers potentially sustaining local immune activity. Therapeutically, outcomes appear to favor immunomodulatory strategies over approaches targeting the filler alone.

Conclusions
DIRs to HA fillers appear to be associated with systemic immune activation in susceptible individuals,

indicating that the filler may act as a passive bystander embedded within an immune-primed microenvironment. This conceptual observation challenges the conventional filler-centric model and provides a clinically relevant framework for understanding variability in timing and risk observed in practice, with implications for risk stratification, procedural timing, and targeted management. Recognition of this pattern may support more precise prevention strategies and improve therapeutic outcomes in aesthetic practice.

EA DV CONGRESS
VIENNA
30 SEP - 3 OCT 2026

Abstract N°: 3303

Treatment with Barzolvolimab Improves Urticaria Control and Quality of Life in Patients with Chronic Inducible Urticaria

Martin Metz[1, 2], Ana Maria Giménez-Arnau*[3], Nazreen Hussen[4], Jurate Staikūnienė-Kozonis[5], Tomas Slomskis[6], Essack Mitha[7], Neetu Talreja[8], Jonny Peter[9], Dorothea Terhorst[10, 11], Bradley Bloom[12], Haolan Lu[12], Lan Duan[12], Jonathan Bernstein[13]

[1] Institute of Allergology, Charité-Universitätsmedizin Berlin, corporate member of Freie Universitäts Berlin and Humboldt-Universitäts zu Berlin, Berlin, Germany

[2] Fraunhofer Institute for Translational Medicine and Pharmacology ITMP, Immunology and Allergology,, Berlin, Germany

[3] Department of Dermatology, Hospital del Mar Research Institute, Universitat Pompeu Fabra, Barcelona, Spain

[4] WorthWhile Clinical Trials, Gauteng, South Africa

[5] CD8 Clinic, Kaunas, Lithuania

[6] Center of Allergy Diagnosis and Treatment, Vilnius, Lithuania

[7] Newtown Clinical Research, Johannesburg, South Africa

[8] The Allergy Group and Treasure Valley Medical Research, Boise, Idaho, United States

[9] Division of Allergy and Clinical Immunology, University of Cape Town, and Allergy and Immunology Unit, University of Cape Town Lung Institute, Cape Town, South Africa

[10] Institute of Allergology, Charité-Universitätsmedizin Berlin, corporate member of Freie Universitäts Berlin and Humboldt-Universitäts zu Berlin, Berlin, Germany

[11] Fraunhofer Institute for Translational Medicine and Pharmacology ITMP, Immunology and Allergology, Berlin, Germany

[12] Celldex Therapeutics, Inc., Hampton, New Jersey, United States

[13] University of Cincinnati College of Medicine and Advanced Allergy Group/Bernstein Clinical Research Center, Cincinnati, Ohio, United States

Introduction

In a Phase 2 study, barzolvolimab (anti-KIT antibody) was associated with significantly higher complete response rates compared with placebo to negative provocation tests and was well tolerated at 12 weeks (W12) in patients with cold urticaria (ColdU) and symptomatic dermographism (SD) inadequately controlled by antihistamines. Here we report impact on urticaria control and quality of life (QoL) at 20 weeks (W20).

Materials and Methods

In this randomized, double-blind, placebo-controlled trial (NCT05405660), patients with ColdU (n=96) and SD (n=97) received barzolvolimab subcutaneous (SC) at 150 mg every 4 weeks (Q4W), 300 mg every 8 weeks (Q8W), or placebo for W20 with a 24-week follow-up. Change from baseline (CFB) in urticaria control test (UCT) and proportion of patients achieving Dermatology Life Quality Index (DLQI) of 0 or 1, at W20 were assessed. Analysis of covariance (ANCOVA) was used to compare the changes from baseline at W20 in UCT and DLQI between the barzolvolimab dose groups versus placebo which included treatment group, the respective baseline endpoint score and the randomization stratification factor (baseline ANC) as fixed effects. The proportions of patients with DLQI = 0 or 1 at Week 20 for each barzolvolimab dose group versus placebo were compared using a Cochran–Mantel–Haenszel (CMH) test stratified by the randomization stratification factor.

Results

In patients with ColdU, baseline mean UCT scores ranged from 4.9 to 5.8, and DLQI scores ranged from 12.6 to 14.1. W20, mean (SD) CFB in UCT was 6.7 (5.2), *P*=0.002; 7.8 (5.3), *P*=0.0001; and 3.1 (3.7) in the 150 mg Q4W, 300 mg Q8W, and placebo groups, respectively. The proportion of patients achieving DLQI scores of 0 or 1 at W20 was 62%, *P*=0.0011; 61%, *P*=0.001; and 20% across the same groups.

In patients with SD, baseline mean UCT scores ranged from 5.3 to 5.5, and DLQI scores ranged from 13.0 to 14.1. At W20, mean (SD) CFB in UCT was 6.3 (5.1), *P*=0.0001; 7.2 (3.6), *P*<0.0001; and 2.2 (3.1) in the 150 mg Q4W, 300 mg Q8W, and placebo groups, respectively. DLQI scores of 0 or 1 were achieved by 45%, *P*=0.0108; 50%, *P*=0.0044 and 13% of patients in these same groups.

Conclusions

Barzolvolimab treatment resulted in significant improvement in UCT and DLQI at W20 of treatment.

EA DV CONGRESS
VIENNA
30 SEP - 3 OCT 2026

Abstract N°: 3322

A Phase 3 Randomized, Double-Blind, Placebo-Controlled, Multicenter, Parallel-Group Study of Barzolvolimab in Participants With Cold Urticaria and Symptomatic Dermographism: Trial-In-Progress

Martin Metz*[1, 2], Romi Saini[3], Jonny Peter[4], Ana Maria Giménez-Arnau[5], Bradley Bloom[6], John Vaile[6], Philip Golden[6], Armend Lokku[6], Jonathan Bernstein[7]

[1] Institute of Allergology, Charité-Universitätsmedizin Berlin, corporate member of Freie Universitäts Berlin and Humboldt-Universitäts zu Berlin, Berlin, Germany

[2] Fraunhofer Institute for Translational Medicine and Pharmacology ITMP, Immunology and Allergology,, Berlin, Germany

[3] John Hopkins Allergy and Asthma Center, Baltimore, Maryland, United States

[4] Division of Allergy and Clinical Immunology, University of Cape Town, and Allergy and Immunology Unit, University of Cape Town Lung Institute, Cape Town, South Africa

[5] Department of Dermatology, Hospital del Mar Research Institute, Universitat Pompeu Fabra, Barcelona, Spain

[6] Celldex Therapeutics, Inc., Hampton, New Jersey, United States

[7] University of Cincinnati College of Medicine and Advanced Allergy Group/Bernstein Clinical Research Center, Cincinnati, Ohio, United States

Introduction

Activation of mast cells (MCs) drives the development of itch, wheals, and angioedema in patients with chronic inducible urticaria, including those with cold urticaria (ColdU) or symptomatic dermographism (SD). MCs require the activation of the KIT receptor for differentiation, maturation, and survival. Thus, targeting MCs with barzolvolimab, a monoclonal anti-KIT antibody, could improve symptoms and quality of life among patients with ColdU or SD, particularly those who remain symptomatic despite H1 antihistamine treatment. In a placebo-controlled Phase 2 study (NCT05405660), barzolvolimab demonstrated clinically meaningful and statistically significant improvements in disease activity, including achievement of complete response (negative provocation tests), reductions in symptoms, and improved quality of life in participants with ColdU or SD. This Phase 3, randomized, double-blind, placebo-controlled study (NCT07266402) aims to assess the efficacy and safety of barzolvolimab in patients with antihistamine-refractory ColdU or SD.

Materials and Methods

The trial aims to enroll 240 participants (ColdU, n=120; SD, n=120). Participants (≥18 y) included in the trial will have either a diagnosis of ColdU or SD for ≥3 months prior to screening with the presence of recurrent pruritic wheals with or without angioedema due to ColdU or SD for ≥6 weeks despite treatment with a stable regimen of up to 4 times the approved dose of H1-antihistamines. Participants with ColdU or SD must also develop a wheal at the provocation site within 10 minutes after provocation using TempTest® at any temperature or FricTest® with ≥3 pins, respectively, at both screening and randomization.

The length of the study is approximately 72 weeks per participant and is divided into 4 distinct periods: a screening period (up to 4 weeks), a 24-week placebo-controlled treatment period, a 28-week open-label active treatment period, and a 16-week follow-up period (Figure 1).

Following a screening period of 14 to 28 days, participants will be randomized (1:1) into either the treatment arm

(a 450 mg loading dose on Day 1 followed by subcutaneous barzolvolimab 150 mg every 4 weeks [Q4W]) or the matching placebo arm. During the placebo-controlled treatment period (Weeks 0-24), participants will receive double-blind treatment Q4W. At the Week 24 visit, participants from each cohort will enter the open-label active treatment period (Weeks 24-52) and begin receiving barzolvolimab 300 mg every 8 weeks through Week 52. During the follow-up period (Weeks 56-68), no treatment will be given.

The primary efficacy endpoint is the proportion of participants with a complete response to a provocation test at Week 12 (ie, complete response in critical temperature threshold [CTT] after the TempTest® 4.0 for participants with ColdU or complete response in critical friction threshold [CFT] after the FricTest® 4.0 for participants with SD). Key secondary endpoints assessing the superiority of barzolvolimab vs placebo include complete response to provocation test at Weeks 4 and 24, improvement in patient-reported numerical rating of clinical symptoms of itch and hives at Weeks 12 and 24, improvement in clinical symptoms of itch and hives at Weeks 12 and 24 after a provocation test, improvement in dermatological quality of life at Week 12, and improvement in CTT or CFT for ColdU or SD populations, respectively, at Weeks 4, 12, and 24. The safety of barzolvolimab will also be assessed.

This global study intends to enroll patients at 73 sites across 7 countries. It is currently recruiting throughout the United States, Germany, Lithuania, Poland, South Africa, Spain, and the United Kingdom.

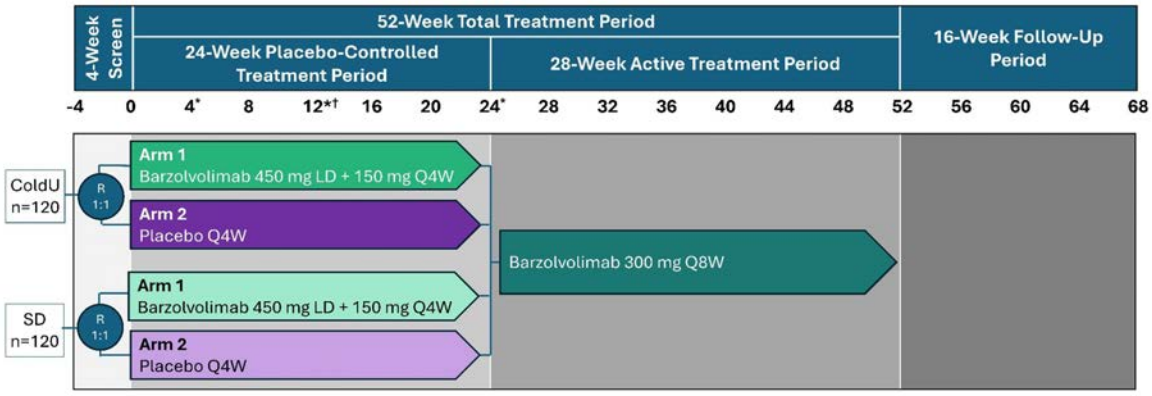

Schematic of study design describing a Phase 3, randomized, double-blind, placebo-controlled, multicenter, parallel-group study of barzolvolimab in participants with cold urticaria or symptomatic dermographism *Key secondary endpoints include complete response to provocation test at Weeks 4 and 24, improvement in clinical symptoms of itch and hives at Weeks 12 and 24, improvement in clinical symptoms of itch and hives at Weeks 12 and 24 after a provocation test, improvement in dermatological quality of life at Week 12, and improvement in CTT or CFT for ColdU or SD populations, respectively, at Weeks 4, 12, and 24. †The primary endpoint—the proportion of patients with a complete response to a provocation test (ie, complete response in CTT after the TempTest® 4.0 for participants with ColdU or complete response in CFT after the FricTest® 4.0 for participants with SD)—will be assessed at Week 12. CFT, critical friction threshold; ColdU, cold urticaria; CTT, critical temperature threshold; LD, loading dose; Q4W, every 4 weeks; Q8W, every 8 weeks; R, randomization; SD, symptomatic dermographism.

EA DV CONGRESS
VIENNA
30 SEP - 3 OCT 2026

Abstract N°: 3324

Barzolvolimab Treatment Leads to Achievement of Both Complete Response As Well As No Impact of Disease on Quality of Life in Chronic Spontaneous Urticaria

Martin Metz*[1, 2], John Anderson[3], Jeffrey Leflein[4], Maia Gotua[5], Neetu Talreja[6], Steven Greenberg[7], Ashley Hinton[7], Armend Lokku[7], Lan Duan[7], John Vaile[7], Jonathan Bernstein[8]

[1] Institute of Allergology, Charité-Universitätsmedizin Berlin, corporate member of Freie Universitäts Berlin and Humboldt-Universitäts zu Berlin, Berlin, Germany

[2] Fraunhofer Institute for Translational Medicine and Pharmacology ITMP, Immunology and Allergology,, Berlin, Germany

[3] University of Alabama, Birmingham and VA Medical Center, Clinical Research Center of Alabama, AllerVie Health, Birmingham, Alabama, United States

[4] Allergy and Immunology Associates of Ann Arbor, Ann Arbor, Michigan, United States

[5] Center of Allergy and Immunology, Tbilisi, Georgia

[6] The Allergy Group and Treasure Valley Medical Research, Boise, Idaho, United States

[7] Celldex Therapeutics, Inc., Hampton, New Jersey, United States

[8] University of Cincinnati College of Medicine and Advanced Allergy Group/Bernstein Clinical Research Center, Cincinnati, Ohio, United States

Introduction

CSU symptoms place a substantial burden on patients' quality of life. In a Phase 2 study in patients with antihistamine-refractory chronic spontaneous urticaria (CSU) (NCT05368285), barzolvolimab (anti-KIT mAb) demonstrated significant benefits in Urticaria Activity Score over 7 days (UAS7), with 71% of participants receiving barzolvolimab 150mg Q4 weeks and 52% of those receiving 300mg Q8 weeks achieving a complete response (UAS7 = 0), representing the absence of itch and hives after 52 weeks of treatment. Treatment with barzolvolimab also had a significant impact on quality of life as measured by the Dermatology Life Quality Index (DLQI) with up to 82% of participants achieving a DLQI score of 0 or 1, indicating no impact of CSU on quality of life, at Week 52. Here, we report benefits of barzolvolimab on itch and hives and their relationship with quality of life over time in the 150mg Q4W and 300mg Q8W treatment groups.

Materials and Methods

This double-blind trial randomized patients to receive placebo or barzolvolimab subcutaneously at 75mg Q4W, 150mg Q4W, or 300mg Q8W for 16 weeks followed by 36 weeks of active treatment and 24 weeks of follow-up. During active treatment, the placebo and 75mg Q4W groups were re-randomized to either 150mg Q4W or 300mg Q8W. In a post hoc analysis, the relationships between UAS7, ISS7, HSS7 and DLQI over time by Pearson correlation coefficients (r) were investigated. The relationships between attainment of complete disease control (UAS7 = 0) and no impact of CSU on quality of life (DLQI = 0/1) over time using Chi square tests were determined.

Results

Attainment of itch-free status (ISS7 = 0) increased progressively from 17.7% and 19.6% at Week 2 to 73.7% and

52.3% at Week 52 for barzolvolimab 150mg Q4W and 300mg Q8W, respectively. Similarly, attainment of hive-free status (HSS7 = 0) increased progressively from 19.6% and 19.6% at Week 2 to 73.7% and 59.1% at Week 52 for barzolvolimab 150mg Q4W and 300mg Q8W, respectively. At Week 76, 28 weeks after the final dose of barzolvolimab, 41.2% and 35.3% maintained itch-free status while 52.9% and 35.3% maintained hive-free status for 150mg Q4W and 300mg Q8W, respectively.
Positive correlations (r) between change from baseline DLQI and changes from baseline in UAS7, ISS7, and HSS7 over time for the 150mg Q4W/300mg Q8W treatment groups were between 0.390 and 0.524, all $P<0.001$. The proportion of patients achieving UAS7 = 0 and DLQI = 0/1 conjointly in the 150mg group increased from 19.6% (Week 4) to 53.3% (Week 12) and 68.4% (Week 52). A similar pattern was noted for the 300mg Q8W treatment group with attainment of UAS7 = 0 and DLQI = 0/1 conjointly in 22.5% (Week 4), 35.6% (Week 12), and 50.0% (Week 52) of patients. At Week 76, 28 weeks after the final dose of barzolvolimab, the proportion of patients maintaining UAS7=0 and DLQI = 0/1 conjointly was 34.4% and 29.4% for 150mg Q4W and 300mg Q8W, respectively.

Conclusions

Benefits of barzolvolimab treatment in itch, hives, and urticaria activity positively correlated with improvements in quality of life. The proportion of patients that achieved both complete response and no effect of disease on quality of life increased over time during treatment and persisted in many of these patients 7 months after the last dose of barzolvolimab. Barzolvolimab represents a promising treatment for CSU, offering the possibility of complete response and improved quality of life in antihistamine-refractory patients with CSU.

EA DV CONGRESS
VIENNA
30 SEP - 3 OCT 2026

Abstract N°: 3330

Prolonged and Improved Quality of Life Off Treatment in Patients With Chronic Spontaneous Urticaria Treated With Barzolvolimab

Martin Metz*[1, 2], John Anderson[3], Jeffrey Leflein[4], Maia Gotua[5], Neetu Talreja[6], Deena Maurer[7], Steven Greenberg[7], Elsa Paradise[7], Lan Duan[7], Jonathan Bernstein[8]

[1] Institute of Allergology, Charité-Universitätsmedizin Berlin, corporate member of Freie Universitäts Berlin and Humboldt-Universitäts zu Berlin, Berlin, Germany
[2] Fraunhofer Institute for Translational Medicine and Pharmacology ITMP, Immunology and Allergology,, Berlin, Germany
[3] University of Alabama, Birmingham and VA Medical Center, Clinical Research Center of Alabama, AllerVie Health, Birmingham, Alabama, United States
[4] Allergy and Immunology Associates of Ann Arbor, Ann Arbor, Michigan, United States
[5] Center of Allergy and Immunology, Tbilisi, Georgia
[6] The Allergy Group and Treasure Valley Medical Research, Boise, Idaho, United States
[7] Celldex Therapeutics, Inc., Hampton, New Jersey, United States
[8] University of Cincinnati College of Medicine and Advanced Allergy Group/Bernstein Clinical Research Center, Cincinnati, Ohio, United States

Introduction
In a phase 2, double-blind, placebo-controlled study in patients with antihistamine-refractory chronic spontaneous urticaria (CSU) (NCT05368285), barzolvolimab (anti-KIT antibody) demonstrated sustained benefits with a complete response (7-day urticaria activity score [UAS7]=0) in up to 41% of patients 7 months (Week 76) after the last dose; barzolvolimab was well tolerated. Here, we describe post-treatment health-related quality of life (QoL) among patients who achieved well-controlled disease (UAS7 ≤6) at Week 52.

Materials and Methods
Among 78 patients completing 52 weeks with 150 mg every 4 weeks or 300 mg every 8 weeks barzolvolimab, 55 (70.5%) achieved at least well-controlled disease at Week 52. Fifty of these patients with Dermatology Life Quality Index (DLQI) scores at Week 76 were further evaluated in an exploratory analysis.

Results
At entry, mean (SD) UAS7=31.1 (7.4) and mean (SD) DLQI=15.6 (7.6). Of these patients, 68% had severe disease. At Week 52, 88% of patients had a complete response (UAS7=0), 100% had well-controlled urticaria, and 94% had DLQI 0/1 (no impact of disease on patient's life). Prolonged, improved off-treatment QoL was maintained despite clearance of barzolvolimab and normalized serum tryptase, a mast cell biomarker. Remarkably, 52% of these patients had continuous, well-controlled disease throughout the post-treatment follow-up period, with 84.6% demonstrating DLQI 0/1 at Week 76.

Conclusions
Among patients who achieved at least well-controlled disease after 52 weeks of treatment with barzolvolimab, sustained improvement in QoL off treatment was observed 28 weeks after the last dose, suggesting disease modification.

EADV Congress 2026, VIENNA
30 SEPTEMBER - 03 OCTOBER 2026
POWERED BY M-ANAGE.COM

EA DV CONGRESS
VIENNA
30 SEP - 3 OCT 2026

Abstract N°: 3445

Convergence of Type 2 Inflammation: Translating EU5 Asthma Biologic Insights into Dermatology Practice

Colleen Carpinella[1], Andrew Stankus*[1], Shirley Chen[1], Sophia Recchilungo[1], Jordan Talia[2]

[1] Spherix Global Insights, Exton, PA, United States
[2] Mount Sinai Health System, New York, NY, United States

Introduction
The evolving asthma biologics landscape in the EU5 offers important cross-disciplinary insights for dermatology, particularly given shared type 2 (Th2) inflammatory pathways. As biologics targeting IL-4/13, IL-5, and upstream mediators reshape asthma care, parallel mechanisms are driving innovation in dermatologic conditions such as atopic dermatitis and prurigo nodularis. Understanding how respiratory specialists navigate treatment complexity, comorbidity burden, and heterogeneous phenotypes provides a valuable analog for optimizing advanced systemic therapy use in dermatology.

Objectives: To gain insight into the asthma patient journey across lines of therapy, with a focus on biologic initiation, sequencing, and management of difficult-to-treat populations, and to identify implications for dermatologic disease management.

Materials and Methods
Market Dynamix™: Asthma EU5 2026 included a quantitative survey of 253 physicians (215 pulmonologists, 38 allergists) across France, Germany, Italy, Spain, and the UK, supplemented by 8 qualitative interviews, conducted between January and February 2026. The study evaluated treatment paradigms, biologic utilization, patient types, and unmet need.

Results
Biologics are well-established in asthma but remain concentrated in advanced disease (22% to 30% of severe compared to 6% to 8% of moderate patients reportedly on biologics). However, only 53% of biologic-treated moderate-to-severe patients achieve disease control, highlighting a persistent unmet need. This mirrors dermatology, where incomplete response remains common in moderate-to-severe atopic dermatitis.

Unmet need is most pronounced among biologic-experienced patients (29% to 47% of physicians cite extremely high unmet need) and those with non-eosinophilic phenotypes (49% of pulmonologists report extremely high unmet need), where treatment options remain limited despite the emerging use of broader agents such as tezepelumab. This underscores a key parallel to dermatology's treatment-refractory and biomarker-ambiguous populations, where treatment unmet need is also most evident.

Dupilumab leads on perceived efficacy (56% of physicians highly satisfied with dupilumab cite high overall efficacy) and comorbidity benefit across Th2-driven diseases (43% of physicians report comorbidity benefit), reinforcing the value of therapies with multi-indication utility (e.g., atopic dermatitis, asthma, prurigo nodularis) and supporting a more integrated, system-wide approach to patient management across specialties. Moreover, physicians prioritize reduction in exacerbations and durability of response over traditional endpoints (e.g., lung function improvement), signaling a shift toward holistic disease-control metrics that align closely with dermatologic goals, such as flare prevention, sustained skin clearance, and improved quality of life.

Mechanism-driven differentiation is increasingly critical: 65% of physicians see upstream targeting (e.g., TSLP

inhibition) as most promising in asthma, with 43% citing broad, biomarker-independent efficacy. This has implications for dermatology, where heterogeneous disease drivers may make multi-pathway agents attractive for more consistent outcomes.

Conclusions

These findings highlight increasing convergence across respiratory and dermatologic immunology, driven by shared Th2 biology and similar challenges in patient heterogeneity and treatment response. Insights from asthma, including the importance of biomarker independent efficacy and comorbidity management, have direct implications for dermatology, particularly in optimizing treatment sequencing and guiding future pipeline innovation in chronic inflammatory skin diseases.

EADV CONGRESS
VIENNA
30 SEP - 3 OCT 2026

Abstract N°: 3461

nemolizumab in post burn pruritus : a case series

Benoit Ben Said*[1]

[1] CHU LYON CENTRE, dermatology, burn unit, Lyon, France

Introduction

Post-burn pruritus is one of the most prevalent and debilitating long-term sequelae of cutaneous burn injury, affecting up to 90% of survivors at hospital discharge and persisting beyond two years in more than 70% of patients, particularly in those with deep dermal or full-thickness burns and grafted areas. It severely impairs sleep, scar maturation, mental health and overall quality of life. Conventional management — H1-antihistamines, gabapentinoids, topical corticosteroids, emollients, pressure garments, silicone sheets and scar-directed laser therapies — remains insufficient in a substantial proportion of patients, and no targeted biologic therapy is currently approved in this indication. Interleukin-31 (IL-31), a Th2-derived "itch cytokine" signalling through a heterodimeric IL-31RA/OSMRβ receptor expressed on cutaneous sensory neurons, keratinocytes, fibroblasts and immune cells, has emerged as a central pruritogen in cutaneous wound healing. IL-31, IL-31RA and OSMR are significantly overexpressed in the epidermal basal layer of post-burn hypertrophic scars compared to adjacent non-burned skin (Lee et al., *J Pathol Transl Med* 2018).

Case Presentation

Three adult patients (aged 42, 68 and 73 years) with chronic, severe pruritus persisting for 1, 2 and 3 years respectively after a thermal, chemical and flame burn, all third-degree and treated by split-thickness skin grafting during the acute phase, were managed off-label with subcutaneous nemolizumab, a humanised monoclonal antibody targeting IL-31RA. The regimen used was the one approved for atopic dermatitis and prurigo nodularis: a 60 mg subcutaneous loading dose at week 0, followed by 30 mg every 4 weeks from week 4. All three patients had previously failed a combination of high-dose oral H1-antihistamines, potent topical corticosteroids and gabapentin titrated to tolerance. Off-label use was discussed individually and written informed consent was obtained. Itch intensity was assessed using the Peak Pruritus Numeric Rating Scale (PP-NRS, 0–10) at baseline and at month 3. Scar quality was evaluated clinically at each visit, focusing on erythema, thickness, pliability and pigmentation. Tolerability was monitored clinically and biologically at every visit.
Baseline PP-NRS scores were 10, 9 and 8 (mean 9.0), reflecting maximal-to-severe pruritus in all three patients. At month 3, PP-NRS had fallen to 2, 1 and 2 (mean 1.7), corresponding to absolute reductions of 8, 8 and 6 points — far exceeding the 4-point clinically meaningful improvement threshold — and to near-complete itch relief in all three patients. In parallel, a clinically meaningful improvement in scar quality was observed in every case, with reduced erythema, softening of hypertrophic areas and improved pliability over the grafted zones. Tolerance was excellent, with no injection-site reactions, no infections, no asthenia and no laboratory abnormalities through 3 months of follow-up.

Conclusion

In this case series, nemolizumab produced rapid, marked and consistent relief of severe refractory post-burn pruritus, together with a concomitant improvement in scar quality, in three grafted patients with heterogeneous burn aetiologies. These observations support a dual pathophysiological role of the IL-31/IL-31RA axis in post-burn itch and fibrotic scar remodelling, plausibly linked to the TGF-β–cDC2–IL-31 pathway. Although serum IL-31 levels correlate with itch intensity in atopic dermatitis, prurigo nodularis and uremic pruritus, dedicated serum data in burn patients are still lacking — an ancillary translational study coupling PP-NRS, POSAS scoring and serial serum

IL-31 quantification is warranted, and prospective controlled trials of nemolizumab in this orphan indication are justified.

EA DV CONGRESS
VIENNA
30 SEP - 3 OCT 2026

Abstract N°: 3483

Oral Lumbricus rubellus Extract as a Potential Immunomodulatory Therapy in Atopic Dermatitis: Effects on Interleukin-33 Levels

Sari Miftahul Jannah*[1], Sri Handaryati[1], Farida Tabri[1], Widya Widita[1]

[1] Department of Dermatology, Venereology and Aesthetic of Faculty of Medicine, Hasanuddin University, Makassar, Indonesia

Introduction

Atopic dermatitis is a chronic inflammatory dermatosis characterized by epidermal barrier dysfunction and type 2 immune dysregulation, in which alarmin cytokines, particularly interleukin-33 (IL-33), play a pivotal upstream role in initiating and amplifying inflammation. IL-33 drives Th2 polarization, barrier impairment, and persistent pruritus. Targeting upstream mediators represents a rational adjuvant therapeutic strategy. *Lumbricus rubellus* contains bioactive compounds, including lumbrokinase, glycoprotein G-90, and antimicrobial peptides, with documented anti-inflammatory, antioxidant, and immunomodulatory properties. However, its effect on IL-33 in atopic dermatitis remains insufficiently elucidated. This study aimed to evaluate the impact of oral *Lumbricus rubellus* extract on serum IL-33 levels and clinical severity in patients with atopic dermatitis

Materials and Methods

A randomized controlled, pretest–posttest trial was conducted in 78 patients with mild-to-moderate atopic dermatitis recruited via consecutive sampling. Subjects were allocated into an intervention group receiving oral *Lumbricus rubellus* extract and a control group receiving standard therapy with emollient (petrolatum) alone. Treatment was administered for four weeks with age-adjusted dosing. Outcomes were assessed at baseline and week 4, including serum IL-33 quantified by enzyme-linked immunosorbent assay (ELISA) and clinical severity measured using the SCORAD index. Intra- and intergroup differences, as well as correlations between variables, were analyzed using paired and independent sample t-tests according to data distribution.

Results

The intervention group demonstrated a significant reduction in IL-33 levels from 60.25 ± 5.34 pg/mL to 44.67 ± 5.34 pg/mL (Δ −15.58; 95% CI −18.10 to −13.06; $p<0.001$), whereas the control group showed no meaningful change (65.58 ± 5.35 to 65.68 ± 5.24 pg/mL; Δ +0.10; $p=0.930$). The between-group difference in mean change was highly significant (−15.58 ± 6.38 vs −1.02 ± 7.79; $p<0.001$). Concordantly, SCORAD scores in the intervention group decreased significantly from 26.98 ± 3.87 to 19.49 ± 4.25 (Δ −7.21; 95% CI −8.34 to −6.06; $p<0.001$), while the control group exhibited a paradoxical increase from 34.54 ± 3.36 to 37.33 ± 8.11 (Δ +2.79; $p=0.011$), with a significant between-group difference (−7.21 ± 5.58 vs +2.79 ± 6.49; $p<0.001$). Correlation analysis revealed no significant association between changes in IL-33 levels and SCORAD scores in either the intervention group ($r = −0.034$; $p=0.842$) or the control group ($r = −0.189$; $p=0.188$).

Conclusions

Oral administration of *Lumbricus rubellus* extract significantly reduces serum IL-33 levels and improves clinical severity in atopic dermatitis. The absence of a linear correlation between IL-33 reduction and clinical improvement suggests a multifactorial therapeutic response beyond a single cytokine pathway. These findings support the potential role of *Lumbricus rubellus* as an immunomodulatory adjuvant targeting upstream inflammatory mechanisms in atopic dermatitis.

EADV Congress 2026, VIENNA
30 SEPTEMBER - 03 OCTOBER 2026
POWERED BY M-ANAGE.COM

EA DV CONGRESS
VIENNA
30 SEP - 3 OCT 2026

Abstract N°: 3487

Ethnic differences in the autoantibody profile of patients with chronic spontaneous urticaria

Sarbjit Saini[1], Martin Metz*[2], Michihiro Hide[3], Theodoulos Rodosthenous[4], Alexandre Avrameas[5], Christoph Kollenda-Strunk[6], Ann-Sophie Lindemann[6], Annika Loredana Kilian[6], Petra Budde[6], Manuel Bräutigam[6], Hans-Dieter Zucht[6], Bruno Cenni[5], Ulf Gehrmann[5], Nadine Chapman-Rothe[5], Sibylle Haemmerle[5]

[1] Division of Allergy and Clinical Immunology, Department of Medicine, Johns Hopkins University School of Medicine, Baltimore, MD, United States

[2] Institute of Allergology, Charité - Universitätsmedizin Berlin, Corporate Member of Freie Universität Berlin and Humboldt-Universität zu Berlin, Fraunhofer Institute for Translational Medicine and Pharmacology ITMP, Immunology and Allergology, Berlin, Germany

[3] Department of Dermatology, Hiroshima City Hiroshima Citizens Hospital, Department of Dermatology, Graduate School of Biomedical and Health Sciences, Hiroshima University, Hiroshima, Japan

[4] Novartis Pharmaceuticals UK Ltd, London, United Kingdom

[5] Novartis Pharma AG, Basel, Switzerland

[6] Oncimmune - Alden Scientific Immune GmbH, Dortmund, Germany

Introduction

Chronic spontaneous urticaria (CSU) is characterised by the spontaneous occurrence of itchy wheals and/or angioedema without any definite trigger, lasting for more than 6 weeks. Autoantibodies may be important drivers of pathology in CSU. As ethnicity and race have been reported to impact both disease characteristics and autoantibody profiles, we investigated whether patients from different ethnic or racial backgrounds with CSU present with distinct autoantibody profiles.

Materials and Methods

Immunoglobulin E (IgE) and immunoglobulin G (IgG) autoantibodies were measured against a pre-selected panel of 58 antigens using a bead-based, multiplexed antigen array. The array included established CSU-related antigens (e.g., TPO, FcεRI, IgE) and potential novel antigens identified in a pilot study. Analysis was performed on serum samples from up to 130 Asian, 114 Hispanic and 320 Caucasian patients with CSU from the BISCUIT (NCT05048342) and REMIX-1/-2 clinical trials (NCT05030311, NCT05032157), that evaluated the safety and efficacy of remibrutinib, an oral, highly selective Bruton's tyrosine kinase inhibitor.

Results

Median IgE levels, proportion of chronic urticaria (CU)-Index positive patients and mean disease duration were significantly different among Asian, Caucasian and Hispanic patients with CSU. However, principal component analysis using autoantibody data did not yield distinct race/ethnicity-based clusters when adjusting for these covariates. While global variance patterns were similar across ethnicities, we detected specific differences across selected autoantibodies using univariate pairwise analyses. Twenty IgG and 15 IgE autoantibody levels were significantly higher in at least one of the three subpopulations. Caucasian patients with CSU had significantly higher IgG autoantibody levels against, for example, FcεR1A and MPO than Hispanic and Asian patients, and higher IgG autoantibodies against IgE as compared to Asian patients but not Hispanic patients. IgE autoantibody

levels against MPO, TGM2 and CUZD were significantly higher in Caucasian patients than in Hispanic and Asian patients.

Conclusions

Our analysis highlights significant differences in disease characteristics between patients of different ethnic and racial backgrounds, which may reflect differences in disease pathogenesis or differences in regional treatment regimen. We did not observe a major impact of ethnicity on the IgG or IgE autoantibody profiles. Instead, the impact of ethnicity on autoantibody profiles, however, was subtle, with Caucasian patients with CSU presenting a more prominent autoimmune profile than Asian and Hispanic patients with CSU. The finding that both IgG and IgE autoantibodies against MPO were significantly elevated in Caucasian patients with CSU may hint at a more pronounced role for neutrophils in disease pathogenesis in this population. Our data suggest that autoantibody results from patients with CSU should be interpreted in the context of race/ethnicity, which limits the power of specific autoantibody tests as universal diagnostic/prognostic biomarkers for disease or treatment outcomes in CSU.

EA DV CONGRESS
VIENNA
30 SEP - 3 OCT 2026

Abstract N°: 3527

Sclerotic Type Cutaneous Graft Versus Host Disease Developing After Herpes Zoster: A Case of Wolf Isotopic Response

Melike Butuner Akcan*[1], Ozge Karstarlı[1]

[1] Pamukkale University, Faculty of Medicine, Department of Dermatology and Venereology, Denizli, Türkiye

Introduction

Graft-versus-host disease (GVHD) is an immune-mediated condition that occurs following allogeneic hematopoietic stem cell transplantation and frequently involves the skin. Chronic cutaneous GVHD may present with lichenoid and sclerotic features, sometimes mimicking other dermatoses. Wolf isotopic response refers to the occurrence of a new, unrelated skin disorder at the site of a previously healed dermatosis, most commonly following herpes zoster. Herein, we report a case of sclerotic-type cutaneous GVHD arising in areas previously affected by herpes zoster.

Case Presentation

A 57-year-old male patient underwent allogeneic hematopoietic stem cell transplantation in 2021 for B-cell acute lymphoblastic leukemia. In 2024, he developed persistent cutaneous lesions localized to areas previously involved by herpes zoster. Dermatological examination revealed multiple coalescing plaques on the right lumbar region, scapular area, and lateral abdomen, characterized by central ivory-white sclerosis surrounded by hyperpigmentation, reaching up to 20 cm in diameter. The lesions initially presented as pruritic, erythematous-violaceous, shiny plaques and gradually evolved into sclerotic lesions. Nail examination demonstrated longitudinal ridging affecting multiple fingernails and dorsal pterygium in one nail.

Histopathological examination of a punch biopsy showed epidermal atrophy with flattened rete ridges and marked dermal hyalinization extending from the superficial to deep dermis, involving adnexal structures. Masson trichrome staining highlighted increased collagen deposition, while elastic orcein staining revealed fragmentation and degeneration of elastic fibers. Clinicopathological correlation supported the diagnosis of sclerotic-type cutaneous GVHD.



Unilateral dermatomal distribution on the right side of the trunk,central ivory-white sclerotic patches

Conclusion

This case demonstrates that chronic GVHD can progress from a lichenoid to a sclerotic phase and may arise in areas previously affected by herpes zoster, consistent with a Wolf isotopic response. This association is rare and has been reported only in a limited number of cases in the literature. It suggests that local immune dysregulation and an altered cutaneous microenvironment following viral infections may act as potential triggers for secondary dermatoses. In clinical practice, it should be kept in mind that complex immune-mediated conditions such as GVHD may develop in previously affected dermatomal areas, even long after the initial disease. Accurate diagnosis relies on detailed patient history, careful dermatological examination, and histopathological correlation. Early recognition of sclerotic GVHD is crucial, as timely initiation of therapy may help prevent irreversible fibrosis and functional impairment.

EA DV CONGRESS
VIENNA
30 SEP - 3 OCT 2026

Abstract N°: 3577

Multi-Omic Profiling of Skin and Serum Identifies Baseline Predictors of Tralokinumab Response and Resolves Barrier Recovery in Atopic Dermatitis

Can Zeyneloglu*[1], Danielle Fehr[2, 3], Milad Ameri[3, 4], Nick Li[3, 4], Ceren Bicer[1, 5], Anna White[3, 4], Cezmi Akdis[1, 3, 6], Marie-Charlotte Brueggen[3, 6, 7]

[1] Swiss Institute for Allergy and Asthma Research, Davos, Switzerland

[2] Department of Dermatology, University Hospital Zürich, Zürich, Switzerland

[3] Faculty of Medicine, University of Zürich, Zürich, Switzerland

[4] Department of Dermatology, University Hospital Zürich, Zürich, Zürich, Switzerland

[5] Institute of Immunobiology, Kantonsspital St. Gallen, St. Gallen, Switzerland

[6] Christine Kühne-Center for Allergy Research and Education (CK-CARE), Davos, Switzerland

[7] Department of Dermatology, University Hospital Zürich, Zürich, Faculty of Medicine, University of Zürich, Zürich, Christine Kühne-Center for Allergy Research and Education (CK-CARE), Davos, Zürich, Switzerland

Introduction

Atopic dermatitis (AD) is driven by epidermal barrier dysfunction and IL-13 dependent type 2 immunity. The IL-13 neutralizing monoclonal antibody tralokinumab is approved for moderate-to-severe AD, but roughly 30 to 40% of patients respond suboptimally and no companion biomarker informs selection. Combining barrier impedance, skin transcriptomics, imaging mass cytometry, and serum proteomics with stability-selected predictive modelling, we sought to determine whether responders and non-responders are molecularly distinct before treatment and to map the on-treatment molecular trajectory of barrier recovery.

Materials and Methods

Twenty adults with moderate-to-severe AD (median baseline SCORAD 46) initiated tralokinumab in a monocentric prospective cohort, with assessments at weeks 0, 4, and 16. Each visit captured SCORAD, electrical impedance spectroscopy (EIS) of lesional skin, lesional biopsies, and blood. Biopsies were profiled by bulk RNA-seq and imaging mass cytometry; serum by Olink targeted proteomics. Response was defined a priori as SCORAD-50 at week 16. Predictive serum biomarkers were identified via bootstrapped elastic net stability selection followed by Firth penalized logistic regression with leave-one-out cross-validation.

Results

14 of 20 patients (70%) achieved SCORAD-50 at week 16, with a median SCORAD reduction of 58%. SCORAD and EIS were inversely correlated ($\rho = -0.54$, $p = 3.8 \times 10^{-5}$), validating EIS as a non-invasive barrier readout. Pre-treatment profiles separated responders from non-responders concordantly across bulk RNA-seq, imaging mass cytometry, and serum proteomics, supporting a multi-modal predisposition signature for tralokinumab response. In skin, baseline differences localized to lipid metabolism, epigenetic regulation, and inflammation pathways, with immune deconvolution showing myeloid enrichment in responders. In serum, PSIP1 emerged as the most stable baseline predictor of response (AUC=0.87), and a longitudinal decrease in CD28 between weeks 0 and 16 added orthogonal stratification.

On treatment, lesional skin across all patients showed coordinated downregulation of type 2 immune, chemokine signaling, and HDAC activity programs alongside upregulation of keratinization and barrier function genes. GSVA confirmed suppression of type-2 inflammation pathways already evident at week 4 (Δ=−1.7) and recovery of cornified envelope and keratinization programs by week 16 (Δ=+1.9. A response-stratified longitudinal gene set enrichment analysis showed coherent inflammatory reversal (IL-4/IL-13, IFN-α/β, IFN-γ, IL-10 signaling, neutrophil degranulation) and barrier healing in responders, with attenuated or non-existent pathway shifts in non-responders. Serum proteomic shifts paralleled skin transcriptomic recovery, supporting blood as a tractable surrogate compartment.

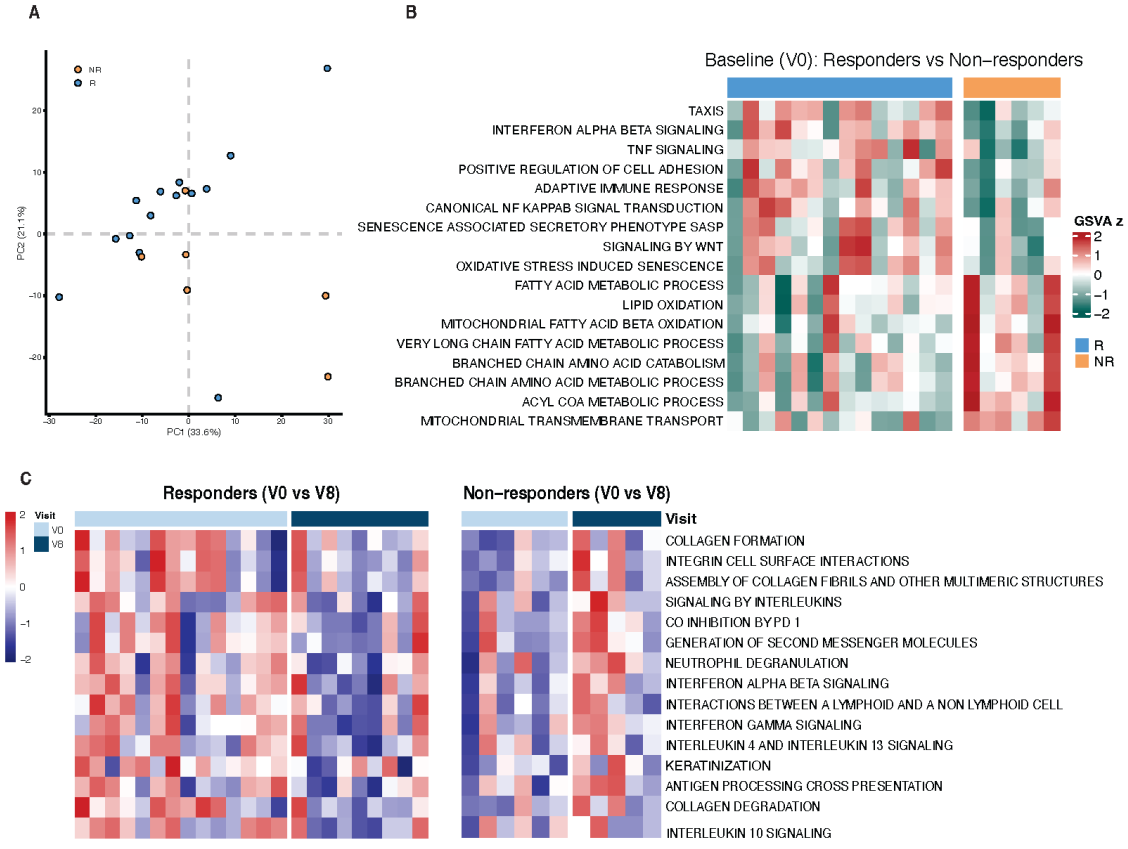

Figure 1: Molecular distinction between tralokinumab responders (R, blue) and non-responders (NR, orange) in moderate-to-severe atopic dermatitis. (A) Baseline (V0) skin-transcriptomic PCA separates R from NR along PC1 (33.6%) and PC2 (21.1%). (B) Baseline GSVA heatmap reveals reciprocal pre-treatment programs: R show elevated inflammatory signaling (IFN-α/β, TNF, NF-κB, adaptive immunity, SASP, WNT), while NR show elevated mitochondrial fatty acid and branched-chain amino acid metabolism. (C) Response-stratified longitudinal Reactome heatmaps (V0 = week 0, V8 = week 16) show coherent reversal of inflammatory programs (IL-4/IL-13, IFN-α/β, IFN-γ, IL-10, neutrophil degranulation) and re-engagement of keratinization in R, with attenuated or divergent shifts in NR. Color: GSVA/pathway z-score.

Conclusions

A pre-treatment molecular signature distinguishing responders from non-responders across skin transcriptomic, tissue immune, and serum proteomic compartments, anchored by serum PSIP1, identifies likely responders to tralokinumab in moderate-to-severe AD. On-treatment multi-modal profiling resolves the molecular trajectory of barrier recovery and type-2 reversal. After confirmation in independent cohorts, this signature could enable a pre-

treatment serum assay to guide biologic selection among IL-13, IL-4Rα, and JAK targeted therapies.

EADV CONGRESS
VIENNA
30 SEP - 3 OCT 2026

Abstract N°: 3589

A genome-wide association study of contact allergy to p-phenylenediamine identifies six novel loci

Fieke Rosenberg[1], Weixin Zhou[1], Laura Loman[1], Ilja Nolte[1], Peter van der Most[1], Harold Snieder[1], Marie-Louise Schuttelaar*[1]

[1] University Medical Center Groningen, University of Groningen, Groningen, Netherlands

Introduction
p-Phenylenediamine (PPD), a potent sensitizer commonly found in hair dyes and black henna tattoos, has been investigated in several candidate gene studies on contact allergy. However, the genetic factors underlying PPD contact allergy remain unclear. We therefore aimed to identify and characterize genetic loci associated with PPD contact allergy.

Materials and Methods
We conducted a discovery genome-wide association study (GWAS) with 150 PPD-positive patch tested cases and 7,553 controls from the population-based Lifelines cohort. Additionally, we performed a sensitivity analysis in a subsample of 82 polysensitized PPD cases. We replicated our findings in an independent Lifelines sample (228 cases and 6,191 controls).

Results
Our discovery GWAS identified six novel loci associated with PPD contact allergy (locus 6p23, 6q24.2, 10q22.3, 10q24.31, 11q23.3, 15q15.1), including a deleterious SNP near *PHACTR2* (6q24.2), a vitiligo-associated SNP (11q23.3), and links to significant changes in expression of *DDX6* (11q23.3) and *PLCB2* (15q15.1) in blood and skin and toalternative splicing of *PHLDB1* (11q23.3) and *PAK6* (15q15.1) in skin. Three of the six loci (6p23, 10q22.3, 15q15.1) were also associated with polysensitization and locus 6p23 was replicated.

Conclusions
This study identified six genetic loci associated with PPD contact allergy, of which three were also associated with polysensitization in PPD cases and locus 6p23 was replicated in an independent sample, underscoring the robustness of our findings.

EADV CONGRESS
VIENNA
30 SEP - 3 OCT 2026

Abstract N°: 3770

Human ß-defensin 2 as a connection between infection and allergic skin diseases: current knowledge from medical literature

Dajana Smoljan Filipović*[1, 2], Liborija Lugovic Mihic[1, 2], Maja Štrajtenberger[3], Asja Stipić-Marković[4], Ema Barac[1], Marinko Artuković[5]

[1] Sestre Milosrdnice University Hospital Centre, Department of Dermatology and Venerology, Zagreb, Croatia

[2] School of Dental Medicine, Zagreb, Croatia

[3] Department of Pulmonology, Special Hospital for Pulmonary Diseases, Zagreb, Croatia

[4] Department for Respiratory Infections, Dr. Fran Mihaljević University Hospital for Infectious Diseases, Zagreb, Croatia

[5] Clinical Hospital "Sveti Duh", Zagreb, Croatia

Introduction

Human ß-defensin (HBD2) is an antimicrobial peptide produced by epithelial cells, keratinocytes and macrophages in response to microbial exposure and pro-inflammatory cytokines. Besides its antimicrobial activity, HBD2 contibutes to immune regulation throuh chemotaxis, toll-like receptor (TLR) activation and mast cell degranulation via the Mas-related G protein-coupled receptor member X2 (MRGPRX2), thereby promoting IgE-independent pseudoallergic reactions. Increasing evidence suggests that HBD2 is involved in inflammatory and allergic akin diseases, including atopic dermatitis (AD), psoriasis, chronic spontaneous urticaris (CSU) and angioedema.

Materials and Methods

In this short review, we wanted to summarize current kowledge of the role of HBD2 in dermatological and allergic conditions, with emphasis on CSU and angioedema. Thus, we analyzed medical literature from the PubMed database. Relevant original articles and review papers were identified using the keywords "human ß-defensin 2", "allergic skin diseases", "atopic dermatitis", "urticaria", and "angioedema". Studies evaluating the expression serum levels, and immunological role of HBD2 in dermatological and allergic disorders were included and analyzed.

Results

Elevated serum and tissue levels of HBD2 have been demonstrated in several inflammatory skin diseases, particulary psoriasis, AD, CSU, and lichen-planus like graft-versus-host disease. In AD, altered HBD2 expression has been associated with impaired skin barrier function, disease severity, and dysregulated innate immunity. HBD2 has also been proposed as a potential biomarker in AD together with inducible nitric oxide synthase and matrix metalloproteinases. In CSU, infections and inaflammatory mediators stimulate mast cells, basophils, and keratinocytes, increasing HBD2 production. Patients with CSU exhibit significantly higher serum HBD2 levels compared with healthy controls, expecially in the presence of concomitant angioedema. Elevated HBD2 levels correlate with increased translationally controlled tumor protein (TCTP) levels and decreased peripheral basophil counts, suggesting a role in mast cell and basphil activation. HBD2 may further contribute to neurogenic inflammation and itch through MRGPRX2-mediated, IgE-independent pathways. Higher HBD2 levels and increased disease activity were significantly associated with the presence of angioedema in CSU patients according to logistic regression analysis.

Conclusions

Current evidence indicates that HBD2 plays an important immunomodulatory role in inlammatory and allergic skin

disease. In CSU, particularly when associated with angioedema, elevated HBD2 levels may reflect mast cell and basophil activation and represent a potential biomarker of disease activity and inflammatory burden. Given its antimicrobial, pro-inflammatory and immunomodulatory properties, HBD2 may also have future therapeutic implications. However, additional clinical and molecular studies are needed to clarify its pathogenic role and diagnostic value in specific dermatological patients subgroups.

EADV CONGRESS
VIENNA
30 SEP - 3 OCT 2026

Abstract N°: 3778

IVIG therapy and hypersensitivity: the chameleon of infusion reactions

Michelle Hattemer*[1], Laura Busse[1], Natalija Novak[1]

[1] University Hospital Bonn, Centre for Skin Diseases, Department of Dermatology and Allergology, Bonn, Germany

Introduction
Intravenous immunoglobulin therapy (IVIG) is a cornerstone of treatment for immune-mediated diseases. Although generally well tolerated, side effects occur in up to 5–15 % of infusions. The classification according to the Gell and Coombs scheme into Type I to Type IV reactions can be applied, with both true allergic and non-allergic hypersensitivity reactions playing a role. Pathophysiologically, in addition to IgE-mediated mechanisms (Type I), immune complex reactions (Type III), direct complement activation (non-allergic hypersensitivity reactions) and T-cell-mediated hypersensitivity (Type IV) are also relevant.

Materials and Methods
Case reports:

1) A 78-year-old patient with inflammatory neuropathy received 3 cycles of IVIG therapy (2 g/kg body weight) over 3 months. Two weeks after the last dose, the patient developed a macular exanthema. Diagnosis: drug-induced exanthema (Type IV).

2) A 70-year-old patient with multifocal motor neuropathy (MMN) developed a mild maculopapular exanthema a few days after the first dose of IVIG therapy (2 g/kg body weight) and a pronounced maculopapular, partly urticarial exanthema one week after the second dose. Diagnosis: Drug-induced exanthema with an immediate-type urticarial component (Type I/IV).

3) A 62-year-old patient with distal-predominant sensorimotor polyneuropathy developed generalised pruritus with urticaria approximately 2 hours after the first administration of IVIG therapy. Diagnosis: Grade I anaphylaxis (Type I), DD non-allergic hypersensitivity reaction.

4) An 88-year-old female patient with immune-mediated necrotising myopathy (IMNM) received IVIG therapy (1 g/kg) from 2023 to 2024 regularly. In 2026, IVIG reinduction was performed. A few hours after the start of the infusion the patient developed flushing with a globus sensation. Diagnosis: Grade II anaphylaxis (Type I), DD non-allergic hypersensitivity reaction.

5) A 53-year-old male patient with sensorimotor axonal demyelinating polyneuropathy developed disseminated erythrosquamous and itchy plaques approximately 2 weeks after the first administration of IVIG therapy (2 g/kg body weight). Diagnosis (histological): immune-mediated psoriasiform or eczematous dermatitis.

Results
The case vignettes reflect the heterogeneity of IVIG-associated hypersensitivity reactions described in the literature. The rarer immediate reactions (Type I) occur within minutes to hours of the start of the infusion and are based on IgE-mediated mechanisms or – more frequently – on non-allergic hypersensitivity due to direct mast cell activation or complement activation by IgG aggregates. Management of complications includes acute anaphylaxis treatment as well as cardiopulmonary stabilisation in potentially life-threatening cases. Over time, allergological

provocation and avoidance testing enable risk stratification for subsequent infusions.

Frequently occurring delayed Type IV reactions typically manifest 1–2 weeks after infusion as a exanthema and are based on T-cell-mediated sensitisation, which may escalate upon re-exposure. Further diagnostic investigation using epicutaneous patch testing and lymphocyte transformation tests can provide information critical to the course of treatment.

Type III reactions (e.g. serum sickness-like courses) have been described but are rare; type II reactions play a minor role in the IVIG context. In the differential diagnosis, the broad spectrum of infusion-associated adverse drug reactions should always be considered, particularly as these can mimic allergic complications.

Conclusions
Classification by reaction type (types I–IV) is crucial for determining the course of action and further diagnosis. Permanent discontinuation of therapy is rarely necessary; in the absence of an alternative preparation, structured desensitisation or premedication may be considered. Rapid diagnosis and interdisciplinary collaboration between neurology, allergology and dermatology are essential in this regard.

EA DV CONGRESS
VIENNA
30 SEP - 3 OCT 2026

Abstract N°: 3892

Bruton's Tyrosine Kinase Inhibitors in the Treatment of Chronic Spontaneous Urticaria: A Systematic Review of the Latest Evidence

Aleksandra Frątczak*[1], Weronika Nowicka[2], Anna Kożuch[2], Wiktor Kruczek[1, 2, 3], Anna Tekielak[1, 3], Bartosz Miziołek[1], Beata Bergler-Czop[1]

[1] Department of Dermatology, School of Medicine in Katowice, Medical University of Silesia, Katowice, Poland
[2] Students' Scientific Association at the Department of Dermatology, School of Medicine in Katowice, Medical University of Silesia, Katowice, Poland
[3] Doctoral School, Medical University of Silesia, Katowice, Poland

Introduction
Chronic spontaneous urticaria (CSU) is an inflammatory dermatological condition in which mast cells are considered one of the key pathogenic factors. The disease is characterized by the recurrence of pruritic wheals, with or without angioedema. It appears without a known trigger and persists for more than six weeks. CSU may significantly impair patients' quality of life and daily functioning. First-line treatment consists of second-generation H1-antihistamines. However, recent reports suggest a potential therapeutic role for Bruton's tyrosine kinase (BTK) inhibitors in patients who do not respond adequately to standard treatment. Although BTK inhibitors were initially used in B-cell malignancies, their potential in dermatological diseases has recently gained increasing attention. The aim of this study was to summarize current knowledge on the impact of BTK inhibitors in the treatment of patients with CSU, with particular focus on treatment efficacy and adverse events.

Materials and Methods
A systematic literature review was conducted in accordance with the PRISMA guidelines. PubMed, Embase, and Scopus databases, along with studies registered on ClinicalTrials.gov, were searched from database inception to April 2026. Eligible studies included 7 publications addressing adult patients diagnosed with CSU and treated with BTK inhibitors, particularly remibrutinib, rilzabrutinib, and fenebrutinib. Only original studies, including phase II and III clinical trials, were included. Studies were screened by one reviewer and verified by at least one additional reviewer.

Results
BTK inhibitors, including remibrutinib, rilzabrutinib, and fenebrutinib, demonstrated rapid and clinically significant activity in patients with antihistamine-refractory CSU. Importantly, treatment response was observed within the first week of therapy, including improvements in pruritus as well as the number and severity of wheals. A decrease in overall disease activity, assessed by the Weekly Urticaria Activity Score (UAS7), was also noted. BTK inhibitors were generally well tolerated, with most adverse events assessed as mild to moderate in severity. The most frequently reported adverse events included mild infections, headache, and

gastrointestinal symptoms.

Conclusions

BTK inhibitors may represent an effective therapeutic option for patients with antihistamine-refractory CSU, especially in moderate-to-severe disease. Current management strategies primarily provide symptomatic control, while BTK inhibitors may offer rapid suppression of disease activity in patients inadequately controlled by standard therapy, which remains a significant clinical challenge in European healthcare systems and routine clinical practice. However, further studies are needed to establish their long-term efficacy and safety in CSU treatment.

EADV CONGRESS
VIENNA
30 SEP - 3 OCT 2026

Abstract N°: 4044

Characterization of a novel in vitro model of human skin-derived mast cells

Adrien Brulefert*[1], Fabienne Guyard[1], Vincent Morin[1], Julien Oré[1], Benjamin Hébrard[1], Valérie Hamon De Almeida[1]

[1] QIMA Life Sciences, QIMA Bioalternatives SAS, Gençay, France

Introduction

Mast cells drive immunity, inflammation, tissue repair, and diseases like allergy, asthma, and autoimmunity. Because rodent cells may not fully recapitulate human mast cell biology, we developed and characterized an in vitro model of primary human dermal mast cells from skin explants as a more translational platform for mechanistic and pharmacologic studies.

Materials and Methods

Mast cells were obtained from surgical skin discard by enzymatic digestion followed by magnetic separation to enrich the CD117+ cell population. Isolated cells were profiled by transcriptome analysis (Affymetrix) and phenotyped by flow cytometry. Functional responsiveness was assessed using short- and long-term activation assays to measure mediator release and surface activation markers. Degranulation and mediator production in response to activating stimuli and the capacity of known inhibitors to suppress these responses were quantified by measuring histamine, TNFα, PGE2, IL-8 and IL-13. CD63 expression was used as a marker of activation.

Results

The enriched CD117+ population exhibited transcriptional and phenotypic features consistent with human mast cells. Stimulation with compound 48/80 induced upregulation of CD63 and a rapid six-fold increase in histamine release relative to control cells during short incubations ($p < 0.05$). Longer exposures led to significantly increased secretion of TNF-α and IL-8 ($p < 0.05$), as well as PGE2 and IL-13 ($p < 0.001$). The mast cell stabilizer cromoglycate reduced stimulus-induced histamine release by seven-fold ($p < 0.05$). Inhibitory reference compounds dexamethasone and indomethacin attenuated the release of the measured mediators.

Conclusions

We present a human primary dermal mast cell model derived from skin explants that displays expected activation markers and mediator profiles and responds to established inhibitors. This system offers a human-relevant tool for studying mast cell biology and for screening or profiling compounds that modulate mast cell activation in contexts such as allergy, asthma and dermatological disease.

EA DV CONGRESS
VIENNA
30 SEP - 3 OCT 2026

Abstract N°: 4117

Cutaneous Toxicities of Targeted Therapies: A Dermatologic Challenge with Oncologic Implications

Hafsa Laouni*[1], Zakia Douhi[1], Ikram Bejja[1], Saadia Boughaleb[1], Meryem Soughi[1], Sara Elloudi[1], Hanane Baybay[1], Fatima Zohra Mernissi[1]

[1] Dermatology Department, HASSAN II University hospital, Fès, Morocco

Introduction

Targeted therapies (TTs) play a pivotal role in oncodermatology and have revolutionized the prognosis of several malignancies, with a more favorable toxicity profile compared with conventional chemotherapy. However, they are associated with a distinct spectrum of adverse events, predominantly affecting the skin, which are often correlated with therapeutic efficacy. This study aimed to emphasize the crucial role of oncodermatology by characterizing the cutaneous adverse events associated with TTs and optimizing the multidisciplinary management of patients receiving these treatments.

Materials and Methods

We conducted a single-center, retrospective, descriptive study including patients treated for various malignancies with targeted therapies who developed dermatological adverse events (DAEs). All patients underwent a complete dermatological examination. The identification and grading of adverse events were based on a non-exhaustive review of the literature. A multidisciplinary therapeutic decision was subsequently made for each patient.

Results

A total of 54 patients were included, with a mean age of 61.5 years and a female predominance (62.9%). A wide spectrum of DAEs was observed, mainly involving the skin and its appendages, while mucosal involvement was less frequent. Most patients presented with multiple concurrent manifestations. Acneiform eruptions were the most frequent DAEs, occurring in 48.1% of patients, all of whom were receiving EGFR inhibitors. The onset occurred 2–4 weeks after treatment initiation, with severity ranging from grade 1 to grade 4, grade 2 being the most common. Among patients with acneiform eruptions, 50% were treated with panitumumab, 23.1% with cetuximab, 15.4% with afatinib, 7.7% with erlotinib, and 3.8% with gefitinib. Hand–foot syndrome was the second most frequent DAE, with a significant impact on quality of life, observed in 30.9% of patients (13 cases). Of these, 53.8% were treated with multikinase inhibitors, 38.5% with anti-EGFR agents, and 7.7% with pembrolizumab. A lichenoid eruption was reported in 2 patients (4.8%), both treated with imatinib. A maculopapular rash was observed in 1 patient (2.4%) receiving imatinib; it was generally mild and transient and did not require treatment discontinuation, except in cases progressing to severe cutaneous adverse drug reactions such as DRESS, which occurred in 2 patients (4.8%) treated with imatinib. Pigmentary disorders presenting as vitiligo-like reactions were noted in 2 patients with melanoma treated with pembrolizumab. Regarding adnexal involvement, paronychia was the most frequent manifestation, observed in 8 patients (19%), including 7 patients treated with anti-EGFR agents and 1 patient treated with imatinib. It was associated with pyogenic granuloma in 4 cases. All hair changes occurred in patients receiving EGFR inhibitors: female hirsutism with increased terminal facial hair was reported in 2 patients, and eyelash hypertrichosis associated with eyebrow and scalp alopecia was observed in 1 patient.

Conclusions

Dermatological toxicities affecting the skin, mucosae, hair, and nails are frequent and heterogeneous in patients treated with targeted therapies. These adverse events can significantly impair quality of life, negatively affecting treatment adherence and potentially compromising therapeutic efficacy and progression-free survival. Close collaboration between dermatologists and oncologists is therefore essential. Our findings are consistent with previously published data, highlighting acneiform eruptions and adnexal involvement associated with EGFR inhibitors, lichenoid and maculopapular reactions related to imatinib, and hand–foot syndrome induced by multikinase inhibitors.

EA DV CONGRESS
VIENNA
30 SEP - 3 OCT 2026

Abstract N°: 4201

Comparative Efficacy and Safety of FDA-Approved Oral Targeted Therapies for Moderate-to-Severe Plaque Psoriasis: A Systematic Review and Bayesian Network Meta-Analysis of Randomized Controlled Trials

Elvira Lesmana Lesmana*[1], Eliza Lesmana[2], Hanny Nilasari[1], Eyleny Meisyah Fitri[1], Windy Keumala Budianti[1], Endi Novianto[1]

[1] Department of Dermatology and Venereology, Faculty of Medicine Universitas Indonesia, Dr. Cipto Mangunkusumo National Central General Hospital, Jakarta, Indonesia
[2] School of Computing and Data Science, The University of Hong Kong, Hong Kong, Hong Kong

Introduction

Three oral targeted therapies are approved for moderate-to-severe plaque psoriasis: apremilast (phosphodiesterase-4 inhibitor), deucravacitinib (selective allosteric tyrosine kinase 2 inhibitor), and icotrokinra (first-in-class oral interleukin-23 receptor antagonist peptide). Despite shared indication, no unified analysis comparing all three agents has been conducted, leaving clinicians without a comprehensive evidence base for treatment selection. We aimed to compare the relative efficacy and safety of all approved oral targeted therapies using a Bayesian network meta-analysis (NMA).

Materials and Methods

A systematic review and Bayesian NMA were conducted in accordance with PRISMA-NMA guidelines (PROSPERO: CRD420261350746). MEDLINE, Cochrane Library, Embase, and Scopus were searched from inception to May 2026. Additional studies were identified through hand-searching the reference lists of included studies and relevant systematic reviews. Eligible studies were Phase 3 RCTs in adults with moderate-to-severe plaque psoriasis (PASI ≥12, body surface area ≥10%) receiving icotrokinra 200 mg once daily, deucravacitinib 6 mg once daily, or apremilast 30 mg twice daily, versus placebo or an active comparator, at week 16. Co-primary outcomes were PASI 75 and physician global assessment (PGA) 0/1. Secondary outcomes included PASI 90, PASI 100, and treatment-emergent adverse events (TEAE). Risk of bias was assessed using Cochrane RoB 2.0, certainty of evidence using CINeMA.

Results

Eight Phase 3 RCTs (N=5,350; ESTEEM 1 and 2, POETYK PSO-1, -2, and -3, ICONIC-LEAD, ICONIC-ADVANCE 1 and 2) were included. All trials had a low risk of bias. The network included direct head-to-head evidence between icotrokinra and deucravacitinib (ICONIC-ADVANCE 1 and 2). Network consistency was confirmed across all comparisons (all p>0.10). All three agents significantly outperformed placebo. For PASI 75, treatment hierarchy by SUCRA was: icotrokinra (OR 23.78, 95% CrI 12.72–44.50; SUCRA=1.000), deucravacitinib (OR 11.75, 95% CrI 8.96–15.95; SUCRA=0.667), and apremilast (OR 6.14, 95% CrI 3.27–11.51; SUCRA=0.334). This hierarchy was consistent across PASI 90, PASI 100, and PGA 0/1. Direct evidence confirmed icotrokinra superiority over deucravacitinib: PASI 75 (OR 2.02, 95% CrI 1.42–2.79), PASI 90 (OR 2.56, 95% CrI 1.67–3.62), and PGA 0/1 (OR 1.96, 95% CrI 1.46–2.55; all P[ICO>DEU]≥99.8%). Deucravacitinib significantly outperformed apremilast across all outcomes. Results were consistent across both sensitivity analyses. Regarding safety, icotrokinra was the only agent with a point estimate below 1.00 for TEAE versus placebo (OR 0.85, 95% CrI 0.51–1.43; SUCRA=0.965), with no credible increase in adverse-event risk. Deucravacitinib (OR 1.30, 95% CrI 1.04–1.64) and apremilast (OR 1.50, 95% CrI 0.89–2.52)

showed credible or near-credible increases in TEAE risk. The posterior probability that icotrokinra had fewer TEAEs than deucravacitinib was 99.3%.

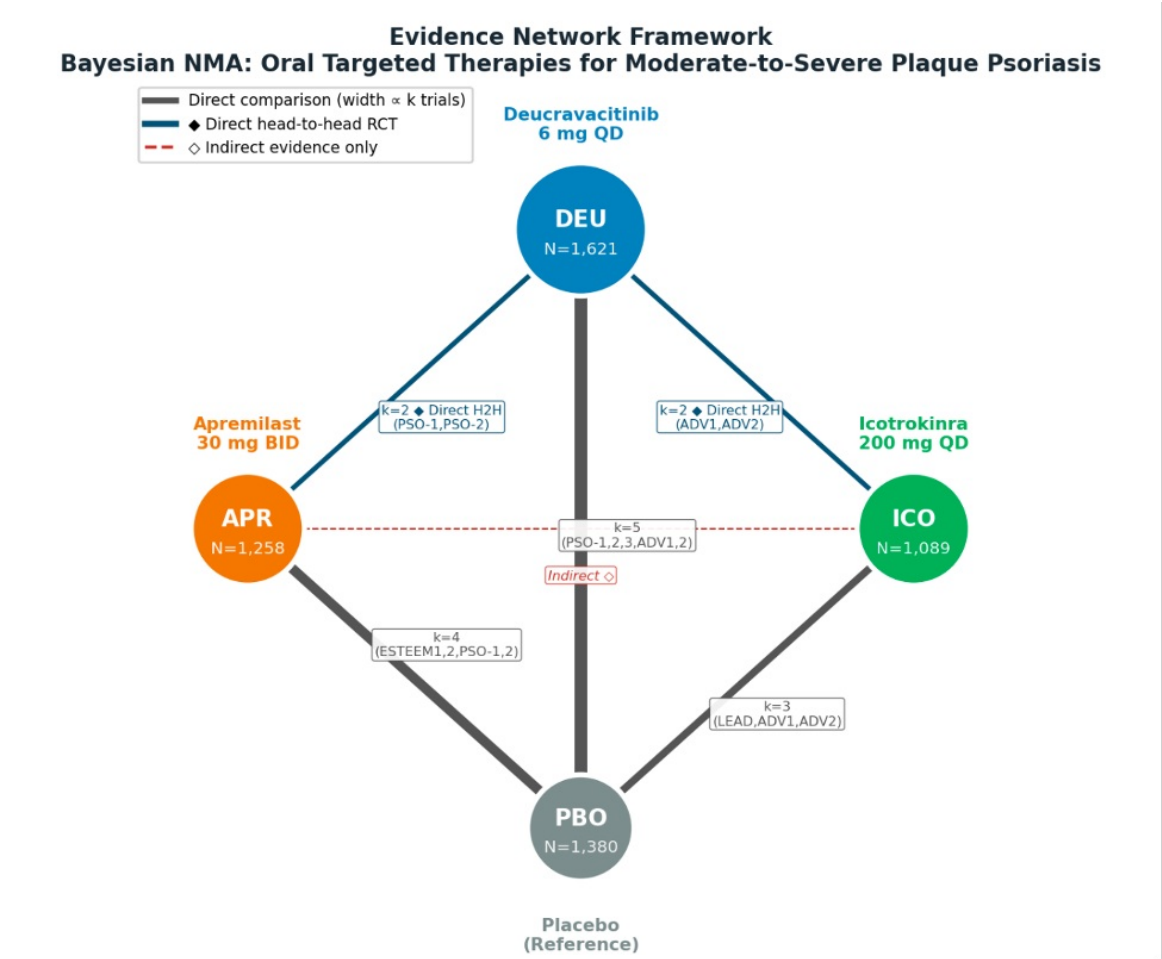

Figure 1. Evidence network for the Bayesian network meta-analysis comparing approved oral targeted therapies for moderate-to-severe plaque psoriasis. Node size is proportional to the number of randomized participants. Edge width is proportional to the number of trials per direct comparison. Blue solid lines indicate direct head-to-head randomized comparisons between active treatments; grey solid lines indicate direct comparisons versus placebo; red dashed line indicates the only indirect-evidence comparison (icotrokinra vs apremilast). APR, apremilast; DEU, deucravacitinib; ICO, icotrokinra; PBO, placebo

Conclusions

This Bayesian NMA, incorporating the first direct head-to-head evidence between icotrokinra and deucravacitinib, demonstrates a consistent efficacy hierarchy across all outcomes: icotrokinra>deucravacitinib>apremilast. Icotrokinra was the only agent with a point estimate below 1.00 for TEAE versus placebo, with 99.3% posterior probability of having fewer adverse events than deucravacitinib. These findings support icotrokinra as the most efficacious and best-tolerated approved oral targeted therapy for moderate-to-severe plaque psoriasis.

EADV CONGRESS
VIENNA
30 SEP - 3 OCT 2026

Abstract N°: 4271

FAERS Pharmacovigilance Disproportionality Analysis: Serious Adverse Events Associated with Lanadelumab Administration for Hereditary Angioedema Prophylaxis

Adalia-Cristiana Iancu*[1, 2], Yara Shhab[1], Marwan Kobtan[3], Shady Elrashidy[4], Shatha Al Aqarbeh[5], Alexandru-Ioan Draghici[6]

[1] Carol Davila University of Medicine and Pharmacy, Bucharest, Romania
[2] Victor Babes University of Medicine and Pharmacy, Timisoara, Romania
[3] Cairo University Hospitals Kasr Al Ainy, Cairo, Egypt
[4] Matarreya Teaching Hospital, Cairo, Egypt
[5] Near East University, Nicosia, Cyprus
[6] Iuliu Haţieganu University of Medicine and Pharmacy, Cluj-Napoca, Romania

Introduction
Hereditary angioedema (HAE) is a rare genetic disorder caused by excessive bradykinin production, leading to recurrent subcutaneous and submucosal edema. Lanadelumab, a fully human anti-plasma kallikrein monoclonal antibody approved in August 2018, is the first biologic indicated for long-term HAE prophylaxis. Spontaneous reports from pharmacovigilance systems such as the FDA Adverse Event Reporting System (FAERS) have flagged potentially serious hypersensitivity, neurologic and cardiopulmonary reactions warranting systematic evaluation. Unlike prior FAERS studies, this study uses a disease-matched active comparator design and is the first to isolate rash macular as a distinct signal.

Materials and Methods
A retrospective pharmacovigilance disproportionality analysis was conducted using FAERS data from August 2018 through Q3 2025, extracted via the DiAna package (v2.1.0) in R (v4.5.2). The exposure group included reports listing lanadelumab as primary or secondary suspect; the comparator group included reports listing other HAE prophylactics (berotralstat, C1-inhibitor products, conestat alfa), using an active comparator design to control for confounding by indication. Reports were included if designated as serious per FDA criteria, including death, hospitalization, life-threatening event, disability or other medically important condition, and confirmed non-duplicate via DiAna's RB_duplicates algorithm. The 405 overlapping reports were excluded from both groups, yielding 2,171 serious lanadelumab reports and 6,986 serious comparator reports. Analyzed outcomes were serious adverse events coded by MedDRA Preferred Terms across four domains: respiratory, cardiovascular, dermatologic/hypersensitivity and neurologic. Signal detection used the Reporting Odds Ratio (ROR) and Information Component (IC) with Bonferroni correction (ROR lower 95% CI >1, IC lower 95% CI >0, n >=3 cases). Three pre-specified sensitivity analyses were performed: primary suspect reports only, single suspect drug reports only and US-origin reports only.

Results
Both groups reflected expected HAE demographics: the lanadelumab group was 73% female with a median age of 48 years, while the comparator group was 62% female with a median age of 41 years. Rash macular was the only confirmed signal in the primary analysis (ROR 9.39, 95% CI 2.47–52.50; n=11), remained significant when restricted to primary suspect reports (ROR 8.32, 95% CI 1.77–51.47; n=6) and was the strongest signal in US-origin reports (ROR 17.26, 95% CI 2.09–791.27). Rash macular had a median time-to-onset of 1 day post-administration (n=4);

testing was non-significant, likely due to small sample size. Chest pain showed a weak primary signal (ROR 1.41, 95% CI 1.02–1.94; n=64) that strengthened in both the single-suspect analysis (ROR 3.73, 95% CI 1.56–9.57) and US-only analysis (ROR 3.33, 95% CI 2.05–5.42). The US-origin analysis produced the broadest signal pattern, additionally identifying urticaria (ROR 3.18, 95% CI 2.07–4.90), dizziness (ROR 2.49, 95% CI 1.71–3.61), rash (ROR 2.01, 95% CI 1.25–3.19) and dyspnoea (ROR 1.72, 95% CI 1.22–2.40). Rash demonstrated a statistically non-uniform time-to-onset distribution (p=0.002, median 82 days), as did tachycardia (p=0.040, median 45.5 days). Classic HAE symptoms showed no disproportionate reporting relative to comparators, suggesting effective disease control with lanadelumab.

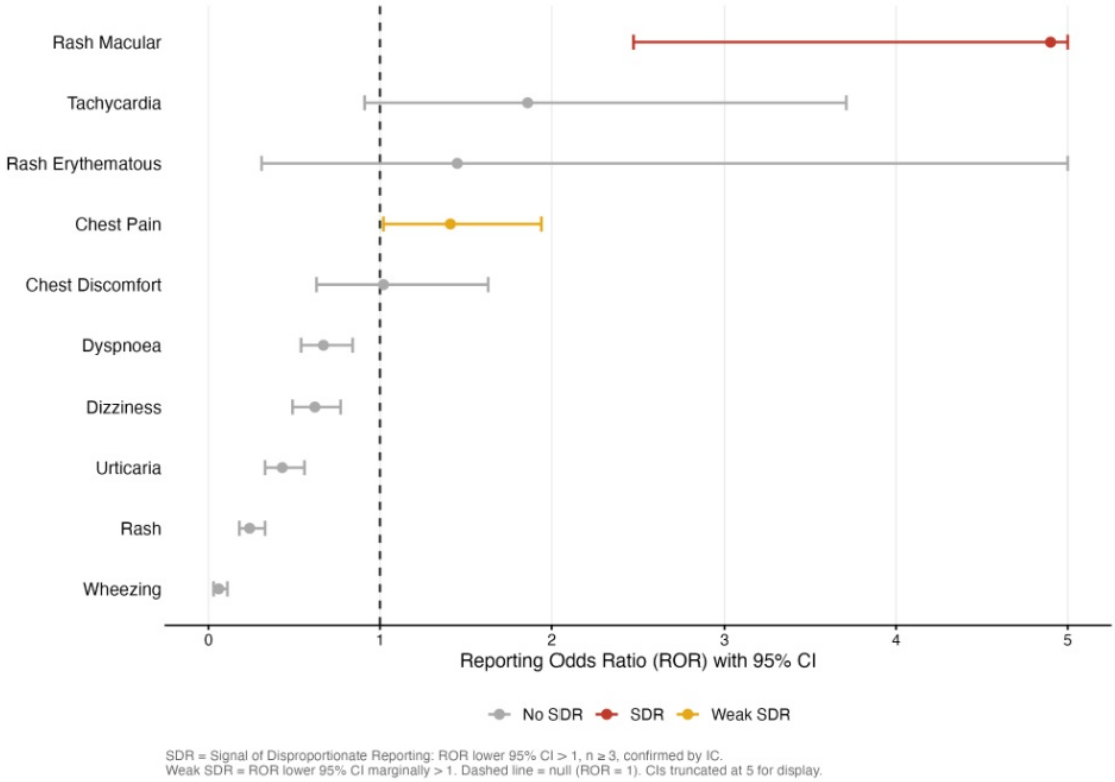

Conclusions

This study provides the first active-comparator pharmacovigilance evidence for lanadelumab in FAERS. Rash macular was identified as a novel disproportionate adverse event signal, distinct from injection-site erythema and maculopapular rash. Time-to-onset analysis suggests a potential acute hypersensitivity mechanism not previously characterized. Secondary signals, particularly chest pain and urticaria, were most apparent in US-origin reports and may reflect a broader post-injection hypersensitivity pattern. Together, these findings add real-world safety context that clinical trials alone could not capture.

EA DV CONGRESS
VIENNA
30 SEP - 3 OCT 2026

Abstract N°: 4405

Epidemiological Trends in Allergic Diseases and Allergen Immunotherapy: A Retrospective Analysis of 11,889 Adult Patients in a German Dermatology and Allergology Center

Spyridon Kostaras*[1], Iman Abdelrahman[1], Tetiana Kazmerchuk[1], Evgenia Makrantonaki[1, 2, 3]

[1] Derma Center Wildeshausen, Wildeshausen, Germany

[2] Brandenburg Medical School Theodor Fontane, Department of Dermatology, Venereology and Immunology, University Hospital, Ruppin-Brandenburg, Germany

[3] Ulm University Hospital, Department of Dermatology and Allergology, Ulm, Germany

Introduction

Allergic diseases have shown a continuous increase in prevalence over recent decades and represent a major public health challenge worldwide. Environmental influences, urbanization, climate change, and increasing exposure to aeroallergens are considered important contributing factors. Parallel to the growing burden of allergic diseases, allergen-specific immunotherapy (AIT, hyposensitization) has gained increasing importance as the only causal treatment option for IgE-mediated allergies. In dermatological and allergological routine care, increasing numbers of patients seek diagnostic evaluation and long-term therapeutic management for allergic disorders.

Objectives

The aim of this study was to analyze the prevalence and distribution of allergic diseases as well as the utilization of allergen-specific immunotherapy in a large patient cohort treated in a dermatological outpatient clinic.

Methods

A retrospective observational analysis was performed including 11,889 adult patients presenting to a specialized dermatology and allergology center. Patient records were evaluated regarding age distribution, clinical diagnoses, and implementation of allergen-specific immunotherapy. Allergic diseases were categorized into atopic eczema, contact eczema, allergic rhinitis, asthma bronchiale, urticaria/angioedema, drug exanthema, food allergy, and anaphylaxis. Subgroup analyses were performed for patients aged 18–65 years and patients older than 65 years.

Results

Overall, allergic diseases represented a substantial proportion of dermatological consultations. In patients aged 18–65 years (n=7,810), allergic diagnoses accounted for approximately 30% of all cases. The most prevalent diagnosis in this group was atopic eczema (50%), followed by contact eczema (16%), urticaria/angioedema (12%), allergic rhinitis (9%), drug exanthema (6%), asthma (4%), food allergy (2%), and anaphylaxis (1%).

In patients older than 65 years (n=4,079), allergic diseases accounted for approximately 26% of all cases. Similar to the younger cohort, atopic eczema represented the most common diagnosis (50%). However, contact eczema was more frequent in elderly patients (24%), whereas allergic rhinitis (6%), asthma (2%), and urticaria/angioedema (8%) were comparatively less common. Drug exanthema accounted for 7% of diagnoses, while food allergy (2%) and anaphylaxis (1%) remained relatively rare.

Analysis of allergen-specific immunotherapy demonstrated a marked predominance in younger patients. A total of 91% of all hyposensitization therapies were performed in patients aged 18–64 years, whereas only 9% were initiated in patients older than 65 years.

Conclusions

This large real-world analysis demonstrates the substantial and persistent clinical relevance of allergic diseases in

dermatological practice across all age groups. Atopic eczema represented the leading allergic diagnosis in both younger and elderly patients, while contact eczema showed increased prevalence in older individuals. Despite the considerable burden of allergic disease in elderly patients, allergen-specific immunotherapy was performed predominantly in younger populations. These findings underline the growing importance of structured allergological diagnostics and individualized therapeutic strategies, particularly in the context of demographic change and the increasing prevalence of chronic allergic diseases.