EADV CONGRESS
VIENNA
30 SEP - 3 OCT 2026

Abstract N°: 28

Explainable AI-assisted remote monitoring of chronic wounds in dermatology: prospective app-based feasibility study (WUNDERKINT)

Tassilo Dege*[1], Luisa Deutzmann[1], Vanessa Borst[2], Samuel Kounev[2], Astrid Schmieder[1]

[1] Department of Dermatology, Venereology and Allergology, University Hospital Würzburg, Würzburg, Germany
[2] Department of Computer Science, University of Würzburg, Würzburg, Germany

Introduction
Chronic wounds require frequent follow-up, but in-person assessment alone may miss clinically relevant changes between visits. AI-supported mobile monitoring may improve longitudinal documentation by combining patient-reported outcomes with standardized image-based wound assessment. In addition to automated wound segmentation and size tracking, explainable AI (XAI) approaches can support clinical plausibility and trust in dermatology workflows. To evaluate the feasibility and clinical relevance of a patient-centered app-based chronic wound monitoring pathway using AI-assisted wound assessment and longitudinal symptom and quality-of-life tracking in routine dermatologic care.

Materials and Methods
This ongoing prospective, non-interventional 24-week study (DRKS00038408) includes adults with chronic wounds recruited at a university dermatology center. Participants perform weekly app-based self-documentation (wound photo, symptoms, short quality-of-life items), with optional teleconsultation. The pathway is designed for direct patient use in routine care without mandatory wound manager support or physician-performed image acquisition between scheduled visits. AI modules support automated wound measurement and longitudinal change detection; XAI visual overlays enhance interpretability of image-based assessments. The present analysis used available baseline and paired baseline/follow-up data from the current cohort. Outcomes were analyzed descriptively with paired exploratory comparisons.

Results
The baseline cohort comprised 34 participants with a mean age of 52.1 years (SD 16.1) and mean BMI of 32.6 kg/m² (SD 8.7). Sex distribution was nearly balanced between men and women. Wound etiologies were heterogeneous; venous leg ulcer was most common (50.0%), followed by pyoderma gangrenosum (26.5%), a proportion reflecting the tertiary referral pattern of the recruiting university center. AI-based wound measurements could be generated and longitudinally retrieved automatically from serial app images, enabling structured remote follow-up. XAI overlays showed good concordance with human rater assessment patterns, supporting clinical interpretability of AI-based image analysis. Over time, patient-reported outcomes improved: DLQI decreased from 11.63 to 7.95 ($p=0.035$), Wound-QoL decreased from 2.08 to 1.27 ($p=0.0069$), and WHO-5 increased from 13.29 to 16.53 ($p=0.035$). HADS anxiety and depression scores also decreased numerically, but without statistical significance ($p=0.379$ and $p=0.341$). Follow-up documentation additionally contained healed-wound entries in a relevant subset. In one case, suspected cellulitis was identified during remote monitoring and managed via teledermatology consultation, helping to prevent further clinical deterioration.

Conclusions
Explainable AI-supported, patient-centered app-based monitoring of chronic wounds appears feasible and clinically relevant in dermatology, with encouraging improvements in dermatology-specific quality of life, wound-related quality of life, and well-being over time. The combination of patient self-monitoring, AI-based objective

wound assessment, XAI-supported interpretability, teledermatology-triggered early intervention, and longitudinal PROM capture is highly relevant for teledermatology and decentralized wound care.

EA DV CONGRESS
VIENNA
30 SEP - 3 OCT 2026

Abstract N°: 79

Dynamic Alterations in the Skin Microbiome Following Ablative CO2 Laser Resurfacing: Implications for Healing and Barrier Recovery

Anne-Laure Demessant-Flavigny*[1], Shermine Warde[1], Maria Delage[2], Alban Mathieu[3], Guénaëlle LE DANTEC[4], Caroline Lefloch[1], Magali Moreau[5]

[1] La Roche-Posay Laboratoire Dermatologique, Levallois-Perret, France
[2] L'Oréal Research and Innovation, Aulnay-Sous-Bois, France
[3] Centre Hospitalier Universitaire (CHU) Québec-Université Laval, Quebec, France
[4] L'Oréal Research and Innovation, Chevilly-Larue, France
[5] L'Oreal Research and Innovation, Clak NJ, United States

Introduction

The skin microbiome, integral to skin barrier, plays a critical role in cutaneous health and wound healing. Ablative CO_2 laser resurfacing, a common dermatological procedure, induces controlled epidermal wounds, modeling re-epithelialization kinetics post-laser dermabrasion. While the macroscopic effects are well-characterized, its dynamic impact on skin microbiota requires further elucidation. This study investigates skin microbiome changes post-CO_2 laser treatment and their implications for wound repair.

Materials and Methods

A randomized split-back study enrolled 25 subjects with one side undergoing CO_2 laser and the other side untreated. On the treated side, laser treatment was performed at Day 2 by a dermatologist on one zone (2cmX2cm). Wound healing clinical scoring, trans-epidermal water loss (TEWL) and microbiome sampling were followed over time. Regarding microbiome sampling, after DNA extraction, it was characterized using in-house 16S metagenomic pipeline, and *S. aureus* was specifically quantified using targeted quantitative PCR.

Results

Targeted qPCR and 16S metagenomic analysis revealed profound, temporary disruptions in the skin microbiome following laser treatment. While microbial richness significantly decreased at Day 9 and recovered by Day 19, marked compositional shifts were observed as early as Day 4. These changes were primarily driven by a transient over-colonization of *Staphylococcus* spp. Specifically, *S. aureus*, undetected at baseline, was detected in 44% of the panel by Day 4. A high *S. aureus* load was identified as a significant driver of delayed kinetics, correlating with slower clinical wound healing scores and impaired barrier recovery (TEWL) compared to non-carriers.

Conclusions

These findings underscore the profound, albeit temporary, disruption of microbial homeostasis by ablative laser therapy and highlight a link between specific microbial shifts and healing kinetics. In particular, *S.aureus* transiently over-colonized half the panel. Interestingly, the presence and

quantity of *S. aureus* significantly correlated with slower wound healing and barrier recovery.

EADV CONGRESS
VIENNA
30 SEP - 3 OCT 2026

Abstract N°: 135

Hair Follicle Transplantation Promotes Chronic Wound Healing: Insights into Regenerative Mechanisms from a Translational Study

Traidit Thianthanyakij*[1, 2], Zhongxin Sun[3], Xi Chu[4], Jufang Zhang[4]

[1] Department of Plastic and Cosmetic Surgery, School of Medicine, Tongii University, No.389 Xincun Road, Shanghai 200065, China, Shanghai, China

[2] Institute of Aesthetic Plastic Surgery and Medicine, School of Medicine, Tongji University, No.389 Xincun Road, Shanghai 200065, China, Shanghai, China

[3] Department of Hand Microsurgery and Plastic Reconstructive Surgery, Ningbo No.6 Hospital, Ningbo, Zhejiang, 315040, P.R China, Ningbo, China

[4] Department of Plastic and Cosmetic Surgery, Affiliated Hangzhou First People's Hospital, School of Medicine, Westlake University, Hangzhou, Zhejiang, 310006, P.R China, Hangzhou, China

Introduction

Chronic wounds remain a major clinical challenge due to persistent inflammation, impaired extracellular matrix remodeling, and delayed tissue regeneration. Previous studies have suggested that hair follicles can promote wound healing, and several clinical reports have described the use of follicular grafts to improve ulcer repair. However, these studies primarily focused on clinical outcomes, and the biological mechanisms underlying follicle-mediated regeneration remain poorly understood. In particular, the molecular pathways and cellular interactions through which hair follicles influence the wound microenvironment have not been systematically investigated. Therefore, this study aimed not only to evaluate the clinical efficacy of hair follicle transplantation in chronic wounds but also to explore the underlying regenerative mechanisms.

Materials and Methods

This translational study combined clinical evaluation with mechanistic investigation. Patients with chronic wounds were treated with autologous hair follicle transplantation and followed prospectively to evaluate wound healing outcomes. Healing rate and time to wound closure were assessed during follow up. To explore the biological mechanisms involved, transcriptomic analysis of wound tissue was performed to identify gene expression changes associated with tissue repair. In addition, in vitro coculture experiments using hair follicle stem cells and fibroblasts were conducted to investigate paracrine signaling and extracellular matrix production. An in vivo diabetic wound model was further used to validate the regenerative effects of follicle derived signals.

Results

Hair follicle transplantation significantly accelerated wound healing compared with standard wound care. Treated wounds demonstrated higher healing rates and shorter time to closure during follow-up. Transcriptomic analysis revealed upregulation of genes associated with extracellular matrix remodeling, collagen synthesis, and tissue regeneration. Pathway enrichment analysis indicated activation of ECM–receptor interaction, focal adhesion, and MAPK signaling pathways. In vitro coculture experiments showed that hair follicle stem cells enhanced fibroblast proliferation, migration, and extracellular matrix synthesis through paracrine signaling. In diabetic wound models, follicle-derived signals improved wound closure, reduced inflammatory mediators, and promoted collagen organization.

Conclusions

Hair follicle transplantation represents a clinically feasible regenerative approach for chronic wound management.

While previous clinical studies have demonstrated the therapeutic potential of follicular grafting, the present study provides additional mechanistic insights into how hair follicles influence tissue repair. Our findings suggest that hair follicles function as regenerative biological units capable of reprogramming the wound microenvironment through paracrine signaling and enhanced extracellular matrix remodeling. These results highlight a potential mechanistic basis for follicle-mediated wound healing and support the development of follicle-based regenerative strategies for chronic ulcer treatment.

EADV CONGRESS
VIENNA
30 SEP - 3 OCT 2026

Abstract N°: 148

Spatiotemporally-Tunable double-layered microneedle confers immunoregulation to improve wound healing in diabetes

Wenzheng Xia*[1], Meng Hou[2]

[1] shanghai ninth hospital, Shanghai, China

[2] shanghai pulmonary hospital, Shanghai, China

Introduction

Impaired wound healing and ulcer complications are a major cause of disability and mortality in diabetic patients, often associated with reduced physical function and diminished quality of life. The underlying mechanism involves dysregulated macrophage plasticity, in which macrophages fail to transition from a proinflammatory to a reparative state, along with impaired angiogenesis, collectively leading to non-healing wounds. There is a pressing clinical need for advanced treatment strategies to promote diabetic wound healing.

Materials and Methods

Microneedle (MN) patches represent an effective approach for transdermal drug delivery, and recent research has focused on developing smart systems capable of sensing and responding to the pathological wound microenvironment. Using single-cell RNA sequencing, we identified a persistent proinflammatory state in macrophages and disrupted cellular crosstalk between macrophages and endothelial cells in diabetic wounds.To address these abnormalities, we designed a novel double-layered microneedle patch that co-encapsulates reactive oxygen species (ROS)-responsive nanoparticles containing IL-33 and glutathione (GSH)-responsive nanoparticles loaded with Roxadustat (Rox).

Results

This integrated nanoplatform enables programmed and sequential drug release in response to the wound microenvironment, thereby promoting macrophage polarization and angiogenesis in a spatially and temporally controlled manner.In diabetic mouse models, the MN patch significantly improved wound healing by modulating local immune responses and enhancing tissue repair. Specifically, it facilitated the transition of proinflammatory macrophages to an anti-inflammatory phenotype and robustly stimulated angiogenesis. RNA sequencing analysis of wound macrophages further revealed that Ddit4 expression was upregulated following treatment and played a key functional role in regulating macrophage polarization and promoting vascularization.

Conclusions

By combining a macrophage modulator (IL-33) and an angiogenesis inducer (Rox) within a smart microneedle system, we achieved simultaneous immune normalization and enhanced angiogenesis. This strategy provides a promising and comprehensive technology for the treatment of diabetic wounds, with improved efficacy, safety, and patient compliance.

EA DV CONGRESS
VIENNA
30 SEP - 3 OCT 2026

Abstract N°: 418

Photobiomodulation Using Multispectral LED Therapy in Treatment-Resistant Ulcerative Necrobiosis Lipoidica

Eleftheria Pantelidi*[1], Polly Stevenson[2], Louise Nevitte[2], Kyriaki Mitsaki[3], Victoria Vilenchik[4], Daniel Keith[2, 5]

[1] The Hillingdon Hospitals NHS Foundation Trust, Uxbridge, United Kingdom
[2] North Bristol NHS Trust, Bristol, United Kingdom
[3] Royal United Hospitals Bath NHS Foundation Trust, Bath, United Kingdom
[4] CHEC Swindon, Community Dermatology Service, Swindon, United Kingdom
[5] Faculty of Health & Life Sciences, University of Bristol, Bristol, United Kingdom

Introduction

Necrobiosis lipoidica (NL) commonly presents as brown-yellow plaques, usually affecting the anterior shins. These plaques are usually characterised by a violaceous ill-defined border and telangiectasias. NL is traditionally found in patients with diabetes, however, not exclusively. It often requires combined therapy, with different treatment approaches, as it can be challenging to achieve remission. Photobiomodulation (PBM) has emerging evidence in wound healing of various conditions which are resistant to conventional treatment. There is limited literature for the use of PBM in the management of NL. To our knowledge, this is the first reported case of clinical remission of NL after PBM.

Case Presentation

Case report:
This report describes a case of treatment-resistant biopsy proven NL in a 34-year-old female. The condition affected her lower limbs bilaterally and presented with severe progressive and painful ulcers, which progressed gradually over 7 years. Her past medical history was significant for poorly controlled type 2 diabetes and obesity.

Over the course of disease progression, several management options had been used. However, adequate control of NL had not been achieved. Most treatment approaches were proven to be ineffective. A number of these presented with side effects. Three approaches produced a modest effect but presented with some limitations.

Topical corticosteroids, intralesional corticosteroids, topical timolol, 308nm excimer pulsed light phototherapy, ciclosporin, topical calcineurin inhibitors, and dapsone, were shown to be ineffective. Photodynamic therapy, ciclosporin, and dapsone were poorly tolerated. The effect of photodynamic therapy was unclear.

NL was improved by compression bandaging, 585nm pulsed dye laser, and hydroxychloroquine. However, compression bandaging was not tolerated. 585nm pulsed dye laser slowed the progression of the disease but did not reverse changes. Hydroxychloroquine showed a moderate effect and was continued, but a plateau was reached.

The treatment approaches mentioned, in addition to diabetic control and weight loss, were not successful in achieving disease remission. The next step would involve the use of biologics, such as infliximab. PBM using LED was used to bridge the time interval needed to fund biologic treatment.

Intervention:
PBM was delivered using the Dermalux Tri-Wave MD device. Until today, 16 sessions have been performed. These

consist of blue (415nm), red (630nm) and near infrared (830nm) LED light. Each session lasted 20 minutes, and the time interval between adjacent treatments was 1 to 6 weeks.

Results:
The outcome of NL after PBM was shown to be superior to the other management approaches already tried to date. Her condition continues to gradually improve. After treatment, improvement in pain, swelling, and gradual re-epithelisation of ulcers were noted. Specifically, the total ulcerated surface area was reduced by 70-75% after completion of 16 PBM sessions. Additionally, the infection rate markedly reduced. Previously, she required 5 hospital admissions for antibiotics. Post PBM, only one course of flucloxacillin was needed. Funding for infliximab has been approved. However, given the ongoing clinical benefit of the current treatment, use of biologics has been deferred to maximise the positive effects of PBM.

Conclusion
This case report highlights the complexity of management of treatment-resistant NL. It emphasises the emerging role of PBM using LED for NL, either as a bridging strategy, a useful adjunct, or a stand-alone treatment. Due to the rarity of the condition, there is limited available literature to assess the clinical benefits of PBM in NL. Hence, we contribute this case to the available evidence to suggest further management approaches for treatment-resistant NL.

EADV CONGRESS
VIENNA
30 SEP - 3 OCT 2026

Abstract N°: 462

Accelerated Early-Stage Wound Healing by a Novel Hydrogel-based Dressing in a Streptozotocin-Induced Diabetic Rat Model

Hui-Chun Chang[1], Po-Chuen Hsieh[2], Jhao-Yang Tsai[3], Cheuk-Kwan Sun[4], Yi-Shan Liu*[5]

[1] Kaohsiung veterans general hospital, Kaohsiung, Taiwan

[2] Department of Pharmacy, College of Pharmacy and Health care, Tajen University, Pingtung, Taiwan

[3] National Taiwan University Hospital & National Taiwan University, Taipei, Taiwan

[4] School of Medicine for International Students, College of Medicine, I-Shou University& Department of Emergency Medicine, E-Da Hospital, Kaohsiung, Taiwan

[5] Department of Dermatology, E-Da Hospital & I-Shou University, Kaohsiung, Taiwan

Introduction

This study aimed to evaluate the therapeutic efficacy of chlorine dioxide incorporated into a novel hydrogel-based dressing scaffold (poloxamer 188) for enhancing wound healing using a diabetic rat model.

Materials and Methods

Diabetes was induced in male adult Sprague-Dawley rats via intraperitoneal streptozotocin injections (65mg/kg). Full-thickness excisional wounds (1.5 × 1.5 cm) were created on the dorsal skin. Subjects were randomly assigned to the study group (chlorine dioxide hydrogel-based dressing) or the comparator group (Fespixon cream). Wound sizes were monitored on postoperative days (POD) 0, 1, 4, 7, 10, and 14. On POD 14, histological examination was performed using Hematoxylin and Eosin (H&E stain) and Masson's Trichrome staining to assess tissue regeneration.

Results

Mixed repeated measures ANOVA demonstrated a significantly higher wound contraction rate in the study group during the early and middle phases of healing (POD 0–10) compared to the comparator group ($p < 0.001$). Histopathological examination on postoperative day 14 demonstrated nearly complete re-epithelialization in both treatment groups (Figure 1A & B). Additionally, the extent of collagen deposition was comparable between the study and comparator groups (Figure 1C & D). Histological analysis revealed a medium effect size ($r = 0.31$) in collagen deposition within the study group. Both groups exhibited similar semi-quantitative scores for inflammatory cell infiltration, fibroblast accumulation, and angiogenesis.

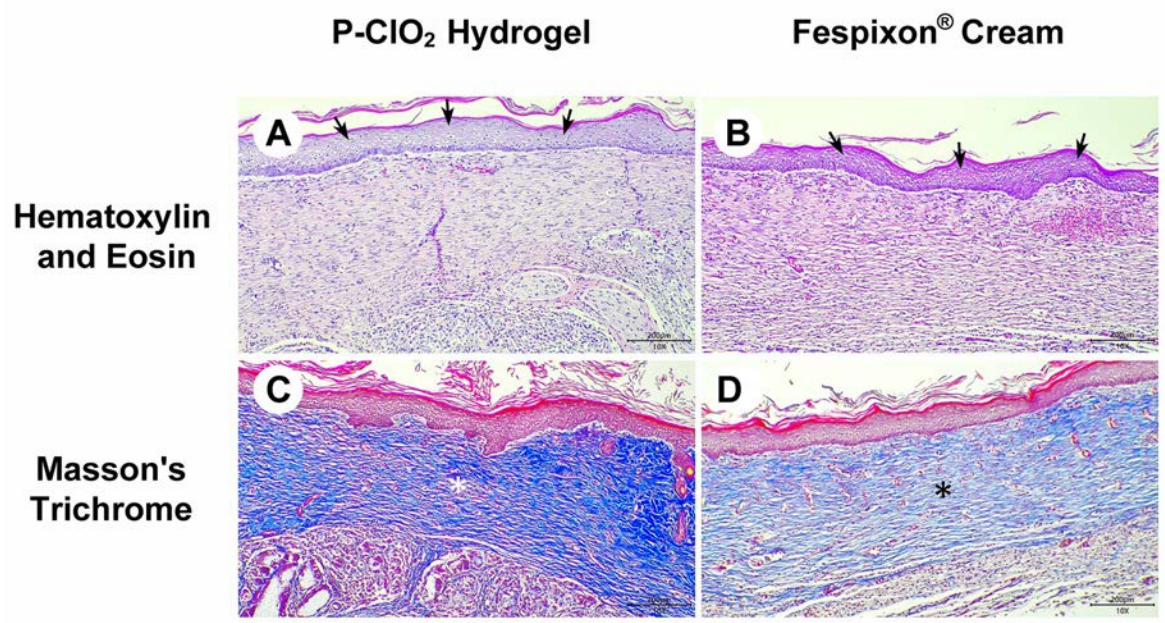

Figure 1 Histopathological analysis on postoperative day 14 using two staining techniques, showing (A & B) notable re-epithelialization (arrow), as well as (C & D) marked collagen deposition (asterisk) in both groups.

Conclusions

Our findings indicate that chlorine dioxide in a poloxamer 188 hydrogel-based dressing significantly enhances early-stage wound healing in diabetic rats compared to Fespixon cream. These results suggest that this novel scaffold holds potential for managing diabetic cutaneous wounds and reducing the risk of secondary infections.

EADV CONGRESS
VIENNA
30 SEP - 3 OCT 2026

Abstract N°: 483

LED therapy in burn management: a clinical evaluation of 54 Cases

ikrame bejja*[1], hanane baybay[1], Saadia Boughaleb[1], Zakia Douhi[1], Meryem Soughi[1], Sara Elloudi[1], Fatima Zohra Mernissi[1]

[1] department of dermatology, University Hospital Center Hassan II, fez, Morocco

Introduction

Burn injuries result from the destruction of the skin barrier by thermal, electrical, chemical, or radiation agents and represent a frequent reason for emergency consultations. Their severity depends on depth, extent, and location, influencing vital, functional, and aesthetic prognosis. Management is based on a multidisciplinary approach involving local care, pain management, and sometimes surgery. Recently, Light Emitting Diode (LED) therapy has shown promise due to its biostimulatory and anti-inflammatory properties, promoting wound healing and modulating pain. The primary objective was to evaluate the efficacy of LED therapy in the management of acute burns. Secondary objectives included assessing the tolerance to LED therapy and identifying predictive factors of favorable or unfavorable therapeutic response.

Materials and Methods

This was a retro-prospective study conducted in our department of dermatology between January 2022 and July 2024. It included all patients with acute first- and second-degree burns who received LED sessions based on the following protocol: blue light at 4 J/cm2, yellow at 12 J/cm2, red at 8 J/cm2, and infrared at 12 J/cm2, resulting in a total fluence of 36 J/cm2 and total energy of 21.6 kJ per session lasting 8 minutes. Patients with chronic burns, pathological scars, or photosensitivity were excluded. Treatment efficacy was assessed based on pain, pruritus, and clinical signs of inflammation, using the POSAS 2.0 score at 1 and 6 months after the burn.

Results

Among the 54 patients, sixty-six percent were women with an average age of thirty-nine years and thirten percent were children. The average affected body surface area was 11% (range: 1–35%). Limbs were the most commonly affected area (75.9%), followed by the head (57.4%), trunk and breast (7.4% each), and genital area (1.85%). Circumferential burns were observed in 33.3% of cases, and 18 patients required hospitalization with an average stay of 7 days (range: 4–44 days). LED therapy was initiated on average 9.31 days after injury (range: 1–30 days), with an average of 2.18 sessions per week (2–3 sessions/week) and a total number of sessions ranging from 2 to 34, averaging 7.9. POSAS score analysis showed a clear improvement in scar quality between 1 and 6 months, with a high proportion of low scores from both patients (PSAS) and observers (OSAS), reflecting strong agreement between subjective and clinical assessment. At 6 months, 95.9% of patients and 85.7% of clinicians reported low scores, indicating favorable scar healing. Improvements were especially notable in color, pliability, and surface. Better outcomes were associated with specific predictive factors: burned surface area ≤11%, early LED initiation (within the first week), superficial burns, younger age (<39 years), and outpatient management. These findings support the reliability of the POSAS score in evaluating post-burn scar quality.

Conclusions

In our sample, LED therapy demonstrated effectiveness in burn care by accelerating healing, reducing pain and pruritus, and limiting scarring complications, all while maintaining good overall tolerance.

EADV CONGRESS
VIENNA
30 SEP - 3 OCT 2026

Abstract N°: 488

Efficacy of Vacuum-Assisted Closure in Managing of Trophic Ulcers in Hansen's Disease: A Prospective Interventional Pilot study.

Jinisha Jain*[1]

[1] Dr. DY Patil Medical College, Pun, Jawaharlal Nehru Medical College, Pune, India

Introduction
Trophic ulcers in Hansen's disease result from motor paralysis, sensory loss, and autonomic dysfunction. Common treatments include saline or collagen dressings, Platelet-rich plasma therapy, topical agents like phenytoin, growth factors, and surgical options. These ulcers carry psychosocial stigma and often resist standard therapies, demanding simpler, cost-effective solutions. Vacuum-assisted closure (VAC) serves as a novel and effective option formanaging chronic, non-healing ulcers in leprosy.

Materials and Methods
A prospective interventional pilot study was conducted after institutional ethics committee approval. Patients with trophic ulcers due to Hansen's disease were included; those with diabetic, vascular, malignant origin, or secondarily infected ulcers were excluded. Following debridement and irrigation, VAC was applied using a wall suction device, Ryle's tube, sterile foam, and adhesive drapes, maintaining 75–125 mm Hg pressure. Dressings were changed every 3 days for at least 3 sessions or until the ulcer size reduced below 1 cm^2. Ulcer dimensions were assessed using Imito Measure App. Statistical analysis was performed using SPSS v25 and Microsoft excel.

Results
Ten patients were enrolled. The mean ulcer area decreased from 4.94 cm^2 (SD 3.37) to 1.19 cm^2 (SD 1.00). The average number of VAC sessions was 2.3 (SD 0.82), with a mean healing time of 9.1 days (SD 3.35). The reduction was statistically significant (Paired t-test: $t = 3.69$, $p = 0.005$). Larger ulcers required more sessions and longer healing time.

Conclusions
VAC therapy significantly enhances granulation tissue formationand wound contraction, promoting faster healing with fewer dressing changes and reduced hospital visits. It is a safe, low-costalternative to conventional treatments, especially beneficial in settings where PRP is inaccessible. Limitations: Small sample size absence of a control group, and limited follow-up restrict generalizability of the findings.

EADV CONGRESS
VIENNA
30 SEP - 3 OCT 2026

Abstract N°: 509

Chronic Radiodermatitis after Fluoroscopy-Guided Aneurysm Embolization

Manuel Sánchez-Arjona*[1], Claudia Sarró Fuente[1], Mónica Ramos Caballo[1], Lourdes Fajardo-Lucena[1], Margarita Pich-Aguilera Blasco[1], Federico Vidal-Fondo Sánchez[1], Ana Mónica Margüello Bautista[1], Victoria Ortiz[1], Cristian Fernando Caballero Linares[1], Gaston Roustan Gullón[1]

[1] Hospital Universitario Puerta de Hierro Majadahonda, Majadahonda, Madrid, Spain

Introduction

Chronic radiodermatitis is a slowly progressive and insidious condition that develops after prolonged or repeated exposure to ionizing radiation, being common in oncologic patients receiving radiotherapy. Clinically, it encompasses a broad spectrum of findings, including skin atrophy, partial or complete loss of adnexal structures, telangiectasias, pigmentary changes, fibrosis, ulceration, and even the development of cutaneous malignancies. In recent decades, the use of image-guided interventional procedures has increased significantly. These procedures rely on fluoroscopy and cineangiography, which can sometimes be prolonged and technically complex, thereby increasing patient exposure to ionizing radiation. As a result, radiation-induced skin injuries have been increasingly reported, including radiodermatitis in this clinical setting.

Case Presentation

A 60-year-old man with history of ischemic heart failure, chronic obstructive pulmonary disease, and chronic liver disease related to alcohol use and nonalcoholic steatohepatitis underwent endovascular embolization of a mycotic aneurysm under fluoroscopic guidance. Several days after the procedure, erythema developed over the lateral thoracic wall. Seven weeks after the intervention, the lesion had evolved into a sharply demarcated rectangular plaque characterized by erythema, desquamation, crusting, and areas of superficial ulceration, corresponding to fluoroscopic radiation field (Figure 1). The patient denied environmental and occupational exposure to other sources of ionizing radiation. The findings were consistent with radiation-induced dermatitis secondary to fluoroscopic exposure during the procedure.

Radiation-induced skin injury secondary to fluoroscopically guided interventions is an uncommon but likely underrecognized complication, particularly in complex or prolonged procedures such as vascular embolization or interventional cardiology. Unlike conventional radiotherapy, fluoroscopy delivers radiation in a non-fractionated manner without skin-sparing effects, which increases the risk of deterministic cutaneous damage when threshold doses are exceeded.

Deterministic skin effects are dose-dependent and occur above well-established thresholds. Early transient erythema may appear at doses around 2 Gy, while more clinically significant reactions are typically observed above 5 Gy. Chronic radiation dermatitis, characterized by fibrosis, atrophy, telangiectasia, and ulceration, is associated with cumulative doses exceeding approximately 10 Gy. More severe manifestations such as moist desquamation or necrosis may occur at doses above 15–20 Gy.

Fluoroscopically guided procedures can reach or exceed these thresholds, particularly in technically demanding cases. Reported average skin doses vary widely depending on the procedure: approximately 2.5 Gy for diagnostic cardiac catheterization and up to 6–7 Gy for percutaneous coronary interventions, with even higher doses possible in prolonged or repeated procedures.

Several procedural and patient-related factors increase the risk of radiodermatitis, including prolonged fluoroscopy time (>60 minutes), high cumulative air kerma (>5 Gy), large dose-area product (>500 Gy/cm^2), and repeated interventions over a short period.

From a clinical standpoint, the diagnosis is often delayed due to the latency between exposure and symptom onset, which can range from days to months or even years. The geometric configuration of the lesion is a key diagnostic clue, as observed in our patient.



Sharply demarcated rectangular plaque characterized by erythema, desquamation, crusting, areas of superficial ulceration and scarring, corresponding to radiation field.

Conclusion

Awareness among clinicians remains crucial, as early recognition may prevent progression to chronic and irreversible skin damage. Current recommendations suggest clinical follow-up in patients exposed to doses ≥5 Gy, as well as documentation of radiation metrics during the procedure. Preventive strategies include minimizing fluoroscopy time, optimizing beam angulation, using dose-reduction technologies, and ensuring adequate operator training.

EADV CONGRESS
VIENNA
30 SEP - 3 OCT 2026

Abstract N°: 537

A Case Series: The Effectiveness of Octenidine Dihydrochloride Dressing in Managing Chronic Wounds

Keni Istasaputri Mardiana*[1], Windaru Cahyaning Ratri[1]

[1] RSUD Tebet, Tebet Sub District, Jakarta District, DKI Jakarta 12810, Indonesia, Jakarta, Indonesia

Introduction
Chronic wounds affect approximately 5% of the adult population. Chronic wounds are defined as wounds that have failed to progress in an orderly and timely manner. In a developing country, the problem of chronic wounds is closely related to the high cost of treatment and is further compounded by the limited coverage of universal health insurance. Clinicians must rely on their clinical judgment and the available evidence to make critical and cost-effective decisions to provide quality care to patients.Prompt wound management is needed to optimize wound healing. Prevention of infection is a key element because chronic wounds can support bacterial growth. Ideal topical agents should have antimicrobial efficacy without negatively affecting wound healing. Octenidine dihydrochloride (OCT) is a cost-effective antiseptic solution with broad-spectrum antimicrobial activity that maintains optimal moisture balance and promotes autolytic debridement.

Case Presentation
This case series describes three outpatient cases: (1) a patient with a decubitus ulcer, (2) a patient with a diabetic ulcer, and (3) a patient with a traumatic ulcer. All wounds were cleansed with saline and treated with OCT-soaked gauze dressings to provide a moist wound environment, in combination with oral antibiotics. The dressings were changed every 8–10 days in the outpatient clinic.During the study, wound-healing characteristics and treatment costs were analyzed. Healing parameters were assessed by reductions in wound size and edge advancement. At the second follow-up visit (8–10 days), no further improvement was noted. Dressing changes were performed without significant adverse reactions or cytotoxic effects. Significant improvement was observed after the third follow-up visit (24–30 days) in all three patients, resulting in accelerated healing and reduced ulcer size. Wound size reductions were 92% (patient 1), 75% (patient 2), and 80% (patient 3).The OCT dressing had the lowest treatment cost, with each dressing change costing approximately IDR 400,000–500,000 (€24–€30) per visit. Consequently, the total cost for three times follow-up outpatient visits was about IDR 1,200,000–1,500,000 (€72–€90).

Conclusion
In this case series, all three patients with chronic wounds treated with OCT dressings progressed to healing without adverse effects. The results suggest that OCT dressing is cost-effective, well-tolerated, and suitable for treating chronic wounds.

EADV CONGRESS
VIENNA
30 SEP - 3 OCT 2026

Abstract N°: 618

Nicolau syndrome (embolia cutis medicamentosa) after subcutaneous injection of Glatiramer acetate (Copaxone)

Nicolas Kluger*[1, 2, 3], Lauri Tolkki[3]

[1] Aava medical Centre, Dermatology, Kerava, Finland
[2] Tampere University Hospital, Dermatology, Tampere, Finland
[3] Helsinki University Hospital, Dermatology, Helsinki, Finland

Introduction

Glatiramer acetate (GA, copolymer-1, Copaxone®) is a highly immunogenic polypeptide that is approved in the treatment of relapsing-remitting forms multiple sclerosis (MS). It induces a shift of the immune reaction from a T-helper 1 (Th1) to a Th2 response possibly through immune mimicry. GA is administrated by daily subcutaneous injection.Since 2003, an increasing number of publications have reported the occurrence of cutaneous necrosis due to Nicolau syndrome. We report here an illustrative new case.

Case Presentation

A 52-year-old woman with a history of depression and MS had been treated by GA since 2020 presented in February 2025 a discoloration of the skin right after subcutaneous injection in the left arm with a dark center and clearer halo. Injection technique has been indentical as usual. After 48h, she displayed a stellate purplish patch with a map-like border at the site of injection surrounded by a whitish area of discolouration, itself surrounded by an inflammatory erythema. The area extended and became more painful. At day 5, she had a purpuric patch with a beginning of epidermal damage. At day 9, the epidermis was necrotic and the patch surronded by an inflammatory rim. Upon presentation at day 16, she displayed a 5 x 5 cm dry necrotic patch surrounded by a 0.5 cm inflammatory halo. The skin was still warm to the touch and the wound still painful. On the right arm, she had palpable lipoatrophy in relation to past GA injection. A biopsy of the inflammatory edge showed a thrombotic process in the dermal vessels. A diagnostic of Nicolau syndrome was made. Conservative management included local corticosteroid ointments, mechanical debridement, wound dressing and negative pressure wound therapy (NPWT). Two months after the culprit injection, inflammation has alleviated and the wound has considerably improved. However, she still need NPWT. GA injections have been maintained.

Conclusion

GA is administrated by daily subcutaneous injection. Therefore, transient injection site reactions (localized erythema, induration, pruritus or pain) occur disregard the injection technique between 20 to 60% of all cases, lasting from several hours to several days before resolution. Nicolau's syndrome (embolia cutis medicamentosa) is a severe unpredictable and unpreventable complication related to injection itself. The pathogenesis is not well understood : embolic occlusion of arteries from injection, perivascular inflammation, mechanical injury to blood vessels, sympathetic nerve stimulation, or prostaglandin synthesis blockade (causing vasospasm and ischemia). According to a recent review, 34 cases have been reported. They affect more ofter women, can occur up to 10 years after GA initiation and can locate either on the upper limbs, lower limbs or abdomen. Our case acts as a reminder of the rare but typical side effect of GA. Of note, wound healing is rather long.

EADV CONGRESS
VIENNA
30 SEP - 3 OCT 2026

Abstract N°: 628

Regenerative Scar Management Using Enzyme Therapy (A Biological Approach to Fibrosis Modulation and Tissue Remodeling)

Iva Stoilova*[1]

[1] Dermavist Clinic - Dermatology & Laser Therapy, Plovdiv, Bulgaria

Introduction

Scars result from disrupted wound healing, characterized by excessive fibrosis, altered collagen architecture, and impaired tissue function. Traditional approaches often rely on mechanical, thermal, or chemical destruction, with variable outcomes and risk of recurrence. Advances in wound biology highlight the role of enzymatic imbalance and extracellular matrix dysregulation in pathological scarring. The objective is to evaluate enzyme therapy as a regenerative strategy in scar management, focusing on the biological modulation of fibrosis.

Materials and Methods

Patients with various scar types, including hypertrophic, keloid, atrophic, post-surgical, and traumatic scars, underwent protocol-based enzyme therapy. Recombinant enzymes were used to modulate extracellular matrix components and regulate fibrotic collagen. Treatment planning was individualized according to scar characteristics. Therapy was applied alone or within multimodal protocols. Clinical evaluation included visual assessment, standardized photography, and patient-reported outcomes, with follow-up at defined intervals.

Results

Clinical observations demonstrated progressive softening of fibrotic tissue, improved elasticity, and better integration with surrounding skin. The treatment showed high tolerability and no significant adverse events. When combined with other modalities, enzyme therapy supported more controlled remodeling.

Conclusions

Enzyme therapy represents a regenerative alternative to conventional scar treatments by addressing underlying biological mechanisms of fibrosis. This approach may offer a safe and adaptable option in contemporary scar management, particularly in complex cases.

EADV CONGRESS
VIENNA
30 SEP - 3 OCT 2026

Abstract N°: 680

Adjunctive therapy with salmon-derived exosomes in the management of pressure ulcers: A case series in the Philippines

Gloriana Julia Teope*[1], Ivan Arni Preclaro[1], Celeste Lopez[1]

[1] Department of Health - Tondo Medical Center, Manila, Philippines

Introduction
Chronic pressure injuries (PIs) in medically complex patients often exhibit a persistent inflammatory state and impaired remodeling, rendering them refractory to standard wound care. This case series, the first reported in the Philippines, evaluates the pro-reparative potential of topical salmon-derived exosomes as an adjunctive treatment to modulate inflammation and stimulate angiogenesis. The study investigates whether these nano-sized extracellular vesicles, enriched with bioactive peptides, can overcome the inhibitory microenvironment of advanced-stage PIs to facilitate tissue regeneration.

Case Presentation
Three Filipino male patients, ages 45 to 79, with Stage II–IV pressure injuries and significant comorbidities predisposing to delayed healing—including HFrEF, coronary artery disease, type 2 diabetes mellitus, and chronic kidney disease—were evaluated. All subjects received a therapeutic protocol consisting of twice-daily standard wound care, including sterile normal saline cleansing and silver sulfadiazine cream, augmented by adjunctive topical salmon-derived exosome spray twice a day for 14 days. Patient 1, a 79-year-old with a Stage II lower extremity injury and multiple cardiovascular comorbidities, achieved complete granulation and re-epithelialization within the two-week period. Patient 2, a 76-year-old with a Stage III sacral injury and poorly controlled diabetes, demonstrated progressive wound contraction, robust development of healthy granulation tissue, and a marked reduction in necrotic slough and peri-wound inflammation. Patient 3, a 45-year-old with a Stage IV gluteal injury associated with Pott's disease and severe immobility, exhibited enhanced wound bed vascularity, progressive epithelial migration, and narrowing of wound margins by day 14. No local or systemic adverse events attributable to the adjunctive exosome therapy were observed across the series.

Conclusion
Pressure injuries involve multifactorial pathogenesis where prolonged mechanical stress leads to ischemia and chronic inflammation, creating a significant clinical burden. While standard management emphasizes wound care and off-loading, healing remains prolonged; stage II ulcers typically require weeks to a month, while stage III and IV injuries can take four months to two years to close. In this context, salmon-derived exosomes serve as potent regenerative adjuncts, delivering bioactive cargos that modulate inflammation and stimulate angiogenesis to bypass the inhibitory microenvironment of chronic wounds.

The favorable clinical responses observed—notably the complete re-epithelialization of a stage II PI in 14 days and the rapid development of well-vascularized granulation tissue in stage III and IV cases—suggest that adjunctive topical salmon-derived exosome therapy accelerates the transition from the inflammatory to the proliferative phase.

These outcomes are especially significant for advanced-stage PIs, which are traditionally recalcitrant and carry high morbidity risks in medically complex patients. While limited by a small sample size and an uncontrolled design, the consistent pattern of improvement across all stages highlights the potential of exosome-based interventions

as a well-tolerated and effective regenerative strategy. Ultimately, this series provides a necessary clinical foundation for larger randomized controlled trials to establish definitive efficacy and optimize dosing protocols in dermatologic practice.

EA DV CONGRESS
VIENNA
30 SEP - 3 OCT 2026

Abstract N°: 748

Personalized Monitoring of Skin Barrier Changes in Pressure-Prone Areas in Patients with Limited Mobility During Early Post-Stroke Rehabilitation: A Clinical Case Series

Daria Vorobeva*[1, 2], Tatiana Gaydina[1, 2], Anton Dvornikov[1]

[1] Национальный исследовательский медицинский университет имени Пирогова, Москва, Russian Federation

[2] Федеральный центр цереброваскулярной патологии и инсульта, Москва, Russian Federation

Introduction

Patients with limited mobility after stroke are at high risk of pressure-related skin damage and other forms of skin barrier impairment associated with prolonged pressure, moisture, friction, and shear. In routine practice, visual skin assessment remains essential, but it may not always detect early functional skin changes before clinically visible damage appears. For this reason, objective instrumental monitoring of skin barrier parameters may provide clinically relevant additional information in high-risk patients. Corneometry reflects stratum corneum hydration, whereas sebumetry may provide complementary information on the skin surface condition. The present clinical case series aimed to characterize changes in biophysical skin barrier parameters in pressure-prone anatomical areas in patients with limited mobility during early post-stroke rehabilitation while receiving standardized preventive skin care.

Case Presentation

This prospective clinical case series included three patients in the early rehabilitation period after stroke with marked mobility limitation and high risk of skin barrier impairment. Although all patients were considered high risk, they differed substantially in age, sex, stroke type, neurological deficit, degree of functional dependence, nutritional status, associated comorbidities, and the pattern of mechanical loading. These differences represented three clinically relevant risk profiles: prolonged constant pressure, asymmetric loading, and trophic tissue vulnerability. Daily measurements were performed over a 30-day period using corneometry and sebumetry in typical pressure-prone areas, namely the sacral region, both heels, and both scapular areas. All patients received a standardized preventive care regimen including regular repositioning, pressure offloading, skin microclimate and moisture control, hygiene care, timely linen changes, and once-daily topical application of dexpanthenol to intact skin in at-risk areas. Clinical skin assessment and documentation were performed throughout follow-up. In all three cases, corneometry values showed a positive trend over time, suggesting improved skin hydration during preventive care. The most pronounced changes were observed in the sacral region and heels in completely immobile patients. In the patient with hemiparesis, symmetrical anatomical areas showed asymmetric changes, likely reflecting uneven mechanical load distribution. Sebumetry values remained low in all monitored areas and did not show clinically meaningful short-term change. During the full observation period, the skin remained intact in all monitored sites, without erosive or ulcerative defects. These findings indicate that repeated site-specific measurements may capture individualized patterns of skin barrier response even in patients with a similarly high overall risk profile.

Conclusion

This clinical case series demonstrates the feasibility of personalized daily skin barrier monitoring in patients with limited mobility during early post-stroke rehabilitation. Dynamic corneometry, used together with clinical examination and routine skin assessment, may help identify heterogeneous local risk patterns in pressure-prone areas and support individualized preventive skin care in the inpatient setting. In this small series, corneometry

appeared more informative than sebumetry for short-term bedside follow-up. The observed inter-site and side-to-side variability suggests that local mechanical loading and patient-specific clinical factors should be considered when interpreting instrumental skin data. These observations support the potential value of objective biophysical monitoring as an adjunct to standard preventive care in high-risk patients. Larger prospective studies are needed to confirm these findings, define clinically meaningful thresholds and trajectories, and establish standardized endpoints for skin barrier monitoring in this setting.

EA DV CONGRESS
VIENNA
30 SEP - 3 OCT 2026

Abstract N°: 751

A miRNA Cocktail Orchestrates Coordinated Cellular Responses to Promote Diabetic Wound Healing

Yejing Huang*[1], Dongqing Li[1]

[1] Hospital for Skin Diseases, Institute of Dermatology Chinese Academy of Medical Sciences & Peking Union Medical College, Nanjing, China

Introduction
Chronic wounds, particularly diabetic ulcers, impose significant health and economic burdens globally because of their complex pathology and the limited availability of therapeutic approaches. Multiple microRNAs (miRNAs) orchestrate key biological processes involved in wound healing. However, single-miRNA therapies may be insufficient to overcome the multifaceted barriers of impaired wound repair. Efforts to discover more effective wound therapies continue unabated. Here, we investigate the therapeutic potential of a multi-miRNA strategy to enhance diabetic wound healing.

Materials and Methods
In this study, we developed a miRNA cocktail that targets multiple critical phases of wound repair, including inflammation, re-epithelialization, granulation tissue formation, and angiogenesis. The therapeutic cocktail comprised locked nucleic acid–modified mimics of miR-19b-3p, miR-132-3p, and miR-31-5p, along with an inhibitor of miR-92a-3p, which are delivered via in vivo-jetPEI to ensure efficient local uptake, addressing the multifaceted nature of wound repair mechanisms. The wound healing efficacy of the miRNA cocktail was systematically evaluated in murine models of acute and chronic wounds.

Results
Local application of the miRNA cocktail to wounds markedly enhanced acute wound healing in wild-type mice, outperforming the effects of the individual miRNAs across multiple evaluative parameters. Moreover, the miRNA cocktail accelerated diabetic wound healing by orchestrating coordinated cellular responses at the wound site, significantly attenuating inflammatory cytokine expression and CD68+ macrophage migration, while promoting re-epithelialization, angiogenesis, and granulation tissue formation. Notably, the cocktail also facilitated nerve regeneration within the wound area at day 30 postinjury.

Conclusions
Our findings suggest that this miRNA cocktail has a potential therapeutic value for revitalizing the healing process in chronic wounds. Therefore, further investigations in controlled clinical trials are warranted to confirm the efficacy and applicability of this miRNA cocktail in a clinical setting.

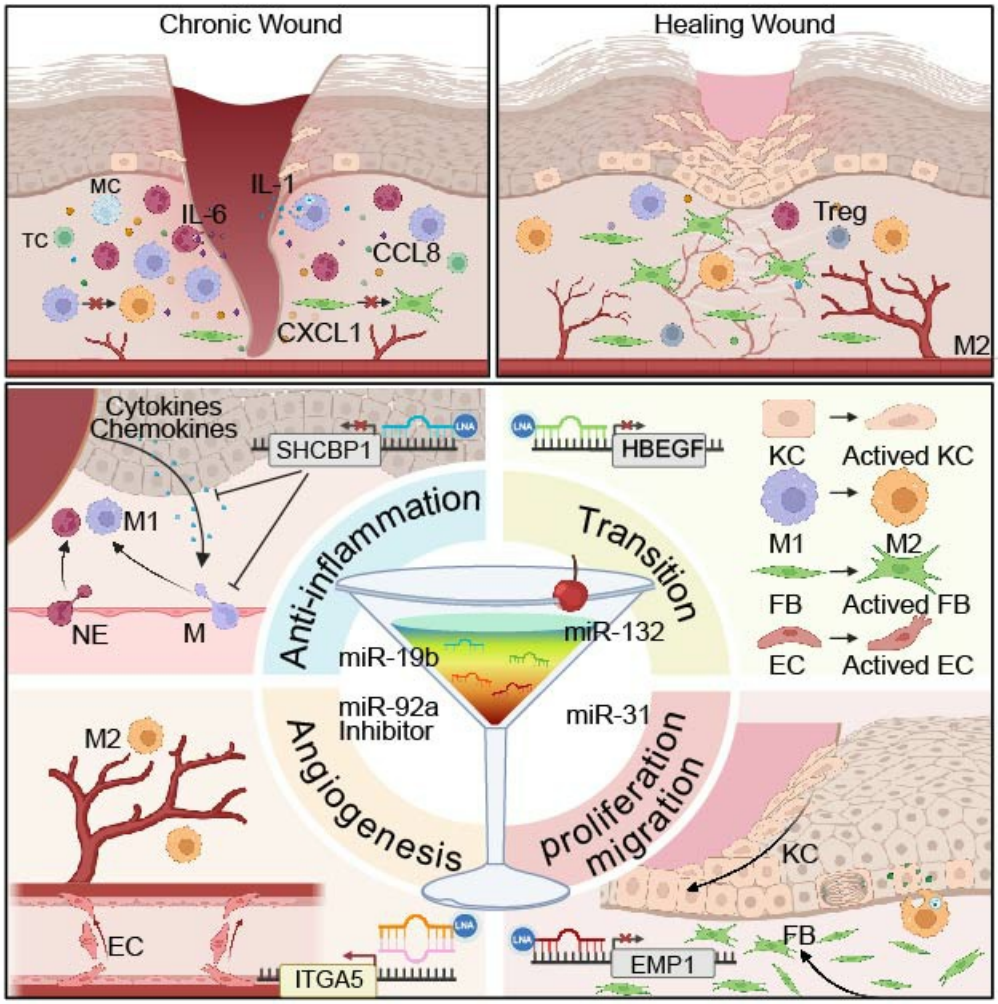
Chronic Wound
Healing Wound
MC
IL-1
IL-6
TC
CCL8
CXCL1
Treg
M2
Cytokines
Chemokines
SHCBP1
HBEGF
KC
Actived KC
M1
M2
FB
Actived FB
EC
Actived EC
M1
NE
M
Anti-inflammation
Transition
miR-19b
miR-132
miR-92a
Inhibitor
miR-31
M2
Angiogenesis
proliferation
migration
KC
EC
FB
ITGA5
EMP1

EA DV CONGRESS
VIENNA
30 SEP - 3 OCT 2026

Abstract N°: 764

Dysregulated Fibroblast-Immune Interactions in Keloid Scars: Insights from Single-Cell and Spatial Transcriptomics Analyses

Hyeewon Seo[1], Ji Hwan Moon[2], Si-Hyung Lee[3, 4], Dong Hun Lee[3, 4], Hyun je Kim[1, 4, 5], Ji Su Lee*[3, 6], Jung-Won Shin[3, 7]

[1] Department of Biomedical Sciences, Seoul National University Graduate School, Seoul, Korea, Rep. of South
[2] Samsung Genome Institute, Samsung Medical Center, Seoul, Korea, Rep. of South
[3] Department of Dermatology, Seoul National University College of Medicine, Seoul, Korea, Rep. of South
[4] Department of Dermatology, Seoul National University Hospital, Seoul, Korea, Rep. of South
[5] Department of Microbiology and Immunology, Seoul National University College of Medicine, Seoul, Korea, Rep. of South
[6] Department of Dermatology, Seoul Metropolitan Government – Seoul National University (SMG-SNU) Boramae Medical Center, Seoul, Korea, Rep. of South
[7] Department of Dermatology, Seoul National University Bundang Hospital, Seongnam, Korea, Rep. of South

Introduction
Keloids are fibroproliferative disorders defined by excessive extracellular matrix (ECM) deposition extending beyond original wound boundaries. While mechanical tension is a major driver of fibrosis, ear keloids frequently occur in low-tension areas, suggesting that intrinsic fibroblast programs and local cell-cell interactions may drive fibrosis. This study aims to map fibroblast states and identify key fibroblast–other cell (including immune cell) interaction circuits in ear keloids using single-cell RNA-seq and spatial transcriptomics.

Materials and Methods
Single-cell RNA sequencing (10X Genomics Chromium 3' v4) was performed on keloid (n=6), peri-lesional (n=3), and healthy control (n=5, public data) skin samples. Spatial transcriptomic profiling was conducted using NanoString GeoMx DSP in 6 patients with paired keloid and peri-lesional tissues. Fibroblast-dominant regions of interest (ROIs) were stratified into four zones: peri-lesional dermis, keloid with normal-looking collagen, keloid with fibrillar collagen, and keloid with mature keloid collagen.

Results
We identified 13 fibroblast subtypes grouped into 4 functional states: pro-inflammatory (G1; enriched in normal skin), pro-fibrotic (G2; enriched in keloid), antigen-presenting fibroblasts (ap-fibroblasts; G3; enriched in normal and peri-lesional skin but depleted in keloid), and vascular-interface fibroblasts (G4). G3 ap-fibroblasts expressed high levels of CD74 and MHC class II molecules (HLA-DRA, DRB1, DPA1, DPB1, DQB1). Notably, these cells lacked the IFN-γ/chemokine storm (lower CXCL9/10/11, IL-6, ICAM1, CD86, HLA-DMA/DMB), suggesting a constitutive ap-fibroblast–like state rather than reactive MHC-II upregulation. Trajectory analysis suggested that progressive loss of ap-fibroblasts may reflect collapse of a local regulatory niche in keloid. Spatial transcriptomics validated these findings: ap-fibroblast scores were highest in normal-collagen zones and progressively reduced toward mature keloid. $CD4^+$ effector memory T cells (CD4 Tem) mirrored ap-fibroblast distribution and showed strong spatial correlation with ap-fibroblast scores ($r=0.83$, $p<0.001$).

Conclusions
Ear keloids harbor distinct fibroblast states with progressive loss of ap-fibroblast-like cells and associated CD4

Tem depletion as lesions mature. The ap-fibroblast regulatory niche may represent a novel biomarker of keloid activity and a potential therapeutic target for early intervention to prevent fibrotic progression.

EA DV CONGRESS
VIENNA
30 SEP - 3 OCT 2026

Abstract N°: 834

Treatment of chronic wounds with cold plasma: a randomised, single-blind, placebo-controlled clinical study

Robert Strohal*[1], Martina Mittlböck[2], Gilbert Hämmerle[3], Lisa Gebhardt[4]

[1] Landeskrankenhaus Feldkirch, Feldkirch, Austria

[2] Center for Medical Data Science, Institute for Clinical Biometrics, Medical University of Vienna, Spitalgasse 23, Vienna, Austria

[3] Central Ambulance of Wound Care, Department of Nursing, Academic Teaching Hospital Bregenz, Bregenz, Austria, Bregenz, Austria

[4] terraplasma medical GmbH, Germany, Garching near Munich, Germany

Introduction

Chronic wounds are a major public health challenge, impairing patients' quality of life and causing high healthcare costs. Standard treatment remains difficult despite modern dressings. Cold atmospheric plasma (CAP) has emerged as a promising therapy. CAP generates reactive oxygen and nitrogen species, which inactivate bacteria (including multidrug-resistant strains) and stimulate intracellular regeneration pathways in human cells. CAP also reduces wound pH – a key factor for healing, as chronic wounds are often alkaline. Previous studies showed faster granulation, wound area reduction, and infection control with CAP. This prospective, multicentre, randomised, single-blind, placebo-controlled trial aimed to investigate whether CAP treatment (plasma care device) combined with best practice wound care is superior to placebo (sham device) in healing chronic wounds of various origins and phases.

Materials and Methods

This prospective, multicentre, two-arm, randomised, single-blind study (April–October 2023, two Austrian centres) included 70 adults with chronic wounds. Patients received either plasma care® plus best-practice wound care or a placebo device plus best-practice care (35 per group). CAP/placebo applications (60 s) followed a fixed 42-day schedule; dressings were changed every second day (weekends: every third day). Wound area (digital), pH, pain (VAS), infection (PGA), exudate, tolerability and subjective sensation were recorded. Primary endpoint: wound area at day 42 (absolute size, dynamics). Secondary endpoints: pH, pain, infection, exudate, tolerability, sensation. Statistical analyses followed intention-to-treat (log-transformed t-tests, Wilcoxon, mixed linear models, chi-square, logistic regression, Kaplan–Meier with log-rank; two-sided $p \leq 0.05$; SAS 9.4). Sample size (35/arm) provided ~80% power to detect a ≥2.2-fold difference in mean wound area at day 42. Mean age ~68 years, predominantly venous leg ulcers. Ethics approval (Declaration of Helsinki) and written informed consent (including photo documentation) were obtained.

Results

In this randomised, single-blind trial (70 patients with chronic wounds), CAP treatment was significantly superior to placebo. After 42 days, the geometric mean wound area was 0.012 cm^2 in the CAP group vs. 0.805 cm^2 in the placebo group ($p < 0.0001$). Complete healing occurred in 54.3% of CAP patients vs. only 5.7% of placebo patients. CAP accelerated healing dynamics: average wound area reduction per visit was 0.70 cm^2 (CAP) vs. 0.36 cm^2 (placebo). pH normalised faster with CAP (7.73 vs. 9.11 at day 42; $p < 0.0001$). Pain relief (VAS score 1) was achieved by day 7 with CAP, while placebo patients still reported pain at day 42. Exudate was healed or weak in 82.9% of CAP patients vs. 17.1% of placebo ($p < 0.0001$). Both devices were well tolerated, with no serious adverse events. CAP treatment was safe and effective.

Conclusions

The study concludes that cold atmospheric plasma (CAP) combined with best practice wound care significantly reduces wound area, accelerates healing, and improves key secondary outcomes: pH normalisation, pain relief, exudate control, and complete wound closure. CAP outperformed placebo treatment across all major endpoints. The plasma care device is safe, well tolerated, and highly effective for chronic wounds of various aetiologies and healing phases. Importantly, CAP promotes rapid healing without requiring additional adjunctive therapies, which may lower treatment costs and reduce the economic burden on healthcare systems. These findings support CAP as a promising therapeutic option for clinical practice, offering both clinical benefits for patients and economic advantages for providers.

EADV CONGRESS
VIENNA
30 SEP - 3 OCT 2026

Abstract N°: 874

SNHG26 orchestrates pro-fibrotic fibroblast maintenance via PTBP1-mediated alternative polyadenylation of AKT3 in dermal fibrosis

Ling Pan*[1], Dongqing Li[1]

[1] Hospital for Skin Diseases, Institute of Dermatology, Chinese Academy of Medical Sciences, Nanjing, China

Introduction

Fibrosis is characterized by excessive extracellular matrix (ECM) deposition, leading to tissue distortion and organ dysfunction. Fibroblasts are the principal effector cells in dermal fibrosis. Once aberrantly activated, they secrete excessive collagen-rich ECM and sustain a self-amplifying cycle of fibrosis. Although the TGF-β/Smad pathway is a central regulator of fibroblast activity, its broad role across tissues limits its therapeutic specificity. Recent studies have identified additional pro-fibrotic pathways and fibroblast subsets, particularly mesenchymal fibroblasts, as major contributors to ECM production, but the mechanisms maintaining their fibrotic phenotype remain unclear. Post-transcriptional regulation has emerged as a key determinant of fibrosis progression. Alternative polyadenylation (APA), regulated by RNA-binding proteins such as PTBP1, modulates mRNA stability and translation and has been increasingly implicated in fibrosis. Long noncoding RNAs also participate in gene regulation. Our previous work identified SNHG26 as a wound-healing–associated lncRNA, leading us to hypothesize that it contributes to cutaneous fibrotic remodeling.

Materials and Methods

SNHG26 expression in pathological scar tissues was assessed by RNAscope and RT-qPCR. Nuclear-cytoplasmic fractionation combined with RT-qPCR was used to determine its abundance and subcellular localization in scar-derived fibroblasts. RNA sequencing following SNHG26 knockdown was performed to identify differentially expressed genes and enriched biological processes. EdU staining, immunofluorescence, and wound-healing assays were used to evaluate the effects of SNHG26 on fibroblast proliferation, migration, and extracellular matrix (ECM) synthesis. To investigate the in vivo role of SNHG26, single-cell RNA sequencing was conducted on scar tissues from fibroblast-specific SNHG26 knockout mice to characterize changes in cellular composition, fibroblast heterogeneity, and signaling pathways. A fibroblast transplantation model in nude mice and a scar model using fibroblast-specific Snhg26 knockout mice were established to assess the impact of SNHG26 silencing on fibrotic tissue formation and ECM deposition. Potential SNHG26-interacting proteins were predicted using catRAPID and validated by RNA pull-down and RNA immunoprecipitation assays. Rescue experiments, involving either RBP overexpression after SNHG26 knockdown or SNHG26 overexpression after interacting protein silencing, were performed to evaluate their combined effects on fibroblast phenotypes. Long-read transcriptome sequencing and luciferase reporter assays were further used to examine how the SNHG26–RBP interaction regulates downstream post-transcriptional events. To identify upstream regulators of SNHG26, cytokine screening assays were performed in fibroblasts, followed by pathway inhibitor screening and CUT&TAG analyses to define key signaling pathways and transcription factor binding sites responsible for its constitutive expression. Finally, a mouse scar model, an ex vivo keloid culture model, and a nude mouse keloid xenograft model were used to evaluate the therapeutic potential of local SNHG26 silencing.

Results

SNHG26 is markedly upregulated in hypertrophic scars and keloids, where it drives fibroblast activation and pathological ECM deposition. Fibroblast-specific depletion of SNHG26 attenuated scar formation in mice and shifted fibroblast composition by reducing mesenchymal fibroblasts while expanding papillary fibroblasts.

Mechanistically, SNHG26 binds PTBP1 to promote distal polyadenylation and stabilization of AKT3 mRNA, thereby enhancing fibrogenic signaling.Furthermore, we identify the TNFα–ERK1/2–STAT3 pathway as an upstream inducer of SNHG26 expression.

Conclusions

SNHG26 is a central regulator of fibroblast activation and cutaneous fibrosis. By acting through the SNHG26-PTBP1-AKT3 axis, it sustains pro-fibrotic states and may serve as a promising therapeutic target for pathological scarring.

EADV CONGRESS
VIENNA
30 SEP - 3 OCT 2026

Abstract N°: 880

Calciphylaxis in End-Stage Renal Disease: A Retrospective Case Series

Corinna Schneider*[1], András Kovács[1], Anita Katalin Hanyecz[1], Csaba Gyömörei[2], Zsuzsanna Lengyel[1]

[1] University of Pécs, Department of Dermatology,- Venereology and Oncodermatology, Pécs, Hungary
[2] University of Pécs, Department of Pathology, Pécs, Hungary

Introduction
Calciphylaxis (calcific uraemic arteriolopathy, CUA) is a rare but frequently fatal complication of end-stage renal disease, driven by vascular calcification and resulting in painful ischemic skin necrosis. Despite increasing recognition, outcomes remain poor and management is not standardized.
We present a case series highlighting clinical trajectories, key risk factors, and outcomes under a multidisciplinary treatment approach.

Case Presentation
We retrospectively analyzed four patients with clinically and histologically confirmed calciphylaxis treated at our center between 2024-2026. Clinical data, comorbidities, therapies, and outcomes were evaluated.

The cohort (2F/2M; mean age 64.7 years) included three dialysis patients and one pre-dialysis patient who later required renal replacement therapy.

Vitamin K antagonist use was identified in all cases as a major modifiable risk factor. All patients presented with painful necrotic lower limb ulcers and elevated inflammatory markers.

Treatment included sodium thiosulfate, cinacalcet, intensive wound care, optimized pain management therapy and discontinuation of vitamin K antagonists.

Despite this, mortality remained high (50%) due to sepsis. However, survivors achieved marked clinical improvement, with complete or near-complete wound healing. Favorable outcomes were associated with strict parathyroid hormone control, optimized calcium-phosphate balance, and aggressive wound management.

Conclusion
Calciphylaxis remains a life-threatening condition with substantial mortality despite intensive therapy. Our findings reinforce three key clinical messages:
(1) early recognition is critical,
(2) multidisciplinary management is essential and
(3) vitamin K antagonists represent an important, potentially avoidable risk factor.

Optimizing mineral metabolism alongside rigorous wound care appears central to improving outcomes. Further prospective studies are urgently needed to define evidence-based treatment strategies.

EADV CONGRESS
VIENNA
30 SEP - 3 OCT 2026

Abstract N°: 944

Acute assault-related skin injuries with threatened tissue loss: a dermatologic two-case series highlighting adjunctive hyperbaric oxygen therapy

Yavuz Aslan*[1], Ilknur Özcan[2]

[1] Sultan Abdulhamit Han Research and Training Hospital, Department of Underwater and Hyperbaric Medicine, İstanbul, Türkiye

[2] Medical Park Atasehir Hospital Department of Dermatology and Vunerology, İstanbul, Türkiye

Introduction

Acute traumatic skin and soft-tissue injuries may rapidly progress to necrosis, infection, persistent inflammation, and clinically significant tissue loss, leading to functional and cosmetic sequelae. Early recognition of threatened skin viability and prompt multidisciplinary intervention are essential for favorable outcomes. We present two assault-related cases of complex acute skin injury to highlight clinical evolution, wound-healing response, and the supportive role of adjunctive hyperbaric oxygen therapy (HBOT) in dermatologic wound management.





Figure 1. Initial presentation of Case 1 showing extensive edema, inflammatory soft-tissue involvement, and necrotic skin loss on the dorsum of the hand following a human bite injury.

Case Presentation

Case 1 involved a 60-year-old man with type 2 diabetes who developed an infected necrotic wound on the dorsum of the hand after a human bite sustained during an altercation. The lesion showed marked edema, progressive soft-tissue involvement, and risk of functional loss. He was managed with close wound surveillance, serial dressings, repeated debridement, and adjunctive HBOT. Over the course of treatment, edema regressed, tissue loss was controlled, healthy granulation tissue developed, and progressive re-epithelialization was observed. After 28 HBOT sessions, complete healing was achieved without amputation, and active hand function was preserved.

Case 2 involved a female police officer who developed traumatic skin compromise involving the glabellar and nasal dorsum region after blunt facial trauma occurring 7 days after hyaluronic acid filler injection. Following filler dissolution, she was referred for supportive wound-healing treatment. She was treated with local wound care, minor debridement, and adjunctive HBOT. Serial clinical follow-up demonstrated gradual resolution of crusting, erythema, and soft-tissue breakdown. Complete healing was achieved after 16 HBOT sessions, with a favorable cosmetic outcome and no need for reconstructive intervention.



Figure 2. Intermediate stage of Case 1 after serial debridement, showing reduction of necrotic tissue and development of a viable wound bed with progressive granulation.

Conclusion

These two cases emphasize that assault-related acute skin injuries may follow a rapidly progressive course with threatened tissue viability and risk of functional or cosmetic morbidity. In selected high-risk wounds, early multidisciplinary management combined with adjunctive HBOT may help control necrosis and edema, support granulation and re-epithelialization, and improve healing outcomes.



Figure 3. Final appearance of Case 1 demonstrating marked resolution of edema, complete wound healing, and preservation of hand integrity after multidisciplinary wound care and adjunctive hyperbaric oxygen therapy.

EA DV CONGRESS
VIENNA
30 SEP - 3 OCT 2026

Abstract N°: 974

The leg ulcer that explained everything

Faiza Boukhobza*[1], Hanane Baybay[1], ikram bejja[1], Saadia Boughaleb[1], Zakia Douhi[1], Meryem Soughi[1], Sara Elloudi[1], Fatima zahra Mernissi[1]

[1] Dermatology departement HASSAN II University Hospital, FES, Morocco

Introduction
Leg ulcers are well known complications of homozygous sickle cell disease, affecting up to 75% of patients. Their occurrence in sickle cell trait (HbAS) is exceptional, accounting for fewer than 2% of published sickle cell ulcer cases and posing a significant diagnostic challenge.

Case Presentation
A 45-year-old man, born of a consanguineous marriage, presented with a history of bilateral ischemic stroke (2022) and recurrent myocardial infarctions (2022–2023), for which no unifying etiology had been identified. He then developed chronic progressive bilateral leg ulcers, accompanied by lower limb edema and severe, sleep-disrupting pain refractory to standard analgesia.

Examination revealed multiple large ulcers with irregular contours and non-indurated bases in the lower half of both legs. A vascular etiology was initially suspected, prompting local wound care and comprehensive vascular imaging; however, no abnormalities were identified. Skin biopsies at ulcer margins were performed to exclude infectious and malignant etiologies, demonstrating a chronic inflammatory infiltrate, fan-shaped neovascular structures, fibrin deposits within vessel walls

and luminal narrowing consistent with a vasculopathic pattern. A systematic workup targeting modifiable factors impairing wound healing was performed; Laboratory investigations showed microcytic hypochromic anemia with an abnormal hemolysis workup. Hemoglobin electrophoresis was then conducted confirming HbAS, and thereby providing a unifying diagnosis for all prior unexplained vascular events.

Management was multimodal, conducted in close collaboration with a hematology team. It comprised high-dose folic acid supplementation, appropriate wound dressings, drainage physiotherapy, gabapentin for pain relief, LED phototherapy, laser treatment to improve skin quality and promote tissue regeneration, calcium channel blockers, and aggressive hydration to mitigate the acidotic milieu known to potentiate HbS polymerization, resulting in significant dermatological improvement. Beyond wound healing, this comprehensive approach was also aimed at reducing the risk of recurrent vasculopathic complications.



Coalescent large ulcerations covered by fibrinous slough and superficial necrosis, with bilateral edema

Conclusion

This case challenges the long-held assumption that sickle cell trait confers a benign phenotype. HbAS can, in certain individuals, drive a severe vasculopathic cascade. The leg ulcer, often dismissed, proved here to be the key diagnostic clue. In the absence of established guidelines, management must be guided by pathophysiological rationale and individual clinical profile; in this case, a targeted approach achieved wound healing and improvement in quality of life. This diagnosis also provided closure to the patient and opened the door to genetic counseling and preventative screening of his offspring.



60-day follow-up : notable regression of ulcerations with early re-epithelialization and reduction of edema.

EA DV CONGRESS
VIENNA
30 SEP - 3 OCT 2026

Abstract N°: 1175

A chronic self-inflicted upper arm wound in a child with 22q13 microduplication syndrome successfully treated with platelet-rich fibrin

Ayushman Bindal*[1]

[1] Charak Hospital, Indore, Lady Hardinge Medical College, New Delhi, Indore, India

Introduction

A 7-year-old girl presented with a chronic non-healing wound over the left upper arm caused by repetitive self-inflicted trauma in the setting of autism spectrum disorder and hyperactivity. She had associated microcephaly, dysmorphic facial features, seizures, developmental delay, and autistic behavior. Chromosomal microarray revealed a duplication corresponding to 22q13.1–13.33 cryptic duplication syndrome. Duplications involving 22q13 are known to be associated with developmental delay, behavioral abnormalities, seizures, dysmorphic features, and autism spectrum disorder, although the phenotype is variable. Self-injurious behavior is common and often persistent in autism spectrum disorder, frequently impairing wound healing due to repeated trauma that disrupts re-epithelialization and granulation.

Case Presentation

The ulcer had persisted for nearly four years due to recurrent picking and self-mutilation despite conventional dressings and local wound care. On examination, a chronic ulcer was noted over the left upper arm with scant granulation tissue and clear evidence of repeated manipulation (Figure 1). Given the prolonged non-healing course, autologous platelet-rich fibrin (PRF) dressing was planned after counseling the family and obtaining consent.

Two sittings of PRF dressing were performed following appropriate wound bed preparation. PRF, a second-generation platelet concentrate, provides a fibrin scaffold rich in platelets, leukocytes, and growth factors, promoting angiogenesis, granulation tissue formation, and tissue repair. After the first sitting, healthy granulation tissue appeared with noticeable improvement in the wound bed. Following the second sitting, there was a marked reduction in wound size with progressive healing and development of healthy granulation tissue that had failed to form for several years (Figure 2). No adverse events were observed. Concurrently, the family was advised regarding behavioral supervision and prevention of repeated trauma.



Conclusion

This case is clinically noteworthy as it highlights the coexistence of a rare neurodevelopmental syndrome, chronic self-mutilation, and a long-standing recalcitrant wound that showed significant response to PRF therapy. Although PRF has primarily been studied in chronic ulcers of other etiologies, its use in a self-inflicted wound in a child with 22q13 microduplication syndrome appears unusual. This observation suggests that PRF may serve as a useful adjunctive treatment in selected pediatric patients with neurobehavioral disorders when conventional wound care fails, while underscoring the importance of concurrent management of self-injurious behavior for sustained healing.



EA DV CONGRESS
VIENNA
30 SEP - 3 OCT 2026

Abstract N°: 1247

Comparative Efficacy of Platelet-Rich Plasma, Platelet-Rich Fibrin, and Conventional Therapy in Chronic Non-Healing Skin Ulcers: A Randomised Clinical Trial

Mohamed Aboshabana Hussein*[1], Eman Mohamed Salah Ahmed[2], Heba Mahmoud Diab[3]

[1] Department of Dermatology and Venereology, Faculty of Medicine, Kafrelsheikh University, Kafr el-Sheikh, Egypt
[2] Department of Dermatology, Andrology, Sexual Medicine and STDs, Faculty of Medicine, Capital University, Cairo, Egypt
[3] Department of Dermatology, Venereology and Andrology, Faculty of Medicine, Ain Shams University, Cairo, Egypt

Introduction
Dermatology presents a significant difficulty with chronic non-healing ulcers. Autologous platelet concentrates, such as Platelet-rich plasma (PRP) or Platelet-rich fibrin (PRF), facilitate tissue repair by providing a continuous release of growth factors that speed wound healing.

Materials and Methods
36 patients, with chronic non-healing ulcers aged 18 to 65, were randomly selected for this prospective randomized clinical trial, which was divided into three groups: PRP (Group A), PRF (Group B), and conventional therapy. Venous blood was subjected to standardized centrifugation protocols, which involved the extraction of autologous platelet concentrates from venous Blood and then used them weekly for eight sessions. We used ImageJ software analysis at baseline, 4 weeks, and 8 weeks to assess the healing rate and reduction in the ulcer area. The assessment of pain was done using the Visual Analogue Scale (VAS).

Results
PRF showed more effective ulcer reduction than both PRP and the standard treatment methods. The PRF group showed an 81.4% reduction in ulcer surface area after 8 weeks, while the PRP group showed 47.6%, and the control group showed 26.1% ($p < 0.001$). The PRF group achieved complete healing in 58.3% of patients, whereas the PRP group achieved this in 41.7% of patients, and the control group reported no healing cases. No significant differences in pain scores were observed between groups, and participants experienced no adverse effects.

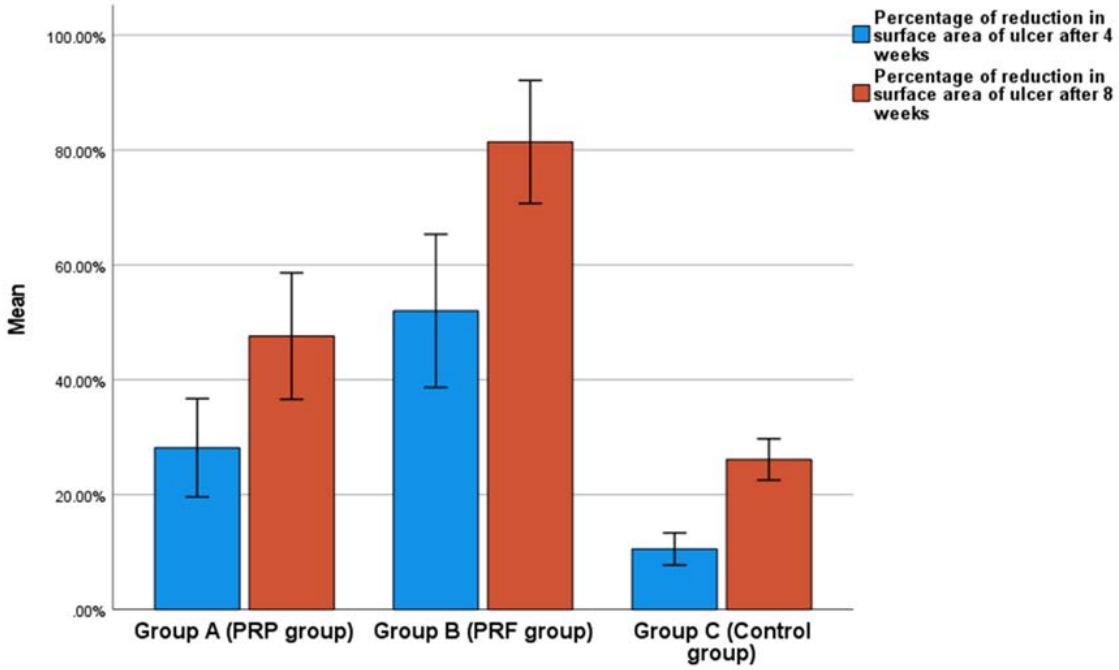

Multiple bar chart shows comparison between the studied groups regarding percent reduction in ulcer surface area on follow up. Reproduced from: Salah EM, Aboshabana Hussein M, Diab HM. Comparative Efficacy of Platelet-Rich Plasma, Platelet-Rich Fibrin, and Conventional Therapy in Chronic Non-Healing Skin Ulcers: A Randomised Clinical Trial. Wound Repair and Regeneration. 2026;34:e70151. https://doi.org/10.1111/wrr.70151 . © 2026 The Wound Healing Society. Published by Wiley.

Conclusions

PRF was superior to PRP and conventional therapy in healing chronic diabetic and venous ulcers, an effect attributed to its longer duration of growth-factor release within a fibrin scaffold. PRF is a low-cost, autologous, and accessible regenerative alternative in the management of chronic wounds.

"Data derived from a study published in *Wound Repair and Regeneration*."

EA DV CONGRESS
VIENNA
30 SEP - 3 OCT 2026

Abstract N°: 1448

Comparative Efficacy and Safety of Therapeutic Modalities and Delivery Methods in MSC-Based Treatments for Chronic Non-Healing Cutaneous Ulcers: A Systematic Review

Faizal Dzaky Rahmadika*[1], Lili Legiawati[2], Amy Yulita[3], Brigitta Lauren[3], Nasya Amalia[3]

[1] Centre for Pharmaceutical Medicine Research, Faculty of Life Science and Medicine, King's College London, London, United Kingdom, Dermatology and Venereology Department, Faculty of Medicine, Universitas Indonesia, Jakarta, Indonesia, Dermatology and Venereology Department, Cipto Mangunkusumo Hospital, Jakarta, Indonesia, London, United Kingdom

[2] Dermatology and Venereology Department, Cipto Mangunkusumo Hospital, Jakarta, Indonesia, Jakarta, Indonesia

[3] Dermatology and Venereology Department, Faculty of Medicine, Universitas Indonesia, Depok, Indonesia, Depok, Indonesia

Introduction

Chronic non-healing cutaneous ulcers pose a severe clinical burden with high recurrence, amputation risks, and resistance to standard care. Mesenchymal stem cells (MSCs) and their cell-free derivatives (exosomes, conditioned media) offer active wound healing potential via paracrine, immunomodulatory, and pro-angiogenic mechanisms. However, clinical translation currently shows a distinct disparity, favoring Diabetic Foot Ulcers (DFUs), leaving venous leg ulcers and pressure ulcers underrepresented in trials and practices. This systematic review evaluates the efficacy and safety of MSCs and their derivatives across all chronic cutaneous ulcers to synthesize current evidence, compare therapeutic modalities, and highlight the research gap.

Materials and Methods

A comprehensive literature search was conducted across four major electronic databases (PubMed, Scopus, Cochrane Library, and ScienceDirect) alongside Clinicaltrials.gov. Inclusion criteria focused on human clinical studies (randomized controlled trials, prospective open-label trials, and proof-of-concept studies) treating adult patients with chronic ulcers using MSCs (whole-cell) or cell-free products (exosomes, stromal vascular fraction, conditioned media). Primary outcomes included wound closure rates, reduction in wound surface area, and time to healing. Secondary outcomes focused on safety metrics and adverse events. Data extraction, risk-of-bias assessments, and comparative analyses of cell types and delivery mechanisms were systematically performed.

Results

Overall, MSC-based interventions demonstrated superior efficacy over conventional care. A comparative analysis revealed that while whole-cell interventions occasionally exhibited more rapid initial wound closure (e.g., 78% vs. 41% by Day 7 in Grade 1 DFUs), cell-free derivatives ultimately achieved equivalent long-term healing rates (100% closure by week 8). Analysis of delivery methods shows distinct clinical advantages dependent on the wound microenvironment. Perilesional injections effectively bypass superficial necrotic or exudative layers to deliver precise therapeutic substances directly to the deeper vascular beds, as evidenced by umbilical cord derivatives achieving 100% closure within 4.2 weeks. Conversely, topical exosome hydrogels provide a sustained paracrine release ideal for superficial epithelialization, achieving 62% full recovery at 6 weeks (vs. 20 weeks for standard care), although their efficacy may be attenuated by heavy wound exudate or thick slough. Meanwhile, systemic (intravenous) and intramuscular deliveries proved advantageous for patients with concurrent peripheral artery disease, alleviating limb ischemia while giving >95% wound closure. Safety profiles were highly favorable across all modalities, with no serious treatment-related adverse events reported. Localized deliveries reported only mild,

transient erythema or exudation, whereas systemic administrations noted isolated, self-resolving fever. No serious treatment-related adverse events occurred.

Conclusions

MSCs and their cell-free derivatives represent highly effective, safe adjunctive therapies for chronic cutaneous ulcers. Cell-free derivatives offer comparable long-term efficacy to whole cells while mitigating live-cell logistical complexities. Furthermore, delivery methods must be strategically tailored to the specific ulcer microenvironment, with topical gels for superficial granulating wounds, perilesional injections for deeper recalcitrant ulcers, and systemic routes for ischemia-complicated wounds. Large-scale randomized trials are urgently needed to expand these tailored regenerative therapies beyond DFUs into venous and pressure ulcers.

EA DV CONGRESS
VIENNA
30 SEP - 3 OCT 2026

Abstract N°: 1451

INGUINAL AND INTERGLUTEAL ISCHEMIC ULCERS: THE CLINICAL CHALLENGE OF VASCULAR ANATOMY IN AN ATYPICAL DERMATOLOGICAL PRESENTATION

Georgeta Urcan*[1], Bogdan Florea[1], Ruxandra-Maria Cutus[1]

[1] Dermatology Department, Clinical Emergency Hospital, Cluj-Napoca, Romania

Introduction

Cutaneous manifestations of peripheral arterial disease (PAD) typically follow a distal-to-proximal gradient, with ulcers most commonly localized on the toes, heels, or pretibial areas. Proximal ischemic involvement, specifically in the inguinal and intergluteal regions, is an exceptional clinical occurrence due to the robust collateral circulatory network provided by the deep femoral and internal iliac artery branches. When such lesions occur, they frequently masquerade as primary dermatological conditions, including neutrophilic dermatoses, infectious processes or malignancies. This "diagnostic mimicry" often leads to therapeutic delays, which can be critical in patients with advanced systemic atherosclerosis.

Case Presentation

We present the case of a 56-year-old female patient with a complex medical history, including Stage IV PAD (Fontaine classification), poorly controlled type 2 diabetes mellitus, grade I obesity, and a 30-pack-year smoking history. The patient presented for pain in her left toes and rapidly progressing ulcers located in the left inguinal fold and the intergluteal cleft, with an evolution of approximately 14 days.

Clinical examination revealed deep tissue defects with irregular, "punched-out" necrotic borders, covered by adherent fibrino-purulent slough and showing evidence of early fistulous tract formation. Given the morphology and localization, initial differential diagnoses focused on Pyoderma Gangrenosum (PG), Hidradenitis Suppurativa (Hurley stage III), or Ecthyma Gangrenosum. However, the absence of pathergy and the patient’s systemic vascular profile prompted a more extensive evaluation.

A crucial diagnostic clue was the concomitant presence of severe digital ischemia on the left foot, manifesting as dry gangrene of the fifth digit. This distal-proximal "mismatch" suggested a high-level vascular obstruction rather than localized skin disease. Emergency Computed Tomography Angiography (CTA) revealed a critical, multisegmental occlusion of the common iliac arteries, compromising the primary inflow to the pelvic and proximal thigh regions.

The management required a rapid, multidisciplinary approach involving dermatologists, radiologists and interventional cardiologists. The patient underwent endovascular revascularization via bilateral common iliac artery balloon angioplasty to restore proximal perfusion. Concurrently, systemic broad-spectrum antibiotic therapy was administered to manage secondary bacterial contamination, alongside specialized moisture-retentive wound dressings.

Post-revascularization, the proximal ulcers showed a remarkable healing trajectory, with significant granulation tissue formation within the first week. The distal digital gangrene, being irreversible, necessitated a limited amputation of the fifth toe. This case underscores the "vascular trap" in dermatology: had the lesions been misdiagnosed as Pyoderma Gangrenosum and treated with high-dose systemic corticosteroids, the resulting immunosuppression and lack of perfusion could have led to catastrophic tissue loss or sepsis.

Conclusion

Proximal ischemic ulcers serve as a rare but definitive red flag for severe, limb-threatening arterial obstruction. In the presence of atypical ulcerations in skin folds, clinicians must maintain a high index of suspicion for vascular etiology, especially in patients with metabolic comorbidities. A thorough understanding of vascular territories and a low threshold for angiographic assessment are essential to differentiate ischemic "mimickers" from primary inflammatory dermatoses, ultimately ensuring limb salvage and patient survival.

EA DV CONGRESS
VIENNA
30 SEP - 3 OCT 2026

Abstract N°: 1467

Amniotic Membrane Allografts in Chronic Vascular Leg Ulcers: A Prospective Evaluation of Tolerance, Pain Relief, and Wound Healing

Badr Amal*[1], Leila Bendaoud[1], Meryem Aboudouraib[1]

[1] Facutly of Medicine of Marrakech Cadi Ayyad University, BioScience Laboratory University Cadi Ayyad, Dermatology Department of University Hospital Mohammed VI, MARRAKESH, Morocco

Introduction

Chronic vascular leg ulcers represent a persistent therapeutic challenge, especially in cases resistant to optimized medical and surgical management. Human amniotic membrane (HAM) has been used in venous ulcer treatment since 1910 and has gradually expanded into ophthalmology, dermatology, and surgical practice. Its biological properties include low immunogenicity, safety, bacteriostatic activity, and stimulation of tissue repair. The placenta is particularly rich in growth factors such as endothelins 2 and 3, vascular endothelial growth factor (VEGF), and the angiopoietin receptor Tie-2, all of which may enhance angiogenesis and tissue regeneration. We report our experience with amniotic membrane allografting in chronic vascular leg ulcers.

Materials and Methods

Aims and Objectives:

The primary aim of this study was to assess the tolerance of amniotic membrane grafts in patients presenting with chronic vascular ulcers. Secondary objectives included evaluation of pain reduction using a visual analogue scale (VAS) and assessment of wound healing progression.

Methods:

This prospective study enrolled patients hospitalized in the dermatology department for vascular leg ulcers unresponsive to standard local and surgical treatments. Conventional management included mechanical debridement of necrotic tissue, infection control, and exudate management.

Five chronic ulcers located on the left leg, evolving for approximately five years and characterized as hyperalgesic and refractory, were included. Amniotic membranes were harvested, processed, preserved, and transported by the tissue bank, which ensured complete donor serological monitoring.

After obtaining informed consent, grafts were applied under sterile conditions using forceps, positioning the fetal side in direct contact with the ulcer bed. Four ulcers received amniotic membrane grafts, while one ulcer served as a control. Secondary dressings consisted of non-adherent tulle gras combined with adapted compression therapy using a Velpeau bandage. The preservation solution was systematically sent for bacteriological examination following graft placement.

Patients were clinically evaluated at days 7, 15, 21, and 49.

Results

Amniotic membrane application was well tolerated, with no allergic, inflammatory, or infectious adverse events observed. A reduction in ulcer size was noted following graft placement. Pain improvement was also reported. However, one ulcer demonstrated clinical worsening at day 49. Overall, preliminary observations suggest a beneficial effect on granulation tissue formation, connective and endothelial tissue development, and re-

epithelialization.

Conclusions

In this small prospective series, amniotic membrane allografts showed good tolerance and potential efficacy in reducing pain and promoting healing in chronic vascular leg ulcers. Although the results are encouraging, they remain preliminary. Limitations include the small sample size, limited membrane availability from tissue banks, and the risk of recurrence. Randomized controlled studies are required to confirm the therapeutic value of amniotic membrane grafting in chronic vascular ulcers.

EADV CONGRESS
VIENNA
30 SEP - 3 OCT 2026

Abstract N°: 1472

Non-uremic calciphylaxis in a liver transplant recipient

Lía Salomé Abeledo*[1], Juana Sanguinetti[1], Pedro Barbosa[1], Berenice Fouces[1], Corina Busso[1]

[1] Hospital Universitario Austral, Pilar, Buenos Aires, Argentina

Introduction

Calciphylaxis is a severe vasculopathy characterized by calcification of small dermal and subcutaneous vessels and is associated with high mortality, mainly due to sepsis. Although it is classically associated with chronic kidney disease (uremic form), a non-uremic variant exists, occurring in the absence of advanced renal disease and with normal calcium–phosphate metabolism. This form has been associated with chronic liver disease, hypoalbuminemia, and hypercoagulable states, among other factors. It presents with painful plaques and nodules, livedo racemosa, and retiform purpura, progressing to cutaneous necrosis and ulceration.

Case Presentation

A 60-year-old male patient with a history of alcoholic cirrhosis, hepatocellular carcinoma, and liver transplantation, currently under immunosuppressive therapy, presented with lower limb ulcers of several months duration. These were initially interpreted as venous ulcers in another institution, requiring debridement and isolation of *Proteus vulgaris*, for which he received two weeks of meropenem.

He was referred to our center due to altered liver function tests. During hospitalization, he reported severe pain in the ulcers. Physical examination revealed two ulcers with a granulating base and fibrinous areas with violaceous borders on the distal left lower limb, and additional ulcers with necrotic bases and erythematous indurated borders on the lateral aspect of the left leg and right thigh. These lesions were surrounded by livedo racemosa and associated with painful nodules on both thighs and areas of retiform purpura.

Given the suspicion of calciphylaxis, vasculitis, or infectious etiology, a skin biopsy with immunofluorescence and cultures was performed.

Laboratory tests showed positive antinuclear antibodies and hypoalbuminemia (3.01 g/dL), while the remaining immunological, coagulation, and serological studies were unremarkable. Calcium–phosphate metabolism was within normal ranges (serum calcium 8.8 mg/dL, ionized calcium 1.22 mmol/L, phosphorus 5.4 mg/dL).

Soft tissue ultrasound revealed diffuse small calcifications in the subcutaneous tissue of both thighs, and radiography showed vascular calcifications in bilateral lower limbs.

Histopathology demonstrated epidermal ulceration, fibrinoid thrombi, and calcium deposits in the walls of deep dermal small vessels (Von Kossa staining positive). Direct immunofluorescence and cultures were negative.

A diagnosis of non-uremic calciphylaxis was made, and treatment with thrice-weekly sodium thiosulfate was initiated, with clinical improvement of the lesions.

Conclusion

Non-uremic calciphylaxis should be considered in the differential diagnosis of painful cutaneous ulcers and

vasculopathic lesions, even in the absence of renal failure and with normal calcium–phosphate metabolism. Early recognition allows appropriate diagnostic work-up, including skin biopsy with Von Kossa staining, and facilitates timely initiation of treatment.

EADV CONGRESS
VIENNA
30 SEP - 3 OCT 2026

Abstract N°: 1494

Dysregulated NAMPT signaling underlines the immune-suppressive microenvironment in venous leg ulcers

Jiating Wang*[1], Dongqing Li[1]

[1] Hospital for Skin Diseases, Institute of Dermatology, Chinese Academy of Medical Sciences & Peking Union Medical College, Nanjing, China

Introduction

Venous leg ulcers (VLUs) are the most common form of lower extremity ulceration,with a rising prevalence among the elderly. Despite their clinical significance, the molecular mechanisms underlying VLU remain poorly defined.

Materials and Methods

VLU and healthy skin samples were collected at Hospital of Dermatology, Chinese Academy of Medical Sciences.The study was approved by the Research Ethics Committee of the Hospital of Dermatology, Chinese Academy of Medical Sciences & Peking Union Medical College (Approval No.: 2021-KY-059). This study was carried out using the following methods: human sample collection, animal experiments, single-cell RNA sequencing, bioinformatic analyses, analysis of public datasets, in vitro cellular models (including fibroblast and macrophage isolation, coculture, treatment, and qRT-PCR), histological analysis, multiplex immunohistochemistry, and statistical analysis.

Results

In this study, we constructed a comprehensive single-cell transcriptional atlas of VLUs, unveiling a widespread immunosuppressive microenvironment within the lesions. Specifically, stromal cells exhibited attenuated inflammatory responses coupled with enhanced fibrotic activity. Keratinocytes and endothelial cells demonstrated increased proliferative and angiogenic activity, respectively, yet both cell types showed markedly reduced antigen-presenting capacity. Immune cell compartments displayed profound dysfunction characterized by marked reductions and impaired functionality of dendritic cells, polarization of macrophages toward an anti-inflammatory M2 phenotype, and enrichment of T cell exhaustion signatures. Notably, cell–cell communication analysis revealed diminished crosstalk between immune and structural cell populations. Mechanistically, we identified NAMPT-mediated signaling as a critical regulator of myeloid-stromal crosstalk. Targeted depletion of NAMPT in macrophages disrupted fibroblast-mediated inflammatory responses and impaired wound healing, whereas exogenous NAMPT administration reactivated immune responses and promoted tissue repair in chronic wounds.

Conclusions

Collectively, these findings provide a comprehensive molecular framework for understanding immune–stromal dysfunction in VLUs and position NAMPT as a central immune regulator and promising therapeutic target for chronic wound treatment.

EADV CONGRESS
VIENNA
30 SEP - 3 OCT 2026

Abstract N°: 1503

Evaluating the Impact of Biologic Class on Pain Reduction and Wound Closure in Pyoderma Gangrenosum: Evidence from a Prospective Cohort

Moira Shea*[1], Katelyn Downey[1], Alec Furst[1], Kurt Bowen[1], Jaclyn Roland-McGowan[1], Jordan Gillespie[1], Alex Ortega Loayza[1]

[1] Oregon Health & Science University, Portland, United States

Introduction

Pyoderma gangrenosum (PG) is a rare inflammatory neutrophilic dermatosis characterized by painful ulcerations and delayed, often prolonged, wound healing. Although the inflammatory mechanisms underlying PG continue to be investigated, the marked heterogeneity of the disease poses an ongoing challenge to the development of targeted and effective therapies. The use of biologic medications, including tumor necrosis factor-alpha (TNF-α) inhibitors and interleukin 23 (IL-23) inhibitors, has been a growing area of interest in the treatment of PG. Current literature on the topic is primarily sourced from case reports or series and semi-systematic reviews, and have demonstrated the strongest evidence for TNF-inhibitor biologics. This study aimed to compare the real-world effectiveness of both TNF and IL-23 biologic medications in the treatment of PG.

Materials and Methods

This study utilized the Pyoderma Gangrenosum Study (PyGaS) prospective patient registry. Inclusion criteria were adults with classical ulcerative PG with documented injection dates for either a TNF-α or IL-23 (including both IL-23 and combination IL-12/IL-23) biologic medication, and an available baseline pain score, defined as the average pain over the past 7 days (scale of 0-10), within 60 days prior to and 14 days after biologic initiation. Patients were excluded if they did not have at least one follow-up visit with pain assessment after initiation.

Results

Forty-seven patients met inclusion criteria (24 IL-23 inhibitor, 23 TNF inhibitor), including three patients who received trials of multiple biologics, with one patient switching classes of biologic medications. Most common medications include adalimumab (8/23) and infliximab (15/23) for TNF inhibition and ustekinumab (12/24) for IL-23 inhibition with fewer patients receiving risankizumab, guselkumab, and tildrakizumab. Clinically meaningful pain improvement (≥2-point reduction on a 10–point scale) occurred in 72% of IL-23-treated and 68% of TNF-treated patients. Kaplan–Meier analysis demonstrated no significant difference in time to improvement between groups (log-rank p=0.89; Figure 1). In Cox proportional hazards models adjusted for baseline pain and opioid use, biologic class was not associated with time to improvement (TNF vs IL-23 HR 1.25, 95% CI 0.60–2.59, p=0.55). Early pain improvement at 12 weeks was observed in 33% of IL-23–treated and 35% of TNF-treated patients. Median time to healing was approximately 20.5 months for TNF-treated patients (range 1.5–87.5 months) and 17 months for IL-23–treated patients (range 3–44.5 months) with no statistically significant difference between groups (p=0.7). A higher proportion of TNF patients achieved complete healing overall (57% vs 50%).

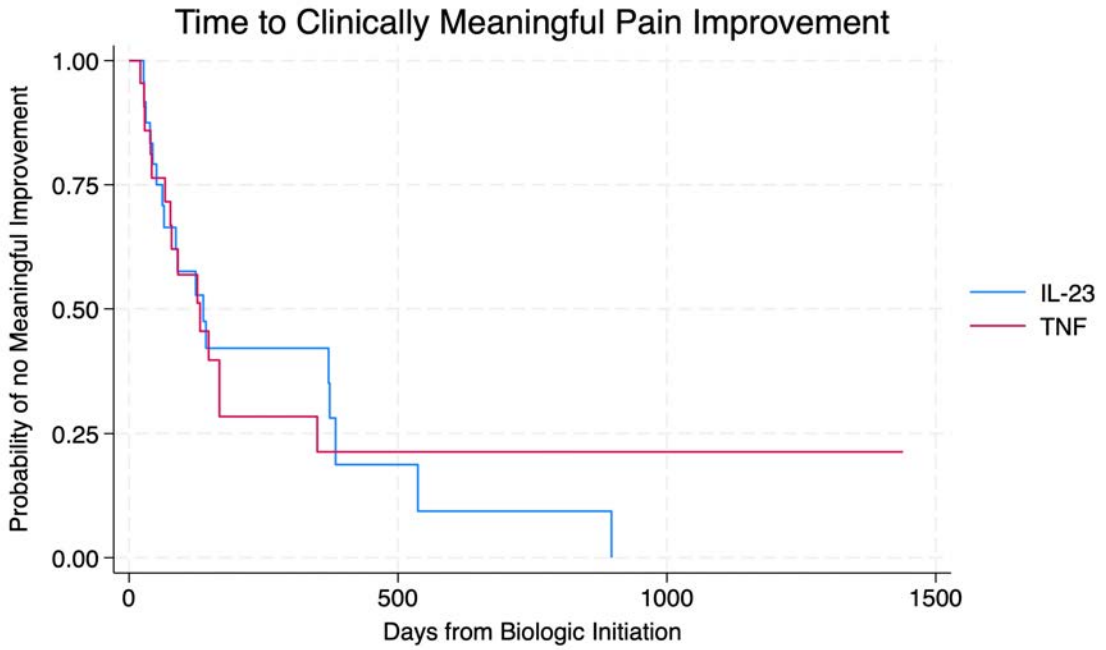

Figure 1. Time to Clinically Meaningful Pain Improvement by Biologic Class. Kaplan–Meier curves showing time from biologic initiation to clinically meaningful pain improvement (≥2-point reduction on the 0–10 numeric rating scale) among patients treated with IL-23 inhibitors (blue) and TNF inhibitors (red). The y-axis represents the probability of not yet achieving clinically meaningful pain improvement. Patients without improvement were censored at last follow-up.

Conclusions

In this real-world prospective cohort of patients with classic pyoderma gangrenosum, IL-23 and TNF inhibitors demonstrated comparable effectiveness with respect to clinically meaningful pain reduction and overall healing outcomes. Healing rates were similar to those reported in the STOP GAP trial, although time to complete healing remained highly variable. These findings support IL-23 inhibition as a potential therapeutic alternative in PG, particularly for patients with contraindications to TNF-α blockade. Although TNF inhibitors have previously been evaluated in PG, clinical trials of IL-23 inhibition have not yet been conducted and represent an important next step. Notably, despite the prolonged and often incomplete healing course characteristics of PG, most patients experienced meaningful reductions in pain, highlighting the value of patient-reported outcomes in treatment assessment. Taken together, these findings suggest that biologic therapy may affect not only healing, but also the symptom burden of disease, particularly pain.

EA DV CONGRESS
VIENNA
30 SEP - 3 OCT 2026

Abstract N°: 1563

Diagnostic Dilemmas and Therapeutic Shifts: A Case of Calciphylaxis With Full-Spectrum Lesions and Reflections on Alternative Therapy

peng lu*[1], Bingning Jiang[1], Liuqing Yang[1], Dan Shu[1], Yihui Zhou[1], Yongwei Pan[1], Yi Zhao[1]

[1] Beijing Tsinghua Changgung Hospital, School of Clinical Medicine, Tsinghua University, Beijing, China

Introduction

Calciphylaxis is a rare and highly challenging microvascular calcification syndrome, primarily occurring in patients with chronic kidney disease. Although the one-year mortality rate is reported to be as high as 45%–80% , current international guidelines still lack clear, high-level evidence-based recommendations for first-line therapy. Consequently, clinical decision-making remains heavily dependent on multi-disciplinary empirical protocols.

Case Presentation

A 75-year-old female with end-stage kidney disease (ESKD) on long-term abdominal hemofiltration was admitted to the intensive care unit. She presented with a mild coma and a necrotic limb that had rapidly progressed over the preceding two weeks. Despite the escalation of antimicrobial therapy, the condition remained refractory. The ulcers—initially of uncertain etiology—continued to expand and deepen, eventually extending to the joint capsule. Given the progressive tissue necrosis,radical amputation was considered.

Dermatological consultation identified a full spectrum of pathognomonic lesions: early-stage firm white calcified nodules, livedo reticularis, sclerodermatous plaques, and refractory ulcers. Histopathological examination confirmed calcium deposition in the arteriolar microvasculature, rectifying the diagnosis.

Regarding management, although sodium thiosulfate (STS) is widely considered the empirical first-line therapy , its use was deferred due to the patient’s severe renal impairment, metabolic destabilization, and history of recurrent diarrhea and allergies. Instead, a multi-modal strategy was adopted: short-term Methylprednisolone (40 mg QD for 4 days) was administered to alleviate the acute inflammatory cascade , alongside oral Cinacalcet (25 mg QD) to precisely modulate the calcium, phosphorus, and parathyroid hormone (iPTH) levels. Following systemic optimization and the recovery of the patient’s mental status, the strategy shifted from "radical amputation" to "targeted debridement and surgical reconstruction via flap transfer and split-thickness skin grafting. Serum ionized calcium levels were closely monitored to ensure cardiac safety. At the 10-day postoperative follow-up, the flap demonstrated excellent viability and perfusion, achieving successful limb salvage.

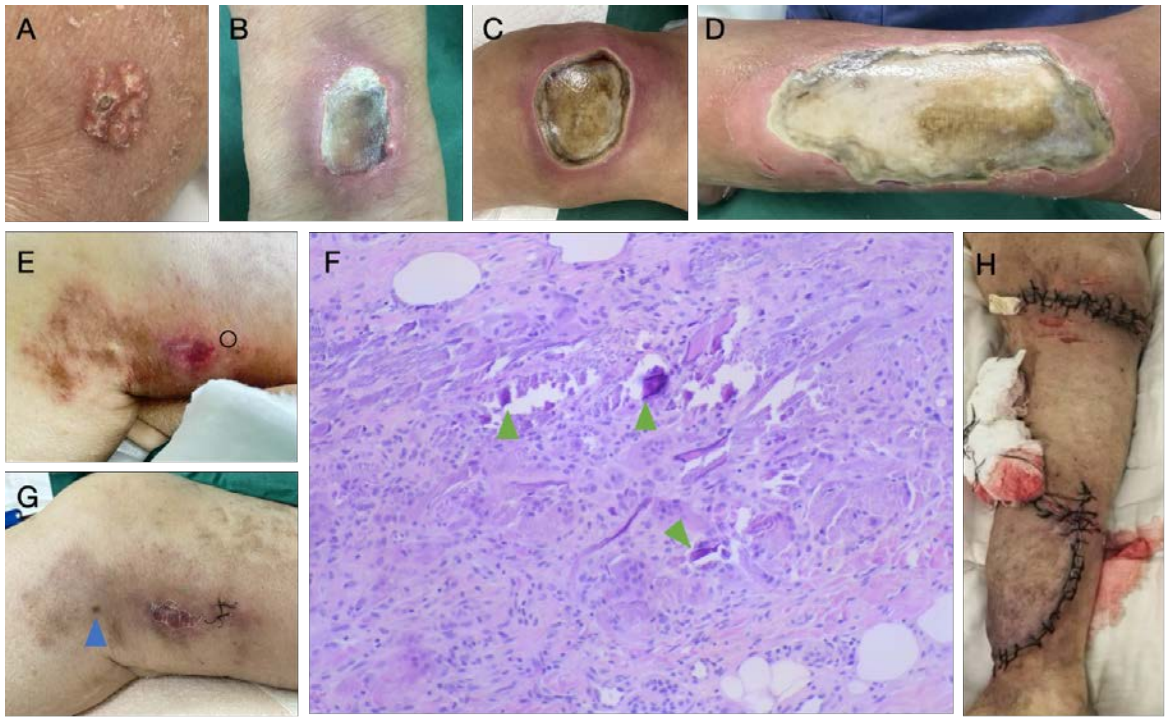

Figure 1. Clinical, Pathological, and Therapeutic Features of the Patient with Calciphylaxis. A. White subcutaneous calcified nodules on the skin of the left forearm. B. Ulceration on the flexor surface of the right wrist. C. Ulceration on the extensor surface of the left knee. D. Ulceration on the extensor surface of the left lower leg. E. Livedo reticularis, sclerodermatous plaques, and erythematous patches on the medial aspect of the right thigh. The black circle indicates the site of the diagnostic punch biopsy. F. Histopathology of the punch biopsy (H&E staining, 100x): Basophilic calcification deposits are visible within the arteriolar walls (indicated by green arrows). G. Therapeutic response of the skin lesions on the right thigh (from panel E) after treatment. Following the diagnosis, the patient received Methylprednisolone (40mg qd for 4 days) and continued Cinacalcet (25mg qd for 7 days). One week later, the sclerotic areas softened, erythema faded, and the prominence of calcified deposits significantly diminished (indicated by blue arrows). H. Clinical photograph during the dressing change on postoperative day 4 following debridement and sural nerve flap reconstruction of the left lower limb ulcer.

Conclusion

Clinicians should maintain high suspicion for calciphylaxis in dialysis patients with necrotic ulcers. The classic lesion spectrum demonstrated in this case serves as an essential educational tool for MDTs. Regarding treatment, we suspect that short-term corticosteroids play a dual role: acutely arresting inflammatory progression and buffering against surgery-induced Koebnerization. For patients intolerant to STS, Cinacalcet is a viable alternative. In refractory cases with compromised microcirculation, precise reconstruction followed by close monitoring may significantly improve limb salvage and prognosis.

EADV CONGRESS
VIENNA
30 SEP - 3 OCT 2026

Abstract N°: 1608

Investigating the Role of Compression Therapy in the Healing of Acute Lower Leg Wounds: A Pilot Study

Mara Mihailescu*[1], Chloe Devoy[1], Laurie Parsons[1]

[1] University of Calgary, Calgary, Canada

Introduction

Chronic wounds are defined as those that fail to heal within 6-weeks. The most common chronic wounds are lower leg ulcers. Compression therapy for chronic lower legs wounds (>6 weeks) is standard of care as it counteracts gravity, increases arterial flow, improves venous pumping, reduces venous pooling, and releases anti-inflammatory mediators. Wounds that fail to heal result in continuous management, increased infection risk, and decreased quality of life. Acute wound healing treatments focus mainly on mechanical protection and infection control. We propose a pilot study investigating whether compression improves healing in acute lower leg wounds (ALLWs) using 'Tubigrip', an accessible and low-cost therapy effective in chronic wound care. Early intervention for ALLWs in populations vulnerable to the development of chronic wounds improves patient quality of life and reduces healthcare costs. Few interventions specifically target wound healing efficiency or the prevention of chronic wounds. Therefore, further research on compression wear for ALLWs could fill this gap and improve patient care.

Materials and Methods

A pilot quasi-experimental study will be conducted at a single emergency department in Lethbridge, Alberta. Participants aged 55-80 with ALLWs > 1 inch in diameter located on the lower leg below the tibial tuberosity and above the ankle will be enrolled. Participants can receive any intervention in the ED including stitches or antibiotics (IV or oral). Exclusion criteria includes: hospital admission, compression use in the prior 3 weeks, latex allergy, active congestive heart failure, and known peripheral vascular disease or arterial insufficiency. All other patient comorbidities will be included and tracked. We will not exclude any participants based on their home medications. Participants will be provided with Tubigrip® in the ED and be taught how to self-apply the device a home. Participants will have follow up with Homecare for an initial intake and every week after that. Toe-brachial index scores will be taken at the initial homecare visit to ensure the ongoing safety of compression use. Two layers of Tubigrip®, to achieve 15 mmHg of compression at the ankle should be worn at minimum 10 hours/day on the affected leg, ideally during all waking hours and when ambulating. Weekly wound photos and measurements will be collected by Homecare for 6 weeks. After this time, non-healed wounds will be referred for further treatment.

Wound photos, wound morphology (descriptive), and wound measurements will be analyzedusing descriptive statistics to summarize outcomes in ALLW healing using compression. Qualitative analysis of the photos for morphology may be used. In addition, regression analysis may be used to determine whether demographic variables or comorbidities in the patient population impact ALLW healing using compression. Participants will be provided with new Tubigrip every 3 weeks by Home care to ensure a consistent and adequate level of compression.

Results

Wound photos, morphology, and measurements will be analyzed using descriptive statistics to summarize outcomes in acute lower leg wound healing using compression. This will include: size of the wound on intake and

the degree of change in wound size, percentage of granulation tissue to slough at the wound bed at various time points, and percentage of wounds that became infected during the study period. Patient quality of life will also be measured throughout the 6 weeks using Wound-QoL-14.

Conclusions

This study aims to determine whether 15 mmHg of Tubigrip compression therapy provides similar healing benefits in ALLWs as in chronic lower leg wounds among adults aged 55-80. We hypothesize that 15 mmHg of compression at the ankle will decrease healing times and prevent progression of ALLWs into chronic wounds in this population despite patient comorbidities and etiology of acute wound.

EADV CONGRESS
VIENNA
30 SEP - 3 OCT 2026

Abstract N°: 1612

Cannabidiol in Wound Healing: Mechanistic Insights and Emerging Clinical Evidence

Hajar Dahmani*[1], Ouiame El Jouari[1], Salim Gallouj[1]

[1] University Hospital Center Mohammed VI of Tangier, Tangier, Morocco

Introduction
Wound healing, particularly in chronic wounds, remains a major therapeutic challenge despite advances in wound care. Persistent gaps in management highlight the need for innovative therapies targeting inflammation, oxidative stress, pain and tissue repair.
Cannabidiol (CBD), a non-psychoactive phytocannabinoid, has emerged as a promising candidate through its interaction with the cutaneous endocannabinoid
system. To provide an updated overview of the role of CBD in wound healing by analyzing its mechanisms of action and available in vitro, in vivo and clinical evidence.

Materials and Methods
A narrative literature review was conducted using PubMed, Scopus and Google Scholar databases up to January 2026.
The search strategy combined keywords related to cannabidiol (CBD), cannabinoids, endocannabinoid system, wound healing, chronic wounds
and skin repair.
Eligible studies included in vitro and in vivo experimental studies, animal models, clinical studies (interventional and observational), as well as case series and case reports. Studies not directly addressing wound healing or lacking CBD-specific outcomes were excluded. After screening titles, abstracts and full texts, more than 20 studies were included. Data were qualitatively synthesized to analyze mechanisms of action, preclinical findings and clinical outcomes related to CBD in wound healing.

Results
CBD demonstrated anti-inflammatory, antioxidant and analgesic properties through modulation of the endocannabinoid system, TRP channels and PPARγ pathways. Preclinical studies showed enhanced keratinocyte and fibroblast proliferation, improved migration, accelerated re-epithelialization and extracellular matrix remodeling, particularly in impaired healing models. Clinical studies explored CBD-based therapies in chronic ulcers, systemic sclerosis-related digital ulcers, epidermolysis bullosa and calciphylaxis-associated wounds. Reported benefits included reduced pain and pruritus, decreased analgesic use, improved quality of life, enhanced granulation tissue formation and accelerated wound closure. However, current evidence remains limited by small sample sizes, heterogeneous formulations and predominance of observational data.

Conclusions
CBD represents a promising and innovative molecule in wound healing, supported by a strong biological rationale and encouraging early clinical signals across several chronic and refractory wound types. Nevertheless, significant gaps remain, and well-designed randomized controlled trials are needed to define its therapeutic role and establish standardized treatment protocols.

EA DV CONGRESS
VIENNA
30 SEP - 3 OCT 2026

Abstract N°: 1676

Extramammary Paget Disease: A Diagnostic, Dermoscopic, and Histopathologic Challenge

Kevin Ramón García Fong*[1], Edwin Jesús Pardo Escalera[2], Luisa Mariana Guerrero Escudero[2], María Elisa Vega Memije[2], Sonia Toussaint-Caire[2]

[1] Hospital General Dr. Manuel Gea González, Universidad Nacional Autónoma de México, Instituto Nacional de Ciencias Médicas y Nutrición Salvador Zubirán, Ciudad de México, Mexico
[2] Hospital General Dr. Manuel Gea González, Ciudad de México, Mexico

Introduction

Extramammary Paget disease (EMPD) is an uncommon cutaneous neoplasm that typically involves apocrine-rich areas, such as the anogenital region. Its nonspecific clinical presentation often results in misdiagnosis, delayed treatment, and potential complications. Moreover, EMPD may recur and, in invasive variants, can behave aggressively, making histopathological confirmation, staging, and close follow-up essential (1–3).

Case Presentation

We present the case of a 71-year-old man with systemic arterial hypertension, chronic smoking, and recently diagnosed, poorly controlled type 2 diabetes, admitted for severe diabetic ketoacidosis. During the initial evaluation, Fournier's gangrene was suspected. Physical examination revealed a single 15 × 20 cm ulcer localized to the left inguinal region. Moderate seropurulent exudate was present. Dermoscopy showed milky-red areas, poorly structured white areas, white clots, polymorphous vessels, papillomatosis, and ulceration (Figure 2). The lesion had progressed over 10 years. The patient reported mild pain and denied weight loss or B symptoms. No palpable lymphadenopathy was identified.

Laboratory studies were consistent with metabolic decompensation. Contrast-enhanced computed tomography of the chest and abdomen revealed a right renal mass (5.2 × 4.2 × 4.5 cm) with infiltration into hepatic segment VI, along with findings compatible with pneumonia, without evidence of pulmonary neoplastic infiltration or lymphadenopathy.

An incisional biopsy was performed. Histopathological examination revealed an ulcerated epithelial neoplasm extending from the epidermis into the mid-reticular dermis, with an asymmetric, poorly circumscribed, infiltrative pattern. The remaining epidermis showed irregular acanthosis. A proliferation of epithelioid cells was observed predominantly in the lower third of the epidermis, with pagetoid migration (Figure 1A). Immunohistochemistry (IHC) demonstrated strong cytokeratin 7 (CK7) positivity (Figure 1B) and cytokeratin 20 (CK20) negativity, supporting the diagnosis of primary intraepidermal EMPD (1–3). Urology and Medical Oncology were consulted for surgical management and consideration of radiotherapy.

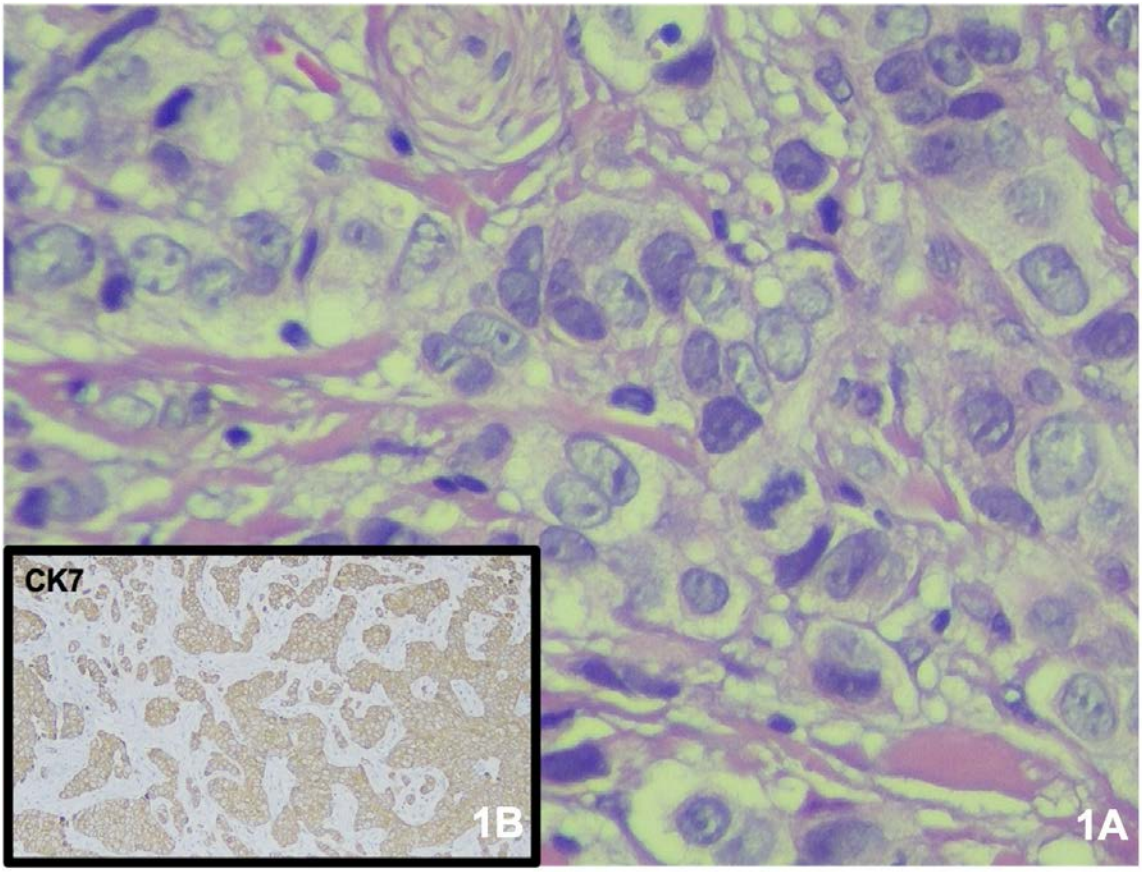

Figure 1. Histopathological study. A) Hematoxylin and eosin-stained skin section (100×) showing cells with large, pleomorphic, hyperchromatic nuclei and abundant eosinophilic cytoplasm, some with intracytoplasmic vacuoles. B) Immunohistochemistry showing strong cytoplasmic CK7 positivity in the neoplastic cells.

Conclusion

This case illustrates the diagnostic challenge of EMPD, particularly when it mimics infectious or inflammatory dermatoses. Early biopsy is essential in chronic lesions of apocrine-rich areas, especially when they are unilateral, persistent, ulcerated, or poorly responsive to conventional treatment. IHC is crucial for distinguishing primary from secondary EMPD and for excluding histopathological mimickers (1–3).

The tomographic finding of a renal mass is clinically relevant because EMPD may coexist with internal malignancies. A reported series of penoscrotal EMPD found synchronous or metachronous neoplasms in a significant proportion of patients, supporting the need for oncologic screening at diagnosis and during follow-up (4–7). Depth of invasion is also a key prognostic factor, as invasive EMPD, particularly with reticular dermal involvement, lymphovascular invasion, or nodal disease, has been associated with higher rates of metastasis and disease-specific mortality (1,7).

From a therapeutic perspective, margin-controlled surgery, including Mohs micrographic surgery, has demonstrated higher cure rates than conventional wide local excision. Medical Oncology evaluation, structured clinical surveillance, and patient education are recommended (3,6,7). Selected cases may benefit from topical imiquimod and/or local radiotherapy (8,9).

In conclusion, EMPD should be considered in the differential diagnosis of chronic unilateral inguinal or anogenital ulcers. Dermoscopy (Figure 2), histopathology, and immunohistochemistry are essential for diagnosis, and staging and long-term surveillance should address the risks of invasion, metastasis, recurrence, and associated internal malignancies (10).

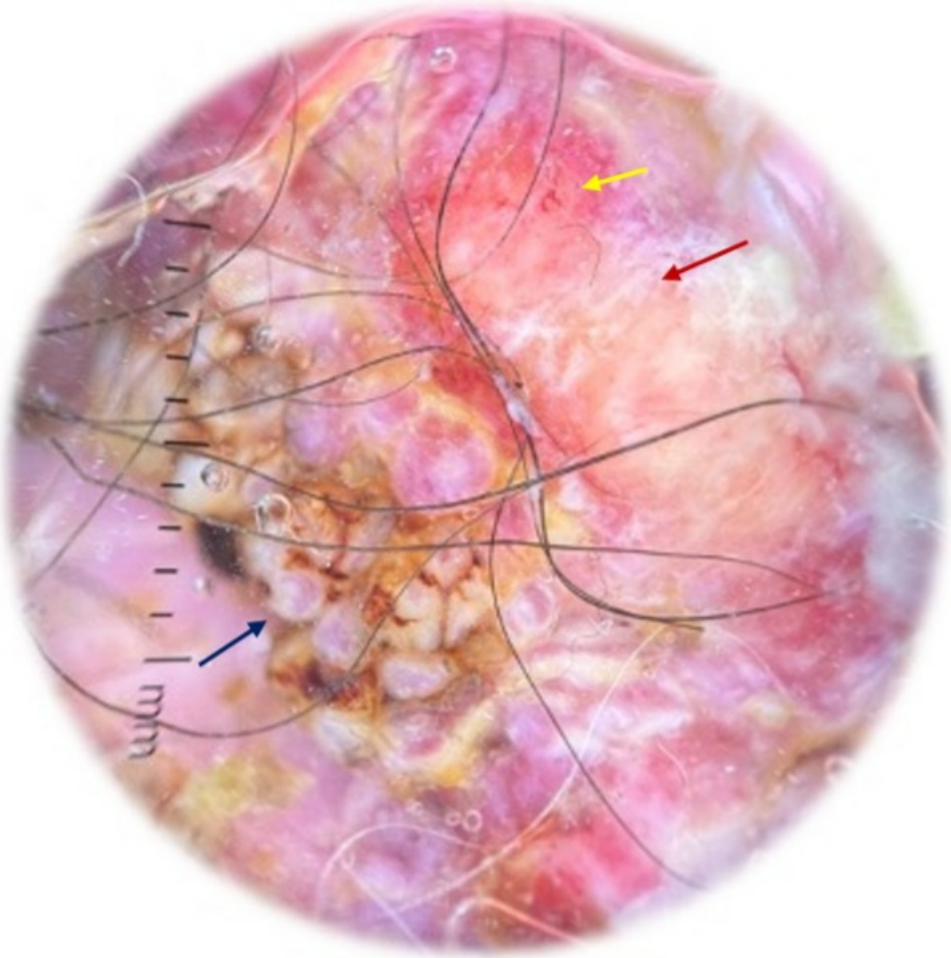

Figure 2. Dermoscopy: polymorphous vessels (yellow arrow), milky-red areas (red arrow), and papillomatosis (blue arrow).

EA DV CONGRESS
VIENNA
30 SEP - 3 OCT 2026

Abstract N°: 1694

Exploring the Molecular Mechanism of Nrep Regulation of Wound Healing Based on A Conditional Knockout System

Xingyan Liu*[1], Li Wan[2], Guangbo Yuan[2], Chujing Liu[2], Yulin Fan[2], Chengliang Deng[1], Guangchao Xu[1]

[1] The Affiliated Hospital of Zunyi Medical University, Zunyi, China

[2] Zunyi Medical University, Zunyi, China

Introduction

The molecular mechanisms regulating tissue repair after skin injury remain incompletely understood. Changes in molecular regulation during wound healing often lead to two distinct outcomes: scar formation or scarless healing. Notably, oral wounds generally heal more favorably than skin wounds. Therefore, exploring key factors in the oral mucosal environment and clarifying the differences between oral mucosal and skin wound healing may aid in developing new therapeutic strategies.Transforming Growth Factor-β (TGF-β) plays a crucial role in promoting wound healing but is also closely associated with scar formation. Neuronal Regeneration Related Protein (Nrep), a key regulator of the TGF-β signaling pathway, may play an important role in this process. Nrep is thought to regulate wound healing by influencing fibroblast proliferation, epidermal stem cell migration, dermal microvascular endothelial cell migration, myofibroblast differentiation, as well as wound vascularization and inflammation; however, its precise mechanisms remain unclear.In this study, we identified the major cell populations and mechanisms of Nrep-mediated regulation in wound healing using conditional knockout mouse models. We further applied bioinformatics approaches to identify key factors involved in scarless healing of the oral mucosa.

Materials and Methods

The molecular mechanisms underlying skin wound repair remain incompletely understood, often resulting in either scar formation or scarless healing. Notably, oral wounds exhibit more favorable healing outcomes than skin wounds, suggesting distinct regulatory mechanisms.Transforming Growth Factor-β (TGF-β) is essential for wound repair but is also implicated in fibrosis. Neuronal Regeneration Related Protein (Nrep), a key modulator of the TGF-β signaling pathway, may regulate wound healing by influencing fibroblast proliferation, epidermal stem cell and endothelial cell migration, myofibroblast differentiation, as well as angiogenesis and inflammation; however, its precise role remains unclear.Here, using conditional knockout mouse models, we identified key cell populations and mechanisms underlying Nrep-mediated wound healing. Bioinformatics analyses further revealed critical factors associated with scarless healing in the oral mucosa.

Results

Database screening showed that Nrep was highly expressed in fibroblasts mainly during wound healing. Wound healing was significantly slower after Nrep knockdown, and all genes related to extracellular matrix collagen deposition were down-regulated. In Col1a2-Nrep$^{-/-}$ mice wound healing was accelerated and the sarcomeric layer thinned. Bioinformatics analysis of tail samples from mice on days 14 and 21 of trauma revealed high expression of immuno-validation-related signals. Co-expression analysis identified eight gene modules enriched in the wound healing phase of human skin and oral mucosa, of which module M8 was the only module enriched in the basal state of the oral mucosa, suggesting that the genes in module M8 may have key factors mediating the

healing of unscarred wounds. Bioinformatics analysis of tail wound samples from day 14 and 21 Col1a2-Nrep$^{-/-}$ mice and genes in module M8 revealed that Nrep may be mediating oral mucosal scarless wound healing through IGF2. The IGF2 protein was purified by prokaryotic expression, and IGF2 was found to promote the proliferation and migration of HaCat cells. In a total cortical defect model, IGF2 promoted wound re-epithelialisation and accelerated wound healing.

Conclusions

Nrep mainly acts on fibroblast populations during wound healing, and the absence of Nrep in fibroblast populations promotes inflammatory responses during wound healing and stimulates an increase in IGF2 secretion to promote wound re-epithelialisation. Ultimately, we identified the main cellular population of Nrep and validated its role in skin wound healing, which provides a new strategy for wound treatment.

EADV CONGRESS
VIENNA
30 SEP - 3 OCT 2026

Abstract N°: 1695

Thrombophilia and the skin: leg ulceration as a red flag for protein C deficiency

nihed hachemi*[1], Boumediene Dahmani[1]

[1] Department of Dermatology and Venereology, Tlemcen University Hospital, Tlemcen, Algeria

Introduction

Protein C deficiency is a major thrombophilic disorder that predisposes individuals to severe thromboembolic events. While its classic cutaneous manifestations include purpura fulminans or warfarin-induced skin necrosis, chronic necrotic ulcers are less common and often misdiagnosed. This case highlights the importance of screening for hypercoagulable states in young patients presenting with atypical leg ulcers, where clinical features may mimic inflammatory or infectious dermatoses.

Case Presentation

A 38-year-old male with a significant medical history of recurrent superficial venous thrombosis of the lower limbs and deep vein thrombosis (DVT) of the upper limb was admitted for a persistent leg ulcer evolving for one month. Clinical examination revealed a well-circumscribed, circular ulcer on the left leg with undermined, indurated borders and an elevated margin. The ulcer bed was irregular and granulating, featuring a central yellowish-to-white necrotic eschar, surrounded by erythematous and edematous skin. Laboratory investigations showed neutrophil leukocytosis and an elevated C-reactive protein (CRP) at 30 mg/L. While soft tissue ultrasound confirmed associated cellulitis, and Doppler studies revealed bilateral venous insufficiency with arterial atheromatous infiltration, the definitive diagnosis was established through hemostasis testing, which identified a constitutional protein C deficiency.

The diagnostic process in this case was challenging due to the morphological features of the lesion. The undermined and elevated borders initially suggested *Pyoderma Gangrenosum*; however, the patient's extensive history of multifocal thrombosis (both upper and lower limbs) strongly pointed toward a thrombotic vasculopathy. Protein C deficiency induces a state of permanent hypercoagulability, leading to cutaneous micro-thrombosis, subsequent tissue ischemia, and necrosis. In this instance, the associated cellulitis and systemic inflammatory response were likely secondary to the infection of the ulcerated site. Identifying this deficiency is critical, as it mandates a specific therapeutic approach combining local wound care with long-term anticoagulation, while requiring extreme caution during the introduction of vitamin K antagonists to avoid exacerbating skin necrosis.

Conclusion

This case emphasizes that atypical leg ulcers in young patients, particularly those with a personal history of thrombosis, must trigger a systematic thrombophilia workup. Early diagnosis of protein C deficiency is essential to tailor the antithrombotic strategy, ensure proper wound healing, and prevent potentially life-threatening systemic complications.

EA DV CONGRESS
VIENNA
30 SEP - 3 OCT 2026

Abstract N°: 1737

The Effects and Mechanisms of Trehalose on Anti-oxidative Stress and Wound Healing Capacity of Umbilical Cord Mesenchymal Stem Cells

Xingyan Liu*[1], Zheng Wang[2], Guangchao Xu[1], Chengliang Deng[1]

[1] The Affiliated Hospital of Zunyi Medical University, Zunyi, China
[2] Kungming Medical University, Kungming, China

Introduction
Oxidative stress injury is a significant factor limiting the application of mesenchymal stem cells (MSCs) in tissue repair. Trehalose possesses properties that resist oxidative stress and stabilize biological macromolecules; however, mammalian cells lack the ability to synthesize endogenous trehalose. This study focuses on two strategies: exogenous trehalose pretreatment and TPS1 gene engineering-mediated endogenous trehalose synthesis. It systematically evaluates their effects on the antioxidant capacity and wound healing promotion of umbilical cord-derived MSCs, and explores the related molecular mechanisms, providing experimental evidence for enhancing the survival and therapeutic efficacy of MSCs in oxidative stress-induced injury microenvironments.

Materials and Methods
Human umbilical cord-derived MSCs were isolated and identified by trilineage differentiation and flow cytometry. Trehalose effects were evaluated via pretreatment (Tre-MSCs) and TPS1 overexpression (TPS1-MSCs, adenoviral). After optimizing conditions, cells were characterized for phenotype, differentiation, proliferation, migration, and trehalose synthesis. Conditioned media were applied to keratinocytes, endothelial cells, and fibroblasts to assess proliferation, migration, and tube formation.Oxidative stress models (H_2O_2, serum deprivation) were used to evaluate ROS, viability, mitochondrial function, apoptosis, and senescence (DHE, CCK-8, Annexin V/7-AAD, MitoTracker, β-galactosidase). A full-thickness skin defect mouse model assessed MSC retention and wound repair via imaging, histology, and immunohistochemistry.Mechanisms were analyzed by transcriptomics (RNA-Seq; GO, KEGG, GSEA), RT-qPCR, Western blot, and immunofluorescence, focusing on repair-related secretory factors and NRF2 signaling. ML385 was used to verify pathway involvement, and secretory proteomics assessed differentially secreted proteins.

Results
Umbilical cord-derived MSCs displayed typical MSC phenotypes and differentiation capacity. Both trehalose pretreatment (Tre-MSCs) and TPS1 overexpression (TPS1-MSCs) enhanced regenerative functions, promoting keratinocyte proliferation/migration and endothelial tube formation, while Tre-MSCs additionally inhibited fibroblast activity.Under oxidative stress, both strategies reduced ROS, preserved viability, and alleviated mitochondrial damage, apoptosis, and senescence; TPS1-MSCs further showed increased proliferation. In vivo, both improved wound healing, accelerating re-epithelialization and angiogenesis; Tre-MSCs reduced fibrosis, whereas TPS1-MSCs showed prolonged retention and enhanced mid–late stage repair.Transcriptomic and protein analyses indicated suppression of inflammation/oxidative stress pathways and activation of repair-related programs, with both strategies converging on NRF2 signaling activation (e.g., HMOX1 upregulation and NRF2 nuclear translocation). NRF2 inhibition reversed these effects, and secretory proteomics confirmed altered repair-associated secretion profiles.

Conclusions

Exogenous trehalose pretreatment enhances oxidative stress tolerance in human umbilical cord-derived MSCs by reducing ROS accumulation, maintaining viability, and promoting early wound repair through paracrine effects, including improved re-epithelialization, angiogenesis, and reduced fibrosis. Similarly, TPS1 gene transduction enables MSC engineering without altering fundamental biological characteristics, conferring endogenous trehalose synthesis, increasing proliferative capacity, improving oxidative stress resistance, and enhancing in vivo retention at wound sites, thereby further promoting repair. Both strategies likely exert their protective effects via SQSTM1-associated NRF2–HMOX1 antioxidant signaling.

EA DV CONGRESS
VIENNA
30 SEP - 3 OCT 2026

Abstract N°: 1851

Use of a cream containing a post-biotic ingredient in optimizing wound healing and reducing post-inflammatory hyperpigmentation in skin of color : Clinical and patient-centered outcomes

Jennifer Theunis[1], Léane Seignard[1], Christophe Lauze[1], Aline Stennevin*[2], Gautier Doat[2]

[1] R&D Department, Pierre Fabre Dermo-Cosmetics & Personal Care, Toulouse, France

[2] Medical Department, Laboratoires Dermatologiques Eau Thermale AVENE, Lavaur, France

Introduction

Skin of color is particularly prone to developing pigmentary alterations, notably post-inflammatory hyperpigmentation, even after superficial skin injuries. In this population, the use of targeted dermo-cosmetic treatment is crucial to promote optimal wound repair while limiting dyschromia and preserving an aesthetically satisfying outcome. Beyond clinician-assessed and instrumentally measured efficacy, patient-perceived benefits and satisfaction are key elements to consider when evaluating such treatments. In this study, we evaluated a cream formulated with a post-biotic ingredient on superficial wounds induced by a standardized Er:YAG laser model, in comparison with an untreated control area, integrating both objective outcomes and patient-reported perceptions.

Materials and Methods

Healthy volunteers with skin phototype IV to VI were enrolled in this clinical study. Standardized epidermal injuries was created under local anesthesia on the forearms (two 1 cm^2 lesions per subject) using an Er:YAG laser of 2940 nm. This device enables precise, stepwise ablation of cutaneous tissue while limiting residual thermal injury. One lesion was treated with a cream containing a post-biotic ingredient for 18 days, while the contralateral site remained untreated and served as a control. Wound repair dynamic was evaluated by the investigator through clinical examinations throughout the 19-day follow-up study period. The quality of wound healing and post-inflammatory hyperpigmentation were also assessed by the investigator both *in vivo* and using standardized photographs acquired with the C Cube imaging system. Skin texture homogeneity was quantified using this same device.

Patients also completed, at the end of the study, a questionnaire designed to assess their perceived efficacy of the product as well as its cosmetic properties.

Results

Twenty-two healthy volunteers aged 22 to 48 years were included in this monocentric, comparative study. The study population comprised 9 subjects with skin phototype IV, 11 with phototype V, and 2 with phototype VI.

On the treated site, a significantly faster and higher-quality wound repair was observed compared with the untreated area. Complete re-epithelialization was clinically assessed by the investigator 3 days earlier on the treated side versus the untreated side ($p = 0.0032$). Moreover, wound healing quality, evaluated using a numerical rating scale (NRS), was significantly superior on treated side at day 12 ($p = 0.0002$), day 15 ($p = 0.0002$), and up to the end of the study at day 19 ($p = 0.0031$). This improved healing quality was associated with a marked restoration of skin texture on the treated site, as evidenced by C Cube imaging analysis, showing that the skin had recovered 97% of its texture homogeneity by day 19.

The product also demonstrated a significant effect on the reduction of post-inflammatory hyperpigmentation (PIH) compared with untreated areas. PIH, clinically assessed by NRS, was significantly reduced on treated side at day 12 ($p = 0.0008$), day 15 ($p = 0.0068$), and day 19 ($p = 0.0041$), reaching a 68.8% decrease on day 19.

Beyond clinician-based and instrumental assessments, efficacy was also strongly perceived by the participants. At the end of the study, subjects rated the repairing effect of the product 8.33/10. Cosmetic acceptability of the cream was high, with scores of 9/10 for ease of application and 9.36/10 for the pleasant sensation upon application.

Conclusions

This study shows for the first time that a cream containing a post-biotic ingredient significantly accelerates and improves quality of superficial wound repair in skin of color, while reducing post-inflammatory hyperpigmentation. Objective clinical and imaging data were consistent with high patient-perceived efficacy and excellent cosmetic acceptability.These findings support its use as an effective dermo-cosmetic product to optimize aesthetic outcomes after superficial skin injuries in skin of color and improve their quality of life.

EA DV CONGRESS
VIENNA
30 SEP - 3 OCT 2026

Abstract N°: 1857

Integrated Barrier Repair and Anti-Hyperpigmentation Efficacy of a New SPF50+ Repairing Cream: Clinical and In Vitro Evidence

Jennifer Theunis[1], Maité Noizet[1], Marine Rodeghiero[1], Aline STENNEVIN*[2], Gautier Doat[2]

[1] R&D Department, Pierre Fabre Dermo-Cosmetics & Personal Care, Toulouse, France

[2] Medical Department, Laboratoires Dermatologiques Eau Thermale AVENE, Lavaur, France

Introduction

UV radiation is a well-established factor in the induction and exacerbation of pigmentary disorders, particularly when the epidermal barrier is disrupted and skin repair processes are still ongoing. In the context of dermatological procedures or inflammatory skin conditions, strict photoprotection is recommended to minimize the risk of post-inflammatory hyperpigmentation. However, complete avoidance of UV exposure is difficult to achieve on chronically photo-exposed areas where incidental exposure is frequent. In this setting, a topical treatment combining barrier-repairing properties with high, broad-spectrum photoprotection may offer a relevant strategy to support skin recovery and prevent UV-induced pigmentation. The present work aimed to assess the efficacy of a new SPF50+ repairing cream. The cream contains a post-active ingredient from thermal spring water and features a unique filter that protects against UVA, UVB, and blue light, offering broad-spectrum SPF50+ protection. The evaluations used both *in vivo* and *in vitro* models to assess its impact on skin healing and its ability to prevent UV-induced hyperpigmentation.

Materials and Methods

The repairing and anti-marks efficacy of the cream was first evaluated *in vivo* in a 3-week clinical study under dermatological supervision in 87 subjects presenting various types of skin irritation, including post-dermatological procedures (peels, laser), excoriated acne, post-tattoo irritation and superficial scratches. Clinical scorings and spectrophotometric measurements were performed to assess irritation resolution and residual marks. In parallel, a standardised skin injury model using an Erbium:YAG laser was conducted on the forearms of 18 women, with two comparable lesions induced per subject: according to a randomisation scheme, one lesion was treated with the product twice daily for 18 days, while the contralateral lesion remained untreated. Lesion evolution was documented over a 3-week period using standardised macrophotography. The preventive effect of the repairing cream against UV-induced hyperpigmentation was investigated *in vitro* on melanised reconstructed human epidermis exposed to UV stress, by evaluating its ability to limit the formation of pigmented spots.

Results

In vivo, the repairing efficacy of the cream was rated effective or very effective by the investigator in 82% of subjects after 2 days of application and in 97% after 3 weeks, while anti-marks efficacy reached effective or very effective levels in 74% and 89% of subjects at the same time points, respectively. These clinical assessments were consistent with a significant reduction in physical signs (–27%, $p<0.0001$) and functional symptoms (–86%, $p<0.0001$) from day 2, as well as a significant decrease in erythema, with the a* parameter reduced by –17% after 2 days and –34% after 3 weeks (both $p<0.0001$), supporting the anti-redness effect of the product. In the Er:YAG laser model on 18 women, photographic analysis demonstrated significantly faster skin repair in treated lesions compared with untreated controls, with a 4-day gain in healing time ($p<0.0001$). After 3 weeks, residual erythema

persisted on untreated areas, whereas no residual erythema was observed on treated lesions. Finally, in the *in vitro* model of UV-induced hyperpigmentation using melanised reconstructed human epidermis, preventive applications of the repairing cream resulted in a significant increase in lightness (L* +7%, $p<0.001$ vs UV control), corresponding to a marked colour change perceptible to the human eye ($\Delta E=7.5$), indicating an effective prevention of UV-induced hyperpigmentation.

Conclusions

This new SPF50+ repairing cream delivers rapid relief of irritated skin, speeds up post-procedure repair, reduces residual erythema and marks, and prevents UV-induced hyperpigmentation *in vitro*. These findings support its use as an integrated dermocosmetic option to optimize post-irritation and post-procedure outcomes and to limit secondary pigmentary disorders for photo-exposed areas.

EADV CONGRESS
VIENNA
30 SEP - 3 OCT 2026

Abstract N°: 1871

Biostimulatory Injectables and Novel Neuromodulators for Skin Quality Enhancement: A Scoping Review of Long-Term Full-Face Rejuvenation Outcomes

Mouna Azaroual*[1], Mohd Faizan Siddiqui[2]

[1] CHU Mohammad VI, Marrakesh, Marrakesh, Morocco

[2] International Medical Faculty, Osh State University, Osh, Kyrgyzstan

Introduction

Minimalistic aesthetic surgery has progressed to include more than volumization to complete skin quality enhancement. Biostimulatory injectables and newer neuromodulators are being more and more used to improve dermal structure, elasticity and general face rejuvenation. Nevertheless, there is still evidence of their long-term, full-face results, which is still fragmented. To map and synthesize the available data on the biostimulatory injectables and novel neuromodulators in an organised manner, and their use in enhancing skin quality and long-term facial rejuvenation.

Materials and Methods

A scoping review was conducted in accordance with PRISMA-ScR guidelines. The searches were performed with electronic databases in PubMed, Scopus, and Web of Science, and the studies published within the last 10 years (2016 to 2026) were selected. The first search returned 748 records. The full-text articles were then evaluated against the eligibility criteria set by the researchers after eliminating the duplicates and narrowing down the search results to articles that met the inclusion and exclusion criteria. There were 14 studies that were included in total in our study. The studies that were eligible included clinical trials, cohort studies, and observational studies assessing biostimulatory agents and new neuromodulators. The data were plotted on the treatment regimens, the outcome variables, the post-treatment time period and the effectiveness in terms of skin quality and full-face rejuvenation.

Results

In the 14 studies incorporated, biostimulatory injectables, especially calcium hydroxylapatite, poly-L-lactic acid and hybrid preparations, have shown consistent results in dermal remodelling, such as in increase in collagen production, skin elasticity and skin thickness. These were maintained through the follow-up periods of 12-24 months with some studies showing gradual improvement with time as the neocollagenesis continued. Newer neuromodulators with longer acting preparations demonstrated long-term effectiveness over traditional agents, and new studies have indicated additional effects other than muscle relaxation, such as better skin texture, fewer pore visibility, and sebaceous activity control. Combinations of biostimulatory fillers with neuromodulators had better results in complete face rejuvenation, and both movable and non-movable aspects of aging. The patient-reported outcomes reported a high degree of satisfaction especially in global aesthetic improvement and skin quality parameters. Nevertheless, there was a significant heterogeneity in the study designs, treatment regimens, measures of outcomes and follow-up. One of the gaps was identified as a shortage of standardized measures of skin quality and a lack of head-to-head comparative trials.

Conclusions

It is the transformation of the traditional volume-based corrective approach to the regenerative and skin quality-related aesthetic approaches, which are identified in this scoping review. The biostimulatory injectables offer long-term structural and biological benefits by stimulating collagen, whereas new neuromodulators can be used to do more than wrinkle-reduction, expanding the benefits of treatment to the overall quality of skin. The dual-modality paradigm of full-face rejuvenation seems to be the most effective and sustainable when combined in treatment, which is in line with the contemporary aesthetic practice. However, the existing evidence base has been constrained by variability in methods and lack of long-term and high-quality comparative data. Future studies must focus on standardized outcome measures, objectivity in skin quality measurements and sound longitudinal tests to determine the best protocols and evidence-based recommendations towards full face rejuvenation.

EADV CONGRESS
VIENNA
30 SEP - 3 OCT 2026

Abstract N°: 1915

Rare association between pyoderma gangrenosum and active pulmonary tuberculosis – case report

Georgiana Marin*[1], Diana Dîrzu[1], Alina Elena Spînu[1], Bianca Elvira Ignătescu[1], Roxana Paraschiva Ciobanu[1], Mihaela Cojocaru[1], Roxana Diaconu[1], Daciana Elena Brănișteanu[1]

[1] Grigore T. Popa University of Medicine and Pharmacy, University Clinical Railways Hospital, Iasi, Romania

Introduction

Pyoderma gangrenosum (PG) is a rare, non-infectious condition, part of the group of neutrophilic dermatoses, which causes deep, painful skin ulcers with purple undermined edges and a rapidly progressive course. It is frequently associated with systemic diseases, such as: inflammatory bowel diseases, rheumatic diseases and hematological malignancies.

Case Presentation

We present the clinical case of a 31-year-old patient, a driver on a farm in the Netherlands, previously in good health, who presented to the Dermatology Clinic for the appearance of well-demarcated ulcerations with purple edges, intensely painful, on the thighs. Following clinical, laboratory and histopathological investigations, the diagnosis of ulcerative PG was confirmed and systemic corticosteroid therapy was initiated. 2 months later, the patient was diagnosed with secondary miliary pulmonary tuberculosis and tuberculostatic treatment was started, with favorable evolution of the skin lesions.

In the literature, there are few reported cases of PG associated with tuberculosis with different localizations: testicular, lymph node, colonic, osteoarticular, pulmonary, pleural. Our case adds to this limited list and thus strengthens the observed association between the two conditions.

Conclusion

In pyoderma gangrenosum it is important to exclude an association with chronic infections, especially a latent infection with Mycobacterium. Further research is needed to help establish a possible etiological link between these two clinical entities.

EADV CONGRESS
VIENNA
30 SEP - 3 OCT 2026

Abstract N°: 1949

Staged Topical Management of Grade II Facial Burns in Skin of Color: A 2-Year Case Study of Complication-Free Recovery

Tiar Marina Octyvani*[1, 2]

[1] Department of Dermatology, Venereology, and Aesthetics, Faculty of Medicine, Universitas Trisakti, Jakarta, Indonesia

[2] Department of Dermatology, Venereology, and Aesthetics, Primaya Evasari Hospital, Jakarta, Indonesia

Introduction

Facial thermal burns in individuals with Fitzpatrick skin types IV-VI carry a high morbidity risk due to post-inflammatory hyperpigmentation (PIH) and hypertrophic scarring. While acute care focuses on re-epithelialization, a "therapeutic gap" often exists during the transition from wound closure to aesthetic stability. This case demonstrates a practical, staged dermatological protocol using early anti-inflammatory modulation to arrest melanogenesis and fibroblastic hyperactivity in high-risk skin types.

Case Presentation

A 53-year-old female (Fitzpatrick type IV) presented with a second-degree (partial-thickness) thermal burn involving 4% total body surface area (3% facial involvement) following a gas explosion. Initial management involved immediate irrigation. A three-phase topical protocol was implemented:

- **Phase I (days 1–6; re-epithelialization):** Treatment focused on maintaining a moist environment while reducing the risk of bacterial infection, using twice-daily normal saline wet dressings and a combination of lanolin and mupirocin ointment. Oral azithromycin (500mg/day for 5 days) was also administered.
- **Phase II (days 7–11; suppression of inflammation):** Upon clinical wound closure, the tissue remained erythematous. To suppress the inflammation and prevent PIH, mometasone furoate 0.1% in a lanolin base was applied once daily for 5 days. This potent corticosteroid was selected for its rapid anti-inflammatory action and transient hypopigmenting effect to counteract predicted melanocyte hyperactivity. Strict SPF 50+ photoprotection was initiated.
- **Phase III (maintenance):** The patient transitioned to a moisturizer containing madecassoside to facilitate collagen organization and barrier repair, alongside continued rigorous photoprotection with SPF50+.

At the 2-year follow-up, the patient exhibited an absence of PIH, erythema, or scarring. Skin texture and pigmentation were clinically indistinguishable from surrounding non-injured tissue. No adverse effects from the short-course corticosteroid, such as atrophy or telangiectasia, were observed.

Conclusion

The success in treating facial burns in skin of color requires more than just wound closure; it necessitates active intervention during the "aesthetic window"—the first 7 days post-re-epithelialization. This protocol demonstrates that a short, controlled course of potent topical corticosteroids can safely suppress the inflammatory drivers of PIH and scarring. For dermatologists globally, this staged approach—moving from antimicrobial protection to aggressive anti-inflammatory modulation and finally barrier repair—offers a reproducible, evidence-based strategy to ensure that functional recovery is matched by high-quality aesthetic outcomes in pigmented skin.

EADV CONGRESS
VIENNA
30 SEP - 3 OCT 2026

Abstract N°: 1955

Experiences of a Street Health Wound Care Clinic: A Retrospective Cohort Study

Miranda Branyiczky*[1], Jack Lawrence[1], Jodi Gilchrist[2], Kelly Waters[2], Mohannad Abu Hilal[3], Brent Mcleod[4]

[1] Michael G. DeGroote School of Medicine, McMaster University, Hamilton, Canada

[2] The Research Institute of St. Joseph's Hamilton, Hamilton, Canada

[3] Division of Dermatology, McMaster University, Hamilton, Canada

[4] Family Medicine, Faculty of Health Sciences, McMaster University, Hamilton Paramedic Service, City of Hamilton, Hamilton, Canada

Introduction

People experiencing homelessness (PEH) face significant barriers to healthcare access, including stigma, fragmented primary care, competing survival priorities, and unstable living conditions. These barriers contribute to a disproportionate burden of preventable and undertreated skin disease, traumatic injuries, and chronic wounds. Wound care is particularly challenging, as effective management often requires regular follow-up, adherence to treatment plans, and hygienic conditions that may be difficult to maintain. This study describes the implementation of a low-barrier wound care clinic (WCC) for PEH, including patient characteristics, wound care needs, and provided treatments.

Materials and Methods

A retrospective review of electronic medical records was conducted of all adults (≥ 18 years) who attended the WCC during its three-month pilot period (October–December 2024). The clinic operated as a weeknight drop-in service embedded within a trusted community non-profit organization that also offered meals, harm reduction supplies, and street health programming. Care was provided by community paramedics and nurses under remote physician supervision, with point-of-care fluorescence imaging and telemedicine consultation used as needed to support assessment, guide treatment, and optimize antimicrobial prescribing. Of 61 cases reviewed, 51 wound-related cases met inclusion criteria. Descriptive statistics were used to summarize demographic, clinical, treatment, and referral characteristics.

Results

Over 35 clinic days, 51 unique patients were treated (76.5% male, mean age 42.0 ± 10.5 years; Table 1). Nearly all patients had no fixed address (96.1%). The presenting concerns, which included lacerations, burns, abscesses, blunt injuries, and lower-extremity ulcers, reflected the high burden of traumatic and environmental injuries faced by this population (Table 2). Wounds most commonly involved the hands (25.5%) and legs (27.5%). Patients attended a mean of two visits; while over half of patients were seen only once, 41.2% returned for follow-up, with an average follow-up duration of 28.0 ± 28.1 days.

Most patients received wound cleansing and dressing (88.2%), and one patient required wound packing. Dressings were individualized based on wound characteristics. Antibiotics were prescribed in 29.4% of cases, most commonly cephalexin, cefuroxime, trimethoprim-sulfamethoxazole, and doxycycline. Wound cultures were obtained in 15.7% of cases. Point-of-care fluorescent imaging was used in 47.1% of patients and assisted with bacterial detection, targeted swabbing, antimicrobial stewardship, and serial monitoring of healing. Referrals were

made for 62.7% of patients, including to emergency care (17.6%) and long-term shelter-based services (43.1%) for ongoing primary care, wound management, mental health, foot care, and HIV services. Beyond wound management, the clinic also provided basic supportive care, including foot care, clean socks, over-the-counter medications, health education, and linkage to community resources.

Table 1. Demographic characteristics of patients treated for wounds and injuries in the Wound Care Clinic (n=51).

Characteristic	n	%
Age, years, mean ± SD	42.0 ± 10.5	
Age group, years		
18-20	0	0
20-29	4	7.8
30-39	12	23.5
40-49	21	41.2
50-59	7	13.7
>60	2	3.9
Unknown	5	9.8
Sex		
Male	39	76.5
Female	11	21.6
Transgender	1	2.0
Ethnicity		
Caucasian	37	72.5
Black	3	5.9
Indigenous	2	3.9
Unknown	9	17.9
Housing Status		
No fixed address	49	96.1
Public housing	1	2.0
Private residence	1	2.0
Number of visits per patient		
1 total	30	58.8
2 total	12	23.5
3 total	4	7.8
4-6 total	1	2.0
7-10 total	4	7.9

Table 2. Clinical and management characteristics of patients experiencing homelessness attending the Wound Care Clinic (n=51).

Characteristic	n	%
Presenting complaint		
Wound	**24**	**47.1**
Laceration	6	11.8
Burn	3	5.9
Unspecified	15	29.4
Injury	**12**	**23.5**
Fracture	1	2.0
Blunt trauma	1	2.0
Unspecified	10	19.6
Abscess	**4**	**7.8**
Unspecified	**11**	**21.6**
Wound location		
Face/Head	9	17.6
Trunk	2	4.0
Arm	3	5.9
Hand	13	25.5
Leg	14	27.5
Foot	4	7.8
Multiple areas	6	11.8
Service provided		
Cleaned/dressed	45	88.2
Fluorescent imaging	24	47.1
Antibiotics	15	29.4
Culture and sensitivity swab	8	15.6
Packed	1	2.0
Referrals made		
Chronic management	22	43.1
Acute management	9	17.6

Table 1. Demographic characteristics of patients treated for wounds and injuries in the Wound Care Clinic (n=51). Table 2. Clinical and management characteristics of patients experiencing homelessness attending the Wound Care Clinic (n=51).

Conclusions

This study demonstrates that a community-based, trauma-informed, low-barrier wound care clinic is both feasible and effective in engaging PEH who may otherwise face significant barriers to care. Embedding wound services within an established harm reduction and street health setting fostered trust, improved accessibility, and

facilitated connection to longitudinal medical and social supports. Portable fluorescent imaging and telemedicine further enhanced assessment and antimicrobial decision-making. Although limited by incomplete documentation, short follow-up, and lack of outcome tracking beyond the clinic, these findings support integrating wound care into community outreach frameworks. Expanded models incorporating outreach, housing navigation, and addictions services may further improve health equity while reducing avoidable emergency department utilization and healthcare costs.

EA DV CONGRESS
VIENNA
30 SEP - 3 OCT 2026

Abstract N°: 1985

Topical Timolol and Hyaluronic Acid: A Novel Approach to a Recalcitrant Post-Saphenectomy Kite-Shaped Ulcer

Amr Ghareeb*[1]

[1] Al-Azhar university hospitals (EL-Hussien Hospital , Cairo), cairo, Egypt

Introduction
Wound dehiscence and chronic ulceration following Great Saphenous Vein (GSV) harvesting for Coronary Artery Bypass Graft (CABG) are significant causes of morbidity. These ulcers often become chronic due to impaired localized healing and surgical site tension. We present a case where topical beta-blockers and hyaluronic acid successfully managed a geometric surgical ulcer complicated by persistent edema.

Case Presentation
A 62-year-old female presented with a persistent leg ulcer of six months' duration. The ulcer developed along the surgical tract of a GSV harvest for CABG. Physical examination revealed a linear, deep ulcer with a distinctive "kite-shaped" morphology: the superior aspect measured 5 cm in diameter, narrowing to a 2 cm linear downward extension. Notably, the limb exhibited significant localized edema, which contributed to wound gaping and prevented spontaneous closure. The wound bed was necrotic, partially covered by an adherent eschar, with sloping edges.

The patient underwent two sessions of surgical debridement to remove necrotic tissue and revitalize wound margins. Following debridement, a dual topical regimen was initiated consisting of daily hyaluronic acid gel and Timolol 0.5% drops.
Discussion:
Chronic surgical wounds post-CABG often resist standard care. In this case, the unusual kite-shaped configuration mirrored the surgical harvest site. While hyaluronic acid provides a moist environment and promotes tissue repair, the addition of topical Timolol represents a targeted therapy. Beta-adrenergic antagonists, like Timolol, are known to promote re-epithelialization by modulating keratinocyte migration and reducing the inhibitory effects of catecholamines on wound healing.



Comparison of the ulcer at initial presentation (Left) and complete re-epithelialization (Right) after 8 weeks of treatment

Conclusion

The ulcer achieved complete healing within two months of initiating the dual topical therapy and debridement. This case highlights that topical Timolol, combined with hyaluronic acid, may be an effective, non-invasive, and cost-effective strategy for managing recalcitrant surgical site ulcers that fail to respond to conventional wound care.

EA DV CONGRESS
VIENNA
30 SEP - 3 OCT 2026

Abstract N°: 1986

Recurrent Postoperative Hematomas as the Initial Cutaneous Clue to Mild Hemophilia A

Bingning Jiang*[1], Lu Peng[1], Fan Yu[1], Dian Chen[1], Yi Zhao[1]

[1] Beijing Tsinghua Changgung hospital, Beijing, China

Introduction

Mild hemophilia A (HA) is an X-linked bleeding disorder caused by deficiency or dysfunction of factor VIII (FVIII). Patients with mild HA are often asymptomatic in daily life, and abnormal bleeding may only become apparent following trauma or surgery. Dermatologic procedures are generally considered low-risk; however, recurrent postoperative hematomas or delayed wound healing can be the first clinical sign of an underlying coagulopathy. Early recognition is crucial for safe perioperative management, appropriate treatment, and long-term follow-up, as well as for family screening and genetic counseling.

Case Presentation

A 25-year-old man presented with recurrent postoperative hematomas and delayed wound healing following excision of sebaceous cysts on the forehead (2018, 2021, and 2025). Initial procedures were complicated by delayed hematoma formation resolving over 1–2 months. In 2025, preoperative laboratory evaluation revealed mildly prolonged activated partial thromboplastin time (APTT, 33.8 s) with other hematologic parameters within the normal range. Surgical excision proceeded smoothly, but on postoperative day 7, a delayed hematoma of approximately 30 mL developed, necessitating surgical evacuation. Multiple pinpoint bleeding sites were observed along the wound edges without identifiable vascular injury. Hemostasis was achieved using bipolar electrocoagulation, pressure dressing, and intravenous tranexamic acid (0.5 g). Secondary intention healing occurred over approximately one month.

The patient reported a lifelong tendency to bruise and occasional gingival bleeding, with no history of joint or visceral hemorrhage. Family history was notable for maternal subcutaneous nodules without known bleeding disorders. Genetic testing identified a hemizygous pathogenic F8 variant (c.2149C>T, p.Arg717Trp) and a heterozygous likely pathogenic MYH9 variant (c.4756C>T, p.Gln1586*), both maternally inherited. FVIII activity was 9.2%, confirming a diagnosis of mild HA, potentially compounded by subtle platelet dysfunction due to MYH9. In July 2025, the patient developed massive upper gastrointestinal bleeding from a duodenal ulcer, managed successfully with red blood cell transfusion and FVIII replacement.

This case highlights that even mild HA can present with significant postoperative bleeding after low-risk dermatologic procedures. Early recognition, combined with laboratory evaluation and genetic testing, is essential to guide perioperative management and prevent severe hemorrhagic complications.

Conclusion

Recurrent postoperative hematomas may serve as the first cutaneous manifestation of mild HA. Clinicians should maintain high suspicion in patients with repeated post-surgical bleeding or delayed wound healing and promptly perform coagulation testing and genetic evaluation. Early diagnosis facilitates safe surgical planning, appropriate perioperative management, and long-term follow-up, while providing critical information for family counseling. This case underscores the importance of recognizing subtle bleeding manifestations in dermatologic practice and highlights the value of multidisciplinary collaboration for optimizing patient care.

EA DV CONGRESS
VIENNA
30 SEP - 3 OCT 2026

Abstract N°: 1996

Beyond Overall Accuracy: Evaluating AI Wound-Monitoring Applications for Darker Skin Tones

Ahsan Raza Raja*[1], Zoha Fazal[2], Aisha Sethi[3]

[1] Department of Medicine, Aga Khan University, Karachi, Pakistan

[2] Stanford University School of Medicine, Palo Alto, California, United States

[3] Department of Dermatology, Yale University School of Medicine, New Haven, Connecticut, United States

Introduction

AI-enabled wound-monitoring applications support wound detection, segmentation, measurement, tissue classification, pressure injury staging, burn assessment, and surgical wound triage. Many wound-care decisions depend on visual signals that may be less apparent or differently expressed on darker skin tones, including erythema, inflammation, ischemic change, pressure-related discoloration, bruising, and periwound color change. We aimed to synthesize limitation domains that may affect AI wound-monitoring performance on darker skin tones, summarize diagnostic performance metrics where reported, and identify mitigation strategies.

Materials and Methods

A structured narrative review with evidence mapping was conducted for literature from 2010 through 2026, prioritizing studies from 2018 onward. Eligible sources included peer-reviewed literature on artificial intelligence, machine learning, deep learning, computer vision, smartphone imaging, mobile wound platforms, and telewound tools for diabetic foot ulcers, pressure injuries, chronic wounds, burns, surgical wounds, and general wound assessment. Studies were categorized by wound type, AI task, input data, performance metrics, skin tone measurement, subgroup reporting, and equity-relevant reporting. Sensitivity, specificity, accuracy, AUC, F1 score, Dice coefficient, IoU, precision, recall, and calibration were extracted where available. Skin tone reporting was classified as Fitzpatrick type, Monk Skin Tone scale, manual skin tone label, race or ethnicity, geographic proxy, image diversity without stratification, or not reported.

Results

Identified AI wound-monitoring studies reported overall performance for segmentation, classification, staging, and triage, but skin-tone-stratified diagnostic performance was rarely available. Overall metrics included sensitivity and specificity for diabetic foot ulcer detection, Dice or IoU for wound and tissue segmentation, F1 score or stage-specific sensitivity for pressure injury classification, AUC for burn assessment, and sensitivity, specificity, positive predictive value, and negative predictive value for surgical wound triage. Direct subgroup evidence was limited. In surgical wound triage, one study reported overall sensitivity of 89% with explicit light and dark skin tone analysis; sensitivity was lower for incisional separation and discoloration in darker skin tones, although selected specificity and negative predictive value measures favored darker skin tones. In burn assessment, performance varied by task, with burn identification reported as more accurate in darker Fitzpatrick skin types and surgery classification more accurate in lighter skin types. Across diabetic foot ulcer, chronic wound, pressure injury, and mobile wound app studies, skin-tone-stratified sensitivity and specificity were generally not reported, limiting direct assessment of equity performance. Seven limitation domains were identified: dataset representation, image acquisition and lighting, color-dependent clinical wound signals, annotation and ground-truth bias, algorithmic generalizability, deployment inequities, and reporting and regulatory transparency. Mitigation strategies included intentional inclusion of darker skin tones, standardized skin tone metadata, standardized wound photography, color calibration or image normalization, skin-tone-stratified reporting, external validation, calibration reporting, human-in-the-loop safeguards, and post-deployment equity monitoring.

Conclusions

AI wound-monitoring applications are promising, but current evidence is often insufficient to confirm equitable performance across skin tones. Overall accuracy may obscure task-specific vulnerabilities when dermatologically important wound signals are color-dependent or inconsistently represented. Future studies should report skin tone metadata, subgroup diagnostic performance, calibration, and clinically relevant failure modes to support deployment in diverse dermatology and wound-care settings.

EADV CONGRESS
VIENNA
30 SEP - 3 OCT 2026

Abstract N°: 2054

Characterizing Recurrence Patterns in Pyoderma Gangrenosum after Initial Healing using Prospective Registry Data

Jordan Gillespie[1], Jaclyn Roland-McGowan[1], Katelyn Downey[1], Emile Latour[1], Alex Ortega Loayza*[1]

[1] Oregon Health & Sciences University, Portland, United States

Introduction

Pyoderma gangrenosum (PG) is a rare neutrophilic dermatosis that has been known to recur after initial healing, yet the characteristics of patients with recurrent PG in real-world settings are poorly described. Recurrence estimates, when reported, vary significantly, with rates ranging from 15% to 61%. Given these limitations in the existing literature, we aimed to evaluate recurrence patterns in a prospective PG registry cohort to inform clinical practice and future research.

Materials and Methods

Data were acquired from a prospectively maintained 5-year registry of well-characterized adult patients with PG seen between December 2019 and March 2026 at a PG specialty center. A cohort was created of patients with PG who had documented healing defined as complete ulcer re-epithelialization during that timeframe. Two subgroups were defined: those with sustained healing and those who recurred. Local recurrence was defined as the reappearance of PG at the same anatomical site as the initial ulcer, including within a previous scar, while distal recurrence was defined as the development of a new PG lesion at a separate anatomical site after clinician-confirmed healing of the initial ulcer.

Descriptive statistics were used to evaluate recurrence characteristics. Categorical variables were compared using chi-square or Fisher's exact tests; continuous variables were compared using t-tests, or Wilcoxon rank-sum tests, as appropriate. Kaplan-Meier methods estimated a cumulative incidence of recurrence while Cox proportional hazards modeling analyzed recurrence predictors.

Results

116 patients with PG healed during follow-up, and of these, 41 (35.3%) experienced a recurrence (95% Confidence Interval [CI] for recurrence proportion: 26.7%-44.8%). Thirty-two patients (78%) had local recurrences compared to 9 patients (22%) with distal recurrences. The mean time from initial healing to recurrence was 8.9 months (standard deviation [SD] 8 months), and at the first visit following recurrence, the mean ulcer wound age was 1.4 months (SD 1.6 months, range 0.2–6 months) while the mean size was 4.8 cm^2 (SD 7.9 cm^2, range

0.2–35 cm^2). In the 41-patient recurrence cohort, there were 56 discrete recurrence episodes identified. Thirty-one of these episodes (55.5%) had no clinical follow-up between initial healing and recurrence, and the mean time between healing and first follow-up was 122.6 days (median 51 days).

Univariable analysis showed that history of diabetes mellitus (hazard ratio [HR] 2.12, 95% CI: 1.13-3.97, p=0.019) and ever-smoking (HR 1.82, 95% CI: 0.98-3.37, p=0.058) were nominally associated with recurrence. Statistically significant differences between the cohort of patients with sustained healing and those who recurred included age (p=0.033), history of diabetes (p=0.006), and ulcer age at presentation (p=0.046). Using a Kaplan–Meier recurrence-free survival curve (Figure 1), the cumulative risk of PG recurrence was calculated as 27.0% (95% CI: 18.1-35.0) and 41.3% (95% CI: 30.4–50.5) at 1 and 5 years. In a subanalysis stratified by PG subtype (classic versus peristomal), peristomal PG had a higher hazard of recurrence (adjusted HR 2.10, 95% CI: 0.95-4.65, p=0.069).

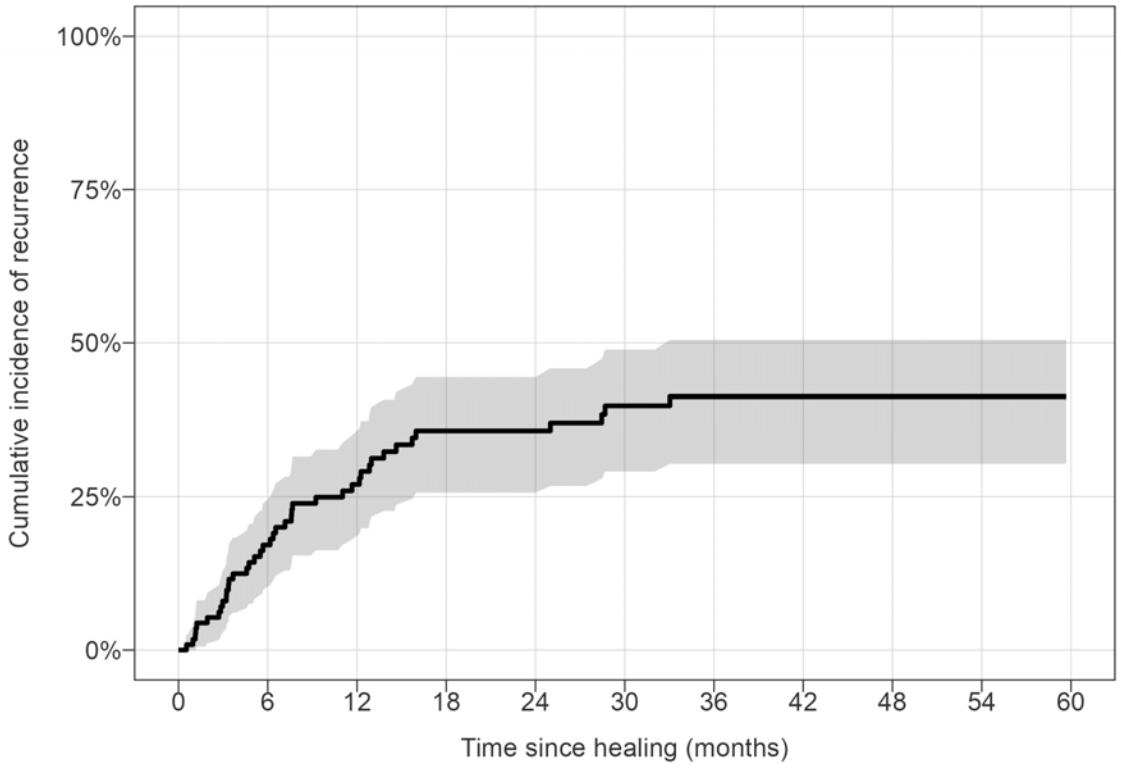

Estimated probability of PG recurrence from initial healing to five years post-healing calculated using the Kaplan–Meier recurrence-free survival curve. The shaded region signifies the 95% confidence interval.

Conclusions

This study underscores the relapsing nature of PG. Recurrence was observed in approximately one-third of patients and showed nominal associations with a history of diabetes and prior tobacco use. Importantly, the risk of recurrence remained elevated up to five years following ulcer healing, suggesting that maintenance therapy after ulcer closure may be more critical than previously recognized. Exploratory analysis suggested a higher hazard of recurrence in peristomal compared with classic PG, though confidence intervals were wide. Future studies will aim to identify individual predictors of recurrence and explore potential genetic factors contributing to disease relapse.

EA DV CONGRESS
VIENNA
30 SEP - 3 OCT 2026

Abstract N°: 2204

Chronic Bilateral Breast Ulcers: Beyond Appearances, Non-Uremic Calciphylaxis

Ahmed Yassine Righi*[1], Saliha Takheroubt[1], Issam TABLIT[1], Samira Zobiri[1]

[1] University of Health Sciences of Algiers, Algiers, Algeria

Introduction

Calciphylaxis is a rare and severe vascular disorder characterized by calcification of small arteries leading to thrombosis and cutaneous ischemia. Although this condition is classically associated with end-stage renal disease, so-called non-uremic forms have been described in patients without renal impairment, often with metabolic comorbidities such as diabetes or hypertension. Breast involvement is extremely uncommon and may mimic infectious or tumoral conditions, making the diagnosis challenging. We report a case of bilateral non-uremic breast calciphylaxis occurring in a patient without renal disease, illustrating the diagnostic difficulties posed by this atypical entity.



image showing left breast ulcer

Case Presentation

A 69-year-old woman with diabetes and hypertension, without known renal failure, was admitted for painful chronic bilateral breast ulcerations.

Clinical examination revealed two deep ulcers with a fibrinous base, surrounded by a violaceous halo, associated with atrophic scars in other cutaneous areas. Two biopsies were performed and showed non-specific findings, describing ulceration with diffuse chronic inflammation.

The phosphocalcium and renal workup were normal except for a slightly elevated urea level. Liver function tests and coagulation parameters were also normal. Breast imaging revealed bilateral diffuse vascular calcifications

without suspicious mass, classified as BI-RADS 2. Ultrasound showed no axillary lymphadenopathy or ductal abnormalities.

Bacteriological and mycological samples, as well as the autoimmune workup, were negative.

The diagnosis of non-uremic breast calciphylaxis was retained after exclusion of differential diagnoses and based on the clinical, radiological, and contextual findings. Management consisted of local wound care and symptomatic support.

Breast calciphylaxis is a rare clinical presentation, particularly in the absence of renal insufficiency. In patients with metabolic risk factors, as in our case, it may occur without major biological abnormalities, making diagnosis even more complex. The breast localization can be misleading and is often mistaken for a tumor or severe infection, potentially delaying appropriate management. Histology is frequently non-specific and does not always allow a definitive diagnosis. Imaging may provide important clues by demonstrating diffuse vascular calcifications without a suspicious mass. When this clinical presentation is recognized, calciphylaxis should be considered even in the absence of a uremic context. Early diagnosis may prevent inappropriate treatments or unnecessary surgical interventions.



xray of the right breast showing evident calcium deposits on arteries

Conclusion

This case illustrates a rare form of non-uremic calciphylaxis with bilateral breast involvement in a patient without

renal disease but with classic metabolic risk factors. The originality of this observation lies in its unusual clinical presentation, characteristic breast imaging findings, and the absence of specific histological features. It highlights the importance of considering this diagnosis in chronic painful breast ulcerations of unclear etiology in order to guide appropriate management.



image showin right breast ulcer

EA DV CONGRESS
VIENNA
30 SEP - 3 OCT 2026

Abstract N°: 2315

Three Dimensions of Wound Healing: AI-Assisted Planimetric, Volumetric,and Clinimetric Assessment of Chronic Wounds

Monika Molnarova[1], Alessio Lampis*[1], Oliver Kubesch[1], Harald Schnidar[1]

[1] SCARLETRED Holding GmbH, Vienna, Austria

Introduction

Objective assessment and monitoring of chronic wound evolution is critical for optimizing treatment administration and improving patient outcomes. This technical validation study investigates the potential of AI-driven image analysis to objectively track key wound features, including 2D surface area, volumetric measurements, and tissue composition, offering a promising framework for objective, longitudinal chronic wound monitoring to support clinical decision-making.

Materials and Methods

The Scarletred® Vision Software as a Medical Device (SaMD) platform, operating through an iOS application on smartphones, served as the image acquisition framework throughout this study. A central component of the Scarletred® Vision system is its skin patch, which provides a standardized chromatic and geometric calibration reference within each image, enabling precise, scale-accurate derivation of both 2D surface area measurements and 3D volumetric estimations directly from smartphone-acquired images.

A dataset of 519 image-mask pairs was assembled spanning a variety of clinical studies and chronic wound etiologies, including diabetic wounds, pressure ulcers, venous ulcerations, pyoderma gangrenosum, and epidermolysis bullosa. This diversity of wound types and acquisition contexts reflects real-world clinical variability to ensure model robustness and generalizability. Image data was preprocessed and augmented, with both RGB and LAB color space representations explored and optimal feature combinations identified for each downstream task.

Results

For automated wound boundary detection, a Convolutional Neural Network (CNN) was trained to delineate the wound area from surrounding healthy skin. Model performance was assessed using the Intersection over Union (IoU) and F-score metrics, yielding an F1-score of 0.83 and an IoU of 0.72. These results demonstrate reliable automated segmentation of wound boundaries, from which precise surface area measurements are derived.

For pixel-wise tissue classification within the detected wound area, a subset of 45 images was annotated by experts across nine distinct tissue types. A superpixel-based feature extraction approach was adopted to account for local spatial variability, including colorimetric, positional, and textural descriptors. A Random Forest classifier trained on this feature space achieved an overall accuracy of 0.97, enabling robust characterization of wound tissue composition and quantitative retrieval of healthy versus pathological tissue proportions.

Simultaneously with RGB image acquisition, depth information is captured by the Scarletred® Vision app and processed into a 3D mesh of the wound region. Wound topography is computed relative to the surrounding healthy skin, which serves as a region-specific reference accommodating arbitrary body curvature at the wound site. From the tilt-corrected mesh, clinically relevant metrics are derived: maximum depth and elevation and total volume, reported in physical units through the Scarletred® reference patch as a spatial calibration anchor. Three-dimensional renders of the wound with RGB, topography, or volumetric overlays support visual inspection and

longitudinal comparison. System accuracy was characterized on calibrated gauge block phantoms, yielding volumetric errors below 20% and a spatial resolution of 0.3 mm.

Conclusions

Notably, this technical validation demonstrates that reliable automated planimetric, volumetric, and clinimetrically relevant wound assessment can be achieved from standardized smartphone-based image acquisition. By combining AI-assisted wound segmentation, tissue composition analysis, and calibrated 3D volumetric reconstruction, this approach permits scalable, objective, and longitudinal chronic wound monitoring in real-world clinical settings. This work lays the foundation for a comprehensive and accessible decision-support tool designed to standardize wound assessment, support clinical trial endpoints, and enhance evidence-based decision-making in routine wound care.

EA DV CONGRESS
VIENNA
30 SEP - 3 OCT 2026

Abstract N°: 2347

Kaposi sarcoma masquerading as chronic infectious fasciitis: a diagnostic pitfall

salma larabi*[1]

[1] Department of dermatology, Ibn Sina University Hospital ,Rabat , Morocco, rabat, Morocco

Introduction
Kaposi sarcoma (KS) is a vascular neoplasm associated with human herpesvirus 8 (HHV-8), characterized by a broad clinical spectrum. Atypical presentations may closely mimic infectious or inflammatory conditions, leading to delayed diagnosis and inappropriate management.

Case Presentation
We report the case of a patient who, since late 2021, developed violaceous papulo-nodular lesions on the dorsum of the left foot. These lesions were initially interpreted as infectious in origin and treated over a prolonged period with systemic and topical antifungals, antibiotics, and local wound care, without clinical improvement.

The disease progressively worsened, with extension of erythematous-violaceous lesions. In 2025, inter-digital intertrigo appeared, followed by a warm, non-painful edema of the left lower limb extending above the knee, without fever or pain, initially attributed to a vascular or drug-related cause.

Subsequently, the clinical course deteriorated with superinfection, pain, and extensive soft tissue involvement. Imaging revealed findings suggestive of soft tissue fasciitis without bone involvement, leading to antibiotic therapy with partial improvement of the edema.

Given the persistent atypical evolution, a plantar skin biopsy was eventually performed in September 2025. Histopathological examination confirmed Kaposi sarcoma, with CD34, HHV-8, and ERG positivity. The lesion was initially masked by a chronic infectious and inflammatory-like presentation mimicking soft tissue fasciitis. The patient was referred for oncologic management, and radiotherapy was proposed due to loco-regional extension.

Conclusion
Kaposi sarcoma includes four main clinical variants: classic, endemic, iatrogenic, and epidemic (HIV-associated), with highly polymorphic cutaneous and soft tissue manifestations. Atypical presentations may closely simulate chronic infection or inflammatory conditions such as fasciitis, particularly in the presence of superinfection, thereby reinforcing diagnostic confusion.

The absence of response to appropriately conducted antimicrobial therapy, progressive evolution, and loco-regional extension should prompt early consideration of an underlying neoplastic process. Imaging may help assess disease extent but remains non-specific, as it cannot reliably distinguish between infectious, inflammatory, and tumoral etiologies.

Definitive diagnosis relies on histopathological and immunohistochemical examination (CD34, HHV-8, ERG). This case highlights Kaposi sarcoma as a rare but important mimicker of chronic infectious fasciitis. Persistent, atypical lesions unresponsive to adequate antimicrobial therapy should prompt early biopsy to ensure timely diagnosis and appropriate oncologic management.

EADV Congress 2026, VIENNA
30 SEPTEMBER - 03 OCTOBER 2026
POWERED BY M-ANAGE.COM

EA DV CONGRESS
VIENNA
30 SEP - 3 OCT 2026

Abstract N°: 2580

Wound Healing in Motion: An Artificial Intelligence-Powered Assessment of Wound Area and Tissue Composition Sensitive to Debridement and Longitudinal Change

Samantha Bestavros*[1], Katerina Bavaro[2], Rachel Tyli[3], Tahirih Nasseri[1], Heba Tallah Mohammed[4], Samia Rahman[4], Robert Fraser[4, 5], Sheila Wang[4, 6, 7]

[1] Temerty Faculty of Medicine, University of Toronto, Toronto, Canada

[2] The Michener Institute of Education, Toronto, Canada

[3] Department of Laboratory Medicine and Pathobiology, Temerty Faculty of Medicine, University of Toronto, Toronto, Canada

[4] Swift Medical, Toronto, Canada

[5] Arthur Labatt Family School of Nursing, Faculty of Health Sciences, University of Western Ontario, London, Canada

[6] Division of Dermatology, Department of Medicine, Women's College Hospital, Toronto, Canada

[7] Division of Dermatology, Department of Medicine, Temerty Faculty of Medicine, University of Toronto, Toronto, Canada

Introduction

Reliable assessment of wound area and tissue composition is essential for guiding therapeutic interventions, informing debridement and infection control strategies, optimizing dressing selection, and evaluating healing progression over time. The current standard of wound assessment relies heavily on subjective visual evaluation (e.g., visual estimation and ruler-based measurements) and clinician judgment. However, these methods may oversimplify complex wound geometry and fail to capture tissue heterogeneity, potentially contributing to variable treatment courses and unfavourable outcomes. Objective measurement tools may reduce the challenges raised by these methods, in turn supporting more standardized and reliable clinical decision-making. This descriptive exploratory evaluation study examines the clinical utility of an artificial intelligence (AI)-powered smartphone application that objectively quantifies wound area and percentage of granulation tissue, slough, and eschar. The edge-computing, point-of-care tool also enables capture of post-debridement changes and monitors wound progression over time.

Materials and Methods

The AI algorithm was developed using 17,000 expert-labelled wound images and trained on an additional 465,000 calibrated images. Forty-nine wound photographs were obtained from 39 patients (59% male) at a wound care clinic, including venous, arterial, and pressure ulcers, as well as post-surgical wounds and pyoderma gangrenosum. A fiducial was used for scale calibration.

Results

The mean patient age was 67.3 years (range: 28 to 97 years). The application measured a mean wound area of 9.0 cm^2 (range: 0.4 to 58.2 cm^2) and identified granulation in 79.6% of wounds, slough in 30.6%, and eschar in 18.4%. In one demonstrative case, pre- and post-debridement photographs quantified immediate post-intervention changes, capturing a wound area reduction from 8.6 cm^2 to 6 cm^2 and a tissue composition shift from 70% eschar to 80% granulation. Exploratory longitudinal measurements were tracked in four patients over a mean of 20.5 weeks (range: 1 to 50 weeks). Mean wound area decreased

by 0.5 cm² (range: -3.5 to +0.5 cm²). Granulation tissue changes varied across patients, with two patients showing increases in granulation (+20% and +30%), one patient showing a decrease in granulation (−50%), and one patient demonstrating no change in granulation over time. These longitudinal findings illustrate the application's ability to quantify dynamic changes in wound healing.

Conclusions

The findings of this study suggest the capability of the AI application to generate objective wound area and tissue composition measurements. Within this descriptive study, the application recorded immediate post-debridement changes and captured longitudinal progression, highlighting its potential to complement clinical evaluation and improve consistency in wound monitoring. By reducing subjectivity in assessment, this tool may support more informed clinical decision-making and improved management strategies. In addition, this technology may facilitate earlier identification of non-healing wounds, enabling timely and appropriate intervention. Future studies with larger and more diverse patient populations are warranted to assess the tool's performance across various wound types and clinical settings.

EADV CONGRESS
VIENNA
30 SEP - 3 OCT 2026

Abstract N°: 2627

AI Precision Imaging and Analysis for Epidermolysis Bullosa: Advancing Digital Clinimetry and Photometry

Monika Molnarova*[1], Chiara Agostini[1], Harald Schnidar[1]

[1] SCARLETRED Holding GmbH, Vienna, Austria

Introduction

Accurate assessment of Epidermolysis Bullosa (EB) lesions is essential for monitoring disease progression and optimizing treatment strategies. However conventional lesion evaluation methods necessitate in-person visits, posing a significant burden for patients. Our proof-ofconcept study aimed to improve EB lesion assessment using single-image analysis, facilitating remote evaluation and reducing the need for in-person clinical visits.

Materials and Methods

Our research utilized 157 images from 29 patients diagnosed with EB. Images were captured using the Scarletred®Vision mobile app, a clinically validated Software as a Medical Device (SaMD) platform. This imaging tool enabled high-quality image capture in a real-world setting, providing consistency and precision across various environments.

The images were analyzed using a combination of advanced image processing techniques and deep learning models. A deep learning model pre-trained to assess psoriasis images was finetuned and used on 157 EB images to obtain an in-depth segmentation of EB lesions, delineating the affected tissue. In addition to lesion segmentation, we applied a second model specifically trained to detect open wounds. This model differentiated between intact and broken skin, enabling the identification of wounds that may require further medical attention or monitoring.

Additional image processing techniques were employed to detect and count the number of blisters within the segmented lesion areas. By leveraging augmented signal maps, the system identified the boundaries of the blisters by enhancing the contrast between the lesions and surrounding tissue, allowing quantification of blisters.

Results

We developed a robust system capable of automatically detecting and analyzing EB lesions. The deep learning-based convolutional neural network (CNN) model effectively segmented EB lesions, accurately isolating affected areas from healthy tissue. This segmentation enabled more targeted analysis of the images, facilitating precise blister quantification through the image processing pipeline. Furthermore, the open wound detection model demonstrated its capability to identify regions of broken skin, providing valuable insights into lesion severity which may support wound care decisions. The combination of lesion segmentation, blister counting, and open wound detection resulted in a comprehensive system providing detailed insights into EB progression, offering a powerful tool for remote disease monitoring.

Conclusions

By leveraging smart imaging technologies and deep learning algorithms, we developed an automated system for analyzing EB lesions, aiding clinicians in remote monitoring and personalized treatment planning. The findings of our research lay the foundation for integrating image processing and AI tools into remote diagnostic practices, enhancing accessibility, efficiency, and improving patient outcomes for rare and chronic skin conditions like EB.

EADV CONGRESS
VIENNA
30 SEP - 3 OCT 2026

Abstract N°: 2659

Automated 3D wound surface estimation: a computer vision approach for accurate clinical assessment

Corrado Zengarini*[1, 2], Davide Griffa[1, 2], Lorenzo Dall'Olio[3], Yuri Merli[1, 2], Luca Rapparini[1, 2], Bianca Maria Piraccini[4], Michela Starace[1, 2], Gastone Castellani[1], Daniel Remondini[3], Michelangelo La Placa[1, 2], Nico Curti[3]

[1] Department of Medical and Surgical Sciences, University of Bologna, Bologna, Italy

[2] Dermatology Unit, IRCCS Azienda Ospedaliero-Universitaria di Bologna, Dermatology Unit, IRCCS Azienda Ospedaliero-Universitaria di Bologna, Bologna, Italy

[3] Department of Physics and Astronomy "Augusto Righi", University of Bologna, Bologna, Italy

[4] Ambulatorio Piraccini, Bologna, Italy

Introduction

Accurate measurement of wound surface area remains a major challenge in clinical practice, often relying on manual segmentation and 2D approximations that ignore depth and curvature and these limitations contribute to variability, reduced reproducibility, and inaccurate monitoring. Especially when measuring convex or irrecular surfaces. For this reason We aimed to develop and validate automated methods for precise 3D wound surface estimation monocular depth estimation and geometric surface reconstruction.

Materials and Methods

We developed two automated approaches (conic fit and triangulation) to estimate wound surface area from a standard 2D image, an AI-generated depth map, and a reference marker. Depth estimation was obtained using the pretrained ZoeDepth architecture, while surface reconstruction relied on either Delaunay triangulation or conic surface fitting. Methods were first validated on synthetic datasets with known ground truth, testing the effects of curvature and shape complexity. Performance was then evaluated on 89 real wound images acquired with smartphone cameras and segmented by two independent operators. Ground truth measurements were obtained using graph paper planimetry. Accuracy was assessed using mean absolute error (MAE), mean absolute percentage error (MAPE), and correlation analysis

Results

On synthetic datasets, both methods achieved high accuracy, with relative errors below 1%. In real-world data, average relative errors were approximately 30%, largely attributable to inter-operator variability in manual segmentation, accounting for up to 80% of total error. Both methods showed strong correlation with ground truth ($r > 0.93$, $p < 0.001$). The conic fit method slightly outperformed triangulation in smoother geometries, whereas triangulation showed better performance on highly irregular surfaces and faster computation times.

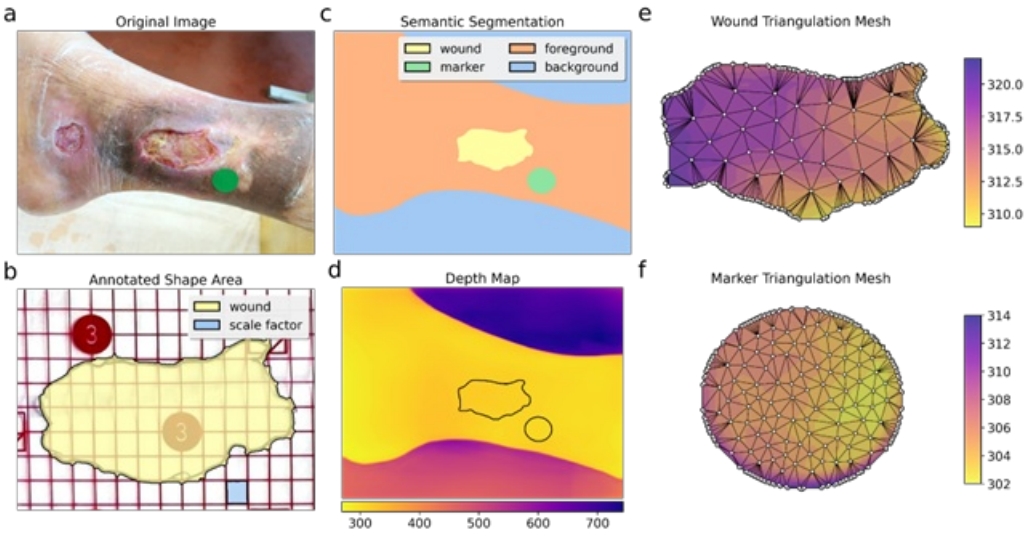

Automated wound analysis pipeline. From left to right: smartphone-acquired wound image, semantic segmentation, AI-generated depth map, and triangulation-based 3D surface reconstruction of wound and reference marker. Ground truth area was obtained using graph-paper planimetry.

Conclusions

The proposed methods enable accurate and scalable 3D wound surface estimation using standard smartphone imaging combined with depth estimation and geometric reconstruction. Human segmentation remains the major source of variability, supporting the future integration of fully automated segmentation pipelines. These approaches may improve objectivity, reproducibility, and longitudinal monitoring in wound care.

EA DV CONGRESS
VIENNA
30 SEP - 3 OCT 2026

Abstract N°: 2750

Anatomical Biomechanics and the Efficacy of Postoperative Imiquimod in Keloid Recurrence: A Systematic Review and Meta-Analysis

Mohammed A. Zailai*[1], Osama Mobarki[1], Mohammed Ebrahim Marouai Mojiri Mojiri[1], Khlood Alattas[1], Amal Badri[1], Rauf Mawkili[1], Alhassan Thubab[2], Khlood Magfouri[2], Rena Alharbi[1], Eyad A. Alamir[1], Khalid Alattas[3]

[1] Jazan University, Faculty of medicine, Jazan, Saudi Arabia

[2] Jazan University, faculty of Pharmacy, Jazan, Saudi Arabia

[3] Department of Dermatology, King Fahad Central Hospital, Jazan, Saudi Arabia, Jazan, Saudi Arabia

Introduction

Keloids frequently recur after surgical excision.
Postoperative imiquimod 5% is used to reduce recurrence; however, outcomes vary across anatomical sites.
We hypothesized that mechanical tension may explain this variability.

Materials and Methods

A PRISMA-based systematic review and meta-analysis was conducted (PROSPERO: CRD420261341112).
PubMed and Web of Science were searched from inception to March 2026.
Eight studies comprising 110 lesions were included.
Recurrence proportions were pooled using a random-effects model with Freeman–Tukey transformation.
Subgroup analysis was performed based on anatomical tension: low (auricular), mixed, and high (trunk).

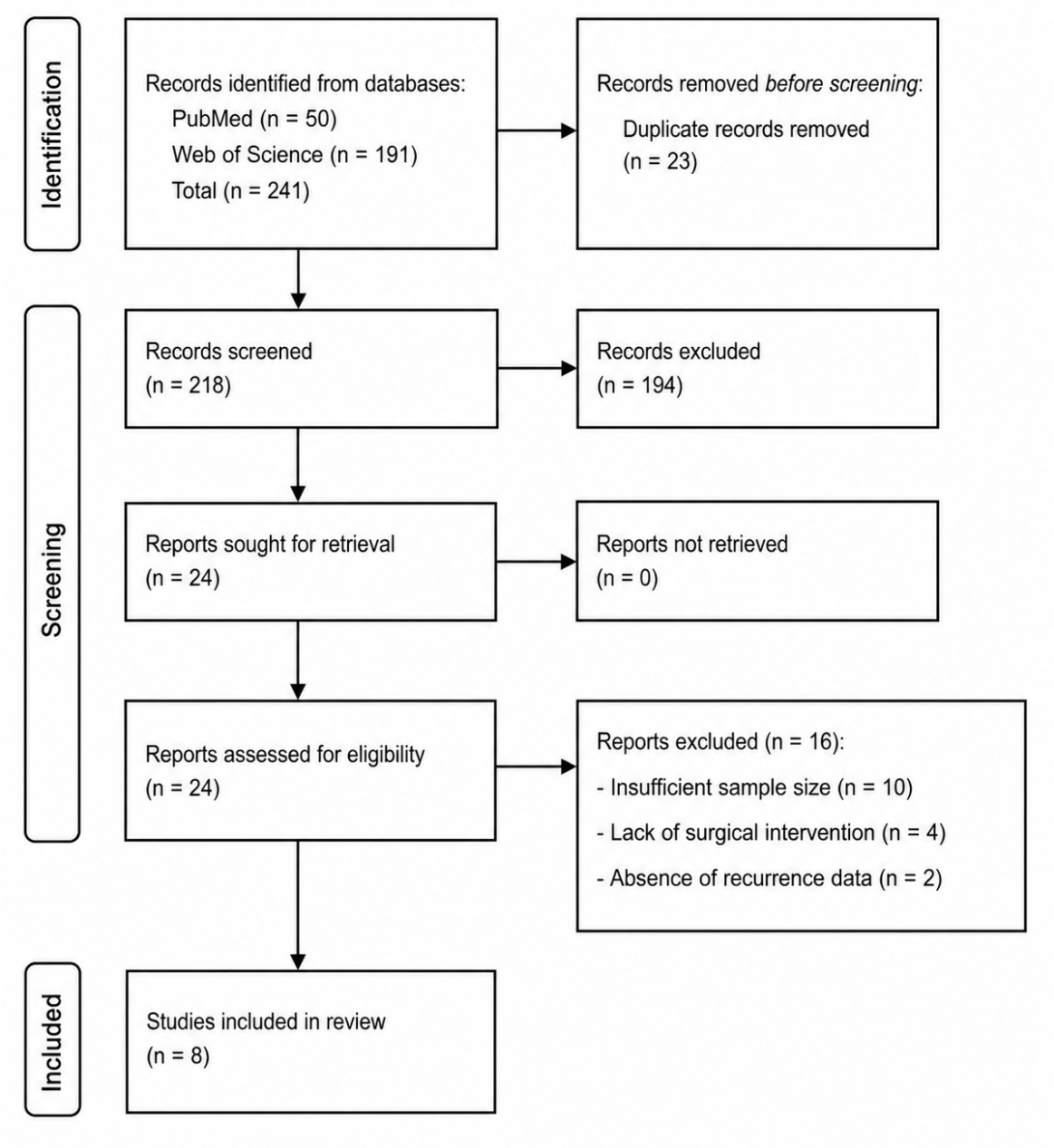

The study selection process is summarized in the PRISMA flow diagram (Figure 1).

Results

Overall recurrence was 19.3% (95% CI: 1.0–48.4%), with substantial heterogeneity (I^2 = 88.4%).

Subgroup analysis demonstrated a clear gradient across anatomical tension categories:

Low-tension sites: 4.1%

Mixed sites: 27.9%

High-tension sites: 100% (single study)

Recurrence increased progressively with mechanical tension

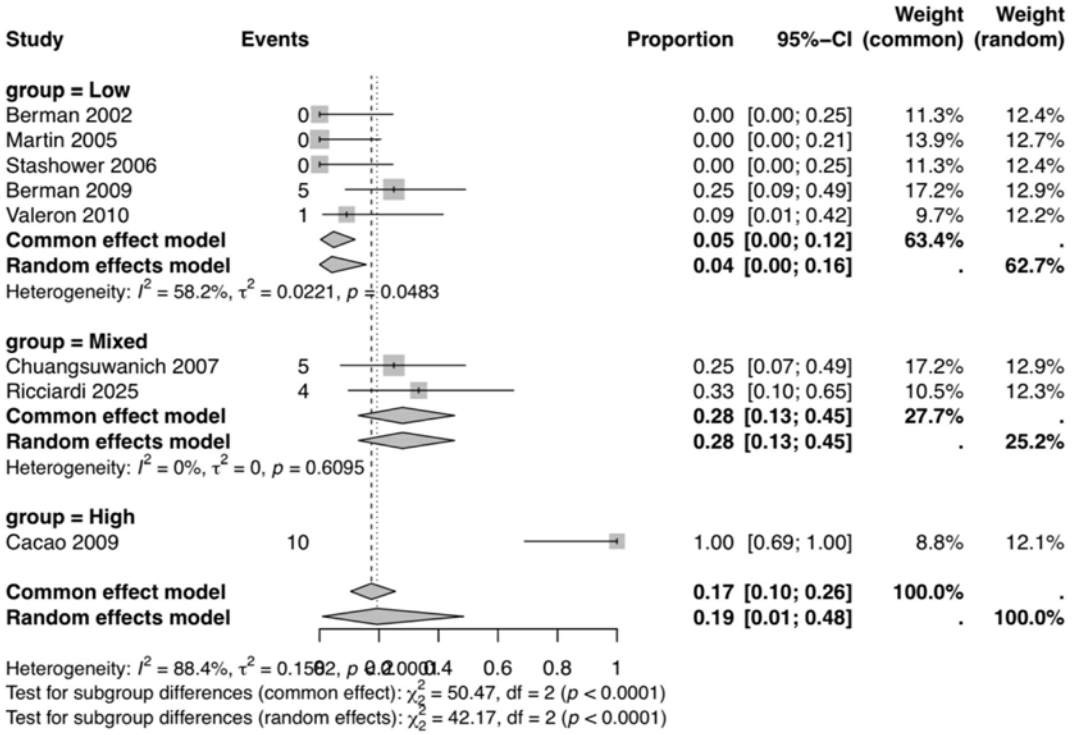

Figure 2 presents the forest plot of pooled recurrence proportions stratified by anatomical tension.

Conclusions

Imiquimod appears effective in low-tension areas but less effective in high-tension regions. Anatomical biomechanics likely influence treatment response and should guide site-specific strategies.

EA DV CONGRESS
VIENNA
30 SEP - 3 OCT 2026

Abstract N°: 2877

Systemic therapies in pediatric pyoderma gangrenosum: a systematic review

Mayeesha Khan*[1], Miranda Branyiczky[1], Angie Moshutz[2], David Croitoru[3]

[1] Michael G. DeGroote School of Medicine, McMaster University, Hamilton, Canada

[2] Faculty of Medicine and Health Sciences, McGill University, Montreal, Canada

[3] Department of Medicine, University of Toronto, University Health Network, Toronto Western Hospital, Toronto, Canada

Introduction

Pyoderma gangrenosum (PG) is a rare, debilitating neutrophilic dermatosis with limited treatment guidance in pediatric populations. Management is largely extrapolated from adult data, and age-related differences in presentation and treatment response remain underexplored. This study systematically reviews systemic therapies in pediatric PG, comparing clinical characteristics and outcomes across infants (<2 years), children (2–12 years), and adolescents (13–18 years).

Materials and Methods

MEDLINE and Embase were searched for studies reporting pediatric patients (≤18 years) with PG treated with systemic therapy. Data were extracted on demographics, comorbidities, lesion characteristics, pathergy, treatment class, outcomes, recurrence, and adverse events. Descriptive subgroup analyses were performed by age cohort and relative risk was calculated for recurrence rates within subgroups.

Results

Ninety-five studies describing 124 pediatric patients were included (mean age 8.2±6.0 years; 25 infants, 60 children, 39 adolescents). Overall, 39.5% of cases were idiopathic. The most common associated conditions were anemia (12.9%), Crohn's disease (12.1%), and ulcerative colitis (11.3%), with inflammatory bowel disease being most prevalent in adolescents. Amongst all included patients, ulcerative PG was the most common subtype (91.1%), with lower extremity involvement in 72.6% of cases. Infants more frequently presented with head and neck involvement (56.0%), pathergy (72.0%), and multiple lesions (88.0%), compared to children and adolescents. Systemic corticosteroids were used in 87.9% of cases. TNF-α inhibitors were the most frequently used steroid-sparing agents in this cohort, followed by calcineurin inhibitors. Stratified by age group, steroid-sparing agents most commonly involved TNF-α inhibitors in infants (36.0%) and adolescents (23.1%), and dapsone in children (23.3%).

Among cases treated with systemic corticosteroids alone, 71.4% achieved complete resolution and 28.6% improved, though 37.5% experienced recurrence after remission. Non-steroidal therapies demonstrated high clearance rates (85.7%) with lower recurrence (25.0%), supporting their role in long-term treatment.. Among therapies used in >2 cases, cyclophosphamide had the highest clearance rate (100%, 5/5), followed by IVIG (90.9%, 10/11), methotrexate (88.9%, 8/9), IL-1 inhibitors (80.0%, 4/5), calcineurin inhibitors (76.9%, 20/26), and TNF-α inhibitors (75.0%, 21/28). Sulfasalazine had the lowest clearance rate (33.3%, 1/3), while azathioprine had the highest no-response rate (37.5%, 3/8). Adverse events, occurring in 12 cases (9.7%), included steroid-related growth and endocrine effects (4.8%, n=6), infections (3.2%, n=4), and mortality (1.6%, n=2).

Conclusions

Pediatric PG demonstrates age-related differences in clinical presentation, recurrence, and outcomes. While

systemic corticosteroids remain first-line therapy, their use presents unique challenges in children who may be susceptible to endocrine and growth impacts of their long-term use. Antibiotics and systemic immunosuppressants were commonly used in cases with greater severity at presentation or that were refractory to initial steroid treatment. Biologics, including TNF-α inhibitors are increasingly used, with fewer adverse events compared to corticosteroids. High recurrence rates support consideration of steroid-sparing strategies for prolonged treatment and highlight the need for further cohort studies and clinical trials focused on PG treatment in pediatric populations.

EADV CONGRESS
VIENNA
30 SEP - 3 OCT 2026

Abstract N°: 2973

Gelatine Spray Enhances Wound Healing Compared to 0.9% Sodium Chloride in Wistar Rats

Grace Hertalin Patiung*[1], Stefan Cahyadi[1], Widya Widita[1], Khairuddin Djawad[1], Upik Miskad[2]

[1] Department of Dermatology, Venereology, and Aesthetic Medicine, Faculty of Medicine, Hasanuddin University, Makassar, Indonesia
[2] Department of Anatomical Pathology, Faculty of Medicine, Hasanuddin University, Makassar, Indonesia

Introduction
Wound healing is a complex and tightly regulated biological process involving haemostasis, inflammation, proliferation, and remodelling. Although 0.9% sodium chloride is widely used as a conventional dressing to maintain a moist wound environment, it lacks intrinsic bioactive properties that actively promote tissue repair. Gelatine, a biocompatible biomaterial derived from collagen and structurally similar to the extracellular matrix, has emerged as a promising candidate due to its ability to support cell adhesion, angiogenesis, and tissue regeneration. This study aimed to compare the effectiveness of gelatine spray with 0.9% sodium chloride in accelerating wound healing and modulating key inflammatory and angiogenic biomarkers

Materials and Methods
A true-experimental post-test-only control group study was conducted using 27 male Wistar rats randomly allocated into three groups: control, 0.9% sodium chloride, and gelatine spray. Standardized full-thickness excisional wounds were created, followed by daily topical treatment. Wound healing was assessed macroscopically by measuring wound diameter and microscopically by evaluating granulation tissue formation, re-epithelialization, and inflammatory cell infiltration. Levels of interleukin-6 (IL-6) and vascular endothelial growth factor (VEGF) were quantified using enzyme-linked immunosorbent assay. Evaluations were performed on days 2, 7, and 14. Statistical analysis was conducted with a significance threshold of $p<0.05$.

Results
Gelatine spray demonstrated statistically significant superiority in wound healing outcomes compared to both 0.9% sodium chloride and control groups. Wound diameter reduction was consistently greater in the gelatine group across all observation time points, with the most pronounced effect observed on day 14 ($p<0.05$). Histopathological evaluation revealed significantly enhanced granulation tissue formation and re-epithelialization in gelatine-treated wounds ($p<0.05$), indicating accelerated progression through the proliferative phase. At the molecular level, VEGF expression was significantly upregulated, reflecting enhanced angiogenesis, while IL-6 levels were significantly reduced, indicating effective modulation of the inflammatory response ($p<0.05$). In contrast, the 0.9% sodium chloride group demonstrated slower wound contraction, less pronounced histological improvement, and more modest changes in biomarker expression. Collectively, these findings indicate that gelatine spray not only accelerates macroscopic wound closure but also enhances key biological processes essential for tissue repair. These effects were consistent across macroscopic, histological, and molecular endpoints, supporting a robust and reproducible therapeutic benefit.

Conclusions
Gelatine spray showed superior efficacy in accelerating wound healing compared to 0.9% sodium chloride by promoting angiogenesis, enhancing tissue regeneration, and reducing inflammation. These findings highlight the potential of gelatine spray as an effective and biologically active alternative for wound management.

EADV CONGRESS
VIENNA
30 SEP - 3 OCT 2026

Abstract N°: 3035

Chronic ulcerations of the nape of the neck: consider post-zoster cutaneous ulcerations

Rayenne Benhizia*[1], Tarek Mansoul[1], RIADH BOUSSAID[1], khadidja Bouarroudj[1], asma Bouhila[1], amel Ghorfi[1], lilia Kaghouche[1], safa Djebes[1], Ahmed Samaouel Chehad[1]

[1] Department of Dermatology, University Hospital of Constantine, Constantine, Algeria

Introduction

Post-zoster cutaneous ulcerations represent chronic lesions occurring after herpes zoster infection, secondary to profound nerve injury induced by the virus. They are commonly associated with post-herpetic neuralgia, characterized by persistent neuropathic pain, burning dysesthesia, and sensory impairment. Subsequent hypoesthesia and paresthesia may promote repeated, frequently self-induced trauma, resulting in chronic non-healing ulcerations.

Case Presentation

A 77-year-old man with a past medical history of hypertension and anxiety disorder, and a history of chewing tobacco use, presented with a chronic ulceration of the nape of the neck, progressively evolving over a three-year period.
The lesion was associated with severe pruritus and localized pain.
The patient reported a prior episode of herpes zoster affecting the same area, which preceded the onset of the ulceration.
Physical examination revealed a well-circumscribed, roughly triangular ulceration located on the nuchal region, measuring 13 cm in its greatest diameter, arising on an atrophic and dyschromic cutaneous background.
Neurological examination showed localized hypoesthesia, accompanied by a burning sensation and intense intermittent lesion-related pruritus. The pruritus was rated 9/10 on the numeric rating scale and triggered an uncontrollable urge to scratch, although it was not associated with sleep disturbance.
Laboratory investigations were unremarkable, except for evidence of an inflammatory syndrome.
Complete blood count, liver, renal and thyroid function tests, fasting plasma glucose, and HIV serology were all within normal limits.
Treatment with gabapentin was initiated, with progressive dose escalation up to 300 mg three times daily. The patient was also counseled on the importance of occlusive dressing to prevent inadvertent mechanical trauma.
Clinical evolution was favorable, with complete healing of the ulceration.

Conclusion

Post-herpetic neuropathic ulceration represents a rare but debilitating clinical entity characterized by chronic skin breakdown secondary to sensory nerve dysfunction in the area previously affected by the varicella-zoster virus (VZV). The underlying pathophysiology involves a complex interplay of paresthesia, neuropathic pruritus, and chronic pain, which frequently triggers involuntary scratching and repeated self-inflicted trauma. While the onset of these lesions can range from weeks to years following the initial zoster infection, successful management necessitates an early, multidisciplinary approach focused on mechanical protection to halt injury and pharmacological intervention—such as gabapentin or carbamazepine—to address the neurological drivers. Ultimately, while reconstructive surgery remains an option for persistent cases, a combined strategy of sensory symptom control and behavioral prevention is essential to improve patient outcomes and achieve satisfactory healing.

EA DV CONGRESS
VIENNA
30 SEP - 3 OCT 2026

Abstract N°: 3149

TOGETHER: Real-world healing outcomes and disease burden in pyoderma gangrenosum across North America

Katelyn Downey*[1], Anisah Alladeen[2], Robert Micheletti[3], David Croitoru[4, 5], Lily Acheampong[4, 5], Pauline Vo[6], Steven Feldman[6], Payton Trimark[7], Bridget Shields[7], Yun Yu[8], Jeong Youn Lim[8], Alex Ortega Loayza[1]

[1] Department of Dermatology, Oregon Health & Science University, Portland, United States
[2] Weill Cornell Medical College, New York, United States
[3] Department of Dermatology, Perelman School of Medicine, University of Pennsylvania, Philadelphia, United States
[4] Division of Dermatology, Department of Medicine, Women's College Hospital, Toronto, Canada
[5] Division of Dermatology, Department of Medicine, University Health Network, Toronto, Canada
[6] Department of Dermatology, Wake Forest School of Medicine, Winston-Salem, United States
[7] Department of Dermatology, University of Wisconsin, Madison, United States
[8] Biostatistics Shared Resource, Knight Cancer Institute, Oregon Health & Science University, Portland, United States

Introduction
Pyoderma gangrenosum (PG) is a rare neutrophilic dermatosis characterized by painful ulcerations, substantial morbidity, and an unpredictable clinical course. Despite increasing use of advanced therapies, real-world, multicenter data describing healing outcomes and disease burden remain limited, particularly in North American populations.

Materials and Methods
We performed a retrospective multicenter study of 133 patients with classic (n=110) or peristomal PG (n=23) treated across five sites in North America between 2020 and 2025. The primary endpoint was healing of the target ulcer, defined as the largest ulcer at initial presentation, with healing defined as complete re-epithelialization. Time-to-healing analyses were performed using Kaplan-Meier methods, with healing treated as the event of interest and patients without healing censored at their last available follow-up. Differences in healing distributions were compared using the log-rank test. Healing proportions between ulcer depth groups were compared using Pearson's chi-square test. Multivariable Cox proportional hazards regression was performed adjusting for baseline ulcer surface area and ulcer duration. Secondary endpoints included change in ulcer surface area, treatment patterns, and disease burden, including flares, recurrences, surgical interventions, and healthcare utilization.

Results
Among 133 patients, 94 (71%) achieved complete healing during the study period. Median time to healing was 10 months (95% CI: 8–14 months) after initial presentation. Most patients presented with multilesional disease (≥2 ulcers; 70%), moderate-to-severe ulcer depth, defined as extension to the subcutaneous tissue or deeper (63%), a median ulcer surface area of 29 cm^2 (IQR 6–77 cm^2), and a median ulcer duration of 4 months (IQR 2–11 months).

Patients with moderate-to-severe depth ulcers were less likely to achieve healing compared to those with more

superficial ulcers (62% vs 86%, p=0.004) and experienced delayed time to healing (log-rank p=0.020; Figure 1). In multivariable Cox regression adjusting for baseline ulcer surface area and duration, moderate-to-severe ulcer depth remained independently associated with delayed healing (aHR 0.65, 95% CI [0.43, 0.98], p=0.042). Baseline ulcer duration was also independently associated with delayed healing (p < 0.001).

Nearly all patients required combination systemic therapy (96%), including 38% who received biologic therapy, and 45% experienced at least one treatment failure requiring treatment escalation. Disease burden was substantial, with 40% experiencing at least one flare with increase in target ulcer size, 35% developing new ulcers prior to target ulcer healing, and 25% experiencing recurrence after healing during the study period. Additionally, 21% underwent at least one PG-related surgical procedure, including surgical debridement, grafting, or amputation. Healthcare utilization was high, with 39.1% of patients requiring at least one hospitalization or emergency department visit directly attributable to PG during the study period.

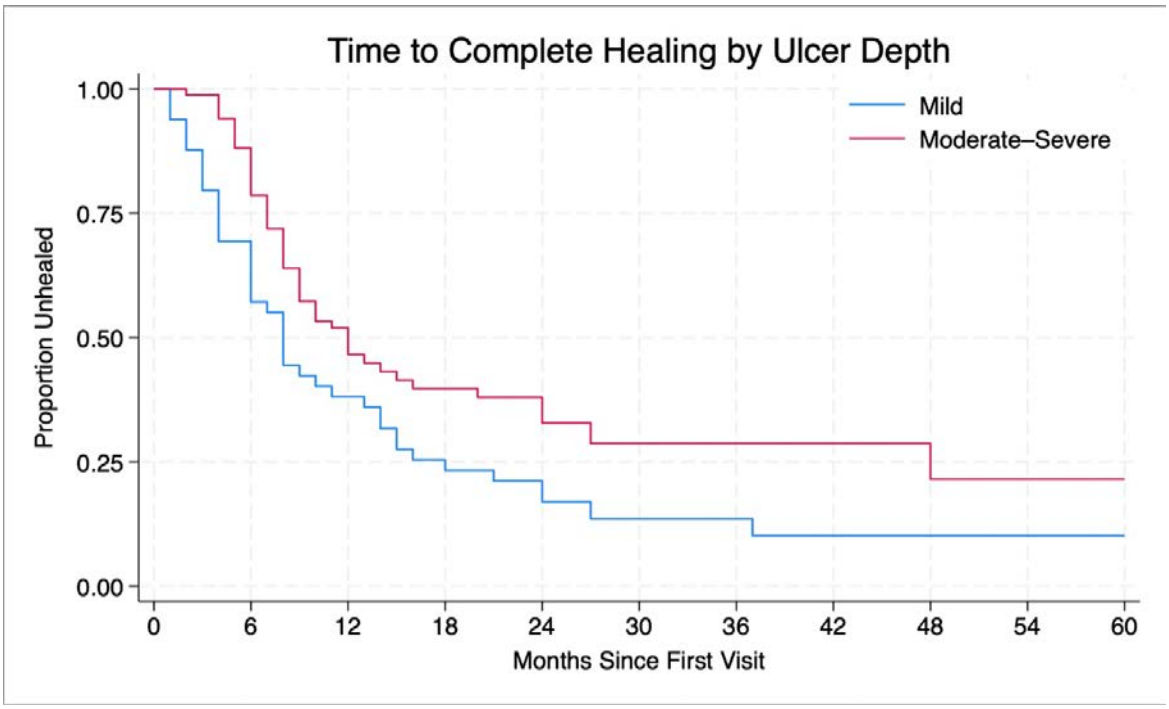

Figure 1. Time to complete healing stratified by ulcer depth. Patients with ulcers of moderate-to-severe depth experienced delayed healing compared to those with ulcers of mild depth (Kaplan–Meier, log-rank p=0.020).

Conclusions

In this real-world, multicenter, North American cohort, PG was characterized by prolonged healing times, high treatment burden, and substantial morbidity. Moderate-to-severe ulcer depth and longer baseline ulcer duration were independently associated with delayed healing. Patients frequently required multiple systemic therapies, experienced treatment failures and disease flares, and often required surgical intervention and acute care services. These findings highlight the substantial disease burden and healthcare utilization associated with PG and underscore the need for improved understanding of factors associated with healing outcomes and disease course.

EADV CONGRESS
VIENNA
30 SEP - 3 OCT 2026

Abstract N°: 3180

Subcutaneous calcinosis after calcium heparin injection

Hamzaoui Soumia*[1], chikhbled nadjet[1], Oussalah Wassila[1], Serradj Amina[1]

[1] Oran University Hospital Establishment, faculté de médecine d'Oran., Oran, Algeria

Introduction
Subcutaneous calcinosis, defined by dermal and hypodermal calcium deposits, is a rare adverse effect occurring after subcutaneous injection of calcium heparin (1). We report the case of a patient with renal failure (RF) who developed subcutaneous calcinosis at the sites of calcium heparin injections, with a favorable outcome.

Case Presentation
A 52-year-old woman with no significant medical history presented with ulcerated erythematous plaques with fibrinous deposits on both arms. Two weeks prior, the patient had suffered a pulmonary embolism due to extensive ilio-femoro-popliteal venous thrombosis, complicated by shock and acute renal failure, which was treated with thrombolysis and subcutaneous injections of calcium heparin administered exclusively in both arms. Phosphocalcic parameters were normal, while renal function was impaired (creatinine: 45.81 mg/L, urea: 2.58 mg/L). Histological examination revealed variable dermal calcium deposits in the deep dermis without necrosis or thrombosis. A diagnosis of subcutaneous calcinosis induced by calcium heparin was established, and cessation of the injections was advised. Local evolution was favorable within a few weeks without specific treatment.

Conclusion
Iatrogenic subcutaneous calcinosis secondary to calcium heparin injection is a rare and poorly known entity, occurring preferentially in patients with severe renal insufficiency, in whom calcium heparin is frequently prescribed (1). The pathophysiology remains poorly understood. Phosphocalcic disorders and local skin trauma appear to be involved, the latter likely contributing in our patient (2,3). Clinically, cutaneous calcinosis lesions are non-specific, presenting as firm papules, nodules, or plaques that are warm and erythematous at the injection sites (1,4). The main diagnostic argument is histopathological examination, which reveals dermal and/or hypodermal calcium deposits without necrosis or thrombosis (1,4). The course is generally slow but spontaneously favorable without specific treatment (1).
The primary differential diagnosis is calciphylaxis, particularly calcifying panniculitis, which mainly affects the thighs and abdomen, presenting as subcutaneous nodules or plaques that rapidly progress to necrosis in the context of general health deterioration. Concurrently, renal function deterioration is observed. Histologically, calciphylaxis is characterized by calcium deposits and thrombosis in small vessels with endovascular fibrosis. The prognosis is poor and may result in patient death (5).
Based on anamnesis, clinical presentation, histology, and evolution, a diagnosis of iatrogenic subcutaneous calcinosis secondary to calcium heparin injection was established in our patient, with favorable outcome after cessation of treatment.

EA DV CONGRESS
VIENNA
30 SEP - 3 OCT 2026

Abstract N°: 3291

Functional Remodeling of NK Cells in Keloids: Chronic Type I Interferon Signaling Drives the IFN-γ/Amphiregulin Imbalance via NR3C1 Activation

Ying Zhao*[1]

[1] The Second Affiliated Hospital Zhejiang University School of Medicine, Hangzhou, China

Introduction

Keloid is a fibrotic disorder characterized by excessive fibroblast proliferation, collagen deposition, and disrupted inflammatory microenvironment. As a core component of innate immunity, the functional status of natural killer (NK) cells in keloid remains poorly elucidated. This study aimed to investigate the phenotypic and functional alterations of NK cells in patients with keloid, with a particular focus on the imbalance mechanism of two pivotal functional molecules, interferon-γ (IFN-γ) and amphiregulin (AREG). We further clarified the regulatory roles of type I interferon signaling and glucocorticoid receptor (NR3C1) pathway in this imbalance, so as to provide novel targets for the immunotherapy of keloid.

Materials and Methods

Peripheral blood samples as well as keloid lesional and perilesional skin tissues were collected. Serum IFN-β levels in keloid patients were determined, and the exhausted phenotypic characteristics of NK cells were detected after long-term IFN-β stimulation. NK cells producing AREG and IFN-γ were co-cultured with fibroblasts to assess their effects on fibroblast proliferation, α-SMA expression and collagen secretion. Single-cell RNA sequencing (scRNA-seq) was used to analyze transcriptomic differences in NK cells between keloid patients and healthy controls, with a focus on the expression patterns of type I interferon-stimulated genes (ISGs) and glucocorticoid receptor NR3C1. The regulatory mechanism of AREG expression was verified by in vitro stimulation with IFN-β or glucocorticoids. Finally, a keloid mouse model was used to in vivo validate the inhibitory effect of AREG on IFN-γ-mediated fibroblast apoptosis and collagen degradation.

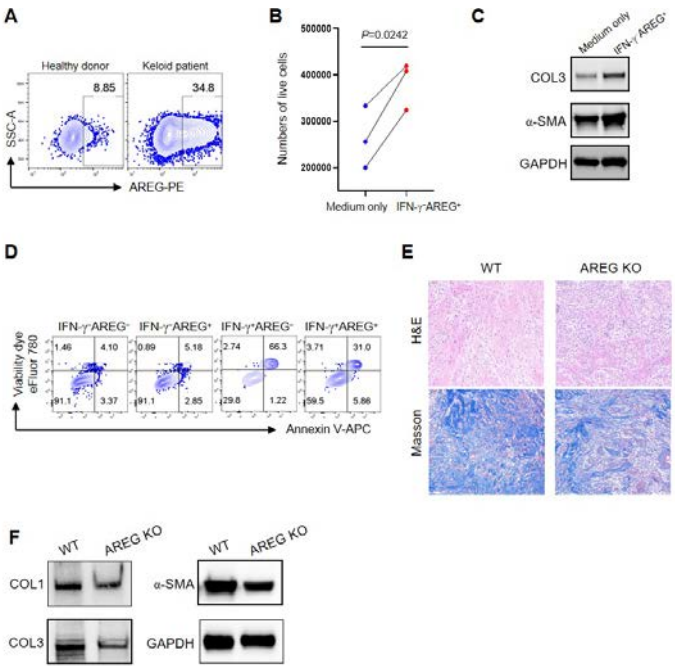

Figure 1. Elevated AREG in keloid patients promotes fibroblast proliferation and collagen deposition

A. Flow cytometry was used to detect the percentage of AREG-producing NK cells in peripheral blood after PMA plus ionomycin stimulation. The proportion of AREG$^+$ NK cells was significantly higher in keloid patients than in healthy controls.

B. Fibroblasts were treated with NK cell-derived AREG-containing supernatant for 6 days, and cell counting showed obvious fibroblast proliferation.

C. Western blot analysis revealed increased expression of COL3 and α-SMA in fibroblasts after 6-day stimulation with NK cell-derived AREG supernatant.

D. The apoptotic rate of keloid fibroblasts was markedly lower in the presence of IFN-γ plus AREG$^+$ NK cell supernatant compared with IFN-γ plus AREG$^-$ NK cell supernatant.

E. In a keloid xenograft mouse model with NK cell adoptive transfer, H&E (left) and Masson staining (right) showed significantly enhanced collagen degradation in the AREG knockout (KO) group relative to the wild-type (WT) IFN-γ$^+$AREG$^+$ NK group.

F. Western blot analysis of tissue samples from the keloid xenograft mouse model demonstrated lower expression of COL1, COL3 and α-SMA in the AREG KO group than in the WT group.

Results

NK cells in the peripheral blood and lesional tissues of keloid patients showed decreased IFN-γ secretion. Long-term exposure to type I interferon signaling reduced IFN-γ production and proliferative capacity of NK cells, upregulated inhibitory receptors, induced mitochondrial dysfunction, suppressed PI3K-AKT pathway activity, and drove NK cell exhaustion. Peripheral NK cells from keloid patients had elevated AREG production. NK cell-derived AREG supernatant promoted fibroblast proliferation, α-SMA expression and collagen secretion. In keloid mouse models and cultured fibroblasts, AREG inhibited IFN-γ-induced fibroblast apoptosis and collagen degradation. Upon short-term IFN-β stimulation, ISG15$^+$ NK cells secreted more AREG than ISG15$^-$ counterparts, suggesting AREG upregulation is closely linked to type I interferon pathway activation that induces NK cell exhaustion. Single-cell RNA sequencing of peripheral NK cells revealed higher NR3C1 expression in keloid patients than in healthy controls, with the keloid-specific ISG$^+$ NK cell cluster C2 exhibiting the highest NR3C1 level. Glucocorticoids specifically induced AREG expression in NK cells via NR3C1 activation. Glucocorticoid stimulation further confirmed that NK cells from keloid patients released more AREG than those from healthy individuals, indicating hyperactivation of the glucocorticoid pathway in keloid NK cells, which is probably associated with type I interferon signaling activation.

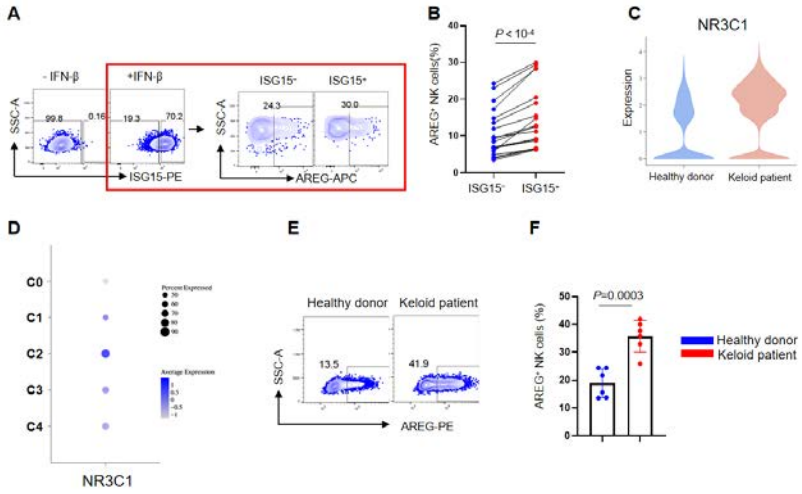

Figure 2. Type I interferon-induced NK cell exhaustion and NR3C1 activation may contribute to AREG upregulation in keloid patients
A+B. NK cells were pretreated with IFN-β for 16 h followed by stimulation with PMA plus ionomycin. Flow cytometry showed that ISG15$^+$ NK cells produced higher levels of AREG than ISG15$^-$ NK cells. C. scRNA-seq analysis of peripheral blood NK cells from keloid patients and healthy controls revealed significantly higher NR3C1 expression in NK cells of keloid patients. D. Further scRNA-seq analysis indicated that the keloid-specific ISG$^+$ NK cell cluster (C2) exhibited higher NR3C1 expression than other NK subclusters. E+F. Peripheral blood NK cells from keloid patients and healthy individuals were stimulated with dexamethasone (Dex). NK cells from keloid patients secreted more AREG than those from healthy controls.

Conclusions

NK cells in keloid patients exhibit a unique functional remodeling. Chronic type I interferon signaling drives NK cell exhaustion (reduced IFN-γ, impaired proliferation), while upregulating NR3C1 to enhance glucocorticoid responsiveness and promote AREG overexpression. The low IFN-γ/high AREG imbalance drives fibroblast hyperproliferation and collagen deposition. Our findings uncover crosstalk between type I interferon and glucocorticoid pathways in NK cells, offering new insights into keloid immunity and potential therapeutic targets.

EA DV CONGRESS
VIENNA
30 SEP - 3 OCT 2026

Abstract N°: 3300

Autologous platelet-rich plasma as adjunctive therapy in chronic venous ulcers: a caseseries comparing two therapeutic modalities

Gabriela Otero*[1], Maria Meneses[1, 1, 1, 1], Lourdes Echarte[1, 1, 1], Migdacelys Albolaez[1, 1, 1], Dilcia Villalvir[1, 1, 1, 1], Laura Vazquez[1, 1, 1, 1], Crisitina Touriño[1, 1, 1], Rodolfo Torres[2]

[1] Hopsital de clinicas, Montevideo, Uruguay

[2] School of Medicine, University of Buenos Aires, Buenos Aires, Argentina

Introduction

Background

Chronic venous ulcers of the lower limbs represent a frequent therapeutic challenge, with high chronicity rates and a significant impact on quality of life. Autologous platelet-rich plasma (PRP) has emerged as a potential therapeutic alternative due to its high content of growth factors that may promote wound healing.

Case Presentation

Objective

To evaluate the impact of two modalities of autologous PRP as a complementary treatment in chronic venous ulcers.

Methods

A case series of patients with chronic venous ulcers was conducted. Initially, all patients received conventional medical treatment for 3 months. Non-responders or partial responders were subsequently treated with autologous PRP (perilesional injection or topical gel), administered every 2 weeks for 3 months. Clinical outcomes, serial planimetry, and adverse events were assessed.

Results

Four patients with chronic venous ulcers were included. One patient achieved complete healing during conventional treatment. The remaining three patients, classified as non-responders or partial responders, received PRP, showed heterogeneous responses depending on treatment modality and product characteristics.
The patient treated with injectable PRP showed the greatest response, with an 82.6% reduction in ulcer area at month 6 and subsequent complete healing at month 10 during extended follow-up. Patients treated with PRP gel showed more limited reductions (14.4% and 23%), with a progressive decrease in ulcer size. Beyond area reduction, all PRP-treated cases showed clinical improvement of the wound bed, including decreased exudate, resolution of fibrin, and increased granulation tissue, indicating a more favorable healing environment.TGreater response was associated with higher PRP composition, with better outcomes observed in cases with higher platelet concentration and leukocyte content. No treatment-related adverse events were reported.

Conclusion

Conclusion

Autologous PRP may represent a useful adjunctive therapeutic strategy in chronic venous ulcers, particularly in cases refractory to conventional treatment. Its effect appears to be influenced by the biological composition of the product, especially platelet concentration and leukocyte content. Further studies with larger sample sizes are needed to confirm these findings.

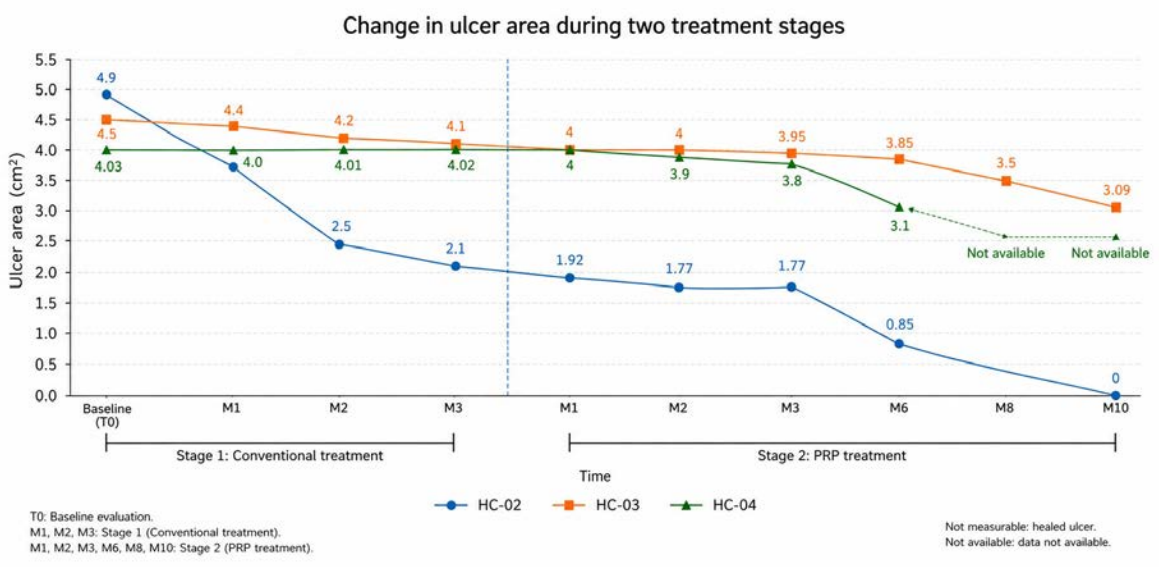
Change in ulcer area during two treatment stages
Ulcer area (cm²)
5.5
5.0
4.5
4.0
3.5
3.0
2.5
2.0
1.5
1.0
0.5
0.0
4.9
4.4
4.2
4.1
4
4
3.95
3.85
3.5
3.09
4.5
4.03
4.0
4.01
4.02
4
3.9
3.8
3.1
Not available
Not available
2.5
2.1
1.92
1.77
1.77
0.85
0
Baseline (T0)
M1
M2
M3
M1
M2
M3
M6
M8
M10
Stage 1: Conventional treatment
Stage 2: PRP treatment
Time
HC-02
HC-03
HC-04
T0: Baseline evaluation.
M1, M2, M3: Stage 1 (Conventional treatment).
M1, M2, M3, M6, M8, M10: Stage 2 (PRP treatment).
Not measurable: healed ulcer.
Not available: data not available.

EA DV CONGRESS
VIENNA
30 SEP - 3 OCT 2026

Abstract N°: 3339

Leg ulcer beyond vascular causes: when the dermatologist remains at the forefront

Fatima-Ezzahraa Zeroual*[1], Charles Huvet[1], Florent Grange[1]

[1] Department of Dermatology, Valence Hospital Center, Valence, France

Introduction
The common etiologies of leg ulcers (chronic venous insufficiency, peripheral arterial disease, necrotic angiodermatitis) are well known to dermatologists and are often readily suspected on clinical examination. When these causes are absent, dermatologists may consider rarer conditions such as pyoderma gangrenosum or metabolic disorders. We report an exceptional and potentially severe cause identified during the initial dermatological workup in outpatient consultation, the management of which led to ulcer healing.

Case Presentation
A 78-year-old woman with no relevant medical history (notably no hypertension or diabetes) presented with a painful leg ulcer persisting for two years. Clinical examination revealed a well-demarcated, oval ulcer on the anterior aspect of the lower third of the right leg, measuring approximately 3 cm in its largest diameter, with a fibrinous base and sharp borders, surrounded by an erythematous perilesional halo (Figure). Both arterial and venous Doppler ultrasonography were normal. Routine laboratory workup revealed isolated thrombocytosis at 784 G/L as the only abnormality. Histological examination performed twice showed a dermal neutrophilic infiltrate and microthrombi.

The initial course was marked by progressive enlargement of the ulcer despite appropriate local wound care, resistance to topical corticosteroids, failure of a full-thickness skin graft, and persistent pain despite analgesic treatment (Figure).

A bone marrow aspirate performed to investigate thrombocytosis revealed normocellular marrow with mild megakaryocytic hyperplasia and occasional large atypical cells, consistent with a myeloproliferative neoplasm. A JAK2 mutation was detected with an allelic burden of 18%.

The diagnosis of essential thrombocythemia was therefore established, and treatment with hydroxyurea was initiated. The clinical course was subsequently marked by rapid improvement, leading to complete healing within two months (Figure). No recurrence was observed after one year of follow-up.

Discussion:
Cutaneous ulcers are a rare and poorly documented mode of presentation of myeloproliferative neoplasms. Essential thrombocythemia (ET) most commonly presents with thrombotic or hemorrhagic complications. Cutaneous manifestations remain uncommon, the most frequently reported being erythromelalgia, acrocyanosis, and livedo reticularis.

Exceptionally, cases of essential thrombocythemia revealed by a leg ulcer have been reported: Lopes et al. (1) described a vasculitic leg ulcer revealing ET with a JAK2 mutation; Sekine et al. (2) reported a case of necrotic ulcer of the fifth toe leading to the diagnosis of ET in the absence of peripheral arterial disease. These observations highlight that ET may present with painful distal cutaneous lesions mimicking vascular or traumatic ulcers.

In ET, thrombocytosis, platelet dysfunction, and the JAK2 mutation (even in the absence of marked thrombocytosis) promote distal microthrombosis and microvascular occlusion. Resulting tissue hypoxia, together with local inflammation and impaired microcirculation, may lead to fibrinous, painful, and treatment-refractory ulcers, as observed in our patient. The clinical presentation of an ischemic lesion without macrovascular disease or identifiable cause may be suggestive.

Early recognition of this etiology is crucial, as cytoreductive therapy not only promotes ulcer healing but also prevents potentially severe systemic complications of this hematologic disorder.



Figure. clinical evolution of the ulcer

Conclusion

Chronic ischemic ulcerations may reveal an underlying myeloproliferative neoplasm. This presentation should be added to the spectrum of cutaneous manifestations classically associated with hematologic disorders, such as neutrophilic dermatoses, vasculitic purpura, or specific cutaneous infiltrations.

EA DV CONGRESS
VIENNA
30 SEP - 3 OCT 2026

Abstract N°: 3349

Interest of a repairing cream containing Rhealba oat and SPF50 sunscreen in the management of impaired skin integrity: an international, prospective real-world and multicentric study

Elena Conde-Montero[1], Valérie Mengeaud[2], Alexia Brocario*[2]

[1] Dermatology Department, Hospital Universitario Infanta Leonor y Virgen de la Torre, Madrid, Spain
[2] Medical Direction, Laboratoire Dermatologique A-DERMA, Lavaur, France

Introduction

The skin is an effective barrier against environmental aggressions, such as solar radiation, microorganisms, chemical products and mechanical stress.

Disruption of this skin barrier may occur following traumatic skin injuries which are frequently encountered in everyday life and after dermatological procedures such as laser treatments or minor surgery.

Factors affecting re-epithelialization include trauma type and the associated inflammation, location lesion depth, sun exposure, age, and genetics. To accompany the healing process, physicians regularly prescribe the use of a dermo-cosmetics to help to improve the skin condition.

In this study we assess the perceived efficacy and the tolerance of a protective repairing cream containing Rhealba oat and SPF50+ used in real life, according to usual practice of dermatologist.

Materials and Methods

This was an international, prospective, open label, real world, multicenter study conducted by 53 dermatologists in three European countries. Subjects aged ≥2 years presenting with acute, uncomplicated superficial skin wounds were enrolled.

The product was used after dermatological procedures (e.g. laser, minor surgery) or for minor superficial acute wounds, according to usual practice, and applied for 5 weeks.

Perceived efficacy was assessed using overall skin quality (0–10 NRS), perceived repairing efficacy (4 points scale, from not effective to very effective), and severity of skin marks (4 points scale, from none to severe).

Tolerance was rated on a 4 points scale (from poor tolerance to very good tolerance).

Changes from baseline were analyzed.

Results

A total of 605 subjects (aged 3–86 years; mean: 41; 94% adults; all phototypes) were included.

The repairing cream was mainly used for mild to moderate superficial wounds (92%) and predominantly on face (60%). The product was applied twice daily in the majority of cases (85%) for a mean duration of 5 weeks.

Main causes of skin injury varied by age group: insect bites and cuts in children, excoriated acne in teenagers, and post-dermatological procedure in adults.

When used post-dermatological procedure the repairing cream is initiated within 24 hours after the procedure.

After 5 weeks, a significant improvement in impaired skin was observed.

Perceived repairing efficacy was rated as effective to very effective in 98% of subjects after laser treatment or minor surgery. This was associated with a improvement in skin quality (+70% post laser; +66% post minor surgery; $p<0.001$) and a significant reduction in visible skin marks, including erythema (−77% and −67%, respectively; $p<0.001$).

Tolerance was rated as good to very good by physicians in nearly all cases (100% post laser; 98% post minor surgery).

Overall satisfaction was high, with 99% of dermatologist and subject agree to pursue with this repairing cream.

The absence of a control group and the reliance on subjective assessments are important limitations.

Conclusions

The repairing cream was well tolerated and positively rated in routine practice for the management of acute uncomplicated superficial skin wounds, including post-procedural injuries. Improvements in skin quality and visible skin marks were observed over 5 weeks.

EA DV CONGRESS
VIENNA
30 SEP - 3 OCT 2026

Abstract N°: 3460

Concomitant therapy of surgical shave excision and intralesional injections for ear keloids

Jennifer Tran*[1, 2], Shantel Lultschik[2], Jessica Ho[2, 3], Sheetal Sapra[2], Kevin Dong[2], Klaudija Gusic[2]

[1] Schulich School of Medicine and Dentistry, London, Canada
[2] Oakville Skin & Dermatology at ICLS, Oakville, Canada
[3] McGill University, Montreal, Canada

Introduction

Keloids are hypertrophic scars that commonly arise in the ear region. Due to the increased commonality of piercings in the ear region, keloid formation is more likely here than in other body areas. Ear keloids present cosmetic and psychological issues for patients due to their highly visible locations and are often management challenges for physicians. Many treatment options exist; however, there are no specific guidelines toward a single best treatment.

Currently, there are no studies evaluating the use of surgical shave excision followed by intralesional (IL) corticosteroid and botulinum toxin injections for ear keloid treatment. Due to the lack of evidence, physicians are providing a range of treatment options with limited efficacy and high recurrence rates. The primary objective of this study is to evaluate the effectiveness of the concomitant surgical shave excision with IL triamcinolone acetonide (TA) and onabotulinumtoxinA injections in order to make recommendations for using this treatment combination for the management of ear keloids. The secondary objectives are to evaluate the safety and patient satisfaction of this treatment system.

Materials and Methods

A retrospective medical chart review was conducted followed by a prospective patient questionnaire. The retrospective review consisted of patients who received treatment of concomitant surgical shave excision followed by IL TA and onabotulinumtoxinA injections for the treatment of ear keloids. All patients received treatment at one outpatient dermatology clinic site. Dosages of TA ranged from 10 mg to 50 mg per treatment, with the most commonly used dosage being 10 mg. Dosages of onabotulinumtoxinA ranged from 2 units to 15 units per treatment, with the most commonly used dosage being 5 units. Clinician determines the ideal dose for each keloid based on size of keloid. The electronic database was used to identify all patients who met the study criteria from 1 January 2015 to 24 February 2021. This was followed by a prospective patient questionnaire in the same patient population. The patient questionnaire was administered via a telephone call during which the patient had the option to provide or deny consent to the prospective questionnaire portion of the study.

Results

A total of 45 patients were included, consisting of 84.4% females (n = 38) and 15.6% males (n = 7) with a mean age of 25.5 years. Through retrospective chart review, early recurrence was seen in 6.7% of patients (n = 3), and via the prospective patient questionnaire, 11.1% of patients noted

early keloid recurrence (n = 5). Of the patients who expressed their level of satisfaction in-clinic, 96.0% (n = 24) reported being satisfied or very satisfied and 4.0% (n = 1) were dissatisfied. Satisfaction was also assessed through the prospective patient questionnaire; of those who consented to the questionnaire, 100.0% (n = 24) were satisfied or very satisfied. Only 20.0% (n = 9) of all patients reported experiencing side effects, consisting of pruritus (11.1%; n = 5), tenderness (4.4%; n = 2), pain (2.2%; n = 1), and mild atrophy (2.2%; n = 1).

Conclusions

This study demonstrates the effectiveness of concomitant surgical excision and IL TA and onabotulinumtoxinA injections for ear keloids with a low recurrence rate. The high patient satisfaction, minimal to mild side effects, and great cosmetic results suggest this combination should be considered as a treatment alternative for ear keloids. However, future research involving large-scale studies with comparative designs and long-term follow-up is required to determine the value of this treatment modality for keloid management.

EADV CONGRESS
VIENNA
30 SEP - 3 OCT 2026

Abstract N°: 3597

Clinical Efficacy and Tolerability of a Multi-Repair Cream containing Cooper, Zinc and Aquaphilus dolomiae extract in the Healing Process of Superficial Lesions

Bruna Bravo[1], Fernanda Chaves[2], Desiree Santander*[3], Gautier Doat[4], Aline Stennevin[4]

[1] Clinica Bravo Cosmiatria & Dermatologia, Rio de Janeiro, Brazil

[2] Medical Affairs Brazil, Pierre Fabre Dermo-Cosmetics & Personal Care, Rio de Janeiro, Brazil

[3] Medical Affairs Americas, Pierre Fabre Dermo-Cosmetics & Personal Care, Mexico City, Mexico

[4] Medical Department, Laboratoires Dermatologiques Eau Thermale AVENE, Lavaur, France

Introduction

Optimal post-procedural skin repair is essential to ensure effective healing, restore skin barrier function, and minimize the risk of complications such as infection, delayed healing, and poor scar quality. The use of topical formulations that provide immediate hydration, support tissue repair, and reinforce the cutaneous barrier plays a key role in improving clinical outcomes following dermatological procedures, particularly when they incorporate active ingredients designed to promote skin regeneration while protecting against opportunistic infections. In this context, the present study aims to evaluate the efficacy of a multi-repair cream in enhancing the healing process, improving scar quality, and preventing post-procedural complications.

Materials and Methods

A total of 26 participants, male and female, aged 21 to 75 years, all skin phototypes (I–VI), were included. The study duration was 14 days, with clinical evaluations conducted at baseline (Day 1), Day 7 and Day 14. Subjects with dry and/or irritated skin, associated or not with underlying conditions, including superficial excoriations and fissures without signs of untreated infection. Participants in the post-procedural phase following dermatological interventions, including chemical or electrical cauterization, microdermabrasion, very superficial peels, cryotherapy, and minor surgical procedures with simple sutures.

Results

The product demonstrated significant efficacy in reducing erythema and improving the overall healing process after 7 days of use, with visible improvements in skin recovery, including reduced irritation and enhanced skin repair. In addition, subjective evaluations showed positive outcomes, with 70.5% of participants reporting a very good improvement in skin healing. The product was well tolerated, with no significant adverse effects reported.

Conclusions

The results suggest that the Multi-Repair Cream containing Cooper, Zinc and *Aquaphilus dolomiae* extract is effective in promoting skin recovery, with significant improvements observed as early as 7 days of use. The positive subjective evaluations further support its beneficial effects on skin comfort and appearance. Additionally, the product was well tolerated, reinforcing its suitability for use in individuals with compromised or post-procedural skin. These findings highlight the importance of appropriate post-procedural care as a critical step in optimizing clinical outcomes. The integration of a product with demonstrated reparative and soothing properties may help

minimize the risk of adverse effects, such as prolonged irritation or post-inflammatory hyperpigmentation, while enhancing overall treatment results.

EA DV CONGRESS
VIENNA
30 SEP - 3 OCT 2026

Abstract N°: 3649

Subcutaneous Thrombotic Vasculopathy Syndrome with Concomitant LeukocytoclasticVasculitis Following Intravenous Injection of Crushed Oxycodone and MethylphenidateTablets

Paweł Głuszak*[1], Nina Łabędź[1], Maksymilian Markwitz[1], Adriana Polańska[1], Monika Bowszyc-Dmochowska[1], Marian Dmochowski[1], Aleksandra Dańczak-Pazdrowska[1]

[1] Department of Dermatology, Poznan University of Medical Sciences, Poznan, Poland

Introduction

Subcutaneous thrombotic vasculopathy syndrome (STV) is an ultra-rare, non-inflammatory vascular disorder of the skin, characterized by thrombotic occlusion of small vessels, predominantly affecting the subcutaneous tissue, and potentially mimicking vasculitis both clinically and histopathologically. Aim of this study was to present a case of STV with overlapping features of leukocytoclastic vasculitis.

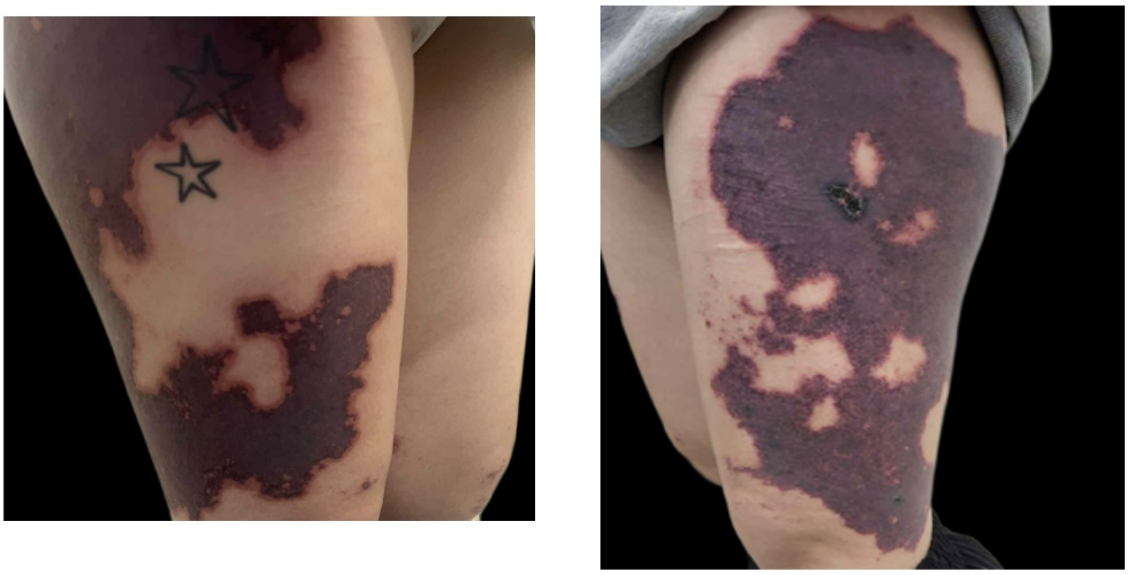

Clinical presentation at admission. Confluent, painful, violaceous purpuric patches involving both thighs, consistent with retiform purpura.

Case Presentation

A 23-year-old woman with a history of borderline personality disorder and polysubstance use disorder presented with rapidly progressive, painful, ulcerating retiform purpura, most prominent on the lower extremities, accompanied by fever up to 39°C. Prior hospitalization for suspected infective endocarditis was inconclusive, with negative blood cultures and unremarkable imaging. Doppler ultrasonography revealed superficial venous thrombosis, and anticoagulation was initiated but prematurely discontinued by the patient. Shortly thereafter, new purpuric lesions developed. On admission, extensive violaceous purpuric patches with hemorrhagic bullae and erosions were observed. Laboratory tests showed markedly elevated inflammatory markers (CRP 125.5 mg/L), severe thrombocytopenia (30 × 109/L), and mild coagulation abnormalities, while autoimmune and thrombophilia work-up was largely unremarkable. The patient reported intravenous administration of crushed oral oxycodone and methylphenidate tablets. Histopathological examination of a deep skin biopsy revealed widespread fibrin-rich

thrombi occluding small vessels of the dermis and subcutaneous tissue, with largely preserved vessel wall structure and focal leukocytoclastic changes. Direct immunofluorescence demonstrated fine granular deposits of IgA, IgG1, and C3 in multiple vessels of the superficial vascular plexus. The patient was treated with systemic corticosteroids, dapsone, and low-molecular-weight heparin, resulting in marked clinical improvement and no new lesion formation at follow-up.

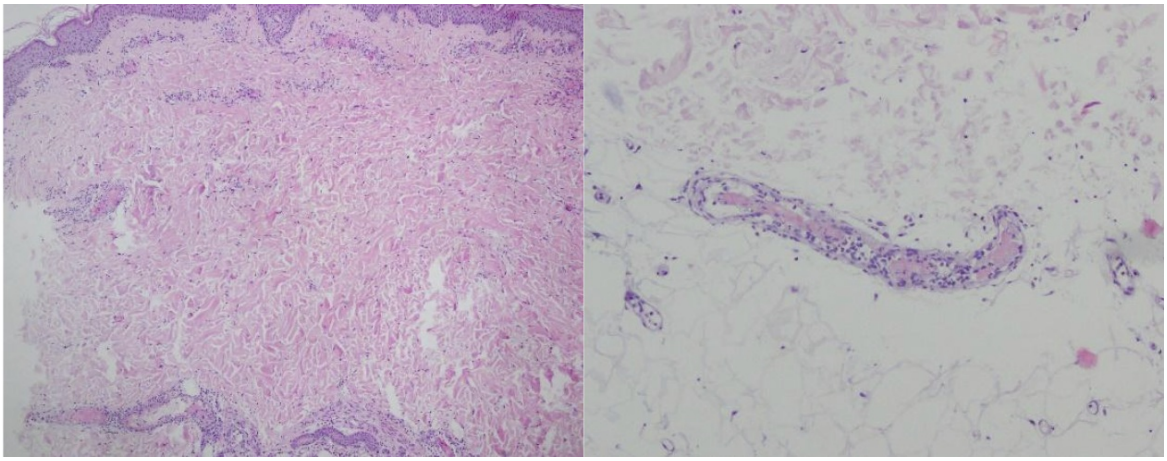

Histopathological examination. On the left, showing vessels of the superficial and deep dermal plexus (H&E stain, original magnification ×4). On the right, subcutaneous tissue with a small vessel occluded by a fibrin-rich thrombus. The vessel wall is largely preserved, with focal neutrophilic infiltration (H&E stain, ×200).

Conclusion

This case highlights the diagnostic challenges of STV and suggests a potential role of intravenous injection of crushed oral medications as a triggering factor leading to microvascular occlusion and secondary thrombosis.



Clinical improvement after treatment. Marked regression of retiform purpura with partial re-epithelialization and residual post-inflammatory erythema and hyperpigmentation was observed eight weeks after therapy. Residual necrotic crusts are still present.

EA DV CONGRESS
VIENNA
30 SEP - 3 OCT 2026

Abstract N°: 3734

Comparative Effectiveness of Keloid Surgery: A Real-World Study

Haitham Ben-Aissa[1], Michael Wilkerson[2], Amina El Ayadi*[2]

[1] The university of Texas at Austin, Austin, United States
[2] The University of Texas Medical Branch, Galveston, United States

Introduction
Keloids pose a significant dermatological challenge due to their high recurrence rates following surgical intervention. A recent comprehensive scoping review highlighted substantial heterogeneity in surgical techniques and outcome reporting, underscoring the need for standardized evaluation of treatment effectiveness. This review identified excision alone with 50-80% recurrence, while excision combined with radiotherapy or intralesional corticosteroids showed lower rates (10-20% and 20-40%, respectively).

Objective: Building on these insights, this TriNetX-based retrospective cohort study aimed to evaluate the real-world comparative effectiveness of keloid excision alone versus excision combined with laser therapy on 3–12-month recurrence rates.

Methods: Utilizing a large, de-identified electronic health record database (TriNetX Research network, 112 healthcare organizations), two cohorts were established: patients with keloid diagnosis (ICD-10: L91.0) undergoing (1) excision alone (CPT: 114xx series, n=39,296) and (2) excision combined with laser therapy (CPT: 11400-11446, 17000, 17003, 17004 within 3 months, n=8,750). Patients in both cohorts were excluded if they received other adjunctive therapies (radiation, cryo, intralesional injections). Propensity score matching was performed to balance baseline demographics, resulting in 6,932 patients per cohort. The primary outcome was keloid recurrence, defined as a subsequent L91.0 diagnosis or repeat keloid-specific procedure, assessed in a time window from 90 to 365 days post-index event. Recurrence was quantified using the "Number of Instances" analysis.

Results: After propensity score matching, the mean number of keloid recurrence instances was significantly lower in the excision with laser therapy cohort (mean = 1.349, SD = 0.914) compared to the excision alone cohort (mean = 1.818, SD = 1.822). A T-test confirmed this difference was statistically significant ($t=7.052$, $df=1929$, $p<0.001$). Keloid recurrence instances were also reduced with adjunct intralesional injections compared to controls ($p< 0.0001$)

Conclusion: This real-world evidence suggests that combining keloid excision with laser therapy or with intralesional injections significantly reduces the mean number of recurrence instances within 3 to 12 months compared to excision alone. These findings support the use of adjunctive laser therapy to improve outcomes in keloid management and provide valuable data to inform clinical guidelines and future prospective trials.

EADV CONGRESS
VIENNA
30 SEP - 3 OCT 2026

Abstract N°: 3752

Atypical Bipolar Ulcerations as a Rare Presenting Sign of Acute Leukemia

KHAWLA MOUFID*[1], Meryem Soughi[1], IKRAME BEJJA[1], Saadia Boughaleb[1, 1], Douhi Zakia[1], Sara Elloudi[1], Hanane Baybay[1], Fatima Zohra Mernissi[1]

[1] Department of Dermatology, Hassan II University Hospital, FEZ, Morocco

Introduction

Bipolar mucosal ulcerations, simultaneously involving the oral and genital mucosae, represent a rare and sometimes misleading presentation. Although infectious or inflammatory causes are often considered first, these lesions may also reveal a severe systemic disease, particularly a hematologic malignancy. Their atypical or progressive course, especially when associated with laboratory abnormalities, should prompt an early and thorough etiologic work-up.

Case Presentation

We report the case of a 56-year-old woman with type 2 diabetes who was admitted for painful, deep oral and genital ulcerations evolving for two months, associated with marked deterioration of general condition and fever.

Laboratory tests revealed severe pancytopenia, with hemoglobin at 6.5 g/dL, neutrophils at 410/mm^3, and platelets at 97,000/mm^3, associated with a major inflammatory syndrome. Infectious investigations were negative. Histopathological examination showed a deep ulceration covered by fibrinoleukocytic exudate, with an inflammatory infiltrate rich in altered neutrophils, without vasculitis, granuloma, or identifiable pathogen.

Due to worsening pancytopenia, bone marrow examination was performed and revealed 29% blasts with myeloperoxidase positivity, confirming the diagnosis of acute myeloid leukemia. The clinical course was unfavorable, complicated by agranulocytosis followed by fatal septic shock.

Conclusion

This case highlights the importance for dermatologists of considering an underlying hematologic malignancy in patients presenting with atypical, persistent, or bipolar mucosal ulcerations, particularly when associated with unexplained hematologic abnormalities. Early hematologic assessment, including bone marrow examination when indicated, is essential to avoid diagnostic delay.

EA DV CONGRESS
VIENNA
30 SEP - 3 OCT 2026

Abstract N°: 3787

Cold Atmospheric Plasma in the Management of Chronically Infected Ulcers: A Case Series

Ana-Maria Toma*[1], Maria-Alexandra Timofte[1], Andra Ioana Copilău[1], Cătălina-Ioana Naum[1], Alexandra-Andreea Mihu[2], Malina Haidautu[2], Simona Shirley[3], Ana-Maria Forsea[1], Mara Mădălina Mihai[1]

[1] Elias Emergency University Hospital- Department of Oncologic Dermatology, Bucharest, Romania
[2] Carol Davila University of Medicine and Pharmacy, Bucharest, Romania
[3] UAB Heersink School of Medicine, Birmingham, United States

Introduction
Chronic ulcers complicated by persistent bacterial colonization and biofilm formation represent a major therapeutic challenge, often leading to delayed healing and increased morbidity.
Conventional treatments frequently fail to adequately control microbial burden, particularly in the presence of biofilm.
Cold atmospheric plasma has emerged as a novel therapeutic approach, demonstrating antimicrobial activity and potential to promote wound healing through multiple mechanisms.
We present a case series evaluating the microbiological and clinical effects of cold plasma therapy in patients with chronically infected ulcers.

Materials and Methods
We conducted a case series including 5 patients with chronic ulcers, defined as lesions with a duration of more than 6 weeks, presenting with clinical signs of infection and confirmed bacterial colonization.
All patients received cold atmospheric plasma therapy using the kINPen® MED device (NeoplasMed), applied once daily for 5 consecutive days.
Microbiological assessment was performed by collecting bacterial samples from the ulcer surface before treatment initiation and after completion of the 5-day protocol, in order to evaluate changes in bacterial colonization.
Clinical outcomes were assessed using the RESVECH score for wound severity and a pain score, recorded before and after treatment.

Results
All patients demonstrated a reduction in bacterial colonization following 5 days of cold atmospheric plasma therapy. In several cases, a decrease in the number of identified bacterial strains was observed. Clinically, all ulcers showed improvement, mostly reflected by a reduction in RESVECH scores. In addition, patients reported a decrease in pain levels after treatment. The treatment was well tolerated, with no significant adverse effects recorded.

Conclusions
Cold atmospheric plasma appears to be a promising adjunctive therapy in the management of chronically infected ulcers, demonstrating both antimicrobial effects and clinical improvement in wound status.

The observed reduction in bacterial colonization, together with improvement in RESVECH scores and pain, suggests a potential role in both infection control and wound healing.

Further studies with larger patient cohorts are needed to confirm these findings.

Funding: This work was supported by a grant of the Ministry of Research, Innovation and Digitization, CNCS/CCCDI – UEFISCDI, project number PN-IV-P2-2.1-TE-2023-1449, within PNCDI III.

EADV CONGRESS
VIENNA
30 SEP - 3 OCT 2026

Abstract N°: 3819

Time dependent loss of adhesion in silicone foam dressings may compromise postoperative wound environment stability

Neda Bolouri*[1], Payam Pourmand[2]

[1] Frimley Park Hospital, Camberley , Surrey, United Kingdom

[2] Royal Institute of Technology (KTH), Fibre and Polymer Technology, Polymeric Materials, Stockholm, Sweden

Introduction

Silicone foam dressings are widely used in postoperative dermatological wound care and scar prevention due to their ability to maintain a moist wound environment and minimise mechanical trauma during removal. Preservation of an occlusive wound interface is essential for keratinocyte migration, re-epithelialisation, and optimal scar modulation. However, the in vivo functional durability of these dressings over routine wear periods remains poorly characterised. Progressive loss of adhesion may compromise wound occlusion and alter the postoperative wound environment. The aim of this study was to assess whether time-dependent changes in silicone foam dressing integrity may affect maintenance of a stable postoperative wound environment relevant to epidermal repair and scar formation.

Materials and Methods

A retrospective clinical audit of 100 postoperative dermatological surgery patients treated with silicone foam dressings was performed to assess early dressing failure requiring unplanned replacement. Explanted dressings collected at 3, 5, 7 and 14 days were compared with unused controls. Mechanical properties were evaluated using tensile testing (strain at break) and peel adhesion testing. Material stability was assessed using thermogravimetric analysis (TGA).

Results

Early dressing failure requiring replacement occurred in 10% of patients prior to the intended wear duration. Peel adhesion decreased progressively during clinical wear, with approximately 36% reduction by day 7 compared with unused controls. Mechanical extensibility (strain at break) declined concurrently, indicating progressive loss of dressing conformity and structural integrity. The greatest reduction in functional performance occurred between days 5 and 7. In contrast, Thermoa gravimetric (TGA) profiles remained unchanged, suggesting preserved chemical structure despite progressive mechanical degradation.

Conclusions

Silicone foam dressings demonstrate clinically relevant time-dependent loss of adhesion and mechanical integrity during routine postoperative use, despite preserved material chemistry. Progressive impairment of dressing conformity and occlusive function may disrupt maintenance of the moist wound environment required for optimal epidermal repair and scar modulation. Increased trans-epidermal water loss secondary to impaired occlusion may alter the postoperative wound microenvironment during a critical phase of healing. These findings suggest that currently recommended wear durations may not accurately reflect the functional lifespan of silicone foam

dressings in vivo and support reconsideration of dressing change intervals in postoperative dermatological care.

EA DV CONGRESS
VIENNA
30 SEP - 3 OCT 2026

Abstract N°: 4157

Therapeutic Efficacy and Molecular Mechanisms of Cold Atmospheric Plasma in Wound Regeneration and Dermato-Oncology: A Comprehensive Review

Alyaa T. Sharshar*[1], Nancy Emmanuel[2]

[1] Ain Shams University, Cairo, Egypt

[2] Department of Dermatology, Hospital das Clínicas da Faculdade de Medicina da Universidade de São Paulo, São Paulo, Brazil

Introduction

Plasma, the fourth state of matter, was first introduced by Tonks and Langmuir in 1929 to describe a glowing ionized gas in a tube. Cold atmospheric plasma (CAP) is a weakly ionized gas produced at atmospheric pressure and low temperature (<40°C), that operates by generating a synergistic "cocktail" of reactive oxygen and nitrogen species (RONS), electrons, ions, UV radiation, and transient electric fields. There are many modes of delivery of CAP that include direct dielectric barrier discharge (DBD), indirect plasma jets, or plasma-activated media (PAM). Several CAP devices are currently accredited for medical use (e.g., kINPen MED). This review aims to synthesize existing evidence regarding the safety, efficacy, and underlying molecular mechanisms of CAP in treating chronic wounds and malignant skin lesions.

Materials and Methods

A comprehensive literature analysis of peer-reviewed preclinical research was conducted. Search strategies encompassed major databases (PubMed, Scopus, Science Direct) utilizing keywords such as "cold atmospheric plasma," "angiogenesis," "wound healing," and "dermatology" for the period of 2016–2026. Preclinical in vitro cell cultures, ex vivo tissue explants (e.g., reconstructed human epidermis, isolated stratum corneum), and in vivo animal models were included.

Results

For regeneration in preclinical wound models, CAP-derived RONS act as secondary messengers to activate critical signaling pathways, including PI3K/AKT, MAPK (ERK1/2), and NF-κB, which drive keratinocyte and fibroblast proliferation and migration. CAP promotes NRF2 nuclear translocation, enhancing antioxidant responses and DNA repair. Significant modulation of the cytokine microenvironment is observed, specifically the upregulation of VEGF, FGF-2, EGF, TGF-β, and IL-10, alongside the targeted inhibition of pro-inflammatory factors like TNF-α and IL-1β during the resolution phase promoting angiogenesis. Together, these mechanisms accelerate the closure of diabetic foot ulcers (observed in both rodent and canine models), burn wounds, and radiation-induced skin injuries. Hyperspectral imaging confirms immediate increases in tissue oxygen saturation and microcirculation. CAP can also treat allergic contact dermatitis using argon plasma and can stimulate hair follicle regeneration in mice by generating nitric oxide. In oncology, CAP induces selective apoptosis in melanoma and squamous cell carcinoma through the PI3K-AKT-ZEB1 axis and HSP90 cleavage.

Conclusions

CAP is a relatively new, safe, and non-invasive modality that promotes regeneration while exhibiting selective anti-tumor activity. Current limitations include the lack of standardized dosimetric protocols across different plasma

devices. Future directions should focus on precision delivery and translating these in vivo mechanisms into human clinical trials to establish long-term safety monitoring in dermato-oncology.

EA DV CONGRESS
VIENNA
30 SEP - 3 OCT 2026

Abstract N°: 4179

Multi-omic definition of the skin organoid secretome reveals stage-specific molecular programs that accelerate acute wound repair

Ying Zou*[1], Shen Hao[2]

[1] Shanghai Skin Disease Hospital, Shanghai, China

[2] Eastern Hepatobiliary Surgery Hospital and National Center for Liver Cancer, Naval Medical University, Shanghai, China

Introduction
Skin organoids hold great promise for regenerative medicine, yet their clinical translation has been constrained by the safety concerns inherent in live-cell transplantation.

Materials and Methods
Here we demonstrate that the conditioned medium of human epidermal keratinocyte-derived skin organoids (SOCCM) contains a defined secretome signature sufficient to promote acute wound healing without cell engraftment. By integrating organoid transcriptomics with high-sensitivity Olink proximity extension assay-based proteomics of the conditioned medium, we identify a 29-molecule secretome signature enriched for pro-proliferative, pro-angiogenic, and immunomodulatory factors—including CSF3, TGFA, VEGFA, and a family of defensins—that are concurrently upregulated at both the transcript and secreted-protein levels during organoid expansion.

Results
By integrating organoid transcriptomics with high-sensitivity Olink proximity extension assay-based proteomics of the conditioned medium, we identify a 29-molecule secretome signature enriched for pro-proliferative, pro-angiogenic, and immunomodulatory factors, such as CSF3, TGFA, VEGFA, and a family of defensins, which are concurrently upregulated at both the transcript and secreted-protein levels during organoid expansion.

Cross-species mapping of this secretome signature onto the transcriptome of a murine acute wound model reveals that these molecules align precisely with both the early inflammatory (day 3) and the later proliferative/remodeling (day 5) transcriptional programs of wound repair. Functional validation confirms that SOCCM enhances fibroblast migration, promotes endothelial tube formation, and suppresses NF-κB–mediated macrophage inflammation in vitro. In a murine full-thickness wound model, SOCCM treatment accelerates wound closure by ~34% at day 9, accompanied by improved collagen deposition, enhanced re-epithelialization, and increased neovascularization.

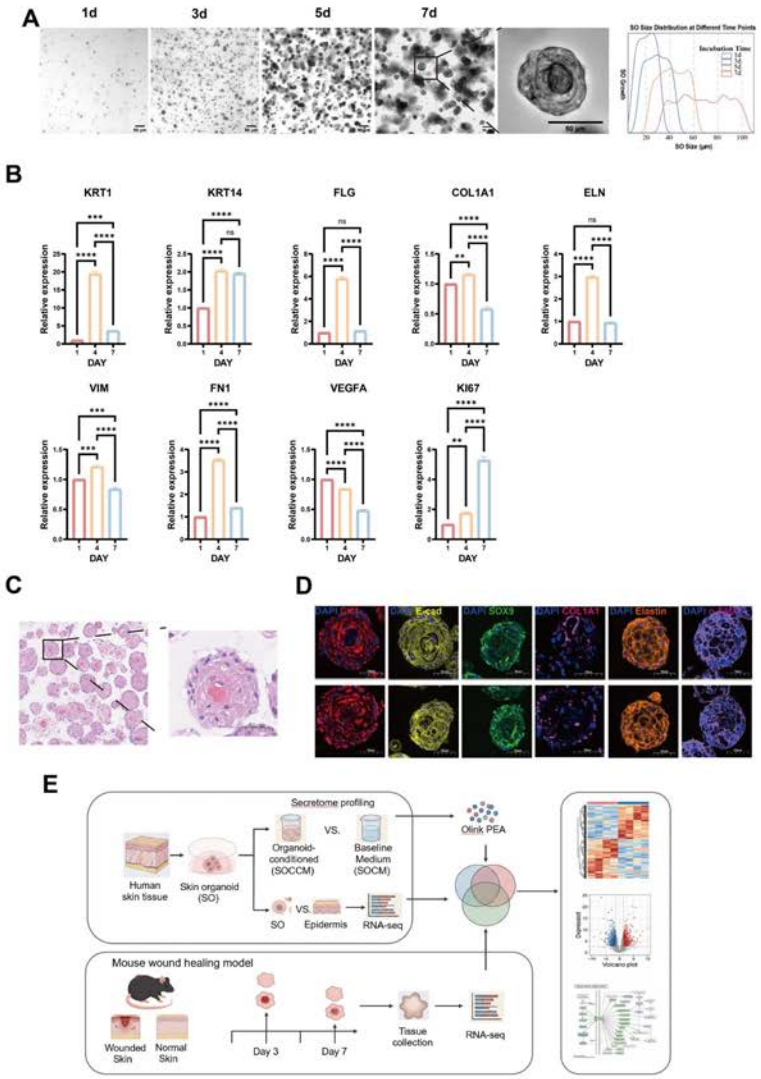

Conclusions

These findings establish the skin organoid secretome as a cell-free therapeutic modality for acute skin injury, and provide a conceptual framework for harnessing organoid paracrine biology—rather than organoid transplantation—as a regenerative strategy.

EADV CONGRESS
VIENNA
30 SEP - 3 OCT 2026

Abstract N°: 4254

Multimodal spectral analysis of slough in chronic wounds

Assem Nurlybayeva[1], Philippe Moguelet[2], Ellie Tang[3], Marie-Claire Schanne-Klein[4], Ariane Deniset[1], Hester Colboc*[5]

[1] Institute of Physical Chemistry, Paris-Saclay University, Orsay, France
[2] Sorbonne Université, Paris, France
[3] Inserm UMRS 1155, Paris, France
[4] Laboratoire d'Optique et Biosciences, Ecole polytechnique, CNRS, INSERM, Palaiseau, France
[5] Sorbonne Université, Hôpital Rothschild, Paris, France

Introduction

Slough is a common feature of chronic wounds that refers to devitalized tissue and a possible barrier for the progression of healing. Its fundamental understanding may contribute to improvement of wound debridement and treatment strategies. Therefore, main objective of the study is to characterize structure and chemical composition of slough through multimodal and multiscale analysis.

Materials and Methods

Wound debridement samples were collected from an initial cohort of 14 patients with various chronic wounds. They were grouped in two categories based on adherence of slough to the wound bed: 7 non-adherent and 7 adherent. Histological staining and scanning electron microscopy (SEM) provide insights into tissue structure, while complementary use of infrared (IR) micro-spectroscopy and two-photon fluorescence second-harmonic generation (SHG) (multiphoton) microscopy allow chemical speciation.

Results

Non-adherent and adherent slough demonstrate differences in both tissue structure and chemical composition. In case of non-adherent slough, there is a characteristic "honeycomb" fibrous protein matrix, which is likely to be fibrin (Figure 1.A). On the other hand, adherent slough includes both fibrous matrix and necrotic dermis, with sophisticated organization of the latter resembling collagen fibers (Figure 1.B). This is supported by multiphoton microscopy, where SHG signal characteristic of collagen is detected in adherent slough. Both types of slough display presence of bacterial aggregations and immune response cells. Detection of biofilm in these samples challenges modern clinical indicators for differentiation of slough and wound biofilm.

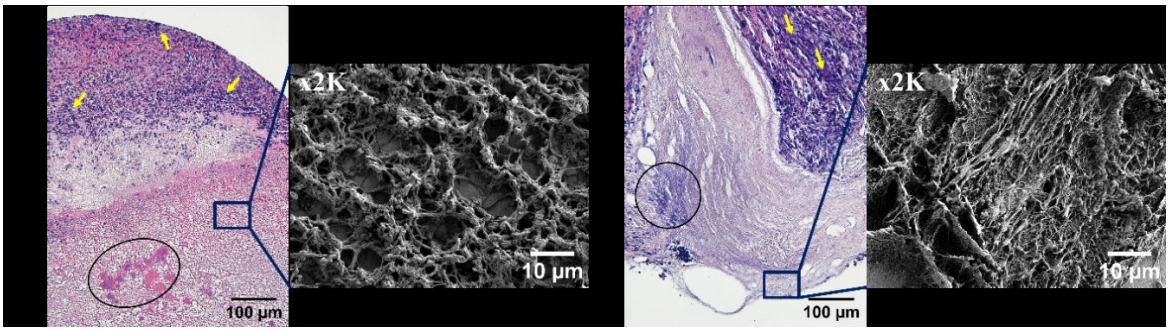

Hematoxylin & eosin staining and SEM images of A) non-adherent slough and B) adherent slough representative samples. H&E staining illustrates highly inflammatory nature of slough: neutrophils (yellow arrows) and bacterial aggregations (black circles).

Conclusions

Multimodal and multiscale analysis of slough has demonstrated promising results for fundamental understanding of chronic wound environment. This has been a first attempt for complementary use of optical, IR, SHG and electron microscopy on slough samples, opening a new direction for non-destructive, spatially resolved chemical characterization of biological tissues.

EADV CONGRESS
VIENNA
30 SEP - 3 OCT 2026

Abstract N°: 4276

Continuous Integral Debridement

Dieter Mayer[1], Ewa Klara Stuermer[2], Caroline Dowsett[3], Hester Colboc*[4]

[1] University Hospital of Zurich, Zurich, Switzerland
[2] Vascular Medicine University Heart and Vascular Center Hamburg University Medical Center, Hamburg, Germany
[3] East London NHS Foundation Trust, London, United Kingdom
[4] Sorbonne Université, Hôpital Rothschild, Paris, France

Introduction

Wound debridement is a cornerstone of wound bed preparation, yet its implementation remains inconsistent, particularly in non-specialist settings. The 2024 *Journal of Wound Care* (JWC) consensus introduced integral debridement, defined as the combined use of complementary debridement methods. However, this concept does not fully address the dynamic recurrence of microbial and non-microbial barriers to healing, including rapid biofilm reformation.

Materials and Methods

The aim of this consensus was to develop a practical, evidence-informed framework that operationalises integral debridement into a reproducible and continuous approach across clinical settings. An international multidisciplinary expert panel convened by JWC in 2026 reviewed current evidence, clinical practice patterns, and existing frameworks (including TIME/TIMERS). Through structured discussion and consensus development, key principles for optimising wound bed preparation were defined, focusing on repeated intervention and biofilm control.

Results

The panel determined that effective wound bed preparation requires regular, repeated intervention throughout the healing trajectory. This led to the development of continuous integral debridement (CID), a cyclical four-step approach comprising cleanse, debride, re-cleanse and dress (CDCD), performed at each dressing change. CID aims to disrupt biofilm, reduce bioburden and control inflammation by consistently removing barriers to healing. It aligns with TIME/TIMERS and complements antibiofilm strategies such as Wound Hygiene, while extending them through its emphasis on continuity.

Conclusions

CID provides a simple, structured and reproducible framework applicable to both specialists and non-specialists. Its implementation may improve healing outcomes, reduce chronicity and support standardised, evidence-based wound care.

EADV CONGRESS
VIENNA
30 SEP - 3 OCT 2026

Abstract N°: 4343

Light-Emitting Diode (LED) Therapy in the Treatment of Chronic Leg Ulcers

Chaimae Bouhamdi*[1], Hanane Baybay[1], Kawtar El fid[1], Faiza Boukhobza[1], IKRAME BEJJA[1], Saadia Boughaleb[1], Zakia Douhi[1], Meryem Soughi[1], elloudi sara[1], Fatima Zohra Mernissi[1]

[1] Dermatology Department, Hassan II University Hospital, Fez, Morocco

Introduction

Chronic leg ulcers (CLUs) are persistent lower-limb wounds failing to heal after ≥3 months of appropriate care or remaining unhealed after 12 months, causing substantial morbidity. Photobiomodulation (PBM) using light-emitting diodes (LEDs) is a non-thermal modality capable of modulating inflammation and promoting tissue repair.

This study aimed to evaluate the therapeutic impact of adjunctive polychromatic LED PBM on healing outcomes and symptom burden—including pain, pruritus, and aesthetic discomfort—in CLUs.

Materials and Methods

We conducted a six-year prospective analytic study including 126 patients with CLUs treated with conventional wound care (control, n = 75) or adjunctive LED PBM (n = 51). PBM was delivered using a polychromatic Triwings LED device with three panels emitting violet–blue, yellow–green, red, and infrared wavelengths, using two protocols: varicose ulcer (48 J/cm²) and infected wound (64 J/cm²). Healing was categorized as poor (<50% reduction in ulcer size), moderate (50–75%), good (>75%), or complete epithelialization. Pain, pruritus, and aesthetic discomfort were assessed on 0–5 scales.

Results

Mean age was 56 years and 69% were male. The main etiologies were chronic venous insufficiency (27.8%) and erysipelas (23.8%). Ulcers were most frequently located on the distal third of the leg (74.6%), and superinfection was the main complication (53.2%). In the LED group, the varicose protocol was applied in 47% and the infected protocol in 52.9%. Fluence was 64 J/cm² in 69% and 48 J/cm² in 31%. Treatments were performed mainly once weekly (54.9%) or every 72 hours (39.2%). Sessions lasted 10–12 minutes in 76.5%; 69% received <24 sessions, 29% >24 sessions, and 2% exactly 24 sessions.

Healing responses differed between groups. Complete epithelialization occurred in 21.6% of LED-treated patients versus 41.3% in controls, whereas good healing (>75% reduction in ulcer size) was more frequent in the LED group (31.4%) than in controls (21.3%). Moderate healing occurred in 13.7% and 8%, and poor healing in 21.6% and 17.3%, in the LED and control groups respectively. LED therapy was significantly associated with good healing (>75%) ($p = 0.015$) and complete epithelialization ($p = 0.004$), while no significant associations were observed for moderate or poor healing. Unfavorable evolution was rare, with aggravation in 1.9% versus 6.7% and stationary lesions in 1.9% versus 17.3%, in LED-treated patients and controls respectively, without significant association. Following LED therapy, pain decreased from 72.5% to 42%, with absence of pain increasing from 27.5% to 58% ($p < 0.001$). Pruritus decreased from 15.7% to 8% without significance, while aesthetic discomfort improved significantly ($p = 0.015$). Treatment tolerance was favorable with transient burning (35.3%) and erythema (23.5%), both mild and self-limited.

Conclusions

Although complete epithelialization was higher in controls, LED PBM was significantly associated with advanced wound improvement (>75%), suggesting stimulation of intermediate repair phases rather than direct acceleration of final epithelial closure. PBM induces mitochondrial activation, ATP production, fibroblast proliferation, angiogenesis with improved microcirculation, and extracellular matrix remodeling, promoting granulation tissue formation and wound contraction, while neuromodulatory effects reduce nociceptive signaling and pain which we found significant. In our multispectral protocol, regenerative red and near-infrared wavelengths, germicidal blue light, and anti-inflammatory yellow light act synergistically. Our findings support LED PBM as a safe adjunctive therapeutic modality for enhancing wound repair and reducing symptom burden in CLUs.

EADV CONGRESS
VIENNA
30 SEP - 3 OCT 2026

Abstract N°: 4403

Efficacy and safety of topical timolol in chronic venous ulcers: A randomized controlled trial.

Luis Gerardo Espinosa Bañuelos*[1], Azyadeth Gracián Castro[1], Marcela Hernández[1], María Elisa Vega Memije[1], Judith Dominguez[1]

[1] Hospital General Doctor Manuel Gea González, Ciudad de México, Mexico

Introduction
Chronic venous ulcers, a frequent complication of venous insufficiency, have a negative socioeconomic impact and decrease quality of life. Compression therapy is still the standart of care, but despite the variety of topical therapies available, a standardized protocol has not yet been established. Our objective was to evaluate the safety and efficacy of topical timolol versus saline solution, both in combination with standard compression therapy, by assessing the percentage of ulcer area reduction in patients with chronic venous insufficiency at six weeks of treatment.

Materials and Methods
A randomized, single-blind, placebo-controlled clinical trial was conducted involving patients with chronic venous ulcers. Participants were randomly assigned to two groups: the experimental group, receiving elastic compression and topical timolol (ophthalmic drops, one drop per cm^2), and the control group, receiving elastic compression and saline solution. Four measurements were performed at 2-week intervals over a 6-week follow-up period, with the ulcer area calculated using ImageJ software. At each follow-up visit, patients were specifically screened for adverse events. Additionally, the Dermatology Life Quality Index (DLQI) and the Chronic Venous Insufficiency Questionnaire (CIVIQ-20) were administered to evaluate the impact of the treatment on the patients' quality of life.

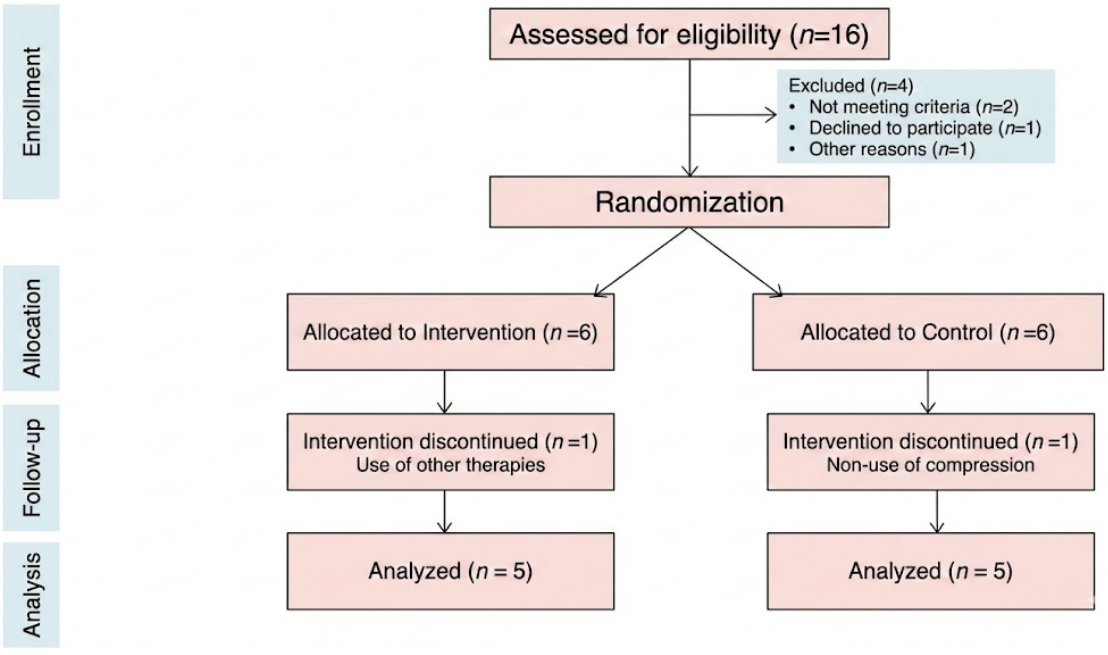

Figure 1. CONSORT Flow diagram

Results

A total of 10 patients were enrolled (n= 5 per group), with mean ages of 60.8 years in the experimental group and 70.8 years in the control group. Regarding the primary endpoint, the experimental group achieved a 92.26% mean reduction in ulcer area at 6 weeks, compared to 5.17% in the control group ($p = 0.047$). No significant difference was observed between groups in CIVIQ-20 scores ($p = 0.055$). However, a statistically significant improvement was noted in DLQI scores for the experimental group compared to the control group ($p = 0.042$). No local or systemic adverse events were reported in the timolol-treated group.

Table 1. Ulcer Area and Healing Progression

Saline Solution Group (Control)

Patient No.	Initial Measurement (cm^2)	2-Week Measurement (cm^2)	4-Week Measurement (cm^2)	6-Week Measurement (cm^2)	Healing Percentage
1	3.1	3.0	2.9	2.9	3.40%
2	10.1	10.0	9.8	9.8	2.00%
3	7.9	7.8	7.8	7.6	3.80%
4	2.1	2.0	2.0	2.0	4.80%
5	1.9	1.8	1.7	1.5	21.06%
				Total Mean	**5.17%**

Topical Timolol Group (Experimental)

Patient No.	Initial Measurement (cm^2)	2-Week Measurement (cm^2)	4-Week Measurement (cm^2)	6-Week Measurement (cm^2)	Healing Percentage
1	5.2	4.4	1.0	0	100%
2	9.9	6.2	4.2	0	100%
3	3.8	3.1	0.3	0	100%
4	18.1	14.1	10.2	7.0	61.32%
5	2.6	2.0	1.2	0	100%
				Total Mean	**92.26%**

Image measure – Control group



Image measure – Experimental group



Table 2. Ulcer area and healing progression. Image 2. Image measure in control group, Image 3. Image measure in experimental group.

Conclusions

Timolol proved to be an effective and safe adjuvant topical therapy for accelerating the healing of venous ulcers. Further investigation with a larger sample size is required to standardize this novel topical therapy.

EA DV CONGRESS
VIENNA
30 SEP - 3 OCT 2026

Abstract N°: 4490

Beyond the Teeth: An Odontogenic Cutaneous Fistula Revealing a Pyogenic Granuloma

Sonia Monica Barbu*[1]

[1] Spitalul Clinic Colentina, București, Romania

Introduction

Cutaneous sinus tracts of odontogenic origin represent an uncommon extraoral manifestation of chronic dental infection, most frequently associated with persistent periapical or periodontal inflammation. These lesions may clinically mimic a wide spectrum of dermatological, infectious, or neoplastic conditions, often resulting in delayed diagnosis and inappropriate treatment. Management generally involves elimination of the odontogenic source through endodontic treatment or extraction, combined with surgical management of persistent cutaneous lesions when necessary.We present a chronic odontogenic cutaneous fistula associated with pyogenic granuloma formation in an edentulous woman, emphasizing the diagnostic challenges posed by its atypical long-term evolution and the importance of considering multiple differential diagnoses, including cutaneous malignancy.

Materials and Methods

A 54-year-old woman presented with a painful cutaneous lesion located on the mental region, evolving progressively over a period of seven years. Dermatological examination revealed a solitary erythematous nodular lesion measuring approximately 1 cm, with central ulceration, hemorrhagic crusting, and a draining sinus opening associated with exuberant granulation tissue. The lesion was tender on palpation. Clinical examination showed a completely edentulous patient with a history of chronic dental infection and recurrent periodontal abscesses predating tooth loss. The patient reported persistent intermittent drainage from the lesion and acknowledged postponing dental care for several years because of severe dental anxiety. Mobilization of the overlying skin demonstrated adherence to the mandibular bone with localized retractility of the inflamed tissue, suggestive of a chronic fistulous tract. Her medical history was significant for a previous cutaneous squamous cell carcinoma of the right thigh.Considering the chronic ulcerated appearance and oncologic history, differential diagnoses included pyogenic granuloma, cutaneous sinus tract of odontogenic origin, squamous cell carcinoma, infected epidermal cyst, actinomycosis, and chronic osteomyelitis. An incisional punch biopsy (4 mm) was performed at the peripheral edge of the lesion, including both ulcerated and adjacent inflammatory tissue, in accordance with recommendations for chronic ulcerated facial lesions suspicious for inflammatory or neoplastic pathology. Histopathological examination was complemented by correlation with the clinical findings.

Results

Histopathological examination demonstrated lobular capillary proliferation embedded in an edematous stroma associated with mixed inflammatory infiltrate and granulation tissue, consistent with pyogenic granuloma. No cytological atypia or malignant

proliferation suggestive of squamous cell carcinoma was identified. Clinicopathological correlation supported the diagnosis of a chronic odontogenic cutaneous fistula with reactive pyogenic granuloma arising at the external fistulous opening secondary to longstanding periodontal infection. The patient was referred for maxillofacial and dental evaluation in order to investigate residual mandibular infectious foci and to establish definitive therapeutic management.

Conclusions

Odontogenic cutaneous fistulas remain an important diagnostic pitfall in dermatological practice, particularly in patients with prolonged disease evolution and atypical presentations. Chronic inflammatory lesions of the lower face may simulate infectious, reactive, or malignant processes, especially in individuals with a personal history of cutaneous carcinoma. This case highlights the importance of careful clinicopathological correlation and consideration of odontogenic sources in chronic draining facial lesions, even in edentulous patients. Early recognition may prevent years of unnecessary evolution, repeated treatments, and diagnostic delay.

EA DV CONGRESS
VIENNA
30 SEP - 3 OCT 2026

Abstract N°: 4570

Treatment outcomes in peristomal pyoderma gangrenosum: a systematic review

Romy Shenderey*[1], Katya Peri[2], Carly Burow[3], Suzanne Li[4], Grace Xiong[4], Fangyi Xie[4], David Croitoru[4]

[1] University of Ottawa, Ottawa, Canada
[2] McGill University, Montreal, Canada
[3] University of Western Ontario, London, Canada
[4] University of Toronto, Toronto, Canada

Introduction
Peristomal pyoderma gangrenosum (PPG) is a rare neutrophilic dermatosis that develops around stoma sites, causing pain, stoma dysfunction, and high recurrence rates. No evidence-based treatment guidelines exist, with management informed primarily by case reports and general pyoderma gangrenosum data. In refractory cases, diagnostic reconsideration is warranted, as other etiologies of peristomal irritation can be mistaken for PPG, and inappropriate immunosuppression may impede healing. This review aims to synthesize current data on PPG treatment outcomes and, in doing so, update the existing literature (Afifi et al, 2018).

Materials and Methods
Embase, MEDLINE, Cochrane Central Register of Controlled Trials, Scopus, and Web of Science were searched from inception to March 2026, following PRISMA 2020 guidelines (CRD420261286387). English-language case reports, case series, cohort studies, and clinical trials addressing PPG treatment were included. Screening and data extraction were performed in duplicate and disagreements were resolved with consensus of a third reviewer. Primary outcomes were treatment response (partial response, complete remission, no response). Secondary outcomes included adverse events, recurrence, and follow-up duration. Risk of bias was assessed using Joanna Briggs Institute critical appraisal tools. Pooled proportions are reported with Wilson score 95% confidence intervals, and continuous measures as sample-size–weighted means or medians.

Results
104 studies met inclusion criteria (62 case reports, 26 case series, 8 retrospective cohort, 5 prospective cohort, 2 case-control, 1 randomized controlled trial), describing 476 cases, a 42.1% increase from the 2018 review. Most patients were female (70.0%) with mean age 40.1 years. Common underlying diseases included Crohn's disease (40.3%, 169/419), ulcerative colitis (27.0%, 113/419), and malignancy (11.0%, 46/419). Mean time from ostomy placement to PPG onset was 47.8 months. Topical corticosteroids as monotherapy achieved remission in 64.0% (80/125) of patients [95% CI 55.3–71.9%]; topical calcineurin inhibitors achieved remission in 43.6% (34/78) [95% CI 33.1–54.6%] as monotherapy. Intralesional triamcinolone, as monotherapy achieved remission in 26.1% (6/23) [95% CI 12.6–46.5%]. Systemic corticosteroids achieved remission in 60.6% (40/66) [95% CI 48.6–71.5%] as monotherapy and 85.1% (74/87) [95% CI 76.1–91.0%] in combination therapy. Anti-TNF agents achieved remission in 47.8% (33/69) [95% CI 36.5–59.4%] as monotherapy and 76.0% (19/25) [95% CI 56.6–88.5%] in combination therapy. Relapse occurred in 23.3% of patients (77/331) [95% CI 19.1–28.2%]. Patients were followed for a median of 6.7 months (IQR:10). Surgical intervention was reported in 133 patients; stoma relocation had a notable 32.2% (19/59) [95% CI 21.7–44.9%] recurrence rate. Adverse events were reported in 23.9% (22/92) [95% CI 16.4–33.6%] of patients, although underreporting is likely. Emerging therapies including tofacitinib and risankizumab showed efficacy in refractory cases, with tofacitinib demonstrating efficacy in four cases and

risankizumab in two cases. Study limitations include publication bias, heterogeneity, restriction to English-Language literature, pooled remission estimates and treatment selection by indication (based on severity).

Conclusions

PPG can be effectively treated with topical, intralesional and systemic approaches. Current evidence supports optimized wound and ostomy care, individualized escalation to local, systemic, or biologic therapy. Notably, caution should be exercised with stoma relocation, given relatively high recurrence rates in almost one third of patients. Given the treatment-refractory prospective registry-based studies using standardized remission, recurrence, follow-up, and adverse-event definitions. Emerging biologics and JAK inhibitors represent promising options for refractory disease. Future prospective studies and randomized controlled trials with standardized outcome measures are needed.

Treatment	Response type, n (%)					Complete Remission 95% CI
	Complete	Partial	None	Worsened	Unspecified	
Topical and Intralesional						
Corticosteroids Monotherapy (n=125)*	80 (64.0)	24 (19.2)	13 (10.4)	0 (0.0)	8 (6.4)	55.3–71.9
Corticosteroids Combination Therapy (n=33)	31 (93.9)	2 (6.1)	0 (0.0)	0 (0.0)	—	80.4–98.3
Calcineurin inhibitors Monotherapy (n=78)*	34 (43.6)	37 (47.4)	3 (3.8)	0 (0.0)	4 (5.1)	33.1–54.6
Calcineurin inhibitors Combination Therapy (n=13)	11 (84.6)	2 (15.4)	0 (0.0)	0 (0.0)	—	57.8–95.7
Intralesional Steroids Combination Therapy (n=24)	16 (66.7)	7 (29.2)	1 (4.2)	0 (0.0)	—	46.7–82.0
Intralesional Steroids Monotherapy (n=23)	6 (26.1)	1 (4.3)	16 (69.6)	0 (0.0)	—	12.6–46.5
Sucralfate (n=3)	0 (0.0)	0 (0.0)	3 (100.0)	0 (0.0)	—	0.0–56.2
Systemic Immunosuppressants						
Corticosteroids Monotherapy (n=66)	40 (60.6)	22 (33.3)	4 (6.1)	0 (0.0)	—	48.6–71.5
Corticosteroids Combination Therapy (n=87)	74 (85.1)	9 (10.3)	3 (3.4)	1 (1.1)	—	76.1–91.0
Calcineurin inhibitors Monotherapy (n=23)	13 (56.5)	5 (21.7)	5 (21.7)	0 (0.0)	—	36.8–74.4
Calcineurin inhibitors Combination Therapy (n=16)	11 (68.8)	4 (25.0)	1 (6.2)	0 (0.0)	—	44.4–85.8
Anti-metabolites Combination Therapy (n=15)	9 (60.0)	3 (20.0)	3 (20.0)	0 (0.0)	—	35.8–80.2
Anti-metabolites Monotherapy (n=13)	7 (53.8)	1 (7.7)	5 (38.5)	0 (0.0)	—	29.1–76.8
Antibacterials						
Antibiotics Monotherapy (n=28)	19 (67.9)	5 (17.9)	4 (14.3)	0 (0.0)	—	49.3–82.1
Antibiotics Combination Therapy (n=27)	22 (81.5)	4 (14.8)	1 (3.7)	0 (0.0)	—	63.3–91.8
Antimycobacterials (n=3)	3 (100.0)	0 (0.0)	0 (0.0)	0 (0.0)	—	43.9–100.0
Antifungals (n=1)	1 (100.0)	0 (0.0)	0 (0.0)	0 (0.0)	—	20.7–100.0
Antivirals (n=1)	1 (100.0)	0 (0.0)	0 (0.0)	0 (0.0)	—	20.7–100.0
Biologics						
Anti-TNF Monotherapy (n=69)	33 (47.8)	18 (26.1)	18 (26.1)	0 (0.0)	—	36.5–59.4
Anti-TNF Combination Therapy (n=25)	19 (76.0)	3 (12.0)	3 (12.0)	0 (0.0)	—	56.6–88.5
IL-12/23 inhibitors (n=13)	8 (61.5)	5 (38.5)	0 (0.0)	0 (0.0)	—	35.5–82.3
IL-23 inhibitors (n=4)	2 (50.0)	2 (50.0)	0 (0.0)	0 (0.0)	—	15.0–85.0
JAK inhibitors (n=3)	1 (33.3)	2 (66.7)	0 (0.0)	0 (0.0)	—	6.2–79.2
Other						
IVIG (n=9)	7 (77.8)	2 (22.2)	0 (0.0)	0 (0.0)	—	45.3–93.7
Sulfasalazine (n=9)	9 (100.0)	0 (0.0)	0 (0.0)	0 (0.0)	—	70.1–100.0
Colchicine (n=2)	1 (50.0)	0 (0.0)	1 (50.0)	0 (0.0)	—	9.5–90.6
Mesalazine (n=1)	0 (0.0)	1 (100.0)	0 (0.0)	0 (0.0)	—	0.0–79.4
Natalizumab (n=1)	1 (100.0)	0 (0.0)	0 (0.0)	0 (0.0)	—	20.7–100.0

**Eight patients on topical corticosteroid monotherapy had outcomes reported as PR/NR without further specification; similarly, four patients on topical calcineurin inhibitor monotherapy had outcomes reported as PR/NR without further specification. These are included in the denominator (n) but counted as Unspecified.*

Statistical analysis: 95% confidence intervals for complete remission proportions calculated using the Wilson score method, preferred over the normal approximation for small samples and proportions near 0% or 100%.