EA DV CONGRESS
VIENNA
30 SEP - 3 OCT 2026

Abstract N°: 152

A Prebiotic and panthenol-containing repair balm improves tolerability of topical 5-Fluorouracil field therapy for actinic keratoses: a randomised controlled trial

Anne Tseng*[1, 2], Regina Yu[1], Susan Brown[1], Nicholas Muller[1, 2], Samuel Tan[1, 2], Edwige Roy[1], Suzanne Nguyen[3], Delphine Kerob[3, 4], Kiarash Khosrotehrani[1, 2]

[1] The Frazer Institute, The University of Queensland, Brisbane, Australia

[2] The Princess Alexandra Hospital, Department of Dermatology, Brisbane, Australia

[3] La Roche-Posay Laboratoire dermatologique, Levallois-Perret, France

[4] Saint Louis Hospital, Department of Dermatology, Paris, France

Introduction

Topical 5-Fluoruoracil (5-FU) is an effective field therapy for actinic keratoses (AKs) with proven chemopreventive benefit; however, treatment-limiting local skin reactions frequently impair tolerability and adherence in clinical practice. Our aim was to determine whether adjunctive use of a dermocosmetic balm containing vitamin B5, Madecassoside and a prebiotic complex improves tolerability and treatment adherence to topical 5% fluorouracil (5-FU) field therapy for actinic keratoses compared with standard of care alone.

Materials and Methods

We conducted a single-blind, randomised controlled trial involving adults prescribed topical 5% fluorouracil for actinic keratoses on the face/scalp or hands/forearms. Participants were randomised 1:1 to standard care (5-FU twice daily) or intervention (5-FU twice daily plus a Dermocosmetic Balm containing vitamin B5, madecassoside and a prebiotic complex (named DC) applied 30 minutes after 5-FU). Participants were stratified by treatment site and whether they were on immunosuppressive therapy (organ transplantation). Primary outcomes were treatment adherence, defined as completion of ≥42 applications over four weeks, and worst local skin reaction (LSR) score during treatment using a validated severity scale. Secondary outcomes included LSR scores at weeks 1–4, itch and pain scores, Dermatology Life Quality Index (DLQI), treatment interruptions, and actinic keratosis counts. Statistical analyses compared outcomes between groups, with subgroup analyses performed according to stratification variables.

Results

Fifty-nine participants consented and 50 completed the study (27 intervention, 23 control). Completion of ≥42 applications occurred in 59% of the intervention group and 52% of controls. Mean total applications were similar between groups (40 vs 40). The intervention group demonstrated lower mean worst LSR scores compared with standard care (9.2 vs 10.2). Severity scores were significantly reduced in the intervention group at day 14 ($p=0.0435$) and day 21 ($p=0.0054$), with the greatest benefit observed in face/scalp treatments. DLQI scores were significantly improved in facial treatment subgroups receiving the intervention DC, particularly among participants completing ≥42 applications. No significant differences in pain scores were observed.

Conclusions

Although the adjunctive or a DC repair balm did not significantly increase overall treatment completion, it significantly reduced local skin reaction severity and improved quality of life, particularly for facial field cancerisation therapy. Adjunctive barrier repair and skin care may enhance tolerability of topical 5-FU and support patient experience during actinic keratosis treatment.

EA DV CONGRESS
VIENNA
30 SEP - 3 OCT 2026

Abstract N°: 181

Propylene glycol herbal extracts for topical application: In vivo/in vitro irritation potential assessment

Marija Tasic-Kostov*[1], Dragana Pavlovic[1], Sanja Stojanović[1, 1], Stevo Najman[1]

[1] University of Niš-Faculty of Medicine, Niš, Serbia

Introduction

Propilene glycol (PG) is used as a common pharmaceutical excipient in dermopharmaceutics and cosmetics. When used as an extraction solvent, PG improves anti-inflammatory, antibacterial, and antioxidant properties of herbal extracts for topical use. However, uncertainty in PG potential to induce skin irritation and sensitisation contributes its bad reputation. Nowdays, in order to emphasize a specific benefit of cosmetic it is often claimed that it is "propylene glycol free", together with „paraben free" or „mineral oil free" claims. The aim of this study was to determine the suitability of PG as an extraction solvent for herbal extracts intended for topical application regarding skin irritation potential, by: (1) evaluating the in vitro cytotoxicity of Lady's Mantle PG extract using L929 fibroblast cells; and (2) assessing the in vivo effects of PG and PG extract on human skin by measuring biophysical parameters (TEWL, erythema index, and pH). Lady's Mantle (Alchemilla vulgaris L.) was used due to its traditional use in treating skin disorders.

Materials and Methods

Dry plant material was extracted with PG to obtain the extract of Lady's Mantle (AP). For in vitro examination a mouse fibroblastscell line (L929, ATCC (Washington DC, USA) was used. PG A. vulgaris extract (AP) diluted in complete DMEM was tested (concentration range 0.3125 to 50 mg/ml). Control contained cells grown only in culture medium. PG was tested alone as PG 80% and PG 45% solution. MTT test was performed after the incubation period of 24 hours.

In vivo safety was assessed via parameters – TEWL, erythema index (EI) and pH, measured prior to and 60 min upon cessation of 24h occlusive treatment. 12 healthy female volunteers (23.4±1.1 years) were recruited. Two spaces on the flexor side (3x3cm) of forearms were treated, one with PG alone, and the other with PG extract (AP). Additional site was left as a non-treated control under occlusion. Samples were applied 0.016 g/cm^2 and spread, skin immediately covered with Parafilm® and then with cotton adhesive tapes.In vivo measurements were performed in accordance with the Declaration of Helsinki, the volunteers signed a written consent. TEWL was measured using Tewameter®TM 210, EI using Mexameter®MX 18, pH using pHmeter®900 (all Courage + Khazaka, Germany).This double blind study was performed using non-invansive method, approved by the local Ethical Committee on Human Research of the Faculty of Medicine in Niš, Serbia.

Results

The results of MTT test show that only high examined concentrations of the PG extract (5-50 mg/ml for AP, Fig. 1b) were cytotoxic for cells, with a statistically significant reduction of cell viability. Concentration-dependent cell viability was observed. No significant cytotoxic effects were observed at concentrations below 2.5 mg/mL of extract (Fig. 1b). When PG alone was examined, PG80 reduced cell viability to 55.53 ± 11.2%, while the same dilution of PG45 reduced cell viability to 74.44 ± 7.67%.

For in vivo study, a 24-hour occlusion with both the 10% PG solution and the A. vulgaris PG extract (AP) led to minor fluctuations in skin barrier function, redness and pH. Neither PG alone nor the PG herbal extract caused measurable skin irritation or disruption of the skin barrier integrity under the test conditions.

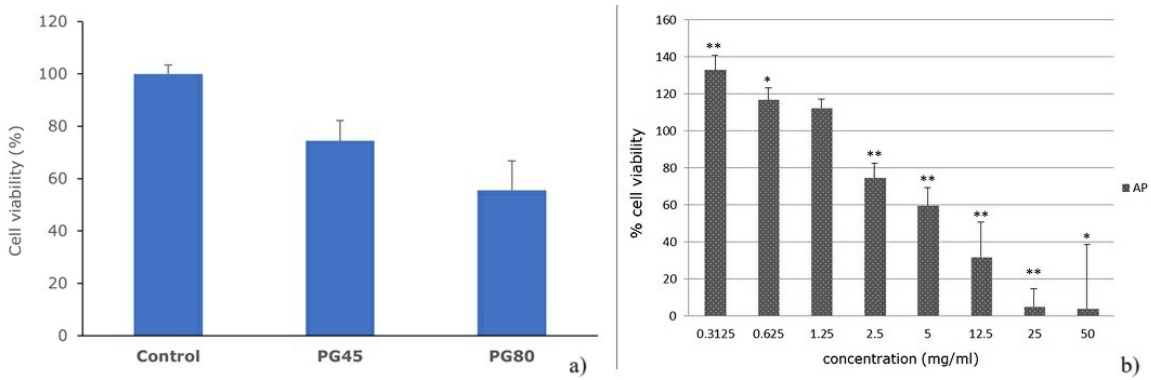

Figure 1.

Conclusions

In the in vitro cytotoxicity test, we demonstrated that the A. vulgaris PG extract exhibits a satisfactory safety profile on L929 fibroblast cells, maintaining cell viability at concentrations relevant for topical use. Second, by assessing the in vivo effects on human skin, we confirmed that neither PG per se nor the PG extract induced significant alterations in crucial biophysical skin parameters. Based on these complementary findings, we can conclude that PG is a highly suitable extraction solvent. It allows the formulation of dermopharmaceutics and cosmetics containing bioactive plant extracts, safe and effective for topical application, minimizing the risk of skin irritation while meeting therapeutic needs.

EA DV CONGRESS
VIENNA
30 SEP - 3 OCT 2026

Abstract N°: 228

Clinical study of RLS-1496 topical cream: targeting senescence and oxidative stress via GPX4 inhibition in patients with actinic keratosis

Mary Spellman*[1], Edward (Ted) Lain[2], ALBERTO VITARI[1], Alex Laslavic[1], Marco Quarta[1], Frederick Beddingfield[1]

[1] Rubedo Life Sciences, Inc., Mountain View, United States

[2] Austin Institute for Clinical Research, Plugerville, United States

Introduction

Actinic keratoses (AKs) are scaling red lesions on chronically sun-exposed skin that could evolve into squamous cell carcinoma (SCC). Accumulation of senescent cells in the epidermis and dermis of photodamaged skin may contribute to the pathogenesis of this age-dependent skin disease. RLS-1496 cream is an investigational, first-in-class, adaptive senotherapeutic drug product that potently inhibits the antioxidant enzyme glutathione peroxidase 4 (GPX4). This induces ferroptosis (non-apoptotic, iron-dependent, regulated cell death) of senescent cells and also leads to an antioxidant reset in stressed, pre-senescent cells through the nuclear factor erythroid 2-related factor 2 (NRF2) pathway, contributing to a pro-repair/regenerative effect.

Materials and Methods

This phase 1b/2a, multi-center, open-label, single-dose, clinical study assessed the safety, tolerability, clinical activity, and pharmacodynamics (PD) of topically applied RLS-1496 1% cream for the treatment of AK lesions on adult male and female patients. Eligible patients with 4-12 clinically typical, discrete AK lesions on each forearm were enrolled and dosed for 28 consecutive days with RLS-1496 1% cream on a predefined 100 cm2 area on the left forearm and followed for an additional 28 days. The right forearm served as an untreated control. Primary endpoints were the frequency and incidence of adverse events (AEs) assessed through Day 57 and the rate of AK lesion clearance following treatment. Changes from baseline in selected PD parameters were assessed from lesional biopsies taken on Days 1 and 29.

Results

Twenty-four (24) patients were enrolled and treated for 28 days. RLS-1496 1% cream was well-tolerated with no application site reactions reported. There was a singular adverse reaction of moderately severe dermatitis (adjacent to the application site) that resolved within one week. All other treatment-emergent AEs (TEAEs) were mild-to-moderate in severity and considered not related to treatment. There were no SAEs and no patient discontinued the study due to an AE. The mean percent change in total AK lesion counts from baseline (Day 1) to Day 29 was -38.3% for the RLS-1496-treated forearm compared to -5.2% for the untreated control forearm. At Day 57, the results were -43.5% and -11.3% for active and untreated control, respectively. A minimum of 75% clearance of AK lesions treated with RLS-1496 1% cream was observed in 25.0% and 34.8% of forearms on Days 29 and 57 and in 0.0% of untreated control forearms at the same timepoints. Analysis of PD biomarkers demonstrated 33% GPX4 target engagement (TE). Spatial transcriptomics and multiplex immunostaining confirmed an AK-specific senescent cell signature and potential treatment-related changes in senescence and disease markers.

Conclusion

In this phase 1b/2a study, 4 weeks of topical treatment with RLS-1496 1% cream was associated with a favorable safety and tolerability profile and resulted in clinically meaningful clearance of AK lesions compared to untreated control. Analysis of PD biomarkers demonstrated TE in AK lesions and impact on senescence and disease

biomarkers. Further clinical investigation of RLS-1496 cream in AK is warranted.

EA DV CONGRESS
VIENNA
30 SEP - 3 OCT 2026

Abstract N°: 500

Successful Treatment of Cryotherapy Resistant Verruca Vulgaris with 18% Aluminum Chloride Solution: A Report of 4 Cases

Pinar Hararci Yildirim*[1], sabir hasanov[2], Didem Dinçer[2], Efsun Tanacan[3]

[1] Elmadag State Hospital, Ufuk University Medical Faculty, Ankara, Türkiye
[2] Private Practice, Ufuk University Medical Faculty, Ankara, Türkiye
[3] Ankara Etlik City Hospital, Ufuk University Medical Faculty, Ankara, Türkiye

Introduction

Warts, caused by Papillomavirus, are benign intraepidermal proliferations commonly seen in children and adults. It infects people through direct or indirect contact. It may cause pain and cosmetic problems, and affect the quality of life. Invasive and non-invasive methods such as salicylic acid, cryotherapy, imiquimod, intralesional 5-fluorouracil, and electrocauterization take part in the treatment. The ideal treatment method is expected to be as painless as possible, require minimum number of treatment sessions/hospital admissions, and leave no scar. In this study, we present 4 cryotherapy resistant verruca cases treated successfully with 18% aluminum chloride solution.

Case Presentation

This report presents four cases of verruca treatment with aluminum chloride solution following unsuccessful cryotherapy. A 24, 5, 10 and 16 years old patients with verruca resistant to cryotherapy, applied the %18 aluminum chloride solution on the lesions nightly for approximately a month, resulting in complete lesion resolution. These cases highlight the effectiveness of aluminum chloride as an alternative treatment for verrucas when cryotherapy fails or is poorly tolerated.

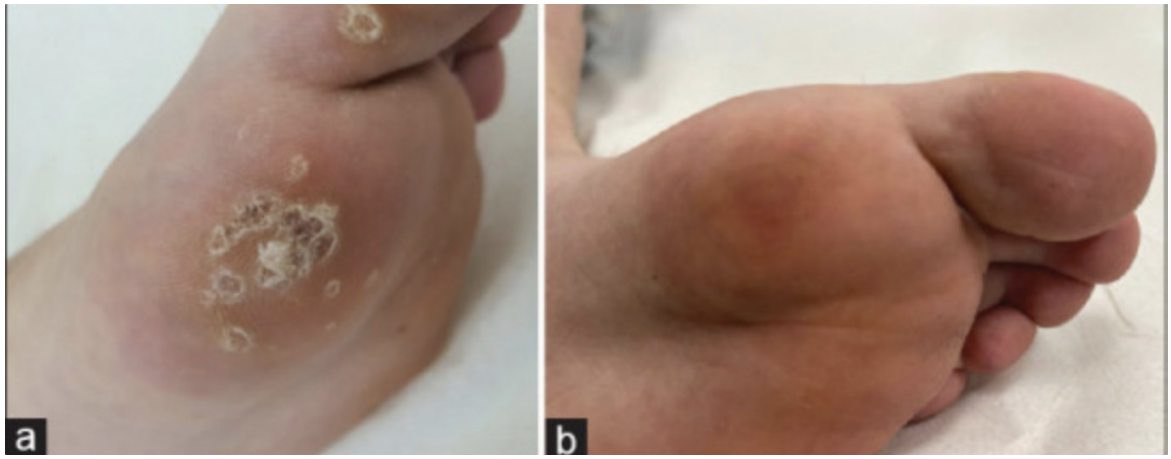

Conclusion

An 18% aluminum chloride solution is supposed to be a safe and effective treatment option for verruca. Aluminum chloride solution should be compared to other treatment options to determine its effectiveness and the risk of relapse of verruca.

EA DV CONGRESS
VIENNA
30 SEP - 3 OCT 2026

Abstract N°: 554

Efficacy, tolerability and 1-year long term safety with tirbanibulin 1% ointment in patients with actinic keratosis applied over a field up to 100 cm² and up to 2 treatment courses

Julia Welzel*[1], Jacek C. Szepietowski[2, 3], Carla Ferrandiz Pulido[4], Giovanni Pellacani[5, 6], Klara Mosterd[7, 8], Raquel Otero[9], María Luisa Tamarit Latorre[9], Guillermo Castilla-Fernández[9], Hilary Siddall[10], Ignasi Pau-Charles[9], Thomas Dirschka[11]

[1] University Hospital Augsburg, Augsburg, Germany
[2] Division of Dermatology, Venereology and Clinical Immunology, Faculty of Medicine, Wroclaw University of Science and Technology, Wrocław, Poland
[3] 4th Military Hospital, Wrocław, Poland
[4] Hospital Universitari Vall d'Hebron, Barcelona, Spain
[5] Sapienza University of Rome, Rome, Italy
[6] Umberto I Polyclinic, Rome, Italy
[7] Maastricht University Medical Center+, Maastricht, Netherlands
[8] GROW Research Institute for Oncology and Reproduction, Maastricht, Netherlands
[9] Almirall R&D, Sant Feliu de Llobregat, Spain
[10] Almirall, Uxbridge, United Kingdom
[11] CentroDerm Clinic Wuppertal, Wuppertal, Germany

Introduction

Actinic keratosis (AK) is a pre-cancerous skin disease resulting from the atypical proliferation of keratinocytes that may progress to invasive squamous cell carcinoma (SCC). Tirbanibulin 1% ointment is approved for treating AK on the face or scalp in Europe over a field up to 25 cm^2, and in the United States over a field up to 100 cm^2. This study aimed to evaluate tirbanibulin's efficacy, tolerability and 1-year long-term safety when applied to fields larger than 25 cm² and up to 100 cm².

Materials and Methods

This is a phase 3, multicenter, randomized, double-blind, vehicle-controlled study (NCT06135415) with a 16-week treatment and response assessment period (Core study), and a long-term follow-up (LTFU) period up to 48 weeks. Patients with ≥4 to ≤12 AK lesions on the face or the scalp in a field of between 25 and up to 100 cm^2 were randomized 2:1 to tirbanibulin or vehicle. All received a 5-day treatment course; those not achieving complete clearance (CC) at Day (D) 57 or recurrent patients received a second treatment course. Primary efficacy endpoint of the Core study was the mean percent change from baseline in AK lesion count at D57. Key secondary efficacy endpoints were CC, defined as 100% clearance of AK lesions and partial clearance (PC), defined as ≥75% clearance of AK lesions, assessed at D57 and D113 (for patients receiving a second treatment course). Safety was assessed by the incidence and severity of adverse events (AEs), and AEs of special interest. Local tolerability signs (LTS), also known as local skin reactions, (erythema, flaking/scaling, crusting, swelling, vesiculation/pustulation and erosion/ulcerations within the treated area) were graded on a scale from 0 (absent) to 3 (severe). During the LTFU period, patients who achieved CC at D57 or D113 had the opportunity to receive tirbanibulin if they had recurrences or new AK lesions, with an off-treatment period of 16 weeks between treatment courses. Patients who did not achieve CC at either D57 or D113 had access to standard of care and did not receive further study treatments during the LTFU period and underwent telephone safety assessments (AEs and concomitant

medications review).

Results

187 patients were randomized to tirbanibulin and 93 to vehicle (mean age: 73.4 years; male: 83.9%). Tirbanibulin demonstrated a clinically meaningful and statistically significantly greater mean percent reduction in AK lesions from baseline to D57 versus vehicle (least-square mean reduction from baseline: 64.2% vs 25.2%; $p<0.001$; median: 84.5% vs 20.0%; nominal $p<0.001$). At D57, higher percentage of patients achieved CC and PC with tirbanibulin (41.2% and 58.8%, respectively) compared to vehicle (15.1% and 20.4%); the improvement was further increased at D113 (tirbanibulin: 56.1% CC and 65.2% PC vs vehicle: 23.7% CC and 25.8% PC), all these comparisons being statistically significant between groups ($p<0.001$). Most treatment emergent AEs were mild or moderate local skin reactions that did not lead to treatment discontinuation. The most frequent LTS were mainly mild to moderate erythema and flaking/scaling. LTS peaked around D8 after each course and generally resolved or returned to baseline by D29 after each course. Among patients who achieved CC following 1 treatment course of tirbanibulin, 55.2% remained clear of AK lesions approximately 1 year after starting treatment. A total of 76.8% of patients who achieved CC after 1 or 2 treatment courses (tirbanibulin or vehicle) did not require treatment per the Investigator's judgement during LTFU period. Safety was consistent with previous studies; no new concerns were identified over 48 weeks.

Conclusions

Tirbanibulin showed significantly greater efficacy and consistent tolerability and long-term safety for AK treatment fields up to 100 cm^2 compared to vehicle, with a favorable benefit–risk profile maintained over longer-term follow-up.

EA DV CONGRESS
VIENNA
30 SEP - 3 OCT 2026

Abstract N°: 574

Beyond Standard Lipid Panels: Elevated Lipoprotein(a) in Young Adults with Prior Isotretinoin Exposure

Joanna Zygadło*[1], Grzegorz Procyk[2], Leszek Blicharz[1], Joanna Czuwara[1], Olga Ciepiela[3], Paweł Balsam[2], Lidia Rudnicka[1]

[1] Department of Dermatology, Medical University of Warsaw, Warsaw, Poland
[2] First Department of Cardiology, Medical University of Warsaw, Warsaw, Poland
[3] Department of Laboratory Medicine, Medical University of Warsaw, Warsaw, Poland

Introduction
Isotretinoin-induced dyslipidaemia is a well-documented adverse effect. In recent years, lipoprotein(a) [Lp(a)] has been recognized as an independent cardiovascular risk factor. Although Lp(a) levels are largely genetically determined, they may be modulated by non-genetic factors, including lifestyle, hormonal disturbances, inflammation, pharmacotherapy, and chronic kidney disease. To date, only a few studies have assessed the influence of active isotretinoin therapy on Lp(a) levels, yielding contradictory findings. Current European Society of Cardiology (ESC)/European Atherosclerosis Society (EAS) guidelines recommend measuring Lp(a) in each adult at least once during a lifetime and a level ≥105 nmol/L should be considered a risk-enhancing factor. To the best of our knowledge, no data exist on the association between prior isotretinoin therapy and Lp(a) concentration. Therefore, this study aimed to evaluate Lp(a) concentrations in a cross-sectional cohort of young adults with and without prior isotretinoin exposure.

Materials and Methods
In this cross-sectional study, we enrolled young, healthy volunteers aged 19-26 years. Participants receiving isotretinoin at the time of blood sampling were excluded from the primary analysis. Acne severity was classified based on self-reported clinical subtypes as mild (comedonal), moderate (papulopustular) or severe (nodulocystic). Fasting blood samples were analyzed for Lp(a) (nmol/L), high-sensitivity C-reactive protein (hsCRP), total cholesterol (TC), high-density lipoprotein (HDL) cholesterol, low-density lipoprotein (LDL) cholesterol, non-HDL cholesterol, triglycerides, and glycated haemoglobin (HbA1c). Elevated Lp(a) was defined using clinically relevant threshold according to current ESC/EAS guidelines. Fisher's exact test was used to compare categorical data. A p-value < 0.05 was considered statistically significant. The study was approved by the institutional ethics committee.

Results
In this study, the final cohort comprised 100 participants: 13 with prior completed isotretinoin therapy (median time since discontinuation: 5.0 years) and 87 unexposed participants. The median age was 23 years (IQR 21–24), 73.0% were female, and the median BMI was 21.7 kg/m^2. The groups did not differ in age (p = 0.320), sex (p = 0.329), and other baseline characteristics. Participants with prior isotretinoin exposure had a significantly higher prevalence of Lp(a) ≥105 nmol/L: 46.2% versus 16.1% (odds ratio 4.47, 95% confidence interval 1.30–15.31, p = 0.021). The association was even stronger at the ≥125 nmol/L threshold (OR = 7.43, 95% CI 2.04–27.00, p = 0.004). Lp(a) showed no correlation with acne severity (ρ = 0.019, p = 0.853). Severe acne did not differ significantly between the isotretinoin and unexposed groups (23.1% vs 30.6%, p = 0.739). In a sensitivity analysis including four participants currently receiving isotretinoin, the association remained significant (OR = 4.73, p = 0.016).

Conclusions
This is the first study to report Lp(a) levels after completion of isotretinoin treatment. Prior isotretinoin treatment

may be associated with elevated Lp(a) concentrations. This observation requires confirmation in larger cohorts.

EADV CONGRESS
VIENNA
30 SEP - 3 OCT 2026

Abstract N°: 682

Use of Oral Isotretinoin in the Management of Lichen Amyloidosis: A Case Report

Merve Markal Bay*[1], Fadime Kilinc[1], Zeynep Koca[2]

[1] Department of Dermatology and Venereology, Ankara Bilkent City Hospital, Ankara, Türkiye
[2] Department of Pathology, Ankara Bilkent City Hospital, Ankara, Türkiye

Introduction

Primary localized cutaneous amyloidosis (PLCA) is a rare condition characterized by the deposition of amyloid proteins in the skin without systemic involvement. Its subtypes include macular, lichen (papular), and nodular forms; lichen amyloidosis (LA) is distinguished by hyperpigmented, hyperkeratotic papules with a tendency to coalesce, particularly on the pretibial regions, accompanied by intense pruritus. Although the pathogenesis has not been fully elucidated, the "itch–scratch cycle" associated with chronic pruritus and friction, leading to keratinocyte damage and subsequent deposition of keratin-derived proteins as amyloid in the dermis, is considered the primary mechanism. Histopathologically, amorphous eosinophilic material in the papillary dermis and epidermal hyperplasia with hyperkeratosis may be observed; special stains such as crystal violet or Congo red (showing apple-green birefringence under polarized light) aid in diagnosis. Clinically, it may overlap with prurigo nodularis and lichen simplex chronicus, leading to potential misclassification; however, LA is not associated with systemic amyloidosis, and routine screenings are typically unremarkable.

Case Presentation

A 39-year-old male patient presented with a three-year history of skin-colored, papular, pruritic lesions located on the extensor surfaces of the lower extremities. According to the patient's history, a prior skin biopsy performed at another center had been interpreted as prurigo nodularis. Based on this diagnosis, the patient had received treatment with acitretin 25 mg, topical corticosteroids, and emollients for eight months at the same center, without clinical improvement. Dermatological examination revealed no additional pathological findings. In the systemic history, the patient reported the use of atorvastatin for hypercholesterolemia. A repeat skin biopsy was performed at our clinic. The preliminary diagnoses included papular mucinosis, lichen amyloidosis, and colloid milium. Histopathological examination demonstrated amyloid deposition with crystal violet staining, consistent with cutaneous amyloidosis. Further evaluation revealed no evidence of systemic involvement. In this patient, who had not responded to previous topical therapies, laboratory investigations were reviewed and treatment with oral isotretinoin was initiated, along with a combination of mometasone furoate and salicylic acid, and alternating topical tacrolimus ointment. After two months of treatment, a marked improvement was observed in both pruritus and the clinical appearance of the lesions.

Conclusion

This case demonstrates that lichen amyloidosis may be misdiagnosed as prurigo nodularis in chronic pruritic papular dermatoses, highlights the importance of histopathological confirmation (particularly with readily available stains) in clarifying the diagnosis, and suggests that retinoid-based combination therapies may provide significant short-term clinical improvement.

EA DV CONGRESS
VIENNA
30 SEP - 3 OCT 2026

Abstract N°: 702

Reconciliation of topical treatment prescriptions upon hospital admission

Victor Schumacker*[1]

[1] King's Mill Hospital, Mansfield, Nottingham, United Kingdom

Introduction

Medicines reconciliation on hospital admission is a critical component of patient safety and effective clinical care. While significant emphasis is placed on oral and systemic medications, topical therapies are frequently overlooked despite their important role in the management of chronic conditions such as eczema. Failure to accurately document and continue these treatments may result in avoidable symptom exacerbation, reduced patient comfort, and prolonged hospital stays. Previous studies have demonstrated that up to 67% of medication histories contain inaccuracies, contributing to approximately 27% of inpatient prescribing errors (1). This audit aimed to evaluate the accuracy and completeness of topical medication reconciliation at a local hospital and to identify areas for improvement in current admission practices.

Materials and Methods

1. A prospective audit was conducted across three inpatient wards to minimise specialty-specific bias between 12 January 2026 and 14 February 2026
2. Patients were included if they were admitted during the study period and reported regular use of at least one topical medication prior to admission
3. SystemOne electronic records were used to identify pre-existing topical prescriptions, which were subsequently cross-checked against admission documentation and inpatient drug charts
4. For medications that were reconciled, the completeness of prescribing details (including site of application, frequency, and quantity) and evidence of administration were assessed
5. For medications that were omitted, the presence or absence of a documented clinical rationale was reviewed.

Results

A total of 50 patients (aged 37–94 years) were included, with equal representation across the three wards. All patients reported using at least one topical medication at home, with the majority using one (66%), followed by two (26%), and three or more (8%).

In total, 68 topical medications were identified, with the most commonly prescribed being emollients (44%), ibuprofen gel (32%), barrier creams (28%), and topical corticosteroids (12%). The primary indications included eczema and dry skin conditions (68%), osteoarthritis (32%), and pressure sore prevention or management (26%).

On admission, 78% of patients had at least one topical medication documented; however, only 54% were formally reconciled onto inpatient drug charts. Among reconciled medications, prescribing quality was high, with 93% containing complete instructions, and 81% of these were subsequently administered during the inpatient stay. In contrast, among unreconciled medications, only 35% had a documented reason for omission. Furthermore, 22% of patients had no topical medications recorded at all on admission and did not receive any related treatment during their hospital stay.

Conclusions

This audit demonstrates that although the quality of prescribing is high when topical medications are reconciled, a

substantial proportion are omitted during the admission process. This represents a gap in medicines optimisation and poses a potential risk to patient safety and comfort. Increased awareness among admitting clinicians is required to ensure that topical therapies are given appropriate consideration.

Next steps: as a result of these findings, targeted interventions have been developed, including educational posters and visual prompt stickers in clerking booklets, to encourage more comprehensive medication histories and topical medicine reconciliation. Re-audit will be required to assess the effectiveness of these measures in improving reconciliation rates.

(Please note this audit is currently awaiting a second cycle in order to see the impact of the intervention)

Topical Medications Matter!

Creams, ointments, gels & patches are medications too!



Inpatients who had their regular topical medications on their arrival meds	Inpatients who actually had their topical medication reconciled
78%	**54%**

Quick Reminder for Admissions & Ward Reviews

- Ask about regular topical prescriptions
- Prescribe them with the correct dose, frequency and site
- Document if they are intentionally withheld



Don't forget the skin!

If it's prescribed at home, it should be given in hospital.

Topical Medication Checklist

- ☐ Do they use regular topical prescriptions?
- ☐ Have you prescribed these with the correct **dose, frequency, and site**?
- ☐ If not prescribed, have you **documented the reason** why?

EA DV CONGRESS
VIENNA
30 SEP - 3 OCT 2026

Abstract N°: 928

Efficacy of Intermittent, Cyclical Azithromycin in Pediatric Pityriasis Lichenoides: A Case Series

Zaid Almustafa*[1], Nujud Alshammari[1]

[1] Qatif Central Hospital/Prince Mohammed bin Fahd Hospital, Eastern Health Cluster, Saudi Arabia, Qatif, Saudi Arabia

Introduction

Pityriasis lichenoides (PL) is an inflammatory skin disease of unknown etiology that can occur in children as well as adults. Two main, occasionally overlapping, clinical forms have been extensively described in the literature: an acute form known as pityriasis lichenoides et varioliformis acuta (PLEVA) and a chronic form called pityriasis lichenoides chronica (PLC). Whereas PLEVA typically presents with a pleomorphic papular exanthem with secondary crusting and erosions with or without fever, PLC usually has a protracted course of scaly papules characteristically healing with collarette scales and hypopigmentation. Diagnosis is primarily clinical, with biopsy reserved for atypical cases. While the etiology remains elusive, potential causes include infections, medications, and less commonly lymphoproliferative disorders. First-line treatment options consist of topical steroids and calcineurin inhibitors, phototherapy with narrowband UVB, oral antibiotics, and for resistant chronic cases, systemic immunomodulatory or immunosuppressant treatments. Although macrolides, specifically erythromycin and to a lesser extent clarithromycin, are widely accepted therapies for children and adults, data regarding the use of azithromycin remain limited. There is still no consensus on the optimal dosing regimen, or duration for azithromycin in the management of PL.

Case Presentation

We report two cases of PL in preschool children. Case 1, a 4-year-old healthy girl, presented with a pleomorphic exanthem for one month, preceded by rhinitis. She had palpable slightly enlarged cervical lymph nodes. Bacterial culture from a pharyngeal swab yielded negative results. The presentation was consistent with the clinical diagnosis of PL. As other macrolides were not available as an oral suspension, and UVB phototherapy was not easily accessible to parents, the patient was started on azithromycin. Case 2 is also a 4-year-old girl who presented with a classical clinical features of PL for 6 months associated with cervical lymphadenopathy. She had a recent contact with a brother diagnosed with streptococcal pharyngitis. Three pharyngeal swabs taken on Week 1, Week 24, and Week 28 were all negative. Over the course of the disease, she did not respond to topical steroids and oral amoxicillin-clavulanate 45 mg/kg/day for 7 days. Phototherapy was declined by caregivers due to transportation issues. As azithromycin was the only macrolide available as oral suspension at that time, treatment with oral azithromycin was initiated.Both patients received a treatment regimen with azithromycin monotherapy in given in cycles. Each cycle consisted of azithromycin 10 mg/kg/day on day 1 followed by 5 mg/kg/day on days 2-5. All cycles were at two-week intervals with up to four cycles scheduled. Patient 1 received a total of two cycles; complete clearance was observed after the first cycle. In patient 2, complete clearance was achieved after the second cycle and completed a total of three cycles. No exacerbations or adverse events were reported.

Conclusion

Our cases illustrate the successful use of azithromycin in the management of pediatric PL. Although no bacterial pathogens were isolated, the clinical response suggests a potential immunomodulatory mechanism. This contributes to limited body of evidence on the use of azithromycin for the treatment of PL. Consequently, in the event of unavailability, intolerance, or lack of a suitable formulation of erythromycin, azithromycin could represent a viable alternative. Furthermore, our observations suggest the effectiveness and excellent tolerability of the

intermittent and cyclical administration of azithromycin. This approach reduces the cumulative dose, duration of drug exposure, and caregiver burden compared with daily dosing. Further data are required to establish the safety profile and optimal dosing regimen.

EA DV CONGRESS
VIENNA
30 SEP - 3 OCT 2026

Abstract N°: 987

Characteristics of Best-Selling Topical Pain Relief Medications at Major Online Retailer

Joshua Burshtein*[1], Aaron Burshtein[2]

[1] University of Illinois Chicago, Chicago, United States
[2] Icahn School of Medicine at Mount Sinai, New York, United States

Introduction

The treatment of chronic pain focuses on improving physical and emotional well-being. Chronic pain treatment is a multimodal endeavor integrating medical and psychological therapies. There are a variety of cutaneous conditions that have neuropathic and inflammatory pain[1]. Non-opioid therapies are becoming increasingly prevalent as a treatment modality for both acute and chronic pain patients. Topical analgesics are a form of non-opioid therapies that are commonly used to target hand and knee osteoarthritis, musculoskeletal pain, neuropathic pain, peripheral neuropathy[1]. Topical analgesics are available in various formulations and offer pain alleviation with few drug-drug interactions. Absorption rate, skin sensitivity, and cosmetic application are important considerations for analgesic choice[2]. Topical analgesics are at times used concurrently with cosmetic topical creams. Due to the limited side effects, topical analgesic creams allow for improved clinical outcomes with enhanced medication compliance.

Materials and Methods

A cross-sectional study was performed. Amazon.com was queried under the "Pain Relief Medications and Treatments" category on October 15th, 2023. The results were sorted by "Best Seller." No other restrictions on search were selected. Data for the 50 best-selling products was collected. For medications with multiple sizes, the largest size option was considered. Medications targeting hemorrhoids were excluded. This study did not require IRB approval.

Results

The median price for a medication was $16.86 ($5.99-$39.99). The median price per ounce was $4.24 ($1.49-$20.00). The average consumer rating was 4.4/5, with an average of 7,564 consumer reviews. The 'Joint and Muscle' category contained 78% of the products, the next highest being 'Arthritis' (12%), 'Nerve Pain' (8%), and 'Plantar fasciitis' (2%) [Figure 1]. Cream was the predominant vehicle type (76%), followed by gel (6%). The most abundant active ingredient was menthol (38%), then arnica (28%), 4% lidocaine (18%), and camphor (10%) [Figure 2]. Lidocaine 5% was present in one product. Regarding class of medication, 66% were natural, 16% were lidocaine, and 10% contained non-steroidal anti-inflammatory drugs. Overall, only 26% contained an FDA-approved ingredient (either NSAIDs or Lidocaine). Top marketing claims included non-greasy (52%), maximum strength/powerful (42%), natural/plant-derived (32%), deep penetrating (22%), fragrance/odor free (20%), long-lasting (16%), soothing (14%), targets nerves (14%), fast-acting (12%), and doctor-recommended (10%).

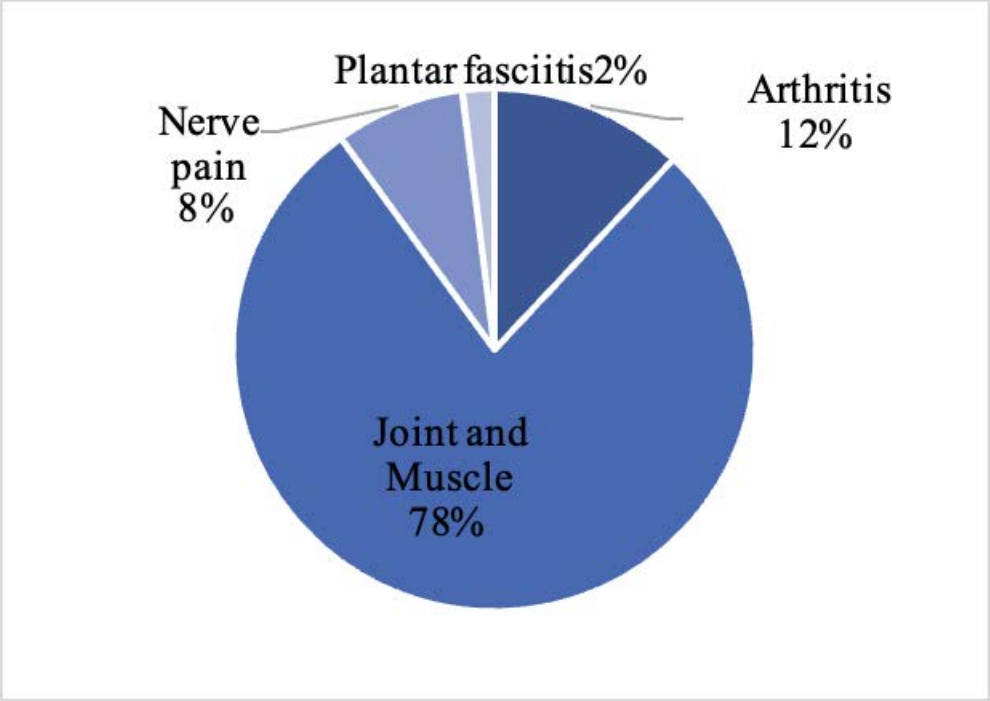

Figure 1. Indication of Topical Analgesics

Conclusions

Topical analgesics are a mainstay of treatment for various pain conditions. There is minimal literature describing consumer purchasing preferences of topical analgesics. We found that with a median price per ounce of $4.24 and average consumer rating of 4.4/5, there are a variety of affordable topical analgesics with relatively high consumer ratings. Prior analyses have detailed the various topical analgesics, their mechanisms of action, and their efficacy[3]. Our results demonstrate a high consumer satisfaction with the most common topical analgesics.

While ingredients are important for patients, we found consumers value a cream formulation for topical analgesics. Marketing direct to consumer has influence on type of topical analgesic purchased. Consumers value cosmetic texture, including “non-greasy” and “fragrance/odor free” application, and claims of strength of medication, such as “maximum strength/powerful”.

There are a variety of affordable topical pain medications with high consumer ratings. Products contain a diversity of active ingredients, though most are not FDA-approved.

1. Hayoun-Vigouroux M, et al. Acta Derm Venereol. 2022;102:adv00742
2. Greive K, et al. Clin Cosmet Investig Dermatol. Published online July 2015:405
3. Maloney J, et al. Curr Pain Headache Rep. 2021;25(2):7

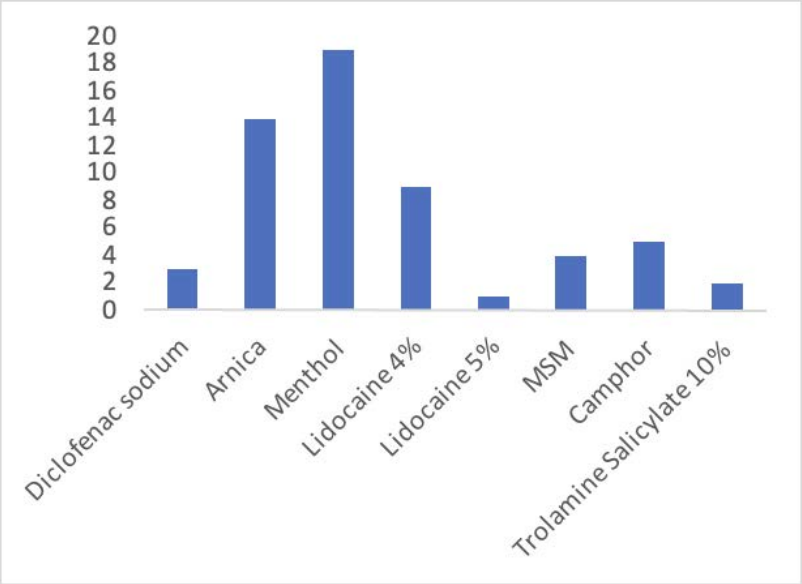

Figure 2. Active Ingredient Among 50 Best-Selling Topical Analgesics

EA DV CONGRESS
VIENNA
30 SEP - 3 OCT 2026

Abstract N°: 1087

A Systematic Review of Case Reports and Case Studies on Retinoid Treatment in Porokeratosis: Subtype Variation, Morphology and Therapeutic Outcomes.

Lavinia Miclea*[1], Ahmad Naqeshbandi[2]

[1] University of Chester, Chester, United Kingdom

[2] Royal Cornwall Hospital NHS Trust, Truro, United Kingdom

Introduction

Porokeratosis is a rare and clinically heterogeneous disorder of keratinisation, presenting with annular plaques and keratotic papules and associated with an increased risk of malignant transformation.
Despite this, there are no standardised treatment guidelines, and clinical management remains a challenge in clinical practice. Retinoids are frequently used due to their regulatory effects on keratinocyte proliferation and differentiation, however, evidence supporting their efficacy remains limited and is predominantly derived from case reports and small case series. This study aims to systematically evaluate published evidence on retinoid therapy in porokeratosis, focusing on treatment response in relation to therapy type, duration, and clinical heterogeneity, with the intention of informing therapeutic decision-making.

Case Presentation

A systematic review was conducted in accordance with PRISMA guidelines. A structured search of PubMed and Embase databases was performed, restricted to studies published from 2000 onwards, identifying twenty-three case reports and two case series, comprising 28 patients with clinically or histologically confirmed porokeratosis treated with topical or systemic retinoids. Inclusion criteria required clear documentation of treatment regimen and clinical outcomes. Extracted variables included porokeratosis subtype, retinoid type, treatment duration, anatomical distribution, and categorised treatment response. Due to the small sample size and uneven subgroup distribution, inferential analysis was limited to key variables using the Fisher-Freeman-Halton Exact test. Partial clinical improvement was the most frequently reported outcome, observed in the majority of cases, while complete responses were less common. No statistically significant association was identified between treatment response and either retinoid type or porokeratosis subtype. In contrast, treatment duration demonstrated a statistically significant association with response ($p = 0.022$), suggesting improved outcomes with prolonged therapy. A further significant association between porokeratosis subtype and anatomical distribution ($p = 0.033$) supports underlying clinical and morphological heterogeneity.

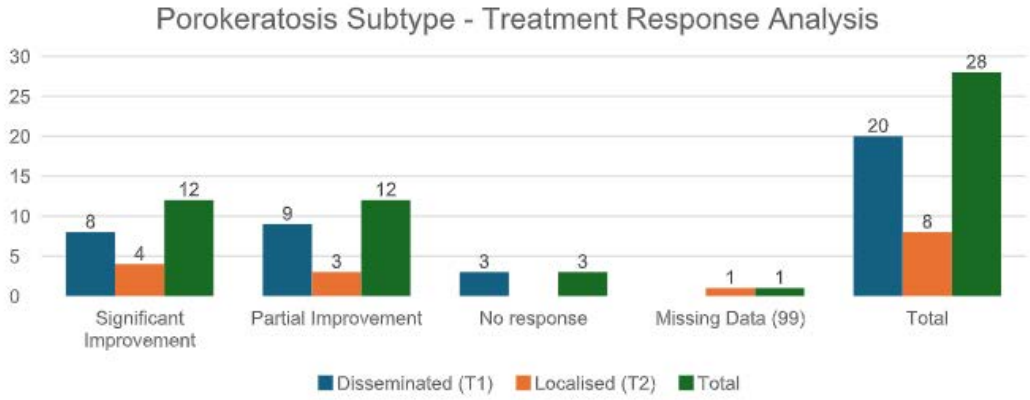

Figure 5. Distribution of treatment response by porokeratosis subtype.

Type of PK * Treatment Response Crosstabulation

			Treatment Response			
			1	2	3	Total
Type of PK	1	Count	8	9	3	20
		Expected Count	8.9	8.9	2.2	20.0
		% within Type of PK	40.0%	45.0%	15.0%	100.0%
	2	Count	4	3	0	7
		Expected Count	3.1	3.1	.8	7.0
		% within Type of PK	57.1%	42.9%	0.0%	100.0%
Total		Count	12	12	3	27
		Expected Count	12.0	12.0	3.0	27.0
		% within Type of PK	44.4%	44.4%	11.1%	100.0%

Chi-Square Tests

	Value	df	Asymptotic Significance (2-sided)	Exact Sig. (2-sided)	Exact Sig. (1-sided)	Point Probability
Pearson Chi-Square	1.398[a]	2	.497	.616		
Likelihood Ratio	2.131	2	.345	.616		
Fisher-Freeman-Halton Exact Test	1.049			.836		
Linear-by-Linear Association	1.161[b]	1	.281	.349	.230	.155
N of Valid Cases	27					

a. 4 cells (66.7%) have expected count less than 5. The minimum expected count is .78.

b. The standardized statistic is -1.077.

Figure 6. Fisher-Freeman-Halton Exact test Crosstabulation between treatment response and porokeratosis subtype.

Conclusion

Retinoid therapy in porokeratosis is associated with variable and predominantly partial clinical responses, highlighting the complexity of this disorder and the limitations of current therapeutic approaches. Treatment duration appears to play a more important role in influencing outcomes than the specific retinoid used, which may have implications for clinical management and patient counselling, particularly in setting realistic expectations regarding response. The marked heterogeneity in disease presentation and the absence of high-quality comparative data limit the ability to establish subtype-specific treatment strategies. These findings highlight the constraints of case-based evidence, including small sample size and potential publication bias, and emphasise the need for standardised outcome measures and larger prospective studies to better inform therapeutic decision-making.

EADV CONGRESS
VIENNA
30 SEP - 3 OCT 2026

Abstract N°: 1188

Inadvertent Percutaneous Drug Absorption Following Skin-to-Skin Contact: A Review of Case Reports

Taylor Skinner*[1], Rebecca Law[1], Howard Maibach[2], Shawn Bugden[1]

[1] Memorial University of Newfoundland, St. John's, Canada

[2] University of San Francisco, San Francisco, United States

Introduction
Topical medications are commonly used for their localized therapeutic effects. However, their potential for drug transfer via skin-to-skin contact is becoming more apparent. Accidental exposures can result in systemic absorption in non-treated individuals, often leading to unexplained clinical symptoms and delays in diagnosis. This review examines case reports of inadvertent percutaneous drug transfer, with a focus on identifying high-risk medications and the factors that increase the risk of absorption following contact.

Materials and Methods
Literature searches were conducted through multiple online databases, such as PubMed and Embase, with a focus on articles published within the last 20 years (2004-2025) to reflect more up to date information available. A total of 1445 articles were imported to screening with the use of Covidence software. Ultimately, 25 case reports were found to be applicable and relevant.

Results
Nearly all of the case reports of accidental exposure occurred to children (21 out of 25) and the majority involved topical testosterone formulations (22 out of 25). Outside of hormone exposure, only one case involved a topical corticosteroid while the other two case reports discussed topical anticholinergics. Common symptoms reported in inadvertently-exposed children include premature pubertal changes, which is consistent with the known systemic effects of early androgen exposure. Factors that likely contribute to secondary exposure were explored, including the altered pharmacokinetic properties of pediatric skin compared with adults, the provision of compounded high-concentration medication formulations, as well as improper occlusion of areas where a drug has been applied.

Conclusions
These findings highlight the importance of counselling patients on appropriate application techniques for all topical medications, but especially hormonal therapies. Clinicians regularly prescribing topicals should emphasize strategies to minimize the risk of transfer, such as covering application sites, and the risks associated with secondary exposure after application, particularly for pediatric populations.

Ultimately, the takeaway message of this review is that awareness of skin-to-skin medication transfer is essential for accurate diagnosis and the prevention of avoidable adverse events. As topical therapies remain prevalent in dermatologic care, recognizing the potential for secondary exposure is increasingly relevant to both clinical practice and public health.

EA DV CONGRESS
VIENNA
30 SEP - 3 OCT 2026

Abstract N°: 1197

Refractory anal intraepithelial neoplasia grade III successfully treated with Imiquimod

Nicole Karin Gherghel*[1], Nora Krumrey[1], Carmen Loquai[1]

[1] Fachklinik Hornheide, Münster, Germany

Introduction

Anal intraepithelial neoplasia (AIN) grade III represents a high-grade squamous intraepithelial lesion with significant risk of progression to invasive carcinoma. Management of extensive perianal disease remains challenging due to anatomical constraints and the risk of functional impairment associated with surgical approaches. Non-surgical treatment strategies are therefore frequently pursued, although persistence and recurrence are common.

Case Presentation

A 42-year-old female patient with HPV-associated AIN III presented with extensive, partly circumferential perianal involvement on a background of melanotic melanosis. Initial diagnosis was established histologically following detection of a pigmented lesion during routine examination. Previous histology had already demonstrated high-grade squamous intraepithelial lesions, with no evidence of invasive malignancy on additional diagnostic work-up. Given the extent of the disease, with a perianal lesion measuring 3 cm, and the associated risk of functional impairment from wide local excision, a conservative treatment approach was chosen. The patient underwent two cycles of photodynamic therapy (PDT), which was well tolerated and induced local inflammatory reactions, but resulted in only limited clinical improvement. Subsequent mapping biopsies revealed persistent, widespread AIN III, highlighting the multifocal nature of the disease.

The patient’s medical history was notable for a cervical carcinoma treated with conization 12 years earlier, supporting a likely HPV-associated disease context.



Conclusion

In view of persistent disease and patient preference to avoid surgery, topical therapy with imiquimod 5% cream was initiated five times weekly for six weeks. Treatment was well tolerated without significant adverse effects. Clinically, marked regression of the perianal lesions was observed. Histological reassessment after completion of therapy demonstrated complete clearance of AIN III, with no residual dysplasia or malignancy. Residual findings were limited to benign melanotic melanosis and reactive inflammatory changes.

This case illustrates the therapeutic challenges in extensive and multifocal perianal AIN III and the limitations of photodynamic therapy as monotherapy in this setting. Sequential therapy with topical imiquimod resulted in complete histological remission. The case highlights the importance of repeated histological assessment, including mapping biopsies, to accurately evaluate treatment response and guide subsequent management. Furthermore, it supports the role of immunomodulatory therapy as an effective non-surgical alternative in patients with refractory disease.

In extensive, multifocal and therapy-refractory AIN III, sequential treatment with imiquimod may achieve complete remission. Conservative management strategies may represent an effective alternative to surgery, laser therapy or

radiotherapy in anatomically sensitive regions, particularly when these approaches are limited by the risk of functional impairment, provided that close clinical and histological follow-up is ensured.

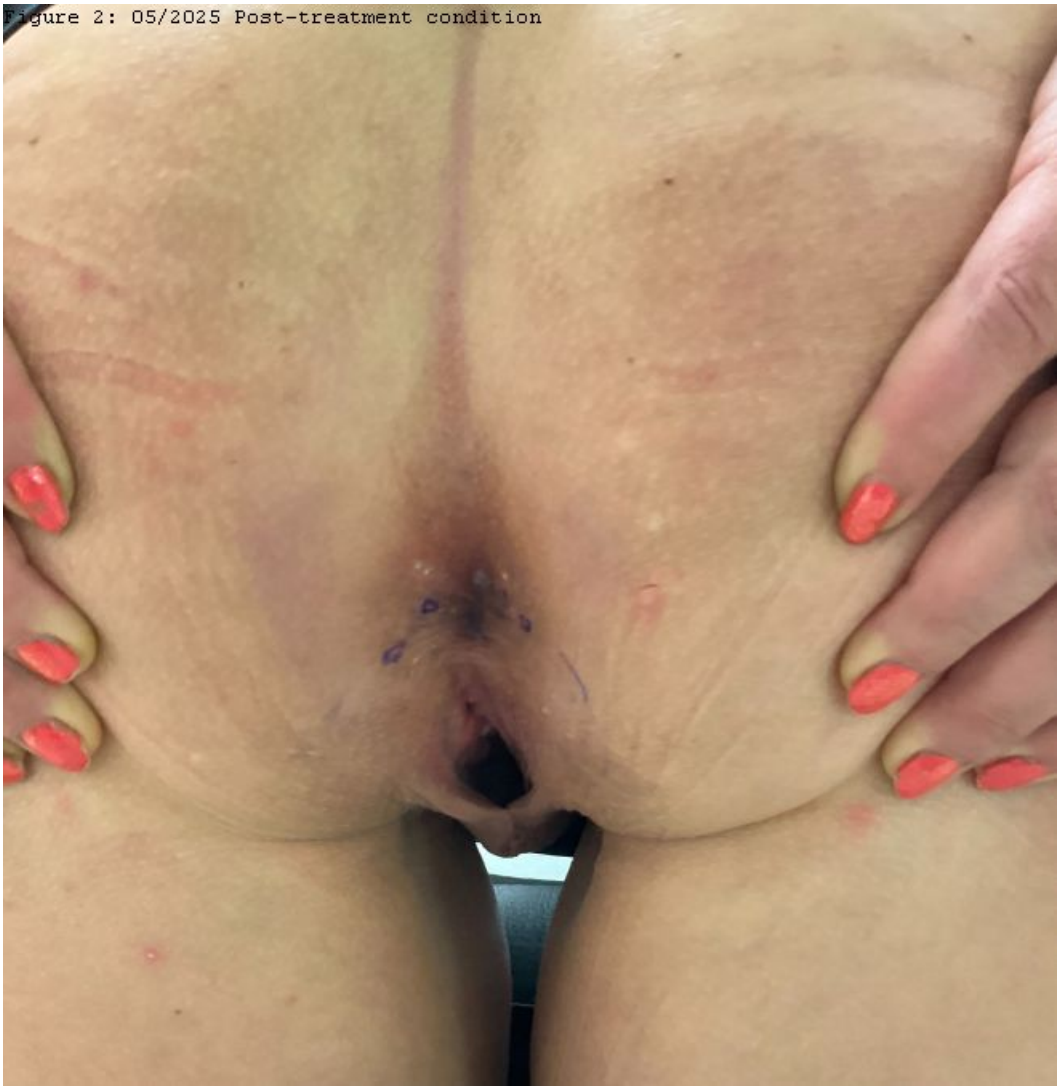

EADV CONGRESS
VIENNA
30 SEP - 3 OCT 2026

Abstract N°: 1322

Topical Imiquimod in Mycosis Fungoides: A Systematic Review of Published Clinical Evidence

Kerem Balan*[1]

[1] Hacettepe University, Department of Dermatology and Venereology, Ankara, Türkiye

Introduction
Topical imiquimod has emerged as a potentially useful skin-directed therapy in selected patients with mycosis fungoides (MF), particularly in localized or treatment-refractory disease. However, the available evidence remains dispersed across case reports, case series, retrospective cohorts, and preliminary studies, and no focused synthesis of topical imiquimod in MF is currently available. We therefore aimed to systematically review the published clinical evidence on topical imiquimod use in MF, with emphasis on treatment settings, regimens, outcomes, and tolerability.

Materials and Methods
A systematic search of PubMed and Scopus was performed to identify studies reporting the use of topical imiquimod in histopathologically confirmed MF. Case reports, case series, retrospective studies, pilot studies, and conference abstracts with extractable clinical outcome data were considered eligible. Related entities within the MF spectrum were reviewed separately when clinically relevant. Data on study design, patient number, disease subtype and stage, treatment regimen, response, adverse events, and follow-up were extracted and synthesized qualitatively because of marked heterogeneity across studies.

Results
A total of 18 studies were included. The available evidence consisted predominantly of individual case reports and small case series, supplemented by retrospective cohorts, pilot studies, and conference-level data. Topical imiquimod was most commonly used for localized, treatment-refractory, or anatomically challenging lesions, including patch/plaque-stage MF, folliculotropic MF, and selected tumor-stage disease. Across the case-based literature, complete or near-complete clinical responses were frequently reported, particularly in localized plaque-stage and folliculotropic MF, with some patients demonstrating durable remission. Broader observational studies suggested more variable benefit, although clinically meaningful responses were still observed in selected patients. Treatment regimens varied substantially, ranging from several weekly applications to daily use, and concomitant or prior therapies were common. Local inflammatory reactions, including erythema, irritation, pain, erosion, and ulceration, were the most frequently reported adverse events and often accompanied treatment response. Preliminary data also suggested that combination with localized radiotherapy may enhance efficacy, although this observation remains exploratory.

Conclusions
Topical imiquimod appears to be a promising skin-directed option for selected patients with MF, especially in localized, refractory, or site-restricted disease. The current evidence supports activity across plaque-stage, folliculotropic, and selected tumor-stage presentations, but remains limited by small sample sizes, heterogeneous treatment schedules, inconsistent follow-up, and likely publication bias. The proposed immune-mediated mechanism of action, illustrated in Figure 1, provides a biologically plausible framework for these observed responses. Larger prospective studies are needed to better define optimal patient selection, dosing strategies, durability of remission, and the role of imiquimod in combination regimens.

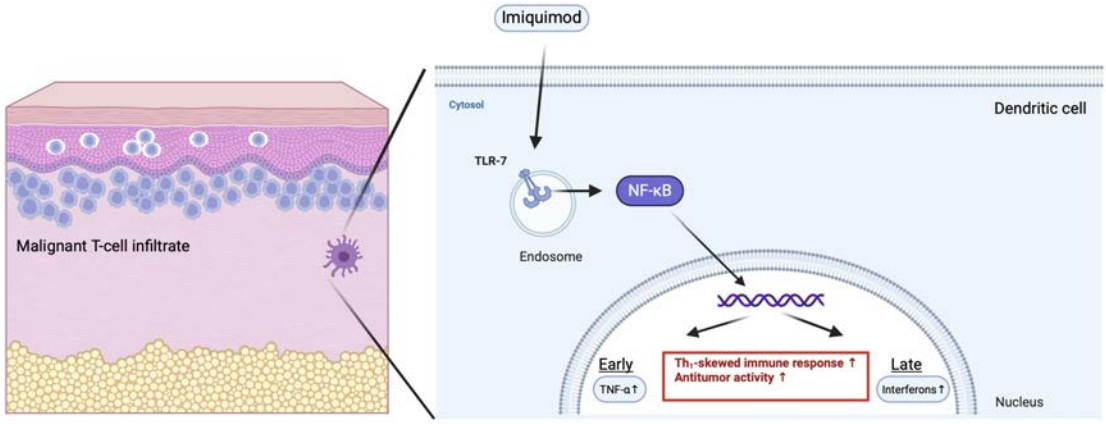

Figure 1. Schematic illustration of the proposed immune-mediated antitumor mechanism of topical imiquimod in mycosis fungoides. Imiquimod activates toll-like receptor 7 (TLR7) in dendritic cells, leading to NF-κB signaling, cytokine induction, a Th1-skewed immune response, and enhanced antitumor activity against malignant T-cell infiltrates.

EA DV CONGRESS
VIENNA
30 SEP - 3 OCT 2026

Abstract N°: 1338

Comparison of the side effect profiles of weekly versus daily dose escalation regimen of Apremilast: An open-label randomized controlled trial

Akshay Sankar P*[1], Satyaki Ganguly[1], Arvind Shukla[1]

[1] ALL INDIA INSTITUTE OF MEDICAL SCIENCES, RAIPUR, RAIPUR, CHHATTISGARH, India

Introduction

Apremilast is an oral phosphodiesterase-4 inhibitor that modulates immune responses by increasing intracellular cyclic adenosine monophosphate (cAMP) and anti-inflammatory cytokine IL-10, while reducing pro-inflammatory cytokines such as interferon-γ, IL-2, IL-12/23, IL-8, and tumour necrosis factor (TNF). It is FDA-approved for the treatment of psoriasis, psoriatic arthritis, and oral ulcers in Behçet disease. It is used off-label for conditions like lichen planus, cutaneous sarcoidosis, atopic dermatitis, and chronic aphthous stomatitis. It is generally well tolerated, with common side effects including headache, nausea, upper respiratory infections, nasopharyngitis, and diarrhoea. The recommended dose of apremilast for adults with psoriasis or psoriatic arthritis is 30 mg twice daily. Treatment is initiated at 10 mg in the morning, with the dose increased by 10 mg each day, reaching the target dose of 30 mg twice daily by day 6 (Daily dose escalation).

Our study aims to compare the frequency of adverse effects like nausea, headache, and abdominal pain between weekly and daily apremilast dose escalation, identify causes of discontinuation, and determine a better-tolerated regimen.

Materials and Methods

Our study is an Open-label Randomized Controlled Trial (RCT). The study included 125 participants. This included 64 (51.2%) patients in the daily dose-escalation group and 61 (48.8%) in the weekly dose-escalation group. The escalation of the apremilast dose by 10 mg was done daily in the control group, and the escalation of the apremilast dose by 10 mg was done weekly in the intervention group**.** The absence or presence and frequency of the side effects, and the number of dropouts were assessed in the 2nd and 7th weeks.

Results

In the daily group, 38 participants (59.4%) were males, and 26 (40.6%) were females, whereas in the weekly group, 37 participants (60.7%) were males and 24 (39.3%) were females. The mean age of the study population was 41.09 ±15.29 years with a range from 18-90 years. There was no significant difference between the two groups concerning age and gender. Among the diagnoses in whom apremilast was started, psoriasis vulgaris had the highest frequency, observed in 59 participants (47.2%). This was followed by palmoplantar psoriasis in 25 participants (20.0%) and hand and foot eczema in 24 participants (19.2%).

Headache was the leading adverse event noted (44 cases, 69.3%), followed by nausea (12 cases, 18.8%). Abdominal pain and upper respiratory tract infection (URTI) were reported less frequently, with 8 cases each (12.5%). There was a significant difference ($p \leq 0.05$) between the two groups for any AEs, nausea, abdominal pain, headache, and upper respiratory tract infection. In the daily group, 5 participants (7.8%) reported nausea in the morning and evening, compared to none in the other group, showing a statistically significant difference ($p = 0.026$). In the daily group, 8 participants (12.5%) developed headache in the evening and 4 participants (6.3%) in

the night, compared to none in the weekly group, with both differences being statistically significant (evening: p = 0.0043; night: p = 0.0463). The mean duration of headache was 121.11 ± 60.28 minutes in the daily group (n = 27) and 150 ± 42.42 minutes in the weekly group (n = 2), with no statistically significant difference between the groups. The drug was discontinued by 16 participants (25.0%) in the daily group compared to 4 participants (6.5%) in the weekly group, and this difference was statistically significant (p = 0.0048). The mean day of withdrawal was 11.19 ±8.25 days in the daily group (n = 16) and 26.25 ±8.81 days in the weekly group (n = 4), with the difference being statistically significant (p = 0.005).

Conclusions

Weekly dose escalation of apremilast reduces adverse effects compared to rapid titration, improving tolerability and adherence, and can be considered as a practical alternative in patients prone to intolerance.

EA DV CONGRESS
VIENNA
30 SEP - 3 OCT 2026

Abstract N°: 1476

Application of a complex of topical agents based on cycloastragenol to correct signs of premature aging

Denis Zaslavsky[1], Alexey Taganov[2], Maria Provotorova[3], Elizaveta D. Zaslavskaya[1], Daria Kozlova*[1]

[1] Saint-Petersburg State Pediatric Medical University, Saint-Petersburg, Russian Federation
[2] Russian Medical Academy of Continuous Professional Education, Moscow, Russian Federation
[3] Russian Academy of Natural Sciences, Moscow, Russian Federation

Introduction

Human aging is a physiological and dynamic process that occurs over time. Given the increasing attention paid to aesthetics every year, preventing premature skin aging is considered a highly relevant issue. Modern authors propose various molecular theories for skin aging, explaining this process by the cellular senescence theory or by impaired cellular DNA repair and telomere loss, point mutations in extranuclear mitochondrial DNA, and oxidative stress. Signs of skin aging include hyperpigmentation, loss of elasticity, wrinkles, atrophy, and erythema. Deviations in epidermal barrier parameters (skin hydration and transepidermal water loss (TEWL), erythema, pigmentation and elasticity) can signal the first signs of skin deterioration even before clinically evident changes appear. The aim of our study was to evaluate the potential of modern topical serum and cream formulations containing the active ingredient cycloastragenol (CAG), peptides, and antioxidants in correcting epidermal barrier parameters in adult women with the first signs of premature skin aging. CAG is an antioxidant and a hydrolysis product of the main active ingredient of *Astragalus membranaceus Bunge*. Bunge is a plant used in traditional Chinese medicine, known for its adaptogenic (Qi-tonifying) properties. *Astragalus membranaceus Bunge* has been used for over 2,000 years and is still found in herbal preparations. It is known to strengthen the immune system, act as a diuretic and hepatoprotector, and also possess anti-aging, anti-stress, antihypertensive, and antibacterial properties. Given all the beneficial properties of this molecule, the effectiveness of CAG in topical facial skin care products is of interest.

Materials and Methods

A prospective observational study was conducted at the Dermatovenereology Department. 30 women of phototype 2, aged 27 to 40, signed informed consent forms. All women applied the CAG-containing serum and cream twice daily for 28 days. All participants underwent skin moisture, TEWL, erythema, pigmentation, and elasticity measurements using the Multi Skin Test Center 750 device before (Visit 0), two weeks later (Visit 1), and four weeks later (Visit 2). Results were recorded in Complete Skin Investigation software as conventional units (CU) ranging from 0 (min) to 100 (max), and from 0 to 20 CU for TEWL only. Mean group values were recorded, and baseline and final mean values were compared to assess changes. At Visit 2, satisfaction with the topical treatments was assessed using the Topical Therapy Satisfaction Index-10 (TTSI-10).

Results

All participants completed the study as planned. Based on the results from Visit 0 to Visit 2, skin moisture levels in the group increased by 13.1% (from 51.1 CU to 57.8 CU). Erythema intensity decreased by 7.3% (from 30.1 CU to 27.9 CU), and pigmentation severity decreased by 28.8% (from 11.8 CU to 8.4 CU). TEWL levels also decreased by 40% (from 3.5 to 2.1 CU) from Visit 0 to Visit 2, and skin elasticity increased by 20.6% (from 58.6 CU to 70.7 CU). On the 45th day, the

elasticity indicator increased by 28% from the initial value and amounted to 74.6 CU. The average satisfaction with the results of topical application, based on the TTSI-10 questionnaire, was 18.6 points, which corresponded to the high satisfaction range (15 to 20 points).

Conclusions

Based on the obtained results, the use of the CAG molecule, which has already proven effective in several in vitro and in vivo clinical trials as an antioxidant and telomerase activator, can be proposed as one approach to preventing aging. Analysis of the study results suggests that the use of the CAG molecule in anti-aging facial skin products leads to the restoration of epidermal barrier properties and improved physiological processes in the skin.

EA DV CONGRESS
VIENNA
30 SEP - 3 OCT 2026

Abstract N°: 1558

A GMP-compliant formulation of regeneratively active polyphosphate (polyP) : A new and exciting approach to restore the disturbance of the calcium(Ca2+) balance in patients with atopic dermatitis (AD) - bench to bedside -

Hadrian Nassabi*[1], Werner E.G. Müller[2], Meik Neufurth[2], Heinz C. Schröder[2], Xiaohong Wang[2]

[1] SRH Waldklinikum Gera, Institute for Physiological Chemistry, University Medical Center of the Johannes Gutenberg University, Mainz 55128, Germany, Gera, Germany
[2] Universitätsmedizin der Johannes Gutenberg-Universität Mainz, Mainz, Germany

Introduction

The predominant approaches to treat AD are topical immunomodulators, like corticosteroids, calcineurin inhibitors and PDE4 inhibitors. They are first-line options for localized itch, unfortunately associated with negative long-term side effects. Interestingly, all of them interfere with Ca^{2+} bursts; like cortisone interfere with the Ca^{2+} uptake, or with nonselective cation channel that mediating Ca^{2+} and Na^{+} influx; or PDE4 controls Ca^{2+} at the level of the ryanodine receptor (RyR2). Ca^{2+} was identified as an indirect, but essential key player. An impaired cellular Ca^{2+}-gradient leads to the penetration of irritants and allergens, the activation of nerve cells, resulting in itching, an overactive immune response with the release of various mediators (i.e. histamine, cytokines, etc.). Moreover, enzymatic dysfunctions, deficiency in key collagen-processing enzymes and the metalloproteinases cause a disrupted synthesis of collagen. The addition of polyP to neuronal cell cultures showed a formation of a coaservate with Ca^{2+}, thereby significantly reducing Ca^{2+}- concentrations. This, in turn, reduces the calcium influx into cells and blocks the release of inflammatory mediators, resulting in a significant improvement on clinical symptoms. This great potential of polyP is demonstrated both experimentally and in patients with AD, treated with a new topical formulation.

Materials and Methods

The effect of polyP was investigated in vitro using PC 12: primary embryonic neuronal cells, as well as endothelial HUVEC cultures exposed to polyP. The determination of the $Ca2^{+}$ -concentration followed the procedure by Grynkiewicz et al. 1985 and Perović et al. 1998. Short polyP chains (10 -50 Pi units) were synthesized using the method by Leitao et al. 1995. Analysis and size distribution of the labelled Na-polyP product were determined electrophoretic and microscopical. Initial clinical attempts using a cream formulation of 5% urea, 600 µg of polyP and an aqueous emulsifying unguent, were administered to patients with AD in a head-to-head areal comparison to a steroid-containing cream after informed consent to proof the concept. Treatment outcomes were assessed using DLQI, itch score (VAS), EASI and SCORAD. Photographic documentation was taken to visualize the clinical results.

Results

Exposure of the neurons/glial mixed cell culture with histamine caused, after an incubation period of 3 d, apoptosis. During the same incubation period in the absence of histamine, the neurons were prevented by Na^{+}-polyP. A direct proof showed the elimination of the Ca^{2+} burst around the neuronal/glial mixed cell culture by Na^{+}-polyP. This finding is caused by the coacervate formation, which occurs during apoptosis via exchange of the cation Na^{+} versus Ca^{2+}. In the presence of Na^{+}-polyP the initially spindle-shaped HUVEC cells start to produce fibrils, which become assembled into collagen bundles improving the collagen synthesis. In the clinical attempt, no difference was found compared to the steroid-containing cream; both itching and erythema were equally

controlled with both preparations (standard versus new therapy) and led to a significant improvement in patients' comfort, as assessed both objectively and subjectively.

Conclusions

Topical application of polyP combines two key properties: it mitigates the massive calcium influx by normalizing the Ca^{2+} -concentrations forming a coaservate with polyP, resulting in stabilization of the histamine and cytokine metabolism. Moreover, it boosts the ATP levels, thereby improving the metabolic energy deficit restoring the immunological homeostasis, as well as the collagen synthesis. Therefore, it had been pressing to apply the Ca^{2+} chelator polyphosphate, to test for efficacy in the treatment of AD. It appears to be a genuine alternative to existing topical treatment, particularly as an alternative to steroids, eliminating the negative side effects. A prospective controlled study seems inevitable

EA DV CONGRESS
VIENNA
30 SEP - 3 OCT 2026

Abstract N°: 1596

A Clinical Study to Assess the Efficacy of a Post-operative Recovery Cream Containing Eperua Extract, Ceratonia Siliqua Extract, Oleamido Octadecanediol, Niacinamide and Acetyl Tetrapeptide When Applied After Fractional Ablative Laser In a Majority of Fitzpatrick Skin Types IV-VI

Jill Waibel[1], Julie de la Cruz[1], Chelsea Steele[1], Peter Bittar[1], Nicole Joy[1], Patricia Brieva*[2], Stacy White[2]

[1] University of Miami Miller School of Medicine, Miami Dermatology and Laser Institute, Miami, United States

[2] SkinCeuticals, New York, United States

Introduction

Ablative fractional lasers are often used in dermatology to treat signs of photoaging including texture irregularities, pigmentation and rhytids. While ablative lasers are effective in melanin-rich skin (Fitzpatrick types IV-VI), post-laser procedure outcomes are often associated with a high risk of post-inflammatory pigmentation (PIH) and scarring that may persist for several weeks. Similarly in Fitzpatrick types I-III PIE (post-inflammatory erythema) and edema are among the most common adverse events. Standard of care post-ablative laser protocols are often limited in effective and safe treatments options to mitigate these bothersome post-procedure side-effects; relying mainly on petrolatum-based ointments as an occlusive to support hydration, decrease pain and increase healing with full improvement not observed for a week or longer. The recovery cream contains a proprietary blend of six ingredients including an anti-inflammatory plant derived extract, amino acids, a plant-derived polysaccharide, ceramides, peptides, and niacinamide that work synergistically to promote epithelialization, reduce inflammation, stimulate growth factors, and target dyspigmentation. This study aims to assess the efficacy and safety of a novel post-operative recovery cream in decreasing pigmentation, edema and erythema, while providing improvement in facial rhytids following facial fractional ablative carbon dioxide (CO2) and Erbium laser treatment on photodamaged skin.

Materials and Methods

A 6-week study was conducted on 44 female and male subjects Fitzpatrick type I-VI, ages 40-70 with mild-to-moderate signs of photoaging including pigmentation, fine lines, and global wrinkles. At baseline (D-14) subjects applied the recovery cream twice daily in conjunction with a cleanser and sunscreen. On the day of procedure (D0) all subjects received fractional ablative laser CO2 to all facial areas, except for the peri-ocular area where the Erbium fractional laser was applied. Immediately following laser treatment, the novel cream was applied and thereafter subjects continued the pre-treatment skincare regimen for a total of 4 weeks post-procedure. Clinical efficacy was assessed by the investigator at baseline, 3 days, 5 days, 7 days, and 4 weeks post-laser procedure. Objective tolerance was evaluated at immediately post-ablative laser (Imm), 3, 5, 7 days and week 4. Subjective tolerance, photography and the subject self-assessment questionnaire were conducted during the study.

Results

Our study demonstrates as early as Day 3 post-ablative laser compared to immediately post-laser; the topical recovery cream treatment results in greater statistically significant improvement in erythema and edema which continued to statistically improve at 7 days, 5 days and week 4. Similarly compared to baseline, the topical cream results in higher statistically significant improvement in pigmentation and global wrinkles, with endurance of statistically significant improvement thru week 4. Subjects reported a mild level of pain when the recovery cream

was applied immediately following CO2 and Erbium fractional ablative laser treatment. There were no major adverse events before, during the procedure and all subsequent post-procedure visits.

Conclusions

This novel post-operative recovery is an effective and safe treatment option that decreases post-operative pigmentation, edema and erythema and improved global wrinkles following facial fractional ablative CO2 and Erbium laser treatment for photoaging in all Fitzpatrick skin types.

EA DV CONGRESS
VIENNA
30 SEP - 3 OCT 2026

Abstract N°: 1718

Effect of Dimethyl Fumarate on giant cell formation

Christos Zouboulis[1], David Ferrari[2], Petra Hoyer[3], Rena Danneberg[3], Hartmut Kroll[3], Undine Lippert*[2]

[1] Department of Dermatology, Venereology and Immunology, Universitaetsklinikum Ruppin-Brandenburg, Brandenburg Medical School Theodor Fontane, Neuruppin, Germany

[2] Department of Dermatology, Venereology and Allergology, University Medical Center Göttingen, Göttingen, Germany

[3] Institute for Transfusion Medicine Dessau, Red Cross Blood Transfusion Service NSTOB, Dessau, Dessau, Germany

Introduction

Several reports have mentioned a therapeutic effect of fumaric acid esters (FAEs) in granulomatous skin diseases such as necrobiosis lipoidica, granuloma annulare, and sarcoidosis. Histological findings in granulomatous disorders demonstrate a dermal infiltrate of multi-nucleated giant cells (MGC) and T cells. However, data on possible effects of FAEs on cell fusion are rare. Since cells from the monocyte–macrophage lineage are precursors of MGC we investigated the potential impact of FAEs on human monocyte survival and most importantly their ability to fuse and form giant cells.

Materials and Methods

Primary human monocytes were isolated from peripheral blood mononuclear cells (PBMC) of healthy donors via density gradient centrifugation and magnetic bead-activated cell sorting. Cell viability and purity was tested via flow cytometry analysis (FACS). Isolated monocytes were cultured for 72h with 50% conditioned medium and with or without FAEs at different concentrations. Conditioned medium was used to induce the formation of MGC. It was obtained by cultivation of PBMC with concanavalin A for 72h. Thereafter, cells were centrifuged and the supernatant was collected and stored at -20°C until use. Prednisolone (1µM) served as positive control for inhibition of giant cell formation. After 72h cells were stained with May-Grünwald-Giemsa dye and the number of nuclei within MGC (≥ 3 nuclei/cell) in a representative area and the total number of nuclei in the same area were counted. The fusion index (FI) percentage was obtained by calculating (number of nuclei within MGC/ total number of nuclei counted) x 100.

Results

Cell viability (YOPRO/7AAD staining) and cell purity (anti-CD14 and anti-CD33 antibody staining) of isolated monocytes were always over 95%. Incubation of isolated monocytes with conditioned medium induced the formation of MGC mostly from Langhans type cells and 6-fold less from foreign body type cells. Dimethyl fumarate (DMF) reduced cell fusion at biologically relevant concentrations from 7µM up to 21µM. We analyzed no higher concentration since we found that DMF concentrations above 21µM induced cell death in over 20% of cells mainly via necrosis. Interestingly, the number of MGC did not change significantly with concentrations from 7 to 14µM DMF. However, the number of MGC with ≥ 6 nuclei decreased with increasing DMF concentration, while the number of MGC with fewer nuclei (MGC ≤ 5) increased. At 21µM DMF the total number of MGC also decreased and the number of fused nuclei (MGC ≥ 6) dropped severely by up to 80%. Monomethyl fumarate, Ca^{2+}-, Mg^{2+}- and Zn^{2+}-ethyl hydrogen fumarate had no effect in parallel studies.

Conclusions

The results of this study may improve our knowledge of the therapeutic impact of FAEs on granulomatous diseases, for which they are currently only used in an off-label capacity.

EADV CONGRESS
VIENNA
30 SEP - 3 OCT 2026

Abstract N°: 1967

Apremilast for severe and refractory subcorneal pustular dermatosis

Laura Sulaiman*[1], Mirain Phillips[2], Jenny Hughes[2]

[1] University Hospital Wales, Cardiff, United Kingdom
[2] Princess of Wales Hospital, Bridgend, United Kingdom

Introduction

Subcorneal Pustular Dermatosis (SCPD) is a rare, chronic and relapsing neutrophilic dermatosis of unknown aetiology which is characterised by recurring crops of tender, flaccid vesico-pustules typically involving the trunk and flexural sites.

Case Presentation

An 85-year-old lady with a 23-year history of recalcitrant, painful and widespread SCPD had failed to respond to multiple systemic agents including methotrexate, acitretin, ciclosporin, minocycline, colchicine, and partially responded to topical clobetasol propionate and oral corticosteroids. Treatment with dapsone resulted in life-threatening agranulocytosis and admission to intensive care. Biologic treatments including ustekinumab and adalimumab were also ineffective. Over the years, a combination of bath and oral PUVA had been the only means of providing disease control, temporary relief of flares and improved quality of life. Thus, the safe recommended lifetime number of treatments was quickly exceeded. Further phototherapy was only carried out in exceptional circumstances with discussion of the risks associated with high cumulative exposure.

In 2024, the patient had developed stage 1a melanoma and basal cell carcinomas. Apremilast was commenced aiming to reduce the reliance on phototherapy for disease control.

Conclusion

Apremilast is a phosphodiesterase-4 inhibitor, licensed in dermatology for the treatment of moderate to severe plaque psoriasis. A handful of case reports describe successful use of apremilast in SCPD. Apremilast is thought to work through downregulation of pro-inflammatory mediators including TNF-alpha, IL-6, IL-8, IL-17 and IL-23. This suggests a potential therapeutic role for apremilast in SCPD by modulating neutrophil-driven inflammation and its clinical and immunologic overlap with pustular psoriasis.

Treatment of the patient with apremilast at a dose of 30mg twice daily resulted in 90% improvement of SCPD within the first 8 weeks. Eighteen months after initiation of therapy, her disease remains well controlled with minimal need for adjunctive topical clobetasol propionate and no further phototherapy.

Our case supports the use of apremilast as a safe and effective off-label therapeutic option in severe and refractory SCPD.

POWERED BY M-ANAGE.COM

EADV CONGRESS
VIENNA
30 SEP - 3 OCT 2026

Abstract N°: 2063

Factors Influencing Methotrexate Administration Route in Patients with Psoriasis: A Retrospective Observational Study

Ilze Upeniece*[1], Marta Kaķe[2]

[1] Riga 1st hospital, Riga Stradinš University, Riga, Latvia

[2] Riga Stradiņš University, Riga East Clinical University Hospital, Riga, Latvia

Introduction

Methotrexate (MTX) remains a cornerstone systemic therapy for moderate-to-severe psoriasis. MTX can be administered orally or subcutaneously (SC), with evidence suggesting that SC administration may offer improved bioavailability and reduced gastrointestinal adverse effects. However, factors influencing the choice of administration route remain poorly characterized. Understanding these determinants may help optimize treatment selection and identify potential prescribing biases.

Materials and Methods

Methotrexate prescriptions were retrospectively analyzed from April 1, 2022 to April 6, 2026, at a single tertiary dermatology center. Period selection - post-COVID-19 pandemic period. Only first MTX prescriptions for patients with psoriasis (ICD-10: L40) were included. The primary outcome was MTX administration route (oral vs. subcutaneous). Potential predictors included: (1) disease factors – psoriasis duration, BSA, PASI, high-risk features; (2) patient factors – age, liver disease, gastrointestinal disease, metabolic comorbidity, smoking, alcohol use; and (3) physician factors – prescribing volume (≤10, 11–30, >30 patients) and clinical experience (<10 vs. ≥10 years). Univariate and multivariate logistic regression analyses were performed using SPSS version 17.

Results

A total of 360 patients were included (52.2% male; mean age 47.3 ± 15.0 years). Median disease duration was 10 years (IQR 2–20; n = 299), median BSA 15.0% (IQR: 10.0–29.75; n=160), and median PASI 13 (IQR 10–20; n=135). High-risk psoriasis features were documented in 241 patients (70.9%; n=340). Psoriatic arthritis was documented in 36 patients (10%). Oral MTX was prescribed in 217 patients (60.3%), SC in 143 (39.7%).

On univariate analysis, BSA (p=0.003), psoriatic arthritis (p=0.006), and physician experience (p<0.001) were significantly associated with MTX route. No significant associations were found for age, sex, PASI, disease duration, high-risk features, or other comorbidities or lifestyle factors.

Two multivariate logistic regression models were constructed. In Model 1 (n=360), physician experience ≥10 years (OR = 2.96, 95% CI 1.82–4.81, $p < 0.001$) and presence of psoriatic arthritis (OR = 2.49, 95% CI 1.20–5.15,$p = 0.014$) were significant independent predictor of SC MTX initiation. Model 2 (n=160, including BSA), both physician experience (OR = 5.48, 95% CI 1.81–16.59, $p = 0.003$) and disease extent (OR = 1.03 per 1% increase in BSA, 95% CI 1.01–1.06, $p = 0.006$) independently predicted SC use. Psoriatic arthritis were not significant after adjustment in either model.

Conclusions

Physician experience ≥10 years is the strongest predictor of SC MTX initiation, independent of disease severity

and patient factors. Disease extent (BSA) also influences route selection. These findings suggest that MTX administration route in psoriasis is primarily driven by physician-related factors rather than clinical indicators. Limitations include the retrospective design, incomplete documentation of clinical variables, and single-center setting.

EADV CONGRESS
VIENNA
30 SEP - 3 OCT 2026

Abstract N°: 2069

EFFICACY OF BLEOMYCIN ADMINISTERED VIA THE MICROINFUSION OF DRUGS TECHNIQUE (MMP) IN THE TREATMENT OF RECALCITRANT WARTS: A CASE REPORT

Maria Jose Mancero Rodríguez*[1], Jessica Noemi Alvear Celi[1], Judith Polo[1], Ana Amelia Bezerra Milfont[1]

[1] Policlinica Geral do Rio de Janeiro, RIO DE JANEIRO, Brazil

Introduction

To present a clinical case demonstrating the efficacy and safety of intralesional bleomycin administered using the microinfusion of drugs technique (MMP) in an immunosuppressed pediatric patient with recalcitrant common warts, previously treated with conventional therapies without satisfactory response.

Materials and Methods

A comprehensive review of the literature was carried out for this case.

Results

A 13-year-old male patient, with a single kidney, a history of renal transplantation due to polycystic kidney disease, and currently on immunosuppressive therapy, presented with a one-year history of multiple exophytic lesions with a verrucous surface, well-defined, located on both palms, causing significant functional impairment. He had previously received topical treatment with salicylic acid without response. During the initial evaluation, a combination of procedures was performed over several sessions, including cryotherapy, shaving, and application of 35% trichloroacetic acid. However, there was minimal improvement and, notably, intense pain during each intervention. Due to the refractory nature of the condition, treatment with bleomycin was initiated using the microinfusion of drugs technique (MMP) in two sessions, spaced four weeks apart. The treatment was well tolerated, with no significant adverse effects. After the second session, complete resolution of the lesions and functional improvement were observed.

Although common warts are a benign condition, their treatment can be challenging, especially in recalcitrant cases in the pediatric population, and may negatively impact quality of life and functionality. While established therapeutic options exist, their results can be limited. The use of bleomycin via the MMP technique has emerged as a therapeutic alternative, demonstrating effectiveness in the treatment of recalcitrant common warts, as shown in the present case.

Conclusions

The administration of bleomycin using the MMP technique may represent an effective and better-tolerated alternative for recalcitrant warts in immunosuppressed patients, especially when conventional treatments have failed.

EA DV CONGRESS
VIENNA
30 SEP - 3 OCT 2026

Abstract N°: 2125

Vitamin D and the Skin: Mechanisms, Dermatoses, and Emerging Genetic Insights

Maroua Sakhri*[1]

[1] Independent Author, Algiers, Algeria

Introduction

Vitamin D plays a key role not only in skeletal homeostasis but also in regulating skin homeostasis and modulating immune responses. The skin represents both a primary site of vitamin D biosynthesis and a target organ for its biological activity. Here, we discuss the role of vitamin D in skin physiology and dermatoses, with an emphasis on keratinocytes as key cells in these mechanisms and vitamin D receptor (VDR) polymorphisms as a future direction.

Materials and Methods

- **Metabolism, Keratinocyte Effects, and Dermatological Implications of Vitamin D**

Two main sources of vitamin D have been identified: an exogenous source from oral intake and dietary supplementation, and endogenous production, which requires exposure to sunlight—specifically UVB radiation.This vitamin D is inactive; it is converted in the skin to cholecalciferol and then hydroxylated in the liver and kidneys to form the active metabolite, 1,25-dihydroxyvitamin D.keratinocytes play a major role in converting locally vitamin D3 into its active form through the enzymes CYP27A1 (25-hydroxylase) and CYP27B1 (1-hydroxylase). These cells also express the VDR, enabling this hormone to regulate every step of the differentiation process. In addition, vitamin D stimulates the synthesis of filaggrin, loricrin, antimicrobial peptides, and long-chain fatty acids as well as the formation of the cornified envelope in the stratum granulosum. It also enhances the innate immune function of keratinocytes by stimulating the expression of toll-like receptor (TLR2) and its co-receptor CD14. Therefore, vitamin D is thought to be involved in the pathophysiology of several skin diseases, including psoriasis, atopic dermatitis (AD), and acne, suggesting its potential therapeutic effects in the management of these conditions. Furthermore, the occurrence of hair loss in patients with vitamin D–dependent rickets type II highlight the importance of vitamin D in hair follicle. Anti-inflammatory and immunoregulatory effects have also been demonstrated ;however, the underlying mechanisms are not yet fully understood (figure 01).

Several studies have suggested the therapeutic effects of oral vitamin D supplementation in psoriais. Nevertheless, the topical formulation remains the preferred option due to its tolerability and established safety profile. In other conditions, such as AD and acne, a beneficial effect has also been suggested; however, further research is necessary.

- **Future perspective**

In addition to vitamin D deficiency, genetic polymorphisms in the VDR gene may alter ligand–receptor affinity or transcriptional activity and have been implicated in both the pathogenesis of numerous cutaneous disorders and patient responses to vitamin D supplementation. These findings represent an important direction for future research, offering a better understanding of the physiopathology of various conditions and highlighting the need for a personalized approach to their management.

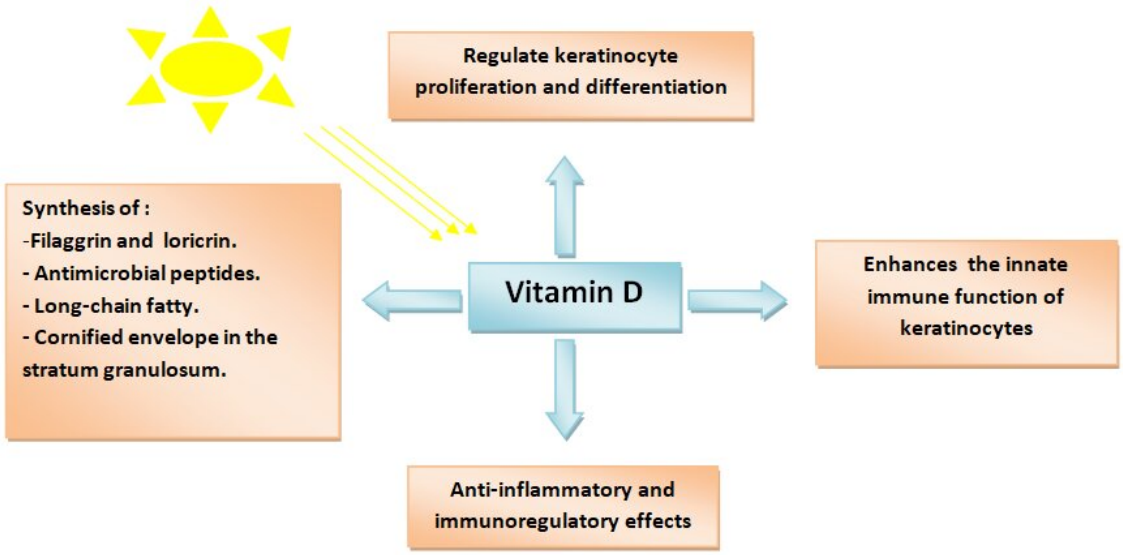

Figure 01: Role of vitamin D in the skin

Conclusions

Vitamin D plays a crucial role in maintaining skin homeostasis through its immunomodulatory, antiproliferative, and barrier-supporting effects. Genetic variability in VDR and limited evidence for oral supplementation highlight the need for personalized and targeted therapeutic approaches.

EADV CONGRESS
VIENNA
30 SEP - 3 OCT 2026

Abstract N°: 2181

Sirolimus in Tuberous Sclerosis Complex: From Facial Remodeling to Visceral Salvage

KHALDI HANANE FADOUA*[1, 2], Mahi Ilhem[1, 2], DAHMANI Boumediene[1, 2], Benhamed Nardjes[2]

[1] Department of Dermatology and Venereology, CHU Tlemcen, Tlemcen, Algeria

[2] Faculty of Medicine, Dr. Benzerdjeb Benaouda, Tlemcen, Faculty of Medicine, Dr. Benzerdjeb Benaouda, Tlemcen, Tlemcen, Algeria

Introduction

Tuberous Sclerosis Complex (TSC) is a rare multisystemic phacomatosis with autosomal dominant inheritance. This congenital disorder is characterized by the development of hamartomas across multiple organs. Treatment strategies are tailored to the severity of organ involvement and often require a non-codified multidisciplinary approach. Based on our clinical observation, we report the efficacy of mTOR inhibitors (Sirolimus) in a complex case of TSC.

Case Presentation

A 17-year-old female patient with no significant medical history presented with a polymorphic cutaneous phenotype suggestive of TSC. Clinical examination revealed florid facial angiofibromas, a fibrous plaque on the scalp, achromic macules, a "shagreen patch" on the trunk, as well as periungual Koenen tumors and oral fibromas with dental pits. This dermatological presentation prompted a systemic investigation, which revealed major multivisceral involvement: neurological (cortical tubers, subependymal nodules, and giant cell astrocytoma), ophthalmological (retinal hamartomas), and cardiac (rhabdomyoma). Imaging also confirmed the presence of bilateral renal cortical angiomyolipomas and hepatic involvement. Meeting eight major and one minor criteria according to international consensus, the patient was started on an mTOR inhibitor (Sirolimus, 2 mg/day) due to the systemic lesional burden. At six months, the evolution showed spectacular improvement, with subtotal regression of facial angiofibromas and a significant volumetric reduction of visceral angiomyolipomas. The stabilization of cardiac and retinal lesions, combined with excellent long-term clinical and biological tolerance, highlights the efficacy of Sirolimus as a cornerstone for the coordinated management.

The pathophysiology of TSC is based on the constitutive activation of the mTOR pathway (TSC1/2), and its inhibition by Sirolimus has revolutionized the multisystemic prognosis. Dermatologically, it induces rapid regression of facial angiofibromas by inhibiting angiogenesis. This efficacy is confirmed systemically with a reduction in renal angiomyolipoma volume of over 50%, stabilization of respiratory decline in lymphangioleiomyomatosis, and significant responses in subependymal giant cell astrocytomas , epilepsy, retinal hamartomas. However, this action is strictly suppressive: Sirolimus acts as a cytostatic brake without eliminating hamartomatous cells, leading to a risk of tumor rebound upon discontinuation. This necessitates a long-term therapeutic strategy justifying rigorous monitoring of Sirolimus blood levels.

Conclusion

Systemic Sirolimus represents a decisive therapeutic turning point for complex multisystemic forms of TSC. By exerting pleiotropic control over cutaneous and systemic involvements, this targeted therapy has become the cornerstone for significantly improving patient quality of life.

EADV CONGRESS
VIENNA
30 SEP - 3 OCT 2026

Abstract N°: 2341

Topical Corticosteroid–Induced Adrenal Insufficiency:A Series of Six Cases

raouia Roumili*[1], Kholoud Afeissa[2], Dali osmane Rima[1], tinhinane benbrahim[2], fella laissaoui[1], ihsen chikh[2], Baya Moussaoui[2], mira chikhaoui[1], sahel houria[1]

[1] Dermatologie, C.H.U Lamine Debaghine, bab elouad, Algeria
[2] C.H.U Lamine Debaghine, BAB ELOUAD, Algeria

Introduction

Prolonged and/or inappropriate use of topical corticosteroids (TCS), particularly those of very high potency, may lead to suppression of the hypothalamic–pituitary–adrenal (HPA) axis and, more rarely, to adrenal insufficiency (AI). We report a series of six cases of AI observed in the Dermatology Department of CHU Bab El Oued in Algiers between June 2023 and June 2025.

Materials and Methods

We collected all patients hospitalized for various dermatoses complicated by AI between June 2023 and June 2025 in the Dermatology Department of CHU Bab El Oued in Algiers. AI was biologically confirmed by measuring basal serum cortisol at 8 a.m. and performing a Synacthen stimulation test*, or was suspected based on clinical signs suggestive of AI associated with measurements of basal cortisol at 8 a.m., ACTH, and urinary cortisol. Clinical, biological, and outcome data were obtained from patients' medical records.

Results

Six patients were included: three children (two boys and one girl; mean age 4 years, range 21 months–7 years) and three adults (one man and two women; mean age 46 years, range 29–67 years).

Indications for TCS use were psoriasis (n=3), seborrheic dermatitis (n=1), cutaneous xerosis (n=1), and pityriasis rubra pilaris (n=1). All patients had received very high-potency TCS, used in a prolonged and unsupervised manner, with a mean duration of ten years.

The most frequent clinical manifestations of AI included asthenia (n=6), striae and cutaneous atrophy (n=4), and signs of corticosteroid excess (n=1), notably moon face, buffalo hump, thin limbs, and hypertrichosis. Hypotension (n=1) and hypertension (n=1) were also observed.

The diagnosis of TCS-induced secondary AI was confirmed by low basal serum cortisol at 8 a.m. (n=5), low urinary cortisol (n=1), low ACTH levels (n=6), and a Synacthen stimulation test (n=1).

After discontinuation of TCS, all patients received hydrocortisone replacement therapy. The outcome was favorable in five patients; one patient died following treatment discontinuation

Conclusions

Few cases of AI secondary to TCS use have been reported to date. This complication is mainly described in atopic dermatitis and less frequently in psoriasis. In our series, it was observed in three patients with psoriasis, while no cases of atopic dermatitis were recorded.

It is generally associated with prolonged and unregulated use of TCS. Other contributing factors include the extent of treated body surface area, occlusion, and cutaneous inflammation, all of which may enhance TCS penetration and systemic absorption. Signs of corticosteroid excess may sometimes predominate, whereas signs of AI remain subtle, leading to diagnostic challenges, as observed in one of our patients.

This series highlights the risk of AI secondary to TCS use, particularly in cases of prolonged, unsupervised use of very potent agents. It underscores the importance of carefully tailored use of TCS in order to minimize this risk.

EA DV CONGRESS
VIENNA
30 SEP - 3 OCT 2026

Abstract N°: 2476

Treatment Options for Different Variants of Cutaneous Warts; A Clinical Therapeutic Trials.

Haider Al-Sabak*[1]

[1] Professor & Consultant Dermatologist/ Head of Dermatology & Laser department/ College of Medicine/ University of Kufa, Najaf, Iraq

Introduction

Background: Warts, are benign epidermal proliferations caused by human papillomavirus (HPV), present in various clinical forms, including verruca vulgaris, plane warts, and other cutaneous types. Management remains challenging due to recurrence, patient discomfort, and variable response rates. Recent advances have explored diverse therapeutic modalities with varying efficacy and safety profiles.

Objective: To summarize and evaluate current therapeutic options done in our Dermatology center for different variants of warts, including laser-based therapies and intralesional immuno- or chemotherapeutics, based on recent clinical trial data from Iraqi patients.

Materials and Methods

1. **A clinical trial involving 35 patients with 105 common warts demonstrated that long pulsed Nd:YAG laser (1064 nm) yielded a complete response in 91.43% of lesions with a low recurrence rate (2.08%). Adverse effects were mild, underscoring its safety and efficacy.**
2. **A separate study on 34 patients with Plane Warts using long pulsed Nd:YAG laser 532 nm showed an excellent response in 86.36% of cases, with a cumulative clearance rate reaching 89.9% after three sessions and a recurrence rate of just 4.5%.**
3. **Intralesional Vitamin D3 (600,000 IU) injections in a cohort of 40 patients with common Warts showed complete response in 81.9% of lesions after four sessions, with only one case of recurrence noted over 6 months. Side effects were minimal.**
4. **An Intralesional 5-Fluorouracil (50 mg/mL) administered biweekly for 50 patients with cutaneous warts up to six sessions was proposed, with outcomes of 82.5% complete clearnce and only 10% of poor response.**
5. **A clinical trial involving 41 patients with Common Warts injected with MMR Vaccine (0.3 mL per wart) showed 80.4% complete response and only 7% of no results of up to five sessions, over six months.**

Results

we recognize very good and promising results from these 5 studies, with no or minimal side effects.

Conclusions

The treatment of warts must be tailored according to the wart variant and patient profile. Laser therapies, particularly long pulsed Nd:YAG at both 1064 nm and 532 nm wavelengths, demonstrated high clearance rates with minimal side effects.

Intralesional therapies, including Vitamin D3, 5-fluorouracil, and MMR vaccine, offer cost-effective and

non-invasive alternatives with promising efficacy and tolerability. These findings support the integration of laser and immunotherapeutic strategies in wart management, warranting further comparative trial.

EA DV CONGRESS
VIENNA
30 SEP - 3 OCT 2026

Abstract N°: 2526

MDC-75: A Novel Solution for the Painless Removal of Superficial Skin Lesions

Thierry Passeron*[1], Philippe Andres[2], Mikhail Verozub[3], Philippe Reynier[3], Gitanjali Petkar[4]

[1] Department of Dermatology, Centre Hospitalier Universitaire de Nice, Côte d'Azur University, Nice, France, INSERM U1065, Centre Méditerranéen de Médecine Moléculaire (C3M), Côte d'Azur University, Nice, France, Nice, France

[2] Clipeum Pharma, Grasse, France

[3] R&D Pharma, Monaco, Monaco

[4] CIDP, Centre International de Développement Pharmaceutique, Phoenix, Mauritius

Introduction

Benign skin lesions generally do not require treatment unless they cause cosmetic concerns, psychological distress, or physical discomfort. The physical removal of small benign skin lesions is well established in dermatology and includes techniques such as cryotherapy, electrocautery, shave excision, and laser therapy. While generally safe, these procedures may lead to local side effects and complications, including pain, inflammation, blistering, oozing, bleeding, infection, delayed healing, scarring, or pigmentary changes.

Chemical destruction (cauterization, mummification) represents an alternative approach, involving the application of caustic agents to induce controlled tissue necrosis and removal of superficial lesions. MDC-75 is an acid-based topical medical device designed for the safe and effective treatment of benign superficial skin lesions in adults. Its active component, alpha-chloropropionic acid, acts via a self-limiting protein denaturation process, leading to irreversible cellular damage and controlled mummification of the treated tissue.

Materials and Methods

Two open-label, monocentric clinical trials were conducted in Mauritius to evaluate the safety and performance of MDC-75. Both studies followed similar designs and included adult patients presenting with superficial benign skin lesions: warts, acrochordons, seborrheic keratoses, isolated low grade actinic keratoses, and benign non-active dermal nevi.

Each patient received up to three applications of MDC-75, with a follow-up after the final application. The evaluation included both clinical assessments and patient-reported outcomes. Efficacy was measured through changes in lesion size (from baseline to final visit), investigator global assessment, a global assessment of improvement, and patient satisfaction. Safety was assessed at each visit based on adverse events, local tolerance, immediate pain scores, and the presence of scarring or dyspigmentation at study end.

Results

A total of 51 patients (41 females, 10 males; mean age: 47 years) enrolled and completed the studies. The study population was ethnically diverse, including Caucasian, Indian, Asian, African, and mixed backgrounds. Skin phototypes ranged from II to VI, with a predominance of phototype IV. In total, 87 lesions were treated: 25 acrochordons, 29 benign nevi, 15 common warts, 7 actinic keratoses, and 11 seborrheic keratoses.

MDC-75 demonstrated significant efficacy across all evaluated parameters. Quantitative measurements (volume)

showed consistent and sustained reductions from the earliest time point, indicating both rapid onset and continued lesion regression. At the final assessment, 72% of lesions, irrespective of type, were rated by investigators as either resolved or markedly improved (detailed below).

Lesion reduction by less than 50% was observed only with benign dermic naevi 27.6% and common warts 6.7%. MDC-75 demonstrated activity in every lesion.

The treatment was well tolerated, with a transient mild inflammation and no reported adverse reactions. Pain levels were minimal: 61% of patients reported no pain, and 96% reported pain scores ≤2 on a 0–10 scale. Among 51 patients, 64.7% reported PIH, one patient reported hypopigmentation on 2 lesions, and one patient reported a hypertrophic scar, resolved post-study (Week 13) with a residual PIH. PIH was barely visible in 25% of cases, mild in 50% and moderate in 25%.

Patient-reported outcomes on 11-point scale reflected high satisfaction rates with an average satisfaction score of 8.75/10 and a strong willingness to recommend the treatment with an average score of 9.22/10.

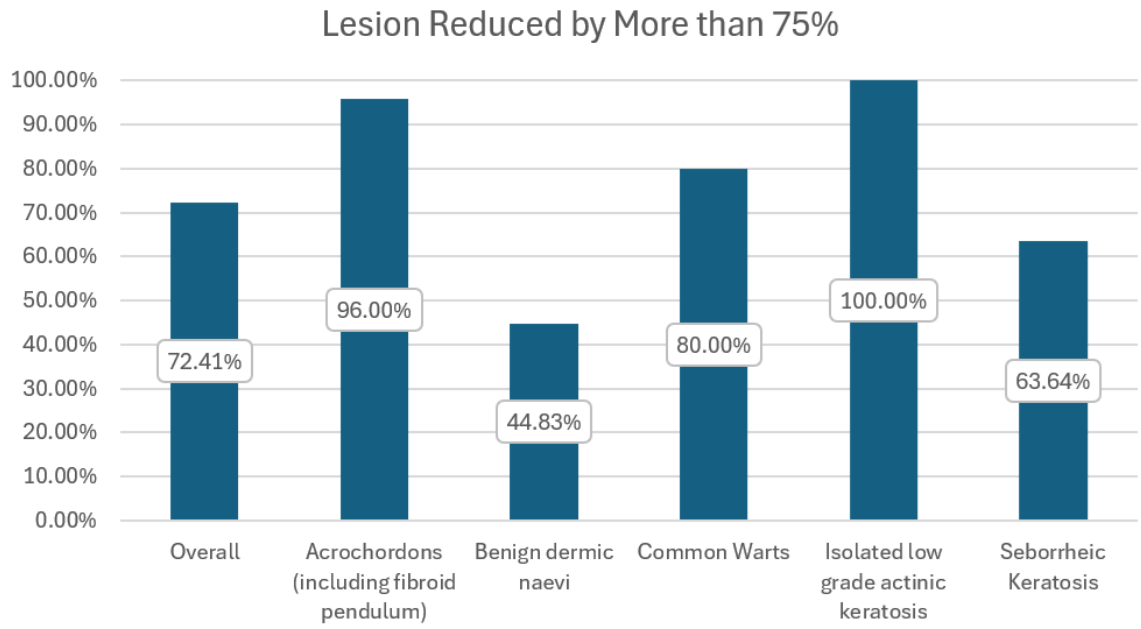

Treatment success: lesions reduced by more than 75%

Conclusions

MDC-75 is a novel medical device that provides a simple, effective, and nearly painless option for the treatment of benign superficial skin lesions in the dermatology office setting.

EADV CONGRESS
VIENNA
30 SEP - 3 OCT 2026

Abstract N°: 2541

Topical corticosteroid phobia among the general population: a cross-sectional study using the TOPICOP scale

Fares Alammari*[1]

[1] College of Medicine, Almaarefa university, Riyadh, Saudi Arabia

Introduction
Topical corticosteroids are among the most frequently prescribed treatments for inflammatory and pruritic dermatological conditions. When used appropriately, they demonstrate a favorable safety and efficacy profile. However, increasing concern regarding their potential adverse effects has led to the emergence of topical corticosteroid phobia, which may negatively impact treatment adherence and clinical outcomes. Understanding the magnitude and determinants of this phenomenon in the general population is essential to improve patient education and therapeutic compliance.

Materials and Methods
A cross-sectional observational study was conducted included 160 randomly selected adult participants from the general population. Data were collected using a self-administered online questionnaire distributed through social media platforms over a three-month period. The questionnaire assessed demographic characteristics, previous use of topical corticosteroids, and beliefs, fears, and behaviors related to their use. Topical corticosteroid phobia was evaluated using the validated TOPICOP scale. Statistical analysis was performed using standard statistical software, with a significance level set at $p \leq 0.05$.

Results
A total of 160 participants were included in the analysis, with a predominance of female respondents. More than half of participants reported prior use of topical corticosteroids. The median global TOPICOP score indicated a moderate to high level of corticosteroid phobia. A statistically significant association was identified between educational level and the degree of corticosteroid phobia. A substantial proportion of participants expressed fear of using topical corticosteroids despite limited knowledge of their adverse effects. Additionally, most respondents reported a need for reassurance when prescribed these medications, and many admitted to prematurely discontinuing treatment.

Conclusions
Topical corticosteroid phobia is common within the general population and appears to be largely driven by misconceptions and insufficient knowledge. This fear may lead to poor adherence and suboptimal treatment outcomes. Targeted educational strategies and clear communication by healthcare professionals are crucial to address misconceptions, reassure patients, and promote the safe and effective use of topical corticosteroids.

EA DV CONGRESS
VIENNA
30 SEP - 3 OCT 2026

Abstract N°: 2601

Restoration of skin barrier ultrastructure and lipid composition by a 10% Urea-based topical formulation in very dry skin: An in vivo controlled study using transmission electron microscopy

Katharina Weitzel*[1], Hendrik Mießner[1], Stephan Daehnhardt-Pfeiffer[2], Dorothee Dähnhardt[2], Tanja Bussmann[1], Julia Gallinger[1]

[1] Beiersdorf AG, Hamburg, Germany

[2] Microscopy Services Dähnhardt GmbH, Flintbek, Germany

Introduction

Very dry skin (xerosis) is associated with reduced stratum corneum hydration, disorganization of intercellular lipid lamellae, and depletion of key epidermal barrier lipids such as ceramides, free fatty acids, and cholesterol. These alterations impair barrier integrity and contribute to skin roughness, discomfort, pruritus and susceptibility to irritation. Urea, a natural moisturizing factor (NMF), is known not only for its hygroscopic properties but also for its ability to modulate epidermal differentiation and barrier-related lipid metabolism. However, *in vivo* evidence linking urea-based topical care to ultrastructural barrier normalization and biochemical lipid restoration remains limited. This study aimed to evaluate the effects of a 10% urea-based leave-on formulation including natural moisturizing factors and ceramides on skin hydration, barrier ultrastructure, and lipid composition in subjects with very dry skin.

Materials and Methods

In a single-center, investigator-blinded, intra-individual comparison study, 32 female and male subjects (30–76 years) with very dry skin on the lower legs applied a 10% urea-based leave-on formulation twice daily to one leg for two weeks, while the contralateral leg remained untreated. Skin hydration was assessed by corneometry at baseline (t0) and after 14 days (t1). Barrier ultrastructure was evaluated by transmission electron microscopy following non-invasive stratum corneum sampling (Lipbarvis®), quantifying normalized intercellular lipid lamellae length (nICLL). Skin lipid composition (cholesterol, free fatty acids, ceramides EOS, NP and AP) was analyzed by high-performance thin-layer chromatography. Statistical analyses compared changes versus baseline and untreated control.

Results

At baseline, subjects exhibited very low hydration levels (mean ~15 a.u.) and severely reduced nICLL values (~46 nm/1000 nm^2), consistent with pronounced barrier impairment. After two weeks, treated skin showed a significant increase in stratum corneum hydration compared with baseline and untreated control (mean +21.3 a.u.). Barrier ultrastructure improved markedly, reflected by a strong improvement in nICLL values (+134 nm/1000 nm^2 vs. baseline), while no change occurred on untreated skin. Barrier lipid levels increased significantly following treatment, including free fatty acids and ceramides EOS, NP and AP versus baseline and untreated control, as well as significantly increased cholesterol levels versus baseline. The formulation was well tolerated, with no product-related incompatibility reactions reported.

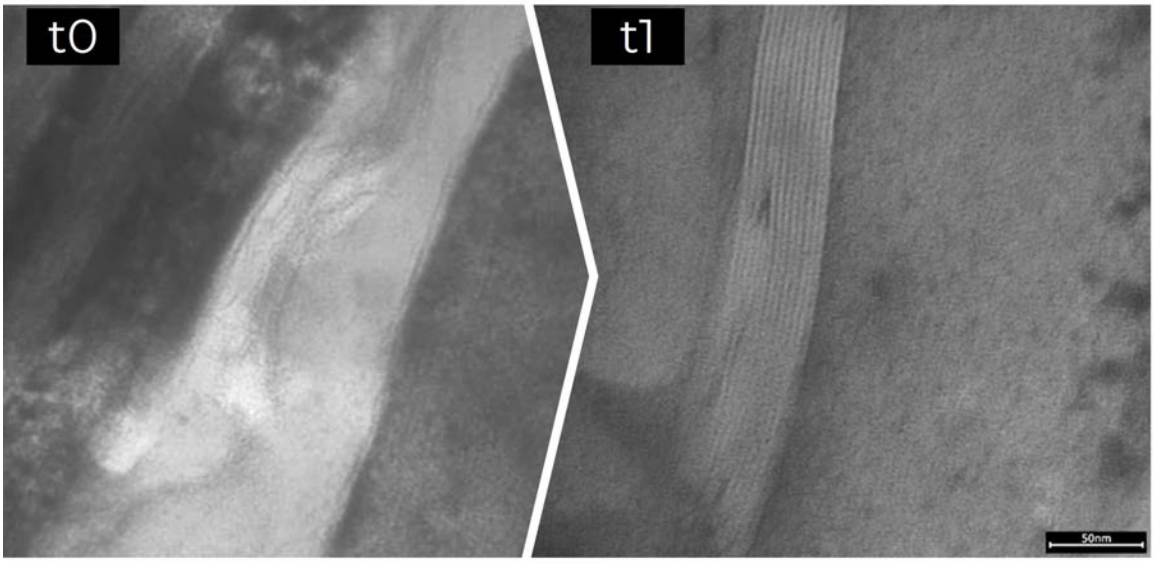

Transmission Electron Microscopy (TEM) images of the intercellular lipid lamellae in the intercellular space at baseline (t0) and after two weeks of topical treatment (t1)

Conclusions

The results demonstrate that topical application of a 10% urea-based formulation not only increases superficial hydration but also restores the structural and biochemical hallmarks of a functional skin barrier. The pronounced recovery of lipid lamellae organization, free fatty acids and key ceramides suggests true barrier repair rather than transient moisturization. These findings support the use of urea-based active formulations as an effective approach for managing very dry skin.

EA DV CONGRESS
VIENNA
30 SEP - 3 OCT 2026

Abstract N°: 2793

Cutaneous and Systemic Adverse Events Associated with Topical Corticosteroid Use: A Targeted Literature Review

Alexandra Golant*[1], Adam J. Friedman[2], Mark G. Lebwohl[1], Douglas DiRuggiero[3], Scott Snyder[4], Robert Higham[4], Brett Stephenson[4]

[1] Icahn School of Medicine at Mount Sinai, New York, United States

[2] George Washington University School of Medicine and Health Sciences, Washington, DC, United States

[3] Skin Cancer and Cosmetic Dermatology Center, Rome, United States

[4] Arcutis Biotherapeutics, Inc., Westlake Village, United States

Introduction

Since the 1950s, topical corticosteroids (TCS) have been used to treat chronic inflammatory dermatoses such as atopic dermatitis, psoriasis, and seborrheic dermatitis. Starting soon after TCS introduction, there was mounting evidence for an association between their application and cutaneous and systemic adverse effects, particularly with prolonged use, high-potency formulations, and application to high-risk areas. These considerations can cause hesitancy in maintaining an appropriate treatment plan, exacerbating or prolonging disease. A targeted literature review was performed to identify relevant case studies and case series describing adverse events (AEs) reported for patients treated with TCS.

Materials and Methods

A literature search of titles and abstracts published from August 2015–2025 in PubMed and Google Scholar was performed in September 2025. Search terms included “corticosteroids” OR “topical steroid” AND “topical” OR “cutaneous” OR “dermal” AND "drug-related side effects and adverse reactions" OR "safety" OR "side effect" OR “complication” AND "case report" OR “case series”. Non-human and non-English reports, as well as those without safety outcomes, were excluded. There were three reviewers involved in publication screening and selection.

Results

Over the 10-year period, 1191 publications were identified, 98 full-text articles were reviewed, and 45 were included. Articles were excluded if confounding medications were involved and a direct relationship of the reported AE to TCS was unclear. The 45 final articles represented 85 patients. Publications included adult (53.3%) and pediatric (40.0%) patients (4 not reported) and there was global representation across 16 countries. TCS were applied daily in 31.1% of the publications and for >1 year and 1–12 months in 44.4% and 28.9%, respectively. Cutaneous AEs (eg, skin atrophy, striae, telangiectasia, hypopigmentation) were reported in 44.4% of publications and were largely associated with prolonged or high-potency TCS use. Systemic AEs were reported, including hypothalamic-pituitary-adrenal axis suppression/adrenal insufficiency (44.4%) and Cushing syndrome (40.0%); these were typically associated with high-potency TCS, occlusion, application to extensive body surface area, or prolonged duration of exposure. Other systemic complications (ie, hypertension, osteonecrosis or osteoporosis, metabolic abnormalities) and ocular complications were reported in 22.2% and 8.9% of identified publications, respectively. Reports were from outpatient (31.1%), inpatient (17.8%), and emergency (13.3%) settings, indicating that AEs occurred across the spectrum of mild to severe and nonserious to serious. Many cases involved

inappropriate use patterns (ie, self-medication, over-the-counter access [which varies by country], excessive dosing, prolonged use without medical supervision, and application to high-risk areas [eg, face and diaper region of pediatric patients]), suggesting key drivers of AEs were treatment gaps and chronic exposure.

Conclusions

Overall, these results emphasize the need for improvements to prescribing practices (appropriate TCS potency selection and limiting duration of use), health care provider awareness and education, and ongoing monitoring of both AEs and cumulative steroid dose and frequency of refills. They also highlight a broader unmet need for alternative therapies that provide effective disease control (specifically for chronic conditions) without the limitations associated with TCS.

EADV CONGRESS
VIENNA
30 SEP - 3 OCT 2026

Abstract N°: 2934

Off-label isotretinoin in refractory steatocystoma multiplex: sustained disease control and reduced procedural burden

Eduarda Gregório Arnaut Lima*[1], Dayra Moronta[1], Ana Amelia Milfont[1], Maria Jose Mancero[1], Alan Moscardo[1], Ivan Semenovitch[1]

[1] Policlínica Geral do Rio de Janeiro, Rio de Janeiro, Brazil

Introduction

Steatocystoma multiplex is a rare adnexal disorder characterized by multiple dermal cysts and a chronic relapsing course. Procedural treatment approaches may be limited by repeated relapse and residual scarring, while oral isotretinoin represents a potential off-label treatment in selected cases. We report a patient with long-standing, procedure-refractory steatocystoma multiplex who achieved marked and sustained improvement with isotretinoin therapy, highlighting a potential scar-sparing strategy.

Case Presentation

A 30-year-old woman presented with multiple nodular lesions involving the anterior thoracic region, dorsum, neck, and face since childhood, with new lesions appearing during growth, as well as intermittent inflammatory flares. She had previously undergone several surgical and local procedures, but lesions repeatedly recurred and left multiple scars. Previous antibiotic therapy improved inflammatory painful purulent episodes but did not prevent the development of new lesions. On examination, there were numerous skin-colored to erythematous papules and nodules of variable size, some firm and mobile, with atrophic cicatricial changes in previously treated areas. Clinical, histopathological, and ultrasonographic findings were consistent with steatocystoma multiplex. Low-dose isotretinoin 20 mg/day was initiated off-label, with routine laboratory monitoring. After 12 months of clinical improvement, isotretinoin was progressively tapered to a low-frequency maintenance regimen without recurrence of new lesions. During 18 months of follow-up, active lesions progressively regressed, no new lesions developed, and clearance of the facial lesions was achieved. The patient reported marked reduction in disease burden, treatment satisfaction and improved quality of life. The therapy was well tolerated, without clinically relevant adverse events or laboratory abnormalities.

Conclusion

In refractory steatocystoma multiplex, isotretinoin may provide meaningful disease control, reduce the need for repeated procedures, limit further scarring, and improve patient-reported quality of life. This case highlights a potential off-label therapeutic strategy for a chronic, recurrence-prone adnexal disorder with substantial procedural morbidity and patient burden.

EA DV CONGRESS
VIENNA
30 SEP - 3 OCT 2026

Abstract N°: 2935

FROM REGULATORY WARNINGS TO CLINICAL ACTION: A SAFETY CHECKLIST BEFORE INITIATING SECOND-GENERATION IMMUNOMODULATING DRUGS FOR INFLAMMATORY DERMATOSES

Stine Haysen[1], Lykke Skaarup[2], Simon Poulsen[3], Tue Kragstrup[2], Christian Vestergaard[1], Kenneth Thomsen*[1]

[1] Department of Dermatology and Venereology, Aarhus University Hospital, Institute for Clinical Medicine, Aarhus University, Aarhus N, Denmark

[2] Department of Rheumatology, Aarhus University Hospital, Aarhus N, Denmark

[3] Institute for Clinical Medicine, Aarhus N, Denmark

Introduction

The therapeutic landscape in inflammatory dermatology is rapidly expanding, with biologics and targeted synthetic therapies now available across psoriasis, hidradenitis suppurativa, atopic dermatitis, alopecia areata, urticaria, prurigo nodularis, pemphigus, bullous pemphigoid, vitiligo, cutaneous lupus erythematosus and other inflammatory dermatoses. While these treatments have transformed patient care, their increasing use has introduced complex and drug-class-specific safety considerations. Contraindications, boxed warnings, special warnings and precautions are often distributed across EMA Summary of Product Characteristics (SmPC) and FDA Prescribing Information (PI), making comprehensive pre-treatment safety assessment time-consuming in daily clinical practice. We aimed to systematically consolidate regulatory safety information into a clinically accessible checklist to support safer and more standardized initiation of second-generation immunomodulating drugs.

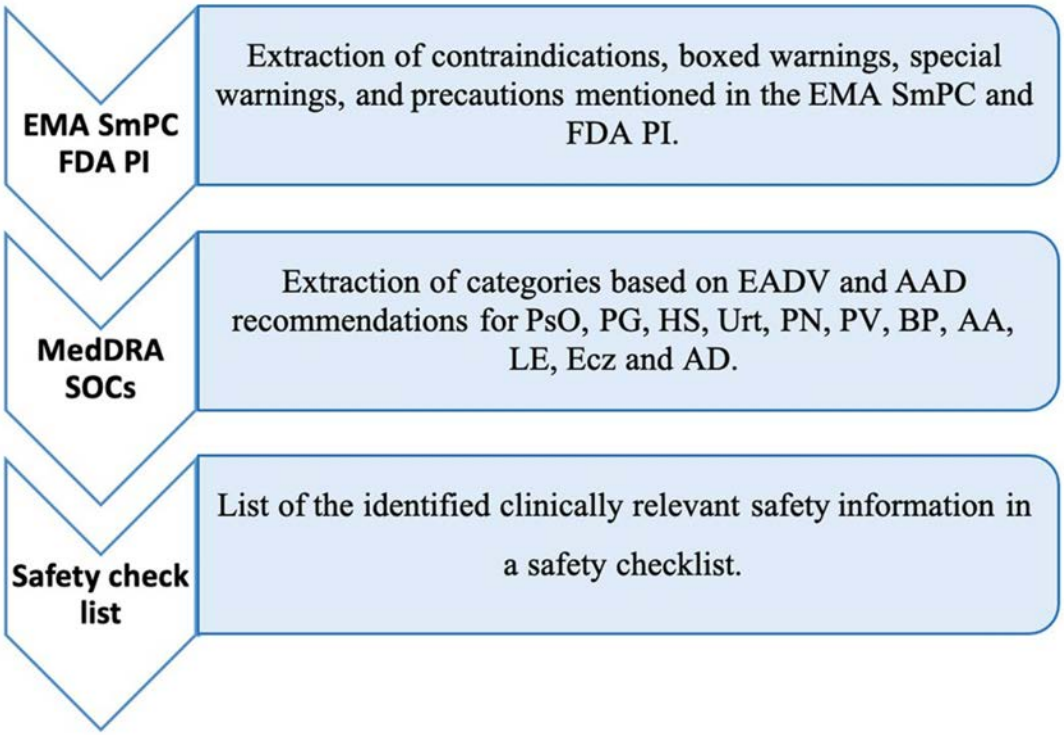

Overview of the workflow. All contraindications, boxed warnings, special warnings, and precautions were manually extracted from EMA SmPCs and FDA PIs. The extracted information was then

categorized according to MedDRAra-SOCs, and the identified relevant safety information were systematically organized in a safety checklist.

Materials and Methods

We conducted a systematic review of EMA and FDA regulatory documents for second-generation immunomodulating therapies approved for adult inflammatory dermatoses. Both systemic and topical therapies were included. Contraindications, boxed warnings, special warnings and precautions were manually extracted from EMA SmPCs and FDA PIs by two independent reviewers, with discrepancies resolved by author consensus. Extracted safety information was categorized according to MedDRA System Organ Classes (SOC) and further translated into clinically meaningful warning categories. Relevant EADV, AAD and expert consensus guidelines were used to adjust and contextualize warnings, enabling development of a practical drug-class-level safety checklist designed for clinical use.

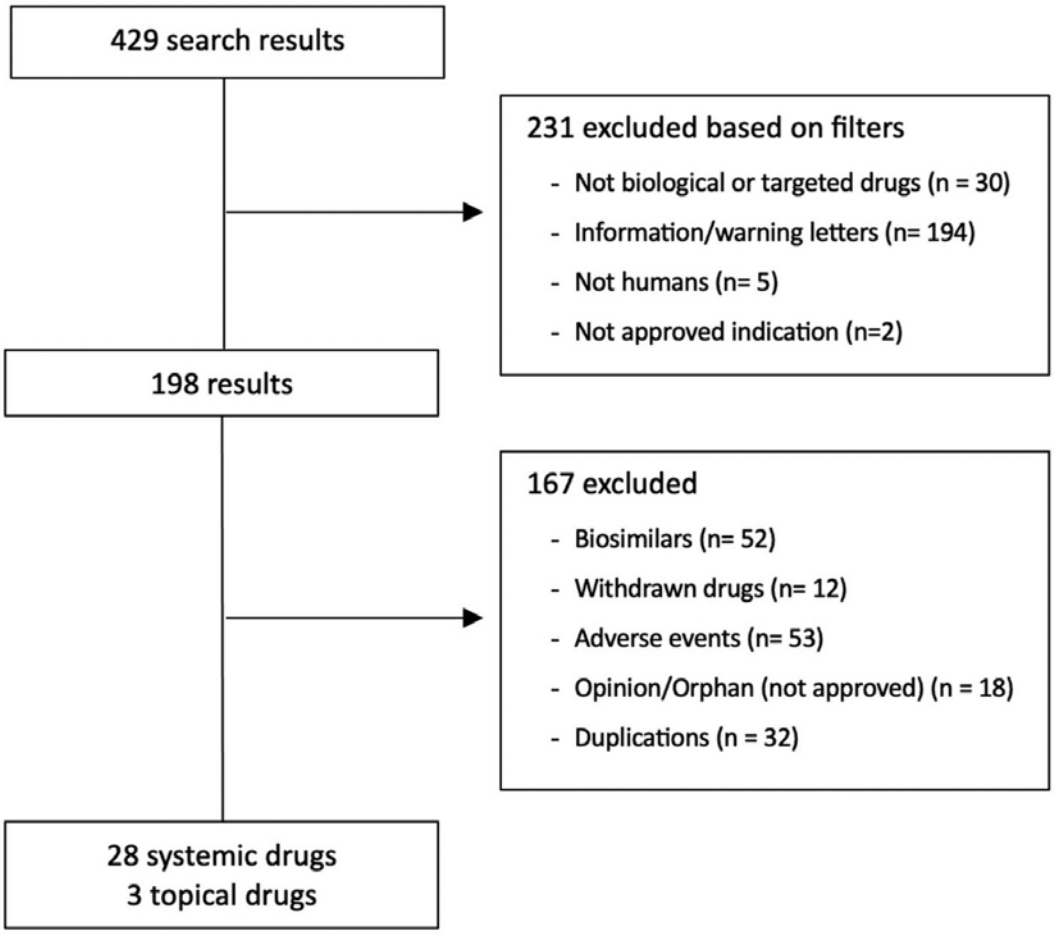

F flowchart outlining the FDA and research process. Of 429 initial records, 231 were excluded based on filters leaving 198 results. A further 167 were excluded due to being biosimilars, withdrawn drugs, adverse events, nor approved drugs or duplications. A total of 31 drugs were included: 28 systemic drugs and 3 topical drugs.

Results

From 429 initial regulatory records, 31 original second-generation immunomodulating drugs were included: 28 systemic and 3 topical therapies. The resulting safety checklist summarizes clinically relevant warnings across major drug classes, including anti-CD20, TNF inhibitors, IL-12/23, IL-23, IL-17, IL-13, IL-4/13, IL-31, IL-36, anti-IgE, anti-BAFF, interferon inhibitors, JAK inhibitors, TYK2 inhibitors and PDE4 inhibitors. Most drug classes carried warnings related to infections. Herpes zoster was reported for anti-CD20, IL-12/23 inhibitors, interferon inhibitors, JAK inhibitors and TYK2 inhibitors, while hepatitis reactivation was reported for anti-CD20, TNF inhibitors, IL-17 inhibitors, anti-BAFF, JAK inhibitors and TYK2 inhibitors. Malignancy risk, including skin cancer, was mentioned for

several drug classes, while other serious warnings included progressive multifocal leukoencephalopathy, demyelinating disease, major adverse cardiovascular events, heart failure, thrombosis, hepatic and renal impairment, cytopenia, dyslipidaemia, inflammatory bowel disease, psychiatric adverse events and serious cutaneous reactions. The final checklist provides a rapid overview of safety considerations before treatment initiation and translates regulatory complexity into an accessible clinical format.



The safety check list showing clinically important warnings for second-generation immunomodulatory therapies. Warnings were adjusted based on consensus in EADV and AAD guidelines for PsO, HS, Urt, PN, PV, BG, PG, AA, VIT, SLE, Ecz and AD. Color codes: White = no warning; Orange = warning; Dark orange = upgraded; and Bright orange = downgraded.

Conclusions

This work provides a systematic, clinically oriented safety checklist for second-generation immunomodulating drugs used in inflammatory dermatoses. By consolidating EMA and FDA warnings into a practical overview, the checklist may support dermatologists in structured pre-treatment risk assessment, interdisciplinary communication and safer therapeutic decision-making. Beyond its immediate clinical utility, the framework offers a scalable model for continuous pharmacovigilance: as new therapies, indications and safety signals emerge, the checklist can be updated and expanded. This establishes a foundation for a continuously maintained digital safety platform that could provide clinicians with real-time, indication-specific and patient-contextualized guidance before initiating advanced immunomodulatory therapy.

EA DV CONGRESS
VIENNA
30 SEP - 3 OCT 2026

Abstract N°: 3082

A Systematic Review of Case Reports and Case Studies on Retinoid Treatment in Porokeratosis: Subtype Variation, Morphology and Therapeutic Outcomes.

Lavinia Miclea*[1], Ahmad Naqeshbandi[2]

[1] University of Chester, Chester, United Kingdom

[2] Royal Cornwall Hospital NHS Trust, Truro, United Kingdom

Introduction

Porokeratosis is a rare and clinically heterogeneous disorder of keratinisation, presenting with annular plaques and keratotic papules and associated with an increased risk of malignant transformation. Despite this, there are no standardised treatment guidelines, and clinical management remains a challenge in clinical practice. Retinoids are frequently used due to their regulatory effects on keratinocyte proliferation and differentiation, however, evidence supporting their efficacy remains limited and is predominantly derived from case reports and small case series. This study aims to systematically evaluate published evidence on retinoid therapy in porokeratosis, focusing on treatment response in relation to therapy type, duration, and clinical heterogeneity, with the intention of informing therapeutic decision-making

Case Presentation

A systematic review was conducted in accordance with PRISMA guidelines. A structured search of PubMed and Embase databases was performed, restricted to studies published from 2000 onwards, identifying twenty-three case reports and two case series, comprising 28 patients with clinically or histologically confirmed porokeratosis treated with topical or systemic retinoids. Inclusion criteria required clear documentation of treatment regimen and clinical outcomes. Extracted variables included porokeratosis subtype, retinoid type, treatment duration, anatomical distribution, and categorised treatment response. Due to the small sample size and uneven subgroup distribution, inferential analysis was limited to key variables using the Fisher-Freeman-Halton Exact test. Partial clinical improvement was the most frequently reported outcome, observed in the majority of cases, while complete responses were less common. No statistically significant association was identified between treatment response and either retinoid type or porokeratosis subtype. In contrast, treatment duration demonstrated a statistically significant association with response ($p = 0.022$), suggesting improved outcomes with prolonged therapy. A further significant association between porokeratosis subtype and anatomical distribution ($p = 0.033$) supports underlying clinical and morphological heterogeneity

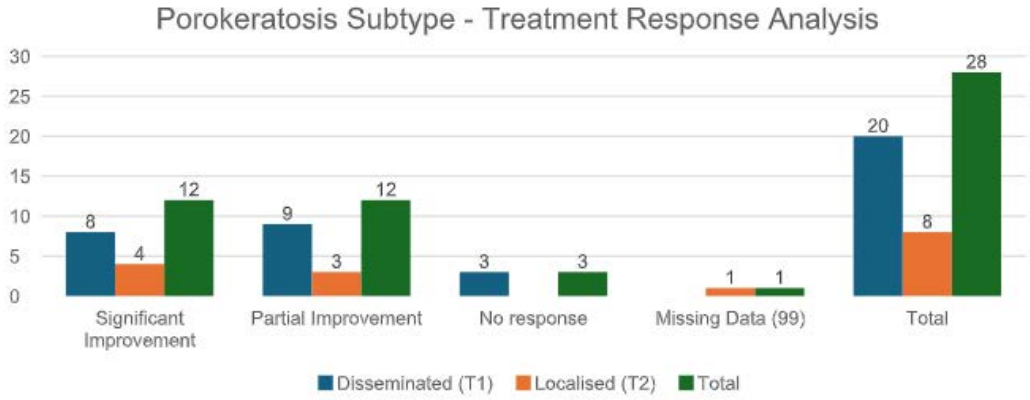

Figure 5. Distribution of treatment response by porokeratosis subtype.

Type of PK * Treatment Response Crosstabulation

			Treatment Response			
			1	2	3	Total
Type of PK	1	Count	8	9	3	20
		Expected Count	8.9	8.9	2.2	20.0
		% within Type of PK	40.0%	45.0%	15.0%	100.0%
	2	Count	4	3	0	7
		Expected Count	3.1	3.1	.8	7.0
		% within Type of PK	57.1%	42.9%	0.0%	100.0%
Total		Count	12	12	3	27
		Expected Count	12.0	12.0	3.0	27.0
		% within Type of PK	44.4%	44.4%	11.1%	100.0%

Chi-Square Tests

	Value	df	Asymptotic Significance (2-sided)	Exact Sig. (2-sided)	Exact Sig. (1-sided)	Point Probability
Pearson Chi-Square	1.398[a]	2	.497	.616		
Likelihood Ratio	2.131	2	.345	.616		
Fisher-Freeman-Halton Exact Test	1.049			.836		
Linear-by-Linear Association	1.161[b]	1	.281	.349	.230	.155
N of Valid Cases	27					

a. 4 cells (66.7%) have expected count less than 5. The minimum expected count is .78.

b. The standardized statistic is -1.077.

Figure 6. Fisher-Freeman-Halton Exact test Crosstabulation between treatment response and porokeratosis subtype.

Conclusion

Retinoid therapy in porokeratosis is associated with variable and predominantly partial clinical responses, highlighting the complexity of this disorder and the limitations of current therapeutic approaches. Treatment duration appears to play a more important role in influencing outcomes than the specific retinoid used, which may have implications for clinical management and patient counselling, particularly in setting realistic expectations regarding response. The marked heterogeneity in disease presentation and the absence of high-quality comparative data limit the ability to establish subtype specific treatment strategies. These findings highlight the constraints of case-based evidence, including small sample size and potential publication bias, and emphasise the need for standardised outcome measures and larger prospective studies to better inform therapeutic decision-making

EA DV CONGRESS
VIENNA
30 SEP - 3 OCT 2026

Abstract N°: 3136

Evaluating the synergistic photo-protective properties of a multi-component regimen comprising Flavonoids, Proxylane, Rhamnose, Gentiopicroside, and Dipotassium Glycyrrhizate against UV-induced damage in ex vivo human skin models

Anna Guiotto[1], Patricia Brieva[2], Hina Choudhary[2], Giuseppe Valacchi*[3, 4, 5]

[1] Plants for Human Health Institute, NC Research Campus, NC State University, Kannapolis, United States

[2] SkinCeuticals, New York, United States

[3] Department of Animal Sciences, Plants for Human Health Institute, NC Research Campus, NC State University, KANNAPOLIS, United States

[4] Department of Environmental and Prevention Sciences, University of Ferrara, Ferrara, Italy

[5] Kyung Hee University, Department of Food and Nutrition, Seul, Korea, Rep. of South

Introduction

Photoaging is driven by chronic ultraviolet exposure and is characterized by oxidative damage, collagen loss, and extracellular matrix remodeling. This study utilized a human skin explant model to investigate the enhanced photo-protective efficacy of a layered topical regimen—incorporating A.G.E Cream with Dipotassium Glycyrrhizate with supplemental Proxylane and Flavonoids—relative to a baseline A.G.E Serum complex of Flavonoids, Proxylane, Rhamnose, and Gentiopicroside under UV radiation.

Materials and Methods

Skin biopsies from three donors were exposed daily to 200 mJ/cm2 UV radiation for up to 5 days. To reproduce a regimen-like application, explants were pretreated twice daily with serum alone or with the combination of serum and cream. Morning treatment was followed by ultraviolet exposure after 30 minutes, while evening treatment was performed without irradiation. Samples were collected at Day 1 and Day 5. Immunofluorescence analysis was used to assess 4-hydroxynonenal protein adducts as a marker of lipid peroxidation, type I collagen as a marker of dermal matrix integrity, and matrix metalloproteinase-2 as a marker of matrix degradation.

Results

Ultraviolet exposure significantly increased 4-hydroxynonenal levels at both time points. The combination of serum and cream provided greater protection against oxidative damage than serum alone, which showed significant activity mainly at Day 5. Repeated ultraviolet exposure reduced type I collagen expression, particularly at Day 5, whereas the combined regimen more effectively preserved collagen levels at both time points. In non-irradiated explants, the combined treatment also appeared to enhance collagen expression after prolonged application. Matrix metalloproteinase-2 expression increased after ultraviolet exposure at Day 1 and Day 5. Both regimens reduced this response, but the combination showed a stronger inhibitory effect.

Conclusions

Overall, the combined use of regimen building serum and cream provided broader and more consistent protection than serum alone against key molecular features associated with ultraviolet-induced photoaging,

supporting its potential as an effective topical strategy against environmental skin damage.

EADV CONGRESS
VIENNA
30 SEP - 3 OCT 2026

Abstract N°: 3142

Oxygen Nanobubbles improve cutaneous oxygenation and prime the skin endogenous defensive responses without affecting skin barrier properties

Giuseppe Valacchi[1, 2, 3], Malak Alghamdi[3], Anna Guiotto[3], Alessandra Pecorelli[1], Zvi Yaniv[4], Vivian Bucay*[5]

[1] Department of Environmental and Prevention Sciences, University of Ferrara, Ferrara, Italy
[2] Kyung Hee University, Department of Food and Nutrition, Seul, Korea, Rep. of South
[3] Plants for Human Health Institute, NC Research Campus, NC State University, Kannapolis, United States
[4] AO2SKIN, 4509 Freidrich Ln., Suite 408,, Austin, United States
[5] Bucay Center for Dermatology and Aesthetics, San Antonio, Texas, United States

Introduction
The present study investigated whether topical Oxygen Nanobubbles can improve oxygen availability in human skin and whether this effect is associated with a mild adaptive redox response rather than oxidative damage. Human skin is characterized by physiological oxygen gradients, and hypoxia-inducible factor 1 alpha (HIF-1α) is a central sensor of reduced oxygen availability, whereas nuclear factor erythroid 2-related factor 2 (NRF2) orchestrates antioxidant defense programs in response to redox stimuli. In the framework of redox biology, a moderate and beneficial adaptive response can be described as oxidative eustress rather than oxidative distress (Chettouh-Hammas and Grillon, 2024; Yuan et al., 2024; Sies, 2021; Kim and Hong, 2026).

Materials and Methods
Skin biopsies were obtained from five volunteers treated topically with Oxygen Nanobubbles and collected at baseline (T0), 30 minutes, and 60 minutes after application. Immunofluorescence analyses were performed for HIF-1α, 4-hydroxynonenal protein adducts, NRF2, NAD(P)H quinone dehydrogenase 1 (NQO1), heme oxygenase 1 (HO-1), filaggrin, and involucrin.

Results
HIF-1α significantly decreased after treatment, indicating improved tissue oxygenation. 4-hydroxynonenal protein adducts also decreased, suggesting reduced lipid peroxidation-mediated protein damage. Although NRF2 did not reach statistical significance, it showed an increasing trend coherent with the induction of NQO1 and HO-1, supporting activation of the NRF2 pathway. Filaggrin and involucrin were preserved, indicating no detectable impairment of tissue integrity or barrier-associated differentiation markers.

Conclusions
Overall, these findings indicate that Oxygen Nanobubbles not only effectively oxygenate skin tissue without detectable structural alteration but also appear to render the tissue more prepared to face a subsequent oxidative challenge by stimulating endogenous NRF2-dependent cytoprotective mechanisms.

EADV CONGRESS
VIENNA
30 SEP - 3 OCT 2026

Abstract N°: 3333

Intravenous micafungin as a potential rescue treatment for recurrent suspected Trichophyton indotineae dermatophytosis: a four-case series

Ceyda Tetik Aydoğdu*[1], Aslan Yürekli[2], Gamze Çömlekçi[1], Emine Tugba Alatas[1], suzan demir pektas[1], Muhammed Özarslan[3], Cihan Yeşil[4]

[1] Muğla Sıtkı Koçman University, Faculty of Medicine, Department of Dermatology, Muğla, Türkiye
[2] Health Science University, Gülhane Military Medicine Faculty, Ankara, Ankara, Türkiye
[3] İzmir Tepecik Research and Education Hospital, İzmir, Türkiye
[4] Muğla Sıtkı Koçman University, Faculty of Medicine, Department of Infectious Diseases, Muğla, Türkiye

Introduction
Terbinafine-resistant *Trichophyton indotineae*, a member of the *T. mentagrophytes* complex, has emerged as an important cause of recalcitrant dermatophytosis worldwide. Recurrent disease despite systemic azole therapy remains a therapeutic challenge. This case series aimed to discuss intravenous micafungin as a potential alternative treatment option in patients with recurrent suspected *T. indotineae* infection.

Case Presentation
Four patients with widespread recurrent dermatophytosis were evaluated. The first two patients were a married couple presenting with pruritic erythematous annular plaques involving the trunk, inguinal region and extremities. The other two patients were sisters with bilateral inguinal erythematous scaly plaques. All patients had positive potassium hydroxide examination at baseline and had previously received systemic antifungal therapy, including itraconazole and/or fluconazole, with initial improvement followed by recurrence. Skin scrapings were evaluated by MALDI-TOF MS colony identification. After consultation with infectious diseases, all patients were hospitalized and treated with intravenous micafungin 100 mg/day. The married couple received micafungin for 14 days, while the two sisters received treatment for 10 days. Marked clinical regression of lesions was observed in all four patients within a short treatment period. Repeat potassium hydroxide examination after treatment showed no detectable hyphae. No new recurrence was observed during follow-up: 4 months in the first two patients and 3 months in the other two patients. The treatment was clinically well tolerated.

Conclusion
This four-case series suggests that intravenous micafungin may be considered as a potential rescue treatment in recurrent dermatophytosis clinically suggestive of *T. indotineae*, particularly in patients who relapse after conventional systemic antifungal therapy. Although echinocandins are not standard treatments for dermatophyte infections, their rapid antifungal activity and favorable tolerability may offer a therapeutic advantage in selected refractory cases. Larger studies with species confirmation, antifungal susceptibility testing and longer follow-up are required to clarify the role of micafungin in resistant dermatophytosis.

EA DV CONGRESS
VIENNA
30 SEP - 3 OCT 2026

Abstract N°: 3486

Clinical Studies on the Efficacy and Safety of Crisugabalin and Pregabalin in Relieving Chronic Itchy Skin Diseases

Yueshuai Zhang*[1], Ao GUO[1], Tian Tian[1], Ruoqing Wang[1], Chen Tu[1], Ping Liu[1]

[1] The Second Affiliated Hospital of Xi'an Jiaotong University, Xi'an, China

Introduction
To investigate the efficacy and safety of crisugabalin and pregabalin in relieving chronic pruritic skin diseases.

Materials and Methods
In this prospective controlled study, 109 patients with chronic pruritus poorly responsive to conventional antihistamines and topical medications, treated at our Dermatology Outpatient Department from February to December 2025, were divided into three groups based on the treatment regimen: control group (conventional treatment, n=43), crisugabalin group (conventional treatment plus crisugabalin besylate 20 mg once daily at bedtime, n=32), and pregabalin group (conventional treatment plus pregabalin 75 mg once daily at bedtime, n=34). All treatments lasted two weeks. Changes in symptom and sign scores assessed by relevant scales were compared before and after treatment, and adverse reactions were recorded.

Results

After two weeks of treatment, the primary endpoint was the reduction from baseline in the Numerical Rating Scale (NRS) score for pruritus. The reductions in the crisugabalin group and pregabalin group were (5.47 ± 2.45) points and (4.74 ± 2.00) points, respectively, both significantly higher than that in the control group (2.60 ± 2.22) points, with statistically significant differences ($P < 0.05$). No statistically significant difference was observed between the two treatment groups ($P > 0.05$).

Regarding secondary endpoints, the crisugabalin group and pregabalin group were significantly superior to the control group in terms of the Xie-Kawashima Itch Severity Scale, the 5-D Itch Scale, the Dermatology Life Quality Index (DLQI) score, and the MOS-SS Sleep Scale score ($P < 0.05$), while no significant differences were found between the two treatment groups ($P > 0.05$).

The improvement in the Hospital Anxiety and Depression Scale (HADS) score in the crisugabalin group was significantly better than that in the control group ($P < 0.05$). The pregabalin group also showed improvement compared with the control group, but the difference did not reach statistical significance ($P > 0.05$).

In terms of safety, the incidence of adverse reactions was 21.9% in the crisugabalin group, 35.3% in the pregabalin group, and 16.3% in the control group. All adverse events were well tolerated, and no serious adverse reactions occurred.

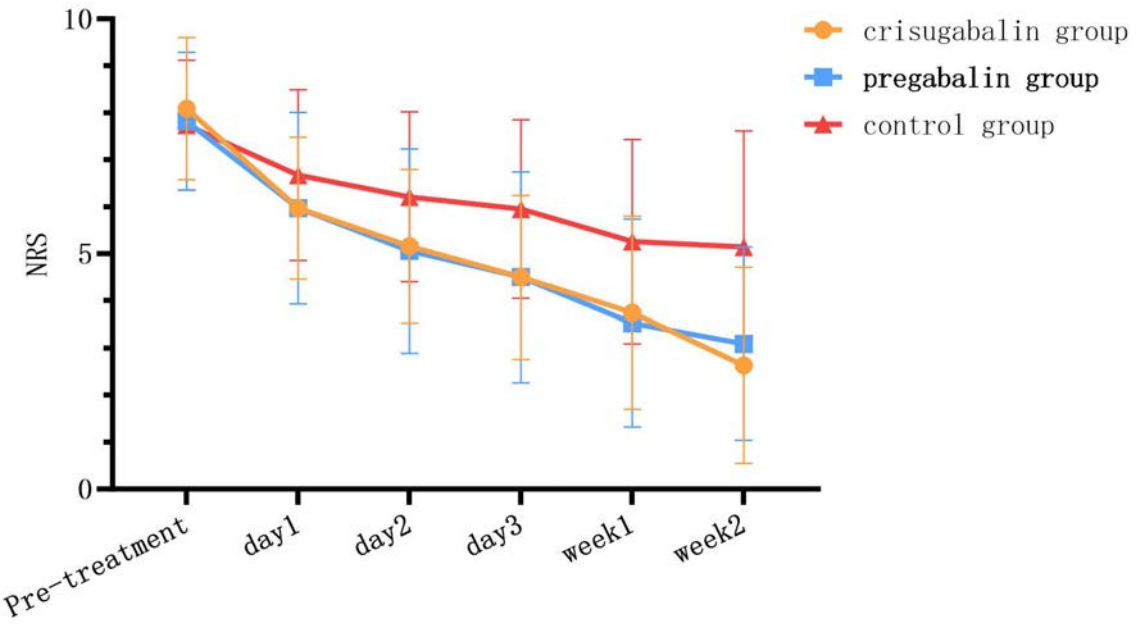

Curves of NRS score changes in the three groups

Conclusions

On the basis of conventional treatment, the addition of either crisugabalin or pregabalin effectively improves pruritus symptoms, sleep quality, and quality of life in patients with chronic pruritic dermatoses, with a favorable safety profile. Among the two, crisugabalin demonstrates superior benefits in improving emotional status and better control of adverse reactions, thus offering higher clinical application value.

EA DV CONGRESS
VIENNA
30 SEP - 3 OCT 2026

Abstract N°: 3645

Changes in scalp microbiota, pruritus biomarkers and sebum lipids in Seborrheic Dermatitis: a clinical study comparing the efficacy of a Piroctone Olamine/Ciclopirox Olamine-based shampoo with Standard Medical Care

Marguerite Lévêque[1], Mélanie Froliger[1], Lucille Darras[1], Céline Huyghe[1], Sandrine Alvarez Georges[1], Nathalie Chansard[1], Christophe Lauze[1], Sophie Baradat[1], Virginie Ribet[2], Valérie MENGEAUD*[2]

[1] R&D Department, Pierre Fabre Dermo-Cosmetics & Personal Care, Toulouse, France
[2] Medical Department, Laboratoires Dermatologiques DUCRAY, Lavaur, France

Introduction

Seborrheic dermatitis (SD) is a chronic recurrent dermatosis characterized by flakes, pruritus and erythema, affecting sebum-rich areas such as the scalp. Pruritus undoubtedly negatively impacts the quality of life of patients affected by SD. A new shampoo (WS0060) containing an antifungal combination of Piroctone Olamine/Ciclopirox Olamine and an antipruritic complex was developed to treat scalp SD.

Previous clinical studies have demonstrated its high tolerance and rapid effectiveness on dandruff, intense and recurring pruritus and erythema.

The objective of this study is to compare the beneficial effects of WS0060 shampoo with those of a Standard Medical Care (SMC, 2% ketoconazole shampoo) after 4 weeks of use in subjects with mild to moderate SD, and to assess changes in scalp microbiota, pruritus biomarker expression and sebum lipid content underlying clinical efficacy.

Materials and Methods

This monocentric, blinded label randomized 4-week study was conducted in two parallel groups of subjects with mild to moderate scalp SD associated with erythema and pruritus (criteria) having a recent prescription of SMC (2% Ketoconazole shampoo) not yet initiated. WS0060 shampoo was applied thrice a week when SMC was applied twice, completed with a third neutral shampoo. Efficacy was evaluated 3 days after the first application (D4) and after 1, 2 and 4 weeks of use (respectively D7, D15 and D29). The evaluation included clinical scoring of dandruff and erythema, and auto-assessment of the scalp discomfort sensations (pruritus and burning sensations). The perceived hair-care benefits of both products were also evaluated by subjects. Adverse events were assessed at each visit.

Swab samplings were performed in lesional areas at baseline and at the three following visits to investigate the evolution of six strains of scalp microbiota including three species of *Malassezia* known to be involved in scalp SD dysbiosis (digital droplet PCR analysis) and to quantify biomarkers of pruritus (S cathepsin, Histamine) through conventional protein assay analyses (ELISA, HTRF). Cigarette papers were used to collect sebum from the affected areas at baseline and during all subsequent visits, to analyze sebum lipid composition (SpiderMass technology).

Results

58 subjects completed this study. From D4 to D29, both products provided a significant decrease in dandruff and erythema score, in pruritus and burning sensations. No significant difference was observed for all clinical

evaluations between WS0060 shampoo and SMC. WS0060 shampoo showed better perceived hair-care benefits than SMC, especially for hair moisturizing and detangling efficacy at D29. No subject reported adverse events linked to WS0060 shampoo.

Both products displayed a significant inhibition of *Malassezia restricta*, which occurred faster with WS0060 shampoo (from the first application). However, SMC resulted in an incomplete microbiota rebalancing effect, as it simultaneously increased *Staphylococcus capitis* abundance. Cathepsin S and Histamine expressions were decreased in both groups, reaching significance after 2 weeks of treatment with SMC and from the first application with WS0060 shampoo. The inhibition of histamine expression in SD lesional areas was significantly stronger with WS0060 shampoo than with SMC. Three pro-inflammatory lipids, oxylipins (9-HODE/13-HODE), arachidonic acid and linoleic acid, were also significantly reduced from the first application with the WS0060 shampoo, whereas a significant reduction was observed with the SMC only on D22.

Conclusions

The study results show that WS0060 shampoo has clinical efficacy in scalp SD treatment that is statistically comparable to SMC, while providing better perceived hair-care benefits. It also induces significant biological modulation of three key pillars of SD physiopathology (microbiota balance, pruritus biomarker expression and pro-inflammatory lipid content in sebum) occurring from the first application.

EADV CONGRESS
VIENNA
30 SEP - 3 OCT 2026

Abstract N°: 3746

In Vivo Electrochemical Assessment Reveals Formulation-Dependent Variability in Cutaneous Antioxidant Activity

Kashika Sareen*[1], Dusan Sajic[2, 3, 4], Smail Meziane[5]

[1] University of British Columbia Department of Medicine, Vancouver, Canada

[2] McMaster University, Hamilton, Canada

[3] DermaSkin Institute, Guelph, Canada

[4] Guelph Dermatology Research, Guelph, Canada

[5] University of Loraine, European Institute of Antioxidants, Head of Department, Nancy, France

Introduction

Topical antioxidants are widely incorporated into photoprotective and anti-aging regimens because of their ability to mitigate ultraviolet-induced oxidative stress and reactive oxygen species-mediated cutaneous injury. However, biologic activity is highly formulation dependent and cannot be inferred solely from ingredient composition. Variability in antioxidant form, concentration, pH, vehicle characteristics, stabilizing systems, and co-antioxidant interactions may substantially influence cutaneous bioavailability and functional redox activity. Despite increasing integration of antioxidant cosmeceuticals into dermatologic practice, comparative in vivo characterization of functional antioxidant response across formulations remains limited.

We evaluated formulation-dependent differences in acute cutaneous antioxidant response among commercially available topical antioxidant systems using a noninvasive electrochemical skin oxidative stress assay.

Materials and Methods

A comparative within-subject in vivo study was conducted using PAOT-Skin technology, an electrochemical methodology designed to assess skin oxidative stress status through integrated oxidant-antioxidant activity at the cutaneous interface. Six commercially available antioxidant systems were evaluated under standardized environmental conditions, including a multi-antioxidant vitamin C formulation, a botanical polyphenol antioxidant formulation, a sodium ascorbate-based antioxidant peptide formulation, a growth factor-associated antioxidant formulation, a pigment-modulating antioxidant formulation, and a ferulic acid-stabilized vitamin C/E formulation. Formulations were evaluated as complete delivery systems rather than isolated active ingredients to better reflect clinically relevant biologic performance. Following standardized topical application to designated treatment sites, PAOT-Skin Scores were measured at baseline and at 30- and 120-minute intervals. The primary outcome was change in PAOT-Skin Score from baseline. Secondary outcomes included temporal response characteristics, persistence of antioxidant activity, and interindividual variability.

Results

All formulations demonstrated measurable modulation of cutaneous antioxidant capacity; however, marked differences in response kinetics, magnitude, durability, and reproducibility were observed.

The multi-antioxidant and ferulic acid stabilized vitamin C/E combination demonstrated an early and sustained increase in antioxidant activity. In contrast, comparator formulations demonstrated more heterogeneous responses of delayed onset and attenuated activity at 30 and 120 minute intervals. Differences in response distribution further suggested variability in formulation-dependent biologic reproducibility. Exploratory combination testing demonstrated enhanced early antioxidant activity following combined application of the multi-antioxidant vitamin C formulation and the ferulic acid-stabilized vitamin C/E formulation relative to individual application alone, suggesting the possibility of synergistic or complementary redox effects between select antioxidant systems.

Conclusions

Topical antioxidant systems demonstrate substantial formulation-dependent variability in functional cutaneous antioxidant activity when assessed using real-time in vivo electrochemical analysis. Differences in onset, magnitude, persistence, and reproducibility of antioxidant response support formulation-dependent bioavailability as a clinically relevant determinant of topical antioxidant performance. These findings highlight the limitations of evaluating cosmeceuticals based solely on ingredient composition and support the use of functional in vivo methodologies to better characterize biologic activity within the cutaneous microenvironment. Further investigation is warranted to determine how acute electrochemical antioxidant responses correlate with molecular photoprotection, long-term clinical outcomes, and optimization of topical antioxidant combination strategies.

EADV CONGRESS
VIENNA
30 SEP - 3 OCT 2026

Abstract N°: 3937

Objective Assessment of Facial Redness Improvement with an Anti-Redness Barrier Cream in Skin-of-Color Populations with Sensitive Skin and Rosacea: A Pilot Split-Face Comparative Study

Adhimukti Tathyahita Sampurna*[1], Sonia Hanifati[1], Irene Dorthy Santoso[1]

[1] Bamed Clinic, Jakarta, Indonesia

Introduction
Facial redness is a common dermatologic concern in sensitive skin and rosacea and may be associated with impaired skin barrier function, neurovascular dysregulation, and inflammatory responses. Emerging supportive-care approaches incorporating barrier-supportive and soothing ingredients may help modulate pathways associated with facial redness and cutaneous discomfort. However, objective imaging-based clinical data evaluating facial redness in skin-of-color populations remain limited. This study aimed to evaluate improvement in facial redness following use of an anti-redness barrier cream in patients with sensitive skin and rosacea in skin-of-color populations using objective imaging analysis.

Materials and Methods
A prospective split-face comparative study was conducted in 18 Indonesian participants with Fitzpatrick skin phototypes III–V presenting with sensitive skin and rosacea. Participants applied the tested anti-redness barrier cream containing barrier-supportive, humectant, and soothing ingredients on one side of the face and a barrier-supportive moisturizer containing established moisturizing and skin-conditioning ingredients on the contralateral side for 1 week. Facial redness was evaluated using standardized VISIA imaging analysis under consistent positioning and lighting conditions at baseline, 15 minutes after application, and after 1 week. Primary outcomes included absolute and percentage changes in redness counts from baseline. Paired comparisons between sides were analyzed using the Wilcoxon signed-rank test. Responder analysis was additionally performed using binary improvement outcomes and analyzed using McNemar exact test.

Results
A total of 18 participants were included (16 females and 2 males; mean age 28.5 ± 5.7 years). At 15 minutes, the tested cream demonstrated a favorable numerical trend compared with comparator, although the between-side difference was not statistically significant (mean redness count change: -1.61 vs +0.06; p = 0.154).

After one week, greater reduction in facial redness was observed on the tested side compared with the comparator side. Mean absolute change in redness count was -8.56 ± 8.95 on the tested side versus +0.72 ± 10.88 on the comparator side. Mean percentage change in redness count was -23.8% ± 20.8 on the tested side compared with -2.8% ± 28.2 on the comparator side. Paired analysis demonstrated a statistically significant between-side difference after 1 week (Wilcoxon signed-rank test, Z = -3.297, p< 0.001).

Responder analysis showed improvement in 77.8% (14/18) of participants on the tested side compared with 38.9% (7/18) on the comparator side. McNemar exact test confirmed a statistically significant difference in responder proportions between sides (p = 0.016).

Conclusions

In this pilot split-face comparative study involving skin-of-color populations with sensitive skin and rosacea, the tested anti-redness barrier cream demonstrated significant short-term improvement in facial redness after 1 week compared with a barrier-supportive moisturizer comparator. Objective imaging analysis showed greater reduction in redness counts and a higher proportion of clinical responders on the tested side. These findings support the potential role of barrier-supportive topical approaches for adjunctive redness management in skin-of-color populations. Ongoing follow-up evaluation may further clarify the durability of redness improvement over time.

EADV CONGRESS
VIENNA
30 SEP - 3 OCT 2026

Abstract N°: 4094

Biocompatibility and collagen gene upregulation by a novel topical cannabidiol formulation in ex vivo human skin

Marnie Peterson*[1], Tobias Ripsom[2], Isabel Laubach[3]

[1] Galyna.co, Perfectus Biomed/NAMSA, Denver, United States

[2] Galyna.co, Denver, United States

[3] Perfectus Biomed/NAMSA, University of California Davis, Jackson, United States

Introduction

The skin endocannabinoid system modulates keratinocyte and fibroblast biology relevant to dermal homeostasis with cannabinoid signalling shown to influence collagen synthesis, inflammation and barrier function. Topical cannabidiol (CBD) is a cannabinoid with numerous known benefits for the health of skin and is therefore a candidate for collagen-supportive dermatological applications. However, cannabinoid bioavailability at the viable epidermis is rate-limited by poor stratum corneum penetration without a matched lipid carrier. The aim of this study was to evaluate a novel cannabidiol plus lipid topical composition for biocompatibility and COL1A1 gene-expression effects on *ex vivo* human skin explants.

Materials and Methods

A two-phase *ex vivo* human skin explant (HSE) study (5 mm biopsies; n = 2 to 3 biological replicates per condition) was conducted. Phase 1: biocompatibility by MTT assay was conducted on HSEs following 10 µL topical application of CBD-containing test composition (A1), its vehicle base (A2), or controls (saline, Tween 20, Triton X-100, SDS) and incubation for 24, 48, and 72 h. Data are represented as n=3 with values as mean ± SD. Phase 2: COL1A1 gene expression by RT-qPCR on homogenized HSEs at the same timepoints following exposure to A1, A2, or saline was conducted. Relative quantification by the ΔΔCt method using β-actin as the reference gene with fold-change reported as $\log_2$. Data are represented as n=2 with values as mean ± SD.

Results

A1 and A2 maintained high skin tissue viability (≥ 88%) across all timepoints relative to saline and consistent with non-irritating profiles. At 72 h, A1 demonstrated pro-regenerative tissue viability (130.6 ± 13.9%) exceeding both A2 (99.4 ± 2.2%) and saline. The cytotoxic controls: Tween 20, Triton X-100, and SDS showed 40.4 ± 10.9%, 5.6 ± 0.2%, and 2.6 ± 0.5% viability at 72 h, respectively. A1 upregulated COL1A1 gene expression relative to saline at all timepoints ($\log_2$ ΔΔCt: 5.85 ± 1.91 at 24 h, 2.75 ± 0.24 at 48 h, 6.19 ± 2.57 at 72 h). The vehicle base alone (A2) produced an attenuated, non-sustained response ($\log_2$ ΔΔCt: 3.33 ± 0.47 at 24 h, 2.08 ± 0.57 at 48 h, −1.11 ± 1.19 at 72 h), indicating that the persistent collagen-gene increase in expression at 72 h is attributable to the cannabidiol component, not the lipid carrier alone.

Conclusions

A novel cannabidiol + lipid topical composition is biocompatible on *ex vivo* human skin and upregulates COL1A1 gene expression at 24, 48, and 72 h, with the sustained 72-hour response attributable to the cannabidiol component rather than the vehicle base. These findings support further investigation of this composition for dermatological applications targeting collagen-supportive skin biology and regenerative-dermatology indications.

POWERED BY M-ANAGE.COM

EADV CONGRESS
VIENNA
30 SEP - 3 OCT 2026

Abstract N°: 4128

Mitigating 'Ozempic Face': A Dual-Action Topical Strategy Modulating GLP-1 Receptor Pathways and Protecting the Dermal Matrix Against Accelerated Senescence

Alvaro Silva[1], Bettina Gruber[1], Tugstênio Souza[2], Renata Britto[1], Luana Hoffmann[3], Isabela Rossato*[1], Carolina Catarino[2]

[1] Research and Development Department, Grupo Boticário, Paraná, Brazil;, Safety Assessment and Alternative Methods Department, Grupo Boticário, Paraná, Brazil, Instituto Euvaldo Lodi (IEL), Paraná, Brazil, São José dos Pinhais, Brazil

[2] Safety Assessment and Alternative Methods Department, Grupo Boticário, Paraná, Brazil, São José dos Pinhais, Brazil

[3] Consumer Science Department, Grupo Boticário, São José dos Pinhais, Brazil

Introduction

Rapid weight loss associated with the use of GLP-1 agonists has been linked to cutaneous alterations, including sagging, volume loss, and the accentuation of wrinkles. These changes are likely due to the abrupt reduction of subcutaneous support and increased vulnerability of the Extracellular Matrix (ECM). This study aimed to develop a biomimetic-peptide blend (Palmitoyl Hexapeptide-12, *Vitis vinifera* seed extract, and *Epilobium fleischeri* leaf extract) and investigate its potential to protect the ECM and restore relevant cutaneous metabolic pathways.

Materials and Methods

An integrated approach combined *in vitro* enzymatic inhibition, molecular docking against the GLP-1 receptor (GLP-1R) , and untargeted lipidomics/transcriptomics on 3D skin models.

Results

A clinical study assessed visible efficacy. The blend preserved skin structural integrity, exhibiting strong antienzymatic activity with 98% inhibition of collagenase and 44% inhibition of elastase. Molecular docking identified that, despite low structural similarity to classical agonists, five key constituents of formulation possess high affinity for GLP-1R. The physiological relevance of this interaction was validated via *in silico*, confirming the modulation of insulin signaling and lipid metabolism genes specifically in the dermis and subcutaneous adipose tissue. Addressing critical senescence hallmarks, multi-omics analysis revealed a profound metabolic reprogramming: untargeted lipidomics evidenced the restoration of mitochondrial bioenergetics (upregulation of Acylcarnitines) and the management of inflammaging (via PGF1a derivatives), alongside functional barrier maturation (Cer-EOS synthesis). The clinical outcome validated this cascade of molecular events, resulting in visible improvements in skin firmness, density, and smoothness observed after only 14 days of use.

Conclusions

This formulation offers a scientifically validated strategy to manage GLP-1 agonist-induced skin changes. By coupling ECM protection with the topical modulation of GLP-1R pathways, it effectively mitigates the structural impact of accelerated weight loss.

EA DV CONGRESS
VIENNA
30 SEP - 3 OCT 2026

Abstract N°: 4163

Cutaneous Microenvironment Modulation Following Laser Resurfacing and Chemical Peel: A Split-Face Study

Arini Widodo*[1], Amanda Wardani[1], Kamila Islami[1]

[1] Dermalogia Clinic, Jakarta, Indonesia

Introduction

Post-procedure skin recovery remains a significant challenge in aesthetic dermatology, particularly in higher phototype skin at increased risk of prolonged inflammation, epidermal barrier dysfunction, and post-inflammatory hyperpigmentation (PIH). Laser resurfacing and chemical peels induce controlled epidermal injury associated with increased transepidermal water loss (TEWL), erythema, oedema, discomfort, and transient alteration of the cutaneous microenvironment. Beyond structural barrier disruption, procedural interventions may also influence pilosebaceous activity and microbiome equilibrium, potentially contributing to inflammatory sequelae during healing.

Recent ecobiological approaches emphasize preservation of skin homeostasis and microbiome-supportive recovery rather than excessive disruption of the epidermal ecosystem. Quantitative imaging systems such as the VISIA Complexion Analysis System may provide objective assessment of multidimensional post-procedural skin changes beyond conventional clinical evaluation.

The objective of this study is to evaluate cutaneous tolerance, epidermal barrier recovery, and quantitative VISIA imaging changes following topical restorative skincare after thulium laser resurfacing and chemical peel procedures.

Materials and Methods

This observational, open-label, split-face study included adults undergoing facial thulium laser resurfacing or chemical peeling associated with superficial epidermal disruption. Subjects received a daytime photoprotective restorative formulation and a nighttime barrier-repair formulation for 14 days following the procedure.

The formulations incorporated biomimetic moisturizing, antioxidant, soothing, and barrier-supportive ingredients including asiaticoside, acetyl dipeptide-1 cetyl ester, ectoin, tocopherol, sodium hyaluronate, and glycerin. The daytime formulation additionally incorporated broad-spectrum UVA and UVB filters to minimize ultraviolet-induced inflammation and reduce PIH risk.

Primary endpoints included investigator- and subject-assessed cutaneous tolerance at baseline, Day 7, and Day 14. Secondary endpoints included erythema, oedema, desquamation, PIH, functional symptoms, soothing effect, patient satisfaction, TEWL measurements, and VISIA imaging parameters. Thirty-one subjects with Fitzpatrick phototypes III–V were included; mean age was 33.5 years.

Results

All subjects completed the study with excellent compliance. No adverse events were reported throughout follow-up. At baseline, erythema was present in 100% of subjects and oedema in 45%. By Day 14, complete resolution of erythema, oedema, and desquamation was observed in all subjects, while mild PIH occurred in one subject only (3%).

Rapid improvement was observed across pain, discomfort, burning sensation, tightness, itching, and dryness, with complete resolution by Day 14. TEWL progressively decreased from 14.16±5.19 g/m^2/h immediately post-procedure to 12.48±4.63 g/m^2/h at Day 14, corresponding to an 11.9% reduction while remaining within the physiological facial range.

VISIA imaging demonstrated the strongest improvement in porphyrins, increasing from 66.5±32.2 at baseline to 90.7±11.0 at Day 7 and remaining elevated at Day 14 (83.5±22.7; p=0.006; r=0.597). Red areas also improved significantly at Day 7 (p=0.044). No adverse changes were observed across spots, pores, wrinkles, brown spots, or UV spots.

Parameter	D0 Mean±SD	D7 Mean±SD	D14 Mean±SD	D0 → D7 p-value	D0 → D14 p-value	Effect sizer (D14)	95% CI (D0–D14)	Improved at D14
Spots	72.6±25.2	69.0±26.5	71.8±26.9	0.829 ns	0.738 ns	0.185 (small)	[−5.9, +4.0]	13/31
Wrinkles	43.4±22.7	43.4±20.7	45.6±24.5	0.734 ns	0.447 ns	0.212 (small)	[−4.1, +8.7]	17/31
Texture	56.2±28.2	48.3±28.9	49.7±28.8	0.001 **	0.063 ns	0.470 (medium)	[−12.9, −0.4]	10/31
Pores	53.3±34.3	54.7±33.1	54.2±33.5	0.681 ns	0.387 ns	0.335 (medium)	[−2.5, +3.9]	15/31
UV Spots	93.9±5.7	95.6±5.8	94.7±6.3	0.015 *	0.160 ns	0.474 (medium)	[−1.5, +3.2]	17/31
Brown Spots	78.5±15.9	79.2±15.4	79.0±16.4	0.537 ns	0.382 ns	0.234 (small)	[−0.9, +1.9]	18/31
Red Areas	56.3±22.7	58.9±20.7	**57.4±22.1**	0.044 *	**0.369 ns**	0.290 (small)	[−1.5, +3.8]	**17/31**
Porphyrins	66.5±32.2	90.7±11.0	**83.5±22.7**	<0.001 ***	**0.006** **	0.597 (large)	[+6.1, +28.7]	**23/31**

*p<0.05 **p<0.01 ***p<0.001 ns=not significant. Scores are percentile ranks (0–100); higher = better. Wilcoxon signed-rank test, two-sided. Effect size r: small (<0.3), medium (0.3–0.5), large (>0.5). CI: bootstrap 95% CI for mean change D0→D14.

Conclusions

Topical restorative skincare following laser resurfacing and chemical peel demonstrated excellent cutaneous tolerance, progressive epidermal barrier recovery, low incidence of PIH, and significant quantitative improvement in VISIA porphyrins and erythema. Concurrent improvement in TEWL and imaging parameters supports the role of biomimetic, microbiome-supportive, antioxidant, photoprotective, and barrier-restorative skincare strategies in modulating the post-procedural cutaneous microenvironment in higher phototype skin.

EA DV CONGRESS
VIENNA
30 SEP - 3 OCT 2026

Abstract N°: 4196

Are Topical Calcineurin Inhibitors a Steroid-Sparing Alternative to Corticosteroids in Seborrheic Dermatitis? A Systematic Review and Meta-Analysis of Randomized Controlled Trials

Maria Lúcia Paysano*[1], Barbara Antonia Dups Talah[2], Luis Henrique Rios Moreira Rego[3], Larissa Fontoura[4], Michele Kreuz[5]

[1] Instituto de Dermatologia Professor Rubem David Azulay - Santa Casa da Misericórdia do Rio de Janeiro, Rio de Janeiro, Brazil
[2] Pontifical Catholic University of Paraná, Curitiba, Brazil
[3] State University of Piaui, Teresina, Brazil
[4] Feevale University, Novo Hamburgo, Brazil
[5] Lutheran University of Brazil, Canoas, Brazil

Introduction
Seborrheic dermatitis is a chronic relapsing inflammatory dermatosis frequently involving cosmetically and functionally sensitive areas, including the face and intertriginous regions. Although topical corticosteroids are effective for short-term control, repeated or prolonged use may be limited by cutaneous adverse effects. Topical calcineurin inhibitors, such as tacrolimus and pimecrolimus, are widely used as steroid-sparing agents in clinical practice; however, their comparative efficacy against topical corticosteroids remains supported by limited randomized evidence.This systematic review and meta-analysis aimed to evaluate the efficacy and safety of topical calcineurin inhibitors compared with topical corticosteroids in patients with seborrheic dermatitis.

Materials and Methods
A systematic search was performed in PubMed, Cochrane Library, Web of Science, and Scopus up to April 2025 using terms related to seborrheic dermatitis, topical calcineurin inhibitors, tacrolimus, pimecrolimus, and corticosteroids. Randomized controlled trials comparing topical calcineurin inhibitors with topical corticosteroids in patients with seborrheic dermatitis were eligible for inclusion.

The primary outcome was the final clinical severity score after treatment. Mean differences with 95% confidence intervals were pooled using a random-effects inverse-variance model. Heterogeneity was assessed using the I^2 statistic. Safety outcomes were summarized descriptively. Statistical analyses were performed using R software.

Results
Three randomized controlled trials including 112 patients were analyzed. Among them, 69 were male and 43 were female, with a weighted mean age of approximately 32.9 years. Included comparisons evaluated pimecrolimus or tacrolimus versus topical corticosteroids, while non-relevant treatment arms were excluded from the quantitative analysis. Topical calcineurin inhibitors showed comparable efficacy to corticosteroids in reducing clinical severity scores, with a pooled mean difference of −0.06 favoring calcineurin inhibitors, although this result was not statistically significant (95% CI: −0.32 to 0.21; p = 0.67). Between-study heterogeneity was low (I^2 = 1.4%), suggesting consistent findings across trials. Mild adverse events were reported more frequently in some calcineurin inhibitor arms, particularly with pimecrolimus, but no serious adverse events were observed in any included study.

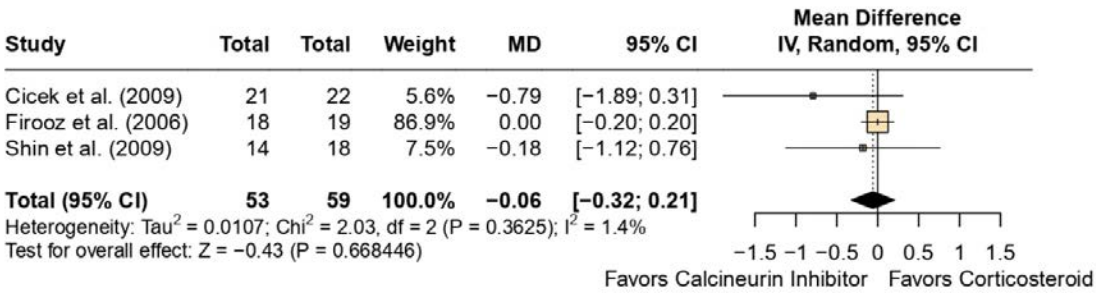

Figure 1. Forest Plot of the mean difference in final clinical severity scores comparing topical calcineurin inhibitors (TCIs) to topical corticosteroids in seborrheic dermatitis.

Conclusions

Topical calcineurin inhibitors demonstrated similar efficacy to topical corticosteroids in the treatment of seborrheic dermatitis, based on limited randomized evidence. These findings support their role as steroid-sparing agents, particularly in facial and intertriginous areas where repeated corticosteroid use may be undesirable. However, the small number of trials and limited sample size preclude definitive conclusions, highlighting the need for larger randomized studies assessing long-term efficacy, tolerability, and relapse prevention.

EADV CONGRESS
VIENNA
30 SEP - 3 OCT 2026

Abstract N°: 4261

Science-guided application of PDRN in cosmetics: Chemical, biological, and clinical characterizations

Nan HUANG*[1], Wenyi XIA[1], Fenjiao HUO[1], Yun WANG[1], Jing LI[1], Xingzuo LIU[1], Jun GAO[1], Yueqing NIU[1], Kung Chi HSU[1], Ji ZHANG[1], Yu GAO[1]

[1] L'Oreal Research & Innovation, Shanghai, China

Introduction

Polydeoxyribonucleotide (PDRN) is a DNA-derived biomaterial traditionally sourced from salmonid sperm. Since more than 2 decades ago, PDRN has been recognized for its tissue repair, anti-inflammatory, and regenerative properties. The present knowledge attributes PDRN's biological activity to two primary mechanisms: the activation of adenosine A2A receptors—which downregulates pro-inflammatory cytokines and promotes collagen synthesis—and the DNA salvage pathway, which provides essential nucleotides for efficient cellular repair and proliferation. In aesthetic medicine, PDRN has been shown to be able to promote skin wound healing via topical application, or injected intradermally as "skin boosters". Aside from a few small, single-center, and often open-labeled studies, large scale randomized clinical trial on PDRN's aesthetic efficacy remain to be further conducted. On the other hand, PDRN has also been incorporated into skin care products, for soothing, repair, healing, and rejuvenation benefits through topical applications. Herein, a series of translational research is introduced around the development of a probiotic-derived PDRN produced via bio-fermentation of *Lactobacillus sakei* strains, as science and evidence backed cosmetic application of probiotic PDRN.

Materials and Methods

The PDRN material was analyzed chemically, using agarose gel electrophoresis, DNA sequencing, and Qubit probes. Then, comprehensive in vitro assays, using primary human keratinocytes, dermal fibroblasts, and macrophages were conducted to assess its proliferation, cell morphology, cytoskeleton regulation, ECM protein expression, bioenergetic potential, and anti-inflammatory effects. Subsequently, PDRN penetration in the skin was indirectly examined using Raman confocal microscopy. Following the in vitro studies, a clinical efficacy of a skin care serum containing this serum was evaluated in a 28-day study involving Chinese female subjects aged 25-40. The performance of the topical serum was compared head-to-head against a hyaluronic acid (HA) "skin booster" aesthetic injectable procedure.

Results

The PDRN material is purified to a specific, narrow chain length of approximately 200 base pairs in the form of double strand DNA, while UV spectrometry confirmed its purity as nucleic acid. In addition, DNA-sequencing and data matching confirmed that the source of the PDRN was indeed probiotic *Lactobacillus sakei*. In primary keratinocytes and fibroblasts, the PDRN dose-dependently increased their proliferation, at concentrations as low as 125 µg/mL. In addition, cellular ATP production was increased by 47% under PDRN treatment. Also in dermal fibroblasts, the PDRN increased the expression of COL1, COL4, FBN-1 and ELN, while decreasing senescent cell n (p16+) number. RNA-seq results clearly indicated that the PDRN treatment was activating purine metabolism, collagen-integrin interaction, and DNA repair pathways, as well as inhibition of prostaglandin mediated inflammation, Jak-stat, and MMP pathways. At the same time, Raman confocal imaging in ex vivo human skin confirmed that it could at least penetrate into the viable epidermis.

In direct comparison with a professional HA "skin booster" injectable procedure, the topical PDRN serum demonstrated remarkable "booster-like" efficacy by showeing increasingly evident cumulative benefits. By the end of the study, the serum achieved superior improvements in 15 aging endpoints—including hydration, trans-epidermal water loss (TEWL), elasticity, skin tone, and texture—and maintained parity with the injectable procedure in five others.

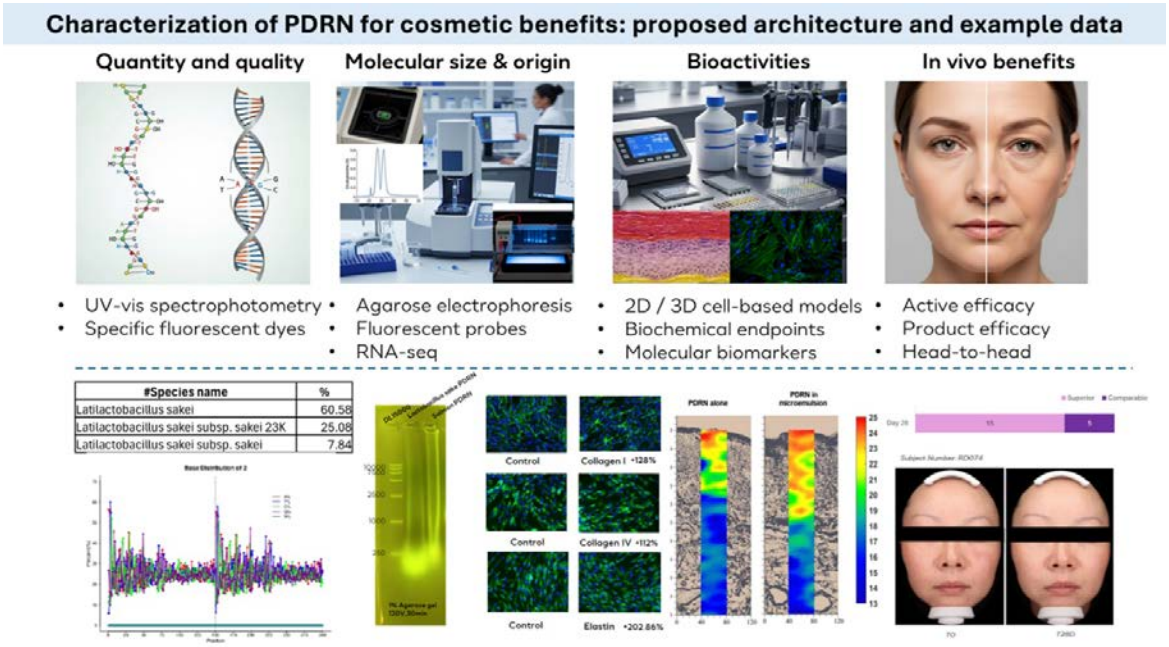

Conclusions

In conclusion, this research provides a robust scientific blueprint for translating complex medical bioactives into effective topical treatments. By combining precise biotechnology with advanced formulation engineering and rigorous clinical testing, the study demonstrates that probiotic-derived PDRN can deliver professional-grade regenerative benefits in a daily-use cosmetic format.

EA DV CONGRESS
VIENNA
30 SEP - 3 OCT 2026

Abstract N°: 4349

Evaluation of the Sulfotransferase activity in Androgenetic alopecia patients using genotyping of SULT1A1 to predict the individual's response to oral minoxidil.

Dilip Kumar*[1]

[1] Dr.B.R.Ambedkar Medical College and Hospital, Bangalore Medical College and Research Institute, Bengaluru, India

Introduction

Androgenetic Alopecia is the most common cause of hair loss, characterized by a gradual loss of terminal hairs in a patterned distribution. Progressive involvement of frontal, temporal, and mid scalp regions is observed. It begins at puberty and most cases start between 15-25 years. About 30% of men will have AGA by the age of 30, upto 50% by 50 years and 80% by the age of 70 years. Genetic predisposition and Androgens play a key role in its pathogenesis. There are two FDA approved drugs - Topical Minoxidil and Oral Finasteride. Minoxidil is a pro-drug requiring bio-activation into minoxidil sulfate. The enzyme that catalyzes this reaction is minoxidil sulfotransferase. Lower follicular SULT1A1 activity threshold is required for bioactivation of Oral Minoxidil compared to Topical Minoxidil. This could be due to the extensive metabolization of Oral Minoxidil by the liver SULT1A1. Therefore, an overall SULT1A1 activity should be evaluated in order to predict the individual's responses to Oral Minoxidil. The capacity to evaluate SULTA1A1 activity before treatment would enable physicians to rule out non- responders to OM. Additionally, a predictive test could help determine if higher doses should be used in patients with low enzymatic activity. In this study, our aim is to evaluate the Sulfotransferase activity by performing genotyping of SULT1A1 gene of patients with patterned hair loss.

Materials and Methods

All patients with clinically diagnosed androgenetic alopecia attending trichology outpatient department are included in this study. It's a Cross-sectional study. The following patients were included for the study - Males in the age group 18-60 years with Androgenetic alopecia. The sample size of the study was 50. After detailed history, Clinical and Trichoscopic examination.A sterile buccal swab sample from each patient was collected and was sent for genetic analysis to Trichogene labs. Genotyping of the SULT1A1 was be performed on Realtime Polymerase Chain Reaction instrument. The assay reported alleles : GG, GA , and AA. Several studies associated the GG allele with high metabolism while the GA and AA alleles were associated with low metabolism.

Outcome measures:

Responders: those with alleles GG

Partial/poor responders: those with alleles GA

Non-responder: those with alleles AA

Results

Mean age – 31.32 years

Androgenetic alopecia Grade 3 (24 pts) – most common among the patients in our study.

Out of 50 patients, 9(18%) pts were responders and 38(76%) pts were partial responders and 3 pts(6%) were non responders according to SULT1A1 Genetic test.

Conclusions

Androgenetic alopecia is the most common form of hair loss in men. Two FDA-approved AGA treatments are topical minoxidil and oral finasteride. It is hypothesized that **sulfotransferase enzyme activity is important as it correlates with minoxidil response for the treatment of AGA.** Using Genetic analysis of SULT1A1, we can predict the **patient's response to minoxidil** and if required add minoxidil boosters. Thus, **Sulfotransferase gene analysis** would be a valuable tool for dermatologist to better guide AGA treatments.

EA DV CONGRESS
VIENNA
30 SEP - 3 OCT 2026

Abstract N°: 4360

Global Burden and Population based Variation on Topical Steroidal Phobia using TOPICO Scores: A Systematic Review and Meta-Analysis.

Fellisha Marwein*[1], Yathish Balachander[1]

[1] Clinical Fellow NIHR Clinical Research Facility Royal Liverpool University Hospital, Liverpool, United Kingdom

Introduction

Topical corticosteroid phobia (corticophobia) is increasingly recognized as a major contributor to poor treatment adherence and inadequate disease control in chronic inflammatory dermatoses, particularly atopic dermatitis. The Topical Corticosteroid Phobia (TOPICOP) scale has emerged as the most widely validated instrument for quantifying corticosteroid-related fears among patients, caregivers, and healthcare professionals. However, population-based variations in corticophobia severity remain poorly characterized globally. This systematic review and meta-analysis aimed to evaluate the burden of corticophobia using TOPICOP-based studies and compare phobia severity across diverse dermatologic populations.

Materials and Methods

This systematic review and meta-analysis was conducted per PRISMA guidelines using a predefined PICO framework: Population (patients, caregivers, and healthcare professionals exposed to topical corticosteroids), Intervention/Exposure (assessment using the TOPICOP questionnaire), Comparator (population-based subgroup comparisons), and Outcome (mean TOPICOP percentage scores and corticophobia severity), with the protocol registered with PROSPERO (CRD420261395814). Literature searches were performed across PubMed, Cochrane Library, Scopus, ScienceDirect, and Web of Science from inception to February 2026. Cross-sectional, observational, and validation studies reporting quantitative TOPICOP outcomes were included. Mean percentage TOPICOP scores and standard deviations were pooled using Comprehensive Meta-Analysis software version 3.7 under a random-effects model. Studies reporting medians and interquartile ranges were converted to estimated means and standard deviations using validated statistical approaches. Subgroup analyses were conducted across adult patients, pediatric caregivers, pediatric populations, and healthcare professionals. Risk of bias was assessed using ROBINS-I and RoB 2 tools. Publication bias was evaluated using funnel plot assessment and Egger's regression analysis.

Results

Fourteen cohorts from Europe, Asia, and the Middle East were included, representing diverse populations with atopic dermatitis, chronic hand eczema, and pediatric inflammatory dermatoses. Overall methodological quality was moderate, with low selection bias across most studies but variability in reporting quality and population representativeness. The pooled mixed-effects analysis demonstrated an overall mean TOPICOP score of 44.36% (95% CI 43.76–44.95), indicating moderate-to-high global corticophobia, with substantial heterogeneity (I^2 = 99.17%). Parents of pediatric atopic dermatitis patients demonstrated the highest pooled corticophobia burden (52.57%), followed by pediatric populations (55.34%) and adult populations (51.70%). Among healthcare professionals, pharmacists demonstrated the highest corticophobia scores (48.5%), whereas dermatologists exhibited the lowest (32.3%). Sensitivity analyses demonstrated consistent findings across subgroup analyses. Funnel plot inspection demonstrated mild asymmetry; however, Egger's regression analysis did not demonstrate statistically significant publication bias.

Conclusions

This meta-analysis demonstrates a substantial global burden of topical corticosteroid phobia across patients, caregivers, and healthcare professionals. Caregivers of pediatric patients and non-dermatology healthcare providers demonstrated particularly elevated corticophobia levels, potentially contributing to treatment avoidance, undertreatment, and impaired long-term disease control. These findings highlight the urgent need for targeted corticosteroid education strategies, adherence-focused counseling, and standardized patient communication frameworks in dermatologic practice. The study further supports the utility of the TOPICOP scale as a globally reproducible instrument for evaluating corticosteroid-related fears across diverse healthcare settings.

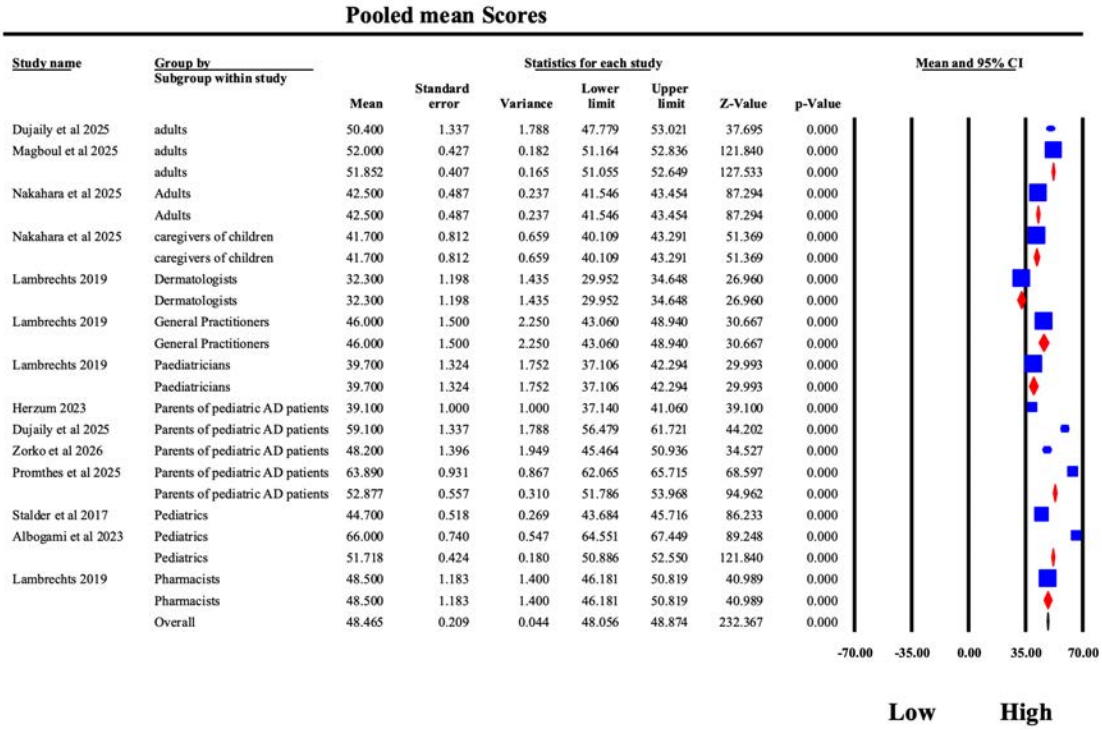

Figure 1:Forest plots on the Pooled Mean TOPICOP Scores sub-grouped on different population

EADV CONGRESS
VIENNA
30 SEP - 3 OCT 2026

Abstract N°: 4509

Dapsone's Deception: masking hyperglycaemia via falsely low HbA1c

Mariam Abu Jubain*[1], Shaima Elsarafy[1]

[1] University Hospitals of Leicester NHS Foundation Trust, Leicester, United Kingdom

Introduction

Dapsone is widely used in dermatology for conditions such as dermatitis herpetiformis, bullous disorders, vasculitis, and neutrophilic dermatoses. It is known to cause haemolysis and can interfere with HbA1c assays, producing spuriously low results that may mask true glycaemia. Diabetic guidelines for monitoring HbA1c advise that HbA1c should not be relied upon in conditions affecting red cell turnover. A literature review identified multiple case reports of falsely low or misleading HbA1c readings and consequent delayed or missed diabetes diagnoses in patients receiving dapsone. We reviewed routine clinical records to quantify paired pre-dapsone and post - dapsone changes in measured HbA1c associated with dapsone exposure and to place our findings in the context of previously published reports.

Materials and Methods

We performed a retrospective case-series review of anonymised records from a single dermatology service. Records were included if they contained at least one HbA1c measurement before and one after documented or presumed dapsone exposure; values were expressed consistently as percent (%) for reporting, with IFCC units (mmol/mol) converted as needed. For each case, we used the last pre-dapsone HbA1c and the first available post-dapsone HbA1c to calculate absolute change. Where identifiable in the records, obvious confounding factors (for example, concurrent medications or conditions likely to affect HbA1c) were excluded from the paired comparisons. Patients known to have diabetes who were receiving dapsone were retained and analysed. Analyses were descriptive (counts, mean, median, range) and reported both % and mmol/mol equivalents for clarity.

Results

Twenty-two records met inclusion for paired analysis. Overall, measured HbA1c fell: the mean change was −0.95% (≈ −10 mmol/mol) with a median fall of −1.00% (≈ −11 mmol/mol). Individual changes ranged from a 2.2 percentage-point drop (≈ −24 mmol/mol) to a 0.3 percentage-point rise (≈ +3 mmol/mol). Twelve of 22 patients (55%) experienced a decrease of at least 1.0% (≥ ~11 mmol/mol), and six patients (27%) had post-treatment HbA1c below 4.0% (i.e., < ~20 mmol/mol). Notable individual declines included roughly −24 mmol/mol (−2.2%), −23 mmol/mol (−2.1%), and −20 mmol/mol (−1.8%); these declines were seen in patients both with and without documented diabetes, including several known diabetics receiving dapsone. Where identifiable in the records, obvious potential confounders were excluded from the paired comparisons.

Conclusions

A substantial proportion of paired records demonstrated clinically meaningful reductions in measured HbA1c following dapsone exposure, consistent with previously published case reports of falsely low HbA1c in patients on dapsone. These findings reinforce that dapsone may produce spuriously low HbA1c values capable of masking true glycaemic status. Clinicians should therefore interpret HbA1c cautiously in patients taking dapsone and consider alternative assessments such as capillary glucose monitoring or fructosamine.