EADV CONGRESS
VIENNA
30 SEP - 3 OCT 2026

Abstract N°: 50

From Ulcer to Erythroderma: A Rare Case of Adalimumab-Induced Paradoxical Erythrodermic Psoriasis in Pyoderma Gangrenosum

Ali Fakih*[1], Nada Sabbah[2], Omar Hamzeh[3]

[1] Dermatology Department, Hammoud Hospital University Medical Center, Lebanese University, Beirut, Lebanon
[2] Anatomic Pathologist, Lebanese American University, Beirut, Lebanon
[3] Rheumatology & Autoimmune Diseases, Mount Lebanon Hospital University Medical Center, Beirut, Lebanon

Introduction

Tumor necrosis factor-alpha (TNF-α) inhibitors are widely used in the management of systemic inflammatory diseases. Paradoxical psoriasis is a well-recognized adverse event associated with TNF-α inhibitors; however, most reported cases involve plaque, pustular, or palmoplantar variants, while erythrodermic psoriasis (EP) remains exceptionally rare. We report a case of biopsy-confirmed erythrodermic psoriasis induced by adalimumab in a patient treated for pyoderma gangrenosum.

Case Presentation

A 69-year-old patient with pyoderma gangrenosum was initiated on adalimumab after inadequate response to systemic prednisone (1 mg/kg/day). The patient remained on a stable maintenance dose of oral corticosteroids (10 mg/day) without recent tapering. After six injections of adalimumab, the patient developed progressive generalized erythema and scaling involving more than 80% of the body surface area, consistent with erythroderma. There was no personal or family history of psoriasis. Skin biopsy revealed psoriasiform acanthosis with parakeratosis and a superficial lymphocytic infiltrate, supporting the diagnosis of erythrodermic psoriasis. Alternative triggers, including corticosteroid withdrawal, were excluded. Given the temporal relationship with adalimumab and compatible clinicopathologic findings, a diagnosis of paradoxical erythrodermic psoriasis was established. Adalimumab was discontinued, and the patient was managed with intensive topical corticosteroids and emollients while maintaining the stable oral prednisone dose (10 mg/day). This led to rapid and marked resolution of the erythroderma, further supporting the diagnosis of a paradoxical drug reaction. To address the persistently active pyoderma gangrenosum, systemic treatment was switched to cyclosporine. However, while the erythrodermic psoriasis remained in remission, the PG lesions showed only partial stabilization and remained active, highlighting the significant therapeutic challenge of managing primary inflammatory disease after severe anti-TNF-induced adverse events.

Conclusion

This case underscores that although anti-TNF–induced erythroderma can be effectively managed by drug withdrawal and topical therapy, the underlying disease—Pyoderma Gangrenosum—may remain refractory. It highlights the need for alternative systemic strategies and illustrates the clinical challenge of balancing the resolution of severe adverse events with the ongoing management of the primary inflammatory condition.

EA DV CONGRESS
VIENNA
30 SEP - 3 OCT 2026

Abstract N°: 74

Allopurinol-Induced DRESS Syndrome A Clinical Gateway to Diagnosing Hereditary Hemochromatosis

salah eddin awawde*[1], Taibi Lynda[1], Lamia Ould Iddir[1], Imene Mahiou[1], FATMA ZOHRA ZEMOURI[1], Asma Haciane[1], Samira Zobiri[1]

[1] Mustapha University Hospital Center, Dermatology and venereology, Sidi M'Hamed - alger, Algeria

Introduction

DrugReaction with Eosinophilia and Systemic Symptoms (DRESS) is a life-threatening toxidermia characterized by a long latency period,hematological abnormalities, and multi-organ involvement. While Allopurinol isa leading trigger—particularly in patients with Chronic Kidney Disease (CKD)—the clinical severity often reflects thepatient's underlying physiological vulnerability. Hereditary Hemochromatosis(HH) is a systemic iron-overload disorder that often remains clinically silent,manifesting as isolated metabolic or endocrine failures until an acutesystemic event occurs. We report a case where an acute episode of DRESSacted as a "biological stress test," unmasking a long-standing systemiciron overload through a pathognomonic clinical cluster of "bronzediabetes," hypotrichosis, and infertility.

Case Presentation

A44-year-old male was hospitalized in November 2024 following the introductionof Allopurinol for hyperuricemia. The patient’s medical background was acomplex mosaic of systemic failures: insulin-dependent Type 2 diabetes (T2DM),diabetic retinopathy, open-angle glaucoma, hypothyroidism, and stage 3 CKD.Notably, the patient reported a history of primary infertility (no children).The acute episode began with a generalized, infiltrated erythema and purpura, F°38.5°C), and severe mucosal ulcerations of the lips and softpalate. Laboratory investigations confirmed marked hypereosinophilia,acute-on-chronic renal failure, and significant hepatic cytolysis accompanied by pancreatic inflammation (elevated lipase). Management includedimmediate cessation of Allopurinol, IV methylprednisolone, intensivehyperhydration, and antiviral coverage.

As theinflammatory phase of the DRESS syndrome subsided under corticosteroid therapy,the clinical focus shifted toward persistent, non-drug-related findings thatpointed toward a unified diagnosis of iron overload:

Cutaneous Markers: Following acute desquamation a generalized greyish-bronze hyperpigmentation (melanoderma) became strikingly evident. Physical examination revealed a hypotrichosis with thinning of the axillary and pubic regions.

Hepatic Transition:the initial cytolysis was replaced by a secondary, intense cholestatic jaundice and persistent hepatomegaly, suggesting a liver parenchyma already saturated and fragile.

Systemic Synthesis: The presence of "Bronze Diabetes" (pigmentation + T2DM), combined with the patient’s history of infertility and hypothyroidism, formed a pathognomonic clinical constellation.

The DRESS syndrome acted as an "oxidative trigger," making these previously silent signs medically visible.

thispatient, the diagnosis of Hemochromatosis serves as the common denominator forhis extensive multi-organ history. The absence of children and the rarityof body hair are classic clinical signatures of iron deposition in thepituitary gland, leading to hypogonadotropic hypogonadism. This endocrinefailure, occurring alongside "Bronze Diabetes," highlights thesystemic nature of the iron overload.Thepathogenesis of the patient’s comorbidities—diabetes, hypothyroidism, andglaucoma—can be directly attributed to chronic iron deposition in

the pancreas,thyroid gland, and the anterior segment of the eye, respectively. Theinflammatory "flare" of the DRESS syndrome likely accelerated thevisible hyperpigmentation and exacerbated the cholestasis. In the context ofCKD, oxypurinol accumulation triggered the DRESS, but the underlyingiron-saturated state determined the catastrophic nature of the hepatic andpancreatic outcome

Conclusion

This case shows how DRESS syndrome can act as a "biological stress test," unmasking silent Hereditary Hemochromatosis. Triggered by Allopurinol, the reaction's resolution revealed a "bronze" hyperpigmentation. Combined with infertility, hypotrichosis, and diabetes, this formed a pathognomonic cluster of systemic iron overload. Clinicians must look beyond toxidermia to identify underlying vulnerabilities, as acute inflammation can reveal long-standing metabolic disorders

EADV CONGRESS
VIENNA
30 SEP - 3 OCT 2026

Abstract N°: 97

A clinical first: A selective tyrosine kinase inhibitor, Deucravacitinib triggering bullous pemphigoid in a psoriasis patient

Madeleine Kelly*[1], Cathy Reid[1]

[1] Townsville University Hospital, Townsville, Australia

Introduction

Bullous pemphigoid is an acquired autoimmune subepidermal blistering disease. Drug-associated bullous pemphigoid should be considered in patients presenting with a new bullous eruption following the initiation of medication. The association between Bullous pemphigoid development and certain drugs including loop diuretics, gliptins or biologics (anti tumour necrosis alpha agents and anti- interleukin 17) drugs has been well known. Deucravacitinib, a selective tyrosine kinase 2 (TYK2) inhibitor currently used in the treatment of psoriasis has not yet been reported to trigger bullous pemphigoid.

Case Presentation

A 55-year-old male presented with a new-onset erythematous, urticated, and pruritic eruption with early vesicles two years after commencing deucravacitinib for psoriasis. A cutaneous drug eruption was suspected. Punch biopsies were performed. Histopathology demonstrated features consistent with pre-bullous pemphigoid, including mild spongiosis and focal parakeratosis with neutrophilic debris. Direct immunofluorescence revealed strong linear IgG/IgG4 and C3 deposition along the dermoepidermal junction. Enzyme-linked immunosorbent assay testing for BP180 and BP230 antibodies were negative. Deucravacitinib was discontinued and potent topical corticosteroids were initiated resulting in complete resolution within two weeks. The clinicopathological findings, together with resolution following drug withdrawal supported the first reported case of drug-induced bullous pemphigoid by Deucravacitinib.

Conclusion

Bullous pemphigoid is a potential life-threatening condition, primarily affecting those over 60. It is a differential diagnosis in older patients with pruritus. Although there have been case reports of other tyrosine kinase inhibitors inducing bullous pemphyigoid, this is the first case of Deucravacitinib. These cases had positive direct immunofluorescence but not always circulating autoantibodies. The main goal in BP treatment is effectively managing clinical manifestations. Discontinuation of the culprit drug and initiation of topical or systemic corticosteroids is typically adequate treatment. Dermatologists should keep this rare but life-threatening adverse effect in mind and be cautious on identifying the disease and initiating treatment as early as possible.

EA DV CONGRESS
VIENNA
30 SEP - 3 OCT 2026

Abstract N°: 103

Acute Pustular Dermatosis in Psoriasis: Differentiating the Underlying Cause

Filipe Monteiro*[1], Inês Tribolet de Abreu[1], Gustavo Silva[1], Inês Pereira Amaral[1], Ivânia Soares[1], Pedro de Vasconcelos[1], Sonia Fernandes[1], Joana Antunes[1]

[1] Unidade Local de Saúde Santa Maria, Lisboa, Portugal

Introduction

Acute generalized exanthematous pustulosis (AGEP) is a severe cutaneous reaction, most commonly triggered by medications, characterized by the sudden onset of sterile pustules on an erythematous base. Clinically, it presents with fever, malaise, and widespread pustular eruptions that may mimic other pustular dermatoses. Diagnosing AGEP can be particularly challenging in patients with a history of pustular psoriasis, as the clinical and histopathological features of these conditions often overlap. Distinguishing between drug-induced pustulosis and a flare of underlying psoriasis is critical, as management strategies and prognostic implications differ. Accurate diagnosis requires careful integration of patient history, clinical presentation, histopathologic findings, and temporal association with potential triggers.

Case Presentation

A 62-year-old woman with a history of generalized pustular psoriasis, well controlled on guselkumab, presented to the emergency department with a sudden-onset, widespread dermatosis. The eruption began as erythematous papules and macules, progressing rapidly to confluent violaceous patches accompanied by cutaneous pain, pustules, and pus lakes involving the trunk, face, and extremities. The patient reported a recent accidental burn, after which she had started oral flucloxacillin, completing five days of therapy before the onset of the eruption. Her last dose of guselkumab had been administered seven days earlier, and she had been on a stable regimen for several years.Given the clinical uncertainty between a flare of generalized pustular psoriasis and acute generalized exanthematous pustulosis (AGEP), a skin biopsy was performed. Histopathology revealed irregular acanthosis and psoriasiform epidermal hyperplasia, hypogranulosis, and subcorneal spongiform pustules containing numerous eosinophils. These findings were accompanied by marked superficial dermal edema and a perivascular lymphocytic infiltrate with interstitial eosinophils, consistent with AGEP rather than psoriasis exacerbation.Laboratory evaluation showed hemoglobin of 13.7 g/dL, leukocytes 9.7 × 10^9/L, platelets 391 × 10^9/L, C-reactive protein 46.4 mg/L, AST 253 U/L, and ALT 588 U/L, with preserved renal function. Following discontinuation of the antibiotic and initiation of systemic and topical corticosteroid therapy, the patient demonstrated marked improvement of the skin lesions within four days.

Conclusion

This case underscores the considerable diagnostic challenge in differentiating acute generalized exanthematous pustulosis from a flare of generalized pustular psoriasis in patients with a known history of psoriatic disease. Several features strongly supported a diagnosis of AGEP. Clinically, the eruption appeared shortly after initiation of oral flucloxacillin, establishing a clear temporal relationship with drug exposure. The rapid evolution of erythematous macules and papules into coalescent violaceous patches with widespread sterile pustules, combined with notable cutaneous pain, is more characteristic of a drug-induced pustulosis than a typical psoriatic flare. Histopathologic findings reinforced this distinction: the presence of subcorneal pustules with abundant eosinophils, marked dermal edema, and perivascular lymphocytic infiltrates with interstitial eosinophils are classic features of AGEP, whereas generalized pustular psoriasis usually demonstrates psoriasiform epidermal hyperplasia with fewer eosinophils and less dermal edema. Finally, the patient’s rapid clinical improvement following cessation

of the antibiotic and initiation of systemic and topical corticosteroids further supports a drug-triggered reaction.This case emphasizes the importance of integrating clinical history, histopathology, and therapeutic response when evaluating pustular eruptions in patients with underlying psoriasis.

EA DV CONGRESS
VIENNA
30 SEP - 3 OCT 2026

Abstract N°: 147

Herbal Does Not Mean Harmless: A Case of Turmeric-Associated AGEP

Madeleine Dumke*[1], Zaina Rashid[2], Vian Al-Rubaie[2], Hongyu Yang[3]

[1] Midwestern University Arizona College of Osteopathic Medicine, Glendale, United States
[2] La Peau Dermatology, Mesa, United States
[3] Tri-State Pathology Associates, St. Vincent Evansville Hospital, Evansville, United States

Introduction

Turmeric (Curcuma longa) is a widely used dietary supplement generally regarded as safe, though rare cutaneous hypersensitivity reactions have been reported. Acute generalized exanthematous pustulosis (AGEP) is a severe cutaneous adverse reaction characterized by the abrupt onset of sterile, nonfollicular pustules, often triggered by medications. Only a limited number of cases have linked ingested turmeric to hypersensitivity reactions, including AGEP.

Case Presentation

An 86-year-old woman presented with an acute pustular eruption that developed three days after initiating an over-the-counter turmeric supplement. Although the labeled serving size recommended three 750 mg capsules daily, the patient reported ingesting six capsules per day for two consecutive days, corresponding to an estimated intake of ~4,500 mg daily. On the third day, she developed a pruritic rash. She discontinued the supplement after two days but delayed medical evaluation for approximately two weeks.On examination, residual erythema with scattered resolving monomorphic pustules was observed on the thighs and abdomen. A shave biopsy was performed. Histopathologic evaluation demonstrated subcorneal pustular dermatitis with subcorneal vesicles containing numerous neutrophils (Figure 1). A superficial perivascular dermal lymphocytic infiltrate was present, and neutrophils admixed with parakeratosis in small collections were identified within the overlying stratum corneum. These findings supported a pustular drug eruption and were consistent with acute generalized exanthematous pustulosis (AGEP).Treatment included intramuscular triamcinolone acetonide 40 mg/mL, 1.5 mL, topical clobetasol 0.05% ointment twice daily for two weeks, and loratadine 10 mg daily for one month for symptomatic relief. Clinical improvement was observed following treatment.Given the rapid onset after short-term high-dose turmeric ingestion, supportive pathology findings, and absence of alternative triggers, the clinical presentation was most consistent with AGEP.

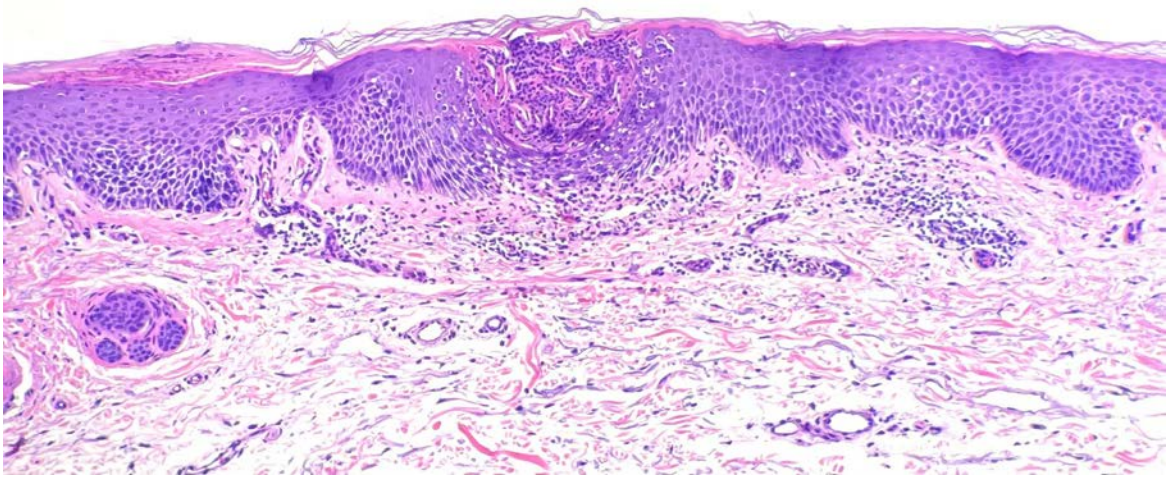

Figure 1. Subcorneal pustular dermatitis with a subcorneal vesicle containing numerous neutrophils.

Conclusion

This case suggests that turmeric may function as a sensitizing agent capable of triggering hypersensitivity reactions. As the use of herbal supplements continues to increase, clinicians should recognize that over-the-counter products are not inherently benign and may cause severe cutaneous adverse reactions. Given limited regulatory oversight and variability in dosing, careful supplement history is essential when evaluating acute pustular eruptions. Although turmeric-associated AGEP remains rare, emerging evidence suggests it should be considered in the differential diagnosis of acute pustular eruptions.

EADV CONGRESS
VIENNA
30 SEP - 3 OCT 2026

Abstract N°: 202

Cutaneous Immune-Related Adverse Events Vary by Cancer Type During PD-1 Blockade: A Multi-Cohort Analysis

Khalaf Kridin*[1], Ralf Ludwig[2]

[1] Galilee Medical Center, Nahariya, Israel, Nahariya, Israel

[2] University of Lubeck, Lubeck, Germany, Lübeck, Germany

Introduction

Immune-related cutaneous adverse events (irCAEs) are the most common toxicities associated with programmed cell death protein 1 (PD-1) inhibitors, yet tumor-specific patterns across different cancer indications remain incompletely characterized. We aimed to compare the risk of irCAEs among patients treated with PD-1 antagonists for cutaneous squamous cell carcinoma (cSCC) relative to melanoma, non-small cell lung cancer (NSCLC), head and neck squamous cell carcinoma (HNSCC), hepatocellular carcinoma (HCC), and renal cell carcinoma (RCC).

Materials and Methods

We conducted a retrospective cohort study using the TriNetX Global Collaborative Network. Patients treated with cemiplimab, nivolumab, or pembrolizumab were identified and propensity-score matched across cancer indications based on demographics and comorbidities. Outcomes included nonspecific rash, pruritus, psoriasis, atopic dermatitis (AD), bullous pemphigoid (BP), and vitiligo. Hazard ratios (HRs) were estimated using Cox regression.

Results

Matched cohorts included cSCC compared with melanoma (n=11,470 per group), NSCLC (n=11,620), HNSCC (n=9,031), HCC (n=4,474), and RCC (n=10,387). Relative to melanoma, cSCC demonstrated similar risks of inflammatory irCAEs but a significantly lower risk of vitiligo (HR 0.38). Compared with NSCLC, cSCC showed higher risks of rash (HR 1.31), pruritus (HR 1.36), AD (HR 1.49), BP (HR 1.55), and vitiligo (HR 2.30). Compared with HNSCC, cSCC had increased risks of rash (HR 1.14), pruritus (HR 1.21), and vitiligo (HR 1.64). Compared with HCC and RCC, cSCC demonstrated higher risks of rash and AD, while pruritus was slightly less frequent in HCC and RCC cohorts. Tumor-specific differences persisted across early and late follow-up periods.

Conclusions

Patients with cSCC treated with PD-1 inhibitors display a distinct irCAE profile, supporting tumor-specific dermatologic monitoring and suggesting tumor biology influences checkpoint inhibitor–associated skin toxicity.

EA DV CONGRESS
VIENNA
30 SEP - 3 OCT 2026

Abstract N°: 220

Toxic epidermal necrolysis probably due to cosmetic cream: a case report

Hatice Uce Ozkol[1], İlknur Yorğun Özdemir[1], Sena Uçan*[1]

[1] Van Yüzüncü Yıl Üniversitesi Faculty of Medicine, Dermatology, Van, Türkiye

Introduction

Toxic epidermal necrolysis (TEN) is a rare but severe, life-threatening mucocutaneous reaction, most commonly triggered by systemic medications. Topically applied agents are infrequently implicated. Here we describe a 21-year-old female who developed TEN, likely related to the use of an over-the-counter (OTC) cosmetic cream.

Case Presentation

A previously healthy 21-year-old woman presented one month after initiating self treatment for solar lentigo using a whitining cream of Middle Eastern origin. She initially experienced malaise, followed by pruritic and burning erythematous maculopapuler eruptions starting on the face and neck and later spreading to the upper extremities. At first evaluation in an emergency department, she was diagnosed with contact dermatitis and treated with ıntravenous corticosteroids and antihistamines. Despite this, the eruption progressed, eventually involving the entire body including extremities, prompting referral to a tertially dermatology clinic. She denied any recent medication use or infection. Vital signs were within the normal limits except for a body temperature of 38°C.
At the first examination, two skin biopsies were obtained, including frozen section and punch biopsy, with preliminary diagnoses of TEN, Steven Johnson Syndrome, DRESS, and maculopapular drug reaction.The frozen section biopsy result was not consistent with TEN.
Despite treatment with systemic corticosteroids, antihistamines and cyclosporine, the patient's rash spread. On the fourth day, she lost consciousness and was admitted to the intensive care unit. Large blisters formed on the face, neck, extremities, and trunk. Severe mucosal involvement affected the oral, ocular, and genital areas. Diffuse erythema , intense pruritus and pain were noted.
Due to the worsening of the condition, the patient was clinically diagnosed with TEN and intravenous gammaglobulin (IVIG) was started at a dose of 2 g/kg. Ocular involvement was managed with topical moxifloxacin and artificial tears.
Clinical improvement was observed by the fourth day of IVIG therapy, with re-epithelialization of erode areas. After two weeks, the patient was with minimal sequelae. Follow-up revealed postinflammatory hyperpigmentation, while mucosal and ocular findings had resolved completely.

Conclusion

TEN secondary to topical agents is exceedingly rare. In this case, despite all the questioning, the patient hadn't mentioned using any cream from the beginning and also she had discontinued the suspected cream four weeks prior to presentation, making causality assessment challenging. Currently, no specific laboratory test confirms TEN and diagnosis remains primarily clinical.
Management is largely supportive, including fluid-electrolyte balance, nutritional support, temperature regulation and infection prevention. Adjunctive therapies such as corticosteroids, cyclosporine, and intravenous gammaglobulin (IVIG) are used, althought consensus regarding their efficacy is lacking.
The widespread use of cosmetic products may contribute to an increased incidence of adverse cutaneous reactions. This case highlights the importance of awareness regarding potentially severe reactions associated with topical cosmetic products.

EA DV CONGRESS
VIENNA
30 SEP - 3 OCT 2026

Abstract N°: 229

Acute Generalized Exanthematous Pustulosis Induced by Pistacia lentiscus Essential Oil

almeghari widad*[1], FATMA ZOHRA ZEMOURI[1], atawna omar[1], Taibi Lynda[2], Samira Zobiri[1]

[1] Mustapha University Hospital Center, Alger, Algeria
[2] CHU MUSTAPHA, Alger, Algeria

Introduction

Acute generalized exanthematous pustulosis (AGEP) is a rare, severe drug reaction characterized by the sudden onset of numerous small, sterile, non-follicular pustules on an erythematous background, often accompanied by fever and neutrophilia. Less commonly, other triggers have been reported, including infections, topical products, acidic vapors, mercury, and even spider bites.We report a case of AGEP secondary to topical application of Pistacia lentiscus essential oil.



Clinical examination revealed diffuse erythroderma

Case Presentation

A 15-year-old patient with no significant medicalhistory, presented with erythroderma evolving over 15days. The patient reported the onset of skin lesionsseven days after starting topical application of Pistacialentiscus essential oil for moisturizing purposes. Therewas no recent drug intake, prior drug reaction, orhistory of psoriasis.Clinical examination revealed diffuse erythroderma with multiple small, non-follicular pustules on an erythematous base,

predominantly on the lowerlimbs. Mucosal involvement was alsonoted, with erythematous lesions of the hard palate.General examination showed a fever of 39°C, markedfacial edema, and tender inguinal lymphadenopathy.Histopathological examination of a skin biopsy revealedspongiform pustules rich in neutrophils in theepidermis. The dermis showed edema with a mixedinflammatory infiltrate. Laboratory tests demonstratedleukocytosis with neutrophilic predominance (16 $\times 10^9$/L) and mild eosinophilia (<0.5 $\times$ 10^9/L), withoutvisceral involvement.All clinical, biological, and histological findings wereconsistent with AGEP according to EuroSCAR criteria.The patient was treated with systemic corticosteroids at0.5 mg/kg/day, alongside immediate discontinuation ofthe essential oil.The course was favorable, with progressive skindesquamation and complete resolution of lesionswithin four days of treatment initiation and withdrawalof the offending product.
AGEP is a rare and severe form of drug eruption, presesnting as the acute onset of sterile, non-follicular pustules on an erythematous base, often accompanied by fever and leukocytosis.
The evolution is generally rapid and favorable, with spontaneous resolution is possible after withdrawal of the causative agent. Histologically, lesions are characterized by subcorneal and/or intraepidermal pustules associated with papillary dermal edema and a mixed inflammatory infiltrateThe incidence of AGEP is estimated at 1–5 cases per million inhabitants per year. with over 90% of cases, a drug-related cause is identified.In this case, the absence of any drug intake or underlying pathology, along with the temporal relationship with topical exposure to Pistacia lentiscus essential oil, strongly suggests a triggering role . This is further supported by the onset after topical application, suggesting possible individual or genetic susceptibility.Pistacia lentiscus, commonly known as the mastic tree, is an evergreen shrub widely distributed in the Mediterranean region and traditionally used in herbal medicine.Its therapeutic uses are diverse: decoctions of aerial parts or resin are traditionally employed for cough, sore throat, eczema, gastric pain, kidney stones, and jaundice. The essential oil is somtimes recommended by non-medical practitioners for chronic inflammatory intestinal diseases.Severe cutaneous reactions such as AGEP induced by plantbased preparations remain exceptional. Other reported cutaneous adverse effects of Pistacia lentiscus essential oil include contact dermatitis , erythema , pruritus , and mild skin irritation . The underlying pathophysiological mechanisms are not fully understood.



Clinical examination revealed diffuse erythroderma

Conclusion

We report a case of acute generalized exanthematous pustulosis induced by topical application of Pistacia lentiscus essential oil, a situation rarely described in the literature. This case highlights the importance of considering plant extracts as a potential, though rare, cause of AGEP and emphasizes the need for caution regarding the safety of herbal products.



Clinical examination revealed diffuse erythroderma with multiple small, non-follicular pustules on anerythematous base, predominantly on the lowerlimbs.

EA DV CONGRESS
VIENNA
30 SEP - 3 OCT 2026

Abstract N°: 251

Autoimmune Bullous Diseases Associated with Immune Checkpoint Inhibitors: An Analysis Based on a Systematic Review

Min Zou*[1], Kun Zhan[1], Wei Li[1]

[1] West China Hospital, Sichuan University, Chengdu, China

Introduction

Immune checkpoint inhibitors (ICIs) targeting PD-1, PD-L1, and CTLA-4 have transformed oncological practice but are accompanied by an expanding spectrum of immune-related adverse events. Autoimmune bullous diseases (AIBDs) represent a rare yet potentially life-threatening subset, encompassing bullous pemphigoid (BP), lichen planus pemphigoides (LPP), mucous membrane pemphigoid (MMP), pemphigus, and linear IgA bullous dermatosis (LABD). Although emerging evidence suggests that ICI-induced AIBDs (ICI-AIBDs) diverge clinically from their classical counterparts, a comprehensive characterisation of the full disease spectrum—particularly rarer subtypes—and systematic exploration of factors influencing patient survival remain lacking. This study aimed to synthesise available evidence on clinical presentation, diagnosis, management, and outcomes of ICI-AIBDs, and to tentatively explore prognostic determinants of survival.

Materials and Methods

Following PRISMA guidelines and prospective PROSPERO registration, a systematic search of five databases—PubMed, Embase, Web of Science, CNKI, and Wanfang—was conducted from inception to June 2025, using controlled vocabulary and free-text terms related to ICIs and AIBDs. All studies reporting at least one case of ICI-associated AIBD with individual patient data were eligible without language restriction. Cases with pre-existing AIBD prior to ICI initiation, duplicates, and studies without full text were excluded. Two investigators independently screened literature, with disagreements resolved by a third reviewer. Study quality was assessed using Joanna Briggs Institute tools. Descriptive analyses were performed for all extracted variables. Univariable Cox regression screened factors associated with survival ($P < 0.05$), which were subsequently entered into a multivariable Cox model. Kaplan–Meier curves were generated, with between-group differences assessed by log-rank tests.

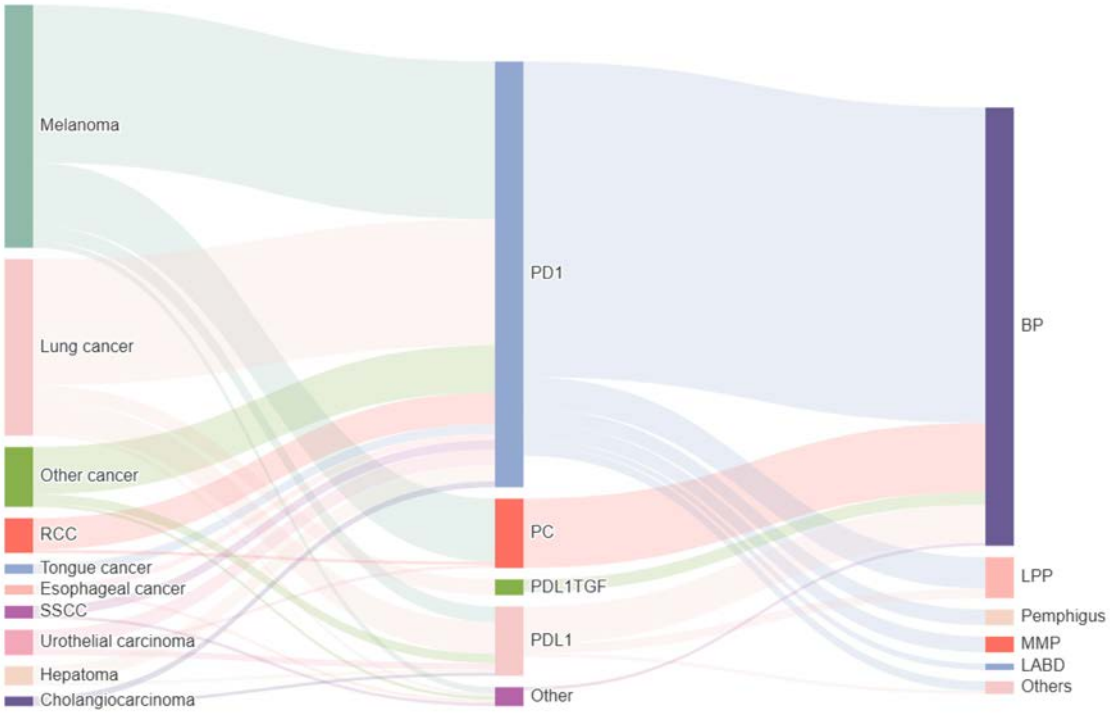

Figure 1. Sankey diagram illustrating the directional relationships among primary malignancies, administered immune checkpoint inhibitors, and subsequent autoimmune bullous diseases. Abbreviations: RCC, renal cell carcinoma; SSCC, skin squamous cell carcinoma; PD1, programmed cell death 1 (PD-1); PC, PD-1 + cytotoxic T lymphocyte-associated antigen 4 (CTLA-4); PDL1, programmed cell death ligand 1 (PD-L1); PDL1TGF, PD-L1 + transforming growth factor β (TGF-β); BP, bullous pemphigoid; LPP, lichen planus pemphigoides; MMP, mucous membrane pemphigoid; LABD, linear IgA bullous dermatosis.

Results

A total of 188 publications (151 case reports, 34 case series, 3 cohort studies) yielding 319 patients were included. The ICI-AIBD spectrum comprised BP (n = 254, 79.6%), LPP (n = 34, 10.7%), MMP (n = 11, 3.4%), pemphigus group (n = 7, 2.2%), and LABD (n = 5, 1.6%). The overall median age was 70.0 years (IQR 63.0–77.0), with 71.2% males, and a median ICI-to-AIBD latency of 6.2 months (IQR 3.0–12.4). PD-1 inhibitors accounted for 82.1% of implicated agents.

BP exhibited the longest latency (median 7.4 months), and prodromal symptoms—predominantly pruritus, erythema, and atypical rash—preceded classical lesions by a median of 2.0 months in 61.6% of BP patients. ICI-LABD showed a reversed sex predominance (80.0% female) compared with classic LABD.

Systemic glucocorticoids were the principal treatment across subtypes (80.4% overall), while biologic use increased substantially, with dupilumab emerging as the most utilised biologic agent (10.2%) compared with prior reports. Overall AIBD remission was achieved in 87.2% of patients.

Among 222 patients with survival data, 36 (16.2%) died over a median follow-up of 5.0 months, with tumour progression being the leading cause of death (47.2%). In multivariable Cox regression, female (HR 2.35; 95% CI 1.10–5.02; P = 0.020) and pemphigus group (HR 7.09; 95% CI 1.87–26.96; P = 0.003) were associated with higher mortality, whereas topical glucocorticoid use appeared protective (HR 0.44; 95% CI 0.21–0.93; P = 0.025). ICI discontinuation was not significantly associated with overall survival.

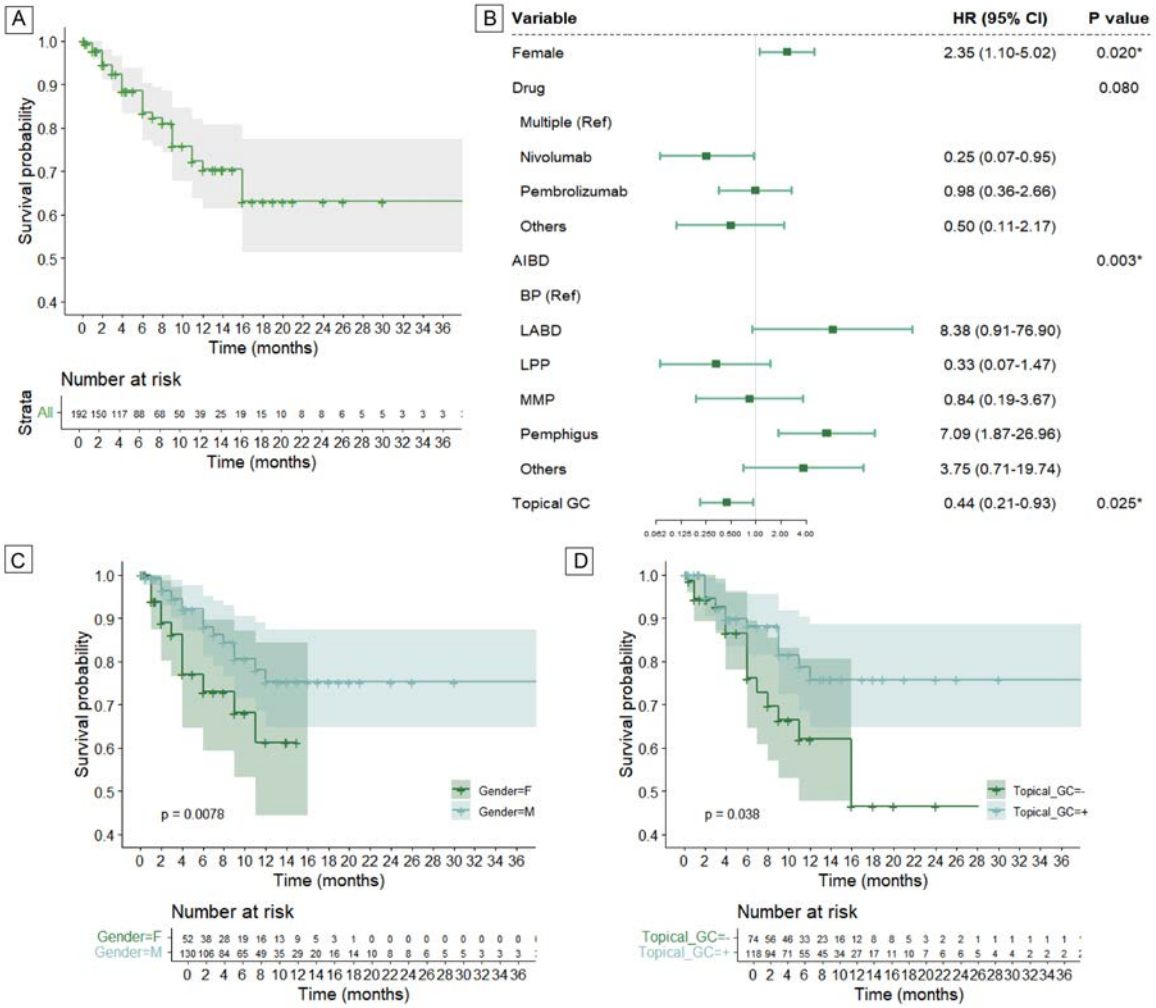

Figure 2. Survival analysis of patients. (A) The survival curve of overall patients; (B) The forest plot of multiple factor Cox regression analysis results; (C) and (D), The survival curves plotted based on gender and the use of topical glucocorticoids or not (between-group differences were evaluated using log-rank tests). Survival curves were not plotted for AIBD subtypes and drug with multiple groups. Abbreviations: Ref, reference; BP, bullous pemphigoid; LABD, linear IgA bullous dermatosis; LPP, lichen planus pemphigoides; MMP, mucous membrane pemphigoid; GC, glucocorticoids.

Conclusions

This study delineates the full clinical spectrum of ICI-AIBDs across 319 patients, demonstrating BP as the dominant subtype with distinct clinical features including a prolonged prodromal phase. Exploratory survival analysis tentatively identifies female sex and pemphigus subtype as risk factors for mortality, while topical glucocorticoids may confer a survival advantage. These findings offer actionable insights for individualised therapeutic decision-making and underscore the need for dedicated prospective studies.

EA DV CONGRESS
VIENNA
30 SEP - 3 OCT 2026

Abstract N°: 292

DRUG REACTION WITH EOSINOPHILIA AND SYSTEMIC SYMPTOMS (DRESS) SYNDROME ASSOCIATED WITH CARBAMAZEPINE USE IN AN 11-YEAR-OLD BOY: A CASE REPORT

Enovwo Obaro Omatighene*[1]

[1] DELTA STATE UNIVERSITY ABRAKA, DELTA STATE UNIVERSITY TEACHING HOSPITAL OGHARA, ENOFES MEDICALS AND HEALTH LIMITED OGHARA, Abraka, Oghara, Nigeria

Introduction

Drug Reaction with Eosinophilia and Systemic Symptoms (DRESS) syndrome is a severe, potentially fatal, idiosyncratic drug reaction first formally defined by Bocquet in 1996 . The syndrome typically manifests 2–8 weeks after exposure to the offending medication and is characterized by fever, extensive cutaneous eruption, facial edema, lymphadenopathy, hematologic abnormalities (eosinophilia and/or atypical lymphocytosis), and internal organ involvement, most commonly hepatic.The estimated incidence ranges from 1 in 1,000 to 1 in 10,000 exposures, with mortality rates reported up to 10%. Anticonvulsants such as carbamazepine, phenytoin, phenobarbital, and lamotrigine remain leading triggers, particularly in children. Carbamazepine alone accounted for 27% of cases in a large case series of 172 patients. We present a pediatric case of carbamazepine-induced DRESS syndrome with systemic involvement, highlighting diagnostic considerations, therapeutic approach, and correlation with contemporary literature.

Case Presentation

An 11-year-old boy was referred to our dermatology unit with a 6-day history of progressively generalized erythematous rash accompanied by intense pruritus and high-grade fever (39.3–40.9 °C). The eruption began on the hands, spread to the forearms, and became generalized within 4 days. Facial puffiness and generalized lymphadenopathy were noted. Three weeks prior, patient had been newly diagnosed with seizure disorder and commenced on carbamazepine therapy. There was no prior history of drug hypersensitivity.

Cutaneous examination revealed a diffuse, symmetrical, generalized eruption involving the face, anterior and posterior trunk , abdomen, and both upper and lower extremities, affecting the majority of the body surface area. The eruption was characterized by numerous erythematous to dusky hyperpigmented macules and infiltrated papules, many of which coalesced into poorly circumscribed plaques. The lesions demonstrated a morbilliform configuration, with areas of confluence producing sheet-like erythema. The surface exhibited fine scaling and generalized xerosis, with early desquamative changes. Scattered areas of post-inflammatory hyperpigmentation were evident between active inflammatory lesions.

Laboratory evaluation showed
White blood cell count: 19.4 × 10^9/L (rising to 27.8 × 10^9/L by day 4),
Atypical lymphocytes: 85.7%
Eosinophilia: >10%Hemoglobin: 10.7 g/dL
Platelets: 590–630 × 10^9/L
ALT: 54.9 U/L
Alkaline phosphatase: 270 U/L
Potassium: 3.2 mmol/L
Serologic tests for HIV 1 & 2, HBsAg, and HCV were negative.

Based on the European Registry of Severe Cutaneous Adverse Reactions (RegiSCAR) scoring system [4,7], the patient fulfilled more than five criteria, establishing a definitive diagnosis of DRESS syndrome.

Management and Outcome
Carbamazepine was immediately discontinued. He received intravenous methylprednisolone 500 mg in 500 mL normal saline daily for 3 days, followed by oral prednisolone at 0.5 mg/kg/day with gradual tapering. Adjunctive therapy included antihistamines, emollients, and supportive care. Fever subsided by the third day of systemic corticosteroid therapy, cutaneous lesions and facial edema improved significantly. He was discharged after 10 days on admission with marked clinical resolution.

The patient has been followed up over three clinic visits without any new complaints. He was initiated on Levetiracetam, with good clinical response and no recurrence of seizures. Notably, there have been no features suggestive of Drug Reaction with Eosinophilia and Systemic Symptoms during the follow-up period.

Conclusion
DRESS syndrome should be suspected in patients presenting with fever, rash, facial edema, and hematologic abnormalities following exposure to Carbamazepine. This case highlights key features of Drug Reaction with Eosinophilia and Systemic Symptoms and underscores the importance of early recognition. Prompt drug withdrawal and timely corticosteroid therapy are critical to reducing morbidity and preventing severe outcomes

EA DV CONGRESS
VIENNA
30 SEP - 3 OCT 2026

Abstract N°: 326

Toxic Epidermal Necrolysis with Severe Gastrointestinal Mucosal Involvement: A Case Report

Wei Wu*[1], Xin-gang Wu[1]

[1] Hangzhou Third People's Hospital, Hangzhou, China

Introduction

Toxic epidermal necrolysis (TEN) with extensive gastrointestinal mucosal involvement and critical digestive symptoms is uncommon. Herein, we report a case of TEN presenting with severe gastrointestinal mucosal involvement that was inconsistent with the cutaneous manifestations. The patient was successfully treated with a combination of adalimumab and upadacitinib, achieving favorable re-epithelialization and recovery of both the skin and gastrointestinal mucosa.

Case Presentation

A previously healthy 54-year-old female presented to the dermatology ICU with a 3-day history of generalized edematous erythema and pruritus after self-medication with cefradine and paracetamol for fever. Physical examination revealed extensive epidermolysis (BSA>30%) with painful erosions of oral, ocular (including symblepharon), and genital mucosae (Panel a-c). The diagnosis of toxic epidermal necrolysis (TEN; SCORTEN:3) was made. The patient developed severe gastrointestinal manifestations disproportionate cutaneous involvement, including fever, nausea, vomiting, abdominal pain and profuse diarrhea. Colonoscopy demonstrated diffuse intestinal inflammation with mucosal erosion (Panel f-g). Histopathological examination of the biopsy specimens confirmed intestinal mucosal inflammation, erosions, and epithelial necrosis. Combination therapy with TNF-α inhibitor and upadacitinib was initiated. At the 4-week follow-up, complete cutaneous re-epithelialization and significant gastrointestinal improvement were observed (Panel de,h).

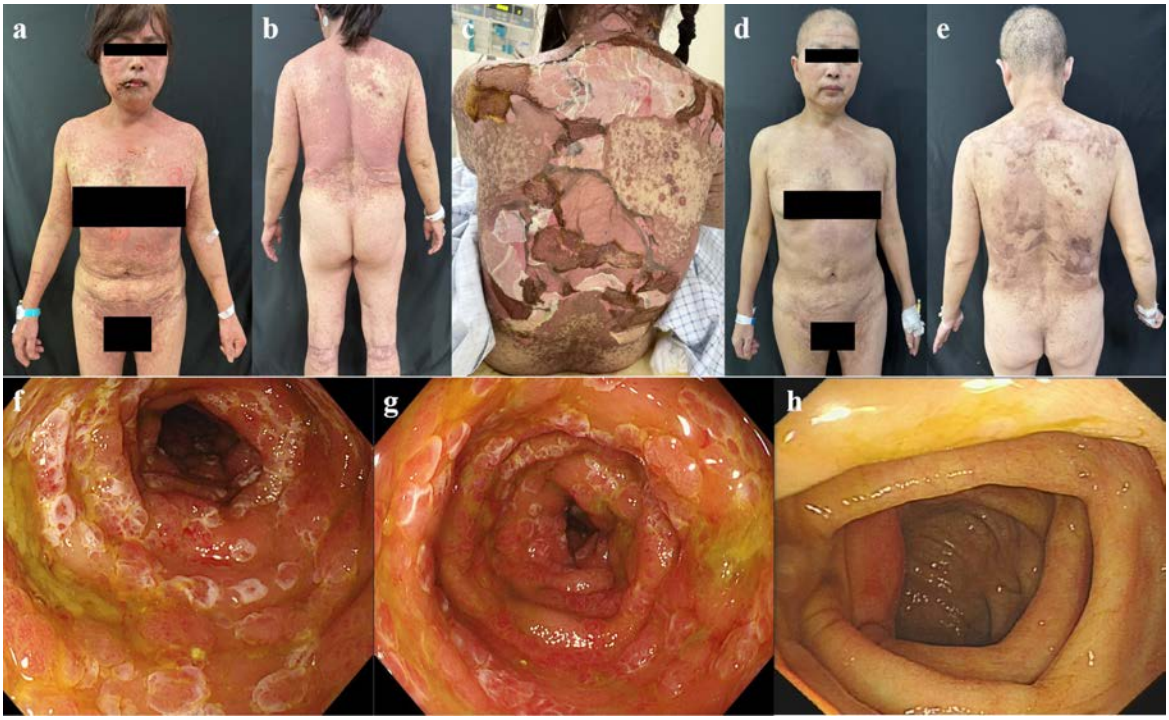

Figure legends. a, b, c: Cutaneous manifestations before treatment; d, e: Cutaneous manifestations after treatment; f, g: Colonoscopic manifestations before treatment; h: Colonoscopic manifestations after

treatment.

Conclusion

This case report presents the successful treatment of toxic epidermal necrolysis with severe gastrointestinal mucosal involvement using adalimumab combined with upadacitinib.

EA DV CONGRESS
VIENNA
30 SEP - 3 OCT 2026

Abstract N°: 328

Association of enfortumab vedotin–related skin toxicity with survival outcome in urothelial carcinoma: a real-world study

Yu-Hsuan Ho*[1], Yi-ju Chen[1]

[1] Department of Dermatology, Taichung Veterans General Hospital, Taichung, Taiwan

Introduction
Enfortumab vedotin (EV) has significantly improved survival in locally advanced and metastatic urothelial carcinoma (la/mUC), but cutaneous toxicities are common. However, treatment response remains heterogeneous, and no clinically validated biomarkers currently exist to predict patient outcomes. Emerging evidence suggests that EV-related skin toxicity may be associated with favorable outcomes, although prior studies have been limited by retrospective designs, small sample size, and potential immortal time bias.
This study aimed to investigate the association between EV-related skin toxicity and all-cause mortality in a large-scale, real-world population of patients with UC.

Materials and Methods
This retrospective cohort study utilized the TriNetX US Collaborative Network database. Patients with UC treated with EV were categorized into ST-cohort (developed skin toxicity within 1 month post first EV prescription) and NST-cohort (did not develop skin toxicity within 1 month post first EV prescription). The index date was the day of first EV prescription. To reduce immortal time bias, patients who died within 1 month after EV initiation and those with severe cutaneous adverse reactions were excluded from the primary analysis, and a 1-month landmark design was applied. 1:1 propensity score matching (PSM) was performed based on current age, age at index, sex, race, primary tumor locations, comorbidities, laboratory parameters, and prior exposure to chemotherapy or immunotherapy. The primary outcome was 1-year all-cause mortality, analyzed using Kaplan-Meier and Cox regression analyses. Subgroup analyses were conducted according to clinically relevant variables, including age, sex, comorbidities, laboratory data and prior immunotherapy exposure. Sensitivity analyses were performed to assess the robustness of the findings, including alternative definitions of skin toxicity, varying landmark time points, different follow-up durations, exclusion of patients with potentially confounding pre-existing skin disease or recent immunotherapy exposure, and replication of the primary analysis in the larger TriNetX Research Network.

Results
Among 3161 EV-treated patients, 490 were assigned to the ST-cohort and 2548 to the NST-cohort. 486 patients remained in each cohort after PSM. The cumulative incidence of mortality was presented in Figure 1. During follow-up, mortality occurred in 94 patients (19.4%) of the ST-cohort and 123 patients (25.4%) of the NST-cohort ($P < .0255$). The 1-year cumulative incidence of mortality was significantly lower in the ST-cohort (24.21%; 95% confidence interval [CI], 20.17%-28.91%) than in the NST-cohort (34.41%; 95% CI 29.61%-39.75%; $P = .0031$). EV-related skin toxicity was associated with a lower risk of all-cause mortality (hazard ratio [HR], 0.668; 95% CI, 0.511-0.874). The association remained generally consistent across subgroup analyses and multiple sensitivity analyses.

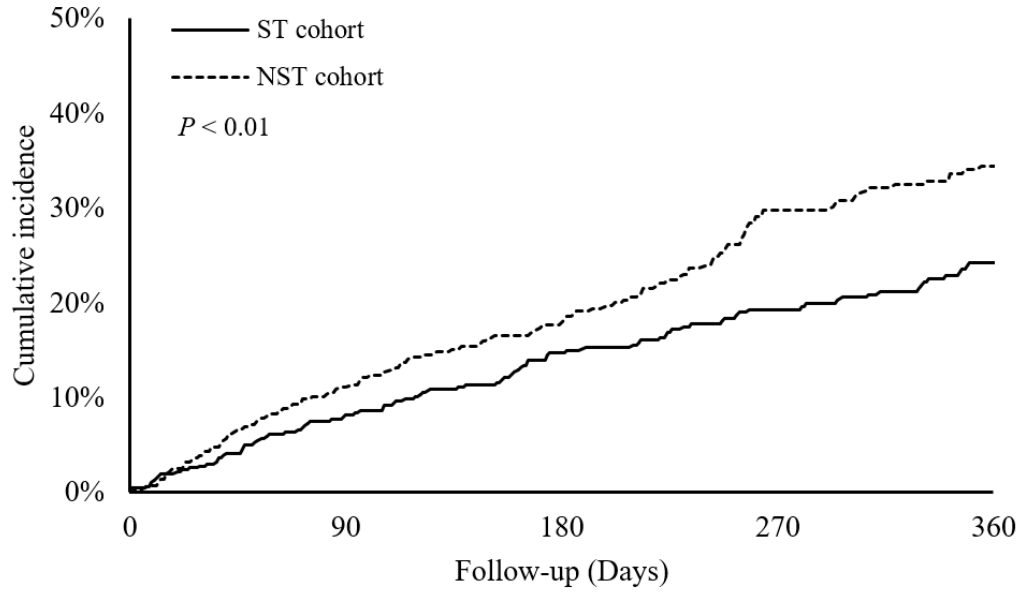

Number at risk

ST	486	455	429	398	380
NST	486	444	406	370	327

Figure 1. Cumulative incidence of mortality in the ST-cohort vs the NST-cohort. The differences between the 2 study cohorts were determined by log-rank test. ST-cohort, skin toxicity cohort; NST cohort, no skin toxicity cohort.

Conclusions

EV-related skin toxicity was associated with significantly lower all-cause mortality in patients with UC. Early skin toxicity may serve as a clinically accessible surrogate marker for treatment efficacy and warrants prospective validation.

EA DV CONGRESS
VIENNA
30 SEP - 3 OCT 2026

Abstract N°: 338

PD-1 inhibitor induced progressive immunotherapy-related mucocutaneous eruption – a report of 2 cases

Li Houng Chen*[1], Benjamin Ho[1]

[1] National Healthcare Group - National Skin Centre, Singapore, Singapore

Introduction

Immune checkpoint inhibitors (ICI) have been associated with life-threatening severe cutaneous adverse reactions. Steven-Johnson syndrome/toxic epidermal necrolysis (SJS/TEN) is by far the most common, with EGFR inhibitors being the most frequent drug class associated [1]. Increasingly, PD-1 inhibitors have also been reported to cause SJS/TEN. In the context of PD-1 inhibitor use, a close mimic of SJS/TEN both clinically and histologically has been recently described. Progressive immunotherapy-related mucocutaneous eruption (PIRME), refers to a generalized bullous reaction with full-thickness epidermal necrosis. We present 2 cases.

Case Presentation

Case 1: A 69-year-old Chinese male with metastatic NSCLC presented with blistering lower limb rashes. He had started palliative pembrolizumab 2 weeks prior and had been on sulfamethoxazole-trimethoprim (Bactrim) for 4 months.
Examination showed forehead erythema, erythematous to dusky patches on the trunk and limbs, and blisters/erosions on the feet. Nikolsky sign was positive on the right trunk and feet. Oral and genital mucosa were spared.
PIRME was diagnosed, with Bactrim as the likely culprit in the setting of recent pembrolizumab.Biochemistry showed no end-organ involvement.
Skin biopsy revealed a subepidermal blister with a necrotic epidermal roof, compact hyperkeratosis, and parakeratosis. Basal vacuolar change, apoptotic keratinocytes, and a superficial perivascular lymphohistiocytic infiltrate with pigmentary incontinence were noted. No eosinophils were seen. Direct immunofluorescence was negative.
He was treated with oral prednisolone (0.5 mg/kg/day) with a gradual taper (10 mg/week). Following cessation of the culprit drug, his condition improved.

Case 2: A 71-year-old Chinese male with multifocal hepatocellular carcinoma was started on second-line nivolumab. Eleven days after the first dose, he developed conjunctival injection and lip erosions, with erythematous plaques on the face and dusky purpuric papules on the trunk and limbs, some with vesicles and bullae. Nikolsky sign was negative; mucosa and genitalia were spared.Initial impression was SJS secondary to nivolumab. Ophthalmology excluded ocular involvement.
Investigations showed no end-organ involvement.Skin biopsy demonstrated interface dermatitis with epidermal dyskeratosis and occasional eosinophils; DIF was negative.
Lesions improved over 4 days with re-epithelialization of lip erosions.
Three days later, he received cefazolin and piperacillin-tazobactam for fever. One day after antibiotics, he developed new confluent purpuric and targetoid plaques with erosions over the neck, trunk, and limbs, with tense bullae at lesion borders. Nikolsky sign was positive over the neck. New facial dusky patches with ear lobe edema appeared; mucosa and genitalia remained uninvolved.
A revised diagnosis of PIRME was made, likely triggered by antibiotics in the context of recent nivolumab. Repeat biopsy showed interface dermatitis with a subepidermal blister and a lymphocytic infiltrate with increased eosinophils; DIF remained negative.

He was treated with oral ciclosporin (3.95 mg/kg/day for 10 days) and high-potency topical steroids, with eventual recovery.

Conclusion

It is important for clinicians to recognize PIRME as a distinct clinical entity and appreciate its key differences from SJS/TEN, which hold important implications for management and prognostication. Further studies are warranted to explore potential molecular markers that may reliably differentiate between these entities and to define optimal immunosuppressive regimens. Clinicians should also remain vigilant for the development of PIRME in patients receiving immune checkpoint inhibitors, particularly given the possibility of prolonged latency periods.

EA DV CONGRESS
VIENNA
30 SEP - 3 OCT 2026

Abstract N°: 407

Raynaud's phenomenon associated with concomitant use of topical minoxidil

Juan De Luque Fernández*[1], Irene Suárez Vergne[1], María del Señor Gómez Marín[1], José Manuel Rodríguez Torres[1], Manuel Latorre García[1], Helena Vidarte Rebertos[1], JL Sanz-Cabanillas[1], Pedro Gomez Arias[1], Miguel Juan Cencerrado[1], Manuel Galán-Gutiérrez[1], Antonio Vélez García-Nieto[1]

[1] Hospital Universitario Reina Sofía (Córdoba) - Servicio de Dermatología, Córdoba, Spain

Introduction

Raynaud's phenomenon (RP) is a vasospastic disorder characterized by transient episodes of ischemia in acral regions (mainly the fingers), typically triggered by cold or stress and presenting with a triphasic color change (pallor, cyanosis, and rubor). It can be classified as primary or secondary, the latter being associated with systemic diseases or certain drugs, especially vasoconstrictors. Minoxidil, widely used for androgenetic alopecia, is a vasodilator that has even been explored as a treatment for RP, albeit without success. Additionally, an unexpected case of angina pectoris due to coronary vasospasm has been reported in association with systemic minoxidil use, possibly due to a reflex sympathetic response to drug-induced vasodilation (Pavrey et al, 2025). In this context, we present a clinical case suggesting a possible association between topical minoxidil use and the onset of RP.



Raynaud’s phenomenon possibly associated with the use of topical minoxidil after contact with the fingertip pad. Images provided by the patient at the time of the episode.

Case Presentation

A 29-year-old male, smoking 10 cigarettes per day and with no other relevant medical history, presented with brief, recurrent episodes over three days consisting of color changes in the second finger of the left hand, accompanied by local paresthesia. The patient associated symptom onset with the recent use of 5% topical minoxidil, initiated one week earlier, using the pulp of the affected finger for application. He described a characteristic sequence of pallor followed by a violaceous hue and subsequent erythema, with spontaneous resolution within seconds.Physical examination was unremarkable, with no signs of sclerodactyly, ulcers, or residual scars. The patient provided images consistent with the described episodes. An extensive workup was performed, including laboratory tests with autoimmunity panel, capillaroscopy, chest X-ray, upper gastrointestinal endoscopy, and electroneurography, all of which were normal.Given the suspicion of RP, protective measures against cold exposure were recommended. However, episodes persisted for two weeks, leading to discontinuation of topical minoxidil, after which symptoms completely resolved. Reintroduction of the drug reproduced the episodes, supporting a possible causal relationship, and it was therefore definitively discontinued. The patient was subsequently started on oral minoxidil (2.5 mg/day), with no recurrence of symptoms after three months of follow-up.

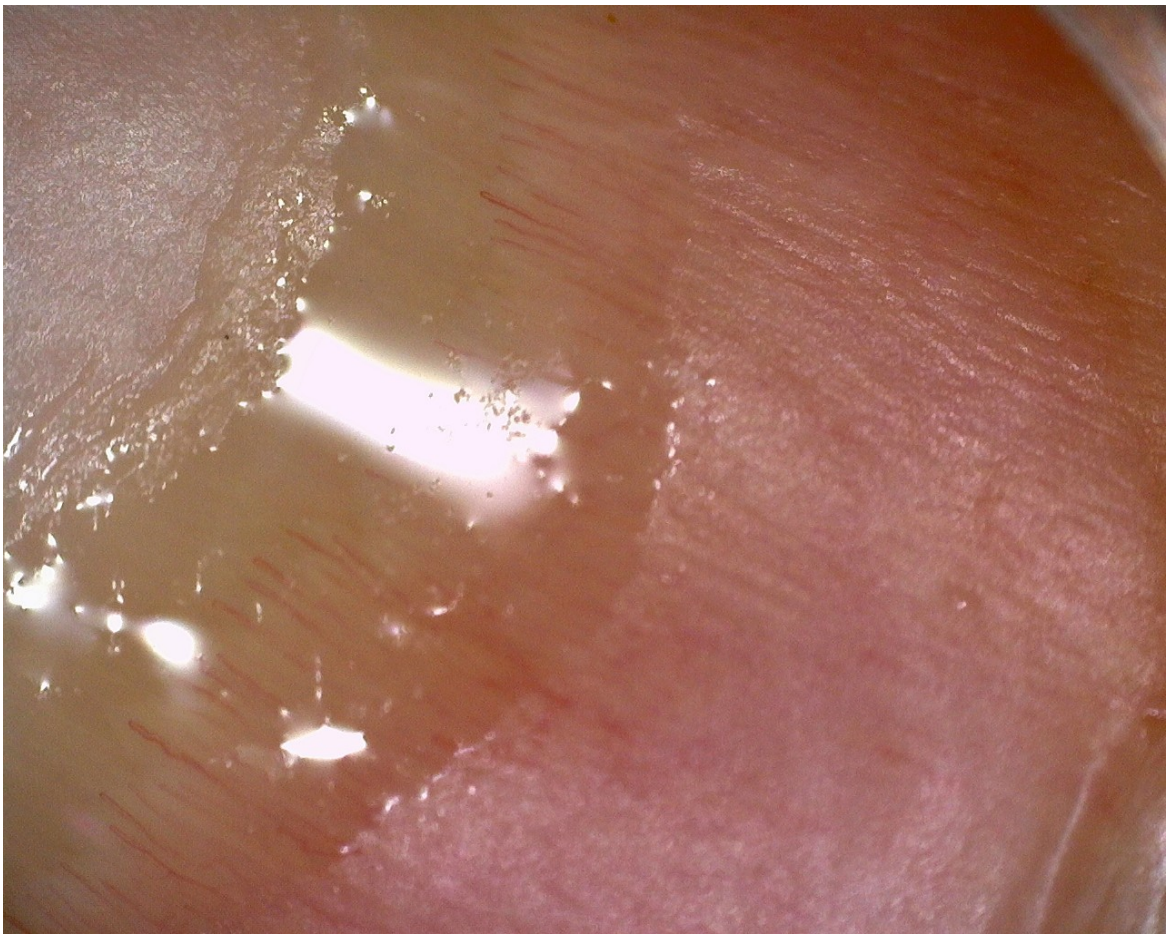

Capillaroscopy of the second finger of the patient’s left hand. No abnormalities are observed.

Conclusion

This case suggests a possible association between topical minoxidil use and the development of localized Raynaud’s phenomenon, likely mediated by a reflex vasospastic mechanism in susceptible individuals in conjunction with cold exposure. Resolution after drug withdrawal and recurrence upon re-exposure support this hypothesis. This vasomotor effect, not previously described for topical minoxidil, highlights the importance of considering unusual adverse effects of commonly used medications and performing a thorough, targeted history in patients with newly onset RP.



Recurrence of Raynaud’s phenomenon during the reintroduction of topical minoxidil. Image provided by the patient at the time of the episode.

EADV CONGRESS
VIENNA
30 SEP - 3 OCT 2026

Abstract N°: 474

Benzoyl Peroxide Use and Cancer Incidence: A Nationwide, Population-Based Study

Kao Sung Tsai*[1]

[1] Guangyan Dermatology Clinic, School of Chinese Medicine, Graduate Institute of Integrated Medicine, Ph.D. Program for Translational Medicine, China Medical University, Taichung City, Taiwan

Introduction
Benzoyl peroxide (BPO) is a mainstay of topical acne therapy. Recent reports suggest that BPO can degrade into benzene, a known human carcinogen, under thermal or ultraviolet stress. However, epidemiologic evidence linking topical BPO use to long-term cancer risk remains sparse.

Materials and Methods
This study conducted a nationwide, retrospective cohort study using data from the Taiwan National Health Insurance Research Database (2000–2021). Patients prescribed BPO were compared with a control group matched 1:1 on age, sex, and index year. The primary outcome was the incidence of hematologic and solid malignancies, identified via ICD-9/10 codes and Registry for Catastrophic Illness Patients. Cox proportional-hazards models were used to estimate adjusted hazard ratios (aHRs) with 95% confidence intervals (CIs).

Results
Among 3,405,028 patients, BPO use was associated with an increased risk of trachea, bronchus, and lung cancer (aHR, 1.44) in those under 20 years of age. In patients aged 20–60 years, BPO use was associated with significantly higher risks of non-Hodgkin lymphoma (aHR, 1.16), thyroid cancer (aHR, 1.20), trachea, bronchus, and lung cancer (aHR, 1.10), non-melanoma skin cancer (aHR, 1.25), and urinary tract cancer (aHR, 1.23). In those aged >60 years, BPO use was associated with significantly increased risks of non-Hodgkin lymphoma (aHR, 1.36) and non-melanoma skin cancer (aHR, 1.44). Cumulative incidence curves demonstrated a divergence over time in the risks of non-Hodgkin lymphoma, thyroid cancer, non-melanoma skin cancer, and urinary tract cancer ($p < 0.001$).

Conclusions
Exposure to BPO was associated with a modest but statistically significant increase in the risk of certain hematologic and solid malignancies in this Taiwanese population. Further studies are required to establish causality and evaluate the impact of product formulation and storage on benzene-related risks.

EADV CONGRESS
VIENNA
30 SEP - 3 OCT 2026

Abstract N°: 531

Pembrolizumab-Associated Scleroderma in a Patient with Metastatic Melanoma: A Case Report

Arina Vashkevich*[1], Yulia Semiletova[2], Irena Belousova[3], Maksim Zinkevich[4], Maya Gulordava[1], Marina Karnaukhova[1], Arina Kogadey[1], Polina Reztsova[1]

[1] I.I. Mechnikov North-Western State Medical University, Saint Petersburg, Russian Federation
[2] N.I. Pirogov High Medical Technologies Clinic, Saint Petersburg, Russian Federation
[3] Medical Military Academy, Saint Petersburg, Russian Federation
[4] Leningrad Regional Clinical Hospital, Saint Petersburg, Russian Federation

Introduction

Immune checkpoint inhibitors (ICIs), particularly anti–PD-1 agents such as Pembrolizumab, are widely used in oncology but may induce immune-related adverse events (irAEs), including rare fibrosing dermopathies. Scleroderma-like syndromes represent an uncommon complication, often lacking classical autoimmune features and posing diagnostic challenges.

Case Presentation

A 36-year-old female with metastatic melanoma (ICD-10 C43.5) received pembrolizumab (200 mg every 3 weeks). Her oncologic history included primary melanoma of the trunk with sentinel lymph node involvement. From August 2022, she was treated with targeted therapy (dabrafenib plus trametinib). Disease progression was documented on CT in October 2023 with regional lymph node metastases, leading to initiation of immunotherapy.Pembrolizumab was administered from January 2024 to July 2025 (24 cycles), resulting in complete radiologic response by June 2025. After approximately 18 months of therapy, the patient developed progressive skin induration, edema, and stiffness of the upper and lower extremities, associated with functional limitation (CTCAE grade 2).

Histopathological examination (March 2026) revealed marked sclerosis of the reticular dermis, thickened collagen bundles, epidermal atrophy with loss of adnexal structures, and fibrosis extending into the subcutaneous tissue with septal thickening, accompanied by mild perivascular lymphohistiocytic infiltrate. These findings were consistent with scleroderma-like changes.Systemic evaluation showed no evidence of internal organ involvement on CT and no melanoma progression at the time of dermatologic manifestation. ECOG performance status was 1. Rheumatologic assessment suggested a systemic connective tissue process, while autoimmune serology remained inconclusive.Pembrolizumab was discontinued due to suspected irAE. Systemic corticosteroid therapy (prednisolone up to 1 mg/kg with tapering) led to partial improvement and subsequent stabilization.

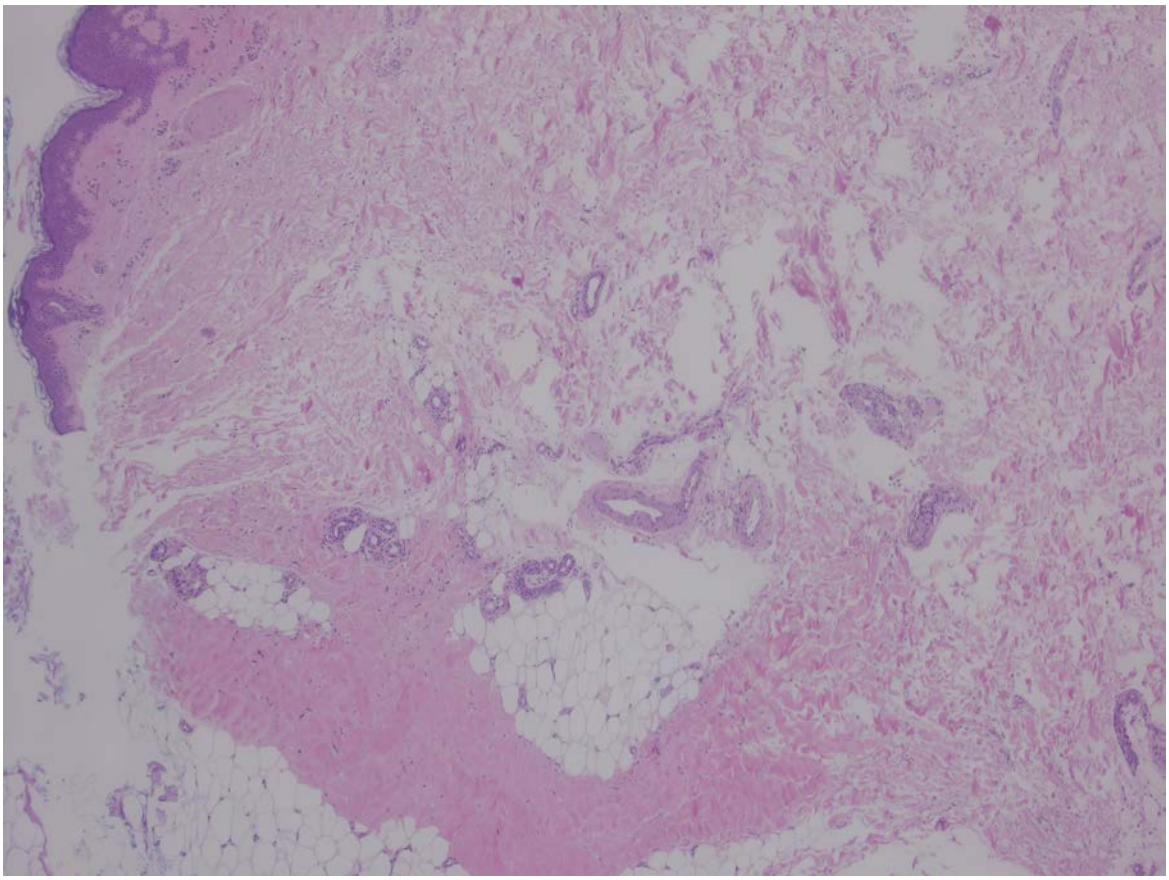

Histopathological examination (March 2026) revealed marked sclerosis of the reticular dermis, thickened collagen bundles, epidermal atrophy with loss of adnexal structures, and fibrosis extending into the subcutaneous tissue with septal thickening, accompanied by mild perivascular lymphohistiocytic infiltrate.

Conclusion

Pembrolizumab-associated scleroderma is a rare irAE that may occur after prolonged treatment, even in the setting of complete tumor response. The absence of significant systemic involvement and inconclusive autoantibody profile may distinguish it from idiopathic systemic sclerosis. Early recognition is essential to optimize management and balance oncologic efficacy with immune toxicity.

EADV CONGRESS
VIENNA
30 SEP - 3 OCT 2026

Abstract N°: 552

Vildagliptin-Induced Symmetrical Drug-Related Intertriginous and Flexural Exanthema (SDRIFE): A Rare Case Report

Asya Almila Can*[1], Cem Leblebici[1], Ayşe Esra Koku AKsu[1]

[1] Istanbul Training and Research Hospital, Istanbul, Türkiye

Introduction

Symmetrical Drug-Related Intertriginous and Flexural Exanthema (SDRIFE), historically known as "Baboon Syndrome," is a specific type IV hypersensitivity reaction. It is characterized by a sharply demarcated, symmetrical erythema in the gluteal and intertriginous areas following systemic drug administration. While β-lactam antibiotics are the most frequent triggers, the role of Dipeptidyl Peptidase-4 (DPP-4) inhibitors is rarely documented. Vildagliptin, a common DPP-4 inhibitor, is known to modulate T-cell activity via CD26 inhibition, which may predispose patients to unique cutaneous adverse reactions. We report a rare case of SDRIFE in a 58-year-old female patient, triggered by vildagliptin.

Case Presentation

A 58-year-old female patient presented to our dermatology clinic with a sudden onset of a pruritic, symmetrical erythematous rash involving the major skin folds. Her medical history revealed a recent diagnosis of Type 2 Diabetes Mellitus, for which vildagliptin (50 mg bid) had been initiated exactly seven days prior to the eruption. Physical examination demonstrated sharply demarcated, vivid erythematous patches localized symmetrically in the inguinal regions, gluteal cleft, axillary vaults, and inframammary folds. No vesicles, pustules, or mucosal involvement were observed, and the patient remained afebrile with no systemic symptoms. Laboratory investigations, including complete blood count and inflammatory markers, were within normal limits. To confirm the diagnosis, a punch biopsy was performed from the active border of the inguinal lesion. Histopathological examination revealed superficial perivascular lymphocytic infiltration with eosinophils, mild dermal edema, and focal epidermal spongiosis, all of which were consistent with a drug-induced eruption (SDRIFE). Based on the clinical morphology, the temporal relationship, and the supportive histopathology, a definitive diagnosis of vildagliptin-induced SDRIFE was established. Vildagliptin was immediately discontinued and replaced with an alternative antidiabetic agent. Therapeutic management included a short course of oral corticosteroids (0.5 mg/kg/day prednisolone) in addition to topical corticosteroid therapy and oral second-generation antihistamines. Following the initiation of systemic treatment and drug cessation, the lesions showed significant regression within 48 hours and achieved complete resolution within one week.

Conclusion

This case provides compelling clinical and histopathological evidence that vildagliptin can be a potent, albeit rare, systemic trigger for SDRIFE. While the cutaneous side-effect profile of DPP-4 inhibitors is predominantly characterized by bullous pemphigoid, this report expands the known dermatological spectrum of vildagliptin to include type IV delayed-type hypersensitivity manifested in a classic "Baboon" distribution.

EA DV CONGRESS
VIENNA
30 SEP - 3 OCT 2026

Abstract N°: 556

Effective Use of 3% Topical Allopurinol in Intractable Granulomatous Tattoo Reaction: Case Report and Review

Vivian Wong*[1], Daryan Ghaemi[1], Camille Strackbein[2]

[1] Rosalind Franklin University the Chicago Medical School, Chicago, United States
[2] Skin Wellness Physicians, Naples, United States

Introduction

Granulomatous reactions to tattoo ink present a therapeutic challenge for both patients and clinicians, often proving refractory to conventional treatments and, in some cases, requiring escalation to systemic immunomodulatory therapies with limited success. Here, we present a case of a recalcitrant granulomatous tattoo reaction that achieved complete resolution with topical allopurinol, highlighting a novel, well-tolerated, non-steroidal therapeutic option for this difficult-to-treat condition.

Case Presentation

A 45-year-old man presented with an 8-week history of eczematous, partially lichenified papules and plaques overlying a new black-ink tattoo placed two months prior on the right forearm. He previously tolerated black ink tattoos without complications. Prior treatment with oral cephalexin for presumed infection showed no improvement and no clinical evidence of infection was noted on exam. The patient was initially treated with topical clobetasol propionate ointment without improvement. Subsequent bacterial cultures were negative despite empiric treatment with doxycycline and mupirocin. Punch biopsy was performed, with pathology confirming a granulomatous tattoo reaction; bacterial, fungal, and mycobacterial tissue cultures were negative. The patient was then started on topical allopurinol 3% solution applied twice daily, with improvement in a month and resolution in 3 months.



Granulomatous reaction

Conclusion

A review of the literature demonstrates that multiple therapies have been used to treat granulomatous tattoo reactions and cutaneous sarcoidosis, while topical therapies remain an area of ongoing investigation. Reported treatments include topical and intralesional corticosteroids, tacrolimus, allopurinol, hydroxychloroquine, topical pimecrolimus 1% cream, JAK1/2 inhibitors such as ruxolitinib 1.5% cream, and photodynamic therapy using topical methyl aminolevulinate, all with reported success.In our case, the patient showed significant improvement one month after starting topical allopurinol, with complete resolution at three months. This treatment duration compares favorably with many existing therapies, which often require prolonged courses or escalation to systemic agents with variable outcomes. While oral allopurinol has demonstrated efficacy in treating granulomatous reactions, it carries a risk of systemic adverse effects, including rare but severe hypersensitivity reactions such as Stevens–Johnson syndrome and toxic epidermal necrolysis. In contrast, topical allopurinol provides localized therapy with minimal systemic absorption, reducing the risk of systemic toxicity. Although topical allopurinol is not commercially available in the United States, it can be compounded (approximately $55 for a 30-g preparation), providing a safe and affordable treatment option for recalcitrant granulomatous tattoo reactions.



Following treatment

EADV CONGRESS
VIENNA
30 SEP - 3 OCT 2026

Abstract N°: 567

Temozolomide-induced Toxic Epidermal Necrolysis: Rare but Life-Threatening Adverse Event in a Patient with Glioblastoma

Gabriela Mariana Iancu*[1, 2], Andra Maria Criveanu[1]

[1] County Clinical Emergency Hospital of Sibiu, Dermatology Department, Sibiu, Romania
[2] Lucian Blaga Univeristy of Sibiu, Faculty of Medicine, Sibiu, Romania

Introduction

Glioblastoma is the most aggressive primary malignant tumor of the central nervous system, requiring a multimodal therapeutic approach that typically includes surgical resection followed by radiotherapy and chemotherapy. Temozolomide, an oral alkylating agent, represents the first-line chemotherapeutic option, generally well tolerated but occasionally associated with severe adverse reactions. Among these, toxic epidermal necrolysis (TEN) is a rare yet life-threatening mucocutaneous reaction, characterized by widespread epidermal necrosis and detachment. Prompt recognition is crucial due to its high morbidity and mortality.

Case Presentation

We report the case of a male oncologic patient with a recent history of surgically treated right temporal glioblastoma, undergoing radiotherapy and chemotherapy with Temozolomide. Approximately four weeks after treatment initiation, the patient developed an episode of acute cholestatic hepatitis attributed to medication. Shortly after, he presented with a diffuse cutaneous eruption in the form of extensive erythematous maculopapular and target-like lesions, a positive Nikolsky sign, tense bullae on the palmar and plantar surfaces, and epidermal detachment affecting around 30% of the body surface area, along with mucosal involvement. Laboratory investigations revealed leukocytosis with neutrophilia, hepatic cytolysis and cholestasis, a systemic inflammatory response as well as positive blood cultures isolating three bacterial species. The temporal relationship and absence of alternative triggers supported a probable causal association, leading to the diagnosis of Temozolomide-induced toxic epidermal necrolysis complicated by sepsis of cutaneous origin. The SCORTEN severity score was 2, indicating a predicted mortality of 12%, however, concomitant sepsis, acute cholestatic hepatitis, and underlying malignancy likely increased the overall mortality risk beyond that predicted by SCORTEN. Management required a multidisciplinary approach, including immediate withdrawal of the suspected drug, administration of high-dose systemic corticosteroids, broad-spectrum antibiotics, intensive supportive care with fluid and electrolyte correction, and local wound management. The patient showed a progressively favorable course, with gradual re-epithelialization and improvement in general condition.

Conclusion

This case highlights the importance of recognizing Temozolomide as a potential trigger of TEN and underscores the need for heightened pharmacovigilance in oncologic patients. It also illustrates the potential limitations of SCORTEN in complex patients with multiple comorbidities, such as malignancy and secondary sepsis.

EADV CONGRESS
VIENNA
30 SEP - 3 OCT 2026

Abstract N°: 577

Acute giant urticaria of the erythema marginatum type (Marfan-like), induced by the use of Lomifen (Clomiphene citrate) for primary infertility: an unusual case report.

omar boudghene stambouli*[1]

[1] Medical Practice of Dermatology and Venereology Former Head of Dermatology at Tlemcen, Tlemcen, Algeria

Introduction
Erythema marginatum of Marfan, characterized by cutaneous lesions with vasculitis, classically suggests an immunological process encountered in connective tissue diseases, serum sickness, and certain particular forms of drug allergy.However, circinate urticaria may develop without a clearly identified etiological context.

Case Presentation
We report an unusual case of erythema marginatum of Marfan (EMM) induced by the use of Lomifen (clomiphene citrate).
Two days after taking the medication, a generalized eruption appeared
A 25-year-old married woman with primary infertility for 5 years was treated with Lomifen 50 mg (clomiphene citrate), at a dose of 3 tablets per day.
The patient was not taking any other medications.
The entire skin surface was affected by acute giant urticaria presenting as giant erythema marginatum of Marfan.
From an evolutionary standpoint, discontinuation of the suspected and causative drug (Lomifen) led to complete remission of the eruption.
Lomifen is a drug frequently used in daily practice to treat certain forms of infertility. It acts as an ovulation inducer.

Conclusion
Adverse effects do not occur systematically in all patients; they may include lower abdominal pain, insufficient cervical mucus, heavy menstrual bleeding, frequent urination, visual disturbances, tachycardia, and dizziness.From a dermatological standpoint, the most commonly reported effect is hair loss.Erythema marginatum of Marfan has never been reported.Circinate urticaria may occur without a clearly identified etiological context.

EADV CONGRESS
VIENNA
30 SEP - 3 OCT 2026

Abstract N°: 593

Determinants of the Severity of Lyell Syndrome: Epidemiological and Clinical Profile, Role of the Implicated Molecule, and Time to Onset

Wissal Souhail*[1, 2], layla Bendaoud[1, 2], maryem Aboudourib[1, 2], Ouafa Hocar[1, 2], Said Amal[1, 2]

[1] Dermatology Department, Arrazi Hospital, Mohammed VI University Hospital, Marrakech, Marrakech, Morocco
[2] Biosciences Research Laboratory, FMPM, Cadi Ayyad University, Marrakech, Marrakech, Morocco

Introduction
Lyell syndrome, or toxic epidermal necrolysis, is a rare and severe drug-induced cutaneous reaction characterized by extensive epidermal necrosis associated with severe mucosal involvement and high mortality. Medications constitute the main cause of this reaction.The severity of the disease is usually assessed using the SCORTEN prognostic score. However, certain factors related to the causative drug, particularly the implicated molecule and the time to onset of symptoms, may also influence the clinical course and the severity of the disease.The aim of this study was to analyze the determinants of severity of Lyell syndrome by examining the epidemiological and clinical profile of patients as well as the role of the implicated molecule and the time to onset.

Materials and Methods
This was a retrospective descriptive and analytical cohort study conducted over 10 years in the intensive care and dermatology departments. Forty patients hospitalized for Lyell syndrome, defined by body surface area involvement (BSA ≥10%), were included. Severity was assessed according to the extent of skin detachment and the initial SCORTEN score. The time to onset between drug exposure and the onset of symptoms was classified into <7 days and 7–28 days.Statistical analysis was performed using SPSS software, with data verification and visualization conducted in Python. Quantitative variables are expressed as mean ± standard deviation or median, and qualitative variables as frequencies and percentages. Associations between variables were analyzed using the χ^2 test, with a significance level set at $p < 0.05$.

Results
Forty patients with Lyell syndrome were included. The mean age was 44.9 ± 25.9 years, with a female predominance (male/female ratio = 0.6). The mean detached body surface area was 39.5 ± 21.4%; 50% of patients had involvement of 10–30% and 50% had >30%. The time to onset was <7 days in 55% of cases and 7–28 days in 45%.Mucosal involvement was observed in 100% of patients: isolated ocular involvement in 47.5%, involvement of all mucosal sites in 42.5%, and isolated oral involvement in 10%. Ocular manifestations were dominated by conjunctivitis (47.5%), followed by keratitis (32.5%) and corneal ulceration (20%).The initial SCORTEN score (n = 34) was 3.12 ± 1.04 (median 3). The most frequently implicated drugs were allopurinol (30%), lamotrigine (12.5%), NSAIDs (10%), paracetamol (10%), and amoxicillin–clavulanic acid (10%). The in-hospital mortality rate was 31%.Forms with 10–30% involvement occurred mainly within <7 days (80% vs 20%), whereas forms with >30% involvement occurred more frequently between 7–28 days (70% vs 30%) ($\chi^2 = 8.18$; $p = 0.004$).Analysis of the 13 individual molecules did not show an association with severity ($p = 0.092$). After grouping into therapeutic classes, forms with >30% involvement were more frequently associated with antibiotics and NSAIDs, whereas forms with 10–30% involvement were more often linked to allopurinol ($p = 0.034$).Patients with SCORTEN ≥3 more frequently had a detached surface area >30% (64.3% vs 16.7%) ($p = 0.016$). The association between SCORTEN and time to onset was not significant ($p = 0.188$). After therapeutic grouping, SCORTEN ≥3 was more frequent with antibiotics and antiepileptic drugs, whereas SCORTEN <3 was predominantly associated with allopurinol ($p = 0.027$).

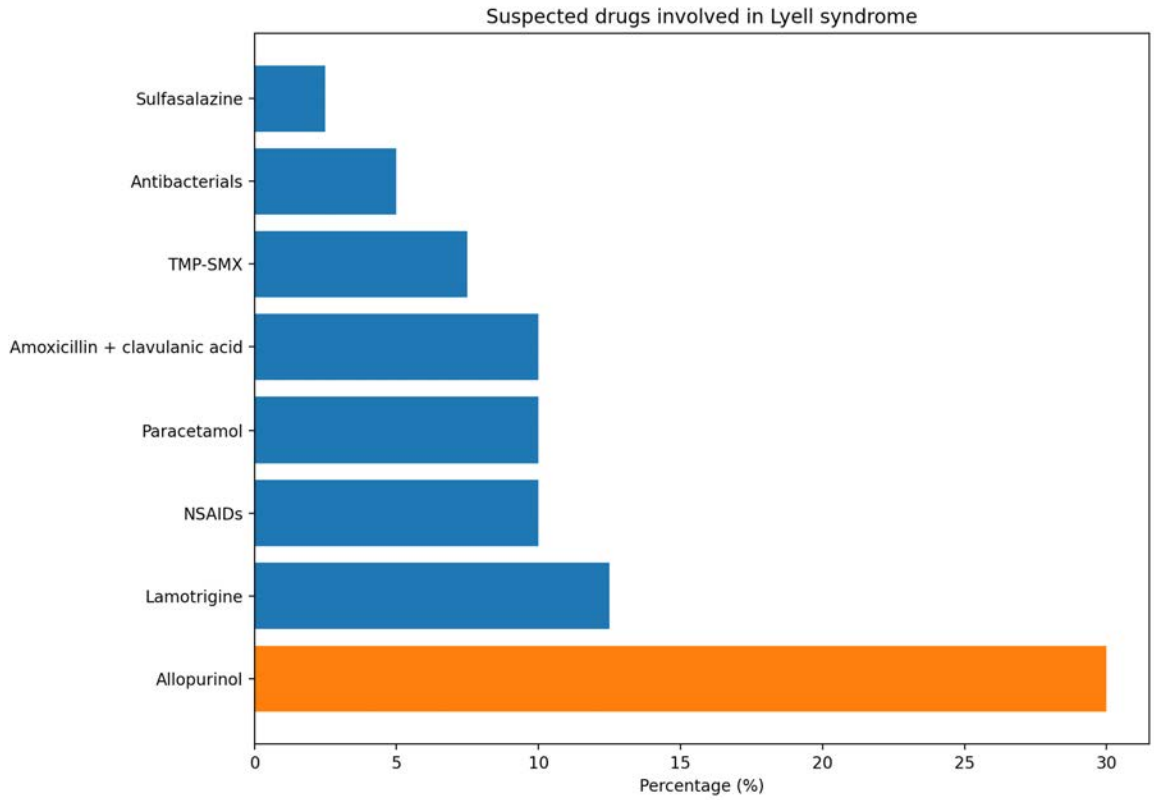

suspected drugs in lyell syndrome

Conclusions

The severity of Lyell syndrome is closely related to the extent of skin detachment and the initial SCORTEN score. The most severe forms occur more frequently when the time to onset is 7–28 days and after exposure to certain drug classes, particularly antibiotics and NSAIDs. Early identification of these factors remains essential to optimize prognostic assessment and patient management.

EADV CONGRESS
VIENNA
30 SEP - 3 OCT 2026

Abstract N°: 612

Impact of Corticosteroid Exposure on the Course of Lyell Syndrome: Severity, Mortality, and Long-Term Sequelae

Wissal Souhail*[1, 2], Layla Bendaoud[1, 2], Maryem Aboudourib[1, 2], Ouafa Hocar[1, 2], Said Amal[1, 2]

[1] Dermatology Department, Arrazi Hospital, Mohammed VI University Hospital, Marrakech, Marrakech, Morocco
[2] Biosciences Research Laboratory, FMPM, Cadi Ayyad University, Marrakech, Marrakech, Morocco

Introduction
Lyell syndrome, or toxic epidermal necrolysis, is a severe drug-induced cutaneous reaction characterized by extensive epidermal necrosis and high mortality. Prognosis is generally assessed using the SCORTEN score, which allows estimation of disease severity and mortality risk.The role of systemic corticosteroids in the management of Lyell syndrome remains controversial. Some studies suggest a potential benefit on the early course of the disease, whereas others have not demonstrated a clear impact on mortality.The objective of this study was to evaluate the association between corticosteroid exposure during the acute phase and the course of Lyell syndrome by analyzing changes in SCORTEN, mortality, and the occurrence of long-term cutaneous and ocular sequelae.

Materials and Methods
This was a retrospective analytical cohort study conducted among patients hospitalized for Lyell syndrome (BSA ≥10) in the dermatology and intensive care departments over a 10-year period.Patients were divided into two groups according to the presence or absence of corticosteroid exposure. Quantitative variables were expressed as mean ± standard deviation, and qualitative variables as frequencies and percentages. Comparisons were performed using Student's t-test, the Chi-square test, or Fisher's exact test, depending on the conditions of application.Statistical analyses were performed using SPSS software, with verification of calculations using Python. A p-value < 0.05 was considered statistically significant.

Results
Forty patients with Lyell syndrome were included in this study. Among them, 30% received corticosteroid therapy during the acute phase, whereas 70% were not exposed to corticosteroids. Initial severity, assessed by SCORTEN at admission, was comparable between the two groups (3.09 ± 0.54 vs 3.13 ± 1.22).However, the evolution of severity showed a significant difference between the groups. At day 5, the mean SCORTEN was lower in the corticosteroid-exposed group (2.18 ± 0.60) than in the non-exposed group (3.52 ± 1.97). The change in score (ΔSCORTEN) showed a decrease in patients exposed to corticosteroids (−0.91 ± 0.54), whereas an increase was observed in the group without corticosteroid therapy (+0.39 ± 1.12), reflecting a more favorable clinical evolution in the corticosteroid group.Overall mortality in the cohort was 32.5%. No deaths were observed among patients exposed to corticosteroids, whereas 46.4% occurred in the non-exposed group. This difference was statistically significant (p = 0.007).Analysis of long-term complications showed a higher frequency of cutaneous and ocular sequelae in patients exposed to corticosteroids. Cutaneous dyschromia was observed in 91.7% of corticosteroid-exposed patients compared with 39.3% in the non-exposed group (p = 0.004).Chronic pruritus was also more frequent in the corticosteroid group (75% vs 32.1%, p = 0.018). Ocular sequelae were observed in 100% of corticosteroid-exposed patients compared with 53.6% in the non-exposed group (p = 0.004). In contrast, the frequency of genital sequelae did not differ significantly between the groups (25% vs 7.1%, p = 0.30).

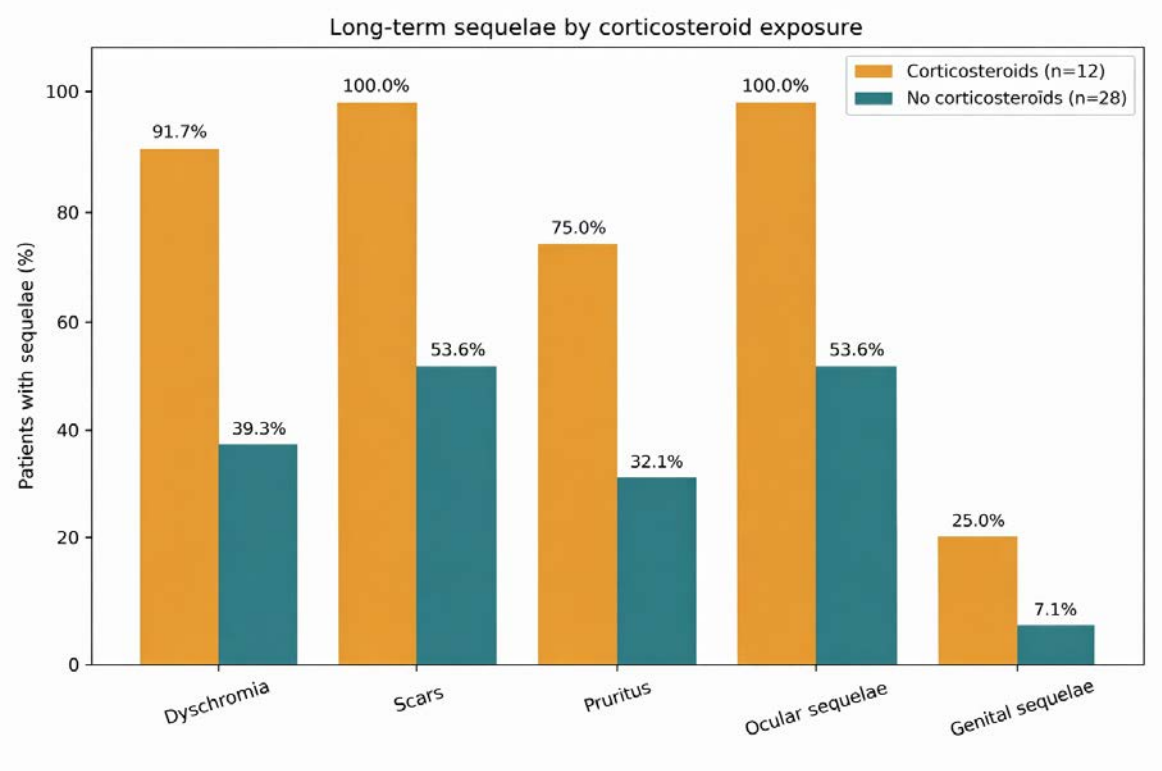

Long term sequalae by corticosteroid exposure

Conclusions

Our results are consistent with a still non-consensual body of literature: they support the hypothesis of a potential early benefit of corticosteroids on the initial dynamics of the disease and survival, while not excluding the possibility of significant late morbidity.Prospective studies, ideally multicenter, with adjustment for initial severity and mucosal involvement, are necessary to clarify the true role of corticosteroid therapy in Lyell syndrome.

EADV CONGRESS
VIENNA
30 SEP - 3 OCT 2026

Abstract N°: 623

Herpes Zoster Ophthalmicus Post-Botox Injection: A Case Report

Lenah AlMarzouk*[1]

[1] Dammam Medical Complex, Dammam, Saudi Arabia

Introduction
Herpes Zoster Ophthalmicus (HZO) is a rare but serious condition caused by the reactivation of the varicella-zoster virus in the ophthalmic branch of the trigeminal nerve.

Case Presentation
We present a case of a 40-year-old medically free female who developed symptoms suggestive of herpes zoster ophthalmicus after receiving a Botulinum toxin type A (BoNT-A) injection. The patient presented with a burning sensation on the right side of the forehead, extending below the right eye and temporal scalp area, which started 5 days post-Botulinum toxin type A (BoNT-A) injection. Despite azithromycin and ibuprofen, the symptoms persisted. On examination, an edematous erythematous plaque over the ophthalmic dermatome with crustation was noted, leading to the diagnosis of herpes zoster ophthalmicus. The patient was initiated on acyclovir 800 mg five times a day along with acyclovir cream application at the affected site. A follow-up after 7 days revealed significant improvement with the patient reporting no further complaints.

Conclusion
This case highlights a rare occurrence of herpes zoster ophthalmicus following Botulinum toxin type A (BoNT-A) injection. Timely diagnosis and appropriate antiviral therapy such as acyclovir are essential in managing this condition effectively.

EADV CONGRESS
VIENNA
30 SEP - 3 OCT 2026

Abstract N°: 629

Acitretin-Induced Sixth Nerve Palsy in a Child with Generalized Pustular Psoriasis

Meriem Mhiri*[1], Amina Aounallah[1], Ghariani Nejet[1]

[1] Dermatology Department, Farhat Hached University Hospital, Sousse, Tunisia, sousse, Tunisia

Introduction

Oral retinoids are widely used in dermatology for their keratolytic and anti-inflammatory properties. Their use requires careful monitoring due to potentially serious adverse effects, most notably teratogenicity and dyslipidemia. However, ophthalmological complications associated with these agents remain insufficiently documented.

Case Presentation

We report the case of a 10-year-old girl with generalized pustular psoriasis treated with acitretin at a dose of 0.4 mg/kg/day for four months, who presented to the emergency department with acute-onset diplopia. Clinical examination revealed bilateral sixth cranial nerve palsy, without other neurological abnormalities. Fundoscopic examination showed bilateral grade II papilledema, with no additional findings. Brain imaging excluded associated intracranial hypertension. Acitretin-induced ophthalmological toxicity was considered the most likely diagnosis, leading to immediate discontinuation of the drug. The outcome was rapidly favorable, with complete resolution of symptoms within a few days and no recurrence over a two-year follow-up period. The patient’s psoriasis was subsequently managed with infliximab.

Conclusion

Acitretin is associated with a range of ophthalmological adverse effects. The most common and benign include dry eye syndrome and color vision disturbances. However, rare but serious complications have been reported, including sixth cranial nerve palsy, as observed in our patient. Papilledema is another potential adverse effect, which may be asymptomatic and detectable only on fundoscopic examination, but can also be associated with intracranial hypertension. This risk appears to be increased with concomitant use of tetracyclines. Additionally, maculopathies and retinopathies have been described. This case highlights the importance of ophthalmological monitoring in patients receiving oral retinoids, particularly in the presence of visual or neurological symptoms. Early recognition of these rare but potentially serious adverse effects is essential to ensure prompt management and prevent long-term complications.

EADV CONGRESS
VIENNA
30 SEP - 3 OCT 2026

Abstract N°: 654

ENOXAPARIN INDUCED BULLOUS HEMORRHAGIC DERMATOSIS: RARE BUT NOT TO BE FORGOTTEN ENTITY

Karthi Kishore*[1], Rohit Kothari, MD[2]

[1] MILITARY HOSPITAL SHILLONG, SHILLONG, India

[2] buckinghamshire healthcare trust, amersham, United Kingdom

Introduction

Low molecular weight heparins (LMWHs) are widely used for thrombosis prophylaxis in patients with hypercoagulable states, especially malignancy. They are associated with several recognized dermatological adverse effects, including injection site hematoma, eczematous eruptions, skin necrosis, heparin-induced thrombocytopenia, osteoporosis, alopecia, and raised serum transaminases. Bullous hemorrhagic dermatosis (BHD) is a rare and often overlooked cutaneous adverse reaction to LMWH, first reported by Dyson et al. in 2004. It presents as tense hemorrhagic bullae at sites distant from the subcutaneous injection site.Only a few cases of this entity have been reported, but awareness is important because LMWH has become an essential part of thromboembolic disease management. We report a case of BHD caused by enoxaparin in a patient with pulmonary thromboembolism.

Case Presentation

A 27-year-old female with carcinoma cervix stage 1B, status post operation, was admitted with pulmonary thromboembolism after sudden-onset dyspnea and oxygen desaturation. She was started on enoxaparin 60 mg subcutaneously twice daily. Two days later, she developed multiple non-tender, non-pruritic hemorrhagic vesicles over the inner aspect of the left leg, which later coalesced into a large bulla. There were no similar lesions elsewhere, no lesions at the injection sites, and no mucosal involvement. Laboratory evaluation showed anemia (Hb 9.2 g/dL), while coagulation parameters, including PT, aPTT, INR, and fibrinogen, were normal. Based on the clinical findings and laboratory results, a diagnosis of enoxaparin-induced bullous hemorrhagic dermatosis was made. Enoxaparin was discontinued and replaced with apixaban. The lesions resolved within 10 days of stopping enoxaparin, leaving post-inflammatory hyperpigmentation.

Conclusion

Enoxaparin is a LMWH derived from depolymerized heparin and is commonly used in the prevention and treatment of thromboembolic disorders such as pulmonary venous thromboembolism and myocardial infarction. Cutaneous adverse effects include hematoma, ecchymosis, nodular eruptions, erythematous plaques, contact dermatitis-like eruptions, cutaneous necrosis, and urticarial rash. BHD is a rare adverse effect, more often reported with heparin than with LMWH. Lesions typically appear 5–21 days after starting therapy as tense hemorrhagic bullae over the trunk or extremities, with the injection site usually spared. Histopathology usually shows intraepidermal bullae without vasculitic, thrombotic, or inflammatory changes, helping distinguish it from heparin-induced skin necrosis and contact dermatitis.The pathogenesis remains unclear, although a type IV hypersensitivity reaction has been proposed. Since the patient had recently been started on enoxaparin, the reaction was likely idiosyncratic. This case emphasizes the need for clinicians to recognize this rare condition, ensure careful drug history, and differentiate it from bullous pemphigoid, bullous vasculitis, epidermolysis bullosa acquisita, and heparin-induced skin necrosis. Management requires stopping heparin or its analogues and switching to an anticoagulant with a different mechanism of action.

EA DV CONGRESS
VIENNA
30 SEP - 3 OCT 2026

Abstract N°: 658

DRESS Syndrome Presenting as Erythroderma with Pemphigus-like Histological Findings: A Clinicopathological Diagnostic Challenge

Ayesha Siraj*[1], Muneeza Rizwan[1]

[1] Fazaia Post Graduate Medical Institute, Pakistan Air Force Hospital, Islamabad, Pakistan

Introduction

Drug reaction with eosinophilia and systemic symptoms (DRESS) is a severe, potentially life-threatening drug-induced hypersensitivity reaction characterized by delayed onset, extensive cutaneous eruption, hematological abnormalities, and multisystem involvement. Mortality is approximately 10%, most commonly due to hepatic failure. Although morbilliform rash is typical, erythroderma is rare and may obscure diagnosis. Histopathology can be nonspecific, most commonly showing spongiotic or interface dermatitis with eosinophils. We report a diagnostically challenging case of erythrodermic DRESS in a patient with rheumatoid arthritis, showing pemphigus-like histology with systemic involvement.



Trunk at presentation; erythematous to hyperpigmented morbilliform drug eruption after progressing

to erythroderma at presentation.

Case Presentation

A 55-year-old woman with recent diagnosis of seropositive rheumatoid arthritis presented with fever for 7 days and rapidly progressive rash for the last 5 days. She had received hydroxychloroquine, leflunomide, tofacitinib, and etoricoxib for 6 weeks, with uncertain adherence, and stopped all drugs 2 weeks prior due to gastrointestinal symptoms. Illness began with fever followed by maculopapular rash starting on face and upper limbs, progressing within 48 hours to >90% body surface area involvement with burning, pruritus, facial edema, exfoliation, and mild dysphagia. Examination showed fever (99°F), tachycardia (109 bpm), and diffuse dusky erythema with extensive desquamation. Oral mucosa had hemorrhagic crusting; genital mucosa was spared; no blisters were seen. Additional findings included bilateral parotid enlargement, xerostomia, xerophthalmia, periorbital edema, pallor, and pedal edema.

Laboratory tests revealed leukocytosis (TLC 43,000/µL), eosinophilia (50%), hyponatremia, raised CRP (95 mg/L), and elevated ALT (402 U/L). Viral serology and cultures were negative. Imaging showed hepatosplenomegaly, ascites, bilateral parotitis, and generalized lymphadenopathy raising suspicion of lymphoma. Skin biopsy showed subepidermal blister with mixed inflammatory infiltrate, spongiosis, and dermal edema. Direct immunofluorescence demonstrated intercellular IgG and C3 deposition suggestive of pemphigus-like pattern. Lymph node biopsy showed reactive hyperplasia; bone marrow, flow cytometry, and cytogenetics excluded malignancy.

With a RegiSCAR score of 7 and exclusion of other causes, diagnosis of definite DRESS syndrome was made. All suspected drugs were stopped and systemic corticosteroids were initiated (IV hydrocortisone followed by oral prednisolone with taper). Supportive care included topical steroids, emollients, antihistamines, and organ monitoring. Patient improved gradually with resolution of fever, eosinophilia, and transaminitis, followed by regression of lymphadenopathy and hepatosplenomegaly. Cutaneous involvement reduced to <20% over 4–6 weeks with residual xerosis and nail shedding.



Face at presentation: Diffuse facial edema with erythematous to hyperpigmented rash causing

extensive desquamation and perioral fissuring, reflecting severe cutaneous inflammation.

Conclusion

This case underscores the extreme diagnostic complexity of DRESS syndrome when it presents in an atypical erythrodermic form with extensive systemic involvement and misleading histopathological findings. The presence of pemphigus-like changes on skin biopsy created significant diagnostic confusion, initially raising concern for autoimmune blistering disease, while concurrent generalized lymphadenopathy and hepatosplenomegaly strongly suggested an underlying lymphoproliferative disorder. In such settings, reliance on a single diagnostic modality can be misleading, and strict clinicopathological correlation becomes essential. Early recognition, prompt withdrawal of all potential culprit drugs, and timely initiation of systemic corticosteroids resulted in favorable clinical recovery in this patient. The case further reinforces the importance of multidisciplinary collaboration in managing complex and misleading cases to avoid unnecessary immunosuppresion.



Limbs after 2 weeks: Resolution of erythematous rash with residual post inflammatory hyperpigmentation and desquamation.

EADV CONGRESS
VIENNA
30 SEP - 3 OCT 2026

Abstract N°: 697

A Blue Warning: When Therapy Turns to Cyanosis; Gemcitabine-Induced Acrocyanosis

Sarah Zemrani*[1], Christina Tarabay[1], Emmanuel Ribereau Gayon[1], Stephane Dalle[1]

[1] Department of Dermatology, Lyon Sud Hospital, Hospices Civils de Lyon, Lyon, France, LYON, France

Introduction

Cutaneous toxicities of chemotherapeutic agents are frequent but vascular manifestations remain rare and potentially severe. Gemcitabine, widely used in hematologic malignancies, has been associated with uncommon vascular adverse events. We report a case of acute acrocyanosis revealing gemcitabine-induced vascular toxicity in a patient treated for Sézary syndrome.

Case Presentation

A 72-year-old man with a history of Sézary syndrome diagnosed in December 2024 was admitted for administration of gemcitabine after failure of prior treatment with mogamulizumab associated with extracorporeal photochemotherapy. His medical history included a basal cell carcinoma. He was a former smoker and reported occasional alcohol consumption.

The disease course was marked by initial treatment with photopheresis followed by mogamulizumab due to worsening pruritus and circulating Sézary cells. Despite transient hematologic improvement, the patient developed progressive cutaneous involvement and lymphadenopathy. Lymph node biopsy confirmed transformation into a large-cell T-cell lymphoma (CD30-/CCR4+), leading to initiation of gemcitabine monotherapy.
After approximately one week of treatment, the patient reported the sudden onset of bluish discoloration of the second, third, and fourth fingers of the right hand, associated with paresthesia, burning pain, and decreased sensitivity.

Clinical examination revealed acrocyanosis of the distal phalanges with prolonged capillary refill time and tenderness on palpation. The remainder of the cutaneous and general examination was unremarkable.
Laboratory tests showed mild anemia and elevated inflammatory markers, without other significant abnormalities.
Doppler ultrasonography demonstrated decreased distal arterial flow in the affected fingers.

Given the temporal relationship with treatment and the absence of other etiologies, a diagnosis of gemcitabine-induced vascular toxicity was retained. Gemcitabine was discontinued, and the patient was hospitalized for intravenous prostacyclin (iloprost) therapy.

Conclusion

This case highlights a rare but potentially serious vascular toxicity of gemcitabine presenting as acute acrocyanosis. In patients treated for cutaneous T-cell lymphoma, new-onset acral discoloration and sensory symptoms should prompt early vascular assessment. Rapid recognition and treatment interruption are essential to prevent progression to irreversible ischemic complications.

EADV CONGRESS
VIENNA
30 SEP - 3 OCT 2026

Abstract N°: 739

A case of symmetrical drug-related intertriginous and flexural exanthema(SDRIFE) induced by semaglutide.

Tae Young Han*[1], Yun Jeong Choi[1], Hyunkyung Lee[1], Jae Eun Choi[1]

[1] Department of Dermatology, Nowon Eulji Medical Center, Eulji University, Seoul, Korea, Rep. of South

Introduction

Semaglutide is a long-acting glucagon-like peptide-1 (GLP-1) receptor agonist widely prescribed for type 2 diabetes and obesity due to its superior efficacy in glycemic control and weight reduction. While gastrointestinal symptoms are its most common adverse effects, various cutaneous reactions—including injection-site nodules and bullous pemphigoid—have been increasingly reported. Symmetrical drug-related intertriginous and flexural exanthema (SDRIFE) is a rare type IV hypersensitivity reaction characterized by sharply demarcated, symmetric erythema in flexural areas without systemic involvement. Although SDRIFE has been previously associated with a compounded formulation of semaglutide, it has not yet been reported in connection with a commercially manufactured, FDA-approved formulation. We herein report the first rare case of SDRIFE induced by a standardized commercial semaglutide preparation.

Case Presentation

A 49-year-old woman with no significant medical history presented with pruritic, symmetric, and oozing erythematous patches in the axillae, groin, and antecubital fossae. The eruption emerged two weeks after her fourth weekly injection of commercial semaglutide (0.25 mg) for weight management. She denied any history of drug allergies or exposure to new topical products, foods, or potential contact allergens. Physical examination revealed characteristic sharply demarcated intertriginous lesions with no systemic symptoms or injection-site reactions. Laboratory findings, including complete blood count and autoimmune profiles, were normal. A skin biopsy from the forearm showed spongiotic dermatitis with perivascular lymphocytic and eosinophilic infiltration, consistent with drug-induced dermatitis. With a Naranjo score of 7, a "probable" causal relationship was established. Following the discontinuation of semaglutide and a brief course of oral methylprednisolone, antihistamines, and topical corticosteroids, the lesions resolved completely within two weeks. No recurrence has been observed to date.

Conclusion

This case represents the first report of SDRIFE associated with a commercially manufactured semaglutide formulation (Wegovy®). Unlike previous reports involving compounded versions where impurities were suspected, this case suggests that the standardized GLP-1 analogue itself may act as a hapten or trigger T-cell sensitization. The delayed presentation (two weeks after the fourth dose) likely reflects the long elimination half-life of semaglutide and progressive immune sensitization. As the use of GLP-1 receptor agonists continues to rise globally, clinicians should be vigilant of SDRIFE as a potential cutaneous adverse reaction. This report expands the known dermatological spectrum of semaglutide and emphasizes the importance of clinical recognition in managing systemic hypersensitivity to this class of drugs

EA DV CONGRESS
VIENNA
30 SEP - 3 OCT 2026

Abstract N°: 774

Clinical Application of a Biomimetic Barrier-Repairing Lip Balm in Patients with Isotretinoin-Induced Cheilitis: A Case Series

Siying Ruan*[1], Yiyun Xu[1], Wei Zhu[1]

[1] Shanghai CORDAY Biotechnology Co., Ltd, Shanghai, China

Introduction

Isotretinoin-induced cheilitis is a highly prevalent and challenging adverse effect in dermatologic practice. By suppressing sebaceous secretion and disrupting epidermal differentiation, isotretinoin compromises the labial mucosal barrier, leading to persistent dryness, desquamation, fissuring, and pain. These symptoms markedly impair quality of life and adherence to acne therapy. Current management relies largely on passive occlusion with petrolatum-based emollients, with limited evidence for products offering active barrier restoration and multi-target symptom relief. This case series evaluated the clinical efficacy and safety of a biomimetic barrier-repairing lip balm in patients with isotretinoin-induced cheilitis.

Case Presentation

Isotretinoin-induced cheilitis is a highly prevalent and challenging adverse effect in dermatologic practice. By suppressing sebaceous secretion and disrupting epidermal differentiation, isotretinoin compromises the labial mucosal barrier, leading to persistent dryness, desquamation, fissuring, and pain. These symptoms markedly impair quality of life and adherence to acne therapy. Current management relies largely on passive occlusion with petrolatum-based emollients, with limited evidence for products offering active barrier restoration and multi-target symptom relief. This case series evaluated the clinical efficacy and safety of a biomimetic barrier-repairing lip balm in patients with isotretinoin-induced cheilitis.

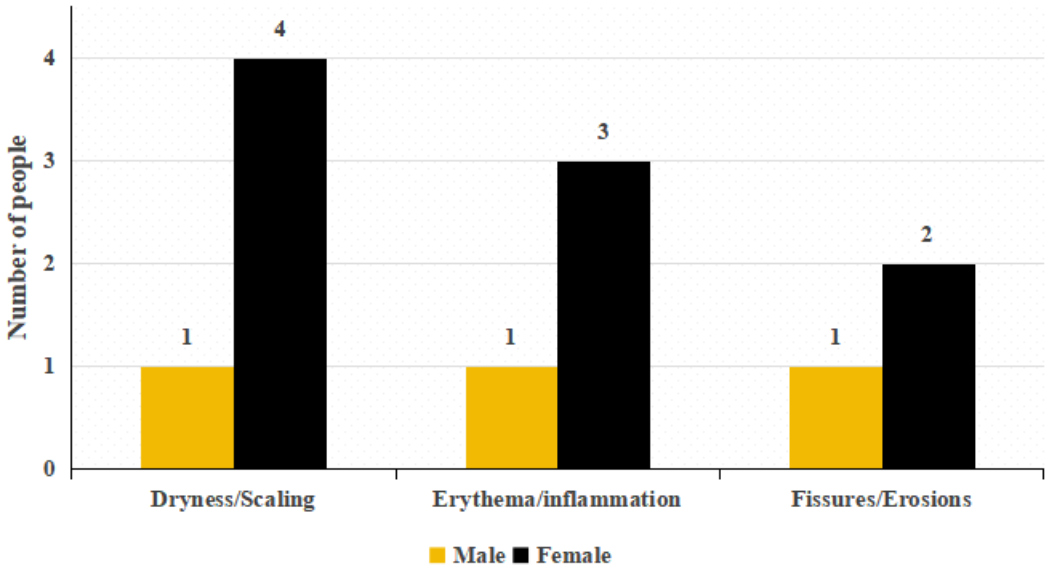

Figure. Distribution of Key Clinical Signs by Sex in Five Patients with Isotretinoin-Induced Cheilitis.

Conclusion

After 28 days, all five patients with isotretinoin-induced cheilitis demonstrated significant clinical improvement with excellent tolerability (Table). Clinically, one patient's composite severity score decreased from 7 at baseline to 0 at day 28, and two additional patients achieved complete symptom resolution—outcomes attributable to the balm's occlusive petrolatum-wax base combined with biomimetic lipids (squalane, cholesterol, and hydroxypropyl dipalmitoylamine MEA), which actively replenish intercellular lipids to restore barrier integrity. Objective assessments further substantiated functional barrier repair: among three patients undergoing TEWL measurements, the baseline mean of 63.16 g/m^2/h—indicative of severe barrier impairment—declined by 24% to 54% post-treatment, confirming the efficacy of this lipid-replenishing strategy in controlling TEWL; one patient evaluated by SCH demonstrated an increase from 35.71 a.u. to 59.15 a.u. (>65% improvement), reflecting enhanced intrinsic moisture retention facilitated by barrier reconstruction. Dermatoscopically, two patients exhibited reorganization of the stratum corneum from a disorganized, scaly appearance to a smooth, uniform layer, accompanied by fading of background erythema and telangiectasia—changes consistent with the anti-inflammatory and soothing effects of commiphora myrrha oil, vitamin B derivatives, and oil-soluble licorice extract on neurosensory irritation and microvascular reactivity. No local irritation or adverse events were reported throughout the study period. These preliminary findings suggest that a biomimetic, multi-targeted lip repair balm can concurrently address the barrier disruption and sensory hypersensitivity underlying isotretinoin-induced cheilitis, offering a safe and practical adjunct to optimize patient adherence and quality of life during acne therapy.

Case	Severity	Assessment Parameter	Baseline (D0)	Endpoint (D28)	Improvement
3	Severe	Dermoscopy: Scaling/Fissure/Erythema Score (0–3)	3 / 3 / 2	0 / 0 / 0	Complete resolution
1	Severe	TEWL (g/m²/h)	63.4	48.2	↓ 24.0%
2	Severe	TEWL (g/m²/h)	74.8	34.6	↓ 53.7%
4	Moderate	TEWL (g/m²/h)	51.3	25.8	↓ 49.8%
5	Mild	Dermoscopy: Lip Wrinkle Score (0–3)	3	1	↓ 2 points

Scoring: 0 = none, 1 = mild, 2 = moderate, 3 = severe.

Table. Objective Outcome Measures at Baseline and Day 28 in Five Patients with Isotretinoin-Induced Cheilitis.

EADV CONGRESS
VIENNA
30 SEP - 3 OCT 2026

Abstract N°: 789

Clinical Spectrum, Culprit Drugs, and Outcomes of Fixed Drug Eruption: A 13-Year Retrospective Study

Auratsaya Pimolpan*[1], Kunlawat Thadanipon[2], Kumutnart Chanprapaph[1], Wannada Laisuan[3], Ploychompoo Srisuwanwattana[1], Pranee Svetvilas[1], Penpun Wattanakrai[1], Namthong Wittayabusarakam[1], Wimolsiri Iamsumang[1]

[1] Division of Dermatology, Department of Medicine, Faculty of Medicine, Ramathibodi Hospital, Mahidol University, Bangkok, Thailand

[2] Department of Clinical Epidemiology and Biostatistics, Faculty of Medicine Ramathibodi Hospital, Mahidol University, Bangkok, Thailand

[3] Division of Allergy, Immunology and Rheumatology, Department of Medicine, Faculty of Medicine Ramathibodi Hospital, Mahidol University, Bangkok, Thailand

Introduction

Fixed drug eruption (FDE) is a delayed-type hypersensitivity reaction that may lead to severe cutaneous adverse reactions. Although patterns of causative drugs have changed over time, recent data from Thailand are still limited. This study aimed to evaluate the clinical characteristics, culprit drugs, treatments, laboratory findings, and outcomes of patients with FDE, and to identify risk factors associated with severe disease or generalized bullous fixed drug eruption (GBFDE).

Materials and Methods

Medical records of patients diagnosed with FDE between 2013 and 2025 were retrospectively reviewed. Clinical features, laboratory investigations, implicated drugs, and factors associated with GBFDE were analyzed.

Results

A total of 284 patients with FDE were included, of whom 8.8% had GBFDE. The mean age at diagnosis was 48.8 years, and 63.7% were female. The median number of FDE episodes was two, with a median latency period of one day. The extremities and trunk were the most frequently affected sites, accounting for 45.3% and 34.5% of cases, respectively, while mucosal involvement was observed in 15.5% of patients. Among the 284 patients, non-steroidal anti-inflammatory drugs (NSAIDs) were the most common culprit drug class (59.2%), particularly etoricoxib (39.1%), followed by other analgesics and antipyretics (22.5%), and antimicrobial agents (20.6%). Patch tests on lesional skin were positive in 29.8%, most frequently for etoricoxib, whereas no positive reactions were observed on normal skin. Logistic regression showed that mucosal involvement and exposure to NSAIDs were significantly associated with the development of GBFDE (OR 9.72, 95%CI 4.04-23.34, $p<0.001$ and OR 4.72, 95%CI 1.05-21.24, $p=0.043$).

Conclusions

NSAIDs, especially etoricoxib, were the most frequent causative drugs. Factors significantly associated with GBFDE included mucosal involvement and NSAIDs exposure. Patch testing on lesional skin may be a useful tool for identifying culprit drugs, particularly etoricoxib.

EA DV CONGRESS
VIENNA
30 SEP - 3 OCT 2026

Abstract N°: 816

Kaposi's Sarcoma Induced by Corticosteroid Therapy for Bullous Pemphigoid in a Patient with Prostate carcinoma

Eya Bouzaien*[1], Anissa Zaouak[1], Houda Hammami[1]

[1] Dermatology Department, Habib Thameur Teaching Hospital, Tunis, Tunisia

Introduction

Bullous pemphigoid (BP) is the most common autoimmune subepidermal blistering disease in the elderly, caused by autoantibodies against BP180 and BP230. Kaposi sarcoma (KS) is a rare vascular neoplasm that has occasionally been reported in association with BP. We report a case of KS induced by corticosteroid therapy for bullous pemphigoid in a patient with prostate carcinoma (PC).

Case Presentation

An eighty-five-year-old man with a history of arterial hypertension was referred to our dermatology department for a 1-month history of diffuse bullous eruption. Clinical examination revealed tense, mostly clear blisters arising on healthy skin. The lesions were diffuse, affecting the trunk, limbs, and mucosal surfaces. The Nikolsky sign was negative. There were no systemic symptoms, specifically no pyrexia, cachexia, or fatigue. Routine blood tests were within normal ranges. Histopathology suggested BP, showing features of subepidermal blisters with eosinophils on histology. Direct immunofluorescence microscopy (DIF) demonstrated linear deposits of immunoglobulin G and C3 at the basal membrane zone (BMZ). ELISA detected circulating autoantibodies directed against the BP180. The patient was started on topical dermocorticosteroids (clobetasol propionate, 30 g/day). After one month, the BP remained uncontrolled, leading to combination therapy with oral corticosteroids at 0.5 mg/kg/day. Given urinary complaints, subsequent investigations revealed a markedly elevated serum prostate-specific antigen (PSA) level of 68 ng/mL. A prostate biopsy demonstrated an acinar-type prostatic carcinoma (PC) infiltrating approximately 5% of the prostate, with a Gleason score of 7. Staging studies revealed multiple bone and liver metastases. The patient's prostate cancer progressed, requiring hormonal therapy, and he was referred to a specialized oncology center. Two months after starting systemic corticosteroids, the patient developed multiple violaceous hyperkeratotic papulonodules on the legs, palms, forearms, and feet. Dermoscopy showed purple-pink peripheral scales, small brown globules, and a rainbow pattern. Histopathologic examination revealed numerous vessels forming slit-like spaces, erythrocyte extravasation, and vessels protruding into other vessels. The sample tested positive for HHV-8. Kaposi's Sarcoma (KS) was confirmed. Serological testing for HIV was negative. The patient's BP was subsequently controlled, allowing gradual tapering of systemic corticosteroids. The patient was then lost to follow-up and ultimately died from general deterioration related to metastatic disease.
Herein, we report a case of corticosteroid-induced KS in a patient with PB associated with PC. To our knowledge, Paraneoplastic PB is most frequently linked to hematologic malignancies, while associations with solid organ tumors are uncommon. Production of antibodies to tumor-specific antigens that might cross-react with the BMZ would explain the relationship between carcinoma and PB. Another theory suggested that secondary production of anti-BMZ antibodies by the tumor cells occurred through secretion of a substance that could damage the basement membrane. While topical or systemic corticosteroids remain the mainstay of treatment of BP, prolonged immunosuppression may predispose patients to neoplastic processes, including iatrogenic KS. KS in immunosuppressed patients was first described in transplant recipients receiving cyclosporine, but only a few cases have been reported in patients treated with systemic corticosteroids for PB.

Conclusion

Clinicians should remain vigilant for the development of secondary neoplasms when prescribing prolonged systemic corticosteroids, particularly in elderly and immunocompromised patients.

EADV CONGRESS
VIENNA
30 SEP - 3 OCT 2026

Abstract N°: 817

Dipeptidyl peptidase-4 inhibitor–induced bullous pemphigoid: a case series of four patients

Eya Bouzaien*[1], Anissa Zaouak[1], Houda Hammami[1]

[1] Dermatology Department, Habib Thameur Teaching Hospital, Tunis, Tunisia

Introduction

Bullous pemphigoid (BP) is an autoimmune subepidermal blistering disease that may be drug-induced. Dipeptidyl peptidase-4 inhibitors (DPP-4i), widely used in type 2 diabetes, have been increasingly implicated. We report the clinical, immunopathological, and therapeutic features of four cases of DPP-4i–associated BP.

Case Presentation

Four elderly patients (two men, two women; mean age: 80 years) with type 2 diabetes developed BP following exposure to DPP-4 inhibitors. Two patients were treated with vildagliptin for 6–12 months and presented with widespread tense bullae on erythematous or urticarial bases, involving up to 35% of the body surface area. One of them exhibited mucosal involvement and nail changes (paronychia and onychomadesis). A third patient, on sitagliptin for 2 months, developed localized tense bullae on acral sites over an eczematous background, without mucosal involvement. The fourth patient, recently exposed to vildagliptin, presented with extensive bullous and hemorrhagic erosive lesions involving the face and trunk, with oral mucosal involvement. Histopathology consistently showed subepidermal blistering without acantholysis. Direct immunofluorescence demonstrated linear deposition of IgG and C3 along the basement membrane zone in all cases. Anti-BP180-NC16 Antibodies were positive. Withdrawal of the suspected DPP-4 inhibitor, combined with appropriate therapy (including systemic corticosteroids in one case), resulted in complete remission in all patients.
DPP-4 inhibitors are increasingly recognized as triggers of BP, particularly in elderly diabetic patients. Unlike previously reported non-inflammatory phenotypes with negative anti-BP180 antibodies, our cases exhibited marked inflammatory features and positive serology, suggesting clinical and immunological heterogeneity depending on the implicated agent. The pathogenic mechanisms remain unclear but may involve enhanced pro-inflammatory cytokine activity following DPP-4 inhibition in keratinocytes and T lymphocytes. Establishing causality remains challenging due to frequent comorbidities in this population. However, the favorable outcome after drug withdrawal supports a drug-induced origin.

Conclusion

DPP-4 inhibitor–induced BP should be suspected in any diabetic patient presenting with new-onset blistering disease. Early recognition and prompt discontinuation of the offending agent are crucial for optimal outcomes.

EA DV CONGRESS
VIENNA
30 SEP - 3 OCT 2026

Abstract N°: 824

A Preventable Fatality? Lessons From Suspected Grade 4 Pembrolizumab-Induced Bullous Pemphigoid and the Cost of No Dermatologic Access

Dimitra Xenopoulou*[1], Mohammed Lak[2]

[1] SUNY Downstate Health Sciences University, Brooklyn, United States
[2] NYC H+H/Queens, Queens, United States

Introduction

Immune checkpoint inhibitor (ICI)-induced bullous pemphigoid (BP) is a rare but potentially fatal cutaneous immune-related adverse event (cirAE), occurring in ~0.3% of treated patients. BP is the most common immunobullous cirAE (~39% of cases), with 92.9% associated with PD-1/PD-L1 inhibitors. Severe Grade 4 BP may clinically mimic toxic epidermal necrolysis (TEN) when >30% body surface area (BSA) is involved with extensive erosions, fluid/electrolyte disturbances, and critical illness.

The differential diagnosis includes BP, SJS/TEN, bullous lichenoid dermatitis, linear IgA bullous dermatosis, pemphigus vulgaris, erythema multiforme, and DRESS. While initial management with systemic corticosteroids (prednisone/IV methylprednisolone 1–2 mg/kg/day) and IVIG overlaps across severe bullous dermatoses, histopathologic confirmation guides escalation therapy, dupilumab and rituximab for BP vs. etanercept and cyclosporine for SJS/TEN, per the National Comprehensive Cancer Network (NCCN) Management of Immune Checkpoint Inhibitor-Related Toxicities algorithm. BP carries ~22% 1-year mortality; extensive disease (>30% BSA) markedly increases risk (HR 7.19–9.84).

We report a fatal case of clinically suspected pembrolizumab-induced Grade 4 BP to highlight the importance of early recognition and guideline-directed management.

Case Presentation

A 72-year-old female with stage IIIB triple-negative breast cancer and significant comorbidities (CKD-3, COPD, PEG-dependent functional decline) receiving neoadjuvant pembrolizumab, paclitaxel, and carboplatin (KEYNOTE-522 regimen) presented with altered mental status, febrile neutropenia, and tense bullae on the lower extremities one day after cycle 4. Initial sepsis workup was negative. Oncology consultation occurred 48 hours after admission.

The eruption was attributed to pembrolizumab, as BP is a well-established irAE of PD-1 inhibitors and not classically linked to paclitaxel or platinum agents. Over subsequent days, bullae progressed and ruptured, causing widespread erosions exceeding 20% BSA. Serial skin assessments were limited, and progression was not systematically documented.

Absence of on-site dermatology precluded skin biopsy with direct immunofluorescence (DIF) and serologic testing (anti-BP180/BP230 antibodies), the gold standard for diagnosis. Without histopathologic confirmation, management could not be appropriately tailored.

The patient received dexamethasone instead of prednisone or IV methylprednisolone (1–2 mg/kg/day); notably, dexamethasone is not included in the NCCN Immune Checkpoint Inhibitor Toxicity algorithm for bullous

dermatitis. IV diphenhydramine was given for symptom relief, although it has no disease-modifying role. Escalation therapies—including IVIG (2 g/kg over 2–5 days) and rituximab—were not initiated.

By hospital day 5, she developed systemic deterioration consistent with severe barrier loss: progressive anemia (Hb 8.6→6.1 g/dL without overt bleeding), refractory hypotension, anuria, and severe lactic acidosis. She died within 6 hours of ICU transfer due to multiorgan failure.

Conclusion

This case demonstrates that ICI-induced BP may present with TEN-like severity and a rapidly fatal trajectory when bullae rupture and barrier integrity is lost. Key teaching points: (1) dexamethasone is not interchangeable with prednisone/methylprednisolone per NCCN guidelines; (2) antihistamines have no disease-modifying role in BP; (3) delayed oncology consultation and absent dermatologic access contributed to diagnostic and therapeutic delays; (4) histopathologic confirmation should be pursued urgently to guide appropriate escalation therapy.

Institutions administering ICIs without on-site dermatology should implement standardized pathways for expedited biopsy, serology, and immediate guideline-directed treatment. Early recognition and appropriate corticosteroid selection are critical to reducing mortality in severe cirAEs.

EA DV CONGRESS
VIENNA
30 SEP - 3 OCT 2026

Abstract N°: 832

Long-term safety profile of nemolizumab over 2 years in moderate-to-severe atopic dermatitis and prurigo nodularis: Post hoc analysis from ARCADIA LTE and OLYMPIA LTE trials

Jonathan I. Silverberg[1], Matthias Augustin*[2], Sébastien Barbarot[3], Marjolein de Bruin-Weller[4], Sarina Elmariah[5], Melinda Gooderham[6, 7], Richard B. Warren[8], Agnes Drahos[9], Liliana Ulianov[10], Soo Yeon Cheong[11], Christophe Piketty[9], Raj Rout[12], Sarah Coquis-Knezek[11], Sonja Ständer[13]

[1] Department of Dermatology, The George Washington University School of Medicine and Health Sciences, Washington DC, United States
[2] University of Hamburg Medical Center Eppendorf Helipad, Hamburg, Germany
[3] University Hospital of Nantes, Nantes, France
[4] Department of Dermatology and Allergology, Utrecht University/UMC Utrecht, Utrecht, Netherlands
[5] University of California San Francisco, San Francisco, United States
[6] Skin Centre for Dermatology, Peterborough, Canada
[7] Department of Medicine, Queens University, Kingston, Canada
[8] Dermatology Centre, Northern Care Alliance NHS Foundation Trust, University of Manchester, Manchester Academic Health Science Centre, NIHR Manchester Biomedical Research Centre, Manchester, United Kingdom
[9] Galderma R&D, Zug, Switzerland
[10] Galderma R&D, Lausanne, Switzerland
[11] Galderma Laboratories, Dallas, United States
[12] Galderma, London, United Kingdom
[13] Center for Chronic Pruritus, Department of Dermatology, University Hospital Münster, Münster, Germany

Introduction

Nemolizumab, an interleukin-31 receptor alpha antagonist, is approved in several countries for moderate-to-severe atopic dermatitis (AD) in adults and adolescents and for prurigo nodularis (PN) in adults. In pooled analyses from phase 3 pivotal trials, nemolizumab showed a favourable safety profile in AD and PN, with the most common adverse events (AEs) being mild/moderate cutaneous adverse events (CAEs) mainly eczema. Given the chronic nature of AD and PN, evaluation of long-term cutaneous safety is clinically relevant. This analysis characterised the clinical features of CAEs during long-term treatment with nemolizumab over 2 years.

Materials and Methods

This post hoc safety analysis included patients with AD and PN enrolled in long-term extension (LTE) trials following participation on prior nemolizumab trials. In the ARCADIA LTE (NCT03989206), adults and adolescents from phase 2/3 trials and newly recruited adolescents with moderate-to-severe AD were enrolled; in OLYMPIA LTE (NCT04204616), adults with PN were enrolled from phase 2b/3 trials.

Safety outcomes assessed during long-term nemolizumab treatment included treatment-emergent AEs, with specific evaluation of serious adverse events (SAEs), and CAEs; summarised as exposure-adjusted incidence rates (EAIR) and exposure-adjusted event rates (EAER) per 100 patient-years (PY). Severity, latency, duration, management and study drug action associated with CAEs were descriptively assessed.

Results

The 2-year interim LTE data (cut-off 21-Jul-2024) included 1901 (AD) and 508 (PN) patients treated with nemolizumab and served as the dataset for this post hoc analysis.

Overall AEs and SAEs data were from the interim analysis. In AD, AEs were reported in 1510/1901 (79%) patients (EAIR 114.4/100 PY) and SAEs in 154/1901 (8%) patients (EAIR 4.1/100 PY). The most common AEs by preferred term were COVID-19 (372/1901; 20%), nasopharyngitis (370/1901; 19%) and dermatitis atopic (344/1901; 18%), reflecting flares or worsening of underlying AD. In PN, AEs were reported in 452/508 (89%) patients (EAIR 197.5/100 PY) and SAEs in 83/508 (16%) patients (EAIR 9.1/100 PY). The most common AEs were COVID-19 (144/508; 28%), nasopharyngitis (100/508; 20%) and upper respiratory tract infection (68/508; 13%).

Among safety areas of interest evaluated in this post hoc analysis, CAEs were the most frequent, occurring in 544/1901 (29%) patients with AD (EAIR 17.0/100 PY; EAER 24.1/100 PY) and in 228/508 (45%) patients with PN (EAIR 34.1/100 PY; EAER 54.3/100 PY).

Eczema-like events were the most common CAEs, reported in 385/1901 (20%) patients with AD (EAIR 11.1/100 PY; EAER 15.3/100 PY) and in 110/508 (22%) patients with PN (EAIR 13.1/100 PY; EAER 18.1/100 PY). In AD, eczema-like CAEs predominantly reflected disease flares, whereas in PN they may represent distinct eczematous lesions, suggesting heterogeneity across indications. Across both indications, these events were generally mild (events: 57% [AD]; 78% [PN]) or moderate (events: 39% [AD]; 22% [PN]) in severity and resolved without sequelae (events: 74% [AD]; 66% [PN]), mainly with topical therapies (events: 47% [AD]; 50% [PN]). Study drug interruption (events: 2% [AD]; 1% [PN]) or drug withdrawal (events: 5% [AD]; 3% [PN]) due to eczema-like CAEs was uncommon. Median latency to the first eczema-like event was 172.0 days (AD) and 151.5 days (PN); based on evaluable events, median event duration was 29 days (AD; N_{ev}=954) and 40 days (PN; N_{ev}=544).

Rates of autoimmune (1% [AD]; 1% [PN]), psoriasiform (<1% [AD]; 2% [PN]) and exfoliative (<1% [AD]; <1% [PN]) CAEs were low and no severe cutaneous adverse reactions (SCARs) were identified.

Conclusions

Long-term treatment with nemolizumab over 2 years demonstrated a favourable, well-tolerated cutaneous safety profile in patients with AD and PN. The sustained manageability of CAEs, along with the absence of new or unexpected cutaneous safety signals, supports the maintenance of this safety profile with prolonged use of nemolizumab.

EADV CONGRESS
VIENNA
30 SEP - 3 OCT 2026

Abstract N°: 839

Optimized management of enfortumab vedotin-related dermatological toxicity: a real-world study

Estelle Parriel*[1], Anouk Perego-Langlais[2], Saskia Oro[3], Vincent Sibaud[1]

[1] IUCT Oncopole, Toulouse, France
[2] Henri Mondor hospital, oncology, creteil, France
[3] Henri Mondor hospital, creteil, France

Introduction

Enfortumab vedotin (EV) is an antibody-drug conjugate combining a nectin-4-directed IgG1 monoclonal antibody with monomethyl auristatin E (MMAE) and represents now the first-line therapy for patients with locally advanced or metastatic urothelial carcinoma, in combination with anti PD-1 pembrolizumab. Although EV has improved overall patient survival, it has been identified a specific safety profile dominated by the rapid development of often benign, but potentially severe, dermatological toxicity in nearly 50% of cases

Materials and Methods

We report here the retrospective real-life data obtained in two expert French oncodermatology centres between May 2019 and December 2025, on a large population of patients exposed to EV (monotherapy or in association with pembrolizumab) and developing dermatological toxicities. All patients were systematically evaluated by an expert dermatologist and graded according to a dedicated algorithm previously validated by "dermatology for cancer patients" EADV Task Force recently.

Results

Only patients with clinical symptoms suggestive of EV-related skin toxicity were finally included. We identified 168 patients treated with EV (monotherapy, n=89 or in association with pembrolizumab, n=79). Forty-five patients presented a skin toxicity (27% of the total cohort), including 44% treated in monotherapy and 56% in combination with anti PD-1.

Fourteen patients experienced a grade 1 (31%), 28 patients a grade 2 (62%) and 3 patients a grade 3 toxicity (7%).

Median time to onset of skin lesions after the first EV infusion was 14 days (IQR 7-28).

All patients experiencing a grade 1 toxicity continued EV therapy with (43%) or without dose reduction (57%). No recurrence has occurred.

For grade 2 toxicity, treatment was discontinued in a minority of patients (n=7, 25%). EV therapy was resumed in the other 21 patients, with dose reduction of one level in all cases: 81% did not experience recurrence (n=17). The remaining four patients with initial grade 2 reaction experienced grade 2 (n=2) or grade 3 (n=2) recurrences. EV therapy was then permanently discontinued in three of these patients and reintroduced with a dose reduction by two steps for the remaining patient with grade 2 toxicity.

Finally, EV therapy was discontinued in all patients with grade 3 toxicity.

Dermatological toxicity induced by enfortumab vedotin is very frequent and remains potentially severe with 69% of grade 2/3 toxicity in our large patient population.

However, our results confirmed that, with appropriate dermatological monitoring, particularly using this previously validated algorithm, a large majority of patients can continue this live-saving therapy despite dermatological toxicity. In our cohort, EV was maintained in more than 70% of patients developing skin reactions (with or without

dose reduction), including 100% of those with grade 1 and about two-thirds of those with grade 2 toxicity.

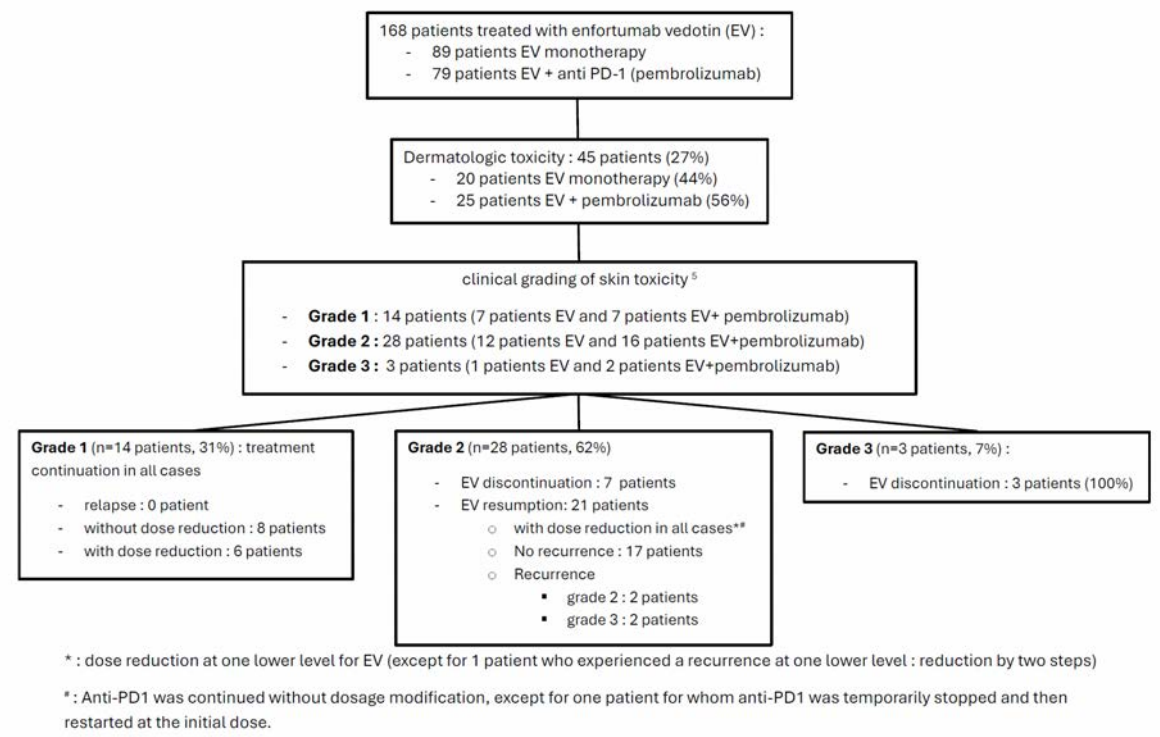

flowchart of patients

Conclusions

Finally, managing the toxicity of enfortumab vedotin involves a multidisciplinary approach in collaboration with oncologists and enhances the role of the dermatologist in this context. Caution is still warranted for the most serious reactions, particularly severe grade 2 and grade 3 reactions.

EA DV CONGRESS
VIENNA
30 SEP - 3 OCT 2026

Abstract N°: 914

Sulfasalazine-induced fixed drug eruption with a pellagra-like distribution: an uncommon clinical mimic

Samantha Paulina Peña-Lozano*[1], Rosa Guevara-Castillo[1], Marissa Quintal-Ramirez[1], Erika Alvarado-Arana[1]

[1] Centro Médico Nacional La Raza "Dr. Antonio Fraga Mouret", Mexico City, Mexico

Introduction

Fixed drug eruption (FDE) is a cutaneous adverse drug reaction characterized by the recurrence of lesions at the same anatomical sites upon re-exposure to the causative agent.Although its pathophysiology is not fully understood, there is evidence that the process is primarily mediated by CD8+ T lymphocytes, and it is therefore considered a type IVc hypersensitivity reaction in which these cells play a central role. FDE represents a significant proportion of cutaneous adverse drug reactions, with an estimated prevalence of approximately 18.7%; however, some series have reported higher frequencies, reaching up to 50% in certain settings.It can occur at any age, with a higher incidence in the third and fourth decades of life. The mean duration from symptom onset to diagnosis has been reported to be approximately 1.9 years.More than 100 drugs have been implicated as triggers, most commonly antibiotics—particularly trimethoprim-sulfamethoxazole—as well as nonsteroidal anti-inflammatory drugs and paracetamol.Among these, sulfasalazine is a disease-modifying antirheumatic drug belonging to the sulfonamide group, widely used in inflammatory conditions such as rheumatoid arthritis and inflammatory bowel disease. It has been associated with a broad spectrum of cutaneous adverse reactions, ranging from mild exanthematous eruptions to severe conditions such as Stevens-Johnson syndrome, toxic epidermal necrolysis, and DRESS syndrome. However, its association with fixed drug eruption is exceedingly rare, with evidence limited to isolated case reports. Given the rarity of sulfasalazine as a causative agent and the potential for atypical clinical presentations, we report a case of fixed drug eruption with a pellagra-like photodistributed pattern.

Case Presentation

A 59-year-old woman with a history of rheumatoid arthritis treated with chloroquine and recent initiation of sulfasalazine (two months prior) presented with a one-month history of erythematous-violaceous macules on the dorsal hands, face, and chest, following the initiation of sulfasalazine.Dermatological examination revealed a disseminated dermatosis involving the head, trunk, and upper extremities, affecting the malar region, forehead, dorsal hands, and the V-area of the chest. The lesions consisted of macules of varying sizes that coalesced into larger plaques, with a brownish-gray coloration, poorly defined borders, and a smooth surface.Given the suspicion of sulfasalazine-induced fixed drug eruption versus pellagra due to the photodistributed pattern, a punch biopsy was performed.Histopathological examination demonstrated interface dermatitis with focal and diffuse necrosis of basal keratinocytes, abundant dermal melanophages, and a superficial perivascular infiltrate, findings consistent with fixed drug eruption.The patient was referred to internal medicine to rule out pellagra; laboratory studies were within normal limits. Sulfasalazine was discontinued, and methotrexate was initiated.Treatment with topical clobetasol 0.05% once daily for two months resulted in progressive improvement. At the last follow-up, the patient was in the resolution phase, with scaling and residual hyperpigmentation.

Conclusion

Sulfasalazine-induced fixed drug eruption is an exceptionally rare entity, with evidence limited to isolated case reports in the literature. However, sulfasalazine, as a sulfonamide with well-recognized immunogenic potential, has been associated with a broad spectrum of cutaneous adverse reactions, supporting its role as a plausible pathogenic trigger in our case.This case is particularly notable due to its photodistributed pattern, mimicking a nutritional dermatosis, specifically pellagra, which may lead to diagnostic challenges.Recognition of this atypical

presentation is essential, as prompt identification and withdrawal of the offending drug lead to resolution and prevent recurrence,

EADV CONGRESS
VIENNA
30 SEP - 3 OCT 2026

Abstract N°: 947

Lichenoid Drug Eruption Associated with Elexacaftor/Tezacaftor/Ivacaftor Therapy

Aline Bertarello[1], Emilia Vieira[1], Isabella Brixner[2], Gabriela Escobar*[1]

[1] Hospital de Clinicas de Porto Alegre, Porto Alegre, Brazil
[2] Private Practice, Porto Alegre, Brazil

Introduction

Lichen planus (LP) is a mucocutaneous inflammatory disorder with heterogeneous clinical manifestations, typically characterized by violaceous papules and plaques. Drug-induced lichenoid skin eruptions (DLSE) may closely mimic LP both clinically and histopathologically. These reactions usually develop weeks after drug exposure and tend to resolve following its discontinuation. To date, DLSE associated with elexacaftor/tezacaftor/ivacaftor (ETI), a therapy used in the management of cystic fibrosis, have not been reported in the literature. Therefore, this case highlights a previously undescribed adverse reaction, underscoring the importance of recognizing rare cutaneous manifestations that may arise in clinical practice.

Case Presentation

A 44-year-old man with cystic fibrosis initiated therapy with elexacaftor/tezacaftor/ivacaftor (ETI). Ten months after treatment onset, he developed pruritic skin lesions, initially affecting the palms and subsequently spreading to the dorsal aspects of the hands and feet. He denied the use of any other medications during this period.

Physical examination revealed multiple violaceous, polygonal papules and plaques distributed over the palms, dorsum of the feet, extensor surfaces of the legs, flexor aspects of the forearms, and the back. Dermoscopic evaluation demonstrated Wickham striae. Mucosal involvement was also noted, with areas of white reticular pattern in the oral cavity and on the penile mucosa.

Based on the clinical findings, lichenoid drug eruption, possibly associated with ETI use, was suspected. A skin biopsy from a lesion on the dorsum of the right hand showed lichenoid interface dermatitis, with Civatte bodies, focal subepidermal clefting (Max-Joseph spaces), irregular “saw-tooth” acanthosis, and wedge-shaped hypergranulosis supporting the diagnosis.

As ETI therapy was maintained, treatment with twice-weekly phototherapy combined with topical clobetasol was initiated, leading to marked clinical improvement. Owing to persistent residual lesions, systemic hydroxychloroquine was subsequently introduced. Phototherapy was discontinued after seven months, and hydroxychloroquine after four months, with sustained remission and no evidence of recurrence to date.

Conclusion

Drug-induced lichenoid skin eruptions are adverse drug reactions characterized by erythematous-violaceous and symmetrical papules, resembling LP both clinically and histologically. Moreover, LP and DLSE share a common immunological mechanism, evidenced by elevated levels of IFN-γ. Among the drugs most frequently associated with the development of DLSE are immune checkpoint inhibitors, followed by tyrosine kinase inhibitors and anti-TNF-α monoclonal antibodies. The average interval between the start of drug therapy and the onset of DLSE was 15.7 weeks (range: 0.1–208 weeks), and after discontinuation of the drug, the median time to resolution was 14.2 weeks (range: 0.71–416 weeks).

Regarding the adverse effects reported for ETI, cutaneous manifestations such as rash, acne, eczema, and pruritus have been described. However, to date, there are no reports in the literature of drug-induced lichenoid skin eruptions associated with this therapy, highlighting the rarity and novelty of the present case.

In conclusion, this report describes a previously unrecognized cutaneous adverse reaction related to ETI, characterized by a lichenoid eruption in a clinical setting where such an association has not yet been documented. This observation broadens the spectrum of dermatological effects potentially linked to ETI and emphasizes the need for heightened clinical awareness of atypical presentations in patients undergoing this treatment. The recognition and reporting of rare adverse events such as this are crucial for strengthening pharmacovigilance, informing clinical practice, and optimizing the long-term care and safety of patients with cystic fibrosis.

EA DV CONGRESS
VIENNA
30 SEP - 3 OCT 2026

Abstract N°: 948

Skin, hair, and nail manifestations following an anthracycline-based chemotherapy regimen and its risk factors: a preliminary prospective study

Dini Daniaty Imam*[1, 2], Larissa Wibawa[1, 2], Aida Hoemardani[1, 2], Andika Rachman[2, 3], Muhammad Ilyas[2], Endi Novianto[1, 2]

[1] Department of Dermatology and Venereology, Dr. Cipto Mangunkusumo National Hospital, Jakarta, Indonesia
[2] Faculty of Medicine, Universitas Indonesia, Jakarta, Indonesia
[3] Department of Internal Medicine, Dr. Cipto Mangunkusumo National Hospital, Jakarta, Indonesia

Introduction
Skin, hair, and nail (SHN) manifestations are relatively common adverse effects of chemotherapy that can significantly affect the quality of life of cancer patients. However, little is known about the incidence of these manifestations among patients receiving anthracycline-based chemotherapy or their associated risk factors. This study aimed to explore SHN manifestations and identify their associated risk factors in cancer patients who received anthracycline-based chemotherapy.

Materials and Methods
A prospective single-arm observational study was conducted from April to September 2023 at Dr. Cipto Mangunkusumo National Hospital, Jakarta, Indonesia. Adult patients receiving their first cycle of an anthracycline-based regimen were enrolled and followed up weekly by phone from enrollment until the second cycle. SHN manifestations were defined as any changes in the skin, hair, or nails during the regimen. The Common Terminology Criteria for Adverse Events (CTCAE) version 5.0 was used as the reference framework. Additional relevant manifestations not included in CTCAE ver 5.0, such as skin infections, were also documented. Baseline variables, including age, systemic comorbidities, body mass index (BMI), Eastern Cooperative Oncology Group (ECOG) performance status, hemoglobin level, and chemotherapy dose, were recorded.

Results
During the study period, 86 patients were screened and 67 enrolled. Two patients dropped out due to personal choice to discontinue chemotherapy, leaving 65 patients in the final analysis. All patients (age 45.45±11.90 years, 75.4% female) developed SHN manifestations. The most common categories were hair (89.2%), followed by nail (87.7%) and skin (75.4%). The most frequent specific manifestations were anagen effluvium (89.2%), melanonychia (87.7%), xerosis (58.5%), and hyperpigmentation (50.8%). The earliest manifestations were xerosis followed by anagen effluvium. No statistically significant associations were found between SHN manifestations and older age, systemic comorbidity, nutritional status, ECOG performance status, anemia, or chemotherapy dose. However, patients with nail manifestations had a higher BMI (23.90±3.99 vs. 20.22±4.75 kg/m^2; p=0.02), and patients with hair manifestations received a higher median chemotherapy dose (50 [20–100] vs. 30 [25–60] mg/m^2, p=0.04). After controlling for age group, systemic comorbidity, nutritional status, ECOG performance status, use of alkylating agent, and dose, exploratory multiple regression showed that female sex (adjusted OR [aOR] 8.45, 95%CI 1.86–38.45; p=0.006) and anemia (aOR 5.09, 95%CI 1.25–20.79; p=0.024) were associated with higher odds of xerosis.

Conclusions

All cancer patients who received anthracycline-based chemotherapy in this study developed SHN manifestations. The most frequent skin findings were xerosis and hyperpigmentation, anagen effluvium was the most common hair abnormality, and melanonychia was the most common nail abnormality. Patients with nail manifestations had a higher BMI, while those with hair manifestations received higher median chemotherapy dose. In exploratory within-cohort analyses, no statistically significant associations were identified between SHN manifestations and older age, systemic comorbidity, nutritional status, performance status, anemia, or chemotherapy dose. However, female sex and anemia were associated with higher odds of xerosis.

EADV CONGRESS
VIENNA
30 SEP - 3 OCT 2026

Abstract N°: 964

Post-Discharge Multisystem Morbidity in Stevens–Johnson Syndrome and Toxic Epidermal Necrolysis: A Retrospective Single-Center Study

Zeynep Cansu Dündar*[1], Harbiye Canat[1]

[1] Clinic of Dermatology and Venereal Diseases, Başakşehir Çam and Sakura City Hospital, University of Health Sciences, Istanbul, Türkiye, İstanbul, Türkiye

Introduction
Stevens–Johnson syndrome (SJS) and toxic epidermal necrolysis (TEN) are rare but life-threatening mucocutaneous reactions, most commonly triggered by medications. Beyond their acute phase, these conditions are associated with prolonged hospitalization, intensive care requirements, and substantial post-discharge morbidity. This study aimed to evaluate the demographic characteristics, baseline laboratory parameters, hospitalization data, treatment regimens, clinical course, and post-discharge outcomes of hospitalized patients with SJS/TEN.

Materials and Methods
We retrospectively reviewed patients hospitalized with SJS/TEN at our tertiary care center between June 2020 and January 2025. Demographic characteristics, culprit agents, treatment regimens, length of hospital stay, and need for intensive care were recorded. Post-discharge visits were categorized according to involved organ systems and analyzed in relation to clinical and laboratory parameters.

Results
A total of 41 patients were included, comprising 27 with SJS and 14 with TEN. Because 3 patients died during hospitalization, post-discharge analyses were performed in 38 patients. The mean age was 36.3±19.1 years, and the mean length of hospital stay was 14.8±13.4 days. The most common culprit agents were nonsteroidal anti-inflammatory drugs, antibiotics, and antiepileptic drugs. Systemic corticosteroid monotherapy was the most frequently used treatment in the SJS group, whereas combination therapy was preferred in the TEN group, most commonly methylprednisolone, intravenous immunoglobulin, and cyclosporine. During follow-up, 78.9% of discharged patients (n=30) developed at least one systemic complaint. The most frequent post-discharge presentations involved the respiratory system (34.2%), infectious causes (26.3%), the gastrointestinal system (23.7%), ocular involvement (23.7%), and dermatologic complaints (21.1%). Ocular presentations were significantly more common in patients with TEN (p=0.016) and in those requiring intensive care (p=0.035). In secondary analyses, C-reactive protein was significantly associated with length of hospital stay (p=0.037), while neutrophil count (p=0.033) and creatinine level (p=0.026) were significantly associated with intensive care requirement. Creatinine level was also significantly associated with respiratory-system-related post-discharge presentations (p=0.043).

Conclusions
Our findings suggest that SJS/TEN is not solely an acute mucocutaneous disorder but is also associated with a considerable burden of multisystem morbidity after discharge. The higher frequency of ocular complications in TEN and in patients requiring intensive care highlights the importance of close, multidisciplinary follow-up. In addition, elevated CRP, creatinine, and neutrophil levels during the acute phase may serve as clinically useful biomarkers for predicting disease course. Larger, multicenter studies are needed to better define the long-term consequences of these rare but severe disorders.

EA DV CONGRESS
VIENNA
30 SEP - 3 OCT 2026

Abstract N°: 964

Probable Sennoside-B-Induced Erythema Annulare Centrifugum

Çınar Yıldız*[1], Banu Yaman[2], İdil Ünal[1]

[1] Ege University Department of Dermatology and Venereology, İzmir, Türkiye
[2] Ege University Department of Pathology, İzmir, Türkiye

Introduction

Erythema annulare centrifugum (EAC) is a reactive erythematous dermatosis characterized by annular, slowly expanding erythematous plaques with central clearing. It is considered as a hypersensitivity reaction pattern associated with a wide variety of triggers, including infections, malignancies, autoimmune disorders, and medications.[1] Although numerous drugs have been associated with EAC, this case suggesting sennoside-B as a potential trigger particularly underscores the clinical importance of obtaining a detailed drug history in patients presenting with annular erythematous eruptions.

Case Presentation

A 46-year-old male patient with no significant medical history presented with annular erythematous plaques that initially appeared on the anterior thigh three days after initiation of sennoside-B therapy and subsequently spread to the posterior thighs, legs, abdomen, back, and arms (Figure 1). Dermatological examination revealed well-demarcated annular plaques with indurated erythematous borders and central clearing. No scaling was observed. Diascopy did not reveal complete blanching, and Wood's lamp examination showed no fluorescence. The patient denied any subjective symptoms such as pruritus, burning, or pain. The initial differential diagnoses included granuloma annulare, annular elastolytic giant cell granuloma, subacute cutaneous lupus erythematosus and secondary syphilis, in addition to erythema annulare centrifugum. A punch biopsy was obtained from an active lesion on the arm. Histopathological examination demonstrated sparse lymphocytic exocytosis in the epidermis and a dense superficial and deep perivascular mononuclear inflammatory infiltrate, predominantly composed of lymphocytes, forming a characteristic perivascular pattern consistent with erythema annulare centrifugum (Figure 2). Laboratory investigations, including viral serologies (HIV, HCV), thyroid function tests, routine hematological and biochemical tests, were within normal limits. A detailed medication history revealed recent use of oral sennoside-B for chronic constipation. The drug was discontinued. Complete clinical regression of the lesions was observed approximately two weeks after discontinuation, without the need for systemic therapy (Figure 3). No recurrence was observed during follow-up while the patient avoided re-exposure to the drug. Causality assessment using the Naranjo probability scale suggested a probable drug-induced reaction. Written informed consent was obtained from the patient for the publication of this case report and accompanying images.

Conclusion

This case represents, to the best of our knowledge, the first reported case of sennoside-B-induced erythema annulare centrifugum. Causality assessment using the Naranjo probability scale further supported a probable drug-induced reaction. Clinicians should be aware that sennoside derivatives may act as potential triggers of EAC. Careful and detailed drug history should be considered a fundamental component of the diagnostic work-up in patients presenting with annular erythematous eruptions, in order to ensure accurate diagnosis and timely management.

EADV Congress 2026, VIENNA
30 SEPTEMBER - 03 OCTOBER 2026
POWERED BY M-ANAGE.COM

EADV CONGRESS
VIENNA
30 SEP - 3 OCT 2026

Abstract N°: 990

Epidermolysis bullosa acquisita induced by ianalumab used in the treatment of autoimmune haemolytic anaemia: a paradoxical immunological phenomenon

Wei Sheng Chong*[1], Denise Tsang[1], Benjamin Ho[1], Ding Yuan Wang[1], Derek Lim[1], Yen Loo Lim[1]

[1] National Skin Centre, Singapore, Singapore

Introduction

Ianalumab is a fully human monoclonal antibody with a novel dual mechanism of action that depletes B cells and inhibits their activation and survival via B-cell activating factor receptor (BAFF-R) blockade. It is a drug currently under investigation for autoimmune conditions. Here we present a case of epidermolysis bullosa acquisita (EBA) induced by ianalumab used in the treatment of autoimmune haemolytic anaemia (AIHA), and discuss the possible mechanisms behind this paradoxical immunological phenomenon.

Case Presentation

A 30-year-old woman presented with a generalised blistering eruption. Her history was significant for warm autoimmune haemolytic anaemia (AIHA) which had relapsed despite rituximab. She was then treated with four monthly infusions of ianalumab but developed a pruritic rash in the third month of treatment with subsequent blistering. Examination showed numerous tense bullae admixed with prurigo-like lesions and erosions on the face, trunk, upper and lower limbs. There were also erosions on her lips and oral mucosa. Skin biopsy showed a subepidermal blister with an infiltrate comprising eosinophils and neutrophils. Her direct immunofluorescence showed linear IgG and C3 along the basement membrane zone. Indirect immunofluorescence demonstrated a floor pattern. An enzyme-linked immunosorbent assay (ELISA) with the recombinant NC-1 domain of type VII collagen was positive at 191 U/ml (normal < 20 U/ml). Anti-bullous pemphigoid 180 and 230 antibodies, desmoglein-1 and desmoglein-3 antibodies were negative. Immunoblotting with essence of human dermis demonstrated circulating IgG4 autoantibodies against type VII collagen, with no reactivity to the p200 antigen detected. An autoimmune screen for systemic lupus erythematosus was negative. A diagnosis of ianalumab-induced epidermolysis bullosa acquisita (EBA) was made. Further doses of ianalumab were held off. She received treatment with intravenous immunoglobulin 2 g/kg in combination with mycophenolate mofetil 1.5 g twice daily and prednisolone 35 mg daily. Partial remission was observed after two months.

Conclusion

We report a case of epidermolysis bullosa acquisita (EBA) induced by ianalumab used in the treatment of autoimmune haemolytic anaemia (AIHA). The abrupt onset of EBA in a young patient following ianalumab administration makes a pure coincidental event unlikely. We hypothesise that B-cell depletion could create a T helper 1 (Th1)-dominant milieu, or lead to a loss of immune tolerance that predisposes to the development of EBA. It is also possible that a chronic state of severe B-cell depletion induced by ianalumab creates an immunological landscape that favours the pathogenesis of EBA through various mechanisms involving the modification of T helper cell response and cytokine signalling. Our findings highlight the complex interplay between B-cell and T-cell dynamics in autoimmune pathogenesis.

POWERED BY M-ANAGE.COM

EA DV CONGRESS
VIENNA
30 SEP - 3 OCT 2026

Abstract N°: 1012

Baricitinib Treatment for PD-L1 inhibitor-induced Lichenoid Drug Eruption

Xinyi Chen*[1], Juan Bai[1], Jianjun QIAO[1]

[1] Department of Dermatology, The First Affiliated Hospital, Zhejiang University School of Medicine, Hangzhou, China

Introduction

Immune checkpoint inhibitors (ICIs) such as programmed cell death ligand (PD-L1) are widely used in cancer treatment via down-regulating cytotoxic T lymphocytes, ultimately reshaping the immune microenvironment for anti-tumor responses. However, these agents are frequently associated with cutaneous immune-related adverse events (cirAEs), including maculopapular eruptions, lichenoid dermatitis, and severe reactions such as Stevens-Johnson syndrome/toxic epidermal necrolysis. CirAEs usually significantly impair the patient's quality of life and may prompt premature ICI cessation. Corticosteroids are the first-line therapy for cirAEs, without attenuating the anti-tumor efficacy of checkpoint inhibitors. However, long-term therapy with systemic corticosteroids confers infection and metabolic risks, and many cases are corticosteroid refractory. Thus, effective interventions are required to promptly control the lesion without exerting any adverse effects on the tumor. Herein, we reported one rapid treatment of pembrolizumab (a PD-L1 inhibitor) -induced lichenoid drug eruption with baricitinib（a Jak2 inhibitor）.

Case Presentation

A 73-year-old man presented to our department with a 2-month history of generalized plaques, nodules, with itch. The patient had received pembrolizumab (an anti-PD-1 monoclonal antibody) for lung cancer since 2024. Approximately one week after the lastest pembrolizumab infusion on 10th July 2025, scattered erythematous lesions appeared on his dorsal hands, accompanied by pruritus, and spread to the head, distal extremities, trunk, and genital region. Physical examination revealed well-demarcated erythematous plaques and firm nodules with mild scaling, predominantly distributed in the aforementioned areas. Skin biopsy revealed hyperkeratosis, scattered parakeratosis, acanthosis, wedge-shaped hypergranulosis, liquefactive degeneration of basal cells, and a band-like lymphohistiocytic infiltrate in the superficial dermis—histopathological features consistent with lichenoid drug eruption. Based on these findings, a diagnosis of pembrolizumab-induced lichenoid drug eruption was established.

In addition to discontinuing pembrolizumab, to minimize the adverse effects associated with long-term glucocorticoid use, we opted for combination therapy with baricitinib 2mg twice daily and methylprednisolone 40mg daily, supplemented with topical high-potency glucocorticoids. After 5 days of treatment, no new lesions developed, pruritus was alleviated, and the existing lesions gradually thinned. The dosage of methylprednisolone was then tapered progressively. 2 weeks later, significant improvement of the rash was observed: the plaques shrank gradually and scaling was reduced . One and a half months later, glucocorticoids were discontinued, and baricitinib was 2 mg twice weekly. only faint erythema and scattered macules persisted. After 2 months, baricitinib was discontinued and the rash improved significantly .

Conclusion

This case supports baricitinib as a rapid, effective treatment for anti–PD-1–induced lichenoid drug eruption, facilitating ICI treatment continuity and minimizing steroid-related morbidity. More investigations are needed to elucidate the effectiveness and safety of JAKi for treating criAEs.

EADV CONGRESS
VIENNA
30 SEP - 3 OCT 2026

Abstract N°: 1139

Overlap between chikungunya infection and rivaroxaban-induced DRESS syndrome: diagnostic challenge and potential immunological interplay

Mariana Santos[1], Maria Clara Linhares*[1], Gabriela Neves[1], Isabella Oliveira[1], Fernanda Giacometo[1], Thaís Kato[1], João Antonio[1]

[1] Hospital de Base, São José do Rio Preto, Brazil

Introduction

Acute febrile exanthems represent a significant diagnostic challenge, particularly in regions endemic for arboviruses. Chikungunya virus infection typically presents with fever and a maculopapular rash, though purpuric forms may occur. Concurrently, DRESS syndrome (Drug Reaction with Eosinophilia and Systemic Symptoms) is a potentially severe delayed hypersensitivity reaction characterized by cutaneous rash, fever, eosinophilia, and systemic involvement, most notably hepatic. The clinical overlap between these conditions, coupled with the limitations of isolated serology, may complicate the diagnosis and delay appropriate management.

Case Presentation

A 31-year-old female patient, who had been receiving rivaroxaban 20 mg/day for the past two months for deep vein thrombosis, presented with a 10-day history of a papular exanthema. The eruption initially appeared on the trunk with a centripetal distribution, subsequently evolving into purpuric lesions, facial edema, and fever. She denied recent antibiotic use or travel history. At admission, the patient presented with fever and remarkable facial edema.

Laboratory investigations revealed positive IgM and negative IgG for Chikungunya; other infectious serologies were negative. Elevated liver enzymes were noted (AST 184 U/L, ALT 217 U/L, GGT 279 U/L). The patient's clinical status deteriorated, necessitating ICU admission due to the progression of facial and cervical edema and persistent febrile peaks. Laboratory findings revealed leukocytosis (23.950/mm^3), significant eosinophilia (2.778/mm^3), and an exacerbation of hepatic impairment.

Upon suspicion of rivaroxaban-induced DRESS syndrome, the drug was discontinued and replaced with enoxaparin. Treatment was initiated with systemic methylprednisolone and bilastine. A skin biopsy was performed, revealing vacuolar interface dermatitis, which was consistent with the clinical hypothesis of a maculopapular drug eruption. Following these interventions, the patient experienced resolution of fever and progressive improvement in both clinical and laboratory parameters.

Discussion

Distinguishing between viral exanthems and severe cutaneous adverse reactions (SCARs) remains challenging, particularly in endemic areas. While chikungunya may present with a diffuse and, rarely, purpuric rash, it is typically associated with leukopenia and mild hepatic alterations. In the present case, the presence of marked eosinophilia, leukocytosis, pronounced facial edema, and progressive hepatic dysfunction strongly supports the diagnosis of DRESS syndrome. The latency period of approximately 8 weeks between the initiation of rivaroxaban and the onset of clinical symptoms is highly consistent with DRESS syndrome. Although direct oral anticoagulants are rarely implicated, there are existing reports of severe cutaneous adverse reactions associated with these agents.

The isolated IgM positivity for chikungunya must be interpreted with caution, taking into account potential cross-reactivity and serological persistence. Furthermore, viral infections can act as modulators of the immune response, amplifying drug hypersensitivity reactions. In this context, it is plausible that the chikungunya infection acted as an

immunological triggering or amplifying factor for the drug response, establishing a multifactorial model for the development of DRESS. The integration of clinical, laboratory, and longitudinal findings was fundamental for achieving the correct diagnosis and ensuring appropriate management.

Conclusion

Differentiating between viral exanthems and DRESS syndrome requires a meticulous and integrated clinical evaluation. The presence of eosinophilia, progressive hepatic dysfunction, and sustained clinical deterioration should alert clinicians to a severe drug eruption, even in the setting of positive serology for arboviruses. The potential interplay between viral infection and drug reaction reinforces the complexity of these cases.

EADV CONGRESS
VIENNA
30 SEP - 3 OCT 2026

Abstract N°: 1146

Delayed Inflammatory Reaction to Hyaluronic Acid Fillers Triggered by Dupilumab: A Novel Case Report Suggesting an Immune-Mediated Mechanism

Abdullah Almeziny*[1]

[1] College of Medicine, Imam Mohammad Ibn Saud Islamic University, Riyadh, Saudi Arabia, Riyadah, Saudi Arabia

Introduction

Delayed inflammatory reactions to hyaluronic acid (HA) fillers are uncommon but increasingly recognized complications, typically presenting weeks to months after injection. These reactions are thought to be immune-mediated and may be triggered by external factors, including infections, systemic illnesses, or medications. However, the role of biologic therapies in precipitating such reactions remains poorly understood. We report a novel case of recurrent delayed inflammatory reactions to HA fillers following initiation of dupilumab, highlighting a potential immunological interaction.

Case Presentation

A 34-year-old female with chronic rhinosinusitis refractory to prior surgical management underwent uneventful intradermal HA filler injections in the malar region using a microdroplet technique under sterile conditions. The procedure was well tolerated, with no immediate or early complications. Three months later, the patient initiated dupilumab therapy (600mg).

Within one hour of the first dose, she developed facial warmth followed by painful bilateral swelling at the sites of previous filler injections, progressing to firm nodules within 24 hours. Notably, **similar reactions consistently recurred after each subsequent dupilumab dose**, affecting the same anatomical sites, although with gradually reduced severity. The reproducibility of the reaction with repeated dosing strongly suggested a drug-triggered phenomenon.

Clinical examination revealed firm, mildly tender subcutaneous nodules localized to the cheeks without erythema, discharge, or systemic manifestations. Hypersensitivity testing was negative. Management included intralesional hyaluronidase injections, resulting in gradual reduction in nodule size. However, **re-exposure to dupilumab repeatedly triggered recurrence of nodules**, necessitating additional hyaluronidase treatments, with progressive improvement over time.

Conclusion

This case highlights a previously underreported association between dupilumab therapy and delayed inflammatory reactions to HA fillers, with **clear recurrence following each drug exposure**, supporting a strong causal relationship. A plausible mechanism may involve dupilumab-mediated modulation of IL-4 and IL-13 pathways, potentially enhancing pro-inflammatory responses and promoting granulomatous reactions at prior filler sites.

Clinically, this underscores the importance of careful patient selection and counseling when performing aesthetic procedures in individuals receiving biologic therapies. Awareness of this reproducible reaction pattern is essential for early recognition and management. Intralesional hyaluronidase appears effective for symptom control.

Further studies are needed to better understand the immunological mechanisms and to guide safe integration of aesthetic procedures in patients undergoing biologic therapy.

EADV CONGRESS
VIENNA
30 SEP - 3 OCT 2026

Abstract N°: 1158

JAK inhibitors for the off-label treatment of two stevens-johnson syndrome cases: tofacitinib vs. ivarmacitinib

Ziyu Yuan[1], Chunlan Zhang[1], Dandan Zang[2], Xin Du[1], Feng Wang*[1]

[1] Department of Dermatology, Second Affiliated Hospital of Anhui Medical University, Hefei, China
[2] Center for Scientific Research, Anhui Medical University, Hefei, China

Introduction

Stevens-Johnson syndrome (SJS) and toxic epidermal necrolysis (TEN) are life-threatening cutaneous adverse reactions characterized by extensive epidermal necrosis and detachment. The efficacy and risks of conventional therapies, including glucocorticoids, cyclosporine, and intravenous immunoglobulins, remain controversial. Although TNF-α inhibitors have emerged as a promising therapeutic option, the optimal treatment window is frequently missed in clinical practice. Recent advances based on spatial proteomics have identified JAK/STAT signaling as a key driver of the inflammatory response in SJS/TEN, prompting exploratory treatment of JAK inhibitors in combination with glucocorticoids in clinical practice.

Case Presentation

Here, we present two cases of SJS initially treated with a JAK inhibitor (JAKi) in combination with methylprednisolone. **Case 1:** A 40-year-old male treated with methylprednisolone (1.0 mg/kg daily, intravenous injection) and the pan-JAK inhibitor tofacitinib (5 mg twice daily, oral). **Case 2:** A 60-year-old female treated with methylprednisolone (1.0 mg/kg daily, intravenous injection) and ivarmacitinib (4 mg twice daily, oral), a highly selective JAK1 inhibitor. Although both patients achieved full recovery, the clinical courses differed markedly. Notably, the two cases varied in the time to arrest disease progression (7 days vs. 2 days after JAKi treatment), timing of corticosteroid tapering (day 13 vs. day 7), and total hospital stay (23 days vs. 10 days). Both patients experienced no adverse reactions.

Conclusion

A comparison of these two cases suggests that early initiation of a JAK inhibitor in combination with systemic corticosteroids may lead to a favorable outcome. Furthermore, ivarmacitinib appeared to be associated with a more rapid response than tofacitinib in these two cases; however, this observation warrants validation in future large-scale randomized controlled trials.

EA DV CONGRESS
VIENNA
30 SEP - 3 OCT 2026

Abstract N°: 1166

Clinicopathologic Correlation in Fatal TEN: Mesalazine as the ALDEN-Confirmed Culprit in HIV-Associated Epidermal Necrolysis

Ludivine Marie Rose Compain*[1], Maria Fernanda De La Cruz Ferrera[1], Monica Navarrete[1]

[1] Hospital Regional de Alta Especialidad de La Península de Yucatán, Mérida, Mexico

Introduction

Toxic epidermal necrolysis (TEN) is an uncommon, severe cutaneous adverse drug reaction (ADR) whose occurrence in people living with HIV (PLWH) is associated with higher morbidity and mortality. ADR incidence is markedly increased in this population, estimated up to 100-fold, due to factors including polypharmacy, slow acetylator phenotype, relative glutathione deficiency, CD4+ count <200 cells/µL, latent CMV/EBV infection, and elevated CD8+ counts (>460 cells/µL). In PLWH, most ADRs are linked to trimethoprim–sulfamethoxazole (TMP–SMX), other sulfonamides and penicillins, accounting for 75% of cases. TMP–SMX reactions occur in >2–8% of the general population but in >43% of PLWH and up to 69% in AIDS, partly explained by systemic glutathione depletion. ADRs to antiretrovirals (notably NNRTIs), anti-tuberculosis drugs, NSAIDs and anticonvulsants are also common. A population-based case-control study identified 5-aminosalicylates (including mesalazine) as associated with TEN, with an absolute risk of 1.9-4.3/100 000 new users, and ALDEN score application suggested likely causality for this association, suggesting this reaction is extremely rare. Our objective is to report a case of fatal TEN induced by mesalazine in a patient with newly diagnosed HIV infection, applying the ALDEN algorithm for formal drug causality assessment, and to discuss therapeutic alternatives for ulcerative colitis in high-risk populations.

Case Presentation

A 36-year-old man with chronic alcohol use presented with ascites and hematochezia. Diagnostic paracentesis suggested portal hypertension (serum-ascites albumin gradient >1.1 g/dL); abdominal ultrasound supported chronic liver disease with portal hypertension. Viral hepatitis panel was negative; HIV ELISA was positive. Colonoscopy revealed pancolitis with predominant rectal involvement, mesalazine 500 mg PO every 8 hours was started and the patient was discharged. One month later he was readmitted with odynophagia, dysphagia, fever and nausea and progressive dermatologic lesions: generalized confluent erythematous maculopapular rash, nonpruritic, asymmetric, involving trunk and limbs with oral and conjunctival mucosal involvement. In the ED he developed dyspnea. HIV viral load was 212,400 copies/mL and CD4+ count 230 cells/µL. TMP–SMX prophylaxis was initiated. During internal medicine admission, the rash evolved to confluent erythematoviolaceous macules with epidermal necrosis, flaccid bullae (positive Nikolsky sign), severe cutaneous pain (face, trunk, extremities, genitals), purulent conjunctivitis, and hemorrhagic oral erosions with dysphagia. Body surface area (BSA) involvement exceeded 30%, consistent with TEN and ALDEN algorithm classifies mesalazine causality as "Probable" (score +4) and excludes TMP-SMX (score 0) as a causative agent, since TMP-SMX was initiated four days after the onset of dermatologic manifestations, si mesalazine was discontinued. Analgesia and methylprednisolone boluses yielded no improvement. Skin biopsy was performed and ciclosporin 3 mg/kg/day was started. The patient progressed to cellulitis, tissue hypoperfusion and shock, and died. Skin histopathology was consistent with TEN.

Conclusion

This case represents a rare but important pharmacovigilance signal: mesalazine-induced TEN in a PLWH with

formal causality assessment using the ALDEN algorithm. The exclusion of TMP-SMX by timeline (initiated 4 days after symptom onset) strengthens the causal attribution to mesalazine. Clinicians managing ulcerative colitis in PLWH should consider the elevated baseline risk of severe cutaneous adverse reactions in this population and may favor alternative agents such as vedolizumab when clinically appropriate. This case underscores the importance of applying validated causality assessment tools (ALDEN) in complex polypharmacy scenarios and maintaining high clinical suspicion for SCARs in PLWH, even with drugs traditionally considered low-risk.

EADV CONGRESS
VIENNA
30 SEP - 3 OCT 2026

Abstract N°: 1182

Development of Nivolumab-Induced Bullous Pemphigoid in a Patient with Malignant Melanoma: Case Report

Mahir Anıl Beşiktaş*[1], Miraç Zengin Uçar[1], Tugba Kevser Uzuncakmak[1]

[1] Istanbul University-Cerrahpasa, Cerrahpasa Medical Faculty, Dermatology, ISTANBUL, Türkiye

Introduction

Bullous pemphigoid is an autoimmune subepidermal blistering disorder characterized by autoantibody formation against components of the basement membrane zone. It predominantly affects elderly patients and presents with intense pruritus, urticarial plaques, and tense bullae. Drug-induced bullous pemphigoid is a well-recognized variant that may occur weeks to months, or even longer after exposure to the triggering agent.

Nivolumab is a fully human IgG4 monoclonal antibody targeting programmed cell death-1 (PD-1) and is widely used as an immune checkpoint inhibitor in the treatment of advanced malignancies, particularly malignant melanoma. Although highly effective, it is associated with immune-related adverse events, including various cutaneous reactions.

Case Presentation

A 46-year-old male patient with a history of diabetes mellitus was diagnosed with malignant melanoma of the scalp in 2012. The patient had no evidence of metastasis and was followed under nivolumab therapy.

In August 2025, he developed generalized pruritus followed by rapidly progressive, widespread bullous lesions involving the trunk and extremities. Dermatological examination revealed multiple tense bullae, some of which had ruptured, resulting in erosions and yellow crusted lesions. No mucosal involvement was observed.

A punch biopsy was performed from the dorsum of the hand under the clinical suspicion of bullous pemphigoid. Histopathological examination was consistent with bullous pemphigoid. Direct immunofluorescence demonstrated linear deposition of IgG and C3 along the basement membrane zone, confirming the diagnosis.

The patient was hospitalized and treated with systemic corticosteroids and omalizumab. Based on clinical course, histopathological findings, immunofluorescence results, and temporal association, nivolumab-induced bullous pemphigoid was considered the most likely diagnosis.

Conclusion

Immune checkpoint inhibitors such as nivolumab have significantly improved outcomes in advanced malignancies; however, they may induce a spectrum of immune-related cutaneous adverse effects. Bullous pemphigoid, although rare, is an important and potentially severe dermatological complication associated with anti–PD-1 therapy.

Early recognition and prompt initiation of appropriate immunosuppressive treatment are essential for disease control. Dermatologists and oncologists should remain vigilant for autoimmune blistering diseases in patients receiving immune checkpoint inhibitors, and multidisciplinary management is crucial for optimal outcomes.

EADV Congress 2026, VIENNA
30 SEPTEMBER - 03 OCTOBER 2026
POWERED BY M-ANAGE.COM

EADV CONGRESS
VIENNA
30 SEP - 3 OCT 2026

Abstract N°: 1306

Allopurinol-induced DRESS syndrome: a clinical entry point towards the diagnosis of hereditary hemochromatosis

salah eddin awawde*[1], Imene Mahiou[1], Lamia Ould Iddir[1], Taibi Lynda[1], FATMA ZOHRA ZEMOURI[1], kacimi asma[1], Samira Zobiri[1]

[1] Mustapha University Hospital Center, Dermatology and venereology, Sidi M'Hamed - alger, Algeria

Introduction
Drug Reaction with Eosinophilia and Systemic Symptoms (DRESS) is a severe, life-threatening cutaneous adverse reaction (toxidermia) characterized by a long latency period, hematological abnormalities, and multi-organ involvement. While allopurinol is a leading trigger—particularly in patients with chronic kidney disease (CKD) due to reduced metabolite clearance—the clinical severity often reflects the patient's underlying physiological vulnerability. Hereditary hemochromatosis (HH) is a systemic iron-overload disorder that often remains clinically silent, manifesting only as isolated metabolic or endocrine failures until an acute systemic event occurs. We report a unique case where an acute episode of DRESS acted as a "biological stress test," unmasking a long-standing systemic iron overload through a pathognomonic clinical cluster of "bronze diabetes," hypotrichosis, and infertility.

Case Presentation
A 44-year-old male was hospitalized in November 2024 following the introduction of allopurinol for hyperuricemia. The patient’s medical background was a complex mosaic of systemic failures: insulin-dependent type 2 diabetes mellitus (T2DM), diabetic retinopathy, open-angle glaucoma, hypothyroidism, and stage 3 CKD. Notably, the patient reported a history of primary infertility (no children). The acute episode began with generalized, infiltrated erythema and purpura, high fever (38.5°C), and severe mucosal ulcerations of the lips and soft palate. Laboratory investigations confirmed marked hypereosinophilia, acute-on-chronic renal failure, and significant hepatic cytolysis **([insert value])** accompanied by pancreatic inflammation (elevated lipase). Management included the immediate cessation of allopurinol, intravenous methylprednisolone (**[insert value]** mg/kg/day), intensive hyperhydration, and antiviral coverage.

Conclusion
As the inflammatory phase of the DRESS syndrome subsided under corticosteroid therapy, the clinical focus shifted toward persistent, non-drug-related findings that pointed toward a unified diagnosis of iron overload:

- **Cutaneous Markers:** Following acute desquamation, a generalized greyish-bronze hyperpigmentation (melanoderma) became strikingly evident. Physical examination revealed a marked rarity of body hair (hypotrichosis) with thinning in the axillary and pubic regions.
- **Hepatic Transition:** While the initial cytolysis improved, it was replaced by secondary, intense cholestatic jaundice and persistent hepatomegaly, suggesting a liver parenchyma that was already saturated and fragile.
- **Systemic Synthesis:** The presence of "bronze diabetes" (pigmentation + T2DM), combined with the patient’s history of infertility and hypothyroidism, formed a pathognomonic clinical constellation. The DRESS syndrome acted as an "oxidative trigger," making these previously silent signs medically visible.

In this patient, the diagnosis of hemochromatosis serves as the common denominator for his extensive multi-organ history. Primary infertility and hypotrichosis are classic clinical signatures of iron deposition in the pituitary

gland, leading to hypogonadotropic hypogonadism. This endocrine failure, occurring alongside "bronze diabetes," highlights the systemic nature of the iron overload.

The pathogenesis of the patient’s comorbidities—diabetes, hypothyroidism, and glaucoma—can be directly attributed to chronic iron deposition in the pancreas, thyroid gland, and the anterior segment of the eye, respectively. The inflammatory "flare" of the DRESS syndrome likely accelerated the visible hyperpigmentation and exacerbated the cholestasis. In the context of CKD, oxypurinol accumulation triggered the DRESS syndrome, but the underlying iron-saturated state determined the catastrophic nature of the hepatic and pancreatic outcomes.

EA DV CONGRESS
VIENNA
30 SEP - 3 OCT 2026

Abstract N°: 1328

Acneiform Rash from EGFR Inhibitor Therapy: Durable, Mechanism-Directed Reduction with Topical LUT014 (B-RAF Inhibitor) in a Phase 2, Randomized, Double-Blind, Placebo-Controlled Trial

Anisha B. Patel*[1], Ofer Purim[2], Zev A. Wainberg[3], Veronica Rotemberg[4], Iman Imanirad[5], Efrat Dotan[6], Nicole R. LeBoeuf[7], John Khoury[8], Richard Zuniga[9], Abhishek Marballi[10], Esther Tahover[11], Anil Veluvolu[12], Samuel Bailey[6], David B. Greenberg[13, 13], Adil Akhtar[14], Omar Pacha[15], Fiorinda F. Muhaj[1], J. Randolph Hecht[16], Kara D. Miller[5], Lauren M. Guggina[7], Vanessa Wookey[17], Pamela Miel[8], Hema Vankayala[18, 18], Larisa Ryvo[2], Sumant Ramachandra[6], Jonathan E. Benjamin[6], Noa Shelach[6], Benjamin W. Corn[19], Mario E. Lacouture[4], Antoni Ribas[16]

[1] University of Texas MD Anderson Cancer Center, Houston, United States
[2] Shaare Zedek Medical Center, Jerusalem, Israel
[3] Jonsson Comprehensive Cancer Center at the University of California Los Angeles, Los Angeles, United States
[4] Memorial Sloan Kettering Cancer Center, New York, United States
[5] H. Lee Moffitt Cancer Center, Tampa, United States
[6] Lutris Pharma, Tel Aviv, Israel
[7] Dana-Farber/Brigham Cancer Center, Boston, United States
[8] The Oncology Institute of Hope & Innovation, Cerritos, United States
[9] NY Cancer and Blood Specialists, East Islip, United States
[10] Multicare Institute for Research, Tacoma, United States
[11] Assuta Medical Center, Tel Aviv, Israel
[12] Wills-Knighton Health, Shreveport, United States
[13] Hackensack Meridian Health, Hackensack, United States
[14] Revive Research Institute, Sterling Heights, United States
[15] University of Texas, MD Anderson Cancer Center, Houston, United States
[16] UCLA Jonsson Comprehensive Cancer Center, Los Angeles, United States
[17] Fox Chase Cancer Center, Philadelphia, United States
[18] Cancer Specialists of North Florida, Fleming Island, United States
[19] Institute of Radiotherapy at Tel Aviv Medical Center, Jerusalem, Israel

Introduction

EGFR inhibitors (EGFRI) are foundational therapies in metastatic colorectal cancer (CRC), non-small cell lung cancer, and head and neck squamous cell carcinoma. Acneiform, papulopustular eruption of the head, neck, and upper trunk develops in up to 90% of treated patients and leads to pain, pruritus, and, in severe cases, spontaneous bleeding of the affected areas. Further, this toxicity is a leading driver of dose delays, dose reductions, and discontinuation of anti-cancer therapy. Acneiform eruption is a direct consequence of on-target, off-tumor EGFR blockade in keratinocytes, yet current prophylaxis and therapies target the downstream inflammatory infiltrate rather than the suppressed MAP kinase signaling that initiates the toxicity.

Materials and Methods

LUT014 gel is a novel topical B-RAF inhibitor designed to restore MAP kinase signaling via paradoxical MAPK pathway activation. In a Phase 2 multi-center, randomized, double-blind, placebo-controlled trial (NCT04759664), 118 adult CRC patients on cetuximab or panitumumab EGFRI with Common Terminology Criteria for Adverse Events (CTCAE) v5.0 Grade 2 or non-infected Grade 3 EGFRI-induced rash received LUT014 0.1% gel (n=39), 0.03%

gel (n=40), or placebo gel (n=39), applied once daily for 28 days, followed by a 28-day observation period. The composite primary endpoint (Treatment Success) was measured at Day 28 and required ≥1 grade improvement in CTCAE v5.0 acneiform rash or ≥5-point improvement in patient symptoms via the Functional Assessment of Cancer Therapy (FACT)-EGFRI-18 skin-specific score (13 items), and absence of Treatment Failure (EGFRI dose reduction, delay, or discontinuation for rash; antibiotic initiation or escalation for rash; or study-drug discontinuation for worsening rash).

Results

Baseline characteristics were well matched across arms. Treatment Success was achieved in 71.8% of the 0.1% gel arm (95% CI 55.1–85.0), 52.5% (36.1–68.5) of the 0.03% gel arm, and 38.5% (23.0–55.0) of placebo (0.1% vs. placebo p=0.003; 3-arm p=0.012). CTCAE v5.0 one-grade improvement was achieved in 56.4%, 45.0%, and 15.4%, respectively (p=0.0002 and p=0.0042 vs. placebo; 3-arm p=0.0006). FACT-EGFRI-18 5-point improvement was achieved in 53.8%, 42.5%, and 28.2% (p=0.021 and p=0.184 vs. placebo; 3-arm p=0.071). CTCAE v5.0 grade distributions in both LUT014 arms remained stable from Day 28 to Day 55, indicating benefit may persist beyond the 28-day treatment window. Among LUT014 0.1% gel recipients, Treatment Success was achieved in 78.9% of patients with baseline systemic antibiotic use versus 42.1% on placebo (n=19 each; p=0.0202), and in 65.0% of patients without baseline antibiotics versus 35.0% on placebo (n=20 each; p=0.0578), demonstrating benefit independent of baseline antibiotic use. EGFRI therapy interruption or reduction occurred in 10.3% of LUT014 0.1% gel recipients versus 28.2% in the placebo arm (p=0.0443), supporting continued EGFRI therapy at prescribed dosing.

Safety: LUT014 showed a placebo-like safety profile. Drug-related adverse events were most commonly mild, local skin reactions including self-limited pruritus or burning sensation after study drug application. No dose-limiting toxicities or Grade 4 or 5 events occurred, and no new systemic safety signals were identified.

Conclusions

Topical LUT014 0.1% gel provides durable, mechanism-directed benefit for EGFRI-induced acneiform rash in CRC patients receiving cetuximab or panitumumab, independent of baseline systemic antibiotic use, and reduces EGFRI non-adherence. This novel topical B-RAF inhibitor restores keratinocyte MAPK signaling compared to current symptom-directed anti-inflammatory therapies. As MAPK-targeted oncology expands (RAS and pan-RAF inhibitors), effective management of on-target cutaneous toxicity will be increasingly important for preserving anti-cancer dose intensity and patient quality of life.

EADV CONGRESS
VIENNA
30 SEP - 3 OCT 2026

Abstract N°: 1432

Semaglutide: a new player in drug-induced linear IgA dermatosis?

Biljana Gorgievska-Sukarovska*[1], Mirjana Sekulovski[2]

[1] Dermatology and Venereology Unit, Zabok General Hospital, Faculty of Dental Medicine and Health Osijek, Josip Juraj Strossmayer University of Osijek, Zabok, Croatia
[2] Dermatology and Venereology Unit, Zabok General Hospital, Zabok, Croatia

Introduction
Linear IgA bullous dermatosis (LABD) is a rare autoimmune blistering disease that affects both adults and children. In adult form of the disease, a drug-induced etiology must be considered, and the disease usually resolves upon withdrawal of the offending drug.

Here, we report a case of semaglutide-associated linear IgA dermatosis in a patient with diabetes mellitus.

Case Presentation
A 74-year-old female patient was referred to our department with serous blisters, vesicles and erosions on the right knee. Subsequently, bullae appeared arranged in a circular “string of pearls“ pattern, without any mucosal involvement. Systemic therapy with 40 mg of prednisolone daily was initiated, with poor clinical response. The lesions gradually spread to the forearms, lower legs and lower abdomen.

Five months prior, semaglutide therapy had been initiated, due to poor glycemic control.

A skin biopsy was performed for histopathological examination and direct immunofluorescence (DIF).

Histopathology revealed a subepideremal blister and neutrofilic infiltrates.

DIF revealed linear deposits of IgA along the dermoepidermal junction.

Serologic test for tissue transglutaminase (tTG) IgA and IgG antibodies was negative.

Despite systemic corticosteroid therapy, the condition remained poorly controlled. Suspecting semaglutide as a potential trigger of the diseases, the medication was discontinued. Following the withdrawal of semaglutide, the symptoms resolved completely.

Conclusion
Complete regression of symptoms after withdrawal of semaglutide suggests that this medication can be implicated as a primary etiologic factor of the linear IgA dermatosis in our patient.

Therefore, the possibility of drug-induced blistering diseases, particularly linear IgA bullous dermatosis should be considered in patients on semaglutide therapy.

EA DV CONGRESS
VIENNA
30 SEP - 3 OCT 2026

Abstract N°: 1462

Cutaneous psoriasis triggered by topical imiquimod in a patient with latent genetic predisposition

Olga Potentini*[1], Sophia Benatti[1], Gabriela Orozco[1], Thiago Jeunon[2], Claudia Maia[1], Omar Lupi[1]

[1] Policlínica Geral do Rio de Janeiro, Rio de Janeiro, Brazil
[2] ID Investigação em Dermatologia, Rio de Janeiro, Brazil

Introduction

Imiquimod (IMQ) is a topical toll-like receptor 7 (TLR7) agonist widely prescribed for actinic keratoses, superficial basal cell carcinoma, and genital warts. By activating the TLR7/NF-κB/IL-23/Th17 axis, IMQ mimics core pathogenic pathways of psoriasis and may trigger or exacerbate the disease in genetically predisposed individuals. A recent systematic review identified only 11 published cases of IMQ-induced psoriasis, underscoring the rarity and clinical relevance of each new report. We report a case in which topical IMQ triggered de novo cutaneous psoriasis and simultaneously unmasked pre-existing subclinical axial PsA, highlighting the shared TLR7-driven immunopathogenesis and its diagnostic implications.

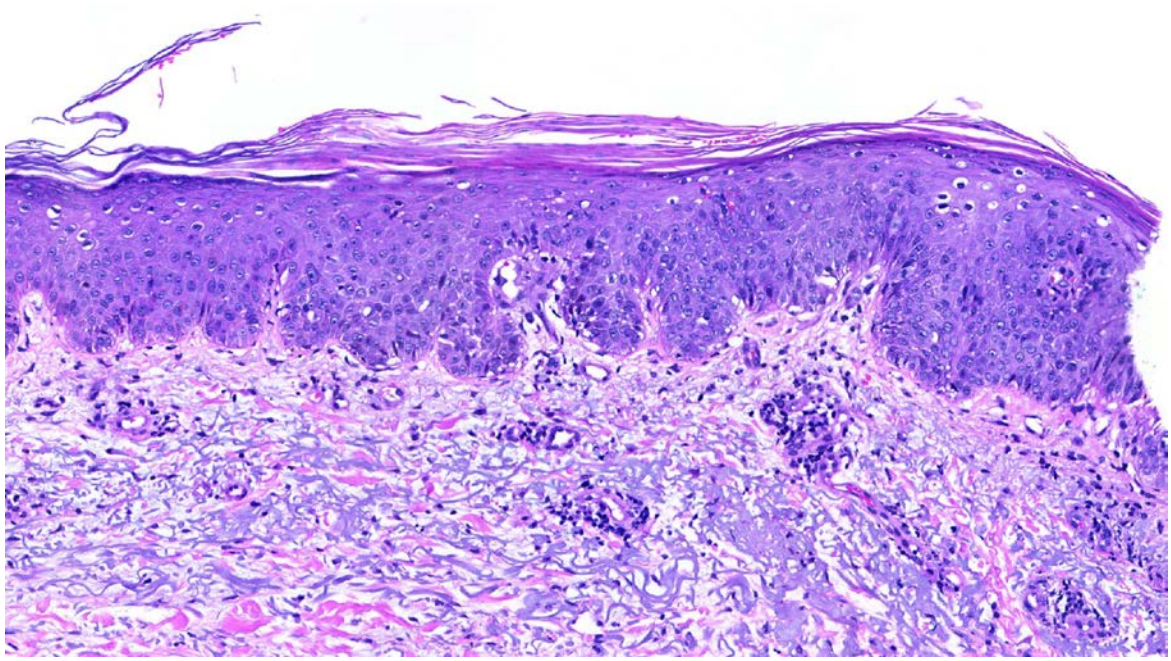

Skin biopsy (H&E) showing psoriasiform hyperplasia with hypogranulosis, parakeratosis, and superficial mononuclear infiltrate, consistent with early-onset psoriasis.

Case Presentation

A 76-year-old male, ex-smoker, with no personal history of psoriasis but a positive first-degree family history (sibling with mild psoriasis), was prescribed IMQ 5% cream for actinic keratoses on the face. He developed a severe local inflammatory reaction at the application sites, followed by a disseminated psoriasiform eruption on the trunk and extremities, with Koebner phenomenon at the treated areas. Skin biopsy revealed psoriasiform hyperplasia with hypogranulosis and parakeratosis, consistent with early-

onset psoriasis. On further investigation prompted by chronic low back pain, magnetic resonance imaging demonstrated bilateral sacroiliitis grade III–IV, with anteroinferior cortical erosions, bilateral capsuloligamentous ossification, and foci of ankylosis predominantly on the left side.The Classification Criteria for Psoriatic Arthritis (CASPAR) were fulfilled with 4 points (current psoriatic skin disease, positive family history, radiographic sacroiliitis), confirming axial psoriatic arthritis. Cutaneous lesions initially responded to systemic corticosteroids but relapsed upon discontinuation. Biologic therapy with an anti-IL-17 agent was proposed for simultaneous control of cutaneous and articular disease.

IMQ activates plasmacytoid dendritic cells via TLR7, triggering a type I interferon burst and downstream IL-23/IL-17A production that recapitulates the immunological cascade of psoriasis. In genetically susceptible individuals carrying risk alleles such as HLA-Cw6, this pharmacological stimulus may unmask latent disease. The guttate-pattern eruption observed in our patient is consistent with the acute IFN-alpha-driven, Th1/CD4-dominant phenotype characteristic of early psoriasis. Notably, the patient had longstanding sacroiliac symptoms predating IMQ use, suggesting that the drug triggered overt cutaneous psoriasis and enabled diagnosis of pre-existing subclinical axial PsA rather than causing joint disease de novo.

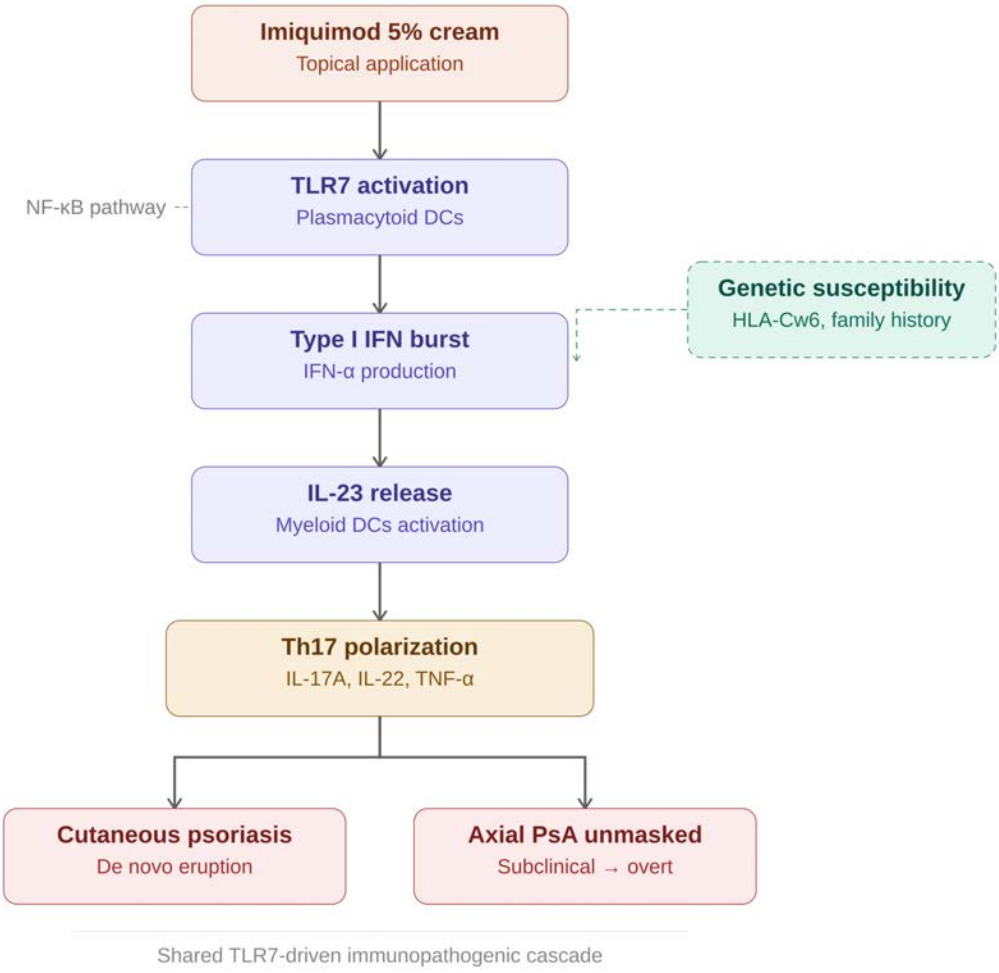

Proposed immunopathogenic cascade: topical imiquimod activates TLR7/pDC/IFN-α/IL-23/Th17 axis, triggering cutaneous psoriasis and unmasking subclinical axial PsA in a genetically susceptible host.

Conclusion

This case highlights the potential of topical IMQ to trigger or exacerbate psoriatic disease involving both cutaneous and articular domains in a patient with latent genetic predisposition.The shared immunopathogenic mechanism between IMQ and psoriasis reinforces the need for targeted history-taking

regarding personal and family history of psoriasis before prescribing IMQ, particularly in fair-skinned dermatological patients with multiple actinic keratoses who are frequent candidates for this therapy.

EADV CONGRESS
VIENNA
30 SEP - 3 OCT 2026

Abstract N°: 1524

Drug rash with eosinophilia and systemic symptoms (DRESS) induced by sulfasalazine: severe presentation in a patient with hyper-IgD syndrome

Branka Bonaci-Nikolic*[1], Ivica Jeremic[2], Tatjana Terzic[1], Miloš Nikolić[1]

[1] University of Belgrade School of Medicine, Department of Dermatology and Venereology, University Clinical Center of Serbia, Belgrade, Serbia

[2] Imedic Polyclinic, Belgrade, Serbia

Introduction

Drug rash with eosinophilia and systemic symptoms (DRESS), is a rare (1/1,000–10,000 exposures), but potentially fatal (10%) reaction, which occurs 2–6 weeks after starting new therapy. We report a case of severe DRESS in a patient with hyper-IgD syndrome, one of the genetically defined autoinflammatory syndromes, characterized by reduced activity of mevalonate kinase and lifelong recurrent febrile attacks of a noninfectious origin.

Case Presentation

A 28-year-old man with hyper-IgD syndrome developed a sulfasalazine-induced DRESS, complicated by eosinophilic myocarditis (EM).

Two weeks after sulfasalazine introduction (given for arthritis), the patient developed fever, facial/neck edema, rash, cervical lymphadenopathy, and cardiogenic shock; malaise and shortness of breath that had commenced 24 hours before. He was tachypneic (20/min), hypotensive (60/10 mmHg), tachycardic with a gallop rhythm and dull heart sounds. A diagnosis of cardiogenic shock was made and therapy with oxygen, fluids, inotropic agents, methylprednisolone (120 mg i.v.) and antibiotics was initiated. Despite this treatment, the patient died 8 hours after admission. On admission, blood tests revealed: leukocytosis 18.4 $x10^9$ (78% neutrophils without eosinophilia and atypical lymphocytes) and the following results: elevated C-reactive protein (151 mg/L) and ferritin (19.5 µg/L), creatine kinase (313 U/L), troponin T (1.6 µg/L), aspartate aminotransferase (287 U/L) and alanine aminotransferase (238 U/L). Metabolic acidosis (HCO_3 4.6 mmol/L, pH 7.16, pCO_2 1.7 kPa) was present. Chest X-rays showed cardiac enlargement. Plasma N-terminal pro-B-type natriuretic peptide was elevated at 215 ng/L (normal <100 ng/L). The diagnosis of DRESS was confirmed by the first 5 of 6 diagnostic criteria: 1. Maculopapular rash developing 2–6 weeks after starting new therapy; 2. Lymphadenopathy; 3. Fever (>38°C); 4. Leukocytosis >$10x10^9$/L without atypical lymphocytes and eosinophilia, but with prominent tissue eosinophilia; 5. Hepatitis (ALT>100 U/mL) and 6. Human Herpes Virus 6 reactivation (not tested). The autopsy revealed hemophagocytosis, while acute heart failure caused by necrotizing EM was established as the cause of death. Genetic testing showed two heterozygous mutations in the gene for mevalonate kinase in exone 11 (C.1129G>A leading to P.V377I) and exone 6 (C.564.G>A leading to P.W188X) on 12q24.11.

Conclusion

Due to the increase of IL-1 family cytokines in hyper-IgD syndrome, our patient had the hyperacute course of DRESS, complicated by eosinophilic myocarditis.

This is a rare case of DRESS in a patient with hyper-IgD syndrome that had an atypical presentation, rapid

evolution and poor outcome. No blood eosinophilia together with tissue eosinophilia, as found in our patient, has been previously described. Therefore, the absence of blood eosinophilia does not rule out the diagnosis of DRESS. Variability in clinical and laboratory presentation and concomitant use of anti-inflammatory drugs may delay the diagnosis of DRESS in patients with autoinflammatory syndromes. Differential diagnosis of facial/neck edema and rash must include DRESS after 2–6 weeks of starting new therapy. A prompt diagnosis, immediate withdrawal of the offending drug and immunosuppressant therapy may decrease mortality in severe DRESS.

EADV CONGRESS
VIENNA
30 SEP - 3 OCT 2026

Abstract N°: 1545

When Antiviral Infusion Mimics Acute Coronary Syndrome: Suspected Kounis Syndrome During Intravenous Penciclovir for Herpes Zoster

Lu Wang*[1]

[1] Hospital, Tianjin China, China

Introduction

Background

Intravenous antiviral therapy is widely used in dermatology for herpes zoster; however, acute cardiovascular complications related to hypersensitivity reactions remain under-recognised. Kounis syndrome, an allergic acute coronary syndrome, may present without cutaneous manifestations, creating a diagnostic blind spot in dermatology practice.

Case Presentation

Case presentation

A 51-year-old woman with herpes zoster received her first intravenous infusion of penciclovir. Within 5 minutes, she developed abrupt chest tightness and dyspnoea, accompanied by nausea and vomiting, without rash or urticaria. Oxygen saturation decreased to 95%. Electrocardiography revealed sinus bradycardia with transient ST-segment changes in leads V1–V4.

Assessment

The strong temporal association with drug exposure, reversible electrocardiographic changes, absence of myocardial injury, and favourable response to withdrawal support a hypersensitivity-mediated coronary event. In the absence of typical allergic features, the presentation was considered consistent with suspected Kounis syndrome rather than primary coronary pathology.

Conclusion

Discussion

This case illustrates an under-recognised clinical scenario in dermatology: antiviral infusion–related acute coronary syndrome mimics. The lack of cutaneous signs may obscure the allergic origin, leading to misinterpretation as primary cardiac disease or nonspecific infusion reactions. Early recognition requires awareness that hypersensitivity-related coronary events can present predominantly with cardiopulmonary symptoms.

Conclusion

Acute chest symptoms with transient ST-segment changes shortly after antiviral infusion should prompt consideration of suspected Kounis syndrome, even in the absence of rash or hypotension. Prompt drug discontinuation and supportive management are essential. Increased awareness of this atypical presentation may improve patient safety in dermatology settings.

EA DV CONGRESS
VIENNA
30 SEP - 3 OCT 2026

Abstract N°: 1568

Extensive Paradoxical Acneiform Eruption Associated with Adalimumab in a Patient with Crohn's Disease.

Imene Mahiou*[1], Issam TABLIT[1], Samira Zobiri[1]

[1] mustapha bacha hospital center, algiers, Algeria

Introduction
Paradoxical cutaneous reactions induced by TNF-α inhibitors are increasingly recognized. While psoriasiform eruptions are the most frequently reported, acneiform reactions remain uncommon and poorly characterized.

Case Presentation
A 27-year-old woman with Crohn's disease treated with adalimumab 40 mg every 2 weeks since November 2025 presented with an extensive acneiform eruption occurring 48 hours after an injection in March 2026. Dermatological examination revealed inflammatory papules, nodules, and folliculitis involving the scalp, face, trunk, back, upper limbs, and pubic area, with preserved general condition. Fifteen days later, she developed bilateral hip pain with reduced right hip mobility.

Laboratory investigations showed an inflammatory syndrome. Bacterial cultures and mycological examination were negative. Histopathology demonstrated neutrophilic folliculitis. Pelvic radiography revealed bilateral sacroiliitis, whereas bone scintigraphy was unremarkable.

The patient was treated with doxycycline 100 mg/day combined with potent topical corticosteroids, leading to significant clinical improvement.

Conclusion
Paradoxical reactions under TNF-α inhibitors are increasingly recognized adverse events. They are defined by the onset of inflammatory manifestations usually expected to improve with anti-TNF therapy. While psoriasiform eruptions are the most frequently reported cutaneous reactions, acneiform eruptions remain rare. Their pathophysiology is still poorly understood but may involve cytokine imbalance induced by TNF-α blockade, particularly activation of interferon-α and IL-17 pathways, leading to neutrophilic inflammation.

In our patient, the temporal relationship between adalimumab injection and lesion onset, the sterile microbiological investigations, and the histological finding of neutrophilic folliculitis strongly supported a paradoxical acneiform reaction. Differential diagnoses such as infectious folliculitis, Malassezia folliculitis, hidradenitis suppurativa, and steroid-induced acne were excluded.

The subsequent occurrence of bilateral sacroiliitis is noteworthy and may reflect a broader autoinflammatory process triggered by TNF-α inhibition. Similar associations between paradoxical cutaneous and osteoarticular manifestations have occasionally been reported.

Extensive acneiform eruption should be recognized as a potential paradoxical adverse event of adalimumab. Early identification is essential to avoid misdiagnosis and optimize therapeutic management

Management remains challenging and is not standardized. Tetracyclines and topical anti-inflammatory treatments

may be effective in mild-to-moderate cases without discontinuation of biologic therapy. Our patient showed significant improvement with doxycycline and potent topical corticosteroids.

EA DV CONGRESS
VIENNA
30 SEP - 3 OCT 2026

Abstract N°: 1578

Diclofenac-induced AGEP mimicking generalized pustular psoriasis in a psoriatic patient: a case report

Omar Atawna*[1], Taibi Lynda[1], Seddiki Meriem[1], Imene Mahiou[1], kacimi asma[1], FATMA ZOHRA ZEMOURI[1], Rania Rouikha[1], Samira Zobiri[1, 1]

[1] Mustapha University Hospital, Algiers, Algeria

Introduction

The occurrence of inaugural acute generalized pustulosis in a psoriatic patient constitutes a major diagnostic challenge. Two main diagnoses should be considered: generalized pustular psoriasis (GPP) and acute generalized exanthematous pustulosis (AGEP). Their clinical similarity makes differentiation difficult, although their management differs. Analysis of the drug context is essential to guide the diagnosis (1,2).

Case Presentation

A 54-year-old man with type 2 diabetes, chronic unclassified inflammatory rheumatism, a family history of psoriasis, and followed for psoriasis vulgaris, was admitted for a first episode of acute generalized pustulosis evolving over three weeks, rapidly extending to the entire tegument, in a febrile context (38.5°C) associated with general deterioration.

Dermatological examination revealed a diffuse erythematous-pustular eruption composed of pearly white non-follicular pustules, grouped in sheets sometimes annular, associated with thick greyish-green scales (traditional ash-based treatment), with involvement of the axillary folds and burning sensation without pruritus.

Only on the second day of hospitalization, after persistent questioning, did the patient reveal self-medication with diclofenac suppositories initiated three days before the onset of skin lesions and continued until admission.

Laboratory investigations showed leukocytosis (20.78 G/L) with neutrophilia, inflammatory syndrome (CRP 315 mg/L), and normocytic normochromic anemia at 10.8 g/dL.

A skin biopsy was performed, showing non-specific histological findings.

Withdrawal of diclofenac associated with symptomatic treatment resulted in rapid favorable evolution, marked by acral desquamation in large sheets after approximately one week.

Discussion

In a psoriatic patient presenting with a first pustular episode, distinguishing AGEP from GPP represents the main diagnostic and therapeutic challenge because of radically different management strategies (2,3).

AGEP is a rare acute drug eruption, most often drug-induced. Antibiotics are the most frequent causes, whereas NSAIDs, particularly diclofenac, are less commonly implicated (1,3).

In our observation, several arguments support AGEP: the short interval between drug intake and lesion onset, flexural involvement, favorable evolution after drug withdrawal, and desquamation in large sheets. The EUROSCAR score (8) confirmed the diagnosis (1).

Conversely, GPP usually follows a more chronic course with recurrent flares, often on an active psoriatic background, and requires systemic treatment (2).

Although the histological findings of the skin biopsy did not exclude the diagnosis of AGEP, they emphasized the need for rigorous clinical analysis and precise drug history assessment to ensure appropriate management.

Conclusion

Any acute generalized pustulosis in a psoriatic patient should prompt investigation for a drug-induced cause. Diclofenac-induced AGEP represents a diagnostic pitfall with GPP, and distinguishing between them is essential for appropriate management (1–3).

EA DV CONGRESS
VIENNA
30 SEP - 3 OCT 2026

Abstract N°: 1580

Mucosal Involvement, Nikolsky Sign, and Drug History: Any Diagnosis Beyond Stevens–Johnson Syndrome?

Mert Bardak*[1], Ece Gokyayla[1], Anil Inan[1]

[1] Ege University Hospital Department of Dermatology and Venereology, Izmır, Türkiye

Introduction
Radiation recall dermatitis (RRD) is an inflammatory skin reaction that develops within a previously irradiated field following exposure to certain systemic agents, most commonly chemotherapy. The interval between radiotherapy and drug exposure can range from days to years. Capecitabine is among the more commonly implicated agents and has been associated with severe reactions; lapatinib, a dual HER1/HER2 tyrosine kinase inhibitor, has also been reported as a trigger in isolated cases. RRD following whole-brain radiotherapy (WBRT) is rarely described, and its clinical presentation can closely mimic Stevens–Johnson syndrome (SJS) — particularly when mucosal involvement and skin fragility are prominent features.

Case Presentation
A 75-year-old woman with stage IV invasive ductal carcinoma (ER+++, PR−, HER2 2+) and multiple metastases (hepatic, pulmonary, cerebral, cerebellar) was referred to our dermatology department with a rapidly progressive facial eruption. After multiple lines of prior systemic therapy including trastuzumab-based regimens and trastuzumab emtansine, disease progression prompted initiation of lapatinib combined with capecitabine. She had received WBRT at 30 Gy in 10 fractions, completed only two days before chemotherapy initiation. Her medical history included type 2 diabetes mellitus and interstitial lung disease managed with methylprednisolone 8 mg/day.

On approximately day three of chemotherapy, progressive periorbital erythema and conjunctival discharge developed, followed by extension to the forehead, scalp, neck, and periauricular region, with oral mucosal involvement causing dysphagia. A positive Nikolsky sign and oral erosions had prompted a clinical diagnosis of SJS at the referring center.

Dermatological examination revealed confluent erythema with hemorrhagic crusting and superficial erosions over the forehead, bilateral periorbital regions, scalp, and neck, with near-complete eyelid closure due to edema. Oral examination showed hemorrhagic crusting at the lip margins and bilateral commissures with diffuse mucosal erythema. Crucially, all lesions were strictly confined to the WBRT field, with no truncal or extremity involvement.

An urgent frozen section punch biopsy excluded full-thickness epidermal necrosis, ruling out SJS. A second punch biopsy demonstrated interface dermatitis with basal vacuolar degeneration, single-cell keratinocyte necrosis, lymphocyte exocytosis, and a mixed perivascular and interstitial inflammatory infiltrate — consistent with a drug reaction and RRD.

Chemotherapy was discontinued, and systemic methylprednisolone was initiated at 32 mg/day, tapered over three weeks to the patient's pre-existing maintenance dose of 8 mg/day. Topical corticosteroids and mucosal sucralfate were also applied. Marked clinical improvement was evident within 24 hours, with complete resolution by day fourteen.



Conclusion

RRD following WBRT can present with mucosal erosions, a positive Nikolsky sign, and widespread facial involvement — a constellation that strongly raises concern for SJS/TEN. In this case, the initial clinical impression was SJS, driven precisely by these features. However, strict confinement of all lesions to the WBRT field, with complete sparing of the trunk and extremities, was the key finding that redirected the diagnosis. A positive Nikolsky sign is not pathognomonic for SJS/TEN and can occur in any condition with significant epidermal-dermal cohesion loss. Frozen section biopsy was decisive, excluding full-thickness epidermal necrosis and preventing unnecessary escalation of immunosuppression. This case underscores that mucosal involvement and skin fragility do not automatically mean SJS/TEN — particularly in a patient with recent radiotherapy and systemic therapy. Asking where the radiation was delivered may be the single most important diagnostic step in this clinical scenario.



EA DV CONGRESS
VIENNA
30 SEP - 3 OCT 2026

Abstract N°: 1589

From Checkpoint to Crisis: A Case of Nivolumab-Triggered SJS/TEN Overlap and the Diagnostic Challenge of PIRME

Adeline Lam Runyi*[1], Brian Keng Yong Chia[1]

[1] Department of Dermatology ,Sengkang General Hospital, Singapore, Singapore

Introduction

Stevens–Johnson syndrome and toxic epidermal necrolysis (SJS/TEN) are rare but life-threatening severe cutaneous adverse reactions (SCARs). With the proliferation of immune checkpoint inhibitors (ICIs), clinicians are increasingly encountering both classic SJS/TEN and SJS/TEN-like reactions termed "Progressive Immunotherapy-Related Mucocutaneous Eruption" (PIRME). Distinguishing these entities is critical, as they carry different prognostic and therapeutic implications.

Case Presentation

Case:

A 65-year-old Chinese woman with metastatic gastric adenocarcinoma presented with a rapidly progressive blistering eruption and mucosal involvement three weeks after initiating treatment with nivolumab, oxaliplatin, and capecitabine. Physical examination revealed 25% total body surface area (TBSA) involvement with 20% epidermal detachment, hemorrhagic lip crusting, atypical targetoid lesions, and a positive Nikolsky sign. Minimal ocular involvement was noted.

The ALDEN score was 5 for nivolumab (very likely) and 2 for oxaliplatin/capecitabine. The SCORTEN was 3, predicting a 35.3% mortality rate. Skin biopsy demonstrated a vacuolated interface dermatitis with near-full thickness epidermal necrosis and negative direct immunofluorescence (DIF), confirming SJS/TEN overlap. The patient was transferred to a specialized burns unit and received subcutaneous etanercept. While she successfully recovered from the cutaneous crisis, she eventually succumbed to her underlying malignancy.

Discussion:

Nivolumab can trigger both SJS/TEN and PIRME. While clinically similar, PIRME typically features a more prolonged latency (often months), more gradual progression, less frequent ocular/mucosal involvement, and a more favorable response to corticosteroids compared to classic SJS/TEN. In this case, the rapid 3-week onset and severity favored a diagnosis of SJS/TEN. Distinguishing these two is vital: true SJS/TEN necessitates permanent cessation of the ICI, whereas PIRME may, in highly selected cases, allow for cautious treatment continuation or rechallenge under close supervision.

Conclusion

This case underscores the necessity of early differentiation between ICI-induced SJS/TEN and PIRME. Accurate diagnosis dictates the choice of immunomodulatory therapy and guides the high-stakes decision regarding the future of the patient’s oncologic treatment.

Take home message:

In ICI-treated patients presenting with blistering, a shorter latent period and rapid detachment favor SJS/TEN,

while a more indolent course and lower mucosal burden suggest PIRME. Given the differing management pathways, early dermatology involvement and biopsy are mandatory.

EA DV CONGRESS
VIENNA
30 SEP - 3 OCT 2026

Abstract N°: 1603

Molecular profiling of cutaneous immune related adverse events reveals CXCL13 associated ectopic lymphoid structure formation and targetable inflammatory patterns

Max Emmerich*[1, 2], Anne-Laure Cattin[1], Teena Thakur[1], Stephanie Hepworth[1], Marija Miletic[1, 2], Kim Edmons[2], Justine Korteweg[2], Kevin Mulder[1], Laura Boddy[2], James Larkin[2], Samra Turajlić[1, 3]

[1] The Francis Crick Institute, London, United Kingdom
[2] The Royal Marsden Chelsea, London, United Kingdom
[3] Cancer Research UK Manchester Institute, Manchester, United Kingdom

Introduction

Immune checkpoint inhibtors (ICIs) have transformed outcomes for an ever increasing range of malignancies. However, the majority of patients treated with these agents develop immune related adverse events (irAEs). irAEs are characterised by off-target damage to healthy tissues, which mimics conventional inflammatory disease. Cutaneous irAEs are the most common events induced by checkpoint blockade, but their molecular mechanisms remain poorly characterised. Thus, treatment strategies for severe cutaneous irAEs remain largely dependent on corticosteroid administration, which can impair anti cancer outcomes. We utilised single cell RNA sequencing, spatial transcriptomics, and multiplex immunofluorescence to ascertain the molecular mechanisms of cutaneours irAEs.

Materials and Methods

Two skin biopsies were collected from 8 patients with cutaneous irAEs, 3 on treatment controls, and 4 untreated controls. One biopsy was dissociated and processed for 10X Chromium Next-GEM single cell RNA and TCR sequencing. The other was processed for histology. All samples underwent 6-plex mIF (CD4, CD8, FoxP3, CD23, CD79A, Ki67) and two samples underwent Visium HD spatial transcriptomics. Sequencing data analysis was performed in R using Seurat and mIF results were evaluated using the Indica Labs Halo AI platform. Matched plasma samples collected at baseline, cycle 2 of immunotherapy administration and irAE onset were profiled using the Alamar NULISAseq 250-plex inflammation panel.

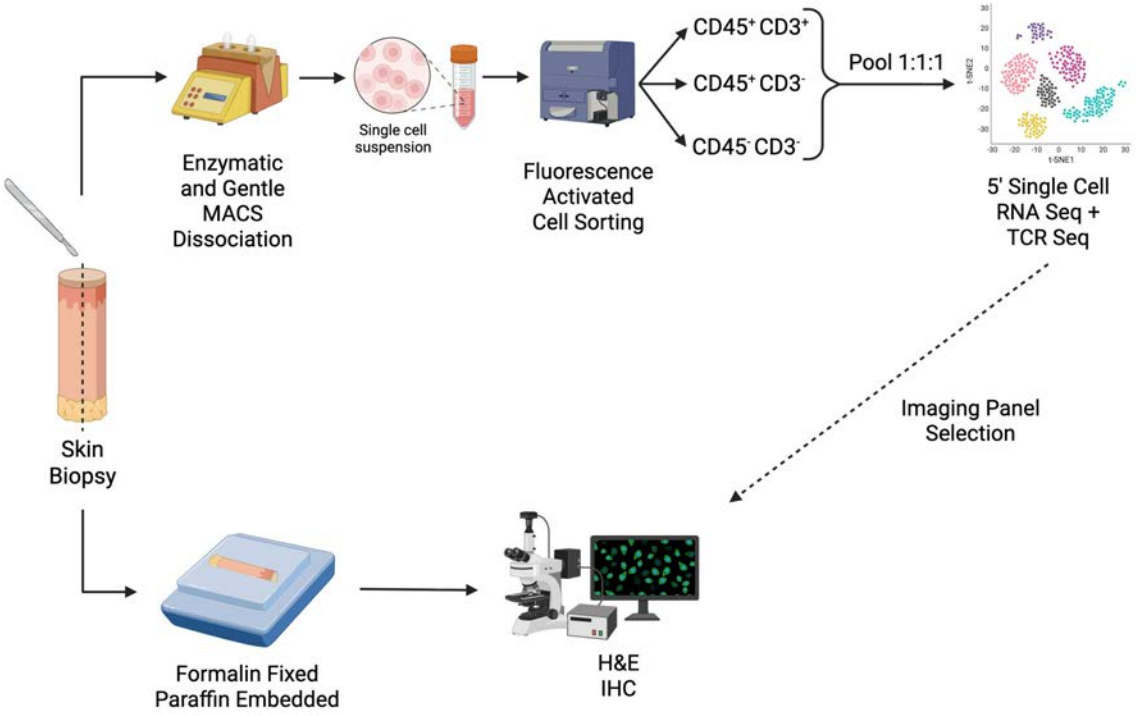

Skin processing workflow

Results

Transcriptomic analysis revealed an enrichment of proliferating CD4 and CD8 T cells, effector cytotoxic CD8 T cells, pro-inflammatory macrophages, IgM and memory B cells, and inflammatory fibroblasts in cutaneous irAEs compared to controls. Differential expression analysis demonstrated upregulation of interferon gamma response genes (*CXCL9, CXCL10, CXCL10, BATF2*), B-cell related genes (*MS4A1, FCRL1, FCRL3*), stress keratins (*KRT6A, KRT6C*), alarmins (*S100A7, S100A8, S100A9*), and downregulation of barrier maintenance genes (*CLDN8, HMGCS2*) in cutaneous irAEs compared to controls. In addition, irAEs were characterised by significant upregulation of *CXCL13* and *IL21*, which promote tertiary lymphoid structure (TLS) formation in tumours, and ectopic lymphoid structure (ELS) formation in inflamed tissues. Histologically, irAEs were characterised by the appearance of perivascular ELSs. Multiplex IF confirmed that these aggregates comprised T-cell, B-cell, proliferating B-cell, and follicular-dendritic cell like populations. Visium HD spatial transcriptomics confirmed high expression of CXCL13 in these ELSs, as well as the presence of class-switched plasma cells producing IgA and IgG1. Pseudobulk inflammatory signature scoring according to Seremet et al. 2024, Nature Comms revealed shared interferon gamme mediated inflammation across irAEs, but striking heterogeneity in inflammatory mechanisms beyond this. Individual patients were molecularly characterised by predominant Th17, Th1, Th2, and eosinophilic inflammatory patterns. Evaluation of plasma proteomic data cross-validated the upregulation of CXCL9, CXCL10, CXCL11, IFNG, and CXCL13 in peripheral blood.

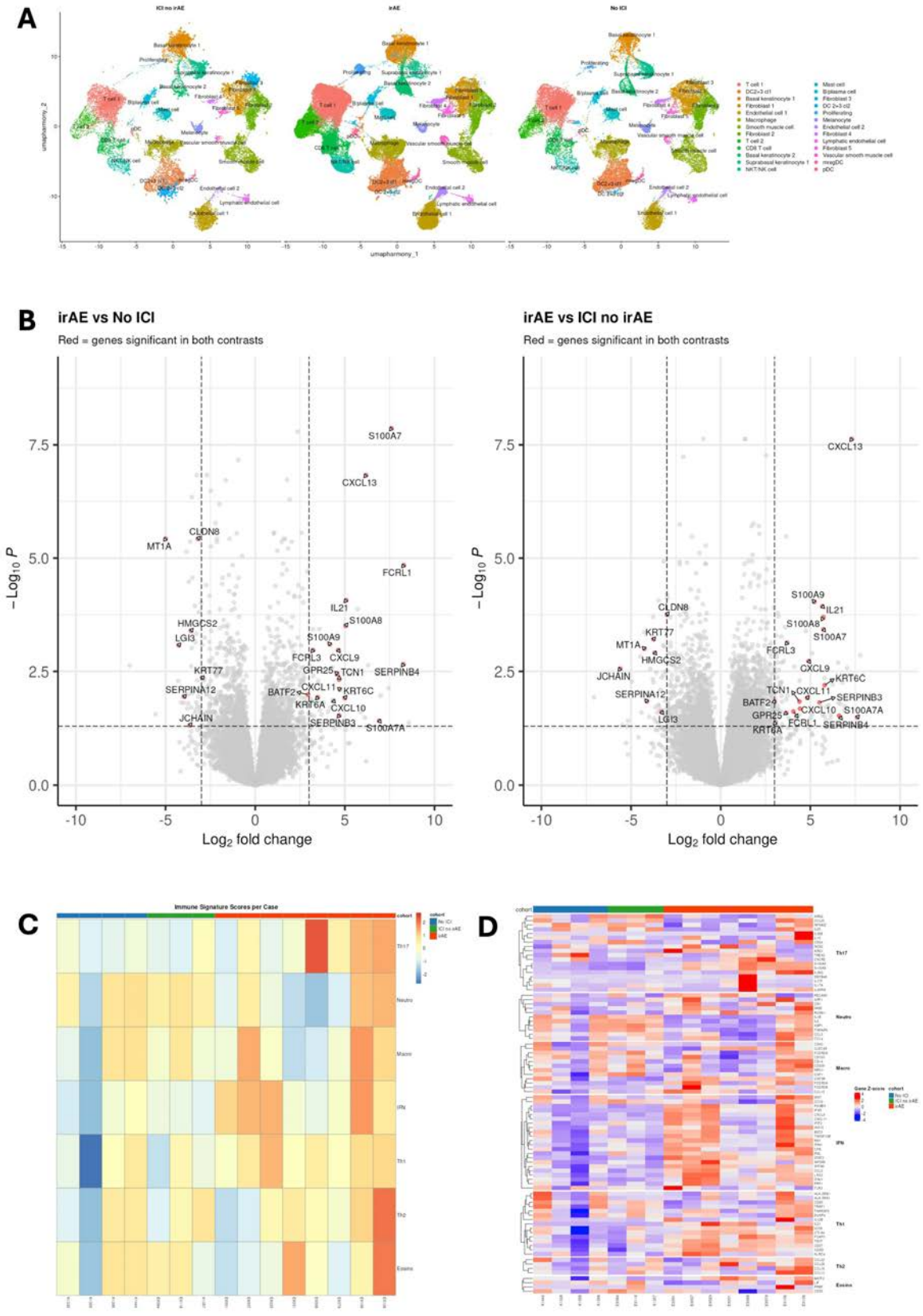

Single cell RNA sequencing results A Cell populations across the whole dataset B Peudobulk differential expression analysis C Immune signature scoring D Immune signature scoring with individual gene visualisation

Conclusions

We present a deeply characterised cohort of patients with cutaneous irAEs. Molecular profiling reveals dysregulation across T-cell, non-T immune cell, and non-immune cell populations. irAEs share a common signature of interferon mediated inflammation and are characterised by the formation of ELSs associated with *CXCL13* and mature class-switched B-cell responses. Interferon responses and TLS formation are known to be

enriched in tumours of ICI responders. Thus, our dataset reveals intriguing and novel shared inflammatory mechanisms between irAEs and cancer, which could account for the observed clinical association between irAEs and ICI benefit. Treatments that aim to mitigate irAEs should therefore avoid abrogating interferon-mediated responses. Immune signature scoring represents a powerful means to select targeted alternative immunosuppressants.

EADV CONGRESS
VIENNA
30 SEP - 3 OCT 2026

Abstract N°: 1637

Infusion-Site Cutaneous Reactions During Continuous Subcutaneous Foslevodopa/Foscarbidopa Therapy: Real-World Experience and Management

Martina Part*[1], Maria Simaljakova[1]

[1] Dept. of Dermatovenerology, Faculty of Medicine and University Hospital in Bratislava, Comenius University in Bratislava, Bratislava, Slovakia

Introduction

Continuous subcutaneous foslevodopa/foscarbidopa infusion is an emerging treatment for patients with advanced Parkinson's disease and motor fluctuations, providing more stable levodopa exposure and reducing motor fluctuations and dyskinesia. Infusion-site reactions represent the most common adverse events and may limit tolerability and adherence. This study aims to characterize the spectrum and management of cutaneous complications associated with this therapy in real-world clinical practice.

Case Presentation

We present a case series of patients with advanced Parkinson's disease who developed cutaneous complications during continuous subcutaneous foslevodopa/foscarbidopa infusion. Between January and April 2026, six patients were referred from the Center for Extrapyramidal Disorders due to infusion-related skin complications. Diagnosis was based on patient history, clinical examination, and palpation. Laboratory investigations (including inflammatory markers) and microbiological cultures were performed when indicated. Ultrasonography was used to differentiate inflammatory nodules, deeper soft tissue involvement, and abscess formation. Lesions were predominantly located in the abdominal area, with one case involving the breast. The most common findings were abscess formation (n=3), erysipelas (n=2), induration (n=2), and inflammatory nodules (n=2). Hematoma, aseptic cellulitis, and contact allergic reactions were also observed. Multiple lesion types occurred concurrently in one individual patient. The development of skin complications may have been related to suboptimal aseptic handling of the infusion cannula. Management was primarily conservative and guided by clinical, laboratory, and ultrasonographic findings, including topical anti-inflammatory therapy and systemic antibiotics. Surgical incision and drainage were required in one case.
All patients showed clinical improvement within days, with residual subcutaneous induration. Therapy with subcutaneous foslevodopa/foscarbidopa was continued in all cases using non-affected infusion sites.

Conclusion

Despite the increasing use of this therapy, real-world data on the management of local skin reactions associated with continuous subcutaneous foslevodopa/foscarbidopa infusion remain limited. A diverse range of allergic, inflammatory, and infectious lesions may occur during treatment. Improved understanding of these adverse events may help optimize patient management and support sustained use of this therapeutic modality.
Most reactions can be effectively managed with conservative approaches, enabling continuation of therapy. Optimization of aseptic technique and a multidisciplinary approach may help minimize complications.

EADV CONGRESS
VIENNA
30 SEP - 3 OCT 2026

Abstract N°: 1646

Clinical overlap syndrom of acute generalized exanthematous pustulosis and toxic epidermal necrolysis

Rahmoun Rym*[1], Oussalah Wassila[1], Serradj Amina[1]

[1] Department of Dermatology, EHU 1st November, oran, Algeria

Introduction

Toxic epidermal necrolysis (TEN) and acute generalized exanthematous pustulosis (AGEP) are two rare and severe drug eruptions that differ in clinical presentation, pathological features, treatment and prognosis, ,However they may share some characteristics that's why the distinguishing between these two entities can be difficult raising the hypothesis of an overlap syndrome.

We report a case of a clinical overlap syndrome NET – AGEP.

Case Presentation

We present the case of a 53-year-old patient with a medical history of psoriasis vulgaris, high blood pressure and a thyroidectomy following a papillary carcinoma. The patient had an acute pneumonia and consulted two days after for an erythroderma surmounted by non-follicular pustules, epidermal detachment affecting nearly 30% of his body surface area, a positive Nikolsky sign, and conjunctivitis, our patient had fever, cough and deterioration of his general condition. Laboratory tests revealed leukocytosis. (17,800/mm^3) with 15.000/ mm^3 of neutrophils, and a C-reactive protein level of 430 mg/L. the skin biopsy found sterile subcorneal and intraepidermal pustules, spongiosis, perivascular inflammatory infiltrate and a dermis oedema, however none necrosis keratinocytes was observed.

The epidermal detachment, the positive Nikolsky sign and the conjunctivitis favored the NET; while the non follicular pustules, hyperneutrophilia as the rapid improvement of the skin lesions suggested the AGEP. We suspected an overlap syndrome; nevertheless the absence of necrosis keratinocytes led us to retain only a clinical overlap syndrome.

It is noteworthy that no medication intake was reported in the month preceding the onset of symptoms.

Conclusion

Overlap is a rare entity, although it does exist, this underlines the importance of recognizing these forms, which present additional severity compared to classic drug eruptions;

Therefore, it should be considered in every presentation or suspicion of a SCAR and confirmed by a skin biopsy in order to provide a definitive diagnosis and treatment.

EADV CONGRESS
VIENNA
30 SEP - 3 OCT 2026

Abstract N°: 1668

A Novel Therapeutic Strategy for the management of Toxic Epidermal Necrolysis: Adalimumab in Combination of Upadacitinib

Xin-gang Wu*[1]

[1] Hangzhou Third People's hospital, zhejiang, China

Introduction

Background: Toxic epidermal necrolysis (TEN) is a rare, life-threatening severe cutaneous adverse reaction driven by uncontrolled activation of the JAK/STAT and interferon signalling pathways, as recently identified by spatial proteomics. Conventional immunosuppressive therapies offer limited efficacy with substantial adverse events.

Case Presentation

Objective: To evaluate the effectiveness and safety of combination therapy with adalimumab (anti-TNF-α) and upadacitinib (a selective JAK1 inhibitor) in patients with TEN.

Methods: We retrospectively analyzed 10 patients diagnosed with TEN between January 2024 and June 2025. All received adalimumab (80 mg subcutaneously in week 1, then 40 mg in week 2) plus oral upadacitinib (30 mg once daily). Primary endpoint was time to complete skin re-epithelialization; secondary endpoints included time to complete skin/mucosal healing, pain relief, in-hospital mortality, and adverse events.

Results: The combination achieved marked clinical efficacy in all 10 patients. Median time to skin re-epithelialization was 3.5 days (IQR: 2.8–5.5). Median times to complete skin and mucosal healing were 8.0 days (IQR: 5.0–13.0) and 10.0 days (IQR: 7.0–15.0), respectively. Median time to complete pain relief was 8.0 days (IQR: 5.0–12.0). Observed in-hospital mortality was 0%, substantially lower than the SCORTEN-predicted mortality of 12.1% (IQR: 3.2%–18.0%). Treatment-emergent adverse events (mild-to-moderate liver dysfunction, conjunctivitis, pulmonary infection) were manageable without treatment discontinuation. Median hospital stay was 12.5 days (IQR: 9.5–15.3). At 2-week follow-up, all patients showed complete lesion resolution and normalized organ function, with no recurrence at 3 months.

Conclusion

Targeting the JAK/STAT pathway—identified as a key pathogenic driver of TEN—with upadacitinib combined with adalimumab represents a promising, effective, and safe therapeutic strategy, warranting further prospective validation.

EADV CONGRESS
VIENNA
30 SEP - 3 OCT 2026

Abstract N°: 1686

Unreported Chemotherapy-Induced Rash: Expanding the Spectrum of Cutaneous Toxicities

Samiksha Shankar Shetty*[1]

[1] Aster CMI Hospital, Bengaluru, India

Introduction

Newer targeted chemotherapy drugs are known to cause skin reactions. we are reporting 3 cases of drug rashes caused by different agents and are uncommon.

Case Presentation

Case 1 – A 63 year old female with Acute Myeloid Leukemia was started on Injection Azacytidine after which patient presented with erythematous plaques all over the body and underlying sepsis. Diagnosis of sweet's syndrome was made clinically and biopsy showed lymphocytic infiltration. Patient was treated with oral steroids and topicals with which improvement was observed.

Case 2 – A 64 year old woman presented with generalized erythematous rashes and edema with systemic symptoms. She was a known case of Carcinoma of Breast and was started on adjuvant Abemaciclib. Skin Biopsy showed eosinophilic infiltration favouring Drug hypersensitivity syndrome with deranged Liver function tests. Patient was treated with oral steroids and showed improvement.

Case 3- A 75 year old male with periampullary adenocarcinoma was given 2 cycles of chemotherapy with gemcitabine and capecitabine. After 1st cycle, patient developed erythematous papules and plaques(non-blanchable) over bilateral lower limbs. After the 2nd cycle, it gradually progressed to involve the back. Skin biopsy was done for confirmation and was diagnosed as drug induced purpuric rash and was treated with oral steroids.

Conclusion

Chemotherapy agents have increased survival rate in many patients. Despite the benefits, they often provoke side effects on the skin which impair quality of life in patients and require discontinuation of therapy. Timely diagnosis of such rashes are very important for best outcome.

EADV CONGRESS
VIENNA
30 SEP - 3 OCT 2026

Abstract N°: 1694

When Two High-Risk Drugs Collide: Allopurinol-Induced DRESS Syndrome Exacerbated by Cotrimoxazole

nihed hachemi*[1], Boumediene Dahmani[1]

[1] Department of Dermatology and Venereology, Tlemcen University Hospital, Tlemcen, Algeria

Introduction

DRESS syndrome (Drug Reaction with Eosinophilia and Systemic Symptoms) is a severe and potentially life-threatening toxiderma. It typically occurs 2 to 6 weeks after the introduction of the causative drug, particularly allopurinol, whose toxicity is increased in cases of polypharmacy.

Case Presentation

We report the case of a 73-year-old female patient with a history of hypertension, AFib, gout, and a non-functional lithiasic kidney, who received allopurinol treatment three weeks before the onset of symptoms. The progression was marked by a flu-like syndrome followed by tonsillitis and a urinary tract infection, which prompted the intake of several antibiotics, including amoxicillin-clavulanic acid, ciprofloxacin, cotrimoxazole (Bactrim), and pristinamycin. The patient was admitted for a febrile generalized maculopapular eruption evolving for 20 days, associated with facial edema and oral mucosal involvement. Biological assessment revealed leukocytosis at 25,000/mm^3 with hypereosinophilia at 3,143/mm^3 and lymphocytosis at 7,647/mm^3. There was marked liver involvement characterized by cytolysis with AST at 5.9 times the normal limit and ALT at 9.1 times the normal limit, associated with cholestasis (GGT at 4.4 times normal and ALP at 178 UI/L). Renal involvement was also noted with elevated creatinine. The diagnosis of DRESS syndrome was confirmed based on consistent clinical and biological arguments. Management relied on stopping the suspected drugs and starting systemic corticosteroid therapy, with a favorable outcome marked by the regression of skin lesions and progressive normalization of liver and renal function.

DRESS syndrome is a delayed drug hypersensitivity reaction involving complex immunological mechanisms The onset delay observed in our case, occurring three weeks after the introduction of allopurinol, is typical. This drug is recognized as one of the main causes of DRESS, particularly in elderly patients with comorbidities. Polypharmacy, especially the successive introduction of several antibiotics including Bactrim, likely contributed to the aggravation of the clinical presentation. The multi-organ involvement observed—specifically hepatic, renal, and hematological—testifies to the gravity of this condition. Management essentially relies on the immediate discontinuation of the causative drug and the initiation of systemic corticosteroid therapy in case of visceral involvement, combined with close monitoring to prevent complications.

Conclusion

DRESS syndrome is a diagnostic emergency where prognosis depends on rapid management Allopurinol is a primary cause, and its presentation can be worsened by cotrimoxazole. Early recognition is essential for a favorable outcome.

EADV CONGRESS
VIENNA
30 SEP - 3 OCT 2026

Abstract N°: 1701

Dupilumab and granuloma annulare: a paradoxical dual role as trigger and therapy.

Anna Porta-Vilaro*[1], Núria Riera-Martí[1], Vicente Exposito-Serrano[1]

[1] Hospital Parc Taulí De Sabadell, Sabadell, Spain

Introduction

Granuloma annulare (GA) is a benign granulomatous dermatosis with a complex pathogenesis involving both Th1 and Th2 immune pathways. Dupilumab, a monoclonal antibody targeting IL-4 receptor α, has been associated with paradoxical cutaneous reactions. We report two cases of GA arising during dupilumab therapy and review the literature, including cases in which dupilumab has been successfully used to treat GA.

Case Presentation

Two women aged 67 and 63 years developed GA during dupilumab therapy for atopic dermatitis and asthma, respectively. The first patient presented after 10 months with interstitial GA affecting intertriginous areas, achieving complete resolution after dose spacing. The second developed asymptomatic plaques on the extremities after four years of treatment; histopathology confirmed interstitial GA, with partial improvement after drug discontinuation and topical corticosteroids.

Including our cases, four reports of dupilumab-associated GA have been described, typically in patients over 60 years with long-standing disease. Notably, one of our patients represents the only reported case in which dupilumab was prescribed for asthma rather than atopic dermatitis. Latency ranges from 4 months to 4 years. In previously reported cases, lesions were often generalized and could persist despite drug withdrawal, supporting a non-strictly causal relationship.

Conversely, dupilumab has shown efficacy in refractory generalized GA, including cases resistant to multiple previous systemic therapies including anti-TNF agents. Reported patients experienced rapid improvement after dupilumab, with flattening of lesions within weeks and near-complete clearance by 3–4 months. Favorable responses have been associated with pruritus and eosinophilic infiltration, suggesting a Th2-driven phenotype.

These contrasting findings support a context-dependent mechanism in which Th2 blockade may either promote Th1-driven granulomatous inflammation or suppress pathogenic Th2 activity depending on disease stage and immune profile.

Conclusion

Dupilumab may act both as a trigger and as a therapeutic agent in GA, highlighting a paradoxical immunological effect. Recognition of this dual role is important in clinical practice. Further studies are needed to identify predictors of response and guide management.

EA DV CONGRESS
VIENNA
30 SEP - 3 OCT 2026

Abstract N°: 1720

Dermatological effects of GLP-1 receptor agonists: AAD Denver 2026 survey

Bruno Halioua*[1], Yaron BenHayoun[2], Virginie Ribet[3], Valérie MENGEAUD[3], Charles Taieb[2, 4, 4, 4]

[1] Société Française des Sciences Humaines de la Peau, Paris, France
[2] ORDAAT [Skin Knowledge], Paris, France
[3] Laboratoire Dermatologique Ducray, Lavaur, France
[4] European Market Maintenance Assessment, FONTENAY SOUS BOIS, France

Introduction

GLP-1 receptor agonists (semaglutide, tirzepatide, liraglutide) are undergoing unprecedented therapeutic expansion. The 2026 AAD in Denver devoted a dedicated session to them ("Metabolic Revolution") and presented the first Phase 3b trial combining a GLP-1 agonist (tirzepatide) with a biologic in psoriatic arthritis (TOGETHER-PsA, Merola et al.). Meanwhile, 5.75% of adverse effects reported with arGLP-1 are cutaneous, with probable under-reporting (Fat MN et al., JDD, 2026). This study documents the blind spot of this revolution: cutaneous adverse effects in real-world settings.

Materials and Methods

Self-administered questionnaire distributed at the AAD 2026 (Denver, 25–30 March 2026). N = 73 US dermatologists. Variables: practice setting, years of experience, volume of patients on GLP-1 agonists, observed cutaneous effects, molecular causality score vs. weight loss (0–10), medical recognition, priority actions.

Results

75% have over 20 years' experience; 68% practise in private practice; 45% see > 15 patients/month on GLP-1 agonists. 90.3% have observed skin effects (58.3% occasionally, 20.8% frequently). The three predominant effects: telogen effluvium (58.9%), xerosis (42.5%), nail changes (27.4%). A positive spontaneous signal emerges: improvement in hidradenitis suppurativa. Median imputability score = 5/10 (mean 4.6 ± 2.4), reflecting uncertainty between the direct effect of the drug and the consequences of weight loss. 54.7% of respondents with an opinion consider these effects to be underestimated or only partially recognised. Priorities: informing patients prior to treatment (n = 40) and developing official follow-up guidelines (n = 27).

Conclusions

These data do not contradict the results presented at the AAD 2026 — they highlight a blind spot in those findings. Whilst TOGETHER-PsA demonstrates the therapeutic benefit of arGLP-1s in inflammatory skin diseases, our survey reveals real-world cutaneous adverse effects in a general patient population. The divergence of the TOGETHER-PsA curves as early as week 4 (, before any weight loss) suggests a direct effect of the molecule, which is precisely what our median score of 5/10 reflects. Telogen effluvium, xerosis and nail changes are the three priority signals to be incorporated into future guidelines. Patient information and official follow-up recommendations are the most urgent actions.

EADV Congress 2026, VIENNA
30 SEPTEMBER - 03 OCTOBER 2026
POWERED BY M-ANAGE.COM

EA DV CONGRESS
VIENNA
30 SEP - 3 OCT 2026

Abstract N°: 1723

A Rare Case of Urticarial Vasculitis Triggered by the PCSK9 Inhibitor Evolocumab: Histologically Confirmed with Rechallenge

Manuel Bernardo Rodrigues Costa*[1], Rafael Baptista Santos[1], Rúben Nogueira Costa[1], Patrícia Moreira Gomes[1], Carolina Leal[2], Alberto Mota[1, 3, 4]

[1] Department of Dermatology and Venereology, Unidade Local de Saúde do São João, Porto, Portugal
[2] Department of Pathology, Unidade Local de Saúde do São João, Porto, Portugal
[3] Departamento de Medicina, Faculdade de Medicina da Universidade do Porto, Porto, Portugal
[4] RISE-Health, Faculdade de Medicina, Universidade do Porto, Porto, Portugal

Introduction
Urticarial vasculitis is a clinicopathological entity characterized by urticarial lesions lasting longer than 24 hours and histological evidence of small-vessel inflammation. Drug-induced forms, including those associated with biologic agents, are typically mediated by type III hypersensitivity reactions.

Case Presentation
A 54-year-old man with a history of myocardial infarction and dyslipidemia was followed for refractory hypercholesterolemia. Subcutaneous evolocumab was initiated. After three months, he developed a pruritic urticarial plaque on the abdomen, which resolved spontaneously following treatment discontinuation and oral antihistamines.

Five months later, evolocumab was reintroduced. Two days after the second injection, the patient developed multiple erythematous-violaceous urticarial plaques persisting for more than 48 hours, associated with pain, mild pruritus, fever (38.0°C), and arthralgias. Laboratory evaluation showed neutrophilia, elevated C-reactive protein (140 mg/L), and increased liver enzymes. Complement levels were normal, and autoimmune and infectious workup was negative.

Histopathological examination of a punch biopsy revealed preserved epidermis and a neutrophil-rich infiltrate involving small dermal vessels with focal fibrinoid necrosis and dermal edema.

Treatment with oral prednisolone (0.5 mg/kg/day) and bilastine resulted in complete clinical and laboratory resolution. Evolocumab was permanently discontinued. No recurrence was observed during one year of follow-up.



Clinical presentation

Conclusion

The temporal relationship, resolution after drug withdrawal, recurrence with greater severity upon re-exposure, and exclusion of alternative causes strongly support a causal association. The delayed onset after initial exposure and accelerated recurrence are consistent with immune complex–mediated mechanisms. Although cutaneous hypersensitivity reactions to PCSK9 inhibitors are described, vasculitic manifestations are exceedingly rare. To our knowledge, this represents the first histologically confirmed case of urticarial vasculitis associated with evolocumab.

EADV CONGRESS
VIENNA
30 SEP - 3 OCT 2026

Abstract N°: 1729

A case of hydroxychloroquine-induced acute generalised exanthematous pustulosis (AGEP) progressing to a toxic epidermal necrolysis (TEN)-like presentation

Sadaf Rehman*[1], Dimple Jain[1], Dana Yateem[1], Mareen Jacob[1], Rebecca Ketteman[1], Marta Jackowiak[1]

[1] The Royal Shrewbury and Telford NHS Trust, Department of Dermatology, Shrewbury, Shropshire, United Kingdom

Introduction

Acute generalised exanthematous pustulosis (AGEP) is a rare severe cutaneous adverse reaction, most commonly drug induced. is a recognised trigger, though uncommon. While AGEP may occasionally overlap clinically with severe epidermal necrolysis, progression to a toxic epidermal necrolysis (TEN)-like presentation is exceptionally rare. We report a case of hydroxychloroquine-induced AGEP with rapid progression to a TEN-like phenotype, highlighting diagnostic challenges and the importance of early recognition.

Case Presentation

A 69-year-old man presented with a 6-day history of a rapidly progressive pustular and maculopapular eruption, fever (>39°C), rigors and pruritus, four weeks after commencing hydroxychloroquine 200 mg twice daily and prednisolone for inflammatory arthralgia. Examination demonstrated widespread sterile pustules on erythematous skin involving trunk, groin and limbs, clinically in keeping with AGEP. Hydroxychloroquine was stopped immediately and treatment initiated with systemic corticosteroids, emollients, fluids and supportive care.

Within 24 hours, he deteriorated rapidly, developing blistering, >90% epidermal involvement, extensive desquamation, positive Nikolsky sign, and ocular, oral and genital mucosal involvement, producing a TEN-like clinical picture. Laboratory findings showed marked neutrophilic leukocytosis, rising inflammatory markers and acute kidney injury secondary to dehydration. Due to severity, he was transferred urgently to a regional burns unit before histology was available.

Skin biopsy demonstrated intracorneal and subcorneal neutrophilic pustules with spongiotic vesiculation, supporting AGEP rather than TEN. EuroSCAR score was 8–12, confirming definite AGEP. Despite dramatic TEN-like progression, histopathology supported an AGEP/TEN overlap phenotype. Following specialist supportive management, the patient made a full recovery without sequelae.

Conclusion

This case highlights a rare and severe TEN-like presentation of hydroxychloroquine-induced AGEP. Although extensive epidermal detachment and mucosal involvement may mimic TEN, histopathology remains crucial in distinguishing overlap presentations. Awareness of this rare phenotype is important, particularly given the prolonged and sometimes severe course associated with hydroxychloroquine-induced AGEP. Early drug withdrawal, prompt escalation of supportive care and early transfer to specialist centres may be life-saving.

EADV CONGRESS
VIENNA
30 SEP - 3 OCT 2026

Abstract N°: 1740

Facial erythema nodosum: a rare adverse event of Azacitidine in a patient with acute myeloid leukemia

Luciana Antoniolli*[1]

[1] Hospital Regina, Novo Hamburgo, Brazil

Introduction

Erythema nodosum (EN) is the most common form of panniculitis, often manifesting as a reactive process to infections, systemic diseases, or medications. Azacitidine, a hypomethylating agent used for acute myeloid leukemia (AML), is frequently associated with cutaneous side effects, but drug-induced EN remains an infrequently reported phenomenon.

Case Presentation

A 60-year-old female patient with AML was evaluated by the Dermatology consultancy team due to the worsening of subcutaneous lesions during the hospitalization. The patient was undergoing treatment with multiple medications, including Azacitidine. Physical examination revealed multiple indurated, subcutaneous nodules on the face and cervical region. Some lesions were erythematous and painful, while others showed spontaneous regression. Soft tissue ultrasound identified ill-defined hypoechoic nodular structures in the subcutaneous tissue, with up to 1.2cm in diameter, without detectable vascularity on Doppler. An incisional biopsy was performed. Histopathological analysis demonstrated a preserved epidermis and elastosis in the dermis. The hypodermis exhibited a chronic inflammatory infiltrate involving both lobules and septa (mixed panniculitis), without evidence of granulomas, vasculitis, or malignancy. Fungal staining (GMS) was negative. Based on the temporal correlation with Azacitidine administration and the histopathological findings, a diagnosis of drug-induced erythema nodosum was established. The patient showed spontaneous resolution of the cutaneous lesions in the following months without any specific treatment, but unfortunately passed away due to the progression of the underlying AML.

Conclusion

In the context of hematological malignancies, differentiating drug-induced panniculitis from leukemic infiltration (leukemia cutis) or infectious processes is crucial for appropriate clinical management. This case highlights the importance of recognizing Azacitidine as a potential trigger for erythema nodosum. Dermatologists should remain vigilant for atypical presentations of EN, such as facial involvement, when associated with medications.

EADV CONGRESS
VIENNA
30 SEP - 3 OCT 2026

Abstract N°: 1744

Dupilumab-Induced Angioedema in Atopic Dermatitis: A Rare Adverse Event

João Henrique Aurich*[1], Hudson Rezende[1], Nara Cristina Tasso Almeida Carvalho[2], Mariana Menezes de Mauro[3]

[1] UNILUS, Fundação Lusíada, Santos, Brazil

[2] Centro Universitário de Araraquara (UNIARA), ARARAQUARA, Brazil

[3] Universidade São Francisco, BRAGANÇA PAULISTA, Brazil

Introduction

Dupilumab, a monoclonal antibody targeting IL-4Rα, inhibits IL-4 and IL-13 signaling and is widely used in moderate-to-severe atopic dermatitis. Its safety profile is well established, with conjunctivitis and injection-site reactions being the most frequently reported adverse events. Hypersensitivity reactions are uncommon, and angioedema has only rarely been described.

Case Presentation

Treatment for severe atopic dermatitis (EASI > 21; DLQI = 12) was initiated with dupilumab in a 28-year-old woman, using a 600 mg loading dose followed by 300 mg every two weeks. Shortly after the second dose, she developed acute tongue angioedema requiring emergency care, with rapid improvement after systemic corticosteroids and antihistamines. Despite this event, therapy was maintained. One week after the third injection, a second episode occurred, this time involving the upper lip. Given the recurrence, further evaluation was performed. Laboratory tests, including complete blood count, liver function tests, inflammatory markers, complement C4 levels, and quantitative and functional C1 esterase inhibitor, were all within normal limits, excluding hereditary and acquired forms of angioedema. There was no previous history of angioedema or relevant allergic disease.

Conclusion

This case highlights angioedema as a rare but clinically relevant adverse event associated with dupilumab. The recurrence after re-exposure and the temporal relationship with drug administration suggest a sensitization mechanism.

Although dupilumab remains a safe and effective therapy, awareness of this potential reaction is important for early recognition and appropriate management, helping to avoid unnecessary morbidity during biologic treatment.

EADV CONGRESS
VIENNA
30 SEP - 3 OCT 2026

Abstract N°: 1748

Ambroxol as an uncommon trigger of non-pigmenting fixed drug eruption: a case report

Emanuel Chew*[1], Cristina Beltrán[1], Sonia Mingaud[1]

[1] Instituto Mexicano del Seguro Social, CDMX, Mexico

Introduction

Fixed drug eruption (FDE) is a delayed type IV hypersensitivity reaction characterized by recurrent lesions at the same anatomical sites upon re-exposure to the offending drug. The non-pigmenting variant is uncommon and may be underrecognized. Ambroxol, a widely used mucolytic agent, has been rarely implicated as a causative drug.

Case Presentation

A 73-year-old male with a history of vitiligo presented with a recurrent dermatosis following ambroxol intake for an upper respiratory tract infection. He reported a similar episode one year earlier associated with the same drug. Cutaneous findings appeared within approximately 24 hours after drug exposure and consisted of multiple well-demarcated erythematous and edematous plaques, round to oval in shape, with violaceous centers, distributed over the upper and lower extremities. The largest lesion measured 12 × 5 cm. Pruritus intensity was reported as 7/10. No mucosal involvement was observed.

Dermatological examination confirmed disseminated lesions involving the forearm, hand, thigh, knee, and feet. Residual acral depigmented macules consistent with vitiligo were noted. The recurrent pattern at identical sites, shorter latency upon re-exposure, and increased number and size of lesions supported the diagnosis of non-pigmenting FDE. Ambroxol was identified as the likely trigger based on temporal association and reproducibility.

The offending drug was discontinued, and the patient was treated with topical low-potency corticosteroids, oral antihistamines, and emollients, with subsequent clinical improvement.

Conclusion

This case highlights ambroxol as an uncommon trigger of non-pigmenting fixed drug eruption. Recognition of this rare presentation and careful drug history are essential for accurate diagnosis and prevention of recurrent episodes. Increased awareness may help identify underreported causative agents in FDE.

EA DV CONGRESS
VIENNA
30 SEP - 3 OCT 2026

Abstract N°: 1779

DISSEMINATED ERUPTION OF ECTOPIC SEBACEOUS GLANDS AS A LATE SEQUELA OF ANTIRETROVIRAL-INDUCED TOXIC EPIDERMAL NECROLYSIS

Karen Daneiby Mondragon*[1], OSCAR GUZMAN[2]

[1] Fundacion Valle Del Lili, Universidad Icesi, Cali, Colombia

[2] Fundacion Valle Del Lili, Cali, Colombia

Introduction

Disseminated eruption of ectopic sebaceous glands is an exceptional late cutaneous sequela of Stevens-Johnson syndrome/toxic epidermal necrolysis (SJS/TEN). Very few cases have been reported in the literature, most of them associated with anticonvulsants or nonsteroidal anti-inflammatory drugs. We present the case of a patient with more than 100 facial ectopic sebaceous glands following toxic epidermal necrolysis induced by antiretroviral therapy.

Author / Year	Sex / Age	Drug associated with SJS/TEN	Time to onset	Distribution	Histological confirmation	Treatment
Moosbrugger & Adams, 2011	F / 18	Lamotrigine	4 months	Face and chest	Yes	Fractional laser, isotretinoin
Park et al., 2016	F / 27	Amoxicillin / acetaminophen	3 months	Face	Yes	Er:YAG + CO_2 laser, topical tretinoin
Habre et al., 2016	M / 21	Oxcarbazepine	Not specified	Face	Yes	Mechanical dermabrasion
Fang et al., 2021	M / 21	Ibuprofen / tenoxicam	3 months	Face	Yes	Oral isotretinoin
Current case	F / 41	Dolutegravir + TDF/FTC	Several months later	Face (>100 lesions)	Yes	Azelaic acid, adapalene plus clindamycin

TABLE 1: Table modified from Fang YH et al.

Case Presentation

A 41-year-old female patient with a known past medical history suffered a workplace accident with biological risk in 2021, for which she initiated post-exposure HIV prophylaxis with dolutegravir, emtricitabine, and tenofovir disoproxil fumarate. Fifteen days later, she developed toxic epidermal necrolysis, requiring management in an

intensive care unit and a burn unit. During dermatological follow-up, she presented with nail abnormalities, hair loss, and the progressive appearance of multiple small, whitish papules with central depression, diffusely distributed on the face, with more than 100 lesions counted.

Dermoscopy showed intraepidermal lipid accumulations suggestive of ectopic sebaceous glands. Due to the unusual distribution of the lesions and the history of SJS/TEN, a skin biopsy was performed on the right cheek, which revealed dermal fibrosis and sebaceous glands not associated with the pilosebaceous unit. Based on these findings, diagnoses such as sebaceous hyperplasia, milium cysts, syringomas, eruptive xanthomas, and multiple sebaceous nevi were ruled out, establishing the diagnosis of disseminated eruption of ectopic sebaceous glands.

Selective fulguration of the larger lesions and topical treatment with adapalene, clindamycin, and subsequently azelaic acid were prescribed, with partial response. Systemic isotretinoin was ruled out due to the risk of exacerbating the xerosis associated with Sjögren's syndrome secondary to TEN.

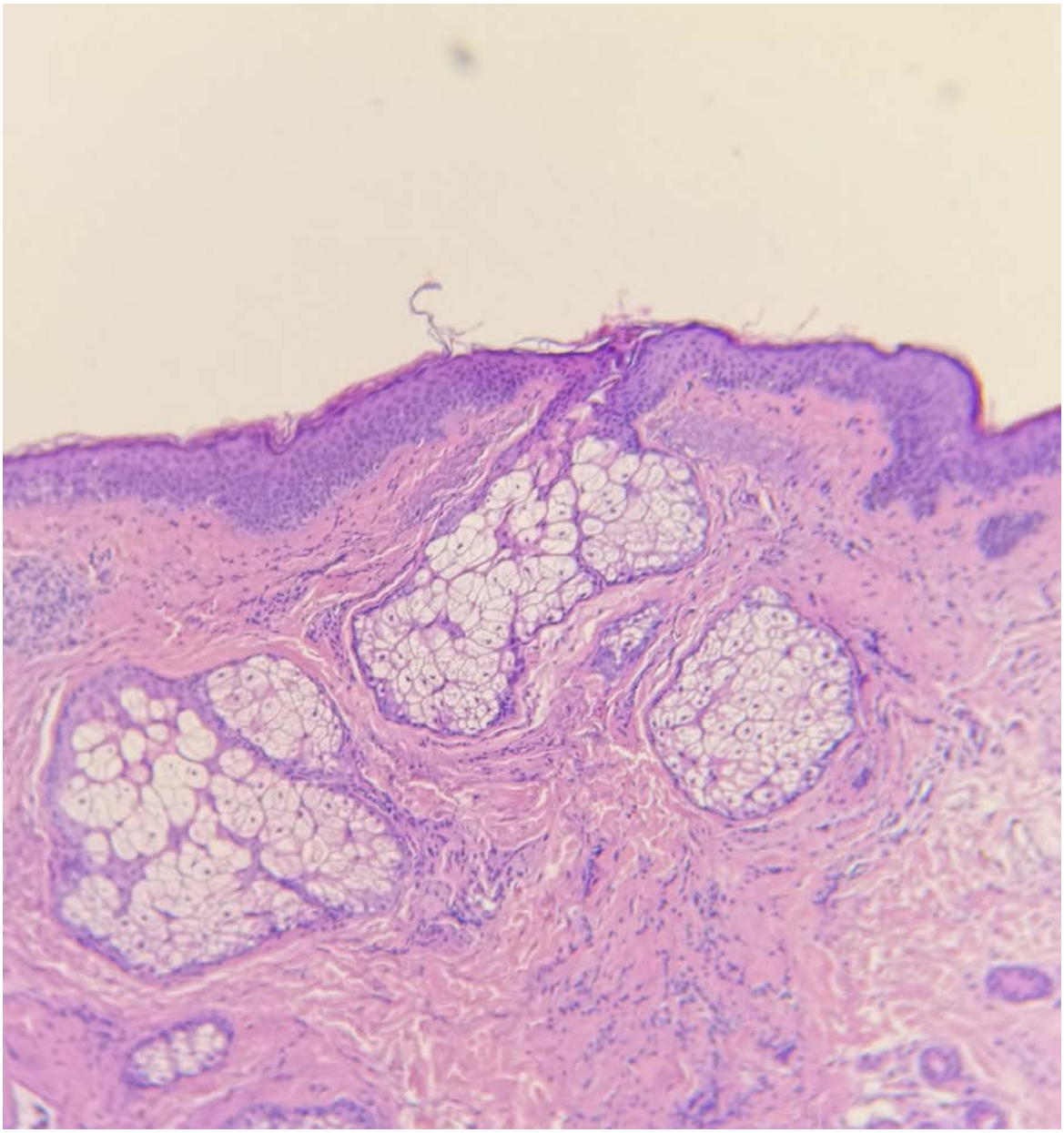

IMAGE 1: Hematoxylin-eosin 10x: fibrosis and presence of sebaceous glands not associated with a pilosebaceous unit.

Conclusion

This case is relevant because it represents an exceptionally rare sequela of SJS/TEN, with massive facial

predominance and triggered by antiretrovirals, unlike previously described cases. Its recognition allows for the avoidance of misdiagnoses and unnecessary treatments and highlights the importance of long-term dermatological follow-up in surviving patients with SJS/TEN.

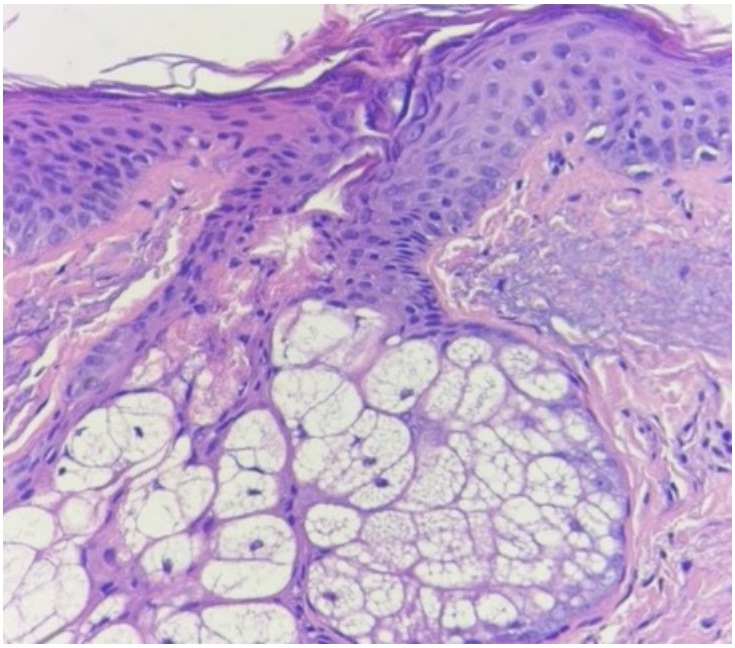

IMAGE 2: Hematoxylin-eosin 20x: sebaceous glands at higher magnification

EA DV CONGRESS
VIENNA
30 SEP - 3 OCT 2026

Abstract N°: 1796

Skin and mucosal side effects associated with GLP-1 receptor agonists: a multinational case-control study

Bianca Maria Piraccini[1, 1, 1, 1], Valérie MENGEAUD[2], Virginie Ribet[2], Alexandre COUTTET[3], Nuria PEREZ CULLELL[3], Charles Taieb[4], Bruno Halioua*[5]

[1] Dermatology Unit, Department of Experimental, Diagnostic and Specialty Medicine, University of Bologna,, Bologna, Italy

[2] Laboratoire Dermatologique Ducray, Lavaur, France

[3] Pierre Fabre, Toulouse, France

[4] European Market Maintenance Assessment, FONTENAY SOUS BOIS, France

[5] Société Française des Sciences Humaines de la Peau, Paris, France

Introduction

GLP-1 receptor agonists (GLP-1 RAs) are seeing widespread adoption for the treatment of type 2 diabetes and obesity. Their rapid spread has been accompanied by the emergence of dermatological signals, including the widely publicised phenomenon of ‘Ozempic face’ (facial hollowing linked to rapid loss of subcutaneous volume), as well as reports of skin rashes, dryness and mucosal manifestations from pharmacovigilance databases. The data published to date are based primarily on case series or analyses lacking a comparator group, which makes it impossible to distinguish the effects specific to GLP-1 RAs from dermatological manifestations attributable to type 2 diabetes, obesity or weight loss itself.

The objective hadto characterise the cutaneous, facial and mucosal effects in GLP-1 RA users, compared with a control group of patients with type 2 diabetes and/or obesity who are not exposed to the treatment

Materials and Methods

A multinational cross-sectional study (France, United States, Brazil, Mexico) including 575 GLP-1 RA users and 1,329 controls (type 2 diabetes and/or obesity, BMI >30) with no exposure to GLP-1 RAs, recruited from a representative sample in each country. The assessment focused on skin problems, facial changes, skin reactions, dyschromia, as well as oral and mucosal manifestations. Weight loss was measured over a 3-month period. A stratified analysis of weight loss was performed.

Results

GLP-1 RA users (mean treatment duration 18.5 months; median 9 months) had significantly higher prevalences for: pruritus 60.7% vs 50.9% (OR = 1.49 [1.22-1.82], p<0.001), of which 26.3% were entirely facial oval modification 27.4% vs 8.2% (OR = 4.15 [3.05-5.65], p<0.001); skin texture changes 28.5% vs 11.2% (OR = 3.05 [2.48-3.76], p<0.001); nausea 42.6% vs 12.5% (OR = 5.22 [4.20-6.49], p<0.001); taste alteration 24.5% vs 8.3% (OR = 3.54 [2.46-5.10], p<0.001); overall oral health problems 52.3% vs 38.4% (OR = 1.76 [1.43-2.17], p<0.001); taste alteration 24.5% vs 8.3% (OR = 3.54 [2.46-5.10], p<0.001). At least one skin-related adverse event was reported by 86.8% of users vs 72.1% of controls (p=0.002). Paradoxically, a at least one dermatological manifestation was reported by 86.8% of GLP-1 users, possibly linked to metabolic improvement despite facial wasting. In a subgroup analysis restricted to patients who had lost weight, the differences persisted (skin rash 51.4% vs 20.1%, ×2.6; facial

hollowing 20.9% vs 8.5%, ×2.5; confirmed change in taste), demonstrating that weight loss alone does not explain these manifestations.

Conclusions

This large-scale case-control study, featuring an appropriate T2D/obese control group, highlights a distinct cutaneous-mucosal profile associated with GLP-1 RAs: rashes, facial remodelling (sunken cheeks, altered facial contours), cutaneous xerosis, oral-dental disorders and taste disturbance. The persistence of these associations after stratification by weight loss suggests specific mechanisms, independent of weight reduction — possibly linked to direct effects on skin and mucosal hydration, on the redistribution of subcutaneous tissue, and on skin homeostasis. Routine dermatological monitoring should be incorporated into prescribing protocols. Longitudinal studies are needed to establish temporal relationships, pathophysiological mechanisms and reversibility upon discontinuation of treatment.

EA DV CONGRESS
VIENNA
30 SEP - 3 OCT 2026

Abstract N°: 1799

Association between GLP-1 receptor agonists and nail disorders: results from a multinational case-control study

Bianca Maria Piraccini[1], Valérie MENGEAUD[2], Virginie Ribet[2], Alexandre COUTTET[3], Nuria PEREZ CULLELL[3], Charles Taieb[4], Bruno Halioua*[5]

[1] Dermatology Unit, Department of Experimental, Diagnostic and Specialty Medicine, University of Bologna,, Bologna, Italy
[2] Laboratoire Dermatologique Ducray, Lavaur, France
[3] Pierre Fabre, Toulouse, France
[4] European Market Maintenance Assessment, FONTENAY SOUS BOIS, France
[5] Société Française des Sciences Humaines de la Peau, Paris, France

Introduction
GLP-1 receptor agonists (GLP-1 RA) are experiencing considerable growth in the treatment of type 2 diabetes and obesity. While their association with alopecia has already been reported, nail disorders remain largely unexplored, with rare and anecdotal pharmacovigilance reports. Since the nail matrix shares rapid cell turnover mechanisms with the hair follicle, an impact of these treatments on nail health constituted a legitimate line of investigation.

Materials and Methods
A multinational cross-sectional study (France, United States, Brazil, Mexico) including 575 GLP-1 RA users and 1,329 controls (type 2 diabetes and/or obesity, BMI >30) with no exposure to GLP-1 RA, recruited from a representative sample in each country. Targeted assessment: unusual hair loss, loss of hair volume/density, dandruff and scalp erythema, nail fragility, dyschromia, changes in thickness, onycholysis and ridges/grooves. Weight loss was measured over a 3-month period, and a stratified analysis was performed to distinguish the drug effect from the weight loss effect.

Results
GLP-1 RA users (mean treatment duration 18.5 months; median 9 months) reported weight loss over 3 months more frequently than controls (76.3% vs 47.3%; p<0.001). At least one nail disorder was reported by 66.3% of GLP-1 RA users versus 52.8% of controls (p<0.001). Nail detachment was the most prominent nail disorder, with a prevalence multiplied nearly sevenfold in the exposed group (39.3% vs 8.7%, OR = 6.84 [5.30-8.81], p<0.001). Other parameters were also significantly more frequent: dyschromia (45.6% vs 17.0%, OR = 4.09 [3.29-5.08], p<0.001), onycholysis (49.2% vs 29.7%, OR = 2.29 [1.87-2.80], p<0.001), fragility (58.3% vs 51.1%, OR = 1.34 [1.09-1.65], p=0.005) and ridges/grooves (46.8% vs 31.8%, OR = 1.89 [1.55-2.31], p<0.001) (all p<0.001). When the analysis was restricted to patients who had actually lost weight, the differences between the two groups remained significant.

Conclusions
This large-scale case-control study reveals a novel nail signal under GLP-1 RA, dominated by onycholysis with a

prevalence multiplied nearly sixfold. The persistence of the associations after stratification by weight loss suggests a specific pharmacological mechanism affecting keratinized structures with rapid turnover. Systematic dermatological screening including nail examination should be integrated into the follow-up of patients treated with GLP-1 RA.

EADV CONGRESS
VIENNA
30 SEP - 3 OCT 2026

Abstract N°: 1820

Paradoxical psoriasis with follicular involvement after rituximab in multiple sclerosis

Omar AlRubaish*[1], Hamad Almutlaq[1], Ahmed AlEssa[1], Duaa Alahmady[2]

[1] Imam Abdulrahman Bin Faisal University (IAU), King Fahad Hospital of the University, Khobar, Saudi Arabia
[2] Ministry of Health (MOH), Almadinah, Saudi Arabia

Introduction

Rituximab is a chimeric monoclonal antibody that targets CD20-positive B lymphocytes, and it is employed as a treatment option for autoimmune diseases like multiple sclerosis. Its mechanism of action involves B-cell depletion, which result in the modulation of humoral and cellular immune responses.

Although rituximab is generally well tolerated, some dermatologic side effects have been reported with its use, including infusion reaction, infection and immune-related skin eruptions. Paradoxical psoriasis is the most commonly described paradoxical reaction with the use of TNF inhibitors, although such paradoxical reactions have been observed with the use of other biologic agents as well.

New-onset psoriasis with the use of rituximab is less commonly described; however, it has been reported in some clinical scenarios. We present a case of new-onset psoriasis with significant follicular involvement following rituximab therapy in a patient with multiple sclerosis.

Case Presentation

A 30-year-old female with relapsing–remitting multiple sclerosis (RRMS), diagnosed in 2013, presented with progressive generalized skin lesions. She previously received interferon beta-1a and dimethyl fumarate, discontinued in 2022 due to side effects, and had been on rituximab since April 2023. Two prior infusions were uneventful. Following the third infusion in September 2025, she developed erythematous papules over the upper limbs within hours, spreading over days to the lower limbs, chest, abdomen, and buttocks. There was no pain or pruritus, and no history of infection, new medications, or topical use.

Baseline investigations, including complete blood count, liver, renal, and thyroid function tests, were normal except for microcytic anaemia. Examination showed numerous erythematous follicular hyperkeratotic papules with fine scales on a dry, erythematous background (Figure 1), symmetrically distributed over the upper arms, thighs, lower legs, and buttocks. Intervening skin showed erythema and fine scaling. Papules demonstrated follicular accentuation (Figure 2). Palms, soles, genitalia, scalp, hair, and nails were spared.

Differentials included follicular psoriasis, keratosis pilaris, pityriasis rubra pilaris, follicular eczema, drug-induced folliculitis, and lichen spinulosus. Keratosis pilaris was unlikely due to acute onset with diffuse erythema and scaling; pityriasis rubra pilaris due to absence of orange-red plaques, palmoplantar keratoderma, and cephalocaudal spread; and infectious folliculitis due to lack of pustules or symptoms.

Psoriasis was favored clinically, and biopsy confirmed regular psoriasiform acanthosis, hypogranulosis, and confluent parakeratosis with neutrophils in the stratum corneum forming Munro microabscesses (Figure 3). Suprapapillary thinning was present. The epidermis showed parakeratosis, neutrophils, mild acanthosis, mild spongiosis, and hypogranulosis (X10). Prominent follicular involvement with parakeratosis and neutrophils in follicular ostia, dilated papillary dermal vessels, and superficial perivascular infiltrate were seen (Figure 4), without interface change.



Figure 1. Clinical overview showing numerous symmetrical erythematous follicular hyperkeratotic papules over the upper arm.



Figure 2. Close-up view demonstrating follicular papules with fine scale and perifollicular erythema.

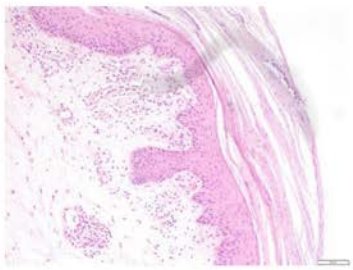

Figure 3. Examined sections reveal a skin punch biopsy composed of epidermis and dermis.
The epidermis shows parakeratosis, neutrophils (Munro Microabscess), mild acanthosis, mild spongiosis, and hypogranulosis. (X10 power).

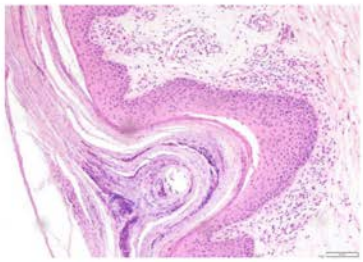

Figure 4. Follicular involvement with parakeratosis and neutrophils, dilated vessels in the papillary dermis, and superficial perivascular mixed inflammatory infiltrate. (X10 Power).

Figure 1: Clinical overview showing numerous symmetrical erythematous follicular hyperkeratotic papules over the upper arm. Figure 2: Close-up view demonstrating follicular papules with fine scale and perifollicular erythema. Figure 3: Examined sections reveal a skin punch biopsy composed of epidermis and dermis; The epidermis shows parakeratosis, neutrophils (Munro Microabscess), mild acanthosis, mild spongiosis, and hypogranulosis. (X10 power). Figure 4: The section shows follicular involvement with parakeratosis and neutrophils (black arrow), dilated vessels in the papillary dermis, and superficial perivascular mixed inflammatory infiltrate. (X10 Power).

Conclusion

This case highlights a rare presentation of rituximab-induced psoriasis with prominent follicular involvement in a patient with multiple sclerosis. Although uncommon, paradoxical psoriasiform eruptions should be considered in

patients receiving biologic therapies. Early recognition and histopathological confirmation are essential for accurate diagnosis and management. Clinicians should remain vigilant for atypical cutaneous reactions associated with rituximab, even after prior uneventful infusions, to ensure timely intervention and improved patient outcomes.

EA DV CONGRESS
VIENNA
30 SEP - 3 OCT 2026

Abstract N°: 1894

A novel case of phenotypic evolution in indapamide-associated severe cutaneous adverse reaction with serial histopathological progression from acute generalised exanthematous pustulosis-like eruption to toxic epidermal necrolysis.

Amer Almaghrabi*[1], Claudia Roberts[1], Natasha Harper[1], Jaideep Bhat[1]

[1] University Hospitals Birmingham NHS Trust, Birmingham, United Kingdom

Introduction

Severe cutaneous adverse reactions (SCARs) often present with overlapping clinical and histological features early in their course. Distinguishing acute generalised exanthematous pustulosis (AGEP), drug reaction with eosinophilia and systemic symptoms (DRESS) and toxic epidermal necrolysis (TEN) may therefore be challenging; and require serial clinicopathological reassessment, due to evolving phenotypes. Reports of biopsy-confirmed phenotypic progression from AGEP-like eruption to TEN associated with indapamide, remain exceedingly limited.

Case Presentation

A man in his 70s developed a severe SCAR seven days following initiation of indapamide for hypertension. He presented with a five-day history of coryzal symptoms and non-productive cough, followed by acute deterioration with pyrexia, lethargy and progressive dyspnoea. A widespread maculopapular eruption developed during admission, rapidly evolving into a pustular eruption with facial oedema and subsequent erythroderma.

Despite withdrawal of the suspected drug, the eruption progressed within 48 hours to involve approximately 80–90% body surface area, with development of purpuric lesions, blistering, and limited epidermal detachment. The patient became systemically unwell with features of multiorgan dysfunction requiring intensive care admission for haemodynamic and respiratory support. Human metapneumovirus was detected on respiratory viral testing.

During the later course of admission, eosinophilia and mild hepatic enzyme derangement developed in conjunction with marked facial oedema, suggesting overlapping DRESS-spectrum features within an evolving SCAR phenotype. However, these abnormalities resolved rapidly without requirement for prolonged systemic immunosuppression. Mucosal involvement remained limited throughout - mild haemorrhagic lip crusting and subjective oral discomfort without significant erosive mucosal change, an atypical feature in the context of extensive SJS/TEN.

Initial histopathological examination demonstrated an oedematous dermis with suppurative folliculitis and peri-folliculitis, without evidence of epidermal necrosis. In view of rapid clinical progression, a repeat biopsy performed 48 hours later showed confluent full-thickness epidermal necrosis with minimal inflammatory infiltrate, consistent with evolving TEN. Direct immunofluorescence studies were negative.

ALDEN causality assessment supported a probable association with indapamide, although interpretation was limited by concurrent viral infection and exposure to multiple antimicrobial agents during admission.

Management included immediate cessation of indapamide, intensive supportive care, barrier nursing, fluid resuscitation, electrolyte correction, and application of non-adherent dressings with regular emollient therapy. A short course of systemic corticosteroids was administered during the acute inflammatory phase. The patient demonstrated gradual clinical improvement, with cessation of new blister formation, resolution of organ

dysfunction, and progressive re-epithelialisation.

Conclusion

To our knowledge, this case represents a rare biopsy-confirmed example of phenotypic evolution from an AGEP-like eruption to TEN, highlighting the dynamic and overlapping nature of SCARs. Rapid clinical progression despite drug withdrawal should prompt early repeat histopathological assessment. Indapamide represents a plausible trigger for TEN, although causality should be interpreted cautiously in the context of concurrent viral infection and exposure to multiple antimicrobial agents. Careful documentation and specialist follow-up are essential to guide future drug avoidance strategies, rather than indiscriminate class-wide contraindication.

EADV CONGRESS
VIENNA
30 SEP - 3 OCT 2026

Abstract N°: 1917

DRESS Syndrome Following DAIR for Prosthetic Joint Infection: An Overnight Diagnostic and Management Challenge

John McHardy*[1]

[1] University Hospitals Sussex NHS Foundation Trust, Royal Sussex County Hospital, Brighton, United Kingdom

Introduction

Drug Reaction with Eosinophilia and Systemic Symptoms (DRESS) is a rare, but potentially life-threatening, severe cutaneous drug reaction characterised by rash, eosinophilia, and systemic involvement.

In patients who have undergone debridement, antibiotics, and implant retention (DAIR) for septic arthritis, diagnosis can be difficult due to overlap with ongoing infection, particularly during overnight presentations when dermatology input is unavailable. Identification of the causative agent is complicated by the need for prolonged multi-antibiotic therapy.

The decision to initiate systemic corticosteroids is complex, requiring balance between the risk of untreated DRESS progression versus the risk of immunosuppression in a patient with a known infection, as well as the possibility that corticosteroids may reduce the diagnostic yield of subsequent skin biopsy.

Case Presentation

A man in his sixties underwent a DAIR procedure for prosthetic knee joint septic arthritis. Perioperatively, he received IV gentamicin and teicoplanin. Microbiology subsequently isolated *Bordetella holmesii*, and he was commenced on a three month course of oral ciprofloxacin and doxycycline.

Shortly following the DAIR he developed a localised erythematous abdominal rash which progressively evolved into near-generalised erythroderma over several weeks. He presented to the on-call medical team overnight with fatigue, nausea and thirst after the rash rapidly progressed over a three day period, despite discontinuation of the ciprofloxacin and doxycycline.

Examination demonstrated a diffuse erythematous maculopapular eruption covering more than 90% of the patients body including the scalp and oral mucosa with superficial desquamation of the the forearms and ears. The anus and genital mucosa were spared. There were no pustules, vesicles, bullae or erosions. Nikolsky sign was negative. He remained haemodynamically stable and apyrexial. There was no palpable lymphadenopathy. The liver edge was palpable but non-tender.

Overnight investigations revealed leukocytosis (22.5 $\times 10^9$/L) with marked eosinophilia (6.0 $\times 10^9$/L; 26.6%). Liver and renal function was normal. There was proteinuria +1 on urinalysis. His pH and lactate were normal. RegiSCAR score was 3, consistent with possible DRESS syndrome.

The key clinical question of whether to start systemic corticosteroids overnight raised the following

dilemma:

- If the patient had evolving DRESS, failure to start steroids risked further disease progression and potential critical illness.
- If the patient was stable enough to wait for a biopsy, early steroid administration risked altering histopathological features and reducing diagnostic certainty.
- However, if the presentation reflected systemic *Bordetella holmesii*, immunosuppression could exacerbate the infection.

Ultimately, as the patient remained well, the decision was made to hold steroids pending punch biopsy of the skin. This happened the next morning and showed, *"minimal parakeratosis, spongiosis, subtle interface change, papillary dermal oedema with subepidermal clefting, and a sparse superficial dermal infiltrate composed predominantly of eosinophils and lymphocytes."* This was consistent with a drug reaction such as DRESS but was not pathognomonic.

Following MDT discussion the patient was diagnosed with DRESS Syndrome. Antibiotics were changed to co-trimoxazole and a weaning regime of oral prednisolone was started along with topical clobetasol propionate, topical clobetasone butyrate, regular 50:50 soft white paraffin and oral fexofenadine. He rapidly improvement and was discharged five days later with planned dermatology, orthopaedic and ID follow up.

Conclusion

This case highlights the diagnostic and therapeutic complexity of DRESS in post-DAIR patients exposed to multiple antibiotics who present to the medical team overnight. The decision to start steroids requires careful balancing of the risks of delaying treatment, potential worsening of infection and preservation of diagnostic histology.

EADV CONGRESS
VIENNA
30 SEP - 3 OCT 2026

Abstract N°: 1952

Oxcarbazepine-induced Stevens-Johnson syndrome with a recall phenomenon in the irradiated field during treatment with immune checkpoint inhibitor immunotherapy

Jorge Martín-Nieto González*[1], Belén Rodríguez Sánchez[1], Luis Angel Zamarro Díaz[1], Marina de la Puente Alonso[1], Andrea Fuentes Bellas[1], Daniel de Ramón Rueda[1], Raquel Horcajo Ortega[1], Alba Bergaz Alonso[1], Victoria Robles Almazan[1], María Córdoba García-Rayo[1], Luis Jiménez Briones[1]

[1] Hospital Gregorio Marañon, Madrid, Spain

Introduction

Stevens-Johnson syndrome (SJS) is a severe mucocutaneous reaction mediated by immunological mechanisms, usually induced by drugs. Radiotherapy and immune checkpoint inhibitors can act as triggers or potentiators, promoting amplification of the cytotoxic response against keratinocytes.

Case Presentation

A 63-year-old man with metastatic squamous cell lung carcinoma undergoing treatment with carboplatin-paclitaxel and pembrolizumab, who had started oxcarbazepine four weeks earlier for epilepsy. After receiving the second course of radiotherapy to the thoracic region, he developed a rash with intense erythema and blisters, initially confined to the irradiated field, which subsequently spread beyond that area, associated with severe skin pain, a positive Nikolsky's sign, and involvement of the oral, ocular and genital mucosa. A clinical diagnosis of SSJ was established. Skin biopsy revealed vacuolar interphase dermatitis with extensive keratinocyte necrosis, consistent with SJS. The patient was admitted to hospital, the suspected drugs were discontinued, and treatment was initiated with systemic corticosteroids at a dose of 1 mg/kg, combined with a single dose of etanercept, resulting in a favourable clinical course and progressive re-epithelialisation without mucocutaneous sequelae.



Maculopapular rash, more pronounced in the irradiated area, with zones of epidermal detachment.

Conclusion

Cases of SJS with noticeably limited or intensified distribution in previously irradiated areas have been reported, interpreted as manifestations of the ‘radiation recall’ phenomenon. In addition to being potential causes of severe toxic dermatoses, immune checkpoint inhibitors may act as amplifiers of the cytotoxic response triggered by a causative drug, in an immunological ‘second hit’ model. Ionising radiation may contribute as an initial tissue impact by inducing subclinical damage to keratinocytes, the release of neoantigens and local T-cell activation, thereby promoting the amplification of the cutaneous reaction.

We present a case of oxcarbazepine-induced SJS, with an initial pattern of enhancement in the irradiated field and progression in the context of anti-PD-1 immunotherapy, which likely acted as a facilitator and amplifier of the immunocytotoxic response. Early recognition of these therapeutic interactions in cancer patients is essential for the immediate withdrawal of the causative drug and the optimisation of multidisciplinary management.

EA DV CONGRESS
VIENNA
30 SEP - 3 OCT 2026

Abstract N°: 1981

Facial Acute Localized Exanthematous Pustulosis in a Child

Naia Oillarburu*[1], Juliette Mazereeuw-Hautier[1], Maella Severino-Freire[1]

[1] Larrey Hospital, University Hospital of Toulouse, Toulouse, France

Introduction

Acute generalized exanthematous pustulosis (AGEP) is a rare and potentially severe drug-induced eruption, mainly affecting adults and characterized by an acute erythematous eruption and sterile pustules, primarily involving large skin folds. Localized forms (ALEP) are rare, especially in children, in whom they are often underrecognized. We report a new case of pediatric facial ALEP, with the aim of improving recognition and understanding of this rare form of drug-induced toxidermia.

Case Presentation

A 5-year-old boy was referred to our department for a facial eruption. His past medical history included bilateral ureteropyelic dilatation with vesicostomy and Still's disease, treated with baricitinib, canakinumab, and systemic corticosteroids. Twenty-four hours prior, he had received amoxicillin–clavulanic acid for pyelonephritis. On examination, he presented with severe erythematous and pustular lesions involving the entire face, with a few mild lesions on the trunk and limbs. His general condition remained stable, and he was afebrile. Skin histology revealed intracorneal pustules with neutrophilic exocytosis. The EuroSCAR score was 9, consistent with definite AGEP, likely transposable to ALEP. Based on clinical, anamnestic, and histological findings, facial ALEP was diagnosed. The eruption resolved rapidly after discontinuation of the antibiotic. Patch testing three weeks later was positive for amoxicillin and amoxicillin–clavulanic acid, with a flare-up reaction; tests repeated at three months were negative (sensitivity 50-80%). Intradermal test is planned but has not yet been performed.



Erythematous and pustular lesions involving the entire face, ears and scalp.

Conclusion

Fewer than 40 cases of ALEP have been reported, including ~10 pediatric cases, most involving the face. ALEP is mainly drug-induced in adults, particularly by antibiotics, whereas in children reported triggers are more diverse, including antibiotics (such as amoxicillin–clavulanic acid) as well as non-drug causes (insect bites, plant exposures…) being more represented. Early recognition is essential to promptly discontinue the suspected drug, guide allergy testings, and establish recommendations for future prescriptions. We report a new case of pediatric facial ALEP, with the aim of improving recognition and understanding of this rare form of drug-induced toxidermia.

EADV CONGRESS
VIENNA
30 SEP - 3 OCT 2026

Abstract N°: 1991

EPIDEMIOLOGICAL, CLINICAL, AND BIOLOGICAL CHARACTERISTICS OF DRESSSYNDROME IN ELDERLY PATIENTS: A RETROSPECTIVE STUDY OF 21 CASES

FATIMA ZAYOUN*[1], Hanane Rachadi[1], Fatima Zahra Benhayoun[1], Bochra Baghad[1], Soumiya Chiheb[1]

[1] Ibn Rochd University Hospital Center, CASABLANCA, Morocco

Introduction
DRESS syndrome is a severe drug-induced reaction characterized by a cutaneous eruption, eosinophilia, and visceral involvement. Its onset is typically delayed, occurring several weeks after
the introduction of the offending drug. Elderly patients represent a particular clinical population due to age-related physiological changes and a frequently complex therapeutic context. The aim of our study was to analyze the epidemiological, clinical, and biological characteristics of DRESS syndrome in elderly patients. We conducted a retrospective study in the dermatology department of
our institution from 2000 to March 2026, including 21 patients aged 65 years or older hospitalized for DRESS syndrome. Data were collected from medical records and included demographic
characteristics, comorbidities, suspected drugs, time to symptom onset, clinical manifestations, and biological abnormalities.

Case Presentation
The mean age was 72 years, with 38% men and 62% women. Most patients had at least one comorbidity, mainly hypertension (76%), diabetes (52%), and gout (33%), and polypharmacy was
common. Allopurinol was the most frequently implicated drug (85.7%). Among exposed patients, 33.3% had documented gout, while the indication was unclear in 66.7%, possibly corresponding to
asymptomatic hyperuricemia. Other drugs included phenobarbital, an antibiotic, and aspirin (4.7% each).
The mean delay between drug initiation and symptom onset was 24 days. Clinically, all patients presented with a diffuse rash, most often maculopapular (85.7%), frequently associated with facial edema (71.4%) and cheilitis (57.1%). Lymphadenopathy was observed in 47.6% of cases. Biologically, eosinophilia was present in 90.5% of patients, hepatic cytolysis in 47.6%, and renal
involvement in 61.9%. The mean RegiSCAR score was 2.29.

Conclusion
DRESS syndrome is a rare and severe cutaneous adverse drug reaction whose specific features in elderly patients remain insufficiently documented. In this population, polypharmacy and the high
prevalence of comorbidities contribute to the occurrence of severe drug-related adverse events. Epidemiological data suggest that the increased rate of adverse drug reactions with age is mainly
related to the accumulation of medications rather than age itself.
In our study, the time to symptom onset and sex distribution were similar to those reported in the literature, and the cutaneous manifestations were comparable to those observed in younger patients. However, renal involvement appeared more frequent in our cohort compared with younger populations, whereas the rate of hepatic cytolysis was similar. Allopurinol was the most frequentl implicated drug (85.7%). Among exposed patients, 33.3% had documented gout, while the indication for treatment was unclear in 66.7%, possibly corresponding to asymptomatic
hyperuricemia.
Overall, DRESS in elderly patients shows clinical features similar to those in younger adults but appears to be

associated with a higher frequency of visceral involvement, particularly renal. These findings highlight the need for careful prescribing practices and increased vigilance in elderly patients, as well as further studies focusing on this population.

EA DV CONGRESS
VIENNA
30 SEP - 3 OCT 2026

Abstract N°: 2023

Effectiveness and Safety of Tofacitinib as Adjunctive therapy for DRESS: A Real World Study

Xiaoyu Wang*[1], Yingying Yan[2], Yinchu Cheng[2], Jiachen Sun[1], Jinzhu Guo[1], Hua Zhang[3], Shengfeng Wang[4], WENHUI WANG[1]

[1] Department of Dermatology, Peking University Third Hospital, Beijing, China
[2] Department of Pharmacy, Peking University Third Hospital, Beijing, China
[3] Research Center of Clinical Epidemiology, Peking University Third Hospital, Beijing, China
[4] Department of Epidemiology and Biostatistics, School of Public Health, Key Laboratory of Epidemiology of Major Diseases, Peking University, Ministry of Education, Beijing, China

Introduction

Introduction: DIHS/DRESS is a severe delayed-type adverse drug reaction with mortality rates of 1.2-6.1%[1-4]. While systemic glucocorticoids are the standard treatment, steroid resistance, intolerance, and relapse during tapering remain problematic. Tofacitinib, a selective JAK inhibitor, has demonstrated efficacy in case reports of refractory DRESS[5, 6]. However, large-scale studies are lacking. This study aims to evaluate the effectiveness and safety of tofacitinib as adjunctive therapy in DRESS patients.

Materials and Methods

Methods: We retrospectively included patients with DRESS who were treated from January 2018 to March 2025. Treatment comprised systemic glucocorticoids alone or combined with tofacitinib, determined by shared decision-making based on disease severity, treatment response and complications. Multivariable regression analysis was used to adjust for confounding by indication. Primary outcome was duration of glucocorticoid therapy; secondary outcomes included clinical improvement and safety.（see Figure 1）

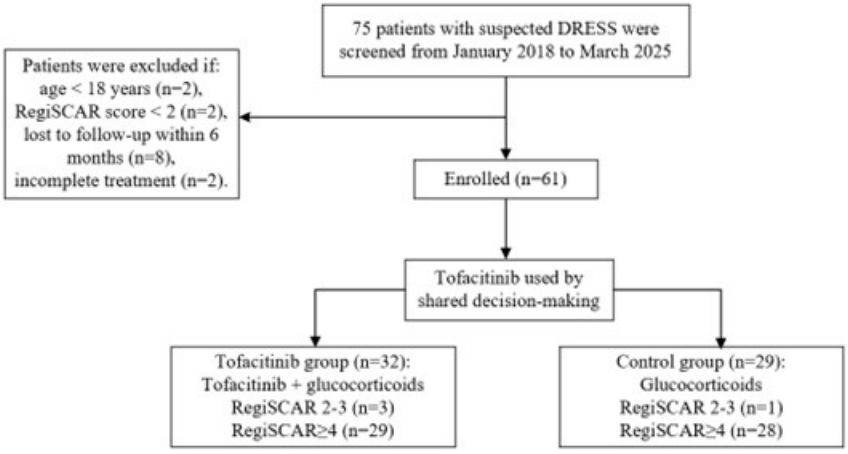

Figure 1. Study protocol and patient allocation. DRESS cases were allocated into one of two groups: the tofacitinib group and the control group.

Results

Results: Sixty-one patients were included (60.7% female; median age 47.0 years). The tofacitinib group was younger (41.0 vs 55.0 years, $p = 0.073$). Most patients (55.7%) had severe disease by Delphi criteria, with similar distribution between groups ($p = 0.806$). Allopurinol was the most common culprit drug (39.3%). Median latency period (26.0 days) and comorbidities were comparable between groups.

Common cutaneous signs included facial edema (77.0%), skin infiltration (75.4%), desquamation (63.9%), and purpura (37.7%). Systemic features comprised eosinophilia (78.7%), fever (75.4%), lymphadenopathy (60.7%), and atypical lymphocytosis (42.6%). The liver was most frequently affected (75.4%), followed by kidneys (34.4%), lungs (29.5%), and heart (19.7%). No significant differences were observed between groups, demonstrating balanced baseline characteristics.

In the tofacitinib group, patients received 9.0 days of glucocorticoid monotherapy (468.0 mg) before tofacitinib addition. Response occurred within 3.0 days. Resolution times were: atypical lymphocytes 2.0 days, rash 3.0 days, eosinophils 7.0 days, liver enzymes 14.5 days. Glucocorticoid tapering began at 4.0 days. Post-tofacitinib glucocorticoid duration was 43.0 days (860.0 mg). Median tofacitinib duration was 47.5 days (407.5 mg).

Compared with control group, adjunctive tofacitinib was associated with shorter time to rash improvement [10.0 (7.3-13.8) vs 14.0 (10.5-18.5) days; $p = 0.013$], reduced glucocorticoid treatment duration [54.0 vs 89.0 days; $p < 0.001$], and lower cumulative glucocorticoid dose [1478.0 vs 2160.0 mg prednisolone equivalent; $p = 0.018$]. In adjusted analyses, tofacitinib remained significantly associated with a 32.5% reduction in glucocorticoid duration ($p = 0.020$); however, the reduction in cumulative dose (22.7%) did not reach statistical significance ($p = 0.138$). No significant differences were observed in mortality (0.0% vs 10.3%; p = 0.102) or relapse rates (6.3% vs 17.2%; $p = 0.346$) (see Table I).

No deaths or serious adverse events occurred with tofacitinib. Adverse event rates were comparable between groups. Infections (folliculitis, furuncles) did not worsen. Hematologic changes were DRESS-related. No malignancies or cardiovascular events occurred. Glucocorticoid-related complications (hyperglycemia 25.0%, hypertension 6.3%, electrolyte disturbances 9.4%) improved with steroid tapering.

Table I. Treatment outcomes between the tofacitinib and control groups

	Tofacitinib group (n=32)	Control group (n=29)	Overall population (n=61)	*p* value
Significant improvement of rash (days)	10.0 (7.3, 13.8)	14.0 (10.5, 18.5)	12.0 (8.0, 15.0)	0.013
Total glucocorticoid dose (mg)	1478.0 (1016.0, 2221.0)	2160.0 (1461.5, 3014.5)	1996.0 (1224.5, 2771.5)	0.018
Total glucocorticoid duration (days)	54.0 (42.3, 72.5)	89.0 (72.5, 120.0)	73.0 (51.5, 99.5)	<0.001
Maximum glucocorticoid dose (mg)	60.0 (40.0, 65.0)	53.0 (40.0, 60.0)	60.0 (40.0, 60.0)	0.158
Hospitalization period (days)	18.0 (12.0, 24.5)	15.0 (12.0, 24.8)	15.0 (12.0, 24.8)	0.640
Relapse of DRESS	2 (6.3%)	5 (17.2%)	7 (11.5%)	0.346
all-cause mortality	0 (0.0%)	3 (10.3%)	3 (4.9%)	0.102
Lipid increasing	18（18/24, 75.0%）	10（10/18, 55.6%）	28（66.7%）	0.186
Infection	5 (15.6%)	10 (34.5%)	14 (23.0%)	0.088

Table I. Treatment outcomes between the tofacitinib and control groups Note: DRESS, Drug reaction with eosinophilia and systemic symptoms. Elevated lipids were defined as post-treatment cholesterol, triglycerides, or LDL-C levels exceeding baseline and normal limits. Only patients with follow-up data were analyzed.

Conclusions

Conclusion: In this retrospective cohort study, adjunctive tofacitinib was associated with faster clinical improvement, shorter glucocorticoid duration, and a comparable safety profile in DRESS patients. However, large-scale randomized controlled trials are needed to validate these findings. As tofacitinib remains off-label for DRESS, clinicians should carefully assess risks and benefits through shared decision-making to ensure patient safety.

EA DV CONGRESS
VIENNA
30 SEP - 3 OCT 2026

Abstract N°: 2027

Cutaneous toxicities of anti-GPRC5D bispecific antibodies for multiple myeloma: retrospective study

Alfonso Gotor-Rivera*[1], Alberto Blanco Sánchez[1], Belén Rodríguez-Sánchez[2], Joaquín Martínez-López[1], Pablo Ortiz-Romero[1], Fatima Tous-Romero[1]

[1] Hospital Universitario 12 De Octubre, Madrid, Spain
[2] Hospital General Universitario Gregorio Marañón, Madrid, Spain

Introduction

G protein-coupled protein receptor, family C, group 5, member D (GPRC5D) is an orphan receptor primarily expressed in plasma cells and hard, keratinized tissue. Talquetamab is a bispecific monoclonal antibody targeting T-cell CD3 receptor and GPRC5D, promoting T-cell-mediated killing of GPRC5D-positive multiple myeloma (MM) cells. Due to the expression of this receptor in keratinized tissues, a high incidence of cutaneous toxicities has been reported by clinical trials.

Most common adverse event reported has been cytokine release syndrome (81.7%), as wells as other hematologic toxicities and opportunistic infections. Dermatologic toxicities are ascribed to an on-target off-tumor effect, with nail-related adverse events in 27-57% and skin-related side effects in 67-70% of participants in randomized controlled trials. Despite this high dermatological burden, real-world evidence of talquetamab toxicities is still lacking.

Materials and Methods

We conducted a retrospective observational single-center study to evaluate cutaneous toxicities in patients who had received talquetamab for the treatment of MM from March 2021 to February 2026. A literature search in PubMed, Embase and Cochrane was performed to identify manuscripts related to cutaneous talquetamab toxicities, retrieving 9 articles for the discussion.

Results

A total of 32 patients were eventually included. Mean (Standard deviation) age was 61.41 (12.39) years, with 19 (59..37%) men. Mean (SD) follow-up was of 374.91 (408.10) days). Treatment dose was the standard 0.8 mg/kg every 2 weeks, with most of the patients (62.5%) under talquetamab monotherapy. 12.5% of cases presented autoimmune comorbidities and 18.75% presented dermatological conditions, with three cases of psoriasis, one basal cell carcinoma and two previous lenalidomide-induced cutaneous toxicities.

A total of 87 dermatological-related adverse events were recorded, with up to 28 (87.5%) of patients presenting at least 1 skin-related side-effect. Only 24 events (27.95% of the total) underwent evaluation by a Dermatologists, with 5 of these (15.62%) being biopsied.

Mean time to side-effect onset varied greatly according to the specific toxicity considered. For cutaneous side effects, mean (SD) time to onset was 27.65 (23.01) days from treatment initiation). The most common event was unspecified exanthema (37.5%) followed by xerosis (33.33%) and injection-site reaction (12.5%). Palmoplantar involvement was common (46.88%), with a mean (SD) onset of 30.13 (13.73) days. Less common events included psoriasis, erythematous nodules, urticaria and folliculitis.

Nails were affected in 75% of patients, with onychomadesis, distal onycholysis and total onychodystrophy being the most common forms of presentation. This toxicity was of late onset, with a mean (SD) of 98.68 (183.56) days. Dysgeusia and xerostomia affected all the cohort at different treatment cycles, but clinically-confirmed mucositis was only demonstrated in 11 (34.38%) cases, with a fast onset of mean (SD) of 16.45 (13.35) days.

Treatment was administered for 67 events (77.01%), with topical corticosteroids and systemic corticosteroids being the most common therapies. Moisturizers, antihistamines and keratolytic ointments were used ad adjuvant therapies. Talquetamab therapy was only modified in 3 patients, with 1 dose delay and 2 spacings of administration, yet no patient required interruption due to cutaneous side-effects.

At database lock, only 9 (28.13%) patients continued treatment. Causes of discontinuation included progression in 17, neurologic toxicity in 2, worsening of general condition, acute myeloid leukemia and death. A significantly longer survival was evidenced in patients with any dermatological adverse event (mean (SD) of 433.44 (417.86) days) compared with no adverse events (58.8 (88.03) days) (p 0.0158); although significant heterogeneity is evident.

Conclusions

Our series highlights the critical role of dermatological assessment and expands the clinicopathological spectrum.

EADV CONGRESS
VIENNA
30 SEP - 3 OCT 2026

Abstract N°: 2066

Proportion, Clinical Patterns, and Associated Factors of Cutaneous Adverse Effects to Systemic Antineoplastic Therapies Among Patients Attending Cancer Care Centre at Kilimanjaro Christian Medical Center

Gloria Mwenda*[1]

[1] Regional Dermatology Training Center, Kilimanjaro, Tanzania

Introduction
chemotherapy-induced cutaneous adverse effects (CAEs) are among the most frequent and distressing physical and emotional non-hematological toxicities in oncology. These dermatological sequelae not only impact patients' quality of life and psychosocial wellbeing but may also lead to treatment interruptions, dose modifications and poor adherence and in worst case scenario treatment abandonment.

Materials and Methods
a hospital based cross sectional study will be conducted at KCMC from January 2026 to April 2026. Eligible participants will include patients currently receiving chemotherapy. Data will be collected using structured questionnaires, clinical examination and chart reviews. The common terminology criteria for adverse events (CTCAE) version 5.0 will e used to grade severity of CAEs. Descriptive statistics will estimate the proportion and types of CAEs, while logistics regression will identify associated risk factors

Results
The results of this study will fill a critical knowledge gap of these chemotherapy-induced CAEs. The findings will also support early identification, evidence based patient counselling and development of context-appropriate dermatological management protocols, ultimately improving cancer care outcomes at KCMC

Conclusions
The results of this study will fill a critical knowledge gap of these chemotherapy-induced CAEs. The findings will also support early identification, evidence based patient counselling and development of context-appropriate dermatological management protocols, ultimately improving cancer care outcomes at KCMC

EADV CONGRESS
VIENNA
30 SEP - 3 OCT 2026

Abstract N°: 2069

From Analgesic to Adversary: Toxic Epidermal Necrolysis Caused by Nimesulide

Mia Kovacevic[1], Marijana Vicic*[1]

[1] Clinical Hospital Center Rijeka, Medical Faculty University of Rijeka, Rijeka, Croatia

Introduction

Stevens-Johnson syndrome (SJS) and toxic epidermal necrolysis (TEN) are rare but life-threatening, severe drug adverse reactions, most often triggered by medications. They represent a disease spectrum differing by the extent of skin detachment (SJS <10%, TEN >30%). The incidence is estimated at 1–2 cases per million annually. Frequent causative agents include analgesics, antibiotics, and anticonvulsants. Reactions typically occur within the first two months of therapy initiation.

Case Presentation

We report a case of a patient with a severe drug-induced allergic reaction manifesting as SJS progressing to TEN. A patient presented with a skin exanthem, conjunctivitis, and lip lesions a few hours after taking analgesics (paracetamol/propiphenazone/codeine phosphate and nimesulide) for a migraine attack. Medical history revealed frequent use of mentioned analgesics for migraines and a previous severe allergic reaction to a bee/wasp sting. Clinical examination revealed a diffuse macular rash on the head, neck, upper trunk, and arms, as well as conjunctival erythema, lip oedema, and oral erosions.

On the third and fourth days of illness, the skin condition worsened with spreading rash, atypical macular target lesions, desquamation, and a positive Nikolsky sign. The patient experienced severe pain, dysphagia, somnolence, and general deterioration. The infectious workup was largely negative, except for borderline positive IgM for *Mycoplasma pneumoniae* and *Chlamydophila pneumonia*, along with a normal chest X-ray. Laboratory findings showed elevated inflammatory markers, transaminases, hypoalbuminemia, and mild electrolyte disturbances. Histopathology confirmed a vesiculobullous reaction, and the SCORTEN score was <3.

Initial therapy included systemic corticosteroids, antihistamines, and gastroprotection. Due to clinical deterioration, cyclosporine (5 mg/kg/day) was introduced on day three. Local treatment included corticosteroids, antibiotics, moist wound care, specialized eye care, oral cavity, and pharynx care. Supportive therapy encompassed hydration, nutrition, analgesia, infection prevention, and thromboprophylaxis.

By day ten, significant clinical improvement was noted, with regression of mucocutaneous lesions and re-epithelialization. Corticosteroids and cyclosporine were gradually tapered. Follow-up CAST-ELISA testing for NSAIDs (lysine-acetylsalicylic acid, acetaminophen, diclofenac, and ibuprofen) was negative. However, nimesulide could not be tested due to its unavailability and lack of approval in Europe.

Conclusion

SJS/TEN are severe, potentially fatal allergic drug reactions characterized by rapid progression and high mortality rates (TEN 25–35%), primarily due to extensive skin and mucosal damage leading to serious systemic complications. Early recognition, urgent diagnosis, and multidisciplinary management are crucial to improve survival and reduce long-term sequelae such as symblepharon and ectropion of the eyes, skin scarring, mucosal strictures, nail dystrophies, and diffuse hair loss. This case illustrates the typical clinical course of SJS/TEN, demonstrating the importance of timely therapeutic intervention in preventing severe complications and achieving favourable outcomes. It also highlights the urgent need for clear, standardized treatment guidelines to ensure

optimal management of these life-threatening conditions.

EADV CONGRESS
VIENNA
30 SEP - 3 OCT 2026

Abstract N°: 2100

A case of generalised dermal hypersensitivity reaction secondary to Epcoritamab

Edwina Tang*[1], Mehrdad Lavaei[2], Kartthik Shanmugam[3], Maneesha Vatve[1]

[1] Dermatology Department, University Hospital of North Durham, County Durham and Darlington NHS Foundation Trust, Durham, United Kingdom

[2] Pathology Department, University Hospital of North Durham, County Durham and Darlington NHS Foundation Trust, Durham, United Kingdom

[3] Haematology Department, University Hospital of North Durham, County Durham and Darlington NHS Foundation Trust, Durham, United Kingdom

Introduction

After approval by the United States Food and Drug Administration agency in 2023, Epcoritamab has since been used as a monotherapy for the treatment of adult patients with relapsed or refractory diffuse large B-cell lymphoma (DLBCL) or follicular lymphoma. It is a humanised immunoglobulin G1 bispecific antibody against CD3 and CD20 antigens, produced in Chinese hamster ovary cells by recombinant DNA technology. Epcoritamab, for DLBCL, is administered weekly from Cycle 1 to 3, fortnightly from Cycle 4 to 9 and then every four weeks, until disease progression or unacceptable toxicity presents itself. The most common adverse effects reported in an ongoing non-randomised, single arm GCT3013-01 study in patients taking Epcoritamab were cytokine release syndrome (CRS), injection site reactions, fatigue, viral infections, neutropenia, musculoskeletal pain, pyrexia and diarrhoea. Rarer fatal adverse reactions include pneumonia, viral infections and ICANS. Only one case report describing Epcoritamab injection site skin reaction was identified on our literature search. We present a case of epcoritamab induced drug rash in a 59 year-old female patient with DLBCL.

Case Presentation

A 59 year-old female patient presented to the dermatology department with a new generalised rash after starting Epcoritamab subcutaneous injections 10 months ago for DLBCL. She described noticing an initial rash affecting her eyelids and neck at the start of her treatment before developing a more pruritic generalised rash after each Epcoritamab injections. With subsequent treatments, the severity of the rash was worse and the length of time to resolution of rash was progressively longer.

Patient has stage four DLBCL with bulky abdominal disease and high risk of central nervous system (CNS) relapse. She received 6 cycles of Rituximab, Cyclophosphamide, Doxorubicin, Vincristine and Prednisolone (R-CHOP) chemoimmunotherapy and 2 cycles of high dose Methotrexate for CNS prophylaxis. Despite showing complete metabolic response at the end of her treatments, she had a relapse of her disease 4 years later. She further received 2 cycles of Rituximab, Gemcitabine, Dexamethasone and Cisplatin (RGDP) before being commenced on third line treatment with Epcoritamab injections. Her other regular medications include fexofenadine and as required paracetamol. She takes prophylactic cotrimoxazole and aciclovir but these were started years ago with the initial chemoimmunotherapy treatments for DLBCL.

On examination, patient had bilateral periorbital erythematous rash and swelling. There was a generalised pruritic eczematous rash across her torso and all four limbs. She also developed acute eruptive seborrhoeic keratoses at the same time of her rash.

Given the history and examination findings, the differential diagnoses were of a drug induced rash, cutaneous lupus or new onset eczema.

Punch biopsies were taken from her back and right thigh. The histology demonstrated a subacute psoriasiform eczematous inflammatory reaction with a prominent eosinophilic infiltrate, consistent with a dermal hypersensitivity reaction. Drug reaction was the most likely histological diagnosis. There was no evidence of lupus or malignancy.

A weaning course of oral prednisolone at 0.5mg/kg/day dose was commenced alongside betamethasone valerate 0.1% ointment and hydrocortisone 1% ointment for her periorbital rash. Her rash was steroid responsive where improvement to her rash and resolution of her eruptive seborrhoeic keratoses were observed after just two weeks.

Conclusion

Given that Epcoritamab is a relatively new treatment, there is currently no published cases or studies on its potential cutaneous toxicity. Little data is available if cutaneous toxicity secondary to Epcoritamab is dose dependent or if its elimination half-life may help predict best treatment regime with the least cutaneous toxicity. This case report increases awareness of potential adverse cutaneous drug reaction for both clinician and patient utilising Epcoritamab.

EADV CONGRESS
VIENNA
30 SEP - 3 OCT 2026

Abstract N°: 2146

Acneiform eruptions associated with Janus kinase inhibitors in dermatology: incidence, clinical characteristics and association with therapeutic response in a real-world setting.

Carmen García Moronta*[1], Daniel Muñoz Barba[1], Manuel Sánchez-Díaz[1], Salvador Arias-Santiago[1]

[1] Hospital Universitario Virgen de las Nieves, Granada, Spain

Introduction
Janus kinase inhibitors (JAKi) have rapidly expanded in dermatology, yet their safety profile remains incompletely defined. Acneiform eruptions have emerged as a frequent but underrecognized adverse event, with uncertain clinical implications. This study aimed to determine their incidence and clinical features, identify factors associated with their development, and assess their potential role as a marker of therapeutic response.

Materials and Methods
A retrospective observational study was conducted at the Dermatology Department. Patients treated with baricitinib, ritlecitinib, abrocitinib, upadacitinib, deucravacitinib, or topical ruxolitinib were included. Sociodemographic, clinical, and treatment-related variables, as well as data on acneiform eruption, were collected.

Results
A total of 172 patients were included (mean age 38.9 ± 17.1 years; 59.3% female), of whom 31 (18%) developed acneiform eruption. The highest incidence was observed with upadacitinib (34.1%), although no statistically significant differences were found between treatments. Eruptions predominantly involved the face (83.9%) and were generally mild, being managed mainly with topical therapy. Complete resolution was achieved in most patients (87.5%), and treatment discontinuation was rare. Younger age was independently associated with a higher risk of eruption. A significant association between acneiform eruption and improved therapeutic response at 6 months was observed in patients with alopecia areata treated with baricitinib ($p = 0.028$) and in those with vitiligo treated with topical ruxolitinib ($p = 0.049$), with a similar trend in atopic dermatitis treated with upadacitinib.

Conclusions
Acneiform eruption is a common and clinically relevant adverse event in patients treated with JAKi, typically mild but potentially informative. Its association with improved therapeutic outcomes in selected settings suggests that it may represent a clinically accessible marker of treatment efficacy.

POWERED BY M-ANAGE.COM

EADV CONGRESS
VIENNA
30 SEP - 3 OCT 2026

Abstract N°: 2266

From traditional remedy to severe complication: acute erythroderma following ash application in pemphigus foliaceus

NOUSSAIBA CHEMLAL[1], BOUMEDIENE DAHMANI[1], KAMILA BOUCHENAK KHALADI*[1]

[1] Department of Dermatology, CHU Tlemcen, Aboubakr Belkaid, Faculty of Medicine, Tlemcen, Dermatology Association of the Wilaya of Tlemcen (ADWIT), TLEMCEN, Algeria

Introduction

Pemphigus foliaceus is a superficial autoimmune bullous dermatosis mediated by autoantibodies directed against desmoglein 1, responsible for intraepidermal acantholysis.

Its course is typically chronic, with localised or generalised forms. Progression to Erythroderma remains rare and often reflects severe disease worsening.

Triggering or aggravating factors include infections, medications, and cutaneous insults. Traditional practices, particularly the application of irritant substances, are poorly described but may play an important role.

Case Presentation

We report the case of a 50-year-old man followed for initially localized pemphigus foliaceus.

In the context of resorting to traditional herbal therapy, the patient applied ash over the entire body surface for therapeutic purposes.

A few days after this application, he experienced rapid worsening of his skin condition, with diffuse extension of lesions and the onset of exfoliative erythroderma, associated with superficial crusted erosions predominantly involving the trunk and limbs.

Skin biopsy confirmed the diagnosis of pemphigus foliaceus (superficial acantholysis).

The patient was managed with systemic corticosteroid therapy combined with local care, with a favorable outcome marked by progressive regression of erythroderma.

DISCUSSION

Progression to erythroderma in the course of pemphigus foliaceus is rare but well described. It corresponds to a severe form related to massive extension of the acantholytic process.

In our case, the triggering factor appears to be the application of ash, an alkaline substance with potential irritant properties, suggesting an exogenous aggravating role. Although no identical case has been specifically reported, several data from the literature support this mechanism.

Chemical or physical skin injuries are known to induce or exacerbate dermatoses via a Koebner phenomenon or “Koebner-like” effect, involving disruption of the epidermal barrier and increased exposure of cutaneous antigens, thereby amplifying the autoimmune response.

At the immunopathological level, this barrier disruption may lead to enhanced antigen presentation by cutaneous

dendritic cells, activation of autoreactive T lymphocytes, and increased production of anti–desmoglein 1 autoantibodies.

The absence of other triggering factors strengthens the hypothesis of a contributory role of ash application in the observed clinical decompensation.

Conclusion

This case highlights the potential role of traditional practices in the aggravation of autoimmune dermatoses.

The application of irritant substances such as ash may cause significant disruption of the skin barrier, promoting exacerbation of pemphigus foliaceus to an erythrodermic form.

Raising patient awareness regarding such practices is essential to prevent complications.

EA DV CONGRESS
VIENNA
30 SEP - 3 OCT 2026

Abstract N°: 2273

Methotrexate -Associated stevens johnson syndrome in the management of cesarean scar pregnancy: A rare and severe toxicity .

ARIJ YOUSSEF*[1]

[1] Center of Maternity and Neonatology of Tunis, La Rabta, Tunis, Tunisia

Introduction

Methotrexate (MTX) is a first-line treatment for ectopic pregnancies, including cesarean scar pregnancies. Although generally well tolerated, it can exceptionally cause multi-organ toxicity with variable severity among patients, including rare but severe manifestations such as Stevens–Johnson syndrome (SJS). We report the case of a patient who developed Stevens–Johnson syndrome following methotrexate administration for a cesarean scar pregnancy in Department D at the Maternity and Neonatology Center of Tunis.

Case Presentation

A 34-year-old woman, G3P1A1, with a history of a single previous cesarean section and no significant medical or allergic history, was admitted for vaginal bleeding at 6 weeks of amenorrhea.

Clinical examination revealed mild dark endouterine bleeding without associated clinical signs.

Transvaginal ultrasound showed an isthmic gestational sac with a visible yolk sac but no embryonic cardiac activity, located within the previous cesarean scar embedded in the anterior isthmic uterine wall. The residual myometrial thickness measured 2 mm. The cervical canal was empty with a normal uterine cavity. The imaging was highly suggestive of a cesarean scar pregnancy type II (exogenous invasive form) according to the Timor-Tritsch classification. Doppler ultrasound demonstrated increased peri-trophoblastic vascularization with low-resistance flow surrounding the sac, consistent with the diagnosis.

A diagnosis of cesarean scar pregnancy was established.

Treatment consisted of systemic methotrexate at a dose of 1 mg/kg (60 mg total), combined with local intra-amniotic methotrexate injection under ultrasound guidance.

On day 4 post-treatment, the patient developed sore throat and hoarseness, followed by painful aphthous-like erosions of the oral cavity and gingiva, involving the lips, labial commissures, and palate (Figure 1). On day 5, erythematous and ulcerative vulvar plaques with oozing lesions appeared (Figure 2).

On day 7, she developed extensive mucocutaneous erosions with confluent erythematous infiltrated plaques involving the palms and soles, as well as necrotic, crusted, and erosive lesions affecting the décolleté, neck, inner thighs, and legs (Figures 3 and 4). A diagnosis of Stevens–Johnson syndrome was strongly suspected.

Biological workup revealed bicytopenia with severe leukopenia (1,200/mm^3) and anemia (Hb 6.8 g/dL), while platelet counts were initially normal. Hepatic and renal function tests were within normal limits.A skin biopsy showed diffuse and confluent keratinocyte necrosis with massive apoptosis, basement membrane alteration, interface dermatitis with vacuolar changes, and a mild inflammatory infiltrate, consistent with toxic epidermal necrolysis (Stevens–Johnson syndrome).

A chest X-ray was normal. ENT examination revealed diffuse oral mucosal erosions with early erosive pharyngitis and hemorrhagic gingival crusting.

Ophthalmologic examination was normal. The pharmacovigilance causality assessment estimated a probability of 90% for methotrexate-induced Stevens–Johnson syndrome.

Conclusion

Methotrexate represents an important therapeutic option in the management of non-ruptured ectopic pregnancies, including cesarean scar pregnancies, when clinical conditions permit. Before initiating treatment, it is essential to exclude an ongoing intrauterine pregnancy and to assess β-hCG levels, as well as hepatic and renal function and complete blood count.

Methotrexate represents an important therapeutic option in the management of non-ruptured ectopic pregnancies, including cesarean scar pregnancies, when clinical conditions permit. Before initiating treatment, it is essential to exclude an ongoing intrauterine pregnancy and to assess β-hCG levels, as well as hepatic and renal function and complete blood count.

EA DV CONGRESS
VIENNA
30 SEP - 3 OCT 2026

Abstract N°: 2319

Hand-Foot Syndrome and Nail Shedding Induced by Capecitabine: A Case Report

FATIMA ZAYOUN*[1], Bouchra Baghad[1], fatima zahra benhayoun[1], hanane rachadi[1], Soumiya Chiheb[1]

[1] Ibn Rochd University Hospital Center, CASABLANCA, Morocco

Introduction

Hand-foot syndrome, also known as palmar-plantar erythrodysesthesia, is a common cutaneous adverse effect associated with several chemotherapeutic agents, particularly fluoropyrimidines such as capecitabine. It typically presents with erythema, edema, pain, and desquamation involving the palms and soles, which may significantly impair patients' quality of life.

We report the case of an elderly patient who developed hand-foot syndrome associated with nail shedding in the setting of capecitabine-based chemotherapy for rectal adenocarcinoma.

Case Presentation

A 72-year-old patient, followed for rectal adenocarcinoma and treated with capecitabine-based chemotherapy, presented with the progressive onset of painful lesions affecting the hands and feet over several weeks.

Dermatological examination revealed bilateral and symmetrical palmar-plantar erythema associated with diffuse desquamation and local tenderness, consistent with hand-foot syndrome.

Furthermore, the patient reported spontaneous shedding of several nails occurring approximately six months earlier, without any history of local trauma or periungual infection. Nail examination demonstrated abnormalities affecting multiple digits, characterized by onychomadesis corresponding to proximal detachment of the nail plate, reflecting transient involvement of the nail matrix.

A pharmacovigilance assessment was conducted to identify the potentially causative agent. Based on the chronological relationship between drug exposure and symptom onset, as well as available literature data, capecitabine was considered the most likely agent responsible for these cutaneous and nail manifestations



Dermatological examination revealed bilateral and symmetrical palmar erythema with edema and desquamation, associated with nail abnormalities including onycholysis and onychomadesis.

Conclusion

Hand-foot syndrome is a well-recognized cutaneous adverse event associated with chemotherapy, particularly fluoropyrimidines such as capecitabine. Its incidence may reach 50 - 60% among patients receiving this agent, although severe forms remain less common.

The pathophysiology of this cutaneous toxicity remains incompletely understood. Several mechanisms have been proposed, including drug accumulation in eccrine gland-rich areas, repeated exposure to microtrauma at palmar and plantar sites, and direct toxicity of 5-fluorouracil metabolites on keratinocytes.

Clinically, hand-foot syndrome usually manifests as erythema of the palms and soles associated with dysesthesia, edema, and desquamation. In more severe cases, lesions may progress to painful fissures leading to significant functional impairment.

Associated nail disorders such as onycholysis, Beau's lines, and onychomadesis are more rarely described in the literature. These manifestations may result from transient toxic injury to the nail matrix induced by chemotherapy.

In our case, the pharmacovigilance investigation strongly suggested capecitabine as the primary causative agent, in agreement with previously reported literature data.

Management is mainly based on symptomatic measures, including the use of emollients and topical corticosteroids, as well as dose adjustment or temporary interruption of chemotherapy in severe cases of cutaneous toxicity.

This case highlights the importance of careful dermatological monitoring in patients receiving fluoropyrimidines,

as well as the value of pharmacovigilance investigations in identifying the causative agent. Early recognition of these adverse effects may improve patient management and optimize tolerance to anticancer treatment.

EADV CONGRESS
VIENNA
30 SEP - 3 OCT 2026

Abstract N°: 2323

Injection Site Reaction Monitoring Reimagined: AI-Powered Detection and Inclusive Quantification

Oliver Kubesch*[1], Monika Molnarova[1], Chiara Agostini[1], Harald Schnidar[1]

[1] SCARLETRED Holding GmbH, Vienna, Austria

Introduction

Injection Site Reactions (ISRs) are common adverse effects of injectable treatments, negatively impacting patient comfort, adherence, and overall treatment outcomes. Timely and precise identification of these reactions is vital for effective clinical intervention and improved patient safety. The objective of this study is to leverage artificial intelligence (AI) and advanced image processing to automate the detection and evaluation of ISRs, consequently enhancing clinical monitoring capabilities and patient care.

Materials and Methods

The dataset comprised 2178 clinical images from 117 subjects undergoing injectable therapies. Scarletred®Vision, a Software as a Medical Device (SaMD) platform that has been clinically validated and approved, was utilised in conjunction with a calibration skin patch to ensure consistent and standardised image acquisition.

Initial data exploration involved categorising images based on skin types using the Individual Typology Angle (ITA) to address variability in ISR presentation. Subsequently, image processing was applied to highlight key ISR features and a custom Convolutional Neural Network (CNN) was developed to accurately detect and segment ISR areas.

Results

The AI model demonstrated robust performance in accurately detecting ISRs and distinguishing affected areas from healthy skin with a weighted F1 score of 0.8. ISR characteristics such as redness intensity and extent dimensions can be quantified, significantly improving consistency compared to traditional manual assessments.

Conclusions

This study highlights the effectiveness of AI-enhanced imaging in the objective evaluation of ISRs, significantly improving safety monitoring and clinical management. The Scarletred® Mobile App facilitates remote, patient-driven documentation, enabling proactive monitoring and timely clinical interventions. Furthermore, the approach promotes inclusive technologies and equitable performance of AI tools across diverse skin types, supporting ethical and effective digital health solutions.

EA DV CONGRESS
VIENNA
30 SEP - 3 OCT 2026

Abstract N°: 2327

Erythema Multiforme: Clinical Characteristics, Epidemiology, Treatment, and Etiological Factors

Imane Chraiki*[1], Bendaoud Layla[1], Mariem Aboudourib[1], Ouafa Hocar[1], Said Amal[1]

[1] Dermatology-Venereology Department, Mohamed VI University Hospital, Marrakesh, Morocco

Introduction

Erythema multiforme (EM) is an acute mucocutaneous disorder with an immune-mediated mechanism, clinically characterized by typical target lesions, with or without mucosal involvement of variable severity, allowing differentiation between minor and major forms. The aim of this study was to describe the clinical, epidemiological, and etiological features, as well as the therapeutic management of patients with EM.



Clinical image of oral mucosal involvement showing pseudomembranous erosions.

Case Presentation

This is a retrospective, descriptive study including 18 cases of EM managed in the dermatology department between 2020 and 2025. Collected clinical data included age, sex, triggering factors, cutaneous and mucosal involvement, severity of lesions, as well as treatment outcomes.

The study included 18 patients with EM, with a mean age of 31.4 years and a male-to-female ratio of 0.82 (55% female). A history of EM was found in 27.8% of patients. Orolabial herpes was reported in 72% of cases, genital herpes in 22%, and a recent respiratory infection in 23%. Drug intake prior to the episode was noted in 16% of cases.

The mean time to lesion onset was 11 ± 3 days. Typical target lesions were observed in 72% of cases, bullae in 44%, atypical lesions in 33%, and purpura in 11%. Cutaneous involvement predominantly affected the upper and

lower limbs (66% each), followed by the palms and soles (61%), the trunk and the face. Mucosal involvement was present in 78% of patients, mainly oral (78%), then genital and ocular.

The major clinical form accounted for 67% of cases. Etiology was attributed to HSV in 73% of cases, *Mycoplasma pneumoniae* in 16%, and drug exposure in 11%. From a therapeutic perspective, 66% of patients received acyclovir and 34% antibiotics. Discontinuation of the suspected drug and systemic corticosteroid therapy were each implemented in 11% of patients, while local care was provided in 95% of cases. Hospitalization was required in 67% of patients, with a mean duration of 6.72 days. The mean time to recovery was 15.22 days, and the recurrence rate was 5.56%.



Clinical image showing characteristic target lesions.

Conclusion

EM is an immune-mediated dermatosis most commonly associated with herpes simplex virus infection or medications. Management depends on disease severity and recurrence, with mild forms requiring symptomatic treatment, whereas recurrent forms may require antiviral prophylaxis.

EA DV CONGRESS
VIENNA
30 SEP - 3 OCT 2026

Abstract N°: 2336

Impact of dermatological toxicities on quality of life in breast cancer patients exposed to adjuvant endocrine therapy

Vincent Sibaud[1], Kautar Tagdichti[2], Delphine Lasalle[3], Ralph Niarra[3], Gautier Doat[4], Aline Stennevin*[4]

[1] Oncodermatology Department, Toulouse University Cancer Institute (IUCT)/Oncopole, Toulouse, France

[2] RWE Department, Pierre Fabre Laboratories, Boulogne, France

[3] R&D Department, Pierre Fabre Laboratories, Boulogne, France

[4] Medical Department, Laboratoires Dermatologiques Eau Thermale AVENE, Lavaur, France

Introduction

The BCARE (Breast Cancer Adjuvant Real-world Evaluation of dermatological adverse events) study investigates the impact of dermatological toxicities on quality of life (QoL) in patients with early-stage breast cancer (EBC) undergoing adjuvant endocrine therapy (excluding patients receiving concomitant targeted therapies and/or presenting relevant or severe comorbidities). The development of dermatological toxicities, such as skin inflammation, hair/nail changes, and dry skin, and their potential impact on patients' physical, functional, emotional, and social well-being has not been studied until now. Despite the improved efficacy of anticancer therapies, managing these dermatological toxicities remains a challenge.

Materials and Methods

This cross-sectional, non-interventional study uses the Dermatology Life Quality Index (DLQI) questionnaire as primary outcome to measure QoL related to dermatological toxicities in female patients aged 18 and above with histologically confirmed EBC undergoing adjuvant endocrine monotherapy initiated 2 to 3 years ago.

It is being conducted across nine centers in four countries (France, Greece, Italy, and Spain; FPI Nov 22, 2024). Patients who have received concomitant targeted therapies and/or have had relevant or severe comorbidities are excluded. Secondary outcomes include dermatological QoL assessed using Skindex-16, Hairdex, and ItchyQoL questionnaires, and the description of dermatological toxicities at inclusion.

Results

An intermediate analysis of 42 patients revealed that while most experienced minimal QoL disruption, dermatological side effects such as itching, irritation, and emotional distress were reported. According to the DLQI, 41.5% of patients experienced a small impact on their life, while 20.4% reported emotional effects via the Skindex-16.

Skin care behaviors were proactive: 83.3% of patients used skincare products, with 77.1% applying emollients daily. Sensitive skin hygiene products were used by 60%, and 85.7% of these patients applied them daily. Adapted makeup was used by 22.9%, with 88% incorporating it into their daily routine. Additionally, 37.1% engaged in enhanced moisturizing or soothing practices such as thermal water sprays.

Sun-protective behaviors were also prevalent, with 73.8% limiting sun exposure and 69% using adapted sun protection. All patients who used sun protection applied sunscreen, typically only during sun exposure.

Conclusions

These findings suggest that while dermatological toxicities from hormone therapy may not significantly impair daily functioning, they do affect emotional well-being and prompt changes in skincare routines. Addressing both physical symptoms and emotional impacts through targeted support could enhance patient experience and overall well-being during endocrine therapy.

EA DV CONGRESS
VIENNA
30 SEP - 3 OCT 2026

Abstract N°: 2365

Beyond the expected rash: Two exceptional cutaneous toxicities caused by pembrolizumab.

Julia Barouille*[1], Carlos Martin[2], Javier Brandoni[2], Juan Facundo Larrañaga[3], Rosa Kitagawa[2]

[1] Hospital Municipal Juan E. de La Fuente, General Belgrano, Argentina

[2] Private Practice, La Plata, Argentina

[3] Juan de La Fuente´s Hospital, General Belgrano, Argentina

Introduction

Immune checkpoint inhibitors have represented a significant advance in cancer treatment. However, their use is not without unwanted reactions, known as immune-related adverse effects, with cutaneous reactions being particularly common. Current knowledge regarding immunorelated cutaneous adverse effects comes primarily from clinical practice reports, the most frequent being rash, vitiligo, pruritus, and effluvium; however, these types of drugs can cause a wide variety of dermatoses as novel as immunotherapy itself. In this paper, we share two cases of interest due to their florid and rarely reported clinical presentations.

Case Presentation

Case 1: A 61-year-old man (phototype III) with a medical history of varicella, herpes simplex virus type 1, dyslipidemia, grade 1 hypertension, and stage III (T4 N1) clear-cell renal carcinoma—currently in the third month of a pembrolizumab (200 mg every 3 weeks) regimen—presented with lesions along the occipital nerve dermatome, consisting of a cluster of blisters on an erythematous base accompanied by neuropathic pain. The condition was initially interpreted as herpes zoster, and treatment with acyclovir and pregabalin was initiated. During subsequent follow-ups, the lesions evolved into crateriform formations with ulcerated, fibrinous centers, raised borders, and honey-colored crusts; consequently, laboratory tests, a CT scan, and a skin biopsy were performed, leading to a diagnosis of keratoacanthoma with a herpetiform occipital distribution. Acyclovir and pembrolizumab were discontinued, while topical 2% mupirocin cream was maintained, resulting in complete remission of the skin lesions.

Case 2: An 82-year-old man with phototype II and severe photodamage, undergoing treatment with pembrolizumab for thick melanoma in the right scapular region, presented with a generalized monomorphic exanthem composed of 5 mm pearly white papules with increased consistency, otherwise asymptomatic showing generalized distribution on the skin and scalp. An incisional biopsy was performed, reporting inclusion cysts. Adjuvant immunotherapy was discontinued, resulting in remission of the described lesions. The final diagnosis was milium-like epidermal cysts associated with pembrolizumab.

Conclusion

The presentation of these two clinical cases involving rare and severe cutaneous adverse effects associated with pembrolizumab highlights the complexity and challenge that new immuno-oncology therapies represent for clinical management. The accurate and timely identification of cutaneous adverse manifestations is essential to avoid major complications and to optimize patient treatment. In this context, interdisciplinary teamwork proves to be indispensable, integrating oncologists, dermatologists, and other specialists for a comprehensive evaluation and appropriate management.

The involvement of the dermatologist is crucial in the differential diagnosis of skin lesions, allowing for distinction between immune-mediated cutaneous reactions, infections, skin cancer, and paraneoplastic syndromes, among

others. This contributes to more accurate clinical decisions regarding the continuation or modification of pembrolizumab treatment, thereby ensuring better safety and quality of life for patients.These two cases emphasize the need for collaborative protocols and continuous training to address the challenges posed by cutaneous adverse effects in the context of emerging immunotherapeutic treatments.

EA DV CONGRESS
VIENNA
30 SEP - 3 OCT 2026

Abstract N°: 2444

Whole-genome sequencing and studies using AlphaFold suggest that HLA-B*13:01 may be a universal biomarker associated with drugs that frequently cause drug eruptions

Kana Inoue*[1], Yoshio Kusakabe[2], Takayoshi Sakurai[3, 3], Buntaro Yamaguchi[3], Chisato Sunaga[3], Hiroomi Hosaka[3], Taisei Mushiroda[4], Riichiro Abe[5], Hideaki Watanabe[3, 6]

[1] Showa Medical University Northern Yokohama Hospital,, Department of Dermatology, Showa Medical University School of Medicine, Yokohama, Japan
[2] Center for the Development of Pharmacy Education Faculty of Pharmacy, Meijo University, Nagoya, Japan
[3] Department of Dermatology, Showa Medical University Northern Yokohama Hospital, Yokohama, Japan
[4] Laboratory for Pharmacogenomics, RIKEN Center for Integrative Medical Sciences, Yokohama, Japan
[5] Division of Dermatology, Graduate School of Medical and Dental Sciences, Niigata University, Niigata, Japan
[6] Department of Dermatology, Showa Medical University Northern Yokohama Hospital, Department of Dermatology, Showa Medical University School of Medicine, Yokohama, Japan

Introduction
Severe drug eruptions, such as Stevens-Johnson syndrome (SJS)/toxic epidermal necrolysis (TEN) and drug-induced hypersensitivity syndrome (DIHS/DRESS), are disorders with high mortality rates that often cause organ damage and leave lasting sequelae. While various studies have examined the mechanisums of drug eruptions, research into the genetic background remains insufficient. Regarding severe drug eruptions, several reports have identified associations between drugs and HLA carried by patients.

Materials and Methods
We performed whole-genome sequencing analysis and AlphaFold-based investigations on the top 10 drugs most likely to cause severe drug eruptions, as collected by the Japanese SCAR Group.

Results
The drugs most frequently reported to cause drug eruptions, in descending order, were carbamazepine, lamotrigine, and allopurinol. Whole-genome sequencing analysis revealed HLA associations with several drugs. Furthermore, for these drugs, HLA-B*13:01 was identified as a “universal biomarker,” with patients carrying it exhibiting a high odds ratio. Surprisingly, research using the AI technology AlphaFold also suggested that drugs prone to causing drug eruptions may be more likely to occur in HLA-B*13:01 carriers. Three-dimensional structural analysis suggested that HLA-B*13:01 possesses a pocket structure where drugs readily bind. Moreover, it was found that drugs exhibit strong binding affinity at this pocket. Furthermore, drugs that readily bind to HLA-B*13:01 were found to share common chemical structural formulas.

Conclusions
This study demonstrated through whole-genome sequencing analysis and AlphaFold-based research that HLA-B*13:01 is a universal biomarker for drugs prone to causing drug eruptions.

EADV CONGRESS
VIENNA
30 SEP - 3 OCT 2026

Abstract N°: 2451

Photo- and Heat-Induced Drug Eruption Associated with Combined Trametinib and Tebentafusp Therapy in Metastatic Uveal Melanoma: A Case Report

Cătălina-Ioana Naum*[1], Mara Madalina Mihai[1, 2], Ana-Maria Forsea[1, 2]

[1] Spitalul Universitar de Urgență Elias București, București, Romania
[2] 'Carol Davila' Faculty of Medicine, București, Romania

Introduction

Uveal Melanoma is a rare malignancy distinct from cutaneous melanoma, characterized by poor prognosis and limited response to systemic therapies in advanced stages. Recent advances in targeted therapies and immunotherapy, including Trametinib and Tebentafusp, have improved disease control and overall survival in selected patients. However, cutaneous toxicities remain the most frequent adverse effects associated with these agents. Acneiform eruptions are commonly linked to trametinib, whereas cytokine-mediated skin reactions occur frequently during tebentafusp therapy. Nevertheless, the spectrum of cutaneous adverse events induced by the combination of these treatments remains insufficiently characterized.

Case Presentation

We report the case of a 45-year-old woman with metastatic uveal melanoma who developed an atypical polymorphous cutaneous eruption during combined treatment with tebentafusp, initiated in June 2023, and trametinib, introduced in August 2024. The eruption appeared abruptly 10 days after starting trametinib, initially involving photo-exposed areas of the face, anterior neck, upper chest, and back as acneiform lesions. Despite multiple systemic courses of doxycycline and azithromycin associated with topical corticosteroids and antibiotic preparations containing neomycin and hydrocortisone acetate, the eruption progressively worsened and disseminated to the trunk and limbs. Clinical examination revealed generalized erythematous macules, papules, and finely scaly pruritic plaques with poorly defined borders and reticulated distribution, suggesting a photo- and heat-induced pathogenesis.

Laboratory investigations demonstrated elevated lactate dehydrogenase levels of 1147 U/L (normal range: 135–214 U/L), amylase of 113 U/L (normal range: 30–110 U/L), and lipase of 216 U/L (normal range: 10–140 U/L). Magnetic resonance imaging revealed progression of hepatic and pancreatic metastatic lesions. Differential diagnosis included overlapping drug-induced eruptions, cutaneous lupus erythematosus, and contact dermatitis. Two punch biopsies from lesions on the left arm demonstrated histopathological features consistent with spongiotic dermatitis, while direct immunofluorescence was negative. Lymphoblastic transformation testing and intradermal hypersensitivity testing for both oncologic therapies yielded negative results.

Due to severe cutaneous toxicity and radiological disease progression, treatment with trametinib and tebentafusp was discontinued. Systemic corticosteroid therapy with gradual tapering, combined with topical metronidazole-containing preparations, resulted in significant improvement of the eruption and pruritus. Owing to progressive metastatic disease, treatment with Dacarbazine was initiated. However, considering the possibility of paradoxical imaging progression under immunotherapy, future reintroduction of Tebentafusp remains under consideration.

Conclusion

Cutaneous toxicities associated with combined trametinib and tebentafusp therapy may present with complex and

atypical clinicopathological patterns extending beyond classical acneiform eruptions. To our knowledge, this represents the first reported case of a photo- and heat-induced polymorphous spongiotic dermatitis associated with this therapeutic combination. Histopathological and immunohistochemical evaluation were essential for establishing the diagnosis and excluding autoimmune or infectious etiologies. This case highlights the importance of early recognition of uncommon cutaneous adverse reactions in patients receiving targeted therapies and immunotherapy, as prompt multidisciplinary management may improve patient outcomes and therapeutic decision-making. Furthermore, the observation raises important questions regarding potential synergistic mechanisms between trametinib- and tebentafusp-induced immune pathways, the prognostic significance of cutaneous toxicity patterns, and optimal management strategies in advanced uveal melanoma patients receiving combination therapy.

EADV CONGRESS
VIENNA
30 SEP - 3 OCT 2026

Abstract N°: 2477

Severe mucocutaneous toxicity from inadvertent daily methotrexate in psoriasis: a preventable prescribing error

Lais Acioli Lins[1], Gabriela Santos Bastos Jacob[1], Vanessa Marcato[1], Milena de Oliveira[1], Mateus Char[1], Thays Herbst[1], Elisandra Barbara Pontes Carlos*[1], Izabelle Bonini[1], Luciane Donida Bartoli Miot[1], Luciana Patrícia Fernandes Abbade[1]

[1] UNESP, Botucatu, Brazil

Introduction

Methotrexate remains a cornerstone therapy for psoriasis and is conventionally administered on a once-weekly basis. Prescription errors, particularly inadvertent daily administration, are a recognized cause of severe toxicity and can lead to life-threatening complications, especially when folic acid supplementation is absent. We report a case of severe methotrexate toxicity due to inappropriate daily use in a patient with psoriasis vulgaris, highlighting clinicopathological correlation and management.

Case Presentation

A 56-year-old female with psoriasis vulgaris was under dermatological follow-up. During an outpatient visit, laboratory tests were ordered in preparation for initiation of acitretin therapy, due to refractoriness to topical treatment and absence of joint symptoms.

Between consultations, the patient attended another healthcare service where a general practitioner prescribed methotrexate 5 mg daily without folic acid supplementation; this regimen was continued for approximately one month.

At the dermatology follow-up she reported improvement of psoriatic plaques; however, she developed severe mucocutaneous toxicity, including painful ulcerations of the upper and lower lips, associated with restricted mouth opening and impaired oral intake. Additional findings included painful ulcerative lesions characterized by an erythematous halo, a violaceous inner border, and a hemorrhagic base, located on the posterior distal region of the right lower limb, above the calcaneus measuring 4 centimeters, and on the middle phalanx of the fourth finger of the right hand, measuring 3 centimeters, as well as tenderness in the right upper quadrant.

Hospital admission was indicated for further investigation. Laboratory testing revealed significant hematological abnormalities, including leukopenia, monocytopenia, thrombocytopenia and a decrease in baseline hemoglobin. An incisional biopsy of a lower limb ulcer was performed, and histopathological examination demonstrated leukocytoclastic vasculitis with fibrinoid necrosis, nuclear debris and erythrocyte extravasation, associated with keratinocyte necrosis, acantholysis and neutrophilic microabscesses. These findings were considered compatible with drug-induced skin injury.

Methotrexate was discontinued immediately, and treatment with calcium folinate and filgrastim was initiated. The patient showed progressive clinical and laboratory improvement and was discharged after nine days of hospitalization.

Conclusion

Methotrexate toxicity is frequently associated with prescription errors, particularly regarding dosing frequency,

with inadvertent daily administration instead of the recommended weekly regimen remaining a relevant issue in clinical practice.
Mucositis and cytopenias are early manifestations, while cutaneous ulcerations may signal more severe toxicity. Early recognition and prompt initiation of folinate rescue therapy are essential to reduce morbidity.
This case underscores the importance of appropriate prescribing practices, with emphasis on weekly dosing and folic acid supplementation, as well as the need for clear patient education and implementation of effective medication safety strategies — including periodic review of ongoing medications —to reduce the occurrence of severe and preventable adverse events.

EADV CONGRESS
VIENNA
30 SEP - 3 OCT 2026

Abstract N°: 2559

Stevens-Johnson Syndrome Triggered by Carbamazepine Misuse for Migraine: A Severe Adolescent Case Report

Claudio Lelis Souza[1], Ana Laura Ritter[1], Mônica Linhares Sachett*[2], Guilherme Gonçalves Nascimento[2], Brian Vicente[2], Ana Clara Freitas[1]

[1] unifenas, alfenas, Brazil

[2] FMABC, Santo Andre, Brazil

Introduction

Stevens-Johnson Syndrome (SJS) is a rare, life-threatening mucocutaneous adverse drug reaction, often triggered by medications like carbamazepine, with an incidence of 1-2 cases per million annually. It predominantly affects children and young adults, presenting with fever, mucosal erosions, and widespread epidermal detachment. Early recognition and aggressive immunosuppression are crucial to reduce mortality, which can exceed 10% in severe cases.

Case Presentation

A 14-year-old female adolescent presented to the emergency department with fever and a 2-day history of fissured lip lesions, progressing to pruritic cervical exanthem, scalp involvement, and genital dissemination. Initial maculopapular lesions evolved into widespread bullae covering nearly the entire tegument, accompanied by mucosal erosions (lips, tongue, hard palate), odynophagia, dysuria, burning sensation, and headache. She reported recent alcohol consumption followed by migraine, for which she mistakenly ingested her mother's carbamazepine (an anticonvulsant) in the dark. Due to severity, she was transferred to the intensive care unit. Diagnosis of SJS was confirmed clinically and histopathologically. Treatment included cyclosporine A (100 mg every 8 hours), intravenous immunoglobulin (2.7 g/kg for 3 days), and methylprednisolone pulse therapy. She had a favorable outcome, discharged after 21 days with only residual pigmentary sequelae.

Conclusion

This case underscores the risks of medication misuse, particularly carbamazepine in adolescents self-treating migraine. Prompt ICU transfer and multimodal immunosuppression were key to survival. Heightened awareness of iatrogenic triggers is essential to prevent delays in SJS management and improve prognosis.

EADV CONGRESS
VIENNA
30 SEP - 3 OCT 2026

Abstract N°: 2611

Vandetanib-Associated Cutaneous Lupus

Paula Arratibel Goenaga*[1], Maria Asunción Arregui Murua[1], Natalia Valero Montalvo[1], Nerea Infante Gonzalo[1], Sandro de Urban Chamorro San Juan[1], Susana Vildósola Esturo[1], Hirune Cembrero Saralegui[1], Ingrid Hiltun Cabredo[1], Mary Yohana Silva Carmona[1], Nerea Ormaechea Pérez[1]

[1] Hospital Universitario Donostia, Donostia-San Sebastián, Spain

Introduction

Drug-induced lupus is an uncommon entity that may present with cutaneous and/or systemic manifestations. Several drugs, including some tyrosine kinase inhibitors (TKIs), have been associated with lupus-like syndromes. Vandetanib, a TKI used in medullary thyroid carcinoma, has been linked to phototoxic reactions and, less frequently, to cutaneous lupus.

Case Presentation

A 63-year-old woman presented with a three-week history of cutaneous lesions affecting the face, trunk, and extremities. She had a history of medullary thyroid carcinoma and had been receiving vandetanib for two months. Physical examination revealed violaceous facial erythema and well-demarcated edematous plaques on the shoulders, elbows, dorsal aspects of the hands and feet, and knees, as well as scattered lesions on the upper back and neckline. There was no mucosal involvement, and the patient did not report systemic symptoms. Laboratory tests showed positive antinuclear antibodies (ANA, titer 1:1280, speckled pattern), negative extractable nuclear antigens (ENA), low C4 levels, and normal C3 levels. Histopathology demonstrated interface dermatitis with hydropic degeneration of the basal layer and a perivascular lymphocytic infiltrate, consistent with lupus. Vandetanib was discontinued, and treatment with topical corticosteroids and hydroxychloroquine was initiated, leading to complete resolution of the lesions within 4 months. Treatment with cabozantinib was subsequently started and was well tolerated, followed by salvage surgery with a good oncological outcome.

Conclusion

In this case, the compatible clinical features, the temporal relationship with the initiation of vandetanib, and the analytical and histological findings supported the diagnosis of vandetanib-induced lupus. In this entity, clinical suspicion is essential for early diagnosis and prompt withdrawal of the causative drug.

EA DV CONGRESS
VIENNA
30 SEP - 3 OCT 2026

Abstract N°: 2622

Management of Severe Scalp Granulomatous Lesions Secondary to Amivantamab with Hypertonic Saline and Trichloroacetic Acid: A case report

Carolina Pires Lellis*[1], Adriana Pessoa Mendes[2], Isabela Silva de Oliveira[3], Karin Perez Pavani[3]

[1] Irmandade Santa Casa de Misericórdia de São Paulo, São Paulo, Brazil

[2] Irmandade Santa Casa de Misericórdia de São Paulo, AC Camargo Cancer Center, São Paulo, Brazil

[3] AC Camargo Cancer Center, São Paulo, Brazil

Introduction

Epidermal growth factor receptor (EGFR) inhibitors are essential for treating metastatic cancer (1). Amivantamab is a bispecific antibody that binds simultaneously to EGFR and MET (mesenchymal-epithelial transition factor), blocking tumor growth and inducing the destruction of lung tumors (2). Since EGFR also regulates the proliferation of the epidermis and hair follicles, cutaneous side effects are frequently observed.

Acneiform eruptions are the earliest manifestations, followed by xerosis and fissures. Paronychia and hair growth alterations appear in later stages (1). Compared to previous therapies, Amivantamab may present distinct adverse reactions, requiring optimized management (3). We report the case of a patient with lung cancer undergoing Amivantamab treatment who developed severe cutaneous effects.

Case Presentation

A 57-year-old male patient was diagnosed with metastatic lung adenocarcinoma in May 2023. After disease progression on Osimertinib, a new protocol with Carboplatin, Pemetrexed, and Amivantamab was initiated in February 2024. Due to the papulopustular rash associated with the medication, the patient was already taking prophylactic doxycycline (200 mg/day). However, throughout 2024, he experienced scalp flare-ups with secondary infections, treated with cephalosporins, sulfamethoxazole/trimethoprim, and topical corticosteroids.

In February 2026, the papulopustular eruption worsened significantly, presenting with honey-colored (meliceric) crusts and purulent discharge. Amivantamab was temporarily suspended, and oral antibiotic therapy was administered for 14 days. Following the resolution of the acute infection, the patient developed friable granulomas across the entire scalp in areas previously affected by the papulopustular lesions.

Doxycycline was reintroduced, and topical treatment began to reduce the lesions. A 20% hypertonic NaCl dressing was used for two weeks to control exudate and reduce tissue tension. Following clinical improvement, weekly applications of 30% Trichloroacetic Acid (TCA) were initiated on each granulomatous lesion. The patient showed significant regression of the lesions, allowing for the continuation of Amivantamab treatment (Figure 1).

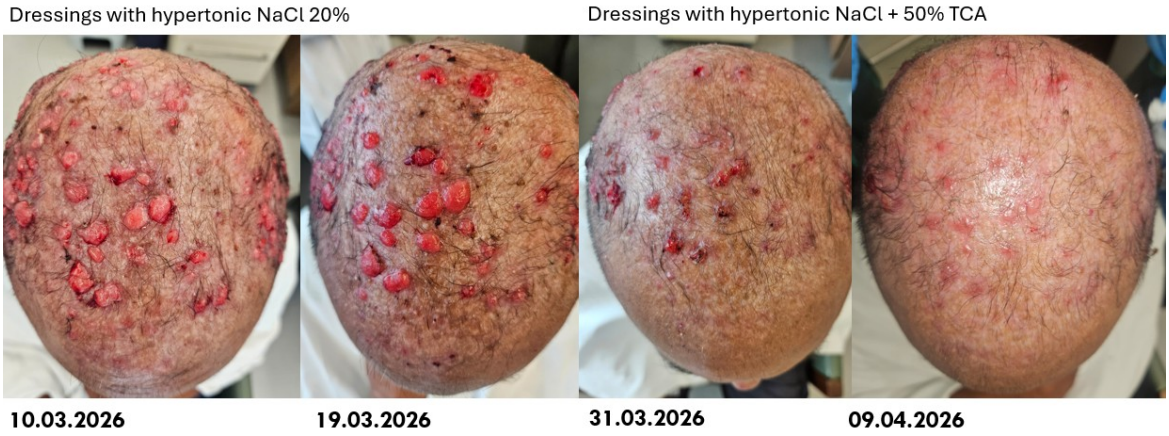

Conclusion

While EGFR inhibitors cause less systemic toxicity than traditional chemotherapy, their cutaneous reactions severely impact quality of life. Papulopustular eruption is the primary effect, typically occurring in seborrheic areas but capable of extending to the scalp (4)

Pyogenic granuloma-like lesions are primarily described in the periungual region. However, in oncology centers, these lesions have been increasingly observed in areas of prior trauma or infection specifically in patients using Amivantamab. This aligns with the reported case, where granulomas emerged over the site of the previous dermatosis.

Treatment options include surgery, laser, or chemical ablation (cryotherapy, silver nitrate, phenolization, or TCA). The use of hypertonic solutions (20% NaCl) helps reduce exudate and facilitates wound edge closure. Early recognition of these lesions is fundamental to providing adequate support and ensuring the continuity of oncological treatment.

EA DV CONGRESS
VIENNA
30 SEP - 3 OCT 2026

Abstract N°: 2626

Imatinib mesylate-Induced oral and cutaneous lichenoid eruption: A Case Report

Catherine Castelo Branco*[1], Simone Sant'Anna Gonçalves Barbosa[2], Julia de Almeida Nunes Murta[1], Maria Luísa Valadares[1], Luciana Pantaleão[2], Karin Soares Cunha[2], Danielle Castex Conde[2], Leticia Cogo Marques[3], Arley Silva Junior[2], Livia Pino[1], Carlos Arthur de Figueiredo Athayde[1]

[1] Fluminense Federal University, Antonio Pedro University Hospital, Department of Dermatology, Niterói, Rio de Janeiro, Brazil

[2] Fluminense Federal University, Antonio Pedro University Hospital, Department of Pathology, Niterói, Rio de Janeiro, Brazil

[3] Technological Innovation Cell of Odontoclínica Central da Marinha, Rio de Janeiro, Brazil

Introduction

Lichenoid eruptions (LE) are inflammatory mucocutaneous reactions mainly associated with drug exposure. They result from a delayed hypersensitivity response mediated by cytotoxic T lymphocytes, leading to keratinocyte apoptosis and damage to the epithelial-connective tissue [1,2]. Clinically, LE presents as pruritic erythematous-violaceous papules and plaques, usually affecting the trunk and extremities, with eczematous or psoriasiform features. Oral involvement is uncommon and resembles oral lichen planus, with asymmetric whitish striae, erosions, and ulcerations [3]. Diagnosis relies on clinicopathological correlation and medication history. We report a case of cutaneous and oral LE associated with imatinib therapy in a patient with chronic myeloid leukemia (CML).

Case Presentation

A 66-year-old woman with hypertension, diabetes mellitus, congestive heart failure, hypothyroidism, depression, and CML had been receiving imatinib mesylate 400 mg/day for 18 months. Lesions developed approximately eight months after treatment initiation, while the remaining medications had been unchanged for six years.

Physical examination revealed pruritic erythematous scaly plaques on the chest, abdomen, back, lower limbs, and gluteal region. Oral examination showed non-removable white striae on the tongue, buccal mucosa, hard palate, and labial mucosa, associated with erosive areas causing difficulty with food intake. Laboratory tests and serologies were unremarkable. Dermoscopy demonstrated Wickham striae.

Incisional biopsies were performed. Cutaneous histopathology showed orthokeratotic epidermis with irregular acanthosis, necrotic keratinocytes, and basal vacuolar degeneration. The superficial dermis showed a lichenoid lymphohistiocytic infiltrate with scattered eosinophils, a mild deep perivascular inflammatory infiltrate and focal erythrocyte extravasation. Oral histopathology demonstrated hyperorthokeratotic and hyperparakeratotic areas, acanthosis, atrophy, focal basal layer degeneration and civatte bodies. The underlying connective tissue exhibited a moderate band-like chronic subepithelial lymphocytic infiltrate. Clinicopathological correlation confirmed the diagnosis of LE and oral lichenoid lesions (OLLs).

Initial treatment included systemic corticosteroids, emollients, and oral antihistamines, with partial improvement. Due to persistent lesions, imatinib was replaced with dasatinib 100 mg/day. Fifteen days after withdrawal, complete remission of oral lesions and only residual cutaneous hyperpigmentation were observed.

Conclusion

Imatinib is a first-generation tyrosine kinase inhibitor widely used for CML and gastrointestinal stromal tumors. Although generally well tolerated, it may induce cutaneous adverse effects [4,5], while LE and mucosal involvement remain uncommon [6].

The latency period ranges from one to twelve months and appears dose-dependent, occurring mainly with doses ≥400 mg/day [5]. Although the patient was receiving other medications potentially associated with LE, the temporal association and lesion remission after imatinib discontinuation support its causal role.

In oncologic patients, discontinuation of the offending agent is not always feasible because of the risk of progression of the underlying disease. Switching to second- or third-generation tyrosine kinase inhibitors may represent an alternative, as these agents are associated with fewer adverse effects [6]. However, in the present case, substitution with another first-generation tyrosine kinase inhibitor did not result in further cutaneous adverse events.

A review of the literature identified 50 reported cases of oral adverse effects associated with imatinib therapy [7]. Oral hyperpigmentation was the most common manifestation, followed by OLLs, which were reported in 42% of patients. Thus, this case highlights the importance of oral examination in drug-induced reactions, given their potential impact on patients' quality of life.

EADV CONGRESS
VIENNA
30 SEP - 3 OCT 2026

Abstract N°: 2660

Along the Lines of Blaschko: A Linear Lichenoid Eruption Associated With Pembrolizumab

Margarida Vaz Lopes*[1], Milton Rosa[1], Bruno Vendeira[1], Gustavo Almeida-Silva[1], Marta Barbosa[1], Irina Medvedyeva-Havenko[1], Pedro de Vasconcelos[1, 2], Joana Antunes[1, 2], Paulo Filipe[1, 2]

[1] Dermatology Department, Hospital de Santa Maria, Lisbon, Portugal

[2] Dermatology University Clinic, Faculty of Medicine, University of Lisbon, Lisbon, Portugal

Introduction

Lichen planus is an immune-mediated inflammatory dermatosis characterized by pruritic, violaceous papules that favor the extremities. Lichenoid or lichen planus–like eruptions may represent cutaneous adverse drug reactions, including the well-recognized toxicity associated with immune checkpoint inhibitors (ICIs), particularly anti–PD-1 agents. Linear forms with a Blaschkoid distribution are rare and may pose a diagnostic challenge.

Case Presentation

We report the case of a 34-year-old woman with triple-negative breast cancer treated with neoadjuvant chemotherapy, oncologic surgery, radiotherapy, and adjuvant capecitabine plus pembrolizumab. She was referred to the Dermatology Department for evaluation of a unilateral skin eruption that developed a few weeks after initiation of adjuvant treatment. Physical examination revealed pruritic, erythematous-violaceous, infiltrated, scaly linear plaques distributed along the lines of Blaschko, involving the posterior aspect of the left leg and ipsilateral trunk. No oral or genital mucosal involvement nor nail changes were observed.

The main differential diagnoses included lichen striatus and a therapy-related lichenoid eruption. A skin biopsy was performed. Histopathology showed features consistent with lichen planus, including wedge-shaped hypergranulosis with overlying orthokeratotic hyperkeratosis, basal cell vacuolar degeneration with scattered necrotic keratinocytes, and a band-like lymphocytic infiltrate in the superficial dermis. In clinicopathologic correlation, these findings supported the diagnosis of linear lichen planus.

Topical clobetasol propionate cream was initiated, resulting in progressive improvement with reduced infiltration and pruritus. Complete resolution was observed after completion of pembrolizumab according to the planned oncologic regimen.

Conclusion

ICI-related lichen planus-like eruptions have been increasingly described and may rarely present with atypical patterns, including a linear Blaschkoid distribution. Although concomitant medications may have contributed, the temporal relationship, clinical morphology, and histopathologic findings strongly support an ICI-related cutaneous adverse event. Management is usually conservative, with topical corticosteroids being effective in most cases. Early recognition is essential to avoid unnecessary interruption of oncologic therapy and to optimize multidisciplinary care.

EADV CONGRESS
VIENNA
30 SEP - 3 OCT 2026

Abstract N°: 2695

Acneiform eruption induced by gefitinib in EGFR-mutated lung squamous cell carcinoma: successful management with doxycycline and topical therapy

Julia Cascardo Géo de Siqueira*[1], Maria Eduarda Cesar Garcez[1], Amanda Quintaes[1], Aline Bressan[1], Bruno Nunes[1]

[1] Pedro Ernesto University Hospital, Rio de Janeiro State University (UERJ), Rio de Janeiro, Brazil

Introduction

Epidermal growth factor receptor (EGFR) tyrosine kinase inhibitors, such as gefitinib, are associated with a high incidence of cutaneous adverse events, particularly acneiform eruptions. These reactions may affect treatment adherence but can also correlate with therapeutic response. A gefitinib-induced acneiform eruption is described, with successful dermatological control enabling uninterrupted oncologic therapy.

Case Presentation

A 70-year-old male with EGFR-mutated lung squamous cell carcinoma (exon 19 deletion) with locally advanced disease, referred from oncology to dermatology, received gefitinib 250 mg daily. Six months after treatment initiation, he developed a papulopustular eruption involving seborrheic areas of the face, neck, upper trunk, and upper extremities, associated with erythema and crusted lesions. Additionally, the patient reported darkening of hair color during treatment. No systemic symptoms were observed.

Dermatological evaluation confirmed an acneiform eruption consistent with EGFR inhibitor toxicity. Skin biopsy revealed epidermal hyperkeratosis, irregular acanthosis, intraepidermal pustule formation and a moderate perivascular mononuclear inflammatory infiltrate in the dermis, supporting a drug-induced inflammatory follicular process.

The patient was treated with oral doxycycline 200 mg daily combined with topical therapy including antibacterial and keratolytic agents, emollients and photoprotection. Sustained combined therapy resulted in marked clinical improvement and complete resolution of the eruption, without requiring gefitinib dose reduction or interruption. A favorable oncologic response was also achieved, with adequate disease control and stability.

Conclusion

Acneiform eruption is the most common cutaneous toxicity associated with EGFR inhibitors, typically presenting within weeks of therapy initiation. Although the pathogenesis involves disruption of epidermal homeostasis and follicular inflammation, most cases are manageable with oral tetracyclines and topical anti-inflammatory agents. Notably, skin toxicity correlate with oncologic response, reinforcing the importance of maintaining targeted therapy whenever possible.

This case highlights the effectiveness of combined systemic doxycycline and topical management in controlling moderate to severe gefitinib-induced acneiform eruption, allowing continuation of targeted anticancer treatment without dose reduction or discontinuation. Early recognition and appropriate management are essential to optimize dermatologic outcomes and to maintain oncologic therapy adherence.

EADV CONGRESS
VIENNA
30 SEP - 3 OCT 2026

Abstract N°: 2706

Erosive pustular dermatosis of the scalp during amivantamab therapy: a rare and specific anti-EGFR/anti-MET toxicity

Mira Tfaily*[1], Candice Lesage[1]

[1] L'Institut du Cancer de Montpellier, Montpellier, France

Introduction

Amivantamab is a bispecific monoclonal antibody targeting both EGFR and MET pathways, recently approved for the treatment of selected EGFR-mutated non-small cell lung carcinomas. Cutaneous adverse events are among the most frequent toxicities associated with EGFR inhibition and commonly include papulopustular eruptions, xerosis, pruritus, paronychia, and hair alterations. In contrast, severe inflammatory scalp involvement remains exceedingly uncommon. Emerging reports suggest that amivantamab may induce a distinctive pattern of scalp toxicity characterized by erosive and pustular lesions, clinically consistent with erosive pustular dermatosis of the scalp. This entity may follow a severe course with extensive erosions, chronic inflammation, secondary infection risk, and potential progression to cicatricial alopecia. Owing to the recent introduction of amivantamab in clinical practice, recognition and optimal management of these severe cutaneous adverse events remain poorly defined.

Case Presentation

A 72-year-old patient treated with amivantamab for EGFR-mutated pulmonary adenocarcinoma presented after two treatment cycles with a severe inflammatory dermatosis of the scalp characterized by diffuse, painful and exudative erosions with thick adherent crusts. The clinical presentation was highly suggestive of erosive pustular dermatosis of the scalp. Initial management with doxycycline 100 mg twice daily, combined with topical betamethasone and cetirizine, failed to achieve clinical improvement. The eruption progressed despite transient interruption of amivantamab therapy. Given the severity and persistence of the lesions, systemic corticosteroid therapy with methylprednisolone at 0.4 mg/kg/day was initiated, resulting in rapid and marked clinical improvement, with re-epithelialization of erosive lesions, resolution of exudation, and significant pain control.

Conclusion

Severe forms of erosive pustular dermatosis of the scalp may belong to the spectrum of cutaneous toxicities induced by amivantamab. Although acneiform eruption, xerosis, pruritus, and nail toxicity are well-recognized adverse events of anti-EGFR therapies, this pattern of scalp involvement appears exceptional and potentially specific to this agent. Rare cases of inflammatory scalp reactions associated with amivantamab have been reported in the literature under various clinical presentations. In our case, standard supportive measures, including tetracycline-class antibiotics, topical corticosteroids, and temporary treatment interruption, were insufficient. The rapid response to systemic corticosteroids suggests their potential benefit in extensive, inflammatory, and painful forms.

Amivantamab may induce severe erosive pustular dermatosis of the scalp, with a rare and specific clinical pattern, and systemic corticosteroid therapy may be effective in forms refractory to standard management.

EA DV CONGRESS
VIENNA
30 SEP - 3 OCT 2026

Abstract N°: 2711

Clinico-pathological study of Cutaneous adverse Drug Reactions at a Tertiary care centre in North-east India - A hospital based Cross-sectional study

Saqib Raza Hasan Khan*[1], Shikha Thakur[1], Anita Marak[1], Biswajit Dey[1]

[1] North Eastern Indira Gandhi Regional Institute of Health & Medical Science, Shillong, India

Introduction

Cutaneous adverse drug reactions (CADRs) are among the most common manifestations of adverse drug reactions, ranging from mild self-limiting eruptions to severe life-threatening conditions such as Stevens–Johnson syndrome/toxic epidermal necrolysis (SJS/TEN) and drug reaction with eosinophilia and systemic symptoms (DRESS). The clinical spectrum and causative drugs vary across geographic and ethnic populations. Literature from this region remains limited despite its unique ethnic diversity and prescribing practices. This study aimed to evaluate the clinical and histopathological spectrum of CADRs and identify the commonly implicated drugs at a tertiary care centre..

Materials and Methods

A hospital-based cross-sectional study was conducted in the Department of Dermatology from June 2024 to May 2025. Consecutive sampling was performed, and all patients clinically diagnosed with cutaneous adverse drug reactions (CADRs) who consented for histopathological evaluation were included in the study. Detailed demographic, clinical, and drug histories were recorded. Skin punch biopsy was performed in all recruited patients, and histopathological examination was carried out using hematoxylin and eosin staining. WHO-UMC causality assessment criteria were used for causality assessment, and SCORTEN scoring was applied in SJS/TEN cases. Data were analysed using descriptive statistics.

Results

A total of 51 patients with CADRs were included, corresponding to a prevalence of 0.59% among dermatology outpatients. The mean age was 40.1 ± 15.4 years, with male predominance (58.8%). Fixed drug eruption (FDE) was the most common CADR (37.3%), followed by drug-induced exanthem (19.6%). Severe CADRs included SJS/TEN (13.7%) and DRESS (11.8%). Antibiotics were the most frequently implicated drug class (49.1%), followed by NSAIDs (15.6%) and antiepileptics (11.7%). Polypharmacy and fixed-dose combinations were frequently observed. Clinically, lesions showed marked morphological heterogeneity, including macules, plaques, bullae, pustules, erosions, and erythroderma. Severe reactions were commonly associated with systemic involvement, particularly hepatic, renal, and hematological abnormalities. Histopathological examination demonstrated heterogeneous but characteristic reaction patterns. Interface dermatitis, especially lichenoid and vacuolar patterns, was the predominant finding, followed by spongiotic dermatitis and mixed inflammatory patterns. Frequent histological features included basal cell vacuolar degeneration, spongiosis, necrotic keratinocytes, pigment incontinence, and dermal inflammatory infiltrates rich in lymphocytes and eosinophils. Multiple histopathological patterns often coexisted within the same biopsy specimen.

Conclusions

CADRs represent a clinically diverse and diagnostically challenging group of disorders. FDE and drug-induced exanthem were the predominant reaction patterns, while severe CADRs contributed substantially to morbidity. Antibiotics, NSAIDs, and antiepileptics were the leading implicated drug groups. Histopathological examination served as an important supportive diagnostic tool, particularly in clinically overlapping presentations. The study highlights the importance of early recognition, clinicopathological correlation, rational prescribing practices, and region-specific pharmacovigilance data in improving patient safety and reducing morbidity associated with CADRs.

EA DV CONGRESS
VIENNA
30 SEP - 3 OCT 2026

Abstract N°: 2713

Cutaneous toxicities of immune checkpoint inhibitors: a systematic review of distribution profiles and prognostic implications across therapeutic classes

Maryam Benssied*[1], RACHID FRIKH[1], SABER BOUTAYEB[2]

[1] Department of Dermatology, Military Hospital of Instruction Mohammed V, RABAT, Morocco

[2] Mohammed VI Center for Research and Innovation, RABAT, Morocco

Introduction

Immune checkpoint inhibitors (ICIs) have revolutionized the management of advanced malignancies. Among immune-related adverse events (irAEs), cutaneous toxicities represent the most frequent and earliest manifestations, posing a significant diagnostic and therapeutic challenge in dermato-oncology. Despite their clinical relevance, a comprehensive class-specific characterization remains lacking.

Materials and Methods

A systematic review was conducted following PRISMA guidelines, based on a PubMed search of publications up to December 2024, with no initial date restriction. Phase II and III randomized controlled trials reporting cutaneous adverse events graded according to CTCAE v5.0 were eligible. Eighteen trials were included, encompassing 5,978 patients treated with anti-PD-1, anti-PD-L1, anti-CTLA-4 agents, or combination regimens, across multiple tumor types including melanoma, urothelial carcinoma, and non-small cell lung cancer.

Results

Overall cutaneous toxicities (all grades) were reported in 30–50% of patients. Pruritus was the most prevalent manifestation, with weighted mean rates of 14.3% (anti-PD-1), 10.1% (anti-PD-L1), 31.6% (anti-CTLA-4), and 22.2% (combination regimens). Rash followed a similar pattern: 13.0%, 12.2%, 29.6%, and 14.0%, respectively. Anti-CTLA-4 agents were associated with early-onset (weeks 3–6), diffuse maculopapular eruptions, while anti-PD-1 agents induced later reactions (weeks 6–12), predominantly lichenoid, psoriasiform, or eczematous in morphology. Vitiligo was nearly exclusively reported under anti-PD-1 therapy and emerged as a potential biomarker of favorable tumor response. Combination regimens carried the highest risk of cutaneous toxicity in both frequency and severity.

Table 1. Cutaneous Toxicity Profiles by ICI Class — Summary of Systematic Review Findings

Based on 18 randomized controlled trials (n = 5,978 patients) | CTCAE v5.0 grading

ICI CLASS	PRURITUS (%)	RASH (%)	ONSET	PREDOMINANT MORPHOLOGY	SEVERITY RISK
Anti-PD-1	14.3%	13.0%	Weeks 6–12	Lichenoid, psoriasiform, eczematous, vitiligo	Low–Moderate
Anti-PD-L1	10.1%	12.2%	Weeks 6–12	Mild eczematous, maculopapular rash	Low
Anti-CTLA-4	31.6%	29.6%	Weeks 3–6	Diffuse maculopapular eruption, urticaria	Moderate–High
Combination (anti-PD-1 + anti-CTLA-4)	22.2%	14.0%	Variable	Overlap patterns, severe irAE spectrum	Highest

ICI: immune checkpoint inhibitor · irAE: immune-related adverse event · CTCAE: Common Terminology Criteria for Adverse Events · PD-1: programmed cell death protein 1 · PD-L1: programmed death-ligand 1 · CTLA-4: cytotoxic T-lymphocyte-associated protein 4. Percentages represent weighted mean rates (all grades) across included trials.

Systematic review (PRISMA) | PubMed search up to December 2024 | 18 RCTs included

Conclusions

This systematic review demonstrates distinct class-specific cutaneous toxicity profiles under ICI therapy, with a predominance of mild-to-moderate reactions but specific high-risk patterns warranting vigilance. Early dermatological input within oncological follow-up is essential. Certain cutaneous manifestations — notably vitiligo and lichenoid eruptions — may represent non-invasive clinical biomarkers of immunotherapy efficacy, supporting a paradigm shift toward integrated dermato-oncological monitoring.

EADV CONGRESS
VIENNA
30 SEP - 3 OCT 2026

Abstract N°: 2739

Cutaneous drug reaction induced by enfortumab-vedotin: a review through three cases.

María Isabel Coll-Camps*[1], Blanca Garcia-Agúndez[1], Pablo Bonete-Villaescusa[1], Clara Buendía-Martínez[1], Sonsoles Berenguer-Ruiz[1], Mario Aparicio-Dominguez[1], Patricia Muñoz-Hernández[1], Mar Llamas-Velasco[1], Raquel Sampedro-Ruiz[1]

[1] Hospital Universitario De La Princesa, Madrid, Spain

Introduction

Enfortumab vedotin (EV) is a monoclonal antibody that targets nectin-4 conjugated to monomethyl auristatin E. It has been approved since 2024 in Spain as first-line treatment for advanced urothelial carcinoma (UC). Cutaneous toxicity associated with EV is common, with an incidence of up to 49% patients, of witch approximately 10% present a severe form. These manifestations exhibit marked clinical heterogeneity. As of today there are no management standardized protocols.

Case Presentation

We present three cases of cutaneous toxicity associated with EV. The first case involved a 72-year-old woman with advanced UC, treated with EV and pembrolizumab (PZ) as second-line therapy. She developed alopecia, pruritus, and vesicular lesions in flexural areas after 9 months of treatment. The second case involved a 78-year-old woman with metastatic UC treated with EV as third-line therapy. She presented with a symmetrical, predominantly intertriginous and flexural rash 48 hours after starting with EV. The third case is a 60-year-old man with metastatic urothelial carcinoma treated with EV and PZ as first-line therapy. Sixteen days later, he developed bilateral pretibial erythematous plaques with deep ulcerations and associated lymphedema.

Histopathological examination showed epidermal dysmaturation with ring-burst mitoses in all cases. Cases 2 and 3 presented with severe cutaneous toxicity (grade 2 and 3 according to CTCAE). Therapeutic management included high-potency topical corticosteroids in all cases. Regarding EV, the dose was maintained in the first case, reduced by 20% in the second, and in the third, due to the greater intensity and extent of the lesions associated with subsequent infusions, definitive discontinuation was indicated. Currently, cases 1 and 2 remain asymptomatic after 7 and 3 months of follow-up, respectively. In case 3, the drug is currently suspended.

Conclusion

Consistent with the literature, our cases reflect the clinical variability of cutaneous toxicity associated with EV. In case 2 and 3, toxicity appeared during the first cycle of EV, as previously described; however, in case 1 appeared in the fourteenth cyle of EV which suggests that it should also be considered in any new late cutaneous manifestation after starting the drug. Given its increasing use as first-line therapy in advanced ulcerative colitis, specialized dermatological management is key to ensuring the safety of patients who benefit from taking the drug.

POWERED BY M-ANAGE.COM

EADV CONGRESS
VIENNA
30 SEP - 3 OCT 2026

Abstract N°: 2819

Behind the Diphtheria Mask: Unmasking Angioimmunoblastic T-Cell Lymphoma Amid Apparent Drug Hypersensitivity

Shamin Gholami Noudeh*[1], Yasmine Safta[1], Richard Daly[1], Richard Watchorn[1]

[1] Beaumont Hospital, Connolly Hospital, Dublin, Ireland

Introduction

Angioimmunoblastic T-cell lymphoma (AITL) is a rare and aggressive peripheral T-cell lymphoma frequently associated with constitutional symptoms, immune dysregulation, eosinophilia and polymorphous cutaneous eruptions that may mimic infection or drug hypersensitivity. Distinguishing lymphoma associated skin manifestations from true drug reactions can be diagnostically challenging, particularly in patients exposed to multiple antimicrobials.

Case Presentation

A 59-year-old man presented with recurrent severe tonsilitis causing profound dysphagia secondary to bilateral tonsillar swelling. He was managed for sepsis in the context of persistent tachycardia, hypovolaemia and recurrent pyrexia. Blood cultures and Monospot testing were negative.

Prior to admission he had received multiple courses of antimicrobials including co-amoxiclav, phenoxymethy|pencillin and metronidazole. During his admission he received co-amoxiclav, metronidazole, ceftriaxone, meropenem and intravenous dexamethasone according to a diphtheria treatment protocol. Corynebacterium diphtheria was detected on PCR throat swab, although it was not isolated on culture. Lactate dehydrogenase was elevated at 531 U/L (reference range 120-246 U/L).

During administration of the diphteria antitoxin, he developed flushing and tachycardia, requiring temporary interruption of infusion before completion. The following day he developed a widespread erythematous maculopapular eruption involving the chest, abdomen and back without mucosal involvement. A hypersensitivity reaction to the antitoxin was initially suspected given the temporal association and preceding infusion reaction. Serial eosinophils rose from 0.32 $\times 10^9$/L to 0.60 $\times 10^9$/L prior to antitoxin administration, peaking at 0.95 $\times 10^9$/L before normalising. Two skin biopsies showed spongiotic dermatitis with perivascular inflammation and rare eosinophils and neutrophils, in keeping with drug hypersensitivity reaction.

The eruption improved following withdrawal of suspected agents and topical mometasone 1%. Despite this, the patient remained systemically unwell with ongoing tachycardia, pyrexia and clinical deterioration requiring intensive care. Re-exposure to piperacillin/tazobactam and meropenem was associated with recurrence of the rash, further supporting a drug related process. Persistent lymphadenopathy prompted haematological investigation. Lymph node biopsy showed an abnormal T cell infiltrate, and excisional biopsy confirmed Angioimmunoblastic T-cell lymphoma, partially CD30 positive. The patient commenced chemotherapy and will likely be considered for stem cell transplant after six cycles of treatment.

Conclusion

This case highlights the diagnostic difficulty in distinguishing drug hypersensitivity reactions from cutaneous manifestations of AITL, particularly in the setting of severe infection, multiple antimicrobial exposures and corticosteroid therapy.

Although skin histopathology suggested drug hypersensitivity, interpretation was complicated by the known association of AITL with eosinophilia, immune dysregulation and polymorphous eruptions that may mimic drug

reactions clinically and histologically. While recurrence after antimicrobial re-exposure supported a drug component, the rash was likely multifactorial, potentially reflecting both drug and lymphoma-related processes. Persistent systemic inflammation, eosinophilia and recurrent rash despite infection management should prompt consideration of an underlying haematological malignancy when features overlap.

EA DV CONGRESS
VIENNA
30 SEP - 3 OCT 2026

Abstract N°: 2837

Practice-Based Management of Cutaneous and Nail Toxicities in Breast Cancer: A Six-Case Series

Dragana Marušić*[1], Vedrana Bulat[2], Liborija Lugović-Mihić[3], Lucija Zanze[4], Ema Barac[4], Bruno Špiljak[5]

[1] General Hospital Karlovac, Karlovac, Croatia

[2] Sestre Milosrdnice University Hospital Centre, Department of Dermatology and Venereology, Zagreb, Croatia

[3] Sestre Milosrdnice University Hospital Centre, Department of Dermatology and Venereology, Zagreb, Croatia, School of Dental Medicine, Department of Dermatology and Venereology, Zagreb, Croatia

[4] Family Physician Office, University Hospital Centre Sestre Milosrdnice, Zagreb, Croatia

[5] University of Zagreb, School of Dental Medicine, Department of Oral Medicine, Zagreb, Croatia

Introduction

Cutaneous and nail adverse events are among the most common non-haematologic toxicities in breast cancer and occur across chemotherapy, targeted therapy, hormonal therapy, radiotherapy, and immunotherapy. They are highly visible, often painful, and may significantly impair quality of life, leading to psychosocial distress, reduced treatment adherence, and, in severe cases, dose reductions, treatment delays, or discontinuation of effective oncologic regimens. In addition to skin and nail involvement, mucosal changes may also arise as part of the toxicity spectrum of modern oncologic therapies and should be carefully recognised and managed in clinical practice. As treatment regimens become more complex and multimodal, the spectrum of skin, nail and mucosal reactions broadens, underscoring the need for early recognition, accurate classification, and multidisciplinary supportive care.

Case Presentation

We retrospectively reviewed six breast cancer patients who developed clinically relevant cutaneous and/or nail toxicities during systemic treatment and were evaluated in a dermatology setting. For each case, we considered the oncologic regimen, clinical morphology and distribution of lesions, temporal association with treatment, and working diagnosis, and management decisions were aligned with current evidence-based recommendations for prevention and treatment of toxicities related to chemotherapy and targeted therapy. Representative clinical photographs were selected for poster presentation to illustrate typical patterns and practical therapeutic approaches.

The series included palmar erythema with desquamation consistent with hand–foot syndrome in a patient receiving capecitabine, a palmar targetoid eruption compatible with erythema exudativum multiforme following adjuvant chemotherapy, and two nail presentations associated with anthracycline–taxane-based regimens, namely onychomadesis with subungual haemorrhages and a periungual pyogenic granuloma localised to the proximal nail fold. Additional toxicities comprised a sharply demarcated phototoxic erythema with maculopapular rash confined to sun-exposed areas after fluorouracil-based chemotherapy and an erythematous, scaly drug-induced dermatitis of the lower leg in a patient treated with ribociclib and letrozole, reflecting emerging cutaneous reactions to CDK4/6 inhibitor–containing regimens. Management across these scenarios relied on morphology-adapted supportive care, including emollient- and corticosteroid-based topical regimens, patient education on avoidance of heat, friction, and ultraviolet exposure, procedural treatment of periungual vascular tissue where indicated, and close collaboration with oncology regarding possible dose modification or temporary interruption in more severe cases.



Figure 1. Representative clinical photographs of the six described cases: (A) palmar erythema with superficial desquamation compatible with hand–foot syndrome in a patient on capecitabine; (B) targetoid eruption on the palms consistent with erythema exudativum multiforme; (C) proximal nail plate shedding (onychomadesis) with overlying subungual haemorrhages during anthracycline–taxane treatment; (D) periungual vascular papule consistent with pyogenic granuloma occurring after taxane-based chemotherapy; (E) sharply demarcated erythema with a maculopapular component restricted to sun-exposed sites following fluorouracil-based chemotherapy; (F) erythematous, scaly dermatitis of the lower leg interpreted as a drug-induced reaction in a patient treated with ribociclib and letrozole

Conclusion

This six-case series illustrates the diversity of cutaneous and nail toxicities encountered in breast cancer patients, from classic hand–foot syndrome and chemotherapy-induced phototoxic reactions to nail changes and inflammatory dermatoses related to contemporary combination therapies. By integrating dermatologic expertise into routine oncologic care and applying morphology-directed, evidence-based interventions, many of these visible and distressing adverse events can be mitigated, helping to maintain treatment adherence and improve the overall therapeutic experience of breast cancer patients. The accompanying clinical images provide a visual framework for recognising these reactions and implementing timely, supportive care in everyday practice.

EA DV CONGRESS
VIENNA
30 SEP - 3 OCT 2026

Abstract N°: 2867

Black Hairy Tongue in a 9-Month-Old Infant Following Amoxicillin-Clavulanate Therapy: A Rare Pediatric Case Report.

Adriana Beltrão*[1], Carolina Cruz[1], Carla De Marque[1], Gustavo Bedin[1]

[1] University of Mogi das Cruzes, Sao Paulo, Brazil

Introduction

Black hairy tongue (BHT), also known as lingua villosa nigra, is a rare benign condition characterized by discoloration, elongation, and hypertrophy of the filiform papillae on the dorsal surface of the tongue. Although commonly reported in adults, BHT is uncommon in children and exceptionally rare in infants. Several antibiotics, including amoxicillin-clavulanate, have been associated with defective desquamation of the filiform papillae, leading to the formation of elongated hair-like projections.

Case Presentation

A 9-month-old infant developed black discoloration of the tongue seven days after initiation of amoxicillin-clavulanate therapy for bacterial pneumonia. Two days after the appearance of the lesion, a white plaque developed over the pigmented area. The patient had no history of poor oral hygiene, dietary changes, or other known risk factors associated with black hairy tongue.

Clinical examination was consistent with black hairy tongue associated with antibiotic use (Figure 1). The patient's mother was instructed to gently brush the tongue using a silicone finger toothbrush designed for infants. No additional treatment was prescribed. Complete resolution of the lesions was observed after two weeks.

Differential diagnoses considered included oral hairy leukoplakia, pigmented fungiform papillae, acanthosis nigricans, Addison's disease, and exogenous staining caused by food colorants.



Figure 1. Progressive clinical evolution of black hairy tongue in a 9-month-old infant associated with amoxicillin-clavulanate therapy. (A) Initial presentation with dark discoloration of the dorsal tongue surface seven days after initiation of antibiotic therapy. (B) Development of a white plaque over the pigmented area nine days after antibiotic initiation. (C) Complete resolution of the lesions fifteen days later following conservative management with gentle tongue brushing.

Conclusion

This case highlights black hairy tongue as a rare and self-limited adverse effect of amoxicillin-clavulanate therapy in infancy. Recognition of this benign condition is important to avoid unnecessary diagnostic investigations and treatments. Conservative management with reassurance and gentle tongue brushing was sufficient for complete resolution.

EADV CONGRESS
VIENNA
30 SEP - 3 OCT 2026

Abstract N°: 2885

Pemphigoid-like bullous drug eruption associated with rivaroxaban: A case report

Hind Majdoul*[1], Fouzia Hali[1], Fatimazahrae Benhayoun[1], Bouchra Baghad[1], Hanane Rachadi[1], Soumiya Chiheb[1]

[1] Dermatology and Venereology Department, Ibn Rochd University Hospital, Casablanca, Morocco

Introduction

Bullous pemphigoid (BP) is the most common autoimmune blistering disease in the elderly. Certain drugs may induce clinical presentations resembling BP; however, distinguishing true drug-induced BP from a pemphigoid-like eruption can sometimes be challenging, particularly in the absence of specific immunopathological findings. Direct oral anticoagulants (DOACs), especially rivaroxaban, have recently been associated with rare bullous eruptions of this type.

We report a case of a pemphigoid-like bullous drug eruption probably induced by rivaroxaban, highlighting the diagnostic challenges posed by these borderline presentations.

Case Presentation

A 76-year-old female patient with a history of hypertension treated with ramipril and acetylsalicylic acid and two previous cardioembolic ischemic strokes in 2021 and 2023, after which treatment was modified by the introduction of rivaroxaban and rosuvastatin, presented with a pruritic bullous skin eruption that appeared two months after initiation of the new medications, with preserved general condition. Dermatological examination revealed a generalized bullous eruption composed of tense bullae, partially confluent, arising on an urticarial base, without associated mucosal or adnexal involvement. Skin biopsy demonstrated an intraepidermal split with acantholysis and eosinophilic infiltrate, suggestive of superficial pemphigus. However, given the clinicopathological discordance, a second biopsy with direct immunofluorescence (DIF) was performed. This showed a subepidermal blister without acantholysis, associated with a mild eosinophilic infiltrate, consistent with a bullous dermatosis of the pemphigoid type. Nevertheless, in the absence of specific immunopathological findings, notably negative direct and indirect immunofluorescence (IIF), the diagnosis of bullous pemphigoid could not be definitively established, favoring instead a pemphigoid-like bullous drug eruption. Pharmacological assessment using the Bégaud method showed low but compatible intrinsic imputability (I1C1S1) for all three medications. Despite a stronger bibliographic imputability for ramipril (B4), the chronological relationship between drug introduction and lesion onset, together with literature data, mainly pointed toward rivaroxaban. Management consisted of initiating topical therapy with very potent corticosteroids using clobetasol propionate 0.05% cream at an initial dose of 30 g/day with gradual tapering, combined with withdrawal of the suspected drug, rivaroxaban, which was replaced by apixaban in consultation with the cardiologist. The outcome was favorable within a few weeks, with no recurrence after more than one year of follow-up.

Conclusion

Bullous drug eruptions associated with DOACs are rare and likely underrecognized. Among these agents, rivaroxaban is the most frequently reported in pemphigoid-type bullous dermatoses. Clinically, these eruptions often resemble classic bullous pemphigoid, with tense, pruritic bullae on an urticarial background in elderly patients. Histology may reveal a subepidermal blister with eosinophilic infiltrate, although immunopathological

findings are often inconsistent. The distinction between true drug-induced BP and pemphigoid-like drug eruptions remains challenging, especially when DIF and IIF are negative. Our case illustrates these diagnostic difficulties. Although the clinical presentation strongly suggested BP, persistently negative DIF and IIF findings favored a pemphigoid-like bullous drug eruption rather than definite BP. The compatible temporal relationship, rapid improvement after rivaroxaban withdrawal, and absence of recurrence after more than one year support the probable involvement of rivaroxaban. This case underlines the need to consider pemphigoid-like drug eruptions in patients developing atypical bullous dermatoses while receiving DOACs.

EA DV CONGRESS
VIENNA
30 SEP - 3 OCT 2026

Abstract N°: 2891

Kratom-induced Hyperpigmentation: An Emerging Entity for Facial Hyperpigmentation

Michelle Sze Yiu Leung*[1], Vladislav Degtiarev[1], Chaocheng Liu[2]

[1] University of Alberta, Edmonton, Canada

[2] University of British Columbia, Vancouver, Canada

Introduction

Kratom (Mitragyna speciosa), a Southeast Asian tree historically consumed in Thailand and Malaysia for stimulant and analgesic effects, has rapidly expanded globally as a self-medication for opioid withdrawal, chronic pain, anxiety, and depression. Although systemic adverse effects of kratom are well described, kratom-induced hyperpigmentation remains poorly understood and poses an emerging diagnostic challenge for clinicians. This systematic review synthesizes current evidence on the diagnosis and management of this emerging entity.

Materials and Methods

MEDLINE, Embase, CINAHL, PubMed, and Scopus were searched from inception to February 2026 (registration CRD420261320042). Seventeen reports describing patients with clinically or histologically diagnosed hyperpigmentation attributed to current or prior kratom use were included and analyzed for demographics, exposure characteristics, clinical features, histopathology, proposed mechanism, and treatment outcomes.

Table 1. Study Characteristics

Characteristic	Number of studies
Mean age, years (n = 15)[a]	46.3
Sex, % (n)[a]	
Female	26.7 (4/15)
Male	73.3 (11/15)
Country, % (N = 17)	
United States of America	70.6 (12/17)
Thailand	23.5 (4/17)
Malaysia	5.9 (1/17)
Ethnicity, % (n)[a]	
Caucasian	53.3 (8/15)
Thai	13.3 (2/15)
Not reported	33.3 (5/15)
Comorbidities, % (n)[b]	
Substance use disorder	33.3 (5/15)
Mental health condition	26.7 (4/15)
Chronic pain	13.3 (2/15)
Osteoarthritis	13.3 (2/15)
Dermatological conditions	13.3 (2/15)
Seizure	13.3 (2/15)
Other	33.3 (5/15)
Not reported	13.3 (2/15)
Sun exposure, % (n)[a]	
Frequent sun exposure	20.0 (3/15)

Frequent sun exposure	20.0 (3/15)
Not reported	80.0 (12/15)
Most common reported locations, % (n = 14)[c]	
Face	100.0 (14/14)
Arms	64.2 (9/14)
Neck	64.2 (9/14)
Hands	50.0 (7/14)
Average kratom usage duration, years (n = 12)[d]	9.9
Average duration of hyperpigmentation at presentation, years (n = 9)[e]	2.5
Average latency from kratom initiation to hyperpigmentation onset, years (n = 9)[f]	5.5
Kratom usage frequency, % (N = 17)	
Daily	76.5 (13/17)
Not reported	23.5 (4/17)
Kratom consumption form, % (N = 17)[g]	
Drink/liquid	35.3 (6/17)
Leaves	23.5 (4/17)
Powder	17.6 (3/17)
Capsule	17.6 (3/17)
Paste	5.9 (1/17)
Not reported	17.6 (3/17)
Hyperpigmentation treatment modality, % (N = 17)	
Kratom cessation	35.3 (6/17)
Sun protection/avoidance	35.3 (6/17)
Topical creams	17.6 (3/17)
Laser therapy	5.9 (1/17)
Other	5.9 (1/17)
Not reported	47.1 (8/17)

[a] Vicknasingam (2010), Saingam (2013), and Eaimchaloay (2019) were excluded from the calculation because their reported values refer to the entire kratom-using cohort, not specifically to the subset of individuals who developed hyperpigmentation. Alhadyani (2025) contributed two case reports. Total n = 15.
[b] Eaimchaloay (2019) was excluded as the study reported comorbidities as did or did not have "underlying disease" but did not specify what is classified as "underlying disease." Vicknasingam (2010) and Saingam (2013) were also excluded as they were cohort studies.
[c] Saingam (2013) was excluded as the location was not specified; study reported "regular users in the study had dark skin." Tunsuriyawong (2002) was excluded as location was not specified; study reported sun-exposed areas were affected with sparing of buttock and upper thighs. Eaimchaloay (2019) was excluded as location was not specified, but 41.9% of total users reported hyperpigmentation.
[d] Saingam (2013), Eaimchaloay (2019), Vicknasingam (2010), Gandhi (2024), and Valle (2025) were excluded as narrative descriptions varied or were not reported.
[e] Suwanlert (1975), Vicknasingam (2010), Saingam (2013), Eaimchaloay (2019), Powell (2022), Johnson (2023), Gandhi (2024), and Goyal (2025) were excluded as narrative descriptions varied or were not reported.
[f] Suwanlert (1975), Vicknasingam (2010), Saingam (2013), Eaimchaloay (2019), Powell (2022), Johnson (2023), Goyal (2025), and Valle (2025) were excluded as narrative descriptions varied or were not reported.
[g] Percentages exceed 100% as some studies reported multiple forms of kratom consumption.

List of the 17 included studies, with study design.

Analytical Cross-Sectional Studies

1. **Vicknasingam, 2010:** Vicknasingam B, Narayanan S, Goh TB, Mansor SM. The informal use of ketum (Mitragyna speciosa) for opioid withdrawal in the northern states of peninsular Malaysia and implications for drug substitution therapy. *Int J Drug Policy.* 2010;21(4):283-288. doi:10.1016/j.drugpo.2009.12.003
2. **Eaimchaloay, 2019:** Eaimchaloay S, Kalayasiri R, Prechawit S. Characteristics and physical outcomes of kratom users at a substance abuse treatment center. *Chula Med J.* 2019;63(3):179-185. doi:10.58837/CHULA.CMJ.63.3.6

Qualitative Research

3. **Saingam, 2013:** Saingam D, Assanangkornchai S, Geater AF, Balthip Q. Pattern and consequences of krathom (Mitragyna speciosa Korth.) use among male villagers in southern Thailand: A qualitative study. *Int J Drug Policy.* 2013;24(4):351-358. doi:10.1016/j.drugpo.2012.09.004

Case series

4. **Alhadyani, 2025:** Alhadyani AA, Samaan C, Munavalli GS. The 730 nm picosecond titanium sapphire laser for treatment of kratom-induced hyperpigmentation. *Lasers Surg Med.* 2025;57(5):373-382. doi:10.1002/lsm.70019

Case reports

5. **Suwanlert, 1975:** Suwanlert S. A study of kratom eaters in Thailand. *Bull Narc.* 1975;27(3):21-27.
6. **Tunsuriyawong, 2002:** Tunsuriyawong S, Jerasutas S. Generalized hyperpigmentation from kratom. In: *Interhospital Dermatology Conference*; 2002.
7. **Powell, 2022:** Powell LR, Ryser TJ, Morey GE, Cole R. Kratom as a novel cause of photodistributed hyperpigmentation. *JAAD Case Rep.* 2022;28:145-148. doi:10.1016/j.jdcr.2022.07.033
8. **Johnson, 2023:** Johnson KM, Lause M, Chung C, Massick S. Kratom ingestion associated with photodistributed hyperpigmentation. *Int J Dermatol.* 2023;62:e494-e495. doi:10.1111/ijd.16650
9. **Suleman, 2023:** Suleman S, Khan R, Ioffe B, Chisholm C. Photodistributed hyperpigmentation in a chronic kratom user. *Int Clinc Med Case Rep Jour.* 2023;2(15):1-5.
10. **Gandhi, 2024:** Gandhi I, Wang X, Fishman S. Rare case of photodistributed hyperpigmentation linked to kratom consumption. *Cutis.* 2024;114(3):E7-E9. doi:10.12788/cutis.1100
11. **Patel, 2024:** Patel S, Phelan N. Photo distributed gray-blue hyperpigmentation due to kratom use. *J Integr Dermatol.* Published online February 1, 2024.
12. **Cortes, 2025:** Cortes J, Haft M, Seidman J, Paravar T. Chronic photodistributed hyperpigmented patches in a middle-aged man. *JAAD Case Rep.* 2025;66:199-202. doi:10.1016/j.jdcr.2025.08.031
13. **Goyal, 2025:** Goyal SP, Varughese N. Kratom-induced photodistributed hyperpigmentation: a case report. *SKIN.* 2025;9(6):2752-2756.
14. **Morris, 2025:** Morris S, Patton SBW, Hatch M. Kratom-associated hyperpigmentation in an elderly male: a case report. *J Dermatol Physician Assist.* 2025;19(2):36-41. doi:10.1097/jdpa.0000000000000056
15. **Tassavor, 2025:** Tassavor B, Eun CY, Nikolskaia O, Jobarteh-Williams R. Hyperpigmentation from chronic kratom use: a case report and review of the literature. *Cureus.* 2025;17(2):e79804. doi:10.7759/cureus.79804
16. **Valle 2025:** Valle K, Wingate K, Tinker D, Dilworth D. Unveiling kratom's dark side: case report implicating the botanical ingredient as a culprit in recalcitrant photo-exposed hyperpigmentation. *JAAD Case Rep.* 2025;59:101-104. doi:10.1016/j.jdcr.2025.02.017
17. **Kamoua, 2026:** Kamoua R, Paradine K, Rohan CA, McDaniel M, Perkins D. Novel histopathologic features of diffuse blue-gray hyperpigmentation associated with kratom use: a case report and literature review. *J Cutan Pathol.* 2026;0:1-6. doi:10.1111/cup.70055

Table 1. Study Characteristics

Results

Cases originated from the United States (70.6%), Thailand (23.5%), and Malaysia (5.9%). Mean age was 46.3 years (26.7% female; 53.3% Caucasian). Substance use disorder (33.3%) and mental health conditions (26.7%) were the most common comorbidities. Mean duration of kratom use was 9.9 ± 11.0 years; mean latency from initiation to pigmentation onset was 5.5 ± 7.3 years (range 1 to >20 years), and mean duration of hyperpigmentation at presentation was 2.5 ± 2.1 years. The face was involved in all cases and the arms in 64.2%. Lesions were typically dark blue-gray, photo-distributed patches, frequently sparing the knuckles when on the hands (33.3%). All consumption forms were reported: tea/liquid extracts (35.3%), leaves (23.5%), powder (17.6%), capsules (17.6%), and paste (5.9%); daily use was reported in 76.5%. Biopsies in 13 patients (86.7%) showed superficial dermal melanophages containing clustered red-brown, nonpolarizable pigment. Fontana–Masson stain was positive in

10/15 (66.7%); Prussian blue iron stain was negative in all 9/15 (60.0%) cases where performed, supporting melanin- rather than hemosiderin-containing pigment deposition. The proposed mechanism involves systemic absorption of mitragynine and 7-hydroxymitragynine, which complex with melanin and accumulate within dermal melanophages, with chronic ultraviolet exposure driving photoactivation, melanogenesis, and pigment retention. Topical hydroquinone-based regimens (17.6%) yielded no meaningful improvement at 8 weeks, 3 months, or 6 months. Sun protection alone produced limited benefit. Kratom cessation was advised in 35.3%; in the only two adherent cases, pigmentation persisted at 16 months and 3 years. A series of 730 nm picosecond titanium–sapphire laser treatments spaced 4–6 weeks apart produced marked clearance in two patients (13.3%) from a single case series.

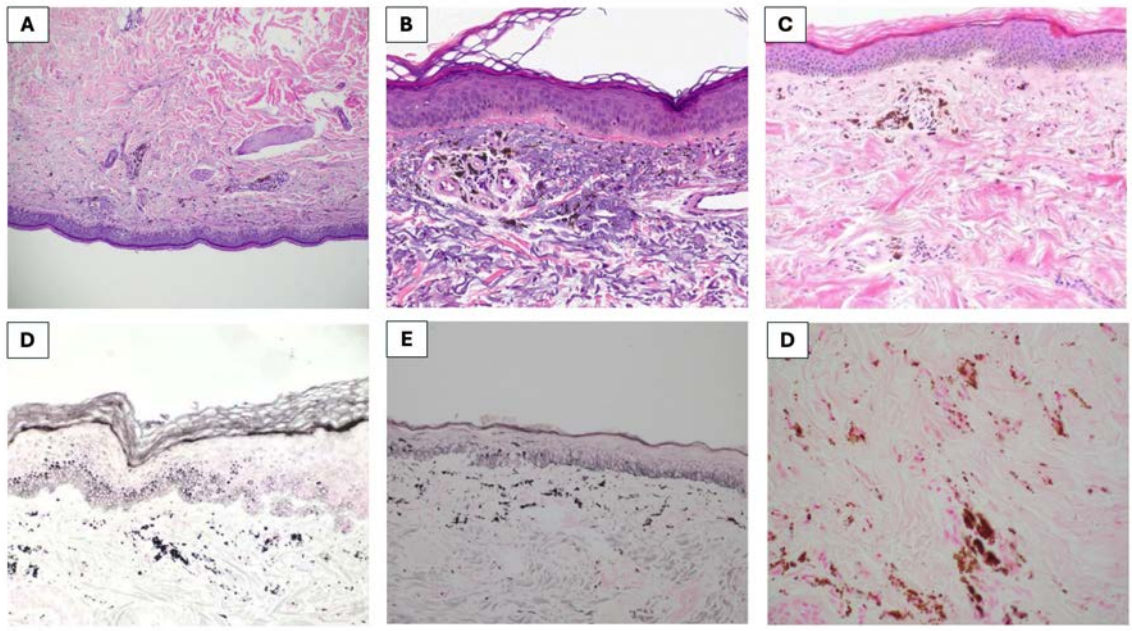

Figure 1. Histopathologic features of kratom-induced hyperpigmentation across four independent biopsy-confirmed cases. (A) Hematoxylin and eosin (H&E), 10×: intact epidermis with preserved rete-ridge architecture; pigment is confined to the superficial dermis with mild mononuclear infiltrate and no melanocytic proliferation. (B) H&E, higher power: refractile brown pigment within perivascular dermal histiocytes (melanophages). (C) H&E, 100×: clusters of red-brown granular pigment within papillary-dermal melanophages, in the absence of dermal inflammation. (D) Fontana-Masson, 100×: diffuse positivity of dermal pigment for melanin (black argentaffin granules) in the same case as (C). (E) Fontana-Masson: independent confirmation of melanin within dermal histiocytes in a second case. (F) Perls Prussian blue: pigment is negative for iron, ruling out hemosiderin and excluding minocycline-type deposition. Panels A and F reproduced from Suleman et al., Int Clinc Med Case Rep Jour 2023;2(15):1–5; panel B from Cortes et al., JAAD Case Rep 2025;66:199–202; panels C and D from Goyal & Varughese, SKIN J Cutan Med 2025;9(6):2752–2756; panel E from Valle et al., JAAD Case Rep 2025;59:101–4. All images are reproduced under CC BY 4.0 with minor cropping for layout.

Conclusions

Kratom-induced hyperpigmentation is an emerging dermal pigmentary disorder presenting as blue-gray, photo-distributed patches following chronic use of any kratom formulation, with onset that may be early or delayed. Pathogenesis likely involves drug–melanin complex deposition. Topical therapies have shown limited success, while laser therapy appears promising. With limited reported European literature despite increasing local kratom use, clinicians, particularly in Europe, should maintain a high index of suspicion for this diagnosis, regardless of recency of exposure, and pursue biopsy in patients with unexplained photo-distributed blue-gray hyperpigmentation.

EA DV CONGRESS
VIENNA
30 SEP - 3 OCT 2026

Abstract N°: 2916

Methotrexate Injection for Psoriasiform, Eczematous and Lichenoid Cutaneous Immune-related Adverse Events: A Prospective Cohort Study

Yuchen Shen[1], Junxia Huang[1], Ji Yang*[1]

[1] Zhongshan Hospital Fudan University, Dermatology, Shanghai, China

Introduction

Immune checkpoint inhibitors (ICIs) are widely used in cancer therapy but frequently induce cutaneous immune-related adverse events (cirAEs), which may impair quality of life and lead to ICI interruption. Psoriasiform, eczematous and lichenoid eruptions are among the common inflammatory cirAE subtypes. Methotrexate (MTX), a conventional systemic immunomodulator, may represent a steroid-sparing option for these conditions. This study aimed to evaluate the effectiveness and safety of MTX therapy initiated by injection in patients with psoriasiform, eczematous and lichenoid cirAEs.

Materials and Methods

We conducted a real-world, single-centre, prospective observational cohort study. Twenty-nine patients with cirAEs were enrolled and treated with either MTX therapy or non-MTX therapy. Patients were included in the MTX group only if MTX was initiated by injection, either continued as injection or subsequently switched to oral MTX for maintenance. The cohort included 13 patients with psoriasiform cirAEs (10 MTX, 3 non-MTX), 9 with eczematous cirAEs (6 MTX, 3 non-MTX), and 7 with lichenoid cirAEs (all MTX). Disease severity and patient-reported outcomes were assessed at baseline and weeks 1, 2, 3, 4, 8, 12 and 24 using Psoriasis Area and Severity Index (PASI), Eczema Area and Severity Index (EASI), Lichen Planus Severity Index (LPSI), Physician Global Assessment (PGA), body surface area (BSA), Peak Pruritus Numerical Rating Scale (PP-NRS) and Dermatology Life Quality Index (DLQI). Safety was evaluated by treatment-emergent adverse events (TEAEs).

Results

Among patients with psoriasiform cirAEs, 80.0% (8/10) in the MTX group achieved PASI75 at week 4, whereas no patients in the non-MTX group achieved PASI75 at week 4 (0/3), suggesting faster skin improvement with MTX injection treatment (p=0.0350). However, no significant between-group difference was observed in PASI90 responses at week 12. In eczematous cirAEs, 83.3% (5/6) of patients in the MTX group achieved EASI75 at week 4, compared with 0% (0/3) in the non-MTX group, further supporting the rapid therapeutic effect of MTX-injection-containing therapies (p=0.0476). The reduction in PP-NRS at week 4 was also greater in the MTX group, suggesting faster pruritus relief (p=0.0238). In lichenoid cirAEs, 71.4% (5/7) of patients achieved LPSI75 or a ≥2-point reduction in PGA at week 12, with marked improvements in week-4 PP-NRS (p=0.0017) and week-12 DLQI (p=0.0042). Overall, 3 of 23 MTX-treated patients experienced TEAEs (13.0%), including elevated liver enzymes (n=1), fungal pneumonia (n=1), and skin ulceration (n=1). No serious adverse events were observed.

Conclusions

MTX therapy initiated by injection showed promising clinical activity across psoriasiform, eczematous and

lichenoid cirAEs, with rapid and clinically meaningful improvements in skin severity, pruritus and quality of life. Safety events were manageable, and no serious adverse events were observed. These findings support MTX injection as a potential steroid-sparing option for psoriasiform, eczematous and lichenoid cirAEs, warranting further validation in larger controlled studies.

EADV CONGRESS
VIENNA
30 SEP - 3 OCT 2026

Abstract N°: 2916

SDRIFE Induced by Erlotinib: First Reported Case

Khadija Essekakri*[1], Bouchra Baghad[1], Soumiya Chiheb[1]

[1] University hospital Ibn Rochd, CASABLANCA, Morocco

Introduction

Symmetrical Drug-Related Intertriginous and Flexural Exanthema (SDRIFE), also known as Baboon Syndrome, is a rare delayed hypersensitivity drug eruption characterized by symmetrical erythematous involvement of flexural and intertriginous areas after systemic drug exposure. Commonly implicated medications include beta-lactams, antifungals, and biologic agents. Although cutaneous toxicities related to Erlotinib are frequent, SDRIFE-like presentations remain exceptionally rare. We report the first described case of SDRIFE induced by Erlotinib.

Case Presentation

A 54-year-old woman followed for lung adenocarcinoma was initially treated with Paclitaxel and subsequently placed on Erlotinib 150 mg/day since October 2024. Her dermatologic history under treatment included recurrent acneiform eruptions of the face and trunk and painful paronychias partially responsive to cyclines. She had also previously developed an oozing erythematous plaque at the site of a Heimlich valve, compatible with localized contact eczema, leading to device removal.

Ten months after Erlotinib initiation, the patient developed a non-pruritic symmetrical erythematous eruption involving the inframammary, inguinal, and intergluteal folds. The lesions consisted of oozing erythematous plaques with irregular borders, without mucosal involvement or systemic symptoms. Skin biopsy confirmed a drug eruption consistent with toxidermia. The reaction was classified as Grade 3 according to CTCAE because of lesion extent and functional impairment. Management consisted of gentle local care, emollients, healing dressings, and close clinical monitoring.

Conclusion

Symmetrical Drug-Related Intertriginous and Flexural Exanthema is a well-defined clinicopathological entity characterized by symmetrical flexural involvement in the absence of systemic signs, most likely mediated by a delayed type IV hypersensitivity reaction. We report the first documented case of Grade 3 SDRIFE secondary to Erlotinib occurring ten months after treatment initiation. This case highlights the importance of recognizing delayed and atypical cutaneous toxicities associated with EGFR inhibitors and underlines the need for close collaboration between dermatologists and oncologists to optimize patient management.

EA DV CONGRESS
VIENNA
30 SEP - 3 OCT 2026

Abstract N°: 2920

When treatement worsens the condition : Azathioprine hypersensitivity in a patient with Acquired Epidermolysis Bullosa

Khadija Essekakri*[1], Bouchra Baghad[1], Soumiya Chiheb[1]

[1] University hospital Ibn Rochd, CASABLANCA, Morocco

Introduction

Acquired epidermolysis bullosa (EBA) is a rare autoimmune blistering disease mediated by autoantibodies directed against type VII collagen. Its management is challenging and relies on the combination of several therapeutic agents. Azathioprine is commonly prescribed; however, its use may be limited by adverse effects. Among these, hypersensitivity reactions remain exceptional, reported in only 1–2% of exposed patients across all clinical settings.

Case Presentation

We report the case of a patient with EBA confirmed clinically, histologically, by direct immunofluorescence, and by salt-split skin testing. First-line treatment with dapsone proved ineffective.

Azathioprine was subsequently introduced; however, a few days after treatment initiation, the patient developed fever and a diffuse exanthema with skin detachment involving less than 10% of the body surface area, associated with peripheral blood eosinophilia, without visceral involvement.

Immediate discontinuation of azathioprine resulted in a gradual and complete clinical recovery.

Hypersensitivity reactions to azathioprine are rare and largely anecdotal. The literature reports only a limited number of isolated cases, which may manifest as systemic symptoms such as fever, cutaneous involvement, or, more rarely, multiorgan involvement. These reactions are unpredictable and doseindependent, underscoring the need for close clinical monitoring during azathioprine therapy.

The present case is distinguished by a limited form, characterized by mild systemic symptoms, restricted cutaneous involvement, and isolated eosinophilia without visceral impairment.

The early onset of symptoms, their idiosyncratic nature, and the requirement for immediate drug discontinuation emphasize the need for heightened vigilance when initiating azathioprine.

The use of alternative immunosuppressive agents or biologic therapies (mycophenolate mofetil, rituximab, intravenous immunoglobulins) remains essential in refractory or intolerant cases.

Conclusion

This case illustrates the therapeutic complexity of EBA, marked by dapsone inefficacy and the occurrence of a rare azathioprine hypersensitivity reaction limited to diffuse exanthema with eosinophilia. It highlights the importance of rigorous clinical follow-up, awareness of the rarity yet potential severity of this complication, and the consideration of individualized alternative therapeutic strategies.

EADV Congress 2026, VIENNA
30 SEPTEMBER - 03 OCTOBER 2026
POWERED BY M-ANAGE.COM

EADV CONGRESS
VIENNA
30 SEP - 3 OCT 2026

Abstract N°: 2945

Imatinib Induced Cutaneous Pseudolymphoma/Lymphoma in the Treatment of Gastrointestinal Stromal Tumor

Dunja Kisić*[1], Danijela Milcic[1, 2], Martina Bosic[3], Mirjana Milinkovic[1, 2]

[1] Clinic of Dermatology and Venereology, University Clinical Center of Serbia, Belgrade, Serbia
[2] University of Belgrade - Faculty of Medicine, Department of Dermatology and Venereology, Belgrade, Serbia
[3] Institute for Pathology, Faculty of Medicine, University of Belgrade, Belgrade, Serbia

Introduction

Gastrointestinal stromal tumor (GIST) is the most common mesenchymal tumor of the gastrointestinal tract, characterized by high malignant potential. The introduction of the tyrosine kinase inhibitor imatinib has greatly improved survival rates in patients with metastatic disease. Although imatinib is the gold standard treatment for advanced and metastatic GIST, it is associated with various adverse reactions, including those involving the skin.

Case Presentation

We present a 52-year-old female patient, who underwent surgery for a small intestinal tumor, later histologically confirmed as GIST. Several months later abdominal metastases were detected and imatinib therapy was initiated. After one month, the patient developed pruritic, erythematous plaques on the face, trunk and extremities which were initially treated with antihistamines and topical corticosteroids with no improvement. Histopathology of the skin biopsy revealed epidermal acanthosis and hyperkeratosis with focal parakeratosis, epidermotropism with discrete lymphocyte atypia and focal basal vacuolar degeneration. The dermis displayed a superficial, partially band-like lymphocytic infiltrate, with focal areas of atypical lymphocytes. Immunohistochemical analysis showed CD4 positivity with partial loss of CD5 and complete loss of CD7, along with PD positivity. FISH confirmed CDKN2A gene deletion without c-MYC or TP53 rearrangements. Based on these findings, two differential diagnoses were considered: imatinib-induced interface dermatitis and pseudolymphomatous skin reaction (mycosis fungoides-like) or the development of mycosis fungoides as a consequence of imatinib therapy. The therapy was initiated with acitretin, prednisone and topical corticosteroids. Imatinib therapy was continued due to its effective control of metastatic disease, as confirmed by follow-up MRI scans showing regression of metastases. After four months on this therapy regime, acitretin was discontinued due to significant hair loss, while skin lesions showed significant clinical regression.

Conclusion

We present a rare case of either a pseudolymphomatous (mycosis fungoides-like) skin reaction induced by imatinib or the development of mycosis fungoides secondary to imatinib therapy. Unfortunately, the patient was lost to further follow-up, which prevented definitive differentiation between these two entities and long-term monitoring of the clinical course. This case highlights the diagnostic challenge of imatinib-associated cutaneous lymphoid infiltrates and underscores the need for multidisciplinary management and continued patient follow-up in such complex clinical scenarios.

EA DV CONGRESS
VIENNA
30 SEP - 3 OCT 2026

Abstract N°: 2965

Personalized supportive treatment of maculopapular, psoriasiform and lichenoid immune-related dermatological adverse events: a prospective randomized controlled trial

Anastasiya Syryseva*[1], Evgenia Shatokhina[2], Natalia Danilova[3], Aleksandra Polonskaia[2], Ilya Pokataev[1], Larisa Kruglova[2]

[1] Moscow State Budgetary Healthcare Institution «Oncological Center No.1 of Moscow City Hospital named after S.S. Yudin, Moscow Healthcare Department», 117152, Moscow, Russian Federation., Faculty of Fundamental Medicine, Federal State Budget Educational Institution of Higher Education M.V.Lomonosov Moscow State University, 119991, Moscow, Russian Federation

[2] Dermatovenerology and Cosmetology Department, «Central State Medical Academy» Department of Presidential Affairs of the Russian Federation, 121359, Moscow, Russian Federation

[3] Internal Medicine Department, Medical Research and Educational Center Lomonosov Moscow State University, 119991, Moscow, Russian Federation, Faculty of Fundamental Medicine, Lomonosov Moscow State University, 119991, Moscow, Russian Federation, Moscow, Russian Federation

Introduction

Dermatological immune-related adverse events (dirAEs) are common toxicities of PD-1/PD-L1 inhibitors and may compromise oncological treatment and quality of life. Current guidelines rely heavily on systemic corticosteroids, which may interfere with antitumour immunity and limit ICI efficacy. Steroid-sparing options such as methotrexate and hydroxychloroquine may provide more sustained control of dirAEs.

Materials and Methods

We conducted a single-centre, open-label, prospective, randomized controlled trial (2023–2026). Of 304 patients screened with suspected dirAEs on PD-1/PD-L1 therapy, 204 met inclusion criteria. Patients underwent diagnostic punch biopsy, after which the following phenotypes were analyzed: maculopapular rash (MPR, n=87), psoriasiform rash including psoriasis flare (PSR, n=76), and lichenoid rash (LR, n=41). Patients were randomized 1:1 within each phenotype. The distribution by group is presented in Table 1.
Patients were assessed at baseline (V1), 1 (V2), 3 (V3), and 6 months (V4) using CTCAE v5.0, BSA (MPR), PASI (psoriasiform), LPASI (lichenoid), and DLQI.

204 patients were included in the study						
Phenotype	**Maculopapular rash (n=87)**		**Psoriasiform rash (n=76)**		**Lichenoid rash (n=41)**	
Group	**1A (n=44)**	**1B (n=43)**	**2A (n=38)**	**2B (n=38)**	**3A (n=21)**	**3B (n=20)**
Treatment	**topical tacrolimus + topical corticosteroid + emollient**	**topical betamethasone + emollient**	**methotrexate 15 mg/week + emollient**	**oral prednisolone 10 mg/day + emollient**	**hydroxychloroquine 400 mg/day + emollient**	**oral prednisolone 10 mg/day + emollient**

Table 1. Study design: distribution of 204 patients across three rash types and randomization to investigational and comparator treatment groups.

Results

Baseline characteristics

The groups were balanced within each phenotype across all indices (all $p>0.05$).

Baseline severity was predominantly grade II in all six Groups (≥71%). By V4, no grade II events remained; grade I residual disease persisted only in comparator Groups (1B 9.3%; 2B 52.5%; 3B 50.0%), while investigational Groups achieved complete clearance in most patients. No grade ≥III events occurred.

Maculopapular rash (MPR)

Group 1A showed a significant advantage from V2: median BSA 8.0% vs 11.0% in Group 1B. By V4, all patients in Group 1A achieved complete clearance, while 9.3% of Group 1B retained grade I lesions. DLQI improved significantly faster in Group 1A from V2 (median 5.5 vs 8.0). All between-Group differences at V4 reached $p<0.001$ (Mann–Whitney U).

Psoriasiform rash (PR)

Prednisolone (Group 2B) produced faster early regression: V2 PASI 3.75 vs 5.7 in Group 2A. However, by V4 methotrexate delivered superior and more durable control: median PASI 0.2 vs 1.2 ($p<0.001$, Mann–Whitney U), with a parallel DLQI advantage (0 vs 3.0; $p<0.001$). At V4, no patient on methotrexate had grade II disease vs 52.5% grade I in Group 2B. Prednisolone gives faster initial response, methotrexate more sustained control.

Lichenoid rash (LR)

At V2, LPASI was comparable between Groups 3A and 3B, but DLQI was lower with hydroxychloroquine. At V3, a clear LPASI advantage emerged in Group 3A (median 5.0 vs 9.0; $p<0.001$, Mann–Whitney U). By V4, Group 3A reached complete clearance (LPASI 0), while Group 3B retained residual disease (LPASI 6.0). DLQI mirrored the LPASI trajectory ($p<0.001$). Within-Group dynamics across V1–V4 were significant in all six Groups ($p<0.001$, Friedman test).

All severity and DLQI dynamics are shown in Figure 1.

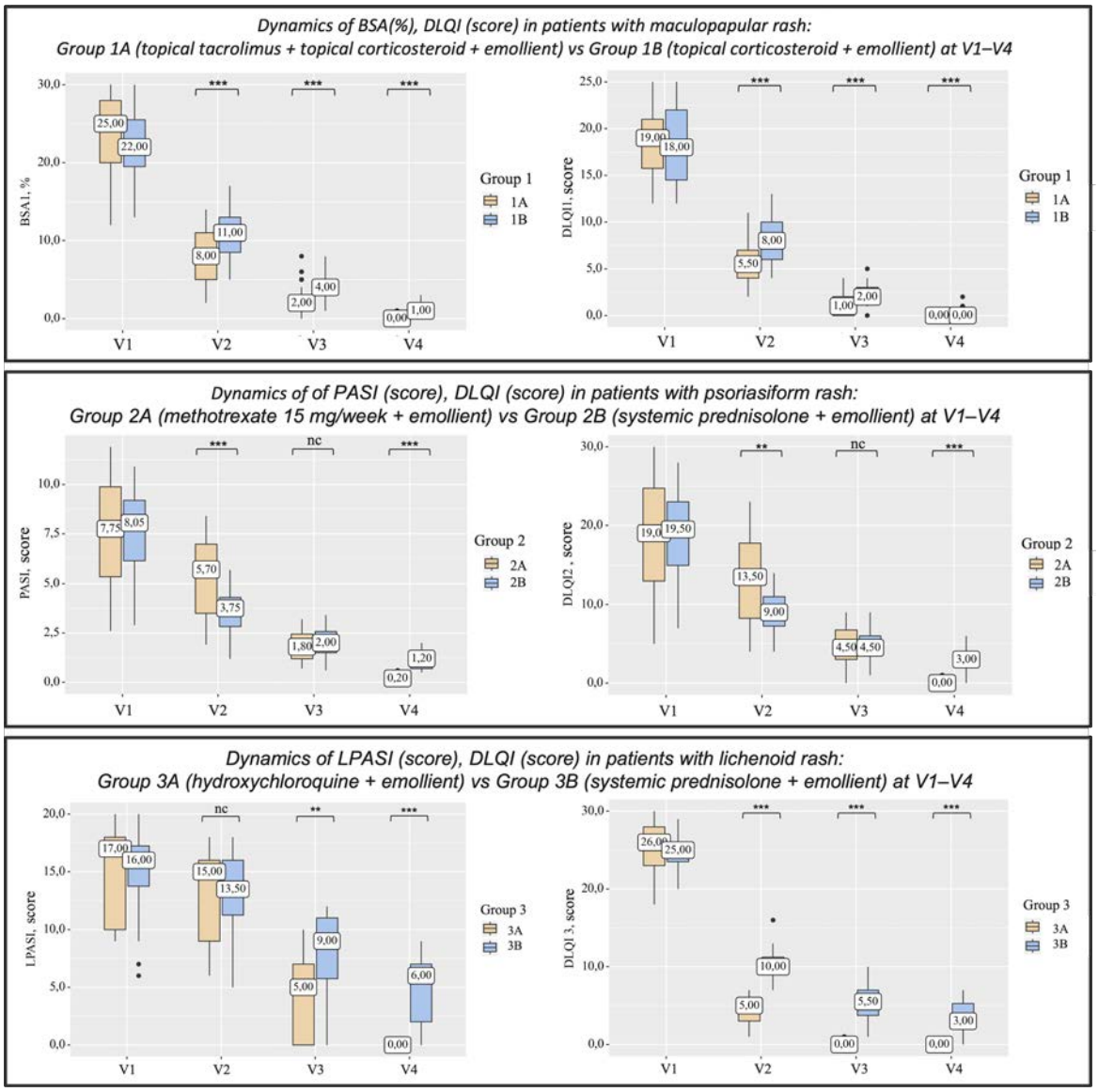

Figure 1. Dynamics of disease severity and quality of life across study Groups at V1–V4 in three cutaneous phenotypes: maculopapular rash (BSA, DLQI; Groups 1A vs 1B), psoriasiform rash (PASI, DLQI; Groups 2A vs 2B), and lichenoid rash (LPASI, DLQI; Groups 3A vs 3B). **p<0.01; ***p<0.001; nc — not significant.

Conclusions

Dermatological irAEs are heterogeneous and benefit from phenotype-tailored therapy. Topical tacrolimus combined with a topical corticosteroid outperforms corticosteroid alone in maculopapular rash. Methotrexate provides more durable control than prednisolone in psoriasiform rash. Hydroxychloroquine is superior to prednisolone in lichenoid rash. Supportive therapy was administered throughout the entire course of antitumour immunotherapy without interruption or dose reduction. Phenotype-based stratification enables effective, steroid-sparing management, preserves antitumour immune response, and improves quality of life, supporting its integration into routine onco-dermatology practice.

EADV CONGRESS
VIENNA
30 SEP - 3 OCT 2026

Abstract N°: 3004

Common dermatology medication triggers a dermatological emergency: Stevens-Johnson Syndrome caused by doxycycline

Nathaly Liliana Castro Barreto*[1], Harold Farit Arenas Torrado[1], Hector Perez[1]

[1] Universidad Nacional de Colombia, Bogotá, Colombia

Introduction

Stevens–Johnson syndrome (SJS) and toxic epidermal necrolysis (TEN) are rare, severe drug-induced reactions characterized by epidermal detachment and mucosal involvement. While commonly linked to antibiotics, anticonvulsants, and NSAIDs, doxycycline is a rare trigger of SJS/TEN. We report a case of SJS/TEN following doxycycline exposure in a young patient with Sjögren's syndrome, highlighting the importance of early recognition and drug withdrawal.

Case Presentation

We present the case of a 23-year-old female patient with a history of Sjögren's syndrome who, after treatment with doxycycline (100 mg/day for 5 days) prescribed by a private dermatologist for rosacea, developed flaccid blisters affecting 60% of her body surface, including mucosal involvement, 13 days later. In this context, she required monitoring in the intensive care unit and simultaneously developed a complication due to sepsis from bacteremia with isolation of Escherichia coli and Staphylococcus epidermidis, which were managed with cefepime and linezolid.

Owing to the described body surface involvement, treatment was initiated with prednisone pulses and subsequently at a dose of 50 mg/day. However, in the absence of a clinical response, cyclosporine (100 mg/day) and topical corticosteroids were administered, resulting in a favorable response within 2 weeks.

Stevens-Johnson Syndrome (SJS) and toxic epidermal necrolysis (TEN) are part of the spectrum of the same entity, which is based on a severe, immunologically mediated hypersensitivity mechanism and is potentially life-threatening. Its incidence is approximately 1–6 cases per million persons/year and can occur at any age. Higher incidences have been identified in Black and Asian populations. Risk factors include human leukocyte antigen genes, human immunodeficiency syndrome, malignancy, and connective tissue diseases; however, Sjögren's syndrome has not been proposed as a risk factor for this condition. The medications most frequently associated with SJS/TEN include antibiotics (28% of cases) from the sulfonamide and aminopenicillin groups, nonsteroidal anti-inflammatory drugs, and anticonvulsants such as phenytoin, lamotrigine, carbamazepine, and allopurinol.

Early identification of the triggering drug and its withdrawal is decisive in changing the patient's prognosis, with a mortality rate of up to 51% having been described. Doxycycline is an antibiotic widely used in dermatology because of its efficacy and tolerability in treating diseases such as acne, rosacea, and skin infections. It has rarely been associated with SJS/TEN, which can delay diagnostic suspicion when the condition begins with fever, morbilliform rash, and rapid progression to mucosal erosions and epidermal detachment. In this context, the chronology between drug exposure and symptom onset is particularly important.

Management should be multidisciplinary and include intensive support, pain control, skin barrier care measures, monitoring for infectious complications and ocular or mucosal involvement, in addition to the inclusion of immunomodulatory therapies according to the severity of the condition.

Conclusion

This case highlights doxycycline as a rare but serious trigger of SJS/TEN in a young patient with Sjögren's syndrome, emphasizing the need for strict pharmacological vigilance regarding medications commonly used in dermatology and medicine.

EADV CONGRESS
VIENNA
30 SEP - 3 OCT 2026

Abstract N°: 3025

Sorafenib-Induced Hand-Foot Syndrome in a Cirrhotic Patient

Ranya Marsou*[1]

[1] Mohammed V University in Rabat, Rabat, Morocco

Introduction

Hand-Foot Skin Reaction (HFSR) is a frequent cutaneous adverse event associated with certain targeted anticancer therapies, particularly multikinase inhibitors. It is characterized by painful palmoplantar erythema, often accompanied by hyperkeratosis in pressure-bearing areas, and may significantly impair quality of life or require modification of oncologic treatment. This case emphasizes the importance of early recognition of this toxicity to optimize management and allow continuation of anticancer therapy.

Case Presentation

A 61-year-old man with probable post-hepatitis B cirrhosis complicated by hepatocellular carcinoma was treated with sorafenib 200 mg for 8 days, associated with spironolactone, furosemide and ciprofloxacin. He presented with a 3-day history of painful bilateral foot erythema associated with a burning sensation. A similar episode had occurred two months earlier during sorafenib therapy, leading to temporary discontinuation before reintroduction.

Clinical examination revealed an afebrile patient in otherwise good general condition with bilateral violaceous erythema of the feet, painful on palpation, associated with hyperkeratotic plaques on the heels and metatarsal heads, plantar desquamation, and mild palmar erythema, consistent with grade 2 HFSR according to the CTCAE (Common Terminology Criteria for Adverse Events) classification. Lower limb edema, massive ascites, toenail onychomycosis, and cutaneous xerosis were also noted.

Management included topical clobetasol, emollients, urea-based keratolytics and preventive measures such as wide footwear and avoidance of pressure and friction.

Conclusion

Although not life-threatening, sorafenib-induced HFSR may cause substantial functional impairment and negatively affect patients' quality of life. Early recognition allows prompt implementation of appropriate therapeutic and preventive measures, thereby limiting lesion severity and supporting optimal continuation of anticancer therapy.

EA DV CONGRESS
VIENNA
30 SEP - 3 OCT 2026

Abstract N°: 3066

Safety Profiles of Ivarmacitinib versus Tofacitinib in Vitiligo Treatment: A Retrospective Comparative Analysis

Dongjie sun*[1]

[1] The First Affiliated Hospital of Kunming Medical University, Kunming, China

Introduction

Vitiligo is a common autoimmune skin disorder. CD8+ T cells produce interferon (IFN), which induces activation of the JAK-STAT pathway, leading to immune-mediated melanocyte apoptosis and subsequent depigmentation. JAK inhibition represents a promising therapeutic approach by disrupting this pathogenic process. This real-world study aimed to compare the safety profiles of two JAK inhibitors, ivarmacitinib and tofacitinib, in the treatment of vitiligo.

Materials and Methods

A total of 40 patients were retrospectively enrolled, including 25 in the ivarmacitinib group and 15 in the tofacitinib group. The median treatment duration was 12 weeks (range: 8-24 weeks). Laboratory parameters, including complete blood count, lipid profile, and coagulation function, were collected during the treatment period for safety analysis.

Results

Hematologic changes: In the ivarmacitinib group, hemoglobin levels increased in 20% and decreased in 4%; white blood cell (WBC) counts decreased in 8%; In the tofacitinib group, hemoglobin elevation was observed in 20%, WBC reduction in 13%.

Lipid changes: In the ivarmacitinib group, LDL-cholesterol (LDL-C) increased in 16%; total cholesterol increased in 20%; HDL-cholesterol (HDL-C) decreased in 12%. In the tofacitinib group, LDL-C increased in 33%; total cholesterol increased in 27%; HDL-C decreased in 13%.

Coagulation changes: In the ivarmacitinib group, prothrombin time (PT) was prolonged in 4%; activated partial thromboplastin time (APTT) was normal in all patients. In the tofacitinib group, PT was prolonged in 20%; APTT was prolonged in 13%.

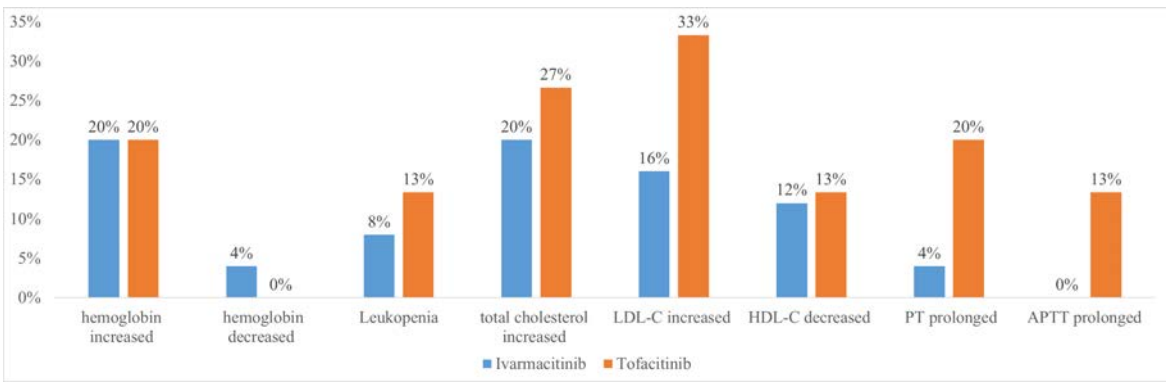

Figure 1 Safety Profiles of Ivarmacitinib versus Tofacitinib

Conclusions

Both JAK inhibitors demonstrated generally manageable safety profiles. However, Ivarmacitinib demonstrated a more favorable safety profile, with lower incidences of LDL-C elevation (16% *vs* 33%), PT prolongation (4% *vs* 20%), and APTT prolongation (0% *vs* 13%). Larger prospective studies are warranted to confirm these preliminary results.

* The terms "increase" and "decrease" refer to levels above or below the normal range.

EADV CONGRESS
VIENNA
30 SEP - 3 OCT 2026

Abstract N°: 3070

Paradoxical Psoriatic Alopecia Induced by Golimumab: Diagnostic Clues from Trichoscopy and Histopathology

Márcio Fellipe Menezes Viana*[1], Bárbara de Galvão e Brito Medeiros[1], Breno Dias[1], Andrea Fernandes Eloy da Costa França[1], Flávia Thomé França[1], RENATA FERREIRA[1]

[1] unicamp - universidade estadual de campinas, campinas/SP, Brazil

Introduction

Tumor necrosis factor-alpha (TNF-α) inhibitor-associated psoriatic alopecia (TIAPA) is a paradoxical inflammatory reaction characterized by overlapping psoriatic and alopecic features. Histopathological findings may differ from classical psoriasis and include eosinophils, plasma cells, and sebaceous gland atrophy.[1–5]

Case Presentation

An 18-year-old woman with seronegative rheumatoid arthritis developed progressive scalp scaling and hair loss two months after starting Golimumab. Examination revealed extensive alopecic plaques with diffuse erythematous scaling.

Trichoscopy demonstrated yellow dots, black dots, short regrowing hairs, and increased vellus hairs, partially mimicking alopecia areata (Fig 1). Histopathological examination showed regular psoriasiform epidermal hyperplasia, parakeratosis, intracorneal neutrophils, reduced terminal-to-vellus hair ratio, and marked sebaceous gland atrophy (Fig 2). Perivascular and peri-adnexal inflammatory infiltrates composed of lymphocytes, neutrophils, and eosinophils were observed, sparing the hair bulb.

Clinicopathological correlation supported the diagnosis of TIAPA. Golimumab was discontinued and Risankizumab was initiated, resulting in progressive inflammatory improvement and complete hair regrowth after five months (Fig 3).

Conclusion

TIAPA remains diagnostically challenging because clinical and trichoscopic findings may overlap with psoriasis, alopecia areata, and primary cicatricial alopecias.[3,5] In our case, sebaceous gland atrophy represented a particularly relevant diagnostic clue. Although uncommon in classical psoriasis, sebaceous gland reduction has emerged as a characteristic finding in TIAPA and may help differentiate paradoxical psoriatic alopecia from isolated scalp psoriasis.[5]

Additionally, eosinophils within perifollicular inflammatory infiltrates favor a drug-induced inflammatory process rather than conventional psoriatic disease.[5] The absence of significant lichenoid interface dermatitis or advanced perifollicular fibrosis also argues against primary cicatricial alopecia.

Complete hair regrowth following biologic switching reinforces the potentially reversible nature of follicular damage in TIAPA when early recognition and intervention are achieved. Recognition of hybrid inflammatory patterns combining psoriasiform epidermal changes, eosinophils, and sebaceous gland atrophy may improve diagnostic accuracy in patients developing scalp inflammation during anti-TNF therapy.

References

1. Osório F, et al. Dermatology. 2012;225:163-7.
2. Xie W, et al. Front Immunol. 2022;13:847160.
3. Reiss-Huss S, et al. Arch Dermatol Res. 2025;317:799.
4. Segaert S, Hermans C. Am J Clin Dermatol. 2017;18:771-87.
5. Afanasiev OK, et al. J Cutan Pathol. 2017;44:563-9.

EADV CONGRESS
VIENNA
30 SEP - 3 OCT 2026

Abstract N°: 3142

Acute generalized exanthematous pustulosis with features of toxic epidermal necrolysis in an adolescent with systemic lupus erythematosus

Juan Sebastian Sanchez Solarte*[1], Miguel Angel Nieto Bayona[1], Maribel Trujillo Hernandez[2]

[1] Universidad Nacional de Colombia, Bogotá, Colombia

[2] Fundación Hospital de La Misericordia, Bogotá, Colombia

Introduction

Acute generalized exanthematous pustulosis (AGEP) is a severe type IVd hypersensitivity reaction traditionally characterized by sterile, non-follicular pustules. While often self-limiting, atypical "TEN-like" variants can emerge, presenting with extensive epidermal detachment that mimics toxic epidermal necrolysis (TEN). In patients with systemic lupus erythematosus (SLE), the diagnostic landscape is further complicated by the "TEN-like lupus" phenotype, where massive basal cell apoptosis results in full-thickness skin sloughing. Furthermore, overlapping phenotypes between AGEP, TEN, and other drug reactions frequently occur, challenging traditional classifications.

Case Presentation

A 16-year-old female with a recent diagnosis of SLE (hematological, neurological, serous, and renal involvement) and atypical hemolytic uremic syndrome (aHUS) developed an acute eruption of non-follicular pustules on her limbs and trunk. Potential triggers included amoxicillin, diclofenac, hydroxychloroquine, eculizumab, cyclophosphamide, and lacosamide. Following a review of her medications, amoxicillin was identified as the culprit drug and subsequently withdrawn. Despite baseline systemic corticosteroids, the condition progressed over four days into a severe bullous state with extensive facial erosions and a positive pseudo-Nikolsky sign
Skin biopsy revealed an intraepidermal pustular bulla with an edematous dermis showing a mixed perivascular inflammatory infiltrate of lymphocytes and eosinophils. Additional findings included extravasation of erythrocytes and neutrophils along with focal vasculitic changes. The pathology was reported as compatible with a mixed drug reaction. Due to the rapid progression and extensive skin detachment, the patient was transferred to the Intensive Care Unit and treated with intravenous immunoglobulin (IVIG) at 1 mg/kg/day for two days, resulting in complete resolution within 72 hours.

Conclusion

This case illustrates the diagnostic challenge of "TEN-like AGEP," where the confluence of pustules leads to significant epidermal sloughing. The histopathological findings of intraepidermal pustules and focal vasculitis were crucial for the diagnosis, as they differ from the full-thickness epidermal necrosis typical of classic TEN. Furthermore, the patient's underlying SLE required a careful distinction from "TEN-like lupus" (ASAP), where the autoimmune process itself triggers massive epidermal cleavage. The existence of mixed histopathological features suggests a potential overlap syndrome between different severe cutaneous adverse reactions. While AGEP is often self-limiting, the failure of baseline corticosteroids to arrest the progression in this complex case highlights the need for rescue therapies. The rapid success of IVIG in this patient underscores its effectiveness in halting the inflammatory and apoptotic cascade in refractory TEN-mimics.

EADV CONGRESS
VIENNA
30 SEP - 3 OCT 2026

Abstract N°: 3198

Cemiplimab-induced pemphigus foliaceus in a patient with advanced cutaneous squamous cell carcinoma

Filip Bosnić*[1], Nika Filipović Mioč[1], Mirela Krišto[1], Ivana Prkačin[1], Nikola Ferara[1], Ivana Starčević[1], Mislav Mokos[1], Dragun Katarina[1], Leo Košuta[2], Mirna Šitum[1]

[1] Sestre milosrdnice University Hospital Center, Department of Dermatology and Venereology, Zagreb, Croatia
[2] School of Medicine, University of Zagreb, Zagreb, Croatia

Introduction

Immune checkpoint inhibitors, such as cemiplimab, have significantly changed the therapeutic approach to advanced cutaneous squamous cell carcinoma (cSCC). However, disruption of immune homeostasis may lead to immune-related adverse events (irAEs), with the skin being one of the most commonly affected organs. Bullous autoimmune dermatoses represent a smaller but clinically important subgroup of these adverse events. While bullous pemphigoid is the most frequently reported blistering irAE associated with PD-1 inhibitors, intraepidermal acantholytic disorders such as *pemphigus foliaceus* (PF) remain exceedingly rare. The proposed mechanism involves PD-1 pathway blockade with loss of peripheral tolerance, activation of autoreactive T lymphocytes, and secondary B-cell stimulation resulting in pathogenic autoantibody production against desmoglein 1.

Case Presentation

A 38-year-old female patient presented in February 2025 with a rapidly enlarging presternal erosion measuring 9 x 6.5 cm with irregular borders and two central nodules. Histopathological examination of an excised nodule demonstrated atypical, mitotically active, squamous epithelial cells with focal acantholysis, consistent with squamous cell carcinoma (SCC). PET/CT revealed pathological FDG uptake in nodular thickening of the anterior thoracic wall and suspicious bilateral axillary lymph nodes. Ultrasound-guided fine needle aspiration of axillary nodes showed no malignant cells. Multidisciplinary tumor board assessment classified the disease as locally advanced inoperable cSCC, and treatment with cemiplimab was initiated. The first of five cycles of immunotherapy was initially well tolerated. Approximately one week later, the patient developed widespread sharply demarcated erosions involving the trunk, abdomen, pubic region, and extremities. Oral mucosal involvement was absent. The patient was admitted to our hospital in June 2025. Laboratory findings demonstrated elevated inflammatory markers, hypoalbuminemia, and anemia. Histopathology from lesional skin revealed intraepidermal acantholysis with superficial inflammatory infiltrates containing neutrophils and sparse eosinophils. Direct immunofluorescence showed intercellular IgG deposition predominantly in the upper epidermis. Serology demonstrated positive anti-desmoglein 1 antibodies, while anti-desmoglein 3, BP180, and BP230 antibodies were negative, confirming the diagnosis of pemphigus foliaceus. Treatment included systemic corticosteroids, local corticosteroid therapy, supportive skin care, thromboprophylaxis, and antibiotics. Progressive re-epithelialization and regression of lesions were observed during hospitalization. Follow-up dermatologic and oncologic examinations demonstrated gradual resolution with residual post-inflammatory hyperpigmentation. Control PET/CT showed complete metabolic and morphological regression of previously described lesions and no evidence of active malignant disease.

Conclusion

This case illustrates a rare presentation of cemiplimab-induced pemphigus foliaceus in a patient treated for locally advanced cSCC. The temporal association between initiation of PD-1 inhibition and onset of blistering disease, together with characteristic histopathology, direct immunofluorescence, and serological findings, strongly

supports an immune-mediated mechanism. Unlike paraneoplastic pemphigus, the patient demonstrated a classic PF phenotype characterized by superficial acantholysis, intercellular IgG deposition in the upper epidermis, positive anti-Dsg1 antibodies, negative anti-Dsg3 serology, and absence of mucosal involvement. Early recognition of rare dermatologic immune-related adverse events is essential for timely diagnosis and treatment, enabling better control of autoimmune complications. Interestingly, the development of pronounced cutaneous irAEs has been associated in several studies with stronger antitumor immune activation and, consequently, more favorable oncologic outcomes

EA DV CONGRESS
VIENNA
30 SEP - 3 OCT 2026

Abstract N°: 3261

When flexures look septic: febrile purpuric flucloxacillin-induced SDRIFE

Alicia Kwan Su Huey*[1], Shilpa Manupati[1]

[1] Manchester University NHS Foundation Trust, Greater Manchester, United Kingdom

Introduction

Symmetrical drug-related intertriginous and flexural exanthema (SDRIFE) is an uncommon cutaneous adverse drug reaction most frequently associated with beta-lactam antibiotics. It is classically recognised as a symmetrical flexural eruption with little or no systemic involvement. Diagnostic uncertainty may arise when SDRIFE presents with fever, purpura and raised inflammatory markers, prompting treatment for suspected infection while severe drug eruption is excluded.

Case Presentation

A 26-year-old man presented acutely with a rapidly progressive burning and pruritic rash after starting flucloxacillin for a toenail and skin infection. The eruption was first noted on the abdomen five days after flucloxacillin initiation and became more widespread the following day. It involved the anterior chest wall, abdomen, flanks, back, axillae, groin, antecubital fossae, genital area and lower limbs. Examination showed widespread erythematous maculopapular change, with darker purpuric haemorrhagic involvement in the axillary and inguinal folds, and petechial change over the wrist flexures, palms and dorsum of the feet. The face was spared, with no facial swelling, conjunctival involvement, blistering or mucous membrane involvement.

He was febrile at 38.8°C and tachycardic, with WCC 14.5 × 10^9/L, CRP 60 mg/L, sodium 131 mmol/L and lactate 1.8 mmol/L. He was initially managed as clinically septic, with concern for a significant drug eruption, and received intravenous fluids, chloramphenicol, systemic corticosteroid and antihistamine. However, procalcitonin was normal, blood cultures showed no growth, renal and liver function remained normal, and eosinophils were not raised. Syphilis and HIV testing were negative. Dermatology review of the clinical evolution and serial inpatient images favoured flucloxacillin-induced SDRIFE, with no evidence of DRESS or severe cutaneous adverse reaction. Intravenous chloramphenicol and intravenous corticosteroid were stopped. He was treated with a short course of super-potent topical corticosteroid to affected areas, emollients and soap substitute, with oral prednisolone taper once infection was excluded. The ward team was advised to monitor for lymphadenopathy, blistering, Nikolsky sign and mucosal involvement.

On repeat dermatology review, the eruption was markedly improved, with reduced erythema and extent. There was no mucous membrane involvement or lymphadenopathy. CRP, full blood count, renal and liver function had normalised, and multiple blood cultures remained negative. He was discharged with topical therapy, emollients, red-flag advice and documentation of penicillin-class allergy.

Conclusion

This case highlights a clinically important diagnostic pitfall: SDRIFE may look systemically alarming when fever, purpuric flexural change and inflammatory marker elevation accompany an otherwise pattern-recognisable drug eruption. The teaching point is not simply that SDRIFE occurred after flucloxacillin, but that flexural symmetry, beta-lactam timing, facial and mucosal sparing, absence of blistering, normal eosinophils, preserved liver and renal function, normal procalcitonin and negative cultures helped distinguish febrile purpuric SDRIFE from

bacterial sepsis, DRESS and evolving severe cutaneous adverse reaction. SDRIFE should remain an important differential in acutely unwell patients with dramatic flexural eruptions after beta-lactam exposure, as early recognition can support safe de-escalation while maintaining focused monitoring for severe drug reaction features.

EA DV CONGRESS
VIENNA
30 SEP - 3 OCT 2026

Abstract N°: 3263

Epidermal Growth Factor Receptor Inhibitors and Nail Toxicity Adverse Events: A Systematic Review and Network Meta-analysis

Sasitorn Yenyuwadee*[1], Nicha Wareesawetsuwan[2], Korakot Leelathanakorn[1], Sukrit Kanchanasurakit[3], Leena Chularojanamontri[1]

[1] Department of Dermatology, Faculty of Medicine Siriraj Hospital, Mahidol University, Bangkok, Thailand
[2] Department of Medicine, Beth Israel Deaconess Medical Center, Harvard Medical School, Boston, 02215, Massachusetts, United States
[3] Department of Pharmaceutical Care, Division of Clinical Pharmacy, School of Pharmaceutical Sciences, University of Phayao, Phayao, Thailand

Introduction
Epidermal growth factor receptor inhibitors (EGFRis) are widely used in the treatment of solid malignancies and are frequently associated with dermatologic adverse events. Nail adverse events substantially impact patients' quality of life, require supportive treatment, and may compromise adherence to anticancer therapy. However, the comparative risk of nail toxicity across different EGFR inhibitor agents and generations remains insufficiently defined.

Objective: To evaluate and compare the risk of nail adverse events among EGFR inhibitors used for cancer treatment through a systematic review and network meta-analysis.

Materials and Methods
A systematic review of CENTRAL, PubMed, and Embase was conducted to identify phase II/III randomised controlled trials enrolling patients with cancer who received EGFRi monotherapy in at least one treatment arm, from database inception to July 2025. Eligible trials reported nail adverse events and/or dermatologic toxicities. Network meta-analysis was performed using a consistency model with surface under the cumulative ranking area (SUCRA) analysis. Risk of bias was assessed using the Cochrane Risk of Bias tool version 2.0. Pairwise meta-analysis was used for selected direct comparisons, particularly between second- versus first-generation and third- versus first-generation EGFR-TKIs for nail and rash adverse events. Subgroup analyses were performed for all-grade toxicity and severe toxicity, defined as CTCAE grade ≥3.

Results
After screening 11,480 records, 30 RCTs involving 12,060 patients were included. Network meta-analysis was performed to compare individual EGFRis and other treatments. Among the included studies, 16 trials compared EGFRis with other EGFRis, whereas 14 compared EGFRis with other systemic therapies (Figure 1a). The pooled incidence of nail adverse events among EGFRi-treated patients was 14.6% (95% CI, 11.2–19.0), with the highest incidence observed in second-generation EGFR-TKIs at 24.5% (95% CI, 15.5–36.5). In the agent-level network analysis, the three agents associated with the highest risk of nail toxicity were afatinib, furmonertinib, and panitumumab. At the agent level, afatinib showed a significantly higher risk of nail toxicity than dacomitinib (risk ratio [RR], 29.72; 95% CI, 3.15–280.17), gefitinib (RR, 7.85; 95% CI, 2.00–30.86), and erlotinib (RR, 11.66; 95% CI, 2.99–45.54). No significant difference was observed between gefitinib and erlotinib (RR, 1.48; 95% CI, 0.43–5.16)

(Table 1). In pairwise generation-based subgroup analyses, second-generation EGFR-TKIs were associated with significantly higher risks of both all-grade nail toxicity and severe nail toxicity compared with first-generation EGFR-TKIs (RR, 3.36; 95% CI, 2.09–5.40; P<0.001, and RR, 3.20; 95% CI, 1.41–7.26; P=0.01, respectively) (Figure 1b). First and third-generation EGFR-TKIs did not differ significantly in nail toxicity (P=0.34 for all-grade toxicity and P=0.67 for severe toxicity). For rash or maculopapular rash, no statistically significant differences were detected among EGFR-TKI generations or among available EGFR-directed agents.

Figure 1: (a) Network Plot of comparison among EGFR inhibitors and comparator treatment in the included randomized controlled trial. (b) Forest plot comparing the risk of all-grade nail toxicities between second-generation and first-generation EGFR-TKIs.

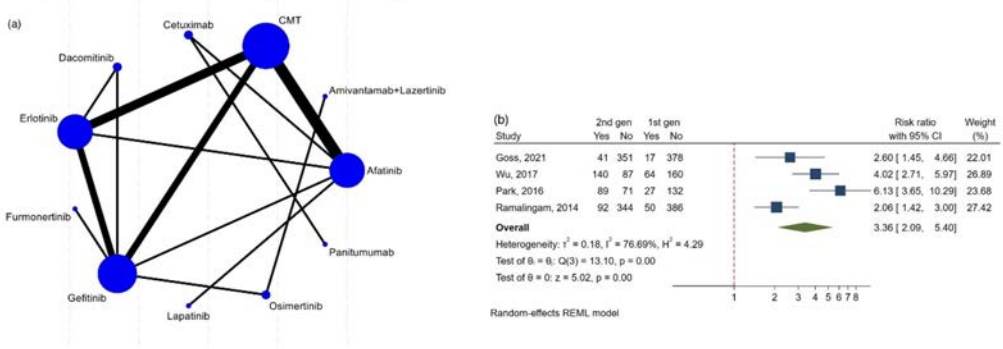

Table 1: League table of network meta-analysis comparing the relative risk of nail toxicity among EGFR inhibitors and comparator treatments

Afatinib										
1.44 (0.06,36.49)	**Furmonertinib**									
3.62 (0.03,442.79)	2.52 (0.01,732.18)	**Panitumumab**								
4.61 (0.08,272.65)	3.21 (0.02,511.25)	1.28 (0.10,16.22)	**Cetuximab**							
4.61 (0.09,246.60)	3.21 (0.02,471.73)	1.28 (0.00,481.89)	1.00 (0.00,213.17)	**Lapatinib**						
7.85 (2.00,30.86)	5.47 (0.29,102.57)	2.17 (0.02,278.69)	1.70 (0.03,106.45)	1.70 (0.03,96.42)	**Gefitinib**					
9.03 (0.50,161.78)	6.29 (0.13,304.23)	2.49 (0.01,598.30)	1.96 (0.02,250.92)	1.96 (0.02,230.69)	1.15 (0.09,14.59)	**Osimertinib**				
11.66 (2.99,45.54)	8.12 (0.34,196.21)	3.22 (0.03,414.28)	2.53 (0.04,158.27)	2.53 (0.04,143.36)	1.48 (0.43,5.16)	1.29 (0.08,21.87)	**Erlotinib**			
21.84 (0.47,1013.16)	15.21 (0.15,1560.37)	6.04 (0.01,2522.26)	4.73 (0.02,1127.58)	4.73 (0.02,1046.70)	2.78 (0.08,100.23)	2.42 (0.19,30.33)	1.87 (0.04,83.27)	**CMT**		
29.72 (3.15,280.17)	20.70 (0.59,720.43)	8.21 (0.05,1445.89)	6.44 (0.07,581.01)	6.44 (0.08,530.58)	3.78 (0.51,28.02)	3.29 (0.13,83.62)	2.55 (0.36,18.19)	1.36 (0.02,82.57)	**Dacomitinib**	
41.53 (10.63,162.27)	28.92 (1.06,787.58)	11.48 (0.11,1152.78)	9.00 (0.19,420.65)	9.00 (0.21,378.07)	5.29 (1.15,24.30)	4.60 (0.24,89.07)	3.56 (0.77,16.42)	1.90 (0.04,93.50)	1.40 (0.13,14.55)	**Amivantamab+Lazertinib**

Figure 1: (a) Network Plot of comparison among EGFR inhibitors and comparator treatment in the included randomized controlled trial. (b) Forest plot comparing the risk of all-grade nail toxicities between second-generation and first-generation EGFR-TKIs. Table 1: League table of network meta-analysis comparing the relative risk of nail toxicity among EGFR inhibitors and comparator treatments

Conclusions

This systematic review and network meta-analysis demonstrate that the risk of nail toxicity is not uniform across EGFR inhibitors. Second-generation EGFR-TKIs, particularly afatinib, appear to confer the highest risk of nail adverse events, including severe toxicity, whereas first- and third-generation EGFR-TKIs show comparable risks. Rash risks did not differ significantly across treatment groups. These findings support anticipatory counselling, closer nail monitoring, and early preventive management in patients receiving second-generation EGFR-TKIs.

EA DV CONGRESS
VIENNA
30 SEP - 3 OCT 2026

Abstract N°: 3275

Bullous pemphigoid induced by an aromatase inhibitor (letrozole)

Maarcha Rayene*[1], Lemya Mezdour[1], salah eddin awawde[1], Issam TABLIT[1], Saliha Takheroubt[1], Samira Zobiri[1]

[1] Departement of dermatology, Mustapha unviersity hosiptal, Algiers, Algeria

Introduction

Bullous pemphigoid (BP) is a subepidermal autoimmune blistering disease mediated by autoantibodies against hemidesmosomal proteins BP180 and BP230. It primarily affects elderly patients and is the most frequent autoimmune bullous disorder. Drug-induced forms account for approximately 10–20% of cases, most commonly associated with diuretics, antibiotics, and DPP-4 inhibitors. Aromatase inhibitors are extremely rare triggers, with only isolated reports in the literature.

Case Presentation

We report the case of a 53-year-old woman with a history of luminal breast carcinoma diagnosed in 2020, treated with surgery, chemotherapy, radiotherapy, and endocrine therapy, achieving complete remission.

Following disease recurrence in 2025, letrozole therapy was initiated. Twenty-five days later, she developed an acute, rapidly progressive pruritic eruption. Initial lesions consisted of widespread urticarial plaques evolving into tense vesicles and bullae. The eruption was generalized, involving trunk and extremities, with palmoplantar involvement and suspected oral mucosal lesions. Nikolsky sign was negative.

Skin biopsy revealed a subepidermal blister. Direct immunofluorescence showed linear IgG deposition along the basement membrane zone. ELISA detected circulating anti-BP180 antibodies. Laboratory findings included peripheral eosinophilia and elevated total IgE levels.

A diagnosis of bullous pemphigoid was established.

Letrozole was discontinued immediately. Treatment with potent topical corticosteroids combined with systemic corticosteroids led to rapid clinical improvement, with cessation of new blister formation and significant reduction of pruritus within two weeks.

Discussion

Drug-induced BP is increasingly recognized. While diuretics, antibiotics, and DPP-4 inhibitors are the most frequently implicated agents, aromatase inhibitors remain exceptionally rare triggers. Only a few cases of letrozole-associated bullous eruptions have been described, often lacking complete immunological confirmation.

The pathophysiology of BP involves a breakdown of immune tolerance to BP180 and BP230, leading to autoantibody formation and complement activation at the dermal–epidermal junction. Drug-induced cases may result from antigenic modification, epitope exposure, or immune system dysregulation.

In this case, causality is strongly supported by: (1) a short latency period after drug initiation, (2) absence of alternative triggers, (3) compatible histological and immunological findings (positive direct immunofluorescence and anti-BP180 antibodies), and (4) favorable evolution after drug withdrawal and corticosteroid therapy.

Estrogen deprivation induced by aromatase inhibition may contribute to immune dysregulation, as estrogens exert modulatory effects on both innate and adaptive immunity. Their reduction may promote a pro-inflammatory environment and facilitate autoantibody production, although this mechanism remains hypothetical.

Conclusion

Letrozole may represent a rare trigger of bullous pemphigoid. BP should be considered in patients developing blistering eruptions under aromatase inhibitor therapy. Early diagnosis, supported by histology and immunological testing, and prompt discontinuation of the suspected drug are essential for favorable outcomes.

EADV CONGRESS
VIENNA
30 SEP - 3 OCT 2026

Abstract N°: 3316

Carbamazepine-Induced Erosive Oral Lichen Planus

Alberto Sáez Vicente*[1], Noelia García Muñoz[1], Silvia Salinas Moreno[2], Marta Folcrá González[1], Carolina Garrido Gutiérrez[1], Ricardo Valverde Garrido[1], Iolanda Prats Caelles[1]

[1] Hospital Universitario Infanta Sofía, Dermatology, Madrid, Spain
[2] Hospital Universitario Infanta Sofía, Pathology, Madrid, Spain

Introduction

Erosive lichen planus (ELP) is an uncommon variant of lichen planus characterised by chronic and painful ulceration affecting the skin and mucous membranes, with a particular predilection for the oral and genital mucosae. In some cases, ELP may be drug-induced, resulting in lichenoid reactions that are clinically and histopathologically indistinguishable from idiopathic lichen planus.
Carbamazepine is a widely prescribed antiepileptic agent associated with a variety of cutaneous adverse reactions, whereas erosive involvement of the oral mucosa remains infrequent.

Case Presentation

42-year-old man with a history of trigeminal neuralgia, treated with carbamazepine 200 mg three times daily for six months, presented with painful oral lesions that had developed two months after initiation of the antiepileptic therapy. He had previously received topical clobetasol propionate in an adhesive oral preparation, achieving partial improvement but with persistence of several lesions.
Clinical examination revealed 3–6 mm erosions involving the lower labial semimucosa, oral mucosa and lateral borders of the tongue, with a whitish appearance suggestive of Wickham striae on the labial lesion.
Given the suspicion of carbamazepine-induced ELP, a biopsy was performed, demonstrating interface dermatitis consistent with a lichenoid drug eruption. Treatment with oral prednisone 30 mg daily in a tapering regimen over 30 days failed to produce clinical improvement. Carbamazepine was therefore gradually withdrawn, without recurrence of trigeminal neuralgia, and complete re-epithelialisation of the oral lesions was observed within two months.

Conclusion

Carbamazepine-induced lichenoid reactions are uncommon, particularly when involving the oral mucosa in an erosive form. In cases of persistent lichenoid oral lesions, a drug-induced aetiology should be considered. Compatible histopathological findings together with resolution following withdrawal of the offending agent are key elements for diagnosis. Reporting such cases contributes to improved recognition and management of this uncommon entity.

EA DV CONGRESS
VIENNA
30 SEP - 3 OCT 2026

Abstract N°: 3351

Adverse dermatologic events reported following the use of semaglutide: A cross-sectional analysis of a national pharmacovigilance database

Sarah Aly*[1], Adam Mouncef[1], Miranda Branyiczky[2], Cathryn Sibbald[3], Jeffrey Donovan[4, 5]

[1] McGill University, Montreal, Canada

[2] McMaster University, Hamilton, Canada

[3] The Hospital for Sick Children (SickKids), Toronto, Canada

[4] University of British Columbia, Vancouver, Canada

[5] Donovan Hair Clinic,, Whistler, Canada

Introduction

Semaglutide, a glucagon-like peptide-1 (GLP-1) receptor agonist approved for type 2 diabetes mellitus and obesity, has seen rapidly expanding use worldwide. Semaglutide's safety profile has been well-documented, with trials primarily emphasizing gastrointestinal adverse events such as nausea, diarrhea, vomiting, and constipation. However, there is a growing number of reports describing cutaneous adverse drug reactions (ADRs) with GLP-1 receptor agonists, including eczematous reactions, alopecia, pruritus, and paresthesia. As the use of semaglutide continues to expand, pharmacovigilance databases provide the opportunity to evaluate rare ADRs in real-world populations. To date, no such analysis has been reported in the Canadian population. This study aimed to describe dermatologic ADRs reported with semaglutide in a national adverse reaction database.

Materials and Methods

ADR reports were retrieved from the Canada Vigilance Adverse Reaction Online Database (Health Canada), which contains spontaneous and study-related post-marketing reports submitted between January 1, 1965 and October 31, 2025. Using the advanced search interface, semaglutide was selected under the Suspect Health Product Search Criteria (active ingredient search term "semaglutide"), and dermatologic ADRs were filtered by selecting the MedDRA System Organ Class (SOC) "Skin and subcutaneous tissue disorders." No restrictions were applied for seriousness, source, sex, age, outcome, or dates. Duplicate reports were removed, and only a single unique dermatologic ADR per patient report was included. Extracted results were validated by two independent reviewers. Dermatologic reactions were consolidated into diagnostic groupings to reduce redundancy (e.g., eczema/dermatitis grouped).

Results

A total of 14,267 semaglutide-associated adverse event entries were identified (July 2018 to October 2025). After duplicate removal, 310 unique reports were included. Female patients predominated (234/310, 75.5%), with a mean age of 56.9 years. Mean BMI was 32.6 (n=111). Semaglutide was the suspect product in 99.0% of reports. The most frequently reported grouped dermatologic ADRs were rash (n=53), pruritus (n=24), erythema (n=19), angioedema (n=18), and burning/paresthesia (n=17). Among female patients, rash (92.5%), pruritus (83.3%), and erythema (78.9%) predominated. Hyperhidrosis (70.0% male) and drug eruption (66.7% male) demonstrated higher male representation. Less commonly reported ADRs included psoriasis (n=14), blistering disorders (n=8), erythema nodosum (n=5), and skin laxity (n=4). Outcomes were most frequently not recovered/not resolved

(52.3%); 82.9% were classified as serious, though the most common criterion was “other medically important condition” (75.5%). Hospitalization was reported in 20.0% of cases, with higher proportions in angioedema (50.0%), hyperhidrosis (50.0%), and alopecia (50.0%).

Conclusions

Dermatologic ADRs associated with semaglutide in this national database were heterogeneous, with rash, pruritus, erythema, angioedema, and burning/paresthesia being the most frequently reported. These findings are broadly consistent with prior scoping reviews and international registry analyses. The female predominance may reflect higher semaglutide use for weight management among women or sex-based differences in reporting. Angioedema and hyperhidrosis were associated with the highest hospitalization rates, suggesting these presentations may carry greater clinical significance. These findings contribute to post-marketing surveillance data in Canada and support the recognition of a wide range of dermatologic ADRs associated with semaglutide. Medical professionals prescribing or caring for patients on semaglutide should remain vigilant for cutaneous ADRs and counsel patients on their potential risk.

EA DV CONGRESS
VIENNA
30 SEP - 3 OCT 2026

Abstract N°: 3367

Skin toxicities induced by breast cancer treatments: Prevalence, risk factors, and clinical consequences

Hédi Chabanol*[1], Lauriane Segaux[1], Amandine Servy[2], Alexia Savignoni[3], Florence Canouï-Poitrine[1], Isabelle Fromantin[4]

[1] Laboratoire CEpiA, Université Paris-Est Créteil, Inserm, IMRB U955, Créteil, France
[2] Institut Curie, Medical Oncology Department, Paris, France, Paris, France
[3] Institut Curie, Biometry Department, Paris, France, Paris, France
[4] Institut Curie, Wound and Care Research Unit, Paris, France, Paris, France

Introduction

Anticancer treatments are responsible for numerous adverse effects, particularly cutaneous and nail toxicities, which may significantly impair patients' quality of life. Despite preventive measures, these toxicities remain frequent and may lead to treatment modifications. Cutaneous and nail toxicities appear to follow different timelines, with some effects occurring later and persisting after treatment discontinuation. Nail toxicities, often underestimated in oncology, have a considerable functional impact and therefore warrant a specific and independent analysis.

To date, management strategies remain poorly personalized. This study aimed to identify risk factors for cutaneous and nail toxicities to improve prevention and management, particularly through objective skin evaluation before treatment initiation.

Materials and Methods

A prospective study was conducted at Institut Curie between 2020 and 2023 in patients treated for breast cancer. Cutaneous and nail toxicities were assessed according to the NCI-CTCAE classification (v5.0) at treatment initiation, monthly for 4 months, and then at 8 months. The consequences of grade >2 toxicities on anticancer treatment were described, including dose modifications and temporary or permanent treatment discontinuation.

Analyses compared grade ≥2 versus grade <2 toxicities (cutaneous and nail toxicities analyzed separately) using Chi-square tests.

Skin hydration levels were measured before treatment initiation using a corneometer (CM825®, Courage + Khazaka Electronic GmbH, Cologne, Germany) on the cheek, décolleté, palm of the hand, and sole of the foot to objectively assess baseline skin condition. Palmar-plantar measurements did not allow assessment of the association with grade ≥2 nail toxicities. Multivariable logistic regression models were used to identify risk factors for cutaneous and nail toxicities.

Results

A total of 249 patients were included in the study, among whom 54 (21.7%) experienced grade ≥2 cutaneous toxicity. Overall, 147 events were reported, including 92 cutaneous toxicities, associated or not with 55 nail toxicities. Cutaneous toxicities, mainly xerosis (36.7%) and hand-foot syndrome (18.5%), occurred early, whereas nail toxicities, only onycholysis, appeared later during treatment or even after treatment discontinuation.

Among all recorded events, 19 (12.9%) required modification of anticancer treatment (dose reduction and/or temporary interruption and/or permanent discontinuation).

Overweight was significantly associated with an increased risk of grade ≥2 cutaneous toxicity across all locations ($p=0.001$), as were alcohol consumption and polypharmacy ($p<0.05$).

Phototype also influenced risk, with a significant association observed for darker phototypes at the feet level ($p<0.001$).
No risk factors were identified for grade ≥2 nail toxicities.
Baseline skin hydration level appeared to be an independent risk factor for the occurrence of cutaneous toxicities, with significant associations observed at face ($p=0.011$) and hand ($p=0.005$) levels.

Conclusions

This study highlights a substantial frequency of cutaneous and nail toxicities in patients treated for breast cancer, which may lead to anticancer treatment modifications. The later onset of nail toxicities underscores the importance of maintaining recommended supportive care measures throughout follow-up, including after treatment discontinuation.
Furthermore, baseline skin hydration level appears to be an independent predictive factor for the occurrence of cutaneous toxicities. Objective assessment of initial skin condition therefore supports the value of a more personalized dermatological management approach for patients receiving anticancer treatments, integrating systematic evaluation from treatment initiation onward.

EADV CONGRESS
VIENNA
30 SEP - 3 OCT 2026

Abstract N°: 3369

Systemic Inflammatory Syndrome and Probable DRESS Following Atogepant Initiation

Celina Kazumi Iwasa*[1], Andreea Nicoleta Cifrea[1], juliana moura[1]

[1] West Middlesex University Hospital, Isleworth, United Kingdom

Introduction

Atogepant, a calcitonin gene-related peptide (CGRP) receptor antagonist, is used for the preventive treatment of migraine. While generally well-tolerated, rare systemic inflammatory reactions have been associated with CGRP inhibitors. We report a case of a probable Drug Reaction with Eosinophilia and Systemic Symptoms (DRESS) syndrome following atogepant initiation.

Case Presentation

A 45-year-old man with a history of chronic migraines was started on atogepant 60mg daily. Two weeks later, he presented with fever, myalgia, headache, an itchy rash, and facial and hand swelling.

His past medical history includes beta-thalassaemia trait, mesenteric panniculitis, and GORD. He denied any known drug allergies.

Investigations revealed a peak C-reactive protein of 204 mg/L, peak ALT of 206 U/L, eosinophilia (0.6 $x10^9$/L), lymphopenia (0.9 $x10^9$/L), and thrombocytopenia (133 $x10^9$/L). Urinalysis showed proteinuria and haematuria. Extensive infective and autoimmune screens, including respiratory viruses, EBV, CMV, and ANA, were negative. A skin biopsy demonstrated a mixed spongiotic and interface dermatitis with a superficial perivascular lymphocytic infiltrate, scattered eosinophils, and pigment incontinence.

Atogepant was discontinued on admission. He was treated with a 7-day course of intravenous ceftriaxone for a suspected but unproven infection, and topical betamethasone 0.1% and emollients for the rash, which subsequently resolved.

Conclusion

The clinical presentation, timing, and investigation findings in this case are consistent with a systemic inflammatory reaction. Based on the RegiSCAR scoring system, this case was classified as a probable DRESS syndrome with a score of 5. This case highlights the importance of recognising CGRP inhibitors as a potential cause of severe cutaneous adverse reactions like DRESS syndrome.

EADV CONGRESS
VIENNA
30 SEP - 3 OCT 2026

Abstract N°: 3379

Docetaxel-induced psoriasiform eruption in a patient with paraneoplastic dermatomyositis: A diagnostic challenge

Ahd Jday*[1], mariem tabka[1], Mohamed Bouzgarrou[2], Feryel Amri[1], Asmahane Souissi[1], Ines Chelly[3], Mourad Mokni[1]

[1] Dermatology Department, Rabta Hospital, Tunis, Tunisia
[2] Department of Internal Medicine, Rabta Hospital, Tunis, Tunisia
[3] Department of Anatomopathology, Rabta Hospital, Tunis, Tunisia

Introduction

Docetaxel is a taxane widely used in the treatment of various solid malignancies. While its cutaneous adverse effects, including acral erythema and nail toxicity, are well documented, docetaxel induced psoriasis or psoriasiform eruptions remain exceedingly rare, with only a few cases reported in the literature.
We report a severe psoriasiform eruption temporally associated with docetaxel therapy in a patient with paraneoplastic dermatomyositis.

Case Presentation

A 49 year old man, followed for nasopharyngeal carcinoma T1N3Mx associated with anti-TIF1γ positive paraneoplastic dermatomyositis, presented with a diffuse erythematosquamous eruption. The skin lesions developed two months after the initiation of chemotherapy containing docetaxel. Dermatological examination revealed well demarcated erythematosquamous psoriasiform plaques involving the face, trunk, and extremities, with an estimated body surface area involvement of 40 percent. No personal history of psoriasis was reported. Histopathological examination revealed significant keratinocyte necrosis and the Naranjo probability scale score was 4, indicating a possible adverse drug reaction.
Although the initial pharmacovigilance assessment remained cautious, docetaxel was considered the most likely culprit drug based on the temporal relationship, the progressive worsening during treatment exposure, and the favorable outcome after treatment completion. The clinical course was marked by a gradual and marked regression of the lesions following completion of chemotherapy and withdrawal of docetaxel, without requiring systemic antipsoriatic therapy.

Conclusion

Taxane induced psoriasiform eruptions are uncommon adverse cutaneous reactions. The distinction between true drug induced psoriasis and psoriasiform drug eruption remains challenging, particularly in patients without a personal history of psoriasis. Several published cases have suggested that docetaxel may either trigger de novo psoriasis in genetically predisposed individuals or induce a psoriasis-like toxic eruption. The underlying pathophysiological mechanisms remain poorly understood but may involve immune dysregulation with activation of pro-inflammatory cytokine pathways and T-cell mediated responses. Previous reports have also suggested a potential role of memory T cells in chemotherapy induced psoriatic eruptions.
In our patient, the absence of a personal history of psoriasis, the presence of keratinocyte necrosis on histology, and the favorable evolution after discontinuation of docetaxel support the hypothesis of a drug induced psoriasiform eruption rather than unmasking of pre-existing psoriasis. However, a triggering effect on an underlying predisposed immune background cannot be formally excluded.

This case is further distinguished by the coexistence of paraneoplastic dermatomyositis, which considerably complicated the diagnostic assessment because of the potential overlap between inflammatory and treatment-related cutaneous manifestations in the oncologic setting.

EA DV CONGRESS
VIENNA
30 SEP - 3 OCT 2026

Abstract N°: 3389

Macrophage activation syndrome following DRESS syndrome: a diagnostic challenge

zineb selka*[1]

[1] CHU Docteur Tidjani Damardji, Mansourah, Algeria

Introduction

DRESS syndrome (Drug Reaction with Eosinophilia and Systemic Symptoms) is a severe drug-induced skin reaction that can be life-threatening. It is characterized by erythrodermia accompanied by facial swelling, fever, lymphadenopathy , and multiorgan involvement . The onset of symptoms typically occurs between two to six weeks after the introduction of the offending medication

Case Presentation

This concerns patient B.R., 29 years old, with no notable medical history, recently diagnosed with **ankylosing spondylitis** and started on **sulfasalazine** (Salazopyrin) six weeks ago.

The patient presented to our facility with a moderate decline in general health, featuring a **generalized pruritic maculopapular erythematous eruption** with facial edema. Mucosal involvement was noted, specifically odynophagia and hemorrhagic spotting on the hard palate. Palpation of the lymph node areas revealed multiple mobile and painful **lymphadenopathies**. An abdominal ultrasound showed Stage 1 splenomegaly.

Initial laboratory results (**CBC**) showed lymphopenia with **atypical lymphocytes** on peripheral blood smear. Liver function tests were abnormal, with cytolysis . A diagnosis of **DRESS syndrome** was confirmed with a **RegiSCAR score of 6**.

We initially prescribed topical corticosteroids, prednisone mouthwashes, and systemic corticosteroid therapy .

Twelve hours after starting corticosteroids, the patient developed a **persistent fever** and an extension of the rash. Corticosteroids were temporarily suspended due to suspicion of **viral reactivation**. After 48 hours of persistent fever, follow-up blood work revealed **thrombocytopenia**. Upon completing a workup for **Macrophage Activation Syndrome (MAS)**, results showed elevated ferritin, triglycerides, and LDH.

A diagnosis of MAS was confirmed. Systemic corticosteroids were reintroduced at a dose of **1 mg/kg of methylprednisone** . The patient responded well to the treatment: the rash disappeared, lymphadenopathy and splenomegaly regressed, and biological markers normalized. Corticosteroids were tapered progressively over a period of **6 months**.

DRESS is an uncommon but severe drug-induced skin reaction that can be life-threatening. The mortality rate is high, around **10%**. Several classification systems for diagnostic criteria exist; the most commonly used is the **RegiSCAR** system.**MAS (SAM)** is a multi-systemic disease linked to an intense activation of the immune system; its pathophysiology remains poorly understood. Our patient’s case met the MAS criteria established in 2004 and modified in 2009. The primary causes of secondary MAS fall into three categories:

1. **Neoplasia**
2. **Infectious diseases:** particularly those caused by the herpes virus group .
3. **Autoimmune conditions**

In our patient's case, a viral etiology via **EBV or HHV6 reactivation** was the most likely trigger. Although reported

cases of DRESS associated with MAS are few, it is very common to observe elements of hemophagocytosis during the course of DRESS. Furthermore, there is a significant **overlap** between the diagnostic criteria for DRESS and MAS.

Consequently, the apparent rarity of MAS occurring during DRESS might be explained by this overlap in diagnostic criteria, especially since **hemophagocytosis** may be absent at the beginning of the progression and is not exclusively specific to MAS (it can also occur during septic shock). The pathophysiological mechanism of MAS during DRESS is not fully elucidated; some implicate the reactivation of a herpes group virus (particularly HHV6). Regardless of the mechanism, the prognosis for secondary MAS remains unfavorable, The treatment for secondary MAS is not standardized. Systemic corticosteroid therapy is the most frequently used therapeutic alternative. The benefit of intravenous immunoglobulins (IVIG) remains a subject of debate

Conclusion

Macrophage Activation Syndrome (MAS) is a rare but serious complication of DRESS syndrome; it is essential to recognize the signs of MAS in order to initiate early treatment and prevent a fatal outcome.

EA DV CONGRESS
VIENNA
30 SEP - 3 OCT 2026

Abstract N°: 3420

Bilateral Arm Necrosis Revealing Nicolau Syndrome: A Case Report

Omayma El Khiari*[1], Sihame Alaoui[2], Narjess Er-rachdy[2], Najoua Ammar[2], Syrine Hamada[2], Mariame Meziane[2], Nadia Ismaili[2], Laïla Benzekri[2]

[1] Ibn Sina University Hospital,, Rabat, Morocco

[2] Ibn Sina University Hospital, Rabat, Morocco

Introduction

Nicolau syndrome, also known as embolia cutis medicamentosa, is a rare but potentially severe complication of injectable therapies, characterized by immediate intense pain at the injection site followed by livedoid changes that may progress to cutaneous necrosis. Initially described after intramuscular injections, it has also been reported following subcutaneous administration. Cases associated with interferon β-1a in multiple sclerosis remain exceptional.

Case Presentation

A 43-year-old patient with multiple sclerosis, treated with subcutaneous interferon β-1a for 10 months, presented with painful lesions at injection sites. The condition began six weeks earlier with an erythematous papule on the right arm that rapidly evolved into a necrotic ulcer. A similar lesion subsequently appeared on the contralateral arm. The patient reported inadequate rotation of injection sites.

Clinical examination revealed bilateral erythematous-necrotic plaques localized to injection areas. Dermoscopy showed a central yellowish area corresponding to fibrinous material, associated with irregular brown-black zones suggestive of necrosis or hemorrhage, surrounded by an erythematous halo. These findings were non-specific and required clinicopathological correlation.

Ultrasound and Doppler studies excluded deep infection and major vascular occlusion. Histopathological examination demonstrated fibrinoid necrosis of vascular walls associated with thrombosis of small dermal vessels, supporting the diagnosis of Nicolau syndrome and reinforcing the hypothesis of an ischemic-thrombotic mechanism.

Interferon therapy was discontinued in collaboration with the neurology team, and an alternative treatment was initiated. Management included surgical debridement, local wound care, topical beta-blocker therapy, and photobiomodulation. The outcome was favorable, with progressive healing and partial loss of tattoo pigment within scarred areas, reflecting the deep dermal extension of the necrotic process.

Conclusion

Nicolau syndrome is a rare but serious complication of injectable therapies whose pathophysiology remains incompletely understood. Histopathological findings, particularly vascular thrombosis and fibrinoid necrosis, support a predominantly ischemic and thrombotic process. Dermoscopic findings are not specific and should be interpreted cautiously in conjunction with clinical and histological features. Early recognition of severe post-injection pain and livedoid changes is essential to prevent extensive tissue necrosis, permanent scarring, and functional or aesthetic sequelae.

EADV Congress 2026, VIENNA
30 SEPTEMBER - 03 OCTOBER 2026
POWERED BY M-ANAGE.COM

EADV CONGRESS
VIENNA
30 SEP - 3 OCT 2026

Abstract N°: 3427

Fixed Drug Eruption Triggered by Phenytoin Use During Acute Seizure Episodes

Claudio Lelis Souza[1], Brian Vicente[2], Renata Bezerra[2], Ana Laura Ritter[1], Guilherme Gonçalves Nascimento*[2]

[1] Universidade Prof.Edson Antônio Velano - UNIFENAS, Alfenas, Brazil

[2] Intituto da Pele da Faculdade de Medicina do ABC - FMABC, Santo André, Brazil

Introduction

Phenytoin is a widely used anticonvulsant indicated for the treatment of status epilepticus as well as focal and generalized tonic–clonic seizures. Despite its wellestablished clinical efficacy, phenytoin has a narrow therapeutic index and has been associated with a broad spectrum of cutaneous adverse drug reactions, ranging from mild exanthematous eruptions to severe and potentially life-threatening conditions such as Stevens–Johnson syndrome and toxic epidermal necrolysis. Among these reactions, fixed drug eruption (FDE) represents an uncommon T-cell-mediated delayed hypersensitivity reaction characterized by the recurrent development of erythematous macules or plaques at the same anatomical sites following re-exposure to the offending agent, frequently resulting in residual hyperpigmentation.

Case Presentation

We report the case of a 21-year-old male patient referred to the Dermatology outpatient clinic due to recurrent cutaneous lesions arising after episodes of epileptic seizures requiring emergency hospital care. According to his mother, the patient had a history of epilepsy since the age of five years, initially associated with febrile episodes. He had been prescribed continuous lamotrigine therapy; however, over the previous two years, poor treatment adherence had led to frequent interruptions of medication use, resulting in recurrent generalized tonic–clonic seizures. During emergency admissions, intravenous phenytoin was repeatedly administered for acute seizure control. Following each exposure to phenytoin, the patient developed recurrent cutaneous lesions characterized by grayish hyperpigmented macules and plaques involving the back, axillary regions, and perioral area, associated with erosive lesions affecting the labial and genital mucosae. Although the lesions gradually improved over subsequent weeks, they consistently recurred at the exact same anatomical sites after each new administration of phenytoin. The temporal relationship between phenytoin exposure and fixed recurrence of the lesions, together with the characteristic clinical presentation, supported the diagnosis of phenytoin-induced fixed drug eruption. Phenytoin was permanently discontinued, and the importance of strict adherence to maintenance therapy with lamotrigine was strongly emphasized in order to prevent further seizures and subsequent re-exposure to the causative agent. The patient and his family were also instructed to inform healthcare professionals in future emergency settings about the contraindication to phenytoin use.

Conclusion

This case highlights the importance of early recognition of anticonvulsant-induced fixed drug eruption, particularly in patients repeatedly exposed to emergency anticonvulsant therapy. Prompt identification and definitive withdrawal of the offending drug are essential to prevent recurrence and progression to more severe forms of drug-induced cutaneous reactions.

EA DV CONGRESS
VIENNA
30 SEP - 3 OCT 2026

Abstract N°: 3457

Is Eosinophilia Mandatory in DRESS? A Case Series Evaluating Peripheral and Tissue Eosinophilia and Their Correlation with Severity of Transaminitis

Sahan Viduranga*[1], Udhishtran Arudchelvam[1], Surani Jayakody[1], Samadhi Ranmohottige[1], Indira Kahawita[1]

[1] Dermatology Unit, National Hospital of Sri Lanka, Colombo, Sri Lanka

Introduction
Drug Reaction with Eosinophilia and Systemic Symptoms (DRESS) is a severe, potentially life-threatening hypersensitivity reaction, with the liver being the most commonly involved visceral organ. Although eosinophilia is traditionally regarded as a hallmark feature, it may not be consistently present in all cases. The objectives of this study were to assess the relationship between peripheral blood and tissue eosinophilia in DRESS syndrome and their association with the severity of transaminitis.

Materials and Methods
A retrospective case series was conducted on 12 consecutive inpatients diagnosed with DRESS. Cases were classified using the RegiSCAR scoring system as possible, probable, or definite. Clinical data were extracted from medical records, including presenting features, culprit drugs, indications for therapy, and latency between drug exposure and symptom onset.

Peripheral blood eosinophilia was categorised as none (0–699 cells/μL or <10%), mild (700–1499 cells/μL or 10 - 19.9%), and severe (≥1500 cells/μL or ≥20%) based on RegiSCAR criteria. The severity of transaminitis was classified as mild when AST or ALT less than four times the upper limit of normal (ULN), moderate when between four and fifteen times ULN, and severe when greater than fifteen times ULN, according to a Delphi-based international consensus.

Results
Among the 12 patients, five were classified as possible, six as probable, and one as definite DRESS. The most common culprit drug was sulfasalazine (n=5). Other implicated drugs included leflunomide, carbamazepine, lamotrigine, allopurinol, vancomycin, piperacillin-tazobactam, and co-trimoxazole, with one case attributed to each. The latency period ranged from 16 to 69 days.

Eight patients developed peripheral eosinophilia, while four did not. Skin biopsy was available in 11 patients, of whom six demonstrated eosinophils on histopathology. Two patients had tissue eosinophils despite the absence of peripheral eosinophilia. Histology did not reveal eosinophils in five patients, four of them had peripheral eosinophilia.

Elevated AST and ALT levels were observed in 10 and 8 patients, respectively. Among those with elevated AST, six had eosinophilia, while four of eight patients with elevated ALT had eosinophilia. Importantly, all four patients without eosinophilia demonstrated at least mild elevations in both AST and ALT.

Conclusions

Peripheral blood eosinophilia in DRESS syndrome is neither uniformly present nor consistently correlated with histopathological findings. Furthermore, it does not reliably correlate with the severity of transaminitis, as significant hepatic involvement may occur even in its absence. Therefore, eosinophil count alone is an unreliable marker for both diagnosis and assessment of hepatic injury severity, and its absence should not preclude early recognition of DRESS syndrome.

EADV CONGRESS
VIENNA
30 SEP - 3 OCT 2026

Abstract N°: 3485

Amivantamab-Induced Erosive Pustular Dermatosis of the Scalp

Stefany Kraevska*[1], Mina Saleva - Stateva[1], Miroslava Mihova[1], Elena Petrova[1], Snejina Vassileva[1], Lyubomir Dourmishev[1], Kossara Drenovska[1]

[1] Aleksandrovska Hospital, Sofia, Bulgaria

Introduction

Erosive pustular dermatosis of the scalp (EPDS) is a rare condition of unclear aetiology, clinically defined by pustules, erosions and crusts that progressively evolve into post-lesional cicatricial alopecia. It shows a marked predilection for elderly patients, mostly women and a higher prevalence among fair phototypes with actinic damage. Immunotherapy and targeted therapies have been linked to the pathogenesis of EPDS-like eruption of the scalp. Epidermal growth factor receptor (EGFR) inhibitors such as gefitinib, afatinib, and panitumumab have been related to rare EPDS-like reactions with scarring alopecia developing a few months to up to 3 years after the initiation of therapy. We report a rare case of EPDS following an EGFR amivantamab administration.

Case Presentation

A 69-year-old woman presented with scalp erosions of 5 months duration, which were eventually related to her fifth infusion of amivantamab administered for a concomitant moderately differentiated lung cancer. Three days prior to the current admission she has received another amivantamab infusion which was followed by disseminated pustular rash. On observation, the scalp was affected by multiple erosions, densely adherent crusts covering the whole capillitium, confluent into extensive plaques with focal purulent discharge, alongside cicatricial alopecia plaques. Additionally, disseminated umbilicated pustules, erosions and excoriations covered by haemorrhagic crusts were present on the trunk and extremities.
Routine laboratory parameters showed mild leukocytosis and elevated CRP. Microbiological investigation isolated Staphylococcus aureus. PCR for Varicella zoster virus from a pustule was negative, ruling out varicella. Histological examination demonstrated a subcorneal pustule filled with abundant neutrophils, mild epidermal spongiosis and a moderate round-cell infiltrate around the hair follicle. Based on the clinico-laboratory findings, a diagnosis of amivantamab-induced Erosive Pustular Dermatosis of the Scalp was suggested. Treatment included discontinuation of the culprit drug, moderate doses of systemic corticosteroids and antibiotics, as well as emollients and topical gentamicin, leading to a favorable therapeutic response within the first month.

Conclusion

Amivantamab is a bispecific monoclonal antibody targeting EGFR and mesenchymal-epithelial transition (MET), commonly used for treatment of non-small cell lung cancer (NSCLC). EGFR is abundantly expressed in keratinocytes, dendritic cells, connective tissue cells and cutaneous appendages. Its inhibition disrupts the physical skin barrier, damages hair follicles and activates immune responses, resulting in acneiform eruptions and papulo-pustular exanthema. EGFR also participates in the hair growth cycle, so its blockade produces thin, brittle hair, while MET inhibition has been linked to hair depigmentation and xerosis. Amivantamab is a promising treatment option for patients with NSCLC. Nevertheless, its cutaneous adverse drug reactions such as EPDS must be taken into account, and a careful risk-benefit assessment together with appropriate dermatological management is warranted.

POWERED BY M-ANAGE.COM

EA DV CONGRESS
VIENNA
30 SEP - 3 OCT 2026

Abstract N°: 3489

The Psychotropic Blues: Drug-Induced Blue Skin Discoloration and Pseudocyanosis — A Comprehensive Review

Pigi Vlachou*[1], Korina Tzima[1], Alexandros Katoulis[1]

[1] 2nd Department of Dermatology and Venereology, National and Kapodistrian University of Athens, Medical School, "Attikon" General University Hospital, Athens, Greece, Athens, Greece

Introduction
Cyanosis is a cardinal clinical sign of hypoxemia, yet bluish skin discoloration does not invariably indicate impaired oxygenation. Pseudocyanosis — bluish-gray pigmentation of the skin in the presence of normal arterial oxygen saturation — may result from heavy metal accumulation or use of certain medications, most notably psychotropic agents. Although drug-induced hyperpigmentation is well described in dermatology, bluish discoloration specifically linked to psychiatric medications remains poorly recognised. Clinicians frequently misattribute such pigmentation to cardiopulmonary disease, prompting unnecessary emergency investigations. The present work synthesises current evidence on psychotropic drug-induced pseudocyanosis, elucidates drug-class-specific pathogenic mechanisms, and promotes multidisciplinary clinical awareness.

Materials and Methods
To comprehensively examine the clinical features, epidemiology, and pathogenic mechanisms of pseudocyanosis induced by psychotropic agents — with particular emphasis on phenothiazines, tricyclic antidepressants, and second-generation antipsychotics — a comprehensive analysis of published case reports, case series, and mechanistic studies was conducted via systematic database searches. Studies reporting bluish or grayish skin discoloration associated with psychotropic medications were included, with attention to clinical presentation, histopathological confirmation, implicated agents, and proposed pigmentation mechanisms.

Results
Pseudocyanosis has been documented with phenothiazines (most frequently chlorpromazine), tricyclic antidepressants (imipramine, desipramine, amitriptyline), and second-generation antipsychotics (clozapine, olanzapine, risperidone). Early studies reported a 1–2.9% prevalence of hyperpigmentation in long-term chlorpromazine users. Clinically, discoloration appears exclusively on sun-exposed areas — face and distal extremities — sparing facial wrinkles and mucous membranes, though nail beds and ocular structures (sclera, cornea, lens) may be involved. Onset is gradual and dose-dependent. Pathogenic mechanisms differ by drug class. For phenothiazines, electron microscopy reveals dermal deposition of melanin and drug metabolites in a perivascular distribution, with UV light activating tyrosinase and forming drug-melanin complexes. For tricyclic antidepressants, disruption of normal melanogenesis produces an abnormal phaeomelanin-drug metabolite complex, given the structural similarity between imipramine and chlorpromazine. A 2024 case described onset after 50 years of imipramine use with melanin-devoid lesions, suggesting additional mechanisms remain uncharacterised. For atypical antipsychotics, clozapine's partial D2 receptor agonism may influence melanocyte activity, as dopamine receptors are implicated in melanogenesis. Cases of pseudocyanosis with olanzapine and risperidone have also been reported. Laser therapy (Q-switched ruby and picosecond lasers) has been explored for treatment. Polypharmacy and underreporting hinder epidemiological estimates.

Conclusions
Psychotropic drug-induced pseudocyanosis is an under-recognised adverse effect spanning multiple psychiatric

drug classes, with distinct and incompletely understood mechanisms. Clinician awareness among psychiatrists, dermatologists, and emergency physicians is essential to ensure accurate diagnosis and avoid unnecessary investigations. Discontinuation or substitution of the causative agent may allow partial improvement. Larger prospective studies, standardised dermatologic monitoring, and systematic reporting are needed.

EADV CONGRESS
VIENNA
30 SEP - 3 OCT 2026

Abstract N°: 3498

Drug Rash with Eosinophilia and Systemic Symptoms Associated with Brentuximab Vedotin: A Rarely Reported Case in the Literature

Huriye Aybüke Koç[1], Doğan Sezgin*[2], Özge Aydın[3]

[1] Giresun University, Faculty of Medicine, Department of Dermatology, Giresun, Türkiye
[2] Giresun Training and Research Hospital, Department of Dermatology, Giresun, Türkiye
[3] Giresun Training and Research Hospital, Department of Pathology, Giresun, Türkiye

Introduction
DRESS is a drug reaction characterized by eosinophilia and systemic symptoms. Clinically, it presents with facial edema, fever, lymphadenopathy, amorbilliform rash, and systemic organ involvement. Laboratory findings may include leukocytosis, atypical lymphocytes, eosinophilia, andabnormalities in liver and renal function tests. The rash typically begins as pruritic morbilliform lesions on the face, upper trunk, and upper extremities,progressively becoming diffuse and infiltrated. In addition to cutaneous findings, hematologic abnormalities and impaired liver and renal function tests arecommonly observed. Here, we report a case of DRESS that developed following the use of brentuximab vedotin for the treatment of CD30+ cutaneous T-cell lymphoma.

Case Presentation
A 48-year-old male patient presented to the outpatient clinic with complaints of skin eruptions. He had been under follow-up for CD30+ cutaneous T-celllymphoma for six months. Following the diagnosis, chemotherapy with adriamycin, bleomycin, vinblastine, and dacarbazine was initiated. Due to lackof response to this treatment, therapy was switched to brentuximab vedotin. One month after initiating brentuximab, mildly pruritic erythematous lesionsdeveloped on the arms and legs. The rash was accompanied by a fever of 38.6 °C and prominent midline facial edema, especially in the periorbital region.Dermatological examination revealed mild erythematous brownish macules and papules on the bilateral arms and legs, along with midline facial edemamore pronounced in the periorbital area patient also had cervical lymphadenopathy. Laboratory tests showed newly developed eosinophilia ($0.88 \times 10^3/\mu L$), with no other abnormalities. A punch biopsy was taken from an erythematous papule on the arm with preliminary diagnoses of DRESS andcutaneous lymphoma infiltration. Histopathological examination revealed focal parakeratosis, basal vacuolar degeneration, mild dermal edema,erythrocyte extravasation, and a prominent perivascular lymphohistiocytic infiltrate including eosinophils, consistent with DRESS. Based on the updatedRegiSCAR diagnostic criteria, the patient scored 4 points, indicating a high probability of DRESS. He was referred to cardiology, neurology, and gastroenterology for evaluation of possible internal organ involvement; however, no pathology was detected. In consensus with the hematologydepartment, it was decided to continue brentuximab treatment, initiate systemic methylprednisolone at a dose of 32 mg/day, apply mometasone furoateointment to the erythematous maculopapular lesions on the arms and legs, and closely monitor liver and kidney function tests as well as hemogramparameters. The patient remains under follow-up.

Conclusion
DRESS syndrome is a severe and potentially life-threatening delayed drug hypersensitivity reaction characterized by diffuse cutaneous eruptions, hematologic abnormalities such as eosinophilia, and internal organ involvement,

most commonly affecting the liver and kidneys. It typically develops 2–6 weeks after exposure to the offending drug, with antiepileptics, antibiotics, NSAIDs, and allopurinol being the most frequently implicated agents. Diagnosis is based on clinical, laboratory, and systemic findings, with the RegiSCAR criteria widely used for classification. Immediate discontinuation of the causative drug and systemic corticosteroid therapy remain the mainstay of treatment. Although brentuximab vedotin is known to cause various cutaneous adverse reactions, DRESS associated with this agent has been reported only rarely. This case highlights the importance of recognizing DRESS in patients receiving brentuximab vedotin who develop fever, rash, and systemic involvement, emphasizing the need for early diagnosis and prompt treatment to reduce morbidity and mortality.

EADV CONGRESS
VIENNA
30 SEP - 3 OCT 2026

Abstract N°: 3500

Severe VZV-induced Hepatitis complicating DRESS Syndrome: A diagnostic and therapeutic challenge

Mahi Ilham*[1], Adil zerrouk[1], Mohammed Mous[1, 1], Boumediene Dahmani[1]

[1] Faculty of Medicine of Tlemcen Dr.BenzerdjebBenaouda algeria aboubakr belkaid university, CHU Tlemcen, Tlemcen, Algeria

Introduction

Drug Reaction with Eosinophilia and Systemic Symptoms (DRESS) syndrome is a severe cutaneous adverse reaction frequently associated with the reactivation of herpesviruses, most commonly HHV-6. While VZV reactivation is well-documented in immunocompromised patients, its occurrence during DRESS syndrome is rare and can lead to life-threatening visceral complications, such as severe hepatitis. We report a challenging case of DRESS syndrome complicated by systemic VZV reactivation and acute liver failure

Case Presentation

26-year-old female developed DRESS syndrome (jaundice 35xULN, cytolysis 15xULN) 8 days after starting sulfamethoxazole/trimethoprim, which was continued for an additional week despite the rash. After initial stabilization under 1.5 mg/kg/day of methylprednisolone, a sudden relapse occurred at 48 hours with varicella keratitis and pancreatitis (lipase 2xULN) without any cutaneous vesicles. VZV reactivation was confirmed (IgM+/IgG+). Early diagnosis led to an immediate switch in strategy: targeted antiviral therapy and IVIG (2 g/kg) were initiated, while corticosteroids were rapidly tapered. This approach successfully halted multi-organ failure, leading to full recovery.

This "sine herpete" form represents only 5% of visceral VZV cases (2024 review). While documented in severely immunocompromised patients, it is rarely reported in DRESS, where high-dose steroids likely masked skin signs while triggering viremia.

Conclusion

Early diagnosis and a rapid shift from immunosuppression to antiviral therapy (Acyclovir/IVIG) are life-saving. In DRESS, any biological escape must prompt immediate VZV screening, even in the absence of typical vesicles.

EA DV CONGRESS
VIENNA
30 SEP - 3 OCT 2026

Abstract N°: 3613

Hydroxychloroquine and Anti-SAE Dermatomyositis: An Autoimmune Profile at Risk of Drug Eruption

Billal Alibakir[1], haoui hanane[1], Serradj Amina*[1]

[1] Ehu oran, Oran, Algeria

Introduction

Patients with dermatomyositis (DM) may develop cutaneous adverse reactions under hydroxychloroquine (HCQ). Anti-SAE antibodies define a DM subset with predominantly cutaneous involvement (diffuse erythema, pruritus) (3), and their positivity significantly increases the risk of HCQ-induced cutaneous reactions. We report a case of a patient with anti-SAE–positive DM who developed HCQ-induced drug eruption.

Case Presentation

Ms. B.A., a 43-year-old pregnant woman (18 weeks of gestation, G4P1 with two previous miscarriages), presented early in pregnancy with cutaneous DM characterized by heliotrope rash, Gottron papules, and a shawl sign. Treatment with HCQ (Plaquenil® 400 mg/day) was initiated.

After 15 days, she developed a diffuse skin eruption including facial, trunk, and limb erythema, facial edema, fever, and intense pruritus. Lesions were erythematous, poorly demarcated, irregular in appearance, and partially associated with superficial ulcerations.

Laboratory findings showed anemia (Hb 9.3 g/dL), mild hepatic cytolysis, and atypical lymphocytes on peripheral blood smear. Immunological work-up revealed positive speckled ANA and anti-SAE antibodies.

Given the temporal relationship, the anti-SAE immunological profile, and clinical improvement after HCQ withdrawal, a diagnosis of HCQ-induced drug eruption was retained. The patient was managed with topical corticosteroids and antihistamines, with subsequent clinical improvement.

This case highlights the particular susceptibility of anti-SAE–positive DM patients to HCQ-related cutaneous adverse reactions. In the study by Wolstencroft et al., 50% of anti-SAE patients developed a rash under HCQ compared with 16% of other DM patients (1). Pruneda et al. reported a similar case, further supporting the association between anti-SAE antibodies and HCQ-induced toxicity (2).

Our patient presented a typical profile described in the literature: predominantly cutaneous DM, anti-SAE positivity, pregnancy as a potential triggering factor, and rapid onset of generalized rash after HCQ introduction. As reported in recent cohorts (4,5), early drug discontinuation combined with symptomatic treatment generally leads to favorable outcomes



Hydroxychloroquine-induced drug eruption

Conclusion

Anti-SAE antibodies in DM are associated with a higher risk of HCQ-induced cutaneous eruptions (1). This case emphasizes the importance of autoimmune profiling in guiding treatment decisions. In anti-SAE–positive DM, HCQ should be prescribed with caution. At the earliest sign of skin eruption, prompt discontinuation of the drug and appropriate management are essential

EA DV CONGRESS
VIENNA
30 SEP - 3 OCT 2026

Abstract N°: 3630

Etanercept versus Systemic Corticosteroids for Generalized Bullous Fixed Drug Eruption: A Comparative Cohort Study

Chun-Bing Chen*[1], Wan-Chen Lin[1], Wen-Hung Chung[1]

[1] Linkou Chang Gung Memorial Hospital, Taoyuan, Taiwan

Introduction
Generalized bullous fixed drug eruption (GBFDE) is a rare but potentially life-threatening severe cutaneous adverse reaction characterized by widespread bullae and erosions involving ≥10% of body surface area (BSA). Although immediate withdrawal of the culprit drug and supportive care remain essential, optimal systemic therapy for severe GBFDE has not been established. Systemic corticosteroids are commonly used but may be associated with infectious, gastrointestinal, metabolic, and wound-healing complications. Given the cytotoxic T-cell-mediated pathogenesis of GBFDE and the potential role of tumor necrosis factor-α (TNF-α) in epidermal injury, etanercept may represent a targeted corticosteroid-sparing therapeutic option. This study aimed to compare the clinical effectiveness, safety, and immunologic effects of etanercept versus systemic corticosteroids in patients with GBFDE.

Materials and Methods
We conducted a retrospective cohort study of 37 patients with GBFDE treated within the Chang Gung Memorial Hospital system in Taiwan between 2006 and 2025. GBFDE was defined by characteristic fixed drug eruption lesions with widespread vesiculobullous lesions and erosions involving ≥10% BSA across at least three anatomical regions. Eighteen patients received subcutaneous etanercept 50 mg twice weekly, while 19 patients treated with systemic corticosteroids served as controls. Clinical outcomes included time to complete re-epithelialization, complications, and in-hospital mortality. Plasma cytokine, chemokine, and cytotoxic protein profiles were analyzed in etanercept-treated patients before and after treatment and compared with healthy donors.

Results
The study included 18 patients treated with etanercept and 19 treated with systemic corticosteroids. Baseline characteristics were largely comparable between groups, including age, sex, mucosal involvement, and latency from drug exposure to symptom onset. However, the etanercept group had significantly greater baseline BSA detachment than the corticosteroid group (30.0% vs. 18.6%, p=0.033), indicating more severe initial skin involvement. Despite this, etanercept was associated with significantly faster complete re-epithelialization compared with systemic corticosteroids, with a median time of 14 days versus 26 days, respectively (hazard ratio 4.65, 95% CI 2.13–10.18; log-rank p<0.001). No treatment-related adverse events were observed in the etanercept group. In contrast, the corticosteroid group experienced more frequent and occasionally severe complications, including nosocomial infections and gastrointestinal bleeding. In-hospital mortality was comparable between groups.

Plasma immune profiling demonstrated that acute GBFDE was associated with significant elevations of Th1-, Th2-, and Th17-related cytokines, proinflammatory cytokines, chemokines, and cytotoxic mediators, including IFN-γ, IL-4, IL-5, IL-6, IL-17A, TNF-α, GM-CSF, CXCL8, CXCL9, CXCL10, CCL4, and granulysin. Following etanercept treatment, most elevated inflammatory mediators showed declining trends, with significant reductions in IL-4, IL-5, IL-17A, CXCL9, CXCL10, and granulysin, suggesting modulation of inflammatory and cytotoxic pathways.

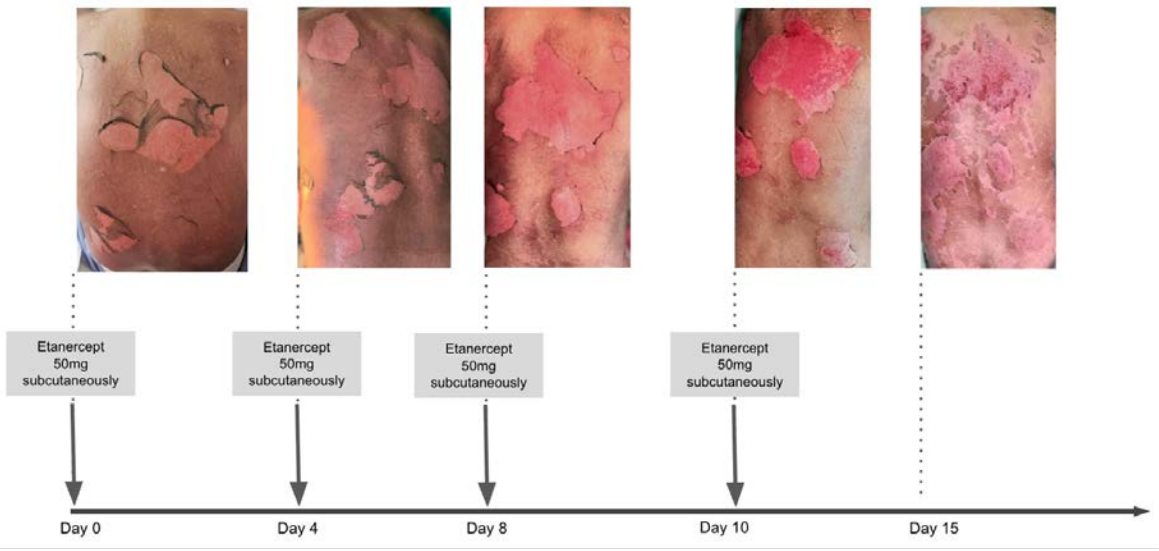

Representative clinical course of a 78-year-old male patient with generalized bullous fixed drug eruption successfully treated with etanercept

Conclusions

Etanercept was associated with significantly faster skin re-epithelialization and a more favorable safety profile than systemic corticosteroids in patients with GBFDE, despite greater baseline disease severity in the etanercept-treated group. The observed reductions in inflammatory cytokines, chemokines, and cytotoxic mediators provide mechanistic support for TNF-α blockade as a targeted therapeutic strategy in GBFDE. These findings suggest that etanercept may serve as a corticosteroid-sparing option for severe GBFDE, although larger prospective studies are warranted to confirm its efficacy and define optimal treatment regimens.

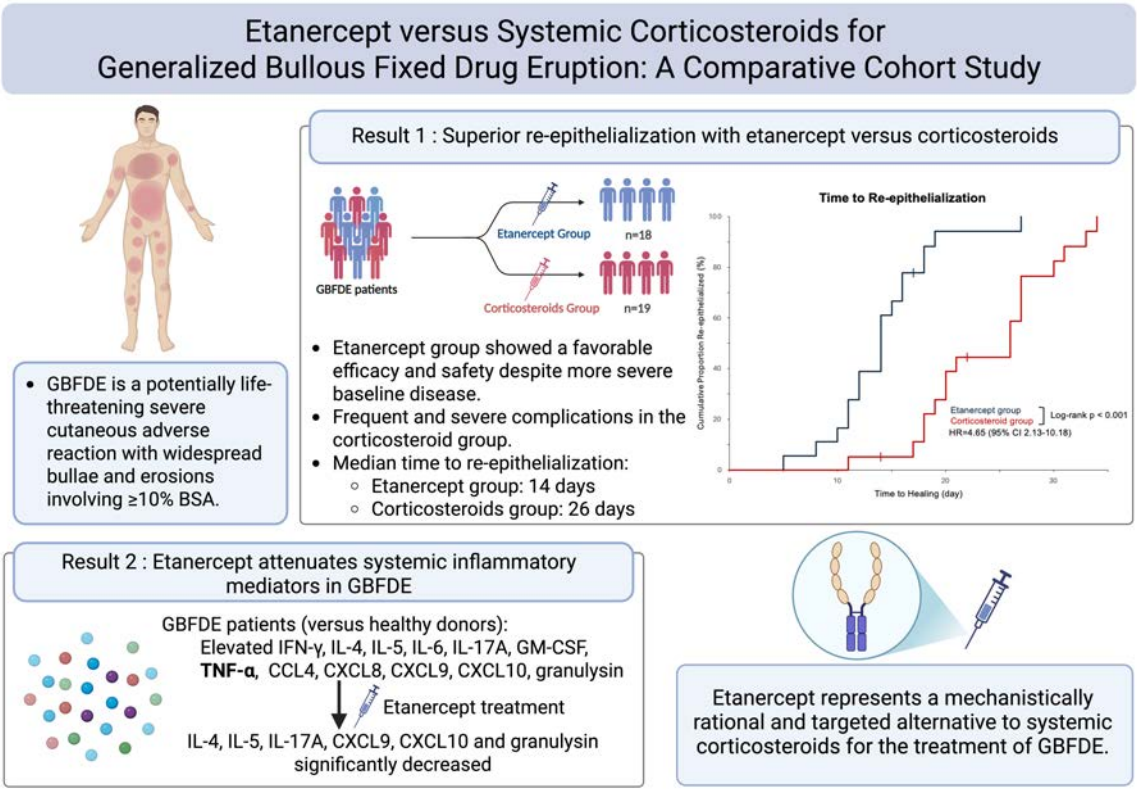

EA DV CONGRESS
VIENNA
30 SEP - 3 OCT 2026

Abstract N°: 3635

Clinical Patterns and Pharmacovigilance Trends of Cutaneous Adverse Drug Reactions in India: Insights from Pharmacovigilance Programme of India (PvPI) Alerts

Kajomi Shingala*[1], Dipesh Nariya[1]

[1] M P Shah Medical College, Jamnagar, India

Introduction
Cutaneous adverse drug reactions (CADRs) represent one of the most frequent manifestations of adverse drug reactions encountered in clinical practice and constitute a major cause of dermatologic consultations, hospital admissions, treatment interruption, and drug-related morbidity. In India, the epidemiology of CADRs is influenced by high antimicrobial consumption, over-the-counter drug availability, polypharmacy, infectious disease burden, and diverse genetic susceptibility patterns. Clinical presentations range from mild exanthematous eruptions and fixed drug eruptions to severe cutaneous adverse reactions (SCARs) such as Stevens–Johnson syndrome (SJS), toxic epidermal necrolysis (TEN), drug reaction with eosinophilia and systemic symptoms (DRESS), and acute generalized exanthematous pustulosis (AGEP). Despite increasing recognition of CADRs, underreporting and variability in pharmacovigilance practices continue to limit accurate estimation of their burden in India.

Materials and Methods
A structured narrative review was conducted using PubMed, Scopus, and Google Scholar databases to identify Indian and international literature on CADRs published up to March 2025. Search terms included “cutaneous adverse drug reactions,” “drug eruptions,” “SJS,” “TEN,” “DRESS,” “AGEP,” “pharmacovigilance,” and “India.” Prospective and retrospective clinical studies, epidemiological analyses, systematic reviews, pharmacovigilance reports, and key immunopathogenesis and management studies were reviewed. In parallel, dermatology-related adverse drug reaction alerts issued by the Indian Pharmacopoeia Commission under PvPI between January 2020 and March 2025 were analyzed to identify emerging reporting patterns and safety signals.

Results
Indian studies indicate that CADRs account for approximately 10–30% of reported adverse drug reactions, with maculopapular eruptions being the most common presentation, followed by fixed drug eruptions, urticaria, and severe CADRs such as SJS/TEN and DRESS. Antimicrobials, NSAIDs, antiepileptics, and antitubercular drugs are the predominant causative agents. Indian cohorts appear to report a relatively higher proportion of severe CADRs compared with western datasets, possibly due to differences in prescribing practices, infectious disease burden, and pharmacogenetic susceptibility.

Analysis of PvPI alerts from 2020–2025 demonstrated evolving pharmacovigilance trends, with fixed drug eruption, DRESS, and AGEP among the most frequently reported CADRs. Antibiotics and NSAIDs remained the leading implicated drug classes, while uncommon reactions such as lichenoid eruptions, SDRIFE, bullous pemphigoid, and drug-induced hyperpigmentation highlighted the expanding CADR spectrum.

Diagnosis increasingly relies on scoring systems such as RegiSCAR and EuroSCAR, histopathology, and causality assessment tools including WHO-UMC and Naranjo algorithms. Management prioritizes prompt withdrawal of the offending drug and syndrome-specific immunomodulation. Emerging approaches including HLA-guided prescribing, AI-assisted pharmacovigilance, and electronic CADR alert systems may improve early detection and reduce preventable morbidity.

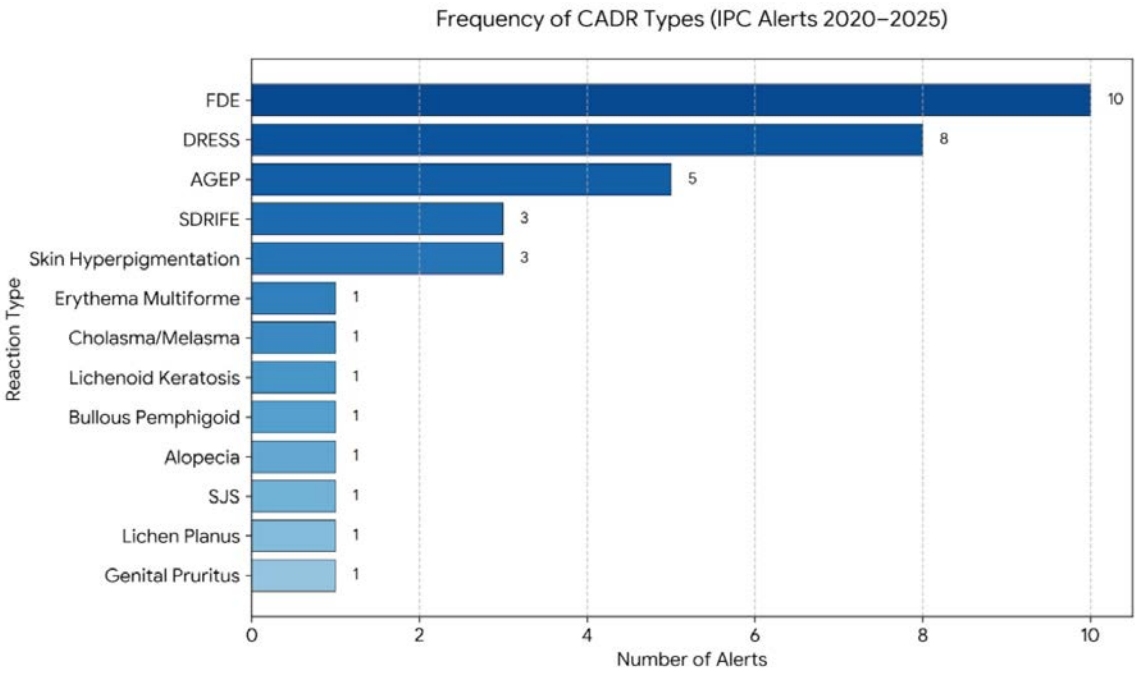

Figure 1: Frequency distribution of cutaneous adverse drug reaction (CADR) types reported in IPC Drug Safety Alerts (2020–2025).

Conclusions

CADRs remain an important and evolving challenge in Indian dermatology and pharmacovigilance practice. Indian epidemiological patterns demonstrate unique regional features, including substantial involvement of antimicrobials, NSAIDs, antiepileptics, and antitubercular drugs, alongside a notable burden of severe hypersensitivity reactions. Strengthening clinician awareness, structured reporting through PvPI, pharmacogenomic screening, and integration of digital pharmacovigilance strategies are essential for improving patient safety and reducing CADR-related morbidity and mortality in India.

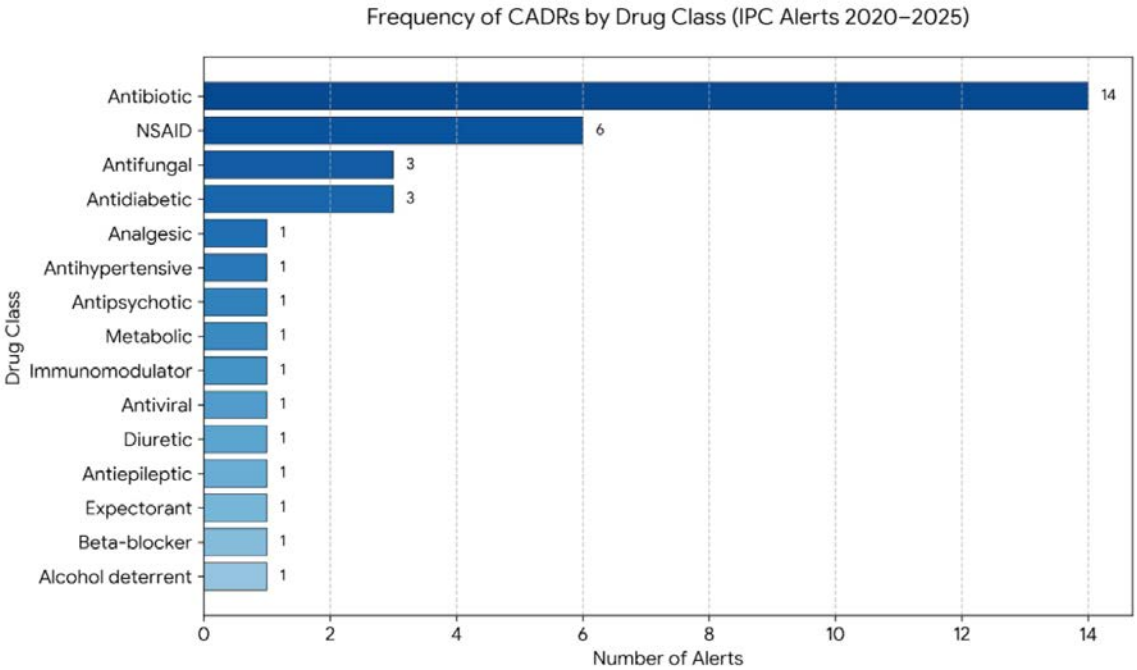

Figure 2: Drug class–wise distribution of CADRs reported in IPC Drug Safety Alerts (2020–2025), highlighting antibiotics and NSAIDs as the predominant implicated classes.

EA DV CONGRESS
VIENNA
30 SEP - 3 OCT 2026

Abstract N°: 3664

When Dermatological Therapy Goes Wrong: A Case Series of Unexpected Adverse Reactions to Systemic Treatments

Vera Plužarić*[1], Maja Tolušić Levak[2], Marija Sola[3], Igor Kuric[4], Iva Sabljic[5], BOZICA KURTOVIC[6], Iva Milić Vranješ[7]

[1] Department of Dermatology and Venerology, University Hospital Osijek, • Department of Laboratory Medicine and Pharmacy, Faculty of Medicine, Josip Juraj Strossmayer University of Osijek, Osijek, Croatia

[2] Department of Dermatology and Venerology, University Hospital Osijek, • Department of Histology and Embryology, Faculty of Medicine, Josip Juraj Strossmayer University of Osijek, Osijek, Croatia

[3] Department of Dermatology and Venerology, University Hospital Osijek, Osijek, Croatia

[4] Department of Dermatology and Venereology, University Hospital Osijek, Department of Dermatovenereology, Faculty of Medicine, University of Osijek, Osijek, Croatia

[5] Department of Dermatology and Venereology, Internal Medicine Department, General County Hospital Vinkovci, Vinkovci, Croatia

[6] Department of Dermatology and Venereology, University Hospital Osijek, Osijek, Croatia

[7] Clinic of Obstetrics and Gynecology, University Hospital Osijek, Department of Obstetrics and Gynecology, Faculty of Medicine, J.J. Strossmayer University, Osijek, Croatia

Introduction

Systemic therapies for inflammatory skin diseases have transformed dermatological practice, offering effective disease control for psoriasis and autoimmune blistering disorders. However, adverse drug reactions remain a significant clinical challenge. Bimekizumab, a dual IL-17A/F inhibitor, demonstrates serious hypersensitivity reactions at 0.1 per 100 patient-years. Guselkumab, an IL-23 inhibitor, shows adverse events at 169 per 100 patient-years during long-term treatment. Azathioprine-induced hepatotoxicity affects approximately 2.7% of patients, typically within the first months of therapy. We present three cases illustrating diverse adverse reactions to commonly used systemic dermatological therapies, emphasizing the importance of vigilant monitoring and early recognition.

Case Presentation

Case 1: Progressive Hypersensitivity to Bimekizumab

A female patient with plaque psoriasis initiated bimekizumab 320 mg subcutaneously. Following the first injection, she developed pruritus without visible cutaneous changes. Three days after the second injection, she presented with generalized urticaria and angioedema requiring immediate intervention. Bimekizumab was permanently discontinued, and the patient was successfully switched to an alternative biologic agent with subsequent tolerance and no further reactions.

Case 2: Cutaneous Adverse Effects with Guselkumab

A male patient receiving guselkumab 100 mg for plaque psoriasis developed progressive xerosis and diffuse non-scarring alopecia. Symptoms began after the first injection and

progressively worsened following the second administration during the induction phase. Comprehensive dermatological and laboratory evaluation excluded thyroid dysfunction, nutritional deficiencies, and other alternative etiologies. These findings were attributed to guselkumab therapy, representing an uncommon cutaneous adverse effect of IL-23 inhibition.

Case 3: Azathioprine-Induced Hepatotoxicity in Pemphigus

A patient with pemphigus vulgaris initiated azathioprine 50 mg daily as steroid-sparing immunosuppressive therapy. After one month of treatment, routine laboratory monitoring revealed acute hepatitis with
transaminases exceeding five times (ALT, AST) to twenty-five times (GGT) the upper limit of normal. Azathioprine was immediately discontinued, and liver function tests normalized within four weeks following drug withdrawal, confirming drug-induced hepatotoxicity. The patient was subsequently managed with alternative immunosuppressive therapy.

Conclusion

These cases underscore critical safety considerations in systemic dermatological therapy. Bimekizumab-associated hypersensitivity, though uncommon, can manifest with progressive severity upon repeated exposure, progressing from pruritus to urticaria and angioedema. This pattern demonstrates potential sensitization and emphasizes the importance of patient education regarding delayed hypersensitivity symptoms. Cutaneous adverse effects including xerosis and alopecia with IL-23 inhibitors warrant systematic recognition and documentation in real-world practice, despite overall favorable safety profiles in large-scale studies. Azathioprine hepatotoxicity predominantly occurs within the first three months of therapy and is reversible upon prompt discontinuation, supporting the critical importance of baseline hepatic assessment and regular monitoring. Clinicians should maintain a high index of suspicion for adverse reactions, implement appropriate surveillance protocols, and ensure early recognition for optimal patient safety and outcomes

EADV CONGRESS
VIENNA
30 SEP - 3 OCT 2026

Abstract N°: 3678

Non-healing penile ulcer emerging on the background of twenty years of topical corticosteroid use and a redundant foreskin: an iatrogenic and anatomical trap mimicking syphilis, Behçet disease and penile intraepithelial neoplasia

Millena de Freitas Ribeiro*[1], Letícia Silva Andrade[1], Isabella Freire Pedrini[1], Isabel Anuda Brum de Andrade[1], Daniel Pereira[1], Isadora Prado Juliani[1], Anna Oliveira[1], Raquel Buosi[1], Isabela Garibaldi Cucolicchio[1], Tiago Arouche[1], Ana Gabriela Lopes[1], Flávia Colares[1], Patrick Wanderson dos Santos[1], Marcelo Lyra[1]

[1] Hospital Central do Exército, Rio de Janeiro, Brazil

Introduction

Plasma cell balanitis, also known as Zoon balanitis (ZB), is a chronic benign inflammatory dermatosis of the glans and prepuce affecting uncircumcised middle-aged and elderly men. A redundant foreskin, chronic moisture and friction are well-recognized pathogenic drivers, and recurrences are common without definitive anatomical correction. Topical corticosteroids are widely prescribed despite limited long-term efficacy and a well-characterized adverse-effect profile on genital skin, including atrophy, delayed wound healing and steroid-withdrawal phenomena. Ulcerated forms of ZB are uncommon and may mimic urgent differentials such as syphilis, Behçet disease and penile intraepithelial neoplasia. We report an ulcerated ZB arising on the background of two decades of topical corticosteroid use and a redundant foreskin.

Case Presentation

A 61-year-old uncircumcised male, with hypertension, insulin-dependent type 2 diabetes mellitus and dyslipidaemia, presented with a 3-month history of an enlarging glans ulcer with intermittent purulent and occasionally blood-tinged discharge, without pain, pruritus, dysuria, fever or weight loss. On directed history, he reported approximately twenty years of near-continuous topical triamcinolone acetonide use, initially prescribed for recurrent balanitis and subsequently self-maintained, with repeated relapses over the years. He denied new sexual partners, genital trauma, orogenital ulcers, uveitis, arthritis or gastrointestinal symptoms. Examination disclosed a redundant, poorly retractable foreskin and a single ovoid, well-demarcated ulcer with raised erythematous borders and a purulent base on the glans, without regional lymphadenopathy or mucocutaneous lesions elsewhere.Dermoscopy disclosed a central ulceration with amorphous yellowish-white areas, short linear vessels, a peripheral whitish halo and perilesional erythema, features consistent with an inflammatory rather than a malignant vascular pattern. Direct mycological examination and fungal culture were negative, with non-specific bacterial growth. A comprehensive sexually transmitted infection panel (VDRL, FTA-ABS IgG/IgM, anti-HIV-1/2, HBsAg, anti-HBs, anti-HCV, anti-HTLV-1/2) was non-reactive; HSV IgG was positive with negative IgM. Incisional biopsy disclosed epithelial exulceration and, in the upper dermis, a mixed inflammatory infiltrate composed of lymphocytes, plasma cells and eosinophils, without vasculitis or granulomas, establishing the diagnosis of plasma cell (Zoon) balanitis.

Conclusion

This case illustrates how anatomical and iatrogenic factors may converge to produce an atypical ulcerated ZB. A redundant foreskin perpetuates the chronic moisture and friction that sustain recurrences, while two decades of uninterrupted topical corticosteroid use probably contributed to epithelial atrophy, delayed healing and an ulcerated phenotype. Poorly controlled diabetes mellitus further compounded impaired wound repair. Syphilis was excluded by sequential negative treponemal and non-treponemal tests; Behçet disease was ruled out by the absence of oral aphthae, ocular or articular involvement, and by compatible histopathology; penile intraepithelial

neoplasia and invasive squamous cell carcinoma were excluded by biopsy. Management priorities are corticosteroid withdrawal, transition to a topical calcineurin inhibitor, strict glycaemic control and consideration of circumcision, which remains the most effective long-term option in recurrent anatomically driven disease.

EA DV CONGRESS
VIENNA
30 SEP - 3 OCT 2026

Abstract N°: 3728

Persistent Erythema Dyschromicum Perstans Like Hyperpigmentation Associated with Cyclin Dependent Kinase 4/6 Inhibitor Therapy In Metastatic Breast Cancer

Büşra Kaya[1], Berkay Temel[1], Gülay Keyik*[1], Melike Urgancı Gökpınar[2], Özlem Erdem[2], Esra Adışen[1]

[1] Gazi University Department Of Dermatology, ankara, Türkiye

[2] Gazi University Department Of Pathology, ankara, Türkiye

Introduction

Cyclin dependent kinase 4/6 (CDK4/6) inhibitors are increasingly used in combination with endocrine therapy for hormone receptor-positive/human epidermal growth factor receptor 2-negative (HR+/HER2−) advanced breast cancer. The most frequently reported cutaneous adverse events include alopecia, xerosis, stomatitis, and maculopapular eruptions. Pigmentary reactions remain exceptionally rare. Erythema dyschromicum perstans (EDP), also known as ashy dermatosis, is characterized by slate, gray hyperpigmented macules and patches associated histologically with pigment incontinence and dermal melanophages. This case shows a patient who developed persistent EDP-like hyperpigmentation during CDK4/6 inhibitor therapy.

Case Presentation

A 42 year old woman presented with gradually progressive gray-brown skin discoloration associated with mild pruritus for approximately 3 years. Her medical history was significant for metastatic HR+/HER2− breast carcinoma diagnosed in 2021. The first biopsy demonstrated mixed invasive ductal and invasive cribriform carcinoma. The patient received 8 cycles of neoadjuvant chemotherapy followed by total mastectomy and axillary lymph node dissection in July 2021. Histopathologic examination showed mixed invasive ductal, invasive lobular, and invasive cribriform carcinoma with lymphovascular invasion and metastatic involvement of 2 axillary lymph nodes. Bone metastases involving the sacrum and iliac bone were identified during follow-up.

After surgery, the patient underwent approximately 5 weeks of radiotherapy to the breast and axillary region together with single session high dose radiotherapy to metastatic bone lesions. No pigmentary abnormalities developed during chemotherapy, radiotherapy, or the immediate postoperative period. Subsequently, combined letrozol and ribociclib treatment was initiated. Following treatment initiation, the patient gradually developed progressive hyperpigmentation.

Dermatologic examination revealed multiple ill defined gray-brown hyperpigmented patches involving the upper back, shoulders, lateral trunk, and lumbar region. The lesions were predominantly truncal rather than photodistributed and did not correspond to irradiated fields. There is no mucosal involvement, scaling, or active erythematous borders (figure 1).

Histopathologic examination showed marked melanin incontinence and dermal melanophages within the superficial dermis without amyloid deposition (figure 2). Clinicopathologic correlation together with the temporal relationship to therapy supported the diagnosis of EDP-like drug induced hyperpigmentation.

Differential diagnoses included lichen planus pigmentosus, postinflammatory hyperpigmentation, macular amyloidosis, and radiation associated pigmentation. However, the delayed onset after radiotherapy and the absence of field correspondence argued against radiation recall or radiation induced pigmentation.

Conclusion

Pigmentary eruptions associated with CDK4/6 inhibitors are uncommon. Previously reported cases demonstrated predominantly photodistributed involvement with interface lichenoid dermatitis. In contrast, this patient showed persistent truncal involvement. The delayed onset after systemic therapy initiation and the clinicopathologic findings strongly suggested a drug related pigmentary eruption.

This case highlights a rare EDP-like hyperpigmentation associated with CDK4/6 inhibitor therapy in metastatic breast cancer. Recognition of uncommon pigmentary toxicities is important to avoid unnecessary investigations and inappropriate discontinuation of oncologic treatment.

EADV CONGRESS
VIENNA
30 SEP - 3 OCT 2026

Abstract N°: 3738

Differential Risk of Paradoxical Alopecia between Secukinumab and Ixekizumab: A Comparative Pharmacovigilance Analysis Using EudraVigilance and FAERS Database

Madalina Bucur*[1], Gabriela Moroi[1], Letitia Carina Olteanu[2]

[1] University of medicine and pharmacy "Carol Davila", Bucharest, Romania

[2] Department of Clinical Pharmacology, "Pius Brinzeu" County Emergency Clinical Hospital, Timișoara, Romania

Introduction

Interleukin-17 inhibitors (IL-17i) are cornerstone biologic therapies for immune-mediated dermatologic diseases, particularly psoriasis. Despite their efficacy, IL-17i may trigger paradoxical cutaneous reactions. Most existing literature focuses on TNF-α inhibitors, leaving a gap in comparative real-world data between IL-17A-specific agents such as secukinumab and ixekizumab. This study aimed to compare alopecia-related reporting patterns for secukinumab versus ixekizumab using the EudraVigilance and FDA Adverse Event Reporting System (FAERS) databases.

Materials and Methods

A comparative pharmacovigilance analysis was performed using reports from EudraVigilance and FAERS up to May 2026. Alopecia-related adverse events were identified using MedDRA Preferred Terms, including "alopecia", "alopecia areata", "alopecia scarring", "alopecia totalis", and "alopecia universalis". Secukinumab was compared with ixekizumab. Disproportionality was assessed using the reporting odds ratio (ROR) and proportional reporting ratio (PRR), with 95% confidence intervals (CI). Sex distribution was also analyzed.

Results

In EudraVigilance, 880 alopecia-related reports were identified for secukinumab, of which 95.1% occurred in females, compared with 103 reports for ixekizumab, of which 76.7% occurred in females. Secukinumab showed a higher alopecia-related disproportionality signal than ixekizumab, with an ROR of 3.70, a PRR of 3.61, and a 95% CI of 3.01–4.55.

In FAERS, 3,706 alopecia-related reports were identified for secukinumab, of which 82.4% occurred in females, compared with 307 reports for ixekizumab, of which 75.9% occurred in females. The alopecia-related disproportionality signal was again higher for secukinumab than for ixekizumab, with an ROR of 2.77, a PRR of 2.73, and a 95% CI of 2.47–3.12.

Conclusions

A consistently higher disproportionality signal for alopecia-related adverse events was identified for secukinumab compared with ixekizumab across both EudraVigilance and FAERS. A marked female predominance was observed for both agents, particularly for secukinumab. These findings suggest potential differences in paradoxical alopecia reporting between IL-17A inhibitors and highlight the importance of dermatologic monitoring during biologic therapy. Further real-world and comparative studies are warranted to better characterize the underlying mechanisms, causality, and clinical relevance of alopecia-related adverse events associated with IL-17 inhibition.

EA DV CONGRESS
VIENNA
30 SEP - 3 OCT 2026

Abstract N°: 3757

Improving Timely Access to Topical Therapy and Dressings for Severe Cutaneous Adverse Reactions: A Quality Improvement Initiative

Florence Garty[1], Stephanie Adeyemi*[1], Hannah Wainman[1], Charlotte Michelmore[1], Laura Crosby[1], Rebecca Dingle[1], Sarah HANBY[1], Karen Sefton[1], Katrina Thomas[1], Sarah Battaglia[1], Christina Knights[1], Sidrah Choudhry[1]

[1] University Hospitals Bristol and Weston NHS Foundation Trust, Bristol, United Kingdom

Introduction

Severe cutaneous adverse reactions including Toxic Epidermal Necrolysis (TEN), Stevens-Johnson Syndrome (SJS), Erythema Multiforme Major and immunobullous disorders are rare but associated with significant morbidity and mortality due to the risks of multiorgan involvement and extensive skin failure. Loss of epidermal integrity results in severe pain, fluid loss and high infection risk. Early application of appropriate topical therapies and non-adherent dressings is critical ideally within hours of presentation. Delays in accessing dressings and emollients are frequently observed particularly in inpatient settings.

The aim of this project was to evaluate current practice regarding the timeliness of topical therapy and dressing initiation and to improve access by introducing a standardized "ideal dressings and topicals box'' for acute admissions with a target of treatment initiation within 8 hours.

Materials and Methods

A retrospective baseline audit was conducted at a UK tertiary dermatology centre where patients referred to the on-call dermatology service between 2023–2025 with severe cutaneous reactions (TEN, SJS, EM major, and widespread blistering disorders) were reviewed. Data collected included time to topical therapy, dressing use and documentation quality. A clinician survey assessed perceived delays and barriers to timely care.

Results

The patient audit identified ten patients. Topical therapy was initiated on the day of presentation in 60% of patients while 40% experienced delays of greater than 8 hours. 80% of patients lacked clear documentation of dressing type and length of duration of use.

The clinician survey responses indicated that only 60% of patients received dressings within 12 to 24 hours, 20% of patients within 24 to 48 hours and 20% of patients after more than 48 hours. Clinician reported barriers included delays obtaining supplies from the dressings store, limited ward stock and inefficiencies in interdepartmental communication.

An "ideal dressings and topicals box'' was developed to standardize and expedite care. Contents include antimicrobial soap substitute, emollient, non-adherent contact layer, absorbent secondary dressing, tubular bandage and adhesive remover. Dressing selection was according to the local hospital dressings formulary. A *Guide to Dressing Management for Severe Skin Reactions Including Skin Detachment and Blistering* was developed for ward staff. This introduced key concepts such as gentle cleansing, preservation of detached epidermis, blister decompression, liberal emollient use, application of non-adherent dressings and avoidance of adhesive products. Topical steroids were not included in the box as these remain clinician prescribed. Emphasis

was placed on analgesia, infection surveillance and ensuring ongoing supply for dressing changes. Advice was also given on how to safely insert and secure a cannula in fragile skin.

Conclusions

The introduction of a standardized dressing and topical therapy box, supported by a clear clinical protocol, aims to reduce delays in accessing appropriate wound care, risk of infection, fluid loss and pain for patients presenting with severe cutaneous adverse reactions.

EA DV CONGRESS
VIENNA
30 SEP - 3 OCT 2026

Abstract N°: 3758

Erythema Multiforme Induced by Albendazole: A Case Report

Ouissal Hormi*[1], Nassiba Zerrouki[1], Nada Zizi[1]

[1] Department of Dermatology, Venereology and Allergology, Mohammed VI University Hospital Center, Oujda, oujda, Morocco

Introduction

Drug-induced erythema multiforme (EM) is a rare and poorly described variant of erythema multiforme. It is most often triggered by herpes simplex virus infections and, rarely, by adverse drug reactions. We report a case of albendazole-induced erythema multiforme in a patient with a hepatic hydatid cyst, highlighting its clinical and histopathological features, favorable outcome, and the importance of early recognition and pharmacovigilance.

Case Presentation

A 50-year-old patient with end-stage renal disease, on thrice-weekly hemodialysis, was diagnosed with a hepatic hydatid cyst one month prior. The patient was prescribed albendazole at a dose of one tablet daily for 10 days. Twenty days after completing the course, he presented to the emergency department with pruritic erythematous papular lesions on the limbs, which had been evolving over five days. The patient had no history of herpes, pneumonia, or other infections. On physical examination, multiple well-defined erythematous maculopapular targetoid lesions were observed on the upper and lower limbs, some confluent into plaques, measuring 1–4 cm in diameter, with a symmetrical distribution. (Figure1) There was no mucosal involvement. The remainder of the physical examination was unremarkable. Laboratory tests revealed no abnormalities. Skin biopsy demonstrated a pericapillary lymphohistiocytic infiltrate in the superficial dermis without vascular wall abnormalities, along with mild lymphocytic exocytosis in the epidermis.

The diagnosis of drug-induced EM was established based on the clinical presentation and medication history. A pharmacovigilance report was submitted. The patient's clinical course was favorable, with spontaneous regression of the lesions over 20 days.



Conclusion

Erythema multiforme is an acute mucocutaneous eruption, most often triggered by infections, particularly herpes simplex virus, or by drugs. Drug-induced EM represents a type IV hypersensitivity reaction, mediated by T cells, leading to keratinocyte apoptosis and inflammation. While antibiotics, NSAIDs, and certain other medications are commonly implicated, antiparasitic drugs such as albendazole are rarely reported as triggers.

Albendazole, a benzimidazole derivative widely used for helminth infections including hydatid disease, generally has a high safety profile. Nevertheless, hypersensitivity reactions can occur, ranging from mild cutaneous eruptions to severe conditions like toxic epidermal necrolysis. In this case, the temporal association with drug intake, absence of alternative triggers, and characteristic clinical and histopathological features support albendazole as the causative agent.

Clinically, EM manifests as macules, papules, and characteristic target lesions, sometimes coalescing into plaques. Histological findings typically include perivascular lymphohistiocytic infiltrates, dermal edema, and mild epidermal changes. Severe cases may show epidermal necrosis and blister formation. Most drug-induced EM cases resolve spontaneously within three to five weeks without permanent sequelae, although recurrences can occur with re-exposure to the offending agent.

This case underscores the need to consider albendazole as a rare cause of erythema multiforme, with prompt drug discontinuation, early recognition, and pharmacovigilance reporting being essential to prevent complications and ensure full recovery.

EADV CONGRESS
VIENNA
30 SEP - 3 OCT 2026

Abstract N°: 3806

Carbamazepine-Induced Toxic Epidermal Necrolysis in a Young Female with Epilepsy Successfully Managed with Intravenous Immunoglobulin-Based Combination Therapy

Kajomi Shingala*[1], Dipesh Nariya[1]

[1] M P Shah Medical College, Jamnagar, India

Introduction

Toxic epidermal necrolysis (TEN) is a rare but life-threatening severe cutaneous adverse reaction characterized by extensive epidermal detachment and mucocutaneous involvement, most commonly triggered by medications. Aromatic antiepileptic drugs, particularly carbamazepine, are among the leading causative agents. Mortality associated with TEN remains substantial, and despite the use of multiple immunomodulatory approaches including corticosteroids, and intravenous immunoglobulin (IVIG), optimal treatment strategies remain controversial. In resource limited settings, additional challenges related to cost, availability, and resource limitations further influence therapeutic decisions and treatment protocols.

Case Presentation

A 20-year-old female with a known history of epilepsy for three years presented to a tertiary care center with multiple rapidly progressive erythematous lesions involving the face, trunk, and extremities associated with oral ulceration for two days. She also complained of generalized pruritus, fever, malaise, throat pain, difficulty speaking, weakness, mild respiratory discomfort, and bilateral ocular discharge. One month prior, the patient had experienced convulsions and received treatment at another healthcare facility. During a subsequent follow-up visit, carbamazepine 200 mg twice daily was added to her existing medications. Approximately two days following initiation of carbamazepine therapy, she developed generalized itching followed by progressive widespread cutaneous eruptions and mucosal involvement.

On admission, general examination revealed poor condition with temperature of 100.4°F, pulse rate of 126/min, respiratory rate of 16/min, blood pressure of 100/70 mmHg, and oxygen saturation of 98% on room air. Dermatological examination demonstrated extensive erythematous lesions with epidermal detachment and oral and ocular mucosal involvement consistent with TEN. The temporal relationship between carbamazepine initiation and onset of symptoms strongly suggested carbamazepine-induced TEN. Carbamazepine was immediately discontinued, and intensive supportive care was initiated, including intravenous fluid replacement, electrolyte management, antibiotics, non-adherent dressings, topical emollients, and systemic corticosteroids. Intravenous immunoglobulin was administered at a dose of 1 g/kg for three days as part of combination immunomodulatory therapy. The patient demonstrated gradual improvement with reduction in mucosal symptoms, progressive re-epithelialization of affected skin, and favorable clinical recovery during hospitalization.

Conclusion

IVIG has been proposed to inhibit keratinocyte apoptosis through blockade of Fas–Fas ligand interactions, although evidence regarding its efficacy in TEN remains heterogeneous. In LMIC settings such as India, treatment decisions frequently depend on resource availability, cost considerations, and institutional practices, leading to variability in IVIG utilization and dosing protocols. Combination immunomodulatory approaches may represent a practical strategy in selected severe cases where rapid disease control is necessary. This case highlights carbamazepine as an important trigger of TEN and emphasizes the importance of early recognition, immediate

withdrawal of the offending drug, and multidisciplinary supportive care. It also underscores the need for evidence-based and context-specific treatment protocols for IVIG use in TEN, particularly in resource-limited healthcare settings.

EADV CONGRESS
VIENNA
30 SEP - 3 OCT 2026

Abstract N°: 3807

Urticarial Drug Eruption Following Elexacaftor/Tezacaftor/Ivacaftor Therapy in a Child With Cystic Fibrosis

Ege Uğur*[1], Muazzez Çiğdem Oba[1], Burhan Engin[1]

[1] Cerrahpaşa Faculty of Medicine, Department of Dermatology and Venereology, Istanbul, Türkiye

Introduction

Elexacaftor/Tezacaftor/Ivacaftor therapy has significantly improved outcomes in patients withCystic Fibrosis. However, cutaneous adverse reactions associated with CFTR modulators are increasingly being recognized. Although urticaria-like and erythema multiforme-like eruptions have rarely been reported, their clinicopathological characteristics remain insufficiently characterized.

Case Presentation

An 11-year-old boy with Cystic Fibrosis presented with widespread pruritic erythematous eruptions that developed 12 days after initiation of Elexacaftor/Tezacaftor/Ivacaftor therapy. Dermatological examination revealed diffuse urticarial and maculopapular plaques involving the trunk, back, extremities, face, and postauricular regions, some demonstrating atypical targetoid morphology (Figure 1). Mild conjunctival injection and lip erythema were observed without significant oral mucosal involvement (Figure 2).

Histopathological examination demonstrated focal basal vacuolar degeneration and superficial perivascular lymphohistiocytic infiltrates with eosinophils, consistent with drug eruption. Characteristic histopathological findings of erythema multiforme were absent. Viral exanthem was not supported histopathologically. Based on clinicopathological correlation, the patient was diagnosed with urticarial drug eruption associated with ETI therapy.

The eruption regressed with oral cetirizine therapy despite continuation of ETI treatment, and no recurrence or progression was observed during follow-up.

Conclusion

This case highlights a rare cutaneous adverse reaction associated with Elexacaftor/Tezacaftor/Ivacaftor presenting with urticarial and erythema multiforme-like clinical features. Recognition of these eruptions is important for accurate diagnosis and differentiation from viral exanthems and erythema multiforme. Clinicopathological correlation remains essential in establishing the diagnosis of ETI-associated cutaneous drug reactions.

EADV CONGRESS
VIENNA
30 SEP - 3 OCT 2026

Abstract N°: 3815

Acute Generalized Exanthematous Pustulosis Triggered by Amoxicillin-Clavulanate in a Patient With Severe Atopic Dermatitis Successfully Treated With Etanercept: A Case Report

Deema Makkawi*[1], Reem Alghamdi[1], Alshymaa Mofareh[1], Khalid Alhawsawi[2]

[1] Umm Alqura university, Makkah, Saudi Arabia

[2] King Abdulaziz medical city, Jeddah, Saudi Arabia

Introduction

Acute generalized exanthematous pustulosis (AGEP) is a rare, severe cutaneous adverse reaction most commonly triggered by medications, particularly antibiotics. We report a challenging case of AGEP arising in a patient with severe atopic dermatitis (AD), successfully managed with etanercept.

Case Presentation

A 23-year-old male with a longstanding history of AD presented with a severe flare of eczema and was started on cyclosporine 150 mg twice daily and amoxicillin/clavulanic acid (Augmentin) 1 g twice daily. Within 24 hours of treatment initiation, he developed rapidly progressive generalized skin eruptions associated with worsening dermatitis. He denied fever or other systemic symptoms.

Dermatological examination demonstrated numerous tiny non-follicular pustules with widespread collarette scaling and diffuse crustations overlying pre-existing lichenified eczematous plaques. Laboratory investigations, including complete blood count, renal profile, liver function tests, and electrolytes, were within normal limits.

Based on the characteristic clinical presentation and temporal relationship to medication exposure, a diagnosis of AGEP was established. Cyclosporine and Augmentin were immediately discontinued. Due to the extensive cutaneous involvement and severe inflammatory presentation, etanercept 50 mg subcutaneously once weekly was initiated. Marked clinical improvement was observed within days, with complete resolution of the acute pustular eruption after the third dose, allowing treatment discontinuation. The patient was subsequently started on upadacitinib 30 mg daily for long-term AD control, achieving excellent clinical response within weeks.

Conclusion

This case highlights the diagnostic challenge of AGEP occurring in the setting of severe AD and supports the potential utility of etanercept as an effective therapeutic option in severe or rapidly progressive AGEP. Early recognition and prompt withdrawal of the offending agents remain essential to achieving favorable outcomes.

EA DV CONGRESS
VIENNA
30 SEP - 3 OCT 2026

Abstract N°: 3831

Generalized Pustular Figurate Erythema – A Literature Review with desciption of GPFE following Saw Palmetto Supplement Intake in a Patient with Androgenetic Alopecia

Wiktor Kruczek*[1, 2, 3], Aleksandra Frątczak[2], Mikołaj Łanocha[2], Iga Litwińska[3], Mirosław Śnietura[4], Bartosz Miziołek[2], Beata Bergler-Czop[2]

[1] Doctoral School, Medical University of Silesia, Department of Dermatology, School of Medicine in Katowice, Medical University of Silesia, Students' Scientific Association at the Department of Dermatology, School of Medicine in Katowice, Medical University of Silesia, Katowice, Poland

[2] Department of Dermatology, School of Medicine in Katowice, Medical University of Silesia, Katowice, Poland

[3] Students' Scientific Association at the Department of Dermatology, School of Medicine in Katowice, Medical University of Silesia, Katowice, Poland

[4] Department of Pathomorphology and Molecular Diagnostics, Medical University of Silesia, Katowice, Poland

Introduction

Generalized pustular figurate erythema (GPFE) is a severe cutaneous adverse drug reaction, most commonly associated with hydroxychloroquine exposure. It is currently regarded as a distinct clinical entity within the spectrum of pustular drug eruptions, although historically it has been variably classified as atypical or recalcitrant acute generalized exanthematous pustulosis (AGEP). Compared with classical AGEP, GPFE demonstrates a delayed onset: typically 2-3 weeks after drug initiation, along with a more protracted, treatment-resistant course and heterogeneous morphology. Clinically, GPFE is characterized by widespread sterile, non-follicular pustules arising on erythematous targetoid plaques that coalesce into annular or arcuate patterns. The aim of this study is to present the first reported case of generalized pustular figurate erythema triggered by a hair growth supplement containing *Serenoa repens* (saw palmetto) in a patient with androgenetic alopecia, and to synthesize current evidence regarding its clinical features, differential diagnosis, and management strategies.

Materials and Methods

A systematic review was conducted to evaluate the clinical features, triggers, and management of generalized pustular figurate erythema, including EMTREE and MESH approaches, conducted according to the PRISMA guidelines. Searching was as broad as possible from the inception of the database until April 2026. Studies were included if they presented individual case reports or case series involving GPFE. Exclusion criteria encompassed reviews and articles lacking specific therapeutic outcomes. After screening, 7 articles presenting 10 individual patient cases were included in the final analysis. Additionally, a novel case of GPFE in 34-year old woman after saw palmetto intake was reported and analyzed.

Results

During hospitalization, the patient was treated with intravenous dexamethasone (8 mg/day for 7 days), cefuroxime (1.5 g twice daily for 7 days), oral loratadine (10 mg four times daily), and topical clobetasol 0.05%. Upon discharge, oral methylprednisolone was gradually tapered, and emollient therapy with hydrocortisone 1% ointment was continued. Complete resolution of skin lesions was achieved without scarring or post-inflammatory pigmentation. Lesions regressed gradually, evolving into violaceous patches followed by desquamation. The

literature review identified 7 articles describing 10 patients with GPFE, although the true incidence is likely underestimated due to limited recognition and frequent misclassification as AGEP, atypical targetoid AGEP, or generalized pustular psoriasis. All previously reported cases were associated with hydroxychloroquine exposure. Compared with classical AGEP, GPFE appears to show greater resistance to corticosteroid therapy; among hydroxychloroquine-induced cases, corticosteroid resistance was observed in 8/10 patients with targetoid lesions versus 2/10 patients without targetoid morphology.

Conclusions

This report expands the spectrum of potential GPFE triggers by describing the first known case associated with a hair growth supplement containing Serenoa repens. GPFE should be considered in patients presenting with delayed-onset pustular eruptions with annular or targetoid morphology, particularly when refractory to corticosteroid therapy. Recent reports suggest that ixekizumab may be an effective option in steroid-resistant cases. Greater awareness of this rare entity may improve diagnostic accuracy and facilitate prompt withdrawal of the causative agent. Moreover, this case highlights that over-the-counter supplements are not biologically neutral and may cause severe adverse reactions, whereas targeted, evidence-based treatment of androgenetic alopecia could potentially provide better clinical outcomes with lower risk. Further studies are needed to establish optimal diagnostic and therapeutic strategies for GPFE.

EADV CONGRESS
VIENNA
30 SEP - 3 OCT 2026

Abstract N°: 3865

Post-traumatic stress following drug-induced cutaneous reactions: An underestimated and frequent complication

Salma Moujahid*[1], Ouissal Hormi[1], Nada Zizi[1], Nassiba Zerrouki[1]

[1] Department of Dermatology, Venereology and Allergology, Mohammed VI University Hospital, Oujda, Morocco

Introduction
Drug-induced skin reactions can be severe and life-threatening, such as DRESS, SJS/TEN, and AGEP, and are often associated with significant psychological distress. Post-traumatic stress disorder (PTSD) following drug-induced skin reactions is underestimated, despite its major impact on patients' quality of life and follow-up care. This study aims to assess its prevalence and identify associated clinical factors.

Materials and Methods
We conducted a retrospective descriptive and analytical study over a two-year period including all patients hospitalized for drug-induced skin reactions. PTSD was assessed remotely using the IES-R score. Collected data included the type of drug reaction, mucosal involvement, intensive care unit admission, length of hospital stay, and sociodemographic characteristics. Descriptive and analytical analyses were performed to identify factors associated with PTSD.

Results
Thirty-nine patients were included in the study, comprising 26 women (66.7%) and 13 men (33.3%), with a mean age of 50.12 ± 15 years. The observed drug-induced skin reactions included benign maculopapular exanthema in 14 patients (35.9%), DRESS syndrome in 9 patients (23.1%), Stevens–Johnson syndrome/toxic epidermal necrolysis (SJS/TEN) in 9 patients (23.1%), acute generalized exanthematous pustulosis (AGEP) in 6 patients (15.4%), and SDRIFE in 1 patient (2.5%). Mucosal involvement was present in 10 patients (25.6%), and 7 patients (17.9%) required intensive care unit admission. The mean length of hospital stay was 10.2 ± 4.3 days. An IES-R score consistent with probable post-traumatic stress disorder was found in 15 patients (38.5%). High IES-R scores were significantly associated with severe drug reactions (DRESS, SJS/TEN, and AGEP) (p=0.01), mucosal involvement (p=0.02), particularly ocular and oral involvement, as well as intensive care unit admission (p=0.01). In addition, longer hospital stays were associated with higher IES-R scores (12.1 ± 4.0 days vs 9.0 ± 3.8 days, p=0.03). Female sex was also associated with higher IES-R scores (p=0.04), whereas no significant association was observed with age.

Conclusions
Post-traumatic stress disorder is a frequent and underrecognized complication of drug-induced skin reactions, particularly in severe forms. Early screening and psychological support are essential to improve patient follow-up and quality of life.

EA DV CONGRESS
VIENNA
30 SEP - 3 OCT 2026

Abstract N°: 3904

DRESS Syndrome: A Tertiary Centre Case Series with Comparative Analysis of Clinical Presentation, Histopathology and Laboratory Findings

Juliana Moura*[1], Celina Iwasa[2], Andreea Cifrea[2]

[1] Chelsea Westminster Hospital NHS Foundation Trust, Isleworth, United Kingdom
[2] West Middlesex University Hospital, Isleworth, United Kingdom

Introduction

Drug Reaction with Eosinophilia and Systemic Symptoms (DRESS) is a rare, potentially life-threatening adverse drug reaction with an estimated mortality of approximately 5%. Over 40 causative drugs have been identified in the literature. Clinical presentation is highly variable, with symptoms typically emerging 2–8 weeks after drug introduction. Its pathogenesis involves T-cell dysfunction and viral reactivation. This study aimed to characterise the clinical presentation, laboratory findings, histopathological features, management, and outcomes of DRESS syndrome cases identified across a two-site tertiary trust over a 3-year period.

Materials and Methods

A retrospective analysis was performed of cases of DRESS syndrome diagnosed between 2023 and 2026 across two UK public hospitals sites pertaining to the same NHS trust. Cases were classified using RegiSCAR criteria. Data collected included demographics, culprit drug, latency, cutaneous and systemic features, laboratory results, viral serology, histopathology, management, and follow-up outcomes.

Results

Twelve cases were identified: 8 definite (RegiSCAR ≥6), 3 probable (RegiSCAR 5), and 1 possible (RegiSCAR 4). The cohort comprised 7 females and 5 males, aged 34–96 years (median 56 years). Culprit drugs included aromatic anticonvulsants (carbamazepine n=2, lamotrigine n=1), antibiotics (n=4), sulfasalazine (n=1), naproxen (n=1), and antimycobacterials (n=1). Notably, one case was attributed to atogepant, a calcitonin gene-related peptide (CGRP) receptor antagonist, with an unusually short latency of approximately 2 weeks; a novel association warranting pharmacovigilance attention. Both carbamazepine cases were prescribed for trigeminal neuralgia.

Hepatic involvement occurred in 9/12 cases (75%), with peak ALT ranging from 81 to 1350 U/L. Renal impairment was documented in 4/12 (33%). Eosinophilia was absent in 2/12 cases, highlighting that its absence does not exclude DRESS. Skin biopsy was performed in 9/12 patients; the predominant histological pattern was perivascular lymphohistiocytic infiltrate with variable tissue eosinophilia and interface vacuolar change, consistent with published DRESS histopathology. Direct immunofluorescence was negative in all 4 cases tested, excluding autoimmune blistering disease. HHV-6 quantitative PCR was performed in only 4/12 patients, representing a workup gap identified as a limitation.

Systemic corticosteroids were initiated in 10/12 patients; 2 cases required escalation to intravenous pulse methylprednisolone. In one case, systemic steroids were not prescribed despite dermatology recommendation, reflecting multidisciplinary diagnostic discord. No deaths occurred (0% mortality). The most severe complication was steroid-induced psychosis in a 74-year-old patient requiring MHA Section 2 detention, aripiprazole, and transfer to inpatient psychiatric care. Post-DRESS autoimmune sequelae were observed in 3 patients (25%), including chronic spontaneous urticaria, new ANA positivity, and Graves disease developing 18 months after the acute episode.

Conclusions

DRESS syndrome represents a complex multisystem disorder with highly variable clinical, laboratory, and histopathological features. This series highlights a novel putative culprit (atogepant), the risk of significant iatrogenic morbidity from corticosteroids (including severe neuropsychiatric complications) and the importance of long-term autoimmune surveillance post-resolution. These findings reinforce the need for early recognition, standardised workup including viral reactivation studies and skin biopsy, and an individualised, multidisciplinary approach to management.

EADV CONGRESS
VIENNA
30 SEP - 3 OCT 2026

Abstract N°: 4133

When Skin Toxicity Predicts Treatment Success: Prognostic Value of Anti-EGFR–Induced Acneiform Rash

Hafsa Laouni*[1], Zakia Douhi[1], Ikram Bejja[1], Saadia Boughaleb[1], Lamiae Amaadour[2], Meryem Soughi[1], Sara Elloudi[1], Hanane Baybay[1], Nawfel Mellas[2], Fatima Zohra Mernissi[1]

[1] Dermatology Department, HASSAN II University hospital, Fès, Morocco
[2] Oncology departement, HASSAN II University hospital, Fès, Morocco

Introduction

Epidermal growth factor receptor (EGFR)–targeting monoclonal antibodies represent a cornerstone in the treatment of several solid malignancies. However, due to EGFR expression in the skin, these therapies frequently induce dermatologic toxicities, particularly acneiform eruptions, which may impair quality of life and compromise treatment continuation. These cutaneous adverse events often occur early during therapy, highlighting the importance of identifying patients at risk. Predicting their occurrence and severity could allow implementation of preventive strategies and optimization of patient management.

Materials and Methods

We conducted a single-center, retrospective, analytical, and descriptive study including patients treated for various malignancies with anti-EGFR therapy between 2019 and 2025. Eligible patients had received at least one cycle of anti-EGFR therapy during the study period. Demographic, clinical, oncological, and treatment-related data were extracted from electronic medical records. Cutaneous toxicities were assessed from treatment initiation until treatment discontinuation or last follow-up and graded according to the Common Terminology Criteria for Adverse Events (CTCAE v5.0).

A minimum follow-up period of six months after initiation of anti-EGFR therapy was required to evaluate oncological.

The primary objective was to identify baseline demographic and clinical risk factors associated with the development of acneiform eruptions. The secondary objective was to assess the association between the occurrence of acneiform eruptions and overall survival.

Results

During the study period, 42 patients were included. The cohort comprised 57.1% women, with a mean age of 57 years. Digestive cancers were the most frequent (54.8%), followed by lung cancers (31%) and head and neck carcinomas (14.3%). Administered treatments were mainly panitumumab (40.5%), cetuximab (28.6%), gefitinib (11.9%), afatinib (9.5%), and erlotinib (9.5%), with concomitant chemotherapy in 57.1% of cases.

Cutaneous eruption occurred in 61.9% of patients, with a mean onset time of 2 weeks. Statistical analysis demonstrated that combination therapy with chemotherapy was significantly associated with an increased risk of eruption ($p = 0.044$). No significant association was found with sex (58.3% in women vs 66.7% in men; $p = 0.582$), obesity (66.7% vs 61.1%; $p = 0.795$), smoking status (55.6% vs 63.6%; $p = 0.658$), diabetes (33.3% vs 64.1%; $p = 0.290$), hypertension (50% vs 62.5%; $p = 0.722$), cancer type, or type of anti-EGFR therapy. None of these factors showed a significant association with eruption severity grade.

From a prognostic perspective, a significant association was observed between tumor outcome and both the occurrence and severity of cutaneous eruption. All patients who achieved clinical tumor improvement developed a cutaneous eruption ($p = 0.023$). Conversely, disease progression was significantly more frequent among patients without eruption (66.7% vs 33.3%; $p = 0.001$).

Tumor improvement was observed in 26.9% of patients, all presenting a grade ≥2 eruption, showing a statistically significant association ($p = 0.05$). Disease progression occurred in 23.1% of patients, among whom 83.3% had grade 1 eruption ($p = 0.01$). Tumor stability was observed in 69.2% of patients with grade ≥2 eruption and in 30.8% of those with grade 1 eruption, without statistical significance.

Conclusions

Our findings confirm the high frequency of cutaneous eruptions associated with anti-EGFR therapy. The significant association between eruption occurrence and combined anti-EGFR and chemotherapy treatment is consistent with previous literature, suggesting a potentiating effect of combination therapy on skin toxicity.

Furthermore, our results support the hypothesis that acneiform eruption may represent a clinical biomarker of response to anti-EGFR therapy. This association may contribute not only to prognostic assessment but also to patient reassurance regarding potential treatment efficacy.

EADV CONGRESS
VIENNA
30 SEP - 3 OCT 2026

Abstract N°: 4144

Upadacitinib as a therapeutic alternative in refractory mogamulizumab-associated cutaneous reactions: a single-center case series of 9 patients

Paula Hernández Madrid*[1], José Luis Alejo Fernández-Baillo[1], Elena Porres López[1], María Concepción Postigo Llorente[1], Pablo Ortiz Romero[1], Jorge Arroyo Andrés[1], Alba Calleja Algarra[1], Daniel Falkenhain López[1]

[1] Hospital Universitario 12 de Octubre, Madrid, Spain

Introduction
Mogamulizumab is a monoclonal antibody targeting the CCR4 protein, approved for the treatment of refractory mycosis fungoides and Sézary syndrome. Mogamulizumab-associated cutaneous reactions (MAR) may occur in up to 60% of patients treated with this drug and represent the most common cause of treatment discontinuation. Furthermore, these reactions may pose a diagnostic challenge, as they can be difficult to distinguish from the underlying disease, as well as a therapeutic challenge, since they may persist beyond drug withdrawal despite the use of various systemic treatments.

Materials and Methods
We present a retrospective observational single-center case series of 9 patients with refractory MAR persisting despite drug discontinuation and multiple systemic treatments, significantly impacting quality of life, who received upadacitinib between March 2025 and May 2026.

Results
A sustained favorable clinical response of MAR following initiation of upadacitinib was observed in 5/9 patients, while 9/9 reported improvement in pruritus. Regarding lymphoma control, 4/9 patients experienced progression of their underlying disease; notably, these cases corresponded to those with poor disease control prior to upadacitinib initiation. The remaining 5/9 patients maintained stable lymphoma disease.

Conclusions
There is limited literature and a clear lack of established guidelines for the management of MAR, highlighting the need to explore new therapeutic options in refractory cases that do not respond to conventional treatment with corticosteroids and methotrexate.

In our experience, upadacitinib appears to be a promising therapeutic option for the management of refractory MAR, as well as a highly useful alternative for short- to medium-term pruritus control. No significant adverse effects were observed. Future studies should assess a potential association between its use and progression of the underlying disease, although this relationship does not appear likely, as disease progression was observed only in patients who already had poor baseline disease control prior to upadacitinib initiation.

EA DV CONGRESS
VIENNA
30 SEP - 3 OCT 2026

Abstract N°: 4147

Characteristics, Management, and Outcomes of Rare Topical 5-Fluorouracil-Induced Cutaneous Eruptions: A Systematic Review

Darshana Seeburruth*[1], Amal Khan[2], E. Dimitra Bednar[3], Edgar Akuffo-Addo[3], Philip Doiron[3, 4]

[1] Temerty Faculty of Medicine, University of Toronto, Toronto, Canada
[2] Faculty of Health Sciences, McMaster University, Hamilton, Canada
[3] Division of Dermatology, Department of Medicine, University of Toronto, Toronto, Canada
[4] Division of Dermatology, Women's College Hospital, Toronto, Canada

Introduction
5-Fluorouracil (5-FU) is a cytotoxic antimetabolite approved for the treatment of various malignancies. In dermatology, it is indicated for the topical treatment of actinic keratoses/actinic field damage and superficial basal cell carcinomas. It is also frequently used off label for squamous cell carcinoma in situ, condylomas/HPV-mediated disease, and other conditions. While localized irritation, erythema, and dryness are well-recognized and expected side effects, increasing case reports have described rare and potentially severe cutaneous eruptions associated with its use. This systematic review highlights these uncommon adverse events and provides insights into their management and outcomes.

Materials and Methods
Embase and MEDLINE databases were searched from inception following PRISMA guidelines. Study quality was appraised using the Oxford Centre for Evidence-Based Medicine 2011 Levels of Evidence. After independent screening by two reviewers, 18 articles encompassing 40 participants were included. Included studies consisted of retrospective studies (5.6%; 1/18), case series (5.6%; 1/18), and case reports (88.9%; 16/18).

Results
The mean patient age was 47.4 years (range: 13-71), with a female predominance (65.0%; 26/40). Common reasons for topical 5-FU use were HPV-associated vaginal lesions (45%; 18/40), actinic keratosis (38%; 15/40), and squamous cell carcinoma in situ (5%; 2/40).

Rare cutaneous eruptions included chronic ulceration (45.0%; 18/40), scrotal dermatitis from inadvertent exposure (12.5%; 5/40), allergic contact dermatitis (7.5%; 3/40), systemic toxicity-associated erosions and ulcerations (5.0%; 2/40), and keratoacanthoma (5.0%; 2/40). Single reported cases (2.5%; 1/40 each) included full-thickness ulceration, pemphigus foliaceus, generalized pustular drug eruption, necrotizing reaction, bullous pemphigoid, psoriasis, rosacea, distant seborrheic dermatitis-like eruption, eczema herpeticum, and impetigo.

Twenty-six eruptions (65.0%) were biopsy-confirmed, and two patients (5%) underwent dihydropyrimidine dehydrogenase (DPD) deficiency testing, both of whom tested negative. The mean latency period was 9.4 days. Most eruptions were de novo (97.5%; 39/40), with one case (2.5%) representing a flare of pre-existing rosacea. The mean Naranjo score was 4.7 across all studies.

Discontinuation of 5-FU led to spontaneous resolution in 25.0% (10/40) of cases. Among those who required additional treatment, topical therapy alone was used in 34.6% (9/26) of cases, most commonly topical

corticosteroid monotherapy (11.5%; 3/26). Systemic treatments were used in 38.5% (10/26), most commonly topical and oral corticosteroid combination therapy (20%; 3/15), oral corticosteroid monotherapy (13.3%; 2/15), and oral antibiotic monotherapy (6.7%; 1/15). Surgical excision was effective in six cases involving keratoacanthoma or chronic ulceration (23.1%; 6/40). The mean treatment duration was 18.8 days. Eruptions resolved in 85.0% (34/40) of cases, while 15.0% (6/40), involving chronic or full-thickness ulcerations, did not achieve resolution. Mean follow-up was 5.3 months. Recurrence of eruptions occurred in four patients (10%).

Conclusions

5-FU induces apoptosis in rapidly dividing cells by inhibiting thymidylate synthase and disrupting DNA synthesis. Resulting cellular damage may trigger pro-inflammatory cytokine release and an inflammatory response, potentially explaining the rare cutaneous eruptions observed. Most cases resolve with drug discontinuation or anti-inflammatory therapy. Although rare, severe systemic reactions have been reported with topical use in patients with complete DPD deficiency; however, incidence is exceedingly low and routine screening is not recommended. Our findings demonstrate a broad spectrum of rare topical 5-FU-induced cutaneous eruptions and highlight the importance of clinical vigilance and follow-up when prescribing this therapy.

EA DV CONGRESS
VIENNA
30 SEP - 3 OCT 2026

Abstract N°: 4169

Characteristics, Management, and Outcomes of Uncommon Imiquimod-Induced Cutaneous Eruptions: A Systematic Review

Darshana Seeburruth*[1], Eunice Aluko[1], E. Dimitra Bednar[2], Edgar Akuffo-Addo[2], Philip Doiron[2, 3]

[1] Temerty Faculty of Medicine, University of Toronto, Toronto, Canada

[2] Division of Dermatology, Department of Medicine, University of Toronto, Toronto, Canada

[3] Division of Dermatology, Women's College Hospital, Toronto, Canada

Introduction

Imiquimod is a topical immune response modifier commonly used in dermatology. While erythema, pruritus, and burning are well-known local reactions, rare cutaneous eruptions have increasingly been reported. This systematic review evaluates the characteristics, management, and outcomes of these uncommon reactions.

Materials and Methods

Embase and MEDLINE databases were searched from inception following PRISMA guidelines. Study quality was appraised using the Oxford Centre for Evidence-Based Medicine 2011 Levels of Evidence. After independent screening by two reviewers, 93 studies involving 126 participants were included.

Results

The mean patient age was 57.5 years (range: 5-91); 51.6% were male. Common indications for imiquimod use were condylomata acuminata (26.2%; 33/126), actinic keratosis (22.2%; 28/126), and basal cell carcinoma, mainly superficial and nodular (22.2%; 28/126).

Rare cutaneous eruptions included vitiligo or vitiligo-like hypopigmentation (26.2%; 33/126), hyperpigmentation (14.3%; 18/126), psoriasis or psoriasis-like eruptions (11.1%; 14/126), lichenoid eruptions (7.9%; 10/126), erythema multiforme (7.1%; 9/126), pemphigus (7.1%; 9/126), lupus erythematosus or lupus-like eruptions (6.3%; 8/126), pityriasis rubra pilaris (4.0%; 5/126), erosive pustular dermatosis of the scalp (3.2%; 4/126), keratoacanthoma (2.4%; 3/126), squamous cell carcinoma (2.4%; 3/126), bullous eruptions (1.6%; 2/126), epidermoid cysts (1.6%; 2/126), and melanoma (1.6%; 2/126). Single cases (0.8% each) included severe eczema exacerbation with pustules, morbilliform exanthem, Stevens-Johnson syndrome, and vasculitis.

Sixty-eight eruptions (54.0%) were biopsy-confirmed, with a mean latency of 56.7 days. Most eruptions were new-onset (88.1%), while 11.9% were exacerbations of pre-existing conditions. Psoriasis, melanoma, squamous cell carcinoma, vitiligo-like hypopigmentation, pityriasis rubra pilaris, and erythema multiforme occurred as both new and worsening eruptions. Among eight biopsy-confirmed cutaneous malignancies, three reflected progression of known disease, including two cases of squamous cell carcinoma in situ and one case of melanoma. Of the five new-onset cases, three had prior biopsies diagnosing actinic keratosis, squamous cell carcinoma in situ, and superficial basal cell carcinoma. Post-imiquimod biopsies revealed more advanced pathology, including well-differentiated squamous cell carcinoma, keratoacanthoma, and melanoma, respectively. The mean Naranjo score across all studies was 5.8.

Imiquimod discontinuation led to spontaneous resolution in 12.70% (16/126) of cases. For those requiring

treatment after discontinuation, topical corticosteroid monotherapy was most frequently used (25.0%; 14/56). Systemic treatments were effective in 42.9% (24/56) of cases, with oral corticosteroid monotherapy being the most common (20.8%; 5/24). In one case of new-onset erythrodermic psoriasis, infliximab led to complete resolution. Treatments that enabled continued use of imiquimod were topical corticosteroids (1.6%; 2/126), topical calcineurin inhibitors (0.8%; 1/126), and photodynamic therapy (0.8%; 1/126). The mean treatment duration was 167.8 days. Eruptions completely resolved in 43.6% of cases (55/126), partially resolved in 11.9% (15/126), and remained unresolved in 10.3% (13/126). The mean follow-up was 23.5 months. Recurrence of eruptions occurred in 5.6% (7/126), and 14.3% (18/126) experienced a relapse of the condition originally treated with imiquimod.

Conclusions

Imiquimod may activate immune cells via Toll-like receptors, inducing Th1-associated cytokines including TNF-α, IFN-α, IL-6, and IL-12. This dysregulated response may explain many rare cutaneous eruptions, while others such as squamous cell carcinoma, keratoacanthoma, and melanoma may be coincidental or reflect underlying disease progression. These findings highlight a broad spectrum of uncommon imiquimod-associated eruptions and the need for clinical vigilance and follow-up when prescribing this therapy.

EA DV CONGRESS
VIENNA
30 SEP - 3 OCT 2026

Abstract N°: 4170

Ribociclib-induced vitiligo-like depigmentation: A case series of three breastcancer patients

Salma Nefzi*[1], Meriem Tabka[1], Feriel Amri[1], Asmahen Souissi[1], Mourad Mokni[1]

[1] Dermatology department, La Rabta Hospital, Tunis, Tunisia

Introduction
Cyclin-dependent kinase 4/6 (CDK4/6) inhibitors, particularly ribociclib, have become the standard of care for advanced hormone receptor-positive/HER2-negative (HR+/HER2−) breast cancer. Although their safety profile is generally favorable, an increasing number of cutaneous adverse events (cAEs) have been reported in recent years. Among these, vitiligo-like depigmentation represents a rare but increasingly recognized entity, predominantly associated with ribociclib. We report three cases of ribociclib-associated vitiligo-like depigmentation.

Materials and Methods
We report three female patients, aged 43, 45, and 70 years, treated for HR+/HER2− metastatic breast cancer with ribociclib combined with fulvestrant, letrozole, and anastrozole, respectively.

Results
The three patients were referred for progressive asymptomatic depigmented macules that developed 8 to 14 months after treatment initiation. Clinically, the lesions consisted of bilateral and symmetrical non-scaly depigmented macules, predominantly involving photo-exposed areas, particularly the face and dorsal hands, with extension to the limbs in two patients. None of the patients had a personal or family history of vitiligo, thyroid disease, or autoimmune disorders. Drug imputability, assessed using the Naranjo Adverse Drug Reaction Probability Scale, was scored as 5 in all three cases, supporting a probable causal relationship between ribociclib and the depigmentation. Given the asymptomatic nature of the lesions and the favorable oncological response, ribociclib therapy was maintained without dose reduction or discontinuation in all patients.

Conclusions
Vitiligo-like depigmentation is a rare cutaneous adverse event of CDK4/6 inhibitors and has been predominantly reported with ribociclib. Pharmacovigilance data suggest a median onset delay of approximately 8–12 months, consistent with the chronology observed in our patients. All patients exhibited a remarkably similar clinical presentation characterized by bilateral, symmetrical, non-scaly depigmented macules predominantly affecting photo-exposed areas. This reproducible distribution pattern may suggest a potential role of ultraviolet exposure in promoting or amplifying melanocyte damage in susceptible individuals.
The exact pathophysiological mechanisms remain poorly understood. Proposed hypotheses include CDK4/6 inhibitor-induced melanocyte senescence, immune-mediated melanocyte destruction through enhanced T-cell cytotoxic activity, and oxidative stress-related melanocyte apoptosis.

Vitiligo-like depigmentation should be recognized as a potential delayed cutaneous adverse event of ribociclib therapy. Awareness of this entity is essential to prevent misdiagnosis and avoid unnecessary interruption of effective oncological therapy. Close collaboration between dermatologists and oncologists is important to optimize patient management while maintaining effective anticancer treatment.

EADV CONGRESS
VIENNA
30 SEP - 3 OCT 2026

Abstract N°: 4337

Spectrum of Immunotherapy-Associated Cutaneous Adverse Reactions: A Retrospective Single-Center Analysis

Neda Delic*[1], Dusan Skiljevic[1, 2], Andrija Ilic[3], Jelena Peric[1, 2], Jelena Stojkovic-Filipovic[1, 2]

[1] University Clinical Center of Serbia, Clinic of Dermatology and Venereology, Belgrade, Serbia
[2] University of Belgrade Faculty of Medicine, Department of Dermatology and Venereology, Belgrade, Serbia
[3] University of Belgrade Faculty of Medicine, Belgrade, Serbia

Introduction
Immunotherapy has become a standard treatment modality for numerous malignancies; however, it is frequently associated with immune-mediated cutaneous adverse events that may affect patients' quality of life and the continuity of oncologic treatment. The aim of this study was to analyze the frequency and clinical spectrum of cutaneous adverse reactions in patients treated with immune checkpoint inhibitors, as well as their severity and impact on oncologic treatment continuation.

Materials and Methods
This retrospective descriptive study included patients evaluated at our referral center for cutaneous reactions to antineoplastic therapy between January 2022 and January 2026. Patients who developed dermatologic adverse events during immunotherapy were analyzed. Data regarding patients' demographics, malignancy type, time of onset, clinical presentation, and dermatologic management were collected.

Results
Forty-one patients with cutaneous reactions related to immunotherapy were included in the analysis, of whom 6 (14.6%) were receiving concomitant conventional chemotherapy and one (2.4%) a KRAS inhibitor. The female-to-male ratio was 1.6:1, the mean age was 65 years and the most common underlying malignancy was lung cancer. The most frequently observed cutaneous reactions were exanthema (N=10; 24.4%), eczematous (N=7; 17.1%), lichenoid (N=6; 14.6%) and psoriasiform eruptions (N=5; 12.2%). Three cases of bullous reactions, including two of bullous pemphigoid, and three cases of acneiform eruptions were also recorded. More than half of reactions appeared within the first three months of immunotherapy initiation (53.8%). In two-thirds of cases the oncologic treatment was continued without disruption, although 68.4% of patients required systemic dermatologic therapy.

Conclusions
Cutaneous adverse events associated with immunotherapy encompass a broad spectrum of inflammatory and immune-mediated dermatoses. Early recognition and a multidisciplinary approach enable adequate management of these toxicities and continuation of oncologic treatment without significant compromise of therapeutic outcomes.

EA DV CONGRESS
VIENNA
30 SEP - 3 OCT 2026

Abstract N°: 4355

A Systematic Review of Patient-Reported Adverse Events Attributable to Negative Expectation and a Proposed Framework for Distinguishing Pharmacology from Psychology

Zeel Lightwala*[1], Krish Lightwala[1]

[1] Belarusian state medical university, Minsk, Belarus

Introduction
Biologic therapies have transformed outcomes in psoriasis, atopic dermatitis, and hidradenitis suppurativa, yet real world drug survival remains substantially lower than clinical trial efficacy would predict. A significant driver of treatment discontinuation is the emergence of patient reported adverse events that are often mild, subjective, and pharmacologically unexpected. The nocebo effect, defined as adverse symptoms arising from negative treatment expectation rather than the active molecule, has been extensively documented in neurology, cardiology, and pain medicine but remains profoundly underrecognized in dermatology.

Materials and Methods
We performed a systematic review of Phase 3 and Phase 4 randomized controlled trials and prospective observational studies of biologic therapies approved for psoriasis, atopic dermatitis, and hidradenitis suppurativa, published between January 2010 and March 2026. Databases searched included PubMed, Embase, and the Cochrane Central Register of Controlled Trials. Inclusion required trials with a placebo or active comparator arm and detailed reporting of patient reported adverse events by system organ class. For each included trial, we extracted the adverse event profile of the placebo arm and compared it with the specific side effects highlighted in the corresponding informed consent documentation and patient information leaflets, where publicly available. The primary outcome was the nocebo magnitude, defined as the rate of adverse events in the placebo arm that matched the risk emphasized profile from informed consent materials, expressed as a proportion of total placebo arm adverse events. A secondary analysis compared subjective symptoms like headache, fatigue, and nausea against objective laboratory abnormalities. We then developed a four domain Nocebo Attribution Score based on symptom timing relative to first dose, specificity to the informed consent content, absence of corroborating objective findings, and response to expectation reframing interventions.

Results
Twenty eight trials encompassing 14,672 patients in placebo arms met inclusion criteria. The pooled rate of adverse events in placebo arms was 48.3 percent, and the symptom profile demonstrated a striking concordance with the specific risks emphasized in informed consent documents. In trials where patient information leaflets prominently listed headache and fatigue as potential side effects, the incidence of these exact symptoms in the placebo arm was 2.3 to 3.1 times higher than in trials where these were not emphasized. Nausea reporting in placebo arms correlated significantly with the length and detail of gastrointestinal risk descriptions in consent forms. The most frequently reported placebo arm symptoms were headache at 11.4 percent, fatigue at 8.9 percent, nasopharyngitis at 7.2 percent, and nausea at 5.6 percent, a pattern that mirrors the general adverse event warning profile across most biologic consent documents rather than any specific pharmacologic mechanism. Objective laboratory abnormalities in placebo arms, including transaminase elevation and neutropenia, occurred at rates indistinguishable from background population prevalence and showed no correlation with informed consent content, supporting the specificity of the nocebo effect to subjective, symptom based complaints. Among patients who discontinued therapy due to adverse events, approximately 22 percent did so based exclusively on subjective symptoms with no objective correlate.

Conclusions

The nocebo effect accounts for nearly one quarter of biologic discontinuations attributed to adverse events. The Nocebo Attribution Score offers a practical clinical tool to identify psychologically driven symptoms, potentially improving drug survival through expectation reframing rather than unnecessary treatment switches. The dermatology community must recognize that how we communicate risk shapes the tolerability experience of our most effective therapies.

EADV CONGRESS
VIENNA
30 SEP - 3 OCT 2026

Abstract N°: 4551

Cyclosporine Use in Epidermal Necrolysis and Its Impact on Mortality: Evidence from a Natural Experiment and Meta-Analysis

Ahmad shafi Antar*[1], abdul basit[1], Muslim khan[1]

[1] Liaquat university of medical and health sciences jamshoro Sindh, Pakistan, jamshoro, Pakistan

Introduction
Epidermal necrolysis (EN), including Stevens Johnson syndrome and toxic epidermal necrolysis, is a rare, severe, drug induced cutaneous disorder associated with high mortality. Although several immunomodulatory therapies have been used, their effectiveness remains uncertain, and treatment strategies vary widely across centers. Cyclosporine has been proposed as a potential disease modifying agent due to its immunosuppressive effects, but robust comparative evidence is limited.

Materials and Methods
A retrospective and ambispective observational study was conducted including patients diagnosed with EN admitted to two tertiary burn units in Madrid between 2001 and 2015. A natural experiment design was applied, where hospital assignment served as an instrumental variable due to proximity-based patient referral. Outcomes included in-hospital mortality, compared between cyclosporine and non-cyclosporine therapies (mainly intravenous immunoglobulin and corticosteroids). Analyses included intention to treat, as-treated, and instrumental variable approaches, adjusted for SCORTEN and body surface area involvement. A systematic review and meta-analysis of published case series using observed versus expected mortality ratios was also performed.

Results
A total of 71 validated EN patients were included, with 49 receiving cyclosporine and 22 receiving non-cyclosporine treatments. Mortality was significantly lower in cyclosporine-treated patients across all analytical approaches. Instrumental variable analysis demonstrated a marked reduction in mortality risk (MRR 0.09; 95% CI 0.00–0.49), while adjusted as-treated analysis confirmed a similar protective effect. Observed versus expected analysis showed reduced mortality in the cyclosporine group (MRR 0.42; 95% CI 0.14–0.99). The meta-analysis of five external studies, combined with the present data, yielded a pooled mortality reduction of approximately 60%, with consistent results across studies and no significant heterogeneity.

Conclusions
Cyclosporine use in epidermal necrolysis is consistently associated with a substantial reduction in mortality across multiple analytical approaches and independent studies. Despite the observational nature of available evidence, findings strongly support cyclosporine as a potentially effective therapeutic option in EN. However, controlled prospective studies are still needed to confirm its role as a standard of care.