EA DV CONGRESS
VIENNA
30 SEP - 3 OCT 2026

Abstract N°: 278

A Case of Gianotti-Crosti Syndrome Secondary to Mpox

Annabelle Lim*[1], Albana Krasniqi[2], Richard Griffiths[2], Bernard Ho[2]

[1] University Hospital Southampton NHS Foundation Trust, Southampton, United Kingdom
[2] St George's University Hospitals NHS Foundation Trust, London, United Kingdom

Introduction

Mpox (formally monkeypox) is an orthopoxvirus infection that gained global clinical recognition during the major global outbreak in 2022. It can present with non-specific systemic symptoms as well as characteristic dermatological features. Gianotti-Crosti syndrome (or papular acrodermatitis of childhood) is a benign, self-limiting papular rash seen in children that is often secondary to a viral infection. We report the first documented case of mpox-associated papular acrodermatitis seen in an immunocompromised MSM individual.

Case Presentation

A 44-year-old male presented to the emergency department with a 5-day history of anal pain, rectal bleeding, perineal pain, dysuria and pain on ejaculation. He also reported a rash affecting the hands and back. He denied systemic, abdominal or testicular symptoms. A trial of topical haemorrhoid cream provided no relief. An sexually transmitted infection screen performed the previous day was negative, although he was empirically started on aciclovir for presumed herpes infection. His past medical history included asthma and Hodgkin lymphoma treated with two stem cell transplants. He reported regular unprotected sexual activity with a male partner and was taking HIV pre-exposure prophylaxis (PrEP). On examination, there were scattered pustular lesions on his hands, buttocks and penis, along with erythema over the buttocks and condylomatous-appearing lesions. Punch biopsies were taken from two sites. Histology from the dorsal index finger demonstrated a mixed spongiotic, lichenoid and perivascular dermatitis pattern, consistent with Gianotti-Crosti syndrome (fig. 1a and 1b) while a perianal biopsy showed ulceration, necrosis and mixed inflammation suggestive of orthopoxvirus infection (fig. 2a and 2b), confirmed by positive mpox PCR swab.

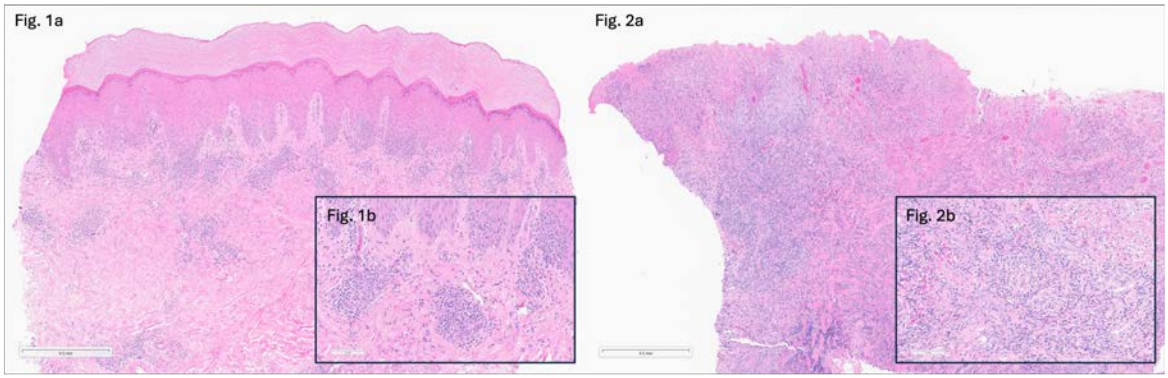

Fig. 1a Acral skin with hyperkeratosis, acanthosis and spongiosis, along with established lichenoid inflammation and a tight perivascular lymphocytic infiltrate in the dermis.

Fig. 1b Lichenoid inflammation in the basal epidermis and a lymphocytic vasculitis pattern (tight perivascular lymphocytic inflammation with endothelial cell swelling and red cell extravasation).

Fig. 2a Extensive epidermal ulceration with fibrinopurulent slough, underlying granulation tissue, necrosis and mixed inflammation.

Fig. 2b Infiltrates consisting of lymphocytes, histiocytes and numerous eosinophils. There is a small amount of necrosis towards the top of the image.

Conclusion

Mpox was first reported in humans in 1970. There are two principal strains (clades), with clade IIb mpox causing

the recent global outbreak. It can present with general ‘flu-like’ symptoms, including fever, headache, malaise, body aches and lymphadenopathy. Although the characteristic dermatological features include umbilicated vesicles, pustules, pseudopustules and erosions, emerging evidence suggests mpox can present with atypical cutaneous manifestations, particularly in immunocompromised individuals. This case highlights that the first presentation of mpox may be atypical. With the recent increase in cases, it is important to be familiar with how mpox may present as it requires a high degree of clinical suspicion to avoid diagnostic delay.

EA DV CONGRESS
VIENNA
30 SEP - 3 OCT 2026

Abstract N°: 494

Isolated ulceronodular lip lesion in a male patient with primary syphilis misdiagnosed as squamous cell carcinoma

Fatma Güven*[1], Abdullah Kutay Masat[1], Tubanur Cetinarslan[1], Görkem Eskiizmir[2], Peyker Temiz[3], Aylin Türel Ermertcan[1]

[1] Manisa Celal Bayar University, Department of Dermatology and Venereology, Manisa, Türkiye
[2] Manisa Celal Bayar University, Department of Otorhinolaryngology-Head Neck Surgery, Manisa, Türkiye
[3] Manisa Celal Bayar University, Department of Pathology, Manisa, Türkiye

Introduction

Syphilis is known as the "great imitator" and is a sexually transmitted infection caused by the spirochete Treponema pallidum. Primary syphilis typically presents as a painless ulcerated lesion in the genital region; however, lesions may occur at any site of inoculation and may show variable clinical features. Extragenital presentations, may mimic other conditions and lead to diagnostic challenges.

Case Presentation

We report a case of a 37-year-old man presenting with a primary syphilitic chancre located on the lower lip. The patient initially presented to the otorhinolaryngology clinic with a persistent lesion and underwent biopsy with an initial clinical suspicion of squamous cell carcinoma. Histopathological examination revealed no evidence of neoplasia, and further investigations, including imaging and cytological evaluation, were inconclusive. The patient was subsequently referred to the dermatology clinic. Clinical examination revealed a painless verrucous plaque on the lower lip and accompanying oral mucosal lesions. The diagnosis of syphilis was made by clinical and dermoscopic examination, serological testing and histopathological findings. The patient was treated with intramuscular penicillin, resulting in complete clinical resolution and serological improvement at follow-up.

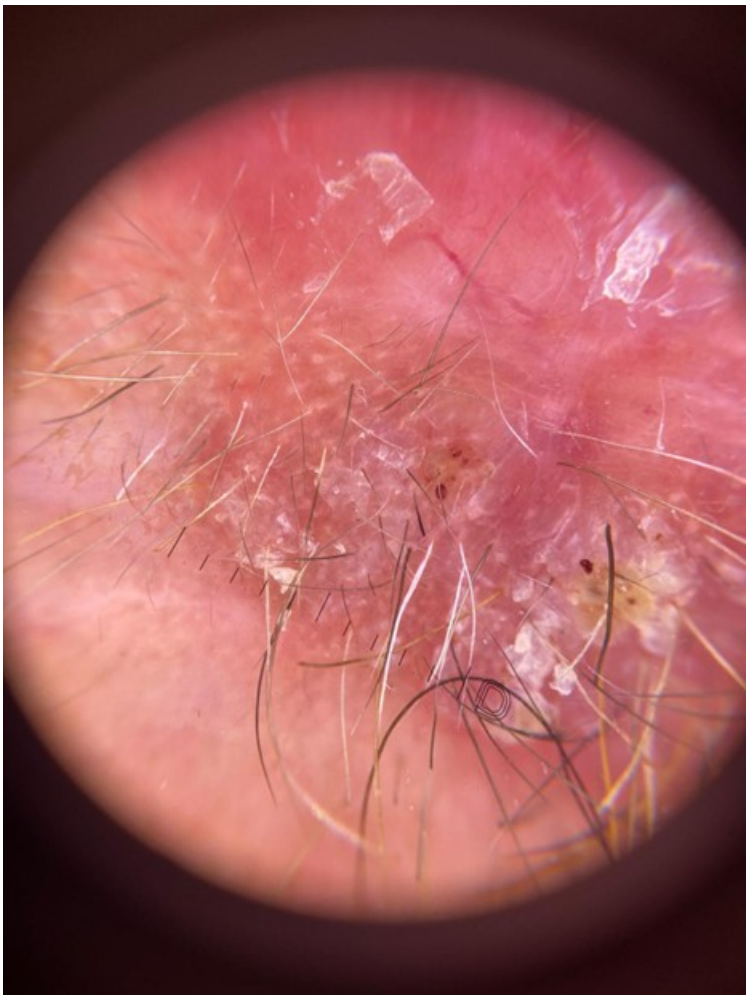

Dermoscopic image of the lesion showing central erosion, peripheric white globules and scales on a coppery orange background

Conclusion

Syphilis should be considered in the differential diagnosis of atypical lesions of the lip. Although dermoscopic findings are not specific, dermoscopy may serve as a useful adjunctive tool in excluding malignant conditions.

EADV CONGRESS
VIENNA
30 SEP - 3 OCT 2026

Abstract N°: 570

Epidemic Characteristics of HPV Infection and Influencing Factors of Clinical Outcomes in the Early Vaccination Era in China

Jiahe Zhang*[1], Hao Cheng[1]

[1] Sir Run Run Shaw Hospital, School of Medicine, Zhejiang University, Hangzhou, China

Introduction
Human papillomavirus (HPV) infection represents a significant public health burden in China, where cervical cancer ranks as the leading female reproductive malignancy. Despite introducing HPV vaccines in 2016, China remains in the early vaccination stage with notably low coverage (10.15% first-dose rate nationally) and marked regional disparities. Current epidemiological data predominantly derive from pre-vaccination eras or focus on female cervical screening, leaving significant gaps regarding male infection patterns, clinical outcomes, and post-vaccination type distribution. This retrospective study aimed to characterize HPV epidemic features during the initial vaccination phase, analyze genotype distribution and infection patterns, evaluate clinical outcomes by demographic characteristics, and compare regional prevalence patterns across China.

Materials and Methods
We retrospectively analyzed data from 2,041 patients diagnosed with HPV-related diseases at outpatient clinics of *** Hospital, *** University School of Medicine (four campuses) between January 2022 and December 2024. Inclusion criteria required documented diagnoses (condylomata acuminata, anogenital warts, or HPV infection) with valid HPV DNA genotyping. Exclusions comprised negative results or non-specific reports lacking genotype details. HPV DNA was detected using PCR-based reverse dot blot hybridization (BHF-VI system) targeting 24 genotypes (6 low-risk: 6/11/42/43/44/81; 18 high-risk: 16/18/31/33/35/39/45/51/52/53/56/58/59/66/68/73/82/83). Definitions included high-risk infection (any of 18 types), persistent infection (same type positive at ≥12-month intervals), clearance (two consecutive negatives), and recurrence (re-positive after negativity). Statistical analyses employed SPSS 25.0 with χ^2 tests (two-tailed $P < 0.05$). Spatial heterogeneity was assessed through a literature review of 25 comparable regional studies nationwide.

Results
The cohort comprised 1,238 males (60.7%) and 803 females (39.3%), with a mean age of 32.8±10.6 years. The five predominant genotypes were HPV6 (20.1%), HPV11 (13.3%), HPV52 (7.8%), HPV16 (6.3%), and HPV51 (5.7%). HPV16 ranked first among high-risk types in males, while HPV52 predominated in females. Single infections accounted for 52.4%, dual infections 26.9%, and multiple infections 20.7% (up to an octuple infection observed). High-low risk mixed infections constituted 71.5% of coinfections. Clearance rates differed significantly by pattern: single infections achieved ~65% clearance at 12 months, whereas multiple infections showed <7% clearance at 24 months, with females demonstrating inferior viral clearance compared to males. Age-specific analysis revealed female positivity increased post-menopause (peak 77.8% at >65 years), while males exhibited a bimodal "M" distribution peaking at 35-45 and 55-65 years. Geographic heterogeneity was substantial: HPV16 demonstrated high prevalence in Northeast China (Liaoning 40.8%) and North China (Hebei 22.5%), whereas HPV52 formed a "Yangtze River Basin prevalence belt" in East China (Anhui 29.4%, Jiangsu 21.8%, and Shanghai 27.4%).

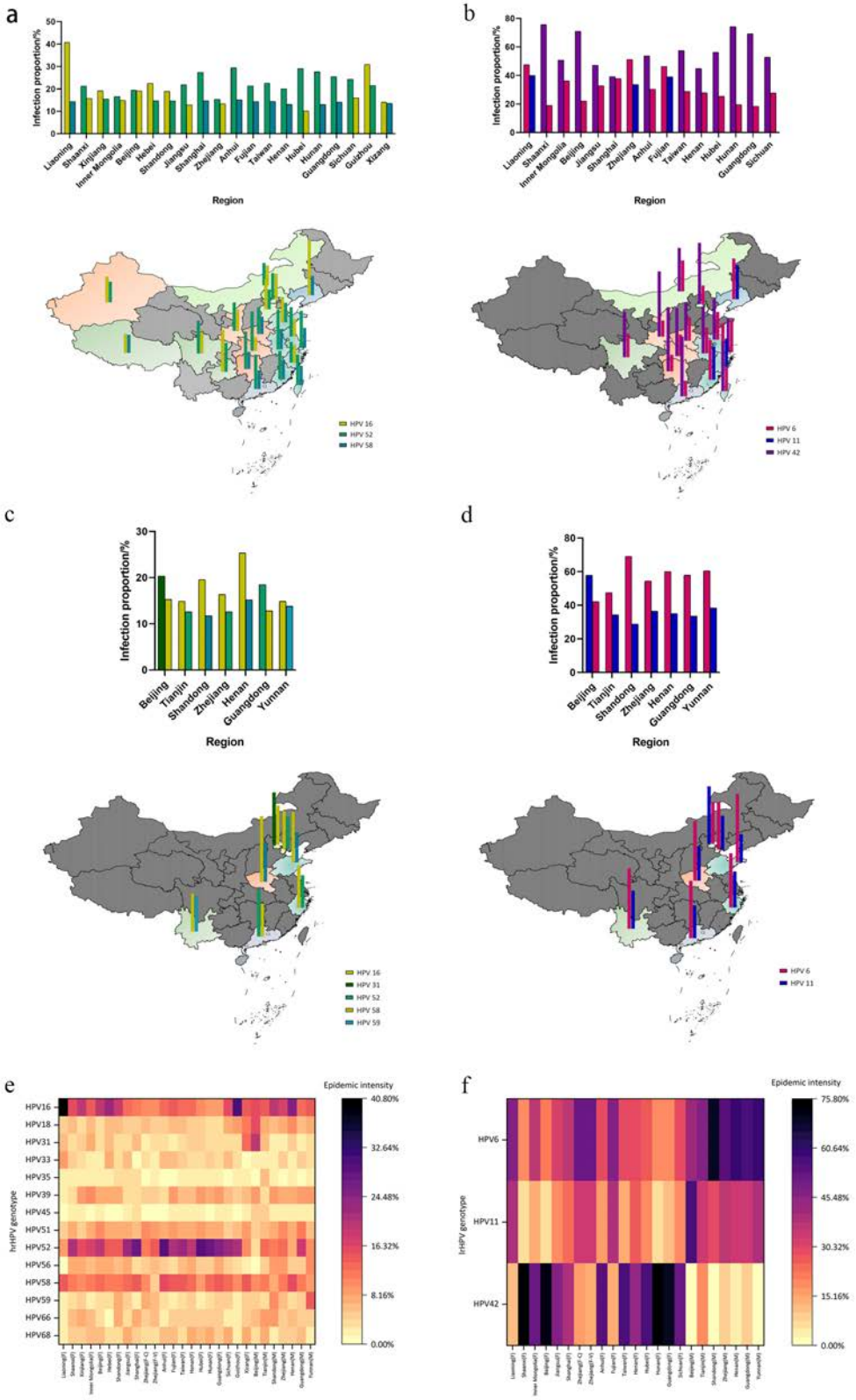

a) Spatial distribution of the three most prevalent high-risk HPV genotypes (HPV 16, 52, 58) in females. HPV 16 showed the highest prevalence in Liaoning Province (40.8%), followed by Guizhou (30.9%) and Hebei (22.5%), with lower prevalence across East China (<15%). HPV 52 exhibited clustered dominance in East China, with the highest prevalence in Anhui (29.4%), Hubei (29.1%), and Shanghai (27.4%). HPV 58 prevalence was higher in southern regions, peaking in Anhui (15.1%), Shanghai (14.7%), and Taiwan (14.4%). b) Spatial distribution of the three most prevalent low-risk HPV genotypes (HPV 6, 11, 42) in females. HPV 42 was the predominant genotype across most regions, exceeding 50% prevalence in all included provinces/regions except Zhejiang, Fujian, and Liaoning, where HPV 6 and HPV 11 were more common. c) Spatial distribution of high-risk HPV genotypes in males. A greater diversity of high-risk genotypes was observed, with HPV 16, 31, 52, 58, and 59 showing regional predominance. HPV 16 was universally prevalent across the seven provinces

analyzed. d) Spatial distribution of low-risk HPV genotypes in males. HPV 6 and HPV 11 were the predominant low-risk types. HPV 11 showed a high prevalence in Beijing (57.8%), while HPV 6 ranked first in the other six provinces. e) Regional prevalence and gender differences in high-risk HPV genotypes. HPV 16 in females displayed a significant east-west gradient, with high prevalence in Northeast and North China (Liaoning 40.8%, Hebei 22.5%, Beijing 19.1%) that decreased southeastward. In males, HPV 16 was highest in Henan (25.3%) and Shandong (19.5%). HPV 52 in females formed a "Yangtze River Valley" cluster (Anhui 29.4%, Hubei 29.1%, Shanghai 27.4%). HPV 58 in males maintained higher levels in Henan (15.2%) and Zhejiang (12.1%). f) Regional prevalence and gender differences in low-risk HPV genotypes. In females, HPV 42 showed a north-high, south-low pattern, with high prevalence in Shaanxi (75.6%) and Beijing (71.1%), and low prevalence in East and South China (Zhejiang, Shanghai, Guangdong <20%). In males, HPV 6 showed high prevalence in northern provinces (Shandong 69.1%, Henan 60.1%), while HPV 11 formed a single high peak in Beijing (57.8%).

Conclusions

During China's early vaccination phase, HPV epidemiology shows distinct characteristics dominated by non-vaccine high-risk types (HPV52/51) and low-risk types (HPV6/11). Multiple infections exhibit refractory, persistent clinical courses with poor clearance rates, necessitating aggressive intervention. Significant regional heterogeneity exists, with HPV16 predominating in northern regions and HPV52 in eastern coastal areas. The high male infection burden (60.7% of cases) and gap in male vaccination highlight critical gaps in current prevention strategies. These findings support expanding immunization to males and prioritizing nine-valent vaccine deployment in HPV52/58-prevalent eastern regions to optimize resource allocation and accelerate cervical cancer elimination.

EADV CONGRESS
VIENNA
30 SEP - 3 OCT 2026

Abstract N°: 574

Management of Giant Condyloma Acuminatum (Buschke-Löwenstein Tumor) in a Severely Immunocompromised Patient

David Kakulashvili*[1]

[1] Kani Clinic, Aversi Clinic, Tbilisi, Georgia

Introduction

Giant condyloma acuminatum (GCA), also known as Buschke–Löwenstein tumor, is a rare, locally aggressive variant of anogenital warts associated predominantly with HPV types 6 and 11. Although histologically benign, GCA demonstrates extensive local invasion, high recurrence rates, and a potential risk of malignant transformation. Profound immunosuppression, particularly in patients with advanced HIV infection, is a major predisposing factor and significantly complicates therapeutic management. We present a challenging case of GCA in a severely immunocompromised patient with advanced HIV infection, highlighting diagnostic, therapeutic, and epidemiological considerations.



The clinical photo. It start from the anal area and goes on groin area. (15-20cm)

Case Presentation

A 35-year-old male presented to our clinic with a 3-year history of progressive, large, cauliflower-like masses in the anogenital and groin regions. Size 15-20 cm. The lesions had significantly increased in size over the past several months, causing local discomfort and difficulty with hygiene. Upon clinical presentation, the first priority was to establish the patient's underlying health status given the extensive and atypical nature of the lesions. An initial HIV screening was performed, which returned a positive result. This was followed by a confirmatory test and a baseline immunological assessment, which revealed a critical CD4+ T-cell count of 12 cells/mm^3.Based on the natural history of untreated HIV infection and the degree of immunological depletion, it is clinically estimated that the patient had been living with active HIV for approximately 10 years prior to diagnosis.

This case highlights the synergy between clinical expertise and AI. We utilized First Georgian Medical AI - "Doctorium AI" (Doctorum.com) to analyze dermoscopic patterns, providing a digital "second opinion" for lesion classification.
To confirm the clinical diagnosis and exclude malignant transformation, a 4mm punch biopsy was performed. Histopathological examination revealed marked acanthosis, parakeratosis, and the presence of koilocytes, consistent with Condyloma Acuminatum. Importantly, there was no evidence of basement membrane disruption or cellular atypia, ruling out invasive Squamous Cell Carcinoma. Managed Cryotherapy: Administered in-clinic once every 14 days. Topical Imiquimod 5% cream: Applied by the patient at home once every 3 days for 8 weeks. The lesions showed visible signs of regression, with a decrease in the 'cauliflower-like' density and an improvement in local hygiene. No signs of severe secondary infection or systemic complications. This early success suggests that combining physical ablation with immunomodulation can effectively control Giant Condyloma Acuminatum even while the patient is in the initial phase of immune reconstitution following the start of ART.



Dermoscopy

Conclusion

Our experience demonstrates that a multimodal, non-surgical approach is a highly effective "treatment of choice" when surgical intervention is contraindicated. By combining the physical cytoreduction of cryotherapy (every 14 days) with the immunological stimulation of topical imiquimod 5% (every 3 days), we achieved significant clinical regression within an 8-week period. This success was further supported by the initiation of Antiretroviral Therapy (ART), which is essential for systemic immune reconstitution.Furthermore, the epidemiological finding that the patient’s wife and children remained HIV-negative despite his decade-long undiagnosed status highlights the importance of routine screening and the complexities of viral transmission within discordant families.



During of treatment 6/8 weaks.

EA DV CONGRESS
VIENNA
30 SEP - 3 OCT 2026

Abstract N°: 636

Psoriasis in people living with HIV: clinical characteristics, treatment outcomes and real-world insights

Eleni Paparizou[1], Evdoxia Panou*[1], Varvara Vasalou[1], Evangelos Daskalakis[1, 1], Nikoletta Tsavalopoulou[1], Ioanna Paschou[1], Elena Stoumpi[1], Vasileios Paparizos[1], Alexander Stratigos[1], Electra Nicolaidou[1]

[1] Andreas Syngros Hospital, Athina, Greece

Introduction
Psoriasis in people living with HIV (PLWH) represents a complex and often challenging clinical entity, frequently associated with increased severity, atypical presentations and therapeutic difficulties. Despite major advances in antiretroviral therapy (ART), cutaneous manifestations remain common and may reflect underlying immune dysregulation. Psoriasis may precede HIV diagnosis or arise during the course of infection, occasionally with a more aggressive or treatment-refractory phenotype. However, reported prevalence rates remain inconsistent, and real-world data on clinical characteristics and management are limited. In particular, concerns regarding immunosuppression have historically restricted the use of systemic and biologic therapies in this population.

Materials and Methods
We conducted a retrospective descriptive study of HIV-positive patients followed at a tertiary referral center in Athens, Greece, between January 1988 and December 2021. Patients with clinically and/or histologically confirmed psoriasis were included. Data collected included demographic characteristics, comorbidities, virological and immunological parameters (viral load, CD4+ T-cell counts), psoriasis subtype and clinical severity (Physician's Global Assessment, PGA), as well as treatment strategies and outcomes at 6 months.

Results
Among 2,070 PLWH, 71 patients (3.4%) were diagnosed with psoriasis. The majority were male, with a mean age of approximately 40 years at HIV diagnosis. Psoriasis preceded HIV diagnosis in 58% of cases. A high burden of comorbidities was observed, affecting 79% of patients, with psychiatric disorders being the most frequent.Immunologically, a substantial proportion of patients presented with advanced immunosuppression, with 36.6% having CD4+ counts <100 cells/mm^3 at some point during follow-up, while 31% had CD4+ counts >500 cells/mm^3.Plaque psoriasis was the predominant phenotype (80%), with a spectrum of severity ranging from mild to extensive disease. Other clinical variants, including inverse, nail, erythrodermic and palmoplantar psoriasis, as well as mixed phenotypes, were also observed.All patients received ART, and 79% were treated for psoriasis, mainly with topical therapies. A smaller proportion required systemic treatment or phototherapy. At 6 months, 73% of treated patients demonstrated significant clinical improvement, while 14% showed partial response and 13% relapsed, most commonly due to poor adherence. Notably, 8 patients improved following ART initiation alone.Importantly, a subset of patients received biologic therapy (ustekinumab), achieving complete skin clearance without adverse events or evidence of virological or immunological deterioration. These findings align with emerging literature supporting the cautious use of biologics in selected PLWH.

Conclusions
The prevalence of psoriasis in PLWH was comparable to that of the general population. ART appears to contribute to disease improvement, highlighting the role of immune reconstitution in psoriasis pathogenesis. The wide spectrum of clinical presentations and immunological status reflects the heterogeneity of this population. Treatment outcomes are influenced by adherence and comorbidities, particularly psychiatric conditions. While topical therapies remain first-line, biologic agents may represent a safe and effective option in selected patients, in

line with accumulating real-world evidence.

EA DV CONGRESS
VIENNA
30 SEP - 3 OCT 2026

Abstract N°: 755

Demographic, Behavioral, and Clinical Profiles of Newly Diagnosed HIV Patients in an Urbanized Low-Income Setting: A Retrospective Study (2020–2024)

Diana Jean Marie Pobre-Eder*[1], Christian Tan[1], Maria Katrina Manalili[1], Kara Melissa Torres-Culala[1], Reagan Grey Reyes[1], Lian Jamisola[1], Jovanni Templonuevo[1], Roberto Antonio Pascual[1]

[1] DOH-Tondo Medical Center, Tondo, Manila, Philippines

Introduction
The Philippines continues to experience a rapidly expanding Human Immunodeficiency Virus (HIV) epidemic, particularly in densely populated urban settings. Localized epidemiologic data are essential to understand transmission dynamics and guide targeted interventions. This study aimed to describe the demographic, behavioral, and clinical profiles of HIV-positive patients diagnosed from 2020 to 2024.

Materials and Methods
A retrospective descriptive study was conducted using 108 anonymized medical records of confirmed HIV-positive patients. Data were extracted from institutional HIV program records, including demographics, sexual behaviors, condom use, substance use, and indications for testing. HIV diagnosis was established through a rapid diagnostic algorithm with confirmatory testing per national standards. Descriptive statistics (frequencies and percentages) were used for analysis.

Results
The cohort was predominantly male (93.5%), single (96.3%), and concentrated in the 25–34 age group (53.7%), with a mean age of 29.25 ± 7.31 years. The highest number of diagnoses occurred in 2024 (36.1%), demonstrating a post-pandemic surge.

Sexual transmission was the primary mode, with 51.9% reporting male-to-male sexual contact and 32.4% reporting bisexual behavior. High-risk behavior was ongoing, with 72.2% reporting recent condomless sex. Clinically, 88.0% were symptomatic at diagnosis, and 90.7% underwent testing following healthcare provider recommendation, indicating predominantly late-stage detection.

Parameter	Key Result
Age group (25–34)	53.7%
Male sex (at birth)	93.5%
MSM behavior	51.9%
Bisexual behavior	32.4%
Recent condomless sex	72.2%
Symptomatic at diagnosis	88.0%
Provider-initiated testing	90.7%
Peak year (2024)	36.1%

Table 1. Table. Summary of major demographic, behavioral, and clinical findings among HIV-positive patients (N=108), demonstrating predominance of young males, high-risk sexual behaviors, and delayed diagnosis.

Conclusions

The epidemic is concentrated among young, sexually active males engaging in same-sex and bisexual behaviors, with persistent high-risk practices. The predominance of symptomatic presentation and provider-initiated testing highlights delayed diagnosis and missed opportunities for early detection. These findings emphasize the urgent need for proactive, community-based screening strategies, targeted prevention for key populations, and improved access to early HIV testing and care.

EACONGRESS
VIENNA
30 SEP - 3 OCT 2026

Abstract N°: 787

Demographic, Behavioral, and Clinical Profiles of HIV Patients in a Densely Populated Urban Setting in the Philippines: A Retrospective Study in a Tertiary Public Hospital (2020–2024)

Diana Jean Marie Pobre-Eder*[1], Maria Katrina Manalili[1], Christian Tan[1], Kara Melissa Torres-Culala[1], Reagan Gray Reyes[1], Lian Jamisola[1], Jovanni Templonievo[1], Roberto Antonio Pascual[1]

[1] DOH-Tondo Medical Center, Tondo, Manila, Philippines

Introduction

The Philippines continues to experience a rapidly increasing Human Immunodeficiency Virus (HIV) burden, particularly in densely populated urban areas where transmission networks and structural barriers to care intersect. Delayed diagnosis remains a major challenge, contributing to ongoing transmission and poor clinical outcomes. This study aimed to describe the demographic, behavioral, and clinical profiles of HIV-positive patients diagnosed in a tertiary public hospital serving a high-burden urban population

Materials and Methods

A retrospective descriptive study was conducted using anonymized medical records of 108 confirmed HIV-positive patients diagnosed from 2020 to 2024. Data were obtained from institutional HIV program records and included demographic characteristics, sexual behaviors, condom use, substance use, and indications for testing. HIV diagnosis was established using a rapid diagnostic algorithm with confirmatory testing in accordance with national guidelines. Descriptive statistics were used to summarize data as frequencies and percentages.

Parameter	Description
Study design	Retrospective descriptive
Setting	Tertiary public hospital serving a high-burden urban population
Study period	2020–2024
Sample size	108 patients
Data source	Institutional HIV program records
Analysis	Frequencies and percentages

Study Design and Population Overview A U-shaped trend is observed, with a marked increase in diagnoses in 2024 representing the highest burden during the study period.

Results

The cohort was predominantly male (93.5%) and single (96.3%), with a mean age of 29.25 ± 7.31 years. Most cases were concentrated among individuals aged 25–34 years (53.7%), followed by 18–24 years (25.0%). Sexual transmission was the primary mode, with 51.9% reporting male-to-male sexual contact and 32.4% reporting

bisexual behavior. High-risk behavior was ongoing, with 72.2% reporting condomless sex within the past year.

Late diagnosis was a key feature: 88.0% were symptomatic at presentation, and 90.7% underwent testing following healthcare provider recommendation. Additionally, 76.9% had no prior HIV testing. Trend analysis showed a U-shaped pattern, with a peak in 2024 (36.1%), representing the highest number of diagnoses during the study period.

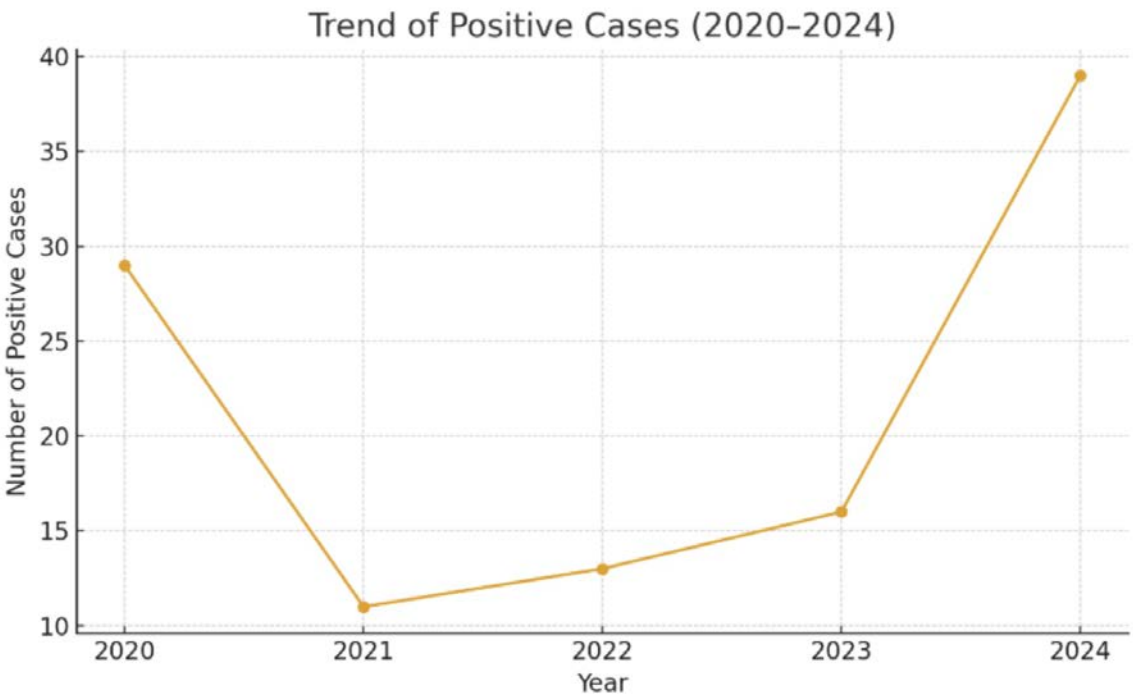

A U-shaped trend is observed, with a marked increase in diagnoses in 2024 representing the highest burden during the study period.

Conclusions

HIV infection in this high-burden urban setting is concentrated among young, sexually active males engaging in same-sex and bisexual behaviors, with ongoing high-risk practices. The predominance of symptomatic presentation, inpatient diagnosis, and provider-initiated testing suggests delayed diagnosis and missed opportunities for early detection.

Findings should be interpreted within the study context, as data from a tertiary public hospital may overrepresent advanced and symptomatic cases compared to community-based settings.

Nonetheless, detection remains largely reactive. Strengthening community-based screening, expanding routine and targeted testing, and improving access to preventive interventions are essential to promote earlier diagnosis, reduce transmission, and improve outcomes.

EADV CONGRESS
VIENNA
30 SEP - 3 OCT 2026

Abstract N°: 861

Iterative Development of a self-test technology: testing for STI among MSM

Bettina Trettin*[1, 2], Mette Maria Skjøth[1], Nadja Munk[1]

[1] Odense Universitetshospital, Odense C, Denmark
[2] Syddansk Universitet, Odense M, Denmark

Introduction
The incidence of sexually transmitted infections such as chlamydia, gonorrhea, and syphilis is disproportionately high among men who have sex with men (MSM) compared to the general population. European surveillance data indicate increasing incidence, particularly for gonorrhea and syphilis, while chlamydia is frequently asymptomatic and therefore underreported. At our sexual health clinic, a self-test technology is offered as a walk-in option. Thus, any testing is without contact with a health care professional and patients could be tested for chlamydia and gonorrhea with a urine sample or a vaginal swab. However, it is considered important that MSM have equitable access to self-testing technologies for screening of sexually transmitted infections. Our sexual health clinic expanded the existing technology to ensure its applicability and usability for MSM.

Materials and Methods
To enhance usability for MSM, the technology was adapted to enable self-sampling from the pharynx and rectum. In addition, MSM not receiving PrEP treatment were able to order blood tests for syphilis. Grounded in a participatory design framework, the study adopted an ethnographically informed qualitative approach, employing participant observation and structured interviews (n=9) to explore patients' experiences and use of the technology.

Results
In total, 111 MSM used the technology during a period of 10 months, of which 20 (18,2 %) tested positive for gonorrhea and 15 (13,5 %) for chlamydia and three patients tested positive for both. Thus 32 patients (28,8 %) tested positive for either chlamydia, gonorrhea or both. Furthermore, 29,8 % ordered a blood test for syphilis, unfortunately data regarding the outcome of those tests are unknown. Patients experienced the self-test technology that was easy and flexible to use. They emphasized the importance of feeling anonymous and included in a public health service. Adjustments to the technology were applied iteratively based on the qualitative findings.

Conclusions
The iterative adaptation of the self-test technology improved its usability and accessibility for MSM, supporting more inclusive STI screening. The high positivity rate highlights its clinical relevance, while user experiences emphasize the importance of anonymity and flexibility. Further work is needed to strengthen data integration, particularly for syphilis testing.

EADV CONGRESS
VIENNA
30 SEP - 3 OCT 2026

Abstract N°: 908

Secondary Syphilis Presenting as Lues Maligna with Prozone Phenomenon in an HIV-Negative Filipino Male: A Case Report

Ma. Brina Angela Barin*[1], Zharlah Gulmatico-Flores[1], Elisa Rae Coo[1]

[1] Jose R. Reyes Memorial Medical Center, Manila, Philippines

Introduction

Syphilis, caused by Treponema pallidum, is a sexually transmitted infection characterized by a wide spectrum of clinical manifestations across its stages. Secondary syphilis, often referred to as the "great imitator," can mimic numerous dermatologic conditions, posing diagnostic challenges. Malignant syphilis (lues maligna) is a rare and aggressive variant, typically associated with immunocompromised states but increasingly reported in immunocompetent individuals. Furthermore, diagnostic difficulty may be compounded by false-negative serologic tests, such as in the prozone phenomenon. With the global resurgence of syphilis, recognition of atypical presentations is essential for timely diagnosis and management.

Case Presentation

A 38-year-old Filipino male with a history of high-risk sexual behavior, alcohol intake, and prior methamphetamine use presented with progressively enlarging hyperkeratotic, annular, and nodular plaques with crusting, ulceration, and eschar formation involving the face, trunk, extremities, and genital area, notably sparing the palms and soles. Initial evaluation included serologic testing, which revealed a nonreactive rapid plasma reagin (RPR) test but a Treponema pallidum hemagglutination (TPHA). Additional workup, including potassium hydroxide preparation and tissue culture, identified concurrent superficial fungal elements and bacterial colonization. Serologic testing showed nonreactive HIV test results. Histopathologic examination demonstrated psoriasiform hyperplasia with basal layer vacuolization and a dense lichenoid infiltrate rich in plasma cells, supporting the diagnosis of secondary syphilis. Given strong clinical suspicion, repeat RPR testing was performed and yielded high titers of 1:265, consistent with the prozone phenomenon. The patient was treated with a single intramuscular dose of benzathine penicillin G (2.4 million units), resulting in rapid clinical improvement. Within one month, lesions showed marked flattening and regression, with no new lesions observed, and by two months, near-complete resolution was noted along with a four-fold decline in RPR titers, confirming adequate therapeutic response.

Conclusion

This case highlights an atypical presentation of secondary syphilis as malignant syphilis in an immunocompetent patient, complicated by a false-negative initial RPR. It underscores the importance of maintaining clinical suspicion, repeating serologic testing, and correlating histopathologic findings to ensure timely diagnosis and effective management.

EA DV CONGRESS
VIENNA
30 SEP - 3 OCT 2026

Abstract N°: 924

Multisite Distribution of Mollicutes in Men Who Have Sex with Men and Coinfection Patterns with Other Bacterial STIs

Dr Anshuman Dash*[1], Niti Khunger[2], Sumathi Muralidhar[2], Dr. Prakhar Srivastava[2]

[1] All India Institute of Medical Sciences, Bhubaneswar, India, BHUBANESWAR, India
[2] Vardhman Mahavir Medical College and Safdarjung Hospital, New Delhi, India

Introduction
Sexually transmitted infections (STIs) remain a major concern among men who have sex with men (MSM), with a high burden of asymptomatic and extragenital infections. While Neisseria gonorrhoeae and Chlamydia trachomatis are well studied, genital Mollicutes such as Mycoplasma and Ureaplasma species are increasingly recognized but remain poorly understood. These organisms are often asymptomatic and may contribute to transmission and coinfection dynamics. Extragenital sites like the rectum and oropharynx act as important reservoirs, yet are frequently under-screened. We aimed to evaluate the anatomical distribution and multisite prevalence of genital Mollicutes and other bacterial sexually transmitted infections (STIs) among men who have sex with men (MSM), and to assess associations with sexual behavioral factors.

Materials and Methods
This cross-sectional study was conducted over 18 months among 100 MSM attending an STI clinic at a tertiary care center in New Delhi, India. Demographic and behavioral data were collected using standardized questionnaires followed by HIV test. Screening for Neisseria gonorrhoeae (NG), Chlamydia trachomatis (CT), and genital Mollicutes including Mycoplasma genitalium (MG), Mycoplasma hominis (MH), Ureaplasma urealyticum (UU), and Ureaplasma parvum (UP) was performed using real-time PCR on urethral, rectal, and oropharyngeal swabs. Statistical analysis included descriptive statistics and Chi-square testing.

Results
The overall STI prevalence was 96%, reflecting a substantial burden of both classical and emerging pathogens. Among Mollicutes, Ureaplasma urealyticum (24%) was most prevalent, followed by Mycoplasma hominis (21%), Mycoplasma genitalium (17%), and Ureaplasma parvum (8%). Neisseria gonorrhoeae was detected in 40% of participants, while Chlamydia trachomatis was identified in 9%. All Mollicute infections were asymptomatic, whereas 80% of gonococcal and 77.8% of chlamydial infections were symptomatic.Coinfection analysis showed M. genitalium was most commonly associated with N. gonorrhoeae (29.4%). Notably, 85% of gonorrhea cases had at least one additional infection, including M. hominis (30%) and U. urealyticum (30%). Among CT-positive individuals, 88.9% had concurrent infections, most frequently with M. hominis and U. urealyticum (44.4% each). Site-wise distribution revealed urethral predominance of M. genitalium (64.7%) and U. parvum (62.5%), while M. hominis (42.9%) and U. urealyticum (37.5%) were more common in rectal samples. Behaviorally, M. hominis was significantly associated with paid sex (χ^2=10.045, p=0.002), and U. urealyticum with inconsistent condom use (χ^2=6.067, p=0.047).

Conclusions
This study highlights a high burden of STIs among MSM, with predominantly asymptomatic, multisite Mollicute infections and significant extragenital involvement. Symptom-based, single-site screening is likely to miss many infections, enabling ongoing transmission and reinfection. Frequent coinfections with pathogens such as Neisseria gonorrhoeae and Chlamydia trachomatis further complicate management. The distinct anatomical distribution

underscores the importance of extragenital screening. These findings support the need for comprehensive multisite molecular testing, along with targeted behavioral interventions, to improve detection, guide treatment, and strengthen STI control strategies in high-risk populations.

EADV CONGRESS
VIENNA
30 SEP - 3 OCT 2026

Abstract N°: 925

Beyond first impressions: an evolving vascular dermatosis in a young patient

Chandana B Y*[1]

[1] Kempegowda Institute of Medical Sciences, Bengaluru, India

Introduction

Kaposi sarcoma (KS) is a vascular neoplasm associated with human herpesvirus 8, typically occurring in immunocompromised individuals. Early cutaneous lesions may be nonspecific and mimic benign or inflammatory dermatoses thus, posing a diagnostic challenge in patients without known risk factors or clinical suspicion of immunosuppression.

Case Presentation

An 18-year-old male with no known comorbidities presented with a solitary erythematous nodule over the chin which bled on touch. The lesion was insidious in onset and had gradually increased in size over one month from 0.5x0.5cm to 2x2cm. In view of the history, pyogenic granuloma was considered and the lesion was treated with electrocautery.

One month later, he returned to our out patient department with multiple erythematous plaques and nodules over the face, trunk and bilateral upper and lower limbs. Skin biopsy was performed at this stage which suggested features of erythema elevatum diutinum. The patient was initiated on Tablet Dapsone 100mg once daily after normal G6PD values. However, he was subsequently lost to follow-up.

After another month, he presented to the Emergency Department with fever, rapidly progressive erythematous to violaceous nodules over face, neck, trunk, bilateral upper and lower limb associated with facial puffiness and bilateral lower limb edema.
Laboratory evaluation revealed pancytopenia with normal liver and renal function tests, raising suspicion of underlying immunosuppression. Serological testing confirmed HIV infection with a CD4 count of 174 cells/µL and antiretroviral therapy was initiated.

Given the aggressive clinical progression, a repeat skin biopsy was performed with differentials of Bacillary angiomatosis, Angiosarcoma and Kaposi sarcoma.

Histopathological examination of the erthematous nodules over forearm showed spindle cell proliferation and slit like vascular spaces.
Followed by immunohistochemistry (CD31, CD34, ERG, FLI1 positivity; Ki-67 approximately 20%, LANA1 positivity) which confirmed a vascular neoplasm consistent with Kaposi sarcoma.
Cervical lymph node biopsy showed features of reactive lymphoid hyperplasia.
PET-CT imaging demonstrated disseminated disease with involvement of lymph nodes above and below the diaphragm, pleura, skin, and liver.

The patient was then refered to a Oncologist and was started on systemic chemotherapy using bleomycin and vincristine (BV regimen), resulting in marked clinical improvement and significant metabolic response on follow-up imaging. There was resolution of most lesions and reduction of disease in 4 months duration.



Before and after chemotherapy

Conclusion

This case highlights the diagnostic challenges posed by early presentations of Kaposi sarcoma in young individuals without known risk factors, leading to delay in recognition. Rapid progression and systemic involvement underscore the aggressive nature of KS in untreated HIV. A high index of suspicion and early evaluation for underlying immunosuppression are essential in patients with evolving vascular lesions to enable timely diagnosis and improved outcomes.

EADV CONGRESS
VIENNA
30 SEP - 3 OCT 2026

Abstract N°: 1055

NDUFA4L2-mediated ZBP1 lactylation inhibits keratinocyte PANoptosis to drive HPV6/11 immune evasion

Boya Zhang*[1]

[1] Sir Run Run Shaw Hospital, School of Medicine, Zhejiang University, Hangzhou, China

Introduction
Condyloma acuminatum is a highly recurrent sexually transmitted infection caused by low-risk HPV types. Current clinical management relies primarily on physical ablation of visible lesions and non-specific immunomodulatory interventions; however, no antiviral therapy targeting HPV replication or persistence is yet available. Viral persistence hinges critically on immune evasion-particularly suppression or dysregulation of host innate and adaptive immune responses. Emerging evidence indicates that low-risk HPV actively reprograms host cell metabolism to support viral genome maintenance and progeny production. Concurrently, the infected host may deploy multiple forms of programmed cell death-including apoptosis, pyroptosis, and ferroptosis-as intrinsic defense mechanisms to eliminate virus-infected keratinocytes. Elucidating how low-risk HPV modulates these intersecting pathways of metabolic reprogramming and regulated cell death holds significant promise for identifying novel therapeutic targets to disrupt viral persistence and reduce recurrence.

Materials and Methods
Integrated experimental approaches included cytological analysis, molecular immunological assays, high-resolution mass spectrometry (MS) and liquid chromatography–tandem mass spectrometry (LC-MS/MS)–based proteomic and metabolomic profiling, genome-wide expression microarray analysis, untargeted metabolomics sequencing, chemically synthesized small interfering RNA (siRNA) , quantitative real-time PCR (qRT-PCR), and immunohistochemical staining.

Results
Our studies demonstrated that HPV6/11 potently inhibits PANoptosis in keratinocytes. Single-cell sequencing analysis further revealed aberrant cellular energy metabolism in condyloma acuminatum tissues, with a marked upregulation of the mitochondrial respiratory chain regulatory protein NDUFA4L2.Further experimental studies have shown that that HPV6/11 E7 interacts with HIF-1α to enhance its stability, thereby driving NDUFA4L2-mediated metabolic reprogramming. This process leads to intracellular lactate accumulation, which in turn induces lactylation of the key PANoptosis protein ZBP1. Such modification blocks the assembly of the PANoptosome and suppresses the release of damage-associated molecular patterns (DAMPs), ultimately establishing an immune microenvironment conducive to viral persistence.

Conclusions
HPV6/11 E7 stabilizes HIF-1α to upregulate NDUFA4L2 and induce metabolic reprogramming, which promotes ZBP1 lactylation, inhibits keratinocyte PANoptosis, and facilitates viral persistence.

EA DV CONGRESS
VIENNA
30 SEP - 3 OCT 2026

Abstract N°: 1111

Fractionated Electrocoagulation Combined with Delayed Photodynamic Therapy for Treating Giant Perianal Condyloma Acuminatum: A Case Report

Qiying Zhang*[1], Xuefeng Fu[1], Hui Sun[2], Lvjun Zhang[1], Meiyan Wang[1]

[1] Jinhua Municipal Central Hospital, Jinhua, China

[2] Huzhou Central Hospital, Huzhou, China

Introduction

Giant condyloma acuminatum is a rare, locally invasive anogenital tumor, strongly associated with human papillomavirus infection. Anal condyloma acuminatum is characterized by a long latency period and a high recurrence rate. This case report outlines an innovative therapeutic strategy that combines staged fractional electrosurgery with delayed photodynamic therapy, emphasizing the significance of treatment sequencing for optimal outcomes. The 3-week interval between these modalities is crucial, as it permits inflammatory resolution while preserving targeting precision for any residual disease.

Case Presentation

A 75-year-old man presented with a perianal mass emitting a foul odor. The skin lesion appeared a year ago and rapidly grew, gradually producing an unpleasant smell. He experienced difficulty with defecation and discomfort while squatting. Distressed by the lesion's appearance and odor, he sought definitive treatment. Physical examination showed a verrucous mass approximately 13 cm × 7 cm × 5.5 cm around the anus, obscuring the anal opening . Laboratory tests showed: Treponema pallidum tests: TPPA and RPR (negative); HIV antigen/antibody screening: negative; Acetic acid whitening test: positive. Pelvic CT revealed a large soft tissue mass in the perianal region. Skin biopsy showed epidermal hyperkeratosis with parakeratosis, acanthosis, elongated dermoepidermal ridges, and numerous koilocytes in the granular and upper spinous layers. HPV-DNA testing was positive for type 6. These findings led to a diagnosis of giant perianal condyloma acuminatum.

Considering the patient's advanced age, extensive lesion involvement, and the critical location in the perianal region, the medical team held a multidisciplinary consultation. After thorough communication with the patient and obtaining informed consent, we devised a phased treatment plan combining electrocoagulation with photodynamic therapy. The initial procedure was conducted under local anesthesia using a high-frequency electrosurgical unit to excise the perianal exophytic mass through staged electrocoagulation. The primary goal of this phase was to remove the main tumor mass and expose the anal canal. During surgery, concomitant internal hemorrhoids and anal canal condylomas were also identified. A second electrocoagulation procedure was performed the following week to treat the anal canal condyloma, followed by routine wound care.

In the third week after surgery, new warts appeared in the perianal and anal canal regions. To address this, a combined ALA-PDT therapy was implemented. The procedure involved applying a 20% aminolevulinic acid (ALA) hydrochloride solution as a wet compress to the affected areas. After 3 hours of shielding from light, the area was exposed to a 635nm LED light source for 20 minutes, resulting in a cumulative energy density of 96J/cm^2. This treatment was administered weekly for 6 consecutive weeks. During the photodynamic therapy phase, any newly emerging perianal warts are promptly removed using electrocoagulation.

During treatment, the intervals between recurrences of perianal warts progressively increased, and the emergence of new warts steadily declined. Eventually, all warts in the perianal region and anal canal were entirely eliminated.

Furthermore, internal hemorrhoids showed partial regression, no significant scarring appeared around the anus, and anal sphincter function was preserved. Over a 12-month follow-up period, there was no recurrence of warts, and HPV-DNA test results were negative. The patient reported satisfaction with the treatment outcomes.

Conclusion

The combination of staged electrocoagulation and delayed photodynamic therapy offers an optimized approach for treating giant condyloma acuminata. This method effectively clears macroscopic lesions and controls microscopic infections by physically reducing tumors and inactivating targeted areas. The approach's low recurrence rate and high tissue preservation make it a promising candidate for broader adoption.

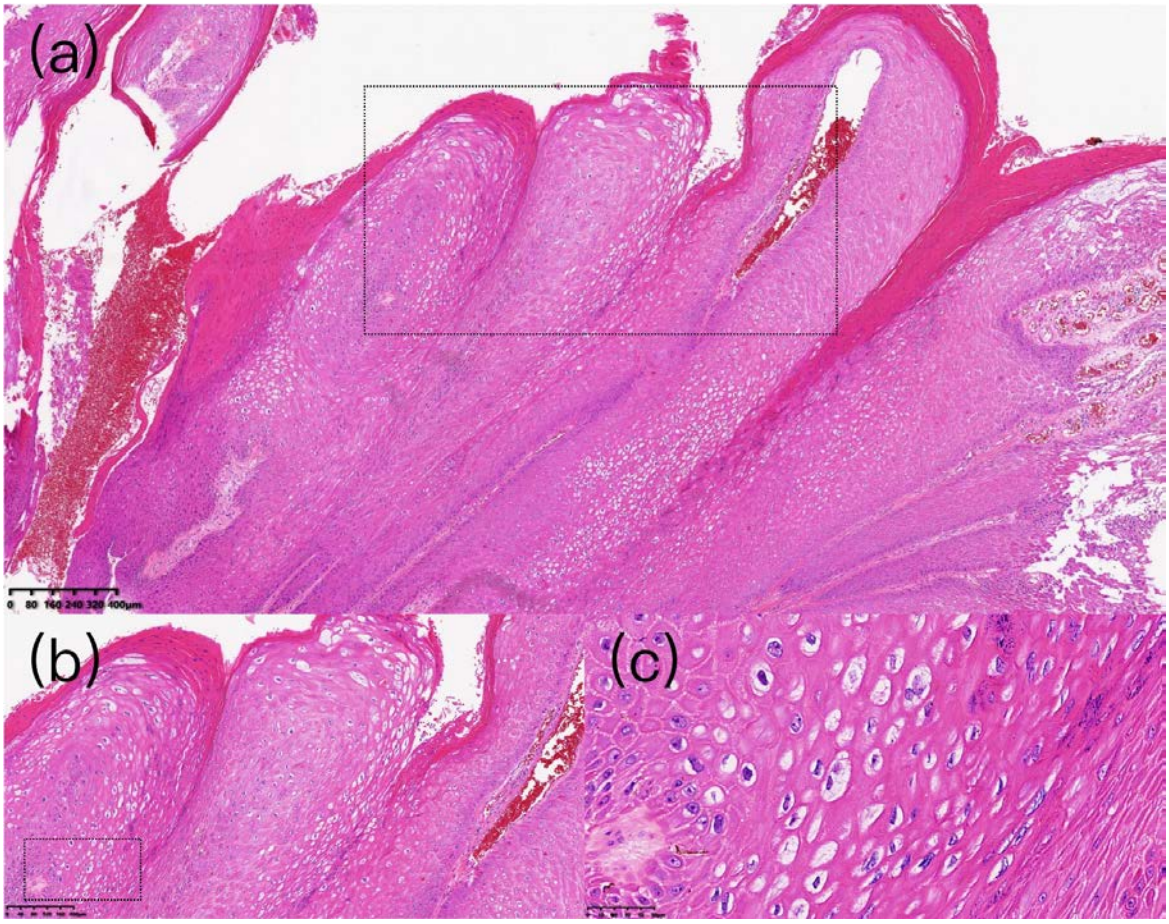

Fig. 1. Histopathological microscopic view revealed epidermal hyperkeratosis accompanied by parakeratosis, acanthosis, elongated dermoepidermal ridges, and numerous koilocytes observed in the granular layer and upper spinous layer. (HE staining, original magnifications: [a]×40; [b]×100;[c]×400).

EA DV CONGRESS
VIENNA
30 SEP - 3 OCT 2026

Abstract N°: 1169

ERRORS IN THE DIAGNOSIS OF SECONDARY SYPHILIS

Nodira Saipova*[1], Muyassar Allaeva[1], Гайратилло Тохтаев[1]

[1] Tashkent State Medical University, Tashkent International University KIMYO, Ташкент, Uzbekistan

Introduction
The report presents a rare clinical case of recurrent secondary syphilis. The patient was observed in various specialized institutions with diagnoses of anemia, sarcoma, and non-Hodgkin lymphoma. He was subsequently referred to a dermatovenerologic dispensary with a diagnosis of toxicoderma.

Case Presentation
Patient K., born in 2000, applied to the consultative polyclinic of the Tashkent Regional Dermatovenerologic Dispensary with a referral diagnosis: Toxicoderma?

Anamnesis morbi: according to the patient, he has considered himself ill for three years. The disease was associated with enlargement of cervical lymph nodes; the patient consulted a surgeon at his place of residence. After biopsy, he was referred to an oncologist. Based on biopsy results, the diagnosis was: maxillofacial sarcoma? The patient was hospitalized in the regional oncological dispensary, where he received chemotherapy. The patient's condition worsened; a severe form of chronic anemia was revealed. He was hospitalized in the hematology department. In March 2020, he received inpatient treatment at the Institute of Hematology with the diagnosis: severe chronic anemia, maxillofacial sarcoma? He was discharged with some improvement. After repeated lymph node biopsy, the diagnosis was: non-Hodgkin lymphoma. With progression of the skin process, he consulted a dermatovenerologic dispensary at his place of residence, where the diagnosis toxicoderma? was made. The patient was referred to the regional dermatovenerologic dispensary.

Status localis (at admission): the skin pathological process is widespread, symmetrical and localized on the skin of the abdomen, back, upper and lower extremities, chest, scalp, inner thighs, palms and soles, and genital area (Photo 1–4). Almost complete hair loss on the scalp, eyelashes (Pincus sign positive) and eyebrows (Darier sign positive) is noted. On the scalp: patches of hair of different lengths, erosions covered with serohemorrhagic crusts, resolving flat papules with peripheral scaling (Biett's collarette). Oral mucosa pink, without pathology; carious changes noted in teeth.

Results of laboratory investigations:

Complete blood count hemoglobin 120; erythrocytes 4.0×10^{12}; color index 0.91; leukocytes 5.4; eosinophils 5%; lymphocytes 29%; monocytes 1%; ESR 8 mm/h.

Biochemical blood test total bilirubin 17.1 µmol/L, direct 10.1 µmol/L, indirect 7.0, ALT 25 U/L, AST 26 U/L.

Urinalysis: volume 110 ml; specific gravity 1018; protein absent; glucose absent; epithelium 3–5; leukocytes 3–5; erythrocytes absent; mucus +.

Urethral smear: leukocytes 4–6; epithelium 6–12; gonococcus absent; chlamydia absent; trichomonas absent; gardnerella absent; candida absent.

Bacterial culture: gonococci detected.

Serological reactions: TPHA 4+ (titer 1:1520); RIF-200 3+; RIF-abs 4+; RMP 3+; immunochromatographic assay anti-Treponema pallidum ±; RIBT 75%; RW 2+ 2+.

HIV test negative.

Final diagnosis: Lues II recidiva A51.3 (papula syphilitica ad palmaris et plantaris, polyadenitis specifica, alopecia. Seroreactions 4+).

Concomitant: chronic gonorrhea. Non-Hodgkin lymphoma? Diagnoses of anemia and toxicoderma excluded.

In connection with the established final diagnosis, syphilis treatment was carried out according to the standards of the Ministry of Health of the Republic of Uzbekistan (2021).

Benzylpenicillin 1 million IU 4 times daily every 6 hours; total dose 80 million IU over 20 days.



Photographs of the patient before treatment.

Conclusion
Conclusion:

Thus, as a result of etiological antisyphilitic therapy, complete resolution of the skin rash was observed, which had previously been regarded as toxicoderma, thereby confirming the final diagnosis of syphilis. The diagnosis was further supported by characteristic clinical presentation and strongly positive specific serological reactions.



On day 20 of treatment.

EADV CONGRESS
VIENNA
30 SEP - 3 OCT 2026

Abstract N°: 1243

Mpox infection in a patient with history of syphilis and anorectal abscess: case report

Ana Sofia Gil Herrera[1], Ana Beatriz Crocker Sandoval*[2], Guillermo Solís[3], Aldo Gilberto Arrazola[4]

[1] School of Medicine and Health Sciences, Tecnológico de Monterrey, Zapopan, Jalisco, Mexico
[2] Dermatology Private Practice, San Javier Hospital, Zapopan, Jalisco, Mexico
[3] Jalisco Dermatological Institute, Zapopan, Jalisco, Mexico
[4] Private Practice, San Javier Hospital, Zapopan, Jalisco, Mexico

Introduction

Mpox is an emerging zoonotic disease caused by an Orthopoxvirus, which gained global attention during the 2022 outbreak due to its rapid spread to non-endemic countries. Currently, the main route of transmission is sexual contact. Most reported cases have been in men who have sex with men (MSM); however, anyone can contract the disease.

The disease begins with general symptoms such as fever, headache, and lymphadenopathy, this last characteristic being a distinguishing feature compared to other similar diseases. Skin lesions then appear, usually between 1 and 4 days after the fever, located on the genitals, perianal area, face and extremities.

The lesions progress through five stages - macules, papules, vesicles, pustules and crusts - over a period of 2 to 4 weeks. They are deep, well-defined, and have a characteristic central umbilication, which facilitates their clinical identification.

The diagnosis is confirmed by real-time PCR (RT-PCR) using samples from the skin lesions.

Case Presentation

A 40-year-old man with a history of untreated syphilis and anorectal abscess presented for an evaluation due to presence of genital skin lesions following high-risk sexual activity. Initial examination revealed multiple well-defined umbilicated vesicles measuring 3-8 mm with a necrotic depressed center localized to the genital area. The patient was initially afebrile with no lymphadenopathy; however, one week later, he subsequently developed fever, odynophagia and progression of lesions, with dissemination to the left upper extremity characterized by papular lesions measuring 4-6 mm on an erythematous base.

Given the clinical suspicion of Mpox, a biopsy and real-time polymerase chain reaction (RT-PCR) of the lesion were performed, which confirmed the presence of Mpox viral DNA.

Histopathological examination revealed necrosis with reticular degeneration and eosinophilic cytoplasmic inclusions, identifiable as Guarneri bodies (Figure 1), supporting the diagnosis of Orthopoxvirus infection. Due to the known association between Mpox and STDs, serologic testing was performed, confirming active syphilis coinfection.

The management included home isolation and supportive care, including paracetamol and a cream formulated with oat seedling extract and a copper-zinc-magnesium complex for the lesions. Targeted antibiotic therapy with doxycycline 100 mg every 24 hours was initiated for syphilis. The clinical course was favorable, with symptom resolution and no reported complications.

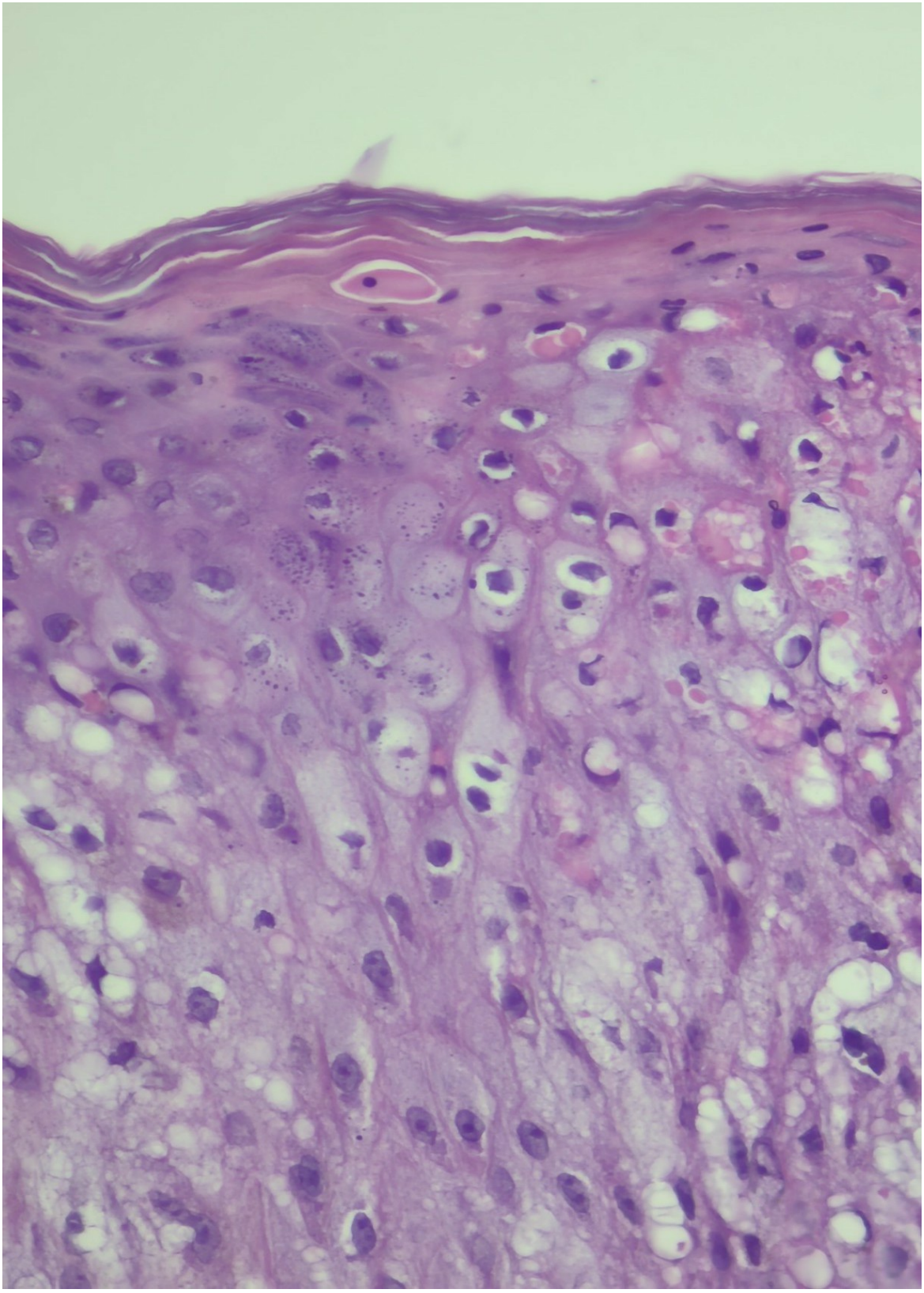

Figure 1. Histopathological study (H-E, 40x), Highlighting the eosinophilic cytoplasmic inclusions of 10-15 microns, within the cytoplasm of the keratinocytes, compatible with Guarnieri bodies.

Conclusion

Mpox has transitioned from an endemic zoonosis to a global public health concern, largely driven by human-to-human transmission, particularly through sexual contact. Coinfection with STDs is common, reported in up to 20-50% of cases. In a series of cases, 3.7% of patients diagnosed with Mpox had a coinfection with syphilis. In this context, syphilis represents a key differential diagnosis, as both conditions may present with genital lesions.

However, characteristic differences exist: syphilis lesions typically present as painless chancres localized at the site of inoculation, whereas Mpox lesions are often vesiculopustular, umbilicated, and may become generalized. Even though syphilis and Mpox share risk factors, such as high-risk sexual behaviors and a history of STDs, there is no causal relationship between these two infections.

Early diagnosis relies on clinical suspicion supported by epidemiological risk factors and confirmatory RT-PCR testing, which remains the gold standard. Most cases follow a self-limited course and require only symptomatic management; however complications may occur, particularly in immunocompromised patients.

This case highlights the importance of considering Mpox in patients presenting with genital lesions and risk factors for STDs, even in non-classical populations. Early recognition, confirmatory testing, and comprehensive STD screening are essential for appropriate management and to reduce transmission.

EADV CONGRESS
VIENNA
30 SEP - 3 OCT 2026

Abstract N°: 1395

Ocular symptoms as the first manifestation of secondary syphilis with central nervous system involvement – the importance of ophthalmologic–dermatologic collaboration

Mikołaj Cichoń*[1], Barbara Sikorska[2], Katarzyna Czajkowska[3]

[1] Department of Dermatology, Venereology and Allergology, Medical University of Gdansk/University Clinical Centre in Gdansk,, Gdańsk, Poland

[2] Department of Ophthalmology, Kociewskie Health Center in Starogard Gdański, Poland, Starogard Gdański, Poland

[3] Department of Dermatology, Venereology and Allergology, Medical University of Gdansk/University Clinical Centre in Gdansk, Gdańsk, Poland

Introduction

Syphilis is a systemic bacterial disease transmitted through sexual contact, caused by *Treponema pallidum*. One of its less common forms is syphilis with involvement of the central nervous system (CNS). The diagnosis of neurosyphilis is based on clinical symptoms (e.g., ophthalmic findings) and cerebrospinal fluid (CSF) examination results.

Case Presentation

A 29-year-old patient presented to the Emergency Department in Starogard Gdański with progressive visual deterioration over several days. Ophthalmic examination revealed, bilaterally: reduced visual acuity, signs of panuveitis, and optic disc inflammation. The patient was admitted to the Ophthalmology Department for further diagnostics. Examination showed numerous precipitates and synechiae on the corneal endothelium, aqueous flare, inflammatory opacities in the vitreous body, elevation and blurred margins of the optic discs, tortuosity of retinal vessels, intraretinal hemorrhages, and white inflammatory foci. Screening tests were ordered for infectious and non-infectious causes of bilateral uveitis. During diagnostics, due to a positive USR test and after initial dermatologic consultation, serological tests of peripheral blood and CSF were performed to confirm *Treponema pallidum* infection. After obtaining positive VDRL (1:128) and TPHA (1:10240) results in the blood, the patient was transferred to the Department of Dermatology, Venereology and Allergology at the University Clinical Center in Gdańsk for further treatment. Examination revealed disseminated macular and papular lesions located on the skin of the trunk, limbs, and soles, without pruritus or other complaints—typical of a rash in the course of secondary syphilis. CSF results: pleocytosis 65/µl, protein concentration 68.1 mg/dl, TPHA (+) 1:5120, VDRL (−). Tests for HIV, HBV, and HCV infections were negative. Secondary syphilis and neurosyphilis were diagnosed. Treatment included intravenous crystalline penicillin at a dose of 24 million units per day in divided doses every 4 hours for 14 days, followed by a single intramuscular dose of benzathine penicillin 2.4 million units on the day after completion of intravenous therapy. The patient remains under the care of a venereology outpatient clinic, with follow-up CSF examination planned 6 months after completion of treatment.

Conclusion

Neurosyphilis may occur at any stage of *Treponema pallidum* infection. Bilateral uveitis with an atypical ophthalmic presentation and no identifiable ophthalmic cause requires exclusion of syphilis.

EADV CONGRESS
VIENNA
30 SEP - 3 OCT 2026

Abstract N°: 1496

Immune Status and Apoptotic Signaling in Giant Condyloma Acuminata: A Cross-Sectional Study in HIV-Infected Patients

Endra Yustin Ellistasari*[1], pratiwi primisawitri[1], Prasetyadi Mawardi[1], Suci Widhiati[1], cahyono hadi[1], Khoirunnisa Khoirunnisa[1], hastika oktaningrum[1]

[1] Rsud Moewardi, Faculty of Medicine Sebelas Maret University, -, Surakarta, Indonesia

Introduction

Giant condyloma acuminata (GCA) represents an aggressive manifestation of human papillomavirus (HPV) infection, marked by high recurrence and a potential for malignant transformation, particularly in individuals with human immunodeficiency virus (HIV). HPV-driven oncogenesis involves disruption of apoptotic pathways, including caspase-3 activation, while CD4 T-cell count reflects host immune competence. However, the relationship between immunosuppression and apoptotic activity in GCA remains inadequately defined. This study aimed to investigate the association between CD4 T-cell counts and caspase-3 expression in HIV-infected patients with GCA.

Materials and Methods

A cross-sectional study was conducted in 18 HIV-infected patients with clinically and histopathologically confirmed GCA. Caspase-3 expression was evaluated using immunohistochemistry and categorized as negative, weak, or moderate according to the Allred scoring system. CD4 T-cell counts were retrieved from medical records and stratified into <200 and ≥200 cells/μL. Statistical analysis was performed using Fisher's Exact test, with $p<0.05$ considered statistically significant.

Results

Patients with CD4 counts <200 cells/μL more frequently demonstrated weak caspase-3 expression, whereas those with CD4 counts ≥200 cells/μL predominantly exhibited negative expression. Statistical analysis revealed a borderline association between CD4 T-cell counts and caspase-3 expression ($p=0.05$), indicating a tendency toward higher caspase-3 expression in patients with more severe immunosuppression.

Conclusions

A borderline association was observed between CD4 T-cell counts and caspase-3 expression in GCA, suggesting that the degree of immunosuppression may influence apoptotic signaling. This finding points toward a potential interaction between host immune status and HPV-related cellular responses, although confirmation in larger, adequately powered studies is required.

EADV CONGRESS
VIENNA
30 SEP - 3 OCT 2026

Abstract N°: 1579

Delayed Mpox Vaccination and Increased STI Burden Identify High-Risk PrEP Users with Incident Mpox Infection: A Longitudinal Cohort Study

Jan Luca Liebberger[1], Verena Schlätker[1], Sandeep Nambiar[1], Isabel Mordhorst[1], Tilman Erler[1], Adriane Skaletz-Rorowski[1], Anja Potthoff*[1]

[1] WIR – Walk In Ruhr, Center for Sexual Health and Medicine, Interdisciplinary Immunological Outpatient Clinic, Department of Dermatology, Venereology and Allergology, Ruhr-University Bochum, Bochum, Germany

Introduction

Following the global Mpox outbreak in 2022, men who have sex with men (MSM), particularly those using PrEP, were disproportionately affected. This study compares PrEP users with and without incident Mpox infection regarding STI burden and vaccination patterns.

Materials and Methods

A longitudinal cohort of 1,042 PrEP users (August 2017–March 2026) was analysed. After exclusion of prior or unclear Mpox cases, 1,017 Mpox-negative and 20 Mpox-positive individuals were included. Clinical data were assessed at six-month intervals. STI diagnoses and Mpox vaccination status were compared.

Results

Median age at PrEP initiation was comparable (33 vs. 34 years), with similar MSM proportions (95.2% vs. 100%). Incident Mpox infection occurred in 20/1,037 participants (~1.9%), with 60% occurring during the 2022 outbreak.

Median time to infection was 3.75 years after PrEP initiation. Mpox-positive individuals showed delayed vaccination uptake, with no vaccinations during the first three years. Completed vaccination rates were lower (20.0% vs. 34.8%), with breakthrough infections in 10%.

Temporal trends demonstrated delayed vaccination uptake in Mpox-positive individuals, resulting in a persistent gap in cumulative vaccination coverage (Figure 1). Mpox-positive patients had a higher STI burden, with 100% vs. 70.3% having ≥1 STI, particularly gonorrhoea (70.0% vs. 40.8%) and chlamydia (80.0% vs. 43.7%).

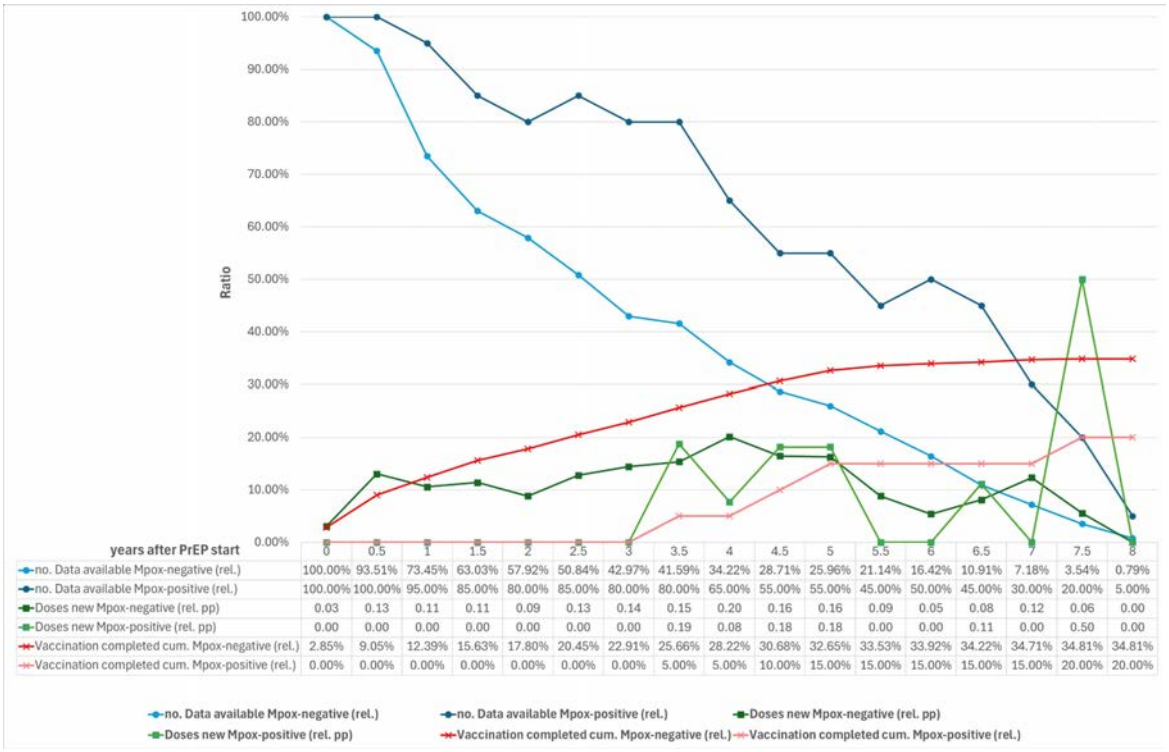

years after PrEP start	0	0.5	1	1.5	2	2.5	3	3.5	4	4.5	5	5.5	6	6.5	7	7.5	8
no. Data available Mpox-negative (rel.)	100.00%	93.51%	73.45%	63.03%	57.92%	50.84%	42.97%	41.59%	34.22%	28.71%	25.96%	21.14%	16.42%	10.91%	7.18%	3.54%	0.79%
no. Data available Mpox-positive (rel.)	100.00%	100.00%	95.00%	85.00%	80.00%	85.00%	80.00%	80.00%	65.00%	55.00%	55.00%	45.00%	50.00%	45.00%	30.00%	20.00%	5.00%
Doses new Mpox-negative (rel. pp)	0.03	0.13	0.11	0.11	0.09	0.13	0.14	0.15	0.20	0.16	0.16	0.09	0.05	0.08	0.12	0.06	0.00
Doses new Mpox-positive (rel. pp)	0.00	0.00	0.00	0.00	0.00	0.00	0.00	0.19	0.08	0.18	0.18	0.00	0.00	0.11	0.00	0.50	0.00
Vaccination completed cum. Mpox-negative (rel.)	2.85%	9.05%	12.39%	15.63%	17.80%	20.45%	22.91%	25.66%	28.22%	30.68%	32.65%	33.53%	33.92%	34.22%	34.71%	34.81%	34.81%
Vaccination completed cum. Mpox-positive (rel.)	0.00%	0.00%	0.00%	0.00%	0.00%	0.00%	0.00%	5.00%	5.00%	10.00%	15.00%	15.00%	15.00%	15.00%	15.00%	20.00%	20.00%

Figure 1. Temporal trends of data availability (blue), newly administered Mpox vaccine doses per person per half-year (green), and cumulative proportion of fully vaccinated individuals (red) in Mpox-positive and Mpox-negative PrEP users over time since PrEP initiation. Some individuals received Mpox vaccination after prior infection, which may limit the comparability of the newly administered Mpox vaccine doses and cumulative vaccination proportions shown.

Conclusions

PrEP users with incident Mpox infection exhibited higher STI burden and delayed vaccination uptake, identifying a clinically relevant high-risk subgroup. These findings support targeted vaccination and intensified STI screening despite declining Mpox incidence.

EADV CONGRESS
VIENNA
30 SEP - 3 OCT 2026

Abstract N°: 1745

What is the impact of online postal self-sampling (OPSS) on sexually transmitted infection (STI) testing service delivery in England.

Lucy Timney*[1], Ben Kasstan-Dabush[1]

[1] University of Edinburgh, Edinburgh, United Kingdom

Introduction

Over a million acquired sexually transmitted infections (STIs) are reported by the World Health Organisation everyday worldwide, and 364,750 new STI cases were reported in England in 2024. Untreated STIs can cause serious long-term morbidity and even death, highlighting the importance of effective STI testing to enable prompt diagnosis, treatment and limitation of disease spread, with implications being highly relevant at global level. Use of online postal self-sampling (OPSS) as an alternative to clinic-based STI testing was first introduced in England in 2006, and has rapidly expanded in recent years, particularly accelerating with the COVID-19 pandemic as an alternative to in-person clinic STI testing. However, evaluation of its impact on service delivery for prompt diagnosis is limited. The aim of this study was therefore to investigate the impact of OPSS on STI testing service delivery in England.

Materials and Methods

A comprehensive structured literature search, using Boolean logic, was conducted in three academic databases (PubMed, Scopus and Web of Science) covering the time-period of 2015-2025. This identified 877 articles and, after removal of duplicates and screening based on defined inclusion and exclusion criteria, and application of a 'snowballing technique', 23 eligible articles remained for detailed analysis. Reflexive thematic analysis of these articles was undertaken, with NVivo 15 used to assist the thematic coding process, in order to identify the effects of OPSS on key areas of STI testing service delivery in England.

Results

The key areas of STI service delivery identified, which related to the impact of OPSS were: characteristics of users; accessibility; patient and clinical outcomes and service efficiency. The analysis identified that OPSS increased STI testing uptake overall, with positive aspects of privacy, reduced stigma and convenience reported. It was evident that white, asymptomatic females from less deprived areas were most likely to use OPSS STI testing, and men who have sex with men, transgender, non-binary and black people and both the very young and the older populations were less likely to use OPSS, highlighting inequity in uptake and use. Thus, social patterning of OPSS STI testing usage was observed, which was particularly relevant to those who may be at increased risk for STIs. Positivity rates of OPSS STI testing were low, consistent with users mainly being asymptomatic. However, outcomes relating to uptake of, and time to treatment were lacking. Sampling errors were low for swab samples, but home blood testing was more prone to error, indicating a need for improved methodology and advice on self-sampling. The importance of safeguarding and the fear of disclosure were raised as concerns, with emphasis on the need for integration of OPSS STI testing within broader sexual health services (SHS). Notably, subsequent clinic attendance rates of OPSS users were low, indicating that OPSS STI testing services were suiting most users' needs.

Conclusions

OPSS has had a significant impact on STI testing service delivery in England, with strengths and limitations identified and with the provision of opportunities to streamline services and increase choice for individuals. This review has highlighted substantial gaps in the current evidence-base, with the need for further research to fully understand the impact of OPSS on STI testing service delivery. Policy and service design adaptations are required to ensure that OPSS STI testing enables equitable and holistic care, with increased targeting of specific populations and integration with in-person clinics and wider SHS. The findings of this study may provide important information to facilitate optimisation of STI testing and to inform future studies of STI service delivery globally.

EADV CONGRESS
VIENNA
30 SEP - 3 OCT 2026

Abstract N°: 1774

Secondary Syphilis: A Case Series

Dolla Logunova*[1], Nadia Giner Cerdá[1], Malena Finello[1], Daniel Blaya Imbernón[1], Ángel González García[1], Elena Pérez Zafrilla[1], Alba Nácher Albiach[1], Laura Giménez Cuenca[1], Jorge Magdaleno Tapial[1], Esther Díez Recio[1], Pablo Hernández Bel[2]

[1] CHGUV, Valencia, Spain

[2] University of Valencia, Valencia, Spain

Introduction

Secondary syphilis is one of the great clinical imitators in dermatology. Among its atypical manifestations, an annular pattern is an uncommon variant that can resemble a wide range of inflammatory and infectious dermatoses. This study aimed to describe 4 cases with annular secondary syphilis and to review the clinical and histopathologic features reported in the literature.

Case Presentation

Materials and Methods: We performed a retrospective descriptive study of four patients diagnosed with secondary syphilis presenting with annular lesions at our institution. Clinical, serologic, histopathologic, immunohistochemical, treatment, and outcome data were collected. In addition, a narrative review of the literature was conducted through a PubMed search for published cases of annular secondary syphilis.

Results: Three patients with annular secondary syphilis were identified, all of whom were living with HIV. Clinically, lesions appeared as annular plaques with central clearing and an erythematous border; genital involvement was present in 2 cases. One patient experienced 2 separate episodes of secondary syphilis, both showing a similar annular morphology. Histopathologic examination revealed perivascular lymphoplasmacytic infiltrates, often with periadnexal involvement and, in some cases, interface change. In the narrative review, the genital and facial regions were the most commonly reported sites, while the most frequent histopathologic findings included plasma cell–rich infiltrates, perivascular distribution, and periadnexal or perifollicular involvement.

Conclusion

Annular secondary syphilis is an uncommon but clinically important presentation because of its broad differential diagnosis. Our series, together with the literature review, suggests the presence of recurring clinical and histopathologic features, particularly annular morphology, a superficial lymphoplasmacytic infiltrate, and frequent perivascular and periadnexal involvement. Early recognition may help prevent diagnostic delay and inappropriate treatment.

EADV CONGRESS
VIENNA
30 SEP - 3 OCT 2026

Abstract N°: 1961

Insights into the Evolving Clinico-Epidemiological Trends of Syphilis : A 10-Year Retrospective Study from North India !

Ashna Jain*[1], Taru Garg[1], Sampurna Dash[1]

[1] Lady Hardinge Medical College, New Delhi, India, New Delhi, India

Introduction

Syphilis, a sexually transmitted infection caused by *Treponema pallidum,* remains a significant public health concern owing to its diverse clinical manifestations and rising incidence in recent years. Changing sexual practices, increased high-risk behaviour, and epidemiological overlap with human immunodeficiency virus (HIV) infection have contributed to this re-emergence. This study analyzed the clinico-epidemiological profile and temporal trends of syphilis in a tertiary care centre in North India.

Materials and Methods

Records of 600 patients diagnosed with syphilis who attended the Suraksha Clinic at a tertiary care centre in North India between March 2015 and March 2025 were analysed.

Results

An increasing trend in syphilis cases was observed over the study period. The male to female ratio was 1.35:1, with a mean age of 29.2 ± 7.93 years. High risk behaviour was reported in 79.3% of patients, with unprotected intercourse being the most common risk factor (75%). Majority of patients presented in the latent stage (65%), followed by primary (21.3%), and secondary (13%) stages of syphilis. HIV co-infection was observed in 10.6% of patients.

Conclusions

The increasing burden of syphilis is concerning and necessitates strengthening of screening programmes, promotion of safer sexual practices, and early identification of co-infections to control disease transmission.

EADV CONGRESS
VIENNA
30 SEP - 3 OCT 2026

Abstract N°: 1999

Rapid emergence of mpox clade Ib in Spain: epidemiological, clinical, and virological comparison with clade IIb in a multicentre cohort

José Riera Monroig*[1], Alba Catala[1], Laura Fuertes[2], Maider Arando[3], Patricia Álvarez[3], Elena Sendagorta Cudós[4], Adrián Alfonso[4], Susana Muñoz[5], Sofía Pérez del Pulgar[6], Irene Fuertes[1], José Luis Blanco[7]

[1] Sexual Health Program, Dermatology Department, Hospital Clínic de Barcelona, Barcelona, Spain
[2] Dermatology Department, Fundación Jiménez Díaz, Madrid, Spain
[3] Infectious Diseases Department, Hospital Vall D'Hebrón, Barcelona, Spain
[4] Dermatology Department, Hospital La Paz, Madrid, Spain
[5] STI Unit, Hospital Germans Trias i Pujol, Badalona, Spain
[6] Microbiology Department, Hospital Clínic de Barcelona, Barcelona, Spain
[7] HIV Unit, Infectious Diseases Department, Hospital Clínic de Barcelona, CIBER de Enfermedades Infecciosas (CIBERINFC), Barcelona, Spain

Introduction

Since 2025, mpox clade 1b has emerged in Europe with increasing evidence of sustained community transmission. Comparative data with clade 2b in real-world settings remain limited.

Materials and Methods

We conducted a multicentre observational study across five centres in Spain including consecutive mpox cases diagnosed between October 2025 and March 2026. Cases were stratified by viral clade (1b vs 2b) and compared within the same timeframe. A historical cohort of clade 2b cases from Monkeypox outbreak in Spain was used for external comparison. Severe disease was defined as a composite endpoint including hospitalisation, death, or clinically relevant mucosal or organ complications.

Results

A total of 48 patients were included, of whom 20 (42%) had clade 1b and 28 (58%) clade 2b infection. The median age was 38 years (IQR 33–45), and most patients were male (94%), with transmission predominantly occurring in men who have sex with men. HIV infection was present in 40%, and 50% had received at least one vaccine dose. Systemic symptoms were reported in 77% of cases. Cutaneous involvement was universal, most frequently affecting the genital (63%) and perianal (40%) regions. Mucosal involvement was similar in both clades (30% vs 36%; p=0.7). Severe mpox occurred in 2 (4%) cases, both in clade 1b (2/20 vs 0/28; p=0.08). Compared with the 2022 clade 2b cohort, vaccination was more frequent (46% vs 0%; p<0.001), and systemic symptoms were less common among vaccinated individuals (62% vs 88%; p=0.02).

Conclusions

The rapid emergence and establishment of mpox clade 1b with sustained community transmission in sexual networks represents a relevant epidemiological shift. Although differences in severity appear modest, a trend towards increased severity in clade 1b—particularly among unvaccinated individuals—supports reinforcing epidemiological and genomic surveillance, including monitoring for potential interclade recombination, and prioritising vaccination strategies in populations at risk.

EADV CONGRESS
VIENNA
30 SEP - 3 OCT 2026

Abstract N°: 2107

Epidemiological and clinical trends of syphilis over a decade in a tertiary hospital: the emerging role of Dermatology Emergency Departments

Daniel Blaya Imbernón*[1, 2], Malena Finello[1], Angel Gonzalez[1], Elena Pérez Zafrilla[1], Alba Nácher Albiach[1], Laura Giménez Cuenca[1], Nadia Giner Cerdà[1], Dolla Logunova[1], Andres Grau Echevarría[1], Jorge Magdaleno Tapial[1], esther diez recio[1], Pablo Hernandez Bel[1, 2]

[1] Hospital General Universitario De Valencia, Valencia, Spain

[2] University of Valencia. Medicine Department, Valencia, Spain

Introduction

Syphilis is a systemic sexually transmitted infection with a particularly relevant clinical expression in Dermatology and significant public health implications. This study aims to describe diagnostic trends and the epidemiological and clinical characteristics of patients diagnosed with syphilis at Hospital General Universitario de Valencia over a ten-year period.

Materials and Methods

A retrospective observational study was conducted using a hospital-based database including 3,457 diagnoses of sexually transmitted infections. Cases diagnosed with syphilis between June 2015 and December 2024 were selected. Demographic, epidemiological, clinical, and serological variables were analyzed. Descriptive, temporal, and comparative analyses were performed..

Results

A total of 383 patients with syphilis were included. An increasing trend in diagnoses was observed throughout the study period, with a transient decrease in 2020 followed by a subsequent rise, reaching a peak in 2024 (n=62). Most patients were male (345; 89.61%), with a mean age of 37.6 ± 13.1 years. Early stages were the most frequent, with similar proportions of primary (141 cases; 36.8%) and secondary syphilis (161 cases; 42.0%). The most common presenting complaints were genital ulcers and cutaneous rash; however, a relevant proportion of cases were diagnosed concomitantly with other sexually transmitted infections or through positive serological screening in contacts and asymptomatic individuals. HIV co-infection was identified in 99 patients (25.85%), and 32 were receiving pre-exposure prophylaxis. Regarding healthcare setting, 257 diagnoses (82.6% of available data) were made in the Emergency Department.

Conclusions

Our findings confirm an increase in syphilis cases in recent years and highlight dermatology emergency services as a key setting for diagnosis, particularly in early stages. Detection through serological screening and in the context of other sexually transmitted infections reinforces the role of dermatologists in early identification and comprehensive management of the disease.

EADV CONGRESS
VIENNA
30 SEP - 3 OCT 2026

Abstract N°: 2271

Ectopic pigmented condyloma acuminata mimicking seborrhoeic keratoses: an unusual presentation with early Buschke–Löwenstein tumour evolution

Fatima Zahra Hammoud*[1], Chourouq Mustapha Eid[1], Lina Mouline[1], Ammar Najoua[1], Syrine Hamada[1], Mariame Meziane[1], Nadia Ismaili[1], Laila Benzekri[1]

[1] Department of Dermatology, Mohamed V University of Rabat, Ibn Sina University Hospital, Rabat, Morocco

Introduction

Condyloma acuminata are common manifestations of human papillomavirus (HPV) infection. Pigmented seborrhoeic keratosis-like variants represent an uncommon and potentially misleading clinical presentation, particularly in ectopic locations. Buschke–Löwenstein tumour (BLT) is a rare locally aggressive form of giant condyloma acuminatum associated with destructive growth and malignant potential. We report an unusual case of ectopic abdominal and genital pigmented condyloma acuminata mimicking seborrhoeic keratoses with features suggestive of early BLT transformation.

Case Presentation

A 53-year-old man presented to our dermatology department for evaluation of multiple presumed seborrhoeic keratoses. Dermatological examination revealed numerous hyperpigmented verrucous papules and plaques involving the lower abdomen, suprapubic area, pubis, and penile shaft. Several lesions displayed a sharply demarcated “stuck-on” appearance closely resembling seborrhoeic keratoses. Closer examination additionally identified confluent papillomatous and cauliflower-like vegetating masses affecting the genital region, raising suspicion for extensive condyloma acuminata with early Buschke–Löwenstein tumour transformation.

The lesions had progressively enlarged over several years and remained asymptomatic. The patient had never previously sought medical attention because of embarrassment and progressive habituation to the lesions. The ectopic abdominal distribution and seborrhoeic keratosis-like morphology represented a significant diagnostic pitfall.

A complete sexually transmitted infection (human immunodeficiency virus, syphilis, hepatitis B and hepatitis C) screening was performed, and proved negative. Differential diagnoses included pigmented seborrhoeic keratoses, bowenoid papulosis, verrucous carcinoma and giant condyloma acuminatum. Histopathological examination and HPV genotyping were planned to confirm HPV-related condyloma acuminatum and exclude invasive squamous neoplasia. Given the extent of the lesions and concern for incipient Buschke–Löwenstein tumour, multidisciplinary management involving dermatology and urology teams was initiated.

Conclusion

This case highlights an unusual presentation of pigmented condyloma acuminata mimicking seborrhoeic keratoses and emphasizes the importance of complete genital examination, even in patients consulting for apparently benign lesions. Seborrhoeic keratosis-like genital lesions should prompt consideration of HPV-related disease, particularly when lesions are multiple, progressive or associated with papillomatous growth. Early recognition of Buschke–Löwenstein tumour remains crucial to prevent delayed treatment, local destruction and malignant transformation.

EADV Congress 2026, VIENNA
30 SEPTEMBER - 03 OCTOBER 2026
POWERED BY M-ANAGE.COM

EA DV CONGRESS
VIENNA
30 SEP - 3 OCT 2026

Abstract N°: 2286

Clinio-epidemiological and serological study of syphilis

Meghana Phiske*[1], Nikita Samal[1], Riya Maheshwari[1], Shailesh Patil[1], Smriti Venkatesh[1], Het Modi[1], Shylaja Someshwar[1]

[1] MGM Institute of Health Sciences, Navi Mumbai, India

Introduction

Syphilis, a sexually transmitted infection caused by *Treponema pallidum,* had global decline post 1990. The annual number of syphilis cases remained relatively consistent until 2019, and there was a significant decrease in syphilis incidences between 2020 to 2021 owing to the COVID pandemic. However, since 2022, there was sudden rise in the number of patients with syphilis. This recent data from the global literature, especially the last decade, gives an impression of its re-emergence as a major public health problem. There is wide variation in the syphilis prevalence rates in various countries, including India. In 2024, India saw its re-surgence with increase in primary and secondary syphilis. An increasing prevalence has been reported, especially post-2015, in countries including Canada, the United States, England, and Australia. Factors contributing to recent increase include rising latent syphilis due to increased screening, increased healthcare accessibility, post-COVID-19 pandemic, changing sexual behaviours, particularly among MSM, early adolescent sexual exposure, and gaps in sexual health education

Case Presentation

Aims and objectives: Prospective study describe clinicodemographic and serological characteristics of syphilis in a tertiary hospital in India.

Materials and methods: Study included clinically diagnosed syphilis patients enrolled over 6 months. Demographic details, sexual history, clinical examination and investigations were studied.

Results: Total 41 patients were enrolled, mean age was 26.7 years, males (75.6%) outnumbered females (19.5%) and there was one transgender (4.9%). Mean duration of complaints was 73.5% Mean age of first sexual exposure was 17 years. Most common complaint was VDRL positivity (42%), TPHA positivity (20%), asymptomatic dark flat lesions (20%), red raised lesions (9%), no lesions (9%), discharge (5%) and painless raw areas (5%). Glans penis (20%) was commonest site involved. 75% had no active lesions. 20% had extragenital involvement. Hyperpigmented macules/patches, erythematous papules and ulcer were seen in 14.5%, 9.5% and 9.5% respectively. Protected sexual activity was seen in 38%. Exposure was penovaginal in (62%) and penoanal in (38%). 42% had multiple sexual partners .85% had exposure to unknown partners. 10% had syphilis in past. VDRL positivity was 100%, titres 1:8 to 1:10240. Most common diagnosis was secondary syphilis (47%), latent syphilis (41.5%), secondary syphilis plus genital warts (9.8 %), secondary syphilis plus herpes genitalis (5%) and secondary syphilis plus gonorrhoea (5%). HIV reactivity was seen in 28%. 20% HIV postive patients had negative CSF-VDRL.

Conclusion

There is resurgence of syphilis, with majority being latent syphilis, caused by multiple factors. Hence more population-based multicentre studies are required especially from India to confirm the exact rising trends of syphilis, which go a long way in better prevention and management of syphilis.

EADV CONGRESS
VIENNA
30 SEP - 3 OCT 2026

Abstract N°: 2325

Intraurethral Genital Warts: A Rare Presentation of Human Papillomavirus Infection - A Case Series

YUGANSH GAUTAM*[1], Abhilasha Negi[1], Niti Khunger[1]

[1] Vardhman mahavir medical college and safdarjang hospital, New Delhi, India

Introduction

Genital wart, caused by human papillomavirus (HPV), is considered to be the most common sexually transmitted disease. Isolated urethral wart is encountered in 0.5%–5% of men with genital warts. Intraurethral warts, caused by HPV infection, are rare and pose diagnostic and therapeutic challenges due to their location and potential for recurrence. Few cases have been reported in the literature, often manifesting with symptoms such as dysuria, urethral discharge, and discomfort. This case series aims to elucidate the clinical presentation, diagnostic modalities, treatment strategies for patients with intraurethral warts.

Case Presentation

Case synopsis:
Case 1: A 27 year old, bisexual male presented with complaints of dysuria and intermittent urethral discomfort for 3 months. Physical examination revealed urethral erythema and papillomatous growths along the anterior urethra. He was diagnosed with intra-meatal urethral wart and treated with radiofrequency ablation, after ruling out proximal urethral extension through urethroscopy.
Case 2: A 20 year old, sexually promiscuous heterosexual male presented with pink lesions at the tip of his penis of 2 months duration. On pressing apart the urethral meatal lips, multiple small papillary masses were seen emerging from the urethral meatus. He was treated using a combination of radiofrequency ablation and 100% TCA application.
Case 3: A 28 year old, homosexual male with multiple sexual partners presented with a complaint of dysuria and observed growth inside the urethra for the past 4 weeks. Initially, he noticed discomfort during urination, accompanied by occasional urethral discharge. Over time, he became aware of a small, painless growth within the urethra that gradually increased in size. Upon examination, a cauliflower-like growth was visualized at the distal urethra, extending proximally. The growth was approximately 1 cm in diameter and was associated with mild erythema of the surrounding mucosa. He was treated using radio-frequency ablation.

Conclusion

Intraurethral warts are a rare manifestation of HPV infection, often challenging clinicians due to their location and associated symptoms. Diagnosis requires a high index of suspicion and may necessitate urethroscopy for visualization. Treatment modalities vary and should be tailored to individual patient factors and lesion characteristics to optimize outcomes. Long-term follow-up is crucial due to the potential for recurrence and the risk of HPV-associated complications.

POWERED BY M-ANAGE.COM

EA DV CONGRESS
VIENNA
30 SEP - 3 OCT 2026

Abstract N°: 2363

The Inguinal Masquerade: Mpox Presenting as a Pseudotumor Before Cutaneous Involvement

Gerardo Uriel Viquez Burboa*[1], Gabriel Esteban Arellano Flores[1]

[1] Instituto Mexicano del Seguro Social, Mexico City, Mexico

Introduction

During the 2022 multicountry mpox outbreak, genitourinary manifestations emerged as underrecognized presentations capable of preceding classic cutaneous involvement by days to weeks. Inguinal lymphadenopathy and orchioepididymitis may coalesce into a pseudotumor that closely mimics inguinal hernia, lymphogranuloma venereum, or—as in our case—molluscum contagiosum, triggering unnecessary hospitalization, antibiotic exposure, and invasive workup. We report a case of mpox-associated inguinal pseudotumor presenting a full week before the appearance of pathognomonic skin lesions, underscoring a critical diagnostic window in which dermatological awareness can prevent harm. To date, fewer than 15 cases of mpox-associated orchioepididymitis have been reported in the literature, and inguinal pseudotumor formation as the sole initial manifestation—in the complete absence of cutaneous lesions—remains exceedingly rare, with no prior cases documented in the context of emergency department misdiagnosis and inpatient admission.



Figure 1. Mpox lesion in the inguinal-genital region demonstrating advanced ulcero-necrotic stage with confluent hemorrhagic crusting, seropurulent exudate, and surrounding satellite pustules at varying stages of evolution. This distribution pattern, involving the genital and inguinal skin, is consistent with the site of primary inoculation and correlates directly with the ipsilateral orchioepididymitis and inguinal pseudotumor identified on scrotal ultrasound. The coexistence of lesions at multiple evolutionary stages — early pustules and advanced ulceration — within the same anatomical region illustrates the rapid local progression characteristic of mpox in immunocompetent MSM.

Case Presentation

A 43-year-old man who has sex with men (MSM), with no relevant medical history, presented to the emergency department with a one-week history of painful left inguinal swelling, scrotal edema, and constitutional malaise.

Molluscum contagiosum was initially suspected, prompting a two-day hospital admission. Inguinal hernia and lymphogranuloma venereum were also considered; empirical ceftriaxone was initiated. No cutaneous lesions were present at admission. Seven days after inguinal onset, a disseminated pustular eruption with erythematous halos developed across both upper limbs, the anterior and posterior trunk, and the pubic region. Mpox was confirmed by polymerase chain reaction (PCR) from a cutaneous lesion; biopsy was deferred given the clinically characteristic morphology in conjunction with a positive PCR. Scrotal ultrasound demonstrated orchioepididymitis with multiple inguinal lymphadenopathies forming a confluent pseudotumor**.** Concurrent sexually transmitted infections were excluded: *Chlamydia trachomatis* and HIV testing were negative. Ceftriaxone was discontinued. Management was conservative—analgesics and anti-inflammatory agents—with outpatient follow-up over eight months. Complete resolution of the pseudotumor was documented at month seven.



Figure 2. Characteristic cutaneous lesions of mpox on the dorsum of the hand, appearing seven days after the initial inguinal presentation. Multiple discrete pustules with central umbilication, white-gray purulent exudate, and surrounding erythematous halo are observed — morphological features

consistent with mpox infection and instrumental in raising clinical suspicion in the context of a positive PCR result. No biopsy was performed given the clinically diagnostic appearance.

Conclusion

This case establishes that mpox-associated orchioepididymitis and inguinal pseudotumor formation can be the sole presenting manifestation of infection, antedating cutaneous lesions by up to one week—precisely the interval during which misdiagnosis is most consequential. Molluscum contagiosum, lymphogranuloma venereum, and inguinal hernia represent the principal diagnostic pitfalls. In MSM presenting with painful inguinal mass, scrotal involvement, and constitutional symptoms, mpox must be elevated in the differential diagnosis regardless of the absence of skin lesions. PCR from any available lesion is sufficient; biopsy is not required. Clinicians should defer invasive procedures and broad-spectrum antibiotics pending virological confirmation, as conservative management yields complete resolution. We propose a pragmatic clinical algorithm: in any MSM presenting with painful inguinal mass and systemic constitutional symptoms, mpox PCR should be obtained at first contact, antibiotic therapy withheld pending results, and invasive procedures deferred. This sequence—**suspect, test, withhold**—could have prevented both the hospital admission and the antibiotic exposure in our patient.

EA DV CONGRESS
VIENNA
30 SEP - 3 OCT 2026

Abstract N°: 2403

Persistent high-risk HPV types cause recurrence of high-grade anal dysplasia: A case report

Louise Itzlinger*[1], Steffi Silling[2], Lukas Watzke[3], Alexander Kreuter[4], David Chromy[1]

[1] Department of Dermatology, Medical University of Vienna, Vienna, Austria

[2] Institute of Virology, National Reference Center for Papilloma- and Polyomaviruses, University Hospital Cologne and University of Cologne, Cologne, Germany

[3] Department of Pathology, Medical University of Vienna, Vienna, Austria

[4] Department of Dermatology, Venereology and Allergology, Helios St. Elisabeth Hospital Oberhausen, University of Witten/Herdecke, Oberhausen, Germany

Introduction

If left untreated, high-risk human papillomavirus (HR-HPV)-related high-grade anal dysplasia may progress to anal cancer. Thus, international guidelines recommend screening for high-risk populations. Key risk factors for anal (pre-)cancer include iatrogenic immunosuppression, human immunodeficiency virus (HIV) infection, smoking, and prior HPV-associated disease. This case report showcases the challenges associated with diagnosing and treating high-grade anal dysplasia.

In accordance with current guidelines, a patient at high-risk for anal cancer was subjected to screening with digital-anorectal exam, anal cytology and HR-HPV typing, and consecutively followed-up with high resolution anoscopy (HRA). Biopsies for histopathology were obtained as necessary.

Case Presentation

The patient is a 58-year-old man diagnosed with late-stage HIV infection two years before ($CD4^+$-T-lymphocyte nadir 39cells/mcL). He is now stable on antiretroviral therapy. Anal swab testing revealed active anal infection with HR-HPV types 16 and 59.

During the initial HRA, an acetowhite lesion with strong punctations as vascular pattern was found in the anterior quadrant. Two biopsies were obtained and confirmed high-grade anal dysplasia (anal intraepithelial neoplasia °III). Office-based electrocautery ablation was deployed twice within 4 months to treat the lesion. On follow-up, three months later, the lesion had cleared almost entirely; 85%-trichloroacetic acid was used to treat the remaining disease. However, at the next follow-up three months later, the lesion had reoccurred, and histology confirmed high-grade dysplasia relapse. This prompted a third electrocautery treatment. As of latest follow-up, there was no evidence of HPV-related lesions found during HRA, yet swab testing remained positive for HPV-16 and HPV-59 across all assessments.

Within a year, this patient at highest risk for anal cancer had a total of seven HRAs with therapeutic intervention applied in four sessions.

Conclusion

In accordance with recent evidence, guidelines now recommend screening for anal cancer precursor lesions in high-risk populations like people living with HIV or people on immunosuppressive therapy. While treatment of such lesions significantly reduces the incidence of anal cancers, diagnostic procedures and consecutive treatments are resource intensive as they require high-resolution anoscopy. Since the main culprit of the disease, in this case

HPV-16 and HPV-59, cannot be cleared due to an insufficient immunoresponse, ‘disease control’ is potentially a more realistic management goal to pursue than ‘cure of disease’. Ultimately, better understanding of the biology of anal HPV-related lesions is required to identify high-grade dysplasia at risk for progression towards cancer.

EADV CONGRESS
VIENNA
30 SEP - 3 OCT 2026

Abstract N°: 2416

The Great Imitator revisited: Malignant Syphilis in an immunocompromised host

Xenevra Adriana Vence-Nogueira*[1], Caridad Elena Morales Munera[1]

[1] Dermatology Department, Hospital de Sant Pau, Barcelona, Spain

Introduction

Malignant syphilis (MS) is a rare and severe variant of secondary syphilis caused by *Treponema pallidum*, classically associated with advanced immunosuppression, particularly in patients with HIV infection. Its incidence has increased in parallel with the global resurgence of syphilis, making recognition of its atypical clinical manifestations increasingly relevant. We aimed to analyze the differential diagnosis of nodulo-necrotic dermatoses in patients with HIV and to highlight the clinical and laboratory findings that support the diagnosis of MS over other opportunistic, inflammatory, or neoplastic conditions.

Case Presentation

A 32-year-old man with HIV infection and recent interruption of antiretroviral therapy presented with a 3-week history of fever, myalgias, and the progressive development of more than 50 cutaneous lesions. His viral load at presentation was 47,428 copies/mL. Physical examination revealed multiple erythematous-violaceous papules and nodules, approximately 1 cm in diameter, infiltrated, and showing central necrosis with crust formation. The lesions were distributed over the face, trunk, and extremities. In the context of immunosuppression and this characteristic morphology, a broad differential diagnosis was considered, including malignant syphilis, bacillary angiomatosis, lymphomatoid papulosis, pityriasis lichenoides et varioliformis acuta, cryptococcosis, atypical mycobacterial infection, leishmaniasis, and Kaposi sarcoma and Monkey Pox.

Laboratory testing revealed a negative monkeypox PCR result and a rapid plasma reagin titer of 1:1024, markedly increased from a previous titer of 1:2, strongly supporting the diagnosis of active syphilis. The patient was treated with intramuscular benzathine penicillin G, 2.4 million units, with rapid clinical improvement and marked flattening of the lesions. A skin biopsy performed 15 days after treatment initiation, due to persistence of residual nodules, showed chronic perivascular lymphoplasmacytic dermatitis with elastophagocytosis. Warthin–Starry staining, *T. pallidum* immunohistochemistry, and polymerase chain reaction were negative, findings interpreted in the context of post-antibiotic bacterial clearance.

Conclusion

Malignant syphilis typically presents with disseminated papules that evolve into ulceronecrotic or hyperkeratotic nodules, predominantly affecting the face, scalp, trunk, and extremities, whereas palmoplantar involvement is less frequent. Constitutional symptoms commonly precede the cutaneous eruption. Although histopathological findings may be nonspecific, particularly after treatment initiation, the combination of compatible clinical features, markedly elevated non-treponemal titers, and prompt therapeutic response to penicillin remains highly suggestive of the diagnosis.

In conclusion, malignant syphilis should be considered a leading diagnostic possibility in patients with HIV presenting with nodulo-necrotic lesions and systemic symptoms. Early recognition is essential given its current resurgence and its broad clinical overlap with infectious, inflammatory, and neoplastic dermatoses commonly encountered in immunocompromised hosts.

EADV Congress 2026, VIENNA
30 SEPTEMBER - 03 OCTOBER 2026
POWERED BY M-ANAGE.COM

EADV CONGRESS
VIENNA
30 SEP - 3 OCT 2026

Abstract N°: 2442

Changing trends in syphilis across the COVID-19 era: a 6-year clinicoepidemiological and laboratory analysis

Divya Madonna Dsouza*[1], Martis Jacintha[1]

[1] Father Muller Medical College Hospital, Mangalore, India

Introduction
Syphilis is a re-emerging sexually transmitted infection, with changing trends observed in the post-COVID-19 era. This study aimed to evaluate the clinicoepidemiological characteristics and laboratory profile of syphilis across pre-, intra-, and post-pandemic periods.

Materials and Methods
A retrospective analysis was conducted over 6 years (January 2018 to May 2024). Demographic and clinical data, hematological parameters, Venereal Disease Research Laboratory (VDRL) titres, and Treponema pallidum hemagglutination assay (TPHA) results before and after treatment were retrieved from records. Neutrophil-to-lymphocyte ratio (NLR) was calculated as a marker of systemic inflammation.

Results
A total of 106 patients were included (80 males, 26 females). Eleven patients reported homosexual orientation and seven were bisexual. Latent syphilis was the most common presentation (78 cases), followed by secondary (22), primary (3), tertiary (2), and congenital syphilis (1). Five patients were co-infected with HIV. Treatment with intramuscular benzathine penicillin was administered to 93 patients, while 13 declined therapy. Temporal distribution showed 33 cases (31.13%) before, 25 (23.58%) during, and 48 (45.28%) after the COVID-19 pandemic. Comorbidities were present in 41 patients. Twelve had concurrent sexually transmitted infections, and 31 had coexisting dermatological conditions. High-risk sexual behaviour was reported in 40 patients. Serological outcomes included cure in 33 patients, non-response in 13, serofast state in 8, treatment failure in 1, and recurrence in 7, while 44 patients were lost to follow-up. At baseline, VDRL was non-reactive in 25 patients; titres were <1:8 in 52 and ≥1:8 in 26 patients. TPHA titres were <1:1280 in 53 and ≥1:1280 in 46 patients. NLR was within normal range (1–2) in 44.61% and elevated (2–17) in 55.39%. Adverse pregnancy outcomes were observed in 7 patients, of whom 4 had elevated NLR.

Conclusions
An increasing trend of syphilis was observed in the post-pandemic period. Elevated NLR in a substantial proportion of patients suggests an underlying systemic inflammatory state and may be associated with adverse pregnancy outcomes. Strengthening patient counselling, partner notification, and follow-up strategies is essential to reduce treatment default and improve disease control.

EA DV CONGRESS
VIENNA
30 SEP - 3 OCT 2026

Abstract N°: 2459

The many faces of neurosyphilis: a clinicopathological re-evaluation of historical cases

Victoria Alber*[1, 2], Myriam Lamrayah[2], Justine Falciola[2], Laurence Toutous Trellu[1, 2]

[1] Hôpitaux universitaires de Genève, Genève, Switzerland

[2] Université de Genève, Genève, Switzerland

Introduction

Neurosyphilis (NS) remains a diagnostically challenging condition due to its heterogeneous clinical presentation and overlap with neurological and psychiatric disorders. Long recognized as the "Great Imitator," its natural history is best captured in historical cohorts, which provide a unique opportunity to reassess its multisystem phenotype using contemporary criteria.

This study aims to characterize the clinical spectrum and hospital admission context of NS and compare it with non-NS controls in a matched historical cohort.

Materials and Methods

We conducted a retrospective clinicopathological study starting from a brain biobank and using linked patient-level and stay-level datasets from a psychiatric hospital archive. Patients reports were collected between years 1883 and 1986, and classified as NS (n=74) or controls (n=74) based on historical clinician-reviewed diagnosis. Clinical manifestations were assessed at the patient level, including CNS involvement, neuropsychiatric, neurosensory, cardiovascular, and systemic manifestations, as well as symptoms burden. Admission characteristics were analyzed at the stay level (n=275 stays), including entry reason categories, diagnostic classification (ICD-10, DSM-IV), and length of stay. Comparisons between groups used Fisher's exact test and Mann-Whitney U test.

Results

The cohort (n=148) included 59.5% men and 40.5% women. Mean age at death did not differ significantly between groups (60.2 vs 63.2 years, p=0.206). NS patients displayed a heterogeneous clinical profile. Among NS patients, 85.1% (95% CI: 75.3-91.5%) presented with any CNS involvement, (e.g. personality changes, cognitive decline), 18.9% (11.6-29.3%) neurosensory/cranial nerve involvement, and 12.2% (6.5-21.5%) had cardiovascular syphilis. Secondary syphilis manifestations were present in 29.7% and primary chancres in 16.2%.

Admission patterns differed markedly (p<0.001). Among NS stays, 49.1% were for NS/general paresis (GP) presentations versus 0% in controls. Controls were more frequently admitted for mood disorders (25.2% vs 4.3%), primary psychotic disorders (8.8% vs 0.9%), and substance-related conditions (17.6% vs 7.8%). Using ICD-10 classification, 55.2% of NS admissions were coded as organic mental disorders (F0) versus 10.1% of controls. Median length of stay did not differ significantly between groups (93 vs 88 days, p=0.47), though NS patients had less successive hospitalisations (median 1 vs 2, p=0.034).

Conclusions

Over a century, NS presented as a broad and non-specific clinical syndrome with substantial phenotypic variability.

While the majority of NS cases exhibited neuropsychiatric features (88%), nearly one-fifth showed neurosensory manifestations and over one-quarter had systemic involvement, highlighting the multisystem nature of the disease. In our context, the high proportion of "unspecified" diagnoses at admission (54.3% in NS vs 13.2% in controls) and association with functional psychiatric presentations particularly underscored the diagnostic challenge. Although old and contemporary to a period where syphilis was more active in Europe, this clinicopathological analysis emphasizes the importance of maintaining a high index of clinical suspicion in atypical neuropsychiatric presentations, particularly when organic features coexist with psychiatric symptoms.

EADV CONGRESS
VIENNA
30 SEP - 3 OCT 2026

Abstract N°: 2477

The Relationship Between Human Papilloma Virus Subtype and Persistence of Condylomata Acuminata

Olivia Christy Kaihatu*[1], Mohammad Syahruddin[1], Idrianti Idrus[1], Khairuddin Djawad[1]

[1] Hasanuddin University, Dr. Wahidin Sudirohusodo Central General Hospital, Makassar, Indonesia

Introduction
Condylomata acuminata (CA), or genital warts, is a common sexually transmitted infection caused by Human Papillomavirus (HPV). While most HPV infections resolve spontaneously, CA lesions often persist or recur. High-risk HPV subtypes and co-infection with HIV are recognized contributors to lesion persistence, increasing clinical management challenges and potential malignancy risk. This study aimed to examine the relationship between specific HPV subtypes and the persistence of condylomata acuminata, as well as to identify sociodemographic, sexual behavior, and clinical factors, including HIV status and lesion location, associated with persistent CA.

Materials and Methods
An analytical observational cross-sectional study was conducted at our hospital, involving 85 patients with CA. Data were collected on sociodemographic characteristics, sexual behavior, and clinical conditions, with emphasis on HIV status and lesion location (perianal vs. genital). HPV genotyping was performed using polymerase chain reaction (PCR) to detect high- and low-risk subtypes. Bivariate and multivariable logistic regression analyses were used to assess associations and identify independent predictors of persistent lesions.

Results
Among 85 patients, 16 (18.8%) had persistent CA, while 69 (81.2%) had non-persistent lesions. HIV-positive status ($p=0.012$) and perianal lesion location ($p=0.005$) were significantly associated with persistence. High-risk HPV subtypes, including HPV-26, HPV-58, HPV-59, and HPV-68, were more frequently detected in persistent cases ($p=0.010$), with HPV-68 identified as the strongest independent predictor (OR=18.92; 95% CI 1.76–310.53; $p=0.0203$). Co-infection with both high- and low-risk HPV subtypes was also strongly associated with persistence ($p<0.001$).

Conclusions
Persistence of condylomata acuminata is strongly linked to high-risk HPV subtypes, particularly HPV-68, as well as HIV-positive status and perianal lesion location. These findings support the use of HPV genotyping to identify high-risk and immunocompromised patients, aiding targeted monitoring and treatment strategies. Further research is recommended to explore the role of HPV subtypes in CA persistence, especially in high-risk populations.

EA DV CONGRESS
VIENNA
30 SEP - 3 OCT 2026

Abstract N°: 2481

Exuberant Skin Manifestation and Syphilitic Hepatitis in Patient with Syphilis and HIV Co-Infection

Gabriela Oliveira Campos[1], Ana Laura Lopes da Silva*[1], Raphaela Bastos Sobral[1], Roberto Bueno Filho[1]

[1] Ribeirão Preto Medical School, University of São Paulo, Ribeirão Preto, Brazil

Introduction

Syphilis is known as the "great imitator" due to its remarkable ability to mimic a wide range of dermatoses, including pityriasis rosea, drug eruptions, psoriasis, and vasculitis. Its cutaneous manifestations become even more polymorphic in the context of HIV coinfection, in which immune dysregulation leads to more extensive, atypical, and persistent presentations. The involvement of mucous membranes, palms, and soles makes timely diagnosis both challenging and clinically significant.

Case Presentation

A 45-year-old man with HIV infection on antiretroviral therapy presented with a 3-month history of a progressive generalized eruption. He reported unprotected sexual exposure six months prior. The eruption initially affected the upper limbs and rapidly disseminated. A drug eruption secondary to meloxicam was suspected, and systemic corticosteroids were prescribed without improvement.

Dermatological examination revealed a symmetrical eruption of densely infiltrated erythematous papules involving the entire body, including palms and soles, with characteristic peripheral scaling (Biett's collarette). Oral and genital mucosae were also involved. Mild lymphadenopathy and hepatomegaly were noted.

Laboratory tests showed a decline in immune control, with CD4+ T-cell count decreasing from 460 to 325 cells/mm and HIV viral load increasing from previously undetectable levels (<50) to 950 copies/mL during active syphilis. Inflammatory markers were elevated. Syphilis serology was strongly reactive (VDRL 1:128, FTA-ABS and TPHA positive). Liver enzymes demonstrated a cholestatic pattern (ALP 999 U/L; GGT 277 U/L), suggestive of syphilitic hepatitis. Skin biopsy revealed plasma cell-rich perivascular dermatitis with focal fibrinoid vasculitis.

The patient received intramuscular benzathine penicillin (2.4 million units weekly for 3 weeks), achieving complete clinical resolution of cutaneous lesions, normalization of liver enzymes, suppression of HIV viral load, and recovery of CD4+ T-cell count within 20 weeks.

Conclusion

Secondary syphilis in HIV-positive patients frequently presents with atypical morphologies, including papular, nodular, and lichenoid lesions. In this case, the eruption mimicked a drug reaction, leading to inappropriate corticosteroid use. Biett's collarette is a subtle but valuable clinical sign that should prompt investigation for syphilis.

Coinfection may transiently increase HIV viral load and reduce CD4+ counts, reflecting pathogen interaction and potential impact on disease control. The presence of cholestatic liver abnormalities highlights the importance of recognizing syphilitic hepatitis in this context.

Syphilitic hepatitis should be considered in HIV patients with active syphilis and cholestatic liver abnormalities, typically showing elevated alkaline phosphatase and gamma-glutamyl transferase with relatively preserved transaminases. Diagnosis is mainly clinical and supported by serology and response to treatment. In this case, the marked cholestatic pattern without alternative causes suggested hepatic involvement by *Treponema pallidum*.

Secondary syphilis should be systematically considered in disseminated eruptions in immunocompromised patients, particularly when lesions involve palms, soles, and mucosae or fail to respond to empirical therapy. Recognition of key features such as Biett's collarette and appropriate serological testing are essential to avoid diagnostic and therapeutic errors. Syphilitic hepatitis should also be recognized as a potential systemic manifestation, especially in the presence of unexplained cholestatic liver abnormalities.

EADV CONGRESS
VIENNA
30 SEP - 3 OCT 2026

Abstract N°: 2542

Doxycycline Prophylaxis (Doxy-PEP): Are We Preventing STIs or Creating Resistance? - A 15-Patient Case Series on Real-World Implementation

Farhat Khan*[1]

[1] Bansal hospital, bhopal, India

Introduction

The global dermatological community is witnessing a perfect storm in sexual health. The bacterial sexually transmitted diseases (STI) rates, particularly syphilis and chlamydia, has reached record highs across the world. Doxycycline Post-Exposure Prophylaxis (Doxy-PEP)—200mg of doxycycline taken within 72 hours of unprotected sex, has emerged as a disruptive preventative tool. However, a critical tension exists: while Doxy-PEP offers a powerful shield against infection, it introduces the sword of potential antimicrobial resistance (AMR) and disruption of the skin and gut microbiomes. This study evaluates a small cohort of patients using Doxy-PEP to determine its impact on infection rates and the commensal skin microbiome.

Materials and Methods

A retrospective case series was conducted on 15 male patients (mean age 32) at a specialized dermatology and venereology clinic over a 12 months period. All patients had a history of recurrent bacterial STIs (>2 infections in the previous year) and were prescribed 200mg of doxycycline to be taken within 72 hours of unprotected sexual contact. Patients underwent 3 monthly screenings for STIs and skin swabs of the anterior nares and axilla to monitor for *Staphylococcus aureus* colonization and tetracycline resistance.

Results

The implementation of Doxy-PEP resulted in a significant reduction in clinical infection:

- Efficacy:Total bacterial STI incidence dropped by 73% compared to the previous 12 months. Specifically, no cases of early syphilis were detected in the cohort during the study period.
- Microbiome Trends:Out of the 15 patients, 3 (20%) showed a conversion from tetracycline-sensitive to tetracycline-resistant *aureus* in skin swabs by month nine.
- Atypical Presentations:One patient presented with a decapitated inflammatory response—mild, non-specific urethritis that was initially masked by the prophylactic dose, delaying definitive treatment for three weeks.
- Patient Adherence:12 of 15 patients reported high satisfaction, though 4 noted mild gastrointestinal distress, a trending side effect in real-world usage.

Conclusions

In this 15 patient series, Doxy-PEP proved to be a highly effective "shield" against syphilis and chlamydia. However, the 20% shift in skin flora resistance highlights a looming "double-edged sword" effect. These results suggest that for the 2026 clinical landscape, Doxy-PEP should not be a

"one-size-fits-all" solution. We recommend a "Targeted Prophylaxis" model: prioritizing Doxy-PEP for high-incidence individuals while implementing mandatory 6-monthly microbiome resistance monitoring to ensure we are not trading an STI surge for a localized antibiotic resistance crisis.

EADV CONGRESS
VIENNA
30 SEP - 3 OCT 2026

Abstract N°: 2544

STIs Beyond Genitals: Cutaneous Manifestations Every Dermatologist Must Recognize!

Farhat Khan*[1]

[1] Bansal hospital, Bhopal, India

Introduction

In the 2026 clinical landscape, the Venereology-Dermatology overlap has never been more critical. As bacterial STI rates, specifically syphilis, urge globally, the primary presentation is increasingly shifting away from the genitals to extragenital skin surfaces. Because these lesions often mimic common dermatoses, the dermatologist is the most likely specialist to encounter them first. This study evaluates the diagnostic traps of extragenital STIs and the biological cost of delayed recognition.

Materials and Methods

A 12-month prospective observational study was conducted on 30 patients who presented to a general dermatology clinic with extragenital cutaneous lesions that were subsequently confirmed as STIs through clinical examination & serology . Patients were screened for:

1. Morphological Mimicry: The frequency with which STI lesions resembled non-contagious conditions like Pityriasis Rosea, Psoriasis, or Lichen Planus.
2. The Silent" Sites: Distribution across the oral mucosa, palms, soles, and perianal regions.
3. Diagnostic Delay: The time between initial skin symptom and definitive STI diagnosis.

Results

The data revealed a significant gap between skin presentation and correct diagnosis:

- The Great Imitator: 53% (16/30) of the cohort presented with Secondary Syphilis. Of these, 10 patients (62%) were initially misdiagnosed with Pityriasis Rosea or viral exanthems because the trunk was the primary site of concern.
- The Palmoplantar Key: While 80% of the syphilis patients had lesions on the palms or soles, only 20% of clinicians performed a full-body check including these areas during the initial consultation.
- Oral & Perianal Signals: 30% (9/30) of patients presented with "painless" oral erosions or perianal papules that were initially treated as Aphthous Stomatitis or Condyloma Acuminata without STI screening.
- The Cost of Delay: The average Diagnostic Gap was 21 days. During this period, 40% of the patients unknowingly continued high-risk sexual behaviour, highlighting a major public health failure in early recognition.

Conclusions

Extragenital STIs are the "stealth pathogens" of modern dermatology. In this 30-patient series, the majority of diagnoses were missed at the first point of contact because the lesions did not fit the genital script. It’s important

to understand that we advocate for the High-Suspicion Protocol. Any atypical palmoplantar rash or non-healing mucosal erosion must be considered an STI until proven otherwise.

EA DV CONGRESS
VIENNA
30 SEP - 3 OCT 2026

Abstract N°: 2584

Factors Associated with Delayed Healthcare-Seeking Among Patients with Sexually Transmitted Infections: Beyond Stigma and Shame

Huy Le*[1], Nguyen Vu Hoang[2], Chuyen Thi Hong Nguyen[1]

[1] University of Medicine and Pharmacy at Ho Chi Minh City, Ho Chi Minh, Viet Nam
[2] Ho Chi Minh City Dermatology Hospital, Ho Chi Minh, Viet Nam

Introduction
STIs represent a critical global health burden, with over one million new curable cases daily. Untreated infections cause serious consequences, including infertility and increased HIV susceptibility. Delayed healthcare-seeking in sexually transmitted infections (STIs) contributes to ongoing transmission, delayed diagnosis, and increased risk of complications. While stigma and shame are commonly considered major barriers to care, illness perception and symptom interpretation may also significantly influence healthcare-seeking behavior. This study aimed to determine the prevalence of delayed healthcare-seeking among symptomatic STI patients and to evaluate the associations between illness perception, stigma, shame, clinical characteristics, and delayed presentation.

Materials and Methods
A cross-sectional study was conducted in 150 adults (≥18 years) with clinically confirmed symptomatic STIs. Participants completed structured questionnaires including the Brief Illness Perception Questionnaire (B-IPQ) and the STD-Related Stigma and Shame Scale. Delayed healthcare-seeking was defined as presentation more than 7 days after symptom recognition. Associations between delayed presentation and clinical or psychosocial factors were analyzed using Chi-square/Fisher's exact tests and univariable logistic regression.

Results
Overall, 57.3% of patients delayed seeking healthcare. Delayed presentation varied significantly according to clinical manifestations and disease type. Patients with painless genital lesions showed substantially higher delay rates than those with dysuria (66.1% vs. 9.1%, $p<0.001$). Delayed care was most frequent in genital warts (67.7%) and syphilis (59.4%), but uncommon in gonorrhea (5.9%) ($p<0.001$). Patients who continued sexual activity despite symptoms were significantly more likely to delay care compared with those who abstained (84.0% vs. 52.0%, $p=0.003$). Distance from healthcare facilities was also associated with delayed presentation ($p=0.004$). Among illness perception dimensions, greater perceived ability to self-manage symptoms was independently associated with delayed healthcare-seeking (OR=1.13, 95% CI: 1.01–1.27, $p=0.031$). In contrast, stigma and shame scores were not significantly associated with delay.

Conclusions
Delayed healthcare-seeking was highly prevalent among patients with STIs and appeared to be driven more strongly by symptom interpretation and perceived self-management capacity than by stigma or shame. Painless or less alarming symptoms may contribute to delayed presentation and continued sexual activity during the infectious period, increasing the risk of community transmission. These findings highlight the importance of

targeted educational and behavioral interventions focused on symptom recognition, misconceptions regarding self-treatment, and early clinical evaluation.

EADV CONGRESS
VIENNA
30 SEP - 3 OCT 2026

Abstract N°: 2599

When Serology Fails, the Lens Prevails: Bridging the Window Period in Mixed Genital Ulcer Disease

Keshav Yadav*[1]

[1] Vardhman Mahavir Medical College and Safdarjung Hospital, New Delhi, India

Introduction

Introduction: Primary syphilis, the "Great Imitator," frequently presents a diagnostic conundrum during the "window period." This diagnostic opacity is further compounded in cases of Genital-Ulcer-Disease (GUD) co-infections, where the painful nature of concurrent lesions may mask the classic indolent presentation of a syphilitic chancre.

Case Presentation

Case Description: A 35-year-old heterosexual male presented with a 5-day history of multiple penile ulcers following high-risk exposure 14-days prior. Examination revealed a dual morphology: a large (3x2cm), non-tender, indurated ulcer with a yellowish-white slough extending from the glans to the coronal sulcus, alongside multiple smaller, exquisitely tender, superficial erosions. While Tzanck-smear revealed multinucleated giant cells, initial Dark-ground-microscopy (DGM) and serological markers (VDRL and TPHA) were non-reactive, placing the patient in a critical "serological blind spot."

Dermoscopic evaluation: In the absence of laboratory confirmation, dermoscopy was utilized as an "Optical Bridge." Examination of the indurated ulcer revealed a pathognomonic central white structureless area superimposed on a reddish-orange background, indicative of dense granulomatous infiltrate and hemosiderin deposits. High-magnification visualized polymorphic vessels within the peripheral rim.

Based on clinical-dermoscopic correlation, the patient was treated with a single intramuscular dose of 2.4 MU Benzathine-Penicillin-G and oral Acyclovir. Complete resolution was observed within 14 days, with subsequent seroconversion (VDRL/TPHA-positivity) confirming the diagnosis post-hoc. This case reinforces a vital clinical pearl: "Pain does not rule out syphilis." In high-volume settings, the prominent pain of herpetic erosions can lead to the premature-closure of a diagnosis, causing clinicians to overlook concurrent primary syphilis.

Conclusion

Conclusion: This report highlights the limitations of the "Syndromic Approach" in mixed GUD infections. By providing objective morphological evidence during the serological window period, dermoscopy serves as a critical tool for early intervention, ensuring the immediate break in the chain of transmission for syphilis in high-risk populations.

EA DV CONGRESS
VIENNA
30 SEP - 3 OCT 2026

Abstract N°: 2604

Retrospective study of Mycoplasma genitalium antimicrobial resistance: Analysis with previous clinic data

Irena Dezelak*[1, 2], Nusa Pernat[1], Maja Benko[1], Andreja Murnik Rauh[1]

[1] Department of Dermatovenerology, University Clinical Centre Ljubljana, General hospital Jesenice, Ljubljana, Slovenia

[2] Faculty of Medicine, University of Ljubljana, Ljubljana, Slovenia

Introduction

Mycoplasma genitalium (MG) is an emerging sexually transmitted infection (STI) known to cause nongonococcal urethritis in men and associated with cervicitis and pelvic inflammatory disease in women. European IUSTI guidelines recommend nucleic acid amplification testing (NAAT) for accurate MG diagnosis and suggest an extended azithromycin (AZI) regimen as the primary treatment, with moxifloxacin (MOXI) as second line treatment and minocycline (MINO) as third line treatment. Our clinic's 2018 study revealed significant macrolide resistance and a notable prevalence of MG in asymptomatic patients, particularly women. This prompted the implementation of routine MG testing with resistance detection for all patients attending the clinic. The continuous surge in patient numbers and new instances of MOXI resistance have further encouraged investigations into prevalence changes, treatment efficacy, and evolving resistance patterns, to assess the extent of increases in infection rates and resistance levels.

Materials and Methods

This retrospective study analysed data from symptomatic and asymptomatic patients attending our STD clinic from January 1st, 2022, to September 1st, 2023, comparing it with our previous study conducted from January 1st, 2017, to September 1st, 2018, five years apart. Testing for antibiotic resistance was conducted using a commercial PCR-based assay demonstrating mutations in the 23S rRNA gene associated with macrolide resistance, and a mutation in the parC gene linked to moxifloxacin resistance. Resistance in the previous study was based on empirical observations, determined by unsuccessful treatment outcomes. A total of 5972 clinical samples from 3413 patients were examined, including 1730 samples from 1198 women and 4242 samples from 2215 men. The age range for MG positive women was 19 to 53, with an average of 30.2, and for MG positive men, it was 21 to 68, with an average of 36.3.

Results

131 (3.84%) patients tested positive for *Mycoplasma genitalium* (MG), comprising 23 women and 108 men, with 65 of the men identifying as having sex with men (MSM). Among these, 11 women and 67 men exhibited symptoms. 3 women and 58 men were solely MG positive while 20 MG-positive women and 50 MG-positive men also had co-infections with other sexually transmitted bacteria. Macrolide resistance was confirmed in 7 women and 68 men, with no MOXI resistance in women and 5 instances in men. Treatment outcomes can be seen in Table 2. Two patients with confirmed resistance to both macrolides and MOXI did not respond to MINO and were subsequently placed under observation.

Table 1: Prevalence of MG infection and presence of antibiotic resistance

	MG positive Female (%)	MG positive Male (%)	Symptomatic Female (%)	Symptomatic Male (%)	Macrolides resistance (%)	MOXI resistance (%)
2017/2018	9 (1.45)	25 (2.47)	5 (55.6)	20 (80.0)	10 (29.41)	0 (0.00)
2022/2023	23 (1.92)	108 (4.88)	11 (47.8)	67 (62.0)	75 (57.25)	5 (3.82)
Increase/decrease	+33%	+98%	-14%	-23%	+95%	/
p value	0.493	**0.001**	0.694	0.089	**0.004**	0.584

Table 2: Treatment outcomes

	First line treatment, no. treated (% success)			Average first line success	Second line treatment, no. treated (% success)	
	AZI	**MOXI**	**MINO**		**MOXI**	**MINO**
2017/2018	24 (58)			58%	1 (100)	3 (100)
2022/2023	46 (100)	77 (87)	8 (88)	92%		10 (90)
Increase (p value)				59% (0.00001)		

Table 1: Prevalence of MG infection and presence of antibiotic resistance. Table 2: Treatment outcomes by study period. AZI = azithromycin; MOXI = moxifloxacin; MINO = minocycline. Values expressed as number treated (% success). Bold p values indicate statistical significance.

Conclusions

The prevalence of MG has risen significantly over the five-year period between our 2017-2018 study and our 2022-2023 data, with a noticeable decrease in symptomatic male cases, suggesting a shift towards more asymptomatic infections. The introduction of resistance testing for all samples has significantly improved the success of first-line treatments. Furthermore, there has been a significant increase in macrolide resistance, accompanied by the new emergence of moxifloxacin resistance. These results highlight the importance of testing all patients who visit our clinic for MG, with a focused emphasis on monitoring resistance to address emerging challenges in treatment efficacy.

EA DV CONGRESS
VIENNA
30 SEP - 3 OCT 2026

Abstract N°: 2744

Syphilis mimicking lymphoma: when the great imitator becomes a diagnostic trap

Evdoxia Panou*[1], Vasiliki Nikolaou[1], Antonios Chlinos[1], Antonios Tsimpidakis[1], Leonidas Marinos[2], Electra Nicolaidou[1]

[1] Andreas Syngros Hospital, Athina, Greece
[2] Nosokomeio Evangelismos, Athina, Greece

Introduction

Secondary syphilis is a well-established "great imitator", capable of reproducing a broad spectrum of inflammatory, infectious and neoplastic dermatoses. While its protean clinical presentation is widely recognised, its capacity to closely mimic cutaneous lymphoproliferative disorders remains less well appreciated. Importantly, this mimicry may not be limited to clinical morphology or conventional histopathology, but may also extend to immunophenotypic and molecular findings, including dense lymphoid infiltrates and apparent T-cell clonality. Such overlap can pose a substantial diagnostic challenge, particularly in cases presenting with atypical, infiltrated or treatment-resistant lesions suggestive of cutaneous lymphoma or pseudolymphoma. We report a case of secondary syphilis presenting with clinicopathological and molecular features highly suggestive of a cutaneous lymphoproliferative disorder, underscoring the importance of recognising syphilis as a potential lymphoma mimicker in order to prevent misdiagnosis, unnecessary investigations and inappropriate management.

Case Presentation

A 45-year-old male presented with a chronic, progressive and generalised eruption of several months' duration and was referred to a tertiary cutaneous lymphoma clinic. Clinically, widespread infiltrated erythematous plaques involving a large body surface area raised strong suspicion for a lymphoproliferative disorder. The eruption was persistent, extensive and unresponsive to prior empirical treatments.

Histopathological examination demonstrated a dense, polymorphous dermal lymphoid infiltrate with predominantly perivascular distribution, composed of mixed B- and T-cell populations and a prominent plasmacytic component. Immunohistochemical analysis revealed a predominance of CD3-positive T lymphocytes with CD4>CD8 profile, alongside scattered B cells and numerous plasma cells showing light chain predominance. The overall pattern raised concern for a lymphoproliferative process, including marginal zone or lymphoplasmacytic lymphoma.

In the absence of definitive diagnostic features, additional molecular studies were performed. These demonstrated evidence of lymphoid clonality, further reinforcing the initial impression of an underlying lymphoproliferative disorder.

However, subsequent serological testing revealed markedly elevated syphilis titres, consistent with secondary syphilis. The patient was treated with intramuscular benzathine penicillin G, resulting in rapid and complete resolution of the eruption within two weeks.

Conclusion

This case underscores the capacity of secondary syphilis to act as a convincing mimicker of cutaneous lymphoma,

with overlap extending across clinical morphology, histopathological architecture and molecular findings. In particular, persistent, atypical or treatment-refractory eruptions associated with dense lymphoid infiltrates and apparent clonality may create a compelling impression of a lymphoproliferative disorder. Nevertheless, these findings should be interpreted with caution, as infectious dermatoses such as syphilis may generate pronounced reactive lymphoid responses that closely resemble lymphoma. Syphilis should therefore remain a key differential diagnosis in patients with unexplained or atypical cutaneous eruptions, even when multiple diagnostic modalities appear to support a lymphoproliferative process. Recognition of this diagnostic pitfall is critical to avoid misclassification, unnecessary oncological investigations, and inappropriate management, while enabling prompt and definitive antimicrobial treatment.

EADV CONGRESS
VIENNA
30 SEP - 3 OCT 2026

Abstract N°: 2751

Secondary syphilis in an HIV-positive patient masquerading as toxicoderma: diagnostic challenges in a clinical case

Vasyl Striukov*[1], Tetiana Sviatenko[1], Nataliia Hrechkina[2]

[1] Dnipro State Medical University, Dnipro, Ukraine

[2] Professor Svyatenko's Medical Centre, Dnipro, Ukraine

Introduction

Secondary syphilis is characterised by significant clinical polymorphism and can mimic a wide range of inflammatory skin conditions. In HIV-positive patients, the course of the disease is often atypical, which complicates timely diagnosis. We present a clinical case of secondary syphilis with a toxicoderma-like clinical presentation and an atypical medical history.

Case Presentation

An 18-year-old patient with congenital HIV infection, who was receiving antiretroviral therapy, presented with complaints of a rash and itchy skin, which had been troubling him for 1.5 months. No history of allergies. A detailed medical history, including information from the parents, revealed no data regarding the use of medications, dietary supplements, or narcotic or psychoactive substances. Physical examination revealed no signs associated with possible use of psychoactive substances, nor was any drug-induced reaction detected.

During the initial examination, a grouped erythematous rash with scaling was observed on the skin of the face and upper half of the trunk, clinically resembling toxicoderma. Isolated papules with a Biot's collar were found on the palms, which gave rise to suspicion of a syphilitic process. The mucous membranes and soles were free of rashes. Additional diagnostic difficulties were associated with the patient's denial of sexual activity.

To confirm the diagnosis, a skin punch biopsy and serological screening for syphilis were ordered during the initial consultation. The histological examination revealed changes characteristic of a syphilitic process in combination with a skin mycosis. Serological screening showed a positive result for total IgM, IgG and IgA antibodies to Treponema pallidum – 6.22, with a reference value of >1.1.During a consultation with a venereologist and a more detailed medical history, it was established that the patient had kissed a male partner outside his country of residence. The patient also reported a painless lesion on the gingiva on the lingual surface, which initially resembled an erosion; at the time of examination, it was a firm, elastic, painless induration without an erosive defect. The results of additional serological testing showed a positive RPR titer of 1:1280; IgG to Treponema pallidum was positive; IgM to Treponema pallidum was 0.5 (negative) (reference values: negative < 1, positive > 1). The microprecipitation reaction and RPR test were positive. A diagnosis of secondary syphilis was established. Individuals from the patient's close household contacts were examined; serological results were negative. Prophylactic treatment and further serological monitoring were recommended. A few days after the initial examination, the patient noted hair loss, which within a short time became almost total.

The patient underwent specific treatment in accordance with current clinical guidelines. At the start of therapy, a temporary worsening of skin manifestations and an increase in body temperature were observed, which was interpreted as a Jarisch-Herxheimer reaction (the elevated temperature subsided spontaneously after a few hours). The erythematous rash did not fully resolve by the end of treatment, which is likely due to concomitant skin mycosis and post-inflammatory changes. A follow-up serological examination showed seroconversion of the non-treponemal tests (RPR and MPP), indicating a positive serological response.

Conclusion

This case illustrates the difficulties in diagnosing secondary syphilis in an HIV-positive patient, characterised by a clinical picture of toxicoderma, a limited number of typical syphilitic manifestations, and a misleading medical history. The key clinical sign that led to a suspicion of syphilis during the initial examination was the presence of isolated papules with a Biot’s collar on the palms.This case highlights the need to include syphilis in the differential diagnosis of generalised inflammatory rashes, even in the absence of a typical sexual history and a classic clinical presentation.

EA DV CONGRESS
VIENNA
30 SEP - 3 OCT 2026

Abstract N°: 2827

Co-infection of Mpox, Latent Syphilis and Condyloma acuminata in HIV-positive patient : Diagnostic and Therapeutic Challenge

Jihan Rosita*[1], Hanny Nilasari[2]

[1] Pasar Minggu District Public Hospital, Jakarta, Indonesia

[2] dr Cipto Mangunkusumo Hospital, Jakarta, Indonesia

Introduction

WHO has announced Mpox as Public Health Emergency of International Concern (PHEIC) on August 14th 2024. As well as in Indonesia, Mpox was also an emerging outbreak in 2024. There was an uprising of Mpox cases particularly those in HIV-positive patients. Per August 24th 2024, there were 88 confrmed cases of Mpox in Indonesia, 59 of them were found in Jakarta. 76.3% of the confirmed cases were male who have sex with male (MSM). Studies have documented that 29-76% Mpox patients may have concurrent sexually transmitted infections (STIs). This case was an old case from 2024 which documented multiple STIs in one MSM patient during Mpox outbreak in Jakarta.

Case Presentation

A 28-year-old man with multiple bumps and fluid-filled lesions on his face and genital since one week before admission to the hospital. The number of lesions have increased and spread to the trunk and extremities. He had a fever for 2 days before the lesions first appeared. He also experienced a sore throat, fatigue, body ache and nausea. He went to Primary Health Care for treatment and suspected as Mpox case, then he was referred to the District Public Hospital. He has been diagnosed HIV-positive on ARV treatment for the past year. Patient reported having sexual intercourse 3 days before the symptoms appeared. Sexual contact occurred with a male partner, involving anal-genital and oro-genital without condom. Dermatological examinations revealed multiple erythematous papules, pustules, and crusts on face, trunk, genital and extremities. The lesions prominently located on genital. There were also multiple small hyperpigmented bumps in anal region. Palpable inguinal lymph nodes enlargement was also found. Hematologic laboratory results revealed blood cell counts within normal limits and increased ESR. Syphillis serologic test showed VDRL reactive 1:64 and TPHA reactive 1:1280. Mpox PCR was examined in Public Health District Laboratory. Swab from the crusts lesions on genital showed positive results, and oropharyngeal swab also showed positive results. He was treated with symptomatic agents such as paracetamol, cetirizine, omeprazole and supplementation of vitamin C. Topical treatments consist of normal saline wound dressing and application of topical antibiotic. For the latent syphilis, Benzatine Penicillin 2.4 million Unit was administered intramuscularly for 3 times in total with 1 week period inbetween. The third injection was administered in the outpatient clinic. Treatment for anal condyloma acuminata decided to be suspended until the patient discharged from the hospital. Clinically the patient showed a good response to the treatment. He was hospitalized for 20 days.

Conclusion

In 2023-2024, there was an uprising cases of Mpox globally. Most of confirmed cases found in male adult patients and sexually transmitted. Multiple STIs can be found in Mpox patients particularly the ones in immunosuppresive condition such as HIV-positive patients. Studies show a high overlap Mpox infection and Syphilis case among

MSM and bisexual men. It may be correlated with their sexual behaviour which can facilitate the entry of the Mpox virus, leading to co-infection. Therefore, it is important for Mpox patients to be tested comprehensively for another STIs. Both Mpox and Syphilis can be presented with genital or anal sores, so we need to distinguish between syphilis chancre and Mpox in order to make an accurate diagnosis. In immunosppresive patient, we must be cautious for the possibility of fatal complications of Mpox. In such condition, Mpox treatment must include administration of antiviral agent. Multiple STIs brought a significance challenge in Mpox treatment resulted in longer hospital length of stay. Treatment involves separate, targeted therapy for each disease.

EADV CONGRESS
VIENNA
30 SEP - 3 OCT 2026

Abstract N°: 2873

Evaluation of Epidemiological Trends of Syphilis in Ukraine, 2021–2025

Glib Bondarenko[1], Sergiy Unuchko[1], Iryna Namli*[1], Valentyna Volkoslavska[1], Tetiana Gubenko[1], Valentyna Kutovaya[1], Olga Bilokon[1]

[1] SE "Institute of Dermatology and Venereology of National Academy of Medical Sciences of Ukraine", Kharkiv, Ukraine

Introduction

The incidence of numerous infections, including sexually transmitted infections (STIs) rises rapidly during the wartime due to a strained healthcare system and massive forced displacement of the population. In 2023, 41 051 confirmed cases were reported in 29 EU/EEA countries, representing a 13% increase compared to 2022, and a doubling compared to 2014. The rate of registered syphilis cases in Ukraine steadily declined over the 2010–2020 period: from 16.3 per 100.000 population in 2010 (reaching levels seen in European Union (EU) and Central and Eastern European (CEE) countries by 2019 at 5.9 per 100.000) to 3.8 per 100.000 population in 2020.

Materials and Methods

Data were extracted from the reports of Public Health Center of the Ministry of Health of Ukraine for period 2021–2025.

This database includes case counts for syphilis and congenital syphilis. Syphilis cases were assessed based on biological sex (male and female).

Results

During the period of 2021–2025, the number of newly registered syphilis cases in Ukraine was as follows: 1,540 in 2021; 2,053 in 2023; 2,320 in 2024; and 2,547 in 2025, representing a 29.85% increase between 2022 and 2023.

The proportion of male patients with confirmed syphilis increased from 61.2% (942 individuals) in 2021 to 66.0% (1,682 individuals) in 2025. Conversely, the proportion of female patients decreased from 38.8% (598 women) in 2021 to 34.0% (865 women) in 2025.

Since 2021, a significant rise in all forms of syphilitic infection was registered: early syphilis increased by 29.6% (from 1016 cases in 2021 to 1317 cases in 2025); early latent syphilis by 85.2% (463 cases to 839); late syphilis by 82.4% (182 cases to 332); and unspecified syphilis by 162.7% (341 to 896 cases).

During the 2021–2025 period, the proportion of patients with early syphilis decreased from 65.9% to 51.7%; however, the share of late syphilis cases rose from 11.8% to 13.03%, and other/unspecified forms increased from 22.1% to 35.1%.

Notably, in 2025, late syphilis was more prevalent among men, accounting for 56.0% (186 cases) compared to 39.0% (71 cases) in 2021.

In 2025, 123 women had confirmed syphilis detected during pregnancy screening, and two cases of congenital syphilis were reported.

Conclusions

Recent epidemiological trends highlight a shifting and increasingly concerning burden of syphilis in Ukraine. Syphilis displayed a dramatic change, with a 65.4% increase over the period of 2021–2025 and a 29.85% rise between 2022 and 2023 alone. In 2025, syphilis cases were consistently higher among males, with the most significant sex-based disparity seen in early syphilis cases (69.8% among males and 30.2% among females).

Our data highlight persistent challenges in national syphilis response due to the ongoing war in Ukraine. Integrating dual HIV/syphilis rapid tests into national policy for both pregnant women and key populations could be a successful approach in the prevention of syphilis.

EA DV CONGRESS
VIENNA
30 SEP - 3 OCT 2026

Abstract N°: 2874

Secondary Syphilis Mimicking Rapidly Progressive Psoriasiform Exacerbation in Psoriasis Vulgaris

Jonas Rüth*[1], Nikolaos Stavropoulos[1], Isabel Mordhorst[1, 2, 3], Anja Potthoff[1, 2, 3], Vasileios Dervenis[1]

[1] Department of Dermatology, Venereology and Allergology, St. Josef Hospital, Ruhr University Bochum,, Bochum, Germany

[2] WIR-Walk In Ruhr - Center for Sexual Health and Medicine,, Bochum, Germany

[3] Interdisciplinary Immunological Outpatient Clinic, Center for Sexual Health and Medicine, Department of Dermatology, Venereology and Allergology, Ruhr-Universität Bochum,, Bochum, Germany

Introduction

Secondary syphilis may present with a broad spectrum of cutaneous manifestations and clinically mimic inflammatory dermatoses, including psoriasis vulgaris. Diagnosis may be challenging, particularly in patients with pre-existing chronic inflammatory skin disease. We report a histologically and immunohistochemically confirmed case of secondary syphilis presenting as rapidly progressive psoriasiform exacerbation in psoriasis vulgaris.

Case Presentation

A 43-year-old male patient with a more than 20-year history of moderate plaque psoriasis (PASI 11.1; DLQI 11) presented with involvement of the scalp, genital region, trunk and extremities, including therapy-resistant scalp and genital lesions. Nail psoriasis was additionally present, whereas psoriatic arthritis was rheumatologically excluded despite arthralgia. Anamnestically, no sexual risk contacts were reported and the exact time of infection remained unclear.

During preparation for biologic therapy, the patient developed rapidly progressive papular psoriasiform lesions accompanied by marked increase in pruritus (PP-NRS 7/10), sleep disturbance, exhaustion, and transient thoracic and respiratory symptoms. Emergency cardiac and pulmonary diagnostics showed no relevant abnormalities. Compared with the patient’s chronic plaque psoriasis, the newly developed lesions were characterized by rapid dissemination, pronounced pruritus and partial refractoriness to topical antipsoriatic therapy. Additional genital involvement was observed, while palms and soles were spared.

Histopathological examination of two skin biopsies revealed psoriasiform epidermal hyperplasia with interface dermatitis and superficial perivascular and periadnexal lymphoplasmacytic infiltrates. Immunohistochemical analysis demonstrated numerous Treponema pallidum organisms within the epidermis and inflammatory infiltrates, overall consistent with secondary syphilis. Serological testing confirmed active Treponema pallidum infection with positive VDRL and TPHA reactivity, whereas HIV serology and additional STI screening remained negative.

Treatment with benzathine benzylpenicillin under Jarisch-Herxheimer prophylaxis was initiated. Due to persistent neurological and ophthalmological symptoms despite unremarkable cerebrospinal fluid findings and absence of tertiary organ involvement, treatment escalation to intravenous Penicillin G was performed in suspected probable tertiary syphilis. This resulted in complete regression of syphilitic skin manifestations and serological response with conversion from initially positive to negative VDRL during 9-month follow-up. TPHA titers progressively declined from 1:4660 prior to treatment to 1:2522 after completion of intravenous antibiotic therapy and 1:301 at latest follow-up.

Following successful anti-infective treatment, therapy with Tildrakizumab 100 mg was initiated according to the approved treatment regimen. Rapid clinical improvement of psoriasis vulgaris was observed, with PASI reduction to 4.1 after four weeks and complete skin clearance (PASI 100) after 12 weeks. Complete remission was maintained throughout a follow-up period of 38 weeks without additional topical therapy.

Conclusion

This case highlights the differential diagnostic relevance of secondary syphilis in rapidly progressive psoriasiform exacerbations in psoriasis vulgaris. Histopathological, immunohistochemical and serological examinations were crucial for establishing the correct diagnosis in this clinically misleading presentation. Following adequate anti-infective treatment, IL-23 inhibitor therapy resulted in sustained complete psoriasis remission without clinical or serological evidence of infectious reactivation during follow-up.

EA DV CONGRESS
VIENNA
30 SEP - 3 OCT 2026

Abstract N°: 2912

Syphilis in India: A Clinico-Demographic Study of Serologically Reactive Patients

ABHILASHA NEGI*[1], Prashant Verma[1]

[1] vmmc and safdarjung hospital, New Delhi, India

Introduction

Syphilis remains a significant public health concern worldwide, and early diagnosis and treatment are crucial for preventing long-term complications. This study aimed to explore the clinico-demographic features of patients with serologically reactive syphilis attending a sexually transmitted infection (STI) clinic in India, with a focus on factors such as sex, HIV status, literacy, occupation, and marital status, in order to identify potential risk factors associated with syphilis reactivity.

Materials and Methods

This cross-sectional study was conducted at Safdarjung Hospital, New Delhi, with data collected from 548 patients (293 males and 255 females) who sought care between October and December 2024. Among them, 80 patients were found to be serologically reactive for syphilis, based on VDRL and TPHA testing. Demographic and clinical data were collected, including HIV status, literacy level, occupation, and marital status. Descriptive statistics were used to summarize the data, and Chi-Square tests of independence were employed to examine associations between syphilis reactivity and the clinico-demographic variables.

Results

Among the 548 participants, 14.6% tested positive for serologically reactive syphilis. A significant association was found between syphilis reactivity and HIV status ($p < 0.05$), with HIV-positive individuals being more likely to test positive for syphilis. Sex and occupation ($p < 0.05$) were also significantly associated with syphilis reactivity. Males had a higher prevalence of syphilis reactivity compared to females ($p < 0.05$). No significant associations were observed between marital status or literacy level and syphilis reactivity.

VARIABLE	CATEGORY	REACTIVE	NON-REACTIVE	P-VALUE
SEX	Male	69 (23.5%)	224 (76.5%)	<0.05
	Female	11 (4.3%)	244 (95.7%)	
HIV STATUS	Positive	19 (35.8%)	34 (64.2%)	<0.05
	Negative	61 (12.2%)	434 (87.8%)	
OCCUPATION	Service/Business	14 (25.5%)	41 (74.5%)	<0.05
	Labourer/Daily wage	29 (23.8%)	93 (76.2%)	
	Housewife	7 (6.0%)	110 (94.0%)	
	Others/Unemployed	30 (11.2%)	237 (88.8%)	
EDUCATION	Illiterate	22 (15.8%)	117 (84.2%)	>0.05
	Primary/Secondary	28 (14.5%)	165 (85.5%)	
	Higher Secondary+	30 (13.9%)	186 (86.1%)	
MARITAL STATUS	Married	57 (14.3%)	343 (85.7%)	>0.05
	Unmarried/Divorced	23 (15.3%)	125 (84.7%)	

Conclusions

This study highlights significant demographic factors associated with syphilis reactivity, particularly HIV status, sex, and occupation. The findings emphasize the need for targeted interventions among high-risk groups, such as HIV-positive individuals and certain occupational categories, to prevent the spread of syphilis. Further research is warranted to explore additional factors influencing syphilis prevalence and to refine screening and prevention strategies in STI clinics.

EA DV CONGRESS
VIENNA
30 SEP - 3 OCT 2026

Abstract N°: 2913

outh at Risk: Prevalence of Chlamydia trachomatis Infection in North India

ABHILASHA NEGI*[1], Poonam Puri[1]

[1] vmmc and safdarjung hospital, New Delhi, India

Introduction

Chlamydia trachomatis (CT) is one of the most common bacterial sexually transmitted infections (STIs), often asymptomatic but associated with pelvic inflammatory disease, infertility, and adverse pregnancy outcomes. Despite its significance, prevalence data in Indian youth remain scarce.

Objectives: To estimate the prevalence of CT infection among sexually active youth attending an STI clinic and assess its coexistence with other genital infections.

Materials and Methods

Methods: A hospital-based cross-sectional study was conducted over 18 months (March 2024–September 2025) at the STI clinic of an apex regional institute in North India. A total of 140 youth aged 18–29 years with a history of sexual exposure were enrolled. Demographics, sexual history, and clinical features were documented. Laboratory testing included DFA, ELISA for anti-chlamydial antibodies, urine PCR, HIV, and syphilis serology. Additional tests were performed for other genital ulcer/discharge syndromes.

Results

The prevalence of CT infection detected by DFA was 12.86% (18/140). Majority of participants were female (62.9%), with mean age 24.5 years. Risk behaviours included premarital sex (75.7%), low condom use (64.3% never used), and multiple sexual partners (14.3% ≥5 partners). Among infected individuals, 61.1% were female, 72.2% had co-existing genital infections, most commonly molluscum contagiosum (27.8%), anogenital warts (16.7%), and herpes genitalis (11.1%). No partner tested positive for CT, though few had other STIs. ELISA showed moderate sensitivity (55.6%) and high negative predictive value (92.8%) compared with DFA. All urine PCR results were negative.

CHARACTERISTICS	CT POSITIVE (N=18)	CT NEGATIVE (N=122)
Mean age (years)	24.22 ± 2.86	24.51 ± 3.04
Gender (Female)	61.11% (11)	63.11% (77)
Gender (Male)	38.89% (7)	36.89% (45)
Marital status (Married)	16.67% (3)	25.4%
Age at first sex <18	22.2% (4)	28.7%
No. of sexual partners ≥5	27.8% (5)	12.3%

PARAMETERS	KEY FINDINGS
Prevalence	**12.86%** (18/140) by DFA; urethral highest (8.57%)
Demographics	62.9% female; 75.7% unmarried; mean sexual debut 20.2 years
Risk factors	0% consistent condom use; 14% ≥5 lifetime partners
Co-infections	72% had ≥1 STI (anogenital warts 27.8%, molluscum contagiosum 27.8%)
Diagnostics	DFA superior to ELISA (sensitivity 55.6%, specificity 84.4%)



Conclusions

Conclusion: The study demonstrates a high prevalence of CT (12.9%) among sexually active youth, with frequent co-infections and behavioural risk factors. Findings highlight the urgent need for routine screening of both symptomatic and asymptomatic individuals, promotion of condom use, and partner notification strategies. Strengthening access to molecular diagnostics such as PCR could improve detection and control of this hidden burden in resource-limited settings.

Strengths: Reveals prevalence of CT among youth identifying even asymptomatic infections and co-infections for a broader epidemiological view. Use of serology and DFA provided insights where molecular methods are limited.

EADV CONGRESS
VIENNA
30 SEP - 3 OCT 2026

Abstract N°: 2940

Cutaneous Art, Infectious Consequences: A Case of Syphilis Following Tattooing

Tilman Erler*[1, 2], Adriane Skaletz-Rorowski[1, 2], Anja Potthoff[1, 2]

[1] WIR - Walk In Ruhr, Zentrum für Sexuelle Gesundheit und Medizin, Bochum, Germany
[2] Interdisziplinäre Immunologische Ambulanz, Zentrum für Sexuelle Gesundheit und Medizin, Klinik für Dermatologie, Venerologie und Allergologie, Ruhr-Universität, Bochum, Germany

Introduction

An infection with Treponema pallidum has long been associated with sexual activity. Not without reason, the disease has also been referred to as Morbus amoris or “Cupid’s disease,” both allusions to the Roman god of love Amor, also known as Cupid. However, syphilis can also occur in monogamous relationships. Therefore, in the presence of a typical clinical presentation, syphilis infection should be considered even in the absence of multiple sexual partners. In such cases, rarer routes of transmission must be taken into account.

Case Presentation

A 44-year-old woman presented with hair loss, aphthous lesions of the oral mucosa, and extensive skin lesions on the trunk and feet. She had previously been treated for tinea corporis et pedum, but without success. She had been advised to undergo testing for sexually transmitted infections, although she reported being in a monogamous relationship with her partner for many years. Serological testing revealed a TPHA titer of 1:3000 and a VDRL titer of 1:32. Her partner’s serology also demonstrated an active syphilis infection.

Both partners denied any external sexual contacts. During a detailed retrospective investigation, the man’s visit to a tattoo convention approximately six months earlier emerged as temporally relevant. Several days after receiving a fresh tattoo, a painless ulcer had developed within the tattoo motif, which resolved spontaneously without treatment.

This was considered the most likely route by which the syphilis infection entered the relationship. Thus, the patient was ultimately diagnosed not with tinea, but with secondary syphilis presenting with roseola syphilitica, alopecia specifica, oral plaques muqueuses, and a psoriasiform plantar syphilid. Following treatment with intramuscular depot benzathine penicillin, all symptoms regressed. Her asymptomatic partner received simultaneous treatment.



Roseola Syphilitica, Psoriasiform Plantar Syphilid

Conclusion

Although syphilis is still primarily transmitted through sexual contact, less well-known routes of infection may also play a role. Piercings and tattoos can serve as entry points for Treponema pallidum. Needle sharing associated with intravenous drug use or uncontrolled blood transfusions (virtually excluded in Europe) may also lead to infection. Therefore, in cases with a typical clinical presentation, appropriate serological testing remains essential even when the patient history initially appears inconsistent with syphilis infection.

EADV CONGRESS
VIENNA
30 SEP - 3 OCT 2026

Abstract N°: 3000

The Digital Epidemiology of Syphilis: Dating Apps and Sexual Risk Behaviour Among MSM in India

YUGANSH GAUTAM*[1], Abhilasha Negi[1], Shikha Bansal[1]

[1] Vardhman mahavir medical college and safdarjang hospital, New Delhi, India

Introduction
Syphilis remains a major concern among men who have sex with men (MSM), with digital platforms reshaping partner-seeking behaviours. This study aimed to assess behavioural risk factors—particularly dating app use—among MSM diagnosed with syphilis, in order to understand transmission patterns and guide targeted digital interventions.

Materials and Methods
A cross-sectional study was conducted at a tertiary care STI (Sexually Transmitted Infection) clinic in India from September 2024 to January 2025. A total of 150 adult men were consecutively recruited, of whom 82 (54.7%) identified as MSM. All participants completed a structured questionnaire evaluating app usage patterns, number of sexual partners in the past 6 months, condom use, STI testing frequency, HIV status, and partner notification practices. Syphilis was diagnosed using VDRL and TPHA tests.

Results
Of the 82 MSM enrolled, 52 (63.4%) were diagnosed with syphilis. Among them, 44 (84.6%) reported using dating apps to meet sexual partners—20 (38.5%) “always,” 15 (28.8%) “sometimes,” and 9 (17.3%) “never.” Syphilis positivity was significantly higher among “always” users compared to “never” users ($p = 0.01$). Regarding ease of finding partners via apps, 30 (57.7%) found it “very easy,” 13 (25.0%) “moderately easy,” and 9 (17.3%) “difficult.” Inconsistent condom use was reported by 40 (76.9%) of syphilis-positive MSM ($p = 0.02$). App users had a median of 6 partners in the past 6 months, compared to 2 among non-users ($p = 0.006$). Only 18 (34.6%) had notified all partners, while 17 (32.7%) partially notified, and 17 (32.7%) had not notified any. Although 34 (65.4%) had undergone STI testing in the past year, only 10 (19.2%) adhered to quarterly screening. HIV co-infection was found in 12 (23.1%) of syphilis-positive MSM.

Conclusions
This study underscores the strong link between dating app use and high-risk sexual behaviour in MSM, contributing to higher syphilis prevalence. Beyond risk, dating apps could serve as proactive tools for prevention—by integrating sexual health education, testing reminders, and partner notification features—to help curb the syphilis epidemic in MSM populations, particularly in resource-limited settings.

EACONGRESS
VIENNA
30 SEP - 3 OCT 2026

Abstract N°: 3011

Impact of sexually transmitted infections on mortality in a cohort of people living with HIV

Julia Barouille*[1], Juan Pablo Stagnaro[2], Diego Ameri[2], Jessica Monroig[3], Jimena López Piñeyro[3]

[1] Juan de La Fuente´s Hospital, University Center of Microbiology and Parasitology, Faculty of Medical Sciences, National University of La Plata, La Plata, Argentina

[2] University Center of Microbiology and Parasitology, Faculty of Medical Sciences, National University of La Plata, La Plata, Argentina

[3] Health Secretariat of Florencio Varela, Florencio Varela, Argentina

Introduction

Sexually transmitted infections are known to increase HIV transmission. However, their impact on mortality in people living with HIV/AIDS remains poorly understood. Studying this relationship is relevant to better identify high-risk patients and optimize treatment and care strategies.The aim of this study was to evaluate the impact of sexually transmitted infections on mortality in a cohort of people living with HIV.

Materials and Methods

We conducted an open cohort study including people living with HIV from a South American city between january 2012 and december 2025. We analyzed demographic, clinical and laboratory variables including: CD4 count at baseline, viral load, opportunistic events, coinfections, mental health conditions, history of sexually transmitted infections . A multivariate logistic regression model was built to identify independent predictors of mortality. Model caibration and discrimination were assessed using Homer-Lemeshow test and ROC curve analysis.

Results

A total of 712 patients were included. Mean age at diagnosis was 31 years old, and overall mortality was 18.5%. Notably: less tan 25% had CD4 counts below 200, only 59% achieved undetectable viral load, 65% were adherent to tratment, and 34% had a history of sexually transmitted infections. The model showed good discriminative capacity with an AUC of 0.84. The strongest independent predictor was the presence of opportunistic events adjusted OR 2.93. Other independent risk factors included : Hepatitis C virus coinfection (aOR 2.29) older age at diagnoses, mental health conditions (aOR2.8<9. <protective factors included: antiretroviral adherence (aOR 0.31), higher educational level (aOR 0.18). Importantly, sexually transmitted infections were not independent.

Conclusions

In this cohort, mortality was mainly determined by opportunistic events, hepatitits C virus coinfection and psychosocial factors. While STI were not independently associated with mortality, they may identify vulnerable populations, requiring targeted interventions. Improving adherence and addressing mental health, remains as key opportunities to reduce mortality. The last in HIV, is not only biological, it is deeply influenced by social and behavioral factors. These ones must be strongly considered when designing new therapeutic strategies aimed at maintaining adherence to current treatments, thus equalizing the quality of life of this population with those who do not live with HIV/AIDS, until the not-so-distant ideal goal of eradicating the HIV virus from humanity is achieved.

EADV Congress 2026, VIENNA
30 SEPTEMBER - 03 OCTOBER 2026
POWERED BY M-ANAGE.COM

EA DV CONGRESS
VIENNA
30 SEP - 3 OCT 2026

Abstract N°: 3048

Vaginal Lactobacillus Profiles and Their Determinants in Reproductive-Age Women: Implications for Microbial Balance

Shabrina Ari Rahmaniar*[1], Deisy Vania[1], Anni Adriani[1], Farida Tabri[1], Suryani Tawali[1]

[1] Hasanuddin University, Dr. Wahidin Sudirohusodo Central General Hospital, Kota Makassar, Indonesia

Introduction

Lactobacillus is the predominant vaginal microbiota in healthy women and plays a key role in maintaining vaginal homeostasis. In healthy women of reproductive age (15–49 years), the vaginal microbiota is typically characterized by low microbial diversity and the dominance of specific Lactobacillus species, particularly *Lactobacillus crispatus*, *Lactobacillus gasseri*, *Lactobacillus jensenii*, and *Lactobacillus iners*, which define community state types (CSTs). *L. crispatus* is considered a key determinant of vaginal microbiota stability due to its stronger antimicrobial activity, whereas *L. gasseri* has relatively lower antifungal activity. In contrast, *L. iners* produces lower amounts of lactic acid and hydrogen peroxide, providing less optimal protection and often being associated with a transitional state toward dysbiosis.

In addition to Lactobacillus spp., the normal vaginal microbiota may include other commensal microorganisms in low abundance, such as *Gardnerella vaginalis*, *Atopobium vaginae*, *Prevotella spp.*, *Bacteroides spp.*, *Streptococcus spp.*, *Staphylococcus spp.*, and *Corynebacterium spp.*, which are still considered part of eubiosis as long as they do not dominate the vaginal ecosystem. The composition of vaginal microbiota is influenced by a complex interplay of endogenous and exogenous factors, including age, hormonal status, menstrual cycle, sexual behavior, contraceptive use, genital hygiene practices, antibiotic exposure, comorbidities, lifestyle factors, and ethnicity. These factors may contribute to inter-individual variability and shifts between eubiosis and dysbiosis, which can impact reproductive health outcomes.

Materials and Methods

This observational study included 90 women of reproductive age (18–49 years) who met the inclusion criteria. Vaginal swab specimens were taken and the number of vaginal microflora was measured using *Humq PCR-realtime ™* kit for L crispatus, *L. gasseri, L jensenii* and *L iners*. Data were analyzed by Mann Whitney and Kruskal Wallis tests.

Results

A total of 90 women of reproductive age were included. *Lactobacillus iners* was the predominant species (mean 5.64 ± 3.10 log DNA copies/mL), followed by *L. crispatus* (2.49 ± 3.14), *L. gasseri* (1.20 ± 2.25), and *L. jensenii* (0.92 ± 1.81). All Lactobacillus species showed higher abundance in women aged 18–35 years; however, statistical significance was observed only for *L. iners* ($p=0.041$) and *L. jensenii* ($p=0.033$). No significant associations were found between Lactobacillus abundance and other factors, including ethnicity, contraceptive use, sexual behavior, comorbidities, medication use, vaginal hygiene practices, or fluor albus symptoms (all $p>0.05$), although variations in distribution were observed across groups.

Conclusions

In reproductive-age women the composition of vaginal microbiota is mainly influenced by age with higher Lactobacillus abundance in younger individuals. Other factors such as drug use comorbidities vaginal discharge sexual behavior contraceptive methods hygiene practices and ethnicity do not show a significant association. These findings indicate that age-related physiological factors have an important role in maintaining vaginal microbial balance and may affect susceptibility to dysbiosis and infection.

EA DV CONGRESS
VIENNA
30 SEP - 3 OCT 2026

Abstract N°: 3140

Features of the immune status in HIV-positive patients with dermatological diseases and sexually transmitted infections

Iuliia Shcherbakova*[1, 2], Glib Bondarenko[2], Sergiy Unuchko[2]

[1] Shupyk National Healthcare University of Ukraine, dermatovenereology, allergology, clinical and laboratory immunology, SE "Institute of Dermatology and Venerology of the National Academy of Medical Sciences of Ukraine", Kharkiv, Ukraine
[2] SE "Institute of Dermatology and Venerology of the National Academy of Medical Sciences of Ukraine", Kharkiv, Ukraine

Introduction
As HIV progresses, the body's immunological reactivity changes significantly. In most cases, there is a combination of HIV with other diseases that affect the body's immunological reactivity. Dermatological diseases and sexually transmitted infections associated with HIV infection are characterized by a severe course and resistance to therapy.

Materials and Methods
Eighty individuals were observed. Group I consisted of 50 HIV-positive patients aged 19 to 64 years. All patients received antiretroviral therapy and treatment for comorbidities. Thirty-two patients had concomitant STIs, and 18 patients had dermatological pathology. The comparison group (Group II) included 30 people - practically healthy donors.

Results
The subjects' total lymphocyte counts in peripheral blood, CD3+, CD3+/CD4+, and CD3+/CD8+ indices were determined, as well as their viral load before and after courses of therapy, determined according to the diagnosis of comorbidity. It was revealed that the most pronounced changes in patients affect the parameters characterizing the absolute and relative number of T-lymphocytes in the peripheral blood. The average content of T-lymphocytes in the peripheral blood of patients before treatment was 291.18 ± 36.22 cells / mm3. After treatment, this indicator increased to 465.4 ± 38.22 cells / mm3, which was significantly lower than the indicator in the control group, which was 827.19 ± 36.84 cells / mm3. In 20.4% of patients, the number of CD4 + lymphocytes was above the lower limit of normal, thus exceeding 500 cells / mm3. In 44.9% of patients, the number of T-helpers was less than 200 per mm3. In some patients, this indicator was very low: 28% had a value below 100, and 10% had a value below 20.

Following therapy, T-helper cell levels increased significantly, with the average for the group being 350.3 cells/mm^3. Only 7 patients (14%) had values below 200, 4 of whom were in the dermatological group. A significant positive correlation was found between T-helper cell counts before and after treatment ($\rho = 0.6977$).

Analysis of Group I indicators revealed no correlation between T-helper cell count and viral load, the most important indicator of viral replication activity. In the group with T-helper cell counts below 250 in peripheral blood, the average viral load did not differ significantly from the overall group and was 184 548 cells/mm^3. A more detailed analysis of these indicators revealed a negative correlation in the group of patients with T-helper cell levels above 150 cells/mm^3. This corresponds to the period of the disease from the onset of T-helper

decompensation until their levels drop to critical values. During this period, an increased viral load increases the likelihood of T-helper cell infection and subsequent death. When T-helper cell levels are between 150 and 200 cells/mm^3, there is no clear correlation between this indicator and viral load. Apparently, a significant decrease in T-helper cell count reduces the number of cells in which viral replication can occur, which reduces the number of viral particles circulating in the blood.

After treatment, a positive correlation was found between viral load and indicators such as the total lymphocyte count and peripheral blood T-lymphocytes. This correlation persisted after treatment.

Conclusions

An important indicator of therapy effectiveness is the degree of viral load reduction—the ratio of these indicators before and after treatment. The data obtained indicated a significant reduction in viral load after treatment, in some patients almost a hundredfold.

EA DV CONGRESS
VIENNA
30 SEP - 3 OCT 2026

Abstract N°: 3259

Porphyria Cutanea Tarda and HIV: A 27-Year Follow-Up Case

Alessandra Krykhtine*[1], Giselle Seabra[1], Marcia Ramos-e-Silva[1], Beatriz Moritz Trope[1, 1]

[1] FEDERAL UNIVERSITY OF RIO DE JANEIRO, Rio de Janeiro, Brazil

Introduction

Porphyrias are a group of disorders of heme biosynthesis and are clinically categorized as cutaneous and non-cutaneous forms. Porphyria cutanea tarda (PCT) results from inhibition of the enzyme uroporphyrinogen decarboxylase (UROD). Contributing environmental factors include alcohol consumption, smoking, increased estrogen levels, hepatitis C virus (HCV) infection, and less frequently, human immunodeficiency virus (HIV) infection. PCT is classified into: Type 1 (sporadic), accounting for 80% of cases without a pathogenic UROD variant; Type 2 (familial), with heterozygous pathogenic UROD variants; and Type 3, characterized by absence of UROD pathogenic variants associated with HFE gene mutations. HIV-associated PCT is included in Type 1.

The pathophysiology linking HIV infection to PCT lesions remains poorly understood. One hypothesis involves increased heme oxygenase activity as a response to chronic HIV-related inflammation. HIV-associated hepatic dysfunction may also alter the cytochrome P450 system, increasing oxidative damage and impairing enzymes involved in heme synthesis. Accumulated porphyrins in plasma and capillaries become activated upon sunlight exposure, triggering immune-mediated reactions with free radical release and consequent damage to the papillary dermis and basement membrane.

The most affected areas include the dorsum of the hands, forearms, neck, face, and ears. In prolonged or recurrent disease, hypertrichosis, pigmentary alterations, scarring, and milia may develop.

Case Presentation

A 25-year-old man was diagnosed with HIV infection in 1995, with his wife identified as the index case. Antiretroviral therapy (AZT + 3TC + IDV) was initiated at that time, although adherence was poor. In 1999, he reported the appearance of skin lesions on the dorsum of the hands and feet, associated with urinary changes, prompting dermatologic evaluation. Physical examination revealed hypochromic and erythematous atrophic scars, hemorrhagic blisters, clear vesicles on the hands and feet, frontoparietal hypertrichosis, elongated eyelashes, and brownish skin discoloration. Laboratory evaluation demonstrated HIV viral load of 16,000 copies/mL, CD4+ T-cell count of 174 cells/mm^3 (15%), CD8+ T-cell count of 870 cells/mm^3 (75%), and CD4/CD8 ratio of 0.2. He was receiving prophylactic sulfamethoxazole-trimethoprim. There was no family history of blistering skin diseases, although he reported social alcohol consumption. Urine examination under Wood's lamp demonstrated pink fluorescence. Initial diagnosis of PCT was proposed. Qualitative and quantitative urinary and fecal porphyrin analyses were positive. Serologies for hepatitis A, B, and C were negative. Skin biopsy of a blister confirmed the histopathological diagnosis of porphyria. The patient was treated with photoprotection, alcohol cessation counseling, chloroquine 150 mg weekly, and hematologic evaluation, without indication for phlebotomy at that time. Over 27 years of follow-up, he experienced two relapses of PCT lesions, both associated with interruption of antiretroviral therapy and periods of therapeutic resistance requiring multiple regimen changes. As adherence improved and undetectable viral load was achieved, cutaneous disease remained stable over subsequent years.

Conclusion

PCT may be considered an environmentally influenced disease, as exposure to risk factors reduces UROD activity, increasing circulating porphyrins and leading to oxidative tissue damage and cutaneous manifestations. The

association between PCT and HIV is rare, and this 27-year follow-up highlights the importance of controlling risk factors, particularly adherence to antiretroviral therapy, in achieving disease stabilization. Furthermore, advances in HIV treatment have improved long-term adherence, reducing not only opportunistic infections but also manifestations associated with immunosuppression, such as PCT.

EADV CONGRESS
VIENNA
30 SEP - 3 OCT 2026

Abstract N°: 3304

Host-cell Methylation Markers for Detecting HPV-related High-grade Anal Dysplasia

David Chromy*[1], Steffi Silling[2], Alexander Kreuter[3], Anja Potthoff[4], Nathalie Auer[5], Ulrike Wieland[2], Stefan Esser[5]

[1] Department of Dermatology, Medical University of Vienna, Vienna, Austria
[2] Institute of Virology, National Reference Center for Papilloma- and Polyomaviruses, University Hospital and University of Cologne, Cologne, Germany
[3] Department of Dermatology, Venereology and Allergology, Helios St. Elisabeth Hospital Oberhausen, Oberhausen, Germany
[4] Department of Dermatology, Venereology and Allergology, Ruhr-University Bochum, Bochum, Germany
[5] Department of Dermatology and Venereology, University Hospital Essen, University Duisburg-Essen, Essen, Germany

Introduction
Host-cell methylation markers are a promising tool for advancing non-invasive diagnostics for detecting anal high-grade squamous intraepithelial lesions (HSIL), alongside established methods such as cytology, HPV typing, and oncogenic HPV E6/E7 mRNA. Anal cancer screening and treatment of precursor lesions are recommended in several countries; however, the capacity of high-resolution anoscopy (HRA) as the gold standard is limited. Pre-selection of the target populations before HRA is warranted. In this study, we assessed non-invasive diagnostics, including methylation markers (ASCL1/ZNF582), in anal swabs to detect histologically confirmed HSIL (hHSIL).

Materials and Methods
Men who have sex with men living with HIV undergoing HRA were recruited, and anal swabs were obtained for non-invasive diagnostics. Abnormal findings during HRA were biopsied, and the highest grade of dysplasia was used as a reference to calculate diagnostic performance. This abstract comprises a preliminary analysis of samples with completed methylation analysis (292/398). This project is supported by the EADV (PPRC-2023-0054) and the German National Reference Center for Papillomaviruses.

Results
Two hundred ninety-two anal swabs with 417 corresponding histological samples were included. ZNF582 achieved an area under the curve (AUC) of 0.60 (95%-CI 0.53-0.66), and ASCL1 an AUC of 0.63 (95%-CI 0.56-0.70) for detecting hHSIL. The optimal sensitivity and specificity of ZNF538 and ASCL1 in swabs to detect hHSIL were 82.1% and 33.3%, and 83.2% and 35.7%, respectively. As for conventional biomarkers, anal cytology at ‘atypical squamous cells of undetermined significance’ (ASC-US) achieved a sensitivity of 82.7% and a specificity of 33.0%, HPV-16 54.4% and 77.9%, high-risk(HR) HPV 84.5% and 36.8%, E6/E7-mRNA 87.4% and 40.9% for hHSIL detection. Triage by HR-HPV or HPV-16 beforehand did not improve the other´s test performances.

Conclusions
While methylation markers ZNF538 and ASCL1 in anal swabs corresponded to anal disease, the test performance for hHSIL was suboptimal in this preliminary analysis. The final results of this study will further explore the interplay between methylation, conventional non-invasive diagnostics, and anal disease.

EADV CONGRESS
VIENNA
30 SEP - 3 OCT 2026

Abstract N°: 3339

Impact of AI-Driven Standardized Counseling on STD Knowledge and Treatment Adherence in a Tertiary Care Center

Keshav Yadav*[1]

[1] Vardhman Mahavir Medical College and Safdarjung Hospital, New Delhi, India

Introduction

Introduction: In high-volume tertiary centers, "stigma-induced silence" and "counseling fatigue" frequently compromise the quality of STI history-taking and patient education. At an apex STI center, we evaluated the SHAPE *(Sexual Health Awareness, Promotion, and Evaluation)* protocol, a multi-modular digital interface designed to bridge the gap between initial triage and comprehensive sexual health promotion in a resource-constrained, high-stigma environment.

Materials and Methods

Materials and Methods: A prospective implementation study (N=100) was conducted at a tertiary care center in India. The protocol integrated: (1) Digital Pre-Checkup: A QR-code-facilitated tool for discreet capture of syndromic, behavioral, and partner data; (2) Clinical Optimization: Real-time data summaries, covering complaints like genital ulcers, discharge, and growths (warts/molluscum/malignancies) to psychosexual concerns (erectile-dysfunction/dyspareunia etc) were provided to clinicians to streamline consultations and screening; (3) AI-Driven Counseling: Standardized post-evaluation modules on safe-sex adoption and treatment adherence; and (4) e-Partner Notification (ePN): An anonymous digital referral system for presumptive treatment and follow ups. Clinical literacy was evaluated via the validated STD Knowledge Questionnaire (STD-KQ) in a pre-post format.

Results

Results: The digital protocol demonstrated superior diagnostic fidelity; 86% of participants disclosed high-risk behaviors overriding stigma-led non-disclosure during routine verbal history taking. ($p < 0.05$). Clinical literacy showed marked improvement: the mean STD-KQ score rose from a baseline of 11.6 ± 4.2 to 23.4 ± 2.8 ($p < 0.05$). Partner engagement was robust, with 82% index cases utilizing ePN, facilitating the clinical presentation of 1.6 partners per index patient. The follow-up adherence also increased from routine to 78%.

Conclusions

Conclusion: The SHAPE protocol effectively dismantles socio-cultural barriers to STI care by providing a digital "safe space" that facilitates honest disclosure. By offloading routine tasks to AI-driven platforms, centers can provide high-fidelity, standardized sexual health promotion that improves patient literacy and partner tracking.

POWERED BY M-ANAGE.COM

EA DV CONGRESS
VIENNA
30 SEP - 3 OCT 2026

Abstract N°: 3365

The Changing Face of Venereology: Uncommon STI Presentations with Significant Clinical Implications

PRIYA MOTE*[1], Swagata Tambe[1], Kirti Jangid [1]

[1] seth v c gandhi and m a vora muncipal general hospital, mumbai, India

Introduction
Sexually transmitted infections (STIs) and HIV-associated dermatoses exhibit varied and atypical mucocutaneous manifestations, often causing diagnostic challenges. We aimed to highlight uncommon presentations encountered in a tertiary care STI clinic. Five patients with diverse STI and HIV-associated dermatoses were evaluated through detailed clinical examination, sexual history, serological investigations, and histopathological assessment where indicated.

Case Presentation
Case 1 : A 48-year-old divorced male presenting with well to ill-defined erythematous macules and plaques over bilateral lower limbs for one week.Multiple flesh-colored macerated papules were present over the perianal region.History of high-risk sexual behavior was elicited.Serological evaluation revealed reactive rapid plasma reagin (RPR) with a titre of 1:32, while HIV serology was non-reactive.A diagnosis of secondary syphilis with condyloma lata was made,and the patient was treated with single dose of intramuscular benzathine penicillin G 2.4 million units.

Case 2 : A 29-year-old unmarried female presenting with multiple erythematous scaly indurated plaques over the face,chest,back,and extremities for one and a half months.Palms and soles were spared.Associated curdy white vaginal discharge was present, along with history of sexual exposure to a known male partner.Saline mount,Gram staining and potassium hydroxide (KOH) examination of vaginal discharge were performed,of which KOH mount demonstrated candidal elements suggestive of vulvovaginal candidiasis.RPR was reactive with a titre of 1:64,while HIV serology was non-reactive. Based on clinicohistological & serological correlation,a diagnosis of granulomatous secondary syphilis with concurrent vulvovaginal candidiasis was established.The patient was managed with a single dose of intramuscular benzathine penicillin 2.4 million units along with tab fluconazole 150 mg stat for vaginal discharge.

Case 3 : A 29-year-old unmarried man who has sex with men (MSM) presenting with tender coppery-red plaques over the palms and soles along with cervical and inguinal lymphadenopathy.Serological investigations revealed reactive RPR with a titre of 1:32 and reactive HIV serology.CD4 count was 358 cells/mm^3.Existing opportunistic infections were ruled out.A diagnosis of secondary syphilis with concurrent retroviral disease was made.The patient was treated with three weekly doses of intramuscular benzathine penicillin and initiated on tenofovir, lamivudine, and dolutegravir (TLD) therapy.

Case 4 : A 37-year-old unmarried male with history of high-risk sexual behavior who presented with multiple reddish to violaceous mildly indurated plaques over the chest,back,forearms and face for one month.He was a known case of pulmonary tuberculosis receiving antitubercular therapy.Oral candidiasis was present.HIV serology

was reactive and hepatitis B surface antigen was positive.Histopathological examination of a skin lesion confirmed Kaposi sarcoma.The patient was diagnosed with advanced retroviral disease with Kaposi sarcoma.However,the patient unfortunately succumbed within one week of diagnosis before definitive oncological or antiretroviral treatment could be initiated.

Case 5 : A 31-year-old male living with HIV on tab TLD presenting with a solitary verrucous mass measuring approximately 5×7 cm over the right pubic region and groin associated with tender right superficial inguinal lymphadenopathy.Cliniohistopathological findings were suggestive of Buschke–Lowenstein tumor.The patient was managed with wide local excision.

Conclusion

This case series highlights the diverse and atypical manifestations of sexually transmitted infections and HIV-associated dermatoses, ranging from secondary syphilis to Kaposi sarcoma.Careful mucocutaneous examination, detailed sexual history, and timely serological evaluation are essential for early diagnosis, prompt treatment, and reduction of disease-related morbidity and transmission.

EADV CONGRESS
VIENNA
30 SEP - 3 OCT 2026

Abstract N°: 3532

Effectiveness of Pristinamycin and Minocycline against Fluoroquinolone-resistant Mycoplasma genitalium Infection: A Study of Consecutive Patients Attending a Sexual Health Clinic

Simone Høstgaard*[1], Suhella Tulsiani Drud[2], Lars Haukali Omland[3], Laura Glismann[1], Thomas Roland Pedersen[2], Helle Kiellberg Larsen[4], Maja Studsgaard[5], Jørgen Skov Jensen[2], Kirsten Salado-Rasmussen[6]

[1] Department of Bacteria, Parasites and Fungi, Statens Serum Institut, Department of Dermato-Venereology, Bispebjerg University Hospital, Copenhagen, Denmark

[2] Department of Bacteria, Parasites and Fungi, Statens Serum Institut, Copenhagen, Denmark

[3] Department of Bacteria, Parasites and Fungi, Statens Serum Institut, Department of Clinical Medicine, University of Copenhagen, Department of Infectious Diseases, Copenhagen University Hospital, Rigshospitalet, Copenhagen, Denmark

[4] Department of Dermato-Venereology, Bispebjerg University Hospital, Department of Clinical Medicine, University of Copenhagen, Copenhagen, Denmark

[5] Department of Dermato-Venereology, Bispebjerg University Hospital, Copenhagen, Denmark

[6] Department of Bacteria, Parasites and Fungi, Statens Serum Institut, Department of Dermato-Venereology, Bispebjerg University Hospital, Department of Clinical Medicine, University of Copenhagen, Copenhagen, Denmark

Introduction

Mycoplasma genitalium is a sexually transmitted pathogen that can cause urethritis, cervicitis, pelvic inflammatory disease, and potentially reproductive complications. Increasing antimicrobial resistance, particularly to first-line azithromycin (macrolide-resistant *M. genitalium*) but also to second-line moxifloxacin (fluoroquinolone-resistant *M. genitalium*), has created an urgent need for effective alternative treatments. In current treatment guidelines, pristinamycin is the preferred third-line option for dual resistant *M. genitalium*, and minocycline will often be used if pristinamycin treatment fails to cure or is unavailable.

Materials and Methods

We conducted a retrospective study in a Danish Sexual Health Clinic from September 2019 to December 2023. We included all individuals with fluoroquinolone-resistant *M. genitalium*. We compared the effectiveness of pristinamycin (the third-line drug of choice) with that of minocycline (which was used when pristinamycin was unavailable or had failed to cure), and a test of cure (TOC) was performed 21–90 days after treatment.

Logistic regression was used to estimate odds ratios (ORs) for cure, defined as a negative TOC, with 95% confidence intervals (CIs), adjusted for treatment round and sex. Analyses were restricted to treatment episodes with an available TOC. We repeated the analyses stratified on sex and treatment round (1 vs. >1).

Results

Among 48 patients, 68 pristinamycin or minocycline treatment episodes were included; 33 in females and 35 in males. Overall, 44 treatment episodes involved pristinamycin, and 24 treatment episodes involved minocycline. TOC results were available for 64 treatment episodes, with cure observed in 51 (80%), including 35/42 (83%) among pristinamycin-treated episodes and 16/22 (73%) among minocycline-treated episodes. In treatment episodes with an available TOC, the unadjusted OR for cure with pristinamycin vs. minocycline was 1.25 (95% CI

0.33–4.35), and the adjusted OR was 0.22 (95% CI 0.01–1.78). In stratified analyses, the OR for cure with pristinamycin vs. minocycline was 0.98 (95% CI 0.20–4.56) for females, 2.20 (95% CI 0.08–59.54) for males, and 1.11 (95% CI 0.22–6.41) for treatment round >1 (*Figure 1*).

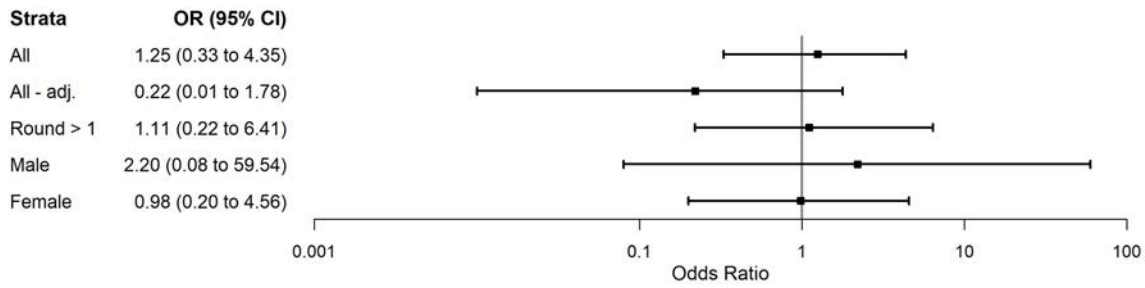

Figure 1. Plot of ORs for cure comparing pristinamycin versus minocycline in fluoroquinolone-resistant M. genitalium for treatment episodes with an available TOC, stratified by sex and treatment round (>1). Error bars indicate 95% CIs. Abbreviations: OR, odds ratio; CI, confidence interval; adj, adjusted.

Conclusions

Minocycline showed effectiveness comparable to that of pristinamycin in treating fluoroquinolone-resistant M. genitalium, and we were unable to demonstrate a difference in effectiveness between the two treatments. However, the relatively small sample size limits statistical power and raises the possibility of type II error. Despite this limitation, these findings suggest that minocycline may be a potential alternative to pristinamycin for patients with dual resistant *M. genitalium* infection, although these results should be interpreted with caution, given the small sample size. Nevertheless, given minocycline's availability and lower cost compared with pristinamycin, it may be considered a reasonable third-line treatment option.

EADV CONGRESS
VIENNA
30 SEP - 3 OCT 2026

Abstract N°: 3796

A solitary pedunculated genital papule mimicking a skin tag: dermoscopic and histopathological clues to atypical condyloma acuminatum

Fatima Zahra Hammoud*[1], Lina Mouline[1], Chourouq Mustapha Eid[1], Ammar Najoua[1], Syrine Hamada[1], Mariame Meziane[1], Nadia Ismaili[1], Laila Benzekri[1]

[1] Department of Dermatology, Mohamed V University of Rabat, Ibn Sina University Hospital, Rabat, Morocco

Introduction

Condyloma acuminatum is a common HPV-related sexually transmitted infection usually presenting as multiple verrucous or cauliflower-like anogenital papules. Solitary pedunculated lesions with a smooth surface are uncommon and may represent a diagnostic pitfall, particularly in older patients. In such atypical presentations, dermoscopy and histopathology play a key role in excluding benign fibroepithelial lesions and early squamous neoplasia.

Case Presentation

A 65-year-old man presented with a slowly enlarging asymptomatic genital lesion evolving over several months. Clinical examination revealed a solitary soft pedunculated pink-whitish papule located within the inguinal fold, clinically suggestive of an acrochordon.

Dermoscopy showed a lobulated papillomatous architecture composed of whitish clods separated by pale septa, associated with focal linear-irregular and glomerular vessels over a pink background, along with subtle keratotic areas. No ulceration or melanocytic criteria were observed.

Given the atypical solitary presentation, differential diagnoses included fibroepithelial polyp, verruca vulgaris, adnexal tumor, and early verrucous squamous proliferation.

Complete surgical excision was performed. Histopathological examination demonstrated papillomatosis, acanthosis, compact hyperkeratosis, and koilocytic atypia, confirming condyloma acuminatum.

Subsequent sexually transmitted infection screening was performed and revealed no associated infection. Follow-up was uneventful, without recurrence.

Conclusion

This case highlights an unusual solitary pedunculated presentation of condyloma acuminatum clinically mimicking a skin tag. In genital locations, isolated pedunculated papules should not systematically be considered benign fibroepithelial lesions. Dermoscopy may provide subtle clues suggestive of HPV-induced epithelial proliferation; however, histopathological confirmation remains essential in atypical cases. Recognition of these misleading presentations may improve early diagnosis and appropriate sexually transmitted infection management.

EA DV CONGRESS
VIENNA
30 SEP - 3 OCT 2026

Abstract N°: 3873

The Growing Burden of Acquired Syphilis in Brazil From 2015 to 2024

Jhony Everson Gonçalves*[1], Pedro Theil Melcop de Castro[1], Natália de Souza Silva[1], Nádia Jussara de Medeiros[1]

[1] Faculty of Medicine, University of São Paulo (FMUSP), São Paulo, Brazil, São Paulo, Brazil

Introduction
Acquired syphilis is a sexually transmitted infection caused by *Treponema pallidum*, primarily transmitted through sexual contact, differing from congenital syphilis, which results from vertical transmission from mother to child during pregnancy. Despite being preventable and treatable, acquired syphilis remains a major public health challenge in Brazil. Over recent years, the country has experienced increasing notification rates, important regional disparities, and persistent concerns regarding surveillance quality and access to diagnosis and treatment. Understanding the epidemiological behavior of acquired syphilis is essential for strengthening prevention policies and improving public health strategies. This study aimed to characterize the epidemiological profile of acquired syphilis in Brazil between 2015 and 2024, analyzing temporal trends and distributions according to sex, age group, educational level, geographic region, case classification, and clinical outcomes.

Materials and Methods
An ecological and descriptive study was conducted using secondary data obtained from the Brazilian Information System for Notifiable Diseases (SINAN). All reported cases of acquired syphilis notified between 2015 and 2024 were included. Variables analyzed included year of notification, sex, age group, educational level, region of notification, case classification, and clinical evolution. Data were analyzed descriptively using absolute frequencies and proportions. Due to ongoing data consolidation, 2024 was considered a partial notification year.

Results
Between 2015 and 2024, Brazil recorded 1,404,815 cases of acquired syphilis. Notifications increased progressively from 68,578 cases in 2015 to 249,021 in 2023, with a temporary decline in 2020 during the COVID-19 pandemic period. Men accounted for 60.8% of reported cases, while women represented 39.2%. Adults aged 20–39 years were the most affected group, corresponding to 58.6% of all notifications, followed by individuals aged 40–59 years (22.9%). Adolescents aged 15–19 years accounted for 9.3% of cases, while individuals aged 60 years or older represented more than 115,000 notifications throughout the study period.

Most cases were classified as confirmed (77.7%), whereas 17.5% remained inconclusive. Clinical evolution was reported as cure in 49.6% of notifications; however, outcome information was missing or ignored in 50.2% of cases. Deaths directly attributed to syphilis were rare, representing only 0.05% of notifications. The Southeast region concentrated nearly half of all reported cases (48.7%), followed by the South (22.4%) and Northeast (14.9%) regions. Educational level presented substantial missing information, limiting more detailed socioeconomic analyses.

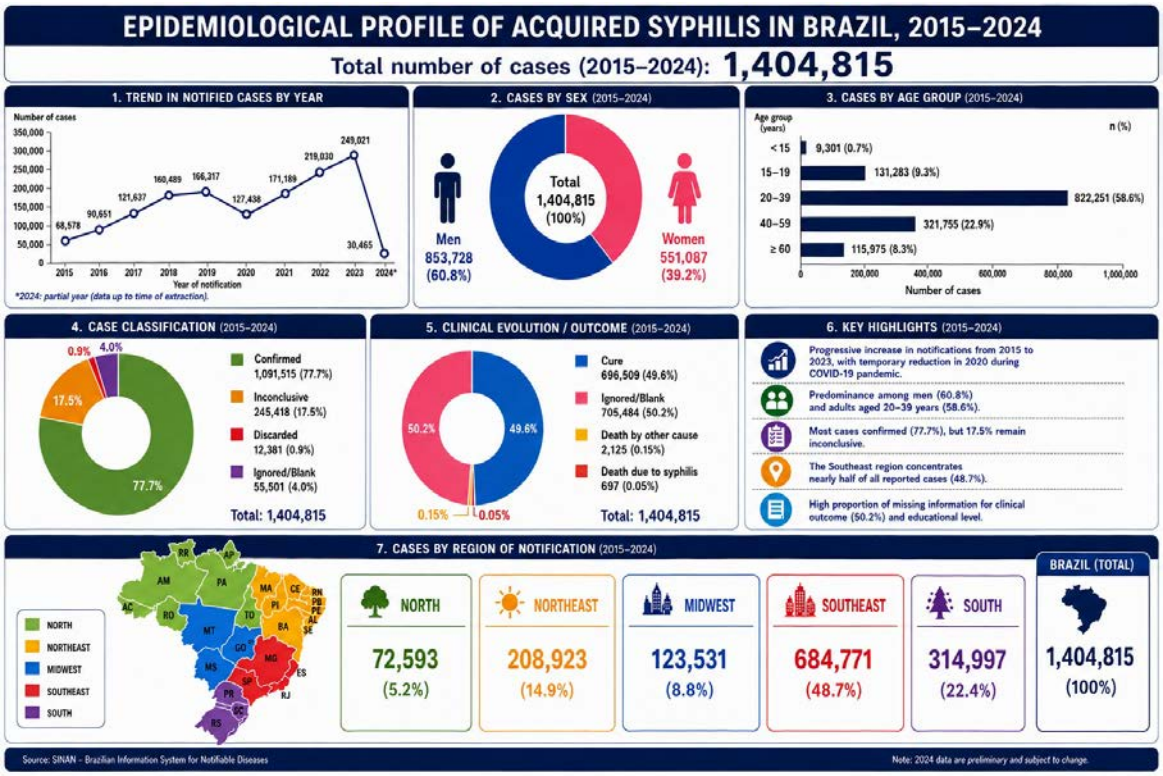

Figure 1. Epidemiological Overview of Acquired Syphilis in Brazil, 2015–2024

Conclusions

Acquired syphilis notifications in Brazil increased substantially between 2015 and 2024, with a temporary reduction during the COVID-19 pandemic followed by a marked post-pandemic resurgence. The disease predominantly affected men and young adults and demonstrated important regional inequalities. Despite improvements in diagnostic confirmation, significant limitations in surveillance data completeness remain, particularly regarding socioeconomic variables and clinical outcomes. These findings reinforce the need for strengthened prevention strategies, expanded access to testing and treatment, and improved quality of epidemiological surveillance systems in Brazil.

EA DV CONGRESS
VIENNA
30 SEP - 3 OCT 2026

Abstract N°: 3874

A rash worth testing? Evaluating seborrheic dermatitis as an HIV indicator condition

Anna Gwóźdź[1], Wiktor Kruczek*[2, 3], Wiktoria Bajek[1], Martyna Kubicka-Figiel[2], Aleksandra Frątczak[2], Bartosz Miziołek[2], Beata Bergler-Czop[2]

[1] Students' Scientific Association at the Department of Dermatology, School of Medicine in Katowice, Medical University of Silesia, Katowice, Poland

[2] Department of Dermatology, School of Medicine in Katowice, Medical University of Silesia, Katowice, Poland

[3] Doctoral School, Medical University of Silesia, Department of Dermatology, School of Medicine in Katowice, Medical University of Silesia, Students' Scientific Association at the Department of Dermatology, School of Medicine in Katowice, Medical University of Silesia, Katowice, Poland

Introduction

Seborrheic dermatitis (SD) is a frequent chronic inflammatory dermatosis characterized by erythema, scaling, and pruritus. This condition most commonly affects the scalp, face, chest, back, axillae, and groin. The diagnosis is usually based on clinical presentation. The presence of SD has been described in people living with HIV (PLWH). Its role as a potential indicator condition for HIV has been explored, especially in the case of delayed diagnosis. The aim of this study was to perform a systematic review of available evidence on the frequency of SD in HIV-positive patients and to assess whether SD may be a reason to justify HIV testing.

Materials and Methods

A comprehensive literature search was performed in PubMed, Embase, and Scopus from database inception to April 2026 using MeSH and EMTREE terms and relevant keywords. Eligible studies included observational, cross-sectional, case-control, and clinical cohort studies reporting the prevalence of SD in PLWH or HIV diagnoses indicated by the occurrence of SD. The review was conducted following PRISMA guidelines.

Results

A total of 59 studies were included. In the available literature, SD was a common mucocutaneous manifestation in PLWH. Several studies suggested an association with immune suppression or with HIV infection. While most studies assessed the prevalence of SD in PLWH, fewer studies directly assessed HIV prevalence among patients with SD. Overall, the evidence suggests an association between SD and HIV infection. This supports the concept of SD as a potential indicator for HIV testing.

Conclusions

SD is a clinically important dermatosis in PLWH. The available evidence suggests that SD may be a potential clinical clue for consideration of HIV testing, especially when other risk factors are present. Detection of skin disorders may help with earlier HIV diagnosis and improve management of HIV-associated diseases. This may be particularly relevant for limiting healthcare costs in low-resource countries. Earlier identification of HIV infection through recognition of SD may contribute to a swift initiation of antiretroviral therapy and improved patient outcomes. However, despite current data, this topic requires additional

scientific research in order to reach a definitive conclusion.

EA DV CONGRESS
VIENNA
30 SEP - 3 OCT 2026

Abstract N°: 4109

Psychosocial Burden of Anogenital Warts in Vietnamese Women: Assessment Using the HPV-QoL Instrument

Hung Tran*[1], Vo Thi Doan Phuong[2], Chuyen Thi Hong Nguyen[1]

[1] University of Medicine and Pharmacy at Ho Chi Minh City, Ho Chi Minh, Viet Nam
[2] Ho Chi Minh City Dermatology Hospital, Ho Chi Minh, Viet Nam

Introduction
Anogenital warts caused by Human Papillomavirus (HPV) are among the most common sexually transmitted infections and may substantially impair psychological well-being, sexual health, and social functioning, particularly in women. Despite the increasing burden of HPV-related diseases in Vietnam, data regarding disease-specific quality of life (QoL) impairment remain limited. Generic dermatology or health-related QoL instruments may not adequately capture important HPV-related concerns such as fear of contagion, recurrence, and sexual distress. This study aimed to evaluate QoL in women with anogenital warts using the validated Human Papillomavirus Quality of Life (HPV-QoL) instrument and to identify associated sociodemographic and behavioral factors.

Materials and Methods
A cross-sectional study was conducted in 154 women aged ≥18 years with clinically confirmed anogenital warts attending a dermatovenereology outpatient clinic. Participants completed a structured questionnaire incorporating the validated HPV-QoL instrument. Scores were transformed to a 0–100 scale, with higher scores indicating better QoL. Associations between QoL scores and sociodemographic or behavioral variables were analyzed using Spearman's rank correlation and Kruskal–Wallis tests.

Results
The mean overall HPV-QoL score was 41.87 ± 27.36, indicating substantial QoL impairment. Among the six evaluated domains, the Social domain showed the highest mean score (68.34 ± 35.85), followed by General Well-being (56.33 ± 31.02) and Psychological Well-being (50.32 ± 33.26). The most severely affected domains were Contagiousness (35.06 ± 34.39), Health concerns (35.63 ± 31.47), and Sexuality (40.48 ± 37.35). Older age was positively correlated with better QoL scores (Spearman's rho = 0.1606, p = 0.0467), whereas educational level showed a significant association with QoL impairment (Spearman's rho = -0.1635, p = 0.0428). Significant differences in QoL were also observed according to the reported source of infection (p = 0.0093) and frequency of condom use (p = 0.0097).

Conclusions
Female patients with anogenital warts experience substantial psychosocial and sexual quality of life impairment, particularly regarding fear of transmission, health-related concerns, and sexuality. Disease-specific QoL assessment using the HPV-QoL instrument may provide clinically meaningful insights beyond conventional evaluation. Integrating psychological support and sexual health counseling into routine clinical management may help improve patient-centered outcomes in women with HPV-related disease.

EADV Congress 2026, VIENNA
30 SEPTEMBER - 03 OCTOBER 2026
POWERED BY M-ANAGE.COM

EACDV CONGRESS
VIENNA
30 SEP - 3 OCT 2026

Abstract N°: 4164

AIDS/HIV Mortality in Europe from 2012 to 2023: a Comparative Temporal Analysis

Luísa Ribeiro Romiti*[1], Jacqueline Salvoni[1], Helio Miot[2]

[1] University of Santo Amaro, São Paulo, Brazil

[2] Unesp Universidade Estadual Paulista, Botucatu, Brazil

Introduction

Despite major advances in antiretroviral therapy (ART), HIV/AIDS related mortality in Europe remains uneven across countries. Although ART has reduced mortality and transformed HIV into a chronic condition, these improvements have not occurred uniformly. Late diagnosis and gaps in the continuum of care, particularly among migrant populations, remain important factors sustaining mortality in the region, suggesting that treatment availability alone is insufficient to ensure equitable outcomes.

Materials and Methods

This ecological descriptive study analyzed age-standardized HIV/AIDS mortality rates(MR) across 39 European countries using secondary data obtained from Eurostat database between 2012-2023. Age standardization was applied to account for differences in population age structure, allowing direct comparison between countries. The analysis included European Union countries, European Free Trade Association countries, and countries in the process of enlargement. Were excluded: Albania, Montenegro, North Macedonia, Georgia, Moldova, and the United Kingdom due to missing data. For descriptive analysis, countries were ranked according to age-standardized MR in 2023, with emphasis on the five highest and lowest-burden settings. Temporal trends were assessed using log-linear regression models estimating annual percent change(APC) and 95% confidence intervals(95% CI). Trends were considered significant when $p<0.05$. APC was considered not estimable for countries with zero values because logarithmic transformation was not possible.

Results

The mean age-standardized HIV/AIDS MR across analyzed European countries showed a significant decline between 2012 and 2023 (APC:-5.13%;95% CI:-6.27 to -3.97;$p<0.001$) (Figure 1). Mortality progressively decreased after 2013, stabilized in 2020-2021, temporarily increased in 2022, and reached its lowest level in 2023. In 2023 (Figure 2) (Figure 3), the highest MR were observed in Latvia(2.88), Estonia(2.29), Portugal(1.33), Lithuania(1.08), and Spain(0.55), whereas the lowest were found in Slovakia(0.08), Finland(0.07), Liechtenstein(0.00), Iceland(0.00), and Slovenia(0.00). Significant reductions were identified in Latvia, Estonia, Portugal, and Spain, while Lithuania maintained a non-significant trend despite remaining among the highest-burden countries. Slovakia showed a significant upward trend despite low absolute mortality(APC:6.95%;95% CI:0.23-14.12;$p=0.044$).

These findings show that HIV/AIDS mortality in Europe declined without full convergence.Persistently high mortality in countries such as Latvia and Estonia, despite significant APC reductions, likely reflects historical epidemic burden, delayed diagnosis, and inequalities across the continuum of care. Portugal, although still among the countries with the highest mortality in 2023, showed one of the steepest declines over time, suggesting improved testing and treatment access despite the lasting impact of late diagnosis. Migration may further contribute to these inequalities, as migrants often face barriers to testing, treatment continuity, and retention in care despite broad ART availability. Because late diagnosis is strongly associated with worse prognosis, migration-related disparities may help explain why some countries do not achieve mortality reductions proportional to

treatment coverage alone. Persistent mortality inequalities therefore reflect not only treatment access, but also structural barriers affecting continuity of care and timely diagnosis.

Figure 1. Mean age-standardized AIDS/HIV mortality rates per 100.000 inhabitants in European countries, 2012 to 2023.

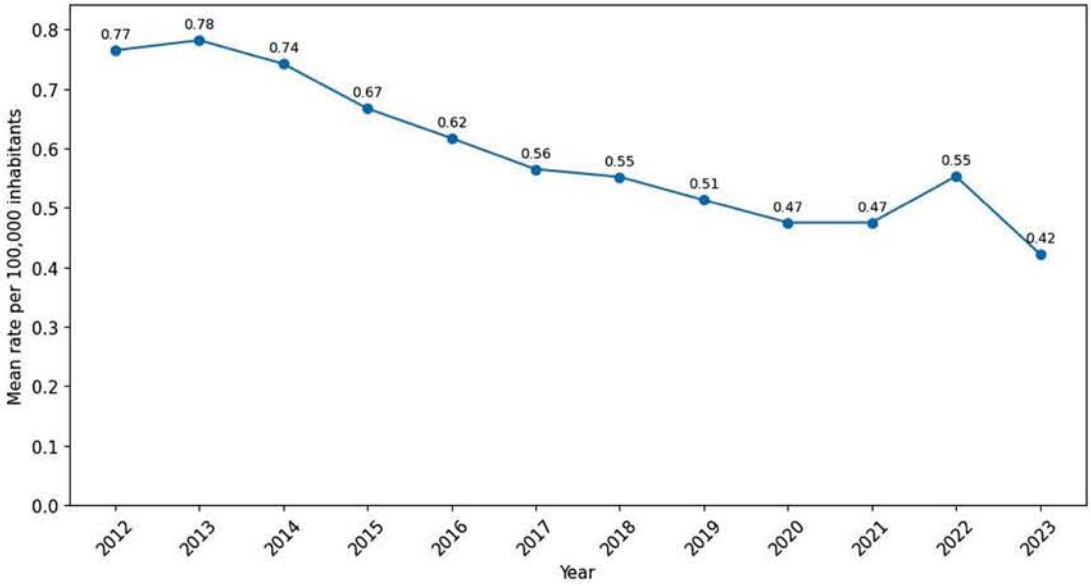

Source: elaborated by authors based on Eurostat data.

Figure 2. Age-standardized AIDS/HIV mortality rates in European countries in 2023, expressed per 100.000 inhabitants

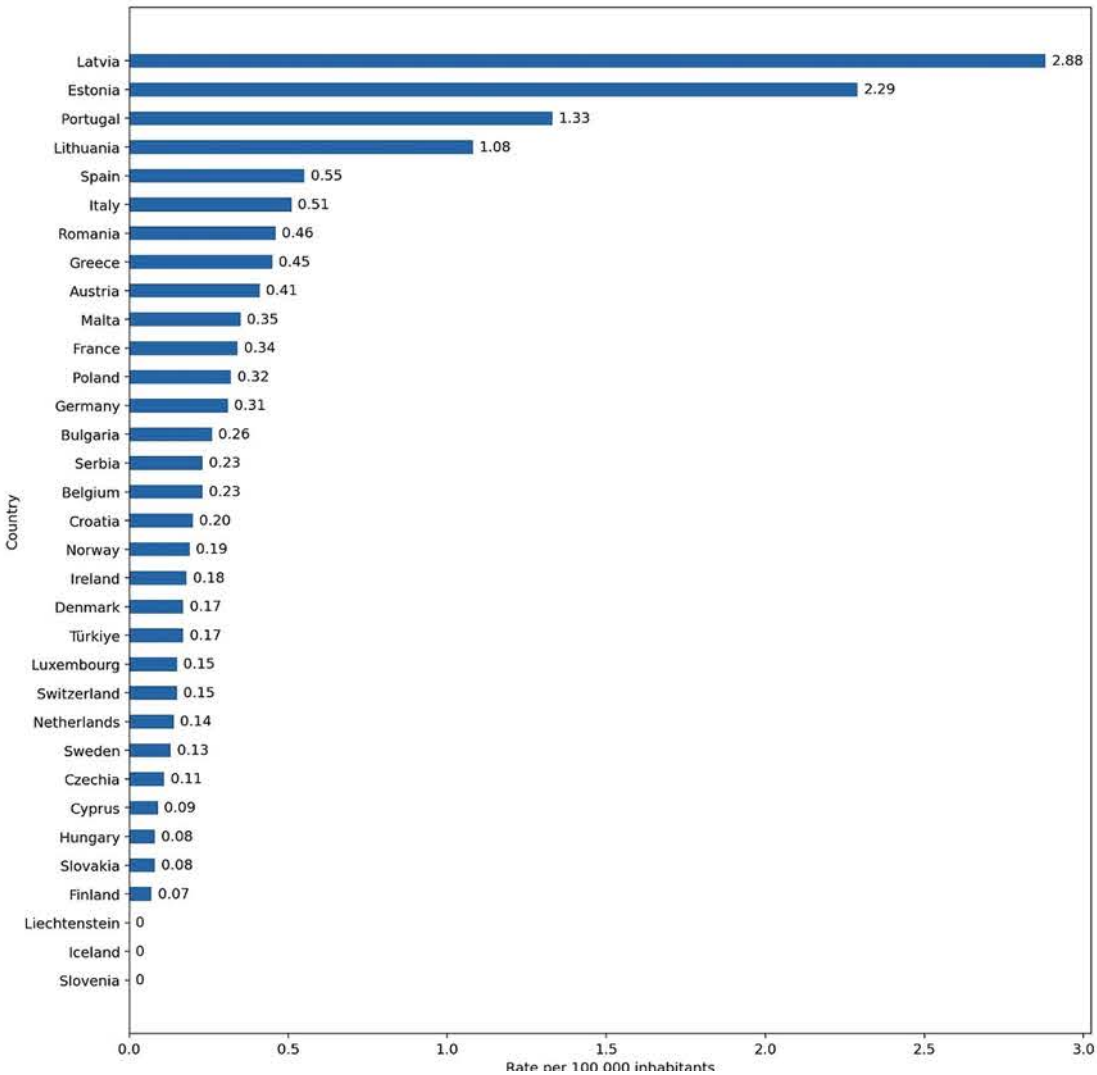

Source: elaborated by authors based on Eurostat data.

Figure 3. Annual Percent Change in age-standardized AIDS/HIV mortality rates per 100.000 inhabitants in European countries, 2012 to 2023.

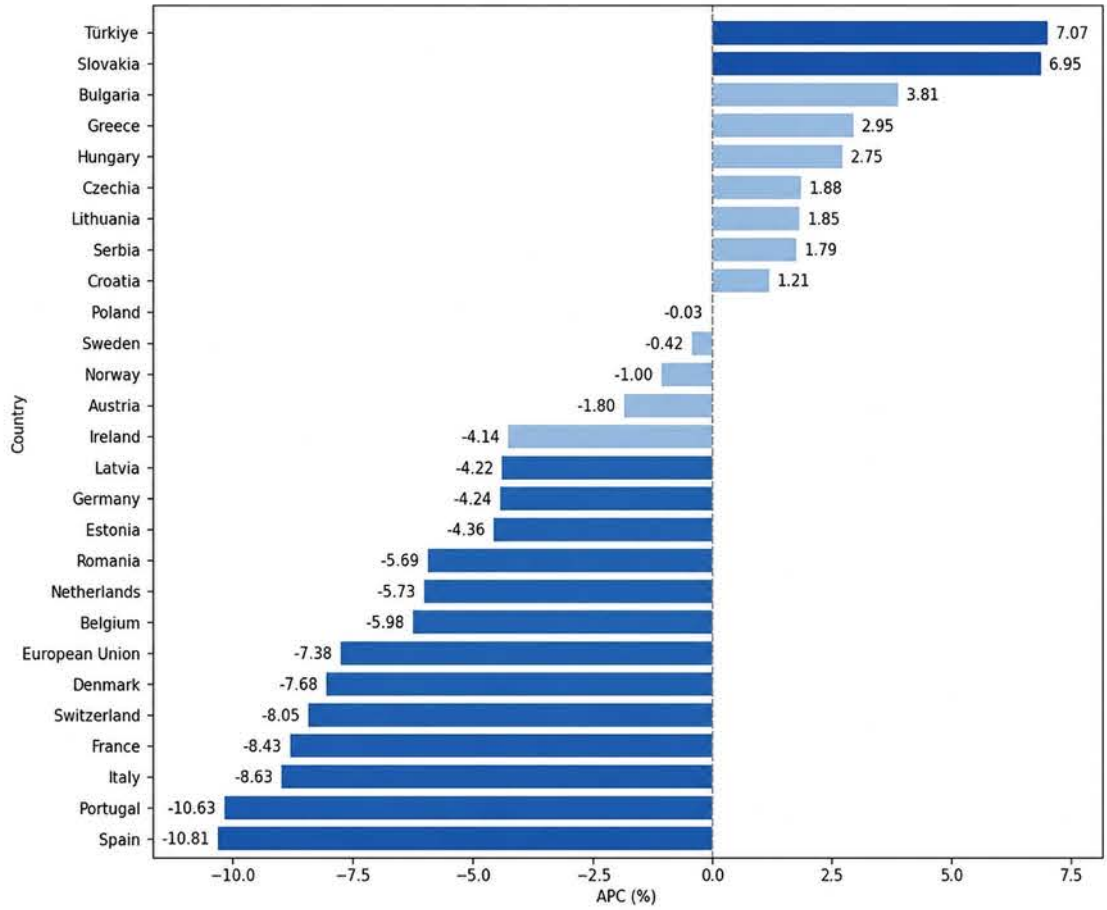

Dark blue bars represent countries with statistically significant trends ($p<0.05$), while light blue bars represent countries without statistical significance. The dashed vertical line at 0 marks the point of no annual change. *APC=Annual Percent Change; Source: elaborated by authors based on Eurostat data.*

Source: Elaborated by the authors based on EUROSTAT data.

Conclusions

HIV/AIDS mortality in Europe declined sharply between 2012 and 2023, but not equitably. The current pattern reflects the expansion of ART alongside persistent structural barriers, with late diagnosis, especially among migrant populations, remaining a key limitation to further mortality reduction. Future reductions will likely depend not only on maintaining ART availability, but also on strengthening early diagnosis, linkage to care, retention in treatment, and equitable healthcare access for vulnerable populations.

EADV CONGRESS
VIENNA
30 SEP - 3 OCT 2026

Abstract N°: 4248

Rising Incidence of Syphilis and the Potential Impact of the COVID-19 Pandemic: A Single-Center Retrospective Study from 2017-2024

Natalia Welc*[1], Maksymilian Markwitz[1], Julia Woźna[1, 2], Adriana Polańska[1], Ryszard Żaba[1], Kevin Kavanagh[3]

[1] Department of Dermatology and Venereology, Poznan University of Medical Sciences, Poznan, Poland

[2] Doctoral School, Poznan University of Medical Sciences, Poznan, Poland

[3] Department of Biology, Maynooth University, Maynooth, Ireland

Introduction

Syphilis remains a major public health challenge worldwide, with a marked resurgence observed in many countries over recent years. Despite the availability of effective diagnostic tools and treatment, changing sexual behaviors, population mobility, and gaps in prevention strategies continue to contribute to increasing transmission rates. The COVID-19 pandemic further disrupted healthcare systems, sexually transmitted infection (STI) screening, access to diagnostic services, and continuity of care, potentially influencing both syphilis transmission dynamics and case detection. This study aimed to analyze temporal trends and selected sociodemographic, epidemiological, and clinical characteristics of patients diagnosed with syphilis between 2017 and 2024, with particular emphasis on the potential impact of the COVID-19 pandemic.

Materials and Methods

A retrospective analysis was performed on patients diagnosed with syphilis in the Department of Dermatology and Venereology between 2017 and 2024. Demographic, epidemiological, and clinical variables were assessed, including sex, place of residence, sexual contacts, disease stage, symptomatic presentation, HIV co-infection, prior STI history, and substance use. Temporal trends in annual incidence were analyzed using Poisson regression and Spearman correlation. Additional comparisons were conducted between the pre-pandemic (2017-2019) and pandemic/post-pandemic (2020-2024) periods, as well as between the early (2020-2021) and later (2022-2024) pandemic phases. Fisher's exact test and $\chi 2$ analysis were used where appropriate, with $p < 0.05$ considered statistically significant.

Results

A total of 582 patients with syphilis were included. A significant increasing temporal trend in annual syphilis diagnoses was observed between 2017 and 2024 (Poisson regression, $p < 0.001$; Spearman's $\rho = 0.83$, $p = 0.010$). The number of annual cases remained relatively stable before the pandemic (44-51 cases/year in 2017-2019), declined in 2020 (40 cases), and subsequently increased markedly from 2021 onward. The mean annual number of cases in the later pandemic/post-pandemic period increased by approximately 84% compared with the pre-pandemic years ($p < 0.001$). This increase was driven predominantly by male patients, whereas the rise among women was not statistically significant. Men and urban residents predominated throughout the study period. Significant temporal associations were identified between year of diagnosis and type of sexual contact ($p = 0.037$), disease stage ($p = 0.0004$), HIV co-infection ($p = 0.013$), and symptomatic presentation ($p = 0.002$). Compared with the pre-pandemic period, symptomatic syphilis was more frequently observed during the pandemic/post-pandemic years (72% vs. 57%, $p = 0.0025$), and patients with a prior history of STIs were significantly more common (12% vs. 3%, $p = 0.0012$). No major differences were observed between the early and later phases of the pandemic.

Conclusions

This study demonstrates a significant increase in syphilis incidence between 2017 and 2024, with a transient decline during the first year of the COVID-19 pandemic followed by a pronounced and sustained rise in subsequent years. The temporary reduction in diagnoses in 2020 likely reflected restricted healthcare access, reduced STI screening, and underdiagnosis during the early pandemic period, whereas the later increase may indicate delayed detection, restoration of healthcare services, and ongoing transmission within high-risk populations. Although the overall sociodemographic profile of patients remained relatively stable, significant changes in symptomatic presentation, disease stage, HIV co-infection, and transmission patterns were observed over time. These findings highlight the substantial indirect impact of public health crises on STI surveillance and emphasize the need for resilient screening programs, uninterrupted access to diagnostic services, and targeted prevention strategies.

EA DV CONGRESS
VIENNA
30 SEP - 3 OCT 2026

Abstract N°: 4274

A retrospective cross-sectional study of clinical spectrum of syphilis in tertiary care center.

Sakshi Nehete*[1], Swagata Tambe[1], Kirti Jangid[1]

[1] Seth V C Gandhi and M A Vora Municipal General Hospital, Ghatkopar east., Mumbai, India

Introduction

Syphilis is a sexually transmitted disease with diverse, often nonspecific clinical features. It typically manifests in primary, secondary, and latent stages. Given its nonspecific presentation, correlating symptoms with the patient's sexual history is crucial for accurate diagnosis and management decisions, particularly in secondary syphilis.

Aims and Objectives:

Aim

To study clinical and serological profile of patients presenting with clinical spectrum of syphilis.

Objectives

- To study clinical and serological profile of patients with syphilis.
- To assess HIV co-infection and associated complications.
- To highlight the diagnostic challenges of syphilis due to its nonspecific presentations, especially in secondary syphilis.

Materials and Methods

A retrospective analysis of 229 patients was conducted. Detailed history with focus on sexual behavior, general and cutaneous examination, serological investigations and associated conditions like HIV were studied. Cases were categorized as primary, secondary and latent syphilis based on clinical correlation.

Results

Diagnosis	No of cases (N)	Mean age	Sex (F, M, transgender)	Common clinical findings	Sexual history
Primary	6 (2.62%)	25.8 yrs	2,3,1	Solitary erythematous plaque/ulcer over penile shaft or glans with induration	Predomi heterose vaginal intercour
				Multiple	Predomi

Overall Trends

Male predominance (141 males: 78 females: 10 transgender)

Latent syphilis is most common type (90.82 %)

Age group: Most common age group affected is 26-35 years (74, 32.31%). Second most common age group affected is 18-25 years (73,31.87 %) followed by 36-45 years (35, 15.28 %) followed by

more than 55 years (21, 9.17%). The 46–55 years age group accounted for 18 cases (7.86%), followed by the paediatric age group (<10 years) with 8 cases (3.49%), highlighting that syphilis should also be considered as a potential differential diagnosis in children. The majority of patients belonged to the 26–35 years age group, which constituted the mean age group of the study population.

Out of the pregnant women who registered for Antenatal care,20 tested positive for RPR (Rapid Plasma Reagin). Of these 20 women, one tested positive for HIV co-infection. 12 out of 20 women had less than 1:8 or low titres of RPR (60%). The remaining 8 women (40%) tested positive for RPR higher than or equal to 1:8. When neonates delivered by these 20 women were tested for syphilis, 7 neonates were found to be positive.

All patients were treated according to the latest National AIDS Control Organisation (NACO) guidelines (2024), with Benzathine penicillin G administered based on the stage of syphilis.

All seropositive pregnant women (n=20) received three weekly doses of Benzathine penicillin G 2.4 million units intramuscularly for three consecutive weeks.

All neonates were managed in accordance with the latest National AIDS Control Organisation (NACO) guidelines (2024).

Conclusions

Syphilis continues to exhibit diverse and nonspecific clinical manifestations, posing diagnostic challenges, particularly in secondary syphilis. In our study, latent syphilis was the most common presentation, emphasizing the importance of routine serological screening even among asymptomatic individuals. Detailed sexual history, combined with clinical and serological correlation, remains essential for accurate diagnosis and staging. HIV co-infection and seropositivity among antenatal women underscore the need for routine screening programs, early diagnosis, prompt treatment, partner notification, and counselling regarding safe sexual practices to reduce disease transmission and associated morbidity.

EADV CONGRESS
VIENNA
30 SEP - 3 OCT 2026

Abstract N°: 4335

B-Cell Activation and Coagulation Abnormalities in the Serofast State After Early Syphilis Treatment

Martyna Kiołbasa*[1], Konrad Kaminiów[1], Damian Kadylak[2], Maciej Pastuszczak[1]

[1] Medical University of Silesia, Katowice, Szpital Specjalistyczny w Zabrzu, Zabrze, Poland

[2] Uniwersyteckie Centrum Kliniczne, Gdańsk, Poland

Introduction

A considerable number of individuals treated for early syphilis do not achieve the anticipated ≥4-fold reduction in non-treponemal antibody titers despite receiving guideline-based therapy, posing a frequent clinical challenge. Although this serofast condition is commonly regarded as a possible indicator of therapeutic failure, additional antibiotic courses often provide little benefit, implying that mechanisms other than persistent infection may be involved. Since non-treponemal assays detect anticardiolipin-directed antibodies, we proposed that prolonged serological positivity could be linked to infection-induced immune imbalance rather than continued *Treponema pallidum* activity.

Materials and Methods

This prospective investigation enrolled 36 adults diagnosed with early syphilis who received standard treatment with benzathine penicillin. After 6 months, 11 patients lacking an adequate serological response underwent cerebrospinal fluid examination; 3 individuals diagnosed with neurosyphilis were subsequently excluded. The remaining cohort was divided into serofast patients (n = 8) and serologically cured patients (n = 25). An additional group of 11 healthy volunteers served as controls. Plasma samples obtained before treatment and during follow-up were assessed for phospholipid-sensitive coagulation parameters, antiphospholipid antibodies, serum B-cell activating factor (BAFF) concentrations, and circulating B-cell counts.

Results

Compared with serologically cured participants, serofast patients showed persistent prolongation of phospholipid-dependent coagulation tests (all qBH < 0.01; δ = 0.75–0.83). They additionally demonstrated elevated BAFF concentrations and increased peripheral B-cell numbers both prior to and following therapy. Posttreatment VDRL titers were strongly associated with BAFF levels (ρ = 0.93, p < 0.001), B-cell counts (ρ = 0.73, p < 0.001), as well as several coagulation-related variables.

Conclusions

Sustained non-treponemal seroreactivity following treatment of early syphilis appears to be linked with enhanced B-cell activity and abnormalities in phospholipid-dependent coagulation pathways. After excluding neurosyphilis, these observations support the concept that the serofast state may represent an infection-induced immune-mediated phenotype rather than evidence of ongoing *T. pallidum* infection, which may have important consequences for posttreatment clinical management.