EA DV CONGRESS
VIENNA
30 SEP - 3 OCT 2026

Abstract N°: 14

Early Educational Mediation in Vitiligo: A School-Based Public Health Tool to Promote Tolerance and Reduce Stigmatization

Martine Carré[1], Corinne Dechelette*[2, 3]

[1] ASSOCIATION FRANCAISE DU VITILIGO, Paris, France

[2] PEAUrigami Art médical - LA PEAU AUTREMENT, Toulouse, France

[3] SFSHP - Société Française des Sciences Humaines sur la PEAU, Paris, France

Introduction

Background:Vitiligo is a visible chronic skin disorder associated with significant psychosocial impact. Despite being medically harmless and non-contagious, misconceptions and stigmatization remain common. Early childhood represents a critical period in the development of social perceptions of difference; therefore, early educational interventions may help foster tolerance and empathy. This project is part of the educational collection Analogical Skin, Book 4, The Taste of Skin, which proposes a sensory and visual analogy comparing common dermatoses to cakes in order to make dermatological diversity more accessible to children.

Materials and Methods

An exploratory qualitative study was conducted to evaluate the acceptability and perceived relevance of an educational mediation tool based on a visual analogy designed to raise children's awareness of vitiligo and help reduce stigmatization. An online questionnaire was distributed by the French Vitiligo Association (AFV). The pedagogical approach relied on a visual analogy (marble cake) combined with a simple medical explanation of vitiligo (pathophysiology, non-contagious nature). Responses from patients, parents of affected children, and education professionals were analyzed using descriptive and thematic methods.

Results

A total of 148 participants completed the questionnaire. The majority of respondents (77.7%) considered the approach accessible, engaging, and helpful in facilitating dialogue with children. Reported benefits included improved understanding of vitiligo, reassurance regarding its non-contagious nature, and a perceived normalization of visible skin differences. However, some respondents expressed concerns about potential misinterpretations or teasing, highlighting the need for pedagogical supervision involving teachers and patient association representatives.

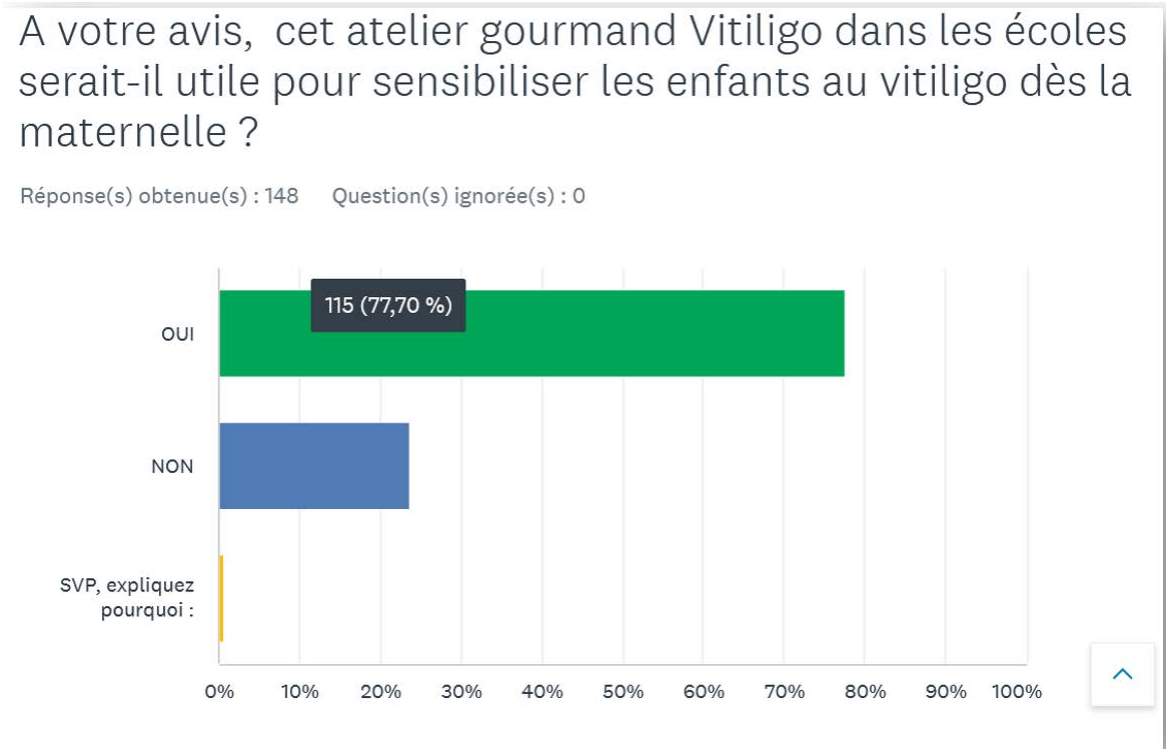

Conclusions

Educational approaches based on visual analogies may represent a relevant tool for early vitiligo awareness in school settings. When integrated within a structured educational framework and developed in consultation with patient communities, such strategies could help promote tolerance and reduce stigmatization of visible skin differences from an early age, in line with the recommendations of the European Dermatology Forum consensus on the management of vitiligo (JEADV, 2013).

EA DV CONGRESS
VIENNA
30 SEP - 3 OCT 2026

Abstract N°: 23

Biophysical Characteristics of Vitiligo-Affected Skin Before and After Complex Treatment Using Cell Technologies

Kateryna Karpenko*[1]

[1] Virtus, Odesa, Ukraine

Introduction
Vitiligo is an acquired chronic disorder belonging to the group of dyschromias. Its pathogenesis is associated with reduced melanin production and melanocyte loss; however, the underlying mechanisms remain incompletely understood, which complicates treatment. This study aimed to assess the biophysical characteristics of vitiligo-affected skin before and after complex treatment and to evaluate their potential relevance for patient management.

Materials and Methods
A total of 107 patients aged 19–65 years with confirmed vitiligo were included in the study. A comparative assessment of the biophysical characteristics of vitiligo-affected skin was performed in two groups before treatment and 16 weeks after treatment initiation: the main group (56 patients), who received melanocyte-keratinocyte suspension (MKS) and automezoconcentrate (AMC) as part of a complex treatment approach, and the comparison group (51 patients), who received conventional treatment. Conventional treatment included UVB phototherapy and topical calcineurin inhibitors. The complex treatment protocol included induction of pigmentation in donor skin using 311-nm UVB, punch biopsy of donor skin, transfer of the specimen to a biotechnology laboratory for preparation of an individualized MKS, intradermal administration of MKS, and subsequent 311-nm UVB phototherapy. All participants underwent ultrasound assessment of skin lesions to measure epidermal and dermal thickness, Doppler sonography of skin microcirculation to determine volumetric blood flow, corneometry to assess skin hydration, and dermoscopy to evaluate pigmentary and vascular features.

Results
Before treatment, decreased hydration was observed in 62 (57.9%) patients; in the overall study population, hydration was 36.0 [29.0; 48.0] units. Altered blood flow according to Doppler sonography was detected in 20 (19.0%) patients; in the overall study population, the volumetric blood flow rate was 0.07 [0.06; 0.09] ml/cm3/min. Dermoscopic examination showed complete pigment loss in 99 (92.5%) patients and partial pigment loss in 8 (7.5%) patients. At 16 weeks after treatment initiation, the hydration level was 48.0 [44.0; 52.0] units in the main group and 42.0 [32.5; 48.5] units in the comparison group ($p<0.001$). Repigmentation of 75% or more was observed in 38 (67.9%) patients in the main group and in 26 (51.0%) patients in the comparison group. No statistically significant difference in dermoscopic pigment signs was found between the groups at 16 weeks ($p=0.373$). At the same time point, the volumetric blood flow rate was 0.09 [0.07; 0.09] ml/cm3/min in the main group and 0.07 [0.06; 0.08] ml/cm3/min in the comparison group ($p<0.001$).

Conclusions
Vitiligo-affected skin was characterized by decreased hydration and altered microcirculation. Changes in biophysical parameters were observed during follow-up and may reflect functional disturbances relevant to melanogenesis. The findings suggest that dynamic assessment of biophysical skin characteristics may be useful in the evaluation of treatment response in patients with vitiligo. Further study may help clarify the role of such parameters in optimizing treatment approaches.

EA DV CONGRESS
VIENNA
30 SEP - 3 OCT 2026

Abstract N°: 35

Unusual presentation of facial becker nevus with marked cosmetic concern in a young female - A rare case report

Riya Kalawat*[1], Moin Siddiqui[1]

[1] Eras Lucknow Medical College and Hospital, Lucknow, India

Introduction

Becker melanosis also known as becker nevus is begin epidermal cutaneous hamartoma characterized by well-defined hyperpigmented macule with overlying hypertrichosis. It was first described by S. becker in 1949. It typically manifests during adolescence, with strong male predominance. (1) It is commonly present over proximal upper trunk and shoulders. It rarely involve areas such as face, neck, extremities, abdomen and hips. Facial involvement in becker nevus is rare and its occurance in females is particularly uncommon. Further it is cosmetically concerning and can mimic other causes of hyperpigmentation or localized hypertrichosis. (2) Hence, we report an unusual case of localized hypermelanosis occurring at an unusual location in a young female, presenting with prominent hypertrichosis. Facial hyperpigmentation with hypertrichosis in a female patient represents an unusual presentation and can lead to diagnostic confusion with other pigmentary and endocrine disorders. Therefore, this case highlights need to consider becker nevus in the differential diagnosis of localized facial hyperpigmentation with excessive hair growth.

Case Presentation

A 20-year-old female presented to dermatology outpatient department with single dark colored lesion over the chin since birth. She also complained of increase in hair growth over dark patch from 6 months. On cutaneous examination single well defined hyperpigmented macule of size 5 x 10 cm was present over right mandibular region, neck and some extension over the oral mucosa. It showed prominent hair growth as compared to the surrounding skin and the other side of the face. No other site was involved. No history of similar complaints in the family. No history of any extracutaneous manifestations and musculoskeletal abnormalities. Dermoscopy evaluation showed blotchy hyperpigmentation with perifollicular hypopigmentation. On basis of history, clinical and dermoscopic examination diagnosis of becker nevus was made. And patient was started with combination of ND YAG laser and IPL laser to tackle hyperpigmentation and hypertrichosis.

Table 1- Previously published cases of patients with facial becker nevus

S No.	Author	Age/Sex	Country	Presentation
1.	Acharya R et al (2018)	19/M	Maldives	Hyperpigmented patch (5×10 cm) with geographic pattern over the distal half of the left cheek, chin, and neck [7]
2.	Yao H et al (2024)	16/M	China	Brownish perifollicular macules with hypertrichosis on the left cheek as opposed to the same location on the other side of the face. [2]
3	Our case	20/F	India	single well defined hyperpigmented macule (5x10 cm) over right mandibular region, neck and some extension over the oral mucosa

Conclusion

Facial becker nevus in a female patient is very rare and cosmetically concerning. Treating clinicians should also consider becker nevus as a differential diagnosis even in female patients with lesions showing concurrent melanosis and hypertrichosis. Early recognition allows appropriate counselling and tailored management, particularly in cosmetically distressing cases.

EA DV CONGRESS
VIENNA
30 SEP - 3 OCT 2026

Abstract N°: 39

Comparative study on the therapeutic efficacy of topical bimatoprost (0.03%) ophthalmic solution and tacrolimus (0.1%) ointment in stable vitiligo.

Riya Kalawat*[1], Kshitij Saxena[1], Amarjeet Singh[1]

[1] Eras Lucknow Medical College and Hospital, Lucknow, India

Introduction

Vitiligo is a chronic autoimmune disorder characterized by loss of melanocytes, leading to depigmented macules and significant psychological burden. Topical calcineurin inhibitors such as tacrolimus are widely used as a first line therapy for vitiligo.Bimatoprost, a prostaglandin F2α analogue, has demonstrated melanogenesis-stimulating properties and is emerging as a potential therapeutic alternative. However, comparative studies between bimatoprost solution and other therapies are limited.This study aimed to compare the efficacy and safety of topical bimatoprost 0.03% ophthalmic solution and tacrolimus 0.1% ointment in patients with stable vitiligo. Hence bimatoprost can be a newer treatment modality with minimal side effects.

Case Presentation

A randomized comparative study was conducted in 50 patients with stable vitiligo involving <5% body surface area. Patients were divided into two groups, Group A were advised to apply topical bimatoprost 0.03% ophthalmic solution over the lesion twice daily for 12 weeks and Group B was advised to apply topical tacrolimus 0.1% ointment over the lesion twice daily for 12 weeks. Follow up was done at 4,8 and 12 weeks. Efficacy was assessed using the Vitiligo Area Scoring Index (VASI), subjective scoring and photographic documentation. Both the groups showed statistically significant reduction in VASI scores ($p<0.001$). In group A, mean VASI decreased from 1.23±1.39 to 0.21±0.23 (82.9% reduction), while in Group B it decreased from 1.40±1.43 to 0.30±0.35 (78.6% reduction).Bimatoprost demonstrated a faster onset of repigmentation, particularly in facial lesions, although overall efficacy between both the groups was comparable. Subjective improvement was also similar. Therefore, bimatoprost was very well tolerated with few patients showing hypertrichosis. Tacrolimus on the other hand was associated with transient burning and itching. No serious side effects were reported in both the modalities.

Table 1 - Comparative evaluation of VASI Reduction and Subjective Outcomes in Group A (Bimatoprost 0.03% ophthalmic solution) and Group B (Tacrolimus 0.1% ointment) at 4, 8 and 12 weeks.

Time Period	Group (N=50)	VASI (Vitiligo Area Scoring Index) Score					Subjective Outcome				
		Mean VASI± SD	Mean change in VASI ±SD	% change	'p' value (Paired t-test)	Inter group comparison (Unpaired t-test)	Excellent	Good	Moderate	Poor	p value
Baseline	A (N=25)	1.23± 1.39	-	-	-	t=0.421; p=0.676	-	-	-	-	-
	B(N=25)	1.40± 1.43	-	-	-		-	-	-	-	-
4 weeks	A (N=25)	0.76± 0.83	-0.46± 0.62	-37.4	t=3.75; p=0.001	t=0.877; p=0.385	1 (4.0%)	7 (28.0%)	9 (36.0%)	8 (32.0%)	0.789
	B (N=25)	1.00± 1.03	-0.40± 0.55	-28.6	t=3.63; p=0.001		0	7 (28.0%)	10 (40.0%)	8 (32.0%)	
8 weeks	A (N=25)	0.47± 0.49	-0.76± 0.99	-61.8	t=3.82; p=0.001	t=1.000; p=0.322	0	7 (28.0%)	11 (44.0%)	7 (28.0%)	0.747
	B (N=25)	0.65± 0.76	-0.74± 0.93	-52.9	t=3.93; p=0.001		0	7 (28.0%)	11 (44.0%)	5 (20.0%)	
12 weeks	A (N=25)	0.21± 0.23	-1.02± 1.22	-82.9	t=4.17; p<0.001	t=1.013; p=0.316	2 (10.0%)	13 (52.0%)	8 (32.0%)	2 (8.0%)	0.966
	B (N=25)	0.30± 0.35	-1.10± 1.26	-78.6	t=4.35; p<0.001		3 (12.0%)	13 (52.0%)	7 (28.0%)	2 (8.0%)	

Conclusion

Bimatoprost 0.03% ophthalmic solution is a less explored treatment modality which is effective in reducing disease severity. It is as effective as tacrolimus 0.1% ointment in treatment of stable vitiligo. While both the therapies showed comparable overall efficacy, Bimatoprostm may provide earlier repigmentation, particularly in cosmetically sensitive areas. Therefore bimatoprost can be a alternative threapeutic modality in stable vitiligo, although larger studies and longer follow up are needed.

Abstract N°: 72

A Clinical, Quality Of Life And Dermatoscopic Evaluation Of Facial Melasma.

Rashmi Sriram*[1]

[1] BGS MCH HOSPITAL, bengaluru, India

Introduction

Melasma is a common acquired hypermelanoses of multifactorial etiology ,characterized by symmetric brown macules over the sun exposed areas . It is classified clinically as epidermal, dermal and mixed , depending on clinical features and wood's lamp examination.1 Dermascopy in melasma is used for differentiation from other hyperpigmentary disorders, monitoring of treatment and the related adverse effects. Early subtle cases of melasma can be detected on dermatoscopy.2 Dermatoscopy can help in differentiating melasma from other conditions with facial hyperpigmentation, i.e. lichen planus pigmentosus, photomelanosis, seborrheic melanosis, nevus of Ota, ochronosis, lentigines, freckles, etc. especially since a biopsy on face is best avoided3. The aim of the study is to characterize clinical , quality of life and dermoscopic pattern of melasma in asian population as limited studies are available.

Materials and Methods

This descriptive study included 150 patients with facial melasma over a two-year period (January 2016 to January 2018). Clinical evaluation involved recording demographic data, melasma pattern, MASI score for severity, and quality of life assessment using the MELASQOL questionnaire. Dermoscopic examination was performed using a Dermlite DL3 dermascope, and findings were documented. Data were analyzed using descriptive statistics, Mann-Whitney U test, and Kruskal-Wallis tests.

Results

Females comprised 69.3% of participants, with a mean age of 40.3 ± 9.1 years. The centrofacial pattern was predominant (67.4%), followed by malar (31.3%) and mandibular (1.3%). The mean duration of melasma was 4.3 ± 3.7 years. MASI scores indicated moderate severity, with a mean of 25.6 ± 9.1. Quality of life impact varied, with 19.3% bothered all the time and 32.0% not or sometimes bothered. Dermoscopic evaluation revealed a predominance of the reticuloglobular pattern (52.7%), followed by granular (18.0%), unpatterned (16.0%), and telangiectatic (12.0%) patterns. Significant trends included increased reticuloglobular features with higher sun exposure and variations in dermoscopic patterns by gender and comorbidity status. No significant differences were observed in MASI scores or duration across melasma patterns.

Conclusions

The study highlights the predominance of centrofacial melasma with moderate clinical severity and variable quality of life impact in the Asian population. Dermoscopy proves valuable for non-invasive diagnosis and monitoring, with reticuloglobular patterns correlating with sun exposure. Integrating clinical, dermoscopic, and quality of life assessments can guide personalized management strategies to optimize treatment outcomes and improve patient quality of life.

EADV CONGRESS
VIENNA
30 SEP - 3 OCT 2026

Abstract N°: 94

Acquired Dermal Macular Hyperpigmentation: A Compartment-Based Pathophysiologic Framework for Therapeutic Repurposing

Hitaishi Mehta*[1]

[1] Post Graduate Institute of Medical Education and Research, Chandigarh, India

Introduction
Acquired dermal macular hyperpigmentation (ADMH), encompassing lichen planus pigmentosus, erythema dyschromicum perstans, and pigmented contact dermatitis/Riehl's melanosis, is a cosmetically distressing and therapeutically challenging disorder that predominantly affects individuals with skin of color. Although traditionally viewed as a pigmentary disorder, emerging evidence suggests that ADMH represents a low-grade interface dermatosis driven by environmental exposures and immune-mediated injury.

Materials and Methods
The objective of this review was to synthesize current evidence on etiologic triggers and cellular mechanisms underlying ADMH. This narrative synthesis integrates clinical observations, histopathologic findings, and recent molecular studies to outline a mechanistic framework linking environmental triggers to interface damage and persistent dermal pigmentation.

Results
Current evidence supports a model in which keratinocyte stress and altered epidermal signaling initiate disease, followed by CD8+ T-cell mediated interface damage, basal keratinocyte apoptosis, and melanin incontinence. Dermal melanophages contribute to pigment persistence, while fibroblasts and stromal signaling may amplify chronicity through paracrine effects. This framework allows ADMH to be viewed by pathogenic compartments: keratinocyte-driven initiation, T-cell–mediated injury, macrophage-mediated pigment retention, and fibroblast-associated stromal persistence. Therapeutically, these pathways suggest rational repurposing of immunomodulators, keratinocyte-directed agents such as isotretinoin, macrophage/pigment-clearance approaches, autophagy-promoting strategies, and emerging senolytic or fibroblast-targeted interventions.

Conclusions
ADMH should be conceptualized as a biologically active interface disorder rather than pigment deposition alone. A compartment-based therapeutic model may provide a more rational foundation for future targeted treatment studies.

EA DV CONGRESS
VIENNA
30 SEP - 3 OCT 2026

Abstract N°: 101

Quality and Reliability of Melasma-Related Content on TikTok: A Cross-Sectional Analysis Using Validated Scales

Thais Barros Felippe Jabour*[1], Ana Carolina Putini Vieira[1], Ana Carolina Ventura de Santana de Jesus[2], Ana Clara Felix de Farias Santos[3], Daniel Simao de Andrade[1]

[1] University of Santo Amaro, São Paulo, Brazil

[2] Escola Bahiana de Medicina e Saúde Pública, Salvador, Brazil

[3] City University of São Paulo, São Paulo, Brazil

Introduction

Melasma is a chronic, recurrent, and multifactorial hypermelanosis that mainly affects women of reproductive age and individuals with darker phototypes. Given its therapeutic complexity and cosmetic impact, many patients seek health information on social media. TikTok has emerged as a major source of lay dermatological content, although it also carries substantial potential for the spread of inaccurate information.

Materials and Methods

This cross-sectional observational study evaluated melasma-related videos on TikTok. A new account was created to minimize prior algorithmic influence. Using the hashtag #melasma, the 100 most popular videos were selected for analysis. Each video was independently assessed by two dermatologists using the modified DISCERN (mDISCERN; 0-5) and Global Quality Scale (GQS; 1-5), with higher scores indicating greater reliability and quality. Data on creator type, content format, mention of risk factors, and recommended treatments were collected. Engagement metrics, including views, likes, shares, and saves, were also recorded. Statistical analyses were performed using R version 4.5.0.

Results

Among the 100 videos analyzed, educational content predominated (63%), followed by patient testimonials (24%), documentary-style videos (11%), and procedural demonstrations (2%). Regarding authorship, 44% were produced by physicians, 35% by patients, and 21% by non-physician professionals. GQS scores were highest in educational videos (2.43 ± 0.98) and physician-created content (2.57 ± 1.00). Intermediate scores were observed among non-physician professionals (1.86 ± 0.91), whereas patient-generated videos showed the lowest quality scores (1.51 ± 0.74). A similar pattern was found for mDISCERN, with the highest mean scores among physicians (2.45 ± 1.04) and educational videos (2.33 ± 1.00), intermediate values among non-physician professionals (1.67 ± 1.02), and the lowest among patients (1.26 ± 0.70), documentary-style videos (0.91 ± 0.30), and procedural content (0.00). Notably, 65% of videos did not mention etiological or risk factors. Among the 86% that discussed treatment, topical therapies predominated (78%), followed by photoprotection (16%) and procedures (6%). The most frequently cited treatments included hydroquinone, tranexamic acid, niacinamide, glycolic acid, tinted and non-tinted sunscreens, azelaic acid, kojic acid, tretinoin, and vitamin C. In terms of engagement, videos by non-physician professionals had the highest mean number of views (1.63M ± 2.57M), followed by patients (1.27M ± 1.66M) and physicians (744K ± 1.24M). However, physician-created videos had the highest mean number of saves (7,360 ± 11,968) and shares (3,534 ± 7,512).

Conclusions

Melasma-related videos on TikTok showed a clear mismatch between informational quality and public reach. Although physician-created content achieved the highest reliability scores, it reached fewer viewers than content

produced by non-physician professionals and patients, which showed lower scientific quality. The predominance of treatment-focused videos with limited discussion of etiology, prevention, and pathophysiology may contribute to misleading self-care practices and unrealistic therapeutic expectations. These findings highlight the need for a stronger strategic presence of dermatologists on social media and reinforce the importance of digital health literacy and evidence-based communication in the online environment.

EADV CONGRESS
VIENNA
30 SEP - 3 OCT 2026

Abstract N°: 117

Auditory Evaluation in Patients with Vitiligo and Its Relationship with Oxidative Stress

Hatice Busra Karaman*[1], Emine Tamer[2], Ozcan Erel[2], Burak Hazır[2], Aygul Satır[2], Mehmet Kadir Ercan[2]

[1] Sincan Eğitim ve Araştırma Hastanesi, ankara, Türkiye
[2] Ankara Bilkent Şehir Hastanesi, Ankara, Türkiye

Introduction
Vitiligo is an acquired chronic depigmenting skin disease characterized by the loss of melanocytes. Its pathogenesis involves various mechanisms such as oxidative stress, inflammatory mediators, and autoimmunity. Studies have shown that vitiligo not only affects the skin but also leads to auditory abnormalities through the loss of melanocytes in the inner ear. Melanocytes are found in regions crucial for hearing metabolism and contribute to the electrical potential for cochlear hair cell function. Oxidative stress can directly damage hair cells, leading to hearing loss. This study aims to evaluate accompanying auditory disorders in vitiligo patients and investigate the pathogenesis of auditory disorders from the perspective of oxidative stress.

Materials and Methods
The study enrolled 80 patients with vitiligo and 80 age- and sex-matched healthy volunteers as controls. Conventional pure-tone audiometry and high-frequency audiometry were performed in both groups. Hearing threshold levels were evaluated at frequencies ranging from 0.25 to 8 kHz for pure-tone audiometry and from 9 to 12.5 kHz for high-frequency audiometry. In addition, serum total superoxide dismutase (SOD) enzyme activity, thiol–disulfide homeostasis, and ischemia-modified albumin (IMA) levels were measured in both the patient and control groups.

Results
Hearing loss was detected in 34 (42.5%) of vitiligo patients, while in 17 (21.3%) of the control group. The presence of hearing loss was statistically higher in the vitiligo group (p=0.017). Increasing age and late onset age in vitiligo patients were found to be associated with an increase in hearing loss. There was no statistically significant in thiol disulfide balance and IMA levels between vitiligo patients and control group (p>0.05). The median and interquartile range of total SOD activity were found to be 5.5 (4.37-7.86) U/L in the patient group and 4.66 (2.62-6.11) U/L in the control group. Total SOD activity was significantly higher in vitiligo patients than control group (p=0.013). A total SOD activity value >4.51 was found to be 71% sensitive and 50% specific for vitiligo. There was no statistically significant difference in oxidative stress markers between vitiligo patients with and without hearing loss (p>0.05).

Conclusions
Our study is the first to evaluate the relationship between hearing loss and potential hearing loss with oxidative stress markers in vitiligo patients. Elderly vitiligo patients and/or those with late-onset vitiligo are at risk for sensorineural hearing loss development. Although the pathogenesis of hearing loss and a parameter that could serve as a biomarker could not be determined in this study, further research focusing on broader pathways that may play a role in pathogenesis will shed light on this issue.

EADV CONGRESS
VIENNA
30 SEP - 3 OCT 2026

Abstract N°: 155

Rapid Repigmentation in Vitiligo with Crisaborole 2% Ointment

Shraddha Mahobia*[1]

[1] Peoples College of Medical Sciences and Research Centre, Bhopal, India

Introduction

Segmental vitiligo (SV) is a localized, often early-onset form of vitiligo with a unilateral distribution and rapid stabilization. Topical corticosteroids and calcineurin inhibitors remain mainstays but are limited by side effects and variable efficacy. Crisaborole 2% ointment, a selective phosphodiesterase-4 (PDE4) inhibitor, downregulates proinflammatory cytokines such as TNF-α, IL-17, and IL-23, implicated in melanocyte cytotoxicity. Although widely used in atopic dermatitis, its potential role in vitiligo has not been well characterized

Materials and Methods

Objective

To assess the clinical efficacy and tolerability of crisaborole 2% ointment as monotherapy in inducing repigmentation in segmental stable vitiligo unresponsive to prior treatment.

Methods

A prospective, open-label interventional study was conducted involving 12 patients (8 females, 4 males; mean age 23.6 ± 5.1 years) with segmental stable vitiligo for at least 12 months. All participants had shown minimal or no response to previous topical corticosteroids and/or calcineurin inhibitors and had no new lesions in the past year.Crisaborole 2% ointment was applied twice daily to affected areas for 16 weeks. Clinical evaluation was performed at baseline and every 4 weeks using:Vitiligo Area Scoring Index (VASI)Physician Global Assessment (PGA)Standardized digital photographyAdverse events and patient satisfaction were documented at each visit.

Results

Progressive perifollicular repigmentation was observed from week 8 onwards in most patients. At week 16:83% (10/12) achieved >50% repigmentation50% (6/12) achieved >75% repigmentationMean VASI reduction: 62.4 ± 11.2% ($p < 0.01$)PGA: “marked improvement” in 75% of casesFacial and truncal lesions responded more rapidly than acral lesions. Side effects were mild and transient, including short-lasting erythema and burning in 2 patients during the initial week. No systemic or pigmentary adverse events were recorded. Overall patient satisfaction was high, with 11 of 12 patients (92%) reporting significant improvement in confidence and willingness to continue treatment.

Conclusions

Crisaborole 2% ointment demonstrated notable efficacy and safety in achieving repigmentation in segmental stable vitiligo refractory to conventional therapy. By attenuating local inflammatory mediators through PDE4 inhibition, crisaborole may create a permissive microenvironment for melanocyte regeneration and pigment spread. Its non-steroidal nature, excellent tolerability, and ease of use make it a promising addition to the therapeutic armamentarium for localized vitiligo. Larger randomized studies are encouraged to validate these findings and explore its synergistic potential with phototherapy or surgical repigmentation methods.

POWERED BY M-ANAGE.COM

EA DV CONGRESS
VIENNA
30 SEP - 3 OCT 2026

Abstract N°: 161

Efficacy and safety of ritlecitinib in patients with nonsegmental vitiligo (NSV): results from the Tranquillo 2 Part Ia and Tranquillo Phase 3 randomized, double-blind, placebo-controlled, multicenter clinical trials

Iltefat Hamzavi*[1], David Rosmarin[2], Thierry Passeron[3, 4], Tatjana Lukic[5], Pranab Ghosh[6], Jose Rivas[7], Roni Adiri[8], Edward Nagy[9], Samantha Kurosky[5], Ernest Law[5], Jing 'Daisy' Zhu[9], Viktoria Eleftheriadou[10, 11, 12], Seemal R Desai[13, 14], Flora Xiang[15], Naoki Oiso[16], Khaled Ezzedine[17]

[1] Multicultural Dermatology Center, Henry Ford Health, Hamzavi Dermatology Specialists, Detroit, MI, United States
[2] Indiana University School of Medicine, Indianapolis, IN, United States
[3] University Côte d'Azur, Centre Hospitalier Universitaire Nice, Department of Dermatology, Nice, France
[4] University Côte d'Azur, Institut National de la Santé et de la Recherche Médicale (INSERM), U1065, C3M, Nice, France
[5] Pfizer Inc, New York City, United States
[6] Pfizer Inc, Cambridge, United States
[7] Pfizer SLU, Madrid, Spain
[8] Pfizer Pharmaceutical Israel Ltd, Herzliya, Israel
[9] Pfizer Inc., Collegeville, United States
[10] Dermatology, Royal Wolverhampton NHS Trust, Wolverhampton, United Kingdom
[11] Insititute of Applied Health Research, College of Medical and Dental Sciences, University of Birmingham, Birmingham, United Kingdom
[12] Walsall Manor Hospital, Walsall Healthcare NHS Trust, Walsall, United Kingdom
[13] Department of Dermatology, University of Texas Southwestern Medical Center, Dallas, TX, United States
[14] Innovative Dermatology, Plano TX, United States
[15] Department of Dermatology, Huashan Hospital, Fudan University, Shanghai, China
[16] Department of Dermatology, Kindai University Nara Hospital, Nara, Japan
[17] Department of Dermatology, Henri Mondor University Hospital and Université Paris-Est Créteil Val de Marne, Paris, France

Introduction

NSV is an autoimmune skin disease characterized by pigment loss due to melanocyte destruction. In a Phase 2b study of NSV treatment, ritlecitinib, an oral JAK3/TEC family kinase inhibitor, was efficacious & well-tolerated over 48 wk. The Phase 3 Tranquillo 2 (NCT06072183) Part Ia & Tranquillo (NCT05583526) studies evaluated the efficacy, safety, & tolerability of ritlecitinib 100 mg (R100) & ritlecitinib 50 mg (R50) vs placebo (PBO) (Tranquillo 2 Part Ia) and R50 vs PBO (Tranquillo) in patients with NSV over 52 wk.

Materials and Methods

Patients aged ≥18 y (Tranquillo 2) or ≥12 y (Tranquillo) with a diagnosis of active or stable NSV for ≥3 mo, body surface area (BSA) involvement 4%-60%, facial BSA ≥0.5%, Facial Vitiligo Area Scoring Index (F-VASI) ≥0.5 & Total (T)-VASI ≥3 were included. In Tranquillo 2 Part Ia, patients were randomized 3:1:1 to receive R100, R50, or PBO for 52 wk; in Tranquillo, patients were randomized 2:1 to receive R50 or PBO for 52 wk. In both trials,

coprimary endpoints were the proportion of patients achieving ≥75% improvement in F-VASI from baseline (F-VASI75) & T-VASI50 at Wk 52 in the R100 group (Tranquillo 2) or the R50 group (Tranquillo) vs PBO. Key secondary endpoints included % change from baseline (%CFB) in F-VASI/T-VASI at Wk 24/36/52, the proportion of patients achieving F-VASI75/T-VASI50 at Wk 24/36 & T-VASI75 at Wk 52, & Patient Global Impression of Severity–Face/Vitiligo (PGIS–F/V) response at Wk 52. In Tranquillo 2, R50 vs PBO comparisons were not alpha-controlled. Safety was monitored throughout both studies.

Results

The overall Tranquillo program included 2174 patients with NSV across 271 sites worldwide. In Tranquillo 2 Part Ia, 622, 206, & 208 patients received R100, R50, and PBO, respectively. Mean age was 47.5 years. A significantly higher proportion of patients receiving R100 vs PBO achieved F-VASI75 (21.9% vs 2.4%; *P*<0.000001) & T-VASI50 (13.0% vs 2.4%; *P*<0.000001) at Wk 52 (**Fig 1A**). %CFB in F-VASI at Wk 24/36/52 & F-VASI75 response at Wk 24/36 were significantly greater for R100 vs PBO (*P*<0.05; **Table**). %CFB in T-VASI at Wk 24/36/52 & T-VASI50 response at Wk 36 were significantly greater for the R100 group vs PBO (*P*<0.05; **Table**). PGIS−F/V responses at Wk 52 for R100 vs PBO, respectively, were 42.9% vs 18.3% & 32.3% vs 17.3% (*P*<0.05). In the R100, R50, vs PBO groups, treatment-emergent adverse events (TEAEs) occurred in 67.7%, 60.0%, & 62.0% of patients; treatment-emergent serious AEs (TESAEs) occurred in 3.4%, 2.9%, & 3.4% of patients. The most common TEAEs across R100, R50, & PBO were upper respiratory tract infection (URTI, 8.9%, 6.8%, 3.4%), nasopharyngitis (7.9%, 6.3%, 7.3%) & headache (4.0%, 3.4%, 5.4%). In Tranquillo, 401 patients (26 adolescents) received R50 & 202 (13 adolescents) received PBO. Mean age was 44.8 years. A significantly higher proportion of patients receiving R50 vs PBO achieved F-VASI75 (12.5% vs 2.5%; *P*<0.000001) & T-VASI50 (9.0% vs 2.0%; *P*=0.000073) at Wk 52 (**Fig 1B**). %CFB in F-VASI and %CFB in T-VASI for R50 were significantly greater vs PBO as early as Wk 24 and continued through Wk 52 (*P*<0.05; **Table**). PGIS−F/V responses at Wk 52 for the R50 vs PBO groups, respectively, were 35.0% vs 12.2% & 23.3% vs 16.6% (*P*<0.05). In the R50 & PBO groups, TEAEs occurred in 81.0% & 77.1% of patients (TESAEs: 2.0% & 2.5% of patients). The most common TEAEs across R50 & PBO were URTI (14.0% & 10.9%), blood creatinine phosphokinase increased (11.0% & 8.0%) & nasopharyngitis (10.5% & 9.5%).

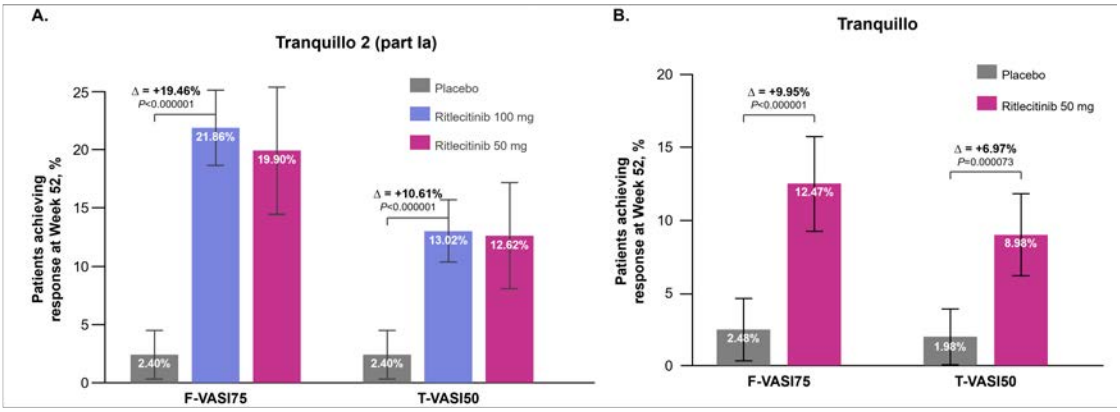

Figure 1. Coprimary endpoints (F-VASI75 & T-VASI50 at Week 52) for the (A) Tranquillo 2 Part Ia and (B) Tranquillo clinical trials. In Tranquillo 2 Part Ia, type I error for the ritlecitinib 100-mg group vs placebo was controlled at 2-sided alpha of 0.05; the comparison between ritlecitinib 50-mg dose vs placebo was not alpha controlled. In Tranquillo, type I error for the ritlecitinib 50-mg group vs placebo was controlled at 2-sided alpha of 0.05. Response rate was calculated as the number of responders / the total number of patients (%). Whiskers show 95% CI. Δ is defined as the difference between either ritlecitinib 100 mg vs placebo (Tranquillo 2 Part Ia) or ritlecitinib 50 mg once-daily vs placebo (Tranquillo). F-VASI75, ≥75% improvement on the Facial Vitiligo Area Scoring Index from baseline; T-VASI50, ≥50% improvement on the Total Vitiligo Area Scoring Index from baseline.

Conclusion

In 2 Phase 3 NSV studies comprising 2174 patients across 271 sites globally, oral ritlecitinib achieved statistically significant and clinically meaningful improvements compared with PBO in facial and total-body repigmentation

across primary and key secondary efficacy endpoints. Improvements were observed by Wk 24 and increased through Wk 52. The safety profile was consistent with those in prior ritlecitinib studies, with no new signals identified.

	Tranquillo 2 Part 1a			Tranquillo		
	Ritlecitinib 100 mg N=622	Placebo N=208	*P* Value	Ritlecitinib 50 mg N=401	Placebo N=202	*P* Value
F-VASI at Week 24, LSM (SE), %CFB	-19.44 (1.34)	-6.16 (2.04)	<0.05	-17.49 (1.50)	-6.83 (1.96)	<0.05
T-VASI at Week 24, LSM (SE), %CFB	-10.16 (0.75)	-4.25 (1.14)	<0.05	-6.51 (1.00)	-1.59 (1.31)	<0.05
F-VASI at Week 36, LSM (SE), %CFB	-27.52 (1.56)	-7.86 (2.39)	<0.05	-23.22 (1.73)	-6.24 (2.26)	<0.05
T-VASI at Week 36, LSM (SE), %CFB	-15.32 (0.92)	-3.46 (1.40)	<0.05	-10.00 (1.26)	0.15 (1.65)	<0.05
F-VASI at Week 52, LSM (SE), %CFB	-34.63 (1.72)	-8.97 (2.63)	<0.05	-29.77 (2.14)	-4.14 (2.79)	<0.05
T-VASI at Week 52, LSM (SE), %CFB	-21.04 (1.13)	-3.67 (1.73)	<0.05	-13.83 (1.53)	1.74 (2.00)	<0.05
F-VASI75 at Week 24, n (%)*	43 (6.91)	1 (0.48)	<0.05	18 (4.49)	1 (0.50)	<0.05
T-VASI50 at Week 24, n (%)*	22 (3.54)	3 (1.44)	>0.05	13 (3.24)	1 (0.50)	<0.05
F-VASI75 at Week 36, n (%)*	80 (12.86)	3 (1.44)	<0.05	33 (8.23)	3 (1.49)	<0.05
T-VASI50 at Week 36, n (%)*	36 (5.79)	2 (0.96)	<0.05	22 (5.49)	2 (0.99)	<0.05
T-VASI75 at Week 52, n (%)*	17 (2.73)	3 (1.44)	>0.05	12 (2.99)	1 (0.50)	<0.05
PGIS−F at Week 52, n (%)†	265 (42.88)	38 (18.27)	<0.05	140 (35.00)	24 (12.18)	<0.05
PGIS−V at Week 52, n (%)†	200 (32.26)	36 (17.31)	<0.05	93 (23.25)	33 (16.58)	<0.05

Table. Key secondary endpoints for the Tranquillo and Tranquillo 2 Part Ia clinical trials. Type I error was controlled at 2-sided alpha of 0.05. In Tranquillo 2 Part Ia, the ritlecitinib 50-mg dose was not part of the prespecified, alpha-controlled statistical testing hierarchy. CFB, change from baseline; F-VASI, Facial Vitiligo Area Scoring Index; F-VASI75, ≥75% improvement on F-VASI from baseline; LSM, least-squares mean; PGIS–F, Patient Global Impression of Severity–Face; PGIS–V, Patient Global Impression of Severity–Vitiligo; SE, standard error; T-VASI, Total Vitiligo Area Scoring Index; T-VASI50, ≥50% improvement in T-VASI from baseline; T-VASI75, ≥75% improvement in T-VASI from baseline. *Proportion of patients achieving F-VASI75, T-VASI50, or T-VASI75. †Proportion of patients achieving a ≥1-point improvement in facial/total body vitiligo in patients with mild, moderate, or severe facial/total body vitiligo at baseline, or ≥2-point improvement in patients with very severe facial/total body vitiligo at baseline.

EA DV CONGRESS
VIENNA
30 SEP - 3 OCT 2026

Abstract N°: 209

Efficacy and Safety of Upadacitinib in Adolescents and Adults for Treatment of Non-segmental Vitiligo at Week 76 and in Combination With NB-UVB Therapy

Julien Seneschal*[1], Thierry Passeron[2, 3], Benjamin D. Ehst[4], Irina Turchin[5, 6, 7], Petra Staubach-Renz[8], Raja K. Sivamani[9, 10, 11, 12], Amit G Pandya[13], Jung Min Bae[14], Xiaoqiang Wu[15], Smitha Suravaram[15], Irina Fish[15], Henrique Teixeira[15], Stavonnie Patterson[15], Bethanee J Schlosser[15], Iltefat Hamzavi[16, 17], Albert Wolkerstorfer[18]

[1] CHU de Bordeaux, Dermatology and Pediatric Dermatology, National Reference Center for Rare Skin Disorders, Hôspital Saint-André, UMR 5164,F-33000, Bordeaux, France
[2] Department of Dermatology, Centre Hospitalier Universitaire de Nice, Côte d'Azur University, Nice, France
[3] INSERM U1065, Centre Méditerranéen de Médecine Moléculaire (C3M), Côte d'Azur University, Nice, France
[4] Oregon Medical Research Center, Portland, OR, United States
[5] Brunswick Dermatology Centre, Fredericton, Canada
[6] Dalhousie University, Department of Medicine, Halifax, Canada
[7] Probity Medical Research, Waterloo, Canada
[8] University Medical Center, Johannes Gutenberg University, Department of Dermatology, Mainz, Germany
[9] Integrative Skin Science and Research, Sacramento, CA, United States
[10] California Northstate University, College of Medicine, Elk Grove, CA, United States
[11] Pacific Skin Institute, Sacramento, CA, United States
[12] Zen ReGen, Sacramento, CA, United States
[13] Palo Alto Foundation Medical Group, Sunnyvale, CA, United States
[14] Department of Dermatology, St. Vincent's Hospital, College of Medicine, The Catholic University of Korea, Seoul, Korea, Rep. of South
[15] AbbVie Inc., North Chicago, IL, United States
[16] Multicultural Dermatology Center, Department of Dermatology, Henry Ford Health, Detroit, MI, United States
[17] Hamzavi Dermatology Specialists, Detroit, MI, United States
[18] Netherlands Institute For Pigment Disorders, Department of Dermatology, Amsterdam, Netherlands

Introduction

Non-segmental vitiligo (NSV) is a chronic immune-mediated disease characterized by skin depigmentation due to a loss of melanocytes. Upadacitinib (UPA) is an oral, once-daily, selective, and reversible small-molecule JAK inhibitor with demonstrated efficacy and safety in two phase 3 trials (Viti-Up) through 48 weeks (Passeron et al. *Lancet*. 2026:408:636-48). UPA has been approved by the European Medicines Agency and United Arab Emirates for treatment of NSV in adults and adolescents. Narrow-band ultraviolet B (NB-UVB) phototherapy has been shown to be effective in producing clinically meaningful repigmentation for patients with NSV, with greater improvements seen when combined with an adjunctive therapy (Seneschal et al. *JEADV.* 2023;37[11]:2185-95). Here we extend findings from Viti-Up through 76 weeks of treatment and evaluate the efficacy and safety of UPA in combination with whole-body NB-UVB phototherapy for the treatment of adults with NSV.

Materials and Methods

Viti-Up is comprised of 2 ongoing randomized, placebo (PBO)-controlled phase 3 studies (Viti-Up-1/Viti-Up-2)

assessing safety and efficacy of UPA (15 mg) administered once-daily. Skin repigmentation was evaluated based on achievement of ≥75% improvement in Facial Vitiligo Area Scoring Index (F-VASI 75) and ≥50% improvement in Total Vitiligo Area Scoring Index (T-VASI 50) at 76 weeks. Following the 48-week PBO-controlled period A in Viti-Up-1/Viti-Up-2, patients either continued UPA or were switched from PBO to UPA for the 112-week open-label extension (OLE) period B. Alternatively, eligible patients from period A at NB-UVB-capable sites continued to Study 3, designed to evaluate combination therapy with UPA and NB-UVB. At week 48, patients receiving UPA or PBO in period A were re-randomized at Study 3 entry to either UPA monotherapy or UPA + whole-body NB-UVB phototherapy administered twice weekly for approximately 28 weeks (period B1). Re-randomization was stratified by baseline disease severity in Study 3 (T-VASI ≤10 vs T-VASI >10). Non-responder imputation was used for analysis for period A and in Study 3; observed cases was used for the OLE.

Figure 1. Study designs for (A) Viti-Up-1/Viti-Up-2 and (B) Study 3

(A) Viti-Up-1/Viti-Up-2

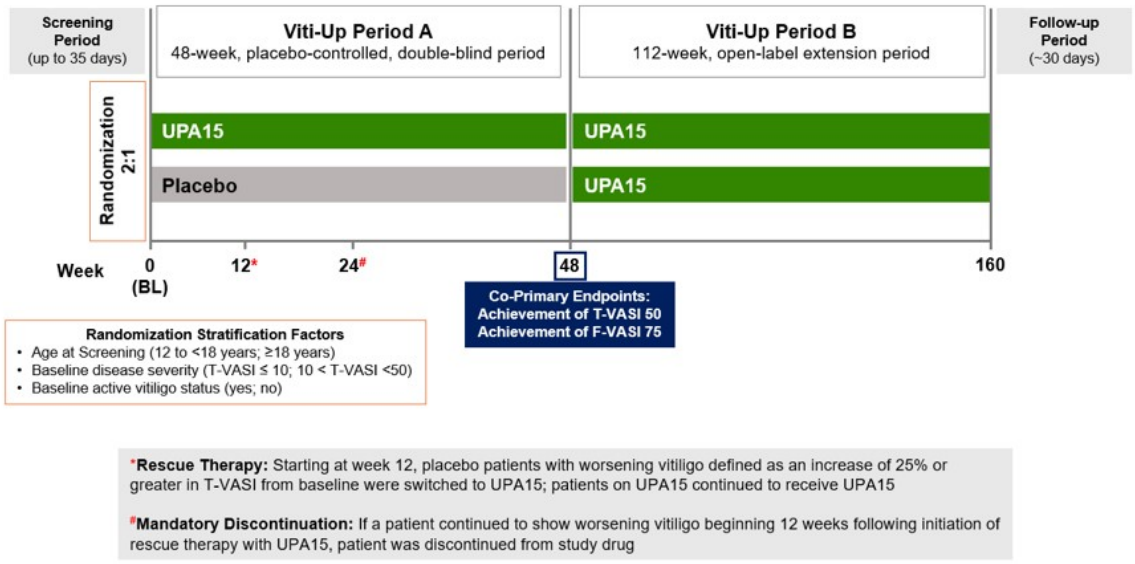

(B) Study 3

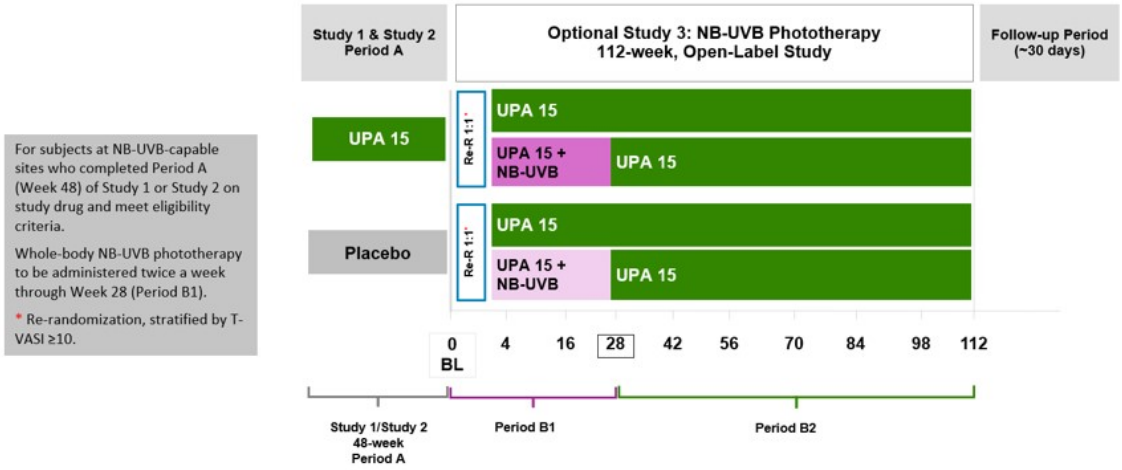

BL, baseline; F-VASI, Facial Vitiligo Area Scoring Index; NB-UVB, narrow-band ultraviolet B; PBO, placebo; Re-R, re-randomized; T-VASI, Total Vitiligo Area Scoring Index; UPA, upadacitinib. T-VASI 50, at least 50% reduction in T-VASI score from baseline; F-VASI 75, at least 75% reduction in F-VASI score from baseline.

Results

A total of 209 patients continued through week 76 in Viti-Up-1 (PBO/UPA, N=69;UPA/UPA, N=140) and 221 in Viti-Up-2 (PBO/UPA, N=69;UPA/UPA, N=152). At week 76, 24.5% and 16.9% of patients in the PBO/UPA group and 55.1% and 47.4% in the UPA/UPA group in Viti-Up-1 and Viti-Up-2, respectively, achieved F-VASI 75. T-VASI 50 was achieved by 18.4% and 13.6% of patients in the PBO/UPA group and 42.5% and 40.1% of patients in the UPA/UPA group in Viti-Up-1 and Viti-Up-2, respectively at week 76.

Eighty-four adults (56% female/mean age 46.6 years [SD 12.2]) continued to Study 3 and were re-randomized to receive either UPA (PBO/UPA, N=15;UPA/UPA, N=27) or UPA+NB-UVB (PBO/UPA+NB-UVB, N=15;UPA/UPA+NB-UVB, N=27). In Study 3, 40.0% (PBO/UPA) and 37.0% (UPA/UPA) of patients receiving UPA alone and 46.7% (PBO/UPA+NB-UVB) and 59.3% (UPA/UPA+NB-UVB) of patients receiving UPA+NB-UVB achieved F-VASI 75. Similarly, 20.0% (PBO/UPA) and 33.3% (UPA/UPA) of patients receiving UPA alone and 33.3% (PBO/UPA+NB-UVB) and 63.0% (UPA/UPA+NB-UVB) of patients receiving UPA+NB-UVB achieved T-VASI 50.

Compared to baseline, all Study 3 groups receiving UPA had improvements in F-VASI 75 and T-VASI 50. Safety results for Viti-Up-1/Viti-Up-2 week 76 and Study 3 week 28 were consistent with UPA's known safety profile; no new safety signals were reported.

Figure 2. Achievement of F-VASI 75 and T-VASI 50 across time in Viti-Up-1/Viti-Up 2 (A, B) and Study 3 (C, D)

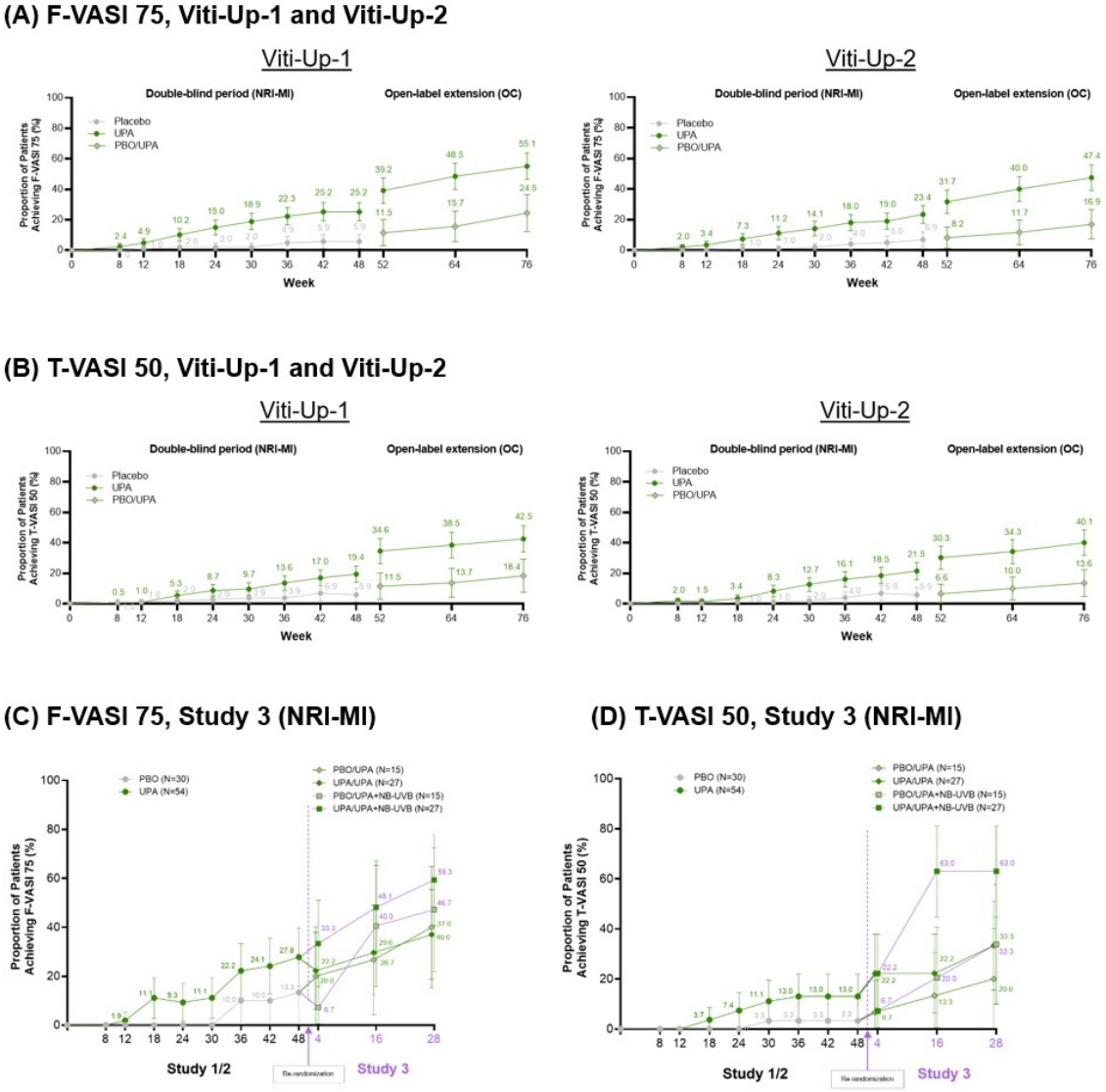

F-VASI, Facial Vitiligo Area Scoring Index; NB-UVB, narrow-band ultraviolet B; NRI-MI, non-responder imputation incorporating multiple imputation; OC, observed cases; PBO, placebo; T-VASI, Total Vitiligo Area Scoring Index; UPA, upadacitinib

Conclusion

Patients with NSV treated with UPA experienced improvements through 76 weeks in Viti-Up, with increasing rates of F-VASI 75 and T-VASI 50 achievement for patients continuing on UPA, and for patients shifting from PBO to UPA after 48 weeks. Combining UPA with NB-UVB therapy in Study 3 further enhanced efficacy of UPA compared to UPA monotherapy regardless of preceding treatment (PBO vs UPA), and efficacy rates continued to increase on the UPA treatment with and without NB-UVB, with no apparent plateau and no new safety signals.

EA DV CONGRESS
VIENNA
30 SEP - 3 OCT 2026

Abstract N°: 230

Effectiveness, safety and tolerability of tofacitinib 2% ointment vs tacrolimus 0.1% ointment in localised vitiligo : Investigator Blind, Randomized Controlled Trial

Anupam Das*[1]

[1] KPC Medical College and Hospital, KOLKATA, India

Introduction
Management of vitiligo remains a challenging task, inspite of the presence of numerous molecules in our armamentarium. With the arrival of tofacitinib ointment in the market, physicians have been found to use the same with significant success. However, there is a dearth of literature regarding the comparison of tofacitinib and other time tested molecules like corticosteroids and calcineurin inhibitors, in vitiligo.

Materials and Methods
The objectives were to compare the effectiveness, safety and tolerability of tofacitinib 2% ointment vs tacrolimus 0.1% ointment in localised vitiligo, and also, compare the improvement in quality of life. A single-centre, investigator-blind, randomised, active-controlled, parallel-group Phase IV trial was conducted on stable and localised vitiligo of either sex. Patients were randomised into two groups (1:1 allocation ratio), and allocation concealment was ensured by SNOSE technique. Assessing physician was not aware of the treatment allocation. Outcome measures included in the study were vitiligo area scoring index (VASI), vitiligo disease activity score (VIDA) and dermatology life quality index (DLQI). Calculated sample size was 68 (5% alphaerror, 80% power, 10% drop-out). After screening and baseline visit, patients in both groups were followed up at 4nd, 8th and 12th week for efficacy and safety parameters.

Results
Intention-to-treat analysis showed significant improvement in VASI (Friedman's analysis of variance, $P < 0.01$) in both groups at the end-of-treatment visit (12th week). Improvement was noted from 4 weeks onwards in group A (tacrolimus) and eight weeks onwards in group B (tofacitinib) (post-hoc Dunn's test, $P < 0.001$). Intragroup comparison showed similar results,($P < 0.05$, analysis of covariance test with baseline VASI as covariate). A similar result was obtained with VIDA. DLQI significantly improved in both the groups. Adverse events like local burning, stinging and irritation, were noted in both the groups, but the frequency was higher in tofacitinib group.

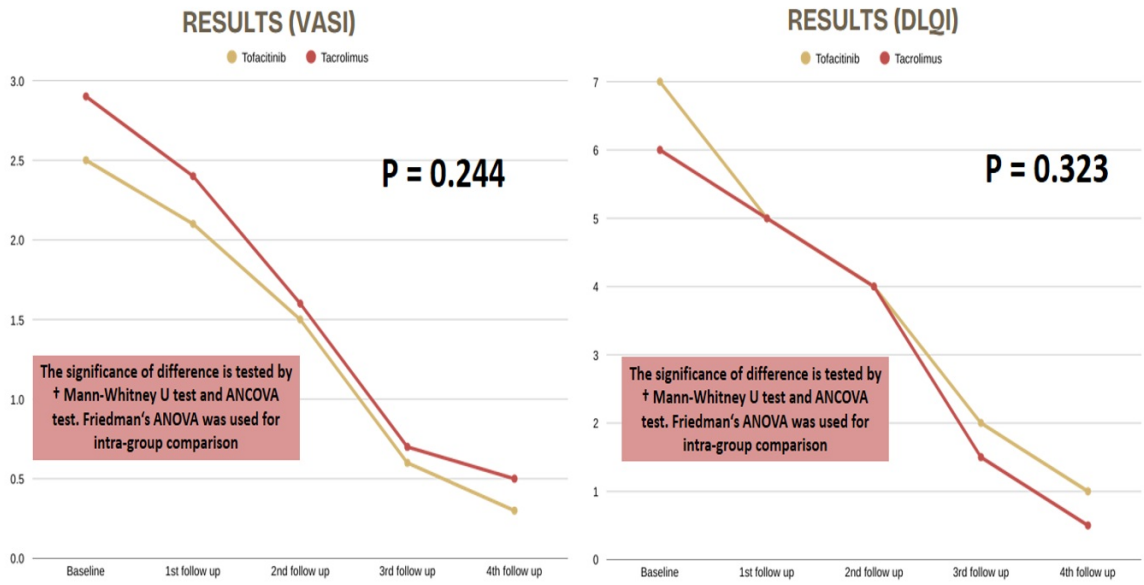

Summary of the progress of VASI and DLQI scores for the three groups. Intragroup comparison shows statistically significant improvement in both the groups. However, on intergroup comparison, no difference was noted.

Conclusions

Both tofacitinib 2% ointment and tacrolimus 0.1% ointment are safe and effective agents in the treatment of vitiligo, however, the cost of therapy and adverse events are higher with tofacitinib.

EADV CONGRESS
VIENNA
30 SEP - 3 OCT 2026

Abstract N°: 308

Comparative study between topical hydroquinone 4% alone versus its combination with intradermal autologous platelet-rich plasma in the treatment of melasma: A split-face randomized controlled trial

Chanisa Kiatsurayanon*[1]

[1] Institute of Dermatology, Bangkok, Thailand

Introduction
Melasma is a prevalent pigmentary disorder affecting sun-exposed facial areas. While intradermal platelet-rich plasma (PRP) therapy has shown potential benefits, objective data on its efficacy in melasma treatment remain limited. This study evaluates the effectiveness of combining PRP with 4% hydroquinone (HQ) compared to HQ monotherapy.

Materials and Methods
Twenty patients received intradermal PRP injections on one randomly assigned side of the face at baseline and at week 2, 4 and 6. HQ cream was applied bilaterally throughout the study. Treatment efficacy was assessed using the hemi-modified Melasma Area and Severity Index (mMASI), melanin index via Mexameter®, skin elasticity via Cutometer® (R2 parameter), a quartile-based patient satisfaction scale, and monitoring for adverse effects. Assessments were conducted at baseline and at week 2, 4, 6, 10 and 14.

Results
Both groups exhibited a decline in melanin index, reaching the lowest levels at week 6. Post-treatment, pigmentation rebounded in the HQ-only group but remained stable in the PRP + HQ group through week 14. mMASI scores decreased significantly in both groups, with a greater reduction in the PRP + HQ group ($p < 0.001$ vs. $p = 0.012$). R2 values were better preserved in the PRP + HQ group (0.371 ± 0.092) compared to the HQ-only group (0.299 ± 0.104; $p = 0.026$), indicating that PRP may help counteract HQ-induced decreased skin elasticity. Patient satisfaction improved over time. Adverse effects, primarily mild edema and erythema, were transient.

Conclusions
Combining intradermal PRP with topical HQ enhances treatment efficacy, maintains skin elasticity, and may reduce HQ-associated side effects in melasma management.

EA DV CONGRESS
VIENNA
30 SEP - 3 OCT 2026

Abstract N°: 354

Achieving Cosmetic Improvement in a case of concurrent LPP and FFA- diagnostic and therapeutic challenges.

Rucha Kagne*[1]

[1] Dr Rucha's ZENE Skin Hair Laser Clinic, Mumbai, India

Introduction

Lichen planus pigmentosus (LPP) is a rare cutaneous pigmentary disorder of unknown etiology, with female predominance, between the third and fourth decades of life. Lichen planus pigmentosus is frequently associated with frontal fibrosing alopecia in darker phototipes. It should be considered in patients affected by scarring alopecia with a pattern of lichen planopilaris and areas of skin hyperpigmentation revealing perifollicular hyperpigmentation refractory to multiple treatments. This case illustrates diagnostic and therapeutic challenge in face of perifollicular hyperpigmentation and scaring alopecia.

Case Presentation

A 40-year-old dark-skinned peri-menopausal woman visited clinic with the complaint of itchy forhead hyperpigmentation non-progressive since 1 year which was refractory to superficial chemical peel and marginal alopecia in the frontal hairline over the past 6 months, not responding to topical 5% minoxidil. On examination, discrete and confluent brown macules with diffused borders were noticed on sun-exposed areas like forehead and neck. On scalp examination bilateral marginal recession of frontoparietal hairline was observed. Clinical and dermatoscopy evaluation was done on regular intervals. The patient was treated with 6 sessions done 3 weeks apart of picosecond 785nm laser done showing dermatoscopic improvement. Multiple sessions (often 4-6) spaced 3-4 weeks apart are typically planned for significant improvement in pigmentation. Best utilized when the condition is stable (not actively spreading) to avoid worsening of the lesions. Scalp was treated with three injections of triamcinolone and started with low dose oral minoxidil with changes on trichoscopy. The etiology is unknown, and it is believed that immunological mechanisms and chemical and physical agents such as sun, mustard oil, henna hair dye and amla oil may play an important role in the pathogenesis of the diseaseThe dermoscopy of LPP can reveal reduction of the follicular openings, follicular hyperkeratosis, keratotic plugs, perifollicular erythema, white dots, interfollicular vessels with single loops, arborizing vessels and pigment network. Blue-grey structures in an annular or speckled pattern can also be found and may represent basal layer degeneration, and also melanophages in the papillary dermis with signs of interface dermatitis and pigmentary incontinence.Picosecond (pico) laser with dual wavelengths (1064 nm and 785 nm) precisely targeting varied pigment depths are an effective, safe, and precise treatment for LPP, particularly for reducing stubborn dermal melanin deposits with minimal risk of post-inflammatory hyperpigmentation. Pico lasers are excellent at shattering deep dermal pigment, which is commonly seen in the gray-brown pigmentation of LPP. They work by breaking down pigment into finer particles via photoacoustic action, allowing the body to clear them.Multiple sessions (often 4-6) spaced 3-4 weeks apart are typically planned for significant improvement in pigmentation. Best utilized when the condition is stable (not actively spreading) to avoid worsening of the lesions.

Conclusion

This case illustrates the diagnostic and therapeutic challenge when facing difficult cutaneous hyperpigmentation on the forehead and neck region and alopecia management on the scalp and resistant to conventional local treatments, with marked improvement after pico laser for LPP and oral minoxidil and topical steroid for the control of FFA . Use of pico laser indicates significant reductions in pigmentation and high patient satisfaction. Despite the

positive result achieved in this case, more studies are needed to evaluate the role of pico laser in patients with LPP
.

EA DV CONGRESS
VIENNA
30 SEP - 3 OCT 2026

Abstract N°: 416

Environmental etiology suspected in familial Riehl's melanosis: diagnostic challenges and dermoscopic clues

Assia El Bouhmadi*[1], Bouchra Baghad[1], Hanane Rachadi[1], Soumiya Chiheb[1]

[1] CHU Ibn Rochd, CASABLANCA, Morocco

Introduction

Riehl's melanosis (RM), also known as pigmented contact dermatitis, is a chronic acquired hyperpigmentation typically affecting the face and neck. Its etiology often involves exposure to exogenous agents, though identifying the trigger is frequently challenging.

Case Presentation

We report two cases of RM in two sisters, aged 55 and 45 years, who developed slowly progressive facial hyperpigmentation evolving for 20 and 15 years, respectively. Both presented with well-demarcated gray-brown reticulated pigmentation on the temples, along with multiple diffuse hyperpigmented macules on the forehead, cheeks, and perioral region. Dermoscopy revealed pigmented pseudonetwork, brown-gray dots and granules, slight flour-like scaling, and a perifollicular white halo. Histopathology showed pigment incontinence with pilosebaceous involvement, hyperkeratosis, and dermal fibrosis. Detailed history uncovered a shared exposure to stagnant water from an abandoned well prior to symptom onset, raising suspicion of chronic contact with environmental contaminants. No other cosmetic, occupational, or pharmacologic triggers were identified. Both patients were treated with 2% hydroquinone and oral tranexamic acid.



The image shows a well-demarcated gray-brown reticulated pigmentation on the temples

Conclusion

These cases highlight a rare environmental cluster of RM potentially linked to polluted well water, emphasizing the importance of thorough environmental history-taking in unexplained pigmentary disorders. Dermoscopic and histological findings were consistent with classic RM, though the marked dermal fibrosis likely reflected the longstanding evolution of the lesions. RM remains difficult to treat, and the absence of randomized controlled trials limits evidence-based therapeutic strategies. The occurrence of RM in two sisters following shared exposure to stagnant well water suggests a possible environmental etiology. Comprehensive history-taking and clinicodermoscopic-histological correlation are critical for diagnosis. Improved understanding of RM pathogenesis is needed to guide more effective treatments.

EADV CONGRESS
VIENNA
30 SEP - 3 OCT 2026

Abstract N°: 431

Histopathological and immunohistochemical study of hypopigmented patches in trichrome non-segmental vitiligo

Mona Abdelhafiz*[1], Ghada Omar[1], Nafissa El- Badawy[2], Radwa Kamel[1]

[1] Dermatology, Venereology and Andrology Department, Faculty of Medicine for Girls, Al-Azhar University, Cairo, Egypt, Cairo, Egypt

[2] Pathology Department, Faculty of Medicine, Ain Shams University, Cairo, Egypt, Cairo, Egypt

Introduction

Vitiligo is a multifactorial autoimmune disease affecting 0.5-2% of the world's population, characterized by the loss of melanocytes from the epidermis and resulting in white patches of skin. Trichrome vitiligo is characterized by three distinct pigmentary zones: an achromic center, an intermediate zone of hypochromia, and surrounding unaffected skin. A comprehensive understanding of the pathogenesis within the trichrome area, particularly the role of CD8+ and CD4+ T lymphocytes, is critical to establishing effective therapeutic strategies. The main goal of this study is to describe the unique histopathological and immunohistochemical characteristics of non-segmental trichrome vitiligo, with a particular emphasis on CD4+ and CD8+ T lymphocytes in the various pigmentary zones of a single lesion. This research aims to enhance our understanding of the pathogenesis and disease activity in this specific vitiligo subtype, providing a more detailed insight into the dynamic process of melanocyte destruction and immune cell infiltration.

Materials and Methods

This observational, cross-sectional study enrolled thirty patients with trichrome non-segmental vitiligo. Vitiligo Disease Activity (VIDA) score was used to assess disease activity, categorizing patients into stable and active groups. Under local anesthesia, four-millimeter punch biopsies were obtained from affected vitiliginous skin, trichrome areas, and adjacent apparently normal skin from each patient. Tissue samples were formalin-fixed, paraffin-embedded, and sectioned for histopathological and immunohistochemical staining to assess the expression of CD4+ and CD8+ T lymphocytes. The number of CD4+ and CD8+ T lymphocytes was assessed semi-quantitatively by an expert consultant pathologist. Five high-power fields (HPF) (400x magnification) representing hot spots were examined per section.

Results

Our study demonstrated a statistically significant increase in CD4+ T lymphocytes in vitiligo and apparently normal skin compared to trichrome areas ($P < 0.001$). Conversely, CD8+ T lymphocytes were significantly higher in the trichrome area than in vitiligo or apparently normal skin ($P < 0.001$). In all areas, the median CD8+ T cell count was higher in the dermis/DEJ than the epidermis. Spearman's rank correlation analysis revealed that a significant positive correlation was found between disease activity (VIDA scores) and CD8+ T cell numbers in trichrome areas ($r = 0.688$, $P < 0.001$). Both CD4+ T and CD8+ T cell subsets were predominantly elevated in active versus stable vitiligo, resulting in a significantly lower CD4+/CD8+ ratio in active cases ($P < 0.05$). Histopathological examination of biopsies from the three areas revealed a statistically significant epidermal thinning in vitiligo (60.0%) compared to trichrome (33.3%) or apparently normal skin areas (6.7%) ($P < 0.001$), likely due to widespread vacuolar degeneration. Dermal lymphocytic infiltration was also significantly higher in the vitiliginous and trichrome areas compared to the apparently normal skin area ($p < 0.001$). These results are consistent with earlier reports of perilesional T-cell clusters, while specifically emphasizing the distinct immunological characteristics of the trichrome zone.

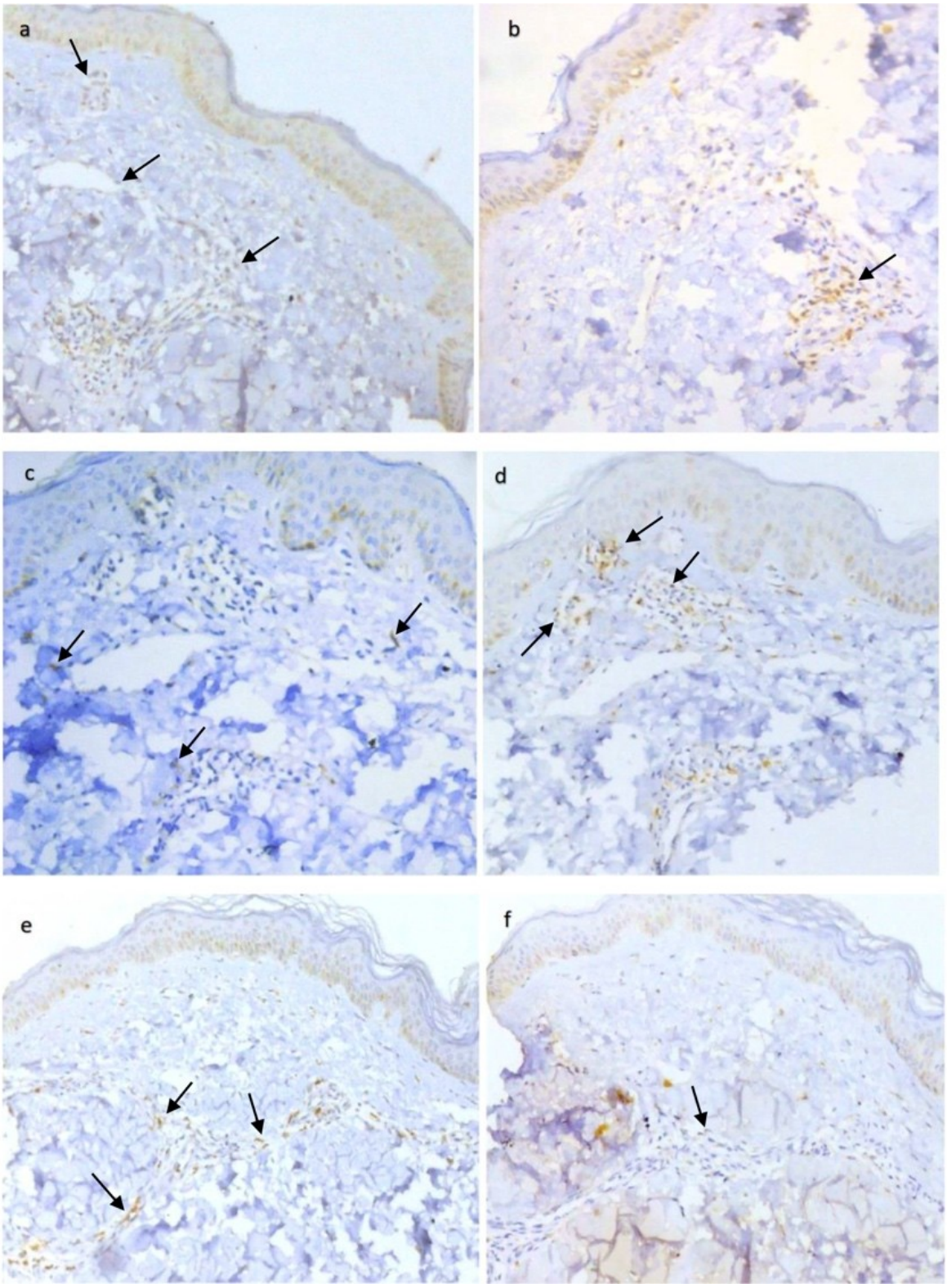

Skin biopsies of trichrome non-segmental vitiligo show CD4+ and CD8+ T-lymphocytes in epidermis, dermis and DEJ at 200× magnification (IHC stain) (a) Apparently normal skin biopsy showing CD4+ T-lymphocytes. The number of CD4+ T (50) cells (b) apparently normal skin biopsy showing CD8+ T lymphocytes. The number of CD4+ T lymphocytes is obviously more than the number of CD8+ T lymphocytes in the apparently normal skin area (c) Skin biopsy of the trichrome area reveals a reduced number of CD4+ T-cells (26) compared to the apparently normal skin area (d) Skin biopsy of trichrome area reveals CD8+ T-cells (80) cells targeting the melanocytes at the DEJ and are observed adjacent to melanocytes (e) Skin biopsy of vitiligo area, showing CD4+ (54) T lymphocytes (f) Skin biopsy of vitiligo area, showing CD8+ (14) T lymphocytes in the dermis less than CD4+ T lymphocytes in the same area

Conclusions

The trichrome sign represents a critical transitional phase in vitiligo activity, characterized by a distinct "immunological bridge" where CD8+ T cells peak. To our knowledge, this is the first study to correlate VIDA scores with immunohistopathological changes specifically in trichrome vitiligo. The high CD8+ T cell population in these areas directly mirrors clinical activity, suggesting that the trichrome area is the primary site of melanocyte destruction. These results point out the value of the trichrome sign as a clinical marker for active disease and suggest that VIDA score reliably reflects underlying histopathological inflammation, which may assist in tailoring immunosuppressive therapy.

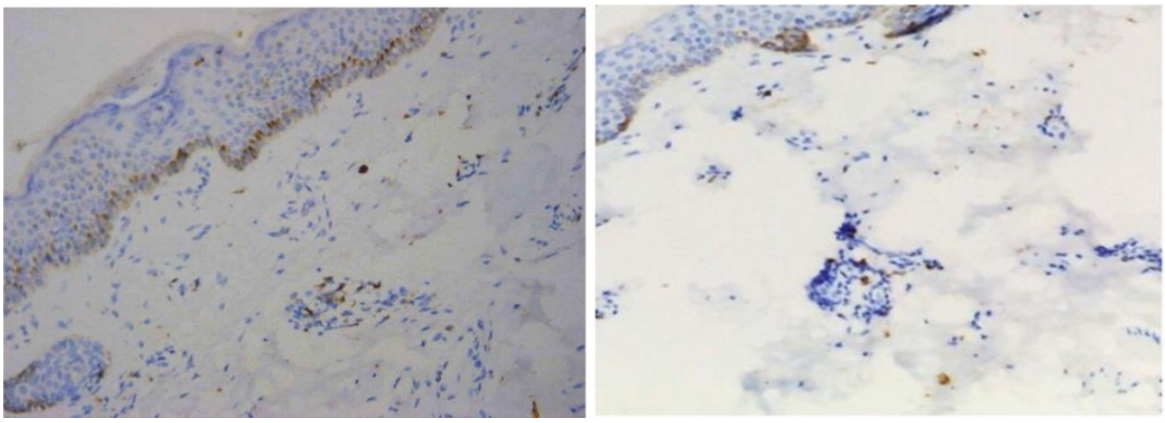

Skin biopsies in cases of trichrome non-segmental vitiligo with CD8+ T-cells in the epidermis, dermis and DEJ at a magnification 200× (IHC) A skin biopsy from the trichrome area of an active case of trichrome vitiligo, revealing the presence of numerous CD8+ T lymphocytes in the dermis, epidermis and the DEJ, the number of CD8+ T cells (30) is evidently elevated (Left). A skin biopsy from a stable case reveals a reduced number of CD8+ T cells (12) than in the active case (Right).

EA DV CONGRESS
VIENNA
30 SEP - 3 OCT 2026

Abstract N°: 477

Voluntary skin depigmentation: motivations, practices, adverse effects, and risk perception

Ouissal Hormi*[1], Salma Moujahid[1], Souha Denna[1], Nassiba Zerrouki[1], Nada Zizi[1]

[1] Department of Dermatology, Venereology and Allergology, Mohammed VI University Hospital Center, Oujda, oujda, Morocco

Introduction
Voluntary skin depigmentation, also known as cosmetic skin lightening, is a growing public health concern. It involves the use of topical products diverted from their medical purpose, such as corticosteroids, hydroquinone, and informal or homemade preparations, and is associated with serious cutaneous and systemic complications. Sociocultural and aesthetic motivations are central, but risk perception remains limited. This study aims to assess motivations, usage patterns, adverse effects, and risk perception related to this practice.

Materials and Methods
A cross-sectional study was conducted among 120 adult women attending dermatology consultations. A structured questionnaire collected data on sociodemographics, motivations for depigmentation, products used, reported adverse effects, and risk perception.

Results
Among the 120 participants, 72 (60.9%) reported current or past use of skin depigmenting products. The mean age of users was 28.3 ± 6.7 years, with 81.9% residing in urban areas. Most users were employed (58.3%) or students (25.0%), and 41.7% had a secondary education level. This suggests that voluntary depigmentation is prevalent among young adult women, particularly in urban settings.The main motivations reported were a desire for lighter skin (72.7%), social pressure from family, peers, or community (33.6%), and influence of social media or public figures (21.1%). Multiple motivations were common, as 41.7% of participants cited two or more reasons for engaging in depigmentation. Younger participants (<30 years) were more influenced by social media and celebrity trends compared to older women.Regarding product use, corticosteroids were the most commonly used (62.5%), followed by hydroquinone (41.4%), and informal or homemade preparations purchased on the informal market (29.7%). Daily use was reported by 68.1% of users, with duration ranging from a few weeks to more than two years. Only 21.9% had consulted a healthcare professional before starting, and 65.3% were unaware of potential adverse effects, highlighting widespread unsupervised use.Adverse effects were frequent, with 84.4% of users reporting at least one complication. Striae were the most common (56.2%), followed by facial hypertrichosis (31.2%), steroid-induced acne (28.1%), paradoxical pigmentary changes (18.7%), and skin atrophy (14.1%). Some participants also reported systemic symptoms, such as headache or fatigue (5.5%). Multiple adverse effects were common, with 43% experiencing two or more complications. Users of informal or homemade products reported a higher frequency of unexpected adverse effects compared to those using commercial preparations. Long-term use (>1 year) was associated with more severe outcomes, particularly striae and skin atrophy.Despite these frequent complications, only 39.8% of users perceived voluntary depigmentation as a potentially harmful practice. Moreover, only 22.2% reported that they would consider discontinuing it, indicating a significant gap between experienced adverse effects and risk perception.

Conclusions
Voluntary skin depigmentation is highly prevalent (60.9%) and driven primarily by aesthetic ideals, social pressure, and media influence. Corticosteroids and hydroquinone dominate product use, often without medical supervision.

Adverse effects are frequent and sometimes systemic. Risk perception remains low despite frequent complications. These findings highlight the need for targeted awareness campaigns, healthcare professional involvement, media engagement, and stronger regulation to limit access to harmful depigmenting products.

EA DV CONGRESS
VIENNA
30 SEP - 3 OCT 2026

Abstract N°: 490

The Best Treatment for Facial Hyperpigmenntation

Bana Aburajab*[1]

[1] PPU, Hebron, Palestine

Introduction

“What is the best treatment for facial hyperpigmentation?”—a question frequently encountered in daily practice and amplified by social media, where generalized recommendations and over-the-counter (OTC) products are often promoted as universal solutions. However, facial hyperpigmentation is not a single entity but a manifestation of diverse underlying pathologies. This presentation challenges the concept of a “one-size-fits-all” treatment by emphasizing the critical role of accurate diagnosis through five illustrative clinical cases.

Case Presentation

Five patients presented with persistent facial hyperpigmentation, all of whom had previously used multiple OTC products and social media-recommended remedies without improvement.Case 1: A patient developed exogenous ochronosis following prolonged use of unregulated, high-concentration hydroquinone mixtures. Diagnosis was confirmed histopathologically. Management required immediate cessation of the offending agents and implementation of targeted procedural therapies.Case 2: A case of actinic lichen planus/lichen planus pigmentosus, presenting as progressive facial pigmentation. The patient was managed with anti-inflammatory treatment and strict photoprotection, highlighting the inflammatory nature of the condition.Case 3: A patient initially presenting with facial hyperpigmentation was subsequently diagnosed with systemic lupus erythematosus (SLE). The pigmentation represented a cutaneous manifestation of systemic disease, requiring systemic immunomodulatory therapy rather than topical depigmenting agents.Case 4: Severe hypothyroidism (TSH 30) was identified in a patient with diffuse facial hyperpigmentation. Significant improvement was observed following correction of the underlying endocrine disorder.Case 5: A patient with extensive solar lentigines underwent successful treatment with laser therapy, demonstrating the effectiveness of device-based interventions in appropriately selected cases.Across all cases, prior use of generalized treatments and OTC remedies failed to produce meaningful improvement, underscoring the importance of accurate diagnosis.

Conclusion

Facial hyperpigmentation should not be treated as a uniform cosmetic condition but as a clinical sign requiring thorough evaluation. The notion of a single “best treatment” is fundamentally flawed and may lead to mismanagement or delayed diagnosis. These cases illustrate that effective treatment depends on identifying the underlying etiology and tailoring therapy accordingly. This presentation advocates for a shift from trend-driven treatments to precision-based dermatologic care.

EA DV CONGRESS
VIENNA
30 SEP - 3 OCT 2026

Abstract N°: 504

Efficacy and Safety of the combination of Methotrexate and NB-UVB for the Treatment of Active Vitiligo: Results from Randomized, non-comparative, Double-Blind, Phase 2 Study

Ribal Merhi[1], Christine Germain[2], Eric Frison[2], Nicolas ANDREU[1], sarah cazenave[1], Sitraka Rasolofo[1], Eve Barré[3], Caroline Lacoste[4], Juliette Mazereeuw-Hautier[5], Jerome Marie[6], Thomas Jouary[7], Hervé Maillard[8], Katia Boniface[9], Julien Seneschal*[1]

[1] Department of Dermatology and Pediatric Dermatology, National Reference Center for Rare Skin Diseases, Hôpital Saint-André,, Bordeaux, France

[2] Medical Information Unit, Bordeaux University Hospital, Pellegrin Hospital, 33000, Bordeaux, France., bordeaux, France

[3] Department of Dermatology and Pediatric Dermatology, National Reference Center for Rare Skin Diseases, Hôpital Saint-André, bordeaux, France

[4] Safety and Vigilance Unit, Clinical Research and Innovation Direction, Bordeaux University Hospital, Bordeaux, France., Bordeaux, France

[5] Hôpitaux de Toulouse, Toulouse, France

[6] Dermatology Department, Périgueux General Hospital, avenue Georges-Pompidou, 24000 Périgueux, Perigueux, France

[7] Department of Dermatology, Francois Mitterrand Hospital, Pau, France., Pau, France

[8] Department of Dermatology, Le Mans Hospital, France., Le Mans, France

[9] Univ. Bordeaux, CNRS, Immuno ConcEpT, UMR 5164, F-33000 Bordeaux, France, Bordeaux, France

Introduction

Vitiligo is a chronic autoimmune disease associated with skin depigmentation. Disease activity is largely regulated by interferon-γ-induced activation of the Janus kinase (JAK) signaling pathway. Methotrexate (MTX) is an immunomodulatory agents used for the management of several chronic inflammatory disease. Narrowband-UVB (NB-UVB) is the standard treatment in vitiligo to promote repigmentation. The objective of this trial was to evaluate the efficacy and safety of oral MTX in adult patients with active vitiligo in combination with NB-UVB.

Materials and Methods

In this 32-week randomized, non-comparative, double-blind, multicentre phase 2 study (NCT04237103), adult patients diagnosed with active non-segmental vitiligo with depigmentation covering ≥10% total body surface area were randomized 3:1 to MTX, 15 mg every week, or placebo (PLA) for 32 weeks, alone for the first 8 weeks and then in combination with NB-UVB twice a week up to week 32. The primary endpoint was the mean percentage change from baseline (%CFB) in the Total-Vitiligo Area Scoring Index (T-VASI) score at week 32 in the MTX group, with its 90%CI upper bound compared to a sufficient repigmented surface threshold of 42.9% Key secondary endpoints reported here ar the mean %CFB of F-VASI, the achievement of T-VASI50 and F-VASI75 at week 32, and adverse events (AE). Analyses of other secondary efficacy endpoints (VETF, VES, DLQI and Skindex29) are ongoing.

Results

Between May 2023 and February 2025, 32 participants were randomized (MTX n=23; PLA, n=9), in 5 dermatology departments. Although 45 participants were initially planned, recruitment was prematurely discontinued due to treatment expiration, resulting in a smaller-than-expected sample size. Median (IQR) age was 50.5 (40.2—54.0) years, 22 (69%) were female, and 29 (91%) had skin phototypes II-III. Baseline mean (SD) T-VASI and F-VASI values were respectively 26.1 (16.6) and 1.2 (1.1), in the MTX group and 14.6 (7.7) and 1.0 (0.8), respectively in the PLA group. One participant was lost-to-follow-up (MTX group) and one participant withdraw study participation (MTX group). After a median follow-up of 7.6 (IQR 7.2—7.9) months, the mean T-VASI %CFB was -47.5% (90%CI, -55.7 to -39.4) for the MTX group and -12.9% (90%CI, -34.6 to 8.8) for the PLA group. The mean F-VASI %CFB was -32.3% (90%CI, -51.1 to -13.6) for MTX group and -20.3% (90%CI, -72.8 to 32.2) for PLA group. Proportion of responders in MTX and PLA were respectively 52% and 25% for T-VASI50, and 26% and 37% for F-VASI75. Among 66 AE reported for 20 (87%) participants in the MTX group, 37 in 16 (70%) participants were related or possibly related to the study treatment. Among 19 AE reported for 8 (89%) participants in the PLA group, 5 in 5 (56%) participants were related or possibly related to the study treatment. One participant in the PLA group experienced a serious AE (grade 4 neutropenia), leading to treatment discontinuation.

Conclusions

While the observed mean T-VASI %CFB was favorable, the prespecified efficacy criterion for MTX in combination with NB-UVB was not met, as the 90%CI included the predefined threshold of −42.9%. Given the favorable safety profile and the smaller-than-planned sample size (23 enrolled vs 33 planned), these findings may nevertheless suggest a promising treatment effect warranting further evaluation in a larger study.

EADV CONGRESS
VIENNA
30 SEP - 3 OCT 2026

Abstract N°: 506

Topical Metformin in the Treatment of Melasma

Houda Talbi*[1], Yousef Almheirat[1], Mohammed Alem[2], Zineb Alami[2], Nassiba Zerrouki[1, 3], Nada Zizi[1, 3]

[1] Mohammed VI University Hospital, Department of Dermatology, Venereology and Allergology, Oujda, Morocco
[2] Mohammed VI University Hospital, Hospital Pharmacy, Oujda, Morocco
[3] Faculty of Medicine and Pharmacy, Mohammed First University, Laboratory of Epidemiology, Clinical Research and Public Health, Oujda, Morocco

Introduction
Melasma is a common acquired facial hyperpigmentation, particularly prevalent in darker phototypes,and is associated with a significant psychosocial burden. Conventional treatments such as hydroquinone,azelaic acid, chemical peels, and laser therapies provide variable results and are often limited by adverseeffects, cost, and poor long-term tolerance. Metformin, widely used for its metabolic effects, has recentlydemonstrated anti-inflammatory and depigmenting properties through modulation of oxidative stressand melanogenesis. This study aimed to evaluate the efficacy and tolerability of topical metformin inpatients with melasma.

Materials and Methods
A prospective, single-center clinical study was conducted including 20 patients with melasma. A 30%topical metformin formulation was prepared from oral tablets incorporated into a standardhydroalcoholic vehicle. The product was applied once daily for 12 weeks. Clinical severity was assessedusing the Melasma Area and Severity Index (MASI) at baseline and every four weeks. Safety andtolerability were evaluated by clinical examination and patient interview. Statistical analysis wasperformed using paired comparisons, with a significance threshold set at $p < 0.05$.

Results
The study included 20 patients (18 women, 2 men) with a mean age of 38.9 ± 7.1 years. Dark phototypespredominated. The mean baseline MASI score was 8.89 ± 6.6. After 12 weeks of treatment, the meanMASI decreased to 6.9 ± 5.6, corresponding to a mean reduction of 1.94 points (22.4%), which was highlysignificant ($p = 0.00008$). A moderate improvement (25–50%) was observed in 45% of patients, while 45%showed a mild improvement (<25%), 10% showed no response. The maximal individual improvementreached 40.4%. Tolerability was excellent, with only one transient case of mild erythema and dryness,without treatment discontinuation. Overall satisfaction was high, with 75% of patients reportingmoderate to high satisfaction.

Conclusions
Topical metformin 30% demonstrated a significant clinical improvement in melasma with an excellentsafety profile. Its accessibility, low cost, and good tolerability make it a promising alternative or adjunctivetherapy, particularly in settings where conventional treatments are limited by availability or adverseeffects. Larger controlled trials with longer follow-up are warranted to better define its place in thetherapeutic strategy for melasma.

Abstract N°: 510

Case of naevus of Ota

Makhliyokhon Zokhidova*[1]

[1] Republican Specialized center of Dermatovenerology and Cosmetology, Tashkent, Uzbekistan

Introduction

Naevus of Ota, naevus of Ito and naevus of Hori are special melanocytic naevi that have a slate-brown or blue/grey colouring. They are forms of dermal melanocytosis in which naevus cells are found deep within the dermis. It is a type of dermal melanocytic hamartoma, which means there are an increased number of melanocytes, or melanin-producing cells, in the tissues.

Case Presentation

34-year-old patient came to our clinic with complaints about spots on the skin of her face. Spots of grayish-blue color are located on one half of the face. The spots have clear borders, uneven outlines. According to the patient, the spots have been present since birth, they used to be small in size, over time they increased in size.



Conclusion

Picosecond lasers have been found to be effective at treating naevus of Ota. This laser targets the melanocytes and destroy the pigmentation. Picosecond lasers is reliable and effective treatment and it is resulted in significant improvement in pigmentation. Therefore, we recommended picosecond laser for the treatment of this patient.

EADV CONGRESS
VIENNA
30 SEP - 3 OCT 2026

Abstract N°: 518

Synergistic Depigmenting Efficacy and Superior Cutaneous Tolerability of Topical 20% Azelaic Acid Combined with 3% Tranexamic Acid in a Solar-Simulated Hyperpigmentation Model

Qian Yu*[1], yunping he[1], yue wang[1], Beilei Cai[1]

[1] Zhiyan Biotechnology Co., Wuxi, China

Introduction

Melasma and acquired hyperpigmentation pose significant therapeutic challenges, as they involve complex etiologies beyond localized melanocyte hyperactivity, encompassing underlying vascular alterations and chronic UV-induced inflammation. Conventional monotherapies frequently induce localized barrier disruption and paradoxical post-inflammatory hyperpigmentation (PIH). Current pathophysiological paradigms underscore the necessity of multi-target interventions. Azelaic acid (AZA) serves as a potent, competitive intracellular inhibitor of tyrosinase, while tranexamic acid (TXA) antagonizes the extracellular plasminogen-plasmin pathway, thereby suppressing the release of pro-melanogenic prostaglandins and angiogenic vascular endothelial growth factor (VEGF). We hypothesized that topically amalgamating these agents generates a dual-axis blockade against melanogenesis. This study aims to prospectively evaluate the human skin safety profile and the in vivo depigmenting efficacy of a novel topical formulation containing 20% AZA and 3% TXA.

Materials and Methods

A single-arm prospective clinical trial was conducted incorporating 30 healthy volunteers. To assess the initial cutaneous tolerability and irritant potential, a patch test was executed with dermatological evaluations for erythema and edema conducted at 0.5h, 24h, and 48h post-application. To evaluate clinical efficacy objectively, standardized focal hyperpigmentation was experimentally induced across the cohort utilizing a solar-simulated radiation (SSR) model, effectively negating constitutive pigmentation variations. Using the post-SSR induction values as the standardized baseline, subjects applied the active formulation (20% AZA + 3% TXA) to the target regions twice daily for 4 consecutive weeks. Objective biophysical parameters were quantified weekly using narrow-band reflectance spectrophotometry to determine the Melanin Index (MI) and colorimetry to calculate the Individual Typology Angle (ITA°). These metrics were continuously corroborated by expert visual skin color grading.

Results

The formulation exhibited an exceptional safety profile, successfully negating the notorious irritation associated with high-concentration dicarboxylic acids. In the closed patch test, 100% of the subjects exhibited a Grade 0 skin reaction at the 0.5h, 24h, and 48h observation nodes, with zero recorded incidences of erythema, edema, or pruritus. During the 4-week interventional efficacy phase, continuous topical application yielded highly significant, time-dependent improvements across all quantified parameters. Skin lightness, objectively measured by ITA°, demonstrated a robust linear elevation from a post-SSR baseline of 22.09 to 29.64 at week 4. Concurrently, the epidermal melanin concentration, quantified by the MI, exhibited a precipitous decline from a baseline of 199.26 to 140.53. These bioengineering endpoints aligned perfectly with the subjective visual skin color grading, which significantly improved from 8.30 at baseline to 7.37 at the study's conclusion, with zero adverse events recorded.

Conclusions

The topical combination of 20% Azelaic Acid and 3% Tranexamic Acid is exceptionally well-tolerated and highly efficacious in rapidly ameliorating acquired hyperpigmentation. The profound reduction in Melanin Index and

corresponding elevation in ITA° validate its capacity to degrade SSR-induced melanin synthesis effectively. Crucially, the absence of cutaneous irritation indicates that TXA's potent anti-inflammatory properties act as a pharmacological buffer, successfully neutralizing the inherent irritant potential of 20% AZA. By simultaneously targeting intracellular tyrosinase catalysis and extracellular plasmin-mediated inflammatory signaling cascades, this dual-agent formulation precisely matches the complex pathological architecture of melasma, presenting a safe, non-cytotoxic, and highly viable alternative for long-term clinical management.

EA DV CONGRESS
VIENNA
30 SEP - 3 OCT 2026

Abstract N°: 521

A prospective cohort study to determine the prognostic factors in non-segmental vitiligo from a tertiary care centre

Lipsa Kumari*[1], shreya K. Gowda[1], Sunil Nagpal[1], Shivam Pandey[1], Vishal Gupta[1], Kanika Sahni[1], M. Ramam[1], Somesh Gupta[1]

[1] AIIMS, New Delhi, New Delhi, India

Introduction

Vitiligo is a common acquired depigmenting disorder with an unpredictable clinical course, particularly in non-segmental vitiligo (NSV). Identifying reliable clinical predictors of disease activity, progression, and treatment response is crucial for early risk stratification and individualized management. Our Aim was to identify clinicodemographic and clinical factors influencing disease progression, larger extent, repigmentation, treatment dependency, patient satisfaction, and psychosocial impact in patients with NSV.

Materials and Methods

This single-center prospective cohort study was conducted at a tertiary care center between July 2023 and June 2025. A total of 275 patients with non-segmental or mixed vitiligo were enrolled and followed for 12 months. Clinical evaluation included documentation of demographic variables and 16 predefined clinical markers such as koebnerization, trichrome pattern, confetti lesions, leukotrichia, and site involvement. Disease extent was assessed using body surface area (BSA). Outcomes measured at 6 and 12 months included disease progression, repigmentation (investigator global assessment), treatment dependency, vitiligo noticeability scale (VNS), and psychosocial burden (VISS-22, DLQI, C-DLQI, F-VIS). Multivariate analyses were performed to identify predictors of outcomes. Principal Component Analysis (PCA) was first applied to reduce dimensionality and summarize the multivariate clinical dataset into orthogonal components that captured the maximum variance across severity indices, disease activity measures, treatment parameters, and repigmentation outcomes. Clustering was subsequently performed on the PCA-derived components. Collinearity analysis demonstrated significant interrelationships among clinical variables (Figure 1).

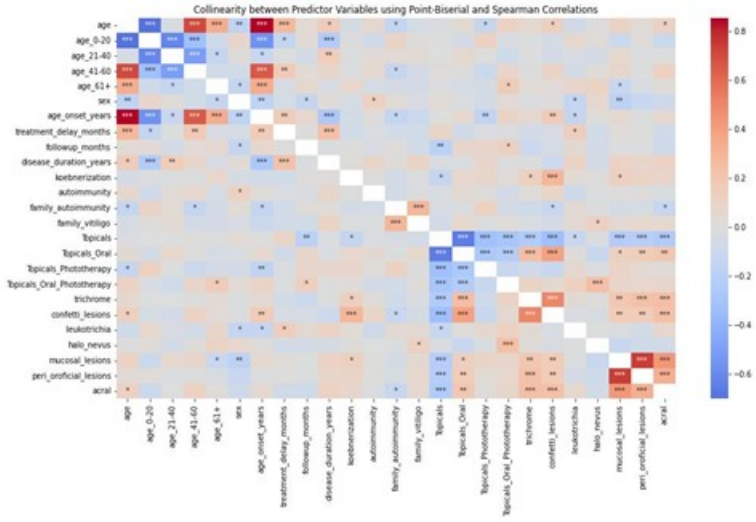

Heatmap showing collinearity among variables

Results

Larger baseline BSA associated with longer duration of diseaseolder presentation/onset (OR1.03, p=0.046), koebner phenomenon (OR 2.10, p=0.033), trichrome (OR 3.10, p=0.001),confetti lesions (OR 3.29, p=0.001), leukotrichia (OR 3.69, p<0.001), acral (OR 2.19,p=0.037), and periorificial involvement (OR 2.09, p=0.043). These persisted at 12 months(except periorificial involevment). Early age of onset (0–15 years) was protective (OR 0.47,p=0.047). For progression, Nnone of the predictors were statistically significant at 6 months.At 12 months, family history of autoimmunity was statistically significant (OR 3.15, p=0.03).Among clinical markers, leukotrichia was the only significant predictor of poorrepigmentation (OR 2.50; p=0.047). Other markers (trichrome, acral/mucosal) showed non-significant trends toward poorer response. Confetti lesions (OR 2.69–2.93, p≤0.002) andtrichrome pattern (OR 2.13–2.21, p≤0.025) were robust predictors at 6 and 12 months, whileearly onset was protective (OR 0.49, p=0.036 at 6 months) against treatment dependency.Leukotrichia (OR 2.96–3.97, p≤0.007) and acral lesions (OR 2.45, p=0.039 at 12 months)were associated with higher noticeability (lower satisfaction). Combination therapy reducednoticeability (OR 0.64–0.67, p<0.05). Early-onset disease linked to higher familypsychosocial burden (F-VIS; OR 2.62–3.17, p≤0.002). In adults/children ≥16 years,leukotrichia, mucosal/periorificial involvement, and onset 16–30 years was associated withworse DLQI/C-DLQI. Cluster analysis identified distinct subgroups with high-risk markers (confetti/trichrome,leukotrichia, acral/mucosal involvement) showing greater extent, dependency, and poorer outcomes both at 6 and 12 months with decreasing heterogeneity at 12months with treatment.

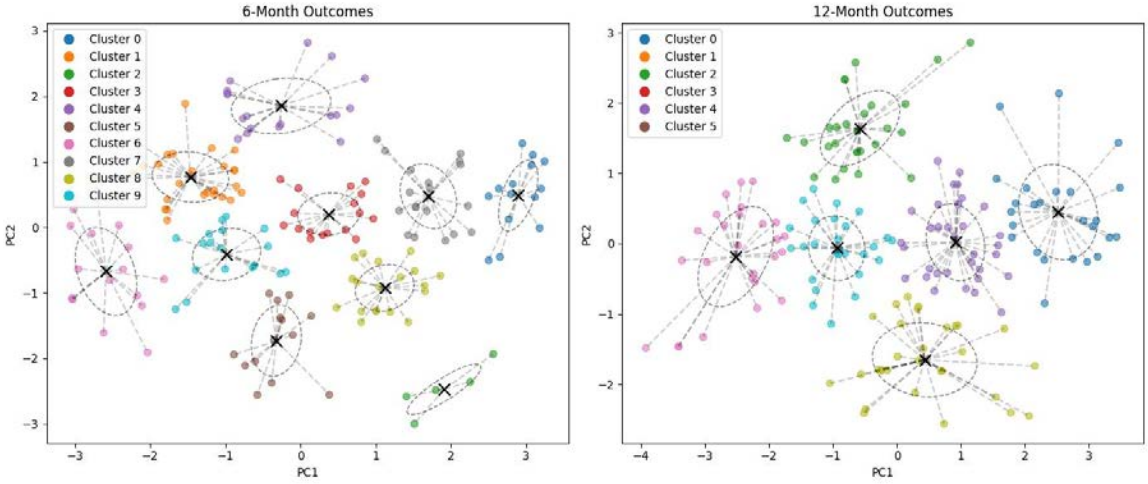

Principal cluster analysis at 6 and 12 months

Conclusions

Clinical markers such as leukotrichia, trichrome and confetti patterns, koebnerization, and mucosal or periorificial involvement are strong predictors of poor prognosis in NSV. Family history of autoimmunity predicts long-term progression and treatment dependency. Early identification of these factors enables risk stratification, guides therapeutic decision-making, and improves patient counseling.

EA DV CONGRESS
VIENNA
30 SEP - 3 OCT 2026

Abstract N°: 522

fficacy and Safety of a Novel Topical Formulation Combining 15% Azelaic Acid and 2% Tranexamic Acid in the Treatment of Acne-Induced Post-Inflammatory Hyperpigmentation

Qian Yu*[1], yunping he[1], yue wang[1], Beilei Cai[1]

[1] Zhiyan Biotechnology Co., Wuxi, China

Introduction
Acne-induced post-inflammatory hyperpigmentation (PIH) and post-inflammatory erythema (PIE) represent highly prevalent and aesthetically distressing sequelae, particularly driven by persistent cutaneous inflammation, epidermal barrier disruption, and aberrant keratinocyte-melanocyte crosstalk. Conventional monotherapies often fail to address the entire pathological cascade simultaneously and carry inherent risks of localized cutaneous irritation. This study aims to systematically evaluate the human application safety, objective multi-dimensional efficacy, and epidermal barrier-restoring properties of a synergistic topical formulation comprising 15% azelaic acid and 2% tranexamic acid in mitigating active acne lesions and reversing secondary dyschromia.

Materials and Methods
A tripartite clinical evaluation was conducted in strict adherence to standardized dermatological safety and efficacy protocols. Phase I assessed cutaneous compatibility via continuous patch testing on 30 healthy volunteers. Phase II utilized an ultraviolet (UV)-induced pigmentation model in 30 healthy subjects to isolate and evaluate anti-melanogenic efficacy. The formulation was applied topically twice daily for 28 consecutive days, with objective quantification achieved via the Individual Typology Angle (ITA°) and Melanin Index (MI), utilizing baseline post-irradiation data as normative controls. Phase III enrolled 30 subjects presenting with active facial acne and seborrhea. Following an identical 28-day, twice-daily application regimen, therapeutic efficacy was quantified via individual lesion erythema (colorimetric a* value), total lesion area, porphyrin area percentage, and Investigator's Global Assessment (IGA) scores. Furthermore, sebaceous regulation, transepidermal water loss (TEWL), and holistic facial red zone metrics were continuously monitored to evaluate barrier integrity and anti-inflammatory capacity.

Results
In Phase I, zero instances of adverse cutaneous reactions, such as erythema or edema, were observed among the 30 subjects, indicating an optimal dermatological safety profile and excellent skin compatibility. In Phase II, the 28-day intervention yielded a statistically significant increase in ITA° and a corresponding significant decrease in MI compared to baseline. This confirms the formulation's capacity to effectively interrupt melanin deposition and accelerate pigmentary clearance, directly targeting the core pathological mechanism of PIH. Phase III demonstrated significant reductions in individual acne lesion a* values, overall lesion area, porphyrin area ratio, and total IGA scores, confirming substantial suppression of active acne pathways. Concurrently, the formulation facilitated a significant decrease in TEWL and skin sebum content, indicating robust barrier repair and microenvironment optimization. Facial red zone area and intensity were significantly diminished, highlighting the profound soothing properties of the complex. Subjective evaluation revealed uniformly high participant satisfaction regarding both sensory attributes and multi-dimensional clinical improvement.

Conclusions
The combination of 15% azelaic acid and 2% tranexamic acid provides a highly tolerable, exceptionally safe, and multimodal therapeutic paradigm. By simultaneously downregulating active acne inflammatory pathways,

suppressing melanogenesis, and restoring stratum corneum integrity, this formulation effectively intercepts the pathophysiological continuum of acne-induced PIH and PIE, establishing it as a highly viable clinical intervention for complex pigmentary and inflammatory dermatoses.

EADV CONGRESS
VIENNA
30 SEP - 3 OCT 2026

Abstract N°: 564

Vitiligo-like leukoderma as an adverse effect of ribociclib

Paloma Seidel*[1], Kerstin Steinbrink[1], Markus Böhm[1]

[1] University Hospital Münster, Münster, Germany

Introduction

Vitiligo-like leukoderma has emerged as a rare but increasingly recognized cutaneous adverse event associated with cyclin-dependent kinase (CDK) 4/6 inhibitors, a class of targeted therapies widely used in advanced hormone receptor–positive, HER2-negative breast cancer. While common dermatologic side effects include alopecia, maculopapular rash, and pruritus, depigmenting disorders remain poorly characterized. We report a case of CDK4/6 inhibitor–induced vitiligo-like leukoderma in a patient with metastatic breast cancer and discuss its clinical and histopathological features.

Case Presentation

A 67-year-old woman presented with progressively developing whitish skin lesions since December 2023. The lesions initially appeared on the dorsal hands and feet and later extended to the forearms and face. Early symptoms included transient erythema and pruritus with a moderate impact on quality of life (DLQI 8). Her oncologic history was notable for hormone receptor–positive, HER2-negative breast cancer diagnosed in 2015, with liver metastases since November 2020. Following liver metastasectomy in July 2021, she received ongoing therapy with fulvestrant and denosumab. After prior treatment with palbociclib (September 2020–April 2023), therapy was switched to ribociclib in May 2023. At presentation, the patient was in complete remission.Dermatological examination revealed well-demarcated depigmented patches on the face (0.35% BSA,), both forearms (2.5% BSA each), and upper back (0.2% BSA), partially with hypochromic borders. Histopathological analysis demonstrated a markedly reduced melanocyte density in perilesional skin (Melan-A and SOX-10 staining) and decreased melanin (Fontana-Masson staining), while lesional skin showed complete absence of melanocytes and melanin.Based on the clinical course and timing, a diagnosis of ribociclib-induced vitiligo-like leukoderma was made. As the patient was most concerned by her facial lesions, topical mometasone furoate was started using an interval regimen for six months followed by topical tacrolimus 0,1%. This resulted in significant repigmentation of the facial lesions.

Conclusion

Vitiligo-like leukoderma represents a novel and clinically relevant adverse effect of CDK4/6 inhibitors, particularly ribociclib. It predominantly affects sun-exposed areas and may occur with variable latency after treatment initiation. The underlying pathogenesis is not fully understood but may involve immune-mediated melanocyte destruction and altered keratinocyte–melanocyte interactions. There is no evidence-based therapy, and treatment remains anecdotal. Our case demonstrates that topical corticosteroids and tacrolimus can be beneficial for facial lesions. Awareness of this entity is essential to distinguish it from idiopathic vitiligo and to guide patient counseling and management. Further insights into its mechanisms may contribute to a better understanding of vitiligo pathogenesis and the development of targeted therapies.

EADV CONGRESS
VIENNA
30 SEP - 3 OCT 2026

Abstract N°: 690

Long-term Progressive Ashy Dermatosis (Erythema Dyschromicum Perstans) with Histopathological Confirmation and Persistent Laboratory Abnormalities: A Case Report.

Ziyad Fathi Alatrash*[1], Heba Hassan Ahmed Sultan.[1], Sultan Hasan Ahmed.[2], Ahmed Mohamed abdurazig Elalem[1], SUROUR A.NUSAYR[3], Msara J.Haider[1]

[1] Faculty of Medicine, University of Tripoli, Tripoli, Libya, Al Aziziyah, Libya

[2] Volgograd State Medical University, Volgograd, Russia, Volgograd, Russian Federation

[3] Faculty of medicine, University of Tripoli, Tripoli, Libya, Al Aziziyah, Libya

Introduction

Erythema dyschromicum perstans (EDP), also known as ashy dermatosis, is an acquired pigmentary disorder characterized by gradually progressive grayish macules, typically affecting the trunk and proximal extremities. The condition is usually asymptomatic and follows a chronic course. Its etiology remains unclear, and diagnosis may be challenging due to overlap with other pigmentary disorders.

Case Presentation

A female patient developed hyperpigmented skin lesions at approximately 16 years of age. The lesions initially appeared on the abdomen and gradually progressed over more than 10 years to involve the trunk, axillae, groin, and upper thighs. The lesions were asymptomatic and not associated with pruritus.At an early stage, the condition was misdiagnosed as a fungal infection and treated with antifungal therapy without clinical improvement.A skin biopsy obtained from the abdomen demonstrated dermal melanocytosis with melanophages and no evidence of malignancy. Dermatological evaluation at a tertiary center supported the diagnosis of erythema dyschromicum perstans.

Conclusion

This case demonstrates a long-term progressive course of erythema dyschromicum perstans with histopathological confirmation. The findings highlight the chronic nature of the condition, diagnostic challenges, and the presence of persistent laboratory abnormalities.

EA DV CONGRESS
VIENNA
30 SEP - 3 OCT 2026

Abstract N°: 715

Automated Segmentation of Pigmented Lesions Using Local Contrast Features Against Surrounding Skin

Kimi Iinuma*[1], Kazuyasu Fujii[1], Atsushi Otsuka[1]

[1] Kindai University Faculty of Medicine, Department of Dermatology, Osaka, Japan

Introduction

Pigmented skin lesions encompass a wide spectrum of conditions, ranging from benign disorders such as post-inflammatory hyperpigmentation (PIH), melasma, and solar lentigines, to malignant diseases including melanoma and basal cell carcinoma. These lesions significantly impact patients' quality of life and prognosis. Accurate and reproducible assessment of pigmented lesions is crucial for evaluating treatment efficacy, monitoring disease progression, and comparing therapeutic interventions across clinical studies. Traditional evaluation methods rely on visual scoring systems such as the Melanin Index or physician global assessment, which are inherently subjective and prone to inter- and intra-observer variability. Manual annotation of lesion boundaries is time-consuming and impractical for large-scale studies. Therefore, there is a growing need for automated, objective quantification systems that can provide consistent and reproducible measurements of pigmented lesion characteristics.

Materials and Methods

We developed a deep learning-based segmentation model utilizing a 4-channel input architecture. The input consists of standard RGB color channels combined with a novel local contrast difference map as the fourth channel. The contrast map was computed by calculating the difference between each pixel's intensity and its local neighborhood mean using Gaussian blur. This approach specifically highlights regions that are darker than the surrounding skin, which is the defining characteristic of pigmented lesions. The dataset was split into independent training and validation sets, with the validation set held out and not used during model training. Ground truth annotations were created using manual polygon delineation by trained dermatologists. To accelerate the annotation process for additional training data, we employed a pseudo-labeling strategy where initial predictions from the model were generated automatically and subsequently reviewed and corrected by expert physicians. Data augmentation techniques including horizontal and vertical flipping, rotation, and brightness/contrast adjustments were applied during training. The model was trained using a combined Focal-Dice loss function optimized with the Adam optimizer.

Results

The proposed method achieved a Dice similarity coefficient of 0.87 on the held-out validation set. Notably, the addition of the local contrast channel significantly improved segmentation performance compared to the RGB-only baseline model, which achieved substantially lower accuracy on full-resolution inference (mean Dice: 0.85 vs 0.40). The system demonstrated robust performance across various skin types and lesion morphologies. In addition to binary segmentation masks, the system computes quantitative metrics including total lesion area, mean pigmentation intensity within detected regions, and a composite pigmentation score that integrates both area and intensity measurements. Processing time averaged less than one second per image on standard hardware, making the system suitable for clinical workflow integration.

Conclusions

We have developed an automated segmentation system for pigmented skin lesions that leverages local contrast features to explicitly encode the fundamental characteristic that lesions appear darker than surrounding normal

skin. This approach provides objective, reproducible quantification that can support clinical decision-making and enable standardized outcome assessment in therapeutic trials. The pseudo-labeling workflow significantly reduces the annotation burden while maintaining high-quality ground truth data. Future work will focus on expanding the training dataset, validating performance across diverse ethnic populations, and integrating longitudinal tracking capabilities for treatment response monitoring.

EA DV CONGRESS
VIENNA
30 SEP - 3 OCT 2026

Abstract N°: 717

Navigating the Treatment Modalities of Lichen Planus Pigmentosus: A Systematic Review

Azhar Alali[1], Mohammed Alahmadi*[1], Sara Alghamdi[2], Fatimah Alkhuraisi[1], Lama Albelowi[3], Sarah Almohammdi[3], Ola Farhan[4]

[1] Department of Dermatology, King Fahad General Hospital, Medina, Saudi Arabia
[2] Department of Dermatology, King Fahad Hospital, Al-Baha, Saudi Arabia
[3] Department of Dermatology, King Salman bin Abdulaziz Medical City, Medina, Saudi Arabia
[4] College of Medicine, Alrayan Medical Colleges, Medina, Saudi Arabia

Introduction
Lichen planus pigmentosus (LPP) is a rare skin condition in darker-skinned individuals characterized by slate-gray or brown pigmentation in sun-exposed areas. Its cause is unclear, and there is no universally effective treatment, underscoring the need for improved diagnostic and therapeutic options.

Materials and Methods
This systematic review was conducted in adherence to the guidelines for Systematic Reviews and Meta-Analyses (PRISMA). A comprehensive search has been conducted to gather studies assessing available treatment modalities of LPP. The search was carried out through PubMed, Web of Science, Medline, Wiley, and EBSCO. Following the initial database search, titles and abstracts were independently screened by two reviewers to select relevant studies that met predefined inclusion criteria. The same reviewers assessed eligibility through a full-text screening of the selected articles, with disagreements resolved through consultation with a third reviewer. Data were extracted using a standardized form that included study characteristics (author, year, design, country, total sample size, age, gender distribution, study and disease duration, skin phototype, and comorbidities), as well as intervention-related data and efficacy and safety outcomes.

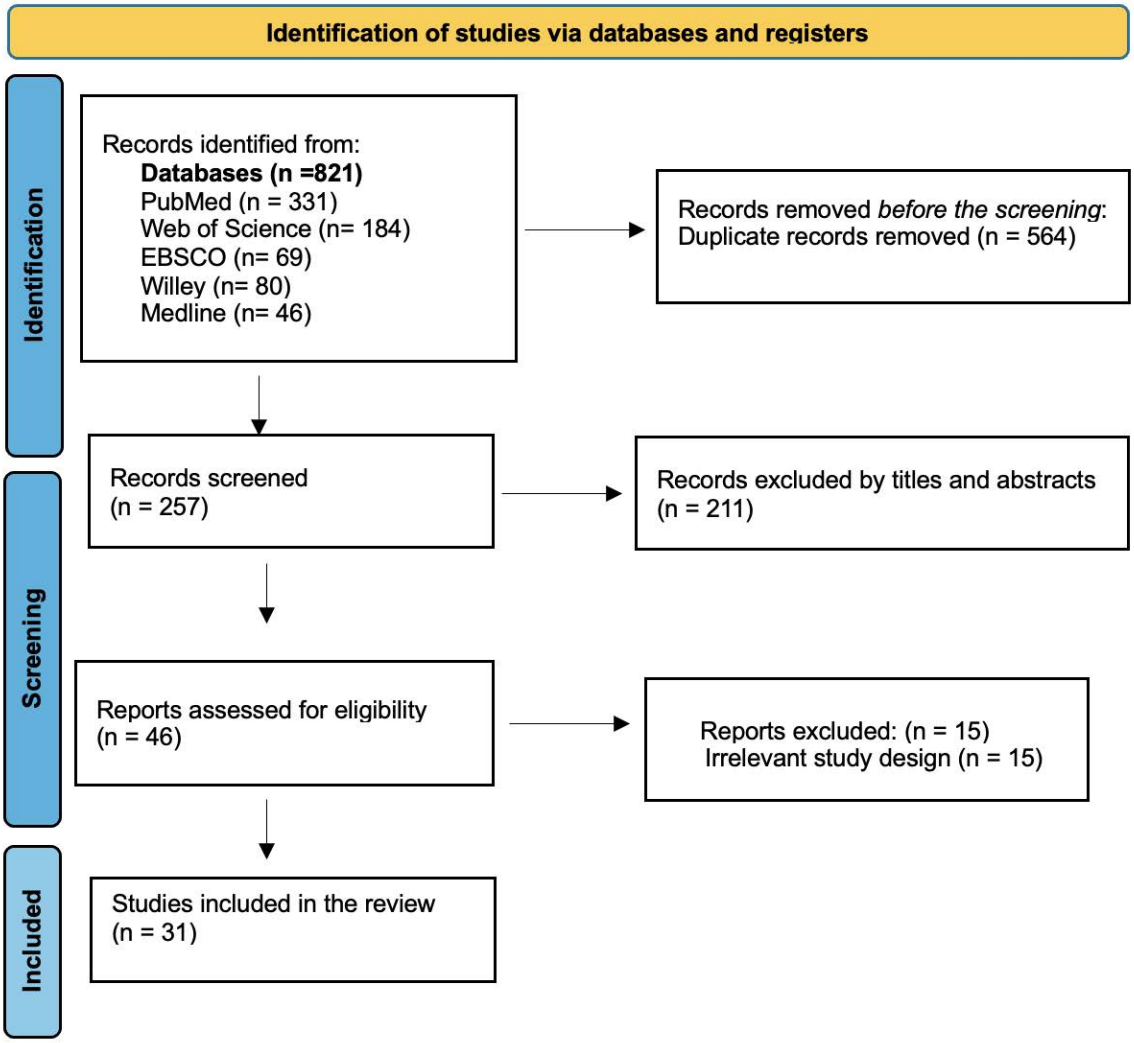

PRISMA Flowchart

Results

31 published studies, conducted between 1979 and 2025, were included in this systematic review. The final selection of studies involved 944 patients and reflected methodological diversity, including case reports, case series, and non-randomized observational studies. Treatment options for LPP are limited and mostly based on small studies. Platelet-rich plasma (PRP) may reduce pigmentation, and low-dose isotretinoin can stabilize early disease. Mycophenolate mofetil is beneficial for resistant cases, while JAK inhibitors have shown promise. Procedural therapies, such as lasers, have helped in persistent cases. The LPPI variant showed mixed treatment outcomes. Overall, effectiveness is inconsistent, underscoring the need for larger studies to establish optimal management strategies.

Conclusions

In summary, LPP and its variants, like LPP-inversus, are uncommon skin disorders characterized by varied pigmentation patterns, making them challenge to diagnose and treat. In this systematic review, we reported different studies that included a wide variety of treatment modalities, including traditional topical therapies, such as corticosteroids, which often yield limited results. However, systemic treatments such as low-dose isotretinoin and mycophenolate mofetil, along with laser treatment, chemical peels, and combinations of methods, can lead to noticeable improvements in some cases. It's also important to note that there are rare connections with conditions like hepatitis C, metal allergies, drug-induced pigment changes, and paraneoplastic effects, emphasizing the need for comprehensive evaluations. Ultimately, this highlights the necessity for personalized treatment plans that may involve multiple strategies. There's a pressing need for controlled studies to develop standardized approaches for effectively managing these complex, often difficult conditions.

EADV CONGRESS
VIENNA
30 SEP - 3 OCT 2026

Abstract N°: 723

Early high-resolution dermoscopic features predict response to topical ruxolitinib in nonsegmental vitiligo

Gianluca Tavoletti*[1], Caterina Marchini[1], Gabriele Argenziano[1], Stefano Pasi[1], Emanuela Passoni[1], Angelo Valerio Marzano[1], SILVIA ALBERTI VIOLETTI[1]

[1] Fondazione IRCCS Ca' Granda Ospedale Maggiore Policlinico, Milan, Italy

Introduction
Vitiligo is a chronic autoimmune disorder characterized by melanocyte loss and significant psychosocial burden. Topical ruxolitinib, a JAK1/2 inhibitor, has recently demonstrated efficacy in nonsegmental vitiligo; however, early predictors of response in real-world settings remain unclear. While dermoscopy and reflectance confocal microscopy have been proposed as tools for early assessment, the potential role of high-resolution dermoscopy (HRD, up to 400×) has not been systematically explored.

Materials and Methods
We designed a prospective observational study including adult patients with nonsegmental vitiligo treated with ruxolitinib 1.5% cream. Patients receiving recent systemic or topical therapies were excluded. Target lesions were evaluated at baseline and early follow-up visits. HRD (400×) was used to assess predefined features, including perifollicular pigmentation, follicular activation patterns, microvascular morphology, and early pigment network changes. Clinical response was defined by the appearance of perifollicular or interfollicular repigmentation. Associations between early HRD findings and subsequent clinical response are being explored.

Results
Preliminary observations suggest that HRD enables detection of subtle early changes not appreciable at standard magnification. In particular, perifollicular hyperpigmented halos and early follicular activation appear more frequently in lesions that subsequently show repigmentation. These findings support the hypothesis that early activation of follicular melanocyte reservoirs may represent a key mechanism of response.

Conclusions
High-resolution dermoscopy may represent a noninvasive and widely accessible tool for early prediction of response to topical ruxolitinib in nonsegmental vitiligo. Further data from this ongoing study will help validate these preliminary observations.

EADV CONGRESS
VIENNA
30 SEP - 3 OCT 2026

Abstract N°: 795

COMPARISON OF EFFICACY AND SAFETY OF ORAL CORTICOSTEROID MINI PULSE (OMP) VERSUS ORAL TOFACITINIB IN STABILIZATION AND REPIGMENTATION OF ACTIVE VITILIGO – A RANDOMIZED CONTROLLED TRIAL

Prajakta Waghmare*[1]

[1] All India Institute of Medical Sciences, Jodhpur, India

Introduction
Oral steroid mini pulse is a known treatment modality for active vitiligo. Oral tofacitinib may have a therapeutic role but current evidence supporting its role is limited. Therefore, we conducted a comparative trial to study the efficacy and safety of these two modalities in arresting the disease progression in active vitiligo.

Materials and Methods
Total 76 patients were randomized into two groups. Group 1 received betamethasone oral mini pulse 5 mg on 2 consecutive days/week and group 2 received tofacitinib 5 mg OD for 2 weeks followed by 5 mg BD. Therapies were tapered gradually after arrest of disease progression (ADP) and were continued for 6 months. Dermoscopy findings, quality of life, correlation of serum IL6 levels with duration of disease stability and adverse effects were noted.

Results
Overall, the mean time for ADP was 2.53 + 0.60 months. It was lower in the OMP group (2.52 + 0.11) as compared to the tofacitinib group (2.54 + 0.10) but the difference was insignificant (p value = 0.8). ADP was attained in 29 patients in group 1 and 28 patients in group 2 at the end of 4 months. The extent of repigmentation (VASI), improvement in patient and investigator assessment score (PGA and IGA), quality of life (VIS 22), and clinical marker of disease activity (VSAS) were comparable in both groups ($p>0.05$). The change in serum IL-6 levels from baseline to 6 months decreased progressively with shorter disease stability periods ($p = 0.60$).

Conclusions
Oral tofacitinib is equally effective in causing ADP and repigmentation. As vitiligo is a chronic disease with no definitive treatment endpoint, we proposed a novel approach involving the tapering of medication following disease stabilization to minimize the potential side effects associated with long-term therapy.

EA DV CONGRESS
VIENNA
30 SEP - 3 OCT 2026

Abstract N°: 806

Patient-Reported Vitiligo Journey, Management, and Stigma in China: Findings from the National Health and Wellness Survey

Xinghua Gao*[1], Leihong Xiang[2], Jiamin Chang[3], Matthew Brouillette[4], Roni Adiri[5], Nikoletta Sternbach[6], Samantha Kurosky[7], Mojgan Sadrarhami[7], Yinghui Li[8], Genevieve Gauthier[9], Yanan Wang[8], Griffith Bell[10], Milena Gianfrancesco[11]

[1] The First Hospital of China Medical University, Liaoning, China
[2] Department of Dermatology, Huashan Hospital, Fudan University, Shanghai, China
[3] Department of Dermatology, Beijing Hospital, National Center of Gerontology, Institute of Geriatric Medicine, Chinese Academy of Medical Sciences, Beijing, China
[4] Pfizer Inc., Collegeville, United States
[5] Pfizer Pharmaceuticals Israel Ltd, Herzliya Pituach, Israel
[6] Oracle Life Sciences, Austin, United States
[7] Pfizer Inc, New York City, United States
[8] Pfizer Inc, Beijing, China
[9] Pfizer Canada ULC, Kirkland, Canada
[10] Pfizer Inc, Cambridge, United States
[11] Pfizer Inc, San Francisco, United States

Introduction
Vitiligo is a chronic autoimmune skin disease that is characterized by white patches and/or macules of depigmented skin as a result of melanocyte destruction by the immune system. People with vitiligo frequently experience psychosocial burden and significant quality-of-life impairment. The objective of this study was to estimate the prevalence of vitiligo in urban China and explore the vitiligo patient journey and disease burden.

Materials and Methods
Data are from the 2025 National Health and Wellness Survey (NHWS) conducted by Oracle Life Sciences, a population based, self-reported cross-sectional online survey. Participants were adults (≥18 years) in urban China. Results were weighted to reflect demographic distributions of the adult population in urban China.

Results
A total of 20 001 participants were included in this analysis (weighted: N=747.5M). Among these, 0.84% self-reported ever experiencing vitiligo and 0.53% self-reported clinically diagnosed with vitiligo (males, 0.62%; females, 0.43%). All measures presented are for respondents with self-reported clinically diagnosed vitiligo (**Table**; unweighted: n=104; weighted: n=3.9M). At time of survey, mean (SD) age was 52.3 (16.3) years. Based on the PHQ-9 scale, 38.9% showed "Mild depression" and 24.2% "Moderate-to-severe depression" symptoms. Mean (SD) time since first vitiligo diagnosis was 16.7 (13.2) years and 69.3% reported mild disease at first diagnosis. The majority of participants reported experiencing some degree of stigma, including shame (84.1%), prejudice (90.8%), and discrimination (82.9%), because of their vitiligo. Facial involvement was reported by 48.5%, while 40% reported depigmentation of the hands, palms, or fingers. For those currently using a medical treatment for their vitiligo (39.3%), the most common reported were topical (78.0%) and oral (61.4%) treatments. Among individuals who reported not currently receiving medical treatment or light therapy (40.9%), the top three reasons included “Treatment did not work” (46.3%), “No active vitiligo” (41.0%) and “Cost of treatment was too high”

(26.5%).

Table. Characteristics of adults in China who self-reported clinically diagnosed vitiligo

	Diagnosed vitiligo population Weighted N=3.9 M
Demographic characteristics	
Mean age, years (SD)	52.3 (16.3)
Sex, female, %	40.0
Married, %	74.9
University degree or above, %	42.5
Employed, %	50.2
Clinical characteristics	
Current or former smoker, %	31.6
Overweight/obese (BMI ≥25), %	37.2
PHQ-9 Score, %	
0-4, "None-Minimal"	36.8
5-9, "Mild depression"	38.9
10-14, "Moderate depression"	18.0
15-19, "Moderately severe depression"	4.3
20-27, "Severe depression"	1.9
Vitiligo characteristics	
Diagnosing provider type, %	
Dermatologist	72.7
Immunologist	8.8
Other/Not reported	18.5
Mean (SD) time since first diagnosis, years	16.7 (13.2)
Mean (SD) age at first diagnosis, years	36.5 (18.4)
Self-reported severity of vitiligo at first diagnosis, %	
Mild	69.3
Moderate	14.0
Severe	2.9
Very severe	2.2
Don't know/Unknown/Not reported	11.6
Self-assessed severity of vitiligo at time of survey, %	
Mild	75.0
Moderate	22.1
Severe	2.9
Perceived stigma, %	
Shame	84.1
Prejudice	90.8
Discrimination	82.9
Currently receiving vitiligo treatment, %	39.3
Topical treatments	78.0
Oral treatments	61.4
Injection in areas of skin color change	7.8
Injectable treatments	18.8
Other types of treatments	13.3
None of the above	2.0

BMI, body mass index; M, million; PHQ-9, Patient Health Questionnaire-9.

Conclusions

The prevalence of self-reported ever-experienced vitiligo in adults in China was 0.84% and self-reported clinically diagnosed with vitiligo was 0.53%, in alignment with previously published data from China. Most participants

reported some level of embarrassment, judgement, and negative treatment from others because of their vitiligo. There is an unmet need for new, effective treatments for vitiligo.

EA DV CONGRESS
VIENNA
30 SEP - 3 OCT 2026

Abstract N°: 807

Real-World Psychosocial Burden, Quality of Life, and Disease Management of Non-Segmental Vitiligo in the United States

Nada Elbuluk[1], Christian Atkinson[2], Seemal R Desai[3, 4], Neil Reynolds[2], Iltefat Hamzavi[5], Charley Cooper[2], Samantha Kurosky*[6], Morgan Fox[2], Roni Adiri[7], Mojgan Sadrarhami[6], Yousaf Aftab[8], Genevieve Gauthier[9], Griffith Bell[6], Khaled Ezzedine[10, 11]

[1] Keck School of Medicine, University of Southern California, Los Angeles, United States
[2] Adelphi Real World, Bollington, United Kingdom
[3] Innovative Dermatology, Plano, United States
[4] Department of Dermatology, University of Texas Southwestern Medical Center, Dallas, United States
[5] Vitiligo Treatment and Research Center, Henry Ford Health, Detroit, United States
[6] Pfizer Inc, New York City, United States
[7] Pfizer Pharmaceuticals Israel Ltd, Herzliya Pituach, Israel
[8] Pfizer Ltd, Tadworth, United Kingdom
[9] Pfizer Inc., Kirkland, Canada
[10] Department of Dermatology, Hôpital Henri Mondor, Créteil, France
[11] EpiDermE (Epidemiology in Dermatology and Evaluation of therapeutics), Institut Mondor de Recherche Biomédicale, Inserm U955, Université Paris Est Créteil (UPEC), Créteil, France

Introduction

Non-segmental vitiligo (NSV) is an autoimmune-mediated disease leading to depigmented skin lesions. Beyond depigmentation, individuals may experience impacts to their psychosocial health, daily activities, and overall quality of life (QOL). However, impacts range substantially from none to very severe, indicating additional contextual factors beyond a diagnosis may impact disease burden. This study aims to quantify the burden of NSV in adults in the US and examine how different clinical presentations may contribute to heterogeneity in psychosocial and QOL outcomes.

Materials and Methods

A non-interventional cross-sectional survey of adults with NSV was conducted in the US. Participants were referred into the study by physicians who confirmed the NSV diagnosis. Data were collected between May and October 2025. Participation in the survey was voluntary. Patients were remunerated for their time only. The survey collected self-reported information from the respondents on demographics, clinical characteristics, and outcome measures including the Self-Assessment Vitiligo Extent Score (SA-VES; a measure of % body surface area [BSA] with vitiligo lesions), Dermatology Life Quality Index (DLQI; a skin-specific QOL measure with scores ranging from 0 to 30 where a higher score indicates a greater impact), Vitiligo Impact Patient scale (VIPs; a vitiligo-specific QOL measure with scores ranging from 1 to 95 where a higher score indicates a greater impact), and the Patient Global Impression of Severity (PGIS; a self-assessed measure of vitiligo severity). Variables were analysed descriptively and stratified by BSA, years since initial vitiligo diagnosis (disease duration), and affected body region.

Results

In the sample of 200 adults, mean age was 48.2 years, 64% were female, and 42% had been diagnosed in the last 5 years. 82% were diagnosed by a dermatologist. 28% were Fitzpatrick Skin Type (FST) I/II, 48% FST III/IV, and 25% FST V/VI. At the time of the survey, 48% of patients used topical corticosteroids and 27% used a topical JAK inhibitor to manage their vitiligo; 9% had received no treatment. Half of respondents described their vitiligo as stable in the last 3 months; 59% reported slow progression of vitiligo since diagnosis. Respondents had vitiligo lesions on their face (34%), rest of the head and neck (47%), hands (44%), remaining upper extremities (62%), genitalia/groin (16%), torso (55%), and lower extremities (55%). Mean DLQI score was 4.8; 26% of patients reported a DLQI score corresponding to no effect, 41% a small effect, 24% a moderate effect, and 10% a very large or extremely large effect. Mean VIPs score was 25.2. 42% of patients indicated moderate-to-severe vitiligo on their face, and 38% indicated moderate-to-very severe vitiligo on their total body. DLQI, VIPs, and face/body severity stratified by BSA, duration of disease, and affected body region are presented in **Table 1**. Disease burden varied across patient and clinically defined subgroups, with numerically higher mean DLQI scores among those with shorter disease duration and vitiligo on the head/neck. Mean VIPs scores did not vary substantially across disease duration or body region. Both measures suggest non-linear relationships between QOL impacts and affected BSA. QOL impacts, measured by the DLQI, trended higher with greater severity on both the face and body.

	Total Sample	Duration of Disease (years)			Affected Body Region							% BSA Affected					
		≤5	6 to 10	>10	Face	Rest of head and neck	Hands	Rest of upper extremities	Genitalia/ Groin	Torso	Lower extremities	0-1%	2-5%	6-10%	11-25%	26-50%	>50%
DLQI Score[a]																	
Total N	**200**	**84**	**43**	**73**	**67**	**93**	**88**	**124**	**32**	**109**	**110**	**78**	**77**	**15**	**14**	**12**	**4**
Mean	4.8	5.0	5.9	3.8	4.4	5.7	4.6	5.2	4.0	5.0	4.9	3.0	6.0	6.2	7.2	4.2	2.5
SD	4.72	5.16	5.69	3.20	5.06	4.53	4.84	4.94	4.19	4.92	5.18	3.47	4.69	5.47	7.65	3.66	2.38
VIPS Score[b]																	
Total N	***200***	***84***	***43***	***73***	***67***	***93***	***88***	***124***	***32***	***109***	***110***	***78***	***77***	***15***	***14***	***12***	***4***
Mean	25.2	23.9	26.4	25.9	25.4	31.2	26.1	28.1	27.8	27.2	27.8	17.0	27.9	27.7	40.2	31.4	50.5
SD	21.83	19.90	24.88	22.27	23.92	22.15	23.49	22.31	26.25	23.15	23.17	16.85	20.83	18.16	31.18	26.08	32.48
Severity on the Face[c]																	
Total N (%)	***67***	***27***	***15***	***25***	***67***	***27***	***32***	***39***	***21***	***36***	***36***	***25***	***24***	***4***	***4***	***6***	***4***
None	4 (6)	1 (3.7)	1 (6.7)	2 (8)	4 (6)	1 (3.7)	2 (6.2)	1 (2.6)	1 (4.8)	1 (2.8)	2 (5.6)	1 (4)	2 (8.3)	-	-	-	1 (25)
Mild	35 (52.2)	15 (55.6)	6 (40)	14 (56)	35 (52.2)	13 (48.1)	15 (46.9)	22 (56.4)	13 (61.9)	14 (38.9)	20 (55.6)	20 (80)	9 (37.5)	2 (50)	3 (75)	1 (16.7)	-
Moderate	23 (34.3)	9 (33.3)	7 (46.7)	7 (28)	23 (34.3)	9 (33.3)	12 (37.5)	11 (28.2)	4 (19)	16 (44.4)	11 (30.6)	4 (16)	12 (50)	1 (25)	1 (25)	5 (83.3)	-
Severe	4 (6)	2 (7.4)	1 (6.7)	1 (4)	4 (6)	3 (11.1)	2 (6.2)	4 (10.3)	2 (9.5)	4 (11.1)	2 (5.6)	-	1 (4.2)	1 (25)	-	-	2 (50)
Very severe	1 (1.5)	-	-	1 (4)	1 (1.5)	1 (3.7)	1 (3.1)	1 (2.6)	1 (4.8)	1 (2.8)	1 (2.8)	-	-	-	-	-	1 (25)
Severity on the Total Body[d]																	
Total N (%)	***200***	***84***	***43***	***73***	***67***	***93***	***88***	***124***	***32***	***109***	***110***	***78***	***77***	***15***	***14***	***12***	***4***
None	18 (9)	6 (7.1)	4 (9.3)	8 (11)	6 (9)	4 (4.3)	9 (10.2)	6 (4.8)	1 (3.1)	5 (4.6)	9 (8.2)	8 (10.3)	5 (6.5)	2 (13.3)	1 (7.1)	1 (8.3)	1 (25)
Mild	107 (53.5)	57 (67.9)	17 (39.5)	33 (45.2)	31 (46.3)	40 (43)	41 (46.6)	61 (49.2)	11 (34.4)	54 (49.5)	55 (50)	61 (78.2)	36 (46.8)	4 (26.7)	2 (14.3)	4 (33.3)	-
Moderate	67 (33.5)	19 (22.6)	21 (48.8)	27 (37)	24 (35.8)	44 (47.3)	32 (36.4)	49 (39.5)	15 (46.9)	43 (39.4)	39 (35.5)	9 (11.5)	34 (44.2)	8 (53.3)	11 (78.6)	5 (41.7)	-
Severe	4 (2)	2 (2.4)	-	2 (2.7)	2 (3)	1 (1.1)	2 (2.3)	4 (3.2)	1 (3.1)	3 (2.8)	3 (2.7)	-	2 (2.6)	1 (6.7)	-	1 (8.3)	-
Very severe	4 (2)	-	1 (2.3)	3 (4.1)	4 (6)	4 (4.3)	4 (4.5)	4 (3.2)	4 (12.5)	4 (3.7)	4 (3.6)	-	-	-	-	1 (8.3)	3 (75)

BSA = body surface area; DLQI = Dermatology Life Quality Index; SD = standard deviation; VIPS = Vitiligo Impact Patient Scale.
[a]Score ranges from 0 to 30 with a higher score indicating greater impact on quality of life. Scores ranging from 0 to 1 correspond to no effect, 2 to 5 a small effect, 6 to 10 a moderate effect, and 11 to 30 a very large/extremely large effect on the respondent's life.
[b]Score ranges from 0 to 95 with a higher score indicating greater impact due to vitiligo.
[c]Self-assessed severity of vitiligo on the face only at the time of the survey.
[d]Self-assessed severity of vitiligo on the body (including the face) at the time of the survey.

Conclusions

Adults with NSV reported substantial psychosocial burden and QOL impacts, highlighting that the burden of NSV extends beyond visible symptoms alone. Variations in QOL were observed across clinical subgroups and measurement instruments, suggesting multiple patient factors impact burden severity across a wide variety of QOL dimensions. Despite the notable impacts of vitiligo, treatment use suggests ongoing gaps in available treatments, including reliance on conventional therapies associated with limited effectiveness and/or safety profiles that prohibit long-term maintenance.

EADV CONGRESS
VIENNA
30 SEP - 3 OCT 2026

Abstract N°: 821

Diagnostic Pitfalls in Pediatric Depigmentation: Familial Piebaldism Revealed by Clinical Clues and LC-OCT Imaging

Alessia Paganelli*[1, 2], Alessandra Corrente[1], Cristina Cristofoletti[1], Qinyi Chen[1], Tiziano Ingegnere[1], Laura Colonna[1], Mauro Picardo[1]

[1] IDI-IRCCS Istituto Dermopatico dell'Immacolata, Rome, Italy

[2] Link Campus University, Rome, Italy

Introduction

Vitiligo is an acquired depigmenting disorder characterized by progressive loss of melanocytes, often presenting with well-demarcated depigmented macules. However, several congenital conditions, such as piebaldism, may mimic vitiligo and lead to diagnostic uncertainty, particularly in pediatric patients. Differentiating between these entities is crucial due to differences in prognosis, genetic implications, and management. Advanced non-invasive imaging techniques, including line-field confocal optical coherence tomography (LC-OCT), may support diagnostic clarification.

Case Presentation

We report the case of two sisters referred to our tertiary dermatology center with a suspected diagnosis of vitiligo. Both patients presented with stable depigmented patches involving the forehead, the trunk and the limbs, distributed symmetrically. Clinical examination revealed additional distinctive features, including a congenital white forelock, poliosis, and spots of normal pigmentation within the depigmented areas. The lesions had been present since birth without evidence of progression. These findings raised suspicion of piebaldism rather than vitiligo. LC-OCT imaging demonstrated features consistent with melanocyte absence in affected areas and preservation within pigmented islands, supporting the clinical hypothesis. No inflammatory changes suggestive of active vitiligo were observed.

Conclusion

This case highlights the importance of careful clinical evaluation in distinguishing piebaldism from vitiligo, particularly in familial presentations. Key diagnostic clues include congenital onset, lesion stability, characteristic distribution, and associated features such as poliosis and white forelock. LC-OCT may serve as a valuable non-invasive tool in supporting diagnosis. Accurate identification of piebaldism is essential to avoid unnecessary treatments and to provide appropriate genetic counseling.

EADV CONGRESS
VIENNA
30 SEP - 3 OCT 2026

Abstract N°: 842

Impact of Vitiligo on Quality of Life in the Pediatric Population

Syrine Ben Hadj Hassen*[1], Maha Lahouel[1], Jacem Rouatbi[1], Sarra Saad[1], Nadia Ghariani[1], Sana Mokni[1], Amina Aounallah[1], najet ghariani[1], Mohamed Denguezli[1]

[1] Hôpital Farhat Hached, Sousse, Tunisia

Introduction
Vitiligo is a chronic acquired depigmenting disorder characterized by the loss of functional melanocytes. While its clinical presentation is benign, its psychosocial repercussions can be profound, particularly in children and adolescents undergoing critical phases of identity formation and social integration. The psychological burden of vitiligo in pediatric populations remains underexplored in North African settings. This study aimed to evaluate the impact of vitiligo on quality of life and to identify associated psychological factors in affected children and adolescents.

Materials and Methods
We conducted a cross-sectional prospective study in the Dermatology Department of Farhat Hached University Hospital, Sousse, Tunisia, between April 2025 and January 2026. Among 96 patients with vitiligo, 26 (27.1%) were aged ≤18 years. Quality of life was assessed using the Children's Dermatology Life Quality Index (CDLQI) in patients aged 5–16 years and the Vitiligo Quality of Life (VitiQoL) questionnaire. Psychological status was evaluated using the Hospital Anxiety and Depression Scale (HADS). Clinical variables included disease extent (Vitiligo Extent Score), lesion visibility, disease activity, and genital involvement.

Results
Nineteen children completed the CDLQI, with a mean score of 4 ± 6, reflecting an overall mild impact. However, 26.2% of patients reported a moderate to very large impairment (CDLQI ≥7), identifying a clinically relevant vulnerable subgroup. VitiQoL assessment provided convergent results, highlighting a heterogeneous and patient-dependent burden, with greater impairment observed in domains related to emotional well-being and self-perception. Anxiety symptoms (HADS-A positivity) were significantly associated with impaired quality of life ($p = 0.026$), consistently across both CDLQI and VitiQoL measures. No cases of clinically significant depression were identified. Importantly, objective disease characteristics—including extent, visibility, disease activity, and genital involvement—were not significantly associated with quality of life scores.

Conclusions
Our findings suggest that the psychosocial impact of vitiligo in pediatric patients is heterogeneous and not solely determined by clinical severity. Anxiety appears to be a key driver of quality of life impairment, underscoring the importance of systematic psychological screening. These results advocate for a multidisciplinary management approach integrating dermatological care with psychological support, particularly for at-risk pediatric subgroups.

EADV CONGRESS
VIENNA
30 SEP - 3 OCT 2026

Abstract N°: 846

A Hollistic Approach to the Management of Post- Inflammatory Hyperpigmentation in High Fitzpatrick Skin Types: An Observational Clincal Study

Mohammed Bashir Danmallam*[1]

[1] Nigermed Skincare center, Abuja, Nigeria

Introduction

Post - inflammatory hyperpigmentation (PIH) is a common and often persistent dermatological condition, particularly prevalent in individuals with higher Fitzpatrick skin types. Acne vulgaris represents one of the leading causes of PIH in skin of color,frequently resulting in prolonged dysphoria due to an exaggerated melanogeic response following inflammation

This observational clinical study aimed to evaluate the effective of a holistic, sequential treatment approach for the management of PIH in patients with high Fitzpatrick prototypes, addressing both the inflammatory trigger and pigmentation alterations.

Case Presentation

A 6- month observational cl8nical study was conducted in Nigeria in patients with high Fitzpatrick prototypes presenting with with PIH, with or without active acne.
Patients with acne were initially treated with a topical regimen combining anti -inflammatory, keratolytic,and sebum- regulating agents; oral isotretinoin was added in severe cases. Once acne acne was controlled, a topical depigmenting treatment targeting melanogenesis ,including a challenge- derived molecule was initiated. Patients without acne directly received the depigmenting protocol.
Clinical follow- up was performed to assess pigmentation and skin tone.

Results:

All patients showed improvement over the study period. In subjects with active acne, early improvement was observed during the initial treatment phase,likely associated with the reduction of inflammation and lesion count. Following acne resolution,the introduction of the depigmenting treatment resulted in a progressive reduction of hyperpigmentation and improved skin tone homogeneity.
Patients without acne also demonstrated significant improvement with the depigmenting protocol alone. Consistent treatment adherence was associated with enhanced clinical outcomes.

Conclusion

A sequential treatment approach targeting both inflammation and melanogenesis appears to be effective in management of PIH in high Fitzpatrick skin types. Addressing the inflammatory trigger prior to initiating depigmenting therapy may optimise outcomes, leading to improved skin tone,uniformity and reduction of hyperpigmentation.

EADV CONGRESS
VIENNA
30 SEP - 3 OCT 2026

Abstract N°: 852

Role of anxiety-related α-synuclein in melanocyte pigment regulation and the pathogenesis of melasma

Shanglin Jin*[1], Xuanxuan He[1], Chengfeng Zhang[1]

[1] Huashan Hospital, Fudan University, Shanghai, China

Introduction
Melasma is a common hyperpigmentary disorder with a complex pathogenesis. Clinical observations increasingly link psychological stress, such as anxiety, to the development and exacerbation of melasma; however, the molecular mechanism connecting mental stress to hyperpigmentation remains poorly understood. This study investigates the role of α-synuclein (α-Syn), a protein traditionally associated with neurological stress, in the "neuro-skin" interaction network, aiming to identify its regulatory effects on melanocyte function and its potential as a therapeutic target in melasma.

Materials and Methods
Methods: A multi-dimensional approach was employed involving cell cultures, human skin explants, and animal models. First, the expression and spatial distribution of α-Syn in human skin were localized. To simulate stress in vitro and ex vivo, primary human melanocytes and skin tissues were treated with UVB radiation combined with Corticotropin-Releasing Factor (CRF). We measured melanin content, tyrosinase (TYR) activity, and the expression of melanogenic genes (MITF, TYR, TRP1) and α-Syn. Functional recovery was assessed via targeted α-Syn knockdown. Finally, a melasma-like mouse model (progesterone combined with UVB) was subjected to chronic restraint stress (CRS) to evaluate systemic and local oxidative stress markers (SOD, lipofuscin) and pigment metabolism.

Results
α-Syn was found to be widely expressed in skin cells, with the highest expression observed in melanocytes. Immunofluorescence co-localization confirmed that α-Syn is primarily distributed in the cytoplasm and cell membrane of melanocytes along the basal membrane zone. Both in vitro and ex vivo models showed that UVB and CRF stimulation significantly upregulated melanin content, TYR activity, and α-Syn expression. Knockdown of α-Syn effectively blocked the stress-induced promotion of melanogenesis. In the animal model, chronic restraint stress significantly promoted melanin production and exacerbated melasma-like lesions, characterized by elevated TYR and lipofuscin levels and decreased SOD activity, accompanied by significant α-Syn upregulation.

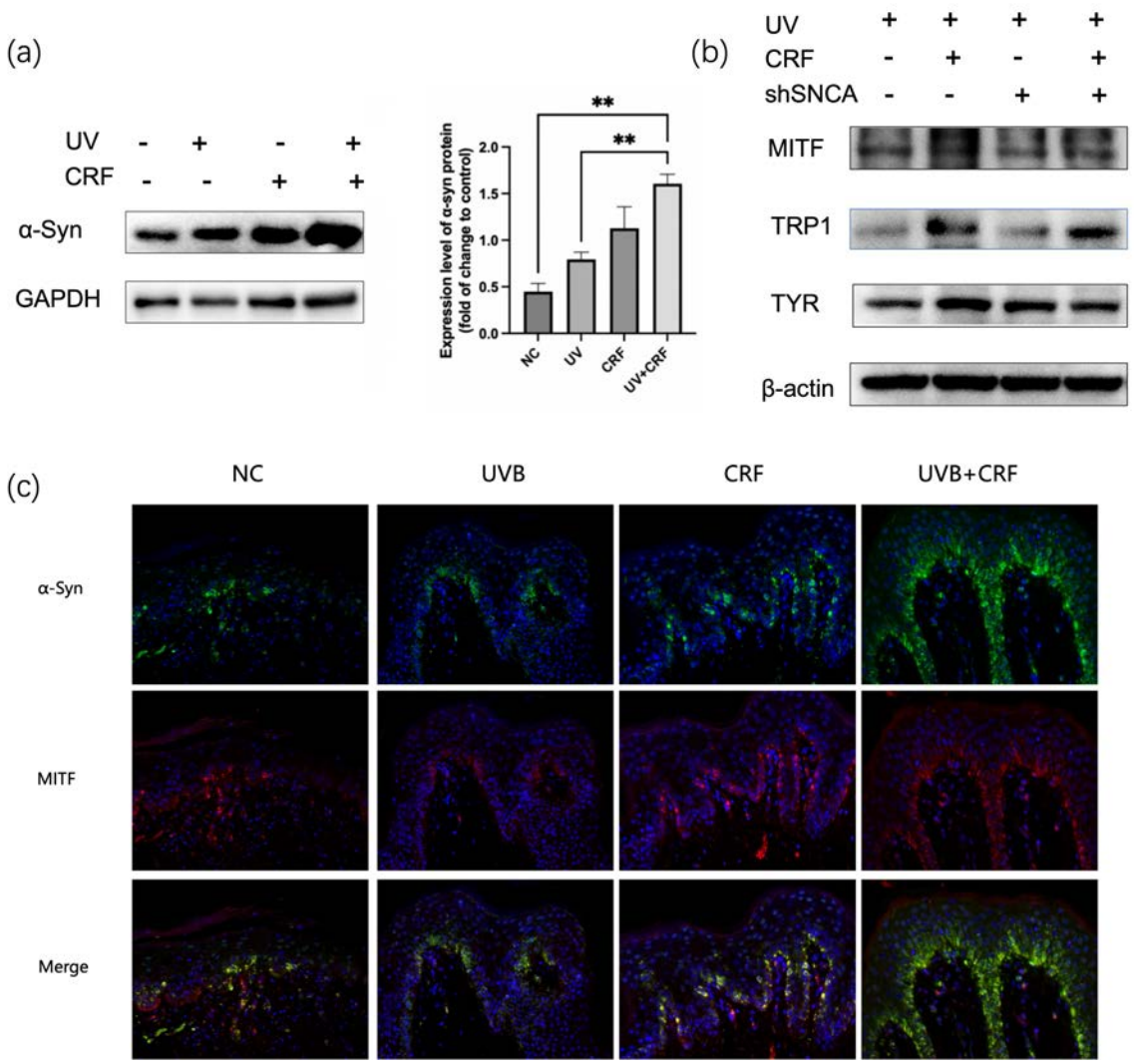

Expression characteristics and regulatory role of α-Syn in melanogenesis

Conclusions

This study demonstrates for the first time that α-synuclein acts as a critical "molecular switch" in anxiety-induced pigmentation. Stress signals drive the progression of melasma by activating α-Syn and its downstream pathways, which in turn enhances melanogenesis and oxidative stress. Inhibition of α-Syn can effectively reverse this pathological process. These findings provide a novel theoretical basis for developing therapeutic strategies targeting α-Syn or its related stress signaling pathways in the treatment of melasma.

EA DV CONGRESS
VIENNA
30 SEP - 3 OCT 2026

Abstract N°: 884

A diagnostic challenge: clinicodermoscopic and histopathological correlation of erythema dyschromicum perstans in a patient with HIV infection

Giovanna Aldonza Rios López*[1], Marisol Ramírez Padilla[1], María Ochoa Campollo[1], Jesús Rivas Rodríguez[1], Karen Hernández Jaime[1, 1], Paola Chavez Contreras[1, 1]

[1] General Rectory Building of the University of Guadalajara, Guadalajara, Mexico

Introduction

Erythema dyschromicum perstans is an acquired dermal hyperpigmentantation disorder characterized by grayish macules with a chronic course. It may mimic other pigmentary conditions such as lichen planus pigmentosus, and dermoscopic features remain incompletely defined.



Case Presentation

A 54-year-old male with type 2 diabetes mellitus and human inmunodeficiency virus infection under antiretroviral therapy (undetectable viral load) presented with a chronic, asymptomatic dermatosis. Dermatological examinatio revealed assymetrical, monomorphic eruption consisting of bluish-gray macules coalescing into patches involving the periorbital region, neck, and lips. Dermoscopy revealed a homogeneous gray-blue background with multiple scattered bluish-gray dots and ill-defined borders. consistent with dermal melanophages.

Histopathological examination demonstrated focal acanthosis and basal layel hyperpigmentation, along with dilated dermal vessels, a mild lymphocytic infiltrate, and numerous melanophages, confirming the diagnosis of erythema dyschromicum perstans.



Conclusion

Erythema dyschromicum perstans represents a diagnostic challenge due to its overlap with other dermal pigmentary disorders. Dermoscopy plays a key role in the evaluation of acquired dermal hyperpigmentation, allowtin visualization of gray structureless areas and blue-gray dots corresponding to dermal melanophages, which can aid in differentiating erythema dyschromicum perstans from other conditions such as lichen planus pigmentosus. This case highlights the importance of clinicodermoscopic and histopatholofical correlation, as well as the potential role of immune dysregulation in patients with HIV infection.



EADV CONGRESS
VIENNA
30 SEP - 3 OCT 2026

Abstract N°: 900

Skin tone dissatisfaction and use of skin-lightening practices: impact on quality of life and dermatological consultation behavior

Houda Talbi*[1], Nassiba Zerrouki[1, 2], Nada Zizi[1, 2]

[1] Mohammed VI University Hospital, Department of Dermatology, Venereology and Allergology, Oujda, Morocco
[2] Faculty of Medicine and Pharmacy, Mohammed First University, Laboratory of Epidemiology, Clinical Research and Public Health, Oujda, Morocco

Introduction
Skin tone is a key component of individual identity and social perception. In many populations, dissatisfaction with natural skin tone is common and may drive the use of skin-lightening practices. These behaviors are associated with potential dermatological complications and may contribute to psychosocial distress, yet remain insufficiently characterized in routine dermatological settings.
To determine the prevalence of skin tone dissatisfaction and skin-lightening practices among dermatology patients, and to evaluate their impact on quality of life and healthcare-seeking behavior.

Materials and Methods
A cross-sectional analytical study was conducted using a structured anonymous questionnaire administered to patients consulting for dermatological conditions. Patients were consecutively recruited. Collected data included sociodemographic characteristics, type of dermatosis, perception of skin tone, use and type of lightening practices, motivations, and occurrence of cutaneous adverse effects. Quality of life was assessed using the Dermatology Life Quality Index. Comparative analyses were performed using chi-square and Student's t-tests, with statistical significance set at $p < 0.05$.

Results
A total of 98 patients were included. The mean age was 28.7 ± 9.8 years, with a female predominance of 78.1%. The most frequently reported conditions included acne, pigmentary disorders, and inflammatory dermatoses. Skin tone dissatisfaction was reported by 52.0% of participants.Among these individuals, 38.8% reported the use of skin-lightening practices, including cosmetic formulations, homemade mixtures, and topical agents. The main reported motivations were aesthetic concerns, social influence, and the perception of lighter skin as more desirable.Patients engaging in these practices presented a higher frequency of dermatological complications, particularly irritant dermatitis, dyschromia, and acneiform eruptions. Quality of life impairment was significantly greater in this group, with a mean Dermatology Life Quality Index score of 10.6 ± 5.1 compared to 6.3 ± 3.9 in non-users, reflecting a higher psychosocial burden ($p = 0.02$).Delayed dermatological consultation was reported in 31.6% of cases and was frequently associated with prior use of non-medical products.

Conclusions
Skin tone dissatisfaction and the use of lightening practices are common among dermatology patients and are associated with both cutaneous adverse effects and significant impairment in quality of life. These findings highlight the role of sociocultural and aesthetic factors in shaping patient behavior and emphasize the need for targeted patient education, regulation of cosmetic products, and early dermatological intervention to prevent complications and improve patient outcomes.

EADV CONGRESS
VIENNA
30 SEP - 3 OCT 2026

Abstract N°: 979

Picosecond laser therapy followed by pulsed radiofrequency microneedling therapy and application of rose stem cell derived exosomes A novel third-line treatment option for recalcitrant cases of melasma

David Njoo*[1]

[1] David Njoo Skin & Laser Clinics, Amersfoort, Netherlands

Introduction
Recalcitrant melasma is defined as melasma not responding to first- or second-line treatments such as topical and oral agents, chemical peels and energy-based devices independent of the severity of the disease. A variety of studies have suggested that the resistance to therapy is likely caused by the presence of severe photo-ageing in the dermis including disruption of the basement membrane, senescent fibroblasts and hypervascularization.

Materials and Methods
In this prospective case series study from a tertiary melasma treatment centre, we present the results of a novel third-line combination treatment consisting of picosecond laser therapy followed by pulsed radiofrequency (RF) microneedling and manual application of rose stem cell derived exosomes, referred to as the "triple-treat-therapy". By employing 3 different treatment modalities we aimed to target 3 important pathological issues in melasma simultaneously: the excess of melanin, the hyperstimulation of melanin synthesis and the photo-damage in the dermis. Twelve consecutive female patients fulfilling the criteria of recalcitrant melasma (Fitzpatrick Skin Type II to VI) were included in our clinical trial. Participants applied at daytime a niacinamide 5% serum and an iron-oxide based tinted sunscreen with spf 50 and at nighttime a balm containing rose stem cell derived exosomes. Our triple treat combination therapy was performed within 4 sessions at a 6-weekly interval. Follow up was done by comparing the modified Melasma Area and Severity Index (mMASI) before each treatment session and at 6 weeks after the fourth session. Patient satisfaction was graded on a 5-point scale, ranging from 0=very dissatisfied to 5=very satisfied. Standardized photographic documentation was completed during each clinical visit. Side effects were noted during each visit.

Results
Our clinical study demonstrates a significant reduction in mMASI scores 6 weeks following completion of treatment (from 9.97 to 2.93; $p<0.05$). Patient satisfaction score on completion of our clinical study was high at a mean of 4.67/5.0 Apart from a transient erythema directly after each treatment, no other side effects were reported.

Conclusions
In conclusion, this study demonstrates significant treatment and safety efficacy in the use of a third-line combination treatment with a picosecond laser, pulsed RF microneedling device and topical exosomes for patients with recalcitrant melasma.

EADV CONGRESS
VIENNA
30 SEP - 3 OCT 2026

Abstract N°: 1004

Blaschkoid Lichen Aureus of the Upper Limb: A Rare Segmental Presentation Associated with Neuro-Mechanical Triggering Factors

Aimane Zaim*[1], Zakia Douhi[1], Ikrame Bejja[1], Saadia Boughaleb[1], Meryem Soughi[1], Sara Elloudi[1], Hanane Baybay[1], Mouna Rimani[2], Fatima Zahra Mernissi[1]

[1] Department of Dermatology, Hassan II University Hospital, Sidi Mohamed Ben Abdellah University, Fez, Morocco
[2] Department of Pathological Anatomy Hassan, Rabat, Morocco

Introduction

Pigmented purpuric dermatoses (PPD) comprise a group of cutaneous disorders characterized by petechiae, purpura, and pigmented macules or patches resulting from capillaritis with erythrocyte extravasation and hemosiderin deposition. Lichen aureus (LA) is an uncommon PPD subtype, clinically marked by golden to reddish-brown lesions and histologically by a lichenoid infiltrate. Although LA can affect various sites, it predominantly involves the lower limbs. Its pathogenesis remains incompletely understood and has been linked to venous insufficiency, trauma, contact allergens, medications, infections, and immune dysregulation. We report a rare case of Blaschkoid LA of the upper limb, highlighting dermoscopic–histopathological correlation and potential novel triggers.

Case Presentation

A 45-year-old woman with degenerative cervical spondylolisthesis at C4–C5, associated with chronic right upper limb paresthesia, presented with a 4-month history of pruritic reddish-brown macules, papules, and patches in a linear Blaschkoid distribution along the right supraclavicular region, arm, and forearm. Dermoscopy showed a yellowish to coppery-red background with multiple red-purple dots and globules. Histopathology revealed focal lymphocytic exocytosis without atypia, mild lichenoid interface dermatitis, superficial and deep perivascular lymphocytic infiltrates, dilated capillaries, and mild erythrocyte extravasation. Based on clinicodermoscopic and histopathological correlation, segmental Blaschkoid LA was diagnosed. There was no history of trauma, drug intake, or insect bites; however, the patient reported repeated massage of the affected limb using olive oil and aloe vera gel to relieve neuropathic symptoms prior to lesion onset. Treatment with high-potency topical steroids resulted in marked clinical improvement, with only residual light-brown macules observed at 3-month follow-up.

Conclusion

Blaschkoid LA is a rare and clinically challenging variant. Dermoscopy aids diagnosis by revealing a brownish to coppery-red background related to hemosiderin deposition, multiple red dots or globules corresponding to dilated capillaries and erythrocyte extravasation, and a brown pigmented network reflecting basal layer hyperpigmentation. While conventional LA is linked to increased intraluminal pressure and capillary fragility, the Blaschkoid distribution in our patient suggests localized neurovascular and mechanical factors. Degenerative cervical spondylolisthesis with chronic paresthesia may have triggered neurogenic inflammation and microvascular dysregulation via vasoactive neuropeptides, increasing capillary permeability. Repeated mechanical massage and topical applications could have caused endothelial microtrauma and barrier disruption, acting as a Koebner-like phenomenon. In the context of genetically mosaic skin following Blaschko’s lines, these factors likely promoted localized

capillaritis, leading to a segmental Blaschkoid presentation of LA.

EA CONGRESS DV
VIENNA 30 SEP - 3 OCT 2026

Abstract N°: 1008

Preclinical and Clinical Studies for a Combination of Aspalathus linearis and Polypodium leucotomos Extracts in Preventing Damage and Hyperpigmentation Induced by High-Energy Visible Light

Sérgio Schalka[1], Michelle Sabrina[2], María Gallego Rentero[3], Marta Mascaraque[3], Maria Vitale*[4], Luisa Haya Rodríguez[4], Ana López Sánchez[4], Ángeles Juarranz[3], Salvador González Rodriguez[5]

[1] Medcin Pesquisa, Osasco, Brazil
[2] Medcinvitro, Sao Paulo, Brazil
[3] Universidad Autonoma de Madrid, Cantoblanco, Spain
[4] Cantabria Labs, Madrid, Spain
[5] Universidad de Alcala de Henares, Alcalá de Henares, Spain

Introduction

Even when ultraviolet (UV) is considered the most harmful part of the spectrum, visible light constitutes most of the solar radiation reaching the Earth's surface (after infrared light). Particularly high-energy visible light (HEVL) causes important skin alterations, such as the production of reactive oxygen species (ROS), aging, and hyperpigmentation. These effects are particularly relevant in darker skin phototypes, melasma, and post-inflammatory hyperpigmentation. Conventional sunscreens primarily reduce the incidence of UV radiation but offer limited protection against HEVL-induced pigmentation; therefore, innovative strategies are warranted. In this context, recent research has unveiled the intracellular signaling pathways activated by HEVL (blue light), highlighting important roles of autophagy in melanogenesis. In this respect, the combination of *Aspalathus linearis* and *Polypodium leucotomos* extracts has previously demonstrated antioxidant efficacy, DNA-protective, and pigmentation-modulating properties. Thus, the objective of this study is to investigate the impact of this botanical ingredient on the intracellular signalling triggered by HEVL exposure and to assess its clinical potential in mitigating the molecular and clinical effects induced by HEVL exposure.

Materials and Methods

In preclinical analysis, cellular viability (MTT), ROS (DHFDA), and melanin production (spectrophotometry) are evaluated in human melanocytes subjected to prolonged blue light exposure. The role of autophagy in melanin production is evaluated using markers such as CLU, LC3B, ATG7, and PAX3. Other molecular pathways are also evaluated (*opsin 3*, CREB, p38, ERK, MITF, and TYR). Subsequently, a prospective, single-center, interventional study including 10 healthy subjects with skin phototypes IV–V is proposed. The study includes: a non-exposed area (negative control), an exposed unprotected area (positive control), a site protected with SPF50 sunscreen (comparator), and a site protected with the same SPF50 and including the combination of extracts (test area). Products are applied 15 minutes before exposure to HEVL (240-J/cm^2, equivalent to~90 minutes of sun exposure) on four consecutive days. Clinical assessments include visual scoring of pigmentation (IPD/PPD), colorimetric measurements, and standardized polarized light photography (each visit). On day 4, 2-mm biopsies are collected from each site for histological evaluation of melanin content (Fontana-Masson) and gene expression analysis (PCR), focusing on *opsin 3* and *metalloproteinase-1* (*MMP1*).

Results

In the preclinical analysis, the combination of botanical extracts was able to reduce melanin levels induced by HEVL in melanocytes. Accordingly, lower levels of ROS were detected in the irradiated cells under the ingredient treatments. The molecular markers are currently under assessment. On the other hand, in the clinical study, the ingredient of interest remarkably reduced the clinical and biological effects of HEVL exposure on the skin, including intensity of pigmentation, melanin quantification, expression of *opsin 3*, and expression of *MMP-1*. Importantly, the sunscreen containing the botanical combination showed an improvement vs the comparator in all parameters assessed, becoming the differences statistically significant in pigmentation at the first two time points, and *MMP1* levels.

Conclusions

There is a growing interest in understanding blue light-triggered skin damage and hyperpigmentation, the prevention of which is of key importance in special populations. Thus, this research increases the understanding of the intracellular mechanisms mediating the preventive action of a botanical ingredient and assesses its clinical effects in a commercial formulation, opening doors to its use in photoprotective strategies to address important dermatological concerns.

EADV CONGRESS
VIENNA
30 SEP - 3 OCT 2026

Abstract N°: 1013

Role of Fibroblasts in Persistent Pigmentation in Acquired Dermal Macular Hyperpigmentation

Apoorva Sharma*[1], Priyansh Gupta[2], Debajyoti Chatterjee[1], Keshavamurthy Vinay[1], Davinder Parsad[1], Muthu Kumaran[1]

[1] Postgraduate Institute of Medical Education and Research (PGIMER), Chandigarh, India
[2] Postgraduate Institute of Medical Education and Research, Chandigarh, India

Introduction

Acquired dermal macular hyperpigmentation (ADMH) encompasses dermal pigmentary disorders, including lichen planus pigmentosus (LPP), Ashy dermatosis, and Riehl's melanosis, characterised by small and large, discreet and coalescing slate grey to brown colored pigmented macules and patches. The reasons for the long-term persistence of dermal hyperpigmentation have been elusive. The latest research highlights the crucial role of dermal fibroblasts and fibroblast-derived factors in regulating skin pigmentation.

Materials and Methods

To investigate the ultrastructural presence of melanin within dermal fibroblasts in ADMH and assess their potential contribution to persistent pigmentation. Transmission electron microscopy (TEM) was performed on lesional skin biopsies from all ADMH patients. Samples were fixed in 3% glutaraldehyde and processed for semithin (1 µm) and ultrathin (70–90 nm) sectioning, stained with uranyl acetate and lead citrate, and examined under a transmission electron microscope (Joel, Peabody MA 01960, USA). Lesional and perilesional skin biopsies were obtained from three patients with longstanding ADMH. TEM was performed on lesional samples. Biopsies from post-inflammatory hyperpigmentation and melasma served as positive controls.

Results

TEM revealed electron-dense melanin granules within dermal macrophages and, notably, within fibroblasts/fibrocytes in ADMH lesional skin. Perilesional skin showed fewer melanin-laden fibroblasts. In contrast, control samples demonstrated melanin exclusively within macrophages, with fibroblasts remaining pigment-free. Fibroblasts often contained melanin without classical phagolysosomal structures, suggesting non-canonical uptake mechanisms.

Conclusions

Dermal fibroblasts may act as a reservoir for melanin in ADMH, contributing to chronic and treatment-resistant pigmentation. Targeting fibroblast-mediated pigment handling and signaling pathways may represent a novel therapeutic strategy for ADMH.

EADV CONGRESS
VIENNA
30 SEP - 3 OCT 2026

Abstract N°: 1017

Visible light induces skin darkening in vivo: comparative pilot studies reveal enhanced susceptibility in melasma and its mitigation by a human tyrosinase inhibitor

Tobias Mann[1], Kerstin Eggers[1], Tamara Rogers*[1], Julia Riedel[2], Manuela Lütgens[2], Lisa Thiele[2], Nadine Moeller[1], Julia Weise[2], Ludger Kolbe[1]

[1] R&D Discovery, Beiersdorf AG, Hamburg, Germany

[2] R&D Consumer & Core Innovation, Beiersdorf AG, Hamburg, Germany

Introduction

Melasma is a prevalent, recurring hyperpigmentation disorder presenting as dark spots on sun-exposed skin. While research on pigmentation has traditionally focused on ultraviolet (UV) radiation, the contribution of visible light (VIS) was long underestimated. Clinical observations that optically opaque, tinted facial products reduce melasma darkening have suggested a role for VIS in hyperpigmentation. In this study, we investigated the effects of VIS on melasma and compared skin responses to UV and VIS irradiation, both individually or in combination. In addition, we assessed whether repeated VIS-induced pigmentation can be attenuated by daily application of the tyrosinase inhibitor Thiamidol. Our findings demonstrate increased VIS sensitivity in melasma lesions and show that Thiamidol significantly reduces VIS-induced pigmentation in healthy skin.

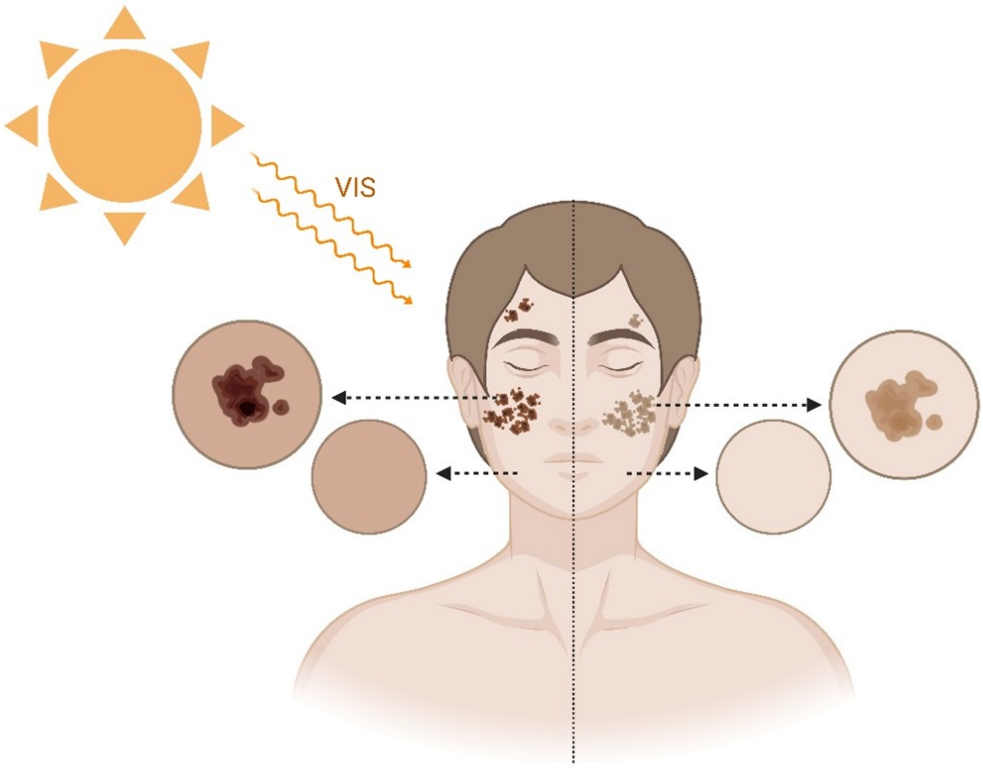

Visible light (VIS)-induced skin darkening.

Materials and Methods

Three controlled, randomized, and blinded in vivo studies were conducted in accordance with the Declaration of Helsinki and ICH-GCP guidelines. VIS (400–700 nm) and UV (290–400 nm) irradiation were generated using a solar simulator, with VIS doses of 150–200 J/cm^2 and UV exposure of 0.15 or 0.3 minimal erythema doses (MED).Study I assessed VIS- and UV-induced tanning on the lower back of healthy volunteers (8 females, 3 males, aged 20 to 62 years, all phototype IV) using repeated irradiations, with skin color quantified by spectrophotometry and digital imaging. Study II (6 females, aged 47 to 73 years, phototype I to IV (1x I, 3x II, 1x III, 1x IV)) evaluated VIS-induced pigmentation in melasma lesions compared with adjacent normal facial skin following a single VIS exposure. Study III (14 females, 5 males, aged 21 to 62 years, all phototype IV) investigated protection against VIS-induced pigmentation using twice daily a topical formulation containing 0.2% Thiamidol versus vehicle. After one week of pre-treatment and baseline color assessment, lower back test sites were irradiated with VIS following application of test formulations for 4 consecutive days. Skin color changes were analyzed by spectrophotometry. For in vitro assays, melanocytes were cultured with or without Thiamidol (1 µM), irradiated with VIS after three days and incubated for further three days before melanin analysis.

Results

Repeated irradiation of normal human skin with VIS induced a significant and progressive tanning response compared with baseline and non-irradiated skin. Skin darkening was detectable after the first exposure, increased with repeated irradiation, and persisted for at least one week after the final exposure. UV irradiation also induced tanning, with higher doses (0.3 MED) producing earlier and more pronounced darkening than lower doses (0.15 MED). Combined UV and VIS exposure induced the most pronounced pigmentation, depicting progressive darkening after the last irradiation, indicative of delayed tanning.In a second study, hyperpigmented melasma lesions showed greater susceptibility to VIS-induced darkening than adjacent normal skin. Although both areas exhibited immediate pigmentation after VIS exposure, melasma lesions remained significantly darker after 24 hours, indicating prolonged pigmentation.Thiamidol significantly inhibited VIS-induced pigmentation in vitro and in vivo. While all irradiated areas darkened following VIS exposure, Thiamidol-treated skin showed significantly less pigmentation and faster lightening over time, demonstrating its protective effect against VIS-induced skin darkening.

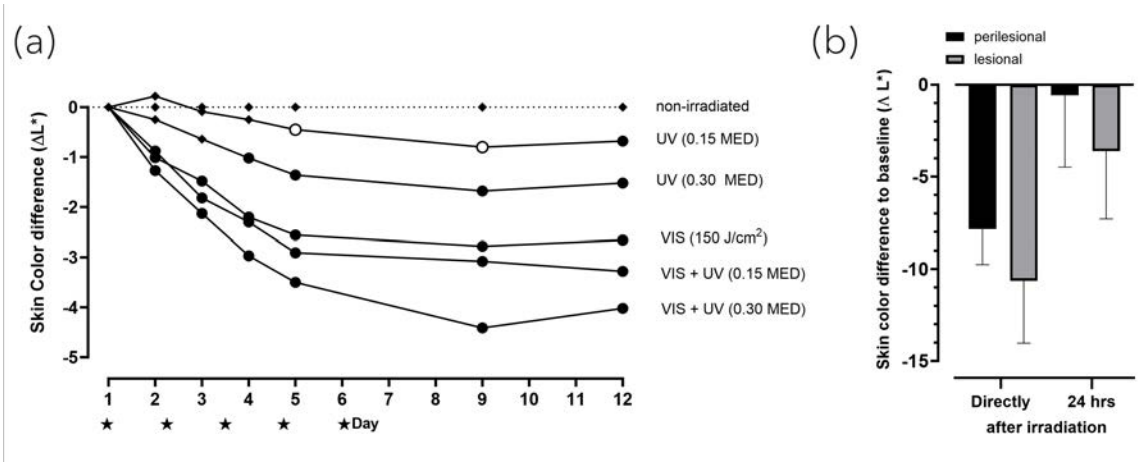

Difference in skin brightness (L* value) (a) after irradiation of human skin with VIS±UV (b) of perilesional and lesional melasma spots directly and 24 h after irradiation with 200 J/cm^2 VIS.

Conclusions

Visible light has a stronger impact on skin pigmentation than previously recognized, with melasma lesions showing increased susceptibility compared with normal skin. The increased melanin production observed after combined VIS + UV exposure emphasizes the need for photoprotection beyond UV, while treatment with Thiamidol significantly reduced VIS-induced skin darkening, offering a promising solution against VIS-induced hyperpigmentation.

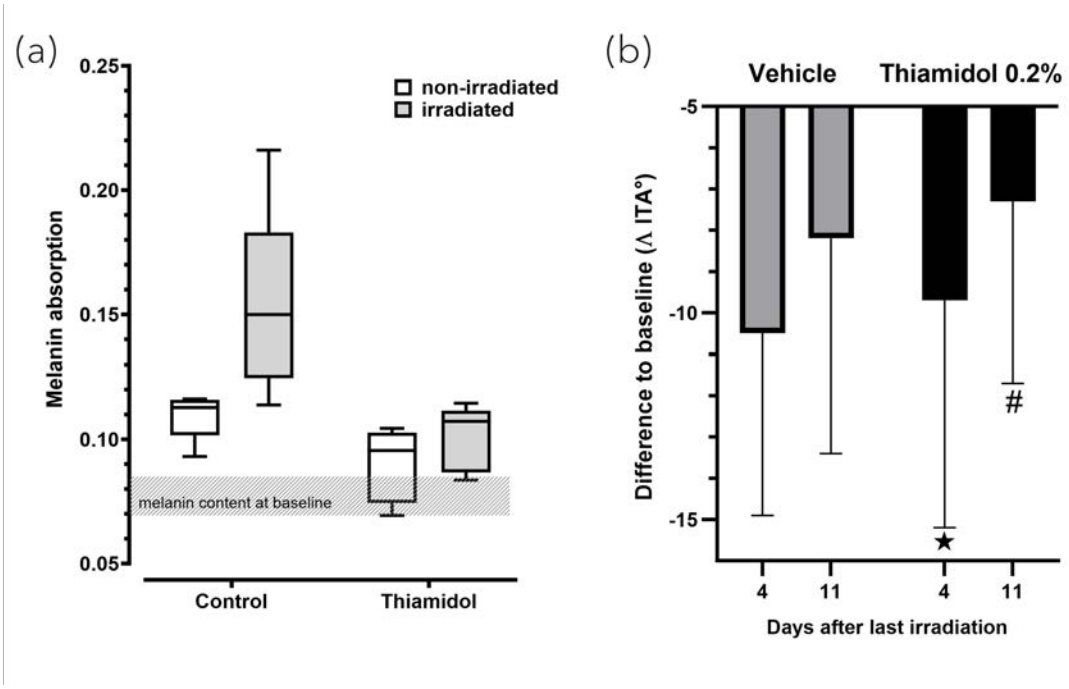

Thiamidol significantly inhibited VIS-induced pigmentation. (a) Human melanocytes ± Thiamidol (1 µM) were irradiated with 150 J/cm² VIS and analyzed after post-irradiation incubation. (b) Changes in ITA° values following four VIS irradiations (150 J/cm²) in vivo, comparing a Thiamidol-containing formulation with vehicle.

EADV CONGRESS
VIENNA
30 SEP - 3 OCT 2026

Abstract N°: 1031

Follicular Lichen Planus Pigmentosus with Inverse and Varioliform Patterns: A Case Report and Review of the Literature

Aimane Zaim*[1], Zakia Douhi[1], Ikrame Bejja[1], Saadia Boughaleb[1], Meryem Soughi[1], Sara Elloudi[1], Hanane Baybay[1], Mouna Rimani[2], Fatima Zahra Mernissi[1]

[1] Department of Dermatology, Hassan II University Hospital, Sidi Mohamed Ben Abdellah University, Fez, Morocco
[2] Department of Pathological Anatomy Hassan, Rabat, Morocco

Introduction

Lichen planus pigmentosus (LPP) is a chronic acquired hyperpigmentary disorder, predominantly affecting individuals with darker skin phototypes. It usually presents as asymptomatic dark-brown to slate-gray macules on sun-exposed areas. Several clinical variants have been described, including diffuse, reticular, blotchy, perifollicular, annular, gyrate, and rarer segmental, linear, blaschkoid, zosteriform, mucosal, poikilodermatous, and inverse forms. Follicular LPP (FLPP) is an exceedingly rare and likely underdiagnosed variant, with only 11 cases reported to date. We report an unusual case of FLPP with inverse distribution and varioliform presentation**,** highlighting previously unreported patterns and reviewing the literature.

Case Presentation

A 47-year-old woman (Fitzpatrick skin type IV) with resolved hepatitis B presented with a 1-month history of occasionally pruritic varioliform erythematous papules with centrally depressed dark-brown areas, associated with small erythematopigmented macules, distributed in an inverse pattern involving the axillae, intermammary, and umbilical regions. The oral mucosa, scalp, nails, and genitalia were spared. Dermoscopy revealed central dark-brown areas, perifollicular brown dots and globules, bent hairs, and whitish scales. Histopathology showed pigmented lichenoid interface dermatitis with follicular involvement, follicular atrophy, and concentric perifollicular fibrosis. A diagnosis of inverse FLPP was established. Treatment with a rotating topical regimen of retinoic acid, hydroquinone, and fluocinonide resulted in rapid resolution of infiltrated lesions, leaving residual hyperpigmentation.

Conclusion

FLPP is a rare variant of LPP, characterized by greyish follicular macules without scarring or alopecia. Reported cases show a slight female predominance, younger age at onset (mean 35.6 years), and preferential involvement of the trunk, upper limbs, and neck, while facial lesions are uncommon. The inverse distribution observed in our patient has not been previously reported and may reflect local factors such as friction, occlusion, and the immunologic microenvironment of intertriginous skin, potentially favoring follicular immune activation. Dermoscopic findings include a perifollicular pigment network with brown and blue-gray dots, globules, and scaling. Histopathologically, FLPP overlaps with both LPP and lichen planopilaris. The unprecedented varioliform morphology likely results from intense follicular-centered lichenoid inflammation causing follicular epithelial damage and perifollicular fibrosis. FLPP is associated with disease instability and often requires aggressive treatment. Reported therapies include potent topical steroids, topical tacrolimus, and systemic agents, with disease stabilization achieved in approximately 11.4 weeks, while pigmentary improvement remains limited.

EADV Congress 2026, VIENNA
30 SEPTEMBER - 03 OCTOBER 2026
POWERED BY M-ANAGE.COM

EA DV CONGRESS
VIENNA
30 SEP - 3 OCT 2026

Abstract N°: 1051

Prevalence of Metabolic Syndrome in Mexican Adults With Nonsegmental Vitiligo

Martha Alejandra Morales-Sánchez*[1, 2], Verónica Mondragón-Luna[1], Bruno Alain Torres-Maqueda[1]

[1] Centro Dermatológico Dr. Ladislao de la Pascua, IMSS para el Bienestar Ciudad de México, Facultad de Medicina, Universidad Nacional Autónoma de México, Mexico City, Mexico

[2] Facultad de Medicina, Universidad Nacional Autónoma de México, Mexico City, Mexico

Introduction

Vitiligo is a chronic acquired depigmenting disorder with systemic inflammatory implications rather than being solely a cutaneous condition. Recent research has focused on its association with cardiometabolic abnormalities, particularly metabolic syndrome (MetS). Persistent low-grade inflammation, oxidative stress, and shared immune pathways have been proposed as potential mechanisms linking vitiligo and metabolic dysfunction. In various case series, cross-sectional studies, and meta-analyses, MetS has been reported in approximately 25% to 40% of patients with vitiligo. (1, 2) A dedicated meta-analysis of six studies involving 734 patients estimated a pooled MetS prevalence of 29.6% (95% CI 20.6-38.6), while a broader meta-analysis of cardiovascular risk factors reported a similar comorbidity rate of 28.3%.(3) Individual studies have consistently shown rates ranging from approximately 23% to 40%, often exceeding those observed in matched controls, although some smaller cohorts have reported lower figures. (4,5) Despite this accumulating evidence, most data originate from Asian, Middle Eastern, and European populations, with few studies from Latin America. Therefore, we evaluated the prevalence of MetS and characterized the body composition of a cohort of Mexican adults with nonsegmental vitiligo.

Materials and Methods

A cross-sectional study was conducted at the Centro Dermatológico Dr. Ladislao de la Pascua, a tertiary dermatology referral center in Mexico City. Adult participants with nonsegmental vitiligo were evaluated consecutively using a standardized clinical protocol. The extent of the disease was quantified using the Vitiligo Extent Score. Anthropometric measurements included weight, height, body mass index, and routine vital signs. Laboratory assessments included fasting glucose, lipid profile, and uric acid levels. Body composition was evaluated using an OMRON HBF-514C monitor, which provided estimates of body fat percentage, visceral fat, and muscle mass. Metabolic syndrome (MetS) was defined as the presence of at least three of the five harmonized diagnostic criteria. Descriptive statistics were used to summarize the demographic, clinical, metabolic, and body composition variables.

Results

The study comprised 153 patients, of whom 69.3% were women. The mean age of the patients was 43.6 years (SD 16.6). The median affected body surface area was 1.14% (IQR 0.24-6.88), indicating a generally limited but heterogeneous disease extent. Metabolic syndrome (MetS) was identified in 28.1% of the participants (43/153), a prevalence closely aligned with pooled estimates from international studies. The mean body mass index was 26.1 kg/m2 (SD 5.04); 46.8% of participants were classified as overweight and 17.0% as obese, indicating that nearly two-thirds had excess weight. The mean body fat percentage was 36.53% (SD 8.62), mean visceral fat was 8.55% (SD 3.37), and mean muscle mass was 27.33% (SD 5.86). These data suggest a substantial burden of adiposity and unfavorable body composition in this cohort, despite the relatively low median vitiligo extent.

Conclusions

Metabolic syndrome (MetS) was prevalent in this cohort of Mexican adults with nonsegmental vitiligo and was

associated with a high incidence of excess adiposity and adverse body composition. The observed prevalence aligns closely with estimates reported in the international literature and provides valuable data from an underrepresented Latin American population. Our findings advocate for the integration of cardiometabolic screening into routine care for patients with vitiligo, even those without extensive skin involvement, highlighting the necessity of a more comprehensive approach to patient management. Longitudinal studies are warranted to elucidate the temporal, mechanistic, and potentially bidirectional relationships between vitiligo, systemic inflammation, and metabolic risk.

EA DV CONGRESS
VIENNA
30 SEP - 3 OCT 2026

Abstract N°: 1054

Efficacy and Tolerability of 2-Mercaptonicotinoyl Glycine, a Novel Melanogenesis Inhibitor: A Multicenter, Real-World, Observational Study

Ying Zou[1], Liming Wu[2], Xiaoyang Wang[3], Rui Li*[4], Caixia Ye[4], Yijie Zheng[4]

[1] Shanghai Skin Disease Hospital, Shanghai, China, Shanghai, China
[2] The First People's Hospital of Hangzhou, Hangzhou, China
[3] Beijing Anzhen Hospital, Capital Medical University, Beijing, China
[4] La Roche Posay, L'Oréal Dermatological Beauty, L'Oréal China, Shanghai, China

Introduction

Pigmentary disorders represent a common concern that substantially compromises skin health and imposes a marked impact on patients' quality of life. Conventional sunscreens frequently provide inadequate protection against ultra-long UVA radiation (380–400 nm), a key waveband responsible for mediating photodamage and UV-induced carcinogenesis. Accordingly, this 84-day clinical study was conducted to assess the efficacy and tolerability of a brightening sunscreen with enhanced ultra-long UVA protection. The primary outcomes evaluated included its ability to alleviate skin dyschromia and reduce the appearance of hyperpigmented spots with daily continuous application.

Materials and Methods

A total of 200 patients with pigmentary disorders were enrolled and categorized based on treatment adherence: high-adherence (daily application; n=89), partial-adherence (alternate-day application; n=97), and low-adherence (<alternate-day application; n=14). Efficacy and tolerability were evaluated via questionnaires at baseline (Day 0) and at the end of the 84-day study period (Day 84).

Results

1. Compared with baseline, significant improvements were observed in patients' clinical symptoms (pigmentation severity, prominence, and distress), skin status (skin glossiness, skin tone uniformity, surface area covered by lentigines or melasma, and pigmentation severity), and quality of life (perceptions of social avoidance and social exclusion) at Day 84 (Figure 1A-C).

2. No statistically significant differences were found between the full and the partial adherence groups in overall assessment, tolerability, or skin status at Day 84. However, pigmentation prominence was significantly lower in the full adherence group (Figure 2A), and quality of life scores were significantly higher in some items (Figure 2B).

3. Nearly 80% of patients reported overall improvement with the intervention. 13% reported significant improvement (Figure 3A). Tolerability was rated as moderate or higher by 99% of dermatologists and patients, and 62% rated it as excellent (Figure 3B). Overall, 91% of dermatologists and 89% of patients were satisfied. Half of the dermatologists would recommend the intervention to other patients, and over 90% of patients would reuse or recommend it (Figure 3C).

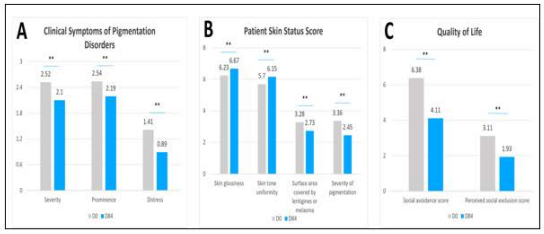

Figure 1. (A) Clinical symptoms, (B) Skin status, and (C) Quality of life at Day 0 and Day 84. *p < 0.05, **p < 0.001.

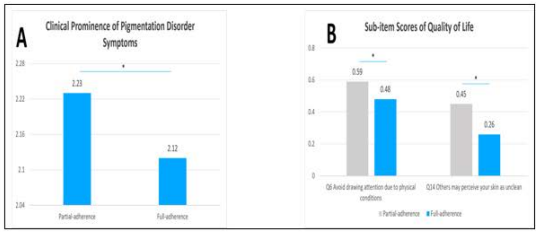

Figure 2. (A) Clinical prominence of pigmentation disorder symptoms. (B) Sub-item scores of quality of life. *p < 0.05, **p < 0.001.

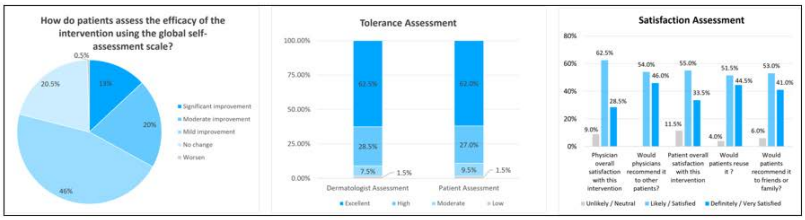

Figure 3. (A) Patient global assessment. (B) Tolerance assessment of dermatologists and patients. (C) Satisfaction assessment of dermatologists and patients.

Figure 1. (A) Clinical symptoms, (B) Skin status, and (C) Quality of life at Day 0 and Day 84. *p < 0.05, **p < 0.001 Figure 2. (A) Clinical prominence of pigmentation disorder symptoms. (B) Sub-item scores of quality of life. *p < 0.05, **p < 0.001. Figure 3. (A) Patient global assessment. (B) Tolerance assessment of dermatologists and patients. (C) Satisfaction assessment of dermatologists and patients.

Conclusions

This study demonstrates that 2-MNG-mediated intervention, which targets melanogenesis at its source, significantly improves the clinical manifestations of hyperpigmentation, with excellent tolerability and a meaningful beneficial effect on quality of life. A positive correlation was observed between application frequency and therapeutic efficacy, with greater compliance associated with superior outcomes. High satisfaction rates reported by both subjects and investigators indicate that 2-MNG represents a reliable therapeutic strategy for the long-term management of pigmentary disorders.

EADV CONGRESS
VIENNA
30 SEP - 3 OCT 2026

Abstract N°: 1091

Real-world efficacy and safety of oral JAK inhibitors and systemic glucocorticoids in progressive non-segmental vitiligo: a prospective comparative study

Yijie Xuan*[1], Zhe Zhu[1], Yijian Zhu[1], zhongyi xu[1], Yaqi Dong[1], Flora Xiang[1], Chengfeng Zhang[1]

[1] Department of Dermatology, Huashan Hospital, Fudan University, Shanghai, China

Introduction

Progressive non-segmental vitiligo (NSV) is characterized by ongoing immune-mediated melanocyte destruction and often requires timely systemic intervention to suppress disease activity and preserve repigmentation potential. Systemic glucocorticoids (GCs) remain widely used in routine practice, but their efficacy varies and long-term use is often limited by tolerability. Oral Janus kinase (JAK) inhibitors have emerged as promising therapeutic options for NSV. However, direct real-world comparisons between GCs and different oral JAK inhibitors in progressive NSV remain limited. In addition, although the IFN-γ/CXCL10 axis is central to NSV pathogenesis, longitudinal biomarker data linked to clinical response in routine practice is still limited. We therefore compared early clinical outcomes of GCs, tofacitinib, upadacitinib, and ritlecitinib in progressive NSV, and assessed whether CXCL10 dynamics were associated with treatment response.

Materials and Methods

This real-world study included 75 patients with progressive NSV treated with oral mini-pulse GCs (prednisone 20 mg/day on 2 consecutive days weekly, n=23), tofacitinib (5 mg twice daily, n=22), upadacitinib (15 mg once daily, n=17), or ritlecitinib (50 mg once daily, n=13). Standardized clinical and Wood's lamp photographs were obtained at baseline, Week 8, and Week 16. Disease severity was assessed using total and facial Vitiligo Area Scoring Index (T-VASI and F-VASI). Serum CXCL10, CXCL9, IL-1β, IL-6, and IFN-γ were measured longitudinally. To reduce baseline disease heterogeneity in this non-randomized cohort, efficacy was expressed as percentage improvement from baseline. Within-group changes versus baseline, between-group comparisons versus GCs, and Spearman correlations were analyzed.

Results

Baseline characteristics, including age, sex, disease duration, family history, baseline T-VASI, baseline F-VASI, and VitiQOL, were broadly comparable across groups. By Week 16, oral JAK inhibitors showed better early clinical response than GCs across total-body and facial endpoints. The mean percentage improvement in T-VASI was -0.66% with GCs, 9.85% with tofacitinib, 4.18% with upadacitinib, and 17.1% with ritlecitinib. Mean percentage improvements in F-VASI were -1.44%, 27.0%, 18.6%, and 18.6%, respectively. Within-group improvements from baseline were significant for tofacitinib, upadacitinib, and ritlecitinib, whereas GCs showed no significant change. Post hoc comparisons at Week 16 showed superior T-VASI improvement with ritlecitinib versus GCs, and superior F-VASI improvement with tofacitinib and ritlecitinib versus GCs. Responder analyses were concordant with these trends: T-VASI50 was achieved in 13.6% of tofacitinib-treated patients

and 15.4% of ritlecitinib-treated patients, but in none of the GCs- or upadacitinib-treated patients. F-VASI50 was achieved in 28.6%, 14.3%, and 8.33% of patients receiving tofacitinib, upadacitinib, and ritlecitinib, respectively, compared with 0% in the GC group. These findings suggest that oral JAK inhibitors may provide stronger early signals of repigmentation than GCs in progressive NSV, particularly for facial disease. Serum CXCL10 declined more prominently in oral JAK inhibitor-treated patients than in the GCs group, and CXCL10 change correlated with T-VASI percentage improvement from baseline (Spearman R=0.49, p=0.0016), linking biomarker modulation to clinical benefit. No serious adverse events were observed. Common adverse events included acne, gastrointestinal discomfort, and weight gain in the GCs group, while one tofacitinib-treated patient reported gastrointestinal discomfort.

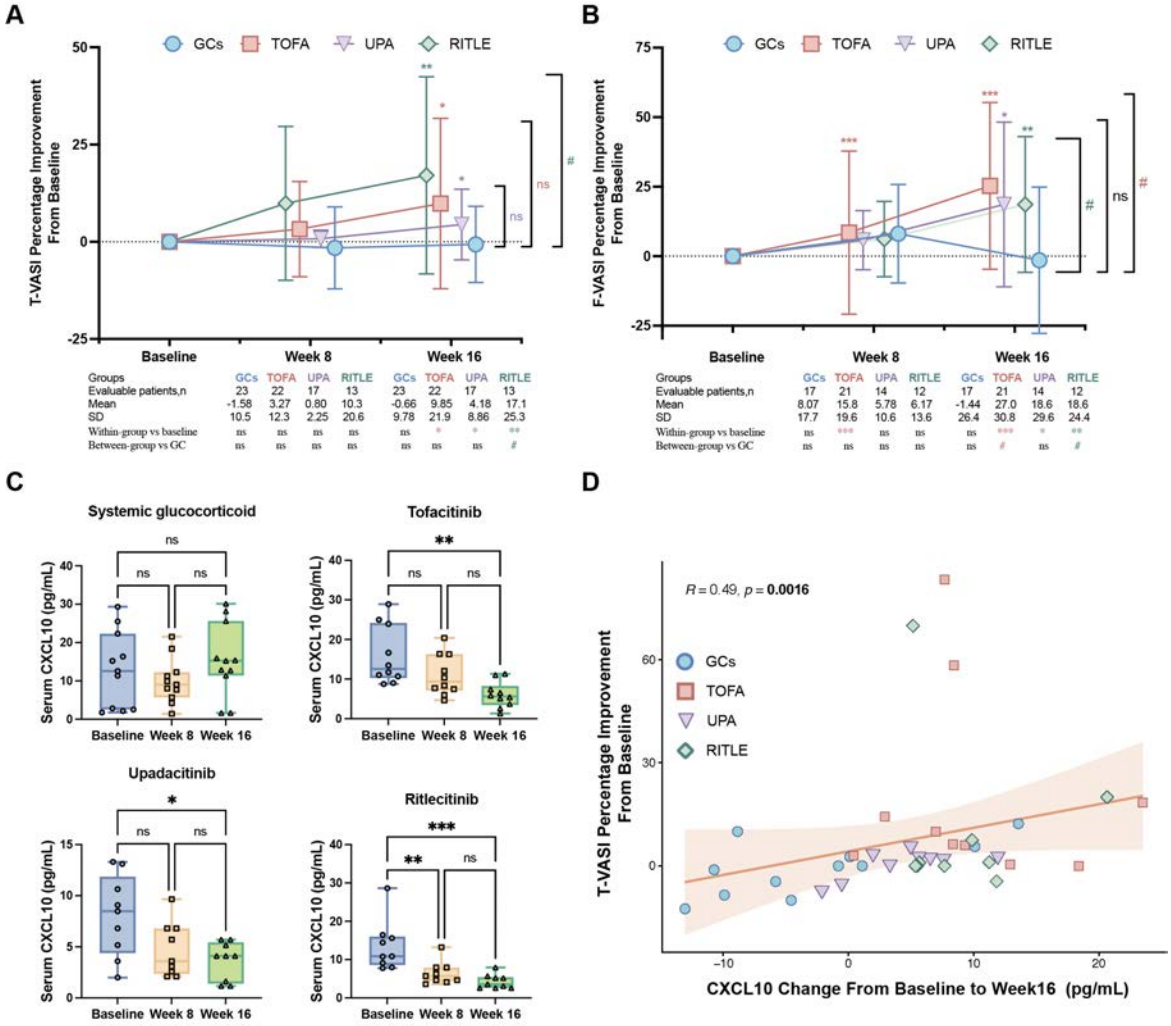

Comparative clinical response and CXCL10 dynamics in progressive non-segmental vitiligo. (A) Percentage improvement in T-VASI from baseline at Week 8 and Week 16. (B) Percentage improvement in F-VASI from baseline at Week 8 and Week 16. (C) Longitudinal serum CXCL10 changes at baseline, Week 8, and Week 16 in each treatment group. (D) Spearman correlation between CXCL10 change from baseline and T-VASI percentage improvement from baseline (R=0.49, p=0.0016). Data are shown as mean ± SD. *P<0.05, **P<0.01, ***P<0.001 versus baseline; #P<0.05 versus GCs. GCs, systemic glucocorticoids; TOFA, tofacitinib; UPA, upadacitinib; RITLE, ritlecitinib; T-VASI, total Vitiligo Area Scoring Index; F-VASI, facial Vitiligo Area Scoring Index.

Conclusions

In progressive NSV, oral JAK inhibitors showed superior early clinical signals than systemic glucocorticoids by Week 16 in this real-world cohort. CXCL10 decline was associated with clinical improvement, supporting its potential role as a candidate biomarker for treatment monitoring.

These findings provide comparative early treatment data for NSV over 16 weeks.

EA DV CONGRESS
VIENNA
30 SEP - 3 OCT 2026

Abstract N°: 1116

Why do some skin types pigment more? Risk factors for post-inflammatory hyperpigmentation

Ouissal Hormi*[1], Lamis El yamani[1], Salma Moujahid[1], Nour Haddar[1], Imam Khadija[1], Nassiba Zerrouki[1], Nada Zizi[1]

[1] Department of Dermatology, Venereology and Allergology, Mohammed VI University Hospital Center, Oujda, oujda, Morocco

Introduction
Post-inflammatory hyperpigmentation (PIH) is a frequent sequela of inflammatory skin conditions, presenting as persistent dark macules after lesion healing. It is a common reason for consultation, especially in darker phototypes due to its aesthetic and psychological impact. Its variability between individuals suggests the role of multiple factors. This study aimed to identify the clinical, behavioral, and environmental risk factors associated with its occurrence and severity.

Materials and Methods
This was a retrospective, descriptive, and analytical study conducted in a dermatology department. Patients presenting with facial dermatoses between January 2023 and January 2026 were included.Patients were divided into two groups: those who developed PIH and those who did not. Logistic regression analysis was performed, including both univariate and multivariate analyses. A p-value < 0.05 was considered statistically significant.

Results
A total of 389 patients with facial dermatoses were included. Among them, 214 patients (55%) developed PIH.The mean age of patients with PIH was 26.1 ± 5.9 years, slightly higher than in those without PIH (23.7 ± 6.2 years). A female predominance was observed in both groups, with 70% females among patients with PIH, although this difference was not statistically significant.Higher skin phototypes (IV–V) were a major risk factor: 65% of these patients developed PIH compared to 38% of those with phototypes II–III (OR = 3.5; 95% CI: 2.1–5.8; p < 0.001). Patients with phototype V exhibited the most persistent forms.Inflammatory acne was the leading cause of PIH (60%), followed by contact dermatitis (20%) and infectious dermatoses (12%), while other conditions (including lupus, atopic dermatitis, and dermatomyositis) accounted for 8%.The severity of the initial inflammation strongly influenced PIH risk: 70% of patients with severe inflammation developed PIH versus 36% with mild-to-moderate inflammation (OR = 4.3; 95% CI: 2.5–7.2; p < 0.001).Consultation delay was also significant: PIH occurred in 60% of patients consulting after more than six months compared to 42% of those consulting earlier (OR = 2.1; 95% CI: 1.3–3.3; p = 0.002).Risk behaviors were associated with increased PIH occurrence. Among patients frequently manipulating their lesions, 64% developed PIH versus 48% among those who did not (OR = 1.9; 95% CI: 1.2–3.0; p = 0.004).Unprotected sun exposure was also associated with a higher risk (62% vs 45%; OR = 2.0; 95% CI: 1.2–3.2; p = 0.003). The use of irritating or depigmenting cosmetic products was reported in 40% of PIH cases and was associated with increased risk (OR = 1.7; 95% CI: 1.1–2.7; p = 0.02).The mean duration of PIH persistence was 7.4 ± 3.1 months, with prolonged forms (>12 months) observed in 22% of patients, mainly in darker phototypes. Cheek and mandibular areas were the most frequently affected sites.Multivariate analysis identified independent risk factors for PIH:Phototype IV–V (adjusted OR = 3.1; 95% CI: 1.8–5.2; p < 0.001)Severity of initial inflammation (adjusted OR = 3.7; 95% CI: 2.1–6.4; p < 0.001)Consultation delay >6 months (adjusted OR = 1.9; 95% CI: 1.1–3.1; p = 0.01)Lesion manipulation (adjusted OR = 1.6; 95% CI: 1.0–2.6; p = 0.04)Unprotected sun exposure (adjusted OR = 1.8; 95% CI: 1.1–2.9; p = 0.02)These findings suggest that PIH results from an interaction between intrinsic factors (phototype, inflammation severity) and extrinsic factors (patient behavior and sun exposure).

Conclusions

Post-inflammatory hyperpigmentation is influenced by multiple clinical and behavioral factors, including skin phototype, inflammation severity, consultation delay, sun exposure, and lesion manipulation.Early identification of high-risk patients allows the implementation of preventive strategies, including prompt management of inflammatory dermatoses, patient education, and strict photoprotection.

EA DV CONGRESS
VIENNA
30 SEP - 3 OCT 2026

Abstract N°: 1144

Pilot Study on the Efficacy and Safety of Oral Tyrosinase Inhibitor With or Without 755-nm Picosecond Laser for Melasma

Ruri D. Pamela*[1]

[1] General Soedirman National Defense Central Hospital, Jakarta, Indonesia

Introduction
Melasma is a chronic, relapsing pigmentary disorder with significant quality-of-life burden, and remains one of the most challenging conditions in dermatology. Conventional treatments fail to address systemic and inflammatory drivers of recurrence. Oral Tyrocutin is a novel plant-derived bioactive complex (Cuscutin, p-Coumaric Acid, Ferulic Acid, OPCs) targeting tyrosinase activity, inflammatory signaling, UV-induced oxidative stress, and dermal microcirculation — an "inside-out" approach to pigment control. This pilot study evaluated the efficacy and safety of oral Tyrocutin as monotherapy and in combination with 755-nm picosecond laser for melasma.

Materials and Methods
This prospective, parallel-group, open-label pilot study enrolled 15 female subjects aged 30–60 years with dermatologist-diagnosed melasma (n=5 per group). Group 1: picosecond 755-nm laser only (2 sessions, Week 0 and Week 4). Group 2: laser + oral Tyrocutin (4 tablets/day, Week −2 to Week 10). Group 3: oral Tyrocutin monotherapy (4 tablets/day, Week 0–8). All subjects used standard sunscreen; no other depigmenting agents were permitted. Primary outcome: mMASI score change from baseline to Week 8. Secondary outcomes included subjective questionnaire (0–10 scale), skin analyzer, and standardized photography.

Results
Oral Tyrocutin monotherapy produced a 66.7% mMASI reduction at Week 4 (mMASI 5.4→1.8 and 3.6→1.2), with no adverse events. Combination therapy (laser + Tyrocutin) achieved the greatest improvement: 83.3% mMASI reduction at Week 8 (mMASI 7.2→1.2), also with no adverse events. All Tyrocutin-treated subjects reported excellent tolerability. Skin analyzer and standardized photography corroborated clinical findings, confirming improved skin tone, pigmentation evenness, and luminosity.



Female subject, 50 years of age. Treatment: 2 sessions of 755-nm picosecond laser (Week 0 and Week 4) combined with oral Tyrocutin 4 capsules/day over 8 weeks. Baseline mMASI = 7.2; Week 8 mMASI = 1.2. Improvement: 83.3%. No adverse events reported.

Conclusions

Oral Tyrocutin demonstrated clinically meaningful efficacy and an excellent safety profile as both monotherapy and adjunct to picosecond laser. The combination approach yielded superior outcomes, suggesting a synergistic "outside-in and inside-out" benefit. These results support Tyrocutin as a promising systemic option for chronic pigment management. Larger randomized controlled trials are warranted to confirm efficacy across diverse phototypes and establish long-term maintenance protocols.

EA DV CONGRESS
VIENNA
30 SEP - 3 OCT 2026

Abstract N°: 1211

Novel Peptide-Based Cream versus Hydroquinone 4% for Melasma: A Randomized Split-Face Study

Jobelline Mae Fernandez*[1]

[1] Rizal Medical Center, Pasig City, Philippines

Introduction
Melasma is a multifactorial condition driven by ultraviolet radiation, oxidative stress, genetic susceptibility, and hormonal influences, resulting in increased melanogenesis. Therapeutic strategies that target multiple stages of melanin synthesis may provide comparable efficacy with improved tolerability, particularly for patients requiring long-term management.

Materials and Methods
A randomized, double-blind, split-face clinical trial was conducted among 40 patients with epidermal melasma and Fitzpatrick skin types II–V. Participants applied a novel multimodal peptide cream on one side of the face and hydroquinone 4% on the contralateral side for 12 weeks. Efficacy was assessed using the modified Melasma Area and Severity Index (mMASI), Physician Global Assessment, and Patient Global Assessment, while safety was evaluated through reported adverse events

Results
Both treatments resulted in a significant reduction in melasma severity over time. There was no statistically significant difference in mMASI scores between the two groups at 12 weeks. However, the novel multimodal peptide cream demonstrated faster initial improvement, with significantly better physician-assessed outcomes during the first two months. By month three, treatment outcomes were comparable between both groups. No adverse events were reported in the multimodal peptide group, while mild side effects, including pruritus and burning sensation, were observed in the hydroquinone group.

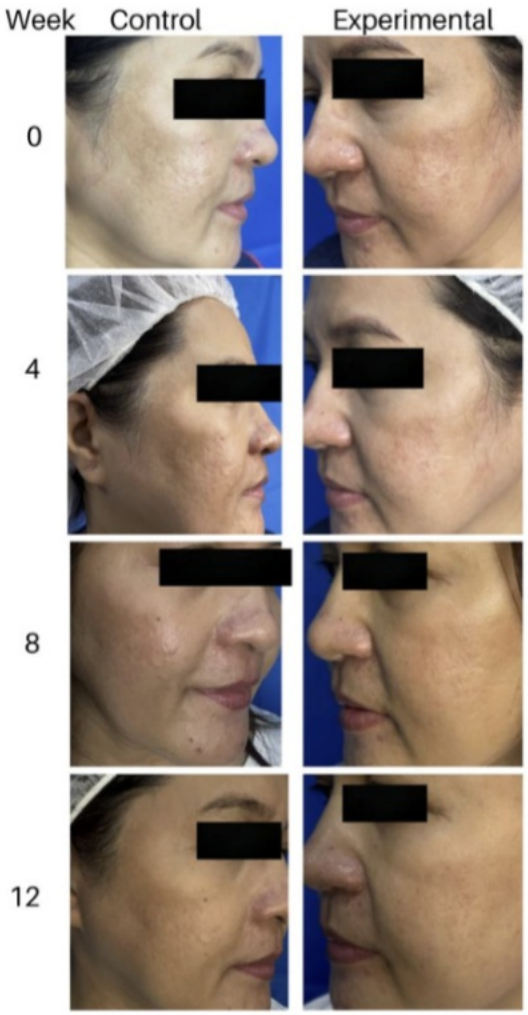

Figure 6. Photography of a patient comparing control and experimental side at weeks 0, 4, 8 and 12

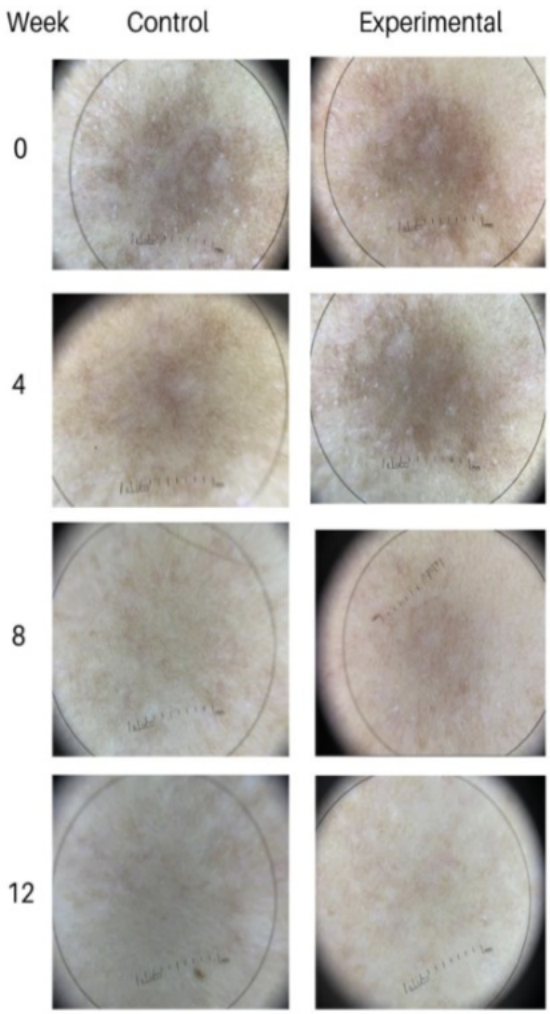

Figure 7. Dermoscopy of a patient comparing control and experimental side at weeks 0, 4, 8 and 12

Conclusions

The novel multimodal peptide cream is non-inferior to hydroquinone 4% in efficacy and demonstrates a superior safety profile. It represents a promising alternative for long-term melasma management and supports the shift toward safer, multimodal treatment strategies.

EA DV CONGRESS
VIENNA
30 SEP - 3 OCT 2026

Abstract N°: 1218

A Rare Case of Blaschkoid Lichen Planus Pigmentosus and Becker's Nevus with Concurrent Lichen Planopilaris

Aastha Choudhary*[1]

[1] Pt. Madan Mohan Malviya Hospital, Delhi, India

Introduction

Lichen planus pigmentosus (LPP) is an uncommon variant of lichen planus characterized by insidious, slate-gray to brown pigmentation, occasionally following Blaschko's lines. Becker's nevus is a relatively common cutaneous hamartoma, while its follicular variant is rare. Although isolated associations between Becker's nevus and lichen planus have been reported, the colocalization of blaschkoid LPP with follicular Becker's nevus is exceptionally rare. The concurrent presence of lichen planopilaris further adds to the uniqueness of this presentation and raises the possibility of shared pathogenic mechanisms.

Case Presentation

A 24-year-old male presented with asymptomatic brown macules over the left shoulder, gradually increasing in size over three years. Five months prior to presentation, he noted the onset of pruritic, grayish-brown pigmentation adjacent to these lesions, which progressed rapidly in a linear distribution involving the left upper limb up to the wrist and anteriorly extending to the neck and chest. He also reported itchy patches of hair loss over the scalp.

Cutaneous examination revealed two distinct types of lesions: (1) discrete, perifollicular, light- to dark-brown macules measuring 3–5 mm over the left shoulder, associated with increased hair growth, and (2) coalescing gray-brown macules arranged in a linear pattern with a sharp midline cutoff, extending from the left upper back to the wrist. Three well-defined patches of cicatricial alopecia were noted over the left occipital scalp. Nails and mucosae were spared.

Dermoscopy demonstrated islands of accentuated pigment network with perifollicular hypopigmentation in the first set of lesions, while the linear lesions showed diffuse gray-brown pigmentation with scattered dots and globules suggestive of pigment incontinence. Trichoscopy revealed perifollicular scaling, mild erythema, and loss of follicular openings.

Histopathological examination confirmed the diagnosis of follicular Becker's nevus, lichen planus pigmentosus, and lichen planopilaris. Based on clinical, dermoscopic, and histopathological correlation, a diagnosis of colocalized blaschkoid LPP with follicular Becker's nevus and concurrent lichen planopilaris was made.

Conclusion

This case highlights an extremely rare colocalization of two uncommon entities—blaschkoid LPP and follicular Becker's nevus—along with lichen planopilaris. The coexistence of these conditions suggests a possible shared pathogenic pathway involving follicular and melanocytic units, potentially mediated by inflammatory or autoimmune mechanisms. Recognition of such associations is important to improve diagnostic accuracy and to better understand the interplay between pigmentary and follicular disorders.

EADV Congress 2026, VIENNA
30 SEPTEMBER - 03 OCTOBER 2026
POWERED BY M-ANAGE.COM

EA DV CONGRESS
VIENNA
30 SEP - 3 OCT 2026

Abstract N°: 1230

Targeting Melanin Production: The Safety of Tyrosinase Inhibition

Steffen Erler*[1], Ludger Kolbe[1], Abdulkarim Najjar[1], Andreas Schepky[1], Ahmed Kamal[1], Daniela Lange[1], Tamara Rogers[1]

[1] Beiersdorf AG, Hamburg, Germany

Introduction

Hyperpigmentation remains a persistent dermatological challenge with limited treatment options. Among available strategies, tyrosinase inhibition stands out as the current most effective and safest approach for suppressing melanin synthesis.Thiamidol is a highly specific tyrosinase inhibitor developed through more than a decade of targeted research and extensive toxicological evaluation. This work assesses the safety of Thiamidol, focusing on cytotoxicity, genotoxicity, off-target effects and exposure assessment. To further assess its safety in real-world use, we incorporate findings from a naevi study in which the use of a Thiamidol-containing product was evaluated to ensure that it does not interfere with dermatological diagnosis or skin health monitoring.

Materials and Methods

Cytotoxicity and genotoxicity were evaluated based on standard OECD test guideline in vitro assays. Pharmacological profiling was performed with the SAFETYscanTM E/IC50 SELECT service (Eurofins Discovery, San Diego, USA). Increasing concentrations of Thiamidol (0.1 µM to 10 µM) were tested in a total of 78 assays performed utilizing various output reads. Exposure assessment was based on a physiologically based pharmacokinetic model (PK-Sim) and results from in vitro dermal permeation and biotransformation studies, as well as clearance measurements in human hepatocytes. These data were integrated into a whole-body simulation to assess repeated topical exposure. A naevi study with 40 subjects (mean age 48.5 ± 9.9 years; 8 male, 32 female) was conducted over 168 days with a Thiamidol-containing product. Test materials were applied twice daily to each naevus and a 5 mm adjacent skin margin. Imaging was performed using the MacIS-XL system, a Canon EOS 5D Mark II, Canon EOS 5D Mark III and DermLite Foto II Pro™. Color calibration was ensured using the X-Rite ColorChecker®.

Results

Thiamidol has a low potential for cytotoxicity and is not genotoxic. Thiamidol exhibits virtually no off-target biological activity with signals only for NET and weak inhibition of COX1, COX2, MAOA and DAT. With low dermal absorption and rapid metabolism, a physiologically based pharmacokinetic model shows estimated levels well below established safety thresholds. A dedicated naevi study compared Thiamidol-treated and vehicle-treated lesions and found no significant differences in naevi size or skin color a*. For b*, no changes occurred in the spot itself, while Thiamidol reduced surrounding b* values, confirming its measurable skin-brightening effect without impairing diagnostic visibility. Structurally, Thiamidol inhibits tyrosinase through a unique thiazole 2-amino moiety and does not form reactive quinones linked to various toxicities and pathologies. Clinical data across all skin types, together with extensive post-market surveillance, demonstrate tolerability and efficacy.

Conclusions

Thiamidol demonstrates a strong safety profile supported by rapid metabolism, absence of bioaccumulation, and negligible systemic exposure. Its temporary and reversible activity in skin requires repeated application but contributes to its classification as a cosmetic ingredient. Thiamidol inhibits tyrosinase through a unique thiazole 2-amino structure and does not form reactive quinones associated with cytotoxicity, genotoxicity and other

adverse effects. Clinical data across all skin types, together with extensive real-world use, consistently show excellent efficacy and good skin tolerability. Importantly, a dedicated naevi study demonstrated that Thiamidol-containing products do not impair dermatological diagnostic visibility, supporting safe long-term use in skin health monitoring. Overall, Thiamidol is a top-performing candidate and well-tolerated option for reducing the appearance of hyperpigmentation.

EA DV CONGRESS
VIENNA
30 SEP - 3 OCT 2026

Abstract N°: 1269

Unilateral patterned facial pigmentation after tire explosion successfully treated with combined laser therapy

Yeji Jang*[1]

[1] Hallym Sacred Heart Hospital, Anyangsi, Gyeonggido, Korea, Rep. of South

Introduction

Traumatic tattoos caused by exogenous particle implantation are well recognized, but patterned pigmentation after high-pressure explosion injuries is rarely reported. Such lesions may differ from conventional traumatic tattoos in morphology and treatment response. We report a case of unilateral patterned facial pigmentation after tire explosion that showed marked improvement with repeated combined laser therapy.

Case Presentation

A 67-year-old man presented with hyperpigmented lesions on the left cheek after a tire explosion during automotive repair. The lesions developed immediately after the injury and showed a distinctive unilateral branching and linear pattern, suggesting high-pressure particulate implantation rather than conventional traumatic tattooing. Treatment was performed after topical anaesthesia using a combination of carbon dioxide laser pinhole technique, picosecond 1064-nm laser, and Q-switched neodymium-doped yttrium aluminum garnet 1064-nm laser. Sessions were repeated at 2-week intervals from December 2025 to April 2026 for a total of 10 treatments. Progressive lightening of pigmentation and reduction in lesion contrast were observed, resulting in marked cosmetic improvement. No significant adverse events occurred; only mild transient erythema and oedema developed after each session and resolved spontaneously within a few days.

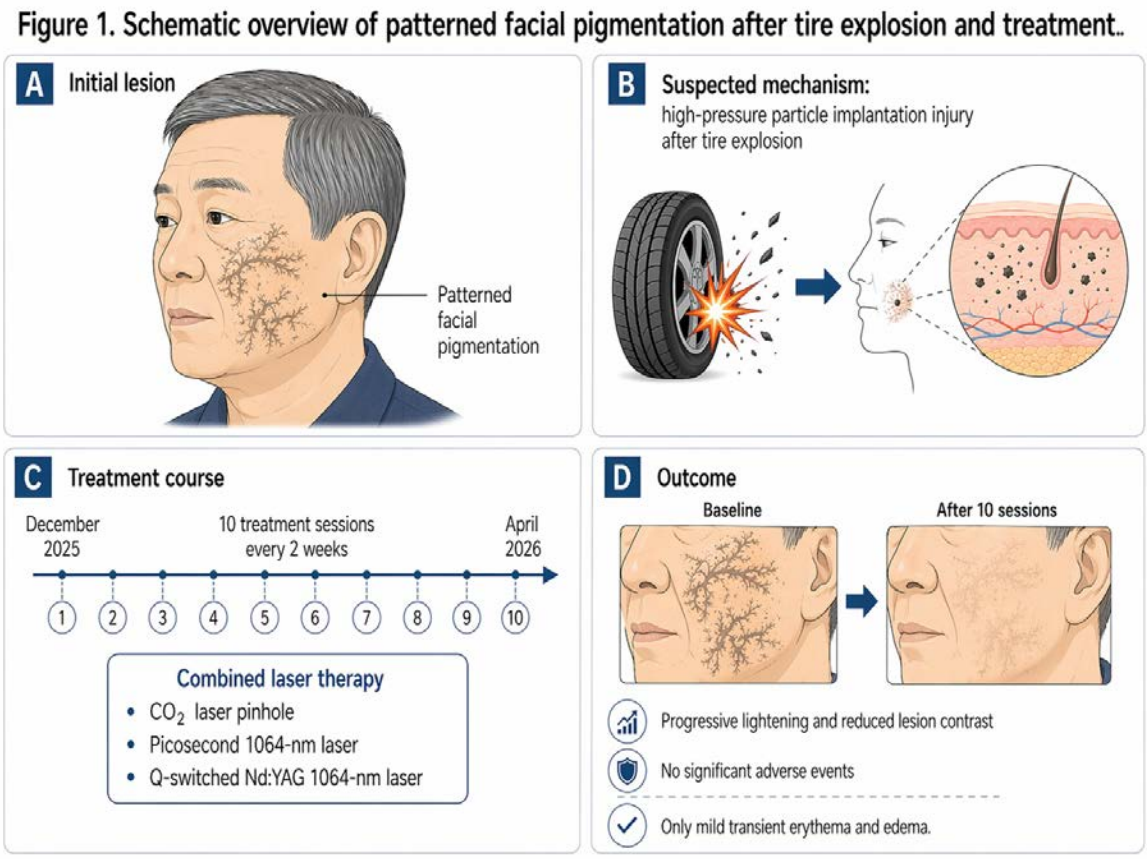

Figure 1. Schematic illustration of patterned facial pigmentation after tire explosion and serial combined laser treatment. (A) Initial branching hyperpigmentation of the left cheek. (B) Proposed mechanism of high-pressure particle implantation injury. (C) Ten sessions of combined laser therapy performed at 2-week intervals. (D) Progressive improvement in pigmentation with no significant adverse events apart from mild transient erythema and edema.

Conclusion

This case highlights an unusual form of explosion-related patterned facial pigmentation suggestive of high-pressure particle implantation. Repeated combined laser therapy produced meaningful cosmetic improvement without significant adverse events and may represent a practical treatment option for selected cases of traumatic implantation pigmentation.

EADV CONGRESS
VIENNA
30 SEP - 3 OCT 2026

Abstract N°: 1270

Non-cultured Cellular Grafting of Stable Vitiligo using ViticellTM System

Boon Kee Goh*[1]

[1] SKIN PHYSICIANS, SINGAPORE, Singapore

Introduction

Patients with stable vitiligo refractory to medical treatment and phototherapy are suitable candidates for autologous non-cultured cellular grafting. However laboratory-based preparation of autologous epidermal suspension is facing increasing regulatory controls from local health authorities throughout developed countries. There is a growing interest, therefore, in the use of FDA-approved or CE-marked commercial cell preparation kits.

Case Presentation

Aim

To evaluate the efficacy of Viticell medical device in the surgical treatment of stable vitiligo through autologous non-cultured cellular grafting

Materials and Methods

Five patients with stable vitiligo that failed to re-pigment adequately by medical treatment and phototherapy were recruited. Donor skin (ultra-thin split skin graft) was harvested manually using Silver's dermatome. Epidermal cell preparation was performed according to the protocol described in the medical device. Briefly, donor skin was incubated in recombinant trypsin, followed by washing in buffered saline, before mechanical dislodgement of melanocytes by separation and breaking up of the epidermis and dermis. The cell suspension was thickened by hyaluronic acid before applying to CO2 laser-ablated vitiligo recipient sites, and secured with collagen dressings followed by Hypafix bandage. All patients received twice weekly phototherapy either with home-based UVB device or outpatient Excimer light phototherapy for 4 to 6 weeks post-surgery. Percentage of re-pigmentation was assessed at 6 and 12 weeks post-surgery. Adverse effects (if any) were recorded.

Results

Five patients (1 male, 4 females), aged between 21 to 64 years old, with ethnicity of 3 Chinese and 2 Indian were treated between May to September in 2025. Duration of vitiligo was between 3.5 to 6 years. Three of them had segmental vitiligo and 2 had focal vitiligo. All patients demonstrated at least 75% re-pigmentation by week 12. Slight colour mismatch was noted in all cases. No adverse effects were noted.

Conclusion

Autologous non-cultured cellular grafting using Viticell medical device is effective and safe in re- pigmenting stable vitiligo. All the 5 cases demonstrated good to excellent results. Success however is also dependent on the skill set of the operator, as this surgical procedure requires proper training and is a learning curve.

EA DV CONGRESS
VIENNA
30 SEP - 3 OCT 2026

Abstract N°: 1300

Giant Congenital Melanocytic Naevus with activating STRN3-BRAF fusion treated with Trametinib

Wing Yi Kwok*[1], daniel ng[1]

[1] Tuen Mun Hospital, Hong Kong, Hong Kong

Introduction

Congenital melanocytic nevi (CMN) are clonal proliferations of benign melanocytes during embryogenesis, affecting around 1 to 3 percent of newborns. A small subset of patients develop proliferative nodules arising from CMN with intense pruritus. Previous management strategies such as surgical resection has limited efficacy and are associated with significant clinical risks. The use of novel targeted therapies may improve patient outcomes. We present a case of giant CMN and neurocutaneous melanosis successfully treated with trametinib.

Case Presentation

A 34-week male neonate born with mild respiratory distress syndrome, with otherwise unremarkable birth history, was noted to have a giant melanocytic naevus at birth affecting most of his back, extending to his left flank, left upper arm and neck. Multiple satellite lesions were present over his back, both upper limbs and both lower limbs. MRI brain and spine performed at 1 month old showed T1 hyperintense signals at left cerebellum and right thalamus, suggestive of melanin deposition and neurocutaneous melanosis. Over 6 months, he developed multiple firm erythematous nodules over his giant CMN with maximum thickness of 3cm, associated with severe pruritus, resulting in bleeding after scratching and poor quality sleep. The symptoms were not responding to topical steroids and antihistamines. A progress MRI at 6 months showed interval increase in the size of T1 hyperintensity over left cerebellum, and multiple new tiny T1 hyperintense foci over right inferior cerebellar hemisphere, while his neurological examination remained normal with no history of seizures.

A biopsy from a proliferating melanocytic nodule showed compound melanocytic naevus with no atypia or evidence of malignancy. Genotyping for the childhood cancer panel returned negative with no clinically significant variants detected in the BRAF, NRAS, HRAS genes. RNA sequencing was later carried out and identified an activating STRN3::BRAF fusion.

At 21months old, trametinib was started at a dose of 0.032mg/kg/day five days per week. After 4 weeks of treatment, there was obvious reduction in the thickness and resolution of the erythema over the giant naevus, with no more itchiness and good quality of sleep. FDLQI improved from a score of 16/30 before treatment to 6. Over the next 12 months, the maximal thickness of his giant CMN was reduced to 1cm, while the maximum diameter remained static at 20cm. The parents noted improved range of movement for his neck and shoulder and improvement in his mood and irritability. No clinically relevant drug side effects were noted. A follow-up MRI brain at 3-years-old showed resolution of T1 hyperintensities at right thalamus, right cerebellum, medullary cervical junction.

Conclusion

Trametinib is a MEK-inhibitor targeting the MAPK-pathway responsible for regulating cell proliferation, differentiation and apoptosis. Its use was effective in treating a giant CMN with novel STRN3::BRAF activating fusion, resulting in clinical improvement of the lesion and improvement in quality of life for the patient and family.

Trametinib was well tolerated and had less risks compared to surgical excision. Continuation of therapy was associated with resolution of intracranial melanosis.

EADV CONGRESS
VIENNA
30 SEP - 3 OCT 2026

Abstract N°: 1312

Comprehensive analysis of solar lentigo reveals impaired energy metabolism and NAD dysfunction

Rokhyun Kim*[1], Man S Kim[1, 2], Yoonsung Lee[1, 2], Bark-Lynn Lew[3], Soon-Hyo Kwon[3]

[1] Center for Space Biomedical Sciences, NEXUS Institute, Kyung Hee University, Yongin, Korea, Rep. of South
[2] Translational-Transdisciplinary Research Center, Clinical Research Institute, Kyung Hee University Hospital at Gangdong, College of Medicine, Kyung Hee University, Seoul, Korea, Rep. of South
[3] Department of Dermatology, Kyung Hee University Hospital at Gangdong, Kyung Hee University College of Medicine, Seoul, Korea, Rep. of South

Introduction
Solar lentigo (SL) is a common benign hyperpigmented skin lesion associated with chronic ultraviolet exposure and skin aging. While senescent phenotypes in keratinocytes and fibroblasts have been implicated in SL pathogenesis, the specific alterations in energy metabolism remain poorly understood. This study aimed to investigate energy metabolism alterations in SL through an integrated multi-system level analysis encompassing transcriptomic, proteomic, and in silico metabolic flux analyses.

Materials and Methods
Skin samples from seven SL patients were collected and processed for RNA sequencing. Differentially expressed genes were identified using DESeq2, and clustering analysis was performed using ConsensusClusterPlus. A constraint-based metabolic flux simulation was implemented using the Recon1 human genome-scale metabolic model to evaluate flux changes across key energy-associated pathways. Protein-protein interaction networks were constructed using STRING and Cytoscape, and KEGG pathway mapping was performed using PathView.

Results
The integrated analysis revealed a widespread downregulation of energy metabolic pathways in SL. Key glycolytic and PPP enzymes including G6PD, PKLR, and HK2 were downregulated, with corresponding reductions in NADPH-producing reactions. In OXPHOS, significant downregulation was observed in complexes I, II, IV, indicating impaired electron transport chain function. Fatty acid oxidation was broadly suppressed; however, CPT1 was notably upregulated. NAD metabolism analysis revealed an unstable NAD production state, with upregulated sirtuin family expression and disrupted NAD synthesis.

Conclusions
This multi-system level analysis demonstrates a comprehensive dysfunction of energy metabolism in solar lentigo, characterized by coordinated downregulation across glycolysis, PPP, TCA cycle, fatty acid oxidation, and OXPHOS. These findings suggest new insights into the metabolic basis of age-related skin pigmentation disorders.

EADV CONGRESS
VIENNA
30 SEP - 3 OCT 2026

Abstract N°: 1363

Real world clinical improvement and drug use in patients with non-segmental vitiligo treated with ruxolitinib cream.

Manuel Sanchez-Diaz*[1], Sofia Haselgruber[1], Daniel Muñoz Barba[1], Maria Rosa Cantudo-Cuenca[2], Salvador Arias-Santiago[1]

[1] Dermatology Department. Hospital Universitario Virgen de las Nieves, Granada, Spain

[2] Hospital Pharmacy. Hospital Universitario Virgen de las Nieves, Granada, Spain

Introduction

Non-segmental vitiligo (NSV) is a chronic autoimmune disease with a great impact on quality of life. Topical corticosteroids, calcineurin inhibitors and phototherapy have been the main treatments for NSV. Recently, ruxolinitib cream has emerged as one therapeutic option for NSV patients. However, real-world data on the effectiveness, safety and actual use of topical ruxolitinib in non-segmental vitiligo (NSV) are limited. The aim of this study was to assess real-world effectiveness and safety of topical ruxolitinib in adult NSV patients and to analyse treatment consumption and its relationship with disease severity and clinical response.

Materials and Methods

Retrospective observational study including adults with NSV treated with ruxolitinib cream for at least 6 months. Disease severity was evaluated at baseline, 3 and 6 months using T-BSA, F-BSA, T-VASI and F-VASI. Treatment exposure was estimated as dispensed mg of product per month. Associations between consumption, baseline severity and clinical improvement were analysed.

Results

Forty-one patients were included (mean age 48.3 years; 65.9% women). Mean ruxolitinib use was 151 ± 134 mg/month. When adjusting by basal T-BSA, the mean total use of ruxolinitib cream during 6 months treatment was of 98,39mg per unit % of BSA which would correspond to a consumption of 196.78 mg of cream per unit of basal BSA over a period of one year . Significant improvements were observed in facial severity (F-BSA and F-VASI, both $p<0.001$) and in total disease (T-BSA $p=0.02$; T-VASI $p<0.001$) at 3 and 6 months. However, no association was found between treatment consumption and baseline severity or clinical improvement (all $p>0.50$). Adverse events were mild and mainly local (pruritus/irritation and acneiform eruptions), with no discontinuations.

Conclusions

Topical ruxolitinib was effective and well tolerated in real-world adult NSV, particularly for facial involvement. Higher real-life treatment consumption was not associated with greater clinical benefit.

EA DV CONGRESS
VIENNA
30 SEP - 3 OCT 2026

Abstract N°: 1378

E3 Ubiquitin Ligase U Drives Melanogenesis via CSK Ubiquitination and ERK Pathway Activation: Mechanistic Insights and Targeted Inhibition Strategies

Shanghong Li*[1, 2, 3, 4, 5], Wenbin Zhou[1, 2, 3, 4, 5], Lin Liang[1, 2, 3, 4, 5], Qiankun Zeng[1, 2, 3, 4, 5], Xiaowei Liang[1, 2, 3, 4, 5], Hong Liu[1, 2, 3, 4, 5], Xiang Chen[1, 2, 3, 4, 5], Xinwei Kuang[1, 2, 3, 4, 5]

[1] Department of Dermatology, Xiangya Hospital, Central South University, Changsha, China
[2] FuRong Laboratory, Changsha, China
[3] National Engineering Research Center of Personalized Diagnostic and Therapeutic Technology, Changsha, China
[4] Hunan Key Laboratory of Skin Cancer and Psoriasis, Changsha, China
[5] National Clinical Research Center for Geriatric Disease, Changsha, China

Introduction
Hyperpigmentation disorders, particularly melasma, represent a significant unmet clinical need in dermatology. E3 ubiquitin ligases are well-established as critical regulators of cellular signaling; however, the specific role of E3 ubiquitin ligase U in the regulation of melanogenesis remains uncharacterized.

Materials and Methods
Publicly available transcriptomic datasets were integrated to evaluate the association between U expression and cutaneous melanin content across diverse ethnic populations. Expression levels were validated through multiplex immunohistochemistry (mIHC) on clinically obtained pigmented nevus specimens. To delineate the functional role of U in melanogenesis, CRISPR/Cas9-mediated U knockout models were generated in both human and murine melanoma cell lines, human melanocytes, and zebrafish embryos. Co-immunoprecipitation (Co-IP) assays were conducted to validate the physical interaction between U and C-terminal Src kinase (CSK), and to demonstrate U-dependent ubiquitination and subsequent proteasomal degradation of CSK. Downstream effects on ERK signaling were systematically dissected through phosphoprotein profiling. Via structure-based virtual screening coupled with surface plasmon resonance (SPR) validation, EA was identified as a candidate small-molecule inhibitor of U. The depigmenting efficacy and safety profile of EA were comprehensively evaluated across a multitiered preclinical model system, encompassing human melanocyte cultures, zebrafish embryos, ex vivo human foreskin explants, and a physiologically relevant murine melasma model induced by combined ultraviolet irradiation and progesterone administration.

Results
Transcriptomic analysis revealed a robust, statistically significant positive correlation between U expression and melanin content across all analyzed ethnic cohorts. Consistently, mIHC analysis of pigmented nevi demonstrated markedly elevated U protein expression in specimens with high pigmentation compared with those with low pigmentation. Genetic ablation of U reproducibly reduced melanin synthesis, suppressed tyrosinase enzymatic activity, and downregulated key melanogenic effectors — including MITF (microphthalmia-associated transcription factor), TYR (tyrosinase), TRP1, and TRP2 — across all cellular and organismal models examined. Mechanistically, U was found to promote melanogenesis by mediating ubiquitination and proteasomal degradation of CSK, thereby activating downstream ERK signaling and consequently upregulating MITF-driven melanogenic enzyme expression, representing a previously unrecognized regulatory axis. SPR analysis confirmed the direct, highly selective, and high-affinity binding of EA to the U protein (KD = 5.88 μM). Functionally, EA demonstrated potent, dose-dependent inhibition of U function *in vitro*, significantly attenuating both MITF expression and tyrosinase activity. Subsequent *in vivo* and *ex vivo* assessments further confirmed that EA induced

significant, reproducible depigmentation across all models tested, without evidence of cytotoxicity or tissue damage.

Conclusions

This study identifies, for the first time, a U–CSK–ERK signaling axis as a previously unrecognized central driver of pathological melanogenesis. By establishing U as a master regulatory node upstream of MITF and demonstrating its druggability with the selective inhibitor EA, we provide both compelling mechanistic and translational evidence supporting U as a promising therapeutic target for pigmentary disorders, including melasma. EA exhibits robust target engagement, favorable selectivity, and consistent anti-melanogenic activity across multiple biologically relevant models, thereby providing a solid foundation for the clinical development of U-targeted depigmenting therapies.

EADV CONGRESS
VIENNA
30 SEP - 3 OCT 2026

Abstract N°: 1428

Early Improvement of Acne-Associated Post-Inflammatory Hyperpigmentation with Topical 2-Mercaptonicotinoyl Glycine and Niacinamide

Marcele Trindade[1], Leticia Azevedo[1], Bianca Fuser[1], Emilia Ulerio[1], Eduarda Gregório Arnaut Lima*[1]

[1] Policlínica Geral do Rio de Janeiro, Rio de Janeiro, Brazil

Introduction

Post-inflammatory hyperpigmentation (PIH) is a frequent and therapeutically challenging sequela of acne vulgaris, often persisting beyond the resolution of inflammatory lesions and contributing substantially to cosmetic burden and treatment dissatisfaction, particularly in patients with higher Fitzpatrick skin phototypes, in whom inflammatory stimuli more readily induce excess melanin deposition. Effective topical strategies capable of improving PIH while maintaining tolerability in acne-prone skin remain limited. Niacinamide has recognized anti-inflammatory and melanin-transfer-inhibiting properties, while 2-mercaptonicotinoyl glycine (2-MNG) provides complementary inhibition of melanogenesis through covalent binding to melanin precursors. Despite growing interest in combination topical approaches for PIH, real-world clinical data on the concurrent use of niacinamide and 2-MNG in patients with active acne and PIH remain scarce. This case aimed to evaluate the short-term response of acne-associated PIH to a topical regimen combining niacinamide and 2-MNG using objective clinical assessment tools.

Case Presentation

A 30-year-old woman with Fitzpatrick skin phototype III presented with post-inflammatory hyperpigmentation associated with inflammatory acne lesions. A topical regimen consisting of a gentle cleanser, a twice-daily serum containing niacinamide and 2-MNG, and daily broad-spectrum SPF 60 photoprotection was initiated. No systemic treatments or procedural interventions were performed during the observation period. Clinical response was assessed at baseline and after 30 days using the Post-Acne Hyperpigmentation Index (PAHPI) and the Investigator's Global Assessment (IGA), in addition to standardized photography. After 30 days, the PAHPI score improved from 10 to 3, indicating marked reduction in hyperpigmentation, while inflammatory acne severity also improved (IGA 2 to 1). Visible reduction in pigmentation intensity and inflammatory lesion count was observed, with no adverse effects reported and good treatment adherence throughout follow-up.

Conclusion

In this real-world case, a topical regimen combining niacinamide and 2-MNG was associated with early improvement in acne-associated post-inflammatory hyperpigmentation, with additional reduction in inflammatory acne lesions and positive tolerability over 30 days. The complementary mechanisms of the two agents, melanin precursor capture by 2-MNG and melanin transfer inhibition plus anti-inflammatory properties by niacinamide, may confer additive benefit in the PIH-plus-active-acne phenotype, where both ongoing inflammation and pigment deposition must be simultaneously addressed. These findings suggest that this combination may represent a useful topical approach for patients with acne-related PIH. Although limited by the single-patient design, this observation supports further investigation of this regimen in larger prospective studies in order to establish the optimal duration and reproducibility across diverse skin phototypes and PIH aetiologies.

EA DV CONGRESS
VIENNA
30 SEP - 3 OCT 2026

Abstract N°: 1509

Clinical Evaluation of Platelet-Derived RNA Nanoparticle (PDRN) Fillers in Regenerative Aesthetic Dermatology

Sonia Tekchandani*[1]

[1] Consulting Aesthetic Dermatologist, Co-founder, Medical director at TenderSkin International, Faculty at national & international conferences, Life member - IADVL, AAM, CDSI, Mumbai, India

Introduction

PDRN is composed of low-molecular-weight DNA and RNA fragments, typically derived from purified biological sources such as salmon sperm. These bioactive molecules are known to promote tissue repair, stimulate fibroblast activity, enhance collagen synthesis, and improve microcirculation. Their mechanism of action involves stimulation of adenosine A2A receptors, leading to increased angiogenesis, reduced inflammation, and enhanced extracellular matrix production. As a result, PDRN not only improves skin texture and elasticity but also addresses pigmentation irregularities and signs of aging.

PDRN filler treatments are particularly advantageous in delicate and challenging areas such as the periorbital (under-eye) region and perioral (lip) area, where traditional treatments may yield suboptimal results or carry higher risks. The improvements achieved with PDRN are gradual yet profound, with visible changes often appearing within a week and continuing to progress over several months. This makes PDRN an ideal option for patients seeking natural-looking enhancement combined with long-term skin rejuvenation.

The present study aims to evaluate the clinical efficacy of PDRN fillers in treating various pigmentary and degenerative skin conditions that have shown limited response to conventional in-clinic procedures.

Materials and Methods

This prospective clinical study included 100 patients aged between 25 and 60 years, representing diverse skin types and dermatological conditions. A biologically derived PDRN solution extracted from salmon sperm was used at a concentration of 2%.

The treatment protocol involved administering PDRN via deep intradermal injections into the affected areas. Target regions included the periorbital area, perioral region, lips, facial pigmentary zones, and dorsum of the hands. The injections were performed using fine-gauge needles under aseptic conditions to ensure precision and minimize discomfort.

Each patient underwent a total of three treatment sessions, spaced one month apart. Pre-treatment evaluation included detailed clinical assessment, photographic documentation under standardized lighting conditions, and grading of pigmentation severity. Post-treatment evaluations were conducted at one week after each session and at the end of three months.

Results

The study demonstrated significant clinical improvement across multiple parameters in the majority of patients. Progressive improvement was noted with each subsequent session, with the most pronounced results

evident at the three-month follow-up. Patients with periorbital and perioral melanosis showed marked lightening of pigmentation and improved skin texture.

Cases of melasma and pigmentary demarcation lines demonstrated moderate to significant improvement, particularly in patients who had previously been resistant to conventional therapies. Patients with lichen planus pigmentosus (LPP) also showed visible reduction in hyperpigmentation, although results varied depending on disease chronicity.

Hand rejuvenation outcomes included improved skin elasticity, reduction in fine wrinkles, and enhanced overall skin quality. The treated skin appeared more youthful, hydrated, and radiant.

Patient satisfaction scores were high, with the majority reporting noticeable improvement in skin appearance and texture. The treatment was well tolerated, with minimal side effects such as transient erythema and mild swelling at injection sites, which resolved spontaneously within a few hours to days.

Conclusions

In conclusion, PDRN fillers represent a valuable addition to the armamentarium of regenerative aesthetic treatments. They are especially effective in managing challenging pigmentary conditions and delicate anatomical areas where traditional therapies may fall short. Further large-scale studies and long-term follow-up are recommended to validate these findings and explore additional applications of this innovative treatment modality.

EADV CONGRESS
VIENNA
30 SEP - 3 OCT 2026

Abstract N°: 1577

The First Documented Case of Depigmented Fixed Food Eruption

Lam Quang Nguyen*[1], THI THU TRANG NGUYEN[1]

[1] Vinmec Central Park International Hospital, Ho Chi Minh City, Viet Nam

Introduction
Fixed food eruption (FFE) is a rare cutaneous adverse reaction characterized by recurrent lesions that appear at identical anatomical sites upon re-exposure to an offending food. While classical FFE typically resolves with residual hyperpigmentation, progression to depigmentation is exceptionally unusual. A review of the literature reveals no prior documentation of a depigmented food-induced variant. This report discusses a 32-year-old male presenting with depigmented fixed food eruption, aiming to highlight this novel variant and emphasize the importance of identifying dietary triggers in evolving pigmentary lesions.

Case Presentation
A 32-year-old male presented with a multi-year history of recurrent, well-demarcated, erythematous-to-violaceous macules and patches scattered across the face, lips, trunk, and extremities. The eruptions were consistently triggered by the ingestion of rice noodles and a specific traditional beef noodle soup. The episodes commenced eight years prior, occurring up to 5–10 times annually. Initial manifestations included intense pruritus, burning sensations, and occasional blistering, which typically subsided after three days, leaving residual hyperpigmentation. Over the past four years, the chronically affected hyperpigmented skin progressively evolved into depigmented white patches. Extensive laboratory investigations, including comprehensive allergen-specific IgE panels for various foods, yielded negative results. Skin biopsies from both the forearm and thigh were obtained for histopathological evaluation. Immunohistochemical staining for Melan-A demonstrated focal melanocyte depletion, presenting positive staining in the forearm but negative staining in the thigh. Following the precise identification of the dietary triggers, the patient strictly avoided these foods, resulting in a complete cessation of flare-ups for over 18 months.

Discussion:

This case highlights a completely novel presentation of FFE characterized by post-inflammatory melanocyte loss leading to depigmentation. The primary differential diagnosis was vitiligo superimposed on previous FFE lesions. However, vitiligo was systematically excluded because the depigmentation was strictly localized within the boundaries of the original FFE lesions, possessed ill-defined borders, did not coalesce into larger typical vitiligo patches, and absent on previously unaffected skin. The exact pathogenesis remains elusive but is hypothesized to involve an immune-mediated destruction of melanocytes, potentially driven by chronic localized inflammation from repeated dietary antigen exposure. The contrasting Melan-A staining supports the hypothesis of progressive melanocyte loss in chronic lesions.

Conclusion
This case demonstrates the diagnostic challenges of differentiating evolving FFE from classic pigmentary disorders like vitiligo. Depigmented fixed food eruption is an atypical and previously unreported variant. Early and comprehensive diagnostic workup, including detailed dietary history and histopathology, is essential. A high level of suspicion for FFE should be maintained in patients with relapsing, site-specific cutaneous lesions with evolving

pigmentary changes. Timely identification and strict avoidance of the causative food can prevent recurrent inflammatory episodes and irreversible melanocyte destruction.

EA DV CONGRESS
VIENNA
30 SEP - 3 OCT 2026

Abstract N°: 1581

Exogenous silver nitrate pigmentation on acrochordons mimicking cutaneous metastases

Carolina Droguett[1], Paulina Naranjo Arce[1], Diego Mendez-Villanueva*[1], Stefania Toso[1]

[1] Universidad de Santiago de Chile, Santiago, Chile

Introduction

Cutaneous metastases are an uncommon but clinically significant manifestation of advanced malignancy, with an estimated prevalence of 0.6–10.4% among cancer patients. Their polymorphic presentation; including papules, nodules, or plaques ranging from pink to bluish-black, may mimic several benign dermatoses. Although metastatic melanoma is the most frequent cause of pigmented cutaneous metastases, similar lesions may also arise from breast, lung, or gastrointestinal carcinomas.

Exogenous pigmentation caused by silver compounds represents an uncommon but important differential diagnosis. Localized argyria results from dermal silver deposition and irreversible pigmentation, whereas exogenous silver nitrate pigmentation is limited to the stratum corneum and may resolve with epidermal turnover. Both entities may clinically resemble melanocytic or metastatic lesions. However, self-application of silver nitrate onto preexisting benign lesions has not previously been described as a confounding factor mimicking cutaneous metastases.

Case Presentation

A 74-year-old female patient with a medical history of hypertension, dyslipidemia, and glaucoma, without a prior history of skin cancer, was evaluated following a high-priority referral from a public teledermatology platform. The initial referral indicated a suspected neoplastic nevus.

Clinical photographs showed multiple lesions involving the neck, bilateral supraclavicular region, and upper back, including blackish-purple hyperpigmented macules with irregular borders and nodular papules of variable size, some pedunculated (Figs. 1a–d). The lesions had progressively enlarged over two years. Their multiplicity, dark pigmentation, and cervicothoracic distribution raised clinical concern for cutaneous metastases.

During teledermatology assessment, the lesions were interpreted as atypical pigmented lesions secondary to manipulation, prompting referral for in-person evaluation. Targeted questioning revealed the lesions had originally been pink and the patient had repeatedly self-applied silver nitrate, resulting in progressive darkening. One lesion without chemical manipulation preserved the baseline appearance of an acrochordon (Figure 1d).

The final interpretation corresponded to multiple acrochordons with exogenous silver nitrate pigmentation mimicking cutaneous metastases. Discontinuation of self-medication and in-person dermatologic evaluation were recommended.



Figure 1. Clinical presentation of exogenous silver nitrate pigmentation over acrochordons mimicking cutaneous metastases. (a–c) Multiple blackish-purple hyperpigmented macules and pedunculated nodular lesions involving the neck and bilateral supraclavicular region, with irregular pigmentation and progressive darkening secondary to repeated self-application of silver nitrate. The multiplicity, dark coloration, and cervicothoracic distribution generated clinical suspicion for cutaneous metastases. (d) Pinkish-violaceous pedunculated lesion without chemical manipulation, consistent with the baseline appearance of an acrochordon prior to silver nitrate exposure.

Conclusion

This case describes an unusual presentation of exogenous silver nitrate pigmentation caused by prolonged self-application onto benign acrochordons, clinically mimicking cutaneous metastases. Unlike previously reported cases related to accidental, occupational, or iatrogenic exposure, the exposure in this patient was deliberate and maintained for approximately two years.

Exogenous pigmentation profoundly altered the typical appearance of acrochordons, transforming benign lesions into alarming pigmented nodules suggestive of metastatic disease. The cervical and supraclavicular distribution further increased diagnostic concern.
This case is particularly relevant in teledermatology, where the absence of palpation and dermoscopy may limit evaluation of pigmented lesions. Directed questioning regarding self-medication and home remedies was essential to establish the correct diagnosis and avoid unnecessary invasive procedures.
Exogenous silver nitrate pigmentation should be considered in the differential diagnosis of atypical pigmented lesions, particularly when clinical appearance and history are discordant.

EADV CONGRESS
VIENNA
30 SEP - 3 OCT 2026

Abstract N°: 1641

Condition-Specific Planning of Energy-Based Device Treatments in Pigmentary Disorders of Skin of Color

Hafiza Fathan Rasyid*[1]

[1] ONELIFE+ Integrated Health Center, South Jakarta, Indonesia

Introduction

Background:

Energy-based devices (EBDs) are increasingly used in the management of pigmentary disorders in skin of color. However, pigmentary conditions are often approached under a simplified procedural logic based on the visible presence of pigment alone, despite important differences in inflammatory activity, recurrence tendency, treatment tolerance, and risk of post-inflammatory hyperpigmentation (PIH). In skin of color, this oversimplification may reduce both safety and outcome predictability. Current literature increasingly supports a more individualized, indication-specific approach to energy-based treatment planning in pigment-prone populations.

Objective:

To propose a condition-specific planning framework for EBD treatment of pigmentary disorders in skin of color, emphasizing that procedural strategy should be guided not only by pigment visibility, but by the biologic and clinical behavior of the underlying disorder.

Materials and Methods

Relevant literature on EBD use in skin of color, pigmentary sequelae, PIH prevention, and condition-specific procedural outcomes was reviewed and interpreted through a clinical decision-making lens. Particular attention was given to factors that may modify treatment response, including inflammatory background, pigment reactivity, prior treatment exposure, and expected recovery dynamics.

Results

Reviewed evidence suggests that pigmentary disorders in skin of color should not be managed under a uniform EBD paradigm. Clinical outcomes appear to vary according to the underlying indication, degree of active or subclinical inflammation, prior treatment history, and the capacity of the skin to tolerate additional procedural injury. This may help explain why a modality that performs well in one pigmentary presentation may produce limited benefit, prolonged recovery, or increased PIH risk in another. A condition-specific framework therefore offers a more clinically meaningful approach than device-centered decision-making alone, shifting treatment planning from “which device targets pigment” to “which procedural strategy best matches this disorder in this skin.”

Conclusions

In skin of color, effective EBD treatment of pigmentary disorders requires more than technical familiarity with energy delivery. It requires condition-specific planning grounded in disease behavior, inflammatory context, and pigment-related risk. Reframing pigment treatment in this way may improve patient selection, counseling, procedural safety, and outcome consistency, while offering a more refined educational model for aesthetic and procedural dermatology.

POWERED BY M-ANAGE.COM

EA DV CONGRESS
VIENNA
30 SEP - 3 OCT 2026

Abstract N°: 1679

Advances in Cell-Based and Cell-Free Therapies for Vitiligo: Current Evidence and Future Directions

Mona Homayouni*[1], Zinah Sharara[1], Mohammed Al Abadie[1]

[1] Midlands medical academy. United Kingdom, London, United Kingdom

Introduction

Vitiligo is a chronic pigmentary disorder associated with significant psychosocial burden and limited long-term therapeutic success. Despite advances in topical therapies, systemic immunomodulators, and phototherapy, many patients experience incomplete or short-lived repigmentation. This therapeutic gap has driven increasing interest in regenerative strategies, including cell-based and cell-free approaches.

Materials and Methods

A narrative review of clinical, translational, and experimental studies published over the past decade was conducted using PubMed to identify relevant literature on regenerative therapies in vitiligo. The review focused on cell-based approaches, including melanocyte transplantation and mesenchymal stem cells (MSCs), as well as cell-free modalities such as platelet-rich plasma (PRP), exosomes, and secretomes. Selected studies were analyzed and categorized according to therapeutic modality, mechanisms of action, and clinical outcomes.

Results

Autologous melanocyte–keratinocyte transplantation remains the most validated intervention, achieving >50% repigmentation in a substantial proportion of patients, with durable outcomes reported. Hair follicle–derived cell therapies and mesenchymal stem cell–based approaches demonstrate regenerative and immunomodulatory potential, although clinical evidence remains limited. Cell-free therapies, including PRP and exosomes, were found to enhance melanocyte proliferation, reduce oxidative stress, and modulate immune responses. Meta-analyses indicate that combination approaches especially those integrating narrowband UVB phototherapy or laser modalities, were associated with improved outcomes, with some studies reporting repigmentation rates exceeding 90%. However, heterogeneity in study design, lack of standardized protocols, and limited large-scale randomized trials remain important limitations.Overall, these therapies demonstrated favorable safety profiles, with predominantly mild and transient adverse effects.

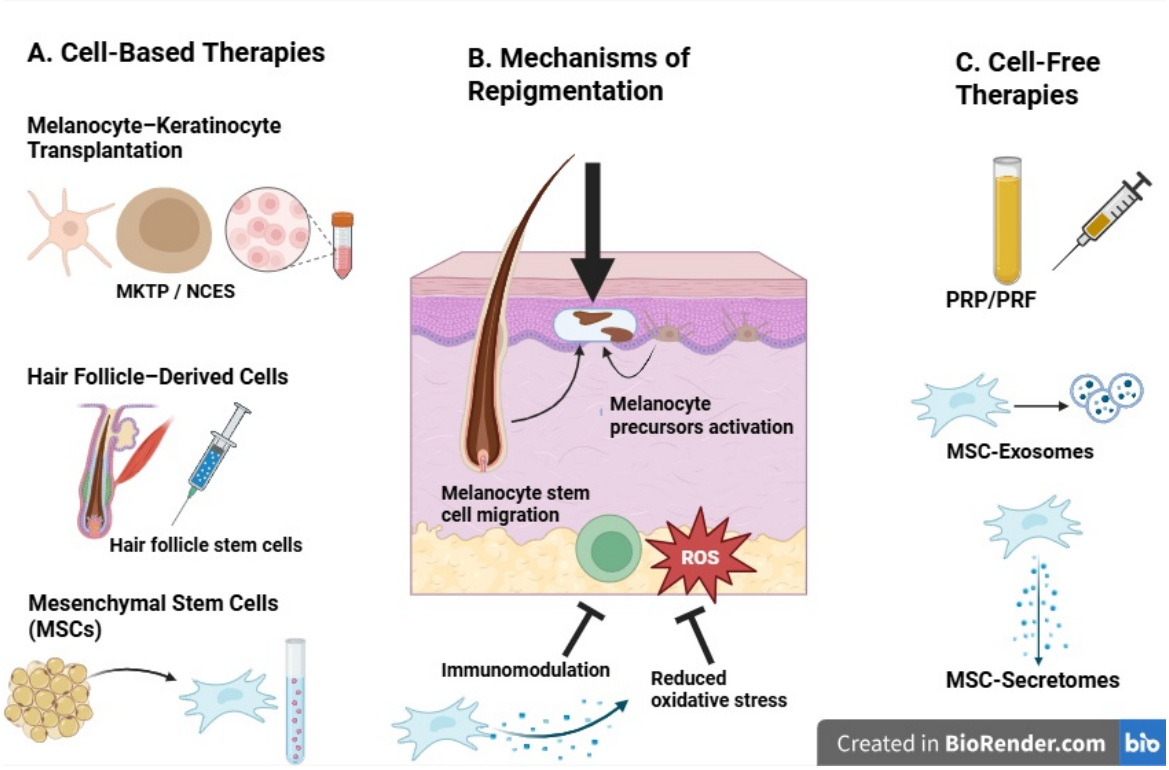

Figure 1. Overview of regenerative strategies in vitiligo, including cell-based therapies, mechanisms of repigmentation, and emerging cell-free approaches.

Conclusions

Regenerative therapies represent a promising and evolving frontier in vitiligo management. While current evidence supports their efficacy—particularly in stable disease—further high-quality studies are required to establish standardized protocols, long-term outcomes, and optimal patient selection.

EA DV CONGRESS
VIENNA
30 SEP - 3 OCT 2026

Abstract N°: 1685

Efficacy and tolerability of a 2-mercaptonicotinoyl glycine-containing serum in patients with pigmentary disorders: a 3-month observational study in the GCC and Levant

Chadan Naji*[1], Tara BARDAWIL[1], Maya El khoury[2], Lina Alkurdi[3], Sandra Moawad[4], Luluah almubarak[5], Eman Almokhadeb[6], Ghaydaa Gholam[7], ABDULELAH AL JARALLAH[8], Yasmin Al-Fayez[9], Heba Abdulla[10], Najah SINNO[10]

[1] Novomed Clinic, Dubai, United Arab Emirates
[2] Mediclinic, Dubai, United Arab Emirates
[3] HMS Mirdif Hospital, Dubai, United Arab Emirates
[4] Emirates Specialty Hospital, Dubai, United Arab Emirates
[5] Prince Sultan Military Medical City, Riyadh, Saudi Arabia
[6] King Saud University, Riyadh, Saudi Arabia
[7] Reviva Clinic, Jeddah, Saudi Arabia
[8] Bisha University, Asir Region, Saudi Arabia
[9] Nava Clinics, Jeddah, Saudi Arabia
[10] L'Oreal Middle East, Dubai, United Arab Emirates

Introduction
Pigmentary disorders, including melasma and post-inflammatory hyperpigmentation, are common conditions that can adversely affect visible disease burden, psychosocial wellbeing, and quality of life. This study aimed to evaluate the efficacy, tolerability, and patient-reported benefit of a serum containing 2-mercaptonicotinoyl glycine, an ingredient that captures melanin precursors, and niacinamide, used as monotherapy or adjunctive to local treatment over a 3-month period in patients with pigmentary disorders in routine dermatology practice across the GCC and Levant.

Materials and Methods
Patients presenting to dermatologists' offices in the GCC and Levant between July 2024 and January 2025 with at least one pigmentary disorder who were prescribed a serum containing 2-mercaptonicotinoyl glycine and niacinamide for 3 months were enrolled for this observational study. The serum was used either as monotherapy or adjunctive to depigmenting treatments, including hydroquinone, tranexamic acid, and/or a triple-combination depigmenting cream containing hydroquinone, tretinoin, and a corticosteroid. Patients were assessed at baseline and end of treatment through clinical examination and patient self-report. Endpoints included dermatologist-rated changes in hyperpigmentation severity and visibility, patient-reported bother, global assessment of efficacy, perceived changes in radiance and skin evenness, pigmentation extent and intensity, stigmatization burden using the Patient Unique Stigmatization Holistic tool in Dermatology (PUSH-D), tolerability, compliance, and satisfaction.

Results
A total of 851 patients were included in the efficacy analysis population. Participants had a mean age of 36.8 years and 84.7% were female. Phototypes III and IV were observed in 39.4% and 41.8% of patients, respectively. Diagnosed pigmentary disorders included melasma (48.3%), post-inflammatory hyperpigmentation (37.4%), solar

lentigo (13.0%), and others (1.29%). All reported improvements at month 3 were statistically significant (P<0.001). Dermatologists reported at least a 1-grade improvement in hyperpigmentation severity in 79.7% of patients and in visibility of the pigmentation disorder in 81.1%. At least a 1-grade improvement in how much the condition was bothersome was reported in 78.4% of patients. 97.4% of patients reported at least a light improvement of their pigmentary disorder, with the mean patient-reported improvement in skin radiance and skin evenness reaching 59.2% and 51.7%, respectively, while the surface area affected by spots or melasma decreased by 40.3% and pigmentation intensity by 44.1%. Psychosocial benefit was also observed, with mean burden reductions of 65.3% in PUSH-D total score. High level of tolerance was reported by 84.2% of dermatologists and 80.7% of patients, and excellent satisfaction was reported by 90.2% of dermatologists and 89.8% of patients Compliance was considered very good in 78.6% of patients.

Conclusions

In routine clinical practice across the GCC and Levant, 3 months of treatment with aserum containing 2-mercaptonicotinoyl glycine and niacinamide, used either alone or in combination with local therapies, was associated with significant clinical improvement, meaningful patient-perceived benefit, reduced stigmatization burden, good tolerability, high compliance, and high satisfaction. These findings support its use for pigmentary disorders in regional practice.

EA DV CONGRESS
VIENNA
30 SEP - 3 OCT 2026

Abstract N°: 1707

Riehl's Melanosis: A Retrospective Study of 34 Cases

Jianjian Zhu*[1], Yang Bin[2], Mengjie Cui[3], Xiaojiao Zhao[1], Miao Wan[1], Xiaoyuan Yu[4], Xin Li[4]

[1] Changde Hospital, Xiangya School of Medicine, Central South University (The first people's hospital of Changde city), changde, China

[2] Southern Medical University, guangzhou, China

[3] Xiangya Hospital, Central SouthUniversity, changsha, China

[4] The first people's hospital of Changde city, changde, China

Introduction

Riehl's melanosis is an acquired hyperpigmentation disorder that predominantly affects middle-aged women. It typically characterized by numerous small (several millimeters in diameter or reticular acquired pigmented macules on the face, neck, and upper chest(Kumarasinghe et al., 2019), which markedly affect patients' quality of life and social interactions (Woo et al., 2020). The etiology and pathogenesis of Riehl's melanosis remain unclear; however, factors such as genetic predisposition(Jung et al., 2020), ultraviolet radiation(Bishnoi et al., 2019), type IV hypersensitivity reactions induced by sensitizers(Bishnoi et al., 2019; Kim et al., 2023), and autoimmune mechanisms (Lai et al., 2022)may contribute to its development. The treatment of Riehl's melanosis is extremely challenging, and early diagnosis is crucial for timely intervention to prevent disease progression and shorten the treatment course.

Riehl's melanosis is an acquired pigmentation disorder that typically affects the face, neck, and upper chest, with a focus on the forehead and zygomatic and/or temporal region. Clinical manifestations, dermoscopy, Reflectance confocal microscopy (RCM), and histopathological examination are valuable tools for diagnosis(Ding et al., 2023). Nevertheless, existing studies lack a comprehensive comparative analysis of clinical data and auxiliary examination results. This retrospective study aims to analyze the clinical data and auxiliary examination data of Riehl's melanosis to provide a reference for its early diagnosis.

Materials and Methods

A total of 34 patients diagnosed with Riehl's melanosis via clinical data and auxiliary examinations including dermoscopy, reflectance confocal microscopy, or skin pathology were enrolled from the Department of Dermatology, Southern Medical University Hospital of Dermatology, and the Department of Dermatology, Changde First People's Hospital, between 2018 and 2024. A retrospective analysis was conducted on their general information, medical history, clinical features, dermoscopic findings, reflectance confocal microscopic findings, skin histopathological results, and laboratory test results.

Results

Results32 (94.1%) were female, with a mean age of 44.4 years and mean disease duration of 4 years. Twelve (35.3%) had identifiable triggers, mainly contact with skincare products/cosmetics (4/7, 57.1% of triggered cases). Typical lesions were fine reticular pigmented macules on the face and neck (21/34, 61.8%). Histopathologically, moderate-to-severe pigment incontinence, superficial vascular dilatation, and lymphocytic infiltration were prominent. Dermoscopy showed 100% pseudonetwork of brown/gray dots and telangiectasia, and reflectance

confocal microscopy revealed 100% superficial dermal melanin incontinence and perivascular inflammation. Abnormalities were found in antinuclear antibodies (4/12, 33.3%) and 25-hydroxyvitamin D_3 levels (5/12, 41.7%).

Conclusions

Conclusion Riehl's melanosis predominantly affects middle-aged women with a chronic course. Non-invasive techniques (dermoscopy and Reflectance confocal microscopy) and histopathology have characteristic findings for diagnosis. Abnormalities in autoimmune-related markers and vitamin D_3 levels warrant clinical attention.

EADV CONGRESS
VIENNA
30 SEP - 3 OCT 2026

Abstract N°: 1708

A retrospective observational study of oral ivarmacitinib and narrow-band ultraviolet-B in refractory progressive vitiligo

Jin Chen*[1], Yi Ou[1], Xinyi Shao[1]

[1] The First Affiliated Hospital of Chongqing Medical University, Chongqing, China

Introduction
Established JAK inhibitors exhibit efficacy in mitigating the inflammatory processes; however, monotherapy yields suboptimal skin repigmentation outcomes. Consequently, this real-world study evaluates the combination of ivarmacitinib and narrowband ultraviolet B (NB-UVB) in patients with treatment-refractory, progressive vitiligo.

Materials and Methods
A retrospective study was conducted in vitiligo patients who had received oral ivarmacitinib and NB-UVB for 12 weeks. The primary endpoint was change from baseline in total Vitiligo Area Scoring Index (T-VASI) at Week 12. Secondary endpoints included Facial VASI (F-VASI), body surface area (BSA), Vitiligo Disease Activity Score (VIDA), and Dermatology Life Quality Index (DLQI).

Results
A total of 58 patients were included. By week 12, the average T-VASI had decreased from 1.31 ± 2.41 to 1.17 ± 2.27 ($P < 0.0001$), with an improvement of 10.69%. The mean time required from active to stable status was 1.03 ± 0.18 weeks. Additionally, statistically significant reductions were observed in BSA, DLQI and VIDA ($P < 0.05$). No severe adverse events were observed.

Conclusions
In summary, treatment with oral ivarmacitinib combined with NB-UVB could halt the progression of depigmented lesions and promote repigmentation in patients with vitiligo. Therefore, ivarmacitinib combined with NB-UVB may serve as an effective therapeutic regimen for refractory progressive vitiligo.

EA DV CONGRESS
VIENNA
30 SEP - 3 OCT 2026

Abstract N°: 1719

SARS-CoV-2 Vaccination and Reduced Mortality and Metastatic Burden in Melanoma: Evidence from a Retrospective Multi-Institutional Analysis utilizing TriNetX

Isha Gandhi[1], Robert Adler*[2], Michael Kozlov[2], Emily Cowen[2], Katerina Svigos[2], Bari Genoa[3], Jeffrey Weinberg[4]

[1] University of Minnesota Twin Cities Medical School, Minneapolis, United States

[2] State University of New York Downstate Medical Center, Brooklyn, United States

[3] Infinity Dermatology, New York, United States

[4] Icahn School of Medicine, New York, United States

Introduction

To our knowledge, no large-scale, multi-institutional analysis has directly analyzedpotential associations between COVID-19 vaccination and melanoma outcomes using TriNetX. We conducted a population-level, five-year retrospective cohort study using the TriNetX database to determine associations between COVID-19 vaccination and morbidity and mortality outcomes in melanoma.

Materials and Methods

Patients with a diagnosis of cutaneous melanoma (ICD-10: C43) who received an mRNA SARS-CoV-2 vaccine (n=56,715) were compared with melanoma patients without vaccination (n=254,539); those with other major malignancies were excluded. Propensity score matching (1:1) was performed on age, sex, race/ethnicity, key comorbidities, and healthcare utilization variables, yielding two balanced cohorts of 50,131 patients each. Outcomes, including brain, lung, liver, and total metastases, sentinel lymph node biopsy (SLNB), wide local excision (WLE), immunotherapy (ex. pembrolizumab), mortality, and composite comorbidities (malaise, pain, sleep disorders, depressive episodes), were compared using risk ratios (RRs) and Kaplan-Meier survival analysis, excluding patients who previously had a diagnosis of the outcomes.

Results

Among patients with cutaneous melanoma, those that received COVID-19 vaccination had significantly lower five-year mortality risk compared with those that did not (RR 0.519, 95% CI 0.497-0.542, p<0.001). Risk of brain (RR 0.403, 95% CI 0.357-0.455, p<0.001), lung (RR 0.427, 95% CI 0.384-0.475, p<0.001), liver (RR 0.421, 95% CI 0.367-0.483, p<0.001), and overall metastasis (RR 0.45, 95% CI 0.427–0.474, p < 0.001) as well as SLNB (RR 0.482, 95% CI 0.462-0.503, p<0.001) and WLE (RR 0.572, 95% CI 0.555-0.589, P<0.001) were significantly lower in patients with melanoma who received the COVID19 vaccine.

Outcome	Vaccinated (%)	Not Vaccinated (%)	Risk Diff (95% CI), p	RR (95% CI)	OR (95% CI)	HR (95% CI)	χ^2 (p)
Total metastases	1,916 (4.2%)	4,301 (9.3%)	-0.051 (-0.054 to -0.048), p<0.0001	0.45 (0.43-0.47)	0.43 (0.40-0.45)	0.43 (0.41-0.45)	1007.9 (p<0.0001)
Brain metastases	363 (0.7%)	893 (1.8%)	-0.011 (-0.012 to -0.009), p<0.0001	0.40 (0.36-0.46)	0.40 (0.35-0.45)	0.39 (0.34-0.44)	246.9 (p<0.0001)
Lung metastases	482 (1.0%)	1,124 (2.3%)	-0.013 (-0.015 to -0.011), p<0.0001	0.43 (0.38-0.48)	0.42 (0.38-0.47)	0.41 (0.37-0.46)	287.0 (p<0.0001)
Liver metastases	285 (0.6%)	675 (1.4%)	-0.008 (-0.009 to -0.007), p<0.0001	0.42 (0.37-0.48)	0.42 (0.36-0.48)	0.40 (0.35-0.46)	176.5 (p<0.0001)
Sentinel LN biopsy	2,818 (6.1%)	6,248 (12.6%)	-0.065 (-0.069 to -0.062), p<0.0001	0.48 (0.46-0.50)	0.45 (0.43-0.47)	0.45 (0.43-0.47)	1325.6 (p<0.0001)
Death	2,896 (5.8%)	5,568 (11.1%)	-0.054 (-0.057 to -0.050), p<0.0001	0.52 (0.50-0.54)	0.49 (0.47-0.51)	0.51 (0.49-0.53)	898.8 (p<0.0001)
Wide local excision	5,448 (13.8%)	10,737 (24.1%)	-0.103 (-0.108 to -0.098), p<0.0001	0.57 (0.56-0.59)	0.50 (0.49-0.52)	0.51 (0.50-0.53)	1685.8 (p<0.0001)
Weight loss	1,987 (4.2%)	2,457 (5.2%)	-0.010 (-0.012 to -0.007), p<0.0001	0.81 (0.77-0.86)	0.81 (0.76-0.86)	0.80 (0.75-0.85)	56.4 (p<0.0001)
Immunotherapy	1,704 (3.5%)	2,261 (4.5%)	-0.010 (-0.013 to -0.008), p<0.0001	0.77 (0.73-0.82)	0.77 (0.72-0.82)	0.74 (0.70-0.79)	87.8 (p<0.0001)
Composite well-being	5,743 (20.0%)	6,791 (21.1%)	-0.011 (-0.018 to -0.005), p = 0.001	0.95 (0.92-0.98)	0.93 (0.90-0.97)	0.93 (0.90-0.96)	17.0 (p<0.0001)

Conclusions

Overall, our study supports an association between COVID-19 vaccination and reduced metastasis, comorbidity burden, and mortality in melanoma patients. These findings could help increase public support for vaccinations and help broaden their indication beyond infection prevention. Limitations include retrospective design, potential miscoding, misclassification bias, potential for type I error, and unmeasured confounders, such as socioeconomic status. Additionally, association does not prove causation.

Limitations include retrospective design, potential miscoding, misclassification bias, potential for type I error, and unmeasured confounders, such as socioeconomic status. Additionally, association does not prove causation. However, results were validated through Kaplan-Meier analysis, quantitative bias analysis, and externally validated with a prior smaller-scale publication. Moreover, the large sample size, robust matching and support by both risk and event-free-survival analysis improve generalizability and minimize bias.

EA DV CONGRESS
VIENNA
30 SEP - 3 OCT 2026

Abstract N°: 1825

Waardenberg syndrom:; A case Series

Zareen Saqib Suleri*[1]

[1] khawaja Muhammad Safdar Medical College Sialkot, Suleri Children and General Hospital, Sialkot, Pakistan

Introduction

WS was first described by and named after P.J Waardenberg in 1951.[2] It includes spectrum of manifestations all caused by congenital neural crest cell abnormalities. This has an estimated incidence of 1 in 20-40000. Patients present with congenital sensorineural deafness, heterocromic irides, skin and hair hypopigmentation and various eye abnormalities. We report a series of four patients having specific features of this syndrome.

Waardenberg Consortium

2 major or 1 major + 2 minor criteria constitute diagnosis

	Major criteria	Minor criteria
1	Sensorineural hearing loss	Skin hypopigmentation
2	Heterochromia iridis/blur iris/bright blue iris	Synophrys
3	Hair hypopigmentation/white forelock/white hair at other body sites	Broad nasal root
4	Dystopia canthorum	Hypoplasia of alae nasi
5	Presence of 1st degree relative previously diagnosed	Premature greying of hair (before 30 years)

waardenberg consortium

Case Presentation

First case is 14 year old boy who presented in dermatology outpatient clinic with hypopigmented patches over abdomen, both hands and right arm since birth alongwith grey hair at frontal scalp. He was born out of consanguineous marriage at full term by normal vaginal delivery. His developmental history was also normal except that he had congenital deafness and mutism. Physical examination revealed broad nasal root, synophrys, dystopia canthorum, heterochromic irides, hypoplastic nasal alae and multiple freckles over face (**Figure1, 2**). Visual acuity was normal in both eyes.

Second case is elder sister of above mentioned patient. A 23 years old girl having small vitiligo like macules over hands since birth. She also had congenital deafmutism, broad nasal root, increased intercanthal distance, synophrys, bilateral blue eyes, white hair over scalp (dyed with hena) and freckles over face (**Figure 3, 4**).

Our third patient is maternal cousin of above two patients, 18 year old female with bilateral blue eyes, medial eyebrows, broad nasal root, piebald like skin patches over face, upper and lower limbs. She had white forelock (not appreciable due to hair dye) and depigmented eyebrow and eyelash hair. She is also deaf and mute since birth and had multiple hyperpigmented macules over face (**Figure 5, 6**).

Fourth patient is a 7 year old boy; brother of case 3 having bilateral blue eyes. This patient was also suffering from deafness since birth. Additional features included dystopia canthorum, synophrys, broad nasal root, vitiligo like patches over limbs, brown macules over face and hpoplastic nasal alae. (**Figure 7, 8**).

None of our patients had musculoskeletal abnormalities, gastrointestinal manifestations or mental deficiency or retardation. Routine laboratory investigations including Blood complete count, liver and renal function, ultrasound abdomen was normal. Audiometery of all four patients showed bilateral sensorineural deafness.

The physical examination of parents and rest of the siblings of all four patients did not reveal any abnormality of hair, eyes and skin color. However two siblings had extensive freckling over face. The pedigree of the family is depicted in **figure 9**.

All these features favor the diagnosis of classical Type I Waardenberg syndrome according to diagnostic criteria (**table 1**). The presence of freckles along with features of WS I in all the affected persons of this family constitute a finding that has not been reported locally till date to the best of our knowledge. Previously only one study from China describes freckles in association with WS.

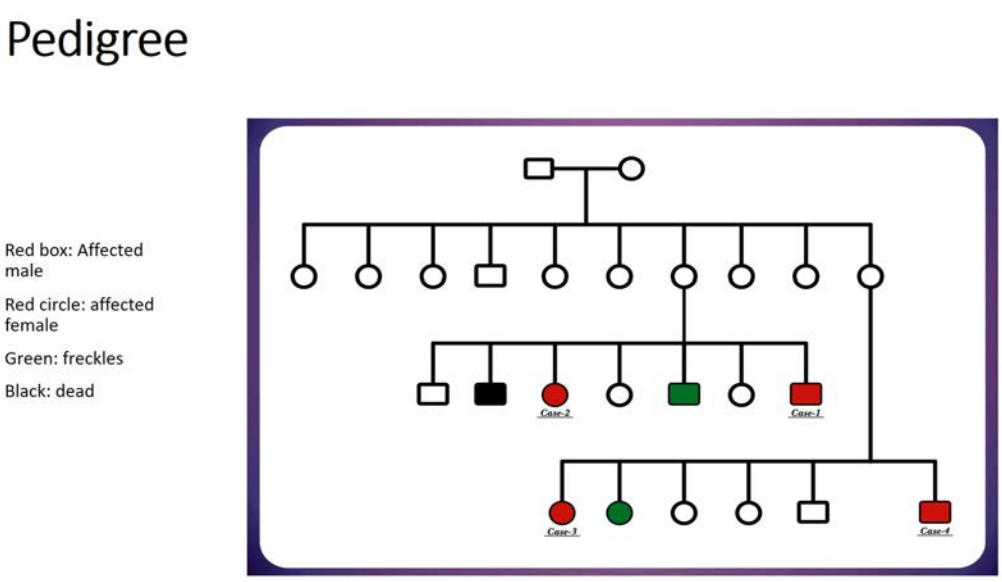

pedigree of affected family: Red box: Affected male Red circle: affected female Green: freckles Black: dead

Conclusion

There is no definitive treatment for WS. Early diagnosis of these patients can lead to early rehabilitation and vocational training. This can prevent significant social dependence of patient and financial burden over family and society. Also gene mapping may lead to identification of different mutation or additional gene in this case as a rare clinical feature i.e. freckles, suggests or it could be an incidental finding.

EADV CONGRESS
VIENNA
30 SEP - 3 OCT 2026

Abstract N°: 1877

Cobblestone facial papules: an atypical presentation of a deposition disease

Juan Sebastian Rodriguez Safi[1], Sofia Martinez-Guerrero*[1], Elkin Peñaranda[1]

[1] Fundación Universitaria Sanitas., Bogotá, Colombia

Introduction

Lichen amyloidosis is the most common form of primary localized cutaneous amyloidosis, characterized by amyloid deposition in the papillary dermis derived from keratinocyte degeneration. It typically presents as pruritic, hyperkeratotic papules on the extensor surfaces of the lower limbs. Facial involvement is rare and may lead to diagnostic challenges due to its clinical overlap with acquired dermal hyperpigmentation disorders such as erythema dyschromicum perstans and lichen planus pigmentosus. We report an unusual case of exclusively facial lichen amyloidosis highlighting its atypical presentation and diagnostic considerations.

Case Presentation

A female patient presented with an 18-month history of progressive facial skin changes characterized by grayish macules, depressed areas, and papular lesions. She reported prior use of topical treatments, likely including betamethasone for approximately two months, without improvement. She denied a history of acne or other relevant dermatological conditions. Her medical history was unremarkable, except for current breastfeeding.

Physical examination revealed multiple brown-grayish plaques composed of coalescent papules with a cobblestone-like appearance, predominantly affecting the face. Initial differential diagnoses included erythema dyschromicum perstans and disorders associated with cutaneous deposits.

A skin biopsy demonstrated a superficial perivascular lymphocytic infiltrate with melanophages and globular eosinophilic deposits in the papillary dermis. The epidermis showed occasional necrotic keratinocytes. These findings supported the diagnosis of lichen amyloidosis.

Treatment was initiated with topical tacrolimus 0.1% ointment on alternate nights, combined with a topical retinoid serum and strict photoprotection. The patient showed clinical improvement, including reduction in hyperkeratotic papules, improvement in skin texture, and increased homogeneity of skin tone.

Conclusion

This case illustrates an uncommon presentation of lichen amyloidosis confined to the face, without involvement of typical anatomical sites. Its clinical resemblance to pigmentary disorders may delay diagnosis. Histopathological evaluation remains essential for confirmation. Clinicians should consider lichen amyloidosis in the differential diagnosis of hyperpigmented facial papules, particularly when exhibiting a cobblestone pattern. Early recognition may facilitate appropriate management and improve clinical outcomes.

EADV CONGRESS
VIENNA
30 SEP - 3 OCT 2026

Abstract N°: 1932

Acute facial hyperpigmentation induced by cosmetic use: an atypical presentation of epidermal post-inflammatory hyperpigmentation

Sihame Alaoui*[1], Oumaima Berradi[1], Syrine Hamada[1], Najoua Ammar[1], Narjess Errachdy[1], Nadia Ismaili[1], Mariam Meziane[1], Laila Benzekri[1]

[1] Ibn Sina University Hospital, Rabat, Morocco

Introduction

Facial pigmentary disorders are common, particularly in individuals with darker phototypes. While melasma and post-inflammatory hyperpigmentation (PIH) are well-recognized, acute-onset hyperpigmentation may be triggered by cosmetic products containing irritant or photosensitizing agents. Such presentations can be diagnostically challenging, especially in the absence of overt clinical inflammation.

Case Presentation

A 54-year-old woman with no significant medical history presented with sudden-onset facial hyperpigmentation developing within 48 hours. She reported no pruritus, pain, or recent medication use.

Clinical examination revealed homogeneous, symmetric brown hyperpigmentation with ill-defined borders involving the forehead, cheeks, nose, and chin, without associated inflammatory lesions. General examination and laboratory investigations, including hormonal assessment, were unremarkable.

Further history disclosed recent use of a cosmetic lightening cream containing retinol, β-carotene, and collagen.

Dermoscopy showed a homogeneous brown pigmentation with a diffuse pigment network, fine pigmented globules, and perifollicular accentuation, without features suggestive of melanocytic proliferation.

Histopathological examination demonstrated marked basal layer hyperpigmentation with a normal epidermal architecture, without spongiosis, lichenoid changes, or significant dermal inflammation, supporting an epidermal pigmentary process.

A diagnosis of epidermal post-inflammatory hyperpigmentation was retained.



Diffuse, symmetrical brown facial hyperpigmentation involving the forehead, cheeks, nose, and chin, with ill-defined borders and homogeneous distribution, without visible inflammatory signs.

Conclusion

This case highlights an atypical presentation of post-inflammatory hyperpigmentation, characterized by an acute onset following cosmetic use. Although PIH is typically associated with clinically evident inflammation, it may occur in the absence of visible inflammatory signs, likely reflecting subclinical irritation and melanocyte activation.

Topical agents such as retinoids are known to disrupt the epidermal barrier and induce irritation, particularly in darker phototypes, thereby promoting melanogenesis. In contrast to more commonly reported cosmetic-induced pigmentary disorders, such as exogenous ochronosis, which develop after prolonged exposure, this case illustrates a rapid-onset and reversible epidermal pigmentation pattern.

Recognition of cosmetic-induced PIH and its atypical presentations is essential to avoid misdiagnosis and unnecessary investigations, and to guide appropriate management.

EADV CONGRESS
VIENNA
30 SEP - 3 OCT 2026

Abstract N°: 1947

Long-term real-world effectiveness of ruxolitinib cream in vitiligo: a multimodal assessment combining clinical outcomes, quality of life, and confocal microscopy

Luigi Gargiulo*[1], Matteo Bianco[1], Marco Ardigò[1], Antonio Costanzo[1], Alessandra Narcisi[1]

[1] Dermatology Unit, IRCCS Humanitas Research Hospital, Department of Biomedical Sciences, Humanitas University, Rozzano, Italy

Introduction

Ruxolitinib cream has redefined the management of vitiligo, yet key gaps remain regarding long-term real-world effectiveness, patient-reported outcomes, and objective biomarkers of response. In particular, the relationship between clinical repigmentation, quality of life (QoL), and early biological changes is poorly understood. Reflectance confocal microscopy (RCM) enables in vivo, non-invasive visualization of skin architecture and may identify early treatment-related changes preceding visible repigmentation. We aimed to provide a comprehensive long-term real-world assessment of ruxolitinib cream, integrating clinical outcomes, QoL, and RCM-derived biomarkers.

Materials and Methods

We conducted a monocentric real-world observational study including consecutive patients with non-segmental vitiligo treated with ruxolitinib cream. Patients were followed longitudinally with standardized clinical and instrumental assessments. Disease severity was evaluated at baseline, week 12, week 24 and week 52, assessing both F-VASI and T-VASI. The primary endpoint was the proportion of patients achieving F-VASI 75 at all timepoints (facial repigmentation of at least 75% compared with baseline). Quality of life was assessed with DLQI and VitiQoL questionnaires. Safety was recorded throughout follow-up. A subset of patients underwent serial RCM imaging to assess dynamic changes at the epidermal and dermo-epidermal junction levels and to explore early predictors of response. Long-term outcomes were analyzed at predefined timepoints.

Characteristic	Value
Male sex	140 (41.4%)
Phototype	
I	2 (0.6%)
III	163 (48.2%)
V	2 (0.6%)
Family history of vitiligo	105 (31.1%)
Previous therapies	
Topical therapies	97 (28.7%)
Phototherapy	67 (19.8%)
Systemic therapies	23 (6.8%)
Surgical therapies	14 (4.1%)
No prior therapy	47 (13.9%)
Affected areas	
Head and neck	187 (55.2%)
Upper limbs	143 (42.2%)
Lower limbs	128 (37.8%)
Trunk	156 (46.0%)
Acral areas	76 (22.4%)
Mucosal areas	18 (5.3%)
Disease severity	
F-VASI, baseline	1.0 ± 0.7
T-VASI, baseline	4.7 ± 2.8
Adverse events	26 (7.7%)
Focus on quality of life	
DLQI, baseline	11.2 ± 6.1
DLQI, last follow-up	5.1 ± 5.2
Familiarity for autoimmune diseases	54 (16.0%)
Thyroid disease	97 (28.7%)
Alopecia areata	4 (1.2%)
Atopic dermatitis	2 (0.6%)
	Mean ± SD
BMI	24.3 ± 5.9
Disease duration, years	14.9 ± 12.5
F-VASI, baseline	1.0 ± 0.7
T-VASI, baseline	4.7 ± 2.8

Table 1. Clinical and demographic characteristics of our population

Results

A total of 338 patients were included. Sustained and clinically meaningful reductions in F-VASI and T-VASI were observed over long-term follow-up, with the highest response rates in facial areas. Importantly, improvements were progressive over time, supporting the long-term benefit of treatment. In particular, F-VASI 75 was achieved by 20.4% of patients at week 24 and by 50.0% at week 52. T-VASI 50 (repigmentation of at least 50% of vitiligo of the body) was reached by 21.7% and 39.0% of patients at weeks 24 and 52, respectively. QoL significantly improved in parallel with clinical response, with a marked reduction in DLQI e VitiQoL scores starting from week 12, indicating a substantial patient-perceived benefit. RCM identified distinct response-associated patterns, including early reappearance of melanocyte-related reflectance and progressive restoration of dermo-epidermal junction integrity. Notably, these changes were detectable before clinically visible repigmentation in a subset of patients, highlighting the potential of RCM as an early biomarker of treatment response. Treatment was well tolerated, with no new safety signals.

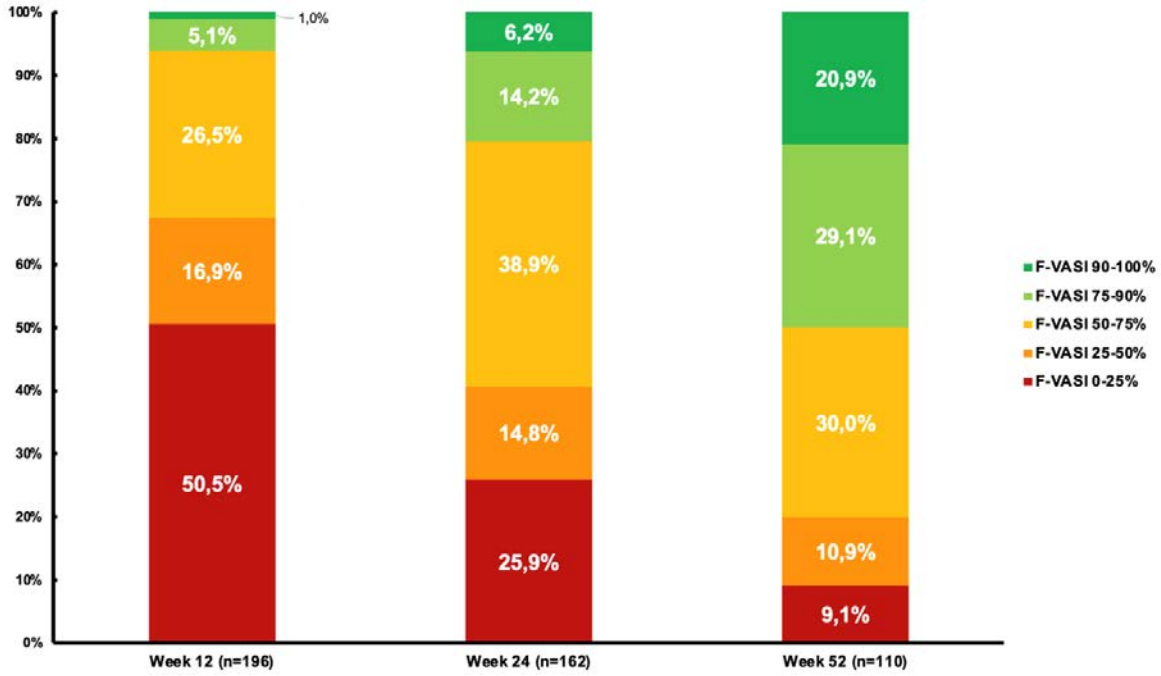

Figure 1. Effectiveness of ruxolitinib cream in our 52-week study, showing substantial improvement in terms of F-VASI

Conclusions

This study provides one of the first integrated long-term real-world evaluations of ruxolitinib cream in vitiligo, demonstrating sustained effectiveness and significant QoL improvement. Beyond clinical repigmentation, RCM captures early microstructural changes that may anticipate treatment response, supporting its role as a non-invasive biomarker. These findings reinforce the concept of a multidimensional assessment of vitiligo and support a more personalized, biomarker-driven therapeutic approach.

EADV CONGRESS
VIENNA
30 SEP - 3 OCT 2026

Abstract N°: 1957

56-Day Clinical Study of Skin Tone and Pigmentation Improvement: Efficacy and Safety Assessment of a Novel Anti-Dark Spot Sunscreen with Ultra-Long UVA Protection

Baiyu Li[1], Mingjie Zhu[2], Yang Wang[2], Xiaofeng He[2], Rui Li*[1], Yipin Yuan[2], Zailin Zhu[2], Yijie Zheng[1]

[1] La Roche Posay, L'Oréal Dermatological Beauty, L'Oréal China, Shanghai, China

[2] Research and Innovation Center, L'Oréal China, Shanghai, China, Shanghai, China

Introduction

Traditional sun protection often fails to fully block ultraviolet (UV) radiation. Ultra-long UVA (380-400 nm) plays a significant role in skin photodamage and synergizes with other UV radiation to accelerate skin cancer progression. This study aims to evaluate the effect of an anti-dark spot sunscreen with ultra-long UVA protection on skin tone and dark spots in the Asian population after continuous use for 56 days.

Materials and Methods

A total of 105 subjects were enrolled in the study and assigned to the instrument group (n=42) and the questionnaire group (n=63). Subjects applied the test product to their entire face and neck each morning. After a 14-day washout period, instrument measurements and questionnaire assessments were conducted at baseline (D0), 15 minutes after product application (D0T15min), and on days 7 (D7), 14 (D14), and 56 (D56).

Results

1. After product use, the appearance ofpigmented and brown spots decreased significantly at each time point compared with Their mean optical densities decreased significantly on D28 and D56. The area of UV spots increased significantly on D7 but decreased significantly by D56, whereas the mean spot optical density decreased significantly at each time point (Figure 1).
2. Melanin area and density, granular melanin area and density, and diffuse melanin area and density were significantly reduced on D28 and D56 compared with baseline (Figure 2).
3. After product use, melanin content decreased significantly at all time points. ITA° of spot regions, and L*, b*, and ITA° in non-spot regions improved significantly across all time points. Skin gloss improved significantly within 15 minutes and remained elevated thereafter. Skin translucency (Alpha value) showed a numerical improvement at 15 minutes and reached statistical significance from D7 onward (Figure 3).
4. After 56 days of product use, all clinician-assessed skin parameters improved significantly. Subject satisfaction exceeded 97% across all items, and 100% indicated willingness to continue use. No local or systemic skin adverse reactions occurred during the study.



Figure 1. VISIA-CR 5.0 CP images, brown images, and UV spot images in the facial spot assessment region at all time points before and after product use



Figure 2. FF-OCT images of the facial spot assessment region before product use and on days 28 and 56.

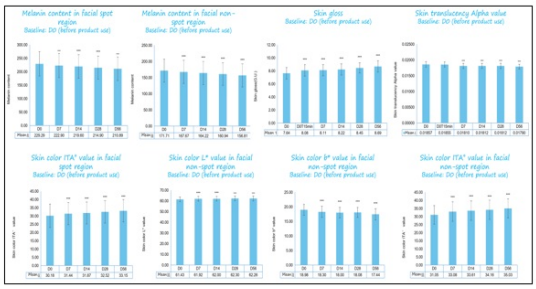

Figure 3. Skin color test values, melanin content, gloss, and translucency in facial assessment regions before and after product use (compared to D0, *p < 0.05, **p < 0.01, ***p < 0.001)

Figure 1. VISIA-CR 5.0 CP images, brown images, and UV spot images in the facial spot assessment region at all time points before and after product use. Figure 2. FF-OCT images of the facial spot assessment region before product use and on days 28 and 56. Figure 3. Skin color test values, melanin content, gloss, and translucency in facial assessment regions before and after product use (compared to D0, *p < 0.05, **p < 0.01, ***p < 0.001)

Conclusions

This study demonstrates that the anti-dark spot sunscreen significantly reduces spots and brightens skin with rapid onset. It showed no adverse reactions and high subject satisfaction, supporting its use as an integrated sun protection and repair regimen for long-term use in the Asian population.

EA DV CONGRESS
VIENNA
30 SEP - 3 OCT 2026

Abstract N°: 1971

Differential impact of several melanogenesis inhibitors on pheomelanin to eumelanin ratio

Clement Crochemore[1], Shosuke Ito[2], Safa Ben Hassine[1], Delphine Kerob[3], Thierry Passeron[4], Kazumasa Wakamatsu[2], Emilie Warrick*[1]

[1] L'Oreal Research and Innovation, Aulnay sous Bois, France
[2] Institute for Melanin Chemistry, Fujita Health University, Toyoake, Aichi, Japan
[3] La Roche-Posay Laboratoire Dermatologique, Levallois-Perret, France
[4] Centre Hospitalier Universitaire de Nice, Université Côte d'Azur, Nice, France

Introduction

In skin, the amount, composition, and distribution of melanin pigments drive constitutive pigmentation and determine sensitivity to UV exposure. Melanocytes produce two chemically distinct types of melanin: the insoluble, black to brown eumelanin, and the alkaline-soluble, yellow to reddish-brown pheomelanin. Both pigments are derived from dopaquinone (DQ) produced from tyrosine by tyrosinase. In the presence of cysteine, rapid reaction with DQ leads to the formation of cysteinyl-dopa moieties that are oxidized to benzothiazine intermediate (BT), which gradually polymerizes to form pheomelanin. In the late stage of pheomelanin production, the BT moiety is converted to a benzothiazole (BZ) moiety. When cysteine is depleted, DQ spontaneously reacts to form the eumelanin polymer. The relative ratio of eumelanin to pheomelanin determines human skin photoprotection. Eumelanin is photoprotective by absorbing UV rays and dissipating the energy, thus protecting from UV-induced damages. In contrast, pheomelanin acts as a photosensitizer and can enhance the UV-induced production of reactive oxygen species. Pheomelanin has also been implicated in UV-independent development of melanoma through oxidative damage.

Pigmentary disorders are frequent worldwide, and different molecules targeting melanogenesis have been recently developed. Here, we investigated the effect of melanogenesis inhibitors with different modes of action on eumelanin and pheomelanin content: 2-mercaptonicotinoyl glycine (2-MNG), a quencher of melanin precursors; cysteamine (CysA), a melanogenesis inhibitor hypothesized to have a similar mode of action as 2-MNG by sequestering dopa oxidation products; and the tyrosinase inhibitor 4-*n*-butylresorcinol (4-nBR). All compounds have demonstrated their clinical efficacy in treating melanin hyperpigmented disorders.

Materials and Methods

Normal human melanocytes were treated for 72 hours with 2-MNG, CysA or 4-nBR at equimolar concentrations (50 µM, 200 µM), in the presence of L-tyrosine (500 µM). Global melanin content was quantified by absorbance measurements at 340 nm. Melanin monomer units were analyzed through specific degradation products by HPLC. Eumelanin was measured via the PTCA (pyrrole-2,3,5-tricarboxylic acid) marker, while pheomelanin was assessed using two markers: 4-AHP (4-amino-3-hydroxyphenylalanine) and TTCA (thiazole-2,4,5-tricarboxylic acid).

Results

Global absorbance at 340 nm showed a dose-dependent inhibition of melanin with 2-MNG and 4-nBR. Surprisingly, CysA failed to reduce global melanin and even induced a pro-pigmenting effect at low concentration. To investigate this discrepancy, we performed detailed eumelanin and pheomelanin analyses. 2-MNG and 4-nBR

induced a dose-dependent decrease in both eumelanin and pheomelanin markers. CysA only demonstrated significant inhibition at high concentration on PTCA and TTCA markers. Conversely, the 4-AHP marker (BT-pheomelanin) showed a significant 3-fold increase with CysA at low concentration. We showed that CysA in the presence of DQ forms a CysA-DOPA adduct which then could be oxidized into CysA-pheomelanin, explaining the 4-AHP increase. 2-MNG also forms adducts with DQ which do not undergo oxidation into pheomelanin.

Conclusions

This study demonstrates that the effects of 2-MNG and CysA on melanin differ radically. 2-MNG effectively reduces the production of both melanin types, with a decrease in the pheomelanin/eumelanin ratio (TTCA/PTCA and 4-AHP/PTCA). CysA, although inhibiting eumelanin and cysteine-derived pheomelanin at high concentration, independently induces the formation of CysA-pheomelanin, resulting in an increase in the BT-pheomelanin/eumelanin ratio (4-AHP/PTCA). This specific conversion suggests that CysA could alter the pigmentary profile towards potentially photosensitizing pheomelanin forms. These results highlight the importance of evaluating qualitative pigment changes beyond global melanin reduction when evaluating safe compounds to manage hyperpigmentation.

EA DV CONGRESS
VIENNA
30 SEP - 3 OCT 2026

Abstract N°: 1994

Efficacy of upadacitinib in adults with extensive non-segmental vitiligo: Analysis of stabilization endpoints through 48 weeks in Viti-Up

Nanja van Geel*[1], Reinhart Speeckaert[1], Khaled Ezzedine[2], Sylvester Uwumarogie[3], Xiaoqiang Wu[3], Stavonnie Patterson[3], Albert Wolkerstorfer[4]

[1] Ghent University Hospital, Department of Dermatology, Ghent, Belgium

[2] Hôpital Henri Mondor, Université Paris-Est Créteil, EpiDermE (Epidemiology in Dermatology and Evaluation of therapeutics), Department of Dermatology, Créteil, France

[3] AbbVie Inc., North Chicago, United States

[4] Department of Dermatology, Netherlands Institute for Pigment Disorders, Amsterdam University Medical Centers, Amsterdam Institute for Infection and Immunity, University of Amsterdam, Amsterdam, Netherlands

Introduction

Non-segmental vitiligo (NSV) is an autoimmune skin disorder resulting in depigmentation due to a loss of melanocytes. Stabilization and prevention of future disease spread is a key treatment goal for vitiligo. Upadacitinib (UPA) is a selective once-daily Janus kinase inhibitor which has demonstrated efficacy for the treatment of NSV across 48 weeks in two identical phase 3 studies (Viti-Up) with no new safety signals reported. The Vitiligo Disease Activity Score (VDAS) and Vitiligo Disease Improvement Score (VDIS) are instruments that measure disease evolution (including progression/activity and improvement/repigmentation) and capture the dynamic changes of vitiligo over time. Here we report vitiligo disease evolution based on VDAS/VDIS at 12, 24 and 48 weeks of treatment in study 2 of Viti-Up.

Materials and Methods

Of those patients with active disease progression (VDAS > 0) at week 12 (PBO, N = 2; UPA15, N = 6) a greater proportion receiving UPA15 vs PBO achieved a decrease in vitiligo disease activity at both week 24 and 48 (UPA15, 3/6 [50%], PBO, 0%). A greater number of patients receiving UPA15 vs PBO achieved stabilization of vitiligo (VDAS = 0) at week 12 (20% [4/20] vs 10% [1/10]) and 24 (25% [5/20] vs 0% [0/9]); at week 48, 1 of 3 (33.3%) patients receiving PBO and 4 of 17 (23.5%) of patients receiving UPA15 reached stabilization (VDAS = 0). The proportion of patients achieving both repigmentation (VDIS > 0) and no vitiligo activity (VDAS = 0) was greater for UPA15 vs PBO at week 12 (15% [3/20] vs 10% [1/10]), week 24 (25% [5/20] vs 0% [0/9]), and week 48 (23.5% [4/17] vs 0% [0/3]). Safety has been reported previously.

Results

Treatment with UPA15 resulted in less activity of disease (greater stabilization) over time compared to PBO. Additionally, a greater proportion of patients on UPA reported no disease activity and experienced improvement of their vitiligo over 48 weeks. Findings in the current analysis indicate that treatment of NSV with UPA15 results in greater stabilization of vitiligo disease activity compared to PBO.

Conclusions

Treatment with UPA15 resulted in less activity of disease (greater stabilization) over time compared to PBO. Additionally, a greater proportion of patients on UPA reported no disease activity and experienced improvement of their vitiligo over 48 weeks. Findings in the current analysis indicate that treatment of NSV with UPA15 results in

greater stabilization of vitiligo disease activity compared to PBO.

EADV CONGRESS
VIENNA
30 SEP - 3 OCT 2026

Abstract N°: 2011

Epidemiological and clinical profile of childhood vitiligo: A single-center experience

Chourouq Mustapha Eid*[1], Fatima Zahra Sassine[1], Fatima Zahra Hammoud[1], Laila Benzekri[1]

[1] Centre Hospitalier Ibn Sina, Dermatology Department, Rabat, Morocco

Introduction

Vitiligo is an acquired pigmentary disorder characterized by the progressive loss of melanocytes. It affects 0.5–2% of the global population, with approximately 25% of cases occurring before the age of 10 years. Few studies have specifically described the clinical characteristics of vitiligo in children.

The aim of this study was to evaluate the epidemiological and clinical features of pediatric vitiligo.

Materials and Methods

A descriptive retro-prospective single-center study was conducted in a dermatology setting over a one-year period (November 2024 to November 2025).

The study included 116 patients under 18 years of age diagnosed with vitiligo.

Results

A total of 116 patients were included, with a female predominance (62.1%). The mean age was 9.8 years, with most patients aged 10–17 years (53.4%).

A family history of vitiligo was reported in 30.2% of cases, most frequently among second-degree relatives. An atopic background was noted in 25% of patients, thyroid disorders in 7%, and associated alopecia areata in 1%.

The mean age at onset of lesions was 7 years, with a mean disease duration of 2 years. Disease onset occurred before puberty in 88% of cases. Psycho-emotional triggering factors were identified in 26.7% of patients, and pruritus was reported in 20%.

Non-segmental vitiligo accounted for 62.3% of cases, compared with 37.7% segmental vitiligo. The vulgaris form was predominant (80%). The most frequent locations were the face (58%), upper limbs (34.8%), and lower limbs (26%). Mucosal and anogenital involvement was observed in 19% of patients, while nail involvement was reported in 16.4%. Cutaneous involvement affected less than 20% of body surface area in 88.7% of patients.

Conclusions

Pediatric vitiligo predominantly affects girls, typically begins before puberty, and is mainly non-segmental and limited in extent. Family history and psycho-emotional factors appear to play a notable role in disease occurrence.

EA DV CONGRESS
VIENNA
30 SEP - 3 OCT 2026

Abstract N°: 2015

Tinted Sunscreen Versus Foundation for Camouflage in Vitiligo: A Pilot Randomized Controlled Trial

Prameyuda Watchirakaeyoon*[1], Pornjira Wattanasillawat[1], Punyanut Yothachai[1], Nuttaporn Nuntawisuttiwong[1], Suthasinee pattaravadee[1], Chayada Chaiyabutr[1], Supenya Varothai[1], Chanisada Wongpraparut[1], Narumol Silpa-Archa[1]

[1] Department of Dermatology, Faculty of Medicine Siriraj Hospital, Mahidol University, Bangkok, Thailand

Introduction

Vitiligo camouflage can improve cosmetic appearance and quality of life. While foundation is widely used for concealment, tinted sunscreen offers the additional benefit of photoprotection. However, comparative data on camouflage efficacy, particularly across different skin phototypes and with shade optimization remain limited. This study aimed to compare the efficacy of tinted sunscreen and foundation using both objective colorimetric measures and subjective cosmetic assessments.

Materials and Methods

In this prospective, within-subject randomized controlled pilot trial, 20 adults with vitiligo (10 with Fitzpatrick skin phototype [SPT] III and 10 with SPT IV) applied tinted sunscreen and foundation across two sessions, using both lighter and darker shades, resulting in a total of four applications. The amount of tinted sunscreen and foundation applied to lesional areas was standardized at 2 mg/cm². Color matching was objectively assessed using the Individual Typology Angle (ITA), defined as the difference in ITA between treated vitiliginous (lesional) skin and adjacent perilesional skin. Cosmetic effectiveness was evaluated using the Vitiligo Noticeability Scale (VNS; range 1–5), as rated by both patients and dermatologists. Treatment success was defined as a VNS score ≥4, corresponding to “a lot less noticeable” (4) to “no longer noticeable” (5). Paired analyses were conducted to compare outcomes between products and across sessions.

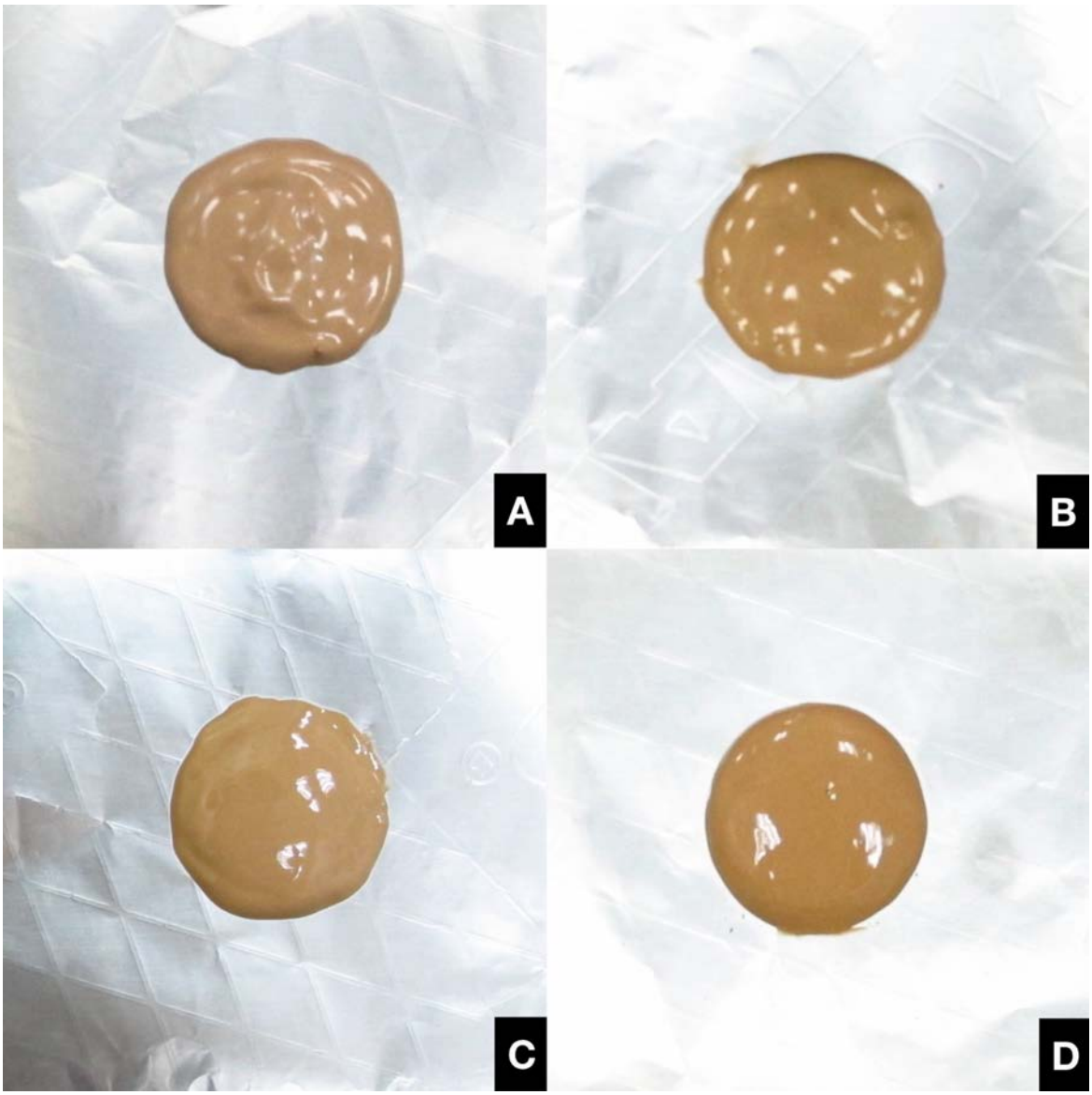

Camouflage products used. (A) Light-shade tinted sunscreen (B) Dark-shade tinted sunscreen (C) Light-shade foundation (D) Dark-shade foundation

Results

Out of 20 cases, two vitiliginous lesions of comparable size were selected for each participant. Lesion sites included the hands and wrists in 13 cases (65%), the face in 3 cases (15%), and the neck and upper chest in 4 cases (20%). The mean ITA of lesional skin was 57.9 ± 9.6 in SPT III and 45.8 ± 24.1 in SPT IV. Figure 1A shows the mean ITA after application of the four camouflage products. Foundation demonstrated significantly lower ITA values than tinted sunscreen for both light and dark shades across both SPT groups. Figure 1B illustrates the ΔITA between lesional and perilesional skin. In both SPT III and IV, darker-shaded camouflages resulted in a smaller difference compared to lighter shades, and the foundation showed lower ITA changes than the tinted sunscreen. Despite the superior objective color match achieved with foundation compared to tinted sunscreen, cosmetic treatment success (VNS ≥ 4) did not differ significantly between the products. Darker shade optimization significantly improved dermatologist-rated outcomes for tinted sunscreen, whereas patient-rated outcomes were similar across both shades of foundation and tinted sunscreen (Figure 1C).

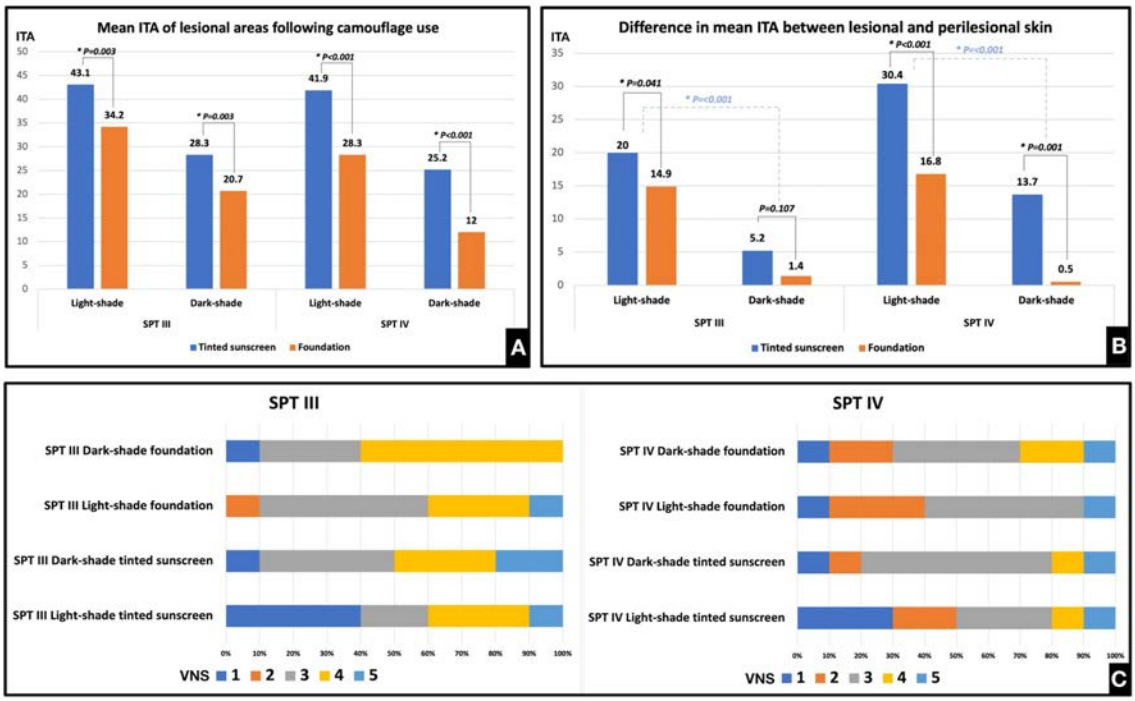

Figure 1. Effects of camouflage on color match and cosmetic outcomes in vitiligo. (A) Mean ITA of lesional skin following application of tinted sunscreen (blue) and foundation (orange) using lighter and darker shades, stratified by skin phototype (SPT III and IV). (B) Difference in mean ITA between lesional and perilesional skin after camouflage application. Lower values indicate better color match. (C) Distribution of patients' Vitiligo Noticeability Scale (VNS) scores (1–5) VNS ≥4 indicates treatment success. P-values represent paired comparisons between products (tinted sunscreen vs foundation) and between shades (lighter vs darker) within each condition.

Conclusions

Foundation provided superior objective color matching than tinted sunscreen; however, both products achieved comparable cosmetic outcomes. Tinted sunscreen remains a valuable alternative due to its similar perceived effectiveness and added photoprotective benefit. Larger studies are warranted to confirm these findings and further explore long-term outcomes and patient preferences.

EADV CONGRESS
VIENNA
30 SEP - 3 OCT 2026

Abstract N°: 2103

Explicating the microbiome in vitiligo: A systematic review

Angelica Fernandes*[1], Aaliya Irfan[1], Su Aye[1], Jaspreet Kaur[1], Faisal Ali[1]

[1] University of Lancashire, Preston, United Kingdom

Introduction

Vitiligo is an autoimmune disorder causing depigmentation of skin. Recent studies have unveiled the role of the microbiome in multiple autoimmune disorders. The intrinsic role of the microbiome in pigmentary disorders remains incompletely understood.
The main aim of this systematic review is to identify gut and skin dysbiosis patterns to understand the role of the microbiome in the pathogenesis of vitiligo and combineit with blood metabolites to find potential ways to utilise this for the management of vitiligo.

Materials and Methods

This systematic review was carried out using the PRISMA guidelines. The research question was formulated using the PICO framework and the objective of this systematic review was to analyse the role of gut and skin microbiome in the pathogenesis of vitiligo. This was further explored to determine whether gut and skin biomarkers could be used as a potential diagnostic tool. An extensive search of relevant literature was conducted on databases including Pubmed and Google Scholar from September 2015 to September 2025. The key words utilised were (‘vitiligo’ OR ‘depigmenting disorders’) AND (‘gut microbiome’ OR ‘gut microbiota’ OR ‘skin microbiome’ OR ‘skin microbiota'). Our search results yielded 4428 articles, of which 4399 articles were selected by title screening. An abstract screening was conducted on these 66 articles, resulting in 17 papers being chosen for full text screening.

Results

On analysis of the selected studies, alterations in the gut microbiome of vitiligo patients were identified. The *Firmicutes-to-Bacteroidetes* ratio was increased, characterized by a decrease in *Bacteroidetes* and an increase in *Firmicutes*. Additional microbial shifts included elevated levels of *Proteobacteria* (phylum) and *Gammaproteobacteria* (class/family),while *Enterococcus* was very low in overall abundance.
Metabolomic profiling showed significant differences in metabolites, with reduced levels of L-glutamic acid, nicotinic acid, and indole, and elevated levels of oleamide, stearamide, creatine, cuminaldehyde, and taurine in vitiligo patients compared to controls.

Conclusions

Combining gut microbiome and metabolomic data demonstrated strong predictive accuracy for the presence of vitiligo. These findings suggest that combined microbial and metabolic signatures may serve as potential diagnostic or disease-monitoring biomarkers; however, more research on larger participant groups is required.

EA CONGRESS
VIENNA
30 SEP - 3 OCT 2026

Abstract N°: 2105

Integrated Topical, Systemic, and Pulsed Dye Laser Therapy for Vascular Melasma

Linda Terán Sarmiento*[1], Cindy Tipán Abril[2], Dayan Muñoz Aguirre[1], Fabián Cruz Murillo[1], Luis Tipaz Chingal[3], Carla Vásquez Olmedo[2], Fabiana Padilla Terán[4], Diego Padilla Terán[4], Francisco Javier Luna[5], David Moreno[6], Cristina Wöhlke Vendruscolo[7]

[1] Vision and Skin Laser Surgical Center, Quito, Ecuador
[2] Universidade UTE, Quito, Ecuador
[3] Universidad Central del Ecuador, Quito, Ecuador
[4] Universidad Internacional del Ecuador, Quito, Ecuador
[5] Beiersdorf México, Ciudad de México, Mexico
[6] Beiersdorf Ecuador, Quito, Ecuador
[7] Beiersdorf AG, Hamburg, Germany

Introduction

Melasma is a chronic, relapsing pigmentary disorder with a multifactorial pathophysiology involving melanocytic hyperactivity, inflammation, and a well-recognized vascular component. Increasing evidence suggests that dermal vascular proliferation, endothelial dysfunction, and angiogenic mediators play a critical role in disease severity, persistence, and recurrence. Conventional monotherapy approaches, particularly topical depigmenting agents, frequently result in incomplete responses and high relapse rates. Consequently, therapeutic strategies targeting multiple interconnected pathways (melanogenesis, inflammation, and angiogenesis) have gained increasing relevance in the management of vascular melasma. To evaluate the efficacy, safety, and durability of a multimodal treatment protocol combining topical depigmenting therapy, systemic angiogenic modulation, and selective vascular laser technology for the management of vascular melasma.

Case Presentation

Twelve female patients with clinically diagnosed melasma with a vascular component were evaluated between 2021 and 2025. All participants provided informed consent and were independently assessed by two blinded dermatologists to minimize observer bias. Clinical and objective evaluations were performed using standardized digital photography and 3D imaging technology to quantify pigmentary and vascular indices. Disease severity was assessed using the modified Melasma Severity Index (mMASI), Melasma Severity Scale (MSS), and Clinical Erythema Scale (CES) at baseline, intermediate, final (one month after the last laser session), and maintenance follow-up visits.

The therapeutic protocol was divided into three sequential phases. The initial stabilization phase focused on controlling hyperpigmentation and erythema through a topical regimen based on Isobutylamino Thiazolyl Resorcinol (Thiamidol) applied four times daily, combined with strict photoprotection and oral tranexamic acid (250 mg twice daily), maintained until clinical stabilization. The technological phase consisted of four monthly sessions of sequential rhodamine intense pulsed light (r-IPL 550–680 nm) followed by pulsed dye laser (PDL 595 nm) targeting the vascular component. The maintenance phase included continued topical Thiamidol-based therapy, strict photoprotection, and annual laser sessions, with follow-up up to 36 months. Data were analyzed using SPSS v21, with continuous variables expressed as mean ± standard deviation; comparisons between phases were performed using the Wilcoxon signed-rank test ($p < 0.05$). **Results:** Twelve women (mean age 46.1 years) with Fitzpatrick phototypes III (42%) and IV (58%) were included. At baseline, all patients presented severe melasma (mean mMASI 9.6) and moderate to severe erythema (CES 3.0). After the initial phase, significant reductions in pigmentation (mMASI 5.1; $p = 0.002$) and erythema (CES 2.1; $p = 0.005$) were observed. The addition of r-IPL and PDL led to further improvement, with final mMASI decreasing to 3.5 ($p = 0.012$) and CES to 1.3 ($p = 0.004$), indicating mild melasma and marked vascular improvement. Benefits were sustained during maintenance, with no recurrences or significant adverse events.

Conclusion

A combined protocol integrating tyrosinase inhibition (Thiamidol), angiogenic modulation (oral tranexamic acid), and selective vascular laser therapy (r-IPL/PDL) demonstrated significant, clinically meaningful, and durable reductions in both pigmentation and erythema in patients with vascular melasma. The sustained remission, excellent tolerability, and absence of recurrence up to 36 months support this multimodal approach as an effective therapeutic strategy, particularly in Latin American populations with intermediate skin phototypes, where relapse and post-inflammatory hyperpigmentation are frequent clinical challenges.

EADV CONGRESS
VIENNA
30 SEP - 3 OCT 2026

Abstract N°: 2106

Dermatological Care in Skin of Colour Patients: A Retrospective Audit of Management at the Queen Elizabeth University Hospital, Glasgow

Aparna Potluru*[1], Amrita Randhawa[1], Rachel Gardner[1]

[1] Queen Elizabeth University Hospital, Glasgow, United Kingdom

Introduction
Skin of Colour (SOC) patients are at increased risk of dyspigmentation and scarringDelayed diagnosis across a range of dermatological conditions is common. Accurate documentation of skin type, appropriate counselling regarding pigmentary risk and the use of evidence-based management strategies are key components of SOC-competent dermatological care. However, adherence to these practices in routine clinical settings remains unclear. The aim of our study was to characterise the spectrum of dermatological conditions presenting in SOC patients over a three-month period and to evaluate documentation of skin type, pigmentary risk counselling and management practices.

Materials and Methods
A retrospective audit was conducted using clinic data from general dermatology clinics. Data collected included demographics, ethnicity, documented skin type, diagnoses, pigmentary risk counselling, SOC-specific morphology and management plans.

Results
A total of 257 SOC patients (132 female, 125 male) were seen, comprising 104 new and 153 return patients. The patients ranged in age from under 20 to over 80, with the largest proportion aged 20–39. Most patients were from Asian backgrounds, with a majority being Pakistani and Indian Skin type was documented in only 9 cases. Pigmentary concerns were recorded in 44 patients, not documented in 180 patients and were not applicable in 28 cases. Low counselling rates were documented in acne and inflammatory dermatoses, despite established associations with dyspigmentation and scarring in SOC patients. Regarding SOC morphology, findings were documented in 59 patients, absent in 169 patients, and not applicable in 28 cases.

Conclusions
Documentation of skin type, SOC-specific features and pigmentary risk counselling was suboptimal. Although evidence-based treatments were commonly prescribed, management of residual pigmentary sequelae was infrequently addressed despite its significant psychosocial impact. Targeted interventions, including structured documentation prompts and clinician education, are planned. We aim to establish a dedicated SOC service at our centre in Glasgow to improve the quality, consistency and equity of dermatological care for SOC populations.

EA DV CONGRESS
VIENNA
30 SEP - 3 OCT 2026

Abstract N°: 2224

Real-world psychosocial burden, quality of life, and disease management of non-segmental vitiligo in the United Kingdom

Viktoria Eleftheriadou[1, 2, 3], Christian Atkinson[4], Neil Reynolds[4], Charley Cooper[4], Samantha Kurosky*[5], Morgan Fox[4], Roni Adiri[6], Yousaf Aftab[7], Khaled Ezzedine[8, 9]

[1] Vitiligo Clinical And Research CEntre (Vitiligo CARE) for adult and paediatric patients, Royal Wolverhampton NHS Trust, Wolverhampton, United Kingdom
[2] Wallsall Healthcare NHS Trust, Wallsall, United Kingdom
[3] Institute for Global Health and Wellbeing, School of Medicine, Keele University, Staffordshire, United Kingdom
[4] Adelphi Real World, Bollington, United Kingdom
[5] Pfizer Inc, New York, United States
[6] Pfizer Pharmaceuticals Israel Ltd, Herzliya Pituach, Israel
[7] Pfizer Ltd, Tadworth, United Kingdom
[8] Department of Dermatology, Hôpital Henri Mondor, Créteil, France
[9] EpiDermE (Epidemiology in Dermatology and Evaluation of therapeutics), Institut Mondor de Recherche Biomédicale, Inserm U955, Université Paris Est Créteil (UPEC), Créteil, France

Introduction
Non-segmental vitiligo (NSV) is an autoimmune disease leading to depigmented lesions of varying size on the skin. NSV is known to impact psychosocial health, daily activities, and quality of life (QOL); however, individuals with NSV experience these impacts differently, suggesting that contextual factors beyond the extent of lesions may contribute to disease burden. This study explored the associations between vitiligo disease characteristics and QOL among adults with NSV in the UK.

Materials and Methods
A non-interventional cross-sectional survey was conducted among adults in the UK with clinician-confirmed NSV from July to December of 2025. Patients were referred into the study via the physician who confirmed the NSV diagnosis. Participation in the survey was voluntary. Respondents were remunerated for their time only. The survey collected data on patient demographics, clinical characteristics, and outcome measures including the Self-Assessment Vitiligo Extent Score (percent of affected body surface area [BSA]), Dermatology Life Quality Index (DLQI; a skin-specific QOL measure with scores ranging from 0 to 30, with a higher score indicating a greater impact), Vitiligo Impact Patient Scale (VIPs; a vitiligo-specific QOL measure with scores ranging from 1 to 95, with a higher score indicating a greater impact), and Patient Global Impression of Severity (face [PGIS-F] and total body [PGIS-V]; a self-assessed measure of vitiligo severity).

Results
Among 160 respondents, the mean age was 41.6 years, 54% were female, and 55% were diagnosed in the last 10 years. At the time of the survey, 38% of patients were receiving topical steroids, 33% were receiving phototherapy, and 30% were receiving oral steroids, among other medications. Lesions were most common on upper extremities (88%) and hands (76%). 72% and 70% of respondents self-assessed moderate to severe vitiligo on their body and

face, respectively. DLQI and VIPS stratified by duration of disease, affected body region, and BSA are presented in **Table 1**. The mean DLQI score was 7.1 (“moderate effect”), with 15% reporting “no effect”, 32% a “small effect”, 28% a “moderate effect”, and 25% a “very/extremely large effect”. QOL impacts, as measured by the DLQI, generally trended higher with greater severity on both the face and total body. The mean VIPs score was 29.5. Disease burden varied across clinical subgroups, with generally numerically higher mean DLQI and VIPS scores among those with shorter disease duration, vitiligo on the face/rest of head and neck, and higher percentage of affected BSA.

Conclusions

This real-world study demonstrates an impact of NSV on QOL in UK adults. The high prevalence of moderate to severe facial and total body involvement, along with the association between vitiligo on the face/affected BSA and higher DLQI and VIPs scores, underscores the need for effective treatment strategies that can improve perceptions of vitiligo severity and reduce psychosocial/QOL impacts. These findings emphasize the importance of addressing both the physical and psychosocial burden of vitiligo.

Table 1. DLQI and VIPs scores stratified by duration of disease, affected body region, and BSA

	Total Sample	Duration of Disease (years)		
		≤5	6 to 10	>10
DLQI Score[a]				
Total N	***160***	***55***	***33***	***72***
Mean	7.1	8.1	9.4	5.4
SD	5.61	5.00	6.67	5.02
VIPS Score[b]				
Total N	***160***	***55***	***33***	***72***
Mean	29.5	35.6	36.3	21.7
SD	18.31	14.54	18.74	17.90

	Total Sample	Affected Body Region						
		Face	Rest of head and neck	Hands	Rest of upper extremities	Genitalia/ Groin	Torso	Lower extremities
DLQI Score[a]								
Total N	***160***	***73***	***109***	***122***	***141***	***19***	***78***	***70***
Mean	7.1	8.9	8.1	7.5	7.4	4.7	6.8	6.2
SD	5.61	6.26	5.93	5.50	5.72	4.68	4.98	5.06
VIPS Score[b]								
Total N	***160***	***73***	***109***	***122***	***141***	***19***	***78***	***70***
Mean	29.5	36.2	32.9	30.5	29.9	21.3	31.6	27.8
SD	18.31	19.26	19.22	17.46	18.38	17.44	16.05	17.74

	Total Sample	% BSA Affected			
		0-1%	2-5%	6-10%	>10%
DLQI Score[a]					
Total N	***160***	***2***	***98***	***46***	***14***
Mean	7.1	2.0	6.1	8.4	10.4
SD	5.61	2.83	4.94	6.27	6.12
VIPS Score[b]					
Total N	***160***	***2***	***98***	***46***	***14***
Mean	29.5	7.0	26.2	33.4	42.7
SD	18.31	9.90	16.76	19.14	18.09

BSA = body surface area; DLQI = Dermatology Life Quality Index; SD = standard deviation; VIPS = Vitiligo Impact Patient Scale.

[a]Score ranges from 0 to 30 with a higher score indicating greater impact on quality of life. Scores ranging from 0 to 1 correspond to no effect, 2 to 5 a small effect, 6 to 10 a moderate effect, and 11 to 30 a very large/extremely large effect on the respondent's life.

[b]Score ranges from 0 to 95 with a higher score indicating greater impact due to vitiligo.

EADV CONGRESS
VIENNA
30 SEP - 3 OCT 2026

Abstract N°: 2236

Autoimmune Comorbidities Among Patients with Vitiligo in the United States

Matthew Brouillette[1], Roni Adiri*[2], Genevieve Gauthier[3], Mojgan Sadrarhami[4], Milena Gianfrancesco[5], Griffith Bell[6], Iltefat Hamzavi[7], Seemal R Desai[8, 9], Khaled Ezzedine[10, 11]

[1] Pfizer Inc., Collegeville, United States
[2] Pfizer Pharmaceuticals Israel Ltd, Herzliya Pituach, Israel
[3] Pfizer Canada ULC, Kirkland, Canada
[4] Pfizer Inc, New York, United States
[5] Pfizer Inc, South San Francisco, United States
[6] Pfizer Inc, Cambridge, United States
[7] Vitiligo Treatment and Research Center, Henry Ford Health, Detroit, United States
[8] Department of Dermatology, University of Texas Southwestern Medical Center, Dallas, United States
[9] Innovative Dermatology, Plano, United States
[10] Department of Dermatology, Hôpital Henri Mondor, Créteil, France
[11] EpiDermE (Epidemiology in Dermatology and Evaluation of therapeutics), Institut Mondor de Recherche Biomédicale, Inserm U955, Université Paris Est Créteil (UPEC), Créteil, France

Introduction

Vitiligo is a chronic autoimmune skin disease characterized by white macules and patches of depigmented skin as a result of melanocyte destruction. Vitiligo is often associated with other autoimmune comorbidities; however, the specific types of autoimmune comorbidities that occur in patients with vitiligo and how they differ by age and race has not been widely studied. This study assessed the incidence of diagnosed autoimmune comorbidities in patients diagnosed with vitiligo overall and stratified by age and race.

Materials and Methods

This retrospective cohort analysis of US administrative claims data (Optum® Clinformatics® Data Mart [CDM] Date of Death and Race [DODR] Monthly) included patients diagnosed with vitiligo (International Classification of Disease [ICD]-9-CM or ICD-10-CM) between January 1, 2008 and June 30, 2024. Patients with vitiligo had ≥1 inpatient (IP) or two outpatient (OP) claims ≥30 days apart and/or ≥1 OP claim with a dermatologist as the diagnosing provider type. The control cohort consisted of individuals with no evidence of vitiligo diagnosis matched 4:1 to vitiligo patients based on age, sex, region, and race. The index date for the vitiligo cohort was defined as the first diagnosis of vitiligo observed over the period covered by the database; for the control cohort, each subject was assigned the same index (calendar) date as their matched vitiligo patient. Continuous enrollment of ≥12 months pre- and post-index date was required, with variable length follow-up. The analysis excluded those with a pre-index (enrollment date to index date -1) diagnosis of vitiligo, skin and subcutaneous tissue diseases, psychiatric comorbidities, or autoimmune comorbidities. Incidence rates (IRs; per 1,000 person-years) and 95% confidence intervals (CIs) of autoimmune conditions during follow-up were calculated overall and stratified by age and race.

Results

A total of 9,741 patients with vitiligo and 38,964 controls were included in the analysis. In both cohorts, 50.63% of individuals were female, 69.23% were Caucasian, and the mean (standard deviation [SD]) age was 50.37 (21.63) years. The IR (95% CI) per 1,000 person-years for any autoimmune/autoinflammatory disease in patients with vitiligo and controls was 49.29 (47.09, 51.57) and 26.81 (25.97, 27.67), respectively, with the greatest differences seen for dermatologic diseases (26.09 [24.55, 27.70] vs 9.85 [9.36, 10.36]), endocrine diseases (9.64 [8.74, 10.61] vs 6.18 [5.79, 6.58]), and gastrointestinal diseases (3.56 [3.03, 4.16] vs 2.39 [2.16, 2.65]) (Table 1). Among dermatologic diseases (grouped term), the IR of alopecia areata, atopic dermatitis, and psoriasis was higher among patients with vitiligo than controls across all age and race subgroups. Among endocrine diseases, the IR of autoimmune thyroiditis was higher among patients with vitiligo than controls for all age and race categories, except for the African American group. While the IR of most individual gastrointestinal diseases was not notably different between patients with vitiligo and controls, the IR (95% CI) of celiac disease was higher in patients with vitiligo than controls for the 18-44 year age group (1.99 [1.22, 3.08] vs 0.71 [0.46, 1.05]), 45-64 year age group (1.38 [0.79, 2.24] vs 0.47 [0.28, 0.74]) and among the Caucasian group (1.46 [1.07, 1.94] vs 0.70 [0.55, 0.87]).

Conclusions

A greater incidence of autoimmune comorbidities diagnosed post index date was observed among patients with vitiligo than controls, particularly for dermatologic diseases and autoimmune thyroiditis. The incidence of certain comorbidities, such as celiac disease, appeared higher in patients with vitiligo than controls among specific age and race groups. Results highlight a need for proactive screening and coordinated management of autoimmune conditions in those with vitiligo. Further studies are needed to assess the relative timing of development of autoimmune comorbidities with respect to vitiligo diagnosis.

Table 1. Incidence rates of autoimmune/autoinflammatory diseases among patients with vitiligo and matched controls

Comorbidity, IR per 1000 person-years, (95% CI)	Patients with vitiligo (N=9,741)	Control subjects (N=38,964)
Any autoimmune/ autoinflammatory disease	49.29 (47.09, 51.57)	26.81 (25.97, 27.67)
Dermatologic diseases*	**26.09 (24.55, 27.70)**	**9.85 (9.36, 10.36)**
Diseases of the eye§	1.45 (1.12, 1.85)	1.51 (1.33, 1.72)
Endocrine diseases†	**9.64 (8.74, 10.61)**	**6.18 (5.79, 6.58)**
Gastrointestinal diseases‡	**3.56 (3.03, 4.16)**	**2.39 (2.16, 2.65)**
Hematologic diseases¶	2.45 (2.02, 2.96)	1.89 (1.68, 2.12)
Neurological diseases#	0.93 (0.67, 1.26)	0.85 (0.71, 1.01)
Rheumatologic diseases‖	5.91 (5.21, 6.67)	5.07 (4.73, 5.44)

CI, confidence interval; IR, incidence rate.

All individuals in the study were followed until the earliest of either: 1) death; 2) end of the study period [June 30, 2025]; or 3) end of enrolment in the database. Continuous enrolment duration was not included as one of the matching criteria. IRs for new onset of select conditions were calculated with person-time at risk starting on the index date and ending on the date of either: 1) death; 2) end of study period; 3) the event of interest; or 4) end of enrolment in the database. IRs per 1,000 person-years were calculated based on the number of new events divided by the sum of person-time during the at-risk period and multiplied by 1,000. Events that were not the event of interest did not censor each patient's follow-up time.

*Grouped term including alopecia areata, atopic dermatitis, dermatomyositis, linear morphea, pemphigus vulgaris, psoriasis, scleroderma; §Term includes uveitis; †Grouped term including Addison's disease, autoimmune thyroiditis, Graves' disease, type 1 diabetes mellitus; ‡Grouped term including celiac disease, Crohn's disease, inflammatory bowel disease, ulcerative colitis; ¶Grouped term including idiopathic thrombocytopenic purpura, pernicious anaemia; #Grouped term including Guillain-Barre syndrome, multiple sclerosis, myasthenia gravis; ‖Grouped term including rheumatic fever, rheumatoid arthritis, Sjogren's disease, systemic lupus erythematosus.

EA DV CONGRESS
VIENNA
30 SEP - 3 OCT 2026

Abstract N°: 2261

Effectiveness, safety and tolerability of cysteamine 5% cream vs triple combination cream vs hydroquinone 4% cream in the treatment of epidermal melasma : an open label randomized controlled clinical trial

Anupam Das*[1]

[1] KPC Medical College and Hospital, KOLKATA, India

Introduction
Triple-combination (TC) cream (fluocinolone acetonide 0.01%, hydroquinone 4%, and tretinoin 0.05%) is USFDA approved (and the gold standard) for the treatment of melasma. Topical 5% cysteamine has emerged as a novel alternative. Hydroquinone 4% is another efficacious alternative However there is scarcity of data comparing these three modalities.

Materials and Methods
An institution based open label randomized controlled parallel group comparative study was conducted over 117 patients, with a clinical diagnosis of epidermal melasma confirmed by dermoscopy and Wood's lamp examination. All three groups received a broad spectrum sunscreen, with one group receiving cysteamine 5 % cream, another group receiving triple combination cream, and the other group 4% hydroquinone cream for 6 weeks. Patients were followed up at weeks 2, 4 and 6. The effectiveness parameters were Melasma Severity Scale (MSS), Modified Melasma Area Severity Index (m MASI), Investigator global assessment of hyperpigmentation (IGA) and DLQI (Dermatology Life Quality Index). Safety parameters were spontaneously reported adverse events as well as adverse events elicited by the clinicians. For reporting the adverse reactions, Naranjo's causality assessment scale and WHO-Uppasala Monitoring scale were considered. Global assessment of safety and efficacy was done using the Likert's five point scale (poor, fair, good, very good, excellent). Tolerability assessment was done using the Common Terminology Criteria for Adverse Events (CTCAE)

Results
Pre-treatment mean mMASI scores in the TCC, cysteamine and hydroquinone groups were 11.23±3.23, 10.76±3.59 and 9.86±1.57 respectively. After 4 weeks of treatment, the mean mMASI score decreased to 8.65±2.17 in TCC group, 7.54±2.26 in cysteamine group, and 7.84±2.29 in hydroquinone group. At the end of treatment period (week 6), the mean mMASI score was 5.04±2.56 in the TCC group, 4.10±2.10 in cysteamine group and 4.56±2.32 in hydroquinone group. There was a statistically significant improvement in IGA and DLQI parameters in all the three groups, but there was no significant difference found on intergroup comparison.

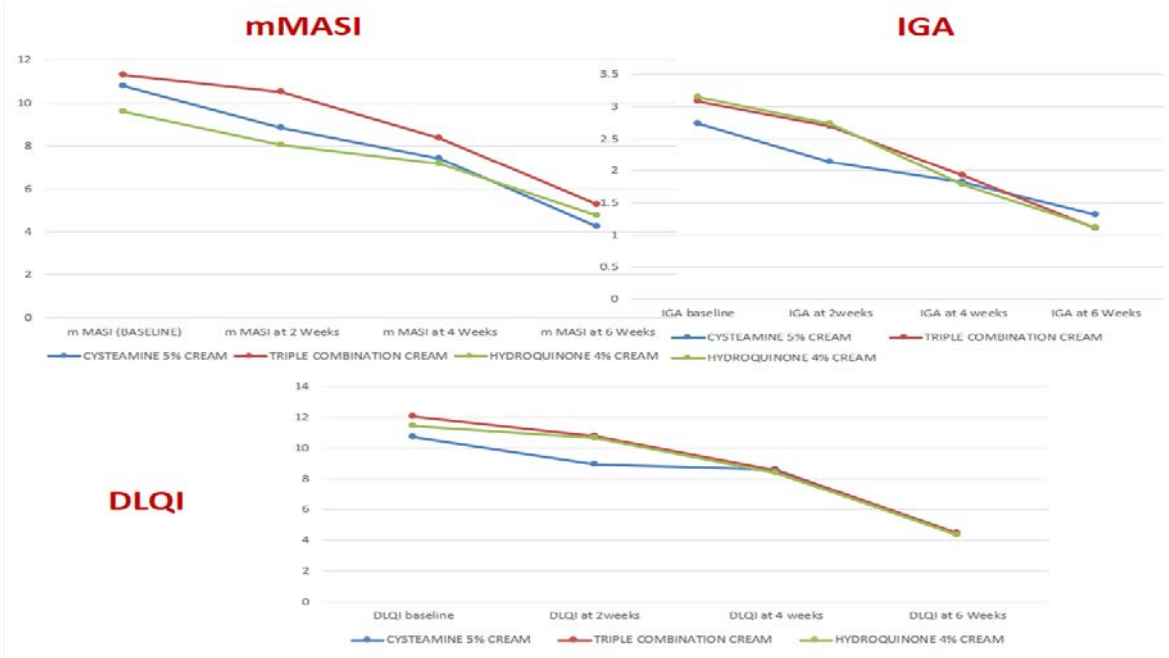

Summary of the progress of mMASI, IGA and DLQI scores for the three groups

Conclusions

At the end of 6 weeks, there was a statistically significant improvement in IGA and DLQI parameters in all the three groups, but there was no significant difference found on intergroup comparison. Cysteamine has emerged as a safe and equally effective and tolerable molecule in the management of epidermal melasma. The study could not be blinded due to different mode of application of the molecules.

EADV CONGRESS
VIENNA
30 SEP - 3 OCT 2026

Abstract N°: 2298

Melasma 2026: Etiology Update and the Evolving Landscape of Topical Depigmenting AgentsMelasma 2026: Etiology Update and the Evolving Landscape of Topical Depigmenting Agents

Mukta Sachdev*[1]

[1] Medical Director, MS Clinical Research Pvt. Ltd., HOD & Consultant, Dermatology, Manipal Hospital, Bangalore, India, Bengaluru, India

Introduction

Our understanding of melasma etiology has evolved substantially beyond the classical triad of UV radiation, hormonal influence, and genetic predisposition. Melasma is now increasingly recognized as a chronic photoaging-related inflammatory disorder, with evidence implicating dermal microenvironmental dysregulation, senescent fibroblast activity, basement membrane disruption, cutaneous neovascularization, oxidative stress-mediated signaling, and subclinical immune activation as key contributors to the initiation and chronicity of focal hypermelanosis. The unique etiological context of facial melasma in skin of color warrants specific consideration, as constitutively elevated melanocyte activity, distinct photoaging patterns, and heightened post-inflammatory hyperpigmentation susceptibility collectively shape disease phenotype, recurrence risk, and therapeutic response in ways that diverge meaningfully from lighter phototypes.

Against this evolving pathophysiological framework, the topical depigmenting armamentarium is undergoing significant expansion. The limitations of established agents, including the cumulative toxicity, mandatory treatment interruptions, and sensitization potential associated with hydroquinone and kojic acid, have driven the development and clinical validation of newer molecules. Next-generation tyrosinase inhibitors, tranexamic acid, cysteamine, and emerging non-hydroquinone brighteners are evaluated in the context of current international consensus recommendations, with a focus on mechanism of action, phototype-specific tolerability, and suitability for long-term continuous use and combination therapeutic strategies in the management of facial melasma.

EADV CONGRESS
VIENNA
30 SEP - 3 OCT 2026

Abstract N°: 2318

A retrospective study of clinical phenotypes, treatment response, and repigmentation patterns in 288 Patients with acral vitiligo

Yijian Zhu*[1], Chengfeng Zhang[1], Flora Xiang[1]

[1] Huashan Hospital, Fudan University, SHANGHAI, China

Introduction
Vitiligo affects 0.5%–2.0% globally. Acral vitiligo (hands/feet) is often resistant to treatment due to sparse hair follicles and limited microcirculation, and significantly impacts quality of life. Although treatment responses vary by anatomical site, systematic comparisons across acral subregions (e.g., dorsal, proximal, distal, palmoplantar) remain limited, with few studies controlling for age, sex, or disease duration. This retrospective study of 288 acral vitiligo cases used a linear mixed-effects model to compare outcomes across subregions, aiming to guide individualized therapy.

Materials and Methods
A retrospective analysis was conducted on 288 patients with acral vitiligo who attended the Department of Dermatology, Huashan Hospital between December 2022 and January 2025. Acral regions were categorized into four anatomical areas: dorsal acral sites (dorsum of hands and feet), proximal acral sites (proximal phalanges of fingers and toes), distal acral sites (middle and distal phalanges), and palmar/plantar sites (palms and soles). The distribution of lesions in each region was recorded. The Vitiligo Area Scoring Index (VASI) was used to assess lesion improvement before treatment and after 12 months of therapy. Repigmentation patterns were also evaluated. Given that most patients had involvement of multiple anatomical regions, resulting in a nested data structure, a linear mixed-effects model was employed for efficacy comparisons and analysis of associated factors, with patient ID included as a random intercept to account for within-individual correlation.

Results
Among the 288 patients, 182 were male (63.19%) and 106 were female (36.81%), with a mean age of onset of 25.67 ± 13.21 years. The number of patients with involvement in each region was as follows: dorsal acral sites, 187 (64.93%); proximal acral sites, 156 (54.17%); distal acral sites, 203 (70.49%); and palmar/plantar sites, 98 (34.03%). A total of 207 patients (71.88%) had involvement of two or more regions. After 12 months of treatment, based on the linear mixed-effects model, the estimated marginal mean VASI improvement rates (mean±standard error) were: dorsal acral sites (44.32±1.58)%, proximal acral sites (39.67±1.72)%, palmar/plantar sites (23.54±2.04)%, and distal acral sites (19.87±1.46)%, with a statistically significant overall difference ($F=15.623$, $P<0.001$). Pairwise comparisons showed no significant difference between dorsal and proximal sites ($P=0.142$), both of which demonstrated superior outcomes compared with palmar/plantar and distal sites ($P<0.001$). No significant difference was observed between palmar/plantar and distal sites ($P=0.458$). Regarding repigmentation patterns, perifollicular repigmentation predominated in dorsal and proximal sites (62.37% and 58.44%, respectively), whereas diffuse repigmentation was more common in palmar/plantar and distal sites (53.06% and 61.58%, respectively). Multivariable linear mixed-effects model analysis showed that, after adjusting for disease duration, baseline BSA, age, sex, age at onset, clinical stage, systemic treatment, and phototherapy, anatomical site (dorsal vs. distal: $\beta=24.45$, 95% CI: 20.16-28.74, $P<0.001$), disease duration ($\beta=-0.85$, 95% CI: -1.26 to -0.44, $P<0.001$), and baseline body surface area (BSA) ($\beta=-1.12$, 95% CI: -1.87 to -0.37, $P=0.003$) were statistically associated with VASI improvement, whereas age, sex, and age at onset were not($P>0.05$).

Conclusions

Treatment response and repigmentation patterns may vary across different anatomical sites in acral vitiligo, with relatively greater improvement observed in dorsal and proximal sites, and more limited improvement in palmar/plantar and distal sites. Anatomical site, disease duration, and baseline BSA were associated with VASI improvement, and may provide reference for evaluating treatment response and informing region-specific stratified approaches in acral vitiligo.

EADV CONGRESS
VIENNA
30 SEP - 3 OCT 2026

Abstract N°: 2328

Acquired Nevus of Ota Occurring After Rituximab Therapy

Bouchra Idrissi Rhenimi*[1]

[1] Clinique notre dame de grace - gosselies, Gosselies, Belgium

Introduction

Nevus of Ota is a dermal melanocytic disorder characterized by bluish-gray facial hyperpigmentation distributed along trigeminal areas. While congenital forms are the most common, acquired presentations developing during adulthood remain uncommon. We report a rare case of acquired nevus of Ota appearing after rituximab therapy.

Case Presentation

A 66-year-old woman with a medical history of type 2 diabetes mellitus, hypertension, and ANCA-associated vasculitis with renal involvement requiring chronic hemodialysis, treated with rituximab, presented with progressive bluish-gray facial pigmentation. According to the patient, the lesions appeared after initiation of rituximab therapy and progressively extended over several years.

Clinical examination revealed irregular bluish-gray hyperpigmented patches involving the zygomatic, temporal, frontal, and periocular regions, with predominance on the left side of the face. Dermoscopic examination showed diffuse structureless blue-gray pigmentation consistent with dermal melanocytosis.

Based on the clinical and dermoscopic findings, the diagnosis of acquired nevus of Ota was retained. The chronological onset after rituximab therapy raised the hypothesis of treatment-associated acquired dermal melanocytosis.



Bluish-gray facial hyperpigmentation involving the zygomatic, temporal, and periocular regions

Conclusion

This case highlights a rare acquired presentation of nevus of Ota occurring after rituximab therapy. Although causality cannot be formally established, the temporal relationship suggests a possible association. Clinicians should be aware of unusual pigmentary disorders arising during immunomodulatory treatments.

EADV CONGRESS
VIENNA
30 SEP - 3 OCT 2026

Abstract N°: 2404

Cross cultural beliefs, stigmatization and quality of life in Vitiligo

Mohammad Jafferany*[1], sophia ma[2], Tarek Zieneldien[2], Isabella Tan[3]

[1] Central Michigan University, Saginaw, United States
[2] John Hopkins University, Baltimore, United States
[3] Robertwood Johnson school of Medicine Rutgerz University, New Brunswick, NJ, United States

Introduction

Vitiligo is an autoimmune condition marked by depigmentation of the skin and is frequently associated with psychosocial distress. Although often dismissed as cosmetic, vitiligo carries a substantial burden influenced by cultural beliefs, stigma, and access to medical education. We aimed to examine the literature on cross-cultural beliefs, stigmatization, psychological comorbidities, and quality of life (QoL) outcomes in individuals with vitiligo.

Materials and Methods

A comprehensive search of PubMed, Embase, and PsycINFO was conducted to identify peer-reviewed studies discussing cultural beliefs, stigma, psychological burden, or QoL in individuals with vitiligo. Inclusion criteria encompassed original studies in English assessing relevant psychosocial or cultural domains.

Results

Twenty-three studies met inclusion criteria. Cultural attributions of vitiligo varied widely, with some populations linking the disease to contagion, divine punishment, or supernatural causes. These beliefs were more prevalent in regions with lower health literacy and limited access to dermatologic care. Stigmatization-manifesting as social exclusion, employment and marital discrimination, and internalized shame-was consistently reported across settings, though more severe in female patients and individuals with darker skin phototypes in certain regions. QoL impairment was greater in African, Middle Eastern, and South Asian populations compared to Western cohorts. Coping strategies included concealment, spiritual reliance, and use of complementary and alternative medicine (CAM).

Conclusions

Vitiligo imposes a global psychosocial burden that is amplified by cultural misconceptions and stigma. Culturally tailored, multidisciplinary interventions-including education, psychological support, and community-based stigma reduction-are crucial to improving outcomes. Future research should focus on high-stigma, underrepresented populations to inform equitable care.

EADV CONGRESS
VIENNA
30 SEP - 3 OCT 2026

Abstract N°: 2443

Evaluation of a Novel Multi-Pathway Targeting Brightening Composition Relative to Reference Compounds

Alexis Paul*[1], Marine Parat[1], Cécile Chamayou-Robert[1], Muriel Pujos[1]

[1] COTY LANCASTER R&D CENTER MONACO, MONACO, Monaco

Introduction

Skin complexion uniformity has long been recognized as a symbol of healthy and young skin. However, achieving this ideal skin complexion remains challenging.
There are many causes of skin color heterogeneity due to hyperpigmentation with sun exposure being a major cause but also hormones, pollution, post inflammatory hyperpigmentation due to acne or other inflammatory disorders. In addition, sun exposure can worsen all types of hyperpigmentation.
Elsewhere, with climate change impact inducing more exposure to sun rays, skin hyperpigmentation related problems might become an increasing skin concern in the world population.
To address this disorder, several reference molecules already exist on the dermo-cosmetic market, like vitamin C, Kojic acid etc.. but they tend to target or claim one single molecular pathway, usually addressing tyrosinase activity and/or synthesis.
From previous internal studies on hyperpigmentation and scientific literature, it has been postulated that simultaneously targeting multiple molecular pathways rather than focalizing on a single target could enhance brightening efficacy.
Thus, several combinations of actives have been screened according to their potential to target simultaneously multiple pathways.
The most effective combination was then assessed through *ex vivo* and clinical studies.

Materials and Methods

The composition was assessed versus a placebo and versus a medical reference molecule: hydroquinone 2% in an *ex vivo* experiment on normal human skin measuring melanin content.
It was tested clinically in a double blind 3 month experimental study involving 3 groups of 15 female Caucasian subjects presenting various sorts of dark spots, applying the composition twice daily. The groups were dispatched as follows: 1 placebo group, 1 group with the tested composition, 1 group with a reference molecule from the market, a resorcinol derivate. The study used both clinical scoring from a Dermatologist and instrumentation via chromametric measurements on defined dark spots versus spotless area.

Results

Ex vivo, the composition showed a statistically significant decrease of melanin content in the skin biopsies and this effect was equivalent to the current golden standard of hydroquinone 2% in the conditions of the experimentation.
In vivo, significant reduction of hyperpigmentation according to clinical scoring by a Dermatologist as well as instrumental chromametric measurements (in particular ITA° and L*), with a monthly increase in efficacy, were observed.
All measurements were significantly superior to placebo. Furthermore, the composition presented significant

superior results versus the resorcinol derivate composition on the market from instrumentation assessments. The composition demonstrated consistent improvements in melanin reduction each month which steadily increased significantly at later time points whereas the resorcinol derivate results showed a plateau after the first month up until 3 months of repeated applications.

Conclusions

We have concluded that our composition was as efficient as hydroquinone 2% in the conditions of the experimentation.

Elsewhere our initial clinical findings indicated that a multi-pathway approach to hyperpigmentation is more effective than targeting a single pathway, even when using a highly efficacious molecule. Future studies will investigate the efficacy of this product on specific types of hyperpigmentation but this first proof of concept study has demonstrated promising results.

EADV CONGRESS
VIENNA
30 SEP - 3 OCT 2026

Abstract N°: 2471

Facial vitiligo as a key determinant of disease burden
Subtitle: The Importance of the Face in Perceived Disease Extent and Impact

Sofie Monsieurs*[1, 2], Reinhart Speeckaert[1, 2], Lise Vanden Broucke[1, 2], Nanja van Geel[1, 2]

[1] Ghent University Hospital, Ghent, Belgium

[2] Faculty of Medicine and Health Sciences, Ghent University, Ghent, Belgium

Introduction

Traditional assessments of vitiligo disease impact and current guidelines primarily rely on "total body surface area affected" (%BSA). Although, they fail to capture the disproportionate impact of lesions in specific body-locations, such as the face, potentially underestimating the true impact on patients. This study aimed (I) to compare cut-off values for disease extent in relation to the level of perceived disease burden of facial and total body vitiligo, and (II) to assess whether differences in impact are experienced between facial and total body involvement within the same patient.

Materials and Methods

In this cross-sectional, comparative study, 255 participants (≥16 years with non-segmental vitiligo) completed a validated questionnaire including the Self-Assessment Vitiligo Extent Score (SAVES), and the Patient Global Assessment (PtGA), a 5-point scale assessing the perceived impact and extent, for the face and total body. PtGAs served as anchor questions to stratify the SAVES through ROC analyses to determine cut-off values for each PtGA category (mild-moderate-high impact). Wilcoxon Signed-Rank tests compared burden scores between face and total body within patients.

Results

Cut-off values to shift between the PtGA categories mild-moderate and high impact, were (absolute total percentage BSA): >0.05% and >0.45% absolute BSA for face, and >1.59% and >3.05% absolute BSA for total body, respectively. Similar patterns were found for PtGA extent showing significantly lower cut-off values for the facial area compared to the total body. Additionally, the within-patients analysis showed a significant higher proportion of patients reporting a greater perceived impact from facial involvement compared with total body involvement.

Conclusions

Patients consistently rate facial lesions as more distressing and burdensome than equivalently sized lesions located on random regions of the body, with a stronger increase in impact levels compared with total body involvement.

EA DV CONGRESS
VIENNA
30 SEP - 3 OCT 2026

Abstract N°: 2475

Eruptive Macular Pigmentation in a Child: A Case Report with Unusual Clinical Presentation

Gabriela Santos Bastos Jacob[1], Elisandra Barbara Pontes Carlos*[1], Lais Souza[1], Milena de Oliveira[1], Hélio Miot[1], Ivanka Martins[1]

[1] UNESP, Botucatu, Brazil

Introduction

Idiopathic eruptive macular pigmentation (IEMP) is a rare and possibly underdiagnosed dermatosis, characterized by the appearance of asymptomatic hyperchromic macules predominantly in children and adolescents, affecting the face, neck, trunk, and extremities. It frequently represents a diagnostic challenge, with clinical overlap with other pigmentary dermatoses. We report a case of IEMP in a 7-year-old child with an unusual clinical presentation and a possible temporal association with vitamin D supplementation.

Case Presentation

A 7-year-old previously healthy female patient was brought by her mother complaining of hyperchromic macules distributed over the body for 6 months. The mother reported onset of the condition following vitamin D supplementation, which had already been discontinued at the time of the consultation. The lesions showed no migration, change in pattern, pruritus, or pain, and there were no associated systemic complaints. Physical examination revealed disseminated hyperchromic macules over the upper limbs, lower limbs, trunk, and face, with no mucosal involvement. Initial diagnostic hypotheses included ashy dermatosis, generalized fixed pigmented erythema, and IEMP. Dermoscopy revealed a peppering pattern, suggestive of pigmentary incontinence, corroborating the diagnostic hypotheses. A punch biopsy was performed, revealing basal layer hyperpigmentation associated with pigmentary incontinence, with no evidence of lichenoid inflammation, interface vacuolar change, or dermal eosinophils, compatible with IEMP. Therapy with 7% glycolic acid cream and photoprotection was initiated, with stabilization and slight improvement of the lesions on follow-up.

Conclusion

IEMP is an uncommon and possibly underdiagnosed dermatosis, first described by Degos et al. in 1978. Differential diagnosis with lichen planus pigmentosus and erythema dyschromicum perstans should be considered, with histopathology being the confirmatory method. Biopsy is essential for accurate diagnosis, allowing clinicians to adequately counsel parents and patients regarding the benign nature of the condition and avoid unnecessary treatments.

In the present case, the mother reported onset of lesions temporally associated with the use of a vitamin D supplement. Although it is not possible to establish a causal relationship, this association warrants documentation, as external triggering factors remain poorly explored in the literature. The etiology of IEMP remains uncertain, and pediatric cases with atypical presentation may initially be confused with cutaneous mastocytosis or neurofibromatosis, reinforcing the need for histopathological investigation.

Dermoscopy demonstrated a peppering pattern, consistent with the pigmentary incontinence evidenced on histology, highlighting the value of the tool in the screening of hyperchromic dermatoses. In general, macules tend to resolve spontaneously over months to years, without residual pigmentation or scarring, although cases of progression from childhood to adolescence have been described, justifying regular clinical follow-up. This report

contributes to broadening the clinical spectrum of IEMP in pediatric dermatology and highlights possible triggering factors yet to be elucidated.

EA DV CONGRESS
VIENNA
30 SEP - 3 OCT 2026

Abstract N°: 2483

Oral Tranexamic Acid for Facial Hyperpigmentation in Frontal Fibrosing Alopecia: A Case Report

Juliana Alvarenga Jordao[1], Barbara Brunca*[1], Enrico Dumbra Bonini[1], Fernanda Blasques de Faria[1]

[1] Hospital PUC Campinas, Campinas, Brazil

Introduction

Frontal Fibrosing Alopecia (FFA), a variant of Lichen Planopilaris, is a cicatricial alopecia characterized by recession of the frontotemporal hairline, frequently associated with eyebrow loss. In addition to follicular involvement, extrafollicular pigmentary manifestations have been increasingly recognized in Frontal Fibrosing Alopecia, particularly Lichen Planus Pigmentosus (LPP), whose diagnosis and treatment may be challenging in clinical practice. (1)

Tranexamic Acid (TXA) has emerged as a therapeutic option for hyperpigmentation disorders due to its antimelanogenic, anti-inflammatory, and antiangiogenic effects, with promising results in dermatology. (2,3)

Case Presentation

A 55-year-old postmenopausal female patient with a histopathological diagnosis of Frontal Fibrosing Alopecia presented with facial hyperpigmentation in photoexposed areas suggestive of Lichen Planus Pigmentosus, including eyelid involvement, a finding relevant in the differential diagnosis with melasma. (Figure 1)

The patient had previously been treated with doxycycline, dutasteride, and minoxidil, achieving stabilization of alopecia; however, facial hyperchromia persisted and proved refractory to topical depigmenting therapies, including tacrolimus, hydroquinone, and topical tranexamic acid.

Oral Tranexamic Acid 250 mg twice daily was initiated after exclusion of thromboembolic history. After 3 months, marked improvement in facial hyperpigmentation was observed, without adverse effects. Treatment was maintained for an additional three months, with scheduled clinical follow-up. (Figure 2)

Pigmentary changes associated with Frontal Fibrosing Alopecia are increasingly recognized and may present in different forms, including hyperchromic macules (melasma-like or LPP), hypochromic/achromic lesions (vitiligo-like), and erythematous lesions (rosacea-like), depending on the degree of local inflammation at the dermoepidermal junction and melanocytic activity. (1)

Lichen Planus Pigmentosus is characterized by poorly defined grayish-to-brown macules, predominantly affecting photoexposed areas. Its association with Frontal Fibrosing Alopecia is more common in higher phototypes, as observed in the present case. (1,4)

The etiopathogenesis of Lichen Planus Pigmentosus remains incompletely understood, although there is evidence suggesting that photosensitizing substances may act as potential triggers.

During the inflammatory phase of LPP, management is primarily focused on controlling inflammation with immunomodulatory therapies, whereas in the residual phase the goal is lesion lightening, using topical agents, systemic therapies, and lasers, although no therapeutic consensus has yet been established. (1)

In dermatology, oral TXA has increasingly been recognized as a promising therapy for melasma and other

hyperpigmentation disorders. It reduces hyperpigmentation through multiple mechanisms, including inhibition of ultraviolet radiation-induced plasmin activity, decreasing keratinocyte–melanocyte interaction and melanin synthesis; reduction of tyrosinase activity, microphthalmia-associated transcription factor, and related proteins (TRP-1 and TRP-2); and modulation of pro-inflammatory and pro-pigmentary mediators such as prostaglandins and endothelin-1. It also exhibits anti-inflammatory and antiangiogenic effects through actions on cytokines, mast cells, and vascular endothelial growth factor, while contributing to skin barrier restoration. (2,3,4)

Oral Tranexamic Acid, usually administered at doses ranging from 250 to 1500 mg/day, proved effective in this difficult-to-manage case of hyperpigmentation. Nevertheless, it should be prescribed with caution and after appropriate screening for thromboembolic and cardiovascular risk factors.

Conclusion

Oral TXA appears to be a promising and well-tolerated option for refractory facial hyperpigmentation associated with FFA. This case highlights its potential in difficult-to-treat pigmentary disorders, although further studies are needed.

EA DV CONGRESS
VIENNA
30 SEP - 3 OCT 2026

Abstract N°: 2483

Clinical efficacy of a dermocosmetic regimen containing the patented MELAGEA™ depigmenting complex in Fitzpatrick IV–V skin: a 42-day prospective study conducted in Sri Lanka

shanika arsecularatne*[1], Michał Rachalewski[1], Renata Debowska[1], Katarzyna Rogiewicz[1], Irena Eris[1]

[1] Dr Irena Eris Centre for Science and Research, Piaseczno, Poland, Piaseczno, Poland

Introduction
Hyperpigmentation disorders, particularly melasma and post-inflammatory hyperpigmentation (PIH), represent a significant therapeutic challenge in patients with skin of color (Fitzpatrick IV–VI), due to increased melanogenic activity, enhanced inflammatory signaling, and a high propensity for persistence and relapse. Therapeutic options in this population are often limited by tolerability concerns and risk of rebound hyperpigmentation. The objective of this study was to evaluate the clinical efficacy and safety of a dermocosmetic regimen containing the patented MELAGEA™ depigmenting complex (ellagic acid and glabridin) in reducing facial hyperpigmentation in individuals with Fitzpatrick IV–V skin.

Materials and Methods
This 42-day prospective, single-arm study was conducted in Sri Lanka and included 22 participants (15 females, 7 males; mean age 39.5 years), all with Fitzpatrick phototypes IV–V. The study population comprised patients with melasma (n=10), PIH scars (n=4), and other hyperpigmentation disorders (n=6). Participants followed a standardized regimen consisting of a cleansing foam (14709), a daytime cream with SPF50+ (14711), and a night cream (14712). The leave-on formulations incorporated the patented MELAGEA™ complex, designed to target key pathways involved in melanogenesis. Assessments were performed at baseline, Day 21, and Day 42 using objective instrumental measurements (melanin index, erythema index, corneometry, sebumetry) and clinical evaluation with the modified Melasma Area and Severity Index (mMASI).

Results
The regimen demonstrated a rapid, progressive, and clinically meaningful improvement in pigmentation parameters. Melanin index decreased from 609.8 at baseline to 529.0 at Day 42 (−13.2%), confirming effective attenuation of pigmentation intensity in darker phototypes. A pronounced clinical response was observed in mMASI scores, which decreased from 7.05 to 3.58 (−50%), indicating a substantial reduction in melasma severity. This magnitude of improvement within 42 days is particularly relevant in Fitzpatrick IV–V populations, where treatment responses are typically slower and less pronounced. Erythema index showed a reduction (425.2 to 401.4), suggesting attenuation of subclinical inflammation. Skin hydration improved (57.1 to 62.8), confirming preservation of epidermal barrier integrity. Lipid content increased (15.3 to 28.4), which may reflect physiological adaptation and requires further investigation whether it resulted from sebum secretion or emollients provided by the formulas. No treatment-limiting adverse events or clinically relevant irritation were reported, supporting a favorable safety and tolerability profile.

Conclusions

A dermocosmetic regimen containing the patented MELAGEA™ complex demonstrated significant and clinically meaningful efficacy in reducing hyperpigmentation in Fitzpatrick IV–V skin, with a favorable safety profile. The marked reduction in mMASI and consistent decrease in melanin index support its role as an effective, non-invasive strategy in the management of pigmentary disorders in skin of color. Importantly, these findings address a high unmet clinical need in patients with darker phototypes, in whom therapeutic options are frequently constrained by tolerability issues and risk of post-inflammatory outcomes. The observed efficacy and safety profile position MELAGEA™ as a valuable adjunct within targeted treatment strategies for hyperpigmentation in skin of color

EA CONGRESS
VIENNA
30 SEP - 3 OCT 2026

Abstract N°: 2596

Efficacy of a 2-MNG-containing serum in the treatment of melasma and post-inflammatory hyperpigmentation in a population from Senegal

Fatimata Ly[1], Delphine Kerob*[2], Margot Broallier[2], Shermine Warde[2]

[1] Department of Dermatology, Cheikh Anta Diop Dakar University, EPS Institute of Social Hygiene, Dakar, Senegal

[2] La Roche-Posay Laboratoire Dermatologique, Levallois-Perret, France

Introduction

Hyperpigmentation disorders including melasma and post-inflammatory hyperpigmentation (PIH) can significantly impact quality of life. Currently, topical conventional agents remain the primary option of front-line treatment for those conditions such as hydroquinone, arbutin and kojic acid, frequently combined with other treatments such as chemical peels or laser therapy. However, these common depigmenting agents can potentially trigger long-term use side effects. In this study, a novel serum containing 2-mercaptonicotinoyl glycine (2-MNG), an ingredient that intercepts melanin precursors, as well as niacinamide, *cystoseira tamariscifolia* extract, LHA, carnosine, retinyl palmitate, dipotassium glycyrrhizate, hyaluronic acid and glycerin has been tested on melasma and PIH.

Materials and Methods

This study was conducted in Senegal from March 2024 to April 2025 and included 19 subjects with epidermal or mixed, mild to moderate melasma (IGA 1 or 2) and 19 subjects with mild to moderate acne-induced post-inflammatory hyperpigmentation (PIH) (IGA 1 or 2) on the face. Subjects applied the serum twice daily in the morning and in the evening for 3 months together with a broad-spectrum SPF/UVA sunscreen in the morning and at midday. Efficacy was assessed clinically using mMASI (Modified Melasma Area and Severity Index), PAHPI (Post-Acne Hyperpigmentation Index) and IGA (Investigator Global Assessment) at D0, 28, 56 and 84. Subjects also self-assessed efficacy and high-quality pictures illustrated the clinical effect of the 2-MNG-containing serum.

Results

In the melasma group, the modified Melasma Area and Severity Index (mMASI score) assessed by the investigator decreased by 65,9% at D84 (from 4,87 to 1,80; $p < 0,01$) and was significant as soon as D28. The efficacy of the serum was positively valued by the subjects at the end of the study on several criteria such as lightening (94% of subjects) and visibility of pigmentation (93% of subjects).

In the PIH group, the Post-Acne Hyperpigmentation Index (PAHPI) assessed by the investigator decreased by 26,7% at D84 (from 9,84 to 7,21; $p<0,05$) and was significant as soon as D56. The Investigator Global Assessment (IGA) demonstrated a significant improvement starting D56 ($p<0,05$) and 76.9% of subjects had an improvement of at least one IGA grade at D84. The efficacy of the serum was positively valued by the subjects on several criteria such as dark spots number (94% of subjects) and color (100% of subjects). High quality pictures illustrated the clinical effect.

Conclusions

The study showed that a new serum containing 2-MNG is effective in the management of melasma and PIH over 3 months of application together with a broad-spectrum SPF/UVA sunscreen. These findings support the use of this serum as an effective dermocosmetic solution for hyperpigmentation disorders and namely melasma and PIH on African skin.

EA DV CONGRESS
VIENNA
30 SEP - 3 OCT 2026

Abstract N°: 2597

Efficacy and tolerability of a 2-MNG-containing serum in the treatment of melasma and solar lentigo in a population from Singapore

Chee-Leok Goh[1], Delphine Kerob*[2], Margot Broallier[2], Shermine Warde[2], Steven Thng[1]

[1] National Skin Centre, Singapore, Singapore

[2] La Roche-Posay Laboratoire Dermatologique, Levallois-Perret, France

Introduction

Hyperpigmentation disorders including melasma and solar lentigo can significantly impact quality of life. Currently, topical conventional agents remain the primary option of front-line treatment for those conditions such as hydroquinone, frequently combined with other procedures such as laser therapy. However, these common depigmenting agents can potentially trigger long-term use side effects. In this study, a novel serum containing 2-mercaptonicotinoyl glycine (2-MNG), an ingredient that captures melanin precursors, as well as niacinamide, *cystoseira tamariscifolia* extract, LHA, carnosine, retinyl palmitate, dipotassium glycyrrhizate, hyaluronic acid and glycerin has been tested on melasma and solar lentigo.

Materials and Methods

This study was conducted in Singapore and included 43 subjects with phototypes II-V including 23 subjects with epidermal or mixed, mild to moderate melasma (IGA 1 or 2) and 20 subjects with solar lentigo with a pigmentation score > 5. Subjects applied the serum twice daily in the morning and in the evening for 3 months together with a broad-spectrum SPF/UVA sunscreen in the morning and at midday. Efficacy was assessed clinically using mMASI (Modified Melasma Area and Severity Index) and Solar Lentigo score at D0, 28, 56 and 84. Subjects also self-assessed efficacy (Patient Global Assessment) and stigmatization with the Patient Unique Stigmatization Holistic tool in Dermatology (PUSH-D). High-quality pictures illustrated the clinical effect of the 2-MNG-containing serum.

Results

In the melasma group, the modified Melasma Area and Severity Index (mMASI score) assessed by the investigator decreased by 34.6% at D84 *vs* baseline (from 4,01 to 2,67; p< 0,01) and was significant as soon as D56. The Patient Global Assessment (PGA) score was significantly improved at each time with an improvement of 78.9% subjects at D84 (p< 0,01). The PUSH-D score showed a significant improvement of stigmatization at each time *vs* baseline with a 48.8% reduction at D84 (p< 0,01).

In the solar lentigo group, the Solar Lentigo Pigmentation Scale assessed by the investigator decreased by 18.2% at D84 *vs* baseline (from 7,40 to 6,05; p< 0,01) and was significant as soon as D56. The Patient Global Assessment (PGA) score was significantly improved at each time with an improvement of 75% subjects at D84 (p< 0,01). The serum was well tolerated in both groups.

Conclusions

The study showed that 2-MNG-containing serum is effective and well tolerated in the management of melasma and solar lentigo over 3 months of application together with a broad-spectrum SPF/UVA sunscreen. These

findings support the use of this serum as an effective and safe dermocosmetic solution for hyperpigmentation disorders and namely melasma and solar lentigo on Asian skin.

EADV CONGRESS
VIENNA
30 SEP - 3 OCT 2026

Abstract N°: 2598

Efficacy and tolerability of a new depigmenting serum in the treatment of melasma and post-inflammatory hyperpigmentation in a population from Brazil.

Sérgio Schalka[1, 2], Delphine Kerob*[3], Guenaelle Ledantec[3], Shermine Warde[3], Mayara Moura[1, 2]

[1] Medcin Skin Research Center, Sao Paulo, Brazil

[2] Biochemistry Department, Chemistry Institute of Sao Paulo University, Sao Paulo, Brazil

[3] La Roche-Posay Laboratoire Dermatologique, Levallois-Perret, France

Introduction

Hyperpigmentation disorders including melasma and post-inflammatory hyperpigmentation (PIH) significantly impact quality of life. Topical dermocosmetic depigmenting products are convenient long-term solutions. This study evaluated the efficacy and tolerability of a serum containing 2-mercaptonicotinoyl glycine (2-MNG), a melanin precursor interceptor, in melasma and PIH.

Materials and Methods

This study was conducted in Brazil and included 24 subjects with mild-to-moderate epidermal or mixed melasma (IGA 1 or 2) and 17 subjects with mild-to-moderate PIH (IGA 1 or 2). Subjects applied the 2-MNG-containing serum twice daily in the morning and evening for 3 months together with a broad-spectrum SPF/UVA sunscreen in the morning and midday. Efficacy was clinically assessed using mMASI (Modified Melasma Area and Severity Index), PAHPI (Post-Acne Hyperpigmentation Index) and a 0-10 solar lentigo pigmentation scale at D0, 28, 56 and 84. Subjects also self-assessed efficacy and stigmatization with the Patient Unique Stigmatization Holistic tool in Dermatology (PUSH-D). Objective measurements were conducted through standardized pictures and colorimetry (ITA and contrast (ΔE-value)).

Results

In the melasma group, a 37.7% decrease of the mMASI score was observed at D84, which was significant from D28 ($p \leq 0.05$). The individual typology angle (ITA) was improved by 4.1 points with a significant contrast decrease (ΔE) *vs.* adjacent area ($p \leq 0.05$) at the end of the study. At D84, 87.5% of subjects self-perceived visual improvement (Patient Global Assessment) and the PUSH-D significantly improved by 69.6% ($p \leq 0.05$).

In the PIH group, a significant 24.7% decrease of the PAHPI score was observed at D84 ($p \leq 0.05$), confirmed by a 7.3-point improvement in ITA and significant contrast decrease (ΔE) *vs.* adjacent area ($p \leq 0.05$). Investigator global assessment (IGA) significantly improved by 26.7% ($p \leq 0.05$) and 100% of subjects self-perceived visual improvement (Patient Global Assessment) at D84. The serum was well tolerated.

Conclusions

This study shows the efficacy and tolerability of a serum containing 2-MNG, an interceptor of melanin precursors, after 3 months of twice a day application together with broad-spectrum sunscreen for melasma and PIH, offering an effective and safe dermocosmetic solution for hyperpigmentation disorders.

EADV Congress 2026, VIENNA
30 SEPTEMBER - 03 OCTOBER 2026
POWERED BY M-ANAGE.COM

EA DV CONGRESS
VIENNA
30 SEP - 3 OCT 2026

Abstract N°: 2695

Which instruments can optimise teledermatology follow-up in vitiligo? A nationwide survey with dual patient–dermatologist perspective

Emmanuel Mahe*[1, 1], Charles Taieb[2, 2], Martine Carré[3, 3], Yaron BenHayoun[4], Mathieu Bataille[5], Philippe Beaulieu[6], Khaled Ezzedine[7]

[1] Hôpital Victor Dupouy, Argenteuil, France
[2] European Market Maintenance Assessment, FONTENAY SOUS BOIS, France
[3] Association Française du Vitiligo, Paris, France
[4] ORDAAT [Skin Knowledge], Paris, France
[5] Hôpital Saint- Vincent-de-Paul, Lille, France
[6] Cabinet de dermatologie, Pontoise, France
[7] Hopital Henri Mondor - APHP, CRETEIL, France

Introduction
Teledermatology achieves diagnostic accuracy comparable to in-person care and is particularly valuable in vitiligo for patients in underserved areas or those avoiding consultation due to stigmatisation. Remote follow-up, however, requires clinical instruments validated and accepted by both parties. Extending our psoriasis framework, we compared patient and dermatologist perspectives on the same set of tools

Materials and Methods
Nationwide cross-sectional survey in France (October 2024 – March 2026; CPP 2025-A02532-47). Patients were recruited via the AFV association, dermatologists via the EMMA database. Nine instruments were evaluated: five validated PROs (VIP, SOL, PUSH-D, DMLQ, SA-VES), three VAS (severity, satisfaction, burden), and a simplified SURFACE tool adapted from the EASI. Both groups rated each instrument (Likert) on ease of use, clinical relevance, teleconsultation aid, and vitiligo-adaptedness. Analyses included descriptive statistics and multivariable logistic regression (N = 645).

Results
Among 897 evaluable patients (79.5% female; mean age 50.8 y), 77.8% were favourable to teleconsultation and 33.4% had used it. Of 532 dermatologists, 40.4% practised teleconsultation (24.6% in vitiligo). Patients rated the SA-VES highest for ease of use (85.9%); dermatologists preferred VAS Severity (94.2%) and VAS Burden (96.0% vitiligo-adapted). The DLQI scored lowest for dermatologists (38.7% adaptedness). Fourteen discrepancies exceeded 20 pp — the largest for VAS Burden (Δ = +53.3 pp, dermatologists higher) and SA-VES ease of use (Δ = −43.2 pp, patients higher). PUSH-D (OR 1.017, p = 0.040) and BSA (OR 0.988, p = 0.003) were independently associated with teleconsultation use.

Conclusions
Results support a teleconsultation toolkit stratified by the initiating party. The SA-VES — patient-easy, physician-costly — should be completed at home pre-consultation; the treatment burden scale requires prior medical explanation. Higher PUSH-D scores predicted teleconsultation use,

suggesting stigmatised patients benefit most, while extensive disease (BSA) acts as a barrier. Proposed minimal toolkit: patient-initiated (SA-VES, VAS Severity); dermatologist-initiated (VIP/PUSH-D, treatment burden scale). Prospective validation and international replication are warranted.

EA CONGRESS
VIENNA
30 SEP - 3 OCT 2026

Abstract N°: 2715

Beyond depigmentation: Dual targeting of mitochondrial oxidative stress and chemokine-driven inflammation as a novel therapeutic avenue in vitiligo

Hanene BZIOUECHE[1], Joëlle Al Choboq*[2], Carine Mainzer[2], Meri K TULIC[1], Thierry Passeron[1, 3]

[1] Université Côte d'Azur, INSERM U1065 Team 12, Centre Méditerranéen de Médecine Moléculaire (C3M), Nice, France

[2] ISISPHARMA, R&D Department, Lyon, France

[3] Centre Hospitalier Universitaire de Nice, Université Côte d'Azur, Nice, France

Introduction

Vitiligo is an acquired chronic skin disorder characterized by a loss of melanocytes resulting in depigmented white patches. Recent studies show a link between skin dysbiosis, mitochondrial damage and immunity in vitiligo patients. More specifically, our previous work demonstrated a significant decrease in protective *Bifidobacterium* in vitiligo skin. In parallel, we have further established that mitochondrial oxidative stress in vitiligo melanocytes, through mitochondrial DNA release, triggers cytokine/chemokine production, ultimately triggering the destruction of epidermal melanocytes. These observations highlight the clinical importance of targeting these two pathways in the progression of the disease.

To further explore the clinical potential of these findings, we searched the literature for bioactive molecules known to target these pathological drivers, identifying sinapine for its potent antioxidant properties, and *Bifidobacterium longum* which is a commensal we have demonstrated to be depleted in lesional skin. Corresponding active ingredients (Act S and Act B respectively) containing these molecules were screened and their efficacy was evaluated on normal (NHK) and vitiligo-like (VHK) stimulated human keratinocytes.

Materials and Methods

To induce ROS overproduction, NHKs were challenged with H_2O_2 (100 µM) or menadione (400 µM). The proportion of ROS-positive cells was quantified by FACS (dihydrorhodamine staining) in the presence or absence of sinapine and Act S. A model mimicking vitiligo specific inflammation was reconstituted by stimulating NHKs with a TH1 cytokine cocktail (IFN-γ and TNF-α, 10 ng/mL). The expression of a key inflammatory mediator (CXCL10) was quantified at both protein and mRNA levels by ELISA and RT-qPCR in the presence or absence of *B. Longum* and Act B. This was further confirmed by western blot and visualized by immunofluorescence.

Results

Sinapine and Act S effectively reduced ROS overproduction in H_2O_2- and menadione-challenged NHKs. Interestingly, Act S demonstrated superior antioxidant potency at the mitochondrial level compared to sinapine in the menadione model (80% vs 37.7%, respectively), validating its biological relevance on this pathway. Similarly, *B. Longum* and Act B potently suppressed the expression of CXCL10, chemokine central to the recruitment of autoreactive $CD8^+$ T cells and melanocyte destruction, with *B. Longum* reducing protein levels by 65.0% and Act B by 63.1% respectively. On top of that, both achieved a consistent 1.38-fold decrease in CXCL10 mRNA expression, further validating their immunomodulatory efficacy.

Conclusions

These results demonstrate that both sinapine and *B. Longum*, as well as their respective active ingredients Act S and Act B, significantly mitigate the two primary drivers of vitiligo pathogenesis in NHKs: mitochondrial oxidative stress and pro-inflammatory signaling. By counteracting the intrinsic mitochondrial antioxidant deficiencies, sinapine and Act S potently reduce ROS-driven melanocyte stress. Simultaneously, *B. Longum* and Act B suppress a key vitiligo-associated inflammatory mediator, CXCL10, central to the recruitment of autoreactive $CD8^+$ T cells and melanocyte destruction, with significant inhibition at the protein stage and consistently supported by important fold-change decreases at the mRNA level.

Together these findings suggest that theses actives act as a dual-targeted strategy, simultaneously addressing the oxidative and inflammatory hallmarks of vitiligo offering a potential novel topical strategy to prevent disease progression.

EADV CONGRESS
VIENNA
30 SEP - 3 OCT 2026

Abstract N°: 2723

Partial repigmentation of vitiligo following excision of halo neavus

Rania Tounsi El Azouani*[1], Feriel Amri[1], Mariem Tabka[1], Donia Afli[1], Asmahene Souissi[1], Mourad Mokni[1]

[1] La Rabta hospital, Tunis, Tunisia

Introduction

Halo nevus is a benign melanocytic lesion characterized by a depigmented halo surrounding a melanocytic nevus. Its association with vitiligo is thought to result from an immune response against melanocytes. In rare cases, excision of the nevus has been associated with improvement of vitiligo lesions.

Case Presentation

A 59-year-old woman with a history of hypertension, rheumatism, and a surgically treated breast cyst presented to our dermatology department for evaluation of a nevus surrounded by depigmented skin, along with depigmented facial patches that had appeared over the previous nine months. According to the patient, the changes began with depigmentation of the nevus, followed by the gradual development of a depigmented halo surrounding the lesion. Several months later, additional depigmented patches appeared on the face. Physical examination revealed an intradermal nevus surrounded by a well-defined round depigmented halo, consistent with a halo nevus. Dermoscopic examination did not reveal a typical melanocytic pattern, likely due to the marked depigmentation of the lesion with absence of visible melanocytic structures. In addition, well-defined depigmented patches were noted in the perioral region, consistent with vitiligo. Topical corticosteroids, tacrolimus, and oral corticosteroid minipulse therapy were prescribed but the patient did not initiate the treatment. As the nevus was cosmetically bothersome for the patient, it was surgically excised. Following excision, partial repigmentation of the vitiligo lesions was observed

Conclusion

The exact pathogenesis of halo nevus and vitiligo remains incompletely understood, although both conditions are thought to share an autoimmune mechanism targeting melanocytes. Halo nevus is considered an immune-mediated phenomenon occurring in benign melanocytic lesions, in which nevus cells may trigger an immune response involving CD8+ cytotoxic T lymphocytes and chemokines such as CXCL10 and CXCR3 induced by interferon-γ. This hypothesis is supported by the presence of a dense lymphocytic infiltrate surrounding the nevus on histopathological examination. Excision of congenital melanocytic nevi is usually performed when lesions present atypical features, show clinical changes, or for cosmetic reasons .Only a few cases of halo melanocytic nevus excision followed by repigmentation of vitiligo have been reported. In our case, the association between halo nevus and vitiligo was observed, and excision of the nevus was followed by partial improvement of the vitiligo lesions. However, recurrence of vitiligo after initial repigmentation has been reported in the literature, suggesting that this autoimmune process may be more complex and not always controlled by removal of the suspected triggering lesion alone. Careful follow-up of our patient is therefore important.

Conclusion : This case suggests a possible link between halo nevus and vitiligo and that nevus excision may be helpful in selected cases. Further studies are needed to better understand this association and its role in preventing recurrence.

EA DV CONGRESS
VIENNA
30 SEP - 3 OCT 2026

Abstract N°: 2728

Imaging Optimization of underlying (or latent) solar lentigines in subjects with solar lentigines on the face

Margot Broallier[1], Caroline Descollonges[2], Margot Vasseur[3], Shermine Warde*[1], Irène Troin[4], Alan Tristao[4], Alix Danoy[5]

[1] La Roche-Posay Laboratoire Dermatologique, Levallois-Perret, France

[2] Complife France, Lyon, France

[3] Damae Medical, Paris, France

[4] L'Oréal Research and Innovation, Chevilly-Larue, France

[5] QIMA Life Sciences, QIMA Newtone SAS, Lyon, France

Introduction

Solar lentigo (SL) is characterized by hyperpigmented lesions occurring in photodamaged skin areas which increase in number and size upon chronological ageing. Solar lentigines are benign lesions but represent one of the most prevalent skin concerns associated with photoaging. Lesions can extend beyond what is visually detectable and though the exact concept of "dormant solar lentigo" as a defined clinical entity is not formally standardized, imaging and molecular studies confirm latent pigment clusters that likely represent early stages of lentigo formation. Since imaging can reveal pigment concentrations not always visible clinically, the objective of this study was to optimize an imaging protocol to enable the visualization of these underlying "dormant" lesions to allow further exploration.

Materials and Methods

15 subjects with solar lentigines in the face participate to this exploratory study. In order to create mapping of dormant spots several imaging technologies were evaluated. Including an imaging system (UVCam®) including both cross-polarized traditional color imaging and cross-polarized UV-A reflectance photography and an imaging system that allows fast and easy hyperspectral images to evaluate specifically melanin content (SpectraFace®). Visible spots were segmented from cross-polarized images, whereas total pigmentation spots were detected using UV-A reflectance photography. Comparison of the two segmentations revealed a set of "invisible" (dormant) spots present in UV-A images but not detectable in conventional images. With hyperspectral images total melanin content was visualized and segmentation between visible and "dormant" spots was effectuated by comparing RGB images with the melanin map. Image analysis to determine either ΔE76 (= color contrast) or grey contrast of spots versus adjacent skin was conducted in various modalities (CP, UV, RGB and melanin content) according to imaging system to differentiate visual spots from "dormant spots". Only isolated spots with $\Delta E76 < 2$ were retained as invisible spots. Finally, 3D skin image stacks were acquired using Line-Field Optical Coherence Tomography (LC-OCT) on identified lesions and adjacent areas at D8. This technique enables in vivo characterization of epidermal architecture-such as thickness and dermo-epidermal junction undulation alongside quantitative and spatial assessment of melanin distribution within the epidermis.

Results

All included volunteers presented dormant spots, regardless of their baseline Density of Pigmentary Spots grade. Both imaging techniques, UVCam and SpectraFace, where able to evidence visible pigmentated spots, however, UVCam images showed a better discrimination and contrast of these lesions (with

surrounding areas) compared with SpectraFace. Analysis of invisible spots confirmed low dE76 values, consistent with their non-visibility in color mode images, while UVCam enabled superior contrast detection under UV modality. LC-OCT analysis showed that a subset of dormant spots presents structural and melanin-related features similar to lentigo lesions, including a more undulated dermal–epidermal junction.

Conclusions

A mapping of “dormant” isolated spots on the face of patients with solar lentigines could open the door to further exploration of these latent lesions with targeting technologies like LC-OCT. With further characterization of subclinical pigmentary and architectural signatures, this approach could provide additional insights into early lesion development and progression, and may ultimately support the development of preventive therapeutic strategies.

EA DV CONGRESS
VIENNA
30 SEP - 3 OCT 2026

Abstract N°: 2731

Beyond tinted sunscreens: a novel invisible sunscreen with MCE filter and 2-MNG active provides equivalent protection against long UVA and HEVL-induced hyperpigmentation

Pascale Renoux*[1], Caroline Lefloch[1], Flament Frederic[2], Loredana Birca[3], Delphine Kerob[1], Francoise Bernerd[4], Ludivine Canchy[1], Henry W. Lim[5]

[1] La Roche-Posay Laboratoire Dermatologique, Levallois-Perret, France

[2] L'Oréal Research and Innovation, Chevilly-Larue, France

[3] Centre International de Développement Pharmaceutique (CIDP), Bucarest, Romania

[4] L'Oréal Research and Innovation, Aulnay-Sous-Bois, France

[5] Department of Dermatology, Henry Ford Health, Detroit, United States

Introduction

Long UVA (340–400 nm) and high-energy visible light (HEVL, 400–450 nm) are major contributors to skin hyperpigmentation, including in melasma. HEVL alone accounts for 47% of visible light-induced pigmentation and worsens UVA1-induced darkening. While tinted sunscreens containingiron oxides provide effective broad-spectrum visible light protection, compliance remainslimited due to skin tone matching constraints.

An invisible sunscreen combining methoxypropylamino cyclohexenylidene ethoxyethylcyanoacetate (MCE), a filter providing extended UVA coverage up to 400 nm, and 2-mercaptonicotinoyl glycine (2-MNG), a melanogenesis inhibitor trapping melanin precursors, was previously shown to prevent HEVL (400–450 nm)-induced hyperpigmentation equivalently to a tinted sunscreen. The present study extends this evaluation to the full long UVA+HEVL spectrum [340–450 nm]. The objective of the study was to compare the efficacy of a novel invisible sunscreen combining MCE and 2-MNG against a marketed anti-pigmentation sunscreen containing a tyrosinase inhibitor, astandard sunscreen with limited long UVA coverage, and 3 tinted sunscreen references containing MCE and iron oxides, in preventing long UVA+HEVL [340–450 nm]-induced pigmentation.

Materials and Methods

A monocenter, double-blind, randomized, comparative study was conducted with 31 healthy volunteers (ages 20–55, phototypes III–IV, ITA° 19–33°) in a single investigational center. Test zones on participants' backs were randomized to receive: the invisible sunscreen formula combining MCE and 2-MNG SPF50+ (Formula A); a marketed anti-pigmentation sunscreen SPF50+ containing a tyrosinase inhibitor (Formula B); a standard SPF50+ sunscreen with limited long UVA coverage (Formula C); and 3 tinted sunscreen SPF50+ formulas each containing MCE with variable amounts of iron oxides (corresponding to light, medium and dark shades) (Formulas D-F). Products were applied at 2 mg/cm² according to a product- and phase specific-application schedule. Volunteers underwent long UVA and HEVL exposure (340–450 nm: 60 J/cm² UVA1 + 50 J/cm² HEVL) for 4 consecutive days. Efficacy was evaluated through Delta E (primary criterion), ΔITA° andclinical pigmentation scoring at multiple timepoints throughout the study period.

Results

The invisible MCE+2-MNG sunscreen formula significantly outperformed both the marketed anti-

pigmentation sunscreen containinga tyrosinase inhibitor and the standard sunscreen with limited long UVA coverage. As observed by a significant difference from D11 for all parameters (delta E, delta ITA°, pigmentation score; $p<0.05$) when compared to formula B (anti-pigmentation sunscreen) and from D9 when compared against Formula C (standard sunscreen). No statistically significant difference was observed in favor of any of the tinted MCE+iron oxides formulas over the invisible MCE+2-MNG formula at any timepoint. No erythema and no adverse events related to the investigational products were recorded.

Conclusions

In a previous study, we demonstrated the protective efficacy of this novel invisible sunscreen combining the MCE filter and the biological active 2-MNG against HEVL-induced pigmentation, similar to a tinted sunscreen containing iron oxides. In the present double-blind study, we confirm these results and further show a protection (comparable to tinted sunscreens) against pigmentation induced by combined long UVA and HEVL exposure. This formula thus offers a tone-free alternative that overcomes compliance issues related to skin tone matching. Moreover, it significantly outperformed both a marketed anti-pigmentation SPF50+ sunscreen containing a tyrosinase inhibitor and a standard SPF50+ sunscreen with limited long UVA coverage, highlighting the potential of combining specific PINGs with a filtering system extending protection up to 400 nm to effectively prevent long UVA & HEVL-induced pigmentation.

EADV CONGRESS
VIENNA
30 SEP - 3 OCT 2026

Abstract N°: 2740

Blue-Black Macules on the Feet: An Occupational Clue to Localized Cutaneous Argyria in a Jewelry Worker

Zeynep Özdemir*[1], Esra Selin Kaya[1], Reyhan Yılmaz[1], Vildan Manav[1], Cem Leblebici[2], Ayşe Esra Koku Aksu[1]

[1] Istanbul Training and Research Hospital, Department of Dermatology and Venereology, Istanbul Training and Research Hospital, Department of Pathology, Istanbul, Türkiye
[2] Istanbul Training and Research Hospital, Department of Pathology, Istanbul, Türkiye

Introduction

Localized cutaneous argyria usually develops at sites of repeated contact with silver-containing materials and may clinically mimic melanocytic or vascular lesions. We report an occupational case of localized cutaneous argyria limited to the dorsal feet and toes.

Case Presentation

A 33-year-old male jewelry worker presented with a one-year history of asymptomatic dark blue-black macules on both feet. Dermatological examination revealed 10–12 flat, well-defined macules measuring 1–3 mm on the dorsum of the feet and toes, with slight extension below the medial malleoli. Lesions were non-palpable, non-blanchable, and showed no erythema, scaling, or ulceration.

The lesion exhibits a predominantly homogeneous and structureless dermoscopic pattern with central gray-brown pigmentation fading into peripheral yellow-brown to honey-colored areas, in the absence of pigment network, vascular structures, steel-blue pigmentation, clustered globules, annular configuration, or perifollicular sparing.

The patient had longstanding occupational exposure to silver and denied trauma, medication use, or topical silver application. The unique localization on the feet was attributed to his habit of working in open slippers, which led to chronic contact with silver dust accumulating on the skin and footwear.

Laboratory findings were normal, systemic and ophthalmologic examinations were unremarkable.

A punch biopsy from the left fourth toe was performed. Histopathology demonstrated characteristic yellow-brown granular deposits along adnexal and vascular basement membranes, while stains for melanin, iron, and amyloid were negative.

Discussion

Occupational exposure to metallic silver is a recognized cause of localized argyria. Silver deposition typically occurs along basement membranes of adnexal and vascular structures and represents an important histopathologic clue.

The differential diagnosis crucially includes melanoma, blue nevus, ochronosis, and hemosiderin pigmentation. The absence of melanin and iron on special stains, together with the characteristic dermal deposits, helps distinguish argyria from these entities. Careful occupational history is essential to prevent misdiagnosis as malignant melanocytic or vascular lesions. Importantly, both systemic and ocular examinations were unremarkable, reinforcing the diagnosis of a localized occupational form.

Conclusion

Occupational localized argyria should be considered in the differential diagnosis of acral blue-black macules, particularly when dermoscopic findings are non-melanocytic and histopathology demonstrates characteristic basement membrane silver deposition.

References

1. McClain CM, et al. Localized Cutaneous Argyria: Two Case Reports and Clinicopathologic Review. Am J Dermatopathol. 2013;35(7):e115–e118.
2. Mota L, Dinis-Oliveira RJ. Clinical and Forensic Aspects of the Different Subtypes of Argyria. J Clin Med. 2021;10(10):2086.
3. Georgiadou N, et al. Occupational Localized Cutaneous Argyria with Pseudo-ochronosis. Am J Dermatopathol. 2021;43(11):822–826.

EA DV CONGRESS
VIENNA
30 SEP - 3 OCT 2026

Abstract N°: 2758

Upadacitinib Suppresses Inflammatory Pathways and Enhances Melanocyte-Associated Biomarker c-Kit in Non-Segmental Vitiligo: Phase 3 Biomarker Analysis

Anand K Ganesan[1], Jessica Shiu[1], Patrick Brunner[2], Mehdi Rashighi[3], Reinhart Speeckaert*[4], Rethavathi Janarthanam[5], Stavonnie Patterson[5], Sylvester Uwumarogie[5], Sara Murdock[5]

[1] Department of Dermatology, University of California, Irvine, California, United States
[2] Department of Dermatology, Icahn School of Medicine at Mount Sinai, New York, New York, United States
[3] Department of Dermatology, UMass Chan Medical School, Worcester, Massachusetts, United States
[4] Department of Dermatology, Ghent University Hospital, Ghent, Belgium
[5] AbbVie Inc., Chicago, Illinois, United States

Introduction
Upadacitinib (oral, once-daily, reversible JAK inhibitor) was evaluated for treating non-segmental vitiligo (NSV) in two replicate phase 3 studies (Viti-Up; NCT06118411). In both studies, greater proportions of patients receiving upadacitinib 15 mg vs placebo achieved the co-primary endpoints of T-VASI 50 and F-VASI 75 at week 48. As reductions in inflammation may facilitate restoration of melanocyte function and subsequent repigmentation, we evaluated changes in serum biomarkers associated with inflammatory activity (CXCL10) and melanocyte pathways (c-Kit) and their correlation to clinical efficacy.

Materials and Methods
Optional serum samples were collected during the 48-week placebo-controlled period. Disease relevant biomarkers, CXCL10 and c-Kit, were analyzed using ELISA. Additional soluble inflammatory protein mediators were analyzed using an Olink panel to assess modulation of pathways implicated in melanocyte destruction.

Results
At baseline, patients exhibited elevated serum CXCL10 levels and reduced c-Kit levels vs healthy controls, with no significant differences between those with active or stable disease (**Figure 1A-B**). Treatment with upadacitinib resulted in rapid and sustained reductions in CXCL10 and increases in c-Kit, while placebo showed minimal changes (**Figure 1C-D**). At baseline, CXCL10 levels did not correlate with T-VASI (R=0.096; P=0.06). By week 48, the correlation increased minimally (R=0.13; P=0.028), remaining weak overall. In contrast, c-Kit levels demonstrated mild negative correlations with T-VASI at baseline (R=−0.23; P<0.0001) and at week 48 (R=−0.25; P<0.001). Moreover, upadacitinib inhibited multiple inflammatory pathways (NK cells and cytotoxic T-cells) implicated in immune-mediated melanocyte destruction.

Figure 1. Serum CXCL10 and c-Kit Dysregulation at Baseline and Longitudinal Modulation With UPA in Patients With NSV

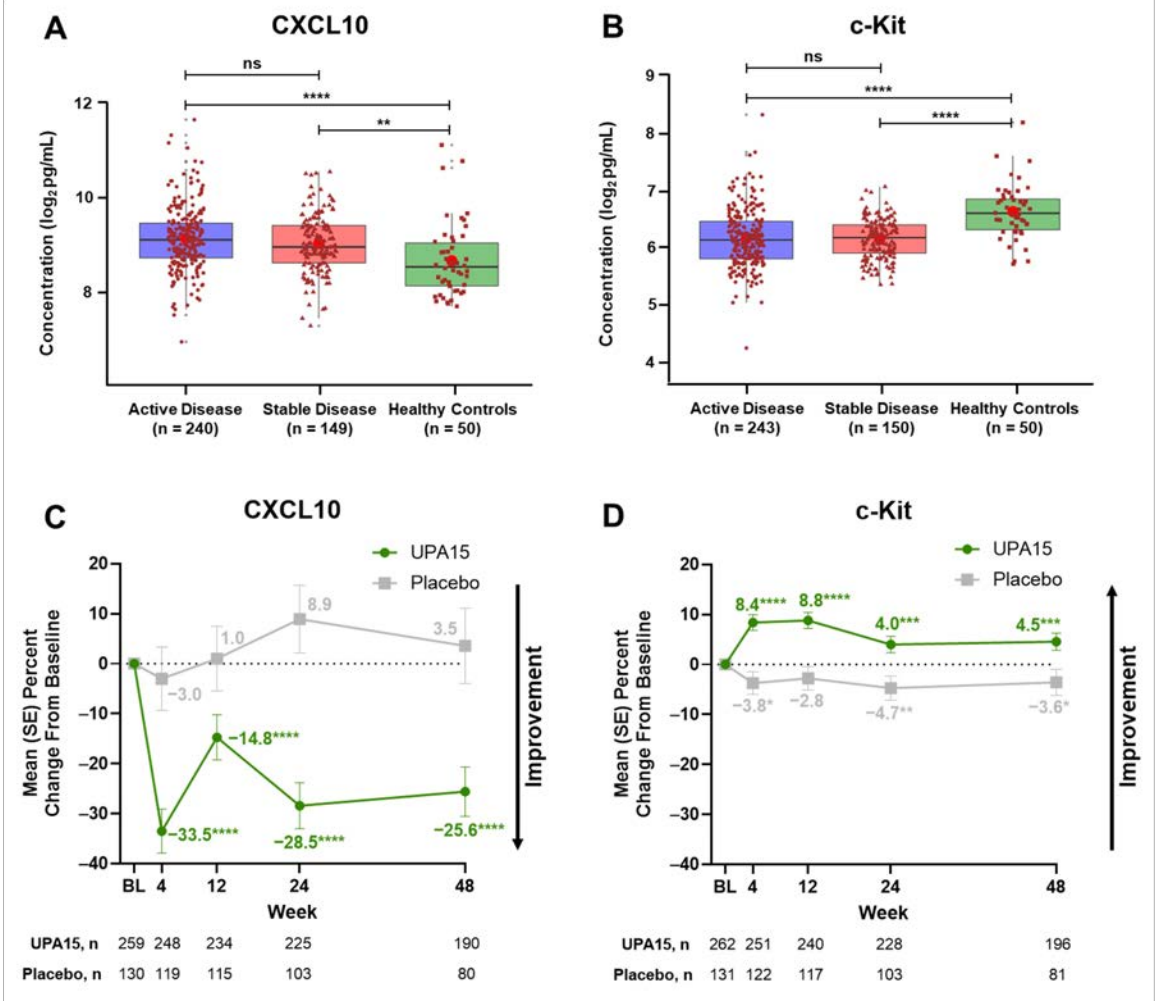

ANOVA, analysis of variance; BL, baseline; ns, not significant; NSV, non-segmental vitiligo; UPA15, upadacitinib 15 mg. Patients were classified as having actively progressing vitiligo at baseline if they had one of the following: new lesions or the progression (enlargement) of existing lesions within 6 months before baseline, or the presence of at least 1 lesion of confetti-like depigmentation, trichrome pattern, and/or Koebner phenomenon type 2B. *P<0.05; **P<0.01; ***P<0.001; ****P<0.0001 vs baseline (based on one-way ANOVA).

Conclusions

CXCL10 and c-Kit were dysregulated in vitiligo regardless of disease activity. Upadacitinib normalized CXCL10 and increased c-Kit toward healthy levels, demonstrating effects on inflammatory and melanocyte pathways. Circulating melanocyte-associated biomarkers such as c-Kit may quantitatively reflect skin pigmentation, though c-Kit is also expressed by other cell types (eg, hematopoietic cells). Collectively, findings suggest that upadacitinib improves vitiligo by mediating systemic inflammatory and melanocyte-related pathways associated with disease pathology.

EA DV CONGRESS
VIENNA
30 SEP - 3 OCT 2026

Abstract N°: 2766

Development of a scale to measure the psychosocial impact of vitiligo in children

Saransh Verma*[1], Shrruthi Velavan[1], Vishal Gupta[1], Sujata Satapathy[2], Neetu Bhari[1], M Ramam[1]

[1] Department of Dermatology and Venereology, All India Institute of Medical Sciences New Delhi, New Delhi, India
[2] Department of Psychiatry, All India Institute of Medical Sciences, New Delhi, India

Introduction

Vitiligo is an acquired pigmentary disorder, caused by the destruction of melanocytes in the epidermis leading to the development of depigmented patches on the skin.

Fifty percent of patients develop vitiligo before the age of 20 years and a quarter of patients before the age of 10 years.

Generic and dermatology-specific scales may underestimate the psychosocial burden of vitiligo as they lack domains commonly affected in vitiligo (e.g., marriage prospects and dietary restrictions) and may include items such as physical symptoms (itching and burning) that are not relevant. Additionally, it is increasingly recognized that children and parents may not share similar views regarding the impact of their illness. Currently, no vitiligo-specific scales are available for use in children and adolescents.

Materials and Methods

The scale for assessing the impact of vitiligo on children was developed in the following phases: item generation, draft scale development and content validity, pre-testing, pilot testing and psychometric evaluation. Semi-structured interviews with thirty children aged 8 – 15 years who were able to communicate their thoughts and feelings. Interviews were transcribed verbatim, and content analysis was performed to generate codes, sub-themes and themes. A draft scale was then prepared based on the verbatim statements, which was reviewed and refined by three dermatologists and a clinical psychologist to ensure content validity. The preliminary scale was administered to 15 patients. Based on their feedback and expert evaluation a pilot scale was developed. The pilot scale was subsequently administered to a separate group of patients and following statistical analysis and expert review the final Childhood – Vitiligo Impact Scale (C-VIS) was prepared. For psychometric evaluation C-VIS, global question (GQ) (assessing patient's perception of their disease on a five point Likert scale), Children's Dermatology Life Quality Index (CDLQI) were administered to 51 patients. Baseline demographic and clinical details were also collected.

Results

Thirty semi-structured interviews with a mean duration of 4 minutes and 26 seconds, were transcribed verbatim and after content analysis 61 codes grouped under 12 sub-themes and 8 broad themes were generated. A draft scale containing 64 items based on the verbatim statements from the interviews was prepared which was further refined by three dermatologists and a clinical psychologist based on their expert evaluation resulting in a 52-item preliminary scale. The preliminary scale was administered to 15 patients to assess comprehension and obtain feedback. Based on patient feedback regarding the preliminary scale items and the evaluation of the scale items by two subject matter experts on clinical relevance, appropriateness, and language a pilot scale containing 18 items was developed. Pilot scale was then administered to 25 patients. Preliminary statistical analysis

demonstrated good internal consistency (Cronbach's alpha = 0.853) and reliability, most inter-item correlations were within the acceptable range (0.15–0.45). Based on these findings and the expert opinion of three dermatologists and a clinical psychologist appropriate changes were made and a final scale with 17 items, with responses assessed on a 4-point Likert scale was finalized. Psychometric evaluation in 51 patients demonstrated strong criterion validity, with a high correlation with patient-perceived severity (GQ) ($r = 0.843$, $p < 0.001$), and strong convergent validity with a high correlation with the Children's Dermatology Life Quality Index (CDLQI) ($r = 0.8298$, $P < 0.001$). Known-groups validity was demonstrated by higher scores in individuals with increasing body surface area of involvement ($p = 0.0602$).

Children – Vitiligo Impact Scale (English)

This questionnaire is meant to measure the effect of vitiligo on your life. Please read every question carefully and answer them according to the best of your understanding.

0 – Not at all 1 – A little 2 – A lot 3 – Very Much

		0	1	2	3
		Not at all	A little	A lot	Very much
1.	My white patches make me feel sad.				
2.	I feel upset when people ask me about my white patches or make comments about them.				
3.	I feel scared that my white patches will get worse.				
4.	I worry that people will avoid me because of my white patches.				
5.	I feel I look different from other children because of my white patches.				
6.	I feel bad when children at school ask me about my white patches.				
7.	Some children don't want to play with me because of my white patches.				
8.	I hesitate to go outside because of my white patches.				
9.	I feel bad that I am asked to avoid some foods because of my white patches.				
10.	I can't wear the clothes I like because the white patches will be visible.				
11.	I can't focus on studies because of my white patches.				
12.	Children don't want to sit with me because of my white patches.				
13.	Children tease me about my white patches.				
14.	I find it hard to make new friends because of my white patches.				
15.	I feel bad when my parents comment about my white patches.				
16.	I feel sad because my parents worry about my white patches.				
17.	I keep looking at my white patches in the mirror				

Children - Vitiligo Impact Scale (C-VIS), containing 17 items with responses assessed on a 4 point likert

scale.

Conclusions

Vitiligo has a significant psychosocial burden in children which is different than in adults. C-VIS is a novel vitiligo-specific quality-of-life (QoL) instrument developed and validated for use in children between the ages of 8 to 15 years.

EA DV CONGRESS
VIENNA
30 SEP - 3 OCT 2026

Abstract N°: 2790

Low-Grade Palatal Mucoepidermoid Carcinoma Occurring in a Patient With Lichen Planus Pigmentosus: A Rare Association

Houda Zouaki*[1], Soumiya Chiheb[1]

[1] Chu Ibn Rochd, Casablanca, Morocco

Introduction

Lichen planus pigmentosus (LPP) is an uncommon variant of lichen planus characterized by acquired hyperpigmented macules involving predominantly photoexposed areas and flexural regions. Mucosal involvement is uncommon, and its malignant potential remains poorly understood. In contrast to oral lichen planus, which is recognized as a potentially malignant disorder, the association between LPP and oral neoplasms has rarely been reported.

Case Presentation

We report the case of a 60-year-old woman followed in our dermatology department for histologically confirmed lichen planus pigmentosus. The disease had evolved for two years, initially presenting with non-pruritic erythematous papular lesions of the face, followed by progressive grayish-brown facial hyperpigmentation extending to the neck. Dermatological examination revealed shiny gray-brown pigmented lesions involving the forehead, temples, chin, and perioral region, associated with frontal fibrosing alopecia and partial eyebrow alopecia. Oral examination showed diffuse buccal mucosal hyperpigmentation.

Skin biopsy demonstrated epidermal atrophy with a lichenoid lymphoplasmacytic infiltrate associated with numerous melanophages, compatible with lichen planus pigmentosus, without signs of malignancy.

One year later, the patient developed a painless, well-limited palatal mass evolving for four months. Histopathological examination of the excised lesion revealed a low-grade mucoepidermoid carcinoma measuring 1.8 cm with healthy surgical margins, without vascular emboli or perineural invasion.

Mucoepidermoid carcinoma is the most common malignant salivary gland tumor of the oral cavity, most frequently involving the palate. Although oral lichen planus has recognized malignant potential, the relationship between lichen planus pigmentosus and oral carcinogenesis remains unclear because mucosal involvement in LPP is uncommon and rarely described. Chronic inflammation and persistent immune-mediated epithelial damage may represent possible contributing mechanisms. However, the coexistence of LPP and palatal mucoepidermoid carcinoma may also be incidental.



lichen planus pigmentosus on the face

Conclusion

This observation highlights a rare association between lichen planus pigmentosus and palatal mucoepidermoid carcinoma. Careful oral examination and long-term surveillance may be of interest in patients presenting with mucosal involvement associated with lichenoid disorders.

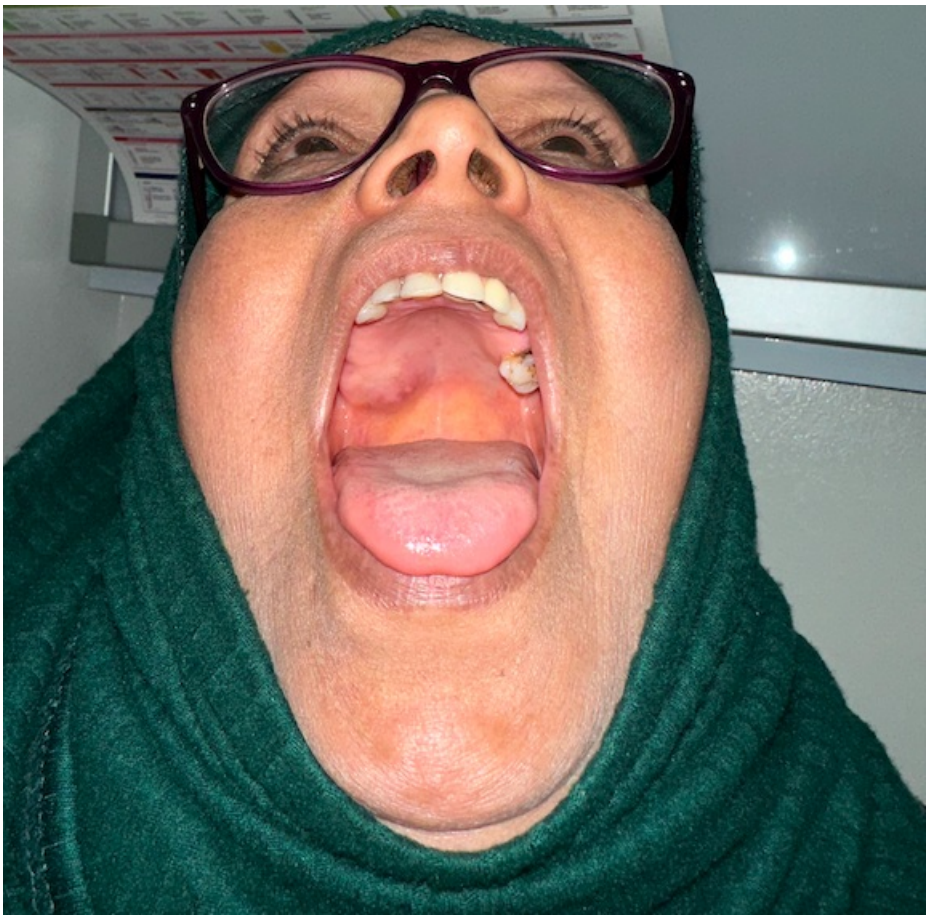

well-limited painless palatal mass

EA DV CONGRESS
VIENNA
30 SEP - 3 OCT 2026

Abstract N°: 2798

Expert Consensus on the Management of Hyperpigmentation Disorders in India: A Modified Delphi Study by the Pigmentary Disorders Society

Rashmi Sarkar*[1], Seema Nair[2], Nathalie Gemayel[3], Natalio Chelala[3], Anupam Das[4], Bhavesh Swarnakar[5], B S Chandrashekar[6], Hitaishi Mehta[7], Indrashis Podder[8], Madhuri Agarwal[9], Muthu Sendhil Kumaran[10], Sonali Langar[11], Surabhi Sinha[12], Sunil Dogra[13], Vinay Keshava Murthy[10], Seemal R Desai[14]

[1] Lady Hardinge Medical College & Associated SSK and KSC Hospitals, New Delhi, India
[2] Beiersdorf Mumbai, Mumbai, India
[3] Beiersdorf Dubai, Dubai, United Arab Emirates
[4] KPC Medical College and Hospital, Kolkata, India
[5] Swarnkar Superspeciality center, Indore, India
[6] CUTIS Academy of Cutaneous Sciences, Bangalore, India
[7] Post Graduate Institute of Medical Education and Research, Chandigarh, India
[8] College of Medicine and Sagore Dutta Hospital, Kolkata, India
[9] Yavana Skin & Hair Ckinic, Mumbai, India
[10] Postgraduate Institute of Medical Education and Research (PGIMER), Chandigarh, India
[11] Skin remedies clinic and laser center, Noida, India
[12] Lady Hardinge Medical College & associated hospitals, New Delhi, India
[13] Postgraduate Institute of Medical Education & Research (PGIMER), Chandigarh, India
[14] University of Texas Southwestern Medical Center, Dallas. Innovative Dermatology, Plano., Texas, United States

Introduction

Hyperpigmentation disorders are prevalent in the skin of colour and carry a substantial psychosocial burden. They are often difficult to manage because of diagnostic overlap, chronicity, recurrence, and limited evidence. Most available guidance is extrapolated from lighter skin phototypes, underscoring the need for practical, context-specific recommendations for Indian patients. To develop evidence-informed consensus recommendations for the diagnosis and management of common hyperpigmentation disorders encountered in Indian dermatology practice

Materials and Methods

A modified Delphi consensus was conducted between August 2025 and January 2026. Thirteen dermatologists with expertise in pigmentary disorders participated; a Chair and an independent international expert ensured scientific rigour without voting. After an exploratory round, four priority conditions were selected: melasma, acquired dermal macular hyperpigmentation (ADMH), post-inflammatory hyperpigmentation (PIH), and periorbital hyperpigmentation (POH). A targeted literature review of the previous 10 years informed statement development, and evidence was graded using the Oxford Centre for Evidence-Based Medicine framework. Two rounds of anonymous online voting using a 5-point Likert scale were undertaken, with an intervening virtual discussion. Consensus thresholds were predefined as high (≥75%), moderate (55%–74%), and low (<55%).

Results

In Round 1, 34 statements across five sections were evaluated: 21 achieved high consensus, 9 moderate consensus, and 4 low consensus. Following the discussion, 8 statements were revised, 2 retained, 3 removed, and 1 added; 11 statements were revoted in Round 2, yielding 32 final high-consensus statements. This consensus provides integrated guidance across four major facial hyperpigmentation disorders (Figure 1). Emphasis was placed on accurate diagnosis and subtype identification across all four disorders, as correct classification of type/phenotype and underlying drivers was considered essential to guide appropriate, individualised management. The consensus also prioritised proactive prevention, relapse minimisation, and photoprotection in Fitzpatrick skin types III–VI, and supported multimodal therapy targeting melanogenesis, inflammation, and triggers while balancing efficacy with safety in darker phototypes. Non-hydroquinone strategies, such as arbutin, azelaic acid, kojic acid, and isobutylamido thiazolyl resorcinol, for hyperpigmentation were also highlighted.

Condition-specific recommendations included topical, oral, and procedural options for melasma management and non-hydroquinone or intermittent regimens for maintenance; recognition of ADMH as a distinct diagnostic group supported by dermoscopy/histopathology, with patch testing when pigmented contact dermatitis is suspected and options such as tacrolimus, low-dose isotretinoin, mycophenolate mofetil, selected peels, and cautious laser use; preprocedural priming and combination topical/laser approaches for PIH; and classification-driven management of POH using dermoscopy and eyelid stretch testing, favouring pigment-targeted topicals, adjunctive peels, and cautious Q-switched Neodymium-doped Yttrium Aluminum Garnet (Nd:YAG) laser use.

Conclusions

This modified Delphi consensus delivers practice-oriented recommendations for the diagnosis and management of melasma, ADMH, PIH, and POH, with relevance to Indian settings and in regions with comparable patient profiles and therapeutic challenges. Its distinguishing strengths are its multimodal, prevention-focused framework; explicit attention to subtype-based diagnosis, recurrence, safety, and diagnostic overlap; and integration of conventional and emerging therapies into clinically applicable pathways. These recommendations may help standardise care while identifying areas requiring stronger regional evidence.

EA DV CONGRESS
VIENNA
30 SEP - 3 OCT 2026

Abstract N°: 2806

Topical Therapy Alone and as a Continuous Perioperative Adjunct to Non-Ablative Fractional Laser in Facial Melasma: Dual Randomized Controlled Trials in Fitzpatrick IV-V Phototypes

Mukta Sachdev*[1], Seema Nair[2], Nathalie Gemayel[3]

[1] MEDICAL DIRECTOR- MS CLINICAL RESEARCH PVT LTD, HOD & CONSULTANT: DERMATOLOGY- MANIPAL HOSPITAL, BANGALORE, INDIA, Bangalore, India

[2] Beiersdorf Mumbai, Mumbai, India

[3] Beiersdorf Dubai, Dubai, United Arab Emirates

Introduction

Melasma management in skin of color remains a major challenge in pigmentary dermatology. Conventional depigmenting agents such as hydroquinone, kojic acid, and azelaic acid have important limitations in darker phototypes, including post-inflammatory hyperpigmentation risk, cumulative toxicity, restricted duration of use, and mandatory washout periods before procedures. Thiamidol (isobutylamido thiazolyl resorcinol), a human-specific tyrosinase inhibitor developed through rational drug design, provides potent, reversible inhibition at low concentrations. Although globally validated and included as a first-line option in the 2025 JEADV Global Consensus on Hyperpigmentation, clinical data in Indian Fitzpatrick IV–V skin (characterized by higher relapse and post-procedural hyperpigmentation risk) remain limited.

To assess the efficacy and safety of a Thiamidol-containing regimen versus photoprotection alone as monotherapy, and to determine whether continuous peri-procedural use enhances outcomes of non-ablative fractional laser without compromising tolerability in Fitzpatrick III–V phototypes.

Materials and Methods

Two prospective, randomized, investigator-blinded, parallel-group controlled trials were conducted over 12 weeks in Indian subjects aged 20–50 years with mild-to-moderate facial melasma (total n=180; 90 per trial). The monotherapy trial compared a twice-daily topical regimen with SPF versus SPF alone. The laser-adjunct trial compared the same regimen plus two sessions of non-ablative fractional Er:Glass laser (Weeks 2 and 6) versus laser with photoprotection only; topical therapy was continued uninterrupted throughout the peri-procedural period. Primary endpoints were modified Melasma Area and Severity Index (mMASI) and Investigator Global Assessment (IGA). Secondary endpoints included MelasQol scores, instrumental assessments, and tolerability.

Results

Both trials demonstrated statistically significant superiority of the topical regimen over controls from Week 2 onward ($p<0.05$). In the monotherapy trial, mMASI reduction reached 71.9% versus 54.1% in controls ($p=0.0035$), and IGA improvement was 59.1% versus 37.6% ($p=0.0001$) at Week 12. In the laser-adjunct trial, combined therapy achieved 83.2% mMASI and 63.6% IGA reductions, compared with 69.2% and 44.1% in laser-only controls ($p=0.0339$ and $p<0.0001$). Despite higher baseline severity in the laser-adjunct trial, final absolute mMASI values were comparable across active treatment arms (~1.5). Significant improvements in MelasQol were observed. No treatment-related adverse events or post-inflammatory hyperpigmentation occurred, and tolerability was rated excellent by all participants.

Conclusions

These dual randomized trials demonstrate that this targeted topical regimen with Thiamidol is a safe and highly effective option for Indian Fitzpatrick IV–V skin. It significantly outperforms photoprotection as monotherapy and, when used continuously as a peri-procedural adjunct, enhances laser efficacy without increasing risk. The findings support its role as a first-line and perioperative standard of care for melasma in skin of color.

EA DV CONGRESS
VIENNA
30 SEP - 3 OCT 2026

Abstract N°: 2815

Efficacy of Upadacitinib in Adults and Adolescents for Treatment of Nonsegmental Vitiligo in Six Body Regions Across 48 Weeks of Treatment from Two Phase 3 Studies (Viti-Up)

Vimal H. Prajapati*[1, 2, 3, 4, 5], Thierry Passeron[6, 7], Irina Turchin[8, 9, 10], Victoria Farley[11, 12], Nada Elbuluk[13], Markus Boehm[14], Harvey Lui[15, 16], Stephanie Hays[17], Xiaoqiang Wu[17], Xiaofei Hu[17], Henrique Teixeira[17], Bethanee J Schlosser[17], Stavonnie Patterson[17], Iltefat Hamzavi[18]

[1] Division of Dermatology, Department of Medicine, University of Calgary, Calgary, Alberta, Canada
[2] Section of Community Pediatrics, Department of Pediatrics, University of Calgary, Calgary, Alberta, Canada
[3] Skin Health & Wellness Centre, Calgary, Alberta, Canada
[4] Dermatology Research Institute, Calgary, Alberta, Canada
[5] Probity Medical Research, Calgary, Alberta, Canada
[6] Department of Dermatology, Centre Hospitalier Universitaire de Nice, Côte d'Azur University, Nice, France
[7] INSERM U1065, Centre Méditerranéen de Médecine Moléculaire (C3M), Côte d'Azur University, Nice, France
[8] Brunswick Dermatology Centre, Fredericton, New Brunswick, Canada
[9] Department of Medicine, Dalhousie University, Halifax, Nova Scotia, Canada
[10] Probity Medical Research, Waterloo, Ontario, Canada
[11] Vivida Dermatology, Las Vegas, Nevada, United States
[12] Clinical Assistant Professor, Kirk Kerkorian UNLV School of Medicine, Las Vegas, Nevada, United States
[13] University of Southern California, Keck School of Medicine, Los Angeles, CA, United States
[14] University of Münster, Münster, Germany
[15] Department of Dermatology and Skin Science, University of British Columbia, Vancouver, British Columbia, Canada
[16] Vancouver Coastal Health Research Institute, Vancouver, British Columbia, Canada
[17] AbbVie Inc., Chicago, Illinois, United States
[18] Henry Ford Health, Detroit, MI, United States

Introduction

Nonsegmental vitiligo (NSV) is an autoimmune inflammatory disease that results in depigmentation of the skin due to a loss of melanocytes. Vitiligo can affect any body area and commonly involves the face and distal extremities. Involvement of face, hands, and genitals is associated with a higher psychosocial burden.(1) It is important that vitiligo therapies address repigmentation of all affected body regions. Upadacitinib (UPA), a selective once-daily Janus kinase inhibitor, has demonstrated efficacy for the treatment of NSV across 48 weeks in two identical phase 3 studies (Viti-Up) with no new safety signals reported. The current post-hoc analysis assessed the responses of patients with NSV to UPA 15 mg (UPA15) vs placebo across six anatomical regions (head/neck, upper extremities [excluding hands], hands, trunk/genitalia, lower extremities [excluding feet], and feet) based on achievement of at least 50% reduction in regional Vitiligo Area Scoring Index (VASI 50) from baseline in the Viti-Up studies.

Materials and Methods

Analyses were mutually exclusive to each region and were conducted using non-responder imputation; only patients with non-zero baseline regional VASI were included.

Results

At week 48, numerically (nominal $P \leq 0.001$) greater proportions of patients receiving UPA15 vs placebo achieved VASI 50 in the head/neck (43.3% vs 13.9%), upper extremities (27.6% vs 7.5%), hands (24.6% vs 7.3%), trunk/genitalia (23.5% vs 8.6%), lower extremities (22.4% vs 9.1%), and feet (12.7% vs 3.9%; Table 1). Treatment with UPA15 resulted in greater repigmentation vs placebo across all anatomic regions based on measures of VASI, with the greatest rate of VASI 50 clinical response seen in the head/neck region.

Table 1. Proportion of patients achieving VASI 50 in each body region at week 48 (ITT_A; NRI)

% (95% CI), n/N	Placebo	UPA15	P value
Head and neck	13.9 (9.1, 18.7) 28/201	43.3 (38.5, 48.1) 178/411	<0.001***
Upper extremities (excluding hands)	7.5 (3.8, 11.2) 15/200	27.6 (23.2, 32.0) 111/402	<0.001***
Hands	7.3 (3.6, 11.0) 14/192	24.6 (20.4, 28.9) 98/398	<0.001***
Trunk/genitalia	8.6 (4.7, 12.5) 17/198	23.5 (19.3, 27.7) 94/400	<0.001***
Lower extremities (excluding feet)	9.1 (5.1, 13.1) 18/198	22.4 (18.3, 26.5) 88/393	<0.001***
Feet	3.9 (1.1, 6.7) 7/181	12.7 (9.3, 16.1) 46/363	<0.001***

ITT_A, intent-to-treat population period A; NRI, non-responder imputation; UPA15, upadacitinib 15 mg. ***P ≤ 0.001. Analysis includes only patients with non-zero baseline regional VASI; all p-values are nominal.

Conclusions

The results of the current post-hoc analysis indicate UPA provides notable repigmentation (2) for adults and adolescents with NSV in all body regions, including those areas that are most commonly involved, socially critical, and/or therapeutically challenging, such as the face, hands, and feet.

EADV CONGRESS
VIENNA
30 SEP - 3 OCT 2026

Abstract N°: 2840

Radiotherapy-Induced Generalized Vitiligo Associated with Thymoma

Ekin Tosyalı*[1], Sidar İlik[1], Ümmühan Şeker[1], Ferdi Öztürk[1], Hayriye Saricaoglu[1]

[1] ULUDAĞ UNIVERSITY DERMATOLOGY AND VENEREOLOGY DEPARTMENT, BURSA, Türkiye

Introduction

Vitiligo is an acquired depigmenting disorder characterized by autoimmune destruction of melanocytes. Radiotherapy-induced vitiligo is a rare entity that is typically confined to irradiated skin; however, generalized involvement has rarely been reported. Proposed mechanisms include oxidative stress, Koebner phenomenon, and radiation-induced activation of melanocyte-directed autoimmunity. Thymoma-associated immune dysregulation may further predispose susceptible individuals to autoimmune cutaneous manifestations.

Case Presentation

A 65-year-old man with a history of hypertension and autoimmune hemolytic anemia underwent thoracoabdominal computed tomography in 2023, which revealed an anterior mediastinal mass consistent with thymoma. Following surgical excision, histopathologic examination demonstrated B2/B3 thymoma. Adjuvant mediastinal radiotherapy consisting of 25 fractions was subsequently administered.

Approximate 10 months after completion of radiotherapy, progressive depigmented macules and patches developed on the scalp, trunk, bilateral upper extremities, and right foot. Dermatologic examination demonstrated well-demarcated widespread depigmentation, with marked accentuation under Wood’s lamp examination. The patient had no personal or family history of vitiligo.

Given the widespread distribution and atypical presentation of the lesions, differential diagnoses included vitiligo, hypopigmented mycosis fungoides, postinflammatory hypopigmentation, and pityriasis versicolor. Three punch biopsy specimens were obtained from the scalp, trunk, and forearm. Histopathologic examination of all biopsy specimens confirmed the diagnosis of vitiligo. MART-1 immunohistochemistry and Masson–Fontana staining demonstrated complete loss of melanocytes and epidermal pigment.

Treatment with topical tacrolimus, topical corticosteroids, and narrowband ultraviolet B phototherapy was initiated.No progression were observed during one year of follow-up but treatment was also ineffective.

Conclusion

Radiotherapy-induced vitiligo is an uncommon adverse effect that is generally limited to irradiated skin; however, generalized involvement has rarely been reported. Most published cases have been associated with breast carcinoma, whereas thymoma-associated generalized vitiligo remains exceedingly rare. In the present case, thymoma-related immune dysregulation and concomitant autoimmune disease may have contributed to radiation-induced melanocyte destruction and subsequent generalized depigmentation. This case emphasizes the potential role of radiotherapy as a trigger for generalized vitiligo in immunologically predisposed individuals and highlights the importance of histopathologic evaluation in patients presenting with extensive or clinically atypical

acquired depigmentation.

EADV CONGRESS
VIENNA
30 SEP - 3 OCT 2026

Abstract N°: 2845

AI-driven Automatic Vitiligo Area Scoring Index (AVASI) for objective severity assessment

Alfonso Medela*[1], Daniel Dagnino[1], Taig Mac Carthy[2], Gerardo Fernandez[2], Andy Aguilar[2], Antonio Martorell[3], Yolanda Gilaberte[4]

[1] Medical Data Science - Legit.Health, Bilbao, Spain
[2] Clinical Endpoint Innovation - Legit.Health, Bilbao, Spain
[3] Manises Hospital, Manises, Spain
[4] Hospital Universitario Miguel Servet, Zaragoza, Spain

Introduction
Vitiligo is a chronic depigmenting disorder affecting approximately 0.4–2% of the global population. Despite its clinical visibility, standardized severity assessment remains challenging due to interobserver variability in estimating the extent of depigmentation. The Vitiligo Area Scoring Index (VASI) is the most widely used tool; however, it relies on manual evaluation, limiting reproducibility and consistency in both clinical practice and research.

Materials and Methods
We developed AVASI (Automatic Vitiligo Area Scoring Index), an artificial intelligence-based system combining deep learning–based lesion segmentation with pose-aware body mapping to automatically compute regional and total VASI scores from standardized clinical photographs. Multiple encoder backbones within a Feature Pyramid Network architecture were evaluated and benchmarked. Model performance was assessed using Intersection over Union (IoU) and F1-score. Human annotator consensus was used as a reference standard.

Results
The best-performing model (EfficientNet-B4) achieved an IoU of 0.59 ± 0.04 and an F1-score of 0.71 ± 0.03. Human annotators achieved an IoU of 0.67 ± 0.02 and an F1-score of 0.78 ± 0.02. Overall, the system demonstrated segmentation performance approaching expert-level agreement.

Conclusions
AVASI enables a reproducible and objective approach for vitiligo severity assessment by automating lesion segmentation and VASI score computation. The system demonstrates performance close to human agreement, supporting its potential to reduce interobserver variability, standardize evaluation, and enhance both clinical practice and research in vitiligo.

EA DV CONGRESS
VIENNA
30 SEP - 3 OCT 2026

Abstract N°: 2959

Effectiveness of the combination of Q-Switched Nd:YAG laser and dermocosmetics containing 2-Mercaptonicotinoyl Glycine and niacinamide for the treatment of melasma in skin of color in clinical practice: a case series.

Fabiana Wanick*[1], Erika Fernandes[2], Mariana Feiges[3], Cauã Ribeiro[4]

[1] Fabiana Wanick Clínica de Dermatologia, RIO DE JANEIRO, Brazil

[2] L'Oréal Dermatological Beauty, RIO DE JANEIRO, Brazil

[3] L'Oréal Dermatological Beauty Brazil, RIO DE JANEIRO, Brazil

[4] cauan.ribeiro@loreal.com, RIO DE JANEIRO, Brazil

Introduction

Melasma is a chronic and acquired focal hyperpigmentary disorder. Its medium- and long-term management is challenging, with a significant impact on quality of life and psychosocial well-being. The multifactorial etiology of melasma often requires combined therapeutic approaches. Recent advances include photoprotection against visible light, hydroquinone-free depigmenting agents such as 2-Mercaptonicotinoyl Glycine (2-MNG, Melasyl™), and laser- and energy-based therapies. Given the constant evolution of these strategies, it is essential to evaluate, in clinical practice, therapeutic combinations that favor patient adherence and satisfaction. A new depigmenting serum including 2-MNG and Niacinamide (MB3) has been developed and well-studied in acne-induced hyperpigmentation and melasma showing non inferiority versus hydroquinone 4% with a superior tolerability. The objective of this case study was to assess the efficacy and tolerability of MB3 serum in adjunct to non-ablative laser for women presenting melasma.

Case Presentation

Ten women, aged between 37 and 64 years, Fitzpatrick phototypes III to V, with facial melasma, were treated at a private clinic in Niterói (RJ, Brazil) in 2025, and underwent two sessions of non-ablative Q-Switched Nd:YAG laser (5 mm spot size, 1500 mJ, 5 Hz, 2 full-face passes, 1200 shots), with a 28-day interval. The protocol was combined with the daily use of MB3 serum and cleansing gel twice daily, in addition to high-coverage sunscreen in the morning. The serum was applied immediately after the laser session. Evaluations were performed at D0, D28, and D56 using mMASI, IGA scale, visual analog scale (VAS) for radiance and texture, and a tolerability scale. Satisfaction questionnaires and standardized photographic records were also obtained. Continuous and progressive significant clinical improvement was observed, including a mean reduction of 58.94% in mMASI, a 50% improvement in the IGA scale, and a two-fold increase in skin texture uniformity and radiance after 56 days of treatment. The protocol showed excellent tolerability, with no adverse events, and 100% of the patients reported satisfaction.

Conclusion

The combination of non-ablative Q-Switched Nd:YAG laser with dermocosmetics containing 2-Mercaptonicotinoyl Glycine and niacinamide, and high-coverage photoprotection promoted clinical improvement, good tolerability, and high satisfaction, expanding the therapeutic options for the treatment of Melasma.



Figure 1: Photographs of patient 4 obtained at D0 and D56.

EADV CONGRESS
VIENNA
30 SEP - 3 OCT 2026

Abstract N°: 2994

Real-world effectiveness of topical ruxolitinib in vitiligo: a 52-week observational study assessed by VISIA®, RCM and LC-OCT

Lorenzo Mercadante*[1], Carolina Dall'Ara[2], Alberto Di Caro[2], Giuseppe Rizzuto[2], Francesca Feresin[2], Maria Elisabetta Greco[2], Francesca Sasso[3], Steven Paul Nisticò[2], Giovanni Pellacani[2], Annunziata Dattola[2]

[1] 1. Unit of Dermatology, Department of Medical and Cardiovascular Sciences, La Sapienza University of Rome, Rome, Italy
[2] Department of Medical and Cardiovascular Sciences, La Sapienza University of Rome, Rome, Italy
[3] Medical department, "Antonio Cardarelli" National Hospital, Naples, Italy

Introduction

Vitiligo is a chronic inflammatory disorder characterized by depigmented patches resulting from the progressive loss of epidermal melanocytes, with a significant impact on patients' quality of life. In recent years, topical ruxolitinib, a selective Janus kinase (JAK1/JAK2) inhibitor, has emerged as an effective therapeutic option by modulating inflammatory pathways involved in disease pathogenesis and promoting repigmentation. The use of non-invasive imaging techniques may provide an objective evaluation of treatment response and repigmentation over time.

Materials and Methods

We conducted a real-world observational study including 206 patients with vitiligo, comprising 115 females and 91 males, treated with topical ruxolitinib applied twice daily. Patients were assessed at baseline and at weeks 12, 24 and 52. Clinical evaluation was performed using the Facial Vitiligo Area Scoring Index (F-VASI). Clinical photographs were obtained in all 206 patients, while VISIA® imaging was performed in 134 patients, Reflectance Confocal Microscopy (RCM) in 57 patients and Line-field Confocal Optical Coherence Tomography (LC-OCT) in 66 patients, enabling a multimodal evaluation of repigmentation. Patients were stratified according to skin phototype using the Fitzpatrick scale. Quality of life was assessed using the Dermatology Life Quality Index (DLQI). All enrolled patients presented non-segmental vitiligo with facial involvement, while approximately 70% also showed extra-facial involvement. Several comorbidities were observed, mainly hypertension (24%), Hashimoto's thyroiditis (17%), and Diabetes mellitus (5%); others, including Fibromyalgia and Celiac disease, were less frequent (3%).

Results

A progressive and sustained clinical improvement was observed over time. Mean F-VASI decreased from 1.11 at baseline to 0.98 at week 12, 0.86 at week 24 and 0.6 at week 52. Clinical photographs documented a progressive improvement of vitiligoid macules over time, with reduction in lesion extension and progressive repigmentation. VISIA® analysis demonstrated a progressive reduction in depigmented areas and improvement of vitiligoid macules, with increasing evidence of repigmentation during follow-up. RCM findings revealed the progressive reappearance of dendritic melanocytic cells at the dermo-epidermal junction together with restoration of the bright papillary rings, already appreciable at week 12 and more pronounced at week 24. LC-OCT evaluation showed progressive perifollicular repigmentation with reappearance of hyper-reflective dendritic melanocytic cells and recovery of melanocyte distribution at the dermo-epidermal junction, starting from week 12 and further

increasing at week 24, consistent with cytoarchitectural repigmentation. Quality of life improved significantly, with mean DLQI decreasing from 18.5 at baseline to 12.2 at week 12, 7.6 at week 24 and 3.1 at week 52. Patients with darker phototypes exhibited an earlier and more pronounced response, already evident at week 12. Treatment was generally well tolerated, with no major safety concerns observed.

Conclusions

In this large real-world cohort, topical ruxolitinib demonstrated rapid onset of action and sustained effectiveness in vitiligo up to 52 weeks, with significant improvements in both clinical severity and quality of life. The integration of advanced imaging techniques such as VISIA®, RCM and LC-OCT enabled an objective assessment of treatment response and repigmentation dynamics. These findings support topical ruxolitinib as an effective therapeutic option in routine clinical practice and highlight its role in the long-term management of vitiligo.

EA DV CONGRESS
VIENNA
30 SEP - 3 OCT 2026

Abstract N°: 3022

Development of a Prospective, Regulatory-Grade Disease Registry to Characterize Real-World Nonsegmental Vitiligo Care

Seemal R Desai*[1, 2], Andrew F. Alexis[3], Pearl E. Grimes[4, 5], Nada M. Elbuluk[6], Victor Huang[7], Tasneem F. Mohammad[8], Andrew Mastro[9], Aaron Sookhoo[10], Yan Valle[11], Peter Wahl[12], Nicole Middaugh[12], Emily J. Tremlett[12], Xuan Li[13], Daniel Sturm[13], Jonathan Uy[13], David Rosmarin[14]

[1] University of Texas Southwestern Medical Center, Dallas, TX, United States
[2] Innovative Dermatology, Plano, TX, United States
[3] Weill Cornell Medicine, New York, NY, United States
[4] University of California, Los Angeles, CA, United States
[5] Vitiligo & Pigmentation Institute of Southern California, Los Angeles, CA, United States
[6] Keck School of Medicine of University of Southern California, Los Angeles, CA, United States
[7] University of California Davis Medical Center, Sacramento, CA, United States
[8] Henry Ford Health System, Detroit, MI, United States
[9] Illinois Dermatology Institute, Chicago, IL, United States
[10] Suncoast Skin Solutions, Brandon, FL, United States
[11] Vitiligo Research Foundation, Toronto, ON, Canada
[12] Thermo Fisher Scientific, Boston, MA, United States
[13] Incyte Corporation, Wilmington, DE, United States
[14] Indiana University School of Medicine, Department of Dermatology, Indianapolis, IN, United States

Introduction

Nonsegmental vitiligo (NSV) is a chronic autoimmune skin disease with substantial psychosocial burden. Although randomized trials have demonstrated efficacy and safety of emerging therapies, important evidence gaps remain in routine clinical care, including understanding unmet need, treatment sequencing, adherence, repigmentation outcomes, and psychosocial impacts across heterogeneous patient subgroups. Given the known limitations of current real-world data (RWD), a rigorous prospective, registry-based approach is needed to generate standardized, longitudinal real-world evidence in adolescents and adults with dermatologist-confirmed NSV.

Objective

Describe the PPD™ CorEvitas™ Vitiligo Registry, which is designed to collect regulatory-grade RWD from dermatology specialty clinical practices who actively assess disease activity, treatment, and clinical and patient-reported outcomes in NSV to address gaps between clinical trial evidence and real-world management of care.

Materials and Methods

The CorEvitas Vitiligo Registry is a prospective, observational cohort of US patients aged ≥12 years with dermatologist-confirmed NSV. Longitudinal data are collected from both patients and their treating healthcare provider during routine clinical encounters under a structured and standardized data collection protocol. Follow-

up is aligned with routine clinical care and occurs approximately every 6 months. After initiation of a new eligible vitiligo medication at enrollment or during follow-up, additional visits are captured within 1–6 months, after which 6-month follow-up resumes. This cadence resets with each new treatment initiation.

Results

Initial size of the registry site network is approximately 50 geographically diverse academic and community dermatology practices in the US, although there is no defined upper or lower limit on the number of patients or sites expected to participate. Data collected from patients and providers includes demographics, socioeconomic and lifestyle factors, height/weight/body mass index, comorbidities, disease history, anatomic distribution, signs of activity to support stable vs active classification (eg, Koebner phenomenon, confetti depigmentation, hypochromic/advancing borders, inflammatory features), and presence of leukotrichia. Selected laboratory measures are captured when available in routine clinical care.

Clinician-reported outcomes include total and facial Vitiligo Area Scoring Index (VASI), body surface area, and Physician's Global Vitiligo Assessment (PhGVA). Patient-reported outcomes (PROs) collected include the Vitiligo Noticeability Scale, Vitiligo-Specific Quality of Life instrument (VitiQoL), Patient Global Assessments (severity/extent/impact), itch numerical rating scale (NRS), Patient Health Questionnaire-4 (PHQ-4; screening for anxiety and depression), and Work Productivity and Activity Impairment (WPAI).

Treatment information is captured in detail (topical, systemic, phototherapy), including dosing/frequency, body areas, start/stop dates, and strength/dosing, as well as reasons for initiation, discontinuation, or not starting therapy.

Conclusions

By pairing validated clinician-reported measures with PROs and detailed treatment data, the CorEvitas Vitiligo Registry will provide a rich source of primary data to address key gaps between trial evidence and that from routine dermatology practice across diverse subgroups to support clinically interpretable, practice-relevant insights as the treatment landscape for NSV continues to evolve.

EA DV CONGRESS
VIENNA
30 SEP - 3 OCT 2026

Abstract N°: 3028

Effectiveness, safety and tolerability of Thiamidol 0.2% cream vs Triple combination cream in epidermal melasma : an investigator blinded randomized controlled clinical trial

Anupam Das*[1]

[1] KPC Medical College and Hospital, KOLKATA, India

Introduction
Triple-combination (TC) cream (fluocinolone acetonide 0.01% , hydroquinone 4% , and tretinoin 0.05%) is approved by US FDA for the treatment of melasma . Thiamidol is a highly effective, patented inhibitor of human tyrosinase that significantly improves moderate-to-severe melasma by regulating melanin production. However, there is a scarcity of data comparing the two options.

Materials and Methods
To compare the effectiveness, safety and tolerability of thiamidol 0.2% cream versus triple combination cream in epidermal melasma. An institution based investigator blinded randomized controlled parallel group comparative study was conducted, over 78 patients, with a clinical diagnosis of epidermal melasma confirmed by dermoscopy and Wood's lamp examination. Both groups received a broad spectrum sunscreen as standard of care, with one group receiving thiamidol 0.2 % cream and the other one triple combination cream for 6 weeks. Patients were followed up at weeks 2, 4 and 6. The effectiveness parameters were Melasma Severity Scale (MSS), Modified Melasma Area Severity Index (m MASI) , Investigator global assessment of hyperpigmentation (IGA) and DLQI (Dermatology Life Quality Index).

Results
Mean age of subjects was 30.56±4.12 and 32.45±3.34 years for thiamidol and TCC group, respectively. Pre-treatment mean mMASI scores in the TCC and thiamidol groups were 11.23±3.23 and 10.76±3.59, p=0.656. After 4 weeks of treatment, the mean mMASI score decreased to 8.65±2.17 in the TCC group and to 7.54±2.26 in the thiamidol group, p=0.332. At the end of the treatment period (week 6), the mean mMASI score was 5.04±2.56 in the TCC group and 4.10±2.10 in the thiamidol group,p=0.134. Thiamidol was able to decrease the mMASI score to a greater degree (30%, 62%) compared to TCC (23%, 55%) at 4 and 6 weeks, respectively, and these differences were strongly statistically significant (P = 0.005 and 0.001 respectively).

Conclusions
Thiamidol 0.2% cream was found to show greater effectiveness in comparison to TCC, and thus it can be considered as a safer, tolerable and efficacious alternative in the management of epidermal melasma.

POWERED BY M-ANAGE.COM

EA DV CONGRESS
VIENNA
30 SEP - 3 OCT 2026

Abstract N°: 3034

Superior Efficacy of Ruxolitinib versus Tacrolimus in Vitiligo: A Head to Head Prospective Real-World Study

Fanny Gomarjoyo[1], Yanhua Liang*[1], Xinxin Yang[1], Ziyuan Li[1], Baoqing Deng[2], Xuejiao Song[3], Xianbo Zuo[3], Xiaoyan Qi[3]

[1] Shenzhen Hospital of Southern Medical University, Shenzhen, China

[2] Department of Dermatology, Shenzhen Baoan Center for Chronic Disease Control, Shenzhen, P.R.China, Shenzhen, China

[3] Department of Big Data Center, Department of Dermatology, NHC Key Laboratory of Clinical Big Data Standardization & Integration, China-Japan Friendship Hospital, Beijing, P.R.China, Beijing, China

Introduction

Vitiligo is a chronic autoimmune depigmentation disorder affecting approximately 0.5-2.0% of the global population. Topical calcineurin inhibitors have been established as first-line non-steroidal therapy, while ruxolitinib cream became the first approved topical JAK inhibitor for non-segmental vitiligo. However, direct head-to-head comparisons between these treatments across different anatomical sites remain limited.

Materials and Methods

This prospective study employed a within-patient split-lesion methodology. Seventy-five patients with non-segmental vitiligo (mean age 33.9±11.3 years, 94.7% adults, 56% female) applied ruxolitinib 1.5% cream twice daily to one trunk lesion and tacrolimus 0.1% ointment twice daily to a comparable contralateral trunk lesion. Facial lesions received ruxolitinib 1.5% cream twice daily (observational arm). The 24-week study assessed the primary endpoint of trunk vitiligo area scoring index (T-VASI) percentage improvement at Week 24. Secondary endpoints included facial VASI (F-VASI), reflectance confocal microscopy (RCM) disease stabilization assessment, vitiligo noticeability scale (VNS), dermatology life quality index (DLQI), and ImageJ software area quantification.

Results

At Week 24, ruxolitinib achieved significantly superior trunk repigmentation compared with tacrolimus (45.8% vs 24.5% T-VASI improvement; $P<0.001$). Treatment response rates showed ruxolitinib superiority across all thresholds: T-VASI50 (74.6% vs 38.7%), T-VASI75 (29.3% vs 9.3%), and T-VASI90 (8.0% vs 1.3%). RCM-confirmed disease stabilization was significantly higher with ruxolitinib at Week 24 (88.0% vs 69.3%; $P<0.001$) and Week 12 (68.0% vs 33.3%; $P<0.001$). Facial lesions treated with ruxolitinib demonstrated 54.5% F-VASI reduction (0.55 to 0.25; $P<0.001$). Patient-reported outcomes showed 90.7% achieving VNS treatment success, with DLQI improving from 7.21 to 3.47 (>4-point reduction = clinically meaningful). ImageJ-confirmed area reduction was 16.3% for facial lesions, 10.1% for trunk ruxolitinib, and 4.7% for trunk tacrolimus ($P=0.012$). Notably, ruxolitinib maintained consistent efficacy regardless of disease duration, whereas tacrolimus showed reduced effectiveness in chronic disease. Safety analysis revealed 13 adverse events total: acne (8.0%), pruritus (4.0%), and application-site erythema (2.7%); no serious adverse events occurred.

Conclusions

Ruxolitinib 1.5% cream provides superior trunk repigmentation compared with tacrolimus 0.1% ointment in non-segmental vitiligo, achieving nearly double the therapeutic benefit with faster and more complete disease stabilization. Efficacy remained consistent across all disease duration subgroups. Both treatments were well tolerated, supporting ruxolitinib as an effective first-line topical monotherapy for non-segmental vitiligo. Limitations include single-center design and 24-week follow-up.

EA DV CONGRESS
VIENNA
30 SEP - 3 OCT 2026

Abstract N°: 3047

Efficacy, tolerance, and impact on perceived stigmatization of a 2-mercaptonicotinoyl glycine-containing serum as adjunctive therapy to laser procedures in patients with pigmentary disorders: an international observational study

Christina Fotiadou[1], Eman Almokhadeb[2], Shermine Warde*[3], Margot Broallier[3], Soline Szymczak[4], Samir Salah[3]

[1] Department of Dermatology and Venereology, School of Medicine, Faculty of Health Sciences, Aristotle University of Thessaloniki, Papageorgiou General Hospital,, Thessaloniki, Greece

[2] Department of Dermatology, College of Medicine, King Saud University, Riyadh, Saudi Arabia

[3] La Roche-Posay Laboratoire Dermatologique, Levallois-Perret, France

[4] Euraxi, Joué-lès-Tours, France

Introduction

Pigmentary disorders, including post-inflammatory hyperpigmentation (PIH), melasma, and solar lentigo, impose a significant psychosocial burden on affected individuals. Laser procedures are increasingly integrated into their clinical management; however, adjunctive depigmenting agents are commonly required to consolidate outcomes. 2-Mercaptonicotinoyl glycine (2-MNG) is a novel active that captures melanin precursors with demonstrated anti-pigmenting properties. This international, multicenter, observational study aimed to evaluate the real-life efficacy, tolerance, and impact on perceived stigmatization of a 2-MNG-containing serum used adjunctively to laser procedures over 3 months, across a broad range of phototypes and geographic regions.

Materials and Methods

Adults (≥18 years, male and female) with confirmed hyperpigmented disorders (epidermal or mixed melasma, PIH, or solar lentigo) initiating a laser procedure were enrolled at dermatology offices across 8 countries. Exclusion criteria included pregnancy and dermal melasma. A 2-MNG-containing serum was applied once or twice daily after laser procedure. Assessments were performed at baseline (Visit D0) and after 3 months (Visit D84). The per-protocol efficacy population (N=182) excluded patients with treatment duration <14 days; the safety population comprised all 187 enrolled patients. Dermatologist-assessed endpoints included: hyperpigmentation severity (6-point scale: 0=none to 5=very severe), pigmentation disorder noticeability (5-point ordinal scale), and degree of patient bother (5-point ordinal scale). Patient self-assessments used 10-point visual analogue scales (VAS) for skin radiance, skin evenness, surface covered by spots/melasma, and pigmentation intensity. Perceived stigmatization was evaluated using the validated Patient Unique Stigmatization Holistic tool in dermatology (PUSH-D). Response rate was defined as the proportion of patients with at least one level decrease between visits.

Results

The per-protocol population (N=182) had a mean age of 40.7 years (SD 13.1), was predominantly female (81.3%), and covered phototypes I–V. Indications included PIH (37.9%), melasma (36.8%), and solar lentigo (24.7%); lesions were primarily facial (92.3%). Highly significant improvements (all $p<0.001$) were observed across all dermatologist-assessed clinical endpoints: response rate for hyperpigmentation severity was 79.7%, for pigmentation disorder visibility 86.1%, and for degree of bother 85.0%. Patient global assessment demonstrated that 98.4% reported at least slight improvement, with 59.3% reporting marked improvement and 12.1% total clearance. Patient-reported mean skin radiance improved by 66.6% and skin evenness by 69.6% (both $p<0.001$).

Surface area covered by spots or melasma was reduced by 50.0% and pigmentation intensity by 54.2% (both $p<0.001$). The PUSH-D total score was significantly reduced by 71.5% ($p<0.001$); the felt-stigma sub-dimension decreased by 70.6% and the enacted-stigma sub-dimension by 73.6% (both $p<0.001$). The 2-MNG-containing serum demonstrated a favorable tolerance profile: 90.9% of patients and 91.9% of dermatologists rated tolerance as "High" or "Excellent". Compliance was rated "Very Well" in 84.0% of patients by dermatologist assessment. 98.9% of dermatologists would recommend the serum to future patients.

Conclusions

In this real-life 3-months observational study, the use of a 2-MNG-containing serum in adjunct to laser procedures demonstrated clinically meaningful, statistically significant improvements in hyperpigmentation severity, visibility, and patient-reported outcomes, along with a favorable tolerance profile, across multiple pigmentary disorder indications and phototypes. The significant reduction in PUSH-D stigmatization score highlights the broader psychosocial value of effective treatment. High compliance and satisfaction rates further support the role of this serum as an effective adjunctive depigmenting agent in laser-based management of pigmentary disorders.

EA DV CONGRESS
VIENNA
30 SEP - 3 OCT 2026

Abstract N°: 3078

Confetti-like macular atrophy: a challenging diagnosis

Marina Barrionuevo Mathias[1], Ana Clara Maia Palhano*[1], Daniel Simao de Andrade[1], Alexandre Michalany[1]

[1] Universidade Santo Amaro (UNISA), São Paulo, Brazil

Introduction

Confetti-like macular atrophy (CLMA) is a rare entity presented with multiple shiny, atrophic macules affecting the upper trunk and extensor surface of proximal upper extremities. Etiology and risk factors remain unknown. Histopathological findings described in previous reports include reduction and fragmentation of elastic fibers, suggesting a possible elastolytic process. Due to the rarity of the disease and the overlap with other acquired atrophic disorders, diagnosis may be challenging and requires careful clinicopathological correlation. Our study aims to report a case of Confetti-like macular atrophy.

Case Presentation

Female, 38 year-old, with no relevant medical history, presented to the Dermatology department with a 2-year history of hypochromic macules on the chest, shoulders, back and proximal arms, without associated symptoms.

She reported previous treatment of the lesions with ketoconazole shampoo and oral fluconazole without clinical improvement. Dermatological examination revealed confluent hypochromic slightly atrophic macules on the upper trunk, proximal arms and chest, scattered among hyperchromic areas (Figure 1). The Zirelli sign was negative. A skin biopsy was performed on the back, showing discrete epidermis atrophy and Voerhoff staining demonstrated a marked reduction in elastic fibers, with focal fragmentation of the remaining fibers. Collagen fibers exhibited preserved morphology and distribution, and no cystic formation was identified. Despite the observed elastolysis, the histopathologic findings were insufficient to support a diagnosis of anetodermic scar. Additionally, hypomelanosis was subtle and not characteristic of guttate leukoderma. At that time, the histological findings favored a residual lesion with post-inflammatory hypochromia, although she had no history of acne or other inflammatory diseases at that location.

After two years she returned to consultation complaining of worsening of the hypochromic macules on the back, without associated symptoms. The case was reviewed, and clinicopathological correlation favored the diagnosis of confetti-like macular atrophy.

Conclusion

CLMA is a rare and likely underrecognized acquired atrophic dermatosis, with very few cases reported in the literature. Differential diagnoses include anetoderma and guttate leukoderma, which may present with hypopigmented atrophic lesions and elastic fiber alterations. In our case, however, histopathological examination did not fulfill the criteria for anetodermic scar, as marked elastolysis was absent. Moreover, the degree of hypomelanosis was not compatible with guttate leukoderma. The combination of characteristic confetti-like hypochromic atrophic lesions and focal elastic fiber fragmentation strongly favored the diagnosis of confetti-like macular atrophy. This report highlights the importance of clinicopathological correlation in recognizing this rare entity and contributes with additional data to the limited literature currently available.

EADV Congress 2026, VIENNA
30 SEPTEMBER - 03 OCTOBER 2026
POWERED BY M-ANAGE.COM

EA DV CONGRESS
VIENNA
30 SEP - 3 OCT 2026

Abstract N°: 3115

Improvements in Repigmentation Over 48 Weeks in Adults and Adolescents With Non-Segmental Vitiligo Treated With Upadacitinib: A Post Hoc Analysis of 2 Replicate Phase 3 Studies

Iltefat Hamzavi*[1], Thierry Passeron[2, 3], Susan Taylor[4], Raj Chovatiya[5, 6], Nanette Silverberg[7], Victor Huang[8], Stavonnie Patterson[9], Guner Sermen[9], Sylvester Uwumarogie[9], Erica Cheng[9], Sharanya Ford[9], Vimal H. Prajapati[10, 11, 12, 13, 14, 15]

[1] Department of Dermatology, Henry Ford Health System, Dermatology Research, Detroit, Michigan, United States
[2] Department of Dermatology, CHU Nice, University Côte d'Azur, Nice, France
[3] 4C3M, INSERM U1065, University Côte d'Azur, Nice, France
[4] Department of Dermatology, Perelman School of Medicine at the University of Pennsylvania, Philadelphia, Pennsylvania, United States
[5] Chicago Medical School, Rosalind Franklin University of Medicine and Science, North Chicago, Illinois, United States
[6] Center for Medical Dermatology + Immunology Research, Chicago, Illinois, United States
[7] Department of Dermatology and Pediatrics, Icahn School of Medicine at Mount Sinai, New York, New York, United States
[8] Department of Dermatology, University of California, Davis, Davis, California, United States
[9] AbbVie Inc., North Chicago, IL, United States
[10] Division of Dermatology, Department of Medicine, University of Calgary, Calgary, Alberta, Canada
[11] Section of Community Pediatrics, Department of Pediatrics, University of Calgary, Calgary, Alberta, Canada
[12] Section of Pediatric Rheumatology, Department of Pediatrics, University of Calgary, Calgary, Alberta, Canada
[13] Dermatology Research Institute, Calgary, Alberta, Canada
[14] Skin Health & Wellness Centre, Calgary, Alberta, Canada
[15] Probity Medical Research, Calgary, Alberta, Canada

Introduction

Non-segmental vitiligo (NSV) is an autoimmune disease with an unpredictable course, characterized by depigmented skin in a bilateral, symmetrical distribution. The efficacy and safety of upadacitinib, a selective oral Janus kinase 1 inhibitor, were evaluated in 2 replicate 48-week phase 3 studies (Viti-Up; NCT06118411) in patients (aged ≥12 years) with NSV, including those with extensive disease. In these studies, a greater proportion of patients treated with upadacitinib vs placebo achieved the co-primary endpoints of ≥50% improvement from baseline in Total Vitiligo Area Scoring Index (T-VASI50) and ≥75% improvement from baseline in Facial Vitiligo Area Scoring Index (F-VASI75) at week 48. To better understand the incremental repigmentation observed over the course of treatment, this post hoc analysis further characterized repigmentation on the total body and face.

Materials and Methods

Patients were randomized 2:1 to upadacitinib 15 mg once daily (UPA15) or placebo (PBO) for 48 weeks; all completers subsequently received UPA15 in a 112-week open-label extension. Post hoc, T-VASI was assessed at weeks 12, 24, 36, and 48 across the following categories: percent improvement from baseline of ≤10%, >10% to ≤20%, >20% to ≤30, >30% to ≤40%, >40% to ≤49%, and >49%; improvement in F-VASI from baseline was assessed at the same time points in categories of ≤15%, >15% to ≤30%, >30% to ≤45%, >45% to ≤60%, >60%

to ≤74%, >74% to ≤90%, and >90%.

Results

At baseline with UPA15 (N=411) and PBO (N=203), respectively, the mean (SD) T-VASI was 17.6 (10.9) and 19.1 (12.3), while the mean F-VASI was 1.1 (.6) and 1.1 (.6). In patients with data at all time points (UPA, N=329; PBO, N=141), a numerically greater proportion of patients with UPA15 vs PBO achieved T-VASI improvement across all category thresholds at all time points from week 12 through week 48 (**Figure 1A** and **1B**). At week 12, >10% and >10 to ≤30% improvements in T-VASI were achieved by 30% and 20% with UPA15 vs 16% and 13% with PBO, respectively. At weeks 24 and 48, respectively, ≥50% improvement in T-VASI was achieved by 10% and 26% with UPA15 vs 3% and 7% with PBO (week 48 data are commensurate with the primary endpoint of the study), a numerically greater proportion of patients with UPA15 vs PBO achieved more than 40% improvement from baseline (34% vs 10%), and other patients also saw improvements of >30% to ≤40% (11% vs 5%) and >20% to ≤30 (14% vs 11%). Similarly, a numerically greater proportion of patients with UPA15 vs PBO achieved improvements in facial repigmentation across all category thresholds through week 48 (**Figure 1C** and **1D**). At week 12, At week 12, 37% and 20% with UPA15 vs 16% and 11% with PBO achieved more than 15% and >15% to ≤45% improvements in F-VASI. At weeks 24 and 48, respectively, 16% and 31% with UPA15 vs 2% and 9% with PBO achieved ≥75% improvement in F-VASI (week 48 data are commensurate with the primary endpoint of the study). After 48 weeks of treatment, a numerically greater proportion of patients with UPA15 vs PBO achieved more than 60% F-VASI improvement (47% vs 12%), and other patients also saw improvements of >45% to ≤60% (11% vs 8%) and >30% to ≤45% (10% vs 9%). More than 90% improvement in F-VASI was achieved by 15% with UPA15 vs 3% with PBO at week 48.

Figure 1. Improvements in Repigmentation Over 48 Weeks in Patients Treated With Upadacitinib or Placebo.

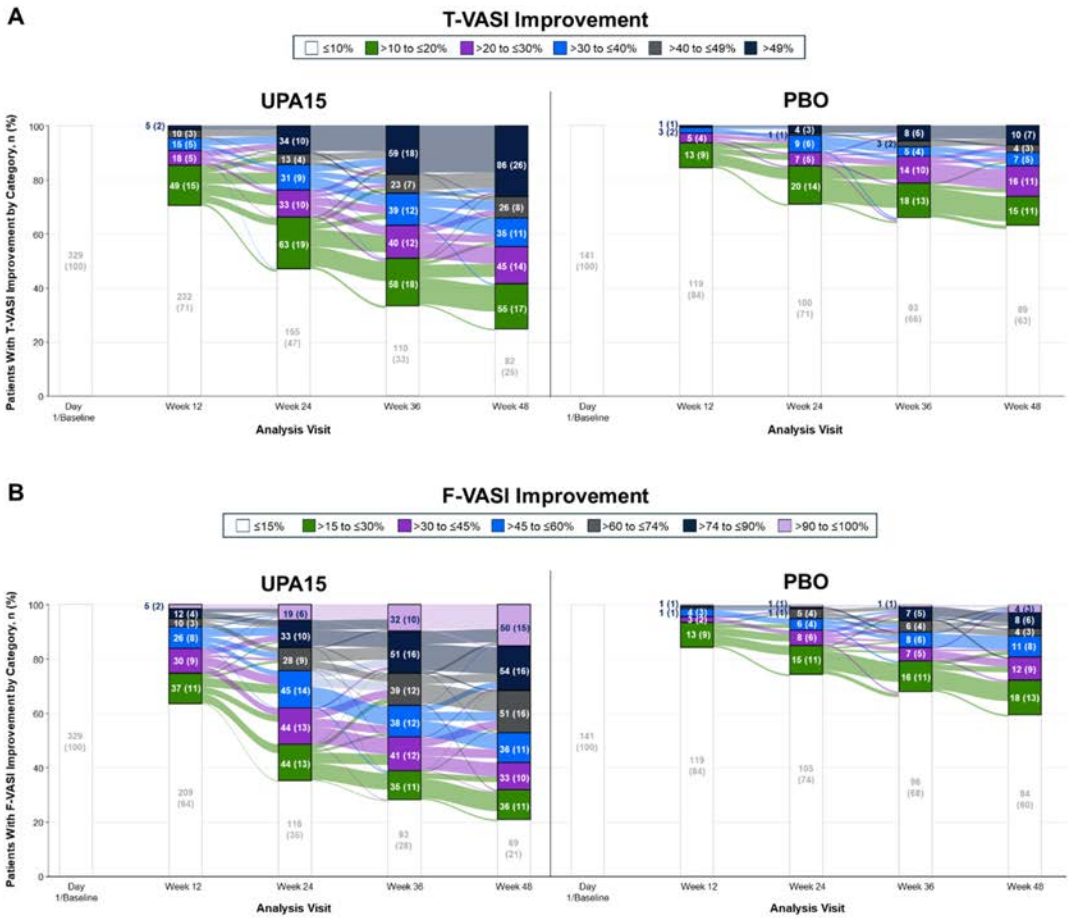

F-VASI, Facial Vitiligo Area Scoring Index; PBO, placebo; UPA15, upadacitinib 15 mg once daily; T-VASI, Total Vitiligo Area Scoring Index.

Post hoc analysis of all randomized patients from Period A in the phase 3 upadacitinib M19-044 clinical trial. Data were pooled as observed; only patients with nonmissing data at all visits were included. All patients were assigned to the lowest category (T-VASI, ≤10%; F-VASI, ≤15%) at baseline.

Conclusions

Setting appropriate treatment expectations is critical to the management of patients with NSV. In this post hoc analysis from 2 phase 3 clinical trials including patients with extensive disease, a greater proportion treated with UPA15 vs PBO achieved incremental improvements in total body and face repigmentation as early as week 12 and continuing through week 48. These findings offer additional insight into the treatment response patterns for patients with NSV treated with upadacitinib that may support important treatment discussions.

EA DV CONGRESS
VIENNA
30 SEP - 3 OCT 2026

Abstract N°: 3128

Associations Between Clinical Response and Patient-Reported Outcomes in Patients With Nonsegmental Vitiligo Treated With Upadacitinib: Results From Phase 3 Trials

Seemal R Desai*[1], Kent A Hanson[2], Ahmed M Soliman[2], Viktoria Eleftheriadou[3], Gabriela Cobos[4], Linda Stein Gold[5], Stephanie Hays[2], Kaili Ding[2], Chao Li[2], Markus Boehm[6]

[1] Innovative Dermatology and Department of Dermatology at the University of Texas Southwestern Medical Center, Dallas, TX, United States

[2] AbbVie Inc., North Chicago, IL, United States

[3] Vitiligo Clinical and Research Centre, New Cross Hospital, The Royal Wolverhampton NHS Trust, Wolverhampton, United Kingdom, Walsall Manor Hospital, Walsall Healthcare NHS Trust, Walsall, United Kingdom, Institute for Global Health and Wellbeing, College of Medicine, Keele University, Staffordshire, United Kingdom

[4] Department of Dermatology, Tufts University, School of Medicine, Tufts Medical Center, Boston, MA, United States

[5] Department of Dermatology, Henry Ford Health System, West Bloomfield, MI, United States

[6] Department of Dermatology, University of Münster, Münster, Germany

Introduction

Nonsegmental vitiligo (NSV), an autoimmune disease characterised by depigmented skin, can substantially impact quality of life (QoL). In Phase 3 Viti-Up trials, upadacitinib (UPA), an oral Janus kinase inhibitor, demonstrated meaningful facial and total body repigmentation in patients with NSV. This Viti-Up post hoc analysis evaluated associations between clinical improvement and patient-reported outcomes (PROs) and compared PRO responses between UPA and placebo (PBO).

Materials and Methods

The ongoing global, PBO-controlled, Viti-Up trials (NCT06118411) included patients aged ≥12 years with NSV on the face and body randomised 2:1 to UPA 15 mg once daily or PBO for 48 weeks. Clinical response was assessed by achievement of the co-primary endpoints: Total Vitiligo Area Scoring Index (T-VASI) 50 or Facial (F)-VASI 75 (categories of percentage improvement in T-/F-VASI were 10; 10–≤25; 25–≤50; 50–≤75; >75 [T-VASI only]; 75–≤90 and >90 [F-VASI only]). Treatment-independent associations between clinical response and PROs were assessed at Week 48. PRO outcomes included mean change from baseline (CFB) in Vitiligo-Specific Quality of Life Instrument (VitiQoL) total score, VitiQoL response (CFB of ≤−9 points), and Patient Global Impression of Change in Vitiligo (PaGIC-V) response (score of 1 [“much better”] or 2 [“a little better”]). PRO outcomes were compared between patients treated with UPA or those receiving PBO, regardless of clinical response. Continuous outcomes were analysed using one-way analysis of variance (group mean difference [MD]), categorical outcomes using chi-square tests (risk difference [RD]), and ordinal outcomes using logistic regression. Cox regression was used to estimate adjusted hazard ratios (aHR) for UPA versus PBO.

Results

Of 614 included patients, mean (SD) age was 44.5 (15.3) years, 50.0% were female, and 32.0% had Fitzpatrick skin types IV–VI. At Week 48, VitiQoL improvement was greater among clinical responders versus nonresponders for T-VASI 50 (MD: 6.75, 95% CI: 2.65–10.85; p=0.001) and F-VASI 75 (MD: 7.01, 95% CI: 3.15–10.87; p<0.001; **Table**). VitiQoL response (9-point improvement) at Week 48 was more frequent in patients achieving T-VASI 50 (RD: 17.47, 95% CI: 5.99–28.95; p=0.003) or F-VASI 75 (RD: 17.52, 95% CI: 6.78–28.24; p=0.001), as was PaGIC-V response (score of 1 or 2; T-VASI 50: RD: 31.58, 95% CI: 23.28–39.88; F-VASI 75: RD: 32.39, 95% CI: 24.35–40.42;

both p<0.001). At Week 48, mean (SD) VitiQoL CFB ranged from −2.98 (15.29) to −7.27 (15.32) to −16.43 (25.97) in patients achieving T-VASI ≤10, 10–≤25, or >75, respectively, and was significantly greater across increasing T-VASI improvement categories versus T-VASI ≤10 (p<0.001). Graded improvements were observed across F-VASI categories, with mean (SD) VitiQoL CFB ranging from −2.81 (15.38; F-VASI ≤10) to −15.19 (19.27; F-VASI >90) points. At Week 48, the proportion of PaGIC-V responders significantly increased with greater T-VASI improvement, from 35.8% in patients with T-VASI ≤10 to 83.3% in those with T-VASI >75 (p<0.0001). Comparable PaGIC-V responses were observed across F-VASI categories. At Week 48, patients treated with UPA versus those receiving PBO were associated with significantly higher rate of achieving VitiQoL (aHR: 1.44, 95% CI: 1.22–1.69; p<0.001) or PaGIC-V (aHR: 3.28, 95% CI: 2.81–3.82; p<0.001) response over time.

Conclusions

Across all patients with NSV in the trial, higher levels of clinical repigmentation were associated with improved PROs, with meaningful improvements in QoL even at intermediate repigmentation levels. These results indicate that patient-perceived benefit accrues incrementally and is not restricted to achievement of stringent trial response thresholds. Additionally, patients treated with UPA were more likely to achieve patient-reported benefit compared with those receiving PBO. Together these results underscore the clinical relevance of partial and incremental repigmentation in NSV.

Table. Week 48 improvement in VitiQoL and PaGIC-V by clinical response or treatment group[a]

	Responders	Non-responders	Group MD (95% CI)	p value[b]
Change from baseline in VitiQoL, mean (SD)				
T-VASI 50	−12.52 (17.78)	−5.77 (16.34)	6.75 (2.65–10.85)	0.001
F-VASI 75	−12.45 (18.12)	−5.44 (16.08)	7.01 (3.15–10.87)	<0.001
	Responders	**Non-responders**	**RD (95% CI)**	**p value[c]**
≥9-point improvement in total VitiQoL score, n (%)				
T-VASI 50	48 (53.93)	132 (36.46)	17.47 (5.99–28.95)	0.003
F-VASI 75	57 (53.27)	123 (35.76)	17.52 (6.79–28.24)	0.001
PaGIC-V score 1 or 2, n (%)				
T-VASI 50	81 (88.04)	214 (56.46)	31.58 (23.28–39.88)	<0.001
F-VASI 75	97 (87.39)	198 (55.00)	32.39 (24.35–40.42)	<0.001
	CFB in VitiQoL, mean (SD)	**p value[b]**	**Achievement of PaGIC-V score 1 or 2, n (%)**	**p value[d]**
T-VASI improvement categories				
≤10	−2.98 (15.29)	<0.001	62 (35.8)	<0.001
10–≤25	−7.27 (15.32)		68 (66.7)	
25–≤50	−8.90 (18.25)		85 (81.0)	
50–≤75	−11.32 (13.91)		60 (89.6)	
>75	−16.43 (25.97)		20 (83.3)	
F-VASI improvement categories				
≤10	−2.81 (15.38)	<0.001	47 (33.1)	<0.001
10–≤25	−4.09 (16.93)		30 (52.6)	
25–≤50	−9.14 (16.95)		45 (60.8)	
50–≤75	−7.07 (15.34)		78 (86.7)	
75–≤90	−10.57 (16.55)		45 (84.9)	
>90	−15.19 (19.27)		50 (90.9)	
	aHR (95% CI)[e] UPA 15 mg	**PBO**	**p value**	
≥9-point improvement in total VitiQoL score	1.44 (1.22–1.69)	Reference	<0.001	
PaGIC-V score 1 or 2	3.28 (2.81–3.82)	Reference	<0.001	

[a]At baseline, eligible patients scored ≥0.5 F-VASI and ≥5–<50 T-VASI. T-VASI scores range from 0–100 and F-VASI scores range from 0–3, with higher scores indicating worse disease. Higher T/F-VASI improvement categories indicate greater percentage of disease improvement from baseline. [b]P-values calculated from one-way ANOVA. [c]P-values calculated using Chi-square test (Fisher's exact test used for cell counts <5). [d]P-values calculated using ordinal logistic regression. [e]Results calculated using Cox regression including cumulative data from weeks 12, 24, 36, and 48, and controlled for age, sex, and skin type.

aHR, adjusted hazard ratio; ANOVA, analysis of variance; CFB, change from baseline; CI, confidence interval; F-VASI, Facial Vitiligo Area Scoring Index; MD, mean difference; PaGIC-V, Patient Global Impression of Change in Vitiligo; PBO, placebo; RD, risk difference; SD, standard deviation; T-VASI, Total Vitiligo Area Scoring Index; UPA, upadacitinib; VitiQoL, Vitiligo-specific Quality of Life Instrument.

EA DV CONGRESS
VIENNA
30 SEP - 3 OCT 2026

Abstract N°: 3143

Evaluation of HO-1 (Heme Oxygenase-1) and Other Antioxidant Enzyme Levels Before and After Phototherapy in Patients with Vitiligo

Gizem Nur Öztürk*[1], Nihal Kundakcı[1]

[1] Ankara University Faculty of Medicine, Mamak, Türkiye

Introduction

Vitiligo is a chronic depigmentation disorder that develops as a result of the selective loss of melanocytes and has a multifactorial etiopathogenesis. In recent years, it has been shown that oxidative stress plays a central role in the onset and progression of the disease, and that deficiencies in antioxidant defense mechanisms facilitate melanocyte damage. In this study, it was aimed to evaluate oxidant–antioxidant parameters and heme oxygenase-1 enzyme levels in patients with vitiligo; to determine factors associated with these parameters and to compare serum levels before and after narrowband UVB phototherapy

Materials and Methods

Our study included 45 patients with vitiligo and 35 healthy controls matched for age and gender, who presented to the our department between June 2024 and June 2025. Age at disease onset, smoking–alcohol use, disease duration, body mass index, history of autoimmune disease, VIDA scores and VASI scores of the vitiligo patients were recorded. Serum levels of malondialdehyde (MDA) as an oxidant parameter, and the antioxidant enzymes catalase (CAT), glutathione peroxidase (GPx), heme oxygenase-1 (HO-1), and nitric oxide (NO) were measured in the patient and control groups using spectrophotometric and ELISA methods. In the vitiligo group, antioxidant–oxidant parameters and VASI–VIDA scores were recorded again before and after 36 sessions of NB-UVB phototherapy and compared. Statistical analyses were performed and $p<0.05$ was accepted as statistically significant.

Demographic Characteristics of Vitiligo and Control Groups

Characteristic	Vitiligo Group (n=45)	Control Group (n=35)	p-value
Gender, n (%)			
Female	26 (57.8)	18 (51.4)	0.571*
Male	19 (42.2)	17 (48.6)	
Age, mean ± SD (min–max)	45.91 ± 16.69 (18–85)	45.09 ± 16.49 (18–78)	0.826**
BMI, mean ± SD (min–max), kg/m²	27.36 ± 5.04 (18.9–37.8)	–	–
Smoking, n (%)			
Yes	12 (26.7)	–	–
No	33 (73.3)		
Alcohol consumption, n (%)			
Yes	2 (4.4)	–	–
No	43 (95.6)		
Family history, n (%)			
No	28 (62.2)	–	–
Yes	17 (37.8)		
History of autoimmune disease, n (%)			
Yes	15 (33.3)	–	–
No	30 (66.7)		
Age at disease onset (years)			
Mean ± SD	26.67 ± 12.74	–	–
Median (min–max)	26 (4–57)		

*SD: Standard deviation; BMI: Body mass index; *Chi-square test; **Mann–Whitney U test.*

Results

Among the 45 vitiligo patients included in the study, 26 (57.8%) were female; the mean age was 45.91 ± 16.69 years and the mean disease duration was 19.24 ± 15.53 years. The control group consisted of 35 subjects with a mean age of 45.09±16.49 years. Patients with VIDA scores >0 were classified as active vitiligo, accounting for 68.9% of all vitiligo cases. No differences were detected between active and stable vitiligo groups in HO-1, CAT, GPx, MDA, and NO levels ($p>0.05$). However, in the vitiligo group, CAT and GPx levels were significantly higher than in the control group ($p=0.021$ and $p=0.012$, respectively), while MDA and NO levels were significantly higher in the control group compared to the vitiligo group ($p=0.004$ and $p=0.015$, respectively). No significant associations were found between age, age at disease onset, smoking–alcohol use, BMI, family history, autoimmune disease history and HO-1, MDA, GPx, NO, or CAT levels in the vitiligo group ($p>0.05$). A significant difference was observed between VASI levels and the presence of autoimmune disease ($p=0.042$). However, no significant relationships were found between VASI and VIDA scores and the other parameters ($p>0.05$). Among the patients who received phototherapy (n=8), decreases in MDA levels ($p=0.204$) and increases in HO-1 and CAT levels ($p=0.036$ and $p=0.182$, respectively) were observed before and after treatment. This biochemical improvement was reflected in a significant decrease in VIDA score from a mean of 4 to 3 and in VASI score from 18.11 ± 18.1 to 14.20 ± 14.38 ($p=0.014$ and $p=0.050$, respectively).

Comparison of Enzyme Levels, VASI and VIDA Scores Before and After Phototherapy

	Before Treatment Mean ± SD Median (min–max)	After Treatment Mean ± SD Median (min–max)	p-value
VASI Score	18.11 ± 18.10 13.05 (1.2–50)	14.20 ± 14.38 11.94 (1–40)	0.050
VIDA Score	4	3	**0.014**
Enzymes			
HO-1 (ng/mL)	0.64 ± 0.72 0.49 (0.05–2.29)	1.18 ± 1.40 0.80 (0.14–4.52)	**0.036**
CAT (IU/mL)	5.58 ± 3.21 5.76 (1.44–11.52)	21.06 ± 33.61 5.04 (1.44–100.80)	0.182
GPx (IU/mL)	239.64 ± 450.04 84.96 (67.70–1353.60)	95.58 ± 24.18 94.32 (63.36–132.48)	0.398
MDA (nmol/mL)	2.31 ± 0.77 2.14 (1.45–3.79)	1.92 ± 0.57 1.94 (0.81–2.66)	0.204
NO (IU/mL)	29.00 ± 5.75 27.63 (22.75–38.50)	28.38 ± 4.63 28.25 (22.75–35.75)	0.889

Mean: mean; SD: standard deviation; M: median; min: minimum; max: maximum; p value: Wilcoxon signed–rank test for statistical significance.

Conclusions

In patients with vitiligo, oxidative stress is markedly increased compared to healthy controls and a significant decrease is observed in antioxidant defense systems particularly HO-1, CAT, and GPx. The significant improvement in these parameters following NB-UVB phototherapy indicates that the treatment is effective not only in promoting repigmentation but also in regulating oxidative stress. This study is the first to evaluate serum HO-1 levels in vitiligo patients together with other oxidant–antioxidant parameters and demographic characteristics. The observed increase in HO-1 levels after phototherapy suggests that HO-1 may serve as an indicator of phototherapy efficacy; however, this finding should be confirmed in studies with larger patient populations. Our study contributes to a better understanding of the pathogenesis of vitiligo and supports the development of antioxidant-based therapeutic strategies.

EADV CONGRESS
VIENNA
30 SEP - 3 OCT 2026

Abstract N°: 3221

Efficacy of Ivarmacitinib in Vitiligo Treatment: A Retrospective Analysis of 7 Cases

Yuanmin He*[1], Hanxiao Mao[1], Ziyuan Zeng[1], Zixian Zhang[1], Qirong Lei[1]

[1] Department of Dermatology, The Affiliated Hospital of Southwest Medical University, Luzhou, Sichuan, China

Introduction

Vitiligo is an acquired depigmenting disorder characterized by melanocyte loss, which imposes substantial psychosocial burden on patients. Janus kinase (JAK) inhibitors have shown therapeutic potential for vitiligo, but clinical evidence for Ivarmacitinib—a highly selective JAK1 inhibitor—remains scarce.To assess the preliminary efficacy of Ivarmacitinib in vitiligo patients using comprehensive clinical and patient-reported outcome measures.

Case Presentation

This retrospective analysis included 7 patients with vitiligo who received topical halometasone ointment twice daily, NB-UVB phototherapy every 72 hours, and oral ivarmacitinib 4 mg once daily, and completed at least 3 months of follow-up. Demographic data including age, gender and disease duration, as well as follow-up duration, were collected. Efficacy was evaluated at baseline and after no less than 3 months of treatment using seven indicators: facial body surface area (F-BSA), total body surface area (T-BSA), facial Vitiligo Area Scoring Index (F-VASI), total Vitiligo Area Scoring Index (T-VASI), Dermatology Life Quality Index (DLQI), Vitiligo-specific Quality of Life scale (VitiQoL), and Vitiligo Disease Activity Score (VIDA). Descriptive statistics were applied to analyze changes in efficacy outcomes.

The 7 patients had a mean age of 23.3 years (range: 16–35 years), with 4 females (57.1%) and 3 males (42.9%). The mean disease duration was 2.2 years (range: 1.0–5.5 years), and the mean follow-up period was 3.3 months (range: 3–4 months). All efficacy metrics showed significant improvements after treatment.F-BSA reduced from 0.0121 to 0.0036 (70.6% decrease), with 42.9% of patients achieving improvement;T-BSA decreased from 0.0406 to 0.0104 (74.3% reduction), with 100% of patients showing improvement;F-VASI declined from 1.14 to 0.15 (86.9% reduction), with 42.9% of patients experiencing improvement;T-VASI fell from 7.48 to 1.08 (85.6% decrease), with all patients (100%) demonstrating improvement;DLQI decreased from 10.00 to 1.86 (81.4% reduction), with 100% of patients reporting improved quality of life;VitiQoL scores dropped from 21.86 to 4.29 (80.4% reduction), with full (100%) patient improvement;VIDA improved from 1.14 to -0.33 (129.2% improvement in disease stability), with 71.4% of patients showing reduced disease activity.

Conclusion

Ivarmacitinib, a highly selective JAK1 inhibitor, effectively improves both objective disease severity (e.g., lesion area, activity) and patient-reported quality of life in vitiligo patients after ≥3 months of treatment. These preliminary findings support Ivarmacitinib as a promising therapeutic option for vitiligo, highlighting the need for larger, prospective trials to confirm its long-term efficacy and safety.

EA DV CONGRESS
VIENNA
30 SEP - 3 OCT 2026

Abstract N°: 3259

Non-invasive imaging for the evaluation of Jak inhibitors efficacy in the management of facial vitiligo

Maria Elisabetta Greco*[1], Francesca Feresin[1], Alberto di Caro[1], Francesca Sasso[1, 1], Ilaria Proietti[2], Luigi Fiorito[3], Nicola Perrotta[4], Giovanni Pellacani[1], Concetta Potenza[2], Steven Nisticò[1], Annunziata Dattola[1]

[1] Dermatology Clinic, Department of Medical and Cardiovascular Sciences, University of Rome, "Sapienza", Rome, Italy, Rome, Italy

[2] Unit of Dermatology, Department of Medical-Surgical Science and Biotechnologies, Sapienza University of Rome, A. Fiorini Hospital, Terracina, Latina, Italy, Latina, Italy

[3] Department of Physiology and Pharmacology "V. Erspamer", Sapienza University, Rome, Italy, Rome, Italy

[4] Department of Physiology and Pharmacology V. Erspamer Sapienza University, Rome, Italy, Rome, Italy

Introduction

Vitiligo is an acquired pigmentary condition characterized by the presence of white patches caused by the death of functional melanocytes in the skin.
The aim of our work is to assess the efficacy of JAK inhibitors in treating facial vitiligo and to investigate microscopic alterations through clinical scales and non-invasive diagnostic tools.

Materials and Methods

Observational, multicenter, real-life study on clinical practice involving 100 participants with non-segmental vitiligo of the face. They applied Ruxolitinib cream (15mg/g) twice a day for three months. Clinical and instrumental assessment was performed at baseline (T0), after 30 days (T1), and after 90 days (T2) evaluating vitiligo extension by using Facial Vitiligo Area Scoring Index (F-VASI) (0=absent to 3=severe), Vitiligo Extent Score of the Face (F-VES BSA), Vitiligo Extent Score (VES grade of extent per region 0=absent to 6= very severe), Physician's Global Vitiligo Assessment (PhGVA) (0=non severe to 4=severe) and Patient Global Vitiligo Assessment of the face (F-PaGVA) (0=non severe to 5=severe). In addition, Dermatology quality of life questionnaire (DLQI) was collected. Instrumental assessments were conducted by recording clinical photos in day light and with Wood’s lamp, using VISIA® 2D (Canfield Scientific), in vivo reflectance confocal microscopic (RCM) (Vivascope 1500®, Vivascope, Munich, Germany) and Line-field Confocal Optical Coherence Tomography (LC-OCT Damae Medical).

Results

The F-VES BSA index showed a mean diminution value of 0.5761 (95% CI: 0.4375-0.7146), with a standard deviation of 0.5810 ($p<0.0001$). The VES-GRADE index presented a mean difference between T0 and T2 of 0.4571 (95% CI: 0.3016- 0.6127), with a standard deviation of 0.6524 ($p< 0.0001$). The PhGVA score had a mean difference of 1.1571 (95% CI: 0.9325-1.3818) with a standard deviation of 0.9423, while the PaGVA score reduction was 1.0290 (95% CI: 0.7497-1.3083), with a slightly higher standard deviation (1.1628), both ($p<0.0001$). The DLQI showed a mean reduction value of 3.1143 (95% CI: 2.4578-3.7708), with a standard deviation of 2.7534 ($p< 0.0001$). In contrast, the F-VASI score index showed a very low mean difference (0.9871; 95% CI: 0.8672-1.1071), with a standard deviation of 0.5030. However, the p-value ($p <0.0001$) still reached statistical significance. Clinical photographs and Wood's lamp
examination show an objective clinical improvement also using VISIA, with an assessment of the improvement in brown spots, standard deviation of differences 3.8314 and $p <0.0001$, and the involvement of fewer pixels in the areas affected by vitiligo.
RCM and LC-OCT have demonstrated the presence of new activated melanocytes in the basal and spinous layers

of the epidermis.

Conclusions

The use of JAK inhibitors has proven effective in reducing the size of white patches. It was supported by improvements in all indices analyzed and by the demonstration of activated melanocytes using non-invasive diagnostics. Inaddition, an increase in patient satisfaction and quality of life was reported.
Further studies are needed to support these findings, but they offer optimistic expectations for the treatment of vitiligo.

EA DV CONGRESS
VIENNA
30 SEP - 3 OCT 2026

Abstract N°: 3284

Phenol-Croton Oil Peel as Adjunctive Therapy for Refractory Facial Vitiligo: A Case Report

Leticia Vidotti Storti*[1], Amal Elkady[1], Katrina Kleinhans[1], Carlos Wambier[1, 2]

[1] Department of Dermatology, Warren Alpert Medical School, Brown University, Providence, United States
[2] University of Miami Leonard M. Miller School of Medicine, Miami, United States

Introduction

Vitiligo is a chronic autoimmune depigmenting disorder characterized by melanocyte destruction and significant psychosocial burden. Current therapeutic options include topical corticosteroids, calcineurin inhibitors, topical Janus kinase (JAK) inhibitors, and narrowband ultraviolet B phototherapy. Phenol-croton oil peel is traditionally used for deep dermal resurfacing in chronic photoaging and is known to induce temporary post-inflammatory hyperpigmentation. Its role in vitiligo management remains controversial. Controlled chemical injury induced by phenol-croton oil has proliferative and inflammatory properties through phorbol esters and neutrophilic extracellular trap formation (NETosis). Phrobol esters in croton oil, including phorbol 12-myristate 13-acetate (PMA), stimulate melanocyte proliferation and melanogenesis through protein kinase C activation, potentially promoting repigmentation. We report a case of severe refractory facial vitiligo with marked repigmentation following serial phenol-croton oil peel treatments.

Case Presentation

A 65-year-old female with Hashimoto thyroiditis presented with severe stable vitiligo involving the forehead, perioral region, chest, hands, upper and lower back, bilateral lower extremities, and feet (Total Vitiligo Area Scoring Index [TVASI]=25, body surface area [BSA]=25%, and Facial VASI [FVASI]=0.6), with preserved facial hair pigmentation. Vitiligo had been clinically diagnosed at approximately 20 years of age, with progressive disease despite multiple therapies. Facial recurrence over recent years became particularly distressing due to difficulty concealing depigmented lesions with cosmetic products.

Previous unsuccessful treatments included topical ruxolitinib 1.5% cream for over 2 years, topical corticosteroids, tacrolimus ointment, narrowband ultraviolet B phototherapy, excimer laser, and microneedling-assisted delivery of 5-fluorouracil and sterile compounded injectable tofacitinib. Nine excimer laser sessions between 2017 and 2018 over the forehead and perioral regions resulted in only mild improvement.

Due to refractory facial disease, serial phenol-croton oil peel procedures were intiated in APril 2024. Initial treatment targeted the perioral region using Hetter's phenol-croton oil 0.8%/35% formulation while topical ruxolitinib was maintained. One month later, significant repigmentation and cosmetic improvement were observed, with high patient satisfaction. Additional sessions targeted the forehead, neck, lower lip, right eyelid, and focal facial lesions using varying formulations and concentrations, including focal phenol 88% application over the forehead.

Progressive facial repigmentation and stabilization of previously active lesions were observed throughout treatment. Although mild recurrence later developed over portions of the forehead and lower lip, the cosmetic appearance remained substantially improved compared to baseline. Due to persistent systemic disease activity, topical ruxolitinib was discontinued and tacrolimus 0.1% ointment initiated, followed by systemic ritlecitinib 50 mg daily in July 2025. At follow-up in February 2026, the patient continued to demonstrate marked facial improvement with decreased dependence on cosmetic camouflage. FVASI improved from 0.6 to 0.18 following peel interventions, while total body involvement remained stable at approximately 25% BSA.

Conclusion

This case highlights the potential utility of phenol-croton oil peel as an adjunctive therapy for severe refractory facial vitiligo. Serial peel treatments were associated with clinically meaningful repigmentation, sustained cosmetic improvement, and high patient satisfaction despite partial recurrence over time. The improvement in FVASI suggests a possible role for phenol-induced regenerative and inflammatory mechanisms in promoting repigmentation. Further studies are needed to evaluate efficacy, safety, and optimal treatment protocols for phenol-croton oil peel in treatment-resistant vitiligo management.

EA DV CONGRESS
VIENNA
30 SEP - 3 OCT 2026

Abstract N°: 3314

Quality-of-Life Impairment and Impact of Treatment in an Open-Label, Phase 2 Study of Ruxolitinib Cream in Patients With Genital Vitiligo

Khaled Ezzedine*[1], Yun Su[2], Haobo Ren[2], Thierry Passeron[3, 4]

[1] Henri Mondor University Hospital and Université Paris-Est Créteil Val de Marne, Paris, France

[2] Incyte Corporation, Wilmington, DE, United States

[3] Centre Hospitalier Universitaire de Nice, Université Côte d'Azur, Nice, France

[4] INSERM U1065, C3M, Université Côte d'Azur, Nice, France

Introduction

Vitiligo substantially affects patients' psychosocial well-being and daily functioning. The Vitiligo Impact Patient scale (VIPs) is a validated vitiligo-specific instrument measuring patient-reported disease burden across multiple domains. A clinical study of ruxolitinib cream in adults with genital vitiligo showed improvements in repigmentation and patient burden over 48 weeks, with greater numerical VIPs total score improvement among patients with Fitzpatrick skin types IV–VI vs I–III (dark vs fair skin). Here we descriptively characterize baseline vitiligo burden and longitudinal change within VIPs domains upon ruxolitinib cream treatment.

Materials and Methods

Adults with nonsegmental vitiligo covering ≤10% total body surface area, including ≥0.25% genital involvement, applied 1.5% ruxolitinib cream twice daily for 48 weeks in a phase 2 open-label study (NCT05750823). Post hoc analyses focused on 19 items of the VIPs instrument (VIPs-19) that are common to patients with fair or dark skin. Normalized VIPs-19 total and domain (psychological, relationships and sexuality, social interaction, and economic constraints) impairment scores were summarized by Fitzpatrick skin type at baseline and every 12 weeks through Week 48. Total scores were normalized on a 0–100 scale (higher scores indicate greater vitiligo burden; reduction from baseline indicates improvement). Descriptive statistical analyses and associated *P* values are supportive, with no multiplicity adjustment.

Results

Forty-nine patients were enrolled, including 24 with fair and 25 with dark skin. Baseline patient-reported vitiligo burden was statistically significantly higher in patients with dark vs fair skin per the VIPs-19 total score (mean, 48.03 vs 23.89; $P<0.001$ per two-sample t test). Differences between dark and fair skin types were observed across VIPs-19 domains, with psychological burden being the most impaired (60.21 vs 36.20, respectively), followed by relationships and sexuality (45.00 vs 20.00), social interaction (39.44 vs 16.38), and economic constraints (37.29 vs 11.52). Across skin types, a high percentage of patients reported that items of psychological impairment frequently ("all the time," "very often," or "often") affected their daily lives, most commonly worry about vitiligo spread, progression, and repercussions on physical appearance.

Upon treatment with ruxolitinib cream, all patients experienced statistically significant improvements in their VIPs-19 total scores vs baseline from Week 12 onwards ($P<0.0001$). Clinically meaningful improvements (ie, ≥15% score reduction per German IQWiG) in burden were achieved by patients with fair skin at Week 12 (mean percentage change from baseline, −21.67%; $P<0.0001$ per paired t test) and those with dark skin at Week 24 (−23.17%; $P<0.0001$). Patients also experienced clinically meaningful improvements by domain: psychological impairment in fair and dark skin at Week 12 (fair, −35.54%; dark, −15.74%; both $P<0.0001$), relationships and

sexuality (fair skin at Week 12, −34.55%, $P<0.05$; dark skin at Week 24, −18.81%; $P<0.0001$), social burden (fair skin at Week 36, −38.85, $P<0.05$; dark skin at Week 24, −18.04, $P<0.0001$), and economic constraints (dark skin only at Week 48, −20.72, $P<0.0001$).

Conclusions

Adults with genital vitiligo had considerable vitiligo burden at baseline. Patients with dark skin reported higher burden than those with fair skin across all comparable VIPs-19 domains, with greatest impairments in psychological burden. Ruxolitinib cream treatment led to clinically meaningful reductions in patients' mean VIPs-19 total score and psychological, relationships and sexuality, and social burden domains across skin types.

EADV CONGRESS
VIENNA
30 SEP - 3 OCT 2026

Abstract N°: 3338

CLINICAL VARIANTS, HISTOPATHOLOGICAL CORRELATION AND DERMATOSCOPIC PATTERNS IN LICHEN PLANUS : A CROSS SECTIONAL OBSERVATIONAL STUDY

Sindhuri Gumma*[1]

[1] Padmashree DR D Y Patil Medical college Hospital- And Research Centre, NAVI MUMBAI, India

Introduction
Lichen planus (LP) is a chronic inflammatory interface dermatosis with diverse clinical presentations involving the skin, mucosae, scalp, and nails. Despite characteristic clinicopathological features, early diagnosis and differentiation of variants remain challenging in routine practice. Dermoscopy has emerged as a valuable non-invasive diagnostic modality that aids in identifying characteristic patterns and correlating them with histopathological findings. This study aimed to evaluate the clinical variants of LP and analyze their dermatoscopic and histopathological correlations in a tertiary care center.

Materials and Methods
A hospital-based cross-sectional observational study was conducted in the Department of Dermatology, Venereology and Leprosy at D.Y. Patil Hospital, Navi Mumbai. Patients clinically diagnosed with lichen planus and its variants were enrolled after informed consent and institutional ethical approval. Detailed clinical evaluation including morphology, site of involvement, duration, symptoms, and associated findings was performed. Dermoscopic examination of lesions was carried out using a dermatoscope and patterns including Wickham striae, pigment distribution, vascular structures, background color, and dots/globules were analyzed. Histopathological examination was performed in all patients to establish clinico-pathological correlation. Statistical analysis was performed to identify significant associations among clinical, dermoscopic, and histopathological parameters.

Results
Classical lichen planus was the most common clinical variant observed. The lower limbs, particularly the legs and dorsum of feet, were the most frequently involved sites. Pruritus was significantly associated with classical LP. Dermoscopic analysis revealed Wickham striae predominantly in a reticular arrangement with diffuse distribution. White coloration of Wickham striae was the most common finding, while brown background pigmentation predominated in most lesions. White and yellow dots were significantly more frequent in lichen planus pigmentosus. Histopathological examination demonstrated melanophages, pigment incontinence, orthohyperkeratosis, band-like lymphocytic infiltrate, basal cell degeneration, and perivascular infiltrates as predominant findings. A significant concordance between dermoscopic and histopathological findings was observed, supporting the utility of dermoscopy as an adjunctive diagnostic tool in LP.

Conclusions

Lichen planus exhibits diverse clinical and dermoscopic patterns with significant histopathological correlation. Dermoscopy serves as a rapid, non-invasive, and reliable diagnostic aid for identifying characteristic features of LP and differentiating its variants. Recognition of specific dermoscopic structures such as Wickham striae, pigment patterns, and vascular morphology may facilitate early diagnosis and improve clinico-pathological accuracy. Integration of dermoscopy into routine dermatological practice can enhance diagnostic confidence and reduce the need for invasive procedures in selected cases.

EA DV CONGRESS
VIENNA
30 SEP - 3 OCT 2026

Abstract N°: 3360

Patient-Reported Outcomes With Upadacitinib in Adults and Adolescents With Nonsegmental Vitiligo: Pooled Results From Two Phase 3 Trials (Viti-Up 1&2) Through Week 48

Khaled Ezzedine*[1, 2], Kent A Hanson[3], Ahmed M Soliman[3], Iltefat Hamzavi[4], Seemal R Desai[5, 6], Thierry Passeron[7, 8], Marni Wiseman[9, 10], Nina Magnolo[11], Ken Okamura[12], Xiaofei Hu[3], Stavonnie Patterson[3], Bethanee J Schlosser[3], Henrique Teixeira[3], David Rosmarin[13]

[1] Department of Dermatology, Hôpital Henri Mondor, APHP, Créteil, France
[2] EA 7379 EpidermE, Université Paris-Est Créteil (UPEC), Créteil, France
[3] AbbVie Inc., North Chicago, IL, United States
[4] Photomedicine and Photobiology Research Unit, Department of Dermatology, Henry Ford Health, Detroit, United States
[5] University of Texas Southwestern Medical Center, Dallas, United States
[6] Innovative Dermatology, Plano, United States
[7] Department of Dermatology, Centre Hospitalier Universitaire de Nice, Côte d'Azur University, Nice, France
[8] INSERM U1065, Centre Méditerranéen de Médecine Moléculaire (C3M), Côte d'Azur University, Nice, France
[9] Section of Dermatology, Department of Medicine, University of Manitoba, Winnipeg, Canada
[10] SKiNWISE Dermatology, Winnipeg, Canada
[11] Department of Dermatology, University Hospital Münster, Münster, Germany
[12] Department of Dermatology, Faculty of Medicine, Yamagata University, Yamagata, Japan
[13] Department of Dermatology, Indiana University School of Medicine, Indianapolis, United States

Introduction

Nonsegmental vitiligo (NSV) is a chronic, unpredictable, progressive, immune-mediated inflammatory skin disease often accompanied by substantial psychosocial burden, including stigma, low self-esteem, and social withdrawal, all contributing to impaired health-related quality of life (HRQoL) (Rosmarin D, et al. *Dermatol Ther* [Heidelb]. 2024;14(6):1633-1647). Upadacitinib (UPA), a selective oral Janus kinase (JAK) inhibitor with higher potency for JAK1 than other JAK isoforms, has demonstrated clinically meaningful total body repigmentation in two pivotal phase 3 NSV trials (Viti-Up-1 and Viti-Up-2), with safety consistent with approved indications. This pooled analysis from Viti-Up-1 and Viti-Up-2 evaluates key patient-reported outcomes (PROs) through week 48.

Materials and Methods

The ongoing global, randomized, double-blind, placebo (PBO)-controlled, multicenter phase 3 Viti-Up trials (NCT06118411) enrolled adults and adolescents (≥12 years) with NSV involving face and body with Facial Vitiligo Area Scoring Index (F-VASI) ≥0.5 and Total Vitiligo Area Scoring Index (T-VASI) ≥5. Participants were randomized 2:1 to UPA 15 mg once daily or PBO for 48 weeks. PRO measures (endpoints) included: Vitiligo Noticeability Scale (VNS; proportion reporting "A lot less noticeable/No longer noticeable"), Vitiligo-Specific Quality-of-Life instrument (VitiQoL; change from baseline in total and domain scores: stigma, behavior, participation limitation), Patient Global Impression of Total Body Color Matching (PGI–CM; proportion reporting "Good/Very good/Excellent match"), Patient Global Impression of Change–Vitiligo (PaGIC–Vitiligo; proportion reporting "A little better/Much better"), and PGIC of Vitiligo Sun Sensitivity (PGIC–Sen; proportion reporting "A little better/Much better"). Binary endpoints were analyzed using the Cochran–Mantel–Haenszel test (non-responder

imputation, NRI) and continuous endpoints using ANCOVA (multiple imputation [MI], except that missing data following treatment discontinuation due to lack of efficacy were handled using return-to-baseline [RTB], RTB–MI).

Results

A total of 614 patients were randomized (UPA, n=411; PBO, n=203). At week 48, a significantly higher proportion of UPA-treated patients rated their vitiligo as "A lot less noticeable" or "No longer noticeable" on the VNS vs PBO (13.6% vs 1.5%; *P*<.001), with numerical differences observed by week 24 (9.2% vs 1.0%; nominal *P*<.001). VitiQoL score reductions (better HRQoL) were greater with UPA vs PBO at week 24 (−8.3 vs -2.7) and week 48 (−7.5 vs -2.5; nominal *P*<.001 for each), with consistent benefits across all VitiQoL domains at weeks 24 and 48. Color match between repigmented and unaffected skin was rated as good or better by a higher proportion of patients receiving UPA vs PBO (week 24: 55.7% vs 34.0%; week 48: 54.5% vs 28.6%; nominal *P*<.001 for each). PaGIC-Vitiligo showed greater proportions of patients rating their vitiligo as "A little better" or "Much better" with UPA vs PBO (week 24: 65.2% vs 30.5%; week 48: 62.8% vs 19.7%; nominal *P*<.001 for each), with a significantly greater proportion reporting "Much better" with UPA vs PBO at week 48 (16.8% vs 2.5%; *P*<.001). Improvements of at least "A little better" were also more frequently reported with UPA vs PBO in sun sensitivity (week 24: 23.8% vs 12.3%; week 48: 29.4% vs 9.9%; nominal *P*<.001 for each). Results are presented in **Table 1**.

Table 1. Summary of Key Patient-Reported Outcomes.

	Week 24			Week 48		
Endpoints n (%), [95% CI] unless otherwise noted	**PBO (n = 203)**	**UPA (n = 411)**	***P* value**	**PBO (n = 203)**	**UPA (n = 411)**	***P* value**
Secondary Endpoints						
VNS score of "A lot less noticeable (4)" or "No longer noticeable (5)" at week 48	-	-	-	3 (1.5) [0.0, 3.1]	56 (13.6) [10.3, 16.9]	<.001
Achievement of PaGIC-V of "Much better (1)" at week 48	-	-	-	5 (2.5) [0.3,4.6]	69 (16.8) [13.2, 20.4]	<.001
Additional Endpoints						
VNS score of "A lot less noticeable (4)" or "No longer noticeable (5)" at week 24	2 (1.0) [0.0, 2.3]	38 (9.2) [6.4, 12.0]	< .001	-	-	-
Change from baseline in VitiQoL Total score, LSM (SE) [95% CI]	-2.7 (1.58) [-5.8, 0.4]	-8.3 (1.28) [-10.8, -5.8]	< .001	-2.5 (1.62) [-5.7, 0.7]	-7.5 (1.32) [-10.1, -5.0]	<.001
Change from baseline in Participant limitation score	-0.3 (0.73) [-1.8, 1.1]	-3.1 (0.58) [-4.2, -1.9]	< .001	-0.4 (0.71) [-1.8, 1.0]	-2.7 (0.57) [-3.8, -1.6]	<.001
Change from baseline in Stigma score	-1.5 (0.63) [-2.7, -0.2]	-3.2 (0.51) [-4.2, -2.2]	< .01	-1.7 (0.67) [-3.0, -0.4]	-3.3 (0.52) [-4.3, -2.3]	<.01
Change from baseline in Behaviors score	-1.4 (0.41) [-2.2, -0.6]	-2.3 (0.33) [-2.9, -1.6]	< .05	-0.9 (0.41) [-1.7, -0.1]	-1.6 (0.34) [-2.3, -1.0]	<.05
PGI-CM score of "Excellent match (0)" or "Very good match (1)" or "Good match (2)"	69 (34.0) [27.5, 40.5]	229 (55.7) [50.9, 60.5]	< .001	58 (28.6) [22.4, 34.8]	224 (54.5) [49.7, 59.3]	<.001
PaGIC-V of "Much better (1)" or "A little better (2)"	62 (30.5) [24.2, 36.9]	268 (65.2) [60.6, 69.8]	< .001	40 (19.7) [14.2, 25.2]	258 (62.8) [58.1, 67.4]	<.001
PGIC-Sen score of "Much better (0)" or "A little better (1)"	25 (12.3) [7.8, 16.8]	98 (23.8) [19.7, 28.0]	< .001	20 (9.9) [5.8, 14.0]	121 (29.4) [25.0, 33.8]	<.001

NRI, non-responder imputation; PaGIC-V, Patient Global Impression of Change–Vitiligo; PBO, placebo; PGI-CM, Patient Global Impression of Total Body Color Matching; PGIC-Sen, Patient Global Impression of Change of Vitiligo Sun Sensitivity; RTB-MI, Return-to-Baseline Multiple Imputation; UPA, upadacitinib; VitiQoL, Vitiligo Quality-of-Life; VNS, Vitiligo Noticeability Scale.

P values and 95% CIs were derived using the Cochran–Mantel–Haenszel test (NRI, binary endpoints) and ANCOVA (RTB–MI, continuous endpoints). *P* values for additional endpoints are nominal. Data are from intent-to-treat population A (ITT_A), comprising all patients randomized at baseline.

Conclusions

In this pooled phase 3 analysis from the Viti-Up trials, UPA-treated patients with NSV experienced improvement across multiple PROs, addressing disease noticeability, HRQoL, color match, overall impression of change, and sun sensitivity compared with PBO. Differences were evident by week 24 and sustained through week 48. These results support the potential of UPA to address both visible disease manifestations and psychosocial impact in NSV management.

EA DV CONGRESS
VIENNA
30 SEP - 3 OCT 2026

Abstract N°: 3399

Impact of Vitamin D Receptor Variants on Non-Segmental Vitiligo Susceptibility and Clinical Phenotype in a Greek Cohort

Polytimi Sidiropoulou*[1], Martha-Spyridoula Katsarou[1], Akylas Fotiadis[2], Annia Tsolakou[1], Charitomeni Vavouli[1], Alexander Stratigos[1], Nikolaos Drakoulis[1], Electra Nicolaidou[1]

[1] National And Kapodistrian University Of Athens, 1st Dept. of Dermatology-Venereology, Medical School, 'A. Sygros' Hospital for Skin and Venereal Diseases, Research Group of Clinical Pharmacology and Pharmacogenomics, Faculty of Pharmacy, School of Health Sciences, Athens, Greece
[2] Aristotle University of Thessaloniki, Thessaloniki, Greece

Introduction
Non-segmental vitiligo (NSV) is a depigmenting disorder involving complex genetic, immunologic and environmental components. Common variants in the vitamin D receptor (*VDR*) gene have been explored in relation to vitiligo, but results remain inconsistent and Greek-specific data are limited. Aim of this study was to investigate the role of the *VDR* FokI (rs2228570), BsmI (rs1544410) and TaqI (rs731236) variants in NSV susceptibility and clinical phenotype in a Caucasian Greek cohort.

Materials and Methods
In this observational cross-sectional study, 966 unrelated Greek subjects, including 161 NSV cases and 805 age-, sex- and ethnicity-matched controls (case-control ratio 1:5), were genotyped for the selected *VDR* variants using real-time PCR followed by melting-curve analysis. Statistical analyses were performed under dominant, recessive, overdominant and allelic genetic models to calculate odds ratios (ORs) with their 95% confidence intervals (CIs), while false discovery rate (FDR) correction was applied to adjust for multiple testing.

Results
Case-control analysis indicated significant associations of BsmI and TaqI with NSV susceptibility. BsmI was associated with NSV risk under the dominant (AA + GA vs. GG: OR (95%CI) 0.603 (0.420-0.867); adjusted p=0.012), recessive (AA vs. GA + GG: OR (95%CI) 0.628 (0.410-0.963); adjusted p=0.044) and allelic (A vs. G: OR (95%CI) 0.689 (0.541-0.877); adjusted p=0.012) models, suggesting that presence of the A allele may protect against NSV. TaqI showed a significant correlation with NSV susceptibility under both the dominant (CC + CT vs. TT: OR (95%CI) 0.646 (0.456-0.916); adjusted p=0.028) and allelic (C vs. T: OR (95%CI) 0.708 (0.553-0.906); adjusted p=0.024) models, indicating a protective effect of the C allele. Intra-patient analyses based on clinical features indicated phenotype-specific contributions: FokI correlated with both age at onset and familial vitiligo, while TaqI was linked to leukotrichia.

Conclusions
This study indicated that *VDR* BsmI and TaqI may affect susceptibility of NSV in the Greek population, while FokI and TaqI may influence clinically relevant traits, including age at onset, leukotrichia and familial clustering of disease. Thus, *VDR* genetic variation may exert population- and/or ethnic-specific effects that could play a role in

NSV initiation and phenotypic expression. Further large-scale studies are needed to validate these findings and clarify the role of vitamin D/*VDR*-related genetic pathways in NSV across different populations.

EA DV CONGRESS
VIENNA
30 SEP - 3 OCT 2026

Abstract N°: 3427

Real-world effectiveness of topical ruxolitinib in non-segmental vitiligo: repigmentation, mental health, and quality-of-life outcomes in an 860-patient multicentre study

SILVIA ALBERTI VIOLETTI*[1], Angelo Valerio Marzano[1], Alessandra Narcisi[2], Gianluca Tavoletti[1], Luisa Carlotta Rossi[1], Maurizio Romagnuolo[1], Matteo Bianco[2], Paolo Amerio[3], Edvige Morea[3], eugenio provenzano[4], Franco Rongioletti[5], Stefania Guida[5], Lorenzo Pinto[6], Alessandra D'amore[6], Maria Concetta Fargnoli[7], Alessia Pacifico[7], Paolo Pacifico[7], Pietro Rubegni[8], Emanuele Trovato[8], Marco Romanelli[9], Alessandra Michelucci[9], Giuseppe Micali[10], Maria Letizia Musumeci[11], Aldo Lajos Di Marco[10], Maddalena Napolitano[12], Luigi Coronella[12], Caterina Foti[13], Alessandro Borghi[14], Lucrezia Pacetti[14], Serena Giacalone[15], Cristina Beatrice Spigariolo[15], Gianluca Nazzaro[1], Simone Ribero[16], Luca Mastorino[16], ANNA BELLONI FONTINA[17], Alvise Sernicola[17], Oriana SIMONETTI[18], Marco Matteucci[18], Eustachio Nettis[19], Luca Stingeni[20], Giovanni Pellacani[21], Annunziata Dattola[21], Iris Zalaudek[22], Raffaele Dante Antonio Caposiena Caro[22], Emiliano Antiga[23], Maria Efesia Baffa[23], Maria Esposito[24], Manfredo Bruni[25], Paolo Sena[26], Pamela Vezzoli[27], Lorenzo Rocca[27], Emanuele Cozzani[28], Giulia Gasparini[28], Niccolò Capurro[29], Paola Savoia[30], Piergiacomo Calzavara-Pinton[31], Mariachiara Arisi[32], Carlo Francesco Tomasini[33], Andrea Michelerio[33], Stefania Barruscotti[34], Mauro Picardo[35], Alessia Paganelli[35], Piergiorgio Malagoli[36, 36], Alessandro Pileri[37], Roberta Giuffrida[37], Santo Raffaele Mercuri[38], Vittoria Giulia Bianchi[38], Giuseppe Argenziano[39], Elisabetta Fulgione[39], Giampiero Girolomoni[40], Martina Maurelli[41], Antonio Costanzo[42], Alessandra Cartocci[43], Ketty Peris[44]

[1] Fondazione IRCCS Ca' Granda ospedale Maggiore Policlinico, SC Dermatologia, University of Milan, Milan, Italy
[2] Dermatology Unit, IRCCS Humanitas Research Hospital, Rozzano, Italy
[3] Gabriele d'Annunzione University of Chieti-Pescara, Chieti, Italy
[4] Azienda ospedaliera di Cosenza, UOC Dermatologia, Cosenza, Italy
[5] IRCCS San Raffaele Scientific Institute, Milan, Italy
[6] Fondazione Policlinico Universitario Agostino gemelli IRCCS, UOC Dermatologia, Roma, Italy
[7] San Gallicano Dermatological Institute, Rome, Italy
[8] University of Siena, Siena, Italy
[9] University of Pisa, Pisa, Italy
[10] University of Catania, catania, Italy
[11] University of Catania, Catania, Italy
[12] University of Naples Federico II, Naples, Italy
[13] Section of Dermatology, Department of Biomedical Science and Human Oncology, University of Bari, Bari, Italy
[14] University of Ferrara, Ferrara, Italy
[15] ASST Valle Olona, Dermatology Unit, Gallarate, Italy
[16] University of Turin, Turin, Italy
[17] University of Padua, Padua, Italy
[18] Polytechnic Marche University, Ancona, Italy
[19] Univerisity of Bari, Bari, Italy
[20] University f Perugia, Perugia, Italy
[21] La Sapienza University of Rome, Rome, Italy
[22] University of Trieste, Trieste, Italy

[23] University of Florence, Florence, Italy
[24] Università De L'Aquila, L'aquila, Italy
[25] Univeristy of L'Aquila, L'aquila, Italy
[26] ASST Ospedale Papa Giovanni XXIII, Bergamp, Italy
[27] ASST Ospedale Papa Giovanni XXII, Bergamo, Italy
[28] University of Genoa, Genoa, Italy
[29] IRCCS San Martino University Hospital, Genoa, Italy
[30] A. Avogadro University of Eastern Piemont, Novara, Italy
[31] Department of Dermatology, University of Brescia, Brescia, Italy
[32] University of Brescia, Spedali Civili di Brescia, Brescia, Italy
[33] University of Pavia, Pavia, Italy
[34] IRCCS Policlinico San Matteo Foundation, Pavia, Pavia, Italy
[35] Istituto Dermopatico Immacolata DI-IRCCS, Rome, Italy
[36] Azienda Ospedaliera San Donato, Milano, Italy
[37] Dermatology Unit- IRCCS Azienda Ospedaliero-Universitaria di Bologna, Bologna, Italy
[38] Vita-Salute San Raffaele University, Milan, Italy
[39] University of Campania “Luigi Vanvitelli”, Naples, Italy
[40] Universita di Verona, Verona, Italy
[41] Department of Medicine, Section of Dermatology and Venereology, University of Verona, Verona, Italy
[42] Istituto Clinico Humanitas, Verona, Italy
[43] Department of Molecular and Developmental Medicine, University of Siena, Siena, Italy
[44] Institute of Dermatology, Catholic University of the Sacred Heart, Rome, Italy

Introduction

Introduction: Topical ruxolitinib 1.5% cream is approved for non-segmental vitiligo based on phase 3 trial data from selected populations. Whether efficacy and patient-reported outcomes translate to routine clinical practice — in older, pre-treated patients with longer disease duration and greater comorbidity burden — remains poorly characterized.

Materials and Methods

Methods: Multicentre retrospective cohort study (July 2024–October 2025) enrolling patients aged ≥12 years with non-segmental vitiligo receiving ruxolitinib 1.5% cream twice daily. Primary endpoints were F-VASI75 and F-VASI90 at 24 and 52 weeks. Secondary endpoints included VNS, DLQI, VitiQoL, GAD-7, and PHQ-9.

Results: Of 860 patients completing 24-week assessment (mean age 47 years; 58% female; disease duration 13.5 years; 84% previously treated), 229 reached 52 weeks at data lock. F-VASI75 rose from 18.5% at 24 weeks to 38.4% at 52 weeks (2.1-fold); F-VASI90 from 5.7% to 25.8% (4.5-fold). Active disease predicted superior early response (F-VASI75 22.5% vs 13.3%, p=0.004), with convergence for F-VASI75 but not F-VASI90 by 52 weeks (33.3% vs 18.0%, p=0.026). VNS ≥4 was achieved in 36.4% at 24 weeks and 55.9% at 52 weeks. DLQI improved by 50% at 24 weeks and 82% at 52 weeks; VitiQoL MCID was achieved in 60% and 84%, respectively. The proportion with moderate-to-severe anxiety (GAD-7 ≥10) fell from 37% at baseline to 11% at 24 weeks and 2% at 52 weeks; moderate-to-severe depressive symptoms (PHQ-9 ≥10) from 19% to 7% and 1%. In multivariable logistic regression, summer treatment initiation (OR 6.7, 95% CI 2.7–16.8) and Koebner phenomenon (OR 1.6, 95% CI 1.04–2.66) were independent predictors of F-VASI75 at 24 weeks. Adverse events were mild in 98.9%; discontinuation rate was 1.5%.

Results

Results: Of 860 patients completing 24-week assessment (mean age 47 years; 58% female; disease duration 13.5 years; 84% previously treated), 229 reached 52 weeks at data lock. F-VASI75 rose from 18.5% at 24 weeks to

38.4% at 52 weeks (2.1-fold); F-VASI90 from 5.7% to 25.8% (4.5-fold). Active disease predicted superior early response (F-VASI75 22.5% vs 13.3%, p=0.004), with convergence for F-VASI75 but not F-VASI90 by 52 weeks (33.3% vs 18.0%, p=0.026). VNS ≥4 was achieved in 36.4% at 24 weeks and 55.9% at 52 weeks. DLQI improved by 50% at 24 weeks and 82% at 52 weeks; VitiQoL MCID was achieved in 60% and 84%, respectively. The proportion with moderate-to-severe anxiety (GAD-7 ≥10) fell from 37% at baseline to 11% at 24 weeks and 2% at 52 weeks; moderate-to-severe depressive symptoms (PHQ-9 ≥10) from 19% to 7% and 1%. In multivariable logistic regression, summer treatment initiation (OR 6.7, 95% CI 2.7–16.8) and Koebner phenomenon (OR 1.6, 95% CI 1.04–2.66) were independent predictors of F-VASI75 at 24 weeks. Adverse events were mild in 98.9%; discontinuation rate was 1.5%.

Conclusions

Conclusions: Topical ruxolitinib drives progressive repigmentation through 52 weeks in routine practice, with a tolerability profile consistent with controlled trials. The sustained resolution of clinically significant anxiety and depression supports inclusion of standardized mental health instruments in future vitiligo trials. Summer initiation and Koebner phenomenon independently predicted early response, with implications for patient counseling and treatment timing.

EA DV CONGRESS
VIENNA
30 SEP - 3 OCT 2026

Abstract N°: 3481

Agminated Lentiginosis and Segmental Café-Au-Lait Macules without Neurofibromatosis Type 1 Criteria: A Rare Case Report

Huriye Aybüke Koç[1], Elif Özenir*[2], Hülya Öksüz Kabadayı[3]

[1] Giresun University, Faculty of Medicine, Department of Dermatology, Giresun, Türkiye
[2] Giresun Training and Research Hospital, Department of Dermatology, Giresun, Türkiye
[3] Giresun University, Faculty of Medicine, Department of Pathology, Giresun, Türkiye

Introduction

Lentigines are oval or irregularly shaped, light brown, dark brown, or black lesions with an average diameter of five millimeters. Agminated lentiginosis (AL) is characterized by clustered lentigines, typically presenting in a segmental distribution on otherwise normal skin; various cases have been reported under distinct medical terms, such as partial unilateral lentiginous or segmental lentiginosis. The differential diagnosis of AL primarily includes segmental neurofibromatosis, nevus spilus, agminated Spitz nevus, and agminated melanocytic nevi. Herein, we present a rare case of AL uniquely accompanied by ipsilateral, segmentally distributed café-au-lait macules.

Case Presentation

A 33-year-old female patient presented to our clinic with a history of numerous pigmented lesions on her back and anterior chest wall since childhood. The patient’s medical history revealed no prior trauma, immunosuppression, or systemic diseases. Her family history was negative for genetic dermatoses, malignant melanoma, or dysplastic nevus syndrome. Dermatologic examination revealed multiple, agminated, light-brown macules distributed segmentally on the right side of the body, strictly respecting the anatomical midline. These lesions occupied an area of 20×30 cm on the back and 33×20 cm on the anterior chest, extending toward the right forearm and neck. Concurrently, within the same segmental distribution, numerous café-au-lait macules with diameters ranging from 1 cm to 4 cm and ipsilateral axillary freckling were observed. No background hyperpigmentation was detected in the skin areas where the agminated lesions were located. Dermoscopy of the lentiginous agminated lesions demonstrated diffuse light brown pigmentation, fingerprint-like structures, and moth-eaten borders. Dermoscopic analysis of the café-au-lait macules revealed homogenous light brown pigmentation, smooth borders, and perifollicular hypopigmentation. Despite the presence of café-au-lait macules and ipsilateral axillary freckling, only four of the café-au-lait macules measured 1.5 cm or larger. Furthermore, the patient lacked neurofibromas, Lisch nodules, optic gliomas, distinctive osseous lesions, or a first-degree relative with the disease. Consequently, the diagnosis of Neurofibromatosis Type 1 (NF1) was not supported based on the National Institutes of Health (NIH) consensus criteria. A punch biopsy was performed from the cafe-au-lait macule on the patient's back. Histopathological examination revealed hyperkeratosis/orthokeratosis in the epidermis, increased basal melanin pigmentation at the dermoepidermal junction, and minimal perivascular lymphocytic infiltration in the superficial dermis. Immunohistochemical analysis showed no evidence of cellular atypia.Based on the clinical, dermoscopic, and histopathological findings, the case was diagnosed as agminated lentiginosis accompanied by café-au-lait macules in the absence of neurofibromatosis. Genetic testing was recommended, and the patient was placed on a regular clinical follow-up schedule.

Conclusion

Segmental neurofibromatosis and nevus spilus are the main differential diagnoses of agminated lentiginosis (AL).

In our case, nevus spilus was excluded due to the absence of background hyperpigmentation. Although some authors consider AL to be a variant of segmental neurofibromatosis, unlike the previously reported cases, our patient did not exhibit any NF1 diagnostic criteria such as neurofibromas, Lisch nodules, or skeletal abnormalities. Nevertheless, considering the possibility that AL may represent a mosaic/incomplete form of NF1, careful long-term follow-up for potential systemic involvement is warranted. In conclusion, this case demonstrates that even in the presence of unilateral café-au-lait macules, the differential diagnosis of AL should be performed meticulously and long-term patient follow-up should not be overlooked.

EA DV CONGRESS
VIENNA
30 SEP - 3 OCT 2026

Abstract N°: 3566

Eruptive Sutton nevi in an adult patient preceding colon adenocarcinoma: Coincidence or immunologic clue?

Speranța-Cristina Andronic*[1], Carmen Comănescu[1]

[1] Colentina Clinical Hospital, Dermatology II, Bucharest, Romania

Introduction

Halo nevi (Sutton nevi) are melanocytic nevi surrounded by a depigmented rim resulting from immune-mediated melanocyte destruction. Together with vitiligo and melanoma-associated hypopigmentation, they belong to the spectrum of immunological leukodermas. Although circulating anti-melanocyte antibodies may be identified in some patients, the principal mechanism of melanocyte damage appears to be lymphocyte-mediated. Halo nevi are most commonly encountered in children and adolescents, whereas the sudden onset of multiple lesions in adulthood is uncommon and has occasionally been reported in association with malignancy, suggesting a possible underlying immune dysregulation.

Case Presentation

We report the case of a 66-year-old woman diagnosed in 2024 with right-sided colon adenocarcinoma (pT3N0Mx), treated by right hemicolectomy followed by adjuvant capecitabine chemotherapy according to the oncologic protocol. The patient presented to our department for the progressive depigmentation of pre-existing melanocytic nevi, first noticed in 2021, approximately three years prior to the diagnosis of colon cancer.
Clinical examination revealed five halo nevi located on the posterior trunk. Three lesions presented as depigmented halos surrounding residual melanocytic nevi, one lesion showed a pink intradermal nevus with a peripheral halo, while another lesion demonstrated almost complete regression of the central nevus with persistent surrounding depigmentation. An additional larger light-brown nevus with terminal hairs and a broad halo measuring approximately 3 cm was also identified.
The patient denied personal or family history of autoimmune disorders, melanoma, or other malignancies. Thyroid disease was excluded during endocrinologic follow-up. Her medical history was notable for nickel allergy, previous occupational exposure to chemical substances, and a 15-year smoking history discontinued in 2020.
Annual clinical and dermoscopic follow-up was recommended in order to monitor the evolution of residual melanocytic lesions and to exclude possible atypical transformation. The patient was also educated regarding strict photoprotection measures, including regular use of broad-spectrum SPF and avoidance of excessive ultraviolet exposure.

Conclusion

Although halo nevi are generally considered benign and easily recognized lesions, the sudden onset of multiple eruptive halo nevi in adulthood remains uncommon and may represent a diagnostic challenge. Several authors have suggested a possible association between eruptive Sutton nevi and underlying malignancies, potentially mediated by incompletely understood immune mechanisms.

Our case highlights the temporal association between the spontaneous appearance of multiple halo nevi and the subsequent diagnosis of colon adenocarcinoma. While current evidence remains insufficient to establish a direct causal relationship between adult-onset eruptive halo nevi and internal malignancies, clinicians should maintain awareness of this potential.

EA DV CONGRESS
VIENNA
30 SEP - 3 OCT 2026

Abstract N°: 3603

Efficacy and Safety of a 2-Mercaptonicotinoyl Glycine containing (MB3) serum versus Hydroquinone cream as neoadjunctive and adjunctive therapy to Low-Fluence 1064 nm Q-Switched Nd:YAG Laser for Melasma and Acne Induced Hyperpigmentation

Irma Bernadette Simbolon Sitohang*[1, 2], lilik norawati ashadi[3], abraham arimuko[3], Silvia Veronica Setiawan[3], Frylie Fremiati[1], Naomi Ahimsa[1], Pute Misilawaty[1], Delphine Kerob[4]

[1] Division of Cosmetic Dermatology, Department of Dermatology and Venereology, Faculty of Medicine, Universitas Indonesia, Dr. Cipto Mangunkusumo Hospital, Jakarta, Indonesia, Jakarta, Indonesia

[2] Medical Staff Unit of Dermatology and Venereology, Universitas Indonesia Hospital, Depok, Indonesia, Depok, Indonesia

[3] Department of Dermatology and Venereology, Department of Dermatology and Venereology, Presidential-Army Central Hospital Gatot Soebroto in Jakarta, Indonesia, Jakarta, Indonesia

[4] La Roche-Posay laboratoire Dermatologique, Levallois-Perret, France, Paris, France

Introduction

Melasma and acne induced hyperpigmentation (AIH), represent a substantial dermatological burden due to their high prevalence and profound impact on patient quality of life. Hydroquinone (HQ) remains a gold standard for pigmentary disorders management, but its clinical utility has many risks such as irritation and in the long-term use, exogenous ochronosis. Low-fluence Q-switched Nd:YAG (QS-Nd:YAG) 1064 nm as toning laser (TL) therapy is a widely utilized intervention, its success is often limited by the risk of post-inflammatory hyperpigmentation (PIH), especially in darker skin phototypes. 2-Mercaptonicotinoyl Glycine is an innovative ingredient able to capture melanin precursors without inhibiting tyrosinase offering a high performance in managing hyperpigmentation. This study evaluates the efficacy and safety of a novel non-HQ MB3 serum as a safe HQ-free alternative prior to and following TL.

Materials and Methods

Two randomized controlled trials, single-blind, were conducted involving women (Fitzpatrick III-V) with melasma and AIH. Subjects underwent a 2-week priming phase with MB3 serum (twice daily) or HQ 2% (nightly), followed by a TL session. Topical treatment was discontinued immediately after the laser procedure and resumed three days later, then continued throughout the 4-week follow-up period. Broad-spectrum SPF/UVA sunscreen was used throughout the study. Efficacy was assessed in using modified Melasma Area and Severity Index (mMASI) for melasma and Post- Acne Hyperpigmentation Index (PAHPI) for AIH, alongside objective Mexameter measurements.

Results

In the melasma trial, 36 subjects were included (n=18 per group). Mean mMASI scores decreased similarly in both groups (MB3: 4.05 to 2.85; HQ: 4.95 to 2.75; $p>0.05$). Objective melanin indices decreased equally without significant inter-group differences. In the AIH trial, 35 subjects were included (MB3 group; n=18, HQ2%; n=17), as one participant withdrew due to an unrelated illness. Mean PAHPI scores improved similarly in both groups (MB3 : 8.94 to 8.06; HQ: 9.56 to 8.72, $p>0.05$). No post-laser PIH was observed in either group throughout the 4-week

follow-up period. Regarding safety, the serum group exhibited significantly fewer early adverse events at visit 2 in the melasma trial (dryness p=0.041; erythema p=0.019) compared with HQ. In the AIH trial, the serum was well-tolerated with only transient, self-limiting side effects. No serious adverse events occurred in either study.

Conclusions

The MB3 serum demonstrates comparable efficacy to HQ 2% as a neoadjunctive and adjunctive solution to TL for both melasma and AIH. With its superior early tolerability and non-cytotoxic approach, it appears to be a safe and effective HQ-free alternative for improving hyperpigmentation and preventing PIH especially in skin of color patients. Larger studies with other dermatological procedures would be interesting in the future.

EA DV CONGRESS
VIENNA
30 SEP - 3 OCT 2026

Abstract N°: 3607

Real-world data of the German National Vitiligo Register VitiBest

Paula Marie Junghanß*[1], Charlotte Willers[1], Jana Larissa Röckendorf[1], Markus Boehm[2], Ralph von Kiedrowski[3], Matthias Augustin[1]

[1] Institute for Health Services Research in Dermatology and Nursing; University Medical Center, Hamburg, Germany

[2] University of Muenster, Muenster, Germany

[3] Company for Medical Study & Service, Selters, Germany

Introduction

Vitiligo is a common skin disease with a prevalence of about 0.9% in Germany. It is associated with numerous autoinflammatory and metabolic comorbidities as well as psychological burden for patients. The development of new treatment options has improved the management of vitiligo; however, novel therapies require real-world evaluation to assess their benefits, risks, and specific treatment profiles, as well as patient needs.

The German VitiBest registry was established in 2024 as the first German prospective, observational registry dedicated to vitiligo. It is supported by the German Dermatological Society (DDG), the Professional Association of German Dermatologists (BVDD), and the regional dermatology networks ("Hautnetze"), and is conducted by the Institute for Health Services Research in Dermatology and Nursing (IVDP). VitiBest aims to generate real-world evidence and improve the understanding of vitiligo in Germany, thereby allowing improvement of patient care.

Materials and Methods

The VitiBest registry started in 08/2024 (ethical approval: 2022-100895-BO-ff). The detailed register is found at: https://www.vitibest.dermregister.com/de/. Data have to be reported at inclusion as well as at months 6, 12, 18, and 24. Collected variables include epidemiologic and demographic characteristics, clinical subtype, disease activity markers, clinical vitiligo severity scores, comorbidities, treatment patterns, treatment satisfaction, health-related quality of life measurements, and several patient-reported outcomes (PROs) such as the EuroQol Visual Analogue Scale (EQ-VAS), the Patient Needs Questionnaire (PNQ), and the Patient Benefit Questionnaire (PBQ). As of April 22, 2026, a total of 18 sites have been activated, and a further 10 centers are currently in the process of activation. The study aims to recruit 1000 patients.

Results

So far, 81 vitiligo patients have been enrolled into the VitiBest registry. Herein, preliminary data of 77 patients are presented. Patients had a median age of 44 years (SD 14.7 yrs). 44% were female, 56% male. Median time from initial diagnosis to entry into the registry was 60 months (min-max. 0-672 months). Types of vitiligo were: segmental (22.1%) and non-segmental (77.9%). Mean affected body surface area (BSA) was 13.4% (SD 20.9). Vitiligo Extent Score (VES) 10.7 (SD 19.3), Facial-Vitiligo Area Scoring Index (F-VASI) 0.5 (SD 0.7).

Overall, markers of active disease were common, with poorly defined lesion borders observed in 79.2% of patients, followed by confetti-like lesions (37.7%) and Koebner phenomenon (20.8%).

Therapies recorded after the inclusion visit included ruxolitinib (83.1%), UV therapy (18.2%), local calcineurin inhibitors (18.2%), systemic corticosteroids (5.0%) or other therapies (1.3%). 2.6% of all patients received no treatment. The Vitiligo Noticeable Scale (VNS) revealed scores of 1–2 (treatment not successful; 34.4% of patients), 3 (treatment partially successful; 6.9% of patients), and 4–5 (treatment successful; 6.8% of patients).

PROs showed a median PNQ sum score of 45.2 (range 0–104) and a median PBQ sum score of 11.0 (range 0–104), indicating relevant patient-perceived needs with limited perceived treatment benefit. Mean Dermatology Life Quality Index (DLQI) was 5.5 (SD 4.4).

Conclusions

The VitiBest registry is the first multicenter German vitiligo registry. First analyzed data show the feasibility and acceptance of the registry. They also provide important insights into patient characteristics as well as patient needs in routine dermatologic care.

EA DV CONGRESS
VIENNA
30 SEP - 3 OCT 2026

Abstract N°: 3619

Twenty-four-week clinical outcomes and safety of oral ivarmacitinib in adults with stable non-segmental vitiligo: a real-world retrospective case series

Guangman Han[1], Jing Yuan*[2], Haonan Zhang[1], Chang E Chui[1], Menghan Di[3]

[1] Tianjin University of Traditional Chinese Medicine, Tianjin, China

[2] Affiliated Hospital of Tianjin Academy of Traditional Chinese Medicine, Tianjin, China

[3] Tianjin Medical University Cancer Institute and Hospital, Tianjin, China

Introduction

Stable non-segmental vitiligo remains difficult to repigment, and conventional therapies may be limited by slow onset, incomplete response, or difficulty maintaining repigmentation. Real-world evidence regarding oral ivarmacitinib remains limited. This study evaluated 24-week repigmentation outcomes and safety of oral ivarmacitinib in adults with stable non-segmental vitiligo.

Materials and Methods

We retrospectively reviewed adults with stable non-segmental vitiligo treated with oral ivarmacitinib at a tertiary dermatology center. Stable disease was defined as no new lesions or enlargement of existing lesions for at least 6 months before treatment. Clinical and demographic data, repigmentation outcomes, concomitant therapies, adverse events, and treatment adjustments were recorded. Outcomes were assessed at baseline and weeks 4, 8, 12, and 24.

Results

Fourteen patients were included (11 men, 3 women; mean age, 31.8 ± 10.7 years). All patients initially received oral ivarmacitinib 4 mg/day; 10 received ivarmacitinib monotherapy, 3 received concomitant narrow-band ultraviolet B (NB-UVB) phototherapy, and 1 received concomitant topical therapy. Perifollicular repigmentation was first observed by week 4 in 12 patients (85.7%). All patients improved from baseline by week 8; 13 patients (92.9%) showed further improvement by week 12; and all patients showed continued improvement from week 12 to week 24. At week 24, median body surface area (BSA) decreased from 1.25% (IQR, 0.48–2.00) to 0.50% (IQR, 0.28–1.38) ($P < 0.001$), median total Vitiligo Area Scoring Index (VASI) decreased from 0.76 (IQR, 0.30–1.50) to 0.29 (IQR, 0.18–0.94) ($P < 0.001$), and median facial Vitiligo Area Scoring Index (F-VASI) decreased from 0.05 (IQR, 0.00–0.14) to 0.02 (IQR, 0.00–0.14) ($P = 0.027$) (Figure 1 and Table 2). Seven patients (50.0%) achieved VASI50. Among 10 patients with baseline facial involvement, 6 (60.0%) achieved F-VASI50 and 2 (20.0%) achieved F-VASI75. In descriptive analyses, VASI50 was achieved by 5 of 10 patients receiving ivarmacitinib monotherapy and 2 of 4 patients receiving concomitant therapy; however, the small sample size and heterogeneous treatment exposure precluded comparative efficacy assessment. Eleven patients (78.6%) had no apparent adverse events. Three patients (21.4%) developed mild folliculitis-related cutaneous adverse events, including 2 cases of folliculitis and 1 case of *Malassezia* folliculitis. No clinically significant hepatic or renal function abnormalities, serious adverse events, or adverse-event-related permanent discontinuations occurred.

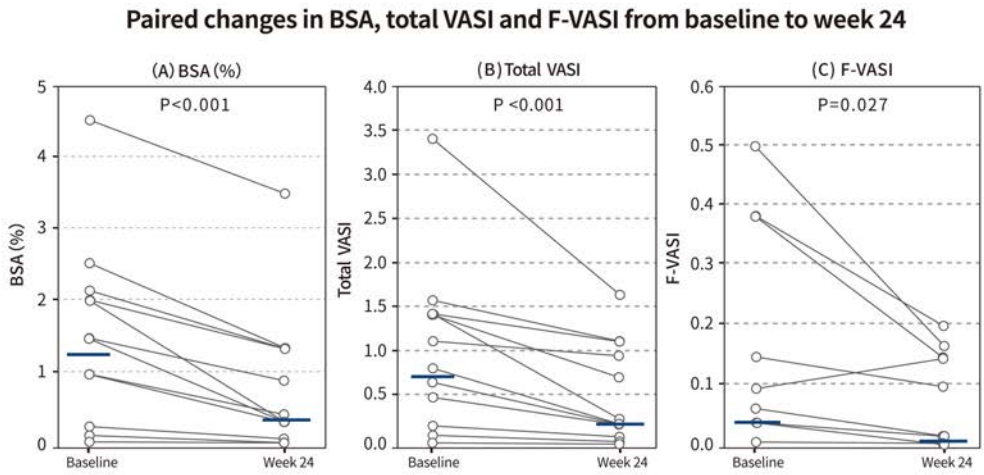

Table 2. Efficacy outcomes from baseline to week 24

Outcome	Baseline	Week 24 / follow-up outcome	P value
BSA, %, median (IQR)	1.25 (0.48–2.00)	0.50 (0.28–1.38)	<0.001
Total VASI, median (IQR)	0.76 (0.30–1.50)	0.29 (0.18–0.94)	<0.001
Overall F-VASI, median (IQR)	0.05 (0.00–0.14)	0.02 (0.00–0.14)	0.027
Perifollicular repigmentation first observed by week 4	—	12/14 (85.7%)	—
Improvement from baseline by week 8	—	14/14 (100.0%)	—
Further improvement by week 12	—	13/14 (92.9%)	—
Continued improvement by week 24	—	14/14 (100.0%)	—
VASI50 at week 24	—	7/14 (50.0%)	—
F-VASI50 among patients with baseline facial involvement	—	6/10 (60.0%)	—
F-VASI75 among patients with baseline facial involvement	—	2/10 (20.0%)	—

Figure 1 and Table 2. Paired changes in body surface area (BSA), total Vitiligo Area Scoring Index (VASI), and facial Vitiligo Area Scoring Index (F-VASI) from baseline to week 24, and efficacy outcomes from baseline to week 24. Horizontal bars indicate median values. P values were calculated using the Wilcoxon signed-rank test. For overall F-VASI analysis, patients without facial involvement were coded as 0.

Conclusions

Oral ivarmacitinib was associated with early and progressive repigmentation and an acceptable short-term safety profile in adults with stable non-segmental vitiligo. These findings should be interpreted as hypothesis-generating because of the small sample size, retrospective design, absence of a control group, and concomitant therapies in some patients. Further prospective controlled studies with longer follow-up are warranted.

POWERED BY M-ANAGE.COM

EADV CONGRESS
VIENNA
30 SEP - 3 OCT 2026

Abstract N°: 3641

Targeting melanin precursors vs. tyrosinase inhibition: A head-to-head clinical comparison of brightening products containing 2-Mercaptonicotinoyl Glycine versus Isobutylamido Thiazolyl Resorcinol in a UV-induced pigmentation model

Mingje Zhu[1], Yang Wang[1], Ming (Kelly) Yang[1], Ji (Rose) Zhang[1], Xiaofeng He[1], Chloé Delaunay[2], Frederique Labatut[2], Delphine Kerob*[3], Anne-Laure Demessant-Flavigny[3], Flament Frederic[4]

[1] L'Oreal Research & Innovation, Shanghai, China

[2] L'Oréal Research and Innovation, Chevilly-Larue, France

[3] La Roche-Posay Laboratoire Dermatologique, Levallois-Perret, France

[4] L'Oreal Research & Innovation, Clichy, France

Introduction

Hyperpigmentation treatments with cosmetics usually target distinct pathways: active such as Isobutylamido Thiazolyl Resorcinol (ITR) inhibits tyrosinase, whereas 2-Mercaptonicotinoyl Glycine (2-MNG) prevents melanin synthesis by capturing its precursors. Despite the proven clinical benefits of both actives independently, there is a lack of head-to-head clinical studies on final products utilizing a standardized methodology. This study aimed to compare the clinical efficacy of a brightening emulsion containing 1% 2-MNG with an on-market emulsion product containing ITR, utilizing a standardized UV-induced pigmentation methodology.

Materials and Methods

A randomized, double-blind, controlled trial was conducted with 32 Asian females (Fitzpatrick skin type III). 5 mini-zones on the subjects' backs were treated with either the 1% 2-MNG complex, vehicle of 2-MNG complex, ITR complex, positive control (7% ascorbic acid), or negative control, starting from D1 to D40. Pigmentation was induced by 0.5 MED of daily UV irradiation for 4 consecutive days (D8-D11). Efficacy was assessed via Chromameter measurements of color difference (ΔE) at D8, D9, D10, D11, D12, D15, D19, D26, D33 and D40 compared with baseline for each mini-zone.

Results

Data from the positive control area showed that 7% ascorbic acid significantly ($p<0.05$) reduced the UV-induced color difference compared to negative control, demonstrating the good reliability of UV induce model. At D12 (next day following the UV irradiation phase), compared with baseline, the area treated with 1% 2-MNG complex exhibited a delta E of 4.24. This was significantly lower ($p<0.05$) than both the Delta E of 6.67 observed in vehicle area and Delta E of 5.71 in ITR-treated area, demonstrating a superior anti-pigmentation effect. Furthermore, during the subsequent product application period (D15 to D40), the 1% 2-MNG complex consistently maintained a significantly lower Delta E ($p<0.05$) at all evaluation time points. The inter-treatment difference in Delta E between the 2-MNG and ITR areas remained consistently superior for 2-MNG (-1.34, -1.20, -1.26, -1.31, -1.30 across D15, D19, D26, D33, and D40 respectively, as shown in Figure 1).

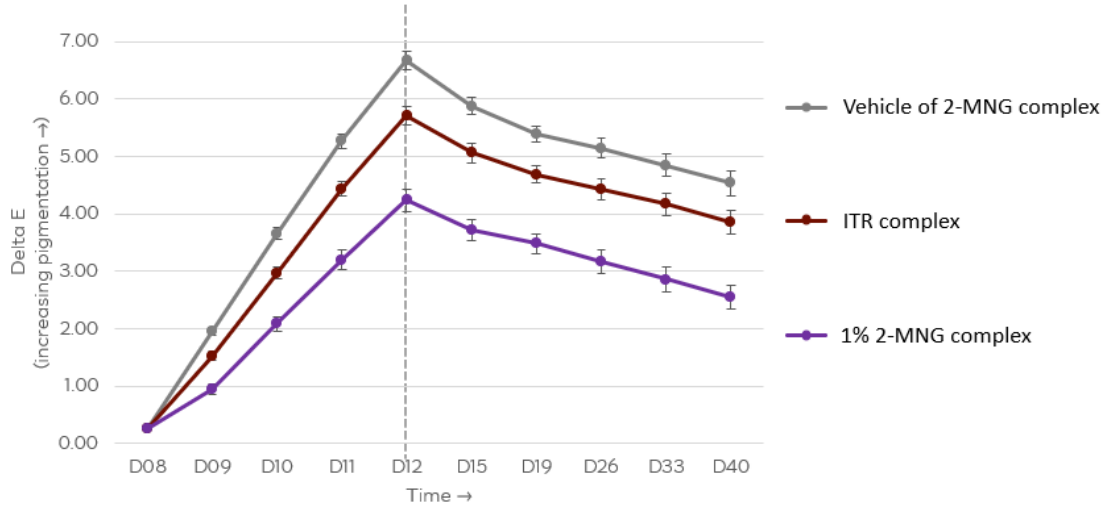

Fig.1 delta E kinetics with 95% confidence interval of 1% 2-MNG complex, its vehicle and ITR complex from D8-D40

Conclusions

This head-to-head study confirms that while both tyrosinase inhibition (via ITR) and melanin precursor capture (via 2-MNG) are effective strategies, the 1% 2-MNG complex demonstrated superior clinical efficacy against UV-induced pigmentation. These findings highlight the clinical relevance of targeting melanogenesis precursors as a highly effective and competitive approach in modern brightening cosmetic formulations.

EA DV CONGRESS
VIENNA
30 SEP - 3 OCT 2026

Abstract N°: 3651

Head-to-head clinical evaluation of brightening serums containing 2-Mercaptonicotinoyl Glycine versus Isobutylamido Thiazolyl Resorcinol using a standardized UV-induced pigmentation model

Mingje Zhu[1], Yang Wang[1], Ming (Kelly) Yang[1], Ji (Rose) Zhang[1], Xiaofeng He[1], Chloé Delaunay[2], Frederique Labatut[2], Delphine Kerob*[3], Anne-Laure Demessant-Flavigny[3], Flament Frederic[4]

[1] L'Oreal Research & Innovation, Shanghai, China

[2] L'Oréal Research and Innovation, Chevilly-Larue, France

[3] La Roche-Posay Laboratoire Dermatologique, Levallois-Perret, France

[4] L'Oreal Research & Innovation, Clichy, France

Introduction

Hyperpigmentation treatments with cosmetics usually target distinct pathways: active such as Isobutylamido Thiazolyl Resorcinol (ITR) inhibits tyrosinase, whereas 2-Mercaptonicotinoyl Glycine (2-MNG) prevents melanin synthesis by capturing its precursors. Despite the proven clinical benefits of both actives independently, there is a lack of head-to-head clinical studies on final products utilizing a standardized methodology. This study aimed to compare the clinical efficacy of an on-market brightening serum containing 0.5% 2-MNG with another on-market serum containing ITR, utilizing a standardized UV-induced pigmentation methodology.

Materials and Methods

A randomized, double-blind, controlled trial was conducted with 30 Asian females (Fitzpatrick skin type III). 4 mini-zones on the subjects' backs were treated with either the 0.5% 2-MNG complex, ITR complex, positive control (7% ascorbic acid), or negative control, starting from D1 to D40. Pigmentation was induced by 0.5 MED of daily UV irradiation for 4 consecutive days (D8-D11). Efficacy was assessed via Chromameter measurements of color difference (ΔE) at D8, D9, D10, D11, D12, D15, D19, D26, D33 and D40 compared with baseline for each mini-zone.

Results

The reliability of the UV induction model was validated by the positive control (7% ascorbic acid), which significantly suppressed color changes compared to the negative control ($p<0.05$). In the head-to-head comparison, the 0.5% 2-MNG complex provided significantly greater protection against UV-induced pigmentation than the ITR complex. Specifically, at D12 (immediately following the irradiation phase), the inter-treatment difference in Delta E (2-MNG vs. ITR) was -2.12 ($p<0.05$). This superior efficacy was robustly maintained throughout the entire recovery period, yielding continuous and significant inter-treatment Delta E differences in favor of 2-MNG: -1.94 at D15, -1.77 at D19, -1.89 at D26, -1.94 at D33, and -1.94 at D40 (all $p<0.05$).

Conclusions

This head-to-head study confirms that while both tyrosinase inhibition (via ITR) and melanin precursor capture (via 2-MNG) are effective strategies, the 0.5% 2-MNG complex demonstrated superior clinical efficacy against UV-induced pigmentation. These findings highlight the clinical relevance of targeting melanogenesis precursors as a highly effective and competitive approach in modern brightening cosmetic formulations.

EADV Congress 2026, VIENNA
30 SEPTEMBER - 03 OCTOBER 2026
POWERED BY M-ANAGE.COM

EADV CONGRESS
VIENNA
30 SEP - 3 OCT 2026

Abstract N°: 3665

EXTESIVE LICHEN PLANUS PIGMENTOSUS INVERSUS: CLINICAL, DERMOSCOPIC, AND HISTPATHOLOGICAL INSIGHTS FROM A RARE CASE

Hasnae Zerhouni*[1], Salma Abid[1], narjess errachdy[1], najoua ammar[1], syrine hamada[1], Mariame Meziane[1], laila benzekri[1], nadia ismaili[1]

[1] Ibn Sina University Hospital, rabat, Morocco

Introduction

Lichen planus pigmentosus inversus (LPPI) is an exceptionally rare variant of lichen planus pigmentosus, with fewer than 100 cases reported in the literature to date. It typically presents as hyperpigmented patches primarily localized to intertriginous areas. We report a compelling case of LPPI with an unusually extensive and atypical distribution to highlight its distinctive diagnostic features.

Case Presentation

A 65-year-old female presented with a 2-year history of progressive, strictly asymptomatic hyperpigmentation. She reported no intake of pigmentation-inducing medications, previous contact allergies, or changes in hygiene products. Laboratory investigations, including fasting blood glucose and hepatitis serologies, were unremarkable. Physical examination revealed well-demarcated, non-infiltrated, violaceous-to-dark-brown patches extensively distributed across the axillary, inframammary, infra-abdominal, and popliteal folds, as well as the intergluteal cleft. Notably, atypical extra-flexural involvement of the shoulders and sacral region was also observed. The face, scalp, nails, and mucosal surfaces were strictly spared. Dermoscopic examination displayed a speckled pattern characterized by an irregular distribution of dark brown dots and globules. Clinical mimickers, including acanthosis nigricans, erythrasma, axillary granular parakeratosis, and contact dermatitis, were considered but ruled out.

A skin punch biopsy revealed an atrophic epidermis with orthokeratotic hyperkeratosis. The dermo-epidermal junction exhibited a subepidermal lymphohistiocytic interface infiltrate obscuring the basement membrane, accompanied by scattered basal apoptotic bodies. The underlying fibrous dermis showed prominent pigment incontinence with numerous melanophages.

Based on the striking clinical, dermoscopic, and histopathological correlation, the diagnosis of LPPI was established. The patient was prescribed twice-daily topical tacrolimus ointment; however, the therapeutic management of LPPI remains challenging, and long-term follow-up is often required.

Conclusion

This case highlights a rare occurrence of LPPI with an unusually extensive, partly extra-flexural distribution, emphasizing the critical role of dermoscopy and skin biopsy in distinguishing it from other flexural hyperpigmentations.

EADV CONGRESS
VIENNA
30 SEP - 3 OCT 2026

Abstract N°: 3671

Efficacy of Upadacitinib in Adults and Adolescents for Treatment of Nonsegmental Vitiligo: Subgroup Analysis at 48 Weeks of Treatment From Two Phase 3 Studies (Viti-Up)

Julien Seneschal*[1], george michael lewitt[2], Nina Magnolo[3], Chih-ho Hong[4, 5], Kim Papp[6, 7], Benjamin D. Ehst[8], Andrew F. Alexis[9], Viktoria Eleftheriadou[10, 11, 12], Xiaofei Hu[13], Minglu Wang[13], Sharanya Ford[13], Henrique Teixeira[13], Stavonnie Patterson[13], Bethanee J Schlosser[13], Pearl Grimes[14]

[1] CHU de Bordeaux, Dermatology and Pediatric Dermatology, National Reference Center for Rare Skin Disorders, Hôspital Saint-André, Bordeaux, France

[2] Illinois Dermatology Institute, DeNova Research, Chicago, Illinois, United States

[3] Department of Dermatology, University Hospital Münster, Münster, Germany

[4] Department of Dermatology and Skin Science, University of British Columbia, Vancouver, British Columbia, Canada

[5] Probity Medical Research, Surrey, British Columbia, Canada

[6] Probity Medical Research and Alliance Clinical Trials, Waterloo, Ontario, Canada

[7] Division of Dermatology, Temerty Faculty of Medicine, University of Toronto,, Toronto, Ontario, Canada

[8] Oregon Health & Science University, Portland, Oregon, United States

[9] Department of Dermatology, Weill Cornell Medicine, New York, New York, United States

[10] Vitiligo Clinical and Research Centre for Adult and Paediatric Patients, New Cross Hospital, Royal Wolverhampton NHS Trust, Wolverhampton, United Kingdom

[11] Walsall Manor Hospital, Walsall Healthcare NHS Trust, Walsall, United Kingdom

[12] College of Medicine and Health, University of Birmingham, Birmingham, United Kingdom

[13] AbbVie Inc., Chicago, Illinois, United States

[14] The Grimes Center for Medical and Aesthetic Dermatology, Vitiligo and Pigmentation Institute of Southern California, Los Angeles, California, United States

Introduction

Nonsegmental vitiligo (NSV) is an autoimmune disease resulting in skin depigmentation due to a loss of melanocytes. Upadacitinib (UPA) is a selective once-daily Janus kinase inhibitor with demonstrated efficacy for the treatment of NSV in adults and adolescents with no new safety signals reported. Herein we report findings for pre-specified subgroups across various demographics and baseline disease characteristics for patients treated with UPA 15 mg (UPA15) or placebo (PBO) from two identical, pivotal phase 3 studies of patients with NSV (Viti-Up).

Materials and Methods

Pre-specified subgroup analyses were conducted for the achievement of each T-VASI 50, F-VASI 75, and F-VASI 50 at week 48, as well as percent change from baseline in each T-VASI and F-VASI at week 48.

Results

Overall, patients receiving UPA15 were similarly likely to demonstrate greater improvements vs PBO in the achievement of each T-VASI 50 and F-VASI 75 across the majority of subgroups including biological sex (male, female), ethnicity, baseline disease severity (T-VASI ≤ 10, T-VASI > 10), baseline status of actively progressing vitiligo (yes), baseline F-VASI (< median, ≥ median), baseline T-VASI (< median, ≥ median), Fitzpatrick skin types, duration of vitiligo since diagnosis (< median, ≥ median), and prior topical therapy for vitiligo (with, without).

Patients in subgroups based on race (White, Asian, Black and Other) and without actively progressing vitiligo also demonstrated greater improvements with UPA15 versus PBO for achievement of F-VASI 75 at week 48; however, for achievement of T-VASI 50 at week 48 for patients in the Asian subgroup or those that did not have actively progressing vitiligo numerical differences favored UPA15 compared to PBO.

Conclusions

Findings indicate that treatment of NSV with UPA provides clinically meaningful repigmentation across important subpopulations of patients with NSV.

EADV CONGRESS
VIENNA
30 SEP - 3 OCT 2026

Abstract N°: 3685

Ferroptosis-related melanocyte vulnerability in vitiligo: a focused mechanistic review

Guangman Han[1], Jing Yuan*[2], Chang E Chui[1], Haonan Zhang[1], Menghan Di[3]

[1] Tianjin University of Traditional Chinese Medicine, Tianjin, China
[2] Affiliated Hospital of Tianjin Academy of Traditional Chinese Medicine, Tianjin, China
[3] Tianjin Medical University Cancer Institute and Hospital, Tianjin, China

Introduction
Oxidative stress is a key pathogenic feature of vitiligo and may reduce melanocyte resilience within the lesional microenvironment. Emerging evidence suggests that iron-dependent lipid peroxidation and ferroptosis-related vulnerability may contribute to melanocyte loss and impaired repigmentation. However, the exact occurrence, specificity, and biological significance of ferroptosis in human vitiligo lesions remain incompletely defined.

Materials and Methods
We conducted a focused mechanistic review of published studies addressing oxidative stress, lipid peroxidation, ferroptosis-related markers, and melanocyte survival pathways in vitiligo. Particular attention was given to the Nrf2 antioxidant response, system Xc−-glutathione-glutathione peroxidase 4 (GPX4) axis, solute carrier family 3 member 2 (SLC3A2), solute carrier family 7 member 11 (SLC7A11), and the SIRT7-SMAD3-ATF3-GPX4 regulatory pathway.

Results
Ferroptosis is characterized by iron-dependent lipid peroxidation and impaired detoxification of phospholipid hydroperoxides. In vitiligo-related contexts, oxidative stress may weaken antioxidant defenses and promote lipid peroxidation, thereby lowering the threshold for melanocyte injury. Reported findings include altered expression of ferroptosis-associated markers in vitiligo lesional epidermis, reduced anti-ferroptotic defenses such as GPX4, and experimental evidence that ferroptosis inducers can decrease melanocyte viability with increased reactive oxygen species, iron accumulation, lipid peroxidation, and suppression of melanogenesis. The system Xc− pathway, composed of SLC3A2 and SLC7A11, supports cystine uptake and glutathione synthesis, thereby maintaining GPX4-mediated lipid peroxide detoxification. Downregulation of SLC3A2 or GPX4 may weaken this defense program and increase susceptibility to lipid peroxide-driven injury. In addition, the SIRT7-SMAD3-ATF3-GPX4 axis may enhance melanocyte resistance to oxidative stress-related ferroptosis by regulating GPX4 expression. Nevertheless, oxidative stress or lipid peroxidation markers alone are insufficient to establish bona fide ferroptosis in vivo. Stronger validation requires ferroptosis-selective rescue approaches, iron chelation, genetic rescue of key nodes such as GPX4 or SLC7A11, and exclusion of alternative cell-death programs.

Conclusions
Ferroptosis-related melanocyte vulnerability may represent a complementary stress layer in vitiligo rather than a single dominant driver of disease. This mechanism may help link oxidative stress, impaired antioxidant defense, melanocyte loss, and unstable repigmentation. Future studies should validate ferroptosis-specific biomarkers in human lesions and vitiligo-relevant models, and determine whether antioxidant or anti-ferroptotic strategies can improve melanocyte survival and durability of repigmentation.

POWERED BY M-ANAGE.COM

EADV CONGRESS
VIENNA
30 SEP - 3 OCT 2026

Abstract N°: 3793

Psychological Distress and Self-Medication in Vitiligo: Implications for Disease Course and Therapeutic Management

Rim ZEROUATI*[1], Mohamed EL AMRAOUI[1], Youssef ZEMMEZ[1], Rachid FRIKH[1], Naoufal HJIRA[1]

[1] Departement of Dermatology, Mohammed V Military Teaching Hospital, Rabat, Morocco

Introduction

Vitiligo is a chronic autoimmune pigmentary disorder characterized by selective melanocyte destruction, resulting in acquired depigmented cutaneous macules. Its estimated global prevalence ranges from 0.5% to 2%, with substantial psychosocial repercussions that may profoundly impair patients' quality of life and emotional well-being.

Diagnosis is primarily clinical and may be supported by Wood's lamp examination, which demonstrates a characteristic bright white fluorescence of affected areas. Conventional therapeutic strategies include topical corticosteroids, calcineurin inhibitors, and narrowband ultraviolet B phototherapy, frequently requiring prolonged treatment duration and sustained adherence. Nevertheless, delayed therapeutic response and treatment-related frustration may encourage self-medication behaviors, potentially leading to severe cutaneous complications and reflecting the significant psychological burden associated with the disease.

Case Presentation

We report the case of a 30-year-old man with no significant past medical history who presented with progressively evolving depigmented cutaneous lesions over a period of one and a half years.

The diagnosis of vitiligo was clinically confirmed by Wood's lamp examination, revealing bright white fluorescence consistent with melanocyte loss. The patient was initially managed with conventional therapy combining topical corticosteroids and topical treatments prescribed by a dermatologist. Despite regular follow-up and appropriate therapeutic adherence, no significant clinical improvement was observed after several months of treatment.

In the context of therapeutic dissatisfaction and psychological distress related to the disease, the patient subsequently initiated unsupervised self-medication consisting of Meladinine (xanthotoxin), onion water applications, and uncontrolled sun exposure. This inappropriate therapeutic approach resulted in severe adverse cutaneous reactions, including burns, marked erythema, and significant skin irritation.

Conclusion

This case highlights the therapeutic complexity of vitiligo, the importance of diagnostic confirmation using Wood's lamp examination, and the potentially harmful consequences of unsupervised self-medication.

It further underscores the major psychological burden associated with vitiligo and its potential impact on therapeutic adherence and disease management. A multidisciplinary approach integrating rigorous medical management, therapeutic education, and appropriate psychological support is essential to prevent high-risk behaviors, improve treatment adherence, and optimize clinical outcomes and quality of life in patients with vitiligo.

EADV Congress 2026, VIENNA
30 SEPTEMBER - 03 OCTOBER 2026
POWERED BY M-ANAGE.COM

EA DV CONGRESS
VIENNA
30 SEP - 3 OCT 2026

Abstract N°: 3815

Topical Ritlecitinib for Refractory Stable Non-Segmental Vitiligo: A Prospective Pilot Study

Eduarda Gregório Arnaut Lima*[1], Antonio Villela[1], Leticia Azevedo[1], Ana Amelia Milfont[1], Ana Julia Nunes[1], Omar Lupi[1], Fabricio Lamy[1]

[1] Policlínica Geral do Rio de Janeiro, Rio de Janeiro, Brazil

Introduction

Vitiligo is a chronic autoimmune depigmenting disorder with substantial psychosocial impact. Non-segmental vitiligo (NSV) is the predominant subtype. A substantial proportion of patients fail to achieve satisfactory repigmentation with established first-line therapies, including corticosteroids, narrowband ultraviolet B (NB-UVB) phototherapy and calcineurin inhibitors. Ritlecitinib is a selective oral JAK3/TEC family kinase inhibitor with phase 2b data supporting its role in NSV and ongoing phase 3 evaluation, with a potential role in modulating T-cell signaling pathways involved in disease persistence. Topical JAK inhibition may deliver targeted immunomodulation while minimizing systemic exposure and adverse effects.

To our knowledge, topical ritlecitinib has not previously been evaluated in vitiligo. We assessed clinical outcomes and tolerability of topical ritlecitinib tosilate compounded in tacrolimus 0.1% ointment in patients with stable NSV refractory to conventional therapies.

Materials and Methods

This prospective, single-center, open-label pilot study enrolled adult patients with clinically stable NSV for ≥12 months, refractory to ≥2 prior therapies including NB-UVB phototherapy, topical tacrolimus to facial lesions for ≥12 months, and topical corticosteroids within the preceding year. Exclusion criteria included pregnancy or breastfeeding, active cutaneous infection, hypersensitivity to tacrolimus or ritlecitinib, segmental vitiligo and systemic immunosuppression. Written informed consent was obtained from all patients.

Patients received topical ritlecitinib tosilate 0.5% (5 mg/g) compounded in tacrolimus 0.1% ointment, applied twice daily to affected facial areas for 6 months. Background therapies on non-target body areas remained unchanged.

Clinical assessments occurred at baseline, 3 months, and 6 months. The primary endpoint was percentage change in Facial Vitiligo Area Scoring Index (F-VASI) at month 6. Secondary endpoints included Physician Global Assessment (PGA), Patient Global Assessment (PGA-P), standardized photographic evaluation and adverse event monitoring. Exploratory endpoints assessed disease activity in non-target body areas.

Results

8 patients were enrolled; 1 was excluded pre-treatment due to tacrolimus hypersensitivity. Of 7 patients treated with topical ritlecitinib, 5 completed 6-month follow-up, 1 remains at month 3, and 1 was lost to follow-up.

Primary endpoint: All 5 completers demonstrated facial repigmentation at month 6. Mean F-VASI reduction was 68.2% (median 74.1%, range 41.18–89.53%). 4 of 5 patients (80%) achieved ≥50% F-VASI improvement and 3 (60%) achieved ≥70% F-VASI improvement. Repigmentation was detectable by weeks 12-16 with progressive

improvement through month 6. Secondary endpoints: At month 6, PGA showed marked improvement in 3 patients and moderate improvement in 2 patients. PGA-P was concordant with physician assessment. Standardized photography confirmed visible facial repigmentation in all completers. Safety: No systemic adverse events occurred. Local tolerability was satisfactory with no treatment discontinuations due to adverse events. Exploratory endpoints: Disease activity in non-target areas occurred in 1 patient (enlargement of body lesions despite facial improvement). 4 patients maintained stable non-target areas. No spontaneous repigmentation occurred in untreated areas.

Conclusions

This pilot study provides preliminary evidence that compounded topical ritlecitinib tosilate 0.5% in tacrolimus 0.1% ointment may induce clinically meaningful facial repigmentation in patients with stable NSV refractory to conventional treatments, with favorable tolerability. The observed clinical response and F-VASI improvement warrant further investigation. Limitations include small sample size, open-label design, absence of a control group, and compounded formulation. Prospective randomized controlled trials are needed to confirm efficacy, optimize concentration, and characterize systemic bioavailability.

EA DV CONGRESS
VIENNA
30 SEP - 3 OCT 2026

Abstract N°: 3901

Multimodal LLMs approximate vitiligo depigmentation area but fail to localize it: benchmarking three frontier models against expert annotation

Yoon Kyoung Kim*[1, 2, 3], Julia Soufflet[2, 3], Lucas Zuliani[2, 3], Mohamed Ali Ben Youssef[2, 3], Jonathan Bar[4], Nanette Silverberg[4], Hang Nguyen[2, 3]

[1] Faculty of Medicine, Imperial College London, London, United Kingdom

[2] Belle Europe, Toulouse, France

[3] Belle.ai, Cambridge, Massachusetts, United States

[4] Icahn School of Medicine at Mount Sinai, New York, United States

Introduction

Accurate quantification of visible depigmentation underpins vitiligo severity assessment, longitudinal monitoring, and patient communication. General-purpose multimodal large language models (LLMs) are increasingly used by clinicians and patients for image-based queries, but whether their image-level estimates of affected area correspond to coherent, clinically interpretable visual localization remains unclear. Simple HSV colour-thresholding remains a common open-source approach but is known to perform inconsistently across skin tones, body sites, and lighting. We benchmarked three frontier multimodal LLMs and an HSV baseline against expert annotation across both image-level estimation and visual explainability.

Materials and Methods

We analysed 31 vitiligo images spanning multiple body sites and Fitzpatrick skin types III–IV and V–VI. The reference standard was expert annotation: a computer-vision–assisted pre-segmentation (skin-region masking and candidate depigmentation masking) was refined to a pixel-level consensus mask by a trained dermatology annotator. Image-level affected area fraction (AAF) was estimated by Gemini 3.1 Pro (preview), Claude Opus 4.7, GPT-5.5, and HSV thresholding, all accessed on 1 May 2026 via their standard public interfaces with default settings. Quantitative agreement with the expert reference was assessed by mean absolute error (MAE), root mean squared error, signed bias, Pearson (r) and Spearman (ρ) correlation, and the proportion of estimates within ±15 percentage points. Visual explainability was assessed by structured qualitative comparison of LLM-attempted heatmap and segmentation-style outputs against the expert reference annotation.

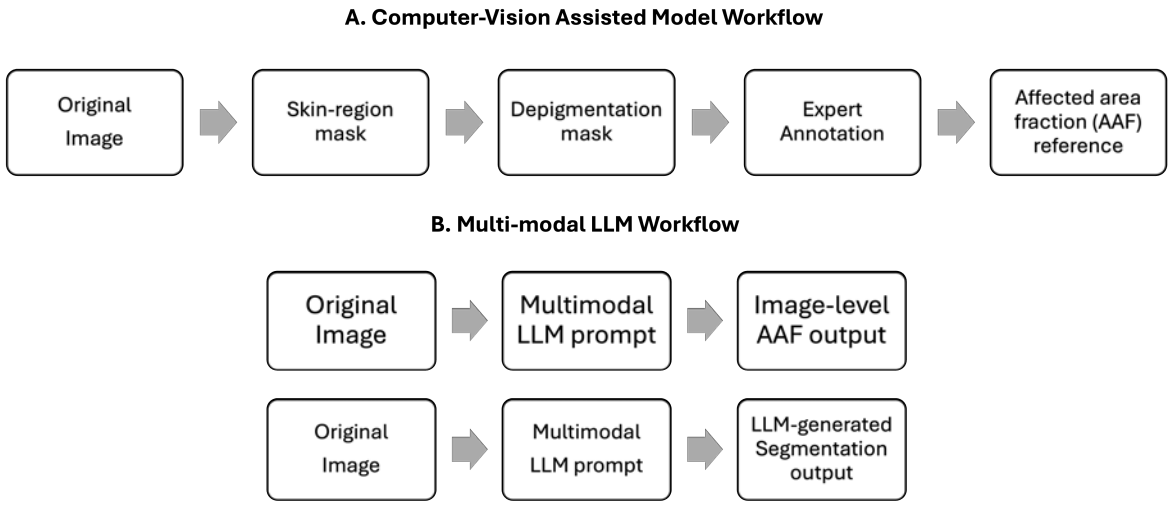

Figure 1. Study workflow. Images were processed through a structured annotation pipeline to generate provisional reference affected area fraction (AAF) estimates after skin-region masking, depigmentation masking, and expert annotation refinement. In parallel, multimodal large language models were prompted to provide image-level AAF estimates and segmentation-style visual outputs. Outputs were compared for quantitative agreement with the structured reference estimate and for qualitative interpretability.

Results

Method	MAE vs AI-assisted AAF	Bias	Pearson r	Spearman r	Within ±15 pp
Gemini 3.1 Pro	9.47	-1.10	0.80	0.83	83.9%
Claude Opus 4.7	10.94	-1.94	0.74	0.77	67.7%
ChatGPT 5.5	11.53	-8.87	0.63	0.80	77.4%
HSV thresholding	26.68	-19.15	-0.26	-0.23	38.7%

Table 1. Quantitative agreement of affected area fraction (AAF) estimates with expert annotation. MAE and bias are reported in percentage points (pp); negative bias indicates underestimation. Pearson r and Spearman ρ assess linear and rank-order agreement. "Within ±15 pp" is the proportion of images with estimates within 15 percentage points of the expert reference.

Gemini 3.1 Pro showed the closest image-level agreement with expert annotation (MAE 9.47 pp; r=0.80; ρ=0.83; 83.9% within ±15 pp). Claude Opus 4.7 showed moderate-to-strong agreement (MAE 10.94 pp; r=0.74; ρ=0.77; 67.7% within ±15 pp). GPT-5.5 preserved good rank order (ρ=0.80; 77.4% within ±15 pp) but systematically underestimated depigmented area (signed bias −8.87 pp; MAE 11.53 pp). HSV thresholding performed poorly, with high error (MAE 26.68 pp), minimal rank or linear correlation (r=−0.26; ρ=−0.23), and only 38.7% of estimates within ±15 pp. Qualitatively, Gemini was unable to generate usable heatmap or segmentation-style outputs; Claude and GPT-5.5 produced visualizations that were frequently mis-localized or anatomically incoherent relative to the expert reference.

Conclusions

Benchmarked against expert annotation, frontier multimodal LLMs approximated image-level depigmentation more closely than HSV thresholding but could not reliably localize where the depigmentation was. The strongest image-level performer (Gemini 3.1 Pro) failed to produce usable visual explanations at all, while Claude Opus 4.7 and GPT-5.5 produced visualizations that did not faithfully correspond to the underlying lesion distribution. This discrepancy between plausible image-level estimates and unreliable localization is an important limitation of current general-purpose multimodal AI for dermatologic assessment, and supports continued evaluation of task-specific approaches that pair quantitative severity estimation with faithful, reproducible visual outputs validated against dermatologist annotation.

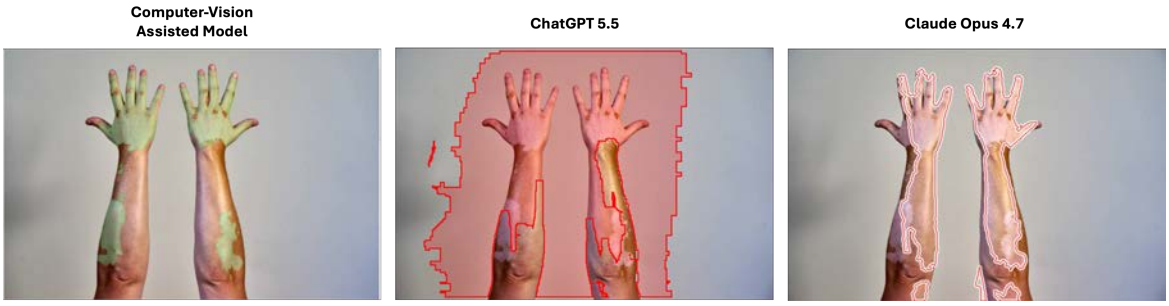

Figure 2. Representative segmentation-style outputs for depigmented vitiligo localization. From left to right: computer-vision-assisted expert annotated model, ChatGPT 5.5, and Claude Opus 4.7. Overlays and outlines indicate regions identified as depigmented. Gemini 3.1 Pro did not return a usable segmentation-style output.

EADV CONGRESS
VIENNA
30 SEP - 3 OCT 2026

Abstract N°: 3988

Evaluation of the PDE-4 Inhibitor in Vitiligo Treatment: Clinical Efficacy and Effects on Melanocyte Proliferation and Melanogenesis

Jian-Qiu Yang*[1], Yi-Fei Yang[2], Hui Xu[2], Yu-Yun Xiong[2], Yu-Mei Li[2]

[1] Jiangyin Hospital of Traditional Chinese Medicine, Jiangyin, China

[2] Department of Dermatology, Affiliated Hospital of Jiangsu University, Zhenjiang, China

Introduction

Vitiligo is a depigmenting disorder causing psychological burden due to cosmetic concerns. Current topical treatments have limitations. PDE-4 inhibition, by reducing pathogenic cytokines and enhancing melanocyte function, is a promising strategy.

Materials and Methods

Objective: To evaluate the efficacy and safety of the PDE-4 inhibitor crisaborole in vitiligo and its effects on melanocyte proliferation and melanin synthesis. **Methods:** Thirty mild vitiligo patients received crisaborole for 16 weeks. VASI change and influencing factors were analyzed. In vitro, human melanocytes were treated with varying crisaborole concentrations; proliferation (CCK-8) and melanin content (NaOH method) were measured.

Results

Results: Of 30 patients, 12 responded (5 markedly). Age, sex, and disease stage did not influence outcome. Lesion location affected response in single-region cases. Head/face lesions showed significant VASI reduction (mean 41.14%, P=0.009). Trunk (P=0.337) and acral (P=0.089) sites showed no significant change. Of 10 patients with ≥2 regions involved, 3 responded (no marked responses), and VASI change was not significant (P=0.954). Adverse events were mild: local pruritus (n=2) and dermatitis-like reaction (n=1), all self-resolved. In vitro, 10^{-5} and 10^{-6} mol/L crisaborole significantly increased proliferation (both $P<0.05$) and enhanced melanin synthesis 1.36- and 1.28-fold vs control.

Conclusions

Conclusion: The PDE-4 inhibitor Crisaborole demonstrates therapeutic efficacy in vitiligo, particularly for lesions on the head and face. Additionally, PDE-4 inhibitor promotes both the proliferation and melanin synthesis function of human epidermal melanocytes in vitro.

EA DV CONGRESS
VIENNA
30 SEP - 3 OCT 2026

Abstract N°: 3995

Development and Validation of a Fully Automated AI-Based Outcome Measure for Facial Depigmentation in Vitiligo Using Standardized UV Imaging

Quentin Marin Dit Bertoud[1], Kevin Roussel[1], DANOY Alix (Newtone) DANOY*[1], Marie Cherel[1], Jean-Michel Delaval[1], Khaled Ezzedine[2, 3], Thierry Passeron[4]

[1] QIMA Life Sciences, QIMA Newtone SAS, Lyon, France

[2] Department of Dermatology, AP-HP, Henri Mondor University Hospital, Créteil, France

[3] Université Paris Est (UPEC), EpiDermE Research Unit, Paris, France

[4] Université Côte d'Azur, CHU Nice, Department of Dermatology, Nice, France

Introduction

Vitiligo is a chronic skin disorder characterized by patchy depigmentation, often affecting visible areas such as the face. Accurate assessment of facial depigmentation is crucial for monitoring disease progression and treatment efficacy. Existing semi-automated segmentation tools for vitiligo, such as Vitil-IA, require manual input and are time-consuming, limiting their scalability in clinical and research settings. Advances in deep learning, especially transformer-based architectures, allow for fully automated and precise segmentation from standardized imaging, potentially improving efficiency and objectivity.

The objective of this study was to develop and validate a fully automated facial vitiligo segmentation method using a state-of-the-art transformer-based deep learning architecture (SegFormer) and compare its performance to the semi-automated Vitil-IA method on standardized ultraviolet (UV) facial images.

Materials and Methods

A multicentric, cross-sectional, prospective study was conducted across multiple tertiary university hospitals specializing in vitiligo. Standardized UV facial images were collected from 104 patients with facial vitiligo: 67 patients (201 images) for model training and 37 patients (111 images) for independent testing. The fully automated Vitil-IA Automatic model was evaluated against the semi-automated Vitil-IA method using Dice coefficient, intersection-over-union (IoU), sensitivity, specificity, and accuracy. Correlation coefficients of depigmentation scores between methods were also calculated.

Results

The automated approach yielded segmentation outputs closely matching the semi-automated method in non-overlapping regions of interest and across diverse skin types. On the test dataset, Vitil-IA Automatic achieved Dice coefficient of 0.85, IoU of 0.76, sensitivity of 0.85, specificity of 0.88, and accuracy of 0.92. Depigmentation scores showed high correlation (R = 0.94) with the semi-automated method. These findings suggest the model can replace manual segmentation steps without loss of accuracy, streamlining workflows for clinical and research applications.

Conclusions

Vitil-IA Automatic, a transformer-based deep learning segmentation tool, enables fully automated, objective, and

rapid quantification of facial vitiligo from standardized UV images. Performance is comparable to semi-automated method Vitil-IA, with significant gains in efficiency, making it a promising tool for large-scale studies and routine clinical monitoring.

A fully automated deep learning model can accurately segment facial vitiligo from standardized UV images, matching semi-automated method Vitil-IA while offering faster, objective, and reproducible assessments suitable for clinical and research use.

EA DV CONGRESS
VIENNA
30 SEP - 3 OCT 2026

Abstract N°: 4035

Comparison of F-VASI and Vitil-IA performance in Detecting Early Changes in Facial Vitiligo

Quentin Marin Dit Bertoud[1], DANOY Alix (Newtone) DANOY*[1], Marie Cherel[1], Jean-Michel Delaval[1], Khaled Ezzedine[2, 3], Thierry Passeron[4]

[1] QIMA Life Sciences, QIMA Newtone SAS, Lyon, France

[2] Department of Dermatology, AP-HP, Henri Mondor University Hospital, Créteil, France

[3] Université Paris Est (UPEC), EpiDermE Research Unit, Paris, France

[4] Université Côte d'Azur, CHU Nice, Department of Dermatology, Nice, France

Introduction

Vitiligo is a chronic depigmenting disorder in which repigmentation is often slow, with clinical trials frequently requiring at least 12 months to capture meaningful treatment responses. In active vitiligo, it is also important to confirm that treatment halts or slows depigmentation early in the therapeutic course. Long-duration studies, however, are costly and may unnecessarily expose patients to ineffective interventions. Methods capable of accurately detecting disease evolution over shorter periods could improve efficiency and patient safety.

Facial Vitiligo Area Scoring Index (F-VASI) is a conventional clinician-reported measure but may lack sensitivity to subtle changes. Recent work has shown that Vitil-IA, a semi-automated segmentation tool for vitiligo using standardized ultraviolet (UV) facial images, accurately and reproducibly quantifies depigmentation.

The objective of this study was to assess and compare the accuracy and sensitivity of Vitil-IA and F-VASI in detecting early changes in facial depigmentation in patients with vitiligo over 12 and 24 weeks.

Materials and Methods

This study was a nested analysis within a multicenter randomized controlled trial evaluating deucravacitinib 12 mg/day in patients with active or inactive diffuse nonsegmental vitiligo. During the six first months of the trial, patients were randomized 1:1 versus placebo. The comparison focused on the ability to detect changes at Week 12 and Week 24 versus baseline using both F-VASI and Vitil-IA. Twenty-six patients who completed evaluations at baseline and at both time points were included. Images were obtained in standard and UV light. Two expert dermatologists reviewed the photographs to verify whether detected changes corresponded to actual clinical variation, ensuring clinical validation of the observations. As the trial is still ongoing, the dermatologists didn't know the treatment arm of the patients.

Results

In 26 of the 52 cases (50%), F-VASI either falsely detected improvement/worsening, overestimated or underestimated changes. Delta errors ranged from 10% to 40% variation in score compared to clinical reviews from experts. Vitil-IA produced only one inaccurate measurement, attributed to improper removal of topical product under the eyes prior to imaging. Furthermore, in 19 of the 52 cases (36.5%), the F-VASI score did not detect change in depigmented areas (worsening or improvement), when it was detected by the Vitil-IA, or sometimes showed variation opposite to the one calculated with the Vitil-IA. In the remaining subjects with the same increasing/decreasing behavior between the two methods, for 5 of them the delta variation from baseline was at least 10 points different between the F-VASI and the Vitil-IA.

Conclusions

F-VASI demonstrated limitations in precision, frequently misestimating early variation in facial depigmentation, which could distort conclusions about treatment efficacy. Vitil-IA offered robust, reproducible assessments in this context, detecting fine changes with minimal error and providing a more objective alternative for early outcome evaluation in vitiligo studies.

The semi-automated UV imaging tool Vitil-IA demonstrated greater sensitivity and specificity than conventional F-VASI in detecting early changes in facial depigmentation, with improved accuracy and reproducibility, and potential to reduce trial duration and patient exposure to ineffective treatments.

EADV CONGRESS
VIENNA
30 SEP - 3 OCT 2026

Abstract N°: 4078

Systemic Metabolic Landscape in Vitiligo: Alterations in the Insulin-IGF Growth Factor Axis

Angela Filoni*[1], Simona Scano[2], Paolo Iacovelli[2], Noemi Aprile[1], Annalisa Marini[2], Alessia Paganelli[3], Anna Pira[3], martina spada[4], Laura Atzori[4], maurizio congedo[1], Giovanni Di Zenzo[3], Mauro Picardo[3], Barbara Bellei[2]

[1] vito fazzi hospital, lecce, Italy
[2] San Gallicano Dermatological Institute, Rome Italy, rome, Italy
[3] Istituto Dermopatico dell'Immacolata, Rome Italy, rome, Italy
[4] University of Cagliari, Cagliari Italy, cagliari, Italy

Introduction
Vitiligo is a chronic autoimmune skin disease characterized by the progressive pigment loss. Beyond its visible impact on skin pigmentation through melanocyte destruction, vitiligo is increasingly linked to systemic health challenges, particularly metabolic and autoimmune comorbidities. Evidence of glucose and lipid metabolism irregularities suggests that the disease is not merely skin-deep. However, the direct connection between clinical severity and systemic metabolic dysregulation remains an area requiring further investigation.

Materials and Methods
The present study aimed to characterize the metabolic landscape within a large, well-defined patient cohort recruited across multiple Italian clinical centers. In addition to documenting clinical parameters, such as disease severity, duration, and family history, comprehensive biochemical analyses were performed. The research focused on antioxidant capacity, cytokine networks, and the quantification of growth factors, including members of the IGF system, IGF binding proteins and fatty acid-binding proteins.

Results
Preliminary findings suggest a significant loss of metabolic coordination in vitiligo patients. In healthy individuals, fasting glucose and insulin levels exhibit a synchronized relationship; however, this regulatory link appears weakened or absent in those with the condition. Notably, the study identified altered levels of IGF-2 in vitiligo subjects, alongside a breakdown in the expected correlation between insulin and this growth factor. Furthermore, while IGF-1 levels showed distinct patterns between the two groups, its inverse correlation with fasting glucose was more pronounced in the vitiligo cohort than in the control group.

The primary novelty of this research lies in identifying the disruption of the insulin-IGF signaling balance.

Conclusions
These results provide a fresh perspective on the pathogenesis of vitiligo, suggesting that systemic metabolic dysregulation may be a core component of the disease and its associated comorbidities.

EA DV CONGRESS
VIENNA
30 SEP - 3 OCT 2026

Abstract N°: 4082

Afamelanotide: A Novel Promising Treatment for Vitiligo - Case Studies from the Randomized CUV105 Clinical Trial and its Extension Phase

Hannah Wanyika*[1]

[1] Kenyatta National Hospital, Jomo Kenyatta University, Kenya Association of Dermatologists, Nairobi, Kenya

Introduction

Vitiligo is an autoimmune depigmenting disorder affecting approximately 1-2% of the global population, where the progressive loss of melanocytes causes depigmented lesions on the skin. The effect of vitiligo on physical appearance results in significant psychological distress to patients, with many experiencing stigma and social isolation. There is currently no licensed pharmacological treatment for generalised (widespread) vitiligo, and many systemic treatments in development rely on immunosuppression, which is not suitable for all patients. Afamelanotide, a systemic, non-immunosuppressive treatment, is currently being investigated in a randomized study (CUV105) for patients with darker skin (Fitzpatrick skin types III-VI). Administered as a bioresorbable subcutaneous implant with adjunctive narrowband ultraviolet B (NB-UVB) phototherapy, afamelanotide stimulates melanogenesis and offers a promising alternative in the therapeutic armamentarium for vitiligo management.

This oral presentation reviews patients who have completed the ongoing CUV105 study and the open label extension phase. The CUV105 study investigates the efficacy and safety of afamelanotide with adjunctive NB-UVB therapy, versus NB-UVB active control. The open label extension phase assesses the impact of afamelanotide with NB-UVB adjunct, after treatment with NB-UVB alone. By examining the repigmentation improvement in these patients, we highlight afamelanotide as a novel and promising non-immunosuppressive option for the treatment of vitiligo.

Materials and Methods

The CUV105 study is a 20-week study with a six-month follow-up in patients with generalized (non-segmental) vitiligo. 210 participants were randomized into two groups: Group A to receive afamelanotide implants and adjunctive NB-UVB phototherapy, and Group B to receive NB-UVB monotherapy. The primary efficacy endpoint is the percentage of participants achieving T-VASI 50 (excluding hands and feet) on Day 140 in those treated with afamelanotide and NB-UVB, compared to NB-UVB alone. Other endpoints include time to onset of repigmentation and maintenance of repigmentation achieved.

Upon study completion, Group B participants had the opportunity to enrol in an open-label extension study, during which they received afamelanotide implants and adjunctive NB-UVB phototherapy.

Results

The oral presentation will review case studies from study participants receiving afamelanotide with adjunctive NB-UVB, both from the CUV105 study and the open label extension, along with data on time to onset of repigmentation, repigmentation at the end of the treatment phase, and maintenance of repigmentation during follow-up.

Previous case studies showed that a significantly faster time to onset of repigmentation was observed in

afamelanotide and NB-UVB Group compared to NB-UVB alone. At the follow-up visit, participants continued to repigment without further treatment of afamelanotide and/or NB-UVB and maintained the repigmentation achieved.

Conclusions

Afamelanotide is a melanogenesis-stimulating agent able to accelerate the repigmentation process in vitiligo and promote more rapid and sustained repigmentation when used with adjunct NB-UVB phototherapy.

EA DV CONGRESS
VIENNA
30 SEP - 3 OCT 2026

Abstract N°: 4092

Simvastatin and non-segmental vitiligo: A new potential treatment option ?

Engi Seif E. Shaker*[1], Sherihan Allam[2], Maaly Mabrouk[1], Nashwa Elgharbawy[1], Shady Abdel Salaam[1]

[1] Faculty of Medicine - Tanta University, Tanta, Egypt
[2] Faculty of Medicine - Mansoura University, Mansoura, Egypt

Introduction

There is a paucity of data about the impact of systemic statins on vitiliginous lesions in non-segmental vitiligo (NSV) patients. To the best of our knowledge, few studies have considered the correlation between lipid disturbances in vitiligo and vitiligo disease activity (VIDA) score. We sought in this study to evaluate the influence of simvastatin on vitiliginous lesions in NSV patients with dyslipidemia and study the correlation between VIDA score and lipid profile.

Materials and Methods

We reviewed the data of NSV patients, above 18 years old. All cases were either newly diagnosed with NSV or previously diagnosed but stopped treatment for at least 3 months before enrollment in this study. Exclusion criteria were patients under any form of vitiligo treatment, systemic diseases, thyroid disorders, any immunosuppressive medications, concomitant dermatological diseases, pregnancy, lactation, obese patients (body mass index [BMI] > 30 kg/m2) and patients receiving any drugs affecting lipid profile. The use of any additional vitiligo treatment, immunomodulating medications, antioxidants, as well as laser therapy or tanning was not allowed throughout the study. The study included 120 NSV patients in addition to 60 healthy individuals with well-matched age, gender, and BMI served as a control group. The study was approved by Research Ethics Committee at our institute. A written informed consent was taken before starting. All studied individuals were subjected to complete history taking, general, and dermatological examination. Vitiligo area severity index (VASI) and VIDA were assessed. A 12-h fasting venous blood sample was withdrawn from each subject. Serum total cholesterol (TC), triglycerides (TG), high-density lipoprotein (HDL), low-density lipoprotein (LDL), and very low-density lipoprotein (VLDL) were measured by the enzymatic colorimetric test.
Comparison between NSV patients and control group was done regarding serum lipid profile. Correlation between lipid profile, VIDA, and VASI scores was done. All vitiligo patients with dyslipidemia were selected and treated with simvastatin 80 mg daily (till normalization of lipid profile or for 4 months, which came first) together with instructions of proper diet intake. Routine liver and renal functions, blood sugar, lipid profile, VIDA, and VASI were reevaluated on monthly basis during simvastatin therapy and again 6 months after the end of simvastatin use.

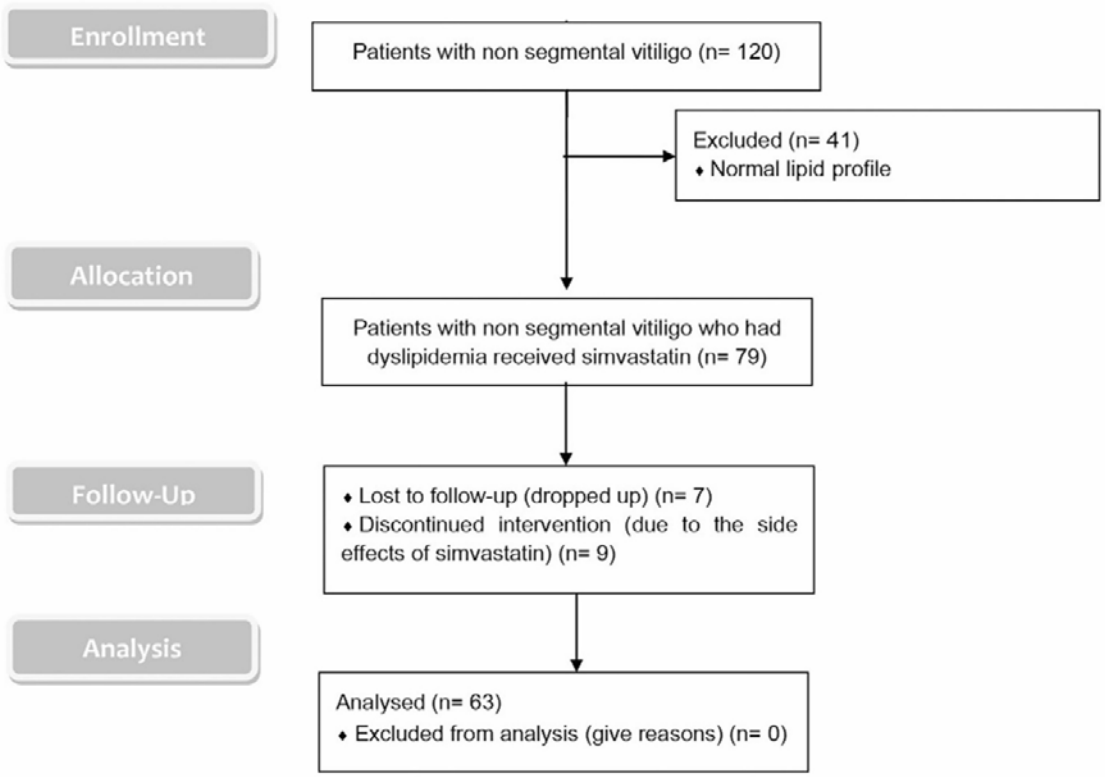

The consort flow diagram of the patients

Results

Serum total cholesterol (TC), triglycerides, high-density lipoprotein (HDL), low density lipoprotein (LDL), very low-density lipoprotein, and LDL/HDL ratio showed statistically significant increases in the NSV than in the control group ($p < 0.001$). There was a statistically significant positive correlation between VIDA and serum levels of TC and LDL and with LDL/HDL ratio. Simvastatin significantly improved the lipid profile and significantly decreased VIDA ($p < 0.011$). Negative moderate correlation was found between the decrease in VIDA and duration of disease ($r = 0.562, p < 0.001$).

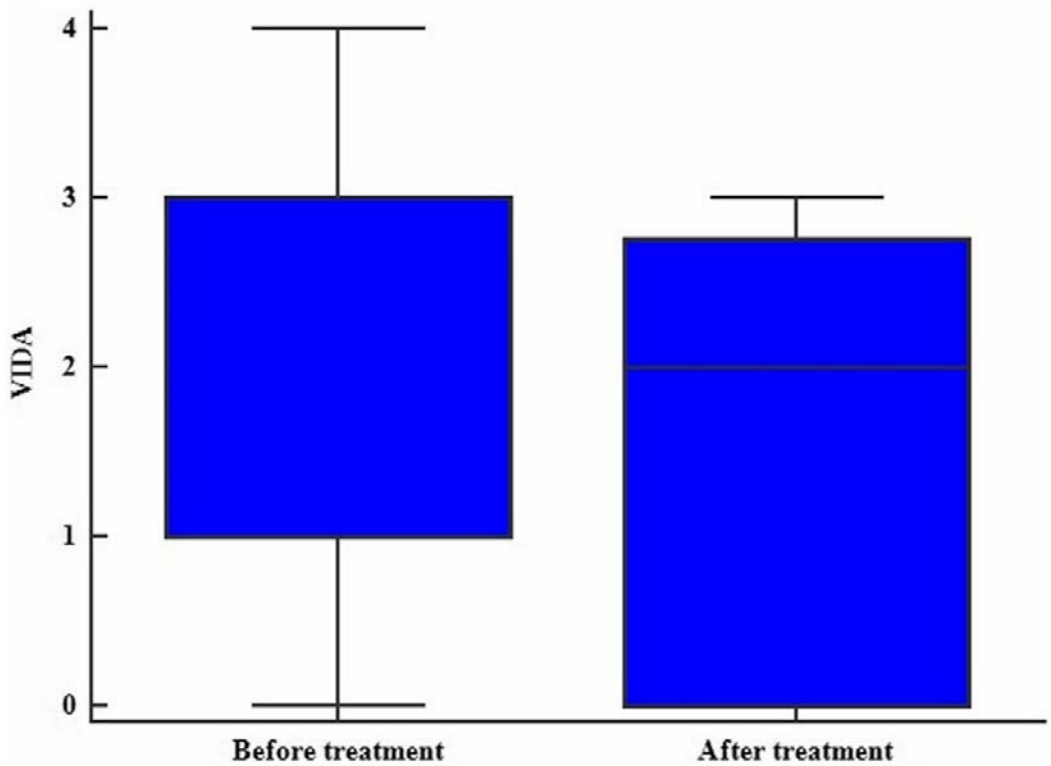

Vitiligo disease activity(VIDA) score before and 6months after the end of simvastatin use showing a statistically significant decrease

Conclusions

Simvastatin 80 mg daily could be a helpful treatment for NSV patients with dyslipidemia, controlling the vitiligo activity and protecting against the hazardous effects of dyslipidemia. Better results can be obtained in patients with short duration of the disease.

EADV CONGRESS
VIENNA
30 SEP - 3 OCT 2026

Abstract N°: 4188

Imiquimod-Induced Vitiligo-Like Hypopigmentation: A Comprehensive Review of Clinical Presentations, Mechanisms, and Therapeutic Implications

Marie Line Chedid*[1], Maria Onaissi[2], Nancy Emmanuel[3]

[1] Medical University of Łódź, Łódź, Poland

[2] Faculty of Medicine & Medical Sciences, University of Balamand, Bsalim, Lebanon

[3] Department of Dermatology, Hospital Das Clinicas of the Faculty of Medicine of the University of Sao Paulo, Sao Paulo, Brazil

Introduction

Imiquimod is a topical immune response modifier and Toll-like receptor 7 agonist widely used in the treatment of superficial basal cell carcinoma, actinic keratosis, genital warts, and several off-label dermatologic conditions. Although generally considered safe and effective, increasing reports have described vitiligo-like hypopigmentation following its application. This review aims to characterize the clinical presentation, proposed mechanisms, treatment outcomes, and broader therapeutic implications of imiquimod-induced depigmentation.

Materials and Methods

A PRISMA guided systematic narrative review was conducted using PubMed, Embase, Scopus, Cochrane Library, and Web of Science from database inception through 2026. Eligible studies included randomized and non-randomized clinical studies, observational studies, case series, and case reports describing hypopigmentation or vitiligo-like depigmentation following topical imiquimod use. Data regarding patient demographics, indication for treatment, time to onset, clinical presentation, histopathologic findings, treatment interventions, and outcomes were extracted qualitatively.

Results

Thirty studies met the inclusion criteria and were included in the final synthesis. Imiquimod-induced depigmentation most commonly presented as well-demarcated localized or regional hypopigmented patches confined to the application site, frequently confirmed by Wood's lamp examination. Onset typically occurred within 4–12 weeks of treatment initiation. Reported risk factors included darker Fitzpatrick skin types and personal or family histories of vitiligo, halo nevi, or post-inflammatory hypopigmentation. In many cases, pigment loss persisted for months to years after treatment discontinuation and was frequently described as partially reversible or irreversible. Proposed mechanisms involve Toll-like receptor 7 activation, resulting in increased CD8+ T-cell activity, Th1-mediated immune responses, pro-inflammatory cytokine release, melanocyte apoptosis, and suppression of melanogenesis-related pathways including tyrosinase and MITF expression. Topical tacrolimus demonstrated partial repigmentation in several reports, whereas corticosteroids and phototherapy showed inconsistent efficacy. Interestingly, imiquimod-induced depigmentation in melanoma patients has been associated with favorable immune activation and improved prognosis. Potential future applications include prevention of repigmentation following laser ablation of congenital melanocytic nevi and experimental depigmenting therapy in extensive vitiligo.

Conclusions

Although uncommon, imiquimod-induced vitiligo-like hypopigmentation represents a clinically significant adverse effect that may result in long-term cosmetic and psychosocial consequences. Increased clinician awareness, careful patient counseling, early recognition of pigmentary changes, and prompt discontinuation of therapy are essential to minimize permanent depigmentation. Further large-scale studies are needed to better define predisposing factors, clarify underlying mechanisms, and establish effective treatment strategies.

EADV CONGRESS
VIENNA
30 SEP - 3 OCT 2026

Abstract N°: 4203

The psychosocial burden of skin pigmentation disorders: a cross-sectional patient survey in the UK

Nabiah Malik*[1], Shahd Elamin[2], Rajani Nalluri[3]

[1] Imperial College Healthcare NHS Trust, London, United Kingdom
[2] Belfast Health and Social Care Trust, Belfast, United Kingdom
[3] Manchester University NHS Trust, Manchester, United Kingdom

Introduction
Pigmentation disorders and related dermatoses can significantly affect patients' wellbeing, especially when lesions are visible or long-standing. This survey looked at how pigmentation and associated skin symptoms affect quality of life in a dermatology setting. Our aim is to identify patients' most bothersome skin symptoms, examine the relationship between pigmentation as a primary concern and Dermatology Life Quality Index (DLQI) scores, and capture the psychosocial effects patients themselves describe.

Materials and Methods
A cross-sectional survey of 40 dermatology patients with a range of inflammatory and pigmentary skin conditions was carried out. Participants identified their main skin concern, their single most bothersome symptom, whether it had been addressed, and how much it affected their life. Free-text responses describing personal impact were also collected, alongside DLQI scores and Fitzpatrick skin type. Descriptive statistics were used to summarise findings, and DLQI scores were compared between those whose main concern was pigmentation-related and those whose was not. All participants provided written informed consent prior to taking part.

Results
Of 40 respondents, 30 (75%) identified pigmentation as their most bothersome symptom. Mean DLQI was 12.4 (median 10.5, range 1-30), reflecting moderate to very large impact on daily life. Those with pigmentation as their primary concern scored higher on average (mean 13.0, median 14.0) compared to those with non-pigmentary concerns (mean 10.5, median 9.0). The majority rated the impact on their life as "very much" or "a lot." In their own words, patients described low self-esteem, embarrassment, using makeup or clothing to hide their skin, avoiding social situations, and difficulties at work.

Conclusions
Pigmentation was the dominant concern in this group and was associated with meaningful quality-of-life impairment. The findings underline how important it is to recognise and address visible pigmentary change as part of routine dermatology care, rather than treating it as a purely cosmetic issue.

POWERED BY M-ANAGE.COM

EA DV CONGRESS
VIENNA
30 SEP - 3 OCT 2026

Abstract N°: 4227

Efficacy and Safety of Intradermal Tranexamic Acid Microinjections in Facial Melasma: A Prospective Clinical Study

Ashutosh Trivedi*[1]

[1] Shri Bhausaheb Hire Government Medical College, Dhule, India

Introduction
Melasma is a chronic acquired hyperpigmentation disorder that commonly affects women with darker skin phototypes and has a significant psychosocial impact. Tranexamic acid has emerged as a promising therapeutic option because of its anti-melanogenic and anti-angiogenic properties. Intradermal microinjections enable targeted drug delivery with minimal systemic exposure. This study aimed to evaluate the efficacy, safety, and patient satisfaction associated with intradermal tranexamic acid microinjections in patients with facial melasma.

Materials and Methods
A prospective clinical study was conducted in adult patients with clinically diagnosed facial melasma. Patients received intradermal tranexamic acid microinjections (4 mg/mL) administered at 1 cm^2 intervals under topical anesthesia at weeks 0, 2, 4, 6, 8, 10, and 12. All participants were advised strict broad-spectrum photoprotection throughout the study period. Disease severity was assessed using the modified Melasma Area and Severity Index (mMASI) at baseline and follow-up visits at weeks 4, 8, and 12. Clinical improvement was additionally assessed using patient-reported satisfaction scores on a 5-point Likert scale. Adverse effects were recorded at each visit.

Results
Thirty-two patients underwent intradermal tranexamic acid therapy. The mean baseline mMASI score was 7.69 ± 2.94, which improved to 7.09 ± 2.73 at week 4, 6.46 ± 2.36 at week 8, and 6.16 ± 2.36 at week 12. The final post-treatment mean mMASI score was 6.13 ± 2.37, corresponding to a mean percentage improvement of 19.62 ± 9.79%. The reduction in mean mMASI score from baseline was statistically significant. Mean patient satisfaction score was 1.84 ± 0.63 on the 5-point Likert scale. Adverse effects were mild and procedure-related, including injection-site pain in 5 patients (15.6%), erythema in 3 patients (9.4%), and burning sensation in 2 patients (6.3%). No serious systemic adverse events were observed. Satisfaction scores were variable despite objective clinical improvement.

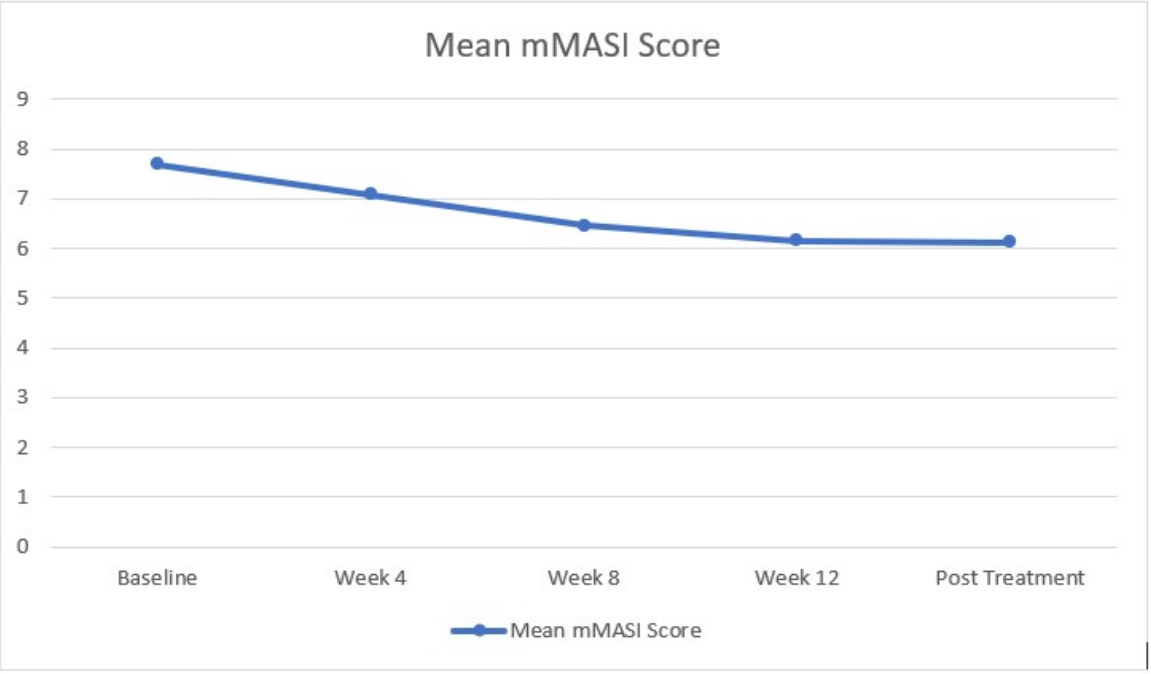

Mean mMASI scores decreased progressively from baseline to post-treatment follow-up. Lower scores indicate clinical improvement.

Conclusions

Intradermal tranexamic acid microinjections produced modest but clinically appreciable improvement in facial melasma with a favourable safety profile and no serious systemic adverse effects. The procedure may serve as a useful therapeutic option in selected patients seeking localized treatment with minimal systemic exposure.

EA DV CONGRESS
VIENNA
30 SEP - 3 OCT 2026

Abstract N°: 4280

Platelet-Rich Plasma Promotes Dermal Melanocyte Progenitor Differentiation via IGFBP-2/RhoA/YAP Signaling and Enhances Repigmentation in Refractory Acral Vitiligo

Min Jiang*[1], Yijian Zhu[1], Leihong Xiang[1]

[1] Huashan Hospital, Fudan University, Shanghai, China

Introduction
Acral vitiligo is the most treatment-resistant subtype of depigmenting disorder, characterized by hairless skin and poor response to conventional therapies. Its refractoriness stems from scarce follicular melanocyte stem cells, mechanical friction, and an anti-melanogenic microenvironment. Current treatments, including topical agents, phototherapy, and JAK inhibitors, yield limited repigmentation in acral sites. Platelet-rich plasma (PRP), an autologous growth factor concentrate, has shown regenerative potential, but its efficacy and mechanism in acral vitiligo remain unclear. Dermal melanocyte progenitors (DMPs) represent a follicle-independent stem cell pool for melanocyte regeneration in glabrous skin. This study aimed to evaluate the therapeutic effect of PRP combined with 308-nm excimer phototherapy in refractory acral vitiligo and elucidate the molecular mechanism driving DMP differentiation.

Materials and Methods
A single-center, prospective, randomized split-body trial enrolled 30 patients with stable acral vitiligo. Twenty patients received monthly intradermal PRP injections plus twice-weekly 308-nm phototherapy on one hand, with the contralateral hand as saline-phototherapy control. Ten patients received PRP monotherapy. Treatment lasted 5 months. Clinical outcomes included Vitiligo Area Scoring Index (VASI), pigment/erythema indices, and standardized photography. Skin biopsies were analyzed by immunohistochemistry for melanocyte and progenitor markers.
In vitro, DMPs were isolated from human glabrous skin and differentiated into melanocytes via a 30-day protocol with 308-nm phototherapy. Bulk and single-cell RNA sequencing profiled transcriptomic dynamics. A glabrous skin organoid model recapitulated in vivo regeneration. Protein microarray screened key PRP effectors. Western blot, immunofluorescence, lentiviral knockdown, and neutralizing antibodies validated the IGFBP-2/RhoA/YAP pathway.

Results
Clinically, PRP + phototherapy significantly enhanced repigmentation versus phototherapy alone. Pigment indices were higher in the PRP group: hand dorsum (44.30 ± 6.17 vs. 36.40 ± 4.94), palms (20.15 ± 3.10 vs. 16.45 ± 4.73), proximal fingers (31.75 ± 3.73 vs. 29.00 ± 3.52), distal fingers (19.90 ± 3.88 vs. 19.45 ± 3.80). VASI improvement rates reached 45.95% (dorsum) and 46.20% (palms), superior to controls. Histology showed increased Nestin+ DMPs and Melan-A+ melanocytes in PRP-treated dermis, with diffuse repigmentation indicating follicle-independent regeneration.
In vitro, DMPs differentiated into mature melanocytes with morphological changes, melanin deposition, and upregulated MITF, TYR, TRP-1/2. Transcriptomics revealed Hippo/YAP and Rho GTPase pathway enrichment during differentiation. PRP enhanced differentiation, increasing melanin, tyrosinase activity, and mature melanosomes (III–IV stage). In organoids, PRP promoted

DMP migration and melanocyte maturation at the dermal-epidermal junction.
Protein microarray identified IGFBP-2 as the key PRP effector. IGFBP-2 activated RhoA and induced YAP nuclear translocation, recapitulating PRP’s pro-differentiation effects. RhoA/YAP inhibition abolished PRP/IGFBP-2 activity. IGFBP-2 neutralization attenuated PRP-induced differentiation, confirming its essential role.

Conclusions

PRP combined with 308-nm phototherapy is safe and effective for refractory acral vitiligo. Mechanistically, PRP delivers IGFBP-2 to activate the RhoA/YAP axis, driving DMP differentiation into functional melanocytes and follicle-independent repigmentation in hairless skin. These findings establish DMPs as a promising melanocyte source and identify the IGFBP-2/RhoA/YAP pathway as a novel therapeutic target, supporting PRP’s clinical use and targeted regenerative therapy development for vitiligo.

EADV CONGRESS
VIENNA
30 SEP - 3 OCT 2026

Abstract N°: 4305

Comparison of Efficacy and Safety of Intralesional Tranexamic Acid Versus Oral Tranexamic Acid Combined with 2% Hydroquinone in Melasma: A Randomised Prospective Interventional Study

Pranomita Sahoo*[1], Yash Dad[1]

[1] Kalinga Institute of Medical Sciences, bhubaneswar, India

Introduction
Melasma is a chronic, relapsing disorder of facial hyperpigmentation predominantly affecting women with Fitzpatrick skin types III–V, carrying significant psychosocial burden in the Indian population. Its multifactorial pathogenesis involves UV radiation, hormonal influences, and genetic predisposition. Tranexamic acid (TXA), via antiplasmin activity, inhibits UV-induced plasminogen activation in keratinocytes, thereby suppressing melanogenesis. While oral TXA is well-established in melasma management, intralesional delivery offers targeted action with reduced systemic exposure. This study compares the efficacy and safety of intralesional versus oral TXA, each combined with 2% hydroquinone, in patients with melasma.

Materials and Methods
This prospective, assessor-blinded, randomised controlled trial was conducted at the Department of Dermatology, Kalinga Institute of Medical Sciences. Forty adults aged 18–50 years with clinically diagnosed melasma and Fitzpatrick skin types III–V were randomised 1:1. Group A (n=20) received intralesional TXA (4 mg/mL) every 4 weeks for 3 cycles plus daily 2% hydroquinone cream. Group B (n=20) received oral TXA (250 mg twice daily) for 12 weeks plus daily 2% hydroquinone cream. Primary outcome was reduction in modified Melasma Area and Severity Index (mMASI). Secondary outcomes included Dermatology Life Quality Index (DLQI) and patient-rated Visual Analogue Scale (VAS), assessed at baseline and 4 weeks post-final treatment by a blinded assessor. Wilcoxon Signed Rank test (intra-group) and Mann-Whitney U test (inter-group) were applied using IBM SPSS v26.

Results
Baseline parameters were comparable between groups (mMASI p=0.947; DLQI p=0.174; VAS p=0.820). Both groups achieved statistically significant within-group improvements. Group A: median mMASI declined from 5.45 (IQR 3.75–7.50) to 4.50 (2.95–5.25) (23.3% mean reduction; p<0.001); DLQI from 11 to 9 (22.6%; p<0.001); VAS from 7 to 5 (25.9%; p<0.001). Group B: median mMASI declined from 5.75 (4.80–6.75) to 4.80 (3.75–5.90) (16.9% mean reduction; p<0.001); DLQI from 10 to 9 (16.7%; p=0.001); VAS from 7 to 5 (18.3%; p=0.002). Inter-group comparison post-treatment revealed no statistically significant differences in mMASI (U=222.5, p=0.547), DLQI (U=180, p=0.602), or VAS (U=247, p=0.211).

Conclusions
Both intralesional and oral TXA combined with 2% hydroquinone produced significant improvements in melasma severity, quality of life, and patient satisfaction over 12 weeks. Group A showed numerically greater reductions across all parameters (mMASI −23.3% vs −16.9%; VAS −25.9% vs −18.3%), but these differences did not reach statistical significance, suggesting comparable overall efficacy. Oral TXA offers convenience and patient acceptability, while intralesional TXA remains a viable targeted alternative, especially when systemic administration is contraindicated. Larger multicentre trials with longer follow-up and dermoscopic evaluation are warranted to establish definitive superiority and long-term safety profiles.

EA DV CONGRESS
VIENNA
30 SEP - 3 OCT 2026

Abstract N°: 4310

A Study to Evaluate the clinico-etiopathological correlates of Acquired Dermal Macular Hyperpigmentation, with special reference to Patch Testing

Anupam Das*[1]

[1] KPC Medical College and Hospital, KOLKATA, India

Introduction

Pigmentary lesions of the face is a common condition encountered among patients presenting to the dermatology OPD in day-to-day practice. Acquired dermal macular hyperpigmentation (ADMH) comprises a significant proportion of these cases. Studies evaluating the role of patch-test in facial ADMH are rare.

Materials and Methods

To evaluate the clinico-etiopathological correlates of facial ADMH and study the role of contact sensitization to different allergens, as an etiological factor behind the development of ADMH. Over a 6-month period, patients attending the OPD with hyperpigmented lesions on the face, were examined. Cases clinically and dermoscopically diagnosed and histopathologically proved as ADMH were enrolled in the study after obtaining proper consent. A detailed history taking and thorough clinical examination was done. Patch-test with Indian Standard Battery was done in all cases and in a few, patch testing was also done with patients' own suspected products. Results were recorded in a preapproved proforma and tabulated

Results

57 patients (25M, 32F) were recruited. Out the 57, 37 had a history of atopy (64.91%), 10 had pigmented lesions elsewhere on the body (17.54%). Patch test was positive in 52.63% (30 patients). Paraphenylene diamine (PPD) was the most common offending agent (6 out of 57 tested, 10.52%), others were Nickel sulphate (5cases, 8.77%), Fragrance (4, 7.01%) and Parthenium (4, 7.01%). Out of 3 patients tested with their own hair care products,out of whom 1 was positive.



Patch test positive reactions in patients of ADMH, observed in our study

Conclusions

Our study showed a higher patch positivity than previous studies, however the positivity was highest for PPD, in keeping with previous studies. It was limited by unavailability of cosmetic series and photo-patch test for more inclusive and specific results. Patch testing is an underutilized tool in daily dermatologic practice. The high positivity rate underscores its importance and utility in detection of underlying causes of such lesions, and increases the possibility for better treatment outcome.

EA DV CONGRESS
VIENNA
30 SEP - 3 OCT 2026

Abstract N°: 4428

comparative study between combined follicular and epidermal cell suspension versus epidermal cell suspension in treatment of stable vitiligo

Engi Seif E. Shaker*[1], Samar Abdelaal[1], Waleed Mostafa[1], Samia Nassar[1]

[1] Faculty of Medicine - Tanta University, Tanta, Egypt

Introduction
Over recent decades, several new surgical techniques have been developed for the treatment of vitiligo . In 1987, autologous epidermal cell transplantation (ECT) was introduced as a novel surgical treatment, and numerous studies have since confirmed its safety and efficacy for repigmentation in vitiligo patients .Building on clinical evidence suggesting the potential role of hair follicles in repigmentation, researchers devel oped hair follicle-derived cell transplantation (FCT), first introduced in 2009 . Subsequent trials demonstrated that FCT is both safe and effective for treating vitiligo. To achieve stable and rapid repigmentation that is aesthetically pleasing, both epidermal cell suspension (ECS) and follicular cell suspension (FCS) are now utilized in surgical treatments for vitiligo. Recently, the combination of ECS and FCS (ECS + FCS) has emerged as a promising new method for treating vitiligo . Despite advancements in treatment, no therapies currently offer a guaranteed cure for vitiligo, due to the disease's unpredictable clinical course and the still poorly understood pathogenic mechanisms underlying its development .
This research aimed to compare the advantages and limitations of ECT versus combined epidermal and FCT in the treatment of stable vitiligo

Materials and Methods

This current research was conducted on 20 vitiligo patients, aged more than 15 years old and less than 50 years, who had stable vitiligo for 1 year or more (vitiligo disease activity (VIDA) score: 0) and three or more small vitiliginous patches similar to each other regarding size and site. All patients were subjected to complete history taking, general and dermatological examination, assessment of the vitiligo area scoring index (VASI), VIDA score and tensity stages of vitiligo extent tensity index (VETI) score.The selected lesions in the patients were bilateral and symmetrical as much as possible or multiple patches in the same anatomical region to make sure that the condition for both methods would be similar. We selected patients with three vitiliginous patches or more The first patch was treated by ECT (group A). The second patch was treated by combining epidermal cell and follicular transplantation (ECS + FCS) (group B). The third patch was considered as a control patch (group C). All the lesions received NB- UVB therapy for 4 months. Frequency was twice a week, not on two successive days.At the four-month mark, treatment efficacy was assessed using clinical evaluations by three blinded dermatologists, dermoscopic analysis using Dermalite 4 to evaluate repigmentation patterns, and patient satisfaction through a five-point scale

Results
A notable improvement in pigmentation was observed in the combined treatment group compared to the epidermal treatment group. Control patches exhibited resistance to NB-UVB
therapy, showing minimal improvement and a slight reduction in depigmentation, in contrast to the treated patches. A significant correlation was found between the site of vitiligo, the tensity stages of the vitiligo extent tensity index (VETI) score after treatment, and the percentage of improvement ($P < 0.05$). Additionally, a

significant relationship was observed
between the vitiligo area severity index score and the tensity stages of the VETI score after treatment, as well as the percentage of improvement (P < 0.05).

		Epidermal (n=20)	Combined (n=20)	Control (n=20)	Fr	*P*
Percentage of improvement	Excellent (90–100%)	2(10.0%)	6(30.0%)	0(0.0%)	27.527*	**>0.001***
	Good (75–90%)	4(20.0%)	7(35.0%)	0(0.0%)		
	Fair (50–75%)	5(25.0%)	4(20.0%)	0(0.0%)		
	Poor (<50%)	9(45.0%)	3(15.0%)	20(10.0%)		
Sig. bet. grps.		**P1=0.040*, P2=0.022*, P3<0.001***				
Pattern of repigmentation	Diffuse	16(80.0%)	16(80.0%)	0(0.0%)	40.0*	**<0.001***
	Marginal	3(15.0%)	3(15.0%)	0(0.0%)		
	Perifollicular	1(5.0%)	1(5.0%)	2(10.0%)		
Sig. bet. grps.		P1=1.000, **P2<0.001*, P3<0.001***				
Percentage of improvement>75%	Excellent / Good	6(30.0%)	13(65.0%)	--	2.646*	**0.008***
VASI score	Before	1.0 (0.95–1.35)	1.0 (0.95–1.35)	1.0 (0.95–1.35)	0.0	1.000
	After	0.91 (0.50–1.28)	0.91 (0.50–1.28)	0.91 (0.50–1.28)		
P4		**0.001***	**0.001***	**0.001***	Z=3.438*	
Patient satisfaction	Highly satisfied	2(10.0%)	7(35.0%)	0(0.0%)	26.561*	**>0.001***
	Satisfied	6(30.0%)	7(35.0%)	0(0.0%)		
	Neutral	6(30.0%)	3(15.0%)	2(10.0%)		
	Dissatisfied	6(30.0%)	3(15.0%)	15(75.0%)		
	Highly dissatisfied	0(0.0%)	0(0.0%)	3(15.0%)		
Sig. bet. grps.		**P1=0.040*, P2=0.022*, P3<0.001***				

Comparison between the three studied groups according to percentage of improvement, pattern of repigmentation, VASI score and patient satisfaction and percentage of improvement > 75% between epidermal and combined patches

Conclusions

Both combined (FCS + ECS) and ECS techniques are effective in producing repigmentation with significant difference in pigmentation outcome in combined method. The findings
from this study establish ECS + FCS as a novel approach in vitiligo surgery for attaining good to excellent repigmentation in a short period with good color match, even in difficult-to-treat vitiligo. Combined (FCS + ECS) is an emerging method with promising results in treatment of vitiligo. Both procedures proved to be safe and simple with reasonable cost compared to the sophisticated cultured cellular grafts. FCS technique requires skilled surgeons in performing FUE.

EADV CONGRESS
VIENNA
30 SEP - 3 OCT 2026

Abstract N°: 4452

Vitiligo: Epidemiological and Clinical Profile of 103 Cases

Safae ELMSAYRYB*[1], radia chakiri[1], chaouche mohammed[1], sokaina chhiti[1]

[1] Department of Dermatology, Mohammed VI University Hospital Center, AGADIR, Morocco

Introduction

Vitiligo is a dermatological disorder classified among leukodermas. It is a disfiguring condition affecting 1.5–2% of the world population. Vitiligo is a benign and non-contagious disease characterized by the appearance of hypochromic or achromic macules. Women represent the majority of patients seeking consultation, which may be explained by the greater psychosocial impact and stigma experienced by females. The aim of our study was to evaluate the clinical and epidemiological characteristics of patients with vitiligo in our setting.

Materials and Methods

This was a descriptive cross-sectional study conducted on 103 patients with vitiligo attending our department over a period of two and a half years, from September 2023 to February 2026.

Results

Over a two-and-a-half-year period, we identified 103 patients with vitiligo. A female predominance was noted, with a male-to-female ratio of 0.49. Patients' ages ranged from 6 months to 76 years, with a mean age of 31 years. The most represented age group was 6–14 years, accounting for 25% of cases. In 27% of cases, patients consulted for reasons other than vitiligo. A family history of vitiligo was reported in 11 patients (10%). Associated autoimmune diseases, including diabetes, psoriasis, alopecia areata, Sjögren's syndrome, lupus, lichen, thyroid disorders, and rheumatic fever, were found in 19 patients (18.4%). The mean disease duration was 2.25 years, ranging from 2 months to 50 years. Clinically, phototype III was the most represented in our series, with a frequency of 52.4%. Non-segmental vitiligo was the predominant clinical form, observed in 66% of cases (n = 68). Segmental forms accounted for only 12.6% of cases, whereas isolated mucosal forms, oral or genital, were observed in 10.6% of cases. The most frequent localization was the facial region (65%), followed by the upper and lower limbs (57%), trunk and back (40.7%), and genital and perianal regions (22%). The Koebner phenomenon was observed in 6 patients (5.8%). The affected body surface area ranged from 1% to 90%, with a mean of 11%. Vitiligo was considered active in 76 patients (73.8%) and stable in 27 patients (26.2%). Quality of life assessment using the DLQI score was performed in 28 patients (27%) and showed an impact ranging from very large (8.7% of cases) to extremely large (4.8%). The CDLQI score, calculated in 12 children, showed an impact ranging from mild (4.8%) to moderate (4.8%) in this population. An autoimmune laboratory workup was performed in only 14 patients (13.5%); only one patient had abnormal findings, consistent with Hashimoto's disease. Skin biopsy was performed in 3 patients and supported the diagnosis of vitiligo in all cases. Therapeutically, topical treatment with corticosteroids and/or calcineurin inhibitors was prescribed in 84 patients (81.5%), while phototherapy was indicated in 19 patients (18.4%). Depigmentation therapy was considered in only one patient with universal vitiligo. Refusal of any treatment was noted in 10 patients (9.7%).

Conclusions

Vitiligo is a common condition in our setting, with a significant impact on patients' quality of life. This study confirms that the impact of vitiligo extends far beyond the cutaneous manifestations. The identified psychosocial burden justifies the implementation of quality-of-life assessment scores in routine practice in order to better tailor therapeutic strategies.

EA DV CONGRESS
VIENNA
30 SEP - 3 OCT 2026

Abstract N°: 4475

Pigmented Facial Demodicosis: Clinical, Dermoscopic, and Therapeutic Findings from a Case Series

Maissa Abid[1], Rim Chaabouni[1], Kmar Turki[1], Malek Cherif*[1], Madiha Mseddi[1], Hamida Turki[1]

[1] Dermatology Department, Hedi Chaker Hospital, Sfax, Tunisia, Sfax, Tunisia

Introduction
Pigmented demodicosis (PD) is an underrecognized yet potentially reversible cause of facial hyperpigmentation associated with Demodex overgrowth. Its clinical presentation may mimic other pigmentary disorders, leading to delayed diagnosis. This study aimed to characterize the clinical, dermoscopic, and therapeutic features of PD and to identify useful diagnostic clues.

Materials and Methods
We retrospectively analyzed 12 patients diagnosed with PD between January 2023 and June 2025. Diagnosis was established through clinical and dermoscopic evaluation, with parasitological confirmation using standardized skin surface biopsy showing Demodex proliferation (>5 mites/cm^2).

Results
The cohort included 9 women and 3 men, with a mean age of 48 years (range: 32–69). Most patients had Fitzpatrick phototypes III–IV. Clinically, PD presented as ill-defined homogeneous, reticular, or speckled facial hyperpigmentation involving either localized areas or the entire face. Associated findings included rugose skin texture, erythematous background, dilated follicular openings, fine scaling, and occasional pustules. Upper eyelid margin hyperpigmentation was observed in half of the patients, and one case mimicked lentigo maligna. Dermoscopy consistently demonstrated perifollicular pigmentation, plugged dilated follicular openings, and whitish gelatinous protrusions corresponding to Demodex tails, frequently associated with telangiectatic erythema and fine scaling. Treatments included topical ivermectin, topical or oral metronidazole, azelaic acid, or combination regimens, alongside systematic photoprotection. Complete clearance of hyperpigmentation was achieved in most patients within 2–12 months, while a minority showed partial recurrent improvement. Dermoscopic follow-up revealed early disappearance of Demodex tails followed by gradual regression of perifollicular pigmentation.

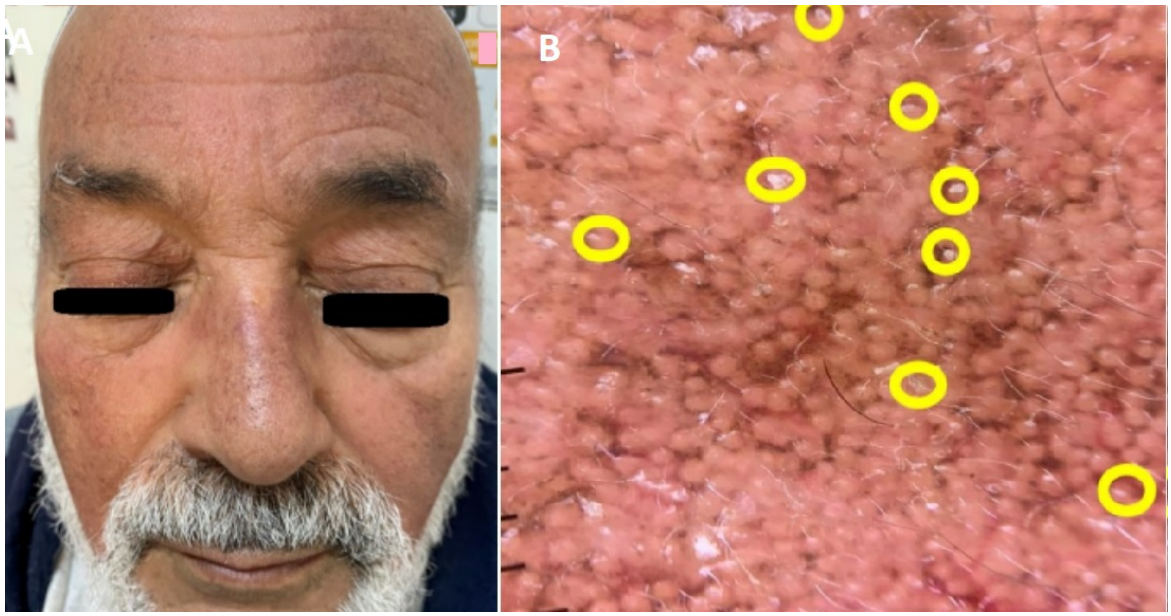

Figure A: Pigmented demodicosis affecting the forehead, bridge of the nose, cheeks, and the free margins of the upper eyelids. B: Dermoscopic image showing Demodex tails surrounded by yellow circles.

Conclusions

Pigmented demodicosis is likely an underdiagnosed cause of facial hyperpigmentation, particularly in patients with darker phototypes. The combination of ill-defined facial pigmentation, rugose texture, perifollicular changes, and characteristic dermoscopic findings—including Demodex tails, plugged dilated follicular openings, perifollicular pigmentation, and an erythematous telangiectatic background—may provide important diagnostic clues. Recognition of this entity is essential because, unlike many chronic pigmentary disorders, PD is potentially reversible, and targeted anti-Demodex therapy can result in gradual but marked clinical and dermoscopic improvement.

EADV CONGRESS
VIENNA
30 SEP - 3 OCT 2026

Abstract N°: 4573

Genetic Polymorphisms in the Response to NB-UVB Phototherapy in Vitiligo: A Prospective Study

Anabell Andrea Lima Galindo*[1], Mauricio Salinas Santander[1, 2], Jorge Alejandro Ocampo Garza[1], Miguel Favela Gálvez[1], Alejandra Brown-Herrera[1], Jorge Ocampo-Candiani[1]

[1] Dermatology Department, Hospital Universitario Dr José Eleuterio González, Monterrey, Mexico
[2] Department of Research, Faculty of Medicine Saltillo Unit, Universidad Autónoma de Coahuila, Saltillo, Mexico

Introduction
Response to narrowband ultraviolet B (NB-UVB) phototherapy in vitiligo varies considerably among patients. Genetic polymorphisms involved in melanogenesis and immune regulation may influence therapeutic outcomes; however, their role in predicting treatment response remains poorly understood.
This study aimed to assess the association between selected genetic polymorphisms, includying TYR rs7129973, VDR ApaI rs7975232 and TaqI rs731236, SCL45A2 rs26722, and the heterozygous CYP2C9*3 allele; and the repigmentation respose in patients with vitiligo undergoing NB-UVB phototherapy.

Materials and Methods
This pilot prospective cohort study included 98 vitiligo patients (BSA 4–96%) treated with 54 NB-UVB sessions. Clinical, biochemical, thyroid, and genetic polimorfisms were analyzed. Repigmentation was assessed using VASI and categorized into quartiles (Q1–Q4).

Results
A total of 98 patients completed all 54 NB-UVB sessions. 53.06% of patients had a poor response (<25% repigmentation, Q1), while 46.94% responded favorably (≥25%, Q2–Q4). The G allele of TYR rs7129973 was associated with lower repigmentation ($P < 0.05$), while VDR *Apa*I rs7975232 showed a trend ($P = 0.056$). The heterozygous CYP2C9*3 allele was significantly associated with a better clinical response to NB-UVB phototherapy ($P = 0.009$).

Conclusions
The G allele of TYR rs7129973 is associated with poor repigmentation in vitiligo patients undergoing NB-UVB phototherapy, suggesting a potential predictive role in treatment response.
Despite the efficacy of NB-UVB phototherapy, response variability remains a challenge in vitiligo. Identifying genetic markers may improve predictive models, guiding more targeted and effective therapeutic approaches.