EA DV CONGRESS
VIENNA
30 SEP - 3 OCT 2026

Abstract N°: 31

Additional Safety and Efficacy Results from HELIOS: A Phase 2, Open-Label, Long-Term Extension Study of Bitopertin in Erythropoietic Protoporphyria

Amy Dickey[1, 2], Gayle Ross[3], Sioban Keel[4], Herbert Bonkovsky[5, 6], Peter Stewart[7], Karl Anderson[8], Manisha Balwani[9], Cynthia Levy[10], Manish Thapar[11], Bruce Wang[12], Brendan McGuire[13], Will Savage[14], Melanie Chin*[14]

[1] Harvard Medical School, Boston, United States
[2] Massachusetts General Hospital, Boston, United States
[3] Royal Melbourne Hospital, Melbourne, Australia
[4] University of Washington, Seattle, United States
[5] Wake Forest University School of Medicine, Winston Salem, United States
[6] Atrium Health Wake Forest Baptist, Winston Salem, United States
[7] Royal Prince Alfred Hospital, Sydney, Australia
[8] University of Texas Medical Branch, Galveston, United States
[9] Icahn School of Medicine at Mount Sinai, New York, United States
[10] University of Miami Miller School of Medicine, Miami, United States
[11] Jefferson Center for Genetic and Metabolic Liver Disease, Philadelphia, United States
[12] University of California San Francisco Porphyria Center, San Francisco, United States
[13] University of Alabama at Birmingham, Birmingham, United States
[14] Disc Medicine, Watertown, United States

Introduction

Erythropoietic protoporphyria (EPP) and X-linked protoporphyria (XLP) result in the toxic accumulation of photoreactive protoporphyrin IX (PPIX) in the skin and other organs. PPIX accumulation causes debilitating phototoxic skin reactions upon exposure to sunlight and, in some cases, life-threatening protoporphyric hepatopathy.

Bitopertin is a selective and orally bioavailable inhibitor of glycine transporter 1 (GlyT1), which imports extracellular glycine into erythroid precursor cells for heme biosynthesis. In prior EPP/XLP clinical studies, treatment with bitopertin resulted in significant reductions in PPIX levels that were associated with improvements in light tolerance (Yeung, 2026; Ross, 2026).

The aim of this study was to evaluate the long-term safety, tolerability, and efficacy of bitopertin in participants with EPP or XLP.

Materials and Methods

HELIOS (NCT05883748) is a multi-center, open-label, long-term extension study of bitopertin for participants who completed prior bitopertin studies. The study is being conducted in the US and Australia, with additional sites opening in the UK and EU, and includes participants ≥12 years of age with a confirmed diagnosis of EPP or XLP. Adult and adolescent participants receive once-daily oral administration of bitopertin 60 mg. The primary endpoints are safety and tolerability. Secondary endpoints include percent change from baseline in whole-blood metal-free PPIX and changes in measures of light tolerance.

Results

As of the data cutoff (01 Nov 2025), a total of 86 participants, including 3 adolescents, had enrolled in HELIOS. Median duration of drug exposure, including previous treatment with bitopertin, was 25.3 months (range: 13.8 months to 32.7 months). To date, 61 of 86 (71%) participants have reported treatment-emergent adverse events (AEs). One adult participant involved in a motor vehicle accident reported multiple serious AEs (SAEs) that were considered not related to study drug. The only other Grade 3 event was a nonserious AE of hypertransaminasaemia in an adult participant, which was also considered not related to study drug. All other AEs were mild or moderate in severity. The most common treatment-emergent AEs reported in >5 participants were COVID-19 (12%), nasopharyngitis (9%), and headache (7%).

Participants initially randomized to placebo had significant reductions in whole blood metal-free PPIX concentration relative to HELIOS baseline at Week 24 (-32.8%; p-value <0.001). Participants receiving bitopertin treatment through AURORA/BEACON and HELIOS had reductions in PPIX that were sustained through one year of bitopertin treatment. Continued improvements in light tolerance were also observed with bitopertin through 24 weeks of treatment in the HELIOS study, and participants had statistically significant increases in total hours spent in light (mean increase of 4.9 hours; p-value <0.001) and time to prodrome (mean increase of 101.8 minutes; p-value <0.001) over two-week intervals relative to baseline.

Conclusions

By reducing PPIX levels, bitopertin targets the underlying pathophysiology of EPP and XLP. Results from HELIOS include participants who have received bitopertin for over 2.5 years and support longer-term efficacy and safety with bitopertin in adult and adolescent patients with EPP or XLP.

EA DV CONGRESS
VIENNA
30 SEP - 3 OCT 2026

Abstract N°: 39

Pigmentation and Oxidative Biomarker Modulation Across All Skin Types (FST I-VI) following Exposure to Boundary Region Wavelengths (Longest Ultraviolet A + High Energy Visible Light): a Controlled Clinical Study

Selina MOSES*[1], Thomas Shyr[1], Karen Meyer[1], Susan Daly[1], Indermeet Kohli[2], Tasneem Mohammad[2], Henry W. Lim[2], Joshua D. Williams[1]

[1] Kenvue Brands LLC, Summit, United States
[2] Henry Ford Medical Center, Detroit, United States

Introduction
Introduction : Current UV filters provide absorbance predominantly in the range of 290-380nm which enable protection against sunburn, photocarcinogenesis, hyperpigmentation and photoaging changes.
Objective 1: To assess the level of pigmentation following an acute exposure of skin to light regimens representative of portions of the natural sunlight spectrum that contain Longest UVA wavelengths with or without HEVL (i.e. 380-400nm or 380-420nm), as compared to non-irradiated control skin.
Objective 2: To evaluate the cutaneous oxidative stress biomarkers that occur with exposure to the two light regimens that contain Longest UVA wavelengths with or without HEVL (i.e. 380-400nm or 380-420nm), as compared to non-irradiated control skin.

Materials and Methods
This study evaluated the cutaneous effects of Longest Ultraviolet A(LUVA), 380-400nm, and LUVA + High Energy Visible Light (HEVL), 380-420nm (Boundary Region Light) on 18 female subjects, n=3 per Fitzpatrick Skin Type(FST) I-VI. Pigmentation was assessed using Investigator's Global Assessment (IGA), chromametry and image analysis. Additionally, catalase activity (U/mg proteins) was measured using a fluorescence assay and malondialdehyde (MDA) concentrations (ng/mg proteins) were measured using GC/MS as biomarkers of cutaneous oxidative stress.

Results
Results demonstrated that all subjects responded to both light regimens by developing immediate and persistent skin pigmentation (IGA). All FST's had dose dependent increase in pigmentation (↓ITA) while FST I/II had a dose dependent increase in redness (↑a*). Immediate pigment darkening (IPD) at 15 minutes and persistent pigment darkening (PPD) at 24 hours were strongest in FST IV requiring the lowest minimum mean energy dose of, 3.63J/cm2 to induce IPD and 15.31J/cm2 for PPD with Boundary Region Light. Mean oxidative stress biomarkers were significantly changed with decrease in catalase activity and increase in MDA concentration at higher doses across all skin types (n=18) for both light regimens. Most significant changes in biomarkers occurred at the highest doses in the FST I subpopulation (n=3) as compared to non-irradiated control.

Conclusions
Hyperpigmentation and oxidative stress in all skin types following boundary region light exposure was established. This will enable evaluation of protection beyond the 290-380nm spectrum in future studies.

Disclosures: This work was sponsored by Kenvue Brands LLC.
Author Disclosures: All authors were employees of their affiliated institutions at the time of the research.

EADV CONGRESS
VIENNA
30 SEP - 3 OCT 2026

Abstract N°: 53

Clinical Demonstration of Lasting Pigmentation in Fitzpatrick Skin Type 5 Following Irradiation with Deep Ultraviolet A and High Energy Blue Light

Selina MOSES*[1], Karen Meyer[1], Susan Daly[1], Indermeet Kohli[2], Tasneem Mohammad[2], Henry W. Lim[2], Joshua D. Williams[1]

[1] Kenvue Brands LLC, Summit, United States
[2] Henry Ford Medical Center, Detroit, United States

Introduction

Sunlight is comprised of ~45% Visible Light (VL) and 4-5% Ultraviolet(UV)A (320-400 nm), both shown clinically to induce erythema and pigmentation. Current UV filters provide protection against UVB and portions of UVA, but the protection level tapers off in the Longest UVA (LUVA), beyond 380 nm into the visible wavelengths.

Objective 1: Clinically elucidate the pigmentation effect of the spectral components of light at boundary region, 380 - 420 nm (Longest Ultraviolet A and High Energy Visible Light) on melano-competent skin.

Objective 2: Study the dose dependent response of pigmentation on melano-competent Skin.

Materials and Methods

The single-center controlled study used a novel, modified multiport 601S, xenon arc solar simulator customized to produce a narrow output radiation spectrum of either LUVA (380-400 nm) alone or Boundary Region light LUVA+HEVL (380-420 nm). Subsites were administered with LUVA doses 2.7, 4.7, 8.2, 14.3, 25, 43.8 J/cm2 and LUVA+HEVL doses 5.3, 9.3, 16.3, 28.6, 50, 87.5 J/cm2. Pigmentation was studied in 8 female subjects, 18 to 40 years old with Fitzpatrick Skin Type V. Visual global assessment scale (0-2) was used to identify pigmentation responses.

Results

LUVA and LUVA+HEVL regimens induced clinically perceptible pigmentation at 15 minutes post-exposure indicating immediate pigment darkening (IPD) and at 24, 48, 72 hour time points post-exposure indicating persistent pigment darkening (PPD). IPD was induced at an average dose of 6.09 J/cm2(380-400 nm) and 17.18 J/cm2(380-420 nm) equating to 1.5 hours of natural sunlight exposure. 50% of the subjects exposed to LUVA and 62.5% to Boundary Region Light exhibited persistent pigmentation at 72 hours.

Conclusions

This study validates the use of the novel boundary region light source in the evaluation of skin pigmentation response to enable future skin protection studies.

Disclosures: This work was sponsored by Kenvue Brands LLC.
Author Disclosures: All authors were employees of their affiliated institutions at the time of the research.

EADV CONGRESS
VIENNA
30 SEP - 3 OCT 2026

Abstract N°: 118

Dual-Action Antioxidant Serum for Ultraviolet-Induced Skin Protection Compared with Placebo

Ashleigh Murtaugh-Frey*[1], Wen-Hwa Li[1], Ramine Parsa[1], Leslie Rank[1], Jessica Maciejewski[1], Giulia Trinchera[2], Giuseppe Valacchi[2], Alessandra Pecorelli[2]

[1] Kenvue Brands LLC, Summit, United States
[2] University of Ferrara, Department of Chemical, Pharmaceuticals, and Agricultural Sciences, Ferrara, Italy

Introduction
Background: Ultraviolet (UV) radiation is a major contributor to oxidative stress and epidermal barrier disruption in human skin. This study investigates the unique efficacy of antioxidant formulation with Vitamin C, Feverfew, and Epigallocatechin gallate(collectively: AOX2.0) in mitigating UV-induced lipid peroxidation and preserving epidermal integrity, using a vehicle formulation as control.

Objectives: To investigate the extended antioxidant effects of topical 15% vitamin C, feverfew, and epigallocatechin gallate (AOX 2.0) serum application against UV irradiation in 2D skin cells and 3D skin models. To assess the impact of topical application of AOX 2.0 on collagen expression and oxidative stress in UV-irradiated human skin explants by immunohistochemical analysis of collagen types I, III, IV, elastin, and 8-OHdG.

Materials and Methods
Keratinocytes, fibroblasts, 3D reconstructed human epidermis, and ex vivo human skin explants were pretreated with AOX2.0 or vehicle and subjected to UV irradiation. Lipid peroxidation was assessed using BODIPY™ 581/591 C11 fluorescence and 4-hydroxynonenal (4-HNE) protein adduct quantification. Epidermal barrier integrity was evaluated through transepithelial electrical resistance (TEER) and immunofluorescent analysis of filaggrin expression.

Results
AOX 2.0 serum demonstrated robust and consistent antioxidant protection across 2D cell lines, 3D RHE, and ex vivo human skin explants, as observed by:
- Significantly reduced UV-induced lipid peroxidation in keratinocytes, fibroblasts, and tissue models, outperforming placebo at all measured timepoints and conditions.
- Dual benefits of reduction in oxidative stress and improved skin barrier function, as shown by increased TEER values and enhanced filaggrin expression following UV exposure.
- Protection of collagen type I, III, IV, elastin, and reduced 8-OHdG under UV-induced damage in ex vivo skin explants.

Conclusions
These results suggest that AOX 2.0 serum may offer protection against UV-induced oxidative damage and support both epidermal and dermal recovery.

Disclosures: This work was sponsored by Kenvue Brands LLC.
The majority of the research presented in this poster was conducted by University of Ferrara,which was commissioned by Kenvue to perform the study.
Author Disclosures: All authors were employees of their affiliated institutions at the time of the research.

EADV CONGRESS
VIENNA
30 SEP - 3 OCT 2026

Abstract N°: 199

Understanding Demographic Differences in Sun Safety: A National SurveyAnalysis of Behaviors and Knowledge

Guia Sylianteg*[1], Joyce Rhoden[1], Kassidy Hubert[1], Toni Anne Lisante[1], Asha Patel Shah[1], Adam Friedman[2]

[1] Kenvue Brands LLC, Summit, United States

[2] George Washington University School Of Medicine and Health Sciences, Washington DC, United States

Introduction

Public engagement in sun-safe behaviors remains inconsistent despite established scientific consensus on the risks of sun exposure. A study was conducted in 2024 to provide a cross-sectional assessment of the current state of sun protection perceptions and behaviors based on a survey of over 5,000 consumers in the United States.

Materials and Methods

Results from a 2024 nationally representative survey on United States respondents assessing sun safety (n=5,118) were analyzed. Scenarios where sun protection was used (recreational versus everyday) and the types of sun protection (e.g. sunscreen, seeking shade, etc.) and compared by generation (Gen Z, Millennials, Gen X, Boomers) and income group categories (<$50k, $50-99k, >$100k) were analyzed.

Results

Across all groups, sun protection behaviors were more prevalent in recreational contexts than in daily routines. Sunscreen application was the most utilized method of protection, yet consistent application and reapplication remained suboptimal (30%) even in recreational situations where sun exposure potential was high. Despite greater lapse in using any sun protection at all regardless of scenario, Boomers were more likely to report no sunburns in the past year (56%), contrasting with Gen Z/Millennials (23–26%) ($p<0.05$). In terms of income, higher income (>$100K) correlated with greater use of any sun protection methods, however were more likely to report getting sunburned vs lower income (<$50K) groups. Lower income groups were significantly more likely to report refraining from using any sun protection methods at all ($p<0.05$), however reporting the least amount of sunburns vs higher income groups ($p<0.05$).

Conclusions

This analysis highlights how different demographic factors may affect sun protection behaviors and even recognition of sunburn. This knowledge can enable health care providers to offer more personalized guidance to patients not only in sun protection habits but in identification of sunburn.

Disclosures: This work was sponsored by Kenvue Brands LLC.
Author Disclosures: Joyce Rhoden, Kassidy Hubert, Toni Anne Lisante, and Asha Patel Shah were employees of Kenvue Brands LLC at the time of the research.
Guia Sylianteng was a contractor of ClinChoice Inc providing services to Kenvue Brands LLC at the time of the research.

EA DV CONGRESS
VIENNA
30 SEP - 3 OCT 2026

Abstract N°: 200

Additional Therapeutic Benefits of a Sunscreen with 2% Niacinamide for Dry Skin: A 56-Day Clinican Study in a Brazilian Population

Isabelle Rennó*[1], Debora Felix[1], Gabriela Moreira[1], Ana Luisa Teixeira[1], Luciano Milanelo[1], Dina Ameen[2], Andressa Peyrot[1], Maria Carolina Semprini[1], Ana Cláudia Cavalcante Espósito Lemos[3], Elimar Elias Gomes[4]

[1] Kenvue Brands LLC, São José dos Campos, Brazil
[2] Kenvue Brands LLC, Summit, United States
[3] University of Western São Paulo, São Paulo, Brazil
[4] Beneficência Portuguesa de Sao Paulo, Sao Paulo, Brazil

Introduction
Consumers are increasingly seeking multibenefit products to simplify their skincare routines. In this context, sunscreens with additional cosmetic benefits may encourage consistent daily use to improve adherence to skin cancer prevention. Skin pigmentary disorders impact appearance, leading to emotional distress and decreased quality of life, while dry skin may be exacerbated by UV exposure. Daily sunscreen use helps prevent pigmentation and contributes to hydration balance.

The objective of this study was to assess the efficacy of a multifunctional, non-tinted SPF 50 sunscreen in improving skin hydration, barrier integrity, and hyperpigmentation, as well as to evaluate the in vitro percutaneous absorption of niacinamide (NA).

Materials and Methods
This study evaluated the efficacy of a broad-spectrum fluid SPF 50 sunscreen containing 2% of Niacinamide and ingredients such as vitamins C and E in improving dry skin after 12 hours, 28 ± 2 days of regular use and facial skin tone uniformity and radiance after 56 ± 2 days. A total of 32 multiethnic Brazilian women aged 19–45 years, presenting uneven facial skin tone due to sunspots, post-inflammatory hyperpigmentation, ephelides, and/or mild melasma, as well as dry skin confirmed by Corneometer® completed the study. Skin hydration and barrier were assessed using a Corneometer® CM 825 and Tewameter® TM 300 measured on the face on treated and untreated areas at baseline and up to 12 hours post-application, and after 28 days of daily use. A facial hydration map was generated, and participants completed self-assessment questionnaires related to skin condition. After 56 ± 2 days, facial skin tone uniformity, radiance, and hyperpigmentation were evaluated through expert grader evaluation, and image analysis using Colorface®. An in vitro permeation test (IVPT) was conducted to evaluate the percutaneous absorption of niacinamide using vertical Franz diffusion cells mounted with human cadaver skin. Niacinamide concentrations in receptor fluid, skin wash, tapes, and skin layers were measured using a UPLC-MS/MS method. Dermatological tolerability and acceptability were monitored throughout the 56 ± 2-day facial application period.

Results
Hydration significantly increased at all time points (2–12 hours, $p < 0.001$) on the treated area compared with the control. After 28 days, hydration improved by 22% vs. baseline ($p < 0.001$). TEWL remained stable, indicating preserved barrier integrity. Additionally, 90.6% of participants reported improved facial hydration. Hydration mapping corroborates these findings, demonstrating visible improvements in facial hydration profiles.
After 28 and 56 days, statistically significant improvements in skin tone uniformity and radiance were clinically observed ($p<0,05$) with a notable reduction in facial spot size measured by the Colorface® system.

The IVPT results showed that niacinamide permeated the skin, with 43.9% ± 12.4 of the applied dose detected within the skin layers, which was significantly higher than the proportion recovered in the receptor fluid (18.7% ± 6.3) at 24 hours ($p < 0.05$).

Conclusions

The multifunctional sunscreen demonstrated benefits beyond primary photoprotection by significantly improving facial skin tone homogeneity, reducing spot size, and enhancing skin hydration. The formulation promoted a short term and sustained hydration from the first application, lasting up to 12 hours, preserved barrier integrity, and delivered clinically perceived benefits after 28 days of continuous use.

Disclosures: This work was sponsored by Kenvue Brands LLC.
Author Disclosures: All authors were employees of their affiliated institutions at the time of the research.

Original presentations submitted to the American Academy of Dermatology 2025 and 2026.

EADV CONGRESS
VIENNA
30 SEP - 3 OCT 2026

Abstract N°: 367

Adenosine Drives Th2/Th1 Imbalance and Skin Barrier Dysfunction in Chronic Actinic Dermatitis via the cAMP/PKA/CREB Axis.

Quan Chen*[1], Huilan Zhu[1], Bihua Liang[1], Huaping LI[1], Fengmei He[1]

[1] Guangzhou Dermatology Hospital, Guangzhou, China

Introduction
Chronic actinic dermatitis (CAD) is a photosensitive inflammatory skin disorder that involves ultraviolet B (UVB) irradiance as a key environmental cofactor in the disease process that results in perturbations of the normal epidermal barrier function as well as immunity. We studied the effects of adenosine (ADO), after the hydrolysis of extracellular ATP, on T cell immunity and dermal barrier function under conditions of UVB-induced CAD.

Materials and Methods
A murine model of CAD was established by treating mice with daily UVB radiation (2.5 J/cm^2) for 15 consecutive days. Mice were treated with the A_2aR antagonist SCH 58261 or the Th2 inhibitor IPD 1151T to study the pharmacological effects. Subsequently, transepidermal water loss (TEWL), histopathological changes, and the expression of associated barrier proteins were investigated. We isolated CD4+ T cells from murine spleens and promoted their differentiation into Th1 or Th2 cells both in vitro. For the characterization of transcriptional profiles and the associated molecular alterations, bulk RNA sequencing (RNA-seq), Western blot, quantitative real-time PCR, enzyme-linked immunosorbent assay (ELISA), flow cytometry (FACS), and immunofluorescence staining were conducted for the analysis of gene expression, protein expression, cytokine secretion, and the activation status of signaling pathways. For the assessment of the alteration of epidermal barrier function, primary mouse keratinocytes were used in the presence of conditioned medium of adenosine-treated Th2 cells (Th2-CM).

Results
These effects were mirrored by increased levels of ATP and ADO in the lesional skin, along with increased expression of CD39, CD73, and A2aR. A bioinformatics search revealed the following: The cAMP signaling pathway was greatly enriched in CAD mouse skin, whereas the balance between Th2/Th1 cells was disrupted. In vitro experiments showed ADO stimulated Th2 cell differentiation and production of type 2 cytokines (IL-4, IL-5, and IL-13), while inhibiting production of the type 1 cytokine IFN-γ. Moreover, it activated the cAMP/PKA/CREB signaling pathway, suppressed mTORC1 signaling and aerobic glycolysis in Th1 cells, as well as promoting STAT6-dependent Th2 cell differentiation independently of mTORC1. The in vivo pharmacological blockade of A2aR or inhibition of Th2 responses mitigated UVB-induced epidermal hyperplasia, collagen degradation, barrier dysfunction, and pathological immune cell infiltration, and restored Th1/Th2 immune balance.

Conclusions
The presence of accumulated ADO brings about the activation of the cAMP/PKA/CREB signaling pathway, leading to the Th2/Th1 imbalance and compromised epidermal barrier integrity, hence augmenting the progression of CAD. The use of A2aR antagonists or Th2 suppression exerts protective effects against UVB-induced damage, making it a promising target in CAD pathogenesis.

EA DV CONGRESS
VIENNA
30 SEP - 3 OCT 2026

Abstract N°: 380

Targeting miR-509-5p to Regulate HIF-1α Signaling for Asian Skin Photoprotection, Hydration and Barrier Integrity: Modulation by a Tea-Derived and Terminalia chebula Botanical Complex

Youssef MAACH*[1], Yulan QU[2], Jing TANG[1], Yue ZOU[1], Shanshan JIANG[1]

[1] R&D Center, Shanghai CHANDO GROUP Co., Ltd., Shanghai, China

[2] R&D Center, Shanghai JAK Technology Co., Shanghai, China

Introduction

Asian and Caucasian populations age differently, illustrating variations in skin biology. Comparative studies in scientific literature support that Asian women's skin is more prone to pigmentation during aging, with wrinkles more appearant around 40–50 years old, while Caucasian women tend to develop wrinkles earlier in a linear pattern. These ethnic variations suggest population-specific molecular responses to environmental stressors, particularly ultraviolet radiation (UVR). MicroRNAs (miRNAs) are small non-coding RNAs that regulate post-transcriptional gene expressions involved in many biological functions. Our epigenetic study investigates miRNA expression changes induced by UVR in Asian skin, compares miRNA expressions between Asian and Caucasian populations, and identifies botanical ingredients capable of modulating miRNAs involved in photoprotection and skin barrier integrity.

Materials and Methods

1. To identifiy miRNAs signature of UVR and ethnic influences, miRNA expression profiling using microarrays (Agilent Human / miRBase V21) was performed on Chinese and French women skin biopsies.Three cohorts designed: UV-exposed (8 Chinese skin - blepharoplasty), UV-photoprotected (7 Chinese skin - abdominoplasty) and Ethnicity (5 photo-protected French skin - abdominoplasty).
2. Target genes of differentially expressed miRNAs were predicted with the validated module of miRWalk 2.0 database. The biological functions of predicted genes were performed using DAVID Bioinformatics Resources V6.8 and network maps were constructed to visualize the miRNA-Gene interactions.
3. in vitro were carried out to validate experimentally by RT-qPCR on human keratinocytes the correlation between the miRNAs and target genes predicted in silico.
4. Screening of botanical extracts capable to regulate miRNA signature in human keratinocytes culture (RT-qPCR).

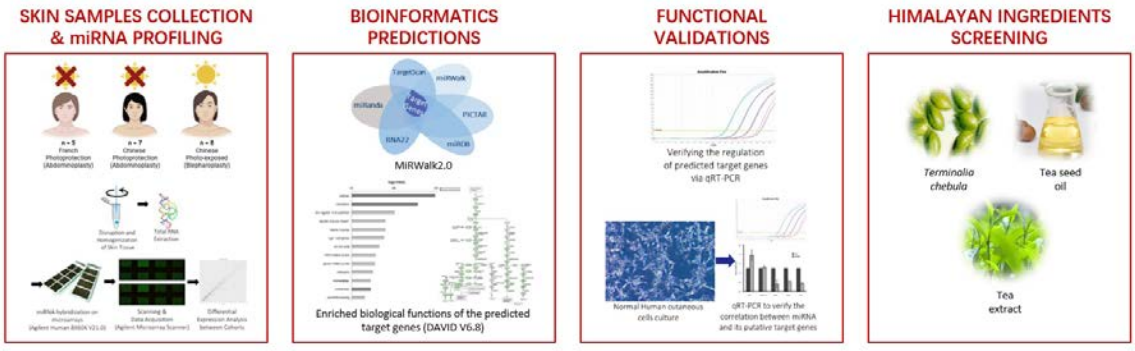

Research methodology for miRNA profiling, bioinformatic prediction, in-vitro validation and ingredient screening.

Results

1. Results from UV-protected versus UV-exposed skin samples showed that hsa-miR-509-5p expression was strongly increased in UV-exposed (fold change +11.12).
2. In silico analysis linked gene HIF-1α (Hypoxia-Inducible Factor-1α) as a potential target of miR-509-5p. qRT-PCR analysis in human epidermal keratinocytes exposed to URV confirmed that UV-induced upregulation of miR-509-5p was associated with decreased HIF-1α gene expression which is a gene involved with skin aging and barrier integrity according to several scientific studies.
3. From ethnic comparison, baseline expression of miR-509-5p was lower in Chinese skin compared with French skin (fold difference +5.6). It highlights miRNA-509-5p as signature of ethnic variation with a stronger influence in skin aging by HIF-1α signalling on French skin, which is aligned with the wrinkle dominant aging of Caucasian women compared to Asian women.
4. Screening of botanical ingredients led us to select compounds to modulate miRNA-509/ HIF-1α axis. Human primary keratinocytes treated with a botanical complex of tea seed oil, tea extract and Terminalia chebula fruit extract significantly reduced miR-509-5p expression (−68%), associated with restoration of HIF-1α expression.

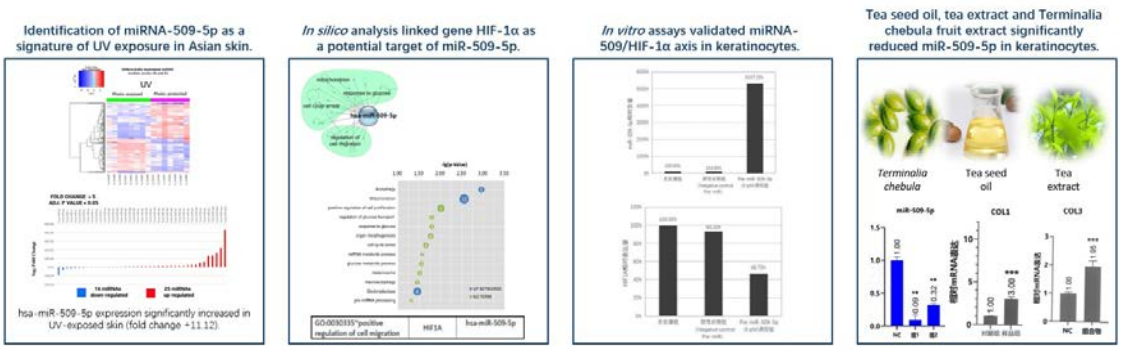

Identification of miRNA-509 and its regulation for skin photo-protection and barrier integrity in Asian skin.

Conclusions

Our study identifies miR-509-5p as a UV-responsive miRNA that regulates HIF-1α pathway in epidermal keratinocytes. Scientific literature highlights that HIF-1α plays an essential role in skin barrier integrity by promoting epidermal renewal through activation of laminin-332 transcription, supporting keratinocyte adhesion and migration. HIF-1α also contributes to oxidative stress protection by reducing mitochondrial reactive oxygen species and preventing apoptosis. HIF-1α regulates wound repair by activating genes involved in angiogenesis and extracellular matrix strengthening. Finally, HIF-1α strengthens skin barrier through regulation of filaggrin expression, a key structural protein for corneocyte integrity and epidermal hydration. Our findings about miR-509-5p/HIF-1α axis regulation in Asian skin under UV stress suggest a novel epigenetic mechanism for photoprotection, skin barrier repair and hydration.

EA CONGRESS
VIENNA
30 SEP - 3 OCT 2026

Abstract N°: 399

Randomized Controlled Pilot Trial: Single-session Intralesional ALA-PDT versus Topical ALA-PDT plus CO2 Laser for Refractory Common Warts

Lei Shi*[1], Yitao Qian[1]

[1] Huadong Hospital, Fudan University Shanghai Key Laboratory of Clinical Geriatric Medicine Shanghai Institute of Geriatric Medicine, Shanghai, China

Introduction

Photodynamic therapy (PDT) is a minimally invasive treatment modality with advantages including favorable efficacy, low recurrence, and the potential for repeated long-term use, and has been widely applied in skin tumors, infectious dermatoses, and inflammatory skin diseases. Current delivery methods for PDT can be divided into topical administration and systemic administration. However, topical delivery such as 5-aminolevulinic acid PDT (ALA-PDT), has limited penetration depth and shows suboptimal efficacy for hyperkeratotic, deeply infiltrative, and bulky lesions; whereas systemic delivery, such as hematoporphyrin monomethyl ether PDT (HMME-PDT), can induce marked phototoxic reactions and requires prolonged strict photoprotection. Therefore, for hyperkeratotic lesions, a novel PDT modality that combines the advantages of both approaches is needed. Intralesional injection may combine the safety of topical administration with the penetration depth required for these lesions, but randomized controlled studies remain scarce. Accordingly, we conducted a clinical trial in refractory common warts, a representative model of deep cutaneous lesions.

Materials and Methods

Patients with refractory common warts, defined as disease duration ≥2 years or poor response after ≥3 prior treatments, were enrolled and randomly assigned in a 1:1 ratio by simple randomization to either the iALA-PDT group or the topical ALA-PDT plus CO_2 laser (tALA-PDT + CO2 laser) group, followed by treatment and blinded assessment. In the iALA-PDT group, 10% ALA solution was delivered directly into the lesions by injection. In the tALA-PDT + CO2 laser group, the wart and the surrounding 2mm skin area were first ablated using superpulsed CO2 laser, and after hemostasis, 10% ALA cream was topically applied. After 2 hours of dark incubation, lesions were illuminated with 633-nm LED red light for 30 minutes. The primary outcome was the total wart volume regression rate at week 16 post-treatment. Secondary outcomes included complete subject cure rate at week 16 post-treatment, PpIX fluorescence positivity rate, recurrence rate, and safety.

Results

A total of 40 eligible participants were enrolled in the trial. After a single treatment, the median total wart volume regression rate in the iALA-PDT group was 100% (40.6%–100%), which was significantly higher than 41.7% (-23.9%–87.0%) in the tALA-PDT + CO2 laser group ($p<0.05$). The complete subject cure rate at week 16 post-treatment in the iALA-PDT group was also significantly higher than that in the tALA-PDT + CO2 laser group: 55% (11/20, 95% CI: 34.2%–74.2%) versus 20% (4/20, 95% CI: 8.1%–41.6%, $p<0.05$). There was no significant difference in PpIX fluorescence positivity rate between the two groups (17/20 vs 15/20, $p>0.05$). The recurrence rate was 0 in both groups. In terms of safety, pain NRS scores did not differ significantly between groups, while post-treatment local adverse reactions were fewer in the iALA-PDT group than in the tALA-PDT + CO_2 laser group.

Total Wart Volume Regression Rate, Complete Subject Cure Rate and Recurrence Rate.

Outcome	Time point post-treatment	ITT population		PP population	
		iALA-PDT (n=20)	tALA-PDT + CO_2 Laser (n=20)	iALA-PDT (n=20)	tALA-PDT + CO_2 Laser (n=18)
Total Wart Volume Regression Rate (Median, Q1-Q3) [1]	Day 0	0% (0-0%)	100% (100-100%)	0% (0-0%)	100% (100-100%)
	Day 3	7.2% (0-31.6%)	100% (100-100%)	7.2% (0-31.6%)	100% (100-100%)
	Day 14	44.9% (14.2-78.1%)	100% (98.2-100%)	44.9% (14.2-78.1%)	100% (100-100%)
	Week 8	71.8% (47.5-97.9%)	57.6% (19.3-78.8%)	71.8% (47.5-97.9%)	63.5% (23.7-80.0%)
	Week 16	100%* (40.6-100%)	41.7% (-28.7-90.8%)	100%* (40.6-100%)	51.5% (-12.3-98.5%)
Cure Rate	Week 8	25%, (5/20)	15%, (3/20)	25%, (5/20)	16.7%, (3/18)
	Week 16	55%*, (11/20)	20%, (4/20)	55%*, (11/20)	22.2%, (4/18)
Recurrence Rate	Week 16	0	0	0	0

Notes: ITT, intent-to-treat; PP, per-protocol; iALA-PDT, intralesional 5-aminolevulinic acid photodynamic therapy; tALA-PDT + CO_2 laser, topical 5-aminolevulinic acid photodynamic therapy plus CO_2 laser; Q1, 25th percentile; Q3, 75th percentile; n, number of patients. [1] Interquartile range. *$p < 0.1$, indicating a significant superior to the tALA-PDT + CO_2 Laser group.

Conclusions

Intralesional PDT is a highly effective and safe treatment for refractory common warts, with broad therapeutic prospects and potential applications in proliferative skin diseases.

EA DV CONGRESS
VIENNA
30 SEP - 3 OCT 2026

Abstract N°: 414

Targeting miR-509-5p to Regulate HIF-1α Signaling for Asian Skin Photoprotection, Hydration and BarrierIntegrity: Modulation by a Tea-Derived and Terminalia chebula Botanical Complex

Youssef MAACH*[1], Yulan QU[2], Jing TANG[1], Yue ZOU[1], Shanshan JIANG[1]

[1] R&D Center, Shanghai CHANDO GROUP Co., Ltd., Shanghai, China

[2] R&D Center, Shanghai JAK Technology Co., Shanghai, China

Introduction

Asian and Caucasian populations age differently, illustrating variations in skin biology. Comparative studies in scientific literature support that Asian women's skin is more prone to pigmentation during aging, with wrinkles more appearant around 40–50 years old, while Caucasian women tend to develop wrinkles earlier in a linear pattern. These ethnic variations suggest population-specific molecular responses to environmental stressors, particularly ultraviolet radiation (UVR). MicroRNAs (miRNAs) are small non-coding RNAs that regulate post-transcriptional gene expressions involved in many biological functions. Our epigenetic study investigates miRNA expression changes induced by UVR in Asian skin, compares miRNA expressions between Asian and Caucasian populations, and identifies botanical ingredients capable of modulating miRNAs involved in photoprotection and skin barrier integrity.

Materials and Methods

1. To identifiy miRNAs signature of UVR and ethnic influences, miRNA expression profiling using microarrays (Agilent Human / miRBase V21) was performed on Chinese and French women skin biopsies. Three cohorts designed: UV-exposed (8 Chinese skin by blepharoplasty), UV-protected (7 Chinese skin by abdominoplasty) and Ethnicity (5 UV-protected French skin by abdominoplasty).
2. Target genes of differentially expressed miRNAs were predicted with the validated module of miRWalk2.0 database. The biological functions of predicted genes were performed using DAVID Bioinformatics Resources V6.8 and network maps were constructed to visualize the miRNA-Gene interactions.
3. In vitro tests were carried to validate experimentally by RT-qPCR on human keratinocytes the correlation between the miRNAs and target genes predicted in silico.
4. Screening of botanical extracts capable to regulate miRNA signature in human keratinocytes culture (RT-qPCR).

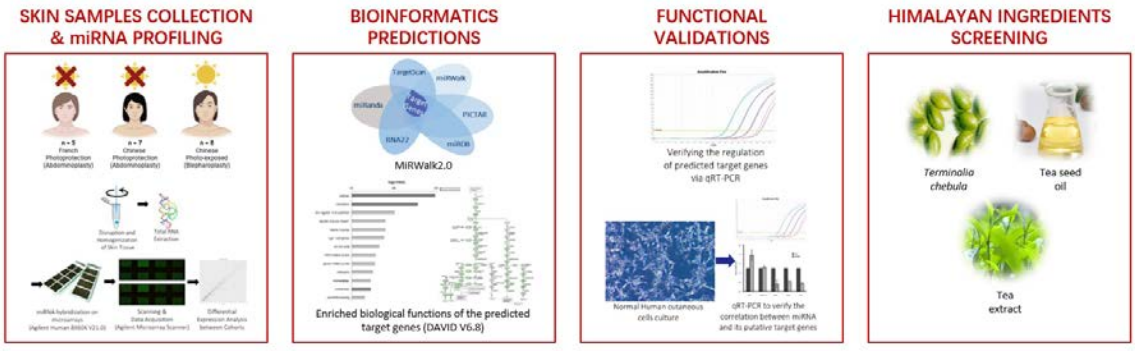

Research methodology for miRNA profiling, bioinformatic prediction, in-vitro validation and ingredient screening.

Results

1. Results from UV-protected versus UV-exposed skin samples showed that hsa-miR-509-5p expression was strongly increased in UV-exposed (fold change +11.12).
2. In silico analysis linked gene HIF-1α (Hypoxia-Inducible Factor-1α) as a potential target of miR-509-5p. RT-qPCR analysis in human epidermal keratinocytes exposed to URV confirmed that UV-induced upregulation of miR-509-5p was associated with decreased HIF-1α gene expression which is a gene involved with skin aging and barrier integrity according to several scientific studies.
3. From ethnic comparison, baseline expression of miR-509-5p was lower in Chinese skin compared with French skin (fold difference +5.6). It highlights miRNA-509-5p as signature of ethnic variation with a stronger influence in skin aging by HIF-1α signalling on French skin, which is aligned with the wrinkle dominant aging of Caucasian women compared to Asian women.
4. Screening of botanical ingredients led us to select compounds to modulate miRNA-509/ HIF-1α axis. Human primary keratinocytes treated with a botanical complex of tea seed oil, tea extract and Terminalia chebula fruit extract significantly reduced miR-509-5p expression (−68%), associated with restoration of HIF-1α expression.

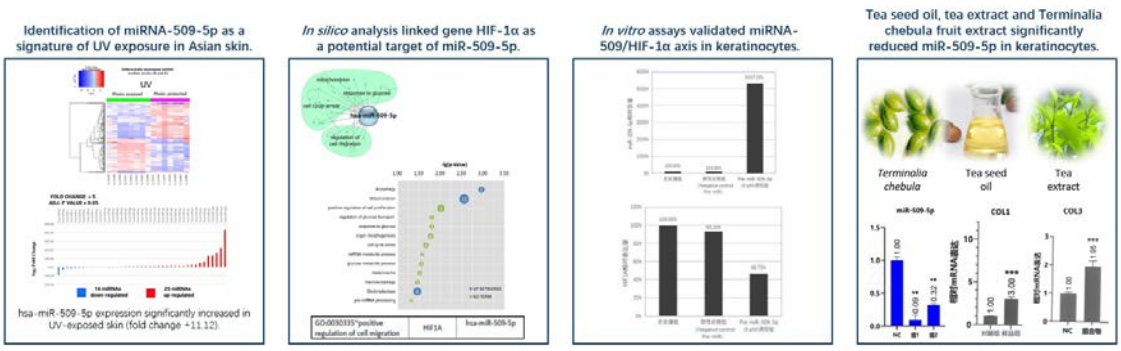

Identification of miRNA-509 and its regulation for skin photo-protection and barrier integrity in Asian skin.

Conclusions

Our study identifies miR-509-5p as a UV-responsive miRNA that regulates HIF-1α pathway in epidermal keratinocytes. Scientific literature highlights that HIF-1α plays an essential role in skin barrier integrity by promoting epidermal renewal through activation of laminin-332 transcription, supporting keratinocyte adhesion and migration. HIF-1α also contributes to oxidative stress protection by reducing mitochondrial reactive oxygen species and preventing apoptosis. HIF-1α regulates wound repair by activating genes involved in angiogenesis and extracellular matrix strengthening. Finally, HIF-1α strengthens skin barrier through regulation of filaggrin expression, a key structural protein for corneocyte integrity and epidermal hydration. Our findings about miR-509-5p/HIF-1α axis regulation in Asian skin under UV stress suggest a novel epigenetic mechanism for photoprotection, skin barrier repair and hydration.

EADV CONGRESS
VIENNA
30 SEP - 3 OCT 2026

Abstract N°: 668

The STING antagonist H-151 attenuates UV-induced skin damage by suppressing STING/NLRP3-mediated pyroptosis

Shasha Zhao*[1], Yan Yan[1]

[1] Department of Dermatology, Plastic Surgery Hospital, Chinese Academy of Medical Sciences and Peking Union Medical College, Beijing, China

Introduction
As the outermost layer of the human body, the skin is susceptible to acute injury from high-dose ultraviolet B (UVB) exposure over a short period, resulting in symptoms such as erythema, swelling, and pain. UVB exposure can induce programmed cell death and inflammatory responses, which contribute to the pathogenesis of various inflammatory skin diseases. The cGAS-STING signaling pathway is a critical regulator of inflammation, activated by misplaced genomic, mitochondrial, and microbial double-stranded DNA. This pathway governs multiple physiological processes, including type I interferon responses, autophagy, cellular senescence, and programmed cell death. Dysregulation of the cGAS-STING pathway is implicated in a range of inflammatory skin disorders. This study aims to investigate the role of the cGAS-STING pathway and the effects of the STING antagonist H-151 on UVB-induced skin damage.

Materials and Methods
Prior to establishing the UVB-induced acute skin injury mouse model, C57BL/6 mice aged 6–8 weeks were divided into six groups: normal control, UVB, STING-/-, STING-/- + UVB, H-151, and UVB + H-151. The H-151-treated groups received intraperitoneal injections of 750 nmol H-151 per mouse in 200 µL of 10% Tween-80 in PBS, as previously described. Mice were injected with H-151 24 hours before UVB irradiation, immediately after, and 24 hours post-irradiation. Skin changes following treatment were documented by standard photography, and biopsies were collected from each treatment area 36 hours after UVB exposure. Activation of the cGAS-STING-NLRP3 pyroptosis pathway and the protective effects of STING knockout or inhibition were assessed using qPCR, western blotting, histological analysis, and immunohistochemistry. Additionally, we developed a topical formulation containing H-151 as the main component, aimed at minimizing potential adverse effects associated with systemic treatment.

Results
After a single exposure to 360 mJ/cm2 UVB irradiation, the mouse skin exhibited erythema, dryness, and keratinization. Histological analysis through H&E staining indicated keratinocyte necrosis, epidermal thickening, and infiltration of inflammatory cells in the dermis. cGAS-STING and pyroptosis-related genes (NLRP3, GSDMD, and IL-6) are upregulated in the skin of a UVB-induced acute skin injury mouse model. This finding suggests that the STING pathway and NLRP3-mediated pyroptosis play crucial roles in the progression of photodamage. STING knockout and H-151 treatment alleviate UVB-induced photodamage symptoms 36 hours after UVB irradiation. The mouse skin showed milder erythema and desquamation than in the UVB group. Histological analysis also revealed decreased keratinocyte necrosis and inflammatory cell infiltration. Meanwhile, the expression of STING/NLRP3/GSDMD/IL-6 decreased in both the STING knockout and H-151 treatment groups. Topical administration of H-151 produces a similar therapeutic effect.

Conclusions
This study suggests that dysregulation of the cGAS-STING signaling pathway plays a role in UVB-induced acute

skin injury. Activated STING stimulates the NLRP3 inflammasome and triggers pyroptosis. This pathway could serve as a potential therapeutic target to attenuate acute skin damage caused by UVB irradiation by suppressing cGAS-STING-NLRP3-mediated pyroptosis. The STING antagonist H-151 demonstrates anti-inflammatory activity in the mouse model. Its topical formulation has potential for treating inflammatory skin diseases associated with UVB-induced damage.

EADV CONGRESS
VIENNA
30 SEP - 3 OCT 2026

Abstract N°: 704

Bullous disease and phototoxic reaction in same patient treated with etanercept

Khaloud Al Hatmi*[1], Aida AlKhalili[2]

[1] Dermatology resident, Oman medical specialty board, Muscat, Oman
[2] Specialist dermatologist, Shinas polyclinic, Shinas, Oman

Introduction

Pemphigus foliaceus (PF) is an autoimmune blistering disorder in which environmental and pharmacologic factors, including ultraviolet (UV) radiation and medications, may precipitate or exacerbate disease. UV exposure can induce acantholysis and enhance autoantibody binding, while phototherapy may unmask previously unrecognized disease. In addition, photosensitizing agents such as tetracyclines and sulfonamides may amplify UV-mediated keratinocyte injury and inflammatory responses.



initial presentation at SQUH following 4 months treatment of NB-UVB for the initial impression of PLC: Generalized symmetric eruption of eroded erythematous papules and plaques coalescing with crusting and post-inflammatory hyperpigmentation over the trunk and proximal limbs.

Case Presentation

We report a patient who initially presented with a pityriasis lichenoides chronica (PLC)-like eruption. Histopathology favored PLC. Narrowband UVB (NB-UVB) phototherapy was initiated, after which the eruption evolved into vesiculobullous and erosive lesions. Repeat biopsy with direct immunofluorescence confirmed PF. Systemic corticosteroids were initiated, and doxycycline was added for its anti-inflammatory effect; however, disease activity worsened. Cotrimoxazole was subsequently introduced for Pneumocystis jirovecii pneumonia prophylaxis in the setting of extensive disease and escalating immunosuppression, after which marked clinical deterioration was observed. Despite pulse-dose corticosteroid therapy, the response remained suboptimal. Cotrimoxazole was withdrawn, and etanercept was administered, resulting in significant clinical improvement.



disease worsening temporally related to phototherapy and photosensitizing medications

Conclusion

This case supports a dual-process model in which NB-UVB phototherapy and doxycycline-induced phototoxicity contributed to the unmasking and progression of PF, while cotrimoxazole exposure was associated with a superimposed drug-related inflammatory reaction that amplified disease severity. Recognition of these interactions is essential to avoid iatrogenic worsening and to guide timely, targeted management.



eventual improvement following withdrawal of the suspected culprit drug and initiation of TNF inhibition.”

EA DV CONGRESS
VIENNA
30 SEP - 3 OCT 2026

Abstract N°: 971

UVA-1 Phototherapy in Psoriasis: A Promising Therapeutic Option

yasser DELLA*[1], Zohra El Osmani[1], Serradj Amina[1]

[1] University of Oran 1, Faculty of Medicine of Oran, oran, Algeria

Introduction

Psoriasis is a chronic immune-mediated inflammatory disease affecting 2–3% of the population. Among treatments for moderate to severe psoriasis, phototherapy—mainly narrowband UVB (NB-UVB)—is widely used due to its efficacy and good safety profile. Less well known is the potential role of UVA-1 phototherapy in psoriasis. We report two cases of psoriasis treated with UVA-1

Case Presentation

The first case concerns a 41-year-old woman with no relevant medical history, presenting with a 7-year history of plaque psoriasis. She had previously received multiple treatments including high-potency topical corticosteroids, methotrexate for 2 years, and ciclosporin. Recently, a positive tuberculin skin test was identified and is currently under investigation, leading to discontinuation of systemic therapy.

Given the localized nature of the disease, localized medium-dose UVA-1 phototherapy was initiated (3 sessions per week, 30 J per session). After two months and a cumulative dose of 720 J/cm^2, a marked improvement corresponding to PASI 75 was observed, with good tolerance. The only adverse effect was skin tanning.

The second case involves a 21-year-old man with palmoplantar psoriasis evolving for 5 years, refractory to topical treatments and methotrexate. The same UVA-1 protocol was used. After two months, significant clinical improvement was observed, with good tolerance and skin tanning as the only side effect.



Clinical photograph of the patient

Conclusion

UVA-1 phototherapy is not traditionally a first-line treatment for psoriasis, but emerging evidence suggests a potential beneficial role, including in plaque psoriasis and palmoplantar forms. UVA-1 penetrates deeper into the dermis than NB-UVB and may induce apoptosis of activated T lymphocytes through specific pathways, including downregulation of anti-apoptotic proteins such as Bcl-2. Medium-dose protocols are the most commonly used in practice, with reported efficacy and good tolerance. The main adverse effect observed is skin tanning, as seen in our two patients. Long-term safety monitoring remains necessary, particularly regarding potential carcinogenic risk. Our experience suggests that UVA-1 phototherapy is a promising therapeutic option in selected cases of psoriasis, although larger studies are needed to better define its place in management

EA DV CONGRESS
VIENNA
30 SEP - 3 OCT 2026

Abstract N°: 1240

Low-Fluence Photodynamic Therapy for Vulvar Lichen Sclerosus: Clinical Efficacy at Reduced Energy Parameters

Katarzyna Beutler-Rucińska*[1], Alina Jankowska Konsur[1], Danuta Nowicka[2]

[1] University Centre of General Dermatology and Oncodermatology, Wroclaw Medical University, Wroclaw, Poland
[2] Division of Aesthetic Dermatology and Regenerative Medicine of the Skin, Wroclaw Medical University, Wroclaw, Poland

Introduction
Photodynamic therapy (PDT) protocols for vulvar lichen sclerosus (VLS) typically employ high fluence parameters (80–150 J/cm^2), which may be associated with significant procedural discomfort. This study aimed to evaluate the clinical efficacy of a novel low-fluence PDT protocol in patients with refractory VLS.

Materials and Methods
Forty patients with refractory VLS underwent PDT using a 10% 5-aminolevulinic acid nanoemulsion applied under occlusive aluminum foil dressing. Unlike conventional high-fluence protocols, our approach utilized significantly lower energy parameters: following a 3-hour incubation period, patients received 10-minute LED illumination (red light, ~635 nm) at 37 J/cm^2 (~77 mW/cm^2), with sessions spaced 4–6 weeks apart. Patients received 1–6 treatment sessions. Clinical outcomes were assessed using the Dermatology Life Quality Index (DLQI) and Female Sexual Function Index (FSFI).

Results
Thirty-seven participants completed the DLQI, and 20 sexually active patients were included in the FSFI analysis. Despite using approximately 50–75% lower fluence than conventional protocols, significant improvements were observed. A greater number of PDT sessions correlated with improved DLQI scores ($\tau = -0.583$; adjusted $p < 0.001$). Significant associations were found between the number of sessions and total FSFI score ($p = 0.014$), as well as desire ($p = 0.016$), arousal ($p = 0.020$), orgasm ($p = 0.020$), and satisfaction ($p = 0.016$) domains. Age ($p = 0.016$) and disease duration ($p = 0.020$) were identified as factors associated with poorer quality of life outcomes.

Conclusions
A low-fluence PDT protocol (37 J/cm^2) demonstrates significant improvements in quality of life and sexual function in patients with refractory VLS. These findings suggest that lower energy parameters may achieve comparable efficacy to high-fluence protocols (80–150 J/cm^2) reported in the literature, while offering potential advantages in tolerability and patient comfort. The cumulative number of sessions appears to be a key determinant of clinical response. Comparative studies directly evaluating low- versus high-fluence protocols are warranted.

EADV Congress 2026, VIENNA
30 SEPTEMBER - 03 OCTOBER 2026
POWERED BY M-ANAGE.COM

EADV CONGRESS
VIENNA
30 SEP - 3 OCT 2026

Abstract N°: 1318

Daily photoprotection with an antioxidant-enriched sunscreen preserves mitochondrial DNA integrity in facial skin in vivo: a randomised, double-blind, vehicle-controlled trial

Uroosa Moqeem[1], Amber Khalil*[2], Anisha Bandyopadhyay[3], Hiva Fassihi[4], Emma Craythorne[4]

[1] Queen's Hospital, Barking, Havering and Redbridge University Hospitals NHS Trust, Romford, United Kingdom
[2] Ninewells Hospital, Dundee, United Kingdom
[3] St George's Hospital, St George's University Hospitals NHS Foundation Trust, London, United Kingdom
[4] St John's Institute of Dermatology, Guy's and St Thomas' NHS Foundation Trust, London, United Kingdom

Introduction
Mitochondrial DNA (mtDNA) damage is a sensitive biomarker of photo-oxidative stress but has not been applied as a primary, non-invasive in vivo endpoint in human photoprotection trials. Objective biomarkers capable of quantifying real-world skin ageing prevention are needed in aesthetic dermatology.

To evaluate whether daily use of an antioxidant-enriched sunscreen preserves mtDNA integrity compared with vehicle, and secondarily to assess mtDNA as a non-invasive biomarker of individual photoprotection response.

Materials and Methods
Adults completed a randomized, double-blind, vehicle-controlled 12-week trial. Cheek swabs were collected at baseline and week 12 and analysed using blinded quantitative PCR. mtDNA damage was expressed as ΔCt, where higher values indicate greater damage. The primary outcome was change in ΔCt. Responders were prospectively defined as ΔCt < 0. Between-group comparisons used non-parametric testing.

Results
Forty-one participants provided valid paired samples (active n=19; vehicle n=18). Mean ΔCt change favoured the active formulation (−0.48 vs +0.35; between-group difference −0.83; 95% CI −1.71 to 0.05; P=0.06). Responder rates were higher with active treatment (73.7% vs 38.9%; P=0.05). Among habitual sunscreen users, mtDNA integrity improved with active treatment (median ΔCt −0.67; P=0.04) and worsened with vehicle (median ΔCt +0.58; P=0.03), with responder rates of 75% versus 25%.

Conclusions
Daily use of an antioxidant-enriched sunscreen was associated with reduced mtDNA damage and higher responder rates compared with vehicle. mtDNA integrity is a sensitive, non-invasive biomarker capable of detecting individual-level photoprotection responses in vivo, with potential application in cosmetic dermatology trials.

EADV CONGRESS
VIENNA
30 SEP - 3 OCT 2026

Abstract N°: 1327

Dose-dependent effects of oral caffeine on UV-induced photoaging: morphometric, collagen and antioxidant changes in rats

Ozge Zorlu*[1], Sevil Karabağ[1], Mazhar Özkan[1], Melisa Beyhan Yılmaz[1]

[1] Tekirdağ Namık Kemal University Faculty of Medicine, Tekirdağ, Türkiye

Introduction
Chronic ultraviolet (UV) exposure promotes oxidative stress, extracellular matrix remodelling and disruption of the dermoepidermal interface, all of which contribute to photoaging. Caffeine is one of the most widely consumed bioactive compounds worldwide; however, its dose-dependent influence on photoaging-related tissue responses remains unclear. This study therefore evaluated the effects of different oral caffeine doses on skin microarchitecture, collagen phenotype and systemic antioxidant enzyme activity in a repeated UV-exposure rat model.

Materials and Methods
Forty female Sprague–Dawley rats were randomized into five groups (n=8/group): Control (sham exposure and vehicle), UV (combined UVA+UVB irradiation and vehicle), UV+caffeine-25 (combined UVA+UVB irradiation with 25 mg/kg caffeine), UV+caffeine-35 (combined UVA+UVB irradiation with 35 mg/kg caffeine), and UV+caffeine-70 (combined UVA+UVB irradiation with 70 mg/kg caffeine). Caffeine or vehicle was administered once daily by oral gavage throughout a 30-day protocol. UV groups underwent progressive repeated combined UVA and UVB exposure every other day for 15 sessions. Serum catalase, glucose-6-phosphate dehydrogenase, glutathione peroxidase (GPx), glutathione reductase (GR), and superoxide dismutase (SOD) levels were measured by ELISA. Skin samples were evaluated histologically using haematoxylin and eosin, Masson's trichrome, elastic van Gieson, and Picrosirius red staining, followed by quantitative Fiji/ImageJ morphometry, which showed excellent intra- and interrater reliability (ICCs predominantly >0.90).

Results
Compared with controls, UV exposure increased epidermal thickness ($p = 0.002$) and type III collagen ($p = 0.002$), while reducing epidermal rete ridge thickness ($p = 0.009$), interdigitation index ($p < 0.001$), GR levels ($p = 0.003$), type I collagen ($p < 0.001$), and the type I/III collagen ratio ($p = 0.022$). Caffeine exposure produced dose-specific, non-uniform changes rather than a consistent directional pattern. Compared with UV alone, The UV+caffeine-25 group showed higher SOD ($p = 0.009$) and lower trichrome-stained area ($p = 0.004$). The UV + Caffeine-35 group showed greater reticular dermis thickness ($p < 0.001$), but lower type I collagen ($p = 0.015$) and a lower type I/III collagen ratio ($p = 0.038$) than the UV group. The UV+Caffeine-70 group showed higher interdigitation index ($p = 0.008$), lower type I collagen ($p = 0.030$), a lower type I/III collagen ratio ($p = 0.029$), and lower GPx levels ($p = 0.008$) than the UV group. Across all animals, GR correlated positively with dermal papilla thickness ($r_s = 0.597$, $p < 0.001$), epidermal rete ridge thickness ($r_s = 0.409$, $p = 0.009$), interdigitation index ($\xi = 0.460$, $p = 0.003$), total collagen ($r_s = 0.509$, $p = 0.001$), type I collagen ($\xi = 0.591$, $p < 0.001$), the type I/III collagen ratio ($\xi = 0.564$, $p < 0.001$), and negatively with epidermal thickness ($r_s = - 0.538$, $p < 0.001$) and type III collagen ($\xi = - 0.534$, $p < 0.001$) (Figure 1).

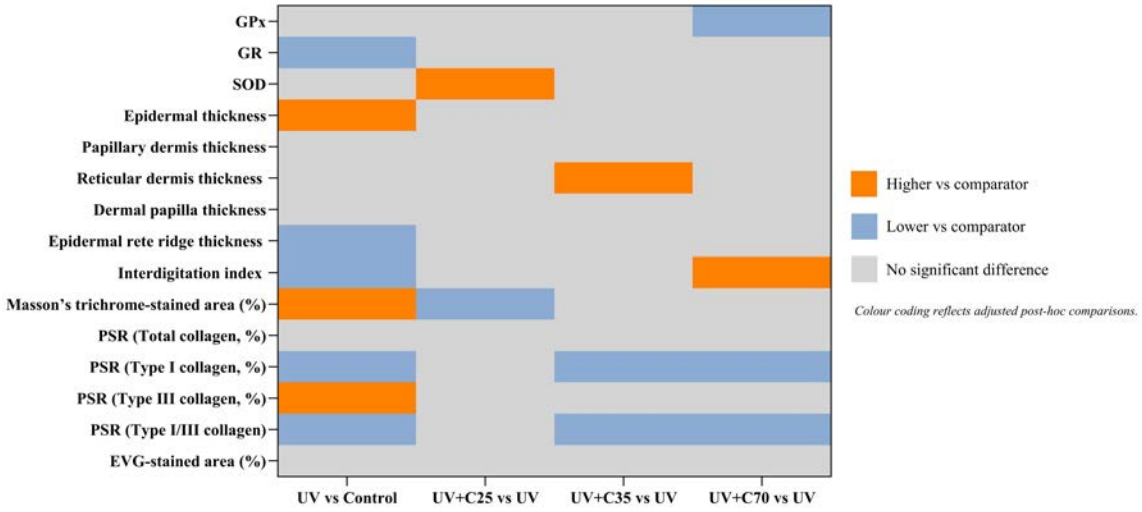

Figure 1. Overview of adjusted post-hoc differences in photoaging-related oxidative, histomorphometric and collagen parameters across experimental groups. Abbreviations: UV, ultraviolet; UV+C25, UV+caffeine-25 mg/kg; UV+C35, UV+caffeine-35 mg/kg; UV+C70, UV+caffeine-70 mg/kg; GPx, glutathione peroxidase; GR, glutathione reductase; SOD, superoxide dismutase; PSR, Picrosirius red; EVG, elastic van Gieson.

Conclusions

In this UV-induced photoaging model, oral caffeine, a common dietary exposure, was associated with heterogeneous, dose-specific structural and oxidative trade-offs. Rather than showing a uniform beneficial or harmful effect, caffeine exposure appeared to differentially influence dermoepidermal architecture, antioxidant status and collagen remodelling according to dose.

EA DV CONGRESS
VIENNA
30 SEP - 3 OCT 2026

Abstract N°: 1333

Light sensitivity in atopic dermatitis: A 7-year retrospective study at a specialist photoinvestigation centre in Thailand

Anunchuda Prasartsak*[1], Pravit Asawanonda[1], Stephen Kerr[2], Robert Sarkany[3], Einapak Boontaveeyuwat[1]

[1] Photodermatology Unit, Division of Dermatology, Department of Medicine, King Chulalongkorn Memorial Hospital, The Thai Red Cross Society and Faculty of Medicine, Chulalongkorn University,, Bangkok, Thailand

[2] Biostatistics Excellence Centre, Faculty of Medicine, Chulalongkorn University, Biostatistics Unit, HIVNAT, Thai Red Cross AIDS Research Centre, Bangkok, Thailand

[3] Photobiology Unit, St John's Institute of Dermatology, Guy's and St Thomas' NHS Foundation Trust, London, United Kingdom

Introduction

Photosensitivity in atopic dermatitis (AD) is increasingly recognised as a contributor to refractory disease and adverse reactions to phototherapy, with a potentially higher impact in Asian populations.

Objectives: To determine the prevalence of photosensitivity among Thai patients with AD and to characterise photobiological patterns.

Materials and Methods

We conducted a retrospective chart review of all referrals to our specialist photoinvestigation centre between January 2017-December 2025 and included patients with pre-existing or newly diagnosed AD with adequate records. Phototesting was performed using narrowband UVB (NBUVB; peak 308nm [297-315 nm] and peak 311 [310–315 nm]), broadband UVB (BBUVB; 280-315 nm), broadband UVA (BBUVA; metal halide, peak 365 [330-450nm]), and solar-simulated radiation (SSR; 280–400 nm). Irradiation doses incrementally increased to determine photobiological responses. Minimal erythema dose (MED) and dermatitis response were assessed at 24 h using quantitative and qualitative grading. Photoprovocation test was performed for up to 7 days when indicated. Photosensitivity in AD was classified as follows: chronic actinic dermatitis (CAD), markedly reduced MEDs (UVB MED <80% of normal and/or UVA MED <30% of normal); photosensitive AD (PSAD), moderately reduced UVA MED (within 30% of the normal range) and/or normal to slightly reduced UVB MED (within 80% of the normal range); photo-exacerbated AD (PEAD), normal MEDs on phototesting with a positive dermatitis response on photoprovocation testing. Patch testing and photopatch testing were undertaken when clinically indicated, and disease course was monitored.

Results

Of the 196 patients undergoing phototesting, 58 patients with AD had sufficiently complete records for analysis (30 M, 28 F; Skin type IV-VI; mean±SD age 44.7 ± 20.8 years). Photosensitivity was identified in 32/58 (55.2%), CAD 6 (18.8%), PSAD 16 (50.0%), PEAD 9 (28.1%) and actinic prurigo (AP) 1 (1.7%). Sex distribution was similar between photosensitive (PhAD) and non-photosensitivity AD (NPhAD) groups. Mean age and time to diagnosis were generally comparable (PhAD 3.1 ±3.4 years; NPhAD 3.9±5.2 years). 22/40 (55%) reported a history of

photoexacerbation or seasonal variation. Facial involvement was near-universal in both groups (NPhAD 23/24, 95.8%%; CAD 6/6, 100%; PSAD 13/14, 92.9%; PEAD 7/7, 100%). Most other distributions did not differ, except for four key sites: generalised scalp involvement (significantly more frequent in PEAD and NPhAD than CAD/PSAD p=0.005, p=0.018), extensor forearm/arm (more frequent in PEAD than NPhAD, p=0.012), and involvement of the dorsum of the hands/feet (both more frequent in PEAD than NPhAD, p=0.012). Culprit wavelengths in CAD were most often combined UVA/UVB (4/6, 66.7%) followed by UVB alone (2/6, 33.3%). In PSAD and PEAD, UVB alone predominated (PSAD 10/16, 62.5%; PEAD 6/9, 66.7%), with fewer showing combined UVA/UVB sensitivity; UVA-only sensitivity occurred only in PSAD (2/16, 12.5%). Among nine patients with PhAD who underwent SSR testing, SSR provided the highest detection yield (8/9, 88.9%) followed by NBUVB 308nm (3/9, 33.3%), BBUVA (2/9, 22.2%), NBUVB 311 nm (1/9, 11.1%). No cases were detected using BBUVB (Table 1). Patch testing was performed in nine patients; contact allergy was identified in 5/9 (55.6%), including three who were also photosensitive. Six patients completed at least 2-year follow-up (CAD n=1; PSAD n=3; PEAD=1; NPhAD n=1). During follow-up period, two cases with PSAD case, one progressed to CAD within month 8, while the other recovered to no photosensitivity within year 6.

Conclusions

Photosensitivity is frequent among Thai patients with AD referred for photoinvestigation. Universal facial involvement and diagnostic delay support early consideration of photosensitivity and concomitant contact allergy. Multisource phototesting particularly SSR testing, may improve detection and phenotypic classification for patients with photosensitive AD.

Table 1. Comparison of phototesting using narrowband and broadband light sources versus solar simulator for detecting photosensitivity in atopic dermatitis

Subtype		Light sources				
Photosensitivity in AD (N)	Case No.	BBUVB	UVB308	UVB311	BBUVA	SSR
CAD (N=3)	1	N	Reduced	N	Reduced	Reduced
	2	ND	Reduced	N	N	Reduced
	3	ND	N	Reduced	Reduced	Reduced
PSAD (N=3)	4	ND	N	N	N	Reduced
	5	ND	N	N	N	Reduced
	6	ND	Reduced	N	N	N
PEAD (N=9)	7	N	N	N	N	Dermatitis response
	8	N	N	N	N	Dermatitis response
	9	N	N	N	N	Dermatitis response

N, normal MEDs; ND, not done; CAD, Chronic actinic dermatitis; PSAD, Photo-sensitive AD; PEAD, Photo-exacerbated AD; Light sources, BBUVB, BroadbandUVB; UVB308 (peak 308, 297-315 nm); UVB311 (peak 311, 310–315 nm); BBUVA, BroadbandUVA; Solar simulator (SSR, 280–400 nm)

Table 1. Comparison of phototesting using narrowband and broadband light sources versus solar simulator for detecting photosensitivity in atopic dermatitis

EADV CONGRESS
VIENNA
30 SEP - 3 OCT 2026

Abstract N°: 1349

MONITORING THE ACUTE EVOLUTION OF MICROSCOPIC SKIN RESPONSES TO GRADIENT UVB IRRADIATION

Zhenguo Wu[1, 2], Haishan Zeng[1, 2], Sunil Kalia[1, 3], Harvey Lui[1, 3], Jianhua Zhao[1], Tashmeeta Ahad*[1, 3]

[1] Photomedicine Institute, Vancouver Coastal Health Research Institute, Vancouver, Canada
[2] Department of Basic and Translational Research, BC Cancer Research Institute, Vancouver, Canada
[3] University of British Columbia Department of Dermatology and Skin Science, Vancouver, Canada

Introduction

The minimal erythema dose (MED) is the lowest UVB dose required to produce perceptible redness on the skin 24 hours after exposure. While commonly used as a standard for assessing photosensitivity, MED has limitations. Visual assessment is subjective as influenced by observer bias and ambient lighting. Melanin can mask the perception of redness, reducing accuracy when assessing darker skin tones. Furthermore, discrete fluence intervals can limit precision, while conventional exposure grids of multiple skin patches (i.e.~1 cm) can be visibly noticeable and disfiguring.

Materials and Methods

To address these limitations, we are exploring a new indicator for determining cutaneous UVB reactivity by serially monitoring skin responses non-invasively over two weeks at a phototesting site using our multimodal in vivo microscopic imaging system. The skin is exposed to a continuous UVB gradient dose delivered within a single mini rectangular window (10 mm x 2). The microimaging system combines reflectance confocal, two-photon fluorescence, and second harmonic generation microscopy to provide multi-contrast, subcellular-resolution, volumetric skin images.

Results

Preliminary results show the presence of a discrete low-reflection and high-fluorescence signal band between the corneal and granular epidermal layers that appears following UVB skin exposure. The thickness of this band appears to be directly proportional to the UVB fluence. Skin color changes within the exposure window also match the thickness change of this hyperfluorescent band, which could be a novel indicator of skin reactivity to UVB that is complementary to conventional MED phototesting.

Conclusions

We propose a novel indicator of skin reactivity to UVB that is more accurate than conventional MED phototesting. This phototesting approach can be applied to different skin types and body sites.

EA DV CONGRESS
VIENNA
30 SEP - 3 OCT 2026

Abstract N°: 1406

Immediate effects of UV radiation on the human skin microbiome: Flow cytometry uncovers rapid, dose-dependent responses

Florian Dimmers*[1], Doreen Reichert[1], Claudia Wigmann[1], Carles Trullas[2], Jaime Piquero-Casals[3], Anthony Brown[2], Monica Foyaca[2], Charlotte Esser[1], Jean Krutmann[1]

[1] IUF - Leibniz-Research Institute for Environmental Medicine, Department of Dermatology, HELIOS Klinikum Krefeld, Academic Teaching Hospital of the University of Aachen, Duesseldorf, Germany
[2] Innovation and Development, ISDIN, Barcelona, Spain
[3] Department of Dermatology, Dermik Multidisciplinary Dermatology Clinic, Barcelona, Spain

Introduction

The impact of ultraviolet radiation (UVR) on the skin microbiome is poorly understood, particularly at early time points. Conventional sequencing approaches are often limited by cost and the complexity of downstream data analysis, especially in high-resolution longitudinal study designs.

This study aimed to investigate immediate and dose-dependent alterations in the human skin microbiome following UV exposure using flow cytometry (FC) as a high-resolution profiling approach.

Materials and Methods

Thirty healthy male volunteers were exposed to solar-simulated UVR (UVA and UVB) at three dose levels (0.5, 0.7, and 1.0 MED) on the lower back. Skin swabs were collected from irradiated and control sites at 30 min, 24 h, and 96 h post-exposure. Microbial community profiles were analysed using FC and a dedicated bioinformatic pipeline. Longitudinal changes were assessed using Bray-Curtis distances, non-metric multidimensional scaling (NMDS), and PERMANOVA with a restricted permutation design.

Results

FC-based profiling revealed significant shifts in microbial community structure as early as 30 minutes after UV exposure, even at suberythemal doses, compared to non-irradiated control sites. While partial recovery was observed at 24 hours, distinct alterations were again detectable at 96 hours. UV-induced changes showed dose-dependent patterns, particularly at later time points, with more pronounced differences at higher exposure levels (e.g., 0.5 vs 1.0 MED at 96 h, $p=0.019$).

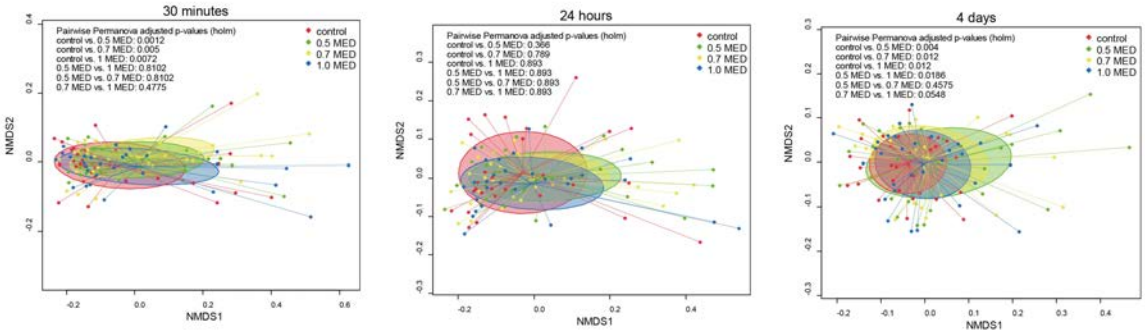

Figure 1: NMDS plots based on Bray-Curtis distances showing UV-induced shifts in microbial community composition over time compared to non-irradiated controls

Conclusions

UV radiation acts as a rapid modulator of skin microbial community structure, even at low, suberythemal exposure levels. Flow cytometry represents a cost- and time-efficient approach to capture early microbiome dynamics and may complement sequencing-based approaches by enabling the targeted identification of relevant exposure levels and time points for subsequent in-depth sequencing analyses.

EADV CONGRESS
VIENNA
30 SEP - 3 OCT 2026

Abstract N°: 1414

Real-world effectiveness of omalizumab in solar urticaria: A multicentre study of 63 patients.

Mark Eisner*[1, 2], Luke Carson[1, 2], Adam Fityan[3], Sally Helen Ibbotson[4], Shagayegh Javadzadeh [5], Zhi Lim[4], Rachel Montgomery[6], Kirsty Rutter[7], Sheila McSweeney[5], Sophie Weatherhead[2]

[1] Newcastle University, Newcastle upon Tyne, United Kingdom
[2] Newcastle Upon Tyne Hospitals NHS Foundation Trust, Newcastle upon Tyne, United Kingdom
[3] University Hospital Southampton NHS Foundation Trust, Southampton, United Kingdom
[4] Ninewells Hospital & Medical School, Dundee, United Kingdom
[5] Guy's and St Thomas' N H S Foundation Trust, St John's Institute of Dermatology, London, United Kingdom
[6] Leeds Teaching Hospitals NHS Trust, Leeds, United Kingdom
[7] University of Manchester, Manchester, United Kingdom

Introduction
Solar urticaria (SU) is a rare photodermatosis that can have profoundly life-impacting consequences. Once clinically suspected, the diagnosis should be confirmed by phototesting. In addition to photoprotection, management is similar to chronic spontaneous urticaria (CSU) with antihistamines and montelukast. As these measures frequently provide insufficient symptom relief, omalizumab, an anti-IgE antibody licensed for CSU, is utilised as an off-label treatment. Real-world data are encouraging, with a response rate of 93.2% in a meta-analysis, but individual studies are small with the largest included case series reporting 20 patients (JCM 14(16):5736). Despite its effectiveness, off-license use of omalizumab for SU is restricted in the United Kingdom (UK); it is licensed for six-month intervals only, with a treatment break required between courses. This study aims to review the real-world effectiveness and usage of omalizumab for SU in a large multicentre cohort.

Materials and Methods
Six UK tertiary photodermatology centres identified phototesting-confirmed SU patients treated with omalizumab. All patients had participated in a previous study (BJD 193(5):1001-1003). Clinical records were reviewed and data recorded for: clinical characteristics, previous treatments, and omalizumab responses. A questionnaire was completed by the centres describing local practices.

Results
Sixty-three patients were identified with a median age of 43 (range 17–84) and 68.0% female. Median baseline IgE was 173 kU/L (range 8–2045). All patients had failed conventional treatment, including maximum tolerated-dose H1 (100%), H2-antihistamines (55.6%), montelukast (69.8%), and phototherapy (34.9%).

Of 60 patients with three-months follow-up: 53 (88.3%) responded, with 45 (75.0%) achieving complete clinical remission. Treatment was well-tolerated, with only 2 (3.3%) having intolerable side effects. Dose escalation was required in 8 patients to achieve control (15.1%). Repeat or prolonged omalizumab courses were needed in 91.5% (n=47). Response assessment varied by centre but included: repeat phototesting, physician global assessment and Urticaria Control Test questionnaires. Funding, eligibility criteria, prescribing and treatment escalation strategies varied significantly across photodiagnostic services.

Conclusions

This represents the largest reported case series of treatment-resistant SU patients treated with omalizumab to date. The extremely high response rates (88.3%) support its effectiveness in clinical practice. The observed heterogeneity in drug access and prescribing strategies highlights a need for guidelines to ensure equitable access to omalizumab for SU patients.

EADV CONGRESS
VIENNA
30 SEP - 3 OCT 2026

Abstract N°: 1444

Seven-day oral supplementation increases minimal erythema dose in photosensitive individuals.

Eva Remenyik*[1], Szimonetta Szabo[1], Eszter Janka[1], Tunde Toka-Farkas[1], Emese Gellen[1]

[1] Department of Dermatology, MTA Centre of Excellence, Faculty of Medicine, University of Debrecen, Debrecen, Hungary

Introduction
To prevent the acute and chronic detrimental effects of solar radiation, photoprotection is widely recommended, including sun avoidance, protective clothing, and sunscreen use. However, adherence may be limited by social norms, occupational factors, and lifestyle preferences. Systemic photoprotection may offer a convenient adjunct. The aim of this study was to evaluate the UVB-protective effects of an oral dietary supplement containing *Polypodium leucotomos*, nicotinamide, vitamin E, zinc, copper, lutein, zeaxanthin, coenzyme Q, and folic acid.

Materials and Methods
Twenty healthy participants (16 females, 4 males; mean age 40.10 ± 9.71 years) received the supplement once daily for 7 days. Minimal erythema dose (MED) was assessed using a Saalmann Multitester. Nine participants with Fitzpatrick skin types I–II (Group I) received UVB doses of 0.04–0.12 J/cm^2, and eleven participants with skin types II–III (Group II) received 0.15–0.3 J/cm^2. MED_0 was measured at baseline, MED_1 after a single dose (day 1), and MED_2 after 7 days. Data were analyzed using the Shapiro–Wilk test and two-way ANOVA with Sidak's post hoc test ($p < 0.05$).

Results
Baseline MED (MED_0) was significantly lower in Group I compared to Group II ($p = 0.003$). No significant change was observed at MED_1 in either group. After 7 days, MED_2 increased significantly in Group I compared to baseline ($p = 0.001$), while the increase in Group II did not reach statistical significance ($p = 0.093$). Although intergroup differences were present at baseline and at MED_1 ($p < 0.001$), no significant difference was observed at MED_2 ($p = 0.194$).

Conclusions
Short-term (24-hour) application of a dietary supplement did not produce measurable photoprotective effects. However, 7-day supplementation increased MED, with a significant effect observed in more photosensitive individuals. These findings suggest that a *Polypodium leucotomos* and nicotinamide-based oral supplement provides systemic photoprotection, particularly in light-skinned individuals who are more photosensitive.

EADV CONGRESS
VIENNA
30 SEP - 3 OCT 2026

Abstract N°: 1545

Evaluation of the Protective Properties of BB Medical Device Cream SPF100+ for Broad-Spectrum Photoprotection and Cellular Safety – In Vitro, Ex Vivo and In Vivo Results

Wiktoria Piskorz[1], Karolina Lendzion*[1], Agnieszka Pawlak[1], Monika Pasikowska-Piwko[1], Renata Debowska[1], Katarzyna Rogiewicz[1], Irena Eris[1]

[1] Dr Irena Eris S.A., Piaseczno, Poland

Introduction

In today's world, there is a growing demand for multifunctional products that combine beauty benefits with effectiveness. This demand has contributed the development of tinted products, combining facial care, protection, and skin tone-evening effect. This study presents a comprehensive *in vitro*, *ex vivo* and *in vivo* evaluation of a new BB cream, classified as a medical device, with a sun protection factor (SPF) of 100+ (formulations 1477 and 1478, corresponding to two shades). The product was specifically designed to provide a broadband protection against ultraviolet B (UVB), ultraviolet A (UVA), high-energy visible (HEV) light, and infrared (IR) radiation and is recommended for patients with pigmentation disorders, hypersensitivity to sunlight or an increased risk of skin cancer.

Materials and Methods

Spectrophotometric *in vitro* assay was used in order to evaluate the penetration of radiation with a wavelength 290-900 nm through the product samples. The protective efficacy at the cellular level was evaluated using L929 murine fibroblasts exposed to UVB radiation in the presence and absence of the tested formulations. DNA damage was quantified through the measurement of cyclobutane pyrimidine dimers (CPDs) using an enzyme-linked immunosorbent assay (ELISA). In order to confirm safety of tested products, cytotoxicity assessment was conducted using the agarose overlay assay. Furthermore, the irritation and sensitization potential was investigated using a human *ex vivo* skin model. *In vivo* dermatological patch-test was conducted in the group of 30 participants with sensitive skin. The patch containing a 25 µL of a product was applied to the skin for 48h and compared to the negative control area (without a product) using the International Contact Dermatitis Research Group (ICDRG) scale. Furthermore, a subjective assessment of the product's effectiveness was made using surveys.

Results

Spectrophotometric *in vitro* analyses demonstrated a high impermeability of the formulation to the UVB, UVA, HEV, and IR spectral ranges, suggesting a broad-spectrum protection capacity. The results indicated also an inhibition of CPD formation (concentration below detection level) in UVB treated cells, protected by the 1477 and 1478 formulation, suggesting effective prevention of pre-mutagenic DNA lesions. Cytotoxicity assessment demonstrated a low cytotoxic effect: Grade 1 according to ISO 10993 – slight changes in cell morphology, which were limited to the area of disc with applied product. No irritation or sensitization responses were detected in *ex vivo* model: tissue viability was higher than the negative control: 111,9% in 1477 and 102,2% in 1478 and IL-18 level was below the negative control. What is more, no irritation or allergic reactions were observed during a dermatological patch-test, supporting the favorable dermatological safety profile of tested products. In the survey evaluation, users confirmed the effectiveness of the products in terms of evening out the skin tone and protection

against discoloration.

Conclusions

Taken together, these results support the classification of the investigated BB cream as a highly effective photoprotective medical device. The formulation provides broad-spectrum radiation protection, contributes to preservation of genomic integrity, and demonstrates good tolerability in cellular and tissue models as well as among the users with sensitive skin. Consequently, it is a promising, safe option for everyday use, combining beautifying properties with effective protection.

EA DV CONGRESS
VIENNA
30 SEP - 3 OCT 2026

Abstract N°: 1619

Successful treatment of Actinic reticuloid with Azathioprine. How to avoid diagnostic mistakes. Case report.

Oleh Frayt*[1], Olena Frait[2]

[1] Private practice, Heroiv UPA street,78, Lviv, Ukraine

[2] Palacky University Olomouc, Faculty of Medicine, Olomouc, Czech Republic

Introduction

Actinic reticulosis (AR) is a severe form of chronic actinic dermatitis (CAD).Due to its eczematous nature, AR is often incorrectly diagnosed as chronic eczema, or sometimes mimics cutaneous T-cell lymphoma both clinically and histologically. The condition is characterized by an extremely low threshold for ultraviolet (UV) radiation and occasionally, visible light.

Case Presentation

We presented the case of a 67 year-old male with more than 5-year history of worsening in summer, pruritic, erythematous and infiltrated papules and plaques. The lesions were primary located on sun-exposed areas (face, neck, hands). The patient worked as a beekeeper. Skin biopsy showed dense polymorphic infiltrate in the upper dermis, with a stellate shape active fibroblasts. Phototesting revealed a significantly reduced Minimal Erythema Dose (MED) to UV radiation. Peripheral blood without Sezary cells.

The patient was started on a strict photoprotection regimen and systemic immunosuppresion with Azathioprine, 150 mg/day (body weight 71 kg). Complete clearance of the skin with total improvement where observed after 7 month of treatment.



#1 before and after treatment

Conclusion

Actinic reticulosis is a debilitating condition that deeply impacts the patient's quality of life.This case highlights the importance of paying attention and taking into consideration the localization of rashes and other complaints, seasonality of rashes, high sensitivity to visible and UV light, anamnesis of life and work history. We should consider AR in the differential diagnosis in case of unsuccessful treatment of chronic eczema, which was mistakenly considered in this patient during previous visits.



#2 before and after treatment

EA DV CONGRESS
VIENNA
30 SEP - 3 OCT 2026

Abstract N°: 1657

EXCIMER LIGHT AND VITILIGO

Abdulathim Mustafa Mohammed Dabbous*[1]

[1] Vitiligo Wunder, Euskirchen, Germany

Introduction
is a psychologically impairing autoimmune disorder inducing skin depigmentation that affects 0.2–1.8% of the population

The mainstay of treatment consists of:

topical/systemic immunosuppressant's and phototherapy.

which serve to stabilize depigmented lesions and to stimulate repigmentation in both stable and unstable vitiligo.

Tissue graft or melanocyte–keratinocyte cell graft transplantation (MKT) provides a more definitive surgical option for patients with stable and localized vitiligo or with segmental vitiligo who have failed repigmentation, despite topical treatments and light therapy.

various types of lasers, used as both monotherapy and combination therapy, have been demonstrated to be effective in the treatment of vitiligo.

The mode of action of these lasers is just as varied as the purpose of intervention.

For Repigmentation or depigmentation alone or combined with other therapy.

photo biomodulation for repigmentation by (excimer lasers
photo ablation for recipient site preparation before grafting (ablative lasers)

tissue stimulation to enhance efficacy of phototherapy (fractional lasers)

photo mechanic interactions for depigmentation (Q-switched lasers

The excimer laser (EL), a targeted phototherapy device, was first described in 2002 for repigmentation of vitiligo.

The EL emits coherent and monochromatic light at 308 nm, which is adjacent to 311 nm narrowband-UVB (NB-UVB) and has similar effects: benefit of adding topical therapy to EL showed superior repigmentation.

Case Presentation



Conclusion

combination therapy with calcineurin inhibitors .(BETTER RESULTS)(SPECIFICAREAS) (INACTIVE)

Other topical drugs included(tacalcitol, calcipotriol, hydrocortisone).

Overall, the drugs could promote the therapeutic effect and clinical outcomes.

There are many studies showed better improvements for ≥75% repigmentation when EL was combined with topical tacrolimus compared to EL alone.(EVEN MY CASES)

however,(insufficient evidence was found for combination therapy with topical vitamin D3 analogues and corticosteroids treatment

All research indicated that lesions on the face, trunk, arms, legs and genitalia (UV sensitive areas)

presented a better response to treatment with Excimer laser than those located on the elbows, back of the hands, knees and soles of the feet (UV resistant areas

: lesions on the back of the hands and soles of the feet reached a repigmen- tation rate of less than 10%, on average, during the 10-week treatment interval.(resistant area) (combination therapy

Finally, according to the actual data, the excimer laser should not be used in monotherapy manner for hands, ankles, and feet.(COMBINATION THERAPY

EA DV CONGRESS
VIENNA
30 SEP - 3 OCT 2026

Abstract N°: 1808

Polydeoxyribonucleotide attenuates dermal fibroblast senescence and enhances macrophage-mediated clearance of senescent cells under UV-induced stress

Xiangyi Wu*[1], Ye Zhong[2], Yan Chen[2], Yuge Yang[2], Ruilong Xia[2], Yanling Wang[2]

[1] Plastic and Reconstructive Surgery, Shanghai Jiao Tong University School of Medicine Affiliated Ninth People's Hospital, Shanghai, China

[2] Shanghai Chicmax Cosmetic Co Ltd, Shanghai, China

Introduction

Skin ageing and extracellular matrix deterioration are closely associated with dermal fibroblast senescence and impaired immune surveillance. Although polydeoxyribonucleotide (PDRN) has been recognized for its bio-reparative activity in dermatology, its effects on cellular senescence and senescent cell clearance remain insufficiently understood. This study aimed to investigate whether PDRN modulates fibroblast senescence, enhances macrophage-mediated clearance of senescent cells, and preserves skin structural homeostasis under UV-related stress, and to explore its translational relevance at the formulation level.

Materials and Methods

A multi-model approach was utilized, including replicative senescent human dermal fibroblasts, THP-1-derived macrophage–fibroblast co-culture systems, and ex vivo human skin explants exposed to UVA/UVB irradiation. Senescence-associated markers (SA-β-gal, p16, p21) and SASP-related cytokines were assessed. Macrophage phagocytic activity was evaluated in relation to CD47 expression in fibroblasts and stabilin-1 (STAB1) expression in macrophages. Intracellular ATP and lysyl oxidase (LOX) expression were analyzed under UVA stress, while epidermal morphology, DNA photodamage (CPDs), and basal proliferation (Ki67) were assessed in UV-exposed explants. In addition, a separate 28-day clinical evaluation of a PDRN-containing topical formulation was conducted in 34 subjects with sensitive skin to assess hydration, elasticity, firmness, and wrinkle-related parameters.

Results

PDRN significantly attenuated senescence-associated phenotypes in dermal fibroblasts, reducing SA-β-gal positivity by up to 57%, p16 expression by up to 76%, and suppressing SASP-related cytokines. In the co-culture model, PDRN enhanced macrophage-mediated phagocytosis of senescent fibroblasts, which was associated with a 41% reduction in CD47 expression in fibroblasts and increased STAB1 expression in macrophages. Under UVA-induced stress, PDRN restored intracellular ATP levels and upregulated LOX expression by approximately 130%, suggesting improved collagen-associated structural support. In UV-irradiated skin explants, PDRN reduced CPD-positive nuclei by 24%, increased Ki67-positive cells by 36%, and increased viable epidermal thickness by 21%. In a separate 28-day clinical evaluation, the PDRN-containing formulation increased stratum corneum hydration by 30.05%, improved elasticity (R2) by 17.07%, and improved firmness (F4) by 20.13%.

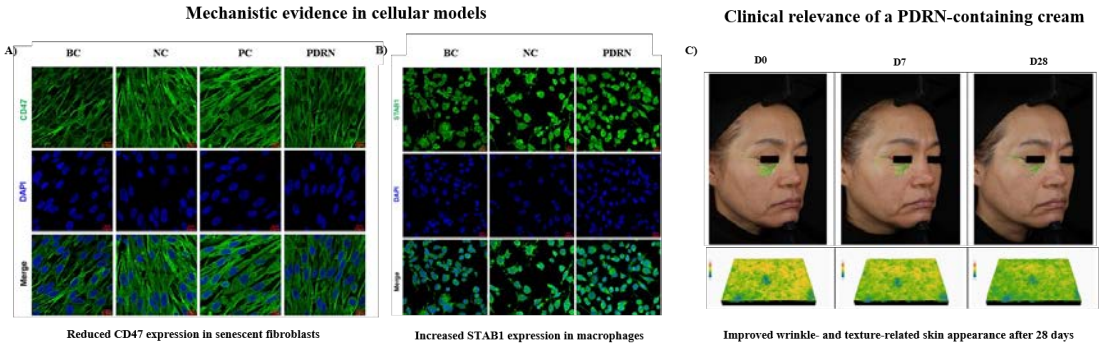

Conclusions

PDRN mitigated fibroblast senescence and was associated with enhanced macrophage-mediated clearance of senescent cells, while supporting extracellular matrix integrity under UV-induced stress. Together with supportive clinical observations, these findings highlight the translational relevance of PDRN as a multifunctional active ingredient for topical formulations targeting skin ageing and photo-damage.

EADV CONGRESS
VIENNA
30 SEP - 3 OCT 2026

Abstract N°: 1955

From complicated to uncomplicated: contrasting pregnancy outcomes in porphyria cutanea tarda

Khoshi Darsen*[1], Henrik Lorentzen[1]

[1] Department of Dermatology, Odense, Denmark

Introduction
Porphyria cutanea tarda (PCT) is the most common form of porphyria and is characterized by photosensitivity, skin fragility, and blister formation. While the disease is well described in the general population, its clinical course during pregnancy is poorly understood, and data on maternal and fetal outcomes are limited.

Cases

We report two pregnancies in women with PCT demonstrating markedly different clinical courses.

Case Presentation
Case 1

A 30-year-old woman with PCT diagnosed in 2021 and concomitant hereditary hemochromatosis initially presented with cutaneous manifestations. The diagnosis was supported by elevated urinary porphyrins and increased ferritin levels. Due to a young age at disease onset and prior episodes of abdominal pain, extensive genetic testing for acute porphyrias was performed, confirming PCT. PCT-specific treatment was discontinued before pregnancy. Iron supplementation was avoided, and the patient was monitored every 2–3 months with urinary porphyrins and blood tests assessing iron metabolism.

During preterm pregnancy, she developed preeclampsia followed by abdominal pain and was subsequently diagnosed with placental abruption. Despite intervention, the course was complicated and required an emergency cesarean section. The neonate was born in a severely asphyxiated condition and developed seizures within hours, necessitating transfer to a tertiary care unit for advanced respiratory support.

Case 2

A 40-year-old woman with genetically confirmed hereditary PCT (UROD mutation), diagnosed at the age of 17, initially presented with cutaneous symptoms and elevated urinary porphyrins. In contrast to Case 1, her pregnancy was managed with regular venesections and followed an uncomplicated course. She delivered a healthy infant without maternal or fetal adverse outcomes.

Conclusion
These cases illustrate the highly variable course of PCT during pregnancy, ranging from uncomplicated outcomes to severe maternal and fetal complications. Pregnancy-related hormonal and metabolic changes may influence

disease expression, particularly in patients with comorbid conditions such as hemochromatosis. However, reliable predictors of adverse outcomes remain poorly defined.

In conclusion pregnancy in women with PCT can be either benign or complicated. Awareness of this variability is crucial to ensure close monitoring and timely, individualized, multidisciplinary management. PCT is rare in women of childbearing age, and potential predictors of pregnancy-related complications warrant further investigation

EADV CONGRESS
VIENNA
30 SEP - 3 OCT 2026

Abstract N°: 1984

Preclinical and Clinical Evaluation of an antiaging Sunscreen formulated with Vigna Aconitifolia seed extract. Effects on Collagen-Related Parameters and Skin Aging

Martin Ost[1], Ina Becker[1], Karen Dodd[2], Georgina Logusso*[3], Gerald PEDRASSI[1]

[1] Global Pharmaceutical Development, Stada arzneimittel, Bad Vilbel, Germany

[2] Global Product Development, Thornton & Ross, Huddersfield, United Kingdom

[3] Global Product Development, STADA Arzneimittel GmbH, Sant Just Desvern, Barcelona, Spain

Introduction

Ultraviolet (UV) radiation is a major extrinsic factor in skin aging and leads to structural and functional alterations such as collagen degradation, loss of elasticity, and wrinkle formation. Chronic UV exposure accelerates these processes and results in cumulative photoaging. In this context, infrared A (IR-A) radiation has also been shown to contribute to matrix degradation by inducing MMP-1 expression in the skin, similar to UVB and UVA radiation; however, the underlying signaling mechanisms are distinct. Sunscreens that combine high photoprotective efficacy against UV and effects of infrared A radiation with additional biological activity therefore represent a promising approach for the management of photoaged skin.

Materials and Methods

A preclinical in vitro study was conducted using reconstructed human 3D skin models to assess the effect of a sunscreen formulation (SPF 50+) containing *Vigna Aconitifolia* seed extract on collagen-related parameters, with Collagen 1A1 levels as the primary endpoint following topical application for up to 72 hours. Based on these findings, a monocentric, 8-week clinical study was performed in 20 healthy subjects (aged 40–70 years) with normal to dry, sensitive skin and visible signs of photoaging.
Participants applied the product once or twice daily under real-life conditions. Instrumental assessments were performed at baseline (T0) and after 56 days (T56), including corneometry (skin hydration), cutometry (firmness, elasticity), and optical 3D measurements (wrinkle depth). Skin tolerability was clinically evaluated under dermatological control.

Results

In the in vitro assessment, the formulation was associated with an increase in Collagen 1A1 levels of 8.74% after 48 hours of application compared to control. In the clinical study, the product was well tolerated by all subjects. Instrumental analysis demonstrated statistically significant improvements across all evaluated parameters after 8 weeks of use. Skin hydration increased by 31.1% ($p < 0.001$). Skin firmness improved by a 9.4% reduction in skin deformability ($p = 0.003$). Skin elasticity increased by 11.8% ($p = 0.007$), and wrinkle depth was reduced by a mean of 20.1% ($p < 0.001$). Subjective assessments indicated very good cosmetic acceptability, with 100% of participants reporting ease of application and 90% reporting no visible white cast.

Conclusions

The investigational product was well-tolerated and showed statistically significant improvements in skin hydration, firmness, elasticity, and wrinkle depth. These clinical results were complemented by *in vitro* findings showing an increase in Collagen 1A1 expression. The data support the formulation's

multifunctional efficacy, providing restorative anti-aging benefits beyond its primary photoprotective function.

EADV CONGRESS
VIENNA
30 SEP - 3 OCT 2026

Abstract N°: 1986

Integrating In Vivo and Ex Vivo Evidence: Evaluation of a facial sunscreen formulated with Helichrysum Angustifolium flower extract in Rosacea-Prone Skin

Martin Ost[1], Ina Becker[1], Karen Dodd[2], Georgina Logusso*[3], Gerald PEDRASSI[1]

[1] Global Pharmaceutical Development, Stada arzneimittel, Bad Vilbel, Germany

[2] Global Product Development, Thornton & Ross, Huddersfield, United Kingdom

[3] Global Product Development, STADA Arzneimittel GmbH, Sant Just Desvern, Barcelona, Spain

Introduction

Rosacea is a chronic inflammatory dermatosis characterized by erythema, skin sensitivity, and vascular dysfunction. Effective daily management requires products that not only provide high tolerability and symptomatic relief but also address underlying structural impairments. Sun protection is crucial to prevent exacerbation. These studies aimed to evaluate the clinical efficacy and safety of a specialized SPF 50+ sunscreen containing *Helichrysum Angustifolium* flower extract and to explore its underlying mechanisms of action using an *ex vivo* human skin model.

Materials and Methods

Two complementary studies were conducted 1) A prospective, 4-week, monocentric clinical study was performed on 22 female subjects with sensitive, rosacea-prone skin. The product was applied once daily. Anti-redness efficacy was assessed by expert grading of redness, instrumental measurement of skin color parameters (Antera 3D®), and subject self-assessment of rosacea signs. 2) A 10-day *ex vivo* study was conducted on living human skin explants. The test product was applied topically, and its effects on the vascular biomarker PECAM-1 (CD31) were analyzed via immunohistochemistry at day 4 and day 10.

Results

The *in vivo* study demonstrated that the product was very well tolerated, with no adverse reactions reported. After 28 days, a statistically significant reduction in skin redness was observed, confirmed by both expert grading (-8.2%, $p<0.0001$) and instrumental analysis of the erythema parameter *a* (-6.9%, $p<0.0001$). Symptomatic improvement was also significant, with subjects reporting a mean decrease in skin burning sensation of -36.1% ($p<0.05$). The *ex vivo* study provided support for these clinical outcomes. A significant and sustained upregulation of PECAM-1 expression was seen, compared to the untreated control (+98% D10), suggesting a reinforcing effect on vascular wall structure.

Conclusions

The product demonstrated to be safe and effective for protection and daily management of sensitive, rosacea-prone skin. It significantly reduces signs of redness while improving the user's comfort. The clinical efficacy is supported by *ex vivo* evidence that suggests a reinforcement of the cutaneous microvascular structure. These findings support its dual efficacy, offering high-level photoprotection alongside benefits for the cosmetic management of rosacea.

POWERED BY M-ANAGE.COM

EADV CONGRESS
VIENNA
30 SEP - 3 OCT 2026

Abstract N°: 1987

Assessment of a Sunscreen formulated with Phyto-lipids and Inulin, in Acne-Prone skin: Tolerability and Efficacy on Skin Parameters

Martin Ost[1], Ina Becker[1], Karen Dodd[2], Georgina Logusso*[3], Gerald PEDRASSI[1]

[1] Global Pharmaceutical Development, Stada arzneimittel, Bad Vilbel, Germany

[2] Global Product Development, Thornton & Ross, Huddersfield, United Kingdom

[3] Global Product Development, STADA Arzneimittel GmbH, Sant Just Desvern, Barcelona, Spain

Introduction

Individuals with acne-prone skin often struggle to find a suitable daily sunscreen that is non -comedogenic and does not exacerbate blemishes. A skin care product should offer high, non-greasy protection while actively helping to manage the visible signs of acne-prone skin. This study aimed to evaluate the reduction of acne prone skin lesions and tolerability of a novel SPF 50+ sunscreen, containing Phyto-lipids and Inulin.

Materials and Methods

A 4-week, monocentric, clinical study was conducted on 20 subjects with sensitive, acne-prone skin (Global Acne grade 1-2). Participants applied the product once daily on their faces. Cosmetic efficacy was assessed by a dermatologist through the counting of inflammatory lesions (papules and pustules) and a Visual Analogue Scale (VAS) evaluation of comedons and redness at baseline and after 28 days. Skin tolerability was clinically monitored.

Results

The sunscreen was very well tolerated, with no reported skin irritation. The product demonstrated a marked effect on the appearance of imperfections. After 4 weeks, a significant reduction was observed in the mean count of papules by 76.8% and pustules by 78.0% ($p < 0.001$ for both). The appearance of comedons was significantly reduced by 17.3%, and overall skin redness diminished significantly by 57.4% ($p < 0.001$). Subjective evaluation confirmed excellent cosmetic acceptance, with 95% of users rating the product as ‘good’ or ‘very good’ and 100% agreeing it was easy to spread.

Conclusions

Daily use of the investigational product was well tolerated in sensitive, acne-prone skin. Beyond the high level of photoprotection, it's also demonstrated significant reductions in both inflammatory and non-inflammatory lesion counts, and improvements in erythema. These findings highlight its dual utility, offering photoprotection as its primary function, and benefits for the management of acne-prone skin.

EADV CONGRESS
VIENNA
30 SEP - 3 OCT 2026

Abstract N°: 2059

Refractory chronic actinic dermatitis successfully treated with dupilumab

Cátia Gonçalves*[1], Beatriz Flores[1], Miguel Coelho[1], Alexandre João[1], Rodrigo Carvalho[1]

[1] Department of Dermatology and Venereology of ULS S. José, Lisbon, Portugal

Introduction

Chronic actinic dermatitis (CAD) is a rare, immunologically mediated photodermatosis characterised by chronic, pruritic, eczematous and lichenified lesions on photo-exposed skin, with objectively confirmed photosensitivity.[1] Its management remains challenging, given the frequent refractoriness to conventional immunosuppressants and the resulting long-term corticosteroid dependence.

Case Presentation

We report the case of a 54-year-old male, originally from India and residing in Portugal for over two decades, first observed in our department in 2010 for a three-year history of extensive, intensely pruritic, erythematous-scaly papules and plaques with marked lichenification, in a strict photo-exposed distribution (face, posterior neck, forearms and dorsa of the hands). The diagnosis of CAD was established that same year, supported by clinical features and histopathology.

Over the following years, the patient was treated sequentially with azathioprine, ciclosporin, mycophenolate mofetil and methotrexate, all with therapeutic failure. Hydroxychloroquine was maintained throughout follow-up as background therapy, well tolerated but insufficient as monotherapy. Disease control was only marginally achieved through prolonged systemic corticosteroid therapy, leading to clinically significant adverse effects, namely osteopenia. The patient was lost to follow-up between 2023 and 2025.

When reassessed in 2025, he presented with severe disease, characterised by hyperkeratotic and lichenified plaques on the forearms, dorsa of the hands, face and posterior neck, extensive facial post-inflammatory hyperpigmentation, and a thick, infiltrated, hypopigmented plaque on the posterior cervical region. After literature review and multidisciplinary discussion, off-label dupilumab was initiated in October 2025, using the standard adult regimen (600 mg subcutaneous loading dose, followed by 300 mg every two weeks).

At the six-month reassessment, there was near-complete resolution of inflammatory lesions, with only residual xerosis and post-inflammatory hyperpigmentation persisting. Critically, complete withdrawal of systemic corticosteroid therapy was achieved, and the patient reported substantial improvement in pruritus and quality of life. No adverse effects related to dupilumab were observed during follow-up.

Conclusion

CAD shares relevant pathophysiological features with atopic dermatitis, namely a predominantly Th2-skewed inflammatory response, with upregulation of IL-4 and IL-13 signalling.[2] This rationale supports the off-label use of dupilumab — a fully human monoclonal antibody targeting the IL-4 receptor α subunit — in CAD. Published case reports and small series have demonstrated rapid clinical improvement, sustained efficacy and a favourable safety profile, often allowing discontinuation of conventional immunosuppressants and systemic corticosteroids.[3],[4]

This case reinforces the emerging role of dupilumab as a valuable option in recalcitrant CAD, particularly in patients with long-standing disease, multiple prior treatment failures and corticosteroid-related morbidity. Further prospective studies are needed to define optimal patient selection and durability of response in this rare and disabling photodermatosis.

EA DV CONGRESS
VIENNA
30 SEP - 3 OCT 2026

Abstract N°: 2099

Fractional CO_2 Laser-Assisted MAL-PDT in Grade II-III Actinic Keratoses: A Prospective Study

Antonio Fai*[1, 2], Dario Fai[3]

[1] Biomedical Centrum (BMC), Lund, Sweden
[2] Doctor RY, Höllviken, Sweden
[3] Servizio di Dermatologia e Fototerapia PTS Gagliano del Capo, Gagliano Del Capo, Italy

Introduction

Actinic keratosis (AK) is a common premalignant lesion arising from chronic ultraviolet exposure, presenting as single or multiple lesions with typical localization on scalp, face, chest, shoulder and arms and characterized by a potential progression to cutaneous squamous cell carcinoma (doi: 10.2340/00015555-3486).

Photodynamic therapy with methyl aminolevulinate (MAL-PDT) is an established treatment for single or multiple grade I–II AK (Olsen classification) and for field cancerization of the face and scalp in immunocompetent individuals. Its efficacy, however, is reduced in hyperkeratotic lesions (Olsen grade II-III) probably due to impaired photosensitizer penetration (doi: 10.1007/s13555-023-00936-w) with higher recurrence rates following PDT, reaching up to 28% within 6–12 months, particularly in thicker lesions or after single-session protocols (DOI: 10.1007/s13555-023-00936-w).

Adjunctive strategies such as lesion debulking and ablative fractional laser (AFXL) have been proposed to enhance drug delivery and improve treatment outcomes, though clinical data remain limited.

Materials and Methods

N = 54 patients with multiple clinically diagnosed Olsen grade 2–3 AKs. All lesions underwent lesion debulking (curettage) followed by fractional CO_2 laser ablation (8W, 28J/cm^2) prior to the MAL-PDT session (Aktilite 37J/cm^2 , 6:30 min)

Patients were evaluated at 1, 3, and 6 months post-treatment.

Results

At 3 months, complete clearance was obtained in 100% of the patients. At 6 months, 6 of the 54 patients (11%) demonstrated recurrence (clearance rate - 89%).

These outcomes compare favourably with previously reported recurrence rates for MAL-PDT, which range up to 28% within the first year depending on lesion characteristics and treatment regimen (DOI: 10.1007/s13555-023-00936-w).

The treatment was well tolerated, with no significant adverse events reported.

Conclusions

At 3 months, complete clearance was obtained in 100% of the patients. At 6 months, 6 of the 54 patients (11%) demonstrated recurrence (clearance rate - 89%).

These outcomes compare favourably with previously reported recurrence rates for MAL-PDT, which range up to 28% within the first year depending on lesion characteristics and treatment regimen (DOI: 10.1007/s13555-023-00936-w).

The treatment was well tolerated, with no significant adverse events reported.

EA DV CONGRESS
VIENNA
30 SEP - 3 OCT 2026

Abstract N°: 2293

Transgenerational Profiling of Cutaneous Aging in Skin of Colour: A Multimodal Imaging Study Across Biological Family Trios in Fitzpatrick Skin Types III-VI

Mukta Sachdev*[1]

[1] Medical Director, MS Clinical Research Pvt. Ltd., HOD & Consultant, Dermatology, Manipal Hospital, Bangalore, India, Bengaluru, India

Introduction

The characterisation of skin aging in individuals with skin of colour remains substantially underrepresented in dermatological literature, with the majority of normative aging data derived from Fitzpatrick I-III populations. Skin of colour exhibits biologically distinct aging trajectories — constitutively higher melanin content, greater dermal collagen density, differential photoaging patterns, and heightened susceptibility to dyspigmentation — that render Caucasian-derived aging frameworks clinically inadequate for this demographic. Critically, the relative contributions of genetic inheritance versus environmental and lifestyle factors to aging phenotype in darker phototypes have never been systematically quantified. Biological family trios, comprising three consecutive generations sharing a common genetic lineage, offer a uniquely powerful study design to delineate heritable aging patterns from acquired ones, enabling the construction of genetically anchored aging trajectories that are specific to skin of colour. No such transgenerational profiling study using validated multimodal imaging has previously been conducted in this population.

Materials and Methods

This is a prospective, observational, cross-sectional profiling study enrolling biological family trios (grandparent, parent, and child) across 10 male and 10 female family sets, yielding a total of 60 subjects per sex (120 subjects overall) spanning Fitzpatrick skin types III-VI. Each trio shares direct biological lineage, enabling within-family genetic anchoring of aging parameters. Multimodal facial imaging is performed using two validated platforms: VISIA-CR (standardised cross-polarised and parallel-polarised photography for surface and subsurface pigmentation, texture, pores, wrinkles, and UV damage quantification) and Antera 3D (three-dimensional topographic mapping of skin texture, melanin distribution, haemoglobin content, and collagen density proxies). Primary outcome parameters include pigmentary aging indices (spot count, UV spots, melanin heterogeneity) and structural aging indices (wrinkle depth and distribution, skin texture irregularity, pore prominence, collagen-related surface parameters). Sex-specific aging trajectories are analysed both within family trios and across the broader cohort. The study is currently ongoing.

Results

Enrolment and imaging are currently in progress. Preliminary observations from early family trios indicate measurable generational gradients in both pigmentary and structural aging parameters, with within-family imaging demonstrating visually concordant aging patterns suggesting heritable phenotypic trajectories. Quantitative multimodal data across the full cohort, including between-generation and between-sex comparisons, will be presented at the time of the congress.

Conclusions

This study addresses a critical and largely unexplored evidence gap in aging dermatology by applying a transgenerational biological family design to the systematic profiling of skin aging in Fitzpatrick III-VI phototypes. By anchoring aging parameters within shared genetic lineages, the study is uniquely positioned to distinguish

heritable aging signatures from environmentally acquired changes in skin of colour — a distinction with direct implications for personalised photoprotection strategies, anti-aging therapeutics, and the development of population-specific normative aging standards. The sex-stratified design further enables characterisation of divergent male and female aging trajectories within the same genetic background, a question with significant relevance to cosmetic dermatology practice. The findings are expected to contribute foundational normative data for skin of colour aging that is currently absent from the literature.

EADV CONGRESS
VIENNA
30 SEP - 3 OCT 2026

Abstract N°: 2317

Photodynamic Therapy with 5-Aminolevulinic Acid Versus Topical Corticosteroids in the Treatment of Oral Lichen Planus

Ahmed Akl*[1], hossam atef[1], AHMED ALMEZAINE[1]

[1] mINISTREY OF HEALTH, Banha, Egypt

Introduction
Oral lichen planus (OLP) is a chronic immune-mediated inflammatory disorder of the oral mucosa associated with pain, burning sensation, and reduced quality of life. Topical corticosteroids remain first-line therapy but are limited by relapse and adverse effects. This randomized clinical trial compared the efficacy and durability of photodynamic therapy with 5-aminolevulinic acid (ALA-PDT) versus topical glucocorticosteroids, with analysis based on lesion location on keratinized and non-keratinized mucosa.

Materials and Methods
Ninety patients with histologically confirmed OLP were randomized to receive either ALA-PDT using a novel oromucosal emulgel containing 5% 5-aminolevulinic acid (five weekly sessions) or topical clobetasol propionate applied twice daily for two weeks. Outcomes included lesion area, clinical severity using the Reticulation-Erythema-Ulceration (REU) index, and patient-reported symptoms assessed by Visual Analog Scale (VAS). Evaluations were performed at baseline, immediately post-treatment, and at six-month follow-up. Subgroup analysis was conducted according to lesion site.

Results
ALA-PDT produced significantly greater reductions in lesion size, REU scores, and VAS values compared with topical corticosteroids, with more durable responses at six months. The benefit was particularly pronounced in lesions located on non-keratinized mucosa, where mean lesion area decreased from 2.64 cm^2 at baseline to 0.56 cm^2 at six months ($p < 0.0001$). Corticosteroid therapy demonstrated initial clinical improvement followed by partial relapse during follow-up. Both treatments were well tolerated, with only mild and transient adverse effects reported.

Conclusions
ALA-mediated photodynamic therapy provides superior and longer-lasting clinical improvement compared with topical corticosteroids in oral lichen planus, particularly for lesions on non-keratinized mucosa. The use of a 5% ALA-loaded oromucosal emulgel enhances treatment efficacy and tolerability. These findings support ALA-PDT as a promising therapeutic alternative for the management of OLP.

EADV CONGRESS
VIENNA
30 SEP - 3 OCT 2026

Abstract N°: 2529

Efficacy and tolerability of localised balneopuvatherapy in palmar-plantar keratoderma in children: a prospective study of 42 patients

Émélie Simone Okouango*[1], Bouchra Baghad[1], Hanane Rachadi[1], Soumiya Chiheb[1]

[1] Department of Dermatology, Ibn Rochd University Hospital, Casablanca, Morocco, Faculty of Medicine and Pharmacy of Casablanca, Hassan II University, Morocco, Casablanca, Morocco

Introduction
Palmar-plantar keratoderma (PPK) in children has a functional impact and significantly impairs quality of life. Balneopuvatherapy is a photochemotherapy technique involving the immersion of a skin area in a bath containing a low-concentration topical psoralen, followed by UVA irradiation. Although it is commonly used in adults, paediatric data remain limited. The objective of our study was to evaluate the efficacy and tolerability of localised balneophototherapy in children with KPP.

Materials and Methods
We conducted a 5-year prospective, single-centre study (January 2021–December 2025) involving patients under the age of 17 who were being treated for KPP of all aetiologies at the Dermatology Department of Ibn Rochd University Hospital, with informed parental consent. The protocol involved palmoplantar immersion in a strong melanin solution (2 mL/5 L of water) for 15 minutes, followed by 15 minutes of air-drying and then UVA irradiation. The initial dose was 0.30 J/cm² (first 2 sessions), then 0.40 J/cm² (3rd to 5th sessions), with a gradual increase of 0.1 J/cm² starting from the 6th session, at a rate of 2 sessions per week. The evaluation criteria were clinical improvement (>50% reduction in lesions), tolerability, and quality of life, assessed at 12 and 24 sessions and then at the end of treatment.

Results
Forty-two patients were included (23 boys, 19 girls; sex ratio 1.2). The mean age was 10.36 years (range 3–16 years). No personal or family history of contact dermatitis or psoriasis was reported. Clinically, all KPP lesions were diffuse, well-defined, and pruritic; 41 cases involved fissures. Nail involvement was noted in 33 patients, including 4 cases of thimble-shaped nails with xanthopachyonychia. The diagnosis was acquired KPP in all cases. A biopsy was performed in 34 patients. Mycological examination was negative. Patch tests (10 patients) were positive in 4 cases (nickel, potassium dichromate, and cobalt). The aetiologies were dominated by psoriasis (33 cases), followed by eczema (4 cases), mycosis fungoides (1 case), and pityriasis rubra pilaris (1 case); 3 cases remained undetermined. All patients received concomitant topical treatment. Thirty-six patients showed marked improvement, including 29 who achieved complete clearance on average after 20 sessions. One case of recurrence was observed, and 6 patients were lost to follow-up. Functional discomfort and fissures improved significantly. No serious adverse effects were observed; mild to moderate post-session erythema occurred in 25 patients. Compliance and satisfaction were excellent.

Conclusions

Localised balneotherapy combined with PUVA appears to be an effective and well-tolerated treatment for childhood psoriasis, particularly in cases resistant to topical treatments. Its positive impact on quality of life and its safety profile make it a relevant alternative to systemic treatments. The limitations of this study include its single-centre design and the absence of a control group. Randomised controlled trials are needed to confirm these results and clarify its role in the therapeutic strategy.

EADV CONGRESS
VIENNA
30 SEP - 3 OCT 2026

Abstract N°: 2567

Evaluation in vitro of the immunomodulatory effect of Rose Bengal photodynamic therapy in human melanoma

Marie Boileau*[1], Anthony Lefebvre[1], Smail Marhfor[1], Guillaume Grolez[1], Anne-Sophie Dewalle[1], Olivier Morales[1], Nadira Delhem[1], Laurent Mortier[1, 2]

[1] Univ. Lille, CHU Lille Inserm, U1366 – CRC Lille CNRS UMR 9020. ONCOTHAI - Assisted Laser Therapy and Immunotherapy for Oncology, Service de Dermatologie, Hôpital Claude Huriez CHU de Lille, France, Lille, France
[2] CHU de lille, Lille, France

Introduction

Photodynamic therapy (PDT) involves the reaction of a photosensitizer (PS) in the presence of oxygen and light producing reactive oxygen species (ROS) that lead to tumor cell death and a specific immunological response, enabling the anti-tumor effect. Rose bengal (RB), known for its antibacterial, antitumor and immunoactive properties, has shown cytotoxicity properties in melanoma at high doses. However, photosensitivity was described as a limiting side effect. We have previously demonstrated the efficacy of PDT with RB (PDT-RB) in inducing *in vitro* melanoma cell death. Our aim is now to evaluate *in vitro,* the potential of PDT-RB to induce an indirect effect on the human immune response, mediated by tumour cell death.

Materials and Methods

Firstly, the direct impact of RB and PDT-RB was assessed on human peripheral blood mononuclear cells (PBMCs) exposed to different doses of RB and PDT-RB and the toxicity, viability and proliferation were measured. Then, the indirect impact of RB-PDT on the immune response was assessed, by studying the effect of RB-PDT tumour death in inducing PBMCs activation. To do this, HBL and LND melanoma cells were treated with doses of RB or PDT-RB leading to 80% cell death (EC80). Tumour cell supernatants were recovered 24 h after PDT-RB under the following conditions: untreated cells (NT), light-treated cells (Illu), cells treated only with RB (RB) and cells treated with PDT-RB (PDT). The proliferation of human PBMCs was then measured by the incorporation of tritiated thymidine after 48, 72 and 120 h of culture with these supernatants.

Results

We observed that RB, when used alone and at EC80[RB] induced a decrease in PBMCs proliferation, while low RB concentrations have no impact. We also showed that EC80-RB induced a significant decrease in PMBCs viability, whereas no significant decrease was observed in the EC80[PDT-RB] condition. Regarding the indirect impact of PDT, we showed an increase in the proliferation of activated PBMCs treated with the supernatants of melanoma lines treated with EC80[PDT-RB].

Conclusions

These results demonstrate the ability of PDT-RB to induce human melanoma cell death and to activate the human immune response. Future experiments will be conducted to gain a better understanding of the immune populations that proliferate and become activated following PDT-RB.

EADV CONGRESS
VIENNA
30 SEP - 3 OCT 2026

Abstract N°: 2590

Health-related quality of life in Danish patients with porphyria cutanea tarda: a cross-sectional study

Batool Ali*[1], Henrik Lorentzen[1], Anne Stockmann[1]

[1] Department of Dermatology, Odense, Denmark

Introduction
Porphyria cutanea tarda (PCT) is a rare metabolic disorder that is characterized by photosensitivity and an increased risk of hepatocellular carcinoma, which may cause considerable lifestyle, psychosocial, and cancer-related burden. However, research on the health-related quality of life in patients with PCT remains scarce.

Objective

We aimed to fill this knowledge gap by thoroughly assessing the dermatologic impact on quality of life (QoL), general QoL, and cancer-related worry in Danish patients with PCT.

Materials and Methods
Methods

This is a cross-sectional study which included adults with PCT, who were followed at the Department of Dermatology, Odense University Hospital between March and December 2025. Patient-reported outcome data was obtained through four validated questionnaires: Dermatology-life Quality Index (DLQI), Visual Analogue Scale (VAS), Cancer Worry Scale (CWS), World Health Organization Quality of Life-BREF (WHOQOL-BREF). All analyses were non-parametric and limited to descriptive statistics and bivariate comparisons.

Results
Forty-four patients were included (median age 67; slight male predominance). Dermatology-related QoL impairment was generally low given the DLQI median of 1 (IQR 0-4). By comparison, perceived disease burden measured by VAS varied widely given the IQR of 5-58. General QoL was mostly preserved, with scores above the mid-scale point across all WHOQOL-BREF domains. DLQI and VAS showed significant weak-to-moderate inverse correlations with all WHOQOL-BREF domains. Cancer-worry was mostly low to slightly moderate (median CWS 14, IQR 11–19), though a minority reported elevated levels.

Conclusions
Our results showed minimal dermatology-specific QoL impairment despite differences in subjective disease burden, which questioned DLQI's ability in capturing core aspects of PCT, hence the need for a PCT-specific severity instrument. PCT could have an impact on patients' general QoL, however, this remained uncertain considering the cross-sectional design and unadjusted confounding. A minority reported elevated cancer-worry, though unknown if directly related to PCT, given the lack of cancer-type specificity in the CWS.

EADV CONGRESS
VIENNA
30 SEP - 3 OCT 2026

Abstract N°: 2674

Actinic Reticuloid Mimicking Chronic Eczema in Darker Skin: A Case Report

Guilherme Gonçalves Nascimento*[1], Luisa Homem de Mello Maciel Campilongo[1], Mariana Campilongo[2], Eduardo Lacaz Martins[1], Carlos D Apparecida Santos Machado Filho[1]

[1] Faculdade de Medicina do ABC, Santo André, Brazil
[2] Centro Universitário São Camilo, São Paulo, Brazil

Introduction

Actinic reticuloid (AR) is a rare and severe form of chronic actinic dermatitis characterized by persistent eczematous photodistributed plaques triggered by ultraviolet radiation and, frequently, visible light exposure. The disease may clinically and histopathologically mimic chronic eczema, cutaneous lupus and cutaneous T-cell lymphoma, frequently leading to delayed diagnosis. Although AR predominantly affects elderly men with lighter phototypes, atypical and exuberant presentations in darker skin types remain underrecognized, particularly in female patients presenting with chronic refractory eczema-like dermatoses.

Case Presentation

A 66-year-old Fitzpatrick V female patient presented with a one-year history of intensely pruritic erythematoviolaceous plaques affecting photoexposed areas, including the face, neck and upper limbs, previously treated as chronic eczema without clinical improvement. Dermatological examination revealed infiltrated lichenified erythematoviolaceous plaques with excoriations and hemorrhagic crusts on the frontal region, as well as multiple confluent photodistributed plaques involving the malar areas, anterior neck and upper chest. Histopathological examination demonstrated spongiotic dermatitis with eosinophils and superficial perivascular inflammatory infiltrate, favoring a chronic hypersensitivity reaction. Laboratory investigation showed negative antinuclear antibodies, anti-DNA and anti-RNP antibodies, with normal serum zinc levels. Due to the exuberant photodistributed pattern, chronic relapsing course, histopathological findings and exclusion of autoimmune disease, the diagnosis of actinic reticuloid was established. Potential photosensitizing medications were discontinued, and the patient was treated with systemic corticosteroids, high-potency topical corticosteroids, antihistamines, hydroxychloroquine and strict photoprotection. Marked improvement in pruritus, erythema and cutaneous infiltration was observed during follow-up, with progressive reduction of active lesions. Intermittent exacerbations occurred after sun exposure and use of potentially photosensitizing medications. Despite recurrent flares and irregular adherence to photoprotection during some periods, the patient evolved with near-complete clinical improvement under combined immunosuppressive therapy and strict photoprotection.

Conclusion

Actinic reticuloid remains an underrecognized and diagnostically challenging photodermatosis, particularly in patients with darker phototypes and atypical clinical presentations. This case highlights the substantial overlap between AR and chronic refractory eczema, emphasizing how delayed recognition and nonspecific histopathological findings may complicate diagnosis. Early clinicopathological correlation, strict photoprotection and prompt immunosuppressive therapy are essential for adequate disease control.

EA DV CONGRESS
VIENNA
30 SEP - 3 OCT 2026

Abstract N°: 2718

Beyond Efficacy: Daily MCE Sunscreen's Superiority Redefines Photoaging Prevention and Public Awareness

Sérgio Schalka[1, 2], Caroline Lefloch[3], Flament Frederic[4], Delphine Kerob[3], Pascale Renoux*[3], Ana Cláudia Cavalcante Espósito Lemos[5], Chengfeng Zhang[6], Renato Moura[7], Piergiacomo Calzavara-Pinton[8], Henry W. Lim[9]

[1] Medcin Skin Research Center, Sao Paulo, Brazil
[2] Biochemistry Department, Chemistry Institute of Sao Paulo University, Sao Paulo, Brazil
[3] La Roche-Posay Laboratoire Dermatologique, Levallois-Perret, France
[4] L'Oréal Research and Innovation, Chevilly-Larue, France
[5] Dermatology Department, Universidade do Oeste Paulista (UNOESTE), Sao Paulo, Brazil
[6] Department of Dermatology, Huashan Hospital, Fudan University, Shanghai, China
[7] Centre International de Développement Pharmaceutique (CIDP), Rio de Janeiro, Brazil
[8] Department of Dermatology, University of Brescia, Brescia, Italy
[9] Department of Dermatology, Henry Ford Health, Detroit, United States

Introduction

Public concern regarding photoaging often outweighs that for skin cancer. However, photoprotection adherence remains low, with 57% regretting insufficient past protection. Yet not all sunscreen formulations offer equivalent photoaging prevention. The objetive of this study was to compare long-term daily use of sunscreen containing Methoxypropylamino Cyclohexenylidene Ethoxyethylcyanoacetate (MCE) offering extended long UVA protection up to 400nm versus usual photoprotection routine in preventing photoaging.

Materials and Methods

This 1-year randomized controlled trial (SOLARDEEP STUDY) included 246 volunteers in Brazil (all phototypes), randomized to MCE-sunscreen or control (usual photoprotection routine, all measures allowed). Global skin quality was assessed using a composite score of 7 facial parameters. Specific aging signs were evaluated via Clinical Atlases. Facial skin pigmentation was measured using standardized imaging (CIE Lab: L*, ITA°). Assessments occurred at baseline, 3, 6, 9, and 12 months.

Results

Daily use of MCE-sunscreen was significantly more effective than control in reducing the global aging score at all timepoints ($p<0.05$). After 12 months, skin quality improved by 22.8% (compared to 0.7% in control group; $p<0.05$). All signs of skin aging were significantly reduced (e.g., forehead wrinkles -23.0%; crow's feet -10.8%; $p<0.05$ vs. control). Skin pigmentation improved, as evidenced by increased L* and ITA° parameters ($p<0.05$). Subgroup analysis confirmed MCE-sunscreen superiority versus SPF50+ users from the control group (n=53).

Conclusions

This study confirms that regular daily use of MCE-sunscreen with extended long UVA protection is more effective than usual photoprotection routine at preventing and reducing clinical signs of photoaging. Given the scarcity of long-term longitudinal photoprotection studies, these compelling results provide powerful evidence promoting consistent daily sunscreen use.

EA DV CONGRESS
VIENNA
30 SEP - 3 OCT 2026

Abstract N°: 2745

PROTECTIVE FACTORS PROVIDED BY THE ORALLY ADMINISTERED ASPA-FERNBLOCK TECHNOLOGY.

Zita Álvarez Bobillo*[1], Yolanda Gilaberte Calzada[1], Tamara Gracia Cazaña[1], José Aguilera Arjona[2], Angeles Juarranz[3], Maria Vitale[4], Alia Safiq[4], Ana López[5], Francisca Rius Diaz[6], Salvador Gonzalez[7]

[1] Dermatology Department, Miguel Servet University Hospital, Zaragoza, Spain

[2] Department of Medicine and Dermatology. Faculty of Medicine, University of Málaga, Málaga, Spain., Laboratory of Dermatological Photobiology. Centre for Medical and Health Research, Malaga, Spain

[3] Department of Cell Biology, Autonomous University of Madrid (UAM), Madrid, Spain., madrid, Spain

[4] Medical Department, Cantabria Labs, Spain., madrid, Spain

[5] R&D Cantabria labs, Spain, madrid, Spain

[6] Department of Preventive Medicine and Public Health, University of Malaga, Malaga, Spain, Malaga, Spain

[7] Department of Medicine and Medical Specialties, Alcalá de Henares University, Madrid, Spain, madrid, Spain

Introduction

The harmful effects of ultraviolet (UV) radiation extend beyond DNA damage and include oxidative stress and immune dysregulation. Whilst conventional sunscreens remain essential, their efficacy is limited against long-wave UVA rays and visible/infrared light. Furthermore, recent research links oxidative stress to a reduction in the vitamin D receptor (VDR). Oral photoprotection is gaining recognition as a complementary option. The combination of Aspalathus linearis (AL) extracts and Polypodium leucotomos (PLE) extract has demonstrated antioxidant, DNA-protective and VDR-preserving properties against exposure to UVB radiation. Preclinical and preliminary clinical studies suggest a synergistic effect that could enhance both topical and systemic photoprotection.

Materials and Methods

We designed a prospective, single-centre, interventional clinical trial to evaluate the oral administration of the new combination in healthy volunteers (n = 20, skin phototypes II–III). Participants received two capsules daily (360 mg of AL-PLE) for 7 days. Controlled UVA irradiation is performed to assess the minimal erythemal dose (MED) and immediate pigmentation responses. Clinical endpoints include changes in erythema and hyperpigmentation measured by colorimetry and the investigator's global assessment. Biopsies of irradiated and non-irradiated skin are analysed to detect markers of DNA photodamage (CPD, 8-oxo-dG), VDR expression levels and modulation of the aryl hydrocarbon receptor. Safety, tolerability and adherence are also assessed by both volunteers and dermatologists

Results

In some volunteers, we have observed an increase in vitamin D receptor (VDR) expression following irradiation, which appears to decrease in volunteers who have taken the supplement. In this case, it cannot be ruled out that, in these volunteers, VDR plays a role in DNA repair. We can therefore conclude that oral Aspa-Fernblock normalises VDR levels following exposure to UVA.

Conclusions

To date, the impact of oxidative stress on the reduction of VDR levels has been demonstrated ex vivo, whilst this study would demonstrate its relationship in vivo. The new combination may represent an innovative complement to topical sunscreens by preserving VDR and enhancing systemic photoprotection. This study provides new insights into the systemic photoprotective

potential of the AL-PLE combination.

EA DV CONGRESS
VIENNA
30 SEP - 3 OCT 2026

Abstract N°: 2801

SunDose: A Patented AI-Assistant for Balanced Dermal Vitamin D Synthesis and Precision Photoprotection

Nebahat Demet Akpolat*[1]

[1] Fatih sultan mehmet educational and traning hospital, DEMET AKPOLAT clinic, ıstanbul, Türkiye

Introduction

The "Vitamin D vs. Photoprotection" paradox remains a major clinical challenge. Standard guidelines often fail because they provide "one-size-fits-all" advice that ignores individual skin phenotypes and, crucially, the exposed Body Surface Area (BSA). This lack of precision leads to poor compliance and an inability to balance dermal Vitamin D synthesis with oncological safety. **SunDose** is a patented digital health ecosystem designed to transform these generic recommendations into a data-driven, personal roadmap to minimize the risks of photoaging and skin cancer.

Materials and Methods

The Innovation & Methodology:
SunDose (Patent Nos: **TR 2020 01138** & **PCT/TR2021/050518**) functions as a real-time medical decision support system based on four core pillars:

1. **BSA-Integrated Calculation:** The system accounts for the specific percentage of exposed skin area, dynamically adjusting the UV dose required for synthesis.
2. **Dynamic Dermal Vitamin D Calculation:** It calculates the exact duration for optimal dermal Vitamin D production by cross-referencing skin phototypes with real-time meteorological data (UV Index, altitude, humidity).
3. **Cumulative UV Load Tracking:** Once the personalized synthesis dose is reached, the system shifts to a rigorous tracking mode to monitor cumulative exposure, aiming to **prevent sub-clinical DNA damage and photoaging.**
4. **AI-Supported Photoprotection:** The assistant recommends specific sunscreen formulations (SPF/PPD and texture) tailored to the user's real-time environmental risk and skin history.

Results

By transitioning from reactive advice to a **precise, personal digital assistant**, SunDose empowers patients to manage their UV exposure scientifically. By including BSA and real-time tracking, it provides a proactive strategy to **minimalize the long-term risks of skin cancer (NMSC)** while ensuring that metabolic needs (Dermal Vitamin D) are met safely.

Conclusions

SunDose represents a shift toward **precision dermatology**. Its ability to resolve the Vitamin D paradox through a patented, AI-driven tracking mechanism offers a scalable, scientific, and oncologically safe solution for

the future of teledermatology.

EA DV CONGRESS
VIENNA
30 SEP - 3 OCT 2026

Abstract N°: 2944

Ultraviolet photography as a tool for promoting adherence to photoprotection.

Cristina Miranda Valverde*[1], José María Cervera Peinado[2], Christian Prado Torres[2], José Aguilera Arjona[2], Enrique Herrera Acosta[1], María Victoria de Gálvez Aranda[2]

[1] Dermatology Department, Virgen de la Victoria, University Clinical Hospital, Málaga, Spain
[2] Photobiology Laboratory, Center for Medical and Health Research (CIMES), University of Málaga, Málaga, Spain

Introduction
At the time of writing, there are high levels of sun exposure within the younger population, with this demographic regularly pursuing activities that involve sunlight. This group lacks the knowledge of the detrimental short- and long-term effects of sun exposure. There are different imaging techniques that allow sunlight induced damage be analysed. The aim of this work was to investigate whether visualising the signs of photoaging shown by ultraviolet flash photography modifies the behaviour of young people in relation to sun exposure.

Materials and Methods
A cross-sectional population-based descriptive study was carried out with medical students. This study consisted of questionnaires to assess phototype, sun exposure habits, and risk factors for skin cancer. Subsequently, flash photographs were taken in both light and dark conditions with an ultraviolet filter of the volunteers' faces. The signs of photoaging (heterogeneity in pigmentation, incipient wrinkles, lentigos, ephelides, etc.) that were seen in the photographs were then shown and explained to the volunteers. Afterwards, a second questionnaire was carried out to analyse whether there was a change in behaviour with respect to sun exposure and to assess the self-perception of photoaging in the volunteers. ClearStone UV-DA software was used to collect and analyse the photographs. The answers to the questionnaires were recorded in Excel, using the IBM SPSS statistical program a comparison was made using the chi-square test.

Results
The questionnaire was completed by 279 students with a median age of 21 years (215 females and 64 males). This distribution of sex was due to the greater presence of women enrolled in the Faculty of Medicine. Phototypes III (40.5%) and IV (33.3%) predominated. Ultraviolet-filtered photographs were obtained from 128 of these students. 147 students (52.7%) had already studied the subject of Dermatology and in this sample there was evidence of a solid knowledge of the risks and benefits of sun exposure. It was striking that in general the population in the sample, with a high cultural level and knowledge in the area of health, maintained habits of excessive sun exposure. 76.7% of the participants acknowledged having actively sought a tan during the last year and 65.2% had spent more than 30 days a year in the sun, either at the beach or pool. The high rate of sunburn should be highlighted (79.9% had burned in the last year once or twice and 27.6% had burned between 3 and 10 times). In terms of photoprotection measures, the use of sunscreen cream stood out in 79% of the students, above physical photoprotection measures such as the use of an umbrella (48%), sunglasses (40%) or a hat (13%). The visualisation of photodamage in images by ultraviolet photography had a clear impact on the population studied. 83.6% of the students changed their perception of photoaging and 77.3% changed their behaviour in photoprotection. Below are some items in which statistically significant differences were observed after the intervention: "sunbathing is good for me" (p=0.009), "I don't like to use sunscreen" (p=0.02); "I use sunscreen" (p=0.008); "I avoid the noon hours (12:00 p.m. - 4:00 p.m.)" (p=0.01).

Conclusions

Ultraviolet photography and image analysis allow subclinical signs of photoaging to be assessed. The visualisation of this photodamage has an impact on the young population in terms of improvement in sun exposure habits and photoprotection measures and its impact can be measured through validated questionnaires. At the clinical level, it translates into the possibility of acting with primary or secondary prevention in the young population with adapted photoprotection measures.

EADV CONGRESS
VIENNA
30 SEP - 3 OCT 2026

Abstract N°: 2957

Sunscreens UV-Filters Decreased Skin Penetration When Associated with Topical Non-Occlusive Polymers

Marius-Anton Ionescu*[1], Luc Lefeuvre[2], Anne Dubuisson[3]

[1] Dermatology Department University Hospital Saint Louis, Paris, France
[2] R&D Uriage Laboratories, Neuilly-sur-Seine, France
[3] R&D Uriage, Neuilly-sur-Seine, France

Introduction

An association of non-occlusive copolymers of vinylpyrrolidone (VP) and phosphorylcholine (PC) included in an O/W emulsion showed reinforcement of the skin barrier in several clinical trials [1,2]. Sunscreens formulated with ultraviolet B (UVB) and ultraviolet A (UVA) radiation filters contain small molecules with a risk of skin penetration [3].

Our objective was to study the skin penetration of UV filters in an *ex vivo* study on human skin maintained under survival conditions.

Materials and Methods

An O/W emulsion (EmA) containing the UV filters butyl methoxy dibenzoylmethane (BMDBM) and ethylhexyl triazone (EHT) without the VP and PC polymers was considered as the control. The VP and PC polymers were included in the EmB emulsion, an O/W formulation based on the same UV filters BMDBM and EHT. EmA or EmB were applied to the surface of human normal skin explants *ex vivo* (skin from the same donor after an abdominoplasty). EmA or EmB at 250 µl (equivalent to 142 mg/cm2), were applied on skin surface. The total contact time was 24 hours. The UV-filters were dosed: a. in the stratum corneum (SC) by skin stripping; b. in complete epidermis + dermis; c. in the receptor fluid. After extraction, the UV-filters were measured in each sample by chromatography (HPLC method).

Results

EmB showed significantly a lower penetration of BMDBM and EHT in the epidermis and dermis compared to EmA. The distribution of the filters in the skin, expressed as a percentage of the product that penetrated was: a. in the stripping of the *stratum corneum*, 27% BMDBM and respectively 24% EHT in EmA versus 26% BMDBM and respectively 21% EHT in EmB; b. epidermis + dermis 31.9% for BMDBM, 30.4% for EHT for EmA versus 17.9% for BMDBM and respectively 8.9% for EHT in EmA.

Conclusions

In a study on *ex vivo* human skin, the EmB (O/W emulsion containing the polymers vinylpyrrolidone VP and phosphorylcholine PC), combined with the UV filters butyl methoxydibenzoylmethane and ethylhexyl triazone, showed less significant skin penetration of the UV-filters compared to the skin penetration of the same UV-filters contained in the EmA (O/W) emulsion without polymers VP and PC.

References

1.Ionescu MA, Lati E, Gasser P, Matta AM, Lefeuvre L, Gougerot A. Barrier skin-protection against irritants and allergens by topical non-occlusive polymers. American Academy of Dermatology Annual Meeting 2006: P21.
2. Matta AM, Cleenewerck MB, Frimat P, Chapalain V, Gougerot A. Evaluation of topical non-occlusive polymers in a series of 71 cases of irritant contact dermatitis in building workers. Arch Mal Prof Environ 2010;71:818-835.
3 Matta MK, Zusterzeel R, Pilli NG, et al. Effect of Sunscreen Application Under Maximal Use Conditions on Plasma Concentration of Sunscreen Active Ingredients. A Randomized Clinical Trial. JAMA 2019;321(21):2082-2091.

EADV CONGRESS
VIENNA
30 SEP - 3 OCT 2026

Abstract N°: 3057

Persistent Interferon Signaling Impairs UV-induced DNA Damage Repair in AK Keratinocytes

Dennis Roggenkamp*[1], Hermann Jan Hütte[1], Leonardo Elsbroek[1, 2], Katja Reuschlein[1], Syrus Karsai[3, 4], Anna Geueke[1], Mareike von Petersdorff-Campen[3], Martina Bresch[3], Volker Steinkraus[3], Peter Weisenseel[3], Peter Wolf[1], Marc Winnefeld[1], Frank Lyko[2], Ludger Kolbe[1]

[1] Beiersdorf AG, Hamburg, Germany
[2] German Cancer Research Center, Heidelberg, Germany
[3] Dermatologikum Hamburg GmbH, Hamburg, Germany
[4] University Medical Center Hamburg-Eppendorf, Hamburg, Germany

Introduction
Actinic keratosis (AK) is a common UV-induced skin lesion with the potential to develop into cutaneous squamous cell carcinoma. While UV radiation is known as one of the key drivers of field cancerization and immunosuppression in human skin, the intrinsic responses of keratinocytes to triggers of chronic or low-dose UV exposure are less understood. By establishing a patient derived in vitro model from AK lesions and comparing it against keratinocytes from healthy but sun-exposed origin, we investigated the AK-specific intracellular stress responses under repeated low-dose UV irradiation conditions.

Materials and Methods
Primary keratinocytes were isolated from biopsies obtained from AK lesions and healthy sun-exposed skin regions. Cultivated keratinocytes were in vitro exposed to low single, repetitive or non-UV irradiation. Morphological and molecular profiles were determined by cyclobutene pyrimidine dimer quantification and bulk RNA sequencing. Involvement of IFN pathway components was tested through immunohistological stainings of actinic, perilesional, and healthy facial skin tissue samples.

Results
Actinic keratinocytes are accumulating more UV-induced DNA damage and show a slower repair capacity than healthy keratinocytes despite transcriptomic upregulation of DNA repair and unfolded protein response pathways. Furthermore, transcriptomic profiling revealed constitutive and UV-enhanced IFN signaling in AK keratinocytes, including upregulation of innate DNA sensing and ISGylation genes. Enrichment analysis of independent public datasets from AK lesions identified chronic IFN pathway activation as a conserved feature in AK. Immunohistological stainings of IFN signaling associated markers ISG15 and UBE2L2 in actinic skin tissue confirmed IFN pathway activation in vivo. Exacerbation of UV-induced cyclobutene pyrimidine dimer formation was induced under IFNα stimulation in AK and healthy keratinocytes, indicating a link between DNA damage accumulation and chronic IFN signaling.

Conclusions
AK derived keratinocytes are more vulnerable to UV irradiation caused cellular damages than healthy keratinocytes. Due to persistent IFN pathway activation, AK keratinocytes are more sensitized to UV-induced DNA damage accumulation. This highlights the role of chronic IFN signaling in AK as an early driver of photocarcinogenesis.

EADV CONGRESS
VIENNA
30 SEP - 3 OCT 2026

Abstract N°: 3082

Unmasking Hidden Photosensitivity in Multiple Sclerosis: The Vital Role of UVA and NB-UVB Phototesting

Ceylan Avcı[1], Berke Atesli*[1], Alperen Ozmen[1], Sevgi Akarsu[1], Turna Aydoğan[1], Serkan Özakbaş[2]

[1] Dokuz Eylul University Hospital, Department of Dermatology and Venereology, Izmir, Türkiye
[2] Medical Point Izmir Hospital, Department of Neurology, Izmir, Türkiye

Introduction
Multiple sclerosis (MS) is a chronic autoimmune demyelinating disease with well-established associations with ultraviolet (UV) radiation. Although Fitzpatrick skin typing is widely used to estimate UV sensitivity, it lacks the precision to detect subtle individual photobiological responses. Phototesting, which provides a more objective, dose-dependent assessment of UV reactivity, has never been investigated in MS. Our goal was to evaluate photosensitivity in MS patients using narrowband UVB (NB-UVB) and UVA phototesting alongside sun protection behaviors and to investigate associations between Fitzpatrick skin type, minimal erythema dose (MED), and lifetime sunburn history.

Materials and Methods
Thirty-four MS patients were enrolled. To eliminate confounding pharmacological effects, phototesting was performed strictly during immunosuppression-free periods and also on patients with no exposure to any photosensitizing medical therapy. Fitzpatrick skin type, lifetime sunburn history, and sun exposure habits (occupational environment, peak-hour exposure) were systematically recorded. NB-UVB and UVA phototesting were conducted using standard protocols. For NB-UVB, the MED was determined 24 hours post-exposure. For UVA, provocative doses (15 J/cm2 and 20J/cm2) were applied to assess abnormal reactivity. Spearman's rank-order correlation was used to assess relationships between clinical and photobiological variables.

Results
The cohort (25 female, 9 male; mean age 36.7±9.5 years) showed a Fitzpatrick distribution of: Type I 2.9%, Type II 32.4%, Type III 50.0%, and Type IV 14.7%. Sun exposure analysis revealed that 55.9% of patients worked primarily indoors, and 64.7% reported moderate exposure during peak hours. A significant 70.6% of patients reported at least one severe lifetime sunburn, with 14.7% experiencing more than 10 incidents.

NB-UVB MED was determined in 19 patients (median 390 mJ/cm^2, range 200–770). **Notably, UVA phototesting demonstrated positive reactions in 8 patients (23.5%). Within this group, 3 patients exhibited a remarkable clinical presentation of sharply demarcated, intense erythema** at 20 J/cm^2, suggesting borderline photosensitivity. Fitzpatrick skin type correlated significantly with NB-UVB MED ($r_s = 0.635$, $p<0.001$) and inversely with lifetime sunburn history ($r_s = -0.501$, $p = 0.003$)confirming the biological validity of the measurements.

Conclusions
Phototesting reveals distinct photosensitivity patterns in MS patients that are not fully captured by subjective Fitzpatrick skin typing. The detection of abnormal UVA responses in nearly 25% of patients—even in the absence of immunosuppressive therapy—suggests an intrinsic alteration in UV reactivity potentially linked to the

underlying disease pathophysiology. The observation of sharply demarcated erythema emphasizes the need for objective photodermatological evaluation. These findings warrant further prospective studies with matched healthy control groups to clarify the clinical implications for MS management and sun counseling.

EA DV CONGRESS
VIENNA
30 SEP - 3 OCT 2026

Abstract N°: 3147

Accelerated indoor daylight photodynamic therapy for actinic keratosis using broad-spectrum RGB LED illumination: a proof-of-concept study

Daan Der Kinderen*[1], Oscar Swinkels[1]

[1] Dermex, Wychen, Netherlands

Introduction

Conventional LED photodynamic therapy (PDT) for actinic keratosis (AK) is highly effective but frequently associated with severe treatment-related pain, particularly during treatment of large scalp or facial fields. In contrast, daylight-PDT demonstrates markedly improved tolerability while maintaining clinical efficacy for superficial AK, morbus Bowen and basal cell carcinoma. We hypothesized that the favorable tolerability profile of daylight-PDT is primarily related to continuous low-fluence broad-spectrum activation of protoporphyrin IX (PpIX) rather than to natural daylight itself. Broad-spectrum RGB LED studio lamps may therefore provide a standardized indoor alternative to daylight-PDT while avoiding the limitations of weather-dependent outdoor treatment.

Materials and Methods

Commercially available broad-spectrum RGB studio LED lamps designed for photographic daylight illumination were evaluated and a system was selected based on spectral composition, overlap with major PpIX absorption peaks, field homogeneity, light output, low heat production, and practical suitability for large-field indoor PDT. Patients with widespread and extensive actinic keratoses of the face or scalp were included. Patients were treated using topical 5-aminolevulinic acid (5-ALA) formulated in a cetomacrogol ointment base. Pretreatment consisted of degreasing with petroleum ether followed by gentle curettage of hyperkeratotic lesions. After a short incubation period of approximately 10-20 minutes, lesions were illuminated using broad-spectrum RGB LED illumination at a lamp distance of 50 cm for 30-60 minutes. Multi-angle and multi-light illumination setups were additionally evaluated. Clinical tolerability, clinical evolution, and photographic documentation were evaluated longitudinally.



Accelerated indoor daylight PDT using multi-angle RGB LED illumination for actinic keratosis.

Results

Treatment was remarkably well tolerated. Patients reported absent of pain during illumination, including during treatment of extensive scalp and facial fields. Increased light intensity achieved by multi-angle and multi-light illumination setups, as well as prolongation of illumination time, did not significantly alter clinical response or patient discomfort. In contrast to conventional narrow-band red LED-PDT, no treatment-limiting pain reactions occurred. Delayed erythema and crusting developed during the days following treatment, consistent with clinically active PDT. Initial clinical improvement of AK lesions and field cancerization was observed despite the markedly improved tolerability profile. The absence of increased discomfort despite increased fluence suggests that intracellular PpIX production kinetics rather than incident light intensity may become the dominant rate-limiting factor under daylight-like low-fluence illumination conditions.



Clinical evolution before, during and after accelerated indoor daylight PDT (15 min incubation, 45 min illumination)

Conclusions

Broad-spectrum RGB LED illumination may provide a standardized indoor alternative to daylight-PDT while maintaining the favorable low-pain profile associated with daylight-based treatment. Accelerated indoor daylight-like PDT using short-incubation topical 5-ALA appears feasible, well tolerated, and clinically active for field treatment of AK. The use of inexpensive commercially available RGB studio lighting systems may facilitate standardized indoor daylight-PDT independent of climate or weather conditions. Controlled prospective studies are warranted to optimize treatment parameters and compare efficacy with conventional PDT protocols.

EADV CONGRESS
VIENNA
30 SEP - 3 OCT 2026

Abstract N°: 3265

Attenuation of HEV blue light-induced fibroblast lipofuscin accumulation via a Triasorb-based formulation

Gautier Doat*[1], Maurício da Silva Baptista[2], Patrick Bogdanowicz[3], Carlos MV Palomino[2], Katherine Tsantarlis[2], Carine Jacques[3], Camille Boudet[1], Hélène Duplan[3], Sandrine Bessou-Touya[3]

[1] Medical Department, Laboratoires Dermatologiques Eau Thermale AVENE, Lavaur, France

[2] Departamento de Bioquimica, Universidade de Sao Paulo, Sao Paulo, Brazil

[3] R&D Department, Pierre Fabre Dermo-Cosmetics & Personal Care, Toulouse, France

Introduction

Lipofuscin is a fluorescent pigment formed from oxidized proteins and lipids that accumulates during both natural and accelerated cellular aging. Keratinocytes exposed to UVA and High Energy Visible Light (HEVL) undergo significant lysosomal damage and accumulate lipofuscin. This study explores whether fibroblasts exposed to UVA and HEVL also experience lipofuscin buildup and assesses the effectiveness of a TriAsorB-containing formulation (F1) in preventing this accumulation in keratinocytes and fibroblasts.

Materials and Methods

HaCaT keratinocytes and human fibroblasts were cultured and then irradiated (UVA or visible light at 410 and 450 nm), with or without application of a sunscreen containing TriAsorb or a placebo. Lipofuscin accumulation, cell viability, and ROS production were measured 48 h after irradiation using specific staining, autofluorescence, the MTT assay, and the CM-H_2DCFDA probe. These parameters were analyzed by microscopy and ImageJ or by spectrofluorimetry.

Results

When fibroblasts are exposed to UVA (356nm; 15 J/cm²), violet (410nm; 30 J/cm²), or blue (450nm; 110 J/cm²) light, there is a notable increase in lipofuscin accumulation. This is demonstrated by integrating the intracellular fluorescent signals of lipofuscin pigments (lesc=488nm, lemi>522nm) and using Sudan-Black staining. The quantum efficiencies of lipofuscin accumulation in skin fibroblasts exposed to UVA, violet, and blue photons, considering lipofuscin quantification, photon energies, sun irradiances, and skin penetrations, show a ratio of 1.0:1.1:0.6. Therefore, anti-aging strategies related to sun exposure should provide balanced protection across the UVA and visible light ranges.

Conclusions

We compared lipofuscin accumulation in unprotected cells to those shielded by F1 or placebo formulations. Both exposed and placebo groups exhibited similar levels of lipofuscin buildup. The F1 formulation effectively protected keratinocytes and fibroblasts from lipofuscin accumulation, with protection efficiencies ranging from 80% to 95%. TriAsorB provides broad-spectrum protection extending into the HEV-Blue light range, significantly preventing lipofuscin buildup and efficiently reducing sun-induced photoaging.

EA DV CONGRESS
VIENNA
30 SEP - 3 OCT 2026

Abstract N°: 3352

Comparative Efficacy of Photodynamic Therapy Versus Cryotherapy for Actinic Keratosis: A Systematic Review and Meta-Analysis of Randomized Controlled Trials.

Saleh Aldraibi[1], Maya Alharbi*[2], Kholoud Alzubaidi[3], Omar Turkistani[1], Abdulmalik Bin Kassim[4], Dhai Almutairi[5], Majid Alhammadi[6], Jumanah Makhtoum[7], Fadi Alghamdi[8]

[1] King Abdulaziz Medical City, Jeddah, Saudi Arabia
[2] King Abdulaziz University Hospital, Jeddah, Saudi Arabia
[3] Umm Al-Qura University, Makkah, Saudi Arabia
[4] Al Imam Muhammad Bin Saud Islamic University, Riyadh, Saudi Arabia
[5] King Khaled General Hospital, Hafar Al Batin, Saudi Arabia
[6] Sheikh Khalifa Medical City, Abu Dhabi, United Arab Emirates
[7] King Abdulaziz University, Jeddah, Saudi Arabia
[8] King Fahad Armed Forces Hospital, Jeddah, Saudi Arabia

Introduction

Background

Photodynamic therapy and cryotherapy are treatment options for actinic keratosis; however, their efficacy and safety remain debated.

Aims

To perform a high-quality systematic review and meta-analysis exploring the efficacy and safety of photodynamic therapy and cryotherapy in actinic keratosis.

Materials and Methods

A systematic search was performed applying the Preferred Reporting Items for Systematic Reviews and Meta-Analyses guidelines. We searched PubMed, Web of Science, Cochrane, Science Direct, Ovid, EBSCO, Wiley, and Google Scholar for randomized controlled trials.

Results

A total of seven studies with 1233 patients were identified. PDT and cryotherapy showed similar success in clearing lesions (RR, 1.02; 95% CI, 0.92-1.13; p = 0.74). While both treatments performed comparably on the head and face (RR, 1.10; 95% CI, 0.94-1.28; p = 0.24), data from one trial suggested cryotherapy might be more effective for lesions on the arms and legs (RR, 0.88; 95% CI, 0.82-0.94; p < 0.05). However, more research is needed to confirm this finding. Cosmetic outcomes were significantly better for PDT (74.62% vs. 49.11%: RR, 1.52; 95% CI, 1.4-1.65; p < 0.00001) than cryotherapy. Similarly, PDT was superior to cryotherapy in patient satisfaction though the overall difference was not statistically significant (RR, 1.43; 95% CI, 0.91-2.25; p = 0.12). PDT was associated

with a significantly higher risk of burning sensations and pain (RR, 1.95; 95% CI, 1.27-3.02; p = 0.002), whereas cryotherapy more frequently led to vesicles and blisters.

Study	Treatment	Total AEs (any event) (*n*/*N*)	Differentiating AE 1: burning/pain (*n*/*N*)	Differentiating AE 2: vesicles/blisters (*n*/*N*)
Szeimies et al. 2002 [20]	PDT (*N* = 102)	43/102 (42.2%)	43/102 (42.2%)	NA
	Cryo (*N* = 100)	22/100 (22.0%)	22/100 (22.0%)	NA
Freeman et al. 2003 [21]	PDT (*N* = 88)	64/88 (72.7%)	NA	NA
	Cryo (*N* = 89)	31/89 (34.8%)	NA	NA
Morton et al. 2006 [22]	PDT (*N* = 119)	74/119 (62.2%)	High incidence (Narrative)	NA
	Cryo (*N* = 119)	86/119 (72.3%)	Low incidence (Narrative)	NA
Kaufmann et al. 2008 [19]	PDT (*N* = 121)	52/121 (43.0%)	High incidence (Narrative)	NA
	Cryo (*N* = 121)	75/121 (62.0%)	Low incidence (Narrative)	NA
Hauschild et al. 2009 [23.	PDT (*N* = 148)	147/148 (99.3%)	NA	47/148 (31.8%)
	Cryo (*N* = 149)	146/149 (98.0%)	NA	86/149 (57.7%)

Note: Reported in this specific comparative adverse event analysis. Percentages in bold indicate data points used for quantitative risk ratio analysis.

Abbreviation: NA, not available.

Conclusions

Lesion clearance may depend on location. It is comparable for head and face lesions, while data from one trial suggests cryotherapy may be better for extremity lesions. PDT is associated with a higher occurrence of pain/burning, while cryotherapy leads to more vesicles/blisters. Future research should focus on standardized protocols, including blinded post-treatment assessments to improve reliability and minimize bias.

Keywords: actinic keratosis; aminolevulinic acid hydrochloride; cryotherapy; methyl aminolevulinate; photodynamic therapy.

EADV Congress 2026, VIENNA
30 SEPTEMBER - 03 OCTOBER 2026
POWERED BY M-ANAGE.COM

EADV CONGRESS
VIENNA
30 SEP - 3 OCT 2026

Abstract N°: 3452

LED Therapy as an Alternative Treatment for Herpes Labialis in a Hemodialysis Patient with Valacyclovir-Induced Neurotoxicity: A Case Report

Afafe JEI*[1, 2], fatimazahrae benhayoune[1, 2], Hanane Rachadi[1, 2], Soumiya Chiheb[1, 2]

[1] Ibn Rochd University Center, casablanca, Morocco

[2] Dermatology departement, Ibn Rochd University Center, casablanca, Morocco

Introduction

Herpes labialis is a common viral infection usually managed with systemic antiviral therapy. However, treatment may become challenging in immunodepressed patients with end-stage renal disease because of the increased risk of drug accumulation and neurotoxicity associated with antivirals such as valacyclovir. Photobiomodulation using LED therapy has emerged as a promising non-invasive therapeutic option with analgesic, anti-inflammatory, and tissue-healing properties. We report a case highlighting the successful use of LED therapy in a hemodialysis patient presenting with herpes labialis after suspected valacyclovir-induced neurotoxicity.

Case Presentation

Une patiente de 45 ans, ayant comme antécédent une insuffisance rénale chronique A 45-year-old female patient, with a history of end-stage renal disease requiring hemodialysis, presented with painful lip lesions related to herpes labialis. She was prescribed valacyclovir 1g/day and topical ciclovir. After the first dose, the patient developed confusion, for which she underwent a brain MRI and blood tests, which were unremarkable. The antiviral was suspected and discontinued; the patient was referred to our center for further evaluation. Examination revealed vesicular lesions arranged in clusters on erythematous skin located on the upper and lower lips, associated with significant burning pain. The patient was started on LED therapy (herpes protocol) with local care, including daily washing and a soothing cream. A marked reduction in pain and the disappearance of the vesicles occurred after the third session.

Conclusion

LED therapy may represent a valuable therapeutic alternative for herpes labialis in patients with renal insufficiency who cannot tolerate systemic antiviral treatment. In our patient, it provided rapid pain relief and complete regression of vesicular lesions within a few sessions. This observation supports the potential role of photobiomodulation as a safe adjunctive or alternative approach in complex clinical settings.

EA DV CONGRESS
VIENNA
30 SEP - 3 OCT 2026

Abstract N°: 3640

UVB phototherapy: an effective therapeutic option in lichen planus pigmentosus

Billal Alibakir[1], YASMINA ABI AYAD[1], Zohra El Osmani[1], Serradj Amina*[1]

[1] Ehu oran, Oran, Algeria

Introduction

Lichen planus pigmentosus (LPP) is a rare variant of lichen planus characterized by brownish macules on photo-exposed areas, more frequently affecting darker phototypes [1]. Its management remains challenging and not standardized, as conventional therapeutic options (corticosteroids, retinoids, immunosuppressants) show limited efficacy [2].
We report a case of lichen planus pigmentosus.

Case Presentation

Mrs. M.F., a 52-year-old woman with a history of dyslipidemia, presented with perioral and chin involvement of LPP. Oral isotretinoin (Curacné®) was initially introduced but was discontinued early due to hepatic cytolysis. Tranexamic acid (250 mg/day for 4 months) was then administered without clinical improvement. The patient subsequently underwent narrowband UVB phototherapy, twice weekly. After 30 sessions, a marked regression of pigmented macules was observed.
LPP remains a challenging condition to manage due to its chronic course, cosmetic impact, and the absence of standardized treatment guidelines [1,2]. Oral retinoids, although used in generalized lichen planus, are limited by their safety profile [2]. In this case, isotretinoin had to be discontinued early.
Tranexamic acid, reported as effective in some series, has shown variable outcomes, with up to 56% partial improvement at 6 months [3]. However, our patient did not respond to this treatment.
Narrowband UVB (NB-UVB) phototherapy represents an effective and better-tolerated alternative. In cutaneous lichen planus, it has demonstrated a major response rate of 71%, with 74% of patients achieving prolonged remission [2]. Its efficacy has been considered comparable to PUVA therapy (86% vs 90.5% success rate) but with a significantly better safety profile (0% vs 26% adverse effects) [4].
Our case supports the usefulness of NB-UVB in refractory pigmentosus lichen planus, with rapid improvement observed as early as the 30th session.



Facial lichen planus pigmentosus

Conclusion

UVB phototherapy appears to be an effective and well-tolerated therapeutic option for lichen planus pigmentosus, particularly in cases resistant or intolerant to systemic treatments [2,4]. Further studies are needed to better define its place in the therapeutic arsenal [1].



After 30 sessions of UVB phototherapy

EADV Congress 2026, VIENNA
30 SEPTEMBER - 03 OCTOBER 2026
POWERED BY M-ANAGE.COM

EA DV CONGRESS
VIENNA
30 SEP - 3 OCT 2026

Abstract N°: 3678

Common European Botanical Triggers of Phytophotodermatitis: A Practical Visual Guide for Clinicians and Patients

Dhanya Kuladeva[1], Katherine Farquhar*[1]

[1] NHS Greater Glasgow and Clyde, Glasgow, United Kingdom

Introduction

Phytophotodermatitis is a phototoxic reaction resulting from contact with photosensitising plant compounds followed by ultraviolet exposure. Despite its characteristic clinical features, it remains under-recognised, often due to incomplete exposure histories or failure to link plant contact with cutaneous findings. Occupational exposure is an important and frequently overlooked contributor, particularly in hospitality (e.g. bartending, food preparation) and agricultural settings, where repeated contact with photosensitising plants is common. This is particularly relevant in younger working populations and seasonal workers. Across Europe, increasing travel, migration, seasonal employment, and cross-regional clinical practice may further increase exposure to unfamiliar botanical triggers and contribute to diagnostic uncertainty. Patients are also often unaware of causative plants, limiting their ability to prevent recurrence.

We aimed to develop a practical, visually oriented educational guide highlighting common botanical triggers and occupational exposure scenarios relevant to European clinical practice to support clinician recognition and patient education.

Materials and Methods

A targeted narrative review of commonly reported phytophotodermatitis triggers encountered in European domestic, occupational, and environmental settings was undertaken. Plant selection was based on recognisable exposure patterns, frequency within published case reports and reviews, and relevance to real-world occupational presentations. Six key botanical triggers were included: citrus fruits (particularly lime), celery, parsley, parsnip, fig, and giant hogweed.

A practical visual guide was subsequently developed focusing on these commonly encountered exposures. Content was structured around typical exposure scenarios, including bartending “margarita dermatitis”, kitchen preparation, agricultural handling, and outdoor work. A photo-based format linked representative plants with real-world contexts, providing both a clinician-facing diagnostic aid and a concise, patient-accessible resource for post-consultation use. Readability, accessibility, and patient understanding were considered throughout resource development, with planned review through the NHS Greater Glasgow & Clyde Clear to All patient information advisory process to optimise patient comprehension and usability.

Results

A limited number of recurrent botanical exposures account for a substantial proportion of recognisable phytophotodermatitis presentations in European practice, many of which occur in occupational settings. Typical features include sharply demarcated erythema, linear or splash-like patterns, occasional blistering, and subsequent hyperpigmentation, often affecting exposed areas such as hands and forearms. Common misdiagnoses include allergic contact dermatitis, chemical burns, cellulitis, bruising, and non-accidental injury.

The visual guide facilitates pattern recognition, prompts targeted occupational and environmental history-taking, and supports practical counselling on exposure avoidance, including workplace-specific advice and sun protection strategies. Its patient-facing format enables continued education beyond the clinical encounter and may reduce recurrent exposure.



Conclusions

Phytophotodermatitis is a distinctive yet frequently overlooked diagnosis across dermatology and acute care settings, particularly in occupational contexts. A concise visual guide highlighting common European botanical triggers and workplace exposure scenarios may enhance diagnostic accuracy, reduce

misclassification, and strengthen both clinician and patient awareness. Its dual clinician–patient focus and emphasis on prevention make it a practical tool for improving recognition and reducing recurrence.

EADV CONGRESS
VIENNA
30 SEP - 3 OCT 2026

Abstract N°: 3708

The Associations of Photoprotection with All-Cause Mortality

Kashika Bharol*[1], Hafsa Hassan[2], Harleen Multani[3], Kiratpreet Sraa[4], Kelly Frasier[5], Alina Bridges[5]

[1] University of Massachusetts T.H. Chan School of Medicine, Worcester, MA, United States
[2] Northeast Ohio Medical University, Rootstown, OH, United States
[3] Meharry Medical College School of Medicine, Nashville, TN, United States
[4] Arizona College of Osteopathic Medicine, Glendale, AZ, United States
[5] Northwell, New Hyde Park, NY, United States

Introduction
Protection against UV light from the sun, such as through sunscreen, protective clothing, and shade, are evidence-based methods of preventing dermatologic disease and cancer. However, the sun also provides essential functions including production of vitamin D, releasing nitric oxide stores from the skin and supporting circadian rhythm. Tension between photoprotection and the physiologic benefits of sunlight has contributed to ongoing discourse regarding the effects of sun protection on mortality.

Materials and Methods
A narrative review was conducted via PubMed and Scopus. The search query included combinations of terms to locate studies either supporting or challenging the merits of photoprotection.

Results
Regular sunscreen use in a randomized skin cancer prevention trial was not associated with increased all-cause or cause-specific mortality over 21 years of follow-up. In observational cohorts, greater ultraviolet exposure was associated with lower all-cause, cardiovascular, and cancer mortality, associations nonlinear and inconsistent across studies. Overall, evidence did not show a mortality harm from photo-protection, and the relationship between sun exposure and mortality remains limited and insufficient for causal conclusions.

Conclusions
Currently, no evidence exists to support the belief that sun protection increases mortality. Some studies have suggested potential systemic benefits of ultraviolet light exposure, but the available data remain observational and are limited by confounding factors and inconsistent associations. The protective role of photoprotection in skin cancer and photoaging is well established. The best-supported approach to promote both dermatologic and overall health continues to follow evidence-based photoprotection practices while maintaining balanced sun exposure.

EADV CONGRESS
VIENNA
30 SEP - 3 OCT 2026

Abstract N°: 3922

MOF-Enabled Delivery of Hydroxysafflor Yellow A Attenuates Cutaneous Photoaging by Restoring Fibroblast Mitochondrial Homeostasis

Jiaqi Xu*[1], Yunsheng Xu[2], Mukai Chen[1]

[1] The First Affiliated Hospital of Sun Yat-Sen University, Guangzhou, Guangdong, China
[2] The Seventh Affiliated Hospital of Sun Yat-Sen University, Shenzhen□Guangdong, China

Introduction
Topical treatment of photoaging remains challenging because currently available options are often limited by tolerability, inconsistent efficacy, and poor durability of response. Hydroxysafflor yellow A (HSYA) has demonstrated antioxidant and cytoprotective activity, but its topical use is constrained by limited local retention and inefficient cutaneous delivery. We therefore developed a metal-organic framework (MOF)-based HSYA formulation to examine whether delivery optimization could enhance the anti-photoaging activity of HSYA beyond that of the free compound and to investigate the underlying mechanism, with particular attention to fibroblast mitochondrial homeostasis.

Materials and Methods
HSYA-loaded MOF nanoparticles (MOF@HSYA) were prepared by encapsulation and characterized physicochemically. Their therapeutic effects were assessed alongside free HSYA in a progressively irradiated UVA/UVB mouse model of photoaging and in human dermal fibroblasts exposed to repeated low-dose UVB. Photoaging-associated phenotypes, skin functional changes, histopathological injury, oxidative stress, cellular senescence, extracellular matrix disruption, and mitochondrial damage were systematically evaluated. Transcriptomic analysis combined with functional validation was performed to identify the main pathway involved.

Results
MOF@HSYA showed stable drug loading and satisfactory physicochemical stability. In vivo, MOF@HSYA alleviated wrinkle formation, skin roughness, loss of hydration and elasticity, epidermal thickening, collagen disorganization, and oxidative stress, with consistently greater benefit than free HSYA. In UVB-exposed fibroblasts, MOF@HSYA reduced senescence-associated β-galactosidase positivity, improved cell viability, downregulated p21 and MMP1, restored COL1A1 expression, decreased intracellular and mitochondrial reactive oxygen species, and mitigated mitochondrial membrane depolarization and ultrastructural injury. Integrated transcriptomic and functional analyses further showed that these protective effects were associated with suppression of the HRAS–ERK–AP-1 pathway and restoration of MRM2-linked mitochondrial homeostasis.

Conclusions
MOF-enabled delivery substantially improved the anti-photoaging efficacy of HSYA and provided superior protection to the free compound in both in vivo and in vitro settings. By connecting therapeutic benefit to recovery of fibroblast mitochondrial homeostasis, this study identifies a mechanistically informative and potentially actionable pathway in cutaneous photoaging and supports MOF@HSYA as a candidate translational strategy for photodamage.

EA DV CONGRESS
VIENNA
30 SEP - 3 OCT 2026

Abstract N°: 4250

Comparative Evaluation of the Antifungal Effect of Blue Light and Luliconazole in an Animal Model of Dermatophytosis

Esin Diremsizoglu*[1], Nilgün Sayman[1], Sema Aşkın Keçeli[2], Büşra Özbek[3], Evren Odyakmaz Demirsoy[1]

[1] Kocaeli University Faculty of Medicine, Department of Dermatology, Kocaeli, Türkiye

[2] Kocaeli Univesity Faculty of Medicine, Department of Microbiology, Kocaeli, Türkiye

[3] Kocaeli University Faculty of Medicine, Department of Pathology, Kocaeli, Türkiye

Introduction

Dermatophytosis remains among the most common superficial fungal infections, while increasing antifungal resistance and limitations of systemic therapies support the search for adjunctive non-pharmacological approaches. Antimicrobial blue light has demonstrated fungicidal activity, especially against *Candida* species in experimental models. However, evidence in dermatophyte infections is limited and, to our knowledge, no in vivo study in a dermatophytosis model has been published. This study evaluated the in vitro and in vivo antifungal efficacy of 460-nm blue light against *Trichophyton mentagrophytes* and compared blue light, topical luliconazole, and their combination in a tinea corporis model.

Materials and Methods

A clinical *T. mentagrophytes* isolate was used. In vitro, Sabouraud dextrose agar cultures were exposed to single-session 460-nm blue light doses of 20, 30, 40, 60, 80, or 120 J/cm^2. The device delivered a fixed output of 40 J/cm^2 per hour, and different doses were obtained by modifying exposure duration. Colony-forming units (CFU) were counted after 7 days and inhibition rates were calculated versus untreated controls. In vivo, 32 male BALB/c mice with experimentally induced tinea corporis were randomized into four groups (n=8 each): untreated infected control, blue light (BL), topical luliconazole (TL), and combined blue light plus topical luliconazole (BLTL). Treatments were initiated on day 8 after infection. Since the highest in vitro efficacy was obtained at 120 J/cm^2, the cumulative in vivo BL dose was set at 120 J/cm^2; considering animal welfare and session duration, this dose was fractionated as 30 J/cm^2 per session on days 8, 10, 12, and 14. TL was applied once daily for 7 days. Clinical scores, including erythema, scaling, and erosion/ulceration, were recorded on days 8 and 15 by a blinded assessor. On day 15, skin fungal burden was expressed as CFU/g, and histopathological scores were assessed based on epidermal changes, inflammatory infiltrate and PAS-positive fungal elements.

Results

In vitro, 460-nm blue light produced dose-dependent inhibition of *T. mentagrophytes* growth. Mean CFU decreased from 68.63±2.62 in controls to 1.13±1.13 after 120 J/cm^2, corresponding to 98.4% inhibition; all blue-light doses differed significantly from control ($p<0.001$). In vivo, baseline day-8 clinical scores were comparable between groups (total score $p=0.864$). On day 15, total clinical scores differed significantly across groups ($p<0.001$), with mean scores of 6.75±1.28 in controls, 4.00±1.20 in BL, 3.00±0.76 in TL, and 2.00±1.07 in BLTL. Change in total clinical score also differed significantly ($p<0.001$); all treatment groups improved more than controls, although differences between treatment groups were not statistically significant. Fungal burden differed significantly across groups ($p<0.001$). Compared with controls (56.5±61.0×10^3 CFU/g), BL reduced fungal burden to 13.8±9.1×10^3 CFU/g (75.5% reduction; $p=0.234$ vs control), TL to 3.0±1.6×10^3 CFU/g (94.7% reduction; $p<0.001$), and BLTL to 0.9±0.3×10^3 CFU/g (98.4% reduction; $p<0.001$). BLTL achieved significantly lower fungal burden than both BL and TL (both $p<0.001$). Histopathological scores also differed across groups ($p=0.004$), with the lowest score in BLTL (1.88±1.13) compared with control (5.43±0.98), BL (3.88±2.17), and TL (2.75±1.91).

Conclusions

460-nm blue light showed dose-dependent in vitro antifungal activity against *T. mentagrophytes*. In the murine tinea corporis model, blue light alone improved clinical scores and reduced fungal burden, but did not achieve significant mycological clearance versus control. The combination of blue light with topical luliconazole provided the greatest reduction in fungal burden and the most favorable clinical and histopathological outcomes, suggesting a potential adjunctive role for blue light in topical antifungal therapy. Further studies are needed to define optimal dose, treatment frequency and application protocols as an essential step toward clinical translation.

EADV CONGRESS
VIENNA
30 SEP - 3 OCT 2026

Abstract N°: 4292

Efficacy of the 308-nm Excimer Lamp in the Treatment of Childhood Vitiligo: A Retrospective Descriptive Study

Afafe JEI*[1], Bouchra Baghad[1], Hanane Rachadi[1], Soumiya Chiheb[1]

[1] Dermatology departement, Ibn Rochd University Center, casablanca, Morocco

Introduction
Vitiligo is a chronic acquired depigmenting disorder that frequently begins during childhood and may significantly impair quality of life. The 308-nm excimer lamp is a targeted ultraviolet B phototherapy modality increasingly used in pediatric dermatology; however, data regarding its efficacy and safety in children remain limited. This study aims to evaluate the efficacy and tolerance of the 308-nm excimer lamp in the treatment of pediatric vitiligo.

Materials and Methods
We conducted a retrospective descriptive study at our Dermatology Department, including patients younger than 18 years treated with a 308-nm excimer lamp between January 2023 and January 2026. Data collected included demographic characteristics, vitiligo subtype, phototype, treatment duration, cumulative dose, repigmentation rate, and adverse events.

Results
Twenty-three children were included, with a mean age of 10 ± 2 years and a female-to-male ratio of 1.56. Nonsegmental vitiligo represented 83% of cases. Facial involvement was the most frequent localization (91%). Patients underwent a mean of 15 ± 5 treatment sessions over 14 ± 3 weeks, with a mean cumulative dose of 5337 mJ/cm^2.

Overall, 75% of lesions achieved repigmentation. Poor repigmentation (<25%) was observed in 15% of lesions, partial repigmentation (25–75%) in 58%, and excellent repigmentation (>75%) in 27%, predominantly in facial lesions. Acral lesions showed the poorest response.

All patients received concomitant topical therapy and 3 patients were on minu-pulses of streroides. Adverse effects were mostly mild and transient, consisting primarily of erythema. No severe adverse events were reported.

Conclusions
The 308-nm excimer lamp appears to be an effective, targeted, and well-tolerated therapeutic option for localized childhood vitiligo, particularly for facial lesions. Larger prospective studies are required to establish standardized treatment protocols and predictive factors of response.

EA DV CONGRESS
VIENNA
30 SEP - 3 OCT 2026

Abstract N°: 4329

Photoprotection Knowledge, Attitudes, and Practices in the General Population: Impact of Dermatological Consultation on Photoprotective Behaviors

Samah Boualem*[1], Ouiame El Jouari[1], Sabrina Oujdi[1], Salim Gallouj[1]

[1] Dermatology Department, University Hospital Center Mohammed VI, Tangier, Morocco, Tangier, Morocco

Introduction
Ultraviolet (UV) radiation is a major environmental risk factor for skin cancer, photoaging, and pigmentary disorders. Although the benefits of photoprotection are well established, adherence to sun-protective measures in the general population remains insufficient. Dermatological consultation may play an important role in improving awareness and promoting adequate photoprotective behaviors. This study aimed to evaluate knowledge, attitudes, and practices regarding photoprotection in the general population and to assess the impact of dermatological consultation on sun-protective behaviors.

Materials and Methods
We conducted a cross-sectional study based on an anonymous online questionnaire distributed via Google Forms among adults from the general population. Inclusion criteria were age ≥18 years, informed consent, and completion of the questionnaire. Incomplete responses were excluded.
The questionnaire collected sociodemographic data, including age, sex, occupation, educational level, Fitzpatrick phototype, and dermatological history, as well as knowledge, attitudes, and practices related to photoprotection. Knowledge was assessed using 10 validated items covering SPF interpretation, sunscreen use, UVA/UVB protection, and photoprotection behaviors. Each correct response was assigned one point, generating a global score ranging from 0 to 10. Knowledge levels were categorized as low (0–3), moderate (4–7), and good (8–10). Attitudes and practices were assessed through multiple-choice questions exploring perceptions of photoprotection, sunscreen use, frequency of application and reapplication, and use of additional sun-protective measures.
Statistical analysis examined associations between knowledge score, sociodemographic variables, and photoprotective practices using appropriate tests.

Results
A total of 323 participants completed the questionnaire. The mean age was 32.4 years, and 70% were female. Most participants had a university-level education (75%). The majority reported Fitzpatrick phototype III.
The mean knowledge score was 4.8 ± 1.9 out of 10, reflecting suboptimal photoprotection knowledge in most participants. Knowledge levels were categorized as low (30%), moderate (55%), and good (15%). Correct responses were most frequent for items related to sunscreen use during sunny conditions and UV effects, whereas lower accuracy was observed for SPF meaning and appropriate application quantity.
Daily sunscreen use was reported by 34% of participants, while 10% reported regular reapplication every 2 hours during sun exposure. Use of additional photoprotective measures such as hats, sunglasses, and protective clothing was reported by 50%, 42%, and 29%, respectively. Consistent photoprotection during winter or indoor daylight exposure remained limited (18%).
A history of dermatological consultation was reported by 37% of participants. Participants with prior consultation

demonstrated significantly higher knowledge scores compared with those without consultation (7 ± 1.2 vs 3 ± 1, $p < 0.05$). In addition, dermatological consultation was significantly associated with higher rates of daily sunscreen use and regular reapplication ($p < 0.05$).
Higher educational level was significantly associated with better knowledge scores ($p < 0.05$). A positive correlation was observed between knowledge score and photoprotective practices ($p < 0.05$). Younger age groups showed better sunscreen use for certain behaviors, although this was not consistent across all practices. Participants with Fitzpatrick phototypes IV–VI were less likely to adopt consistent photoprotective behaviors.

Conclusions

Photoprotection knowledge and practices remain insufficient in the general population. Dermatological consultation appears to play a key role in improving both awareness and sun-protective behaviors. Strengthening dermatological counseling and public education strategies is essential to enhance adherence to photoprotection measures and reduce UV-related skin damage.

EA DV CONGRESS
VIENNA
30 SEP - 3 OCT 2026

Abstract N°: 4339

Rapid, Dose-Dependent Reduction of Plasma Protoporphyrin IX With PORT-77 in Adults with Erythropoietic Protoporphyria: Results from the Phase 2a GATEWAY Study

Melissa Vadnais[1], Amy Chinn[1], Bhavik Shah[2], Alex Vo[1], Pete Schmidt*[1]

[1] Portal Therapeutics, Portal Therapeutics, Portal Therapeutics, Palo Alto, United States

[2] BridgeBio, Palo Alto, United States

Introduction

Background

Erythropoietic protoporphyria (EPP) is a rare, lifelong photodermatosis caused by impaired ferrochelatase activity. This leads to the accumulation of protoporphyrin IX (PPIX) in the plasma. Upon exposure to visible light through the dermal vasculature, PPIX generates reactive oxygen species in the skin. Which results in immediate and severe phototoxic reactions characterized by intense pain, erythema, and edema. These reactions significantly limit sunlight tolerance and quality of life. Circulating plasma PPIX is a key driver of cutaneous phototoxicity and represents a clinically meaningful therapeutic target. PORT-77 is an investigational oral inhibitor of the ABCG2 transporter, the primary protein responsible for transporting PPIX out of red blood cells into plasma. PORT-77 is designed to limit this transport, thereby reducing circulating PPIX levels.

Aims

To evaluate the safety, pharmacokinetics (PK), and pharmacodynamic (PD) effects of PORT-77 on plasma PPIX in adults with EPP.

Materials and Methods

GATEWAY (Phase 2a) was conducted in two parts. Part 1 was a blinded, randomized, placebo-controlled crossover study in which 19 adults with EPP received placebo for 4 days followed by PORT-77 oral suspension (180 mg once daily or 300 mg twice daily) for 4 days. Part 2 was an open-label extension in which 8 participants received PORT-77 300 mg tablets twice daily for 4 days. Plasma PPIX concentrations were measured by LC-MS/MS at serial timepoints. Safety was evaluated through adverse events (AEs), laboratory assessments, and physical examinations. PK parameters were assessed using standard noncompartmental methods.

Results

PORT-77 produced rapid, substantial, and dose-dependent reductions in plasma PPIX. Median decreases were approximately 60% with 180 mg once daily and approximately 75% with 300 mg twice daily. Reductions were observed within hours of treatment initiation and were consistent across a broad range of baseline PPIX levels (22–121 µg/dL), indicating robust activity across disease severity. Suppression of circulating plasma PPIX, the key mediator of cutaneous phototoxicity, was sustained during treatment. PK was dose-proportional, and steady state was achieved within several days. PORT-77 was well tolerated, with no serious AEs or treatment discontinuations. Treatment-emergent AEs were generally mild and occurred more frequently during placebo than during active treatment.

Conclusions

Summary/Conclusion

PORT-77 achieved rapid and pronounced reductions in plasma PPIX, directly targeting the biological driver of

photosensitivity in EPP. The magnitude and speed of PPIX lowering suggest the potential for clinically meaningful reductions in phototoxic reactions and improved sunlight tolerance. These findings support a disease-modifying therapeutic approach for EPP, with the potential to address a major unmet need in dermatologic care. The favorable safety and tolerability profile further supports continued clinical development.

Clinical Relevance

EPP is characterized by extreme light intolerance that profoundly impacts daily life. By substantially lowering circulating PPIX, the central mediator of phototoxic injury, PORT-77 has the potential to translate biochemical improvements into meaningful dermatologic benefit, including reduced pain, increased light exposure tolerance, and improved quality of life for patients with severe photodermatosis.

EADV CONGRESS
VIENNA
30 SEP - 3 OCT 2026

Abstract N°: 4418

Weekly patient-self-administered daylight photodynamic therapy for actinic cheilitis

Pablo Balado-Simó*[1], Adrián Lario-González[2], Jaime Piquero-Casals[3], Daniel Morgado Carrasco[2]

[1] Dermatology Department, Hospital Clínic Barcelona, Barcelona, Spain, Melanoma Group, August Pi Sunyer Biomedical Research Institute (IDIBAPS), Barcelona, Spain, University of Barcelona, Barcelona, Spain., Barcelona, Spain

[2] Dermatology Department, Hospital Clínic Barcelona, Barcelona, Spain, Barcelona, Spain

[3] Dermacentric Health and Aesthetics, Barcelona, Spain., Barcelona, Spain

Introduction

Actinic cheilitis (AC) is a chronic potentially malignant disorder of the lower lip caused by cumulative ultraviolet radiation exposure. Treatment is challenging because it should target both visible lesions and subclinical dysplasia within the actinic field. Conventional therapies, including topical 5-fluorouracil, imiquimod, ablative procedures and conventional photodynamic therapy, may be effective but are often limited by pain, inflammation and poor adherence. Daylight photodynamic therapy (dL-PDT), based on continuous low-irradiance activation of protoporphyrin IX under natural sunlight, is generally better tolerated. However, evidence regarding repeated patient-self-administered dL-PDT for AC remains limited. We aimed to describe the clinical outcomes, tolerability and feasibility of weekly patient-self-administered dL-PDT in patients with AC.

Materials and Methods

We conducted a case series including patients with clinically and/or histopathologically confirmed AC treated between January 2022 and January 2026. All patients received standardized written and verbal instructions for weekly self-administered dL-PDT. Before each session, scales or crusts were gently removed from the vermilion using saline-soaked gauze. A thin layer of methyl aminolevulinate was then applied to the affected area. Within 30 minutes, patients exposed the treated lip to outdoor daylight for 2 hours. After exposure, residual cream was removed and broad-spectrum photoprotection or a physical barrier was applied for the remainder of the day. Clinical assessment was performed at baseline and after 8 weeks, with further follow-up individualized according to response. Clinical response was classified as complete response, partial response, or no response. Local adverse events and pain using a visual analogue scale were recorded.

Results

Eight patients were included: five men and three women, aged 48 to 82 years. Five patients had a history of keratinocytic carcinoma, including one with previous squamous cell carcinoma of the lip. AC was hypertrophic in three patients and presented as erythematous, crusted or atrophic areas in the remaining cases. Three patients had previously received imiquimod, topical 5-fluorouracil or conventional PDT, all of which had been poorly tolerated.

Patients underwent 8 to 10 weekly sessions, with a median of 9 sessions. Complete clinical response was achieved in six patients, corresponding to 75% of the cohort. The remaining two patients showed partial response; both had extensive hypertrophic AC and previous treatment failure. No patient showed clinical progression to invasive keratinocytic carcinoma during follow-up, which ranged from 6 to 24 months. Among complete responders, no clinical recurrences were observed during available follow-up. Treatment was well tolerated in all cases. Adverse events were limited to mild lip irritation, and pain scores remained low, ranging from 1 to 2 on the visual analogue scale. No patient discontinued treatment because of pain, inflammation or functional impairment.

Conclusions

Weekly patient-self-administered dL-PDT appears to be a feasible and well-tolerated field-directed treatment for AC. In this small case series, most patients achieved complete clinical clearance, with minimal pain and no treatment discontinuations. This approach may be particularly useful for patients who are elderly, comorbid, have extensive actinic damage, or poorly tolerate conventional therapies. The home-based nature of the protocol may also reduce hospital visits and improve adherence. Larger prospective studies with histological assessment and longer follow-up are needed to confirm efficacy, define optimal treatment schedules and assess its role in preventing progression to invasive squamous cell carcinoma.

EADV CONGRESS
VIENNA
30 SEP - 3 OCT 2026

Abstract N°: 4453

Redox performance of an oral photoprotector based on P. leucotomos, botanical extracts, and vitamins in lipophilic and hydrophilic phases

Carla Simonetto*[1], SUSANA GOMEZ ESCALANTE[1], SANDRA ISABEL ESCOBAR[1], Carolina Escardó[1], Adrià Ribes[1], Anthony Brown[1], Monica Foyaca[1]

[1] Innovation & Development, ISDIN S.A., Barcelona, Spain

Introduction

Oral photoprotection serves as a complementary strategy to topical sunscreens, aimed at mitigating skin damage induced by UV radiation and visible light through the systemic neutralization of oxidative stress.

The real efficacy of an oral photoprotector depends on the total antioxidant capacity of the full formulation, including potential synergistic effects and its behavior in different biological environments.

The objective of this study was to quantitatively compare the total antioxidant capacity of FP01—containing *P. leucotomos*, *Vitis vinifera*, green tea, vitamins C, D, and E, Selenium, Lutein, Lycopene, and β-carotene—against a commercially available reference product (FP02), using the FRAP assay as an integrated measure of ferric reducing antioxidant capacity.

Materials and Methods

Antioxidant capacity was determined using the FRAP (Ferric Reducing Antioxidant Power) assay, which quantifies the ability of samples to reduce Fe^{3+} to Fe^{2+}

To simulate different biological environments relevant to absorption and bioavailability, the capsules were dissolved in water (hydrophilic medium), corn oil (lipid medium), and DMSO (high-solubility organic solvent).

A concentration range between 0.08 mg/ml and 1.25 mg/ml was evaluated to establish dose-response curves. Statistical comparisons were conducted between products for each concentration and medium.

Results

Both products exhibited dose-dependent behavior in the three evaluated media.

However, FP01 demonstrated a consistently superior and more robust antioxidant capacity than FP02 across all experimental conditions.

- FP01 presented values of 1663.31 µM $FeCl_2$ at 1.25 mg/ml and 174.68 µM $FeCl_2$ at 0.08 mg/ml, maintaining a homogeneous response regardless of the solubilization medium.
- FP02 showed maximum values of 1115.39 µM $FeCl_2$ in water/DMSO and only 469.50 $FeCl_2$ in the lipid medium at the maximum concentration.

This indicates that:

- FP01 achieved approximately 49% higher maximum antioxidant capacity compared to FP02 under hydrophilic

conditions.

- In the lipid medium, the superiority of FP01 was even more pronounced, with an activity more than 3 times higher than FP02.

Differences were statistically significant across all concentrations and media evaluated ($p < 0,05$; $p < 0,01$). Particularly relevant was the marked reduction in activity of FP02 in the lipid medium, suggesting potential bioavailability limitations of its active components in biologically relevant environments. In contrast, FP01 maintained high and stable antioxidant capacity in both aqueous and lipid environments, indicating a formulation optimized for transversal performance.

Conclusions

FP01 demonstrated a significantly superior and more consistent total antioxidant capacity than the reference product FP02. Beyond the presence of individual ingredients, the results evidence that the formulation architecture of FP01 allows for greater absolute antioxidant potency and better performance in different solubilization environments. These findings reinforce the relevance of evaluating the overall antioxidant capacity of the full formulation and position FP01 as an oral photoprotection option with greater systemic antioxidant potential and superior biological versatility.

EA DV CONGRESS
VIENNA
30 SEP - 3 OCT 2026

Abstract N°: 4461

Chronic actinic dermatitis in dark phototypes : diagnostic pitfalls and the added value of phototesting – a 10-case series

Hajar Baali*[1], Mariem Aboudourib[1], Bendaoud Layla[1], Ouafa Hocar[1], Said Amal[1]

[1] Dermatology department, Arrazi Hospital, CHU MOHAMMED VI Marrakech, Marrakech, Morocco

Introduction

Chronic actinic dermatitis (CAD) is a rare and disabling inflammatory photodermatosis characterized by persistent photosensitivity to ultraviolet radiation and occasionally visible light. Its diagnosis remains particularly challenging because of marked clinical and histopathological overlap with other inflammatory and lymphoproliferative dermatoses. Evidence regarding CAD in darker phototypes is scarce. We aimed to describe the clinical spectrum, diagnostic pitfalls, and contribution of phototesting in a series of Moroccan patients with CAD.

Materials and Methods

We conducted a retrospective descriptive study in the dermatology department of Mohammed VI University Hospital, Marrakech, including patients diagnosed with CAD between January 2021 and January 2026. Diagnosis was established based on clinicopathological correlation and photobiological investigations when available. Epidemiological, clinical, histological, therapeutic, and outcome data were analyzed.

Results

Ten patients were included, with a marked male predominance (8/10). The mean age at diagnosis was 66 years (49–76 years). All patients had Fitzpatrick phototypes IV or V and reported chronic cumulative sun exposure, mainly occupational. The mean disease duration before diagnosis was 6.1 years (3 months–12 years), highlighting substantial diagnostic delay.

All patients presented with chronic infiltrated erythematous-squamous lesions predominantly involving photo-exposed areas, associated with intense pruritus and progressive skin thickening. Secondary extension to non-exposed areas occurred in four patients, reflecting advanced disease. Facial involvement was constant and particularly severe in some cases, including one patient with diffuse infiltrative lesions producing a pseudo-leonine facies initially suspected to represent cutaneous T-cell lymphoma.

Several alternative diagnoses had been considered prior to referral, most commonly cutaneous lupus erythematosus, chronic eczema, porphyria cutanea tarda, and cutaneous lymphoma. Histopathological examination consistently demonstrated chronic eczematous dermatitis with hyperkeratosis, acanthosis, and spongiosis associated with a dense dermal lymphocytic infiltrate, occasionally lichenoid and highly suggestive of lymphoproliferative disease. Immunohistochemistry performed in selected cases revealed predominance of CD3+ T lymphocytes without evidence of malignant clonality.

Phototesting was performed in six patients using UVB irradiation (Hexheimer lamp) and revealed markedly decreased minimal erythema doses (MED), with a mean estimated value of approximately 70 mJ/cm^2 despite dark phototypes, confirming abnormal photosensitivity.

All patients received strict photoprotection associated with topical corticosteroids, while systemic corticosteroids were required in extensive forms. Severe or refractory cases were treated with azathioprine or extracorporeal photopheresis, leading to partial or marked clinical improvement in most patients during follow-up.



A. Diffuse infiltrated erythematous facial plaques with leonine facies appearance in chronic actinic dermatitis.
B. Severe infiltrative photodistributed dermatitis with marked facial edema and deep furrowing mimicking cutaneous lymphoma.

Severe infiltrative facial involvement in chronic actinic dermatitis.

Conclusions

CAD in dark phototypes remains underrecognized and may closely mimic inflammatory or lymphoproliferative dermatoses, resulting in prolonged diagnostic delay. Our series highlights the major diagnostic value of phototesting, even in patients with high phototypes, and underlines the importance of multidisciplinary clinicopathological correlation for early diagnosis and appropriate management.