EA DV CONGRESS
VIENNA
30 SEP - 3 OCT 2026

Abstract N°: 37

Beyond the Surface: Exploring a unique paediatric case of an infant at risk of Sturge-Weber syndrome

Abhishek Wilson Pallippattu*[1], Urvi Popli[1]

[1] Glan Clwyd Hospital, Rhyl, United Kingdom

Introduction

Sturge-Weber syndrome (SWS) is a rare neurovascular condition affecting 1 in 50,000 individuals1, characterized by facial capillary malformations and brain and eye vascular abnormalities.

Case Presentation

We report the case of an infant identified as being at very high risk for SWS. The baby was born at term via normal vaginal delivery. During newborn examination, a port-wine stain (PWS) was observed. Dermatology assessment confirmed a PWS noted to be affecting the left hemi-facial including distribution of the trigeminal nerve, upper and lower eye-lids, half of nose, upper and lower lip and cheek. Given this distribution, the lesion was recognized as a very high-risk facial PWS phenotype associated with SWS. Initial management included urgent referrals to ophthalmology to evaluate for glaucoma, paediatrics for ongoing neurological monitoring, and to a tertiary centre to assess eligibility for laser treatment of PWS. The infant has shown any neurological symptoms. However, at 10 weeks of age, swelling around the left eye and intermittent redness were noted. By 16 weeks, ophthalmologic evaluation confirmed secondary glaucoma to the left eye prompting treatment with Timolol 0.25% and Monopost eye drops. At follow-up at 1 year and 8 weeks, the intra-ocular pressure in the left eye remained elevated, prompting a plan for glaucoma tube surgery. Magnetic Resonance Imaging (MRI) Brain at 28 weeks revealed no intracranial abnormalities however, the tertiary centre recommended MRI-Brain with contrast to rule out choroidal angioma or pineal angiomatosis. This scan, performed at 1 year and 4 weeks, again showed no abnormalities. The infant continues to be closely monitored through regular follow-up with dermatology, paediatrics, and ophthalmology.

Conclusion

This case underscores the importance of early diagnosis so that patients can then be under regular surveillance. This can help in early identification of complications such as glaucoma, the most common ocular complication in SWS, as demonstrated in this case.

EADV CONGRESS
VIENNA
30 SEP - 3 OCT 2026

Abstract N°: 47

Atypical Periorbital Edema Mimicking Cellulitis as the First Visible Sign of Orbital Myeloid Sarcoma in Infant Acute Myeloid Leukemia

Aleksandra Osińska*[1], Jakub Szczepański[2], Szymon Pochwatka[2], Karolina Wyżkiewicz[2], Klaudia Marchewka[2]

[1] Medical University of Lublin, Lublin, Poland

[2] Student Scientific Society at the Department of Pediatric Radiology, Medical University of Lublin, Lublin, Poland

Introduction

Periorbital erythema and edema in infants are commonly attributed to infectious or inflammatory dermatoses, including periorbital cellulitis or allergic reactions. However, malignant infiltration may present with similar cutaneous features, leading to potential diagnostic delay.

Case Presentation

A 16-month-old boy with high-risk acute myeloid leukemia developed rapidly progressive unilateral periorbital swelling with visible eyelid edema and globe displacement during induction chemotherapy. The lesion initially clinically resembled inflammatory periorbital cellulitis. There was no overt cutaneous necrosis or ulceration, but progressive edema and asymmetry raised concern for atypical pathology.Dermatologic differential diagnosis included periorbital cellulitis, angioedema, inflammatory pseudotumor, and leukemic cutaneous infiltration. Magnetic resonance imaging revealed a 35 × 28 × 29 mm mass within the lateral orbital cone, consistent with orbital myeloid sarcoma (granulocytic sarcoma), confirming extramedullary leukemic infiltration presenting with prominent periocular soft tissue changes.The course was complicated by neutropenic sepsis and multiorgan failure despite aggressive treatment.

Conclusion

Myeloid sarcoma may clinically manifest with prominent periocular edema mimicking inflammatory dermatoses. In pediatric oncology patients, rapidly progressive or treatment-resistant periorbital swelling should prompt suspicion of neoplastic infiltration. Early imaging is crucial to differentiate inflammatory from malignant etiologies.This case emphasizes that atypical or rapidly evolving periorbital edema may represent malignant infiltration rather than primary dermatologic disease. Dermatologists should consider hematologic malignancy in the differential diagnosis of unusual periocular swelling, particularly in immunocompromised children.

EADV CONGRESS
VIENNA
30 SEP - 3 OCT 2026

Abstract N°: 49

Langerhans Cell Histiocytosis Mimicking Post-Traumatic Lesion in an Immunocompromised Child with T-Cell Acute Lymphoblastic Leukemia: A Diagnostic Challenge

Aleksandra Osińska*[1], Karolina Wyżkiewicz[1], Jakub Szczepański[1], Klaudia Marchewka[1], Szymon Pochwatka[1], Andrzej Materniak[2]

[1] Student Scientific Society at the Department of Pediatric Radiology, Medical University of Lublin, Lublin, Poland
[2] Medical University of Lublin, Lublin, Poland

Introduction

Langerhans cell histiocytosis (LCH) is a clonal inflammatory-neoplastic disorder of myeloid dendritic cells, classified within the spectrum of dermatologic histiocytic diseases. Although skin involvement is common, isolated or predominant osseous presentation may obscure recognition, particularly in immunocompromised children.

Case Presentation

We report a 2-year-old boy undergoing treatment for T-cell acute lymphoblastic leukemia (T-ALL) who developed a rapidly progressive osteolytic lesion of the distal humerus following minor trauma. Initial radiographs were normal, leading to temporary conservative management. Within two weeks, progressive swelling and cortical destruction with periosteal reaction were observed.Ultrasound with color Doppler demonstrated a hypervascular solid lesion rather than fluid collection, raising suspicion of neoplastic proliferation rather than infection. Biopsy confirmed LCH with CD1a, S100, and Langerin positivity. Further imaging revealed multifocal skeletal involvement. No leukemic relapse was identified.The coexistence of LCH and T-ALL required careful therapeutic adjustment. Systemic vinblastine and prednisone were introduced while leukemia therapy was modified to reduce cumulative toxicity. Due to aggressive multisystem involvement, the patient subsequently underwent allogeneic hematopoietic stem cell transplantation (HSCT), achieving complete hematologic remission and metabolic regression of LCH lesions.

Conclusion

LCH belongs to the group of inflammatory-neoplastic dermatologic disorders driven by MAPK pathway activation, frequently involving BRAF mutations. In immunocompromised children, bone lesions may mimic trauma, infection, or secondary malignancy, delaying diagnosis. Early biopsy and immunohistochemical confirmation are essential. This case highlights the importance of considering LCH within the differential diagnosis of rapidly evolving osteolytic lesions in pediatric patients, even during ongoing oncologic treatment. Dermatologic expertise in histiocytic disorders remains crucial for timely diagnosis and multidisciplinary management.

EA DV CONGRESS
VIENNA
30 SEP - 3 OCT 2026

Abstract N°: 96

A Case of Linear Porokeratosis Misdiagnosed as Lichen Striatus Diagnostic Challenges and Lessons Learned

MENGMENG LI*[1]

[1] Department of Dermatology and Venereology, West China Hospital, Sichuan University, Chengdu, China

Introduction

Linear porokeratosis is a rare disorder of keratinization that may clinically resemble other linear dermatoses, resulting in frequent misdiagnosis. Because of its variable presentation and overlap with inflammatory linear skin diseases, accurate diagnosis often requires careful clinicopathological correlation. We report a pediatric case of linear porokeratosis to highlight its distinguishing clinical, dermoscopic, and histopathological features.

Case Presentation

A 4-year-old girl presented with a 4-year history of progressive linear erythema and papules on the right upper limb. She had previously been diagnosed with lichen striatus and treated with topical corticosteroids and tacrolimus, without clinical improvement. Physical examination revealed linear reddish-brown macules and papules involving the right upper limb, chest, and right thumbnail, accompanied by nail dystrophy. Dermoscopy showed uniform linear pigmentation of the skin lesions and characteristic nail plate abnormalities. Histopathological examination demonstrated epidermal parakeratosis and mild perivascular lymphocytic infiltration in the superficial dermis, supporting the diagnosis of linear porokeratosis.



Physical examination revealed linear reddish-brown macules and papules involving the right upper limb, chest, and right thumbnail, accompanied by nail dystrophy

Conclusion

This case demonstrates that linear porokeratosis may present with progressive linear lesions and nail involvement, closely mimicking other linear inflammatory dermatoses such as lichen striatus and linear lichen planus. Accurate diagnosis depends on the integration of clinical manifestations, dermoscopic findings, and histopathological features. Early recognition is important to avoid misdiagnosis and inappropriate treatment.

EADV CONGRESS
VIENNA
30 SEP - 3 OCT 2026

Abstract N°: 141

Accessory Tragus: rare presentation

Asya Almila Can*[1], Cem Leblebici[2], Ayşe Esra Koku Aksu[2]

[1] Istanbul Training and Research Hospital, Istanbul, Türkiye
[2] Istanbul Training And Research Hospital, Istanbul, Türkiye

Introduction
Accessory tragus is a rare congenital lesion arising from aberrant development of the first and second branchial arches. While commonly located in the preauricular area, ectopic localizations such as the neck are exceptionally rare. This case aims to present a 10-year-old boy with a solitary polypoid lesion over the left sternocleidomastoid (SCM) muscle, later confirmed histologically as accessory tragus. The objective is to raise awareness of atypical presentations to avoid misdiagnosis and unnecessary investigations.

Case Presentation
Materials & Methods: A 10-year-old male presented with a congenital, asymptomatic, skin-colored, dome-shaped lesion on the left lateral neck, overlying the SCM muscle. Physical examination revealed a solitary, polypoid lesion measuring 1.4 cm in diameter. The lesion was excised under local anesthesia and sent for histopathological evaluation. Macroscopic and microscopic findings were documented, and literature was reviewed for similar cases. Results: Gross examination revealed a 1.5 × 0.6 × 0.6 cm skin specimen with a yellow-white polypoid mass on the surface. Histopathology showed stratified squamous epithelium, pilosebaceous units, and cartilage, consistent with a diagnosis of accessory tragus. No signs of associated syndromic conditions were observed. Postoperative recovery was uneventful, and cosmetic outcome was satisfactory



Conclusion

Accessory tragus may present in atypical locations such as the neck and mimic other benign congenital lesions. It can be part of syndromic anomalies.Awareness of this rare localization is important for accurate diagnosis and effective surgical management.Histopathological confirmation is essential, particularly when the lesion is not in the typical preauricular region.

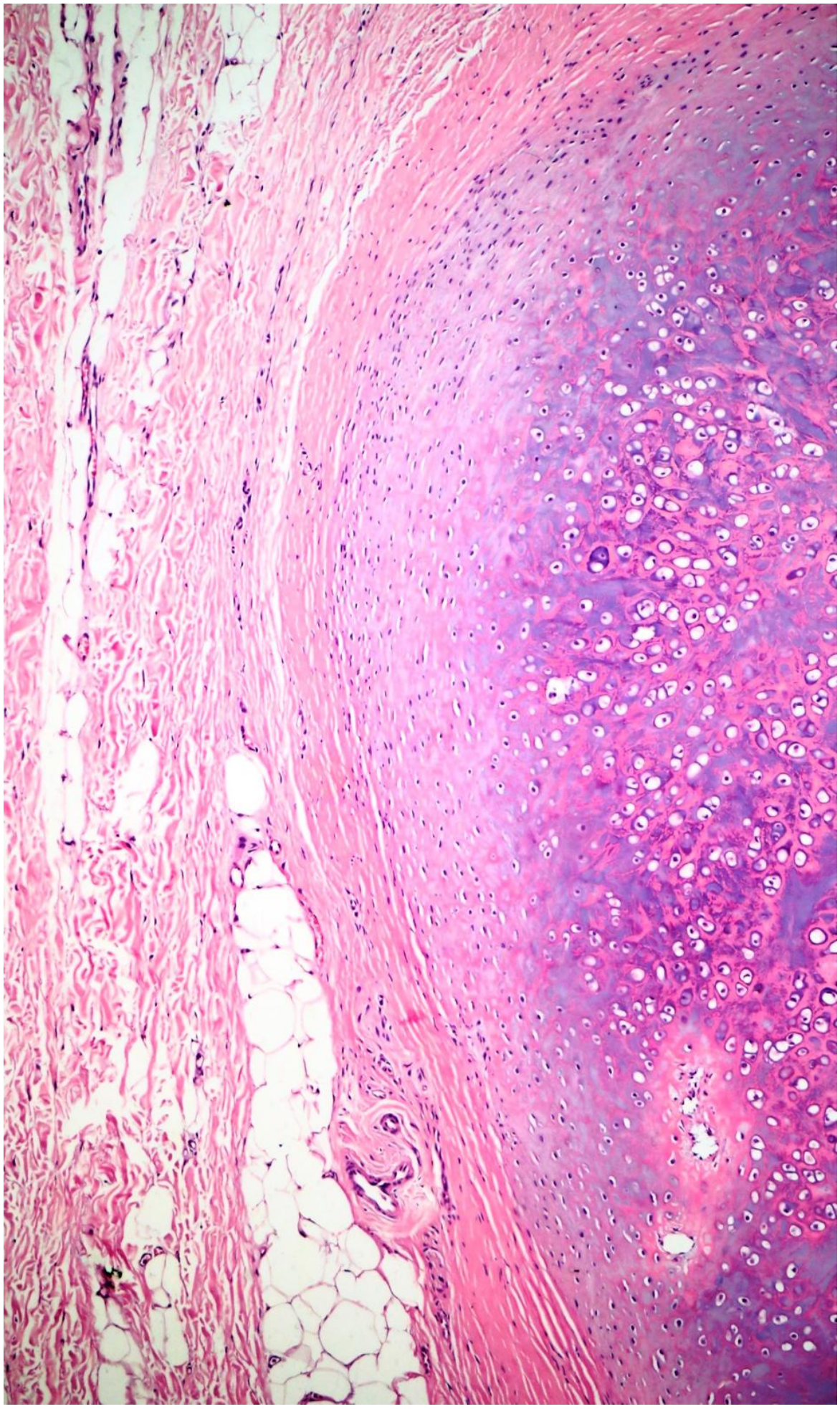

Abstract N°: 172

Neonatal-onset Mitchell syndrome with ACOX1 gain-of-function and a de novo ROBO1 variant: expanding the phenotypic spectrum and supporting a potential oligogenic model

Jose Molina Espinosa*[1], Israel Pérez López[1], Pedro José Ezomo- Gervilla[1], Diego Gallego García[1], Daniel Robles Murcia[1], Ricardo Ruiz-Villaverde[1]

[1] Hospital Universitario Clínico San Cecilio, Granada, Spain

Introduction

Mitchell syndrome (ACOX1-related syndromic epidermal differentiation disorder) is an ultrarare neurocutaneous disease caused by gain-of-function variants in ACOX1, leading to excessive peroxisomal β-oxidation and oxidative stress–mediated multisystem damage. Fewer than 15 cases have been reported to date, typically presenting in childhood with a characteristic triad of inflammatory ichthyosiform dermatitis, progressive leukoencephalopathy, and ocular surface disease.Recent evidence suggests that phenotypic variability may extend beyond this classical presentation, and additional genetic or metabolic factors could modulate disease expression. Early recognition remains challenging, particularly in atypical or early-onset cases.Here, we report a neonatal-onset case of Mitchell syndrome associated with a de novo ACOX1 variant and a co-occurring truncating ROBO1 variant, expanding the clinical and genetic spectrum of the disease.

Case Presentation

A male infant, born at term to non-consanguineous parents after an uneventful pregnancy, presented in the second week of life with a generalized erythematous, desquamative, greasy eruption, initially interpreted as severe infantile seborrheic dermatitis. Scalp hair was sparse, weak, and ocher-colored.At six weeks of age, he developed marked photophobia and reduced spontaneous eye opening. Ophthalmologic examination revealed recurrent bilateral corneal epithelial defects requiring treatment with serum eyedrops and supportive measures. Over the following months, progressive axial hypotonia, poor head control, and failure to thrive became evident.At six months, the patient experienced acute neurological deterioration with recurrent apneas and generalized seizures, requiring intensive care admission. Brain magnetic resonance imaging demonstrated diffuse symmetric periventricular and subcortical leukoencephalopathy.Metabolic evaluation revealed elevated dicarboxylic acids and medium- and long-chain acylcarnitines, with normal very-long-chain fatty acids, suggesting a pseudo–multiple acyl-CoA dehydrogenase deficiency profile.Trio whole-exome sequencing identified two heterozygous de novo variants: ACOX1 c.710A>G (p.Asn237Ser), consistent with Mitchell syndrome, and ROBO1 c.572delG (p.Cys191fs).Cutaneous lesions progressively resolved with topical N-acetylcysteine and emollients, in combination with systemic antioxidant therapy, whereas neurological impairment persisted.

Conclusion

Mitchell syndrome should be considered in infants presenting with inflammatory ichthyosiform dermatitis associated with early neurologic and ocular involvement, even in the presence of atypical metabolic findings. This case expands the clinical spectrum of the disease to neonatal onset and supports a potential role of additional genetic variants as phenotypic modifiers. Early genomic diagnosis is essential, and prompt antioxidant-based interventions may improve cutaneous manifestations, although neurological progression remains the main determinant of prognosis.

POWERED BY M-ANAGE.COM

EA DV CONGRESS
VIENNA
30 SEP - 3 OCT 2026

Abstract N°: 197

Bimekizumab pharmacokinetics, safety and efficacy in adolescents with moderate to severe plaque psoriasis: Long-term data from the open-label BE CONNECTED phase 2 study

Andreas Pinter*[1], Jacek C. Szepietowski[2, 3], Adam Reich[4], Philippa Charlton[5], Fabienne Staelens[6], Delphine Deherder[6], Merran MacPherson[7], Asim Datye[8], Amy Paller[9]

[1] University Hospital Frankfurt, Frankfurt am Main, Germany
[2] Division of Dermatology, Venereology and Clinical Immunology, Faculty of Medicine, Wrocław University of Science and Technology, Wrocław, Poland
[3] Cityclinic: Medical and Psychological Center, Wrocław, Poland
[4] Department of Dermatology, Faculty of Medicine, University of Rzeszów, Rzeszów, Poland
[5] UCB, Morrisville, North Carolina, United States
[6] UCB, Braine-l'Alleud, Belgium
[7] UCB, Slough, United Kingdom
[8] UCB, Oakville, Ontario, Canada
[9] Departments of Dermatology and Pediatrics, Northwestern University Feinberg School of Medicine, Chicago, Illnois, United States

Introduction

Around 30% of patients with psoriasis report symptoms before adulthood, of whom around 16% have moderate to severe disease.[1] Given the chronic nature of paediatric psoriasis, the long-term evaluation of new treatments is crucial.[2]

Bimekizumab (BKZ) is a humanised IgG1 monoclonal antibody that selectively inhibits interleukin (IL)-17F in addition to IL-17A.[3] During the 20-week initial treatment period (ITP) of the BE CONNECTED phase 2 study in adolescents with moderate to severe plaque psoriasis, BKZ demonstrated similar pharmacokinetics (PK), tolerability and high levels of efficacy to studies in adults.[4]

Here, long-term PK, safety and efficacy data are reported for the total duration of the completed BE CONNECTED study.

Materials and Methods

BE CONNECTED (NCT04718896) enrolled adolescents aged ≥12–<18 years (≥30 kg).[4,5] Patients were stratified by baseline weight and randomised 1:1 to open-label BKZ Dose A (≥65 kg: 320 mg every 4 weeks [Q4W]; <65 kg: 160 mg Q4W) or Dose B (≥65 kg: 64 mg Q4W; <65 kg: 32 mg Q4W). After the 20-week ITP, patients who tolerated treatment and achieved Investigator's Global Assessment (IGA) ≤2 at Week 20 could continue the same dose in the 104-week open-label extension (OLE; total duration 124 weeks; final BKZ dose at Week 120). Patients completed a safety follow-up (SFU) period of 20 weeks after the final BKZ dose.

The primary endpoint was BKZ plasma concentration through Week 124 in patients who received ≥1 dose and provided ≥1 plasma concentration measurement. Treatment-emergent adverse events (TEAEs) were assessed from baseline through to the end of the SFU period in patients who received ≥1 dose (safety set). Rates of 100%/≥90% improvement from baseline in the Psoriasis Area and Severity Index (PASI 100/90) and IGA 0/1 are

reported through Week 124 in patients who received ≥1 dose in the OLE, including at Week 20 (open-label set); missing data were imputed as non-response.

Results

Overall, 41 patients received ≥1 BKZ dose in the ITP (safety set; Dose A: n=20; Dose B: n=21) and 39 patients entered the OLE (open-label set; Dose A: n=19; Dose B: n=20). Steady-state geometric mean BKZ plasma concentrations achieved between Weeks 16–20 (Dose A: 20.2–21.6 µg/mL; Dose B: 2.6–2.7 µg/mL) were maintained to Week 124 (Dose A: 17.5 µg/mL; Dose B: 3.1 µg/mL).

Over the full study, 85.0%/81.0% of Dose A/B patients had TEAEs. Two Dose A (10.0%) and three Dose B (14.3%) patients had serious TEAEs; none were treatment-related. No TEAE led to study withdrawal or death. Overall, the most common TEAEs were nasopharyngitis (39.0%), urinary tract infection (19.5%) and upper respiratory tract infection (17.1%). There were no serious, opportunistic or *Candida* infections, and no inflammatory bowel disease or adjudicated suicidal ideation/behaviour.

In the open-label set, all patients receiving Dose A reached PASI 100 at Week 20, and high rates of skin clearance were sustained to Week 124 (PASI 100/90: 78.9%/89.5%; **Figure**). In patients receiving Dose B, 70.0%/90.0% had PASI 100/90 at Week 20, with 65.0% maintaining both outcomes to Week 124. High rates of IGA 0/1 at Week 20 (Dose A/B: 100.0%/95.0%) were sustained to Week 124 (Dose A/B: 89.5%/75.0%).

Figure. PASI response rates from baseline through Week 124 (NRI, OC)

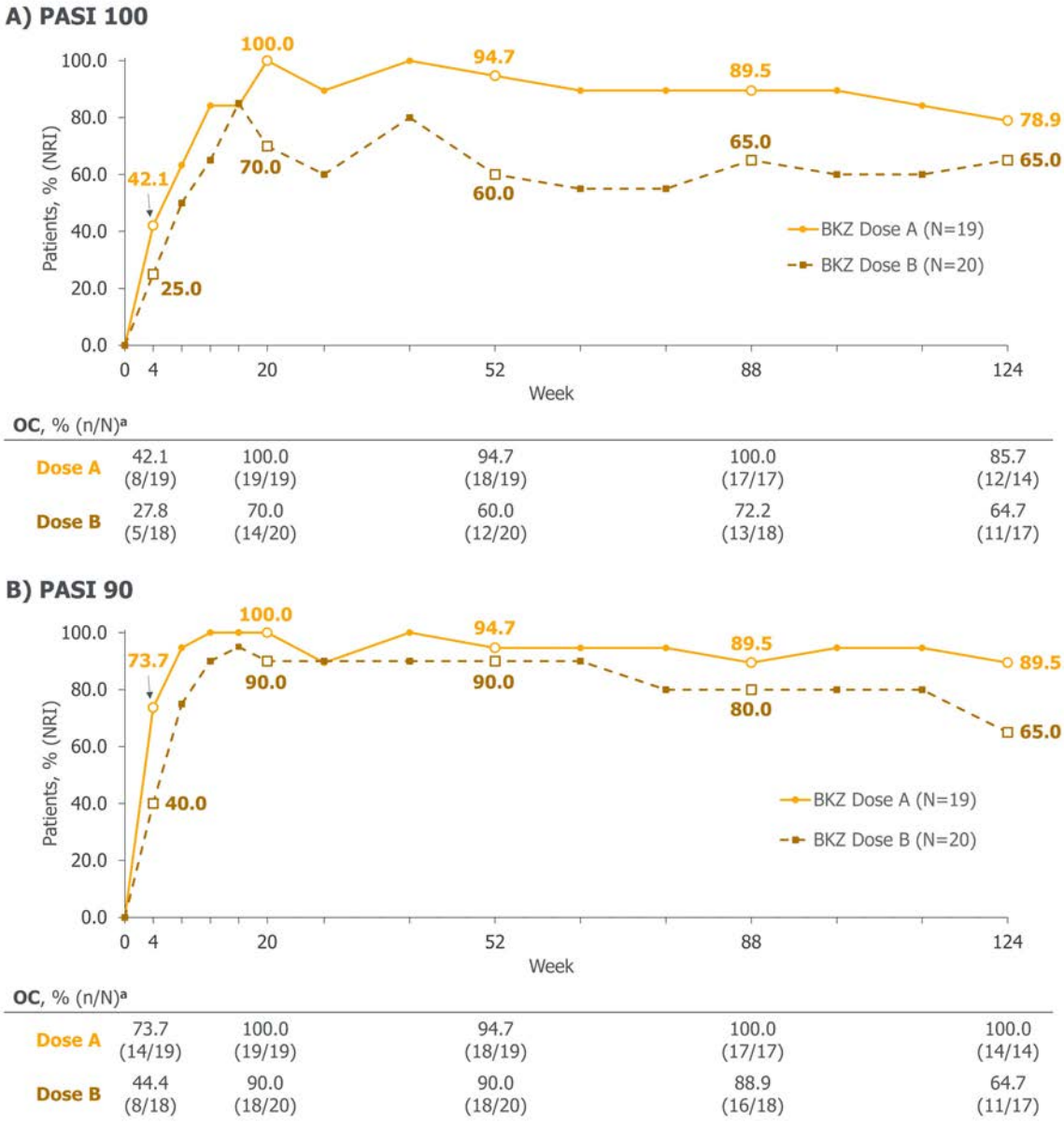

OC, % (n/N)[a]

Dose A	42.1 (8/19)	100.0 (19/19)	94.7 (18/19)	100.0 (17/17)	85.7 (12/14)
Dose B	27.8 (5/18)	70.0 (14/20)	60.0 (12/20)	72.2 (13/18)	64.7 (11/17)

OC, % (n/N)[a]

Dose A	73.7 (14/19)	100.0 (19/19)	94.7 (18/19)	100.0 (17/17)	100.0 (14/14)
Dose B	44.4 (8/18)	90.0 (18/20)	90.0 (18/20)	88.9 (16/18)	64.7 (11/17)

Open-label set includes all patients who received at ≥1 BKZ dose in the OLE (including Week 20). Dose A: BKZ 320 mg Q4W in patients ≥65 kg, BKZ 160 mg Q4W in patients <65 kg; Dose B: BKZ 64 mg Q4W in patients ≥65 kg, BKZ 32 mg Q4W in patients <65 kg. Weight-categorised dosing was based on patients' weight at baseline. [a] Data collected >5 days outside of the 4-week dosing interval were considered missing; therefore, any Week 124 data collected >5 days late (last BKZ dose at Week 120) were excluded from the OC analysis. BKZ: bimekizumab; NRI: non-responder imputation; OC: observed case; OLE: open-label extension; PASI: Psoriasis Area and Severity Index; PASI 90/100: ≥90%/100% improvement from baseline in PASI; Q4W: every 4 weeks.

Conclusions

Through more than 2 years of bimekizumab treatment in adolescents with moderate to severe psoriasis, PK remained within the expected range, aligning with the established PK profile in adults. Both bimekizumab doses were well tolerated, with no safety signals identified. High levels of skin clearance were generally sustained during the OLE, consistent with adult studies,[6,7] with higher clearance rates and bimekizumab plasma concentrations for Dose A vs Dose B.

References

1. Ramond A. Dermatol Ther (Heidelb) 2025;15:3765–76; **2.** Hebert AA. J Dermatol Treat 2022;33:2433–42; **3.** Adams R. Front Immunol 2020;11:1894; **4.** Paller A. Presented at AAD 2026;P73380; **5.** BE CONNECTED:

https://clinicaltrials.gov/study/NCT04718896; **6.** Blauvelt A. J Am Acad Dermatol 2025;93:644–53; **7.** Warren RB. Br J Dermatol 2025;193:44–5.

EADV CONGRESS
VIENNA
30 SEP - 3 OCT 2026

Abstract N°: 201

Evaluating Neurodevelopmental Sequelae of Propranolol Use in Infantile Hemangioma: A Large-Scale Population-Based Study

Khalaf Kridin*[1], Ralf Ludwig[2]

[1] Galilee Medical Center, Nahariya, Israel, Nahariya, Israel

[2] University of Lubeck, Lubeck, Germany, Lübeck, Germany

Introduction

Propranolol is widely adopted as the first-line treatment for problematic infantile hemangioma (IH). Despite its efficacy and widespread use, concerns persist about potential long-term neurodevelopmental risks, given propranolol's ability to cross the blood-brain barrier during early development. We sought to evaluate the long-term risk of neurodevelopmental disorders among patients with IH treated with propranolol compared to those not receiving systemic therapies, and to assess whether delayed initiation of propranolol affects these risks.

Materials and Methods

We conducted a population-based, retrospective cohort study using the TriNetX platform. Children with IH diagnosed before age three were grouped based on treatment exposure: propranolol-treated versus untreated (no systemic therapy). Propensity score matching was performed (1:1) for demographics and comorbidities. The primary outcomes included six neurodevelopmental diagnoses: attention-deficit/hyperactivity disorder (ADHD), behavioral and emotional disorders (BED), speech and language development disorders (SLDD), scholastic skill disturbances (SSD), learning disorders (LD), and autism spectrum disorder (ASD). A subanalysis examined delayed initiation of propranolol (3–12 months and 1–2 years after diagnosis).

Results

After propensity-score matching, 10,143 patients with IH treated with propranolol were compared with 10,143 matched patients with IH not exposed to systemic therapy. Propranolol was not associated with increased risks of ADHD (HR 0.91, 95% CI 0.71–1.17), SSD (HR 0.74, 95% CI 0.54–1.02), or ASD (HR 0.98, 95% CI 0.79–1.21). Conversely, propranolol exposure was associated with significantly reduced risks of BED (HR 0.77, 95% CI 0.68–0.88), SLDD (HR 0.77, 95% CI 0.70–0.85), and LD (HR 0.78, 95% CI 0.66–0.93). No increased risk of any investigated outcome was observed in sex-stratified analyses or among patients who initiated propranolol 3–12 months or 1–2 years after IH diagnosis.

Conclusions

Propranolol treatment for IH was not associated with elevated neurodevelopmental risk and may be linked to a lower incidence of several developmental disorders. These findings support the long-term neurodevelopmental safety of propranolol.

EA DV CONGRESS
VIENNA
30 SEP - 3 OCT 2026

Abstract N°: 216

Periorbital Papules in a Child: Navigating the Granulomatous Differential

Mayra Brandao*[1], Nora Makary[1], Giulia Ruina[1], Charunie Gamage[1]

[1] Lewisham & Greenwich NHS Trust - Queen Elizabeth Site, London, United Kingdom

Introduction
Childhood granulomatous periorificial dermatitis (CGPD) is a rare, benign, self-limiting granulomatous dermatosis characterised by monomorphic periorificial papules and perifollicular non-necrotising granulomas on histology. Its granulomatous morphology necessitates careful distinction from sarcoidosis, lupus miliaris disseminatus faciei (LMDF), and foreign-body reactions. While historically thought to occur predominantly in Afro-Caribbean children, recent evidence demonstrates that it occurs across all racial groups.

Case Presentation
We report a 9-year-old South Asian boy who presented with a one-year history of asymptomatic, monomorphic, copper-brown papules and plaques symmetrically distributed around the eyebrows and lower eyelids. He had a background of periocular vitiligo that had shown repigmentation following Ayurvedic and Unani topical therapies over the preceding year, prior to the evolution of the papules. There were no systemic symptoms, lymphadenopathy, or evidence of visceral involvement. No topical corticosteroid use was reported by the parents; however, steroid adulteration has been documented in up to 38% of traditional Indian medicines.

Skin biopsy demonstrated a perifollicular and perivascular lymphohistiocytic infiltrate within the superficial dermis, with small collections of epithelioid histiocytes forming non-necrotising microgranulomas. There was no caseation, no polarizable foreign material, and periodic acid–Schiff (PAS) staining was negative. The granulomas were small and perifollicular rather than the well-formed, larger, discrete granulomas characteristic of sarcoidosis. LMDF was excluded by the absence of central caseation necrosis, the most reliable histological distinguishing feature. Clinicopathological correlation therefore supported a diagnosis of childhood granulomatous periorificial dermatitis.

Ayurvedic and Unani preparations for vitiligo commonly contain photosensitising psoralens and furanocoumarins, which may act as contact sensitisers or trigger granulomatous reactions. The temporal association with alternative therapies raised the possibility that photosensitising botanical compounds or steroid-contaminated preparations acted as triggers; however, causality could not be established as the products were unavailable for analysis. While granulomatous dermatitis has been linked to herbal and botanical agents, no prior reports have associated these therapies with childhood granulomatous periorificial dermatitis, making this a possible first documented case.

Topical metronidazole was initiated and corticosteroids were avoided. At three-month review, the lesions had flattened significantly, with pre- and post-treatment clinical images demonstrating marked improvement and supporting the expected self-limiting course.

Conclusion
This case expands the phenotypic and demographic spectrum of CGPD to include a predominantly periocular distribution in a child of South Asian heritage, demonstrating that the condition is not confined to Afro-Caribbean skin types. It highlights the critical role of clinicopathological correlation in evaluating granulomatous facial eruptions in children and raises the possibility that photosensitising compounds in traditional therapies may act as

external triggers. Recognition of this association may facilitate timely diagnosis, prevent unnecessary systemic investigation, and allow appropriate reassurance regarding the self-limiting prognosis.

EADV CONGRESS
VIENNA
30 SEP - 3 OCT 2026

Abstract N°: 280

Neonatal bullous cutaneous mastocytosis: a diagnosis challenge

FERHANE IKRAM*[1]

[1] Dermatology Department, EHU 1er Novembre, Oran, Dermatology Department, EHU 1er Novembre, Oran, Dermatology Department, EHU 1er Novembre, Oran, Oran, Algeria

Introduction

Bullous mastocytosis is a very rare form of cutaneous mastocytosis, mainly affecting children (1). We report a case of diffuse cutaneous mastocytosis in its bullous form in a two-month-old infant.

Case Presentation

A two-month-old full-term infant, O.M., with no significant medical history, was admitted for erythematous-pigmented lesions with blistering that appeared on the second day of life (Figures 1, 2, 3).Dermatological examination revealed diffuse erythematous-brown macules predominantly involving the scalp, trunk, and limbs, topped by tense clear-fluid blisters, some ruptured with post-bullous erosions, associated with diffuse thickening of the underlying skin. Darier's sign was positive.There were no palpable lymph nodes or hepatosplenomegaly. The remainder of the clinical examination was unremarkable.Histological examination showed a dense diffuse dermal infiltration of mast cells (Figure 4), with strong CD117 positivity on immunohistochemistry (Figure 5). The diagnosis of bullous diffuse cutaneous mastocytosis (DCM) was therefore established.Serum tryptase levels were markedly elevated (117 mg/L). The absence of organomegaly on ultrasound, normal bone radiographs, and unremarkable laboratory findings ruled out systemic involvement.Treatment with antihistamines (H1 blockers), topical corticosteroids, and avoidance of mast-cell degranulation triggers was initiated, leading to good clinical improvement after 15 days (Figure 6). Cutaneous mastocytoses are rare disorders associated with KIT mutations leading to mast cell proliferation and mediator release, mainly histamine and tryptase (3). They predominantly affect children, with urticaria pigmentosa being the most frequent form (65%) (5).Bullous diffuse cutaneous mastocytosis is rare (~5%) and typically occurs in the neonatal period (5,6). It is characterized by generalized skin involvement with bullae over erythematous or thickened skin. Bullae result from mast cell degranulation releasing proteases and heparin, causing dermo-epidermal junction damage (1).Serum tryptase reflects mast cell burden and may be elevated in children without systemic disease, unlike adults where it often suggests systemic involvement (4,7). Additional investigations are indicated only when systemic disease is suspected.The prognosis is generally favorable with spontaneous regression in early childhood, but regular follow-up is required due to the risk of progression to systemic disease (3,8).

Conclusion

This case highlights the importance of considering diffuse cutaneous mastocytosis in any atypical bullous dermatosis of infancy. Although the prognosis is generally favorable, long-term follow-up is essential to detect early systemic involvement.

EADV CONGRESS
VIENNA
30 SEP - 3 OCT 2026

Abstract N°: 313

Reactive infectious mucocutaneous eruption secondary to Chlamydia pneumoniae mimicking Stevens-Johnson syndrome

Amritha Abhaya Kumar*[1], Avinash Belgi[1], Magda Olechowska[1]

[1] Poole Hospital, Poole, United Kingdom

Introduction

Reactive infectious mucocutaneous eruption (RIME) is a post-infectious inflammatory syndrome characterised by prominent mucositis with limited cutaneous involvement. Originally described in association with Mycoplasma pneumoniae, RIME is now recognised to occur with other respiratory pathogens, including Chlamydia pneumoniae. Due to its rarity and clinical overlap with Stevens-Johnson Syndrome (SJS), RIME remains under-recognised, particularly in paediatric populations.

Case Presentation

We describe a previously healthy 10-year-old girl who presented with a two-week history of cough and coryza, followed by painful oral ulceration initially treated as herpes stomatitis. She subsequently developed bilateral genital labial erosions, conjunctival erythema and discrete erythematous targetoid lesions involving less than 10% of body surface area. Inflammatory markers were elevated, and respiratory pathogen testing identified C. pneumoniae as the sole detectable organism. No recent exposure to medications commonly implicated in SJS was found. Given the presence of severe multi-site mucositis, limited skin involvement, preceding respiratory illness and absence of a drug trigger, the presentation was considered more consistent with C. pneumoniae-associated RIME than classical drug-induced SJS. Initial concern for SJS prompted multidisciplinary supportive management, including ophthalmological assessment, ocular lubrication, intravenous fluids, topical corticosteroids and targeted mucosal care. The patient improved with supportive therapy alone, without progression of cutaneous involvement.

Conclusion

This case highlights the diagnostic challenge in distinguishing RIME from SJS. It also emphasises the importance of recognising RIME as a distinct clinical entity in children presenting with mucositis-predominant disease following respiratory infection. Key clinical features favoured RIME, including mucositis predominance, limited cutaneous involvement and absence of a drug trigger. Differentiating infectious mucocutaneous eruptions from drug-induced SJS has significant implications for acute management, prognosis, long-term follow-up and avoidance of inappropriate drug-allergy labelling. Increased awareness of C. pneumoniae-associated RIME will aid accurate diagnosis and optimise patient care.

EADV CONGRESS
VIENNA
30 SEP - 3 OCT 2026

Abstract N°: 314

Pediatric Lichen Sclerosus: Insights from a Large Multicenter Cohort

Edan Davidson*[1], Roni Twizer[1], Mor Sachs[1], Yasmin Leiba[1], Shoshana Greenberger[2], Hiba Zaaroura[3], Rivka Friedland[4], Ayelet Ollech[5], Amir Horev[6], Vered Molho Pessach[1]

[1] Department of Dermatology, Hadassah–Hebrew University Medical Center, Jerusalem, Israel
[2] Pediatric Dermatology Unit, Dermatology Department, Sheba Medical Center, Ramat Gan, Israel
[3] Department of Dermatology, Rambam Health Care Campus, Haifa, Israel
[4] Division of Dermatology, Beilinson Hospital, Rabin Medical Center, Petah Tikva, Israel
[5] Pediatric Dermatology Service, Shaare Zedek Medical Center, Jerusalem, Israel
[6] Department of Dermatology and Venereology, Soroka Medical Center, Beer Sheva, Israel

Introduction
Lichen sclerosus et atrophicus (LSA) is a chronic inflammatory dermatosis with a strong predilection for the anogenital region that carries the risk for scarring and long- term functional impairment. While well studied in adults, pediatric LSA remains poorly characterized. This study aimed to characterize epidemiological features, potential predisposing factors, clinical presentation, response to treatment and prognosis in the largest pediatric LSA cohort to date.

Materials and Methods
We performed a retrospective multicenter study across six Israeli tertiary medical centers. We identified 283 children diagnosed with genital LSA between 2007 and 2025. Patient demographics, clinical features, disease extent, treatments, and outcomes were collected from medical records. Associations with remission were analyzed using univariate methods.

Results
A total of 283 children were included. The median age at diagnosis was 7 years (range 2–18 years), with strong female predominance (97%), the majority were prepubertal at presentation. Autoimmune comorbidities were noted in 10%. Most patients (83.9%) were symptomatic when referred to a dermatologist, and pruritus was the most common presenting symptom (64%). Median symptom duration prior to dermatologic evaluation was 13.6 months. Extragenital involvement was documented in 15.7% of cases. All patients received topical corticosteroids as first-line therapy, and 52% required more than one treatment modality. Median follow-up duration was 4 months (IQR 0-15), 27% did not return after a single visit, and complete remission at the last visit was documented in 27%. These findings may suggest a favorable short-term course in some patients, although limited follow-up precludes firm conclusions. Longer follow-up duration was significantly associated with higher remission rates ($p = 0.013$), and older age at diagnosis was significantly associated with a lower likelihood of remission ($p = 0.025$). Long-term sequelae were infrequent: clitoral phimosis in 4.2%, labial adhesions in 3.8%, and no malignant transformation was observed.

Conclusions
This Israeli multicenter cohort of 283 children is the largest epidemiological investigation of pediatric LSA to date, and provides valuable insights into the clinical spectrum and natural history of the disease. These findings highlight the need for structured long-term follow-up in pediatric LSA, particularly in older children who may have a less favorable outcome.

EA DV CONGRESS
VIENNA
30 SEP - 3 OCT 2026

Abstract N°: 493

Complete Remission of Dissecting Cellulitis of the Scalp with Adalimumab in an Adolescent with Early-Onset Disease: Biologic Therapy Beyond Hidradenitis Suppurativa

Alexandra-Maria Alexe[1], Carmen Curea[1], Mihaela Cristina David Niculescu*[2]

[1] Colentina Clinical Hospital, Bucharest, Romania

[2] Grigore Alexandrescu Emergency Clinical Children's Hospital, Bucharest, Romania

Introduction

Hidradenitis suppurativa, dissecting cellulitis of the scalp, acne conglobata and pilonidal disease constitute the follicular occlusion tetrad, a group of disorders sharing a common pathogenic mechanism of follicular hyperkeratosis, occlusion, and subsequent follicular rupture with chronic inflammation.While biologic therapy is well established in hidradenitis suppurativa, evidence regarding its efficacy in dissecting cellulitis of the scalp remains limited. We report a severe case of concomitant disease, with particular emphasis on the response of dissecting cellulitis of the scalp to biologic therapy.

Case Presentation

We present the case of an 18-year-old male patient, smoker, with a 5-year history of extensive, diffuse dissecting cellulitis of the scalp and hidradenitis suppurativa involving axillary and inguinal regions bilaterally.
Previous treatments included azithromycin, oral isotretinoin (20 mg/day for 5 months), clindamycin (300 mg twice daily for 7 days), and doxycycline (100 mg/day for 2 months), with limited response.
At baseline, hidradenitis suppurativa was classified as Hurley stage III, with an IHS4 score of 19, indicating severe disease. DLQI was maximal, with marked psychological impairment, social withdrawal, and avoidance behaviors.
Adalimumab therapy was initiated in March 2025, when the patient was 17 years old, using the adolescent dosing regimen (80 mg loading dose followed by 40 mg subcutaneously every 2 weeks). Upon reaching adulthood, treatment was escalated to 40 mg weekly.
At initiation, the patient presented with extensive scalp involvement (~70%), with cicatricial alopecia, keloid scars, inflammatory nodules (n=6), abscesses (n=4), and draining sinus tracts (n=3), associated with persistent pain and suppuration. Hidradenitis suppurativa lesions were present in the axillary and inguinal regions bilaterally, though less extensive.
After 3 months of biologic therapy, a rapid clinical response was observed, with HiSCR achievement (>50% reduction in inflammatory lesions, estimated at 60%) and no new lesions. After 12 months, complete resolution of inflammatory activity was observed at the scalp level, with absence of nodules, abscesses, or active drainage, leaving only residual scarring.Hidradenitis suppurativa showed complete clearance of inflammatory lesions, with no nodules, abscesses, or draining fistulas (IHS4=0). Residual fibrotic sinus tracts and scarring persisted.
No new inflammatory lesions developed during follow-up.Treatment adherence was good throughout the follow-up period; however, the patient continued smoking despite repeated medical advice. Notably, a marked improvement in psychological status was observed, with resolution of social withdrawal, increased self-confidence, and reintegration into age-appropriate social activities, reflected by a significant improvement in quality of life.

Conclusion

This case supports the concept of a shared pathogenic pathway within the follicular occlusion tetrad and highlights the potential efficacy of adalimumab in treating not only hidradenitis suppurativa but also severe dissecting cellulitis of the scalp.While the benefit of biologic therapy in hidradenitis suppurativa is well established, its role in dissecting cellulitis remains less documented. Our findings suggest that early biologic intervention may

effectively control inflammation across the disease spectrum and significantly improve patient quality of life, although established scarring remains irreversible.

EA DV CONGRESS
VIENNA
30 SEP - 3 OCT 2026

Abstract N°: 495

Clinical and Evolutionary Profile of Pediatric Vitiligo: A Tertiary Dermatology Center Experience

Ouissal Hormi*[1], Salma Moujahid[1], Lamis El yamani[1], Nassiba Zerrouki[1], Nada Zizi[1]

[1] Department of Dermatology, Venereology and Allergology, Mohammed VI University Hospital Center, Oujda, oujda, Morocco

Introduction
Vitiligo is an acquired depigmenting disorder characterized by selective melanocyte loss, resulting in well-demarcated white macules. Pediatric vitiligo accounts for a significant proportion of cases and exhibits unique clinical and psychosocial characteristics compared to adults. The disease may substantially impair quality of life due to cosmetic concerns, stigmatization, and psychological vulnerability during childhood. Understanding the clinical presentation, triggers, and therapeutic responses in children is essential to guide early interventions and improve outcomes. This study aims to describe the epidemiological, clinical, dermoscopic, and evolutionary features of pediatric vitiligo, as well as the commonly employed therapeutic approaches in routine practice.

Materials and Methods
A retro-prospective observational study was conducted including children under 18 years followed for vitiligo over a 3-year retrospective period and 8-month prospective period in a tertiary dermatology setting. Data collected included demographics, age at onset, disease duration, triggering factors, family history, autoimmune comorbidities, clinical and dermoscopic features, treatment modalities, and quality-of-life impact assessed by the CHILD-DLQI. Therapeutic outcomes were monitored over follow-up visits.

Results
Fifty-eight children were included (mean age 11.6 ± 3.9 years; 58% female), with the highest representation in school-age children (6–11 years). Mean age at lesion onset was 7.1 ± 3.2 years, and mean disease duration 5.87 ± 1.98 years (range: 2 months–11 years). The average number of consultations before tertiary care was 2.4 ± 1.07, predominantly with dermatologists (75%).Triggering factors were identified in 45% of cases, mainly psychological stress (48%), cutaneous trauma/Koebner phenomenon (34%), and intercurrent infections (18%). Family history of vitiligo was present in 32%, and autoimmune comorbidities were observed in 12%, including atopic dermatitis, diabetes, and thyroid disorders. Phytotherapy was reported in 45% of patients. The mean CHILD-DLQI score was 13.9 ± 9.54, indicating significant quality-of-life impairment.Lesions predominated on the face (52%), followed by upper limbs (21%), trunk (14%), and lower limbs (12%). Nail involvement was rare (7%), manifesting as punctate or linear leukonychia. Dermoscopy revealed achromic areas in all patients, irregular linear and dotted vessels (71.4%), central residual pigmentation (50%), telangiectasia (35.7%), and perifollicular depigmentation (29.8%).Therapeutic approaches included topical corticosteroids (92%), topical calcineurin inhibitors (69%), mini-pulse systemic corticosteroids (23%), NB-UVB phototherapy (15.5%), and ruxolitinib in one patient. All patients received therapeutic education and photoprotection. Follow-up showed complete repigmentation in 71.4%, partial repigmentation in 19%, and progression in 9.5%.

Conclusions
Pediatric vitiligo is a chronic disease with early onset, female predominance, and a notable familial component, highlighting a potential genetic predisposition. Identified triggers, particularly stress and microtrauma, corroborate the literature on disease initiation and exacerbation. Facial involvement, typical in pediatric cases, appears associated with higher repigmentation potential, while nail involvement may reflect greater disease activity.

Dermoscopy proves valuable for identifying active inflammatory signs and monitoring treatment response. Early and tailored therapeutic strategies, including topical immunomodulators, systemic corticosteroids, and phototherapy, resulted in favorable repigmentation rates in the majority of patients.

EADV CONGRESS
VIENNA
30 SEP - 3 OCT 2026

Abstract N°: 515

Reactive Infectious Mucocutaneous Eruptions: A retrospective case series

Rishi Shah[1], Sulaiman Tomy*[1], Moira Adiotomre[1], Tom King[1]

[1] Sheffield Teaching Hospitals NHS Foundation Trust, Sheffield, United Kingdom

Introduction

Reactive infectious mucocutaneous eruption (RIME), previously termed mycoplasma-induced rash and mucositis (MIRM), is a rare mucocutaneous condition characterised by prominent mucositis with typically minimal cutaneous involvement post infection. MIRM was first described as a distinctive clinical entity separate from Steven-Johnson syndrome (SJS) and toxic epidermal necrosis (TEN) by Canavan et al in 2015, discerning MIRM infectious aetiology, milder disease course, favourable prognosis and variation in management. MIRM was later reclassified as RIME to account for various infective aetiologies contributing towards its manifestation.

There has been a rising incidence of RIME across the European continent post COVID-19. Following similar trends, since February 2023 an increased incidence of paediatric RIME has been observed locally in our United Kingdom centre.

Materials and Methods

A retrospective case-series involving six paediatric patients presenting with RIME at our centre between January 2020 and December 2025. Six male patients between the ages of 3-15 years old were identified and consented for the case series. Clinical features, investigations, management and outcomes were reviewed using electronic patient records.

Results

The cohort was exclusively male. RIME was the most frequent initial differential diagnosis (50% of cases), followed by Stevens-Johnson Syndrome (SJS). While all patients received supportive care, systemic treatment including corticosteroids, macrolide antibiotics, and intravenous immunoglobulins (IVIG).

Two patients had complete resolution without relapse whereas four experienced long-term sequelae. Two of them experienced recurrent relapses, one of whom demonstrated subjective improvement after commencement of prophylactic azithromycin. One experienced respiratory complications following Mycoplasma pneumonia, while the other psychological distress and genital mucositis affecting his foreskin.

Individuals who received immunomodulation with corticosteroids were noted to have a shorter disease course. Furthermore, those who had received both a macrolide antibiotics and corticosteroids within 5 days of onset of mucocutaneous symptoms during their initial episode interestingly did not have any relapses.

Conclusions

These cases reinforce that RIME can pose a diagnostic challenge on initial presentation, particularly the overlapping symptomology with SJS. While RIME is typically infection mediated and SJS is drug induced, a subset of paediatric SJS cases attributed to infection may represent misclassified RIME. Distinguishing between these entities is critical, as the diagnosis carries significant implications for clinical prognosis and the long-term

counselling of families regarding future triggers.

Early recognition, prompt infectious screening, and timely immunomodulation and antimicrobial therapy may improve outcomes and reduce disease duration. RIME has a favourable prognosis with no recorded deaths since the 1940's. Nevertheless, RIME can be associated with a substantial symptom burden, especially in recurrent cases, and with long-term sequelae the most common of which is recurrent mucosal inflammation and erosion. At present there is no consensus guidance on optimal management. We highlight the urgent need for paediatric-specific clinical guidelines and further research to establish optimal evidence-based management and prophylactic strategies.

EA DV CONGRESS
VIENNA
30 SEP - 3 OCT 2026

Abstract N°: 606

Efficacy and Safety of Risankizumab in Pediatric Patients With Psoriasis in the OptIMMize-1 Phase 3 Study: Results Through 52 Weeks

Nina Magnolo*[1], Lara Wine Lee[2], Adam Reich[3], Irene Lara-Corrales[4], Akimichi Morita[5], Michael Bukhalo[6], Ascuncion Vicente[7], Toni Anschutz[8], Rosie Lyles[8], Tshepiso Madihlaba[8], Kristina Unnebrink[8], Doug Ashley[8], Dolly Sharma[8], Amy Paller[8]

[1] Department of Dermatology, University Hospital Münster, Münster, Germany

[2] Department of Dermatology and Dermatologic Surgery, Medical University of South Carolina, Charleston, Charleston, United States

[3] 3Department of Dermatology, Faculty of Medicine, Medical College, University of Rzeszów, Rzeszów, Poland

[4] Department of Pediatrics, Division of Dermatology, The Hospital for Sick Children, Toronto, Toronto, Canada

[5] Department of Geriatric and Environmental Dermatology, Nagoya City University, Nagoya, Japan

[6] Arlington Dermatology, Rolling Meadows, Rolling Meadows, United States

[7] Department of Pediatric Dermatology, Hospital Sant Joan de Déu, Barcelona, Spain, Barcelona, Spain

[8] Department of Dermatology, Icahn School of Medicine at Mount Sinai, New York, New York, United States

Introduction

Treatment options for pediatric patients with psoriasis are limited, and new, more advanced therapies are needed. Risankizumab, a humanized immunoglobulin G1 monoclonal antibody that specifically inhibits IL-23 by binding to its p19 subunit, is approved for treating moderate-to-severe psoriasis in adults. Here, we evaluated the efficacy and safety of risankizumab in pediatric patients through 52 weeks.

Materials and Methods

OptIMMize-1 (NCT04435600) was a phase 3, multicenter, 4-part study of risankizumab in pediatric patients with moderate-to-severe PsO. Parts 1 and 3 evaluated pharmacokinetics (not shown). In part 2 period A (P2PA; results previously reported), adolescents (aged 12 to <18 years) were randomized 2:1 to risankizumab or ustekinumab for 16 weeks. At week 16 (start of part 2 period B [P2PB]), patients initially randomized to ustekinumab (UST-RZB group) and risankizumab nonresponders (defined as static Physicians' Global Assessment [sPGA] ≥2; RZB-NR-RZB group) received risankizumab for 36 weeks; risankizumab responders (defined as sPGA of clear/almost clear [sPGA0/1]) at week 16 were rerandomized 1:1 to risankizumab for 36 weeks (RZB-R-RZB group) or withdrawal until a disease flare (defined as sPGA ≥3 on or after week 28; RZB-R-W group). Patients in the RZB-R-W group who experienced a disease flare entered a 16-week retreatment period (part 2 period C [P2PC]). In part 4 (P4), children (aged 6 to <12 years) received open-label risankizumab for 52 weeks. Week 16 co-primary endpoints were ≥75% improvement in Psoriasis Area and Severity Index (PASI75), sPGA0/1, and sPGA0/1 with ≥2-grade improvement (sPGA0/1+≥2GI). At week 52, the proportion of patients achieving ≥75%/≥90%/100% improvement in PASI (PASI75/90/100), sPGA0/1, and sPGA0/1+≥2GI were assessed, as were Child Dermatology Life Quality Index and itch (not shown). Safety was evaluated throughout. Missing efficacy data were handled using nonresponder imputation.

Results

Of 82 adolescents enrolled in P2PA (risankizumab, n=54; ustekinumab, n=28), 81 entered P2PB (RZB-R-RZB, n=22; RZB-R-W, n=21; RZB-NR-RZB, n=10; UST-RZB, n=28). At week 52, patients in the RZB-R-RZB group maintained durable responses (PASI75|90|100, 100%|95.5%|68.2%; sPGA0/1, 95.5%; sPGA0/1+2GI, 90.9%). Response rates for

the RZB-NR-RZB group were: PASI75|90|100, 90.0%|60.0%|30.0%; sPGA0/1, 50.0%; sPGA0/1+2GI, 50.0%; and for the UST-RZB group were: PASI75|90|100, 96.4%|89.3%|46.4%; sPGA0/1, 89.3%; sPGA0/1+2GI, 89.3%. Some adolescents in the RZB-R-W group lost response after risankizumab withdrawal (PASI75|90|100, 57.1%|28.6%|9.5%; sPGA0/1, 42.9%; sPGA0/1+2GI, 33.3%). Among 8 adolescents from the RZB-R-W group who received 16 weeks of risankizumab retreatment (P2PC), response rates were: PASI75|90|100, 87.5%|87.5%|25.0%; sPGA0/1, 62.5%; sPGA0/1+2GI, 62.5%. Among the 30 children who enrolled in P4, week 52 response rates were: PASI75|90|100, 86.7%|80.0%|63.3%; sPGA0/1, 83.3%; sPGA0/1+2GI, 80.0%. Risankizumab was well tolerated in study parts 2 and 4; compared with previous adult psoriasis studies, no additional adverse drug reactions or safety concerns were identified.

Conclusions

In pediatric patients, risankizumab treatment through week 52 generally maintained or improved upon week 16 results. Most adolescents who experienced a flare after withdrawing from risankizumab regained clinical responses after 16 weeks of retreatment. The risankizumab safety profile in children and adolescents was generally consistent with that observed in adult psoriasis studies. Together, these findings support the use of risankizumab to treat pediatric patients with moderate-to-severe psoriasis.

EA DV CONGRESS
VIENNA
30 SEP - 3 OCT 2026

Abstract N°: 624

Efficacy and Tolerability of A Cream Containing 5% Panthenol and Prebiotic Complex on Skin Barrier Repair in Pediatric Cancer Patients Undergoing Antineoplastic Therapy: A Prospective Study

Yi Li[1], Qiongfang Kang[1], Yong Zhan[1], Rui Dong[1], Rui Li*[2], Yijie Zheng[2]

[1] Department of Pediatric Surgery, Children's Hospital of Fudan University, Shanghai 201102, China, Shanghai, China

[2] La Roche Posay, L'Oréal Dermatological Beauty, L'Oréal China, Shanghai, China

Introduction

Antineoplastic therapies frequently induce skin toxicities in pediatric cancer patients, with a reported prevalence of up to 93.7%. Children are particularly susceptible due to an inherently vulnerable skin barrier. These cutaneous adverse events not only impair quality of life but may also necessitate dose modifications, potentially compromising oncological outcomes. The pathophysiology involves a self-perpetuating cycle of barrier dysfunction and microbiome dysbiosis. While ingredients like panthenol and prebiotic complex support skin recovery, clinical evidence in pediatric oncology remains scarce. This prospective study aims to evaluate the efficacy and tolerability of a cream containing 5% panthenol and prebiotic complex in restoring barrier function and alleviating symptoms in this vulnerable population.

Materials and Methods

A total of 40 pediatric patients with cancer aged 4–16 years were enrolled in this study, including 14 males and 26 females. One patient had a history of medication use related to rhabdomyosarcoma. Clinical efficacy and tolerability were assessed at baseline (T0), immediately post-application (T1), 14 days post-application (T14), and 28 days post-application (T28) using instrumental measurements, physician-reported outcomes, and patient-reported outcomes.

Results

1) Instrumental measurement results indicated a significant increase in stratum corneum hydration at T1 and T28 (Figure 1).

2) Physician-reported total skin barrier improvement score and all sub-scores improved significantly at all follow-up time points compared with baseline. Significant improvement occurred immediately after application, and 28-day use resulted in greater improvement than 14-day use (Figure 2).

3) Following product application, the Overall Dry Skin (ODS) scores improved significantly relative to baseline. Significant improvement occurred immediately post-application, and the improvement after 28 days of continuous use was significantly superior to that after 14 days (Figure 3A). Total scores for all self-assessment sensitivity items also improved significantly (Figure 3B).

4) After product application, both objective and subjective tolerance parameters improved significantly. Objective sub-items, including skin desquamation, erythema, peeling, and dryness, improved significantly (Figure 4A-D). Subjective sub-items (prickling, burning, tightness, and itching) showed numerical improvement (Figure 4E-H).

5) Patients' quality of life index scores improved significantly after product application, and the improvement increased with longer use duration (Figure 5).

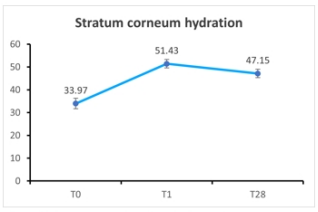

Figure 1. Stratum corneum hydration at different time points (compared to T0, *P < 0.05).

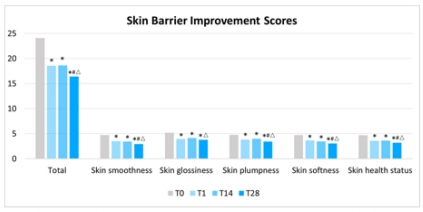

Figure 2. Skin barrier improvement scores at different time points (compared to T0, *P<0.05; compared to T1, #P<0.05; compared to T14, △P<0.05).

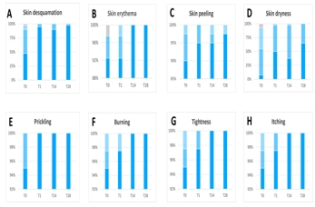

Figure 4. Trend plots of objective and subjective tolerance parameters over time: (A) skin desquamation, (B) erythema, (C) peeling, (D) dryness; (E) prickling, (F) burning, (G) tightness, (H) itching.

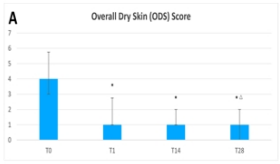

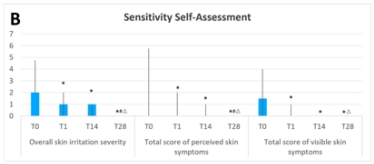

Figure 3. Scores of self-assessed (A) skin dryness and (B) skin sensitivity at different time points (compared to T0, *P<0.008; compared to T1, #P<0.008; compared to T14, △P<0.008; error bars indicate the interquartile range).



Figure 5. Quality of life index scores at different time points (compared to T0, *P<0.017; compared to T14, △P<0.017; error bars indicate the interquartile range).

Figure 1. Stratum corneum hydration at different time points (compared to T0, *P < 0.05). Figure 2. Skin barrier improvement scores at different time points (compared to T0, *P<0.05; compared to T1, #P<0.05; compared to T14, △P<0.05). Figure 3. Scores of self-assessed (A) skin dryness and (B) skin sensitivity at different time points (compared to T0, *P<0.008; compared to T1, #P<0.008; compared to T14, △P<0.008; error bars indicate the interquartile range). Figure 4. Trend plots of objective and subjective tolerance parameters over time: (A) skin desquamation, (B) erythema, (C) peeling, (D) dryness; (E) prickling, (F) burning, (G) tightness, (H) itching. Figure 5. Quality of life index scores at different time points (compared to T0, *P<0.017; compared to T14, △P<0.017; error bars indicate the interquartile range).

Conclusions

This study shows that the skin barrier repair product improves barrier function and skin hydration in pediatric cancer patients, alleviating dryness and sensitivity and enhancing quality of life. A cream containing 5% panthenol and prebiotic complex exhibits a rapid onset of action, with progressively enhanced efficacy observed after 28 days of continuous use, and demonstrates favorable tolerability—providing an evidence-based skincare solution for this vulnerable population.

EA DV CONGRESS
VIENNA
30 SEP - 3 OCT 2026

Abstract N°: 679

Paediatric Cutaneous Mastocytosis – Case series from a tertiary care center

Vidyadhar Rajaram Sardesai*[1], Gautam Kumar Singh[2], Raheel Khan[2]

[1] Bharati Vidyapeeth (Deemed to be University) Medical College, Pune, Pune, India
[2] Bharati Vidyapeeth (Deemed to be University) Medical College, Pune, India

Introduction

Mastocytosis is a rare, heterogeneous group of disorders characterized with an abnormal expansion and accumulation of mast cells in one or more organ system. In paediatric patients, the manifestations are predominantly cutaneous. It commonly results activating mutations in KIT gene, especially KIT D816V. The World Health Organization (WHO) 2016 classification divides the disease into cutaneous and systemic types. This case series highlights the diagnostic importance of histopathology in paediatric cutaneous mastocytosis by presenting a detailed analysis of six patients and comparing histological findings with one another.

Case Presentation

A retrospective study was conducted at a tertiary centre involving six paediatric patients (aged 2–6 years) with dark pigmentation, red patches and itching as their primary dermatological complaints. All underwent clinical, dermoscopic, and histopathological evaluation to establish a diagnosis of Cutaneous mastocytosis (CM). Each patient exhibited positive Darier's sign, characterized by erythema and swelling upon rubbing or stroking. Immunohistochemistry and special stains provided additional diagnostic support. Case details are summarized in Table no.1.

In our case series, all six paediatric patients with varying presentations of CM were evaluated. Most presented with erythematous to hyperpigmented macules, suggestive of maculopapular cutaneous mastocytosis (MPCM), the most common paediatric variant of CM. One patient had a solitary mastocytoma, characterized by a well-circumscribed nodule over back, and another was diagnosed with Telangiectasia macularis eruptiva perstans (TMEP), a rare localized variant. The lesions in our patients appeared within the first year of life, consistent with known epidemiological patterns. Darier's sign was positive in all cases and no systemic symptoms were observed. Classical dermoscopic features observed in CM—such as diffuse light brown blotting, ill-defined yellow-orange blotting, pigment network formation, and reticular vascular patterns—were consistently identified in patients included in our study as well. These findings further support the use of dermoscopy as a valuable non-invasive diagnostic tool in the clinical evaluation. Bone marrow biopsy in one patient, done due to parental concern about possible systemic involvement, showed no evidence of SM.All six patients were treated symptomatically with oral antihistamines (H1 blockers such as cetirizine) for pruritus and mast cell related symptoms. Detailed information regarding medications, dosages, duration of therapy, follow-up, and treatment response is summarized in Table 2.Parents were counselled about trigger avoidance and the importance of ongoing monitoring. Patients were followed up monthly for the first 3 months and subsequently every 3 months, with a total follow-up duration ranging from 12–24 months (mean follow-up-18 months). Response to treatment was monitored at each follow-up visit using clinical assessment and symptom evaluation, including reduction in pruritus severity, decrease in whealing on rubbing (Darier's sign reactivity), reduction in erythema , frequency of flare episodes based on parental reporting, and absence of new lesion development. Disease severity and therapeutic response were additionally assessed using the SCORMA index. Serum tryptase level monitoring was performed in one patient with extensive disease to screen for systemic involvement.In indolent or smoldering forms, symptomatic management like systemic antihistamines, leukotrienes inhibitors, proton pump inhibitors are preferred.

Table 1: Comparative analysis of multiple cases of mucocutaneous mastocytosis

Case no.	Age	Age of onset	Clinical features	Dermoscopy findings	Histopathological findings	IHC (CD117)	Special Stains (Giemsa/ Toluidine)
1	3y/F	6 months	Multiple itchy, brown coloured macules over trunk and bilateral upper and lower limbs. Darier's sign- positive (figure 1-A). There was no episodes of anaphylaxis or any systemic features	Light brown blotches with pigment network, linear vessels	Papillary dermis- predominantly collection of mast cells around capillaries. Mast cells- round to spindle shaped with pale nuclei and abundant eosinophilic cytoplasm. Few lymphocytes, plasma cells and eosinophils present.	Positive	Granules visible in mast cells.
2	4y/M	2 months	Multiple, polysized, hyperpigmented macules over lower limbs and blisters over right lower limb (figure 1-B) Darier's sign- positive. There was no episodes of anaphylaxis or any systemic features	Structureless pink to light brown background with a light brown reticular pigment network is seen. Fine linear vessels (linear or slightly curved) are scattered. (figure 2- A)	Epidermis: Normal Dermis: mild to moderate inflammatory infiltrate with numerous oval to spindle-shaped mast cells . Cells contain with elongated nuclei . (figure 2-B)	Positive	Background tissue is stained blue. Dark blue/dark purple granules are seen scattered throughout the tissue exhibiting metachromasia. (figure 2-C)
3	2y/F	at birth	Solitary raised, dome-shaped reddish-brown nodule over lower back . Darier's sign - positive	Yellow-orange homogeneous area with linear vessels at periphery	Epidermis: Intact with mild hyperpigmentation of basal keratinocytes. Dermis: Dense sheet-like infiltrate of mast cells occupying full thickness of dermis with extension into subcutaneous fat. Mast cells - abundant cytoplasm.	Positive	Granules strongly visible in mast cells.
4	6y/F	2.5 months	Multiple hyperpigmented macules over trunk, bilateral upper and lower limb Darier's sign- positive	Structureless pink background with white scaling, mild peripheral vascular patter	Epidermis: Normal Dermis: Diffuse mast cell infiltration, mainly around vessels and nerves	Positive	Granules visible in mast cells.
5	5y/M	At birth	Erythematous plaque over right heel with mild scaling. Darier's sign- positive (Figure 1-C)	Uniform brown areas with dotted and linear vessels	Epidermis: orthokeratosis Dermis: Moderate mast cell infiltrate in a perivascular and interstitial pattern. Mild fibrosis seen.	-	-
6	3y/M	1.5 months	Hyperpigmented macules and erosions over abdomen. (figure1-D) Darier's sign- positive	Fine pigment network with yellow background, scattered vessels	Epidermis: Unremarkable. Dermis: Scattered and perivascular mast cell infiltrate, sparing the deep dermis.	Positive	Granules visible in mast cells.

Table 1: Comparative analysis of multiple cases of mucocutaneous mastocytosis

Conclusion

By analysing six paediatric cases, this case series reinforces the significance of timely clinical evaluation, histopathology and management of cutaneous mastocytosis.

Table 2: Treatment Details, Duration, and Clinical Response

Case	Treatment Given	Dosage	Duration of Therapy	Follow-up Duration	Response to Treatment
1	Cetirizine	0.25 mg/kg BD	12 months	18 months	Pruritus markedly reduced, no new lesions
2	Cetirizine + Hydroxyzine (night)	Cetirizine 0.25 mg/kg OD; Hydroxyzine 0.5 mg/kg HS	8 months	16 months	Whealing episodes resolved, improved sleep
3	Cetirizine + Short course Prednisolone	Cetirizine 0.25 mg/kg BD; Prednisolone 1 mg/kg/day tapered over 10 days	Antihistamine 12 months	24 months	Rapid control of erythema/blistering
4	Cetirizine	0.25 mg/kg BD	18 months	20 months	Lesion less reactive; no progression
5	Levocetirizine	5 mg BD	12 months	15 months	No new lesions
6	Levocetirizine	5 mg BD	15 months	18 months	Reduced pruritus

Table 2: Treatment Details, Duration, and Clinical Response

EA DV CONGRESS
VIENNA
30 SEP - 3 OCT 2026

Abstract N°: 765

Severe Psoriasis in a Mabry-like Phenotype (ARV1 Mutation): A Potentially Unique Clinical Association

nihed hachemi*[1], Boumediene Dahmani[1]

[1] Department of Dermatology and Venereology, Tlemcen University Hospital, Tlemcen, Algeria

Introduction

Psoriasis is a common chronic inflammatory dermatosis. Its association with rare genetic diseases remains exceptional, particularly within the context of Mabry syndrome and its related "Mabry-like" forms. This constitutes an unusual clinical situation that is rarely reported in the literature.

Case Presentation

We report the case of a 9-year-old girl, initially followed in pediatrics for Mabry syndrome associated with cutaneous psoriasis, with a history of cleft palate and a similar family history in her sister. The diagnosis of psychomotor delay within Mabry syndrome was established at age 2 based on axial hypotonia, global motor and language acquisition delays, facial dysmorphism, epilepsy, and major hyperphosphatasemia at 20 times the normal limit. During follow-up, she developed chronic erythematosquamous lesions diagnosed as psoriasis, which initially responded well to topical corticosteroids. However, she recently experienced a severe flare resulting in diffuse dry erythroderma covering over 90% of the body surface, characterized by pinkish erythema with whitish scales, a scaly "helmet" on the scalp, and nail pitting. Extra-dermatological examination also revealed joint stiffness with fixed deformity and thick otorrhea of the left ear. Genetic testing confirmed a Mabry-like phenotype through an ARV1 gene mutation, and systemic methotrexate was initiated due to the severity of the skin involvement.

Mabry syndrome, also known as Hyperphosphatasia with Mental Retardation Syndrome (HPMRS), belongs to the group of glycosylphosphatidylinositol (GPI)-anchor biosynthesis disorders. It is classically linked to autosomal recessive mutations in genes directly involved in this pathway—notably **PIGV, PIGO, PGAP2, and PGAP3**. These mutations lead to defective anchoring of membrane proteins, which accounts for the characteristic neurological manifestations, dysmorphism, and hyperphosphatasemi. Related "Mabry-like" forms have been described in association with atypical gene mutations not traditionally involved in this pathway, such as **ARV1**, suggesting an expansion of the spectrum of GPI-anchor disorders or the existence of shared, yet poorly understood, pathophysiological mechanisms. In this context, our case highlights a genetically confirmed Mabry-like phenotype associated with **severe psoriasis**. Psoriasis is a multifactorial chronic inflammatory dermatosis involving complex immune mechanisms; it results in keratinocyte hyperproliferation secondary to the overactivation of the phospholipase C signaling system, which subsequently leads to decreased expression of GPI-anchored proteins.To our knowledge, such a distinct association between psoriasis and Mabry or Mabry-like syndrome has not yet been reported in the literature. While this coexistence could be coincidental, it raises the hypothesis that immune disruptions linked to GPI-anchor anomalies may play a role in the pathophysiology of psoriasis, lending this case particular clinical and scientific significance.

Conclusion

This observation highlights a rare and possibly unique association between a Mabry-like phenotype and severe psoriasis. It underscores the importance of recognizing and reporting these atypical forms to enrich our

understanding of the clinical spectrum of GPI-anchor-related anomalies.

Abstract N°: 781

LUPUS PANNICULITIS IN AN 11-YEAR-OLD CHILD WITH TYPE 1 DIABETES MELLITUS

David Polly Thekkinadeth*[1]

[1] PALAKKAD INSTITUTE OF MEDICAL SCIENCES, PALAKKAD, KERALA, India

Introduction

Lupus panniculitis is a rare condition that primarily affects adults and is even more uncommon in children. Its rarity, combined with variable clinical presentations and limited diagnostic tools in pediatric cases, often leads to misdiagnosis or oversight. Additionally, its association with diabetes mellitus warrants further investigation.

Case Presentation

An 11-year-old child, a known case of type 1 diabetes mellitus (DM) on regular medication, presented with thickened, erythematous, plaque-like lesions over both thighs, extending posteriorly and medially. The lesions had been present for five years. A skin biopsy was performed, confirming the diagnosis of lupus panniculitis. Despite receiving treatment for type 1 DM, the patient had not been treated for the cutaneous lesions over the years. She was started on hydroxychloroquine and is currently under evaluation.



Thickened erythematous plaque like lesion over the anterior aspect of bilateral thighs

Conclusion

This case highlights the rarity of lupus panniculitis in children, its association with type 1 DM, and the importance of early diagnosis and appropriate treatment to prevent complications.

POWERED BY M-ANAGE.COM

EADV CONGRESS
VIENNA
30 SEP - 3 OCT 2026

Abstract N°: 800

Cutaneous Manifestations of Mitochondrial Disease: Early Reticulated Hyperpigmentation in a Kearns–Sayre Spectrum Case.

Daniel de Ramón Rueda*[1], Andrea Fuentes Bellas[1], Victoria Robles Almazán[1], Raquel Horcajo Ortega[1], Alba Bergaz Alonso[1], Marina de la Puente Alonso[1], Luis Zamarro Díaz[1], Belén Rodríguez Sánchez[1], Jorge Martín Nieto[1], Rocío García Uzquiano[1], Pablo de la Cueva Dobao[1], Minia Campos Domínguez[1]

[1] Hospital Gregorio Marañón, Madrid, Spain

Introduction

Cutaneous manifestations in mitochondrial diseases are underrecognized and may precede systemic involvement. Due to their high metabolic demand and environmental exposure, the skin may reveal early signs of mitochondrial dysfunction before classical neurological or cardiac features.

Case Presentation

A 10-year-old boy with ADHD, autism spectrum disorder, and short stature, under neurological follow-up for suspected metabolic encephalopathy, was referred for evaluation of asymptomatic symmetric reticulated brown macules involving the neck, flexures, trunk, and lower limbs. Lesions were present since birth and showed seasonal worsening during summer.Histopathology revealed mild epidermal hyperplasia, interpapillary ridge elongation, and pigmentary incontinence with dermal melanophages, without keratin cysts. Doxycycline treatment was ineffective, excluding confluent and reticulated papillomatosis.Brain MRI showed T2/FLAIR hyperintensities with diffusion restriction involving the parieto-occipital white matter, basal ganglia, brainstem, and cerebellum. MR spectroscopy demonstrated decreased N-acetylaspartate and lactate/lipid peaks, consistent with neuronal dysfunction and impaired energy metabolism. Laboratory studies revealed hyperlactatemia (5.8 mM) and elevated alanine. Urinary organic acids suggested a mitochondrial respiratory chain defect.Genetic testing identified a single large-scale mitochondrial DNA deletion (4.5 kb) with 95% heteroplasmy in blood and urine. Cardiac and ophthalmologic evaluations remain normal, with absence of classical Kearns–Sayre manifestations. However, the patient shows early multisystem involvement, including neurodevelopmental features and short stature, consistent with an incomplete Kearns–Sayre spectrum phenotype.

Conclusion

Reticulated hyperpigmentation may represent an early and accessible clinical marker of mitochondrial DNA deletion syndromes. Seasonal worsening suggests a possible role of UV-induced oxidative stress in unmasking underlying mitochondrial dysfunction. Cutaneous involvement may reflect early bioenergetic failure in a metabolically demanding organ system. Recognition of this pattern may facilitate early diagnosis and multidisciplinary evaluation before classical Kearns–Sayre features develop.

EA DV CONGRESS
VIENNA
30 SEP - 3 OCT 2026

Abstract N°: 838

Bilateral Involvement in CHILD Syndrome Successfully Treated with Cholesterol-Lovastatin Combination

Metin Zeyrek*[1], Sibel Ersoy Evans[1], Kerem Balan[1]

[1] Hacettepe University, School of Medicine, Department of Dermatology and Venereology, Ankara, Türkiye

Introduction

Congenital hemidysplasia with ichthyosiform erythroderma and limb defects (CHILD) syndrome is an X-linked dominant disorder primarily affecting the skin and skeletal system. Although the most prominent findings are dermatological and skeletal abnormalities; however multisystem involvement may occur, affecting the central nervous, cardiovascular, respiratory, genitourinary, and endocrine systems. In the majority of cases, unilateral dermatosis and skeletal deformities are the initial manifestations. However, cases with bilateral involvement have also been reported in the literature. The pathogenesis of the disease is typically associated with mutations in NSDHL gene, located on the long arm of the X chromosome atposition 28 (Xq28). These mutations disrupt cholesterol biosynthesis, leading to the clinical manifestations of the syndrome. Cholesterol-lovastatin therapy, which regulates cholesterol levels in the skin, has been previously tried for skin lesions and found to be effective. Herein, we present a case with bilateral involvement and a novel mutation in the NSDHL gene who showed significant improvement with topical cholesterol-lovastatin combination therapy.

Case Presentation

A 7-year-old female presented to thedermatology clinic due to rash in her right armpit and bilateral groins. The rash started aroundthe age of 1 year, first in the groin and then on right armpit. Topical antifungals and topicalcorticosteroids were used for a long time with the diagnosis of seborrheic dermatitis anddiaper dermatitis without much improvement. A skin biopsy was performed from the inguinalregion that revealed parakeratosis, spongiform pustule formation in one area, lack of granularlayer in epidermis, partially regular acanthosis, and suprapapillary thinning. After biopsy, thepatient was diagnosed as pustular psoriasis and topical calcineurin inhibitors, topicalcalcipotriol and various topical corticosteroid creams were recommended none of which wereeffective. Her medical history was remarkable for intrauterine growth retardation (IUGR).After birth, she was hospitalized in the neonatal intensive care unit for 15 days due to verylow birth weight (< 1500 g). She had right renal agenesis and a twin who was succumbed todeath at 10th week of gestation. The patient's mother had 2 spontaneous abortions at 6 and 5weeks' gestations, respectively. Otherwise family history was unremarkable. Dermatologicalexamination revealed fissures on lip commissures (Figure 1A), erythematous, sharplydemarcated hyperkeratotic plaques with yellow oily scales, and occasional maceration onright axilla (Figure 1B), genital area including inguinal areas (Figure 1C). There were alsoerythematous plaques with yellow hyperkeratotic scales on periungual skin of both hands andfeet as well as subungual hyperkeratosis, that was more prominent on the toenails (Figure 1D-E-F). In addition, she had syndactyly of 2-3rd left toes (Figure 1D) and brachydactyly of right5th finger of the right hand (Figure 1F). Based on clinical findings, CHILD syndrome wassuspected and genetic analysis showed a heterozygous mutation in exon 5 of NSDHL genewith c.449T>C (p.Phe150Ser) variant. Consequently, treatment with cholesterol 2%/lovastatin2% topical ointment was started that resulted in complete regression of skin lesions onflexural areas and partial regression on periungual regions at the end of first week. Norecurrence of the lesions was observed at the 2-year follow-up during ongoing treatment (Figure 2).

Figure 1



Figure 2

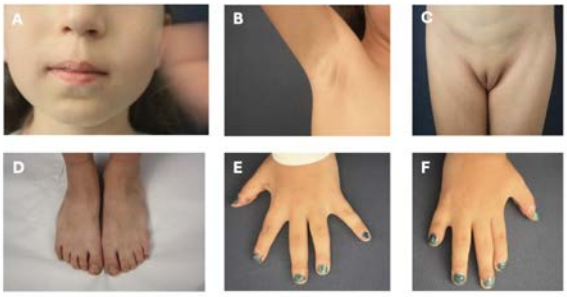

Conclusion

In conclusion, this case represents a rare bilateral presentation of CHILD syndromeassociated with a novel NSDHL mutation. The patient's rapid and sustained improvementwith topical cholesterol–lovastatin therapy highlights the effectiveness of pathogenesis-basedtreatment. This report broadens the known clinical and genetic spectrum of CHILD syndromeand underscores the importance of considering this diagnosis in atypical, treatment-resistantdermatoses accompanied by limb anomalies.

EADV CONGRESS
VIENNA
30 SEP - 3 OCT 2026

Abstract N°: 869

Deep-learning–supported recognition of hypohidrotic ectodermal dysplasia in a child in a tropical climate: a clinical case and practical thermoprotection strategy

SƠN ĐỖ TIẾN*[1, 2], TRẦN THUỲ DƯƠNG[2]

[1] Tâm Anh Hospital, Hanoi, Viet Nam

[2] DermaButter Dermatology Service, Hanoi, Viet Nam

Introduction

Hypohidrotic ectodermal dysplasia (HED, Christ–Siemens–Touraine syndrome) is a rare genodermatosis characterised by hypohidrosis/anhidrosis, xerosis–eczema tendency, hypotrichosis and hypodontia. In hot, humid (tropical) climates, impaired sweating can precipitate hyperthermia, while barrier dysfunction increases eczema and infection risk. Early recognition is often delayed when children are first assessed by paediatricians not specialised in dermatology. Facial deep-learning tools may accelerate syndromic suspicion and trigger earlier prevention counselling.

Case Presentation

A 9-year-old girl presented with lifelong absence of sweating, sparse scalp hair/eyebrows, marked xerosis and abnormal conical teeth. In a non-dermatology paediatric setting, a facial-phenotyping application using a convolutional neural network (DeepGestalt/Face2Gene) analysed a frontal facial photograph and ranked HED among the leading candidate diagnoses, highlighting a compatible facial gestalt (prominent forehead, depressed nasal bridge, full/everted lips). Guided by this output, targeted history confirmed heat intolerance and the inability to sweat, and focused examination of hair, skin and dentition supported a clinical diagnosis of HED and prompt referral planning. Climate-adapted counselling prioritised prevention of heat-related morbidity and restoration of the cutaneous barrier. Core measures included (i) environmental cooling (air-conditioning when possible; avoidance of midday outdoor activity), (ii) evaporative cooling protocols (water spray + fan; cool wet cloths to neck/axillae/groin during exertion), (iii) hydration scheduling and caregiver education on early signs of heat illness, and (iv) intensive emollient therapy after lukewarm bathing with soap-free cleansers; short courses of appropriate anti-inflammatory topical therapy for eczema flares; and low-irritancy mineral photoprotection. Proposed (author-designed) “Tropical HED Heat-Safety Bundle” for non-dermatology clinics and caregivers: a simple checklist + kit concept to standardise counselling at first contact, comprising (1) a heat-risk triage card (anhidrosis history, past overheating episodes, activity restrictions), (2) a home/school cooling plan template (classroom seating near fan/AC, shaded transport, PE exemptions during heat index alerts), (3) an emergency cooling algorithm (rapid clothing removal, mist-and-fan, cool packs to major vessels, seek urgent care), and (4) a barrier-care starter regimen (cleanser + high-lipid emollient + flare plan).

Conclusion

This case illustrates that deep-learning facial phenotyping can support earlier recognition of HED by non-dermatology paediatricians, enabling timely, climate-specific prevention of hyperthermia alongside skin-barrier management. Such tools should complement—not replace—clinical assessment and genetic confirmation when available.

EADV CONGRESS
VIENNA
30 SEP - 3 OCT 2026

Abstract N°: 876

When the Variant Deviates: Neurological Involvement in XP-V

Seddiki Meriem*[1], Saliha Takheroubt[1], Samira Zobiri[1]

[1] Mustapha University Hospital Center, Algiers, Algeria

Introduction

Neurological involvement in xeroderma pigmentosum (XP) mainly affects the severe early forms (XPA, XPD, XPG). XP-V, usually spared, is characterized by the absence of neurological manifestations. We report an atypical case of XP-V associated with ocular myasthenia and neurocognitive impairment.

Materials and Methods

A 13-year-old boy, born from a second-degree consanguineous marriage, was initially managed at the age of 9 for a clinical picture compatible with ocular myasthenia: fluctuating left ptosis, muscular fatigability with exertion, and clear improvement with anticholinesterase treatment. The diagnosis of seronegative myasthenia was retained and confirmed by electromyography. Complementary investigations including brain MRI, EEG, OCT, and thoracic CT scan showed no abnormalities, and AchR and LRP4 serology were negative.In parallel, from the age of 6 the patient presented a significant academic delay (third year of primary school at 13 years old), stuttering, speech articulation disorders, and gait disturbance, contrasting with an initially normal psychomotor development.During a dermatological consultation motivated by a suspicious pigmented lesion, examination revealed facial poikiloderma, diffuse lentigines on photo-exposed areas (décolleté, legs, forearms), moderate to severe photosensitivity, and mild photophobia. The clinical presentation suggested a variant form of xeroderma pigmentosum (XP-V); genetic confirmation is currently in progress.



Facial poikiloderma with diffuse lentigines on photo-exposed areas

Results

Neurological involvement is classically limited to the XPA, XPD, and XPG groups, variably associating cerebellar ataxia, axonal peripheral neuropathy, cognitive impairment, sensorineural hearing loss, motor disorders (spasticity, chorea), oculomotor abnormalities, and cerebellar atrophy on MRI.XP-V is generally described as neurologically spared, with a more favorable overall prognosis. No cases of myasthenia have been reported in XP across all subtypes. This association with XP-V is therefore unprecedented. The coexistence of XP-V and myasthenia, in a

context of consanguinity, raises the question of a possible combined syndrome.

Conclusions

This case suggests a possible expansion of the neurological spectrum of XP-V. It supports the need for neurological follow-up even in forms traditionally considered benign. The association between XP-V and myasthenia has not been described to date.

EADV CONGRESS
VIENNA
30 SEP - 3 OCT 2026

Abstract N°: 898

Jacquet erosive dermatitis- severe form of diaper dermatitis in an infant

Joanna Krzysiek-Daszuta*[1], Aleksandra Lesiak[1], Joanna Narbutt[1]

[1] Medical University of Lodz, Department of Dermatology- Pediatric and Oncological Dermatology, Lodz, Poland

Introduction

Diaper dermatitis is the most common inflammatory eruption in the diaper area of infancy, peaking between 9 and 12 months of age and affecting approximately half of infants. Contributing factors include increased skin pH, microbial overgrowth- particularly Candida albicans- and inadequate hygiene. Additional triggers such as diarrhea, sensitivity or allergy to topical products, and oral antibiotic use may further exacerbate the condition. Jacquet erosive diaper dermatitis (JED) is a rare and severe variant, characterized by well-demarcated erosions, ulcerations, and crater-like lesions in the diaper area. Its alarming clinical appearance, associated pain, and risk of secondary infection may mimic other dermatological or infectious diseases, posing a diagnostic challenge. This poster presents a case of JED, highlighting its clinical features, predisposing factors, differential diagnosis, and management to improve early recognition and appropriate treatment.

Case Presentation

A 14-month-old girl was admitted with a two-month history of progressive skin lesions in the diaper area. Initially presenting as erythematous, erosive lesions in the perianal and sacral regions, the condition evolved into well-demarcated lesions with reddened borders and symmetrical distribution. Despite prior topical therapy, no improvement was observed, and the lesions gradually worsened. On admission, severe diaper dermatitis complicated by bacterial superinfection was diagnosed. Treatment included systemic antibiotics (cefuroxime) and antifungal therapy (fluconazole), along with topical application of 1% pioctanine solution and barrier preparations to support skin healing. Caregivers were instructed on proper hygiene measures, including frequent diaper changes, gentle cleansing, and maintaining a dry environment. Gradual clinical improvement was achieved, and the patient remained under follow-up to ensure complete resolution and prevent recurrence.

Conclusion

Jacquet erosive diaper dermatitis is a rare but severe condition with a more prolonged and complicated course than typical diaper dermatitis. Early recognition and a comprehensive management approach, including pharmacological treatment and meticulous skin care, are essential for optimal outcomes. Proper daily hygiene of the diaper area plays a key role in both treatment and prevention, and increased vigilance is warranted in patients with predisposing risk factors.

EA DV CONGRESS
VIENNA
30 SEP - 3 OCT 2026

Abstract N°: 900

Cutis Verticis Gyrata Secondary to a Cerebriform Intradermal Nevus: A Rare Case in a Pediatric Patient

Amanda Periquito[1], Cristal Meira Feitosa[1], Jessica Jacomasso[1], Luiza Kassuga[1], Mariana Lesqueves*[1], Viviane Tortelli[1], Suzanne Tortelli[1], Yuliana Oros Sucari[1], Ursula Vizzoni[1]

[1] Instituto Nacional de Câncer, Rio de Janeiro, Brazil

Introduction

Cutis verticis gyrata (CVG) is a rare condition characterized by excessive scalp skin on the scalp, producing thick folds that form grooves resembling the gyri of the cerebral cortex. CVG may be classified into two forms: primary (essential and non-essential) and secondary.

The primary non-essential form accounts for 0.5% of patients with intellectual disability; cerebral palsy, epilepsy, cataracts, and blindness may be present. In contrast, the primary essential form is not associated with neurological or ophthalmological abnormalities and presents only with the formation of scalp folds which mimic the cerebral gyri; it appears during puberty and occurs predominantly in males.

Secondary forms of CVG are most frequently represented by pachydermoperiostosis, acromegaly, and cerebriform intradermal nevus. In children, cases of CVG—regardless of etiology—are very rare, and the few reported cases are due to the primary non-essential form, associations with genetic syndromes, and familial cases.

Case Presentation

A 5-year-old male patient presented with a complaint of a progressively enlarging lesion in the scalp region, present since birth. Three years ago, he developed a gradual increase in folds on the scalp. The mother reports a medical history of giant congenital melanocytic nevus (GCMN), without complications.

On examination, there was a normochromic, alopecic mass with a cerebriform appearance, measuring 22 cm2, occupying the parietal and occipital regions bilaterally. The frontal region, trunk, and limbs exhibited pigmented, verrucous lesions with hypertrichosis, associated with a diffuse distribution of satellite lesions. Neurological and ophthalmological examinations were normal; cranial computed tomography showed no evidence of involvement of the cranial vault. Family history was unremarkable.

Skin biopsy revealed an intradermal melanocytic nevus with progressive maturation toward the deeper dermal layers. Nests and cords of nevocytes were present in the deep dermis and subcutaneous tissue, thus characterizing the cerebriform intradermal subtype.

The patient is currently under biannual clinical follow-ups and receives weekly psychological support.

Conclusion

Secondary forms of CVG commonly occur as a result of inflammatory or neoplastic processes that alter the structure of the scalp. One of the rarest variants of this form is the Nevoid CVG, in which intradermal melanocytic nevi are responsible for cutaneous hypertrophy. This condition is known as cerebriform intradermal nevus (CIN) and is characterized by well-demarcated lesions that primarily affect the parietal region of the cranial vault, with a predominance in females.

These lesions are generally present at birth as normochromic or hyperchromic macules that progressively increase in size and become elevated over time. Eventually, they acquire a cerebriform appearance and may lead to alopecia. In addition, symptoms such as pruritus, bleeding, and foul odor—resulting from secondary infections—are common. Consequently, the aesthetic and social impact of CIN can be significant, requiring multidisciplinary management.

The diagnosis of CIN is based on clinical findings and confirmed by histopathology. Histopathological features include: intradermal arrangement of nevocytes with minimal junctional component, potentially involving superficial foci of the hypodermis. Due to the possibility of melanoma development, surgical excision of the lesion is recommended. In the reported case, the procedure has not yet been performed, and the patient remains under close outpatient follow-up, with continuous monitoring to identify any changes in the lesion.

The risk of neurocutaneous melanosis in patients with CIN remains unclear. Additionally, the literature has not yet established a consensus regarding a possible association between CIN and GCMN.

EA DV CONGRESS
VIENNA
30 SEP - 3 OCT 2026

Abstract N°: 954

Lebrikizumab Improves Itch and Sleep in Pediatric Patients with Moderate-to-Severe Atopic Dermatitis: Results from the Phase 3 ADorable-1 Study

Lawrence Eichenfield*[1], Jennifer Ornelas[2], Vimal H. Prajapati[3], Chin-Yi Yang[4], Akio Tanaka[5], Stephan Weidinger[6], Carsten Flohr[7], Elizabeth Swanson[8], Linda K Martin[9], Hany ElMaraghy[10], Evangeline Pierce[10], Priyanka Sen[10], Gaia Gallo[10], Amy Larkin[10], Amy Paller[11]

[1] University of California San Diego School of Medicine, La Jolla, CA, United States

[2] Integrative Skin Science and Research, CA, United States

[3] Dermatology Research Institute, Skin Health & Wellness Center, Probity Medical Research, and University of Calgary, University of Calgary, Calgary, AB, Canada

[4] Department of Dermatology, New Taipei Municipal TuCheng Hospital, Chang Gung Memorial Hospital and Chang Gung University College of Medicine, Taoyuan, Taiwan

[5] Graduate School of Biomedical and Health Sciences, Hiroshima University, Hiroshima, Japan

[6] University Hospital Schleswig-Holstein, Kiel, Germany

[7] St John's Institute of Dermatology, Guy's and St Thomas' National Health Service Foundation Trust and King's College London,, London, United Kingdom

[8] Ada West Dermatology,, St Luke's Children's Hospital, Boise, United States

[9] School of Clinical Medicine, UNSW Sydney & Dermatology Department, Sydney Children's Hospital,, Sydney, Australia

[10] Eli Lilly and Company, Indianapolis, Indiana, United States

[11] Northwestern University Feinberg School of Medicine,, Chicago, IL, United States

Introduction

Itch and sleep disturbance are burdensome symptoms of atopic dermatitis (AD), contributing substantially to disease burden and are important patient-reported outcomes (PROs) for evaluating treatment response. Lebrikizumab (LEB), a high-affinity monoclonal antibody selectively targeting interleukin-13, is approved in adults and adolescents with moderate-to-severe AD. We evaluate PROs related to itch and sleep in pediatric population aged 6 months (m)–<18 years (y) with moderate-to-severe AD treated with LEB over 16 weeks.

Materials and Methods

ADorable-1 (NCT05559359) was a randomized, double-blind, placebo (PBO)-controlled, phase 3 study patients diagnosed with AD for 3–12m (age dependent), Eczema Area and Severity Index ≥16, Investigator's Global Assessment (IGA) ≥3, ≥10% body surface area involvement, and inadequate response to topical therapy. Patients were randomized (2:1) to receive LEB or PBO for 16 weeks and stratified by age at enrollment to either cohort 1 (6y–<18y) or cohort 2 (≥6m–<6y), by disease severity (IGA score 3/4) and geographical region (USA/EU/other). Low-to-medium potency topical corticosteroids were initiated 2 weeks pre-randomization. Dosing was weight-based (≥40 kg: 500 mg Week [W] 0 and W2, then 250 mg every 2 weeks [Q2W] from W4; 15–<40 kg: 250 mg W0, then 250 mg Q4W from W2; 6–<15 kg: 125 mg W0, then 125 mg Q4W from W2). PROs included Pruritus Numeric Rating Scale (NRS; 11-point scale that rates worst itch severity over the past 24 hours; assessed in patients aged 6–<18y), Worst Scratching/Itching (WSI)-NRS (11-point scale that rates worst scratching/itching over the past 24 hours; 6m–<6y), Patient-Reported Outcomes Measurement Information System-Sleep Disturbance (PROMIS-SD; assesses perception of sleep quality, depth, and restoration; 8–<18y), PROMIS-Sleep-Related Impairment (SRI; assesses perception of alertness, sleepiness, and tiredness when awake; 8–<18y), and SCORing AD visual analogue

scale (SCORAD-VAS) itch/sleep (records itch/sleeplessness via 10-cm VAS; 8–<18y). Caregivers completed PROMIS-SD/PROMIS-SRI (5–<8y), SCORAD-VAS itch/sleep (<8y), and WSI-NRS (<6y).

Results

Baseline demographics and disease characteristics were generally comparable between LEB (N=245) and PBO (N=118) groups.

LEB demonstrated early and sustained separation vs PBO on all itch-related outcomes. The mean percent change from baseline in Pruritus NRS was significant by W4 (Least square mean [LSM]: -19.9% vs 1.1%; p=0.006) and sustained through W16 (LSM: -41.3% vs -4.6%; p<0.001). Mean percent change from baseline in WSI-NRS was significant as early as W2 (LSM: -14.3% vs 3.3%; p=0.023) and remained significant through W16 (LSM: -30.6% vs -7.5%; p=0.004). Sleep-related outcomes consistently favored LEB. Mean percent change from baseline in PROMIS-SD score was significant at W16 for both caregiver- (LSM: -12.3% vs -0.2%; p<0.001) and patient-reported (LSM: -9.5% vs -3.7%; p=0.024) assessments. Similarly, caregiver-reported PROMIS-SRI scores were significant at W16 (LSM: -8.7% vs 5.3%; p<0.001). SCORAD-VAS itch/sleep scores showed early separation from W4 with LEB in both patient- (itch, LSM: -25.9% vs -5.3%; p=0.020; sleep, LSM: -36.1% vs -15.2%; p<0.001) and caregiver-reported assessments (itch, LSM: -50.1% vs -14.5%; p<0.001; sleep, LSM: -35.7% vs -15.5%; p=0.002). At W16, mean percent change from baseline for SCORAD-VAS itch/sleep scores also significantly favored LEB in both patient- (itch, LSM: -51.9% vs -16.9%; p<0.001; sleep, LSM: -49.0% vs -13.1%; p<0.001) and caregiver-reported (itch, LSM: -56.3% vs -14.8%; p<0.001; sleep, LSM: -53.2% vs -17.6%; p<0.001) groups (Table).

Conclusions

In pediatric patients with moderate-to-severe AD, LEB demonstrated early (W2-W4) and sustained (through W16) improvements in itch and sleep-related outcomes compared with PBO. These findings support the clinical benefit of LEB in reducing disease burden in this population.

Table: Percent change from Baseline to Week 16 in Itch and Sleep-Related Outcomes Among Pediatric Patients Treated with LEB vs PBO

PROs	Percent change from baseline at week 16 N LSM (SE)		LSM difference (95% CI)	p-value
	LEB	PBO		
Pruritus NRS[a]	184 -41.3 (6.2)	92 -4.6 (7.7)	-36.7 (-50.5, -22.8)	<0.001
WSI-NRS[a, c]	61 -30.6 (6.7)	26 -7.5 (8.5)	-23.1 (-38.9, -7.3)	0.004
PROMIS-SD[b, c] Patient-reported	107 -9.5 (1.9)	48 -3.7 (2.4)	-5.8 (-10.8, -0.8)	0.024
Caregiver-reported	66 -12.3 (2.1)	26 -0.2 (3.1)	-12.0 (-18.4, -5.7)	<0.001
PROMIS-SRI[b, c] Patient-reported	98 -6.5 (2.0)	46 -7.0 (2.6)	0.5 (-4.9, 5.9)	0.867
Caregiver-reported	57 -8.7 (2.4)	23 5.3 (3.5)	-14.0 (-21.5, -6.4)	<0.001
SCORAD-VAS Itch[b, c] Patient-reported	128 -51.9 (6.4)	61 -16.9 (9.2)	-38.3 (-56.0, -20.5)	<0.001
Caregiver-reported	117 -56.3 (6.6)	57 -14.8 (9.7)	-43.7 (-62.2, -25.2)	<0.001
SCORAD-VAS Sleep[b, c] Patient-reported	128 -49.0 (4.7)	61 -13.1 (6.9)	-38.7 (-52.2, -25.2)	<0.001
Caregiver-reported	117 -53.2 (5.8)	57 -17.6 (8.4)	-37.9 (-54.1, -21.6)	<0.001

LSM percent change from baseline, LSM difference (95% CI), and nominal p-values are reported. Negative percent change from baseline indicates improvement. LSM = model-adjusted mean percent change from baseline; SE = standard error of the LSM. aAnalyzed using ANCOVA with adjustment for baseline value and randomization strata. Data after treatment discontinuation were as-observed; remaining missing values were handled using MCMC-MI. N reflects the analysis population for each scale. bAnalyzed using MMRM with adjustment for baseline value and randomization strata. Data after rescue medication or treatment discontinuation were set to missing and handled by MMRM. N reflects the number of participants with non-missing data at Week 16. cTreatment arm comparisons for WSI-NRS, PROMIS-SD, PROMIS-SRI, SCORAD-VAS itch and sleep were conducted post hoc. ANCOVA, analysis of covariance; CI, confidence interval; LEB, Lebrikizumab; LSM, Least square mean; MMRM, mixed models repeated measures analysis; MCMC-MI, Markov Chain Monte Carlo Multiple Imputation;

NRS, Numeric Rating Scale; PBO, placebo; PROs, patient-reported outcomes; PROMIS-SD, Patient-Reported Outcomes Measurement Information System-Sleep Disturbance; PROMIS-SRI, Patient-Reported Outcomes Measurement Information System-Sleep-Related Impairment; SCORAD-VAS, SCORing AD visual analogue scale; SE, standard error; WSI-NRS, Worst Scratching/Itching

EA DV CONGRESS
VIENNA
30 SEP - 3 OCT 2026

Abstract N°: 1045

Low-Dose Oral Minoxidil Initiation in Pediatric Hair Loss (Ages < 12 Years): An International Modified Delphi Consensus Statement

Yagiz Matthew Akiska*[1], Jennifer Fu[2, 3], Leslie Castelo-Soccio[1, 4], Erin Mathes[2], Paradi Mirmirani[5], Taylor Jamerson[2], Cathryn Sibbald[6], On behalf of Pediatric LOMI Delphi Participants[7]

[1] George Washington University School of Medicine and Health Sciences, Department of Dermatology, Washington, DC, United States
[2] University of California San Francisco, Department of Dermatology, San Francisco, United States
[3] Solano Dermatology Associates, Vallejo, CA, United States
[4] Children's National Hospital, Department of Pediatric Dermatology, Washington, DC, United States
[5] The Permanente Medical Group, Vallejo, CA, United States
[6] The Hospital for Sick Children, Division of dermatology, Department of Paediatrics, University of Toronto, Toronto, ON, Canada
[7] Multiple Institutions, N/A, United States

Introduction
Low-dose oral minoxidil (LDOM) is increasingly used off-label in pediatric hair disorders; however, standardized guidance for patient selection, dosing, safety, and monitoring remains limited.

Materials and Methods
To establish consensus-based recommendations for the use of LDOM in children < 12 years of age, a 3-round modified Delphi process was conducted among international experts in hair disorders who treat pediatric patients with LDOM, informed by input from pediatric cardiology, ophthalmology, clinical pharmacology, and a patient advocate. Fifty experts participated in Rounds 1–2 and 49 in Round 3, representing 9 countries; consensus was defined as ≥70% agreement.

Results
A total of 84 consensus recommendations were established from 127 initial items. LDOM was supported for pediatric patients aged ≥4 to <12 years (96%) across conditions involving hair follicle miniaturization (100%), hair cycle abnormalities (100%), and hair shaft disorders (84%), with adjunctive use in select scarring alopecias (98%).

LDOM may be preferred over topical minoxidil in cases of cost-effectiveness (76%), logistical difficulty (94%), poor tolerability or cosmetic concerns (94%), inadequate efficacy (88%), caregiver preference (92%), diffuse hair loss (94%), sensory/tactile sensitivities (96%), or concern for toxicity to animals (74%). Use may also be considered when topical therapy exacerbates inflammatory scalp disease (82%) or when hypertrichosis is a desired effect (72%).

Consensus contraindications include history of pericardial effusion/tamponade (76%) and pheochromocytoma (78%). Precautions include drug–drug interactions (74%), concomitant cardiovascular/vasodilatory therapies (90%), hypotension (92%), arrhythmias (82%), congenital heart disease (86%), renal and hepatic impairment (84%), and relevant family cardiac history (81.6%). Specialty consultation is not routinely required (74%) but is

recommended when precautions (84%), contraindications (96%), or care coordination needs (100%) are identified. Baseline laboratory testing, ECG, and blood pressure monitoring may be considered in select cases (76–100%).

Dosing approaches met consensus criteria for both fixed weight-based and mg/kg strategies. Fixed weight-based dosing is supported (<20 kg: 0.25–0.625 mg; 20–40 kg: 1.25 mg; >40 kg: 1.875 mg; 80%), often favored due to alignment with available tablet formulations. Starting doses of 0.01–0.02 mg/kg/day are also supported (73.5%), offering a flexible alternative when lower or more precise dosing is desired. Dose escalation of 50–100% based on clinical response and tolerability (93.9%) and the use of higher starting doses in select cases (85.7%) met consensus. Dose reassessment every 3–6 months reached full agreement (100%).

LDOM was supported as long-term therapy (96%), with tapering to the lowest effective dose after achieving treatment goals (82%). Combination therapy with spironolactone (80%), oral corticosteroids (96%), Janus Kinase (JAK) inhibitors (98%), and other immunosuppressants (96%) is supported.

Counseling should include monitoring for adverse events such as hypertrichosis (100%), dizziness (100%), abnormal heartbeat (96%), edema (94%), headache (90%), and signs of allergic reaction (80%). Urgent ophthalmologic evaluation is recommended in cases of unexplained vision loss (73.5%). Patients can be counseled that visible improvement in hair growth is expected after ≥3 months, most common between 3–12 months (92%).

Follow-up may be conducted in person (96%) or via telemedicine (70%), with documentation of treatment response via photographs (100%), adverse events (100%), and psychological impact on quality of life (94%). Once clinically stable, follow-up every 6–12 months is supported (100%).

Conclusions

This international consensus provides a structured, pediatric-specific framework for LDOM initiation and management. These findings support LDOM as a non-immunosuppressive therapeutic strategy while addressing dosing, safety, and monitoring in pediatric hair disorders.

EADV CONGRESS
VIENNA
30 SEP - 3 OCT 2026

Abstract N°: 1081

Expanding the spectrum of pediatric acute generalized exanthematous pustulosis: a vaccine-associated presentation

Lesslie Vazquez Rosas*[1], Sofia Carreño Salcedo[1], Arturo López Yañez-Blanco[1], Daniela Copado Alvarez[1]

[1] Instituto Dermatologico de Jalisco "Dr. José Barba Rubio", Zapopan, Mexico

Introduction

Acute Generalized Exanthematous Pustulosis is a rare severe cutaneous adverse reaction characterized by the abrupt onset of numerous sterile, nonfollicular pustules on an erythematous base, sometimes associated with systemic involvement. The incidence is 1 to 5 cases per million per year. Although it can occur at any age, it predominantly affects adults. Up to 90% of cases are drug-induced, while other triggers such as infections, vaccinations, and spider bites have been described. Management is mainly supportive, including withdrawal of the offending agent, topical corticosteroids, and symptomatic treatment; systemic corticosteroids may be considered in severe cases.

Case Presentation

A previously healthy 14-year-old male presented with the sudden onset of pruritic erythematous pustules involving the face, ears, spreading to the neck and trunk, associated with pain and malaise, without fever. He denied recent medication use; however, he had received an influenza vaccine one week prior. Physical examination revealed numerous millimetric, nonfollicular pustules on an erythematous, warm base, with scattered erythematous papules and hemorrhagic crusts. Vital signs were normal. Laboratory tests showed neutrophilia and mild renal involvement. Skin biopsy demonstrated a subcorneal pustule with spongiosis and a dermal infiltrate predominantly composed of neutrophils and eosinophils. Diagnosis of Acute Generalized Exanthematous Pustulosis triggered by influenza vaccination was made. The patient received systemic corticosteroids and topical emollient, with rapid clinical improvement and normalization of renal function. At two weeks, lesions evolved to desquamation with marked reduction of pustules, and complete resolution was observed at four weeks, leaving only postinflammatory hyperpigmentation.

Conclusion

This case highlights a rare pediatric presentation of Acute Generalized Exanthematous Pustulosis associated with vaccination. Although medications remain the main trigger of Acute Generalized Exanthematous Pustulosis, infections are more frequently implicated in children. However, vaccine-associated cases have been rarely reported, predominantly in adults and only one pediatric case have been described. The diagnosis was supported by the characteristic clinical presentation, compatible histopathologic findings, temporal association with vaccination, absence of recent drug exposure, neutrophilia, and rapid clinical resolution. Patch testing may support diagnosis in drug-induced Acute Generalized Exanthematous Pustulosis; however, its role in vaccine-associated cases is poorly established and lack of supporting evidence. Early recognition of atypical triggers is important to establish an accurate diagnosis, avoid unnecessary interventions, and ensure prompt management. Our case contributes to the limited literature regarding vaccine-associated Acute Generalized Exanthematous Pustulosis in children and emphasizes the need to consider immunization as a potential, though rare, precipitating factor.

EA DV CONGRESS
VIENNA
30 SEP - 3 OCT 2026

Abstract N°: 1084

A Childhood Cutaneous Tuberculosis Presenting with Variable Lesions

Towhida Noor*[1]

[1] Matador diagnostic and wellness center, Dhaka, Bangladesh

Introduction

Despite having a BCG vaccination in infancy and effective anti-tubercular chemotherapeutic medicine, TB is still prevailing. Cutaneous tuberculosis accounts for about 1.5% of extrapulmonary cases, and childhood tuberculosis represents 5–15% of TB cases. There is a potential delay in the diagnosis of cutaneous tuberculosis in children of about 10 years. Delay in diagnosis results in the dissemination of the disease and acts as a potential reservoir of infection. The source of infection in a child is mostly past household exposure to TB. Children are more likely to have systemic involvement compared to adults, which can lead to more severe manifestations of the disease and complicate treatment options. There are several clinical types of cutaneous tuberculosis, of which scrofuloderma (SFD) and lupus vulgaris (LV) are common in the pediatric age group. Multifocal tuberculosis is not a very common entity. The reason for sharing this case report is to keep cutaneous tuberculosis in mind when dealing with a chronic skin lesion having variable features that cannot be described with a single disease in a high-tuberculosis-burden area.

Case Presentation

A 13-year-old girl presented to a dermatology private clinic in March 2021 with painful abscesses over the back of the right knee, right elbow, and wrist for one year. She was treated with occasional incision and drainage and several courses of antibiotics with no significant improvement. Gradually she developed hyperpigmented plaques with overlying hyperkeratotic scales on the back of the right knee and ulcerated, oozing lesions over the right elbow and wrist. She was anemic with a below-average BMI and no significant lymphadenopathy. There was an ulcerated erythematous plaque with oozing and crusts over the right wrist, erythematous swelling of the right elbow with pustular oozing, and hyperpigmented indurated plaques with hyperkeratosis over the back of the right knee. She was BCG vaccinated in childhood and had no family history of tuberculosis.

Her investigations reveal a hemoglobin of 10 g/dL and a raised ESR, and the Mantoux test, or purified protein derivative (PPD) tuberculin test, resulted in an induration of 22 mm in diameter after 72 hours. An induration of more than 15 mm in an individual is positive, and it is usually not due to previous BCG vaccination or exposure to environmental mycobacteria.

To exclude all these differentials, lesional skin biopsy for histopathology was the single effective test to be done. As she was noncooperative, a single lesion from the back of the knee was chosen for biopsy, as all other lesions were ulcerated and sore. The histopathology revealed hyperkeratosis and mild acanthosis, and the dermis revealed small granulomas around caseous necrosis, and a few Langerhans giant cells were present. No acid-fast bacilli were seen in the modified Z-N stain. Mycobacterial culture and PCR could not be done due to economic constraints. X-ray of the right elbow joint shows swelling of the soft tissue shadow.

She was diagnosed with lupus vulgaris (right wrist) with scrofuloderma (right elbow joint) and tuberculosis verrucosa cutis (right knee) depending on mostly clinical findings, some histological hints, and a positive PPD test. She was given 4 fixed-dose combination (isoniazid 75 mg + rifampicin 150 mg + pyrazinamide 400 mg + ethambutol 275 mg) or 4FDC tablets as an initiation phase for 2 months and 2 fixed-dose combinations (isoniazid

75 mg + rifampicin 150 mg) or 2FDC as a continuation phase for 7 months.

Conclusion

Cutaneous tuberculosis should be borne in mind while dealing with any chronic lesions not explained by other diseases in tuberculosis-endemic regions. In limited diagnostic settings, a therapeutic drug trial for tuberculosis can be considered in the presence of supporting evidence of the disease.

EA DV CONGRESS
VIENNA
30 SEP - 3 OCT 2026

Abstract N°: 1118

Dermatological Manifestations in Children with Chronic Kidney Disease

Wijdane tebbaai*[1], Bendaoud Layla[1], Aboudourib Meriem[1], Amal Said[1], Hocar Ouafa[1]

[1] Department of Dermatology, Arrazi Hospital, Mohammed VI University Hospital, Marrakech Research Laboratory in Biosciences, Marrakech, Morocco

Introduction
Chronic kidney disease (CKD) in children is frequently associated with cutaneous manifestations related to the disease itself, its metabolic complications, or treatments.
Early recognition is essential to improve management and reduce associated morbidity.
The aim of this study was to determine the incidence of skin alterations in children with CKD and to assess their potential correlations with clinical and biological parameters.

Materials and Methods
This prospective study was conducted over a 3-month period and included 50 children with CKD followed in a pediatric department.Dermatological manifestations were assessed clinically and using dermoscopy (DermLite DL5).Data were analyzed using SPSS software. Statistical analysis included descriptive and analytical approaches using Spearman correlation and Fisher's exact test, with significance set at $p < 0.05$.

Results
The mean age was 9.6 years, with a slight male predominance. Advanced stages of chronic kidney disease (CKD), according to the KDIGO classification, were predominant. Treatment modalities included both hemodialysis and peritoneal dialysis. The main underlying etiologies were urological malformations and glomerulopathies.Cutaneous manifestations were common, with xerosis and pruritus being the most frequently observed. Notably, pruritus was often severe, with 57.1% of patients reporting high intensity on the visual analog scale (VAS). In addition, other dermatological findings included skin pigmentation disorders, infections, purpura, and vitiligo.Furthermore, several nail abnormalities were identified, such as half-and-half nails, koilonychia, onycholysis, splinter hemorrhages, subungual hyperkeratosis, and absence of the lunula. Oral manifestations were also observed, mainly xerostomia and uremic breath.From a biological perspective, hypoalbuminemia and hyperphosphatemia were frequently noted.
Regarding correlations, no significant association was found between xerosis and KDIGO stage ($p = 0.68$). However, a moderate positive correlation was observed between pruritus and CKD stage ($p = 0.11$), along with a moderate association between pruritus and dialysis. Moreover, pruritus was more frequent in patients with hypoalbuminemia and hyperphosphatemia.
Overall, our study demonstrates that dermatological manifestations are highly prevalent in pediatric CKD, with all patients presenting at least one skin complaint. Xerosis and pruritus were the most common findings, in agreement with both pediatric and adult literature. Importantly, pruritus was frequently moderate to severe, highlighting its significant clinical impact.In addition, associated manifestations including pigmentary changes, infections, as well as nail, hair, and oral abnormalities were commonly observed, particularly in advanced stages of CKD. The absence of Kyrle disease in our series is consistent with its variable occurrence in pediatric populations.The lack of correlation between xerosis and CKD stage may be explained by multifactorial mechanisms, such as impaired skin barrier function and reduced sweating. In contrast, pruritus appears to worsen with disease progression and metabolic disturbances.Finally, the association of pruritus with hypoalbuminemia and hyperphosphatemia supports their potential role as contributing factors, possibly through inflammatory

processes and mineral imbalance. The higher prevalence of pruritus in dialyzed patients further suggests an influence of disease severity and treatment-related factors.

Conclusions

Dermatological manifestations are very common in children with CKD and may significantly impact quality of life. Systematic dermatological screening and early multidisciplinary management are essential to improve patient outcomes.

EADV CONGRESS
VIENNA
30 SEP - 3 OCT 2026

Abstract N°: 1128

Eccrine Angiomatous Hamartoma of the Thigh: A Rare Benign Vascular-Eccrine Lesion.

Javier Alcántara-González*[1], Luis-Cristian Perna-Monroy[1], Miriam Cruz-Gómez[1], Ivan Rodrigo-Díaz[1], Silvia Abelenda-Marquina[1], Ana del Rocío Gamero-Rodríguez[1], Tania-Marusia Capusan[1], Arantxa Muñiz-De Lucas[1], Mirko Roedig[1], Thomas Akel-Oberpaur[1], Raquel Cabana-Navia[1], Clara-Inés Martínez[1], Silvia Manso-Cordoba[1], María-Elena Sánchez-Largo Uceda[1]

[1] Hospital Universitario de Torrejón, Torrejón de Ardoz, Spain

Introduction

Eccrine angiomatous hamartoma is a rare, benign tumor characterized by a proliferation of eccrine and vascular structures. We present a new case of this entity.

Case Presentation

A 2-year-old female presents with a lesion on the left thigh present since birth, which has grown proportionally with the patient. On examination, there is a 5.5 × 4.5 cm slightly erythematous patch in a patient with phototype IV, without associated induration or scaling.
A skin biopsy was performed, revealing in the dermis small-caliber vascular structures intermingled with eccrine sweat glands, the latter being clearly increased in number.
Correlation of the clinical and histological findings led to the diagnosis of eccrine angiomatous hamartoma.

Conclusion

Eccrine angiomatous hamartoma is usually present at birth or develops during childhood, but cases of adult onset have been reported. It is typically a solitary lesion on the distal part of limbs. This lesions can cause local pain or hiperhidrosis and they are characterized by the proliferation of eccrine glands and vascular structure on histological study.
Treatment is not usually necessary except in cases with persistent symptoms, excessive sweating, or cosmetic concerns. Surgical excision, botulinum toxin injection and vascular laser therapy have been used.

EA DV CONGRESS
VIENNA
30 SEP - 3 OCT 2026

Abstract N°: 1174

Treatment with delgocitinib cream improves health-related quality of life in adolescents with moderate to severe chronic hand eczema: Results from DELTA TEEN; a randomized, double-blind, vehicle-controlled phase 3 trial

Sonja Molin[1, 2], Francisco J. Navarro-Triviño[3], Ziad Reguiai[4], Sofie De Schepper[5], James Halpern[6], Danielle Marcoux[7], John Su[8, 9], Paweł Brzewski[10, 11], Eydna Didriksen Apol[12], F. Elcin Darendeli[12], Henrik Thoning[12], JiaDe Yu[13], Lawrence F. Eichenfield*[14, 15]

[1] Department of Dermatology, Venerology and Allergy, Charité-Universitätsmedizin Berlin, Berlin, Germany
[2] Division of Dermatology, Queen's University, Kingston, Canada
[3] Department of Dermatology, Hospital Universitario San Cecilio, Granada, Spain
[4] Department of Dermatology, Polyclinique Courlancy, Reims-Bezannes, France
[5] Department of Dermatology, University Hospital of Ghent, Ghent, Belgium
[6] Walsall Healthcare NHS Trust, Walsall, United Kingdom
[7] Department of Paediatrics, Dermatology Division, Sainte-Justine University Hospital Centre, University of Montreal, Montreal, QC, Canada
[8] Department of Dermatology, The Royal Children's Hospital Melbourne, Melbourne, VIC, Australia
[9] Department of Dermatology, Monash University, Eastern Health, Box Hill, VIC, Australia
[10] Specjalistyczny Gabinet Dermatologiczny Aplikacyjno-Badawczy, Kraków, Poland
[11] Department of Dermatology, UAFM Kraków, Kraków, Poland
[12] LEO Pharma A/S, Ballerup, Denmark
[13] Department of Dermatology, Virginia Commonwealth University, Richmond, VA, United States
[14] Departments of Dermatology and Pediatrics, University of California, San Diego School of Medicine, San Diego, United States
[15] Pediatric and Adolescent Dermatology, Rady Children’s Hospital, San Diego, United States

Introduction

Delgocitinib cream is a topical pan-Janus kinase inhibitor approved for the treatment of moderate to severe chronic hand eczema (CHE) in adults. In a recent study, it was demonstrated that adults with moderate to severe CHE have a significantly impaired health-related quality of life (HRQoL) and that treatment with delgocitinib cream for 16 weeks led to clinically meaningful improvements in HRQoL[1]. There are currently no treatments indicated specifically for moderate to severe CHE in adolescents, and there is a paucity of published evidence on how CHE impacts HRQoL in this population. Here, we report the effect of delgocitinib cream on HRQoL in adolescents with moderate to severe CHE.

Materials and Methods

In DELTA TEEN, adolescents (12–17 years of age) with moderate to severe CHE were randomized (3:1) to receive treatment with delgocitinib cream 20 mg/g (N=74) or cream vehicle (N=24) twice daily for 16 weeks (NCT05355818).

The impact of CHE on HRQoL was assessed with the Children’s Dermatology Life Quality Index (CDLQI) at baseline, Week 4, and Week 16. The CDLQI is a validated patient-reported questionnaire that consists of

10 questions covering different domains of life: symptoms and feelings, leisure, school or holidays, personal relationships, sleep, and treatment-related problems. The total CDLQI score ranges from 0–30, with a high score indicating a poor HRQoL.

Post hoc analyses were performed to assess the proportion of adolescents with a CDLQI score of 0 and the distribution of adolescents across CDLQI scores 0–1 (no or minimal impact) and 13–30 (large/very large impact). In addition, post hoc analyses were performed on CDQLI domain scores to assess change from baseline in each CDLQI domain, and the proportion of adolescents with a CDLQI domain score of 0.

Results

The proportion of adolescents with a CDLQI score of 0 was higher in the delgocitinib cream group than in the cream vehicle group at Week 4 and Week 16; the difference was statistically significant at Week 16 (27.0% vs 0%, p=0.005).

The proportion of adolescents with CDLQI scores of 0–1 (no or minimal impact) increased over time in the delgocitinib cream group (baseline: 5.4%; Week 4: 28.4%; Week 16: 40.5%) and in the cream vehicle group (baseline: 0%; Week 4: 16.7%; Week 16: 33.3%). In addition, the proportion of adolescents with CDLQI scores of 13–30 (large/very large impact) decreased over time in the delgocitinib cream 20 mg/g group (baseline: 21.6%; Week 4: 6.8%; Week 16: 4.1%) and to a lesser extent in the cream vehicle group (baseline: 25.0%; Week 4: 16.7%; Week 16: 16.7%).

Across all CDLQI domains, changes from baseline (LS mean±SE) were greater with delgocitinib cream than with cream vehicle at Week 4 and Week 16, except for treatment-related problems. For symptoms and feelings, the difference was statistically significant at Week 16 (-1.83±0.14 vs -0.82±0.25, p<0.001).

Likewise, across all CDLQI domains, the proportions of adolescents with a score of 0 were higher with delgocitinib cream than with cream vehicle at Week 4 and Week 16, except for treatment-related problems at Week 16. For symptoms and feelings, the difference was statistically significantly at Week 16 (48.6% vs 5.0%, p<0.001).

Conclusions

Treatment with delgocitinib cream resulted in considerable improvement in HRQoL in adolescents with moderate to severe CHE. This was consistent with the findings in adults and suggests that delgocitinib cream may represent a valuable treatment option in this population.

References:

1. Bauer A. et al. Contact Dermatitis, 2026; 0:1-9.

EADV CONGRESS
VIENNA
30 SEP - 3 OCT 2026

Abstract N°: 1206

A Paediatric case series of Mycoplasma Pneumoniae associated Reactive Infectious Mucocutaneous Eruption

Wei Ming Benjamin Sim*[1], Salwa Anis[2], Shilpa Manupati[3]

[1] Northern Care Alliance, Salford, United Kingdom
[2] Manchester University NHS Foundation Trust, Manchester, United Kingdom
[3] Manchester University NHS Foundation Trust, Northern Care Alliance, Manchester, United Kingdom

Introduction

Reactive Infectious Mucocutaneous Eruption (RIME) is a rare disease mostly observed in children after a respiratory infection, with Mycoplasma Pneumoniae being the most commonly implicated pathogen (MP-RIME). RIME is characterized by prominent mucosal involvement with limited cutaneous disease and a generally favourable prognosis, but a risk of complications including scarring-associated sequelae.

Materials and Methods

We present 5 cases of MP-RIME, in children aged 7 to 12 years, diagnosed using the paediatric-focused clinical criteria and algorithm proposed by Ramien et al [1]. This study aims to raise awareness of RIME among dermatologists and paediatricians.

Results

The median age at presentation was 12 years (IQR 11-12).

All cases fulfilled diagnostic criteria. Firstly, demonstrating evidence of an infectious trigger with positive PCR testing for MP (one child also tested positive for Influenza B and the Epstein-Barr virus). All cases then met ≥2 of the remaining diagnostic criteria – (i) erosive mucositis involving ≥2 sites (ii) vesicobullous or atypical target lesions involving <10% body surface area (iii) non-contributory medication history [1]. Additional supportive features included skin histology for one case and prodromal symptoms for all cases. Absence of epidermal denudation further strengthened the diagnosis of RIME [2].

All children required inpatient admission, with three transferred to a tertiary Paediatric unit for specialist Paediatric Intensive Care and Burns Service input. Of these, one required intubation and one required emergency tracheostomy. All children received systemic antibiotics and supportive care like pain management, fluid and nutritional support, and skin and mucosal care.

Furthermore, management was complex necessitating multidisciplinary input, involving specialties like Dermatology, Dietetics, Ear Nose and Throat surgery, Gynaecology, Oral and Maxillofacial surgery, Oral medicine, Pain medicine, Plastic surgery, Physiotherapy, Psychology, Respiratory medicine and Urology.

Scarring-associated sequalae included cicatrising conjunctivitis, oral adhesions, bronchiolitis obliterans and balanitis xerotica obliterans.

Conclusions

Clinicians need to consider the possibility of RIME, with infectious triggers beyond MP, in any acutely ill child with severe mucositis and a rash. Cases should be admitted for supportive care and transferred to a tertiary Paediatric

unit if there is disease progression.

EA DV CONGRESS
VIENNA
30 SEP - 3 OCT 2026

Abstract N°: 1260

A study of cutaneous manifestations in overweight and obese paediatric population

Pooja kotian*[1], Arun C. Inamadar[2]

[1] Department of Dermatology, Venereology and Leprosy, Kasturba Medical College Mangalore, Manipal Academy of Higher Education, Manipal, India, Mangalore, India

[2] Department of Dermatology, Venereology and Leprosy, BLDE university, Vijayapura, Vijayapura, India

Introduction

Overweight and obesity are defined as excessive fat accumulation in the body. There has been a significant rise in obesity in recent years. The cutaneous manifestations of obesity emerge early in childhood and impose a future risk of developing metabolic diseases. This study aims to assess the prevalence of various skin manifestations and their correlation with HOMA-IR in overweight and obese paediatric patients.

Materials and Methods

A prospective study of 78 children aged 5 to 18 years was conducted in a tertiary care centre. Demographic data, BMI, clinical examination and HOMA-IR (using fasting insulin and fasting blood glucose levels) were analysed and documented in the study.

Results

Among 78 patients in this study, 49 were males and 29 females, with a mean age of 13.55 ± 2.87 years. Acanthosis nigricans (87.2%) was the most common skin finding, followed by cutaneous infections (78.3%). Other notable findings included striae (73.1%), acrochordons (39.7%), and acne (32.1%). These were more prevalent in children with a BMI >95th percentile and HOMA-IR >2.6.

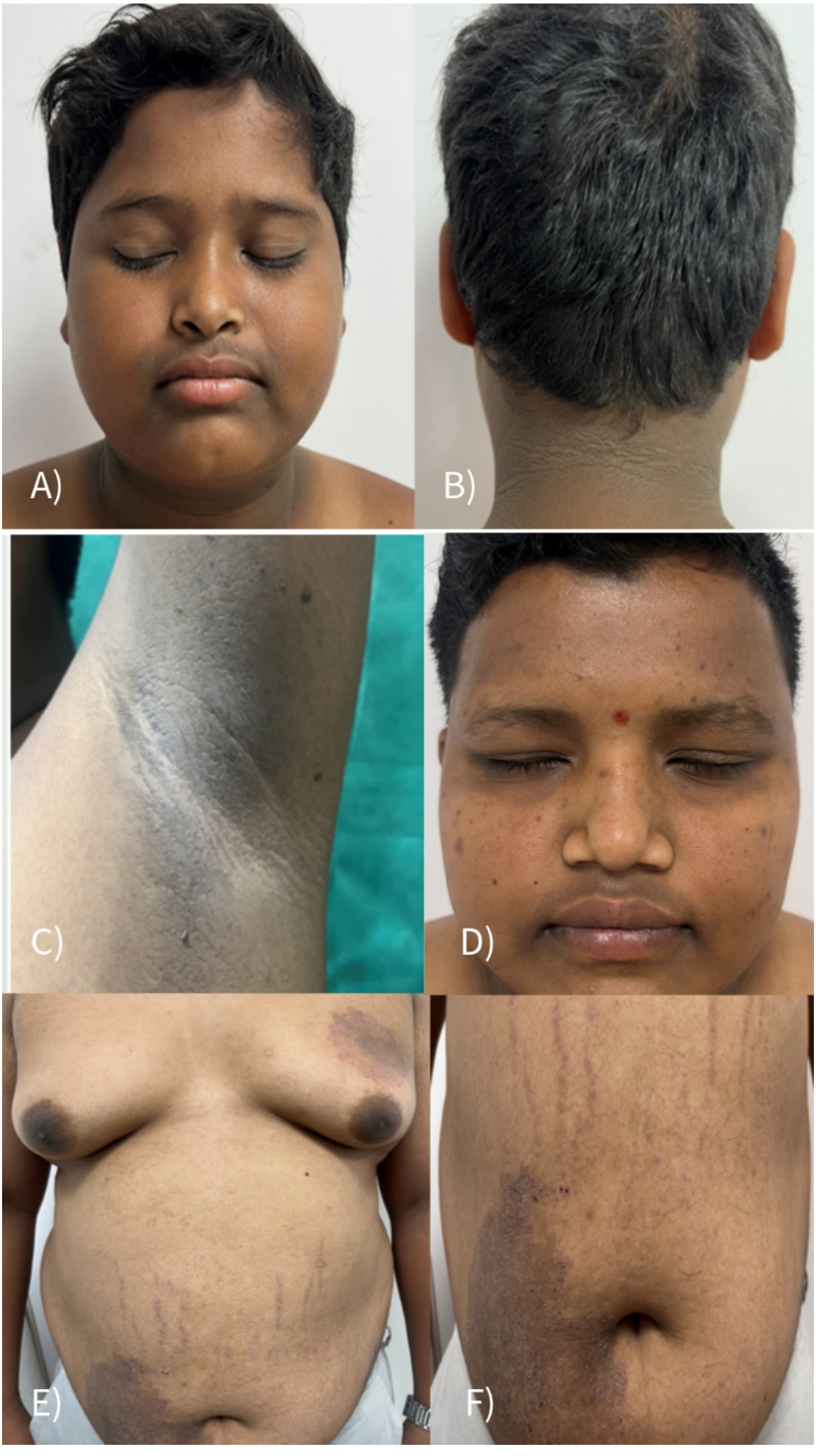
A)
B)
C)
D)
E)
F)

Fig A,B,C : Acanthosis Nigricans along with acrochordons noted over face, nape of neck and axilla in an obese child ; Fig D : Acne vulgaris and acanthosis nigricans noted over the face; Fig E,F : Striae distensiae and dermatophytosis noted over the chest and abdomen.

Conclusions

Overweight and Obesity is a significant health problem and continues to rise in both adult and pediatric populations. It is linked to a wide range of skin conditions, indicating potential future metabolic disorders. Early detection and lifestyle interventions are crucial for preventing long-term complications.

EA DV CONGRESS
VIENNA
30 SEP - 3 OCT 2026

Abstract N°: 1317

Umbilicated papular granuloma annulare: a diagnosis to be considered

Fábio Augusto Peroni Garcia*[1], Mariana Ferreira[2], Julia Loureiro Fontana Bolsoni[3], Nelson dos Santos[4], Flávia Regina Ferreira[3]

[1] UNIVERSIDADE DE SÃO PAULO - USP, UNIVERSIDADE DE TAUBATÉ UNITAU - SÃO PAULO, SÃO PAULO, Brazil
[2] Faculdade de Ciências Médicas e da Saúde de São José dos Campos/SP - HUMANITAS, São José dos Campos, Brazil
[3] UNIVERSIDADE DE TAUBATÉ (UNITAU) - SÃO PAULO, TAUBATÉ, Brazil
[4] Faculdade de Ciências Médicas e da Saúde de Sorocaba - PUC SP, Sorocaba, Brazil

Introduction

Granuloma annulare (GA) is a benign inflammatory dermatosis of not yet fully elucidated etiology, clinically characterized by annular papules or plaques, usually asymptomatic, that predominantly affect the extremities. Although the classic form is common and well documented, less frequent variants — such as disseminated, subcutaneous, perforating, and papular forms — may pose a diagnostic challenge. Among these, we highlight the umbilicated papular variant, which is the focus of this report, characterized by small, firm papules with subtle central depression, and which may mimic other dermatoses with similar clinical presentation.

One of the main differential diagnoses is molluscum contagiosum, a common dermatoviral infection in clinical practice, which also presents with umbilicated papular lesions, particularly in children, young adults, and immunosuppressed patients. Due to the potential for diagnostic confusion, especially in atypical presentations, thorough clinical examination combined with histopathological analysis is essential to minimize misdiagnosis and inappropriate procedures.

Based on these considerations, we report a case of umbilicated papular GA with multiple lesions on the dorsum of the hands, emphasizing the importance of recognizing this dermatosis and its variants, and reinforcing its role in the differential diagnosis of umbilicated papular dermatoses, particularly molluscum contagiosum.

Case Presentation

An 11-year-old boy presented with a history of skin lesions on the hands since the age of two, as reported by his mother. Physical examination revealed plaques and multiple normochromic papules with subtle central umbilication, well-defined and symmetrically distributed on the dorsum of the hands and proximal fingers. The lesions were asymptomatic. The patient had previously undergone multiple treatments for presumed molluscum contagiosum, without success.

A biopsy of one of the lesions revealed histopathological findings typical of GA: in the mid-dermis, a central area of collagen necrobiosis surrounded by an inflammatory infiltrate composed predominantly of histiocytes arranged in a palisading pattern, along with lymphocytes and fibroblasts. The epidermis was preserved, with slight thinning in some areas, and no evidence of perforation or ulceration (Figure).

Based on clinical and histopathological findings, a diagnosis of umbilicated papular GA was established. The patient and his caregiver were informed about the benign nature of the condition and referred to a regional reference center.

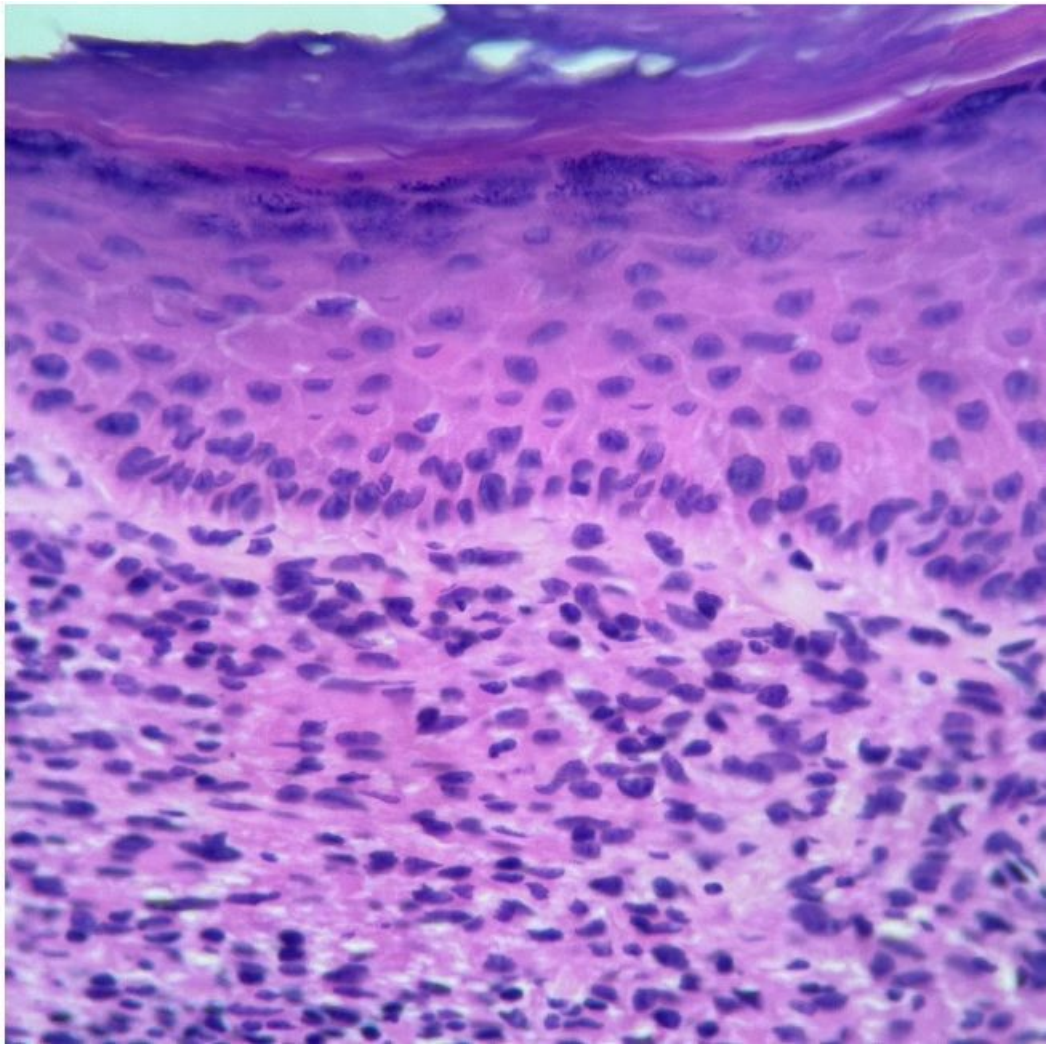

Histopathology (H&E, 100× magnification)

Conclusion

Umbilicated papular GA is a rare variant of the papular form, with few cases reported in the literature. It is thought that the central umbilication results from focal collagen degeneration; however, histopathology typically does not show transepidermal elimination, suggesting an intermediate form between papular and perforating GA.

Clinically, it may be indistinguishable from other dermatoses, particularly molluscum contagiosum, making accurate diagnosis essential to avoid mismanagement. While molluscum contagiosum is a contagious viral infection requiring specific treatments, GA is a benign, non-infectious inflammatory condition with a generally favorable prognosis, although it may be chronic.

Histopathological examination remains crucial for definitive diagnosis, especially in atypical or treatment-resistant cases. Differential diagnoses include lichen nitidus, papular sarcoidosis, and flat warts.

Management ranges from observation to topical or intralesional corticosteroids and cryotherapy in selected cases. This report highlights the importance of recognizing this variant and considering it in the differential diagnosis of umbilicated papular dermatoses.

EA DV CONGRESS
VIENNA
30 SEP - 3 OCT 2026

Abstract N°: 1339

Aplasia cutis congenita associated with monochorionic diamniotic twin pregnancy: clinicoradiological correlation in an infant

Fábio Augusto Peroni Garcia*[1], Ana Clara Maia Palhano[1], Raquel Chiereghin[2], Luciana de Paula Samorano[1], Maria Cecília Rivitti-MacHado[1], Zilda Najjar Oliveira[1]

[1] UNIVERSIDADE DE SÃO PAULO - USP, UNIVERSIDADE DE TAUBATÉ UNITAU - SÃO PAULO, SÃO PAULO, Brazil
[2] Faculdade de Ciências Médicas e da Saúde de Sorocaba - PUC SP, Sorocaba, Brazil

Introduction

Aplasia cutis congenita (ACC) is a rare condition characterized by localized absence of skin at birth, most commonly affecting the scalp, with an estimated incidence of 1:10,000 to 1:20,000 live births. Its etiology is multifactorial, with vascular mechanisms playing a key role. Monochorionic pregnancies and co-twin demise (*fetus papyraceus*) are recognized risk factors, possibly related to intrauterine ischemic events. Clinical presentation ranges from superficial lesions to extensive defects with deep tissue involvement. Imaging methods are essential to assess lesion extent and exclude associated abnormalities. We report a case of extensive ACC with clinicoradiological correlation.

Case Presentation

A 4-month-old female infant presented with a scalp lesion since birth. Physical examination revealed an extensive erythematous cicatricial plaque on the vertex, as well as an atrophic cicatricial plaque on the left mid-back. At birth, the scalp lesion was ulcerated, with spontaneous healing within approximately 15 days.

The pregnancy was monochorionic diamniotic twin gestation, initially with two viable fetuses. It evolved with intrauterine demise of one twin between 13 and 16 weeks, with persistence of findings consistent with a regressing fetus, and no abnormalities in the surviving fetus. The pregnancy progressed to term. The mother had gestational hypothyroidism under treatment and continuous use of sertraline throughout pregnancy. Delivery was vaginal after prolonged labor, with a term newborn appropriate for gestational age.

Dermatologic ultrasound (Figure 2) demonstrated marked thinning of the subcutaneous tissue at the vertex, with only a thin hyperechogenic layer covering the lesion. There was absence of the epicranial aponeurosis and part of the skull, with direct contact with the dura mater and proximity to the superior sagittal sinus. The lesion measured approximately 60 × 45 mm, with an associated bone defect of 45 × 38 mm.

Transfontanellar ultrasound showed no intracranial abnormalities.

Conclusion

This case is consistent with extensive ACC, with deep tissue involvement and exposure of the dura mater, which is associated with a higher risk of complications. The association with monochorionic pregnancy and co-twin demise supports a vascular intrauterine mechanism. The presence of multiple lesions further corroborates this pathophysiology.

Dermatologic ultrasound was essential for assessing lesion depth and extent, while transfontanellar ultrasound helped exclude intracranial abnormalities. In extensive cases, magnetic resonance imaging may be considered for further evaluation.

Caregivers were instructed on strict protection of the affected area due to the risk of trauma and complications. This case highlights the importance of imaging evaluation in extensive ACC and emphasizes its association with intrauterine vascular events, as well as the utility of dermatologic ultrasound in clinical practice.

EADV CONGRESS
VIENNA
30 SEP - 3 OCT 2026

Abstract N°: 1340

Letterer–Siwe Disease Mimicking Common Dermatoses: A Fatal Pediatric Case

Fábio Augusto Peroni Garcia*[1], Mariana Ferreira[2], Beatriz Leite[1], Linda Maria Avelar[1], Flávia Regina Ferreira[1]

[1] UNIVERSIDADE DE TAUBATÉ (UNITAU) - SÃO PAULO, TAUBATÉ, Brazil

[2] Faculdade de Ciências Médicas e da Saúde de São José dos Campos/SP - HUMANITAS, São José dos Campos, Brazil

Introduction

Langerhans cell histiocytosis (LCH) is a rare and complex disorder characterized by clonal proliferation of dendritic cells expressing CD1a, S100, and CD207. Recent evidence supports its classification as an inflammatory myeloid neoplasm associated with activating mutations in the MAPK–ERK pathway. The multisystem form, known as Letterer–Siwe disease, typically affects young children and carries a poor prognosis. Cutaneous involvement occurs in up to 50% of cases and may mimic common pediatric dermatoses, contributing to delayed diagnosis and adverse clinical outcomes.

Case Presentation

A previously healthy 3-year-old boy presented with persistent fever, prostration, and refractory skin lesions. The caregiver reported a six-month history of scalp scaling and crusting, previously treated as seborrheic dermatitis and fungal infection without improvement. In the two weeks prior to admission, the patient developed worsening skin lesions, irritability, and abdominal distension.

Physical examination revealed hepatosplenomegaly, yellowish adherent scalp crusts, erythematous scaly retroauricular plaques, keratotic papules on the trunk, petechiae in the pubic region, and axillary erythema. Laboratory findings showed severe anemia (Hb 5.4 g/dL), leukopenia (3,000/mm^3), thrombocytopenia (147,000/mm^3), hypoalbuminemia, and elevated inflammatory markers. Arterial blood gas analysis revealed hypoxemia (oxygen saturation 86%). Imaging studies demonstrated diffuse reticular infiltrates on chest radiography, mild pericardial effusion on echocardiography, and hepatosplenomegaly on abdominal ultrasound.

Skin biopsy with histopathological and immunohistochemical analysis revealed dermal infiltration by histiocytes with positivity for CD1a and S100, confirming the diagnosis of LCH. The patient was referred for specialized pediatric oncology care and initiated chemotherapy for high-risk multisystem disease. Despite treatment, clinical deterioration occurred, leading to death due to respiratory failure and multiorgan dysfunction two months after diagnosis.

Conclusion

Letterer–Siwe disease is associated with high morbidity and mortality, particularly in cases of delayed diagnosis. Its cutaneous manifestations may mimic common benign dermatoses, contributing to misdiagnosis, delayed recognition, and disease progression. In this context, persistent and treatment-resistant skin lesions should prompt consideration of systemic disease and early histopathological evaluation. This case underscores the pivotal role of dermatologists in recognizing atypical presentations and highlights the importance of a multidisciplinary approach in managing severe forms of LCH.

Persistent and treatment-resistant cutaneous lesions in children should raise suspicion for LCH. Early biopsy and prompt referral are essential to reduce diagnostic delay, although prognosis remains poor in multisystem disease.

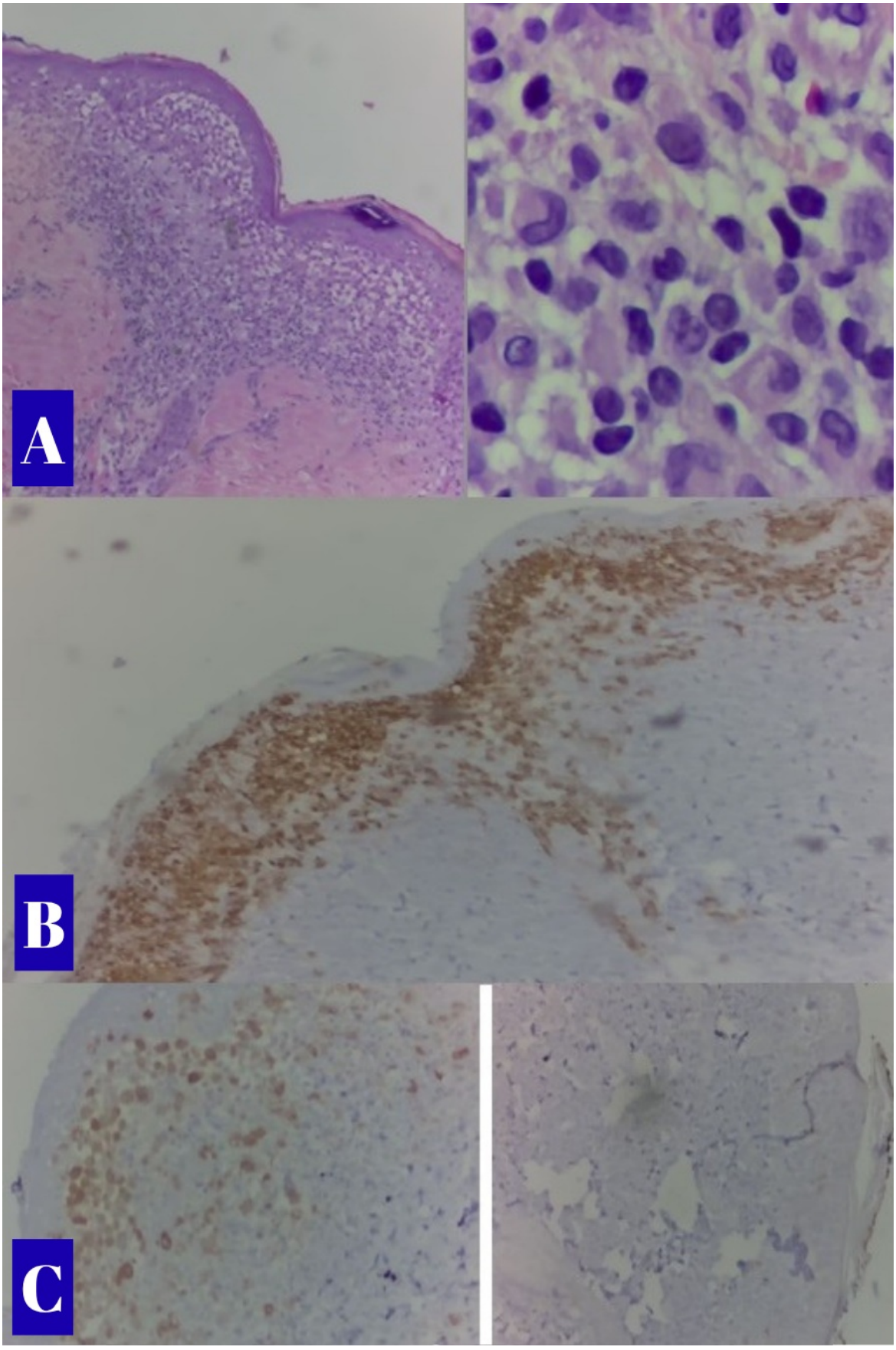

(A) Histopathological examination showing epidermal involvement and dense dermal infiltrate composed of histiocytes with characteristic reniform (kidney-shaped) nuclei, associated with eosinophils (H&E staining). (B–C) Immunohistochemical analysis demonstrating strong positivity of lesional cells for CD1a and S100, supporting the diagnosis of Langerhans cell histiocytosis.

EADV Congress 2026, VIENNA
30 SEPTEMBER - 03 OCTOBER 2026
POWERED BY M-ANAGE.COM

EA DV CONGRESS
VIENNA
30 SEP - 3 OCT 2026

Abstract N°: 1342

A review of pediatric chronic hand eczema with a focus on risk factors, allergens, and management

Katie Yeung*[1], Megan Lowe[2], Jessica Ho[3], Joshua Lowe[4], Sonja Molin[5]

[1] Division of Dermatology, University of Ottawa, Ottawa, Canada
[2] School of Medicine, Queen's University, Kingston, Canada
[3] Division of Dermatology, McGill University, Montreal, Canada
[4] Department of Family Medicine, Queen's University, Kingston, Canada
[5] Klinik für Dermatologie, Venerologie und Allergologie, Charité-Universitätsmedizin Berlin, Berlin, Germany

Introduction
Pediatric chronic hand eczema (P-CHE) is a debilitating condition defined as hand eczema lasting >3 months or recurring ≥2 times per year. Clinically, it may present acutely as pruritic vesicles with erythema, before progressing to scaling, fissures, and lichenification. P-CHE is associated with a significant impact on quality of life and can lead to disruptions in sleep, academic performance, and psychosocial behaviours during the critical childhood developmental years. Despite a lifetime prevalence of 6.5-13.3% and rising 1-year prevalence of 5.2-10.0%, no P-CHE specific treatment guidelines exist. As such, current management relies heavily on extrapolation from adult data and reliance on anecdotal evidence. This review aims to characterise the risk factors, exposure patterns, allergens, and current therapeutic landscape of P-CHE.

Materials and Methods
A systematic review of the PubMed, Embase, CENTRAL, and Clinicaltrial.gov databases was conducted to identify case reports of patients aged <18 years with P-CHE, without an alternate or confounding diagnosis. A secondary structured review was then performed to identify the various P-CHE specific therapeutic modalities.

Results
62 cases were included with a mean age of 10.9 years. Among patients with available data, the majority had a history of atopy (61%) and allergic contact dermatitis was the most common cause of P-CHE (71%). 35 unique sources of allergen exposure were identified, with the top 5 being homemade slime (n = 28), store-bought slime (n = 8), outdoor plants (n = 4), UV-curing methacrylate nail polish (n = 4), and sporting gloves (n = 4). These patterns are distinct from adult CHE, reflecting leisure- and school-based exposures. Patch testing was performed in 87% (54/62) of patients, of which 96% (52/54) tested positive to 1+ allergens. Positive reactions to methylchloroisothiazolinone and/or methylisothiazolinone were the most common. In 53% (33/62), removal of the trigger led to resolution, highlighting the importance of allergen avoidance. Topical corticosteroids and non-pharmacological measures remain the cornerstone of P-CHE management. Topical calcineurin inhibitors and phototherapy offer steroid-sparring alternatives, while topical JAK inhibitors (e.g., delgocitinib) represent a promising emerging class with active trials in adolescents. Although systemic treatments are often avoided due to safety concerns in children, they are essential for achieving adequate control and symptom management in severe or refractory cases. Alitretinoin, methotrexate, and cyclosporine are used cautiously off-label. Dupilumab, approved for pediatric atopic dermatitis (AD), has emerged as a favoured first-line systemic therapy for P-CHE demonstrating efficacy and safety. Similarly, the use of oral JAK-inhibitors is at the forefront of the latest treatment advances. Regardless of treatment choice, patient buy-in and family education encourages adherence and are integral to management.

Conclusions

P-CHE frequently reflects allergic contact sensitization, with the allergen source differing from adults and often related to leisure-time or school activities. Management requires a multifaceted approach encompassing early recognition, patch testing, and allergen avoidance. In severe or refractory cases where topical therapies are insufficient, systemic treatments are essential for disease control and should be used cautiously with appropriate monitoring. The current literature reflects a critical gap in P-CHE specific data, particularly amongst non-atopic subtypes and in the use of systemic therapies. Existing data is primarily derived from limited subgroup analyses within adult predominant trials, or from patients with atopic hand dermatitis enrolled within larger AD studies. Future research must address these gaps to inform guideline development and prioritize international consensus, with the goal of improving patient outcomes.

EA DV CONGRESS
VIENNA
30 SEP - 3 OCT 2026

Abstract N°: 1354

Incontinentia pigmenti without vesiculobullous stage: a diagnostic challenge

Maria Alexandra Gruia*[1], KALMI Noura[2], MALLET Stephanie[3], BENKIMOUN Simon[3], CHARACHON Florine[3], AZIZ Aurore[4], FAVRE Constance[4], PRESCORNIȚĂ Elena-Alexandra[2], PETRICĂ Ana-Maria[2], SANCHEZ Michèle[2]

[1] Centre Hospitalier Henri Duffaut, Dermatology departement, Colentina Clinical Hospital; Dermatology departement, Avignon, France
[2] Centre Hospitalier Henri Duffaut, Dermatology departement, Avignon, France
[3] Hôpitaux Universitaires la Timone, Dermatology departement, Marseille, France
[4] Hôpitaux Universitaires la Timone, Ophtalmology departement, Marseille, France

Introduction
Incontinentia pigmenti (IP) is a rare X-linked dominant genodermatosis caused by mutations in the IKBKG gene. Approximately 10–25% of cases are familial, whereas up to 50% occur sporadically.

It is characterized by four clinical stages—vesiculobullous, verrucous, hyperpigmented, and hypopigmented—which may occur sequentially, overlap, or be absent. The course of the disease may be complicated by ophthalmological, neurological, and dental involvement, with possible alterations of the skin appendages. Among these, ophthalmological and neurological complications are the most significant and should be excluded as early as possible.

The diagnosis is usually suggested by a vesiculobullous eruption in a female newborn, evolving into linear hyperpigmentation along the lines of Blaschko, which gradually fades during adolescence.

Case Presentation
We report the case of a 1-month-old female infant presenting with a linear hyperpigmented eruption present since birth, without any prior vesiculobullous lesions.

She was born after a sixth pregnancy, by vaginal delivery, with normal growth parameters and psychomotor development. Family history revealed hypopigmented vitiligo-like perioral lesions and hyperpigmented Blaschkoid lesions on the lower limbs of the mother. The patient has five siblings (two boys and three girls), all healthy.

Clinical examination showed a reticulated hyperpigmented eruption following the lines of Blaschko, associated with a keratotic papule on the second and third fingers of the right hand. No abnormalities of skin appendages were observed.

The differential diagnosis included linear and whorled nevoid hypermelanosis, other type of pigmentary mosaicism, and an atypical form of incontinentia pigmenti.

Laboratory tests showed no eosinophilia. Histopathological examination revealed pigmentary incontinence without eosinophilic inflammation, making it difficult to definitively distinguish between stage III incontinentia pigmenti and linear and whorled nevoid hypermelanosis.

Genetic testing from blood and skin confirmed a deletion of exons 4 to 10 of the IKBKG gene. This result was

validated by PCR IN2, excluding involvement of the pseudogene IKBKGP1. Ophthalmological examination was normal**.**

The diagnosis of incontinentia pigmenti was confirmed by a major criteria(genetic testing).

A multidisciplinary follow-up was initiated, including dermatological, ophthalmological and neurological monitoring.

Conclusion

Incontinentia pigmenti is a rare genodermatosis that predominantly affects females and may occur sporadically. The diagnosis is usually considered in the presence of a vesiculobullous eruption evolving into verrucous or hyperpigmented stages.

Our case is notable for the absence of the initial vesiculobullous stage, making the diagnosis more challenging. Some authors suggest that such cases may correspond to in utero expression of the first stage, although further studies are needed.

In clinical practice, IP should always be considered in the presence of a Blaschkoid hyperpigmented reticulated pattern in a female infant, given the potential, although rare, of systemic ophtalmological or neurological complications associated with this condition.

EADV CONGRESS
VIENNA
30 SEP - 3 OCT 2026

Abstract N°: 1367

Refractory Juvenile Pityriasis Rubra Pilaris: Successful Treatment with Ustekinumab

Yıldız Gürsel Ürün[1], Mustafa Ürün[1], Derya Çamsul Tarac*[1]

[1] TRAKYA UNİVERSTY, EDİRNE, Türkiye

Introduction

Pityriasis rubra pilaris (PRP) is a rare inflammatory papulosquamous disorder with heterogeneous clinical presentations. The juvenile form may mimic eczema in the early stages, leading to diagnostic delay. In treatment-refractory cases, biologic agents targeting key inflammatory pathways have emerged as promising therapeutic options. Herein, we report a case of juvenile PRP initially misdiagnosed as eczema and demonstrating a marked clinical response to ustekinumab.

Case Presentation

An eight-year-old boy presented with a three-year history of widespread erythematous lesions characterized by fine scaling follicular papules and plaques involving the trunk, extremities, and scalp. His medical and family histories were unremarkable, and mucosal examination was normal. The patient had initially been managed with provisional diagnoses of dermatitis and psoriasis and treated with topical therapies without sustained benefit.

During follow-up, the clinical picture evolved with prominent scalp scaling and the development of orange-colored follicular papules on an erythematous background, coalescing into scaly plaques. No involvement of the knees or elbows was noted, and palmoplantar keratoderma was absent. Dermoscopic examination revealed a characteristic yellow-orange background, follicular keratin plugs, perifollicular halos, whitish scales, and mixed linear and dotted vascular patterns. Histopathological analysis demonstrated alternating orthokeratosis and parakeratosis, epidermal hyperplasia, spongiosis, and superficial perivascular inflammation. A diagnosis of juvenile PRP was established based on clinicopathological correlation. Genetic analysis revealed no CARD14 mutation.

The disease was refractory to topical corticosteroids, calcineurin inhibitors, and emollients. Narrowband UVB phototherapy, acitretin (10–20 mg/day for six months), and methotrexate (0.5 mg/kg for one year) resulted in partial improvement; however, relapse occurred after discontinuation. Due to progressive disease, ustekinumab therapy was initiated at the age of 12 years (45 mg at weeks 0 and 4, followed by maintenance dosing every 12 weeks). Marked clinical improvement was achieved after the loading doses, and this response was maintained during follow-up under maintenance therapy.

Conclusion

Based on the atypical localization and treatment resistance, type V juvenile PRP was considered the leading diagnosis. Although type V is the PRP subtype most commonly associated with CARD14 mutations, these mutations are less frequently observed in sporadic cases. In a case report published in *JEADV* in 2024, Reitmajer et al. described the use of ustekinumab in a genetically CARD14-negative juvenile PRP patient. This report highlights that ustekinumab may be effective not only in CARD14-positive/familial forms but also in CARD14-negative juvenile cases. Consistent with the literature, ustekinumab may represent an effective therapeutic option for refractory juvenile PRP in our case.

EADV CONGRESS
VIENNA
30 SEP - 3 OCT 2026

Abstract N°: 1450

Spiky papules in diaper area

Karol Sabas Ortega*[1], Lydia Corbalan Escortell[1], José Asensio Gómez[1], Javier Soro Miranda[1], Sonia De La Fuente[1], Mariano Ara Martín[1]

[1] Hospital Clínico Universitario Lozano Blesa, Zaragoza, Spain

Introduction

Infantile anogenital digitate keratoses (IADK) is a rare, benign, and underrecognized disorder of keratinization affecting the anogenital region of infants. Recognition of this entity is essential to avoid unnecessary invasive diagnostic procedures, inappropriate treatments, and parental distress.

Case Presentation

A 4-month-old healthy infant boy presented with a 3-week history of asymptomatic lesions located in the perianal median raphe region. There was no relevant personal or family history, nor any history of diarrhea, diaper dermatitis or systemic symptoms. Empirical treatment with topical clotrimazole had been initiated prior to referral without any clinical improvement.

Physical examination showed multiple white, 1-3 mm, spiked, clustered, keratotic papules over a slight erythemathous plaque on perianal raphe region (Figure 1). No maceration, irritation neither inflammation was observed in perilesional skin or other intertriginous areas.

Bacterial and fungal cultures were negative, with no microorganisms identified. A zinc oxide-based barrier emollient was initiated at each diaper change, and complete spontaneous resolution was observed after a 2 month follow-up.

Conclusion

IADK presents as follicular or perifollicular, rigid, spiked keratotic papules confined to the anogenital region. Histopathological findings in previous reports are nonspecific and include orthokeratotic or parakeratotic hyperkeratosis associated to epidermal invaginations. Diferential diagnosis include candidiasis, staphylococcal folliculitis, irritant contact dermatitis and epidermal nevus. Due to the characteristic clinical presentation and its benign course, a skin biopsy is generally not necessary.

Recognition of this rare and benign entity is of key importance due to its anogenital location and broad differential diagnosis. A prompt identification is essential since it avoids unnecessary workup and inadequate therapeutic interventions.

Abstract N°: 1480

Herpetic Whitlow in a Child: An Easily Misdiagnosed Finger Infection

Svetlana Clitman*[1], Agoritsa Gravani[1], Efterpi Zafiriou[1]

[1] Department of Dermatology, University General Hospital of Larissa, Larissa, Greece

Introduction

Herpes simplex virus (HSV) is a common viral infection in childhood. While the orolabial (HSV-1) and genital (HSV-2) regions are most frequently affected, HSV can rarely infect the distal phalanx, causing painful vesicles that may evolve into blisters, known as Herpetic Whitlow. This condition is uncommon in children and may be misdiagnosed as bacterial paronychia or felon, potentially leading to unnecessary surgery or inappropriate antibiotic use. Early recognition is essential for proper management.

Case Presentation

A 2-year-old child was referred to a dermatologist for evaluation after being examined by a pediatric surgeon for vesicular lesions on the little finger of the right hand. The patient had painful vesicles on the finger for one week, following minor trauma to the nail plate three days earlier. The child had received amoxicillin–clavulanic acid for a respiratory infection, which had no effect on the finger lesions, and new vesicles continued to develop.

Dermatological examination revealed grouped vesicles on an erythematous base on the distal phalanx, with no pustular discharge, supporting the diagnosis of herpetic whitlow rather than a bacterial infection. The Tzanck smear was positive, demonstrating multinucleated giant cells consistent with herpes virus infection. Antibiotics were discontinued, and oral acyclovir with supportive care was initiated. The patient showed gradual improvement, with reduction of pain and resolution of lesions over several days.

Conclusion

Herpetic whitlow, though rare in children, should be considered in painful vesicular finger lesions, particularly after minor trauma. Early dermatological assessment prevents unnecessary procedures and antibiotics' administration allowing timely antiviral therapy and favorable outcomes.Symptomatic relief and prevention of secondary infection are the mainstays of therapy. In immunocompetent children, herpetic whitlow usually resolves spontaneously within 2–4 weeks. Incision and drainage should be avoided, as it provides no symptom relief and may cause viremia or bacterial superinfection. In selected cases, nail segment excision may relieve pain by decompressing vesicles along the nail bed. Antiviral therapy (acyclovir, famciclovir, valacyclovir) can shorten symptom duration, especially if initiated within 48 hours of onset. Recurrent cases may benefit from suppressive antiviral therapy, and antibiotics should be used only if secondary infection occurs.

EA DV CONGRESS
VIENNA
30 SEP - 3 OCT 2026

Abstract N°: 1484

Varied and Unique Presentations of Twin Spotting: Expanding the Spectrum of Cutaneous Mosaicism

Ayush Jain*[1], Shruti Garg[1], Niti Khunger[1]

[1] VMMC and Safdarjung Hospital, delhi, India

Introduction

Twin spotting (didymosis) describes the coexistence of two distinct, genetically different cutaneous lesions arising in close proximity against a genetically normal background. It results from mitotic crossing-over of non-sister chromatids during early embryogenesis, generating adjacent cell clones that become homozygous for two different recessive mutations. This phenomenon represents a fascinating subtype of cutaneous mosaicism, with the lesion combination reflecting the timing and lineage of the somatic recombination event. Despite its conceptual elegance, varied and unusual phenotypic combinations remain sparsely documented in the literature. We present three cases that collectively expand the known phenotypic spectrum of twin spotting.

Case Presentation

Case 1: An 11-year-old boy presented with Blaschkoid hyperkeratotic verrucous plaques over the right lateral chest and axilla since infancy, alongside an asymptomatic hyperpigmented patch with mild hypertrichosis over the right upper back, first noted at age 7–8 years. Dermoscopy revealed brown-grey globules, cobblestone-like structures, and fine white streaks. Histopathology confirmed epidermolytic verrucous epidermal nevus (VEN) and Becker's nevus, representing twin spotting driven by two distinct molecular mechanisms: mosaic keratin gene mutation and androgen receptor hypersensitivity, respectively. Genetic counselling was advised given the gonadal mosaicism risk associated with VEN and its potential for transmission as generalised epidermolytic ichthyosis in offspring.

Case 2: A 10-year-old girl presented with congenital blaschkoid hypopigmented macules over the trunk and upper limbs, alongside violaceous to hyperpigmented linear macules and papules over the right leg, developing from age one year. Dermoscopy of the leg lesions showed Wickham striae . Clinico-dermoscopic-histopathological correlation confirmed pigmentary mosaicism with linear lichen planus which was an unusual combination of a developmental mosaic pigmentary disorder and an acquired inflammatory dermatosis occurring within or adjacent to the mosaic segment.

Case 3: A 26-year-old male presented with a longstanding congenital 15 × 4 cm brown plaque surmounted by grouped translucent vesicles imparting a characteristic "frog spawn" appearance, with satellite lesions and an adjacent hyperpigmented hypertrichotic patch with irregular borders. Biopsy from both lesions confirmed lymphangioma circumscriptum and Becker's nevus, thus demonstrating twin spotting involving lesions of distinctly different embryological origins: a vascular malformation and a pigmentary hamartoma.

Conclusion

This case series highlights the broad phenotypic spectrum of twin spotting and reinforces its basis in early postzygotic somatic recombination. The coexistence of morphologically distinct lesions reflects divergent molecular pathways within adjacent clones and also involvement of different embryological lineages. Mosaic skin may also exhibit altered local susceptibility, predisposing to secondary inflammatory dermatoses. Overall, the

variability in clinical presentation is likely determined by the timing and nature of embryonic mutations. Recognition of this phenomenon is important, as the presence of adjacent, dissimilar lesions should prompt consideration of cutaneous mosaicism, with implications for evaluation, molecular characterization, and genetic counseling.

EADV CONGRESS
VIENNA
30 SEP - 3 OCT 2026

Abstract N°: 1508

Neonatal Subcutaneous Fat Necrosis and Hypercalcemia : A Case Report

JaeYoung Sung*[1], Jiwon Bang[1], Sae Hee Kim[1], Seungmin Park[1], Ji Won Lim[1], YiNa Yoon[1], ChangYong Kim[1], Da-Ae Yu[1], YangWon Lee[1], YongBeom Choe[1]

[1] Konkuk university school of medicine, Seoul, Korea, Rep. of South

Case Presentation

A neonate born at 38 weeks and 5 days of gestation via cesarean section for cephalopelvic disproportion was referred to the dermatology department from pediatrics for evaluation of bilateral upper arm skin lesions. The infant had a birth weight of 3,590 g and Apgar scores of 8 and 9 at 1 and 5 minutes, respectively. The mother had insulin-treated diabetes mellitus. On the fourth day of life, erythematous lesions were noted on the lateral aspects of both upper arms during bathing, which subsequently became indurated. On initial assessment, the lesions showed violaceous discoloration without warmth or progression. Laboratory evaluation revealed normal inflammatory markers and metabolic parameters. Dermatologic examination demonstrated erythematous nodules on both upper arms, which had initially been firm but gradually softened over time. The skin lesions improved without specific dermatologic intervention. However, follow-up laboratory testing revealed an elevation in serum calcium levels, and the patient was referred back to the pediatric department for further evaluation and management of hypercalcemia.

Conclusion

Subcutaneous fat necrosis of the newborn is a rare, self-limited panniculitis that occurs in full-term infants during the early neonatal period. Although the cutaneous manifestations often resolve spontaneously, hypercalcemia may develop days to weeks after the onset of skin lesions and can persist even after apparent dermatologic improvement. Therefore, serial monitoring of serum calcium levels for several months is recommended, and timely medical intervention may be required in cases of significant hypercalcemia. Early recognition and close multidisciplinary follow-up are essential to prevent potentially serious complications.

Keywords : Subcutaneous fat necrosis of the newborn, Neonatal panniculitis

EA DV CONGRESS
VIENNA
30 SEP - 3 OCT 2026

Abstract N°: 1513

Genotypic and Phenotypic Profiles of Collodion Babies ina Tertiary Care Center in Riyadh, Saudi Arabia

Sultan Al-Khenaizan*[1], Rahaf Bashihab[1], Aljohara Alkhenaizan[2], Mohammed AlBalwi[1], abdullah Alsaleam[1], Faisal Alghubaywi[1]

[1] king abdulaziz medical city, riyadh, Saudi Arabia
[2] imam mohammad bin Saud university, riyadh, Saudi Arabia

Introduction

Collodion membrane (CM) is a rare neonatal presentation characterized by a shiny, taut, cellophane like membrane that typically sheds within days to weeks after birth. CM is most commonly associated with autosomal recessive congenital ichthyoses, including lamellar ichthyosis (LI) and congenital ichthyosiform erythroderma (CIE). The incidence of CM is estimated between 1 in 50,000 and 1 in 300,000 births. Diagnosis is primarily clinical, supported by features such as ectropion, eclabium, and erythroderma. Genetic testing assists in identifying the underlying etiology and predicting prognosis. 1.2 This study describes the clinical characteristics and genetic mutations observed in collodion babies treated over 23 years at a tertiary care center in Saudi Arabia

Materials and Methods

The research was performed at King Abdulaziz Medical City (KAMC) in Riyadh, Saudi Arabia, with consent from the Institutional Review Board of King Abdullah International Medical Research Center. Participants included patients diagnosed with CM from January 2001 through December 2024. Data collected comprised demographic information, consanguinity status, duration of NICU stay, clinical features, treatments administered, genetic analyses, and any underlying conditions present.

Results

A total of 21 subjects were included in the study; females represented 66.6% of the cohort. All patients (100%) had documented consanguinity. Erythroderma was noted as the most prevalent symptom at 57.1%. The most frequently identified genetic mutation was Ceramide Synthase 3 (CERS3), detected in 33.3% of cases, while lamellar ichthyosis emerged as the predominant underlying condition affecting 43% of participants.

Gene	N	%	Average NICU Stay	Underlying disorder
CERS3	7	33.3%	7.7 D	Lamellar ichthyosis (LI)
ALOX12B	5	23.8%	21.4 D	Congenital ichthysiform erythroderma (CIE)
SPINK5	2	9.5%	Unknown	Netherton Syndrome (NS)
ALOXE3	2	9.5%	35 D	Congenital ichthysiform erythroderma
TGM1	1	4.7%	15 D	Lamellar ichthyosis
CYP4F22	1	4.7%	20 D	Lamellar ichthyosis
PNPLA	1	4.7%	9 D	Congenital ichthysiform erythroderma
SLC27A4	1	4.7%	29 D	Mild xerosis
ST14	1	4.7	9 D	Ichthyosis hypotrichosis
Total	21	100%	16.4 D	

results

Conclusions

CM is a heterogeneous phenotype reflecting multiple genetic etiologies within congenital ichthyoses. Our cohort showed a strong correlation between specific mutations and clinical severity.

CERS3 mutations were the most frequent and produced the least severe neonatal course, consistent with previous literature linking the gene to ceramide biosynthesis and barrier function.

ALOX12B mutations caused more severe erythroderma and longer NICU stays, reflecting defects in epidermal lipid processing.

TGM1 mutations produced severe CM, consistent with its essential role in forming the cornified envelope.

Rare causes such as Netherton syndrome (SPINK5) and PNPLA1 related ichthyosis were also identified.

Management relies heavily on supportive NICU care, including humidified incubators, emollients, infection monitoring, and ophthalmologic care for ectropion. Early genetic diagnosis guides prognosis, counseling, and long term follow up.

Importantly, no deaths occurred, despite reported mortality up to 11% in the first week of life. This likely reflects improvements in neonatal supportive care.

EA DV CONGRESS
VIENNA
30 SEP - 3 OCT 2026

Abstract N°: 1519

Subcutaneous Facial Nodule in Childhood: A Case of Idiopathic Aseptic Facial Granuloma

Begüm Karanfil Atakan*[1], Burçe Can Kuru[1]

[1] Sultan Abdulhamit Han Egitim Arastırma Hastanesi, İstanbul, Türkiye

Introduction

Idiopathic aseptic facial granuloma (IAFG) is a rare, benign, and sterile granulomatous inflammatory condition that typically occurs on the face during early childhood. It can pose significant diagnostic challenges as it clinically mimics other subcutaneous masses, such as pilomatricoma. Although it usually follows an asymptomatic course and often shows spontaneous regression, accurate identification is essential to avoid unnecessary interventions

Case Presentation

A two-year-old male patient presented with an asymptomatic, livid-colored nodule on the right zygomatic region that had been present for three months. The patient's medical history was unremarkable, except for a known limitation in the outward gaze of the left eye. Superficial ultrasonography identified a solid, oval, and heterogeneous dermal mass characterized by a hypoechoic structure with ill-defined borders and post-acoustic enhancement. Additionally, the lesion showed a lack of vascularity on Doppler and a hard consistency on elastography. Based on the differential diagnoses of pilomatricoma and aseptic facial granuloma, an excisional biopsy was performed.

Histopathological examination identified loose granuloma structures composed of epithelioid histiocytes within the dermis. Specialized staining (PAS and AFB/EZN) showed no evidence of microorganisms. The diagnosis was confirmed as aseptic facial granuloma through clinical and histopathological correlation.

A systemic workup for other granulomatous diseases, including a chest X-ray, tuberculin skin test, and laboratory tests, yielded normal results. Ocular assessment confirmed no granulomatous involvement; the patient remained under neuro-ophthalmological follow-up for the pre-existing gaze limitation.

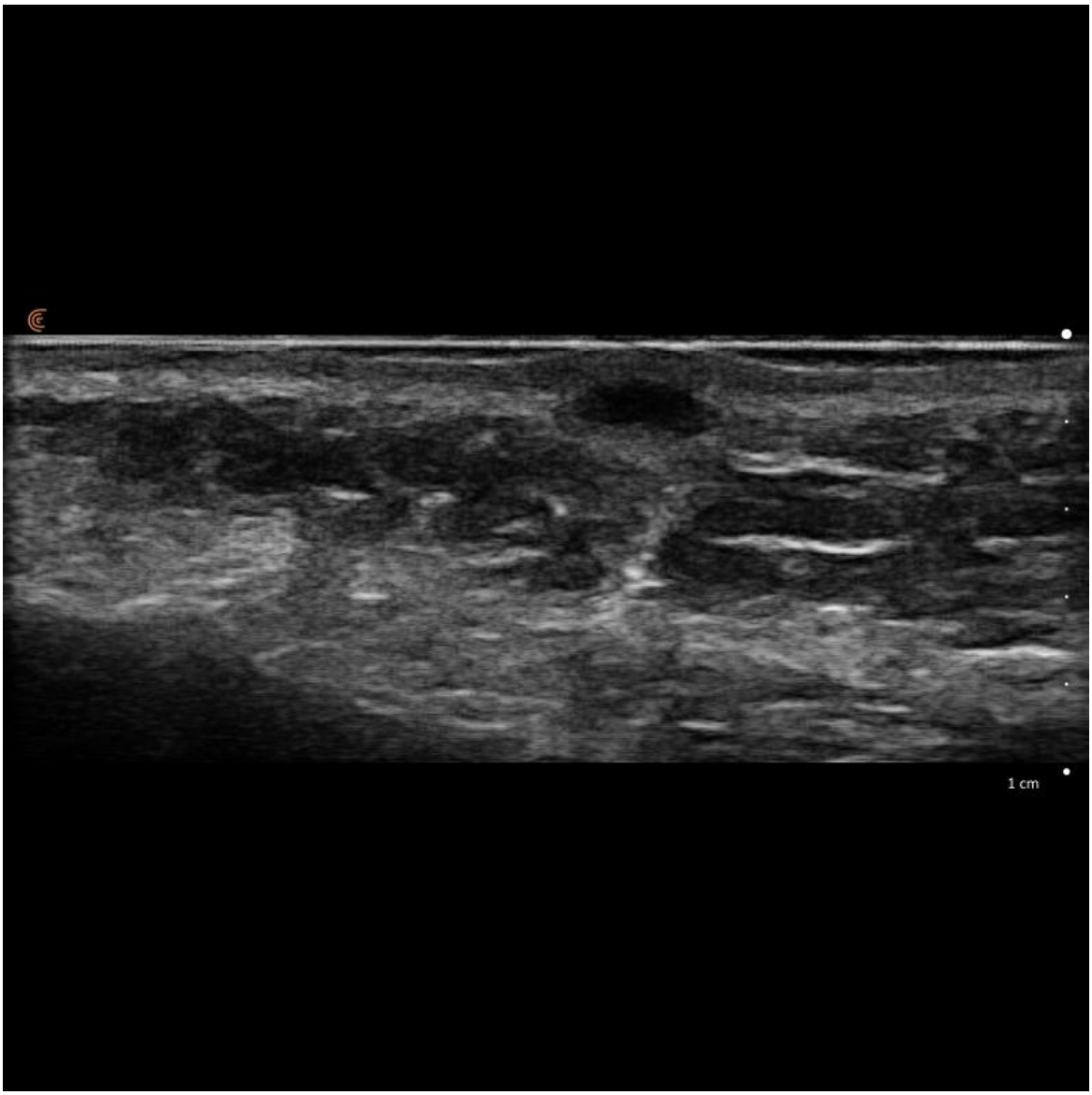

Superficial Usg

Conclusion

IAFG must be considered in the differential diagnosis of asymptomatic facial subcutaneous lesions in children. While it is a benign condition capable of spontaneous resolution, histopathological confirmation may be necessary when clinical suspicion of other surgical lesions (e.g., pilomatricoma) exists. Ultimately, integrating clinical, radiological, and histopathological findings is crucial for an accurate diagnosis and preventing overly aggressive management.

EA DV CONGRESS
VIENNA
30 SEP - 3 OCT 2026

Abstract N°: 1523

Beyond Recurrent Ulcers- Unmasking Juvenile Pemphigus Vulgaris

Khushi Soti*[1], Edwina Tang[2], Vrinda Bajaj[2]

[1] University of Sunderland, Sunderland, United Kingdom
[2] Dermatology Department, University Hospital of North Durham, Durham, United Kingdom

Introduction

Pemphigus vulgaris is an IgG-mediated autoimmune chronic blistering condition characterised by autoantibodies targeting keratinocyte adhesion proteins, Desmoglein 1 and Desmoglein 3 resulting in disruption of intraepidermal adhesion and blister formation. Juvenile pemphigus vulgaris is specific to children between the ages of 12 and 18 and is a rarity that can present with non-specific features initially posing diagnostic and therapeutic challenges.

Case Presentation

A 14 year old female presented to the paediatric ward with fever, intermittent mouth ulcers for 6 months which became persistent, and reduced oral intake, resulting in ten kilogram weight loss over 4 months. Other presenting symptoms included nosebleeds and occasional pain in her knees and both calves. Multiple specialities (rheumatology, ENT, maxillofacial, gastroenterology, ophthalmology, dentistry and dermatology) were involved to investigate and rule out differential pathologies. Clinical examination done by ENT revealed larger erosions to the hard palate and an ulcerated tongue, an inflamed pharynx, uvula and grade III erythematous tonsils. Nasendoscopy revealed ulceration of both aryepiglottic folds. Bloods revealed a raised CRP and ESR of 103-150 and 68 respectively, low iron, transferrin saturation, vitamin D and zinc and a positive HSV. MRI abdomen, thorax, pelvis, thighs and lower legs showed no abnormalities or signs of inflammatory arthritis. The patient presented with new symptoms of bilateral scleral erythema associated with pain on eye movement and generalised abdominal pain. Elevated faecal calprotectin raised concerns of underlying IBD which was later ruled out. Initial oral biopsy revealed ulcerated mucosa with acantholysis and inflammatory infiltrate with immunohistochemistry confirming HSV-1 infection consistent with herpetic stomatitis. Direct immunofluorescence was negative for IgG, IgA, C3 and fibrinogen. This suggested herpetic gingivo-stomatitis. However, subsequent indirect immunofluorescence demonstrated elevated anti-desmoglein 3 antibodies with negative anti-desmoglein 1 and pemphigoid antibodies, confirming the diagnosis of pemphigus vulgaris. Due to limited cases and therefore evidence, there is not much comparative data between various therapeutic modalities for pemphigus vulgaris. There is currently no specific guideline for the management of paediatric pemphigus vulgaris, but the most common treatment used is a systemic corticosteroid. This patient was started on mycophenolate mofetil and oral prednisolone, showing clinical improvement one month later.

Conclusion

Oral mucosal ulceration may be the first clinical manifestation of juvenile pemphigus vulgaris as well as being the only feature which underscores the diagnostic challenges.[1] Early mucosal presentations emphasise the need for a high index of suspicion when evaluating persistent oral ulceration in children. Although progression in the paediatric population is more unpredictable, they generally have a better prognosis than adults with pemphigus vulgaris. Long term immunosuppression requires vigilance for treatment related complications and life

threatening infections, especially in patients with extensive skin disease.

Timely recognition and multidisciplinary management are essential to prevent disease progression and improve outcomes for juvenile pemphigus vulgaris.

References

1. Sriram S, Jayakanth M, Alam T, Saeed S, Hasan S. Juvenile pemphigus vulgaris: A narrative review. Medicine. 2025 May 23;104(21):e42611.

EA DV CONGRESS
VIENNA
30 SEP - 3 OCT 2026

Abstract N°: 1525

Acrodermatitis enteropathica revealed by periorificial dermatitis in an infant with normal zinc levels

Hanane El Halla*[1], Nachwa Kayouh[1], ikram zouine[1], mhaimer soukaina[1], Hajar Lahmidi[1], Chaima El Assali[1], sokaina chhiti[1], chaouche mohammed[1], Radia Chakiri[1]

[1] University hospital Mohammed 6, Agadir, Morocco

Introduction
Acrodermatitis enteropathica is a rare, autosomal recessive disorder caused by zinc deficiency, It typically presents with the triad of periorificial dermatitis, alopecia, and diarrhea, with a spectrum of ocular, gastrointestinal, and mucocutaneous manifestations of varying frequency. Early diagnosis is crucial, as zinc supplementation leads to rapid clinical improvement and prevents complications.

We report the case of a 9 month old infant, full-term, exclusively breastfed, diagnosed with Acrodermatitis Enteropathica, who presented with normal serum zinc levels and showed a marked clinical improvement following zinc supplementation.



Confluent erythematous crusted plaques with overlying scaling.

Case Presentation

A 9-month-old infant, born to non-consanguineous parents and exclusively breastfed, presented with a one-month history of erythematous lesions initially involving the diaper area and neck, progressively spreading, associated with pruritus and profuse diarrhea (>8 stools/day). One week prior to admission, tense bullae appeared in a febrile context.

On examination, dermatological assessment revealed extensive erythematous, crusted, and scaly plaques with periorificial (perioral, periorbital, perianal) and flexural involvement, scattered purpuric lesions, and a tense bulla on the right hand, with a negative Nikolsky sign. Cicatricial alopecia was noted. Ocular examination showed bilateral ectropion.

Given the triad of periorificial dermatitis, alopecia, and diarrhea, the diagnosis of acrodermatitis enteropathica was suspected. Zinc supplementation (5 mg/kg/day) was initiated, and a skin biopsy was realized. Laboratory tests were within normal limits (zinc: 11.7 µmol/L; vitamin B12: 372 pg/mL), with an initial CRP of 157.2 mg/L.

Histopathology supported the diagnosis, showing parakeratosis, reduced granular layer, suprabasal vacuolization, and mild perivascular infiltrate.

A rapid clinical improvement was observed within 3 days with a decrease in CRP to 10.7 mg/L after 6 days.



perianal dermatitis.

Conclusion

This case highlights that the diagnosis of Acrodermatitis enteropathica should not be excluded in the presence of normal serum zinc levels, particularly when the clinical presentation is suggestive. Laboratory values may be misleading or influenced by prior supplementation. Therefore, diagnosis remains primarily clinical. Early therapeutic trial with zinc supplementation is both diagnostic and curative, and is associated with a rapid and dramatic clinical response.



Clinical control image after 5 days.

EADV CONGRESS
VIENNA
30 SEP - 3 OCT 2026

Abstract N°: 1538

A rare presentation of a congenital periorbital dermoid cyst complicated by preseptal cellulitis and sieve-like scarring

Ayliz Akbulut*[1], Ayse Esra Koku Aksu[1]

[1] Istanbul Research and Training Hospital, Istanbul, Türkiye

Introduction
Dermoid cysts are common congenital benign tumors resulting from the entrapment of ectodermal elements during embryonic fusion. While typically presenting as asymptomatic, firm, and non-fluctuant nodules, they can occasionally become complicated by infection or rupture, leading to diagnostic challenges. This report describes a case of a periorbital dermoid cyst that mimics chronic inflammatory processes following an episode of preseptal cellulitis.

Case Presentation
A 3-year-old female patient presented with an erythematous plaque on the right frontotemporal region. The lesion had been present since birth, initially characterized by occasional mild discharge that had later ceased. However, following an episode of preseptal cellulitis three months prior—which required systemic antibiotic therapy—the lesion recurred with increased inflammation.
Physical examination revealed an erythematous plaque that healed with a sieve-like (cribriform) scar, resembling the morphology seen in hidradenitis suppurativa. Additionally, a new cystic papule was noted at the lateral aspect of the right orbital rim. To exclude intracranial communication and assess the extent of the lesion, non-contrast cranial magnetic resonance imaging (MRI) was performed. The imaging revealed a heterogenous, subcentimetric area with ill-defined borders located at the lateral and superior aspects of the right orbit, extending toward the osseous structures. Increased T2-weighted signals and heterogeneity involving the surrounding fatty planes and fascia were observed.
Based on the clinical and radiological findings, a diagnosis of a complicated periorbital dermoid-epidermoid complex was made. The patient was placed on a clinical follow-up schedule.

Conclusion

Periorbital dermoid cysts may not always present as simple subcutaneous nodules. Inflammatory complications such as preseptal cellulitis can significantly alter the clinical morphology, leading to atypical scarring patterns. This case emphasizes the importance of radiologic evaluation to determine bone involvement and the necessity of considering complicated dermoid cysts in the differential diagnosis of recurrent periorbital inflammatory lesions in the pediatric population.

EADV CONGRESS
VIENNA
30 SEP - 3 OCT 2026

Abstract N°: 1615

Congenital Familial Atrichia with Scalp Cysts in a Sibling Pair

Sarra Hanane CHERIFI[1], Assia Zenagui[1], Latifa Abdelmoumene[2], Ghizlene Bouayed[2], Boumediene Dahmani*[1, 1]

[1] Faculty of Medicine, University of Tlemcen, Department of Dermatology and Venereology, Tlemcen University Hospital, Tlemcen, Algeria
[2] Department of Dermatology and Venereology, Tlemcen University Hospital, Tlemcen, Algeria

Introduction

Congenital atrichia with cystic lesions is a rare hereditary disorder characterized by irreversible hair loss shortly after birth followed by the development of follicular cysts. It is typically inherited in an autosomal recessive pattern and is caused by mutations in the HR on chromosome 8p12.

Case Presentation

A 10-month-old boy and his 2-year-old sister, born to consanguineous parents,were evaluated for diffuse alopecia. Hair was present at birth but shed within the first weeks of life, leading to permanent loss of scalp hair and eyebrows. Eyelashes were preserved. Nails, teeth, sweating, growth, and psychomotor development were normal. No similar family history was reported. The older sibling recently developed multiple asymptomatic cystic lesions on the scalp Congenital atrichia results from mutations in the HR, leading to irreversible failure of hair follicle cycling after the first shedding phase. The clinical association of early permanent alopecia, preserved eyelashes, normal ectodermal structures, and later scalp cyst formation strongly supports the diagnosis. The main differential diagnosis is alopecia areata; however, the very early onset shortly after birth, the permanent and complete nature of hair loss, and the subsequent development of follicular cysts strongly support a diagnosis of congenital atrichia.

Conclusion

Congenital familial atrichia with scalp cysts is a distinct clinicogenetic entity. Early recognition is essential to avoid unnecessary treatments and to provide appropriate genetic counseling.

EADV CONGRESS
VIENNA
30 SEP - 3 OCT 2026

Abstract N°: 1649

Recurrent Lipoblastoma in an Infant- a Case Report

Zuzana Nevoralova*[1]

[1] Dermatovenereologic Department, Regional Hospital Jihlava, Jihlava, Czech Republic

Introduction

A 5-months-old male-infant was referred to our Dermatologic Clinic by a pediatric general practicioner because of a rapidly growing formation in the right lumbal region lasting from 2 months of age. The patient was healthy with no permanent medication. Both father and father's father have multiple lipomas histologically verified.

Case Presentation

Objectively, in the right lumbar region, a horizontally located mass of approximately 40x70mm, embedded in the skin, bulging out of the skin was present, the skin above it was slightly purplish. There were no similar formations elsewhere on the body. Because of a rapidly growing an ultrasound examination was planned, followed by excision and histological verification of the mass. The ultrasound examination revealed an isoechoic benign lipoma without vascularization. The mass was completely excised at the age of 5.5 months. A histological examination revealed a lipoma. Immediately after the operation, a horizontally placed scar of 3 cm in length was present in the right lumbar region. The skin was calm, without elevation. Already 3 months after the operation, a soft mass of approximately 20x25mm was palpable under the scar. The skin was without pathology, slightly convex due to the mass. Ultrasound examination revealed unsharply defined, hyperechoic mass measuring 26x20x4mm, most likely a lipoma. The mass grew quite rapidly again. 10 months after the operation the formation was approximately 30x40mm, slightly elevated. Due to repeated colds, the mass was excised only 3 years after the first surgery, at the age of 3.5 years of the child. A histological examination revealed a lipoma. Since then, the patient has been free of recurrence of the tumor. He is 5.5 years old now.

Conclusion

Lipoblastoma is a rare tumor of lipoblasts and their mesenchymal precursor cells occurring almost exclusively in childhood. It is well-circumscribed, benign, does not undergo malignant transformation. It is called lipoblastoma due to its rapid growth. Local recurrences after excision are frequent, usually within 2 months. With this case report, we want to highlight the existence of this very rare diagnosis, which is benign, but due to its rapid growth and possible recurrence, can be very bothersome and stressful for the entire family.

EADV CONGRESS
VIENNA
30 SEP - 3 OCT 2026

Abstract N°: 1664

A Rare and Challenging Clinical Association: Epidermolysis Bullosa Simplex and Congenital Adrenal Hyperplasia in a Pediatric Patient — A Case Report

Laura Sifuentes *[1], Michelle Alitzel Lugo Flores[1], Rocío Concepción Albores Arguijo[1], Yocelin Nallely Lozano Figueroa[1], Valeria Noemi Rizo Hernández[1]

[1] Universidad de Guadalajara, Antiguo Hospital Civil de Guadalajara, Guadalajara, Mexico

Introduction

Epidermolysis Bullosa Simplex (EBS) is a genodermatosis caused by mutations in *KRT5* or *KRT14*, leading to intraepidermal cleavage and blister formation after minimal trauma, friction, or heat exposure. Recurrent blistering causes painful erosions, post-inflammatory hyperpigmentation, and functional impairment. Congenital Adrenal Hyperplasia (CAH), most commonly due to 21-hydroxylase deficiency, is an autosomal recessive endocrine disorder that disrupts cortisol synthesis. The classic salt-wasting form is associated with mineralocorticoid deficiency, androgen excess, virilization, and urogenital malformations. The coexistence of EBS and CAH is exceptionally rare and creates major therapeutic challenges, particularly during invasive procedures, where skin fragility and adrenal decompensation risk require highly individualized multidisciplinary care.

Case Presentation

A 12-year-old female with classic salt-wasting CAH diagnosed at 9 months of age, on chronic prednisone and sodium supplementation, presented with lifelong cutaneous fragility beginning during crawling and early ambulation. She developed recurrent blistering on hands and feet, worsened by heat and friction. Dermatological examination showed polymorphic dermatosis on the lower extremities, with dry hemorrhagic blisters, denuded blister roofs on plantar regions, and residual atrophic scars, as well as blisters located on the oral mucosal. Histopathology revealed a suprabasal blister with chronic dermatitis, consistent with EBS. Immunofluorescence is planned to complete the diagnostic workup. Management required close coordination between Dermatology, Endocrinology, and Urology. Acral protection measures were implemented, including avoidance of occlusive footwear and high-impact activities, along with syndet cleansers, topical clindamycin, and barrier-repair creams. Because of underlying CAH, all invasive procedures require stress-dose glucocorticoids to prevent adrenal crisis, and urological interventions demand extreme caution to avoid iatrogenic blistering.

Conclusion

The coexistence of EBS and CAH represents an exceptional and highly challenging clinical scenario, with no similar cases currently reported in the literature. Epithelial fragility significantly limits the medical and surgical management of CAH, particularly during future urological procedures, where minimal trauma may trigger blistering, delayed healing, and secondary complications. This case illustrates how EB associated with another chronic systemic disease becomes a major therapeutic challenge, requiring modification of standard management strategies to prevent cutaneous and systemic iatrogenic complications. Strict interdisciplinary care involving Dermatology, Endocrinology, and Urology is essential. A possible uncommon genetic association or contiguous gene deletion syndrome should also be considered. Continuous caregiver education, skin protection, and precise hormonal management are crucial to reduce morbidity and improve long-term quality of life.

EADV Congress 2026, VIENNA
30 SEPTEMBER - 03 OCTOBER 2026
POWERED BY M-ANAGE.COM

EA DV CONGRESS
VIENNA
30 SEP - 3 OCT 2026

Abstract N°: 1699

Self mutilating behavior in a 2 year old girl unveiling the diagnosis of a rare entity- MiTES

Fida Anjum*[1]

[1] Yenepoya Medical College, Mangalore, India

Introduction

Midface toddler excoriation syndrome (MiTES) is a newly identified condition that has been linked to a PRDM12 gene mutation. Clinical features of MiTES include infantile-onset excoriations and long-lasting scratch sequelae that are present over the midface, with a preference for the nasal bridge. The disorder was named Mid-face Toddler Excoriation Syndrome (MiTES) to indicate its anatomical location and age of onset. There are only seventeen cases of MiTES reported in the literature. We report a Two-year-old girl who was diagnosed to have MiTES.

Case Presentation

A Two-year-old girl, born of non-consanguineous parents, presented with itchy lesions on the face, which had appeared since the child was one year and six months of age. Parents reported that the child frequently scratched the nose and surrounding regions. Sleep problems were also seen in the child. No developmental delay was seen. No additional such lesions were found on the body.

Bilaterally symmetrical lichenified lesions were observed on the bridge of the nose and surrounding regions, along with several excoriations on the central portion of the face, during the skin examination. The child persistently scratched the bridge of the nose even while being examined clinically.

Standard laboratory tests, such as a complete blood count, uric acid levels, renal function (urea and creatinine), and liver enzyme levels, were all normal. The diagnosis of midface toddler excoriation syndrome (MiTES) was established by history, clinical examination, and investigations. A biopsy for histopathology and genetic testing was not performed. The child was administered emollients, topical and systemic antibiotics, and topical anaesthetic cream. Counselling and management by a child psychologist and psychiatrist were done.

During the follow-up visit in the next month, the skin lesions healed completely with residual scarring.

Conclusion

MiTES is a congenital pain insensitivity disorder associated with mutations in the PRDM12 gene, often involving GCC triplet expansions (16–18 repeats) that lead to functional instability. It closely resembles hereditary sensory and autonomic neuropathy type VIII (HSAN 8), but typically lacks acral ulceration. Given its genetic heterogeneity, other genes may also be involved. Diagnosis is confirmed by molecular testing, initially using Sanger sequencing of PRDM12 exon 5 to detect triplet expansions; if negative, next-generation sequencing panels for congenital pain insensitivity disorders are recommended. Differential diagnoses include other hereditary sensory neuropathies, congenital insensitivity to pain with anhidrosis, familial dysautonomia, Lesch–Nyhan syndrome, dermatitis artefacta, and neurotic excoriations. Management focuses on preventive care, including injury avoidance, maintenance of oral and skin hygiene, and psychiatric support for associated behavioral and emotional issues.

Infantile-onset pruritic midfacial lesions should raise suspicion of MiTES, as affected children may present across dermatology, psychiatry, and paediatric departments.

EADV Congress 2026, VIENNA
30 SEPTEMBER - 03 OCTOBER 2026
POWERED BY M-ANAGE.COM

EA DV CONGRESS
VIENNA
30 SEP - 3 OCT 2026

Abstract N°: 1702

Delgocitinib cream provides rapid improvements in itch and pain symptoms in adolescents with moderate to severe chronic hand eczema: Results from DELTA TEEN

Sonja Molin*[1, 2], Francisco J. Navarro-Triviño[3], F. Elcin Darendeli[4], Eydna Didriksen Apol[4], Line Conradsen Hiort[4], Henrik Thoning[4], Ziad Reguiai[5], Anthony Bewley[6], Amy S. Paller[7]

[1] Department of Dermatology, Venerology and Allergy, Charité-Universitätsmedizin Berlin, Berlin, Germany

[2] Division of Dermatology, Queen's University, Kingston, Canada

[3] Department of Dermatology, Hospital Universitario San Cecilio, Granada, Spain

[4] LEO Pharma A/S, Ballerup, Denmark

[5] Department of Dermatology, Polyclinique Courlancy, Reims-Bezannes, France

[6] Barts Health NHS Trust & QMUL, London, United Kingdom

[7] Departments of Dermatology and Pediatrics, Feinberg School of Medicine, Northwestern University, Chicago, IL, United States

Introduction

Chronic hand eczema (CHE) is an inflammatory skin disease of the hands or wrists and itch and pain are among the most burdensome symptoms of the disease. The symptom burden of CHE varies with disease severity and treatment stage, with a particularly high burden observed among individuals who do not benefit from topical corticosteroids (TCS)[1]. In adolescents with CHE, first-line of treatment is TCS, but treatment options are limited when TCS are inadequate or inappropriate, and no treatments are currently approved specifically for adolescents with moderate to severe CHE. Delgocitinib cream is approved for the treatment of moderate to severe CHE in adults, and in this population, it has been shown to rapidly reduce itch and pain[2]. This post hoc analysis evaluates the efficacy and time to onset of action of delgocitinib cream for itch and pain in adolescents with moderate to severe CHE.

Materials and Methods

DELTA TEEN randomized (3:1) adolescents (12-17 years of age) with moderate to severe CHE for whom TCS were inadequate or inappropriate to twice-daily applications of delgocitinib cream 20 mg/g (N=74) or cream vehicle (N=24) for 16 weeks (NCT05355818).

Itch and pain symptoms were assessed daily in the Hand Eczema Symptom Diary (HESD). HESD is a patient-reported outcome in which the adolescents assessed the worst severity of their itch and pain symptoms over the past 24 hours on a scale from 0 (no itch/pain) to 10 (severe itch/pain).

Post hoc analyses were performed to evaluate mean changes from baseline in daily HESD itch and pain scores during the first 14 days of treatment (Days 0–13). Baseline scores were defined as the last daily assessments performed prior to the date of randomization and Day 0 was defined as the assessments performed after the first IMP application on the date of randomization.

Results

On Day 0, mean changes from baseline in HESD itch and pain scores did not significantly differ between

delgocitinib cream and cream vehicle (itch: -0.64±0.17 vs -0.16±0.31; pain: -0.68±0.23 vs -0.05±0.37).

On Day 1, mean changes from baseline (LS mean±SE) in HESD itch and pain scores were significantly greater with delgocitinib cream than with cream vehicle (itch: -1.03±0.20 vs -0.20±0.35, p=0.040; pain: -1.34±0.22 vs -0.39±0.36, p=0.019).

On Day 2, mean changes from baseline (LS mean±SE) in HESD itch and pain scores were also significantly greater with delgocitinib cream than with cream vehicle (itch: -1.22±0.19 vs -0.41±0.33, p=0.034; pain: -1.63±0.22 vs -0.58±0.36, p=0.011).

Similarly, from Day 3 to Day 13, mean changes from baseline in HESD itch and pain scores were significantly greater with delgocitinib cream than with cream vehicle, except for the mean change for HESD itch on Day 6.

Mean changes from baseline in daily HESD itch and pain scores during the first 14 days of treatment are shown in Figure 1.

Conclusions

Delgocitinib cream rapidly reduced both itch and pain, with onset of action observed as early as 1 day after the first application. These findings are consistent with those from adults[2] and suggest that delgocitinib cream may represent an effective topical treatment option for rapid improvement in itch and pain in adolescents with moderate to severe CHE.

References:

1. Molin S. et al. Acta Derm Venereol 2026; 106: adv44493.
2. Bauer A. et al. Dermatol Ther (Heidelb) (2026) 16:1241–1253.

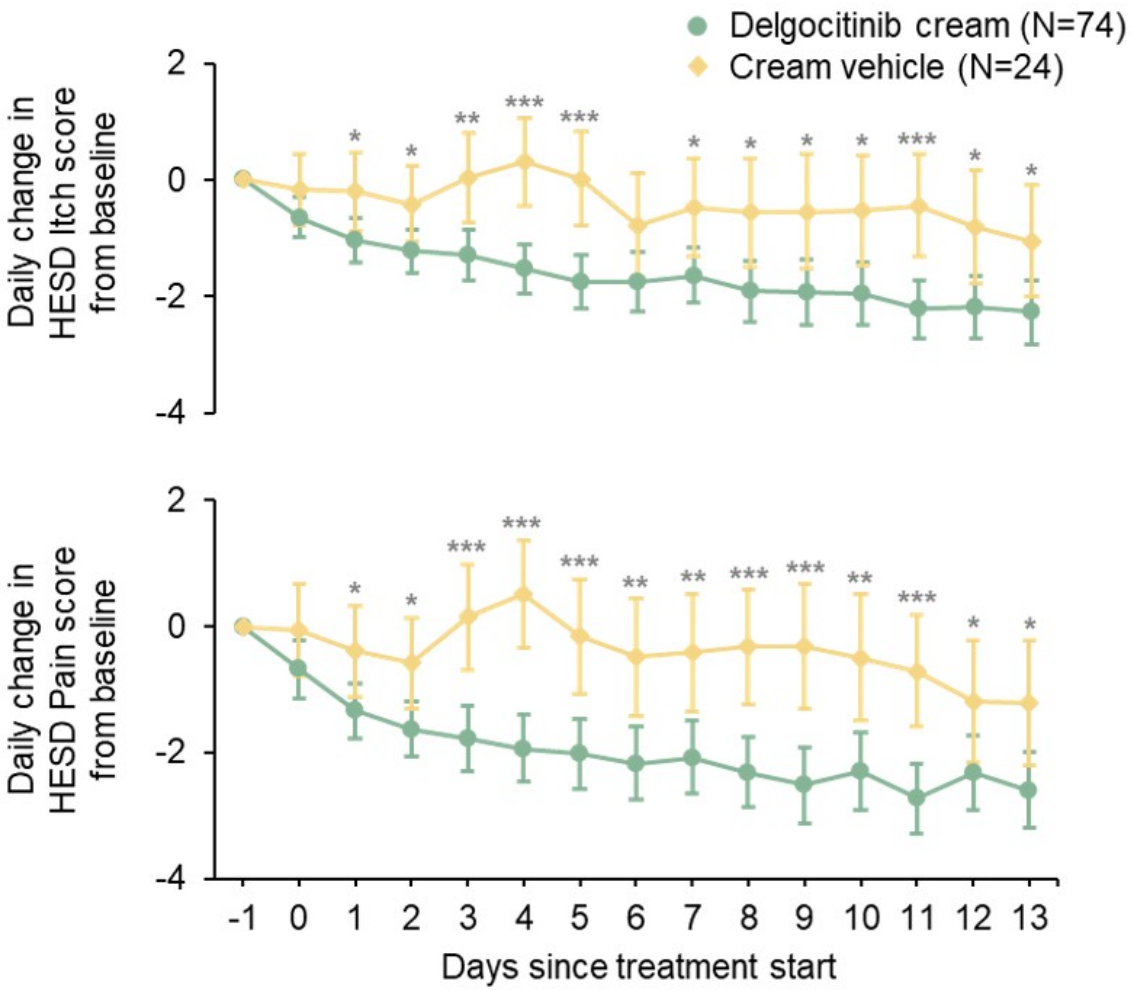

Figure 1. Change in daily HESD itch and pain scores during the first 14 days of treatment in adolescents (12–17 years) with moderate to severe chronic hand eczema who were treated with delgocitinib cream 20 mg/g or cream vehicle in DELTA TEEN. Notes: Baseline scores were defined as the last daily assessments performed prior to the date of randomization (Day -1) and Day 0 was defined as the assessments performed after the first IMP application on the date of randomization. Error bars represent 95% confidence intervals. * P <0.05, ** P <0.01, *** P < 0.001 (ANCOVA). Abbreviations: ANCOVA: Analysis of covariance; HESD: hand eczema symptom diary; IMP: Investigational medicinal product.

EA DV CONGRESS
VIENNA
30 SEP - 3 OCT 2026

Abstract N°: 1757

Recurrent eosinophilic cellulitis in a child successfully treated with dapsone

Magdalini Louka*[1], Ioannis Pagonis[2], Kalliopi Stefanaki[3], Irene Orfanou[2], Manthoula Valari[1]

[1] Pediatric Dermatology Unit, First Department of Pediatrics, Medical School, National and Kapodistrian University of Athens, "Aghia Sophia" Children's Hospital, Athens, Greece

[2] First Department of Pediatrics, Medical School, National and Kapodistrian University of Athens, "Aghia Sophia" Children's Hospital, Athens, Greece

[3] Department of Pathology, "Aghia Sophia" Children's Hospital, Athens, Greece

Introduction

Eosinophilic cellulitis (Wells syndrome) is a rare inflammatory dermatosis with limited reports in children that frequently mimics bacterial cellulitis, often resulting in misdiagnosis, unnecessary antibiotic use, and delayed treatment. It typically presents with the acute onset of pruritic, erythematous, edematous plaques that may evolve into vesicles or bullae and resolve over weeks, often leaving residual hyperpigmentation. Recurrences are common, and systemic symptoms are usually absent. Its pathogenesis remains unclear but is thought to represent a hypersensitivity reaction to various triggers, although many cases are idiopathic. Treatment is not standardized, with corticosteroids as first-line therapy and steroid-sparing agents used in recurrent or corticosteroid-dependent cases.

Case Presentation

An 8-year-old boy with an unremarkable medical history presented with recurrent pruritic papulovesicular eruptions affecting the lower extremities over a four-month period. The initial episode followed minor trauma and was characterized by erythema, swelling, and warmth of the foot, leading to a clinical diagnosis of bacterial cellulitis. Despite multiple courses of oral and intravenous antibiotics, the lack of sustained clinical improvement raised suspicion for a non-infectious etiology. A lesional skin biopsy supported the diagnosis of eosinophilic cellulitis. Systemic corticosteroid therapy was initiated, resulting in rapid clinical improvement. However, repeated relapses occurred during dose tapering, indicating a corticosteroid-dependent course, and the patient was referred to our hospital for further management. The child resided in a rural environment, with recurrent insect bites preceding each flare, suggesting a potential triggering factor.

On initial presentation to our center, physical examination revealed edematous erythematous plaques with vesicles on both feet, similar but milder lesions on one upper extremity and the popliteal region, accompanied by pruritus and pain. During hospitalization, progression of the lesions was observed despite topical therapy with clobetasol propionate. An extensive diagnostic workup was performed to exclude alternative etiologies, including infectious, autoimmune, allergic, and systemic eosinophilic disorders, as well as hematologic malignancies. Laboratory findings demonstrated mild eosinophilia with normal inflammatory markers. A repeat skin biopsy showed dermal eosinophil-rich infiltrate and flame figures in the absence of vasculitis, confirming the diagnosis of eosinophilic cellulitis.

Systemic corticosteroid therapy again resulted in rapid clinical improvement. However, relapses recurred during tapering. Methotrexate was introduced as a steroid-sparing agent but failed to achieve adequate disease control. Subsequently, dapsone was initiated and continued for six months, leading to sustained clinical improvement and remission.

Conclusion

This case highlights the importance of considering eosinophilic cellulitis in children presenting with cellulitis-like lesions unresponsive to antibiotics. Early biopsy is critical for accurate diagnosis and avoidance of unnecessary treatments. Recurrent eosinophilic cellulitis may follow a corticosteroid-dependent course requiring alternative therapeutic strategies. Although evidence in children is limited, our case support dapsone as an effective and well-tolerated steroid-sparing option in refractory cases and may represent a valuable alternative in clinical practice.

EADV CONGRESS
VIENNA
30 SEP - 3 OCT 2026

Abstract N°: 1762

Generalized Spinulous Lichen Nitidus: A Rare Pediatric Presentation

raouia Roumili*[1], Dali osmane Rima[1], narimene alioua[2], mira chikhaoui[2], yasmine namaoui[3], nassima djennane[3], sahel houria[2]

[1] CHU MAILLOT, BAB ELOUAD, Algeria
[2] Dermatologie, C.H.U Lamine Debaghine, bab elouad, Algeria
[3] C.H.U Lamine Debaghine, BAB ELOUAD, Algeria

Introduction

Lichen nitidus (LN) is a rare inflammatory dermatosis with several clinical variants, including the follicular spinulous form. Lichen spinulosus (LS), also infrequent, shares certain clinical features with LN but remains a distinct entity. We report a case presenting clinical characteristics suggestive of both conditions, while histology confirmed LN, illustrating a rarely described mixed presentation.

Case Presentation

An 11-year-old child with a medical history of asthma and allergic rhinitis presented with a generalized pruritic papular eruption evolving over two years, partially improved with topical corticosteroids. Clinical examination revealed diffuse keratotic follicular papules associated with smooth, shiny, non-follicular, raised papules. Palmar and plantar surfaces, nails, hair, and mucous membranes were spared. Histopathological examination of a skin biopsy showed an atrophic epidermis with mild hyperorthokeratosis, associated with a lymphohistiocytic infiltrate in the upper dermis and an overlying parakeratotic stratum corneum. Clinical-pathological correlation led to the diagnosis of the spinulous variant of LN. The patient was treated with oral acitretin at a dose of 0.5 mg/kg/day, resulting in partial improvement.

Conclusion

The follicular spinulous variant of LN is a rare and not yet well-defined entity.
Some authors consider this form to represent a true association between LN and LS when clinical and histological features are distinct, whereas others believe that when histology is typical of LN with a mixed clinical presentation, it is more consistent with a spinulous variant of LN, as was the case in our patient.
Our patient’s atopic background (history of asthma and allergic rhinitis) may suggest a possible association between LN and atopic dermatitis. This has been reported in the literature, suggesting a potential dysimmune pathophysiological link between the two conditions.
Finally, although LN is generally benign and self-limited, its follicular spinulous variant may pose a therapeutic challenge.
We report the case of a child presenting clinically with features of both follicular spinulous LN and LS, but with histological findings consistent with LN.

EADV CONGRESS
VIENNA
30 SEP - 3 OCT 2026

Abstract N°: 1789

Clinical case of two 15-month-old twin girls with Netherton syndrome

Andrey Mun[1], Lola Ibragimova[1], Sunyoung Woo*[1]

[1] Tashkent State Medical University, Tashkent, Uzbekistan

Introduction
Netherton syndrome (NS) is a rare autosomal recessive genodermatosis caused by mutations in the *SPINK5* gene, which encodes the serine protease inhibitor LEKTI. LEKTI deficiency leads to dysregulated epidermal proteolysis, resulting in profound Skin barrier dysfunction, chronic inflammation, and a characteristic clinical triad: congenital ichthyosiform erythroderma (CIE), trichorrhexis invaginata (bamboo hair), and atopic diathesis. This report describes 15-month-old monozygotic twin girls with a severe phenotype of NS, highlighting the clinical challenges in diagnosis and management.

Case Presentation
Two 15-month-old twin girls, born to non-consanguineous parents, presented with generalized erythema and scaling persisting since birth. Both twins exhibited a remarkably concordant clinical course. Physical examination revealed diffuse, bright erythematous plaques with fine scaling. A prominent clinical feature was ichthyosis linearis circumflexa (ILC), characterized by migratory, serpiginous lesions with classic double-edged desquamation. Trichoscopy confirmed trichorrhexis invaginata (bamboo hair), a pathognomonic finding for this condition. Laboratory investigations revealed markedly elevated serum IgE levels (>2,000 IU/mL). Both twins exhibited significant growth retardation (failure to thrive), with weight parameters consistently remaining below the 10th percentile.

Both patients presented at birth with generalized erythroderma and extensive skin desquamation, requiring intensive neonatal monitoring. Clinical examination at the time showed intense, universal erythema accompanied by fine scaling and continuous peeling, resulting in a characteristic exfoliative appearance.

Facial involvement was significant, with erythema and scaling affecting the scalp and perioral regions. The scalp showed sparse, fragile hair, raising early suspicion of hair shaft abnormalities. The trunk and extremities displayed widespread erythematous patches with ill-defined borders and superficial desquamation, consistent with congenital ichthyosiform erythroderma (CIE). Palmar involvement was also notable, characterized by marked erythema and peeling, reflecting severe epidermal barrier dysfunction.

The severity of cutaneous involvement - specifically the early-onset erythroderma and extensive desquamation - strongly suggested a primary genodermatosis. Given the occurrence in identical twins and the subsequent development of pathognomonic hair defects and atopic features, Netherton syndrome (NS) was identified as the definitive diagnosis. While genetic testing for *SPINK5* mutations remains the definitive gold standard, socioeconomic barriers-including the family's financial constraints and the absence of medical insurance-precluded molecular confirmation. In resource-limited settings where genomic diagnostics are frequently inaccessible, clinical diagnosis based on pathognomonic signs and trichoscopic findings remains the most vital diagnostic pillar for clinicians.

The patients were managed with intensive topical emollients (ceramide-based) , low-potency topical

corticosteroids (methylprednisolone) for flare-ups, and high-protein nutritional support to address growth retardation.

Conclusion

This case highlights the severe clinical presentation of Netherton syndrome in monozygotic twins. As NS is frequently misdiagnosed as recalcitrant atopic dermatitis or seborrheic dermatitis, the presence of neonatal erythroderma, combined with double-edged scaling or hair fragility, must prompt immediate clinical suspicion. Early recognition is vital for initiating targeted therapy, managing systemic complications like failure to thrive, and providing accurate genetic counseling.

EADV CONGRESS
VIENNA
30 SEP - 3 OCT 2026

Abstract N°: 1846

Cutaneous Manifestations of DOCK8 Deficiency: Clinic-Immunological Correlation in Two Cases

Bounneche Houda*[1], Tarek Mansoul[1], esma bouhila[1], RIADH BOUSSAID[1], Amel Gherfi[1], khadidja bouarroudj[1], kaghouche lilia[1], safa djebbas[1], Ahmed Samaouel Chehad[1]

[1] Department of Dermatology, University Hospital, Constantine, Algeria

Introduction

Autosomal recessive hyper-IgE syndrome (AR-HIES) due to DOCK8 deficiency is a rare primary immunodeficiency characterized by recurrent cutaneous and systemic infections, severe atopic dermatitis, and increased risk of malignancy. Cutaneous manifestations are highly variable, ranging from severe atopic dermatitis to chronic vegetating pyodermas. We report two related pediatric cases, paternal cousins from consanguineous marriages, presenting with autosomal recessive hyper-IgE immunodeficiency (DOCK8).

Case Presentation

The first case is a 10-year-old girl with severe atopic dermatitis, treated pulmonary TB, recurrent *Pseudomonas aeruginosa* pneumonia with atelectasis, and growth retardation. For 4 years, she had erosive-crusted dermatoses in perineum, inguinal folds, retroauricular, perinasal, and perioral areas, plus erosive cheilitis and oral candidiasis. *Candida albicans* was confirmed; bronchoscopic analysis revealed *P. aeruginosa*. Labs: hyper-IgE 7151 IU/mL, eosinophilia; immunophenotyping: CD3+CD4+ lymphopenia (482/mm^3), inverted CD4/CD8, reduced naïve CD8+ T cells, TEMRA expansion, ↑Th2, ↓Th17. Treated with ciprofloxacin, itraconazole, topical corticosteroids, local care → marked improvement.Her 7-year-old paternal cousin had severe atopic dermatitis, treated miliary TB, one-year ulcerative-vegetating lesions in inguinal folds, intergluteal region, scrotum, neck, scalp, periorificial areas, flat warts, and herpetic keratitis. Histology: epidermal ulceration, pseudoepitheliomatous hyperplasia, dense neutrophilic infiltrate. Cytobacteriology: *Staphylococcus aureus* sensitive to ciprofloxacin. Labs: IgE 3744 IU/mL; immunophenotyping: CD3+CD4+ lymphopenia (230/mm^3), inverted CD4/CD8, ↓naïve CD4+, TEMRA expansion, ↑Th2, ↓Th17. Treated with ciprofloxacin, acyclovir, local care → rapid improvement.

Conclusion

Despite shared background and severe atopic dermatitis, manifestations differed: the girl had erosive-crusted/fungal lesions; the boy had ulcerative-vegetating lesions and viral infections. Differences reflect immunological defects: bacterial susceptibility from CD4+ lymphopenia, naïve T cell reduction, NK dysfunction; fungal susceptibility (girl) from Th17 deficiency; viral susceptibility (boy) from impaired cytotoxic T/NK function, CD4/CD8 inversion, naïve T cell depletion, TEMRA expansion. Pulmonary atelectasis in the girl shows severe respiratory complicationsDOCK8-HIES shows diverse, severe cutaneous involvement. Early recognition and management are critical; hematopoietic stem cell transplantation is the only curative therap

EA DV CONGRESS
VIENNA
30 SEP - 3 OCT 2026

Abstract N°: 1849

Vegetating Pyoderma Revealing Autosomal Recessive Hyper-IgEImmunodeficiency Syndrome

Bounneche Houda*[1], Tarek Mansoul[1], RIADH BOUSSAID[1, 1], Amel Gherfi[1], esma bouhila[1], khadidja bouarroudj[1], kaghouche lilia[1], safa djebbas[1], Ahmed Samaouel Chehad[1]

[1] Department of Dermatology, University Hospital, Constantine, Algeria

Introduction

Vegetating pyoderma is a rare inflammatory dermatosis often indicating underlying immunodeficiency. When associated with chronic viral infections such as herpes simplex
virus (HSV) and human papillomavirus (HPV), and severe atopic dermatitis, DOCK8 deficiency should be suspected. Autosomal recessive hyper-IgE syndrome due to DOCK8
deficiency leads to impaired cutaneous antimicrobial and antiviral immune responses.

Case Presentation

A 7-year-old child born to consanguineous parents, with a history of atopic dermatitis and treated pulmonary tuberculosis, was referred for
a one-year history of chronic dermatosis. A similar case was reported in a paternal relative. Clinical examination revealed eczematous
lesions of skin folds, ulcerative and purulent vegetating lesions involving the inguinal and intergluteal folds, scrotum, scalp, nape of the
neck, and periorificial areas, as well as flat warts on the hands. Ophthalmologic examination showed herpetic keratitis.Histopathology
demonstrated ulceration with pseudoepitheliomatous hyperplasia and a dense neutrophilic dermal infiltrate. Laboratory tests were normal
except for markedly elevated total IgE levels (3744 IU/mL)Immunophenotyping revealed severe $CD3^{+}CD4^{+}$ T-cell lymphopenia ($230/mm^{3}$)
with inversion of the CD4/CD8 ratio, depletion of naïve T cells, expansion of Th2 cells (46%), and reduced Th17 cells (9%). Based on clinical,
biological, and immunological findings, autosomal recessive hyper-IgE syndrome due to DOCK8 deficiency was diagnosed. Treatment with
ciprofloxacin, acyclovir, and local wound care led to marked clinical improvement within 14 days

Conclusion

Vegetating pyoderma is a recognized marker of immunosuppression, either acquired or congenital. In
this case, the association of chronic vegetating lesions, extensive HSV and HPV infections, severe atopic dermatitis, and consanguinity strongly suggested DOCK8 deficiency. This condition is characterized by susceptibility to recurrent bacterial infections and defective antiviral immunity, leading to chronic HSV infections, keratitis, and extensive HPV-induced warts. Elevated IgE levels and characteristic immunophenotypic abnormalities support the diagnosis. Prognosis is poor due to severe infections and increased risk of malignancies, including lymphomas and cutaneous carcinomas.

Chronic vegetating lesions of skin folds associated with HSV and HPV infections should prompt investigation for primary immunodeficiency, particularly DOCK8 deficiency. Early diagnosis is essential to allow timely referral for allogeneic hematopoietic stem cell transplantation, the only curative treatment.

EA DV CONGRESS
VIENNA
30 SEP - 3 OCT 2026

Abstract N°: 1869

An 8-year-old girl with a sudden hair loss

Simona Kordeva*[1], Konstantin Tchernev Jr[2], Valentina Broshtilova-Nikolova[3], Betul Okulmus[1], Georgi Tchernev[1, 2]

[1] Medical Institute of Ministry of Interior - Department of Dermatology and Venereology, Sofia, Bulgaria
[2] Onkoderma- Clinic for Dermatology, Venereology and Dermatologic Surgery, Sofia, Bulgaria
[3] Sofia University Saint Kliment Ohridski, Faculty of Medicine - Department of Internal Diseases, Pharmacology and Clinical Pharmacology, Pediatrics, Epidemiology, Infectious Diseases, and Skin Diseases, Sofia, Bulgaria

Introduction

Folliculitis et perifolliculitis capitis abscedens et suffodiens is a rare, chronic inflammatory scalp disease, presenting with follicular and perifollicular inflammatory nodules, abscesses formation, and scarring alopecia.

We present an 8-year-old girl with a solitary, soft, alopetic lesion located on the parietal region of the scalp (Figure 1a,b). According to the parents, the lesion has been present for approximately one month.



Figure 1a,b: A solitary, soft, alopetic lesion on the parietal region of the scalp.

Case Presentation

Differential diagnoses included aplasia cutis congenita, epidermal cyst, atrophoderma, anetoderma, alopecia areata, and scar tissue.

Routine laboratory tests and a comprehensive hormonal panel were within normal limits. A microbiological smear

showed no pathogenic findings. Color Doppler ultrasonography revealed fluid-filled cavities, interconnected burrowing tracts involving the hair follicles, intense vascularity, and hypoechoic areas in the subcutaneous tissue.

A punch biopsy revealed an intact epidermis and papillary dermis, moderate perivascular and periadnexal round cell inflammatory infiltrate in the deep dermis, and an overlying zone of necrosis prominent in the hypodermis (Figure 2a,b).

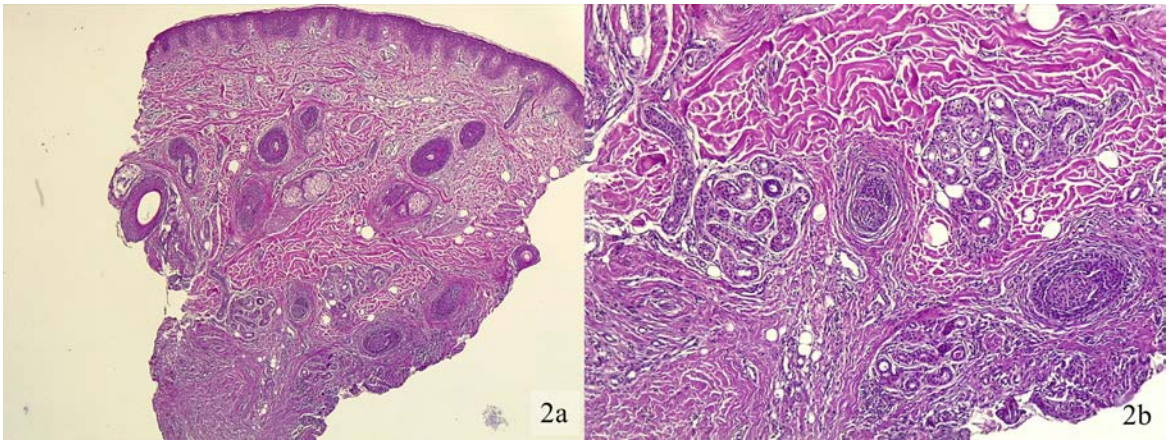

Figure 2a,b: An intact epidermis and papillary dermis, moderate perivascular and periadnexal round cell inflammatory infiltrate in the deep dermis, and an overlying zone of necrosis prominent in the hypodermis. 2a: FPS x 40 x HE 2b: perifollicular round cell inflammation in the deep dermis x 100 x HE

Conclusion

Based on the histological and clinical picture the diagnosis of folliculitis et perifolliculitis capitis abscedens et suffodiens was made. Given the patient's age and limited cooperation, intralesional glycocorticosteroid therapy was recommended.

EADV CONGRESS
VIENNA
30 SEP - 3 OCT 2026

Abstract N°: 1885

Alpha-1-antitrypsin deficiency revealed by panniculitis in an adolescent girl

Émélie Simone Okouango*[1], Hanane Rachadi[1], Fatimazahrae Benhayoun[1], Bouchra Baghad[1], Soumiya Chiheb[1]

[1] Department of Dermatology, Ibn Rochd University Hospital, Casablanca, Morocco, Faculty of Medicine and Pharmacy of Casablanca, Hassan II University, Morocco, Casablanca, Morocco

Introduction

Alpha-1-antitrypsin (AAT) deficiency is an inherited disorder characterised by insufficient serum production of AAT. Although rare and underdiagnosed, it is one of the most common genetic disorders in Europe. It can occur at any age and typically manifests as pulmonary emphysema or liver cirrhosis but more rarely as panniculitis or c-ANCA-associated vasculitis. Diagnosis is based on a decreased serum AAT level. We report the case of a 17-year-old adolescent presenting with panniculitis that revealed AAT deficiency.

Case Presentation

The patient is a 17-year-old adolescent, the second of four siblings, born to parents who were second-degree relatives, with no significant personal or family history. For two months, she had presented with painful dermo-subcutaneous nodules on her upper and lower extremities, some of which softened and then fistulated, discharging an oily fluid, progressing to painful ulcerations. These symptoms were accompanied by unilateral right vulvar oedema, arthralgia, fever, and an altered general condition with unquantified weight loss. The physical examination revealed nodules on the arms and thighs; erythematous-purplish, infiltrated plaques that were very painful, topped by serohematomas on the right flank; as well as ulcerations with a fibrinous base and purplish, scalloped edges, discharging an oily fluid, particularly on the arms and near scars, suggestive of a Koebner phenomenon. Unilateral right vulvar oedema was also noted. Laboratory findings showed an inflammatory syndrome, neutrophilic leukocytosis, and a severely reduced serum AAT level of 0.3 g/L. Serum protein electrophoresis was normal. Immunological testing for vasculitis was negative. Bacteriological cultures were negative. Genetic testing was not performed due to lack of resources. Skin histology revealed dermo-hypodermic neutrophilic infiltration. Chest CT and liver ultrasound were normal. The diagnosis of AAT-deficient panniculitis was established. Treatment with systemic corticosteroids (1 mg/kg/day), combined with doxycycline (100 mg/day), dapsone (100 mg/day), and local care, was initiated, resulting in partial improvement at two months, followed by a favourable clinical and laboratory course.

Conclusion

AAT deficiency is a rare autosomal recessive genetic disorder most commonly associated with the Z variant of the SERPINA1 gene, which predisposes individuals to liver (cirrhosis) and lung (emphysema and chronic obstructive pulmonary disease) involvement of varying severity and, more rarely, skin involvement (panniculitis). Predisposing factors, particularly trauma or surgical procedures, may be present. Clinically, panniculitis presents as painful nodules that frequently progress to softening, fistulisation, and drainage of a characteristic oily fluid. The limbs, buttocks, and trunk are the most common sites, with the possibility of the Koebner phenomenon. The diagnosis is based on decreased AAT levels and, ideally, on genotyping. Histology reveals neutrophilic lobular hypodermitis. There is no therapeutic consensus. AAT replacement therapy is the standard of care but remains costly and difficult to access. Alternatives such as corticosteroids, colchicine, doxycycline, or dapsone may be used. Regular

monitoring is necessary due to the risk of liver fibrosis and cirrhosis, as well as hepatocellular carcinoma, for which the risk is significantly increased. Our case report describes a rare form of panniculitis indicative of an AAT deficiency in an adolescent girl. In the presence of subacute dermo-subcutaneous nodules that have formed fistulas with oily discharge, this diagnosis should be considered, AAT levels should be routinely measured, and the patient should be evaluated for liver and lung involvement.

EADV CONGRESS
VIENNA
30 SEP - 3 OCT 2026

Abstract N°: 1886

Intrafamily clinical variability in Kindler syndrome: a report of two cases

Émélie Simone Okouango*[1], Bouchra Baghad[1], Hanane Rachadi[1], Soumiya Chiheb[1]

[1] Department of Dermatology, Ibn Rochd University Hospital, Casablanca, Morocco, Faculty of Medicine and Pharmacy of Casablanca, Hassan II University, Morocco, Casablanca, Morocco

Introduction

Kindler syndrome (KS) is a rare autosomal recessive genodermatosis caused by mutations in the*FERMT1* gene, leading to defective kindlin-1 and impaired cell adhesion. It belongs to the group of hereditary epidermolysis bullosa. Clinically, it is characterised by skin fragility with trauma-induced blistering, progressive poikiloderma, and photosensitivity. Mucosal involvement especially oral, oesophageal, and urogenital is frequent and may result in severe complications. This report presents two familial cases highlighting phenotypic variability.

Case Presentation

Case 1

A 15-year-old boy, born to consanguineous parents, presented since childhood with recurrent post-traumatic blisters, photosensitivity, and progressive dyschromia evolving to marked skin atrophy. He also had dysphagia and chronic urinary symptoms. Examination showed diffuse poikiloderma, severe atrophy (“cigarette paper” skin), pseudasyndactyly, nail dystrophy, gingival hypertrophy, plantar hyperkeratosis, and urethral stenosis. Investigations revealed dermo-epidermal cleavage, severe oesophageal stricture, and urethral stricture with vesicoureteral reflux. Genetic testing confirmed a *FERMT1 mutation.* Management combined interventional procedures (urethroplasty, oesophageal dilation, and dental care) with medical treatment (emollients, photoprotection, hygiene, and diet). Clinical evolution was favourable with functional improvement at three months.

Case 2

His 11-year-old sister presented with intermittent blistering, acral and facial dyschromia, and photosensitivity since age 3. Examination showed poikiloderma, moderate atrophy, and nail dystrophy without mucosal involvement. Histology revealed intraepidermal cleavage, and genetic testing confirmed a *FERMT1* mutation. She received preventive care, education, and genetic counselling.

Conclusion

Kindler syndrome is a rare hereditary epidermolysis bullosa with autosomal recessive inheritance. Consanguinity in these cases supports this pattern. Although more frequent in certain regions (Middle East, North Africa, South Asia), it occurs worldwide. The disease typically presents with early blistering, progressive poikiloderma, atrophy, and marked photosensitivity. Mucosal involvement often appearing after age 10 is a major determinant of severity. The two siblings illustrate the marked intra-familial phenotypic variability. Diagnosis is mainly clinical, supported by histology, immunofluorescence, and electron microscopy and confirmed by *FERMT1* mutation analysis. Although life expectancy is generally preserved, patients are at risk of mucocutaneous complications and squamous cell carcinoma (≈10% after age 45), requiring long-term monitoring and strict photoprotection. Management is multidisciplinary, focusing on skin care, trauma and infection prevention, treatment of strictures,

and patient education. Kindler syndrome is a rare and likely underdiagnosed condition, especially in developing countries. Early recognition is essential to anticipate complications and initiate appropriate multidisciplinary care, improving functional outcomes and quality of life.

EA DV CONGRESS
VIENNA
30 SEP - 3 OCT 2026

Abstract N°: 1898

Epidermolytic Acanthoma: An Unusual Presentation In A Pediatric Patient

Lina Marcela López González*[1], Elvis Gomez[1], Karen Pinzon[1], Lizeth Sierra Torres[1]

[1] Universidad FUCS, Hospital Infantil de San José, Bogotá, Colombia

Introduction

Epidermolytic acanthoma (EA) is an acquired, benign, and uncommon keratotic lesion that may present as solitary or multiple papules.[1] It predominantly occurs in adulthood and has been described on the trunk, extremities, and especially the genital region, where it may clinically mimic verrucous condyloma associated with human papillomavirus (HPV).[2] Its pathogenesis is linked to mutations in keratin (KRT) 1 and 10 genes, expressed in suprabasal keratinocytes.[2] Clinically, EA presents as an asymptomatic verrucous papule; however, histopathological confirmation is required. Typical findings include epidermolytic hyperkeratosis, hypergranulosis with prominent keratohyalin granules, acanthosis, and vacuolar degeneration of the spinous layer, sometimes accompanied by dyskeratosis.[3] Treatment is generally unnecessary due to its benign and asymptomatic nature, although keratolytics, calcineurin inhibitors, cryotherapy, or excision may be considered.[5] EA is rare, with an estimated incidence of 1 per 300,000 adults and 1 per 200,000 pediatric patients[3] . We report an atypical pediatric case.

Case Presentation

A 5-year-old boy presented with a congenital verrucous lesion on the dorsum of the left hand, progressively extending in a linear distribution toward the elbow, associated with mild pruritus. Physical examination revealed a hyperkeratotic, grayish, exophytic plaque with a rough surface. There was no relevant medical history. Skin biopsy showed hyperkeratosis, papillomatosis, parakeratosis, and acanthosis. The granular and spinous layers exhibited acantholysis and marked keratinocyte vacuolization, with no significant dermal alterations. Based on these findings, treatment with 40% urea and 0.05% retinoic acid was initiated, achieving clinical improvement after four months.

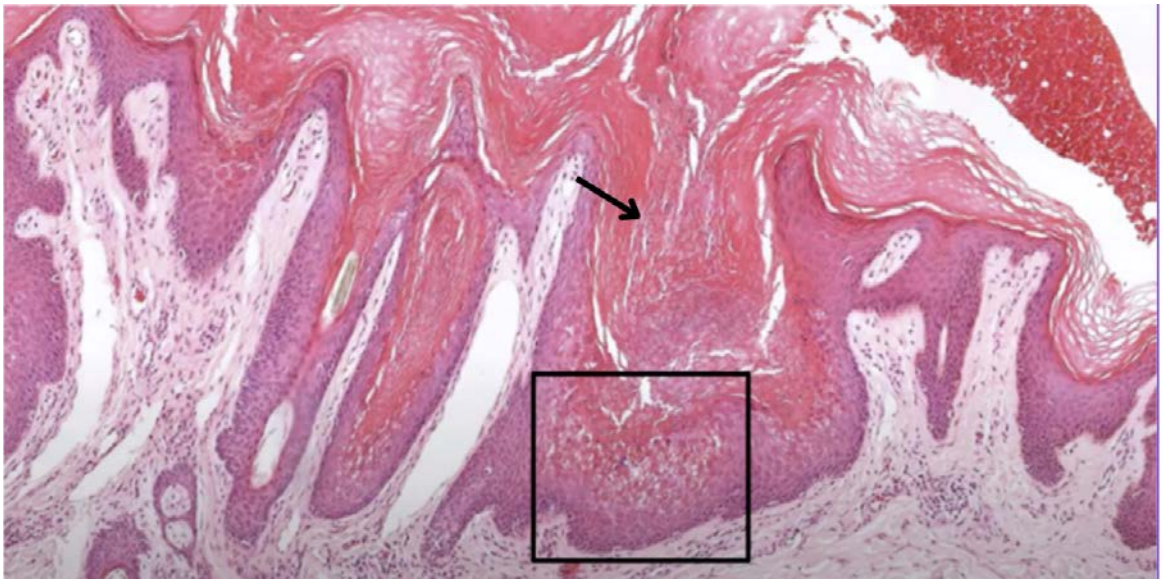

The inset shows acantholytic cells with marked keratinocyte vacuolization. The black arrow indicates compact hyperkeratosis of the stratum corneum and papillomatosis of the epidermis.

Conclusion

EA is a rare benign tumor presenting as verrucous, skin-colored or whitish papules, usually asymptomatic but occasionally pruritic. It typically affects adults aged 50–70 years and is more frequent in males.[1] The condition involves abnormalities in keratinization and epidermal maturation, either congenital or acquired. First described by Shapiro and Baraf in 1970,[6] EA is associated with mutations in keratin 1 and 10, leading to defective intermediate filament formation, cytoskeletal collapse, and subsequent lesion development.[7] Impaired barrier function may also promote keratinocyte proliferation and hyperkeratosis.

Histopathological criteria of epidermolytic hyperkeratosis include: (a) perinuclear vacuolization in spinous and granular layers, (b) poorly defined keratinocyte borders creating a reticulated pattern, (c) increased basophilic keratohyalin-like and eosinophilic trichohyalin-like granules, and (d) compact hyperkeratosis. In pediatric patients, linear epidermal nevus is the most common differential diagnosis. However, EA is exceedingly rare in this population, with limited reports; for example, in a series of 131 cases, only one pediatric patient was identified.[1]

Management is usually conservative. Lesion reduction has been reported with keratolytics (lactic, salicylic, or glycolic acid), as well as with curettage, cryotherapy, or CO_2 laser. Low-potency topical corticosteroids may relieve pruritus, and calcineurin inhibitors have also been described.4

The scarcity of reported cases highlights EA as a rare benign condition in pediatric patients, primarily of cosmetic concern and not associated with systemic disease. Due to its rarity and clinical overlap with other entities, accurate diagnosis relies on clinicopathological correlation.

EA DV CONGRESS
VIENNA
30 SEP - 3 OCT 2026

Abstract N°: 1944

When nail deformity reveals a bone tumor: subungual enchondroma in a child

Oumaima Sbai*[1], Soumiya Chiheb[2]

[1] Hôpital universitaire internationale Cheikh khalifa, casablanca, Morocco
[2] University Hospital bnou Rochd, University Hospital Cheikh khalifa, casablanca, Morocco

Introduction
Enchondroma is a benign cartilaginous tumor arising from hyaline cartilage of endochondral bones, most commonly affecting the small tubular bones of the hands and feet. It typically develops during childhood from residual growth plate cartilage. Clinical presentation is often nonspecific, mainly characterized by pain and deformity, which may lead to diagnostic confusion, particularly with subungual exostosis. Imaging plays a key role in diagnosis and management.

Case Presentation
A 6-year-old girl presented with a progressively painful subungual swelling of the fourth toe associated with nail dystrophy. Clinical examination showed a localized nail deformity without inflammatory signs or involvement of adjacent soft tissues. Joint mobility and neurological examination were normal. Radiography revealed a well-defined intramedullary lytic lesion of the phalanx, suggestive of a subungual enchondroma. The main differential diagnosis was subungual exostosis. Conservative surgical excision with curettage was proposed, followed by clinical and radiological follow-up.

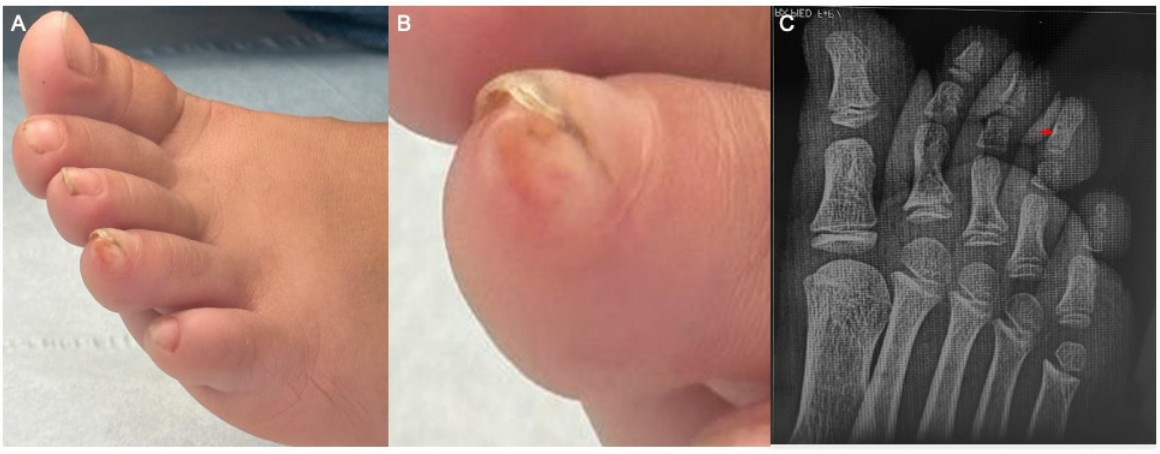

A: Clinical view of the fourth toe showing subungual nail deformity. B: Close-up highlighting nail dystrophy and subungual swelling.C: Radiography showing a well-defined intramedullary lytic lesion of the phalanx (arrow) suggestive of enchondroma.

Conclusion
Subungual enchondroma is an uncommon localization of a relatively frequent benign bone tumor in children and represents a rare cause of painful nail deformity, particularly in the foot. Clinical presentation is often nonspecific,

combining pain and progressive nail dystrophy, which may lead to diagnostic confusion, especially with subungual exostosis. Imaging plays a central role in confirming the diagnosis and excluding other bone lesions. Early recognition allows appropriate conservative surgical management and is associated with an excellent prognosis. Awareness of this entity is essential to avoid diagnostic delay.

EA DV CONGRESS
VIENNA
30 SEP - 3 OCT 2026

Abstract N°: 1973

Post-infectious Pityriasis Rubra Pilaris following Epstein–Barr virus infection in a Pediatric Patient

Lina Mouline*[1], Najoua Ammar[1], Bouchra Idrissi Rhenimi[1], Syrine hamada[1], Mariame Meziane[1], Nadia Ismaili[1], Laila Benzekri[1]

[1] Dermatology Venereology Department, Ibn Sina University Hospital, Rabat, Morocco

Introduction

Pityriasis rubra pilaris (PRP) is a rare papulosquamous disorder of unknown etiology, with various reported triggers including infections, drugs, and immune dysregulation. Viral infections, including Epstein–Barr virus (EBV), have been occasionally implicated, particularly in juvenile forms.

Case Presentation

A 10-year-old girl presented with a 10-day history of a diffuse erythemato-squamous eruption involving the face, trunk, and limbs, associated with palmoplantar keratoderma and painful fissures. Examination revealed widespread follicular hyperkeratotic papules with an orange hue coalescing into plaques with islands of spared skin, involving approximately 60% of the body surface area. Nail involvement and paronychia were also noted.

The eruption was preceded by a febrile episode with parotid swelling and cervical lymphadenopathy. Serological testing showed positive Epstein–Barr virus (EBV) IgM and IgG antibodies, suggesting a recent infection. A comprehensive etiological work-up was otherwise unremarkable, except for lipid abnormalities, in the context of an underlying overweight issue.

Histopathological examination demonstrated alternating orthokeratosis and parakeratosis with follicular plugging and minimal dermal inflammation, consistent with pityriasis rubra pilaris. Based on clinical features and age of onset, a diagnosis of classic juvenile PRP (type III) was established.

The patient was managed with topical corticosteroids and keratolytics, with a partially favorable evolution marked by clinical improvement and intermittent flares during follow-up. Systemic treatments were repeatedly deferred due to perturbated lipid abnormalities, and no significant weight reduction was achieved despite endocrinological management. Narrowband UVB phototherapy was proposed but declined by the patient.

Conclusion

This case supports the role of Epstein–Barr virus infection as a potential trigger of post-infectious PRP, particularly in pediatric patients. Post-infectious PRP has been described as a distinct presentation characterized by acute onset following a viral episode and a generally favorable course.

Although the etiopathogenesis of PRP remains incompletely understood, accumulating evidence suggests that infectious triggers may induce an abnormal immune response leading to dysregulation of keratinocyte differentiation. EBV, through its well-established effects on immune activation and cytokine modulation, may act as a precipitating factor in susceptible individuals.

While classic juvenile PRP is typically self-limited within 1–3 years, relapsing or prolonged courses may occur, as observed in our patient, highlighting the heterogeneity of disease evolution.

This observation underscores the importance of a thorough etiological assessment in acute PRP and supports a

tailored therapeutic approach. Recognition of post-infectious forms may help avoid unnecessary systemic treatments, particularly in pediatric patients, when clinical evolution remains favorable.

EA DV CONGRESS
VIENNA
30 SEP - 3 OCT 2026

Abstract N°: 1983

Neonatal Compartment Syndrome: A Rare Condition

Naia Oillarburu*[1], Juliette Mazereeuw-Hautier[1], Maella Severino-Freire[1]

[1] Larrey Hospital, University Hospital of Toulouse, Toulouse, France

Introduction

Neonatal compartment syndrome is an extremely rare condition in newborns, typically caused by intrauterine ischemia and/or prolonged limb compression. It results in increased pressure within a closed fascial compartment, compromising tissue perfusion and leading to ischemia, with potential irreversible damage to muscles, skin, nerves, and bones. Prognosis depends on early recognition. Despite its stereotypical presentation, the condition is often under-recognized, and published data on histological features and long-term outcomes remain limited. We report a new case to raise awareness of this rare syndrome, particularly with regard to its histopathological features.

Case Presentation

A newborn presented at birth with a fibrinous ulcerated lesion of the right forearm and vesiculobullous lesions of the right hand. The initial neurological status of the affected limb was not documented. At day 13 of life (D13), wrist and hand paralysis was identified during dermatological evaluation, raising suspicion of neonatal compartment syndrome. Histopathological examination of a skin biopsy revealed post-inflammatory cicatricial calcifying lobular panniculitis. A surgical opinion was obtained, and decompressive fasciotomy was not indicated due to the delayed diagnosis and evidence of established ischemic injury. Management consisted of local wound care and daily physiotherapy. The cutaneous lesions healed within 45 days, whereas paralysis persisted at the 3-month follow-up.



Fibrinous ulcerated lesion of the right forearm at birth.

Conclusion

We report a new case of neonatal compartment syndrome with histopathological documentation, which is rarely described. To date, only 86 cases have been reported, all showing a stereotypical clinical presentation. Histopathological findings, when available, mainly show cutaneous and muscular necrosis without detailed microscopic analysis. Management is not standardized, although early fasciotomy (<24 hours) appears to reduce the risk of sequelae, without guaranteeing complete recovery. Long-term follow-up data remain scarce and are mostly limited to short-term outcomes. Reporting additional cases of congenital compartment syndrome is essential to improve understanding of this syndrome, particularly regarding its histopathological features. Long-term studies are needed to better define functional prognosis.

EA DV CONGRESS
VIENNA
30 SEP - 3 OCT 2026

Abstract N°: 2034

Acute hemorrhagic edema of infancy: Clinical features and outcomes from a case series

Laila Zineb Chbihi Moukit*[1], Layla Bendaoud[1], Mariem Aboudourib[1], Ouafa Hocar[1], Said Amal[1]

[1] Department of Dermatology-Venerology, Mohammed VI University Hospital, Biosciences and Health Laboratory, Cadi Ayyad University, Marrakech, Morocco

Introduction
Acute hemorrhagic edema of infancy (AHEI) is a rare disorder of early childhood with poorly understood etiopathogenesis. It is usually a benign condition, diagnosed clinically, with spontaneous resolution. However, exceptional complications may occur.
This case series aims to describe the clinical characteristics of AHEI and to highlight the rare but potential risk of complications.

Materials and Methods
We conducted a descriptive case series including four infants aged 2 to 13 months, with no significant past medical history, diagnosed with AHEI. Clinical, biological, and evolutionary data were collected and analyzed.

Results
All patients presented with abrupt onset of purpuric lesions predominantly involving the limbs, associated with fever. No hemorrhagic syndrome, joint, or gastrointestinal involvement was initially noted. A preceding episode of rhinopharyngitis was identified in one case.

Physical examination revealed clinically stable infants. Firm edema of the extremities was observed in three cases. Cutaneous lesions consisted of purpuric macules, located on the face and extremities in all patients, with a pseudo-cockade appearance in two patients, without necrosis.

Laboratory findings showed isolated leukocytosis without other significant abnormalities.

Management consisted of clinical monitoring. The outcome was favorable in three patients, with spontaneous resolution. However, one infant developed acute intestinal intussusception requiring surgical management.



Lower limb edema with overlying purpuric macules

Conclusions

AHEI is a rare and generally benign condition with a characteristic clinical presentation. However, clinicians should remain vigilant for potential complications, particularly gastrointestinal involvement. Close monitoring is essential despite the usually favorable prognosis.

EA DV CONGRESS
VIENNA
30 SEP - 3 OCT 2026

Abstract N°: 2064

Subcutaneous Fat Necrosis of the Newborn Mimicking a Venolymphatic Malformation

Alperen Karacanoğlu*[1], Vefa Aslı Erdemir[1], Hasan Aksoy[1], Mehmet Salih Gurel[1]

[1] Department of Dermatology and Venereology, Istanbul Medeniyet University, Goztepe Prof. Dr. Suleyman Yalcin City Hospital, Istanbul, Türkiye

Introduction

Subcutaneous fat necrosis of the newborn (SCFN) is a rare, self-limiting panniculitis that usually occurs in term or post-term neonates following perinatal stress. Common predisposing factors include maternal diabetes, preeclampsia, perinatal hypoxia, and therapeutic hypothermia. SCFN typically presents as firm erythematous nodules or plaques; however, it may mimic vascular or infectious conditions and delay diagnosis.

Case Presentation

A 23-day-old male neonate presented with congenital ecchymotic-erythematous lesions on the back and palpable subcutaneous nodulocystic lesions over the right scapular region. The patient was born at 38+1 weeks of gestation by cesarean section with a history of meconium aspiration. The maternal history was significant for insulin-treated gestational diabetes mellitus and preeclampsia. Dermatological examination demonstrated two soft, fluctuant subcutaneous nodulocystic lesions, the largest measuring 3×2 cm, surrounded by reticular erythematous patches on the right scapular area. Laboratory investigations revealed hypercalcemia with a serum calcium level of 13.1 mg/dL during follow-up.

Ultrasonography demonstrated a hyperechoic solid lesion containing tubular vascular structures, raising suspicion for a venolymphatic malformation. During punch biopsy, a whitish, translucent, oily fluid material was released from the lesion, raising suspicion for SCFN. Cytological examination of the material demonstrated necrotic lipocytes on Tzanck smear, while tissue culture showed no microbial growth. Histopathological examination revealed lobular panniculitis with necrotic adipocytes containing characteristic needle-shaped clefts, accompanied by multinucleated giant cells and foamy histiocytes(Figure 1). These needle-shaped clefts, representing dissolved triglyceride crystals within adipocytes, are considered a characteristic histopathological feature of SCFN. Immunohistochemical staining was positive for CD68 and negative for S100. These findings were consistent with SCFN.

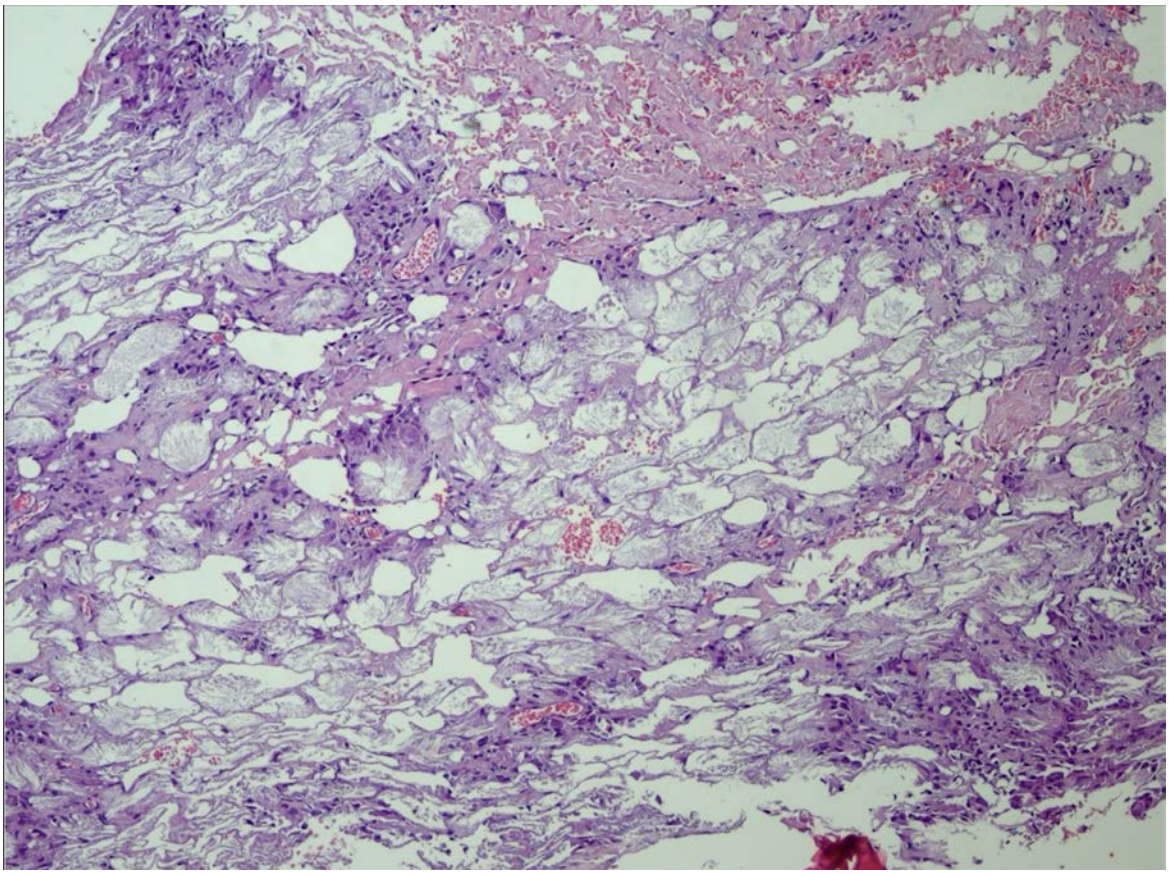

Figure 1 : Lobular panniculitis with necrotic adipocytes containing characteristic needle-shaped clefts accompanied by multinucleated giant cells and foamy histiocytes.

Conclusion

SCFN is associated with tissue hypoxia and impaired perfusion leading to adipocyte injury and granulomatous inflammation. Although the disease usually follows a benign course, hypercalcemia represents the most significant complication and may occur weeks after the appearance of cutaneous lesions. This case highlights an uncommon presentation of SCFN mimicking a venolymphatic malformation. Awareness of atypical clinical and radiological findings is important to avoid diagnostic delay and ensure appropriate monitoring for potentially severe complications such as hypercalcemia.

EA DV CONGRESS
VIENNA
30 SEP - 3 OCT 2026

Abstract N°: 2070

Epidermodysplasia Verruciformis in Dark Skin: Dermoscopic Insights From a Pediatric Case

Kawtar El fid*[1], Hanane Baybay[1], Chaimae Bouhamdi[1], IKRAME BEJJA[1], Saadia Boughaleb[1], Zakia Douhi[1, 1], Meryem Soughi[1], elloudi sara[1], Fatima Zohra Mernissi[1]

[1] Department of Dermatology, Hassan II University Hospital, Sidi Mohamed Ben Abdellah University, Fez, Morocco

Introduction

Epidermodysplasia verruciformis (EV) is a rare inherited genodermatosis associated with increased susceptibility to β-human papillomaviruses and a potential risk of cutaneous malignancy. Although diagnosis mainly relies on clinical and histopathological findings, dermoscopic features of EV remain poorly characterized, particularly in patients with darker skin phototypes.

Case Presentation

An 8-year-old child with phototype VI presented with multiple asymptomatic hypopigmented macules and papules evolving since early childhood. Dermatological examination revealed well-defined lesions with a verrucous and finely scaly surface predominantly involving the forehead, cheeks, and upper trunk. Dermoscopic examination of the forehead demonstrated well-demarcated structureless white areas with interruption of the facial pseudopigment network, associated with fine peripheral white scales and leukotrichic vellus hairs, without detectable vascular structures. Histopathological examination showed hyperkeratosis, mild acanthosis, and enlarged keratinocytes with pale gray-blue cytoplasm, glassy appearance, and perinuclear halos, confirming the diagnosis of epidermodysplasia verruciformis.

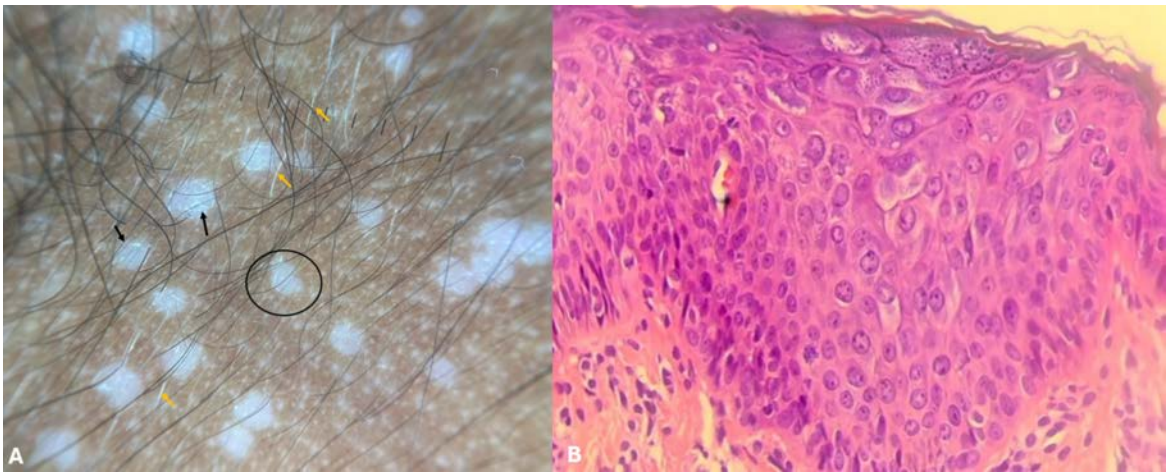

Figure 1. (A) Dermoscopic examination of the forehead showing structureless white areas with interruption of the facial pseudopigment network (black circles), fine peripheral white scales (black arrows), and leukotrichic vellus hairs (orange arrows), without detectable vascular structures. (B) Histopathological examination (H&E, ×200) showing enlarged keratinocytes with pale gray-blue cytoplasm, glassy appearance, and prominent perinuclear halos, associated with mild nuclear dystrophy, consistent with epidermodysplasia verruciformis.

Conclusion

Dermoscopic descriptions of epidermodysplasia verruciformis in darker skin phototypes remain exceedingly rare in the literature. Previously reported dermoscopic findings mainly included hypopigmented or erythematous backgrounds, white scales, dotted vessels, and, less frequently, seborrheic keratosis–like or melanocytic nevus–like patterns. Only a limited number of reports have specifically addressed skin of color, where hypopigmented lesions may create important diagnostic difficulties and mimic other disorders such as pityriasis versicolor. In previously published cases involving dark phototypes, authors described hypopigmented areas associated with white scales and unfocused dotted vessels. Our case additionally demonstrated interruption of the facial pseudopigment network and peripheral leukotrichic vellus hairs without visible vascular structures, findings that remain rarely reported. These observations contribute to expanding the currently known dermoscopic spectrum of EV in phototype VI and highlight the potential role of dermoscopy as a useful noninvasive diagnostic tool in skin of color populations.

EADV CONGRESS
VIENNA
30 SEP - 3 OCT 2026

Abstract N°: 2071

Clinical Improvement of Pediatric Epidermodysplasia Verruciformis Following Topical Adapalene and Adjunctive Homeopathic Therapy

Kawtar El fid*[1], Hanane Baybay[1], Chaimae Bouhamdi[1], IKRAME BEJJA[1], Saadia Boughaleb[1], Zakia Douhi[1], Meryem Soughi[1], elloudi sara[1], Fatima Zohra Mernissi[1]

[1] Department of Dermatology, Hassan II University Hospital, Sidi Mohamed Ben Abdellah University, Fez, Morocco

Introduction

Epidermodysplasia verruciformis (EV) is a rare inherited genodermatosis characterized by increased susceptibility to β-human papillomaviruses and a risk of cutaneous malignancy. Management remains challenging because no standardized curative treatment is currently available, and therapeutic responses are often variable.

Case Presentation

An 8-year-old child with phototype VI presented with multiple asymptomatic hypopigmented macules and papules evolving since early childhood. Dermatological examination revealed well-defined verrucous and finely scaly lesions predominantly involving the face and upper trunk. Histopathological examination confirmed the diagnosis of epidermodysplasia verruciformis, showing hyperkeratosis, mild acanthosis, and enlarged keratinocytes with pale gray-blue cytoplasm and perinuclear halos. The patient was treated with topical adapalene applied once daily. Adjunctive homeopathic therapy was also administered, including Thuya occidentalis 15 CH, Dulcamara 9 CH, and Natrum muriaticum 15 CH, prescribed for one month and repeated twice with one-week treatment-free intervals between cycles. A marked clinical improvement was observed after 3 months, with significant reduction in lesion thickness and scaling. No adverse effects were reported, and no recurrence or progression was observed after 1 year of follow-up.

Conclusion

Management of epidermodysplasia verruciformis remains challenging because no standardized curative therapy is currently available. Topical retinoids such as adapalene may contribute to lesion improvement through modulation of keratinocyte differentiation. In our patient, the combination of topical adapalene with adjunctive homeopathic therapy was associated with marked clinical improvement, good tolerance, and absence of recurrence after 1 year of follow-up. Homeopathy has previously been explored in HPV-related cutaneous lesions because of its proposed immunomodulatory effects, although evidence supporting its efficacy remains limited and largely experimental. To our knowledge, reports describing this combined therapeutic approach in pediatric epidermodysplasia verruciformis are exceedingly rare. Further studies are required to clarify the potential role of adjunctive therapies in the management of EV.

EADV CONGRESS
VIENNA
30 SEP - 3 OCT 2026

Abstract N°: 2136

Nevus Comedonicus Complicated by Hidradenitis Suppurativa–Like Lesions in a Pediatric Patient: Extensive Unilateral Segmental Presentation

Paola Estefania Falla Rivera*[1], Karen Viviana Arevalo Mendez[1], Adriana Zamudio Barrientos[2]

[1] Fundación Universitaria Sanitas, Bogotá, Colombia

[2] Centros Médicos Colsanitas, Bogotá, Colombia

Introduction

Nevus comedonicus (NC) is a rare hamartomatous malformation of the pilosebaceous unit that may occur as an isolated cutaneous finding or as part of nevus comedonicus syndrome. Although uncommon, inflammatory complications resembling hidradenitis suppurativa (HS) have been reported, particularly in pediatric patients. This overlap represents a diagnostic and therapeutic challenge due to chronic inflammation, pain, scarring, and limited response to conventional topical therapies.

Case Presentation

A 10-year-old boy presented with a congenital dermatosis characterized by multiple comedonal lesions involving the right lower limb in a continuous unilateral segmental distribution extending from the inguinal region to the medial malleolus. Lesions had slowly progressed over time. One year before consultation, he developed recurrent painful erythematous nodules with spontaneous drainage, associated with functional limitation and school absenteeism. Previous treatment with topical antibiotics achieved only partial improvement. Physical examination revealed numerous open macrocomedones arranged in a linear pattern associated with inflammatory nodules, atrophic scars, and residual hyperpigmentation involving an extensive continuous area of the extremity. Based on the clinical findings, a diagnosis of nevus comedonicus complicated by hidradenitis suppurativa–like lesions was established. Treatment with systemic retinoids and oral antibiotics was initiated.



Multiple comedonian lesions in the lower middle region, with unilateral segmental distribution continuing from the inguinal region to the medial male.

Conclusion

The association between NC and HS-like lesions is exceedingly rare and has mainly been described in isolated case reports and small case series. Fewer than ten cases have been reported in the literature. Recurrent inflammation over comedonal plaques may lead to painful nodules, abscesses, sinus tract formation, and scarring, prompting some authors to propose the term suppurative nevus comedonicus.This overlap has been interpreted as a shared disorder of follicular occlusion involving the pilosebaceous unit. Mechanical stress and follicular rupture may contribute to secondary inflammation and progression toward HS-like disease. Reported therapeutic approaches include surgical excision for localized disease, systemic retinoids combined with topical therapies, and biologic therapy with tumor necrosis factor inhibitors in refractory cases.

This case is remarkable because of its pediatric onset and its extensive unilateral segmental distribution, an exceptionally uncommon presentation. To our knowledge, this may represent the first reported case from Latin America, as previously published reports predominantly originate from Europe and Asia. The coexistence of NC and HS-like lesions supports the hypothesis of a shared follicular occlusion pathway and suggests a common clinicopathologic spectrum. Early recognition of this association is important to guide prompt systemic treatment in extensive disease, improving both cutaneous outcomes and quality of life.

Referencias

1. Qian G, Liu T, Zhou C, Zhang Y. Naevus comedonicus syndrome complicated by hidradenitis suppurativa-like lesions responding to acitretin treatment. Acta Derm Venereol. 2015; 95:992–993.
2. Sahu P, Aggarwal P, Dayal S, Jain VK. Biologic therapy: a boon for hidradenitis suppurativa-like lesions complicating naevus comedonicus in a prepubertal child. Clin Exp Dermatol. 2018.
3. Ravaioli GM, Neri I, Zannetti G, Patrizi A. Congenital nevus comedonicus complicated by a hidradenitis suppurativa-like lesion: report of a childhood case. Pediatr Dermatol. 2018.
4. Sharma S, Sahu P, Dayal S, Yadav A, Brar K. Nevus comedonicus suppurativa: a report of a novel entityJ Clin Aesthet Dermatol. 2020;13(6):36–39.

POWERED BY M-ANAGE.COM

EA DV CONGRESS
VIENNA
30 SEP - 3 OCT 2026

Abstract N°: 2156

Microneedling and Platelet-Rich Plasma for Pathological Scars in Pediatrics: A Safe and Effective Therapeutic Approach with High Patient Satisfaction

Laura Sifuentes *[1], Rocío Concepción Albores Arguijo[1], Valeria Noemi Rizo Hernández[1], Yocelin Nallely Lozano Figueroa[1], Michelle Alitzel Lugo Flores[2]

[1] Universidad de Guadalajara, Antiguo Hospital Civil de Guadalajara, Guadalajara, Mexico

[2] Universidad de Guadalalajra, Guadalajara, Mexico

Introduction

Pathological scars represent a frequent cause of functional impairment and psychosocial distress in pediatric and adolescent patients, particularly due to pain, pruritus, aesthetic concerns, and negative effects on self-esteem and quality of life. Although platelet-rich plasma (PRP) has demonstrated regenerative benefits in multiple medical fields, it is still not included in current international guidelines for pathological scar management, including those published by Ogawa et al. and subsequent updated recommendations. Evidence in pediatric populations remains especially limited. This study aimed to describe therapeutic response, safety, and patient satisfaction with microneedling combined with PRP for pathological scars in pediatric patients.

Materials and Methods

A retrospective descriptive, observational, real-life study, conducted in accordance with the STROBE guidelines. was conducted including patients aged 8–18 years with pathological scars treated with microneedling and PRP between January 2023 and January 2025. Inclusion criteria required at least three treatment sessions, complete clinical follow-up, and Patient and Observer Scar Assessment Scale (POSAS) evaluation before and after treatment. Clinical-demographic characteristics, scar etiology, Fitzpatrick phototype, scar type, anatomical location, complications, and patient satisfaction were analyzed. Paired Student's t-test was used for POSAS comparison, considering $p < 0.05$ as statistically significant.

Results

Sixteen pediatric patients were included, with a mean age of 13.3 years; 62.5% were female. The most frequent etiology was post-acne scars (56.2%), followed by post-traumatic (25%) and post-surgical scars (12.5%). Atrophic scars were the most common type (68.7%), and facial involvement predominated (81.2%). All patients showed improvement in POSAS scores after treatment. Significant reductions were observed in vascularity (8.1 vs 3.1), pigmentation (7.5 vs 2.6), thickness (5.5 vs 2.5), relief (6.6 vs 2.7), pliability (5.5 vs 2.1), surface area (5.7 vs 2.4), and overall observer opinion (7.6 vs 3.1), all with $p < 0.001$. Regarding safety, no patient developed edema or post-inflammatory hyperpigmentation; transient erythema was the only reported adverse effect. Patient satisfaction was high in all cases.

Parameters	Baseline Score	Final Score	Mean Difference	p-value
Vascularity	8.1	3.1	5.0	<0.001
Pigmentation	7.5	2.6	4.9	<0.001
Thickness	5.5	2.5	3.0	<0.001
Relief	6.6	2.7	3.9	<0.001
Pliability	5.5	2.1	3.4	<0.001
Surface Area	5.7	2.4	3.3	<0.001
Overall Opinion	**7.6**	**3.1**	**4.5**	**<0.001**

Table 1. Observer POSAS scale results in 16 pediatric patients with pathological scars, including mean differences and p-values obtained by paired Student's t-test before and after treatment with microneedling combined with platelet-rich plasma.

Conclusions

Microneedling combined with PRP appears to be a safe, effective, and well-tolerated therapeutic option for pathological scars in pediatric patients, showing significant clinical improvement and high satisfaction rates. Given the limited pediatric evidence and the absence of PRP in current scar management guidelines, these findings support further prospective studies and suggest potential consideration of PRP-based therapies in future treatment recommendations.

EADV CONGRESS
VIENNA
30 SEP - 3 OCT 2026

Abstract N°: 2175

The Diagnostic Challenge of Gianotti-Crosti Syndrome: Navigating a Frequently Misinterpreted Acral Eruption

KHALDI HANANE FADOUA*[1], BOUAYED GHIZLENE[1], Abdelmoumene Latifa[1], Mahi Ilhem[1], DAHMANI Boumediene[1], Benhamed Nardjes[1]

[1] Department of Dermatology and Venereology, CHU Tlemcen, Tlemcen, Algeria

Introduction

Gianotti-Crosti Syndrome (GCS), also known as papular acrodermatitis of childhood, is a benign yet clinically striking cutaneous eruption that remains paradoxically underrecognized in pediatric practice. Although it is a self-limiting condition, its dramatic clinical presentation often acts as a diagnostic pitfall, leading to unnecessary medical interventions. This report illustrates the diagnostic complexities of GCS through the case of an atopic infant presenting with a post-cytomegalovirus (CMV) manifestation.

Case Presentation

We report the case of an 11-month-old male infant (A.R.) with a medical history notable for recurrent bronchiolitis and cow's milk protein allergy. The patient presented with a monomorphous eruption of flesh-colored seropapular lesions of varying ages, with evidence of focal excoriation. The distribution was predominantly acral, involving the face, upper extremities (including palms), and lower extremities (including soles). Notably, the trunk remained entirely unaffected despite the presence of intense pruritus. Initial therapeutic attempts elsewhere, which included presumptive treatment for scabies under antibiotic coverage and the application of topical corticosteroids, proved ineffective. Subsequent etiological screening for (HBV), (EBV), and Coxsackievirus was performed; however, laboratory results revealed CMV seropositivity (IgG: 48), confirming a diagnosis of post-CMV _GCS. Symptomatic management consisting of oral antihistamines and emollients resulted in complete resolution following one month of clinical observation.

GCS is primarily observed in pediatric populations and, more rarely, in young adults. Originally described in association with HBV, it is now frequently linked to a spectrum of pathogens including EBV, CMV, Coxsackievirus, Parvovirus B19, and Respiratory Syncytial Virus (RSV). Post-vaccination cases (Hepatitis A/B, Polio, MMR) have also been documented. Clinically, GCS manifests as a monomorphous eruption of erythematous or flesh-colored flat-topped papules or papulovesicles, typically favoring the extensor surfaces of the limbs. The condition is more prevalent in children with atopic backgrounds, particularly those with atopic dermatitis. While diagnosis is generally clinical in typical cases, an auxiliary workup (CBC, and viral serologies for HBV, HCV, and HIV) is indicated for atypical presentations or adult cases. Treatment remains supportive, as the natural history of the disease is characterized by a favorable, spontaneous resolution.

Conclusion

Despite its relative frequency, GCS remains under-represented in medical literature, leading to anxious patients and redundant prescriptions. When faced with an acral eruption in an infant, clinicians must consider GCS—a quintessential clinical paradox where a distressing presentation masks an entirely benign pathology.

EADV Congress 2026, VIENNA
30 SEPTEMBER - 03 OCTOBER 2026
POWERED BY M-ANAGE.COM

EADV CONGRESS
VIENNA
30 SEP - 3 OCT 2026

Abstract N°: 2176

Cutaneous Manifestations of Vogt-Koyanagi-Harada Syndrome: A Late Marker of a Systemic Emergency.

KHALDI HANANE FADOUA*[1], BOUAYED GHIZLENE[1], Mahi Ilhem[1], DAHMANI Boumediene[1], Benhamed Nardjes[1]

[1] Department of Dermatology and Venereology, CHU Tlemcen, Tlemcen, Algeria

Introduction
Vogt-Koyanagi-Harada (VKH) syndrome is a severe, multisystemic autoimmune disorder. This rare condition follows a complex clinical continuum involving ophthalmological, neurological, auditory, and cutaneous manifestations. We report a case illustrating the "complete" form of VKH, diagnosed retrospectively in a dermatology department.

Case Presentation
A 6-year-old female patient presented with a history of recurrent meningitis in early childhood, which had progressed to bilateral blindness. She was referred to dermatology for recent-onset cutaneous depigmentation located in the peri-ocular ("goggle-like" distribution) and peri-buccal areas, along with several depigmented macules on the trunk. Although the lesions were discreetly squamous, mycological examinations were negative. Wood's lamp examination revealed a stark, milky-white achromia, confirming a diagnosis of vitiligo. A systemic assessment revealed total optic atrophy in the right eye and sub-total atrophy in the left. Magnetic resonance imaging (MRI) identified a Type 1 Chiari malformation associated with signs of intracranial hypertension. Based on these clinical and paraclinical findings, a diagnosis of "complete" VKH syndrome (meeting 5/5 criteria) was established. Following one month of local treatment with tacrolimus (Protopic), the patient showed spectacular and total repigmentation of the integuments. She was subsequently referred to neurosurgery for optimized systemic management.

VKH syndrome is a granulomatous autoimmune pathology characterized by T-cell mediated aggression against melanocytes—sentinel cells shared by the eye, central nervous system, inner ear, and skin. Its clinical evolution is classically triphasic according to the revised American Uveitis Society criteria (2001). Cutaneous manifestations are unique; although they appear late during the convalescent phase—months after the initial uveitic surge—peri-orificial vitiligo, poliosis, and alopecia remain diagnostic pillars of "complete" VKH. This "cutaneous signature" serves as an indispensable retrospective marker, particularly in pediatric or complex cases. While aggressive systemic corticosteroid therapy is the gold standard for preserving visual function, the rapid repigmentation observed with calcineurin inhibitors underscores local immunological reactivity and reaffirms the dermatologist's role in diagnostic validation.

Conclusion
VKH syndrome exemplifies the need for multidisciplinary synergy. Identifying late cutaneous markers allows for a definitive diagnosis and the initiation of aggressive therapy to prevent irreversible sequelae.

EADV CONGRESS
VIENNA
30 SEP - 3 OCT 2026

Abstract N°: 2177

Hyperpigmentation in an Infant: The Shadow of Vitamin B12 Deficiency

KHALDI HANANE FADOUA*[1], BOUAYED GHIZLENE[1], Mahi Ilhem[1], DAHMANI Boumediene[1], Benhamed Nardjes[1]

[1] Department of Dermatology and Venereology, CHU Tlemcen, Tlemcen, Algeria

Introduction

Nutritional deficiencies typically present with polymorphic symptomatology affecting multiple organ systems, which often complicates timely diagnosis. In some instances, cutaneous manifestations serve as the primary clinical sign. We report the case of an infant presenting with distinctive hyperpigmentation that revealed a severe vitamin B12 (cobalamine) deficiency.

Case Presentation

An 8-month-old male infant (O.M.), with no significant medical history, was urgently admitted for a severe deterioration of general health, characterized by lethargy, apathy, and sudden-onset dyspnea. Beyond the immediate cardiorespiratory distress, the initial physical examination identified cardinal dermatological markers: acral maculopapular hyperpigmentation (dorsum of the hands and feet) and cervical involvement, with marked accentuation in the inguinal folds. Furthermore, erosive and oozing lesions were noted in the perineal region.This specific cutaneous semiology guided the laboratory investigations, which revealed major pancytopenia associated with non-regenerative megaloblastic anemia (Hb = 5.4g/dL). Biochemical analysis confirmed collapsed vitamin B12 levels (63.37 pg/mL), while adrenal function (corticotropic axis) remained normal.Emergency parenteral supplementation was initiated (500µg/day for three days, followed by 1000µg/week for one month). This therapy led to a rapid correction of systemic disorders. By the second week of treatment, the mucocutaneous lesions began to resolve. Concurrently, a multidisciplinary etiological investigation was launched to explore potential defects in cobalamin intake, absorption, or transport.

Vitamin B12 deficiency is an entity rarely documented in pediatric populations. The classic clinical presentation is typically dominated by megaloblastic anemia, gastrointestinal disturbances (such as glossitis), and neuropsychiatric manifestations. While mucocutaneous involvement is well-recognized in adults, it remains exceptional in children and is only documented in rare case reports.However, as suggested by Mori et al., cutaneous hyperpigmentation constitutes a precious and early diagnostic marker. It is preferentially localized in the flexural folds, palmar creases, and over the metacarpophalangeal joints, although generalized forms have been described. The underlying pathophysiological mechanism of this hypermelanosis remains debated. The most supported hypothesis suggests increased tyrosinase activity, potentially resulting from decreased levels of reduced glutathione, which normally inhibits this enzyme. Complete regression of these lesions is typically observed within weeks of initiating adequate vitamin supplementation.

Conclusion

The uniqueness of this case lies in the inaugural cutaneous expression of vitamin B12 deficiency. This observation emphasizes the critical importance of suspecting such a deficiency when faced with unexplained hyperpigmentation. Early diagnosis, guided by these dermatological signs, acts as an indispensable "clinical sentinel" to initiate corrective treatment and prevent irreversible neurological complications .

EADV Congress 2026, VIENNA
30 SEPTEMBER - 03 OCTOBER 2026
POWERED BY M-ANAGE.COM

EA DV CONGRESS
VIENNA
30 SEP - 3 OCT 2026

Abstract N°: 2178

Beyond the Classic: Noonan-Neurofibromatosis Syndrome, the Imprint of a Rare Entity

KHALDI HANANE FADOUA*[1], Mahi Ilhem[1], BOUAYED GHIZLENE[1], DAHMANI Boumediene[1], Benhamed Nardjes[1]

[1] Department of Dermatology and Venereology, CHU Tlemcen, Tlemcen, Algeria

Introduction

Noonan-Neurofibromatosis Syndrome (NFNS) is a rare rasopathy characterized by a complex phenotypic overlap. It associates the dysmorphic features of Noonan syndrome (NS) with the cutaneous hallmarks of Neurofibromatosis type 1 (NF1). Molecular data identify it as a variant of NF1 linked to specific mutations in the *NF1* gene, distinguishing it from classic NS. We report a case illustrating this singular entity in an infant.

Case Presentation

The patient, a 10-month-old infant (F.A.) born to a mother with Neurofibromatosis type 1, was referred for the exploration of a left cervical-lateral mass. Clinical examination revealed a complex phenotype where facial dysmorphism evocative of Noonan syndrome—including macrocephaly, hypertelorism, ptosis, a bulbous nasal tip, low-set ears, and a cleft palate—was accompanied by growth retardation, pterygium colli, and a thoracic deformity (pectus excavatum/carinatum).Simultaneously, the patient met four of the seven NIH diagnostic criteria for NF1: multiple (>6) café-au-lait spots (>0.5 cm), bilateral axillary freckling, and a left cervical-lateral plexiform neurofibroma. The deep extension of this neurofibroma accounts for the observed grade 1 exophthalmos. Despite an initially normal cardiac evaluation, the entanglement of these two entities in a subject with a family history of NF1 led to the diagnosis of Noonan-Neurofibromatosis Syndrome (NFNS). MRI imaging and a molecular genetic study of the *NF1* gene were initiated to confirm this complex phenotype linked to a single germline mutation.

NFNS lies at the heart of rasopathies, a group of pathologies characterized by dysregulation of the RAS-MAPK signaling pathway. Although NFNS clinically combines Noonan-like dysmorphism with NF1 stigmas, recent molecular findings define it as a phenotypic variant of NF1. The characterization of the p.L1390F mutation in exon 24, affecting the GAP domain of neurofibromin, perfectly illustrates this etiopathogenesis: this critical zone regulates RAS activity, and its modification induces this unique clinical overlap.Unlike "classic" NF1, NFNS carries a major prognostic distinction due to its significantly higher risk of congenital cardiovascular malformations. This observation underscores the need to deviate from standard protocols: any NFNS diagnosis must imperatively trigger early and systematic cardiological surveillance. Ultimately, the observed phenotypic variability highlights that NFNS results from complex interactions between specific *NF1* mutations and modifier genes, making this syndrome a privileged model for precision medicine.

Conclusion

Noonan-Neurofibromatosis Syndrome stands as a rare phenotypic variant of NF1 characterized by a singular clinical overlap. Its hybrid phenotype mandates increased cardiovascular vigilance and early multidisciplinary follow-up, distinguishing it from classic neurofibromatosis.

EADV CONGRESS
VIENNA
30 SEP - 3 OCT 2026

Abstract N°: 2214

MAP3K3- associated Verrucous Venous Malformation Treated with Trametinib

Ying Shan Cheung*[1], Justin Wong[2], May Liau[1]

[1] Department of Medicine, Division of Dermatology, National University Hospital, Singapore, Singapore
[2] Department of Pathology, National University Hospital, Singapore, Singapore, Singapore

Introduction

Verrucous venous malformations (VVM) are rare congenital vascular anomalies that typically present as hyperkeratotic red-purple plaques that progressively enlarge, over time. Management is often challenging and often involves a multi-pronged approach.

Case Presentation

A 6-year-old female presented with a large left forearm lesion measuring 5.9 × 2.3 × 11.7 cm. The lesion was present since birth and had progressively enlarged over time. There was associated pruritus, tenderness and occasional bleeding. Magnetic resonance imaging revealed a lobulated subcutaneous mass consistent with a low flow vascular malformation, extending from her left elbow to mid-forearm. A skin punch biopsy was performed. Histological features demonstrated epidermal hyperkeratosis and parakeratosis, haphazardly arranged blood vessels within the dermis and subcutis with GLUT1 expression in lesional endothelial cells.

The patient had previously underwent seven sessions of pulsed dye laser therapy with minimal improvement. She was commenced on oral Sirolimus therapy with partial clinical response which plateaued after one year. Repeat MRI demonstrated overall stability in lesion size. The decision was made to pursue somatic genetic testing, which revealed a missense mutation (NM_002401.5, c.1323C>G) in mitogen-activated protein kinase 3 (MAP3K3) Based on this finding, the patient was commenced on Trametinib, an oral MEK inhibitor drug

The patient is on multidisciplinary follow-up with Dermatology, paediatric oncology, plastic surgery, and interventional radiology and continues to be followed by closely. Further treatment options, including surgery and sclerotherapy will be reconsidered depending on therapeutic response.

Conclusion

This case highlights the complexity of managing VVM and highlights the importance of genetic testing in vascular anomalies to guide targeted therapies. MAP3K3 is a key component of the RAS/MAPK/ ERK signalling pathway, which is involved in cell proliferation, differentiation and migration. In this case, MEK inhibitors such as trametinib may offer a promising targeted therapeutic option, particularly when conventional therapies produce suboptimal outcomes.

EA DV CONGRESS
VIENNA
30 SEP - 3 OCT 2026

Abstract N°: 2226

Pityriasis Lichenoides–like Lymphomatoid Papulosis in a Pediatric Patient: A Case Report

Kerim Akcan*[1], Muhammet Taner[1], Ece Barcınlı[1], Burhan Engin[1], Övgü Ülgen[2]

[1] Istanbul University-Cerrahpasa, Cerrahpasa Medical Faculty, Dermatology, Istanbul University-Cerrahpasa, Cerrahpasa Medical Faculty, Pathology, Istanbul, Türkiye, Istanbul, Türkiye

[2] Istanbul University-Cerrahpasa, Cerrahpasa Medical Faculty, Pathology, Istanbul, Türkiye

Introduction

Lymphomatoid papulosis (LyP) is a disorder within the spectrum of CD30-positive primary cutaneous T-cell lymphoproliferative diseases, characterized by a clinically benign course despite histopathological features mimicking malignant lymphomas. Particularly in pediatric cases, the overlap of clinical and histopathological findings with inflammatory and lymphoproliferative dermatoses such as pityriasis lichenoides and mycosis fungoides may lead to diagnostic challenges. Herein, we present a pediatric case with clinical features resembling pityriasis lichenoides, in whom histopathological and immunohistochemical evaluation revealed findings consistent with LyP type D/E.

Case Presentation

A 10-year-old male patient presented with a 7-month history of widespread, non-pruritic annular scaly plaques and papules. His medical history was unremarkable, and he was not on any regular medication. He had previously received oral ivermectin with a preliminary diagnosis of scabies, without clinical improvement. Dermatological examination revealed widespread annular scaly plaques and papules, predominantly on the trunk. There was no history of spontaneous regression or scar formation. Clinical differential diagnoses included pityriasis rosea, pityriasis lichenoides chronica, psoriasis, and allergic contact dermatitis. A 4 mm punch biopsy was obtained from the back (11.12.2025). Topical corticosteroid therapy was initiated, and PUVA treatment was started.

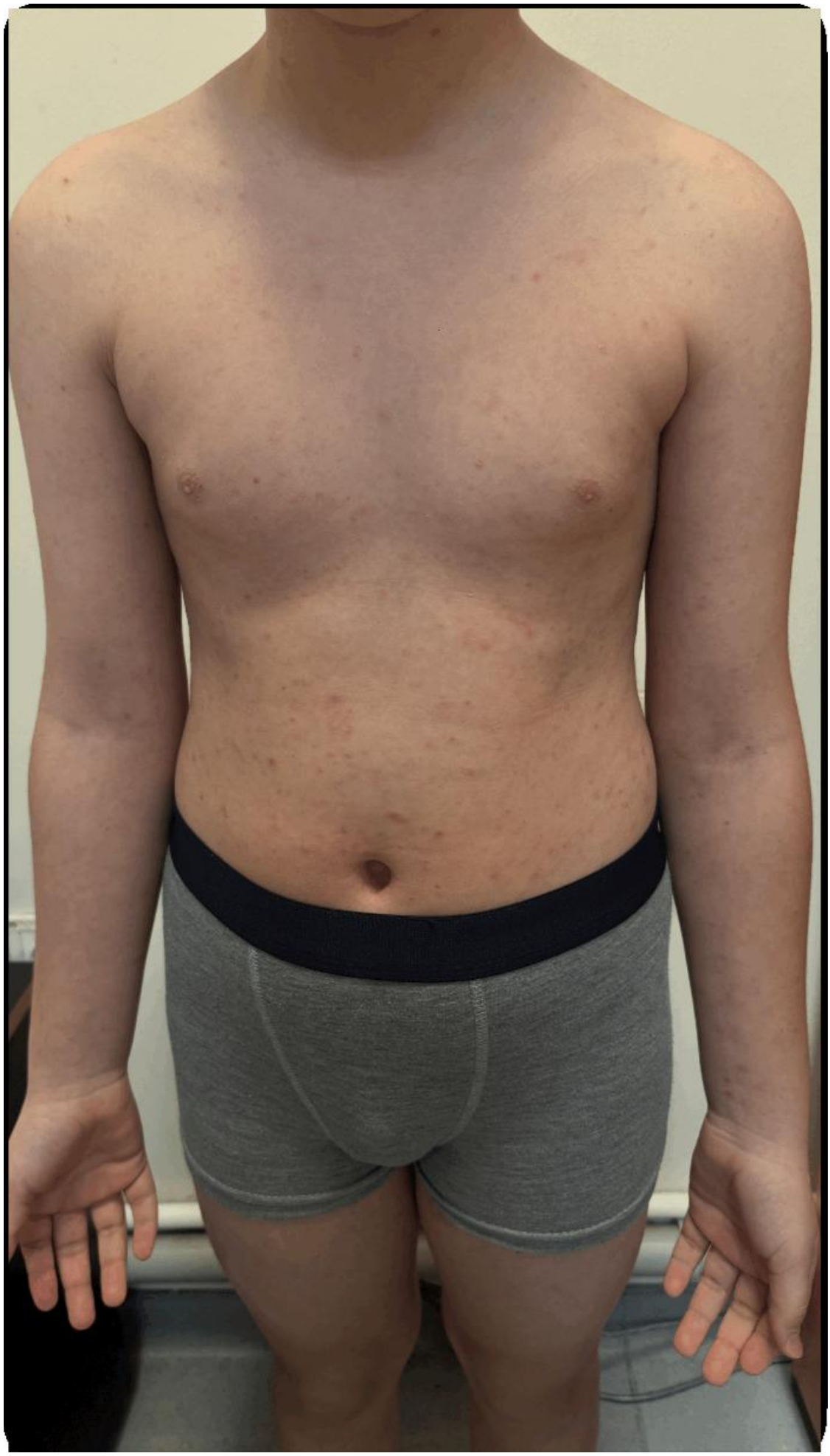

Pityriasis lichenoides-like distribution of lesions in a case of lymphomatoid papulosis

Conclusion

Histopathological examination demonstrated atypical lymphoid cells positive for CD3 and CD2, with marked loss of CD7 expression and partial loss of CD5 expression. The CD4/CD8 ratio was 1/7, indicating a CD8-dominant cytotoxic phenotype. CD30 was weakly positive in approximately 30% of atypical lymphoid cells. Based on clinicopathological correlation, alternative diagnoses were excluded, and the case was evaluated as lymphomatoid papulosis (type D / type E). The patient received a total of 18 sessions of narrowband UVB therapy, resulting in significant clinical improvement. This case highlights the diagnostic challenges of lymphomatoid papulosis in the pediatric population and emphasizes the importance of clinicopathological correlation. Although LyP may histopathologically mimic malignancy, its clinical course is generally benign. Careful follow-up is essential, especially in pediatric patients, to avoid unnecessary aggressive treatments.

EADV CONGRESS
VIENNA
30 SEP - 3 OCT 2026

Abstract N°: 2263

From vaccine to ulcer: an unexpected turn

Hind Majdoul*[1], Bouchra Baghad[1], Soumiya Chiheb[1]

[1] Dermatology and Venereology Department, Ibn Rochd University Hospital, Casablanca, Morocco

Introduction

Pyoderma gangrenosum (PG) is a rare ulcerative neutrophilic dermatosis characterized by rapidly progressive and painful cutaneous ulcerations. Pediatric forms remain exceptional and pose a significant diagnostic challenge due to their clinical polymorphism and the absence of specific histopathological criteria.

Rare cases of post-vaccination PG, particularly following DTaP immunization, have been reported. We describe an original pediatric case illustrating this unusual presentation and highlighting its diagnostic and therapeutic challenges.

Case Presentation

A 5-year-old boy with no significant past medical history presented to the pediatric emergency department with a painful inflammatory swelling of the left shoulder that developed 48 hours after DTaP vaccination at the injection site. The initial clinical presentation was suggestive of a post-vaccination cutaneous abscess, leading to the initiation of empiric antibiotic therapy, without clinical improvement. The lesion subsequently evolved with a rapid increase in size and the development of a cutaneous fistula, prompting surgical drainage that yielded approximately 100 mL of frank pus.

Postoperative evolution was marked by paradoxical worsening, with rapid enlargement of the initial fistula progressing to a large, painful ulceration with a fibrino-hemorrhagic base and exuberant undermined borders. A skin biopsy was then performed, revealing an inflammatory ulceration rich in neutrophilic infiltrates, without granuloma or vasculitis. Bacteriological investigations were negative.

In light of the suggestive clinical presentation and histopathological findings, the diagnosis of post-vaccination pyoderma gangrenosum was established. Management consisted of meticulous local wound care combined with oral corticosteroid therapy at a dose of 1 mg/kg/day with gradual tapering, along with dapsone also at a dose of 1 mg/kg/day. The outcome was favorable, with progressive regression of the lesions.

Conclusion

In our case, the very short interval between DTaP vaccination and lesion onset, together with the strict localization at the injection site, strongly suggests a post-vaccination pathergy phenomenon. This mechanism, classically described in PG, corresponds to an exaggerated inflammatory response triggered by minor cutaneous trauma in predisposed individuals. The initial diagnosis of an infectious abscess is common because of the inflammatory appearance of the lesion and the presence of purulent discharge, thereby exposing patients to potentially aggravating surgical procedures, as observed in our patient. The lack of response to antibiotic therapy, the rapid progression of the lesions, and the negative bacteriological cultures are major arguments supporting an inflammatory rather than infectious etiology.

Although non-specific, histopathological examination remains of major diagnostic value by demonstrating a neutrophil-rich inflammatory infiltrate consistent with PG. Therapeutic management primarily relies on systemic corticosteroids, sometimes combined with immunomodulatory or immunosuppressive agents in more severe forms.

Overall, early recognition of this rare entity is essential to avoid unnecessary and potentially harmful invasive procedures, particularly in an intrinsically vulnerable pediatric population.

EA DV CONGRESS
VIENNA
30 SEP - 3 OCT 2026

Abstract N°: 2285

A pediatric case of nevus comedonicus on grafted skin: Coincidence or pathogenic consequence?

Hind Majdoul*[1], Fatimazahra El Fatoiki[1], Fouzia Hali[1], Soumiya Chiheb[1]

[1] Dermatology and Venereology Department, Ibn Rochd University Hospital, Casablanca, Morocco

Introduction

Comedonal hamartomas, or nevus comedonicus (NC), are rare epidermal malformations of the pilosebaceous unit, typically congenital or arising in childhood. In uncommon instances, NC may develop de novo following skin trauma, burns, infections, or vaccinations—through Koebner or Wolf isotopic responses.

We report an extremely rare case of NC arising in a skin graft, further illustrating how localized skin injury can trigger hamartomatous proliferation.

Case Presentation

A 9-year-old girl with no significant past medical history who suffered a scald burn two years prior, for which she underwent split-thickness skin grafting, presented to our department one year after the graft, with grouped comedonal lesions localized to the graft site, predominantly along its periphery. Clinical examination revealed multiple open comedones arranged in a linear pattern at the edges of the graft, extending across the base of the neck, the lower chest, and the proximal upper limbs. The lesions appeared as dilated follicular openings filled with dark keratin plugs, resembling classic features of nevus comedonicus. Histopathological analysis confirmed the diagnosis of a comedonal hamartoma, showing dilated follicular infundibula filled with lamellar keratin. Treatment included mechanical extraction of comedones and topical retinoids, leading to partial cosmetic improvement. Follow-up showed lesion stability without new flare-ups or complications.

Conclusion

Acquired nevus comedonicus (NC) on grafted or scarred skin is an exceptional entity, reflecting post-traumatic cutaneous mosaicism. Several cases have described NC arising weeks or months after localized skin injury, such as burns, herpes zoster, or deep infections. These lesions are typically asymptomatic, presenting as grouped open comedones over the affected area. Histologically, they feature dilated follicular structures packed with lamellar keratin, minimal inflammation, and no atypia—confirming their benign hamartomatous nature. The pathogenesis is thought to involve postzygotic somatic mutations unmasked by local disruption of the epidermal microenvironment. Koebner and Wolf isotopic responses are implicated, with the latter being most plausible in patients without a pre-existing NC. Management is usually conservative: mechanical comedone extraction and topical retinoids may improve appearance, while surgical excision or ablative options such as CO_2 laser treatments can be considered in persistent or cosmetically bothersome cases. Malignant transformation has not been reported, and most lesions remain stable or resolve spontaneously. In our case, we question whether the lesion represents a truly acquired NC induced by the graft environment or rather a coincidental occurrence of NC during childhood in a grafted area. However, the precise distribution of lesions along the graft margins raises the possibility of a localized trigger, supporting a trauma-related origin rather than mere coincidence. Given the rarity of NC arising on grafted skin, each new case warrants thorough documentation to better understand its pathophysiology and clinical implications.

EADV Congress 2026, VIENNA
30 SEPTEMBER - 03 OCTOBER 2026
POWERED BY M-ANAGE.COM

EA DV CONGRESS
VIENNA
30 SEP - 3 OCT 2026

Abstract N°: 2289

Perplexing case of bleeding in a young girl

Meghana Phiske*[1], Nikita Samal[1], Shylaja Someshwar[1]

[1] MGM Institute of Health Sciences, Navi Mumbai, India

Introduction

Hematohidrosis, also known as hematidrosis and hemidrosis, is a rare condition in which a human being sweats blood. Leonardo Da Vinci described a soldier who sweated blood before battle. Jesus Christ experienced hematohidrosis while praying in the garden of Gethsemane before his crucification as mentioned in the Defenders Bible.

Exact etiology is unknown, believed to be a systemic disease, e.g. it has been associated with vicarious menstruation, a condition in which bleeding occurs from a surface other than mucous membrane of uterine cavity at a time when normal menstruation should take place. Hematohidrosis has been reported with primary thrombocytopenic purpura and can also occur in settings of excessive exertion, psychogenic and other unknown factors. Etiopathogenesis according to Dr. Frederick Zugibe is that multiple blood vessels which are present in a net-like form around sweat gland, constrict under pressure of stress. As anxiety increases, blood vessels dilate to the point of rupture. Blood goes into sweat glands, which push it along with sweat to the surface, presenting as droplets of blood mixed with sweat.

Case Presentation

A 9/female, born out of non-consanguineous marriage, came with bleeding from intact skin from various parts of body since 15 days. Her first episode of bleeding was 6 months ago which had resolved spontaneously. Her last episode was15 days ago, after which the episodes happened daily. There was no history of prior trauma or physical/ mental stress, similar complaints in past/family. Cutaneous examination revealed no active lesions. Presence of blood was photographically documented by relative. Routine blood investigation and psychiatric evulation was normal. Benzidine test, confirmatory for hemathidrosis was positive. There was significant reduction in bleeding episodes after treatment with tab Propranolol 10 mg in divided doses.

Unique and rare case of haematohidrosis, probably youngest from India, (literature mentions case reports in 11 and13 year old) is highlighted.

Conclusion

It is vital to raise awareness about hematohidrosis given its frightening nature and potential for unnecessary testing. Educating physicians globally can help in understanding this rare yet alarming condition, leading to better management and outcomes for patients. Early detection, even in the absence of underlying diseases or psychological stressors, is key for successful treatment and achieving complete remission.

EADV CONGRESS
VIENNA
30 SEP - 3 OCT 2026

Abstract N°: 2332

Multiple spider angiomas in children as a marker of systemic metabolic disorders: controversial association.

Julia Nowowiejska-Purpurowicz*[1], Mario Cutrone[2], Dirk Van Gysel[3], Ramon Grimalt[4], Giuseppe Argenziano[5], Vincenzo Piccolo[5]

[1] Uniwersytet Medyczny W Bialymstoku, Białystok, Poland
[2] Ambulatorio di Dermatologia Pediatrica, Centro di Medicina Mestre, Venice, Italy
[3] Interdisciplinary Unit of Pediatric Dermatology, Vrije Universiteit Brussel (VUB), Universitair Ziekenhuis Brussel (UZ Brussel), Brussels, Belgium
[4] Universitat Internacional de Catalunya, Barcelona, Spain
[5] Dermatology Unit, University of Campania, Naples, Italy

Introduction

Spider angiomas are vascular lesions that are characterized by a small central papule surrounded by dilated radially distributed vessels. They may occur both in children and adults, as solitary or multiple lesions. Whether spider angiomas and their number are associated with comorbidities in children remains a matter of debate. We report two cases of spider angiomas in children in whom additional disorders were diagnosed.

Case Presentation

First patient, a 7-year-old girl, with a 2-year history of spider angiomas, presented to the dermatology ambulatory care. Physical examination revealed several spider angiomas on the trunk and limbs. The patient was affected by non-alcoholic fatty liver disease, diagnosed incidentally 1 year before our observation.

The second patient, a 4-year-old boy with a recent onset of spider angiomas, presented to the dermatology clinic. On the physical examination, several spider angiomas were found on the trunk. The patient underwent a full blood investigation, revealing hypercholesterolemia and an abdominal ultrasound examination that was unremarkable.

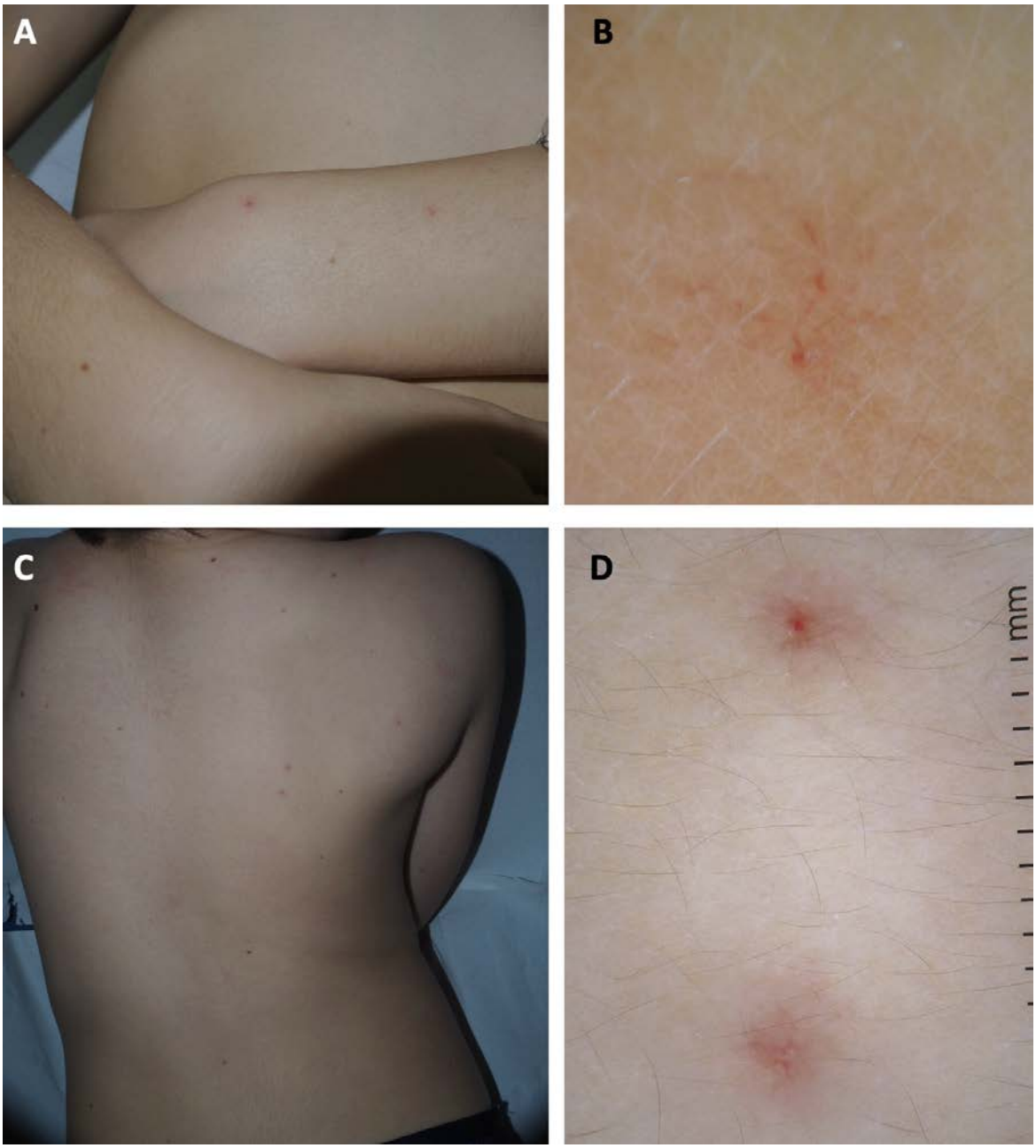

A. Clinical picture of the 7-year-old girl with multiple spider angiomas. B. Dermoscopic picture of the same patient. C. Clinical picture of the 4-year-old boy with multiple spider angiomas. D. Dermoscopic picture of the same patient.

Conclusion

Traditionally, spider angiomas of adults, particularly multiple, have been associated with liver disease, especially cirrhosis. They have also been described in subjects with autoimmune diseases, malnutrition or during pregnancy. As for the potential mechanism of linking spider angiomas with liver disease, neovascularization is proposed, and endothelial growth factor (VEGF) and basic fibroblastic growth factor (bFGF) have been demonstrated to be elevated in the plasma of subjects with liver cirrhosis and spider angiomas. Substances that exert vasodilatory effects have also been considered potential causative agents (alcohol, substance P, increased estrogens). The matter of spider angiomas and associated comorbidities in children remains poorly investigated, and the available literature is sparse. It is believed that sporadic spider angiomas are present in 10–15% of healthy children and young adults. Although in adults the lesions are usually found on the face, neck, and upper trunk, in children, they occur more frequently on the upper extremities. Probably the largest cohort of children with spider angiomas was collected by Alderson, who diagnosed these lesions in 540 of 1138 patients, with a mean of 2.1 per person, whereas the highest observed number in one patient was 12. He did not observe the association between the presence of angiomas in general and hepatitis; however, the potential correlation between the high number of angiomas (>5) in particular and infection was not analyzed. Another large group (460 patients) has been

described by Finn et al. 53% of children with liver disease had at least one spider angioma, and only 11.8% had at least five angiomas; whereas in the group of children without liver disease, 38% have at least one spider angioma, and only 1.64% - more than five lesions. They concluded that the number of spider angiomas in children is probably not associated with chronic liver disease. On the other hand, in another study, young age was a positive predictor of the spider angioma occurrence in patients with liver cirrhosis. The association between spider angiomas and comorbidities is not clear. In available studies involving large groups of patients, the number of angiomas in individual patients was low, which may affect the final conclusion. Hence, in selected cases, we recommend investigating an underlying condition in children. Although spider angioma represents a quite common occurrence in children, we do believe that some elements may support further investigation, i.e. the total number (5 or more), the early occurrence (5 years or less), the eruptive occurrence, and the lack of correlation with photo-exposure.The treatment of spider angiomas includes laser therapy, electrodesiccation or topical timolol. Sometimes they may spontaneously resolve after treatment of the primary condition.

EA DV CONGRESS
VIENNA
30 SEP - 3 OCT 2026

Abstract N°: 2349

Infantile-onset Mycosis Fungoides Masquerading as Refractory Psoriasis: A 10-Year Diagnostic Challenge

salma larabi*[1]

[1] Department of dermatology, Ibn Sina University Hospital ,Rabat , Morocco, rabat, Morocco

Introduction

Mycosis fungoides (MF) is the most common form of cutaneous T-cell lymphoma, but remains rare in childhood. Its clinical polymorphism may closely mimic benign inflammatory dermatoses such as psoriasis, eczema, or pityriasis alba, leading to significant diagnostic delay. Early-onset MF is often hypopigmented and may present with atypical or misleading clinical features.

Case Presentation

We report the case of a girl followed for presumed psoriasis since the age of 2 months, based on erythematous scaly plaques involving the scalp and trunk. Over a 10-year disease course, the patient received multiple systemic and topical treatments, including acitretin, topical corticosteroids, and methotrexate (up to 15 mg/week), with only partial and transient responses and no sustained remission.

At age 10, clinical examination revealed widespread infiltrated hypopigmented plaques involving approximately 70% of the body surface area, associated with palmoplantar keratoderma. Given the chronicity, treatment resistance, and atypical evolution, a skin biopsy was performed.

Histopathological examination demonstrated features consistent with early-stage mycosis fungoides. Immunohistochemistry revealed an atypical T-cell infiltrate expressing CD2, CD3, CD4, and CD5, with loss of CD7 and negativity for CD8. Staging workup, including peripheral blood smear, showed no Sézary cells or extracutaneous involvement, consistent with stage IB (T2N0M0) MF.

Conclusion

Pediatric mycosis fungoides remains a major diagnostic challenge due to its ability to closely mimic chronic inflammatory dermatoses such as psoriasis, particularly in its hypopigmented variant. This overlap, combined with transient responses to immunomodulatory therapies and reluctance to biopsy children, contributes to frequent and prolonged diagnostic delay.

Persistent, atypical, or treatment-refractory dermatoses in children should therefore prompt early histological evaluation. Although generally indolent when diagnosed early, delayed recognition of pediatric MF may lead to unnecessary prolonged systemic treatments and increased disease burden.

Palmoplantar keratoderma, while non-specific, may represent an additional clinical warning sign in otherwise atypical or refractory presentations.

Early biopsy in suspicious cases remains essential to avoid diagnostic delay and improve management outcomes.

EADV CONGRESS
VIENNA
30 SEP - 3 OCT 2026

Abstract N°: 2359

INTEGUMENT-INFANT: Once-Daily Roflumilast Cream 0.05% in Infants Aged 3 to <24 Months With Atopic Dermatitis

Lawrence F. Eichenfield*[1], Mercedes E. Gonzalez[2], Adelaide A. Hebert[3], Vimal H. Prajapati[4], David Krupa[5], Saori Kato[5], Scott Snyder[5], Diane Hanna[5], Melissa S. Seal[5], David R. Berk[5]

[1] Rady Children's Hospital-San Diego and University of California San Diego School of Medicine, San Diego, United States
[2] Pediatric Skin Research, LLC, Coral Gables, United States
[3] UTHealth McGovern Medical School, Houston, United States
[4] Dermatology Research Institute, Skin Health & Wellness Centre, University of Calgary, and Probity Medical Research, Calgary, Canada
[5] Arcutis Biotherapeutics, Inc., Westlake Village, United States

Introduction
Efficacy and safety of roflumilast cream, a highly potent phosphodiesterase 4 inhibitor formulated without potentially irritating ingredients, for mild-to-moderate atopic dermatitis (AD) in patients aged ≥2 years were demonstrated in phase 3 clinical trials. The phase 2, single-arm, open-label INTEGUMENT-INFANT (NCT06998056) study evaluated roflumilast cream 0.05% in infants aged 3 to <24 months with AD.

Materials and Methods
Caregivers of infants aged 3 to <24 months with AD (Validated Investigator Global Assessment for AD [vIGA-AD] mild/moderate [2/3]; ≥3% body surface area affected) applied roflumilast cream 0.05% once daily for 4 weeks. Primary endpoints were safety and application-site tolerability. Exploratory efficacy endpoints included vIGA-AD success (clear/almost clear [0/1] with ≥2-point improvement), vIGA-AD 0/1, ≥75% improvement in Eczema Area and Severity Index (EASI-75), Worst Scratch/Itch-Numeric Rating Scale (WSI-NRS) success (≥4-point improvement), and ≥25% itch improvement per Dynamic Pruritus Score (DPS-25).

Results
There were 101 infants enrolled. Treatment-emergent adverse events were reported for 46.6%, all mild or moderate. Clinicians reported no evidence of irritation for ≥97.9% of infants at week 2 or 4. At week 4, 34.4% (95%CI, 25.6%–44.3%), 49.0% (39.2%–58.8%), 58.3% (48.3%–67.7%), and 60.6% (48.9%–71.1%) achieved vIGA-AD success, vIGA-AD 0/1, EASI-75, and WSI-NRS success, respectively. 46.6% (36.5%–56.9%) achieved DPS-25 within 10 minutes of first application.

Conclusions
Roflumilast was well tolerated and reduced AD signs and symptoms in infants with AD. These results support safe and efficacious use of roflumilast cream in patients as young as 3 months, a population with substantial disease burden and limited evidence-based treatment options.

EA DV CONGRESS
VIENNA
30 SEP - 3 OCT 2026

Abstract N°: 2449

Constitutional mismatch repair deficiency and dermatological phenotype

Emanuele Amore*[1], Morgane Seyler[2], Cassandrè Cremades[3], Philippe Drabent[4], Laura Lenez[5], Lea Guerrini[5], Benedicte Neven[4], Moshous Despina[3], Christine Bodemer[2]

[1] La Sapienza University, Rome, Italy
[2] Necker Enfants Malades Hospital, Department of Pediatric Dermatology, Paris, France
[3] Necker Enfants Malades Hospital, Department of Pediatric Hematology, Paris, France
[4] Necker Enfants Malades Hospital, Department of Pathology, Paris, France
[5] Gustave Roussy Institute, Department of Pediatric Oncology, Paris, France

Introduction

Constitutional mismatch repair deficiency (CMMRD) is a rare autosomal recessive disorder caused by biallelic mutations in DNA mismatch repair genes, leading to early onset cancers (hematologic and brain). Patients may show characteristic café au lait macules and brain anomalies. Although classical immunodeficiency is uncommon systemic lupus erythematosus like features SLE have been reported

Materials and Methods

We retrospectively reviewed the clinical presentation, laboratory findings, imaging data, skin biopsies, and therapeutic responses in a pediatric patient with CMMRD-MSH6. A narrative PubMed literature review was conducted using the keywords “MSH6,” “lupus,” and “CMMRD” to identify clinical reports and recent functional studies addressing the association between MSH6 variants, immune dysregulation, and systemic lupus erythematosus.

Results

The patient initially presented with high fever, hepatosplenomegaly, neurological symptoms, pancytopenia, and markers consistent with macrophage activation syndrome (MAS). A homozygous MSH6 p.Cys783* variant confirmed CMMRD. Treatment with corticosteroids and ruxolitinib gave a rapid remission. After JAK inhibitor withdrawal, the patient developed erythematous papules and plaques with histopathological features compatible with lupus-like connective tissue disease, responsive to ruxolitinib’s reintroduction. Months later, after ruxolitinib’s stop and despite hydroxychloroquine therapy, new cutaneous lesions, fever, and serologic lupus activity (ANA+, anti-DNA+, anti-SSA/Ro+) emerged, confirming SLE reactivation.

Conclusions

This case illustrates a flare of interferonopathy with a lupus-like phenotype in a child with CMMRD due to MSH6 deficiency, supporting emerging evidence that MSH6 variants may predispose to autoimmunity. Previous reports of compound heterozygous MSH6 variants and recent functional studies demonstrate that certain MSH6 variants enhance autoreactive antibody production and induce lupus-like disease in murine models. These findings suggest a link between MMR pathway defects, aberrant B-cell maturation, interferon activation, and SLE. Clinically, the coexistence of CMMRD and lupus presents therapeutic challenges, particularly regarding immunosuppression

and oncologic risks. Awareness of this association is crucial in young patients with SLE, consanguinity, or NF1-like features.

EA DV CONGRESS
VIENNA
30 SEP - 3 OCT 2026

Abstract N°: 2456

Pediatric Generalized Pustular Psoriasis Complicating Chronic Plaque Psoriasis: A Case Report

salma larabi*[1]

[1] Department of dermatology, Ibn Sina University Hospital ,Rabat , Morocco, rabat, Morocco

Introduction

Generalized pustular psoriasis (GPP) is a rare and potentially life-threatening inflammatory dermatosis characterized by the acute onset of widespread sterile pustules associated with systemic symptoms. Pediatric cases remain uncommon and may be triggered by infections, treatment withdrawal, or inadequate disease control. Early recognition is essential because of the risk of severe systemic complications. We report a pediatric case of generalized pustular psoriasis occurring in a child with a history of chronic plaque psoriasis and repeated topical corticosteroid self-medication.

Case Presentation

A 10-year-old boy with plaque psoriasis since the age of 2 years presented with a severe febrile erythrodermic eruption evolving over two months. His medical history was notable for recurrent upper respiratory tract infections associated with repeated psoriasis flares and long-term unsupervised topical corticosteroid use by the family.

Dermatological examination revealed diffuse erythroderma with extensive erythematous scaly plaques covered by multiple sterile pustules and honey-colored crusts, associated with intense pruritus and marked deterioration of the general condition. Palmoplantar examination showed polymorphic lesions including papules, pustules, and pseudo-targetoid lesions.

The patient initially presented with fever (38.7°C), arthralgia, and hyperleukocytosis with neutrophilia reaching 12,000/mm^3. No infectious focus was identified after clinical and laboratory investigations. Serum calcium levels and 8 a.m. cortisol levels were within normal limits.

Given the patient’s history of psoriasis and the characteristic clinical presentation, generalized pustular psoriasis was suspected. Histopathological examination demonstrated psoriasiform epidermal hyperplasia associated with subcorneal spongiform pustules, confirming the diagnosis. Differential diagnoses, particularly acute generalized exanthematous pustulosis and infectious dermatoses, were excluded.

Systemic treatment with methotrexate at a dose of 0.3 mg/kg/week (10 mg/week for a 35-kg child) was initiated, resulting in significant clinical improvement within a few weeks.

Conclusion

Pediatric generalized pustular psoriasis is a rare but severe variant of psoriasis that may occur on pre-existing plaque psoriasis. In this case, recurrent infections and prolonged unsupervised topical corticosteroid use were likely triggering factors.

Early recognition is crucial to prevent systemic deterioration. Differentiation from infectious or drug-induced pustular dermatoses remains challenging and requires clinicopathological correlation.

This case highlights the importance of strict therapeutic supervision in pediatric psoriasis and supports early initiation of systemic therapy such as methotrexate. Caregiver education is essential to prevent inappropriate corticosteroid use and disease exacerbation.

EADV CONGRESS
VIENNA
30 SEP - 3 OCT 2026

Abstract N°: 2457

Diagnostic Challenges in CIPA: Cutaneous and Oral Self-Mutilation in a Child With Normal Psychomotor Development

Naouel Bakiri*[1], Issam TABLIT[1], Saliha Takheroubt[1], Samira Zobiri[1]

[1] Mustapha Bacha Hospital , Dermatology and Venerology, Algiers, Algeria

Introduction

Congenital Insensitivity to Pain with Anhidrosis (CIPA) is a rare hereditary sensory and autonomic neuropathy characterized by absent pain perception and anhidrosis.
Early manifestations frequently include self-mutilating cutaneous and oral lesions. Cognitive impairement ,a hallmark feature,is absent in a minority of patients,making diagnosis even more elusive.
We report a case of CIPA in a cognitively intact 5-year-old child with normal psychomotor development presenting with recurrent oral and digital self-mutilation, emphasizing the diagnostic challenges of this rare condition.

Case Presentation

A 5-year-old boy, born of consanguineous parents, presented with recurrent mutilating digital ulcerations evolving since the age of 2 years. History was remarkable for recurrent unexplained febrile episodes, anhidrosis, and complete insensitivity to painful stimuli. Psychomotor and staturo-ponderal development were normal.
Dermatological examination revealed xerotic skin, a mutilating pulpar ulceration of the third right finger, swollen fingers with signs of phalangeal amputation, fissured plantar keratosis, and nail dystrophy.
Oral examination showed an aphthous ulceration on the lateral border of the tongue associated with worn primary teeth consistent with self-injurious behavior.
Bilateral shoulder joint hyperlaxity was also observed.
Routine laboratory investigations and immunological workup were unremarkable. Anhidrosis was confirmed by the Minor starch-iodine sweat test, while skin biopsy demonstrated absence of sweat glands .Radiographs revealed fractures and osteolysis of the distal phalanges involving the fingers and the left hallux.
Electroneuromyography showed diffuse sensory neuropathy predominantly affecting nociceptive fibers, consistent with hereditary sensory and autonomic neuropathy. Somatosensory evoked potentials were preserved. Genetic analysis could not be performed because of limited technical resources.
Based on the characteristic clinical presentation and supportive paraclinical findings, a diagnosis of Congenital Insensitivity to Pain with Anhidrosis (CIPA) was established. The patient was managed through a multidisciplinary approach including dermatological, dental, orthopedic, and pediatric surgical care.

Conclusion

CIPA is a rare hereditary sensory and autonomic neuropathy caused by loss-of-function mutations in the NTRK1 gene, leading to defective TrkA/NGF signaling and impaired development of nociceptive and autonomic neurons. Clinically, the disorder is characterized by pain insensitivity, anhidrosis, recurrent unexplained fever, and self-mutilating behavior, frequently associated with cognitive impairment of variable severity.

Our case illustrates a rare cognitively intact phenotype of CIPA ,where preserved intellectual function paradoxally delayed diagnostic suspicion.The prominent . cutaneous and oral self-inflicted lesions represented the main presenting manifestations, emphasizing the pivotal role of dermatologists and oral health practitioners in early diagnosis. Early recognition is essential to prevent severe complications, including recurrent fractures, osteomyelitis, joint destruction, septic complications, and perioperative dysautonomic events. Management requires a multidisciplinary approach focused on prevention of self-injury, skin and dental care, orthopedic surveillance, and family education.

EA DV CONGRESS
VIENNA
30 SEP - 3 OCT 2026

Abstract N°: 2539

When Bullae Mislead: A Diagnostic Challenge of Pediatric Bullous Lupus

Nikol Atanasova*[1], Zhenya Stoyanova[2], Iliyana Apostolova[3], Hristo Popov[4], Filka Georgieva[2]

[1] Medical University - Varna, Varna, Bulgaria

[2] UHAT "Saint Marina" LTD - Varna, Department of dermatology and venereology, Medical University Varna, Department of Infectious Diseases, Parasitology, and Dermatovenereology, Varna, Bulgaria

[3] Medical University Varna, Emergency Medical Service Center Varna, Varna, Bulgaria, Varna, Bulgaria

[4] UHAT "Saint Marina" LTD - Varna, Medical University Varna, Department of General and Clinical Pathology, Forensic Medicine and Deontology, Varna, Bulgaria

Introduction

Bullous systemic lupus erythematosus (BSLE) is a rare manifestation of lupus, particularly in pediatric patients, and may clinically mimic other autoimmune blistering diseases, leading to diagnostic delay. Childhood-onset systemic lupus erythematosus is uncommon, accounting for 10–20% of all SLE cases, while bullous lupus represents an even rarer subset, with limited data in children.

Case Presentation

We report a 14-year-old girl presenting with a one-month history of progressive, pruritic, generalized eruption, initially involving the face and subsequently spreading to the trunk and extremities, accompanied by persistent high-grade fever (39–40°C) and cervical lymphadenopathy. Sepsis was suspected and excluded, including negative blood cultures.

Dermatological examination revealed annular and polycyclic plaques with raised active borders studded with vesicles and small tense bullae, forming a characteristic “string of pearls” appearance, surrounding central erosions with yellow crusts. Mucosal involvement was present (hard palate erosion). The clinical presentation strongly suggested linear IgA bullous dermatosis, representing a significant diagnostic pitfall.

Laboratory evaluation demonstrated strongly positive antinuclear antibodies (+++) with a granular pattern. Histopathology showed epidermal atrophy, basal vacuolar degeneration, and keratinocyte necrosis, with focal basement membrane thickening (PAS+). Direct immunofluorescence revealed granular deposition along the dermoepidermal junction (lupus band), establishing the diagnosis of cutaneous lupus erythematosus.

Following initiation of systemic corticosteroid therapy (methylprednisolone 40 mg), rapid defervescence and marked clinical improvement were observed, supporting an underlying autoimmune process. The patient was referred to a tertiary care center for further evaluation of systemic involvement.

Conclusion

Bullous lupus should be considered in febrile pediatric patients presenting with annular blistering eruptions mimicking linear IgA dermatosis. Early clinicopathological correlation and immunofluorescence are critical to avoid misdiagnosis and ensure timely management.

EADV CONGRESS
VIENNA
30 SEP - 3 OCT 2026

Abstract N°: 2598

Giant Bathing Trunk Congenital Melanocytic Nevus in a Child: Absence of Neurocutaneous Melanosis Despite Multiple Satellite Nevi

fikri ouissal*[1], ahmed bouhamidi[1]

[1] Avicenne Military University Hospital Center of Marrakech, marrakech, Morocco

Introduction

Giant congenital melanocytic nevus (GCMN) is a rare congenital melanocytic proliferation associated with an increased risk of melanoma and neurocutaneous melanosis, especially in patients with posterior axial localization and multiple satellite nevi. Beyond medical complications, GCMN may significantly affect quality of life and psychosocial well-being.

Case Presentation

We report the case of a 4-year-old child presenting since birth with a giant congenital melanocytic nevus involving the lumbosacral and gluteal regions in a typical "bathing trunk" distribution. Dermatological examination revealed a large hyperpigmented plaque with marked hypertrichosis associated with multiple satellite nevi distributed over the trunk and lower limbs. No ulceration, bleeding, or suspicious nodular lesions were observed. Neurological examination was normal. Lumbosacral magnetic resonance imaging (MRI), performed because of the posterior axial localization and the presence of multiple satellite nevi, showed no neurological abnormalities or evidence of neurocutaneous melanosis. During follow-up, the lesions remained clinically stable without signs of malignant transformation.

The child developed significant psychological distress related to the cosmetic appearance of the lesions, leading to avoidance of social activities such as swimming pools, beaches, and traditional hammams. After multidisciplinary discussion and detailed counseling regarding therapeutic options, the family opted for conservative management based on regular dermatological surveillance rather than aesthetic surgical intervention.

Conclusion

This case highlights the importance of multidisciplinary long-term follow-up in children with GCMN and emphasizes the psychological burden associated with extensive visible lesions, even in the absence of neurological involvement.

EA DV CONGRESS
VIENNA
30 SEP - 3 OCT 2026

Abstract N°: 2607

Paediatric Dermatofibrosarcoma Protuberans: the potencial role of ultrasound in early detection

Cristina Rubio Flores*[1], Ricardo Valverde Garrido[1], Dulce María Arranz Sánchez[1], Juan Angel Burgos Moreno[1], Tatiana Sanz Sánchez[1], Carolina Garrido Gutierrez[1], Iolanda Prats Caelles[1]

[1] Hospital Infanta Sofía, San Sebastián de los Reyes, Spain

Introduction

Dermatofibrosarcoma protuberans (DFSP) is a rare low-grade cutaneous sarcoma in childhood. Early diagnosis can be challenging because initial lesions often resemble benign conditions.

Case Presentation

A 9-year-old girl was referred for evaluation of a lesion on the ankle that had been present since early childhood. Three years earlier, both clinical and ultrasound assessment had identified a well-defined oval dermal lesion that appeared hypoechoic, mildly heterogeneous, symmetrical, and without detectable vascular flow.

At follow-up, the lesion had progressively enlarged and become firmer on palpation. Ultrasound examination at this stage revealed a hypoechoic dermal mass with extensions into the subcutaneous tissue. Colour Doppler imaging demonstrated minimal, patchy intralesional vascularity.

Histopathological analysis showed a spindle-cell proliferation arranged in fascicles, with mild-to-moderate cytological atypia. Immunohistochemistry was positive for CD34 and negative for factor XIIIa, actin, desmin, and S100. Fluorescence in situ hybridisation confirmed the presence of the COL1A1-PDGFB fusion gene.

After the diagnosis of DFSP was established, the patient underwent excision with delayed Mohs micrographic surgery.

Conclusion

Diagnosing DFSP in children is often more difficult than in adults because the tumour may clinically simulate benign lesions. In addition, the rarity of the disease frequently contributes to delayed recognition, allowing infiltration of deeper tissues before diagnosis. Detecting DFSP at an earlier stage could reduce the need for extensive surgical procedures and minimise functional or cosmetic sequelae.

Several sonographic patterns of DFSP have been described. In paediatric patients, the lesion most commonly appears as a hypoechoic nodule with irregular margins and infiltrative features. Increased vascularity has also been reported in most published cases.

In contrast, our patient showed only minimal vascularisation, which had been completely absent during the initial evaluation. This finding may have contributed to underestimating the biological behaviour of the lesion.

Both the clinical presentation and ultrasound findings of early DFSP may be subtle and nonspecific, leading to low suspicion of malignancy. Nevertheless, features such as heterogeneous echotexture, poorly defined margins, infiltrative growth, and increased vascularity may raise suspicion for DFSP. A high level of clinical awareness is therefore essential, and histopathological examination should be considered whenever this diagnosis is suspected.

EADV Congress 2026, VIENNA
30 SEPTEMBER - 03 OCTOBER 2026
POWERED BY M-ANAGE.COM

Abstract N°: 2610

Pattern of Paediatric Skin Diseases at a National Referral Hospital in Uganda.

Fiona Namutebi*[1]

[1] Old Mulago Hospital, Kampala, Uganda

Introduction
Paediatric skin diseases affect 21% to 87% of children in Africa and constitute up to one-third of outpatient visits to dermatologists and paediatricians. Data on the spectrum of skin diseases among children in Uganda are scarce. Understanding the epidemiology of skin disorders allows for proper planning, budget allocation, and educational initiatives. This study aimed to document the spectrum and frequency of skin diseases among children attending the dermatology outpatient clinic of a national referral hospital.

Materials and Methods
A cross-sectional study was conducted from April 2025 to May 2026 at the dermatology outpatient clinic of a national referral hospital. Children aged 12 years and below with a new diagnosis were included. A patient card was used to capture demographic and clinical details. Diagnoses were primarily made clinically, and where necessary, additional investigations were ordered. Skin diseases were classified into various groups. Statistical analysis was performed using SPSS version 27 and Excel.

Results
Of the 389 children, 208 (53.5%) were female, with a mean (SD) age of 5.1 (4.1) years. The most common categories of skin disease presentations were infections (41.9%, n = 162), followed by eczematous dermatitis (30.2%, n = 117), infestations (13.4%, n = 52), papulosquamous disorders (8.7%, n = 34), and genodermatoses (5.7%, n = 22). Among the infections, fungal infections predominated (42.5%, n = 65), followed by bacterial infections (40.5%, n = 62) and viral infections (17.0%, n = 26).

Conclusions
Skin infections, eczema, and infestations are the most common skin presentations. This study provides a snapshot of skin disorders among children presenting to a tertiary national referral hospital in Uganda. These findings can help inform the expansion of dermatology services, the development of educational programs, and the implementation of preventive measures in lower-level public health facilities, in order to reduce congestion at the national referral hospital skin clinic.

EADV CONGRESS
VIENNA
30 SEP - 3 OCT 2026

Abstract N°: 2640

Necrobiosis Lipoidica in a Diabetic Child: A Rare Pediatric Dermatologic Manifestation Highlighting the Role of Dermoscopy

Nachwa Kayouh*[1], chaouche mohammed[1], Hajar Lahmidi[1], Hanane El Halla[1], sokaina chhiti[1], radia chakiri[1]

[1] Mohamed VI university hospital, dermatology department, AGADIR, Morocco

Introduction

Necrobiosis lipoidica (NL) is a rare chronic granulomatous dermatosis, mainly associated with type 1 diabetes. Its prevalence among diabetic patients is low, and it is exceptionally uncommon in children. Diagnosis relies on clinical, dermoscopic, and histopathological correlation to rule out key differential diagnoses. The disease follows a chronic course, with possible ulceration and, rarely, squamous cell carcinoma in long-standing or ulcerated lesions, requiring close monitoring.

Case Presentation

We report the case of a 14-year-old girl with a 5-year history of type 1 diabetes mellitus, treated with insulin therapy, and a previous episode of diabetic ketoacidosis, who presented with progressive cutaneous lesions of the lower limbs. There was no history of consanguinity or insect bite. The patient was overweight according to age- and sex-adjusted BMI criteria. The lesions had evolved over two years, initially presenting as a pruritic erythematous plaque on the anterior aspect of the right leg, which progressively enlarged despite topical treatment with fusidic acid. Two additional lesions subsequently appeared on the left leg, at intervals of six and one month before consultation. Clinical examination revealed a well-demarcated, infiltrated, round pretibial plaque on the right leg, with an erythematous-violaceous border and a central yellowish-pink, slightly atrophic area. A small central ulceration covered by a yellowish crust was also noted. Two smaller, round erythematous lesions with paler centers were observed on the left leg, corresponding to lesions at different stages of evolution. Dermoscopy of the most advanced lesion showed an orange background, structureless whitish areas, arborizing vessels, a few dotted vessels, superficial scaling, and rosettes. The more recent lesion displayed a pinkish background with less prominent vascular features. Histopathological examination revealed a slightly thinned epidermis and extensive areas of fibrinoid necrobiosis, with eosinophilic, degenerated, and hyalinized collagen surrounded by an epithelioid granulomatous infiltrate rich in histiocytes and lymphocytes. The infiltrate was arranged in perivascular cuffs around vessels with thickened walls and swollen endothelium. These findings supported the diagnosis of NL . Topical corticosteroid therapy was initiated and led to marked clinical improvement within eight weeks.

Conclusion

This case underscores the rarity of NL in childhood and its strong association with diabetes . The coexistence of an older ulcerated plaque and more recent lesions in our patient illustrates the dynamic and polymorphic course of the disease. The presence of overweight status is also noteworthy, as metabolic comorbidities, including obesity, have been described in association with NL. Dermoscopy is a valuable non-invasive diagnostic tool in NL. Characteristic features include a yellow-orange to orange-pink background, structureless whitish areas, and a vascular pattern that may progress from subtle vessels in early lesions to arborizing vessels in more advanced stages. The orange coloration reflects granulomatous infiltration, whereas the white areas correspond to collagen

degeneration. Histopathology remains essential to confirm the diagnosis.

Management of NL remains challenging, with no consistently effective therapy. Inon-ulcerated and asymptomatic cases, simple clinical monitoring may be sufficient. First-line treatment usually relies on potent topical or intralesionnel corticosteroids; however, corticosteroids should be avoided in atrophic areas . Topical tacrolimus may represent a promising alternative. Various systemic therapies, including corticosteroids, dapsone, ciclosporin, antimalarials, and methotrexate, as well as biologics, particularly anti-TNF-α agents, have shown variable efficacy, especially in ulcerated forms. Early recognition of pediatric NL is crucial to guide appropriate management, and prevent complications, particularly ulceration.

EA DV CONGRESS
VIENNA
30 SEP - 3 OCT 2026

Abstract N°: 2784

Stiff Skin Syndrome in a Premature Infant: A Case Report and Literature Review

Nino Beridze*[1], Lela Beridze[2], tea katsitadze[3], Tamara Ebanoidze[4], nato korsantia[5]

[1] Caucasus University, Tbilisi, Georgia
[2] Shota Rustaveli state university, Batumi, Georgia
[3] Health Institute, Tbilisi, Georgia
[4] national center of skin and venerial deseases, Tbilisi, Georgia
[5] tbilisi state medical university, Tbilisi, Georgia

Introduction
Stiff skin syndrome is a rare connective tissue disorder characterized by progressive skin thickening, induration, and limitation of joint mobility. The condition may mimic other neonatal scleroderma-like disorders, making diagnosis particularly challenging in early infancy. Early recognition is essential in order to initiate supportive management and improve functional outcomes. This report presents a clinical case of stiff skin syndrome in a premature infant and reviews its diagnostic and therapeutic considerations.

Case Presentation
We report the case of a male infant born at 33 weeks' gestation with a birth weight of 1900g following spontaneous preterm delivery. The neonatal course included 5 days of incubator support and one month of specialized neonatal care. At one month of age, the infant developed progressive skin shininess, erythema, diffuse induration, and stiffness of the joints associated with decreased mobility. Routine laboratory investigations were within normal limits. Due to the progressive cutaneous manifestations, a skin biopsy was performed to differentiate the condition from other disorders, including Sclerema neonatorum and Subcutaneous fat necrosis of the newborn. Physical examination demonstrated generalized skin hardening and restricted movement of the extremities. Histopathological findings were compatible with stiff skin syndrome. The patient received supportive multidisciplinary management, including thermal care, physiotherapy, massage therapy, and regular application of emollients. Gradual clinical improvement was observed, with reduction of skin induration, improved joint mobility, and achievement of independent walking. At present, the child demonstrates age-appropriate growth and neurodevelopmental progress.

Conclusion
This case highlights the importance of considering stiff skin syndrome in the differential diagnosis of neonatal skin induration disorders. Early diagnosis and supportive multidisciplinary care may significantly improve mobility, functional recovery, and overall prognosis. Increased awareness of this rare condition can facilitate timely recognition and appropriate management.

EA DV CONGRESS
VIENNA
30 SEP - 3 OCT 2026

Abstract N°: 2807

Molluscum Contagiosum: Persistent Burden, Unmet Need, and a Mechanism–Treatment Mismatch Despite Recent Therapeutic Advances

Rich Panico*[1], Sunil S Dhawan[2]

[1] Precefi, Inc., Port Jefferson, United States

[2] Center for Dermatology Clinical Research, Fremont, United States

Introduction

Molluscum contagiosum (MC) is a contagious poxvirus infection caused by molluscum contagiosum virus (MCV; genus *Molluscipoxvirus*). A CDC-authored study reported a historical annual U.S. outpatient visit rate of ~22 per 10,000 persons;[1] with most cases not reaching medical attention, true incidence is considerably higher.[2] MC predominantly affects children aged 1–10 years. In 2023–2024, cantharidin 0.7% (YCANTH) and berdazimer gel 10.3% (Zelsuvmi) received FDA approval as the first dedicated MC therapies. Despite these advances, many cases remain untreated, and the clinical and psychosocial burden persists.[3] Less attention has been paid to how mechanistic limitations of available therapies may themselves shape observed epidemiology and care-seeking behavior.

Materials and Methods

The objective of this abstract is to characterize the persistent unmet need and clinical, psychosocial, and behavioral burden of MC despite recent FDA approvals; evaluate the alignment of current therapies with viral pathophysiology; and examine how therapeutic limitations may shape patient care-seeking.
A targeted review was conducted of epidemiologic data, patient-reported outcomes, and pivotal phase 3 trials of cantharidin 0.7% and berdazimer gel 10.3%.[4,5,6] Outcomes were evaluated alongside mechanism of action, tolerability, and mode of administration. Therapeutic inflection points in onychomycosis and herpes zoster were referenced as comparators.

Results

MC lesions may persist for 8–18 months or longer, with patient-reported duration up to two years in trial populations.[3,6,9] Household transmission rates approach 41%, extending burden across siblings and caregivers.[9] Visible, exposed-area lesions contribute to self-consciousness, activity restriction, and social exclusion in affected children.[6]

Cantharidin demonstrated complete clearance in 46–54% of patients in phase 3 trials but produced local skin reactions in ~97% and requires in-office administration across multiple visits.[4] Berdazimer gel enables at-home application but achieved complete clearance in roughly one-third of patients at 12 weeks.[5]

Mechanistically, MCV replicates exclusively within keratinocytes and employs immune-evasion strategies that limit host clearance. Cantharidin is a vesicant, and berdazimer is a nitric oxide–releasing agent whose mechanism of action in treating MC is unknown. Neither therapy has demonstrated direct, clinically confirmed antiviral activity against MCV.

In a 2009 U.S. survey, 41.6% of healthcare providers selected reassurance that molluscum contagiosum would resolve when asked what advice they would give patients.[7] This parallels dynamics in other dermatologic

conditions prior to consistently effective therapies; in onychomycosis, where approximately half of affected patients historically failed to seek medical advice,[8] oral terbinafine offered improved cure rates and tolerability, repositioning the condition from one largely tolerated without intervention to one actively managed. Analogous inflection points following effective herpes zoster and herpes labialis therapies suggest that observed MC epidemiology may partially reflect treatment-driven care avoidance rather than true disease infrequency.

Conclusions

Despite recent FDA approvals, MC continues to carry substantial clinical and psychosocial burden. The resulting mechanism–treatment mismatch may function not only as a clinical limitation but as a driver of suppressed care-seeking. Current therapies do not consistently achieve complete lesion clearance or meet patient and caregiver needs for tolerability and convenience. Therapies that are both directly antiviral and meaningfully better tolerated may improve clinical outcomes and expand appropriate treatment engagement within a large, underserved patient population.

EA DV CONGRESS
VIENNA
30 SEP - 3 OCT 2026

Abstract N°: 2809

Familial Non-syndromic Aplasia Cutis Congenita Across Three Generations: A Case for Conservative Management

Vittoria Girardi*[1], Samantha Gherbassi[1], Marco Spadafora[1], Silvana Ciardo[1], claudia lasagni[1], Caterina Longo[1]

[1] University of Modena and Reggio Emilia, Modena, Italy

Introduction

Aplasia cutis congenita (ACC) is a rare congenital disorder characterized by localized or extensive absence of the skin at birth, variably involving the epidermis, dermis, subcutaneous tissue, and occasionally bone. Its estimated incidence ranges from 1 to 3 per 10,000 live births, with isolated scalp involvement accounting for most cases. Clinical presentation is highly heterogeneous, ranging from superficial erosions to deep ulcerations. Lesions most commonly affect the scalp, particularly the vertex and parietal regions. Frieden's classification identifies nine clinical subtypes according to lesion distribution, associated abnormalities, and
inheritance pattern. Familial non-syndromic forms are uncommon.

Case Presentation

A full-term female neonate born after an uncomplicated spontaneous pregnancy and delivery presented at birth with multiple ulcerative scalp defects consistent with ACC. Lesions were confined to the scalp, without extracutaneous abnormalities or syndromic associations. There were no clinical signs of involvement of the underlying cranial tissue (Type I ACC according to Frieden's classification). No history of maternal drug exposure or teratogenic risk factors was reported during pregnancy. Family history revealed similar congenital scalp lesions in the patient's father, older sister, and paternal grandmother, supporting a familial autosomal dominant inheritance pattern across three generations. The lesions appeared as multiple well-circumscribed ulcerative defects of variable depth, with a cumulative diameter of 7 cm. Conservative treatment was initiated with daily antisepsis, topical antibiotic therapy, paraffin gauze dressing, and bandaging; topical collagenase was subsequently applied to selected areas. Progressive re-epithelialization was observed, with complete healing achieved after approximately 6 weeks. Post-healing examination revealed smooth alopecic patches. At the initial 6 weeks checkup, dermoscopy showed a lack of follicular openings and prominent vascular structures, findings compatible with ACC sequelae; however, subsequent follow-up at 7 months revealed sparse vellus hair within the healed areas, suggesting partial adnexal preservation. The scalp appeared non-fibrotic, with a satisfactory cosmetic outcome. Cranial imaging, primarily brain MRI or high-resolution ultrasonography, was recommended to rule out underlying structural bone defects or associated intracranial malformations. MRI was declined by patient's parents due to concerns regarding sedation; therefore, a skull radiography was performed and showed no abnormalities.

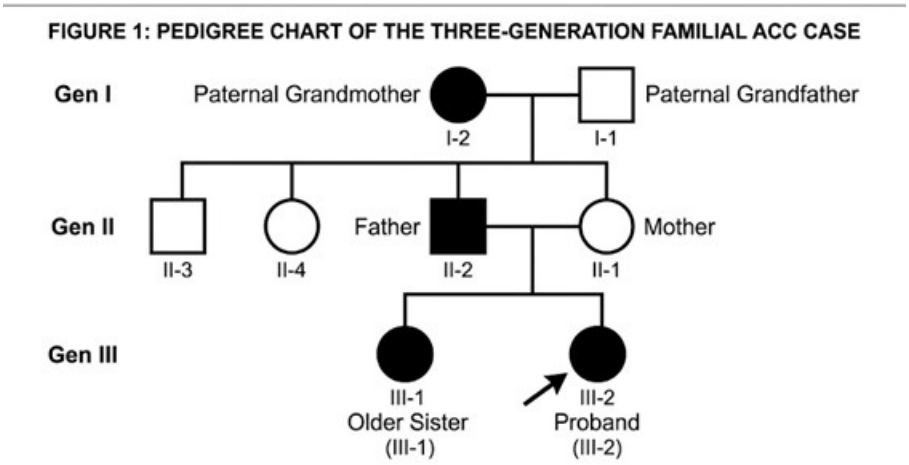

Figure 1. Pedigree chart (NSGC standards)

Conclusion

Familial cases of ACC are infrequently reported; recognition of hereditary patterns is crucial for precise diagnosis, genetic counseling, and tailored clinical management. Differential diagnosis of neonatal scalp lesions should include traumatic, infectious, and syndromic neonatal conditions. Neuroimaging, particularly brain MRI, plays a key role in ruling out deeper involvement, although skull radiography may represent a valid alternative when MRI is not feasible.

We describe a rare familial presentation of multiple scalp ACC involving three generations, with an excellent clinical and cosmetic outcome following conservative management alone. Detailed family history, dermoscopic evaluation, and longitudinal follow-up are crucial for diagnostic accuracy and management planning.

EA DV CONGRESS
VIENNA
30 SEP - 3 OCT 2026

Abstract N°: 2889

Large Congenital Pigmented Epithelioid Melanocytoma in a Newborn: A Case Report

Isadora Rinaldo Scaburi*[1], CRISTIANE GRUBER[1], Laura Serpa[1], GUILHERME FERREIRA ZONTA[1], TAIS GAVA BERSOT[1], Anber Tanaka[1]

[1] Hospital Evangelico Mackenzie, Curitiba, Brazil

Introduction

Pigmented epithelioid melanocytoma (PEM) is a rare melanocytic tumor, described as a distinct entity, intermediate between epithelioid blue nevus and animal-type melanoma. Clinically, it can manifest as an irregular pigmented lesion, frequently mimetizing melanoma. Despite its generally indolent behavior, there is a risk of local recurrence and, occasionally, lymph node involvement, which is why complete resection is mandatory. Congenital cases of PEM are extremely rare, with few reports in the literature. Kikuchi et al. described two congenital cases studied by four-color fluorescent in situ hybridization, confirming the absence of typical melanoma alterations. More recently, molecular studies have identified chromosomal alterations and gene fusions, such as NTRK3-SCAPER, suggesting underlying genetic heterogeneity.

Case Presentation

A female patient, born at term via elective cesarean section, without complications during the gestational period, presented with respiratory distress, requiring nasal CPAP on the first day of life, and was admitted to the neonatal intensive care unit.

At birth, a tumor-like and blue-gray skin lesion was observed on the right shoulder, measuring approximately 7 × 6.5 cm and of softened consistency. The initial suspicion was of venous vascular malformation. Laboratory tests were requested by the pediatric team, which revealed localized intravascular coagulopathy evolving into disseminated intravascular coagulation, with platelet consumption, hypofibrinogenemia, and elevated D-dimer. The patient maintained good general condition and no other clinical changes during hospitalization. After the use of anticoagulation, laboratory monitoring was performed, and the patient was discharged from the hospital for outpatient investigation, during which she maintained adequate weight and height gain and neuropsychomotor development.

The incisional biopsy of the lesion revealed a pigmented epithelioid melanocytoma. Subsequently, the patient underwent complete surgical resection with reconstruction using a latissimus dorsi muscle flap. Given the positivity of the sentinel lymph node, the surgical team opted to perform lymphadenectomy, without specifying the territory in the surgical record.

Although generally benign, PEM can present with local recurrence and, in some cases, lymph node involvement. The treatment of choice is complete surgical excision of the lesion, followed by rigorous clinical follow-up, since the tumor presents with indolent behavior and a low risk of systemic metastases. Although PEM can metastasize to regional lymph nodes, the prognosis remains favorable even in these cases, and therefore, lymphadenectomy should not be routinely performed, and lymph node management should be individualized. The absence of specific guidelines highlights the need for further studies to elucidate the role of lymphadenectomy, especially given the indolent behavior and low risk of systemic progression of PEM.

Conclusion

The management of PEM should prioritize complete surgical excision of the lesion and careful clinical follow-up, considering the generally indolent course and excellent prognosis described in the literature. Lymphadenectomy is not routinely recommended, and lymph node treatment should be individualized.

The initial association with coagulation disorder is not described in the literature on PEM, suggesting that it is a rare clinical coincidence or a possible nonspecific reaction to the tumor. Even so, the case highlights the need for comprehensive investigation and rigorous laboratory monitoring in neonates with extensive congenital skin lesions. The patient remains under regular clinical follow-up, with no evidence of local recurrence or progression to date.

EA DV CONGRESS
VIENNA
30 SEP - 3 OCT 2026

Abstract N°: 2898

Pediatric Cutaneous Mastocytosis: A Single-Center Case Series

Hajar El Hassani Taib*[1], Narjess Er- rachdy[1], Laila Benzekri[1], Nadia Ismaili[1]

[1] Department of Dermatology and Venereology, Ibn Sina University Hospital, Mohammed V University, Rabat, Morocco

Introduction

Cutaneous mastocytosis is a rare disorder characterized by the accumulation of clonal mast cells in the skin, predominantly affecting children. Pediatric forms are usually benign and self-limiting, with spontaneous regression commonly occurring before or during adolescence. Clinical presentations are heterogeneous and include maculopapular cutaneous mastocytosis, solitary mastocytoma, and diffuse cutaneous mastocytosis. Diagnosis is mainly clinical and supported by histopathology and immunohistochemistry, particularly CD117 staining. Although the course is generally favorable, certain clinical features may suggest a higher mast cell burden or a risk of systemic involvement.

In this context, we present a descriptive study of 21 pediatric cases of cutaneous mastocytosis observed over a period of two and a half years, highlighting the clinical variants, diagnostic features, and outcomes, and comparing our findings with the existing literature.

Materials and Methods

We conducted a retrospective and prospective, descriptive, unicentric study over a period of two and a half years, including pediatric patients under 18 years of age with confirmed cutaneous mastocytosis. Diagnosis was based on clinical findings, histopathology, and immunohistochemistry. All patients presented characteristic skin lesions, with systematic assessment of Darier's sign. Skin biopsies revealed dense dermal mast-cell infiltrates with CD117 (KIT) positivity. Serum tryptase levels were measured to assess mast-cell burden, and additional investigations were performed in atypical cases to exclude systemic involvement. Clinical, histological, and laboratory data were obtained from medical records and prospectively collected during patient follow-up.

Results

Over a period of two and a half years, we conducted a descriptive study involving 21 pediatric patients with cutaneous mastocytosis. The cohort included 13 girls and 8 boys, aged from 6 months to 18 years. The mean age at disease onset was 2 years. Clinically, various forms of cutaneous mastocytosis were observed. Five cases of diffuse cutaneous mastocytosis (DCM) were identified, including two bullous forms characterized by spontaneous or inducible blistering.

The majority of patients (16 cases) presented with maculopapular cutaneous mastocytosis (MPCM), the most common clinical form in children. Notably, two MPCM cases exhibited a distinctive "leopard skin" appearance. Darier's sign was positive in all patients, supporting the diagnosis of a mast cell–related dermatosis.

None of the patients showed clinical signs suggestive of systemic mastocytosis. However, some reported symptom exacerbation following the ingestion of certain foods, suggesting a potential role of exogenous triggers. In all cases, the diagnosis was confirmed by histopathological examination of skin biopsies, demonstrating dense

dermal mast-cell infiltrates with diffuse CD117 (KIT) positivity.

Serum tryptase levels were elevated in the majority of patients, reinforcing the mast-cell origin of the disease. Additional investigations to assess systemic involvement, including hematological, biochemical, and imaging studies, revealed no abnormalities, confirming the exclusively cutaneous nature of the disease in our series.

Conclusions

This study highlights the clinical variability of pediatric cutaneous mastocytosis and confirms the predominance of maculopapular cutaneous mastocytosis in early childhood. The presence of atypical forms, such as bullous lesions or “leopard skin” patterns, underscores the need for careful clinical evaluation. Histopathological examination with CD117 staining and serum tryptase measurement remain essential diagnostic tools, although systemic involvement is rare in children.

EADV CONGRESS
VIENNA
30 SEP - 3 OCT 2026

Abstract N°: 2944

Langerhans cell histiocytosis with an atypical presentation: the key role of the dermatologist

assia zenagui*[1], MF Bousouar[1], Latifa abdelmoumen[1], o kouar[1], i mahi[1], B Dahmani[1], C El mezouer[1]

[1] CHU Dr Tidjani Damerdji of Tlemcen, Faculty of Medicine, Tlemcen, Algeria

Introduction
Langerhans cell histiocytosis (LCH) is a rare disorder characterized by the clonal proliferation of Langerhans cells, which may involve multiple organ systems. Multisystem forms are prevalent in children and often present with cutaneous, skeletal, endocrine, and mucosal involvement. Certain atypical presentations can mimic other conditions, particularly inflammatory bowel disease (IBD), representing a significant diagnostic pitfall.

Case Presentation
Observation:

-

A 13-year-old adolescent with a medical history of diabetes insipidus and papillary thyroid carcinoma (status post-thyroidectomy, on replacement therapy) was hospitalized for management of left iliac osteitis.

Clinical examination revealed papulovesicular lesions of the scalp, milia-like aphthosis, macrocheilitis, a cobblestone appearance of the gingival mucosa, hypertrophic gingivitis with dental loosening, and an anal fissure associated with rectal bleeding.

Biological investigations showed an inflammatory syndrome (elevated C-reactive protein and accelerated erythrocyte sedimentation rate) associated with a nutritional deficiency syndrome, including microcytic hypochromic anemia and zinc deficiency. Fecal calprotectin was negative.

Histopathological findings included bone biopsy showing an inflammatory infiltrate rich in neutrophils without granuloma formation, with sterile microbiological culture of the pus. Scalp skin biopsy was consistent with Langerhans cell histiocytosis.

Discussion :

This case illustrates a multisystem form of Langerhans cell histiocytosis involving endocrine, skeletal, and mucocutaneous systems.

The gastrointestinal presentation (anal fissure, rectal bleeding, and oral mucosal involvement) initially suggested an inflammatory bowel disease. However, a clinico-biological discordance allowed this diagnosis to be ruled out.

Skin biopsy, a simple and readily accessible procedure, proved to be the key element in establishing the diagnosis.

Conclusion

Langerhans cell histiocytosis (LCH) should be considered in any atypical clinical presentation involving a combination of cutaneous, mucosal, skeletal, and endocrine manifestations. Misleading presentations, particularly those with gastrointestinal involvement, can significantly delay diagnosis. In these cases, the dermatologist plays a pivotal role, as a skin biopsy remains a rapid, minimally invasive, and decisive diagnostic tool.

EA DV CONGRESS
VIENNA
30 SEP - 3 OCT 2026

Abstract N°: 2946

Inside Pediatric Teledermatology: What 292 Cases Reveal About Real-World Practice

Charbel Skayem*[1], Eden Maradji[1], Romain Samaran[1], Romain Salle[1], Tu-Anh Duong[1]

[1] Hopitaux de Paris, Paris, France

Introduction

For several years, teledermatology (TD) activity has continued to increase in France. TD has demonstrated its usefulness in the management of skin tumors, bacterial infections, and elderly patients, particularly in the context of the declining dermatology workforce in France. The aim of this study was to evaluate the real-world use of TD in a pediatric population.

Case Presentation

This was a retrospective monocentric study including TD consultations for patients younger than 18 years between January 2022 and December 2023. For each TD request, we collected patient demographic data, characteristics of the referring physician, quality of the request, number of exchanges, and the diagnoses proposed by both the referring physician and the dermatologist.

We included 292 TD cases. Among patients, there were 140 girls (48%) with a median age of 7 years (IQR: 2–12 years). Referring physicians included 254 general practitioners (87%), 30 general medicine residents (10%), and 8 pediatricians (3%). The mean number of exchanges was 3.2 (SD ±2.7), with additional clinical information requested in 133 cases (46%) and additional photographs requested in 16 cases (5%). A prescription was issued by the dermatologist in 83 cases (28%), while additional investigations were requested in 45 cases (15%). Fifty-seven patients (20%) were referred for an in-person consultation. Referring physicians proposed a diagnostic hypothesis in 152 cases (52%), of which 99 were confirmed by the dermatologist (65% concordance). The categories of final diagnoses are summarized in Table 1.

Categories	Number of patients, n (%)
Inflammatory dermatoses	82 (28)
Atopic dermatitis	44 (15)
Psoriasis	7 (2)
Tumors	18 (6)
Infectious dermatoses	97 (33)
Bacterial (Impetigo, Ecthyma, Furuncle)	22 (8)
Viral (Chickenpox, Parvovirus B19, Molluscum contagiosum, Wart)	50 (17)
Fungal (Tinea, IIO)	19 (7)
Parasitic (Scabies, Pediculosis)	5 (2)
Prurigo	16 (5)
Alopecia	5 (2)
Pigmentary dermatoses	14 (5)
Non-specific dermatoses	37 (13)
Uncertain diagnosis	13 (4)
Urticaria	10 (3)

Conclusion

Our study shows that the majority of referring physicians were general practitioners, whereas pediatricians made relatively limited use of TD. This is probably related to pediatricians having better dermatological training and lower awareness of tele-expertise networks. Additional clinical information was frequently required for TD requests; however, when good-quality photographs were available, relatively few patients required in-person consultations. Finally, the good diagnostic concordance between referring physicians and dermatologists suggests that many physicians mainly sought diagnostic confirmation and management guidance, even though only one-third of cases required a dermatological prescription. Since most consultations involved common dermatoses (atopic dermatitis, infectious dermatoses) that do not always require specialist expertise, improved training of general practitioners in the diagnosis and management of common pediatric skin diseases could help reduce unnecessary pediatric TD requests within already overloaded tele-expertise networks.

Our study demonstrates that TD is a useful tool in the pediatric population, supporting the management provided by general practitioners.

EADV CONGRESS
VIENNA
30 SEP - 3 OCT 2026

Abstract N°: 2949

Acropustulosis of infancy: diagnostic challenges in two infants with scabies-associated eruptions

Sammar Ali*[1], Catherine Keegan[1], Leonard Timoney[1], Sinead Collins[1]

[1] Department of Dermatology, Our Lady of Lourdes Hospital, Drogheda, Ireland

Introduction

Acropustulosis of infancy is a rare inflammatory dermatosis characterised by a recurrent intensely pruritic acral vesicopustular eruption in young children, occurring most commonly in the first 2 to 3 years of life. Owing to overlapping clinical features, it is often mistaken for scabies, resulting in repeated unnecessary treatment, delayed diagnosis, and significant distress to both the patient and caregiver. Acropustulosis may also occur following scabies infestation, further complicating diagnosis.

We present two infants illustrating the clinical relationships between scabies and acropustulosis of infancy: one initially managed as treatment-resistant scabies, and another in whom acropustulosis emerged following appropriate scabies treatment.

Case Presentation

Case 1. A 17-month-old child was reviewed as an inpatient dermatology consultation for a recurrent intensely pruritic eruption predominantly at the hands and feet, since 6 months of age. Refractory scabies was suspected and further permethrin and oral ivermectin was prescribed.

At 8-week follow-up, persistent acral pustules and excoriations prompted reconsideration of diagnosis. The mother disclosed the child previously received approximately 20 courses of topical therapy for presumed scabies, 13 of which she administered herself due to concern regarding persistent infestation. Household contacts had also undergone repeated treatment, despite being asymptomatic. In addition to treatment prescribed during inpatient review, the child had previously received three courses of oral ivermectin.

The recurrent episodic course, acral predominance, absence of burrows, lack of convincing household transmission, and failure to respond to repeated scabicidal therapy favoured a diagnosis of acropustulosis of infancy. Topical mometasone furoate 0.1% ointment was commenced, resulting in near complete clearance with complete resolution of pruritus and excoriations at 6-week review.

Case 2. A systemically well 7-month-old infant presented with a 3-week history of a vesicular eruption involving the hands, feet, and back. He was treated for presumed hand, foot and mouth disease, with a low index of suspicion for scabies as the family reported household treatment for scabies the year prior. Fusidic acid/betamethasone cream followed by regular emollient therapy resulted in temporary improvement. Bacterial skin swabs were negative.

At 1-month follow-up, recurrence was noted following cessation of topical therapy. Examination demonstrated a burrow on the right foot of the infant, and the caregiver reported pruritus. The infant and household contacts were treated with permethrin cream for scabies simultaneously.

Subsequent review, demonstrated acral pustules without burrows, favouring a diagnosis of acropustulosis of infancy. Topical clobetasone butyrate was prescribed. The acral distribution and clinical evolution following appropriately treated scabies infestation was most consistent with post-scabetic acropustulosis of infancy.

Conclusion

These cases highlight the varied clinical relationship between scabies and acropustulosis of infancy. Acropustulosis may mimic treatment-resistant scabies, resulting in delayed diagnosis and repeated antiscabetic therapy, or may emerge following appropriately treated scabies infestation. Distinguishing features may include recurrent flares of pruritic acral pustules, absence of burrows, lack of household contact involvement, and poor response to appropriate treatment for scabies. Delayed recognition may result in repeated medication exposure, unnecessary ivermectin administration, caregiver anxiety, treatment fatigue, and repeated healthcare burden. It is a clinical diagnosis and should be considered in infants with recurrent intensely pruritic sterile acral pustules despite adequate scabies treatment. Increased awareness of this uncommon condition may facilitate earlier diagnosis and rapid symptomatic improvement with topical corticosteroid therapy.

EA DV CONGRESS
VIENNA
30 SEP - 3 OCT 2026

Abstract N°: 2983

Baboon syndrome secondary to streptococcal infection in a 10-year-old girl.

Najat Chebbawi*[1], Fatima-Zahra Le Fatoiki[1], Hanane Rachadi[1], Bouchra Baghad[1], Fatima zahra Benhayoune[1], Soumiya Chiheb[1]

[1] University Hospital Center Ibn Rochd, Casablanca, Morocco

Introduction

Baboon syndrome is a rare form of flexural erythema. We report a case occurring in the setting of a streptococcal infection.

Materials and Methods

none

Results

A 10-year-old girl presented with a pruritic eruption involving the major flexural areas associated with fever evolving for 4 days, with no history of prior drug intake.

Clinical examination revealed large, well-demarcated, symmetrical erythematous plaques localized to the flexural areas, without mucosal involvement or systemic signs. The remainder of the examination showed erythematous exudative tonsillitis.

The patient reported a similar episode associated with tonsillitis two years earlier, also without any drug exposure. Laboratory investigations during the current episode showed an inflammatory syndrome, and elevated antistreptolysin O (ASO) titers. Skin biopsy revealed a nonspecific inflammatory dermatitis without signs of drug-induced eruption. Patch tests were negative.

A diagnosis of baboon syndrome secondary to streptococcal infection was made. The patient was treated with antibiotics for tonsillitis and emollients for the cutaneous eruption, with good clinical outcome.Baboon syndrome was initially described as being exclusively drug-induced. It is now recognized that it may have multiple etiologies, including contact dermatitis and infectious causes, particularly viral and streptococcal infections.



Conclusions

Clinically, it presents as well-demarcated erythematous lesions symmetrically involving the major flexural areas. In our patient, baboon syndrome was associated with streptococcal infection. The evolution was favorable under symptomatic treatment of the skin eruption combined with appropriate antibiotic therapy for the infection.

EADV CONGRESS
VIENNA
30 SEP - 3 OCT 2026

Abstract N°: 3011

Extensive neonatal panniculitis after ECMO support: a challenging diagnosis

MARIO JUAN PUERTA PEÑA*[1], Emilia García Rivera[1], Eva Chamorro Jiménez[1], Alfonso Gotor Rivera[1], Jorge Arroyo Andrés[1], Alba Calleja Algarra[1], Pablo Luis Ortiz Romero[1], Sara Isabel Palencia Pérez[1]

[1] Hospital Universitario 12 de Octubre, Madrid, Spain

Introduction

Neonatal panniculitis represents a rare and distinctive group of inflammatory disorders of the subcutaneous adipose tissue occurring exclusively in neonates and very young infants. Recognition of these entities is important because they may be associated with severe systemic and metabolic complications.

Case Presentation

We present the case of a 2-month-old full-term female infant transferred to our tertiary care center from Hospital de Salamanca due to severe acute bronchiolitis caused by rhinovirus infection, complicated by refractory respiratory failure requiring veno-arterial ECMO support. Upon transfer, the patient showed hemodynamic instability, edema, delayed capillary refill, hypoglycemia, and stable anemia while on ECMO and norepinephrine support. After improving, ECMO was discontinued and the following day, extensive cutaneous lesions compatible with panniculitis progressively appeared. Dermatologic examination revealed widespread indurated erythematous-violaceous subcutaneous plaques and nodules that coalesced forming a great plaque over the abdomen, groins and arms.

The lesions formed and armor-like distribution without adherence to deeper planes. No progression toward ulceration or systemic inflammatory deterioration was observed.

Given the clinical context differential diagnosis included subcutaneous fat necrosis of the newborn (SCFN), sclerema neonatorum (SN), post-esteroid panniculitis, infectious panniculitis or cold panniculitis. The unusually extensive distribution, minimal inflammatory component and thoracic involvement raised suspicion of SN. However, the patient was full-term, lesions appeared relatively late, and the clinical course was favorable without progression to diffuse skin fixation or systemic deterioration.

Histopathological examination revealed a predominantly lobular panniculitis with extensive fat necrosis and dense mixed inflammatory infiltrates composed of lymphocytes, histiocytes and lipophages. Needle-shaped clefts within adipocytes and histiocytes, corresponding to dissolved triglyceride crystals, were identified, consistent with the characteristic histological pattern of SCFN. No significant septal fibrosis or paucity of inflammation suggestive of SN was observed.

The patient showed progressive spontaneous improvement without evidence of systemic organ involvement or severe metabolic complications. Cutaneous lesions gradually resolved over time with conservative management. The markedly anterior distribution of lesions was interpreted as secondary to prolonged prone positioning during intensive care support.

SCFN is considered the most common panniculitis of the neonate, although diffuse presentations remain exceptional. Hypoxic injury and crystallization of saturated fatty acids within neonatal adipose tissue are believed to play a central pathogenic role. ECMO support, circulatory collapse and prolonged critical illness may further contribute to adipocyte ischemia and tissue injury.

Only isolated cases of panniculitis associated with ECMO have been reported. In our patient, the combination of severe respiratory failure, systemic hypoperfusion and prolonged prone positioning likely contributed to the unusual extensive anterior involvement. The case also highlights the potential clinical overlap between SCFN and SN in critically ill infants, emphasizing the importance of histopathological examination for definitive diagnosis.

Conclusion

We describe an unusual and extensive presentation of SCFN developing after ECMO support in a full-term infant with severe bronchiolitis. Awareness of atypical presentations is essential in critically ill neonates and infants to ensure appropriate monitoring and avoid unnecessary interventions.

EA DV CONGRESS
VIENNA
30 SEP - 3 OCT 2026

Abstract N°: 3117

Assessment of knowledge and training needs in pediatric dermatology among moroccan pediatricians

aouzal mohamed amine*[1], sokaina chhiti[1], Nassma AIT ABDELALI[1], Mortaji Zineb[1], chaouche mohammed[1], radia chakiri[1]

[1] Faculty of Medicine and Pharmacy of Agadir, Ibn Zohr University, Agadir, Morocco, Mohammed VI University Hospital Center of Agadir, agadir, Morocco

Introduction

Skin diseases represent a major reason for pediatric consultations, accounting for more than 30% of consultation motives according to several African and international studies (1) (2). Despite their high prevalence, the initial management of pediatric skin disorders is primarily undertaken by pediatricians, in a setting where specialized training in pediatric dermatology remains insufficient and access to pediatric dermatologists is limited.
This can contribute to significant diagnostic variability and highlights the key role of pediatricians in the early recognition and appropriate referral of dermatologic conditions. In this perspective, a better understanding of current knowledge and clinical practices is essential to guide educational strategies and improve the quality of care. The aim of our study was therefore to assess the level of knowledge among Moroccan pediatricians and identify their main training needs in pediatric dermatology.

Materials and Methods

A descriptive cross-sectional study conducted using a self-administered online questionnaire targeting moroccan pediatricians. A total of 131 pediatricians participated. The questionnaire aimed to evaluate their knowledge, clinical practice, and training expectations in pediatric dermatology.

Results

Among respondents, 64.1% were women and 35.9% were men, with a mean age of 37.8 years (26–70 years). Professional experience levels varied among participants: 6.1% had been practicing for less than one year, 36.6% for 1 to 5 years, 18.3% for 6 to 10 years, 19.8% for 11 to 15 years, and 19.1% for more than 15 years. Regarding practice setting, 38 participants were residents (29.0%), 41 worked in the public sector (31.3%), and 50 practiced in the private sector (38.2%).
A majority of participants (67.2%) had already received training in pediatric dermatology, mainly through seminars (41.2%), university diplomas (40.5%), or practical internships (25.2%), and 95.5% considered this training useful. From a clinical perspective, pediatricians estimated that 5 to 20% of their consultations involved dermatological conditions. Requests for dermatological advice were reported in 5 to 20% of cases for the majority of respondents. Empirical treatment was frequently used, with 48.9% reporting frequent use and 13% very frequent use. Diagnostic confidence remained moderate, with a mean score of 5.36/10.
The most frequently encountered diseases were atopic dermatitis (reported by 93% of respondents), followed by skin infections and vascular malformations. Diagnostic confidence varied considerably according to the condition. It was high for bacterial infections (90.8%), atopic dermatitis (87.8%), and eczema (82.4%). In contrast, it remained low for pigmentary disorders (16%), drug eruptions (15.3%), nail diseases (5.3%), and scalp disorders (4.6%).
Training needs were clearly expressed, with practical workshops being preferred by 71.7% of respondents, followed by multidisciplinary meetings with dermatologists (69.5%) and diploma-based training programs (65.6%). The main barriers encountered in pediatric dermatologic care were treatment costs (67.2%), difficulty

accessing specialized consultation (64.8%), and poor therapeutic adherence (59.5%).

Conclusions

Our study highlights a paradox in which moroccan pediatricians, although frequently exposed to pediatric dermatoses and having received prior training, still report limited diagnostic confidence for certain conditions such as pigmentary disorders, drug eruptions, nail diseases, and scalp disorders. These findings are consistent with international data and emphasize the importance of strengthening practical and collaborative training in order to transform theoretical knowledge into real clinical competence and improve the quality of pediatric dermatologic care.

EADV CONGRESS
VIENNA
30 SEP - 3 OCT 2026

Abstract N°: 3210

Neonatal Digital Necrosis with a Favorable Outcome: Considering Intrauterine Mechanical Compression.

KHAWLA MOUFID*[1], Saadia Boughaleb[1], IKRAME BEJJA[1], Douhi Zakia[1], Meryem Soughi[2], Sara Elloudi[1], Hanane Baybay[1], Fatima Zohra Mernissi[1]

[1] Department of Dermatology, Hassan II University Hospital, FEZ, Morocco
[2] Department of Dermatology, Hassan II University Hospital, Fez, Morocco, FEZ, Morocco

Introduction

Distal ischemic lesions in neonates are rare and may result from thromboembolic events, congenital thrombosis/hypercoagulable states, severe infection, iatrogenic vascular compromise, or intrauterine mechanical factors. Early etiologic assessment is essential to guide management.

Case Presentation

A female neonate from a twin gestation, delivered by cesarean section at an imprecisely determined gestational age, presented on day 1 of life with dry digital necrosis involving the last three toes of the left foot, associated with a serous blister on the second toe, a linear erythematous demarcation surrounding the lesions, and a closed-mesh reticulated livedo pattern.
A complete etiologic work-up was performed. Coagulation tests and thrombophilia screening were negative. Thromboembolic causes were also investigated, including vascular imaging by arterial Doppler ultrasonography of the left lower limb, which showed no abnormalities or arterial occlusion. Maternal screening for autoimmune and systemic diseases was negative. Given these negative findings and the context of twin gestation, an intrauterine mechanical compression mechanism was considered the most plausible etiology. Management was exclusively conservative, consisting of local wound care and warming measures, with progressive healing and preservation of the affected digits.

Conclusion

This case highlights that neonatal distal digital necrosis may have a favorable outcome with conservative management when an extensive etiologic work-up excludes thromboembolic, thrombophilic, infectious, and iatrogenic causes. In the setting of twin gestation, intrauterine mechanical compression should be considered as a plausible diagnosis of exclusion.

EADV CONGRESS
VIENNA
30 SEP - 3 OCT 2026

Abstract N°: 3253

Idiopathic Vulvar Calcinosis Cutis in a Pediatric Patient: A Rare Case Report

Leyla Büşra Öztürkmen*[1], Deniz Yeniay Ökse[1], Gülşen Akoğlu[1]

[1] Gülhane Eğitim Ve Araştırma Hastanesi, Ankara, Türkiye

Introduction

Calcinosis cutis is a condition characterized by the abnormal deposition of calcium salts within the skin and subcutaneous tissues. While scrotal calcinosis is a more frequently reported localized form, vulvar involvement is exceedingly rare. This report describes a pediatric case of idiopathic vulvar calcinosis cutis, highlighting its clinical presentation and the diagnostic necessity of histopathology.

Case Presentation

An 11-year-old girl presented with multiple whitish papules on the mons pubis that had gradually developed over the course of one year. The lesions were asymptomatic. Dermatological examination revealed multiple firm, white-to-yellow papules localized specifically to the mons pubis region.

Due to the unusual clinical presentation, a skin biopsy was performed. The**histopathological examination** demonstrated dermal calcium deposits, confirming the diagnosis of calcinosis cutis. Laboratory investigations ruled out underlying metabolic or systemic disorders, leading to a diagnosis of **idiopathic vulvar calcinosis cutis**.

The management process involved:

- **Initial Treatment:** Monthly curettage using a comedone extractor, which resulted in the partial removal of superficial lesions.
- **Follow-up:** Due to the persistence of deeper lesions and the patient's preference, surgical excision was planned in collaboration with the plastic surgery department.

Conclusion

Vulvar calcinosis cutis is an extremely rare entity, especially in the pediatric population. It should be included in the differential diagnosis when evaluating vulvar papules and nodules. Histopathological confirmation is essential for an accurate diagnosis. Management strategies can range from minimally invasive procedures to surgical excision, depending on the depth and extent of the lesions.

EA DV CONGRESS
VIENNA
30 SEP - 3 OCT 2026

Abstract N°: 3260

Clinical Characterization, Diagnostic and Therapeutic Challenges in Juvenile Localized Scleroderma: A Multicenter Study

Silvia Ojea Varona*[1], Adrián Santiago Lopez Caamaño[1], Catarina Livana Fernández Traba[1], juan manuel ocampo dobalo[1], laura lopez solache[1], alvaro gonzalez gonzalez[2, 2], Benigno Monteagudo Sánchez[1], cristina de las heras sotos[1]

[1] Complejo Hospitalario Universitario Universitario de Ferrol, Ferrol, Spain

[2] Complejo Hospitalario Universitario de A Coruña, A Coruña, Spain

Introduction

Juvenile Localized Scleroderma (JLS) is a multifactorial autoimmune disease characterized by chronic inflammation and progressive fibrosis of the skin and underlying tissues. Typically manifesting in middle childhood (ages 6-9), JLS presents significant clinical variability and high morbidity, with musculoskeletal sequelae occurring in over 40% of cases. This study aims to evaluate the clinical phenotype, diagnostic delays, and therapeutic outcomes in a cohort of pediatric patients.

Materials and Methods

An observational, retrospective multicenter study was conducted over a 10-year period (January 2015 – April 2025). The study included 15 pediatric cases from three Spanish centers: Hospital Virgen del Rocío (Sevilla), CHUAC (A Coruña), and CHUF (Ferrol). Study variables included age of onset, sex, clinical subtype, extracutaneous involvement, and response to systemic treatments.

Results

Demographics: The median age of onset was 10 years (range: 4-14), with a stable demographic phenotype predominantly affecting females (66.7%). Diagnostic Delay: A median diagnostic delay of 12 months was observed. Significantly, 100% of patients diagnosed after 24 months presented with permanent sequelae or functional impotence, compared to 0% in those diagnosed within the first year. Clinical Subtypes: The Linear subtype was the most frequent (47%), followed by circumscribed (27%), pansclerotic (13%), mixed (7%), and generalized (7%). Immunological Profile: 46.7% of patients were positive for Antinuclear Antibodies (ANA), with the highest prevalence in the pansclerotic subtype (100%). Functional Impact: 33% of patients suffered functional impairment, including muscle weakness, joint limitation, and morning headaches in "en coup de sabre" cases. Therapeutic Response: Methotrexate (MTX) was the primary systemic treatment. However, a 40% failure rate was recorded among those who initiated MTX. Adverse effects were reported in 90% of cases. Refractory cases showed promising responses to second-line therapies such as Abatacept, Tofacitinib, and Upadacitinib. Discussion & Complementary ToolsThe study highlights a critical "Window of Opportunity" within the first year of disease to minimize long-term damage. Advanced imaging tools proved vital: Thermography: Showed hyper-uptake in 83.3% of active lesions, detecting "invisible" inflammation. Eco-Doppler: Identified deep inflammation and microvascular activity even in seemingly healthy skin. Capillaroscopy: Remained normal in 85% of cases, serving primarily to rule out systemic sclerosis.

Conclusions

JLS requires early clinical suspicion to prevent irreversible musculoskeletal and functional sequelae. The high failure rate and toxicity of Methotrexate underscore the need to escalate treatment early to biologic agents or JAK

inhibitors in severe or refractory forms. Integrated management using ultrasound and thermography is essential for monitoring subclinical activity and guiding therapeutic adjustments.

EA DV CONGRESS
VIENNA
30 SEP - 3 OCT 2026

Abstract N°: 3268

Bullous pemphigoid in a five-year-old child: a diagnostic challenge in a pediatric patient

Juan Sebastian Sanchez Solarte*[1], Miguel Angel Nieto Bayona[1], Maribel Trujillo Hernandez[2]

[1] Universidad Nacional de Colombia, Bogotá, Colombia
[2] Fundación Hospital de La Misericordia, Bogotá, Colombia

Introduction

Bullous pemphigoid (BP) is an acquired autoimmune subepidermal blistering disease that predominantly affects the elderly. While it is the most common autoimmune blistering disorder in adults, it remains exceptionally rare in the pediatric population, particularly in children older than infants but younger than adolescents. The disease is characterized by autoantibodies against the basement membrane zone antigens BP180 and BP230. In children, BP can present with polymorphic clinical features and histological findings that overlap with other conditions, such as linear IgA bullous dermatosis, making definitive diagnosis a clinical challenge.

Case Presentation

A five-year-old previously healthy male presented with a two-month history of cutaneous lesions that initially appeared as erythematous plaques on the lower limbs before progressing to generalized tense bullae and secondary erosions. The lesions involved approximately 50% of the total body surface area. While mucosal surfaces were spared, lesions were notably present on the palms and soles. Prior to specialized evaluation, the patient was unsuccessfully treated for suspected bullous impetigo and herpes simplex He had also received betamethasone and prednisolone, showing partial improvement followed by immediate relapse upon discontinuation.
Laboratory investigations revealed a massively elevated total serum IgE level of 21,209 UI/ml (normal range: 0–150 UI/ml), while a complete blood count, renal function, and hepatic function tests were within normal limits. Histopathological examination of a skin biopsy demonstrated a subepidermal blister with a mixed fibrino-leukocytic exudate and a marked neutrophilic infiltrate in the papillary and superficial reticular dermis, including microabscesses at the tips of the dermal papillae. Direct immunofluorescence (DIF) was consistent with bullous pemphigoid, showing linear deposition of IgG (++), C3 (++), and IgA (+) along the dermo-epidermal junction. The patient was managed with systemic prednisolone at 1 mg/kg/day, achieving a 90% clinical improvement within days. He was discharged with a tapering corticosteroid regimen

Conclusion

The clinical presentation of bullous pemphigoid in children often differs from the adult form. A hallmark of infantile and childhood BP is the frequent involvement of acral areas, specifically the hands and feet, which is present in almost all reported cases. While adult BP is often associated with neurological diseases or specific drugs, these factors are limited in children, where triggers like vaccinations or infections are occasionally suspected but not fully established

A major diagnostic challenge in this case was the differential diagnosis with linear IgA bullous dermatosis (LBD) (Table 1.). Clinically, the patient exhibited tense bullae in a rosette or ring configuration, and histologically, there was a neutrophil-rich infiltrate, both of which are classic features of LBD. However, the definitive diagnosis of BP was supported by the strong IgG and C3 linear positivity on immunofluorescence and the significant elevation of serum IgE.

The cornerstone of treatment for pediatric BP is corticosteroid therapy, either topical for localized disease or systemic (e.g., prednisolone 1–2 mg/kg/day) for generalized cases. In refractory cases or to minimize steroid-related side effects, second-line or steroid-sparing agents are employed, including dapsone, intravenous immunoglobulins (IVIG), mycophenolate mofetil, and azathioprine. Recent evidence also suggests efficacy for biologics like rituximab, dupilumab and omalizumab in some cases. Despite the potentially severe initial presentation, the overall prognosis for childhood BP is excellent, with most patients achieving rapid and sustained remission.

EA DV CONGRESS
VIENNA
30 SEP - 3 OCT 2026

Abstract N°: 3269

Evaluation of Dermatological Findings in Children and Adolescents with Obesity: A Prospective Cohort Study

Elif Çağla Aydın[1], Merve Demir*[1], Derya Aydın[1], Filiz Gültekin Açıkgöz[2, 2], Mahmut Çamurdan[2], Esra Adışen[1]

[1] Gazi University Faculty of Medicine, Department of Dermatology, Ankara, Türkiye
[2] Gazi University Faculty of Medicine, Department of Paediatric Endocrinology, Ankara, Türkiye

Introduction

Obesity among children and adolescents represents a growing public health concern. Current perspectives define obesity not only as being overweight, but as a multisystem disease impacting nearly all body systems including diverse cutaneous manifestations. Research on the cutaneous findings of obesity in the pediatric and adolescent population remains limited. This study aims to characterize the dermatological findings among children and adolescents with obesity.

Materials and Methods

A prospective cohort study was conducted in dermatology and pediatric endocrinology departments of a tertiary healthcare center, between January and March 2026. Clinical and demographical characteristics, comorbidities, dermatological findings and laboratory parameters were evaluated. Statistical analyses were performed using *IBM SPSS Statistics 31.0.0.0.*

Results

A total of 100 patients, 63 females and 37 males, were included. Patients were divided into three age groups: younger than 10 years (children), 10-14 years (adolescents), and older than 14 years (late adolescents). Clinical and demographical characteristics are presented in ***Table 1***. Dermatological findings are listed in ***Table 2***. Fitzpatrick skin phototypes are demonstrated in ***Figure 1.*** Body mass index (BMI) exhibited a progressive increase with age *($p<0,001$)*, but BMI-standart deviation scores (BMI-SDS) did not vary across age groups*($p=0,123$)*. At least one cutaneous manifestation was present in 94%, occuring more frequently in females (98,4% vs 86,5%, *$p=0,025$*).

The occurrence of skin findings exhibited a progressive increase with advancing age*($p=0,034$)*. Acne vulgaris (AV) demonstrated a threefold higher prevalence in females *($p=0,02$)*. A total of 23 dermatological findings were identified; the most prevalent was striae (39%), followed by acanthosis nigricans (AN) and AV (27%). Striae and AV were more prevalent in late adolescents *($p<0,001$, $p=0,014$)*. Striae, AN, AV, hidradenitis suppurativa (HS), and psoriasis were more prevalent in the insulin-resistant group, although without statistical significance. A family history of obesity was identified in 70%. AN exhibited a nearly threefold increase in patients with a family history *($p=0,012$)*.

Patients were categorized into two groups based on BMI-SDS. 41 patients had a BMI-SDS>3 (severely obese), while 59 patients had a BMI-SDS≤3. Striae, AN and folliculitis were significantly more prevalent in the severly obese group *($p=0,012$, $p=0,007$, $p=0,027$; **Table 3**)*. This group also showed a higher total count of dermatological findings *($p=0,013$)*, positively correlating with BMI-SDS *($p=0,039$, $r=0,206$)*.

Table 1. Clinical and demographical characteristics, and laboratory parameters.

	<10 years (N, %) N=18	10-14 years (N, %) N=28	> 14 years (N, %) N=54
Age (Month)			
• Mean ± SD	94,7 ± 18,8	144,2 ± 14,6	192,5 ± 14,1
• Median (Min – Max)	96,5 (58 – 120)	139,5 (122 – 167)	194,5 (169 – 215)
Gender distribution			
• Female	13 (72,2)	15 (53,6)	35 (64,8)
• Male	5 (27,8)	13 (46,4)	19 (35,2)
BMI* (kg/m^2)			
• Mean ± SD	27,3 ± 6,5	31,7 ± 5,1	35,2 ± 5,3
• Median (Min – Max)	26,6 (20,4 – 50,8)	30,8 (23,2 – 41,3)	34,4 (27,5 – 50,9)
BMI – SDS			
• Mean ± SD	2,8 ± 0,1	2,7 ± 0,1	3,1 ± 0,1
• Median (IQR)	2,7 (2,4 – 3)	2,7 (2,3 – 3,2)	3 (2,5 – 3,7)
Accompanying comorbidities	9 (50)	18 (66,7)	31 (57,4)
Comorbidities			
• Insulin resistance	13 (72,2)	26 (92,9)	46 (85,2)
• Hypothyroidism	1 (5,6)	4 (14,3)	5 (9,3)
• Hypertension	-	2 (7,1)	7 (13)
• Precocious puberty	2 (11,1)	1 (3,6)	1 (1,9)
• Asthyma*	3 (16,7)	5 (17,9)	1(1,9)
• Hepatic steatosis	-	2 (7,1)	4 (7,4)
• Diabetes mellitus type 2	1 (5,6)	-	3 (5,6)
• Familial mediterranean fever	-	1 (3,6)	2 (3,7)
Family history of obesity			
• Present	13 (72,2)	17 (60,7)	40 (74,1)
• Absent	5 (27,8)	11 (39,3)	14 (25,9)
Dermatological findings*			
• Present	15 (83,3)	26 (92,9)	53 (98,1)
• Absent	3 (16,7)	2 (7,1)	1 (1,9)
Laboratory parameters Median (IQR)			
• Fasting plasma glucose (mg/dL)	82,5 (79 – 89,8)	84,5 (81,2 – 89,8)	85,5 (80 – 91)
• Fasting insulin (mU/L)	19,6 (9,6 – 31)	26 (16 – 37,3)	23,2 (14,3 – 32,6)
• HbA1c (%)	5,6 (5,4 – 5,8)	5,5 (5,4 – 5,8)	5,5 (5,3 – 5,6)
• HOMA	3,9 (2,1 – 6,4)	5,5 (3,2 – 8,5)	5,2 (3 – 7,5)
• Total cholesterol (mg/dL)	155,5 (137,5 – 174)	156 (135 – 170)	157 (141 – 181)
• Triglyceride (mg/dL)	102,1 (73,8 – 147,5)	97,3 (74 – 123)	98 (64,7 – 144)
• LDL (mg/dL)	85,5 (74,3 – 109,5)	82 (71 – 97)	88 (71 – 110)
• HDL (mg/dL)	48 (41,8 – 58,3)	49 (39 – 56)	44 (37 – 51)
• TSH (µIU/mL)	2,8 (2,2 – 3,6)	3,2 (2,3 – 4,2)	2,8 (1,8 – 3,9)

* p<0,05, statistically significant.

Table 2. Dermatological findings across age groups.

Dermatological Diagnosis	<10 years (N, %) N=18	10-14 years (N, %) N=28	> 14 years (N, %) N=54
Striae distensae*	-	9 (32,1)	30 (55,6)
Acanthosis nigricans	3 (16,7)	6 (21,4)	18 (33,3)
Acne vulgaris *	2 (11,1)	4 (14,3)	21 (38,9)
Dermatitis	3 (16,7)	4 (14,3)	11 (20,4)
• Seborrheic dermatitis	1 (5,6)	2 (7,1)	10 (18,5)
• Atopic dermatitis	1 (5,6)	-	-
• Contact dermatitis	1 (5,6)	2 (7,1)	1 (1,9)
Folliculitis	1 (5,6)	1 (3,6)	11 (20,4)
Keratosis pilaris	5 (27,8)	3 (10,7)	7 (13)
Pityriasis capitis	-	1 (3,6)	1 (1,9)

Xerosis cutis	-	3 (10,7)	2 (3,7)
Hidradenitis suppurativa	-	-	3 (5,6)
Dermatophytosis • Tinea cruris • Tinea corporis • Tinea pedis	3 (16,7) 2 (11,1) 1 (5,6) -	2 (7,1) 2 (7,1) - -	4 (7,4) 2 (3,7) 1 (1,9) 1 (1,9)
Onychophagia / Onychotillomania	1 (5,6)	3 (10,7)	2 (3,7)
Acrochordon	2 (11,1)	2 (7,1)	1 (1,9)
Hirsutism	-	-	4 (7,4)
Milia / Miliaria	-	2 (7,1)	1 (1,9)
Psoriasis	-	1 (3,6)	1 (1,9)
Pityriasis alba*	2 (11,1)	-	-
Pityriasis versicolor	-	2 (7,1)	-
Pitting	-	1 (3,6)	-
Hypertrichosis	-	1 (3,6)	-
Androgenetic alopecia	-	-	1 (1,9)
Lichen simplex chronicus	-	-	1 (1,9)

* p<0,05, statistically significant.

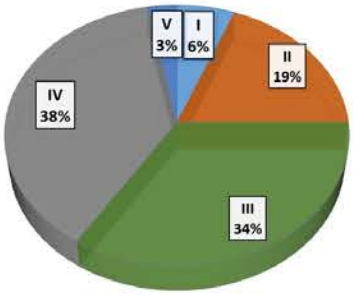

Figure 1. Distribution of Fitzpatrick skin phototypes (I-V).

Table 3. Clinical and demographic characteristics in terms of BMI–SDS.

	Obese patients BMI – SDS≤3, N = 59	Severely obese patients BMI – SDS>3, N = 41	P value
Accompanying comorbidity • Present • Absent	 35 (59,3) 24 (40,7)	 23 (57,5) 17 (42,5)	 0,857
Dermatological diagnosis • Present • Absent	 53 (89,8) 6 (10,2)	 41 (100) -	 0,079
Total number of dermatological findings • Median (Min – Max)	 1 (1 – 2)	 2 (1 – 3)	0,013*
Striae distensae*	17 (28,8)	22 (53,7)	0,012*
Acanthosis nigricans*	10 (16,9)	17 (41,5)	0,007*
Acne vulgaris	16 (27,1)	11 (26,8)	0,974
Dermatitis • Seborrheic dermatitis • Atopic dermatitis • Contact dermatitis	 8 (13,6) 1 (1,7) 3 (5,1)	 5 (12,2) - 1 (2,4)	 0,842 1 0,642
Folliculitis	4 (6,8)	9 (22)	0,027*
Keratosis pilaris	9 (15,3)	6 (14,6)	0,932
Pityriasis capitis	1 (1,7)	1 (2,4)	1
Xerosis cutis	3 (5,1)	2 (4,9)	1
Hidradenitis suppurativa	-	3 (7,3)	0,066
Dermatophytosis • Tinea cruris • Tinea corporis • Tinea pedis	 2 (3,4) 1 (1,7) -	 4 (9,8) 1 (2,4) 1 (2,4)	0,336
Onychophagia / Onychotillomania	3 (5,1)	3 (7,3)	0,687
Acrochordon	3 (5,1)	2 (4,9)	1
Hirsutism	3 (5,1)	1 (2,4)	0,642
Milia / Miliaria	3 (5,1)	-	0,267
Psoriasis	-	2 (4,9)	0,166
Pityriasis alba*	1 (1,7)	1 (2,4)	1
Pityriasis versicolor	2 (3,4)	-	0,511

* p<0,05, statistically significant.

Conclusions

In our study, the age-related progression of BMI underscores the cumulative lifelong burden of obesity. The increasing prevalance of dermatological findings with advancing age may be attributed to an escalating inflammatory load, possibly exacerbated by obesity. The presence of chronic inflammatory dermatoses, such as atopic dermatitis, psoriasis, and HS, emphasizes the significant interplay between obesity and these inflammatory conditions. In late adolescents, higher frequency of striae, likely due to increased skin stretching, emphasizes the need for preventive strategies in pre-adolescents. The approximately threefold increase in AV prevalence during late adolescence may be attributed to augmented hormonal stimulation. The strong association between AN and a family history of obesity, identifies AN as an early cutaneous marker of familial metabolic risk.

The prospective design of our study, along with the comprehensive dermatological examination and detailed clinical profiling, are among its strengths. The relatively small sample size remains a limitation. Our cohort presents a diverse spectrum of dermatological conditions, with remarkable differences across age groups. Considering the increasing importance of obesity, particularly in the pediatric population, our study provides valuable insights. Further, multicenter studies are needed to decrease the dermatological burden of obesity.

EADV CONGRESS
VIENNA
30 SEP - 3 OCT 2026

Abstract N°: 3324

Bullous eruptions in Henoch–Schönlein syndrome in children : an atypical presentation

Zineb Aqasbi Ouahi*[1], Meryem Soughi[1, 1], ikrame bejja[1], Saadia Boughaleb[1], Zakia Douhi[1], Sara Elloudi[1], Hanane Baybay[1], Fatima Zohra Mernissi[1]

[1] Department of Dermatology, Hassan II University Hospital, Fez, Morocco

Introduction

Henoch–Schönlein purpura (HSP) is the most common systemic vasculitis in children, primarily affecting the skin, joints, gastrointestinal tract, and kidneys. It typically presents with palpable purpura involving the lower limbs and buttocks. More rarely, hemorrhagic bullous lesions may occur, representing an uncommon and potentially misleading presentation in children (<2% of cases). Because of its polymorphic clinical presentation, bullous HSP may mimic infectious, autoimmune, genetic, or traumatic bullous dermatoses, making diagnosis challenging. We report a rare case of bullous HSP in a child.

Case Presentation

A 6-year-old boy presented with a five-day history of abdominal pain and diffuse arthralgia involving the large joints, preceded by a flu-like syndrome. Dermatological examination revealed palpable purpura associated with hemorrhagic bullae and vesicles, located on both legs, feet, forearms, and the earlobe, with sparing of the buttocks, trunk, face, and palms. Laboratory investigations showed a normal complete blood count, elevated CRP at 22 mg/dL, preserved renal function with positive proteinuria and microscopic hematuria. Immunological and inflammatory workup (IgG, IgA, IgM, ANA, ANCA-P, ANCA-C, C3, and C4) was within normal limits. Abdominal ultrasound excluded intussusception, while abdominal CT scan demonstrated mild bowel wall thickening consistent with gastrointestinal involvement in the context of the disease. Skin biopsy performed on the third day of hospitalization revealed leukocytoclastic vasculitis involving both the superficial and deep dermis. Direct immunofluorescence did not show IgA deposition in the vessel walls. Based on the clinical, biological, and histological findings, a diagnosis of bullous HSP was established. The patient was treated with intravenous corticosteroids followed by an oral taper, along with symptomatic therapy, resulting in a favorable clinical and biological outcome.

Conclusion

Bullous forms of HSP are rare in children and may pose a diagnostic challenge because of their atypical and polymorphic presentation. This case highlights the importance of considering this entity in childhood bullous dermatoses associated with systemic symptoms in order to establish an early diagnosis and initiate appropriate management. Despite the absence of therapeutic consensus, corticosteroid therapy may provide rapid symptomatic improvement and favorable outcomes in selected cases.

EA DV CONGRESS
VIENNA
30 SEP - 3 OCT 2026

Abstract N°: 3338

Concurrent Psoriasis and Vitiligo in a Child: A Case Report

Dzhemile Dervish*[1], Jana Kazandjieva[1], Vera Traykova[1], Vanina Gabrovska[2], Kalin Lisichki[2]

[1] Group Dermatology and Venerology Practice, EuroDerma Clinic, Sofia, Bulgaria
[2] Acıbadem City Clinic Tokuda Hospital, Sofia, Bulgaria

Introduction

Pediatric psoriasis is a chronic immune-mediated inflammatory disease that may be associated with musculoskeletal manifestations and the development of psoriatic arthritis, significantly impairing quality of life. The coexistence of psoriasis and vitiligo in children is uncommon and raises questions regarding shared immunopathogenic pathways, therapeutic selection, and the potential role of biologic agents in triggering depigmentary disorders.

Case Presentation

We present the case of a 8-year-old girl with chronic plaque psoriasis associated with persistent arthralgia predominantly involving the knee joints, raising suspicion for juvenile psoriatic arthritis. Considering the musculoskeletal involvement and the availability of biologic therapy for children older than 6 years in our country, treatment with adalimumab was initiated. During the course of therapy the patient developed multiple depigmented macules localized both on pre-existing psoriatic plaques on the trunk and back and on previously uninvolved skin, including the face and axillary regions.

Due to the lack of satisfactory clinical improvement in both cutaneous and joint manifestations, a multidisciplinary therapeutic reassessment was conducted in collaboration with pediatric rheumatologists. Treatment was subsequently switched to secukinumab at a dose of 75 mg monthly, with close dermatologic and rheumatologic follow-up.

Following initiation of secukinumab therapy, the patient demonstrated marked clinical improvement of psoriatic skin lesions together with complete resolution of joint symptoms. Concurrently, the vitiliginous lesions showed progressive repigmentation characterized by perifollicular pigmented islands, a finding consistent with vitiligo regression.

Conclusion

The coexistence of psoriasis and vitiligo remains uncommon. A systematic review and meta-analysis demonstrated significantly increased odds of vitiligo in patients with psoriasis and psoriasis in patients with vitiligo, supporting the hypothesis of shared autoimmune pathways involving Th1- and Th17-mediated inflammation.

The development of vitiligo during adalimumab therapy raises the possibility of a paradoxical autoimmune phenomenon induced by TNF-α inhibition and has been increasingly reported in the literature. TNF-α blockade may alter melanocyte homeostasis and dysregulate interferon-driven immune pathways, potentially precipitating autoimmune melanocyte destruction in genetically predisposed individuals.

Several reports suggest that IL-17 inhibition with secukinumab may be associated with stabilization or

repigmentation of vitiligo lesions. Progressive perifollicular repigmentation during ongoing secukinumab therapy has been described in patients with psoriatic arthritis and extensive vitiligo, suggesting a possible modulatory role of IL-17 blockade on melanocyte recovery.

Resolution of adalimumab-associated vitiligo after switching to secukinumab has also been reported, supporting the hypothesis that IL-17 inhibition may contribute to improvement of both psoriasis and depigmentary disease in selected patients.

The differential diagnosis of post-inflammatory hypopigmentation was carefully considered but deemed less likely. The appearance of depigmented lesions in areas without previous psoriasis involvement, particularly the face and axillae, argues against a purely post-inflammatory process. The localization of vitiliginous lesions over psoriatic plaques on the trunk may represent an example of Wolf’s isotopic response.

The concurrent occurrence of psoriasis, joint involvement, and vitiligo in childhood represents a diagnostic and therapeutic challenge. Biologic therapy may be associated not only with disease control but also with paradoxical autoimmune manifestations. This case demonstrates successful control of cutaneous and musculoskeletal symptoms together with repigmentation of vitiligo lesions following transition to IL-17 inhibition, underscoring the importance of an individualized multidisciplinary approach.

EA DV CONGRESS
VIENNA
30 SEP - 3 OCT 2026

Abstract N°: 3372

Pediatric Primary Scarring Alopecia: A Scoping Review

Khanh Linh Tran*[1], Kimia Ameri[1], Kim Tran[2], Jeff Donovan[3, 4]

[1] University of British Columbia, Vancouver, Canada

[2] University of Alberta, Edmonton, Canada

[3] University of British Columbia, Faculty of Medicine, Department of Dermatology, Vancouver, Canada

[4] Donovan Hair Clinic, Whistler, Canada

Introduction

Primary scarring alopecia (PSA) in children and adolescence is a rare inflammatory disorder characterized by permanent follicular destruction and irreversible hair loss, often with significant psychological impact. Evidence guiding diagnosis and management remains limited for this condition, particular in the pediatric population. We performed a scoping review to characterize the clinical features, diagnostic approaches, treatments, and outcomes of pediatric PSA.

Materials and Methods

Based on the PRISMA-ScR guidelines, a systematic search of Ovid MEDLINE, Embase, Web of Science, PubMed and CENTRAL was performed from inception to February 26, 2026 for published studies involving patients ≤17 years with PSA.

Results

Overall, 41 studies, comprising 71 patients were included (mean age 11.3±4.0 years, range 2–17; 2:1 male:female ratio). The most commonly reported scarring alopecias in this population were dissecting cellulitis of the scalp (DSC) followed by lichen planopilaris (LPP), central centrifugal cicatricial alopecia (CCCA), pseudopelade and discoid lupus erythematous (DLE). A biopsy was performed in 56/71 (78.9%) of PSAs whereas trichoscopic findings were reported for 26/71 (36.6%) of patients.

DCS was the most reported PSA (24/71 patients, 33.8%). Trichoscopy was reported in one-third of patients (7/24, 29.2%) and over one-half underwent biopsy as part of the diagnostic workup (13/24, 54.2%). Commonly reported trichoscopic features included yellow dots, black dots, and erythema Treatments for DCS included antibiotics, corticosteroid, and isotretinoin. Over two-thirds of patients achieved partial or complete remission (20/24, 83.3%), with few patients reporting recurrence after treatment (4/24, 16.7%)

LPP was the second most commonly reported PSA (20/71 patients, 28.2%). Although trichoscopic examination findings were reported in a one-quarter (5/20, 25%), most patients received a biopsy as part of the diagnostic work up (17/20, 85%). Almost all patients received corticosteroids (19/20, 95%), and approximately half of the patients were treated with topical minoxidil (6/20, 30%) and immunosuppressants (8/20, 40%). Compared to DCS, outcomes for LPP treatment were more modest as just over half of patients reported partial or complete remission (12/20, 60%), although there was no recurrence in the few patients who were followed up (4/20, 20%).

Other subtypes of reported PSA in this population were CCCA (5/71 patients, 7.0%), pseudopelade (3/71 patients, 4.2%), DLE (2/71 patients, 2.8%), folliculitis decalvans (4/71 patients, 5.6%), and folliculitis decalvans and lichen planopilaris phenotypic spectrum (FDLPPPS) (13/71, 18.3%). Histology was completed in all patients, whereas

trichoscopy was only reported only for patients with FDLPPPS (13/13, 100%) and pseudopelade (3/3, 100%). Disease duration varied greatly between the various types of PSA, from just over half a year for patients with DLE, to 6 years for patients with FDLPPPS.

Common adverse events for patients receiving treatment for DCS and LPP were gastroinestinal upset and pain, whereas adverse event data was not reported for the remaining conditions. Although hair loss is well known to carry a significant psychosocial burden, there was a lack of reporting in pediatric studies in our review. Only 3 studies reported that patients with PSA felt embarrassed in public and that the condition affected their daily functioning. Only 1 study used the Dermatology Life Quality Index to show the improvement in quality of life after treatment.

Conclusions

These findings suggest the heterogeneity in PSA subtype-dependent disease behavior, and varied responses to treatment. Future randomized longitudinal studies involving standardized diagnostic criteria and outcomes could be beneficial for pediatric PSA patient care. There is need to study tricshcopy in pediatric patients as the low reporting may reflect the knowledge and skills of trichoscopy as well as a need to better evaluate the psychosocial impact of these disease.

EADV CONGRESS
VIENNA
30 SEP - 3 OCT 2026

Abstract N°: 3401

Dermoscopy patterns of acral melanocytic nevi in pediatric patients: a cross-sectional study

Valeria Noemi Rizo Hernández*[1], Rocío Concepción Albores Arguijo[1], Diego Rodriguez Mendoza[1], Laura Sifuentes [1], Yocelin Nallely Lozano Figueroa[1]

[1] Department of Pediatric Dermatology, Antiguo Hospital Civil de Guadalajara Fray Antonio Alcalde, Guadalajara, Mexico

Introduction
Acral melanocytic nevi in pediatric patients represent a diagnostic challenge due to the unique anatomical features of palmoplantar skin and the variability of dermoscopic patterns. Most available data derive from adult or mixed populations, with limited studies focused exclusively on children, particularly in Latin American population. A better understanding of dermoscopic patterns in pediatric acral nevi is essential to improve diagnostic accuracy and avoid unnecessary invasive procedures.

Materials and Methods
A cross-sectional, observational, descriptive study was conducted, including 106 acral melanocytic nevi in patients aged 0–18 years evaluated during 2025. Epidemiological variables (age, sex), clinical characteristics (skin phototype, lesion topography, color, size, and duration), and dermoscopic patterns (main and multicomponent patterns) were recorded. Descriptive statistical analysis performed use frequencies, percentages, and measures of central tendency. This study was approved by the Antiguo Hospital Civil de Guadalajara Fray Antonio Alcalde committee (CEI 185/25).

Results
A total of 106 acral nevi were analyzed, with a predominance in boys (61.3%) and a mean age of 10.3 ± SD 4.0 years. The most frequent age groups were school-aged children (40.6%) and adolescents (43.3%). Phototype IV was the most common (60.4%).

The most prevalent dermoscopic pattern was the parallel furrow pattern (35.8%), followed by the lattice-like pattern (23.6%), together accounting for nearly 60% of cases. Other observed patterns included fibrillar (11.3%), transitional (10.4%), reticular (6.6%), ridge globular (5.7%), and globular (3.8%). Multicomponent patterns were identified in 43.4% of lesions.

The most frequent location was the digital region (30.2%), followed by transition areas (20.8%). Light brown was the predominant color (52.8%), and most nevi (67.9%) had a duration longer than 12 months.

Conclusions
In this pediatric study, acral melanocytic nevi showed a predominance of benign dermoscopic patterns, particularly the parallel furrow and lattice patterns. Multicomponent patterns frequently occurred and may reflect variability in dermoscopic presentation in pediatric acral nevi. These findings reinforce the value of dermoscopy as a key non-invasive tool for the evaluation and follow-up of acral nevi in pediatric patients, contributing to safer

clinical decision-making and reducing unnecessary procedures. Further studies in pediatric populations are needed to better characterize dermoscopic patterns across different ethnic groups. These findings may serve as a basis for future longitudinal studies on nevogenesis.

EADV CONGRESS
VIENNA
30 SEP - 3 OCT 2026

Abstract N°: 3413

A small midline punctum with deeper implications: Nasal dermoid sinus cyst in a 12-year-old boy

Anishka Gopinath*[1]

[1] yenepoya medical college, mangalore, karnataka, india, mangalore, India

Introduction

Congenital midline nasal lesions may appear clinically innocuous, yet some conceal a dermal sinus tract with potential intraosseous or intracranial extension. Nasal dermoid sinus cysts are uncommon developmental anomalies and are easily overlooked when they present only as a tiny persistent punctum with intermittent discharge. Recognition is important, as incomplete evaluation or inappropriate intervention may expose the child to serious infective complications.

Case Presentation

A 12-year-old boy presented with a “small hole” over the upper nasal dorsum, noticed soon after birth and persisting without significant increase in size. The lesion was associated with intermittent scant mucoid to mucopurulent discharge, more frequent during episodes of upper respiratory tract infection and allergic rhinitis. There was no history of enlarging swelling on crying or straining, headache, seizures, visual symptoms, recurrent meningitis, or previous severe infection. Examination revealed a solitary pin-point punctum over the midline upper nasal dorsum, just inferior to the glabella, with normal surrounding skin and no tuft of hair, swelling, tenderness, or expressible discharge at presentation. The lesion was non-transilluminant and showed no change with Valsalva manoeuvre. Anterior rhinoscopy and neurological examination were unremarkable.

High-resolution ultrasonography demonstrated a small well-defined hypoechoic tract extending from the cutaneous opening into the superficial subcutaneous tissue overlying the nasal bones, without obvious deeper extension or internal vascularity. A clinical diagnosis of nasal dermoid sinus cyst was considered. MRI was advised to define the complete tract and exclude intracranial communication; CT was discussed for evaluation of bony involvement. However, the parents declined further imaging because of financial constraints and concerns regarding sedation. Complete surgical excision after appropriate radiological delineation was recommended, but the family also deferred surgery. No probing, biopsy, or curettage was attempted. After detailed counselling regarding the risk of occult extension, infection, meningitis, and intracranial abscess, the child was placed on structured follow-up with clear red-flag advice.

Conclusion

This case underscores how a subtle midline nasal punctum may represent a clinically significant congenital sinus tract rather than a trivial cutaneous finding. It also highlights a practical challenge frequently encountered in real-world care: managing potentially high-risk congenital lesions when definitive imaging and surgery are declined. For dermatologists, early suspicion, avoidance of blind instrumentation, appropriate referral, careful documentation of informed refusal, and long-term surveillance are essential. The case is relevant because timely recognition of a small external clue may prevent delayed diagnosis of a lesion with potentially serious deeper consequences.

EA DV CONGRESS
VIENNA
30 SEP - 3 OCT 2026

Abstract N°: 3418

Bullous Pemphigoid in Early Infancy: Diagnostic Investigation and Therapeutic Management in a Case Report

Elisa Nunes Secamilli*[1], Marcio Antonio Haro Adad[2], Raquel Brasil de Souza Matos[3], Adriana Schikiera Martinelli Salathiel[1]

[1] Universidade Estadual de Campinas, Campinas, Brazil
[2] Clinica Adad, Campinas, Brazil
[3] Centro Médico de Campinas, Campinas, Brazil

Case Presentation

We report a case of a 3-month-old boy who presented to our outpatient clinic with a history of tense bullae on the feet that began at 2 months of age, 3 days after vaccination. Since then, the bullae had progressed to involve up to 90% of the body surface area. Histopathological examination showed a subepidermal split with eosinophilic infiltrate. Direct and indirect immunofluorescence were requested but, due to a laboratory error, were not performed. Infantile bullous pemphigoid was diagnosed, possibly triggered by vaccination.

Additional laboratory investigation revealed marked eosinophilia (26,758/mm^3), reduced immunoglobulin levels (IgM 44 mg/dL, IgA 4 mg/dL, IgG190mg/dL IgE 6 IU/mL), and low CD8 count (434 cells/mm^3). The patient was started on prednisolone 2 mg/kg/day for 1 month, with no clinical improvement. Intravenous immunoglobulin (2 g/kg) was then administered, also without improvement, followed 7 days later by dapsone 2 mg/kg/day. After 10 days, due to the severity of the bullous eruption, the patient was admitted to the pediatric intensive care unit (ICU). Methylprednisolone pulse therapy (10 mg/kg/day for 3 days) was administered, but new lesions continued to appear.

As the patient was already 5 months old, off-label treatment with dupilumab 200 mg monthly was initiated. Lesions began to resolve, and the patient was discharged from the ICU. No new lesions appeared after initiation of dupilumab, and the patient has remained free of bullae for 3 months. Prednisolone has been tapered to 1 mg/kg/day and is still being gradually reduced. Whole-exome sequencing did not identify mutations associated with immunodeficiency, and peripheral eosinophilia normalized (84/mm^3).

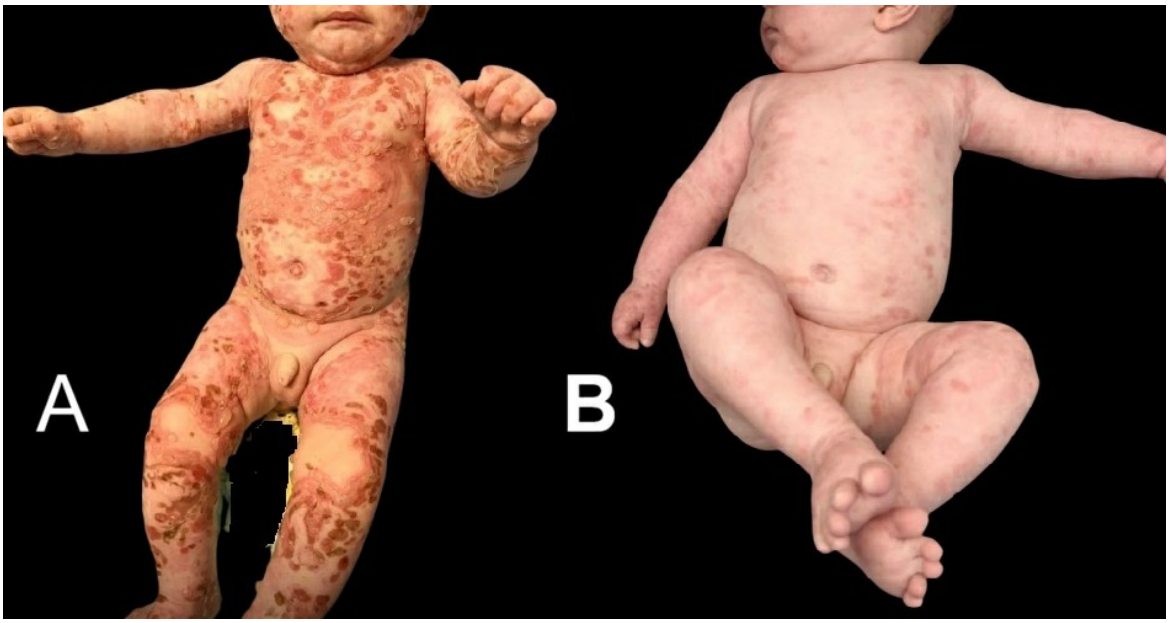

A. Multiple tense bullae in up to 90% of body surface area. B. Resolution of lesions after dupilumab therapy.

Conclusion

Bullous Pemphigoid (BP) is an autoimmune blistering disease that predominantly affects elderly patients, whereas its occurrence in infancy is rare. It is characterized by circulating autoantibodies directed against hemidesmosomal proteins, mainly BP180 and BP230. BP is associated with type 2 inflammation, with upregulation of interleukins 4, 5, and 13, as well as eosinophil recruitment.

In infants, vaccination may act as a triggering factor. There are reports of treatment-refractory infantile BP associated with immunodeficiency, which should always be investigated in this age group. The main differential diagnosis is Linear IgA Bullous Dermatosis.

Infantile BP generally has a more favorable clinical course than adult disease, with better response to treatment and remission usually occurring within the first year after treatment initiation.

A French guideline for autoimmune blistering diseases in children recommends the use of topical corticosteroids for localized disease. In disseminated disease, prednisolone at doses of 0.5–2 mg/kg/day may be used and maintained until 2 weeks after disease control is achieved. If necessary, immunosuppressive agents such as methotrexate and mycophenolate mofetil, as well as intravenous immunoglobulin, may also be considered.

Currently, all biologic agents are considered off-label for BP in infancy, including dupilumab, rituximab, and omalizumab, However, dupilumab is approved for the treatment of atopic dermatitis in children older than 6 months, with a favorable safety profile. In addition, dupilumab has demonstrated efficacy in adults with BP refractory to conventional therapies.

Our patient was refractory to oral and intravenous corticosteroids as well as intravenous immunoglobulin, but achieved excellent disease control with dupilumab. Although an underlying immunodeficiency was initially suspected, whole-exome sequencing did not identify pathogenic variants associated with immunodeficiency, and this is yet to be confirmed.

Dupilumab may represent a therapeutic option for severe infantile BP, including in patients with suspected immunodeficiency, without apparent safety concerns. Nevertheless, further studies are needed to better establish its safety and efficacy in this population.

EADV CONGRESS
VIENNA
30 SEP - 3 OCT 2026

Abstract N°: 3491

Spectacular Response of Pediatric Palmar Scabies to Oral Ivermectin and Antibiotherapy: A Case Report

sbai khadija*[1], Cheab Aicha[1], bouchra baghad[1], hanane rachadi[1], soumiya chiheb[1]

[1] Ibn Rochd University Hospital Center, casablanca, Morocco

Introduction
cabies is a highly contagious parasitic dermatosis caused by *Sarcoptes scabiei var. hominis*. In children, clinical presentation may be atypical and frequently involves the palms and soles, with vesiculo-pustular lesions and intense nocturnal pruritus. Secondary bacterial superinfection due to scratching is common and may complicate management. Oral ivermectin has emerged as an effective therapeutic option in pediatric scabies, particularly in extensive, difficult-to-treat, or complicated forms.

Case Presentation
We report the case of a 13-year-old child with no significant medical history who presented with a pruritic eruption of the palms evolving for two weeks.

Clinical history revealed intense nocturnal pruritus associated with similar symptoms among family members. No systemic symptoms were reported.

Dermatological examination showed erythematous palmar vesiculo-pustules associated with excoriated lesions secondary to scratching.

Dermoscopy was performed and aimed at identifying the “delta-wing sign,” highly suggestive of scabies infestation.

Based on clinical, epidemiological, and dermoscopic findings, the diagnosis of pediatric scabies was retained.

The patient received oral ivermectin at a weight-adapted dose with one administration on day 1 and a second dose on day 8. Treatment was associated with antihistamines, local skin care, and systemic antibiotherapy because of suspected bacterial superinfection.

Family members were treated simultaneously, and environmental decontamination measures including disinfection of clothes, bedding, and linens were implemented. Nail trimming and limitation of scratching were also recommended.

Clinical evolution was remarkable, with rapid regression of pruritus and significant improvement of cutaneous lesions after treatment. The combination of oral ivermectin and antibiotherapy resulted in a spectacular clinical response without complications.

Conclusion
Scabies remains a frequent public health issue in children and may present with misleading clinical manifestations. Palmar vesiculo-pustular lesions associated with nocturnal pruritus and familial involvement are highly suggestive of pediatric scabies.

Dermoscopy is a valuable noninvasive diagnostic tool, allowing visualization of the characteristic “delta-wing

sign," corresponding to the anterior part of the mite.

Oral ivermectin has demonstrated excellent efficacy and tolerability in pediatric scabies, especially in extensive or complicated forms and in situations where topical treatments are difficult to apply. In our patient, the association of ivermectin with antibiotherapy led to rapid symptom resolution and marked clinical improvement.

This observation highlights the importance of early recognition of pediatric scabies and supports the effectiveness of oral ivermectin combined with appropriate management of secondary bacterial infection.

EA DV CONGRESS
VIENNA
30 SEP - 3 OCT 2026

Abstract N°: 3493

Beyond the Acute Illness: Lived Experiences of Paediatric Survivors of Severe Mucocutaneous Eruptions and Their Caregivers

Kate Dear*[1, 2], Amanda Timler[1], Bernadette Ricciardo[1], Michaela Lucas[1, 3], Stephanie Weston[1]

[1] Perth Children's Hospital, Perth, Australia

[2] Chelsea and Westminster Hospital, London, United Kingdom

[3] University of Western Australia, Perth, Australia

Introduction

Severe mucocutaneous eruptions in children encompass Stevens-Johnson syndrome (SJS), toxic epidermal necrolysis (TEN), and reactive infectious mucocutaneous eruption (RIME). Increasing evidence demonstrates substantial long-term physical and psychological morbidity in adult survivors of SJS/TEN, but few studies have been conducted in children. The experiences of those with RIME, which is thought to have a more favourable prognosis than SJS/TEN, has been studied even less. The objectives of this study were to explore the lived experiences, psychological impact and long-term sequelae among survivors of paediatric SJS/TEN and RIME and their caregivers.

Materials and Methods

A qualitative study using semi-structured interviews was conducted with child and young adult survivors of SJS/TEN and RIME and their caregivers, recruited from a tertiary paediatric centre. Interviews were audio-recorded, transcribed verbatim and analysed using reflexive thematic analysis.

Results

Seventeen child/young adult-caregiver dyads were included, comprising 14 participants with RIME, and 3 with SJS secondary to a drug trigger. The age range of children and young adults interviewed was 5 - 21 years with 53% female and 47% male participants. All participants were under the age of 18 when they experienced the acute illness. The average duration of time between acute illness and interview was 15 months (range 6 - 76 months). Four overarching themes were identified. First, children described acute illness, rapid clinical deterioration and hospitalisation as highly traumatic, with pain, disruption to eating and drinking and distressing medical procedures recalled most clearly. Second, caregivers frequently described feeling dismissed, uncertain and responsible, with several describing the perceived need to advocate for their child, frustration regarding lack of diagnostic clarity, and guilt associated with delayed help-seeking. Third, both children and caregivers described persistent fear and hypervigilance following illness, including anxiety regarding future infections, medications and healthcare encounters. Finally, participants described enduring impacts on daily life, including ongoing medical care at home as well as medication burden, disruption to education, and persistent physical and psychological sequelae. Notably, substantial morbidity was reported across both RIME and SJS survivors despite assumptions that RIME carries a more favourable prognosis.

Conclusions

Paediatric SJS/TEN and RIME are associated with traumatic and distressing acute hospital experiences, and significant long-term functional and psychological sequelae extending well beyond the acute illness phase. To our knowledge, this is the first qualitative study exploring the lived experiences of patients with RIME and their caregivers. These findings challenge assumptions that RIME represents a comparatively benign condition and highlight the need for multidisciplinary long-term follow-up and psychological support for all affected children and families.

EADV CONGRESS
VIENNA
30 SEP - 3 OCT 2026

Abstract N°: 3510

Severe mucocutaneous eruptions in children: A tertiary paediatric centre experience over the last decade

Kate Dear*[1, 2], Mudra Shah[1], Bernadette Ricciardo[1], Michaela Lucas[1, 3], Stephanie Weston[1]

[1] Perth Children's Hospital, Perth, Australia
[2] Chelsea and Westminster Hospital, London, United Kingdom
[3] University of Western Australia, Perth, Australia

Introduction

In children, Stevens-Johnson syndrome (SJS) and toxic epidermal necrolysis (TEN) are rare mucocutaneous disorders with high morbidity despite a lower mortality rate in children compared with adults. There is growing consensus that the mechanisms and prognosis of infection-triggered SJS/TEN are distinct from drug-induced disease, with the more recently described entity of reactive infectious mucocutaneous eruption (RIME) describing infection-triggered cases with prominent mucosal involvement. RIME may be recurrent, though the emerging literature suggests a more favourable course with fewer long-term sequelae compared with drug-induced SJS/TEN.The aim of this study was tocharacterise patients seen at our tertiary paediatric institution with SJS, TEN and RIME over a ten-year period and identify long-term sequelae.

Materials and Methods

Relevant patients were identified using ICD-10 codes and a manual search of our drug allergy database was performed for patients admitted to the sole paediatric tertiary centre in Western Australia between August 2015 and August 2025. A retrospective chart review was undertaken and medical records checked for any subsequent presentations or follow up appointments.

Results

RIME was more common in our cohort (n=26) than SJS (n=6). All cases of SJS (body surface area affected <10%) were attributable to drugs. We did not observe any cases of TEN during the study period.

A dramatic cluster of cases of RIME associated with Mycoplasma pneumoniae infection was identified, with one third of cases presenting within an eight-week period in Spring 2024, in keeping with the global resurgence in Mycoplasma pneumoniae cases that occurred following the COVID-19 pandemic.

Patients with SJS were more likely to require intensive care admission compared to those with RIME (33% vs 7.7%, p = 0.048). However, overall hospital length of stay did not differ significantly between groups (SJS: median 9.1 days, range 6.0-11.5, RIME: median 7.1 days, range 0.7 – 32, p=0.288).

There was no significant difference in the frequency of long-term sequelae between groups, however RIME was associated with more functionally significant morbidity. Sequelae seen in the SJS group were limited to mild

manifestations including persistent dry eyes (n=1), and post-inflammatory hyperpigmentation (n=2). No psychological sequelae were documented at follow-up in any SJS patient.

In contrast, RIME patients experienced a broader and more severe spectrum of complications. Functionally significant ocular sequelae (n=3) included epiphora, chronic dry eye (n=1) and nasolacrimal duct obstruction (n=1), requiring multiple surgical procedures. Other sequelae in the RIME group included post-inflammatory hyperpigmentation (n=4), dysphagia and phimosis requiring circumcision. Psychological morbidity was reported in three patients, including depression with suicidal ideation, anxiety, and post-traumatic stress disorder with night terrors. Respiratory complications were also observed (n=4), including bronchiectasis, bronchiolitis obliterans, recurrent respiratory infections and chronic cough requiring bronchodilator therapy.

Conclusions

RIME was more frequently observed than SJS in our cohort, and despite lower rates of intensive care admission, was associated with substantial long-term morbidity, including significant ocular, respiratory and psychological sequelae. These findings challenge the perception of RIME as a uniformly benign condition and highlight the need for structured follow-up and multidisciplinary management to identify and address late complications.

EA DV CONGRESS
VIENNA
30 SEP - 3 OCT 2026

Abstract N°: 3521

Alopecia Areata incognito Associated with Trichotillomania in a Child: The Contribution of Trichoscopy

Ahmed Taha Derdour*[1], Ahmed Samaouel Chehad[1, 1], Tarek Mansoul[1], RIADH BOUSSAID[1], khadidja bouarroudj[1], Safa Djebbas[1], Amel Gherfi[1], kaghouche lilia[1], esma bouhila[1]

[1] University Hospital Dr Ibn Badis, Constantine, Constantine, Algeria

Introduction

Alopecia areata and trichotillomania are common causes of non-scarring alopecia in children. Incognito alopecia areata is an atypical autoimmune disorder, whereas trichotillomania is a compulsive disorder characterized by recurrent hair pulling. Trichoscopy represents a key non-invasive diagnostic and follow-up tool for both conditions.

We report a case of incognito alopecia areata associated with trichotillomania.

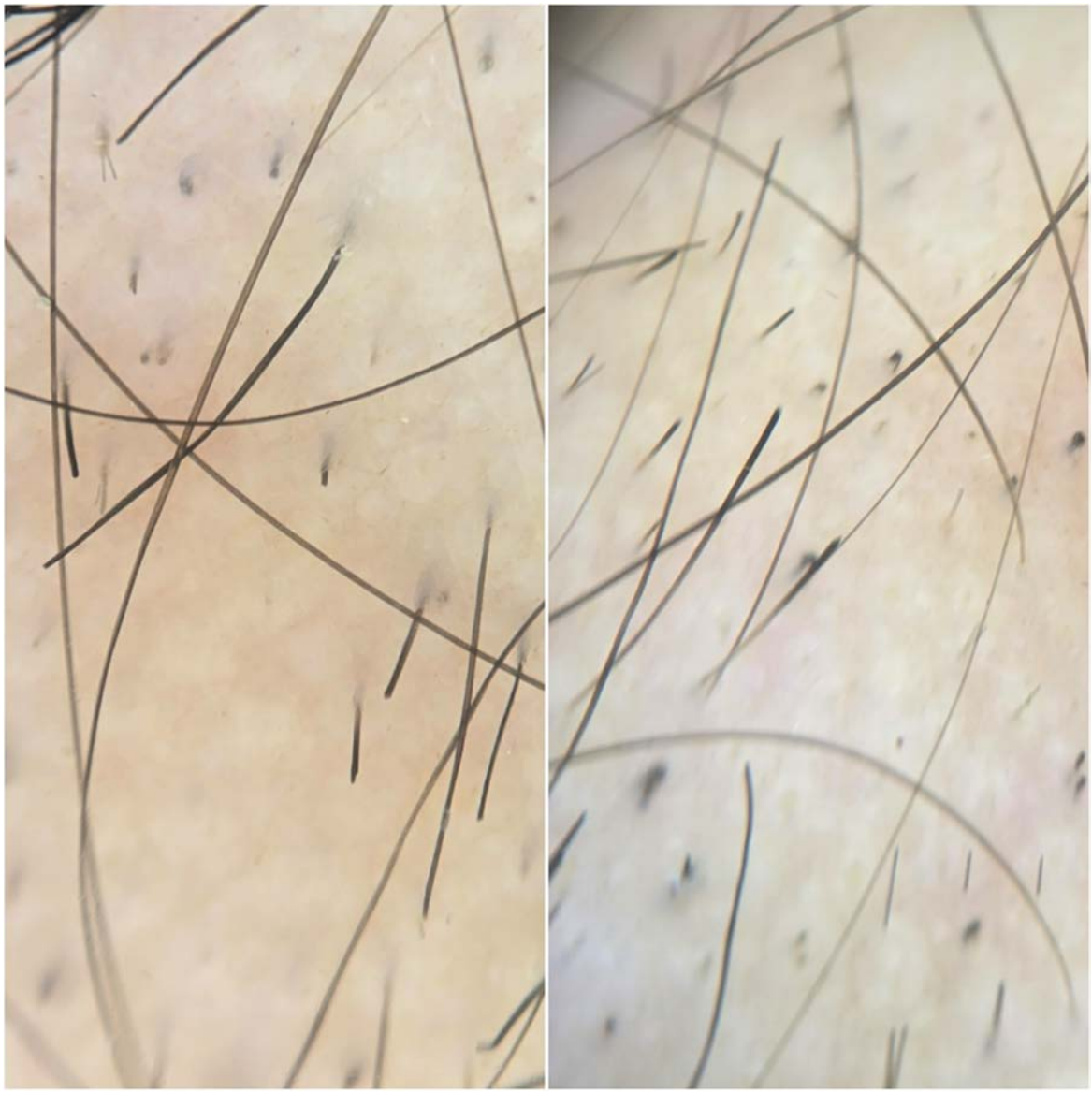

Trichoscopic figure showing the initial aspect: V sign, tulip hairs, tappered hairs, exclamation mark hair,

black dots

Case Presentation

An 8-year-old girl with no significant past medical history was referred to our department for diffuse hair loss evolving over two months. Clinical examination revealed multiple poorly demarcated alopecic patches measuring several centimeters in diameter, predominantly involving the occipital, parietal, and vertex regions. The hair pull test was strongly positive in the perilesional areas. Eyebrow involvement was also noted.

Trichoscopic examination demonstrated findings suggestive of alopecia areata, including numerous exclamation mark hairs and tapered hairs, associated with features indicative of trichotillomania such as trichoptilosis, flame hairs, V-sign hairs, and tulip hairs. Laboratory investigations, including serum ferritin, thyroid-stimulating hormone (TSH), and vitamin D levels, were within normal limits.

Given the suspicion of trichotillomania, further questioning of the mother revealed frequent hair manipulation by the child. Based on the clinical and trichoscopic findings, the diagnosis of concomitant incognito alopecia areata and trichotillomania was established. The patient received treatment for alopecia areata combined with psychological management. Marked clinical and trichoscopic improvement was observed after five weeks of treatment.



trichoscopic figure that shows signs of alopecia areata: exclamation mark hairs and tapered hairs.

Conclusion

Alopecia areata and trichotillomania are among the most common causes of patchy non-scarring alopecia in children. Their coexistence within the same alopecic lesion may considerably complicate the diagnostic approach. In such overlapping presentations, trichoscopy provides substantial diagnostic value by identifying the characteristic features of each entity, as illustrated in our case. It also contributes to therapeutic decision-making and treatment follow-up.

This case also highlights the importance of a meticulous clinical examination, careful observation of the patient during consultation, and thorough history-taking from family members when facing atypical forms of alopecia.

Overall, trichoscopy plays a pivotal role in the differential diagnosis of combined alopecic disorders, particularly the association of alopecia areata and trichotillomania in pediatric patients.



trichoscopic figure after 1 month of treatment showing: velus hairs, pig tail hairs and white hairs

EADV CONGRESS
VIENNA
30 SEP - 3 OCT 2026

Abstract N°: 3523

Topical griseofulvin as a therapeutic treatment in a nurseling

Júlia Bittencourt*[1], Julia Loureiro Fontana Bolsoni[1], Isadora Schmidt[1], Elisandre Natario[1], Veridiana Miranda[1], Flávia Regina Ferreira[1], Elisângela Andraus[1]

[1] TAUBATE UNIVERSITY MUNICIPAL HOSPITAL, TAUBATÉ, Brazil

Introduction

Tinea capitis is a dermatophyte infection of the scalp that is most common in childhood and can present with various clinical manifestations, sometimes hindering the initial diagnosis. In infants, the presentation is not only rare but can also be atypical, leading to differential diagnoses such as seborrheic dermatitis.

Case Presentation

A 1-month-old female patient, born via cesarean section at 37 weeks, was evaluated for a scalp lesion. She was on mixed feeding (breast milk and formula) and had adequate weight gain. The mother reported that the child initially presented with an erythematous and scaly circular scalp lesion, which progressed to yellowish crusts, having been diagnosed and treated as seborrheic dermatitis at another facility. Upon dermatological examination at our department, she presented with a hypochromic macule associated with hair thinning on the scalp. Subsequently, the condition progressed, with an increase in the area of hair thinning and expansion of the lesion. Given the clinical evolution and trichoscopy findings, the hypothesis of tinea capitis was raised, and material was collected for direct mycological examination and fungal culture.

The direct mycological examination was positive, and the fungal culture showed growth suggestive of Microsporum canis. Treatment was initiated with topical terbinafine cream, applied twice daily for one month. After this period, only mild clinical improvement was observed. Due to the patient's age (1 month old) and the lack of established safety data for the use of systemic antifungals in this age group, a topical therapeutic alternative was chosen. A compounded topical formulation of 2% griseofulvin associated with 1% alpha-bisabolol in a cream vehicle was prepared. The concentration used was based on formulations described in veterinary practice, as there is no approved topical indication or standardized formulation for human use. The medication was applied for a period of two months, resulting in significant clinical improvement. After four months of follow-up, complete resolution of the condition was observed.

Clinical images and trichoscopy demonstrated findings compatible with tinea capitis, including "corkscrew" hairs, suggestive of Microsporum canis infection.

Conclusion

This case demonstrates the possibility of an atypical presentation of tinea capitis in a newborn, initially confused with seborrheic dermatitis. It also highlights a therapeutic challenge in this age group, in which systemic antifungal treatment may not be a safe option. The use of a compounded topical formulation of griseofulvin, based on concentrations described in veterinary practice,

showed a good clinical response in this case. Although there are no safety data or standardized guidelines for the topical use of griseofulvin in human infants, the favorable outcome observed suggests that this approach may represent a potential alternative in selected cases where conventional therapy is not feasible.

EADV CONGRESS
VIENNA
30 SEP - 3 OCT 2026

Abstract N°: 3571

Kerion Celsi due to Trichophyton mentagrophytes/interdigitale Complex with secondary bacterial superinfection in a toddler

Maria Lúcia Paysano*[1], Heloisa Albino[1], Juan Miguel Contreras[1], Deborah Morgado[1], Bruna Peon[1], Gabriel Tavares[1], Regina C Schechtman[1], Luna Azulay-Abulafia[1]

[1] Instituto de Dermatologia Professor Rubem David Azulay - Santa Casa da Misericórdia do Rio de Janeiro, Rio de Janeiro, Brazil

Introduction

Kerion celsi is a severe inflammatory form of tinea capitis that may mimic bacterial scalp infections, particularly when associated with pustules, exudation, and crusting. Secondary bacterial infection may further obscure the diagnosis and delay appropriate antifungal treatment. We report a pediatric case initially managed as bacterial scalp infection and suspected methicillin resistant *Staphylococcus*.

Case Presentation

A 1-year-11-month-old child presented with erythematous papules on the lower limbs followed by an inflammatory scalp plaque with pustules, purulent exudation, and fever. Initial diagnoses in emergency settings included impetigo and bacterial scalp infection. Sequential treatment with cephalexin, mupirocin, and amoxicillin-clavulanate resulted in minimal improvement. Dermatologic evaluation raised suspicion for kerion celsi associated with secondary bacterial infection. Sulfamethoxazole-trimethoprim was initiated, resulting in partial improvement with reduction of purulent exudate, suggesting a possible concomitant bacterial superinfection. Direct mycological examination revealed arthroconidia, and fungal culture identified the Trichophyton mentagrophytes/interdigitale complex.

The patient evolved with localized alopecia, adherent crusts, and inflammatory scalp lesions. Clinical, dermoscopic, and mycological findings supported the diagnosis of kerion celsi, while the prominent exudative presentation suggested concomitant bacterial superinfection. Recognition of the fungal component allowed appropriate therapeutic redirection and avoided further delay in diagnosis.

The Trichophyton mentagrophytes/interdigitale complex is not a common causative agent of tinea capitis and may atypically present with a highly inflammatory clinical picture. Dermatophytes, particularly the *T. mentagrophytes/interdigitale* complex, are associated with exuberant inflammatory presentations that may mimic bacterial abscesses or pyoderma. Delayed recognition may lead to repeated antibiotic exposure and an increased risk of cicatricial alopecia.

Conclusion

Kerion celsi should be considered in pediatric patients presenting with exudative or pustular scalp lesions, particularly in cases with incomplete response to antibiotics. Secondary bacterial infection may mask the underlying dermatophytosis and contribute to diagnostic confusion. Early mycological investigation is essential to reduce delayed diagnosis and prevent complications such as scarring alopecia.

EADV CONGRESS
VIENNA
30 SEP - 3 OCT 2026

Abstract N°: 3572

Acute Generalized Exanthematous Pustulosis During Fatal Refractory Shock in Bardet–Biedl Syndrome: A Complex Multidrug Reaction in a Medically Fragile Child

Chaimae Bouhamdi*[1], Zakia Douhi[1], Kawtar El fid[1], IKRAME BEJJA[1], Saadia Boughaleb[1], Meryem Soughi[1], elloudi sara[1], Hanane Baybay[1], Fatima Zohra Mernissi[1]

[1] Dermatology Department, Hassan II University Hospital, Fez, Morocco

Introduction

Acute generalized exanthematous pustulosis (AGEP) is a rare severe cutaneous adverse reaction, usually drug-induced and exceptionally reported in children. It presents with an abrupt febrile erythematous eruption with numerous sterile, non-follicular pustules, typically resolving after withdrawal of the culprit drug. Bardet–Biedl syndrome (BBS) is a rare autosomal recessive multisystem ciliopathy characterized by retinal, renal, neurological, metabolic and sometimes cardiac involvement; progressive renal failure and multisystem disease often require complex pharmacotherapy and may impair drug clearance. We report a paediatric case of EuroSCAR-defined AGEP occurring during refractory septic shock in an adolescent with genetically confirmed BBS and end-stage renal disease, highlighting the diagnostic and pharmacovigilance challenges of severe drug reactions in medically fragile syndromic children.

Case Presentation

A female adolescent with genetically confirmed Bardet–Biedl syndrome, complicated by ocular and cardiac anomalies, end-stage renal disease on haemodialysis, psychomotor delay and epilepsy, was admitted to intensive care for postictal coma requiring intubation. She received phenobarbital, sedative and antiepileptic therapy, followed by broad-spectrum antibiotics including amoxicillin–clavulanic acid and ceftriaxone for septic shock of presumed pulmonary origin.

Four days after admission, she developed febrile diffuse erythroderma with numerous clinically sterile, non-follicular pustules predominating in the major flexural folds. Laboratory tests showed severe anaemia, neutrophilic leukocytosis, eosinophilia and profound thrombocytopenia, which precluded skin biopsy. Generalized pustular psoriasis was considered unlikely because of the absence of personal or family history of psoriasis and the acute drug-related onset. Drug reaction with eosinophilia and systemic symptoms was unlikely given the short latency and absence of lymphadenopathy or hepatic involvement. Stevens–Johnson syndrome/toxic epidermal necrolysis was ruled out by the absence of epidermal detachment and mucosal involvement. Infectious pustular dermatoses were considered less likely given the non-follicular pustules and favourable cutaneous evolution after drug withdrawal. The acute onset, typical morphology, flexural predominance, biological findings, post-pustular desquamation and drug chronology yielded a EuroSCAR score of 9, consistent with definite acute generalized exanthematous pustulosis.

All suspected drugs were withdrawn and reported to pharmacovigilance. Phenobarbital and amoxicillin–clavulanic acid were considered the most probable culprits based on chronology and known drug associations; however, formal pharmacovigilance assessment implicated phenobarbital, amoxicillin–clavulanic acid and ceftriaxone, leading to contraindication of all three. Supportive dermatological care was initiated, while systemic corticosteroids were avoided because of active septic shock. The cutaneous course was favourable, with resolution of pustules, residual desquamation and regression of erythema. Despite dermatological improvement, the patient died from refractory septic shock related to her critical systemic condition.

Conclusion

This case illustrates a severe acute generalized exanthematous pustulosis in a medically fragile paediatric patient with Bardet–Biedl syndrome, end-stage renal disease and complex multidrug exposure. The fatal outcome despite cutaneous improvement highlights the challenge of managing severe drug reactions in rare multisystem disorders, where renal failure, polypharmacy and critical illness may increase vulnerability to adverse drug reactions and complicate culprit identification. AGEP may resolve dermatologically while coexisting with life-threatening systemic illness. Early recognition, immediate withdrawal of suspected drugs, individualized pharmacotherapy, multidisciplinary monitoring and proactive pharmacovigilance are essential in such high-risk patients.

EADV CONGRESS
VIENNA
30 SEP - 3 OCT 2026

Abstract N°: 3659

Sebo-atopic conditions in young children

Khatuna Kudava*[1]

[1] European University, National Center of Dermatology and Venereology, Tbilisi, Georgia

Introduction

Seborrheic and atopic dermatitis are age-related non-contagious inflammatory skin dermatoses in children. Their first appearance occurs during infancy, around three months of age and the diagnosis is often made simply, based on clinical manifestations. Both conditions can be reflected on the scalp. The basis for the development of seborrheic dermatitis is the functional activation of the sebaceous glands and active interaction with the skin microbiome. As a result, skin barrier disorders develop and Malassezia species are often activated. In the case of atopic dermatitis, the manifestation of the inflammatory process and skin dryness is associated with a disorders of the epithelial barrier, a genetically determined deficiency of the protein filaggrin. The main complication is manifested by concomitant staphylococcal infections.

Materials and Methods

Its presented 12 similar cases of children aged 3-5 years with dermatitis of the scalp. Microscopic examination of the scales and digital dermatoscopy of the scalp were used as additional examination.

Results

All of them had a dermatological history of atopic dermatitis for infancies period. During the admission period, none of the patients had any pathology on the skin of the body. All children have the same clinical manifestations; on the scalps were poorly demarcated patches with yellow and white scaly lesions, without hair loss. The conditions were assessed as seborrheic dermatitis. Microscopic examination of the fungus in 6 of them did not confirm the infection. Dermatoscopic examination of 6 patients did not reveal any features suggestive of psoriasis. All patients condition improved within 2-3 months with symptomatic therapy alone.

Conclusions

Seborrheic dermatitis in young children may be considered a transient sebo-atopic condition not associated with Malassezia species. A history of atopic dermatitis may also be an indicator of the process. The data are limited and further observations are needed for definitive conclusions.

EADV CONGRESS
VIENNA
30 SEP - 3 OCT 2026

Abstract N°: 3671

Penile dilated pore of Winer in an Adolescence: A rare clinical pathological entity

Katarina Dragun*[1], Ivana Starčević[1], Filip Bosnić[1], Mislav Mokos[1], IVANA SRSEN VIDOVIC[2], Mirna Situm[1, 3, 4], Iva Blajić[1, 5]

[1] Klinički bolnički centar Sestre Milosrdnice, Zagreb, Croatia
[2] Dermatology practice Metković, Metković, Croatia
[3] School of Dental Medicine, University of Zagreb, Zagreb, Croatia
[4] Croatian Academy of Sciences and Arts, Zagreb, Croatia
[5] Catholic University of Croatia, Medical Studies, Zagreb, Croatia

Introduction
Dilated pore of Winer (DPW) is a benign follicular adnexal neoplasm classically described in middle-aged and older adults, most commonly on the face, neck, or trunk. Genital localization and pediatric and also adolescent presentation on the skin is extremely rare.

Case Presentation
A 15-year-old boy accompanied by his mother presented to our clinic presenting with a solitary lesion located on the lateral side of the penile skin, without any subjective symptoms. Clinical examination revealed a well-demarcated verrucous lesion measuring 8 mm in diameter with a central crateriform opening (Figure 1). The lesion had persisted for several months, causing the patient significant anxiety.

Due to the rarity of such lesions in an adolescent patient of this age, a biopsy was performed. Histopathological examination established the diagnosis of dilated pore of Winer, a benign neoplasm originating from the hair follicle. The lesion was completely excised.

Discussion:

Dilated pore of Winer is considered a benign follicular tumor characterized histologically by a markedly dilated follicular infundibulum containing keratinous debris. It predominantly affects older males, while adolescent presentation and penile involvement are extremely uncommon. Recognition of this entity in atypical anatomical sites is important to avoid misdiagnosis and unnecessary concern regarding sexually transmitted or malignant lesions.

Conclusion
This case highlights the rarity of this diagnosis considering both the patient's age at presentation and the anatomical localization of the lesion. Histopathological examination is crucial for establishing the diagnosis in such cases, particularly in pediatric dermatology and venereology.

EADV CONGRESS
VIENNA
30 SEP - 3 OCT 2026

Abstract N°: 3693

A blinded comparative evaluation of large language models (ChatGPT vs Gemini) for parental counseling in congenital melanocytic nevi

Ceren Kabak*[1], Zehra Ikbal Karabal[2], Özlem Akın Çakıcı[1], Özlem Apti Şengün[1], Ceyda Çaytemel[1], Andac Salman[1]

[1] Acıbadem Mehmet Ali Aydınlar University, Department of Dermatology, Istanbul, Türkiye

[2] Acıbadem Mehmet Ali Aydınlar University, School of Medicine, Istanbul, Türkiye

Introduction

Congenital melanocytic nevi (CMN) are uncommon melanocytic lesions present at birth and often raise parental concerns regarding melanoma risk, surveillance, treatment options, cosmetic outcomes, and long-term prognosis. Consequently, many caregivers seek online health information. As large language models are increasingly used for medical queries, their reliability in providing disease-specific counseling remains uncertain. We aimed to compare the quality and readability of responses generated by ChatGPT and Gemini to common parental questions regarding CMN.

Materials and Methods

Forty clinically relevant questions reflecting common parental concerns about congenital melanocytic nevi were developed by a panel of board-certified dermatologists with clinical expertise in this field, based on frequently encountered questions in routine practice and key topics in patient education. Topics included diagnosis, etiology, lesion classification, expected evolution, melanoma risk, follow-up recommendations, imaging requirements, treatment options, daily skin care, and prognosis. Each question was submitted to Google Gemini 3 Pro and OpenAI ChatGPT Pro (GPT-5.2 Pro), accessed on December 26, 2025, under identical conditions and without additional prompting. Responses were anonymized and blinded prior to evaluation. Three board-certified dermatologists independently assessed all responses using the DISCERN instrument (score range: 16–80; higher scores indicate better quality). Readability was assessed using the Flesch Reading Ease Score (FRES; range: 0–100; higher scores indicate easier readability).

Results

Both models generated responses to all 40 questions. Inter-rater agreement was moderate (ICC=0.55), with fair item-level agreement by Fleiss' kappa (κ=0.34) and an exact three-rater agreement rate of 46.9%. Mean DISCERN scores were comparable between models, with Gemini scoring 37.45 ± 4.11 and ChatGPT scoring 37.28 ± 3.90 (p=0.40), both within the poor-quality range. Gemini responses demonstrated modestly better readability than ChatGPT responses (FRES 28.8 vs 24.6). However, both models produced text within the difficult reading category, which likely limits accessibility for caregivers without a medical background.

Conclusions

ChatGPT and Gemini provided broadly similar-quality responses to parental questions regarding CMN. Although Gemini showed a small readability advantage, both models remained within poor DISCERN quality and difficult readability categories. Large language models may serve as supplementary educational tools for families seeking preliminary information. Still, they should not replace clinician-guided counseling. This is particularly important

when individualized risk assessment or management decisions are required, and highlights the need for expert-developed, high-quality patient education materials across languages.

EADV CONGRESS
VIENNA
30 SEP - 3 OCT 2026

Abstract N°: 3707

Regressive hypopigmented and folliculotropic Mycosis Fungoides in immunocompromised children: Insights from three pediatric cases

Lina Mouline*[1], Meriem Chaouki[1], Bouchra Idrissi Rhenimi[1], Najoua Ammar[1], Mariame Meziane[1], Laila Benzekri[1], Nadia Ismaili[1]

[1] Dermatology Venereology Department, Ibn Sina University Hospital, Rabat, Morocco

Introduction
Pediatric mycosis fungoides (MF) is a rare cutaneous T-cell lymphoma in which hypopigmented and folliculotropic variants are overrepresented and frequently mimic benign inflammatory dermatoses. Their occurrence in immunocompromised children remains poorly documented.

Case Presentation
We report three immunocompromised children presenting with hypopigmented folliculotropic MF with favorable outcomes.

The first patient, a 6-year-old boy in remission from acute lymphoblastic leukemia, developed progressive hypopigmented patches on the face and limbs associated with focal alopecia. The second patient, an 11-year-old boy with Fanconi anemia treated by allogeneic transplantation complicated by chronic lichenoid graft-versus-host disease (GVHD), presented with persistent hypopigmented mildly scaly plaques with spinulosic features on the trunk and limbs. The third patient, a 14-year-old boy undergoing treatment for T-cell acute lymphoblastic leukemia, developed hypopigmented finely scaly plaques involving the trunk, face, and forearms associated with spinulosic changes and focal alopecia.

In all three patients, skin biopsies demonstrated epidermotropic and folliculotropic CD8-predominant lymphocytic infiltrates composed of small atypical lymphocytes with perifollicular distribution, associated with variable epidermotropism and focal spongiotic changes, consistent with early hypopigmented folliculotropic MF.

The first patient was lost to follow-up and reevaluated 5 months later with complete spontaneous clinical regression and absence of residual histological abnormalities on repeat biopsy. The second patient received narrow-band UVB phototherapy initiated for chronic GVHD, resulting in complete regression of lesions within 2 months without recurrence. In the third patient, controlled daylight UV exposure and close surveillance resulted in complete remission within 2 months with no relapse after 6 months of follow-up.

Conclusion
This series highlights the diagnostic complexity and potentially indolent behavior of pediatric hypopigmented folliculotropic MF arising in immunocompromised settings. Clinically, these presentations may mimic pityriasis alba, eczema, dermatophytosis, post-inflammatory hypopigmentation, or chronic GVHD, while histopathological overlap with inflammatory dermatoses, including spongiotic patterns, may further complicate diagnosis.

Recent pediatric MF studies have shown that hypopigmented variants frequently display a CD8-predominant cytotoxic phenotype associated with favorable prognosis and low progression rates. In parallel, recent cohorts of MF arising in immunosuppressed and post-transplant patients reported an overrepresentation of folliculotropic MF and pediatric-onset cases, most remaining early-stage and non-progressive during follow-up. These

observations support a possible link between immune dysregulation, altered immune surveillance, and atypical cutaneous T-cell lymphoproliferations in immunocompromised children.

Hypopigmentation itself has been proposed as a marker of active cytotoxic antitumor immune response, potentially contributing to the regressive evolution observed in our patients.
Our cases emphasize the importance of clinicopathological correlation, repeated follow-up,minimally invasive treatments, and cautious prognostic interpretation in pediatric MF occurring in immunocompromised children.

EA DV CONGRESS
VIENNA
30 SEP - 3 OCT 2026

Abstract N°: 3710

Conservative treatment of congenital onychocryptosis with lateral nail-fold hypertrophy in a 4-month-old infant

Beatriz Farias*[1], Silvia Soutto Mayor[1], Carolina Contin[1], Ana Carolina[1], Amanda Ferrari[1], Iona Moreira[1], João Pedro Carrijo Cunha Camara[1], Juliana Mathias Bertonha[1], Luiza Zetone[1], Mariana Risso[1], Tifany Ito[1], Cristine Zampieri Braga[1], Luana Estanqueiro[1], Renata Lopes[1]

[1] Irmandade Santa Casa de misericórdia de São Paulo, São Paulo, Brazil

Introduction

Congenital onychocryptosis is an uncommon condition in infancy that may present therapeutic challenges. While ingrown nails in adults and in adolecents are often managed surgically when symptomatic or recurrent, the optimal initial approach in neonates and infants is less well established. Early lesions may be mistaken for proliferative or vascular nodules, potentially prompting unnecessary invasive procedures. Current literature supports both conservative care for early, noninfected cases and minor surgical techniques (wedge resection, partial matricectomy) for persistent or complicated disease.[1–3] Reporting effective noninvasive strategies in infants can inform clinical decision-making and help avoid unwarranted surgery.

Case Presentation

A 4-month-old male presented with a right hallux nail abnormality since birth. History revealed a congenital ingrown nail with progressive lateral nail-fold thickening, without pain, fever, drainage, or functional impairment. Examination showed localized, normochromic, firm nodular hypertrophy of the lateral fold with no nail-plate elevation, erythema, warmth, or purulent discharge. No relevant personal, family, or traumatic history was identified. The diagnosis was congenital onychocryptosis with lateral fold hypertrophy. A conservative regimen was instituted: nightly topical betamethasone dipropionate applied to the lateral fold and caregiver-performed traction bandaging of both halluces to relieve lateral pressure and promote nail edge eversion. Treatment was maintained from July to December 2025 (5 months). Monthly follow-up showed progressive softening and regression of the hypertrophic fold, with complete clinical resolution at final examination. Written informed consent was obtained from the legal guardian. The authors declare no conflicts of interest.

Conclusion

Surgical interventions are widely used for persistent onychocryptosis because they often provide durable anatomical correction and symptomatic relief.[3] However, in infants, potential anesthetic risks, small anatomical structures, and the possibility of spontaneous or treatment-responsive improvement support a non-invasive manage approach. Conservative measures aim to reduce local inflammation, control granulation or hypertrophic tissue, and mechanically redirect the nail edge away from the lateral fold. Topical corticosteroids reduce dermal inflammation and may diminish soft-tissue hypertrophy. Traction bandaging provides continuous gentle eversion and decompression of the nail sulcus. Together, these measures address both inflammatory and mechanical contributors to nail embedding. Pediatric series and case reports highlight successful outcomes with conservative care in selected congenital cases, emphasizing individualized treatment with close monitoring.[1,2,4] Differential diagnoses — including pyogenic granuloma (lobular capillary hemangioma), epidermal inclusion cyst, and other vascular proliferations — may mimic or coexist with onychocryptosis. Biopsy or specialist referral is warranted when lesions are atypical, progressive despite treatment, or suspicious for an alternative diagnosis.[4] This case adds to the evidence that noninvasive therapy can achieve full resolution in congenital onychocryptosis without infection or marked nail-plate deformity, thereby avoiding early surgical procedures. Key elements for success included early recognition, and parental education regarding correct application of topical corticosteroids and traction bandaging is essential for treatment adherence and therapeutic success.

In selected infant patients with congenital onychocryptosis and lateral nail-fold hypertrophy who lack

infection or significant nail-plate deformity, a trial of conservative therapy combining topical corticosteroid massage and traction bandaging may lead to complete resolution, obviating the need for immediate surgery. Close clinical surveillance and predefined indications for surgical referral remain essential.

EADV CONGRESS
VIENNA
30 SEP - 3 OCT 2026

Abstract N°: 3764

Post-varicella eyelid necrotizing fasciitis in a 2-year-old child

Chaimae Bouhamdi*[1], Zakia Douhi[1], Kawtar El fid[1], IKRAME BEJJA[1], Saadia Boughaleb[1], Meryem Soughi[1], elloudi sara[1], Hanane Baybay[1], Fatima Zohra Mernissi[1]

[1] Dermatology Department, Hassan II University Hospital, Fez, Morocco

Introduction

Varicella is a common childhood viral infection caused by varicella-zoster virus. Although usually benign, it may be complicated by bacterial skin and soft-tissue infections. Necrotizing fasciitis is exceptional but severe, with rapid progression and potentially life-threatening outcome. We report a rare case of post-varicella necrotizing fasciitis involving the eyelid.

Case Presentation

A previously healthy 2-year-old child, up to date with routine immunizations, developed varicella after intrafamilial exposure and had received non-steroidal anti-inflammatory drugs. His brother, the presumed source of infection, recovered without complications. During the eruption, the child developed a painful, warm, erythematous swelling of the right eyelid arising on a varicella lesion. The lesion rapidly became violaceous and then blackish, progressing to an enlarging tissue defect in a febrile context, with initially preserved general condition.

Craniofacial computed tomography showed infiltration of the right frontotemporal soft tissues and ipsilateral hemiface, without drainable collection or orbital extension, consistent with preseptal palpebrofacial cellulitis. Dermatological examination revealed disseminated varicella lesions at different stages, facial oedema, and a swollen, warm, tender, erythematous-violaceous right eyelid centred by a well-demarcated 4-cm oval ulcer, with regular borders, a clean surface, a fibrinous base and serosanguineous discharge.

The rapidly necrotic evolution, severe local pain, soft-tissue extension, positive finger test and Laboratory Risk Indicator for Necrotizing Fasciitis score of 6 supported the diagnosis of early post-varicella necrotizing fasciitis. The child received urgent broad-spectrum triple intravenous antibiotic therapy, antiviral treatment, local wound care and protective occlusion, with close clinical monitoring. The outcome was favourable, without debridement, fasciotomy or functional sequelae.

Conclusion

Post-varicella necrotizing fasciitis is a rare but severe dermatological emergency. It should be suspected in any painful, rapidly progressive, violaceous or necrotic cellulitis occurring during or after varicella, particularly in young children, secondary household cases or after exposure to non-steroidal anti-inflammatory drugs. Diagnosis remains primarily clinical; the LRINEC score may support suspicion but should not be used in isolation, especially in children, and imaging must not delay urgent treatment. The originality of this case lies in the eyelid location, early recognition and favourable outcome without mutilating surgery.

EADV CONGRESS
VIENNA
30 SEP - 3 OCT 2026

Abstract N°: 3787

Cutaneous Langerhans Cell Histiocytosis in an Infant: A Case Report

feyrouz laradi*[1]

[1] chu bab el oued, Algers, Algeria

Introduction

Langerhans cell histiocytosis is a rare disease characterized by abnormal proliferation of dendritic cells expressing CD1a and CD68. Its clinical presentation is highly variable and may be limited to the skin or involve multiple organs, particularly the bones, pituitary gland, and liver. In young children, isolated cutaneous involvement is especially difficult to identify because it can mimic eczema, psoriasis, or other inflammatory dermatoses. Diagnosis relies on skin biopsy and immunohistochemistry.

This poster describes a case of cutaneous histiocytosis in a two-year-old child and illustrates the diagnostic approach and follow-up strategy.

Case Presentation

The child, aged two years, had no particular medical history. The general condition was good at admission. Dermatological examination revealed erythematous papules arranged in plaques of a few centimeters, with pigmented areas alternating with healthy skin on the cheeks and a xanthelasma-like appearance of the upper and lower eyelids. The mucous membranes and appendages were normal. General examination showed no abnormalities, and lymph node areas were free.

Laboratory investigations were normal. Skin biopsy confirmed the presence of Langerhans cells expressing CD1a and CD68. Chest, skeletal, and skull radiographs were normal, as were abdominopelvic ultrasound, bone scintigraphy, and brain MRI. ENT examination showed no abnormalities or hearing loss, and the endocrine evaluation was also normal.

Initial treatment consisted of topical emollients with regular follow-up in order to identify early any delayed extra-cutaneous involvement.

Conclusion

This case illustrates an isolated cutaneous presentation of Langerhans cell histiocytosis in a two-year-old child. The diagnosis was confirmed by skin biopsy and CD1a/CD68 immunostaining. Specialized and multidisciplinary follow-up is essential to detect any systemic extension, prevent complications, and promptly adapt therapeutic management.

EADV CONGRESS
VIENNA
30 SEP - 3 OCT 2026

Abstract N°: 3789

Reactive Infectious Mucocutaneous Eruption Mimicking Toxic Epidermal Necrolysis in a 2-Year-Old Child

KHAWLA MOUFID*[1], Douhi Zakia[1], IKRAME BEJJA[1], Saadia Boughaleb[1], Meryem Soughi[1], Sara Elloudi[1], Hanane Baybay[1], Fatima Zohra Mernissi[1]

[1] Department of Dermatology, Hassan II University Hospital, FEZ, Morocco

Introduction

Reactive infectious mucocutaneous eruption is an acute post-infectious mucocutaneous disorder, most commonly associated with *Mycoplasma pneumoniae* infection. It is characterized by prominent mucosal involvement, with absent or limited skin lesions in many cases, although more extensive cutaneous involvement may occur and mimic Stevens–Johnson syndrome or toxic epidermal necrolysis. Accurate distinction between these entities is essential because their prognosis, management, and therapeutic implications differ.

Case Presentation

The patient presented with a two-day history of fever and respiratory symptoms. Within a few hours after symptom onset, extensive mucocutaneous lesions developed, including painful erosions of the lips and oral mucosa, conjunctival involvement, and genital erosions.

Cutaneous examination revealed erythematous lesions predominantly involving the trunk and back, associated with epidermal detachment affecting approximately 20% of the body surface area, initially raising suspicion of toxic epidermal necrolysis.

Laboratory investigations showed neutrophilic leukocytosis and a moderately elevated C-reactive protein level, without hydroelectrolyte abnormalities. The patient received supportive care combined with antibiotic therapy. The clinical course was rapidly favorable, with regression of mucocutaneous lesions, progressive re-epithelialization, and no secondary complications.

Conclusion

Reactive infectious mucocutaneous eruption should be considered in children presenting with acute mucocutaneous involvement in the setting of a recent or ongoing infection. Early recognition is essential to distinguish it from Stevens–Johnson syndrome or toxic epidermal necrolysis, avoid inappropriate drug imputability, and guide appropriate supportive management.

EADV CONGRESS
VIENNA
30 SEP - 3 OCT 2026

Abstract N°: 3810

Atypical Facial Erythema in Childhood: The Importance of Differential Diagnosis

Dora Madiraca Glasović*[1], Renata Tomašević[1], Dajana Smoljan Filipović[1], Nika Franceschi[1], Mirna Šitum[1]

[1] Klinički bolnički centar Sestre Milosrdnice, Zagreb, Croatia

Introduction

Facial erythema in children is a common clinical finding that is frequently attributed to atopic dermatitis in everyday practice. However, a similar clinical presentation may occur in a variety of other dermatoses, including infectious diseases, which can represent a diagnostic challenge. In addition, empirical use of topical corticosteroids may alter the clinical appearance and delay the correct diagnosis. The aim of this report is to present the diagnostic challenge of pediatric facial erythema and to emphasize the importance of a thorough differential diagnostic approach, particularly in cases with poor response to standard therapy for atopic dermatitis.

Case Presentation

We present the case of a six-year-old boy referred by an ophthalmologist because of erythema of the left periocular region accompanied by a burning sensation. The child had previously been healthy and was not receiving chronic therapy. Clinical examination revealed a sharply demarcated erythematous plaque with marginal scaling localized in the left periocular area, involving the upper and lower eyelid and supraorbital region, with extension toward the nasal dorsum. Initial treatment prescribed by the ophthalmologist consisted of topical corticosteroid therapy (alclometasone dipropionate) twice daily for seven days, without clinical improvement. The patient was subsequently referred to the Department of Dermatology, where mycological examination identified *Trichophyton mentagrophytes*.

Conclusion

Following confirmation of the dermatophyte infection, topical terbinafine therapy was initiated twice daily for three weeks, resulting in complete regression of the skin lesions.This case highlights that facial erythema in childhood does not necessarily represent atopic dermatitis. In the presence of atypical clinical features, unilateral localization, or lack of response to standard therapy, the differential diagnosis should be broadened to include infectious causes, particularly dermatophyte infections. Early recognition and mycological evaluation are essential for establishing the correct diagnosis, initiating appropriate treatment, and preventing unnecessary use of topical corticosteroids.

EA DV CONGRESS
VIENNA
30 SEP - 3 OCT 2026

Abstract N°: 3812

Braf V600e–Mutated Multisystem Pediatric Langerhans Cell Histiocytosis: A Case Report

Chaimae Bouhamdi*[1], Hanane Baybay[1], Kawtar El fid[1], IKRAME BEJJA[1], Saadia Boughaleb[1], Zakia Douhi[1], Meryem Soughi[1], elloudi sara[1], Fatima Zohra Mernissi[1]

[1] Dermatology Department, Hassan II University Hospital, Fez, Morocco

Introduction

Langerhans cell histiocytosis is a rare clonal myeloid neoplasm with inflammatory features, frequently driven by constitutive activation of the MAPK–ERK pathway. Its clinical spectrum ranges from limited single-system disease to severe multisystem involvement with risk-organ dysfunction. We report a case of high-risk multisystem BRAF V600E–mutated Langerhans cell histiocytosis in a young child, initially revealed by misleading cutaneous manifestations.

Case Presentation

A previously healthy 2-year-old girl presented with progressively worsening disseminated skin lesions evolving over one month in the setting of persistent high-grade fever. Dermatological examination revealed extensive scalp erosions covered with thick adherent yellowish crusts, mimicking severe treatment-resistant seborrheic dermatitis, associated with petechial and red–violaceous purpuric macules on the upper trunk in a characteristic sleeveless-shirt distribution. General examination showed pallor and hepatosplenomegaly. Laboratory investigations revealed pancytopenia, marked systemic inflammation, cholestatic liver dysfunction, and hypoalbuminemia.

Bone marrow biopsy showed moderate medullary hypoplasia. Immunohistochemistry demonstrated numerous CD1a-positive and strongly S100-positive histiocytic cells, consistent with bone marrow involvement by Langerhans cell histiocytosis. Molecular testing identified the BRAF V600E mutation. Systemic staging revealed hepatosplenomegaly, bilateral pulmonary nodules and micronodules, rectosigmoid wall thickening, and a lytic lesion of the left petrous bone extending to the mastoid. Multisystem high-risk Langerhans cell histiocytosis with cutaneous, hematopoietic, hepatic, splenic, pulmonary, digestive, and osseous involvement was established.

Targeted therapy with vemurafenib was considered given BRAF V600E positivity, but it could not be initiated because of financial constraints. The child was therefore treated according to the LCH-III protocol with vinblastine and systemic corticosteroids, followed by continuation therapy. Although induction achieved inactive disease, continuation therapy was complicated by fever, recurrence of typical cutaneous lesions, progression of mastoid osteolysis with focal sigmoid sinus thrombosis, and biological criteria of macrophage activation syndrome, consistent with disease reactivation. After resumption and completion of protocol-based therapy over 14 months, the disease gradually resolved. At last follow-up, the child was clinically stable and asymptomatic, with no active cutaneous lesions, resolution of hepatosplenomegaly, partial regression of mastoid osteolysis, complete regression of pulmonary involvement, and sustained inactive disease.

Conclusion

This case highlights that pediatric Langerhans cell histiocytosis may initially masquerade as common inflammatory dermatoses, including severe seborrheic dermatitis-like eruptions and purpuric truncal lesions. The association of atypical cutaneous findings with fever, cytopenias, hepatosplenomegaly, or liver dysfunction should prompt urgent systemic evaluation. Early histologic confirmation, molecular characterization, multidisciplinary management, and close longitudinal surveillance are essential in high-risk multisystem disease. BRAF V600E status

provides a biologically rational basis for MAPK-pathway inhibition in refractory or reactivated cases.

EA DV CONGRESS
VIENNA
30 SEP - 3 OCT 2026

Abstract N°: 3836

Determinants and evolution of the early neonatal cutaneous microbiome

Han Li*[1], Mary Bohannon[1], Josef Neu[2], Leslie Parker[3], Jennifer Schoch[1]

[1] University of Florida College of Medicine Department of Dermatology, Gainesville, United States
[2] University of Florida College of Medicine Department of Neonatology, Gainesville, United States
[3] University of Florida College of Nursing, Gainesville, United States

Introduction

The neonatal cutaneous microbiome has been linked to cutaneous disease, but the early neonatal microbiome remains poorly characterized. We aimed to capture the evolution of the cutaneous neonatal microbiome across the first month of life as well as its early determinants.

Materials and Methods

We obtained 549 longitudinal volar forearm swabs from 120 preterm neonates in the NICU, alongside paired environmental control swabs, yielding 518 total samples from 5 to 40 days of life. Standardized 16S rRNA sequencing and bioinformatic analysis were performed. Data cleaning included removal of non-bacterial contaminants and filtering variants with < 5 reads. Statistical analyses were performed using phyloseq, lmer, and MaAsLin2 packages in R version 4.5.2.

Results

Alpha diversity, as measured by Shannon and Simpson indices, increased for all infants over time (Shannon: Beta = 0.172, $p < 0.001$; Simpson: Beta = 0.038, $p < 0.001$; Figure 1A). Beta diversity of infants over time, as measured by longitudinal Bray-Curtis distances from each infant's first recorded week of life, demonstrated increasing divergence from baseline (Figure 1B). The initial neonatal microbiome was characterized by Staphylococcus predominance, which steadily transitioned into a more balanced composition of Staphylococcus, Streptococcus, Klebsiella, Serratia, Enterococcus, Corynebacterium, and other genera (Figure 1C). Influencing factors on the diversity of the early microbiome were maternal steroids (Shannon $p = 0.018$), maternal age (Shannon $p = 0.015$), and birth weight (Simpson $p = 0.043$); these associations were no longer observed by 4 weeks of life. Genera that significantly increased in abundance with weeks of life were Klebsiella ($p < 0.001$) Streptococcus ($p < 0.001$), Enterococcus ($p < 0.001$), Veillonella ($p < 0.001$), Gemella ($p < 0.001$), Neisseria ($p < 0.001$), Clostridium ($p < 0.001$), Haemophilus ($p < 0.001$), Stenotrophomonas ($p < 0.001$), Serratia ($p = 0.001$), Shigella ($p = 0.005$), Bacillus ($p = 0.006$), and Raoultella ($p=0.016$). Staphylococcus decreased in abundance over time ($p < 0.001$).

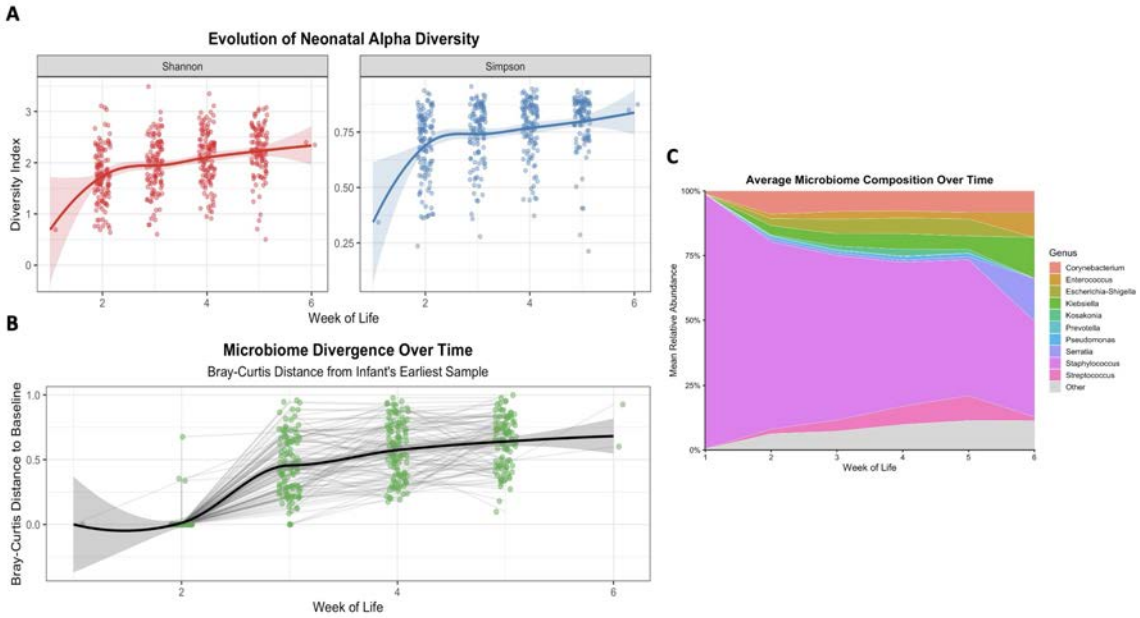

Figure 1. A) Shannon and Simpson diversity over weeks of life. B) Individual infant Bray-Curtis distances from earliest available baseline sample. C) Microbiome composition of dominant genera over time.

Conclusions

The preterm neonatal cutaneous microbiome undergoes rapid diversification during the first month of life, transitioning from Staphylococcus predominance to a more balanced polymicrobial composition. Early diversity is affected by maternal and birth factors that diminish in influence by 4 weeks of life, suggesting that environmental factors may play important roles in microbiome maturation.

EADV CONGRESS
VIENNA
30 SEP - 3 OCT 2026

Abstract N°: 3871

Pool Palms: An Underrecognized Pediatric Frictional Dermatosis

MariaLuisa Schmidt[1], Cristiane Gruber[1], Laura Serpa*[2, 2]

[1] Hospital Evangelico Mackenzie, Curitiba, Brazil

[2] Hospital Evangelico Mackenzie, Hospital de Dermatologia Sanitária do Paraná, Hospital Pequeno Príncipe, Curitiba, Brazil

Introduction

Background:

Pool palms is a benign frictional dermatosis predominantly affecting children and adolescents, resulting from repetitive mechanical trauma caused by contact with rough swimming pool surfaces. Despite its distinctive morphology, it remains underrecognized and is frequently misdiagnosed as infectious, inflammatory, or contact dermatoses, leading to unnecessary investigations and inappropriate treatments (1–3).

Objectives:

To critically review the clinical presentation, diagnostic approach, and differential diagnoses of pool palms, emphasizing key features that support accurate recognition and optimized management.

Materials and Methods

A narrative review was conducted including ≥20 publications in English and Portuguese indexed in major databases. Eligible studies comprised case reports, case series, and reviews addressing epidemiology, clinical findings, dermoscopy, histopathology, and differential diagnoses of friction-induced dermatoses (1–20).

Results

Pool palms typically present as symmetrical, well-demarcated, erythematous, edematous, and occasionally shiny plaques affecting the palmar surfaces, particularly the fingertips and distal palms (1,2). Lesions may be tender, burning, or asymptomatic and usually develop after repeated exposure to abrasive pool edges or floors. Increased susceptibility in children is attributed to prolonged water exposure, immature epidermal barrier, and higher friction during recreational activities.

Dermoscopy is rarely required but may show nonspecific erythema without characteristic vascular structures (7,8). Histopathology demonstrates mild acanthosis, compact hyperkeratosis, and superficial dermal edema, consistent with mechanical irritation rather than primary inflammatory dermatosis (3,4).

The main differential diagnoses include irritant and allergic contact dermatitis, aquagenic keratoderma, juvenile palmar dermatitis, dyshidrotic eczema, and tinea manuum (5–10). Unlike these conditions, pool palms lack vesiculation, chronic fissuring, scaling patterns typical of eczema, or fungal elements. A key diagnostic clue is the clear temporal association with swimming activities and rapid spontaneous resolution following cessation of exposure (2,6).

Management is conservative, consisting of reassurance, avoidance of frictional triggers, and regular use of emollients to restore the epidermal barrier. Topical corticosteroids are generally unnecessary but may be considered in symptomatic cases (1,11). Prognosis is excellent, with spontaneous resolution within days to weeks.

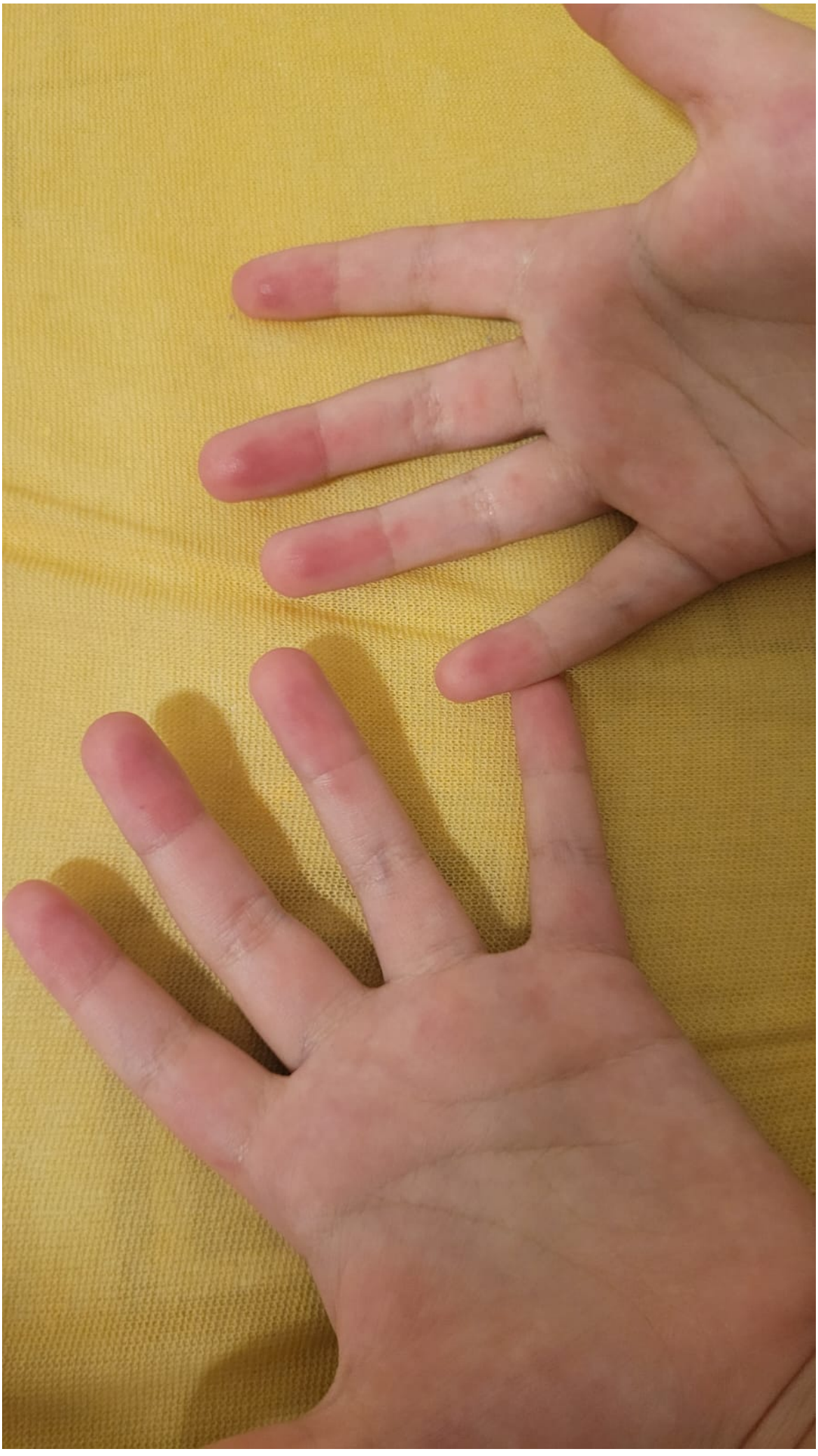

Figure 1. Symmetrical erythematous and edematous plaques involving the distal palmar surfaces and fingertips after repeated exposure to swimming pool frictional surfaces, consistent with pool palms. Personal archive.

Conclusions

Although benign and self-limited, pool palms remains an underrecognized frictional dermatosis that often leads to misdiagnosis, unnecessary therapies, and repeated healthcare visits. Early recognition of its distinctive clinical features and exposure history is essential to avoid diagnostic and therapeutic overtreatment, reduce healthcare burden, and provide timely reassurance to patients and caregivers.

References (Vancouver):

1. Wong LC. Pediatr Dermatol. 2007;24:95.
2. Novoa A. Arch Dis Child. 2016;101:41.
3. Cohen PR. Cutis. 1995;56:221–222.
4. Morgado-Carrasco D. Dermatol Pract Concept. 2020;e2020009.
5. Adams BB. J Am Acad Dermatol. 2002;46:881–899.
6. Barco D. Clin Dermatol. 2014;32:477–482.
7. Zalaudek I. Dermatology. 2006;212:7–18.
8. Tosti A. Br J Dermatol. 2008;159:100–108.
9. Hengge UR. J Am Acad Dermatol. 2006;54:1–15.
10. Larralde M. Pediatr Dermatol. 2010;27:1–8.
11. Ferreira FR. An Bras Dermatol. 2012;87:123–130.
12. Smith SD. Australas J Dermatol. 2016;57:1–10.
13. Ruiz-Maldonado R. Int J Dermatol. 2002;41:1–7.
14. Azulay RD. Dermatologia. 2017.
15. Sampaio SAP. Dermatologia. 2018.
16. Habif TP. Clinical Dermatology. 2016.
17. Bolognia JL. Dermatology. 2018.
18. Weston WL. Pediatric Dermatology. 2011.
19. Leung AKC. 2018.
20. Gupta AK. Lancet. 2003;361:1871–1881.

Condition	Age Group	Clinical Features	Key Distinguishing Features
Pool palms*	Children	Erythematous, edematous plaques on fingertips	Association with swimming; rapid resolution
Irritant contact dermatitis	All ages	Erythema, dryness, fissures	Chemical exposure; poorly demarcated
Allergic contact dermatitis	All ages	Pruritic, vesicular eruption	Delayed hypersensitivity
Aquagenic keratoderma	Adolescents	Whitish papules after water	Rapid wrinkling; transient
Juvenile palmar dermatitis	Children	Dryness, fissures	Chronic; seasonal
Dyshidrotic eczema	Young adults	Deep vesicles; pruritus	Recurrent flares
Tinea manuum	Adults	Scaling; unilateral	Positive KOH
Palmoplantar keratoderma	All ages	Hyperkeratosis	Chronic/genetic

Table 1. Differential diagnosis of pool palms in pediatric patients.

EA DV CONGRESS
VIENNA
30 SEP - 3 OCT 2026

Abstract N°: 3970

Inflammatory Linear Verrucous Epidermal Nevus: A Systematic Review of the Literature

Patrick Silvetti*[1], Leonardo Balestra[1], Piercesare Grimaldi[2], Ignazio Stanganelli[1]

[1] School of Dermatology, University of Parma, Parma, Italy

[2] Physiology Department, Unilink University, Rome, Italy

Introduction

Inflammatory linear verrucous epidermal nevus (ILVEN) is a rare variant of epidermal nevus characterized by erythematous, verrucous, and intensely pruritic papules and plaques distributed along Blaschko's lines. It typically arises in childhood, although adult-onset cases have also been described. Histologically, it shows an alternating pattern of parakeratosis with loss of the granular layer and orthokeratosis with hypergranulosis. Its etiopathogenesis is thought to be related to postzygotic mosaicism and cytokine dysregulation. The clinical picture may mimic linear psoriasis, thus representing a relevant diagnostic challenge.

Materials and Methods

We conducted a systematic review of the literature by searching the PubMed and Google Scholar databases using the terms "inflammatory linear verrucose epidermal nevus" OR "inflammatory linear verrucous epidermal nevus" up to July 2025. Case reports, case series, and reviews in English describing the clinical, histopathological, therapeutic, and prognostic features of this condition were included. After duplicate removal, we obtained a total of 689 references, which were screened by title and abstract by two independent reviewers. Articles that were not relevant or referred to similar but distinct conditions, such as nevus sebaceus of Jadassohn, were excluded. At the end of the selection process, 152 articles on ILVEN published from 1971 to the present were included, reporting a total of 224 cases.

Results

Among the cases described in the literature, 60% occurred in female patients, predominantly in childhood. The most frequent age at onset was below one year of age, with 51% of cases reported as congenital or arising within the first year of life. The incidence then progressively decreased throughout childhood: 24% occurred within 5 years of age, 11% within 10 years, and 5% within 15 years. Although ILVEN is typically a pediatric-onset condition, rarer adult-onset cases have also been reported, accounting for 9% of cases.

The clinical presentation was most frequently unilateral, observed in 86% of cases, and was invariably distributed along Blaschko's lines. The elementary lesions most commonly reported were erythematous, hyperkeratotic, scaly papules and plaques. Pruritus was described as an initial symptom in almost all cases. The most frequently involved anatomical site was the lower limb, followed by the genital–inguinal area, upper limb, trunk, and, more rarely, the head and neck region. No significant triggering factors or associated conditions were identified.

Conclusions

This systematic review provides an updated overview of the clinical spectrum of ILVEN, confirming its predominantly pediatric onset, female predominance, unilateral distribution, and marked predilection for the

lower limbs. The consistent arrangement along Blaschko’s lines supports the role of cutaneous mosaicism in its pathogenesis, while the frequent overlap with psoriasiform clinical and histopathological features highlights the need for careful clinicopathological correlation. Although ILVEN is usually regarded as a benign and localized condition, its chronic course, intense pruritus, and frequent resistance to conventional topical therapies may significantly affect patients’ quality of life. The absence of clearly identifiable triggers or recurrent systemic associations in the reviewed cases further supports its interpretation as a mosaic inflammatory disorder rather than a manifestation of a broader syndromic condition. Overall, ILVEN remains a diagnostic and therapeutic challenge, and standardized reporting of clinical features, histopathology, treatments, and outcomes is needed to improve recognition, differential diagnosis, and evidence-based management of this rare entity.

EA DV CONGRESS
VIENNA
30 SEP - 3 OCT 2026

Abstract N°: 4095

Diagnostic orientation of pediatric vascular anomalies through teledermatology in a tertiary referral centre serving geographically difficult-to-access areas: a retrospective study

Laura Padilla España*[1], Laura Membrillo Ruiz[1], Jose Francisco Millán Cayetano[1], Mario Linares[1]

[1] Hospital Universitario Puerta del Mar, Cádiz, Spain

Introduction

Background:

Teledermatology (TD) has emerged as a valuable tool for improving access to specialist care in pediatric dermatology, particularly in geographically isolated regions. Vascular anomalies often require early diagnostic orientation to optimize management and referral pathways.

Objectives:

To evaluate the usefulness of a teledermatology-based referral system for the diagnostic orientation and initial management of pediatric vascular anomalies in a tertiary centre with a single-access pathway through TD.

Materials and Methods

We performed a retrospective descriptive study including pediatric patients referred for suspected vascular anomalies through a teledermatology platform. Demographic variables, suspected and final diagnosis, image quality, response time, need for face-to-face consultation, treatment initiation, and follow-up modality were analysed. A total of 60 patients were included.

Results

The median age was 1 year (range 0–18 years), with a female predominance (58.3%). Initial suspicion was infantile hemangioma in 81.7% of cases and capillary malformation in 18.3%. Final diagnoses included infantile hemangioma (75%), capillary malformation (16.7%), venous malformation (1.7%), combined malformation (1.7%), and non-vascular lesions (5%).

Image quality was considered good in 73.3% and acceptable in 25% of referrals. Teledermatology response time was ≤1 day in 81.7% of cases. Face-to-face assessment was required in 53.3% of patients. Treatment was initiated directly through TD in 31.7% of cases, while 28.3% started treatment after in-person consultation. Follow-up was conducted exclusively through teledermatology in 30% of patients, whereas 50% required presencial follow-up.

Conclusions

Conclusions:

Teledermatology represents an effective strategy for the early diagnostic orientation and triage of pediatric vascular anomalies, allowing rapid specialist assessment and facilitating treatment initiation in a significant proportion of patients. This model may be especially useful in regions with difficult access to tertiary pediatric dermatology units

EADV Congress 2026, VIENNA
30 SEPTEMBER - 03 OCTOBER 2026
POWERED BY M-ANAGE.COM

EADV CONGRESS
VIENNA
30 SEP - 3 OCT 2026

Abstract N°: 4233

Paediatric Adverse Event Signals Associated with OTC Cosmeceutical Skincare Ingredients in FAERS: A Pharmacovigilance Disproportionality Analysis Coinciding with the TikTok Skincare Boom

Silvia Halteh*[1], Yara Shhab[2], Alesar Abu Al Rub[2], Adalia-Cristiana Iancu[2, 3], Julia Haidar[4], Kashish Patel[5]

[1] Al-Quds University, Jerusalem, Palestine

[2] Carol Davila University of Medicine and Pharmacy, Bucharest, Romania

[3] Victor Babes University of Medicine and Pharmacy, Timisoara, Romania

[4] Elias University Emergency Hospital, Dermatology Department, Bucharest, Romania

[5] Johns Hopkins Bloomberg School of Public Health, Maryland, United States

Introduction

TikTok-driven skincare trends have led to increasing use of adult-formulated OTC cosmeceutical products among children and adolescents. A recent Pediatrics analysis of skincare videos created by users aged 7–18 years found that the most-viewed routines contained an average of 11 potentially irritating active ingredients, including salicylic acid, benzoyl peroxide, retinoids, niacinamide and glycolic acid, alongside multiple allergens from the Pediatric Baseline Series. Despite widespread paediatric exposure to these ingredients through social media-driven skincare practices, no pharmacovigilance study has evaluated real-world adverse event signals associated with these products in paediatric populations. This study aims to identify disproportionality signals for OTC cosmeceutical skincare ingredients across all MedDRA adverse event terms in paediatric FAERS reports, characterise demographic patterns and identify unexpected clinically relevant findings.

Materials and Methods

FAERS data through Q3 2025 were analysed using the DiAna R package (v2.1.0; R v4.5.2). Paediatric reports were defined as age <18 years using the age_in_days variable. Only primary suspected products (role_cod = “PS”) were included. Ingredient searches targeted salicylic acid, benzoyl peroxide, glycolic acid, hyaluronic acid, lactic acid, niacinamide and retinoids identified from social media skincare trend literature and the Paediatric Baseline Series. Pharmaceutical confounders, including aspirin, isotretinoin, systemic tretinoin, corticosteroid combinations, prenatal vitamins and oncology formulations, were excluded. Disproportionality analysis was performed using reporting odds ratios (RORs) with 95% confidence intervals across all MedDRA Preferred Terms. Bonferroni correction was applied to account for multiple testing. Signals were considered confirmed when the lower 95% CI exceeded 1.0 and the Bonferroni-adjusted p-value met significance thresholds. Minimum signal threshold was n≥5 reports.

Results

Among 745,131 paediatric FAERS reports, 3,583 involved targeted cosmeceutical skincare ingredients. Most reports occurred in adolescents aged 12–17 years (78%). Salicylic acid demonstrated confirmed signals for erythema (n=181; ROR 9.79, 95% CI 8.24–11.58) and dry skin (n=155; ROR 10.01, 95% CI 8.34–11.96). An unexpected signal was identified for completed suicide (n=76; ROR 23.41, 95% CI 18.17–29.75), representing the strongest signal within the salicylic acid dataset. Cases were predominantly female adolescents (median age 15 years), suggesting likely salicylate poisoning used as self-harm rather than a pharmacologic effect of topical exposure. Benzoyl peroxide demonstrated confirmed signals for erythema (n=229; ROR 7.85, 95% CI 6.76–9.08), facial swelling (n=141; ROR 26.00, 95% CI 21.57–31.08) and skin burning sensation (n=115; ROR 6.12, 95% CI

5.00–7.43). Hyaluronic acid demonstrated signals for febrile neutropenia (n=13; ROR 10.83, 95% CI 5.60–19.23), DRESS syndrome (n=11; ROR 24.05, 95% CI 11.68–44.59) and infection (n=10; ROR 14.41, 95% CI 6.74–27.41), although these likely reflect injectable or medical use rather than topical cosmetic exposure.

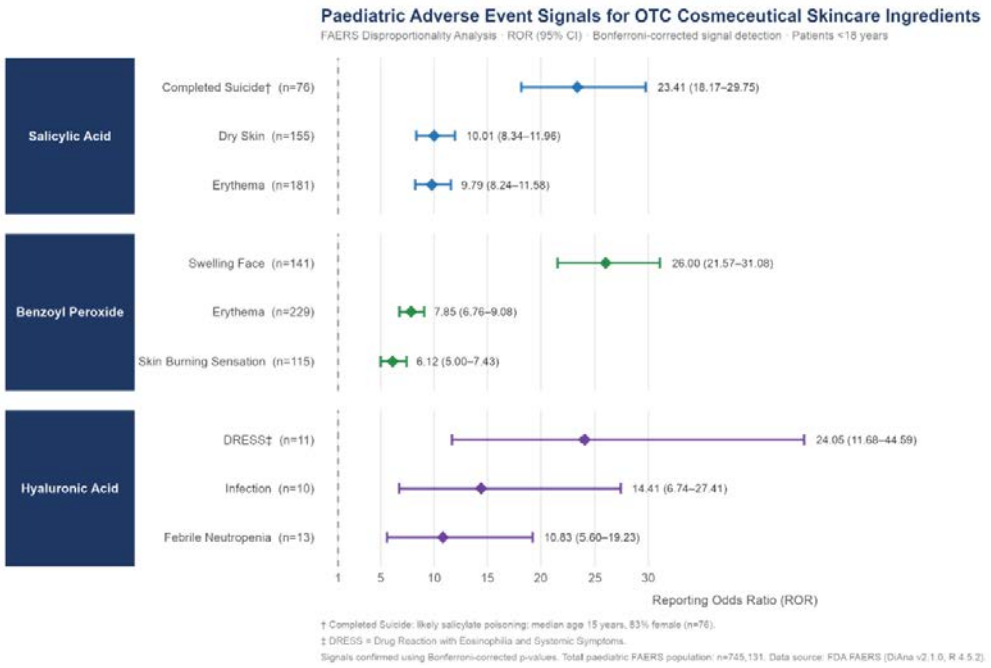

Conclusions

To our knowledge, this study provides the first pharmacovigilance analysis of paediatric adverse event signals associated with OTC cosmeceutical skincare ingredients in FAERS. Confirmed signals included expected irritant dermatologic reactions as well as an unexpected self-harm signal involving salicylic acid-containing products in adolescents. Findings support the need for age-specific skincare safety guidance, clearer paediatric labelling of cosmeceutical products and dermatologist-led public health education addressing TikTok-driven skincare behaviours in minors. The DiAna-based workflow provides a reproducible framework for ongoing surveillance of social media-driven cosmetic exposure trends.

EA DV CONGRESS
VIENNA
30 SEP - 3 OCT 2026

Abstract N°: 4291

Cutaneous manifestations of systemic diseases in children: A prospective study of 108 patients

lalla safia echarif*[1], layla bendaoud[1], Maryem Aboudourib[1], said amal[1], ouafa hocar[1]

[1] Department of Dermatology and Venerology, Mohammed VI University Hospital, Biosciences and Health Laboratory, Faculty of Medicine and Pharmacy of Marrakesh, MARRAKECH, Morocco

Introduction

Systemic diseases in children are a heterogeneous group of often severe disorders. Skin manifestations frequently appear early and play a crucial role in diagnosis. Early detection through close collaboration between pediatricians and dermatologists is essential for optimal management. This study describes the epidemiological profile and cutaneous features of systemic diseases in a pediatric population.



Figure 1 : malar rash in a child with systemic lupus erythematosus

Materials and Methods

This prospective study was conducted within the Departments of Dermatology and Pediatrics at our University Hospital over a 24-month period (January 2024 – December 2025). We included pediatric patients presenting with systemic diseases associated with cutaneous involvement, evaluated in outpatient consultations, day hospitals, or inpatient wards. Demographic, clinical, paraclinical, and therapeutic data were analyzed using Excel software.

Results

The study included 108 patients (63.0% female) with a mean age of 8.6 years. Hospital-based care was common, with 61.1% admitted as inpatients and 38.9% managed via outpatient or day-hospital services.

IgA vasculitis was the most frequent diagnosis, found in 47 patients (43.5%) presenting with purpura. Complications in this group included peritonitis (n=1) and renal involvement (n=10), ranging from proteinuria to progressive renal failure. Behçet's disease affected 14 patients (13.0%), diagnosed by recurrent bipolar aphthosis and uveitis; complications included inferior vena cava thrombosis and bilateral hyalitis.

Lupus was found in 13 patients (12.0%). Skin signs varied by type: acute lupus (n=6) showed a malar rash, chronic/discoid lupus (n=4) caused alopecia, and subacute lupus (n=2) led to photosensitivity. One case of neonatal lupus was recorded. Morphea (8.3%) and scleroderma (2.8%) cases both showed sclerotic plaques, while dermatomyositis (5.6%) featured Gottron papules and a lilac (heliotrope) rash. Kawasaki disease occurred in 5.6% of cases.

Three patients (2.8%) had mixed vasculitides, appearing as associations of lupus–IgA vasculitis , lupus–dermatomyositis, and lupus–scleroderma. Other findings included erythema nodosum with rheumatic/digestive symptoms (1.9%), juvenile idiopathic arthritis with erythema and purpura (1.9%), and Crohn’s disease with mucocutaneous signs (1.9%). A single case of ANCA-associated vasculitis (0.9%) showed purpuric and ulceronecrotic lesions.

Regarding treatment, 25.0% of patients received at least two systemic immunosuppressive or immunomodulatory agents. Corticosteroids alone were prescribed in 17.6% of cases, colchicine in 12.0% (primarily for Behçet's disease), and biological therapy in 4.6%. Therapeutic abstention was retained for 22.2% of the cohort, while 0.9% received local treatment only.



Figure 2: Gottron papules in a child with dermatomyositis

Conclusions

Our findings confirm that screening for clinical and biological "red flags" is essential. Fast, specialized management based on these signs significantly improves the prognosis for children with systemic diseases.



Figure 3 :en coup de sabre morphea with ocular involvement

POWERED BY M-ANAGE.COM

EA DV CONGRESS
VIENNA
30 SEP - 3 OCT 2026

Abstract N°: 4370

The updated results of the 12-week period of the phase III, randomized, double-blind, placebo-controlled study BCD-085-16/PLANETA-KIDS: Netakimab efficacy and safety in pediatric patients with moderate-to-severe plaque psoriasis

Nikolay Murashkin*[1], Andrei Bakulev[2], Pavel Gorodnichev[3], Denis Zaslavskiy[4], Oleg Ziganshin[5], Muza Kokhan[6], Sergei Koshkin[7], Anna Maksimova[8], Julia Kovaleva[9], Tatiana Pak[10], Olga Sidorenko[11], Dmitriy Sonin[12], Bulat Halilov[13], Alkes Khotko[14], Antonina Artemeva[15], Anna Eremeeva[15], Arina Zinkina[15], Julia Lin'kova[15], Elena Kolosova[15], Anton Lutskii[15], Ekaterina Fokina[15]

[1] National Medical Research Center for Children's Health, Moscow, Russian Federation
[2] Central State Medical Academy, Department of Presidential Affairs, Moscow, Russian Federation
[3] Nizhny Novgorod Affiliate of the State Scientific Center of Dermatovenerology and Cosmetology, Nizhny Novgorod, Russian Federation
[4] St. Petersburg State Pediatric Medical University, Saint Petersburg, Russian Federation
[5] Chelyabinsk Regional Clinical Dermatovenerology Dispensary, Chelyabinsk, Russian Federation
[6] Ural Research Institute of Dermatovenerology and Immunopathology, Ekaterinburg, Russian Federation
[7] Kirov State Medical University, Kirov, Russian Federation
[8] Kuzbass Clinical Dermatology and Venerology Dispensary, Kemerovo, Russian Federation
[9] Altai Medical State University, Barnaul, Russian Federation
[10] LLC PeterKlinica, Saint Petersburg, Russian Federation
[11] Rostov State Medical University, Rostov, Russian Federation
[12] Ryazan' Region Clinical Dermatology and Venerology Dispensary, Ryazan', Russian Federation
[13] Veteran's hospital, Kazan, Russian Federation
[14] Clinical Dermatovenereologic Dispensary, Krasnodar, Russian Federation
[15] JSC BIOCAD, Saint Petersburg, Russian Federation

Introduction

Psoriasis is a chronic inflammatory skin disease affecting approximately 1% of children and adolescents, with 35-50% of adult patients experiencing disease onset before age 20. Pediatric psoriasis significantly reduces quality of life and is associated with psoriatic arthritis and comorbidities: obesity, diabetes, and mental health disorders, but treatment options are limited. Netakimab is a recombinant humanized monoclonal IgG1 antibody that specifically binds IL-17A, approved for treating moderate-to-severe plaque psoriasis in adults. The objective of the BCD-085-16/PLANETA-KIDS study is to assess the efficacy and safety of Netakimab versus placebo in patients aged ≥6 years with moderate-to-severe plaque psoriasis. Here we present the results from the first 12-week placebo-controlled period.

Materials and Methods

BCD-085-16/PLANETA-KIDS (NCT06640517) is a randomized, double-blind, placebo-controlled phase III clinical study with an open-label active-comparator arm. 155 male and female patients aged 6 to <18 years with confirmed moderate-to-severe plaque psoriasis were randomized to receive Netakimab (n=83), placebo (n=35) or Adalimumab (n=37). Netakimab dosage was weight adjusted: for patients weighting 50 kg or greater Netakimab dose was 120 mg (two injections 60 mg/ml each), for patients weighting less than 50 kg – 60 mg (one

injection 60 mg/ml). Patients received Netakimab subcutaneously once a week at week 0, 1, 2 (induction) and once every 4 weeks thereafter (maintenance). Patients in the Placebo group received placebo in a blinded manner similar to Netakimab. Adalimumab was administered in an open-label way in doses recommended by the SmPC. In this study co-primary efficacy endpoints are the proportion of patients achieving PASI75 and sPGA0-1 at week 12. The key secondary endpoints are the proportion of patients achieving PASI90/100 and sPGA0, PASI and NAPSI mean change from the baseline, the proportion of patients achieving CDLQI/DLQI and CDLQI/DLQI mean change from the baseline. The exploratory endpoints are PSSI, PPASI, mGPASI. Safety was assessed by adverse events (AEs), serious AEs, and events of special interest.

Results

All randomized patients completed the 12-week period. Netakimab has shown superiority over placebo for both co-primary endpoints. At week 12, PASI75 was achieved by 89.2% (74/83) in Netakimab group vs. 14.3% (5/35) in the placebo group (OR 59.0, 95% CI [16.5; 211.5] ($p<0.0001$). sPGA0/1 was achieved by 83.1% (69/83) vs 8.6% (5/35) (OR 54.9, 95% CI [14.6; 206.5], $p<0.0001$) in the Netakimab and placebo groups, respectively. Secondary endpoints showed remarkable Netakimab superiority over placebo: the proportion of patients achieving PASI90 75.9% vs 5.7%, PASI100 60.2% vs 2.9%, CDLQI/DLQI0/1 71.1% vs 11.4% in the Netakimab and placebo groups respectively, all $p<0.0001$. Significant improvements were observed in nail, scalp, palmoplantar, and genital psoriasis indices. Netakimab response onset was rapid, with significant difference vs placebo, evident by week 2. Over a 12-week period Netakimab showed a favorable safety profile: 34.9% (29/83) of patients in the Netakimab group reported AEs (vs 40.0% in the Placebo group, and 45.9% - in the Adalimumab group). No serious AEs, events of special interest (infections, neutropenia, hypersensitivity, tuberculosis, inflammatory bowel disease), or treatment discontinuations due to AEs occurred in the Netakimab group.

Conclusions

The 12-week results of the BCD-085-16/PLANETA-KIDS phase III clinical study demonstrate Netakimab's high efficacy and favorable safety profile versus placebo in children and adolescents aged ≥6 years with moderate-to-severe plaque psoriasis. Netakimab achieved rapid and significant improvements in skin clearance, quality of life, and symptom reduction, including in difficult-to-treat areas.

EA DV CONGRESS
VIENNA
30 SEP - 3 OCT 2026

Abstract N°: 4410

Comparative the Efficacy of Interventions for Ulcerated Infantile Hemangiomas: a Systemic Review

Shahad Almutairi[1], Ghaid Mohammed*[2], Rahaf Alshahrani[3], Faisal Alenezi[4], Shahad Hanbzazah[5], Rahaf Alsahli[6], Mona Alshanqiti[7], Rahaf Alenezi[8], Atheer Alkenani[9], Nouf Aldhubabian[1], Faisal Alshehri[5], Moteb Alotaibi[10]

[1] King Abdulaziz University for Health Sciences, Jeddah, Saudi Arabia
[2] King Saud bin Abdulaziz University for Health Sciences, Riyadh, Saudi Arabia
[3] Alfaisal University, Riyadh, Saudi Arabia
[4] Ministry of Health, Kuwait City, Kuwait
[5] King Faisal University, Al-Ahsa, Saudi Arabia
[6] Majmaah University, Majmaah, Saudi Arabia
[7] Taibah University, Madinah, Saudi Arabia
[8] Northern Border University, Arar, Saudi Arabia
[9] Umm al-Qura University, Makkah, Saudi Arabia
[10] Qassim University Medical City, Qassim University, Qassim, Saudi Arabia

Introduction
Ulcerated infantile hemangiomas (IHs) represent a clinical challenge associated with significant morbidity, necessitating effective therapeutic interventions. This study aimed to systematically evaluate the effective- ness and safety of various treatments for ulcerated IHs.

Materials and Methods
A systematic review adhering to preferred reporting items for systematic reviews guidelines was conducted by searching PubMed and Cochrane databases for studies published between 2011 and 2023, on interventions for ulcerated IHs. A total of 289 articles were initially identified from the systematic search, of which seven studies met the inclusion criteria for this review.

Results
The included studies highlighted the effectiveness of pharmacological and combination therapies. Oral pro- pranolol resulted in ulcer healing in an average of 17.93 days, with 28.5% of patients achieving a complete response. Patients on nadolol had achieved 75% of shrinkage of IHS and faster than propranolol by 59%. Atenolol emerged as a potential alternative, shown to stop hemangioma growth in 93.4% of patients within 4 weeks. A combination of laser therapy and propranolol yielded a short-term curative effect of 98% compared to 82% in the control group receiving only laser therapy. A higher cure rate of 70% with the combination of surgical resection and pingyangmycin injection compared to 49% for each intervention alone. Recent phar- macological advancements, including propranolol, nadolol, and atenolol, offer promising results for managing ulcerated hemangiomas. Propranolol remains effective for regression, while nadolol provides a predictable pharmacological profile. Atenolol offers the convenience of once-daily dosing with fewer central nervous system-related adverse effects.

Conclusions
The management of ulcerated IHs necessitates a personalized, multidisciplinary strategy.Despite advancements in treatment, further research is needed to close existing knowledge gaps and support the creation of evidence-based clinical guidelines. Such progress would contribute to better therapeutic outcomes and enhance the overall

well-being of infants and their families

EADV CONGRESS
VIENNA
30 SEP - 3 OCT 2026

Abstract N°: 4425

Biologic treatment of pediatric psoriasis: experience from a tertiary care center

Patrícia Moreira Gomes*[1], Ruben Nogueira Costa[1], Rafael Baptista Santos[1], Manuel Costa[1], João Fernandes[1], Ana Nogueira[1], Alberto Mota[1], Maria João Cruz[1]

[1] Department of Dermatology and Venereology, São João Local Health Unit, Porto, Portugal

Introduction

Psoriasis is a chronic, immune-mediated inflammatory disease affecting up to 1.2% of the pediatric population, with approximately one-third of cases beginning before the age of 16 years. Moderate-to-severe disease is associated with a significant impact on quality of life, and biologic agents have emerged as an effective therapeutic option in this setting.

Materials and Methods

A retrospective study was conducted, including patients aged ≤18 years who were diagnosed with psoriasis and treated with biologic therapy at a tertiary hospital. Data collected included demographic characteristics, clinical features, previous treatments, and treatment response.

Results

Sixteen patients were included, 75.0% female, with a median age at diagnosis of 9 years (range 3–16). A positive family history of psoriasis was present in 62.5%. Plaque psoriasis was the most common subtype (81.3%), with predominant involvement of the scalp (87.5%), limbs (87.5%), and trunk (81.3%), followed by the face (68.8%), genital area (31.3%), and nails (6.3%). Psoriatic arthritis was present in one patient (6.3%). All patients had received prior topical therapy; 68.8% were treated with cyclosporine, 43.8% with methotrexate, 6.3% with acitretin, and 6.3% with phototherapy. The median baseline PASI was 12.7 (8–25.8). The median age at initiation of biologic therapy was 14 years (8–17). All patients started adalimumab as first-line biologic therapy, with two primary and two secondary treatment failures. In these cases, therapy was switched to ustekinumab (n=3) and tildrakizumab (n=1). The remaining patients maintained adalimumab with a sustained clinical response. No adverse events were reported during follow-up.

Conclusions

Our findings support the growing role of biologic agents in pediatric psoriasis, with adalimumab demonstrating sustained efficacy in most cases. Nevertheless, therapeutic options remain limited in this age group, highlighting the need for further studies evaluating the efficacy and safety of biologics widely used in adult populations.