EADV CONGRESS
VIENNA
30 SEP - 3 OCT 2026

Abstract N°: 43

Methotrexate-Responsive Orofacial Granulomatosis: A Case Report

Gökçen Çelik*[1], Seda Atay[2], Selda Pelin Kartal[1]

[1] Ankara Etlik City Hospital, Department of Dermatology, Ankara, Türkiye
[2] Private Dermatology Practice, Eskişehir, Türkiye

Introduction

Orofacial granulomatosis (OFG) is a rare chronic inflammatory disorder characterized by recurrent or persistent swelling of the lips and perioral tissues. The etiology remains unclear, and therapeutic responses are often variable. Here, we report a case of OFG with persistent lower lip swelling that demonstrated a favorable clinical response to methotrexate after failure of multiple therapeutic modalities.

Case Presentation

A 32-year-old woman presented with progressive swelling of the lower lip. Initially, the swelling occurred intermittently with spontaneous resolution; however, over time it became persistent. Histopathological examination of a biopsy specimen obtained from the lower lip revealed findings consistent with granulomatous inflammation compatible with orofacial granulomatosis. Systemic evaluation was performed to exclude associated conditions. A chest radiograph showed no hilar lymphadenopathy suggestive of sarcoidosis. Ophthalmologic and cardiac examinations were unremarkable. Colonoscopic evaluation was also performed to rule out inflammatory bowel disease, revealing no pathological findings.The patient initially received intralesional triamcinolone injections to the lower lip at monthly intervals for a total of five sessions without clinical improvement. Subsequently, oral doxycycline (100 mg/day) was initiated but failed to achieve a therapeutic response. Hydroxychloroquine therapy (400 mg/day) was then administered for three months; however, no significant clinical benefit was observed. As the swelling persisted, oral methylprednisolone therapy was initiated. Significant clinical improvement was observed with a dose of 48 mg/day; however, attempts to taper the dose below 16 mg/day after two months, resulted in recurrent lip swelling, indicating steroid-dependent disease.Following these unsuccessful treatments, methotrexate was initiated at a dose of 15 mg/week. Marked regression of the lower lip swelling was observed beginning in the first month of therapy, and no adverse effects were reported. After 18 months of treatment, methotrexate was discontinued; however, recurrence of the lip swelling occurred shortly thereafter, necessitating re-initiation of therapy. The patient has since been maintained on methotrexate for three years with sustained remission and good tolerability.

Conclusion

This case highlights methotrexate as an effective and well-tolerated therapeutic option for refractory orofacial granulomatosis. In patients unresponsive to conventional treatments, methotrexate may represent a valuable steroid-sparing agent capable of inducing and maintaining long-term remission.

EADV CONGRESS
VIENNA
30 SEP - 3 OCT 2026

Abstract N°: 45

When Oral Erosions Herald Recurrence: Mucous Membrane Pemphigoid as a Paraneoplastic Sign of Thymoma

Ali Fakih*[1], Jawad Makarem[2], Nada Sabbah[3], Souad Bou Harb[4]

[1] Dermatology Department, Hammoud Hospital University Medical Center, Lebanese University, Beirut, Lebanon

[2] Hematology Oncology Unit Ainwazein Medical Village, Mount Lebanon, Lebanon

[3] Anatomic Pathologist, Lebanese American University, Beirut, Lebanon

[4] Infectious Disease Consultant, Mount Lebanon Hospital University Medical Center, Clinical Instructor at Balamand University, Beirut, Lebanon

Introduction

Thymomas are epithelial neoplasms of the anterior mediastinum frequently associated with autoimmune paraneoplastic syndromes, most commonly myasthenia gravis and pemphigus. The association between thymoma and mucous membrane pemphigoid (MMP) has rarely been reported in the literature, and its pathophysiological link remains poorly understood. Thymomas can disrupt central immune tolerance, leading to paraneoplastic autoimmunity against basement membrane zone antigens, a phenomenon rarely manifesting as MMP.

Case Presentation

A 64-year-old woman with a history of surgically resected thymoma previously treated with etoposide and carboplatin presented with persistent, treatment-refractory oral ulcerations The mucosal lesions remained refractory despite the discontinuation of chemotherapy and trials of antiviral and antifungal therapies. Clinical examination revealed erosive lesions of the oral mucosa without cutaneous involvement. Histopathological examination demonstrated subepithelial clefting, and direct immunofluorescence (DIF) showed linear IgG deposition along the basement membrane zone, confirming a diagnosis of mucous membrane pemphigoid (MMP). Subsequent positron emission tomography (PET) revealed progression of the thymoma. Following this oncologic reassessment, the patient was started on pemetrexed for tumor progression alongside systemic corticosteroids for the MMP, resulting in clinical improvement of the mucosal lesions.

Conclusion

This case highlights a rare association between thymoma and MMP, where mucosal lesions served as the clinical herald of tumor recurrence. Unlike more common drug-induced toxicities, the persistence of erosions after chemotherapy withdrawal pointed toward a paraneoplastic immune reactivation linked to the loss of central tolerance. This underscores the importance of systemic restaging in patients with new-onset autoimmune blistering diseases and a history of thymic epithelial tumors.

EADV CONGRESS
VIENNA
30 SEP - 3 OCT 2026

Abstract N°: 101

Oral Glycogenic Acanthosis: Clinicopathological Correlation in a Rare Oral Lesion

Filipe Monteiro*[1], Inês Tribolet de Abreu[1], Gustavo Silva[1], Inês Pereira Amaral[1], Ivânia Soares[1], Pedro de Vasconcelos[1], Sonia Fernandes[1], Joana Antunes[1]

[1] Unidade Local de Saúde Santa Maria, Lisboa, Portugal

Introduction

Glycogenic acanthosis (GA) is a benign epithelial alteration characterized by intracytoplasmic glycogen accumulation within squamous keratinocytes. Although most commonly described in the esophagus, involvement of the oral mucosa appears to be rare and likely underrecognized. When presenting as white oral lesions, it may raise clinical concern and mimic other mucosal disorders. We report three cases of oral GA with distinct clinical presentations, highlighting their histopathological features and main differential diagnoses.

Case Presentation

A 58-year-old woman with gastroesophageal reflux disease presented with a long-standing yellowish plaque on the inner lower lip. Histopathology showed acanthotic stratified squamous epithelium with elongated rete ridges and enlarged suprabasal keratinocytes with abundant pale cytoplasm and small central nuclei, without cytologic atypia or dysplasia. Periodic acid–Schiff (PAS) staining demonstrated strong intracytoplasmic positivity that disappeared after diastase digestion (PAS-D), confirming glycogen. A 68-year-old woman with hypertension and dyslipidemia presented with an eroded papule on the buccal mucosa. Biopsy revealed epithelial acanthosis with clusters of glycogen-rich clear keratinocytes and mild perivascular inflammation, without dysplasia. PAS positivity with loss after diastase confirmed glycogen accumulation, and the erosion was interpreted as secondary traumatic change. A 74-year-old man with hypertension and prior actinic keratosis presented with a chronic erythematous plaque on the lower lip, clinically suspicious for actinic cheilitis or squamous cell carcinoma in situ. Histology showed acanthotic squamous epithelium with clear keratinocytes lacking nuclear atypia or architectural disturbance. PAS was positive with loss after diastase digestion, supporting glycogen accumulation.

Conclusion

Glycogenic acanthosis is characterized histologically by enlarged suprabasal keratinocytes with abundant glycogen-rich cytoplasm and preserved nuclear morphology, with PAS positivity that disappears after diastase digestion confirming glycogen. Although well described in the esophagus, involvement of the oral mucosa appears to be rare and likely underrecognized.Recognition of this pattern is essential to distinguish it from other causes of clear cell change, including clear cell squamous cell carcinoma, viral lesions, candidiasis, pagetoid intraepithelial malignancy, and xanthomatous processes, as well as clinically similar entities such as oral lichen planus or leukoplakia. Oral glycogenic acanthosis may present with variable morphology, including plaques, papules, erosions, or erythematous lesions that mimic inflammatory or premalignant conditions. These cases highlight the importance of clinicopathologic correlation and PAS/PAS-D staining for accurate diagnosis and to avoid unnecessary interventions in this benign entity.

EADV CONGRESS
VIENNA
30 SEP - 3 OCT 2026

Abstract N°: 138

The Lip That Wouldn't Settle: Plasma Cell Cheilitis Masquerading as Chronic Angioedema

Vishu Priya Dhanaraj*[1]

[1] Zi Clinic, Chennai, India

Introduction

Lip swelling is a common clinical presentation, most often attributed to angioedema, which is typically acute, transient, and steroid-responsive. Persistence beyond 48–72 hours should prompt evaluation for alternative etiologies, including granulomatous and infiltrative disorders. Plasma cell cheilitis (PCC), a rare benign inflammatory mucositis, is an uncommon diagnostic consideration and rarely presents as isolated diffuse lip swelling.

Case Presentation

A 30-year-old postpartum female presented with persistent, non-tender swelling of the upper lip for nearly one year. The initial episode followed suspected paracetamol-induced angioedema and showed only partial response to systemic corticosteroids. She was subsequently lost to follow-up and re-presented postpartum with persistent, unchanged swelling.There was no history of pruritus, urticaria, respiratory compromise, or systemic symptoms. Examination revealed diffuse, soft, non-erythematous swelling of the upper lip without mucosal erosions, ulceration, or lymphadenopathy. Oral cavity and systemic examinations were unremarkable.

Investigations:
Extensive evaluation for chronic angioedema and systemic causes, including hematological parameters, thyroid profile, serum IgE, complement levels (C3, C4), C1 esterase inhibitor, serum ACE, and pseudocholinesterase levels, was within normal limits.Histopathological examination of a lip biopsy revealed hyperplastic squamous epithelium with mild acanthosis and a dense perivascular lymphoplasmacytic infiltrate with focal plasma cell aggregates, without granulomas or vasculitis—confirming plasma cell cheilitis.

Management and Outcome:
In view of lactation and patient preference to avoid systemic therapy, treatment included topical tacrolimus (0.1%) and triamcinolone (0.05%), combined with intralesional triamcinolone (5–10 mg/mL) at 3–5-week intervals and adjunctive excimer laser therapy. Marked clinical improvement was achieved with significant reduction in lip swelling.

Conclusion

This case underscores plasma cell cheilitis as a rare yet important masquerader of chronic angioedema. Isolated persistent lip swelling without classical mucosal changes can delay diagnosis. Early biopsy is crucial for accurate identification and appropriate management. Recognition of this atypical presentation can prevent misdiagnosis and prolonged ineffective therapy.

Clinical Message:
When “angioedema” doesn’t resolve, rethink the diagnosis—biopsy may reveal rare masqueraders like plasma cell cheilitis.

EA DV CONGRESS
VIENNA
30 SEP - 3 OCT 2026

Abstract N°: 392

Plasmacytoma: A Diagnostic Challenge in Dermatology

Jessica Plata Lira*[1], JULIO CÉSAR BASURTO[1, 2], CAROL ALEXIS MARTÍNEZ[1], ERIKA DE LOURDES SILVA[2], JESÚS LORENZO DERAT[3]

[1] Sinaloa Dermatological Center, Culiacán, Mexico
[2] Faculty of Dentistry, Autonomous University of Sinaloa, General Hospital of Culiacan, Culiacán, Mexico
[3] General Hospital of Culiacan, Culiacán, Mexico

Introduction

Plasmacytoma is an early plasma cell dyscrasia of the axial skeleton or soft tissues. It can be solitary, osseous, or extramedullary, or with minimal bone marrow involvement. It is common in men between 50 and 60 years of age. Solitary extramedullary plasmacytoma affects the oral cavity in 80% of cases. Diagnosis is made by biopsy, observing plasma cells with atypia, immunohistochemistry, and positive CD138, CD38, and MUM1. Additional studies should be ordered to rule out multiple myeloma. Treatment consists of radiotherapy, chemotherapy, or surgery.

Case Presentation

A 71-year-old male patient with a history of smoking presented with a dermatosis located on the left mandible, asymmetrical, consisting of a subcutaneous nodular lesion, adhered to deep planes, with well-defined, regular borders, measuring 4x4 cm in diameter, with a subacute evolution. In the oral cavity, there was increased volume, ulceration, a violaceous color, and telangiectasias. A biopsy of the oral mucosa was performed, hematoxylin and eosin staining, plasma cell neoplasm with atypia arranged in a sheet on vascularized stroma, variation in cell size and hyperchromatism. Immunohistochemistry was CD138, lambda MUM1 positive, compatible with solitary plasmacytoma. One month later, he presented with pathological fractures. A CT scan showed bone lysis of the mandibular body, pleural effusion, lytic lesions in the rib arches and lumbosacral spine. Bone marrow aspirate showed a diffuse infiltrate of immature plasma cells, occupying 75%. The cellularity was consistent with multiple myeloma; however, the patient died from acute respiratory failure.

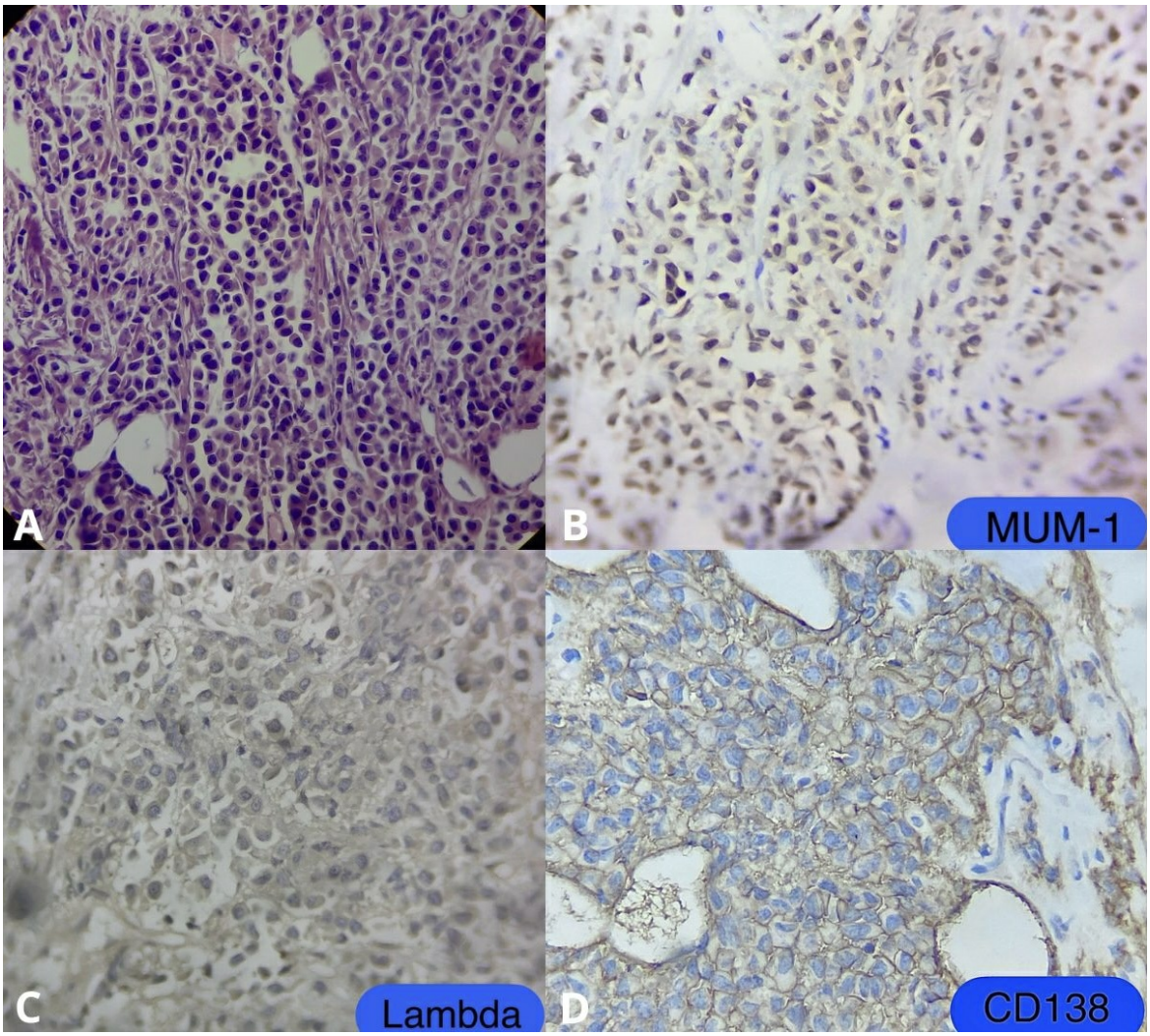

Figure A. At 40X magnification, plasma cells with atypia, variations in cell size, hyperchromatism, and loss of normal structure are observed. Figure B. Immunohistochemical staining for MUM1 positive in the nucleus for multiple myeloma. Figure C. Immunohistochemical staining for Lambda positive. Figure D. Immunohistochemical staining CD138 positive in cytoplasm

Conclusion

Plasma cell dyscrasias in the skin are rare. It is important for dermatologists to understand their spectrum and natural history, to differentiate between benign and malignant lesions in the oral cavity, and, upon detecting a plasma cell dyscrasia, to conduct a comprehensive evaluation in collaboration with relevant specialists in a timely manner to rule out more advanced stages of the disease and provide appropriate treatment, thus improving the prognosis

EADV CONGRESS
VIENNA
30 SEP - 3 OCT 2026

Abstract N°: 536

A CHRONIC VULVAR ULCER AS A CLUE TO MULTISYSTEM LANGERHANS CELL HISTIOCYTOSIS

Mariana Jimena Martinez*[1], Julieta Maria Vera[1], Maria Celeste Sluga[1], Alejandra Wernicke[1], Claudia Ester Marchitelli[1]

[1] Hospital Italiano de Buenos Aires, Buenos Aires, Argentina

Introduction

Chronic vulvar ulcers represent a diagnostic challenge, particularly when they constitute the initial manifestation of an underlying systemic disease. They are defined as ulcerative lesions persisting for more than four weeks, regardless of etiology. The most common causes include infectious, inflammatory, autoimmune, neoplastic, or traumatic conditions; however, rare diseases may present with this clinical pattern and lead to delayed diagnosis. Langerhans cell histiocytosis (LCH) is a rare clonal proliferative disorder of myeloid origin characterized by infiltration of pathological Langerhans cells in single or multiple organs. Although cutaneous involvement is relatively frequent, vulvar involvement presenting as a chronic ulcer is exceptionally rare, with only a limited number of cases reported in the literature. Early recognition is crucial, as it may represent multisystem disease with potentially severe clinical implications.

Case Presentation

A 43-year-old woman with a history of idiopathic diabetes insipidus since 2009 presented with a two-year history of progressive, painful vulvar lesions refractory to multiple empirical treatments. Physical examination revealed an extensive ulcer involving both labia majora and minora, with well-defined raised borders and a granulating base. There was marked architectural destruction of the vulva, including complete loss of the labia minora, clitoris, and clitoral hood. The patient reported severe pain, burning, and pruritus. Histopathological examination demonstrated diffuse dermal infiltration by Langerhans cells. Immunohistochemistry showed positivity for CD1a, Langerin (CD207), and CD68, and negativity for CD34 and cytokeratin AE1/AE3. Molecular analysis revealed the presence of the BRAF V600E mutation, confirming the diagnosis of LCH.Given the patient's significant dyspnea (mMRC grade 3–4), further systemic evaluation was performed. Chest computed tomography and spirometry revealed severe obstructive lung disease (FEV_1 31%, FVC 44%), consistent with pulmonary involvement. The patient was subsequently referred for lung transplantation.Treatment was initiated with systemic corticosteroid therapy for six weeks and high-potency topical corticosteroids (clobetasol propionate) for three months, resulting in complete re-epithelialization of the ulcer. However, the anatomical loss remained irreversible.

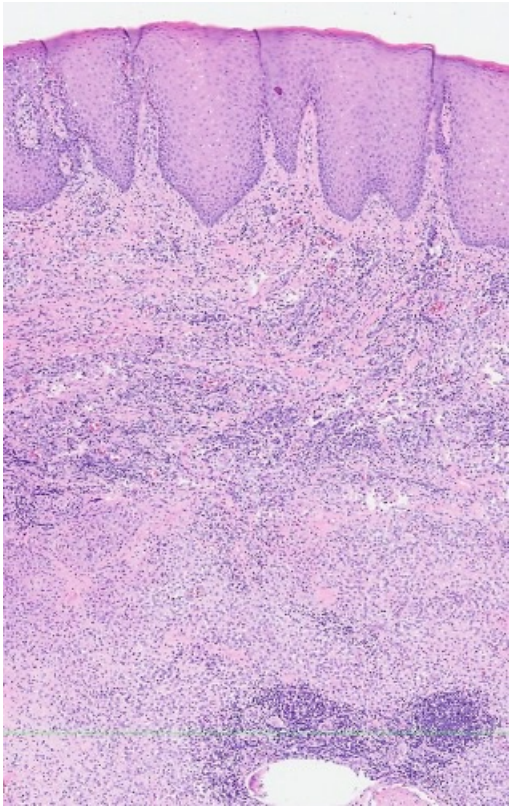

Histopathological examination of the vulvar lesion (hematoxylin and eosin staining) demonstrating a diffuse dermal infiltrate of Langerhans cells. Higher magnification reveals cells with abundant cytoplasm and characteristic reniform (“coffee bean”) nuclei, supporting the diagnosis of Langerhans cell histiocytosis.

Conclusion

Chronic vulvar ulcers require a broad and multidisciplinary diagnostic approach, particularly when lesions are persistent, destructive, or refractory to conventional treatment. Langerhans cell histiocytosis, although rare, should be considered in the differential diagnosis, especially in patients with suggestive systemic features such as diabetes insipidus or respiratory involvement.This case highlights the critical role of early biopsy in atypical vulvar lesions, enabling timely diagnosis of a potentially life-threatening multisystem disease. Dermatologists should be aware that vulvar involvement may represent the first clinical manifestation of LCH, and prompt recognition is essential to prevent disease progression and improve patient outcomes.

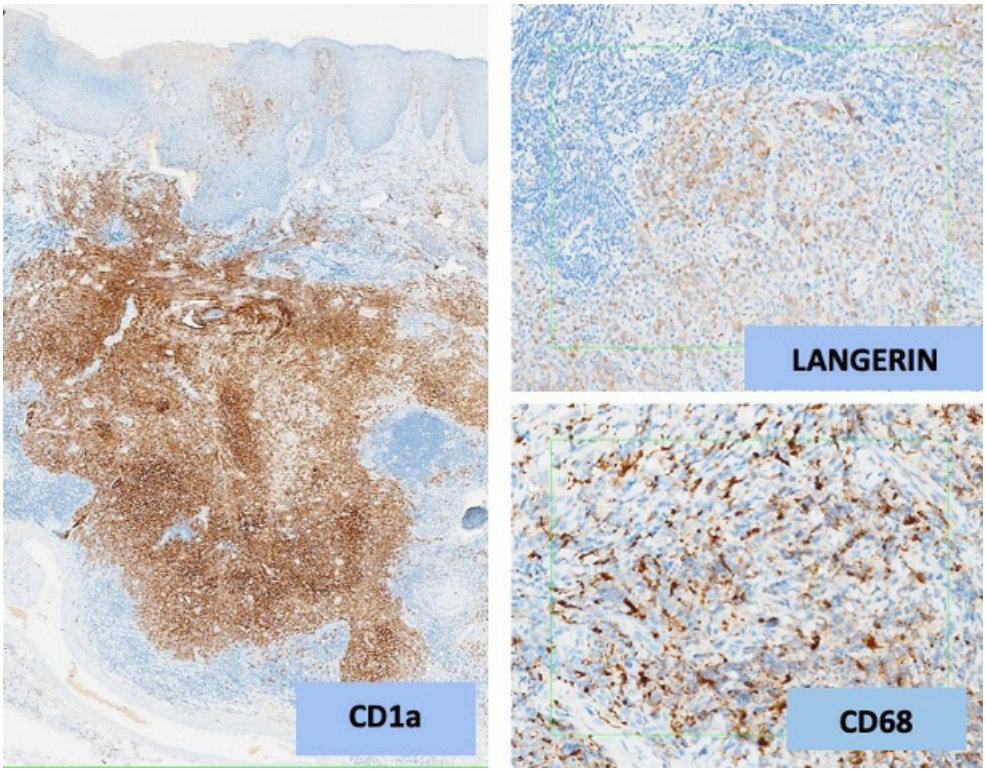

Immunohistochemistry was positive for CD1a, Langerin (CD207), and CD68, supporting the diagnosis of Langerhans cell histiocytosis.

EADV CONGRESS
VIENNA
30 SEP - 3 OCT 2026

Abstract N°: 579

Paraneoplastic pemphigus associated with vulvar squamous cell carcinoma: atypical presentation and diagnostic challenge.

Maria Victória Figueiredo Rebolho*[1], Ana Ferreira Roselino[1], Aline Turatti[1], Roberto Bueno Filho[1]

[1] Ribeirão Preto Medical School - University of São Paulo, Ribeirão Preto, Brazil

Introduction

Paraneoplastic pemphigus (PNP) is a rare and potentially fatal autoimmune disease, most commonly associated with lymphoproliferative neoplasms. It is characterized by severe and polymorphic mucocutaneous manifestations, often mimicking other bullous dermatoses. Although classically linked to hematologic malignancies, its association with solid tumors is less common and poorly described. Diagnosis relies on the correlation of clinical, histopathological, and immunological findings, and early recognition is crucial as it may represent a marker of an underlying neoplasm. Management requires a comprehensive multidisciplinary approach. This study aims to describe a case of atypical PNP associated with vulvar squamous cell carcinoma (SCC), highlighting its diagnostic and therapeutic challenges in a tertiary dermatology referral center.

Case Presentation

A 70-year-old woman with hypertension and prediabetes, without history of smoking or alcohol use, had a prior diagnosis of moderately differentiated vulvar SCC, with incomplete excision performed 6 months prior to the onset of mucocutaneous symptoms. (Figure 1). She developed extensive, painful, ulcerated lesions on the scalp, face and trunk, progressing to the limbs and involving oral and vaginal mucosa. (Figure 2A and 2B) Skin biopsy revealed suprabasal acantholytic dermatosis. She was initially treated with prednisone (20 mg/day) and methotrexate, without improvement of the mucocutaneous lesions. After one month of therapy, she progressed to septic shock of cutaneous origin, along with anemia secondary to bleeding from skin lesions, requiring admission to the intensive care unit.

After clinical stabilization, the patient was transferred to the dermatology ward, where more effective therapies for the control of PNP were initiated. Methotrexate was discontinued, and systemic corticosteroid therapy was optimized with prednisone at 1 mg/kg/day, combined with IV dexamethasone pulse therapy (100 mg/day for 3 consecutive days). Topical management was intensified, alongside comprehensive ophthalmologic and oral mucosal care. Despite these measures, the patient developed multiple complications during hospitalization, including *S. aureus* infective endocarditis, cytomegalovirus reactivation involving oral ulcers, Kaposi varicelliform eruption, and pulmonary thromboembolism requiring full-dose anticoagulation.

Given the clinical suspicion of paraneoplastic pemphigus (PNP) associated with vulvar squamous cell carcinoma, indirect immunofluorescence (IIF) was performed using human skin and rat bladder epithelium. The assay demonstrated intercellular IgG deposition (3+) in the epidermis and intercellular IgG positivity (1+) in rat bladder epithelium. The latter finding, in particular, strongly supports the diagnosis of PNP (Figure 3 A and B).

Following a multidisciplinary discussion with the gynecologic oncology team, rituximab therapy was initiated using the standard pemphigus vulgaris protocol (two intravenous infusions of 1000 mg administered 2 weeks apart). After 4 weeks, the patient showed marked clinical improvement, with no new lesions and substantial re-epithelialization of previously affected áreas (Figure 4).

Conclusion

PNP remains a major diagnostic and therapeutic challenge, particularly in cases associated with solid tumors and with subtle mucosal involvement. This case underscores the importance of clinical suspicion in severe and refractory bullous dermatoses, as well as thorough investigation for underlying malignancies beyond the classic lymphoproliferative spectrum. A multidisciplinary approach and the use of immunosuppressive therapies such as rituximab may be crucial for favorable outcomes. Early recognition is essential to reduce morbidity and mortality, and management of the underlying neoplasm is fundamental for disease control.

EA DV CONGRESS
VIENNA
30 SEP - 3 OCT 2026

Abstract N°: 613

Reactive Infectious Mucocutaneous Eruption (RIME) Successfully Treated With Upadacitinib in Three Adolescents

Colton Jensen*[1], Loretta Fiorillo[2]

[1] University Dermatology Center, Edmonton, Canada
[2] Stollery Childrens Hospital, Edmonton, Canada

Introduction

Reactive infectious mucocutaneous eruption (RIME) is a postinfectious mucocutaneous syndrome of youth characterized by severe mucosal erosions and pain, minimal cutaneous involvement, and potential long-term sequelae (scarring, synechiae, vulvovaginal adhesions). Management remains non-standard, relying on supportive care, antibiotics, and heterogeneous systemic immunomodulators including corticosteroids, cyclosporine, intravenous immunoglobulin, or tumor necrosis factor inhibitors. However, these options carry limitations including common and serious side effects, close monitoring, injection-related pain, and often hospitalization. Oral agents with rapid onset, favourable pediatric safety, and outpatient feasibility remain an unmet need for severe or recurrent cases.

We present a case series of three previously healthy adolescents with RIME managed successfully as outpatients with a short course of the selective Janus kinase 1 inhibitor upadacitinib alongside standard supportive measures.

Case Presentation

Case 1: A 13-year-old male with recurrent RIME presented after infectious respiratory symptoms with extensive painful oral erosions, hemorrhagic nasal crusting, and a urethral meatus erosion. Reluctant for injections or hospitalization (as experienced previously), he received azithromycin 500 mg daily x 3 days, clobetasol propionate 0.05% ointment twice daily to mucosae, and upadacitinib 15 mg orally daily x 7 days. Sequential examinations showed rapid resolution of erythema, crusting, and erosions with near-complete oral re-epithelialization by day 6, paralleling systemic symptom abatement, with no adverse events.

Case 2: A 16-year-old male developed infectious respiratory symptoms for 10 days followed by mucosal sloughing 20 days post-onset, causing dehydration and presentation to hospital. Examination revealed painful erosions to oral, nasal, and genital mucosae, mild erosions to acral sites, and conjunctivitis. He received azithromycin x 5 days, clobetasol propionate 0.05% ointment, and upadacitinib 15 mg daily x 14 days. Though lost to early follow-up, he returned at 3 months reporting swift mucositis resolution post-initiation of upadacitinib with examination confirming healed mucosae, except for a 3-mm left oral commissure adhesion (likely from delayed presentation).

Case 3: A 13-year-old female presented 3 weeks post infectious respiratory symptoms and empiric treatment with amoxicillin, clarithromycin, doxycycline, and systemic corticosteroid. She exhibited severe oral erosions, ocular injection, fever (39.4°C), mildly elevated C-reactive protein, low zinc, and normal chest x-ray. Examination revealed vermillion lip hemorrhagic crusting, oral erosions, and bilateral conjunctival erythema consistent with RIME. She received upadacitinib 15 mg daily x 14 days, lidocaine mouthwash, and zinc supplementation. At 1-week follow-up there was marked systemic improvement permitting normal eating, healing mucosal erosions, and no adverse effects; therapy was completed with full healing and no sequelae.

Conclusion

In all cases, upadacitinib 15 mg daily x 7-14 days alongside macrolides (when appropriate) and topical corticosteroids yielded brisk mucosal healing obviating hospitalization, injections, venous access, routine laboratory monitoring, or intensive oversight—ideal for healthy adolescents. No adverse events emerged.

This series positions short-course upadacitinib as a promising, practical alternative to traditional immunomodulators for severe or recurrent RIME. By presumably modulating exuberant mucosal inflammation, it facilitates early intervention to forestall scarring. Furthermore it is fast-acting, non-injectable, outpatient-administered, and does not require laboratory monitoring. Prospective studies should validate efficacy, refine dosing/timing, assess long-term safety (including infection reactivation), and compare against standards—potentially establishing upadacitinib as first-line for suitable patients without comorbidities.

EADV CONGRESS
VIENNA
30 SEP - 3 OCT 2026

Abstract N°: 645

Severe Oral Contact Dermatitis Induced by Stannous Fluoride: A Diagnostic Challenge and Clinical Mimicry

Juliana Idalgo Feres*[1]

[1] FMRP-USP, Ribeirão Preto, Brazil

Introduction

Allergic contact dermatitis (ACD) affecting the oral mucosa is a diagnostic challenge, often triggered by components of oral hygiene products. Stannous fluoride (SnF_2), widely used for its therapeutic properties, has recently emerged as a potential allergen due to reformulated toothpaste products, capable of inducing severe reactions that mimic infectious or autoimmune conditions.

Case Presentation

A 37-year-old female with a history of treated hepatitis C and recurrent herpes labialis presented with progressive lip edema and oral burning sensation. The condition was initially managed as a recurrence of herpes simplex infection. However, after one week, symptoms worsened, with marked erythema, petechiae, and multiple ulcerations involving the tongue and oral mucosa, progressing to hemorrhagic crusting of the lips.Following failure of antiviral therapy, an extensive workup excluded infectious and systemic causes. Detailed history revealed a recent switch to a long-used toothpaste that had been reformulated to include stannous fluoride, with similar cases anecdotally reported in digital media. Immediate discontinuation of the product led to rapid symptom resolution. Subsequent re-exposure resulted in prompt recurrence of lesions, confirming the diagnosis of ACD to SnF_2.

Conclusion

This case highlights stannous fluoride as a potential cause of severe oral adverse reactions. Diagnosis requires a high index of suspicion and careful assessment of daily-use products to avoid misdiagnosis and inappropriate treatment. Notably, the toothpaste involved was later subject to precautionary regulatory restriction in the patient’s country, raising concerns about the role of this compound as an emerging allergen.

EA DV CONGRESS
VIENNA
30 SEP - 3 OCT 2026

Abstract N°: 784

Labial Melanotic Macules: Clinical Features, Etiology, Histopathology, and Association with Syndromes: A Systematic Review

Sümeyye Aktaş*[1], Amor Khachemoune[2]

[1] NECMETTİN ERBAKAN UNİVERSİTY, KONYA, Türkiye
[2] International School of Medicine, Istanbul Medipol University, İstanbul, Türkiye

Introduction

Labial mucosal macules (LMM) are well-demarcated, hyperpigmented, and flat lesions. Although generally benign, accurate diagnosis of LMMs is essential because they have a broad differential diagnosis, may mimic malignant lesions such as mucosal melanoma, and can be associated with systemic syndromes. This systematic review aimed to investigate the clinical characteristics, etiology, and histopathology of LMM and its association with systemic diseases.

Materials and Methods

A systematic literature search was conducted across PubMed, Google Scholar, and Web of Science databases to identify all reported cases of labial melanotic macules and their associated syndromic conditions, including Laugier–Hunziker syndrome, Peutz–Jeghers syndrome, and Addison's disease. The search covered publications from June 1, 1981, to May 7, 2025.

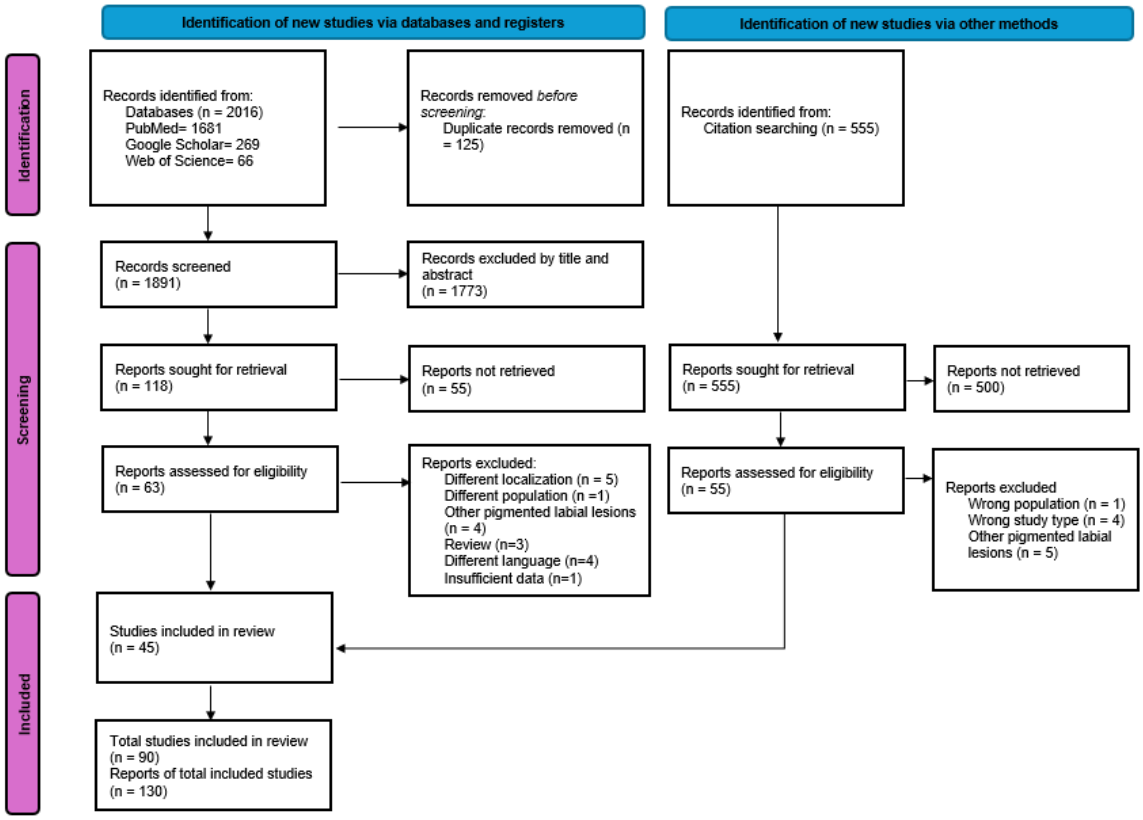

Figure 1: PRISMA flow diagram

Results

A total of 90 studies encompassing 130 patients with labial melanotic macules were included in this review. Among these, 70 patients were diagnosed with Laugier–Hunziker syndrome, 49 with Peutz–Jeghers syndrome, and 2 with Addison's disease, while 9 patients had isolated labial melanotic macules without any associated systemic conditions. LHS presented with melanonychia and hand pigmentation without malignancy, PJS with gastrointestinal tumors, and Addison's disease with systemic features. Histopathology (31 studies) revealed basal layer hyperpigmentation, epidermal hyperplasia, pigment incontinence with melanophages, and normal to slightly increased melanocytes without atypia.

Domain	Laugier–Hunziker Syndrome (LHS)	Peutz–Jeghers Syndrome (PJS)	Addison's Disease (AD)	Isolated Labial Melanotic Macule (LMM)
Nature of condition	Acquired, benign pigmentary disorder [3,12,17,18]	Inherited cancer-predisposition syndrome [19,21]	Endocrinologic disorder due to primary adrenal insufficiency [22,23]	Benign focal melanocytic activation [1,16]
Genetic background	No known genetic mutation; sporadic [17,18]	Germline STK11/LKB1 mutation [19,21,84]	No genetic basis [22]	None identified [16]
Family history	Rarely reported [3,12]	Frequently positive; sporadic cases occur [19,31–36]	Absent [10,11]	Absent [16,52]
Age at onset	Typically adulthood [12,18]	From birth or early childhood [19,21]	Variable; usually adulthood [22]	Any age [1,16]
Distribution of pigmentation	Lips, oral mucosa, nails (melanonychia), acral skin [12,13,24–28]	Perioral, oral mucosa, hands, feet, face, perianal area [19,20]	Diffuse skin and mucosal pigmentation, including lips and gingiva [22,23]	Usually solitary lesion on the vermilion border [1,16]
Systemic involvement	None [3,12]	Gastrointestinal hamartomatous polyposis; multisystem involvement [19,21]	Hormonal deficiency with systemic symptoms [22,23]	None [16]
Malignancy risk	None established [3,12]	Markedly increased lifetime risk of GI and extraintestinal malignancies [19,21,31]	None [22]	None; rare case reports of transformation [15]
Dermoscopic features	Parallel furrow pattern; brown/blue-gray granules; pseudonetwork; fish-scale–like pattern [9,13,18,24–28]	Not specific; limited data [19]	Not characteristic [22]	Regular, symmetric brown lines, dots, or globules; occasional gray hue [1,12]
Reflectance confocal microscopy	Limited data available	Not reported	Not reported	Absence of hyper-reflective basal layer; 2–3 bright dendritic cells per papilla [2]
Clinical implication	Reassurance ± cosmetic treatment	Requires genetic counseling, systemic evaluation, and lifelong surveillance	Requires urgent endocrinologic evaluation and treatment	Observation or biopsy if atypical features present

LHS, Laugier–Hunziker syndrome; PJS, Peutz–Jeghers syndrome; AD, Addison's disease; LMM, labial melanotic macule.

Table 1: Evidence-based comparison of labial melanotic macules and associated syndromes

Conclusions

Our findings suggest that labial melanotic macules may serve as important clinical indicators of underlying systemic diseases and syndromic conditions. Therefore, a comprehensive evaluation to assess potential systemic involvement is essential to exclude clinically significant disorders, including genetic, endocrine, and gastrointestinal

syndromes.

EADV CONGRESS
VIENNA
30 SEP - 3 OCT 2026

Abstract N°: 805

A Painful Smile: When Gingival Erosions Tell a Different Story

Daniel de Ramón Rueda*[1], Andrea Fuentes Bellas[1], Victoria Robles Almazán[1], Raquel Horcajo Ortega[1], Alba Bergaz Alonso[1], Marina de la Puente Alonso[1], Luis Zamarro Díaz[1], Belén Rodríguez Sánchez[1], Jorge Martín Nieto[1], Francisco Arias Lotto[1], Pablo de la Cueva Dobao[1], Ana Almodovar Real[1]

[1] Hospital Gregorio Marañón, Madrid, Spain

Introduction
Mucous membrane pemphigoid is a rare autoimmune blistering disorder predominantly affecting mucosal surfaces and often presenting with nonspecific or isolated oral involvement, which may delay diagnosis. Early recognition is essential to prevent scarring complications and functional impairment.

Case Presentation
A 54-year-old woman with no relevant medical history presented with a 3-year history of painful erosive lesions involving the oral, nasal, and conjunctival mucosa, with occasional involvement of the scalp and upper trunk. She reported significant pain with impaired oral intake and a 5-kg weight loss over the preceding month.Physical examination revealed intense erosive gingivitis affecting both dental arches, with sparing of the remaining oral mucosa. Small erosions were also observed on the upper eyelid and dorsal trunk, with no involvement of the nasal, genital, or conjunctival mucosa.Previous biopsies from oral mucosa had been nonspecific, with negative direct immunofluorescence. Repeat biopsies from gingival mucosa and dorsal skin demonstrated subepidermal blistering with granulation tissue and dermal fibrosis. Direct immunofluorescence showed linear IgG and C3 deposits along the basement membrane. Indirect immunofluorescence revealed low-titer intercellular antibodies (1:10), with weak anti-BP230 positivity.These findings supported the diagnosis of mucous membrane pemphigoid. Given previous refractoriness to systemic corticosteroids, doxycycline, and azathioprine, treatment with intravenous rituximab (two 1 g doses, 2 weeks apart) was initiated. At 3-week follow-up, the patient showed partial clinical improvement with incomplete re-epithelialization of gingival lesions, more pronounced in the upper dental arch, along with improved oral intake. Blood tests confirmed complete B-cell depletion.

Conclusion
Mucous membrane pemphigoid may present with predominant gingival involvement and inconclusive initial biopsies, posing a diagnostic challenge. This case highlights the value of repeat biopsy, including cutaneous sampling, and comprehensive immunofluorescence studies. Rituximab represents an effective therapeutic option in refractory disease, leading to clinical improvement and better quality of life. Early recognition and appropriate management are essential to prevent irreversible mucosal scarring.

EA DV CONGRESS
VIENNA
30 SEP - 3 OCT 2026

Abstract N°: 1187

Acute methotrexate-induced cutaneous ulceration in generalized pustular psoriasis: A case report and review of the literature

Shumukh Alqahtani*[1]

[1] Hera General Hospital, makkah, Saudi Arabia

Introduction

Generalized pustular psoriasis (GPP) is a rare, severe variant of psoriasis characterized by widespread sterile pustules on an erythematous base, often accompanied by systemic symptoms such as fever and malaise. Unlike chronic plaque psoriasis, GPP can be life-threatening and lacks standardized diagnostic criteria, making differentiation from conditions such as acute generalized exanthematous pustulosis essential.
Methotrexate (MTX) is widely used in psoriasis due to its anti-inflammatory and immunosuppressive effects. However, toxicity may result in hepatotoxicity, bone marrow suppression, and mucocutaneous ulceration. While ulceration is reported in plaque psoriasis, it has not been described in GPP. We report a rare case of MTX-induced cutaneous ulceration in GPP and highlight the role of spesolimab as a targeted therapy. This case also contributes to limited data on skin of color.

Case Presentation

A 34-year-old woman with GPP, first diagnosed in 2018 during pregnancy, presented in June 2024 with fever and widespread erythematous plaques and pustules. Initial biopsy showed orthokeratosis, reduced granular layer, and dermal neutrophilic infiltrate. She previously responded to corticosteroids and cyclosporine, achieving remission with MTX 10 mg weekly postpartum. A mild recurrence in 2020 was managed topically.

In 2024, she received IV hydrocortisone in the emergency setting, which worsened her condition. MTX 15 mg weekly with folic acid was initiated after normal baseline labs. After three doses, she developed lip ulcerations and erosions over plaques, sparing mucosa, palms, soles, and scalp.

Laboratory findings showed toxicity: ALT 902 U/L, AST 210 U/L, WBC 2.8×10^9/L, neutrophils 1.1×10^9/L, hemoglobin dropped to 9.2 g/dL, and platelets decreased to 250×10^9/L. MTX was discontinued, and she received IV leucovorin, albumin, and supportive care. MRSA infection was treated with vancomycin.

During admission, new vesicular lesions appeared; Tzanck smear confirmed HSV infection. She improved with acyclovir and was discharged after 9 days. At 12 weeks, she was clear, but relapsed at 16 weeks without fever. A single dose of spesolimab led to rapid resolution within 24 hours.

Conclusion

This case demonstrates that MTX toxicity can occur abruptly in GPP despite prior tolerance and standard dosing. Early signs such as mucocutaneous ulceration should prompt immediate evaluation. Regular monitoring of liver function and blood counts is essential.

Targeted therapy with spesolimab offers a rapid and effective alternative in refractory cases and may redefine GPP management.

EADV Congress 2026, VIENNA
30 SEPTEMBER - 03 OCTOBER 2026
POWERED BY M-ANAGE.COM

EA DV CONGRESS
VIENNA
30 SEP - 3 OCT 2026

Abstract N°: 1235

Oral symptoms on Perimenopausal and Menopausal women: Findings from the IMPACT study

Anthoula Efstathiadou*[1], Claudia DeGiovanni[1], Tanvi Ambulkar[1], Christina Koulouglioti[2], Louise Newson[3], Carrie Llewellyn[4]

[1] Dermatology Department, Brighton General Hospital, Brighton, United Kingdom
[2] University Hospitals NHS Foundation Trust, Brighton, United Kingdom
[3] Newson Research, Stratford Upon Avon, United Kingdom
[4] Department of Primary Care & Public Health, Brighton and Sussex Medical School, University of Brighton and University of Sussex, Brighton, United Kingdom

Introduction
The IMPACT study involved a national survey and in-depth interviews investigating the effects of perimenopause and menopause on different aspects of women's health.

Materials and Methods
A total of 1,457 participants were surveyed and 17 were interviewed, with a mean age of 51.4 years, of whom 83.1% identified as White British. Here, we present the findings relating to oral symptoms.

Results
Mouth symptoms appear to be highly prevalent among women experiencing menopausal changes, as 849 of the 1,457 (58.2%) respondents reported at least one oral symptom. Amongst these, dry mouth was the most common complaint, affecting 57% of respondents. Additional frequently reported symptoms included changes in taste (40%), gum disease (34%), ulcers (24%), and a burning sensation in the mouth (19%). A smaller yet notable proportion reported tooth loss (14%), mouth infections (7%), and a wide range of other issues including cracked lips, swelling, tongue abnormalities, and overall worsening oral health.

Women sought advice for their symptoms from multiple sources, but patterns indicate substantial uncertainty about where to obtain appropriate support. Dentists were the most consulted professionals (26%), followed by GPs (11%), hygienists (10%), and pharmacists (4%). Many women turned to non-clinical resources such as online search engines (9%), social media platforms including Instagram (3%) and Facebook (1.7%), TikTok (0.4%) and podcasts (2.3%). Only 5% used the NHS site and 2.6% the British Menopause Society website to get informed advice. However, 17.3% stated they received no information from any source, and a further 3% did not know where to seek help. These findings reveal an informational gap in menopause-related oral health care. For participants who sought advice for their oral symptoms, this was unhelpful in a fifth of cases. The main reasons quoted included clinicians not associating symptoms with menopause, participants feeling their symptoms were not taken seriously, and that advice provided was vague or not helpful Some responders reported partial improvement of their oral symptoms after they started using hormone replacement therapy. This was particularly noticeable for burning mouth sensation and gum discomfort.

Conclusions
Our study provides insight into the range of oral symptoms experienced by perimenopausal and menopausal women. These symptoms are frequently overlooked, which may leave patients unsupported and seeking advice from non-expert sources. Greater awareness and education are needed to improve recognition and management of these symptoms.

EADV CONGRESS
VIENNA
30 SEP - 3 OCT 2026

Abstract N°: 1413

Severe refractory stomatitis revealing paraneoplastic pemphigus in chronic lymphocytic leukemia: failure of ibrutinib and a favorable response to obinutuzumab

Ana Laura Lopes da Silva*[1], Raphaela Bastos Sobral[1], Gabriela Oliveira Campos[1], Roberto Bueno Filho[1]

[1] Ribeirão Preto Medical School - University of São Paulo, Ribeirão Preto, Brazil

Introduction

Paraneoplastic pemphigus (PNP) is a rare and often severe autoimmune blistering disease associated with underlying neoplasms, particularly lymphoproliferative disorders such as chronic lymphocytic leukemia (CLL) (1). Clinically, it may present with severe mucositis and polymorphic mucocutaneous lesions and a broad autoantibody profile targeting both desmosomal and plakin-related proteins (2).

The pathogenesis is driven by immune dysregulation related to the underlying malignancy. Neoplastic B cells contribute to the loss of immune tolerance and sustained autoantibody production, explaining the overlap of clinical and immunopathological features with other autoimmune blistering and interface dermatoses (2,3).

Diagnosis is challenging when cutaneous lesions are absent. In such cases, the disease may initially be interpreted as infectious or inflammatory mucositis, which often contributes to delayed recognition (2).

Case Presentation

A 62-year-old woman with a history of CLL diagnosed in 2020 presented with progressive painful oral lesions that began in October 2021. At onset, the lesions were described as aphthous-like ulcers but gradually evolved into severe erosive mucositis, associated with dysphagia, odynophagia, and significant weight loss, ultimately requiring enteral nutritional support (Figure 1).

An extensive infectious workup was negative. Histopathological analysis was non-specific. However, direct immunofluorescence revealed intercellular IgG (3+/3+) deposition along with linear fibrinogen (2+/3+) at the basement membrane zone.

Indirect immunofluorescence demonstrated IgG (2+/3+) positivity on both the roof and floor of salt-split skin (Figure 2), as well as IgG (2+/3+) reactivity against rat bladder epithelium (Figure 3). Although no single finding was pathognomonic, these findings supported the diagnosis of PNP in the context of CLL.

Initial treatment with systemic corticosteroids and dapsone resulted in only partial clinical improvement. Targeted therapy with ibrutinib was initiated due to the underlying CLL, with partial mucosal improvement.

Due to persistent disease activity, treatment was escalated to venetoclax in combination with anti-CD20 therapy (obinutuzumab), leading to sustained remission and corticosteroid tapering. At follow-up, the patient remained in remission, with minimal residual mucosal changes (Figure 4).

Conclusion

Isolated severe mucositis may delay PNP diagnosis (2,4). In this setting, a high index of suspicion becomes essential, particularly in patients with known lymphoproliferative disease.

The coexistence of intercellular and basement membrane zone immunoreactivity reflects the broad and heterogeneous autoantibody spectrum characteristic of PNP, demonstrating overlapping features with different blistering and interface disorders (2,5).

This case reinforces the central role of B cells in disease pathogenesis. The underlying neoplastic clone likely contributes not only to tumor burden but also to sustained immune dysregulation and autoantibody production (3,6).

The clinical response observed after therapeutic escalation supports this hypothesis. Ibrutinib, a Bruton tyrosine kinase (BTK) inhibitor, interferes with B-cell receptor signaling and downstream pathways involved in B-cell activation and survival, which may reduce autoantibody production (6,7). In parallel, obinutuzumab, a type II anti-CD20 monoclonal antibody, promotes effective B-cell depletion through enhanced antibody-dependent cytotoxicity and direct induction of cell death.

These mechanisms likely contributed to the sustained clinical remission observed in this patient. These findings support the use of B-cell–directed therapies in refractory PNP associated with hematologic malignancies, warranting further investigation. Early recognition with close collaboration between dermatology and hematology teams remains critical to improving outcomes in this rare but potentially life-threatening condition (1).

EA DV CONGRESS
VIENNA
30 SEP - 3 OCT 2026

Abstract N°: 1419

Paradoxical Mucous Membrane Pemphigoid Emerging under Long-Term Anti-TNF Therapy in a Patient with Coexisting Crohn's Disease and Ankylosing Spondylitis: A Case Report

Beyza Çolpan*[1], Peyker Temiz[2], Serap Öztürkcan[1]

[1] Manisa Celal Bayar University Faculty of Medicine, Department of Dermatology and Venereology, Manisa, Türkiye

[2] Manisa Celal Bayar University Faculty of Medicine, Department of Pathology, Manisa, Türkiye

Introduction

Mucous membrane pemphigoid (MMP) is a chronic, subepithelial autoimmune blistering disease driven by autoantibodies against basement-membrane-zone (BMZ) proteins. Ocular involvement is the most critical site due to the risk of cicatricial complications and irreversible visual loss. Paradoxical autoimmune phenomena such as bullous pemphigoid, psoriasiform eruptions, and lupus-like syndromes are well characterized under anti-tumor necrosis factor (anti-TNF) therapy; however, anti-TNF-associated MMP remains confined to isolated case reports. The proposed mechanism involves suppression of the Th1/Th17 axis by TNF blockade and a shift of immune polarization toward a Th2/humoral response, which facilitates autoantibody production against BMZ antigens. We present a case of MMP with ocular involvement in a patient receiving long-term anti-TNF therapy for Crohn's disease and ankylosing spondylitis (AS), discussed in the context of paradoxical autoimmunity and therapeutic management.

Case Presentation

A 47-year-old man presented with a 50-day history of oropharyngeal ulcerations, vesiculobullous lesions on the trunk and extremities, and right ocular erythema. He had been followed for 16 years for Crohn's disease and AS, receiving azathioprine and mesalazine, with infliximab for one year followed by adalimumab for two years; all current lesions had emerged during anti-TNF therapy. Examination revealed diffuse oral erosions and intact bullae on the buccal mucosa and hard palate. Ophthalmologic assessment demonstrated right conjunctival hyperemia, an inferotemporal symblepharon, and a granulomatous-appearing conjunctival lesion extending toward the cornea. Total IgE was 382 IU/mL. A perilesional skin biopsy showed a subepidermal blister with perivascular dermal inflammation, and direct immunofluorescence (DIF) demonstrated linear IgG and C3 deposition along the BMZ. Oral mucosal biopsies showed subepithelial chronic inflammation, but mucosal DIF was negative due to extensive epithelial denudation (Figure 1). The clinical phenotype and immunopathologic findings were consistent with MMP. Following multidisciplinary evaluation, adalimumab was continued, and intravenous methylprednisolone and topical therapy were supplemented with two cycles of intravenous immunoglobulin (IVIG, 2 g/kg). Visual acuity was fully preserved, the symblepharon remained stable, and clinical remission was sustained over six months of follow-up while adalimumab was continued.

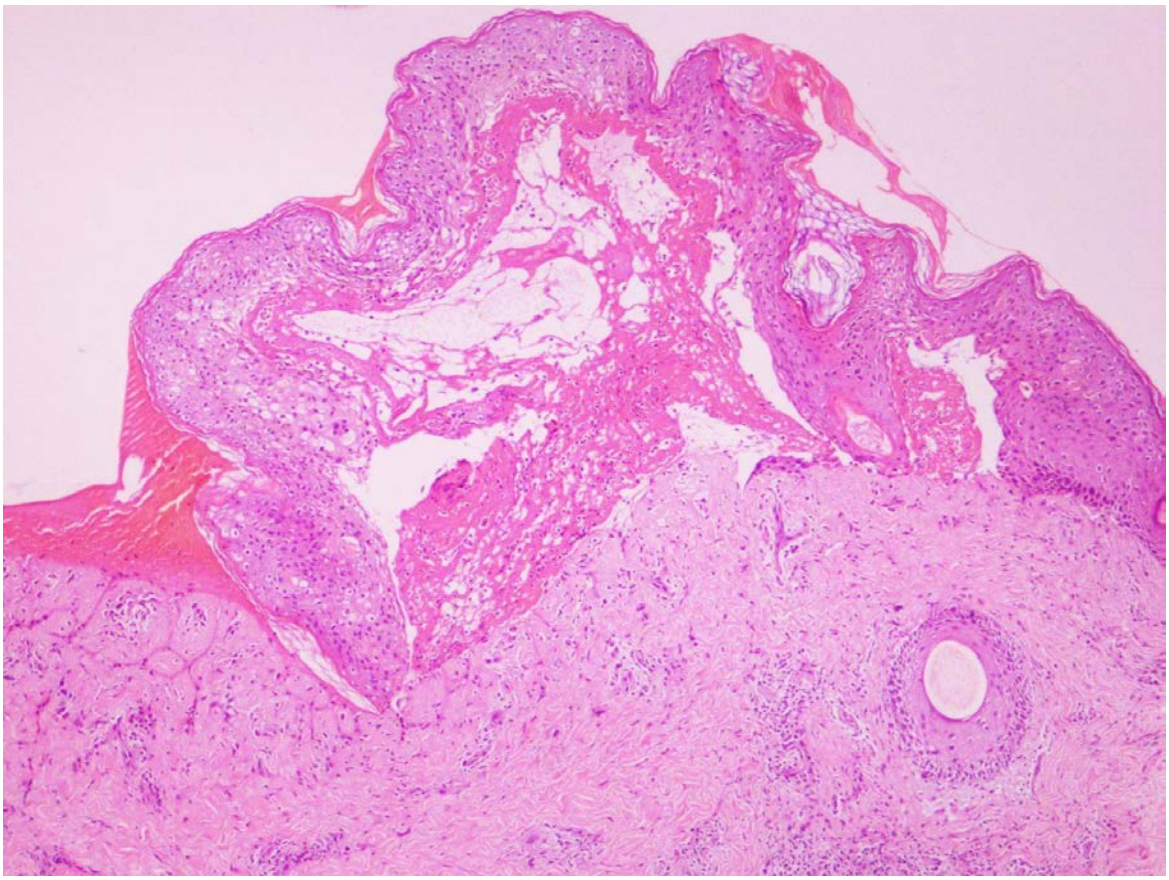

Figure 1. Excisional biopsy from the bullous lesion of the right buccal mucosa and hard palate. A subepithelial blister filled with fibrin and inflammatory cells is observed. The overlying epithelium is intact without acantholysis; a chronic inflammatory infiltrate is present in the lamina propria. Findings are consistent with mucous membrane pemphigoid (H&E, ×40).

Conclusion

MMP developing during long-term anti-TNF exposure can be considered within the spectrum of paradoxical autoimmunity; however, causality cannot be definitively established without dechallenge-rechallenge data. The elevated total IgE may represent an indirect biomarker of a Th2 polarization shift, as a Th2-dominant milieu can simultaneously facilitate IgE class-switching and pathogenic IgG production targeting the BMZ. The main contribution of this case is that remission was achieved with IVIG in a patient in whom biologic therapy could not be withdrawn — suggesting that IVIG may act at the level of autoantibody pathways even when the triggering agent is continued. MMP should be considered in the differential diagnosis of bullous dermatoses arising in patients on anti-TNF therapy; when biologic discontinuation is not feasible, IVIG is an effective and safe option within a multidisciplinary approach.

EA DV CONGRESS
VIENNA
30 SEP - 3 OCT 2026

Abstract N°: 1593

Exploring the Impact of Vulval Symptoms and Associated Dermatological Conditions during Menopause on Quality of Life and Support-Seeking Behaviour in Women

Tanvi Ambulkar*[1], Claudia DeGiovanni[1], Anthoula Efstathiadou[1], Christina Koulouglioti[2], Louise Newson[3], Carrie Llewellyn[4]

[1] Brighton General Hospital, Brighton, United Kingdom

[2] University Hospitals NHS Foundation Trust, Brighton, United Kingdom

[3] Newson Research, Stratford Upon Avon, United Kingdom

[4] Department of Primary Care & Public Health, Brighton and Sussex Medical School, University of Brighton and University of Sussex, Brighton, United Kingdom

Introduction

Vulval symptoms are often highly symptomatic and impair quality of life. In this study, we explored the impact of vulval symptoms and dermatological conditions through menopause on quality of life and support-seeking behaviour in women.

Materials and Methods

A survey of 1457 women was conducted to quantify genital symptoms affecting biological women experiencing perimenopause or post menopause. Additionally semi-structured interviews were conducted with 17 women experiencing skin symptoms in perimenopause or post menopause. Women were additionally asked about where they sought advice for vulval symptoms or treatment options.

Results

Out of 1457 survey respondents, 1003 women (69%) reported genitourinary and sexually related symptoms related to menopause. 1082 women (74%) reported vulval symptoms. Out of 1082 respondents, 722 (67%) reported vulval dryness, 503 (47%) reported vulval soreness, 636 (59%) reported vulval itching, 270 (25%) reported vulval burning, 388 (36%) reported pain during intercourse, 602 (56%) reported urinary symptoms (urgency, frequency, urine leakage), 142 (13%) reported vulval redness, 225 (21%) reported vulval discharge, 240 (22%) reported changes to how their vulva looked and 46 (4.3%) reported 'other' symptoms. . Additionally, lichen sclerosus (77%), lichen planus (79%) and genitourinary syndrome of menopause (94%) were most frequently diagnosed in perimenopause and menopause, compared to pre-menopause. Diagnosing these conditions early can help preclude physical and psychosexual complications that can inevitably occur without timely management.

When evaluating sources of support, the most common source of advice for women was their general practitioner (33%). The other most frequently consulted sources were online search engines such as Google (13%) and other doctors (8.6%). Out of 736 respondents, 609 women (83%) found the advice helpful, with the remaining 127 women (17%) not finding advice beneficial. The most frequent reason for not perceiving advice to be constructive was continuation of the symptom or failure of resolution of symptom(s). Notably, dismissal of symptoms by healthcare professionals and a perceived lack of knowledge by professionals were also quoted as reasons for not finding provided advice beneficial.

A proportion of women also expressed embarrassment, shame and misinterpretation of symptoms as a normal part of menopause as a barrier for seeking advice for vulval symptoms. Out of 1325 women, 85% of women attended their smear test, suggesting that screening tests can form an important point of contact to explore vulval symptoms if done in a sensitive, considerate manner.

Conclusions

In summary, vulval symptoms occurring in menopause can significantly impact an individual's quality of life, underscoring the importance of identifying, acknowledging and addressing them within clinical consultations. The substantial burden of vulval symptoms (in particular vulval dryness and soreness) underscores the importance of eliciting these symptoms within the remit of a clinical consultation but also offering psychological support where appropriate and considering multidisciplinary involvement with gynecology or urology where essential. General practitioners are the most common source of advice for women, highlighting the importance of primary care professionals being able to provide accurate and useful information related to the management and treatment of vulval symptoms. In summary, improved education of both healthcare professionals and women can contribute to reduced delays in care, removal of barriers to accessing healthcare, increased accuracy of diagnosis of vulval symptoms and more efficient management strategies to confidently address these.

EADV CONGRESS
VIENNA
30 SEP - 3 OCT 2026

Abstract N°: 1680

Oral mucosal injury associated with drug-induced osteonecrosis

Gotia Smaranda Laura*[1]

[1] University of Medicine and pharmacy "Victor Babes", Department of Physiology, Timisoara, Romania

Introduction

Bisphosphonates are a class of osteoclasts inhibitors used for bone distructive pathology. It includes zolendronic acid, sodic alendronate. It inhibits osteoclastic bone resorbtion without direct effect on bone formation. It is used in any cancer pathology with bone metastasis, because beside a strong inhibition of bone resorbtion it also have antitumour properties.

Case Presentation

They target osteoclasts, blocking their function by inhibiting the recruitment, shortening lifespan and inhibiting osteoclast activity. Once integrated in bone matrix they can only be removed during bone turnover. In animal studies the halflife varies between 3 and 12 months, but in humans it can be over 10 years.
A significant number of patients undergoing bisphisphonate treatment reported maxilar osteonecrosis. The lesions are located on the mandibula body, bare, necrotic bone areas exposed in the oral cavity, without a tendency to heal for at least 8-12 weeks. The symptoms are almost imperceptible or mild at the onset of the condition, but over time they become severe with demarcation of large bone sequestrations, adjacent suppurations, cutaneous or mucous fistulas, continuous and intense pain. The diagnosis of osteonecrosis of the jaw associated with bisphosphonate therapy is clinical, considering the exposed bone area in the maxillofacial region with a duration of more than 8 weeks, in the absence of radiotherapy to the jaws. If the exposed bone necrotic area has a declared clinical evolution of up to 8 weeks, clinical follow-up is required to detect healing of the soft tissue continuity solution.
Lesions can occur spontaneously or after dental treatments, especially post-extractions. They do not tend to heal spontaneously. healing after flap surgery is difficult, and recurrence of lesions is common.

Conclusion

The most important method is prevention. It includes rigurousoral hygiene, conservative dental treatment where it can be applied, dental treatment with removing all compromised teeth before initiating bisphosphonate therapy. Informing the patient and doctors about the risks of treatment if oral surgery is necessary.

EADV CONGRESS
VIENNA
30 SEP - 3 OCT 2026

Abstract N°: 1797

MEK1/2 inhibition ameliorates clinical lesions in experimental pemphigus vulgaris

Shirin Emtenani*[1], Sabrina Patzelt[1], Maxi Hofrichter[1], Kiana Zarabadi[1], Yang TingYu[1], Christian Probst[2], Enno Schmidt[1, 3]

[1] Lübeck Institute of Experimental Dermatology, University of Lübeck, Lübeck, Germany
[2] Institute of Experimental Immunology, EUROIMMUN AG, Lübeck, Germany
[3] Department of Dermatology, University of Lübeck, Lübeck, Germany

Introduction
Pemphigus vulgaris (PV) is a life-threatening autoimmune blistering disease primarily driven by autoantibodies targeting desmoglein 3 (Dsg3), leading to loss of keratinocyte cohesion and clinically manifesting as blisters and erosions of surface-close mucosal tissues. Current therapies suppress autoantibody production but do not directly restore desmosomal adhesion. Existing preclinical models, including passive transfer of anti-Dsg3 IgG into neonatal mice or adoptive transfer of Dsg3-immunized splenocytes into immunocompromised recipients, are limited in their capacity to evaluate therapeutic interventions in adult, immunocompetent settings.

Materials and Methods
Here, we established an adult mouse model of PV by repeated injections of AK47, a recombinant monospecific anti-Dsg3 IgG1 antibody, into C57BL/6J mice.

Results
Within 12 days, AK47-treated mice reproducibly developed hallmark clinical and histopathological features of PV, including oral erosions, patchy alopecia, suprabasal acantholysis predominantly affecting mucosal tissues, and intercellular IgG deposition. Prophylactic and quasi-therapeutic intravenous immunoglobulin (IVIg), an established therapy for refractory PV, significantly attenuated disease progression. The selective MEK1/2 inhibitor selumetinib, previously shown to block anti-Dsg3 IgG-induced keratinocyte dissociation *in vitro*, reduced disease severity in clinically affected mice and suppressed ERK1/2 phosphorylation in lesional mucosa, supporting a role for MEK/ERK signaling in PV pathogenesis.

Conclusions
This model provides a robust preclinical platform for evaluating desmosome-stabilizing therapies and identifies the MEK/ERK signaling axis as a pharmacologically actionable target in PV.

EA DV CONGRESS
VIENNA
30 SEP - 3 OCT 2026

Abstract N°: 2713

Rare presentation of oral squamous cell carcinoma (SCC) with poor differentiation

Dr. Smriti Venkatesh*[1], Dr. Meghana Phiske[1], Dr. Shylaja Someshwar[1, 2]

[1] Mgm Institute of Health Sciences, Panvel, India

[2] Kasturba Medical College, Mangaluru, India

Introduction

Oral squamous cell carcinoma (OSCC) is most common malignancy of oral cavity. OSCC subtypes based on degree of tumour cell differentiation are well-differentiated (WDSC, most prevalent), moderately differentiated (MDSCC), and poorly differentiated (PDSCC). Submucous fibrosis, smoking, alcohol, betel nut chewing, poor dental hygiene, and malnourishment contribute to OSCC development in Asians. Genetic mutations and epigenetic changes in signalling pathways accumulate to initiate OSCC occurrence, beginning as dysplasia, developing into carcinoma in situ, and becoming malignant. Poorly differentiated OSCC have disparities in disease features, survival, higher risk of distant metastasis and local recurrence. Prognosis of OSCC is based on location of tumour, disease stage, lymph node metastases and patient's general health. Poorly differentiated SCC has worse prognosis and five-year overall survival rate of 30%. are important survival variables.

Case Presentation

A 58/M chronic tobacco chewer had single well-defined, oval, 3x2 cm, erythematous plaque with eroded, ulcerated and macerated surface, on mid portion of left inner side of lower lip, with bleeding points and hyperpigmentation in periphery, since 2 months. Lesions were tender, firm, fixed, indurated. Left buccal mucosa showed single well-defined, round, shallow ulcer, 2x2 cm with slightly eroded surface, with surrounding hyperpigmentation. There was no lymphadenopathy. Dermoscopy (both lesions) revealed white structureless areas , red structureless areas and linear vessels in periphery, s/o SCC. Incisional biopsy revealed proliferation and invasion of dysplastic squamous epithelial cells into dermis forming large irregular nests and bulky masses. Tumour cells demonstrated marked cellular atypia, loss of polarity, and increased mitotic activity. Surrounding dermis showed dense infiltrate of lymphocytes, plasma cells and eosinophils without keratin pearl formation. Findings were s/o poorly differentiated SCC.

Conclusion

In diagnosis, dermoscopy is supportive but biopsy remains gold standard. Early diagnosis and treatment are crucial to stop disease progression, prevent host’s immune suppression, and improve quality of life.

EA DV CONGRESS
VIENNA
30 SEP - 3 OCT 2026

Abstract N°: 3187

Mycophenolate mofetil–induced recurrent oral ulcerations in a pediatric transplant recipient

Hande Ermis Akkus*[1], Alihan Baylan[1], Oyku Bilge Yurtcu[1], Ozan Altuntas[2], Ayse Armutlu[3], Savaş Yaylı[1]

[1] Koç University School of Medicine, Department of Dermatology, Istanbul, Turkey, Istanbul, Türkiye
[2] Koc University Hospital, Department of Otolaryngology / ENT Clinic, Istanbul, Türkiye
[3] Koc University Hospital, Department of Pathology, Istanbul, Türkiye

Introduction

Mycophenolate mofetil (MMF) is a cornerstone of immunosuppression in solid organ transplantation. While generally well tolerated, oral mucosal adverse effects are rare and frequently misattributed to infectious etiologies in immunocompromised patients, leading to diagnostic delays.

Case Presentation

A 13-year-old girl, four months post-renal transplantation presented with progressively enlarging, painful oral ulcerations, accompanied by appetite loss, malaise, and low-grade fever. She was maintained on tacrolimus, mycophenolate mofetil (MMF), and corticosteroids, along with levothyroxine, a proton pump inhibitor, diltiazem, and prophylactic valacyclovir.

Bilateral major aphthous ulcers were observed on the wet labial mucosa near the oral commissures with a vegetative appearance and thick fibrinous exudate, along with a minor aphtha on the ventral tongue.

Although an upper respiratory tract infection occured two weeks prior, recurrent oral ulcers with or without preceding infections were denied. No cutaneous or acral involvement was noted. Genital ulcers, Behçet-related symptoms, recurrent oral ulcers w/wo following respiratory infections , periodic fever, cyclic neutropenia, and autoimmune features were absent.

Due to the atypical presentation of viral infections in immunocompromised patients, a comprehensive workup was performed, including PCR testing for HSV and CMV in serum samples and swab-based PCR of ulcer surface samples, all of which yielded negative results.

Histopathological evaluation of the ulcer biopsy revealed no viral cytopathic changes. Microbiological studies demonstrated filamentous bacteria and cocci on Giemsa staining and fungal spores without hyphal structures on Gomori methenamine silver (GMS) stain, findings considered consistent with secondary colonization. Confoundingly, EBV-PCR from ulcer tissue was positive, while EBER in situ hybridization was negative.

The patient was initially managed with symptomatic treatment and ganciclovir, with an EBV-associated ulcer was considered the leading diagnosis based on positive EBV PCR result and a history of upper respiratory tract infection. MMF was temporarily discontinued due to the development of concurrent neutropenia, while tacrolimus was maintained.

This resulted in prompt clinical improvement, with complete mucosal healing within one month. However, it remained unclear whether recovery was due to antiviral therapy or MMF withdrawal.. Upon normalization of neutrophil counts, MMF was reintroduced; identical oral ulcerations recurred within two weeks, confirming a positive rechallenge.

Due to the necessity of graft preservation, MMF was initially continued with colchicine (1 mg/day), providing only partial relief. As the ulcers progressed and impaired oral intake, MMF was discontinued again and the colchicine dose was increased to 1 mg twice daily. Although MMF-associated ulceration was the primary suspicionthe lesion characteristics raised suspicion for a superimposed or primary viral infection in the setting of immunosuppression (with CMV as the leading consideration); therefore, valganciclovir was initiated. Tissue PCR was not performed due to patient refusal. For significant pain, intralesional corticosteroid therapy was administered. Within days, pain subsided and the ulcerative lesions began to regress. At the two-week follow-up, complete healing with full re-epithelialization was attained.

Conclusion

MMF-induced oral ulceration is an underrecognized adverse effect in transplant recipients. The temporal relationship between MMF exposure, withdrawal, and rechallenge strongly supports a drug-induced etiology. Although detectable EBV DNA initially suggested an EBV-positive mucocutaneous ulcer, negative EBER in situ hybridization and the absence of lymphoproliferative or cytopathic changes in the biopsy made this diagnosis unlikely. Clinicians must maintain a high index of suspicion for MMF-induced toxicity in recalcitrant mucosal ulcers to avoid unnecessary antimicrobial interventions.

EA DV CONGRESS
VIENNA
30 SEP - 3 OCT 2026

Abstract N°: 3300

Vulvar Lichen Sclerosus in Pregnant Women: Characterization of Deliveries and Obstetric Lacerations

Maria J. Sanchez-Zapata*[1], Rochelle Torgerson[1], Alyssa Larish[2], Nessa Aghazadeh Mohandesi[1, 3]

[1] Department of Dermatology, Mayo Clinic., Rochester, MN, United States
[2] Department of Obstetrics and Gynecology, Mayo Clinic., Rochester, MN, United States
[3] Department of Clinical Genomics, Mayo Clinic., Rochester, MN, United States

Introduction

Vulvar lichen sclerosus (LS) is a chronic inflammatory skin disease primarily involving the anogenital region. Its incidence in reproductive-aged women remains unclear, partly due to under-recognition. There is limited information about the clinical course of vulvar LS in pregnancy or its impact on delivery outcomes. This study aims to report on the peripartum treatment course of vulvar LS and define immediate delivery outcomes in affected patients.

Materials and Methods

A retrospective patient cohort was identified and retrieved using an institutional medical informatics tool followed by review of electronic health records. Patients carrying the diagnosis of vulvar LS prior to their delivery between 7/2017 to 4/2026 were included. Basic descriptive statistics were reported where applicable, with a one sample binomial exact test performed to compare rates of genital lacerations between our sample and values reported in the literature.

Results

A total of 69 eligible patients underwent 88 deliveries during the study timeframe. The mean age of vulvar LS diagnosis was 27.6 ± 8.4 years, with seven cases diagnosed at before 18 years of age. Mean age at delivery was 31.9 ± 5.2 years with mean interval between vulvar LS diagnosis and delivery of 5 ± 6.7 years. Topical treatment for LS was used in 88.6% (n=78) of cases prior to pregnancy, only 53.8% (n=42) continued treatment during pregnancy. During pregnancy. clobetasol was the most frequent treatment (83.3%), followed by low to medium potency corticosteroids (14.2%) and calcineurin inhibitors (2.3%). 50 out of 88 (56.8%) cases started or continued treatment in post-partum period. Vaginal delivery occurred in 62.4% of cases (n=55), of those 30.9% (n=17) were first pregnancies, and 3.6% (n=2) were assisted vaginal deliveries. Cesarean occurred in 37.5% (n=33), all performed for various obstetric indications. Obstetric lacerations occurred in 80% (n=44) of vaginal deliveries, with 21.8% first degree, 34.5% second degree, 3.6% third degree and 20% other genital tract lacerations including vaginal, clitoral, periurethral and labial. Obstetric lacerations were observed in all nulliparous vaginal deliveries and in 50% (n=19) of multiparous vaginal deliveries. Perineal laceration rates among nulliparas with LS were higher than reported population rates (82.4% vs 55.6, p=0.03) whereas rates among multiparas were consistent with published literature (55.6% vs 53.2%) with no statistical significance difference (p=0.53). Active treatment during pregnancy was not found to be associated with lower incidence of obstetric lacerations (OR:1.20; CI 95% 0.51-2.82).

Conclusions

Our results suggest a possible association between vulvar LS and higher perineal lacerations rates in nulliparous

patients, with no significant difference observed in multiparous patients. LS remains undertreated during pregnancy, with only half of women receiving active treatment, underscoring the importance of provider and patient education to ensure treatment is continued throughout pregnancy. The relatively small cohort, retrospective nature of our study, and unmatched, population-level comparison group are limitations.

EADV CONGRESS
VIENNA
30 SEP - 3 OCT 2026

Abstract N°: 3539

Paraneoplastic Pemphigus Complicated with Diffuse Large B-Cell Lymphoma: A Case Report

Guomin Li*[1], Ruzeng Xue[1]

[1] Dermatology Hospital, Southern Medical University, Guangzhou, China

Introduction

Paraneoplastic pemphigus (PNP) is a rare, life-threatening autoimmune blistering disease closely associated with underlying malignancies, most commonly hematologic neoplasms. Clinical manifestations are often polymorphous, characterized by persistent oral mucosal erosion combined with various skin lesions, which can easily lead to misdiagnosis. The 2023 EADV guidelines provide clear diagnostic criteria for PNP, emphasizing a multimodal approach including histopathology, immunofluorescence, and antibody testing. Herein, we report a case of PNP confirmed by EADV 2023 criteria, which was later found to be complicated with diffuse large B-cell lymphoma (DLBCL), aiming to provide clinical insights for the early recognition, diagnosis, and management of this disease.

Case Presentation

A 55-year-old female presented to our hospital with 3-month oral mucosal erythema/erosion and 2-week erythematous lesions on the trunk and extremities. She was previously diagnosed with pemphigus elsewhere and treated with methylprednisolone (40 mg/d), cyclosporine (50 mg twice daily) and anti-infective therapy, but showed no response.

Physical examination showed painful, extensive oral mucosal erosion, scattered trunk/proximal extremity erythemas, and negative Nikolsky sign. Chest CT revealed chronic inflammatory foci (excluding Castleman disease); abdominal CT showed enlarged lymph nodes. Endoscopies demonstrated mucosal swelling/erosion and esophageal/gastric cardia ulcers; ELISA showed elevated anti-Dsg3 antibody.

Laboratory tests revealed progressive anemia, marked B-cell lymphocytosis, elevated inflammatory markers and anti-Dsg3 antibody. Histopathology showed keratinocyte necrosis and interface dermatitis. DIF demonstrated IgG intercellular deposition, C3 intercellular and basement membrane deposition; IIF was positive for monkey esophageal epithelium but negative for rat bladder epithelium.

Further antibody profiling using the Cytometric Bead Array showed positive anti-alpha2 macroglobulin-like protein 1 antibody, while all other tested antibodies (antienvoplakin, antiperiplakin, antidesmoplakin I and II) were negative. According to the 2023 EADV guidelines for PNP diagnosis, the patient met clinical suspicion and satisfied the second confirmation pathway (positive anti-alpha2 macroglobulin-like protein 1 antibody), thus confirming the diagnosis of PNP.

The patient received methylprednisolone 70 mg daily for 9 days, followed by 60 mg daily for 7 days, combined with weekly methotrexate 10 mg and 5 days of IVIG at 22.5 g daily. Hematology consultation was recommended for further workup including PET-CT and bone marrow aspiration. Subsequent PET-CT showed multiple enlarged lymph nodes and increased bone marrow uptake, highly suggestive of lymphoma, and lymph node biopsy confirmed B-cell non-Hodgkin lymphoma (diffuse large B-cell lymphoma, stage IV). Unfortunately, the patient developed life-threatening restrictive bronchiolitis during lymphoma treatment and was admitted to the intensive care unit.



Painful, extensive oral mucosal erosion.

Conclusion

This case highlights the clinical complexity of PNP, which often presents with persistent oral erosion and polymorphous skin lesions, easily leading to misdiagnosis as common pemphigus. Early recognition of PNP is critical, and a multimodal diagnostic approach (histopathology, immunofluorescence, antibody testing) based on the 2023 EADV guidelines is essential—PNP can still be diagnosed even if rat bladder IIF and anti-periplakin/anti-envoplakin antibodies are negative. Active screening for underlying malignancy, especially hematologic disorders, is mandatory in PNP patients, as the prognosis is closely related to the underlying tumor. Additionally, clinicians should stay alert for life-threatening complications such as bronchiolitis obliterans. This case provides valuable clinical experience for the diagnosis and management of PNP complicated with hematologic malignancies.

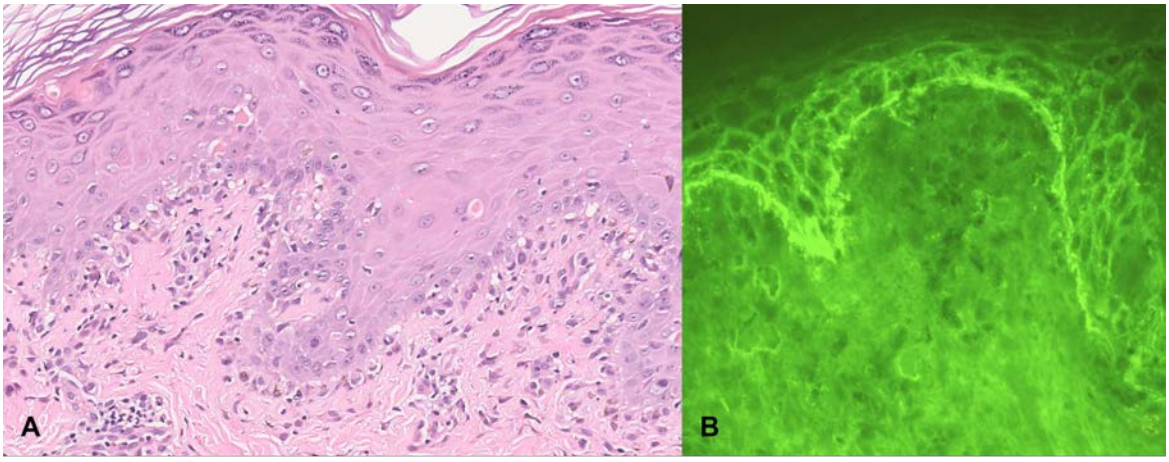

A,Histopathology showed keratinocyte necrosis and interface dermatitis (H & E ×400). B, DIF demonstrated C3 intercellular and basement membrane deposition

EADV CONGRESS
VIENNA
30 SEP - 3 OCT 2026

Abstract N°: 3541

Oral mucosal recurrence of anaplastic thyroid carcinoma: a rare manifestation of relapse

Landy Hayde Lopez Jimenez*[1], Alehymi Jeltsy Toribio agueda[1], Carlos López Durand[1], Linda Garcia Hidalgo[1]

[1] Instituto Nacional de Ciencias Médicas y Nutrición Salvador Zubirán, Ciudad de México, Mexico

Introduction

Anaplastic thyroid carcinoma (ATC) accounts for 1.3% to 9.8% of all thyroid cancers worldwide and is responsible for more than 50% of thyroid cancer-related mortality because of its highly aggressive course.(1) Although locoregional recurrence and distant metastases are common, mucocutaneous involvement is exceptionally rare. Among reported cases of cutaneous metastases from thyroid carcinoma, the anaplastic subtype represents approximately 15%, with the scalp being the most frequent site of involvement. (2,3) Oral mucosal metastasis is even more unusual: in an autopsy series, gingival mucosal involvement accounted for only 2% of metastatic sites, and no specific reports of tongue metastasis were identified. These findings underscore the exceptional nature of oral cavity involvement in ATC. (4)

We report a case of oral mucosal recurrence in a patient with anaplastic thyroid carcinoma arising from papillary thyroid carcinoma, highlighting the importance of recognizing atypical oral lesions as a possible sign of relapse.

Case Presentation

A 66-year-old woman with a history of anaplastic thyroid carcinoma arising from papillary thyroid carcinoma, diagnosed in October 2022 and treated with total thyroidectomy, central neck dissection, and radiotherapy, developed progressive dysphagia in June 2025. Oral examination revealed stomatitis involving the hard palate and dorsal tongue, characterized by multiple millimetric ulcers with erythematous borders, some confluent and asymptomatic. In addition, a stony-hard mass measuring approximately 2 cm was identified on the left lateral border of the tongue. Positron emission tomography demonstrated hypermetabolic activity in the lesion, prompting biopsy. Histopathologic examination of the tongue biopsy demonstrated metastatic anaplastic thyroid carcinoma, with positive immunohistochemical staining for PAX8 and CK7. The patient experienced rapid clinical deterioration and subsequently died.

Conclusion

Oral mucosal involvement in anaplastic thyroid carcinoma is exceedingly rare, and tongue recurrence appears to be exceptional. Therefore, ulcerative or tumoral oral lesions in patients with a history of ATC should prompt suspicion of metastatic relapse rather than benign inflammatory disease. Early recognition and timely biopsy are crucial in this highly aggressive malignancy.

EADV CONGRESS
VIENNA
30 SEP - 3 OCT 2026

Abstract N°: 3724

Beyond the Teeth: An Odontogenic Cutaneous Fistula Revealing a Pyogenic Granuloma

Sonia Monica Barbu*[1], Radu George Ionescu[1], Cătălin Mihai Popescu[1, 2], Raluca Popescu[1, 2]

[1] Colentina Hospital, Dermatology I, Bucharest, Romania

[2] University of Medicine and Pharmacy "Carol Davila", Bucharest, Romania

Introduction

Cutaneous sinus tracts of odontogenic origin represent an uncommon extraoral manifestation of chronic dental infection, most frequently associated with persistent periapical or periodontal inflammation. These lesions may clinically mimic a wide spectrum of dermatological, infectious, or neoplastic conditions, often resulting in delayed diagnosis and inappropriate treatment. Management generally involves elimination of the odontogenic source through endodontic treatment or extraction, combined with surgical management of persistent cutaneous lesions when necessary.We present a chronic odontogenic cutaneous fistula associated with pyogenic granuloma formation in an edentulous woman, emphasizing the diagnostic challenges posed by its atypical long-term evolution and the importance of considering multiple differential diagnoses, including cutaneous malignancy.

Case Presentation

Materials & Methods

A 54-year-old woman presented with a painful cutaneous lesion located on the mental region, evolving progressively over a period of seven years. Dermatological examination revealed a solitary erythematous nodular lesion measuring approximately 1 cm, with central ulceration, hemorrhagic crusting, and a draining sinus opening associated with exuberant granulation tissue. The lesion was tender on palpation. Clinical examination showed a completely edentulous patient with a history of chronic dental infection and recurrent periodontal abscesses predating tooth loss. The patient reported persistent intermittent drainage from the lesion and acknowledged postponing dental care for several years because of severe dental anxiety. Mobilization of the overlying skin demonstrated adherence to the mandibular bone with localized retractility of the inflamed tissue, suggestive of a chronic fistulous tract. Her medical history was significant for a previous cutaneous squamous cell carcinoma of the right thigh.Considering the chronic ulcerated appearance and oncologic history, differential diagnoses included pyogenic granuloma, cutaneous sinus tract of odontogenic origin, squamous cell carcinoma, infected epidermal cyst, actinomycosis, and chronic osteomyelitis. An incisional punch biopsy (4 mm) was performed at the peripheral edge of the lesion, including both ulcerated and adjacent inflammatory tissue, in accordance with recommendations for chronic ulcerated facial lesions suspicious for inflammatory or neoplastic pathology. Histopathological examination was complemented by correlation with the clinical findings.

Results

Histopathological examination demonstrated lobular capillary proliferation embedded in an edematous stroma associated with mixed inflammatory infiltrate and granulation tissue, consistent with pyogenic granuloma. No cytological atypia or malignant proliferation suggestive of squamous cell carcinoma was identified. Clinicopathological correlation supported the diagnosis of a chronic odontogenic cutaneous fistula with reactive pyogenic granuloma arising at the external fistulous opening secondary to longstanding periodontal infection. The patient was referred for maxillofacial and dental evaluation in order to investigate residual mandibular infectious foci and to establish definitive therapeutic management.

Conclusion

Odontogenic cutaneous fistulas remain an important diagnostic pitfall in dermatological practice, particularly in patients with prolonged disease evolution and atypical presentations. Chronic inflammatory lesions of the lower face may simulate infectious, reactive, or malignant processes, especially in individuals with a personal history of cutaneous carcinoma. This case highlights the importance of careful clinicopathological correlation and consideration of odontogenic sources in chronic draining facial lesions, even in edentulous patients. Early recognition may prevent years of unnecessary evolution, repeated treatments, and diagnostic delay.