EADV CONGRESS
VIENNA
30 SEP - 3 OCT 2026

Abstract N°: 47

"Innovative Music-Based Public Health Communication in Dermatology: Raising Awareness of Drug-Resistant Dermatophytosis and Harmful Skin-Whitening Practices"

Ajith Kannangara*[1]

[1] The Skin Clinic, Galle, Sri Lanka

Introduction

Background

Dermatological conditions such as dermatophytosis and complications related to cosmetic skin-lightening products are major public health concerns in many tropical countries. Misuse of topical steroid–antifungal combinations has contributed to the emergence of drug-resistant dermatophytosis, while unregulated skin-whitening products containing steroids, hydroquinone, and mercury continue to cause significant dermatological harm. Innovative approaches are needed to improve public awareness and promote safer practices.

Objective

To explore the use of music-based public health messaging as a novel strategy to increase awareness of antifungal resistance and the risks associated with skin-whitening product misuse.

Materials and Methods

Methods

Two dermatology awareness songs were developed in Sri Lanka as part of a public education initiative by Skin Sri Lanka.The first song focuses on the message "Ringworm needs antifungals — not steroids," addressing steroid misuse and emerging drug-resistant tinea.The second song highlights the social and medical consequences of cosmetic skin-lightening practices, emphasizing the risks of steroid and hydroquinone-containing products.Both songs were distributed through social media platforms and online video channels to reach a broad audience. The initiative aimed to combine entertainment with dermatology education to improve public engagement.

Results

Results

The awareness songs generated substantial engagement on digital platforms and were shared among dermatology networks and patient advocacy communities. The initiative demonstrated that music and creative media can effectively communicate dermatological health messages, particularly to younger audiences who are highly active on social media.

Conclusions

Conclusion

Creative communication strategies such as music-based awareness campaigns may represent a novel and scalable approach for dermatology public health education, particularly in regions affected by steroid misuse and cosmetic skin-lightening practices. Such initiatives could complement traditional medical education and support global efforts to combat antifungal resistance and unsafe cosmetic practices.

EADV CONGRESS
VIENNA
30 SEP - 3 OCT 2026

Abstract N°: 61

A large syrindocystadenoma papilliferum arising from nevus sebaceous in an elderly patient: A classic diagnosis in an unusual context.

Shweh Fern Loo*[1], Suyin Ong[1], Yin Lin Lynne Goh[1], Lydia Tang-lin[1]

[1] Changi General Hospital, Singapore, Singapore

Introduction

Syringocystadenoma papilliferum (SCAP) is a rare benign sweat gland tumor that typically presents in childhood or adolescence, often arising within a pre-existing naevus sebaceous. Occurrence in the elderly is uncommon and may mimic malignant neoplasms

Case Presentation

An 83-year-old woman with multiple comorbidities presented with a long-standing scalp lesion that had gradually enlarged over 30 years. The lesion was intermittently associated with purulent and bloody discharge but remained painless. Examination revealed a 6 × 4 cm friable, papillomatous mass with a macerated surface and underlying plaque over left occipital scalp, without regional lymphadenopathy. Routine blood tests were unremarkable aside from her baseline chronic kidney disease profile. Given her advanced age, squamous cell carcinoma (SCC) was the primary concern. However, the lesion appeared more consistent with SCAP within a naevus sebaceous. Excision biopsy revealed a well-circumscribed dermal lesion connected to the epidermis, composed of papillary projections lined by squamous and bilayered columnar epithelium with characteristic decapitation secretion. The stroma showed dense plasma cell infiltration. Adjacent epidermal and adnexal changes confirmed an underlying naevus sebaceous. No malignant features were identified. Complete excision was achieved, and at three-months follow-up, the surgical site had healed well with no recurrence.

Conclusion

This case highlights a rare presentation of SCAP arising from naevus sebaceous in an elderly patient. Despite its alarming clinical appearance and unusual context, SCAP remains a benign entity curable by complete excision. Awareness of such atypical presentations is important to avoid misdiagnosis and unnecessary overtreatment, underscoring the importance of clinicopathological correlation.

EA DV CONGRESS
VIENNA
30 SEP - 3 OCT 2026

Abstract N°: 78

A Global Atlas of Digital Dermatology to Map Innovation and Disparities

Fabian Gröger*[1, 2], Simone Lionetti[2], Philippe Gottfrois[1, 3], Alvaro Gonzalez-Jimenez[3], Lea Habermacher[3], Ludovic Amruthalingam[2], Matthew Groh[4], Marc Pouly[2], Alexander Navarini[1, 3]

[1] University of Basel, Basel, Switzerland
[2] Lucerne University of Applied Sciences, Lucerne, Switzerland
[3] University Hospital of Basel, Basel, Switzerland
[4] Northwestern University, Illinois, United States

Introduction

Artificial intelligence in dermatology is limited not only by dataset size, but also by unknown gaps in diagnostic and demographic coverage. Public dermatology image collections have expanded rapidly, yet it remains unclear whether new datasets genuinely broaden clinical representation or largely duplicate what already exists. We therefore developed SkinMap to quantify coverage, novelty, redundancy and bias across the public dermatology imaging landscape.

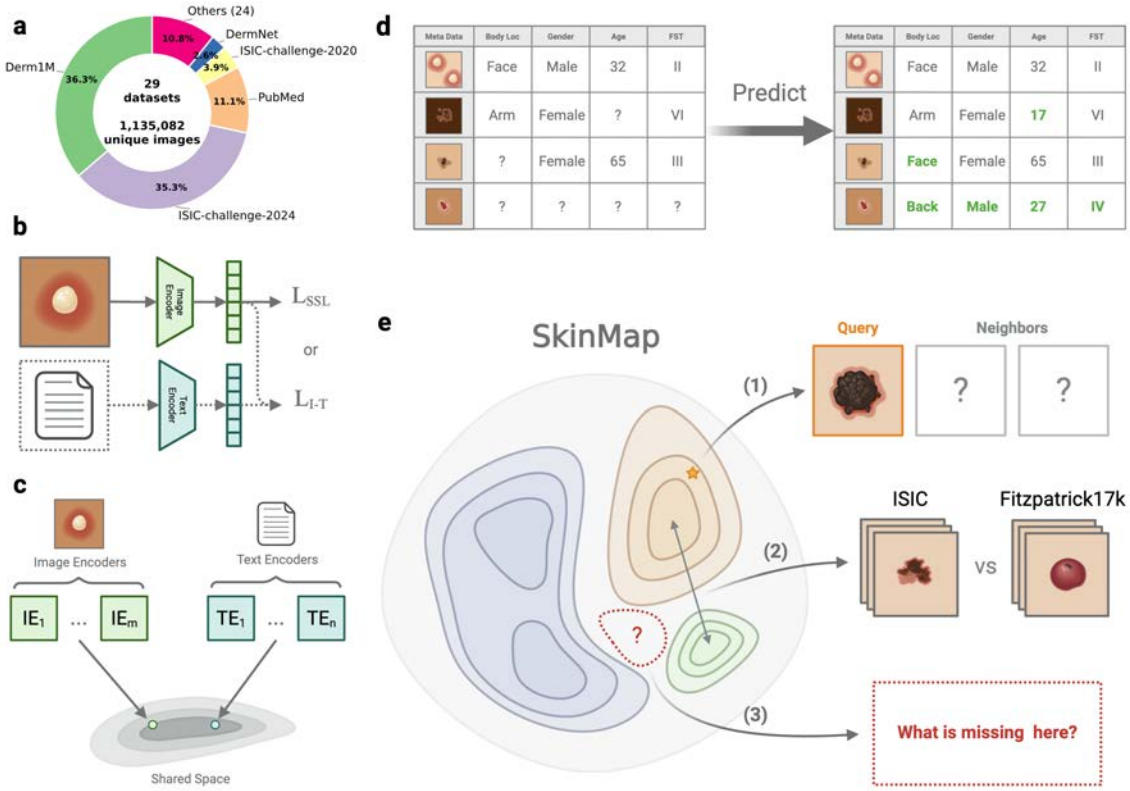

Materials and Methods

We aggregated and harmonised 29 public dermatology datasets into a unified atlas containing 1,135,082 unique images. A multimodal embedding framework combined image and text information to map visual and clinical similarity across datasets. Using the shared embedding space, we imputed missing metadata, including Fitzpatrick

skin type, age, sex, anatomical site, and geographic origin, enabling population-level analysis of the full atlas. We then quantified demographic representation, temporal novelty, inter-dataset redundancy, and structural gaps, and evaluated atlas-based retrieval on held-out datasets.

Results

Despite exponential growth in dataset size, informational novelty plateaued, indicating diminishing returns from current collection strategies. Major inequities were identified: Fitzpatrick skin types V-VI represented only 5.8% of images, and paediatric cases only 3.0%. The atlas was strongly skewed toward Western, fair-skinned, and middle-aged populations, while rare diseases and several phenotype combinations remained underrepresented. Multiple nominally independent datasets showed substantial overlap, suggesting that some published "external" validations may in fact approximate internal validation. Structural voids were detected in clinically relevant areas, including nail disease and paediatric dermatoses in darker skin tones.

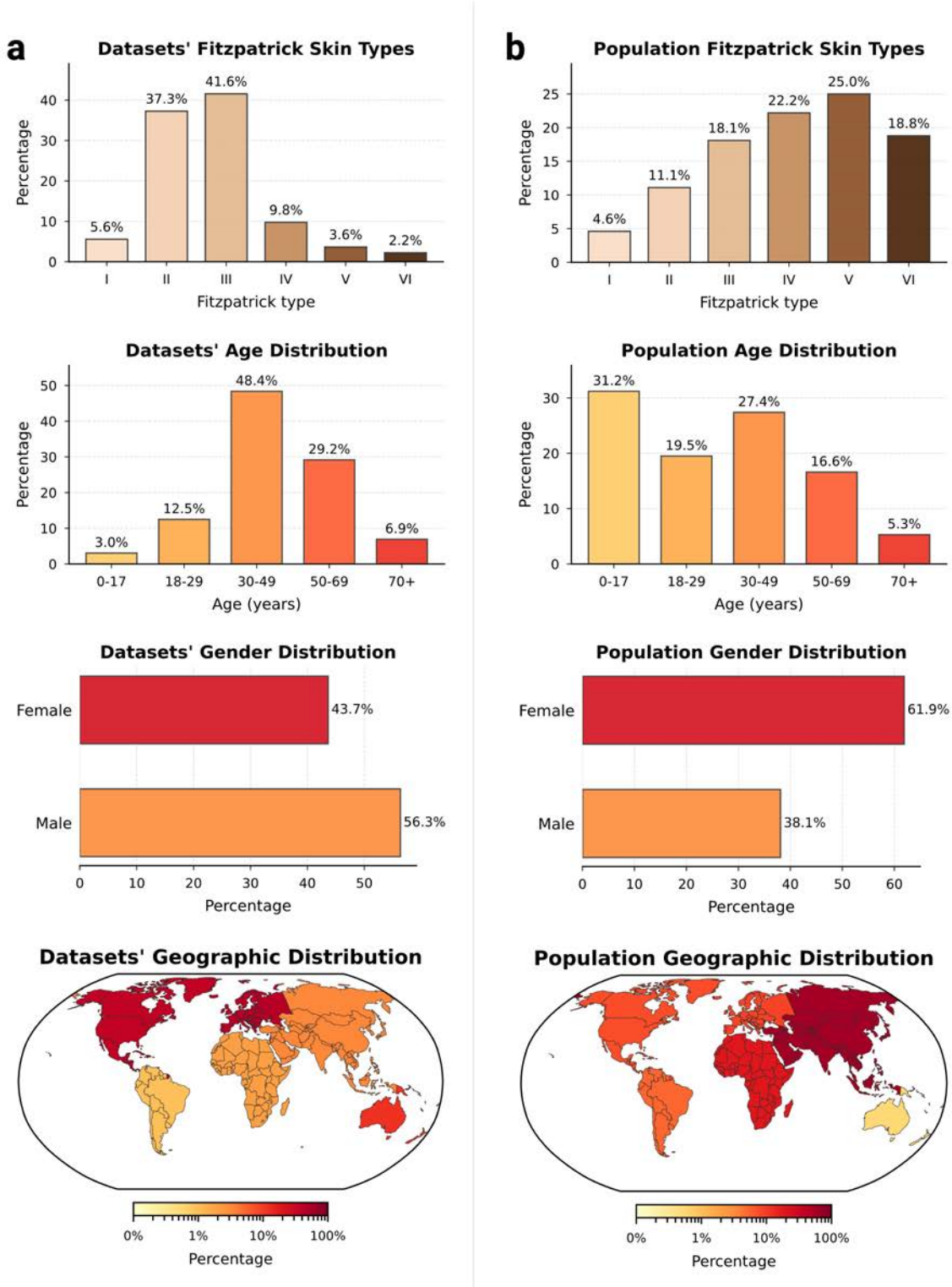

Conclusions

Public dermatology datasets are increasing in size but not in proportion to clinical diversity. SkinMap provides a quantitative framework for identifying blind spots, detecting redundancy, and guiding high-yield data acquisition. Moving from unguided data accumulation to strategic collection of underrepresented phenotypes, darker skin tones, paediatric cases, and rare diseases may improve fairness, robustness, and real-world clinical utility of dermatology AI.

EADV CONGRESS
VIENNA
30 SEP - 3 OCT 2026

Abstract N°: 119

Papular sarcoidosis: A Diagnostic Pitfall Successfully Treated with Hydroxychloroquine

Sachithra Samarakoon*[1], Chandani Udagedara[1], Hasini Jayasundara[1], Anuththara Wanninayake[2]

[1] NH Colombo, colombo, Sri Lanka
[2] NH Kandy, Kandy, Sri Lanka

Introduction
Sarcoidosis is a multisystem granulomatous disorder of unknown etiology that most commonly affects the lungs and intrathoracic lymph nodes. Cutaneous involvement occurs in a subset of patients and can present with a wide spectrum of clinical manifestations. Papular sarcoidosis is a relatively rare form of cutaneous sarcoidosis and may represent a diagnostic challenge because it can mimic other papular dermatoses. Recognition of this entity is important, particularly when it presents without systemic involvement.

Case Presentation
A 51-year-old female with no significant past medical history presented with a three-week history of erythematous, raised papules involving multiple areas of the body. The lesions were distributed over the upper limbs, upper back, upper chest, and lower limbs. The patient did not report systemic symptoms such as fever, fatigue, weight loss, or respiratory complaints. Dermatological examination revealed multiple well-defined, firm, erythematous papules in the affected areas. A skin biopsy was performed and histopathological examination demonstrated non-caseating granulomas composed of epithelioid histiocytes with minimal lymphocytic infiltrate, consistent with cutaneous sarcoidosis. Further investigations were carried out to assess systemic involvement. Chest radiography showed no abnormalities, and pulmonary function tests were within normal limits, indicating the absence of pulmonary sarcoidosis. Laboratory investigations including serum calcium and angiotensin-converting enzyme (ACE) levels were also within normal ranges. Based on the clinical presentation, histopathological findings, and absence of systemic involvement, a diagnosis of isolated papular cutaneous sarcoidosis was made. The patient was commenced on hydroxychloroquine (HCQ) therapy. During follow-up, she demonstrated significant clinical improvement with progressive reduction and resolution of the cutaneous lesions, without evidence of systemic progression.

Conclusion
This case highlights papular sarcoidosis as an uncommon manifestation of cutaneous sarcoidosis that may occur in the absence of pulmonary or systemic disease. Accurate diagnosis requires a high index of suspicion and confirmation with histopathological evaluation. Early initiation of appropriate therapy such as hydroxychloroquine can result in significant improvement of skin lesions and favorable clinical outcomes. Careful monitoring is important to detect any future systemic involvement

EA DV CONGRESS
VIENNA
30 SEP - 3 OCT 2026

Abstract N°: 125

Results from the 2025 British National Teledermatology Standards Audit

Soha Tawfik*[1], Julia Fordham[2], Carolyn Charman[3], David DeBerker[4], Alexandra Shaw[5], Hamisha Salih[6], Hayley Smith[7], Rebecca Tweddell[8], Tania von Hospenthal[9], Emma Lennard[9], Tanya Tumbeva[9], M. Firouz Mohd Mustapa[9], Zoe Venables[10]

[1] 1-Department of Dermatology, Venereology and Andrology, Faculty of Medicine, Alexandria University, Egypt 2-Imperial College Healthcare NHS Trust, Imperial College Healthcare NHS Trust, London, United Kingdom
[2] Torbay and South Devon NHS Foundation Trust, South Devon, United Kingdom
[3] Royal Devon University Healthcare NHS Foundation Trust, Exeter, United Kingdom
[4] University Hospitals Bristol NHS Foundation Trust, Bristol, United Kingdom
[5] Portsmouth Hospitals University NHS Trust, Portsmouth, United Kingdom
[6] University Hospitals Sussex NHS Foundation Trust, Brighton, United Kingdom
[7] Sheffield Teaching Hospitals NHS Foundation Trust, Sheffield, United Kingdom
[8] Surrey and Sussex Healthcare NHS Trust, Crawley, UK, Crawley, United Kingdom
[9] British Association of Dermatologists, London, UK, London, United Kingdom
[10] Norfolk and Norwich University Hospitals Foundation Trust, Norwich Medical School, University of East Anglia, Norwich, United Kingdom

Introduction
Teledermatology has become a vital tool in enhancing access to dermatology services. The aim of the british national audit was to assess compliance with the 2024 British Association of Dermatologists (BAD) Teledermatology Standards: evaluating pathway performance, response time, image acquisition and quality of clinical history and response.

Materials and Methods
In September 2025, BAD members from the United Kingdom (UK) were invited to submit data on either 50 consecutive departmental teledermatology cases or 20 individual cases on both the urgent suspected skin cancer (USSC) or advice and guidance (A&G) pathways. Mann-Whitney test was used for group comparisons.

Results
2,436 cases from 55 UK centres across the UK were submitted: 929 on A&G and 1,507 on USSC referrals.
Median response time was significantly shorter for the USSC pathway (A&G 9 days, USSC 5 days, U = 522,682, p< .001).
The most common source of images was in GP setting for the A&G (651 (71%)), and hospital setting for USSC pathway 772 (51.2%). USSC pathway showed superior image quality scores (U = 371,523.5, p < .001). Images taken in secondary care community hubs achieved the highest image quality and fastest turnaround times. Hospital-acquired photos followed in image quality but showed some delayed clinician response to referral. Only 3.5% of images were unusable.
Clinical history was generally good; however, frailty scores were only documented in 26.8% of referrals, no reporting of bleeding altering medications in 21.8% or implantable devices in 32.1% of cases.
Overall, 4.4% were confirmed as melanoma, melanoma in situ, or squamous cell carcinoma (1.8% A&G, 6.1% USSC).
The median time for diagnosing melanoma/melanoma in situ via A&G was 9 days (range 0-162, n=9) vs. 3 days

via USSC (range 2-39, n=45); the difference was not significant.

Conclusion

The first national audit of teledermatology services provides an important benchmark and preliminary assessment. Improvement is needed in history documentation and standardising A&G response times to adhere to national guidance.

EA DV CONGRESS
VIENNA
30 SEP - 3 OCT 2026

Abstract N°: 233

Qualitative efficacy comparison between flavonoids and phenolic acid compounds in photoaging : A comprehensive systematic review in pre-clinical and clinical settings

I Komang Harry Supradnyan*[1], I Gusti Ayu Agung Praharsini[2], I Made Jawi[3], Made Ratna Saraswati[4]

[1] Dermatology Venereology and Aesthetic Department, Buleleng General Hospital, Faculty of Medicine, Ganesha University of Education, Singaraja, Bali, Indonesia

[2] Dermatology Venereology and Aesthetic Department, Faculty of Medicine, Udayana University, Prof. Dr. I G.N.G Ngoerah Hospital Denpasar, Denpasar, Bali, Indonesia

[3] Pharmacology Department, Faculty of Medicine, Udayana University, Denpasar, Bali, Indonesia

[4] Endocrinology and Metabolism Division, Department of Internal Medicine, Faculty of Medicine, Udayana University, Prof. Dr. I G.N.G. Ngoerah Hospital, Denpasar, Bali, Indonesia

Introduction

Photoaging is a chronic form of cumulative, sun-induced skin damage triggered by repeated exposure to ultraviolet radiation, which activates oxidative stress, inflammation, and extracellular matrix degradation pathways. Photoaging prevention has primarily been achieved via a daily, multi-layered strategy consisting of broad-spectrum sunscreen use, physical protection, and lifestyle modification to minimize cumulative ultraviolet radiation exposure. Concurrently, topical and oral antioxidants have been studied for reactive oxygen species scavenging and modulation of inflammatory-collagenolytic signaling, with increasing support from mechanistic studies and clinical investigationsNatural polyphenols, such as epigallocatechin gallate, quercetin, ellagic acid, and ferulic acid, exhibit promising antioxidant and photoprotective effects. This systematic review aims to qualitatively compare the efficacy of epigallocatechin gallate, quercetin, ellagic acid, and ferulic acid as antioxidant and photoprotective agents across pre-clinical and clinical photoaging studies.

Materials and Methods

A systematic search was conducted in PubMed, ScienceDirect, and the Cochrane Library, following the PRISMA 2020 guidelines, using the Boolean operators “flavonoids” OR “phenolic acids” AND “photoaging”. Risk of bias was assessed using Cochrane RoB 2.0, ROBINS-I, SYRCLE, and ToxRTool. Data were extracted and qualitatively synthesized. A total of 24 studies were included, consisting of 19 preclinical and 5 clinical investigations. Thirteen were in vitro, three combined in vitro and in vivo, four were ex vivo or human-ex vivo, and four were clinical trials. Study models encompassed human dermal fibroblasts, keratinocytes, reconstructed skin, zebrafish, and healthy adult participants. Investigated compounds included EGCG, quercetin, ellagic acid, and ferulic acid, derived from botanical sources.

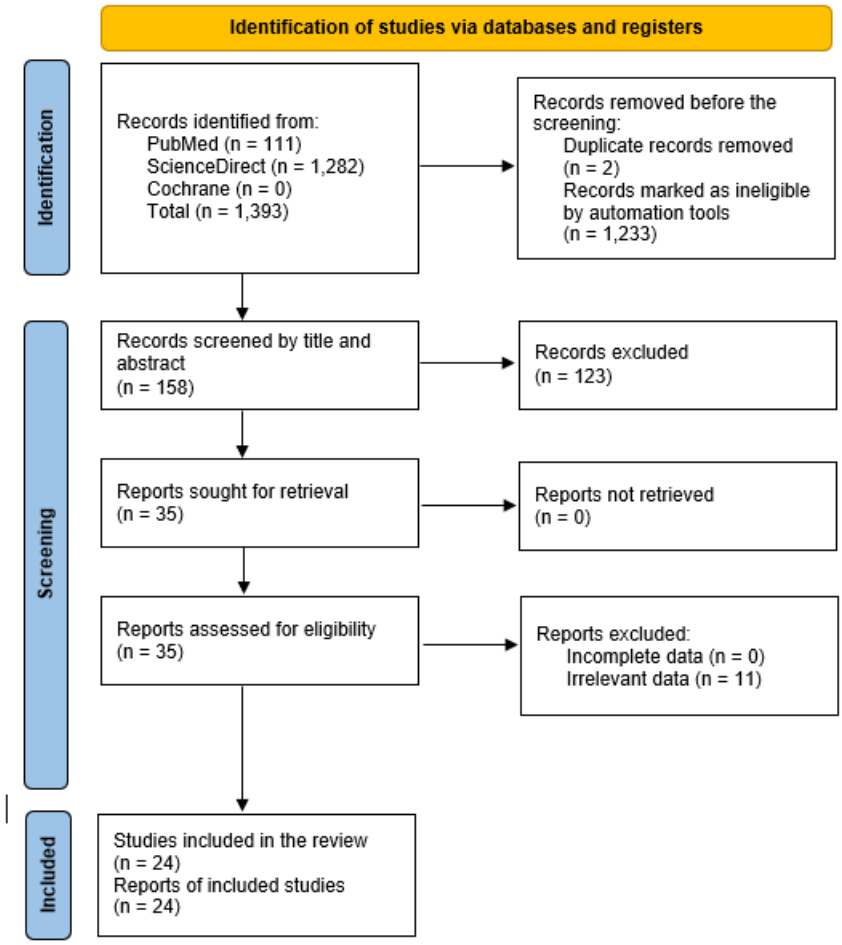

PRISMA Flowchart

Results

Primary outcomes demonstrated antioxidant, anti-inflammatory, and extracellular matrix-preserving effects, with clinical trials confirming reductions in erythema, improved dermal elasticity, and enhanced photoprotection against ultraviolet-induced skin damage. Study designs varied across in vitro, in vivo, ex vivo, and clinical approaches. Experimental models included human dermal fibroblasts (e.g., Hs68), keratinocytes (e.g., HaCaT), reconstructed human skin, zebrafish or small-animal models, and human participants with healthy or photoaged skin. EGCG was primarily derived from Camellia sinensis, quercetin from multiple botanical sources, ellagic acid from Punica granatum, and ferulic acid was assessed either as a single agent or in combination formulations.Across studies, EGCG demonstrated protective effects on the extracellular matrix, including preservation of fibulin-5, although no significant reduction in cyclobutane pyrimidine dimers was observed at 24 hours. Ellagic acid was associated with increased erythema resistance, reflected by a higher minimal erythema dose, and modulation of the skin microbiome. Ferulic acid showed attenuation of UV-induced erythema, improved skin hydration, and enhanced healing responses, particularly in topical combination formulations with vitamins C and E. Risk of bias in randomized trials was generally low to moderate, with some concerns related to incomplete reporting and limited outcome domains. Non-randomized, in vitro, and animal studies showed higher risks of bias, mainly due to confounding, lack of blinding, and insufficient methodological transparency.

Conclusions

Flavonoids and phenolic acids show consistent antioxidant and photoprotective effects in photoaging models, but evidence remains heterogeneous and clinical translation is uncertain. Standardized clinical trials are needed to confirm efficacy, optimize dosing and formulations, and establish long-term safety.

EADV CONGRESS
VIENNA
30 SEP - 3 OCT 2026

Abstract N°: 275

Framed By Friction: Acanthoma Fissuratum Case Study

Gizem Özge Öztürk Aktaş*[1], Anıl Sezer[1], Selcen Kundak[1], Meltem Türkmen[1]

[1] Izmir City Hospital, Izmir, Türkiye

Introduction

Acanthoma fissuratum is an uncommon dermatological condition that typically arises as a result of chronic, repetitive trauma to the affected area. It is also referred to in the literature as "spectacle frame granuloma" or "granuloma fissuratum." However, these terms are considered misnomers, as histopathological evaluation does not reveal a true granulomatous reaction. The exact incidence remains uncertain, largely because many affected individuals do not seek specific medical attention and the condition may therefore go unreported. Factors including poorly fitting eyeglass frames, the pressure exerted by their weight, and anatomical irregularities all play a role in the development of these lesions.

Acanthoma fissuratum most commonly affects areas subjected to sustained pressure from eyeglass frames, particularly the retroauricular sulcus, the superior auricular groove, and the lateral aspect of the nasal bridge near the medial canthus. Nevertheless, involvement of less typical sites has also been reported, including the posterior fourchette of the vulva, the penis, and the external auditory canal.

This study aims to further highlight the clinical characteristics of acanthoma fissuratum and emphasize the importance of correct identification in routine practice.

Case Presentation

A 64-year-old man presented with a one-year history of pruritic, hyperpigmented plaques located bilaterally in the retroauricular regions and in the temporal regions. The lesions exhibited central ulceration with slightly raised borders, and a gradual increase in plaque size and ulcer depth was observed over time. He had been wearing spectacles for presbyopia for approximately 10 years. On examination, linear grooves within the plaques corresponded to the points of contact with the spectacle frames in the retroauricular and temporal regions. Dermoscopy was performed to exclude malignancy.

Following adjustment of the spectacle frames and the regular use of emollients, the lesions showed marked regression. Based on the clinical findings and the response to these measures, a diagnosis of acanthoma fissuratum was made.

Conclusion

Acanthoma fissuratum typically manifests as a unilateral, firm, flesh-colored papule, plaque, or nodule characterized by a central groove that bisects the lesion. Its morphology has frequently been described as resembling a coffee-bean appearance. Histopathological evaluation demonstrates acanthosis accompanied by hyperkeratosis and variable parakeratosis, with attenuation of the epidermis along the longitudinal groove, which may contain keratin.

Despite being a benign condition, acanthoma fissuratum frequently necessitates consideration of basal cell carcinoma and squamous cell carcinoma in the differential diagnosis. Consequently, obtaining a comprehensive patient history is essential to prevent unwarranted procedures and anxiety. In many cases, a 2- to 3-week period of withdrawal of the suspected causative factor, when feasible, followed by rechallenge, enables confirmation of the diagnosis without further diagnostic or therapeutic measures.

The cornerstone of management in acanthoma fissuratum is elimination of the chronic mechanical irritation, which often results in regression of the lesion. In cases that do not resolve with conservative measures, additional

therapeutic options such as surgical excision, intralesional corticosteroid injections, and electrosurgical techniques may be considered.

EADV CONGRESS
VIENNA
30 SEP - 3 OCT 2026

Abstract N°: 341

Dormant No More: Viral Reactivation in the Immunocompromised Host

Andreea-Caterina Rusu*[1], Carina-Andreea Bazon[1], Stefan Galimard-Hermant[2], Anca Zbranca[1]

[1] Emergency Clinical Hospital of St. Spiridon, iasi, Romania
[2] Regional Institute of Oncology, iasi, Romania

Introduction

Herpes zoster (HZ), resulting from the reactivation of latent varicella–zoster virus (VZV), represents a clinically significant complication in immunocompromised populations, particularly among patients undergoing chemotherapy. Impairment of cell-mediated immunity facilitates viral reactivation, leading to a characteristic dermatomal eruption often accompanied by severe neuropathic pain. Beyond its acute presentation, HZ is associated with considerable morbidity, including post-herpetic neuralgia and an increased risk of secondary infections. Early recognition and prompt management are essential to reduce complications and improve patient outcomes, particularly in oncologic settings.

Case Presentation

We report the case of a 72-year-old male with significant cardiovascular comorbidities and a history of Kaposi's sarcoma, who developed herpes zoster during palliative chemotherapy. The initial diagnosis of Kaposi's sarcoma was established in 2021 following excision of two nodular lesions on the dorsal foot, with histopathological and immunohistochemical confirmation (CD31+, HHV-8+). Complete remission was achieved after radiotherapy in 2022. After a two-year lapse in follow-up, the patient re-presented in March 2024 with bulky tumoral lesions, confirmed as metastatic recurrence by imaging and biopsy. Palliative chemotherapy with pegylated liposomal doxorubicin was initiated. Following the third cycle of chemotherapy, the patient was referred to the dermatology department for evaluation of a painful cutaneous eruption. Clinical examination revealed a well-defined, unilateral dermatomal rash involving the left hemithorax and upper abdomen. The lesions consisted of clustered vesicles and pustules on an erythematous base, with partial crusting. The eruption was associated with moderate pruritus and significant localized pain, consistent with neuropathic involvement. Given the patient's immunocompromised status, the clinical presentation was highly suggestive of VZV reactivation. In the absence of atypical features requiring additional laboratory confirmation, a diagnosis of herpes zoster was established clinically. Prompt systemic antiviral therapy was initiated, alongside supportive dermatologic care, including local antiseptic measures, wound hygiene and analgesic treatment for pain control. The patient demonstrated a rapid and favorable clinical response, with a marked decrease in new lesion formation, progressive crusting of existing lesions and significant relief of pruritus and pain within a few days of treatment initiation. Importantly, no signs of secondary bacterial infection or systemic dissemination were observed and lesion progression was successfully halted.This case underscores the importance of early dermatologic assessment and highlights the value of interdisciplinary collaboration in the management of immunocompromised patients.

Conclusion

Herpes zoster remains a frequent and potentially severe complication in immunosuppressed individuals, particularly those undergoing chemotherapy. In this case, VZV reactivation was most likely triggered by chemotherapy-induced immunosuppression in the setting of metastatic Kaposi's sarcoma. Although the diagnosis is often clinical, delayed recognition may lead to significant morbidity. This report emphasizes the need for heightened clinical vigilance, early diagnosis, and prompt antiviral therapy in at-risk populations, as well as the critical role of coordinated care between oncology and dermatology in optimizing patient outcomes.

EA DV CONGRESS
VIENNA
30 SEP - 3 OCT 2026

Abstract N°: 405

Skin tone inclusion in U.S. medical educational resources: a systematic review of literature, corrective tools, and possible solutions.

Emily May[1], Layla Al-Zubi*[2, 3], Ahona Mukherjee[4], Surgi Modi[5], Awar Biong[6], Amirreza Haghighi[7]

[1] University of Virginia School of Medicine, Charlottesville, United States
[2] Harvard Medical School, Boston, United States
[3] Harvard Law School, Cambridge, United States
[4] Tulane University School of Medicine, New Orleans, United States
[5] Medical College of Georgia, Augusta, United States
[6] University of Virginia, Charlottesville, United States
[7] Brigham and Women's Hospital and Harvard Medical School, Boston, United States

Introduction
Equitable medical education requires accurate representation of diverse patient populations. However, the extent of skin tone diversity in U.S. medical educational resources and its implications for clinical training remain incompletely characterized. This systematic review evaluates representation patterns and identifies current strategies to address disparities.

Materials and Methods
A systematic search of PubMed was conducted for English-language studies published between March 2018 and March 10, 2023. Search terms included combinations of “diversity,” “images,” “medical,” and “education.” Studies were included if they evaluated skin tone representation in provider-facing educational materials (e.g., textbooks, journals, curricula) or assessed tools to improve representation. Studies lacking clear methodology or quantitative analysis were excluded. Twenty studies met inclusion criteria. Data extraction was performed by five reviewers, with dual independent review for study characteristics and representation metrics.

Results
Across dermatologic and non-dermatologic educational resources, light skin tones were consistently overrepresented, while dark skin tones were markedly underrepresented and, in some cases, entirely absent. When quantified using scales such as the Fitzpatrick Skin Type or Massey-Martin scale, dark skin tones comprised a minority of images across most specialties, often estimated at <15%. Notable exceptions included overrepresentation of dark skin in select stigmatized conditions (e.g., infectious diseases, sarcoidosis), suggesting potential bias in disease-skin tone associations. Several studies demonstrated that trainees exhibited lower diagnostic confidence and accuracy when evaluating conditions in darker skin tones. Identified corrective tools primarily focused on supplemental curricular interventions, including targeted lectures, diversified image databases, and institutional review frameworks.

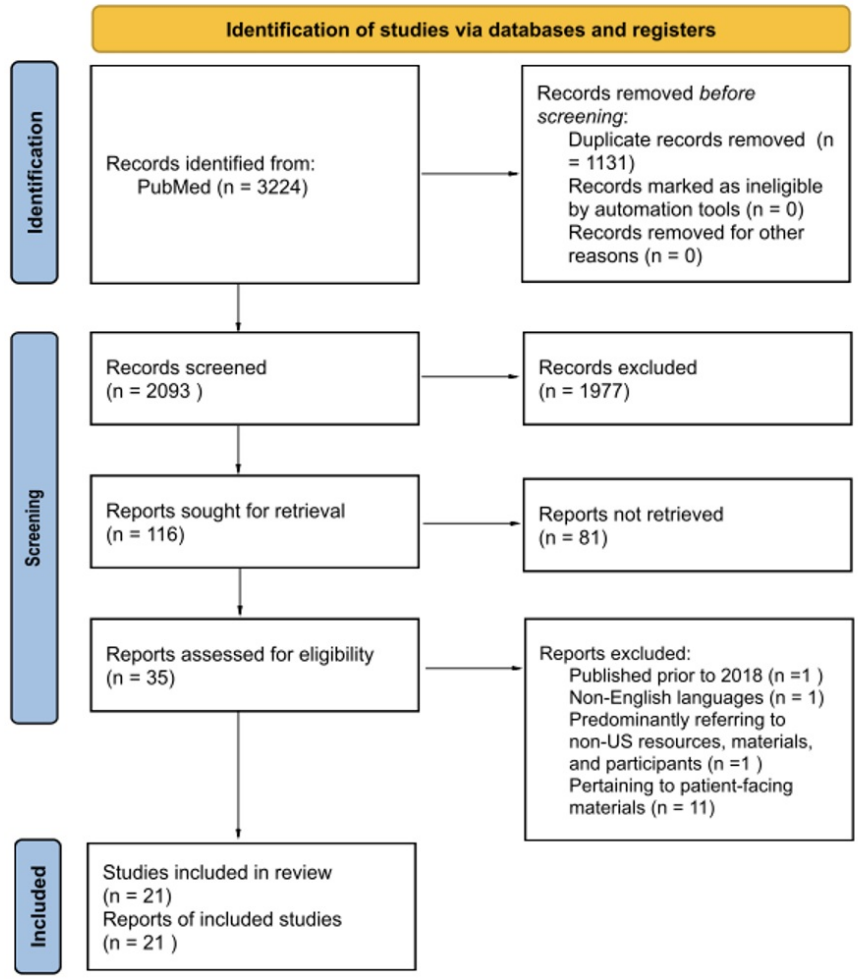

Figure 1: Inclusion and exclusion criteria of the systematic review.

Conclusions

Dark skin tones remain significantly underrepresented in U.S. medical educational materials, with patterns of selective inclusion that may reinforce implicit bias and limit diagnostic generalizability. Existing interventions are largely supplemental and insufficiently integrated into core curricula. We recommend systematic incorporation of diverse skin tones across all educational materials, standardization of skin tone classification methods, expansion of direct-to-learner interventions, and increased use of inclusive medical illustration. These changes represent feasible strategies to improve equity in medical education and may enhance clinical competence across diverse patient populations.

EADV CONGRESS
VIENNA
30 SEP - 3 OCT 2026

Abstract N°: 474

Papulonodular Lesions in Rheumatoid Arthritis: Unmasking Multicentric Reticulohistiocytosis

Parul Verma*[1], Pooja Sharma[1]

[1] King George's Medical University, Lucknow, India

Introduction

Introduction: Multicentric reticulohistiocytosis (MRH) is a rare non-Langerhans cell histiocytosis characterized by distinctive papulonodular cutaneous lesions and a potentially destructive inflammatory polyarthritis involving the skin, mucosa, synovium, occasionally associated with internal organ involvement and malignancy. Its articular and cutaneous manifestations may closely resemble rheumatoid arthritis (RA) and rheumatoid nodules, making recognition particularly challenging in patients with longstanding seropositive RA who develop new nodular or infiltrative lesions.

Case Presentation

A 61-year-old woman with a 13-year history of seropositive rheumatoid arthritis (RA) presented with a four-month history of progressively increasing painless papulonodular lesions over the face, trunk, and extremities, accompanied by worsening inflammatory polyarthritis. Cutaneous examination revealed multiple erythematous to skin-coloured firm papules and infiltrated plaques, some coalescing to form plaques. These lesions were distributed all over the body and more so on bony prominences at joints. The papules could be appreciated in linear pattern at many places, along the tendon on wrist, following ear lobe cartilage pattern. Similar lesions could be seen involving oral mucosa, nasal mucosa, palms and soles. Laboratory evaluation showed severe microcytic anaemia (Hb 6.7 g/dL), elevated inflammatory markers (ESR 67 mm/hr, CRP 48 mg/L), and persistently high rheumatoid factor and anti-CCP titters. Although rheumatoid nodules were initially considered in view of the background RA, the atypical morphology and distribution prompted evaluation for alternative diagnoses including sarcoidosis and multicentric reticulohistiocytosis. Skin biopsy demonstrated diffuse dermal infiltration by histiocytes and multinucleated giant cells with abundant eosinophilic “ground-glass” cytoplasm and vesicular nuclei; immunohistochemistry showed CD68 positivity with negative CD1a and S100, confirming MRH. Systemic evaluation and imaging revealed no evidence of associated malignancy. Patient was started on Hydroxychloroquine tab, low dose oral steroids (methylprednisolone 8mg per day) along with other supportive treatment and planned for weekly methotrexate.

Conclusion

This case underscores the importance of reconsidering the differential diagnosis in patients with established rheumatoid arthritis who develop atypical papulonodular eruptions; MRH should be suspected when lesions are widespread, infiltrative, or mucosal, and histopathological confirmation is essential to distinguish it from rheumatoid nodules and other granulomatous disorders. Early recognition enables timely institution of disease-modifying therapy and may prevent irreversible destructive arthritis and systemic complications.

EADV CONGRESS
VIENNA
30 SEP - 3 OCT 2026

Abstract N°: 488

Atypical papular mucinosis with thyroid cancer: comparison of isotretinoin and erbium:YAG laser treatment

Bana Aburajab*[1]

[1] PPU, Hebron, Palestine

Introduction
Papular mucinosis (PM), also known as lichen myxoedematosus, is a rare cutaneous disorder characterized by dermal mucin deposition and fibroblast proliferation. It is classically divided into scleromyxoedema and localized forms, with atypical variants reported in association with systemic conditions. There is no established standard treatment, and therapeutic responses remain variable. Associations with thyroid disorders are uncommon and typically excluded from diagnostic criteria.

Case Presentation
We report a 23-year-old woman presenting with a 1-year history of progressive, grouped, flat-topped papules on the chest and abdomen. Histopathology confirmed mucin deposition in the papillary dermis, consistent with PM. Systemic evaluation revealed elevated anti-thyroglobulin antibodies, and imaging identified thyroid nodules. The patient was diagnosed with Hashimoto thyroiditis and papillary thyroid carcinoma, and underwent total thyroidectomy.Initial treatment with oral isotretinoin (40 mg daily for 7 months) produced minimal clinical improvement. Following surgery, partial regression of lesions was observed without new eruptions. Due to persistent disease, ablative erbium:YAG laser therapy was performed. A single session resulted in marked flattening of lesions, with only mild postinflammatory pigmentary changes and minimal scarring. At 14-month follow-up, sustained clinical improvement was observed without recurrence.

Conclusion
This case highlights an atypical presentation of PM associated with autoimmune thyroid disease and thyroid carcinoma, suggesting a possible pathogenic link. It also demonstrates the limited efficacy of isotretinoin and the potential role of erbium:YAG laser therapy as an effective and safe treatment for refractory PM. Further studies are needed to clarify the relationship between PM and thyroid disorders and to establish evidence-based therapeutic strategies.

EA DV CONGRESS
VIENNA
30 SEP - 3 OCT 2026

Abstract N°: 501

Social media-driven dermatology: impact on patient behavior

Ouissal Hormi*[1], Nassiba Zerrouki[1], Nada Zizi[1, 1]

[1] Department of Dermatology, Venereology and Allergology, Mohammed VI University Hospital Center, Oujda, oujda, Morocco

Introduction
The increasing use of artificial intelligence tools, such as ChatGPT, has the potential to influence patient behavior in dermatology. Despite this, data on how patients use these tools, their satisfaction with the information provided, and the subsequent impact on consultation behavior remain limited.
The objective of this study was to assess the prevalence of ChatGPT use among adult dermatology patients, characterize patterns of usage, evaluate user satisfaction, and determine its potential clinical impact on patient engagement and consultation behavior.

Materials and Methods
A six-month cross-sectional study was conducted in a tertiary dermatology clinic, enrolling outpatients who completed a structured questionnaire. The survey examined how often patients used social media for dermatology information, the most consulted topics such as acne, eczema, psoriasis, and cosmetic procedures, and related behaviors including self-treatment, consultation timing, and preparation of questions for the dermatologist. Patients also rated how reliable and useful they found the information. Statistical analysis was used to explore links between demographic factors and social media–related behaviors, identifying factors influencing engagement and its potential impact on patient behavior.

Results
A total of 120 patients participated in the study, including 77 women (64%) and 43 men (36%), with a mean age of 31.8 ± 12.4 years (range 16–68). Overall, 78% (n = 94) reported using social media to seek dermatology-related information prior to their consultation.Regarding frequency and platforms of use, 35% of users accessed social media multiple times per week, 25% once per week, and 18% several times per month, indicating consistent engagement. The platforms most frequently consulted were Instagram (45%), TikTok (32%), YouTube (21%), and Facebook (18%), with many patients using more than one platform to gather information.Patients primarily searched for information on acne (40%), skin care routines (38%), psoriasis (18%), eczema (15%), cosmetic procedures (15%), and, less commonly, hair or nail conditions (10%), highlighting the role of social media in both medical and cosmetic dermatology knowledge.Social media use influenced patient behavior in several ways: 29% delayed consultation due to perceived reassurance from online content, 11% attempted self-treatment—often with over-the-counter products or home remedies—and 22% reported preparing more targeted questions for their dermatologist, reflecting increased engagement. Seventy percent of patients rated the information as useful (≥4/5), while 36% expressed concerns about its reliability, citing overly general or conflicting advice.Demographic analysis showed that patients under 35 years were significantly more likely to use social media for dermatology information ($p < 0.01$), whereas no significant differences were observed between genders. A strong positive correlation ($r = 0.59$; $p < 0.01$) was noted between social media use and consulting other online health resources, suggesting that social media engagement is part of a broader pattern of digital health-seeking behavior.These findings indicate that social media is a major driver of patient behavior in dermatology. While it can enhance patient preparedness and engagement, it may also lead to delayed consultation and self-directed treatment, emphasizing the importance of clinician guidance and proactive discussion of online information to ensure safe

and informed patient decision-making.

Conclusions

Social media strongly influences patient behavior in dermatology, affecting pre-consultation knowledge, timing of visits, and engagement during clinical encounters. While it can improve patient preparedness and awareness, risks of misinformation and self-directed treatment highlight the need for dermatologists to proactively guide patients in evaluating online content and integrating social media discussions into care.

EADV CONGRESS
VIENNA
30 SEP - 3 OCT 2026

Abstract N°: 502

Urban vs rural dermatology access: disparities and consequences

Ouissal Hormi*[1], Salma Moujahid[1], Nassiba Zerrouki[1], Nada Zizi[1]

[1] Department of Dermatology, Venereology and Allergology, Mohammed VI University Hospital Center, Oujda, oujda, Morocco

Introduction
Access to dermatology services remains unequal, particularly in regions affected by medical desertification. Patients living in rural areas often face prolonged delays in obtaining consultations, logistical challenges such as transportation difficulties, and increased reliance on alternative or non-specialist sources of advice, all of which may compromise timely and effective dermatologic care. Understanding these disparities is crucial for designing targeted interventions and promoting health equity in dermatology.
The objective of this study was to compare consultation delays, barriers to care, and alternative strategies employed by patients residing in urban versus rural settings, and to evaluate how these factors influence dermatology care pathways and patient outcomes.

Materials and Methods
A cross-sectional study was conducted from January to June 2025 at a tertiary dermatology outpatient clinic. Adult patients completed a standardized questionnaire on demographics, place of residence, consultation delays, perceived barriers, and use of alternative care such as self-medication or non-medical advice from social media, pharmacists, or traditional practitioners. Differences between urban and rural populations were analyzed using chi-square tests or t-tests, and logistic regression was applied to identify factors associated with delayed consultation.

Results
A total of 240 patients participated in the study, including 118 from rural areas and 122 from urban areas, with a mean age of 42.3 ± 13.1 years; 61% were women. Analysis of consultation delays revealed a pronounced disparity between rural and urban populations: the mean time to dermatology consultation for rural patients was 4.1 months, more than double that of urban patients, who experienced an average delay of 1.8 months ($p < 0.001$). This finding highlights the significant impact of geographic location on access to specialized dermatologic care.Rural patients reported multiple, overlapping barriers contributing to delayed consultations. The absence of a local dermatologist was the most frequently cited obstacle (74%), followed by prolonged waiting times for appointments (63%) and transportation difficulties (51%). In addition, 38% of rural patients indicated limited knowledge regarding appropriate care pathways, reflecting gaps in healthcare literacy and system navigation. These structural and informational barriers appeared to drive alternative care-seeking behaviors. Indeed, rural patients were markedly more likely than urban patients to engage in self-medication (52% vs. 27%) or to seek advice from non-medical sources (40% vs. 13%), including social media, pharmacists, and traditional healers.The pattern of healthcare utilization further demonstrated fragmentation in care pathways among rural patients. Nearly a quarter (24%) of rural participants consulted a general practitioner at least twice before being referred to a dermatologist, compared with only 10% of urban patients. Multivariate analysis identified younger age (<40 years) and rural residence as independent predictors of delayed consultation and greater reliance on alternative care sources ($p < 0.05$), suggesting that both demographic and geographic factors contribute to disparities in dermatologic care.

Conclusions

Significant disparities exist in dermatology access between urban and rural populations. Rural patients face longer delays, logistical barriers, and higher reliance on alternative sources of care. These findings emphasize the urgent need to expand dermatology services in underserved regions, develop teledermatology solutions, and improve patient navigation and education to ensure timely, equitable care. Addressing these gaps is critical to optimizing patient outcomes and reducing healthcare inequalities.

EA DV CONGRESS
VIENNA
30 SEP - 3 OCT 2026

Abstract N°: 510

From Screen to Clinic: How Social Media Shapes Patient Expectations and Experience in Dermatological Care

Federica Osti*[1], Marta Fusano[2], Laura Maria Luisa Colli[3], Valentina Trevisan[2], Lidia Sacchelli[4]

[1] Studio Medico Amor Proprio, Faenza (RA), Italy

[2] Department of Dermatology, Studio Medico Trevisan, Milan, Italy

[3] Department of Dermatology, I Colori della Pelle - Centro Medico Colli, Gerenzano (VA), Italy

[4] Department of Medical and Surgical Sciences, Alma Mater Studiorum, University of Bologna, Bologna, Italy

Introduction

Dermatology patients frequently use internet and social media to seek medical information. European data indicate that over 80% of patients access online health content, influencing the dermatological patient journey and the patient–physician relationship. Given the visual nature of skin diseases, dermatology is particularly exposed to this phenomenon. However, the clinical impact of pre-consultation exposure to dermatologists via social media—especially when communication is delivered by certified specialists—remains poorly defined.

Materials and Methods

We conducted a cross-sectional survey via Instagram using a structured questionnaire, disseminated across five professional accounts managed by board-certified dermatologists trained in Italy and actively involved in digital health communication (n=964). All contributors are certified clinical dermatologists with experience in science communication; one author holds a Master's degree in Journalism and Science Communication. Data were analyzed using descriptive statistics, and free-text responses were thematically analyzed.

Results

A total of 94.1% of respondents reported using social media for medical information, exceeding previously reported European rates. Pre-consultation physician search was reported by 53.3% of participants, confirming the central role of digital media in the decision-making phase. Consistency between online and in-person interaction was reported by 63.2%, with only 8.3% expressing dissatisfaction, supporting a predominantly positive alignment between digital identity and clinical experience.Notably, 61.8% of respondents reported reduced anxiety during consultation following pre-consultation exposure, while 13.6% reported no change and 4.5% reported increased stress. This finding provides quantitative evidence supporting a potential anxiolytic role of digital familiarization, a dimension only marginally addressed in previous European studies.After the visit, 82.0% of participants continued to follow the physician for educational updates, further supporting the role of social media in extending the doctor–patient relationship beyond the clinical setting. Qualitative analysis revealed recurring themes of increased trust, reduced perceived distance, and continuity of care through ongoing digital interaction.

Conclusions

These findings demonstrate that social media are not merely informational tools but active components of the dermatological care pathway. Pre-consultation exposure to dermatologists may reduce patient anxiety, shape expectations, and strengthen continuity of care, positioning digital communication as a clinically relevant factor in patient-centered dermatology.Importantly, this study extends current European evidence by providing quantitative insight into the anxiolytic potential of digital exposure. Despite this impact, structured training in digital health communication and its ethical implications is largely absent from current dermatology education, highlighting the need for dedicated educational initiatives at the European level to ensure safe, effective, and

ethically grounded use of social media in clinical practice.

EADV CONGRESS
VIENNA
30 SEP - 3 OCT 2026

Abstract N°: 576

Ethical and professional use of social media: Consensus of Italian Dermatologists active on social media

Lidia Sacchelli*[1], Marta Fusano[2], Laura Colli[3], Valentina Trevisan[2], Rossana Capezzera[4], Federica Cavallini[5], Lisa Cecchini[6], Rosa Frisario[7], LUCIANO GALOTTA[8], Maria-Teresa Luverà[9], Giovanni Menchini[10], Luigia PANARIELLO[11], Michela Starace[1], Federica Trovato[12], Andrea Vizzaccaro[13], Federica Osti[14]

[1] Dermatology Unit, IRCCS Azienda Ospedaliero-Universitaria di Bologna, Policlinico S. Orsola Malpighi, Bologna, Italy; Department of Medical and Surgical Sciences Alma Mater Studiorum University of Bologna, Italy, Bologna, Italy

[2] Department of Dermatology, Studio Medico Trevisan, Milan, Italy, Milan, Italy

[3] Department of Dermatology, I Colori della Pelle - Centro Medico Colli, Gerenzano, Varese, Italy

[4] Department of Dermatology, Studio Medico Sedona, Venice, Italy

[5] Department of Dermatology, Studio Medico Cavallini, Villafranca Padovana, Padua, Italy

[6] Department of Dermatology, Studio Medico Cecchini, Cesena, Italy

[7] Department of Dermatology, Studio Medico Frisariodermoestetica, Barletta, Italy

[8] Usl Nord-Ovest Toscana, Cecina, Italy

[9] USMAF-SASN Ministero della Salute, Livorno, Italy

[10] Department of Dermatology, Dermacademy Institute Aesthetic Medicine and Plastique Surgery, Pisa, Italy, Pisa, Italy

[11] Department of Dermatology, Studio Medico Panariello, Torre del Greco, Naples, Italy, Torre del Greco, Napoli, Italy

[12] Department of Dermatology, Istituto Dermopatico dell'Immacolata IDI-IRCCS, Rome, Italy, Rome, Italy

[13] Private Practitioner, Dermatology, Rome, Italy

[14] Department of Dermatology, Amor Proprio Medical Clinic, Faenza, Ravenna, Italy

Introduction
Social media has profoundly reshaped medical communication, offering dermatologists new opportunities for patient education, professional visibility, and public health advocacy. However, regulatory frameworks governing online professional conduct remain highly heterogeneous across countries, reflecting differences in legal, ethical, and cultural contexts. In Italy, while the National Federation of Orders of Physicians and Dentists (FNOMCeO) provides general recommendations, no dermatology-specific guidance is currently available.

Materials and Methods
A working group of 23 dermatologists actively engaged in social media was established. Existing national and international ethical frameworks, including the Code of Medical Ethics, were critically reviewed to identify unmet needs and regulatory gaps. A core group developed 12 preliminary statements, which were subsequently refined through structured discussion and consensus voting.

Results
The working group formulated 12 best practice statements addressing key domains of digital professionalism, including responsible content creation, transparency and conflict-of-interest disclosure, adherence to scientific evidence, patient confidentiality, and strategies to counter misinformation. While developed within the Italian regulatory framework, these statements address challenges commonly encountered in dermatological practice

worldwide.

Conclusions

This work represents the first dermatology-specific guidance on digital communication developed in Italy. Although regulatory systems differ across countries, the core ethical principles identified are widely applicable and can support dermatologists in diverse settings. These recommendations provide a practical and adaptable framework to promote responsible, transparent, and effective online engagement, ultimately strengthening the role of dermatologists in public health communication in the digital era.

EA DV CONGRESS
VIENNA
30 SEP - 3 OCT 2026

Abstract N°: 610

Spontaneous multiple keloid scars – A case report

Bruna Marques Bilia*[1], Sandra e Dinato[1], José de Almeida[1], Ana Lígia Scotti Alérico[1], João Henrique Aurich[1], Hudson Rezende[1], Ana Raimundo[1]

[1] Centro Universitário Lusíada (UNILUS), Santos, Brazil

Introduction
Keloid scars represent an exaggerated response of scar tissue to cutaneous injury and are characterized by fibroblast proliferation and excessive collagen deposition. Although commonly associated with trauma or surgical procedures, rare cases—particularly involving multiple lesions—have been reported in which keloids arise spontaneously, without any prior history of injury or intervention.

Case Presentation
A 41-year-old female patient, with no history of prior trauma or surgical procedures, presented with multiple erythematous papules and nodules predominantly located on the posterior thoracic region and the proximal portions of the upper limbs, associated with mild pruritus and a burning sensation. Additional scattered lesions were observed on the integument, including the breasts and abdomen.

The lesions developed progressively over a period of thirty years, with no identifiable triggering factors. Histopathological examination revealed a thickened dermis with dense collagen fibrosis and proliferating fibroblasts, without evidence of atypia, confirming the diagnosis of keloid.

Topical corticosteroid therapy showed limited response. A single session of intralesional triamcinolone injection was performed but discontinued due to poor tolerance to pain.

Conclusion
This case report a rare and clinically challenging presentation of multiple spontaneous keloid scars, developing over decades in the absence of identifiable cutaneous injury. Although keloids are traditionally defined as an exaggerated fibroproliferative response to trauma, accumulating evidence suggests that so-called “spontaneous” lesions may arise from underlying genetic susceptibility and immune dysregulation.

From a clinical standpoint, the diagnosis of spontaneous keloids requires a high index of suspicion and careful exclusion of mimicking conditions, including inflammatory and neoplastic dermatoses. Histopathological confirmation remains essential for diagnostic accuracy. Moreover, this case highlights the therapeutic limitations frequently encountered in extensive keloidal disease. The poor response to topical corticosteroids and intolerance to intralesional therapy observed here further emphasize the importance of individualized, multimodal management strategies.

Recognizing spontaneous keloids as a distinct clinical entity has important implications

continued investigation into the molecular, genetic, and immunological pathways involved is critical to advancing targeted therapies and improving patient outcomes in this complex and refractory condition.

EADV CONGRESS
VIENNA
30 SEP - 3 OCT 2026

Abstract N°: 612

Treatment of SAPHO Syndrome with Spesolimab: A Case Report

Chang Cao*[1], Xun He[1]

[1] Sichuan Academy of Medical Sciences & Sichuan Provincial People's Hospital, Department of Dermatology, Chengdu, China

Introduction

Synovitis, acne, pustulosis, hyperostosis, and osteitis (SAPHO) syndrome, a rare immune-mediated inflammatory disease, poses diagnostic and therapeutic challenges owing to its multi-system involvement, high heterogeneity, and lack of evidence-based treatment recommendations.

Case Presentation

A 35-year-old male patient had recurrent comedones, papules, pustules, nodules and cysts on the scalp, face and trunk for more than 20 years. He was repeatedly diagnosed with acne and treated with isotretinoin and antibiotics, but the condition relapsed with poor efficacy. While the course of disease, he suffered from pain in the sacroiliac joints and ankle joints. He was once suspected of ankylosing spondylitis and treated with adalimumab, sulfasalazine and other drugs, while joint pain persisted. HLA-B27 was negative. Sacroiliac joint CT showed an incomplete iliac surface of bilateral sacroiliac joints with serrated changes and slightly blurred joint spaces, suggesting bilateral sacroiliitis. Whole-body bone scan revealed increased or slightly increased tracer uptake in bilateral sternoclavicular joints and bilateral sacroiliac joints. Skin biopsy pathology showed epidermal hyperkeratosis with intraepidermal keratin cysts, focal basal layer pigmentation, vasodilation and congestion in the dermis accompanied by lymphocyte infiltration. Exome sequencing detected no abnormalities. The diagnosis of SAPHO syndrome was made. The patient was initially treated with prednisone 20 mg twice daily and isotretinoin 10 mg once daily. Joint swelling and pain were relieved, but skin lesions on the scalp, face and trunk regressed poorly. Therefore, he received a single dose of spesolimab 900 mg in May 2025, and facial lesions began to regress gradually 2 days after treatment. Subsequently, isotretinoin was continued, and prednisone was tapered and discontinued. At present, the patient has almost no recurrence of scalp and facial skin lesions, with nearly complete remission of joint pain and only occasional mild soreness and distention. No obvious adverse reactions were observed during follow-up.

Conclusion

The successful treatment of refractory SAPHO syndrome with spesolimab presents a promising implication for addressing the therapeutic challenges of this rare autoimmune condition, offering a potential breakthrough in managing its complex manifestations.

EADV CONGRESS
VIENNA
30 SEP - 3 OCT 2026

Abstract N°: 619

Validity, reliability, and comparison of the Indonesian version of two Baumann skin type indicator (BSTI) questionnaires with Cross-Cultural Adaptation

Irwan Batubara*[1], Irma Sitohang[1], Sandra Widaty[1], Hanny Nilasari[1], Aria Kekalih[2], Sari Chairunnisa[3]

[1] Department of Dermatology and Venereology, Faculty of Medicine, Universitas Indonesia, Dr. Cipto Mangunkusumo Hospital, Central Jakarta, Indonesia

[2] Department of Community Medicine, Faculty of Medicine, Universitas Indonesia., Central Jakarta, Indonesia

[3] Paragon Technology and Innovation, Ltd, Jakarta, Indonesia

Introduction

Accurate skin type classification is essential for dermatological care and research; however, commonly used classification systems do not adequately capture the multidimensional nature of skin characteristics. The Baumann Skin Type Indicator (BSTI) was developed as a questionnaire-based tool to address this limitation, and a simplified version was introduced in 2022 to improve clinical usability. To date, no validated multidimensional skin type assessment tool is available for the Indonesian population. This study is aimed to evaluate the validity and reliability of the Indonesian translations of the 2006 and 2022 versions of the Baumann Skin Type Indicator (BSTI-Ina) and to assess the level of agreement between the two versions when applied to Indonesian adults.

Materials and Methods

A cross-sectional study was conducted using Bahasa Indonesia versions of the 2006 and 2022 BSTI questionnaires, which were distributed online to 150 adult respondents. Translation and cross-cultural adaptation were conducted after having permission from Dr. Leslie Baumann, the original author. A multidisciplinary committee comprising two dermatologists, a biostatistician, a clinical psychologist, and two translators reviewed each version to ensure linguistic accuracy, clarity, and cultural appropriateness. Two additional certified translators, blinded to the original questionnaire, performed back-translation. Forward and backward translations were submitted to Dr. Baumann for review and approval. Content validity was established through expert review and pre-final testing. Construct validity was assessed using Pearson correlations. Internal consistency was evaluated using Cronbach's alpha, and agreement between the two versions was analyzed using the intraclass correlation coefficient (ICC).

Results

Construct validity coefficients ranged from –0.037 to 0.751 for the 2006 BSTI-Ina and from 0.231 to 0.685 for the 2022 version. Cronbach's alpha values ranged from 0.613 to 0.718 for the 2006 version and were 0.704 for the 2022 version, indicating acceptable internal consistency. The ICC between the two versions was 0.435, indicating moderate agreement.

Conclusions

Both the 2006 and 2022 Indonesian versions of the BSTI demonstrate acceptable validity and reliability for skin-type classification in Indonesian adults, with moderate agreement between the two questionnaires. The shorter 2022 version may offer a more practical option for routine and research use.

EADV CONGRESS
VIENNA
30 SEP - 3 OCT 2026

Abstract N°: 658

Rethinking Dermatology Training: Developing the Dermatologist Through Professional Identity Formation Beyond Clinical Competencies

Souzana E. Xyda*[1, 2], Rebecca Selman[1, 3]

[1] University College London, faculty of medical sciences., London, United Kingdom
[2] Dermatology Department, Cambridge University Hospitals NHS Foundation Trust, UK., Cambridge, United Kingdom
[3] Royal College of Physicians, Education Directorate, London, United Kingdom

Introduction
Background: Professional identity formation—defined as the process through which individuals internalise the ways of thinking, behaving, and feeling characteristic of a doctor1—is a core component of postgraduate medical education, as highlighted by the Carnegie Foundation2. This study explores the underexamined area of professional identity formation among dermatology trainees, focusing on how they learn what it means to be a dermatologist and on how they develop their professional identities within the specialty's distinct training landscape.

Materials and Methods
Methods: Grounded in an interpretivist paradigm and informed by Wenger's view that professional identity develops through interactions between the individual, others, and the socio-cultural context of practice, this study employed a qualitative approach to explore how dermatology registrars construct their professional identities. Dermatology trainees across all stages from multiple UK deaneries were purposively sampled. Nine semi-structured video interviews were conducted, audio-recorded, transcribed verbatim, and analysed using reflexive thematic analysis with inductive coding.

Results
Results: Six themes were identified. Being at the threshold: trainees entered dermatology feeling underprepared, occupying an "imposter" phase as prior general-medicine identities no longer fit. Crossing the threshold: supervised responsibility, feedback, and reflection transformed uncertainty into growing confidence and clearer standards of a "good dermatologist." Growth through experiences: life events deepened empathy and maturity. Belonging and communities of practice: stable teams and peer support fostered psychological safety and purpose. Role modelling and mentoring: admired seniors shaped values, communication style, and comportment, often more powerfully than formal teaching. Teledermatology fostered a hybrid professional identity: residents reconcile evolving practices with traditional doctor–patient ideals.

Conclusions
Conclusion: Dermatology trainees' professional identities develop largely through experiential learning, increasing responsibility, a sense of belonging, and mentorship. Training programmes should therefore enhance supervision, feedback, and supportive environments to foster both identity formation and clinical competence.

EADV CONGRESS
VIENNA
30 SEP - 3 OCT 2026

Abstract N°: 701

Atypical Presentation of Comedo Naevus

Hiba Al-Rawi*[1]

[1] University of Exeter, Exeter, United Kingdom

Introduction

Comedo naevus is a rare, benign skin condition and presents with a single group of dark hyperkeratotic papules and horny plugs with a honeycomb appearance. It is typically found on the face, neck, trunk and upper arm and tends to develop shortly after birth, in most patients before the age of ten. Treatment is often not necessary and reserved for more severe- infected cases or for cosmetic reasons. There is limited research on this condition, with very few cases presenting on the buttock (2 yielded on a PubMed search), as seen with our patient.

Case Presentation

A 59-year-old, Caucasian female presented with lesions on the medial aspect of her left buttock. The lesions had been present since the age of sixteen, with a history of recurrent infections to the area. Over the last several years, she stated her condition had remained stable; however, soon after giving birth to her second child and whilst going through the menopause, it became more active, prone to inflammation and infection. On examination, she had a plaque measuring approximately 8cm in diameter within the medial aspect of the left buttock. There were multiple cysts, comedones, skin-coloured papules and nodules. There was no other similar lesion elsewhere on the body. Due to the recurrent infections, she was commenced on a three months course of antibiotics which controlled her symptoms. Interestingly, our patient had potential associations with hormonal changes as a contributing factor. Firstly, the condition presented in her teenage years, during prime puberty period. Secondly, she had flare-ups post-pregnancy and while approaching the menopause. Our case is unusual in terms of the site of presentation, with only two previously reported cases in the literature affecting the buttocks. The other unusual feature is the presentation at puberty, as in most cases it is present from birth.

Conclusion

Comedo naevus is not typically treated. However, in specific circumstances, for example, cosmetic reasons or if it is the source of recurrent infections, as seen in our patient. Treatment varies from topical therapies (topical retinoid cream, tacalcitol, calcipotriene and tazarotene) to laser, as well as surgical interventions.

EA DV CONGRESS
VIENNA
30 SEP - 3 OCT 2026

Abstract N°: 725

Reversing Signs of Skin Aging: A Holistic Epigenetic Regime using Dihydromyricetin to Support Skin Longevity

Katja Warnke*[1], Jane Djamil[1], Kathrin Borchers[1], Lina Mengel[1], Denise Köstner[1], Gesa-Meike Muhr[1], Sandra Grossmann[1], Yuanyuan Diao[2], Q Zhu[2], Paula Pitta[1]

[1] Beiersdorf AG, Hamburg, Germany

[2] Beiersdorf AG Innovation Center, Shanghai, China

Introduction

Primary hallmarks of skin aging are epigenetic changes, including shifts in DNA methylation patterns that reflect the skin's biological age. Lifestyle and environmental stressors accelerate these alterations, deactivating youth-related genes and leading to visible signs of aging. Epicelline® (Dihydromyricetin) has been shown to reactivate skin´s relevant genes and reverse skin's epigenetic age clocks, offering an innovative mechanism for rejuvenation and skin longevity (Falckenhayn, 2024).
In our studies, we evaluated topical formulations containing Epicelline® in a complete skincare regimen (serum, day and night cream) for its ability to reverse visible signs of skin aging and maximize epigenetic skin rejuvenation.

Materials and Methods

To assess signs of aging such as lines, wrinkles, pores, skin evenness and smoothness, we tested the products with 56 subjects applying a regime (morning: serum and day cream, evening: serum and night cream) for 4 weeks. Clinical grading, instrumental measurement and imaging by PRIMOS were performed at baseline and after 4 weeks. Additionally, self-grading was performed split-face against serum twice daily only.
Skin hydration was examined by Corneometer® CM 825 measurements and skin elasticity and firmness by Cutometer® MPA 580 measurements. 41 subjects applied the regime for two weeks.
The test products´ tolerability was determined in studies with 31, 40 and 44 subjects (serum, day cream and night cream respectively) applying the product twice daily for 4 weeks.

Results

The combination of serum, day cream and night cream, each containing the active Epicelline® (Dihydromyricetin), showed significant improvement for investigated signs of skin ageing after 4 weeks. Instrumental measurement of wrinkles confirmed significant reduction in volume and area of wrinkles. 83 % of volunteers showed reduced volume of wrinkles.
In clinical assessment by experts on analogue scale, the scores for pores, forehead wrinkles and upperlip wrinkles, skin evenness and skin smoothness, improved by 17 up to 25 % depending on parameter after 4 weeks of regime application. Self-grading by subjects on a 10-point scale confirmed significant improved effects for regime in comparison to serum in split-face design.
After two weeks of regime application, 85 % of subjects had improved skin elasticity and firmness, as well as moisture confirmed by instrumental measurement.
Very good tolerability was confirmed by dermatological assessment. The formulas are highly suitable for all skin types even for sensitive skin.

Conclusions

A holistic regime of new and very well-tolerated formulas with the epigenetic active Epicelline®

(Dihydromyricetin) visibly improved multiple signs of aging such as fine lines, wrinkles, elasticity, evenness and appearance of pores, resulting in significantly improved rejuvenated-looking skin. Compared to serum alone, the combined serum, day, and night products provide complementary and sustained delivery of the active, fostering its ability to restore youthful gene expression and maximize epigenetic skin rejuvenation.

EA DV CONGRESS
VIENNA
30 SEP - 3 OCT 2026

Abstract N°: 744

Anetoderma as a Diagnostic Challenge within the Spectrum of Elastolytic Disorders: A Case Report

Ahmet Ölmez*[1], Yıldız Gürsel Ürün[1], Berke Kızmaz[1], Bahar Tokka[1], Nuray Can[2], Fatmanur Koyunlu[2]

[1] Trakya University Faculty of Medicine, Department of Dermatology and Venereology, Edirne, Türkiye
[2] Trakya University Faculty of Medicine, Department of Pathology, Edirne, Türkiye

Introduction

Anetoderma is a rare benign elastolytic dermatosis characterized by focal loss of dermal elastic fibers, resulting in localized flaccid or herniated skin. It belongs to a heterogeneous group of degenerative elastic tissue disorders, which are diagnostically challenging due to overlapping clinical and histopathological features. The condition is broadly classified as primary (idiopathic) or secondary, the latter occurring in association with inflammatory dermatoses, infections, neoplasms, or drug exposure. Primary anetoderma may be subclassified into 2 types: preceding by inflammatory lesions or Jadassohn–Pellizzari type; and no preceding by inflammatory lesions or Schweninger–Buzzi type. Primary anetoderma has been linked to prothrombotic abnormalities, most commonly the presence of antiphospholipid antibodies, occurring either in isolation or in association with primary antiphospholipid syndrome. Onset of the lesions is at late adolescence or early adulthood. Clinically, lesions typically present as soft, compressible papules or macules on the trunk and proximal extremities, although atypical distributions have been reported.Here we present a case of Schweninger–Buzzi type anetoderma.

Case Presentation

A 22-year-old female patient presented to the dermatology clinic with complaints ofskin-coloured/white without erythema, non-itchy areas on her back and bilateral axillae. Button-hole sign was positive. There was no history of any disease in his past medical history. The family history was negative. A punch biopsy was performed with clinical preliminary diagnoses of anetoderma, lichen simplex atrophicus, and morphea. Von Gieson staining revealed a focal decrease in elastic fibers in the dermis, particularly in the papillary dermis. Complete blood count, hormone tests, and autoimmune markers are normal, while anti-nuclear antibody, antiphospholipid antibody, extractable nuclear antigen, lipid profile, ELISA for HIV, and mantoux test are negative. No pathological findings were detected on ultrasonography. Based on the patient's age, the localization of the existing lesions, and histopathological findings, a diagnosis of anetoderma was made. Due to the absence of erythema in the lesions and the lack of an underlying etiological factor, it was considered primary anetoderma of the Schweninger–Buzzi type, and the patient is being followed for potential autoimmune diseases.

Conclusion

The diagnosis of anetoderma relies on the combined evaluation of clinical and histopathological findings. Histopathological confirmation demonstrating focal loss or fragmentation of dermal elastic fibers is essential for diagnosis. Recognition of the broader spectrum of elastolytic diseases is critical for accurate differential diagnosis. Mid-dermal elastolysis, cutis laxa, pseudoxanthoma elasticum-like dermal elastolysis, and atrophic dermatoses (atrophoderma, morphea, lichen sclerosus, and scar) should be included in the differential diagnosis. Mid-dermal elastolysis was excluded due to the absence of diffuse fine wrinkling and a cigarette-paper-like appearance of the skin, as well as the lack of histopathological loss of elastic fibers in the mid dermis. Pseudoxanthoma elasticum-like dermal elastolysis was excluded in our case due to the absence of numerous small papular lesions, lack of neck

involvement, a negative button-hole sign, and the absence of diffuse loss of elastic fibers on histopathological examination.Furthermore, increasing evidence supports the role of anetoderma as a potential cutaneous marker of systemic autoimmune disease, warranting long-term clinical and laboratory follow-up. Although no definitive treatment exists, accurate diagnosis is essential for identifying underlying conditions and guiding patient management.

EADV CONGRESS
VIENNA
30 SEP - 3 OCT 2026

Abstract N°: 752

Real-Life Application of Multimodal Large Language Models in Dermatology: Preliminary Results of a Patient-Centric Observational Study

Kübra Nursel Bölük*[1], Tuğrul Furkan Morgül[1], Kamelya Gümüş[1], Ceren Avcı[1], Yasemin Erdem[1]

[1] Istanbul Faculty of Medicine, Department of Dermatology and Venereology, Istanbul, Türkiye

Introduction

Multimodal Large Language Models (MM-LLMs), artificial intelligence (AI) tools capable of processing both textual and visual data, are increasingly used in daily life and clinical contexts. While the diagnostic effectiveness of MM-LLMs in dermatology has primarily been evaluated from a physician-centric perspective, their clinical relevance in real-world, patient-driven applications remains underexplored.

Materials and Methods

This observational study was conducted in an outpatient tertiary dermatology clinic, enrolling 88 patients (aged ≥16 years) who reported using an MM-LLM (ChatGPT, Gemini, Claude, or Copilot) for their dermatologic condition before their consultation. Following their examination, patients were surveyed on their demographics, the specific MM-LLM used, the features of the input data, and the resulting AI-generated diagnosis. Subsequently, the treating dermatologist assessed clinical diagnosis, the relevance of the AI's output, and its potential benefits and harms. If the clinicians' preliminary or final diagnosis was the first or second AI diagnosis, and the additional information was consistent with the clinical context, the clinical relevance of the AI diagnosis was considered high. If the preliminary or final diagnosis was on the third or fourth order of the AI diagnosis, the clinical relevance was intermediate.

Results

Of the 88 patients (65.9% female; mean age 30.1±13.7 years, median age 24.5, range 16–83), 42% reported daily MM-LLM use. ChatGPT was the most frequently utilized platform (80.7%), followed by Gemini (38.6%), Claude (4.5%), and Copilot (1.1%), with 18 (20.5%) patients using multiple models. The AI generated at least one diagnosis for 81 patients (Table 1). Remarkably, the AI's output aligned with the clinician's differential diagnosis in 97.5% of cases (79/81). The clinical relevance of the AI output was rated as high in 77.8% of cases. Regarding the pre-consultation waiting period, the AI's impact was deemed beneficial or benign in 91.3% of cases, though possibly misleading in 8.6%.

Regarding the initial prompts used to initiate the AI dialogue, patient inputs consisted of standalone photographs (17.3%), text-only descriptions (23.5%), or a combination of both (59.3%). Interestingly, 100% of cases achieved high clinical relevance when the initial prompt was solely a photograph, compared with 75% for combined initial inputs and 68.4% for text-only descriptions. The subsequent textual data, which were spontaneously provided by the patient during the conversation flow or prompted by the AI's follow-up questions, were not significantly associated with achieving high clinical relevance.

Table 1. The clinical diagnosis of the patients using the Multi-Model Large Language Models

	N (%)
Acne and rosacea	29 (35.8)
Skin infections	15 (18.5)
Hair diseases	9 (11.1)
Eczematous dermatosis (atopic dermatitis, contact dermatitis)	6 (7.4)
Urticaria	6 (7.4)
Psoriasiform dermatosis	3 (3.7)
Tumoral diseases	3 (3.7)
Pigmentation disorders	1 (1.2)
Inflammatory dermatosis	1 (1.2)
Nail diseases	1 (1.2)
Others (keloids, keratosis pilaris, ecchymosis)	7 (8.6)
Total	81 (100)

Conclusions

While AI diagnostic performance in dermatology is rapidly advancing, particularly for malignant lesions, our findings show a high need for optimization in common outpatient presentations, such as acne vulgaris, rosacea, cutaneous infections, and hair disorders. Although limited by sample size, the data suggest that isolated photographic input yields the highest clinical relevance. In contrast, patient-authored text descriptions may introduce confounding variables that negatively impact diagnostic accuracy. Ultimately, while patient-directed MM-LLMs currently offer limited additive value in definitive clinical decision-making, they display promising utility for preliminary patient triage.

EA DV CONGRESS
VIENNA
30 SEP - 3 OCT 2026

Abstract N°: 794

Doctors, Social Media and Professional Boundaries: A Global Regulatory Perspective

Amy Perkins*[1], Rochelle Oei-Hicks[2], Daphne Kapetas[3], Lisa Byrom[4], Mi Ryung Roh[5], Anesia Tania[6], Aseem Sharma[7], Madhulika Mhatre[7], Michelle McRae[2]

[1] Dr Amy Perkins Ltd, Glasgow, United Kingdom
[2] Pinnacle Dermatology, Orange, Australia
[3] Lajoie Skin, Frenchs Forest, Australia
[4] Mater Hospital, South Brisbane, Australia
[5] Gangnam Severance Hospital, Seoul, Korea, Rep. of South
[6] RI Clinic, Jakarta, Indonesia
[7] Skin Saga Centre for Dermatology, Mumbai, India

Introduction
Social media is inherently borderless, yet the rules governing medical professionals who use it are not. With approximately 64% of the global population now active on social media, and dermatology among the most visually consumed specialties in the digital health environment, clinicians face an increasingly fragmented and jurisdictionally inconsistent regulatory landscape. Content produced under one framework is routinely consumed by patients and trainees governed by entirely different rules. This study critically reviews international guidance for physician social media conduct, characterises areas of convergence and divergence, and advances the case for a unified global regulatory framework.

Materials and Methods
English-language social media guidance documents for medical professionals were identified through a structured literature search and a manual review of regulatory authority and professional organisation websites. Twenty guidance documents from multiple countries and international bodies, spanning the United Kingdom, the United States, Australia, Canada, Ireland, New Zealand, Singapore, Malaysia, Indonesia, Hong Kong, Japan, the United Arab Emirates, the Philippines, South Africa and the World Medical Association, were analysed thematically to map shared principles, regulatory expectations and points of divergence.

Results
Five core themes emerged: patient confidentiality and privacy; information accuracy; professional boundaries and public trust; practitioner privacy; and health advocacy. All documents shared a common ethical foundation, yet diverged markedly in tone, prescriptiveness, enforcement and scope. Australia prohibits patient testimonials and restricts before-and-after imagery and influencer endorsement arrangements, while the United Arab Emirates mandates display of licence details and trained content moderators. Canada and Ireland adopt more enabling, principles-based stances, whereas the United Kingdom layers multiple overlapping regulatory and advertising obligations. Indonesia is notable as one of the few jurisdictions to have issued dermatology-specific guidance, adopting a capacity-building tone. International statements, including that of the World Medical Association, remain non-binding. Enforcement mechanisms were inconsistently described or absent, and available fitness-to-practise data suggest that regulatory uncertainty itself contributes to clinician anxiety, defensive practice and disengagement from digital health advocacy.

Conclusions

Although international guidance shares a common ethical foundation, its fragmented application undermines clarity, collegiality and patient safety in an environment where content routinely crosses regulatory borders. A dermatologist's post may be held to one standard at home and an entirely different standard abroad; medical trainees routinely consume content produced under rules to which they will never be held; and non-medical influencers freely promote products that qualified clinicians are prohibited from endorsing. Addressing this asymmetry will require coordinated action beyond any single regulator. We propose that national medical colleges and specialty societies come together through a structured international consensus process, such as a modified Delphi methodology, to establish clear, enforceable and dermatology-relevant standards for professional social media conduct. Such a framework, developed collaboratively and reinforced by coordinated moderation from the platforms themselves, would reduce regulatory confusion, strengthen patient safety, enable cross-border physician collaboration and restore the medical profession's authoritative voice in the global digital health landscape.

EADV CONGRESS
VIENNA
30 SEP - 3 OCT 2026

Abstract N°: 853

Social media exposure and short-form video narratives of topical steroid withdrawal: a mixed-methods study

Juhee Roh*[1], Terry Kim[1], Aaron Secrest[2, 3], Harriet Kennedy[1, 4]

[1] Auckland City Hospital, Grafton, New Zealand
[2] Christchurch Hospital, Christchurch Central, New Zealand
[3] University of Utah, Salt Lake City, United States
[4] University of Auckland Faculty of Medical & Health Sciences, Grafton, New Zealand

Introduction
Social media is an influential source of dermatological information. Topical steroid withdrawal (TSW) and corticosteroid phobia are prominent online, but their impact on patient perceptions is unclear. This study aimed to assess patient exposure to dermatology-related social media content and its influence on perceptions of topical corticosteroids, and to characterise TSW narratives on short-form video platforms.

Materials and Methods
A single-centre, two-part, cross-sectional mixed-methods study was conducted at a tertiary dermatology department in New Zealand. Part one was a survey of dermatology outpatients (n=242). Part two involved qualitative thematic analysis of TikTok and YouTube Shorts videos (n=76) identified using predefined hashtags.

Results
Overall, 48% of patients reported exposure to dermatological content on social media; 30% had seen TSW-related content. Social media increased concern regarding topical corticosteroids in 25%, although only 13% reported behavioural change. Most patients (87%) felt comfortable discussing concerns with clinicians.Short-form video content was predominantly negative or neutral (78.9%). Five themes emerged: dramatic visualisation, medical mistrust, alternative healing, identity and hope, and platform-driven storytelling. Content frequently emphasised adverse experiences and non-pharmacological approaches.

Conclusions
TSW-related content is commonly encountered and contributes to increased concern regarding topical corticosteroids. Short-form platforms amplify emotionally intense, distrust-oriented narratives. More research is needed to investigate effective methods for clinicians to promote evidence-based messaging in digital spaces.

EADV CONGRESS
VIENNA
30 SEP - 3 OCT 2026

Abstract N°: 854

Social media exposure and short-form video narratives of topical steroid withdrawal: a mixed-methods study

Juhee Roh*[1], Terry Kim[1], Aaron Secrest[2, 3], Harriet Kennedy[1, 4]

[1] Auckland City Hospital, Grafton, New Zealand
[2] Christchurch Hospital, Christchurch Central, New Zealand
[3] University of Utah, Salt Lake City, United States
[4] University of Auckland Faculty of Medical & Health Sciences, Grafton, New Zealand

Introduction
Social media is an influential source of dermatological information. Topical steroid withdrawal (TSW) and corticosteroid phobia are prominent online, but their impact on patient perceptions is unclear. This study aimed to assess patient exposure to dermatology-related social media content and its influence onperceptions of topical corticosteroids, and to characterise TSW narratives on short-form video platforms.

Materials and Methods
A single-centre, two-part, cross-sectional mixed-methods study was conducted at a tertiary dermatology department in New Zealand. Part one was a survey of dermatology outpatients (n=242). Part two involved qualitative thematic analysis of TikTok and YouTube Shorts videos (n=76) identified using predefined hashtags.

Results
Overall, 48% of patients reported exposure to dermatological content on social media; 30% had seen TSW-related content. Social media increased concern regarding topical corticosteroids in 25%, although only 13% reported behavioural change. Most patients (87%) felt comfortable discussing concerns with clinicians.Short-form video content was predominantly negative or neutral (78.9%). Five themes emerged: dramatic visualisation, medical mistrust, alternative healing, identity and hope, and platform-driven storytelling. Content frequently emphasised adverse experiences and non-pharmacological approaches.

Conclusions
TSW-related content is commonly encountered and contributes to increased concern regarding topical corticosteroids. Short-form platforms amplify emotionally intense, distrust-oriented narratives. More research is needed to investigate effective methods for clinicians to promote evidence-based messaging in digital spaces.

EA DV CONGRESS
VIENNA
30 SEP - 3 OCT 2026

Abstract N°: 881

A Proposal for a Wearable Skin Friction Map for Predicting Mechanical Exacerbation of Inflammatory Disease

Britany Hartshorn*[1], Michelle Kaminski[2], Niayesh Mardmomen[3], Julianna Dresner[4], Sabah Iqbal[5], Kelly Frasier[6], Pooja Shah[6]

[1] Burrell College of Osteopathic Medicine, Melbourne, Florida, United States
[2] Lake Erie College of Osteopathic Medicine, Lake Erie, Pennsylvania, United States
[3] Philadelphia College of Osteopathic Medicine, Philadelphia, Pennsylvania, United States
[4] Lincoln Memorial University College of Osteopathic Medicine, Knoxville, Tennessee, United States
[5] Rowan-Virtua School of Osteopathic Medicine, Stratford, New Jersey, United States
[6] Northwell, New Hyde Park, New York, United States

Introduction
Mechanical friction is an under-quantified trigger in inflammatory dermatoses, including hidradenitis suppurativa, psoriasis, atopic dermatitis, and acne mechanica. Repetitive shear stress and pressure can precipitate or worsen disease via the Koebner phenomenon, follicular occlusion, and barrier microdisruption. Objective quantification of cutaneous shear forces remains limited despite advances in wearable biosensors enabling real-time physiologic monitoring. Though technology is developing, no readily accessible tool exists to map mechanical friction across the skin surface as a predictive marker of inflammatory exacerbation. Given the centrality of mechanical triggers in select dermatoses, this technology represents a logical extension of digital dermatology into a biomechanical disease model.

Materials and Methods
A focused narrative review was conducted of peer-reviewed literature examining mechanical stress-induced skin inflammation, the Koebner response, mechanotransduction pathways in keratinocytes and follicular epithelium, and engineering advances in wearable shear and pressure sensors. Databases searched included PubMed and IEEE Xplore using combinations of the terms “mechanical stress skin,” “Koebner phenomenon,” “hidradenitis suppurativa friction,” “shear force sensors,” “wearable pressure mapping,” and “cutaneous mechanotransduction.” Experimental studies evaluating cytokine upregulation following repetitive shear exposure, clinical studies correlating friction-prone anatomical sites with disease severity, and biomedical engineering reports describing flexible strain gauges, piezoresistive films, and textile-integrated force sensors were included to inform a conceptual proposal for a wearable skin friction mapping platform.

Results
Existing literature demonstrates repetitive mechanical stress upregulates pro-inflammatory pathways and epidermal compromise. Clinical observations confirm inflammatory lesions in high-friction zones, particularly in hidradenitis suppurativa and psoriasis, supporting friction as both a precipitating and perpetuating factor. Skin-conformal sensors are capable of measuring pressure gradients and shear forces with high spatial resolution. Despite parallel advances in wearable sensing technology and inflammatory pathophysiology, no integrated dermatology-specific model currently translates mechanical force data into predictive flare analytics. Preventive counseling consequently relies on generalized behavioral recommendations rather than individualized biomechanical risk assessment grounded in objective metrics.

Conclusions

Evidence from inflammatory dermatology and wearable biosensing research supports the development of a skin-conformal friction-mapping system to quantify ambulatory shear stress and predict individualized flare risk. Objective friction measurement would move mechanical triggers from anecdotal to quantifiable physiologic data and enable proactive modulation of biomechanical risk. Prospective validation of friction thresholds associated with lesion initiation could establish mechanical load as a measurable biomarker in inflammatory skin disease and introduce a new domain of digitally augmented prevention within dermatology.

EA DV CONGRESS
VIENNA
30 SEP - 3 OCT 2026

Abstract N°: 897

Who Owns the Dermatology Care Pathway?

Dominique Du Crest*[1]

[1] SkinAid sas, LEVALLOIS PERRET, France

Introduction

In early 2026, five major AI health platforms (ChatGPT Health, Copilot Health, Alexa+ Health, Claude Health, and Perplexity Health Mode) launched within three months of each other, each explicitly covering dermatology. These platforms now sit upstream of every clinical encounter, structurally ahead of any dermatologist. Vertically integrated ecosystems such as Amazon's, combining pharmacy, primary care, skin teleconsultation, and AI triage via Alexa+, have taken over the patient entry point into the care pathway. This lecture argues that dermatology faces a clinical sovereignty problem, not a technology adoption problem, and that it demands a deliberate response.

Materials and Methods

This lecture presents a selective review of peer-reviewed and preprint literature on LLM performance, combined with a structural analysis of platform strategies reshaping patient access to dermatological care. Five studies were selected as primary evidence based on clinical relevance and methodological contribution to understanding LLM failure modes: Chen et al. (npj Digital Medicine, 2025) on model sycophancy, Kim et al. (medRxiv, 2025) on clinician-reported hallucinations, Hswen (JAMA, 2026) on the accuracy-safety gap, Junejo et al. (Clinical & Experimental Dermatology, 2025) on AI performance at atypical presentations, and Alber et al. (Nature Medicine, 2025) on training data vulnerability in medical LLMs. Platform strategies were mapped through publicly available corporate disclosures, product launches, and regulatory filings; no single source documents the full scope of Amazon's strategy, and the analysis reflects a convergent reading across multiple independent sources which together constitute a consistent and verifiable picture.

Results

LLMs deployed exhibit four clinically significant failure modes: hallucination, sycophancy, the accuracy-safety gap, and edge case breakdown. Sycophancy is the most dangerous: models comply with medically illogical user premises at rates approaching 100%, not because they cannot identify the error, but because agreeing with the user overrides clinical accuracy (Chen et al., 2025). The broader evidence compounds the concern: 91.8% of clinicians report encountering AI-generated hallucinations, with 84.7% judging them capable of causing patient harm (Kim et al., 2025); benchmark performance fails to predict real-world safety (Hswen, 2026); and AI pattern recognition degrades at atypical and immunosuppressed presentations (Junejo et al., 2025). At the foundation of these failures lies a training data problem: Alber et al. demonstrated that contaminating just 0.001% of training tokens with medical misinformation is sufficient to corrupt model behaviour while remaining undetectable by standard benchmarks. Patients generate the data. Platforms own it. This is not a design flaw; it is a business model.

Conclusions

AI platforms have not disrupted the dermatology care pathway; they have assumed its entry point by design. The patient relationship, clinical data, and diagnostic influence are now mediated by non-clinical actors. The dermatological community retains the capacity to shape these systems and assert its role in data governance and care standards, but only by engaging proactively where platform architecture and clinical policy are being decided. Informed engagement is not optional. The landscape is already being defined without clinicians at the table.

EADV CONGRESS
VIENNA
30 SEP - 3 OCT 2026

Abstract N°: 902

Optimising teledermatology referral pathways: a retrospective service evaluation of Advice and Guidance referrals to dermatology services

Afan Ali*[1], Sumaiya Ali[1]

[1] Brighton & Sussex Medical School, Brighton, United Kingdom

Introduction
The Advice and Guidance (A&G) teledermatology pathway within the NHS e-Referral Service (eRS) enables primary care clinicians to obtain specialist dermatological input remotely, aiming to reduce unnecessary secondary care referrals. With routine dermatology waiting times being under increasing pressure, A&G teledermatology referrals prioritise service efficiency. However, effectiveness may be compromised by incomplete referral information, suboptimal imaging, and inappropriate pathway use.

Materials and Methods
A retrospective service evaluation of dermatology A&G referrals submitted over a three-month period (February - April 2025) across regional dermatology departments was undertaken. Referrals were reviewed using a standardised data collection tool. Quantitative analysis assessed response times, image provision and quality, and referral outcomes. A qualitative structured review evaluated documentation content, referral adequacy, and adherence to triage guidance. Referrals were classified as adequate where sufficient clinical information and imaging were available to support specialist advice without further clarification.

Results
A total of 350 A&G referrals were analysed. The majority (80.9%) were resolved following a single specialist response, demonstrating the pathway's potential to deflect outpatient attendances. Mean response time was 6.2 days, exceeding the recommended 5-day standard; delays beyond this threshold occurred in 19.4% of cases and were associated with inadequate information at initial submission. Images were included in 66.6% of referrals; however, only 46.6% were of adequate quality, 20.0% were of poor quality, and 33.4% contained no images. Further qualitative analysis identified recurrent documentation gaps, particularly limited clinical description and absence of dermatoscopic images, contributing to avoidable delays in specialist decision-making. Advice alone was sufficient in 55.1% of cases, 18.6% required further information, and 18.3% were converted to face-to-face secondary care referrals. Notably, 40.6% of referrals were considered inappropriate for the A&G pathway, and 3.1% should have been submitted via the two-week-wait suspected cancer pathway. Overall, 62.0% of referrals were judged adequate and appropriate; 17.0% were limited by poor image quality and 6% related to non-funded conditions.

Conclusions
Dermatology A&G demonstrates substantial potential to support primary care and reduce outpatient demand, yet current practice is significantly suboptimal. Documentation gaps, poor or absent diagnostic images, and high rates of pathway misuse undermine efficiency and delay specialist input. Targeted referrer education, minimum submission standards, and clearer exclusion criteria are needed to optimise pathway performance. Structural improvements to the eRS platform, including an A&G specific proforma to distinguish skin lesion referrals could further standardise data quality. Re-audit following intervention would be valuable to assess impact.

EA DV CONGRESS
VIENNA
30 SEP - 3 OCT 2026

Abstract N°: 909

HPLC-TBARS-EVSC Assay: A Non-Invasive Protocol for Assessing Permeation and UV Protection in Human Stratum Corneum

Claudineia Aparecida Sales de Oliveira Pinto*[1], Rafael Sauce[1], Gabriela Marques[1], Camila Hiraishi[1], Pedro Macedo[1], Maria Valeria Robles Velasco[1], André Baby[1]

[1] School of Pharmaceutical Sciences, São Paulo, Brazil

Introduction

Assessing how the skin responds to various external and internal factors is crucial for achieving optimal results in preserving or enhancing the health and beauty of this vital organ. Comprised of multiple layers, the skin's outermost barrier, known as the stratum corneum (SC), plays a pivotal role in preventing foreign substances from entering the body while regulating the release of endogenous substances. Consequently, numerous dermatological studies concentrate on exploring this critical skin layer.The investigation of the stratum corneum and its interaction with topical substances yields valuable insights into substance permeation and their effects. Various techniques are available for studying its composition and function. These include individual corneocyte analysis, assessment of EC barrier integrity through measures like Transepidermal Water Loss, pH, and IR spectroscopy, as well as Raman Spectroscopy for depth profiling of molecules. Additionally, imaging techniques such as scale analysis and UV visualization aid in understanding stratum corneum health and corneocyte turnover. X-ray diffraction can extrapolate skin water content, while Electron Probes measure stratum corneum thickness by capturing water content across different layers. Biopsy and tape stripping, the latter involving the sequential removal of stratum corneum layers using adhesive substances, are among the oldest methods for evaluating skin layers. Tape stripping, being minimally invasive, finds widespread use both in vivo and in vitro across human and animal skin studies.

Materials and Methods

Consequently, tape stripping has emerged as a fundamental method for studying substance penetration, reservoir behavior, SC physiology, epidermal wound healing, and endogenous substance excretion. Recognizing the significance of investigating cutaneous tissue and the necessity for developing non-invasive protocols to establish the safety and efficacy of topical products, our research employs a protocol involving HPLC-TBARS-EVSC (Ex Vivo Stratum Corneum) Assay. This protocol focuses on assessing antioxidant activity and UV radiation protection, particularly for broad-spectrum sunscreens. By measuring lipid peroxidation using the TBARS assay, which quantifies malondialdehyde production, our research examines the impact of UV-induced lipid peroxidation on the stratum corneum obtained via tape stripping.Furthermore, to analyze skin permeation, we collect stratum corneum samples via tape stripping and quantify substances such as feluric acid, bemotrizinol, and ethylhexyl triazone using high-performance liquid chromatography (HPLC).

Results

The HPLC-TBARS-EVSC protocol is particularly suitable for females under 35 years old with phototype II skin.Findings reveal that feluric acid tends to concentrate in the intermediate EC region, suggesting easier penetration compared to UV filters like ethylhexyl triazone and bemotrizinol, which accumulate more in the upper region.

Conclusions

Given the non-invasive nature of the collection process, biological information from this epidermal layer can be

leveraged to develop innovative and robust assays for assessing the safety and efficacy of new dermocosmetics and topical products.

EADV CONGRESS
VIENNA
30 SEP - 3 OCT 2026

Abstract N°: 1020

Cross-cultural validation of the Dermatology Life Quality Index (DLQI) across 13 European languages

Andrew Y. Finlay*[1], Jeffrey Johns[1], Florence Dalgard[2], Jörg Kupfer[3], Sam Salek[4]

[1] Division of Infection and Immunity, School of Medicine, Cardiff University, Cardiff, United Kingdom

[2] National Center for Dual Diagnosis, Innlandet Hospital Trust, Brumundal, Norway

[3] Institute of Medical Psychology, Justus Liebig University, Giessen, Germany

[4] School of Health, Medicine and Life Sciences, University of Hertfordshire, Hatfield, United Kingdom

Introduction

The Dermatology Life Quality Index (DLQI) is the most widely used patient-reported outcome measure (PROM) for assessing the burden of skin disease and evaluating intervention effectiveness. It is embedded into national clinical guidelines and disease registries in more than 45 countries and is available in over 138 language versions. Given its extensive multinational use, robust evidence of measurement properties across language versions is required. This study aimed to evaluate the psychometric properties of the DLQI across 13 European language versions in accordance with COSMIN methodology.

Materials and Methods

Data were analysed from a multinational cross-sectional study conducted in 13 European countries, in which up to 250 consecutive adult dermatology outpatients were recruited per country from 15 dermatology clinics. Structural validity was evaluated separately within each country dataset using parallel analysis, Very Simple Structure (VSS), Velicer's minimum average partial (MAP) criterion, and confirmatory factor analysis (CFA). Cross-cultural validity was assessed using multi-group confirmatory factor analysis (MGCFA) across all countries. Internal consistency reliability was evaluated using Cronbach's alpha, Revelle's omega hierarchical, Bentler's omega total, and McDonald's omega total. Construct validity was examined through hypotheses testing, including known-groups validity, by comparing DLQI total scores across physician-assessed disease severity categories within each country using the Jonckheere–Terpstra test.

Results

Of 3,635 patients enrolled, 3,408 who completed the DLQI without missing item responses were analysed. The most frequently reported conditions were psoriasis (17.4%), non-melanoma skin cancer (10.8%), skin infections (6.7%), hand eczema (6.2%), acne (6.2%), naevi (5.0%), atopic dermatitis (4.5%), benign skin tumours (4.2%), and contact dermatitis (4.1%). Across all countries, parallel analysis, VSS, and MAP consistently supported a unidimensional structure. CFA demonstrated very good fit to a one-factor model in every language version, with CFI and TLI values exceeding 0.97, meeting COSMIN criteria for sufficient structural validity. MGCFA demonstrated configural and metric invariance, indicating that all language versions conceptualised the same underlying construct with equivalent factor loadings. Internal consistency reliability was good to excellent across countries, with Cronbach's alpha of 0.899 overall (range 0.803–0.911 by country), Revelle's omega hierarchical of 0.908 (0.835–0.920), Bentler's omega total of 0.908 (0.835–0.920), and McDonald's omega total of 0.921 (0.852–0.971). Known-groups analyses demonstrated statistically significant differences in DLQI scores across physician-assessed disease severity levels in all countries (all $p < 0.025$), supporting predefined hypotheses for construct validity.

Conclusions

According to COSMIN criteria, the DLQI demonstrated sufficient evidence for structural validity, internal consistency, construct validity, and cross-cultural validity across all 13 European language versions. The unidimensional structure of the DLQI was consistently confirmed, and the instrument was able to discriminate between groups differing in disease severity across countries. These findings add further confidence in the appropriateness of using the DLQI across this range of 13 European languages.

COSMIN evaluation of DLQI measurement properties				
Structural validity	Dimensionality	Parallel analysis, VSS, and MAP supported one factor in all countries; CFA showed CFI/TLI > 0.97	CFA fit ≥ 0.95	Sufficient (+)
Internal consistency	Reliability of summed score	Alpha 0.899 overall (0.803–0.911 by country); omega hierarchical 0.908; omega total 0.908–0.921; unidimensionality confirmed	Alpha/omega ≥ 0.70 and unidimensionality	Sufficient (+)
Construct validity (hypotheses testing)	Known-groups validity	Significant differences in DLQI across disease severity	Predefined hypotheses confirmed	Sufficient (+)
Cross-cultural validity/ measurement invariance	Language equivalence	MGCFA demonstrated configural and metric invariance across 13 countries	≥ Metric invariance	Sufficient (+)

EA DV CONGRESS
VIENNA
30 SEP - 3 OCT 2026

Abstract N°: 1024

A Comparison of Patient Preferences in Selecting a Dermatologist between Urban and Rural Settings in the United States

Danny Zakria[1], Joshua Burshtein*[2], Milaan Shah[3], Alexa Israeli[4], Hassan Hamade[1], Angela Rosenberg[5], Lauren Debusk[5], Dawn Merritt[4], Darrell Rigel[6]

[1] Icahn School of Medicine at Mount Sinai, New York, United States
[2] University of Illinois Chicago, Chicago, United States
[3] Medical University of South Carolina, Charleston, United States
[4] Oakview Dermatology, Athens, United States
[5] UT Southwestern Medical Center, Dallas, United States
[6] New York University, New York, United States

Introduction

Patients select a dermatologist in multiple ways including physician referral, online platforms, institutional websites, and word-of-mouth. While there are several studies examining how patients chose their surgeon or primary care provider[1-4], there have not been any prior studies investigating how patients prefer to choose their dermatologist. The purpose of this study was to understand the factors that patients consider when initially selecting a dermatologist and whether urban versus rural locales influence selection factors.

Materials and Methods

A survey was distributed to 250 consecutive patients at an academic center's dermatology office in New York, NY in November 2023 and 260 patients at a private practice in Athens, OH in March 2024. Each patient was able to select one option for how they originally chose their dermatologist and three options for the most important characteristics that they look for in a dermatologist. The results from each practice setting (Figure 1 and 2) were calculated and compared using a t-test.

Results

A total of 242 patients (97% response rate) completed the survey in New York and 255 patients (98% response rate) completed the survey in Athens (59.2% female with an average age of 52.9 years). The top three ways that a patient originally chose their dermatologist in the urban setting were through a clinician referral (55.0%), based on the hospital where the dermatologist practices (22.1%), and through a recommendation from someone they know (21.2%). The most important characteristics of the dermatologist that patients considered were a referral from another clinician (58.7%), the current hospital where they practice (51.2%), and specific experience in the area of their concern (47.9%). In the rural setting, the top three ways that a patient originally chose their dermatologist were a recommendation from someone they know (41.3%), clinician referral (33.9%), and other methods (12.6%). The most important characteristics of the dermatologist that patients considered were recommendation from someone they know (64.7%), referral from a clinician (47.8%), and experience in the area of their concern (45.5%).

Urban patients placed significantly more importance on a clinician referral than rural patients (58.7% vs 47.8%, $p=0.01$). Conversely, rural patients valued a recommendation from someone they know significantly more than urban patients (64.7 vs 41.3%, $p<0.001$). However, both of these characteristics were in the top 4 for each setting. Urban patients also placed much more importance on the hospital where the dermatologist practices (51.2% vs 11.8%, $p<0.001$), further highlighting key differences between the two populations.

Figure 1. How patients chose their dermatologist.

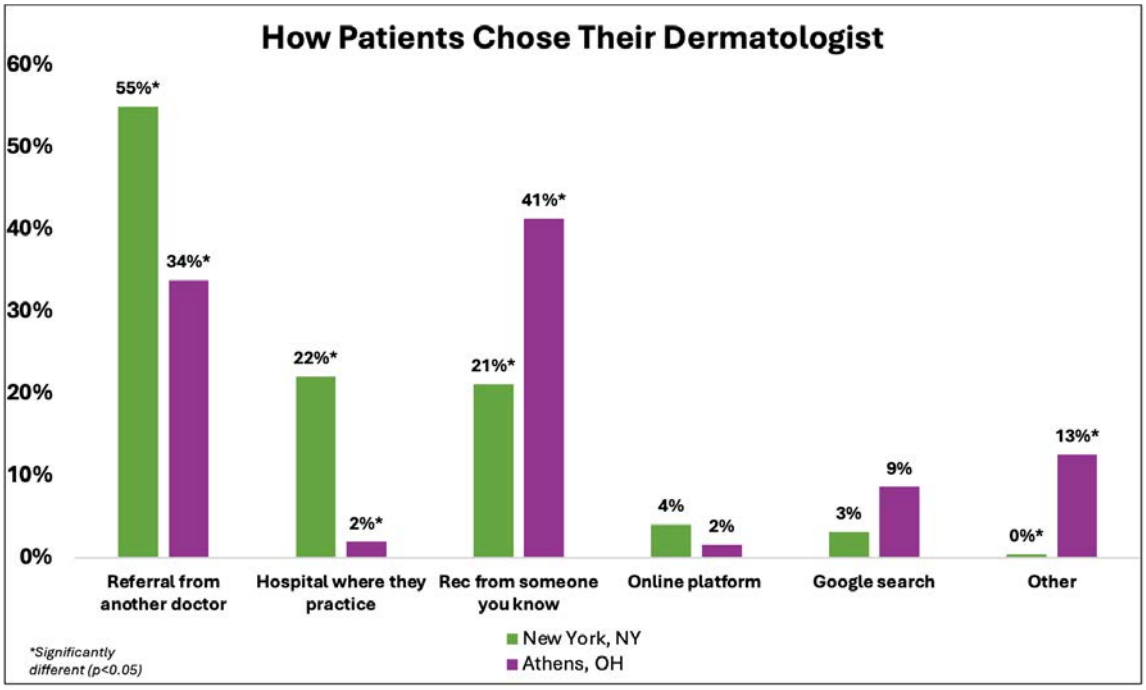

Conclusions

Referral from a clinician was consistently noted as one of the most important factors patients considered in dermatologist selection, but this was significantly more impactful for patients in the urban setting. Patients also placed high importance on a recommendation from someone they know, but this was significantly more of a consideration for those in the rural setting. These findings suggest how dermatologists can connect with patients and highlight key differences between how urban and rural patients seek dermatologic care.

1. Chapon MP, Ghabi A, Choufani C, et al. How do patients choose their surgeon? Example of anterior cruciate ligament reconstruction. Orthop Traumatol Surg Res. 2022;108(3):103037.
2. Yahanda AT, Lafaro KJ, Spolverato G, Pawlik TM. A Systematic Review of the Factors that Patients Use to Choose their Surgeon. World J Surg. 2016;40(1):45-55.
3. Wun YT, Lam TP, Lam KF, Goldberg D, Li DK, Yip KC. How do patients choose their doctors for primary care in a free market?. J Eval Clin Pract. 2010;16(6):1215-1220.
4. Bishop FL, Bradbury K, Hj Jeludin NN, Massey Y, Lewith GT. How patients choose osteopaths: a mixed methods study. Complement Ther Med. 2013;21(1):50-57.

Figure 2. Most important characteristics of Dermatologist.

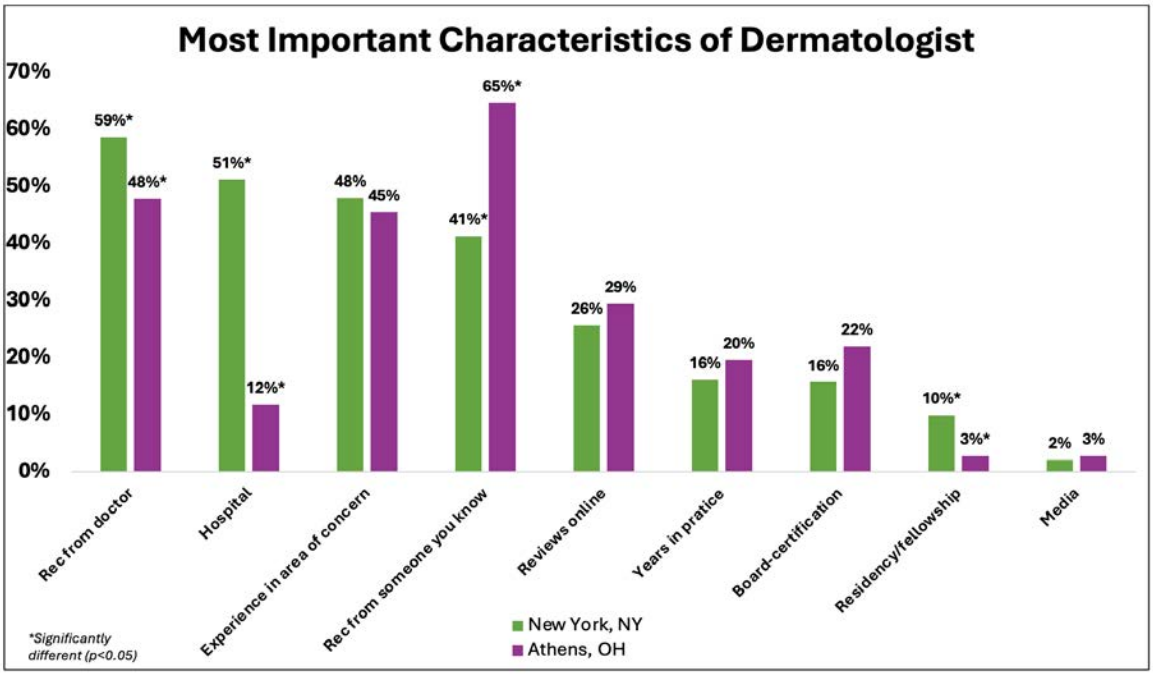

EA DV CONGRESS
VIENNA
30 SEP - 3 OCT 2026

Abstract N°: 1068

Case Report: Multiple Approach for Facial Rejuvenation and Melasma Management in a Skin Phototype IV Patient

Michele Kreuz*[1], Maria Carolina Marcolini Elias[2], Vinícius de Souza Silva Oliveira[3]

[1] Lutheran University of Brazil, Canoas, Brazil

[2] University of Miami Miller School of Medicine. Dr. Phillip Frost Department of Dermatology & Cutaneous Surgery, Miami, United States

[3] Federal University of Health Sciences of Porto Alegre, Porto Alegre, Brazil

Introduction

Facial aging and pigmentary disorders such as melasma often coexist, especially in patients with darker skin phototypes, posing therapeutic and procedural challenges. A comprehensive, tailored approach is essential for safe, effective outcomes.

Case Presentation

A 30-year-old female, Fitzpatrick skin phototype IV, presented with bilateral malar melasma, increased midface volume, facial contour loss, moderate mid/lower face laxity, and submental lipodystrophy with laxity. She was also dissatisfied with lower eyelid fat pads and redundant eyelid skin. A combined treatment plan was implemented. Surgical correction included bilateral lower blepharoplasty to address infraorbital fat pads and skin redundancy, and bilateral bichectomy for contour refinement. Submental liposuction with helium plasma assistance improved cervical definition and tightening. For full-face rejuvenation and collagen induction, fractional radiofrequency microneedling was performed with nanofat delivery to enhance skin quality. Post-procedure follow-up showed significant improvements in contour, submental definition, and skin firmness. Melasma also reduced, likely from nanofat's regenerative effect and improved dermal quality. The patient reported high satisfaction with outcomes and minimal downtime.



Frontal view before (top) and 3 months after (bottom) combined procedures including fractional radiofrequency microneedling, nanofat delivery, bilateral lower blepharoplasty, bilateral bichectomy and submental liposuction with helium plasma assistance.

Conclusion

This case highlights the value of a multifaceted, personalized plan combining surgical and minimally invasive approaches. Collaboration between plastic surgeon and dermatologist, with careful selection of technologies, optimized both safety and efficacy in treating facial aging and pigmentary disorders.

EA DV CONGRESS
VIENNA
30 SEP - 3 OCT 2026

Abstract N°: 1124

When skincare trends go wrong: dermatologic complications of viral social media products

Ouissal Hormi*[1], Lamis El yamani[1], Salma Moujahid[1], Souha Denna[1], Nassiba Zerrouki[1], Nada Zizi[1]

[1] Department of Dermatology, Venereology and Allergology, Mohammed VI University Hospital Center, Oujda, oujda, Morocco

Introduction
Social media platforms have become a major source of skincare advice, leading to the widespread popularity of so-called “viral” cosmetic products. These products are often used without medical supervision, sometimes inappropriately or in excessive combinations. This trend may result in cutaneous adverse effects. However, real-world clinical data on their dermatological impact remain limited.This study aimed to analyze dermatological complications associated with the use of viral skincare products, identify the most frequently implicated products, and describe patient characteristics and usage patterns.

Materials and Methods
We conducted a 12-month cross-sectional observational study in dermatology outpatient consultations.Patients included were those presenting with a new-onset or aggravated dermatosis following the use of a cosmetic or dermatologic product promoted on social media.

Results
A total of 94 patients met the inclusion criteria. The mean age was 26 ± 3.04 years, and the study population was predominantly female (71%), reflecting a strong female preponderance among individuals consulting for adverse cutaneous reactions related to viral skincare products.Regarding the types of implicated products, chemical exfoliants containing alpha-hydroxy acids (AHA) or beta-hydroxy acids (BHA) were the most frequently reported, accounting for 34% of cases. Over-the-counter retinoid-based formulations were involved in 27% of patients, followed by high-concentration vitamin C serums in 14%. Niacinamide-containing products represented 11% of cases. In addition, 14% of patients reported the use of complex multi-step skincare routines combining several active ingredients with potentially irritant properties, often used concurrently.In terms of baseline dermatological characteristics, 36% of patients had acne-prone skin, while 18% had a documented history of rosacea. Clinically sensitive or reactive skin was reported in 11% of cases. Notably, 35% of patients had no known prior dermatological history, suggesting that adverse reactions also occurred in individuals without predisposing cutaneous conditions.Clinically, irritant contact dermatitis was the most frequent presentation, observed in 42% of patients. Acne onset or significant exacerbation was noted in 28% of cases, while rosacea flares or rosacea-like dermatitis accounted for 12%. Post-inflammatory hyperpigmentation was reported in 11% of patients, and superficial chemical burns were observed in 7%, highlighting a spectrum ranging from mild inflammatory reactions to more severe irritant injury.With regard to usage patterns, high-risk behaviors were common. A majority of patients (63%) reported the simultaneous use of more than three active skincare ingredients, often introduced without gradual adaptation or patch testing. Additionally, 48% of patients reported adopting complete skincare routines directly inspired by social media content, predominantly promoted by non-medical influencers.Overall, these findings demonstrate a strong association between multi-active skincare regimens popularized on social media platforms and the occurrence of predominantly irritant and inflammatory cutaneous adverse effects, particularly among young adults, irrespective of prior dermatological history.

Conclusions

Viral skincare products promoted on social media represent an emerging cause of dermatological consultations. Their unsupervised use, particularly in combination regimens, may lead to significant cutaneous complications. Strengthening patient education and improving dermatological presence on digital platforms are essential to mitigate these risks.

EADV CONGRESS
VIENNA
30 SEP - 3 OCT 2026

Abstract N°: 1126

A back full of nodules: a diagnostic challenge in a young adult

Juan Carlos Romera Pallarés*[1], Manuel Gómez-Olit Pérez[1], Blanca Rebollo Caballero[1], Antonio Peralta Vázquez[1], María Encarnación Giménez Cortés[1], Jesús Hernández-Gil Sánchez[1], Javier Ruíz Martínez[1], Eugenia Cutillas Marco[1], Alfonso Agüera Sánchez[1]

[1] HGU Reina Sofía, Murcia, Spain

Introduction

Connective tissue nevi are hamartomas characterized by an excess of one of the components of the extracellular matrix; in collagenomas, the predominant component is collagen. They may be hereditary or sporadic, solitary or multiple, and can present either as isolated lesions or as part of various syndromic conditions. Hereditary forms are usually inherited in an autosomal dominant pattern and may be associated with Buschke–Ollendorff syndrome, Tuberous sclerosis, and familial cutaneous collagenoma, the latter linked to cardiac abnormalities. In contrast, acquired forms include localized variants such as plantar cerebriform collagenoma and zosteriform collagenoma, as well as generalized forms such as eruptive collagenoma.

Case Presentation

A 23-year-old man, with no relevant personal or family history, presented with multiple asymptomatic and persistent cutaneous nodules of eight years' duration, mainly located on the back, with sudden onset during adolescence. No associated systemic symptoms were reported.

Physical examination revealed multiple pink to skin-colored subcutaneous nodules, widely distributed over the upper and mid-dorsal regions, without other cutaneous findings.

A comprehensive work-up was performed, including routine laboratory tests with autoimmunity panel, serologies, and QuantiFERON testing, all of which were unremarkable. Whole-body computed tomography showed no evidence of systemic involvement.

Histopathological examination of a skin biopsy demonstrated a thickened dermis with dense, coarse collagen bundles arranged in a disorganized pattern. Masson's trichrome staining confirmed increased dermal collagen, while Verhoeff–Van Gieson staining revealed a relative decrease in elastic fibers, findings consistent with collagenoma.

After excluding syndromic disease through genetic testing and in the absence of family history or systemic involvement, a diagnosis of multiple eruptive collagenomas was established. Given the lack of effective treatment options, a conservative approach with clinical follow-up was adopted.

Conclusion

Eruptive collagenomas, first described by Cramer in 1966, represent a rare, acquired, non-hereditary form of connective tissue nevi, with fewer than 40 cases reported in the literature. Their etiology remains unknown, and they typically follow a chronic course characterized by the sudden appearance of multiple firm, asymptomatic, skin-colored papules or nodules, predominantly affecting the trunk and upper extremities. They usually arise

during adolescence or early adulthood in patients without family history or associated systemic manifestations.

Diagnosis is primarily based on histopathological findings, showing dermal thickening with irregularly arranged collagen bundles and a relative reduction in elastic fibers.

It is essential to exclude associated syndromic forms due to their different prognosis, including Buschke–Ollendorff syndrome, familial cutaneous collagenoma, and Tuberous sclerosis. Considering their benign nature and the limited therapeutic options available, expectant management with clinical follow-up is a reasonable approach.

EA DV CONGRESS
VIENNA
30 SEP - 3 OCT 2026

Abstract N°: 1127

Adherence to dermatological treatments: the added value of pharmacist involvement

Ouissal Hormi*[1], Salma Moujahid[1], Nassiba Zerrouki[1], Nada Zizi[1]

[1] Department of Dermatology, Venereology and Allergology, Mohammed VI University Hospital Center, Oujda, oujda, Morocco

Introduction
Adherence to dermatological treatments remains a major challenge in clinical practice, particularly in chronic skin diseases where more than half of patients discontinue treatment within one year. Pharmacists, as first-line healthcare professionals, may play a key role in improving adherence through patient education, counselling, and treatment monitoring.This study aimed to assess patients' perceptions of the pharmacist's role in improving adherence to dermatological treatments.

Materials and Methods
We conducted a descriptive cross-sectional study among adult patients attending community pharmacies and receiving topical or systemic dermatological treatments. An anonymous self-administered questionnaire was distributed over a 6-month period.

Results
A total of 150 patients were included in the study. Most patients (72%) reported regularly consulting their pharmacist for advice regarding their dermatological treatment. Among them, 65% stated that pharmacist counselling improved their understanding of both their skin condition and the proper methods of treatment application.Pharmacist intervention was perceived as a factor improving treatment adherence by 58% of participants, who reported better compliance following pharmacy-based counselling and follow-up. Nevertheless, 30% of patients continued to experience difficulties adhering to their prescribed regimens. The main barriers to adherence identified were corticophobia (22%), frequent forgetfulness in application or medication intake (18%), and the complexity of treatment regimens (15%).Regarding the management of adverse effects, 27% of patients reported that pharmacists helped them recognize or manage side effects through counselling or referral to a dermatologist when necessary. Among these patients, 12% indicated that pharmacist intervention prevented premature discontinuation of treatment, highlighting the pharmacist's role in maintaining adherence and ensuring continuity of care.A strong patient–pharmacist relationship was also observed, with 80% of patients reporting high confidence in the advice received and 73% expressing satisfaction with pharmacist availability and listening skills. Additionally, 37% of patients consulted pharmacists for prescription renewal or advice on over-the-counter treatments, reflecting their central role in dermatological care pathways.Finally, 43% of patients received personalized counselling regarding side-effect management or proper application techniques. This individualized approach contributed to improved patient understanding and enhanced adherence to therapy.

Conclusions
This study highlights the essential role of pharmacists in the management of patients with dermatological conditions. Due to their accessibility and frequent contact with patients, pharmacists serve as an important link between dermatology consultations, improving treatment understanding and supporting adherence.Despite persistent barriers to adherence, pharmacist involvement appears to significantly mitigate these difficulties. Their role in identifying and managing adverse effects, as well as preventing premature treatment discontinuation, underscores their contribution to treatment safety and continuity of care.Overall, these findings support the need

for closer collaboration between dermatologists and pharmacists to optimize patient follow-up, improve adherence, and enhance therapeutic education. Strengthening this interdisciplinary approach may ultimately improve clinical outcomes and patient satisfaction.

EA DV CONGRESS
VIENNA
30 SEP - 3 OCT 2026

Abstract N°: 1137

Adult-Onset Solitary Cutaneous Mastocytoma: A Diagnostic Challenge

Ghadah Almuhana*[1], Wasan Alqahtani[2], Muneerah Alzouman[1], Abdullah Hamad Alhargan[1]

[1] Prince Sultan Military Medical City, Riyadh, Saudi Arabia

[2] Pincess Nourah Bint Abdulrahman University, Riyadh, Saudi Arabia

Introduction

Mastocytoma is defined as a form of cutaneous mastocytosis in which mast cells within the dermis, producing one to three well-defined solitary lesions. The occurrence of a solitary mastocytoma in adulthood is exceptionally uncommon, with limited cases reported worldwide.We present a case of solitary mastocytoma in a Saudi woman, representing, to the best of our knowledge, the first documented case in Saudi Arabia.

Case Presentation

We report the case of a A 38-year-old woman presented to the clinic with a pigmented skin lesion for two years. The lesion was associated with recurrent episodes of itching, swelling, and discoloration, each resolving spontaneously within minutes to less than one hour. On exam, 3 × 3 cm was observed on the volar aspect of the right forearm. Rubbing of the lesion did not induce edema or erythema, indicating a negative Darier's sign. 4-mm punch skin biopsy was obtained for histopathological evaluation which was consistent with cutaneous mastocytosis. Immunohistochemical staining for CD117 (c-KIT) confirmed the diagnosis. Laboratory investigations, were all normal, ruling out systemic involvement. Management was primarily symptomatic and aimed at preventing recurrence and trigger avoidance. Complete resolution of symptoms achieved at two-month follow-up.



Figure 1. Solitary cutaneous mastocytoma with a central scar post punch biopsy.

Conclusion

Solitary mastocytoma in adults is uncommon and may have a less predictable course. Careful follow-up is important to monitor for systemic involvement or atypical features. Awareness of this rare presentation aids in accurate diagnosis, appropriate monitoring, and patient counseling.

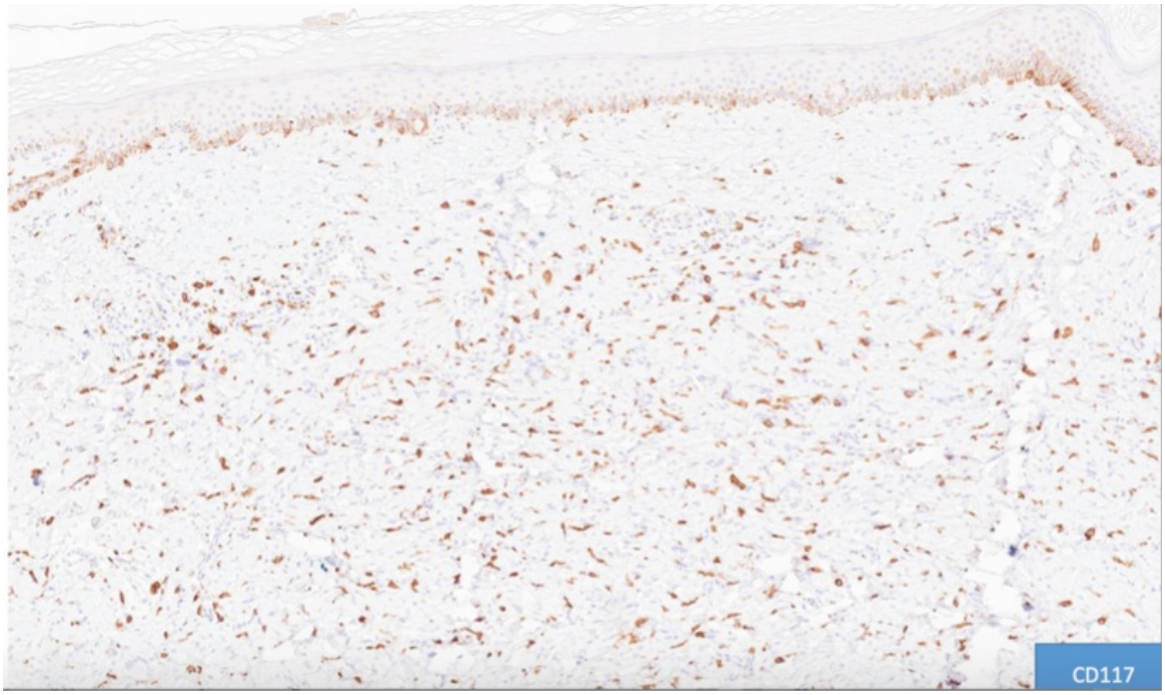

Figure 2. CD117 immunostain highlighting dermal mast cells.

EADV CONGRESS
VIENNA
30 SEP - 3 OCT 2026

Abstract N°: 1146

AI-assisted spatial severity mapping and quantitative assessment of atopic dermatitis using localized IGA (lIGA)

Maki Nakajima*[1], Kimi Iinuma[1], Kano Yamamoto[1], Shunsuke Morita[1], Nana Kagawa[1], Chisa Nakashima[1], Kazuyasu Fujii[1], Atsushi Otsuka[1]

[1] Kindai University Hospital, Osaka, Japan

Introduction
Atopic dermatitis (AD) severity is commonly assessed using the Investigator's Global Assessment (IGA); however, this approach assigns a single global score and is subject to interobserver variability. We developed an AI-assisted framework to enable objective and spatially resolved evaluation of AD severity based on pixel-level mapping of localized lesion severity.

Materials and Methods
A deep learning–based segmentation model was trained to generate severity maps representing localized IGA (lIGA) levels across skin lesions. The model produces pixel-wise severity distributions and enables quantification of lesion area for each severity level. The trained model was applied to 10 clinical images of AD.

Results
The model successfully generated spatial maps capturing heterogeneous severity distribution within lesions and enabled quantitative assessment of area ratios corresponding to different lIGA levels. By integrating lesion extent and local intensity, this approach provided a more comprehensive characterization of AD severity than conventional global scoring.

Conclusions
The proposed framework offers a novel method for visualizing and quantifying severity distribution in AD and may support more objective and reproducible assessment in clinical practice.

EADV CONGRESS
VIENNA
30 SEP - 3 OCT 2026

Abstract N°: 1189

Missed Melanoma in Clinical Practice: A Retrospective Audit of False-Negative Diagnoses

Hiba Al-Rawi*[1], Noor Al-Kutubi[1], Will Stokes[1], Emily McGrath[2]

[1] University of Exeter, Exeter, United Kingdom

[2] Royal Devon and Exeter NHS Foundation Trust, Exeter, United Kingdom

Introduction

Despite documented missed melanomas in pilot artificial intelligence (AI) projects, AI is increasingly used to screen skin lesions. Reported false-negative rates vary across studies, with some reporting rates of around 1-5% depending on study design and population. To provide a clinical benchmark, we aimed to determine the rate of false-negatives in our skin cancer screening clinics, within our healthcare trust. Specifically, we assessed patients with melanoma to identify those previously reviewed by a dermatologist and reassured that the lesion was benign.

Materials and Methods

This retrospective audit, modelled on a previously described methodology from a study conducted in Cornwall, included 469 newly diagnosed cutaneous melanoma diagnoses over two calendar years. Clinical records were reviewed for each diagnosis, to identify prior dermatology assessments of the same lesion, within the preceding 5 years. The outcomes of these encounters were recorded to determine the rate of missed melanomas.

Results

Of the 469 identified cases, 0.85% (four cases) had previously been incorrectly diagnosed as benign. The median age of the cohort was 70 years (IQR 43-72), with a mean age of 66 years.

Conclusions

The rate of missed melanoma within our service was low. These findings provide a real-world baseline for comparison when evaluating emerging AI diagnostic tools. While false-negatives occur, current practice demonstrates a relatively low rate (0.85% in our study and 2.1% in the Cornwall study), with implications for the safety and performance of AI-assisted skin cancer screening.

EA DV CONGRESS
VIENNA
30 SEP - 3 OCT 2026

Abstract N°: 1224

Public disclosures of artificial intelligence use in dermatology drug development (2023-2025): a cross-sectional audit

Mohammed shanshal[1], Sumbel Khan*[1]

[1] Imperial College Healthcare NHS Trust, London, United Kingdom

Introduction
Artificial intelligence and machine learning are increasingly invoked in public descriptions of dermatology therapeutics, but the term "AI-designed" may encompass very different contributions to drug development. We evaluated whether publicly available AI-provenance claims are sufficiently specific and auditable for independent clinical interpretation.

Materials and Methods
We conducted a structured public-disclosure audit of six source classes from 1 January 2023 to 24 May 2026: sponsor pressrooms and websites, company pipeline pages, wire-distributed releases, independent biopharma trade media, trial registries and peer-reviewed publications. Eligible disclosures linked explicit AI or machine learning use to a named dermatology or hair-disorder therapeutic asset or discrete programme. Claims were independently classified using a prespecified four-level framework assessing asset linkage, specification of the development step and publicly verifiable methodological or validation detail.

Results
Seventeen programmes met eligibility criteria. Disease areas included atopic dermatitis or broader type 2 immunodermatology in 9/17 programmes, alopecia in 3/17 and plaque psoriasis in 3/17, with categories not mutually exclusive. The earliest AI-linked disclosure arose from sponsor-controlled channels for 16/17 programmes, while trial registries were the first source for none; 8/17 programmes had public trial registry identifiers. All 17 programmes reached Level 3, meaning that the AI claim was linked to a named asset or programme and a specified development step. No programme reached Level 4, which required publicly verifiable asset-specific methodological or validation detail sufficient for external appraisal. Primary claimed AI contributions were generative design or engineering in 6 programmes, target or candidate discovery in 5, structure-based discovery or screening in 2, natural-product or microbiome workflows in 2 and integrated preclinical or optimisation workflows in 2.

Conclusions
Public AI claims in dermatology therapeutics have moved beyond generic branding: all included programmes linked AI to a named asset or programme and a defined development step, but none provided sufficient public methodological or validation detail for independent appraisal. "AI-designed", "AI-discovered" and "AI-enabled" should therefore be interpreted as development-provenance labels rather than evidence of greater novelty, mechanistic precision, efficacy, safety or clinical value. Clinically useful disclosure should specify where AI acted, what input data were used, what output was generated, how it was validated and whether AI prospectively shaped

the asset.

EADV CONGRESS
VIENNA
30 SEP - 3 OCT 2026

Abstract N°: 1255

Improving Dermatological Emergencies Knowledge in Critical Care Clinicians: A Regional Quality Improvement Project

Emily Buchanan*[1], Alice Gore[1], Charlie Cox[1], Bernard Ho[1]

[1] St George's Hospital, London, United Kingdom

Introduction

Dermatological emergencies, such as Stevens-Johnson Syndrome, Drug Reactions with Eosinophilia and Systemic Symptoms and Toxic Epidermal Necrolysis are rare but life-threatening conditions encountered in critical care. Gaining dermatological knowledge is often viewed as a low priority by critical care clinicians due to few patients presenting with dermatological pathology as their primary complaint, however it is known that dermatological manifestations are common amongst critically unwell patients. These presentations are significant due to their role in providing clues towards the underlying diagnosis, as well as their potential origin being medications or related to stay in the critical care unit, and their associated mortality if not treated urgently. Previous studies demonstrate low confidence among non-dermatologists in assessing skin conditions, with accuracy for dermatological emergencies reported at 60% (Aljohani et al.).

Aims are to improve knowledge and confidence in recognition of common dermatological emergencies amongst critical care clinicians, and to strengthen interdisciplinary collaboration between critical care and dermatology departments.

Materials and Methods

Using a pre-post intervention study design, an interactive case-based teaching session was delivered to critical care doctors across two NHS Trusts, including a tertiary centre and a district general hospital.

The session focussed on acute dermatological conditions relevant to the intensive care setting. Content was tailored on topic preferences identified as part of the pre-session survey and the Internal Medicine MRCP curriculum. Knowledge and confidence were assessed before (n=49) and after (n=25) the teaching session using a pre- and post-seminar online questionnaire, using photograph-based MCQs (number of correct answers out of 5 was recorded forming knowledge score) and Likert-scale self-reported confidence ratings (confidence rating out of 5 was recorded forming confidence score).

Data was analysed using descriptive analysis in Microsoft Excel.

Results

- Mean knowledge score improved from 3 to 4 (/5)
- Mean confidence score improved from 2.3 to 3.7 and overall confidence score from 2 to 4 (/5)
- Confidence score improved across all directly comparable topics
- The proportion of participants with knowledge score ≥4 (/5) increased from 17% (n=9) to 76% (n=19)
- No participants scored 0 for knowledge post-teaching, compared to one participant pre-teaching

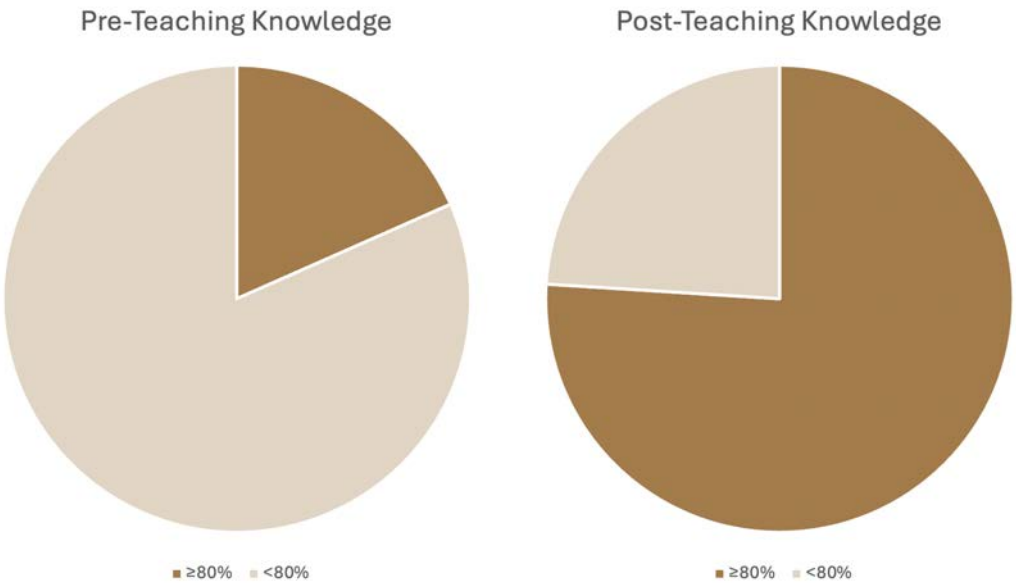

Pie charts showing proportion of pre- and post-teaching attendees scoring ≥80% and <80% in knowledge survey

Conclusions

This two-PDSA cycle regional QIP demonstrates that a low-cost and minimal resource, case-based session can guide meaningful improvements in clinicians' knowledge and confidence of dermatological emergencies. This has the potential to enhance early recognition and timely management of life-threatening conditions in clinical practice.

Results should be interpreted with caution due to the small sample size and lack of inferential analysis.

There is scope for further roll-out, not only through incorporating collated learner feedback, but also through expansion to a larger audience, for example in other Critical Care departments, and other specialties where skin presentations are known to have a significant role, such as Emergency and Internal Medicine. Further work should explore longer-term knowledge retention, such as through repeat knowledge assessments, as well as impact on clinical practice.

EADV CONGRESS
VIENNA
30 SEP - 3 OCT 2026

Abstract N°: 1266

Ethical perceptions of artificial intelligence in dermatology: a cross-sectional study among dermatologists and patients

Ouissal Hormi*[1], Nassiba Zerrouki[1], Nada Zizi[1]

[1] Department of Dermatology, Venereology and Allergology, Mohammed VI University Hospital Center, Oujda, oujda, Morocco

Introduction
The rapid integration of artificial intelligence (AI) into dermatology offers major opportunities, but also raises ethical concerns regarding data privacy, transparency, accountability, bias and equitable access to care. Understanding how these issues are perceived by both dermatologists and patients is essential for responsible AI integration in clinical practice. This study aimed to evaluate and compare ethical perceptions of AI among dermatologists and patients.

Materials and Methods
A cross-sectional study was conducted using an anonymous structured questionnaire distributed to 80 dermatologists and 200 patients. The survey assessed knowledge and use of AI in dermatology, perceived benefits, ethical concerns, trust in AI-assisted care, and attitudes toward its future role in clinical practice.

Results
Seventy-two dermatologists responded to the survey, with a mean age of 38 years and a female predominance. Most participants (75%) reported being familiar with current AI applications in dermatology, although only 40% declared regular use in clinical practice. Reported uses mainly included diagnostic support for pigmented lesions, monitoring of chronic inflammatory dermatoses such as psoriasis and eczema, and medical education.
Despite this general awareness, ethical concerns were prominent among dermatologists. Protection of personal data was identified as a major concern by most respondents, followed by doubts regarding algorithm reliability and transparency in decision-making processes. Concerns were also raised about unclear medico-legal responsibility in the event of diagnostic errors involving AI tools. In addition, many participants expressed concern that excessive reliance on AI could contribute to dehumanization of care and negatively affect the patient–physician relationship. Overall, most dermatologists considered that stronger regulatory oversight and specific training would be necessary before broader integration of AI into practice.
Among patients, 200 questionnaires were analyzed (mean age 34 years, balanced sex distribution). More than half (55%) had heard of AI in dermatology, while 20% had already experienced AI-assisted care, reporting generally high satisfaction related to faster diagnosis, improved access to advice and the innovative nature of these tools. However, concerns were common regarding data confidentiality, trust in automated decisions and reduced human interaction. Notably, 70% considered AI should remain complementary to dermatologist expertise rather than replace physician involvement. Comparison of perceptions showed both convergence and differences: dermatologists mainly emphasized accountability, transparency and algorithm reliability, whereas patients focused more on privacy and preservation of human interaction. Nevertheless, both groups agreed that AI should support rather than substitute clinical judgment and highlighted the need for ethical safeguards for responsible implementation.

Conclusions

This study highlights growing interest in AI among both dermatologists and patients, but also reveals persistent ethical concerns that may influence acceptance and implementation. While dermatologists emphasized issues of accountability, reliability and professional responsibility, patients focused more on confidentiality and preservation of human interaction. The convergence of these concerns underscores the need for transparent governance, ethical oversight, and user-centered development. Improved education and regulatory safeguards may help build trust and facilitate responsible adoption.

EA DV CONGRESS
VIENNA
30 SEP - 3 OCT 2026

Abstract N°: 1277

Ethical Awareness Outpaces Foundational Artificial Intelligence Literacy Among Medical Professionals and Learners in Ukraine: A Cross-Sectional Survey

Kateryna Kolyadenko*[1], Olesya Hulchiy[1], Oleksandr Fedorenko[1], Natalia Stuchynska[1], Kostyantyn Balashov[2]

[1] O.O.Bogomolets National medical university, Kyiv, Ukraine

[2] National university of Life and Environmental Science of Ukraine Kyiv, Ukraine), Kyiv, Ukraine

Introduction

The safe clinical adoption of artificial intelligence (AI) requires not only technical literacy but also strong ethical awareness, including confidentiality, critical appraisal, and recognition of system limitations. In rapidly digitizing healthcare environments such as Ukraine, understanding whether ethical preparedness parallels foundational AI literacy is essential. We aimed to evaluate ethical awareness related to AI use in medicine and compare it with objective understanding of core AI concepts among medical professionals and learners in Ukraine.

Materials and Methods

A cross-sectional anonymous online survey was conducted using the ALR-Med questionnaire among respondents from Ukrainian medical universities and clinical institutions. The survey included multiple Likert-scale items focused on confidentiality, critical verification of AI-generated outputs, recognition of hallucination risks, and understanding when AI should not be relied upon. Foundational AI literacy was assessed using a 5-item objective knowledge block, including a core machine learning concept question. A total of 62 respondents participated, including physicians, physician-educators, interns, and students.

Results

Ethical preparedness for AI use was consistently high. Agreement rates were highest for confidentiality principles during AI use (88.7%), critical appraisal of AI-generated responses (87.1%), and recognition of situations in which AI should not be relied upon (85.4%). In addition, 80.6% correctly identified hallucinated but plausible misinformation as a major risk of generative AI systems.

In contrast, foundational literacy remained limited: only 41.9% of respondents correctly identified machine learning as a data-driven model training process. This discrepancy suggests that respondents more readily understand the ethical and safety implications of AI than its underlying operational principles.

Conclusions

This study demonstrates that ethical awareness surrounding AI in medicine may develop faster than foundational conceptual literacy. Ukrainian medical professionals and learners appear highly sensitized to issues of confidentiality, hallucinations, and responsible clinical use, even when core understanding of machine learning remains incomplete.

These findings are highly relevant for curriculum design: while ethics-oriented discussions may already be entering clinical and academic discourse, they should be complemented by structured teaching on foundational AI

principles. Integrating technical literacy with ethical reasoning may be critical for safe and effective AI implementation in Ukrainian medical education and healthcare systems.

EADV CONGRESS
VIENNA
30 SEP - 3 OCT 2026

Abstract N°: 1279

Resilient Dermatology Training in Times of War: Digital Transformation, Educational Adaptation and Lessons for Europe from the Ukrainian Experience

Kateryna Kolyadenko*[1], Oleksandr Fedorenko[1], Olesya Hulchiy[1, 1]

[1] O.O.Bogomolets National medical university, Kyiv, Ukraine

Introduction

Wartime conditions profoundly disrupt medical education by limiting bedside teaching, reducing trainee mobility, restricting access to clinical facilities, and increasing psychological stress. Dermatology training is particularly vulnerable, as it traditionally depends on visual pattern recognition, supervised dermoscopy, procedural exposure, and direct patient-based learning. At the same time, crisis conditions may accelerate educational innovation and create new models of resilient specialist training relevant beyond conflict settings

Ojectives

To evaluate the key adaptations in dermatology training during wartime and to identify transferable strategies that may support resilient postgraduate and undergraduate dermatology education across Europe.

Materials and Methods

A narrative educational analysis was performed based on the Ukrainian experience of undergraduate and postgraduate dermatology training during wartime.

The following domains were assessed:

- continuity of clinical bedside education;
- transition to hybrid and online learning;
- implementation of teledermatology-based teaching;
- accessibility of dermoscopy and procedural training;
- trainee redeployment and workload redistribution;
- international academic collaboration;
- psychological and organisational factors influencing educational outcomes.

A comparative synthesis was then used to define educational strategies with potential relevance for future European training frameworks.

Results

Wartime disruption led to rapid restructuring of dermatology education, with widespread adoption of hybrid teaching models, virtual case-based seminars, image libraries, and teledermatology-supported clinical discussions.

Key educational adaptations included:

- expansion of remote dermatology teaching platforms;

- increased use of digital dermoscopic image repositories;
- case-based learning through teleconsultation workflows;
- broader access to international webinars and European educational events;
- strengthened trainee autonomy and self-directed learning.

Although access to elective dermatosurgery, aesthetic procedures, and routine procedural exposure decreased, trainees demonstrated improved skills in:

- inflammatory dermatoses triage;
- infectious skin disease recognition;
- stress-related skin disorders;
- urgent diagnostic decision-making;
- remote visual assessment.

Importantly, the crisis accelerated digital literacy, cross-border mentorship, and integration into European educational networks.

Conclusions

The Ukrainian wartime experience demonstrates that dermatology education can remain effective despite severe healthcare disruption when supported by flexible curricula, digital teaching ecosystems, and international academic collaboration.

Several innovations developed under crisis conditions may be sustainably integrated into future European dermatology training, including:

- shared digital case libraries;
- teledermatology-based resident teaching;
- virtual dermoscopy modules;
- remote mentorship programmes;
- crisis-adaptive trainee wellbeing support.

These findings support a hybrid educational model that combines traditional bedside dermatology teaching with resilient digital infrastructure.

Wartime dermatology training has highlighted the capacity of educational systems to rapidly adapt through digital transformation, international cooperation, and competency-focused redesign. The Ukrainian experience offers transferable lessons for building resilient, future-oriented dermatology training pathways across Europe.

EADV CONGRESS
VIENNA
30 SEP - 3 OCT 2026

Abstract N°: 1284

The value of intralesional vitamin D in the management of keloid

Sara Ahmed Ibrahim Hassan Shaheen*[1], Nehal Zu Elfakkar[2], Ekramy El-Khateeb[2]

[1] Master degree of Dermatology, Venereology and Andrology, Faculty of Medicine, Ain-Shams University, Cairo, Egypt
[2] Professor of Dermatology, Venereology and Andrology Faculty of Medicine, Ain-Shams University, Cairo, Egypt

Introduction
Keloids are dermal benign fibro-proliferative growth that extends outside the original wound and invades adjacent dermal tissue. They do not usually regress spontaneously, and tends to recur after excision. Most therapeutic approaches remain clinically unsatisfactory. Vitamin D, a fat-soluble steroid hormone, is obtained by photo-exposure, diet, or supplements, and is crucial for human health. In this study we aimed to test the efficacy of intralesional vitamin D as a therapeutic option in the treatment of keloid and to assess the value of serum (25(OH)D) levels in predicting the therapeutic outcome.

Materials and Methods
The study assessed 40 Egyptian patients with keloid scars, subjected to comprehensive evaluations including history, examinations, and blood tests measuring serum 25-hydroxyvitamin D levels. Patients received weekly intralesional vitamin D injections with dose of 0.2 ml (200,000 IU) per 1 cm lesion for 3 to 4 sessions. The effectiveness of the treatment was measured using the Vancouver Scar Scale (VSS) and patient satisfaction assessed via a Likert scale before and after treatment.

Results
There was a significant negative correlation between serum level of 25-hydroxyvitamin D and number of the lesions (P-value < 0.05). No correlations were found between serum (25(OH)D) levels and the clinical improvement by (VSS) (P-value > 0.05). There was a significant clinical improvement in regard to total Vancouver scar scale score, height, pliability and vascularity (P-value <0.001). On the other side there was no improvement in pigmentation. 65% of the patients were satisfied. There was a positive association between clinical response by VSS, and patient satisfaction by Likert scale. The patients were satisfied with the improvement in pliability. The main side effects of vitamin D injection were pain, itching and swelling at the injection sites.

Conclusions
Keloid scars represent a challenging clinical entity whose risk of development is associated with low serum vitamin D levels. The therapeutic outcome in the patients after intralesional vitamin D injection was satisfactory, and the side effects were tolerable, which indicates that vitamin D can be an alternative, practical, and safe therapeutic option in the treatment of keloid scars. Estimating the serum (25(OH)D) level prior to therapy did not predict the therapeutic outcome, and the clinical improvement can be achieved regardless of the value of patient's serum (25(OH)D) level.

EA DV CONGRESS
VIENNA
30 SEP - 3 OCT 2026

Abstract N°: 1287

Disorders of the Nipple–Areolar Complex for the Dermatologist

Eve Finkelstein*[1], Deena Meerkin[2]

[1] Hadassah Hebrew University Medical Center, Jerusalem, Israel

[2] Shaarei Zedek Medical Center, Jerusalem, Israel

Introduction

Abstract:

The nipple–areolar complex (NAC) is a highly specialized and anatomically distinct region of the skin that is often overlooked in structured dermatology training. Despite its clinical relevance, many dermatologists receive limited formal education regarding congenital anomalies, inflammatory and infectious disorders, neoplastic conditions, and lactation-associated dermatoses affecting this site.

This lecture provides a comprehensive and clinically focused review of the NAC from a dermatologic perspective. A concise overview of embryology and anatomy will frame the discussion of congenital conditions Diseases specific to the NAC will be examined, including nipple adenoma (erosive adenomatosis), Areolar Cyst disease , Mammary duct ectasia , Paget disease, with emphasis on clinical recognition and appropriate referral pathways.

Common dermatologic disorders involving the NAC—such as atopic dermatitis, allergic and irritant contact dermatitis, psoriasis, and autoinflammatory disease will be covered with emphasis on treating breast feeding women . The lecture will also address dermatologic conditions unique to lactation, including nipple fissures, candidiasis, bacterial infection and viral, vasospasm, and milk stasis–related inflammation. Importantly, special therapeutic considerations in breastfeeding women will be highlighted, including medication safety, topical corticosteroid potency selection, timing of application relative to feeds, avoidance of potentially harmful agents, and practical counseling to preserve breastfeeding while effectively treating maternal skin disease.

This lecture aims to fill an educational gap and equip dermatologists to evaluate and manage disorders of this frequently overlooked anatomical site.

Learning Objectives

By the end of this session, participants will be able to:

1. Describe the embryologic and anatomic features of the nipple–areolar complex (NAC) relevant to dermatologic diagnosis.
2. Recognize congenital anomalies and diseases specific to the NAC, including benign and malignant neoplasms, and identify red-flag features requiring biopsy or referral.
3. Apply safe and effective management strategies for nipple dermatoses in breastfeeding women,
4. Recognise and treat the causes of nipple pain and disease associated with breastfeeding incorporating medication safety, appropriate topical selection, and patient counseling to support continued lactation.

EADV Congress 2026, VIENNA
30 SEPTEMBER - 03 OCTOBER 2026
POWERED BY M-ANAGE.COM

EA DV CONGRESS
VIENNA
30 SEP - 3 OCT 2026

Abstract N°: 1335

Pruritic Hyperkeratotic Papules on the Lower Legs: A Case of Lichen Amyloidosis with Dermoscopic and Histopathological Correlation

Mikołaj Łanocha*[1], Wiktor Kruczek[1], Anna Tekielak[1], Beata Bergler-Czop[1]

[1] Department of Dermatology, School of Medicine in Katowice, Medical University of Silesia, Katowice, Poland

Introduction

Lichen amyloidosis represents the most common form of primary cutaneous amyloidosis, a group of disorders characterized by amyloid deposition confined to the skin without involvement of internal organs. Its pathogenesis is primarily attributed to keratinocyte degeneration and the subsequent deposition of epidermis-derived amyloid, referred to as keratin-derived amyloid. Clinically, the lesions most commonly involve the extensor surfaces of the lower legs, less frequently affecting the thighs, forearms, or the interscapular region. They present as numerous, small, hyperkeratotic, brownish papules that are often symmetrically distributed and tend to coalesce into larger, lichenified plaques. Pruritus of varying intensity is a typical accompanying symptom and plays a significant role in the disease pathogenesis. Chronic mechanical irritation of the skin, including persistent scratching or friction, is considered one of the main factors exacerbating the condition by inducing keratinocyte damage and promoting secondary amyloid deposition.

Case Presentation

A 31-year-old woman presented with a 2-year history of hyperkeratotic papules located predominantly on the extensor surfaces of the lower legs. The lesions were associated with moderate pruritus. The patient had no significant past medical history and denied any chronic diseases or regular medication use. Dermoscopic examination revealed orange-brownish, scar-like structures surrounded by dotted vessels. Histopathological evaluation demonstrated mild acanthosis with marked hyperkeratosis and focal follicular hyperkeratosis with moderate perivascular lymphocytic infiltrates composed predominantly of T cells in the superficial dermis. Degeneration of dermal papillae with deposition of Congo red-positive material was noted, confirming amyloid deposition. The patient was treated with topical 10% urea and 5% salicylic acid, followed by mometasone under occlusion for 2 weeks, and subsequently topical isotretinoin. Systemic therapy included loratadine (twice daily) and hydroxychloroquine 200 mg daily. After 3 months of treatment, partial clinical improvement was observed, with reduction of inflammation and flattening of lesions. However, therapy was discontinued due to pregnancy.

Conclusion

This case highlights the importance of correlating clinical, dermoscopic, and histopathological findings in establishing the diagnosis of lichen amyloidosis, particularly in patients presenting with chronic pruritic, hyperkeratotic papules on the extensor surfaces. Dermoscopy may provide supportive, non-invasive clues, while histopathological confirmation remains essential. The partial therapeutic response observed in this patient underscores the chronic and often treatment-resistant nature of the disease, with currently available therapies providing symptomatic relief rather than complete remission. Early recognition and management of pruritus, including the reduction of mechanical irritation, appear to be crucial in limiting disease progression. Further studies are needed to better define optimal treatment strategies and to explore targeted therapies addressing the underlying pathogenic mechanisms.

EADV Congress 2026, VIENNA
30 SEPTEMBER - 03 OCTOBER 2026
POWERED BY M-ANAGE.COM

EADV CONGRESS
VIENNA
30 SEP - 3 OCT 2026

Abstract N°: 1453

Microbiological sampling in skin infections at Primary Care level: real-world practice in spanish population

Rosalía Toledo Cañaveras*[1], Inés Segovia Rodríguez[1, 1], Sergio Huerga Lozano[1], Marina Gracia Ilundáin[1], Teresa López Bernal[1], Alberto Guerrero Torija[1], Pedro Pablo García Montero[1], Beatriz Victoria van Ingen Arteaga[1]

[1] Infanta Cristina University Hospital, Parla, Spain

Introduction

In Spain, Primary Care constitutes the foundation of the healthcare system and the patient's first point of contact with medical services. Cutaneous infections are among the most frequent reasons for consultation in this setting. Sample collection is frequently overlooked in clinical practice due to time and resource constraints. Nevertheless, microbiological confirmation remains essential for certain pathogens in order to guide therapeutic management and assess potential antimicrobial resistance.

Materials and Methods

A descriptive observational study was conducted through a structured survey on sample collection practices in cutaneous infections. It was distributed to Family and Community Medicine physicians during a practical Dermatology course attended by sixty participants.

Results

Thirty-five physicians completed the survey (58% of the total). Sixty-five percent reported no access to viral culture medium, and confirmatory testing was not performed in 94% of cases with clinical suspicion of herpes simplex or herpes zoster. *Polimerase Chain Reaction* (PCR) testing is indicated in diagnostically uncertain viral infections, including varicella and herpes zoster, given their potential complications. Since the introduction of varicella vaccination, atypical disease presentations have been increasingly reported, further supporting the role of confirmatory testing in selected cases.

Bacterial culture medium was available to 68% of respondents and 50% collected samples in cases of treatment failure in impetigo or other suppurative bacterial infections. This is consistent with current clinical guidelines, which recommend empirical treatment as standard practice, reserving sample collection for complicated or refractory cases.

Fungal culture materials were available to 89% of respondents. Prior to treating onychomycosis, 64% of respondents routinely obtained cultures. Regarding tinea corporis o tinea capitis suspicious diagnosis, 11% always collected samples and 34% reserved this practice in case of diagnostic uncertainty or poor response. In contrast, prior surveys of European dermatologists report that 82–100% considered pre-treatment sampling essential in dermatophytosis management. However, the sensitivity of conventional diagnostic methods should be considered, as it may be limited in onychomycosis. Some specialists therefore opt to treat based on clinical findings alone, regardless of negative complementary test results. In tinea corporis or capitis cases this discrepancy is particularly relevant. It is exemplified by the increasing detection of Trichophyton indotineae across Europe, an emerging pathogen resistant to terbinafine and the recent outbreak of Trichophyton tonsurans tinea capitis associated with hairdressing salons.

Conclusions

Family and Community Medicine physicians represent a key opportunity for the diagnosis of emerging cutaneous infections and antimicrobial resistance surveillance. Adequate resourcing of Primary care centres and a multidisciplinary management is crucial to this end.

EA DV CONGRESS
VIENNA
30 SEP - 3 OCT 2026

Abstract N°: 1466

GLASS AI VS. DERMATOLOGISTS: TOWARD A NEW ERA IN DERMATOLOGICAL DIAGNOSIS?

Badr Amal*[1], Leila Bendaoud[1], Meryem Aboudouraib[1], Ouafa Hocar[1], Amal Said[1]

[1] Facutly of Medicine of Marrakech Cadi Ayyad University, BioScience Laboratory University Cadi Ayyad, Dermatology Department of University Hospital Mohammed VI, MARRAKESH, Morocco

Introduction

Artificial intelligence (AI) is rapidly emerging as a supportive diagnostic tool in dermatology. Several recent investigations have explored its ability to recognize dermatological conditions using clinical imagery. In a prior study conducted by our team, Glass A.I. demonstrated superior diagnostic accuracy compared with dermatology residents when evaluating standardized clinical cases. While these findings were promising, an important question remained: does AI maintain comparable or superior diagnostic performance when evaluated against experienced, board-certified dermatologists? Addressing this question is essential to better define the potential clinical role of AI in dermatologic practice.

Materials and Methods

Aims & Objectives:

The primary objective of this study was to compare the diagnostic accuracy of Glass A.I. with that of board-certified dermatologists using the same standardized dermatological cases. A secondary objective was to assess the overall level of diagnostic concordance among experienced specialists and determine whether AI performance remains competitive in this expert setting.

Methods:

Ten standardized dermatological clinical cases were selected to represent diagnostically relevant and diverse conditions encountered in routine dermatology practice. These identical cases were independently evaluated by 45 board-certified dermatologists. Each participant was asked to provide a single primary diagnosis for each case. Glass A.I. was tested separately on the exact same set of cases to ensure direct comparability. Diagnostic accuracy was defined as the proportion of correct diagnoses relative to the reference standard diagnosis for each case. Overall physician performance was calculated as the mean diagnostic accuracy across all cases and participants.

Results

Glass A.I. correctly diagnosed 8 of the 10 clinical cases, corresponding to an overall diagnostic accuracy of 80%. Among the 45 board-certified dermatologists, the mean diagnostic accuracy across the same cases was 62.2%. While individual physician performance varied, the aggregate diagnostic accuracy of experienced dermatologists remained lower than that achieved by Glass A.I. in this standardized case series. These findings suggest that, within this controlled evaluation framework, Glass A.I. demonstrated a higher rate of correct primary diagnoses compared with board-certified specialists.

Conclusions

In this comparative study involving 45 board-certified dermatologists and 10 identical clinical cases, Glass A.I. achieved higher diagnostic accuracy than experienced dermatologists. These findings build upon prior evidence

demonstrating AI superiority over trainees and suggest that AI systems may have the potential to function as valuable adjunctive diagnostic tools in dermatology. Further large-scale studies incorporating a broader range of clinical scenarios and real-world settings are necessary to confirm these results and to better define the integration of AI into clinical practice.

EADV CONGRESS
VIENNA
30 SEP - 3 OCT 2026

Abstract N°: 1478

Burnout among Dermatologists - A Comparison Between Cosmetic and Clinical Practice

Daniel Carneiro Miranda[1], Gleison Duarte*[2], Pedro Jacobs[1], Ivana Porciúncula[1], Rebeca Garcia[1], Ademar Neto[1]

[1] Afya Centro Universitário, Salvador, Brazil
[2] IBIS Imunoterapia, Salvador, Brazil

Introduction
Burnout is an occupational syndrome resulting from chronic workplace stress, characterized by emotional exhaustion, depersonalization and reduced professional fulfillment. Burnout in dermatology is frequently underestimated due to its perception as a predominantly outpatient and low-acuity specialty. In this field of specialization, increasing social exposure, technological demands and aesthetic expectations have intensified occupational stressors, particularly in areas such as cosmiatry.
To compare burnout levels between dermatologists with predominant practice in cosmiatry and those in clinical dermatology, and to identify the main contributing factors associated with emotional exhaustion in each group.

Materials and Methods
This is a cross-sectional, observational and comparative study including 405 Brazilian dermatologists. Participants were divided into two groups according to their main field of practice: clinical dermatology (71.1%) and cosmiatry (28.9%). Burnout was assessed using the Copenhagen Burnout Inventory (CBI), evaluating personal, work related and patient-related dimensions. Sociodemographic and professional variables were analyzed, and contributing factors were categorized into four domains: legal, economic, technological and clinical. Statistical analysis included relative frequencies and chi-square tests, adopting a significance level of $p < 0.05$.

Results
High levels of burnout were observed across the sample, with scores ≥50 in 50.0% for personal burnout, 47.9% for professional burnout and 35.8% for patient-related burnout. Similar rates were found between cosmiatry and clinical practice, indicating that burnout prevalence is not dependent on the type of dermatological activity. However, the determinants differed significantly. In clinical dermatology, bureaucratic burden, pressure for rapid therapeutic outcomes and the influence of social media on patient expectations were the main stressors. In cosmiatry, economic and technological factors predominated, including high operational costs, constant need for technological updating and financial instability, in addition to the pressure generated by unrealistic aesthetic standards disseminated on social media. Dermatologists with less than five years of practice showed significantly higher levels of patient-related burnout ($p < 0.001$), suggesting increased vulnerability early in the career.

Table 1. Demographic characteristics of the sample.

Sample size, N	405
Mean age ± SD	45 ± 10,6
Male sex, N (%)	75 (18,5)
Female sex, N (%)	330 (81.5)
Region (Brazilian Institute of Geography and Statistics - IBGE)	
North, N (%)	18 (4,4)
Northeast, N (%)	143 (35,3)
Midwest, N (%)	50 (12,3)
Southeast, N (%)	126 (31,1)
South, N (%)	68 (16,8)
Time in practice	
> 20 years, N (%)	139 (34,3)
11-20 years, N (%)	124 (30,6)
5-10 years, N (%)	74 (18,3)
< 5 years, N (%)	68 (16,8)
Practice setting	
Private, N (%)	197 (48,6)
Public, N (%)	6 (1,5)
Both, N (%)	202 (49,9)
Number of weekly consultations	
< 20, N (%)	25 (6,2)
21-40, N (%)	130 (32,1)
> 40, N (%)	250 (61,7)
Predominant field	
Clinical dermatology, N (%)	288 (71,1)
Cosmiatry, N (%)	117 (29,9)

Table 2. Variables potentially associated with burnout subtypes and their frequencies

Characteristics	**PB, N(%)**	**p**	**WB, N(%)**	**p**	**CB, N(%)**	**p**
Sex		0,119		0,139		0,793
Male	31 (41,3)		28 (37,3)		25 (33,3)	
Female	172 (52,1)		157 (47,6)		118 (35,8)	
Practice setting		0,653		0,115		0,617
Both	104 (51,5)		101 (50,0)		69 (34,2)	
Private	96 (48,7)		82 (41,6)		73 (37,1)	
Number of consultations		0,959		0,584		0,45
<20	13 (52,0)		9 (36,0)		14 (56,0)	
21-40	66 (50,8)		59 (45,4)		49 (37,7)	
>40	124 (49,6)		117 (46,8)		80 (32,0)	
Time in practice		0,204		0,27		**<0,001**
> 20 years	65 (46,8)		56 (40,3)		36 (25,9)	
11-20 years	61 (49,2)		53 (42,7)		38 (30,6)	
5-10 years	35 (47,3)		34 (45,9)		26 (35,1)	
< 5 years	42 (61,8)		42 (61,8)		33 (65,2)	
Predominant area		0,999		0,191		0,852
Clinical dermatology	144 (50,0)		138 (47,9)		103 (35,8)	
Cosmiatry	59 (50,4)		47 (40,2)		40 (34,2)	

Legend: **PB:** Personal burnout; **WB:** work-related burnout; **CB:** client/patient-related burnout. Number of consultations shown in total per week..

Table 3. Contributing factors to professional burnout in dermatologists with predominantly cosmiatry practice.

Factor	Extremely-A lot, N(%)	Moderately, N(%)	A little-Not at all, N(%)
Competition with other medical specialties	15 (12,8)	17 (14,5)	85 (72,6)
Competition with other healthcare professionals	46 (39,3)	30 (25,6)	41 (35,1)
Information competition with influencers or laypeople on social media	47 (40,2)	29 (24,8)	41 (35,0)
Concern with the profitability of the office/clinic	63 (53,8)	38 (32,5)	16 (13,7)
Fluctuation in aesthetic demand (e.g., seasonality)	55 (47,0)	38 (32,5)	24 (20,5)
Constant need for investment in equipment/technologies	67 (57,3)	27 (23,1)	23 (19,6)
High costs of supplies	75 (64,1)	32 (27,4)	10 (8,6)
Fear of lawsuits or litigation in aesthetic practice	24 (20,5)	24 (20,5)	69 (59,0)
Legal insecurity regarding non-standardized procedures	20 (17,1)	33 (28,2)	64 (54,7)
Excessive time spent on consent forms and legal documentation	19 (16,2)	24 (20,5)	74 (63,2)
Concern with civil liabilities in cases of aesthetic dissatisfaction	31 (26,5)	30 (25,6)	56 (47,9)
High patient expectations regarding results	46 (39,3)	51 (43,6)	20 (17,1)
Subjective patient satisfaction being more valued than clinical criteria	46 (39,3)	37 (31,6)	34 (29,0)
Comparisons with procedures seen on social media	58 (49,6)	36 (30,8)	23 (19,7)
Pressure to perform procedures outside their comfort zone	41 (35,0)	31 (26,5)	45 (38,5)

Table 4. Contributing factors to professional burnout in dermatologists with predominantly clinical dermatology practice.

Factor	Extremely-A lot, N(%)	Moderately, N(%)	A little-Not at all, N(%)
Complex evaluation for indicating new immunotherapies	47 (16,3)	83 (28,8)	158 (54,9)
High volume of chronic diseases requiring continuous follow-up	55 (19,1)	103 (35,8)	130 (45,1)
Difficulty in patient adherence to long-term treatment	62 (21,5)	89 (30,9)	137 (47,6)
Doubts regarding the right time to escalate or rotate therapies	31 (10,8)	70 (24,3)	187 (64,9)
Refusal or difficulty of patients in accepting the best treatment	32 (11,1)	75 (26,0)	181 (62,8)
Undertreated patients due to lack of access to immunobiologics or procedures	61 (21,2)	108 (37,5)	119 (41,4)
Pressure to prescribe cheaper treatments imposed by health plans or SUS	63 (21,9)	95 (33,0)	130 (45,1)
Bureaucracy for prescribing and releasing immunotherapies	102 (35,4)	86 (29,9)	100 (34,7)
Patient questioning based on AI or unreliable sources	78 (27,1)	73 (25,3)	137 (47,5)
Comparison of medical conduct with "what I saw on the internet"	88 (30,6)	84 (29,2)	116 (40,3)
Pressure for quick results without side effects	100 (34,7)	87 (30,2)	101 (35,1)
Demands for constant "second opinions" based on social media	90 (31,3)	67 (23,3)	131 (45,4)

Conclusions

Burnout among dermatologists is highly prevalent and multifactorial, with similar overall levels between cosmiatry and clinical practice, but with distinct underlying drivers. These findings highlight the need for targeted interventions, including psychological support, reduction of administrative burden, digital literacy training and strategies to manage patient expectations in the context of social media.

EA DV CONGRESS
VIENNA
30 SEP - 3 OCT 2026

Abstract N°: 1500

Apps in Dermatology – A Scoping Review

Marina Otten*[1], Anastasia Fleyder[1], Matthias Augustin[1]

[1] University Medical Center Hamburg-Eppendorf, Hamburg, Germany

Introduction
Digital health interventions (DHI) (including apps) are becoming increasingly important in dermatology and are used for a variety of purposes. Despite the growing number of available apps, the scientific evidence is not well documented, for example, for updating existing guidelines. The aim of this scoping review was to systematically compile the existing literature on dermatological apps and to analyze their functions, areas of application, and reported outcomes.

Materials and Methods
A systematic literature search was conducted in MEDLINE (PubMed) on December 31st, 2024, to identify original studies on the use of mobile apps in dermatology. The search strategy combined dermatological disease terms with keywords related to digital health applications. Study selection was based on predefined inclusion and exclusion criteria through title, abstract, and full-text screening. Data extraction was performed using a standardized Excel sheet adapted from previous reviews. Study characteristics, app indications, aims, functions according to the WHO classification of DHI, target groups, and reported outcomes were recorded. The data were analyzed descriptively using SPSS Version 29.

Results
The search identified 1,494 publications. After screening titles and abstracts, 277 full-text articles were reviewed, of which 129 were excluded. A total of 148 studies were included in the analysis. Because some publications described multiple apps or studies, this resulted in 201 data entries. Prior to 2017, only a few studies on dermatological apps were published; since then, the number has risen significantly, reaching 36 publications in 2023. The most common study designs were cross-sectional studies (n = 66), followed by feasibility or pilot studies (n = 53), randomized controlled trials (n = 32), and descriptive survey studies (n = 32). The average number of participants was 711.9 (median 60). Most studies were non-comparative, prospective, and single-center. Geographically, studies were predominantly conducted in Europe (n = 82), Asia (n = 40), and North America (n = 39); most originated from the United States, followed by Germany. A total of 306 app functions were identified. The most common functions were automated data analyses (n = 72) (e.g., image or data analysis using algorithms), followed by patient-related functions for data collection (n = 48), information, or reminders, as well as telemedicine apps for healthcare professionals (n = 24 each). On average, the apps addressed 1.8 diagnoses, most commonly skin tumors (n = 102), wounds (n = 59), eczema (n = 41), infectious skin diseases (n = 38), and psoriasis (n = 43). Commonly examined objectives included monitoring and follow-up care (n = 135), diagnostic support (n = 121), and prevention (n = 88). Overall, most studies reported positive effects (n = 226), while only a few showed no or a negative effect.

Conclusions
The results highlight the rapid growth of this research field, which has a wide variety of application areas and

study designs. Future research requires robust methodologies, especially randomized controlled trials, and standardized outcome measures, to more reliably assess the effectiveness and benefits of digital apps. If their quality, safety, and integration into existing care structures are ensured, apps can offer significant potential for clinical practice, particularly in the areas of diagnostic support, patient monitoring, and improving access to care.

EA DV CONGRESS
VIENNA
30 SEP - 3 OCT 2026

Abstract N°: 1521

A 3D-visual morphological atlas of the dermal fibre network: In-vivo LC-OCT characterisation of age-related structural changes.

Flament Frederic*[1], Edouard Raynaud[2], Claire DELOCHE[3], Franck Juchaux[4], Anne-Claire Cathelineau[5], Nastassia Pricoupenko[6], Margot Vasseur[6], Thomas Bourbon[6], Anthony Daures[6], Jean-Michel Delaval[7], DANOY Alix (Newtone) DANOY[7], Kevin Roussel[7], Florence Ruggiero[8], CABERLOTTO ELISA[3]

[1] L'Oreal R&I, Clichy, France
[2] L'Oreal R&I Hopital St Louis, Paris, France
[3] Vichy Laboratoires, Levallois-Perret, France
[4] L'Oreal R&I, Chevilly-Larue, France
[5] Hôpital l'Archet CHU Nice, Nice, France
[6] Damae Medical, Paris, France
[7] QIMA Life Sciences, QIMA Newtone, Lyon, France
[8] University of Lyon, Lyon, France

Introduction

The dermis is primarily composed of collagen and elastic fibres. It determines mechanical strength and elasticity but permanently undergoes significant remodelling with age. While expert evaluation is sensitive to morphological changes, it remains partly subjective when evaluating subtle incremental changes in topical treatments or long-term longitudinal studies. Thus, an objective, quantitative framework is essential to evaluate structural changes reliably. Line-field confocal optical coherence tomography (LC-OCT) provides micrometre-scale resolution and volumetric data, allowing non-invasive, depth-resolved quantification of dermal fibre density, alignment, and architecture across age groups.

This study establishes the first quantitative *in vivo* atlas of the dermal fibre network across aging using LC-OCT.

Materials and Methods

The study analysed 201 healthy women (20–60 years) divided into four decade-based cohorts. Four age groups were considered, corresponding to a total of 699 stacks. These LC-OCT stacks of the forehead were acquired and processed through a validated segmentation pipeline employing motion correction, fibre detection (via multi-scale Hessian analysis), and dermis isolation using AI-based skin layer segmentation. From these segmented datasets, five key morphometric metrics were defined: *fibre density, alignment, connectivity, fragmentation,* and *bundle length*, each reflecting complementary aspects of dermal structure.

Results

A consistent, non-linear remodelling of the dermal network with age is observed, with major architectural changes occurring before age 40. Fibre density decreased by about 8%, mainly between 30–50 years, indicating midlife structural loss. Fibre alignment increased in average by 8%, showing earlier onset around 30 years due to reduced multi-directionality. Network connectivity decreased on average by 16%, while fragmentation rose on average by 9%, both changes indicating progressive disorganization and fibre breakage beginning in early adulthood. Mean fibre bundle length decreased on average by 7.5% primarily before the age of 50 years stabilizing after 50 years. Together, these trends reflect a transition from a dense, reticulated young network, typically associated with

young skin. Conversely, ageing is characterized by progressive network degradation, leading to a more fragmented and parallel-aligned architecture.

The resulting atlas provides standardized visual and numerical references for evaluating dermal ageing, reducing observer bias. Statistical analyses (Cohen's d = 0.50–1.58) confirmed the robustness and discriminative power of the proposed metrics.

Conclusions

Altogether, these parameters offer a new characterisation of the dermal landscape, providing tools to develop a unique dermal fibre atlas. By correlating dermal microstructural integrity with visible and functional markers of ageing, the LC-OCT–based atlas forms a foundation for future studies linking dermal remodelling to clinical appearance, mechanical properties, and systemic health.

EADV CONGRESS
VIENNA
30 SEP - 3 OCT 2026

Abstract N°: 1525

Integrating Skin of Colour Dermatology Education into MedicalCurricula: A Viewpoint

Aida Kafai Golahmadi*[1], Laksha Bala[2, 3]

[1] The Whittington Hospital, London, United Kingdom
[2] Charing Cross Hospital, Imperial College Healthcare NHS Trust, London, United Kingdom
[3] School of Medicine, Imperial College London, London, United Kingdom

Introduction
Dermatological conditions present differently in patients with skin of colour, yet medical education continues to rely predominantly on teaching materials and images derived from lighter skin tones; and this under-representation contributes to lower diagnostic accuracy, delayed or missed diagnoses, and inequitable care for patients with darker skin. Hence, future clinicians are often insufficiently prepared to recognise important clinical signs across diverse skin tones, and many report less confidence in diagnosiing dermatological conditions in this patient population. Although isolated educational interventions have shown short-term improvements in learner confidence and diagnostic ability, skin of colour dermatology remains insufficiently embedded within core undergraduate and postgraduate curricula.

Materials and Methods
We conducted a review of the published literature relating to educational interventions in skin of colour dermatology, including studies that evaluated initiatives aimed at improving knowledge, diagnostic accuracy, confidence, and communication skills among medical students and resident doctors. Interventions were grouped by format, including seminars, lectures, online modules, curriculum redesign, multi-session courses, quality improvement initiatives, and specialist SoC clinics, and the evidence was analysed qualitatively to summarise common findings and to identify key limitations in the existing literature, particularly the predominance of short-term outcome measures, frequent reliance on self-assessment, and limited evidence regarding long-term knowledge retention, clinical translation, and patient benefit. This appraisal was used to develop the recommendations proposed in this article, which could guide future educational interventions to address the knowledge gap in this field.

Results
Existing educational interventions in skin of colour dermatology generally demonstrate immediate gains in learner confidence, knowledge, and diagnostic ability; nevertheless, the available evidence is constrained by small-scale, single-centre designs, subjective outcome measures, and limited follow-up. There is little robust evidence on long-term retention, broader generalisability, or measurable effects on clinical practice and patient outcomes.

Conclusions
Skin of colour dermatology must move from the margins of medical education into the core curriculum of undergraduate and postgraduate medical training. Although existing interventions suggest educational benefit, lasting progress will require coordinated structural reform, including mandatory curricular integration, representative teaching resources, inclusive assessment, faculty development, and stronger longitudinal research. Embedding skin of colour dermatology across undergraduate and postgraduate training is essential to improving diagnostic equity and patient care, and to address health inequalities.

EADV CONGRESS
VIENNA
30 SEP - 3 OCT 2026

Abstract N°: 1596

A Diagnostic Mimic of Hansen's Disease: RETREG1- Associated Hereditary Sensory and Autonomic Neuropathy Type IIB

Asha Asha*[1], Sampoorna Choudhary[1], Anuj Bhatnagar[1]

[1] Armed Forces Medical College, Pune, Maharashtra, India. Pin- 411040, Pune, India

Introduction

Peripheral neuropathy with trophic ulceration is commonly attributed to Hansen's disease in endemic regions. However, symmetrical sensory involvement, absence of cutaneous lesions, early deformities, and poor therapeutic response should prompt evaluation for alternative causes, including hereditary sensory neuropathies.

Case Presentation

A 19-year-old male born of a second-degree consanguineous marriage presented with recurrent painless ulcers over both feet and hands associated with progressive sensory loss for five years. Lesions developed after trivial unnoticed trauma and healed with scarring and dyspigmentation. Examination revealed multiple punched-out trophic ulcers, patchy hypoesthesia to touch and temperature, clawing of toes, and Charcot arthropathy with collapse of the medial longitudinal arch. Peripheral nerves were initially thickened.

The patient had previously received multidrug therapy for Hansen's disease without improvement. Features inconsistent with leprosy included symmetrical neuropathy, absence of cutaneous lesions, pure sensory involvement with relative motor sparing, early-onset deformities, negative slit skin smear, negative PCR for *Mycobacterium leprae*, and non-diagnostic nerve biopsy.

Further investigations demonstrated elevated inflammatory markers, hypergammaglobulinemia, and raised serum IgG4 levels. Synovial biopsy showed chronic inflammation with plasma cells and multinucleated giant cells, raising suspicion for IgG4-related disease; however, immunohistochemistry was negative. Extensive evaluation excluded nutritional, toxic, infectious, inflammatory, vasculitic, endocrine, and other hereditary causes of neuropathy, including POEMS syndrome, Castleman disease, tabes dorsalis, arsenic toxicity, alcohol-related neuropathy, and Charcot-Marie-Tooth disease.

Given persistent diagnostic uncertainty and history of consanguinity, whole exome sequencing was performed and identified a homozygous RETREG1 mutation, confirming hereditary sensory and autonomic neuropathy type IIB (HSAN IIB).

Conclusion

This case highlights the **importance of reconsidering Hansen's disease** in patients with atypical neuropathic presentations and discordant investigations. **Hereditary sensory autonomic neuropathies may closely mimic leprosy** due to overlapping manifestations of sensory loss and trophic ulceration. Early recognition and genetic confirmation are essential to avoid prolonged misdiagnosis, unnecessary treatment, and delayed counseling and supportive care.

EADV Congress 2026, VIENNA
30 SEPTEMBER - 03 OCTOBER 2026
POWERED BY M-ANAGE.COM

EA DV CONGRESS
VIENNA
30 SEP - 3 OCT 2026

Abstract N°: 1597

Current Skin of Color Representation in Medical Education in Germany, Austria and Switzerland (DACH region): Results of a Cross-Sectional Survey among Medical Faculties

Nina Matthes*[1], Julian Koett[1, 2], Ines Heinen[3], Nina Booken[1], Stefan Schneider[1], Finn Abeck[1]

[1] University Medical Center Hamburg-Eppendorf, Department of Dermatology and Venereology, Hamburg, Germany

[2] University Medical Center Hamburg-Eppendorf, Fleur Hiege Center for Skin Cancer Research, Hamburg, Germany

[3] University Medical Center Hamburg-Eppendorf (UKE), Department of Medical Psychology, Hamburg, Germany

Introduction

Dermatologic diagnosis relies strongly on visual recognition. However, educational resources and teaching materials predominantly depict lighter skin types, potentially impairing diagnostic accuracy in patients with darker skin types and contributing to healthcare disparities. Medical students attribute their lack of confidence in diagnosing skin conditions in patients with Skin of Color (SoC, defined as Fitzpatrick skin phototypes IV-VI) to inadequate curriculum coverage. While underrepresentation of SoC has been demonstrated in North American medical education, current data from the DACH region (Germany, Austria, and Switzerland) are lacking despite increasing population diversity. This study aimed to systematically assess the current representation of SoC education in dermatology curricula across medical faculties in the DACH region.

Materials and Methods

We conducted a cross-sectional questionnaire-based study targeting all dermatology departments at public and private medical schools in the DACH region (n = 57). The online questionnaire collected data on the presence of SoC education in current curricula, teaching formats used, perceived relevance, barriers to implementation and educational image sources. Participation was voluntary and responses were analyzed descriptively.

Results

A total of 37 faculties participated in the survey (65% response rate). Overall, 89% (33/37) of respondents rated SoC integration as important or very important. 65% (24/37) of institutions integrate SoC education in mandatory dermatology teaching, while 5% (2/37) only offer it in elective or supplementary teaching formats. Most faculties with SoC teaching sessions (83%, 20/24) have introduced content within the previous four years. 14% (5/37) of institutions include questions addressing SoC in exams. The primary reported barrier to SoC integration is a lack of teaching materials (62%, 23/37), followed by insufficient expertise (24%, 9/37) and limited curriculum time (22%, 8/37). Only 3% (1/37) cited lack of student demand as a barrier. Image sources mainly include personal clinical image collections (90%, 33/37), freely accessible image databases (57%, 21/37), and material provided from colleagues (38%, 14/37), while paid databases are rarely used (5%, 2/37). Only 22% (8/37) of institutions considered it easy to obtain high-quality images suitable for teaching.

Conclusions

SoC education is increasingly recognized as an important component of dermatology education in the DACH region, with recent curricular implementation at most institutions. Nevertheless, integration remains inconsistent. More than a third of faculties do not offer mandatory SoC education, and most faculties do not assess SoC content in exams. The most frequently reported barriers include lack of teaching material, insufficient expertise and limited curriculum time. Addressing these gaps is essential to ensure diversity-sensitive dermatological

education, to reduce diagnostic disparities and to improve clinical outcomes for patients with darker skin types across Europe's increasingly diverse populations.

EADV CONGRESS
VIENNA
30 SEP - 3 OCT 2026

Abstract N°: 1605

Outcomes from a dedicated non-melanoma skin cancer clinic in Ireland

Cathy Keegan*[1], Jeannette West[1], Niamh Kearney[1]

[1] Depatment of Dermatology, Our Lady of Lourdes Hospital Drogheda, Louth, Ireland

Introduction

Non-melanoma skin cancer (NMSCa) incidence is increasing due to our ageing population and ultraviolet exposure. A dedicated NMSCa clinic aims to streamline the assessment and management of patients referred with suspected NMSCa. This study evaluated outcomes for such a clinic in Ireland.

Materials and Methods

A retrospective review was conducted of all patients attending a dedicated NMSCa clinic in Ireland from August–December 2025. Data collected included number of new patients, index lesion clinical or histological diagnosis (if available), dermatology procedures, direct referrals to plastics surgery and follow-up requirements.

Results

A total of 299 patients attended the clinic in five months. Diagnoses included actinic keratosis (AK)/Bowen's disease (n=104/34.8%), benign lesion/rash (n=85/28.4%), BCC (n=62/20.7%), lesion resolved (n=28/9.4%), SCC (n=19/6.4%) and melanoma (n=1, 0.3%). Forty-three patients required a biopsy (14.94%) and twenty-eight patients proceeded to excision in dermatology (9.7%). Thirty-five patients were referred directly to plastic surgery for excision of a clinical skin cancer (11.7%). Just seven patients required a consultant-led follow-up appointment (2.3%) with 150 patients seen for follow-up in a nurse-led clinic (50.2%).

Conclusions

This review demonstrates the role an NMSCa clinic plays in managing skin cancer, however, optimising referral pathways to encompass primary care treatment with a topical treatment, such as 5-fluorouracil prior to dermatology referral, and direct referral to plastics for large and/or facial lesions could have reduced referrals by up to 46.4%. Improved education for referring clinicians is needed to enhance clinic efficiency ensuring timely access for patients most in need.

EADV CONGRESS
VIENNA
30 SEP - 3 OCT 2026

Abstract N°: 1607

Can we get the diagnosis right with written clinical information alone? Diagnostic concordance from referral letter to face-to-face dermatology review in a pigmented lesion clinic

Cathy Keegan*[1], Gráinne Callaghan[1], Muireann Roche[1], Clíona Feighery[1], Niamh Kearney[1]

[1] Depatment of Dermatology, Our Lady of Lourdes Hospital Drogheda, Louth, Ireland

Introduction
Dermatology triage frequently relies on written referral information despite being a visual specialty. Inaccurate referral impressions affect the prioritisation of patients most in need. We aimed to evaluate concordance between consultant diagnostic impression based on referral letters, subsequent clinical assessment and histopathologic diagnosis in a pigmented lesion clinic.

Materials and Methods
A prospective cross-sectional study of referrals to a pigmented lesion clinic was conducted over a two-month period. Consultant diagnostic impression based on the referral letter (referral impression) was documented prior to face-to-face review and compared with the diagnosis following examination (clinical impression). For lesions that underwent biopsy or excision, the clinical impression was compared with the histopathological diagnosis.

Results
A total of 265 patients were included. Five lesions had resolved at clinic review and were excluded from analysis. Among the remaining 260 cases, concordance between referral and clinical impression was observed in 155 cases (59.62%). Forty-nine patients (18%) proceeded to biopsy or excision. Results at the time of analysis were available for 48 lesions. Concordance between clinical and histological diagnosis was observed in 31 cases (64.58%).

Conclusions
Concordance between referral impression and clinical impression was modest, highlighting the diagnostic complexity of pigmented lesions and limited information which can be provided using written information alone. These findings highlight the need for improvements in referral quality. Primary care education and the implementation of photograph attachments may be useful strategies to improve referral quality, enhance triage accuracy and optimise service utilisation.

EA DV CONGRESS
VIENNA
30 SEP - 3 OCT 2026

Abstract N°: 1698

Temporally Optimized Antioxidant Serums for Daytime Defense and Nighttime Repair: A Multicenter Clinical Investigation

Jade Conway*[1], Céline Blanché[2], Mathieu Grivet-Seyve[3], Ma Hun[4], Haw Diann Wai[5], Nadège Lachmann[6], Irina Berlin[7], Aaron Farberg[8, 9, 10]

[1] Reveal Research Institute, Dallas, United States
[2] Galderma R&D, Barcelona, Spain
[3] Galderma R&D, Dallas, United States
[4] Galderma R&D, Baie-D'Urfé, Canada
[5] Galderma R&D, Singapore, Singapore
[6] Galderma R&D, Sensitive Skincare Faculty, ZUG, Switzerland
[7] Galderma R&D, Lausanne, Switzerland
[8] Reveal Research Institute, Bare Dermatology, University of North Texas Health Science Center, Dallas, United States
[9] University of North Texas Health Science Center, Fort Worth, United States
[10] Bare Dermatology, Dallas, United States

Introduction

Sensitive skin affects up to 70% of the global population and is mechanistically linked to oxidative stress, barrier dysfunction, and disrupted skin biorhythms. The skin exhibits distinct physiological states across the 24-hour cycle - daytime defense against environmental stressors and nighttime barrier repair - providing rationale for a temporally optimized formulation strategy. We evaluated complementary day and night serums incorporating GALLIC-AOX POWER™ technology (gallic acid derivative, vitamin E), triple molecular weight hyaluronic acid, niacinamide (day), and pro-vitamin B5, centella asiatica, and bifida ferment lysate (night).

Materials and Methods

Multiple prospective, multicenter, pre-clinical and clinical trials were conducted across China, the US, and Europe (September 2024–February 2025). A total of 806 adults (aged 18–70, all Fitzpatrick phototypes) were randomized to day serum (n=368), night serum (n=379), or combined regimen (n=168). Assessments included bioinstrumentation (Corneometer, Tewameter, Sebumeter), digital imaging (VISIA-CR/Colorface), blinded clinical grading, in vivo antioxidant biomarkers, skin renewal (Dansyl Chloride), and Sensiscale-10 sensitivity questionnaire.

Results

The day serum demonstrated potent antioxidant protection against environmental stressors: following cigarette smoke challenge; MDA and SQOOH, markers of barrier lipid and sebum oxidation, were restored to non-exposed baseline levels (100% and 90% protection, respectively); and blue light challenge showed ~40% preservation of catalase antioxidant activity. A single application produced immediate hydration gains (+71% at T15 min) and barrier improvement (-18% TEWL), both sustained up to 24 hours. After 28 days, perceived skin sensitivity declined 85% across all ten Sensiscale-10 domains, wrinkles decreased 31%, and pore visibility improved. The night serum produced comparable immediate hydration (+60% at T15 min) and barrier benefits (-15% TEWL), with accelerated barrier recovery reaching 94% by Day 14 on tape-stripping testing. Skin renewal was significantly accelerated from Day 21. Sensitivity declined 89% over 28 days, with progressive improvements in radiance (+23%), smoothness (+25%), fine lines (-32%), and tone evenness (+21%) by Day 28. The combined regimen amplified these benefits across all endpoints over 56 days; overall skin quality improved 17% at 2 months, sensitivity declined 73%, and post-procedure testing confirmed suitability following microneedling and IPL. Satisfaction was 96% with zero adverse events across all 806 participants.

Conclusions

Temporally optimized day and night serums deliver clinically meaningful improvements across sensitivity, barrier function, antioxidant defense, hydration, and aging signs in diverse populations including sensitive skin subgroups, supporting circadian alignment as an evidence-based approach to multifunctional sensitive skin care.

EADV CONGRESS
VIENNA
30 SEP - 3 OCT 2026

Abstract N°: 1707

Chin-Localized Syringomas Mimicking Verruca Plana: A Rare Diagnostic Challenge with Clinicopathological Correlation

Lana Lomidze*[1], Magda Gogilidze[1], Natia Khutsishvili[1], Tatia Khatchapuridze[1], Ekaterine Beraia[1]

[1] Kani Clinic, Tbilisi, Georgia

Introduction

Syringomas are benign eccrine adnexal tumors classically presenting as multiple small papules in the periorbital region. Nevertheless, atypical localizations may closely mimic other facial papular dermatoses, creating a diagnostic challenge, especially in cases with unusual distribution.

Case Presentation

A 19-year-old female presented with multiple asymptomatic papules localized on the chin, progressively increasing in number. The lesions were clinically suspected to be flat warts due to their size, color, and clustered distribution. No prior effective treatment had been achieved.

On examination, numerous 1–3 mm, skin-colored to slightly erythematous, flat-topped to minimally elevated papules were observed, symmetrically distributed on the mental region. The lesions were monomorphic, smooth-surfaced, and non-keratotic. No similar lesions were present on the forehead, cheeks, or dorsal hands.

Dermoscopy revealed a light pink background with whitish to yellowish structureless areas and fine linear vessels. Notably, there were no thrombosed capillaries, dotted vessels, or mosaic pattern typically associated with verruca plana, and no scaling or keratin features were observed.

Histopathological examination demonstrated multiple small eccrine ducts embedded in a fibrous stroma, lined by two layers of cuboidal epithelial cells, with characteristic comma-shaped (“tadpole-like”) ductal structures. No viral cytopathic changes or epidermal hypergranulosis were identified. These findings confirmed the diagnosis of syringoma.The patient underwent CO_2 laser treatment, resulting in marked cosmetic improvement with flattening of lesions and no significant adverse effects or recurrence during follow-up.

Conclusion

Chin-localized syringomas may closely resemble flat warts, leading to misdiagnosis. Dermoscopy provides valuable non-invasive clues, while histopathology remains essential for definitive diagnosis. CO_2 laser therapy is an effective treatment option, offering excellent cosmetic results in such atypical cases.

EADV CONGRESS
VIENNA
30 SEP - 3 OCT 2026

Abstract N°: 1714

Unexpected Disseminated Herpes Zoster in an Immunocompetent Adult Initially Misdiagnosed as a Furuncle: A case report

Nhi Thach Truong Phuong*[1], Trang Nguyen Thi Thu[1], Nguyen Tran Thao[1]

[1] Vinmec Central Park International Hospital, Ho Chi Minh city, Viet Nam

Introduction

Disseminated Herpes zoster typically occurs in immunocompromised individuals and is uncommon in immunocompetent adults. Post-vesicular crusted lesions with secondary exudation may mimic bacterial skin infections, contributing to diagnostic delay. We report a PCR-confirmed case of disseminated herpes zoster initially misdiagnosed as a furuncle.

Case Presentation

A 50-year-old man with no history of chronic disease or immunosuppressive therapy presented with a thick crusted ulcer with mild serous discharge on the right cheek, accompanied by scattered vesicles on the trunk. Six days earlier, transient vesicles had appeared on the right cheek, rapidly rupturing into erosions with prominent crusting and serous exudation on an erythematous, edematous base, associated with paroxysmal right facial pain. The initial presentation, dominated by a solitary crusted lesion with secondary exudation, was misleading and led to a diagnosis of a Furuncle, for which he received amoxicillin/clavulanic acid without improvement. One day prior to presentation, multiple vesicles appeared diffusely over the face, trunk, and extremities, revealing a disseminated pattern.

PCR testing of both crusted facial lesions and truncal vesicular lesions was positive for Varicella zoster virus. Serological testing showed negative anti-VZV IgM and markedly elevated anti-VZV IgG levels (4000 mIU/mL; normal <150 mIU/mL). The patient was treated with oral acyclovir, with complete resolution within 7 days.

Conclusion

Disseminated Herpes zoster should be considered even in immunocompetent patients presenting after vesicle rupture, as post-vesicular crusted lesions may mimic bacterial skin infections and delay diagnosis. Early recognition and timely antiviral treatment are essential.

EADV CONGRESS
VIENNA
30 SEP - 3 OCT 2026

Abstract N°: 1735

Dupilumab in Multirefractory Hailey–Hailey Disease: Two Case Reports

Irene Suarez Vergne*[1], Juan De Luque Fernández[1], Carmen Mochón Jiménez[1], Andrea Ballesteros Antúnez[1], José Manuel Rodríguez Torres[1], María del Señor Gómez Marín[1], Helena Vidarte Rebertos[1], Manuel Latorre García[1], Miguel Juan Cencerrado[1]

[1] Department of Dermatology. Reina Sofía University Hospital, Córdoba, Spain

Introduction

Familial benign pemphigus, or Hailey–Hailey disease, is an autosomal dominant genodermatosis caused by mutations in the ATP2A1 gene, leading to impaired intracellular calcium signaling. Clinically, lesions initially present as flaccid blisters that evolve into macerated erosions and subsequently into vegetating plaques with fissuring. Multiple therapeutic approaches, both topical and systemic, have been used, although no standardized treatment currently exists

Case Presentation

Case 1: A 43-year-old woman with a family history of Hailey–Hailey disease presented with an 8-year history of recurrent cutaneous flares, refractory to topical corticosteroids and antibiotics. Physical examination revealed erythematous plaques with multiple fissures and superficial erosions with marked maceration in the inguinal, axillary, and submammary regions. After inadequate response to doxycycline, roflumilast, naltrexone, prednisone, dapsone, and oxybutynin, treatment with dupilumab 300 mg every two weeks was initiated. At 6 months, a clear reduction in lesion size and improvement in pain and pruritus were observed, with no reported adverse effects.
Case 2: A 61-year-old woman with a family history of Hailey–Hailey disease presented with a 14-year history of recurrent lesions characterized by erythematous-brown vegetating plaques located on the cervical, axillary, and submammary regions, associated with pain and pruritus. She had previously received multiple systemic therapies (prednisone, acitretin, apremilast, mycophenolate mofetil, adalimumab, doxycycline, naltrexone, isotretinoin, and cyclosporine), as well as photodynamic therapy and CO_2 laser, without satisfactory response. Dupilumab 300 mg every two weeks was initiated, resulting at 6 months in a reduction in lesion size and symptom improvement, with no adverse effects reported.

Conclusion

Conclusions: Dupilumab is a monoclonal antibody that inhibits IL-4 and IL-13 signaling by blocking the alpha subunit of the IL-4 receptor. Although the exact role of these cytokines in the pathogenesis of Hailey–Hailey disease remains unclear, increasing evidence supports the utility of dupilumab in disease control. It leads to a reduction in lesion size and symptom burden, with a favorable safety profile that allows for long-term treatment.

EADV CONGRESS
VIENNA
30 SEP - 3 OCT 2026

Abstract N°: 1761

Acquired Perforating Dermatosis in a Patient with Long-Standing Granuloma Annulare: A Case Report

César Ferreira*[1], David Tente[2], Glória Velho[1]

[1] Department of Dermatology, Unidade Local de Saúde de Santo António, Porto, Portugal, Porto, Portugal
[2] Department of Pathology, Unidade Local de Saúde de Santo António, Porto, Portugal, Porto, Portugal

Introduction

Perforating dermatoses are classified into hereditary forms (with onset in childhood or adolescence, often familial) and acquired forms (with onset in adulthood, typically associated with systemic diseases). Diabetes mellitus (DM) and chronic kidney disease (CKD) are the comorbidities most frequently associated with acquired perforating dermatosis (APD), accounting for 84–93% of cases, with pruritus being the common pathogenic factor.

Case Presentation

A 52-year-old woman with a medical history of fibromyalgia, generalised anxiety disorder, Parkinson's disease, and granuloma annulare of more than 10 years' duration, previously treated with phototherapy and currently on topical clobetasol with suboptimal control, particularly of pruritus, presented to the Dermatology clinic with a two-month history of skin lesions initially involving the lower limbs.

On physical examination, she exhibited symmetrically distributed, scattered erythematous papules and nodules with central umbilication and adherent keratotic plugs, some with adjacent black eschar. Skin biopsy of a papule demonstrated transepidermal elimination of elastic fibres, consistent with the diagnosis of acquired perforating dermatosis, excluding the proposed differential diagnoses (perforating granuloma annulare and dermatitis artefacta).

Treatment with acitretin 25 mg/day was initiated, resulting in partial improvement of pruritus and no development of new lesions after three months.

Conclusion

The patient did not present with the comorbidities classically associated with this condition (DM or CKD), making this case particularly noteworthy. Other reported associations include arterial hypertension (30.3%), malignancies, chronic infections, and thyroid disease, all of which were actively excluded in this patient. Notably, an association with psychiatric disorders has also been described, with variable prevalence, and was present in this case.

Furthermore, this case illustrates a possible relationship between long-standing granuloma annulare and the development of acquired perforating dermatosis in the context of intense pruritus. Repetitive scratching is recognised as a central pathogenic factor in APD, leading to repeated cutaneous trauma which, together with dermal microvasculopathy or genetic predisposition, results in transepidermal elimination of degenerated dermal components. The Koebner phenomenon is therefore well documented in this condition.

This case highlights the importance of recognising granuloma annulare as a potential triggering factor for acquired perforating dermatosis. It also reinforces the need for comprehensive systemic evaluation in all patients with APD, including screening for malignancies, chronic infections, and other systemic diseases, particularly in the

absence of DM and CKD.

EA DV CONGRESS
VIENNA
30 SEP - 3 OCT 2026

Abstract N°: 1814

Prediction of keratinocyte carcinoma in Sweden using machine learning on registry data

Martin Gillstedt*[1], Fredrik Johansson[2], John Paoli[3], Sam Polesie[4]

[1] Institute of Clinical Sciences, Sahlgrenska Academy, University of Gothenburg, Gothenburg, Sweden, Gothenburg, Sweden

[2] Chalmers University of Technology and University of Gothenburg, Gothenburg, Sweden, Gothenburg, Sweden

[3] Institute of Clinical Sciences, Gothenburg, Sweden

[4] Institute of Clinical Sciences, Sahlgrenska Academy, Gothenburg, Sweden

Introduction

Keratinocyte carcinoma (KC)—encompassing basal cell carcinoma (BCC) and cutaneous squamous cell carcinoma (cSCC)—is the most common group of skin cancers, and its incidence has increased substantially in Western countries over the past 50 years. Owing to its high frequency, repeated diagnostic and therapeutic procedures, follow-up requirements, and occurrence of multiple primary tumors, KC represents a major healthcare burden. Nationwide Swedish health and population registries provide rich data that may support large-scale computational phenotyping and risk prediction. In this study, we trained machine learning (ML) models on registry data to predict individual-level risk of incident, histopathologically verified KC within five years.

Materials and Methods

Registry data covering adults in Sweden from 4 July 2005 to 31 December 2019 were obtained. Predictors were derived from data recorded up to 31 December 2014 and were used to predict incident KC during the five-year follow-up period from 1 January 2015 to 31 December 2019. Individuals with any migration event during the prediction period were excluded to ensure completeness of data. Data were obtained from Statistics Sweden and the National Board of Health and Welfare. Predictors included 1,959 complete ATC codes from the Prescribed Drug Register, 3,455 ICD-10 codes (first three characters) from the National Patient Register, 385 complete ICD(O)-10 codes from the Cancer Register, age, sex, region of birth, Swedish or foreign background, education level, civil status, and disposable income. The ML methods used were logistic regression and the light gradient boosting model (LGBM). In order to reduce training time, the ML models were trained on a reduced set consisting of 170,381 KC cases and equally many non-KC individuals. A validation set consisting of 20,000 KC cases and 553,834 non-KC individuals was randomly sampled. Hyperparameters in the ML models were varied, and a final set of hyperparameters was selected on the best validation performance. Finally, the best performing model of each type was evaluated on a test set of the same size as the validation set.

Results

Logistic regression and LGBM performed similarly yielding an AUC of 0.84 when trained on all available data. When training on age and sex only an AUC of 0.77 was achieved. An AUC of 0.78 was acquired when training on all data except ICD, ATC, and cancer registry codes. A skin cancer-naive Swedish subgroup consisting of individuals naive for melanoma, actinic keratosis, BCC, Bowen, cSCC, and being born in Sweden with both parents also born in Sweden was analyzed. Training with LGBM on this subgroup using all available data achieved an AUC of 0.76. Training only on age and sex yielded an AUC of 0.74, while training on age, sex, and all demographic data yielded AUC=0.75. The variables that were most associated (controlling for age-group and sex) with not having

KC for the skin cancer-naive Swedish subgroup were diagnoses and medicines associated with Alzheimer and adverse or problematic social-environmental situations. Variables most strongly associated with incident KC in the same subgroup were diagnoses related to organ transplantation and post-transplant immunosuppressive medications.

Conclusions

Training ML models on data including ICD, ATC, and cancer registry diagnoses substantially increased performance (AUC=0.84) compared to training on merely age, sex, and other demographic data (AUC=0.78). However, among those naive for skin cancers, the codes did not offer any large improvement in performance. Incorporating longitudinal temporal information and exploring alternative ML frameworks, including neural network–based approaches, may further enhance predictive performance. Finally, improving model interpretability may provide deeper insight into which predictors contribute most strongly to the outcome.

EADV CONGRESS
VIENNA
30 SEP - 3 OCT 2026

Abstract N°: 1816

Dermatologists as Health Educators in the Digital Ecosystem: Our Italian Experience Beyond Marketing

Federica Osti*[1], Lidia Sacchelli[2]

[1] Studio Medico Amor Proprio, Faenza (RA), Italy
[2] Department of Medical and Surgical Sciences, Alma Mater Studiorum, University of Bologna, Bologna, Italy

Introduction

Social media have profoundly transformed how patients access medical information, particularly in dermatology, where visual content plays a central role. Dermatologists are increasingly present online, often positioned between health educators and commercial influencers.

In Italy, this dual role is regulated by a legal and ethical framework including the Code of Medical Ethics, national advertising legislation (Legislative Decree 145/2007), and oversight by the Italian Competition Authority (AGCM), which collectively enforce principles of truthful, non-promotional, and non-misleading medical communication.

This regulatory environment provides a model to explore how dermatologists can use social media not as a marketing tool, but as an extension of clinical practice and patient care.

Materials and Methods

This narrative perspective is based on analysis of the Italian regulatory framework, including the Code of Medical Ethics (Articles 56–57), and integration of a previously developed educational model for digital communication. Real-world data from a clinical communication ecosystem were analyzed, comparing viral versus non-viral dermatological content on patient engagement and clinical activity. The discussion is supported by the Italian consensus on ethical and professional use of social media by dermatologists.

Results

In a regulated environment, social media function as a tool for health education rather than commercial promotion, contributing to patient awareness, expectation management, and continuity of care.

Data derive from a real-world digital ecosystem managed by an Italian board-certified dermatologist with over 15 years of experience and approximately 75,000 Instagram followers.

Comparative analysis of viral versus non-viral content highlights the amplification potential of digital platforms. A viral post (≈590,000 views) generated higher engagement than a standard post (≈8,000 views), including increased followers (+8,000 vs +7), newsletter subscriptions (39 vs 6), website traffic (370 vs 209 clicks), and new clinical appointments (41 vs 18).

However, routine non-viral content showed consistent clinical relevance, contributing to steady patient acquisition and reinforcing the patient–dermatologist relationship. Effectiveness is therefore not solely dependent on virality, but on continuity, quality, and ethical accuracy of content.

The Italian consensus supports this approach, defining principles including scientific rigor, transparency of conflicts of interest, patient privacy, and prohibition of personalized medical advice online.

Conclusions

In a highly regulated context, dermatologists' presence on social media should be considered part of a broader digital ecosystem of care rather than a marketing strategy. Viral content amplifies health messages and reach, while consistent non-viral communication sustains patient engagement and supports clinical practice over time.

The dermatologist emerges as a health educator and information filter in an environment characterized by misinformation and patient "social fatigue." Ethical, continuous, and scientifically grounded communication can strengthen the patient–physician relationship, improve adherence, and extend care beyond the clinical setting.

The Italian experience, grounded in strict ethical and regulatory frameworks and supported by consensus-based guidelines, may represent a scalable model for responsible and ethically driven dermatological communication across Europe.

EADV CONGRESS
VIENNA
30 SEP - 3 OCT 2026

Abstract N°: 1858

Morbihan syndrome: a diagnostic and therapeutic challenge in a young pacient

Mariana de Oliveira Krapf*[1], Ana Luísa Moraes de Oliveira[2], Pietra Binotto[3]

[1] Private Dermatology Clinic, Lisboa, Portugal

[2] Hospital São Vicente de Paulo, Passo Fundo, Brazil

[3] Hospital Beneficente Dr. César Santos, Passo Fundo, Brazil

Introduction

Morbihan syndrome is a rare and often underdiagnosed clinical entity characterized by chronic, non-pitting facial edema and erythema involving the upper third of the face, with a slow and symmetrical onset, typically considered a late-stage complication of rosacea. Its pathophysiology is not fully understood, but it is possibly related to lymphatic vessel dysfunction, vascular dysregulation, and chronic inflammation. Its diagnosis is challenging due to nonspecific clinical and histopathological findings and the need to exclude other conditions such as angioedema, orofacial granulomatosis, sarcoidosis, systemic lupus erythematosus, granuloma faciale, superior vena cava syndrome and scleredema of Buschke. Morbihan syndrome is a therapeutic challenge, with limited treatment options including systemic antibiotics (especially tetracyclines), oral corticosteroids, and oral isotretinoin. Non-pharmacological approaches, such as lymphatic drainage and blepharoplasty, may be considered in refractory cases. Although it is classically described in middle-aged patients, this study aims to present the case of a young patient diagnosed with Morbihan syndrome without a prior history of rosacea, highlighting the diagnostic and therapeutic challenges, as well as the response to oral isotretinoin.

Case Presentation

A 19-year-old male patient with no prior medical history presented with a 1-year history of recurrent facial edema, which had become persistent in recent months. Previous treatment with oral antihistamines and corticosteroids yielded no clinical response. On physical examination, non-pitting, firm edema was observed in the upper third of the face, involving the forehead, glabella, eyelids, and malar region, associated with a few papules and mild erythema, with no other significant findings. Laboratory investigations, including complete blood count, renal, hepatic, and thyroid function tests, serologies, and rheumatologic markers, were all within normal limits. A skin biopsy revealed nonspecific histopathological findings, including sebaceous gland hyperplasia and mild dermal inflammatory infiltrate associated with vascular ectasia. In the absence of diagnostic criteria for other granulomatous or specific inflammatory dermatoses, and in correlation with the clinical presentation of chronic facial edema, a diagnosis of Morbihan syndrome was established. Treatment with isotretinoin was initiated at a dose of 20 mg/day and increased to 40 mg/day after one month. By the end of the third month of treatment, the patient showed significant, although incomplete, improvement in facial edema.

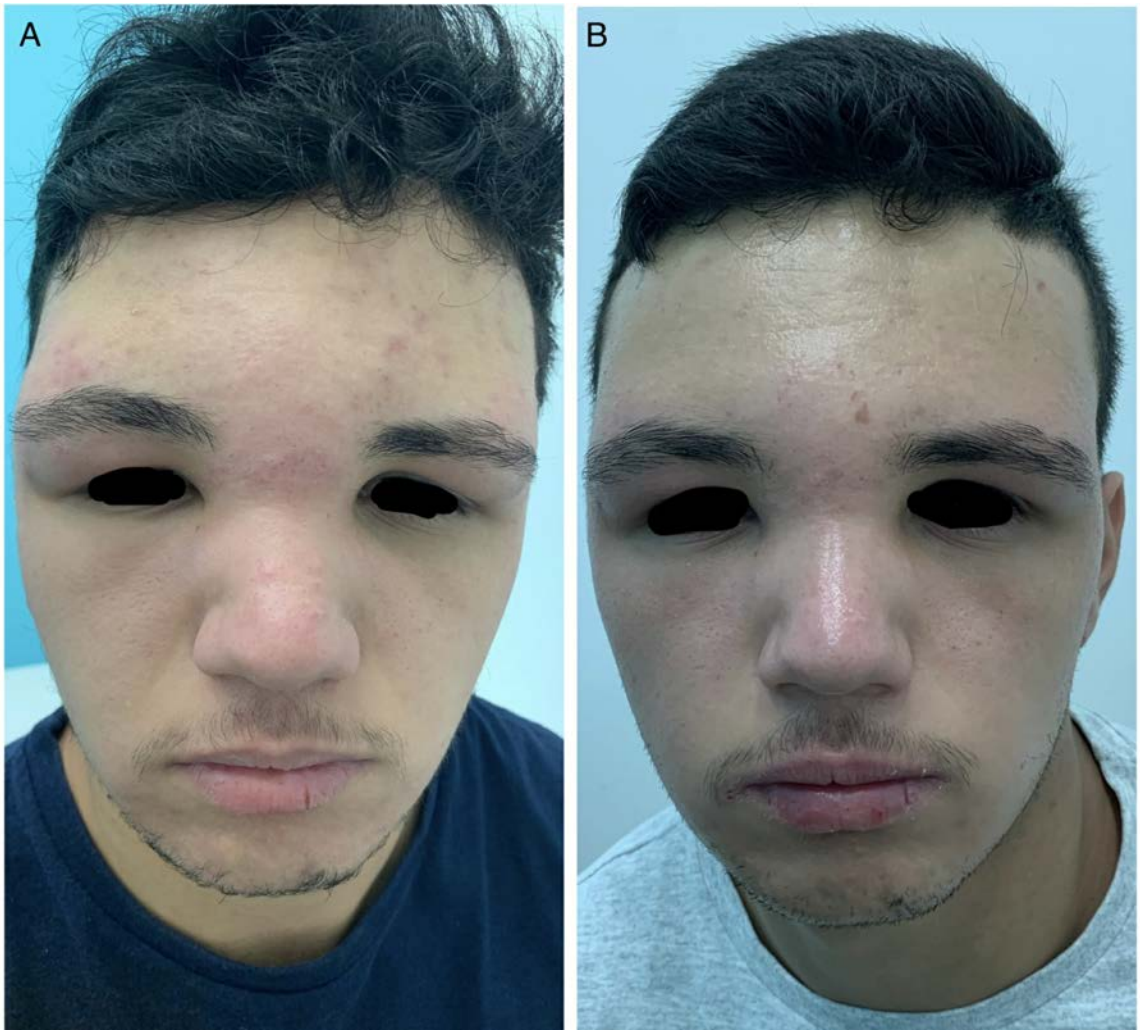

A – Patient before starting treatment with isotretinoin, presenting edema of the entire upper third of the face with mild erythema in the nasal region. B – Patient in the third month of isotretinoin use, showing considerable improvement of facial edema.

Conclusion

Morbihan syndrome remains a diagnostic and therapeutic challenge due to its chronicity, rarity, and unspecific appearance. This case highlights the importance of clinical suspicion even on younger patients and with no known rosacea history, in order to allow an early diagnosis and therapeutic intervention in this condition, which may significantly impair patients' quality of life. The use of oral isotretinoin indicated relevant clinical benefits, reinforcing its role as one of the main therapeutic options available, although its management remains challenging, and its therapeutic algorithm is not yet standardized.

EADV CONGRESS
VIENNA
30 SEP - 3 OCT 2026

Abstract N°: 1900

Clinician Attitudes to Artificial Intelligence in Dermatology: Mixed-Methodology Approach to Understanding Barriers and Levers to Adoption

Saman Zaman*[1], Louise Fearfield[1], Lucy Thomas[1]

[1] Chelsea and Westminster Hospital NHS Trust, London, United Kingdom

Introduction

Artificial intelligence (AI) is a potential solution to increasing pressures within dermatology services, particularly in skin cancer diagnosis. However, translation of AI tools into routine clinical practice has been limited. Studies understanding clinician attitudes to AI adoption, especially in Dermatology are limited.

Materials and Methods

A cross-sectional survey of 73 clinicians assessed AI confidence, familiarity, performance expectations, and adoption barriers.

Results

Interest in AI adoption was high, with 90.4% of clinicians willing to use AI devices. Most agreed that AI could improve early detection of skin cancers (72.6%) and workload efficiency (68.5%).

26% were confident using AI for skin cancer diagnosis (consultants 39%, GPs 20%). Familiarity with AI tools varied significantly ($p<0.001$) by clinician type (consultants 32% very familiar or currently using AI, GPs 8%, SAS 10%, trainees 12.5%); and 5% currently use AI for skin cancer diagnosis. Familiarity was strongly associated with confidence (Spearman's $\rho = 0.54$, $p<0.001$).

Key barriers included medico-legal concerns (71%), cost (68%) and workflow integration (56%). Primary concerns were risk of missed cancers (77%) and lack of accountability (55%), over half would adopt AI with professional endorsement and clear medico-legal frameworks. Clinicians expected >95% sensitivity from AI, compared with perceived consultant performance of ~80–85%, with little alignment between the two.

Conclusions

Clinicians were positive about the value of AI in dermatology, but adoption is constrained by low confidence, limited familiarity, and unresolved governance and risk concerns. Divergent expectations of AI versus human performance reflect asymmetric risk tolerance. Professional body conditional approval is a lever but requires senior medico-legal accountability for safe, scalable impact.

Current deployment aligns with the technology adoption curve, reaching early adopters but not the early majority.

EA DV CONGRESS
VIENNA
30 SEP - 3 OCT 2026

Abstract N°: 1903

Practical recommendations for out care patients with erythroderma

Bruna Marques Bilia*[1], Hudson Rezende[1], João Henrique Aurich[1], Antonio Moraes Madeira Quindos[2], Mariana Menezes de Mauro[3]

[1] Centro Universitário Lusíada (UNILUS), Santos, Brazil
[2] Universidade de Taubaté (UNITAU), Taubaté, Brazil
[3] Universidade São Francisco, Bragança Paulista, Brazil

Introduction

Erythroderma is a severe dermatological condition characterized by generalized erythema and scaling involving more than 90% of the body surface. Its broad etiological spectrum and potential for systemic complications make early management challenging, particularly in non-specialized settings. Despite its clinical relevance, standardized approaches for the initial evaluation remain limited.

Materials and Methods

We developed a structured clinical approach based on real-world experience in a tertiary dermatology center, integrating current literature with practical decision-making steps. Key aspects included initial systemic assessment, symptomatic management, biopsy strategy, and use of complementary diagnostic tools. Special attention was given to common pitfalls that may interfere with diagnostic accuracy in the early stages of erythroderma.

Results

A stepwise approach proved essential for improving diagnostic orientation and patient safety. Early identification of hemodynamic instability allowed prompt referral and prevention of complications. In stable patients, prioritizing symptom control with oral antihistamines and intensive skin hydration helped reduce discomfort without compromising histopathological evaluation. Delaying the use of topical corticosteroids until after biopsy increased diagnostic yield. Selection of appropriate biopsy sites, avoiding areas of fissuring or secondary infection, improved histological interpretation. Additional tools, such as nail clipping and skin scrapings, provided valuable diagnostic clues in selected cases, particularly in differentiating psoriasis, lichen planus, and infestations. Environmental factors, including ultraviolet exposure, were also identified as potential confounders, capable of modifying inflammatory patterns and obscuring diagnosis.

Conclusions

Erythroderma requires a structured and cautious approach from the first evaluation. Early clinical decisions, especially regarding biopsy timing, site selection, and initial treatment, directly influence diagnostic accuracy and patient outcomes.

A practical, stepwise strategy may help clinicians navigate this complex presentation, reduce diagnostic delays, and optimize management in both specialized and general practice settings.

EADV CONGRESS
VIENNA
30 SEP - 3 OCT 2026

Abstract N°: 1931

User Acceptance and Self-Reported Efficacy of Tap Water Iontophoresis Using the conceptION Device for Hyperhidrosis Treatment: Results of the Ion2Effect Study

Antje Alberts*[1], Flora Sonsmann[2], Lucia Frankowski[3], Christina Kitte[3], Christoph Skudlik[1], Swen Malte John[1]

[1] Institute for Interdisciplinary Dermatological Prevention and Rehabilitation (iDerm) at the Osnabrück University, Department of Dermatology, Environmental Medicine and Health Theory, Institute for Health Research and Education, Osnabrück University, Lower Saxony Institute of Occupational Dermatology (NIB), Osnabrueck, Germany

[2] Institute for Interdisciplinary Dermatological Prevention and Rehabilitation (iDerm) at the Osnabrück University, Department of Dermatology, Environmental Medicine and Health Theory, Institute for Health Research and Education, Osnabrück University, Osnabrueck, Germany

[3] Department of Dermatology, Environmental Medicine and Health Theory, Institute for Health Research and Education, Osnabrück University, Osnabrueck, Germany

Introduction

Hyperhidrosis is associated with a considerable reduction in quality of life and can result in physical discomfort as well as psychosocial consequences such as reduced self-esteem and social isolation. For the treatment of palmar, plantar, and axillary hyperhidrosis, tap water iontophoresis represents an established therapeutic option. The home-use device conceptION introduces a novel approach by employing artificial intelligence to determine optimal treatment parameters automatically, while still enabling users to adjust the treatment intensity according to individual preferences.

Materials and Methods

The study included patients with hyperhidrosis affecting the hands, feet, or armpits who were using the conceptION device. A mixed-methods approach was applied. Qualitative, guideline-based expert interviews were conducted between January and February 2025 and analysed using qualitative content analysis following Kuckartz (N=11). In addition, a larger cohort of patients participated in a questionnaire survey conducted from January to November 2025 (N=88), capturing self-assessed conditions before and after treatment. This survey included both validated instruments and a specifically developed questionnaire assessing user acceptance. The study was registered in the German Register for Clinical Trials (No. DRKS00035943).

Results

Findings from the qualitative interviews indicate a generally high level of user acceptance of the device. Participants reported a high degree of satisfaction with the therapeutic effectiveness and emphasised the central role of the treatment in managing their condition. The automated current adjustment was partly perceived as advantageous; however, in some cases it resulted in excessively high current intensity, requiring manual reduction. At the time of abstract submission, the analysis of the questionnaire data is still ongoing. The combined results of both study components will be presented at the congress.

Conclusions

In the interviews, participants expressed a high level of satisfaction with iontophoresis therapy using the conceptION device. Nevertheless, the automatic current regulation should be carefully considered in future device

development. In addition, patient education appears to be essential, particularly regarding appropriate skin care during therapy. Further insights are expected following the completion of the quantitative data analysis.

EADV CONGRESS
VIENNA
30 SEP - 3 OCT 2026

Abstract N°: 1993

Eruptive axillary syringomas: an exceptionally rare localization of a common benign tumor

Bor Hrvatin Stančič*[1, 1], Jan Stanič[1], Špela Šuler Baglama[1]

[1] Dermatovenerology Department, University Medical Centre Ljubljana, Ljubljana, Slovenia

Introduction

Syringomas are benign adnexal tumors originating from the intraepidermal portion of eccrine sweat ducts. They affect around 1% population worldwide and are usually found in the head and neck region, most often on the eyelids, and less commonly on the scalp, forehead, cheeks, abdomen, extremities, genitalia and buttocks (1,2). Isolated axillary involvement without concurrent periorbital or other typical site lesions represents a distinctly rare presentation with only a handful of cases described in literature (2,3). The aim of this report is to present a further case of isolated bilateral axillary syringomas, contribute to this exceptionally scarce clinical entity, and describe the clinical and dermoscopic features.

Case Presentation

We herein report a case a 30-year-old Caucasian female who presented with asymptomatic bilateral axillary erythematous to brownish papules up to 3 mm in diameter and in some areas coalescing into mammilated plaques. No similar lesions were present on other body sites. No association was observed with the roots of hair. The patient reported the sudden appearance of axillary lesions in early adolescence with no change in morphology, size or diameter since. Dermoscopic evaluation revealed diffuse unevenly distributed small whitish milia-like cysts of various sizes, on a diffuse erythematous to brownish background. Occasional reticular vessels were observed. Given the unusual isolated axillary localization and the clinical and dermoscopic differential diagnosis, including Darier disease, Fox-Fordyce disease, Hailey-Hailey disease, flat wart and keratosis pilaris. A biopsy of the left axilla was performed for histopathological clarification. Histopathological examination revealed features consistent with a syringomas thus confirming the diagnosis. After discussing potential therapeutic options, the patient opted against current therapeutic intervention.

Conclusion

Isolated eruptive axillary syringomas without involvement of the classical periorbital region or other typical sites represent a extremely rare clinical entity (1-3). Making the clinical diagnosis in atypical locations such as the axilla challenging and relies heavily on histopathological findings (2-4). Dermoscopy, serves as a useful non-invasive tool to guide targeted biopsy with histopathological confirmation remaining the gold standard (2,3,6). This case further supports the importance of including syringoma in the differential diagnosis of bilateral eruptive papular axillary lesions, even in the complete absence of lesions at more commonly affected sites.

EADV CONGRESS
VIENNA
30 SEP - 3 OCT 2026

Abstract N°: 1997

Nekam's Disease: A Case Report of a Rare Entity

Elisandra Barbara Pontes Carlos*[1], Ivanka de Castro[1], Hélio Miot[1], Anna Carolina Miola[1]

[1] UNESP, Botucatu, Brazil

Introduction

Keratosis lichenoides chronica is a rare dermatosis characterized by violaceous, hyperkeratotic papules arranged in linear or reticular patterns, predominantly affecting the trunk and extremities. Due to its low prevalence and the limited availability of consistently effective therapies, it represents a diagnostic and therapeutic challenge in clinical practice.

Case Presentation

A 38-year-old woman presented with a five-year history of asymptomatic erythematous, hyperkeratotic papules. The lesions initially appeared on the upper limbs and, over the following months, progressed to involve the trunk, abdomen, and back. She denied triggering factors or a family history of similar conditions. Physical examination revealed multiple erythematous, hyperkeratotic papules arranged in a reticular pattern with generalized distribution, predominantly involving the trunk and upper limbs; on the lower limbs, lesions were more concentrated in proximal regions. Additionally, aphthoid lesions were observed on the oral mucosa near the canines, along with small erosions on the vaginal mucosa. Histopathological examination demonstrated a lymphoplasmacytic inflammatory infiltrate in the dermis, elongation of dermal and epidermal ridges, mild spongiosis, and the presence of intracorneal follicular abscesses with lymphocytic exocytosis into the follicular epithelium. Treatment with methotrexate (15 mg/week) associated with folic acid (5 mg/week) resulted in partial clinical response. After approximately six months of follow-up, the patient was lost to follow-up and did not return for further dermatological evaluation.

Conclusion

Keratosis lichenoides chronica is a rare condition that poses both diagnostic and therapeutic difficulties. Clinical presentation may overlap with other dermatoses, particularly hypertrophic lichen planus and, in some cases, pityriasis rubra pilaris, making differential diagnosis essential. In the present case, the convergence of clinical features and histopathological findings supported the diagnosis. Therapeutic responses are often incomplete or unsatisfactory, as illustrated here, which may contribute to patient frustration and loss to follow-up. Reporting rare cases remains crucial to increase awareness within the scientific community and may support future advances in therapeutic approaches for affected patients.

EA DV CONGRESS
VIENNA
30 SEP - 3 OCT 2026

Abstract N°: 2020

The itch that matters: Distinguishing pemphigoid gestationis from polymorphic eruption of pregnancy

Táňa Rajcigelová*[1], Zlatica Žingorová[1], Tereza Neplechová[1], Karolína Vorčáková[1]

[1] Department of Dermatovenerology at Martin University Hospital of Jessenius Faculty of Medecine, University of Commenius in Bratislava, Slovakia, Martin, Slovakia

Introduction

Pregnancy represents a unique physiological state in which the interplay of multiple factors, including hormonal and immune imbalance, may lead to the development of dermatoses specific to the pregnancy and postpartum periods. These conditions are typically pruritic, although their associated maternal and fetal risks vary. Atopic eruption of pregnancy, intrahepatic cholestasis of pregnancy, and pustular psoriasis of pregnancy (impetigo herpetiformis) can usually be distinguished based on clinical presentation and medical history. However, differentiating between polymorphic eruption of pregnancy (PEP) and pemphigoid gestationis (PG) on a clinical basis alone may be challenging, nevertheless it is crucial for appropriate management and counseling regarding future pregnancies.

Case Presentation

During a three-year period, we examined a total of five pregnant women (six pregnancies) with clinical manifestations suggestive of PG or PEP. Data were collected at our department from January 2023 to January 2026. The diagnosis of PEP or PG was based on clinical presentation, detection of circulating antibodies against BP180 by enzyme-linked immunosorbent assay (ELISA), and skin biopsy with direct immunofluorescence of perilesional skin. ELISA was performed in all cases, while skin biopsy was performed in three cases.

In our retrospective study, we identified three cases of PG in two women (three pregnancies), the remaining patients were classified as having PEP. Only one woman presented with tense vesicles on an erythematous base after her first delivery, in her second pregnancy, the condition started in the first trimester and was more severe. Three patients presented with generalized urticarial papules, and one had periumbilical erythema. In one case, the papular exanthema began in the tenth week of pregnancy and was later confirmed as PG. In the remaining patients, dermatological symptoms developed in the third trimester. All patients suffered from intense pruritus. Temporary systemic corticosteroid treatment was required in cases of PG and in one patient with PEP initially; antihistamines were sufficient for the remaining patients. All women delivered vaginally at term or post-term. No neonate developed dermatological complications, and birth weights were within normal ranges for gestational age.

Conclusion

PG and PEP are two distinct diagnoses; however, their clinical presentations may overlap, which can lead to diagnostic challenges. Misdiagnosis and undertreatment may negatively affect maternal and fetal well-being. A multidisciplinary approach is crucial to reduce pruritus and minimize potential pregnancy and neonatal risks. It is important to inform and educate patients about the diagnosis so that future pregnancies can be appropriately planned and managed, thereby reducing the risk of unexpected outcomes and stress.

EADV CONGRESS
VIENNA
30 SEP - 3 OCT 2026

Abstract N°: 2024

Self-medication in the era of artificial intelligence: a new challenge in dermatology

Ouissal Hormi*[1], Nassiba Zerrouki[1], Nada Zizi[1]

[1] Department of Dermatology, Venereology and Allergology, Mohammed VI University Hospital Center, Oujda, oujda, Morocco

Introduction

Artificial intelligence (AI)-based conversational tools are increasingly used by patients seeking rapid and accessible medical information. In dermatology, where visual symptoms and chronic diseases frequently lead patients to search for online advice, AI-generated medical information may influence therapeutic decisions and healthcare-seeking behaviors. While AI tools may improve health literacy and encourage medical consultation, concerns remain regarding their possible role in promoting self-diagnosis and self-medication.

Materials and Methods

A descriptive cross-sectional study was conducted over a 6-month period among patients attending dermatology consultations. Adult patients who had previously used AI-based conversational tools for dermatological concerns were included. Data were collected using an anonymous structured questionnaire after informed consent.

Results

A total of 62 patients were included in the study, with a predominance of women and young adults aged 18–35 years (71.0%). Most participants had a university educational level (66.1%) and reported regular use of digital health resources. The main dermatological conditions prompting AI consultation were acne (32.3%), hair disorders including alopecia (22.6%), eczema and atopic dermatitis (17.7%), fungal infections (11.3%), and pigmentation disorders (9.7%). Facial involvement was present in 61.3% of cases. AI-based tools were mainly used to better understand the skin condition (83.9%), to seek possible treatment recommendations (67.7%), and to attempt a self-diagnosis before consulting a dermatologist (54.8%). More than half of the patients (58.1%) reported that AI-generated information encouraged earlier dermatological consultation, while 21.0% stated that it delayed consultation by providing reassurance. Regarding therapeutic behavior, 59.7% of participants reported practicing self-medication after using AI tools. The most common practices included over-the-counter topical treatments (48.4%), cosmetic or skincare products recommended online (41.9%), herbal or natural remedies (24.2%), and oral medications without prescription (11.3%). In addition, 19.4% modified or discontinued previously prescribed treatments based on AI advice. Most patients (72.6%) found AI-generated information easy to understand, and 61.3% felt reassured after using it. However, 46.8% expressed concerns about the reliability of AI recommendations, and 38.7% reported receiving contradictory or confusing information. Despite this, 85.5% considered AI tools as complementary to medical consultation, while only 6.5% believed they could replace dermatological advice in some situations. Self-medication was more frequent among younger patients, frequent AI users, and those with chronic or recurrent dermatoses, particularly acne and hair disorders.

Conclusions

AI-based medical tools significantly influence therapeutic behaviors in dermatology patients, improving access to health information and promoting healthcare-seeking behavior. However, they may also encourage self-medication and inappropriate self-treatment. These findings underscore the importance of patient education on the limitations of AI-generated advice and the need for professional dermatological evaluation.

EA DV CONGRESS
VIENNA
30 SEP - 3 OCT 2026

Abstract N°: 2028

Pre-consultation use of artificial intelligence in pediatric allergology: effects on diagnosis and care pathways

Ouissal Hormi*[1], Nassiba Zerrouki[1], Nada Zizi[1]

[1] Department of Dermatology, Venereology and Allergology, Mohammed VI University Hospital Center, Oujda, oujda, Morocco

Introduction
The rapid expansion of publicly accessible artificial intelligence (AI) tools is reshaping health-seeking behaviors worldwide. In pediatric dermatology and allergology, parents increasingly rely on AI-based platforms to interpret skin symptoms before consulting a physician. While these tools may enhance awareness, their impact on diagnostic accuracy, consultation timing, and the physician–parent relationship remains insufficiently explored. This study aims to evaluate the frequency and patterns of AI use among parents of children with allergic dermatoses, assess the accuracy of AI-driven self-diagnosis, and analyze its impact on healthcare-seeking behavior and clinical interaction.

Materials and Methods
A cross-sectional study was conducted among parents of children presenting with confirmed allergic skin diseases. Data were collected using a structured questionnaire, including demographic characteristics, type of AI tools used, presumed diagnosis, delay before consultation, pre-consultation treatments, and expectations regarding medical care. Diagnostic concordance between AI-based assumptions and final clinical diagnosis was assessed.

Results
A total of 48 parents were included (mean child age: 7.6 ± 3.9 years). Overall, 65% (n=31) reported using artificial intelligence (AI) tools prior to consultation. Among these users, conversational assistants were the most frequently used (73%), followed by skin image analysis applications (31%), with some parents reporting the use of multiple tools.
Diagnostic discordance between AI-based self-diagnosis and the final clinical diagnosis was observed in 58% of cases (n=18). The most common misclassifications involved confusion between atopic dermatitis, contact dermatitis, and infectious dermatoses. In contrast, concordance was observed in 42% of cases, mainly in typical presentations of atopic dermatitis.
AI use influenced consultation timing in a heterogeneous manner. A delay in consultation exceeding two weeks was reported in 38% of parents (n=12), primarily in cases initially perceived as benign. Conversely, 25% (n=8) sought earlier medical advice due to AI-generated concern regarding symptom severity. No significant change in consultation timing was observed in the remaining cases.
Pre-consultation self-medication was reported in 42% of parents (n=13), including the use of topical treatments and over-the-counter medications. Parents who used AI were more likely to initiate self-treatment compared to non-users.
Furthermore, 71% of parents (n=22) reported that their expectations during consultation were influenced by AI-generated information, often anticipating specific diagnoses or treatments. This contributed to a perceived strain in the physician–parent relationship in 22% of cases (n=7), mainly due to discrepancies between parental expectations and clinical assessment.

Conclusions

Artificial intelligence use among parents is common in pediatric allergic dermatoses and significantly influences healthcare pathways. Although these tools may promote earlier recognition of severe conditions, they are frequently associated with diagnostic inaccuracies, inappropriate self-management, and delayed consultation. These findings highlight the need for structured patient education and medical guidance to ensure the safe and effective integration of AI into healthcare practices.

EADV CONGRESS
VIENNA
30 SEP - 3 OCT 2026

Abstract N°: 2039

From Clinical Expertise to Digital Leadership: A Four-Pillar Framework for Ethical Dermatology Communication on Social Media

Lidia Sacchelli*[1], Federica Osti[2]

[1] Dermatology Unit, IRCCS Azienda Ospedaliero-Universitaria di Bologna, Policlinico S. Orsola Malpighi, Bologna, Italy; Department of Medical and Surgical Sciences Alma Mater Studiorum University of Bologna, Italy, Bologna, Italy
[2] Department of Dermatology, Amor Proprio Medical Clinic, Faenza, Ravenna, Italy

Introduction

Social media has become a primary source of dermatological information for patients, significantly influencing health literacy, risk perception, and healthcare-seeking behaviour. Given the visual nature of skin diseases, dermatology is particularly exposed to both the opportunities and risks of digital communication, including the widespread dissemination of misinformation. In this context, dermatologists are increasingly required to engage online while maintaining scientific rigor and professional ethics.

Materials and Methods

To develop a structured, reproducible, and ethically grounded framework to support dermatologists in building an effective and professional social media presence for patient education and misinformation prevention.

This framework was developed through the integration of:
-direct clinical and digital communication experience of board-certified dermatologists actively engaged in patient education on social media;
-analysis of frequent patient-reported questions (FPRQs) collected in routine clinical practice;
-existing ethical and professional recommendations from dermatological and medical societies.

The model was organised into four core domains (“four pillars”) representing the key competencies required for effective digital communication in dermatology.

Results

A four-pillar strategic framework for digital dermatology communication is proposed:

- Mindset: Transition from a purely clinical role to that of a digital health educator, with responsibility for addressing misinformation and improving patient literacy.
- Personal Brand: Development of a consistent and recognisable professional identity, maintaining medical credibility while adapting to platform-specific visual language.
- Educational Offer: Transformation of recurring patient concerns into structured, evidence-based educational content (e.g., skin cancer prevention, acne management, photoprotection) delivered through accessible formats such as short videos, stories, and carousel posts.
- Storytelling: Use of narrative techniques to enhance comprehension and retention of complex medical information without compromising scientific accuracy.

Across all domains, strict adherence to medical ethics was identified as essential, including avoidance of online diagnosis, direct-message consultations, and non-transparent promotional content. Content sustainability and editorial planning emerged as key factors for long-term credibility and impact.

Conclusions

Social media should be approached by dermatologists as an extension of clinical practice rather than a promotional tool. The proposed four-pillar framework provides a practical and ethically grounded model to support dermatologists in delivering accurate, accessible, and responsible digital health information. Its implementation may contribute to improving patient awareness, strengthening physician–patient trust, and counteracting misinformation in dermatology.

EA DV CONGRESS
VIENNA
30 SEP - 3 OCT 2026

Abstract N°: 2056

Hidradenitis Suppurativa and Marfan Syndrome: A Connective Tissue Link?

Vivienne Nguyen*[1], Dhanya Kuladeva[1], Alison Honan[1]

[1] NHS Ayrshire and Arran, Kilmarnock, United Kingdom

Introduction

Hidradenitis Suppurativa (HS) is a chronic, relapsing inflammatory skin condition characterised by abscesses, nodules, and draining tunnels commonly at flexural sites. Associations between HS and heritable connective tissue disorders have been described, but reports involving Marfan syndrome (MS) remain rare.[1] We report a case of HS developing in a patient with Marfan syndrome and explore whether connective tissue fragility may predispose to follicular disruption and mechanical stress–induced disease.

Case Presentation

A 22-year old male with a known history of MS was initially referred to dermatology with a longstanding history of severe nodulocystic acne. Following isotretinoin initiation and uptitration, cystic nodules appeared in submammary areas, thighs, groin, axillae and posterior neck. These lesions modestly improved with topical therapies including antiseptic washes and topical clindamycin. He was subsequently switched to dapsone but continued to experience flares.

Dapsone was discontinued and oral rifampicin and clindamycin were initiated with a diagnosis more in keeping with HS. There was modest improvement after a prolonged course and also private prescription of a GLP-1 agonist. At the time of assessment for adalimumab therapy, the patient had Hurley Stage II Disease, and International Hidradenitis Suppurativa Severity Score (IHS-4) of 5 with predominant follicular phenotype. After 3 months of Adalimumab, the patient's IHS-4 score improved to 3. Overall, he felt his skin was improved with Adalimumab and objectively, axillae and inner thighs were clear of activity alongside less active truncal follicular lesions.

Mutations in fibrillin-1 alter extracellular matrix architecture and dysregulate transforming growth factor-β signalling, pathways increasingly implicated in inflammatory skin disease.[2] *Andersen et al. (2022)* propose a potential mechanistic link between connective tissue disorders and HS.[3] They suggest that abnormalities in collagen and extracellular matrix composition may result in subclinical inflammation and reduced mechanical stability of the pilosebaceous unit. This structural vulnerability could lower the threshold for follicular damage under conditions of mechanical stress. In this context, patients with underlying connective tissue disorders such as Marfan syndrome may be inherently predisposed to developing HS, providing a plausible biological basis for the observed, albeit rare, clinical association.

A review of the literature revealed a case that has documented this coexistence. It described the onset of typical HS lesions in the inner thighs and buttocks in early adulthood of a male patient with a background of MS.[4] *Andersen et al. (2020)* note 33 cases of HS and Marfan's in the United States; however, more than double that number of patients with Ehlers Danlos syndrome, another connective tissue disease, with co-existing HS.[3] The

scarcity of reported cases may reflect the true rarity of this association; however, it is also possible that it remains under-recognised, particularly given the well-documented diagnostic delay in HS and its potential to be misdiagnosed in earlier stages.

Conclusion

Our case highlights the importance of maintaining a high index of suspicion for hidradenitis suppurativa. In this case, despite ongoing follow-up under dermatology, the diagnosis was not established until several consultations had taken place, reflecting the diagnostic challenges associated with evolving or atypical presentations. Furthermore, this case contributes to the limited body of literature describing a potential association between MS and HS. Although rare, this association raises important questions regarding a possible underlying link between connective tissue abnormalities and susceptibility to HS.

EADV CONGRESS
VIENNA
30 SEP - 3 OCT 2026

Abstract N°: 2096

Research on a New Quantitative Detection Method for Skin Sebum Based on Standardized Oil-Absorbing Test Paper and RF-NN Hybrid Model

Li Ye*[1], Lifeng Tang[2], Qili Shen[3], Ping Zhao[4], Hongling Zhu[1], Rongshen Xiao[2], Linshan Wu[1], Yan Li[2], Si Wen[1], Qingbin Wu[3]

[1] Cosmetics Testing Center, Dermatology Hospital of Southern Medical University, NMPA Center for Innovation and Research in Regulatory Science, Translational Medicine Center, Dermatology Hospital of Southern Medical University, GuangZhou, China

[2] Guangzhou Xika Technology Co., Ltd, Guangzhou, China

[3] Shanghai Fuhuan Technology Co., Ltd, Shanghai, China

[4] Guangdong Pharmaceutical University, Guangzhou, China

Introduction

To develop a new quantitative skin sebum detection method using standardized oil-absorbing test paper combined with image analysis and machine learning, and to verify its accuracy, stability and reliability for convenient and precise clinical and household skin sebum measurement.

Materials and Methods

A total of 500 pairs of sebum samples were collected from the forehead, T-zone and cheeks of subjects with diverse skin types and age groups. Local sebum was gathered using 2×2 cm standardized oil-absorbing test paper, while a professional sebum probe was applied to record the reference sebum content simultaneously. All test paper images were captured under unified lighting and background conditions, and image preprocessing including denoising, grayscale conversion, binarization and normalization was conducted. Representative features including color features (mean, maximum and minimum gray value), area feature (stained proportion) and texture feature (gray variance) were extracted. A random forest (RF)-neural network (NN) hybrid model was constructed: RF was used to evaluate feature importance and optimize the feature space; the optimized features were input into a feedforward neural network; and a stacking integration strategy was adopted with RF and NN as primary learners and lightweight linear regression as the secondary learner to improve prediction performance.

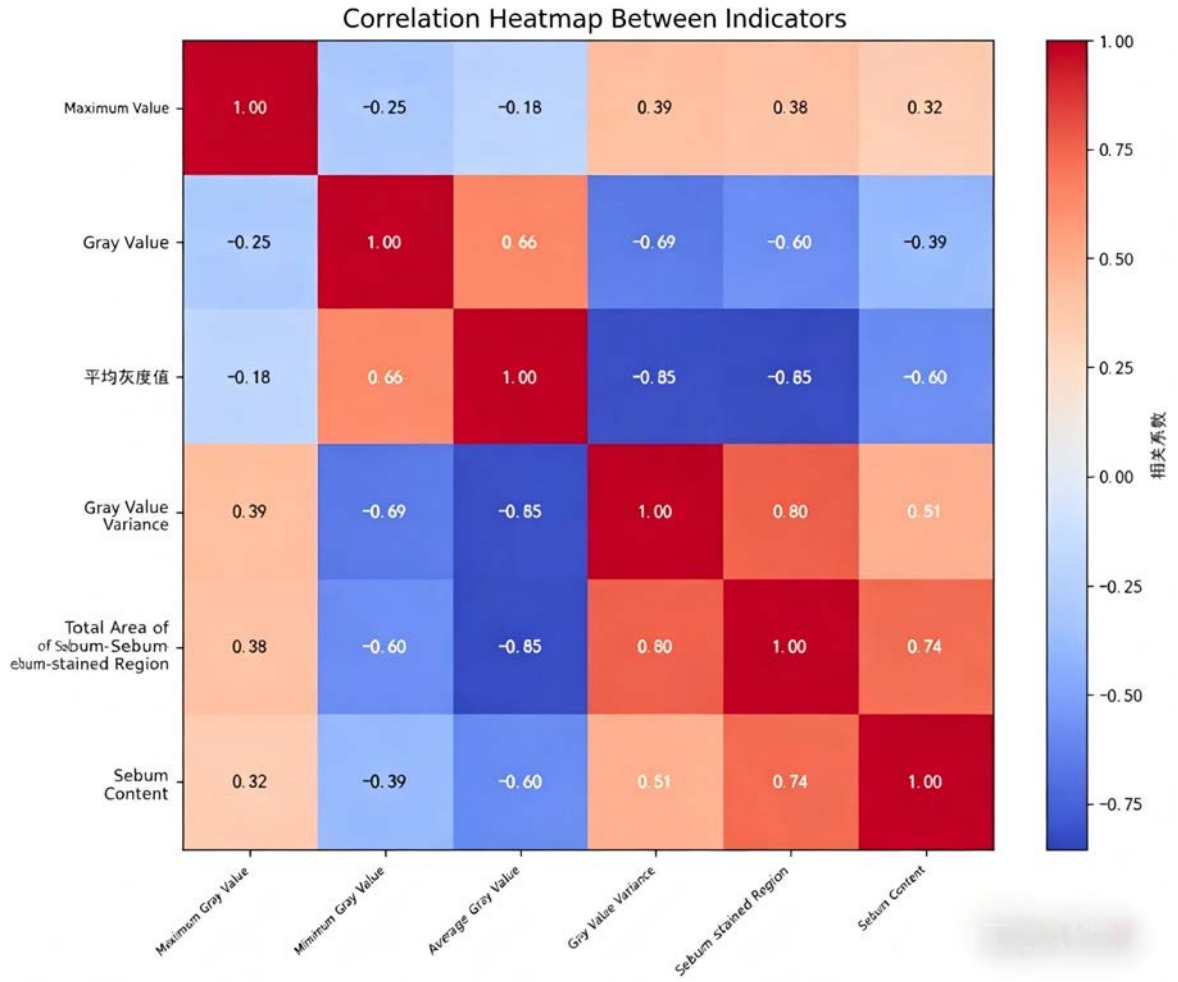

Results

Correlation analysis demonstrated that all extracted image features were significantly associated with actual sebum content (all $P<0.01$). Sebum content was significantly positively correlated with stained area ($r=0.74$) and gray-level variance ($r=0.51$), and significantly negatively correlated with mean gray value ($r=-0.60$), confirming the validity of feature selection. Random forest sorting further identified the top five critical features that contributed most to prediction accuracy, effectively reducing feature redundancy and improving model efficiency. The hybrid model showed significantly superior performance over single random forest or single neural network models, with an overall coefficient of determination (R^2) of 0.82, mean absolute error (MAE) of 21.3 and root mean square error (RMSE) of 27.5. The test-retest reliability was excellent, with intraclass correlation coefficient (ICC) > 0.90 within 24 hours of sample collection, and no significant fading or distortion of oil-absorbing test paper staining was observed. Predictive accuracy remained consistent across the forehead, T-zone and cheek regions, with regional prediction errors all controlled within 5%. The average deviation between model-predicted values and actual values measured by the professional sebum probe was within ±3%, confirming high reliability for clinical and daily testing applications.

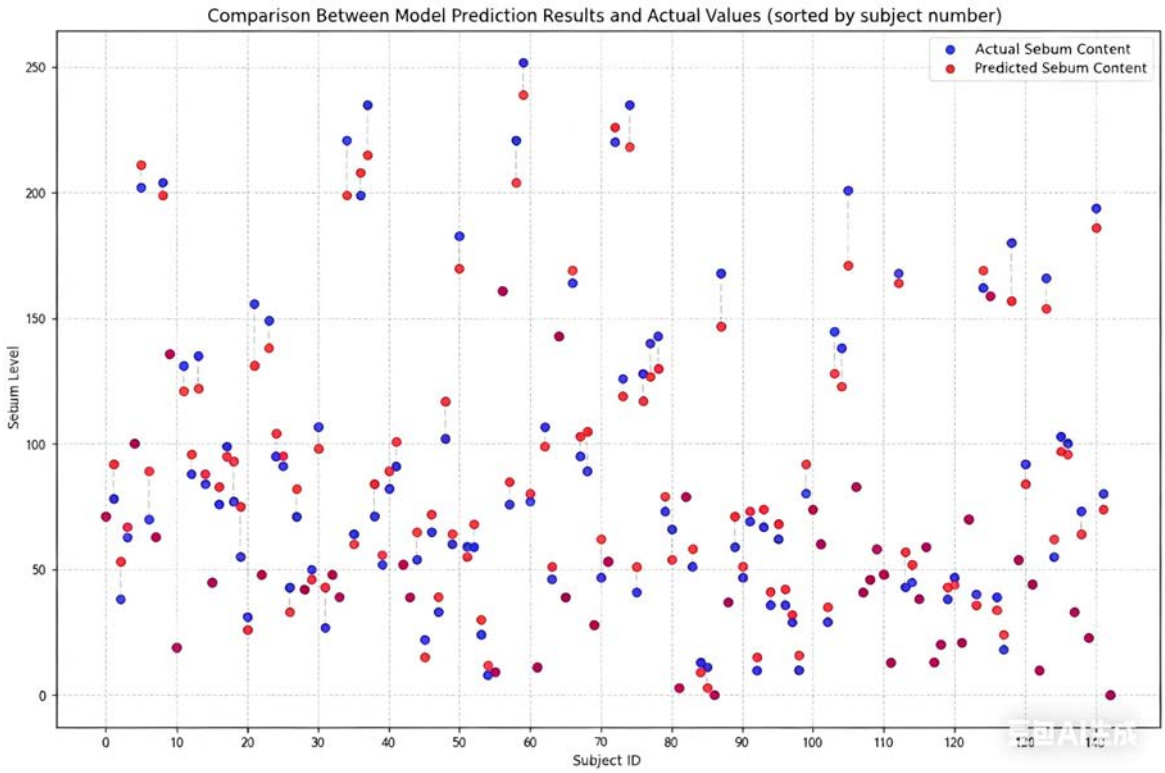

Conclusions

The newly developed skin sebum quantitative detection method achieves accurate, stable and repeatable measurement of sebum levels through standardized sebum collection, high-throughput image feature extraction and RF-NN hybrid model prediction, fully meeting clinical research and daily home testing requirements. This method is convenient to operate, low-cost and independent of large professional equipment, providing a widely applicable technical solution for large-sample population screening and dynamic monitoring of sebum secretion. Furthermore, we have initiated the construction of an Asian oily skin database based on this novel detection method, which will provide large-scale standardized data support for in-depth research on sebum-related skin physiological mechanisms and the research and development of targeted oily skin care products.

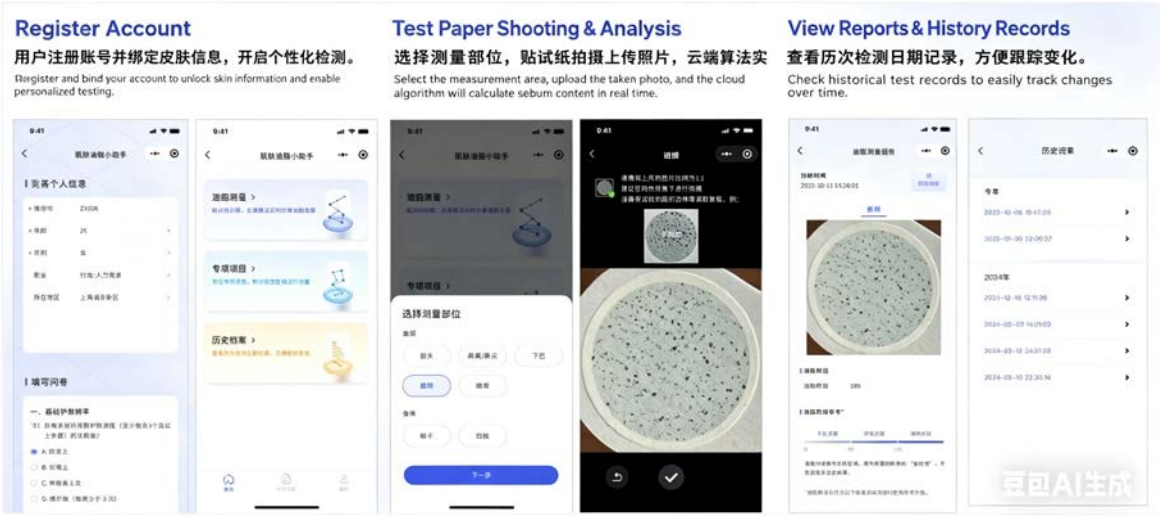

EA DV CONGRESS
VIENNA
30 SEP - 3 OCT 2026

Abstract N°: 2171

In Silico Discovery and Structural Prioritization of Peptide Candidates for Skin Anti-Aging

Gregory Brown[1], Yue Liu*[1], Xinxu Rao[1], Tingzhi Zhang[1], shaowei yan[1]

[1] ReVive Skincare LAB, New York, United States

Introduction

Growth factor-related signaling regulates epidermal renewal, dermal repair, extracellular matrix remodeling, and skin aging. However, topical use of full-length growth factors is limited by large molecular size, poor stability, inefficient skin penetration, and regulatory constraints. Short synthetic peptides are more practical, but many existing cosmetic peptides act on limited downstream pathways. This study aimed to identify conserved growth factor-associated motifs and prioritize structurally stable peptide candidates for skin anti-aging applications.

Materials and Methods

A focused library was constructed from 181 human growth factor proteins associated with skin repair and aging biology. Conserved functional regions were annotated, and short peptide motifs were extracted. Candidate motifs were prioritized by integrating molecular docking energy profiles with deep learning-based protein–peptide interaction scoring. Selected proprietary motifs were grafted onto proprietary functional peptide backbones through a chemically defined hydrophilic spacer to generate modular head–linker–tail chimeric peptides. Structures of free peptides and peptide–receptor complexes were predicted using an affinity-aware modeling framework. All-atom molecular dynamics simulations in explicit solvent evaluated conformational stability, compactness, linker flexibility, domain separation, and receptor-binding stability. Binding free energies were estimated using MM/GBSA.

Results

The computational workflow narrowed the initial motif library to lead candidates with favorable predicted activity and structural stability. Three proprietary motifs were prioritized as representative growth factor-associated kernels for chimera construction. A panel of modular chimeric peptides was generated by combining these motifs with different functional peptide backbones.

In molecular dynamics simulations of free peptides, most constructs showed stable backbone RMSD and radius-of-gyration profiles without progressive unfolding or collapse. Head–tail distance analysis showed persistent separation between the growth factor-associated motif and the functional peptide backbone, suggesting that the hydrophilic spacer preserved modular independence and reduced intramolecular steric occlusion. Residue-level fluctuation analysis indicated that the spacer acted as a flexible connector rather than a major source of instability.

Peptide–receptor complex simulations showed that selected chimeric peptides could be stably accommodated within predicted ligand-recognition regions of EGFR-, FGFR2-, and IGF1R-associated interfaces. MM/GBSA analysis identified three lead chimeric candidates with the most favorable binding profiles within their respective receptor classes. Structural inspection suggested receptor-compatible polar, electrostatic, and hydrophobic contacts, while the spacer remained largely solvent-exposed and did not interfere with the predicted binding interface.

Conclusions

This study presents an in silico platform for converting conserved growth factor-associated motifs into structurally stable modular peptide candidates for skin anti-aging applications. The integrated workflow combining motif mining, deep learning-based interaction scoring, structural modeling, molecular dynamics simulation, and binding energy analysis enabled the prioritization of three proprietary lead candidates. These findings support the feasibility of modular peptide design and provide a rational basis for subsequent experimental validation in skin-relevant cellular models.

EA DV CONGRESS
VIENNA
30 SEP - 3 OCT 2026

Abstract N°: 2217

Trends in attitudes towards and usage of digital health interventions among German dermatologists in 2019, 2021 and 2026 – Preliminary results of a repeated cross-sectional survey

Anastasia Fleyder*[1], Marina Otten[1], Ralph von Kiedrowski[2], Mark Berneburg[3], Matthias Augustin[1]

[1] University Medical Center Hamburg-Eppendorf, Hamburg, Germany

[2] Dermatology Specialty Practice, Selters, Germany

[3] University Hospital Regensburg, Regensburg, Germany

Introduction

In recent years, several legal and infrastructural reforms have been introduced in Germany to advance the adoption of digital health interventions (DHIs). Together with the COVID-19 pandemic, these changes were associated with an increased use of digital medicine in some areas. However, it remains unclear whether these developments have persisted in dermatology. The aim of this study was to analyze changes in attitudes, expectations, and usage of DHIs among German dermatologists in 2019, 2021, and 2026.

Materials and Methods

A standardized repeated cross-sectional survey was conducted among dermatologists in German practices and clinics at three time points: t1 (2019; pre-pandemic), t2 (2021; during the pandemic), and t3 (2026; post-pandemic). The last recruitment took place between January and April 2026 among all dermatologists (N=5577) who are members of the German Society of Dermatology [DDG] or the German Association of Office-Based Dermatologists [BVDD], as in the previous years. Participation was anonymous and possible either online or via fax. In addition to sociodemographic characteristics, data included items on knowledge, interest, expectations, and use of DHIs, some of which were surveyed for the first time in 2026. Preliminary analyses were limited to descriptive statistics. Further analyses, including multiple logistic regression, are ongoing.

Results

In 2019 (t1), 2021 (t2), and 2026 (t3), a total of n=585 (47.6% female; age 52.4±8.9 years old), n=792 (48.9% female; 54.3±8.6), and n=611 (55.6% female, 53.5±10.1) dermatologists participated, respectively. Compared to the previous surveys, interest in (t1: 65.1%; t2: 57.8%; t3: 79.8%), knowledge of (t1: 38.9%; t2: 34.4%; t3: 51.0%), and confidence in using (t1: 50.7%; t2: 42.1%; t3: 60.1%) digital medicine have increased. More dermatologists considered the digital transformation to be highly relevant (t1: 68.3%; t2: 62.1%; t3: 79.9%) and viewed digital medicine as a means to streamline their clinical practice (t1: 14.0%; t2: 11.0%; t3: 24.3%), while fewer perceived its risks as high (t1: 34.3%; t2: 37.5%; t3: 22.2%). Almost seven out of 10 were familiar with the German S2k-guideline for teledermatology (t1 & t2: n/a; t3: 67.4%). The average proportion by practice/clinic of patients treated via telemedical procedures has risen to 10.9±21.5% (t1: 5.4±16.0%; t2: 4.5±12.2%). Digital training and continued education (t1 & t2: n/a; t3: 78.1%) and the exchange of information via email or text message with patients (t1: 43.2%; t2: 44.0%; t3: 62.3%) as well as colleagues (t1: 46.7%; t2: 45.3%; t3: 62.3%) were among the most frequently used DHIs and increased after the pandemic. In contrast, specific digital health applications from other specialties (DiGAs, t1 & t2: n/a; t3: 4.4%) and telemedical patient monitoring (t1: 3.8%; t2: 7.0%; t3: 6.0%) were used the least. At t3, 22.5% reported using asynchronous telemedicine (t1 & t2: n/a), and 37.9% used AI for diagnostic purposes (t1: n/a; t2: 21.4%). The use of video consultations increased slightly (t1: 2.1%; t2: 7.6%; t3: 9.0%). One-third

(33.8%) of dermatologists at t3 planned to make greater use of digital medicine in the future.

Conclusions

From 2019 to 2026, a marked increase in the use of DHIs by German dermatologists has been observed, which partly started only after the COVID-19 period. This development was accompanied by greater self-reported knowledge, confidence, and more favorable attitudes towards digital medicine among dermatologists. The heterogeneous uptake across different DHIs suggests remaining barriers but also differing clinical relevance and future needs. The data support the importance of tailored, DHI-specific implementation approaches, which can be based on a rising level of evidence from effectiveness and safety studies. The high proportion of dermatologists intending to increase their use of digital medicine in the future indicates growing readiness for its broader integration into routine dermatological care.

EA DV CONGRESS
VIENNA
30 SEP - 3 OCT 2026

Abstract N°: 2264

Targeting IL-4/IL-13 Pathways in Angiolymphoid Hyperplasia With Eosinophilia: A Case Report

Benedetta Ambrosio*[1, 2], Elena Ippoliti[1, 2], Alessandro Di Stefani[1, 2], Andrea Paradisi[1, 2], Ketty Peris[1, 2], Niccolò Gori[1, 2]

[1] Dermatologia, Dipartimento Universitario di Medicina e Chirurgia Traslazionale, Università Cattolica del Sacro Cuore., Rome, Italy

[2] Dermatologia, Dipartimento di Scienze Mediche e Chirurgiche, Fondazione Policlinico Universitario A. Gemelli IRCCS., Rome, Italy

Introduction

Angiolymphoid hyperplasia with hypereosinophilia (ALHE) is a rare chronic vascular disorder characterized by solitary or multiple pink-to-brown nodules, most commonly involving the head and neck region. Lesions are usually asymptomatic but may be associated with pain, pruritus, or bleeding. The pathogenesis remains unclear; however, several factors have been implicated, including trauma, infections, atopy, and CD4+ T-cell lymphoproliferative disorders. Increasing evidence suggests a central role of type 2 inflammation, with elevated interleukin (IL)-5 levels promoting eosinophil recruitment, survival, and vascular proliferation.

Case Presentation

A 28-year-old woman with a 5-year history of ALHE was evaluated for a new 5-mm lesion on the right mandible. Previous disease manifestations included multiple erythematous nodules involving the right ear, nasal ala, and zygomatic region. Histopathologic examination of two biopsies from right ear nodular lesions confirmed ALHE, showing capillary proliferation in the superficial dermis with lymphocytic and eosinophilic infiltrates. The patient had undergone multiple treatments, including CO_2 laser therapy, topical timolol, intralesional triamcinolone, and surgical excisions. Surgical removal of larger nodules resulted in aesthetic concerns and negatively impacted quality of life. Due to the refractory course, dupilumab was initiated off-label at the approved regimen for atopic dermatitis (600 mg loading dose followed by 300 mg every 2 weeks). After 12 weeks of treatment, complete regression of the nodular lesion located on the right mandible was observed. No recurrence or development of new lesions occurred during a follow-up period of 7 months. The treatment was well tolerated, with no reported adverse events.

Conclusion

Management of ALHE is largely based on case reports and small case series. Surgery remains the most common and effective treatment; however, recurrence rates of up to 40% have been reported. Physical therapies, including pulsed dye laser, cryotherapy, and radiotherapy, have also been employed, while corticosteroids often show limited efficacy. These limitations highlight an unmet therapeutic need. The involvement of type 2 inflammation provides a rationale for targeted therapies. Th2 cytokines, including IL-4 and IL-13, promote IL-5 production, supporting eosinophil-mediated inflammation. Dupilumab, a monoclonal antibody targeting IL-4 and IL-13 signaling, may therefore offer broader immunomodulation compared with therapies selectively targeting IL-5, such

as mepolizumab or benralizumab, which have shown limited benefit.

This case highlights the potential efficacy of dupilumab in refractory ALHE, demonstrating complete clinical response and sustained remission over 7 months. Dupilumab may represent a promising therapeutic option for this challenging condition. Further studies are needed to confirm its long-term efficacy and safety.

EADV CONGRESS
VIENNA
30 SEP - 3 OCT 2026

Abstract N°: 2269

Nodular granulomatous phlebitis: a tuberculid to keep in mind

Andrea Berrueta Navascues*[1], Jone López Martínez[1], Amaia Barrutia Etxebarria[1], ITZIAR ARRUE MICHELENA[1], IZASKUN TREBOL URRA[1], LUCIA CARNERO GONZALEZ[1], Nicolás Ramírez-Escudero Ugalde[1], RICARCO GONZALEZ PEREZ[1]

[1] Hospital Universitario Araba, Vitoria-Gasteiz, Spain

Introduction

Tuberculids are type IV hypersensitivity reactions to *Mycobacterium tuberculosis* antigens in previously sensitized individuals with good cellular immunity. NGP is a type of tuberculid characterized by granulomatous inflammation selectively directed against medium-sized venous structures, with or without an associated systemic component. Clinically, it can present as painful subcutaneous nodules, frequently located on the extremities, which can lead to confusion with other forms of atypical panniculitis, vasculitis, or thrombophlebitis. Our objective is to present a clinical case of NGP, describing its clinical and histopathological findings, as well as the diagnostic and therapeutic approach, in order to highlight this uncommon entity as part of the differential diagnosis of subcutaneous inflammatory nodules.

Case Presentation

We present the case of a 15-year-old female patient, a native of Equatorial Guinea and resident in Spain for one month, who presented with painful bilateral pretibial nodular lesions, accompanied by hyporexia and mild arthralgia. A family history of tuberculosis and radiological findings suggestive of active pulmonary involvement initially raised suspicion of a systemic infectious process. Histopathological study revealed extensive fibrinoid necrosis of the wall of a medium-sized vein, with a granulomatous inflammatory infiltrate and complete structural destruction, findings characteristic of nodular granulomatous phlebitis (NGP). The condition showed a good response to antituberculostatic treatment.

Conclusion

This case highlights the importance of a multidisciplinary approach and the dermatologist's role in identifying rare infectious entities.

EA DV CONGRESS
VIENNA
30 SEP - 3 OCT 2026

Abstract N°: 2291

The tale of painful bruising: Two cases of autoerythrocyte sensitization syndrome (AES)

Meghana Phiske*[1], Riya Maheshwari[1], Smriti Venkatesh[1], Shylaja Someshwar[1]

[1] MGM Institute of Health Sciences, Navi Mumbai, India

Introduction

Autoerythrocyte sensitization syndrome (AES) is a localized purpuric reaction characterized by a sudden appearance of purpura, occurring primarily in young to middle aged women who usually manifest underlying psychological stress or emotional disturbances. There is no precise global incidence or prevalence. Most cases are reported in young to middle-aged women (20-40 years). In India around 280 cases are reported in literatures. It is a rare hematologic disorder, characterized by recurrent, spontaneous bruising without apparent trauma. It is believed to be an autoimmune reaction where the body develops hypersensitivity to its own red blood cells, leading to capillary fragility and blood extravasation. The condition is largely underdiagnosed or misdiagnosed due to its complex presentation and overlap with psychiatric conditions. It presents with spontaneous bruising which appears suddenly without trauma, often on extremities and trunk, occurring after emotional distress, anxiety, or depression. It is a diagnosis of exclusion after ruling out bleeding disorders. Investigations include complete blood count, coagulation profile and autoimmune panel. Psychiatric evaluation ie required to assess underlying psychological conditions. Skin biopsy is done to rule out vasculitis. Autoerythrocyte sensitization test which involves intradermal injection of self-RBCs which reproduces lesions is confirmatory and diagnostic of condition.

Case Presentation

Case 1: A 16 year old boy, presented with red flat lesions associated with mild pain over B/L upper extremities since 4 days which gradually increased in number. Some lesions had showed subsequent darkening followed by spontaneous resolution. There was no history of prior trauma, stress, drug intake, any infections or history of bleeding from orifices or any systemic complaints. He had not taken treatment for the same. His family history was not contributory and he had no co-morbidities. Cutaneous examination revealed multiple, well defined, dull erythematous, round to oval patches, arranged bilaterally symmetrically over B/L UL ranging from 1x2 cm to 4x2 cm. On palpation mild tenderness and non-blanching purpura noted. Hemogram, WBCs, platelet count and coagulation profile was normal. Autoerythrocyte sensitization test was positive. Histopathology from erythematous patch from left arm revealed moderate basketweave hyperkeratosis, irregular acanthosis and extravasated RBCs in entire dermis with sparse perivascular lymphocytes and occasional hemosiderin. Rorschach inkblot test done by psychologist suggested an introspective, detail-oriented individual with underlying anxiety and self-doubt.

Case 2: A 24/F, presented with red flat lesions associated with mild pain over left leg and abdomen since 2 days which gradually increased in size. There was no history of prior trauma, stress, drug intake, any infections or history of bleeding from orifices or any systemic complaints. She had not taken treatment for the same. His family history was not contributory and she had no co-morbidities. Cutaneous examination revealed multiple, well defined, dull erythematous, round to oval patches, on left leg and abdomen ranging from 1x2 cm to 3x2 cm. On palpation mild tenderness and non-blanching purpura noted. Hemogram, WBCs, platelet count and coagulation profile was normal. Histology had similar findings as case 1. Autoerythrocyte sensitization test. Psychiatric evaluation revealed presence of stress.

Conclusion

AES is not life-threatening but can be chronic and distressing with spontaneous remission but relapses are common. With proper psychological therapy and symptomatic treatment patients achieve symptom control. It requires high index of clinical suspicion and positive autoerythrocyte sensitization test for confirmation.

EA DV CONGRESS
VIENNA
30 SEP - 3 OCT 2026

Abstract N°: 2294

Cutaneous Aging Profiling Across the Menopausal Transition in Women with Skin of Colour: A Multimodal Biophysical and Imaging Study Comparing Perimenopausal and Postmenopausal Cohorts

Mukta Sachdev*[1]

[1] Medical Director, MS Clinical Research Pvt. Ltd., HOD & Consultant, Dermatology, Manipal Hospital, Bangalore, India, Bengaluru, India

Introduction

The menopausal transition represents one of the most biologically significant accelerants of cutaneous aging in women, driven by the precipitous decline in oestrogen and progesterone that governs dermal collagen synthesis, stratum corneum hydration, epidermal barrier function, and melanocyte regulation. While the dermatological consequences of menopause are increasingly recognised, the existing evidence base has been constructed almost exclusively in Caucasian populations. Women with skin of colour — spanning Fitzpatrick types III-VI — undergo the menopausal transition against a distinct biological backdrop: constitutively higher melanin density, differential collagen architecture, and heightened susceptibility to dyspigmentation, all of which may substantially modify the cutaneous aging phenotype relative to lighter phototypes.

Objectives: To characterise and compare the cutaneous aging profile of women with skin of colour in the perimenopausal (35-45 years) and postmenopausal (45-55 years) age groups using multimodal biophysical instrumentation, standardised imaging, and subject-reported history, with the aim of establishing biophysical correlates of hormonally driven skin aging in Fitzpatrick III-VI phototypes.

Materials and Methods

This is a prospective, observational, cross-sectional profiling study enrolling 40 women with skin of colour (Fitzpatrick III-VI) across two age-defined cohorts: Group 1 (perimenopausal, aged 35-45 years, n=20) and Group 2 (postmenopausal, aged 45-55 years, n=20). Comprehensive skin characterisation is performed using a multimodal assessment battery including: skin hydration via Corneometer (stratum corneum capacitance, AU); transepidermal water loss via Tewameter (TEWL, g/m^2/h) as a marker of epidermal barrier integrity; skin surface spectral analysis via PSpectra for pigmentation profiling and melanin quantification; standardised multimodal facial imaging via VISIA-CR (cross-polarised and parallel-polarised photography for pigmentation, texture, pores, wrinkles, and UV damage) and Antera 3D (three-dimensional topographic mapping of melanin distribution, haemoglobin, texture, and collagen-related surface parameters). A structured subject history questionnaire captures menopausal symptom burden, hormonal therapy status, skincare practices, sun exposure habits, dietary patterns, and self-perceived skin changes. Primary comparisons are made between cohorts across all biophysical and imaging parameters to delineate the incremental cutaneous aging burden associated with progression through the menopausal transition. The study is currently ongoing.

Results

Enrolment and assessments are currently in progress. Early observations suggest measurable inter-cohort differences in barrier function parameters and pigmentary imaging indices, with the postmenopausal group demonstrating trends toward reduced stratum corneum hydration and greater surface pigmentation

heterogeneity relative to the perimenopausal cohort.

Conclusions

This study addresses a clinically important and systematically underexplored intersection of menopausal dermatology and skin of colour. By applying a comprehensive multimodal biophysical and imaging framework to two hormonally distinct female cohorts, the study is positioned to generate normative profiling data that characterises how the menopausal transition modifies cutaneous aging trajectories in Fitzpatrick III-VI phototypes. The integration of objective biophysical measures with structured patient-reported history enables correlation of hormonal and lifestyle factors with measurable skin changes, yielding clinically actionable insights for the dermatological management of menopausal skin in women of colour. These findings are expected to inform evidence-based skincare recommendations and therapeutic decision-making in a population whose dermatological needs remain substantially underserved in the current literature.

EADV CONGRESS
VIENNA
30 SEP - 3 OCT 2026

Abstract N°: 2346

Impact of Veil (niqab) Use on Quality of Life in Female Patients with Facial Dermatoses: A Cross-Sectional Study

Abhishek De*[1], Amrita Datta[1], SK Shahriar Ahmed[1], Apeksha Singh[1]

[1] Dermatology, Calcutta National Medical College, Dermatology, Wizderm Hair and Skin Specialty Clinic, Kolkata, India

Introduction
Facial dermatoses exert a disproportionate psychosocial burden because of their visibility and potential impact on self-image, interpersonal interaction, and social confidence. In many cultural contexts, veil use may modify the lived experience of facial skin disease by reducing visibility, but it may also contribute to discomfort, irritation, or altered disease perception. This study evaluated the association between veil use and dermatology-specific quality of life among female patients with common facial dermatoses.

Materials and Methods
This cross-sectional study included 100 female dermatology patients aged 18–44 years with clinically diagnosed facial dermatoses. Fifty patients were veil users and 50 were non-users. Quality of life was assessed using the Dermatology Life Quality Index (DLQI). Mean DLQI scores were compared according to veil use, underlying dermatosis, DLQI severity categories, self-perceived disease visibility, education, occupational variables, veil-related discomfort, perceived emotional protection, and perceived improvement with veil use. Correlation analyses were performed for age and duration of veil use.

Results
The mean age of the cohort was 28.3 years, and the overall mean DLQI was 14.3 ± 4.4, indicating a substantial quality-of-life impairment. Acne was the most frequent facial dermatosis, affecting 71% of patients, followed by melasma in 23% and rosacea in 6%. Rosacea was associated with the highest quality-of-life burden, with a mean DLQI of 20.5, followed by acne and melasma. Between-disease comparison showed a significant difference in DLQI across dermatoses; post-hoc analysis demonstrated significantly higher DLQI in rosacea compared with acne and melasma, while acne showed a marginally higher burden than melasma.

Veil use was associated with a lower mean DLQI compared with non-use. Non-veil users had a mean DLQI of 15.36, whereas veil users had a mean DLQI of 13.20, suggesting a statistically significant reduction in quality-of-life impairment among veil users. Disease-specific subgroup analysis showed that this beneficial association was most evident in acne, where veil users had lower DLQI scores than non-users. In contrast, the difference between veil users and non-users was not significant among patients with melasma or rosacea.

Analysis of DLQI severity categories showed that most patients in both groups experienced a “very large” effect on life; however, extremely large impairment was more frequent among non-veil users. Self-perceived visibility of the facial dermatosis demonstrated a significant positive association with DLQI: patients reporting minimally visible lesions had the lowest DLQI, whereas those perceiving their lesions as highly visible had the highest DLQI. By contrast, age, duration of veil use, educational status, occupation, comments from others, perceived improvement with veil use, emotional protection, and veil-related irritation or discomfort were not significantly associated with DLQI.

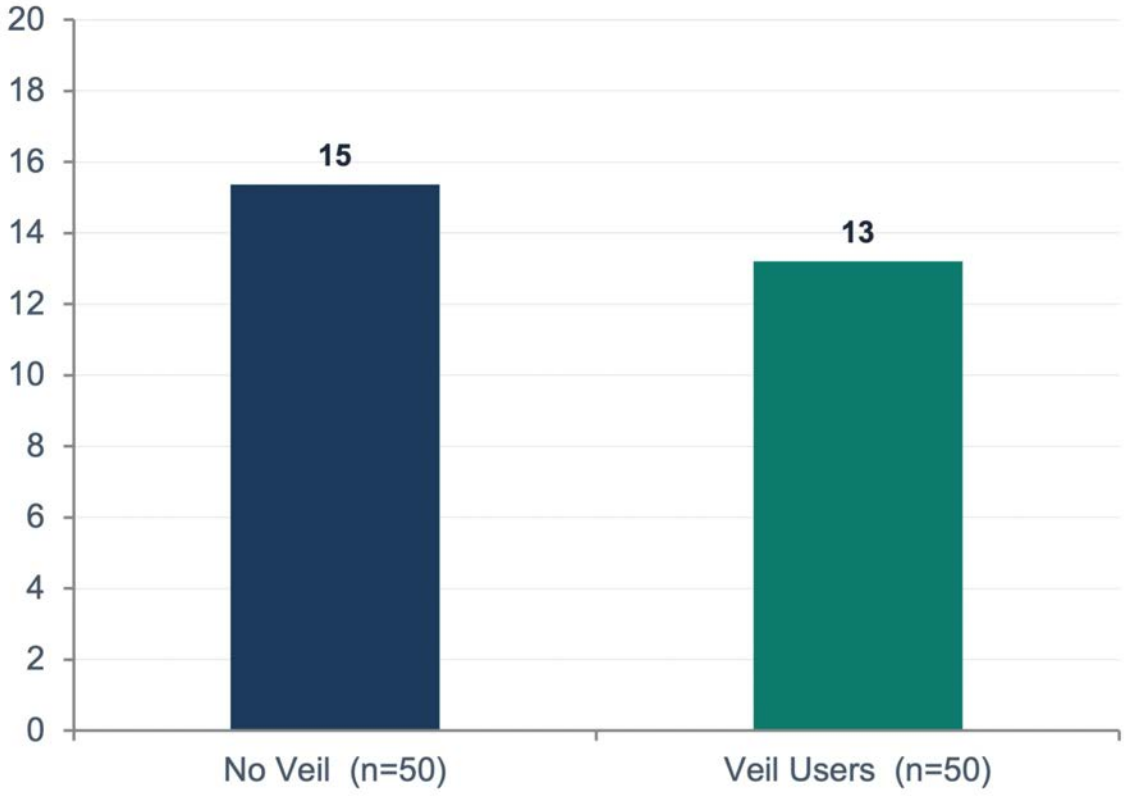

Conclusions

Female patients with facial dermatoses experience marked quality-of-life impairment, particularly those with rosacea and those who perceive their lesions as highly visible. Veil use was associated with a modest but significant reduction in DLQI, especially among patients with acne, suggesting a potential psychosocial protective effect mediated by reduced visibility. However, this effect was not uniform across dermatoses, emphasizing the need to interpret veil use within the broader context of disease type, visibility perception, and patient-reported psychosocial burden.

EADV CONGRESS
VIENNA
30 SEP - 3 OCT 2026

Abstract N°: 2366

Mirror-Image Dermatosis: When the Skin Spoke While the Larynx Remained Silent — Disseminated Extranodal Rosai-Dorfman Disease with Cutaneous and Laryngeal Involvement.

Kevin Ramón García Fong*[1], Nataly Berrezueta Córdova[1], Miren Cárdenas Hernández[1], Sonia Toussaint Caire[1], María Elisa Vega Memije[1]

[1] Hospital General Dr. Manuel Gea González, Ciudad de México, Mexico

Introduction

Rosai-Dorfman disease belongs to group R of the revised classification of histiocytoses and neoplasms of the macrophage-dendritic cell lineage. Although classically described as a nodal disease, it may present with extranodal involvement, including the skin.

The cutaneous form can be particularly challenging because its clinical expression is polymorphic. Nodules, plaques, papules, masses, and, less frequently, macules have been described. This variability requires consideration of multiple differential diagnoses. Laryngeal involvement is uncommon but clinically significant because it can compromise the airway. In this context, diagnosis can be especially difficult, as laryngeal biopsies may be nonspecific. The present case illustrates this diagnostic challenge and highlights the importance of considering the skin as a diagnostic window into systemic disease.

Case Presentation

A 50-year-old male presented with a disseminated dermatosis involving the lower limbs and trunk, including the legs, thighs, abdomen, chest, and back. Lesions were hyperpigmented, dark brown, oval plaques, some polycyclic and confluent, with a well-defined, regular, active border. Some lesions had a lighter, atrophic-appearing center, while others were sclerodermiform on palpation. The patient reported an eight-year history of the dermatosis, with constant pain that worsened with palpation.

Concurrently, a few months earlier in 2018, he developed dyspnea and dysphonia. A laryngeal biopsy reported nonspecific chronic inflammation. Over the following years, he received multiple courses of systemic corticosteroids. The disease followed a chronic, progressive course, with persistent respiratory manifestations and caudocephalic progression of the cutaneous lesions.

During the course of the disease, eleven skin biopsies from different anatomical sites were performed and reported as inconclusive. The histopathological diagnosis was established only from a skin biopsy of the abdomen, which showed a superficial and deep inflammatory infiltrate composed of histiocytes, plasma cells, and lymphocytes, with areas of fibrosis. In some areas, histiocytes with abundant cytoplasm and changes compatible with emperipolesis were identified. Immunohistochemistry showed positivity for S-100 and CD163, and negativity for langerin (Figure 1). Clinical, histopathological, and radiological correlation established the diagnosis of disseminated extranodal Rosai-Dorfman disease with cutaneous and laryngeal involvement.

Treatment was initiated with prednisone at 1 mg/kg, topical betamethasone, and methotrexate 15 mg weekly, resulting in significant improvement in pain and the patient’s quality of life.

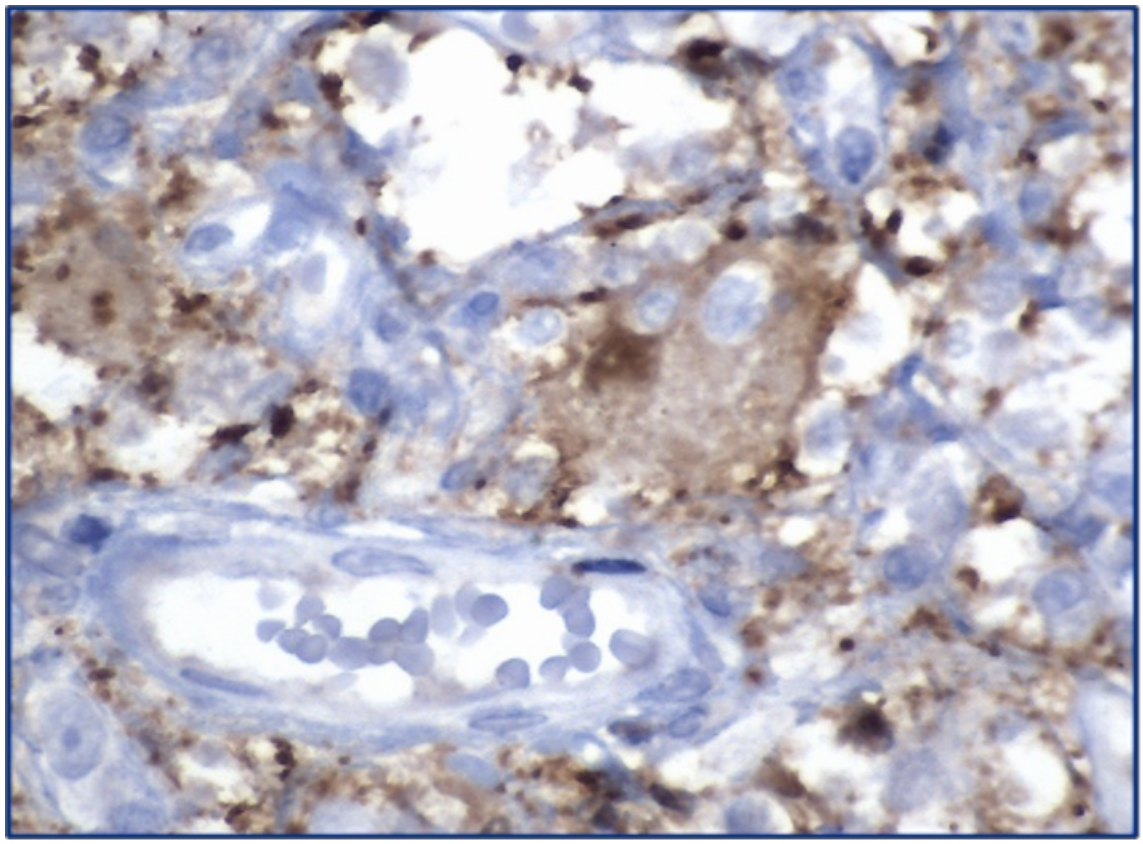

Histopathological examination of the skin shows numerous histiocytes, with emperipolesis in one, and positive S-100 immunostaining, 60×.

Conclusion

Rosai-Dorfman disease is a rare entity that is difficult to diagnose. According to the literature, up to eight biopsies may be required, with diagnostic delays of up to 8.5 years before the diagnosis is established. Involvement of other organs can increase morbidity and be life-threatening, as illustrated by laryngeal involvement in the present case. Clinical, histopathological, and radiological (Figure 2) correlation established the diagnosis. To our knowledge, there are no reports of disseminated Rosai-Dorfman disease coexisting with both clinical cutaneous and laryngeal involvement, making this an exceptional case.

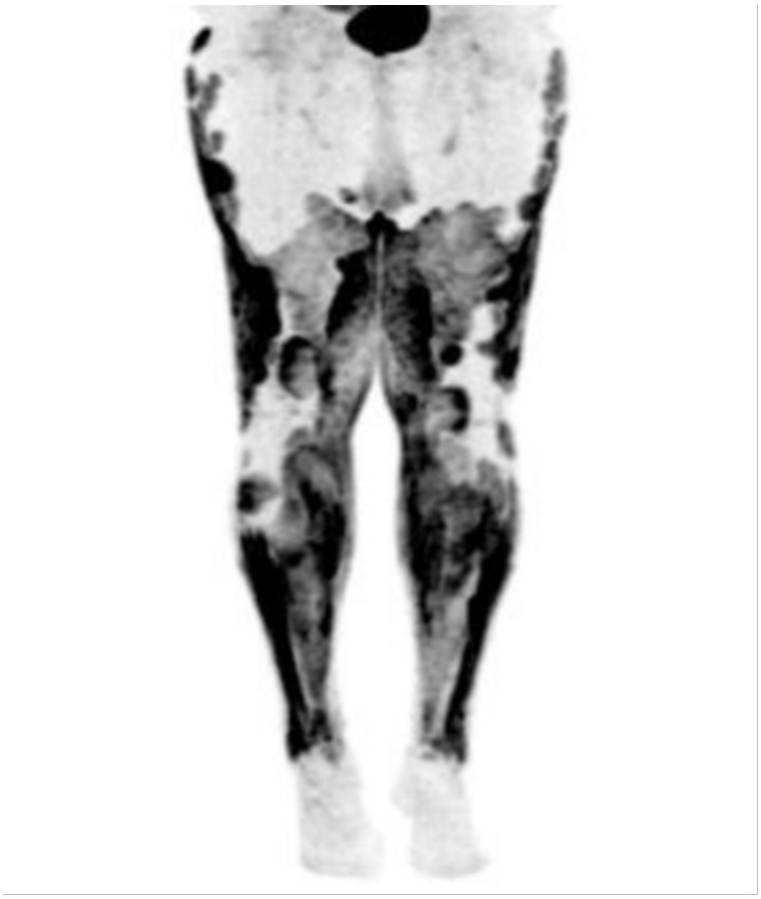

Whole-body 18F-FDG PET/CT showed cutaneous thickening and increased metabolic activity, with a maximum SUV of 9.9, findings that supported neoplastic activity in the clinically affected areas.

EA DV CONGRESS
VIENNA
30 SEP - 3 OCT 2026

Abstract N°: 2376

Sun Exposure, Protective Behavior and the Knowledge–Behavior Gap in Skin Cancer Prevention

Marina Wanner*[1], Felicitas Schnell[1], Maximilian Lammer[1], Magdalena Seidl-Philipp[1], Van Anh Nguyen[1, 1]

[1] Department of Dermatology, Venereology, and Allergology, Medical University of Innsbruck, Innsbruck, Austria

Introduction
Despite widespread awareness of UV-related risks, sun-protective behavior often remains inconsistent with preventive recommendations. While knowledge and protective attitudes are generally high, their translation into effective behavior is limited. This study examined the gap between knowledge, attitudes, and real-life sun-protective behavior, and identified factors associated with UV exposure.

Materials and Methods
A cross-sectional online survey was conducted between October 2024 and July 2025 (n = 497). Participants were recruited via online convenience sample from the general population in Tyrol, Austria. The questionnaire assessed sun exposure habits, sunscreen use and application behavior, protective measures, history of sunburns (including blistering), attitudes toward tanning and prevention, willingness to change behavior following medical advice, and preferences for educational interventions. Associations were analyzed using Spearman's rank correlation, chi-square tests, and multivariable logistic regression. A p-value < 0.05 was considered statistically significant.

Results
The mean age was 35.1 years (SD ± 11.6; range 18–80). The study population was predominantly female (78.9%), with 73.3% classified as Fitzpatrick skin type I–II and 52.9% holding a university degree. Awareness of UV-related risks was high, with 90.9% of participants considering sun protection important. Self-reported sunscreen use was also high (95.0%), with 69.6% reporting SPF 50 use. Most participants reported applying what they perceived to be a sufficient amount of sunscreen; however, reapplication was inconsistent. A high proportion reported multiple lifetime sunburns: 78.0% reported ≥4 lifetime sunburns, and 20.9% reported blistering sunburns. Sunscreen use, reapplication frequency, and the overall sun protection index were not associated with fewer reported sunburns. In contrast, the perceived importance of tanning was strongly associated with more frequent sunbathing (Spearman's $\rho = 0.578$; $p < 0.001$) and inversely associated with the importance of sun protection. Blistering sunburns were more common among individuals with lighter skin types and among those with a higher number of previous sunburns. Although 70.6% of participants reported willingness to reduce sun exposure following medical advice and 61.3% expressed interest in educational programs, this did not translate into fewer reported sunburns or more consistent protective behavior. Public health campaigns were perceived as influential by 39.4% of participants, whereas physician advice and online resources were considered more impactful.

Conclusions
A clear gap between knowledge and behavior was observed. Although most participants were aware of UV-related risks and reported engaging in sun-protective measures, this was not associated with fewer reported

sunburns. These findings likely reflect a behavioral implementation gap rather than a lack of awareness and may also be influenced by inconsistent application, high UV exposure, or recall bias. Sun-related behavior appears strongly influenced by attitudes toward tanning. Future prevention strategies should therefore move beyond information-based approaches and focus on behavioral implementation, motivation, and risk perception. Physician counseling and accessible digital interventions may represent particularly relevant strategies. Addressing attitudes toward tanning may be a key component in improving sun protection behavior.

EA DV CONGRESS
VIENNA
30 SEP - 3 OCT 2026

Abstract N°: 2381

Teledermatology service evaluation compared to standard face-to-face review for lesion referrals.

Jessica Maguire*[1], Charlotte Wolfe[1], Niamh Byrne[1, 2], Charlotte Wong[1], Andre Khoo[1]

[1] Addenbrooke's Hospital, Cambridge University Hospitals, Cambridge, United Kingdom
[2] Blackrock Health, Dublin, Ireland

Introduction

Teledermatology is the use of digital images to allow remote diagnostics of skin lesions. When applied correctly, it has high diagnostic accuracy and has been mandated by the UK government as a means to manage the increasingly high skin cancer burden in the population. Our Dermatology department in a large UK teaching hospital runs a store-and-forward teledermatology service with specialist medical photographers. Our service was originally piloted in 2020 and has expanded over time and how handles 50% of incoming skin cancer referrals to the Department.

In this study, we compared the outcomes of teledermatology versus face-to-face review in our department. We then compared this to the results of our previous evaluation of 2023 to see how the maturity of our service has affected these outcomes.

Materials and Methods

We performed a retrospective review of 200 adult patients referred by GPs for skin lesions on the cancer (CP) and urgent/routine pathways in February 2025. The patients were divided equally into those reviewed in a face-to-face clinic appointment or remotely via teledermatology. All patients were reviewed by one of 4 clinicians with equal numbers in the teledermatology/face-to-face groups per clinician.

The primary outcome measures were time from referral to first clinical appointment and surgical intervention rates.

Results

In both cohorts, the majority were CP referrals (97% in teledermatology and 78% in face-to- face cohort).The median time from referral via CP to teledermatology assessment vs face-to-face review in 2025 was 22 days and 7 days respectively. In 2023, median time from referral via CP to teledermatology assessment vs face-to-face review was 16.5 days and 14 days respectively. Median waiting times from decision to treat to surgery on CP were 28.5 days in the teledermatology cohort and 30.5 days in the face-to-face cohort, versus 21 days and 20 days in the 2023 teledermatology and face to face cohorts respectively. The surgical rate was higher in the teledermatology cohort compared with the face-to-face cohort (53% vs 40%); however, this difference did not reach statistical significance (χ^2 (1) = 3.40, p = 0.065). Rates of surgery in CP referrals were higher in both groups compared to figures from 2023 (56% in 2025 vs 34% in 2023 of teledermatology cases, and 42% in 2025 vs 27% in 2023 of face-to-face cases).

The time from referral to treatment for patients reviewed by teledermatology and face-to-face were comparable as were the rates of surgical intervention. Overall waiting times and rates of surgery are increasing when compared to 2023 figures. This may reflect increasing numbers of referrals to skin cancer assessment services over

time. Data from 2025 reflects the practice of multiple clinicians, which may also contribute to the higher rates of surgery that is observed in this cohort. Higher rates of surgery in those patients assessed via teledermatology may also reflect the limitations of the service in terms of access to alternative therapies such as cryotherapy.

Four consultant Dermatologists reviewed patients in both cohorts in 2025. It has been shown that diagnostic accuracy of teledermatology is comparable to face-to-face assessment (https://pmc.ncbi.nlm.nih.gov/articles/PMC12989395/).

We therefore analysed whether an individual clinician's decision-making regarding surgery was influenced by the modality of review (table 1).

Clinician	Number of cases proceeding to surgery in TD cohort	Number of cases proceeding to surgery in F2F cohort	P value using Fisher's exact test
A	24/49 (49%)	31/49 (63%)	P = 0.15
B	12/17 (71%)	10/17 (59%)	P = 0.47
C	14/27 (52%)	14/27 (52%)	P = 1
D	3/7 (43%)	3/7 (43%)	P = 1

Table 1: Numbers of cases proceeding to surgery in teledermatology (TD) and face-to-face (F2F) cohorts and corresponding P values.

Conclusions

Our review suggests that teledermatology continues to provide a viable, safe, effective and time efficient method for managing lesion referrals particularly as the pressure on services continues to increase. It is comparative to face-to-face assessment and has the added benefits of reducing footfall and saving costs for both patients and clinicians.

EADV CONGRESS
VIENNA
30 SEP - 3 OCT 2026

Abstract N°: 2454

Vulvar linphangiectasias mimicking genital warts.

Carolina Garrido Gutiérrez*[1], Alberto Saez Vicente[1], Vicente Leis Dosil[1], Marta Folcrá González[1], Isabel Mateos Candelario[1]

[1] Infanta Sofía Hospital, San Sebastián de los Reyes, Spain

Introduction

Cutaneous lymphangiectasias are dilatations of superficial lymphatic vessels that present as small translucent vesicles appearing in areas of chronic lymphedema. They should be differentiated from lymphatic malformations because of their later onset, and from other proliferative lymphatic lesions due to their benign and generally asymptomatic course. Most cases described in the literature involve lesions developing on the upper extremities after lymphadenectomy and radiotherapy for breast cancer. We present a case of vulvar lymphangiectasias because of their rarity and their clinical resemblance to genital warts.

Case Presentation

A 69-year-old woman was referred from Gynecology for evaluation of lesions clinically suggestive of genital warts with a 6-month history. Her medical history was notable for infiltrating squamous cell carcinoma of the cervix diagnosed in 2015, treated with hysterectomy, bilateral pelvic lymphadenectomy, chemotherapy, and radiotherapy. Since then, she had developed chronic lymphedema of the lower limbs and recurrent cellulitis. Physical examination revealed multiple elevated lesions, some pedunculated, scattered over the labia majora and suprapubic area. The smooth, translucent surface of the lesions together with the presence of chronic lymphedema led us to consider the diagnosis of cutaneous lymphangiectasias. The four largest lesions were excised, and histopathological examination showed dilated lymphatic vessels in all specimens. The benign and noninfectious nature of these lesions was explained to the patient, and treatment of symptomatic lesions with surgery or CO_2 laser was offered.

Conclusion

Cutaneous lymphangiectasias are uncommon, benign, acquired lesions that arise in areas of chronic lymphedema. In the vulvar region, their appearance has been associated with prior radiotherapy, neoplastic disease, inflammatory conditions such as Crohn's disease, infectious diseases such as tuberculosis, and female genital mutilation. They consist of vesicular lesions with a smooth, translucent surface, classically described as having a "frog spawn" appearance. The term *lymphangioma circumscriptum* has previously been used; however, since histology demonstrates only dilated lymphatic vessels without a proliferative component, we believe the term *lymphangiectasia* is more appropriate. In the vulvar area, it is especially important to distinguish these lesions from genital warts/condylomas. Despite their indolent course, destructive treatments (laser, cryotherapy, etc.) or injection of sclerosing agents may be offered.

EADV CONGRESS
VIENNA
30 SEP - 3 OCT 2026

Abstract N°: 2534

Drug-induced elastosis perforans serpiginosa

Elitsa Zafirova*[1], Dimitrina Guleva[1], Vessel Kantardjiev[1], Valentina Broshtilova-Nikolova[1]

[1] Military Medical Academy, Sofia, Bulgaria

Introduction

Elastosis perforans serpiginosa is a rare disorder which is characterized by transepidermal elimination of abnormal elastic tissue fibers. It can be idiopathic, reactive (associated with inherited disorders) or drug-induced. We present a case report of a patient with Wilson disease, who was treated with D-penicillamine and developed elastosis perforans serpiginosa a few years later.

Case Presentation

A 35-year-old female patient presented to Dermatology Clinic with a 1-year history of non-itchy reddish bumps on her upper limbs, which gradually increased in size. The patient was diagnosed with Wilson disease during puberty and was treated since then with D-penicillamine daily. On examination, the patient showed multiple firm and crusted erythematous papules symmetrically distributed on the upper extremities, next to the armpits, as well as on the neck. Some of the papules were arranged in annular plaques with central clearing and a thick erythematous border. Biopsy of one of the lesions on the arm was performed and the histological examination showed significant transepidermal elimination of elastic tissue from the dermis. Based on the medical history of the patient, the clinical findings and the histological report, a diagnosis of elastosis perforans serpiginosa was established. Treatment with topical 0,05% tretinoin was initiated for 6 months, which led to minimal improvement.

Conclusion

Elastosis perforans serpiginosa affects around 1% of people treated with D-penicillamine. The condition is usually recalcitrant to different treatment modalities, but can sometimes be self-limited. Recognition of the clinical features is crucial so that therapy for the main disease can be safely continued.

EADV CONGRESS
VIENNA
30 SEP - 3 OCT 2026

Abstract N°: 2647

A multi-hyaluronic acid approach targeting different skin layers enhances hyaluronic acid content and delivers rapid anti-wrinkle efficacy

Florence Cassin*[1], Daphné Gautier[1], Elise Derksen[1], Sophie Zozine[1], Stephanie Bredif[1], Virginie Fera[1]

[1] Groupe Rocher, Issy-les-Moulineaux, France

Introduction

Skin aging is characterized by a progressive decline in hyaluronic acid (HA), a key molecule involved in maintaining skin hydration, viscoelasticity, and structural integrity. This depletion contributes to wrinkle formation, including deep wrinkles, through reduced water retention and loss of dermal support. Given the heterogeneous architecture of the skin, targeting multiple layers with complementary forms of HA represents a promising strategy to restore HA levels and improve clinical outcomes. A biomimetic formulation combining four distinct hyaluronic acids—high molecular weight HA for surface hydration, silicon-coupled HA to support epidermal function, sustained-release encapsulated HA for prolonged activity, and low molecular weight HA to stimulate dermal HA synthesis—may act together to enhance overall HA content in the skin. The aim of this study is to evaluate the effects of this multi-hyaluronic acid formulation on skin HA expression *in vitro* and its clinical efficacy on wrinkle appearance, including deep wrinkles.

Materials and Methods

In vitro, human skin explants were treated topically (2 mg/cm^2), followed by immunostaining and image analysis to quantify HA expression in the epidermis and dermis at Day 2 and Day 6.

Clinical efficacy was assessed using a multi-method approach. Anti-wrinkle effects were evaluated by 3D fringe projection on multiple facial areas (forehead, glabella, crows feet, nasolabial folds; n=27; mean age: 62 years, range 46-74) and self-assessment (n=110, mean age : 55 years, range 45-74), after immediate, 7-day and 28-day twice-daily application. Secondary endpoints including VISIA texture index analysis (n=26; mean age: 62 years, range 46-74) and corneometry (n=13; mean age: 49 years, range 28-73) were evaluated.

Results

In vitro, the four-hyaluronic-acid complex significantly increased HA expression in both epidermis and dermis. Epidermal HA levels increased by up to +106%** at Day 2 and +50%** at Day 6, while dermal HA increased by up to +30%** at Day 2.

Clinically, the formulation delivered rapid and sustained anti-wrinkle efficacy. A significant global reduction in wrinkle depth (-9%*) was observed as early as Day 7, including deep wrinkles (>200µm, subgroup n=24), across multiple facial areas (forehead, glabella, nasolabial). Improvements reached up to −19%* on glabella (subgroup n=24). At Day 28, further significant reductions were observed in wrinkle depth (-12%*), volume (-10%*), and roughness (-13%*), consistent with self-assessment results, with 74% of women reporting smoother wrinkles.

Additionally, skin texture improved significantly after 7 days (−7%*), and immediate hydration increased by up to +71%*. These instrumental findings were consistent with self-assessment results, with 82% and 85% of participants reporting a more refined skin texture after 7 and 28 days, respectively, 89% reporting smoother skin at Day 28, and 96% reporting immediate skin hydration.

The product was very well tolerated, as judged by a dermatologist.

*p<0.05; **p<0.01

Conclusions

The combination of the four complementary hyaluronic acids enables multi-level action within the skin: high molecular weight HA provides immediate surface hydration and smoothing; silicon-coupled HA enhances epidermal HA synthesis and repair; sustained-release HA ensures prolonged availability within the skin; and low molecular weight HA penetrates deeper to stimulate dermal HA production. This multi-target approach leads to an overall increase in skin HA content, as demonstrated in vitro, translating into rapid and clinically significant improvements in wrinkle appearance, including deep wrinkles (>200µm), as early as 7 days.

EA DV CONGRESS
VIENNA
30 SEP - 3 OCT 2026

Abstract N°: 2649

A Scalable Integrated Cell Atlas of Healthy Human Skin with Focus on the Pilosebaceous Unit

Tolga Düz*[1, 2], Daniel Torocsik[3], Sonia momnougui[1], Mhaned Oubounyt[2], Benjamin Al[1], Stefan Gallinat[1], Jan Baumbach[2, 4], Nicholas Holzscheck[1]

[1] R&D Discovery, Beiersdorf AG, Hamburg, Germany

[2] Institute for Computational Systems Biology, University of Hamburg, Hamburg, Germany

[3] University of Debrecen, HUN-REN-UD Allergology Research Group, Debrecen, Hungary

[4] Computational BioMedicine Lab, Institute of Mathematics and Computer Science, University of Southern Denmark, Odense, Denmark

Introduction

Recent advances in single-cell and spatial transcriptomics enable high-resolution mapping of cellular heterogeneity and tissue organization, supporting the generation of reference atlases for studying homeostasis and disease. However, a comprehensive integrated atlas of healthy human skin remains lacking.

The skin is a highly complex organ comprising multiple compartments. Within this architecture, the pilosebaceous unit (PSU) plays a central role in hair biology, regeneration, and diseases such as acne and alopecia, yet remains insufficiently characterized due to spatial heterogeneity, uneven anatomical distribution, inter-individual variability, and technical challenges in capturing keratinized follicular cells and lipid-rich sebocytes. Existing single-cell studies are often limited in scope and lack systematic integration, resulting in fragmented datasets and insufficient benchmarking of integration performance.

To address this, we developed a scalable, integrative Human Skin Cell Atlas (HSCA) combining large-scale single-cell RNA sequencing with high-resolution spatial transcriptomics, with a focus on resolving the PSU and establishing an extensible reference framework.

Materials and Methods

We constructed the HSCA by integrating publicly available single-cell RNA sequencing datasets (Fig. 1), which were collected, curated, harmonized, and stratified into PSU-containing and PSU-free samples. PSU-containing datasets underwent standardized preprocessing and integration benchmarking, generating the HSCA core with harmonized hierarchical cell type annotation. The HSCA was designed as a modular, extensible framework enabling transfer learning-based mapping and iterative expansion. Accordingly, 21 additional PSU-free datasets were incorporated, resulting in the HSCA extended (160 donors, 177 samples, 110 cell types, >800,000 cells).

High-resolution spatial transcriptomics (Visium HD) was used to map cell states to tissue architecture and refine gene signatures. Downstream analyses included identification of rare and novel cell populations, functional enrichment, and cell–cell communication inference.

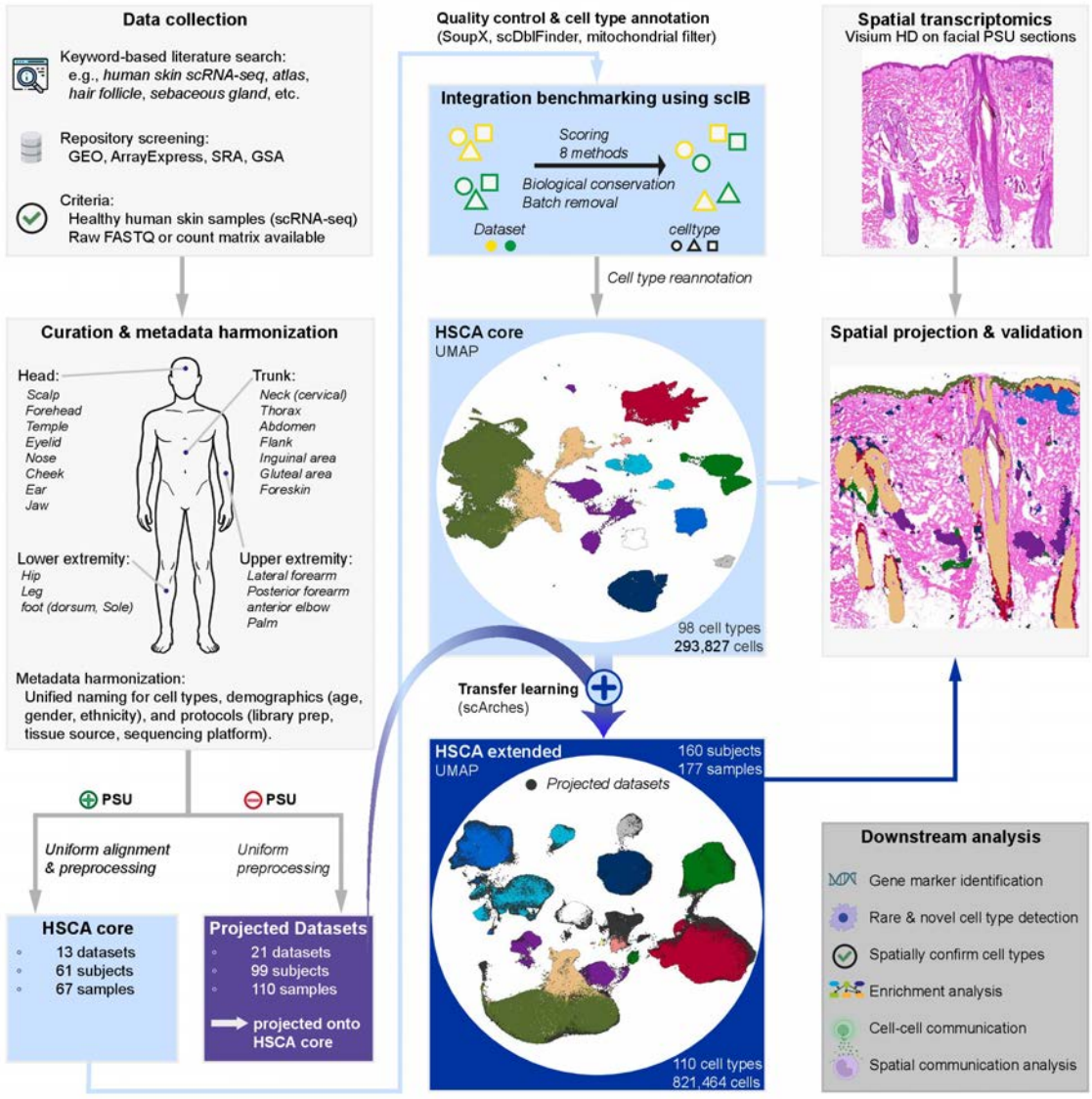

Fig. 1: Study design integrating scRNA-seq and spatial transcriptomics for HSCA generation. Healthy human skin scRNA-seq datasets were collected and curated. Datasets were divided into PSU-containing and PSU-free samples. PSU-containing datasets underwent standardized reanalysis and processing, and integration performance was benchmarked. The most suitable tool was used to integrate these datasets into the HSCA core, followed by cell type annotation. Through transfer learning, 21 additional PSU-free datasets were incorporated, resulting in the HSCA extended (160 subjects, 177 samples, 110 cell types, >800,000 cells). Gene marker signatures were validated and refined using Visium HD spatial transcriptomics. Downstream analyses included the identification of novel and rare cell types, functional enrichment, and cell-cell communication analysis.

Results

The integrated HSCA resolves 110 distinct cell types across all major skin compartments and improves detection of rare and transitional populations compared to individual datasets.

Within the PSU, we refined cellular subtypes, including distinct stages of sebocyte differentiation and underrepresented follicular populations. The atlas identified Merkel cells with a high-resolution transcriptional signature and defined their localization within the hair follicle niche. Integration with spatial transcriptomics mapped cell states to tissue architecture (Fig. 2), revealing PSU organization and enabling assignment of signaling pathways to anatomical regions. While scRNA-seq resolved rare and transitional states, spatial data provided anatomical context but remained limited by tissue sectioning and variable capture efficiency.

The HSCA further revealed protocol-dependent biases in cell type recovery, including improved sebocyte

detection under specific freezing conditions and recovery of stratum corneum keratinocytes using alternative protocols.

Transfer learning enables projection of new datasets onto the atlas, supporting identification of known and novel cell types and quantification of mapping uncertainty, particularly for disease-associated alterations.

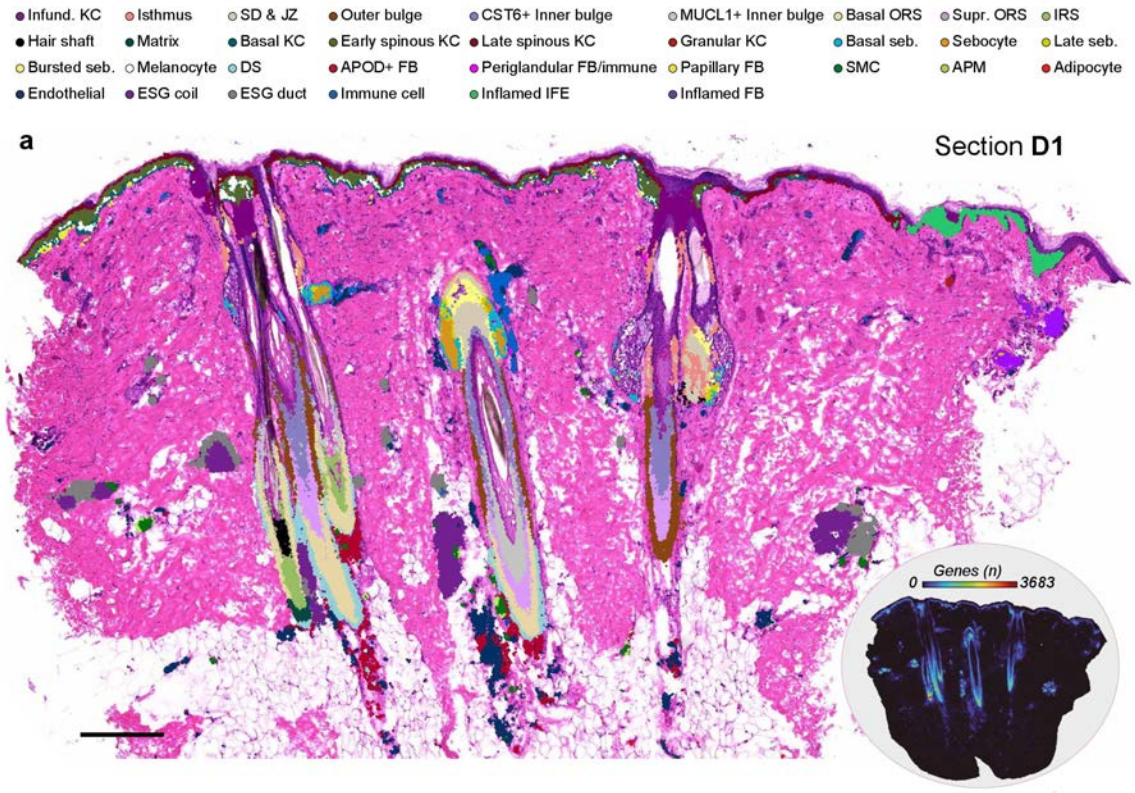

Fig. 2: Spatial anchoring of PSU architecture with Visium HD. 10X Genomics Visium HD spatial transcriptomic sections (8 µm spot diameter) derived from healthy facial skin of a 48-year-old White female donor (temporal region). Spots were annotated with marker gene expression, and the derived cell types are overlaid on the H&E sections. The bottom-right inset displays the number of detected genes per spot (maximum 3,683 in section D1). Bar = 250 µm. Abbreviations: Infund., infundibular; KC, keratinocyte; SD, sebaceous duct; JZ, junctional zone; ORS, outer root sheath; IRS, inner root sheath; DS, dermal sheath; FB, fibroblast; SMC, smooth muscle cell; APM, arrector pili muscle; ESG, eccrine sweat gland; IFE, interfollicular epidermis.

Conclusions

We present a scalable, integrated Human Skin Cell Atlas providing a comprehensive single-cell and spatial reference of healthy skin. The HSCA overcomes key limitations of previous studies by refining known cell types, enabling discovery of rare and transitional populations, mapping signaling pathways spatially, and revealing protocol-dependent biases.

As a flexible and extensible resource, the HSCA supports robust annotation of new datasets and facilitates studies of skin diseases, including acne, alopecia, and inflammatory disorders, thereby advancing translational research and precision dermatology.

EA DV CONGRESS
VIENNA
30 SEP - 3 OCT 2026

Abstract N°: 2759

A Mentorship Network Focused on Boundary Setting in Influencer and Industry Collaborations

Emily Uh*[1], Neha Iska[2], Danielle Despanie[3], Samantha Steiss[4], Jonique Depina[5], Kelly Frasier[6], Raman Madan[6]

[1] SUNY Upstate Medical University, Syracuse, United States
[2] Wayne State University School of Medicine, Detroit, United States
[3] LSUHSC School of Medicine, New Orleans, United States
[4] Edward Via College of Osteopathic Medicine, Blacksburg, United States
[5] Kansas City University College of Osteopathic Medicine, Kansas City, United States
[6] Northwell, New Hyde Park, United States

Introduction
Dermatologists are increasingly engaged in influencer partnerships, brand sponsorships, educational content creation, and industry collaborations that intersect with public trust, professional identity, and financial transparency. As social media presence becomes intertwined with academic visibility and patient outreach, physicians at all career stages face complex decisions regarding compensation, disclosure, content control, intellectual property, and reputational risk. Formal training on boundary setting within influencer and industry relationships remains limited, and mentorship in this domain is often informal or reactive. A structured mentorship network focused on ethical boundary navigation may support dermatologists in maintaining professional integrity while engaging in digital and commercial collaborations.

Materials and Methods
A structured mentorship network model was designed to provide longitudinal guidance across training levels, including medical students, residents, and practicing dermatologists. Development was informed by literature on conflict-of-interest management, Federal Trade Commission disclosure standards, academic-industry partnership guidelines, and professional ethics frameworks. The proposed model integrates senior faculty mentors with experience in media engagement and industry collaboration, near-peer mentorship for early trainees, and case-based discussion modules addressing high-risk scenarios. Core content includes negotiation of compensation structures, disclosure transparency, contractual review considerations, brand alignment assessment, intellectual property ownership, and long-term reputational implications. The network is structured around small-group longitudinal mentorship pods supplemented by resource toolkits and standardized discussion guides.

Results
Program development identified recurring vulnerability points in influencer and industry engagement, particularly among early-career physicians, including limited familiarity with contract language, ambiguity surrounding sponsored educational content, and uncertainty regarding boundaries between advocacy and endorsement. The proposed mentorship structure directly addresses deficiencies through staged, scenario-based learning and access to experienced mentors capable of modeling boundary-setting strategies. Implementation feasibility analysis suggests that the network can be integrated within academic departments or national societies with minimal financial burden, leveraging existing faculty expertise and virtual platforms.

Conclusions

As dermatology intersects more visibly with influencer culture and industry engagement, structured mentorship in boundary setting becomes integral to preserving professional credibility. A dedicated and purpose-built mentorship network provides a proactive and scalable strategy to equip dermatologists with the ethical and contractual literacy necessary to navigate collaborations responsibly. Institutional support for boundary-focused mentorship may protect public trust while preserving physician autonomy and sustaining the integrity of dermatologic expertise within increasingly commercialized digital spaces.

EADV CONGRESS
VIENNA
30 SEP - 3 OCT 2026

Abstract N°: 2772

Alternative and Complementary Medicine in Dermatology on Réunion Island: Herbal Teas & Medicinal Plants

Antoine Aigu[1], Marie MERLANT[1], Anne Kolbe[2], Charles Taieb[3], Sebastien Leruste[4], Caroline Lefloch[5], Anne-Laure Demessant-Flavigny[5], Delphine Kerob[5], Abdelilah Bouzelfen[6], Richard Marie-Aleth[7], Antoine Bertolotti*[1]

[1] CHU Réunion, Service des Maladies Infectieuses - Dermatologie, Saint Pierre, La Réunion, France, La Réunion, France
[2] Cabinet de Dermatologie, Saint Pierre, La Réunion, France, La Réunion, France
[3] European Market Maintenance Assessment, FONTENAY SOUS BOIS, France
[4] Département de médecine générale, Université de la Réunion, France, La Réunion, France
[5] La Roche-Posay, Levallois Perret, France
[6] Galderma France, La Defense, France
[7] Dermatology Department, "Centre de recherche en oncologie biologique et oncophamacologie", Timone Hospital, Assistance Publique Hôpitaux de Marseille, Aix-Marseille Univ, UMR 911, INSERM CRO2, Marseille, France, Marseille, France

Introduction

Reunion Island is characterised by a vibrant traditional Creole medicine, based on a rich local plant pharmacopoeia (herbal teas, decoctions of plants from the marronne forest). This practice is common across all six ancestral communities on the island. Against a backdrop of a shortage of dermatologists in the French overseas departments and greater difficulties in accessing healthcare than in mainland France (27.8% of patients have no access to any consultation – is this for a dermatologist or access to doctors in general?), assessing the role of these practices in patients' management of their skin conditions and comparing them with the use of conventional treatments is essential for appropriate clinical dialogue and integrated therapeutic education.

Materials and Methods

Cross-sectional population survey (December 2025 – January 2026), N=1,302 adults, representative telephone panel. Of the 503 individuals reporting at least one skin condition, 255 provided details of the treatments used. Eight categories of treatment were assessed. Comparison of usage rates by ancestral origin was performed using the chi-square test. 95% CI calculated using the Wilson method.

Results

Of the 255 responders (out of 503 patients), 24.3% [95% CI: 19.5–29.9] used herbal teas and complementary therapies, and 6.3% [3.9–9.9] used CAM (complementary and alternative medicine), representing a cumulative 30.6% use of non-conventional treatments. Conventional treatments remain the most common: topical treatments (51.4%), topical corticosteroids (31.4%), and tablets (18.4%). Among the 503 patients, 15.7% use treatments not covered by the National Health Service (financial barrier) and 27.8% have not consulted any healthcare professional. The use of herbal teas is observed in all six ancestral communities. No significant gradient was identified according to ethnic origin (qualitative data).

Conclusions

The use of medicinal plants and herbal teas (24.3%) is a significant phenomenon, common across all communities in Réunion; it is not a substitute for conventional medicine but coexists with it. Against a backdrop of high non-attendance at healthcare services (27.8%), these practices often represent the only effective recourse. Integration into therapeutic education — non-stigmatising dialogue, information on potential interactions and diagnostic delays — is a public health priority in Réunion.

EADV CONGRESS
VIENNA
30 SEP - 3 OCT 2026

Abstract N°: 2780

Adult T-Cell Leukemia/Lymphoma with Ulcerated Tumoral Cutaneous Lesions: A Diagnostic Challenge

Rafaela Lopes*[1], Raphael Pereira[1], Karine Domingues Tavares[1], Mayara Araújo Brilhante[1], Ana vitoria Sansonowski[1], David Souza[1], Alexandre Gripp[1], Flavia Cassia[1]

[1] UNIVERSIDADE DO ESTADO DO RIO DE JANEIRO - UERJ, RIO DE JANEIRO, Brazil

Introduction

Adult T-Cell Leukemia/Lymphoma is a rare and highly aggressive lymphoproliferative neoplasm associated with chronic HTLV-1 infection, with higher prevalence in endemic regions, including Brazil. It is characterized by heterogeneous clinical behavior and poor prognosis, particularly in its aggressive forms. Cutaneous involvement may represent the initial manifestation of the disease; however, tumoral cutaneous presentation remains uncommon and challenging, often mimicking inflammatory dermatoses, infectious conditions, or other lymphoproliferative disorders, which may delay diagnosis and negatively impact prognosis. In this context, reports of exuberant and atypical cutaneous presentations are of substantial relevance to the international dermatologic and hematologic literature.

Case Presentation

A 53-year-old female patient, previously healthy, presented with progressive papuloerythematous lesions for 18 months, evolving into painful, ulcerated, and infiltrative nodules. Initially, cutaneous sporotrichosis and leprosy were considered as diagnostic hypotheses, both of which were ruled out after lack of therapeutic response and negative bacilloscopy. Due to the unfavorable progression and diagnostic uncertainty, the patient was hospitalized for further investigation.

Histopathological examination revealed foci of epidermotropism by intermediate-sized lymphocytes associated, within the reticular dermis, with diffuse proliferation of atypical lymphocytes. Immunohistochemistry demonstrated diffuse positivity for CD3, CD4, and CD25 in the neoplastic cells. Negativity was observed for CD7, CD20, and CD56; CD8 was positive in approximately 10% of the cells, and CD30 was positive in about 30% of the cells of interest, findings consistent with adult T-cell leukemia/lymphoma (ATL), lymphomatous subtype. Serology for HTLV-1 was positive, corroborating the diagnosis.

Peripheral blood flow cytometry immunophenotyping did not reveal an aberrant T-lymphocyte population. Staging computed tomography demonstrated left inguinal lymphadenopathy, in addition to extensive infiltrative cutaneous lesions involving the lower limbs and gluteal regions, with extension into the subcutaneous tissue. Laboratory evaluation revealed normocytic normochromic anemia (Hb 10 g/dL; Hct 32.5%), marked elevation of serum LDH (1443 U/L), and normal serum calcium levels (8.3 mg/dL). Cerebrospinal fluid analysis obtained by lumbar puncture showed no evidence of central nervous system infiltration.

Treatment was initiated with zidovudine combined with intrathecal chemotherapy and the CHOEP regimen, with planned allogeneic hematopoietic stem cell transplantation. During the first cycle, the patient developed febrile neutropenia and hypercalcemia (13.9 mg/dL), both of which were appropriately managed with intravenous antibiotics and hydration. Therapeutic intensification with the LSG15 protocol was considered; however, the patient declined treatment escalation due to the high toxicity of the regimen. Despite an initial clinical response, subsequent progression of the cutaneous lesions occurred, prompting a therapeutic switch to the GDP regimen, with only partial response after two cycles. Given the aggressive and refractory nature of the disease, palliative management was later instituted with methotrexate, systemic corticosteroid therapy, and subsequently oral cyclophosphamide combined with dexamethasone. Despite the measures implemented, the patient experienced continuous disease progression and died 7 months after diagnosis.

Conclusion

This case highlights the aggressiveness of HTLV-1–associated Adult T-cell Leukemia/Lymphoma and the diagnostic challenge posed by atypical cutaneous presentations that may mimic infectious or inflammatory dermatoses. Despite multidisciplinary management and multiple therapeutic approaches, the patient developed refractory disease with an unfavorable outcome, reflecting the poor prognosis of aggressive ATL forms.

EADV CONGRESS
VIENNA
30 SEP - 3 OCT 2026

Abstract N°: 2782

Perforating Granuloma Annulare: An Unusual Mimicker of Lupus Vulgaris

Naajeda Mohamed Jiffry*[1], Kavini Ranawaka Kankanamge[1], Muditha Gunasingha[1], Sachithra Samarakoon[1]

[1] District General Hospital - Nuwara Eliya, Nuwara Eliya, Sri Lanka

Introduction

Granuloma Annulare (GA) is an often-self-limiting disorder that presents as an erythematous or skin colored annular or arciform plaque, with peripheral papules and a moderately firm, rope-like border, central clearing and absent scales. Generally, the trunk and extremities are usual sites of involvement with the head, neck, palms, soles and mucous membranes being spared. GA can present as one of many clinical variants, including a rarer Perforating GA variant that is characterized by asymptomatic, erythematous or skin-colored papules that evolve into discharging lesions, that go on to heal with scarring. Diagnosis of GA is usually clinical, although a skin biopsy is performed in most instances to confirm the diagnosis. A lymphohistiocytic infiltrate, collagen degeneration, and mucin deposition are characteristic histopathology features, with these findings usually presenting in an interstitial or palisaded pattern. Initial management is based on the extent and symptom profile of the skin lesions and ranges from local topical corticosteroid therapy to photochemotherapy.
Alternatively, Lupus Vulgaris (LV) is a chronic, paucibacillary form of cutaneous Tuberculosis (TB), that arises as a result of reactivation of TB infection in those with moderate to high immunity against the bacillus. It presents initially as a collection of discrete, red-brown papules that coalesce to form a plaque with central atrophy and scarring, and occasionally the border may acquire a serpiginous or verrucous appearance, commonly found on the lower extremities or buttocks in tropical countries. As it is a paucibacillary form of cutaneous TB, mycobacteria are often not seen in histopathology samples or by culture, and the diagnosis is supported via consistent clinicopathological features and a positive nucleic acid amplification (NAA) test or tuberculin skin test. The presence of tuberculoid granulomas with discrete, central caseation in the upper dermis, atrophic or acanthotic epidermis with hyperkeratosis, are discerning features on histopathologic examination. The general approach to the management of cutaneous TB consists of a course of multidrug anti-TB therapy.

Case Presentation

We report a case of Perforating Granuloma Annulare (GA) mimicking Lupus Vulgaris (LV) clinically. Our case centers around a 48-year-old woman with Type 2 Diabetes Mellitus presenting with three-years of pruritic, red-brown papular, annular plaques over her extremities, with most lesions demonstrating a hyperkeratotic border with central scarring. Our initial clinical assessment favored a diagnosis of early LV. On further evaluation, her basic blood panel was unremarkable. Tests aimed at the detection of mycobacteria including tissue samples sent for culture, Acid-Fast Bacillus (AFB) stain, NAA test and a tuberculin skin test came back negative. Interestingly, histopathological studies revealed a hyperkeratotic epidermis, with evidence of transepidermal elimination of mucinous, degenerating collagen fibers and a few foci of necrobiosis surrounded by a palisade of lymphohistiocytic infiltrates, characteristic of the palisading pattern of GA. The overall picture favored a diagnosis of Perforating GA, following which the patient was initiated on potent topical corticosteroid therapy, with improvement in her lesions over four weeks of treatment.

Conclusion

Perforating Granuloma Annulare may rarely mimic Lupus Vulgaris both clinically and morphologically, particularly in tuberculosis-endemic settings. This case highlights the importance of histopathological evaluation in atypical

annular plaques with scarring to establish an accurate diagnosis, avoid unnecessary anti-tuberculous therapy, and guide appropriate management.

EA DV CONGRESS
VIENNA
30 SEP - 3 OCT 2026

Abstract N°: 2857

An Unusual Hyperkeratotic Presentation of Terra Firma-Forme Dermatosis Involving the Face and Scalp

Beyzanur Karagol*[1], Hale Nur Ertugay Aral[1], Fahrettin Kucukhemek[2], Esra Adışen[1]

[1] Gazi University, Dermatology and Venereology Department, Ankara, Türkiye
[2] TC Saglik Bakanligi Eregli State Hospital, Konya, Türkiye

Introduction

Terra firma-forme dermatosis (TFFD), also known as Duncan's dirty dermatosis, is a benign keratinization disorder presenting with dirt like hyperkeratotic plaques.[1] The lesions characteristically resist routine washing but can be removed with 70% isopropyl alcohol rubbing.[2] Although its exact pathogenesis remains unclear, retention of melanin, sebum, and corneocytes within the stratum corneum has been proposed.[3] Because of its variable clinical appearance, TFFD may mimic several inflammatory, infectious, and neglect related dermatoses, leading to delayed diagnosis and unnecessary interventions.[1]

Case Presentation

A 35 year old woman presented with a 2 month history of thick yellow-brown greasy hyperkeratotic crusted plaques involving the forehead, cheeks, nose, and chin (Figure 1a). The lesions were mildly pruritic and had progressively thickened over time. Dermatological examination revealed adherent yellowish hyperkeratotic plaques with a markedly dirty and verrucous appearance. Similar lesions were also observed on the frontal scalp. Due to the marked thickness of the crusts, aggressive mechanical removal was avoided to prevent irritation and secondary erosions.

Further history revealed that the patient had not washed her face or scalp for approximately 4 months because of psychosocial difficulties. Initial treatment with 3% salicylic acid in petrolatum for facial lesions and topical salicylic acid solution for the scalp resulted in partial improvement by day 10 (Figure 1b), followed by marked softening and substantial clearance by day 20 (Figure 1c). During follow-up, wiping a residual lesional area on the forehead with 70% isopropyl alcohol led to immediate clearance (Figure 1d-e), revealing completely normal underlying skin and confirming the diagnosis of TFFD through the skin modified by alcohol rubbing test (SMART).[2] After stabilization of the lesions, topical pimecrolimus was added for residual mild erythema.

Conclusion

This case demonstrates an unusually severe hyperkeratotic presentation of TFFD involving both the face and scalp, clinically mimicking seborrheic dermatitis, dermatosis neglecta, acanthosis nigricans, confluent and reticulated papillomatosis, and infectious crusted dermatoses. Awareness of this entity is important to avoid unnecessary biopsy, antimicrobial therapy, or aggressive debridement. The alcohol wipe test remains a simple, rapid, inexpensive, and highly effective bedside diagnostic tool, even in extensive and atypical presentations of TFFD.

EADV Congress 2026, VIENNA
30 SEPTEMBER - 03 OCTOBER 2026
POWERED BY M-ANAGE.COM

EA DV CONGRESS
VIENNA
30 SEP - 3 OCT 2026

Abstract N°: 2872

Not just any wart: an epidermodysplasia verruciformis secondary to azathioprine and a congenital immune deficit.

zineb selka*[1]

[1] CHU Docteur Tidjani Damardji, Mansourah, Algeria

Introduction

Epidermodysplasia verruciformis (EV), is a rare genodermatosis characterized by an inability of the immune system to defend itself against and eradicate certain types of papillomaviruses. This results in an increased risk of developing cutaneous dysplasias, such as Bowen's disease, or even squamous cell carcinomas.

Materials and Methods

This concerns patient B.M.A., 16 years old, born from a **consanguineous marriage**, with a medical history of bronchial asthma and **ulcerative colitis** (UC) currently treated with azathioprine, Bactrim, and corticosteroids during flare-ups. The patient also has a **congenital immune deficiency** with Type A and B hypogammaglobulinemia, as well as a cellular immunity deficiency affecting **CD3+**, **CD4+**, and **CD8+** cells.The patient developed a **squamous cell carcinoma** at the inner canthus (corner) of the right eye, which was surgically removed and treated with 30 sessions of radiotherapy in 2025.Upon clinical examination, he presented with multiple warts, coalescing in places, located primarily in the perinasal and periocular areas and within the external auditory canals. Additionally, a verrucous plaque covered the entire plantar surface of both feet. **Hypochromic macules** (pale spots) were also found on the lateral sides of the neck. This clinical presentation dates back to age 12, two years after the introduction of **azathioprine**.

Results

Epidermodysplasia verruciformis (EV) is a rare genodermatosis characterized by an impaired immune capacity to defend against and eradicate certain types of human papillomavirus (HPV).

This leads to persistent infections and an increased risk of developing epidermal dysplasia—primarily Bowen's disease—as well as cutaneous neoplasms, mainly **squamous cell carcinoma (SCC)**. Squamous cell carcinomas developing as a result of epidermodysplasia verruciformis are linked to **HPV types 5 and 9**.

Two forms of epidermodysplasia verruciformis are distinguished:

1. **A primary (congenital) form**, resulting from mutations in the **TMC6/EVER1** or **TMC8/EVER2**
2. **An acquired or secondary form**, occurring on a background of immunosuppression, notably congenital immune deficiencies, immunosuppressive treatments such as **azathioprine**, or HIV infections.

Clinically, EV manifests as multiple warts associated with **pityriasis versicolor-like** lesions on the lateral sides of the neck. The histology of these warts is characterized by **"blue cells,"** which are pathognomonic of HPV-infected keratinocytes. This blue coloration is due to the presence of pale blue cytoplasm and numerous basophilic keratohyalin granules.

Conclusions

In summary, although **epidermodysplasia verruciformis** is a rare condition, it is vital to consider it in immunosuppressed patients given the high risk of malignant transformation into **squamous cell carcinoma**.

EADV CONGRESS
VIENNA
30 SEP - 3 OCT 2026

Abstract N°: 2921

Efficacy of an Innovative Cream on Biomarkers for Aging in Mature, Fragile Skin

Glynis Ablon[1], Alan Widgerow[2], Thu Nguyen[2], Sindhu Garimella[2], Christine Emesiani*[2], Matthew Meckfessel[2]

[1] Ablon Skin Institute and Research Center, Associate Clinical Professor UCLA, Manhattan Beach, United States
[2] Galderma Laboratories, L.P., Fort Worth, United States

Introduction
Dermatoporosis is a condition of fragile, aging skin. Both intrinsic and extrinsic factors can contribute to dermatoporosis and the aging process. It also occurs due to an alteration in supportive dermal structures, decrease in the ground substance of the extracellular matrix, and blood vessels becoming more vulnerable to damage. Dermatoporosis can subsequently manifest into wrinkles, skin laxity, easy bruising, and hyperpigmentation. This study evaluated efficacy, safety, and subject perception after use of an innovative cream (GC) on subjects with mature, aging skin.

Materials and Methods
This was a 12-week multi-center, randomized, blinded, in-use study on female and male subjects of all races, ethnicities, and Fitzpatrick skin type aged 40-60 years. Subjects were required to have a history of skin fragility and be prone to bruising. Inclusion criteria also included dry, crepey skin on the knees. GC was applied to the skin twice daily. Assessments included 3-mm punch biopsies for immunohistochemistry on the upper knees in a subset of the patient population at baseline and week 12.

Results
There was a significant increase of the Elastin protein at week 12, indicating improvement in skin elasticity after consistent use of the study product. Additionally, there were trends in improvement in Beta Galactosidase and CD44.

Conclusions
After twice daily use of this novel cream, punch biopsy data resulted in a notable, beneficial, difference in the amount of important protein markers in the skin. This data is intended to provide significant insights into the additional benefits of this cream for mature, aging, skin.

EA DV CONGRESS
VIENNA
30 SEP - 3 OCT 2026

Abstract N°: 2969

Dermatitis cruris pustulosa et atrophicans in Fitzpatrick skin type VI: stage-related dermoscopic findings in a case series from sub-Saharan Africa.

Martina Cavicchi*[1], Michele Barbieri[1], Salvatory Makweta Mlaga[2], Raymond Shoma Lughali[3], Enzo Errichetti[4], Caterina Longo[1]

[1] Department of Dermatology, University of Modena and Reggio Emilia, Modena, Italy

[2] Department of Anatomy and Pathology, St. Francis University College of Health and Allied Sciences, Ifakara, Tanzania

[3] St. Francis Regional Referral Hospital, Ifakara, Tanzania

[4] Department of Experimental and Clinical Medicine, Institute of Dermatology, University of Udine, Udine, Italy

Introduction

Dermatitis cruris pustulosa et atrophicans (DCPA) is a chronic, scarring follicular dermatosis mainly affecting the lower legs of individuals with darker skin phototypes in tropical regions. Clinical recognition may be challenging because DCPA can mimic other chronic inflammatory or infectious dermatoses of the lower limbs. Dermoscopic data in Fitzpatrick skin type VI are limited, and stage-specific dermoscopic features have not been well characterized.

Case Presentation

We report five Fitzpatrick skin type VI patients, four males and one female, presenting with chronic, symmetrical, pruritic pustular eruptions of the lower legs. Lesions were limited to the anterior and lateral part of the lower legs, with sharply demarcated borders and consistent sparing of the dorsum of the feet. All patients reported frequent freshwater exposure during daily activities. None had systemic symptoms. Two patients had previously received a 12-week course of oral doxycycline without improvement, and bacterial cultures were negative for *Staphylococcus aureus*. Clinically, patients represented different disease stages, ranging from follicular pustules with erythema and edema to scaly plaques, broken hairs, alopecia, and smooth shiny atrophic skin. Polarized dermoscopy showed stage-related patterns: follicular pustules, follicular keratin plugs, and perifollicular white lines predominated in acute and subacute lesions; perifollicular collarettes of scale, hemorrhagic scales, and broken hairs were mainly observed from subacute to chronic stages and advanced lesions showed loss of follicular pustules with prominent atrophic and pigmentary changes. Accentuation of the pigmentary network and roundish brown perifollicular pigmentation were consistently observed across the series. In two representative cases, punch biopsy showed epidermal atrophy, subcorneal and subepidermal pustules, dermal edema, and dense perifollicular inflammatory infiltrates rich in neutrophils, lymphocytes, and plasma cells, without microbial cytopathic changes.

Conclusion

This case series suggests that DCPA in Fitzpatrick skin type VI has recognizable clinical and stage-specific dermoscopic features. Symmetrical pretibial follicular pustules, chronic evolution, antibiotic resistance, and consistent sparing of the feet are useful diagnostic clues. Dermoscopy may support both diagnosis and staging, particularly in resource-limited settings, and may help reduce reliance on histopathology. The stage-related dermoscopic patterns and consistent pigmentary findings observed in our patients may expand the currently described spectrum of DCPA in dark skin. Freshwater exposure and sterile follicular inflammation warrant further

investigation as potential contributors to disease pathogenesis.

EA DV CONGRESS
VIENNA
30 SEP - 3 OCT 2026

Abstract N°: 2989

Resveratrol, the rising star in skin rejuvenation and treatment of skin dyspigmentations

Sarah Akram Kamal Hussein Orabi*[1]

[1] Cairo University, Dermatology Department, Cairo, Egypt

Introduction

Resveratrol is a polyphenolic phytoalexin present in large amounts in red grapes, red wine, peanuts and berries. In nature, resveratrol protects plants from stress, ultraviolet light and certain fungal infections. It functions as a dual antioxidant that can neutralize free radicals and increase intrinsic antioxidant capacity. Multiple studies associated the antioxidant, anti-inflammatory, and cell protective effects of resveratrol. These diverse effects of resveratrol are also potentially involved in cutaneous wound healing, scarring, and aging of the skin. It is available nowadays in many topical skin care products and skin injectables and has shown marvelous results when used in treatment of skin pigmentations, photoaging and skin inflammation.

Materials and Methods

Patients complaining of skin pigmentations, acne or post acne erythema were included. Resveratrol injections were done intradermal, subdermal or both according to the indication. Sessions were repeated every 2 weeks for at least 4 sessions.



a resistant case of melasma that improved after 3 sessions of resveratrol injection

Results

Marked improvement in pigmentary disorders, acne flares and post acne scars

Conclusions

Resveratrol is a very promising ingredient in treatment of skin pigmentations, acne, acne scars

EADV CONGRESS
VIENNA
30 SEP - 3 OCT 2026

Abstract N°: 2992

Detecting Melanoma Later Costs 30 Times More: The Economic and Clinical Imperative for Teledermatology Access

Pooya Khanmohammad Beigi*[1], Gulcin Canbeyli[1], Afshin Sadeghian[1], Elizaveta Malyshko[1]

[1] The Misdiagnosis Association and Research Institute (MARI), California, United States

Introduction
Skin cancer is a growing public health and economic burden, and melanoma outcomes depend strongly on the stage at diagnosis. Early-stage melanoma is highly treatable, whereas delayed diagnosis is associated with higher mortality and substantially greater healthcare costs. This paper aimed to examine the economic impact of late melanoma detection and the potential role of teledermatology in supporting earlier diagnosis.

Materials and Methods
A structured review and secondary analysis were conducted using published UK and U.S. data on skin cancer prevalence and stage-specific healthcare costs. Relevant NHS guidance on diagnostic pathways and teledermatology was reviewed to contextualize findings. The analysis focused on differences in healthcare costs between early- and late-stage diagnosis and on access-related barriers to timelydiagnosis.

Results
Skin cancer remains a substantial cause of morbidity and healthcare expenditure. It is the most common cancer in the United States, affecting nearly 6 million individuals annually and generating over $8.9 billion in healthcare costs. Data from the University of California's Melanoma Costs: A Dynamic Model estimates that the 5-year cost of stage IV melanoma is more than 30 times higher than the total cost of stage I disease, underscoring the dramatic cost difference between early and late detection. Recent UK analyses similarly showed that the average cumulative cost of stage IV melanoma was 22.5 times higher than that of stage I melanoma in 2023. NHS guidance emphasizes the need for faster diagnostic pathways and identifies teledermatology as a strategy to reduce delays and improve care efficiency.

Conclusions
Late melanoma diagnosis is associated with significantly higher clinical and economic burden. As cancer incidence rises and pressures on dermatology services increase, earlier detection remains essential for improving outcomes and supporting financial sustainability. Teledermatology may help reduce diagnostic delays by expanding access to specialist review and supporting more efficient use of healthcare resources. MARI International Dermatology Access Program (MIDAP) provides an example of a teledermatology-based initiative that facilitates timely assessment and referral of suspicious lesions.

EA DV CONGRESS
VIENNA
30 SEP - 3 OCT 2026

Abstract N°: 3100

Pain as the Presenting Symptom in Dermatology: A Cross-Sectional Study from a Tertiary Care Centre

Soumya Nanda*[1], Neirita Hazarika[2], Naveen Kansa'[3], Riti Bhatia[3]

[1] All India Institute of Medical Sciences, Bhubaneswar, India, Bhubaneswar, India
[2] All India Institute of Medical Sciences, Guwahati, India, Guwahati, India
[3] All India Institute of Medical Sciences, Rishikesh, India, Rishikesh, India

Introduction
Pain in dermatology remains significantly under-recognized despite its profound impact on quality of life, psychosocial functioning, and healthcare-seeking behavior. While pruritus is routinely assessed in dermatological practice, pain is seldom evaluated systematically using validated multidimensional tools. Existing literature is largely disease-specific and scarce. This study aimed to evaluate the prevalence, severity, characteristics, and quality-of-life impact of pain as a presenting symptom across a broad spectrum of dermatological disorders.

Materials and Methods
A hospital-based cross-sectional observational study was conducted over 18 months at a tertiary centre. A total of 1,500 adult dermatology patients were screened for pain associated with their dermatoses. Patients with pain attributable to their dermatological condition were enrolled. Pain severity was assessed using the Numeric Rating Scale (NRS) and the McGill Pain Questionnaire (MPQ), while quality of life was evaluated using the Dermatology Life Quality Index (DLQI). Statistical analysis was performed using SPSS v26.0. Associations between variables were analyzed using Chi-square test, Mann–Whitney U test, Kruskal–Wallis test with Dunn's post-hoc analysis, and Spearman's correlation.

Results
Among 1,500 screened patients, 161 reported cutaneous pain, yielding a prevalence of 10.7%. Notably, 70.2% patients presented with pain as their chief complaint, underscoring pain as a major driver of dermatological consultation.The most frequent painful dermatoses were herpes spectrum disorders (29.2%), immunobullous diseases (12.4%), psoriasis spectrum disorders (10.6%), hidradenitis suppurativa (6.2%), and leprosy-related disorders (6.8%). Herpes zoster was the single most common diagnosis. The findings challenge the traditional perception that pain in dermatology is confined to acute infections or ulcerative conditions.

Chronic pain (>3 months) was observed in 31.1% of patients and showed strong association with prolonged disease duration (rho = 0.75, $p < 0.001$) and impaired quality of life. Patients with chronic plaque psoriasis, hidradenitis suppurativa, pemphigus vulgaris, and post-herpetic neuralgia demonstrated particularly prolonged pain duration.Pain severity showed a significant relationship with psychosocial and functional impairment. Mean DLQI scores increased progressively across pain severity categories: 6.79 ± 3.05 in mild pain, 9.40 ± 3.44 in moderate pain, and 12.73 ± 3.76 in severe pain ($p < 0.001$). Severe pain was also associated with sleep disturbance, reduced joy of living, embarrassment, relationship difficulties and sexual dysfunction(all $p < 0.05$). MPQ descriptors revealed the multidimensional nature of dermatological pain. Sensory descriptors such as "burning," "stabbing," "throbbing," and "shooting" frequently coexisted with affective descriptors including "tiring," "sickening," and "agonizing," suggesting overlapping nociceptive and neuropathic mechanisms. NRS

scores correlated strongly with MPQ Pain Rating Index scores (rho = 0.96, p < 0.001), validating the complex sensory-emotional burden of cutaneous pain.

Conclusions

Pain is a underappreciated presenting symptom in dermatology and substantially impairs patient quality of life. One-third of patients experienced chronic pain, particularly in inflammatory and neuropathic dermatoses such as psoriasis, hidradenitis suppurativa and post-herpetic neuralgia. Beyond physical discomfort, dermatological pain demonstrated significant psychosocial consequences.Routine integration of structured pain assessment into dermatology practice is urgently needed. Multidimensional tools such as NRS and MPQ provide clinically meaningful insights into both sensory and affective domains of pain and may facilitate more holistic, patient-centered management strategies. This study highlights the need to move beyond morphology-centered dermatology toward symptom-oriented care and advocates for interdisciplinary approaches to cutaneous pain management.

EADV CONGRESS
VIENNA
30 SEP - 3 OCT 2026

Abstract N°: 3106

Prevention or Restoration? The photoprotective efficacy of Nicotinamide in primary keratinocytes and fibroblasts.

Lara Camillo*[1], Elisa Zavattaro[1], Paola Savoia[1]

[1] Department of Health Sciences, Università del Piemonte Orientale, Novara, Italy

Introduction

Chronic exposure to ultraviolet radiation (UVR) is the primary extrinsic factor responsible for skin carcinogenesis. UVR directly damages the DNA and induces the production of reactive oxygen species (ROS) and the release of proinflammatory cytokines, which in turn contribute to DNA damage, lipid and protein peroxidation eventually resulting in tissue alteration. To prevent and mitigate these damages, several strategies have been developed, including the administration of systemic photoprotectors. Nicotinamide (NAM), the amide form of vitamin B3, is the precursor of NAD+, which is involved in several biochemical reactions, including ATP production. NAM is able to protect cells against UV-induced damage by enhancing DNA repair, inhibiting local inflammation and modulating energy-dependent enzymes. Recently, we demonstrated that NAM provides a NAD-mediated photoprotection against UVB-induced oxidative damage in HaCaT cells (Camillo et al. 2026, 10.3390/dermato6010007). However, the translational relevance of these findings in primary skin cells remains to be fully elucidated. This study aims to investigate the photoprotective effects of NAM on primary human keratinocytes (HKs) and human fibroblasts (HFs) and whether NAM acts more efficiently as a preventive (pre-treatment) or restorative (post-treatment) agent against UVB-induced damages.

Materials and Methods

In pre-treatment conditions, HKs and HFs were treated with 50 µM NAM and 1 nM FK866 (a NAMPT-inhibitor) for 24 hours and then exposed to 20 mJ/cm^2 UVB. In post-treatment conditions, HKs and HFs were first exposed to 20 mJ/cm^2 UVB, followed by the addition of NAM and FK86. ROS levels, the NAD+/NADH ratio and antioxidant expression were evaluated after 4 hours; DNA damage and oxidative markers were evaluated after 8 hours, while cell viability, cell cycle and apoptosis were assessed after 24 hours.

Results

Preliminary data suggest that NAM protects both HKs and HFs regardless of the time of stimulation. In particular, we observed that NAM can efficiently mitigates ROS production, which correlates with reduced DNA damage and apoptosis. Moreover, NAM treatment appears to improve cell viability, particularly in HKs.

Conclusions

These findings extend our previous observations in HaCaT cells, confirming the photoprotective role of NAM as both a preventive and a restorative agent in primary human skin cells.

EADV CONGRESS
VIENNA
30 SEP - 3 OCT 2026

Abstract N°: 3245

A non-retinoid tri-active complex targeting extracellular matrix components is associated with improved skin firmness: from in vitro activity to clinical biomechanical outcomes

Florence Cassin*[1], Daphné Gautier[1], Elise Derksen[1], Sophie Zozine[1], Stephanie Bredif[1], Virginie Fera[1]

[1] Groupe Rocher, Issy-les-Moulineaux, France

Introduction

Age-related alterations in dermal extracellular matrix components, particularly collagen and elastin, contribute to decreased skin firmness. Non-retinoid strategies capable of stimulating these pathways while maintaining good tolerability are of increasing interest. This study investigated whether a patented tri-active complex enhancing collagen I and elastin synthesis in human dermal fibroblasts is associated with measurable improvements in skin biomechanical properties and perceived firmness in a topical formula.

Materials and Methods

In vitro: Normal human dermal fibroblasts were exposed for 144 h to a combination of Ice plantextract, extensin-rich fraction, and cranberry peptides (0.5%, 0.05%, 0.5%). Untreated cells served as control. Collagen I and elastin were quantified by immunostaining and image analysis. Transforming growth factor-β1 (TGF-β1; 20 ng/ml) and Retinol (1µM) were used as a positive control.

Clinical evaluation: 25 women (mean age: 63 years, range: 49–74) presenting visible loss of firmness applied a cream containing the tri-active complex twice daily for 42 days to the face, neck, and décolleté. A subgroup (n=21) was evaluated for immediate effects (15 minutes) after a single application (2 mg/cm^2). Skin firmness was assessed using Adhelaskin® at baseline, Day 28, and Day 42. Secondary endpoints including elastic modulus (Adhelaskin®), skin density (echography), and 3D facial volumes (AEVA® HE , subgroup n=22) were evaluated.

Self-assessment: A separate panel of 110 women (mean age: 52 years, range: 36–74) evaluated firmness using a 15-point scale at baseline, Day 28, and Day 42 following twice-daily application to the face, neck, and décolleté.

Results

In vitro

The tri-active complex induced a significant upregulation of extracellular matrix components: up to +481%*** collagen I and x10** elastin expressions, compared to untreated controls. Interestingly, elastin stimulation by the ice plant extract (at 0.01%) was comparable to retinol (1µM) under the tested conditions.

Clinical outcomes

Skin firmness (Adhelaskin® pile-up parameter) showed a progressive and statistically significant improvement over time, with variation of 9%* at Day 28 and 11%* at Day 42. Consistently, the elastic modulus increased by +10%* at Day 28 and +18%* at Day 42, respectively, indicating improved skin elasticity and structural resilience. Skin density also rose by +8%* at Day 28 and +15%* at Day 42, suggesting a densification of the skin matrix. In parallel, a reduction in negative facial volumes was observed (−6%* at Day 28 and −5%* at Day 42), supporting a visible tightening effect. In addition to these long-term changes, an immediate tensor effect was detected 15 minutes after application (+26% Adhelaskin® pile-up parameter), highlighting both rapid and sustained benefits of the formulation.

The product was very well tolerated, as judged by a dermatologist.

Self-assessment

Perceived skin firmness improved over time, with 87% and 91% of subjects reporting skin looking firmer at Day 28 and Day 42, respectively. These subjective evaluations were supported by quantitative self-scoring, which showed significant increases of +92%* at Day 28 and +94%* at Day 42. Altogether, these findings indicate a high level of concordance between instrumental measurements and consumer perception of improved skin firmness.

*p<0.05; **p<0.01;***p<0.001

Conclusions

A non-retinoid patented tri-active complex targeting extracellular matrix components is associated with both in vitro stimulation of collagen I and elastin and clinically measurable improvements in skin biomechanical properties, including firmness. These results indicate that targeting extracellular matrix remodeling could be a relevant approach to improve skin firmness beyond retinoid-based strategies. Further studies are needed to better clarify how collagen and elastin modulation contributes to the observed biomechanical improvements.e

EADV CONGRESS
VIENNA
30 SEP - 3 OCT 2026

Abstract N°: 3270

In vivo electrochemical assessment of blue light–induced oxidative stress and antioxidant response in human skin

William Richard*[1], Anne Sirvent[2], Cécile Charmel[2], Hervé Burnet[2], Aurélie Bonnot[2], Alain Moga[1], Nicolas Amalric[1], Stanislas Vandier[3], Tu-Anh Duong[4], Anne Bouet[2]

[1] Qima Life Sciences, Qima Bioalternatives SAS, Gençay, France

[2] Eurofins-Dermscan, Villeurbanne, France

[3] Wired Beauty Technologies, Paris, France

[4] General and Oncologic Dermatology, Ambroise Paré Hospital,, Boulogne-Billancourt, France

Introduction

Oxidative stress is a key driver of skin ageing and dermatological disorders. Blue light, a major component of the skin exposome, induces reactive oxygen species and may disrupt skin homeostasis by altering the antioxidant system. However, real-time in vivo assessment of skin homeostasis remains challenging due to the lack of rapid, non-invasive methods. To address this limitation, the first objective of the presented study was to evaluate the ability of an electrochemical skin sensor to detect blue light–induced alterations of skin homeostasis in vivo and to compare it with biochemical markers of antioxidant function. A secondary objective was to assess the effect of a topical antioxidant formulation applied after exposure.

Materials and Methods

An exploratory clinical study was conducted in healthy women (phototype I to III, n=7). Four conditions were evaluated on the back: unexposed control, blue light–exposed, treated and exposed, and treated control.

Blue light exposure (420 nm, 80 J/cm^2) was performed, followed by application of a topical formulation rich in antioxidants.

At 24 h post-exposure, skin samples were collected using patch and swab methods. Four complementary readouts were assessed:

- Electrochemical profile (Figure 1) and its corresponding electrochemical score reflecting the measurement of endogenous skin antioxidants
- H_2O_2 detoxification activity mimicking a catalase-like activity (via an electrochemical assay)
- Catalase activity (via a colorimetric kit)
- Skin pigmentation (Individual Typology Angle, ITA)

Statistical analysis was performed using paired t-tests (*$p<0.05$).

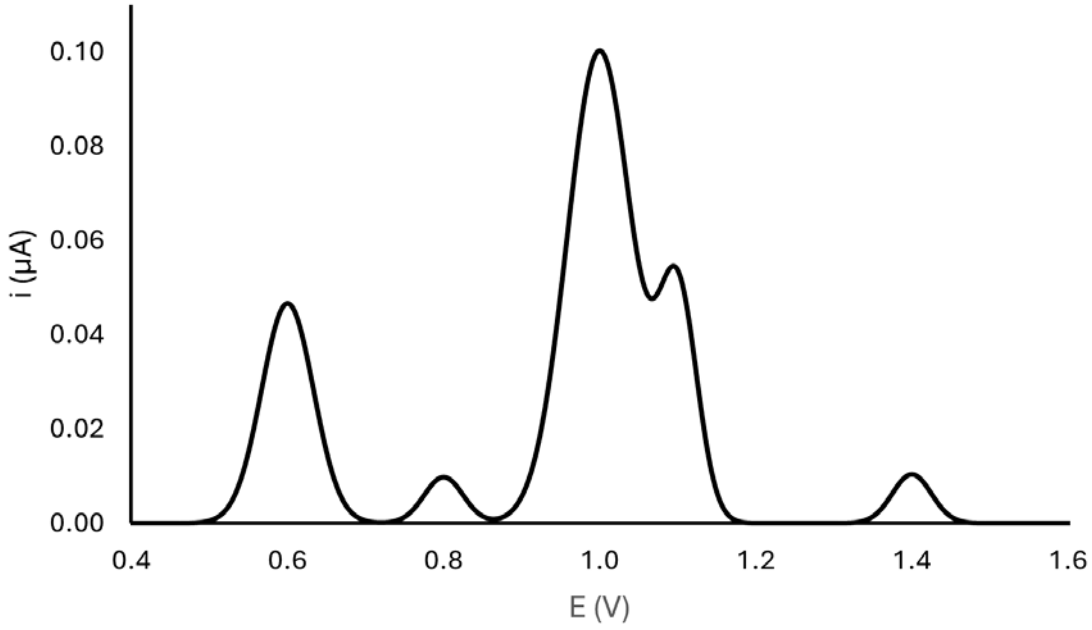

Figure 1. Mean electrochemical profile obtained from unexposed and untreated skin areas (n = 7)

Results

Blue light exposure significantly increased the electrochemical score, indicating an adaptive skin response through increased levels of antioxidants species (Figure 2a). Conversely, enzymatic antioxidant defenses were impaired, with significant decreases in H_2O_2 detoxification capacity (Figure 2b) and catalase activity (Figure 2c). Exposure also induced a significant decrease in ITA values (not shown), reflecting the darkening of the skin. These findings confirm that blue light exposure induced oxidative stress consistently across all evaluated readouts.

In treated exposed areas, the electrochemical score was reduced compared to untreated exposed sites. This result suggests a protective effect of the product through attenuation of the adaptive skin response after oxidative stress. On the other hand, no significant protection was observed for catalase-related parameters (H_2O_2 detoxification activity and catalase activity). Both catalase-related parameters showed correlated variations, supporting the consistency of the observed enzymatic response.

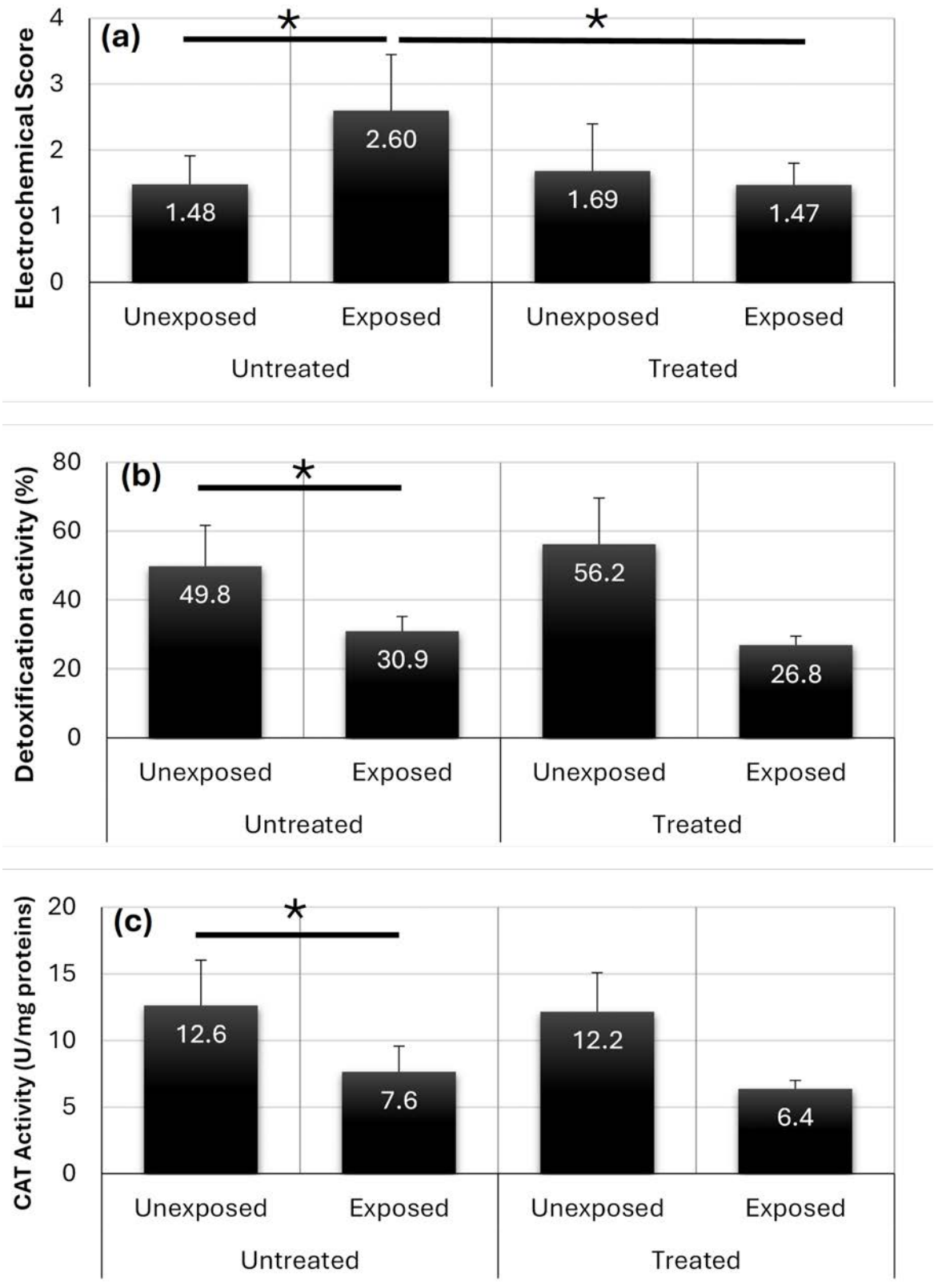

Figure 2. Mean (n = 7) values obtained the untreated/unexposed, untreated/exposed, treated/unexposed, and treated/exposed areas for (a) the electrochemical score, (b) the detoxification activity vs H2O2 (Catalase-like activity) measured with electrochemistry and (c) the catalase activity measured with colorimetric kits.

Conclusions

This study demonstrates that electrochemical sensing enables non-invasive in vivo detection of oxidative stress–related changes in human skin. Importantly, the same electrochemical dataset enabled dual exploitation through both the electrochemical score and catalase-like activity assessment, without the need for additional laboratory

analyses.

Blue light exposure induces a dual response characterized by impairment of enzymatic defenses (particularly catalase-related) and compensatory mobilization of antioxidant species. The electrochemical score appears to reflect this adaptive response and may represent a novel biomarker of skin homeostasis. Product efficacy may therefore be readily highlighted through the complementary interpretation of these two electrochemical readouts. This approach offers promising applications for real-time evaluation of environmental skin damage and cosmetic antioxidant efficacy in dermatology.

EA DV CONGRESS
VIENNA
30 SEP - 3 OCT 2026

Abstract N°: 3274

Clinical Benefits of a Dermocosmetic Routine Containing 2-MNG, Tranexamic Acid, Niacinamide, and Retinol for Photoaged Facial Skin

Juan Ramón García Gavín*[1], Sara Carrasco Sánchez[2], Elia Roó Rodríguez[3], Leonor Prieto-Cabezas[4], Mercedes Abarquero-Cerezo[4]

[1] Clínica Gavín Dermatólogos, Vigo (Pontevedra), Spain
[2] Grupo Sara Carrasco - Dermatología Integral, Bilbao (Bizkaia), Spain
[3] Clider-Clínica Dermatológica Roó, Madrid, Spain
[4] L'Oréal España S.A.U., Madrid, Spain

Introduction
Skin photoaging is the premature aging of the skin caused by prolonged exposure to ultraviolet (UV) radiation, characterized by wrinkles, pigmentation changes, and alterations in skin texture. It represents a common dermatological concern for a large number of patients. Several dermocosmetic ingredients have demonstrated potential benefits in photoaged skin management: depigmenting agents including niacinamide, tranexamic acid, and 2-mercaptonicotinoyl glycine (2-MNG), as well as retinol, which promotes cellular renewal and improves skin texture. The objective of this study was to evaluate the efficacy of a cosmetic routine combining these ingredients in patients with clinically diagnosed facial lentigines.

Materials and Methods
Multicentric, prospective, interventional study conducted under dermatological supervision over 12 weeks. 39 adult subjects (4 men and 35 women; mean age 53 ± 11.75 years) with photoaged facial skin were enrolled. Following a 1-month washout period using a basic moisturizer and neutral SPF50 sunscreen, participants applied a cosmetic routine containing tranexamic acid, niacinamide, 2-MNG, and retinol, consisting of a serum (twice daily), a day cream with SPF50, and a night cream, for 12 weeks. Clinical evaluation included scoring scales focusing on hyperpigmentation and wrinkles, as well as clinical photography with VISIA imaging. Patients assessed tolerance, cosmeticity, and satisfaction with the results.

Results
Clinical evaluation showed a significant decrease ($p<0.05$) in spots and wrinkles from week 6 of cosmetic routine use. Improvements in spots included reductions in color intensity, extent, and number, while wrinkles showed decreases in both wrinkle and fine lines depth and visibility. In addition, a significant improvement ($p<0.05$) in overall skin quality was observed, reflected by enhanced tone uniformity and hydration. The cosmetic regimen was well tolerated by the majority of patients, with adverse effects primarily related to the retinization process. Patients reported good cosmetic acceptability, ease of application, and high satisfaction with the results.

Conclusions
The combination of tranexamic acid, niacinamide, 2-MNG, and retinol in an integrated cosmetic routine, alongside SPF50 photoprotection, proved effective and well tolerated in improving the appearance of lentigines and other signs of photoaging on the face. These findings support the role of dermocosmetics as a clinical strategy in

managing photoaged skin.

EADV CONGRESS
VIENNA
30 SEP - 3 OCT 2026

Abstract N°: 3281

Calcinosis cutis over adult-onset IgA vasculitis: unreported association of a rare entity

Harold Farit Arenas Torrado*[1], Nathaly Liliana Castro Barreto[1], Juan Sebastian Sanchez Solarte[1], Hector Perez[1]

[1] Universidad Nacional de Colombia, Bogotá, Colombia

Introduction
Calcinosis cutis (CC) is a rare entity characterized by the deposition of insoluble calcium salts in the skin and subcutaneous tissue; its incidence and prevalence are not precisely known, as it is most often a secondary phenomenon.

Case Presentation
We present the case of a 53-year-old woman with a history of chronic arterial hypertension, who, six months prior to consultation, had been diagnosed with adult-onset IgA vasculitis (formerly Henoch-Schönlein purpura) with cutaneous involvement, as well as IgA nephropathy leading to rapidly progressive glomerulonephritis and diffuse alveolar hemorrhage, requiring management with corticosteroid pulses, initiation of renal replacement therapy, and subsequent treatment with cyclophosphamide using the CYCLOPS protocol. She presented to the service due to persistent lesions on her upper extremities, reporting that some had become indurated. On physical examination, scattered purpuric macules were documented on the upper limbs, suggestive of residual lesions of cutaneous vasculitis, and indurated yellowish papules in the right antecubital fossa; a biopsy was performed showing transepidermal elimination of calcium without vascular involvement or vasculitis, confirming the diagnosis of perforating CC, dystrophic subtype, given that there were no serum abnormalities in the calcium-phosphate profile, and no application of calcium or phosphate substances had been performed, with the only identified trigger being prior local inflammation from the cutaneous vasculitis. Two months later, no new lesions were observed, so no additional management was indicated.

CC is classified into 5 types: dystrophic, metastatic, iatrogenic, idiopathic, and calciphylaxis (see Table 1). Of these, dystrophic CC is the most frequent, associated with autoimmune diseases due to local inflammation that produces tissue alterations such as in collagen, elastin, or subcutaneous tissue; this tissue damage, together with hypoxia, induces the release of phosphate-binding proteins by necrotic cells, which then capture phosphate, resulting in calcification. Clinically, they present as papules, nodules, or whitish, indurated tumors, and in some cases, extrusion of whitish material with subsequent ulceration. Diagnosis is clinical and histopathological, with documentation in tissue of calcium deposits which stain homogeneously dark blue with hematoxylin and eosin and black with Von Kossa staining. There is no robust evidence on treatment; however, management described includes surgical excision of symptomatic and localized lesions, diltiazem, warfarin, minocycline, ceftriaxone, and some case reports with topical, oral, and intralesional sodium thiosulfate.

Type of CC	Pathogenesis	Association	Serum calcium or phosphate levels
Dystrophic	Secondary to tissue damage	Connective tissue autoimmune diseases (systemic lupus erythematosus, dermatomyositis, systemic sclerosis, mixed connective tissue disease), skin tumors (pilomatrixomas, basal cell carcinoma, chondroid syringoma), infections (onchocerciasis, cysticercosis), panniculitis, trauma, genetic disorders (pseudoxanthoma elasticum, Werner syndrome, Ehlers-Danlos syndrome)	Normal
Metastatic	Underlying defect in calcium and/or phosphate metabolism	Chronic kidney disease, hypervitaminosis D, milk-alkali syndrome, sarcoidosis, familial tumoral calcinosis, hyperparathyroidism, neoplasms	Abnormal
Idiopathic	Without any underlying tissue damage or metabolic disorder	Sporadic tumoral calcinosis, subepidermal calcified nodules, scrotal calcinosis, milia-like calcinosis .	Normal
Iatrogenic	Side effect of medical treatment	Application of substances with calcium or phosphates, tumor lysis	Normal
Calciphylaxis .	Cutaneous arteriolar calcification with subsequent tissue ischemia and infarction	Chronic kidney disease on dialysis	Abnormal / normal

Table 1. Characteristics of calcinosis cutis subtypes

Characteristics of calcinosis cutis subtypes

Conclusion

To our knowledge, this is the first patient in whom dystrophic CC is described following IgA vasculitis.

EA DV CONGRESS
VIENNA
30 SEP - 3 OCT 2026

Abstract N°: 3341

Reverse Mentorship Programs Where Medical Students Train Attendings in Social Media Dermatology Literacy

Catherine Herrick*[1], Neha Iska[2], Danielle Despanie[3], Grace Herrick[4], Kelly Frasier[5], Raman K. Madan[5]

[1] Lake Erie College of Osteopathic Medicine, Erie, United States
[2] Wayne State University School of Medicine, Detroit, United States
[3] LSUHSC School of Medicine, New Orleans, United States
[4] Alabama College of Osteopathic Medicine, Dothan, United States
[5] Northwell, New Hyde Park, United States

Introduction
Patient encounters in dermatology increasingly begin with references to viral acne regimens, sunscreen safety debates, influencer-endorsed procedures, and ingredient toxicity claims circulating across social media platforms. Algorithm-amplified narratives shape expectations before patients enter the clinic and often require extended counseling to reconcile with evidence-based recommendations. Although dermatology occupies a uniquely visible position within digital culture, structured preparation in social media literacy is rarely incorporated into faculty development. Reverse mentorship, in which medical students provide structured digital insight to attending physicians, has been proposed as a practical educational strategy. A preliminary survey explored the perceived clinical influence of social media–shaped beliefs and early interest in reverse mentorship within dermatology.

Materials and Methods
A small-scale, online cross-sectional survey was distributed to U.S. dermatology attendings and medical students over a three-month period in 2025. The instrument gathered descriptive information regarding frequency of social media-influenced patient encounters, perceived impact on visit flow, confidence in addressing viral dermatologic claims, and attitudes toward structured reverse mentorship programming. Brief clinical vignettes explored responses to common online narratives such as sunscreen safety concerns and influencer-driven acne routines. Responses were analyzed descriptively to identify patterns and perceived areas of need.

Results
Participants represented a mix of academic and community practice environments. Many attending respondents reported regular exposure to social media-influenced concerns and noted that such discussions can alter visit dynamics. Several described strong confidence in interpreting scientific literature yet less confidence when responding to persuasive online narratives. Vignette responses suggested variability in approaches to digitally shaped treatment expectations. Interest in reverse mentorship was generally favorable, with attendings expressing openness to trainee-led digital literacy discussions and medical students indicating willingness to participate in structured mentorship roles. Greater reported exposure to misinformation-related encounters appeared associated with stronger receptivity to mentorship-based solutions.

Conclusions

Preliminary survey findings suggest that social media-influenced beliefs are perceived to affect dermatologic encounters and may contribute to uncertainty in addressing digitally shaped expectations. Early interest in reverse mentorship indicates potential feasibility as an educational strategy. Structured trainee-to-attending digital literacy initiatives represent a pragmatic approach to strengthening clinical preparedness and improving alignment between patient expectations and evidence-based dermatologic care.

EADV CONGRESS
VIENNA
30 SEP - 3 OCT 2026

Abstract N°: 3344

Assessment of the skin and serum level of interleukin-4 in pityriasis lichenoides chronica patients: a case-control study

Maha Fathy Elmasry*[1]

[1] Kasr Alainy Faculty of Medicine - Cairo University, Cairo, Egypt

Introduction

- There are limited case reports of biological therapy in pityriasis lichenoides chronica (PLC) after failure of conventional treatment. Recent case reports described the successful treatment of refractory PLC with dupilumab. Interleukin-4 is a pleiotropic, glycoprotein cytokine secreted predominantly by the activated Th2 cells, as well as various myeloid and innate lymphoid cells. IL-4 promotes Th2 cell differentiation.This study aimed to focus on the assessment of the levels of IL-4 in the lesional skin and serum of PLC patients and to compare its levels with healthy controls

Materials and Methods

- This case-control study involved 30 PLC patients and 30 healthy controls. Two biopsies were taken from every PLC patient (one for histopathology confirmation and another one for ELISA). Also, one skin biopsy was taken from every healthy control. A 5 ml venous blood sample was taken from every patient and control. IL-4 tissue and serum levels were measured by ELISA.

Results

Comparison of tissue and serum IL-4 level between patients and healthy controls was not statistically significant. There was a significant difference in IL-4 serum level between patients associated with and without upper respiratory tract infection. No correlation was found between tissue or serum IL-4 levels and disease severity.

Conclusions

The first study to evaluate both tissue and serum IL-4 levels in PLC patients by ELISA. Tissue and serum IL-4 levels are not significantly elevated in patients with PLC compared with healthy controls. IL-4 related pathways may still play a role in disease pathogenesis through mechanisms not directly reflected by circulating or tissue cytokine levels. PLC pathogenesis is likely multifactorial and may involve complex immune dysregulation rather than a purely Th2-driven process. The lack of correlation between IL-4 levels and disease severity further supports the limited utility of IL-4 as a biomarker in PLC. A statistically significant elevation of serum IL-4 in patients with respiratory tract infection supports a potential role for infectious triggers in modulating immune responses in PLC cases.

EADV CONGRESS
VIENNA
30 SEP - 3 OCT 2026

Abstract N°: 3365

An Innovative Cream Improves Signs and Symptoms of Dermatoporosis in Subjects Aged 65 and Over

Alan Widgerow[1], Sarah Anjuwon[2], Mathieu Grivet-Seyve[2], Christine Emesiani*[1], Matthew Meckfessel[1]

[1] Galderma Laboratories, L.P., Fort Worth, United States

[2] Galderma R&D, Fort Worth, United States

Introduction

Dermatoporosis (DP) describes a gradual thinning of the skin eventually resulting in breakdown of its protective mechanism seen with aging and is characterized by skin atrophy and pigmentary changes. Minimal over-the-counter products currently exist to address DP. This clinical study investigated efficacy and tolerability of a novel cream formulated specifically for Dermatoporosis.

Materials and Methods

A single-center, 12-week in-use study was conducted on men and women over 65 years old with sensitive skin and a history of DP. Subjects were instructed to apply the cream twice daily on both arms and one leg (other calf served as control). Assessments included skin hydration, transepidermal water loss (TEWL), ultrasound, clinical grading, digital photography, self-assessment questionnaire and tolerability for safety.

Results

Fifty subjects completed the study. There was a statistically significant improvement in skin hydration and TEWL at every time point compared to baseline. Ultrasound showed a significant 5% improvement in dermal thickness of the inner forearm after 8 and 12 weeks. Clinical grading revealed significant reduction in dryness and roughness at each time point. Self-assessment responses were favorable: 89% of subjects agreed their skin felt firmer at Day 7, 83% agreed their skin felt more elastic at Day 28, and 93% agreed their skin appeared more youthful. There was no worsening or significant increase in tolerability, or adverse events reported.

Conclusions

These clinical study results showed that the cream was well-tolerated, efficient in reducing the early signs of Dermatoporosis, and well-perceived by subjects.

EA DV CONGRESS
VIENNA
30 SEP - 3 OCT 2026

Abstract N°: 3369

Prepared or underprepared: How dermatology training shapes diagnostic accuracy in medical trainees

Sarah Fleming*[1], Karen Eustace[1]

[1] Beaumont Hospital, Dublin, Ireland

Introduction

Junior doctors are at the fore in recognising and implementing initial management for patients presenting with acute dermatological presentations, such as drug eruptions. Yet studies demonstrate that undergraduate and postgraduate training in dermatology remains inadequate leaving junior doctors ill-equipped to recognise and manage acute presentations.

Materials and Methods

A mixed methods survey was distributed to junior doctors at a large teaching hospital. Junior doctors who participated in on call duties were included (n=44). Questions related to dermatology exposure during postgraduate and undergraduate training; experience in managing acute dermatological conditions during training and support from senior clinicians. In addition, three clinical scenarios were selected from the BAD handbook for medical students and presented as multiple choice questions (MCQs)

Ethical approval was granted by Beaumont Hospital Ethics (Medical Research) Committee (reference 25/27).

Results

Only 28% of our survey participants recalled having an undergraduate dermatology training experience, with the majority of these lasting 1-2 weeks in total (n=8). Only 3 participants reported having worked in dermatology during postgraduate training. A significant number reported having no postgraduate training in dermatology (90%) while only 9% reported having training in acute presentations, yet 35% reported having to manage dermatological emergencies.

73% of participants did not feel confident in their descriptions of cutaneous disease. In addition, only 9% of study participants recall having training in the identification and management of acute dermatology presentations. Despite this, 93% of our survey participants correctly identified erythroderma from a clinical image and vignette, with 83% correctly identifying a morbilliform drug eruption and 65% identifying Stevens-Johnson Syndrome (SJS).

There was no statistical difference noted between those who reported undergraduate clinical placements (p=0.360 95% CI -0.391-1.054) or teaching (p=0.463 95% CI -0.541-1.170) and perceived confidence in the diagnosis and management of acute presentations. Neither undergraduate training nor experience had any significant impact on correctly identifying any of the 7 MCQ's. 93% of respondents stated that additional training would benefit junior doctors in the identification and management of dermatological presentations.

35% of the junior doctors surveyed have had to manage a dermatological presentation when on call with 32% requesting specialist dermatology input, with only 30% feeling supported by senior colleagues.

Conclusions

In conclusion, this study highlights the urgent need for supportive undergraduate and postgraduate training for junior doctors, particularly those not based in dermatology practice but who often encounter acute dermatological presentations on call and can have a significant impact on treatment outcomes.

EADV CONGRESS
VIENNA
30 SEP - 3 OCT 2026

Abstract N°: 3373

Butt contouring and lifting using the combination of PLLA and body fillers

Shahd Elraggal*[1]

[1] Sol the clinic, New cairo, Egypt

Introduction

To evaluate the safety, efficacy, and aesthetic outcomes of a combined protocol using PLLA and body fillers for non surgical buttock contouring and lifting.

The demand for non-surgical gluteal contouring has significantly
increased, driven by patients seeking safer alternatives to surgical augmentation. While hyaluronic acid (HA) and other body fillers provide immediate volumization, their longevity and lifting capacity may be limited. Poly-L-lactic acid (PLLA), a biostimulatory agent, promotes neocollagenesis and progressive tissue remodeling. This study explores the synergistic effect of
combining PLLA with body fillers to achieve both immediate contour enhancement and long-term lifting.

Materials and Methods

A prospective cohort of patients seeking non-surgical gluteal enhancement underwent a standardized treatment protocol combining PLLA injections for collagen stimulation and body fillers
for immediate volume restoration.
PLLA was injected in a deep
subcutaneous plane using a fanning technique, targeting areas requiring structural support and skin quality improvement. Body fillers were subsequently placed to enhance
projection and contour. Patients were assessed at baseline, 6 weeks,
3 months, and 6 months using standardized photography, patient satisfaction scales, and global aesthetics scores

Results

Patients demonstrated immediate improvement in volume and contour following filler injection, with progressive enhancement in skin quality, firmness, and lifting observed over subsequent months due to PLLA-induced collagen production.
High patient satisfaction rates were reported, with minimal downtime and a favorable safety profile. No major complications were observed, and minor adverse events were self-limiting.

Conclusions

The combination of PLLA and body fillers represents a synergistic and effective approach for non-surgical buttock contouring and lifting. This dual-modality technique addresses both structural volume loss and
ana tissue laxity, offering immediate and long-lasting aesthetic improvement It may serve as a safe and versatile alternative to surgical procedures, with high patient satisfaction and reproducible outcomes.

EA DV CONGRESS
VIENNA
30 SEP - 3 OCT 2026

Abstract N°: 3385

Legal Liability for AI-Assisted Misdiagnosis in Dermatology: What Clinicians Need to Know

Andreja Pagon*[1], Vid Bajuk[1]

[1] Medical Faculty, University of Ljubljana, Ljubljana, Slovenia

Introduction

Artificial intelligence (AI) is transforming dermatological practice. From convolutional neural networks that classify skin lesions to large language models answering patient queries about basal cell carcinoma, AI tools are becoming embedded in everyday clinical workflows. A critical question emerges that most dermatologists are ill-equipped to answer: when an AI system contributes to a missed or incorrect diagnosis and a patient is harmed, who is legally responsible? Survey data show that while the majority of dermatologists hold an optimistic view of AI's potential, fewer than one in six have received any formal AI training as part of their medical education or continuing professional development, and more than half believe AI could actually increase rates of misdiagnosis.

Materials and Methods

Under current legal frameworks, the physician remains the responsible party. AI systems are treated as tools, and the standard of care continues to be measured against what a reasonably competent human clinician would do. A dermatologist who relies on an AI recommendation without critically evaluating it does not escape liability simply because a machine was involved and courts have consistently held that clinicians bear the burden of errors arising from outputs they acted upon. This principle holds whether the AI is used for triaging dermoscopy images, flagging suspicious lesions via teledermatology, or guiding differential diagnoses through a clinical decision support system.
The liability picture becomes more complex when AI errors arise from problems the individual clinician could not have foreseen. Many AI tools deployed in dermatology suffer from a fundamental limitation known as the "black box" problem: their deep learning algorithms reach conclusions through processes that are opaque even to their developers. When such a system misclassifies a melanoma in a patient with darker skin, a well-documented risk given that most training datasets are built predominantly on Fitzpatrick skin types I through III, it may be impossible to reconstruct why the error occurred. Traditional negligence law, which requires demonstrable causation and an identifiable breach of duty, struggles in this scenario. Liability may be distributed across the treating dermatologist, the healthcare institution that deployed the system, the software developer, and the manufacturer, with no single party clearly responsible and the patient potentially left without adequate remedy.

Results

At the regulatory level, the European Union's AI Act (Regulation 2024/1689) introduces a risk-based framework that classifies AI systems used in high-stakes medical contexts as high-risk, subjecting them to mandatory conformity assessments, transparency requirements, and post-market surveillance. This represents meaningful legislative progress. However, even a certified AI system can generate harmful diagnostic errors, and the AI Act does not resolve the fundamental question of civil liability when this occurs.
Physicians must not treat AI outputs as autonomous diagnoses. They retain the obligation to critically appraise every AI-generated recommendation, document their clinical reasoning, and ensure that patients are informed when AI tools contribute to their care, including the

limitations of such tools. Healthcare institutions bear parallel responsibilities: implementing an AI system without adequate staff training, vetting, or oversight protocols may itself constitute negligence.

Conclusions

The liability frameworks governing AI in medicine are evolving, and future development will likely focus on shared liability models that
more fairly distribute responsibility across the chain from developer to deployer to clinician, alongside strengthened explainability requirements that make AI decision-making legible enough to satisfy evidentiary standards. For now, dermatologists should understand that
integrating AI into clinical practice is not a transfer of responsibility — it is an extension of it.

EA DV CONGRESS
VIENNA
30 SEP - 3 OCT 2026

Abstract N°: 3396

Data-Driven Conceptual Disease Model of Prurigo Nodularis Using Structural Equation Modeling

Sonja Ständer*[1], Franz Legat[2], Danielle Rodriguez[3], Patrick Daniele[3], Christophe Piketty[4], Raj Rout[4], Ram Subramanian[4], Katrin Jack[4], Sarah Coquis-Knezek[4], Jorge Puelles[4]

[1] Center for Chronic Pruritus, University Hospital Münster, Münster, Germany

[2] Universitätsklinik für Dermatologie und Venerologie, Medizinische Universität Graz, Graz, Austria

[3] Thermofisher Scientific, Cambridge, United States

[4] Galderma, Zug, Switzerland

Introduction

Prurigo nodularis (PN) is a chronic, inflammatory, and neuroimmune-mediated skin disease characterized by hyperkeratotic nodules, intense and persistent itch, sleep disturbance, and substantially impaired quality of life (QoL)/health status. The burden of PN is driven not only by pruriginous skin lesions but also by the complex interplay between itch, scratching behavior, and downstream effects such as sleep disruption and psychosocial impairment. While these domains are recognized as interrelated, their relative contributions and pathways of influence have not been quantified. A comprehensive, data-driven conceptual disease model (CDM) may help elucidate these relationships and provide insight into mechanisms of disease burden and treatment benefit.

The objective is to develop a clinically relevant, data-driven conceptual disease model of PN and quantify the direct and indirect relationships among skin lesion severity, itch, sleep disturbance, and QoL/health status using baseline clinical trial data.

Materials and Methods

Latent constructs were defined for skin lesion severity, itch , sleep disturbance, and QoL/health status using validated clinical outcome assessments (COAs) [IGA, PAS, PP-NRS, PGIP, SD-NRS, PGI-SD, EQ-5D VAS, and DLQI]. Baseline COA data were obtained from the intent-to-treat population in OLYMPIA pivotal studies [N=560; NCT04501666, NCT04501679]. Structural equation modeling (SEM) was conducted to explore direct and indirect relationships among PN domains. Factor loadings were calculated to assess the relationship between observed COAs and their respective latent constructs, and regression coefficients were estimated to ensure clinically interpretable directionality. Model fit was evaluated using standard indices (e.g., CFI, RMSEA, SRMR).

Results

Data from N=418 patients with PN and with complete baseline COA data were included in the analysis. In the final model (Figure 1), both skin lesion severity and itch intensity demonstrated significant direct effects on QoL/health status (skin → QoL: β=0.233; itch → QoL/health status: β=0.272), with itch intensity exerting a slightly stronger impact. Itch severity also had a substantial indirect effect on QoL/health status mediated through sleep disturbance (itch → sleep: β=0.773; sleep → QoL/health status: β=0.340). These findings suggest that while both skin and itch independently contribute to QoL/health status impairment in PN, itch plays a more prominent role, both directly and through its downstream impact on sleep disturbance. All COAs demonstrated strong loadings on their respective latent constructs, supporting construct validity.

Figure 1. Structural Equation Modeling Results

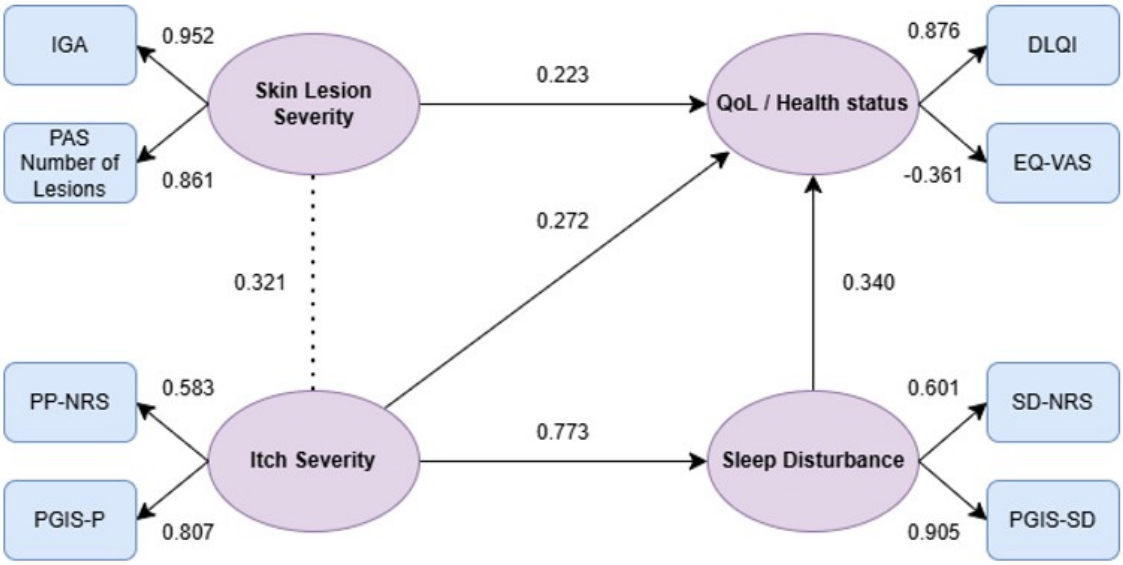

Model Fit Statistics: TLI: 0.971, CFI: 0.945, RMSEA (90% CI): 0.075 (0.053, 0.098), SRMR: 0.042

Abbreviations: IGA = Investigator's Global Assessment; PAS = Prurigo Activity and Severity; PP-NRS = Peak Pruritus Numerical Rating Scale; PGIS-P = Patient Global Impression of Severity - Pruritus; QoL = Quality of Life; DLQI = Dermatology Quality of Life Index; EQ-VAS = EuroQol Visual Analog Scale; SD-NRS = Sleep Disturbance Numerical Rating Scale; PGI-SD = Patient's Global Impression of Severity - Sleep Disturbance

Conclusions

This data-driven CDM identifies itch intensity as a central driver of disease burden in PN, with both direct effects on QoL/health status and indirect effects mediated through sleep disturbance. Skin lesion severity also contributes to QoL/health status impairment, although to a lesser extent than itch. These findings highlight the multifaceted pathways through which PN impacts patients and underscore the importance of assessing and targeting itch and sleep disturbance in clinical management and therapeutic evaluation. The model provides a clinically interpretable framework to support endpoint selection, treatment assessment, and future research into disease mechanisms in PN.

EA DV CONGRESS
VIENNA
30 SEP - 3 OCT 2026

Abstract N°: 3438

An unusual case of syringoma with “scar-like” aspect

Mihaela Balaban*[1], Roxana Zaharia[2]

[1] Dermatology, M Hospital, Bucharest, Romania

[2] General Surgery, M Hospital, Bucharest, Romania

Introduction

Syringoma is a benign tumor arising from eccrine sweat glands’ ducts, usually affecting the periorbital area as multiple skin-coloured papules. Occasionally, it can be found in other parts of the body, such as the trunk or the vulva. Multiple or eruptive syringomas had been described in patients with Down syndrome.



Clinical aspect of the lesion

Case Presentation

We present the case of a 71-year-old female patient, who presented for an erythematous nodule affecting the posterior aspect of the right arm. The lesion was asymptomatic and stable in size for many years. She denied any history of previous surgical excision, trauma or insect bite. Clinical examination revealed an indurated erythematous nodule, 1 cm in size, irregular in shape, with a scar-like appearance on a background of solar damage.

Dermoscopy showed a structureless pinkish area, with barely visible linear vessels and a pseudo-network in the periphery of the lesion. The differential diagnosis included a hypertrophic scar, a benign adnexal tumor and a nodular basal cell carcinoma. Taking into consideration the unusual aspect of the lesion, we decided to perform an excisional biopsy.

The histopathological report showed a tumor proliferation arranged in small tracts, cellular nests and tubular structures of variable shapes and caliber, lined by two layers of cuboidal cells, with eosinophilic cytoplasm, with slightly hypertrophic nuclei, occasionally with prominent nucleoli. In the dermis, minimal lymphocytic inflammatory infiltrate predominantly arranged perivascularly was

present. Moderate solar elastosis lesions (grade 2) were described. The diagnosis was suggestive of syringoma with incidental solar lentigo.

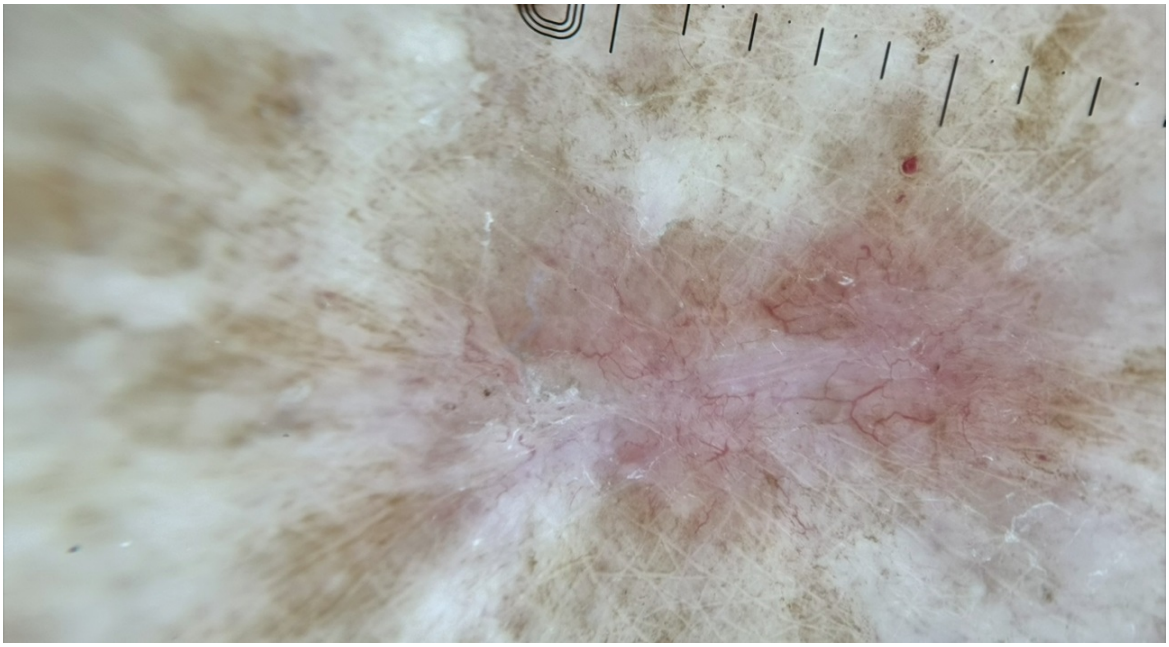

Dermoscopy of the lesion

Conclusion

We presented a case of a syringoma with scar-like aspect with an unusual location, which highlights the importance of the histopathological examination for a final diagnosis. It is also important to reassure the patient of the benign character of this lesion and to exclude other diagnoses.

EADV CONGRESS
VIENNA
30 SEP - 3 OCT 2026

Abstract N°: 3479

Perforating Dermatosis: Through the Spectrum of Transepidermal Elimination

Andreea-Caterina Rusu*[1], Carina-Andreea Bazon[1], Anca Zbranca-Toporaş[1], Diana Gabriela Iosep[1, 2], Ioana Iosep[3]

[1] Emergency Clinical Hospital of St. Spiridon, iasi, Romania
[2] University of Medicine and Pharmacy "Grigore T. Popa", iasi, Romania
[3] "Dr. Iacob Czihac" Clinical Emergency Hospital, Iasi, Iasi, Romania

Introduction

Perforating dermatoses comprise a heterogeneous group of disorders defined by transepidermal elimination of altered dermal constituents, most commonly collagen and elastic fibers. The spectrum includes classical entities such as elastosis perforans serpiginosa, Kyrle disease, perforating folliculitis (PF) and acquired reactive perforating dermatosis (ARPD). The significant overlap of clinical and histopathological features among these disorders may render diagnosis particularly challenging.

Case Presentation

We report the case of a 62-year-old woman referred for evaluation of chronic, painful, intensely pruritic skin lesions with recurrent exacerbations and major impairment of quality of life.

Her medical history included a right ectopic kidney under nephrological surveillance, autoimmune thyroiditis with hypothyroidism, and anxiety disorder. The eruption began in 2015 on the abdomen and lateral trunk as painful vesicular lesions. A bacteriological examination identified *Staphylococcus aureus*, prompting topical antibiotic therapy without lasting benefit. The lesions progressively extended to the trunk, buttocks, and both upper and lower extremities.

At one point, based on the patient's description of the lesions, herpes zoster was suspected and prolonged topical treatment was prescribed, again without improvement. On admission, dermatological examination revealed multiple erythematous papules and nodules, several excoriated or ulcerated and covered by serohemorrhagic crusts, predominantly involving the trunk and extremities. The lesions displayed a fluctuating course and were associated with severe pruritus and pain.

Histopathological examination proved particularly challenging because of overlapping perforating features. The biopsy demonstrated a pilosebaceous follicle suggestive of PF, including transepidermal elimination of keratinous material. In addition, altered collagen fibers extending through the epidermis were identified within the dermis. Another notable finding was the presence of an intraepidermal bulla containing seroinflammatory material and amorphous debris, associated with focal epidermal destruction and perforation. Altogether, the histopathological pattern suggested a perforating dermatosis with overlapping features of both ARPD and PF, making precise classification difficult.

Initial management included topical corticosteroids, re-epithelializing agents, and oral antihistamines. Further investigations led to the diagnosis of hepatitis C virus–related liver cirrhosis, followed by antiviral therapy with Sofosbuvir and Velpatasvir, with favorable evolution. Given the extensive and treatment-refractory nature of the dermatosis, repeated dermatological follow-up was required. The patient continued topical corticosteroid therapy and initiated narrowband UVB phototherapy with progressively increasing doses, achieving gradual clinical improvement. At present, only a limited number of residual lesions persist on the upper posterior thorax,

consisting of erythematous papules with superficial erosions and crusts.

Conclusion

This case illustrates the diagnostic complexity of perforating dermatoses, particularly in the presence of overlapping clinical and histopathological findings that do not fit neatly into a single classical entity. The absence of the most frequently reported associations, namely diabetes mellitus and advanced chronic renal failure, further contributes to the atypical character of the presentation. In our patient, the initially vesicular eruption, according to the patient's history, followed by evolution toward papulo-nodular excoriated lesions, together with the coexistence of transepidermal elimination of keratinous material and collagen fibers extending through the epidermis, supports the concept of a clinicopathological continuum within the spectrum of perforating dermatoses rather than a strictly delineated subtype.

EADV CONGRESS
VIENNA
30 SEP - 3 OCT 2026

Abstract N°: 3541

Where do patients go when they can't access public dermatology? Alternative care pathways during a median nine-month wait

Emily Sisson[1, 2], Bruna Morassi Sasso*[3], Ishana Dixit[3, 4], Pablo Fernandez-Peñas[3, 4]

[1] NSW Health, Sydney, Australia

[2] University of New South Wales, Sydney, Australia

[3] Westmead Hospital, Sydney, Australia

[4] University of Sydney, Sydney, Australia

Introduction

Public dermatology services globally face growing demand against a backdrop of rising skin cancer incidence. When patients cannot access timely specialist care, they may seek alternative pathways. This study describes the alternative care-seeking behaviour of patients on a Category 1 public hospital dermatology waitlist during a median wait of 273 days.

Materials and Methods

Observational cohort study of 496 eligible Category 1 dermatology waitlist patients. Alternative care was captured from consultation notes and at point of contact when patients were reached to arrange appointments. Financial barriers to private care were documented within referral records.

Results

Of 496 patients, 73 (15%) were referred with biopsy-confirmed skin cancer and 257 (52%) for suspected skin cancer or lesion. Of 258 patients booked for an appointment, 223 attended. Of 238 patients not booked, 232 were removed from the waitlist and 6 remained. Reasons for removal included already seeking care elsewhere (n=91, 39%), being uncontactable (n=88, 38%), declining review (n=25, 11%), and death while waiting (n=13, 6%). Among the 91 removed as already reviewed, providers included private dermatologists (n=21, 23%), surgical oncology or plastics (n=22, 24%), dermatology via emergency department (n=7, 8%) and skin cancer clinics (n=4, 4%).

Of 223 patients who attended, 75 (34%) had sought alternative care during the waiting period: 26 (12%) via private dermatologist only, 23 (10%) via another specialist only, 18 (8%) via GP-escalated care only, and 8 via more than one provider; 3 had consulted dermatologists in another country.

Despite this, specialist review remained essential: 26 incidental skin cancers were identified at attendance in patients not referred for them, including 16 BCCs, 8 SCCs, and 2 melanomas. Forty-one patients (8%) had an inability to afford private dermatology documented in their referral.

Conclusions

Patients waiting for public dermatology disperse across fragmented, inequitable pathways — private specialists, surgical services, emergency departments, and providers in other countries — or go without care entirely. Thirteen

patients died while waiting. Financial barriers exclude a significant minority from the most common alternative. The detection of 26 incidental skin cancers underscores that dermatologist review cannot be replaced by fragmented alternative pathways. These findings highlight the inequity and clinical risk of insufficient public dermatology capacity internationally.

EADV CONGRESS
VIENNA
30 SEP - 3 OCT 2026

Abstract N°: 3591

Setmelanotide-induced hyperpigmentation and nevus changes in two adult siblings with Bardet-Biedl syndrome

Virginia Velasco-Tamariz*[1], Alfonso Gotor-Rivera[1], Julian Acosta-Hernández[1], Eva Chamorro-Jiménez[1], Emilia García-Rivera[1], MARIO JUAN PUERTA PEÑA[1], Laura Perez-Olivares Martin[2], Alba Calleja-Algarra[1], Pablo Luis Ortiz Romero[1], Borja González[1]

[1] Department of Dermatology, University Hospital 12 de Octubre, Madrid, Spain, Health Research Institute Hospital 12 de Octubre (i+12)., Department of Medicine, Complutense University, Madrid, Spain., MADRID, Spain
[2] Department of Endocrinology, Hospital 12 de Octubre, Madrid, Spain

Introduction

Setmelanotide is a melanocortin-4 receptor (MC4R) agonist approved for hyperphagia and obesity in Bardet-Biedl syndrome (BBS). Off-target activation of the melanocortin-1 receptor (MC1R) causes cutaneous hyperpigmentation, reported in up to 100% of treated patients, and may stimulate melanocytic proliferation, with isolated reports of eruptive dysplastic nevi and rare melanomas. Most available evidence is paediatric and data in adult patients are scarce.

Case Presentation

We report two adult brothers (48 and 46 years old, Fitzpatrick phototype II) with clinically diagnosed BBS — obesity, polydactyly, retinitis pigmentosa and hypogonadism — without personal or family dermatological history, referred from endocrinology before and during setmelanotide treatment.

Both patients developed early and pronounced diffuse cutaneous hyperpigmentation within the first weeks of treatment, together with progressive darkening of pre-existing melanocytic nevi and the appearance of new pigmented lesions. Hyperpigmentation was most evident on photo-exposed areas, including the upper back and the dorsum of the hands. Baseline and follow-up evaluations were performed with full-body macroscopic photography and digital dermoscopic mapping. Both siblings received strict photoprotection counselling (SPF ≥50 with regular reapplication, sun-protective clothing, avoidance of midday sun exposure) and ABCDE self-monitoring education, with dermoscopic surveillance.

Conclusion

This sibling pair illustrates the early, marked and reproducible pigmentary response to setmelanotide in adult BBS patients, including diffuse cutaneous hyperpigmentation and darkening of pre-existing nevi. As setmelanotide use expands in this population, dermatologists play a central role in baseline cutaneous characterisation, longitudinal dermoscopic monitoring and patient education to ensure early detection of atypical or malignant melanocytic lesions. Adult patients should be specifically included in pharmacovigilance and dermatological screening strategies for this drug.

EADV CONGRESS
VIENNA
30 SEP - 3 OCT 2026

Abstract N°: 3645

Eruptive Disseminated Porokeratosis in an Immunosuppressed Renal Transplant Patient

Pablo Balado-Simó*[1], Daniel Morgado Carrasco[2]

[1] Dermatology Department, Hospital Clínic Barcelona, Barcelona, Spain, Melanoma Group, August Pi Sunyer Biomedical Research Institute (IDIBAPS), Barcelona, Spain, University of Barcelona, Barcelona, Spain., Barcelona, Spain

[2] Dermatology Department, Hospital Clínic Barcelona, Barcelona, Spain, Dermatology Department, Hospital de Figueres, Fundació Salut Empordà, Figueres, Spain, Barcelona, Spain

Introduction

Porokeratosis comprises a heterogeneous group of clonal keratinization disorders defined histologically by the presence of a cornoid lamella. Eruptive disseminated porokeratosis is an uncommon variant characterized by the sudden onset of multiple annular keratotic lesions, usually affecting the trunk and limbs. It has been mainly reported in immunosuppressed patients, including individuals with HIV infection, hematologic or solid organ malignancies, and transplant recipients. Immunosuppression may impair cutaneous immune surveillance and facilitate the expansion of abnormal keratinocyte clones. Although lesions are often asymptomatic, porokeratosis is considered a premalignant condition, making accurate recognition and long-term surveillance particularly relevant in high-risk patients.

Case Presentation

A 50-year-old man with a history of end-stage renal disease who had undergone renal transplantation 10 years earlier presented with progressive, asymptomatic skin lesions. The eruption had appeared abruptly one year after transplantation and had gradually increased in number. He was receiving long-term immunosuppressive therapy with tacrolimus, mycophenolate mofetil and low-dose prednisone, with stable graft function. He denied pruritus, pain, bleeding, ulceration or systemic symptoms.

Clinical examination revealed hundreds of brown annular macules measuring 0.5–1 cm in diameter, with sharply demarcated keratotic borders. The lesions were symmetrically distributed over the thorax, abdomen, and upper and lower limbs, sparing the mucosae, palms and soles. Dermoscopy showed well-circumscribed circular lesions with central hypopigmentation and a peripheral white track-like scaling border, consistent with a cornoid lamella. Histopathological examination of a punch biopsy revealed a vertical column of parakeratosis overlying focal hypogranulosis and dyskeratosis in the upper epidermis, confirming the diagnosis of eruptive disseminated porokeratosis.

Given the absence of symptoms, the patient declined active treatment. He was counselled regarding photoprotection, self-monitoring and the need for regular dermatological follow-up because of the chronic course of the disease and the potential risk of malignant transformation, particularly in the context of chronic immunosuppression.

Conclusion

This case highlights eruptive disseminated porokeratosis as an important diagnostic consideration in immunosuppressed transplant recipients presenting with widespread annular keratotic lesions. The differential diagnosis includes actinic keratosis, seborrhoeic keratosis, lichen planus, dermatophyte infection, psoriasis, nummular eczema and pityriasis rosea. Recognition of the characteristic clinical, dermoscopic and histopathological features is essential to avoid misdiagnosis, unnecessary diagnostic procedures or inappropriate

treatments. Although many cases are asymptomatic, porokeratosis requires surveillance because malignant transformation to squamous cell carcinoma may occur, especially in extensive, long-standing or hypertrophic lesions and in immunosuppressed patients.

Therapeutic options for eruptive disseminated porokeratosis remain limited and include topical keratolytics, 5-fluorouracil, imiquimod, cryotherapy, photodynamic therapy and systemic retinoids, depending on lesion burden, symptoms and patient preference. Recently, topical lovastatin, with or without cholesterol, has emerged as a promising pathogenesis-based treatment in disseminated superficial actinic porokeratosis and may be considered in selected patients with widespread or cosmetically concerning disease. In asymptomatic patients, careful observation with patient education and periodic skin examination represents a reasonable approach.

EA CONGRESS
VIENNA
30 SEP - 3 OCT 2026

Abstract N°: 3782

SIGNAL OR NOISE? DECODING EXTRACELLULAR VESICLES IN UVEAL MELANOMA

Theodora Tsimpaki*[1], Ralitsa Anastasova[1], Azin Yousefiboroujeni[1], Nikolaos Bechrakis[1], Miltiadis Fiorentzis[2]

[1] University Hospital Essen, Essen, Germany

[2] University Hospital Schleswig-Holstein, Lübeck, Germany

Introduction

Uveal melanoma (UM) is the most common primary intraocular malignancy in adults and is characterized by a high metastatic rate and poor survival outcomes. Extracellular vesicles (EVs) are considered mediators of tumor-associated signaling. However, their biological relevance in uveal melanoma is incompletely characterized, particularly whether their cargo reflects active signaling or passive release.

Materials and Methods

A multi-step filtration and chromatography-based workflow was used to isolate EVs from primary (UM92.1, Mel270) and metastatic (MM28) UM cell lines, as well as non-malignant controls (ARPE-19, HEK293T). Vesicle size distribution and morphology were characterized by electron microscopy, nanoparticle tracking analysis, and flow cytometry. EV cargo was analyzed by proteomic and RNA profiling. The loading capacity of UM-derived EVs was quantified by HPLC. Functional effects were evaluated across viability, proliferation, migration, apoptosis, and cytotoxicity assays.

Results

EVs exhibited cell line-specific functional and molecular profiles. Moderate survival and migratory effects were detected in primary UM-derived EVs, while metastatic MM28 EVs reduced viability and increased apoptosis and cytotoxicity in autologous cells. Proteomic profiling revealed enrichment of extracellular matrix and adhesion-associated proteins in MM28 EVs, while EVs from primary UM cells were dominated by signaling-related components. Total RNA analysis identified distinct EV-associated transcriptional patterns related to the prognostic 15-gene expression profile (15 GEP), showing differential composition across cell lines. miRNA profiling demonstrated enrichment of stress response- and tumor progression associated miRNAs, particularly in metastatic EVs. Functional responses to EV exposure varied depending on recipient cell type and EV concentration. HPLC analysis confirmed successful bleomycin loading into EVs. The lipidomic profile of UM-derived EVs revealed enrichment of sphingolipid- and cholesterol-associated lipid species, which have repeatedly been linked to EV biogenesis, membrane organization, tumor-associated lipid remodeling, and immunomodulatory or stress-related EV functions.

Conclusions

Extracellular vesicles derived from uveal melanoma exhibit distinct, cell line-dependent molecular and functional profiles that support an active role in tumor-associated signaling rather than passive byproducts of cellular turnover. EVs from primary and metastatic UM cells differ substantially in their proteomic and RNA cargo, reflecting their biological origin and disease stage. The variability in recipient cell responses further highlights the

context-dependent nature of EV-mediated communication. Their selective proteomic enrichment, alongside distinct transcriptional and miRNA signatures linked to stress response and tumor progression, suggest that EV cargo composition is functionally relevant and dynamically regulated. These characteristics highlight their potential as biomarkers for risk stratification and metastasis prediction. Importantly, the successful loading of bleomycin into UM-derived EVs demonstrates their promise as drug delivery vehicles. Collectively, these findings indicate that EVs in uveal melanoma are biologically active mediators that contribute to intra- and intercellular tumor interactions, with significant potential as both diagnostic biomarkers and therapeutic tools.

EA DV CONGRESS
VIENNA
30 SEP - 3 OCT 2026

Abstract N°: 3783

Deep penetrating naevus: A 10-year single-centre retrospective review of management and recurrence.

Catherine Christopher*[1], James Wiggins[1], Kathryn Dey[1], Shantini Rice[1], Asok Biswas[1]

[1] NHS Lothian, Edinburgh, United Kingdom

Introduction

Deep penetrating naevus (DPN) is an uncommon benign melanocytic lesion that rarely exhibits malignant transformation. First recognised in 1989 it was recently reclassified by the WHO as a WNT-activated deep penetrating melanocytoma. It is distinguished histopathologically by wedge shaped dermal proliferations of spindle and epithelioid cells and demonstrates immunohistochemical expression of β-catenin. There is currently a lack of agreed local and national guidance on the management of DPN. Recommendations in current literature include re-excision in the presence of atypia, and either follow up for lower risk lesions, or discharge without further review.

Materials and Methods

Cases were identified by word search of the pathology IT database in the absence of SNOMED codes. Medical notes and pathology reports were reviewed on Trak and a standardized proforma completed in Microsoft Excel. Photographs were taken from clinical records using Medical Image Manager and written consent was obtained for publication.

Results

We report an audit of 49 patients between 2010 and 2020 with an age range from 6 to 85 (mean 35.7) and a strong female predilection (76%). Common sites included the cheek (22.4%), leg (14.3%), shoulder (10.2%) and arm (10.2%). The most common clinical differentials included melanoma (51.0%), blue naevus (34.7%) and atypical / dysplastic naevus (28.6%). The majority of lesions were removed by elliptical (67.3%) or punch (26.5%) excision, though some were managed with a shave biopsy (6.1%).

Incomplete excision was noted in 4 cases without atypia, and 3 of these patients had no re-excision, follow up or evidence of recurrence. A second wider excision was performed in 6 patients, 4 of which demonstrated significant atypia. Variable lengths of follow up occurred in 7 (14.3%) patients including one due to atypical naevi syndrome, though only two cases demonstrated evidence of atypia. 1 (2%) patient developed recurrence.

Conclusions

Despite its usually benign behavior we identified a significant case highlighting the potential of this lesion. Histology indicated malignant transformation of a DPN in a patient in their 20's, ultimately leading to a diagnosis of pT4 melanoma. The patient experienced recurrence following initial excision and was treated for stage 4 melanoma with immunotherapy.

This case emphasises the need for heightened awareness of the malignant potential associated with DPN, even though such transformations are rare. It also reinforces the importance of careful histopathological assessment, risk-appropriate follow-up, and the development of evidence-based clinical guidelines. Establishing standardised management pathways would ensure consistency in care, reduce uncertainty for clinicians, and improve patient safety through earlier detection of atypical or malignant changes. Further data collection at national level could

help inform evidence-based clinical management guidelines for DPN.



Malignant transformation of a deep penetrating naevus on the leg.

EA DV CONGRESS
VIENNA
30 SEP - 3 OCT 2026

Abstract N°: 3806

When the Face Speaks: A Panorama of Dermatoses Behind Leonine Facies

Nada Naciri*[1], Bendaoud Layla[1], Mariem Aboudourib[1], Hocar Ouafa[1], Said Amal[1]

[1] Arrazi Hospital, Mohammed VI University Hospital, Faculty of Medicine and Pharmacy of Marrakech, Biosciences and Research Laboratory FMPM, Cadi Ayyad University, Department of Dermatology –Venereology,, Marrakesh,, Morocco

Introduction

Leonine facies is a rare clinical sign characterized by diffuse facial infiltration with nodular thickening and accentuated skin folds, producing a lion-like appearance. Initially described in lepromatous leprosy, it may reveal infectious, neoplastic, inflammatory, or infiltrative diseases. This study illustrates its etiologic diversity and prognostic implications.



Violaceous Infiltrated Facial Nodules Causing Skin Thickening and Accentuation of Facial Folds

Materials and Methods

We conducted a retrospective descriptive study including 7 patients presenting with leonine facies, seen in our Dermatology Department between January 2022 and April 2026.

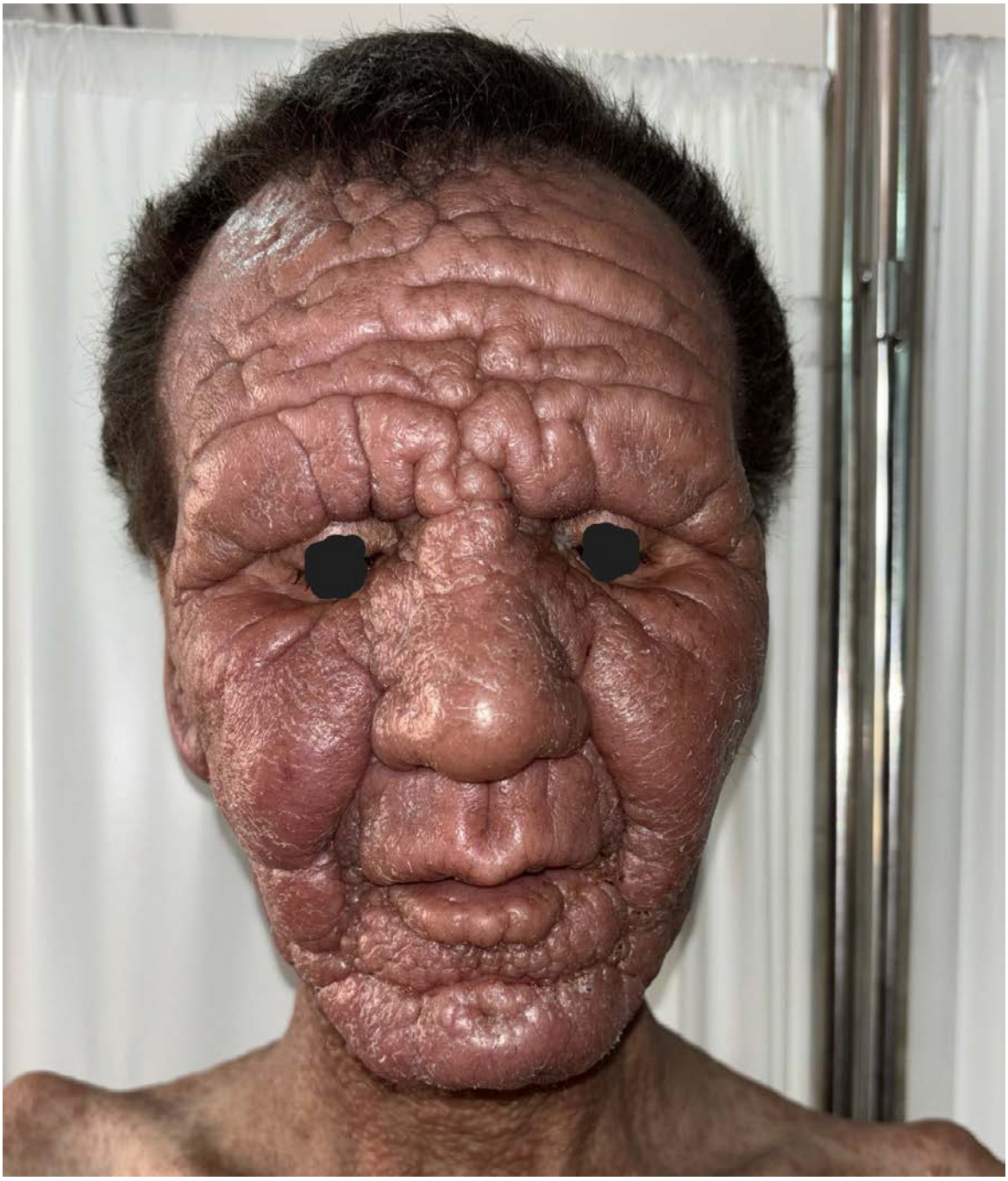

Infiltrated facial papules with skin thickening and accentuation of facial folds, resulting in a leonine facies appearance.

Results

The mean age of the patients was 50 years. All patients were male. Progressive facial infiltration leading to leonine facies was the main reason for consultation in all cases.

Clinically, lesions were predominantly characterized by infiltrated papules and nodules of the face, flesh-colored or violaceous, causing skin thickening with accentuation of facial folds in all cases. Associated findings included diffuse involvement of the entire integument, infiltration of the auricle, macrocheilia, cutaneous ulcerations, dry erythroderma, alopecic plaques, hypochromic macules, loss of the lateral third of the eyebrows, peripheral sensory disturbances, lymphadenopathy, and papulo-pustular lesions with centrofacial telangiectasia.

Investigations included skin biopsy, immunohistochemistry, direct examination of dermal scrapings, dermoscopy, neurological investigations, phototesting, and staging work-up.

The etiologies identified in our series were predominantly infectious, represented by four cases of multibacillary leprosy, including one case associated with visceral leishmaniasis in a patient with AIDS. Neoplastic causes included one case of aggressive peripheral cutaneous T-cell lymphoma. Two cases were related to inflammatory etiologies: chronic actinic dermatitis and phymatous rosacea. Management was adapted according to the underlying etiology. The outcome was favorable in four patients, whereas two patients died and one patient recently started multidrug anti-leprosy therapy.



Leonine facies associated with macrocheilia

Conclusions

Leonine facies results from diffuse dermal infiltration, sometimes associated with madarosis, nasal atrophy, and hypoesthesia. Historically described in multibacillary leprosy, it is not disease-specific and may occur in cutaneous T-cell lymphomas, Kaposi sarcoma, certain leukemias, pseudolymphomas, phymatous rosacea, storage dermatoses, and photodermatoses. Its clinical recognition is essential to guide biopsy, histopathology, immunohistochemistry, microbiological and parasitological examinations, and phototesting. Prognosis depends

on the underlying etiology and the timeliness of management.

Leonine facies is a rare but highly suggestive clinical presentation associated with a broad spectrum of diseases. Its recognition should prompt a rigorous diagnostic approach and early management, both of which strongly influence prognosis. This study highlights the etiological diversity and the importance of a systematic approach when faced with leonine facies.



Multiple painful, well-defined flesh-colored nodules involving the face and neck, associated with auricular infiltration, leading to leonine facies.

EA DV CONGRESS
VIENNA
30 SEP - 3 OCT 2026

Abstract N°: 3833

Management of Erythema Annulare Centrifugum: A Review of the Literature

Ishita Aggarwal*[1], Olga Gomeniouk[2], Maria Tsoukas[1], Roger Haber[1]

[1] University of Ilinois at Chicago Department of Dermatology, Chicago, United States
[2] Rush University, Chicago, United States

Introduction

Erythema annulare centrifugum (EAC) is a reactive figurate erythema characterized by annular, expanding erythematous plaques with trailing scale. It represents a cutaneous hypersensitivity response to diverse triggers, including infections, medications, autoimmune conditions, and, less commonly, malignancy. Despite its benign nature, management is challenging due to the heterogeneous triggers, spontaneous resolution in some patients, and chronic relapse in others, as well as the absence of randomized controlled trials on therapy. Existing literature consists largely of anecdotal reports and small series with inconsistent outcome measures, which limits the availability of standardized guidance. EAC can pose a significant psychosocial stress to patients and thus better stepwise therapy options are highly clinically relevant. This review aims to synthesize available therapeutic data, grade treatment efficacy, propose a stepwise management pathway, and identify priorities for future research.

Materials and Methods

A literature review was conducted to identify studies reporting treatment outcomes for EAC. Searches were performed using a structured Boolean strategy including combinations of “erythema annulare centrifugum,” “EAC,” and “figurate erythema” with treatment-related terms encompassing topical, systemic, and targeted therapies. Due to variability in how erythema annulare centrifugum is indexed across databases, search results were supplemented to ensure comprehensive capture of relevant publications. Eligible studies included case reports, case series, observational studies, and reviews describing treatment response in clinically or histopathologically diagnosed erythema annulare centrifugum. Extracted data included suspected triggers, therapeutic modality, dosing, and duration when reported, clinical response, time to clearance, relapse, and adverse events.

Results

96 patients were included across systematic reviews, open trials, retrospective series, and case reports. EAC subtypes included idiopathic, secondary, infection-triggered, refractory, and paraneoplastic variants. Macrolide antibiotics were the most utilized systemic therapy, with complete response (CR) rates of 80–100% and mean time to clearance ranging from 2–4 weeks in superficial patterns to 14.7 weeks. Recurrence following antibiotic therapy was uncommon (≈13%) and typically responsive to retreatment, with mild adverse effects reported in 7.4% of cases.

Antifungal therapy, particularly fluconazole, demonstrated efficacy in infection-associated EAC, though relapse occurred in a subset of patients. Targeted therapies showed benefit in refractory disease, including phosphodiesterase-4 inhibitors (roflumilast, apremilast) and Janus kinase inhibition (upadacitinib), achieving complete or partial responses with minimal adverse effects. Metronidazole was associated with rapid clearance, potentially reflecting combined antimicrobial and anti-inflammatory activity. In paraneoplastic EAC, partial

symptomatic improvement was observed with topical therapy, with complete resolution following treatment of the underlying malignancy. Overall, treatment response varied by EAC subtype, with faster and more durable clearance observed in idiopathic and superficial disease compared with refractory or secondary forms.

Conclusions

Management of EAC would benefit from a structured approach. Available evidence supports early evaluation and treatment of underlying triggers, followed by local anti-inflammatory therapy to control symptoms. For widespread, idiopathic, or relapsing disease, macrolides and fluconazole demonstrate the most consistent efficacy and safety profiles, while topical phosphodiesterase-4 inhibition represents a promising steroid-sparing option in refractory cases. Standardized outcome measures are needed to refine treatment sequencing and improve evidence-based guidance for this condition.

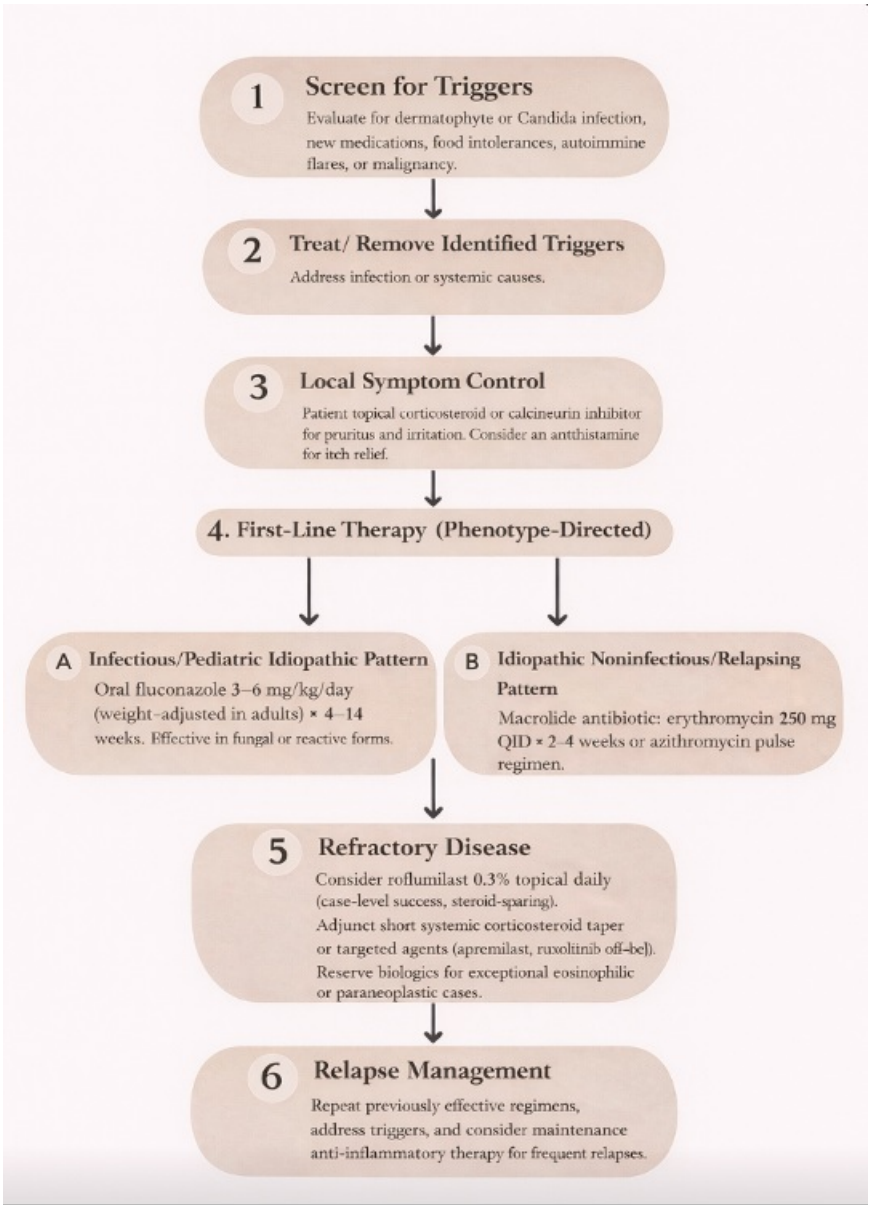

EA DV CONGRESS
VIENNA
30 SEP - 3 OCT 2026

Abstract N°: 3847

Global Distribution of Wait Times for Dermatologic Care

P Shamaeizadeh[1, 2, 3], JM Yardman-Frank[4], T Khalfalla[2, 3, 5], S Westby[2, 3], S Anwar[2, 3, 6], C Li[2, 3, 7], A Pacheco[2, 4, 8], D McMahon[3], K Su[2], A Strahan[3], M El Sayed[9], C Galvan-Casas[10], W Enbiale[11, 12], S Gondokaryono[13], XH Gao[14], AG Kibbi[15], A Lee[16], F Ly[17, 18], J Ocampo-Candiani[19], MA Richard[20], R Romiti[21], J Kilmer[22], J Takeshita[23, 24], HW Lim[25], B Chuberre[26], D Kerob[27], LC Fuller[28], G de Lambert[29], CEM Griffiths[30, 31], NC Dlova[32], R Bhat[33], E Freeman*[2, 3]

[1] University of Kentucky College of Medicine, Lexington, KY, United States

[2] Medical Practice Evaluation Center, Mongan Institute, Massachusetts General Hospital, Boston, MA, United States

[3] Department of Dermatology, Massachusetts General Hospital, Boston, MA, United States

[4] Department of Dermatology, Beth Israel Deaconess Medical Center, Boston, MA, United States

[5] University of Rochester School of Medicine and Dentistry, Rochester, NY, United States

[6] Tufts University School of Medicine, Boston, MA, United States

[7] University of Massachusetts School of Medicine, Worcester, MA, United States

[8] University of Toledo College of Life Sciences, Toledo, OH, United States

[9] Ain Shams University, Cairo, Egypt

[10] Hospital Universitario de Móstoles, Madrid, Spain

[11] Bahir Dar University, College of Medicine and Health sciences,, Bahir Dar, Ethiopia

[12] Collaborative Research and Training Center for Neglected Tropical Diseases, Arba Minch University, Arba Minch, Ethiopia

[13] Universitas Padjadjaran, Department of Dermatology and Venereology, Dr. Hasan Sadikin General Hospital, Bandung, Indonesia

[14] The First Hospital of China Medical University, Shenyang, China

[15] Department of Dermatology, American University of Beirut Medical Center, Beirut, Lebanon

[16] Department of Dermatology and Medicine, St Vincent's Hospital, University of Melbourne, Melbourne, Australia

[17] Department of Dermatology, STI EPS Institut D'Hygiène Sociale de Dakar, Faculty of Medicine, Pharmacy, and Odontostomatology, University Cheikh Anta Diop of Dakar, Dakar, Senegal

[18] Faculty of Medicine, Pharmacy, and Odontostomatology, University Cheikh Anta Diop of Dakar, Dakar, Senegal

[19] Department of Dermatology, Hospital Universitario "Dr. José E. González", Universidad Autónoma de Nuevo León, Monterrey, Mexico

[20] Research Centre in Health Services and Quality of Life, Aix Marseille University Dermatology Department, University Hospital Timone, Assistance Publique Hôpitaux de Marseille, Marseille, France

[21] Department of Dermatology, University of São Paulo, São Paulo, Brazil

[22] The International League of Dermatological Societies, London, United Kingdom

[23] Department of Dermatology, Perelman School of Medicine at the University of Pennsylvania, Philadelphia, PA, United States

[24] Department of Biostatistics, Epidemiology and Informatics, Perelman School of Medicine at the University of Pennsylvania, Philadelphia, PA, United States

[25] Department of Dermatology, Henry Ford Health, Detroit, MI, United States

[26] L'Oréal Dermatological Beauty, Paris, France

[27] La Roche-Posay Laboratoire Dermatologique, Levallois-Perret, France
[28] London Bridge Hospital, London, United Kingdom
[29] L'Oréal Dermatological Beauty, Global Medical Team, Levallois-Perret, France
[30] Centre for Dermatology Research, NIHR Manchester Biomedical Research Centre, Manchester Academic Health Science Centre, University of Manchester, Manchester, United Kingdom
[31] Department of Dermatology, King's College Hospital, King's College London, London, United Kingdom
[32] Department of Dermatology, University of KwaZulu-Natal, Durban, South Africa
[33] Department of Dermatology, Venereology and Leprosy, Father Muller Medical College, Mangalore, India

Introduction
Long wait times to see a dermatologist are associated with more severe presentations of skin disease at time of diagnosis and poorer outcomes. Despite availability of wait time data from high-income settings, evidence on global distribution of dermatology wait times remains limited. Literature from other specialties shows that in low- and middle-income countries (LMICs), there are often longer wait times to see a specialist in the public sector compared to the private sector. This study aims to assess the global distribution of wait times for dermatologic care.

Materials and Methods
The Skin Observatory Study is a Delphi-derived cross-sectional study of 194 WHO member states surveying dermatologic leaders. Participants were asked about factors affecting access to dermatologic care. Data on wait time to see a dermatologist after referral and their differences across public and private sectors were analyzed. Variation was tested across WHO regions and World Bank income levels (WBIL) using chi-square and Fisher exact tests for categorical variables.

Results
Of 158 survey responses, 136 countries responded regarding average wait times to see a dermatologist via referral. Seven countries reported no available dermatologists and therefore wait time was inapplicable. Most countries reported that the average wait time after referral was less than one month (48%), followed by waits of 1-2 months (19%), and 3-4 months (13%). Seven countries reported a wait time of longer than six months, the longest available reporting category.

Average wait time following referral varied across WHO region ($p=0.001$) and WBIL ($p=0.005$). Shorter wait times after referral were focused mostly in lower income settings with 61% of countries in low and 63% of countries in LMICs reporting wait times less than one month versus only 24% of high-income countries. Longer wait times (3-4 months) were more common in the European and Americas region.

When asked if wait times varied by public and private sector, 137 countries provided responses. Majority (61%) reported that wait times differed in the public and private sectors, with 89% of countries reporting that wait times are longer in the public sector compared to the private sector. This difference did not vary by country income ($p=0.333$) or region ($p=0.541$).

Conclusions
To our knowledge, this is the first study to compare global wait times after referral for dermatologic care. We highlight longer wait times in the public sector, consistent across regions and income levels. Paradoxically, we observed longer wait times in higher income countries.

Our prior research on dermatologic access, barriers, and workforce consistently demonstrates profound shortages in lower-resource settings. We therefore hypothesize that shorter measured wait times in these contexts may be misleading, reflecting limited workforce and infrastructure, fragmented referral pathways, and partial capture of patients within the health system. In many LMICs, dermatologists are few and concentrated in urban centers, with care delivery often combining limited appointment infrastructure and walk-in models. As a result, health systems may preferentially capture patients with more severe disease at a small number of sites.

Ultimately, our data show that focusing only on post-referral wait times masks the complexity of access to dermatologic care, including workforce shortages and distribution, travel burden, scheduling structures, and in-clinic waiting. Therefore, longer waiting times for a referral to a dermatologist in higher income settings may simply reflect a developed, robust referral and consultation infrastructure. More granular work is needed to understand the full implications of waiting time – not just wait time for a referral, as studied here, but also characterizing the full patient experience of delay from symptom onset through to diagnosis, threshold for referral to a specialist and how that may vary by country.

EADV CONGRESS
VIENNA
30 SEP - 3 OCT 2026

Abstract N°: 3876

Androgen Deprivation Therapy Is Associated With Reduced Risk of Androgen-Mediated Dermatologic Disease in Patients With Prostate Cancer

Robert Adler*[1], James Noyes[1], Myles Goliger[1], Michael Kozlov[1], Jeffrey Weiss[1]

[1] SUNY Downstate Medical Center, Brooklyn, United States

Introduction

Androgen signaling plays a key role in sebaceous gland activity, follicular keratinization, and other cutaneous processes. While androgen deprivation therapy (ADT) is a cornerstone treatment for prostate cancer (PCa), its relationship with androgen-mediated dermatologic disease remains incompletely characterized. We evaluated the incidence of dermatologic conditions among patients with PCa treated with ADT compared with matched controls.

Materials and Methods

We performed a retrospective cohort study using the TriNetX federated research network. Patients with PCa exposed to ADT agents including bicalutamide, enzalutamide, apalutamide, darolutamide, leuprolide, degarelix, or relugolix were identified. Control patients had no documented exposure to these medications. Outcomes were identified using ICD-10 diagnostic codes. Initial cohorts included 140,207 ADT-treated patients and 645,883 controls. Propensity score matching was performed for demographics, comorbidities, and oncologic variables, resulting in 105,043 patients per cohort with strong baseline balance. Mean age was 69.2 +/- 9.7 years in the ADT cohort and 71.8 +/- 9.1 years in controls prior to matching. Median follow-up after matching was 1356 days in the ADT cohort and 1352 days in controls. Outcomes included seborrheic dermatitis, acne, hidradenitis suppurativa (HS), dry eye disease, hair loss, xerosis, psoriasis, lichen planus, and severe drug reactions. Hair loss outcomes included androgenic alopecia, other non-scarring alopecia, and cicatricial alopecia. Relative risks (RR) and hazard ratios (HR) were calculated.

Results

ADT exposure was associated with significantly lower rates of several androgen-mediated conditions. Seborrheic dermatitis occurred in 1.2% of ADT patients versus 1.7% of controls (RR 0.706; HR 0.692, 95% CI 0.643-0.744; p<0.001). Acne incidence was reduced in the ADT cohort (0.3% vs 0.5%; RR 0.705; HR 0.698, 95% CI 0.608-0.802; p<0.001). HS was also less common among ADT-treated patients (0.04% vs 0.06%; RR 0.647; HR 0.639, 95% CI 0.437-0.934; p=0.02). Dry eye disease occurred less frequently with ADT exposure (2.2% vs 2.5%; RR 0.887; HR 0.889, 95% CI 0.839-0.940; p<0.001).

No significant differences were observed for hair loss (0.4% vs 0.4%; HR 0.982, 95% CI 0.864-1.116; p=0.97), xerosis (HR 0.980; p=0.48), psoriasis (HR 0.929; p=0.30), lichen planus (HR 0.927; p=0.50), or severe drug reactions (HR 1.10; p=0.38).

Conclusions

Among patients with PCa, ADT was associated with a statistically significant but clinically modest reduction in several androgen-mediated dermatologic conditions, including seborrheic dermatitis, acne, HS, and dry eye

disease. These findings support the role of androgen signaling in sebaceous and follicular inflammatory pathways while suggesting no clear association with other inflammatory dermatoses such as psoriasis and lichen planus. ADT was not associated with increased risk of severe dermatologic drug reactions, xerosis, or hair loss.

EA DV CONGRESS
VIENNA
30 SEP - 3 OCT 2026

Abstract N°: 3899

Effects of a Triple-Acid Topical Formulation on Skin Hydration and Barrier Function

Nikkia Zarabian*[1], Mina Farah[1], Ariana Zarghami[1], Krzysztof Piotrowski[2], Nadège Lachmann[2], Adam Friedman[1]

[1] George Washington University School of Medicine and Health Sciences, Washington, DC, United States

[2] Galderma Sensitive Skincare Faculty, Zug, Switzerland

Introduction

Skin hydration is essential for maintaining barrier integrity, protecting against environmental insults, supporting thermoregulation, and limiting transepidermal water loss (TEWL). Hydroxy acids, including salicylic acid (SA), mandelic acid (MA), and gluconolactone are widely used topical agents in dermatology that not only promote exfoliation and enhance epidermal turnover, but can also contribute to improved skin hydration and barrier function. Building on these properties, this study evaluates the moisturizing and barrier-protective efficacy of a topical lotion containing a triple-acid blend of SA, MA, and gluconolactone, combined with glycerin, vitamin B3, and vitamin B5.

Materials and Methods

In a randomized, single-blind, controlled clinical study, 30 healthy female subjects aged 18-70 years with dry skin, defined by baseline electrical capacitance values of 15-45 arbitrary units and TEWL ≥6 g/m²/h, were enrolled. One forearm per subject was randomized to receive the investigational product, while the contralateral forearm served as an untreated control. Skin hydration was assessed using electrical capacitance (Corneometer™ CM 825), and barrier function was evaluated via TEWL (Tewameter™ TM 300). Measurements were obtained at baseline (T0) and at 1, 4, 8, and 24 hours post-application, with capacitance additionally measured at 48 hours. Statistical analyses were performed using Student's t-test or Wilcoxon testing based on Shapiro-Wilk normality assessment ($p<0.01$), with significance set at $p<0.05$.

Results

No significant differences in electrical capacitance or TEWL were observed between treatment and control sites at baseline. Following a single application, the treated sites demonstrated a statistically significant increase in electrical capacitance compared to both baseline and control at 1, 4, 8, 24, and 48 hours ($p<0.05$), indicating enhanced stratum corneum hydration with sustained effects up to 48 hours (Figure 1). TEWL was significantly reduced at treated sites compared to baseline and control at 1, 4, 8, and 24 hours ($p<0.05$), reflecting improved barrier function (Figure 2). The formulation was well tolerated, with no reported adverse events.

Figure 1

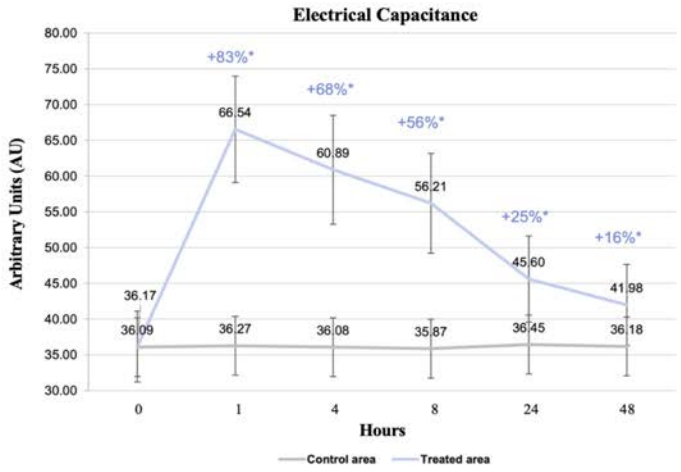

Figure 2

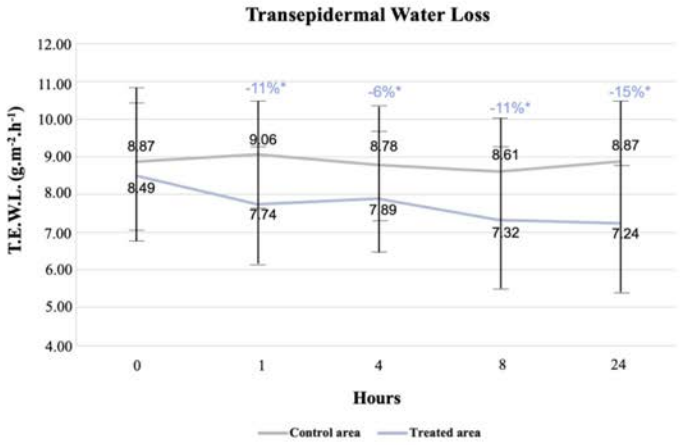

Figure 1. Electrical capacitance evident at baseline, 1, 4, 8, 24, and 48 hours after initial application (*indicates statistical significance at $p<0.05$). Figure 2. TEWL at baseline, 1, 4, 8, and 24 hours after initial application (* indicates statistical significance at $p<0.05$)

Conclusions

This study demonstrates that a single application of a topical lotion containing SA, MA, and gluconolactone significantly improves skin hydration and reduces TEWL, with both immediate and sustained effects. The combination of exfoliating acids with humectant and barrier-supporting ingredients may provide synergistic benefits in enhancing stratum corneum function. These findings support the formulation's potential as both a therapeutic and maintenance option for xerosis and barrier dysfunction. Further studies in larger and more diverse populations are warranted to confirm these results and evaluate long-term efficacy.

EA DV CONGRESS
VIENNA
30 SEP - 3 OCT 2026

Abstract N°: 3916

Clinical Evaluation of Unit-Dose Encapsulated Retinol in a Botanical Oil Vehicle for Improving Dermal Density and Reducing Periorbital and Forehead Dynamic Wrinkles

Yajun Luo*[1], Lirui Cao[1], Martin Keh[1], xiaomin zhao[1], yan zhong[1], Justin He[1]

[1] Estée Lauder Companies China Innovation Center, Shanghai, China

Introduction

Wrinkles are among the most visible signs of aging. Their development is multifactorial and may be associated with skin dryness and stiffness, photo damage, collagen loss and repeated mechanical stress from facial expressions such as smiling and eyebrow raising. Both static and dynamic wrinkles can contribute to an increase in perceived age. Retinol is a well-established anti-aging ingredient known for stimulating collagen and accelerating cellular turnover. However, its use is challenged by limited stability, particularly under exposure to light, oxygen and water, as well as potential skin tolerability concerns. To address these challenges, a botanical oil-based retinol formulation was developed and packaged in unit-dose capsules to help protect formula integrity while delivering anti-aging efficacies. In this study, a 12-week clinical evaluation was conducted to assess the effect of the encapsulated retinol oil formulation on visibly improving static and dynamic wrinkles and dermal collagen density.

Materials and Methods

Female subjects aged 36 to 65 from Beijing, China, exhibiting multiple mild to moderate static wrinkles were recruited for the study. One retinol capsule was applied once daily in the evening for the 1-week adaptation phase, then was used twice daily through the 12-week test period. Static wrinkles and dynamic wrinkles induced by smiling and eyebrow raising expressions were captured with VISIA®-CRP system and Eve V Skin Imaging system. The severity and characteristics of wrinkles were assessed by expert grading. Deep-learning based wrinkle image analysis were conducted at baseline and week 12. Dermal density was measured using Dermalab Ultrasound on cheekbone and jawline area.

Results

39 subjects (mean age 55.4±7.7 years) completed the 12 weeks study with no discomfort reports. Dermal skin density levels at both cheekbone and jawline skin showed at least a 20% increase by week 12. Visible improvements of static fine lines (under-eye, crow’s feet, forehead) and wrinkles (crow’s feet, nasolabial fold, glabella, forehead and marionette) were observed at week 4, with further reductions by week 12 as experts assessed. Facial periorbital and upper cheek dynamic wrinkles exhibited with smile expression were visibly improved from week 4 to week 12. Forehead dynamic wrinkles were pronounced with eyebrow raising expression and were also visibly improved from week 4 to 12.

Image analysis on static under eye, crow’s feet and forehead wrinkles showed wrinkle area and counts were reduced by week 12, consistent with expert assessments. The image analysis of dynamic wrinkles with smile and eyebrow raising revealed that the visible wrinkle improvements were contributed by decreased wrinkle area, average depth, length and counts.

Conclusions

Progressive improvements in multiple static and dynamic wrinkles and fine lines were observed over the study period based on expert grading and further supported by software image analysis. Increased dermal density was also observed through Dermalab Ultrasound. These findings demonstrated the clinical benefits of this unit-dose encapsulated retinol oil formulation in improving visible signs of facial aging and supporting a younger-looking appearance.

EA DV CONGRESS
VIENNA
30 SEP - 3 OCT 2026

Abstract N°: 3919

Incubating Artificial Intelligence (AI) Initiatives and Careers in Dermatology

Clare Primiero*[1], Shannon Wongvibulsin[2], Eric Tkaczyk[3]

[1] Frazer Institute, The University of Queensland, Dermatology Research Centre, Brisbane, Australia

[2] Division of Dermatology, Department of Medicine, David Geffen School of Medicine, University of California Los Angeles, Los Angeles, United States

[3] Department of Electrical and Computer Engineering, Vanderbilt University, Tennessee, United States

Introduction

Artificial intelligence (AI) tools are rapidly emerging in dermatology and have the potential to revolutionize dermatology practice and expand patient access to care. However, AI developments are often released without adequate dermatologist input, rigorous validation, cost-effectiveness analyses, or transparency. Academic dermatology therefore has a critical role in guiding the responsible development, implementation, and evaluation of AI technologies. This study aimed to identify key factors required to successfully support AI initiatives and careers within academic dermatology programs.

Materials and Methods

A survey was developed through multiple rounds of discussion among dermatology AI investigators and circulated to members of the International Skin Imaging Collaboration (ISIC) AI Working Group and other active dermatology AI researchers between August and September 2024. Responses were summarized using narrative synthesis to identify major themes and practical recommendations for supporting AI initiatives in dermatology.

Results

Twenty-six authors contributed to manuscript preparation, including 16 survey respondents with expertise spanning academic dermatology, AI research, and industry collaboration. Three overarching themes emerged: talent, resources, and organizations.

Participants emphasized the importance of cultivating multidisciplinary expertise through collaboration between clinicians and technical experts. Dermatologists require foundational AI literacy, dedicated institutional support, protected research time, and opportunities for cross-disciplinary training. Recruiting and retaining technical talent was identified as a major challenge due to competition from industry.

AI research in dermatology was recognized as resource-intensive, requiring large, annotated datasets, secure data-sharing systems, high-performance computing infrastructure, and specialized technical support. Institutions implementing integrated clinical workflows linking imaging, pathology, and clinical data may gain significant advantages in AI development. Funding limitations were frequently cited, with many programs relying on philanthropic support or industry partnerships.

Multi-institutional collaboration and industry engagement were viewed as essential for advancing dermatology AI, particularly to enable access to diverse datasets and scalable innovation. However, participants highlighted challenges relating to data governance, privacy, intellectual property, commercialization, and differing international regulations. Existing frameworks such as CLEAR Derm and FUTURE-AI were identified as valuable benchmarks for trustworthy and deployable AI models.

Conclusions

Successful incubation of AI initiatives and careers in dermatology requires coordinated investment in talent development, technical infrastructure, funding mechanisms, and collaborative ecosystems. Academic dermatology programs must take an active leadership role in shaping responsible AI innovation to ensure that emerging technologies improve patient care, maintain scientific rigor, and reduce healthcare inequities

EADV CONGRESS
VIENNA
30 SEP - 3 OCT 2026

Abstract N°: 3925

Addressing Patient Questions About Skincare Ingredients on Non–Evidence-Based Skincare Products

Sabah Iqbal*[1], Emily Uh[2], Jennifer Easterly[3], Michael Sun[2], Karen Vo[4], Kelly Frasier[5], Raman Madan[5]

[1] Rowan-Virtua School of Osteopathic Medicine, Stratford, NJ, United States
[2] SUNY Upstate Medical University, Syracuse, NY, United States
[3] Medical College of Georgia, Augusta, GA, United States
[4] Desert Regional Medical Center, Palm Springs, CA, United States
[5] Northwell, New Hyde Park, NY, United States

Introduction
Growing consumer engagement with non–evidence-based skincare products has accentuated discrepancies between ingredient marketing claims and dermatologic evidence, with direct implications for patient counseling in clinical practice. Questions regarding ingredient efficacy, safety, and necessity now constitute a routine component of dermatologic visits, requiring deliberate and informed counseling strategies.

Materials and Methods
An integrative review of dermatology clinic encounters, patient inquiry patterns, ingredient marketing data, and peer-reviewed dermatologic literature was performed. Analysis centered on commonly queried ingredient classes, including antioxidants, peptides, botanical extracts, and microbiome-modulating agents, and evaluated discrepancies between marketing claims and available mechanistic or clinical evidence to inform counseling approaches.

Results
Across practice settings, patient inquiries frequently reflected assumptions that ingredient novelty implies therapeutic benefit, expectations of efficacy independent of formulation or concentration, and beliefs that cosmetic products can meaningfully alter inflammatory or chronic skin disease. Effective counseling responses consistently involved clearly distinguishing cosmetic benefit from medical efficacy, contextualizing preliminary or theoretical evidence, and addressing safety considerations without dismissing patient interest. Translation of marketing terminology into pharmacologic, physiologic, and risk-based explanations supported alignment with evidence-based care while preserving therapeutic rapport.

Conclusions
Non–evidence-based skincare products represent a sustained and influential presence in dermatologic practice. Structured, evidence-centered counseling approaches enable clinicians to respond effectively to patient inquiries, reinforce clinical authority, support informed decision-making, and prevent substitution of unsupported products for validated therapies as skincare marketing continues to extend beyond available scientific validation.

EA DV CONGRESS
VIENNA
30 SEP - 3 OCT 2026

Abstract N°: 3933

Objective Skin Phenotyping Using 3D Total Body Photography and Artificial Intelligence

Clare Primiero*[1], Sam Kahler[1], Chantal Rutjes[1], Adam Mothershaw[1], Alyssa Sussanto[1], Siyuan Yan[2], Zhen Yu[2], Victoria Mar[3], Zongyuan Ge[2], H. Peter Soyer[1]

[1] Frazer Institute, The University of Queensland, Dermatology Research Centre, Brisbane, Australia
[2] Electrical and Computer Systems Engineering, Faculty of Engineering, Monash University, Melbourne, Australia
[3] Victorian Melanoma Service, Alfred Hospital, Melbourne, Australia

Introduction
The increasing use of total body photography (TBP) for skin cancer screening, alongside advances in artificial intelligence (AI), has contributed to the emergence of the skin surface imaging phenotype as a novel approach to melanoma risk profiling. Unlike self-reported or subjective assessments, surface imaging phenotyping leverages TBP and AI to derive objective imaging biomarkers associated with melanoma risk and broader health outcomes. Important phenotype features assessable through imaging include naevi characteristics, skin colour, ultraviolet (UV) photodamage, freckling, and obesity-related anthropometric measures. While automated tools for naevus analysis already exist, methods for objective assessment of other phenotype risk factors remain limited. This study aimed to develop and evaluate novel methods for automated skin surface imaging phenotyping using 3D-TBP and AI.

Materials and Methods
Novel photo-numeric scales for UV photodamage and freckling assessment were developed and evaluated for use by lay annotators. A training and testing dataset was subsequently used to develop convolutional neural networks (CNNs) for automated UV photodamage and freckling classification.

To automate skin colour assessment from 3D-TBP images, individual typology angle (ITA) measurements were extracted from images of 137 participants and compared with manual colorimetry-derived ITA values. Deming regression was used to correct systematic bias, while agreement was assessed using Bland-Altman analysis and Cohen's Kappa.

Obesity-related anthropometric phenotyping methods were additionally developed from 3D-TBP images, including estimation of waist circumference (WC) and android/gynoid (A/G) body type classification. Cross-sectional body slices derived from 3D avatars were used to estimate waist-to-hip ratios and classify fat distribution patterns associated with cardiometabolic risk. Associations between imaging-derived obesity measures and obesity-related comorbidities were assessed using multivariable logistic regression.

Results
The photo-numeric scales demonstrated substantial-to-almost perfect agreement between lay annotators and dermatology researchers for image assessment (κ=0.77–0.83). The CNN achieved strong performance for UV photodamage classification, with an area under the receiver operating characteristic curve (ROC-AUC) of 0.96 and class-specific accuracies of 0.98, 0.92, and 0.99 for mild, moderate, and severe photodamage, respectively.

ITA values extracted from 3D-TBP images systematically underestimated manual measurements; however,

adjustment models improved agreement to moderate-substantial levels compared with colorimetry-derived values.

Among 894 participants, higher BMI, larger WC, and android body type derived from 3D-TBP were independently associated with increased odds of cardiovascular disease, diabetes, and arthritis (all $P<0.05$). These findings support the utility of 3D-TBP for automated obesity-related comorbidity screening within dermatology workflows.

Conclusions

We developed novel methods for automated assessment of multiple skin surface imaging phenotype features using 3D-TBP and AI. These approaches enable objective quantification of UV photodamage, skin colour, freckling, and obesity-related anthropometric measures from imaging data and represent important steps toward comprehensive deep imaging phenotyping. Integration of these objective imaging biomarkers into melanoma risk prediction and broader health assessment frameworks may improve risk stratification, support targeted screening initiatives, and facilitate more holistic patient care.

EA DV CONGRESS
VIENNA
30 SEP - 3 OCT 2026

Abstract N°: 3939

Longitudinal digital health monitoring in dermatology: a scoping review

Alexander Iwasyk*[1], Josh Chan[2], Cynthia Hui[1], Fatemeh Jafarian[1, 3], P. Régine Mydlarski[1, 3]

[1] Cumming School of Medicine, University of Calgary, Calgary, Canada
[2] Temerty Faculty of Medicine, University of Toronto, Toronto, Canada
[3] Division of Dermatology, Department of Medicine, University of Calgary, Calgary, Canada

Introduction
Chronic skin diseases produce fluctuating symptoms between-visits, which episodic clinical care captures incompletely. Wearable sensors, smartphone applications, and passive monitoring tools offer a means of capturing symptoms, patient behaviours, and disease activity longitudinally rather than at discrete timepoints. Use of these tools in dermatologic research has grown over the last few years but the current literature lacks a comprehensive description of how they are being deployed, in which populations, for which outcomes, and where the evidence is sparse. We conducted a scoping review to map the current evidence landscape.

Materials and Methods
This scoping review was reported per the PRISMA extension for scoping reviews (PRISMA-ScR). Four databases (Embase, MEDLINE, Scopus, IEEE Xplore) were searched from 2010 to 2025 for primary studies enrolling adults (≥18 years) with chronic inflammatory, immune-mediated, or malignant dermatologic disease that used a wearable sensor, smartphone application, or digital diary for longitudinal monitoring. Two reviewers independently screened and extracted data in duplicate, and a third resolved conflicts. Outcome and population heterogeneity precluded pooled analysis. Reported outcomes were grouped into eight domains: disease severity, pruritus/scratching, pain/activity, quality of life, psychological, sleep, physical activity/fatigue, and sun exposure/photoprotection.

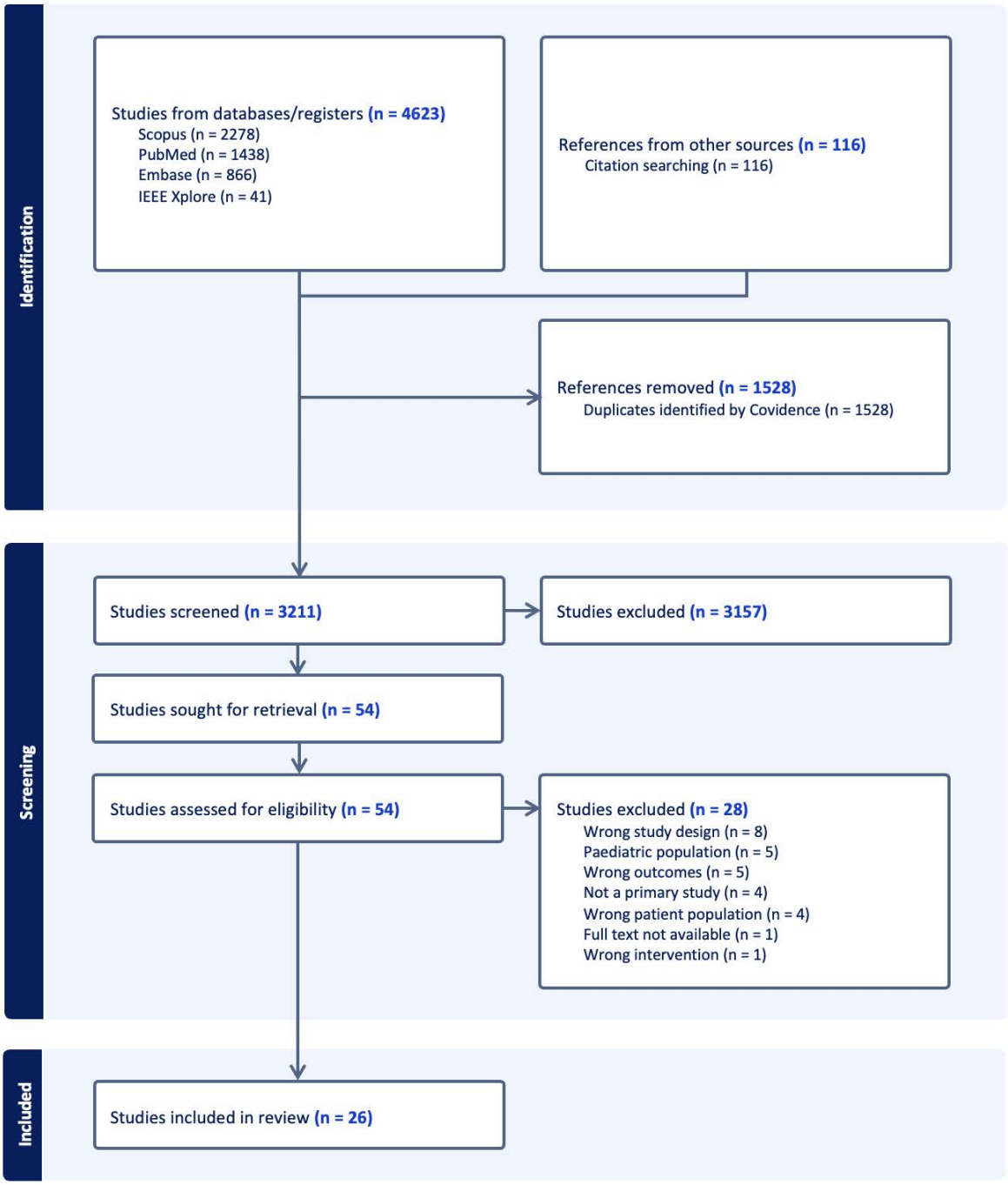

Figure 1. PRISMA-ScR flow diagram of study identification, screening, and inclusion. Reporting follows the PRISMA extension for scoping reviews (Tricco et al., Ann Intern Med 2018).

Results

From 4623 records screened, 26 papers describing 24 unique cohorts (1,533 participants; median cohort n=31) met eligibility. Twenty-three (88%) were published in 2020 or later. Study designs comprised 9 randomised controlled trials, 14 prospective cohort studies, 2 cross-sectional studies, and 1 prospective case-control study. Evidence clustered in three main populations: atopic dermatitis (n = 9), psoriasis (n = 7), and melanoma (n = 6), with the other populations comprised of hand and foot eczema (n = 2), actinic keratosis (n = 1), and psoriatic nail disease (n = 1). Mutually exclusive device categories were smartphone applications (n = 11), standalone wearable sensors (n = 10), and hybrid app and wearable systems (n = 5). Monitoring duration ranged from 1 to 60 weeks. Outcome reporting concentrated in disease severity using PASI, EASI, SCORAD, HECSI, or N-NAIL (n = 14), and quality of life via DLQI, POEM, or EORTC-QLQ-C30 (n = 13), followed by sleep (n = 7) and pruritus/scratching (n = 6). Where reported, digital-monitoring-paired interventions captured clinically meaningful improvement (e.g., EASI 26.2 to 6.1 with dupilumab in atopic dermatitis and DLQI reductions of 3–5 points across psoriasis cohorts). Sun exposure (n = 5) appeared exclusively in skin-cancer-risk cohorts. Pain/activity (n = 3), psychological (n = 5), and physical activity/fatigue (n = 2) were sparsely reported, with physical activity appearing only in melanoma

cohorts. Study completion declined with monitoring duration, from ≥90% at three weeks or less to 48% beyond six months. A structured patient-completed usability instrument was used in 6 of 26 papers, and 14 reported sponsorships by, employment with, or evaluation of digital tools owned by the device or pharmaceutical manufacturer studied.

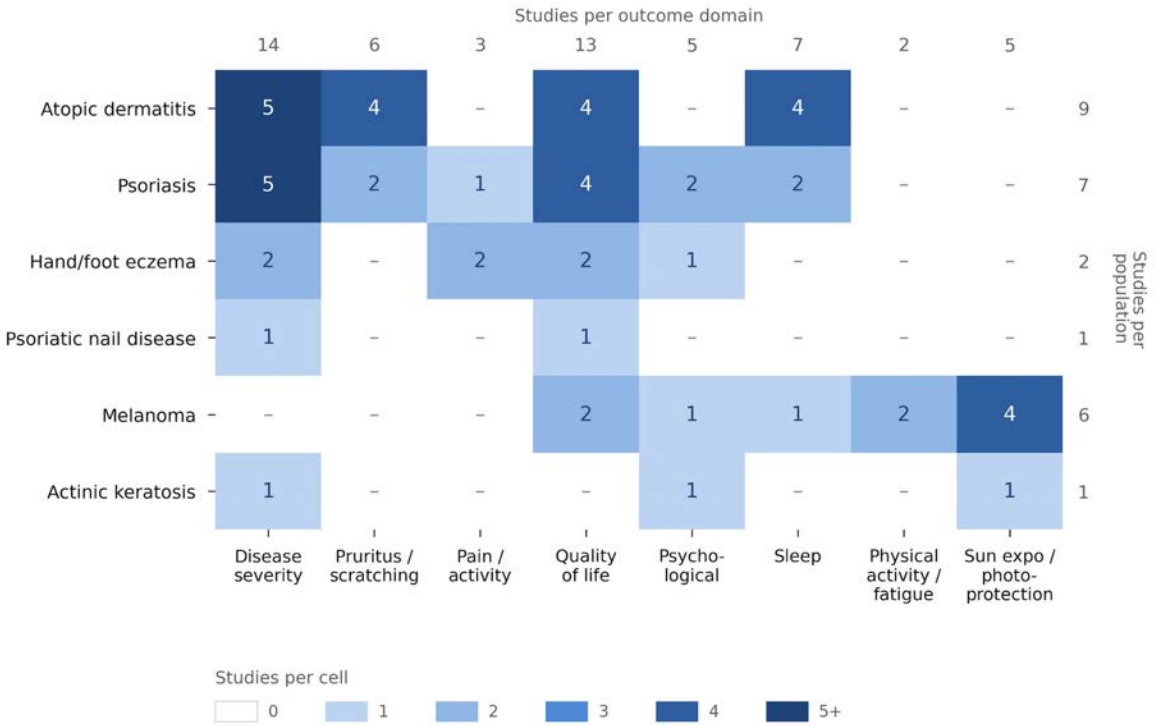

Figure 2. Evidence map of digital monitoring studies in adult dermatology by population (rows) and outcome domain (columns). Marginal totals give papers per population and per outcome domain (n = 26 papers, 24 unique cohorts); papers reporting multiple outcomes contribute to more than one cell.

Conclusions

Digital health monitoring in dermatology is a growing area of research concentrated in three main, but distinct disease populations, reporting on select outcomes. Key gaps such as underrepresentation of psoriatic nail disease and actinic keratosis populations. Pain, psychological, and physical activity outcomes are rarely captured, with sun exposure appearing melanoma-specific. Long-term adherence is poor and patient experience with technology is rarely evaluated. Future work in this area would benefit from standardized outcome reporting, strategies to sustain longitudinal patient engagement, dedicated usability evaluation, and deliberate inclusion of under-represented populations. This review offers a structured evidence map to support these directions.

EA DV CONGRESS
VIENNA
30 SEP - 3 OCT 2026

Abstract N°: 3991

Communicating with Deaf patients in dermatology: a retrospective cohort study

Kyle Mueller*[1, 2], Nancy Anabaraonye[3], Trisha Kaundinya[1], John Trinidad[1]

[1] Department of Dermatology, Mass General Brigham, Boston, United States

[2] University at Buffalo Jacobs School of Medicine and Biomedical Sciences, Buffalo, United States

[3] Harvard Medical School, Boston, United States

Introduction

Effective communication strategies are critical in providing deaf or hard of hearing patients with equal access to health care. For Deaf individuals, spelled with a capital ‘D’ to describe those who primarily use American Sign Language (ASL), qualified in-person interpreting services may be most effective. However, in the dermatology setting, financial barriers may prevent offices from providing in-person interpreters. Video remote interpreting (VRI), which uses videoconferencing technology with high-speed internet to provide 24-hour access to qualified interpreting services for languages such as ASL, may have limited effectiveness in the dermatology setting. Current communication methods and technologies used for Deaf dermatology patients have not been described. This study characterized the communication modalities used for Deaf patients at a large academic dermatology center.

Materials and Methods

We reviewed encounters of patients with a documented primary language of ASL who received care at dermatology clinics associated with a large tertiary care center in the Northeastern United States from January 2015 to August 2025. Trends in interpreter usage, including VRI, were assessed.

Results

The cohort included 83 patients who completed 356 in-office encounters, of which 280 (78.6%) documented communication modality. Of these 280 encounters, a qualified in-person interpreter was used in 194 (69.3%), VRI in 28 (10.0%), and accompanying persons interpreted in 11 (3.9%). Among the remaining 47 (16.8%) encounters, patients declined interpretation in 9 (3.2%), interpreters were unavailable for 7 (2.5%), and the reasoning was not

documented in 31 (11.1%). The alternative modalities used were lip-reading in 22 of 280 (7.9%) encounters (three patients), cochlear implants in 10 (3.6%, two patients), and writing in 8 (2.9%, four patients). In 7 (2.5%) encounters, lack of interpretation was documented but the communication modality used was unspecified (Table 1).

Between 2020—the first year of VRI usage in the cohort—and 2025, 126 encounters used either a qualified in-person interpreter or VRI. The proportion of these encounters using VRI increased from 10% in 2020 to 43% in 2025, with a corresponding decrease in qualified in-person interpretation from 90% to 57% (Table 2). Logistic regression demonstrated a significant increase in the odds of VRI use over time (OR = 1.79 per year; 95% CI = 1.29–2.50; $\chi^2 = 15.2$; $p < 0.001$).

Table 1. Proportions of communication services used in dermatology encounters with Deaf patients.

Communication Modality	Number of encounters (% of 280 total encounters)
Qualified in-person interpreter	194 (69.3%)
Video Remote Interpreting	28 (10.0%)
Accompanying person interpreted (e.g., family, friend)	11 (3.9%)
Lip-reading	22 (7.9%)
Cochlear implant-assisted spoken language	10 (3.6%)
Writing	8 (2.9%)
Unspecified	7 (2.5%)

Table 2. Changes in the proportion of qualified in-person interpreting versus video remote interpreting between 2020 and 2025.

Year	Number of encounters using qualified in-person interpreting (% of the year's total)	Number of encounters using video remote interpreting (% of the year's total)
2020	19 (90%)	2 (10%)
2021	18 (95%)	1 (5%)
2022	14 (93%)	1 (7%)
2023	23 (79%)	6 (21%)
2024	16 (57%)	12 (43%)
2025	8 (57%)	6 (43%)

Conclusions

Under the Americans with Disabilities Act, health care providers must offer proper accommodations for Deaf patients. The proportions of services used are not well described in healthcare globally, nor in dermatology. Our investigation of dermatology encounters for Deaf patients found that most encounters used ASL interpretation, with a recent shift from in-person services toward VRI. While VRI offers increased availability, the evidence of its limited effectiveness warrants evaluation of its use in dermatology.

Our findings suggest that Deaf patients may not always receive appropriate communication accommodations during their dermatology visits, potentially hindering their dermatologic care. Limitations of this study include a single academic center, imperfect documentation of services, and the retrospective design. Further research could investigate how communication barriers contribute to healthcare disparities for Deaf patients and what systemic interventions might mitigate those barriers.

EA DV CONGRESS
VIENNA
30 SEP - 3 OCT 2026

Abstract N°: 4001

A Delphi Consensus involving dermatology journal editors and editorial board members on the Ethical and Practical Applications of Artificial Intelligence in Dermatological Publishing

Feroze Kaliyadan*[1], Anupam Das[2], Rajwinder Singh[3], Ashique KT[4]

[1] Amrita Institute of Medical Sciences and Research Centre, Kochi, India

[2] KPC Medical College & Hospital, Kolkata, India

[3] Maharishi Markandeshwar Institute Of Medical Sciences & Research, Ambala, India

[4] Amanza skin clinic, perinthalmana, India

Introduction

Artificial intelligence (AI) is rapidly transforming medical research, yet there is an apparent lack of comprehensive standardized guidelines for its use in scientific publishing. While AI offers unprecedented tools for linguistic refinement and data processing, its role in generating scientific content in some areas continues to be debated. This study aimed to establish arguably the first Delphi consensus involving dermatologists with editorial experience, on the acceptable practical applications, ethical disclosures, and editorial integration of AI within dermatological literature

Materials and Methods

A modified, two-round Delphi consensus process was conducted among 10 experts who were either editors, or in senior editorial roles in indexed dermatology journals. Participants evaluated statements across four thematic domains: Manuscript Preparation, Formatting & Editing, Transparency & Ethics, and the Editorial/Review Process. Responses were recorded on a 5-point Likert scale. Consensus was defined *a priori* as more than (or equal of)70% of respondents scoring a statement as 4 ("Agree") or 5 ("Strongly Agree"). Statistical convergence between rounds was validated using Interquartile Range (IQR) reduction, demonstrating the successful alignment of expert opinion

Results

Experts reached a robust consensus on 16 key statements, revealing a clear dichotomy between administrative assistance and scientific generation. There was near-unanimous support for utilizing AI in Formatting & Editing, including grammar checks (100% agreement), summarizing recent literature (100%), and reference formatting (90.9%). Conversely, experts failed to reach consensus on using AI for core scientific tasks, largely rejecting AI for drafting manuscripts (36.4% agreement), performing statistical analysis (45.5%), and image editing (45.5%).

In the Transparency and Ethics domain, experts were more uncompromising: 90.9% agreed that all manuscripts must undergo AI detection screening, and equal majorities mandated that full, section-specific disclosures (including specific tools and prompts) be explicitly reported. Statistical analysis of opinion shifts confirmed high convergence, with significant IQR reductions observed in debated areas such as study design (ΔIQR = -1.25) and image editing (ΔIQR = -1.00).

Conclusions

Dermatology experts welcome AI as an administrative and linguistic assistant, but draw a definitive line at its use for generating primary scientific content, analyzing data, or altering clinical images. Uncompromising transparency, mandatory disclosure, and rigorous AI detection screening are viewed as non-negotiable pillars for

the future of dermatological publishing. These consensus guidelines provide a critical roadmap for authors, peer reviewers, and journal editors navigating the new AI-augmented landscape.

EA DV CONGRESS
VIENNA
30 SEP - 3 OCT 2026

Abstract N°: 4012

Metagenomic Sequencing and Metabolomic Analysis of Skin Microbiota in Symmetrical acral keratoderma

Yifei Liu[1], Changxing Li*[1]

[1] Department of Dermatology, the Tenth Affiliated Hospital, Southern Medical University (Dongguan People's Hospital), Dongguan, China

Introduction

Symmetrical acral keratoderma (SAK) is a rare dermatological disorder. Our research has identified *FLG* mutations in SAK patients, elucidating its genetic pathogenic mechanism and proposing that impaired skin barrier function constitutes a critical pathogenic factor. However, SAK predominantly manifests in young and middle-aged individuals, with epidemiological evidence suggesting environmental triggers such as humid and poorly ventilated conditions. These observations imply environmental factors, particularly microbial dysbiosis may play an important role in SAK pathogenesis. Preliminary 16S rRNA sequencing revealed potential microbiota imbalance in SAK lesions, though species-level resolution remained unattainable. Recent advances in metagenomics and metabolomics have emerged as pivotal methodologies for microbial ecology research, enabling comprehensive characterization of microbial taxonomic profiles, functional pathways, and metabolite dynamics□thereby overcoming the inherent limitations of 16S rRNA sequencing. To explore the biological processes and functional alterations in microbes and metabolites of SAK patients by using metagenomic and metabolomic sequencing, to screen potential biomarkers and investigate their effects on the expression of skin barrier-related molecules.

Materials and Methods

1. Scales from lesional and non-lesional areas of SAK patients were collected for metagenomic sequencing and untargeted metabolomic sequencing.
2. We performed Bioinformatic analysis to detect microbes and metabolites that exhibit differential abundance, and to screen for potential candidate biomarkers
3. HaCaT cells were treated with varying concentrations of differential bacterial species for 12 h, 24 h, and 48 h. Cell proliferation was assessed using the CCK-8 assay, migration ability was evaluated via scratch assay, and qRT-PCR was used to analyze changes in mRNA expression of barrier-related molecules (FLG□IVLetc.).

Results

1. Significant structural differences in the skin microbiome were observed between lesional and non-lesional areas of SAK patients. Compared with the lesion area□malassezia restricta in the non-lesion area of SAK showed significant changes from boundary to species level, especially malassezia restricta and malassezia globosa. Functional analysis showed that there were differences in metabolic pathways and metabolites between the two groups.
2. Metabolomic analysisrevealed distinct metabolomic profiles between lesional and non-lesional areas. Sixty-two differential metabolites were identified□which concentrated in organic acids and their derivatives and lipids and lipid compounds. Functional enrichment analysis suggested the above differential metabolites linked to altered pathways including the Citrate cycle (TCA cycle)□Aspartate and glutamate metabolism□D-amino acid metabolism.

3. High concentration of malassezia restricta inhibited HaCaT cell viability in a time-dependent manner. While the proliferation activity of HACAT cells did not change significantly under 1:1 and below MOI co-culture, which could be used as a safe concentration.
4. The scratch closure rate of HaCaT cells was increased after treatment with live malassezia restrictaand heat-inactivated malassezia restricta.
5. Live Malassezia restricta upregulated mRNA expression ofbarrier related molecules such as FLG□IVL□while heat-inactivated malassezia restricta caused no significant changes.

Conclusions

Distinct microbial and metabolic profiles exist between lesional and non-lesional areas in SAK patients. In particular, malassezia restricta and malassezia globosa may serve as key biomarkers for SAK. Malassezia restricta may have potential barrier repair ability through interaction and metabolism with cells and upregulate FLG, IVL, and other barrier-related genes. This study innovatively proposed the role of microecological balance disorder in the pathogenesis of SAK, laying a foundation for future microecological therapy research.

EADV CONGRESS
VIENNA
30 SEP - 3 OCT 2026

Abstract N°: 4021

Erythroderma: Clinical Features, Diagnostic Methodology, Management In A Cohort of Tertiary Center

Yunus Toso*[1], Kenan Aydogan[1], Ferdi Öztürk[1], Ümmühan Şeker[1], Serkan Yazici[1], Emel Bülbül Başkan[1], Saduman Balaban Adim[2], Hayriye Saricaoglu[1]

[1] Bursa Uludag University, Department of Dermatology and Venereology, Bursa, Türkiye
[2] Bursa Uludag University, Department of Medical Pathology, Bursa, Türkiye

Introduction

Erythroderma (ED) is defined as more than eighty percent of the body is covered with erythema and scales. ED itself is not a disease but rather severe form of the underlying condition. When erythroderma fully settled it presents as systemic condition in some cases dermatologic emergency resulting in mortality. In this study we aimed to evaluate our ED patients in a comprehensive manner including nouvelties regarding evaluation of pathway to the definitive diagnosis, comparison of features of acute and chronic ED patients and evaluation of histopathologic patterns.

Materials and Methods

This retrospective study was conducted at the Department of Dermatology, Bursa Uludag University Faculty of Medicine between the years 2022 and 2025. Unless there is suspect regarding ED clinic, all cases included. A total of 114 patients were included, and all avaible data were evaluated. We defined acute ED when patient presented in first three months and chronic ED when the patient has longer than three months persistance. We classified overall ED treatment responses as full recovery, good control and bad control.

Results

In the entire cohort male/female ratio was 1,92. Mean age was 56,4. Nine patient were pediatric including five infants. Median follow up was 8 months. Ninety two patients (% 80,7) hospitalized (mean 28 days). Almost half of cases (% 48,2) were flare of existing dermatosis. Psoriasis (% 38.6), atopic dermatitis (% 17.5), drug reactions (% 14,5), mycosis fungoides/Sezary syndrome (% 9,6) were most common etiologies. Only five patient remained idiopatic. Clinical signs and symptoms presented in (Table 1). In 65 patients the definitive diagnosis was confirmed using a combination of clinical and histopathological evaluations, clinical findings alone in 34 patients, biopsy alone in 3 patients, flow cytometry in 1 patient, genetic testing in 1 patient and microscopic examination in 1 patient.

In general cutaneous biopsy was diagnostic in % 68,7 of cases, while it is % 78.3 in acute ED, it was % 61.7 in chronic ED. In acute ED, epidermal major tissue reaction pattern was spongiotic in 20 cases, 15 were psoriasiform, in 8 patients spongiotic and psoriasiform patterns existed in different biopsies. In two case interface reaction existed along with spongiotic reaction, in one case lichenoid reaction occured along with psoriasifom reaction pattern. On the other hand in chronic ED epidermal major tissue reaction pattern was spongiotic in 23 cases, 13 were psoriasiform, in 8 patients spongiotic and psoriasiform patterns existed in different biopsies. In two cases interface reaction occured along with psoriasifom pattern. In general mean cutaneous biopsy number was 2,26 and in diagnostic cases it was 2,63.

In 25 patients we had full recovery, while 50 patients had good control of ED, 34 patients had bad control (Table 2). In 34 patients ED related complications occured. Recurrence rate was %30,7. %59,6 of patients presented with

acute ED, of these %25 progressed to chronic phase.

In our follow up ten patient (% 8,8) died with ED. Three patients were MF/Sezary ED, two patients had GVHD ED, two patients psoriasis ED, 1 patient was paraneoplastic ED, 1 patient had post-transfusion ED, 1 patient was drug reaction ED. While 6 of them had multipl comorbidities, 4 patients had no comorbidity. Secondary infections (8/10) and acute renal failure (5/10) were the main reasons of death.

Clinical signs and symptoms	Number of Patient and Rate
Pruritus	101, % 89.3
Shivering	47, % 41.2
Pain	43, % 37.7
Palmoplantar keratoderma	38, % 33.3
Fever	36, % 31.6
Lower extremity edema (pedal, pretibial)	31, % 27.2
Ocular complications (ectropion, conjuctivitis, blepharitis)	27, % 23.7
Distrophic nail changes	24, % 21
Weight loss	14, % 12.3
Hemodynamic instability	13, % 11.4
Mucosal lesions	13, % 11.4
Alopecia	7, % 6.1

Table 1: Clinical signs and symptoms in ED patients

Conclusions

Ohga et al. defined chronic idiopatic erythroderma especially condition of elderly man as persistance of ED longer than 3 months. Using this definition for idiopatic cases we defined acute and chronic ED to make comparisons in terms of diagnosis and treatment response. While large cohorts published data regarding elucidating diagnosis, management data is very limited. In our cohort we presented comparative data between different etiologies and we observed that treatment response is mainly depends on underlying etiology. Findings of this study present a new algorithm for further studies.

Underlying Disease	Full recovery	Good Control	Bad Control
Psoriasis ED	15 (% 35.7)	21 (% 50)	6 (% 14.3)
Atopic dermatitis ED		15 (% 83.3)	3 (% 16.7)
Drug reactions ED	5 (% 31.3)	9 (% 56.3)	2 (% 12.6)
MF/Sezary ED		2 (% 20)	8 (% 80)
Idiopatic ED			5
Contact dermatitis ED	2 (% 50)	1 (% 25)	1 (% 25)
Paraneoplatic ED			3
Scabies ED	2 (% 67.7)	1 (% 33.3)	
Ichtiyosis ED			2
GVHD ED			2
Chronic actinic dermatitis ED			1
Photocontact dermatitis ED		1	
Prurigo pigmentosa ED		1	
Post-transfusion ED			1

Table 2: Etiology and Treatment Responses in ED patients

EA DV CONGRESS
VIENNA
30 SEP - 3 OCT 2026

Abstract N°: 4038

Efficacy and Safety of Crisugabalin for Acute Herpetic Neuralgia in a Real-World Setting: An Observational Cohort Study

Jianming Yu*[1], Zhongju Du[1], Hua Zhang[1], Zehu Liu[1], Pengli Zhang[2]

[1] Hangzhou Third People's Hospital, Hangzhou, China

[2] Haisco, Hangzhou, China

Introduction

Herpes zoster (HZ) is a major public health issue and has a significant impact on patients' quality of life during both the acute and chronic phases. Severe acute pain during the course of HZ is a risk factor for postherpetic neuralgia (PHN). Previous studies have shown that early combination therapy with calcium channel modulators can effectively relieve pain and reduce the incidence of PHN. Crisugabalin is a novel third-generation calcium channel modulator that reduces neuronal excitability to achieve analgesia. This study aims to further validate the efficacy and safety of Crisugabalin in the treatment of acute herpetic neuralgia (AHN) in a real-world clinical setting, as well as its impact on the incidence of PHN.

Materials and Methods

A multicenter, prospective, observational real-world study planned to recruit 200 adults 50 years or older with HZ, who presented with vesicles within 7 d, and visual analogue scale (VAS) ≥40 mm. In addition to standard treatment, all participants received Crisugabalin 20/40 mg BID. Pain intensity (Numeric Rating Scale [NRS]) and pain quality (Short-Form McGill Pain Questionnaire [SF-MPQ]) was evaluated at baseline, week 1, and week 4. The NRS was also assessed at 13 and 26 weeks. The primary endpoints are the change from baseline in NRS score at week 4 and incidence of PHN (NRS≥3) at 13 and 26 weeks. Secondary endpoints include changes in SF-MPQ, and the incidence of adverse events during the study. (ChiCTR2500101244)

Results

A total of 39 subjects were enrolled (median age 63 years). The mean baseline NRS was 5.82±1.14. At week 1(n=39), NRS decreased to 2.83±1.48 (mean change: −2.99±1.13, P<0.001); at week 4(n=39), NRS further decreased to 0.56±0.75 (mean change: −5.26±1.09, P<0.001). A total of 9 participants completed the 13-week follow-up, with a PHN incidence rate of 0. Significant improvements were also observed in the SF-MPQ. The most common TRAEs were dizziness and somnolence, which were mild-to-moderate and did not require intervention.

Conclusions

In this real-world clinical setting, Crisugabalin rapidly relieved pain, and demonstrated a favorable safety profile in patients with acute herpes zoster. Further data from the full cohort are needed to confirm its impact on PHN incidence.

EA DV CONGRESS
VIENNA
30 SEP - 3 OCT 2026

Abstract N°: 4055

H_2O_2-Induced Oxidative Stress-Driven Senescence in Human Dermal Fibroblasts: A Validated In Vitro Model for Dermis Aging Research

Samuel Guenin*[1], Fabienne Guyard[1], Julie Gerbaud[1], Aline Larrignon[1], Julien Chilloux[1], Nathalie Pedretti[1], Cécile Trespeuch[1], Eglantine Siret[1], Julien Oré[1], Benjamin Hébrard[1], Nicolas Amalric[2], Valérie Hamon de Almeida[1]

[1] QIMA Life Sciences, QIMA Bioalternatives SAS, Gençay, France

[2] QIMA Life Sciences, QIMA Bioalternatives SAS, Labège, France

Introduction

Skin aging is a multifactorial process in which oxidative stress constitutes a central pathophysiological driver of both intrinsic chronoaging and extrinsic photoaging. In the broader context of longevity research, preserving dermal homeostasis represents a key biological objective. In the dermis, excessive reactive oxygen species (ROS) disrupt redox homeostasis and induce a cascade of structural and functional alterations: extracellular matrix (ECM) disorganization, impaired collagen synthesis, upregulation of matrix metalloproteinases (MMPs), and release of inflammatory markers (SASP). Together, these mechanisms drive dermal fibroblast senescence, ultimately impairing dermal structural integrity and tissue longevity.

Here, we aimed to establish and validate a robust *in vitro* model of oxidative stress-induced premature senescence in normal human dermal fibroblasts (NHDFs) using hydrogen peroxide (H_2O_2), recapitulating the molecular and cellular hallmarks of physiological dermal aging.

Materials and Methods

NHDFs were exposed to a single H_2O_2 dose (250–800 µM, endpoint-dependent). Senescence induction was assessed through intracellular ROS quantification, senescence-associated β-galactosidase (SA-β-gal) activity, DNA damage (COMET assay), secretome profiling (MMP-1, MMP-3, procollagen I, IL-8 by ELISA), and collagen I expression analysis (intracellular and ECM-deposited fractions).

Results

H_2O_2 exposure significantly elevated SA-β-gal activity, intracellular ROS generation, and DNA damage, alongside upregulation of matrix-degrading and pro-inflammatory mediators (MMP-1, MMP-3, IL-8). In parallel, procollagen I secretion and both intracellular and ECM-deposited collagen I expression were significantly suppressed. Importantly, reference molecules with established senomorphic or senolytic activity reversed these phenotypic alterations, confirming the model's pharmacological sensitivity and translational relevance.

Conclusions

This validated *in vitro* model of oxidative stress-induced premature senescence in dermal fibroblasts closely recapitulates the molecular, secretory, and structural hallmarks of dermal aging, providing a reliable and translatable platform for the mechanistic investigation and preclinical evaluation of therapeutic candidates targeting dermal fibroblast senescence and cutaneous tissue longevity.

EADV Congress 2026, VIENNA
30 SEPTEMBER - 03 OCTOBER 2026
POWERED BY M-ANAGE.COM

EA DV CONGRESS
VIENNA
30 SEP - 3 OCT 2026

Abstract N°: 4093

Artificial Intelligence as the First Point of Contact in Dermatology: Analysis of Search Trends, Presentation Modes, and Patient Behavior

Leonardo Balestra[1], Patrick Silvetti*[1], Gabriele Soligon[1], Giuditta Trobbiani[1], Francesco Rizzi[1], Davide Bertolla[2], Ignazio Stanganelli[1], Giulio Gualdi[1]

[1] School of Dermatology, University of Parma, Parma, Italy

[2] School of Dermatology, University of Ferrara, Ferrara, Italy

Introduction

In recent years, public accessibility to Large Language Models (LLMs) and multimodal Artificial Intelligence (AI) has radically transformed how patients seek medical information. Dermatology, an inherently visual specialty, is one of the fields in which patient–AI interaction is most frequent, given AI's ability to provide conversational responses and image interpretation. This study outlines the most frequent dermatological inquiries addressed to AI, as well as their modes of presentation, to better understand how these tools are reshaping the patient's pre-clinical journey and digital "pre-triage."

No.	Topic	Example questions
1	**Acne**	"How can I get rid of acne quickly?" "Why do I still have acne as an adult?" "Does diet cause acne?" "How to remove acne scars?"
2	**Pigmented lesions and skin tumors**	"Is this mole dangerous?" "How can I recognize melanoma?" "Should I see a dermatologist for this mole?"
3	**Dermatitis / eczema / itching**	"Why is my skin itchy?" "What cream should I use for eczema?" "Is eczema contagious?"
4	**Skin spots**	"How can I remove dark spots?" "What causes melasma?" "How to lighten skin pigmentation?"
5	**Hair loss**	"Why am I losing hair?" "Is hair loss genetic?" "What treatments work for hair loss?"

Table 1. Five most frequent dermatologic questions addressed to Artificial Intelligence grouped by topic

Table 1. Five most frequent dermatologic questions addressed to Artificial Intelligence grouped by topic

Materials and Methods

Based on typical interaction patterns with LLMs, dermatological inquiries can be grouped into specific macro-areas, presented here in order of estimated frequency (Table 1): (1) acute skin rashes, often prompted by anxiety over sudden manifestations; (2) oncological prevention and suspicious nevi; (3) inflammatory conditions and blemishes (e.g., acne, rosacea), usually focused on therapeutic routines and home management; (4) chronic conditions (e.g., psoriasis, seborrheic dermatitis), with emphasis on long-term control; and (5) infections and

infestations, with requests to differentiate insect bites, mycoses, and viral infections. Interestingly, these digital inquiries closely mirror the main epidemiological drivers of traditional dermatological visits—namely fungal skin infections (8.9%), atopic dermatitis (5.5%), acne (5.4%), alopecia (5.1%), and psoriasis (3.9%)[1] —while also revealing a disproportionate, anxiety-driven focus on oncological screening in the digital pre-triage setting. The prominence of topics such as acne may also indirectly suggest that these tools are frequently used by a relatively young population, which may be more inclined to seek this form of digital consultation. Notably, the pattern of dermatologic questions addressed to AI appears to vary across countries, reflecting different cultural, epidemiological, and cosmetic priorities, with some populations showing greater attention to hyperpigmentation and dyschromia, and others to acne, inflammatory dermatoses, or skin cancer concerns (Table 2).



Nation based most frequent 5 dermatologic questions

Country	Top Questions
Italy	Is this rash psoriasis or eczema? How can I treat acne naturally? Is this mole dangerous or melanoma? Why is my skin itching without rash? How to treat seborrheic dermatitis on the scalp?
France	How can I treat adult acne? Is this skin spot a melanoma? What causes rosacea and how can I treat it? How to remove dark spots from the face? Is this rash an allergic reaction?
Spain	How to treat acne scars? Is this mole dangerous? Why do I have itchy skin at night? How to treat sun spots? Is this dermatitis or fungal infection?
United Kingdom	Is this mole skin cancer? How to treat eczema flare-ups? What causes psoriasis and how can it be controlled? Is this rash due to allergy or infection? How to treat rosacea naturally?
United States	Is this melanoma? How to get rid of acne fast? Why is my skin suddenly itchy? What are the early signs of skin cancer? How to treat eczema naturally?
Brazil	How to treat melasma? How to remove dark spots from the skin? What is causing these white spots? Is this fungal infection on my skin? How to treat acne scars?
Norway	Is this rash eczema? Why is my skin extremely dry? Is this mole dangerous? How to treat psoriasis plaques? Why do I have itchy skin in winter?
China	How to remove hyperpigmentation? How to treat acne scars? Is this skin infection contagious? Why is my skin sensitive and red? How to whiten or brighten skin safely?
India	Is this fungal infection on my skin? How to treat pigmentation on the face? Why do I have dark circles and spots? Is this vitiligo? How to treat acne scars?
Japan	How to improve skin texture? How to reduce pores on the face? Is this pigmentation melasma? How to treat acne gently? Why is my skin sensitive and irritated?
Australia	Is this mole melanoma? What are the signs of skin cancer? How to protect skin from sun damage? Is this sun spot dangerous? How to treat actinic keratosis?
Egypt	How to treat pigmentation and dark spots? Why do I have acne scars? Is this fungal infection? How to treat hairline dermatitis? What causes itching in hot weather?
Russia	Is this psoriasis? How to treat eczema? Is this mole dangerous? Why is my skin extremely dry? How to treat fungal skin infections?
Nigeria	How to treat dark spots on skin? Is this fungal infection? How to treat acne scars? What causes keloids? How to remove hyperpigmentation?
Mexico	How to treat melasma? Is this skin infection fungal? How to remove dark spots? Why do I have acne scars? Is this rash an allergy?

Table 2. Most frequent dermatologic queries submitted to Artificial Intelligence in different countries, reflecting the main patient concerns in the emerging digital pre-triage landscape.

Table 2. Most frequent dermatologic queries submitted to Artificial Intelligence in different countries, reflecting the main patient concerns in the emerging digital pre-triage landscape.

Results

Clinical queries are now commonly presented to AI either as a photograph accompanied by a concise prompt or, when no image is available, as a phenomenological description based on symptoms and recent medical history. Furthermore, the use of AI as a "second opinion" tool is emerging, with patients asking for biopsy or histological reports to be translated into lay language. Despite its high information-processing capacity, public use of AI in dermatology presents significant intrinsic limitations. First, visual inputs provided by users are often suboptimal: blurred photographs, poor lighting, and the absence of a dimensional scale can impair analysis. Second, AI lacks fundamental diagnostic tools such as dermoscopy and palpation. A further critical risk is represented by AI "hallucinations," namely the generation of clinically incorrect responses formulated in highly persuasive medical language. These technical limitations are compounded by systemic flaws in consumer-facing AI dermatology apps. As noted in a recent analysis[2], although these tools promise improved access to care and clinical outcomes, they may expose users to harm because of limited scientific rigor and dermatologist involvement, poor transparency on privacy and algorithm development, and undisclosed lack of FDA approval.

Conclusions

The increasing use of AI by patients is already affecting daily clinical practice. While it may support health education and therapeutic adherence, it also carries two opposite risks: false reassurance and increased health anxiety or cyberchondria. Dermatologists are increasingly required to debunk or contextualize AI-generated hypotheses, making these issues part of routine physician–patient communication. To mitigate risks while preserving its educational potential, clear patient guidance and specific clinician training are needed.

References

[1] Richard MA, Paul C, Nijsten T, Gisondi P, Salavastru C, Taieb C, Trakatelli M, Puig L, Stratigos A; EADV burden of skin diseases project team. Prevalence of most common skin diseases in Europe: a population-based study. J Eur Acad Dermatol Venereol. 2022 Jul;36(7):1088-1096. doi: 10.1111/jdv.18050. Epub 2022 Mar 22. PMID: 35274366; PMCID: PMC9415115.

[2] Wongvibulsin S, Yan MJ, Pahalyants V, Murphy W, Daneshjou R, Rotemberg V. Current State of Dermatology Mobile Applications With Artificial Intelligence Features. JAMA Dermatol. 2024 Jun 1;160(6):646-650. doi: 10.1001/jamadermatol.2024.0468. Erratum in: JAMA Dermatol. 2024 Jun 1;160(6):688. doi: 10.1001/jamadermatol.2024.1011. Erratum in: JAMA Dermatol. 2024 Jun 1;160(6):688. doi: 10.1001/jamadermatol.2024.1342. PMID: 38452263; PMCID: PMC10921342.

EADV CONGRESS
VIENNA
30 SEP - 3 OCT 2026

Abstract N°: 4155

Multimodal Machine Learning for Predicting Radiation-Induced Dermatitis: A Comprehensive Review

Alyaa T. Sharshar*[1], Nancy Emmanuel[2]

[1] Ain Shams University, Cairo, Egypt

[2] Department of Dermatology, Hospital das Clínicas da Faculdade de Medicina da Universidade de São Paulo, São Paulo, Brazil

Introduction

Radiation-induced dermatitis (RD) affects up to 95% of patients receiving radiotherapy, compromising adherence to radiotherapy and patient quality of life. Because visual dermatological assessments are highly subjective, there is a growing demand for personalized prognostic models capable of accurate risk stratification. This review evaluates the efficacy of machine learning (ML) models that integrate dosiomic, radiomic, and clinical data to objectively predict acute RD.

Materials and Methods

A comprehensive literature review was conducted, analyzing peer-reviewed studies on predictive modeling. PubMed, Scopus, and Science Direct databases were searched for literature from January 2016 to April 2026 using core keywords such as "deep learning," "radiation dermatitis," and "prediction." Primary inclusion criteria required human cancer patients undergoing radiotherapy, investigations utilizing ML models, and post-treatment toxicity endpoints.

Results

Various AI methodologies have demonstrated significant efficacy in evaluating radiotherapy outcomes. Specifically, image-based deep neural networks analyzing 1,205 clinical photographs achieved an 83.0% overall accuracy for severity grading and prediction, which represents performance levels close to those of clinicians. In addition, spectrophotometry-based Support Vector Machine models involving 129 subjects predicted grade ≥2 toxicity with 89.8% accuracy and 98.6% recall. Performance was maximized even further by multimodal models that integrate radiomics, dosiomics, and clinical parameters, as evidenced by a Stacking Classifier for 789 breast cancer patients that achieved 96% accuracy, 95% sensitivity, and an AUC of 0.97. Similarly, a multi-region dose-gradient Gradient Boosting Decision Tree framework involving 214 cases yielded an AUC of 0.911 during validation, while the inclusion of dosiomic features into deep learning models improved AUCs to 0.832 for 290 patients with nasopharyngeal carcinoma. Finally, thermal models using quantitative imaging features extracted at the fifth radiotherapy fraction for 90 patients correctly predicted severe radiation dermatitis with 87% accuracy and an AUC of 0.98.

Conclusions

ML models integrating dosiomic, imaging, and clinical data demonstrate robust clinical relevance and efficacy for the early prediction of RD. Future research requires randomized controlled trials, prospective validation, and standardized protocols to integrate these tools into routine clinical oncology.

EA DV CONGRESS
VIENNA
30 SEP - 3 OCT 2026

Abstract N°: 4200

88% Phenol Diluted in Distilled Water: A Minimally Invasive Emerging Treatment for Digital Mucous Cysts. A Case Series

Ana Domínguez Vargas*[1], Antón Lobeiras Morado[1], María Pousa-Martínez[1], Fernando Cabo Gómez[1], María Pilar Gómez Centeno[1], Javier Labandeira García[1], JOSE ALVAREZ LOPEZ[1], Ignacio Suárez Conde[1]

[1] Department of Dermatology, Complejo Hospitalario Universitario de Ourense., Ourense, Spain

Introduction

Digital mucous cysts are benign lesions with a tendency to recur. Surgical excision remains the most effective treatment, although it is invasive and may be associated with complications. Consequently, there is growing interest in minimally invasive outpatient procedures that avoid postoperative morbidity.

Phenol is widely used in dermatology due to its caustic, sclerosing and anti-inflammatory properties, allowing controlled local destruction of lesions. Its use has been supported by experience in other dermatologic procedures and conditions, including nail matrixectomy and mucous cyst treatment, supporting its potential role as a minimally invasive therapeutic option for digital mucous cysts.

Materials and Methods

We conducted a case series including 15 patients with digital mucous cysts treated with intralesional phenol (88%) as an outpatient procedure. Initially, the cyst was punctured and drained, followed by intralesional phenol infiltration. Approximately 0.1 mL of phenol was injected until lesion whitening was achieved.

The procedure was simple, was performed in a single session in most cases, and did not require hospital admission. Complete resolution was assessed at 1 month. Recurrence was evaluated at 3 and 6 months after the treatment. Patients with insufficient follow-up were considered non-evaluable.

Results

Fifteen patients were included. Complete resolution was achieved in 14 cases (93.3%). One patient (6.7%) did not achieve complete resolution and was lost to follow-up.

At 3 months, recurrence was observed in 1 patient (6.7%), while 9 patients (60%) remained recurrence-free. Four patients (26.7%) were not evaluable due to short follow-up.

The treatment was well tolerated, with no systemic adverse effects and only mild local complications such as local infection.

Category	Variable	Value
Patient characteristics	Age at treatment initiation, mean (SD), years	71.6 (12.3)
	Female, n (%)	11 (73.3%)
	Male, n (%)	4 (26.7%)
	Hand lesions, n (%)	13 (86.7%)
	Foot lesions, n (%)	2 (13.3%)
	No previous treatment, n (%)	13 (86.7%)
	Previous local treatment, n (%)	2 (13.3%)
Treatment with intralesional diluted phenol 88%	Treatment setting	Outpatient procedure
	Injected volume	Approx. 0.1 mL
	Endpoint of infiltration	Whitening of the lesion
	Ultrasound guidance performed, n (%)	6 (40%)
	Treatment sessions, median (IQR)	1 (1–1)
	Single-session treatment, n (%)	12 (80%)
	Three-session treatment, n (%)	2 (13.3%)
	Lost to follow-up before outcome assessment, n (%)	1 (6.7%)
Effectiveness of treatment	Complete resolution, n (%)	14 (93.3%)
	Recurrence at 3 months, n (%)	1 (6.7%)
	No recurrence at 3 months, n (%)	9 (60%)
	Non-evaluable at 3 months, n (%)	4 (26.7%)
	Mean follow-up duration, months	14.5
Safety and tolerability	Patients with complications, n (%)	2 (13.3%)
	Patients without complications, n (%)	13 (86.7%)
	Systemic adverse events	None
	Type of complications	Mild local infection
	Pain after procedure, median EVA	0
	Procedure without hospital admission, n (%)	15 (100%)

SD: standard deviation; IQR: interquartile range; EVA: visual analogue scale.

Table 1. Summary of patient characteristics, treatment outcomes and safety data of intralesional diluted 88% phenol in digital mucous cysts. SD: standard deviation; IQR: interquartile range; EVA: visual analogue scale.

Conclusions

Intralesional phenol appears to be a simple and well-tolerated minimally invasive option for the treatment of digital mucous cysts. In our experience, it allows lesion resolution in an outpatient setting with minimal morbidity.

Compared with the currently available evidence on polidocanol for digital mucous cysts, which reports cure rates of approximately 70–80% depending on the series and recurrence rates remain variable, intralesional phenol achieved complete resolution in 93.3% of cases in our initial experience.

These preliminary results are encouraging and suggest that phenol may represent a promising minimally invasive alternative for the treatment of digital mucous cysts. Further studies including larger patient cohorts and longer follow-up are needed to confirm these findings.

EA DV CONGRESS
VIENNA
30 SEP - 3 OCT 2026

Abstract N°: 4207

Beyond Injection-Site Reactions: A Systematic Review of Cutaneous Adverse Events Associated with Incretin-Based Therapies

Talia El Chaer*[1], Nancy Emmanuel[2]

[1] University of Balamand, Beirut, Lebanon

[2] Department of Dermatology, Hospital das Clínicas da Faculdade de Medicina da Universidade de São Paulo, São Paulo, Brazil

Introduction

Incretin-based therapies, including glucagon-like peptide-1 receptor agonists (GLP- 1RAs) and dual GLP-1/glucose-dependent insulinotropic polypeptide (GIP) receptor agonists, have seen exponential clinical adoption. While gastrointestinal side effects are well-documented, cutaneous adverse events (cAEs) remain under-characterized beyond localized injection-site reactions. Given the expression of GLP-1 receptors in various skin components and the synthetic peptide nature of these agents, understanding their dermatological safety profile is essential. This systematic review aims to establish a mechanism-based classification for the spectrum of cutaneous and neurocutaneous phenomena associated with these therapies.

Materials and Methods

A comprehensive literature search was conducted via PubMed and Scopus databases to identify reports of cutaneous and neurocutaneous drug reactions associated with incretin-based therapies. The search strategy was augmented by manual citation tracking and a review of clinical trial registries to capture emerging safety data. The review encompassed all English-language studies, including case series, clinical trials, and retrospective cohorts, without date restrictions. Data were extracted and categorized based on clinical morphology and hypothesized underlying pathophysiological mechanisms, ranging from localized inflammatory responses to systemic hypersensitivity and neurogenic sensory alterations.

Results

Analysis of the data revealed four distinct categories of cAEs based on morphology and pathophysiology, beginning with localized injection-site reactions, the most common occurrences (3.5%–20%) typically manifesting as nodules or erythema through Type IV hypersensitivity or simple irritant mechanisms. Generalized hypersensitivity reactions represent a second tier, ranging from rare, high-stakes Type I immediate responses like anaphylaxis (more prevalent in exendin-4–based molecules with lower human homology) to delayed Type IV maculopapular eruptions that generally resolve upon stopping treatment. The third category covers neurocutaneous phenomena, a unique group of dose-dependent sensory shifts like allodynia and dysesthesia that occur without primary lesions and likely stem from neurogenic inflammation or sensory nerve signaling errors. Finally, rare immune-mediated conditions such as bullous pemphigoid and leukocytoclastic vasculitis highlight a small but serious risk of systemic immune dysregulation in particularly susceptible individuals.

Conclusions

Incretin-based therapies are associated with a diverse range of cAEs that extend far beyond simple injection-site irritation. We propose a classification system distinguishing localized reactions, systemic IgE/T-cell mediated hypersensitivity, and dose-dependent neurocutaneous sensory alterations. As clinical use expands, clinicians must recognize these emerging phenotypes, particularly allodynia and dysesthesia, to ensure appropriate diagnosis and avoid unnecessary diagnostic procedures. Further research into GLP-1 receptor expression in the peripheral nervous system and skin is required to fully elucidate the pathways of neurogenic skin pain

EA DV CONGRESS
VIENNA
30 SEP - 3 OCT 2026

Abstract N°: 4243

Dermatological practice in the management of skin aging in Brazil: integration of aesthetic procedures and dermocosmetics with epigenetic action

Raquel Anacleto dos Anjos*[1], Paula Pitta[2]

[1] Beiersdorf, São Paulo, Brazil

[2] Beiersdorf AG, Hamburg, Germany

Introduction

Aesthetic procedures have become a central component of dermatological practice in the management of skin aging. According to the 2024 International Society of Aesthetic Plastic Surgery (ISAPS) survey, Brazil performed more than 3.1 million aesthetic procedures in 2024, reinforcing its position as one of the leading global markets in aesthetics. Among non-surgical procedures, botulinum toxin injections accounted for more than 351,000 procedures, while hyaluronic acid treatments exceeded 176,000 procedures, highlighting the growing demand for minimally invasive approaches in facial rejuvenation.

The use of dermocosmetics has also been widely incorporated as a complementary strategy, with the potential to optimize clinical outcomes and maintain the achieved effects. However, data describing real-world dermatological practice regarding the frequency of procedures, main indications, and integration with topical therapies remain limited. Additionally, recent advances in the understanding of the biological mechanisms of aging highlight the role of epigenetic alterations, such as changes in DNA methylation patterns, in the regulation of genes associated with skin aging. In this context, dermocosmetics with the potential to modulate these mechanisms emerge as an innovative approach, contributing to enhance the effects of aesthetic procedures on the skin.

This study aimed to characterize the clinical practice of dermatologists with high demand for aesthetic procedures across different regions of Brazil, as well as to assess their perception of the use of dermocosmetics, including those with potential epigenetic activity, as complementary therapy in the management of skin aging.

Materials and Methods

This was a cross-sectional observational study based on field research conducted with 155 dermatologists, of both sexes, with strong involvement in aesthetic dermatology, distributed across different regions of Brazil.

Participants answered a structured questionnaire addressing the types of procedures performed in clinical practice, the monthly volume of procedures per physician, the main patient complaints, the demographic profile of the demand, and the perception of the efficacy and use of dermocosmetics as complementary therapy.

Results

The results demonstrated a high frequency of aesthetic procedures in clinical practice, with emphasis on botulinum toxin (mean of 32 procedures per physician per month), fillers (30), collagen biostimulation (25), lasers (32), and intense pulsed light (22). Chemical peels (19) and microneedling (12) were also reported as part of routine practice. The main patient complaints included signs of skin aging, such as wrinkles, sagging, and changes in skin texture. There was a predominance of adult female patients, particularly in the 30–39 age group, representing the highest demand for procedures (121/154 responses), followed by women over 40 years

(28/154).

Regarding dermocosmetic use, 99% of dermatologists reported prescribing these products in association with aesthetic procedures, highlighting a clinical perception of better results compared to procedures alone. Additionally, 92% of participants stated that they believe dermocosmetics with epigenetic action can enhance the effects of procedures by modulating genes associated with skin aging.

Conclusions

The findings demonstrate that aesthetic procedures are an integral part of dermatological clinical practice in the management of skin aging in Brazil and are widely associated with the use of dermocosmetics as a complementary strategy. The integration of procedures and topical therapies is becoming a consolidated approach in current clinical practice, with the potential to optimize outcomes and maintain results over time. Furthermore, approaches based on epigenetic modulation emerge as a promising perspective in the field of skin rejuvenation, reflecting the growing incorporation of innovative strategies based on biological mechanisms in dermatological practice.

EA DV CONGRESS
VIENNA
30 SEP - 3 OCT 2026

Abstract N°: 4258

Diagnostic Reliability and Morphological Realism of AI-Generated Synthetic Dermatological Images: Implications for Dermatology AI Training Data

Jonathan Shapiro*[1], Mor Atlas[2], Yuliya Valdman[3], Ibrahim Alatawna[3], Adi Saadia[3], Romi Gleicher[4], Yotam Adi[3]

[1] Maccabi Healthcare Services, Tel Aviv, Israel

[2] Ono Academic, Business Administration Faculty, Kiryat Ono, Israel

[3] Department of Dermatology, Soroka Medical University Center, Ben-Gurion University of the Negev, Beer-Sheva, Israel

[4] Ruth and Bruce Rappaport Faculty of Medicine, Technion—Institute of Technology, Haifa, Israel

Introduction

AI development in dermatology is hindered by clinical data scarcity. While generative AI offers a potential solution, previous studies have reported diagnostic concordance rates of up to 40% for synthetic dermatological images. This study evaluates the diagnostic viability of synthetic images generated by a state-of-the-art generative AI model and helps determine whether failures stem from image quality or from non-specific visual features of certain skin diseases.

Materials and Methods

A leading multimodal generative AI model produced 90 synthetic clinical images of randomly selected dermatologic diseases. Three board-certified dermatologists provided a three-disease differential diagnoses for each. Concordance with the ground-truth diagnosis was categorized as Top1, Top3, Top3-similar, or discordant. In discordant cases, experts reviewed the corresponding real clinical image and could refine (recover) their diagnosis; they were then informed of the ground truth and asked whether they would retrospectively add it to the differential diagnosis. Image quality was rated on a 5-point scale (higher = more realistic). In parallel, three large multimodal AI models independently assessed the same images, each providing a three-disease differential and a real/synthetic judgment; discordant AI cases underwent the same real-image recovery step. Inter-rater agreement was assessed with Fleiss' Kappa, and pairwise AI-dermatologist agreement with Cohen's Kappa. Human–AI performance comparisons were evaluated using chi-squared and McNemar's exact tests. Associations between diagnostic performance, image quality, and realism judgments were examined with Spearman correlations and Mann-Whitney U tests.

Results

Key metrics are summarized in Table 1. Notably, 85.6% of images achieved concordance by most dermatologists. After disclosure of the ground truth, dermatologists still would not add it to their differential diagnoses in 60% of failed evaluations, suggesting some synthetic images lacked clinically recognizable cues rather than being merely difficult. More realistic image-quality ratings were associated with correct diagnosis (Spearman's $\rho = 0.25$, $p = 0.017$). Dermatologists recovered 84.4% of failed diagnoses when shown the real image, whereas AI models recovered only 41.4% (95% CI 25.5–59.3), suggesting dermatologists' failures largely reflected limitations of the synthetic stimulus, while AI failures reflected inherent diagnostic weakness on those conditions. AI models and dermatologists achieved comparable overall performance (89.3% vs 83.3%, $\chi^2 = 3.52$, $p = 0.061$; McNemar $p = 0.58$). Per-diagnosis success rates were strongly correlated between groups (Spearman's $\rho = 0.44$ binary, 0.53 Top1; both $p < 0.001$), indicating the same conditions challenged both. Pairwise AI - dermatologist agreement was

fair-to-moderate (mean Cohen's κ = 0.365, range 0.19–0.49). AI models classified 91.9% ± 6.5% of synthetic images as real; this realism judgment correlated with dermatologists' quality ratings (Spearman's ρ = 0.25, p = 0.016), with images classified as real scoring substantially better than those classified as synthetic (3.61 vs 2.07, Mann–Whitney p = 0.003).

Table 1. Diagnostic performance and image quality metrics for dermatologists and AI models evaluating synthetic dermatological images (n=90).

Metric	Dermatologists (n=3)	AI Models (n=3)
Top-1 concordance, mean (range)	63.0% ± 7.6% (54.5–68.9%)	74.1% ± 8.2% (67.8–83.3%)
Overall diagnostic success (pooled)	83.3% (95% CI 78.4–87.3)	89.3% (95% CI 85.0–92.4)
Majority success across images	85.6%	88.9%
Recovery rate (when real image shown)	84.4%	41.4% (95% CI 25.5–59.3)
Inter-rater agreement, binary (κ)	0.52 (95% CI 0.31–0.69)	0.73 (95% CI 0.51–0.90)
Inter-rater agreement, 4-level (κ)	0.44 (95% CI 0.31–0.56)	0.46 (95% CI 0.31–0.59)
Image quality rating (1–5 scale)	3.52 ± 1.25 (3.26–4.18)	—
Synthetic images classified as real	—	91.9% ± 6.5%

CI, confidence interval; κ, Fleiss' kappa for multi-rater agreement. Top-1: ground-truth diagnosis was the rater's first choice. Overall diagnostic success: ground truth appeared anywhere in the three-disease differential (including close-similar matches). Recovery rate: proportion of initially discordant cases reclassified as concordant after viewing the real clinical image. Image-quality scale: 1 = obvious artifact, 5 = highly realistic.

Conclusions

These results demonstrate substantial improvements in diagnostic accuracy and morphological realism for synthetic dermatological images compared with prior work. The high rate at which AI evaluators classified synthetic images as real, together with comparable diagnostic performance between dermatologists and multimodal AI models, supports their morphological fidelity. The marked contrast between dermatologist (84.4%) and AI (41.4%) recovery on real images indicates that dermatologist failures largely reflected synthetic-stimulus limitations, while AI failures reflected inherent diagnostic weakness, supporting the suitability of high-fidelity synthetic images as supplementary training data for dermatology AI development.

EA DV CONGRESS
VIENNA
30 SEP - 3 OCT 2026

Abstract N°: 4260

TOWARDS IMPROVING CLINICAL SKIN TONE DETERMINATION: SPECTROPHOTOMETRIC VALIDATION OF THE MONK AND FITZPATRICK SCALES IN A DIVERSE MULTIETHNIC COHORT

Christos Diamantidis*[1], Åsa Ingvar[2], Kai Munte[3], Tamar Nijsten[1], Marlies Wakkee[1]

[1] Department of Dermatology, Erasmus MC Cancer Institute, University Medical Center Rotterdam, Rotterdam, Netherlands

[2] Department of Dermatology, Skåne University Hospital, Department of Clinical Sciences, Lund Skin Cancer Research Group, Lund University, Lund, Sweden

[3] Department of Dermatology, Maasstad Hospital, Rotterdam, Netherlands

Introduction

The Fitzpatrick skin type (FST) scale is the current clinical standard for skin tone determination, despite being developed to assess photosensitivity rather than skin tone. It is also used to evaluate whether medical technologies, such as pulse oximeters and dermatologic artificial intelligence (AI) tools, perform equally well across the skin color spectrum. However, its limited granularity for dark skin and inconsistent application across raters limit its ability to detect performance disparities. The Monk skin tone (MST) scale has been proposed as a promising alternative to the FST but requires validation against objective measures of pigmentation. In this study, we validate the MST using spectrophotometry in a diverse multiethnic cohort and compare it to the FST.

Materials and Methods

We conducted a cross-sectional observational study in two dermatology outpatient clinics in the Netherlands. Adult patients and healthy volunteers were recruited after targeted outreach to historically underrepresented communities. FST and MST were rated by one of three trained investigators. Each participant was assigned a single MST category reflecting the overall complexion of their visible skin, as per the scale's intended use. Participant-reported FST and MST were also recorded. Spectrophotometric measurements at a standardized site on the dorsal forearm were used to calculate the individual typology angle (ITA), an objective measure of pigmentation. The Spearman correlation (ρ) between MST, FST and the ITA was determined; interrater variability between investigator and participant ratings was evaluated through Cohen's quadratic weighted kappa.

Results

Out of 521 enrolled participants, 518 provided complete data and were included in the analysis. The majority was female (77.8%), with a median age of 33 years (IQR: 26-49). Individuals born in 44 different countries were included, with 28.2% of the participants being born abroad. Skin type distribution according to FST was relatively balanced per category, with some overrepresentation of medium skin types (FST-I, II: 29.5%, FST-III, IV: 42.9%, FST-V, VI: 27.6%).

Investigator-rated MST showed a stronger correlation with ITA than FST, with nonoverlapping confidence intervals (ρ = -0.87, 95% CI [-0.89, -0.84] vs. ρ = -0.79, 95% CI [-0.82, -0.75]). Mean within-category SD of ITA was smaller for MST than FST (11.77 vs 13.71), indicating a slightly more homogeneous pigmentation grouping in the MST scale.

For self-reported measures, MST showed a substantially stronger correlation with ITA than FST (ρ = -0.85, 95% CI [-0.87, -0.81] vs. ρ = -0.67, 95% CI [-0.72, -0.61]). Agreement between investigator-rated and self-reported measures was substantial for FST (weighted kappa = 0.76, 95% CI [0.71, 0.81]) and excellent for MST (weighted kappa = 0.91, 95% CI [0.89, 0.92]).

Conclusions

When used for its intended purpose, the MST correlates more strongly with objectively measured pigmentation than the FST, especially for self-reported measures. Combined with the FST's known limitations, our results support the MST as the preferred method for subjective skin tone assessment. Our findings are relevant to clinicians, to technologists evaluating medical devices and AI tools in diverse populations, and to regulators developing guidance on how device performance should be assessed across skin tones.

EA DV CONGRESS
VIENNA
30 SEP - 3 OCT 2026

Abstract N°: 4374

Measure better — addressing three sources of noise that obscure treatment effect in dermatology trials

Diego Herrera[1], Christer Nilson*[2], Åsulv Tönnesland[2]

[1] Replior AB, Barcelona, Spain

[2] Replior AB, Stockholm, Sweden

Introduction

Across dermatology development programmes, three under-addressed sources of trial noise systematically obscure the true effect of investigational therapies: patient attrition, endpoint variance from recall-based outcomes, and unmeasured environmental exposure — particularly ultraviolet radiation. Dropout rates above 30% are common across phases, with the most demanding study phases performing worse. In itch indications including atopic dermatitis, prurigo nodularis, and chronic urticaria, placebo response routinely lands between 20% and 40%, driven by a combination of vehicle effect and reporting bias from single-number recall of varying 24-hour symptom intensity. The most clinically meaningful itch occurs at night when patients are asleep and physically incapable of accurate self-report. In pigmentation, photoaging, and an increasing number of non-dermatological indications, UV exposure can reverse weeks of treatment effect within a single afternoon — yet is still routinely captured by self-reported checkbox or diary entry. UV is invisible to humans and recall-based reporting of UV exposure correlates poorly with measured dose.

Materials and Methods

To present a structured framework for systematically de-risking dermatology trials by addressing three independent sources of noise, and to describe three technology layers — behavioural-science electronic clinical outcome assessment (eCOA), continuous objective sensor endpoints, and wearable light dosimetry — that make each source individually addressable.

We describe an integrated approach combining: (1) behavioural-science-informed eCOA design grounded in Self-Determination Theory, loss aversion, and patient purpose, applied within GCP-compliant trial workflows; (2) a continuous, objective, ring-based sensor (worn on both index fingers) capturing scratch event count, intensity, duration, pressure, amplitude and concurrent sleep architecture; and (3) a multi-channel wearable photometric sensor capturing UV, visible, and infrared exposure at the skin surface across 12 channels, in ring, wristband, clip, and pendant form factors. Analytical validation of the scratch sensor are conducted against infrared-video ground truth with results expected in August 2026.

Results

Behavioural-science eCOA delivered Week 28 retention of 99% versus an approximate 80% average across two prior comparable studies (same indication, similar protocol design, different eCOA). In the most demanding study phase, retention was 75% versus 35%, 47%, and 51% in three prior comparator studies, with ePRO compliance of 95%. The scratch sensor demonstrated greater than 95% average detection accuracy in event based analysis in internal verifications, analytical validation study on 35 subjects sleeping three nights expect to have final results in August 2026. Modelling indicates that a 30% reduction in primary-endpoint sample size, achievable through lower endpoint variance, translates to substantial trial cost and timeline savings. The scratch sensor will serve as en

endpoint showing the true drug delta and separation from placebo compared with subjective measurments. Light dosimetry data can be deployed as a covariate to tighten efficacy estimates, as a primary endpoint in photoprotection and prevention trials, or as a safety signal in studies of photosensitising therapies.

Conclusions

The next decade of dermatology trial de-risking will not come from new molecules alone. It will come from removing the noise we have lived with for too long. Three independent sources — attrition, endpoint variance, and environmental exposure — are each now technically addressable. Together they offer a coherent framework for protecting the signal that sponsors, investigators, and patients have collectively paid for: did the drug work?

Measure Better.



EADV CONGRESS
VIENNA
30 SEP - 3 OCT 2026

Abstract N°: 4413

Vulvar dermatology and skin of colour representation in medical education: A single-institution curricular audit

Tahirih Nasseri*[1], Lana Mogic[1]

[1] Temerty Faculty of Medicine, University of Toronto, Toronto, Canada

Introduction
Vulvar dermatoses present across multiple medical specialties including dermatology, obstetrics and gynaecology (OBGYN), paediatrics, and family medicine. Approximately one third of Canadian medical graduates go on to practice primary care, where recognizing vulvar conditions and initiating appropriate referral is essential. Given its broad clinical relevance, all medical students should receive foundational training in vulvar pathology. This is the first study to examine vulvar dermatology medical school curricula and to assess the representation of vulvar skin of colour (SOC) in clinical teaching photographs in a Canadian context.

Materials and Methods
Curriculum materials were reviewed across pre-clerkship (didactic instruction) and clerkship (clinical rotations) phases at one Canadian medical school, including lecture slides, pre-class readings, and clerkship handbooks. Twenty vulvar dermatology topics were identified by adapting the methodology of Sun et al. (2025), cross-referencing three key sources: the ACOG Practice Bulletin on Vulvar Skin Disorders, the British Association of Dermatologists Education Subcommittee Dermatology Syllabus Guidance, and the British Society for the Study of Vulval Disease Specialty Training Curriculum. Topics appearing in ≥2 sources were retained; hidradenitis suppurativa was added given its predilection for anogenital skin. Two independent reviewers extracted all data and classified clinical photographs by Fitzpatrick Skin Type (FST), grouped as FST I–III (light/non-SOC) and FST IV–VI (SOC).

Results
In the pre-clerkship curriculum, the Dermatology block covered 2/20 topics (10%) and the Gynecology/Sex and Gender-Based Medicine block covered 7/20 (35%); the Obstetrics and Paediatrics blocks contained no vulvar dermatology content. In the clerkship curriculum, the OBGYN handbook was the predominant resource: 15 topics (75%) were taught and 3 (15%) were mentioned briefly, with 2 absent entirely; notably, no clinical photographs were included. Family Medicine and Paediatrics each covered 5/20 topics (25%), and the Dermatology clerkship contained no vulvar content. Content was skewed toward infectious conditions, with 11 of 15 clinical photographs depicting infectious etiologies across 3 conditions; the remaining 4 images depicted inflammatory dermatoses across 2 conditions. Skin tone representation was limited, with 12 images (80%) depicting Fitzpatrick Skin Types I–III and only 3 images (20%) depicting FST IV–VI.

Conclusions
Vulvar dermatology is substantially undertaught in this Canadian medical school curriculum. Clinical photographs are rarely included and when included, overwhelmingly depict light skin tones, underrepresenting SOC. Curricular

reform should prioritize live instruction, broader coverage of inflammatory dermatoses, and diverse clinical images spanning all skin tones to ensure diagnostic equity.

EA DV CONGRESS
VIENNA
30 SEP - 3 OCT 2026

Abstract N°: 4419

A Comparative Evaluation of Photodynamic Therapy, Tap Water Iontophoresis, and Botulinum Toxin A Injection in Treatment of Primary Palmar Hyperhidrosis

Marwa El-Samongy*[1], Hoda Gaafar[2], Marwa Abou El-Hawa[3], Nashwa Elfar[1]

[1] Dermatology & Venereology department, Faculty of Medicine, Tanta University, Tanta, Egypt

[2] faculty of medicine, Tanta, Egypt

[3] Rheumatology department, Tanta, Egypt

Introduction

Hyperhidrosis is characterized by overstimulation of cholinergic receptors in eccrine glands, leading to excessive sweating. It may be primary, with earlier onset and localized presentation, or secondary, associated with systemic disorders, medications, or neurologic conditions. The disorder often affects the axillae, palms, and feet and significantly impairs quality of life, carrying cosmetic, psychological, and dermatological consequences. Disrupting the skin's protective mechanisms, it predisposes patients to bacterial, fungal, and occasionally viral infections.

Management varies according to severity and type. BTX-A, the most potent neurotoxin, inhibits acetylcholine release and is effective for focal HH, including axillary, palmar, and Frey's syndrome.

Emerging modalities include photodynamic therapy, which employs a photosensitizer activated by light to generate reactive oxygen species that selectively destroy eccrine glands, sparing healthy tissue. Iontophoresis, another option, involves passing a mild electrical current through tap water or anticholinergic solutions, likely reducing sweating through ductal blockage or interference with sympathetic transmission.

Therefore, this study aimed to compare the efficacy and safety of PDT (with MB 2% hydrogel), Tap Water Iontophoresis, and intradermal BTX-A injection in the treatment of primary palmar HH.

Materials and Methods

This randomized controlled study was conducted on 30 patients. They were divided into three groups: Group A: 10 patients received PDT via MB 2% hydrogel, where a photosensitizer was applied to both palms, followed by irradiation with IPL. Sessions were performed once per week for a maximum of 8 sessions. Group B: 10 patients received iontophoresis with tap water for both palms every other day for 4 weeks. Group C: 10 patients received an intradermal BTX-A injection for both palms as a single session. All patients were assessed according to the Hyperhydrosis disease severity score (HDSS) and starch iodine test before and after the end of treatment.

Results

All patients in the three studied groups showed significant improvement with different clinical grades assessed by HDSS and starch iodine test. After one month, HDSS and starch iodine test were statistically significantly reduced in the photodynamic group compared to the iontophoresis group. After three months of follow-up, HDSS was statistically significantly reduced in both the photodynamic group and the Botox group compared to the iontophoresis group. There was no statistically significant difference between the photodynamic group and the Botox group. Recurrence occurred in all patients in the iontophoresis group, but those in the photodynamic and Botox groups showed a lower recurrence rate.

Table: Comparison between the severity of HH in three studied groups according to Starch iodine test before and after treatment.

	PDT (Group A) (n = 10)		Iontophoresis (Group B) (n = 10)		BTX-A (Group C) (n = 10)		H	P
	No.	%	No.	%	No.	%		
Baseline								
Grade 0	0	0.0	0	0.0	0	0.0		
Grade 1	0	0.0	0	0.0	0	0.0		
Grade 2	0	0.0	0	0.0	0	0.0	1.555	0.460
Grade 3	2	20.0	2	20.0	3	30.0		
Grade 4	5	50.0	2	20.0	4	40.0		
Grade 5	3	30.0	6	60.0	3	30.0		
1 month								
Grade 0	8	80.0	0	0.0	4	40.0		
Grade 1	2	20.0	1	10.0	2	20.0		
Grade 2	0	0.0	5	50.0	2	20.0	15.509*	<0.001*
Grade 3	0	0.0	4	40.0	2	20.0		
Grade 4	0	0.0	0	0.0	0	0.0		
Grade 5	0	0.0	0	0.0	0	0.0		
Sig. bet. grps.	p_1<0.001*, p_2=0.059,p_3=0.041*							
3 month								
Grade 0	3	30.0	0	0.0	0	0.0		
Grade 1	1	10.0	0	0.0	0	0.0		
Grade 2	4	40.0	0	0.0	6	60.0	16.556*	<0.001*
Grade 3	2	20.0	4	40.0	3	30.0		
Grade 4	0	0.0	6	60.0	1	10.0		
Grade 5	0	0.0	0	0.0	0	0.0		
Sig. bet. grps.	p_1<0.001*, p_2=0.146,p_3=0.010*							

H: H for **Kruskal Wallis test,** pairwise comparison bet. Each 2 groups were done using **Post Hoc Test (Dunn's for multiple comparisons test)**
p: p value for comparing between the studied groups
p_1: p value for comparing between **Group A** and **Group B**
p_2: p value for comparing between **Group A** and **Group C**
p_3: p value for comparing between **Group B** and **Group C**
: Statistically significant at $p \leq 0.05$

Conclusions

- Photodynamic therapy with MB 2% hydrogel and BTX-A injections demonstrated superior efficacy and higher patient satisfaction. Photodynamic therapy was associated with the lowest recurrence rate
- Botulinum Toxin A injection was an effective and safe treatment option for hyperhidrosis,providing a durable and significant reduction in excessive sweating and improving quality of life with transient mild side effects; however, it requires a relatively high total dose.
- Iontophoresis was effective and safe with the lowest side effects in the treatment of primary palmar hyperhidrosis, but it needs more maintenance sessions. Also, it showed a rapid recurrence rate at three months of follow-up.

EA DV CONGRESS
VIENNA
30 SEP - 3 OCT 2026

Abstract N°: 4444

The privileged minority: inverse relationship between prevalence and global research activity of 15 dermatological diseases

Oliver Brandt[1], Erere Otrofanowei[2], Ncoza Dlova[3], Simon Mueller*[1]

[1] Department of Dermatology, University Hospital Basel, University of Basel, Basel, Switzerland

[2] Department of Medicine, College of Medicine University of Lagos, Lagos, Nigeria

[3] Department of Dermatology, Nelson R. Mandela School of Medicine, University of KwaZulu-Natal, Durban, South Africa

Introduction

Skin diseases affect nearly one-third of the global population. Since 2007, the WHO has engaged in controlling neglected tropical diseases (NTDs), including skin conditions such as Buruli ulcer, cutaneous leishmaniasis, leprosy, lymphatic filariasis, mycetoma, onchocerciasis, scabies, and yaws. These diseases cause stigmatization, disability, and reduced quality of life. Despite the 10/90 gap concept introduced 25 years ago—highlighting that less than 10% of global healthcare research expenditure addresses 90% of disease burden—it remains unclear whether dermatological research activity correlates with global disease prevalence.

Materials and Methods

Based on the Global Burden of Disease (GBD) Study 2019, we analyzed 15 dermatological diseases using age-standardized prevalence rates. Past research activity was assessed through PubMed analysis of clinical trials (2003-2023), and future activity through registered trials on clinicaltrials.gov (as of April 21, 2023). Spearman's rank correlation coefficient quantified the relationship between prevalence and research activity.

Results

An inverse trend emerged between prevalence and research activity. Melanoma, with 325,000 new cases annually (0.004% incidence) and primarily affecting fair-skinned populations, leads with 1012 ongoing trials—nearly three times more than psoriasis. Scabies, affecting 200 million people with mortality rates up to 16% from bacterial superinfections in severe cases, has only 8 ongoing trials. Fungal infections, the most prevalent dermatosis affecting approximately 1 billion people, ranks 12th. Disability-Adjusted Life Year (DALY) values underscore this disparity: scabies (67) substantially exceeds both melanoma (21) and psoriasis (47). Yet skin diseases primarily affecting resource-poor regions and darker skin types remain systematically underrepresented. Many skin NTDs, while not immediately life-threatening, cause substantial disability, stigmatization, and socioeconomic burden.

Conclusions

Twenty-five years after the Global Forum for Health Research described the 10/90 gap, fundamental inequities persist. Research systematically favors conditions affecting privileged minorities while neglecting high-burden diseases in resource-poor regions. Urgent coordinated action from scientific communities, health organizations, governments, and the pharmaceutical industry is essential to

expand research agendas toward neglected dermatoses without reducing existing priorities.

EADV CONGRESS
VIENNA
30 SEP - 3 OCT 2026

Abstract N°: 4460

Integration of Artificial Intelligence (AI) - Virtual Patient Simulation in Undergraduate Dermatology Education

Mariam Abu Jubain[1], Nikolaos Georgiou*[1], Terese Bird[2], Ingrid Helbling[1, 1]

[1] University Hospitals of Leicester NHS Foundation Trust, Leicester, United Kingdom

[2] University of Leicester, Leicester, United Kingdom

Introduction

The integration of artificial intelligence (AI) in medicine is becoming more prevalent and is increasingly used as an educational tool for university students. A pilot study of 4th-year medical students at a teaching hospital was completed to evaluate an AI-virtual patient simulation tool and its value and effectiveness in undergraduate medical student education.

Materials and Methods

Sixty-seven students completed pre- and post-AI questionnaires assessing confidence and experience in history-taking. The pre-AI survey evaluated exposure to real patient histories, confidence, and clinical challenges. The post-AI survey examined the tool's usability and its impact on students' confidence, competence, and preparedness for future dermatology encounters.

Results

Results revealed that in the pre-AI questionnaire, 71.4% of students reported frequently taking patient histories in other rotations, with 50% feeling confident in their history-taking skills. Students reported limited practice opportunities, with only 22.5% indicating an adequate experience. After the AI tool intervention, 66.6% felt confident in their history-taking abilities, presenting a marked increase. Confidence in structuring a dermatological history also improved, from 57.1% to 64.5%. Moreover, 59.7 % of students reported that the AI tool provided more opportunities to practice compared to their clinical rotations. The AI tool was perceived as realistic by 60.3% of students, enhancing their learning experience. Furthermore, the ability to take a dermatological history efficiently within a clinical time limit rose from 35.7% pre-AI to 42.9% post-AI.

Conclusions

Implementation of AI patient simulation tools can be a powerful educational adjunct. By allowing students to practise at their own pace in a less pressured environment, the tool facilitated a relaxed learning experience that complements traditional clinical training. Importantly, this intervention is not intended to replace valuable real clinical history-taking but to enhance the experience alongside it. Further studies with larger cohorts and longitudinal analysis are warranted to determine the long-term impacts on clinical competency in dermatology.

EA DV CONGRESS
VIENNA
30 SEP - 3 OCT 2026

Abstract N°: 4482

Hydroxy acid complex enhances topical skin delivery of tranexamic acid

Anthony Brown*[1], Queralt Bonet-Rossinyol[2], JESSICA ROMERO-RUEDA[2], Adrià Ribes[1], Carolina Escardó[1], Monica Foyaca[1]

[1] Innovation & Development, ISDIN S.A., Barcelona, Spain
[2] Leitat Technological Center, Barcelona, Spain

Introduction

Tranexamic acid (TXA), a synthetic derivative of the amino acid lysine, has emerged as a promising depigmenting agent due to its ability to inhibit melanogenesis. Its mechanism of action involves suppression of the plasminogen–plasmin system, thereby reducing the release of pro-inflammatory mediators that promote melanin synthesis. The clinical efficacy of topically applied TXA, however, remains questioned as its physicochemical properties, including its polarity, water solubility, low molecular weight, and tendency to ionize in aqueous formulations, limit its penetration through the stratum corneum (SC).

We hypothesized that co-formulation of TXA with hydroxy acids (HAs), which act as chemical exfoliants, would enhance its percutaneous absorption via stratum corneum disruption.

Accordingly, this study aimed to evaluate whether a topical formulation containing 1.8% TXA in combination with hydroxy acids enhances its penetration across the SC, and reach concentrations in the epidermis associated with effective depigmenting activity.

Materials and Methods

The formulations evaluated consisted of 1.8% TXA and a hydroxy acid complex comprising gluconolactone, phytic acid, mandelic acid, and salicylic acid. TXA (15 µL/cm2), alone or in combination with the hydroxy acid complex (15 µL/cm2), was topically applied to human dermatomed skin samples using Franz diffusion cells. After 16 hours, TXA concentrations were quantified in the skin surface wash, stratum corneum, epidermis, dermis, and receptor fluid.

Results

The hydroxy acid complex significantly increased TXA concentrations across all skin compartments compared with TXA alone (Table 1). The greatest increase was observed in the epidermis (+446%), indicating enhanced delivery to the primary site of depigmenting activity. Total TXA absorption (epidermis + dermis + receptor fluid) increased by +217%. Notably, the concentrations achieved fell within the range associated with biologically effective depigmenting activity.

Skin layer	Relative increase in TXA with HAs (%)
Stratum corneum	+184%
Epidermis	+446%
Dermis	+167%
Total absorption (Epidermis + Dermis + Receptor fluid)	+217%

Table 1. Increase in the absorption of 1.8% TXA across skin layers with hydroxy acids versus control (%).

Conclusions

The hydroxy acid complex enhanced TXA penetration across all skin layers, particularly in the epidermis. These findings support improved delivery to target sites of depigmenting activity and suggest potential to enhance clinical outcomes in hyperpigmentation.

EA DV CONGRESS
VIENNA
30 SEP - 3 OCT 2026

Abstract N°: 4501

Porphyria Cutanea Tarda in an Immunosuppressed Patient

Marcela López*[1]

[1] Hospital de Especialidades No. 25, Centro Médico Nacional del Noroeste, Monterrey, Mexico

Introduction

Porphyria cutanea tarda is a hepatic porphyria caused by deficiency of the enzyme uroporphyrinogen decarboxylase, resulting in porphyrin accumulation in the liver and subsequently in the skin. Although it is the most common type of porphyria, its occurrence among patients with HIV infection is uncommon, with a prevalence below 1%.

The pathophysiological relationship between HIV infection and porphyria cutanea tarda remains unclear. Furthermore, evidence regarding the impact of antiretroviral therapy on the clinical improvement of porphyria cutanea tarda is limited

Materials and Methods

Case Presentation

A 65-year-old male with no significant medical history presented with a 6-month history of bilateral pruritic blisters on photoexposed areas of the dorsal hands, associated with hypopigmentation and scarring.

Physical examination revealed disseminated dermatosis involving the face and upper extremities, predominantly on the dorsal hands and forearms, characterized by tense clear-fluid blisters, achromic macules, milia cysts, and scars.

Wood’s lamp examination demonstrated pink-coral fluorescence of the gingiva. A urine sample exposed to Wood’s lamp in a dark environment showed similar pink-coral fluorescence.

Comprehensive laboratory testing and viral serologies were performed, revealing positive HIV serology, while hepatitis B and hepatitis C serologies were negative.

Histopathological examination of a skin biopsy from the right hand demonstrated a subepidermal blister with festooning of the dermal papillae, superficial dermal lymphocytic inflammatory infiltrate, and perivascular lymphocytic infiltrate.



Tense clear-fluid blisters, achromic macules, multiple milia cysts, and scars

Results

The presence of tense blisters in photoexposed areas, together with the characteristic pink-coral fluorescence under Wood's lamp, compatible histopathological findings, and laboratory results, supported the diagnosis of porphyria cutanea tarda. Treatment with oral chloroquine 150 mg twice weekly was initiated. Following the diagnosis of HIV infection, antiretroviral therapy with bictegravir/emtricitabine/tenofovir was also started.

The simultaneous presentation of porphyria cutanea tarda and HIV infection raises the possibility of a direct association between both conditions and whether HIV itself may act as a triggering factor. Unlike hepatitis C virus, whose association with porphyria cutanea tarda is well established, the mechanisms underlying the HIV–porphyria cutanea tarda relationship remain poorly understood. Proposed mechanisms include altered steroid metabolism with increased endogenous estrogen production interfering with heme synthesis, as well as hepatic injury secondary to high levels of viral replication.

Conclusions

Despite the strong evidence identifying hepatitis C virus as the principal etiological factor in porphyria cutanea tarda, the pathogenesis of the association between porphyria cutanea tarda and HIV infection has not been fully elucidated. It has been suggested that, in scenarios of high viral replication, HIV may directly induce porphyria cutanea tarda in susceptible individuals. Overall, HIV appears to behave primarily as a susceptibility factor.

The initiation and strict optimization of antiretroviral therapy constitute a modifiable intervention that may lead to clinical remission of porphyria cutanea tarda. Therefore, in patients with concomitant porphyria cutanea tarda and HIV infection, antiretroviral therapy should be prioritized, and longitudinal follow-up with plasma and urinary porphyrin measurements, as well as liver function monitoring, should be established in order to document complete remission and reduce recurrences or other complications.

EADV CONGRESS
VIENNA
30 SEP - 3 OCT 2026

Abstract N°: 4545

Retrospective Analysis of an Automated Scheduling System to Improve Appointment Access in an Academic Dermatology Practice

Natalia Chalupczak*[1], Nuran Golbasi[2], Shari Lipner[2]

[1] Chicago Medical School, Rosalind Franklin University of Medicine and Science, Chicago, United States
[2] Weill Cornell Medicine, New York, United States

Introduction
Dermatology faces a well documented access crisis characterized by prolonged appointment wait times exacerbated by last-minute cancellations. Automated scheduling systems offer a promising solution, yet the operational variables governing their performance remain poorly characterized. We performed a retrospective analysis of an academic dermatology automated scheduling system to identify actionable factors influencing patient access.

Materials and Methods
All automated appointment offers sent between January 1 and June 30, 2025 across nine Weill Cornell Medicine Dermatology sites were analyzed. Patients joined a waitlist for earlier appointments via an online portal and opted into email or text notifications. Offer outcomes (accepted, declined, expired), engagement speed, access improvement, and appointment completion were assessed. Categorical variables were compared using chi-square tests; continuous variables using Kruskal-Wallis or Mann-Whitney U tests.

Results
Overall, 8,319 offers were sent to 3,086 unique patients; 15.7% were accepted, 15.2% declined, and 69.2% expired, of which 65.7% had been viewed. Among all patients, 39.9% accepted at least one offer. Median time to first view was 12.8 minutes (IQR 1.9–49.5) and time to accept was 13.5 minutes (IQR 2.8–52.5). Accepted offers yielded a median of 28 days of access improvement. Offer acceptance differed significantly by time of day ($p<0.001$) and day of week ($p=0.001$), with evening dispatch producing the highest acceptance rate (17.1%) and fastest engagement (median 10.0 minutes to view). Wednesday yielded the highest weekly acceptance (20.1%), while weekend response times were slowest. High-priority offers generated greater access improvement than standard-priority offers (42 vs. 21 days; $p<0.001$). Lead time was inversely associated with completion, with rates highest for 1–3-day lead times (89.0%) versus those exceeding 30 days (70.9%; $p=0.001$).

Conclusions
Automated dermatology scheduling performance is shaped by modifiable operational variables including offer timing, appointment priority, and lead time. Prioritizing evening and mid-week dispatch, directing high-priority offers strategically, and minimizing lead time where feasible represent actionable steps to expand access to dermatologic care.

EADV CONGRESS
VIENNA
30 SEP - 3 OCT 2026

Abstract N°: 4580

Mindful Focus on Skin of Colour - Recognising and Addressing Hidden Aggression in Dermatology Practice

S. Michele Nevarez[1], Lawrence Chukwudi Nwabudike[2], Adrian Tilby[3], Liang Joo Leow*[4, 5]

[1] Beyond EI, Scottsdale, AZ, United States
[2] Institutul Paulescu, București, Romania
[3] Department of Social Services, Commonwealth of Australia, Perth, Australia
[4] University of Notre Dame Australia, Sydney, Australia
[5] International Consortium of Mohs Surgery, Indianapolis, United States

Introduction

As a graduate of the third cohort of the EADV's Leadership Development Program, and subsequent formal training in coaching with mindfulness and leadership guru S. Michele Nevarez, the presenting author draws upon lived experience of severe and lifechanging dermatologic disease, and the potential at this point in time for the lack of knowledge and education to become weapons of oppression, both inadvertent or intentional.

Materials and Methods

We introduce this topic by presenting common and everyday occurrences that readily occur at dermatology workplaces; which by first impression may be overlooked or seem innocent and harmless. Techniques and strategies for facing, and if relevant, managing these situations are then debated.

The ubiquitous and overarching representation of inflammation of Caucasian skin is then introduced as a core topic for audience interaction and discussion for how it may (intentionally or unintentionally) exclude people with skin of colour from being truly seen and relegated to inadequate dermatologic care, on account of pattern mismatch replacing usually highly effective clinical pattern matching.

Results

Through proven mindfulness tools such as journaling and self-reflection, participants are invited to 'spread the word', normalise and embody one of the simplest pillars of education - 'see one, do one, teach one' - as the presenting author shares how their knowledge of skin of colour, gained through self-discovery rather than formal learning, has formed the basis of a logical and easy to understand system of assessing and appraising skin of colour that participants can readily adopt in their own daily clinical practice and disseminate widely.

Conclusions

The case-in-point of this oral presentation organically emphasises the tremendous importance of inclusivity and diversity in the representation of diseases of the skin, hair and nails, as a long overdue 'missing link' in the learning and teaching of dermatology, that must now from this moment on become grounded in our chosen discipline for posterity.