EA DV CONGRESS
VIENNA
30 SEP - 3 OCT 2026

Abstract N°: 7

A Rare Case of Sweet Syndrome with Isolated Scalp and Hand Involvement

Nur Seyma Borazan*[1], Müzeyyen Gönül[1], Hitay Cemre Metindoğan[2], Murat Alper[2], Selda Pelin Kartal[1]

[1] Ankara Etlik City Hospital, Department of Dermatology and Venereology, Ankara, Türkiye
[2] Etlik City Hospital, Department of Pathology, Ankara, Türkiye

Introduction

Sweet syndrome is an acute febrile neutrophilic dermatosis characterized by the sudden onset of painful erythematous plaques accompanied by neutrophilic dermal infiltration. Although lesions typically involve the face, neck, and upper extremities, atypical and localized presentations may occur. We report a rare case of Sweet syndrome with isolated scalp and hand involvement in a patient with bipolar disorder successfully managed with dapsone.



Case Presentation

A 61-year-old man presented with painful inflammatory skin lesions on the scalp and dorsal aspects of the hands. One week before presentation, he had received topical benzoyl peroxide for acne-like lesions on the scalp at an outside center. Shortly thereafter, the lesions rapidly progressed, becoming pustular, erythematous, and ulcerative. Simultaneously, painful violaceous plaques developed on both dorsal hands.His medical history was notable for bipolar disorder treated with quetiapine and valproic acid for several years. Physical examination revealed

widespread edematous, hemorrhagic crusted and ulcerative plaques on the scalp, along with edematous violaceous erythematous papulonodular and pustular lesions on both dorsal hands. Bacterial cultures from the lesions were negative.Laboratory investigations demonstrated elevated inflammatory markers, including C-reactive protein of 65.24 mg/L, leukocyte count of 15.03 $\times 10^9$/L, and neutrophil count of 10.33 $\times 10^9$/L. Further evaluation for autoimmune and infectious etiologies revealed no significant abnormalities.Punch biopsies obtained from the scalp and dorsal hand demonstrated marked dermal edema with dense neutrophilic infiltration and fibrinoid changes in vessel walls without leukocytoclastic vasculitis. These histopathological findings were consistent with Sweet syndrome.Systemic corticosteroid therapy with oral methylprednisolone (40 mg/day) was initiated, resulting in significant clinical improvement within 72 hours. Due to psychiatric comorbidity, corticosteroid therapy was tapered and discontinued within one month. Maintenance therapy with dapsone (50 mg/day) was subsequently started, and no recurrence was observed during follow-up. The patient continues to be monitored for possible associated systemic diseases and malignancy.



Conclusion

Sweet syndrome may rarely present with isolated scalp and hand involvement, which can pose a diagnostic challenge. In particular, scalp lesions may clinically resemble erosive pustular dermatosis of the scalp. Some authors have suggested that erosive pustular dermatosis may represent a neutrophilic dermatosis or a neutrophilic variant within the spectrum of Sweet syndrome. Awareness of this potential overlap is important for accurate diagnosis and appropriate management.

Abstract N°: 8

Navigating the Diagnostic Spectrum of Sebopsoriasis: Cutaneous and Articular Clues in a Young Female Patient

Catalina Cojocaru*[1], Veronica Mardari[1]

[1] Railway Clinical Hospital, Iași, Romania

Introduction

Sebopsoriasis represents a clinical overlap between seborrheic dermatitis and psoriasis, frequently involving seborrheic areas such as the scalp, face, and presternal region. Its polymorphic presentation and chronic-relapsing course may obscure the diagnosis, particularly when extracutaneous symptoms raise suspicion for systemic involvement. We report the case of a 30-year-old female presenting with lesions suggestive of sebopsoriasis affecting the scalp and posterior thorax, in whom worsening cutaneous lesions and newly reported arthralgia prompted histopathological evaluation to exclude psoriasis with potential psoriatic arthritis.

Case Presentation

A retrospective clinical and paraclinical analysis was conducted in a 30-year-old female who presented with erythematous, well-demarcated plaques covered by greasy scales localized on the occipital scalp and posterior thorax. The patient reported progressive exacerbation over several months despite topical corticosteroids and antifungal therapy. Additionally, she described inflammatory-type joint pain involving the small joints of the hands and knees, with morning stiffness lasting over 30 minutes. Given the atypical progression and associated articular symptoms, a punch biopsy was performed from an occipital lesion. Laboratory investigations included inflammatory markers (ESR, CRP), rheumatoid factor, anti-CCP antibodies, and ANA profile.
Histopathological examination revealed psoriasiform epidermal hyperplasia with elongated rete ridges, parakeratosis with neutrophilic aggregates, a diminished granular layer, and a superficial perivascular lymphocytic infiltrate, findings characteristic of psoriasis vulgaris in a seborrheic distribution. In addition, fungal elements were observed within the follicular ostia on histological examination. No predominant features suggestive of isolated seborrheic dermatitis were identified. Laboratory tests showed mildly elevated inflammatory markers, while rheumatoid factor and anti-CCP antibodies were negative. The clinical correlation between cutaneous findings and inflammatory arthralgia raised suspicion for early psoriatic arthritis, prompting referral to rheumatology for further assessment. Initiation of systemic therapy with methotrexate led to significant improvement of both cutaneous lesions and joint symptoms at follow-up.

Conclusion

This case highlights the diagnostic complexity of sebopsoriasis-like presentations, particularly when accompanied by articular symptoms suggestive of psoriatic arthritis. The clinical overlap between seborrheic dermatitis and psoriasis may delay accurate diagnosis, especially in young patients with atypical progression. Histopathological confirmation plays a crucial role in differentiating these entities and guiding appropriate management. Early recognition of potential systemic involvement requires a multidisciplinary approach integrating dermatology and rheumatology to prevent disease progression and optimize long-term outcomes.

EA DV CONGRESS
VIENNA
30 SEP - 3 OCT 2026

Abstract N°: 26

A Phase 2b Placebo-Controlled Study to Evaluate the Efficacy and Safety of Tulisokibart in Adults With Moderate to Severe Hidradenitis Suppurativa

Alexa B. Kimball*[1], Raja K. Sivamani[2], Alejandra Toro Alvarez[3], Claudia de La Cruz[4], Bénédicte Oules[5], Wenyu Wu[6], Koremasa Hayama[7], Aileen R. Dualan[8], Sarah Baradaran[8], Andrea Maes[8], Jinhao Zou[8], Wen Zhou[8], Jaclyn Anderson[8], Aileen Pangan[8], Iltefat Hamzavi[9], Errol Prens[10]

[1] Harvard Medical School and Beth Israel Deaconess Medical Center, Boston, MA, United States
[2] Integrative Skin and Science Research, Sacramento, Sacramento, CA, United States
[3] Centro de Biociencias, Grupo SURA, Medellin, Colombia
[4] Clinica Dermacros, Santiago, Chile
[5] Department of Dermatology, Hôpital Cochin, AP-HP Centre-Université Paris Cité, Paris, France
[6] Huashan Hospital, Fudan University, Shanghai, China
[7] Division of Cutaneous Science, Department of Dermatology, Nihon University School of Medicine, Tokyo, Japan
[8] Merck & Co., Inc., Rahway, NJ, United States
[9] Henry Ford Hospital, Detroit, MI, United States
[10] Erasmus University, Rotterdam, Netherlands

Introduction
Hidradenitis suppurativa (HS) is a chronic inflammatory skin disease characterized by painful nodules and abscesses that can progress to tunnels, fibrosis, and scarring. Tumor necrosis factor–like cytokine 1A (TL1A) expressed by antigen-presenting cells signals by binding to death receptor 3 (DR3). TL1A is implicated in pathways that initiate and maintain chronic inflammation and may contribute to chronic fibrosis in HS. Tulisokibart is an investigational anti-TL1A monoclonal antibody that blocks TL1A-DR3 signaling, downregulating Th1, Th2, and Th17, thereby potentially disrupting the immuno-fibrotic loop in HS. This is the first study to evaluate the efficacy and safety of TL1A inhibition with tulisokibart in patients with HS.

Materials and Methods
This was a randomized, double-blind, placebo-controlled, multicenter trial in adults 18 to 75 years with HS (NCT06956235). Bayesian design was implemented to augment concurrent controls with historical placebo for the primary endpoint, the proportion of participants achieving Hidradenitis Suppurativa Clinical Response 50 (HiSCR50) at Week 16. Participants had moderate to severe HS defined as ≥5 abscesses and/or inflammatory nodules, lesions in ≥2 distinct anatomical areas, and Hurley Stage II or III in ≥1 area. Participants were randomized 2:2:1:2 (stratified by Hurley Stage [II or III] and concomitant systemic antibiotic [yes or no]) to subcutaneous tulisokibart 480 mg every 2 weeks (high dose), 480 mg every 4 weeks (medium dose), 240 mg every 4 weeks (low dose), or placebo, for 16 weeks, with a loading dose at day 1 (low dose group, 480 mg loading dose; medium and high dose groups, 960 mg loading dose). Secondary endpoints include proportion of participants with HiSCR75 response and change from baseline in Dermatology Life Quality Index (DLQI) total score at week 16.

Results
Among 149 participants (tulisokibart high dose, N=42; tulisokibart medium dose, N=42; tulisokibart low dose, N=21; and placebo, N=44), baseline characteristics such as age, BMI, gender, Hurley stage, and systemic antibiotic

use, were balanced across the treatment groups. At Week 16, HiSCR50 response was achieved in 72.4% (high dose), 64.1% (medium dose), and 51.7% (low dose) of participants receiving tulisokibart compared with 35.1% of those receiving placebo (Bayesian treatment difference [95% credible interval] vs placebo: high dose, 37.3% [17.9, 54.9]; medium dose, 28.9% [9.0, 47.9]; low dose, 16.5% [-8.2, 41.0]; posterior probability of superiority >99% for high dose and medium dose) (figure). Treatment effects as measured by HiSCR50 were observed as early as Week 4. HiSCR75 was achieved at week 16 in 41.2% (high dose), 39.6% (medium dose), and 29.1% (low dose) of participants receiving tulisokibart compared with 15.1% receiving placebo (frequentist treatment difference [95% CI] vs placebo: high dose, 26.8% [9.1, 44.5], medium dose, 24.3% [6.9, 41.6]; and low dose, 13.0% [-5.9, 31.9]) (figure). LS mean change from baseline in DLQI at week 16 was -5.6 (high dose), -3.5 (medium dose), and 0.7 (low dose) in those receiving tulisokibart compared with -2.5 in those receiving placebo (treatment difference [95% CI] vs placebo: high dose, -3.2 [-5.6, -0.7], medium dose, -1.0 [-3.6, 1.5], and low dose, 3.1 [0.1, 6.1]) (figure). Adverse events (AEs) occurred in 42.9%, 47.6%, and 52.4% of those receiving tulisokibart high dose, medium dose, and low dose, respectively, compared with 40.9% of those receiving placebo. Serious AEs were infrequent and occurred at similar rates across the treatment groups (2.4%, 2.4%, and 4.8% for tulisokibart high dose, medium dose, and low dose, respectively, vs 2.3% for placebo). No serious or opportunistic infections were observed in the study.

Conclusion

This Phase 2b study demonstrated dose-related efficacy of tulisokibart in the treatment of participants with moderate to severe HS through Week 16, with consistency across multiple endpoints. Tulisokibart was generally well-tolerated with no safety concerns identified.

A. HiSCR50 Response

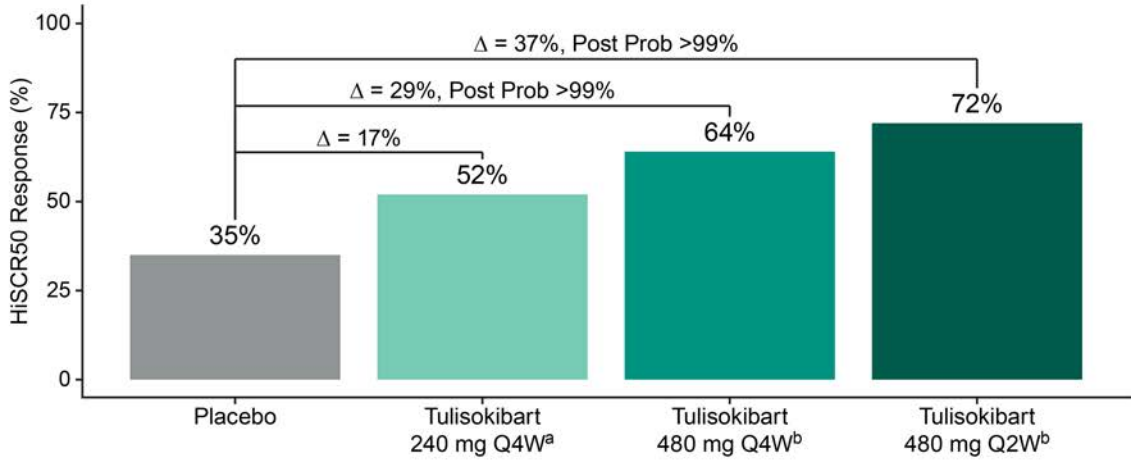

B. HiSCR75 Response

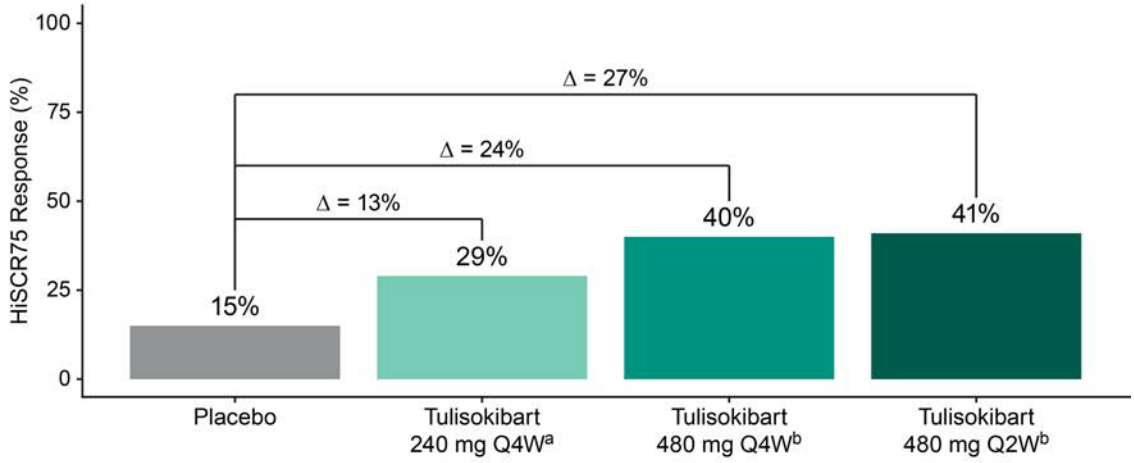

C. DLQI

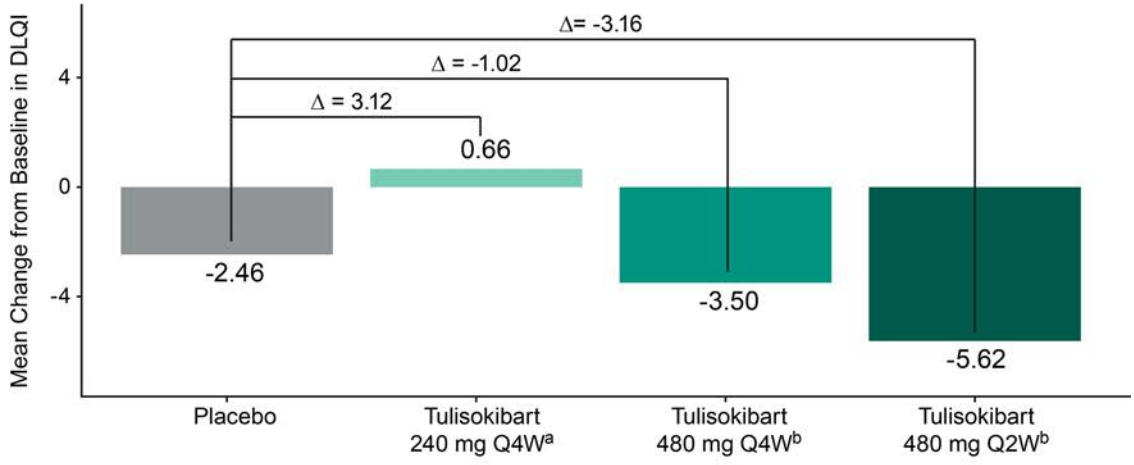

[a]Loading dose: Tulisokibart 480 mg SC at Day 1/Week 0.
[b]Loading dose: Tulisokibart 960 mg SC at Day 1/Week 0.

EA DV CONGRESS
VIENNA
30 SEP - 3 OCT 2026

Abstract N°: 41

Sarcoidosis Unmasked by Skin Biopsy.

Samiksha Shankar Shetty*[1], Shireen Furtado[1]

[1] Aster CMI Hospital, Bengaluru, India

Introduction

Sarcoidosis is a chronic multisystem granulomatous disease of unknown etiology. Although pulmonary involvement is most common, cutaneous manifestations may be seen early or even as the sole presenting feature. Also known as a "great masquerader", clinical morphology is highly diverse. We present such a case with 2 different types of skin lesions resembling lichenoid and follicular disorders.

Case Presentation

A 46 year-old female presented with asymptomatic hyperpigmented lesions over the trunk for 2–3 years, with progression over the preceding year. Multiple small lesions over the upper back which was externally treated as keratoses pilaris for many years. She also complained of extreme muscle pain and joint pains.

Cutaneous examination revealed multiple hyperpigmented to erythematous macules and papules distributed predominantly over the trunk, especially over frictional areas and the upper back. Few lesions over the chest hyperpigemented patches resembling a lichenoid morphology. Based on clinical findings, Lichen planus, Lichen planus pigmentosus, and Prurigo pigmentosa were considered.

There was no history of pruritus, ketogenic diet, prolonged fasting, use of hair dye, or prior similar lesions.

The patient was diagnosed with seronegative arthritis with fibromyalgia by rheumatologist . She had previously received oral corticosteroids (which was discontinued due to cataract) and methotrexate (stopped due to leucopenia). She was subsequently treated with tofacitinib and hydroxychloroquine with minimal improvement.

Laboratory investigations revealed persistently elevated ESR and CRP. ANA profile showed borderline positivity for Pm-Scl. The patient had chronic leucopenia, evaluated by hematology and considered secondary to either drug therapy or underlying disease. HRCT thorax and CT abdomen and pelvis performed one year prior were unremarkable.

Family history was significant for sarcoidosis in her mother, who had perihilar lymphadenopathy and was on treatment.

Skin biopsy demonstrated multiple epithelioid cell granulomas in the upper dermis with Langhans-type giant cells. Mild lymphocytic and plasma cell infiltrate was seen surrounding the granulomas, along with stromal myxoid degeneration. No caseation necrosis was identified.

Based on clinicopathological correlation, a diagnosis of systemic sarcoidosis with cutaneous involvement was established.

Conclusion

Cutaneous manifestations of Sarcoidosis are highly variable and may mimic several dermatologic conditions, earning it the designation of a “great imitator.”

The absence of pruritus, lack of identifiable triggers, and poor response to therapy prompted reconsideration of the diagnosis. Systemic features including sero-negative arthritis, myalgia, elevated inflammatory markers, and leucopenia further suggested a multisystem disorder. The main reason for reconsideration was no improvement in systemic symptoms inspite of treatment for 5-6 years

Histopathological identification of non-caseating granulomas remains the cornerstone of diagnosis. Although pulmonary involvement is common in sarcoidosis, its absence on imaging does not exclude the disease, particularly in extrapulmonary presentations.

This case also highlights the importance of considering sarcoidosis in patients with presumed seronegative arthritis who show suboptimal response to standard therapies.

EADV CONGRESS
VIENNA
30 SEP - 3 OCT 2026

Abstract N°: 72

Bullous Pyoderma Gangrenosum Associated with Anti- phospholipid Syndrome: A Case Report and Literature Review

Yousuf Alwashahi[1], Mayar Albahrani*[2]

[1] Sultanate of Oman, Ministry of Health, Muscat, Oman
[2] Oman Medical Speciality Board, Muscat, Oman

Case Presentation
We report a rare case of a 49-year-old woman with a history of primary antiphospholipid syndrome (APS), glucose-6-phosphate dehydrogenase deficiency, and iron deficiency anaemia who developed rapidly progressive bullous lesions at the site of intravenous cannulation. The lesions subsequently evolved into painful ulcerations with recurrent abscess formation and demonstrated worsening following surgical manipulation, raising suspicion of a pathergy phenomenon. In the context of progressive ulceration and treatment resistance, pyoderma gangrenosum (PG) was strongly suspected. Initial management with systemic corticosteroids and cyclosporin resulted in partial disease control.

APS is a prothrombotic autoimmune disorder characterised by the presence of antiphospholipid antibodies and clinically manifests with recurrent pregnancy morbidity and/or thromboembolic events. Cutaneous manifestations are diverse and range from livedo reticularis to severe necrotic ulceration. PG-like ulcers have been rarely reported in patients with APS and may present a significant diagnostic challenge due to the clinical overlap between thrombotic vasculopathy and neutrophilic dermatosis.

This case highlights the importance of recognising PG-like ulceration and pathergy in patients with APS, particularly when lesions develop following minor trauma such as cannulation. Escalation to biologic therapy resulted in complete resolution of the lesions, and the patient is currently in clinical remission. This case underscores the potential role of biologic therapy in refractory PG-like ulceration associated with APS.

EADV CONGRESS
VIENNA
30 SEP - 3 OCT 2026

Abstract N°: 131

Small plaque parapsoriasis treated with upadacitinib

Lawrence Lin*[1], On Bon Chan[2], Alexander Gin[3]

[1] Department of Dermatology, Royal Melbourne Hospital, Parkville, Australia
[2] Department of Dermatology, Eastern Health, Melbourne, Australia
[3] Department of Dermatology, Alfred Health, Melbourne, Australia

Introduction

Small plaque parapsoriasis (SPP) typically presents as chronic, asymptomatic or minimally pruritic, round-to-ovoid erythematous patches under 5 cm with fine scale. It is an indolent T-cell-mediated dermatosis can be recalcitrant and typically respond poorly to conventional therapies.

Case Presentation

We report the case of a 56-year-old woman who presented with a three-year history of a persistent, largely asymptomatic superficial scaly plaques affecting the upper torso, arms, and progressively the neck and face.

Serial punch biopsies demonstrated compact orthokeratosis and focal parakeratosis, spongiosis, and upper to mid dermal perivascular lymphocytic infiltrate. Lichenoid dermatitis and granulomas were not seen. There is also no evidence of atypical lymphocytes or epidermotropism to suggest cutaneous T-cell lymphoma. Both PAS stain and direct immunofluorescent were negative.

She was commenced on a course of oral prednisolone in addition to tacrolimus, which resulted in a temporary improvement, with rapid relapse on weaning. Phototherapy was inaccessible due to the patient's rural residence and associated travel constraints. A four-month trial of dupilumab resulted in no meaningful improvement. Upadacitinib 15 mg daily was then commenced. Marked improvement was observed within 24 hours of initiation, with complete clearance by day three and sustained remission at three- and nine-month follow-up. Topical therapy was no longer required.

Conclusion

To our knowledge, this represents the first reported use of a JAK inhibitor for small plaque parapsoriasis. The T-cell-mediated cytokine milieu implicated in SPP provides a biologically plausible rationale for selective JAK1 inhibition. Clinicians should consider upadacitinib as an effective, steroid-sparing agent when conventional therapies are ineffective or inaccessible.

EA DV CONGRESS
VIENNA
30 SEP - 3 OCT 2026

Abstract N°: 132

Pityriasis rubra pilaris manifesting after COVID-19 vaccination.

Olga Tarasova*[1]

[1] I.M. Sechenov First Moscow State Medical University, Moscow, Russian Federation

Introduction

According to current epidemiological data, nearly 800 million people worldwide have had COVID-19, and 7 million of them died. The development and use of vaccines against SARS-CoV-2 played a key role in combating the COVID-19 pandemic. Vaccines help build herd immune protection in the population, reducing the risk of infection, severe disease, and hospitalization. The most commonly used vaccines are Comirnaty (BioNTech/Pfizer; BNT162b2), Spikevax (Moderna; mRNA-1273), Covishield (AstraZeneca; AZD1222/ChAdOx1), and the inactivated vaccine CoronaVac (Sinovac). Despite the proven efficacy and safety of these vaccines, adverse cutaneous manifestations have been reported, including allergic reactions, psoriasis, and pityriasis rubra pilaris.

Materials and Methods

A systematic review was conducted using the Medline, Scopus, and PubMed databases. Forty scientific articles were selected that addressed the manifestation of pityriasis rubra pilaris following COVID-19 vaccination, as well as the possible mechanisms underlying the development of this disease. The inclusion criteria were: age over 18 years, an association between the cutaneous manifestation and COVID-19 vaccination, and the development of pityriasis rubra pilaris.

Results

I reviewed all 25 documented clinical cases of pityriasis rubra pilaris associated with SARS-CoV-2 vaccination. Of these, 9 were women and 16 were men. Patients ranged in age from 31 to 85 years. The time to onset of skin manifestations after vaccination ranged from 2 to 30 days.Pityriasis rubra pilaris developed after ChAdOx1 (Vaxzevria, AstraZeneca) vaccination in 7 cases: after the first dose in 6 patients (85.7%) and after the second dose in 1 patient (14.3%). After Pfizer-BioNTech vaccination, Devergie disease developed in 8 cases: after the first dose in 4 cases (50%), after the second dose in 2 cases (25%), and after the third dose in 2 cases (25%). One case was reported after the second dose of Sinopharm BBIBP vaccine. After Moderna vaccination, 5 cases were described: 2 after the first dose (40%), 2 after the second dose (40%), and 1 after the third dose (20%). After CoronaVac vaccination, 4 cases were reported: 1 after the first dose (25%) and 3 after the second dose (75%).
To date, the etiopathogenesis of pityriasis rubra pilaris remains unknown. Possible triggering factors include heredity, trauma, ultraviolet radiation, use of certain medications, autoimmune and oncological diseases, bacterial or viral infection, as well as vaccination. The causal relationship between mRNA vaccines and cutaneous reactions is still under discussion, but proposed triggers include excess type I interferons as a direct effect of vaccine immunogenicity (Th1 response), activation of tissue-resident memory T cells in predisposed individuals (Th17/Th22 response), and vaccine-induced extracellular matrix damage associated with regulatory T-cell imbalance. It is known that common components contained in various vaccines may provoke a wide range of systemic allergic contact dermatitis reactions. The most common causative agents are antibiotics, as well as certain key preservatives such as formaldehyde, propylene glycol, polyethylene glycol, and sorbic acid. Another possible antigenic trigger under consideration is the spike protein. Nucleoside-modified mRNA vaccines against SARS-CoV-2 effectively induce spike protein synthesis in human myocytes, followed by its localization in cutaneous microvessels.

Conclusions

The implementation of COVID-19 vaccines in clinical practice played an important role in halting the progression and spread of this disease. Nevertheless, there appears to be a causal relationship between COVID-19 vaccination and the manifestation of certain skin diseases. Further studies are needed to verify in detail the pathogenetic mechanisms underlying these conditions. This is necessary for the development of pathogenetically grounded therapeutic strategies and preventive measures regarding dermatological complications of vaccination.

EADV CONGRESS
VIENNA
30 SEP - 3 OCT 2026

Abstract N°: 136

Daxdilimab in Moderate-to-Severe Discoid Lupus Erythematous: Efficacy and Safety Results from a Phase 2, Randomised, Placebo-controlled Trial

Victoria Werth*[1], Joseph F. Merola[2, 3], Ben Chong[2], Jörg Wenzel[4], Abidi Bazle[5], Cindy Lui[5], Greg Kricorian[5], Linda Zhu[5]

[1] University of Pennsylvania and Corporal Michael J. Crescenz VAMC, Philadelphia, United States
[2] Department of Dermatology, University of Texas Southwestern Medical Center, Dallas, Texas, United States
[3] Division of Rheumatology, Department of Medicine, UT Southwestern Medical Center, Dallas, Texas, United States
[4] Department of Dermatology, University Hospital Bonn, Bonn, Germany
[5] Amgen Inc., Thousand Oaks, California, United States

Introduction

Discoid lupus erythematosus (DLE) is the most prevalent form of chronic cutaneous lupus erythematosus (CCLE). It is clinically characterised by erythematous scaly lesions occurring on the scalp, face, and ears that may progress to permanent scarring, alopecia and facial disfigurement, negatively impacting quality of life [1]. Plasmacytoid dendritic cells (pDCs) are increased in the lesional skin of patients with cutaneous lupus erythematosus and are key mediators of disease immunopathogenesis through their association with type I interferon biology [2]. Daxdilimab is a human IgG1 monoclonal antibody targeting immunoglobulin-like transcript 7 (ILT7), a cell-surface protein exclusively expressed on pDCs. Binding of daxdilimab to ILT7 results in targeted reduction in the number of pDCs in the tissue and blood [2]. Here, we report results from a phase 2 trial (NCT05591222) evaluating the efficacy and safety of two doses of daxdilimab in patients with DLE.

Materials and Methods

A multicentre, randomised, double-blind, placebo-controlled, parallel-group study enrolled patients aged 18–75 years with chronic, moderate-to-severe, treatment-refractory DLE for ≥ 6 months with active disease at baseline (Cutaneous Lupus Erythematosus Disease Area and Severity Index-Activity [CLASI-A] ≥ 8) and without systemic features. Patients were randomised 1:1:1 to receive low dose (LD) daxdilimab, high dose (HD) daxdilimab, or placebo for 24 weeks, with dosing every 4 weeks from Day 1 through Week 20. The primary efficacy endpoint was mean change in CLASI-A score from baseline to Week 24. Secondary endpoints included the proportion of patients achieving ≥ 50% reduction in CLASI-A score (CLASI-50) and those achieving a score of 0 or 1 on the Cutaneous Lupus Activity Investigator's Global Assessment (CLA-IGA) scale (CLA-IGA 0/1) at Week 24. Safety was assessed up to Week 24. Primary endpoint was analysed in the full analysis set (all randomised patients who received any dose of trial treatment) using a mixed model for repeated measures.

Results

Overall, 72 patients were randomised to LD daxdilimab (n = 24), HD daxdilimab (n = 23), or placebo (n = 25). Baseline demographics and disease characteristics were generally comparable across treatment groups (mean ± SD age, 48.8 ± 12.0 years; 69.4% female). At baseline, the overall mean ± SD CLASI-A and CLA-IGA scores were 15.2 ± 6.30 and 3.1 ± 0.63, respectively. Both doses of daxdilimab met the primary and secondary endpoints. Significant reductions in CLASI-A vs placebo were observed at Week 24, with treatment response evident as early as Week 4. At Week 24, the LS mean difference in change from baseline in CLASI-A vs placebo was –6.0 (90% confidence interval [CI]: –8.7, –3.2; P = 0.0005) for LD daxdilimab and –5.7 (90% CI: –8.5, –2.9; P = 0.0012) for HD daxdilimab (Figure 1A). At Week 24, adjusted response rates (standard error [SE]) were significantly increased for

CLASI-50 (Placebo: 23.7% [8.5]; LD: 61.7% [10.1], P = 0.0037; HD: 62.1% [10.3], P = 0.0044) and CLA-IGA 0/1 (Placebo: 8.9% [5.6]; LD: 60.3% [11.0], P < 0.0001; HD: 51.6% [11.2], P = 0.0007) compared with placebo (Figures 1B and 1C). Daxdilimab was well tolerated, with no serious adverse events or death reported. Overall treatment related adverse events occurred in 58.3%, 56.5% and 60.0% of patients in the LD, HD, and placebo groups, respectively. One patient in the HD group discontinued the study due to arthralgia (Table 1).

Figure 1. (A) LS mean change from baseline in CLASI-A score through Week 24[a], (B) Patients achieving CLASI-50 response through Week 24[b] and (C) Patients achieving CLA-IGA 0/1 response through Week 24[c]

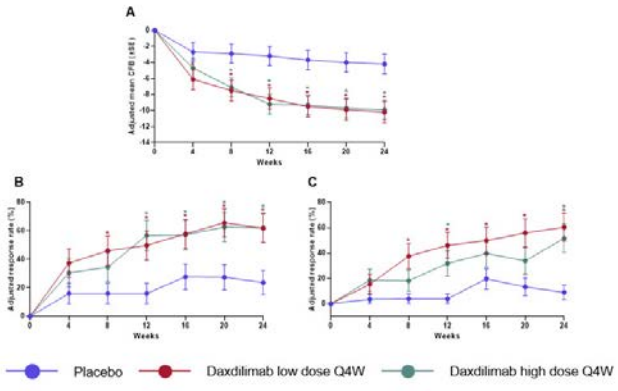

*P<0.05 vs Placebo (two sided).
[a]Results are from MMRM analysis with treatment, visit, visit by treatment interaction, and baseline CLASI-A score included in the model; [b]Results are from logistic regression analysis with treatment and baseline CLASI-A score included in the model; [c]Results are from logistic regression analysis with treatment, baseline CLASI-A (<13, ≥13) and baseline CLA-IGA score included in the model. The CLA-IGA scale ranges from 0 (clear) to 4 (severe).
CFB, change from baseline; CLASI-A, Cutaneous Lupus Erythematosus Disease Area and Severity Index-Activity; CLASI-50, ≥ 50% reduction in CLASI-A score; CLA-IGA, Cutaneous Lupus Activity Investigator's Global Assessment; CLA-IGA 0/1, patients achieving 0 (clear) or 1 (almost clear) on the CLA-IGA scale; LS, least squares; MMRM, mixed model for repeated measures; Q4W, every 4 weeks; SE, standard error.

Table 1: Summary of the key safety findings

n (%)*	Placebo (N = 25)	Daxdilimab LD (N = 24)	Daxdilimab HD (N = 23)	Total Daxdilimab (N = 47)
At least one event	15 (60.0)	14 (58.3)	13 (56.5)	27 (57.4)
At least one investigational product related event	3 (12.0)	6 (25.0)	5 (21.7)	11 (23.4)
At least one event of ≥ grade 3 severity[a,b]	0 (0.0)	0 (0.0)	1 (4.3)	1 (2.1)
At least one event leading to discontinuation of investigational product	0 (0.0)	0 (0.0)	1 (4.3)	1 (2.1)
Most Frequent TEAEs (≥5%)				
Headache	0 (0.0)	4 (16.7)	1 (4.3)	5 (10.6)
Cough	0 (0.0)	2 (8.3)	1 (4.3)	3 (6.4)
Diarrhoea	0 (0.0)	0 (0.0)	3 (13.0)	3 (6.4)
Upper respiratory tract infection	1 (4.0)	3 (12.5)	0 (0.0)	3 (6.4)
Injection site pain	0 (0.0)	2 (8.3)	0 (0.0)	2 (4.3)
Nausea	0 (0.0)	0 (0.0)	2 (8.7)	2 (4.3)
Nasopharyngitis	4 (16.0)	1 (4.2)	0 (0.0)	1 (2.1)
Seasonal allergy	2 (8.0)	1 (4.2)	0 (0.0)	1 (2.1)
Hypertension	2 (8.0)	0 (0.0)	1 (4.3)	1 (2.1)
Influenza	2 (8.0)	0 (0.0)	0 (0.0)	0 (0.0)

*Participants are counted once for each category regardless of the number of events.
[a]Grade 3: Severe, Grade 4: Life-threatening, Grade 5: Fatal.
[b]Grade 3, non-serious severe event of arthralgia was reported in 1 patient (4.3%) in daxdilimab HD group on Day 42 after the patient had received two doses of study treatment. The patient did not receive specific treatment for the event and was referred to a rheumatologist. The investigator considered the event related to daxdilimab, and study treatment was permanently discontinued.
HD, high dose daxdilimab; LD, low dose daxdilimab; TEAEs, treatment emergent adverse events.

Conclusion

Daxdilimab demonstrated significant improvement in the primary endpoint of CLASI-A and consistent efficacy across secondary endpoints, with a favourable safety profile in patients with moderate-to-severe DLE. These findings support the role of pDCs in disease pathogenesis of DLE and the potential of targeting this pathway.

References

1. Drenkard C, et al. Arthritis Care Res (Hoboken). 2019;71(1):95-103.
2. Karnell JL, et al. Sci Transl Med. 2021;13(595): eabf8442.

EADV CONGRESS
VIENNA
30 SEP - 3 OCT 2026

Abstract N°: 140

Serum Cathelicidin, KLK5, TLR2, and TRPV1 Levels in Rosacea: Associations with Disease Characteristics

Ezgi Aktaş*[1], Şeyma Gürbüz[1], Ayşe Elif Tapkı[1], Yavuz Semiz[2]

[1] University of Health Sciences, Prof Dr Cemil Taşçıoğlu City Hospital, İstanbul, Türkiye
[2] University of Health Sciences, Haseki Training and Research Hospital, İstanbul, Türkiye

Introduction
Rosacea pathogenesis involves immune dysregulation, neurovascular dysfunction, and microbial alterations. This study aimed to evaluate serum cathelicidin, kallikrein 5 (KLK5), toll-like receptor 2 (TLR2), and transient receptor potential vanilloid 1 (TRPV1) levels in rosacea patients and investigate their associations with clinical features.

Materials and Methods
A prospective, case-control study including 53 rosacea patients and 35 controls was conducted.

Results
Serum cathelicidin, KLK5, TLR2, and TRPV1 levels were significantly higher in rosacea patients than controls (p= 0.001; p= 0.001; p= 0.024; p= 0.001; respectively). Cathelicidin correlated positively with TLR2 (r= 0.35, p= 0.011) and TRPV1 (r= 0.85, p< 0.001). Patients with skin dryness had lower cathelicidin, TLR2, and TRPV1 levels (p= 0.001, p= 0.043, p= 0.028; respectively). KLK5 was higher in those with pruritus (p=0.015), and TRPV1 was lower (p= 0.036). Cathelicidin was lower in patients reporting hot weather (p= 0.016), tea consumption (p= 0.016), emotional stress (p= 0.005), and physical activity (p= 0.014) as triggers. TRPV1 was lower in patients triggered by dry air (p= 0.018), tea consumption (p= 0.026), emotional stress (p= 0.039), and physical activity (p= 0.001). KLK5 was higher in patients who reported chocolate as a trigger (p= 0.011) and lower in those triggered by emotional stress (p= 0.025). TLR2 levels showed a significant difference between disease subtypes (p= 0.026). Disease severity correlated with TLR2 (r= 0.344, p= 0.012) and TRPV1 (r= 0.285, p= 0.048).

Conclusions
Systemic levels of cathelicidin, KLK5, TLR2, and TRPV1 are increased in rosacea patients and vary by symptoms, triggers, and subtypes.

EADV CONGRESS
VIENNA
30 SEP - 3 OCT 2026

Abstract N°: 142

Serum Kallikrein-5 and Human Beta-Defensin-2 Levels in Patients with Seborrheic Dermatitis: A Case–Control Study

Yavuz Semiz*[1]

[1] University of Health Sciences, Haseki Training and Research Hospital, İstanbul, Türkiye

Introduction
Seborrheic dermatitis (SD) is a common, chronic, relapsing inflammatory skin disorder that primarily affects sebaceous gland–rich areas. Although its pathogenesis is considered multifactorial and involves complex interactions between Malassezia species, sebaceous gland activity, epidermal barrier dysfunction, and immune responses, the role of innate immune mediators in SD remains incompletely understood. Human beta defensin-2 (hBD2), an antimicrobial peptide produced mainly by keratinocytes, and Kallikrein-5 (KLK5), a serine protease involved in epidermal desquamation and skin barrier homeostasis are thought to play important roles in cutaneous innate immunity. The present study aimed to evaluate serum hBD2 and KLK5 levels in patients with SD and to investigate their associations with disease severity and clinical characteristics.

Materials and Methods
This prospective, cross sectional study involved 54 patients diagnosed with SD and 46 healthy controls. Disease severity in SD patients was assessed using the Seborrheic Dermatitis Area Severity Index (SDASI). Serum hBD2 and KLK5 levels were assessed.

Results
No differences were observed in terms of age org ender between two groups (p= 0.720, p= 0.803; respectively). There was no statistically significant difference between the groups regarding smoking status or body mass index (BMI) values (p=0.844, p= 0.218; respectively). Serum hBD2 and KLK5 levels were significantly lower in patients with SD than controls (p= 0.001, p= 0.001; respectively). In patients with SD, neither hBD2 nor KLK5 levels showed significant associations with age, sex, BMI, family history, smoking status, disease duration or disease severity scores (p> 0.05; for all). A strong positive correlation was observed between HBD and KLK5 levels (r = 0.945).

Conclusions
Patients with SD exhibited significantly lower serum hBD2 and KLK5 levels compared with healthy controls. Although, these markers were not associated with disease severity scores or clinical characteristics, the strong correlation between hBD and KLK5 suggests a potential link between antimicrobial defense mechanisms and protease-mediated epidermal regulation. These findings support the possible involvement of innate immune dysregulation in the pathogenesis of SD.

EA DV CONGRESS
VIENNA
30 SEP - 3 OCT 2026

Abstract N°: 151

Subcorneal Pustular Dermatosis presenting with multiple parallel concentric annular plaques resembling erythema gyratum repens

Punyawee Ongsri*[1], Nanchaya Na Bangchang[2], Chanchanit Pruksaseat[3]

[1] Somdech Phra Pinklao Hospital, Bangkok, Thailand

[2] Institute of Dermatology, Bangkok, Thailand

[3] Somdech Phra Nangchao Sirikit Hospital, Sattahip, Chonburi, Thailand

Introduction

Subcorneal pustular dermatosis (SPD), also known as Sneddon–Wilkinson disease, is a rare chronic benign neutrophilic dermatosis first described by Lan Sneddon and Darrell Wilkinson in 1956. It is characterized histologically by subcorneal pustules containing predominantly polymorphonuclear leukocytes, mainly neutrophils with occasional eosinophils. Clinically, SPD presents with recurrent sterile pustules in the subcorneal layer that may coalesce into annular or polycyclic patterns. Diagnosis is based on both clinical and histopathological findings. SPD has been associated with various systemic conditions, including paraproteinemia, hematologic malignancies, solid tumors, inflammatory bowel disease, and rheumatologic disorders. Oral dapsone is considered the first-line therapy. Erythema gyratum repens (EGR), in contrast, is a paraneoplastic dermatosis strongly associated with internal malignancies. First described by Gammel in 1952 in a patient with metastatic breast cancer, EGR typically presents with intensely pruritic, scaly, erythematous annular or serpiginous bands arranged in rapidly migrating concentric patterns, producing the characteristic “wood-grain” appearance. Herein, we report a case of subcorneal pustular dermatosis presenting with an eruption clinically mimicking EGR.

Case Presentation

A woman in her 50s presented with a three-month history of asymptomatic annular erythematous plaques arranged in parallel concentric bands on both breasts, producing a “wood-grain” appearance. The eruption had been unresponsive to previous treatments, including topical corticosteroids, topical antifungal agents, oral antibiotics, and methotrexate. At the initial visit, the differential diagnoses included tinea imbricata and erythema gyratum repens. Direct examination with 10% potassium hydroxide preparation, fungal culture, and bacterial culture were negative. Contrast-enhanced computed topography of the chest and whole abdomen revealed no evidence of malignancy. At the second visit, the patient developed a pruritic erosive erythematous patch with flaccid bullae and pustules on the left areola in addition to the annular plaques. Skin biopsy demonstrated subcorneal collections of neutrophils with irregular acanthosis. Direct immunofluorescence and ELISA testing for anti-desmoglein 1 and 3 antibodies were negative. These findings were consistent with subcorneal pustular dermatosis. Further evaluation revealed no associated systemic conditions previously reported with SPD. Quantitative glucose-6-phosphate dehydrogenase (G6PD) levels were within normal limits. The patient was treated with oral dapsone at a dose of 100 mg daily, resulting in a dramatic clinical response within one month. However, the patient subsequently developed dapsone-induced agranulocytosis, which resolved one month after discontinuation of the medication.

Conclusion

A classic erythema gyratum repens (EGR)–like clinical presentation with a “wood-grain” appearance does not always represent true EGR. Although EGR is primarily a clinical diagnosis and lacks specific histopathological features, skin biopsy remains important to exclude other dermatoses that may present with similar EGR-like patterns. Subcorneal pustular dermatosis (SPD), although rare, should be considered in the differential diagnosis

of patients presenting with chronic or recurrent sterile pustules with annular or polycyclic morphology. Because SPD has been associated with systemic diseases, hematologic disorders, and malignancies, appropriate screening for underlying conditions should be performed once the diagnosis is established.

EA DV CONGRESS
VIENNA
30 SEP - 3 OCT 2026

Abstract N°: 155

JAKPPPOT: a feasibility trial assessing upadacitinib in palmoplantar pustulosis

David Gleeson*[1], Sarah Chapman[2], Neville Qin[3], John Gregory[3], Amelia Mitchell-Gears[3], Jade Pizzato[1], Kingsley Powell[1], Manpreet Sagoo[1], Weiyu Ye[1], Lucy Moorhead[3], Jonathan Barker[1], James Galloway[4], Helen McAteer[5], Richard Woolf[3], Andrew Pink[3], Suzie Cro[6], Satveer Mahil[1], Catherine Smith[1]

[1] St John's Institute of Dermatology, King's College London, Guy's and St Thomas' NHS Trust, London, United Kingdom
[2] Centre for Adherence Research and Education, King's College London, London, United Kingdom
[3] St John's Institute of Dermatology, Guy's and St Thomas' NHS Trust, London, United Kingdom
[4] Centre for Rheumatic Diseases, King's College London, London, United Kingdom
[5] Psoriasis Association, Northampton, United Kingdom
[6] Imperial Clinical Trials Unit, Imperial College London, London, United Kingdom

Introduction
Background

Palmoplantar pustulosis (PPP) is a rare, disabling inflammatory skin disease with substantial unmet need: no therapies are currently licensed in the UK or Europe, and existing off-licence systemic and biologic options show only modest, inconsistent efficacy. Janus kinase inhibitors (JAKi) are mechanistically attractive, targeting multiple inflammatory pathways implicated in PPP, but prospective trial data are lacking. Regulatory safety warnings around cardiovascular and malignancy risk with JAKi, combined with the high smoking prevalence and cardiometabolic comorbidity seen in PPP, may limit their use and complicate future trial recruitment.

Objective

To determine the feasibility of a definitive randomised controlled trial (RCT) of JAKi therapy in PPP and generate an exploratory estimate of treatment effect to inform future sample size calculations.

Materials and Methods
This single-centre, open-label, assessor-blinded feasibility trial (JAKPPPOT) enrolled adults (≥18 years) with dermatologist-confirmed moderate-to-severe PPP at a UK specialist dermatology centre. Participants received upadacitinib 30 mg once daily for 8 weeks (15 mg in higher-risk individuals, per MHRA guidance). Prespecified feasibility endpoints were recruitment (consent rate), adherence (≥80% proportion of days covered), and acceptability (5-point Likert scale: 'completely unacceptable' to 'completely acceptable'). Traffic-light progression criteria (green/amber/red) were prespecified for each domain, requiring ≥40% recruitment, ≥80% adherence (PDC), and ≥80% acceptability to support progression to a definitive trial.

Secondary outcomes included the Palmoplantar Pustulosis Area and Severity Index (PP-PASI), Investigator Global Assessment (PPP-IGA), Dermatology Life Quality Index (DLQI), and safety. Individual patient-level historic placebo data from APRICOT, a closely matched UK multicentre RCT of the IL-1 antagonist anakinra in PPP, provided an exploratory comparator.

Results

Of 67 individuals approached, 28 (41.8%) consented and 20 (71.4%) started treatment (mean age 46.0 years; 85% female; 90% smoking history). Adherence ≥80% was achieved by 19/20 (95%; mean 95.7%, SD 9.7), and 18/19 (94.7%) rated treatment as 'acceptable/completely acceptable'. All pre-specified feasibility progression criteria were therefore met.

Mean PP-PASI fell from 20.3 (SD 10.6) to 4.6 (SD 4.5) at week 8 with upadacitinib, versus 18.0 (10.4) to 15.4 (10.1) with historic placebo (baseline-adjusted difference −12.3, 95% CI −15.8 to −8.9; Figure 1). PP-PASI75 was achieved by 65.0% vs 3.2%, and PPP-IGA clear/almost clear by 45.0% vs 7.1%. DLQI improved from 15.8 (8.2) to 4.6 (5.3) with upadacitinib, versus 13.9 (7.2) to 10.1 (7.1) with placebo (adjusted difference −6.8, 95% CI −9.9 to −3.7). Sensitivity analyses using inverse-probability-of-treatment weighting to adjust for baseline differences between cohorts produced consistent treatment-effect estimates, supporting the robustness of these findings. Following treatment discontinuation, mean PP-PASI rose to 12.2 (SD 8.5) by week 12, suggesting continued therapy may be needed to sustain response.

Upadacitinib was well tolerated: the most common adverse events were headache, acne and upper respiratory tract infection; one unrelated serious adverse event occurred (retinal detachment) and one participant discontinued treatment (weight gain). No participant required rescue topical corticosteroids during the 8-week treatment period, versus 6% with historic placebo.

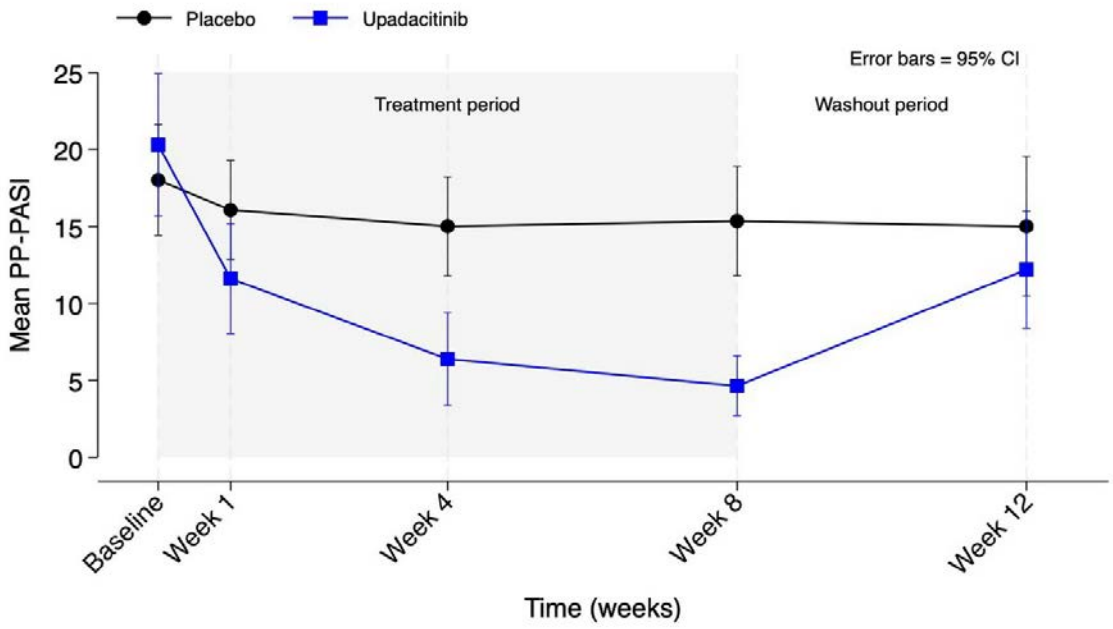

Figure 1: Mean PP-PASI over time in the JAKPPPOT and historic placebo cohorts. PP-PASI: Palmoplantar Pustulosis Psoriasis Area and Severity Index

Conclusion

A definitive trial of JAKi therapy in PPP is feasible, and upadacitinib produced a substantial improvement in disease severity and quality of life relative to historic placebo, albeit in a non-randomised comparison. These findings support progression to a multicentre, active-comparator RCT and position JAK inhibition as a promising strategy to address the considerable unmet therapeutic need in PPP.

EA DV CONGRESS
VIENNA
30 SEP - 3 OCT 2026

Abstract N°: 159

Rapid Dose-Related Responses to an Oral MRGPRX2 Partial Inverse Agonist in Chronic Spontaneous Urticaria

Shuguang Yuan*[1, 2], Haijian Li[2], Yi Li[2]

[1] AlphaMol Science Ltd, Allschwil, Switzerland
[2] AlphaMol Science Ltd (Shanghai), Shanghai, China

Introduction

Mas-related G protein-coupled receptor X2 (MRGPRX2) is a mast cell–restricted receptor that mediates IgE-independent mast cell activation in response to diverse endogenous neuropeptides, inflammatory mediators, and cationic ligands. Increasing evidence implicates MRGPRX2 in the pathogenesis of chronic spontaneous urticaria (CSU), a mast cell–driven disease characterized by recurrent wheals and/or angioedema in the absence of an identifiable external trigger. MRGPRX2 expression and activity may be enhanced in lesional skin and can promote rapid mast cell degranulation and release of histamine, proteases, and other inflammatory mediators, providing a mechanistic pathway complementary to the classical FcεRI–IgE axis. These observations suggest that dysregulated MRGPRX2 signaling may contribute to persistent mast cell activation in subsets of patients with CSU, including those inadequately controlled by existing therapies. Accordingly, pharmacological inhibition of MRGPRX2 represents a promising mechanism-based therapeutic strategy for CSU.

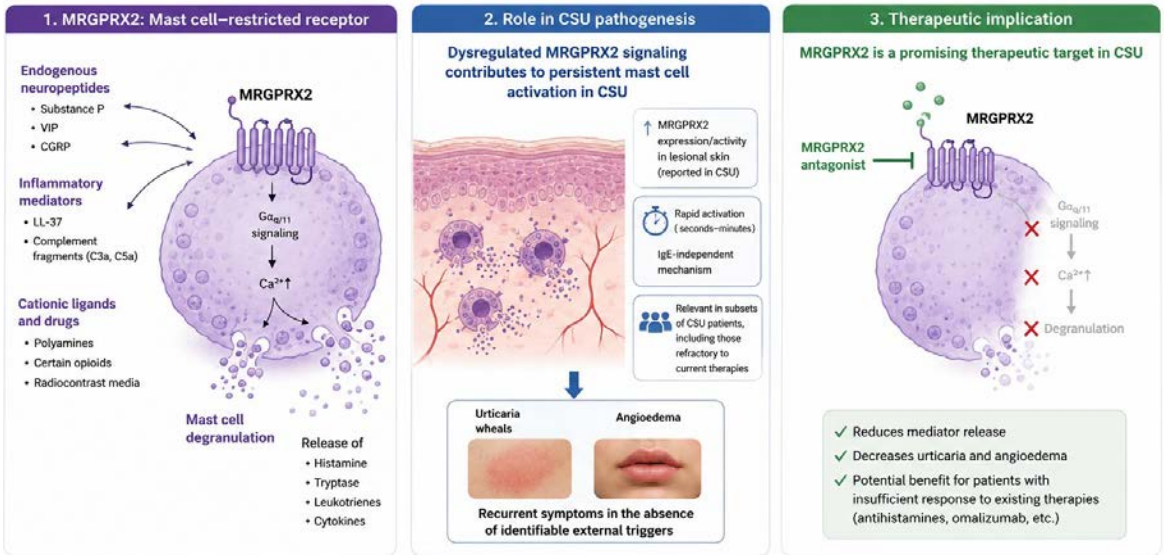

MRGPRX2 mediates rapid, IgE-independent mast cell activation in response to diverse endogenous and exogenous ligands. Dysregulated MRGPRX2 signaling may contribute to persistent mast cell degranulation and the development of wheals and angioedema in CSU. Targeting MRGPRX2 therefore represents a promising mechanism-based therapeutic strategy for patients with CSU.

Materials and Methods

Patients were enrolled in an ongoing 28-day multiple-ascending-dose study. Each dose cohort included eight patients using a 6 active + 2 placebo allocation. Oral once-daily doses of 50 mg and 125 mg were evaluated. Clinical activity was assessed using the 7-day Urticaria Activity Score (UAS7), 7-day Itch Severity Score (ISS7), 7-

day Hives Severity Score (HSS7), Dermatology Life Quality Index (DLQI), Urticaria Control Test (UCT), and Peak Pruritus Numerical Rating Scale (PP-NRS). Safety was additionally informed by a completed Phase 1a single-ascending-dose study.

Results

At 50 mg once daily, active-treated patients showed improvement across disease activity, itch, hives, quality of life, and disease control within 7-14 days. By Day 14, UAS7 decreased by 50-70% in most patients; individual reductions in ISS7, HSS7, and DLQI ranged from 30-56%, 40-63%, and 40-68%, respectively. PP-NRS also decreased, while UCT improved, consistent with better overall urticaria control. Preliminary results at 125 mg once daily showed a faster and greater response. By Day 7, UAS7 had decreased by 58-88% and ISS7 by 50-86% in evaluable active-treated patients. The completed Phase 1a study evaluated single oral doses up to 1000 mg without observed adverse events, and no adverse events have been observed to date in the ongoing multiple-dose study.

Conclusion

Oral MRGPRX2 inverse agonism produced rapid, multi-domain clinical improvement in CSU, with preliminary evidence of an earlier and deeper response at 125 mg than at 50 mg once daily. Together with the favourable early safety profile, these findings provide emerging clinical evidence supporting MRGPRX2 as a therapeutic target in CSU and warrant further evaluation in larger controlled studies.

EADV CONGRESS
VIENNA
30 SEP - 3 OCT 2026

Abstract N°: 161

Pyoderma Gangrenosum revealing IgA Multiple Myeloma: Importance of early diagnosis and targeted treatment

Alexandra Jinariu*[1, 2]

[1] Clinic of Dermatology, Emergency County Clinical Hospital of Bihor, Oradea, Romania
[2] Doctoral School of Biomedical Sciences, University of Oradea, Oradea, Romania

Introduction

Pyoderma gangrenosum is a rare, reactive, non-infectious inflammatory condition that belongs to the group of neutrophilic dermatoses. In approximately 50% of cases, it is associated with underlying systemic diseases, most commonly inflammatory bowel disease and autoimmune disorders, and less frequently hematological malignancies such as monoclonal gammopathies, typically of IgA type.

Case Presentation

We report the case of a 64-year-old hypertensive male, chronic smoker, presenting with multiple, extremely painful lesions on the lower legs, with onset two weeks prior following minor local trauma, suggestive of pathergy. Clinical examination revealed on both calves six erythematous-violaceous plaques, infiltrated, round-shaped ranging from 1 to 4 cm in diameter and one large ulceration, 8 cm in diameter with a prominent undermined, violaceous border, with purulent secretions and necrotic deposits on the surface. All lesions had violaceous halo. During early evolution, the plaque-type lesions rapidly progressed to ulceration. Based on clinical presentation, a diagnosis of pyoderma gangrenosum was made. An incisional biopsy from the lesion edge showed a dense dermal neutrophilic infiltrate with periadnexal and diffuse distribution. Laboratory investigations revealed markedly elevated serum IgA levels (2400 mg/dL; normal <600 mg/dL). Serum protein electrophoresis with immunofixation identified IgA heavy chains with lambda light chains, consistent with monoclonal IgA gammopathy. Bone marrow examination subsequently confirmed the diagnosis of newly diagnosed IgA multiple myeloma. Systemic corticosteroid therapy was initiated with prednisone 40 mg/day, along with local wound care. After 2 weeks, no significant clinical improvement was observed, with progression of lesions and ulceration. Following initiation of hematological therapy with bortezomib, dexamethasone, and cyclophosphamide, rapid clinical improvement occurred. Within 2 weeks, pain significantly decreased, and progressive re-epithelialization of the lesions was observed. At 2-month follow-up, more than 80% re-epithelialization of the ulcerative lesions was documented.

Conclusion

This case highlights the importance of thorough evaluation for underlying systemic diseases in patients with pyoderma gangrenosum. In corticosteroid-refractory cases, identification and targeted treatment of an associated hematological malignancy may be essential for achieving both systemic and cutaneous disease control.

EA DV CONGRESS
VIENNA
30 SEP - 3 OCT 2026

Abstract N°: 182

A Randomized Controlled Cohort Study of 96 Cases: Combined Formulation of Ceramide, White Chia Seed, and Ginger Root-Bisabolol for Improving Skin Inflammation and Barrier Function in Middle-Aged and Elderly

Li Ye*[1], Jianwei Liu[2], Weiren Hu[2], Si Wen[1], Linshan Wu[1], Zhen Yi[1], Xuesong Xian[1], Xiaoyan Fu[1], Jinyin Liang[1], Hongling Zhu[1], Bin Yang[1]

[1] Cosmetics Testing Center, Dermatology Hospital of Southern Medical University, NMPA Center for Innovation and Research in Regulatory Science, Translational Medicine Center, Dermatology Hospital of Southern Medical University, GuangZhou, China

[2] Amway (Shanghai) Technology Development Co., Ltd., Shanghai, China

Introduction

To investigate the regulatory effects on skin inflammation indicators and the improvement value of skin barrier function of an efficacious body lotion containing olive oil-derived ceramide and Nutrilite white chia seed oil liposomes, used alone or in combination with an efficacious facial essence incorporating the anti-inflammatory combination of ginger root extract and bisabolol, in middle-aged and elderly women. This study aims to provide scientific evidence for inflammation management and daily skin care in middle-aged and elderly individuals with sensitive and dry skin.

Materials and Methods

A randomized controlled design was adopted. Ninety-six female subjects aged 45–60 years (with self-reported sensitive, dry, and easily flushed skin) were randomly divided into three groups: blank control group, body lotion monotherapy group (treated with the efficacious body lotion alone), and combination therapy group (treated with the efficacious body lotion combined with facial anti-aging essence), with 32 cases in each group. Blood inflammatory factors (IL-6, TNF-α, and CRP) were detected at baseline (D0) and after 28 consecutive days of use (D28). Instrumental measurements were performed to assess stratum corneum hydration, transepidermal water loss (TEWL), and skin roughness (Ra/Rq) for comprehensive efficacy evaluation. Statistical analysis was conducted using SPSS 25.0, with $P<0.05$ considered a statistically significant difference.

Results

Significant inflammatory regulation was observed. Benefiting from the synergistic anti-inflammatory effects of the ginger root extract-bisabolol complex in vitro (37% inhibition rate of IL-1α and 64% inhibition rate of TNF-α), the combination therapy group showed a 9.42% reduction in blood TNF-α level at D28 compared with D0 ($P<0.01$), and the rate of change in CRP was significantly lower than that in the blank control group ($P<0.01$). In the blank control group, CRP increased by 18.89% ($P<0.01$), while inflammatory factor levels tended to be stable in both treatment groups. Skin barrier function was synchronously improved. In the body lotion monotherapy group, owing to the synergistic effects of olive oil-derived ceramide (mimicking the human natural sebum membrane) and Nutrilite white chia seed oil liposomes, stratum corneum hydration on the arm increased by 31.79% and TEWL decreased by 32.16% (both $P<0.01$). The combination therapy group exhibited superior barrier repair: stratum corneum hydration on the arm increased by 36.71%, arm TEWL decreased by 39.11%, and facial TEWL decreased by 22.55% (all $P<0.01$). Skin roughness was significantly ameliorated. Arm Ra and Rq values in both treatment groups were significantly lower than those in the blank control group ($P<0.01$), and facial texture dispersion in the combination group decreased by 2.44% ($P<0.05$). No adverse events were reported throughout the study, and all treatments were well-tolerated by subjects.

Conclusions

The efficacious body lotion containing olive oil-derived ceramide and Nutrilite white chia seed oil liposomes effectively repairs the skin barrier by mimicking the natural skin lipid structure. When combined with the facial essence containing the anti-inflammatory ginger root extract-bisabolol complex, the regimen exerts synergistic effects of “barrier repair + inflammation regulation”, leading to more efficient reduction in inflammatory factor release and improvement in skin roughness. This combined ingredient formulation targets the core problems of sensitive and dry skin in the middle-aged and elderly population, with favorable safety and targeting properties. It provides a scientifically feasible optimized strategy for daily skin care in this population and holds important clinical application value.

EA DV CONGRESS
VIENNA
30 SEP - 3 OCT 2026

Abstract N°: 227

Complete Response of Amicrobial Pustulosis of the Folds to Infliximab: A Case Report

almeghari widad*[1], Issam TABLIT[1], Saliha Takheroubt[1], Samira Zobiri[1]

[1] CHU MUSTAPHA, Alger, Algeria

Introduction

Amicrobial pustulosis of the folds (APF) is a rare neutrophilicdermatosis, often associated with autoimmune diseases.Treatment is mainly based on systemic corticosteroids.However, frequent relapses and corticosteroid-dependenceencourage the search for alternative therapies, particularlythe use of biologic agents.We report the case of a 53-year-old woman with APF,successfully treated with infliximab, achieving a dramaticclinical response



before

Case Presentation

The patient was a 53-year-old woman with a history ofcorticosteroid-induced diabetes. She was followed indermatology for disseminated pustular lesions, predominantlyinvolving intertriginous areas and the scalp, evolving for 21years.Previous hospitalizations included skin biopsies, which showedintraepidermal pustules with a dermal neutrophilic infiltrate.Cultures of pustular content were repeatedly negative. Thesefindings supported the diagnosis of amicrobial pustulosis ofthe folds.She had received multiple prior treatments (antibiotics,systemic corticosteroids, cyclosporine, and dapsone) withvariable and temporary efficacy. Because of therapeuticfailures and the major impact on her quality of life, infliximabwas initiated according to the following protocol:5 mg/kg at weeks 0, 2, and 6, then every 8 weeks formaintenance.The clinical response was spectacular, with almost completeresolution of skin lesions after the first infusion, along withsignificant improvement in quality of life. Maintenancetherapy allowed sustained remission at 6 months with goodtolerance.
Diagnostic criteria for APF include:Major: pustules involving one or more large or small folds withanogenital involvement; histology showing spongiformintraepidermal pustules and dermal neutrophilic infiltrate;negative culture from an intact pustule.Minor: association with one or more autoimmune diseases;ANAtiter >1/160.Our patient met all the major diagnostic criteria.
Classically, systemic corticosteroids are the mainstay of treatment,but they carry a risk of dependence or adverse effects, requiringimmunomodulators or biologic agents. Infliximab, a TNF-α inhibitor,has been used successfully in several refractory neutrophilicdermatoses. In our case, the patient developed corticosteroidresistance and major side effects (diabetes, obesity, hypertension),in addition to treatment failures. This led us to initiate infliximab,using the psoriasis regimen (dose and frequency), resulting in rapidand complete remission of cutaneous lesions, confirming the keyrole of TNF-α in APF pathophysiology.



after

Conclusion

Amicrobial pustulosis of the folds is a rare neutrophilic dermatosiswith a significant impact on patients' quality of life and atherapeutic challenge. The efficacy of infliximab in our casehighlights its potential role in the treatment of this disease,although it does not have official approval for this indication.Further studies are needed to confirm its

long-term place in APFmanagement.

EA DV CONGRESS
VIENNA
30 SEP - 3 OCT 2026

Abstract N°: 227

The Novel Molecule AB102 Potently Inhibits MRGPRX2-Dependent Mast Cell Activation and Disease-Relevant Gene Transcription

Nina Serwas*[1], Emily Brown[1], Lydia Zhang[1], Diane Nathaniel[1], Casey Mitchell[1], Clement Opoku-Temeng[1], Joice Thomas[1], Sandeep Dhanju[1], Manjunath Lamani[1], Pradeep Nareddy[1], Josh Corbin[1], Venkatesh Kattamuri[1], Monika Yadav[1], Corinne Foley[1], Ehesan Sharif[1], Manmohan Leleti[1], Matthew Walters[1], Soonweng Cho[1], Kelsey Sivick[1], Rustom Falahati[1]

[1] Arcus Biosciences, Hayward, United States

Introduction
Mas-related G-protein coupled receptor X2 (MRGPRX2) triggers rapid IgE-independent mast cell degranulation. MRGPRX2 activation is increasingly recognized as a driver of chronic spontaneous urticaria (CSU) and atopic dermatitis (AD). Supporting this association, affected skin from both conditions shows evidence of mast cell degranulation, and disease severity correlates with endogenous MRGPRX2 agonist levels. Here we describe the characterization of AB102, a potent, selective, and orally-bioavailable small-molecule MRGPRX2 antagonist, and evaluate its ability to suppress MRGPRX2-dependent mast cell activation and inhibit upregulation of signature genes identified as enriched in publicly available AD lesion and CSU wheal datasets.

Materials and Methods
AB102 activity was assessed in the LAD2 human mast cell line and in primary human skin mast cells using fluorometric degranulation assays, ELISA, flow cytometry, and qPCR. RNA sequencing of LAD2 cells stimulated with MRGPRX2-dependent or MRGPRX2-independent agonists was performed to define MRGPRX2 activation-specific signature genes. These signature genes were queried in publicly available AD and CSU transcriptomic datasets. *In vivo* activity of AB102 was evaluated in human MRGPRX2 knock-in (KI) mice using acute agonist-driven models and chronic inflammatory settings.

Results
AB102 showed complete inhibition of MRGPRX2-dependent degranulation and activation in human LAD2 cells and primary human skin mast cells. This inhibition profile was maintained across common MRGPRX2 allelic variants and in physiologically relevant matrices. Complement and IgE-mediated pathways remained unchanged by AB102, confirming specificity for MRGPRX2.

MRGPRX2 activation induced a transcriptional gene signature in LAD2 cells that was enriched in publicly available transcriptomic datasets from AD lesions and CSU wheals. In isolated human mast cells, AB102 inhibited the upregulation of these MRGPRX2 activation signature genes, indicating suppression of a disease-associated transcriptional program.

Consistent with these molecular effects, oral AB102 significantly reduced substance P- and icatibant-induced acute paw swelling and prevented ciprofloxacin-induced systemic anaphylaxis in human MRGPRX2 KI mice. In chronic inflammatory settings, AB102 reduced disease severity and diminished transcriptional changes associated with mast cell-driven pathology.

Conclusions

AB102 is a potent and selective MRGPRX2 antagonist that suppresses the activation of disease-enriched signature genes and blocks mast cell driven responses *in vitro* and *in vivo***.** These findings provide strong preclinical support for the therapeutic potential of AB102 in mast cell-mediated disorders, including AD and CSU.

EADV CONGRESS
VIENNA
30 SEP - 3 OCT 2026

Abstract N°: 290

Systemic Inflammation in Lichen Sclerosus: Exploring the Role of NLR and PLR as Accessible Biomarkers

Alessia Paganelli*[1], Alessandra Corrente[2], Emanuele Scala[2], Dario Didona[2], Giovanni Di Zenzo[2], Cristina Albanesi[2], Francesco Moro[2], Laura Colonna[2], Biagio Didona[2], Roberta Priori[3]

[1] Link Campus University, Rome, Italy
[2] IDI-IRCCS Istituto Dermopatico dell'Immacolata, Rome, Italy
[3] UniCamillus International Medical University, Rome, Italy

Introduction
Lichen sclerosus (LS) is a chronic inflammatory dermatosis traditionally considered a localized disease, although autoimmune associations suggest possible systemic immune involvement. In a large preliminary dataset from our institution, increased neutrophil-to-lymphocyte ratio (NLR) values and correlations with inflammatory markers supported the hypothesis of low-grade systemic inflammation in LS. Whether hematological inflammatory ratios reliably reflect measurable inflammatory activity remains unclear. The aim of the present study is to refine the role of blood-derived inflammatory biomarkers in LS.

Materials and Methods
This single-center retrospective study analyzed laboratory data from patients with LS undergoing routine hematochemical evaluation. NLR and PLR (platelet-to-lymphocyte ratio) were calculated as neutrophil-to-lymphocyte and platelet-to-lymphocyte ratios, respectively. Erythrocyte sedimentation rate (ESR) and C-reactive protein (CRP) were collected as conventional inflammatory markers. Correlation analyses were performed using all available complete cases for each variable pair; therefore, sample size varied according to data availability. Associations between variables were assessed using Pearson and Spearman correlation analyses. Results are expressed as mean ± standard deviation.

Results
Six hundred forty-three patients had available hematological results, with only 84 having complete laboratory data including ESR and CRP and were included in inflammatory correlation analyses. Mean values were: NLR 2.02 ± 0.79, PLR 120.29 ± 53.38, ESR 13.85 ± 10.79 mm/h, and CRP 2.99 ± 4.69 mg/L. NLR showed a significant correlation with CRP (Pearson $r = 0.226$, $p = 0.039$; Spearman $\rho = 0.225$, $p = 0.040$), while PLR showed only a borderline association with ESR. NLR and PLR were strongly correlated (Pearson $r = 0.703$, $p < 0.001$; Spearman $\rho = 0.539$, $p < 0.001$).

Conclusions
These findings refine preliminary observations and support further prospective studies to clarify the clinical utility of NLR and PLR as an accessible biomarker of systemic inflammation in LS. The modest strength of correlations between NLR/PLR and ESR/CRP may be likely due to the relatively small number of patients with a complete dataset of inflammatory parameters and supports the concept of LS as a condition characterized by low-grade systemic inflammation rather than overt systemic activation.

EADV CONGRESS
VIENNA
30 SEP - 3 OCT 2026

Abstract N°: 332

Cocaine-associated inflammatory dermatoses of the face: two cases highlighting diagnostic challenges

Christina Pham*[1], Stella Hofmeyer[1], Theda Napp[1], Matthias Schefzyk[1], Thomas Werfel[1], Vivien Schacht-Stahlbock[1]

[1] Department of Dermatology and Allergy, Hannover Medical School, Hannover, Germany

Introduction

Cocaine use is increasingly recognized as a trigger of inflammatory and vasculopathic skin disease, often related to levamisole adulteration. While retiform purpura and ANCA-associated vasculopathy are well described, other inflammatory dermatoses associated with cocaine exposure may occur and can represent a diagnostic challenge, particularly when involving the orofacial region. Due to its variable clinical and histopathological presentation, diagnosis may be challenging and delayed. Recently, there has been reported novel clinical presentations with cocaine abuse, such as cocaine-induced pyoderma gangrenosum and cocaine-induced plasma cell orificial dermatomucositis (PCOM). We report two young patients presenting with destructive inflammatory lesions of the face associated with cocaine use.

Case Presentation

The first patient, a 27-year-old male, presented with progressive, severely painful ulcerations of the chin, cheek, eyebrow and gluteal region. Although repeated microbiological analyses revealed multiple bacterial pathogens, antibiotic treatment remained ineffective. Given the clinical morphology, severe pain, and progressive inflammatory course, multilocular pyoderma gangrenosum was suspected, and systemic immunosuppression with oral glucocorticoids and ciclosporin A was initiated. Nevertheless, the lesions continued to deteriorate. Histopathological examination revealed a marked pronounced exophytic pseudoepitheliomatous hyperplasia and a neutrophil-rich inflammatory infiltrate compatible with a neutrophilic dermatosis, further supporting the diagnosis of pyoderma gangrenosum. Only after repeated, targeted history-taking did the patient disclose ongoing cocaine use. Following cocaine cessation and escalation of immunomodulatory therapy with adalimumab, a marked clinical improvement was observed, supporting the diagnosis of cocaine-associated pyoderma gangrenosum.

The second patient, 36-year-old female, presented with painful swelling and progressively erosive inflammatory changes evolving over 9 months affecting the oroficial and mucocutaneous region. Clinical examination revealed a hypertrophic, exophytic, partially exudative tumor-like lesion extending from the upper lip and philtrum to the nasal tip. The nasal mucosa appeared involved, with lesions extending from the nasal ostia from both sides. In addition, a hypertrophic plaque measuring approximately 7 mm was present at the left oral commissure. The patient reported a history of long-standing cocaine use for about 10 years, typically twice weekly and predominantly via the left nostril. Histopathological examination demonstrated a dense plasma cell–rich inflammatory infiltrate and a exophytic pseudoepitheliomatous hyperplasia of the epidermis, similarly to the first case. In the clinical context and after exclusion of alternative causes, a cocaine-induced plasma cell oroficial dermatomucositis (PCOM) was diagnosed. Treatment with high-dose systemic corticosteroids resulted in rapid clinical improvement, with reduction in tissue swelling and exsudation.

In both patients, extensive laboratory and microbiological investigations were negative for infectious and autoimmune disease. Recognition of cocaine exposure was essential for diagnostic clarification. The diagnosis of cocaine-associated inflammatory dermatoses remains inherently challenging because both the clinical presentation and the histopathological findings may be non-specific and overlap considerably with infectious,

autoimmune, vasculopathic, and other inflammatory conditions.

Conclusion

These cases illustrate the broad spectrum of cocaine-associated inflammatory dermatoses and highlight that cocaine use may trigger both neutrophilic and plasma cell–rich inflammatory conditions affecting the face. In patients presenting with atypical, destructive, or therapy-refractory orofacial inflammation, cocaine exposure should be actively considered in the differential diagnosis.

EADV CONGRESS
VIENNA
30 SEP - 3 OCT 2026

Abstract N°: 345

Methotrexate for Generalized Granuloma Annulare: Could it be As an Alternative?

Hasan Emre İlgenli*[1], Selami Aykut Temiz[1], İlkay Özer[1]

[1] Necmettin Erbakan University Faculty of Medicine Dermatology Department, Konya, Türkiye

Introduction

Granuloma annulare is one of the most common non-infectious granulomatous diseases of the skin, the etiology of which is not clearly known. It usually has a benign course and spontaneously resolves. Granuloma annulare typically presents as ring-shaped erythematous plaques or papules on the upper extremities. Generalized granuloma annulare is characterized by 10 or more lesions symmetrically distributed on the trunk and extremities. Although it presents clinically as a benign disease, sometimes underlying conditions such as HIV or malignancy may be present(1).

Case Presentation

A 73-year-old female patient presented with erythematous, hardened, ring-shaped plaques on her arms, legs, and face that had been present for a year(Figure 1,2). A biopsy taken from her arm at an external center was consistent with granuloma annulare. The patient, who also had diabetes and hypertension, presented to our clinic after six months of no improvement despite topical and systemic corticosteroid treatments. Initially, she underwent short-term treatment with 40 mg of systemic corticosteroids and 1/8 intralesional corticosteroids for three days to alleviate her symptoms. Following a review of treatment options in the literature for generalized granuloma annulare, maintenance therapy with systemic corticosteroids could not be planned due to her diabetes mellitus. Regarding hydroxychloroquine, after an ophthalmology consultation concerning potential ocular side effects, the specialist diagnosed her with senile macular degeneration, and treatment with hydroxychloroquine could not be initiated. As an alternative treatment option, considering the patient's comorbidities and compliance,the patient was started on weekly 10 mg subcutaneous methotrexate treatment.During 6-monthly follow-up, the patient clinically benefited from the treatment, and the lesions regressed(Figure 3,4).

Conclusion

In conclusion, methotrexate may be a good alternative for clinicians as a second-line maintenance therapy option in cases where topical, intralesional, or systemic corticosteroid treatments have been ineffective as first-line treatment for widespread granuloma annulare, and because it improves long-term patient compliance. In our case, we wanted to report that methotrexate treatment may be beneficial for a patient who could not use systemic corticosteroids due to diabetes and hydroxychloroquine due to ocular pathologies for maintenance therapy(4).

Abstract N°: 355

Upadacitinib- an effective agent in a case of granulomatous cheilitis

Sunil Dattatraya Ghate*[1]

[1] Dr Ghate's Skin, Hair & LASER centre, Kolekar Hospital, Nulife Hospital, Mumbai, India

Introduction

Granulomatous cheilitis (GC) is a rare non-necrotizing granulomatous inflammatory disorder. It is part of the orofacial granulomatosis spectrum & is characterized by intermittent or persistent swelling of the upper and/or lower lip. Its exact cause is not known. Granulomatous cheilitis is a diagnosis by exclusion. Most cases of GC remain isolated. However, it can be associated with systemic diseases such as Crohn disease (CD), sarcoidosis, or Melkersson-Rosenthal syndrome. Current treatment of GC primarily involves topical or intralesional corticosteroids. Various other systemic agents like immunosuppressives & even biologicals have been used with frequent relapses. There is an evidence that Janus kinase–signal transducer and activator of transcription (JAK-STAT) pathway is involved in granuloma formation. We decided to use this drug in view of unresponsiveness to oral steroids.

Case Presentation

A 40 year old female, a known case of diabetes & hypertension presented with 2 years history of recurrent swelling of the lips. She said the reddish swelling appeared first on the upper lip. Lower lip was involved few months later. There was no itching or pain. She said that the lips felt heavy and unsightly. She said the swelling used to subside partially on its own every 3 to 4 months and reappear. But, the lesions were not subsiding over last 6 months and the swelling was in fact increasing in size. She had seen general physicians & a dermatologist for the same. But, a diagnosis of GC was not made. She had received oral prednisolone & antihistamines in the past 6 months with a presumed diagnosis of angioedema. It did not respond to it. On examination, there were erythematous plaques on both the lips. The lesions extended beyond the lip margins onto the cheeks and the chin. The consistency was firm. The lesions were not tender. The gums were swollen and erythematous. The tongue appeared normal. There was no facial palsy. There was no lymphadenopathy. Skin biopsy was done that showed nodular tuberculoid granulomatous inflammation in patchy pattern throughout the submucosa. The granuloma consisted of lymphocytes, histiocytes and occasional plasma cells. Overlying epidermis showed mild spongiosis and slight hyperplasia. These findings were consistent with Granulomatous cheilitis. The baseline investigations including, complete blood cell count, liver function tests, creatinine, lipid profile, urine routine & microscopy were normal. Tests for hepatitis B, C & HIV were negative, Xray chest was normal & quantiferon TB gold test was negative. Other causes like Crohns disease & sarcoidosis were ruled out. After the baseline investigations, she was put on Tablet upadacitinib 30 mg, a selective JAK-1 inhibitor. There was rapid improvement and the lesions regressed by 80% at the end of 3 weeks. There were no adverse effects seen.

Conclusion

Upadacitinib was very effective in the treatment Granulomatous cheilitis in this 40 year old female patient. More such case reports are needed to establish further its role this rare condition.

EA DV CONGRESS
VIENNA
30 SEP - 3 OCT 2026

Abstract N°: 369

Delayed-Onset Prurigo Pigmentosa following Semaglutide induced weight loss: A case report describing a novel association

Jan-Christoph Stadelmann*[1], Chalid Assaf[1], Jannika Dönges[2], Mathias Oymanns[2]

[1] Health and Medical University Düsseldorf/Krefeld, Department of Dermatology and Venereology, Helios Klinikum Krefeld, Düsseldorf, Germany

[2] Department of Dermatology and Venereology, Helios Klinikum Krefeld, Krefeld, Germany

Introduction

Prurigo pigmentosa is an uncommon inflammatory dermatosis typically associated with ketosis and rapid metabolic shifts. Recent data also indicates that cell-mediated immune mechanisms may be involved in its pathogenesis. Semaglutide, a glucagon-like peptide-1 (GLP-1) receptor agonist widley used for weight management, does not directly induce ketosis but leads to marked metabolic alterations. This raises questions regarding indirect mechanisms that could trigger prurigo pigmentosa during the treatments with semaglutide.

To describe a case of prurigo pigmentosa associated with semaglutide-induced weight loss and to discuss possible underlying mechanisms.

Case Presentation

A 39-year-old woman presented with intensely pruritic, reticulated erythematous papules on the central back, anterior chest and intermammary region which developed over a period of two months. The eruption began approximately five months after initiation of semaglutide therapy, during which time the patient experienced a weight loss of 15 kg. Clinical examination, laboratory investigations, direct and indirect immunofluorescence (DIF/IIF), as well as serial skin biopsies were performed.

Results:

DIF and IIF were negative, making immunobullous or autoimmune dermatoses unlikely. Histopathological findings varied according to the state of lesions: Early lesions were characterized by vesiculation with ulceration, vacuolar alteration at the dermoepidermal junction, apoptotic keratinocytes, and a lymphocytic infiltrate admixed with eosinophils and neutrophils. In later stages, epidermal hyperplasia, hyperpigmentation, and discrete pigment incontinence were observed. In the appropiate clinical context, these findings were consistent with prurigo pigmentosa. No classical triggers, such as a ketogenic diet or relevant systemic disease, could be identified. Although semaglutide itself is not known to directly induce ketogenesis, its appetite-suppressing effects may lead to substantially reduced caloric intake, occasionally resembling intermittent fasting and leading to secondary relative ketogenic states. In addition, gastrointestinal side effects could further reduce food intake or contribute to transient malnutrition, potentially creating a catabolic state similar to known triggers of prurigo pigmentosa. The delayed onset observed in this case, however, suggests that additional metabolic or immunologic factors may play a role.Treatment with doxycycline in an anti-inflammatory dose (100 mg twice daily) over six weeks led to a significant clinical improvement, leaving postinflammatory hyperpigmentation. Topical corticosteroids were used as adjunctive therapy during the acute phase.

Conclusion

This case highlights a possible novel association between semaglutide-induced weight loss and prurigo pigmentosa. Secondary ketosis related to reduced caloric intake could represent a contributing factor, although mechanisms beyond classical ketosis are likely to play a role. Given the increasig use of GLP-1 receptor agonists, awareness of this potential link is clinically relevant. Further studies are needed to clarify causality and better understand the underlying pathophysiology.

EADV CONGRESS
VIENNA
30 SEP - 3 OCT 2026

Abstract N°: 391

Palmoplantar lichen planus mimicking hyperkeratotic acral dermatoses: a diagnostic challenge

Citlalli Fernanda Perez Lopez*[1], Daniel Asz Sigall[2]

[1] Hospital Infantil de México Federico Gómez, CDMX, Mexico
[2] Dermalomas, CDMX, Mexico

Introduction

Lichen planus is a chronic inflammatory dermatosis classically characterized by violaceous polygonal papules. However, palmoplantar involvement represents an uncommon clinical variant with atypical manifestations. In these locations, lesions frequently present as erythematous scaly or hyperkeratotic plaques, often lacking the characteristic Wickham striae due to the thicker stratum corneum of acral skin.Because of this atypical morphology, palmoplantar lichen planus may clinically resemble other acral dermatoses such as palmoplantar psoriasis, chronic eczema, or acquired keratoderma, making the diagnosis challenging.

Case Presentation

We report the case of a 70-year-old female patient who presented with a chronic dermatosis involving acral regions, associated with pruritus and burning pain in areas of plantar fissuring.Dermatological examination revealed bilateral and symmetrical involvement of the palms, soles, dorsal feet, ankles, and distal lower legs.The lesions consisted of well-demarcated erythematous scaly plaques with marked hyperkeratosis. On the plantar surfaces, diffuse hyperkeratosis with lamellar scaling and multiple fissures was observed, predominantly in pressure areas, which were associated with burning pain and discomfort during walking.The palms showed hyperkeratotic erythematous plaques with superficial scaling.Additionally, the dorsal feet and distal legs exhibited multiple erythematous-violaceous papules, some of which coalesced into plaques.Based on the clinical morphology, differential diagnoses included palmoplantar psoriasis, chronic hyperkeratotic eczema, acquired keratoderma, and palmoplantar lichen planus.
A skin biopsy was performed. Histopathological examination demonstrated interface dermatitis with a dense band-like lymphocytic infiltrate at the dermoepidermal junction, basal layer vacuolar degeneration, and orthokeratotic hyperkeratosis, findings consistent with lichen planus, confirming the diagnosis of palmoplantar lichen planus.Treatment was initiated with systemic prednisone, topical clobetasol, and keratolytic agents containing urea, resulting in progressive clinical improvement of both cutaneous lesions and associated symptoms.

Discussion: Palmoplantar involvement in lichen planus is uncommon and may present with different clinical morphologies, including hyperkeratotic or erythematous scaly plaques. Unlike classical lichen planus, these lesions frequently lack the typical polygonal papules and Wickham striae, which complicates clinical recognition.Because of their hyperkeratotic acral presentation, these lesions may mimic other inflammatory dermatoses, particularly palmoplantar psoriasis. Therefore, clinicopathological correlation is essential to establish the correct diagnosis.



Clinical and dermoscopic findings of palmoplantar lichen planus. (A) Bilateral palmar involvement showing erythematous hyperkeratotic plaques with superficial scaling. (B) Dermoscopic examination revealing whitish reticular structures consistent with Wickham striae over a violaceous background. (C) Lateral view of the foot demonstrating erythematous hyperkeratotic plaques extending to the ankle. (D) Plantar surfaces showing diffuse hyperkeratosis with lamellar scaling and fissuring, predominantly in pressure areas.Clinical and dermoscopic findings of palmoplantar lichen planus. (A) Bilateral palmar involvement showing erythematous hyperkeratotic plaques with superficial scaling. (B) Dermoscopic examination revealing whitish reticular structures consistent with Wickham striae over a violaceous background. (C) Lateral view of the foot demonstrating erythematous hyperkeratotic plaques extending to the ankle. (D) Plantar surfaces showing diffuse hyperkeratosis with lamellar scaling and fissuring, predominantly in pressure areas.

Conclusion

Conclusion: Palmoplantar lichen planus is an uncommon clinical variant that may mimic other hyperkeratotic acral dermatoses. Recognition of its atypical presentations, along with histopathological confirmation and appropriate therapeutic response, is essential to achieve an accurate diagnosis and guide management.

EADV CONGRESS
VIENNA
30 SEP - 3 OCT 2026

Abstract N°: 405

An Unusual Presentation of Unilateral Rosacea Mimicking Majocchi's Granuloma Successfully Treated with Isotretinoin

Ekaterina Karpushina*[1]

[1] DocMed Clinic, Moscow, Russian Federation

Introduction

Eosinophilic pustular folliculitis (EPF) is a rare inflammatory dermatosis characterized by recurrent sterile follicular papules and pustules with eosinophilic infiltration. It typically presents symmetrically, however, atypical presentations may lead to diagnostic delay and inappropriate treatment.

Case Presentation

A 37-year-old immunocompetent patient presented with a 10-year history of recurrent unilateral facial eruptions. At the age of 24 years, demodicosis had been diagnosed and the patient received metronidazole, topical tacrolimus, with partial improvement. For the past five years, topical tacrolimus 0.1% had been applied twice daily with incomplete response. Lesions remained confined to one side of the face. Histopathological examination revealed features consistent with spongiotic dermatitis with associated vasculitis and a dermal inflammatory infiltrate composed predominantly of lymphocytes, with admixed eosinophils and neutrophils. Periodic acid–Schiff and Grocott staining were negative, excluding fungal infection, including Majocchi's granuloma. Periodic acid–Schiff and Grocott staining were negative, excluding fungal infection including Majocchi granuloma. Following confirmation of the diagnosis, oral isotretinoin was initiated at a dose of 0.3 mg/kg/day (30 mg daily). Complete clinical resolution was achieved after five months of therapy. The treatment was well tolerated. No relapse occurred during an 18-month follow-up period.

Conclusion

This case underscores the diagnostic challenges of atypical unilateral rosacea, which may clinically mimic other conditions such as Majocchi's granuloma. Careful clinicopathological correlation is crucial for establishing the correct diagnosis. Low-dose oral isotretinoin can be considered a safe and effective therapeutic option in treatment-resistant cases.

EA DV CONGRESS
VIENNA
30 SEP - 3 OCT 2026

Abstract N°: 415

Impact on quality of life and patient-reported outcomes of brivekimig for the treatment of particpants with moderate-to-severe hidradenitis suppurativa

Alexa B. Kimball*[1, 2], Christos C. Zouboulis[3], Maryam Shayesteh Alam[4], Alice B. Gottlieb[5], Hessel van der Zee[6], Ziad Reguiai[7], Claudia de La Cruz[8], Hassan Killasli[9], Monika Arenbergerova[10], Marcia Rueckbeil[11], Gauvain Hamkoung[12], Ella Brookes[13], Laurence Lucats[14], Maria Wiekowski[15], Helen Lee[16]

[1] Department of Dermatology, Harvard Medical School, Boston, United States

[2] Beth Israel Deaconess Medical Center, Boston, United States

[3] Department of Dermatology, Venereology and Immunology, Universitaetsklinikum Ruppin-Brandenburg, Brandenburg Medical School Theodor Fontane and Faculty of Health Sciences Brandenburg, Neuruppin, Germany

[4] SimcoDerm Medical and Surgical Dermatology Centre, Ontario, Canada

[5] Department of Dermatology, UT Southwestern Medical Center, Dallas, Texas, United States

[6] 6Department of Dermatology, Erasmus Medical Center, Rotterdam, Netherlands

[7] Department of Dermatology, Polyclinique Courlancy-Bezannes, Reims, France

[8] 8Clínica Dermacross, Santiago, Chile

[9] Section of Dermatology and Infectious Diseases, Department of Medicine, Karolinska Institutet, Stockholm, Sweden

[10] 10Department of Dermatology and Venereology, Third Faculty of Medicine, Charles University, and Královské Vinohrady University Hospital, Prague, Czech Republic

[11] Sanofi, Frankfurt, Germany

[12] Sanofi, Paris, France

[13] Sanofi, Reading, United Kingdom

[14] Sanofi, Gentilly, France

[15] Sanofi, Morristown, United States

[16] Sanofi, Cambridge, United States

Introduction

Hidradenitis suppurativa (HS) is a chronic, complex, debilitating inflammatory skin disease characterized by painful cutaneous nodules, abscesses, and draining tunnels, predominately affecting interginous areas of the skin, which can significantly impair quality of life. Brivekimig is a dual-targeting anti-TNF/OX40L NANOBODY® being investigated for the treatment of moderate-to-severe HS. The efficacy and safety of brivekimig 150 mg administered every 2 weeks were evaluated in the HS OBTAIN randomized, double-blind, placebo-controlled phase 2a trial (NCT05849922) over 16 weeks. Here we report participant experience data from the primary analysis population of biologic-naïve adults with moderate-to-severe HS (N=71).

Materials and Methods

Disease symptoms and quality of life were assessed via the Hidradenitis Suppurativa Skin Pain Numeric Rating Scale (HS-Skin Pain NRS), Peak Pruritus Numerical Rating Scale (PP-NRS), and Hidradenitis Suppurativa Quality of Life (HiSQOL) questionnaire. Treatment effects of brivekimig versus placebo were estimated via least squares [LS] mean difference from an ANCOVA model for change from baseline endpoints (adjusted for baseline Hurley stage and baseline value). For binary endpoints, outcomes by arm are reported after intercurrent event and missing data

handling (i.e. observations after antibiotics rescue therapy, selected prohibited medications, or permanent study intervention discontinuation due to lack of efficacy were replaced using non-response; missing data were imputed as non-response).

Results

Substantial skin pain improvement, defined as ≥3-unit reduction in weekly average HS-Skin Pain NRS among participants with baseline NRS ≥3, was observed for 25% (8/32) versus 7% (1/15) of participants treated with brivekimig versus placebo at Week 2 and maintained consistently throughout Week 16 (31% [10/32] versus 13% [2/15]). Clinically meaningful improvement in itch (≥4-unit reduction in weekly average PP-NRS among participants with baseline PP-NRS ≥4) was achieved at Week 16 by 26% (6/23) versus 9% (1/11) of participants treated with brivekimig versus placebo, respectively. Positive change from baseline in HiSQOL total score at Week 16 was greater for brivekimig with -9.6 than for placebo with -3.9 (LS mean difference of -6.5; 90% CI: -12.5 to -0.5). Relevant improvements in total HiSQOL, defined as a reduction of ≥20-units among participants with baseline HiSQOL ≥20, were achieved by 29% (9/31) of brivekimig-treated versus 7% (1/15) of placebo-treated participants at Week 16. Descriptive results by HiSQOL domain and item indicate that quality of life improvement was driven by better walking, sleep and concentration, whereas exercise capacity and intimacy exhibited mixed results.

Conclusions

Improvement in HS lesions with brivekimig 150 mg every 2 weeks was accompanied by meaningful benefits across skin pain, itch and quality of life outcomes in adults with moderate-to-severe HS. Further confirmation and broader investigation of brivekimig's benefits on HS patient experience data are part of the ongoing BRIGHTEN phase 2b trial (NCT07170917).

EA DV CONGRESS
VIENNA
30 SEP - 3 OCT 2026

Abstract N°: 431

Granulomatous Reaction Within Tattoo Pigment Mimicking Cutaneous Sarcoidosis: Clinical, Dermoscopic and Histopathological Correlation

Gevorg Mkhitarian*[1]

[1] Dermatology Practice, Saint Petersburg, Russian Federation

Introduction

Tattoo-associated granulomatous reactions represent an uncommon inflammatory complication of tattooing and may clinically resemble cutaneous sarcoidosis or other granulomatous dermatoses. These reactions may occur months or even years after tattoo placement and may present a diagnostic challenge due to their variable clinical presentation. Dermoscopy may provide useful diagnostic clues suggesting a granulomatous inflammatory process; however, histopathological examination is often required to establish a definitive diagnosis.



Case Presentation

We report a patient who presented with infiltrated papules and plaques localized strictly within the pigment of a tattoo placed approximately 10 years earlier. The lesions developed gradually and remained confined to the tattooed area without involvement of the surrounding skin.

Dermoscopic examination revealed structureless yellow-orange areas on an erythematous background accompanied by linear vessels, findings that may be suggestive of granulomatous dermatoses.

Given the delayed onset and atypical clinical appearance, a skin biopsy was performed. Histopathological examination demonstrated dermal granulomatous inflammation composed of epithelioid histiocytes and

multinucleated giant cells surrounding exogenous pigment particles within the dermis. These findings were consistent with a granulomatous tattoo reaction.

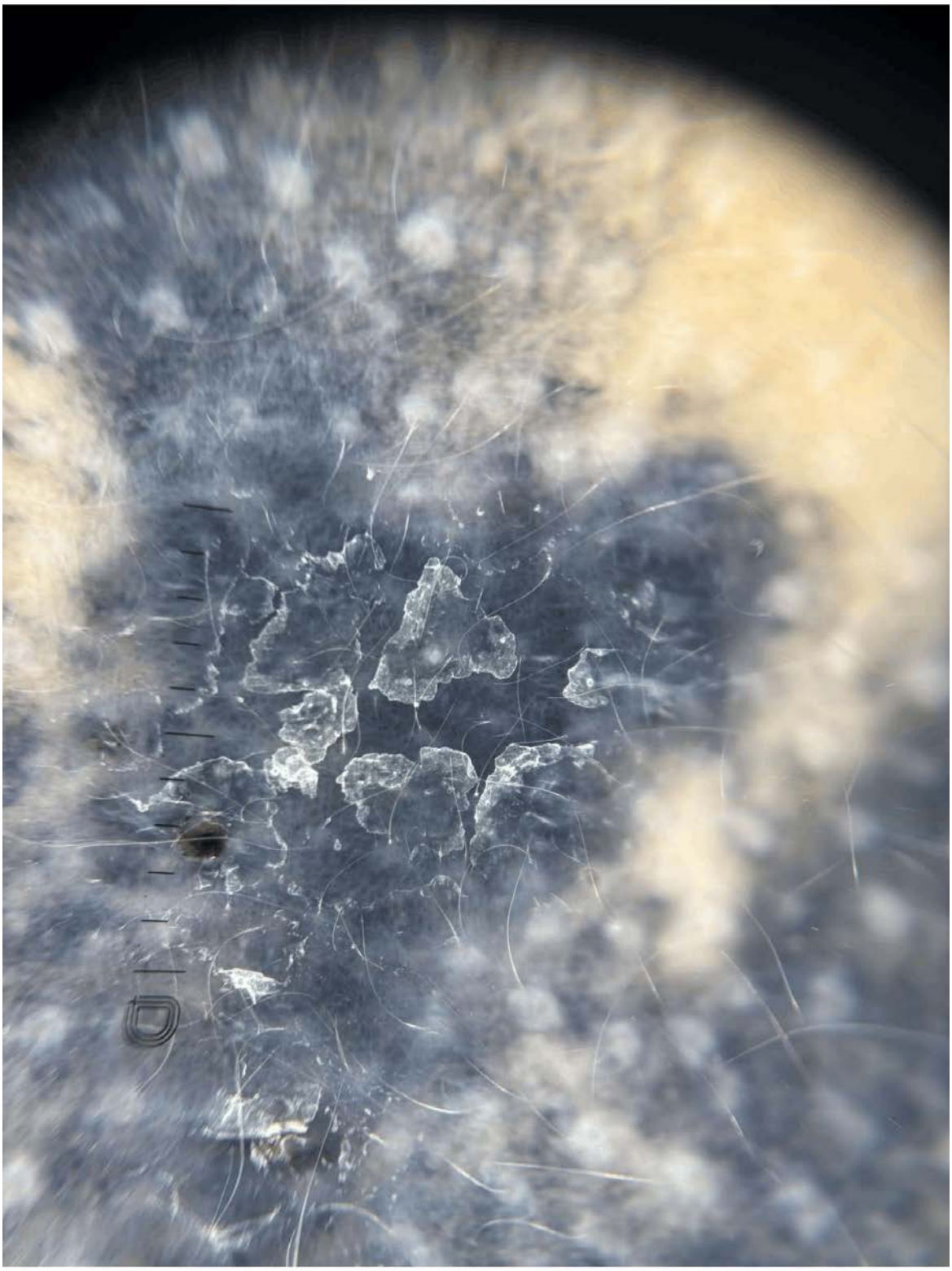

Conclusion

Granulomatous reactions to tattoo pigment may occur many years after tattoo placement and may clinically mimic cutaneous sarcoidosis. Dermoscopy may provide helpful diagnostic clues suggesting granulomatous inflammation; however, histopathological examination remains essential for establishing the diagnosis. Awareness of tattoo-associated granulomatous reactions is important for accurate diagnosis and appropriate management of inflammatory lesions arising within tattooed skin.



EA DV CONGRESS
VIENNA
30 SEP - 3 OCT 2026

Abstract N°: 447

Site-specific relapse in pemphigus is associated with IL-15-driven tissue-resident memory T cells

Xueting Peng*[1], Yale Liu[1], Yumin Xia[1]

[1] The Second Affiliated Hospital of Xi'an Jiaotong University, Xi'an, China

Introduction
Relapse is common in pemphigus vulgaris (PV) despite control of circulating autoantibodies. The mechanisms underlying the anatomical localisation of relapse remain poorly understood. In this study, we aim to define the spatial characteristics of PV relapse and investigate the role of the interleukin (IL)-15-tissue-resident memory T (Trm) cell axis in site-specific recurrence.

Materials and Methods
We analysed lesion distribution and recurrence patterns in 105 patients with relapsing pemphigus and quantified spatial overlap between onset and relapse. Clinical associations were evaluated. Publicly available transcriptomic datasets were analysed to identify candidate pathways. In a biospecimen sub-cohort, circulating T cells, serum cytokines and lesional Trm cells were assessed. Functional effects of IL-15 and relapse serum were examined in vitro using CD3+ T cells.

Results
Relapse preferentially occurred at previously affected anatomical sites, with spatial overlap significantly exceeding that expected by chance, indicating non-random recurrence. Distinct spatial patterns ranging from complete overlap to complete migration were observed. Older age was associated with migratory relapse, whereas early treatment initiation was linked to reduced site-specific recurrence. Spatial patterns were independent of baseline disease severity and autoantibody levels. Analysis of independent transcriptomic datasets identified IL-15 as a consistently upregulated gene in PV. Consistently, relapse was characterised by increased circulating T cells and elevated serum IL-15. Recurrent lesions showed marked enrichment of CD8+ CD103+ and CD4+ CD69+ Trm cells with strong IL-15 expression. In vitro, IL-15 and relapse serum synergistically promoted Trm-like differentiation.

Conclusions
PV relapse exhibits site-specific recurrence consistent with tissue-resident immune memory. The IL-15–Trm axis may contribute to disease persistence and represents a potential target for preventing relapse.

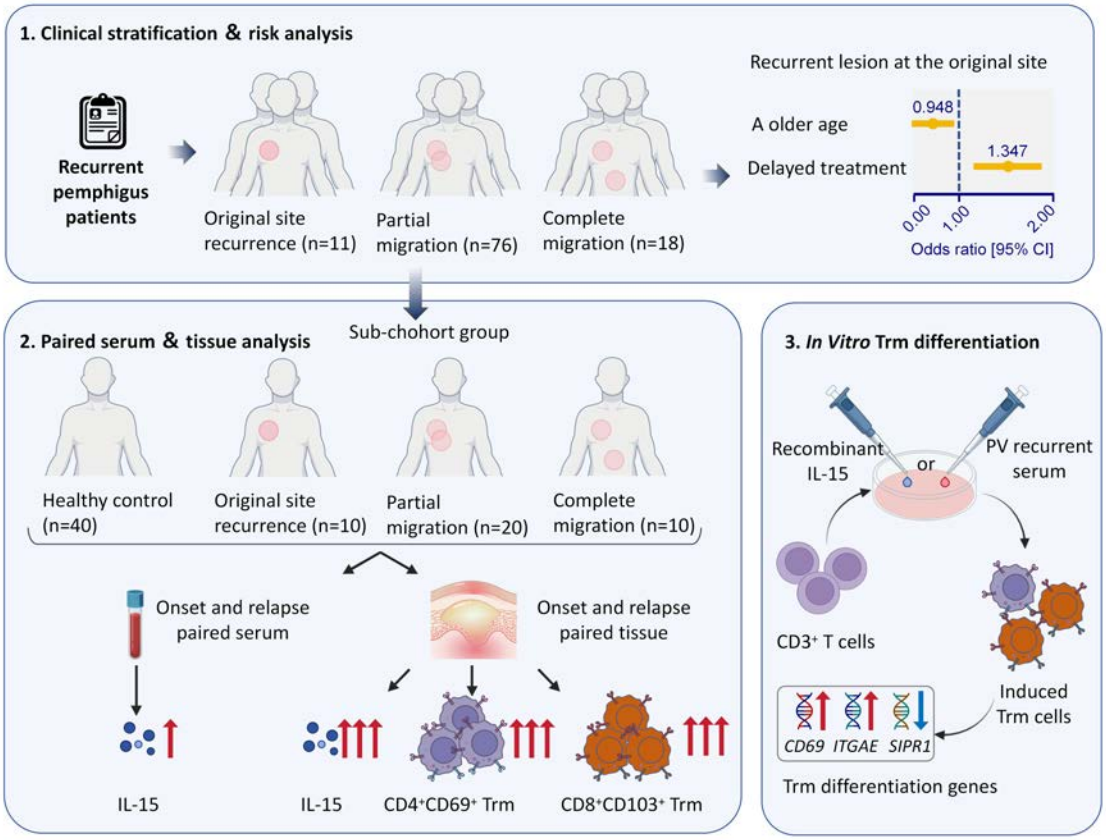
1. Clinical stratification & risk analysis
Recurrent pemphigus patients
Original site recurrence (n=11)
Partial migration (n=76)
Complete migration (n=18)
Recurrent lesion at the original site
A older age
Delayed treatment
0.948
1.347
0.00
1.00
2.00
Odds ratio [95% CI]
2. Paired serum & tissue analysis
Sub-chohort group
Healthy control (n=40)
Original site recurrence (n=10)
Partial migration (n=20)
Complete migration (n=10)
Onset and relapse paired serum
Onset and relapse paired tissue
IL-15
IL-15
CD4+CD69+ Trm
CD8+CD103+ Trm
3. In Vitro Trm differentiation
Recombinant IL-15
or
PV recurrent serum
CD3+ T cells
Induced Trm cells
CD69 ITGAE SIPR1
Trm differentiation genes

EADV CONGRESS
VIENNA
30 SEP - 3 OCT 2026

Abstract N°: 496

Annular lichenoid dermatitis of youth: diagnostic clues from six new cases and an updated literature review

Andrea Danese*[1]

[1] Section of Dermatology, Department of Medicine, University of Verona, Italy, Verona, Italy

Introduction
Annular lichenoid dermatitis of youth (ALDY) is a rare clinicopathological entity first described in 2003 and still likely underrecognized in routine practice. Its clinical presentation may overlap with more common annular dermatoses, making diagnosis challenging. In contrast, histopathology is highly distinctive, with lichenoid/interface changes and a characteristic lymphocytic infiltrate predominantly involving the tips of the rete ridges. We aimed to identify practical diagnostic clues and further define the clinicopathological spectrum of ALDY through six new cases and an updated literature review.

Materials and Methods
Published cases of ALDY were reviewed, and available demographic, clinical, histopathological, treatment, and outcome data were extracted. In parallel, six unpublished patients with clinicopathologically confirmed ALDY were retrospectively assessed. A pooled descriptive analysis was then performed to better delineate the demographic profile, disease spectrum, histopathological hallmarks, treatment patterns, and outcomes of this uncommon disorder.

Results
Seventy-two cases of ALDY were identified in the literature; with the addition of six unpublished cases, the overall cohort comprised 78 patients. Among published cases, a male predominance was observed (41 males, 31 females; male-to-female ratio 1.32:1), which became slightly more evident in the pooled cohort (46 males, 32 females; male-to-female ratio 1.44:1). In individually assessable published cases (n = 37), age ranged from 2 to 79 years, with a mean of 18.6 years and a median of 12 years; after inclusion of the six new cases, age remained 2-79 years, with a mean of 20.8 years and a median of 13 years, indicating that the disease extends beyond the age group suggested by its name. Across the new cases, histopathology consistently showed mild basket-woven hyperkeratosis, preserved granular layer, elongated rete ridges with squared bases, basal keratinocyte apoptosis predominantly at rete ridge tips, and a papillary dermal lymphocytic infiltrate with perivascular/interstitial to lichenoid distribution. Immunohistochemistry showed mainly CD4+ dermal T cells and numerous CD8+ intraepidermal T cells. Follow-up or outcome data were available for 34 of the 37 individually assessable published cases, although follow-up duration was inconsistently reported. Treatment was heterogeneous, with topical corticosteroids used most frequently, followed by topical calcineurin inhibitors. Less commonly used therapies included phototherapy, antibiotics, cyclosporine, and topical ruxolitinib, while a minority of patients received no active treatment. Complete clearance or no evidence of disease was reported in 24 published individual cases, whereas relapse or chronic persistence was documented in 13, often after treatment discontinuation; spontaneous regression and partial improvement were also occasionally described.

Case	Sex	Age (years)	Clinical pattern	Site(s)	Duration (months)	Treatment	Outcome
Case 1	M	9	Erythematous oval plaques with a red-brownish border	Not reported	6	TCS	NED
Case 2	M	14	Erythematous annular plaque	Right flank	12	TCS	NED
Case 3	F	63	Erythematous-violaceous oval and annular patches	Trunk, groin	3	No active treatment	NED (12 months)
Case 4	M	38	Erythematous annular patches	Suprapubic area, trunk	6	TCS	NED
Case 5	M	50	Erythematous annular patches with an erythematous-brownish border and hypopigmented center	Groin, axillary region	5	TCS	Lost to follow-up
Case 6	M	35	Erythematous annular patches with a slightly palpable erythematous-brownish edge and hypopigmented center	Flanks	3	TCS	Lost to follow-up

Table 1. Clinical features, treatment, and outcome of the six unpublished cases of annular lichenoid dermatitis of youth. Abbreviations: TCS, topical corticosteroids; NED, no evidence of disease. Shared histopathological features: All cases showed mild basket-woven hyperkeratosis, a preserved granular layer, elongated rete ridges with squared bases, basal keratinocyte apoptosis predominantly at rete ridge tips, and a papillary dermal lymphocytic infiltrate with perivascular/interstitial to lichenoid distribution. Immunophenotype: Immunohistochemistry showed mainly CD4+ dermal T cells and numerous CD8+ intraepidermal T cells.

Conclusions

ALDY is a distinctive but probably underdiagnosed dermatosis with a recognizable clinicopathological signature. Its rarity, recent clinicopathological definition, overlap with more frequent annular disorders, and broad age range may all contribute to delayed or missed diagnosis. Recognition of its characteristic histopathological pattern, especially the lichenoid/interface infiltrate centered on rete ridge tips, together with clinicopathological correlation, is crucial to distinguish ALDY from mimickers and avoid misclassification. The addition of six new cases strengthens current evidence and refines practical diagnostic clues for this uncommon entity.

EA DV CONGRESS
VIENNA
30 SEP - 3 OCT 2026

Abstract N°: 525

Long-term disease control with subcutaneous spesolimab in GPP patients with or without IL-36RN mutation. Results from the EFFISAYIL ON study

James Krueger*[1], Mark G Lebwohl[2], Akimichi Morita[3], A David Burden[4], Milan J Anadkat[5], Juliann Reardon[6], Ming Tang[7], Christian Thoma[8], Johann E Gudjonsson[9]

[1] Laboratory for Investigative Dermatology, Rockefeller University, New York, NY, United States
[2] The Kimberly and Eric J. Waldman Department of Dermatology, Icahn School of Medicine at Mount Sinai, New York, NY, United States
[3] Department of Geriatric and Environmental Dermatology, Nagoya City University Graduate School of Medical Sciences, Nagoya, Japan
[4] School of Infection and Immunity, University of Glasgow, Glasgow, United Kingdom
[5] Division of Dermatology, Washington University School of Medicine, St. Louis, MO, United States
[6] Boehringer Ingelheim Pharmaceuticals Inc, Ridgefield, United States
[7] Boehringer Ingelheim (China) Investment Co. Ltd, Shanghai, China
[8] Boehringer Ingelheim International GmbH, Biberach, Germany
[9] Department of Dermatology, University of Michigan, Ann Arbor, MI, United States

Introduction
Spesolimab is an anti-interleukin-36 (IL-36) antibody approved for the treatment of generalized pustular psoriasis (GPP). We report long-term efficacy and safety data from patients originating from the approved subcutaneous (SC) dosing regimen from EFFISAYIL 2 trial who rolled over into the EFFISAYIL ON trial and continued to receive SC spesolimab treatment for up to 4 years (n=20, overall population).

Materials and Methods
EFFISAYIL ON (NCT03886246) is an open-label, ongoing 5-year long-term extension of the EFFISAYIL 1 and EFFISAYIL 2 trials. Flare events were as protocol defined. Long-term disease control was defined as achievement of Generalized Pustular Psoriasis Physician Global Assessment (GPPGA) pustulation subscore 0 (pustule clearance) or GPPGA total score 0-1 for at least 90% of visits during the observation period since the first spesolimab SC dose.

Results
Of the 20 patients, 17 were flare event free, reducing the mean cumulative number of flares, from 2.0 flares per year prior to entering the EFFISAYIL 2 trial to 0.1 (0.027,0.372) for 2 years. Long-term disease control was reported for 75% of patients by achieving a GPPGA pustulation subscore of 0 and 80% a total score of 0-1.
Of the six most vulnerable patients (with IL36RN mutation, n=6/20), none were reported with a flare event during the observation period; 100% showed long-term control by achieving pustulation subscore 0 and total score 0-1, respectively.
Of the 20 patients, 19 had evaluable DLQI with a DLQI of 12.1 as average when entering EFFISAYIL 2 trial; 63.2% (12 out of 19) improved to 4 or less and 47.4% (9 out of 19) improved to DLQI 0-1.
Safety data are consistent with the known safety profile of spesolimab.

Conclusions
Long-term SC spesolimab treatment is effective in preventing or reducing the cumulative number of flares in patients with GPP with or without IL36RN mutation, with an unchanged safety profile.

EADV CONGRESS
VIENNA
30 SEP - 3 OCT 2026

Abstract N°: 530

Long-term (≥3 year) efficacy and safety of subcutaneous spesolimab for treatment of generalized pustular psoriasis: Results from the EFFISAYIL program

Johann E Gudjonsson*[1], Alexander A Navarini[2], Richard G Langley[3], James G Krueger[4], Arash Mostaghimi[5], A David Burden[6], Ming Tang[7], Juliann Reardon[8], Christian Thoma[9], Akimichi Morita[10]

[1] Department of Dermatology, University of Michigan, Ann Arbor, MI, United States
[2] Department of Dermatology, University Hospital of Basel, Basel, Switzerland
[3] Division of Clinical Dermatology & Cutaneous Science, Dalhousie University, Halifax, Nova Scotia, Canada
[4] Laboratory for Investigative Dermatology, Rockefeller University, New York, NY, United States
[5] Department of Dermatology, Brigham and Women's Hospital, Harvard Medical School, Boston, MA, United States
[6] Institute of Infection, Immunity, and Inflammation, University of Glasgow, Glasgow, United Kingdom
[7] Boehringer Ingelheim (China) Investment Co. Ltd, Shanghai, China
[8] Boehringer Ingelheim Pharmaceuticals Inc, Ridgefield, United States
[9] Boehringer Ingelheim International GmbH, Biberach, Germany
[10] Department of Geriatric and Environmental Dermatology, Nagoya City University Graduate School of Medical Sciences, Nagoya, Japan

Introduction
Spesolimab is an anti-interleukin-36 monoclonal antibody approved for the treatment of generalized pustular psoriasis (GPP). We report long-term efficacy and safety data from patients with GPP receiving subcutaneous (SC) spesolimab treatment for ≥3 years since their first spesolimab dose in the EFFISAYIL program.

Materials and Methods
EFFISAYIL ON (NCT03886246) is an ongoing open-label, multicenter, 5-year, long-term extension of the EFFISAYIL 1 (intravenous [IV] flare treatment) and EFFISAYIL 2 (SC treatment for flare prevention) trials. Flare events were defined as: meeting a protocol-defined threshold for GPP flare and/or IV spesolimab treatment and/or use of standard of care for GPP, per investigator discretion.

Results
Overall, 159 patients have received at least one dose of SC spesolimab, considering all SC dosing regimens tested; most (n=118, 74.2%) have received long-term treatment (≥3 years). Of these, 74.6% (n=88) remained free of a flare event for ≥3 years and 25.4% (n=30) had at least one flare event. Long-term SC spesolimab treatment led to a reduction in the number of flares from 2.0 flares per year reported prior to entering the EFFISAYIL program to a cumulative mean of 0.13 per year (0.4 over the 3-year period). Safety data were consistent with the known safety profile of spesolimab.

Conclusions
Preliminary results from this open-label study demonstrate that long-term (≥3 years) SC spesolimab treatment is effective in reducing the cumulative number of flares in patients with GPP. Additionally, the safety profile of spesolimab remains unchanged with long-term use.

EA DV CONGRESS
VIENNA
30 SEP - 3 OCT 2026

Abstract N°: 532

Intravenous spesolimab for (re)treatment of generalized pustular psoriasis flares in patients receiving subcutaneous spesolimab: Results from the 5-year, open-label, EFFISAYIL ON extension study

Kenneth B. Gordon*[1], Alexander A Navarini[2], Siew Eng Choon[3], Richard B Warren[4], Milan J Anadkat[5], Ming Tang[6], Juliann Reardon[7], Christian Thoma[8], Mark G Lebwohl[9]

[1] Medical College of Wisconsin, Milwaukee, WI, United States

[2] Department of Dermatology, University Hospital of Basel, Basel, Switzerland

[3] Department of Dermatology, Clinical School Johor Bahru, Hospital Sultanah Aminah Johor Bahru, Monash University, Subang Jaya, Malaysia

[4] Dermatology Centre; and NIHR Manchester Biomedical Research Centre, Northern Care Alliance NHS Foundation Trust & Division of Musculoskeletal and Dermatological Sciences, Manchester Academic Health Science Centre, University of Manchester, Manchester, United Kingdom

[5] Division of Dermatology, Washington University School of Medicine, St. Louis, MO, United States

[6] Boehringer Ingelheim (China) Investment Co. Ltd, Shanghai, China

[7] Boehringer Ingelheim Pharmaceuticals Inc, Ridgefield, United States

[8] Boehringer Ingelheim International GmbH, Biberach, Germany

[9] The Kimberly and Eric J. Waldman Department of Dermatology, Icahn School of Medicine at Mount Sinai, New York, NY, United States

Introduction

Spesolimab is an anti-interleukin-36 monoclonal antibody approved for the treatment of generalized pustular psoriasis (GPP). We report on (re)treatment of GPP flares with intravenous (IV) spesolimab in patients receiving long-term subcutaneous (SC) spesolimab in EFFISAYIL ON.

Materials and Methods

EFFISAYIL ON (NCT03886246) is an ongoing 5-year extension of the EFFISAYIL 1 and EFFISAYIL 2 trials. Patients received SC spesolimab (300 mg every 4, 6, or 12 weeks; dose escalation and de-escalation for flare recurrence/resolution allowed per protocol) for up to 252 weeks. In case of a protocol-defined GPP flare, patients received IV spesolimab 900 mg (≤2 doses within 1 week).

Results

Of 131 patients enrolled from the parent trials, 21 (16.0%) received IV spesolimab to treat a total of 36 flare events (single dose, n=29; double dose, n=7). IV spesolimab demonstrated rapid control of flares: GPP Physician Global Assessment (GPPGA) pustulation subscore of 0 in 50.0% (n=18) of flare treatments at Week 1 and 58.3% (n=21) at Week 2; GPPGA total score of 0/1 in 41.7% (n=15) at Week 1 and 55.6% (n=20) at Week 2. Safety data were consistent with the known safety profile of spesolimab.

Conclusions

Sustained efficacy was observed in most patients treated with SC spesolimab for GPP flare prevention; for those who did experience flares, preliminary results from EFFISAYIL ON demonstrate that IV spesolimab is an effective and well-tolerated treatment. These findings support the complementary roles of IV and SC spesolimab in the long-term management of GPP.

EADV CONGRESS
VIENNA
30 SEP - 3 OCT 2026

Abstract N°: 534

Healthcare professional (HCP) perception of pyoderma gangrenosum (PG): Real-world insights of unmet needs and treatment goals

Afsaneh Alavi*[1], Valentina Dini[2], Robert S Kirsner[3], Roshini Sequeira[4], Alex G Ortega-Loayza[5]

[1] Department of Dermatology, Mayo Clinic, Rochester, MN, United States
[2] Dermatology Unit, Department of Clinical and Experimental Medicine, Ospedale Santa Chiara, Pisa, Italy
[3] Dr. Phillip Frost Department of Dermatology and Cutaneous Surgery, University of Miami Miller School of Medicine, Miami, FL, United States
[4] Boehringer Ingelheim Pharma GmbH, Ingelheim am Rhein, Germany
[5] Department of Dermatology, Oregon Health and Science University, Portland, OR, United States

Introduction
From onset through to treatment, the diagnosis and management of PG is challenging. We explored HCP perceptions of the unmet needs and treatment goals in PG.

Materials and Methods
HCPs were recruited (August–October 2024) to participate in 60-minute individual telephone interviews and 90-minute group interviews with approx. four HCPs per group.

Results
Overall, 63 HCPs from China, France, Japan, and the USA participated in the study (41% dermatologists). Dermatologists tend to have a primary role in diagnosis, treatment decisions, and ongoing PG management, but collaborate with other specialists (e.g., rheumatologists, gastroenterologists) when treating comorbid patients. Due to the rarity of the disease, some HCPs lack clarity on what PG is. HCPs reported feeling pressured or confused due to a reliance on exclusion-based diagnosis, leading to delayed or misdiagnosis. Although HCPs discuss the rarity and cause of PG with patients, many do not proactively provide educational materials during diagnosis.
Treatment decisions are driven by patient comorbidities and PG severity. HCPs reported feeling constrained by limited treatment options and stressed the important unmet need for treatments that achieve rapid symptom improvement and prevent relapse. HCPs reported feeling anxious, confused, and frustrated when patients experience a relapse.

Conclusions
Diagnosing PG remains challenging and often requires a multidisciplinary team approach for treatment. Increasing availability of support and educational materials could help HCPs to better identify PG and prevent misdiagnosis. There is an unmet need for treatments to support wound healing, quickly reduce pain and prevent relapse.

EA DV CONGRESS
VIENNA
30 SEP - 3 OCT 2026

Abstract N°: 535

Successful Treatment of Wells Syndrome with Mepolizumab in the Absence of Peripheral Eosinophilia

Finn Abeck*[1], Inga Hansen-Abeck[1], Frenz Ohm[1], Ute Siemann-Harms[1], Nina Booken[1], Stefan W. Schneider[1]

[1] University Medical Center Hamburg-Eppendorf, Department of Dermatology and Venereology, Hamburg, Germany

Introduction

Wells syndrome is a rare eosinophilic dermatosis that is commonly treated with systemic corticosteroids. However, therapeutic options for refractory disease remain limited. Mepolizumab, a monoclonal anti–interleukin-5 (IL-5) antibody, has demonstrated efficacy in a small number of reported cases, primarily in patients with concomitant blood eosinophilia or other eosinophilic disorders. Here, we report a case of isolated Wells syndrome without peripheral eosinophilia that was successfully treated with mepolizumab.

Case Presentation

A 76-year-old woman presented with a two-year history of intensely pruritic erythematous macules and infiltrated plaques (Figure 1A). Histopathology revealed dense eosinophilic infiltrates with flame figures, consistent with Wells syndrome. Peripheral eosinophil counts were repeatedly within normal limits, and no associated eosinophilic disease was identified. Systemic corticosteroids initially induced clinical improvement; however, relapse occurred during dose tapering. Steroid-sparing therapy with dapsone was discontinued due to anemia. Given the severe pruritus, impaired quality of life, and pre-existing osteoporosis, off-label treatment with mepolizumab was initiated at a dose of 100 mg subcutaneously every four weeks. Marked clinical improvement was observed within four weeks, and complete remission was achieved after three months (Figure 1B). Pruritus resolved completely, quality of life improved substantially, and systemic corticosteroids were fully discontinued. No treatment-related adverse events were observed.



Figure 1 A) erythematous plaques on the back B) complete remission after three months of mepolizumab therapy.

Conclusion

To date, four case reports have described the successful use of mepolizumab in Wells syndrome. In three cases, concomitant blood eosinophilia or other eosinophilic diseases were present (two cases of eosinophilic allergic asthma and one case of eosinophilic granulomatosis with polyangiitis). In only one reported case mepolizumab was used for isolated Wells syndrome, administered at a dosage of 300 mg every four weeks, resulting in complete remission after six months. The present case supports consideration of mepolizumab as a therapeutic option for Wells syndrome after failure of standard therapies or when contraindications limit their use. Notably, IL-5 blockade may be effective even in the absence of peripheral blood eosinophilia or associated eosinophilic disorders.

EA DV CONGRESS
VIENNA
30 SEP - 3 OCT 2026

Abstract N°: 538

Patient Experiences of Lichen Planus in China and the USA: Findings from a Social Media Research Study

Brett King*[1], Mei Go[2], Li Yi[3], Jaclyn Lanthier[4], Gea de Wilt-Jonkers[5], Paolo Tassinari[6], Pallavi Arun[7], Jianjun Qiao[8]

[1] Dermatology Physicians of Connecticut - Fairfield, Conneticut, United States
[2] Novartis Pharma AG, Basel, Switzerland
[3] China Chronic Skin Disease Fund, Beijing Health Alliance Charitable Foundation, Beijing, China
[4] @thelostlabiachronicles, web-based, Canada
[5] Lichen Planus Vereniging, Wijk bij Duurstede, Netherlands
[6] Novartis Farmacéutica, Madrid, Spain
[7] Novartis Healthcare Private Limited, Hyderabad, India
[8] The First Affiliated Hospital, Zhejiang University School of Medicine, Hangzhou, China

Introduction

Lichen planus (LP) is a chronic inflammatory disease of the skin and mucous membranes characterised by itch, pain, and burning sensations in affected areas. Despite an estimated global prevalence of ~1% and a significant quality of life (QoL) burden, LP remains under-recognised.

Social media research (SMR) provides an opportunity to capture real-time patient experiences outside clinical settings.

This study explored online conversations related to oral LP (OLP) and cutaneous LP (CLP) in China and the USA, focusing on key topics (e.g. QoL, patient journeys and unmet needs).

Materials and Methods

A retrospective SMR study was conducted using publicly available social media data from China and the USA in English and Mandarin Chinese posted between July 2023 and July 2025. Posts were first filtered using keyword algorithms before manual review by trained analysts to identify experiences shared by people with LP from patient-centric conversations. Data are reported at the post level (“N”) and by total mentions (“n”), with multiple themes possible per post.

Results

Across platforms, ~21,500 (USA) and ~50,100 (China) mentions of LP were captured, of which 505 (USA) and 500 (China) of the most relevant posts were analysed for deeper insights (**Fig 1**). Reddit in the USA and Xiaohongshu in China served as the main peer-support hubs for people with LP. People with CLP were notably more active on social media in the USA (OLP: 270; CLP: 272) compared to China (OLP: 478; CLP: 26).

In China, most conversations were initiated by female users (86% [n=273]) while greater gender balance was observed in the US (female: 69% [n=118]). Individuals aged 21−40 years were most active online in both countries. SMR studies are reflective of cohorts who are more active on social media and thus may not fully represent the broader population of LP.

The most frequently discussed topics for those with CLP related to affected body parts (China: 26 [n=26]; USA: 130 [n=272]) while for OLP, key conversation topics were on stages of the patient journey (China: 355 [n=478]; USA: 219 [n=270]). Healthcare provider consultation patterns differed between countries: in the USA, dermatologists were most often consulted for CLP (57 [n=75]) and dentists for OLP (39 [n=98]); in China, individuals frequently mentioned traditional Chinese medicine practitioners (67 [n=243]) and stomatologists (46 [n=243]). Diagnostic delays and misdiagnoses were frequently reported.

Where LP severity was identifiable, most individuals in the USA tended to discuss mild symptoms of CLP (66 [n=105]) and OLP (63 [n=119]). In contrast, in China, most OLP posts described the severe nature of their disease (moderate and/or more severe: 272 [n=299]). Increasing CLP severity correlated with more frequent reports of itching and scarring. However, irrespective of severity, the treatment types discussed remained similar.

Both CLP and OLP have substantial impacts on the QoL of people with these conditions, affecting various dimensions and facets of their lives. Functional (USA: 46% [n=35]), physical (China: 47% [n=8]; USA: 46% [n=35]), and emotional challenges (China: 84% [n=16]; USA: 30% [n=23]) were frequently noted by those with CLP, accompanied by feelings of anxiety, frustration, and sadness. With OLP, emotional (China: 72% [n=203]; USA: 41% [n=36]) and functional (China: 38% [n=108]; USA: 61% [n=53]) challenges were common, with individuals reporting an inability to enjoy food.

Across countries and LP subtypes, the greatest unmet need was the lack of effective treatment options to relieve the most bothersome symptoms (China: 94 [N=113]; USA: 12 [N=75]).

Conversation volumes relating to discussions of LP among those suffering from the condition in China and the USA

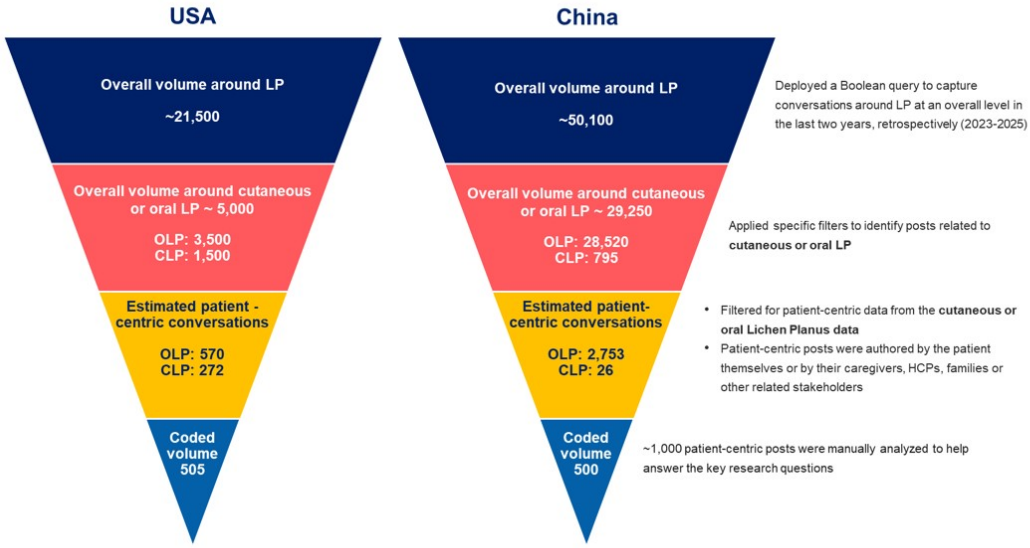

Abbreviations: CLP, cutaneous lichen planus; HCP, healthcare professionals; LP, lichen planus; OLP, oral lichen planus; USA, United States of America.

Conclusions

This SMR study demonstrates the active online engagement of people with CLP and OLP in both China and the USA and highlights the significant physical, functional, and emotional burdens they experience. Despite differences in healthcare pathways across countries, the need for more effective treatments remains the most consistent and substantial unmet need.

EADV CONGRESS
VIENNA
30 SEP - 3 OCT 2026

Abstract N°: 540

Grover's disease in an asymptomatic patient with multiple metabolic comorbidities – A case report

Bianca-Rodica Ivascu*[1], Alexandra Maria Alexe[1], Anca Popescu[1], Maria-Bianca Dragomir[1], Carmen Curea[1]

[1] Colentina Clinical Hospital, IInd Department, Bucharest, Romania, Bucharest, Romania

Introduction

Grover's disease, or transient acantholytic dermatosis, is an uncommon dermatologic condition typically presenting with papular eruption on the trunk and histopathologic acantholysis. While its etiology remains unclear, various systemic conditions and medications have been implicated. Most reported cases manifest as symptomatic pruritic lesions; however, asymptomatic presentations in patients with metabolic comorbidities remain poorly described. This report highlights a case of Grover's disease in a patient with multiple metabolic disorders, which initially did not appear typical for this condition.

Case Presentation

A descriptive analysis was performed on a 62-year-old male patient presenting with a limited number of asymptomatic papular skin lesions. Clinical and dermoscopic examinations were conducted, including detailed evaluation of individual melanocytic nevi. The patient's medical history, comorbidities, and pharmacologic treatments were reviewed, and a histopathological examination was conducted to further characterize the lesions.Seventeen papular lesions, measuring 1–1.5 cm, were observed on the trunk, with the majority located anteriorly (12 lesions) and five posteriorly. Dermoscopy revealed a homogeneous pink-brown pattern with central stellate erosion, discrete erythematous dots and punctiform white structures. The patient's medical history included type 2 diabetes mellitus, treated with oral antidiabetic agents, with suboptimal glycemic control. He had previously received weekly GLP-1 receptor agonist injections for weight reduction, resulting in a total loss of 15 kg after one year of treatment. Other comorbidities included hepatic steatosis, grade I obesity, grade I arterial hypertension, chronic venous insufficiency treated with venotonic therapy, gerontoxon, cortical cataract, and benign prostatic hyperplasia. Lesions had appeared approximately one year prior. Tobacco and occasional alcohol use were reported. Differential diagnoses considered included prurigo, cutaneous melanoma metastases, and lichen planus. Histopathology revealed areas of intraepidermal acantholysis and dyskeratosis, along with a superficial dermal lymphocytic infiltrate. No signs of malignancy were seen. Overall, the findings are consistent, in the clinical context, with Grover's disease (Darier-like pattern) and post-inflammatory hyperpigmentation.

Conclusion

This case highlights that Grover's disease can present asymptomatically with a limited number of lesions, in contrast to the more extensive and pruritic eruptions typically described. Dermoscopic features, particularly central stellate erosions, may aid recognition and help guide the inclusion of Grover's disease in the differential diagnosis, although histopathology remains essential for definitive confirmation. This case is particularly notable because, despite an atypical presentation, Grover's disease was ultimately diagnosed, while other possibilities such as melanoma metastases, lichen planus, and prurigo were initially considered. Clinicians should consider Grover's disease when evaluating similar lesions, especially in patients with multiple metabolic comorbidities.

EADV CONGRESS
VIENNA
30 SEP - 3 OCT 2026

Abstract N°: 580

Bullous lichen sclerosus et atrophicus: A systematic review

Yi-Kuan Chiang*[1, 2], Tzu-Hang Kao[2, 3], Sheng-Hsiang Ma[1, 2, 4]

[1] Department of Dermatology, Taipei Veterans General Hospital, Taipei City, Taiwan
[2] School of Medicine, National Yang Ming Chiao Tung University, Taipei City, Taiwan
[3] Department of Pathology and Laboratory Medicine, Taipei Veterans General Hospital, Taipei City, Taiwan
[4] Institute of Public Health and Department of Public Health, National Yang Ming Chiao Tung University, Taipei City, Taiwan

Introduction
Bullous lichen sclerosus et atrophicus (LSA) is a rare and poorly characterized variant marked by blistering and hemorrhagic features. Evidence to date, largely confined to case reports and small series, shows heterogeneous clinical presentations and management strategies, complicating clinical decision-making. We therefore aim to synthesize all available data on this condition.

Materials and Methods
A systematic literature review of published cases of bullous LSA was conducted. Searches were performed in the Medline (via PubMed) and Scopus databases using predefined search strings, with two authors independently screening studies for eligibility. In addition, all potential cases identified from the institution's clinicopathological database were independently reviewed by the authors. Patient demographics, clinical manifestations, histopathological findings, and treatment strategies from eligible studies were extracted.

Results
In total, 50 cases of bullous LSA from 49 published reports were identified, with one additional institutional case included for analysis (Table 1). Patients were predominantly female (72.5%), with a median age of 63 years (IQR, 55.3–70.8). Lesions most commonly presented as blisters, plaques, and/or hemorrhagic lesions, with a strong predilection for extragenital sites (82.4%). Most were solitary (56.9%) and, when localized, most frequently involved the breast. Radiotherapy and Lyme borreliosis were identified as potential predisposing factors. Histopathology retained classic LSA features but showed prominent dermal hemorrhage and subepidermal blistering. Topical monotherapy was the most commonly adopted approach (53.2%), with high-potency topical corticosteroids utilized in 70.2% of patients. Systemic corticosteroids and immunomodulators were reserved for refractory cases. Novel therapies, including Janus kinase inhibitors, intravenous immunoglobulin, and photodynamic therapy, have shown variable clinical responses. Overall, 65.0% of treated patients achieved complete remission.

Table 1. Summary of the clinicopathological and treatment data.

Feature[a]	Frequency *n* (%)
Sex (M/F)	**14/37**
Median (IQR) age	**63 (55.3-70.8)**
Clinical presentation	**51 (100.0)**
Blister	39 (76.5)
Plaque	34 (66.7)
Hemorrhagic lesion	24 (47.1)
Patch	7 (13.7)
Papule	4 (7.8)
Macule	3 (5.9)
Symptom	**38 (100.0)**
Pruritic	17 (44.7)
Painful	12 (31.6)
Asymptomatic	9 (23.7)
Skin tightness	1 (2.6)
Accompanying feature	**3 (100.0)**
Koebnerization	2 (66.7)
Scarring alopecia	2 (66.7)
Potential triggering factor	**51 (100)**
Radiotherapy	3 (5.9)
Lyme borreliosis	2 (3.9)
Disease type	**51 (100)**
Extragenital	42 (82.4)
Genital	9 (17.6)
Distribution	**51 (100)**
Solitary/localized	29 (56.9)
Multifocal	15 (29.4)
Generalized/extensive	7 (13.7)
Anatomical site for solitary/localized lesions	**29 (100.0)**
Breast	9 (31.0)
Trunk (other than breast)	9 (31.0)
Genitalia	6 (20.7)
Neck	4 (13.8)
Extremity	1 (3.4)

Cont'd	
Histopathology	**51 (100)**
Epidermal atrophy	37 (72.5)
Papillary dermal edema	29 (56.9)
Homogenization of dermal collagen	29 (56.9)
Vacuolar interface	19 (37.3)
Dermal hemorrhage	17 (33.3)
Follicular plugging	10 (19.6)
Subepidermal blister	7 (13.7)
Reduced/fragmentation of elastic fiber	5 (9.8)
Telangiectasia	2 (3.9)
Reduced skin appendage	1 (2.0)
DIF	**10 (100)**
Positive	2 (20.0)
Negative	8 (80.0)
Treatment alternatives	**47 (100)**
None	2 (4.3)
Topical corticosteroid	33 (70.2)
Systemic corticosteroid	6 (12.8)
Topical calcineurin inhibitor	5 (10.6)
Doxycycline	2 (4.3)
Methotrexate	2 (4.3)
Hydroxychloroquine	2 (4.3)
Intralesional corticosteroid	2 (4.3)
Surgical excision	2 (4.3)
Mycophenolate mofetil	1 (2.1)
Colchicine	1 (2.1)
NBUVB phototherapy	1 (2.1)
UVA-1 phototherapy	1 (2.1)
Photodynamic therapy	1 (2.1)
Intravenous immunoglobulin	1 (2.1)
Acitretin	1 (2.1)
Tofacitinib	1 (2.1)
Fractional CO_2 laser	1 (2.1)
Outcome	**41 (100)**
Spontaneous remission	1 (2.4)
Complete remission/significant improvement	26 (63.4)
Partial remission	12 (29.3)
No improvement/deterioration	2 (4.9)

LSA, lichen sclerosus et atrophicus; M, male; F, female; IQR, interquartile range; DIF, direct immunofluorescence; NBUVB, narrowband ultraviolet B; UVA-1, ultraviolet A1; CO_2, carbon dioxide.
[a]Since individual cases may exhibit multiple features within a single category, the percentages may exceed 100%.

Table 1. Summary of the clinicopathological and treatment data.

Conclusions

Our findings suggest that bullous LSA shares epidemiological and histopathological features with classic LSA, supporting a shared disease spectrum. However, its extragenital predominance, marked dermal hemorrhage and subepidermal blistering, and favorable treatment response distinguish it as a distinct clinical entity. Bullous LSA should be considered in the differential diagnosis of bullous dermatoses, particularly in the genital region.

EA DV CONGRESS
VIENNA
30 SEP - 3 OCT 2026

Abstract N°: 581

Striking, disabling, and debilitating presentation of an unusual case of chromoblastomycosis in a temperate climate, associated with bilateral elephantiasis and type I L5/S1 spondylolisthesis due to isthmic lysis.

omar boudghene stambouli*[1]

[1] Medical Practice of Dermatology and Venereology Former Head of Dermatology at Tlemcen, Tlemcen, Algeria

Introduction

Chromomycosis (chromoblastomycosis) is a chronic, localized dermatosis caused by dematiaceous fungi, mainly belonging to the genera Phialophora, Fonsecaea, and Cladosporium.The rapid progression of a case of chromoblastomycosis to bilateral elephantiasis, resulting in a striking, disabling, and debilitating dermatosis in a temperate climate area, associated with type I L5/S1 spondylolisthesis due to isthmic lysis, prompted us to report this unusual and exceptional observation, both for its clinical presentation and its association.



Case Presentation

M.F., a 47-year-old woman, presented with nodular lesions, in some areas ulcerated, psoriasiform and tumoral, multiple, prominent, papillomatous, and sometimes lobulated.

These lesions were entirely covered with a dirty gray epidermis and grayish-yellow crusts, with associated hyperkeratosis and multiple verrucous lesions (Fig. 1) (Fig. 2).

The striking lesions were bilaterally distributed on the dorsum of the feet and the lower third of the legs, particularly on the anterior aspects, with remarkable bilateral elephantiasis.

On the dorsal surface of both hands, pigmented lesions were noted, probably corresponding to the initial stage of the disease.Histological examination of a nodule showed, beneath an acanthotic and sometimes ulcerated epidermis, a polymorphous inflammatory dermal granuloma composed of giant cells, plasma cells, and small foci of abscess formation, as well as, in some areas, rounded brown-pigmented spores corresponding to fumagoid (sclerotic) bodies.Mycological examination revealed that culture of skin scales and histological samples on Sabouraud medium supplemented with antibiotics identified Fonsecaea pedrosoi.

hromoblastomycosis (chromomycosis) is mainly observed in tropical and subtropical regions due to dry climates; however, it may also occur outside these areas, particularly in the context of current warming and increasing aridity in the southern Mediterranean region.In Maghreb countries, chromomycosis is rare; five Moroccan cases have been reported among 30 cases of deep mycoses.Treatment of chromomycosis remains difficult and represents a major challenge of this disease, particularly in forms caused by Fonsecaea pedrosoi, which is considered the most resistant fungal species.



Conclusion

Emphasis should be placed on the prevention of injuries to the legs and feet in endemic areas. Early diagnosis currently remains the best guarantee of definitive cure, through radical surgery or physical treatment modalities.

The combination of 5-fluorocytosine and itraconazole appears to be the treatment of choice for chromomycosis; however, this requires confirmation through larger and comparative therapeutic trials.

EADV CONGRESS
VIENNA
30 SEP - 3 OCT 2026

Abstract N°: 610

Retrospective Analysis of Clinical Presentations and Associations of Granuloma Annulare with Metabolic and Other Comorbidities

Jelena Peric*[1, 2], Neda Delic[1], Natasa Gardinovacki[3], Fatima Hasanin[3], Dusan Skiljevic[1, 2]

[1] University Clinical Center of Serbia, Clinic of Dermatology and Venereology, Belgrade, Serbia
[2] University of Belgrade Faculty of Medicine, Department of Dermatology and Venereology, Belgrade, Serbia
[3] University of Belgrade Faculty of Medicine, Belgrade, Serbia

Introduction
Granuloma annulare (GA) is a chronic, non-infectious granulomatous skin disorder of incompletely understood etiopathogenesis. Possible associations with metabolic disorders, autoimmune diseases and malignancies have been reported, but the findings remain inconsistent and population-level data from our region are limited. This study aimed to characterize the clinical presentations of GA and examine its association with metabolic and other comorbidities.

Materials and Methods
This retrospective study included 73 inpatients with confirmed GAhospitalized in our center between 2015 and 2025. Demographic characteristics, clinical features, comorbidities, treatment protocols and outcomes were analyzed.

Results
A female predominance was observed (74%), and the median age at hospitalization was 59 years. The disseminated form was the most common clinical presentation, observed in 75.3% of patients and significantly more frequent in women (p=0.040), though this may partly reflect the inpatient setting of the study. The upper (75.3%) and lower extremities (72.6%) were the most commonly affected anatomical sites. Trunk involvement was recorded in 54.8% of cases and was more prevalent in patients with comorbidities (p=0.011). The majority of patients were asymptomatic (72.6%), whereas pruritus was reported in 20.5% of subjects. The most prevalent internal comorbidity was arterial hypertension (52.1%), followed by type 2 diabetes mellitus (26.0%) and hypothyroidism (15.1%). Autoimmune diseases were recorded in 13.7% of patients, while malignancies were present in 4.1%. Treatment outcomes did not differ significantly by sex or extent of skin involvement. Disease recurrence was documented in 29% of subjects and showed no significant associations with sex, dissemination of skin lesions or comorbidities, although it was more common in patients treated with systemic corticosteroids (p=0.005).

Conclusions
GA occurred more frequently in women, who also more commonly presented with a disseminated clinical pattern. The relatively high prevalence of metabolic comorbidities, particularly hypertension and type 2 diabetes mellitus, may point to a possible association between GA and metabolic dysregulation, underscoring the importance of comprehensive evaluation of these patients.

Although the retrospective design, inpatient-only population and modest sample size limit the generalizability of presented findings, this study offers valuable real-world data on GA from a single referral center. Future prospective and controlled studies with larger cohorts are needed to clarify the nature and directionality of these associations.

EADV CONGRESS
VIENNA
30 SEP - 3 OCT 2026

Abstract N°: 673

Evaluation of Clinical and Laboratory Characteristics of Patients Diagnosed with Recurrent Aphthous Stomatitis

Rümeysa Öktem*[1], Efsun Tanacan[2], Didem Dinçer[3], Pinar Hararci Yildirim[4], Veysel Duru[5], Fatma Gülru Erdoğan[3]

[1] Kulu State Hospital, Medical Faculty of Ufuk University, Konya, Türkiye
[2] Etlik City Hospital, Medical Faculty of Ufuk University, Ankara, Türkiye
[3] Private Practice, Medical Faculty of Ufuk University, Ankara, Türkiye
[4] Elmadağ State Hospital, Medical Faculty of Ufuk University, Ankara, Türkiye
[5] Beytepe State Hospital, Medical Faculty of Ufuk University, Ankara, Türkiye

Introduction
Recurrent aphthous stomatitis (RAS) is one of the most common inflammatory disorders of the oral mucosa, characterized by recurrent and painful ulcerations. Despite its high prevalence, its etiology remains incompletely understood, and both clinical presentation and laboratory findings may vary among patients. The aim of this study was to evaluate the clinical and laboratory characteristics of patients diagnosed with RAS who presented to our clinic.

Materials and Methods
This retrospective study included patients diagnosed with recurrent aphthous stomatitis who presented to the Dermatology and Venereology outpatient clinic between January 2010 and December 2021. A total of 215 patients were enrolled. Clinical and laboratory data were obtained from standardized RAS follow-up forms and electronic medical records.
Demographic characteristics (age, sex), clinical features (aphthous ulcer type, disease duration, frequency of episodes, and treatment modalities), and laboratory parameters were recorded. Aphthous ulcers were classified as minor, major, or herpetiform based on clinical presentation. Laboratory evaluation included hematological and inflammatory parameters, such as serum vitamin B12, iron levels, ferritin, C-reactive protein (CRP), and neutrophil counts.
All data were analyzed retrospectively. Comparative analyses were performed according to aphthous ulcer type to assess potential differences in laboratory findings.

Results
Of the 215 patients, 70.7% were female. Minor aphthous ulcers were the most common clinical subtype. The majority of patients had a disease duration of ≤3 years. Vitamin B12 deficiency was detected in 28.7% of patients, while 20.9% had iron levels below the reference range.
When laboratory findings were evaluated according to aphthous ulcer type, ferritin, CRP, and neutrophil levels were found to be significantly higher in patients with major aphthous ulcers compared to other subtypes ($p=0.038$, $p=0.015$, and $p=0.005$, respectively). Other demographic and clinical characteristics are summarized in Table 1.

	N	%
Sex		
Female	118	70.7
Male	97	29.3
Aphthous Type		
Major	75	34.9
Minor	123	57.2
Herpetiform	17	7.9
Disease Duration		
≤3 years	137	63.7
>3 years	78	36.2
Hematologic Conditions and Family History		
Iron deficiency	45	20.9
Vitamin B12 deficiency	61	28.37
Family history	28	11.2
Frequency of Aphthous Episodes (per year)		
≤3 times	20	9.3
4–6 times	50	23.2
7–9 times	11	5.1
10–12 times	49	22.7
>12 times	85	39.5
Treatment Received		
Topical treatment	24	11.2
Colchicine	98	45.5
Penicillin	52	24.2

Table 1. Sociodemographic and Laboratory Findings of Patients Diagnosed with Recurrent Aphthous Stomatitis

Conclusions

In this study, approximately one-third of patients exhibited abnormalities in hematological parameters. In addition, inflammatory markers were significantly elevated in patients with major aphthous ulcers. These findings suggest that laboratory evaluation, particularly of hematological and inflammatory parameters, may be useful during the initial assessment and follow-up of patients with RAS.

EADV CONGRESS
VIENNA
30 SEP - 3 OCT 2026

Abstract N°: 700

Hidradenitis Suppurativa With Concomitant Crohn's Disease Is Associated With Broader Anatomic Involvement and Higher Hurley Stage: A Matched Retrospective Cohort Study

Muhammad Zulfiqar*[1], Jordan Lu[1], Larry Borish[1]

[1] Univerisity of Virginia, Charlottesville, United States

Introduction
Current literature on hidradenitis suppurativa (HS) in the context of inflammatory bowel disease (IBD) has yielded conflicting conclusions on whether Crohn's disease (CD) drives HS severity. Prior studies demonstrate a strong epidemiologic association between CD and HS, yet no HS-first study has specifically examined Hurley staging using Crohn's-matched controls. We therefore examined the HS phenotype associated with concomitant CD within an HS-centered cohort

Materials and Methods
We conducted a retrospective matched cohort study within a large academic tertiary-care health system. Sixteen adults with both HS and CD were matched 1:4 by age, sex, and smoking status to HS-only controls. Data collected included Hurley stage at initial HS clinic visit, BMI, anatomic involvement, comorbidities, and prior treatments. Medications were categorized into seven groups: TNF-α inhibitors, non-TNF biologics or small molecule inhibitors (e.g. JAK inhibitors, IL-17 and IL-23 agents), systemic immunosuppressants, corticosteroids, short-course antibiotics, topical therapies, and over-the-counter agents. Descriptive statistics, Fisher's exact tests, and logistic regression were used to assess associations between CD and HS features.

Results
BMI trended lower in the CD cohort (median 29.1 vs 33.8 kg/m2; p=0.076). Hurley stage was significantly higher in the HS-CD cohort, with a greater proportion of Hurley stage III disease (25.0% vs 6.7%; OR 4.67; 95% CI 1.02–21.33). Patients with CD demonstrated greater anatomic involvement (mean 2.4 vs 1.5 sites; p=0.006), including increased axillary involvement (87.5% vs 55.0%; p=0.021). Biologic exposure was markedly higher in HS-CD patients (87.5% vs 11.7%; p<0.0001), while oral antibiotic exposure was lower (43.8% vs 73.3%; p=0.036).

Conclusions
These findings help reconcile conflicting prior literature by highlighting fundamental differences in how HS severity is measured. IBD-centered studies often emphasize systemic inflammatory burden, while HS-centered studies using IHS4 quantify active inflammatory lesions. In contrast, Hurley staging reflects cumulative, and often irreversible, structural damage, including scarring and sinus tract formation. Our results suggest that in patients with concomitant Crohn's disease, increased biologic exposure does not correspond to reduced overall disease burden, but rather reveals a dissociation between inflammatory activity and structural severity. Patients receiving biologic therapy may demonstrate reduced inflammatory lesion counts while still harboring extensive, established structural disease, likely reflecting the well-documented diagnostic delay (7–10 years) in HS. These findings highlight the need for heightened suspicion for more extensive HS in patients with CD and an opportunity to prioritize agents with established efficacy in both conditions — such as TNF inhibitors — when treatment escalation is indicated for either disease, potentially reducing overall treatment burden.

POWERED BY M-ANAGE.COM

EA DV CONGRESS
VIENNA
30 SEP - 3 OCT 2026

Abstract N°: 701

Drug-Induced Sweet Syndrome: A Systematic Review of Triggers, Clinical Features, and Treatment Outcomes

Juliette Gaudreau*[1], An Kateri Vu[2], Océane Juillet[2], Gabrielle Gingras[2], Carolina Lucena Fernandes[2], Elio Kechichian[2]

[1] Faculty of Medicine and Health Sciences - Université de Sherbrooke, Sherbrooke, Canada
[2] Faculty of Medecine and Health Sciences - Université de Sherbrooke, Sherbrooke, Canada

Introduction

Sweet syndrome (SS), or acute febrile neutrophilic dermatosis, is a rare inflammatory condition characterized by fever, leukocytosis, and painful erythematous skin lesions with dense neutrophilic dermal infiltration without vasculitis. Drug-induced Sweet Syndrome (DISS) represents an uncommon but clinically significant subtype. Although several culprit medications have been reported—including granulocyte colony-stimulating factors (G-CSF), azathioprine, all-trans retinoic acid (ATRA), proteasome inhibitors, and antibiotics—data remain fragmented, and early recognition is essential for optimal outcomes.

The objective is to systematically identify drugs associated with DISS and characterize its clinical presentation, management, and outcomes.

Materials and Methods

A systematic search of MEDLINE was conducted on July 2, 2025, using the terms “Sweet syndrome” and “drug.” Eligible studies included case reports in English or French involving human subjects with confirmed DISS and available data on etiology, clinical features, and treatment.

Results

A total of 207 articles comprising 227 patients were included. The median age was 51.6 years, with a slight female predominance (52.8%). The most frequently implicated agents were azathioprine (7.2%), G-CSF (6.8%), ATRA (5.9%), azacitidine (5.1%), trimethoprim–sulfamethoxazole (4.2%), and COVID-19 vaccines (1.3%).The median time to onset was 10.6 days after drug initiation. Most patients presented with multiple painful lesions (93%), predominantly involving the extremities (82%) and face (67.4%). Systemic symptoms included fever (76.7%), pain (67%), and arthralgia (18.9%), while pruritus was uncommon (9.7%). Mucosal involvement occurred in 20.7% of cases, mainly affecting oral and ocular sites. Bullous (14.1%) and ulcerative (8.4%) variants were observed. (Table 1)

Unsupervised clustering analysis identified three distinct clinical phenotypes. A multivariable logistic regression analysis was performed, adjusting for key systemic features. These analyses suggest that drug exposure itself contributed independently from underlying condition to phenotype classification. :

(1) Gastro-intestinal and Inflammatory phenotype (associated with azathioprine), characterized by arthralgia (OR 3.1, 95% CI 1.2–7.9; p=0.02) and gastrointestinal involvement (OR 3.4, 95% CI 1.3–8.5; p=0.01);

(2) Pulmonary systemic phenotype, enriched in ATRA (OR 6.2, 95% CI 2.0–18.8; p=0.002) and G-CSF exposure;

(3) Localized mucocutaneous phenotype, associated with azacitidine (OR 7.9, 95% CI 2.6–23.4; p<0.001) and trimethoprim–sulfamethoxazole (OR 4.8, 95% CI 1.6–14.3; p=0.005).

Most patients were treated with systemic corticosteroids (0.5–2 mg/kg), with a median treatment duration of 28 days.

Table 1. Demographic Characteristics, Clinical Features and Management of Reported Cases of Drug-Induced Sweet Syndrome

Category	Variable	Result
Demography	Number of patient	227
	Mean age (yrs)	51,6
	Male gender (%)	47,1
	Mean time to onset (days)	10,65
Most implicated culprit drug (n)	*Azathioprine*	17
	Granulocyte colony-stimulating factor	16
	All-trans retinoic acid	14
	Azacitidine	12
	Trimethoprim-sulfamethoxazole	10
	Covid Vaccines	4
Clinical features (n)	*Single lesions*	9
	Multiple lesions	210
	Pruritus	22
	Pain	152
	Ocular involvement	23
	Oral mucosal involvement	20
	Genital mucosal involvement	4
	Extremity involvement	186
	Facial involvement	110
	Trunk involvement	132
	Bullous Sweet	32
	Ulcerative Sweet	19
Treatment	Duration (median, days)	28
	Starting dose of systemic corticosteroids (mg/kg)	[0.5-2]

Conclusions

DISS typically occurs within 1–2 weeks of drug initiation and is most frequently associated with antineoplastic and immunomodulatory agents. It commonly presents with painful, multifocal eruptions involving the extremities and face, with possible mucosal involvement. Bullous and ulcerative variants may mimic severe cutaneous adverse reactions. Three distinct clinical phenotypes of DISS are identified: (1) gastro-intestinal and inflammatory, (2) pulmonary and (3) localized mucocutaneous. Early drug withdrawal and corticosteroid therapy remain key to favorable outcomes.

EADV CONGRESS
VIENNA
30 SEP - 3 OCT 2026

Abstract N°: 703

Generalized morphea mimicking early mycosis fungoides: a clinicopathological diagnostic challenge

Sebastián Guerrero-López*[1], Martha Valbuena-Mesa[2]

[1] Pontificia Universidad Javeriana, Bogotá D.C, Colombia

[2] Centro dermatológico Federico Lleras Acosta, Bogotá D.C, Colombia

Introduction

Mycosis fungoides (MF), the most common primary cutaneous T-cell lymphoma, is characterized by clonal proliferation of CD4+ epidermotropic T lymphocytes. Early-stage MF represents a major diagnostic challenge due to subtle and overlapping clinical and histopathological features with inflammatory dermatoses. Morphea, particularly in its early inflammatory phase, may closely resemble MF both clinically and histologically, leading to potential misdiagnosis.

Case Presentation

We report the case of a 65 year old female presenting with erythematous and violaceous plaques, some of which were atrophic, involving the abdomen, flanks, inframammary region, and inner thighs, clinically suggestive of MF. A previous skin biopsy revealed an atypical lymphoid infiltrate suspicious for MF. Immunohistochemistry demonstrated predominance of CD3+ T lymphocytes, mainly CD4+, with loss of CD7 and partial loss of CD5, preserved CD2 expression and marked epidermotropism; CD30 was negative; B lymphocytes CD20+ and T lymphocytes CD8+ were also moderately present. These findings were compatible with MF. Systemic evaluation was unremarkable. The patient was treated with topical clobetasol and narrowband UVB phototherapy.

After 21 phototherapy sessions, the patient developed peripheral erythema, mild edema, and a burning sensation at the lesion margins. Considering these changes, along with the presence of epidermal atrophy in some plaques, a diagnosis of morphea was considered. A new biopsy showed superficial and deep perivascular and interstitial lymphocytic infiltrate with collagen condensation, dermal sclerosis, and presence of plasma cells, findings suggestive of morphea. Although some features, such as epidermotropism and interface changes raised concern for early MF, clinicopathological correlation remained inconclusive. Upon second expert dermatopathology review, the findings were reinterpreted as consistent with generalized morphea, highlighting overlapping features with early MF.

Conclusion

Early MF presents with erythematous patches or plaques with or without scaling or atrophy, mimicking other inflammatory dermatoses such as morphea. One histopathologic finding that may help differentiate the latter from MF is the presence of B lymphocytes and plasma cells. Morphea, in its early stage, presents with more nonspecific histopathological findings such as a lymphocytic perivascular, periadnexal or interstitial infiltrate with presence of histiocytes and/or plasma cells. This case underscores the significant diagnostic overlap between early MF and inflammatory stage morphea, particularly in the context of treatment related histopathological changes. Morphea may closely mimic MF both clinically and histologically, even with supportive immunophenotypic findings. Expert slide review, strict clinicopathological correlation, and cautious interpretation of immunohistochemistry are essential to avoid misdiagnosis. Recognition of this overlap is critical to guide appropriate therapeutic decisions and prevent overtreatment.

EA DV CONGRESS
VIENNA
30 SEP - 3 OCT 2026

Abstract N°: 782

Fibroblasts as Active Regulators of Inflammation in Skin Diseases: Insights from a Bibliometric-Guided Review

Sümeyye Aktaş*[1], Selami Temiz[1], Recep Dursun[1], İlkay Özer[1], Munise Daye[1]

[1] NECMETTİN ERBAKAN UNİVERSİTY, KONYA, Türkiye

Introduction

Once considered passive structural cells, fibroblasts are now recognized as structurally and functionally heterogeneous regulators of immune and inflammatory pathways across diverse skin disorders, including fibrotic, reparative, and inflammatory conditions. In this review, we aim to highlight the importance of fibroblasts in inflammatory skin diseases, with particular emphasis on their involvement in immune signaling and intercellular crosstalk.

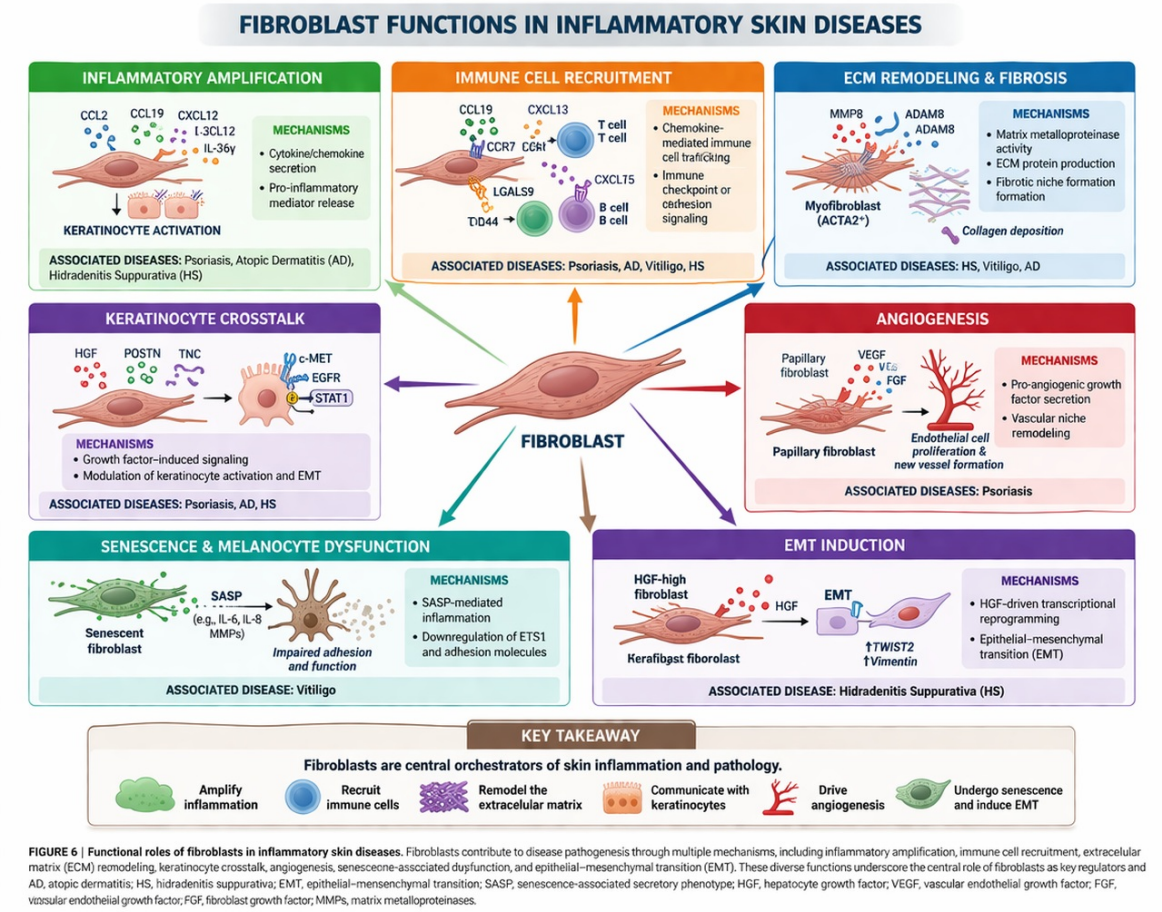

FIGURE 6 | Functional roles of fibroblasts in inflammatory skin diseases. Fibroblasts contribute to disease pathogenesis through multiple mechanisms, including inflammatory amplification, immune cell recruitment, extracellular matrix (ECM) remodeling, keratinocyte crosstalk, angiogenesis, senescence-associated dysfunction, and epithelial–mesenchymal transition (EMT). These diverse functions underscore the central role of fibroblasts as key regulators and AD, atopic dermatitis; HS, hidradenitis suppurativa; EMT, epithelial–mesenchymal transition; SASP, senescence-associated secretory phenotype; HGF, hepatocyte growth factor; VEGF, vascular endothelial growth factor; FGF, vascular endothelial growth factor; FGF, fibroblast growth factor; MMPs, matrix metalloproteinases.

Figure 1: Functional roles of fibroblasts in inflammatory skin diseases. Schematic overview of the major functional roles of fibroblasts across inflammatory skin diseases. Fibroblasts contribute to disease pathogenesis through multiple interconnected mechanisms, including inflammatory amplification via cytokine and chemokine secretion (e.g., CCL2, CCL19, IL-36γ), immune cell recruitment through chemokine signaling (e.g., CXCL13, CCR7 axis), and extracellular matrix (ECM) remodeling driven by collagen deposition and matrix-modifying enzymes (e.g., MMP8, ADAM8). Fibroblasts also engage in bidirectional crosstalk with keratinocytes via signaling pathways such as HGF and EGFR–STAT1,

promote angiogenesis through VEGF and FGF secretion, and contribute to melanocyte dysfunction through senescence-associated secretory phenotype (SASP) signaling. In hidradenitis suppurativa, fibroblasts further drive epithelial–mesenchymal transition (EMT) via HGF-mediated induction of TWIST2 and vimentin. Collectively, these mechanisms position fibroblasts as central regulators of inflammation, tissue remodeling, and disease progression. Abbreviations: AD, atopic dermatitis; HS, hidradenitis suppurativa; ECM, extracellular matrix; EMT, epithelial–mesenchymal transition; SASP, senescence-associated secretory phenotype; VEGF, vascular endothelial growth factor; FGF, fibroblast growth factor

Materials and Methods

Publications indexed in the Web of Science Core Collection (1990–2025) were analyzed using VOSviewer (V. 1.6.20) and the Bibliometrix package in RStudio (V. 4.5.1) to identify research trends, keyword co-occurrence patterns, collaboration networks, and thematic clusters to guide the conceptual framework of this review.

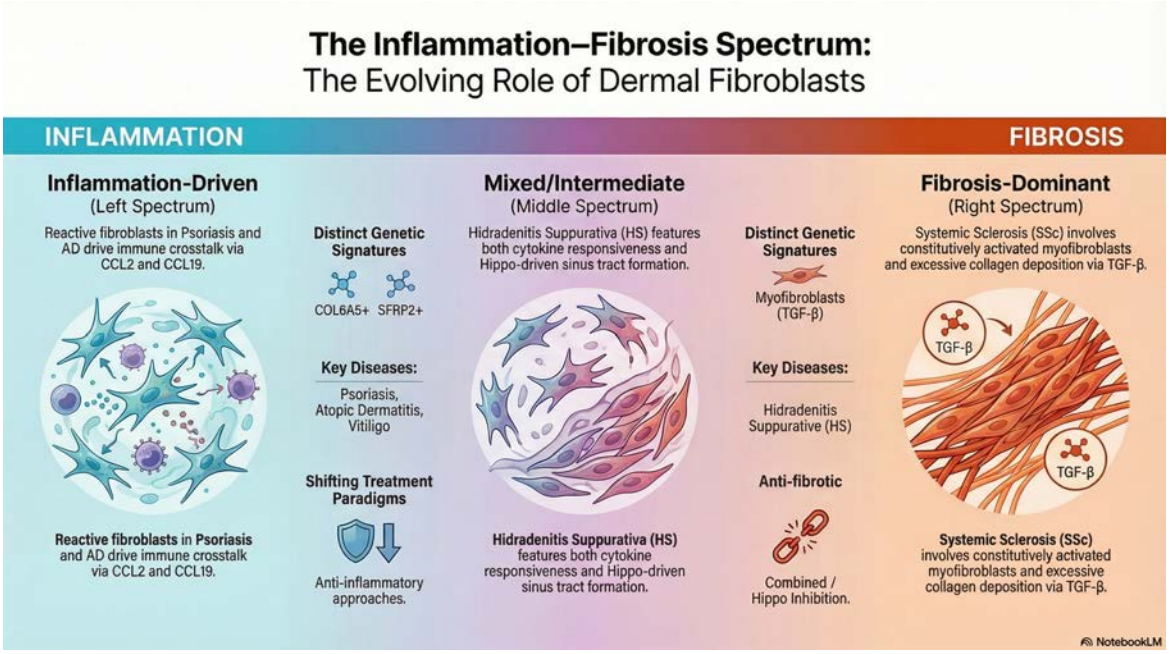

Figure 2: The inflammation-fibrosis spectrum illustrating the evolving role of dermal fibroblasts

Results

The analysis covered 980 WoSCC-indexed publications, showing sustained growth in scholarly interest, with research output rising steadily to a peak around 2019 before stabilizing. Psoriasis, atopic dermatitis, vitiligo, and hidradenitis suppurativa emerged as major inflammatory conditions in which fibroblasts function as active modulators of cytokine signaling, immune cell recruitment, and tissue remodeling. The most prolific author was Sato S, with 18 articles, followed by Asano Y with 17 articles. The Journal of Investigative Dermatology (232 articles) and Experimental Dermatology (93 articles) accounted for the largest share of publications. Rather than acting solely as matrix-producing cells, fibroblasts emerge as central inflammatory cells that integrate immune, epithelial, and stromal responses. Fibrotic disorders such as systemic sclerosis appeared as peripheral yet informative comparators, helping to distinguish inflammation-driven fibroblast activation from fibrosis-dominant processes. Moreover, as fibroblasts are increasingly being targeted therapeutically in inflammatory diseases, this field represents a promising and rapidly evolving area with substantial unmet research needs.

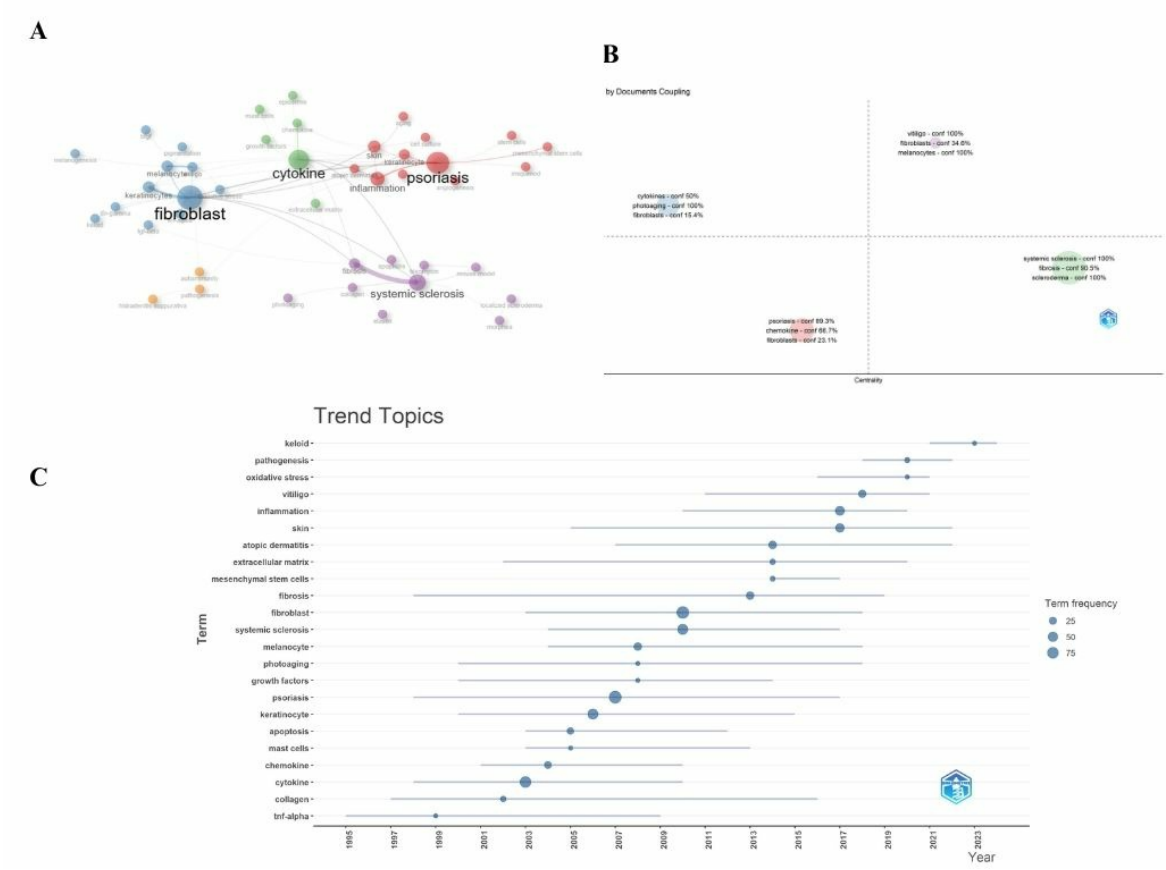

Figure 3: Keyword-based thematic analysis illustrating the central role of fibroblasts in inflammatory skin diseases. (A) Keyword co-occurrence network; (B) clustering based on bibliographic coupling; (C) temporal trends in selected keywords

Conclusions

Overall, this review underscores the paradigm shift in understanding fibroblasts as dynamic regulators of cutaneous inflammation and highlights their potential as therapeutic targets in inflammatory skin diseases.

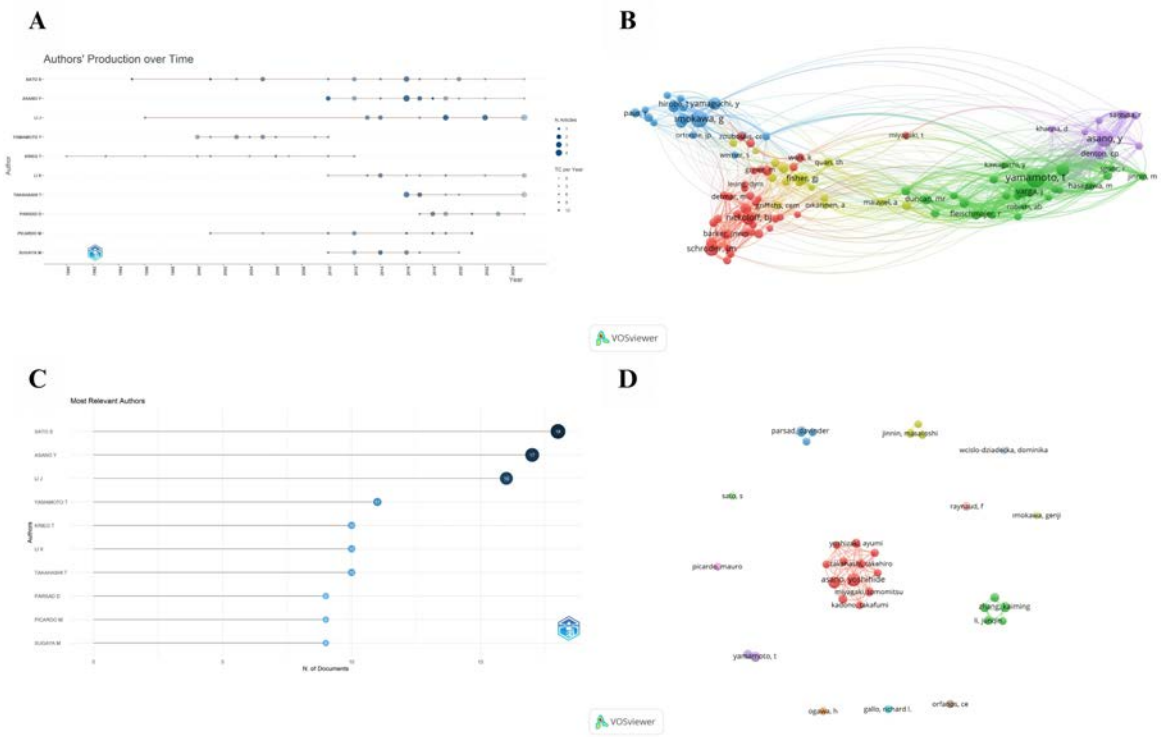

Figure 4: Author productivity and collaboration patterns in fibroblast-related research on inflammatory skin diseases. (A) Temporal distribution of author productivity; (B) co-citation network; (C) most prolific authors; (D) co-authorship network

EADV CONGRESS
VIENNA
30 SEP - 3 OCT 2026

Abstract N°: 808

Generalized morphea associated with primary biliary cirrhosis and sjögren's syndrome: response to methylprednisolone

Eya Bouzaien*[1], Anissa Zaouak[1], Olfa Jouini[2], Dalila Gargouri[3], Houda Hammami[1]

[1] Dermatology Department, Habib Thameur Teaching Hospital, Tunis, Tunisia
[2] Anatomopathology Department, Habib Thameur Teaching Hospital., Tunis, Tunisia
[3] Gastroenterology department , Habib Thameur Teaching Hospital., Tunis, Tunisia

Introduction

Generalized morphea (GM) is a rare fibrosing disorder of the skin and underlying tissues. Management of GM can be complicated when it is associated with other autoimmune diseases. We present a case of a patient with GM associated with primary biliary cirrhosis (PBC) and Sjögren's syndrome, successfully treated with methylprednisolone.

Case Presentation

A 50-year-old female was diagnosed with PBC at the cirrhosis stage in 2019, confirmed by laboratory findings of non-icteric cholestasis and elevated alkaline phosphatase levels (>1.5 times the upper limit of normal). Serological tests showed positive anti-mitochondrial antibodies (AMA-M2) and anti-P210 antibodies. The liver biopsy revealed non-suppurative cholangitis with grade 2, stage 3 interlobular bile duct destruction. Over time, the patient developed symptoms of dry eyes and dry mouth, leading to further investigations. Serological testing revealed positive anti-SSA antibodies. The biopsy of the accessory salivary glands confirmed the diagnosis of Sjögren's syndrome. Concurrently, the patient developed more than four sclerotic plaques, each over 3 cm, symmetrically distributed across the limbs and anterior and posterior trunk. The plaques progressively coalesced, and a skin biopsy revealed epidermal atrophy with thick collagen bundles, consistent with morphea. Importantly, the patient did not exhibit signs of Raynaud's phenomenon, sclerodactyly, digital edema, or other features suggestive of systemic sclerosis. Nailfold capillary changes and the scleroderma kit were negative. Initial management included corticosteroids (1 mg/kg/day), UVB phototherapy, and mycophenolate mofetil (MMF) at 1000 mg/m^2, as methotrexate was contraindicated due to hepatic involvement. Despite these measures, the disease progressed, with further plaque extension and skin involvement. In response to this lack of improvement, the patient was switched to an intensive regimen of methylprednisolone (500 mg/day for three consecutive days, followed by tapering over six months). This approach resulted in significant regression of the sclerotic plaques, with notable improvement in skin flexibility and reduction of systemic symptoms. Liver function remained stable, and no major side effects of corticosteroid therapy were observed during the follow-up period.

Conclusion

This case highlights the complexity of managing patients with overlapping autoimmune diseases such as PBC, generalized morphea, and Sjögren's syndrome. The concurrent presence of these conditions presents therapeutic challenges, as immunosuppressive therapy must be carefully balanced to manage each disease while minimizing adverse effects. In this case, the patient's treatment required a tailored approach combining corticosteroids, phototherapy, and immunosuppressive agents. Methylprednisolone was effective in controlling the morphea and preventing further plaque expansion while maintaining liver function stability.

POWERED BY M-ANAGE.COM

EADV CONGRESS
VIENNA
30 SEP - 3 OCT 2026

Abstract N°: 811

Staphylococcal-scalded skin syndrome in an adult with acquired epidermolysis bullosa mimicking pemphigus presentation

Eya Bouzaien*[1], Anissa Zaouak[1], Imen Hlel[2], Houda Hammami[1]

[1] Dermatology Department, Habib Thameur Teaching Hospital, Tunis, Tunisia
[2] Anatomopathology Department, Habib Thameur Teaching Hospital., Tunis, Tunisia

Introduction

Acquired epidermolysis bullosa (EBA) is a rare autoimmune disease, characterized by the synthesis of anti-collagen VII autoantibodies, leading to epidermal detachment and mucocutaneous blisters. EBA has two major variants: the classical mechano-bullous form and the inflammatory variant. Staphylococcal scalded skin syndrome (SSSS) is a toxin-mediated epidermolytic condition that rarely affects adults. We herein report a case of SSSS in an adult with EBA mimicking a pemphigus presentation.

Case Presentation

A 75-year-old male with a medical history of Parkinson's disease presented to the clinic with multiple erosions on erythematous, painful, and pruritic plaques that had progressively extended across the trunk and extremities. The lesions were bordered by an epidermal collar, and a positive Nikolsky's sign was noted on physical examination. The patient also reported cheilitis and painful erosions on the buccal mucosa. The genital and anal mucosa were also involved, with multiple erosions. An ophthalmological examination demonstrated no evidence of ocular involvement. The diagnosis of pemphigus vulgaris was suspected. Histopathological analysis of the skin lesions revealed epidermal-dermal separation with features typical of various mucocutaneous blistering disorders, including spongiosis, bullous fluid containing neutrophils and eosinophils, and minimal superficial perivascular inflammation. Direct immunofluorescence (DIF) demonstrated linear deposition of IgG and C3 at the dermal-epidermal junction (DEJ), a finding consistent with EBA. Further serological testing, including indirect immunofluorescence and enzyme-linked immunosorbent assay (ELISA), confirmed the presence of circulating anti-collagen VII IgG antibodies. Hence, the diagnosis of EBA associated with SSSS was made. The patient was initially treated with high-dose oral prednisone (1 mg/kg/day) and careful wound care, including topical emollients and antiseptic dressings for the extensive mucocutaneous erosions. Intravenous ampicillin (50 mg/kg per day, divided into three doses) was administered. The prevention of new lesions includes patient education to protect the skin from additional trauma by using soft fabric clothing and non-adherent dressings.
In the mechano-bullous form of EBA, the vesiculobullous lesions usually appear over normal skin, without edema or erythema, in areas that are more subject to pressure and trauma, especially the extensor surfaces of the acral regions (hands, feet, elbows, and knees). The Nikolsky sign is usually absent. Contrarily, the inflammatory forms of EBA present clinical manifestations similar to those found in other autoimmune blistering disorders. In the latter, differential diagnoses include pemphigus vulgaris and paraneoplastic pemphigus.

Conclusion

The diagnosis of EBA relies on clinical suspicion, histopathological findings, and the detection of anti-collagen VII antibodies. While systemic corticosteroids remain a cornerstone of treatment, the potential for adverse effects, including secondary infections, is a significant concern, particularly in elderly patients. SSSS represents a rare complication of these autoimmune bullous diseases and has a high risk of death. Dermatologists should be aware of this complication, especially in the presence of superficial erosions and a positive Nikolsky sign. A quick and accurate diagnosis and treatment of this complication are mandatory to prevent widespread illness and death.

EADV CONGRESS
VIENNA
30 SEP - 3 OCT 2026

Abstract N°: 826

Structure-based virtual screening identifies FDA-approved drug candidates targeting the oncostatin M receptor extracellular domain to disrupt interleukin-31 signaling in atopic dermatitis

Mahir Digis*[1], KISMET KAYA[1], BETÜL DEMİR[1]

[1] FIRAT UNIVERSITY FACULTY OF MEDICINE, ELAZIĞ, Türkiye

Introduction

Interleukin-31 (IL-31) and oncostatin M (OSM) are pivotal mediators of pruritus and cutaneous inflammation in atopic dermatitis (AD). IL-31 signals through a heterodimeric receptor complex comprising IL-31 receptor alpha (IL-31RA) and the oncostatin M receptor (OSMR). Recent evidence indicates that OSM independently sensitizes itch-selective sensory neurons and exacerbates skin inflammation, positioning OSMR as a crucial node for neuro-immune crosstalk. While nemolizumab targets IL-31RA with demonstrated efficacy in phase 3 trials, small-molecule interventions targeting this axis remain restricted to preclinical stages. Furthermore, although the OSMR extracellular domain (ECD) is functionally targetable by biologics, no validated small-molecule pockets on the OSMR ECD have been reported. This study aimed to identify FDA-approved drugs capable of binding the OSMR ECD through structure-based virtual screening using an AlphaFold-predicted structure, aiming to disrupt the IL-31/OSMR signaling axis.

Materials and Methods

The OSMR ECD structure was obtained from the AlphaFold Protein Structure Database . Druggable binding pockets were identified using fpocket ; among 61 detected cavities, Pocket 5—located in the D1 (Ig-like) domain (residues 28–130)—exhibited the highest druggability score and was selected for screening. A library of 2,449 FDA-approved compounds from DrugBank was screened against this pocket using AutoDock Vina (Figure 1). The top 10 candidates (Z-score < -2.0) were subjected to protein-ligand interaction profiling (PLIP) to characterize binding modes, hydrogen bonds, and contact residues. Drug-likeness was assessed using molecular weight, LogP, hydrogen bond donors/acceptors, topological polar surface area, and quantitative estimate of drug-likeness (QED).

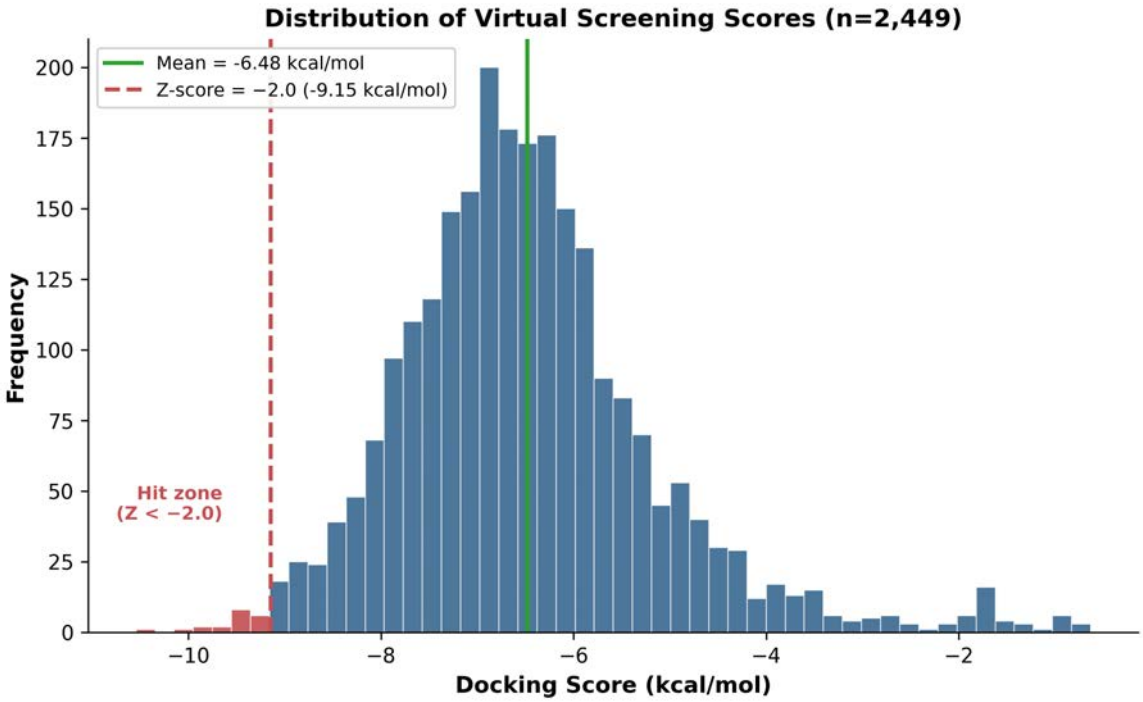

Distribution of docking scores from virtual screening of 2,449 FDA-approved compounds against OSMR ECD Pocket 5. Green line: mean score (−6.48 kcal/mol). Red dashed line: Z-score = −2.0 threshold (−9.15 kcal/mol). Red bars indicate compounds in the hit zone.

Results

The selected pocket showed a druggability score of 0.713 and a volume of 542.9 Å^3. The screening yielded a mean docking score of −6.48 ± 1.33 kcal/mol. The top 10 candidates (scores: −9.476 to −10.544 kcal/mol; Z-scores: −2.25 to −3.05) are summarized in Figure 2A. PLIP analysis revealed five conserved binding residues (ARG29, LEU32, VAL118, PHE123, PHE128) contacted by all 10 ligands, forming a mixed polar-hydrophobic-aromatic pharmacophore (Figure 2B). Eltrombopag formed the most extensive hydrogen bond network (11 H-bonds, shortest: 2.73 Å). Among dermatology-relevant candidates, calcipotriol is already used topically for psoriasis with an established cutaneous safety profile, while azelastine possesses both H1-antihistaminic and anti-inflammatory properties relevant to allergic comorbidities frequently associated with AD. Six of 10 compounds had zero Lipinski violations; the remaining four each had one violation (LogP >5). QED scores ranged from 0.32 to 0.78 (median: 0.55).

A

Rank	Compound	Score (kcal/mol)	Z-score	H-bonds	Conserved residues	Lipinski violations	QED
1	Trilaciclib	-10.544	-3.05	5	5/5	0	0.591
2	Eltrombopag	-10.134	-2.74	11	5/5	0	0.674
3	Tucatinib	-9.943	-2.60	1	5/5	0	0.392
4	Nilotinib	-9.815	-2.51	9	5/5	0	0.389
5	Conivaptan	-9.701	-2.42	2	5/5	1	0.515
6	Lumacaftor	-9.563	-2.32	5	5/5	1	0.476
7	Dihydroergotamine	-9.526	-2.29	3	5/5	0	0.776
8	Calcipotriol*	-9.513	-2.28	3	5/5	1	0.315
9	Azelastine*	-9.477	-2.25	1	5/5	1	0.596
10	Fluspirilene	-9.476	-2.25	3	5/5	0	0.584

Screening: 2,449 FDA-approved drugs (DrugBank); AutoDock Vina 1.2.5; Mean score: −6.48 ± 1.33 kcal/mol
*Conserved residues: ARG29, LEU32, VAL118, PHE123, PHE128. *Dermatology-relevant compounds (highlighted).*

B

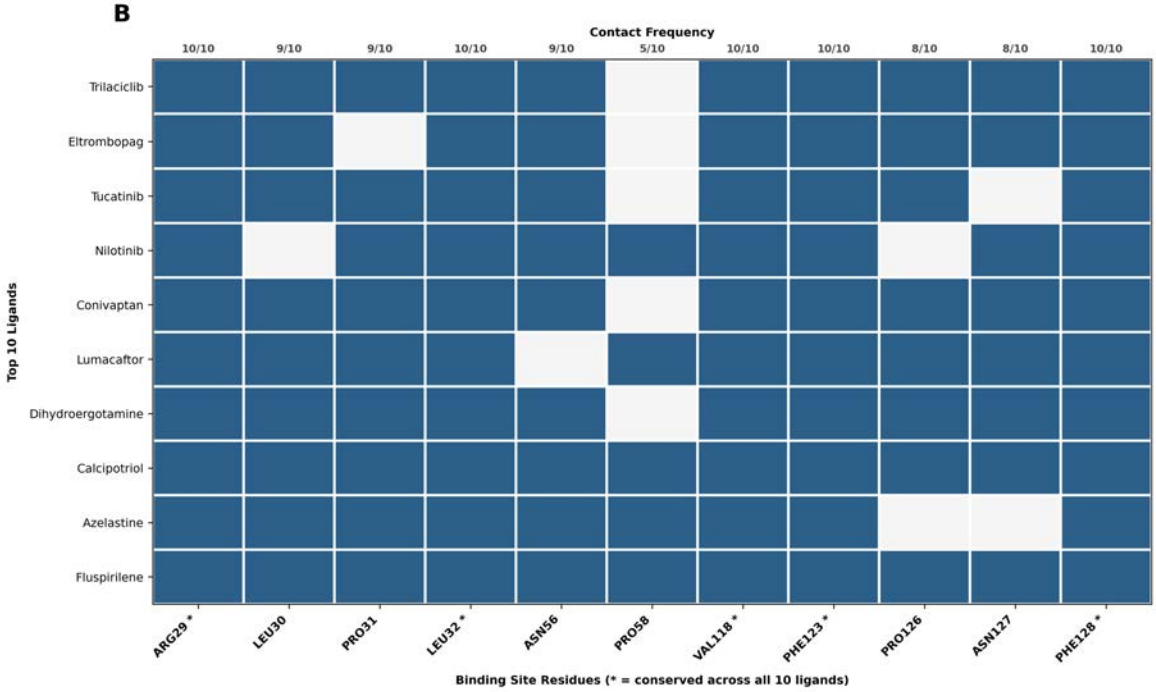

A) Top 10 FDA-approved compounds identified by virtual screening against OSMR ECD Pocket 5. Dermatology-relevant compounds highlighted (*). (B) Protein-ligand contact map showing binding site residue interactions. Conserved residues contacted by all 10 ligands are marked (*). Blue = contact; white = no contact.

Conclusions

This study identified 10 FDA-approved drug candidates with strong predicted binding affinity to the OSMR ECD, a previously unexplored small-molecule target in the IL-31 signaling axis. The identified compounds bind the D1 (Ig-like) domain, which may disrupt IL-31/OSMR complex assembly. Dermatology-relevant compounds calcipotriol and azelastine warrant experimental validation through molecular dynamics simulations and in vitro binding assays.

Acknowledgements: Computing resources used in this work were provided by the National Center for High Performance Computing of Turkey (UHeM) under grant number 1025262025.

EADV CONGRESS
VIENNA
30 SEP - 3 OCT 2026

Abstract N°: 827

Atypical Presentation of Hypereosinophilic Syndrome in a Patient with Skin of Color Successfully Treated with Dupilumab Monotherapy

Chaocheng Liu*[1]

[1] University of British Columbia, Vancouver, Canada

Introduction

Hypereosinophilic syndrome (HES) represents a group of disorders characterized by sustained eosinophilia and multi-organ involvement. Idiopathic HES (iHES) is a diagnosis of exclusion and often poses therapeutic challenges. To date, HES therapies have primarily focused on eosinophilic-depleting biologic agents; however, these agents may provide limited steroid-sparing benefit for cutaneous manifestations.

Case Presentation

We report a 52-year-old woman with long-standing hypereosinophilia and diffuse lymphadenopathy presenting with extensive atypical annular and serpiginous urticarial plaques unresponsive to corticosteroids, methotrexate, and narrow-band ultraviolet B (NBUVB) phototherapy. Comprehensive evaluation excluded autoimmune, infectious, and malignant causes, supporting a diagnosis of iHES. Treatment with dupilumab was initiated, and the patient achieved rapid and sustained remission of pruritus and cutaneous lesions, with an 85% reduction in absolute eosinophil count and 58% decrease in serum IgE over six months.

Conclusion

This case underscores the potential of dupilumab monotherapy in iHES with cutaneous manifestations. Large prospective studies are required to further evaluate the safety and efficacy of dupilumab in patients with HES.

EADV CONGRESS
VIENNA
30 SEP - 3 OCT 2026

Abstract N°: 848

Preclinical characterization of IBI3038, an anti-IGF-1R and anti-IL6 bispecific antibody that potently inhibits skin fibrosis

Yao Xiong[1], Zhimin Zhang*[1], Yuyu Wu[1], Jia Lu[1], Jiayu Hou[1], Feifei Wang[1], Jiajie Fen[1], Zhihai Wu[1], Yuling Song[1], Guogang Yuan[1], Shun Wang[1]

[1] Innovent Biologics (Suzhou) Co., Ltd., 168 Dongping Street, Suzhou Industrial Park, Suzhou, 215123, Jiangsu, China

Introduction

IBI3038 is an innovative first-in-class bispecific antibody currently at the Investigational New Drug (IND) stage, designed to address clinic challenges in fibrosis-related disease, as systemic sclerosis (SSc) or scar formation. In a bivalent format, IBI3038 functions by potent co-blockade of IGF-1R and IL-6 (both cis- and trans- signaling). This molecule is rationally designed to inhibit the two-key process, chronic inflammation and fibroblasts stimulation, during fibrosis development.

Materials and Methods

In vitro binding and blocking activity of IBI3038 was assessed using IL-6 or IL-6/IL-6R complex induced TF-1 and IGF-1 induced cell line proliferation assay. Human dermal fibroblast function assays are used to evaluate the combine effect of dual blockade of IGF-1R and IL-6. The synergy effect of dual blockade of IGF-1R and IL-6 are evaluated on bleomycin induced skin fibrosis model on mice using surrogates.

Results

IBI3038 binds human IGF-1R and IL-6 at nanomolar levels and effectively inhibits IL-6, IL-6/IL-6R complex or IGF-1 induced cell proliferation, with IC50 values around 1 nM. The molecule also robustly suppresses proliferation and HA production on human dermal fibroblast upon IGF-1 and IL-6/IL-6R stimulation. In bleomycin-induced skin fibrosis mice model, dual blockades of IL-6 and IGF-1R superior suppress skin thickening compared with either group of mono-blockade treatment.

Conclusions

An innovative and First-in-class IGF-1RxIL-6 bispecific antibody is characterized for its potent and synergistic inhibition on inflammation and fibrosis development. IBI3038 can potentially bring new treatment and clinical benefits to patients of fibrosis-related disease, as systemic sclerosis.

EADV CONGRESS
VIENNA
30 SEP - 3 OCT 2026

Abstract N°: 857

Efficacy and safety of a selenium sulphide shampoo-based treatment regimen in adolescents with scalp seborrhoeic dermatitis: a retrospective real-world case series

Xiaobei Liu*[1], Shangcong Mao[1], Yi Pan[1], Beilei Cai[1]

[1] Sinomune Pharmaceutical Co., Ltd, Wuxi, China

Introduction
To investigate the efficacy and safety of a treatment regimen based on a shampoo containing 1% selenium sulphide and 1% salicylic acid in adolescents with scalp seborrhoeic dermatitis in real-world clinical practice, and to provide evidence to inform management in this population.

Materials and Methods
This retrospective case series included 16 adolescent patients with scalp seborrhoeic dermatitis who attended dermatology clinics at multiple hospitals between January and March 2026. All patients received a treatment regimen based on a shampoo containing 1% selenium sulphide and 1% salicylic acid; concomitant medication was permitted when clinically indicated. Treatment duration was 2–6 weeks. Erythema, scaling and pruritus were recorded before and after treatment. Efficacy was assessed using the Seborrhoeic Dermatitis Severity Scale (SDSS). Adverse events during treatment were recorded to evaluate safety and tolerability.

Results
A total of 16 patients were included (10 males and 6 females; age range 12–18 years). After treatment, mean total SDSS score decreased significantly from 7.56 ± 2.34 to 2.31 ± 1.96, with a mean difference of 5.25 points (95% CI 4.19–6.31; paired t-test, $p < 0.001$; Cohen's dz = 2.65). Given the small sample size and the discrete nature of the score, sensitivity analysis using the Wilcoxon signed-rank test also confirmed a significant reduction after treatment ($p < 0.001$). Fourteen patients (87.5%; 95% CI 61.7–98.4) achieved clinically meaningful improvement, defined as a reduction of at least 50% in total score. Mean erythema, scaling and pruritus scores also decreased significantly, from 2.25 ± 0.45 to 0.88 ± 0.62, 3.38 ± 1.89 to 0.94 ± 1.34, and 1.94 ± 0.44 to 0.50 ± 0.52, respectively (all $p < 0.001$). Descriptive stratification by concomitant hair loss and fungal test results showed downward trends across subgroups; no inferential subgroup comparisons were made because of the limited sample size. No treatment-related adverse events were recorded, and local tolerability was good.

Conclusions
In real-world clinical practice, a treatment regimen based on a shampoo containing 1% selenium sulphide and 1% salicylic acid was associated with marked improvement in clinical symptoms in adolescents with scalp seborrhoeic dermatitis, with good overall safety and tolerability. These findings support further clinical use in this population.

EA DV CONGRESS
VIENNA
30 SEP - 3 OCT 2026

Abstract N°: 877

Atypical Presentation of Orofacial Granulomatosis: Diagnostic and Therapeutic Challenges

Isabella Hölzle*[1], Clara Wadenpohl[1], Stephan Forchhammer[1]

[1] Department of Dermatology, University Hospital Tübingen, Tuebingen, Germany

Introduction
Orofacial granulomatosis (OFG) is a rare, chronic inflammatory condition usually marked by persistent or recurrent swelling of the lips and surrounding orofacial region. Granulomatous lesions in the orofacial region present a significant diagnostic challenge due to overlapping clinical and histopathological features, particularly in cases where lip swelling is absent. This frequently leads to misdiagnosis, inappropriate treatment, and consequently a delay in establishing the correct diagnosis. The most common differential diagnoses include sarcoidosis, erysipelas, and granulomatous rosacea. This case series describes three cases of patients with orofacial granulomatosis without lip involvement or characteristic intraoral findings, with an emphasis on clinical manifestations, diagnostic challenges, and therapeutic outcomes.

Case Presentation
Case 1. A 57-year-old woman developed bone pain and unilateral erythema and swelling of the right cheek after dental cleaning. A maxillofacial X-ray was normal, and prolonged treatment with doxycycline, erythromycin, and topical betamethasone over five months did not lead to clinical improvement. Punch biopsy showed dermal epithelioid granulomas with dense lymphocytic infiltrate; ACE, sIL-2R, and chest X-ray were normal, excluding sarcoidosis. Systemic methotrexate with an initial 30 mg prednisolone pulse led to improvement after two months and marked response at six months.

Case 2. A 39-year-old woman developed persistent redness and swelling of the right cheek and chin two weeks after PRP “vampire lifting.” Symptoms persisted for seven months despite systemic antibiotics and topical corticosteroids. Biopsy revealed epithelioid granulomas with a moderately dense lymphocytic infiltrate; ACE, sIL-2R, and chest X-ray were normal. Based on clinical and histological findings, OFG was diagnosed, and methotrexate with a 30 mg prednisolone pulse resulted in marked reduction of swelling and erythema within three months.

Case 3. A 40-year-old man presented with a 1.5-year history of swelling and erythema of the right chin with intermittent pruritus. Previous antifungal, antibiotic, and topical corticosteroids were ineffective. His medical history included aggressive B-cell lymphoma in remission. Biopsy showed a deep dermal lymphohistiocytic infiltrate with multinucleated giant cells and small granulomas. OFG was diagnosed, and systemic methotrexate therapy was initiated.

Conclusion
The clinical presentation in our cases deviated markedly from the typical phenotype of orofacial granulomatosis (OFG), which usually involves recurrent or persistent lip swelling and characteristic intraoral findings. Instead, all patients showed only a unilateral erythematous swelling of the mental region extending into the buccal area—an atypical distribution that can easily lead to diagnostic delay or misclassification. Despite this unusual presentation, histopathology revealed epithelioid cell granulomas, lymphohistiocytic infiltrates, and multinucleated giant cells, confirming compatibility with OFG. Management remains difficult due to the lack of controlled studies and the heterogeneous response to reported therapies such as intralesional corticosteroids, systemic glucocorticoids,

clofazimine, fumaric acid esters, or TNF-α inhibitors. Recognizing atypical manifestations is therefore essential to avoid delayed treatment. Given the limited evidence-based options, the favorable response to methotrexate in our case suggests that it may represent a promising therapeutic approach in orofacial granulomatous disease.

EA DV CONGRESS
VIENNA
30 SEP - 3 OCT 2026

Abstract N°: 878

Scalp-Dominant Pemphigus Vulgaris with Severe Oral Involvement: From Acute Steroid Rescue to Durable Remission with Rituximab and Azathioprine

Carmen Mochón Jiménez*[1, 2], Andrea Ballesteros Antúnez[1], Irene Suárez Vergne[1], Juan De Luque Fernández[1, 2], José Manuel Rodríguez Torres[1], Miguel Juan Cencerrado[1], Manuel Galán-Gutiérrez[1, 2]

[1] Department of Dermatology. Reina Sofía University Hospital, Córdoba, Córdoba, Spain

[2] Inflammatory Immune-Mediated Chronic Skin Diseases Laboratory, IMIBIC, Reina Sofia University Hospital, University of Córdoba, 14004, Spain, Córdoba, Spain

Introduction

Introduction: Pemphigus vulgaris (PV) is a potentially severe autoimmune blistering disease in which early control of inflammation and reduction of cumulative corticosteroid exposure are key therapeutic goals. Although mucosal disease is common, extensive scalp-predominant involvement with marked nutritional impairment remains a challenging presentation in daily practice.

Case Presentation

Case report: A 36-year-old man was admitted with rapidly progressive PV after approximately 1 year of initially localized scalp disease, followed over the subsequent weeks by extensive erosive-crusted involvement of the entire scalp, painful oral erosions, tense blisters and scattered erosions on the upper trunk, dysphagia, and marked reduction in oral intake. Examination showed diffuse scalp erosions with crusting and alopecic plaques, together with severe oral mucosal involvement affecting the lips, palate, and buccal mucosa. Histopathology demonstrated suprabasal acantholysis with eosinophilic spongiosis and follicular extension, and a repeat scalp biopsy confirmed findings consistent with PV. Direct immunofluorescence showed weak intercellular IgG deposition. Desmoglein antibodies were positive, whereas BP180, BP230, type VII collagen, and plakin-related antibodies were negative. Because paraneoplastic pemphigus was considered in the differential diagnosis, cross-sectional imaging, upper endoscopy, tumor screening, and extended serological work-up were performed, with no evidence of occult neoplasia or alternative diagnosis.During the first days of admission, the patient required high-dose intravenous methylprednisolone because of severe mucocutaneous activity and inability to maintain adequate oral intake. This produced rapid control of the acute inflammatory phase and progressive recovery of oral tolerance. Within the following days, after infectious screening, immunological assessment, lymphocyte subset analysis, and vaccination review, rituximab was started using the rheumatoid arthritis regimen (1000 mg two weeks apart). Over the next 2 to 3 months, mucosal disease almost completely resolved, scalp erosions re-epithelialized, and systemic corticosteroids could be tapered substantially. Over the following year, prednisone was progressively withdrawn without relapse. To maintain long-term steroid-sparing disease control, azathioprine was introduced and continued as maintenance therapy. At prolonged follow-up, more than 18 months after rituximab initiation, the patient remained clinically asymptomatic, without new flares, with negative circulating epidermal antibodies, preserved immunoglobulin levels, and persistent B-cell depletion early after treatment. During follow-up, secondary osteoporosis attributable to prolonged corticosteroid exposure was identified and required bone-protective treatment and specialist monitoring.

Discussion: This case highlights several clinically relevant points. First, PV may present with scalp-dominant disease and severe oral involvement leading to major nutritional compromise. Second, systemic corticosteroids remain essential for immediate disease control in the acute setting, particularly when mucosal involvement compromises

hydration and feeding. Third, early rituximab consolidation after appropriate pre-treatment evaluation may enable sustained remission and successful corticosteroid withdrawal. Finally, azathioprine can be an effective maintenance strategy in selected patients once remission has been induced, particularly when long-term steroid minimization is a priority.

Conclusion

Conclusion: In severe PV with prominent scalp and oral involvement, a sequential strategy consisting of acute corticosteroid rescue, early rituximab consolidation, and azathioprine maintenance may achieve durable remission while limiting the morbidity associated with prolonged corticosteroid exposure.

EADV CONGRESS
VIENNA
30 SEP - 3 OCT 2026

Abstract N°: 897

Post-cesarean pyoderma gangrenosum mimicking chronic infection: a diagnostic challenge

Surani Anushika Jayakody*[1], Sahan Halambage[1], Indira Kahawita[1]

[1] Department of Dermatology, National Hospital of Sri Lanka, Colombo, Sri Lanka

Introduction

Pyoderma gangrenosum is a rare neutrophilic dermatosis characterized by pathergy and frequently misdiagnosed as infection, paticularly in post surgical wounds. Delayed recognition may result in prolonged morbidity and inappropriate antimicrobial therapy.

Case Presentation

A 29-year-old previously healthy woman presented with a 9-month history of a progressively enlarging, painful lesion over a cesarean section scar performed 2 years earlier, associated with persistent serosanguineous discharge. There were no clinical features suggestive of systemic disease.

Examination revealed a well-demarcated erythematous, indurated plaque measuring 6 x 3 cm, which was tender, with multiple pinpoint oozing points along the active border. No other skin lesions, mucosal involvement, or lymphadenopathy were noted.

The clinical features initially raised suspicion of an infective aetiology. However, extensive microbiological investigations, including bacterial, mycobacterial, fungal, and leishmaniasis cultures, were negative.

Histopathology demonstrated epidermal ulceration with abscess formation, acanthosis, and an underlying lymphoplasmocytic infiltrate without granulomas or identifiable organisms. Mild lobular panniculitis with fat necrosis was present in the subcutaneous tissue. Special stains were negative.

Autoimmune evaluation revealed negative antinuclear antibody, normal complement levels (C3 and C4), and negative direct immunofluorescence, making a connective tissue disease-associated panniculitis unlikely.

The lesion was refractory to multiple antibiotic regimens. Based on clinicopathological correlation and the exclusion of infective and autoimmune causes, a diagnosis of post-surgical pyoderma gangrenosum was made.

Oral prednisolone (1 mg/kg/day) with topical 0.1% tacrolimus applied to the lesion margin resulted in significant clinical improvement. However, recurrence during tapering of systemic corticosteroids necessitated the addition of oral cyclosporine (100 mg/day), leading to complete resolution and successful corticosteroid withdrawal.

Conclusion

Post-surgical pyoderma gangrenosum is an important mimic of chronic wound infection.Early recognition, supported by exclusion of infective and autoimmune causes, is essential to avoid inappropriate treatment and disease progression. Delayed presentation at a previous surgical site may further obscure the diagnosis, contributing to clinical uncertainty. Patient should be counselled regarding recurrence risk in the future pregnancies, particularly following surgical delivery, with consideration of vaginal delivery and multidisciplinary planning.

EADV CONGRESS
VIENNA
30 SEP - 3 OCT 2026

Abstract N°: 910

STEREOseq Profiling Uncovers a Mucosal-Like Epithelial Signature in the Tunnels of Hidradenitis Suppurativa

Qing-Sheng Mi*[1], Peter Dimitrion[2], Jesse Veenstra[1], Iltefat Hamzavi[2], Indra Adrianto[1], Li Zhou[1]

[1] Henry Ford Health and Michigan State University, Detroit, United States

[2] Henry Ford Health, Detroit, United States

Introduction

Hidradenitis suppurativa (HS) is a chronic inflammatory skin disease in which epithelial-lined tunnels are a hallmark of severe, treatment-resistant disease; however, their molecular identity remains poorly defined.

Materials and Methods

To characterize the transcriptomic landscape of HS tunnels, we applied single cell spatiotemporal enhanced resolution omics sequencing (STEREOseq) to paired lesional and non-lesional skin from a patient with Hurley stage III HS, complemented by immunohistochemistry (IHC) and bulk RNA-seq datasets.

Results

Spatial clustering identified eighteen transcriptionally distinct tissue regions, including a tunnel-specific epithelial cluster enriched for keratinocyte differentiation and epithelial morphogenesis pathways. Differential expression analysis revealed a mucosal-like gene signature in HS tunnel epithelium, marked by upregulation of KRT14, KRT13, MUC1, MUC4, MUC20, MUC21, MAL, and SPRR3, alongside antimicrobial peptides PI3 and S100A9. Reference mapping to GTEx datasets demonstrated transcriptional similarity between tunnel epithelium and mucosal tissues —including esophagus and vaginal epithelium—and clear divergence from normal skin, especially in KRT13. Bulk RNA-sequencing data demonstrated significantly increased KRT13 expression in lesional tissue, compared to perilesional tissue. Pairwise comparisons between lesional, perilesional, and healthy control (HC) tissue further revealed elevated KRT13 in lesional compared with perilesional and HC tissue and no difference was found between perilesional and HC tissue. IHC validation in independent HS specimens (n=9) confirmed intense apical KRT13 expression selectively within tunnel and tendril epithelia, absent in perilesional and healthy control epidermis.

Conclusions

Collectively, our findings establish HS tunnels as a transcriptionally distinct epithelial compartment defined by mucosal-like differentiation, rather than as an extension of inflamed epidermis. KRT13 emerges as a robust histologic marker of this phenotype. Aberrant epithelial reprogramming toward a mucosal identity may represent a central and underappreciated mechanism in HS pathogenesis, and targeting mucosal-type differentiation pathways could yield novel therapeutic strategies to prevent tunnel formation and limit chronic disease progression.

EADV CONGRESS
VIENNA
30 SEP - 3 OCT 2026

Abstract N°: 920

Keratinocyte stress drives inflammatory amplification via KRT17–STAT3-IL-6 axis in elderly dermatitis with mixed immune features

Chen Shen*[1], Lu Li[1], Miao Chen[1], Juan Tao[1]

[1] Wuhan Union Hospital, Huazhong University of Science and Technology, Wuhan, China

Introduction
Elderly inflammatory dermatitis is increasingly recognized as a heterogeneous condition that extends beyond classical Type 2 inflammation, yet its key upstream drivers and actionable therapeutic targets remain unclear.

Materials and Methods
In this study, we integrated single-cell transcriptomics, clinical immunophenotyping, and functional experiments to investigate the mechanisms underlying this heterogeneity.

Results
We found that keratinocyte stress–associated KRT17 is markedly upregulated in elderly lesions and closely linked to disease severity and poor inflammatory control. Mechanistically, KRT17 activates STAT3 signaling, leading to increased IL-6 production, which drives a mixed Th2/Th17 inflammatory program and exacerbates epidermal barrier dysfunction. Targeted inhibition of STAT3, particularly through topical intervention, effectively attenuated skin inflammation in both experimental models and elderly patients.

Conclusions
These findings identify a KRT17–STAT3–IL-6 axis that bridges epithelial stress and immune dysregulation in elderly dermatitis. Importantly, this work provides a mechanistic basis for targeting non–type 2 pathways and supports the development of pathway-specific, topical therapeutic strategy for patients with complex or treatment-refractory inflammatory phenotypes.

EADV CONGRESS
VIENNA
30 SEP - 3 OCT 2026

Abstract N°: 933

From Survey to Service: Launching Scotland's First National Hidradenitis Suppurativa Meeting

Dhanya Kuladeva*[1], Vivienne Nguyen[1], Hazel Rooney[2], Alison Honan[1]

[1] Glasgow, United Kingdom

[2] NHS Greater Glasgow and Clyde, Glasgow, United Kingdom

Introduction

Hidradenitis suppurativa (HS) is a painful, chronic inflammatory skin disease with heavy comorbidity burden. Previous literature emphasises the importance of managing HS with specialist and multidisciplinary input to improve patient outcomes. In Scotland, there is currently no national system for cross-board case discussion and multidisciplinary team (MDT) provision for HS is limited. Our aim was to quantify current access to specialised HS services and gauge support for a national HS MDT.

Materials and Methods

We designed a Webropol survey, first shared at the May 2025 Scottish Dermatology Society (SDS) meeting and then distributed via the SDS mailing list with two reminder emails. The survey was open between May 29 - June 30, 2025. Responses were anonymised and analysed descriptively using Webropol and Excel.

Results

Fifty-nine clinicians from all of the Scottish boards with dermatology services took part. Only 5/58 (9%) reported access to a dedicated HS clinic, while 91% had no such service. Among 47 respondents who quantified caseload, most (68%) reported 1–3 patients in the past year needing tertiary input; 21% reported 4–6, and 11% >6, equating to a conservative national burden of ~102–186 patients annually. The majority of these respondents came from boards that noted no specialist clinic.

Biologics were widely used: 93% (n=54) prescribed TNF-α inhibitors, over half used secukinumab (n=32), and a quarter prescribed bimekizumab (n=14). Two-thirds had managed patients using more than one class. Caseloads ranged widely from <5 to >10 patients, though 7% reported none. Of those who reported not using biologics, all of them would welcome and use a Scottish virtual MDT, and 75% (n=3) did not have access to a specialist HS clinic. Surgical access was reported by 79% (n= 46), but this was usually limited to emergency drainage rather than definitive procedures. Encouragingly, support for a national virtual MDT was almost unanimous (97%).

Existing literature highlights the importance of having specialist HS clinics for improved patient outcomes. Eighty-three per cent of respondents reported patients who would benefit from tertiary input, yet only 9% had access to a dedicated HS clinic. Beyond the potential to improve direct care, specialist HS clinics also provide infrastructure for trials, registry participation, and training opportunities for future dermatologists.

Biologic prescribing was common among respondents, with most reporting use of TNF-α inhibitors. Respondents often selected more than one option, implying that prescribing practice extends beyond first-line anti-TNF therapy. This suggests clinicians are escalating through biologics in cases of treatment failure or intolerance, reflecting both the complexity of HS management and the growing therapeutic options.

Surgical access was also variable: many respondents reported support from plastic and general surgery, but free-text comments often described access limited to ad hoc incision and drainage rather than planned excisional or

reconstructive procedures, echoing reports that specialist surgical input for HS remains inconsistent despite its central role in achieving durable remission in severe disease.

Conclusions

In Scotland, no national structure currently exists for MDT discussion of HS cases. In response to the gap identified by our survey, a virtual national HS MDT meeting has been piloted. Meetings review 5–6 cases via Microsoft Teams. Decisions are documented by the referring clinician, and the virtual format ensures that colleagues across Scotland can participate equitably.

Our scoping survey highlights variation in HS care across Scotland, most boards lack specialist clinics, biologic use is common and suggestive of challenging disease, and surgical options are limited. Yet the appetite for change is clear: dermatologists desire a national virtual MDT which would aim to support and advise on the management of this complex disease which in turn may lead to more equitable and coordinated care for HS patients.

EADV CONGRESS
VIENNA
30 SEP - 3 OCT 2026

Abstract N°: 934

Rapidly progressive ulcer mimicking bacterial infection in an elderly patient: a diagnostic challenge of pyoderma gangrenosum

Renata Trindade Gonçalves*[1], Joao Garcia[2], Patricia Kurizky[2], Carmen Paula[2], Jorgeth Motta[2]

[1] University of Brasilia, Brasília, Brazil

[2] University Hospital of Brasília, Brasília, Brazil

Introduction

Pyoderma gangrenosum is a rare neutrophilic dermatosis characterized by rapidly progressive ulceration and considerable diagnostic complexity. Its clinical presentation frequently mimics infectious or malignant conditions, often leading to delayed diagnosis and inappropriate treatments. Early recognition based on clinicopathological correlation is essential for appropriate management.

Case Presentation

A 92-year-old man presented with a progressively enlarging ulcerative lesion on the upper back that initially appeared as a furuncle-like lesion approximately three months earlier. Initial management included systemic antibiotics, topical antimicrobial therapy, and surgical drainage, without clinical improvement.

Dermatological examination initially revealed an infiltrated plaque measuring approximately 5 × 4 cm with violaceous undermined borders, central ulceration, and peripheral pustules. Despite antimicrobial therapy, the lesion demonstrated rapid centrifugal progression, reaching approximately 10 × 8 cm.

Laboratory investigations were largely unremarkable except for mild elevation of inflammatory markers. Extensive microbiological investigation was negative, including bacterial and fungal cultures, and tests for endemic infections such as cutaneous leishmaniasis and mycobacterial disease.

Histopathological examination demonstrated ulcerated epidermis with a dense dermal inflammatory infiltrate predominantly composed of neutrophils, without granulomatous inflammation or evidence of malignancy. Immunohistochemical studies excluded lymphoproliferative disorders.

Considering the compatible clinical findings, neutrophil-predominant inflammatory pattern, and exclusion of infectious and neoplastic etiologies, the diagnosis of pyoderma gangrenosum was established. Systemic corticosteroid therapy was initiated, followed by methotrexate as a corticosteroid-sparing agent, resulting in progressive clinical improvement and gradual re-epithelialization of the ulcer.



Clinical evolution of a rapidly progressive ulcerative plaque on the upper back showing violaceous undermined borders and peripheral pustules, initially mimicking bacterial infection.

Conclusion

This case highlights the diagnostic challenge of pyoderma gangrenosum when the disease initially mimics bacterial infection and progresses despite antibiotic therapy. Rapid enlargement, violaceous undermined borders, and peripheral pustules should raise suspicion for neutrophilic dermatosis. Early recognition and timely initiation of immunosuppressive therapy are essential to avoid unnecessary antimicrobial treatments and invasive procedures.

EADV CONGRESS
VIENNA
30 SEP - 3 OCT 2026

Abstract N°: 937

Chronic Therapy-Resistant Folliculities over Several Years with Sequential Detection of Malassezia and Demodex: A Longitudinal Case Report

Reza Yazdan Panah*[1]

[1] Doctor RY Skin Clinic, Hollviken, Sweden

Introduction
Chronic therapy-resistant folliculitis can represent a diagnostic challenge, particularly when clinical presentation overlaps with inflammatory and infectious dermatoses. Malassezia folliculitis and Demodex-associated folliculitis may mimic acneiform eruptions or other chronic inflammatory follicular disorders. In persistent cases with prolonged clinical course, broader differential diagnoses may occasionally need to be considered.

Case Presentation
We report a patient with chronic folliculitis persisting over several years, characterized by recurrent follicular papules and pustules primarily affecting the trunk. The condition showed limited response to multiple standard therapies. Histopathological examination at an earlier stage demonstrated findings consistent with Malassezia folliculitis. Despite antifungal treatment, the patient experienced persistent or recurrent lesions over time. Subsequent evaluation, including additional diagnostic assessment, revealed the presence of Demodex mites, suggesting a possible mixed microbial etiology contributing to the chronic inflammatory process. The clinical presentation raised differential diagnostic considerations including folliculotropic mycosis fungoides due to the prolonged course and therapy resistance.

Conclusion
This case highlights that clinically typical folliculitis does not always represent a single etiologic entity. Sequential detection of Malassezia and Demodex suggests that overlapping microbial factors may contribute to chronic therapy-resistant disease. Careful longitudinal evaluation, including repeated diagnostic assessment such as biopsy and microscopy, may be necessary in persistent cases. Recognition of mixed etiologies may help guide more targeted therapeutic strategies and improve clinical outcomes.

EA DV CONGRESS
VIENNA
30 SEP - 3 OCT 2026

Abstract N°: 949

Ivarmacitinib treatment for cholinergic urticaria combined with atopic dermatitis: a report of two cases

Ying Sun*[1], Chunye Ma[1], Shuyang Cao[1], Qiunan Teng[1]

[1] Qiqihar Traditional Chinese Medicine Hospital, Qiqihar, China

Introduction

Cholinergic urticaria (CholU) is a common subtype of chronic inducible urticaria, clinically characterized by the appearance of pruritic, pinpoint-sized wheals or angioedema in response to an elevation in core body temperature. Typical triggers include physical exercise, sweating, and emotional stress. The condition predominantly affects young adults [1, 2, 3]. Recent studies have highlighted the important role of the JAK-STAT signaling pathway in the pathogenesis of urticaria. Ivarmacitinib, a highly selective JAK1 inhibitor, exerts anti-inflammatory and immunosuppressive effects through inhibition of the JAK1 signaling pathway. However, clinical data regarding the use of ivarmacitinib in the treatment of cholinergic urticaria remain very limited.

Materials and Methods

We administered ivarmacitinib for 3–6 months to two cases of cholinergic urticaria with coexisting atopic dermatitis. Efficacy was measured by the baseline-to-week change in UAS7 scores, and safety was assessed via adverse event monitoring.

Results

Case 1: A 16-year-old male presented with a six-month history of recurrent generalized urticaria accompanied by a stinging or prickling sensation. He was diagnosed with cholinergic urticaria in combination with atopic dermatitis. Previous therapies, including H1-receptor antagonists, topical corticosteroid ointments, and traditional Chinese herbal decoctions, provided inadequate symptom control. The treatment regimen was subsequently switched to oral ivarmacitinib 4 mg once daily. After 7 months of continuous therapy, the patient's Urticaria Activity Score 7 (UAS7) improved significantly from a baseline of 25 to 3 (Figure 1).

Case 2: A 20-year-old male reported a 5-year history of recurrent generalized wheals, often triggered by fever or emotional stress and associated with a sensation resembling needle pricks. Multiple trials of various antihistamines and traditional Chinese herbal decoctions had yielded suboptimal relief. Treatment was initiated with oral ivarmacitinib 4 mg once daily; due to insufficient symptom improvement, the dose was increased to 8 mg once daily following clinical evaluation. After 3 months of treatment, the patient's UAS7 score decreased from a baseline of 18 to 10 (Figure 1). No safety concerns or adverse events were reported during the treatment period. As of the data cut-off date, both patients remain on ivarmacitinib monotherapy, and no dose-limiting toxicities or serious adverse events have been reported.



Figure 1 Clinical appearance of lesions from baseline to post-treatment assessment

Conclusions

Ivarmacitinib may offer a novel therapeutic avenue for cholinergic urticaria, supported by a favorable safety profile; however, these preliminary findings necessitate confirmation in larger-scale trials.

References

[1] Kim HJ, Lee MG. Cholinergic urticaria: More than a simple inducible urticaria. Australas J Dermatol. 2017;58(4):e193-e198. doi:10.1111/ajd.12496

[2] Kim JE, Eun YS, Park YM, et al. Clinical characteristics of cholinergic urticaria in Korea. Ann Dermatol. 2014;26(2):189-194. doi:10.5021/ad.2014.26.2.189

[3] Zuberbier T, Althaus C, Chantraine-Hess S, Czarnetzki BM. Prevalence of cholinergic urticaria in young adults. J Am Acad Dermatol. 1994;31(6):978-981. doi:10.1016/s0190-9622(94)70267-5

EADV CONGRESS
VIENNA
30 SEP - 3 OCT 2026

Abstract N°: 954

Prurigo Pigmentosa Associated with a Ketogenic Diet: A Case Report

Mariana Luminita Enache*[1], Iuliana Aostacioae[1]

[1] ROMANIAN SOCIETY OF DERMATOLOGY Str. Costache Marinescu 32 CAM. 2, Cod 011286, Sector 1, București., Bucharest, Romania

Introduction

Prurigo pigmentosa, also known as Nagashima disease or "keto rash," is a rare inflammatory skin disorder first described in 1971. Its etiology is not fully understood; however, conditions associated with ketosis—such as fasting, diabetes, and bariatric surgery—are frequently reported in association with this disease.

Case Presentation

A 33-year-old female patient, with no significant past medical history, normal body weight, and following a ketogenic diet, presented with persistent, mildly pruritic maculopapular lesions and erythematous plaques. The lesions were confluent, with centrifugal extension, and located on the flanks, axillary, and abdominal regions. Hematological, biochemical, and immunological investigations were within normal limits. Initial therapy with potent topical corticosteroids and H1 antihistamines was ineffective. In contrast, treatment with doxycycline combined with discontinuation of the ketogenic diet led to resolution of the lesions. Residual post-inflammatory hyperpigmentation with a reticulated pattern persisted.

Conclusion

We present this case to highlight the increasingly recognized association between *prurigo pigmentosa* and the ketogenic diet, with the aim of facilitating early diagnosis and optimizing patient outcomes. Dermatologists should be aware of the temporal relationship between the onset and resolution of the eruption and dietary patterns, particularly ketosis.

EADV CONGRESS
VIENNA
30 SEP - 3 OCT 2026

Abstract N°: 984

Cellular and Cytokine Profiling Implicates TL1A-DR3 Pathway in Hidradenitis Suppurativa

Shahin Aslam[1], Heather Llewellyn*[1], Roger Berton[1], Sam Tyler[1], Abhirup Das[1], Zachary Strongin[1], Xianying Xing[2], Douglas Wilson[1], Johann Gudjonsson[2], Ernesto Munoz[1]

[1] Merck & Co., Inc., Rahway, NJ, United States

[2] University of Michigan, Ann Arbor, Michigan, United States

Introduction

Hidradenitis suppurativa (HS) is a chronic, immune-mediated inflammatory skin disease characterized by recurrent nodules, abscesses, draining tunnels and tissue scarring. With currently available treatments, 40–50% of HS patients fail to achieve meaningful improvement, highlighting the need for new therapies. TL1A (tumor necrosis factor–like cytokine 1A) is a co-stimulatory membrane protein and soluble cytokine expressed by antigen-presenting cells that binds its cognate receptor, DR3, to drive proinflammatory Th1 (TNFα) and Th17 (IL-17A, IL-17F) cytokines, which are clinically validated therapeutic targets in HS. Tulisokibart, a monoclonal TL1A blocking antibody, has shown clinical efficacy in ulcerative colitis and Crohn's disease, as well as suppression of Th1, Th17 and fibrotic gene pathways in intestinal tissue. Here, we performed deep cellular profiling of TL1A and DR3 expression in peripheral blood and skin tissue from HS patients. We also characterized HS patient serum for cytokines relevant to disease activity and TL1A mechanism of action.

Materials and Methods

Serum from HS patients (n=30) and healthy controls (n=20) were analyzed for cytokine levels by Meso Scale Discovery. Peripheral blood mononuclear cells (PBMCs) from HS patients and normal healthy volunteers (n= 10 each) were analyzed for cellular composition and DR3 protein expression by flow cytometry. TL1A and DR3 protein expression were assessed in HS skin lesions and healthy control tissue by immunohistochemistry (IHC).

Results

Serum TNFα, IL-17A, and IL-6 were significantly elevated ($p<0.05$) in HS patients compared to healthy controls. In PBMCs, $CD4^+$ T helper subsets (Th1, Th2, Th17, and Th22) were significantly enriched ($p<0.05$) in HS patients compared with healthy controls. DR3 surface protein was expressed on $CD4^+$ T cells (Treg, naïve, and memory populations), $CD8^+$ T cells, NK cells, NKT cells, and non-classical monocytes in both HS patients and healthy donors. Within the CD4+ T cell population, DR3 expression was significantly higher in memory CD4+ T cells ($p<0.05$) compared to the naïve subset. $CD161^+$ DR3-expressing T cells were also significantly enriched ($p<0.005$) in HS patient PBMCs, consistent with the gene expression profile previously reported in HS lesions (Llewellyn et al., EADV 2025). Additionally, DR3 protein expression was detected in HS lesional tissue by IHC, and TL1A-expressing cells were enriched in HS dermal lesions (tunnels) compared with healthy control tissue.

Conclusions

Here we report data showing expansion of DR3-expressing CD4+ T helper cells in blood of HS patients, including Th17 cells, as well as elevated serum levels of downstream inflammatory cytokines (e.g., TNFα, IL-17A, IL-6). Additionally, we show enrichment of TL1A in HS tissue, particularly in dermal lesions. These findings implicate the TL1A-DR3 pathway in the pathogenesis of HS and support targeting TL1A as a potential therapeutic strategy in this disease.

EADV CONGRESS
VIENNA
30 SEP - 3 OCT 2026

Abstract N°: 995

Mechanical Koebner phenomenon in erythema multiforme: a documented case

salah eddin awawde*[1], Widad Sellami[1], Samira Zobiri[1]

[1] Mustapha University Hospital Center, Dermatology and venereology, Sidi M'Hamed - alger, Algeria

Introduction
Erythema Multiforme (EM) is an acute, self-limiting mucocutaneous hypersensitivity reaction, most commonly triggered by infections (predominantly Herpes Simplex Virus - HSV) or medications. The standard clinical presentation involves a generalized, symmetric eruption of typical target (iris) lesions.

The Koebner phenomenon, defined as the development of typical skin lesions at the site of preceding trauma in an otherwise healthy area, is commonly observed in chronic conditions such as psoriasis, lichen planus, and vitiligo. Its occurrence within Erythema Multiforme, particularly the severe Major variant (EMM)—which involves significant mucosal involvement—is an exceptionally rare and poorly documented finding. We report a unique case of a young male presenting with Erythema Multiforme Major where traumatic injury distinctly localized an isomorphic response, confirmed as a true Koebner phenomenon.

Case Presentation
A 25-year-old male , with no significant medical history, presented with an 8-day history of cutaneous eruption and bilateral conjunctivitis. His medical history revealed a flu-like syndrome one week prior, treated with Xydol (a frequently used medication for him) and Augmentin (taken for the first time). Two days before the skin eruption, the patient experienced a symptomatic cold sore (HSV labialis).

The dermatological eruption evolved sequentially from erythematous papules to vesicular-centered lesions, eventually stabilizing as classic target lesions.

Crucially, physical examination revealed not only a generalized distribution but also a distinct linear arrangement of typical target lesions along a superficial scratch mark on the right forearm, sustained one day before the generalized eruption. Bilateral conjunctivitis and oral mucosal involvement were confirmed. The patient was in good general condition and afebrile. Based on the preceding HSV infection, the recent drug intake, the pathognomonic target lesions, and severe mucosal involvement, a clinical diagnosis of Erythema Multiforme Major with an isomorphic Koebner response was established.

Conclusion
The patient was managed with a conservative yet intensive regimen to address the primary triggers and alleviate severe symptoms. The therapeutic protocol included:

- Antiviral Therapy: Oral Aciclovir (2 g/day for 10 days) to treat the HSV trigger .
- Systemic Anti-inflammatory: Oral Prednisone (0.5 mg/kg/day for 5 days).
- Topical Care: Medicated mouthwash containing corticosteroids, antifungal agents, and antiseptics.

The patient’s condition evolved favorably and rapidly. Within 10 days, all skin lesions showed significant regression, including those in the traumatized linear area. Oral and ocular mucosal involvement stabilized and resolved without secondary sequelae. No new lesions were reported during the intensive 10-day follow-up period.

This case illustrates the classic morphology of Erythema Multiforme Major, most likely triggered by the symptomatic HSV labialis given the 2-day latency period, though the brief flu-like illness and the introduction of a new medication (Augmentin) cannot be entirely excluded as co-triggers.

The uniqueness of this case lies in the documentation of a true traumatic Koebner phenomenon within EMM. While the isomorphic response is well-established in many chronic dermatoses, its description in EM is limited to a few documented cases. The standard pathogenesis of EM involves systemic cytokine release and immune complex deposition in the dermal vasculature.

A Koebner phenomenon implies that localized dermal trauma created a locus of minor resistance, potentially concentrating viral antigens or inflammatory mediators, leading to the isomorphic concentration of target lesions. Recognizing trauma as a cofactor in EM localization is vital for clinicians. This documented rare finding contributes to the understanding of the complex mucocutaneous inflammatory mechanisms of EMM and confirms that isomorphic responses can occur even in acute hypersensitivity reactions.

Abstract N°: 997

Blaschko-linear psoriasis: a documented case report

salah eddin awawde*[1], Khaled Sawalha[1], Samira Zobiri[1]

[1] Mustapha University Hospital Center, Dermatology and venereology, Sidi M'Hamed - alger, Algeria

Introduction

Blaschko-linear psoriasis is an exceptionally rare variant of psoriasis that follows the lines of Blaschko, reflecting underlying genetic somatic mosaicism. Diagnosing this condition is clinically challenging due to its close resemblance to other linear dermatoses, most notably Inflammatory Linear Verrucous Epidermal Nevus (ILVEN). Dermoscopy serves as a vital, non-invasive diagnostic tool to rapidly differentiate these conditions. We present a rare case of Blaschko-linear psoriasis strictly localized to the right upper extremity, uniquely involving the palmar surface.

Case Presentation

A 34-year-old male presented with a three-year history of mildly pruritic, erythematous, scaly plaques localized exclusively to his right upper limb. He had no personal or family history of psoriasis, nor any preceding trauma (negative Koebner phenomenon). Clinical examination revealed well-demarcated linear plaques following Blaschko's lines along the right forearm, dorsal hand, and palm. The palmar lesions exhibited notable hyperkeratosis and superficial fissuring.

To rule out ILVEN, polarized contact dermoscopy was performed. The forearm and dorsal hand plaques displayed a characteristic psoriatic pattern: regularly distributed red dotted vessels on a light red background, covered by patchy white scales. Palmar dermoscopy revealed thick hyperkeratosis with underlying pinpoint red dots visible upon manipulation (Auspitz sign). This uniform vascular pattern confirmed the diagnosis of Blaschko-linear psoriasis. The patient was successfully treated with a topical combination of betamethasone dipropionate and calcipotriol.

Conclusion

This case highlights a rare phenotypic expression of psoriasis with extensive unilateral involvement extending into the palm—an anatomical site infrequently affected in linear variants. Distinguishing Blaschko-linear psoriasis from other linear inflammatory dermatoses is essential for determining the appropriate therapeutic management.

This report emphasizes the immense value of dermoscopy in clinical practice. The detection of homogeneous red dotted vessels is highly specific for psoriasis, allowing clinicians to confidently confirm the diagnosis and potentially avoid invasive skin biopsies.

EADV CONGRESS
VIENNA
30 SEP - 3 OCT 2026

Abstract N°: 1006

Short-Chain Fatty Acids as Modulators of JAK/STAT Signaling in Human Keratinocytes: Implications for Inflammatory Skin Diseases

Angela Filoni*[1], Benedetta Spedicato[2], sara sergio[3], andrea ragusa[4], Michele Maffia[5], Maurizio Congedo[1]

[1] vito fazzi hospital, lecce, Italy

[2] 1 Department of Mathematics and Physics, University of Salento, Lecce, 73100, Italy, 2 Laboratory of Clinical Proteomic, "V. Fazzi" Hospital, Lecce, 73100, Italy, 3 Laboratory of General and Human Physiology, Department of Experimental Medicine, University of Salento, Lecce, 73100, Italy, lecce, Italy

[3] 2 Laboratory of Clinical Proteomic, "V. Fazzi" Hospital, Lecce, 73100, Italy, lecce, Italy

[4] Link Campus University, Roma, Italy

[5] Laboratory of Clinical Proteomic, "V. Fazzi" Hospital, Lecce, 73100, Italy, 3 Laboratory of General and Human Physiology, Department of Experimental Medicine, University of Salento, Lecce, 73100, Italy, lecce, Italy

Introduction

Chronic inflammatory skin diseases, such as psoriasis and atopic dermatitis, are characterized bykeratinocyte hyperproliferation, impaired differentiation, and dysregulated cytokine production.In this context, short-chain fatty acids (SCFAs), in particular acetic and butyric acid, haveemerged as promising bioactive molecules capable of modulating immune and inflammatoryresponses through multiple intracellular pathways, which under physiological conditionscontribute to the regulation of keratinocyte proliferation, differentiation, and epidermal barrierintegrity.

Materials and Methods

This study investigates the effects of SCFAs on human keratinocytes (HaCaT cell line) with afocus on proliferation, migration, and intracellular signaling. Cell viability was evaluated byMTT assay to determine optimal treatment concentrations. Functional analyses, including woundhealing assays, demonstrated that acetic acid significantly reduces keratinocyte migration andproliferation compared to untreated controls, suggesting therapeutic relevance inhyperproliferative conditions.

Results

Western blot analyses revealed that acetic acid treatment downregulates the JAK/STAT3signaling pathway, as evidenced by reduced phospho-STAT3 levels and decreased expression ofits downstream effectors c-Myc and Cyclin D1. Since JAK/STAT3 is a well-established driverof keratinocyte proliferation and survival, its inhibition provides a key molecular explanation forthe observed anti-proliferative effects. Proteomic analysis further supported these findings,highlighting upregulation of Arpin, RAP1A, FBLN1 and NELL2, that are proteins associatedwith cytoskeletal stability, cell adhesion and differentiation, consistent with a phenotypic shifttoward a more differentiated and structurally stable epidermal state.

Conclusions

.These results support SCFAs as innovative candidates for the treatment of inflammatory skindiseases, acting through modulation of JAK/STAT3 signaling and promotion of epidermalhomeostasis.

EADV CONGRESS
VIENNA
30 SEP - 3 OCT 2026

Abstract N°: 1010

Systemic comorbidities in rosacea: a cross-sectional study of 120 patients and phenotype associations

ikrame bejja*[1], Sara Elloudi[1], Saadia Boughaleb[1], Douhi Zakia[1], Meryem Soughi[1], Hanane Baybay[1], Fatima Zohra Mernissi[1]

[1] department of dermatology, University Hospital Center Hassan II, fez, Morocco

Introduction
Rosacea is a chronic inflammatory dermatosis associated with vascular and immune dysregulation. Increasing evidence suggests links between rosacea and systemic comorbidities. This study aimed to describe the epidemiological and clinical characteristics of rosacea and to assess the association between its phenotypes and comorbidities.

Materials and Methods
We conducted a cross-sectional descriptive and analytical study including adult patients diagnosed with rosacea between January 2022 and July 2024. Clinical and histological data were collected when necessary. Demographic characteristics, phototype, clinical phenotypes, and comorbidities were analyzed. Statistical tests were performed to evaluate associations.

Results
A total of 120 patients were included, with a female predominance (84.2%) and a mean age of 46.78 years. Phototype IV was predominant (83.3%). The most frequent phenotypes were erythematotelangiectatic (41.7%) and papulopustular (36.7%), followed by ocular (21.7%) and phymatous forms (3.3%).Comorbidities were identified in 30% of patients, mainly metabolic diseases (16.7%), inflammatory diseases (11.7%), digestive disorders (8.3%), and autoimmune diseases (7.5%). Other associations included dysthyroidism, migraine, neoplasia, and coronary artery disease.Phymatous rosacea was significantly associated with male sex (p=0.012) and older age (p=0.002). Fulminans rosacea was significantly associated with digestive diseases (p=0.018). No other significant associations were found.

Conclusions
Rosacea is associated with a broad spectrum of systemic comorbidities, supporting its systemic dimension. Certain phenotypes, particularly fulminans rosacea, may be linked to specific comorbid conditions. Larger studies are needed to better define these associations and improve patient management.

EA DV CONGRESS
VIENNA
30 SEP - 3 OCT 2026

Abstract N°: 1031

Real-world evaluation of calcipotriol/betamethasone dipropionate PAD-cream (Wynzora®) in chronic plaque psoriasis across two UK dermatology centres

Sonika Sethi Nayyar[1], Kareem Hassanin[2], Bhavnisha Patel[1], Danning Li*[3], Joy Hamilton[2], Sahrish Rashid[1]

[1] Sandwell and West Birmingham NHS Trust, Birmingham, United Kingdom

[2] Walsall Healthcare NHS Trust, Walsall, United Kingdom

[3] South Warwickshire NHS Trust, Warwickshire, United Kingdom

Introduction

Plaque psoriasis is a chronic immune-mediated inflammatory skin disease affecting around 2–3% of the UK population, associated with physical and psychosocial burden. For patients with mild-to-moderate disease, topical therapy remains first-line; however, adherence is often limited by poor cosmetic acceptability. Fixed-dose calcipotriol/betamethasone dipropionate (CAL/BDP) combinations are recommended first-line due to their once-daily dosing and favourable safety profile. Wynzora® cream (CAL/BDP PAD-cream) utilises Polyaphron Dispersion (PAD) Technology to stabilise both active ingredients in an aqueous vehicle, improving skin penetration while enhancing cosmetic acceptability and ease of application. Phase 3 trials have shown non-inferior or superior efficacy versus CAL/BDP gel or suspension, with improvements in Psoriasis Area and Severity Index (PASI), higher rates of Physician Global Assessment (PGA) treatment success, and significant Dermatology Life Quality Index (DLQI) improvements. However, UK real-world data remains limited. This study aimed to evaluated clinical and patient-reported outcomes associated with Wynzora cream in routine dermatology practice.

Materials and Methods

A retrospective evaluation was conducted across two West Midlands, UK dermatology centres. Adult patients with chronic plaque psoriasis prescribed Wynzora cream in routine care were included. Disease severity was assessed using PASI or modified PASI, and quality of life was measured using DLQI. Data were collected at baseline, week 8, and at ≥3 months follow-up. Outcomes included change in PASI and DLQI, achievement of PASI-50 and PASI-75, DLQI improvement of ≥4 points, and DLQI 0–1. Patients without ≥3 months follow-up were excluded. Non-parametric analysis was applied following Shapiro-Wilk testing.

Results

Fifty-five patients were included (median age 42 years), representing an ethnically diverse cohort with mild-to-moderate disease (median PASI 6.7; median body surface area 10%). Investigator Global Assessment severity was mild in 29 patients, moderate in 18, and severe in 8. Notably, 69.1% of patients were receiving concurrent systemic immunosuppressive therapy, reflecting a complex population often excluded from clinical trials. Three-month PASI reduction (median PASI 3.3) displayed a trend towards improvement ($p=0.0852$; Mann-Whitney U, one-tailed) and was statistically significant at six months (median PASI 0.8, $p=0.00389$). Among patients with evaluable six-month PGA data, 7/18 (38.9%) achieved treatment success (clear or almost clear disease or PASI-75), including complete clearance in three patients. This real-world treatment success rate was comparable to pooled phase 3 trial data (43.2%), with no significant difference (two-sided exact binomial test $p=0.814$; 95% CI 0.203–0.614). Patient-reported feedback highlighted high satisfaction driven by the non-greasy, easy-to-apply formulation, with particular benefit reported for scaling and scalp involvement. No serious adverse events or treatment discontinuations due to side effects were observed.

Thematic analysis of free-text feedback demonstrated that most patients found the treatment well tolerated and

cosmetically acceptable, commonly describing it as non-greasy and non-stinging. While many patients reported symptomatic improvement, responses were occasionally partial or short-term, with some patients requiring escalation to systemic therapy due to relapse or inadequate control.

Conclusions

This real-world study supports the effectiveness, safety, and high acceptability of CAL/BDP PAD-cream (Wynzora®) in routine practice. Outcomes were comparable to phase 3 trials despite inclusion of more complex patients receiving systemic therapy. Wynzora represents a valuable topical option that may improve adherence and clinical outcomes in plaque psoriasis.

EA DV CONGRESS
VIENNA
30 SEP - 3 OCT 2026

Abstract N°: 1036

Two Cases of Sneddon-Wilkinson Disease Successfully Treated by Topical Roflumilast

Sophie-Anne Savard*[1], Kevin Watters[2], Alexandre Lemieux[3]

[1] University of Montreal, University of Montreal Hospital Center, Montreal, Canada
[2] McGill University, McGill University Health Centre (MUHC), Montreal, Canada
[3] University of Montreal, Montreal Sacred Heart Hospital, Montreal, Canada

Introduction

Sneddon-Wilkinson disease (SWD) is a chronic inflammatory dermatosis characterized by the relapsing formation of sterile subcorneal pustules, favoring the intertriginous areas.

Oral dapsone remains the first-line treatment, with other options including oral corticosteroids, retinoids, methotrexate, cyclosporine, azathioprine, colchicine, doxycycline, sulphapyridines, nicotinamide, and phototherapy. The more recent use of anti-TNF, IL-23 and IL-17 inhibitors has been reported, as well as acalabrutinib.

We present two patients with chronic SWD refractory to multiple topical and systemic therapies who responded effectively and promptly to roflumilast 0.3% cream.

Case Presentation

*Case **one***

An 89-year-old Caucasian woman was referred for clustered, coalescing pustules on an erythematous base in her armpits, as well as hyperpigmented papules with a few scattered vesiculopustular lesions on her flanks and abdomen (Figure 1. A, B), which had been ongoing for many years. There was no mucosal involvement. She was known for monoclonal gammopathy of undetermined significance. A skin biopsy was performed and revealed a classic subcorneal pustular dermatosis, without the presence of any stainable bacteria or fungi (Figure 1. E, F). Direct immunofluorescence, and bacterial and viral cultures were negative. A diagnosis of SWD was made and she was started on betamethasone valerate cream twice daily, and dapsone 50 mg orally daily. She presented multiple recurrent and persistent painful lesions despite treatment. It was decided to try roflumilast 0.3% cream once daily. At the follow-up visit exactly one week later, complete resolution of the axillary and truncal papulo-pustules was noted (Figure 1. C, D). The patient no longer expressed any complaints, there were no adverse effects, and she kept a complete remission with a maintenance treatment 3 times a week.

Case two

A 74-year-old man presented with a four-year history of burning sensation during repeated episodes of pustular eruptions in the neck folds, armpits and groins. His medical history was limited to inactive ulcerative colitis. Physical examination revealed erythematous patches with superficial pustules surrounded by collarettes of fine scales, and rare hypopyon in the inguinal and axillary regions. The mucosa was spared (Figure 2. A, B, C). Histopathology was consistent with SWD. Immunofluorescence studies were negative, as were bacterial and fungal cultures. He had multiple treatment failures, notably with dapsone (150 mg once daily for 2 years), acitretin (25-50 mg once daily for 1 year), colchicine (0.6 mg twice daily for 2 months), doxycycline and mycophenolate mofetil (up to 1500 mg twice daily). Super-potent corticosteroid cream as needed was also part of the regimen, without symptomatic relief. Roflumilast 0.3% cream was started once daily. Resolution of the lesions was observed

few weeks later and was kept in complete remission with an application 3 times a week (Figure 2. D, E, F).

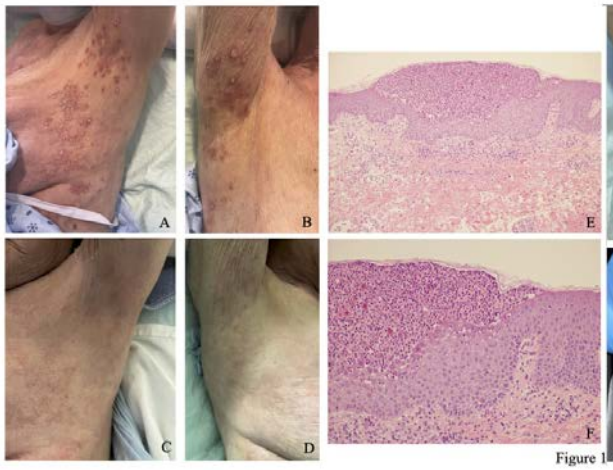

Figure 1



Figure 2

Figure 1. Sneddon-Wilkinson disease in our first case A, B Multiple polycyclic, circinate, and fragile vesiculo-pustules grouped on an erythematous base with scattered erythematous to hyperpigmented papules in the bilateral armpits. C, D Complete resolution of skin lesions after one week of treatment with 0.3% roflumilast topical cream daily. E 4 mm punch skin biopsy of the right arm showing a classic large subcorneal pustule without associated significant acantholysis on histopathology, compatible with SWD (H&E x10). F (H&E x 20). Figure 2. Sneddon-Wilkinson disease in our second case A, B, C Numerous erythematous papules and plaques, some coalescing, with fine desquamation and overlying scattered flaccid pustules, bilaterally axillary and inguinal. D, E, F Complete clearance of cutaneous lesions maintained after 5 months of treatment with daily 0.3% roflumilast cream.

Conclusion

Our cases highlighted spectacular and fast responses with a daily application of roflumilast 0.3% cream in monotherapy following multiple treatment failures. While limited by the small number of patients presented, this may support its use as an easy and well tolerated treatment for SWD, preventing the need of systemic treatments, thus limiting the risk of sides effects and laboratory monitoring.

Its use is being supported by previous cases demonstrating the efficacy of apremilast and oral roflumilast in SWD. The underlying pathophysiology of SWD involves the presence of neutrophilic chemotactic factors including TNF-α and IL-8. By inhibiting PDE4, roflumilast increases intracellular cAMP levels and decreases pro-inflammatory cytokines and immune complex-mediated neutrophil activation.

Further studies would be necessary to confirm our phenomenal findings on larger cohorts. However, the accessibility, favorable safety profile, and ease of application of topical roflumilast make it a very attractive therapeutic option.

EADV CONGRESS
VIENNA
30 SEP - 3 OCT 2026

Abstract N°: 1044

Atypical Palmar Hyperkeratotic Lichen Planus Mimicking Punctate Keratoderma: Importance of Mucosal Examination

Yavuz Selim Pilis*[1], Sueda Sanli Arikan[1], Cem Leblebici[1], Ebru Sarıkaya Tellal[1], Ayse Esra Koku Aksu[1]

[1] University of Health Sciences, Istanbul Training and Research Hospital, İstanbul, Türkiye

Introduction

Lichen planus is a chronic inflammatory mucocutaneous disorder with diverse clinical presentations. Palmoplantar involvement is uncommon and may present with atypical hyperkeratotic lesions, mimicking other keratotic disorders and posing diagnostic challenges.

Case Presentation

A 64-year-old male patient presented with a 2-month history of pruritic hyperkeratotic papules localized to the bilateral palmar surfaces. The lesions had progressively increased in number over time. There was no family history suggestive of hereditary keratoderma. The patient reported occupational exposure to fertilizers; however, no specific toxic exposure was identified.

On clinical examination, multiple bilaterally distributed hyperkeratotic papules confined to the palmar areas were observed, raising suspicion for punctate palmoplantar keratoderma and arsenical keratosis. Other differential diagnoses included verruca and palmoplantar syphilis.

Initial laboratory investigations, including syphilis serology and urinary arsenic levels, were within normal limits.

Histopathological examination of punch biopsy specimens revealed compact orthokeratosis, wedge-shaped hypergranulosis, irregular acanthosis, basal layer vacuolar degeneration, and a band-like lymphocytic infiltrate obscuring the dermoepidermal junction, along with occasional Civatte bodies. These findings were consistent with a lichenoid interface dermatitis.

Further examination revealed reticular white striae on the oral mucosa, consistent with Wickham striae, supporting the diagnosis of mucocutaneous lichen planus.The combined clinical, histopathological, and mucosal findings supported the diagnosis of atypical palmar lichen planus.

Conclusion

Palmoplantar involvement in lichen planus is rare and frequently presents with atypical morphologies. Unlike classical lichen planus, palmoplantar lesions may lack the characteristic violaceous color and can appear as hyperkeratotic papules or plaques, mimicking keratoderma or other hyperkeratotic conditions.

In the present case, the bilateral distribution and keratotic morphology initially suggested punctate keratoderma and arsenical keratosis. However, the absence of relevant exposure history and normal laboratory findings made these conditions unlikely, while negative serology excluded syphilis. Histopathological findings demonstrating a lichenoid interface dermatitis were crucial for diagnosis; nevertheless, clinicopathological correlation was essential due to the atypical clinical presentation.

The identification of Wickham striae on the oral mucosa provided a key diagnostic clue, reinforcing the diagnosis of mucocutaneous lichen planus. This case highlights that atypical palmar lichen planus may closely mimic

keratoderma and arsenical keratosis. Careful mucosal examination and clinicopathological correlation are essential for accurate diagnosis, and lichen planus should be considered in the differential diagnosis of bilateral palmar hyperkeratotic lesions even in the absence of classic cutaneous findings.

EADV CONGRESS
VIENNA
30 SEP - 3 OCT 2026

Abstract N°: 1083

Targeting Inflammation–Barrier Crosstalk: A Pre-Clinical Ex Vivo Study of a Cosmetic Formulation for Skin Comfort and Resilience

Ana Lucia Tabarini Alves Pinheiro*[1], Barbara Carli[1], Layane Cavalcante[2], Lucia Holanda[2], Giulia Maciente[2], Mauricio Frazilho[2], Carla Favaro[2], Marisa Sacuragui[2], Gabriela Leite[1], Gustavo Henrique Silva[1], Carla Lopes[1], Kelen Fabiola Arroteia[1], Samara Eberlin[1]

[1] Kosmoscience Group, Valinhos, Brazil

[2] Mantecorp Skin Care, Hynova, São Paulo, Brazil

Introduction

Skin inflammation and barrier impairment are closely interconnected processes involved in skin sensitivity, discomfort, and premature aging. External aggressors can trigger inflammatory cascades, leading to increased production of cytokines such as interleukin-1 alpha (IL-1α) and activation of transcription factors including nuclear factor kappa B (NF-κB). This response contributes to barrier impairment, which in turn facilitates further penetration of irritants, perpetuating a cycle of inflammation and skin fragility. Targeting both inflammation and barrier integrity is therefore a relevant strategy to improve skin.

Materials and Methods

This study investigated the effects of a cosmetic formulation (DC-23044-28) on inflammatory mediators and barrier-related proteins using human skin ex vivo models. Skin explants obtained from elective surgery were maintained under controlled conditions and treated with the formulation (25–30 mg/cm²). For anti-inflammatory evaluation, explants were exposed to lipopolysaccharide (LPS, 50 µg/mL). IL-1α levels were quantified in culture supernatants and NF-κB in tissue lysates using ELISA. Experimental groups included basal control, LPS-stimulated control, and LPS combined with product treatment.

Results

LPS exposure induced a strong inflammatory response, with a 743.05% increase in IL-1α ($p<0.01$) and a 29.98% increase in NF-κB ($p<0.05$) compared to basal conditions. Treatment with the formulation significantly reduced IL-1α levels by 63.27% and NF-κB by 22.42% versus the LPS group ($p<0.05$), indicating effective modulation of key inflammatory pathways. To assess barrier function and dermal support, collagen type I production was measured in supernatants and filaggrin expression was evaluated by immunofluorescence and semi-quantitative analysis. After 72 hours of treatment, collagen type I showed a non-significant increase of 5.81%. In contrast, filaggrin expression was significantly increased by 42.47% ($p<0.001$), suggesting improved epidermal differentiation and barrier integrity. The combined modulation of inflammatory markers and structural proteins indicates a dual mechanism of action. The reduction of IL-1α and NF-κB suggests attenuation of early inflammatory signaling, while the increase in filaggrin supports barrier reinforcement. These findings are particularly relevant for sensitive or environmentally stressed skin, where inflammation and barrier dysfunction coexist.

Conclusions

In conclusion, the investigated formulation demonstrated significant anti-inflammatory activity and enhancement of epidermal barrier-related proteins in human skin ex vivo models. This integrated biological response supports its potential to improve skin comfort, resilience, and overall skin quality. Further clinical studies are warranted to confirm these effects in vivo.

EADV CONGRESS
VIENNA
30 SEP - 3 OCT 2026

Abstract N°: 1099

Rapid Response of Scalp Hidradenitis Suppurativa to Semaglutide

Caroline Gevaerd*[1], Thomas Vogt[1]

[1] Klinik für Dermatologie, Allergologie und Venerologie - Universitätsklinikum des Saarlandes, Homburg, Germany

Introduction

Hidradenitis suppurativa is a chronic, relapsing inflammatory skin disease with limited therapeutic options, particularly in refractory cases and atypical localizations such as the scalp. Recent evidence suggests that glucagon-like peptide-1 (GLP-1) receptor agonists may offer a novel therapeutic approach due to their anti-inflammatory and metabolic effects.

Case Presentation

We report the case of a patient with Hidradenitis suppurativa involving the scalp. Initial presentation occurred in November 2024 with an eight-week history of painful pustules and inflammatory nodules affecting the scalp. Topical therapy with clindamycin 1% and tretinoin 0.025% showed no clinical improvement. Likewise, systemic treatment with clindamycin 300 mg three times daily failed to achieve a relevant therapeutic response. In January 2025, surgical excision of selected nodules was performed and therapy with secukinumab was initiated; however, no clinical benefit was observed until October 2025. Given the patient's known comorbidities, including obesity and diabetes mellitus, treatment with the GLP-1 receptor agonist semaglutide was initiated in October 2025 at a starting dose of 0.25 mg weekly. This resulted in a rapid and marked remission of cutaneous symptoms within four weeks. Following dose escalation to 0.5 mg weekly, the patient developed a pronounced prurigo-like drug eruption accompanied by severe pruritus. After temporary discontinuation and re-initiation at 0.25 mg weekly, intense pruritus recurred. Adjunctive treatment with pregabalin did not provide adequate symptom control. In the further course, the skin condition deteriorated again, necessitating discontinuation of semaglutide.

Conclusion

GLP-1 receptor agonists have demonstrated promising effects in the current literature regarding improvement of Hidradenitis suppurativa, likely due to their anti-inflammatory properties and beneficial impact on metabolic comorbidities such as obesity and diabetes mellitus. In the present case, a significant clinical response was achieved already at the initial dose; however, dose escalation was not feasible due to pronounced cutaneous adverse effects. This case highlights the therapeutic potential of GLP-1 receptor agonists in Hidradenitis suppurativa, while also emphasizing drug eruptions as a potentially limiting adverse effect.

EA DV CONGRESS
VIENNA
30 SEP - 3 OCT 2026

Abstract N°: 1131

Cutaneous Sarcoidosis: A Retrospective Analysis of Clinical Presentations and Systemic Involvement

Neda Delic*[1], Jelena Peric[1, 2], Andjela Babic[3], Lazar Vicentijevic[3], Dusan Skiljevic[1, 2]

[1] University Clinical Center of Serbia, Clinic of Dermatology and Venereology, Belgrade, Serbia
[2] University of Belgrade Faculty of Medicine, Department of Dermatology and Venereology, Belgrade, Serbia
[3] University of Belgrade Faculty of Medicine, Belgrade, Serbia

Introduction
Sarcoidosis is a non-infectious granulomatous inflammatory disease that can affect multiple organs, with skin being one of the most commonly involved sites and a potential window into the broader disease process. Various cutaneous manifestations have been associated with distinct patterns of systemic involvement and disease course. The aim of this study was to identify potential associations with systemic disease in patients with cutaneous sarcoidosis and to describe the localization and morphological characteristics of specific cutaneous manifestations.

Materials and Methods
This retrospective study included 47 patients with a confirmed diagnosis of cutaneous sarcoidosis who were hospitalized at our clinic over a ten-year period (2015–2025). Cases of non-specific cutaneous manifestations of sarcoidosis (e.g., erythema nodosum) were not included. Demographic data, clinical characteristics, the presence of systemic involvement and other comorbidities, as well as therapeutic approaches and outcomes were analyzed.

Results
Systemic involvement was present in 51.1% of patients, most commonly pulmonary sarcoidosis (48.9%), with isolated cases of hepatic and sinonasal sarcoidosis (2.1% each). Cutaneous lesions were the first disease manifestation in 37.5% of patients, appeared simultaneously with systemic involvement in 33.3% of cases, and followed extracutaneous disease in 29.2%. The majority of patients were female (83%), who were significantly older at disease onset than male patients ($p=0.005$). A history of mechanical trauma at the site of sarcoid lesions was recalled by 10.6% of patients. The most frequent localization of lesions was the head and neck, followed by the lower and upper extremities and the trunk, with 70.2% of patients having involvement of more than one anatomical region. Lupus pernio was observed five times more frequently in patients with systemic sarcoidosis, though this difference did not reach statistical significance. Patients with systemic sarcoidosis more commonly reported palpation-induced tenderness of skin lesions ($p=0.041$). Elevated angiotensin-converting enzyme and chitotriosidase levels were not significantly more frequent in patients with systemic sarcoidosis. Partial regression was the most common outcome (57.8%), with no significant differences in outcomes based on systemic involvement.

Conclusions
More than half of the patients with cutaneous sarcoidosis developed systemic sarcoidosis at some point in their disease course. However, other than palpation-induced tenderness, no significant associations with systemic

disease were identified, likely reflecting the limitations of this study – its modest sample size and retrospective design, along with the inclusion of only specific cutaneous sarcoid lesions. Our findings nonetheless contribute to the characterization of cutaneous sarcoidosis in our patient population and underscore the necessity of evaluating every patient for systemic involvement.

EA DV CONGRESS
VIENNA
30 SEP - 3 OCT 2026

Abstract N°: 1136

Amicrobial pustulosis of the folds mimicking refractory psoriasis vulgaris with extensive extra-flexural involvement in systemic lupus erythematosus

Shady El-Mustafa[1], Sherine El-Mustafa*[1], Yousef Husseiny[2], Mona Abdel-Halim Ibrahim[1]

[1] Faculty of Medicine, Ain Shams University, Cairo, Egypt

[2] Faculty of Medicine, NewGiza University, Giza, Egypt

Introduction

Amicrobial pustulosis of the folds (APF) is a rare and likely underdiagnosed neutrophilic dermatosis strongly associated with autoimmune diseases, particularly systemic lupus erythematosus (SLE). It usually presents with sterile pustular eruptions mainly involving intertriginous areas, but can extend beyond flexural sites. This can cause it to mimic pustular psoriasis, eczema, or cutaneous lupus. Significant clinicopathological overlap with psoriasis commonly leads to misdiagnosis and delayed recognition.

Objectives

To report a complex case of APF in a patient with an established diagnosis of SLE that was initially thought to be psoriasis, highlighting its widespread distribution beyond flexural sites, overlapping histological features, and lasting remission after suitable management.

Case Presentation

A 31 year old female patient with a 15 year history of SLE (positive ANA, discoid lupus, scarring alopecia, oral ulcers, and arthralgia) presented with an 8 year history of recurrent erythematous, scaly, and pustular eruptions. The condition was initially diagnosed as psoriasis vulgaris and treated with topical mometasone furoate (0.1%) with only limited and transient response. Although systemic therapy with hydroxychloroquine and low-dose corticosteroids (prednisolone 5 mg daily, adjusted over time) was maintained, cutaneous lesions progressively extended beyond flexural sites to involve axillae, inframammary folds, anogenital region, periumbilical skin, scalp, retroauricular areas, external auditory canals, periungual skin, extremities, and intranasal mucosa, with associated nail dystrophy.

Two 3-mm punch skin biopsies were performed from a scaly pustular plaque of the left axilla and a scaly erythematous hyperkeratotic plaque of the right knee. Histopathological examination of the left axillary biopsy revealed an acanthotic epidermis with psoriasiform epidermal hyperplasia, overlying parakeratosis with intracorneal aggregates of neutrophils, and mild neutrophilic exocytosis. The upper and mid dermis showed a mild perivascular lymphocytic infiltrate admixed with scattered neutrophils, associated with mild papillary dermal edema, without evidence of vasculitis. In contrast, the right knee biopsy demonstrated more prominent psoriasiform acanthosis with neutrophilic exocytosis and formation of spongiform pustules within the epidermis. The upper dermis showed moderate edema with a mild perivascular mononuclear and neutrophilic infiltrate, and no evidence of vasculitis was identified. The combination of neutrophilic spongiosis with spongiform pustules and dermal neutrophilic infiltrate, in the absence of tortuous dilated dermal capillaries, favored a neutrophilic dermatosis over pustular psoriasis.

Given the presence of SLE and clinicopathological correlation, a diagnosis of APF was established. For the treatment, methotrexate (15 mg) and folic acid (5 mg) once weekly were initiated alongside prednisolone (5 mg) once daily and hydroxychloroquine (200 mg) twice daily, in addition to topical salicylic acid (5%), sulfur (5%), and emulsifying wax in coconut oil (10%). Complete clinical resolution was achieved within 1 month and the methotrexate was continued for 9 months. The patient remained in remission at 1.5 year follow-up without recurrence.

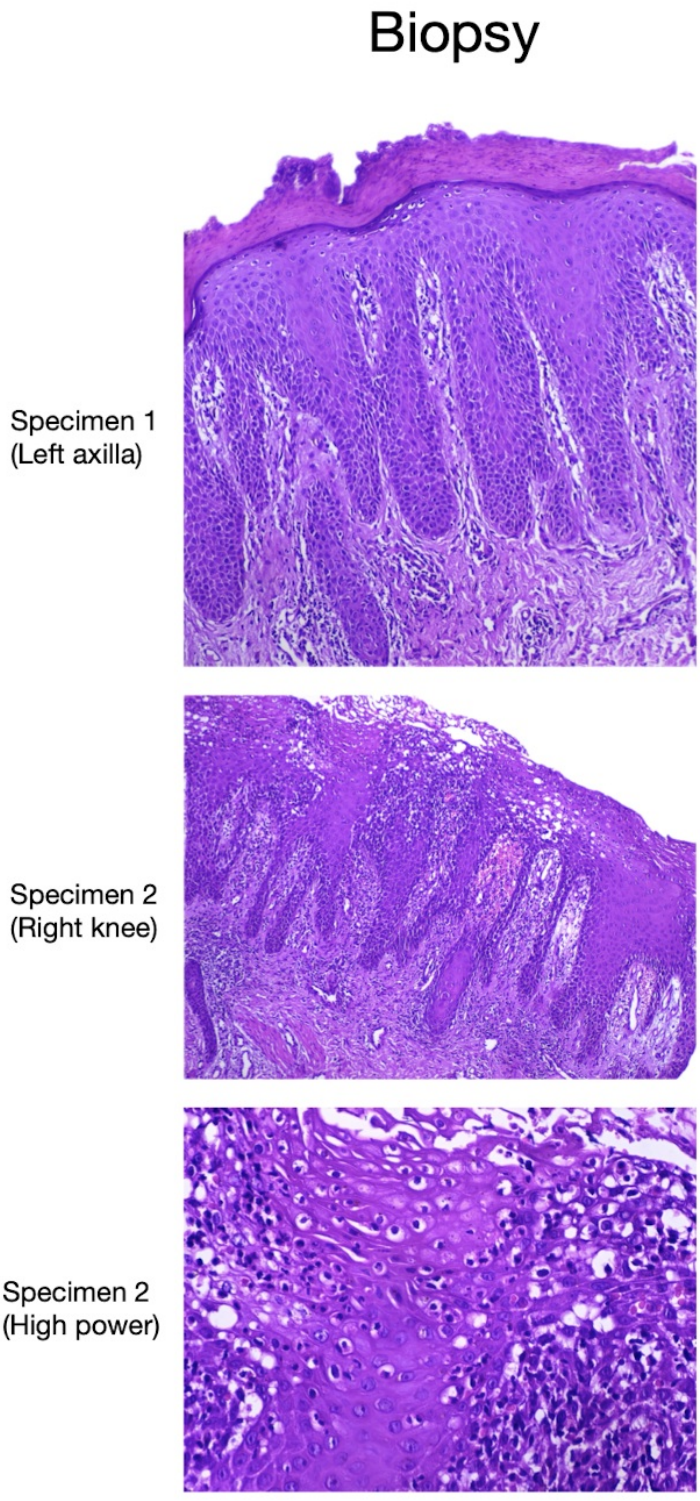

Fig. 1 shows the biopsy showing specimen 1, 2 and a higher power field of specimen 2.

Conclusion

APF should be considered as a differential diagnosis in patients with chronic, relapsing pustular eruptions, especially in those with underlying autoimmune disease such as SLE. Its clinical and histological similarity to pustular psoriasis often results in misdiagnosis and prolonged ineffective treatment. This case is notable for prolonged misclassification as psoriasis and unusually extensive extra-flexural involvement, including intranasal and external auditory canal disease, underscoring that APF may extend beyond classical intertriginous distribution. Recognition of this entity is essential, as accurate diagnosis allows rapid and sustained remission even after years of disease.

EA DV CONGRESS
VIENNA
30 SEP - 3 OCT 2026

Abstract N°: 1185

Pityriasis Rubra Pilaris: From Rapid Response to Refractory Disease - The Need for Therapeutic Flexibility

Andrea Isabel Rodriguez-Sanna*[1], Luis Salvador_Rodríguez[1], Daniel Muñoz Barba[1], Julia Castro Martín[1], David López Delgado[1], Salvador Arias-Santiago[1]

[1] Hospital Universitario Virgen de las Nieves, Granada, Spain

Introduction

Pityriasis rubra pilaris (PRP) is a rare chronic inflammatory papulosquamous dermatosis characterized by follicular hyperkeratotic papules on an erythematous base that coalesce into orange-red plaques with characteristic islands of spared skin, often associated with palmoplantar keratoderma. Classic adult-onset PRP shows a bimodal age distribution, with peaks in the first–second and sixth–seventh decades. Up to 90% of patients develop generalized erythematous plaques, and the disease frequently progresses to erythroderma. Systemic therapy is often required, particularly in extensive or symptomatic disease. Traditionally, oral retinoids and methotrexate have been the mainstay of treatment; however, with the advent of biologic agents targeting the IL-17 and IL-23 pathways, these therapies are increasingly preferred as initial treatment in severe cases due to their favorable safety profile and emerging evidence of efficacy.

Case Presentation

Case 1: A 56-year-old man presented with a 1-month history of pruritic cutaneous lesions that began on the face and progressively spread in a caudal distribution. Examination revealed erythematous scaly plaques with follicular hyperkeratotic papules and palmoplantar involvement. A skin biopsy confirmed the diagnosis of PRP. Initial treatment with acitretin 25 mg/day was administered for 5 months, achieving only partial response. Due to persistent disease activity, secukinumab (anti–IL-17) was initiated, with early clinical improvement noted after the first two induction doses. Treatment was then continued for 6 months, achieving complete remission. Following discontinuation, the patient remained free of relapse during follow-up, with sustained disease control.

Case 2: An 84-year-old man presented with a 1-month history of progressive pruritic erythroderma, initially involving the head and spreading caudally, associated with painful palmoplantar lesions. Examination revealed >90% body surface involvement with islands of spared skin, diffuse scaling, and palmoplantar keratoderma. Histopathology supported a diagnosis of PRP. Initial treatment with isotretinoin 40 mg/day was ineffective. Due to persistent disease, secukinumab was initiated and administered for 8 months, achieving only partial improvement and requiring dose intensification due to persistent disease. Loss of efficacy prompted a switch to risankizumab (anti–IL-23), with no response after completing the induction regimen. Given refractory disease, acitretin 25 mg/day was started and later transitioned to ustekinumab (anti–IL-12/23). Clinical improvement began after ustekinumab induction, with near-complete remission achieved 4 months after initiation.

Conclusion

These cases highlight different therapeutic trajectories in PRP, reflecting the heterogeneity of treatment response in this disease. In the first case, secukinumab led to a rapid and sustained response, with complete remission maintained after treatment discontinuation. In contrast, the second case required treatment intensification and sequential use of multiple biologics due to incomplete or transient responses.

Biologic therapies targeting the IL-17 and IL-23 pathways represent effective options in PRP, particularly in severe disease. While early use in selected severe cases may lead to faster and more sustained remission, these cases also underscore the importance of therapeutic flexibility, as some patients may require switching between different targets to achieve optimal disease control.

EA DV CONGRESS
VIENNA
30 SEP - 3 OCT 2026

Abstract N°: 1214

Successful Treatment of Deep Morphea and Psoriatic Arthritis with Tofacitinib: A Case Report

Špela But*[1], Katja Perdan-Pirkmajer[2], Laura Đorđević Betetto[1]

[1] University Medical Centre Ljubljana, Clinic of Dermatovenereology, Ljubljana, Slovenia

[2] Department of Rheumatology, University Medical Centre Ljubljana, Ljubljana, Slovenia

Introduction

Morphea has been associated with inflammatory, though not typically psoriatic, arthritis. While Janus kinase inhibitors are an established treatment for psoriatic arthritis, they are not currently approved for morphea. However, emerging case reports suggest potential benefit, particularly with tofacitinib. We present a case of deep morphea and psoriatic arthritis with an excellent response to tofacitinib.

Case Presentation

A 27-year-old Caucasian female reported a 2-year history of hyperpigmentation and progressive skin stiffness of the ventral forearms, dorsal shins, feet, and ankles, with reduced ankle mobility. She was diagnosed with psoriatic arthritis at age 16 and had been treated with secukinumab for 1,5 years; the skin changes preceded its initiation. Arthralgia initially improved but worsened in the past 2 months due to missed doses related to recurrent viral infections. At presentation, she reported arthralgia of the shoulders and small joints of the hands, with morning stiffness lasting 20 minutes. The remaining rheumatologic history was unremarkable. She was taking vitamin D supplementation and used naproxen as needed. She had no history of allergies or smoking. Family history was notable only for psoriasis in her grandmother. Examination revealed hyperpigmented, sclerotic, shiny skin with absent hair over the dorsal feet and ankles, extending to the anterior lower legs, with mild wrinkling suggestive of a groove sign. The volar hands showed sclerotic, wrinkled skin with erythema over the wrists. Fingernail pitting suggested concomittant nail psoriasis in the absence of cutaneous psoriatic lesions. Ankle range of motion was reduced, particularly left-sided extension. The remainder of the clinical examination was unremarkable. Skin and subcutaneous tissue biopsy showed deep dermal sclerosis extending into the subcutis, fascial fibrosis, and a moderately dense lymphoplasmacytic infiltrate without significant eosinophils. Direct immunofluorescence was non-specific, and the differential diagnosis included deep morphea and eosinophilic fasciitis. Upon admission, the diagnostic work-up focused on establishing the diagnosis and excluding systemic involvement and potential comorbidities. Extensive laboratory tests and imaging studies, including MRI of the upper and lower extremities, were performed. Laboratory tests showed elevated ESR (25), ANA titer 1:80, and polyclonal hypergammaglobulinemia, interpreted by hematologists as related to the underlying rheumatologic disease. MRI revealed fibrotic infiltration of the subcutaneous tissue and fascia of the lower legs and thighs without muscle or bone involvement, with signs of reactive or inflammatory arthritis of the left ankle and suspected non-insertional Achilles peritendinitis. Based on these findings, deep morphea involving the skin, subcutis, and fascia was diagnosed, along with inadequately controlled psoriatic arthritis. Previous treatments of psoriatic athritis with methylprednisolone, methotrexate, and adalimumab had been discontinued due to inefficacy or adverse effects, and secukinumab had also failed to

achieve an adequate response. Thus, a multidisciplinary dermatology-rheumatology team recommended tofacitinib 5 mg twice daily with oral methylprednisolone 1 mg/kg daily, tapered over 40 days. Clinical improvement in skin elasticity and arthralgia was already observed at 3 months and was more pronounced at 10 months, with reduced skin tightness, resolution of joint swelling and pain, and improved mobility, including the ability to squat without difficulty. No lesion progression or new lesions were observed. No adverse effects were noted.

Conclusion

This case highlights the promising potential of tofacitinib in the treatment of morphea. It also reports an association between morphea and psoriatic arthritis which, to our knowledge, has not been previously described. Despite the overlap's rarity, this case may offer useful insight for clinicians.

EADV CONGRESS
VIENNA
30 SEP - 3 OCT 2026

Abstract N°: 1319

Roflumilast for Ulcers in Behçet's disease: Case report and review

Molly Gunyon*[1], Aliyah King[2], Raquel Lazarowitz[1], Sabrina Hundal[3], Elena Netchiporouk[4, 5]

[1] Faculty of Medicine and Health Sciences, McGill University, Montreal, Canada
[2] Faculty of Medicine, University of Ottawa, Ottawa, Canada
[3] Department of Medicine, University of Calgary, Calgary, Canada
[4] Division of Experimental Medicine, Department of Medicine, McGill University, Montreal, Canada
[5] Division of Dermatology, Department of Medicine, McGill University Health Centre, Montreal, Canada

Introduction
Behçet's disease is a chronic, relapsing multisystem inflammatory disorder characterized primarily by recurrent oral and genital ulcers, often with significant pain and effects on quality of life. Although apremilast is an established PDE4 inhibitor for oral ulcers in BD, roflumilast remains an off-label option with limited published evidence.

This report combines a single-patient case report with a focused literature review.

Case Presentation
The patient was a 27-year-old woman with BD and a history of oral and genital ulcers, uveitis, Crohn's disease, ankylosing spondylitis, endometriosis, and prior melanoma. Her oral ulcers had persisted into adulthood despite multiple therapies. At presentation to our clinic, she also had an acneiform eruption while receiving certolizumab and azathioprine. After failure of doxycycline and topical treatment, oral roflumilast was initiated in January 2025 using gradual dose escalation from 250 mcg three times weekly to 500 mcg every 1–2 days as tolerated; azathioprine was discontinued and certolizumab was maintained. The patient achieved complete resolution of oral ulcers and acneiform lesions, with complete response first observed at 5 months and sustained through 14 months of follow-up, representing her longest remission period to date. Pain improved from 7/10 to 0/10, and no adverse events were reported. The literature review identified four published studies of oral roflumilast for BD-associated mucosal ulceration, including one retrospective cohort, two ambispective cohorts, and one case report, representing 58 patients overall, including 49 with BD. In the reviewed literature, roflumilast doses ranged from 125 to 500 mcg daily for 12 to 52 weeks. Among BD-specific cohorts, oral ulcer counts decreased by 90–95%, genital ulcer counts by 98%, flare frequency by 80.8–89%, and pain scores by 34.6–46.8%. All BD patients outside the mixed cohort experienced at least partial improvement, and 41.7% achieved complete response. Adverse events were common but generally non-severe, most often gastrointestinal or neurologic, with some discontinuations due to tolerability or erythema nodosum flares.

Conclusion
Overall, this case adds to the limited but growing evidence that roflumilast may be an effective option for refractory mucocutaneous BD, with potential practical advantages including potent PDE4 inhibition, convenient dosing, and lower cost relative to apremilast. Larger prospective studies are needed to confirm efficacy, define optimal dosing and duration, and better characterize long-term safety.

Table 1. Published cases and treatment protocols of roflumilast in BD.

First author, Year	N	Mean age (yrs)	RT protocol	Ulcer lesion count (no.)	Pain (/10)	Response	AEs	DC
Chung, 2025*	46 (37 BD)	52.4	250 mcg PO daily x 12 weeks; dose reduced to 125 mcg daily as needed (15.2% reduced)	Baseline 4.4 ulcers in the last 4 weeks lasting 9.8 days	5.2 → 2.5 (-51.9%) at 12 weeks	PR: 76.1%; CR: 30.4% at 8 weeks	35 (76.1%): GI (33), neurological (8)	9 (19.6%) due to AEs
Peñuelas, 2024	11	33.8	250 mcg PO daily (n=8); 125 mcg daily × 7 days → 250 mcg daily (n=2); 125 mcg daily (n=1); x 12 weeks	Oral: 33.7→1.6 (-95%) Genital: 4.5→0.1 (-98%) Flares: 8.4→0.9 (-89%) At 12 weeks	7.7→4.1 (-46.8%) at 12 weeks	PR: 100%; CR overall: 36.4%; CR genital: 90.9% at 12 weeks	6 (54.5%): headache (3), GI (1), back pain (1), nightmares (1)	None
Peñuelas, 2023	1	41	250 mcg PO daily x 26 weeks	Not reported	Not reported	CR at 24 weeks	1 (100%): headache	None
Peñuelas, 2026	11	33.8	500 mcg PO daily (n=6); 250 mcg daily (n=4); 125 mcg daily (n=1); x 52 weeks	Oral: 39.1→3.8 (-90%) duration 11.5→7.2 days (-37%) Genital: 4.8→0.1 (-98%) Flares: 10.4→2.0 (-80.8%) At 52 weeks	7.8→5.1 (-34.6%) at 52 weeks	Not reported	Not reported	3 (27.3%) due to erythema nodosum flare
Our case	1	27	250 mcg PO three times weekly × 1 week → 500 mcg three times weekly × 1 week → 500 mcg every 1–2 days x 61 weeks, ongoing	No oral or genital ulcers at 14-month follow-up.	7 -> 0 (-100%) at 61 weeks	CR at 20 weeks	None	None

Abbreviations: AE, adverse event; BD, Behçet's disease; CR, complete response; DC, discontinuation; PO, orally; PR, partial response; RT, roflumilast treatment; GI, gastrointestinal; yrs, years.

*Data were reported for the overall cohort; BD-specific outcomes were not separately available.
**Represents long-term follow-up of the cohort reported in Peñuelas 2024; only BD-specific data were extracted.

Table 1. Published cases and treatment protocols of roflumilast in BD.

EADV Congress 2026, VIENNA
30 SEPTEMBER - 03 OCTOBER 2026
POWERED BY M-ANAGE.COM

EA DV CONGRESS
VIENNA
30 SEP - 3 OCT 2026

Abstract N°: 1347

Pediatric Subcorneal Pustular Dermatosis Associated with Familial Mediterranean Fever: A Diagnostic Pitfall Mimicking Pustular Psoriasis with Systemic Steroid–Induced Exacerbation

Muazzez Cigdem Oba*[1], Hami Kork[1], Kenan Barut[2]

[1] İstanbul University-Cerrahpaşa, Cerrahpaşa Medical Faculty, Department of Dermatology, İstanbul, Türkiye
[2] İstanbul University-Cerrahpasa, Cerrahpaşa Medical Faculty, Department of Pediatric Rheumatology, İstanbul, Türkiye

Introduction

Subcorneal pustular dermatosis (SPD) is a rare neutrophilic dermatosis, particularly uncommon in children, characterized by recurrent sterile pustules. It may clinically mimic pustular psoriasis and other inflammatory dermatoses, frequently leading to misdiagnosis and inappropriate treatment. Familial Mediterranean Fever (FMF) is an autoinflammatory disease driven by neutrophilic inflammation. The coexistence of SPD and FMF is exceedingly rare and has been only rarely reported in the literature.

Case Presentation

An 11-year-old male presented with a 2-week history of rapidly progressive generalized pustular eruptions on a background of a 2-year history of recurrent lesions initially localized to the gluteal region. Previous treatments included topical corticosteroids and tacrolimus, with partial clinical response.

Dermatological examination revealed diffuse erythematous plaques with nummular scaling and widespread sterile pustules involving the trunk and extremities. Based on the clinical presentation, pustular psoriasis was initially suspected. Systemic methylprednisolone (32 mg/day, 0.5 mg/kg) was initiated; however, this resulted in marked worsening of pustular lesions. In addition, significant hepatotoxicity developed, with elevated transaminase levels (AST 230 U/L, ALT 240 U/L), accompanied by increased inflammatory markers and leukocytosis. During ongoing diagnostic uncertainty, cyclosporine therapy was initiated but subsequently discontinued due to persistent elevation of liver enzymes. Skin biopsy confirmed the diagnosis of subcorneal pustular dermatosis. Direct immunofluorescence examination was negative. Following the exclusion of glucose-6-phosphate dehydrogenase (G6PD) deficiency, dapsone (50 mg/day) was initiated, resulting in a **dramatic clinical response within the first week**, after which the dose was increased to 100 mg/day by the end of the second week. **Complete remission maintained over a 3-month follow-up period**.

Further evaluation revealed a heterozygous MEFV gene mutation (c.2177T>C) on autoinflammatory panel testing, along with a positive family history of Familial Mediterranean Fever. Accordingly, colchicine (0.5 mg twice daily) was initiated and added to ongoing dapsone therapy. The patient has been receiving combined dapsone (100 mg/day) and colchicine (0.5 mg twice daily) for the last two weeks; however, no additional clinical response attributable to colchicine has yet been observed at the time of reporting.

Conclusion

Subcorneal pustular dermatosis is a rare neutrophilic dermatosis that may closely mimic pustular psoriasis, particularly in pediatric patients, often leading to diagnostic uncertainty and inappropriate initial management. In the present case, the initial clinical impression of pustular psoriasis resulted in systemic corticosteroid therapy, which was followed by marked clinical deterioration and hepatotoxicity, highlighting the potential for **systemic steroid–induced exacerbation**.

The coexistence of subcorneal pustular dermatosis and Familial Mediterranean Fever is extremely rare and suggests a shared neutrophil-driven autoinflammatory pathway. This overlap may contribute to both the atypical clinical presentation and the heightened inflammatory response observed in this patient. Recognition of the underlying autoinflammatory condition was crucial in guiding management.

Subcorneal pustular dermatosis should be considered in children presenting with atypical or treatment-resistant pustular eruptions. Misdiagnosis as psoriasis may result in inappropriate therapy and subsequent clinical deterioration.The coexistence of Familial Mediterranean Fever may influence the clinical course and should be considered, particularly in cases with unusual or refractory presentations.

Histopathological confirmation, including direct immunofluorescence, remains essential before initiating systemic therapy.

EA DV CONGRESS
VIENNA
30 SEP - 3 OCT 2026

Abstract N°: 1365

Perforating granuloma annulare in EGPA/GPA overlap ANCA-associated vasculitis: association or coincidence?

Liz Beltrán Medina*[1, 2], Sergio Castillo[1, 2], Isabel Cuellas Rios[1, 2]

[1] Pontificia Universidad Javeriana, Bogotá, Colombia

[2] Hospital Universitario San Ignacio, Bogotá, Colombia

Introduction

Perforating granuloma annulare (PGA) is an uncommon variant of granuloma annulare, representing approximately 5% of reported cases. It is most frequently linked to diabetes mellitus, although infections, trauma, and other triggers have been described. Clinically, PGA presents as umbilicated papules or nodules with a central crust or keratotic plug, predominantly affecting the extremities. Histopathologically, it is characterized by palisading granulomatous inflammation, collagen necrobiosis, mucin deposition, and transepidermal elimination of necrobiotic material. We report a rare case of localized PGA arising in the context of EGPA/GPA overlap ANCA-associated vasculitis.

Case Presentation

A 59-year-old woman with a history of hypertension, prediabetes, and a recent diagnosis of PR3-ANCA–associated vasculitis with an eosinophilic granulomatosis with polyangiitis (EGPA) phenotype, but with severe renal involvement due to pauci-immune extracapillary proliferative glomerulonephritis, findings more commonly associated with granulomatosis with polyangiitis (GPA), suggesting a probable GPA–EGPA overlap syndrome. During her workup, multisystem involvement was documented, including inflammatory polyarthralgia, sensorineural hearing loss, peripheral eosinophilia, chronic rhinosinusitis, right-sided scleritis, and ground-glass pulmonary nodules. She was treated with glucocorticoid pulses, cyclophosphamide, and rituximab, with favorable clinical evolution.

Additionally, she presented with a 2-month history of cutaneous lesions consisting of asymptomatic, bilateral and symmetrical lesions on the elbows, some with a whitish center, extrusion of material, and subsequent spontaneous involution. She denied any history of trauma, insect bites, or other triggering factors. Physical examination revealed three skin-colored nodules on the left elbow, one of them with a central blackish plug, along with residual macules on the contralateral elbow. No lesions were observed at other sites.

A skin biopsy was performed, demonstrating areas of necrobiosis surrounded by palisading histiocytes forming dermal granulomas, with focal extrusion of necrobiotic material through an ulcerated area, without evidence of vasculitis. Alcian Blue staining demonstrated central mucin deposition; PAS, methenamine silver, and Ziehl–Neelsen stains were negative. Direct immunofluorescence was negative. Immunohistochemistry showed positivity for CD68 and negativity for cytokeratins and CD34 . Based on the clinicopathological findings, a diagnosis of perforating granuloma annulare was established. The patient showed spontaneous resolution of the lesions during follow-up.

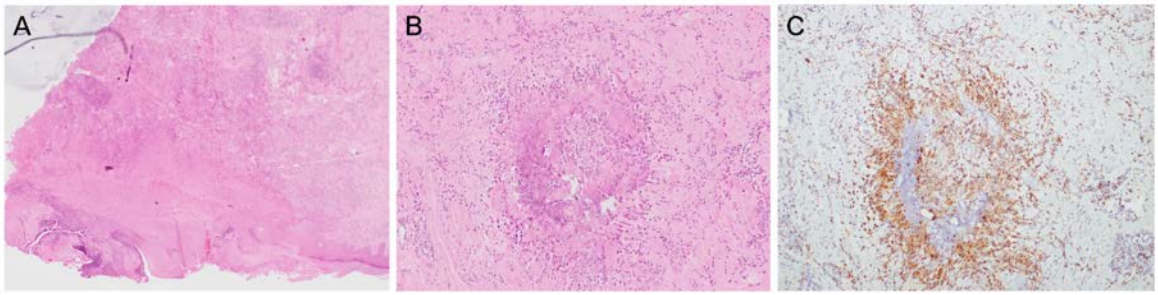

Figure 1. Histopathological findings. (A) Low-power view showing a palisading granulomatous infiltrate surrounding areas of necrobiotic collagen with overlying transepidermal elimination (hematoxylin and eosin, original magnification ×40). (B) Higher-power view highlighting palisading histiocytes and multinucleated giant cells surrounding necrobiotic collagen and mucin (hematoxylin and eosin, original magnification ×100). (C) CD68 immunohistochemistry demonstrating positivity in histiocytes within the granulomatous infiltrate (original magnification ×100).

Conclusion

This case broadens the recognized clinical spectrum of PGA by documenting its occurrence in EGPA/GPA overlap ANCA-associated vasculitis. Awareness of this unusual association is important, as PGA may mimic vasculitic, infectious, or perforating dermatoses in immunologically complex patients. Although coexistence may be incidental, shared granulomatous and immune-mediated pathways merit consideration. Recognition of PGA in this setting can facilitate accurate diagnosis and prevent unnecessary interventions.

EA DV CONGRESS
VIENNA
30 SEP - 3 OCT 2026

Abstract N°: 1374

Systematic Review of Natural Ingredients Used in East Asian Skincare for the Management of Common Inflammatory Skin Diseases

Jaehyun Hwang*[1], Yu Xuan Jin[1], Qi Zuo[1], Lindsay Barnard[1], Monica Li[1]

[1] University of British Columbia, Vancouver, Canada

Introduction
Atopic dermatitis (AD), acne and psoriasis are common chronic inflammatory skin diseases associated with immune dysregulation and psychosocial burden. Conventional therapies are effective but may be limited by adverse effects, contributing to growing interest in natural ingredients derived from East Asian medicine. These ingredients are widely incorporated into Korean, Japanese, and Chinese skincare products; however, evidence supporting their efficacy remains fragmented. This systematic review evaluates randomized controlled trials assessing such ingredients in inflammatory skin diseases.

Materials and Methods
This PROSPERO-registered systematic review (CRD420251088291) followed PRISMA guidelines. MEDLINE, Embase, Web of Science, and CENTRAL were searched from inception through April 2025. Adult randomized controlled trials evaluating natural East Asian skincare ingredients for AD, acne or psoriasis with placebo comparators and standardized outcomes were included. Risk of bias was assessed using the Cochrane RoB2 tool.

Results
Of 1,804 records screened, eight trials published between 1996 and 2022 were included. One trial in AD (n=16) found that green propolis cream improved SCORing Atopic Dermatitis scores at 60 days compared with control, with similar adverse event rates. Two acne trials showed that aloe vera gel reduced papular and pustular lesion counts over 7 days (n=24), while a combination of snail secretion filtrate, Calendula officinalis, and Glycyrrhiza glabra root extract reduced total acne lesions over 12 weeks (n=66); adverse effects (e.g., burning, itching, erythema and scaling) were mild and infrequent (≤2 patients each). Five psoriasis trials demonstrated greater reductions in Psoriasis Area and Severity Index and local PASI scores with Aloe vera (n=40, n= 60), Curcuma xanthorrhiza (n=20), turmeric (n=40), and starch-fortified turmeric (n=60) compared with controls. Adverse effects (e.g., burning, irritation and dryness) were minimal and required no discontinuation.

Conclusions
Natural East Asian ingredients, particularly aloe vera through its anti-inflammatory properties, and potentially turmeric and green propolis, demonstrate modest therapeutic benefit with minimal adverse effects in psoriasis, acne, and AD. However, most outcomes lacked statistical significance, and heterogeneity precluded meta-analysis. Larger, rigorously designed randomized controlled trials are required to clarify efficacy and define the clinical role of these therapies in inflammatory skin diseases.

EADV CONGRESS
VIENNA
30 SEP - 3 OCT 2026

Abstract N°: 1412

GRANULOMATOUS VULVITIS AS A DIAGNOSTIC CHALLENGE: A CASE REPORT

Miłosz Lewandowski*[1, 2], Urszula Maińska[1, 2], Martyna Sławińska[1, 2]

[1] Department of Dermatology, Venereology and Allergology, Faculty of Medicine, Medical University of Gdansk, Gdańsk, Poland
[2] Department of Dermatology, Venereology and Allergology, University Clinical Centre in Gdańsk, Gdańsk, Poland

Introduction

Granulomatous vulvitis is a rare chronic inflammatory disorder of the female genital area and remains a diagnosis of exclusion, particularly because of its potential association with Crohn's disease and sarcoidosis. We present the case of a 48-year-old woman hospitalized for further evaluation of suspected granulomatous vulvitis.

Case Presentation

The patient reported vulvar pruritus, burning, and recurrent inflammatory lesions with erosions involving the labia minora since January 2024. Previous topical corticosteroid therapy was ineffective, while transient clinical improvement was observed after treatment with amoxicillin/clavulanate. Histopathological assessment of two prior biopsies from the vaginal vestibular area was consistent with granulomatous inflammation. One specimen was interpreted as most suggestive of idiopathic granulomatous vulvitis, with Crohn's disease considered less likely. The second showed chronic inflammation with a single non-necrotizing histiocytic granuloma.

An extended diagnostic workup was focused on excluding sarcoidosis and cutaneous manifestations of Crohn's disease. HPV testing, sexually transmitted infection PCR panel, HBV, HCV, HIV, and VDRL were negative. Liquid-based cytology showed no oncologic concern. Colonoscopy revealed no features of Crohn's disease. Chest radiography showed no abnormalities. Serum angiotensin-converting enzyme was within the normal range. ASCA IgA/IgG and pANCA were negative. Mild laboratory abnormalities included borderline anemia, mildly elevated aminotransferases, reduced total serum calcium and low 24-hour urinary calcium excretion, elevated 1,25-dihydroxyvitamin D, and mildly elevated fecal calprotectin. Ophthalmologic consultation excluded contraindications to hydroxychloroquine therapy.

Based on the overall clinical, histopathological, and laboratory assessment, idiopathic granulomatous vulvitis was considered the most likely diagnosis. Hydroxychloroquine 200 mg once daily was initiated, with dermatologic and ophthalmologic follow-up planned.

Conclusion

This case highlights the diagnostic complexity of Granulomatous vulvitis, particularly in the presence of non-uniform histopathological findings, and underscores the necessity of a targeted, multidisciplinary approach to exclude systemic granulomatous disorders before establishing an idiopathic diagnosis

EA DV CONGRESS
VIENNA
30 SEP - 3 OCT 2026

Abstract N°: 1422

Concomitant use of glucagon-like peptide-1 receptor agonists in patients with psoriasis or hidradenitis suppurativa receiving bimekizumab: Cross-sectional analysis of US claims data

Martina L. Porter*[1], Ana Filipa Macedo[2], Janek Rudnik[2], Aijing Shang[3], Evelina van Ree[4], Chao Song[5], Jeremy Schafer[6], Pablo De la Cueva[7]

[1] Beth Israel Deaconess Medical Center, Department of Dermatology, Harvard Medical School, Boston, Massachusetts, United States
[2] UCB, Brussels, Belgium
[3] UCB, Basel, Switzerland
[4] UCB, Breda, Netherlands
[5] UCB, Smyrna, Georgia, United States
[6] UCB, Braine l'Alleud, Belgium
[7] Department of Dermatology, Hospital General Universitario Gregorio Marañón, Madrid, Spain

Introduction

Patients with inflammatory skin diseases, such as psoriasis (PSO) and hidradenitis suppurativa (HS), have higher rates of comorbid obesity and type 2 diabetes mellitus (T2DM) than the general population.[1,2] Glucagon-like peptide-1 receptor agonists (GLP-1RAs) are indicated for the treatment of obesity/T2DM.[3]

Bimekizumab (BKZ), a humanised IgG1 monoclonal antibody that selectively inhibits interleukin (IL)-17F in addition to IL-17A,[4] is approved for the treatment of moderate to severe plaque PSO and HS.[5] Evaluating the extent of concomitant GLP-1RA/BKZ use in routine practice, and characterising patients receiving both treatments, can inform the management of patients with PSO or HS and comorbid obesity/T2DM.

Here, we assessed the prevalence of concomitant GLP1-RA use in BKZ-treated patients with PSO or HS and the characteristics of those receiving both treatments in a cross-sectional analysis of United States (US) claims data.

Materials and Methods

Data were taken from the Komodo Health database, including open/closed claims from Medicare and Commercial insurances (BKZ US approval: Oct 2023 for PSO; Nov 2024 for HS). Eligible patients were ≥18 years, with a PSO/HS diagnosis and ≥1 BKZ claim in the study selection period (01 Nov 2023–07 Dec 2025). Concomitant GLP-1RA/BKZ use was defined as any treatment overlap within this period; index date was the first day of overlap. For patients with treatment overlap before 01 Nov 2023, the index date was 01 Nov 2023; in patients with multiple episodes of concomitant GLP-1RA/BKZ use, the first overlap was the index date.

The primary endpoint was the prevalence of concomitant GLP-1RA/BKZ use for the whole selection period and by year, evaluated for each indication. Data are reported as observed with 95% confidence intervals (CI). Subgroup analyses were performed by sex, age group and comorbidity; a sensitivity analysis was restricted to closed claims only. The secondary endpoint was patient characteristics at index date for those receiving concomitant GLP-1RA/BKZ treatment, summarised descriptively.

Results

During the selection period, 18,665 and 5,082 patients with PSO and HS received BKZ treatment, respectively. Among these patients, the prevalence (95% CI) of concomitant GLP-1RA use was 20.1% (19.5–20.7%) and 23.0% (21.9–24.2%) in PSO and HS (**Figure 1A**). For both PSO and HS, GLP-1RA use was higher in female patients and those aged ≥46–≤65 years (**Figure 1B**). Patients with both obesity and T2DM had higher prevalence of GLP-1RA use vs patients with neither (PSO/HS: 48.1%/49.5% vs 4.2%/4.3%). The sensitivity analysis provided similar prevalence results.

Among PSO/HS patients receiving both GLP-1RA and BKZ (N=3,754/N=1,170), the mean age was 53.6/46.5 years and 62.2%/74.3% were female. For both PSO/HS groups, most patients (76.7%/82.5%) started GLP-1RA treatment before BKZ, 89.6%/84.6% were biologic-experienced and >95% had a cardiometabolic condition. Semaglutide and tirzepatide accounted for ~40% and ~50% of prescribed GLP-1RAs in all BKZ-treated patients, respectively. Dermatologists often prescribed BKZ (PSO: 39.8%; HS: 50.9%) but were rarely the prescribers of GLP-1RAs (PSO: 0.4%; HS: 1.3%).

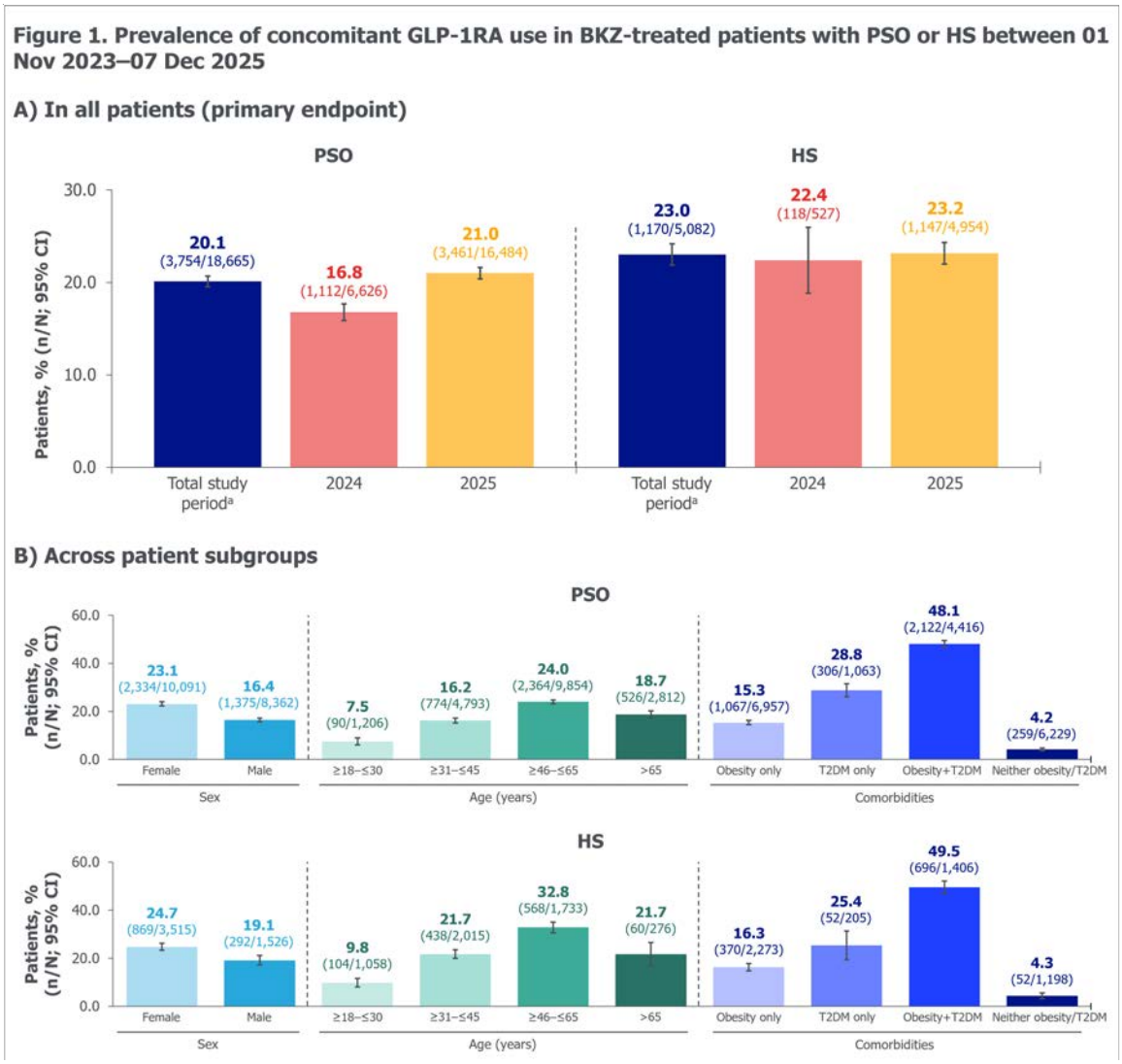

BKZ was approved in the US for the treatment of PSO in October 2023, and HS in November 2024 (FDA. Highlights of Prescribing Information. Available at: https://www.accessdata.fda.gov/drugsatfda_docs/label/2024/761151s010lbl.pdf [Accessed April 2026]). [a] Study selection period: 01 Nov 2023–07 Dec 2025; due to small patient numbers in the HS group in 2023 (off-label use or use for PSO as a comorbidity), 2023 data are not presented separately in this figure, but were as follows: PSO: 12.2% (34/279); HS: 29.4% (5/17). BKZ: bimekizumab; CI: confidence interval; GLP-1RA: glucagon-like peptide-1 receptor agonist; HS: hidradenitis suppurativa; PSO: psoriasis; T2DM: type 2 diabetes mellitus; US: United States.

Conclusions

In routine clinical practice during the study period, concomitant GLP-1RA use (>20% overall) in bimekizumab-treated patients with PSO/HS increased. This, along with the high rates of comorbidities in patients receiving concomitant treatment, reflects a complex and multimorbid population. Most PSO/HS patients initiated bimekizumab after GLP-1RAs, suggesting a continued need for effective treatment of these inflammatory diseases alongside the management of metabolic comorbidities.

References

1. Reich K. Arch Dermatol Res 2015;307:875–83; **2.** Elzawawi KE. Int Wound J 2024;21:e70035; **3.** Nasreen A. eClinicalMedicine 2024;75:102782; **4.** Adams R. Front Immunol 2020;11:1894; **5.** FDA. Highlights of Prescribing Information. Available at: https://www.accessdata.fda.gov/drugsatfda_docs/label/2024/761151s010lbl.pdf [Accessed April 2026].

EA DV CONGRESS
VIENNA
30 SEP - 3 OCT 2026

Abstract N°: 1432

Clinical Efficacy of a Soothing Dermocosmetic Cream as Adjunctive Care for Rosacea Patients Treated with Topical Ivermectine or Metronidazole.

Helena Polena*[1], Arnaud Fontbonne[2], Pauline Chanut[1], Alexane Charreyron[1], Severine CASTEX[1], Sandra Trompezinski[2], Isabelle Benoit[2], Noëlle Remoué[1], Elodie VALIN[1], Bernard Cribier[3], Elodie PRESTAT-MARQUIS[1]

[1] Naos Les Laboratoires, Bioderma, Lyon, France

[2] Institut NAOS, Aix en Provence, France

[3] University Hospital of Strasbourg, Strasbourg, France

Introduction

Rosacea is a chronic inflammatory dermatosis affecting the centrofacial region in approximately 5% of adults worldwide. Tailored, individualized long-term management including dermocosmetics as adjunctive care is essential for improving skin comfort and enhancing tolerance and compliance. Efficacy and tolerance of a soothing ecobiological dermocosmetic formulation (DF) targeting innate immunity, neurogenic inflammation and skin barrier function, was evaluated alone and subsequently in combination with topical Ivermectine or Metronidazole.

Materials and Methods

DF was first evaluated in 21 subjects with mild to moderate vascular rosacea using a split-face application of DF or a neutral cream for 56 days. Investigator Global Assessment (IGA, 4-point scales) and Trans Epidermal Water Loss (TEWL, TM300 Tewameter) were measured. Skin swabs collected at D0 and D28 were analyzed for ceramides NS/AS by LC/MS.

A second clinical evaluation was conducted in 50 subjects with rosacea requiring topical treatment in a multicenter, double-blind controlled comparative study. One group (n=23) applied Metronidazole with DF (n=11) or neutral cream (n=12) while another group (n=27) applied Ivermectine with DF (n=13) or neutral cream (n=14) twice daily for 56 days. From D56 to D84, patients continued applying DF or neutral cream while discontinuing medical treatment. Rosacea symptoms, including erythema, telangiectasia, papules/pustules, functional signs and flushing, were clinically or subjectively evaluated, reflecting the expected effects of medical treatment. Quality of life was also evaluated through a RosaQoL questionnaire and questions assessing negative emotions. Self-perceived skin benefits were also assessed. Subjects had to report any adverse event over the studies.

Results

When used alone, DF significantly reduced symptoms severity (IGA, D28: -11.9%, D56: -22.5%) whereas the neutral cream showed no significant improvement. TEWL significantly decreased with the DF at D14 (-14%) and D56 (-13%) while the neutral cream only statistically reduced TEWL at D56 (-13%). Consistently, DF significantly increased ceramides (+23%) on subjects with vascular rosacea, outperforming the neutral cream. This highlight DF ability to partially compensate for the significant ceramide deficit in rosacea (-48% versus a healthy group), likely due to phytosphingosine ingredient, supporting its efficacy to reinforce skin barrier function and its potential use as adjunctive care.

When DF was combined with Ivermectin/Metronidazole, both protocols showed clinical and functional rosacea symptoms improvement between D0 and D56, reflecting expected treatment effects. Compared to neutral cream groups, patient-reported satisfaction demonstrated that only DF significantly provides immediate skin comfort and a sensation of freshness after first application. During 56 days of the Ivermectine/Metronidazole treatment, DF consistently improved hydration, lasting comfort, and reduced treatment-related discomfort.

While groups with medical treatment associated to DF showed a significative RosaQoL decrease from D28 (D28: -7%; D56: -20%; D84: -17%), groups with neutral cream demonstrated improvement only at D84 (-14%). Negative emotions, particularly anger and vulnerability, were also reduced by the DF at D84 (-81% and -29%, respectively), with no comparable effect for the neutral cream. These results were supported by patient-reported satisfaction, as only DF continued to improve lasting comfort, self-confidence, well-being and quality of life even 28 days post-treatment (D84). Finally, DF was very well tolerated with no adverse events reported, compared to 7 cases reported with neutral cream.

Conclusions

This ecobiological DF effectively alleviates rosacea symptoms and reinforces the skin barrier while improving comfort, quality of life, and tolerance to Ivermectin or Metronidazole, supporting its use as adjunctive care.

EADV CONGRESS
VIENNA
30 SEP - 3 OCT 2026

Abstract N°: 1435

Aggressive Granulomatous Eosinophilic Pustular Folliculitis: A Rare Mimicker of Granulomatous Dermatoses

Chon-Wai Jeremy Chan*[1], Anne-Marie Aubin[2], Matthew Verheyden[3], James Scurry[4], Paul Chee[4]

[1] Concord Repatriation General Hospital, Concord, Australia

[2] The Skin Hospital, Dubbo, Australia

[3] The Skin Hospital, Darlinghurst, Australia

[4] John Hunter Hospital, New Lambton heights, Australia

Introduction

Eosinophilic pustular folliculitis is a rare chronic and relapsing dermatosis characterised by pruritic follicular papulopustules which coalesce into large plaques predominantly distributed in seborrheic areas. In rare instances, eosinophilic pustular folliculitis can present atypically as aggressive granulomas with extensive indurated plaques with predilection on the face.

Case Presentation

We report a 56-year-old Caucasian male who developed progressive granulomatous lesions after his exposure to bushfires four years ago. The lesions initially started on his leg and hands and progressed to involve other areas on the face, chest and back. The patient was initially investigated for cutaneous lymphoproliferative conditions, but repeated biopsies favoured reactive lymphoid proliferation. Other differential diagnoses included autoimmune and infectious causes. Treatment with prednisolone, hydroxychloroquine, itraconazole and subsequently methotrexate all had minimal response. Doxycycline was commenced for atypical infection and improvement to granulomatous lesions were noted. Repeat biopsy on a new nasal plaque revealed granulomatous folliculitis with eosinophils consistent with a granulomatous variant of eosinophilic pustular folliculitis. The patient was commenced on dapsone and continued oral antibiotics with ongoing review.

Conclusion

Currently, there is only one other case of granulomatous eosinophilic pustular folliculitis reported. The cause of eosinophilic pustular folliculitis is unknown with the classic variant most often seen in East Asians and other variants associated with advanced human immunodeficiency virus (HIV), infancy, cancer, or medication. The bushfires which coincided with the onset of the granulomatous process could be a potential trigger leading to the aberrant immune response. Treatment response to dapsone will be monitored and presented.

This case contributes to the limited literature of eosinophilic pustular folliculitis presenting atypically as aggressive appearing granulomas with extensive erythematous indurated plaques. Atypical eosinophilic pustular folliculitis should be considered as a differential diagnosis for patients with facial granulomas and chronic granulomatous dermatoses without a clear cause.

EADV CONGRESS
VIENNA
30 SEP - 3 OCT 2026

Abstract N°: 1476

Cutaneous Sarcoidosis Presenting with Scaly Facial Plaques: A Diagnostic Challenge

Mustafa Ürün[1], Yıldız Gürsel Ürün[1], Asena Kaşoğlu*[1]

[1] Trakya University Faculty of Medicine, Department of Dermatology, Edirne, Türkiye

Introduction
Sarcoidosis is a multisystem inflammatory disease of unknown etiology characterized by non-caseating granulomas (1,2). Although pulmonary involvement is most common, cutaneous involvement occurs in 20–30% of cases and may be the initial manifestation (1,3). Cutaneous lesions are heterogeneous, including erythematous-yellowish papules, plaques, nodules, lupus pernio, and scar infiltration (3,4). Due to this variability, it may mimic conditions such as lupus vulgaris, tuberculosis, cutaneous leishmaniasis, granuloma annulare, necrobiosis lipoidica, and cutaneous lymphoma (2,4). Diagnosis requires clinicopathological correlation and exclusion of other granulomatous diseases (1,2).

Case Presentation
A 61-year-old woman presented with a one-year history of progressive facial erythema unresponsive to topical antibiotics, emollients, and corticosteroids. She had diabetes mellitus and hypertension treated with metformin and perindopril. Examination revealed localized erythematous-yellowish, scaly, mildly infiltrative plaques on the right face. Dermoscopy showed peripheral scaling, yellowish structureless areas, and irregular linear vessels, suggesting tinea faciei, cutaneous leishmaniasis, discoid lupus erythematosus, and porokeratosis. ANA was positive (speckled), ENA negative. Histopathology revealed naked granulomas with epithelioid histiocytes and multinucleated giant cells. Direct immunofluorescence and histochemical stains (PAS, GMS, ENZ) were negative.

The patient was diagnosed with cutaneous sarcoidosis and evaluated for systemic involvement. Ophthalmological and cardiological assessments were normal, and serum ACE was within normal limits. Thoracic CT showed bilateral hilar lymphadenopathy (up to 16×18 mm), mediastinal and abdominal lymph nodes, and multiple pulmonary nodules, more prominent in upper lobes, consistent with pulmonary sarcoidosis. As she was asymptomatic, clinical follow-up was recommended. Treatment with topical corticosteroid and hydroxychloroquine (200 mg/day) was initiated and the patient was scheduled for follow-up every three months.

Conclusion
Conclusion:
Cutaneous sarcoidosis may mimic various dermatological diseases, especially when presenting with facial scaly lesions, creating diagnostic challenges (1,3). Due to clinical and dermoscopic heterogeneity, histopathological confirmation and exclusion of other granulomatous disorders are essential (2,4). Dermoscopic features include translucent orange globules, linear vessels, bright white streaks, and scar-like areas; white scaling (43.47%) and perifollicular scaling (8.69%) have been reported (5). In our case, peripheral scaling contributed to diagnostic difficulty.

Cutaneous findings may be the first or only sign of systemic disease; therefore, patients should be evaluated for systemic involvement (1,2). Even asymptomatic patients may show hilar lymphadenopathy and parenchymal disease on imaging (1,4). Early recognition and multidisciplinary management are essential (2,3).

References:

1. Baughman RP, Valeyre D, Korsten P, et al. ERS clinical practice guidelines on treatment of sarcoidosis. Eur Respir J. 2021;58(6):2004079.
2. Iannuzzi MC, Rybicki BA, Teirstein AS. Sarcoidosis. N Engl J Med. 2007;357(21):2153–2165.
3. Mana J, Marcoval J. Skin manifestations of sarcoidosis. Clin Dermatol. 2007;25(3):276–287.
4. Tchernev G, Patterson JW, Nenoff P, et al. Cutaneous sarcoidosis: The “great imitator”. Am J Clin Dermatol. 2010;11(6):375–382.
5. Kalantari Y, Peymanfar AA, Mahmoudi H, Daneshpazhooh M, Etesami I. Dermoscopy of cutaneous granulomatous disorders: A study of 107 cases. Skin Res Technol. 2023 Jan;29(1):e13273.

EADV CONGRESS
VIENNA
30 SEP - 3 OCT 2026

Abstract N°: 1491

Pyoderma gangrenosum mimicking cutaneous leishmaniasis in an endemic region: a diagnostic challenge with therapeutic implications

María Paula Muñoz Mc Causland*[1], Liz Daniela Beltrán[2], María Fernanda Bustos[3], CLAUDIA MARCELA ARENAS SOTO[3]

[1] Fundación Universitaria Sanitas, Bogotá, Colombia
[2] Pontificia Universidad Javeriana, Bogotá, Colombia
[3] Federico Lleras Acosta, Bogotá, Colombia

Introduction

Pyoderma gangrenosum is a rare neutrophilic dermatosis that may clinically and histopathologically mimic infectious diseases. In endemic regions, cutaneous leishmaniasis is a frequent cause of ulcerative lesions, increasing the risk of misdiagnosis and inappropriate treatment. We report a case of pyoderma gangrenosum initially misdiagnosed as cutaneous leishmaniasis, highlighting the diagnostic challenges and therapeutic implications.

Case Presentation

A 79-year-old man was referred to our dermatology clinic with a 3-month history of a rapidly progressive abdominal ulcer following minor trauma. Before presentation, he had been diagnosed with cutaneous leishmaniasis based on histopathology and a positive direct smear, and treatment with miltefosine had been initiated without clinical improvement. The lesion worsened, with severe disproportionate pain and purulent discharge.

On reassessment, a large ulcer with undermined, violaceous borders and a cribriform appearance was observed, raising suspicion for pyoderma gangrenosum. A repeat dermatopathological review demonstrated a dense neutrophilic infiltrate without evidence of microorganisms, supporting a non-infectious inflammatory process.

The diagnosis of PG was established based on clinicopathological correlation and established Delphi consensus criteria. This case highlights the significant clinicopathological overlap between PG and CL, particularly in endemic settings where the epidemiological context may bias clinical judgment. Key distinguishing features include rapid progression, disproportionate pain, pathergy, and lack of response to antiparasitic therapy. Importantly, misdiagnosis may lead to inappropriate treatment, as management strategies are fundamentally different and potentially opposing.

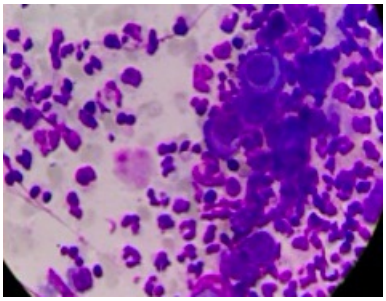

Cytological image showing a dense inflammatory infiltrate predominantly composed of neutrophils,

without evidence of microorganisms.

Conclusion

PG should be considered in the differential diagnosis of rapidly progressive ulcerative lesions, even in endemic areas. Recognition of warning signs and lack of therapeutic response is essential, as early diagnostic reconsideration may prevent inappropriate treatment and improve clinical outcomes.

EADV CONGRESS
VIENNA
30 SEP - 3 OCT 2026

Abstract N°: 1522

Capnocytophaga canimorsus infection with secondary reactive neutrophilic dermatosis with Sweets like features

Supriya Sharma*[1], Nikita Cliff-Patel[1], Rachel Fisher[1], Patrick Bryan[1]

[1] Royal Berkshire Hospital NHS Trust, Dermatology, Reading, United Kingdom

Introduction

Capnocytophaga canimorsus is an anaerobic, gram-negative bacterium that forms part of the normal oral flora of cats and dogs. It can be transmitted to humans and has the potential to cause rapidly progressive, life-threatening sepsis.

Case Presentation

A 27-year-old woman presented with a 7-day history of progressive pain and swelling over the right knee following a cat scratch. She was previously fit and well, with no history of immunosuppression. On examination, multiple dusky, fluctuant nodules were noted, initially localised to the right knee, which rapidly progressed to involve the contralateral lower limb and upper limbs.

The patient deteriorated rapidly, developing septic shock and requiring admission to the intensive care unit, where she was intubated, mechanically ventilated, and commenced on vasopressor support. Despite appropriate broad-spectrum intravenous antibiotic therapy with microbiology input, she continued to develop multiple painful, suppurative subcutaneous abscesses. In the context of septic shock and rapidly progressing bilateral lower limb discharging lesions, plastic surgeon colleagues advised for urgent surgical debridement and washout of the lesions.

Post-operatively, the patient demonstrated a marked rise in inflammatory markers, with a predominant neutrophilia and C-reactive protein levels exceeding 500 mg/L.

The progression of the disease and deteriorating clinical condition combined with rapidly worsening cutaneous lesions with more prominent violaceous borders raised suspicion for an underlying neutrophilic dermatosis. The patient was commenced on high-dose intravenous corticosteroid therapy and a marked clinical improvement was observed within 24 hours of initiating corticosteroid treatment. Histological confirmation of a sweets-like neutrophilic dermatosis was subsequently demonstated, on a background of an infectious picture and extended culture of tissue demonstrated *Capnocytophaga canimorsus* infection.

Conclusion

The patient was discharged and remains under dermatology follow-up, with a gradual tapering of corticosteroid therapy and ongoing community-based wound care. This case celebrates the positive outcome of this patient and highlights this rare condition which is most commonly reported posthumously.

EA DV CONGRESS
VIENNA
30 SEP - 3 OCT 2026

Abstract N°: 1533

Cutaneous Ultrasound: A Window into Monitoring Therapeutic Response in Eosinophilic Fasciitis.

Francisco Javier León Pérez*[1], Carmen García Moronta[1], Andrea Isabel Rodriguez-Sanna[1], Julia Castro Martín[1], Manuel Sánchez-Díaz[1], Salvador Arias-Santiago[1]

[1] Hospital Universitario Virgen de las Nieves, Granada, Spain

Introduction

Eosinophilic Fasciitis (EF) is a rare connective tissue disorder characterized by edema and progressive skin induration. The differential diagnosis with other sclerodermiform conditions is complex, and establishing objective monitoring parameters remains a clinical challenge. The primary objective of this work is to highlight the utility of cutaneous ultrasound (US) as an accessible diagnostic tool and a robust method for quantifying and monitoring therapeutic response in patients with EF.

Case Presentation

We present two clinical cases of women diagnosed with EF through a comprehensive evaluation including clinical examination, laboratory analysis, histopathology, and cutaneous ultrasound.

Case 1 involved a 64-year-old woman presenting with a 3-month progression of skin irregularities on all four limbs, characterized by nodules and "peau d'orange" depressions. Laboratory investigations revealed eosinophilia (410 eosinophils/mm^3), along with elevated CRP and ESR, and the diagnosis of EF was confirmed via biopsy. Following the initiation of prednisone (0.5 mg/kg in a long tapering schedule) and methotrexate (10 mg/week), the patient showed an excellent clinical response, including improved joint mobility and a decrease in eosinophilia to 60/mm^3. Clinical ultrasound of the forearms at baseline identified a dermo-epidermal thickness of 10.1 mm and a fascia thickness of 2 mm; follow-up imaging at 6 months demonstrated a significant reduction in dermo-epidermal thickness to 7.0 mm in the same affected area.

Case 2 involved a 61-year-old woman with a 3-year history of sclerodermiform lesions, polyarthralgia, and clinically compatible urticaria-like episodes. Physical examination showed incipient induration in both pretibial regions and the lateral arms, while histopathology revealed diffuse inflammation between the deep dermis and subcutaneous fat with numerous eosinophils and collagen sclerosis. Currently managed with deflazacort (6 mg/day) and methotrexate (10 mg/week), the patient reports mild improvement across all affected sites. At the time of diagnosis, cutaneous ultrasound facilitated immediate objective confirmation of the edema and infiltration characteristic of EF by distinguishing healthy perilesional skin (0.426 cm thick) from the lesional area, which showed marked dermo-epidermal thickening (0.788 cm) and fascial thickening (0.178 cm).

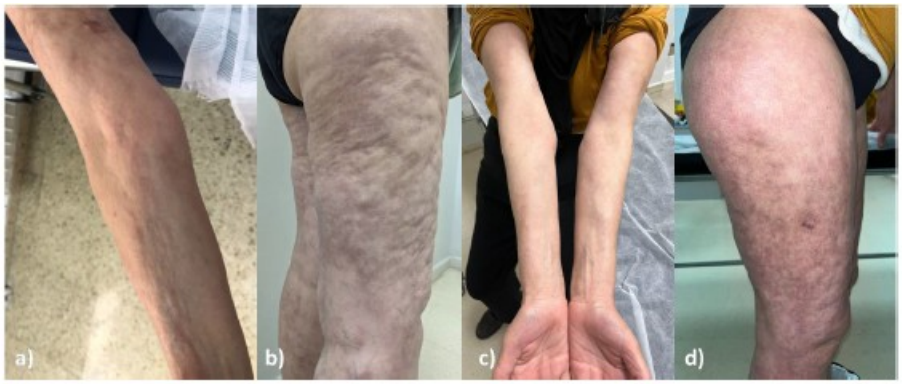

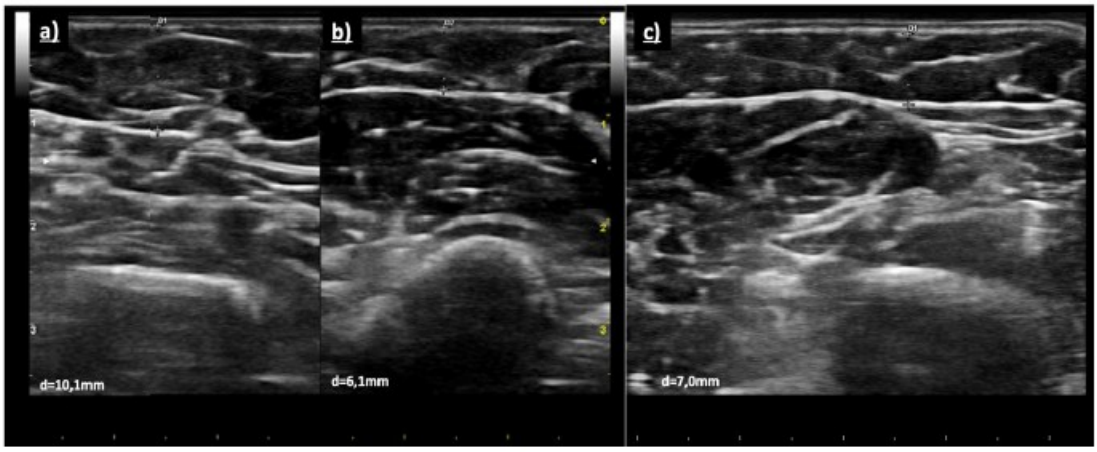

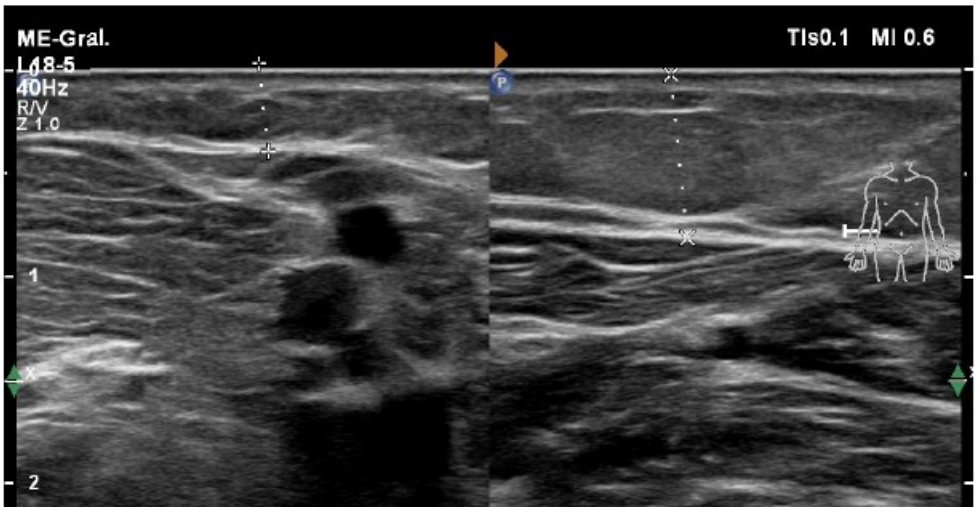

Conclusion

Cutaneous ultrasound is a rapid, accessible, and non-invasive technique that supports the clinical suspicion of EF and provides objective data for therapeutic monitoring. This tool facilitates dynamic disease management and offers a more accessible alternative for close follow-up than magnetic resonance imaging (MRI).

EA DV CONGRESS
VIENNA
30 SEP - 3 OCT 2026

Abstract N°: 1544

Endophenotypic divergence between atopic and non-atopic prurigo nodularis: Clinical features, neural anatomy, and spatial transcriptomic profiling of the dermal microenvironment

Yixin Shao*[1], Lisi Peng[1], Duoqin Wang[1], Hui TANG[1]

[1] Huashan Hospital, Fudan University, Shanghai, China

Introduction
Prurigo nodularis (PN) is a heterogeneous chronic pruritic dermatosis. Reports have shown differences between PN patients with an atopic background (APN) and those without (NAPN) in age of onset, immunophenotype, and treatment response, but the evidence is scattered and lacks systematic validation. Moreover, the spatial molecular characteristics of the immune-neural-stromal microenvironment in the superficial dermis of these two endotypes remain unclear. This study aimed to compare APN and NAPN in clinical features, treatment response, cutaneous neural architecture, and superficial dermal microenvironment, and to explore the molecular basis for endotype subtyping and potential therapeutic targets.

Materials and Methods
A total of 369 PN patients were enrolled and divided into APN and NAPN according to atopic background. Demographic, clinical phenotypic, laboratory, and treatment response data were compared between the two groups. Based on three independent cohorts, lesional and non-lesional skin from APN and NAPN patients as well as normal skin from healthy controls were collected and sequentially used for PGP 9.5 immunofluorescence staining to assess cutaneous neural architecture differences, for bulk-RNA sequencing, and for digital spatial profiling (DSP)-based spatial transcriptomic analysis of the superficial dermis, in order to compare molecular features and identify key differential genes between the two groups.

Results
APN accounted for a higher proportion than NAPN (ratio 2.46:1), with a younger age of onset (49.6 vs. 53.3 years) and significantly higher serum total IgE and eosinophil levels. The proportion of patients achieving an IGA score of 4 was significantly higher in the APN group (44.0% vs. 29.0%), but no significant differences were observed in itch intensity, quality of life, or response rates to standard therapy or dupilumab between the two groups. Bulk-RNA sequencing revealed limited overall transcriptomic differences between lesional skins of the two groups. Neural architecture analysis showed significantly higher superficial dermal nerve fiber density and terminal branching hyperplasia in APN lesions than in NAPN lesions. DSP spatial transcriptomic analysis of this region revealed that differences between the two groups were mainly confined to the $CD45^-$ compartment: NAPN lesions were enriched in pathways related to extracellular matrix remodeling and collagen formation, whereas APN lesions showed upregulation of sensory stimulation-associated pathways. Immune infiltration analysis indicated increased infiltration of eosinophils and regulatory T cells in APN lesions, while $CD8^+$ T cells and γδ T cells were more abundant in NAPN lesions. Receptor-ligand interaction analysis suggested that interaction strength between non-immune and immune cells was significantly higher in NAPN than in APN, with unique interactions involving neurotransmitter transmission, axon guidance, vascular and matrix remodeling. Weighted gene co-expression network analysis (WGCNA) identified 32 NAPN-specifically upregulated genes, among which GRN, AEBP1, and GPX4 showed significant negative correlations with itch severity in NAPN. GSEA functional enrichment indicated

their involvement in inflammation regulation, tissue repair, and anti-oxidative stress. In the non-severe stage, molecular differences between APN and NAPN were pronounced, involving translation/ribosomal pathways, stress responses, and ROBO/SLIT signaling, but these differences diminished in the severe stage.

Conclusions

APN and NAPN exhibit fundamental differences in clinical features, neural architecture, and the superficial dermal microenvironment. APN is characterized by type 2 immune activation, enhanced superficial dermal innervation, and sensory sensitization, whereas NAPN is characterized by $CD8^+$ T cell-dominated cellular immunity and neuro-stromal network remodeling. GRN, AEBP1, and GPX4 are promising protective factors and novel subtype-specific therapeutic targets for NAPN.

EADV CONGRESS
VIENNA
30 SEP - 3 OCT 2026

Abstract N°: 1566

Bullous penile lichen sclerosus: a rare clinical presentation

Michalina Dudra[1], Katarzyna Czajkowska*[2]

[1] Dermatology Student Scientific Circle, Medical University of Gdańsk, Gdańsk, Poland
[2] Department of Dermatology, Venerology and Allergology, Medical University of Gdańsk, Gdańsk, Poland

Introduction

Lichen sclerosus (LS) is a chronic inflammatory dermatosis that predominantly affects the anogenital region and typically presents as atrophic white plaques. Rare clinical variants, including the bullous form, may occur and can pose a significant diagnostic challenge. Bullous LS is particularly uncommon in the genital area, with available evidence largely limited to isolated case reports, and may clinically mimic other blistering or inflammatory dermatoses.

Case Presentation

We report the case of a 46-year-old male presenting with a two-month history of penile lesions characterized by tense, clear fluid-filled blisters. Clinical examination revealed depigmented areas involving the glans penis and the inner foreskin, along with a constrictive ring of the inner preputial layer and visible narrowing of the external urethral meatus. Dermoscopic evaluation showed multiple hemorrhagic globules, linear vessels and white structureless areas. Due to the atypical presentation, a biopsy was performed. Histopathological examination confirmed the diagnosis of lichen sclerosus. The patient was treated with high-potency topical corticosteroid, clobetasol propionate, resulting in marked clinical improvement. Follow-up demonstrated significant regression of lesions, with corresponding dynamic changes in dermoscopic features over time. A urological consultation was obtained, and no indication for surgical intervention regarding the urethral meatal narrowing was identified.

Conclusion

Bullous penile LS represents a rare and potentially misleading presentation. This case highlights not only the importance of histopathological confirmation in atypical genital dermatoses, but also demonstrates the excellent therapeutic response to high-potency topical corticosteroids. The striking clinical and dermoscopic improvement observed in our patient underscores the effectiveness of appropriate treatment and supports its role as the first-line treatment. Early recognition is crucial to ensure prompt management and to avoid unnecessary diagnostic and therapeutic interventions.

EADV CONGRESS
VIENNA
30 SEP - 3 OCT 2026

Abstract N°: 1575

Bullous Sweet's syndrome mimicking cellulitis: a diagnostic pitfall

Rocío Mariscal*[1], Gabriel García-Mayorca[1]

[1] Department of Dermatology, Santo Tomás Hospital, Panama City, Panama

Introduction

Sweet's syndrome is an uncommon inflammatory condition characterized by the abrupt onset of painful erythematous plaques, fever, neutrophilia, and a dense neutrophilic dermal infiltrate. Despite well-described classic features, the clinical presentation is highly heterogeneous. Atypical variants, such as bullous and cellulitis-like forms, can mimic infection and delay treatment.

Case Presentation

We report a 60-year-old male with no significant medical history who presented with an 8-day history of fever, chills, and a painful erythematous lesion on the left lower leg. He reported a similar episode a year prior.

Examination revealed a poorly demarcated, erythematous, warm, and deeply tender plaque with bullous features containing purulent-appearing material. Additional erosions and hematic crusts overlying erythematous plaques were observed on the extremities and trunk. Laboratory tests showed leukocytosis, neutrophilia, and elevated C-reactive protein levels. Soft tissue ultrasound demonstrated subcutaneous thickening and inflammatory changes suggestive of cellulitis.

The patient was admitted and treated with intravenous antibiotics; however, the lesions continued to progress despite therapy. Blood and wound cultures remained sterile, and antinuclear antibodies were negative. A skin biopsy was performed, and histopathological examination revealed a subepidermal bulla with a dense neutrophilic dermal infiltrate without vasculitis, consistent with a neutrophilic dermatosis. The patient fulfilled criteria for Sweet's syndrome and was started on systemic corticosteroid therapy (prednisone 0.5 mg/kg/day), resulting in rapid clinical improvement and complete re-epithelialization within one week.

Conclusion

This case highlights a bullous variant of Sweet's syndrome mimicking cellulitis, a recognized but underdiagnosed presentation that may lead to misdiagnosis. Clinicians should maintain a high index of suspicion in patients with presumed cellulitis who fail to respond to antibiotics, particularly in the presence of sterile cultures. Early skin biopsy should be considered to ensure timely diagnosis, as systemic corticosteroids remain a highly effective first-line treatment and result in rapid resolution.

EADV CONGRESS
VIENNA
30 SEP - 3 OCT 2026

Abstract N°: 1580

CARD14 (rs34367357) Polymorphism and Methotrexate Response in Psoriasis and Psoriatic Arthritis: A Prospective Case–Control Study

Moustafa El Taieb*[1], Eisa Hegazy[2], Essam-Eldin Nada[3]

[1] Aswan University, Aswan, Egypt
[2] Qena University, Qina, Egypt
[3] Sohag University, Sohag, Egypt

Introduction

Psoriasis is a chronic immune-mediated condition with a significant hereditary component that may advance to psoriatic arthritis (PsA), a painful inflammatory joint ailment. Mutations in the CARD14 gene have been associated with illness susceptibility and pathogenesisThis study sought to assess the relationship between the CARD14 (rs34367357) polymorphism and psoriasis as well as psoriatic arthritis, along with its relevance to clinical, laboratory, and therapy response metrics.

Materials and Methods

In this case-control study, 40 healthy controls and 90 patients with psoriasis (30 with moderate severity, 30 with severe severity, and 30 with psoriatic arthritis) were matched for age and sex. A complete blood count, inflammatory markers (CRP, ESR), lipid profile, and assessments of liver and kidney function were conducted on all subjects as part of comprehensive clinical evaluations and standard laboratory tests. All subjects were genotyped for the CARD14 (rs34367357) single nucleotide polymorphism using real-time polymerase chain reaction (PCR). Patients were assessed prior to and following 12 weeks of methotrexate treatment.

Results

Demographic data exhibited no significant differences between patients and controls ($p > 0.05$). Patients with PsA exhibited a greater inflammatory load relative to other subgroups. Methotrexate therapy markedly enhanced inflammatory and lipid markers ($p < 0.001$), accompanied by slight increases in liver enzymes and steady renal function. The distribution of CARD14 (rs34367357) genotypes exhibited a significant difference between patients and controls ($p < 0.001$, OR = 0.085, 95% CI: 0.024-0.295), characterized by a higher prevalence of the GG genotype and G allele in patients. Genotype-specific differences in treatment response were observed, with the AA genotype showing greater improvement in PASI and DAPSA scores compared to AG and GG genotypes.

Conclusions

The CARD14 (rs34367357) polymorphism was substantially correlated with the susceptibility to psoriasis and psoriatic arthritis and exhibited a genotype-dependent influence on the methotrexate response. Patients who possessed the AA genotype exhibited a greater improvement in PASI and DAPSA scores than those with the AG and GG genotypes. These findings endorse CARD14 genotyping as a clinically relevant tool for predicting methotrexate response and steering personalized therapy in psoriatic disease.

EADV CONGRESS
VIENNA
30 SEP - 3 OCT 2026

Abstract N°: 1582

Delayed Diagnosis of Hidradenitis Suppurativa: A Multicenter Cohort Study Highlighting Surgical and Antibiotic Burden Prior to Diagnosis

Ali Fakih*[1], Ali Hamieh[2], Aya Awwad[2], Fouad El Sayed[2]

[1] Dermatology Department, Hammoud Hospital University Medical Center, Lebanese University, Beirut, Lebanon
[2] Dermatology Department, Baabda University Hospital, Lebanese University, Beirut, Lebanon

Introduction

Hidradenitis suppurativa (HS) is a chronic inflammatory skin disease frequently associated with significant diagnostic delays, resulting in disease progression and suboptimal early management.

Materials and Methods

This study aimed to evaluate diagnostic delay, disease severity, and patterns of pre-diagnostic healthcare utilization in a multicenter cohort of patients with HS. We conducted a retrospective study including 77 patients diagnosed by dermatologists across two university hospitals and one private hospital (2024- 2026). Demographic, clinical, and temporal data were collected using a standardized case report form. Diagnostic delay was defined as the interval between patient-reported disease onset and formal diagnosis. Statistical associations were assessed using nonparametric tests (Spearman correlation and Mann-Whitney U test).

Results

Seventy-seven patients were included (66% male; mean age 33.1 years). The mean diagnostic delay was 4.74 ± 4.75 years (median 2.91; range 0.1–21.5). At diagnosis, 55% were Hurley stage I, 38% stage II, and 7% stage III, with a mean International Hidradenitis Suppurativa Severity Score System (IHS-4) of 11.27. Quality of life was significantly impaired (mean Dermatology Life Quality Index [DLQI] 12.93; 55.2% scored >10, indicating severe impact). Diagnostic delay was positively correlated with disease severity (IHS-4: ρ =0.318, p=0.006) and quality-of-life impact (DLQI: ρ=0.304, p=0.012). Furthermore, patients with more advanced Hurley stages experienced significantly longer delays (p=0.006). Prior to diagnosis, 38% (29/77) of patients underwent surgical procedures, predominantly incision and drainage, and these patients had significantly longer diagnostic delays compared to those managed non-surgically (p=0.003).

Conclusions

Diagnostic delay in HS remains substantial and is associated with increased disease severity and impaired quality of life. The high rate of surgical interventions prior to diagnosis highlights a critical period of under-recognition. These findings emphasize the need for improved awareness and earlier referral to dermatology services to reduce disease burden and prevent unnecessary procedures.

EADV CONGRESS
VIENNA
30 SEP - 3 OCT 2026

Abstract N°: 1585

Extensive Antibiotic Exposure and Limited Use of Biologic Therapy in Hidradenitis Suppurativa: A Multicenter Real-World Study

Ali Fakih*[1], Ali Hamieh[2], Aya Awwad[2], Fouad El Sayed[2]

[1] Dermatology Department, Hammoud Hospital University Medical Center, Lebanese University, Beirut, Lebanon
[2] Dermatology Department, Baabda University Hospital, Lebanese University, Beirut, Lebanon

Introduction

Systemic antibiotics are widely used in the management of hidradenitis suppurativa (HS), yet prolonged or repeated courses may indicate a delay in escalating to advanced therapies. Real-life patterns of antibiotic exposure and access to biologic therapies remain insufficiently characterized.

Materials and Methods

This study aimed to evaluate patterns of systemic antibiotic use and biologic therapy, and their relationship with disease severity and diagnostic delay. We performed a retrospective analysis of 77 patients across two university hospitals and one private hospital (2024–2026). Treatment history, including antibiotic exposure and biologic use, was analyzed alongside disease severity using the International Hidradenitis Suppurativa Severity Score System (IHS-4). Associations were assessed using Spearman correlation and the Mann–Whitney U test.

Results

The cohort (n=77) had a mean age of 33.1 years and a mean BMI of 28.6. Current smoking was reported in 72.7% of patients. Overall, 77.9% had received systemic antibiotics, most commonly doxycycline (45%), amoxicillin (43%), clindamycin (26%), and clindamycin–rifampin (14.3%), often as repeated courses. Antibiotic exposure was positively correlated with disease severity (IHS-4) ($\rho = 0.497$, $p < 0.001$), suggesting greater antibiotic exposure in more severe disease. Additionally, diagnostic delay was moderately correlated with increased antibiotic exposure ($\rho = 0.496$, $p < 0.001$). Despite 61.6% of patients having moderate-to-severe disease, only 15.6% (12/77) were receiving biologic therapy. Patients receiving biologics had significantly higher IHS-4 scores than those not receiving biologics ($p = 0.016$).

Conclusions

Patients with HS experience substantial exposure to systemic antibiotics, which is associated with greater disease severity and longer diagnostic delay. The relatively low use of biologic therapy in the context of moderate-to-severe disease suggests a gap between disease burden and treatment patterns. These findings support the need for earlier diagnosis and timely escalation to appropriate therapies to improve patient outcomes.

EADV CONGRESS
VIENNA
30 SEP - 3 OCT 2026

Abstract N°: 1589

Clinical, Laboratory, and Histopathological Features of Pyoderma Gangrenosum: A Single-Center Retrospective Study

Mert Bardak*[1], Ibrahim Akcay[1], Fatih Boynueğrioğlu[1], Ece Gokyayla[1], Idil Unal[1], Nilay Duman[1]

[1] Ege University Hospital Department of Dermatology and Venereology, Izmır, Türkiye

Introduction
Pyoderma gangrenosum (PG) is a rare neutrophilic dermatosis characterized by a variable clinical course and frequent association with systemic diseases. Identifying clinical and laboratory factors that may predict disease course and outcomes remains an important challenge.

Materials and Methods
In this retrospective study, 60 patients diagnosed with pyoderma gangrenosum (PG) based on clinical and/or histopathological findings and followed in our department were included. Demographic data (age, sex), clinical characteristics (lesion localization, number, type, and disease duration), comorbidities, laboratory parameters (complete blood count, C-reactive protein [CRP], erythrocyte sedimentation rate [ESR], biochemical and immunological data), histopathological findings, treatment modalities, and follow-up data were analyzed. Recurrence, treatment response, and lesion healing time were defined as dependent variables. Associations between variables were evaluated using appropriate statistical methods.

Results
Of the patients, 53.3% were female, with a mean age of 52.0±18.7 years. Lesions were most commonly ulcerative (76.7%) and predominantly localized on the lower extremities (56.7%). The recurrence rate was 36.7%. A significant association was found between the presence of inflammatory bowel disease (IBD) and recurrence (OR=10.88, p=0.040). In addition, patients with IBD had a longer lesion healing time compared to those without IBD (median 6 months vs. 3 months, p=0.027). The neutrophil-to-lymphocyte ratio (NLR) showed a trend toward association with recurrence (p=0.089). In contrast, no significant associations were observed between classical inflammatory markers such as CRP, ESR, and albumin and clinical outcomes. No significant relationship was found between other comorbidities or clinical features and prognosis.

Conclusions
In this study, the presence of inflammatory bowel disease (IBD) in patients with pyoderma gangrenosum (PG) was associated with a higher risk of recurrence and delayed healing. Although the neutrophil-to-lymphocyte ratio (NLR) showed a potential association with disease course, further studies with larger cohorts are needed to confirm this finding. In contrast, classical inflammatory markers such as CRP, ESR, and albumin appeared to have limited prognostic value. These findings may contribute to improved risk stratification and clinical management of PG patients.

EADV CONGRESS
VIENNA
30 SEP - 3 OCT 2026

Abstract N°: 1632

Trichoscopic Features of Dissecting Cellulitis of the Scalp: A Case Series Overview

Olha Statkevych*[1], Tetiana Sviatenko[1]

[1] Dnipro state medical university, Dnipro, Ukraine

Introduction
Dissecting cellulitis of the scalp is a chronic inflammatory disorder associated with progressive follicular destruction and scarring alopecia. Early diagnosis is often delayed because of clinical overlap with other scalp disorders and the absence of specific laboratory markers. Trichoscopy may provide valuable non-invasive diagnostic clues for early recognition of this condition.

Case Presentation
A case series of 40 male patients aged 20–55 years with confirmed dissecting cellulitis of the scalp was analyzed. Most patients presented with painful inflammatory nodules, areas of alopecia and chronic relapsing disease predominantly involving the vertex scalp. Trichoscopic examination was performed in areas of active inflammation to assess characteristic diagnostic features.

Conclusion
Trichoscopy represents a valuable non-invasive tool for the early diagnosis of dissecting cellulitis of the scalp. Characteristic findings, particularly “soap-bubble” yellow dots and cutaneous clefts, may serve as practical trichoscopic criteria for differential diagnosis and disease monitoring.

EADV CONGRESS
VIENNA
30 SEP - 3 OCT 2026

Abstract N°: 1656

Wolf's Isotopic Phenomenon Presenting as Psoriasiform Dermatitis after Herpes Zoster Leading to Prolonged Misdiagnosis and Repeated Antiviral Therapy

Milos Nisavic*[1], Irena Komljenović[2], Nevena Đumić[1], Ana Segedi[1], Aleksandra Bukvić Šajinović[1]

[1] University of Novi Sad, Faculty of Medicine, Novi Sad, Serbia

[2] Regena Polyclinic, Novi Sad, Serbia

Introduction

Wolf's isotopic phenomenon (WIP) describes the occurrence of a new, unrelated dermatosis at the site of a previously healed skin disease, most commonly following herpes zoster infection. Clinically, WIP may mimic recurrent infection or primary inflammatory dermatoses, leading to diagnostic delay and inappropriate treatment.

Case Presentation

We present a case and narrative literature review of post-herpetic isotopic responses. A structured PubMed search was performed using the terms ("Wolf isotopic response" OR "isotopic response" OR "Wolf phenomenon") AND ("herpes zoster" OR "varicella zoster"). A total of 116 articles were identified, of which 18 were included after relevance-based screening.

A 73-year-old female patient presented with a 5-month history of recurrent unilateral exudative erythemosquamous plaques on the left abdomen. Initial episodes were clinically interpreted as herpes zoster and treated repeatedly with oral acyclovir therapy over several months. The patient developed persistent erythematosquamous plaques with areas of regression and hypertrophic scars, accompanied by pain in the affected dermatome.

Histopathological examination revealed an epidermis of relatively preserved architecture with dermal fibroplasia, vertically oriented blood vessels, and a perivascular lymphocytic infiltrate, consistent with a post-inflammatory cicatricial process.

Clinical and dermoscopic evaluation confirmed a unilateral lesion with mixed inflammatory and cicatricial features, consistent with WIP with psoriasiform dermatitis-like changes in a post-zoster field.

WIP most commonly follows herpes zoster and presents with a broad spectrum of secondary dermatoses, including inflammatory (psoriasiform, eczematous, lichenoid), granulomatous, autoimmune (bullous pemphigoid, lupus erythematosus), infectious, and neoplastic conditions.

The literature identifies recurrent diagnostic challenges: 1. Lesions are frequently misinterpreted as recurrent herpes zoster or chronic inflammatory dermatoses; 2. Overlapping features of post-herpetic skin remodeling and secondary inflammatory changes may obscure the underlying diagnosis. These patterns underscore the importance of early consideration of WIP in persistent dermatomal eruptions unresponsive to antiviral therapy to avoid diagnostic delay and therapeutic inertia.

Conclusion

WIP should be considered in persistent or recurrent unilateral dermatoses following herpes zoster, especially when unresponsive to antiviral therapy, as early recognition prevents diagnostic delay and inappropriate treatment.

Clinicopathological correlation remains crucial, as histological findings may be subtle and non-specific.

EA DV CONGRESS
VIENNA
30 SEP - 3 OCT 2026

Abstract N°: 1744

Residual Inflammation in Hidradenitis Suppurativa Despite Infliximab Therapy

Tessa Bortoluzzi*[1], Fatima Al-Khawaja[1], Raed Alhusayen[2, 3]

[1] Division of Dermatology, University of Toronto, Toronto, ON, Canada

[2] Division of Dermatology, Faculty of Medicine, Women's College Hospital, University of Toronto, Toronto, ON, Canada

[3] Department of Medicine and Sunnybrook Research Institute, University of Toronto, Toronto, ON, Canada

Introduction

Residual inflammation remains an ongoing integral topic in dermatologic conditions, including hidradenitis suppurativa (HS). It is imperative to consider the implications of HS including persistent inflammation. The primary objective of this study was to assess the prevalence of residual inflammation in individuals with HS on infliximab therapy for at least 16 weeks. Secondary objectives included assessing whether residual inflammation was related to age, sex, Hurley stage, inflammatory comorbidities, metabolic comorbidities, and HS control.

Materials and Methods

A retrospective chart review was performed which revealed nineteen individuals on infliximab for HS with bloodwork completed after being on infliximab for at least 16 weeks. These laboratory tests were reviewed for high sensitivity CRP (hsCRP), erythrocyte sedimentation rate (ESR), lymphocytes, monocytes, neutrophils, and platelets. Note was made of age, sex, prior biologic therapies, inflammatory comorbidities, metabolic comorbidities, Hurley stage, and HS control. Inflammatory comorbidities included psoriasis, inflammatory arthritis, inflammatory bowel disease, and pyoderma gangrenosum. Metabolic comorbidities included diabetes mellitus, hypertension, and dyslipidemia. Markers of residual inflammation in this study included hsCRP, ESR, monocyte-to-lymphocyte ratio (MLR), neutrophil-to-lymphocyte ratio (NLR), platelet-to-lymphocyte ratio (PLR), pan-immune-inflammation value (PIV), and systemic immune-inflammation index (SII). Mean and standard deviation was used to report continuous variables, and counts and frequencies were used to report categorical variables. Mann-Whitney U test and Fisher exact test were used to test for significant differences between individuals with at least one elevated inflammatory marker and those without for continuous and categorical variables, respectively.

Results

Fifteen out of nineteen (78.9%) individuals had at least one of the inflammatory markers elevated. The most frequently increased inflammatory markers were hsCRP (62.5%), ESR (62.5%), and PIV (42.1%). There was not a statistically significant difference between the groups of individuals who had at least one inflammatory marker elevated compared to those with no inflammatory markers elevated in age (p=0.963), sex (p=0.305), Hurley stage (p=0.570), inflammatory comorbidities (p=0.603), or whether HS was well-controlled (p=0.272). The difference in metabolic comorbidities between those who had at least one inflammatory marker elevated and those without any inflammatory markers elevated was approaching statistical significance (p=0.084).

Conclusions

This study revealed that just under 80% of individuals with HS treated with infliximab had residual inflammation. The findings are limited by the small sample size. Further studies are warranted to evaluate residual inflammation in HS treated with other biologic therapies, and with larger sample sizes.

EA DV CONGRESS
VIENNA
30 SEP - 3 OCT 2026

Abstract N°: 1763

Clinical Characteristics and Triggering Factors of Rosacea in Korean Patients According to Sex and Age: A Retrospective Single-Center Study of 245 Cases

Yun Su Eun[1], Whiin Lee[1], Sehwi Jeong[1], Jeongwoo Kim[1], Seong Jun Seo[1], Sung Yul Lee[1], Euy Hyun Chung*[1], Jung Eun Kim[1]

[1] Department of Dermatology, Soonchunhyang University Cheonan Hospital, Soonchunhyang University College of Medicine, Cheonan, Cheonan, Korea, Rep. of South

Introduction

Rosacea is a chronic inflammatory dermatosis with heterogeneous clinical manifestations. Differences in prevalence and clinical subtypes according to age and sex have been reported, but detailed characterization of these patterns remains limited. This study aimed to evaluate differences in clinical characteristics and triggering or aggravating factors of rosacea according to sex and age in Korean patients.

Materials and Methods

This single-center retrospective study included 245 Korean patients diagnosed with rosacea at the dermatology outpatient clinic of Soonchunhyang University Cheonan Hospital from January 2018 to August 2023. We assessed demographic data, clinical characteristics, comorbidities, severity, and triggering or aggravating factors using pre-existing clinical questionnaires, medical records, and clinical photographs. Patients were classified by sex and age(<30, 30–49, ≥50 years) for comparative analyses.

Results

Of 245 patients, 51(20.8%) were male and 194(79.2%) were female. Overall severity was mild to moderate(IGA 2.4±0.7) with no significant difference by sex or age; however, severe rosacea was observed exclusively in female patients. Erythematotelangiectatic rosacea as the most common subtype in both sexes, whereas the phymatous subtype was markedly more prevalent in men. men showed significantly higher severity of primary features, including flushing, persistent erythema, and telangiectasia, compared with women. Regarding secondary features, pruritus and burning/stinging were more frequent in women, whereas phymatous changes were significantly more common in men. For triggering or aggravating factors, alcohol was significantly associated with men, while skincare products, mask use, hormonal changes, and laser treatment were more frequently reported in women. Seborrheic dermatitis was more commonly observed in men, whereas psychiatric diseases were more frequently reported in women. Perioral involvement was significantly more common in women.
Erythematotelangiectatic rosacea was the most common subtype across all age groups, with a decreasing trend with age, whereas the phymatous subtype increased with age; however, these trends were not statistically significant. The severity of primary features was generally comparable across age groups, although telangiectasia showed a slight increase in older patients. Pruritus and burning/stinging were the most common secondary features in all age groups. Emotional changes and temperature were the most frequently reported triggering or aggravating factors, with some variation across age groups. Skincare products were more prevalent in higher in the <30 and 30–49 age groups, while long-term steroid use was more common in the 30–49 age group than in those aged ≥50 years.

Conclusions

These findings demonstrate that rosacea exhibits distinct clinical features and triggering factors according to sex and age, highlighting the importance of personalized management strategies tailored to individual patient characteristics.

EA DV CONGRESS
VIENNA
30 SEP - 3 OCT 2026

Abstract N°: 1770

Hidradenitis suppurativa–derived fibroblasts display a pro-fibrotic phenotype relative to healthy control–derived fibroblasts

Helena Port Linares[1, 2], Carmen Al Youssef[3], Bénédicte Oulès[3], Signe Holm Nielsen*[1]

[1] Nordic Bioscience, Herlev, Denmark

[2] Bispebjerg Hospital, Copenhagen, Denmark

[3] Cutaneous Biology Laboratory, Institut Cochin, INSERM, Paris, France

Introduction

Hidradenitis suppurativa (HS) is a chronic, recurrent inflammatory skin disease characterized by painful nodules, abscesses, and sinus tract formation in intertriginous areas. Persistent inflammation and repeated tissue injury promote dermal remodeling and fibrosis, contributing to irreversible scarring and disease progression. Extracellular matrix (ECM) remodeling releases collagen- and matrix-derived protein fragments into the circulation, which can serve as measurable biomarkers of tissue turnover and fibrosis. Understanding the molecular mechanisms driving fibrosis in HS is essential for developing new treatments. Fibroblasts play a central role in ECM production and remodeling, yet their contribution to fibrotic activity in HS remains insufficiently characterized. This study aimed to investigate ECM formation in fibroblasts derived from HS patients compared with healthy donors by quantifying biomarkers of collagen formation and matrix remodeling, providing insight into the underlying tissue damage and scarring.

Materials and Methods

Primary dermal fibroblasts from HS patients (n = 4 donors) and healthy controls (n = 5 donors) were cultured in 48-well plates (25,000–30,000 cells/well) in medium containing 0.4% fetal bovine serum, ascorbic acid (33.3 µg/mL), and 5% penicillin/streptomycin. Cells were maintained for four days, after which supernatants were collected for biomarker quantification. Four biomarkers related with fibrosis were measured: PRO-C1, formation of type I collagen, PRO-C3, formation of type II collagen, PRO-C6, formation of type VI collagen, FBN-C, C-terminal of fibronectin- cell adhesion, migration and growth marker. Group comparisons were performed using the Mann–Whitney U test. Statistical significance was defined as $p < 0.05$.

Results

HS-derived fibroblasts presented significantly increased formation of type I collagen (PRO-C1) compared with healthy fibroblasts ($p < 0.05$, Figure 1A). Similarly, type VI collagen formation (PRO-C6) was significantly elevated in HS fibroblasts ($p < 0.05$, Figure 1D). Type III collagen formation (PRO-C3) showed a trend toward higher levels in HS fibroblasts; however, this difference did not reach statistical significance. No statistically significant difference was observed in FBN-C levels between HS and healthy fibroblasts.

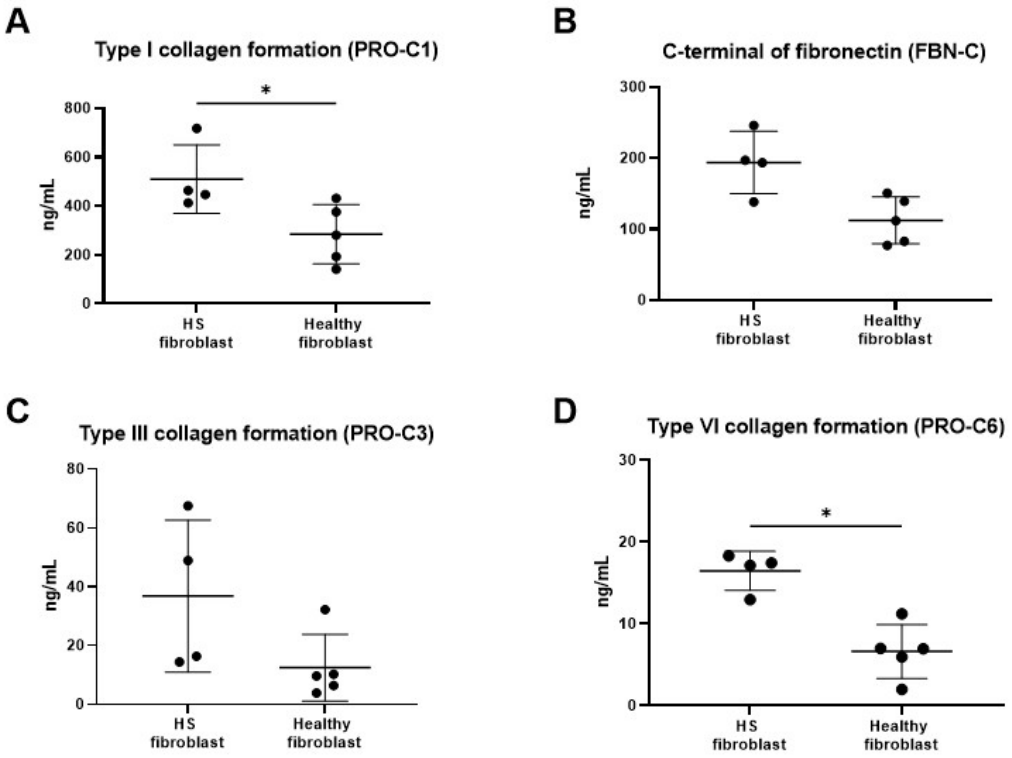

Figure 1. Biomarker levels of collagen formation in fibroblasts derived from patients with HS and healthy donors. Primary dermal fibroblasts from HS patients (n = 4) and healthy donors (n = 5) were cultured for four days. (A) Type I collagen formation (PRO-C1), (B) C-terminal fibronectin fragment (FBN-C), (C) Type III collagen formation (PRO-C3), and (D) Type VI collagen formation (PRO-C6). HS-derived fibroblasts exhibited significantly increased formation of type I and type VI collagen compared with healthy fibroblasts, indicating a pro-fibrotic phenotype. No statistically significant differences were observed for FBN-C or type III collagen formation. Data are presented as individual donor values with mean ± SD. Statistical analysis was performed using the Mann–Whitney U test; *p < 0.05.

Conclusions

Overall, these findings indicate a shift toward a pro-fibrotic phenotype in HS-derived fibroblasts, characterized primarily by increased production of type I and type VI collagen. Targeting fibrotic pathways and ECM remodeling may represent a promising therapeutic strategy to prevent tissue damage and scarring progression in HS.

EA DV CONGRESS
VIENNA
30 SEP - 3 OCT 2026

Abstract N°: 1781

Validation and Responsiveness Assessment of the Rosacea Area and Severity Index in Chinese Patients

Yukun Wang*[1], Hongjie Luo[1], Xian Jiang[1]

[1] West China Hospital, Sichuan University, Chengdu, China

Introduction

Rosacea is a common chronic inflammatory skin disorder that significantly impairs patients' quality of life. The Investigator's Global Assessment (IGA), the most widely used clinical tool for evaluating rosacea severity, is limited by high subjectivity, narrow categorical scale, and inability to detect subtle but clinically meaningful changes. The Rosacea Area and Severity Index (RASI) was recently developed as a composite scoring system that incorporates both intensity of key signs and extent of involvement across four facial areas with area-specific weights. However, independent validation in diverse populations and assessment of its responsiveness to change are still lacking.

Materials and Methods

Six well-trained dermatologists independently scored standardized facial photographs (via VISIA system) of 230 Chinese patients with rosacea using both RASI and IGA. Inter-observer reliability and convergent validity were assessed on baseline images. To evaluate intra-observer reliability and responsiveness to change, a randomly selected subgroup of 60 patients was reassessed 3 months later. In this second session, the same observers re-scored both the baseline photographs and the one-month follow-up photographs of these 60 patients.

Results

RASI total scores showed a strong correlation with IGA at baseline (Spearman's $\rho = 0.726$), with particularly high correlations for rhinophyma ($\rho = 0.965$) and papules/pustules ($\rho = 0.881$). Inter-observer reliability was excellent for both RASI-overall and IGA-overall (intraclass correlation coefficient [ICC] = 0.923 and 0.935, respectively). After 3 months, intra-observer reliability for RASI remained excellent (ICC = 0.971, $P > 0.05$), indicating no significant scoring drift. In the longitudinal responsiveness assessment, RASI demonstrated a higher standardized response mean compared with IGA (0.43 vs. 0.37), with a similar effect size. Notably, among the 35 patients classified as "stable" by IGA (no change across at least four observers), RASI scores still detected statistically significant changes from baseline to follow-up ($P < 0.001$). This superior sensitivity was consistently observed across most RASI sub-scores, including erythema, papules/pustules, and area involvement of the cheeks and forehead.

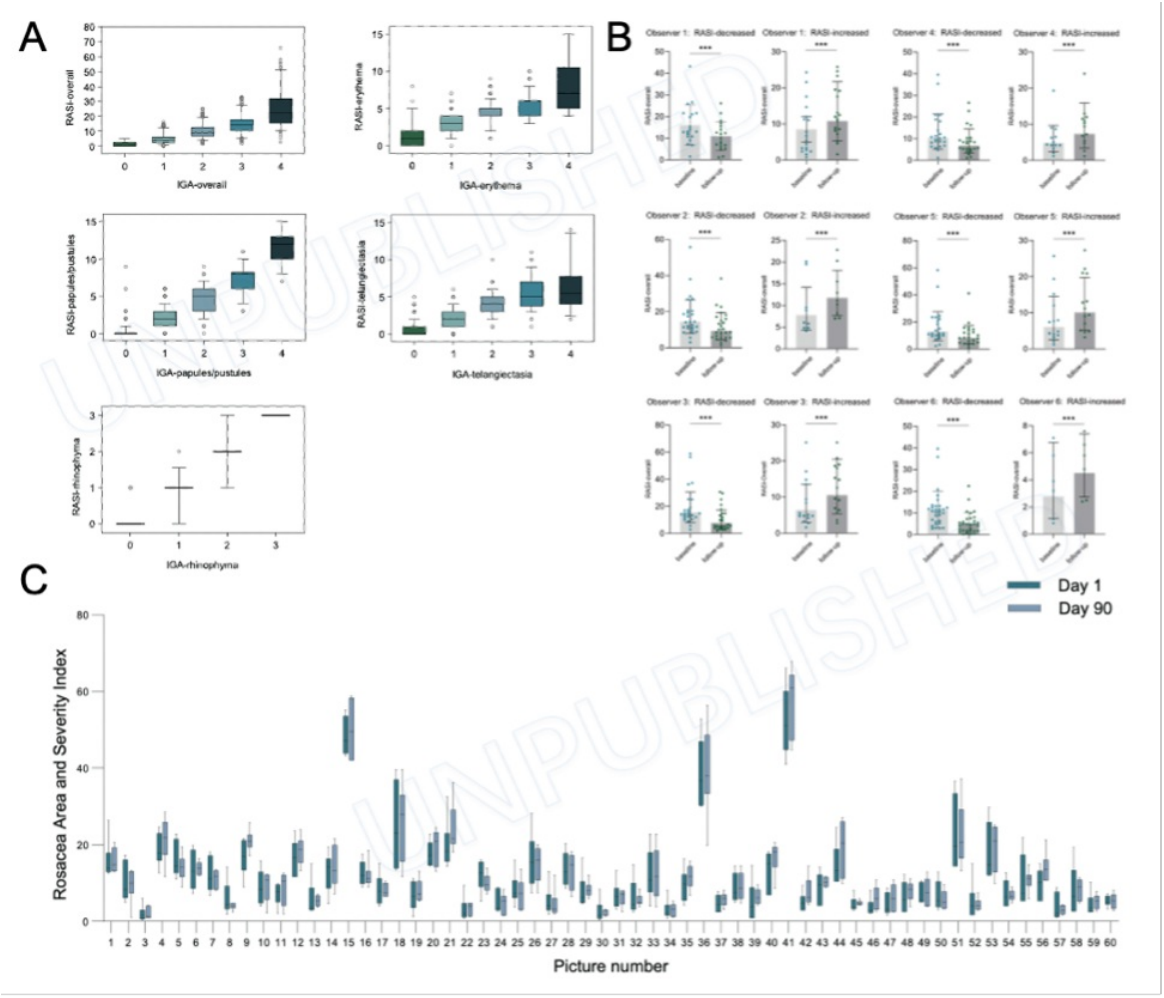

Reliability and validity assessment of RASI and IGA. (A) Correlation analysis between RASI and IGA; (B) RASI scoring of disease changes in rosacea patients by different dermatologists; (C) Intra-observer reliability of repeated RASI scoring after 3 months.

Conclusions

RASI exhibits robust reliability, strong convergent validity, and superior responsiveness compared with IGA in Chinese patients with rosacea. It is particularly capable of capturing disease fluctuations that are difficult to identify using the categorical IGA scale. This objective, sensitive, and quantifiable tool offers substantial value for dynamic rehabilitation monitoring, individualised treatment adjustments, and endpoint selection in clinical trials, thereby supporting its broader clinical application. Further validation in diverse populations and establishment of minimal clinically important differences are recommended.

EA DV CONGRESS
VIENNA
30 SEP - 3 OCT 2026

Abstract N°: 1783

Closing the gap between in vivo & in vitro: Development of a non-invasive ex vivo method to study cutaneous inflammation using skin swabs

Mirja van Bodegraven*[1], Tim Friemauth[1], Moeller Nadine[1], Alexandra Vogelsang[1], Jeannine Immeyer[1], Hendrik Mießner[1], Julia Weise[1]

[1] Beiersdorf AG, Hamburg, Germany

Introduction

Ex vivo analysis of inflammatory biomarkers is crucial for understanding inflammatory skin diseases (e.g. atopic dermatitis) and supporting active compound selection in clinical studies. Linking *in vivo* data of biophysical skin parameters with local cellular inflammatory responses increases translational relevance. However, established *ex vivo* skin sampling methods are often invasive and unsuitable for repeated use in patients. This study aimed to develop and clinically validate a rapid, robust, and non-invasive swab-based *ex vivo* method for inflammatory biomarker assessment in human skin.

Materials and Methods

Skin sampling was performed on a standardized 3 × 3 cm area using PBS-Tween–soaked swabs to collect epidermal material without skin barrier disruption. Swabs were transferred into PBS-Tween containing protease inhibitors and stored at −80 °C until analysis. After thawing, samples were processed for total protein determination and biomarker quantification following manufacturer's instructions. Clinical relevance was evaluated in patients with atopic dermatitis (AD) by comparing lesional and perilesional skin. Samples from healthy volunteers served as controls. Disease severity was assessed using the SCORing Atopic Dermatitis (SCORAD) index.

Results

The swab-based *ex vivo* method reliably detected clinically relevant inflammatory biomarker patterns. In AD patients, lesional skin showed significantly elevated levels of CCL27, IL-8 and ratio IL-1RA/IL-1α compared with perilesional skin. Importantly, biomarker expression correlated positively with clinical disease severity, with higher levels observed in patients with higher SCORAD scores. Healthy skin exhibited consistently low biomarker expression compared with AD lesions, confirming disease specificity.

Conclusions

This study demonstrates that non-invasive skin swabbing is a clinically meaningful approach for *ex vivo* assessment of inflammatory biomarkers. The method enables painless, area-specific, and severity-dependent biomarker profiling in inflammatory skin disease. Its suitability for repeated sampling and its strong correlation with clinical severity support its use in future clinical efficacy studies and translational derm research.

EA DV CONGRESS
VIENNA
30 SEP - 3 OCT 2026

Abstract N°: 1804

Diagnostic Evolution of a Generalized Histiocytic Eruption: From Generalized Eruptive Histiocytosis to Rosai-Dorfman Disease in a Patient with Grade 3A Follicular Lymphoma

Gizem Miray Ayçiçek*[1], Göknur Kalkan[2]

[1] Ankara Bilkent City Hospital, Dermatology Clinic, Department of Dermatology, Ankara, Türkiye
[2] Yildirim Beyazit University, Medical School, Dermatology Clinic, Department of Dermatology, Ankara, Türkiye

Introduction

Generalized eruptive histiocytosis (GEH) is a rare non-Langerhans cell histiocytosis characterized by disseminated papular eruptions. Tumor necrosis factor-alpha (TNF-α) inhibitors are associated with various paradoxical cutaneous reactions; however, GEH in this context appears to be exceptionally rare.

Case Presentation

A 46-year-old man with ankylosing spondylitis, treated with adalimumab since May 2025, developed erythematous to slightly yellowish papules and nodules on the anterior and posterior trunk in October 2025. The lesions subsequently spread to the extremities and later involved the face, resulting in significant psychosocial impact.

Dermoscopy revealed a predominantly structureless erythematous area with subtle yellowish hues and fine linear and serpentine vessels.

Extensive laboratory workup, including complete blood count, comprehensive metabolic profile, antinuclear antibody, anti-Ro and anti-La antibodies, erythrocyte sedimentation rate, serum protein electrophoresis, immunofixation electrophoresis, lipid profile and angiotensin-converting enzyme levels, revealed no evidence of monoclonal gammopathy. Lymph node ultrasonography and PET-CT showed no evidence of systemic involvement.

Histopathological examination demonstrated a dermal infiltrate composed of monomorphic histiocytes with occasional multinucleated forms and accompanying inflammatory cells. Immunohistochemistry showed CD68 positivity and negativity for CD1a, langerin, and CD34, while S100 staining was non-specific, consistent with GEH.

Adalimumab was discontinued in January 2026; however, lesions continued to progress for 6–8 weeks thereafter. Topical clobetasol propionate for 8 weeks and a tapered course of systemic corticosteroids failed to induce clinical improvement. Narrowband UVB phototherapy (twice weekly) was initiated, after which no new lesions developed and partial regression was observed, particularly in facial papules, while truncal and extremity lesions persisted. Phototherapy is ongoing.

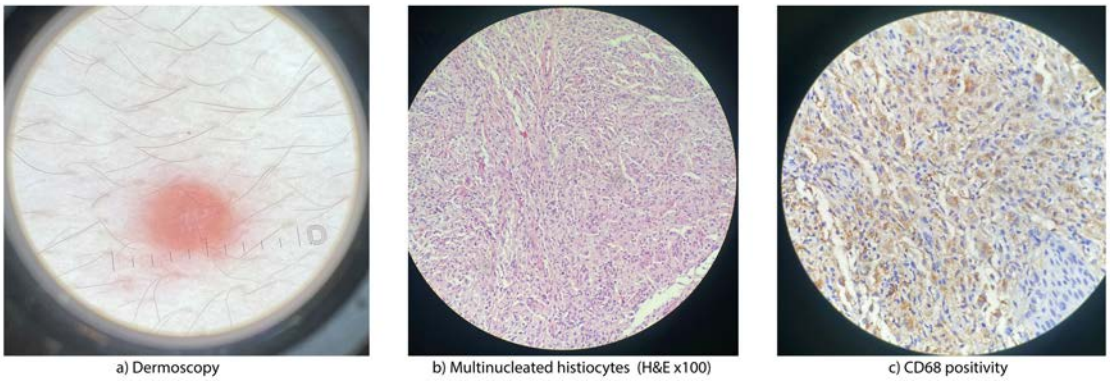

(A) Dermoscopic examination revealing a structureless erythematous area with subtle yellowish hues and fine linear and serpentine vessels. (B) High-power histopathological examination demonstrating dermal infiltration by monomorphic histiocytes with occasional multinucleated forms (H&E, ×100). (C) Immunohistochemical staining showing CD68 positivity in infiltrating histiocytes (×200).

Conclusion

We report a rare case of GEH developing during adalimumab therapy. The temporal relationship supports a possible association with anti-TNF treatment, although continued progression after drug discontinuation and the potential contribution of phototherapy should be considered. The disease was refractory to corticosteroids but stabilized with narrowband UVB, highlighting phototherapy as a potential option in resistant cases.

EA DV CONGRESS
VIENNA
30 SEP - 3 OCT 2026

Abstract N°: 1848

Study design of a phase 2 proof-of-concept randomized, multicentre, double-blind, placebo-controlled trial assessing the efficacy and safety of zasocitinib in moderate-to-severe hidradenitis suppurativa

Alexa B. Kimball[1], Wael Ghattas*[2], Victoria Prince[2], Magdi Vanya[2], Olulade Ayodele[2], Shailly Mehrotra[2], Amit Choudhury[2], John Frew[3]

[1] Beth Israel Deaconess Medical Center, Boston, MA, United States
[2] Takeda Development Center Americas, Inc., Cambridge, MA, United States
[3] Department of Dermatology, Liverpool Hospital, Sydney, NSW, Australia

Introduction

Hidradenitis suppurativa (HS) is an immune-mediated inflammatory skin disease characterized by painful, deep nodules, abscesses and tunnels, primarily affecting the intertriginous areas such as the axillae, groin/inguinal folds and anogenital/perineal regions. There is a need for early, targeted treatment to avoid the long-term severe effects of HS. Zasocitinib (TAK-279) is an oral, allosteric, highly selective and potent tyrosine kinase 2 (TYK2) inhibitor under clinical investigation for the treatment of immune-mediated inflammatory diseases, including psoriasis, psoriatic arthritis, inflammatory bowel disease and HS, with acceptable efficacy and safety demonstrated in psoriasis and psoriatic arthritis. Here, we present the study design and rationale of a phase 2, proof-of-concept trial of zasocitinib in patients with moderate-to-severe HS.

Materials and Methods

This is a phase 2, randomized, multicentre, double-blind, placebo-controlled trial to evaluate the efficacy and safety of zasocitinib in patients with moderate-to-severe HS (NCT07244263).

Eligible patients must be adults (aged ≥18 years) with signs and symptoms of moderate-to-severe HS for ≥6 months, a dermatologist diagnosis of HS with stable HS signs and symptoms for 2 months prior to screening, HS lesions in two distinct areas (with one Hurley Stage II or III) and a total of ≥5 inflammatory lesions at screening and Day 1. Patients must also have a history of inadequate response to an oral antibiotic for HS, or exhibited recurrence, intolerance or contraindication during that course. Key exclusion criteria include presence of >20 draining tunnels at screening or Day 1.

Approximately 90 patients will participate in the trial for approximately 61 weeks. The trial will include a screening phase of up to 35 days followed by a double-blind placebo-controlled period of 16 weeks in which participants will be randomized 2:1 to receive once-daily zasocitinib or placebo. Randomization will be stratified by concomitant antibiotic use (yes or no) and by baseline Hurley Stage (II or III). Following this, all patients will switch to open-label zasocitinib for an open-label period of up to 36 weeks. The trial will conclude with a 4-week safety follow-up period (**Figure**).

The primary endpoint analysis will be conducted on the full analysis set.

Results

The trial is actively enrolling. The primary endpoint is the proportion of patients who achieve Hidradenitis Suppurativa Clinical Response 75 (HiSCR 75) at Week 16. HiSCR 75 is defined as at least a 75% reduction in the total abscess and inflammatory nodule count with no increase in abscess or draining tunnel count, relative to

baseline. The key secondary endpoints are the proportion of participants who achieve HiSCR 50 at Week 16, and the incidence of treatment emergent adverse events throughout the trial. Exploratory endpoints include change from baseline over time in Hidradenitis Suppurativa Quality of Life, Dermatology Life Quality Index and International Hidradenitis Suppurativa Severity Score System.

Conclusions

This phase 2, proof-of-concept trial is designed to assess the efficacy and safety of zasocitinib in patients with moderate-to-severe HS and to support further development of zasocitinib as a convenient, once-daily oral therapy with the potential to improve long-term clinical outcomes.

Figure. Study design of NCT07244263.

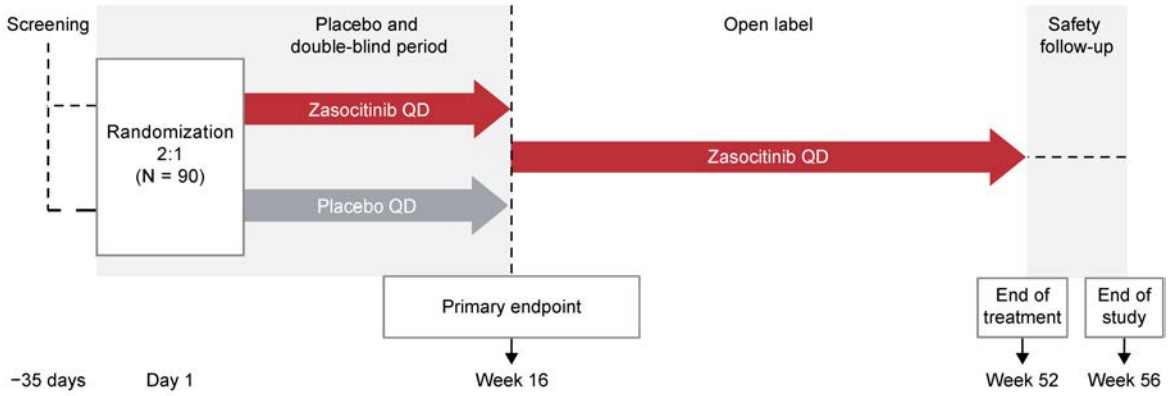

QD, once daily.
At Week 16, patients receiving placebo will switch to open-label zasocitinib QD.

EADV CONGRESS
VIENNA
30 SEP - 3 OCT 2026

Abstract N°: 1874

Bullous Erythema Multiforme Mimicking Sweet's Syndrome

mous mohamed amine[1], Mahi Ilham[1], Boumediene Dahmani*[1]

[1] faculty of medecine aboubekr belkaid university tlemcen, Tlemcen, Algeria

Introduction

Erythema multiforme is an acute inflammatory dermatosis, most often triggered by viral infections, particularly herpes simplex virus. Its clinical presentation may sometimes mimic other febrile infiltrated dermatoses, such as Sweet's syndrome, making the diagnosis challenging. We report a case illustrating this diagnostic confusion.

Case Presentation

A 45-year-old woman with a history of autoimmune hypothyroidism presented with an acute febrile eruption associated with recurrent herpes labialis. Clinical examination revealed painful, infiltrated erythematous papules and plaques, some of them bullous, predominantly involving the trunk and limbs. Complete blood count showed marked leukocytosis (20,510/mm^3) with neutrophilia (19,860/mm^3), which normalized within 48 hours. Liver transaminases were transiently elevated. Abdominal ultrasound and immunological investigations were unremarkable.

Skin biopsy revealed interface dermatitis with apoptotic keratinocytes and a subepidermal blister, consistent with bullous erythema multiforme. Treatment with systemic corticosteroids, topical care, and antibiotic therapy with fusidic acid led to a favorable outcome, with rapid resolution of fever and regression of skin lesions.

The initial clinical and biological presentation suggested Sweet's syndrome, given the presence of fever, painful infiltrated plaques, and marked neutrophilia. However, histopathological examination allowed correction of the diagnosis by demonstrating interface dermatitis rather than a dense neutrophilic dermal infiltrate. The rapid clinical improvement and the context of herpes labialis further supported the diagnosis of bullous erythema multiforme. This case highlights the sometimes subtle boundary between these two entities, particularly in their febrile and corticosteroid-responsive forms.

Conclusion

Bullous erythema multiforme may exceptionally mimic Sweet's syndrome both clinically and biologically. Histopathological examination remains the cornerstone of differential diagnosis. This case emphasizes the importance of an integrated approach combining clinical, biological, histopathological, and contextual data to avoid diagnostic pitfalls.

EA DV CONGRESS
VIENNA
30 SEP - 3 OCT 2026

Abstract N°: 1881

A Rare Cause of a Chronic Unilateral Pigmented Eyelid Plaque: Discoid Lupus Erythematosus

Zeynepnur Aydin Basaran*[1], Seray Külcü Çakmak[1], Mehtap Özcan Aydın[2]

[1] Ankara Bilkent City Hospital Department of Dermatology, Ankara, Türkiye
[2] Ankara Bilkent City Hospital Department of Medical Pathology, Ankara, Türkiye

Introduction
Discoid lupus erythematosus (DLE) is the most common subtype of chronic cutaneous lupus erythematosus and typically affects photoexposed areas such as the scalp and face. Eyelid involvement is uncommon and may mimic inflammatory or neoplastic eyelid disorders, frequently leading to delayed diagnosis and permanent cicatricial sequelae. We present a rare case of isolated unilateral upper eyelid DLE successfully treated with hydroxychloroquine and topical therapy.

Case Presentation
A 65-year-old postmenopausal woman was referred to our dermatology clinic with a 5-month history of a persistent lesion on the right upper eyelid. She complained of pruritus, burning sensation, and intermittent epiphora. Her medical history was significant only for hypertension. Previous ophthalmologic evaluations had resulted in diagnoses of chronic blepharitis and eczematous dermatitis, and several topical antibiotic and corticosteroid treatments had failed to improve the lesion.

Dermatologic examination revealed a poorly defined arciform violaceous-to-dusky brown hyperpigmented patch involving the lateral and central portions of the right upper eyelid. The lesion was infiltrative on palpation without prominent plaque formation. Subtle central atrophy and “cigarette-paper” wrinkling were present. Focal silvery-white adherent scales were noted at the periphery. Loss of follicular ostia within the lesion suggested early cicatricial progression, although the ciliary margin was spared and no madarosis was observed.

Clinical differential diagnoses included lichen planus–like keratosis, actinic keratosis, pigmented lichen planus, morphea, lentigo maligna, actinic lichen planus, and discoid lupus erythematosus. A punch biopsy was performed.

Histopathologic examination demonstrated epidermal atrophy, focal follicular plugging, and dense lichenoid interface dermatitis, confirming the diagnosis of DLE. Numerous dermal melanophages explained the clinical pigmentation. Direct immunofluorescence was negative for C3 and IgG deposition, consistent with late-stage or treated lesions. Laboratory investigations, including ANA, anti-dsDNA, and ENA profile, were within normal limits, supporting isolated cutaneous disease.

Following ophthalmologic evaluation and clearance, hydroxychloroquine 200 mg/day was initiated together with topical hydrocortisone acetate 1%, topical pimecrolimus 1%, and strict photoprotection. Treatment was continued for 5 months.

At follow-up, active inflammation had completely resolved, leaving only faint post-inflammatory hyperpigmentation. Pruritus, burning sensation, and epiphora had fully regressed. No treatment-related adverse effects were observed.

Conclusion

Isolated eyelid DLE is a rare entity that may imitate benign inflammatory dermatoses or malignant eyelid lesions. Persistent unilateral eyelid plaques unresponsive to conventional therapy should prompt histopathologic evaluation. Early recognition and timely initiation of antimalarial therapy may prevent irreversible cicatricial complications and provide favorable clinical outcomes.

EADV CONGRESS
VIENNA
30 SEP - 3 OCT 2026

Abstract N°: 1884

Genital psoriasis

Émélie Simone Okouango*[1], Mounia Ouazzani[1], Hanane Rachadi[1], Bouchra Baghad[1], Soumiya Chiheb[1]

[1] Department of Dermatology, Ibn Rochd University Hospital, Casablanca, Morocco, Faculty of Medicine and Pharmacy of Casablanca, Hassan II University, Morocco, Casablanca, Morocco

Introduction

Psoriasis is a chronic systemic inflammatory condition affecting the skin and joints. It is characterised by erythematous, scaly lesions that can occur on any part of the body, including the genital and perigenital areas (inguinal folds, vulva, penis, scrotum, perianal region, and intergluteal cleft). Genital psoriasis is a common site of involvement, affecting 33% to 63% of patients with psoriasis, but it often remains underdiagnosed and undertreated. It has a major impact on quality of life, particularly due to impaired sexual function and the risk of stigmatisation. Hence the importance of early diagnosis and management. Low- to moderate-potency topical corticosteroids, calcineurin inhibitors, and biologics have demonstrated efficacy, although no clear consensus exists. We report the case of a 54-year-old male patient with genital psoriasis.

Case Presentation

This is a 54-year-old male patient with no significant past medical history who has presented for the past two years with an initially erythematous lesion on the glans penis, which has progressively spread to the elbows, scrotum, and inguinal folds, occurring in the context of afebrile status with no change in general condition. Dermatological examination revealed erythematous-squamous drop-shaped lesions on the elbows, abdomen, and buttocks; annular lesions on the extensor surface of the left forearm; and plaques in the left retroauricular fold and the intergluteal cleft, as well as an infiltrated, moist erythematous lesion in the inguinal folds and perineal region. In the genital area, erythematous-squamous fissured lesions were noted on the glans and in the balanopreputial sulcus. The affected body surface area was estimated at 5%. The initial PASI score was 7. The candle test and bloody dew test were positive. The palmar-plantar regions, oral mucosa, and appendages were spared. Dermoscopy revealed thick white scales on an erythematous background with punctate vessels. The DLQI score was 12/30, indicating a significant impact on quality of life. The mycological culture was negative. Treatment with moderate-strength topical corticosteroids for three weeks resulted in a favourable response, achieving a PASI 75, followed by maintenance therapy with calcineurin inhibitors.

Conclusion

Genital psoriasis is often classified as an inverse or intertriginous form, sometimes ranging from moderate to severe in severity. Although it is usually associated with cutaneous psoriasis, it can present as the initial manifestation, thereby delaying diagnosis and exacerbating its impact on quality of life. Therapeutic management remains a challenge due to the lack of consensus recommendations. First-line treatment relies on low- to moderate-potency topical corticosteroids, followed by calcineurin inhibitors, given the fragility of the genital skin and the risk of side effects. Topical alternatives, such as roflumilast, are also available. Biotherapies, particularly ixekizumab, have demonstrated significant efficacy, while apremilast appears promising despite still limited data. Our case report illustrates a presentation of genital psoriasis, a condition that remains underreported. Particular attention must be paid to screening for this site, which is often overlooked by both patients and clinicians. A

comprehensive clinical examination is essential. The development of specific assessment tools and tailored treatment algorithms appears necessary, particularly to better integrate the impact on quality of life into management decisions.

EA DV CONGRESS
VIENNA
30 SEP - 3 OCT 2026

Abstract N°: 1897

Dissecting Inflammatory Pathways Mediated by IL-1 Family Cytokines: Insights into Chronic Skin Inflammation

Ellen Ezratty*[1], Angelos Papatheodorou[1], Brianna Buonagurio[1], Subhashini Srivatan[1], Kaitlyn Gayvert[1], Joseph Devlin[1], Weikeat Lim[1], Audrey Le Floc'h[1], Jamie Orengo[1]

[1] Regeneron Pharmaceuticals, Tarrytown, NY, United States

Introduction

The interleukin (IL)-1 family cytokines, including IL-1, IL-33, and IL-36, are potent proinflammatory mediators implicated in various inflammatory diseases, particularly skin disorders such as generalized pustular psoriasis (GPP) and hidradenitis suppurativa (HS). These conditions are driven by disrupted epithelial barrier integrity and activation of IL-1 cytokine pathways. Licensed and emerging biologics targeting the IL-1 family show clinical benefit, including anti–IL-36 receptor therapy for GPP and anti–IL-1α/β therapies for HS.

Materials and Methods

Monocytes, key innate immune cells, can initiate inflammation via IL-1 production and amplify chronic inflammatory cycles through proinflammatory cytokines and chemokines that engage both innate and adaptive immunity. We assessed shared and distinct effects of IL-1 family cytokines (IL-1α, IL-1β, IL-33, IL-36α/β/γ) on human primary monocytes in vitro by profiling transcriptional responses (RNASeq) and assaying cytokine/chemokine release (Luminex).

Results

IL-1α and IL-1β elicited the largest transcriptional responses (1,401 and 1,011 differentially expressed genes [DEGs] respectively), IL-36α/β/γ induced 209 DEGs, and IL-33 had minimal effects (9 DEGs). Both IL-1α and IL-1β induced their own and each other's transcripts and upregulated IL1RAP: the receptor subunit shared by IL-1, IL-33, and IL-36. A 162-gene signature was shared between IL-1 and IL-36 stimulation, with IL1A, IL1B, IL36G, and the proinflammatory cytokine IL6 among the most upregulated. Other key differentially expressed genes included chemo-attractants for macrophages and monocytes (*CCL3, CCL4, CCL7, CCL8*), neutrophils (*CXCL1, CXCL5, CXCL6, CXCL8*), and T cells (*CCL19, CCL20, CXCL10, CXCL11*).

Protein-level analyses validated these findings: IL-1α and IL-1β each induced production of the other, and IL-1 stimulation, more strongly than IL-36, induced robust secretion of IL-6, IL-8 (CXCL8), MIP-1α (CCL3), MIP-1β (CCL4), CCL7, CCL8, GRO-α (CXCL1), ENA-78 (CXCL5), GCP-2 (CXCL6), MIP-3β (CCL19), and MIP-3α (CCL20). In HS and GPP sera, Meso Scale Discovery analysis revealed elevated circulating IL-6, IL-8 (CXCL8), and MIP-1α (CCL3), markers associated with monocyte/neutrophil recruitment to tissues. These overlapped with the top IL-1– and IL-36–induced genes in monocytes, highlighting the central role of these pathways in driving inflammation.

Conclusions

This study underscores the role for signaling pathways induced by IL-1 family cytokines in the pathogenesis of GPP and HS. It also highlights the potential contribution of monocytes to immune dysregulation observed in these

chronic skin diseases. Notably, our findings revealed that stimulation of monocytes with IL-1 and IL-36 cytokines not only enhanced their own expression but also promoted the production of one another. Furthermore, the shared gene expression signature induced by IL-1 and IL-36 highlighted their overlapping functions. This interplay likely establishes and perpetuates a chronic inflammatory feedback loop, wherein IL-1 cytokine family signaling serves as both an initiator and maintainer of the pathological immune responses underlying persistent skin inflammation.

EADV CONGRESS
VIENNA
30 SEP - 3 OCT 2026

Abstract N°: 1905

AI-Augmented Teledermatology for Accelerated Diagnosis and Treatment of Inflammatory Skin Diseases: A Multicenter Observational Study

Prajakta Rohokale Sikand*[1]

[1] University of San Francisco, i.m Sechenov Medical University, San Francisco, United States

Introduction
Delayed diagnosis and suboptimal triage of inflammatory dermatoses such as atopic dermatitis and psoriasis contribute to prolonged disease activity, increased healthcare utilization, and reduced quality of life. Despite advances in therapeutics, access to timely dermatological evaluation remains limited in many settings. AI-enabled teledermatology has emerged as a pragmatic strategy to augment diagnostic workflows; however, robust real-world evidence demonstrating its impact on diagnostic timelines and treatment initiation remains limited.

Materials and Methods
We conducted a 12-month multicenter observational study across dermatology clinics and telemedicine platforms. A total of 1,200 patients presenting with suspected inflammatory dermatoses were evaluated using an AI-assisted teledermatology workflow integrating image-based analysis with specialist review.

Outcomes were compared with standard in-person dermatology pathways. Primary endpoints included diagnostic concordance, time to confirmed diagnosis, and time to treatment initiation. Secondary endpoints included patient-reported satisfaction and triage accuracy for moderate-to-severe disease.

AI models were trained on curated, annotated dermatological image datasets and validated against board-certified dermatologists.

Results
AI-assisted teledermatology achieved high diagnostic concordance with in-person assessment (89.4%). Median time to diagnosis was reduced by 42% ($p < 0.01$), with a corresponding 35% reduction in time to treatment initiation, most pronounced in moderate-to-severe disease cohorts.

Triage performance improved, with higher sensitivity for identifying patients requiring early specialist intervention compared to standard referral pathways. Patient satisfaction scores were significantly higher in the AI-assisted group (mean 4.6/5 vs 3.8/5).

Findings were consistent across multiple clinical settings, supporting external validity.

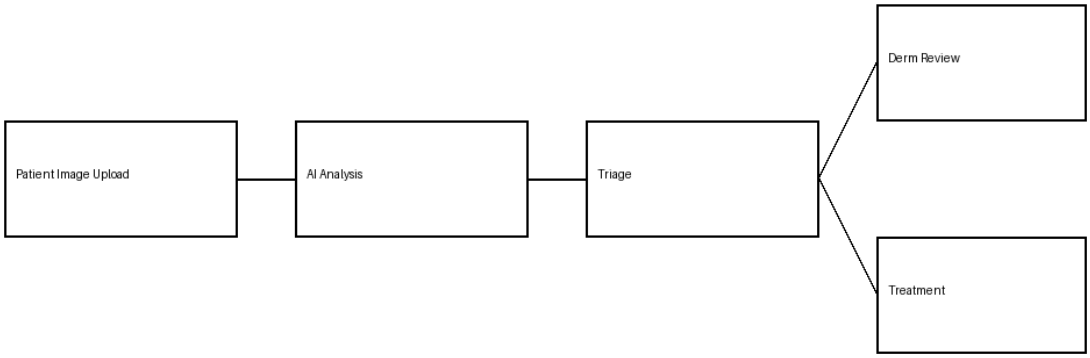

Conclusions

AI-augmented teledermatology significantly accelerates diagnosis and treatment initiation while maintaining high diagnostic concordance with conventional care. Its ability to enhance triage accuracy and reduce care delays supports its integration into routine dermatology workflows.

This scalable model offers a clinically effective approach to improving access and optimizing outcomes in inflammatory skin disease management, particularly in resource-constrained and high-demand settings.

EADV CONGRESS
VIENNA
30 SEP - 3 OCT 2026

Abstract N°: 1945

Nodular Prurigo Revealing HIV Infection: A Case Report

Ouissal Laadime*[1], Bendaoud Layla[1], Ibtissame faouzi[1], Mariem Aboudourib[1], ouafa hocar[1], Amal Said[1]

[1] Department of Dermatology and Venereology, Arrazi Hospital, Mohammed VI University Hospital Center, Marrakech, Morocco

Introduction

Nodular prurigo is a chronic inflammatory dermatosis characterized by intensely pruritic keratotic nodules, often associated with underlying systemic conditions. Among these, human immunodeficiency virus (HIV) infection is a recognized but still under-investigated cause, particularly in cases resistant to conventional treatments. We report a case of nodular prurigo revealing HIV infection, highlighting the importance of etiological screening in atypical chronic prurigo.

Case Presentation

A 51-year-old male farmer with a 20-year history of chronic cannabis use was hospitalized for nodular prurigo evolving over 18 months. Clinical examination revealed multiple intensely pruritic keratotic nodules predominantly located on the extensor surfaces of the limbs, trunk, and back, associated with lichenified, hyperpigmented lesions and scattered excoriated papules. Pruritus was severe, chronic, predominantly nocturnal, and resistant to topical corticosteroids and antihistamines. The patient reported general deterioration with weight loss and asthenia. Skin biopsy findings were consistent with nodular prurigo. Etiological workup revealed positive HIV serology with a detectable viral load (HIV Ag/Ab index positive at 745) and a markedly decreased CD4 count (7 cells/mm³). Infectious, mycological, bacteriological, and tuberculosis investigations were negative. Lymph node ultrasound showed multiple superficial lymphadenopathies. Antiretroviral triple therapy consisting of tenofovir, dolutegravir, and lamivudine was initiated, along with cotrimoxazole prophylaxis. After one month of treatment, there was a marked improvement in pruritus and skin lesions. Subsequently, the patient developed multi-dermatomal herpes zoster, reflecting severe immunosuppression.

Conclusion

This case illustrates the role of nodular prurigo as a sentinel dermatosis of HIV infection. In any case of chronic, diffuse, or treatment-resistant prurigo, HIV screening should be systematically considered to enable early diagnosis and appropriate management.

EA DV CONGRESS
VIENNA
30 SEP - 3 OCT 2026

Abstract N°: 1946

Incretin-based therapies in routine dermatology care: determinants of therapy acceptance in a real-world cohort

Arian Kräling*[1, 1], Julia Suttorp[1], Antonia Raffelhüschen[1], Lisa Gasser[1], Bernard Wijaya[1], Marcio Eisfelder[1], Sascha Gerdes[1]

[1] UKSH Kiel, Department of Dermatology, Venereology and Allergology, Kiel, Germany

Introduction

Obesity is a common comorbidity in chronic inflammatory skin diseases such as psoriasis, atopic dermatitis, and hidradenitis suppurativa. GLP-1 receptor agonists and dual GLP-1/GIP receptor agonists (incretin-based therapies) represent an effective therapeutic option for weight reduction and metabolic improvement. However, their use in routine dermatology care is still limited, and real-world data on patient acceptance rates and factors influencing treatment decisions remain insufficient.

Aim:

To analyze determinants of therapy acceptance of incretin-based therapies in routine dermatology care, with a particular focus on the role of type 2 diabetes mellitus (T2DM) and associated cost coverage.

Materials and Methods

A prospective cross-sectional analysis of 90 patients with chronic inflammatory skin diseases and an indication for incretin-based therapy was performed. Data were collected using structured questionnaires and patient interviews.

Data on underlying dermatologic conditions, therapy acceptance, and reasons for therapy refusal were collected. The presence of T2DM and socioeconomic factors, particularly individual net income, were evaluated in relation to therapy decisions. Other comorbidities were recorded but not analyzed in detail.

Results

Psoriasis was the most common underlying skin disease (n=71). 17 patients (19%) had T2DM as a comorbidity. Overall, 25 patients (28%) accepted therapy, whereas 65 patients (72%) declined. Therapy acceptance differed markedly depending on T2DM status. Patients with T2DM showed a high acceptance rate (82%), whereas patients without T2DM predominantly declined therapy (85%).

The most frequently reported reason for therapy refusal was cost (n=31), followed by preference for lifestyle modification (n=15). Concerns about adverse events (n=8) and the need for additional decision time (n=9) were

less frequently reported, while prior therapy failure was rarely mentioned (n=2).

Patients accepting therapy had a higher median net income (€2000–3000) compared to those declining therapy (€1000–2000). Overall, only slightly more than 30% of patients reporting income had a net income of at least €3000.

Conclusions

Our data identify reimbursement as the central determinant of therapy acceptance. The strong association between T2DM and therapy uptake reflects improved access through reimbursement, whereas in non-diabetic patients, individual economic factors appear decisive. Medical concerns play a comparatively minor role.

In routine dermatology care, the use of incretin-based therapies is therefore primarily driven by accessibility-related factors, especially reimbursement, rather than medical considerations alone. T2DM is closely linked to reimbursement eligibility and facilitates access to therapy.

Expanding cost coverage beyond diabetic populations may improve access and patient care. Until then, incretin-based therapies should be offered to all eligible patients based on BMI and comorbidity profile, given their proven efficacy and an acceptance rate exceeding 25% in our cohort.

EA DV CONGRESS
VIENNA
30 SEP - 3 OCT 2026

Abstract N°: 1968

Transcriptomic characterization of inflammatory skin challenge models and inflammatory skin diseases cutaneous lupus erythematosus, atopic dermatitis, and psoriasis

Digna de Bruin*[1, 2], Ingrid Tomljanovic[3], Manon Jansen[1], Robert Rissmann[1, 2, 4], Matthijs Moerland[1, 2]

[1] Centre for Human Drug Research, Leiden, Netherlands

[2] Leiden University Medical Center, Leiden, Netherlands

[3] Erasmus University Medical Center, Rotterdam, Netherlands

[4] Leiden Academic Centre for Drug Research, Leiden, Netherlands

Introduction

Human inflammatory challenge models are used in early-phase clinical studies to investigate mechanistic and pharmacodynamic properties of (novel) therapeutic compounds. Although these are mechanistic models rather than disease models, early-phase clinical studies that include challenge models are used to show proof-of-mechanism and support the selection of the target patient population(s) for next phase clinical trials. To improve the translatability from model to disease, we aimed to compare specific transcriptomic features of two skin challenge models, the intradermal lipopolysaccharide (ID LPS) and topical imiquimod (IMQ) models, with the characteristics of three inflammatory skin diseases: cutaneous lupus erythematosus (CLE), atopic dermatitis (AD), and psoriasis (PsO).

Materials and Methods

Bulk RNA sequencing data from skin biopsies were available for IMQ, LPS, AD, and PsO from clinical studies. For the CLE cohort, a publicly available dataset was used. Modules representing key immune pathways (Th1, Th2, Th17, type I interferons [IFNs], neutrophilic, macrophagic, and eosinophilic) derived from Seremet et al. (2024) were applied to characterize the main drivers of inflammation. Moreover, we used a subset of signatures collated by Martinez et al. (2022) to further characterize the enrichment of pathways and immune cell types across our datasets. Single-sample gene set enrichment methods (ssGSEA and GSVA) were used to score each gene set. To further compare the various sample groups present in our data, we performed differential gene expression analysis followed by pathway analysis on MSigDB sets (GSEA). CIBERSORTx was used to estimate the abundance scores of 22 immune cell types based on the LM22 reference matrix.

Results

As expected, the dominant immune modules were Th17 for PsO and Th2 for AD, consistent with the literature. The dominant immune modules were IFN, neutrophilic, and macrophagic in the ID LPS model and mainly IFN in the IMQ model. Th2 and Th17 were also positively enriched in both models, more pronounced in ID LPS. The IFN pathway is a key driver of CLE pathophysiology. Therefore, we have included characterization of a cohort of CLE patients in our analysis, which is currently in progress (results expected in May 2026). Moreover, we identified significantly enriched features across the 4 datasets including MSigDB pathways (KEGG, Reactome, Gene Ontology), additional gene signatures as described by Martinez et al. (2022), and CIBERSORTx scores, and are in the process of defining sets of features that are common and unique to each of these.

Conclusions

We identified dominant immune modules, along with distinct and common signatures across inflammatory skin diseases and skin challenge models. By describing features per model and disease within a single framework, we revealed shared characteristics that could enhance the translatability between these challenge models and inflammatory skin diseases.

EADV CONGRESS
VIENNA
30 SEP - 3 OCT 2026

Abstract N°: 2002

Pyoderma Gangrenosum–Like Sporotrichosis: A Diagnostic Pitfall

Ana Lígia Scotti Alérico*[1], Hudson Rezende[1], João Henrique Aurich[1], Mariana Menezes de Mauro[2], Antonio Moraes Madeira Quindos[3]

[1] Centro Universitário Lusíada - UNILUS, Santos, Brazil
[2] Universidade São Francisco, Bragança Paulista, Brazil
[3] Universidade de Taubaté (UNITAU), Taubate, Brazil

Introduction

Sporotrichosis is a subcutaneous mycosis caused by fungi of the *Sporothrix* complex, classically presenting with nodular or ulcerative lesions with lymphatic spread. In endemic regions, it remains a frequent and sometimes underrecognized condition. Atypical presentations may mimic inflammatory dermatoses, including pyoderma gangrenosum (PG), creating a relevant diagnostic challenge and increasing the risk of inappropriate immunosuppressive treatment.

Case Presentation

A 52-year-old male rural worker presented with pustular lesions on the left lower limb following trauma with a wooden fence. Over the course of two months, the lesions progressively enlarged, evolving into an extensive ulcerated and destructive plaque involving most of the leg. He was initially treated with trimethoprim-sulfamethoxazole, followed by ciprofloxacin and clindamycin, without clinical response. A previous biopsy was inconclusive. Given the ulcerative and rapidly progressive nature of the lesion, PG was suspected, and systemic corticosteroid therapy (prednisone 1 mg/kg/day) was initiated. Shortly after, the lesion worsened significantly, with further tissue destruction. The patient was then referred to our service. Considering the epidemiological context and the atypical evolution, an infectious etiology was suspected. A wound swab was collected, and fungal culture confirmed sporotrichosis.

Conclusion

This case illustrates how sporotrichosis can mimic pyoderma gangrenosum, particularly in ulcerative and aggressive presentations. The use of corticosteroids in this context may lead to rapid clinical deterioration. In endemic areas, infectious causes should be carefully considered in the differential diagnosis of ulcerative lesions, especially when there is poor response to antibiotics or unexpected worsening with immunosuppression. Early microbiological investigation, even in the setting of inconclusive histopathology, is essential to establish the correct diagnosis and guide appropriate treatment.

EADV CONGRESS
VIENNA
30 SEP - 3 OCT 2026

Abstract N°: 2004

Dissecting Cellulitis of the Scalp After Hair Transplantation: Coincidence or Trauma-Induced Trigger?

Ingrid Palloma Vieira de Melo*[1], Hudson Rezende[1], João Henrique Aurich[1], Juliana Santos Rodrigues[1], Letícia Ferreira de Hybi Cerqueira[2]

[1] Centro Universitário Lusíada, Santos, Brazil

[2] Centro Universitário CESMAC, Maceió, Brazil

Introduction

Dissecting cellulitis of the scalp (DCS) is a chronic, relapsing inflammatory disorder within the follicular occlusion spectrum, characterized by painful nodules, abscesses, sinus tracts, and scarring alopecia. Its pathogenesis is thought to involve follicular occlusion followed by rupture and a neutrophil-driven inflammatory response. Although intrinsic factors are well recognized, the role of external triggers, particularly mechanical trauma, remains poorly defined.

Case Presentation

We report two cases of DCS arising after follicular unit extraction (FUE) hair transplantation in patients with no prior history of scalp disease. A 38-year-old man underwent FUE in August 2021 with a normal preoperative scalp examination. Eleven months later, he presented with localized pain and focal alopecia. Dermoscopy revealed perifollicular erythema and scaling, and a 4-mm punch biopsy confirmed inflammatory scarring alopecia consistent with DCS. A 41-year-old man underwent FUE in January 2023. Nine months postoperatively, he developed multifocal alopecic patches with erythema. His preoperative evaluation was unremarkable, although he reported a history of adolescent acne. Dermoscopic and histopathological findings supported the diagnosis of DCS. In both cases, the onset of symptoms months after the procedure, in previously unaffected scalps, suggests a possible triggering role of surgical trauma.

Conclusion

These cases raise the possibility that mechanical trauma related to hair transplantation may act as a trigger for DCS in susceptible individuals. While causality cannot be definitively established, the temporal association and known parallels with other follicular occlusion disorders, particularly hidradenitis suppurativa, support a trauma-driven mechanism involving follicular disruption and subsequent inflammation. Recognizing this potential association is clinically relevant, both for early diagnosis and for counseling patients undergoing hair transplantation, and may offer further insight into the pathophysiology of DCS.

EA DV CONGRESS
VIENNA
30 SEP - 3 OCT 2026

Abstract N°: 2008

Pityriasis Rubra Pilaris in a Healthy Adult Male Mimicking Urticaria and Tinea Corporis: A Case Report

Shaher Al Kaabi*[1], Ana Serrano[2], Radiya Al Ajmi[2]

[1] Oman Medical Specialty Board (OMSB), Muscat, Oman
[2] Sultan Qaboos University Hospital (SQUH), MUSCAT, Oman

Introduction
Pityriasis rubra pilaris is a rare (PRP) inflammatory papulosquamous disorder of unknown etiology. Most cases are sporadic, although familial forms with autosomal dominant inheritance and CARD14 mutations have been described. PRP commonly presents with sharply demarcated orange-red or salmon-colored scaly plaques, follicular hyperkeratotic papules, and palmoplantar keratoderma with a characteristic waxy orange hue. Pruritus may occur in the early stages. The diagnosis can be challenging because PRP may mimic dermatophytosis, psoriasis, eczema, or other papulosquamous disorders, particularly before the development of its classic clinical features. There are no specific laboratory tests to confirm PRP; therefore, diagnosis relies on clinical assessment supported by histopathology. The alternating orthokeratosis and parakeratosis, hypergranulosis, acanthosis, broad rete ridges, and superficial perivascular lymphocytic infiltrate in this case supported the diagnosis, while the negative PAS stain helped exclude fungal infection.

We present a diagnostically challenging case of PRP in an otherwise healthy 40-year-old man, with an insidious 12-week pruritic papulosquamous eruption initially diagnosed as urticaria and later treated as tinea corporis, and to highlight the importance of clinicopathological correlation in persistent papulosquamous eruptions unresponsive to conventional therapy.

Case Presentation
A 40-year-old man, non-smoker and non-alcohol consumer, with no known medical illnesses, medication use, herbal intake, or family history of similar skin disease, presented with a 12-week history of bilateral skin dryness and pruritus involving the extensor aspects of the upper limbs, posterior lower legs, and dorsum of the hands and feet, mainly aggravated after sun exposure. He was initially diagnosed with urticaria and treated with oral antihistamines without improvement. The diagnosis was later shifted to tinea corporis after the lesions evolved into well-demarcated erythematous scaly patches with central clearing over the axillary and elbow flexural areas. Despite multiple courses of oral and topical antifungal therapy, the lesions increased in size and number, with extension to the nape of the neck. Systemic review was unremarkable. Scalp, nail, and mucosal examinations were normal. Dermatological examination revealed bilateral waxy palms with an orange hue. Laboratory investigations, including complete blood count, liver function tests, thyroid function tests, urea and electrolytes, lipid profile, and vitamin D level, were within normal limits. Abdominal ultrasound was normal, and screening for hepatitis B, hepatitis C, HIV, and syphilis was negative.

A 3.5-mm punch biopsy was obtained from the left upper arm near the elbow was done that showed alternating orthokeratosis and parakeratosis with confluent hypergranulosis. Mild uniform acanthosis with broad dermal papillae and broad epidermal ridges was noted. The superficial dermis showed a mild perivascular lymphocytic infiltrate admixed with occasional plasma cells. Periodic acid–Schiff stain was negative for fungal elements, and there was no atypia or malignancy. These clinical and histopathological findings were consistent with pityriasis

rubra pilaris.

Conclusion

This case emphasizes that PRP should be considered in persistent erythematous scaly eruptions that fail to respond to antihistamine and antifungal therapy. Recognition of waxy orange palmoplantar changes and early skin biopsy are essential to avoid diagnostic delay and unnecessary treatment. The case also highlights the importance of clinicopathological correlation in diagnosing rare papulosquamous disorders.

EADV CONGRESS
VIENNA
30 SEP - 3 OCT 2026

Abstract N°: 2014

Nodular Vasculitis Associated with Latent Mycobacterium tuberculosis Infection in an Endemic Country: A Case Report

Maria Eduarda Cesar Garcez*[1], Julia Cascardo Géo de Siqueira[1], Maria de Fátima Guimarães Scotellaro Alves[1], Amanda Quintaes[1], Raphael Pereira[1], Luna Azulay-Abulafia[1]

[1] Pedro Ernesto University Hospital (HUPE), State University of Rio de Janeiro (UERJ), Rio de Janeiro, Brazil

Introduction

Nodular vasculitis is a lobular panniculitis frequently associated with hypersensitivity to *Mycobacterium tuberculosis* and is classically included within the spectrum of tuberculids. Its recognition may be challenging, particularly in the absence of documented active tuberculosis, requiring careful clinicopathological correlation and targeted complementary investigation, especially in endemic countries. The aim of this study is to report a case of nodular vasculitis with strong evidence of association with latent tuberculosis infection, highlighting the importance of etiologic investigation in such patients.

Case Presentation

A 30-year-old female patient presented with a 1-year history of "skin spots," initially described as multiple painful "bruises," beginning on the left lower limb and subsequently involving the right lower limb and upper extremities. She reported local pain, a sensation of warmth over the lesions, pedal edema, and arthralgia involving the shoulders and elbows, with worsening at the end of the day. She also developed a 6-kg weight loss over 1 month and hyporexia, without fever. Previous treatment included prednisone 5 mg/day for 20 days and, subsequently, 10 mg/day, with no clinical improvement. Dermatological examination revealed lesions on the upper and lower extremities that were tender to palpation, had a reticulated appearance, and blanched on diascopy. A skin biopsy of a nodule on the left lower limb demonstrated lobular panniculitis with vasculitis, consistent with nodular vasculitis. Etiologic investigation disclosed a scar on the left forearm compatible with a previous phlyctenular tuberculin skin test, a strongly positive tuberculin skin test (PPD) (>10 mm) on the right forearm, a reactive interferon-gamma release assay (IGRA), no previous treatment for latent tuberculosis infection (LTBI), and a household contact history with a father affected by active pulmonary tuberculosis.

The clinical, histopathological, and epidemiological findings were highly suggestive of nodular vasculitis associated with *Mycobacterium tuberculosis* infection. The presence of lobular panniculitis with vasculitis on histopathology, together with a reactive IGRA, a strongly positive PPD, a history of close household exposure to active pulmonary tuberculosis, and the absence of prior LTBI treatment, strongly supported the diagnosis of a tuberculid. The lack of response to low-dose corticosteroid therapy also helped exclude nonspecific inflammatory conditions and reinforced the need for a focused infectious workup. Following diagnosis, the patient was referred to the hospital's Pulmonology Department for follow-up and initiation of treatment for latent tuberculosis infection.

Conclusion

This case underscores the importance of investigating active or latent tuberculosis in patients with lobular panniculitis with vasculitis consistent with nodular vasculitis, particularly in the presence of positive immunologic tests and a suggestive epidemiological background. In endemic areas, the association between nodular vasculitis and tuberculosis infection should be promptly considered, as recognition of this etiology may prevent diagnostic

delay and guide appropriate management. Previous clinicopathological studies have shown that tuberculosis should remain in the differential diagnosis of panniculitides, especially in the presence of strong tuberculin reactivity and systemic symptoms.

EA DV CONGRESS
VIENNA
30 SEP - 3 OCT 2026

Abstract N°: 2021

Extensive Extragenital Lichen Sclerosus Involving Intertriginous areas : A Diagnostic Challenge

Hanane El Halla*[1], chaouche mohammed[1], Chaimaa Hakkaoui[1], Nachwa Kayouh[1], Chaima El Assali[1], Hajar Lahmidi[1], Afaf Ait Bilaou[1], ikram zouine[1], mhaimer soukaina[1], sokaina chhiti[1], Radia Chakiri[1]

[1] University hospital Mohammed 6, Agadir, Morocco

Introduction

Lichen sclerosus (LS) is a chronic inflammatory dermatosis of unclear etiology, characterized by a predilection for the anogenital region and a marked female predominance. Although its pathogenesis remains incompletely understood, autoimmune mechanisms, genetic susceptibility, and hormonal factors are thought to play a contributory role.

Extragenital involvement is reported in approximately 15–20% of cases and may occur either in association with genital lesions or less frequently, as an isolated manifestation. Clinically, extragenital LS typically presents as atrophic plaques that may coalesce over time. However, atypical clinical features, unusual distributions, and involvement of intertriginous areas may obscure the diagnosis and lead to confusion with other dermatoses such as morphea, lichen planus, or vitiligo.

In contrast to genital LS, extragenital forms are generally considered to carry a lower risk of malignant transformation, yet they may still result in significant cosmetic concerns and impaired quality of life, particularly in extensive cases. Histopathological examination remains the gold standard for diagnosis, especially in atypical presentations.

We report a rare clinical occurrence of extensive extragenital lichen sclerosus predominantly involving intertriginous areas, highlighting its uncommon clinical presentation and emphasizing the importance of clinicopathological correlation for accurate diagnosis and appropriate management.



Multiple atrophic erythematous–violaceous plaques with irregular borders, located in the right and left inguinal regions as well as the abdomen

Case Presentation

A 66-year-old woman with a 10-year history of osteoarthritis and a past medical history of left breast cancer treated two years earlier with surgery, followed by radiotherapy and ongoing hormonal therapy, presented with extensive, asymptomatic cutaneous lesions.

Dermatological examination revealed multiple erythematous to violaceous atrophic plaques with irregular borders, symmetrically distributed over the inguinal regions, inframammary folds, and abdomen.

Dermoscopic evaluation showed an erythematous background with a peppering pattern, whitish streaks, and structureless white areas. Based on these findings, a diagnosis of lichen sclerosus was suspected. A skin biopsy was performed and confirmed the diagnosis, demonstrating an atrophic epidermis with compact orthokeratosis and loss of rete ridges. Focal keratotic plugs were observed. The basal layer showed focal vacuolar alteration, associated with a moderate superficial dermal inflammatory infiltrate predominantly composed of mononuclear cells.

The patient was treated with topical clobetasol propionate twice daily for six months, resulting in marked clinical improvement.

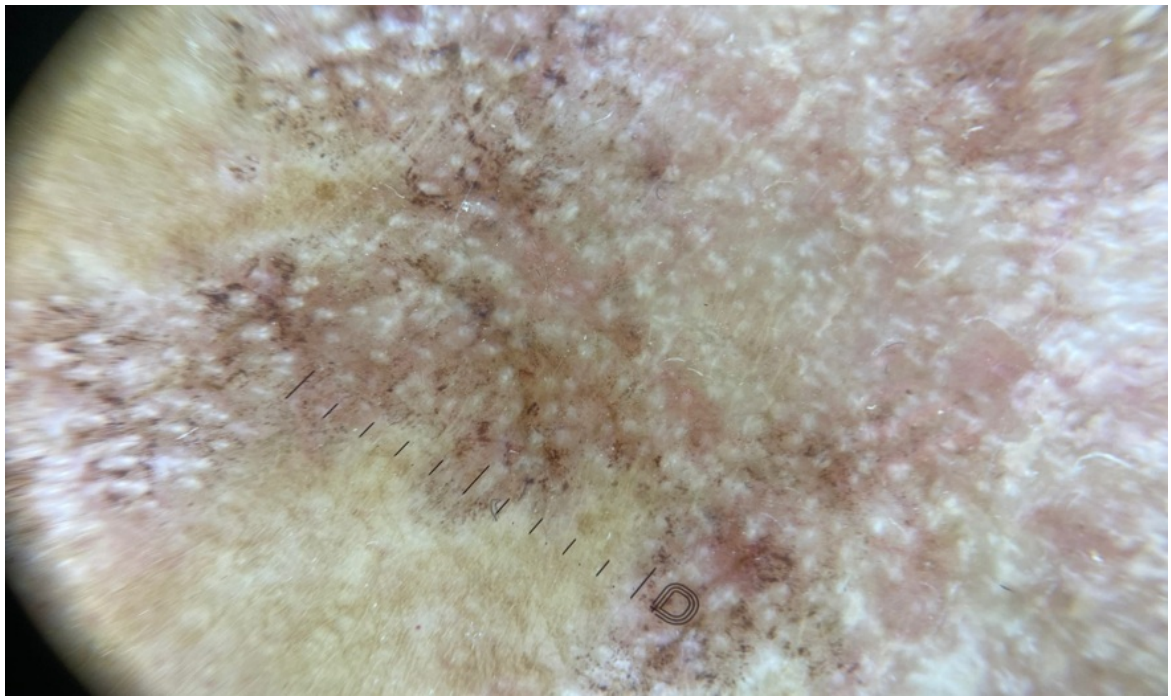

Dermoscopy revealed: erythematous background, a peppering pattern, whitish streaks, and structureless white areas

Conclusion

Extragenital lichen sclerosus is an uncommon and often underrecognized entity, particularly when confined to intertriginous areas. Its atypical clinical presentation may lead to diagnostic delay or misdiagnosis. This case highlights the importance of considering lichen sclerosus in the differential diagnosis of atrophic plaques in unusual locations and underscores the key role of histopathological examination in establishing an accurate diagnosis. Early recognition and appropriate treatment are essential to improve clinical outcomes.

EA DV CONGRESS
VIENNA
30 SEP - 3 OCT 2026

Abstract N°: 2036

Vaccine-Triggered Inflammatory Exacerbation of Latent Silicone Granulomas

Ming Che Chiang*[1]

[1] Department of Dermatology, En Chu Kong Hospital, New Taipei City, Taiwan

Introduction

Liquid silicone, though historically used for soft-tissue augmentation, is associated with severe late-onset complications, most notably **silicone granuloma (SG)**. While these granulomatous reactions typically occur years after injection, their sudden transformation from asymptomatic nodules to aggressive inflammatory plaques can be triggered by systemic immune activation. Recent evidence suggests that mRNA COVID-19 vaccinations may provoke such hyperresponsiveness in areas containing foreign fillers. This report discusses a case of severe SG exacerbation following vaccination and the subsequent therapeutic success of methotrexate.

Case Presentation

A 41-year-old female presented with a 2-year history of painful, progressive skin lesions on her bilateral hips and flanks. She had a history of cosmetic silicone injections 25 years prior. Although mild, asymptomatic induration had developed 20 years post-injection, the condition deteriorated rapidly—marked by intense pain and lesion enlargement—within six months of receiving three doses of the **Pfizer-BioNTech COVID-19 vaccine**.

Clinical & Diagnostic Findings:

- **Physical Examination:** Large, sharply demarcated, purplish plaques and nodules (approx. 18 *14 cm per side) with deep-seated bullae.
- **Imaging:** CT scans showed extensive, heterogeneous soft-tissue infiltration across the lower abdomen, pelvis, and upper thighs.
- **Histopathology:** Skin biopsy revealed characteristic **"Swiss cheese"** cystic spaces and granulomatous inflammation, diagnostic of silicone granuloma. Infectious workups (bacterial, fungal, and mycobacterial) were negative.

Management and Outcome:

The patient's condition was refractory to a 2-month course of oral steroids. She was subsequently transitioned to **systemic methotrexate**. Over 3 months, this regimen led to a significant reduction in erythema, pain, and the resolution of bullous lesions. Due to the clinical improvement and the inherent difficulty of complete surgical excision in migrating fillers, the patient continued with medical therapy.

Conclusion

This case highlights the potential for **COVID-19 vaccines to act as an immunological trigger**, causing long-dormant silicone deposits to transition into symptomatic granulomas. As surgical removal of silicone is often complicated by tissue migration (occurring in approximately 43% of cases), medical management remains a cornerstone of therapy. Our findings suggest that **low-dose methotrexate** is a highly effective alternative for patients with severe, steroid-resistant silicone granulomas.

EADV CONGRESS
VIENNA
30 SEP - 3 OCT 2026

Abstract N°: 2042

Steatotic Liver Disease in Patients with Hidradenitis Suppurativa: A Prospective Cohort Study

Fatemah Sadek*[1, 2], Christopher Willy Schwarz[1], Ditte Marie Saunte[1, 2, 3, 4], Simon F Thomsen[5, 6], Lise Lotte Gluud[2, 7], Maria Victoria Gerdes-Miranda[1], Lone Skov[1, 2], Charlotte Näslund-Koch[1]

[1] Department of Dermatology and Allergy, Copenhagen University Hospital – Herlev and Gentofte, Copenhagen, Denmark

[2] Department of Clinical Medicine, Faculty of Health and Medical Sciences, University of Copenhagen, Copenhagen, Denmark

[3] PHOENIX Research Center, Department of Dermatology and Allergy, Copenhagen University Hospital – Herlev and Gentofte, Copenhagen, Denmark

[4] Unit of Mycology, Department of Bacteria, Parasites and Fungi, Statens Serum Institut, Copenhagen, Denmark

[5] Department of Biomedical Sciences, University of Copenhagen, Copenhagen, Denmark

[6] Department of Dermatology, Bispebjerg Hospital, University of Copenhagen, Copenhagen, Denmark

[7] Gastro Unit, Copenhagen University Hospital, Hvidovre, Denmark, and Department of Clinical Medicine, Faculty of Health and Medical Sciences, University of Copenhagen, Copenhagen, Denmark

Introduction

Hidradenitis suppurativa (HS) is a chronic inflammatory skin disease associated with obesity and metabolic syndrome. Steatotic liver disease (SLD), the hepatic manifestation of the metabolic syndrome, encompasses a spectrum ranging from simple steatosis to advanced fibrosis. A potential link between HS and liver involvement has therefore been proposed. In addition to shared metabolic risk factors, systemic low-grade inflammation in HS may further contribute to hepatic alterations. However, existing evidence remains limited, particularly from studies using transient elastography to assess both steatosis and fibrosis, and prospective data are scarce. This study aimed to investigate hepatic steatosis and fibrosis in patients with HS, and to assess the relationship with disease severity, including changes over 1 year.

Materials and Methods

Patients underwent clinical, anthropometric, and biochemical assessments, including measurements of HbA1c, lipid profile, and liver enzymes. Liver involvement was assessed using transient elastography (FibroScan®), with controlled attenuation parameter (CAP) ≥250 dB/m indicating steatosis) and liver stiffness measurement (LSM) ≥8 kPa, indicating fibrosis. The fibrosis-4 index (FIB-4) was included as a blood-based, non-invasive marker of fibrosis risk, using cut-offs of >1.3 for individuals <65 years and >2.0 for those ≥65 years. HS severity was assessed using the International Hidradenitis Suppurativa Severity Score (IHS4) and Hurley staging. Lifestyle factors, comorbidities, and quality of life were assessed using patient-reported questionnaires. Multivariable linear regression analyses were performed to evaluate associations between HS severity and hepatic parameters, adjusting for relevant covariates, including BMI, age, sex, type 2 diabetes and excessive alcohol intake. Stratified analyses by BMI were conducted to explore potential effect modification.

Results

In this prospective cohort study, 131 adult patients (≥18 years) with a confirmed HS diagnosis were included at

baseline, of whom 89 also completed 1-year follow-up. Steatosis was common, whereas clinically significant fibrosis was rare. At baseline, 46.0% had steatosis, which increased to 51.0% at the 1-year follow-up, with no significant metabolic changes in weight, waist circumference or diabetes observed over time. Three patients (2.3%) had LSM ≥8 kPa at baseline, and four (3.1%) had a FIB-4 above the cut-off. In univariable analyses, IHS4 and CAP were positively associated. However, this association was attenuated after adjustment for confounders, with BMI emerging as the strongest predictor of steatosis ($p < 0.001$). In stratified analyses, IHS4 was positively associated with CAP only among patients with a BMI ≤25, whereas no association was observed in overweight or obese individuals. For fibrosis, in the adjusted multivariable analysis, LSM was positively associated with BMI ($p < 0.001$) and male sex ($p = 0.027$), but not with IHS4. In stratified analyses, IHS4 was not associated with LSM across BMI strata. No associations were observed between BMI or IHS4 and FIB-4 (all $p > 0.05$).

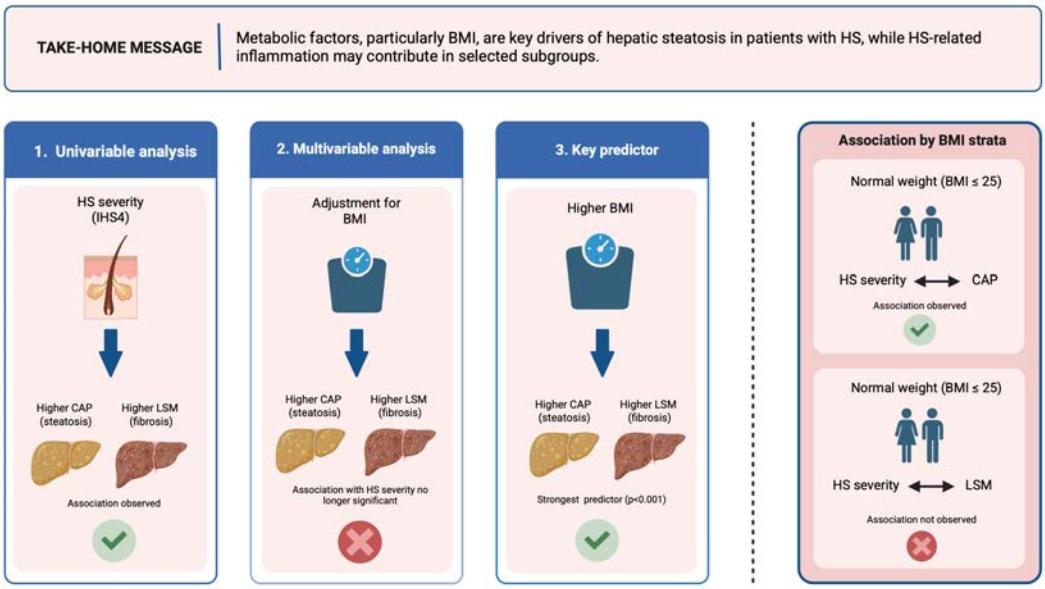

Figure 1. Association between HS severity and liver outcomes. BMI=body mass index; CAP=controlled attenuation parameter; IHS4=International Hidradenitis Suppurativa Severity Score; LSM=liver stiffness measurement.

Conclusions

In this prospective cohort of patients with HS, hepatic steatosis was prevalent, whereas clinically significant fibrosis was rare. Both grades of steatosis and liver stiffness measurements were positively associated with the severity of HS; however, this association appear to be driven mainly by metabolic factors. The observed association between HS severity and steatosis in normal-weight individuals suggests a possible role for HS-related inflammation independent of adiposity. Our data highlight the importance of metabolic risk assessment in patients with HS and indicate that HS-specific inflammatory pathways may contribute to hepatic steatosis in selected subgroups.

EA DV CONGRESS
VIENNA
30 SEP - 3 OCT 2026

Abstract N°: 2051

AI versus Experts: Navigating Challenging Cases in Psoriatic Disease

Lourdes Perez-Chada[1], Victoria Garfinkel*[2], Beth Childs[2], Akhil Bedapudi[2], Michael Woodbury[3], Arianna Zhang[4], Eric Ruderman[5], Anthony Fernandez[6], Philip J Mease[7], Evan Siegel[8], Rebecca Haberman[9], Dafna Gladman[10], Soumya Reddy[9], Alexis Ogdie[11], Jose Scher[9], Ryan Stidham[12], Joseph F. Merola[2]

[1] Dermatology Brigham and Women's Hospital, Boston, United States
[2] UT Southwestern Medical Center, Dallas, United States
[3] Icahn School of Medicine at Mount Sinai, New York, United States
[4] Tufts University School of Medicine, Boston, United States
[5] Northwestern University, Evanston, United States
[6] Cleveland Clinic Foundation House, Cleveland, United States
[7] Swedish Rheumatology - Seattle, Seattle, United States
[8] Arthritis & Rheumatism Associates, Rockville, United States
[9] New York University School of Medicine Health, New York, United States
[10] Toronto Western Hospital, Toronto, Canada
[11] Penn Medicine, Philadelphia, United States
[12] Mayo Clinic College of Medicine & Science-Florida, Jacksonville, United States

Introduction
Treatment guidelines for psoriatic disease provide an important framework for care, but they may not fully address complex, multidomain, treatment-refractory scenarios. As generative artificial intelligence (AI) tools become more accessible, it is important to understand how closely AI-generated treatment recommendations align with expert clinical decision-making.

Materials and Methods
To evaluate concordance among multidisciplinary psoriatic disease experts across clinical scenarios and to assess alignment between expert and AI-generated recommendations. A survey of 44 experienced clinicians was conducted using 17 standardized psoriatic disease scenarios involving inadequate response (IR) to targeted therapy and treatment-resistant disease after multiple mechanism failures. Respondents selected first- and second-choice therapies from a restricted list. AI recommendations were generated with a prespecified deterministic prompt framework. Scenarios were grouped by axial involvement and prior biologic exposure: axial disease with tumor necrosis factor inhibitor (TNFi) IR; non-axial disease with TNFi IR; axial disease with interleukin (IL)-17 inhibitor IR; and non-axial disease with IL-17/IL-23 inhibitor IR. Inter-expert concordance was summarized by the proportion selecting the top agent and Gwet's AC1. AI-expert alignment was defined as the proportion of experts selecting the AI-recommended therapy.

Results
Across all groups, experts generally favored switching to a different mechanism rather than continuing current therapy with an add-on approach. For first-choice decisions, concordance was highest in axial disease with TNFi IR

(78% selected the top agent; AC1 60.0). Lower first-choice concordance was observed in non-axial disease with TNFi IR (51%; AC1 26.6), axial disease with IL-17 inhibitor IR (51%; AC1 24.6), and non-axial disease with IL-17/IL-23 inhibitor IR (69%; AC1 40.3). AI-expert first-choice alignment ranged from 51% to 78% across groups and was consistently lower for second-choice selections (16% to 40%). AI matched the most frequently selected expert therapy across all first-choice scenarios with an expert preference, whereas second-choice recommendations were substantially more heterogeneous.

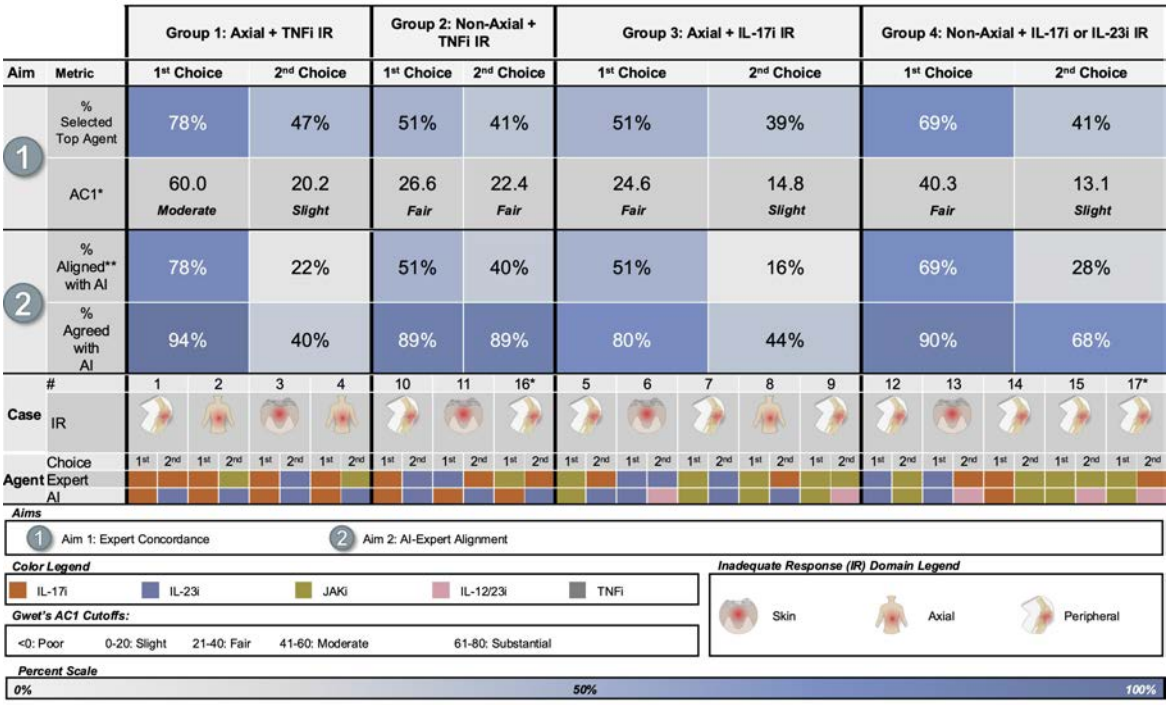

* Gwet's AC1 values are scaled by x100 in the figure (i.e., AC1 × 100; for example, 0.202 displayed as 20.2). Interpretation thresholds are based on established benchmarks in the literature, where AC1 values of <0.00, 0.00–0.20, 0.21–0.40, 0.41–0.60, 0.61–0.80, and 0.81–1.00 correspond to poor, slight, fair, moderate, substantial, and almost perfect agreement, respectively. ** "Aligned with AI" denotes the expert–AI first-choice alignment rate, defined as the proportion of expert respondents whose first-choice treatment selection matched the AI-recommended first-choice therapy for a given clinical scenario. Meanwhile, "% Agreed with AI" denotes the proportion of respondents selecting Agree or Strongly agree on Likert-scale items evaluating the AI-recommended strategy. The proportion selecting the same choice reflects the percentage of respondents choosing a given treatment option (e.g., the most frequently selected first-choice therapy). In contrast, Gwet's AC1 is a chance-corrected inter-rater agreement statistic that quantifies the extent to which agreement among respondents exceeds what would be expected by chance across all response options. Thus, the percentage selecting the top option captures response concentration, whereas AC1 captures overall agreement reliability.

Conclusions

In complex psoriatic disease scenarios, expert treatment preferences showed moderate to fair agreement for first-choice decisions and substantially greater heterogeneity for second-choice options. AI recommendations aligned more closely with expert first-choice than second-choice selections, suggesting potential value as a decision-support tool while also highlighting the need for caution in nuanced multidomain cases. These findings provide a framework for future expert-informed evaluation of AI-assisted treatment strategies in psoriatic disease.

EADV CONGRESS
VIENNA
30 SEP - 3 OCT 2026

Abstract N°: 2067

Pityriasis rubra pilaris type I triggered by a surgical Koebner-like phenomenon: diagnostic pitfalls and stepwise therapeutic management

Maria Alexandra Timofte*[1], Mara Madalina Mihai[1, 2], Andra Ioana Copilau[1], Cătălina-Ioana Naum[1], Ana-Maria Toma[1]

[1] Elias Emergency University Hospital, Bucharest, Romania

[2] Carol Davila Univeristy of Medicine and Pharmacy, Bucharest, Romania

Introduction

Pityriasis rubra pilaris (PRP) is a rare papulosquamous keratinization disorder (estimated incidence 1:50,000). Type I (classic adult) accounts for approximately 55% of cases, characterised by follicular hyperkeratotic papules, cephalocaudal progression, erythroderma with islands of uninvolved skin (*nappes claires*), and palmoplantar keratoderma. Surgical trauma as a Koebner-like trigger for adult-onset PRP type I has been described only exceptionally in the literature. We report such a case, complicated by initially inconclusive histopathology, erythrodermic progression, and resistance to multiple systemic agents.

Case Presentation

A 46-year-old male presented with a 6-week history of pruritic follicular hyperkeratotic papules in a cephalocaudal distribution, originating from the site of a recently excised melanocytic naevus— consistent with a Koebner-like trigger. Extensive workup excluded infectious, immunological, neoplastic, and toxic aetiology.

The initial skin biopsy was interpreted as inconclusive. Despite topical and systemic corticosteroids, the eruption progressed. Over the following weeks, the clinical picture evolved to erythroderma involving >90% BSA with characteristic islands of spared skin, bilateral palmoplantar keratoderma, and hypoalbuminaemia secondary to cutaneous protein loss. A second biopsy with serial sections revealed the pathognomonic alternating orthokeratosis/parakeratosis ("checkerboard pattern") and follicular plugging, confirming PRP type I (Griffiths classification).

The patient showed only partial response to ciclosporin. Combination therapy with methotrexate and acitretin led to near-complete clearance by six months, with anti-IL-17 biological therapy planned if response plateaus.

Conclusion

This case underscores several clinically relevant lessons. Surgical excision can act as a Koebner-like trigger for adult PRP type I — a mechanism exceptionally reported in this subtype and warranting recognition in post-procedural inflammatory eruptions. Early-stage histopathology may be non-diagnostic; serial sectioning and rigorous clinicopathological correlation over time are essential to avoid misdiagnosis and therapeutic delay. Furthermore, erythrodermic PRP refractory to conventional monotherapy may require sequential combination regimens, with biological agents representing a viable next-line option in recalcitrant cases. Despite a potentially prolonged and challenging course, type I adult PRP carries a favourable prognosis, with approximately 80% spontaneous remission expected within 1–3 years.

EADV CONGRESS
VIENNA
30 SEP - 3 OCT 2026

Abstract N°: 2070

Supporting Late-Phase Clinical Development of Upadacitinib: Validation of Three-Dimensional Imaging for Facial Vitiligo Assessment

Amber Abir[1], Avishai Tzur[2], Sandra L. Goss[3], Tiancheng He[3], Stavonnie Patterson[3], Lee Heyman[1], Daniel Mimouni[1], Shany Sherman*[1]

[1] Division of Dermatology, Rabin Medical Center - Beilinson Hospital, Petach Tikva, Israel

[2] Cherry Imaging Ltd., Yokneam, Israel

[3] AbbVie Inc., North Chicago, United States

Introduction

The evaluation of targeted therapies, including the selective Janus kinase 1 inhibitor upadacitinib, in late-phase vitiligo trials underscores the need for reliable and objective tools to assess facial disease extent. Current clinical scores rely on visual estimation and are subject to intra- and inter-rater variability. Three-dimensional imaging may provide an objective alternative for lesion surface quantification.

Materials and Methods

In this non-interventional study, 19 adults with non-segmental vitiligo and facial involvement underwent full-face scanning using a three-dimensional imaging platform integrating multispectral analysis and operator-guided thresholding for lesion demarcation. Reference measurements were obtained from investigator-annotated two-dimensional ultraviolet images. Agreement across 48 predefined facial regions was evaluated using the Dice Similarity Coefficient.

Results

The platform demonstrated good spatial agreement with the reference standard (mean Dice Similarity Coefficient: 0.707). Participants (mean age 47.7 years, Fitzpatrick phototypes I–IV) had a mean Facial Vitiligo Area Scoring Index of 0.94. Skin phototype was positively correlated with agreement (Spearman's $\rho = 0.302$, $p = 0.037$), with higher concordance observed in darker skin tones (Type IV, mean Dice Similarity Coefficient: 0.763). Agreement was higher in flatter facial regions compared to contoured areas.

Conclusions

This three-dimensional imaging platform provides a standardized and objective approach for assessing facial vitiligo lesion area, with good concordance to a reference standard. Further large-scale studies across diverse populations are warranted to confirm its utility in clinical and research settings.

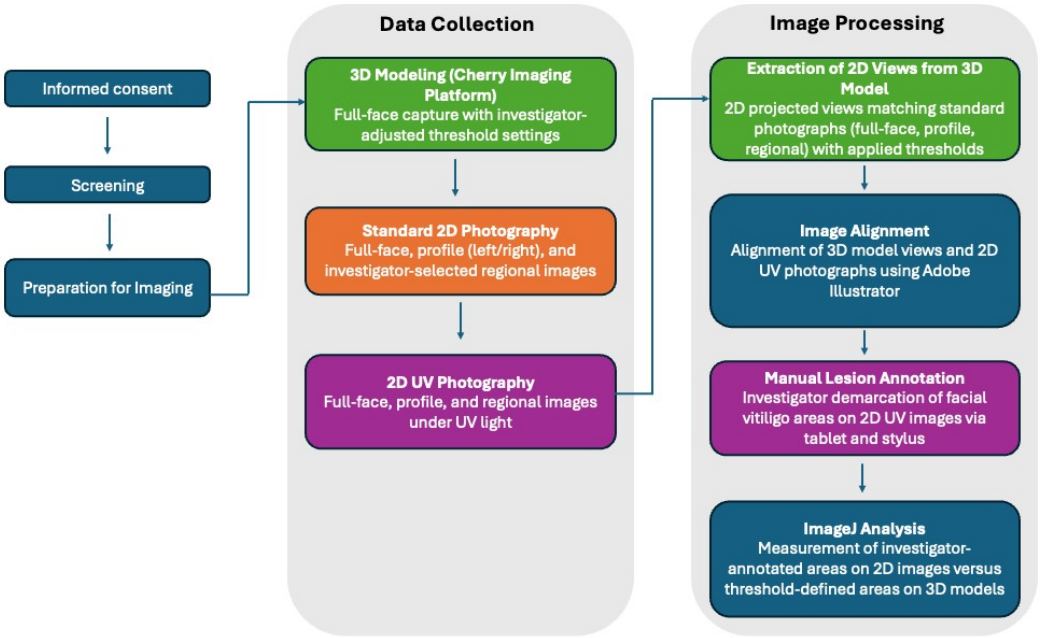

Figure 1: Study design and workflow schematic. Following standardized facial preparation and fiducial marker placement, vitiligo patients underwent evaluation via stereoscopic 3D scanner (Cherry Imaging) and 2D reference photography under UV light. Images were spatially aligned and overlaid for comparison using ImageJ software.

EADV CONGRESS
VIENNA
30 SEP - 3 OCT 2026

Abstract N°: 2095

Atopic dermatitis in the elderly represents a distinct immunological phenotype: a prospective single-cell and spatial multi-omics study

Youngkyoung Lim*[1], Hyunsung Nam[2], Seungmin Cha[3], Anjin Kim[1], Hyun Je Kim[2, 3, 4, 5]

[1] Department of Dermatology, Verterans Health Service Medical Center, Seoul, Korea, Rep. of South

[2] Genomic Medicine Institute, Seoul National University College of Medicine, Seoul, Korea, Rep. of South

[3] Department of Microbiology and Immunology, Seoul National University College of Medicine, Seoul, Korea, Rep. of South

[4] Interdisciplinary Program in Artificial Intelligence, Seoul National University Graduate School, Seoul, Korea, Rep. of South

[5] Department of Dermatology, Seoul National University Hospital, Seoul, Korea, Rep. of South

Introduction
Atopic dermatitis (AD) has long been regarded as a chronic inflammatory skin disease predominantly affecting children and young adults. However, its occurrence in older adults is increasingly recognized, raising the question of whether AD in the elderly constitutes a distinct clinical entity. This study aimed to define the clinical, cellular, and molecular features of AD in the elderly using integrated single-cell and spatial multi-omics approaches.

Materials and Methods
We prospectively enrolled patients aged ≥ 65 years with AD. Lesional and adjacent non-lesional skin, as well as peripheral blood, were collected. Comprehensive clinical, histological, and molecular data were obtained, including single-cell RNA sequencing and spatial transcriptomics. Fifteen patients (mean age 71 years) and age- and sex-matched controls were included.

Results
Multi-omics analysis revealed distinct immunological features of AD in the elderly. Lesional T cells retained canonical Th2 signatures while frequently co-expressing IFN-γ and IL-17-related signatures, indicating a mixed inflammatory phenotype. Spatial transcriptomics identified enriched fibroblast-dendritic cell interaction hubs within lesional skin, suggesting a microenvironment sustaining chronic inflammation. In addition, senescence-associated secretory phenotype (SASP)-related genes were markedly upregulated, indicating age-related immune remodeling.

Conclusions
AD in the elderly represents a distinct, age-associated immunological phenotype rather than a simple extension of conventional AD. These findings provide a framework for improved diagnostic precision and tailored therapeutic strategies for this growing patient population.

EADV CONGRESS
VIENNA
30 SEP - 3 OCT 2026

Abstract N°: 2095

Erythroderma Mimicking DRESS Syndrome Revealing Myeloid Sarcoma

Hajar Lahmidi*[1], sokaina chhiti[1], Chaimae El assali[1], hiba kherbach[1], Hanane El Halla[1, 1], mhaimer soukaina[1], chaouche mohammed[1], radia chakiri[1]

[1] Mohammed VI University Hospital - Department of Dermatology, agadir, Morocco

Introduction
Erythroderma is a dermatological emergency with multiple etiologies, including drug reactions and malignancies. Drug-induced erythroderma, particularly DRESS syndrome, is frequently suspected but may mask underlying neoplastic disease. We report a misleading presentation of erythroderma mimicking DRESS syndrome that revealed a myeloid sarcoma.

Case Presentation
An 81-year-old woman with hypertension, prior urticarial vasculitis, chronic pruritus, and recent initiation of SSRIs and amitriptyline presented with acute pruritic erythroderma evolving over 24 hours.

Examination showed diffuse erythroderma with urticarial plaques, lichenified lesions, and bilateral cervical and inguinal lymphadenopathy, without facial edema. In the context of recent drug exposure, eosinophilia, and systemic features, DRESS syndrome was initially suspected.

Laboratory tests revealed marked eosinophilia (3339/mm³) without circulating blasts; renal and hepatic functions were normal. NGS identified GNB1 and TET2 mutations.

Skin biopsy showed a preserved epidermis with mild hyperkeratosis and focal parakeratosis, without spongiosis or keratinocyte necrosis, and a mild perivascular lymphoplasmacytic infiltrate without vasculitis or epidermotropism, arguing against DRESS.

In contrast, lymph node biopsy revealed a diffuse infiltrate with large atypical cells. Immunohistochemistry demonstrated CD45 and MPO positivity, with CD117/CD68 expression and absence of CD34, supporting myeloid sarcoma.

Initial improvement under topical corticosteroids was misleading. Over 15 months, a relapsing course with persistent eosinophilia and severe pruritus resistant to antihistamines was observed.

Conclusion
Erythroderma in elderly patients requires thorough investigation. Even in a suggestive drug-induced context, alternative diagnoses, particularly hematologic malignancies, must be considered. This case highlights a diagnostic pitfall of myeloid sarcoma mimicking DRESS syndrome.

EA DV CONGRESS
VIENNA
30 SEP - 3 OCT 2026

Abstract N°: 2215

Development and content validity testing of two new Patient Reported Outcome (PRO) instruments in Palmoplantar Pustulosis (PPP)

Andrew E. Pink*[1], Robert Bissonnette[2], Jason Hawkes[3], Joanna Narbutt[4], Rotraut Mößner[5], Petra Arlert[6], Dale Chandler[7], Laura Grant[7], Megan Mayhew[7], Henrik Meincke[6], Anne Marie Schmitt[6], Matthias Augustin[8]

[1] St. John's Institute of Dermatology, Guy's and St. Thomas' NHS Foundation Trust and King's College London, London, United Kingdom
[2] Innovaderm Research, Montreal, Canada
[3] Oregon Medical Research Center, Portland, United States
[4] Department of Dermatology, Pediatric Dermatology and Oncology, Medical University of Lodz, Lodz, Poland
[5] Department of Dermatology, Venereology, and Allergology, University Medical Center, Göttingen, Germany
[6] LEO Pharma, Ballerup, Denmark
[7] Adelphi Values Ltd, Bollington, United Kingdom
[8] Institute for Health Services Research in Dermatology and Nursing, University Medical Center Hamburg, Hamburg, Germany

Introduction

Palmoplantar pustulosis (PPP) is a rare, chronic inflammatory skin condition, affecting the palms and soles, with substantial symptom burden and wide-ranging impacts on daily functioning and health-related quality of life (HRQoL). Despite this burden, limited qualitative evidence exists to characterize the patient experience of PPP, or to inform the development of appropriate patient-reported outcome (PRO) instruments for use in clinical trials. The objective of this study was to develop and evaluate novel PPP-specific instruments; the PPP-symptom assessment (PPP-SA) and PPP-impact assessment (PPP-IA), and to generate content validity evidence, to support their use in a Phase 2a clinical trial.

Materials and Methods

Item generation for the PPP-SA and PPP-IA was informed by: a targeted qualitative literature review of PPP symptoms and impacts; and a critical review of existing clinical outcome assessments (COA) in PPP and related dermatologic conditions. Draft items (PPP-SA: 14 items – 7 palm items, 7 sole items; PPP-IA: 13 items), instructions, recall periods (PPP-SA: 24-hour; PPP-IA: 7-days), and response scales were reviewed by two clinical experts in dermatology and PRO development, and refined prior to patient testing. Following item generation, a cross-sectional qualitative study was conducted with 12 US patients with mild to severe PPP, consisting of 90-minute combined concept elicitation (CE) and cognitive debriefing (CD) interviews (Figure 1).

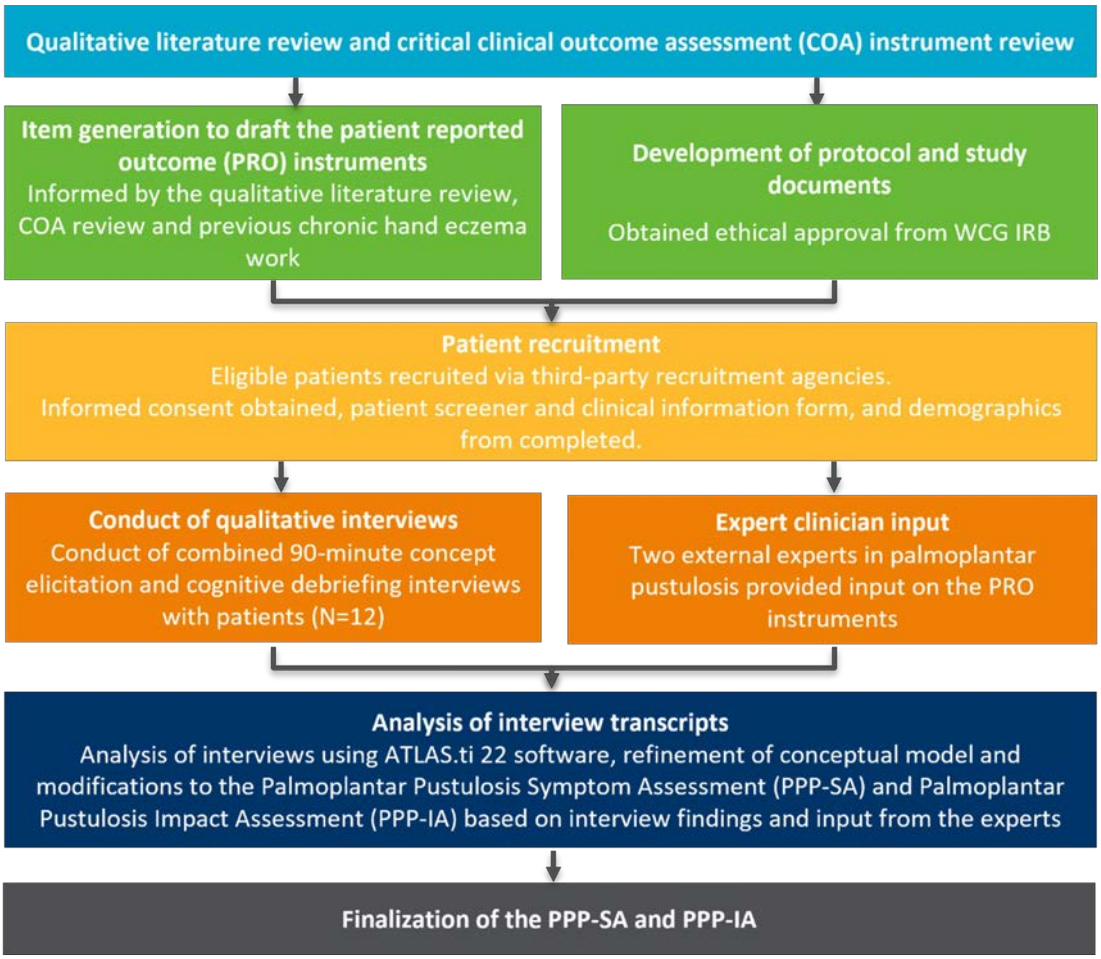

Figure 1. Overview of the study methodology

Results

Across CE interviews, patients reported 16 symptoms, with pustules, pain, itch, cracked skin, peeling/flaky skin, redness, and dryness described by all or nearly all patients. Symptoms varied in frequency, duration, and severity. Pustules were most frequently cited as the most bothersome and the most important to treat, reflecting severity and downstream effects on other symptoms (e.g., pain, itch, peeling). Patients described impacts across six HRQoL domains including activities of daily living, emotional wellbeing, physical functioning, social functioning, sleep, and work, highlighting challenges with daily tasks (e.g., housework), mobility (e.g., walking, exercise), mood (e.g., feeling depressed, frustrated), social participation, sleep continuity, and work productivity. Conceptual saturation was achieved, with the majority of symptoms and all HRQoL impact domains being reported spontaneously, supporting the adequacy of the sample to capture the core symptom and impact concepts of PPP (Table 1).

Findings from the CD interviews demonstrated that patients consistently understood item wording and instructions, applied the 24-hour PPP-SA and 7-day PPP-IA recall periods appropriately, and judged the numerical and verbal response options as acceptable, and easy to use. Items were considered relevant and comprehensive by most patients. Patients also articulated interpretable descriptions of meaningful change (day-to-day for symptoms; week-to-week for impacts), supporting future work on responder definitions and score interpretation. Clinical expert review corroborated clinical relevance and supported retention of all draft PPP-SA and PPP-IA items, with minor refinements made to the PPP-IA examples to improve clarity without altering concepts. Collectively, findings show that the PPP-SA and PPP-IA appropriately capture the key symptoms and HRQoL impacts of PPP, are well understood, and are suitable for use in the ongoing Phase 2a clinical trial.

Table 1. Concept saturation analysis of patient reported symptoms/HRQoL domains

	Group 1 (n=3)			Group 2 (n=3)			Group 3 (n=3)			Group 4 (n=3)		
Signs/symptoms												
Blisters/pustules	✓	✓	✓	✓	✓	✓	✓	✓	✓	✓	✓	✓
Itch	✓	✓	✓	✓	✓	✓	✓	✓	✓	✓	✓	✓
Pain	✓	✓	✓	✓	✓	✓	✓	✓	✓	✓	✓	✓
Peeling/flaky skin	✓	✓	✓	✓	✓	✓	✓	✓	✓	✓	✓	✓
Cracked skin	✓	✓	✓	✓	✓	✓	✓	✓	✓	✓	✓	✓
Dryness	✓	✓	✗	✓	✓	✓	✓	✓	✓	✓	✓	✓
Redness	✓	✓	✓	✓	✓	✓	✓	✓	✓	✓	✓	✓
Burning	✗	✓	✓	✓	✓	✓	✓	✓	✓	✗	✗	✓
Nail involvement	✗	✓	✗	✓	✓	✗	✓	✗	✓	✗	✗	✗
Bleeding	✓	✓	✓	✓	✓	✓	✓	✗	✓	✗	✗	✓
Scaly skin	✓	✓	✓	✗	✓	✓	✓	✗	✗	✗	✗	✓
Thickened skin	✓	✓	✗	✓	✗	✓	✓	✗	✓	✗	✗	✓
Swelling/inflammation	✗	✓	✓	✗	✗	✓	✗	✗	✓	✓	✓	✓
Fatigue	✓	✓	✗	✗	✗	✓	✗	✗	✓	✗	✗	✓
Sensitive skin	✗	✗	✗	✗	✗	✓	✓	✓	✗	✗	✗	✓
Tingling	✗	✓	✗	✓	✗	✗	✗	✗	✗	✗	✗	✓
HRQoL impact domains												
ADL	✓	✓	✓	✓	✓	✓	✓	✓	✓	✓	✓	✓
Emotional wellbeing	✓	✓	✓	✓	✓	✓	✓	✓	✓	✓	✓	✓
Physical functioning	✓	✓	✓	✓	✓	✓	✓	✓	✓	✓	✓	✓
Social functioning	✓	✓	✓	✗	✓	✓	✓	✓	✓	✓	✓	✓
Sleep	✓	✓	✓	✗	✓	✓	✓	✗	✓	✓	✓	✓
Work functioning	✗	✓	✓	✗	✓	✓	✓	✗	✓	✓	✓	✓

Note: ✓ = first spontaneous report of concept/domain, ✓ = concept/domain reported spontaneously, ✓= concept/domain reported after interviewer probe, ✗ = concept/domain not experienced, ✗= concept/domain not discussed with patients. HRQoL = Health related quality of life.

Conclusions

This study generated detailed qualitative evidence on the symptoms and impacts experienced by patients with PPP, including the concepts most salient to the patient experience. The findings contribute to the scarcity of existing literature on the patient burden of PPP and how to best capture this impact. These results provide the first preliminary evidence of content validity for the PPP-SA and PPP-IA, facilitating the evaluation of symptoms and HRQoL with disease specific measures in patients with PPP.

EA DV CONGRESS
VIENNA
30 SEP - 3 OCT 2026

Abstract N°: 2219

Skin Microbiome Dysbiosis in Inflammatory Facial Dermatoses: Prominent Features

Liborija Lugovic Mihic*[1], Iva Fercek[1], Mirta Peček[1, 2], Lucija Zanze[3], Lorena Dolački[1], Dijana Šarić[4]

[1] Klinički bolnički centar Sestre Milosrdnice, School of Dental Medicine Zagreb, Zagreb, Croatia
[2] Health Center Zagreb West, 10000 Zagreb, Croatia, Zagreb, Croatia
[3] Family Physician Office, 10000 Zagreb, Croatia, Zagreb, Croatia
[4] University Medical Centre Ljubljana, Ljubljana, Slovenia

Introduction

Inflammatory facial dermatoses, including atopic dermatitis, acne vulgaris, rosacea, seborrheic dermatitis, and perioral dermatitis, are among the most frequently encountered conditions in dermatological practice. They often follow a chronic or relapsing course and remain therapeutically challenging. Despite clinical differences, these disorders share key pathogenic mechanisms involving epidermal barrier dysfunction, innate immune activation, and alterations of the skin microbiota. A balanced microbiome supports barrier integrity, pH regulation, and immune homeostasis, contributing to cutaneous resilience. Keratinocytes play an active immunological role through the production of antimicrobial peptides, cytokine secretion, and Toll-like receptor (TLR) signaling, linking barrier function with immune responses.

Materials and Methods

This review is based on an analysis of literature published between 2007 and 2025. Relevant studies were identified through Web of Science, Scopus, and PubMed using predefined search terms related to the skin microbiome and inflammatory dermatoses. The review focuses on the role of the skin microbiome in facial dermatoses and related factors.

Results

The diversity of the skin microbiome is influenced by intrinsic factors (age, sex, hormonal status, genetic background, immune function, and overall health) and extrinsic factors (environmental exposure, pollution, lifestyle habits, cosmetic use, hygiene practices, and pharmacological treatments). The facial skin microbiota is mainly composed of Cutibacterium, Staphylococcus, and Malassezia species, with variability influenced by these factors. This variability contributes to differences in disease susceptibility and clinical expression of facial dermatoses. In acne vulgaris, disease activity is associated with specific Cutibacterium acnes phylotypes that drive innate immune activation. In rosacea, increased Demodex density and microbial alterations are linked to TLR-2 activation and enhanced pro-inflammatory cytokine production. Seborrheic dermatitis is strongly associated with Malassezia species, which interact with sebaceous lipids and induce inflammatory responses in susceptible individuals. Perioral dermatitis is frequently associated with epidermal barrier disruption and microbiota imbalance, often triggered by topical corticosteroids or cosmetic exposure. In atopic dermatitis, epidermal barrier dysfunction induces activation of the Th2 pathway, characterized by increased IL-4, IL-5, and IL-13, elevated IgE levels, and eosinophilia, while chronic phases are associated with Th1/Th17 responses. Across all conditions, microbial alterations are closely linked with immune dysregulation.

Conclusion

Skin microbiome dysbiosis is increasingly recognized as an important contributor to the pathogenesis of facial inflammatory dermatoses through complex interactions with the epidermal barrier and the immune system. These interactions may contribute to disease persistence and clinical variability. The microbiome represents a clinically relevant target, with potential implications for diagnosis and treatment. Microbiome profiling may support improved risk stratification and earlier intervention. Targeted modulation of the skin microbiome represents a promising approach for personalized therapeutic strategies aimed at restoring cutaneous homeostasis.

EADV CONGRESS
VIENNA
30 SEP - 3 OCT 2026

Abstract N°: 2221

Generalized PLEVA-like eruption following tetanus vaccination with clinicopathologic discordance in a child

Hoor Al Ghaithi*[1], Raqiya Al Rajaibi[2], Zakiya Al Ajmi[3], Shima Al Khuri[4]

[1] Dermatology, Oman Medical Speciality Board, Muscat, Oman

[2] Dermatology, Rustaq Polyclinic, Ministry of Health, Rustaq, Oman

[3] Pathology, Royal Hospital, Muscat, Oman

[4] Pathology, Oman Medical Speciality Board, Muscat, Oman

Introduction

Papulosquamous disorders such as pityriasis lichenoides et varioliformis acuta (PLEVA) and pityriasis rosea (PR) may demonstrate overlapping clinical and histopathological features. Vaccine-associated eruptions have been increasingly recognized and may present diagnostic challenges.

Case Presentation

An 11-year-old boy presented with a 2-month history of a generalized pruritic eruption that developed 3 days after receiving a tetanus vaccination. Examination revealed numerous erythematous papules distributed over the trunk, face, and extremities. Many lesions demonstrated central necrosis and crusting, with varioliform changes and post-inflammatory hypopigmentation. There was no involvement of the scalp, nails, or mucosa, and no herald patch or classical Christmas-tree distribution was observed.

Histopathological examination showed epidermal hyperkeratosis with mounds of parakeratosis, hypogranulosis, focal spongiosis, irregular acanthosis, and lymphocytic exocytosis. The superficial dermis demonstrated mild edema and a superficial perivascular lymphocytic infiltrate with focal red blood cell extravasation and pigment incontinence. These findings were interpreted as consistent with a pityriasis rosea-like pattern.

The patient was treated with narrowband ultraviolet B phototherapy, resulting in marked clinical improvement.

Conclusion

Despite histopathological findings suggestive of pityriasis rosea, the clinical presentation was highly consistent with PLEVA, given the presence of necrotic and crusted papules and varioliform lesions. The absence of classical features of PR, including a herald patch and typical distribution, further supports this distinction. The short latency following vaccination raises the possibility of a vaccine-triggered inflammatory eruption with overlapping features along the PLEVA–PR spectrum. Histopathological findings in inflammatory papulosquamous disorders may be variable and occasionally nonspecific, further complicating diagnostic interpretation. This case highlights the importance of clinicopathologic correlation in the evaluation of papulosquamous eruptions.

EADV CONGRESS
VIENNA
30 SEP - 3 OCT 2026

Abstract N°: 2229

Topical Calcineurin Inhibitors and Malignancy Risk: A Critical Review

Andreas Wollenberg*[1, 2, 3], Alejandro Arana[4], Michael J. Cork[5], Mette Deleuran[6], Regina Fölster-Holst[7], H. Chih-ho Hong[8], Anita Remitz-Reitamo[9], Diamant Thaçi[2]

[1] Dept. of Dermatology and Allergy, University Hospital Augsburg, Augsburg, Germany
[2] Comprehensive Center for Inflammation Medicine, University of Lüebeck, Lüebeck, Germany
[3] Dept. of Dermatology and Allergy, Ludwig-Maximilian University, Munich, Germany
[4] Epidemiology. RTI-Health Solutions, Barcelona, Spain
[5] Sheffield Dermatology Research, Department of Infection, Immunity & Cardiovascular Disease, University of Sheffield, Sheffield, United Kingdom
[6] Department of Dermatology, Aarhus University Hospital, Aarhus, Denmark
[7] Department of Dermatology, University Clinics Schleswig-Holstein, Campus Kiel, Kiel, Germany
[8] Department of Dermatology and Skin Science, University of British Columbia, Vancouver, Canada
[9] Skin and Allergy Hospital, Helsinki University Central Hospital, Helsinki, Finland

Introduction
Topical calcineurin inhibitors (TCIs) remain a mainstay of atopic dermatitis (AD) treatment. Since 2006, TCIs have carried a boxed warning regarding malignancy risk, despite a lack of conclusive supporting evidence. Consequently, TCI use has declined and both physicians and patients report anxiety regarding TCIs. However, studies have been hampered by inherent biases, including the challenge of disentangling the potential malignancy risks from treatments versus the increased risk from AD itself.

Materials and Methods
This critical review consolidates evidence from three large long-term studies: JOELLE (adult and pediatric cohorts), APPLES (pediatric tacrolimus cohort), and PEER (pediatric pimecrolimus cohort). These studies assessed malignancy incidence in TCI-treated patients compared with topical corticosteroid users or the general population, using healthcare registries and prospective observational cohorts.

Results
JOELLE analyzed >200,000 TCI users across European databases (mean follow-up 6.4 years). While adjusted incidence rate ratios suggested associations for cutaneous T cell lymphoma (1.80), melanoma (1.21), and non-melanoma skin cancer (1.28), these findings were inconsistent between TCIs, limited to early exposure, and could reflect biases previously identified. These biases included confounding by indication, reverse causation, and surveillance bias. APPLES (7,954 pediatric patients; 44,629 person-years) and PEER (7,457 pediatric patients; 20,000 person-years) reported standardized incidence ratios of any malignancy were 1.01 and 1.2, respectively, providing no evidence of risk with TCI exposure. Reported cases were rare and varied in malignancy type, further weakening any causal link to TCI exposure. Across all studies, malignancy events were infrequent, and observed patterns were inconsistent with causative systemic immunosuppression.

Conclusions
Current evidence does not confirm an increased malignancy risk with long-term TCI use in adults or children. Despite historical boxed warnings, the benefit–risk profile remains favorable, supporting existing guideline recommendations for TCIs as a tolerable treatment for short- and long-term AD management, thereby reassuring

both clinicians and patients about the absence of associated malignancy risk.

EA DV CONGRESS
VIENNA
30 SEP - 3 OCT 2026

Abstract N°: 2243

Postoperative pyoderma gangrenosum following breast reduction surgery in early pregnancy: a diagnostic challenge

Maria Jose Cabana Perez*[1], Melissa Garcia Alvarez[1], Oscar Mora[1]

[1] Universidad FUCS, Hospital de San José, Bogota, Colombia

Introduction

Pyoderma gangrenosum (PG) is an underrecognized neutrophilic dermatosis characterized by rapidly progressive, painful ulcers with intense inflammation. The postoperative variant is uncommon and represents a significant diagnostic pitfall, as it closely mimics surgical site infection. Misdiagnosis may lead to inappropriate antibiotic therapy and surgical interventions that can exacerbate the condition through pathergy. Pregnancy is associated with complex immune modulation that may act as a potential trigger and further complicate management.

Case Presentation

A 20-year-old female presented four days after bilateral reduction mammoplasty with wound dehiscence and rapidly progressive ulceration, necrosis, and pruritus. Surgical site infection was initially suspected, and empirical antibiotic therapy was started. Within 24 hours, lesions showed marked progression (approximately 30%), raising suspicion of postoperative PG after initial misdiagnosis. Dermatological evaluation supported the diagnosis, and systemic corticosteroids (1 mg/kg) were initiated. Microbiological cultures remained negative. Histopathological examination revealed a dense neutrophilic infiltrate with abscess formation and areas of liquefactive necrosis, consistent with PG. Clinical improvement was observed following corticosteroid therapy. During follow-up, a 13-week pregnancy was identified, temporally associated with disease onset and considered a potential immunological trigger.

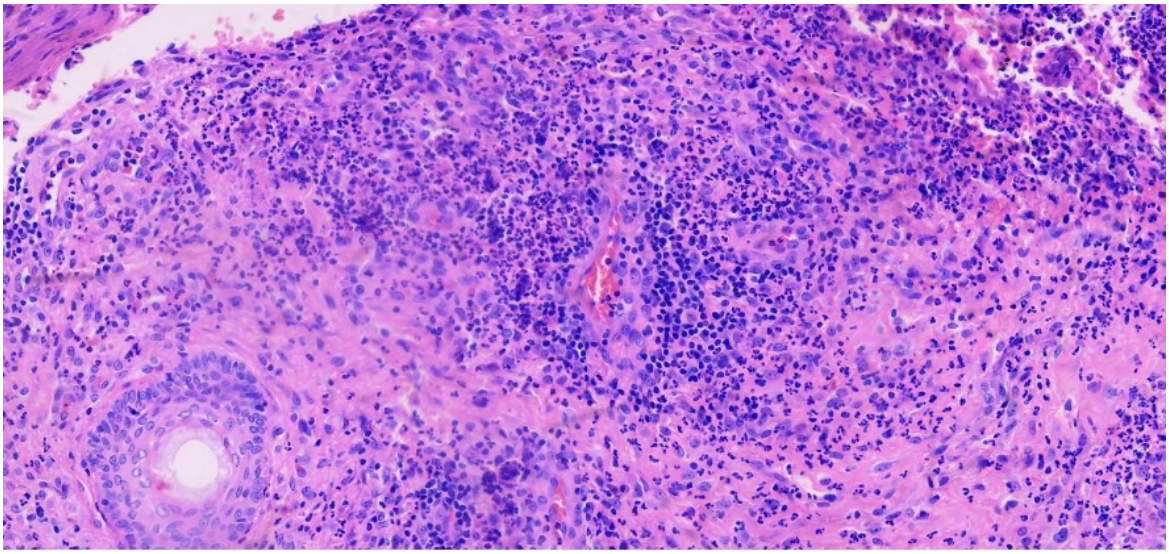

Histopathological findings showing a dense neutrophilic infiltrate with abscess formation and areas of liquefactive necrosis, consistent with pyoderma gangrenosum (hematoxylin and eosin stain, original magnification ×100).

Conclusion

Postoperative PG is an underrecognized condition that may be misdiagnosed as infection, leading to delays in appropriate management and potential worsening due to pathergy. Early recognition, prompt initiation of immunosuppressive therapy, and clinicopathological correlation are essential to prevent inappropriate management and improve outcomes. This case highlights the importance of comprehensive preoperative assessment in women of reproductive age, including pregnancy screening and evaluation of risk factors for inflammatory conditions.

EADV CONGRESS
VIENNA
30 SEP - 3 OCT 2026

Abstract N°: 2244

Validation of a Novel Diagnostic Consensus for Pyoderma Gangrenosum: A Comparative Analysis against PARACELSUS and Delphi Criteria

Mingyan Qi*[1], Bin PENG[1], Longfei Zhu[1], Qinxiao Li[1], Wanyu Zheng[1], Ruitao Fan[1], Cong Yan[1], Songmei Geng[1]

[1] Department of Dermatology, The Second Affiliated Hospital of Xi'an Jiaotong University, Xi'an, China, Xi'an, China

Introduction
Accurate diagnosis of pyoderma gangrenosum (PG) remains challenging. A novel diagnostic consensus, integrating expert experience and clinical evidence, has recently been proposed to address these challenges. To evaluate the diagnostic performance and reliability of this emerging consensus relative to the PARACELSUS score and Delphi criteria.

Materials and Methods
The consensus evaluated in this study was developed by a multidisciplinary group of experts specializing in pyoderma gangrenosum. This retrospective study included 74 patients with ulcerative skin lesions confirmed by histopathology. Cases were evaluated using the national PG consensus, PARACELSUS score, and Delphi criteria. Diagnostic performance was assessed by sensitivity, specificity and overall accuracy, and agreement was evaluated using Cohen's kappa.

Results
The novel consensus, PARACELSUS score and Delphi criteria showed sensitivities of 87.8%, 90.5% and 71.6%, and specificities of 93.5%, 83.2% and 94.4%, respectively. The novel consensus demonstrated a favourable balance between sensitivity and specificity, with the highest overall diagnostic accuracy. Agreement between the national consensus and PARACELSUS score was high ($\kappa = 0.832$), with good agreement observed with the Delphi criteria. Differences between criteria were statistically significant.

Conclusions
The novel consensus demonstrates superior diagnostic accuracy and high agreement with established criteria, suggesting it is a robust tool for the clinical diagnosis of PG. Its implementation could potentially reduce misdiagnosis and optimize management.

EA DV CONGRESS
VIENNA
30 SEP - 3 OCT 2026

Abstract N°: 2258

SAPHO syndrome presenting with palmoplantar pustulosis: a form resistant to conventional therapy

NOUSSAIBA CHEMLAL[1], BOUMEDIENE DAHMANI[1], KAMILA BOUCHENAK KHALADI*[1]

[1] Department of Dermatology, CHU Tlemcen, Aboubakr Belkaid, Faculty of Medicine, Tlemcen, Dermatology Association of the Wilaya of Tlemcen (ADWIT), TLEMCEN, Algeria

Introduction

SAPHO syndrome (Synovitis, Acne, Pustulosis, Hyperostosis, Osteitis) is a rare, heterogeneous condition belonging to the spectrum of auto-inflammatory diseases, characterized by both cutaneous lesions and osteoarticular manifestations.

Palmoplantar pustulosis (PPP) represents the most frequently associated cutaneous manifestation, reported in 50–75% of cases according to published series. Osteo-articular involvement predominantly affects the anterior chest wall, particularly the sternocostoclavicular region, which is considered the most specific site.

This study reports the case of a young man diagnosed with SAPHO syndrome, resistant to conventional treatments**.**

Case Presentation

We report a 36-year-old man with palmoplantar pustulosis evolving over several months, initially treated with topical corticosteroids with limited response. Three months later, he developed inflammatory axial pain and sternoclavicular tenderness. Laboratory investigations showed an inflammatory syndrome, with negative rheumatoid factor and HLA-B27.

Magnetic resonance imaging revealed bilateral sternoclavicular arthritis associated with inflammatory involvement of the manubriosternal joint, and a sacroiliac inflammatory lesion. Bone scintigraphy showed a “bullhead sign” with osteitis of the sternocostoclavicular region.

The diagnosis of SAPHO syndrome was established.

Non-steroidal anti-inflammatory drugs (NSAIDs), corticosteroids, and methotrexate up to 30 mg/week were ineffective, leading to initiation of bisphosphonate therapy.

DISCUSSION:

SAPHO syndrome is a rare, likely underdiagnosed auto-inflammatory disease with incompletely understood pathophysiology, involving genetic susceptibility, innate immune activation, and dysregulation of pro-inflammatory cytokines (TNF-α, IL-1, IL-17), with a possible role of *Cutibacterium acnes*.

It primarily affects the anterior chest wall, especially the sternoclavicular, manubriosternal, and costosternal joints. Sternocostoclavicular involvement (60–80%) is highly suggestive of the diagnosis. In our case, its association with palmoplantar pustulosis was a key diagnostic feature.

In our case, the association of chronic palmoplantar pustulosis and sternocostoclavicular involvement constitutes a major diagnostic clue.

Bone scintigraphy showing the “bullhead sign” is characteristic and strongly supportive of SAPHO syndrome.

Sacroiliac involvement occurs in 10–30% of cases and is often mild or asymptomatic, as observed here.

Management is not standardized. NSAIDs are first-line, while corticosteroids and methotrexate show variable and often limited efficacy in osteoarticular disease. Our case illustrates a refractory form. Bisphosphonates have shown good efficacy by reducing bone pain and inflammatory activity. In resistant cases, biologics (anti-TNF, anti-IL-1, anti-IL-17) may be considered.

Conclusion

This case illustrates a typical presentation of SAPHO syndrome combining palmoplantar pustulosis and anterior osteoarticular involvement.

It highlights the diagnostic value of imaging, particularly bone scintigraphy, as well as the role of bisphosphonates in the management of refractory forms.

EA DV CONGRESS
VIENNA
30 SEP - 3 OCT 2026

Abstract N°: 2267

Hidradenitis suppurativa is characterized by Type 2-skewed inflammatory features when associated with atopic dermatitis: critical appraisal from a case report treated with dupilumab

Niccolò Gori[1, 2], Elena Ippoliti[1, 2], Flaminia Antonelli[1, 2], Luisa Boeti*[1, 2], Ketty Peris[1, 2]

[1] Dermatologia, Dipartimento Universitario di Medicina e Chirurgia Traslazionale, Università Cattolica del Sacro Cuore, Rome, Italy

[2] Dermatologia, Dipartimento di Scienze Mediche e Chirurgiche, Fondazione Policlinico Universitario A. Gemelli IRCCS, Rome, Italy

Introduction

Atopic dermatitis (AD) and hidradenitis suppurativa (HS) are chronic inflammatory skin diseases with a substantial impact on quality of life. Although AD is mainly driven by type 2 inflammation, whereas HS is classically associated with type 1/type 3 immune pathways, increasing evidence suggests potential overlap between the two conditions. Shared mechanisms may include epidermal barrier dysfunction, altered stratum corneum lipid composition, dysregulation of antimicrobial peptides and alterations in the NOTCH signalling. Dupilumab, a monoclonal antibody targeting interleukin (IL)-4Rα and inhibiting IL-4/IL-13 signalling, has been shown to restore several aspects of skin barrier homeostasis in AD. We report a case of concomitant AD and HS showing marked improvement of both diseases during dupilumab treatment.

Case Presentation

A 29-year-old man with a two-year history of HS and concomitant moderate-to-severe AD was referred for worsening of both conditions. Previous treatments, including topical and systemic antibiotics, topical and systemic corticosteroids, and cyclosporine, had provided no meaningful clinical benefit. On examination, HS showed a follicular phenotype with papules, nodules and scarring involving the axillae and groin, consistent with Hurley stage II disease. Eczematous lesions compatible with AD were present on the trunk and neck. Baseline Eczema Area Severity Index (EASI) was 24.6, itch-Numerical Rating Scale (NRS) was 8 and pain-NRS was 7. The patient was otherwise healthy. Laboratory tests were unremarkable, except for increased total IgE levels (2567 IU/mL).

Dupilumab was started with a 600 mg subcutaneous loading dose, followed by 300 mg every two weeks, in association with oral clindamycin for the first 8 weeks. After 8 weeks, AD lesions had almost completely regressed, with EASI decreasing to 2, itch-NRS to 2 and pain-NRS to 1. A marked improvement of HS lesions was also observed. At week 16, after discontinuation of antibiotic therapy, HS lesions were almost completely resolved, and AD had reached complete remission, with EASI 0, itch-NRS 0 and pain-NRS 0. Total IgE levels decreased to 452 IU/mL. Clinical control of both AD and HS was maintained through 24 weeks, with no flare of either disease.

Conclusion

Epidemiological data support an association between AD and HS, with HS patients showing a 2-fold higher risk of AD and AD patients having higher odds of developing HS. This relationship suggests that common pathogenic mechanisms may contribute to disease coexistence. Among these, impaired NOTCH signalling, antimicrobial peptide dysregulation and epidermal barrier abnormalities appear particularly relevant. Altered sphingolipid metabolism, with reduced sphingomyelin and ceramide levels, has been reported in both AD and HS and may

contribute to barrier disruption, inflammatory activation and release of cytokines such as TNF-α.

The improvement observed in our patient is consistent with previous reports describing HS amelioration during dupilumab treatment in patients with concomitant AD. In the early treatment phase, the contribution of systemic clindamycin cannot be excluded. However, the patient had previously failed several systemic antibiotics, including clindamycin, and HS remission was maintained after antibiotic discontinuation, supporting a potential role of dupilumab in both induction and maintenance of clinical response for up to 24 weeks. Restoration of barrier function and modulation of type 2 inflammation may therefore have contributed not only to AD control, but also to the improvement of HS lesions.

This case provides further evidence of a potential pathogenic link between AD and HS and suggests that type 2 inflammation and skin barrier dysfunction may be involved in HS pathogenesis in selected patients. Dupilumab may represent a therapeutic option in patients with concomitant moderate-to-severe AD and HS, although larger studies are needed to clarify its role in HS and identify patients most likely to benefit.

EADV CONGRESS
VIENNA
30 SEP - 3 OCT 2026

Abstract N°: 2269

Association of Systemic Inflammation and Disease Severity with Cardiovascular Disease Risk in Patients with Hidradenitis Suppurativa: A Retrospective Cross-Sectional Study

Duygu Gürler Bağcı[1], Sinem Ayşe Örnek Özdemir*[1, 2]

[1] Department of Dermatology, Health Sciences University Ankara Training and Research Hospital, Ankara, Türkiye
[2] St John's Institute of Dermatology, Guy's and St Thomas' NHS Foundation Trust, London, United Kingdom

Introduction

Hidradenitis suppurativa (HS) is a chronic inflammatory skin disease associated with systemic inflammation. Persistent inflammation may contribute to endothelial dysfunction and atherosclerosis. Although HS has been linked to cardiometabolic comorbidities, the relationship between disease severity, systemic inflammatory burden, and cardiovascular disease (CVD) risk remains unclear. QRISK3 is a validated tool for estimating 10-year CVD risk. We aimed to evaluate the association of systemic inflammatory markers and disease severity with CVD risk in HS patients.

Materials and Methods

Patients with HS who presented to our tertiary hospital between January 2020 and April 2025 were included in this retrospective cross-sectional study. Exclusion criteria included paediatric patients with HS (<18 years), patients with established cardiovascular disease (myocardial infarction, angina, stroke, or transient ischaemic attack), as this is a limitation of the QRISK3 algorithm, and those with a history of malignancy, active infection, pregnancy, or breastfeeding. Demographic, clinical, and laboratory data were obtained from hospital records. Disease severity was assessed using Hurley staging (I: nodules/abscesses; II: recurrent abscesses with limited sinus tracts and scarring; and III: diffuse disease with interconnected sinus tracts and extensive scarring). Systemic inflammation was evaluated using C-reactive protein (CRP), erythrocyte sedimentation rate (ESR), pan-immune inflammation value (PIIV) (neutrophil×platelet×monocyte/lymphocyte), and systemic immune-inflammation (SII) index (platelet×neutrophil/lymphocyte). CVD risk was calculated using QRISK3 and categorized as low (<10%) or high (≥10%). (Ethical approval: E-25-541; 18 June 2025).

Results

A total of 314 HS (63.4% males) patients enrolled in the study. The median age was 38 years (IQR: 30–46), body mass index (BMI) was 29.76 kg/m^2 (IQR: 25.53–34.58), and total cholesterol/HDL ratio was 4.45 (IQR: 3.68–5.5). Overall, 37.3% (n=117) of patients were smokers, 12.7% (n=40) had diabetes mellitus (DM), and 9.2% (n=29) had hypertension (HT). The median CRP was 4.8 mg/L (IQR: 2.1–11), ESR was 6.50 mm/h (IQR: 4–16.25), PIIV was 355.49 (IQR: 251.69–560.52), and SII index was 582.8 (IQR: 436.17–776.46). Hurley stage distribution was 46.8% stage I (n=147), 44.9% stage II (n=141), and 8.3% stage III (n=26). The median QRISK3 score was 1.6 (IQR: 0.4–5.3), and 13.1% (n=41) had high QRISK3 score.

Male sex and smoking were significantly associated with Hurley stages II-III ($p<0.05$), whereas age, total cholesterol/HDL ratio, DM, and HT were not. CRP, PIIV, and SII index were significantly lower in Hurley stage I and increased with disease severity (all $p<0.05$). QRISK3 was significantly higher in patients with Hurley stages II–III ($p=0.011$), as well as in males, smokers, older individuals, and those with DM, HT, elevated total cholesterol/HDL ratios, and higher CRP and ESR levels (all $p<0.05$). QRISK3 showed weak but significant positive correlations with CRP ($r=0.232$) and ESR ($r=0.209$). In multivariable analysis, age, male sex, smoking, CRP level, total

cholesterol/HDL ratio, DM, and HT were identified as independent predictors of high CVD risk, whereas Hurley stage was not.

Conclusions

Cardiovascular disease risk was higher in advanced HS but was not independent, being largely explained by confounders such as male sex and smoking. Although CRP was associated with both HS severity and CVD risk, it likely reflects overall systemic inflammation rather than a direct causal effect of HS-related inflammation. Classical CVD risk factors, including male sex, older age, smoking, DM, and HT and lipid profile, remain the main determinants, highlighting the need for CVD risk assessment in high-risk HS patients.

EA DV CONGRESS
VIENNA
30 SEP - 3 OCT 2026

Abstract N°: 2277

A case of eosinophilic annulare erythema in an adult

Nicolas Kluger*[1], Juha Jernman[2]

[1] Tampere University Hospital, Dermatology, Tampere, Finland
[2] Pathology, Tampere University and Fimlab Laboratories, Tampere, Finland

Introduction

Eosinophilic annulare erythema (EAE) is a rare eosinophilic-related skin disease which manifests with annular erythematous plaques and severe pruritus. It is a rare condition that is challenging to diagnose and to treat. We report a new ilustrative case.

Case Presentation

An 84-year-old man with a history of hypertension, atrial fibrillation, and benign prostatic hyperplasia presented with a chronic itchy rash that had been evolving over the past 6 months. He had previously been diagnosed with lichen planus and treated with a highly potent corticosteroid ointment. Upon presentation, he had an extensive cutaneous eruption from the neck to the toes, consisting of macules and papules on the upper body (chest, trunk, back, and upper limbs), infiltrated papules on the lower back, and annular lesions with a darker centre and an active border on the buttocks, thighs, and legs. He also had oedema of the lower limbs. Mucosae were normal. There were no vesicles, no blisters, nor signs of scabies. Complete physical examination was otherwise normal, except for small lymph nodes in the right axilla and left inguinal fold, and sleeping difficulties due to pruritus.

Laboratory findings included elevated eosinophil count (3,810/mm^3) and IgE (1,535 kU/L). CRP, protein electrophoresis, skin auto-antibodies, and BP180 antibodies were negative. Direct immunofluorescence was negative. Histopathological examination showed abundant perivascular lymphohistiocytic inflammation with eosinophils, compatible with Wells syndrome.

A short course of oral prednisolone (0.5 mg/kg/day) provided rapid relief, but was followed by relapse after rapid tapering of corticosteroids. Prednisolone was reintroduced at 0.5 mg/kg/day in combination with hydroxychloroquine 300 mg/day. The patient is now in remission while slowly tapering oral corticosteroids. A whole-body CT scan ruled out any underlying neoplasia.



Multiple annular erythematous plaques of the lower limbs

Conclusion

Based on the clinical presentation, elevated eosinophilia and histology evocative of Wells syndrome, we diagnosed our patient with EAE.

EAE is a rare, benign inflammatory skin condition characterized by slowly expanding annular plaques, typically appearing on the trunk and extremities. It is histologically defined by a dense perivascular infiltrate rich in eosinophils in the deep dermis. The exact cause remains unknown, though it may be associated with underlying conditions such as infections, autoimmune disorders, or hypersensitivity reactions. It tends to follow a chronic, relapsing course, with lesions that can persist for months to years before spontaneously resolving. Treatment is often challenging and include local corticosteroid ointments, anti-malarial drugs, systemic corticosteroids or dapsone.

EA DV CONGRESS
VIENNA
30 SEP - 3 OCT 2026

Abstract N°: 2290

Substance-Associated Exacerbations of Dissecting Cellulitis of the Scalp: Possible Neuroimmune and Psychopharmacologic Triggers

Areg Chalabyan*[1, 2]

[1] "Armenia" RMC, Yerevan State Medical University after Mkhitar Heratsi, Yerevan, Armenia

[2] Yerevan State Medical University after Mkhitar Heratsi, Yerevan, Armenia

Introduction

Dissecting cellulitis of the scalp (DCS, Hoffmann disease) is a rare chronic neutrophilic cicatricial alopecia characterized by painful nodules, abscesses, sinus tract formation, and progressive scarring alopecia. Although the disease belongs to the follicular occlusion spectrum, its exact pathogenesis remains incompletely understood. Environmental and immunologic factors have been proposed; however, the possible role of psychoactive substances and psychopharmacologic medications as triggering or exacerbating factors has rarely been discussed.



patient 2

Case Presentation

The first patient presented with severe recurrent inflammatory lesions localized predominantly on the scalp, including painful nodules, abscess-like lesions, interconnected sinus tracts, and cicatricial alopecia. According to the patient's history, repeated acute exacerbations consistently occurred after intranasal use of methadone, mephedrone, methamphetamine ("crystal"), and cocaine. Initial partial remission was achieved with systemic retinoid therapy; however, multiple relapses developed following repeated narcotic exposure. After complete discontinuation of psychoactive substances, treatment with doxycycline and intralesional triamcinolone led to marked clinical improvement and prolonged remission. Mild residual exacerbations were later temporally associated with alcohol intake and vaping, which also improved after cessation.

The second patient, affected by severe autism spectrum disorder with aggressive behavior requiring tranquilizers and psychopharmacologic therapy, demonstrated severe inflammatory acneiform eruptions together with

dissecting cellulitis-like lesions involving both the scalp and beard area.



patient 1 before and after treatment

Conclusion

These clinical observations suggest a possible association between psychoactive substances, psychopharmacologic medications, and exacerbation of neutrophilic follicular occlusion disorders such as DCS. Potential mechanisms may include neuroimmune dysregulation, altered innate immune responses, oxidative stress, follicular hyperkeratosis, and inflammatory cytokine imbalance. To our knowledge, direct associations between DCS and narcotic drug exposure have rarely been described. Further studies are needed to clarify whether psychoactive substances and psychotropic medications may represent underrecognized triggering or amplifying factors in susceptible individuals.

EADV CONGRESS
VIENNA
30 SEP - 3 OCT 2026

Abstract N°: 2322

Acquired perforating dermatosis presenting as a solitary forearm ulcer in an immunocompetent adult: a diagnostic challenge

Yuliia Kauke*[1], Miquel Sánchez Martínez[1], Maria Teresa Fernández-Figueras[2]

[1] Clínica Dermatológica Dr. López Gil, Teknon Medical Center, Barcelona, Spain
[2] Hospital Universari General de Catalunya, Barcelona, Spain

Introduction

Chronic-appearing cutaneous ulcers in immunocompetent patients represent a diagnostic challenge due to a broad differential diagnosis including infectious, inflammatory, and neoplastic conditions. Acquired perforating dermatosis is a rare entity characterized by transepidermal elimination of dermal components and is typically associated with systemic diseases such as diabetes mellitus and chronic kidney disease. We report a diagnostically challenging case of a persistent ulcer mimicking infection, ultimately confirmed as acquired perforating dermatosis in the absence of systemic disease.

Case Presentation

Materials & Methods:

A 52-year-old woman presented with a 2-month history of a solitary lesion on the right forearm. The lesion was asymptomatic. The patient denied trauma, systemic symptoms, and had no relevant medical history. No prior treatment had been applied. Clinical examination revealed a well-demarcated oval ulcer measuring approximately 2 × 3 cm with a yellowish fibrinous-granular base and surrounding erythematous, slightly elevated borders. Differential diagnoses included infectious ulcer (including cutaneous leishmaniasis), inflammatory dermatosis, and neoplastic process.

A punch biopsy was performed for histopathological evaluation, and tissue samples were obtained for microbiological culture.

Laboratory investigations, including complete blood count and standard biochemical profile, were within normal limits, with no evidence of diabetes mellitus, renal impairment, or systemic disease.

Results:

Histopathological examination showed a well-demarcated epidermal ulceration with adjacent epidermal hyperplasia. The ulcer base demonstrated transepidermal elimination of vertically oriented collagen bundles, accompanied by abundant neutrophilic infiltrate and cellular debris, consistent with a perforating dermatosis. No *Leishmania* organisms were identified on immunohistochemical staining. Microbiological cultures revealed no growth of pathogenic organisms.

Based on clinicopathological correlation, a diagnosis of acquired perforating dermatosis was established.

Treatment with topical tacrolimus 0.1% ointment was initiated. At 1-month follow-up, significant clinical improvement with progressive re-epithelialization was observed. At 2-month follow-up, complete resolution with residual scar formation was achieved.

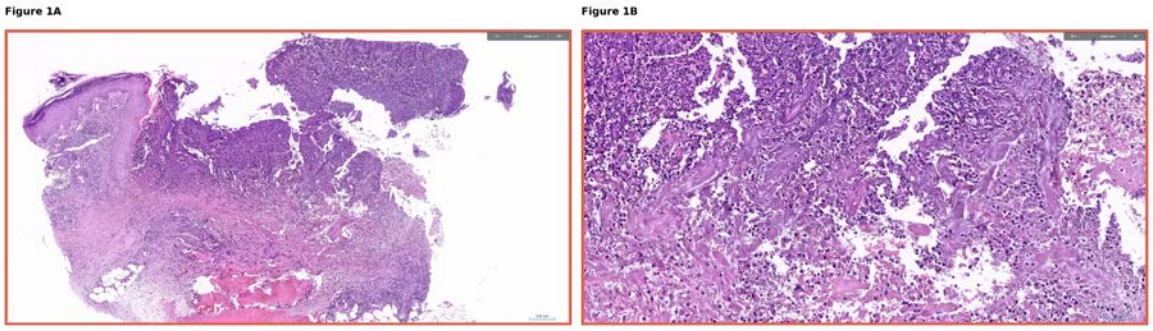

Figure 1. (A) Low-power hematoxylin–eosin section showing ulceration, epidermal hyperplasia, and transepidermal elimination of collagen bundles with underlying inflammatory infiltrate. (B) High-power view demonstrating transepidermal extrusion of eosinophilic collagen bundles with neutrophilic debris

Conclusion

Acquired perforating dermatosis should be considered in the differential diagnosis of persistent non-healing ulcers even in immunocompetent patients without systemic disease. This case highlights an atypical presentation mimicking infectious ulceration and underscores the importance of histopathological evaluation and clinicopathological correlation. Topical immunomodulatory therapy may represent an effective treatment option leading to complete resolution.

EA DV CONGRESS
VIENNA
30 SEP - 3 OCT 2026

Abstract N°: 2352

Incidence, Prevalence, Treatment Patterns, and Healthcare Resource Utilization of Prurigo Nodularis in the US and Germany

Shawn Kwatra*[1, 2], Gil Yosipovitch[3], Sarina Elmariah[4], Theresa Amoloja[5], Amisha Patel[6], Lucy Massey[6], Morel Symons[5], Haobo Ren[5], Annika Vivirito[7], Martin Metz[8, 9], Sonja Ständer[10]

[1] Department of Dermatology, University of Maryland School of Medicine, Baltimore, United States
[2] Maryland Itch Center, University of Maryland School of Medicine, Baltimore, United States
[3] Miami Itch Center, Miller School of Medicine, University of Miami, Miami, United States
[4] University of California San Francisco, San Francisco, United States
[5] Incyte Corporation, Wilmington, United States
[6] Adelphi Real World, Bollington, United Kingdom
[7] InGef – Institute for Applied Health Research Berlin GmbH, Berlin, Germany
[8] Institute of Allergology, Charité - Universitätsmedizin Berlin, Corporate Member of Freie Universität Berlin and Humboldt-Universität zu Berlin, Berlin, Germany
[9] Fraunhofer Institute for Translational Medicine and Pharmacology ITMP, Immunology and Allergology, Berlin, Germany
[10] Center for Chronic Pruritus, Münster University Hospital, Münster, Germany

Introduction

Prurigo nodularis (PN), a subtype of chronic prurigo, is a chronic, inflammatory skin disease characterized by intensely pruritic nodules. PN epidemiology data are limited, in part due to the lack of a unique code for PN in the International Classification of Diseases (ICD) prior to 2015. Reported incidence and prevalence estimates vary substantially owing to heterogeneity in case definitions and differences in study design. In the absence of early treatment approvals, multimodal approaches and off-label therapies are currently used in the management of PN. In the US and EU, biologics have been recently approved for the treatment of adults with PN. This real-world analysis reports the incidence and prevalence of PN, treatment patterns, and healthcare resource utilization (HCRU) in adult patients in the US and Germany.

Materials and Methods

This retrospective, observational cohort study used claims data from the US Merative™ MarketScan® Research Databases and the German Statutory Health Insurance (SHI). The study cohort consisted of patients aged ≥18 years with ≥2 outpatient medical claims (in 2 quarters) with a diagnosis code for PN (ICD 10th Revision; US, L28.1; Germany, L28.1 or L28.2) or ≥1 inpatient medical claims with a diagnosis code for PN during the index period (US, July 1, 2017, to June 30, 2023; Germany, January 1, 2016, to September 30, 2023). Patients also had continuous plan enrollment ≥12 months prior to (baseline period) and ≥12 months following their index date (follow-up period). The index date was defined as the first recorded PN diagnosis within the index period. Baseline clinical characteristics were described in the 12-month baseline period. Incidence and prevalence rates were estimated during the index period in the at-risk and total source populations, respectively. Treatment patterns, HCRU, and costs were described during the follow-up period. The follow-up period for each patient concluded at the earliest of the end of continuous enrollment, death, or the end of the study period (US, June 30, 2024; Germany, September 30, 2024). Data were analyzed descriptively.

Results

A total of 29,151 and 13,963 patients in the US and Germany, respectively, were included in the analysis. Median (interquartile range [IQR]) age was 57.0 (48–64) and 64.0 (52–76) years; 55.5% and 58.0% of patients were female. The incidence rate of PN during the index period was 20.6 and 26.8 per 100,000 person-years in the US and Germany, respectively; prevalence rates were 85.5 and 189.5 per 100,000 people. Incidence and prevalence rates generally increased with age and were higher in females than males. Annual incidence of PN generally decreased over time. In the US and Germany, the most commonly prescribed treatment for PN was topical corticosteroids (63.6% and 80.0%, respectively). Only 3.8% and 2.3% of patients received biologics. At 3 years of follow-up, the median (IQR) number of lines of therapy was 3 (1–5) in the US and 2 (1–3) in Germany. In the US, the median (IQR) duration of first- and second-line therapy was 4.1 (1.2–10.1) and 3.4 (1.0–7.6) months, respectively; in Germany, it was 1.5 (0.5–3.0) and 1.5 (0.7–3.0) months. In the US, 47.7% of patients had PN-related outpatient visits, and mean PN-related total healthcare costs were $738 per patient per year (PPPY). Costs decreased with age, with most related to medication expenses. In Germany, 92.1% of patients had PN-related outpatient visits, and mean PN-related total healthcare costs were €382 PPPY, with comparable costs across age groups.

Conclusions

This analysis provides robust, real-world estimates of the epidemiology of PN. Despite recent biologic approvals, real-world uptake remains minimal, with frequent treatment switching suggesting suboptimal disease control. These findings highlight a substantial unmet need for effective and durable therapies to reduce the clinical and economic burden of PN.

EA DV CONGRESS
VIENNA
30 SEP - 3 OCT 2026

Abstract N°: 2358

Integrated Mixed-Effects Analysis of Pharmacokinetics of Ruxolitinib Cream and Implications on Safety Profile in Patients With Inflammatory Skin Diseases

Jessica Wojciechowski*[1], Robert Bissonnette[2], Christopher Bunick[3], Nicole M. Chase[4], Howard Kallender[1], Jaya Shree Dilli Batcha[5], Amit Roy[5], Kevin Tianxiang Han[1], Vivek S. Purohit[1]

[1] Incyte Corporation, Wilmington, United States

[2] Innovaderm Research, Montreal, Canada

[3] Yale School of Medicine, New Haven, United States

[4] University of Minnesota School of Medicine, Minneapolis, United States

[5] Pumas-AI, Inc., Dover, United States

Introduction

Ruxolitinib (RUX; selective Janus kinase [JAK]1/JAK2 inhibitor) cream is a treatment for inflammatory skin diseases. Plasma concentrations help define the safety and benefit–risk profile of topical drugs. Model-based approaches enable evaluation of dose–concentration relationships in pooled patient populations, accounting for differences in the applied dose while quantifying covariate effects on pharmacokinetic (PK) parameters. A mixed-effects modeling analysis was conducted to (1) quantify the relationship between the applied dose of RUX cream and the resulting steady-state plasma concentrations of RUX (C_{SS}) in patients with atopic dermatitis (AD), vitiligo, prurigo nodularis (PN), and hidradenitis suppurativa (HS) and (2) predict the probability of C_{SS} exceeding the whole-blood half-maximal inhibitory concentration (IC_{50}) for JAK2 inhibition of 281 nM (threshold associated with JAK-mediated myelosuppression). An exploratory analysis assessed the association between C_{SS} and key hematologic parameters.

Materials and Methods

Mixed-effect modeling of the relationship between the average RUX dose per application versus C_{SS} used pooled data from 2354 patients aged ≥2 years contributing 4788 measurable C_{SS} observations across 17 clinical studies (8 conducted in AD, 5 in vitiligo, 3 in PN, and 1 in HS). Linear and nonlinear (E_{max}) relationships were evaluated where model parameters dictated increases in C_{SS} with respect to the average RUX dose per application. Model parameters represented apparent RUX clearance, which is a primary PK parameter. Patient characteristics (eg, body weight, age, sex, race, disease type, disease severity, and geographic region) were tested as covariates. Only factors that meaningfully described the variability in the data were retained. The final model was used to conduct simulations to predict the probability of patients achieving C_{SS} above the 281 nM clinically meaningful safety threshold. Exploratory graphical analysis was performed on the relationships between C_{SS} and select hematology parameters (hemoglobin, neutrophils, and platelets).

Results

The relationship between C_{SS} and average dose per application was best described by an E_{max} model. Body weight, disease indications (HS, vitiligo, AD, and PN), disease severity of AD and PN (Investigator's Global Assessment [IGA] ≥3), pediatric age category, and Europe region were identified as key factors explaining data variability. Compared with the reference (70-kg adult with AD, IGA <3, rest of world), C_{SS} were ~86% higher in HS, ~68% higher in vitiligo, ~13% lower in PN, ~31% higher in AD (IGA ≥3), ~45% higher in Europe, and ~30% lower in pediatrics (aged 2–17 y). Despite these differences, the overall concentrations for the various subgroups

defined by the covariates were low, with median C_{SS} maintaining margins of 6.6- to 46-fold relative to 281 nM across the evaluated subgroups. The predicted probability of C_{SS} >281 nM was also low (0.07%–6% across subgroups). A total of 17 patients (0.8%) in the phase 3 population (n=2173) had C_{SS} >281 nM, and there were no clinically relevant hematologic changes in these patients. Evaluating hematologic parameters by C_{SS} showed an absence of plasma concentration–dependent effects across C_{SS} quartiles in all 3 hematologic parameters and demonstrated maintenance of values within reference ranges.

Conclusions

An E_{max} model adequately described the C_{SS} following topical application of RUX cream. Indication, Europe region, disease severity, and body weight, but not race or sex, were associated with higher C_{SS}; however, these are unlikely to be clinically meaningful as they maintain large margins to the established safety threshold of 281 nM. Across all phase 3 studies, there were no plasma concentration–dependent effects on hematologic parameters; no adverse effects on hematologic parameters were observed, even in the few patients with C_{SS} >281 nM. The results are consistent with the well-tolerated safety profile of 1.5% RUX cream.

EA DV CONGRESS
VIENNA
30 SEP - 3 OCT 2026

Abstract N°: 2362

A Real-World, Claims-Based Algorithm for Identifying Moderate to Severe Prurigo Nodularis

Sonja Ständer*[1], Gil Yosipovitch[2], Sarina Elmariah[3], Theresa Amoloja[4], Joslyn Kirby[4], Amisha Patel[5], Beth Dibben[5], Joseph Cordaro[4], Annika Vivirito[6], Martin Metz[7, 8], Shawn Kwatra[9, 10]

[1] Center for Chronic Pruritus, Münster University Hospital, Münster, Germany
[2] Miami Itch Center, Miller School of Medicine, University of Miami, Miami, United States
[3] University of California San Francisco, San Francisco, United States
[4] Incyte Corporation, Wilmington, United States
[5] Adelphi Real World, Bollington, United Kingdom
[6] InGef – Institute for Applied Health Research Berlin GmbH, Berlin, Germany
[7] Institute of Allergology, Charité - Universitätsmedizin Berlin, Corporate Member of Freie Universität Berlin and Humboldt-Universität zu Berlin, Berlin, Germany
[8] Fraunhofer Institute for Translational Medicine and Pharmacology ITMP, Immunology and Allergology, Berlin, Germany
[9] Department of Dermatology, University of Maryland School of Medicine, Baltimore, United States
[10] Maryland Itch Center, University of Maryland School of Medicine, Baltimore, United States

Introduction
Prurigo nodularis (PN), a subtype of chronic prurigo, is a chronic, inflammatory skin disease characterized by intensely pruritic nodules. PN epidemiology data are limited, especially in the moderate to severe population. In the absence of validated severity scores or detailed clinical assessments in administrative claims databases, developing a claims-based algorithm is essential to identify patients with moderate to severe PN in the real world. This analysis explored proxies for identifying patients with moderate to severe PN using claims data in the US and Germany.

Materials and Methods
This retrospective, observational cohort study used claims data from the US Merative™ MarketScan® Research Databases (July 1, 2016, to June 30, 2024) and the German Statutory Health Insurance (SHI; January 1, 2015, to September 30, 2024). Patients included in the analysis were aged ≥18 years, had ≥2 outpatient medical claims or ≥1 inpatient medical claim with diagnosis codes for PN (International Classification of Diseases 10th Revision; US, L28.1; Germany, L28.1 or L28.2) during the index period, and ≥12 months of continuous plan enrollment during the baseline and follow-up periods. The index date was defined as the first recorded PN diagnosis during the index period (US, July 1, 2017, to June 30, 2023; Germany, January 1, 2016, to September 30, 2023). An algorithm was developed and evaluated using proxies for moderate to severe PN identified from literature and clinical input. Patients were classified as having moderate to severe or lower severity PN based on the presence or absence of ≥1 inpatient admission for PN, ≥1 filled prescription for a systemic agent for PN treatment, ≥1 day of work incapacity due to PN (Germany only), ≥1 urgent care or emergency department (ED) visit for PN, or ≥1 comorbidity indicating psychologic burden.

Results
A total of 29,151 patients in the US (moderate to severe, n=23,871) and 13,963 patients in Germany (moderate to

severe, n=11,625) were included in the analysis. Over 80% of patients met ≥1 proxy for moderate to severe PN (US, 81.9%; Germany, 83.3%). The mean (SD) number of proxies met were 1.3 (0.8) and 1.4 (0.9) in the US and Germany, respectively. The most common proxies were ≥1 psychologic comorbidity (US, 67.1%; Germany, 71.4%) and ≥1 systemic treatment (US, 65.3%; Germany, 53.1%). At least 1 inpatient admission (US, 0.4%; Germany, 13.3%), ≥1 urgent care/ED visit (US, 0.1%; Germany, 0.8%), and ≥1 day of work incapacity (Germany, 2.8%) were less common. The most common treatments among patients with moderate to severe PN in the US were topical and systemic corticosteroids (66.3% and 57.6%, respectively) and gabapentinoids (35.6%), all of which were less common in patients with lower severity PN (51.2%, 18.5%, and 0%, respectively). Among patients in Germany with moderate to severe PN, the most common treatments for PN were topical corticosteroids (82.1%), class I steroids (22.9%), and neuroleptics and antidepressants (22.1%); all were less common in patients with lower severity PN (69.7%, 14.8%, and 0%, respectively). Total PN-related mean healthcare costs (per patient per year) were greater in patients with moderate to severe PN than those with lower severity PN (US, $854 vs $120; Germany, €442 vs €83). A similar trend was also observed for all-cause costs ($17,377 vs $9796 and €8257 vs €3972).

Conclusions

An algorithm to define moderate to severe PN was developed using published studies, clinical input, and data from claims analyses in the US and Germany. Similar proportions of patients (>80%) in the US and Germany met ≥1 proxy for moderate to severe disease, most commonly being psychologic burden and use of systemic treatment. Patients with moderate to severe PN had higher healthcare utilization and costs and greater treatment use than those with lower severity PN, supporting the validity of the algorithm. Further validation using additional datasets and clinically assessed severity measures is needed to refine and strengthen the algorithm.

EA DV CONGRESS
VIENNA
30 SEP - 3 OCT 2026

Abstract N°: 2377

Psychological stress documentation and subsequent risk of chronic inflammatory skin diseases: A large-scale TriNetX real-world cohort study

Philip Curman[1], Emelie Fischer[2], Jasmina Golaboska[3], Kaya Harms[2], Johanna Hempel[2], Julica Huckshold[2], Clara-Elisabeth Löscher[2], Marjam Nadjmabadi[2], Ayumi Maeda[4], Khashayar Pourrahimi[2], Sören Dräger[2], Hatim Kerniss[5], Philipp Klein[2], Bieber Katja[2], Ralf Ludwig*[2]

[1] Karolinska University Hospital, Solna, Sweden

[2] Universität zu Lübeck, Lübeck, Germany

[3] QIMA Life Sciences, QIMA Monasterium GmbH, Münster, Germany

[4] Gifu University, Gifu, Japan

[5] University Hospital Frankfurt, Frankfurt/Main, Germany

Introduction

Chronic inflammatory skin diseases (CISD) affect 20-25% of the population. Psychological stress is considered a modifiable risk factor, yet epidemiologic evidence remains inconsistent, partly due to challenges in capturing stress through clinical documentation. Objective: To investigate whether clinically documented psychological stress is associated with altered risk of incident CISDs.

Materials and Methods

Retrospective cohort study. Individuals with ICD-coded psychological stress diagnoses propensity score-matched to controls on demographics, comorbidities, and healthcare utilization. Incident CISD risk was evaluated using Cox proportional hazards models over 7 years of follow-up. Robustness was assessed through seven sensitivity analyses, positive and negative control outcomes, and model triangulation using multivariable Cox models.

Results

Among 399,615 matched pairs, ICD-coded stress showed no association with incident atopic dermatitis, psoriasis, vitiligo, lichen planus, alopecia areata, acne vulgaris, or rosacea. A modest association was observed for hidradenitis suppurativa (HR 1.27, 95% CI 1.13-1.27). Control outcomes behaved as expected.

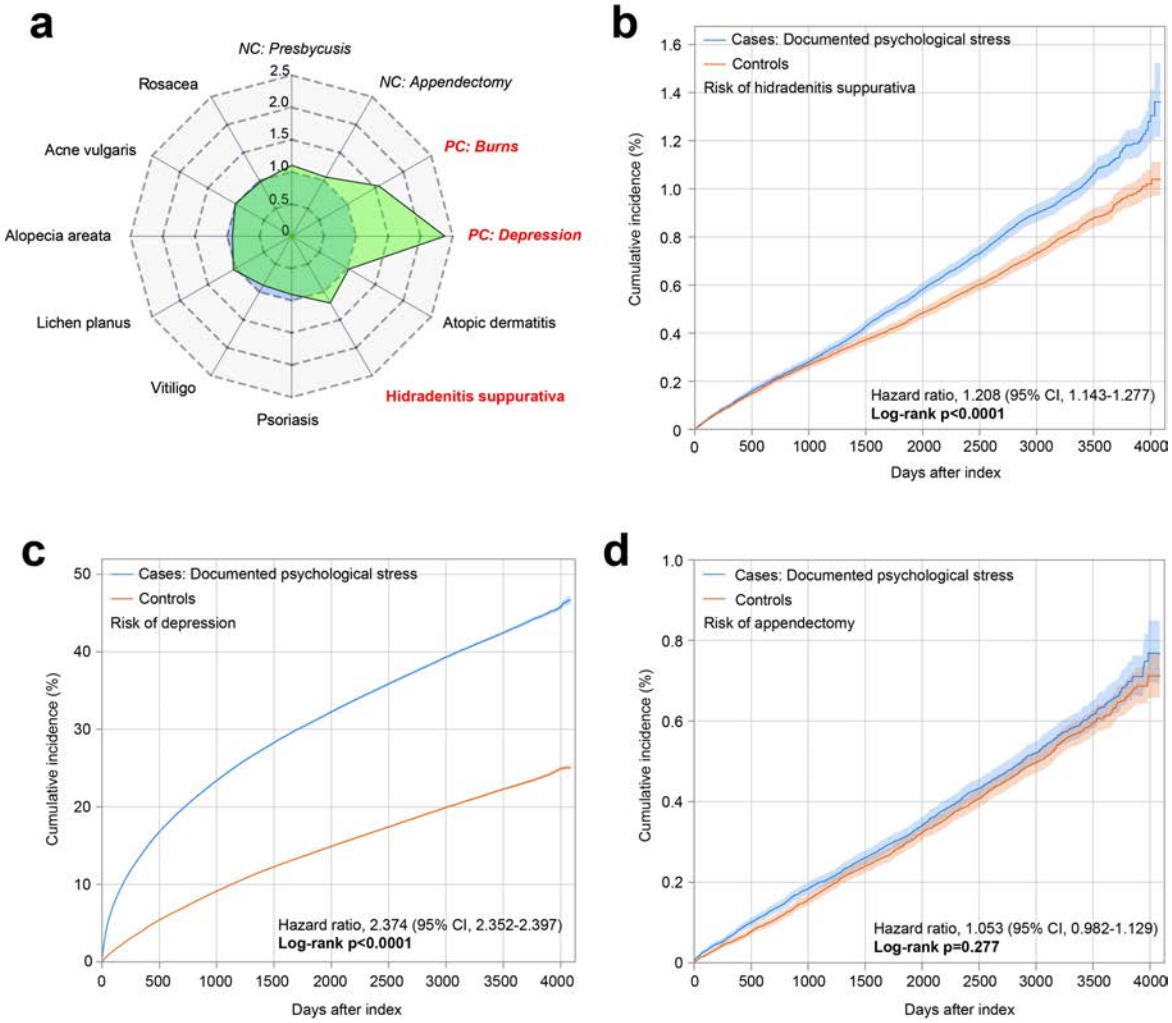

Hazard ratios for incident outcomes following documented psychological stress. (a) Radar plot showing hazard ratios (HRs) for incident dermatologic and control outcomes in the primary analysis. Values represent HR estimates from Cox proportional hazards models comparing individuals with documented psychological stress to matched controls. Negative control outcomes (presbycusis, appendectomy) and positive control outcomes (burns and corrosions of external body surface, depression) are displayed in italics. Red indicates statistical significance after Bonferroni correction. Most chronic inflammatory skin diseases showed no increased risk following stress; a modest association was observed for hidradenitis suppurativa. Shading indicates HR <1 (light blue) or >1 (light gray). (b–d) Kaplan–Meier curves for (b) hidradenitis suppurativa, (c) depression (positive control), and (d) appendectomy (negative control). Shaded areas represent 95% confidence intervals.

Conclusions

Considering the limitation, i.e., incomplete capture of psychological stress, potential diagnostic miscoding, residual confounding by unmeasured stress severity and chronicity, and lack of causal inference, ICD-coded stress diagnoses were not consistently associated with incident CISD, suggesting stress documentation may not be a robust population-level risk factor for CISD onset.

EADV Congress 2026, VIENNA
30 SEPTEMBER - 03 OCTOBER 2026
POWERED BY M-ANAGE.COM

EADV CONGRESS
VIENNA
30 SEP - 3 OCT 2026

Abstract N°: 2393

The Sweet paradox: The diagnostic challenge of a febrile…afebrile dermatosis

Oana-Victoria Herișanu*[1], Patricia Bratu[1], Ana-Olivia Toma[1]

[1] Timișoara Municipal Emergency Clinical Hospital, Timișoara, Romania

Introduction

Sweet syndrome (acute febrile neutrophilic dermatosis), first described in 1964, is a rare inflammatory disorder characterized by the abrupt onset of painful, erythematous-violaceous plaques measuring 2–10 cm in diameter. Its etiopathogenesis encompasses classic forms, malignancy-associated forms, forms associated with inflammatory diseases, and drug-induced forms.

Case Presentation

We report the case of a 50-year-old female patient who presented with edematous erythematous-violaceous plaques (3–30 cm) on the chest and upper limbs, associated with sheet-like palmar desquamation. Although the laboratory workup showed leukocytosis with left shift and elevated C-reactive protein (CRP), the patient remained persistently afebrile. The diagnosis of Sweet syndrome was one of exclusion, requiring differentiation from erythema multiforme and drug-induced eruptions. A distinctive feature was the need to rule out a hematologic malignancy, in which the lesions are frequently ulcerative and neutrophilia is absent. Systemic corticosteroid therapy was initiated. In contrast to typical cases, the therapeutic response was slow, and the attempt to taper the dose precipitated relapses, necessitating a prolonged treatment regimen.

Conclusion

This case highlights the existence of afebrile forms of Sweet syndrome and the difficulty of managing a protracted clinical course under standard treatment, underscoring the importance of rigorous clinico-paraclinical correlation.

EADV CONGRESS
VIENNA
30 SEP - 3 OCT 2026

Abstract N°: 2396

Ixekizumab for refractory pityriasis rubra pilaris: a retrospective five-case series with long-term follow-up

Jone López Martínez*[1], Amaia Barrutia Etxebarria[1], Javier Gimeno[1], Rosa María Escribano de la Torre[1], Sofia Goula Fernández[1], Sonia Heras Gonzalez[1], Ricardo González Pérez[1]

[1] Araba University Hospital, Vitoria - Gasteiz, Spain

Introduction
Pityriasis rubra pilaris (PRP) is a rare inflammatory dermatosis with limited therapeutic options and variable clinical outcomes. Conventional treatments frequently provide incomplete responses or poor tolerability. Increasing evidence supporting the role of the IL-17 pathway in PRP pathogenesis has encouraged the off-label use of IL-17 inhibitors. We report a retrospective case series evaluating the effectiveness and safety of ixekizumab in refractory PRP.

Case Presentation
Five patients (three women and two men; age range 46–76 years) with severe PRP refractory to conventional therapies were treated with ixekizumab. Previous treatments included topical and systemic corticosteroids, acitretin, methotrexate, cyclosporine, phototherapy, and biologic agents including etanercept, adalimumab, ustekinumab, and secukinumab. Two patients presented with erythroderma. All patients achieved significant clinical improvement after ixekizumab initiation, with a mean time to response of 3 months (range 2–4 months). Two patients required concomitant acitretin during treatment, while one patient required combined therapy with oral corticosteroids and methotrexate alongside ixekizumab. One patient achieved sustained remission allowing treatment discontinuation, whereas the rest required ongoing therapy to maintain disease control. Treatment duration ranged from 5 months to 6 years. Ixekizumab demonstrated a favorable safety profile; only one patient experienced mild adverse events (urticaria and oral aphthae), without treatment interruption. No severe adverse events were reported.

Conclusion
This retrospective five-case series supports ixekizumab as an effective and well-tolerated therapeutic option for refractory PRP, including erythrodermic disease and patients previously unresponsive to multiple systemic and biologic therapies. Rapid clinical improvement and sustained long-term responses further support the pathogenic role of the IL-17 axis in PRP and highlight ixekizumab as a promising targeted treatment strategy.

EADV CONGRESS
VIENNA
30 SEP - 3 OCT 2026

Abstract N°: 2438

Efficacy and Safety of Anti-IL-4Rα Stapokibart for Chinese Adults With Moderate-to-Severe Prurigo Nodularis: A Phase 3 Randomized Clinical Trial

Xinghua Gao*[1], Li Zhang[1], Guannan Zhu[2], Jingyi LI[3], Litao Zhang[4], Guohong Hu[5], Liming Wu[6], Lei Shi[7], Yaping Li[8], Xiaoyong Man[9], Siping Zhang[10], Zonghuang Ding[11], Chunxing Xu[12], Xiaodong Li[13], Yi Sun[14], Kunpeng Bian[15], Qingchun Diao[16], Yumei Li[17], Xia Dou[18], Xiaohong Zhu[19], Hongyi Li[20], Songmei Geng[21], Guoqing Zhao[22], Hongyue Yan[22], Haifei Wang[22], Bo Chen[22]

[1] The First Hospital of China Medical University, Shenyang, China
[2] Dermatology Hospital, Southern Medical University, Guangzhou, China
[3] West China Hospital of Sichuan University, Chengdu, China
[4] Tianjin Institute of Integrative Dermatology, Tianjin Academy of Traditional Chinese Medicine Affiliated Hospital, Tianjin, China
[5] Dermatology Hospital of Jiangxi Province, Nanchang, China
[6] Affiliated Hangzhou First People's Hospital, School of Medicine, Westlake University, Hangzhou, China
[7] The First Affiliated Hospital of Ningbo University, Ningbo, China
[8] the Second Xiangya Hospital, Central South University, Changsha, China
[9] Second Affiliated Hospital, Zhejiang University School of Medicine, Hangzhou, China
[10] First Affiliated Hospital of University of Science and Technology of China (Anhui Provincial Hospital), Hefei, China
[11] The First College of Clinical Medical Science, China Three Gorges University, Yichang, China
[12] The First People’s Hospital of Changzhou, The First People’s Hospital of Changzhou, China
[13] Central Hospital Affiliated to Shenyang Medical College, Shenyang, China
[14] Jingzhou Hospital Affiliated to Yangtze University, Hubei Provincial Clinical Research Center for Diagnosis and Therapeutics of Pathogenic Fungal Infection, Jingzhou, China
[15] Nanyang Central Hospital, Nanyang, China
[16] Chongqing Traditional Chinese Medicine Hospital, Chongqing, China
[17] Affiliated Hospital of Jiangsu University, Zhenjiang, China
[18] Peking University Shenzhen Hospital, Shenzhen, China
[19] Wuxi No.2 People's Hospital (Jiangnan University Medical Center), Wuxi, China
[20] Guangdong Provincial Hospital of Traditional Chinese Medicine, Guangzhou, China
[21] The Second Affiliated Hospital of Xi'an Jiaotong University, Xi'an, China
[22] Keymed Biosciences Co., Ltd, Chengdu, China

Introduction

Prurigo nodularis (PN) is a chronic, burdensome skin disease that significantly impair patients’ quality of life, but therapeutic options are limited. Stapokibart is an anti-interleukin-4 receptor alpha (IL-4Rα) monoclonal antibody, which has received approval in China for several type 2 inflamatory diseases, including moderate-to-severe atopic dermatitis. This study aimed to evaluate the efficacy and safety of stapokibart in adults with moderate-to-severe PN.

Materials and Methods

This was a multicenter, randomized, double-blind, placebo-controlled phase 3 study (NCT06424470) conducted in China. It consisted of an up to 4-week screening period, a 24-week treatment period, and an 8-week safety follow-up period. Eligible patients (aged 18-75 years with a diagnosis of PN for ≥3 months) were randomized 1:1 to receive subcutaneous stapokibart 300 mg (600 mg loading dose) or placebo every 2 weeks for 24 weeks. Primary and key secondary endpoints were proportions of patients achieving a ≥4-point improvement from baseline in Worst Itch Numeric Rating Scale (WI-NRS) and an Investigator's Global Assessment for chronic nodular prurigo stage (IGA-CNPG S) score of 0/1 at week 24, respectively. Safety was also assessed.

Results

A total of 200 patients were enrolled (n=100 per group; mean age 44.7 years; 61.0% male; 39.0% female), of whom 91.5% completed 24 weeks of treatment. At week 24, both the primary and key secondary efficacy endpoints were met with statistical significance in the stapokibart group versus palcebo group: WI-NRS response rates were 64.0% vs. 33.0% (difference 31.0%, 95%CI 17.2-43.2, P<0.0001); IGA-CNPG S response rates were 45.0% vs. 14.0% (difference 31.0%, 95%CI 18.6-42.2, P<0.0001) (Figure 1). Stapokibart was also effective at improving patients' quality of life, skin pain, sleep disturbance, and anxiety/depression. The incidence of treatment-emergent adverse events (TEAEs) was similar between the stapokibart and placebo groups (79.0% vs. 73.0%), with almost all events being mild or moderate. No TEAEs leading to treatment discontinuation or death were observed. The most common TEAE was upper respiratory tract infection.

Conclusions

Stapokibart demonstrated high efficacy in adults with moderate-to-severe PN, with a favorable safety profile.

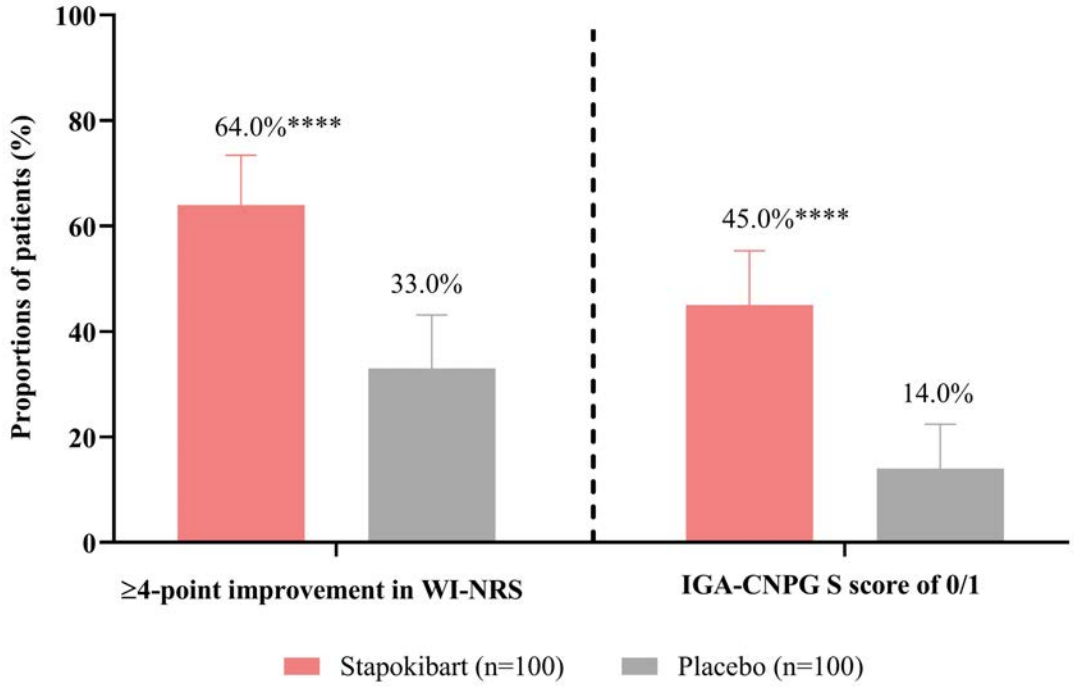

Figure 1 Proportions of patients achieving ≥4-point improvement from baseline in WI-NRS or IGA-CNPG S 0/1 at week 24. ****P<0.0001 versus placebo. Error bars indicated 95% confidence intervals, calculated using the Clopper-Pearson method.

EADV CONGRESS
VIENNA
30 SEP - 3 OCT 2026

Abstract N°: 2447

Pyoderma gangrenosum: association of ulcer size with clinical characteristics and healing outcomes

Jacqueline Jiang*[1, 2], Edmund Wee[3], Dale Jobson[4], Robert Kelly[2]

[1] Skin Health Institute, Melbourne, Australia
[2] St Vincent's Hospital Melbourne, Melbourne, Australia
[3] Southbank Dermatology, Perth, Australia
[4] Royal Melbourne Hospital, Melbourne, Australia

Introduction
Pyoderma gangrenosum (PG) is an ulcerative inflammatory dermatosis that is poorly characterised from a diagnostic and therapeutic perspective. Currently, there is limited evidence to inform patients diagnosed with PG about their likely prognosis, including expected healing times and risk of recurrence. We evaluated the association of ulcer size with clinical characteristics and healing outcomes in patients with PG.

Materials and Methods
We reviewed the medical records of patients with PG presenting to a tertiary hospital with a dermatologist-lead PG clinic from 20 December 2011 to 11 June 2024. We collected data on age, sex, anatomic location, one versus multiple ulcers, pathergy, history of PG-related comorbidities (haematological malignancy, inflammatory arthritis, inflammatory bowel disease), history of healing comorbidities (diabetes mellitus, peripheral vascular disease) and systemic treatment. For the data analysis, we classified cases into small (<64cm2) or large ulcers (≥64cm2 or any tendon or muscle on view). This was based on the size of the largest ulcer, with 64cm2 representing the median size for the study population. Clinical characteristics and healing outcomes of small versus large ulcers were compared, including: rates of initial healing, healing time, recurrence rate, healing after recurrence, level of systemic treatment required and mortality. The fisher exact test, Wilcoxon rank-sum test, logistic and linear regression were used.

Results
81 cases of PG were identified, including 38 (46.9%) small and 43 (53.1%) large ulcers. Initial healing was achieved in 78.9% of small versus 53.5% of large ulcers, with median healing times of 9.5 versus 39.5 months respectively. Recurrence occurred in 26.7% of patients with small ulcers and 65.2% of patients with large ulcers. Large ulcers were associated with a history of multiple ulcers, peripheral vascular disease and higher rates of advanced treatment (biologic or intravenous immunoglobulin therapy) (all $P<0.05$). After adjusting for age, sex, and peripheral vascular disease, large ulcers remained independently associated with lower rates of initial healing, higher rates of recurrence, lower rates of healing after recurrence and longer healing times (all $P<0.05$). Ulcer size was not associated with age, sex, ulcer location, tissue pathergy, inflammatory bowel disease, haematological malignancy, inflammatory arthritis or diabetes mellitus.

Conclusions
PG is a highly morbid condition that is slow to heal and frequently recurs. Ulcer size is an important predictor of

healing outcomes. It is thus a meaningful way of stratifying patients and provides useful prognostic information regarding the expected disease course.

EADV CONGRESS
VIENNA
30 SEP - 3 OCT 2026

Abstract N°: 2460

Histologically Confirmed Vaginal and Cervical Involvement in Vulvar Lichen Sclerosus: An Exceptional Case Report

bousmat rahma hind*[1], chrifi sarah[1], mahi ilham[1], dahmani boumedien[1, 1]

[1] Department of Dermatology, University Hospital Center of Tlemcen, Faculty of Medicine, University of Tlemcen, Algeria, tlemcen, Algeria

Introduction
Lichen sclerosus is a chronic inflammatory dermatosis predominantly affecting the anogenital region, particularly the vulva. Vaginal and cervical involvement remains exceedingly rare and sparsely reported in the literature.

Case Presentation
We report the case of a 31-year-old woman, gravida 2 para 2 (two previous cesarean deliveries), with a history of ocular tuberculosis and Lyme disease, who presented with a 2-year history of severe vulvovaginal pruritus and dyspareunia.

Clinical examination revealed vulvar architectural distortion with resorption of the labia minora, associated with finely scaly perineal erythema and excoriation lesions. Vaginal mucosal involvement was observed. Speculum examination showed suspicious cervical lesions.

Histopathological examination of both vaginal and cervical biopsies confirmed the diagnosis of lichen sclerosus.
Discussion:
Lichen sclerosus typically spares the vaginal mucosa due to its non-keratinized squamous epithelium, making vaginal involvement particularly unusual. Cervical localization is exceptional and may represent a diagnostic challenge, particularly with chronic inflammatory or neoplastic conditions. Such manifestations may be underrecognized in the absence of systematic gynecological examination and targeted biopsies. Dysimmune mechanisms, potentially influenced by hormonal or infectious factors, may contribute to these atypical presentations.

Conclusion
Although vulvar involvement is typical in lichen sclerosus, vaginal and cervical extension is extremely rare. This case highlights the importance of systematic gynecological examination and histological confirmation in atypical presentations to ensure accurate diagnosis and appropriate management.

EA DV CONGRESS
VIENNA
30 SEP - 3 OCT 2026

Abstract N°: 2467

Evaluation of CARD9 Mutations in Patients with Seborrheic Dermatitis Using Next-Generation Sequencing

Himmet Özdemir*[1], Ceyda Tetik Aydoğdu[1], Evren Gümüş[2]

[1] Department of Dermatology, Faculty of Medicine, Muğla Sıtkı Koçman University, Muğla, Türkiye
[2] Department of Medical Genetics, Faculty of Medicine, Muğla Sıtkı Koçman University, Muğla, Türkiye

Introduction

Seborrheic dermatitis is a chronic inflammatory dermatosis characterized by erythematous, greasy scaly plaques predominantly affecting seborrheic areas. Malassezia species are lipophilic yeasts involved in its pathogenesis. The innate immune system, particularly through C-type lectin receptors (CLRs), mediates recognition of Malassezia and initiates immune responses. CLR signaling is linked to adaptive immunity via the CARD9 adaptor protein, leading to dendritic cell–derived inflammatory cytokine production. CARD9 gene variants have been associated with impaired inflammatory responses, fungal infections, and certain chronic inflammatory diseases. These findings suggest that CARD9 variants may predispose individuals to Malassezia-associated diseases.

Materials and Methods

The study included 30 adult patients aged 18-65 diagnosed with seborrheic dermatitis. The medical history of all enrolled patients was collected, and their demographic characteristics, disease duration, and comorbidities were recorded in patient forms.

The severity of the disease was determined using the Seborrheic Dermatitis Area Severity Index (SDASI) score (range 0-12.6) and microscopic fungal examination of the seborrheic dermatitis lesions was performed.

Peripheral blood samples were collected to evaluate the presence of CARD9 mutations. DNA isolation was performed from the collected samples, and the entire CARD9 gene was sequenced using next-generation sequencing (NGS) technology. The obtained data were analyzed using bioinformatic tools and in silico analyses were performed. The clinical significance and reporting of the variants were based on the 2015 criteria recommended by the American College of Medical Genetics and Genomics (ACMG).

Results

A positive, moderate, and statistically significant correlation was found between the SDASI score and the density of Malassezia observed under the microscope ($r=0.546$, $p = 0.002$), indicating that increased fungal density in the lesions was associated with greater clinical disease severity.

A total of 20 different variants were identified in the CARD9 gene through NGS analysis in the 30 SD patients. Of these variants, 4 had previously been identified as functionally significant in the literature and were associated with a reference SNP ID. One of the identified variants, Chr9(hg38):136366983 (CAG>C), was classified as likely pathogenic based on its absence in population databases and its predicted impact on protein function (Table).

Statistical analysis revealed that patients with the Chr9(hg38):136366983 (CAG>C) deletion variant had a significantly older median age at disease onset (29.0 years, min-max: 27-51) compared to those without the variant (21.0 years, min-max: 12-40) ($p=0.029$). The median disease duration for patients with this variant was

120.0 months, while it was 36.0 months for those without the variant (p=0.071).

Additionally, the frequency of the rs10781499 variant was significantly higher in female patients (92.3%) compared to male patients (47.1%) (p=0.017).

Table. CARD9 Gene Variants Identified in Patients with Seborrheic Dermatitis

rs Number	hg38 Coordinate (chr9)	Reference Allele > Alternate Allele	Number of carriers (n = 30)	Functional Effect
rs4077515	136372044	C > T	20	Missense variant (p.Ser12Asn / S12N)
rs10781499	136371953	G > A	20	Synonymous variant (p.Pro42=)
rs10870077	136369439	C > G	20	Intronic variant
rs4075760	136372245	A > G	19	Intronic variant
-	136366983	CAG > C	3	Coding indel (frameshift)

Conclusions

In our study, the rs10781499 variant was significantly more frequent in female SD patients than in male patients, highlighting the importance of considering the immune response to Malassezia in conjunction with genetic variants and biological sex factors.

In patients with the Chr9(hg38):136366983 (CAG>C) deletion variant, disease onset was later in life. Although the difference in disease duration was not statistically significant, a trend toward longer disease duration was observed in variant carriers despite the limited sample size. This variant may be associated with later onset, immunosenescence, and the chronic course of adult-type SD pathogenesis.

The findings provide a foundation for future larger-scale genetic association studies and functional analyses to better elucidate the genetic susceptibility in the pathogenesis of SD.

Funding: The research was supported by Muğla Sıtkı Koçman University Research Support and Funding Office (Grant No: 25/24).

EADV CONGRESS
VIENNA
30 SEP - 3 OCT 2026

Abstract N°: 2493

Refractory Cutaneous B-Cell Pseudolymphoma Successfully Treated with Combined IPL and Fractional Er:YAG Laser: A Case Report

Carolina Julieta Postai de Araujo Santos[1], Ana Vitória Coppoli Siva[1], Laisa Goulart Saviatto Picasky*[1], Angelica Fonseca[1], Leticia Gonzaga[1], Vitória Radichewski[1], Roberto Amorim Filho[1], Gabriella Funchal[1], Gustavo Amorim[1], Angelica Seidel[1]

[1] Santa Tereza Sanitary Dermatology Hospital, São Pedro de Alcântara, Brazil

Introduction

Cutaneous B-cell pseudolymphoma is a benign reactive lymphoproliferative disorder that clinically and histopathologically mimics cutaneous lymphoma.(1,2) It may be associated with various triggers, including infections, drugs, tattoos, and other exogenous stimuli, although many cases remain idiopathic.(2) Clinically, it presents as solitary or multiple erythematous to violaceous papules or nodules, most commonly involving the face, trunk, and upper extremities.(2,3) Histopathologically, it is characterized by dense dermal lymphocytic infiltrates with reactive germinal centers and a polymorphous inflammatory background.(2) Immunohistochemistry demonstrates B-cell predominance (CD20+) with preserved follicular dendritic cell networks (CD21), germinal centers positive for Bcl-6 and negative for Bcl-2, and a high Ki-67 index confined to germinal centers.(2) Diagnosis requires clinicopathologic correlation and, when necessary, molecular studies to exclude lymphoma.(2) Management includes removal of the triggering factor and therapeutic options such as corticosteroids, excision, and physical modalities, including laser-based treatments.(1,4,5)

Case Presentation

A 66-year-old female, smoker, with a history of diazepam and amitriptyline use, presented with an 11-month history of grouped papules forming an indurated plaque on the right malar region. The lesion consisted of erythematous-yellowish papules forming an infiltrated, firm plaque, with no identifiable triggering factor. Histopathologic examination with immunohistochemistry revealed a dense dermal lymphoid infiltrate with nodular architecture, CD20 and CD21 positivity, germinal center expression of Bcl-6, increased Ki-67 index, and polyclonal kappa and lambda light chains.(Fig 1 A-H). A diagnosis of cutaneous B-cell pseudolymphoma was established.

Initial treatment with topical tacrolimus 0.1%, followed by clobetasol propionate 0.05%, resulted in minimal improvement. The patient subsequently underwent microneedling with drug delivery of triamcinolone acetonide 20 mg/mL; however, the procedure was poorly tolerated. The lesion evolved into a less papular, erythematous-violaceous plaque, guiding a change in therapeutic approach.

The patient was then treated with combined intense pulsed light (IPL) and ablative fractional erbium:YAG laser. IPL parameters included filters of 585–510 nm, fluence of 15 J/cm^2, and pulse duration of 10 ms. Er:YAG laser was performed in ablative fractional mode (16 mJ, 3.0 ms, speed 3, three passes). Three sessions at 4–8 week intervals resulted in significant clinical improvement.(Fig 1 I-K)

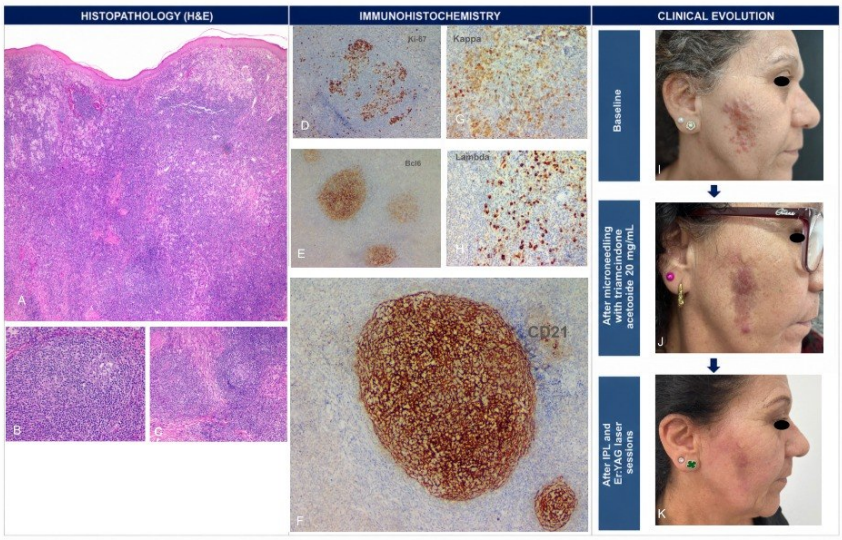

Figure 1. Clinical, histopathological, and immunohistochemical findings of cutaneous B-cell pseudolymphoma. (A- C) Histopathological examination showing dense dermal lymphoid infiltrate with nodular architecture and reactive germinal centers (H&E). (D) High Ki-67 proliferative index restricted to germinal centers. (E) Bcl-6 positivity within germinal centers. (F) CD21 highlighting preserved follicular dendritic cell meshworks (G-H) Polytypic kappa and lambda light-chain expression supporting a reactive lymphoid proliferation. (I) Baseline clinical presentation showing grouped erythematous papules and nodules on the right cheek. (J) Partial improvement after microneedling with drug delivery of triamcinolone acetonide 20 mg/mL, with residual violaceous infiltration. (K) Significant clinical improvement after combined IPL and fractional Er:YAG laser sessions.

Conclusion

Microneedling has been proposed as a therapeutic modality due to its ability to create microchannels that enhance transdermal drug delivery and disrupt dermal inflammatory infiltrates.(4) However, poor tolerability and modest response restricted its use.

The transition to a more erythematous-violaceous plaque suggested predominance of vascular and inflammatory components, supporting the use of energy-based devices. Intense pulsed light (IPL) targets hemoglobin and induces selective photothermolysis, in addition to promoting cytokine-mediated dermal remodeling, contributing to reduction of inflammatory infiltrates.(5)
Furthermore, ablative fractional Er:YAG laser enables precise dermal ablation with controlled tissue removal and induction of dermal remodeling, which may contribute to reduction of the inflammatory infiltrate.(6) The combination of these modalities likely acted synergistically, resulting in significant clinical improvement.

This case highlights the potential synergistic role of microneedling and energy-based devices as minimally invasive therapeutic options for refractory cutaneous B-cell pseudolymphoma.

EA DV CONGRESS
VIENNA
30 SEP - 3 OCT 2026

Abstract N°: 2495

The invisible burden: How psoriasis occupies mind space and shapes daily life

Shelagh Szabo[1], Kathleen Gallant[2], Linzi Dunlevy[2], Lawrence Green[3], Allison Bihari[1], Trichia Asbjoern[1], Alexis Mickle[1], Raquel Vaz[2], Ishan Hirji[4], Shun-Chiao Chang*[4]

[1] Broadstreet Health Economics & Outcomes Research (HEOR), 300–177 West 7th Ave, Vancouver, BC, Canada
[2] IFPA (International Federation of Psoriasis Associations), Stockholm, Sweden
[3] Department of Dermatology, George Washington University School of Medicine, Washington, DC, United States
[4] Takeda Development Center Americas, Inc., Cambridge, MA, United States

Introduction
Plaque psoriasis (PsO) is an immune-mediated systemic disease associated with skin manifestations and significant physical and psychosocial burden, with the potential to affect all aspects of a person's life. While visible plaques, scaling, itch and skin discomfort are well documented, the impact on 'mind space', defined as cognitive and emotional capacity, has not been explored. As therapeutic options expand, understanding how plaque PsO occupies mind space and shapes treatment expectations is critical for advancing patient-centred care. The objective of this study was to determine how plaque PsO affects daily life from the patient perspective, including the impact of bothersome symptoms and the mental effort required to manage the disease and its treatments.

Materials and Methods
A cross-sectional qualitative study was conducted between July and September 2025. Adults with moderate-to-severe plaque PsO from the USA, France and the UK participated. Eligibility required current or prior oral or biologic therapy for plaque PsO and ≥ 3% body surface area involvement or involvement in high-impact areas within the past 2 years. Purposive sampling with quotas ensured diversity in demographic and clinical characteristics. Semi-structured virtual interviews explored participants' mental, emotional and psychosocial experiences of living with plaque PsO. Reflexive thematic analysis was used to identify patterns in how plaque PsO and its management influence mind space. Participant quotations illustrated key points.

Results
Participants' (n = 50) median age at diagnosis was 31 years and median disease duration was 8 years. Reported past or current treatments included injectable biologics (40%), topicals (34%), advanced oral therapies (20%) and conventional oral therapies (20%). At interview, 46%, 42% and 12% of patients reported well-controlled, moderate and poorly controlled symptoms, respectively; 94% had experienced at least 1 flare-up in the past year.
Findings demonstrated that plaque PsO exerts a substantial and under-recognized impact on daily life and mind space, reflected across five themes (**Figure 1**). **Self-perception and social participation:** visible plaques affected sense of self and social interactions, causing stigma, self-consciousness, the choice of plaque-concealing clothes and changes in daily activity participation. **Daily life activities/rituals**: managing plaque PsO required ongoing cognitive and practical effort, including planning routines, monitoring triggers, modifying daily tasks and coordinating treatment activities. This contributes to mental fatigue and becomes all-consuming during flare-ups. **Vigilance and monitoring:** participants described persistent self-monitoring and hypervigilance, with itch, discomfort and flare unpredictability requiring individuals to remain mentally alert for rapid symptom worsening. **Treatment effectiveness and risk of relapse:** symptom improvement frees attention previously occupied by management needs, supporting re-engagement in daily life and decreased impact on mind space. Durable treatment responses and faster onset reduced uncertainty and supported a quicker return to normalcy; however, concerns about diminishing treatment effect and future flares remained. **Supportive connections:** supportive

relationships helped alleviate psychological burden, reducing isolation and the mental load associated with ongoing self-management.

Figure 1. Participant quotations illustrating drivers of mind space impact.

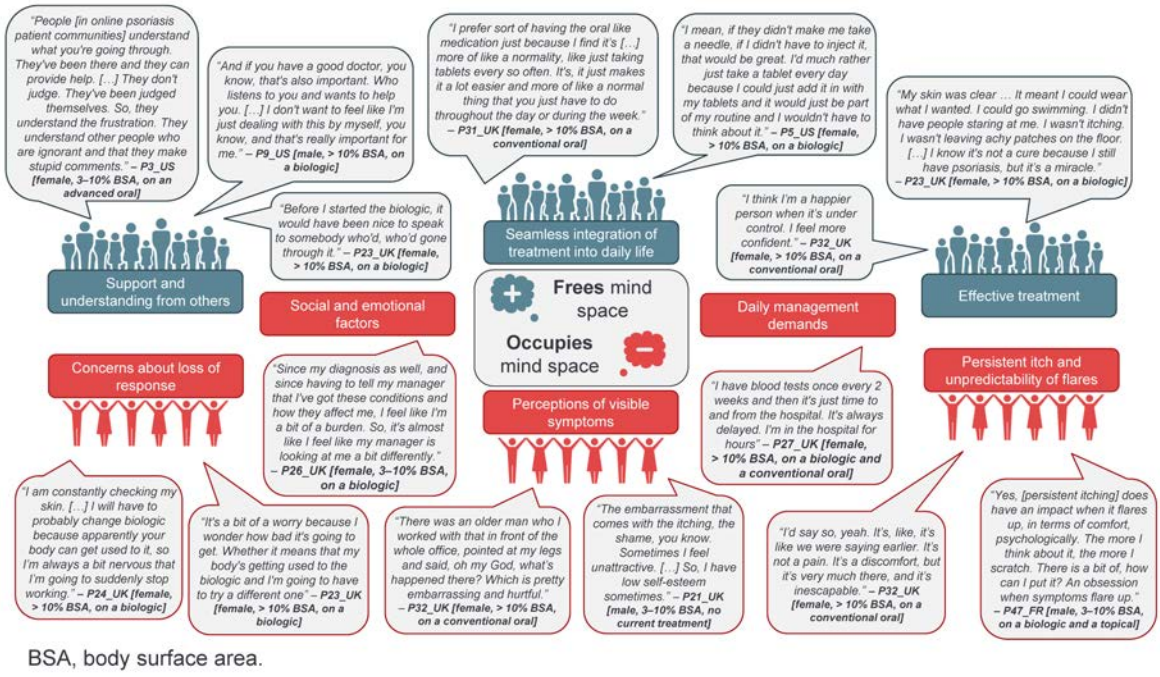

BSA, body surface area.

Conclusions

Plaque PsO imposes physical, psychological, social and treatment-related demands that occupy mind space and shape daily functioning. These findings highlight an overlooked dimension of plaque PsO burden and illustrate how disease management requirements extend far beyond visible symptoms. Treatment benefits that restore identity and cognitive bandwidth may be particularly meaningful. Incorporating mind-space considerations may further strengthen patient-centred care in moderate-to-severe plaque PsO.

EA DV CONGRESS
VIENNA
30 SEP - 3 OCT 2026

Abstract N°: 2497

From burden to balance: Patient perspectives on plaque psoriasis treatment expectations and preferences in a multi-country qualitative study

Allison Bihari[1], Linzi Dunlevy[2], Kathleen Gallant[2], Lawrence Green[3], Alexis Mickle[1], Jessica Stewart[1], Raquel Vaz[2], Ishan Hirji[4], Shun-Chiao Chang*[4]

[1] Broadstreet Health Economics & Outcomes Research (HEOR), 300–177 West 7th Ave, Vancouver, BC, Canada
[2] IFPA (International Federation of Psoriasis Associations), Stockholm, Sweden
[3] Department of Dermatology, George Washington University School of Medicine, Washington, DC, United States
[4] Takeda Development Center Americas, Inc., Cambridge, MA, United States

Introduction
Although biologic therapies have improved outcomes in plaque psoriasis (PsO), many living with the condition continue to face challenges in managing their disease within daily routines and finding treatments that meet their expectations. As the therapeutic landscape expands, understanding patient treatment expectations and preferences has become essential for facilitating shared decision-making. Some information on how individuals evaluate treatment attributes such as convenience, durability, safety and mode of administration are available from quantitative preference studies. However, these methods are less useful for understanding the contextual factors impacting treatment preferences and the concerns patients face when selecting treatments. The objective of this qualitative study was to explore treatment expectations, priorities and preferences among adults with moderate-to-severe plaque PsO across diverse treatment histories and to assess the impact of symptom burden, lifestyle and treatment experience in shaping them.

Materials and Methods
A cross-sectional qualitative study was conducted between July and September 2025 in adults with plaque PsO in the USA, France and the UK. Eligible participants had moderate-to-severe plaque PsO defined by ≥ 3% body surface area involvement or involvement in high-impact areas within the past 2 years, and had current or prior experience with oral or biologic therapy. Purposive sampling with quotas ensured diversity in age, gender, symptom experience, disease severity, plaque location and treatment history. Semi-structured online interviews explored treatment expectations, perceived advantages and disadvantages of different modalities, and practical considerations influencing therapy choice. Transcripts were analysed using conventional content analysis focusing on five attributes: effectiveness, safety, ease of use, mode of administration and speed of action. Participant quotations illustrated key points.

Results
Participants' (n = 50) median age at diagnosis was 31 years and median disease duration was 8 years. Past and current treatment use included biologics (40%), topicals (34%), advanced oral therapies (20%) and conventional oral therapies (20%). In the past year, 94% of patients experienced at least 1 flare-up, with a median of four flares.

Treatment preferences, which varied across participants, centred on reducing overall disease burden and supporting functional and psychological capacity for daily life (**Figure 1**). Effectiveness, particularly durable skin clearance and itch relief, was a key driver of overall treatment preferences, especially among those with severe symptoms or prior negative treatment experiences. Convenience and ease of integration into daily routines were

also important, with oral therapies often preferred by those who work in person or travel frequently. Oral therapies were also of interest to participants with injection hesitancy due to needle anxiety, pain or emotional burden. Safety, including minimizing adverse events and long-term complications, was consistently emphasized. Treatment preferences were also shaped by symptom severity, plaque visibility, lifestyle, life-stage and prior experience. Rapid symptom relief (particularly during flares) was desirable, but some participants emphasized that durable, long-lasting benefits mattered more than immediate, short-lived effects.

Figure 1. Illustrative quotations on treatment priorities by treatment attribute.

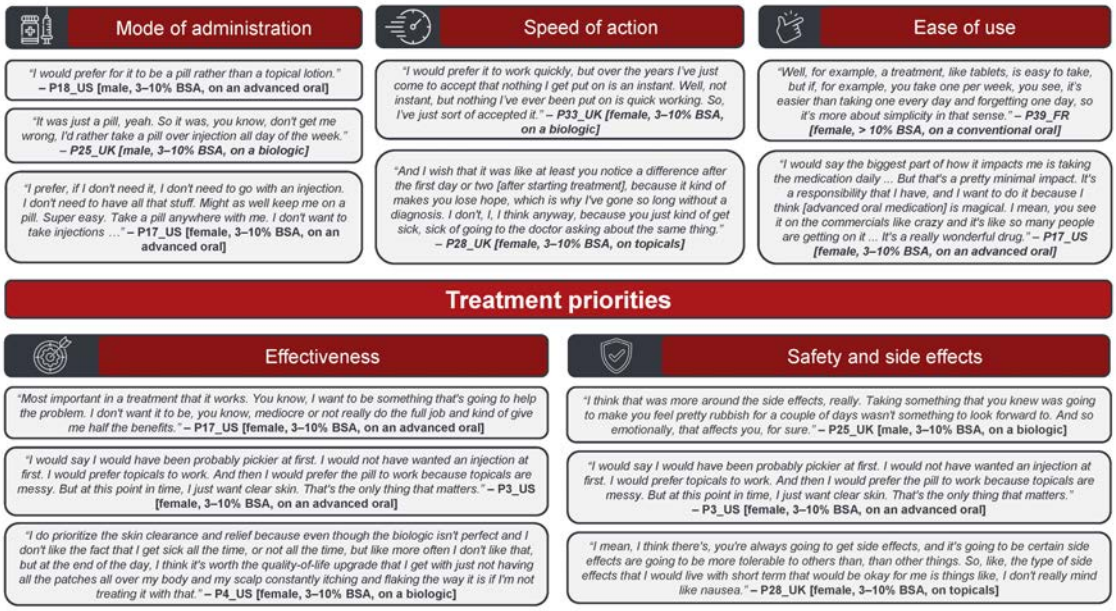

BSA, body surface area.

Conclusions

This multi-country qualitative study provides novel, patient-centred insights into treatment preferences among individuals with moderate-to-severe plaque PsO. Preferences were driven by effectiveness, convenience and safety, were tied closely to daily life and prior treatment experiences, and the extent to which treatments could be easily integrated into routines and reduce management burden. These results offer patient-centred evidence to guide clinical discussions and support preference-aligned therapeutic decision-making.

EADV CONGRESS
VIENNA
30 SEP - 3 OCT 2026

Abstract N°: 2512

Erosive Pustular Dermatosis of the Scalp in an Elderly Patient Hospitalized for Femoral Fracture: A Case Report

Fatima Zahra Sassine*[1], Chourouq Mustapha Eid[1], Meria Saci[2], Michele Sanchez[2]

[1] Ibn Sina University Hospital, Dermatology Derpartment, Rabat, Morocco

[2] Hopital Henri Duffaut, Dermatology Department, Avignon, France

Introduction

Erosive pustular dermatosis of the scalp (EPDS) is a rare chronic inflammatory condition classified within the spectrum of neutrophilic dermatoses, predominantlyaffecting elderly individuals. It is characterized by sterile pustules, crusted erosions, and progressive scarring alopecia. Predisposing factors include chronic actinic damage, advanced androgenetic alopecia (AGA), local trauma, and immunosuppression. EPDS remains underdiagnosed due to its clinical overlap with infectious, neoplastic, and other inflammatory scalp conditions. We report the case of a 72-year-old multimorbid patient with advanced AGA in whom EPDS was incidentally diagnosed during hospitalization for a femoral fracture and successfully treated with potent topical corticosteroid under occlusion.

Case Presentation

A 72-year-old male with a medical history of arterial hypertension and dementia was admitted to the orthopedic department for surgical management of a femoral fracture. The patient presented advanced androgenetic alopecia with significant scalp atrophy and chronic actinic damage. During hospitalization, a dermatological consultation was requested for chronic crusted lesions of the scalp. Clinical examination revealed crusted erosive plaques with purulent discharge on an atrophic, sun-damaged scalp with multiple actinic keratoses consistent with field cancerization. Trichoscopic evaluation demonstrated erythema, dilated vessels, crusts, pustules, and ivory-white cicatricial areas with absence of follicular ostia, findings consistent with EPDS. Bacterial cultures were negative, ruling out a primary infectious etiology. Based on clinical and dermoscopic findings, a diagnosis of EPDS was established.

Given the coexistence of EPDS and field cancerization, systemic retinoid therapy with acitretin was proposed. Acitretin has demonstrated efficacy in both the treatment of EPDS and the chemoprevention of actinic keratoses and non-melanoma skin cancers, making it a particularly attractive option in this clinical setting. However, the patient declined systemic retinoid therapy.

Treatment with clobetasol propionate 0.05% under occlusive dressing was therefore initiated once daily. This approach was supported by evidence identifying potent topical corticosteroids as first-line therapy, with a 93% improvement rate for clobetasol. Occlusion was employed to enhance bioavailability and accelerate therapeutic response. At one-month follow-up, significant clinical improvement was observed with marked reduction of crusting, pustulation, and inflammatory signs.

Conclusion

This case illustrates the successful management of EPDS with potent topical corticosteroid under occlusion in an elderly multimorbid patient. Trichoscopy proved essential for establishing the

diagnosis in a non-dermatological setting. Although systemic acitretin was proposed as a dual therapeutic strategy targeting both EPDS and concomitant field cancerization, the patient declined this option. Clobetasol propionate 0.05% under occlusive dressing nonetheless achieved significant clinical improvement at one month, consistent with published evidence supporting potent topical corticosteroids as first-line therapy. For long-term maintenance, transition to topical calcineurin inhibitors such as tacrolimus may be considered to minimize the risk of corticosteroid-induced cutaneous atrophy. This case highlights the importance of comprehensive dermatological assessment in elderly hospitalized patients and the need for a tailored therapeutic approach when patients decline systemic treatments. Early recognition and appropriate treatment of EPDS can prevent progression to irreversible scarring alopecia.

EA DV CONGRESS
VIENNA
30 SEP - 3 OCT 2026

Abstract N°: 2532

A case of an incomplete P(A)SH SYNDROME

Simona Kordeva*[1], Konstantin Tchernev Jr[2], Valentina Broshtilova-Nikolova[3], Georgi Tchernev[1, 2]

[1] Medical Institute of Ministry of Interior - Department of Dermatology and Venereology, Sofia, Bulgaria
[2] Onkoderma- Clinic for Dermatology, Venereology and Dermatologic Surgery, Sofia, Bulgaria
[3] Sofia University Saint Kliment Ohridski, Faculty of Medicine - Department of Internal Diseases, Pharmacology and Clinical Pharmacology, Pediatrics, Epidemiology, Infectious Diseases, and Skin Diseases, Sofia, Bulgaria

Introduction

Hidradenitis suppurativa (HS) is a chronic inflammatory disease that is frequently associated with syndromes, such as those within the PAPA spectrum. Syndromic HS presents unique management challenges, as it often shows resistance to conventional therapies. Pyoderma gangrenosum is a rare inflammatory neutrophilic dermatosis that is often seen in association within the spectrum of autoinflammatory diseases.

The PAPA spectrum disorders include a group of autoinflammatory diseases characterized by mutations in the PSTPIP1 gene or by clinical manifestations that closely resemble or overlap with those of PAPA syndrome. Each syndrome (PASH, PAPASH, PsAPASH, PASS, PAC, and PAMI syndrome) in this spectrum highlights specific inflammatory pathways and symptoms, providing insight into targeted therapeutic approaches.

Materials and Methods

We present a rare case of incomplete PASH (pyoderma gangrenosum and hidradenitis suppurativa) syndrome (Figure 1a-c; Figure 2a-c).



Fig.1a-c: Pyoderma gangrenosum: Multiple undermined ulcerative lesions on both lower legs (regio cruris), some of which were confluent and irregularly shaped, covered with purulent-hemorrhagic crusts. A violet halo and local erythema were also noted around the lesions. 1a: Lateral view of pyoderma gangrenosum lesions on the right lower leg 1b: Posterior view of pyoderma gangrenosum lesions on the right lower leg 1c: Lateral view of pyoderma gangrenosum lesions on the left lower leg Fig.2a-c: Dermatological examination 2a: Hidradenitis suppurativa: Cicatricial changes and numerous deep and superficial abscesses exuding pus-like material in the gluteal area 2b: Multiple dysplastic nevi on the trunk region 2c: Dysplastic nevus located in the lower left back region

Results

The histological findings were consistent with pyoderma gangrenosum (Fig.3a-c).

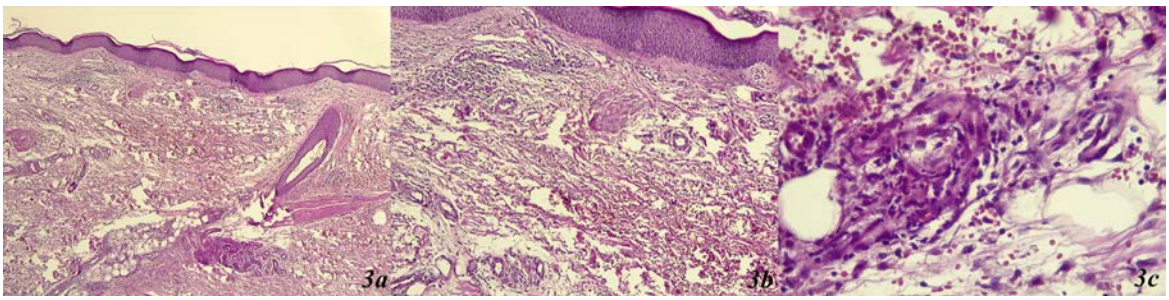

Fig.3a-c: Pyoderma gangrenosum: Orthohyperkeratosis, uneven acanthosis with smoothing of dermo-epidermal undulations, and a myxoid papillary dermis. There was also a moderate interstitial and perivascular round cell inflammatory infiltrate, with occasional eosinophils present in the upper and middle dermal layers. 3a: Pyoderma gangrenosum HEx40 3b: Pyoderma gangrenosum HEx100 3c: Pyoderma gangrenosum HEx200

Conclusions

The patient was successfully managed with a standard combination of antibiotics (ceftriaxone and metronidazole) and corticosteroids (methylprednisolone), followed by immunosuppressant (azathioprine) and corticosteroids (dexamethasone). Following administration of the abovementioned regimen, regression of the pyoderma gangrenosum lesions was observed (Fig.4a-d).

Conventional therapies remain both effective and affordable, providing valuable alternatives for patients.



Fig.4a-d: Dermatological findings: Regression of pyoderma gangrenosum lesions following antibiotic and immunosuppressive therapies, with subsequent crust formation 4a: Medial-posterior view of the lesions located on the right lower leg 4b,c: Medial view of the lesions located on the left lower leg 4d: Lateral view of the lesions located on the left lower leg

EADV CONGRESS
VIENNA
30 SEP - 3 OCT 2026

Abstract N°: 2561

IMPETIGO HERPETIFORMIS IN THE POSTPARTUM PERIOD: A VARIANT OF PUSTULAR PSORIASIS OR A DISTINCT ENTITY?

Samya Berrada*[1], Meryem Soughi[1], Aimane Zaim[1], Ikram Bejja[1], Saadia Boughaleb[1], Zakia Douhi[1], Sara Elloudi[1], Hanane Baybay[1], Fatima Zahra Mernissi[1]

[1] Department of Dermatology, Hassan II University Hospital, Sidi Mohamed Ben Abdellah University, Fez, Morocco

Introduction

Impetigo herpetiformis (IH) is a rare pustular dermatosis traditionally associated with pregnancy, most commonly arising during the third quarter and typically resolving after delivery. Initially considered a pregnancy-specific disorder, IH is now increasingly viewed as a hormonally triggered variant of generalized pustular psoriasis (GPP). However, its exact nosological status remains debated, particularly in cases with postpartum onset or exacerbation. The following examines the position of postpartum IH within the spectrum of pustular psoriasis.

Case Presentation

A 39-year-old multiparous woman (gravida 5, para 5) with a family history of psoriasis in cousins developed erythematous periumbilical lesions during the ninth month of pregnancy. The lesions partiellement partially improved with topical corticosteroids.

Two weeks postpartum, the eruption worsened and became generalized, involving the trunk and extremities, prompting hospitalization.

Dermatological examination showed diffuse erythematous plaques with scaly, crusted surfaces, studded with numerous non-follicular pustules,

some confluent. The Nikolsky sign was negative. Body surface area involvement was estimated at 60%.

Further history revealed similar periumbilical eruptions during her third and fourth pregnancies, both resolving spontaneously after delivery.

On admission, she was afebrile and hemodynamically stable. Laboratory tests revealed leukocytosis (approximately 20,000/mm3) with normal serum calcium levels. Skin biopsy showed neutrophilic pustular dermatitis consistent with pustular psoriasis. The patient was treated topical corticosteroids, and systemic acitretin (30 mg/day). Combined estrogen–progestin oral contraception was initiated. Clinical evolution was favorable, with progressive regression of lesions.

IH shares multiple clinical and histopathological features with GPP, including sterile spongiform pustules of Kogoj, psoriasiform epidermal hyperplasia, and neutrophil-rich dermal infiltrate. A personal or familial history of psoriasis may be present. Furthermore, mutations in the IL36RN gene—associated with GPP—have been identified in some pregnancy-related pustular eruptions, supporting a shared pathogenic pathway. Postpartum exacerbation in our patient reinforces the hypothesis that IH may represent hormonally triggered pustular psoriasis in genetically predisposed individuals.

Conversely, several arguments favor a distinct entity: many patients lack prior psoriasis history; lesions often begin in flexural or periumbilical areas with centrifugal extension; and complete resolution after delivery without chronic recurrence is common. These features have led some authors to consider IH a specific inflammatory dermatosis of pregnancy.

Although IH typically improves after childbirth, postpartum flares challenge the concept of a purely gestational disorder. Rapid hormonal shifts following delivery may act as inflammatory triggers, similar to mechanisms implicated in GPP.

The management of IH is not standardized. During pregnancy, systemic corticosteroids remain the first-line

treatment and are considered the safest and most effective therapeutic option. However, in the postpartum period, therapeutic strategies can be expanded. As the teratogenic risk is no longer a concern, systemic agents commonly used in psoriasis, such as acitretin, methotrexate, or PUVA, may be considered. This supports the concept that IH shares pathogenic and therapeutic similarities with GPP.
In our patient, acitretin was successfully introduced after delivery, leading to clinical improvement.

Conclusion

IH remains a rare but potentially severe pustular dermatosis of pregnancy. Postpartum exacerbation supports the hypothesis of a hormonally triggered form of pustular psoriasis in predisposed patients.Further molecular studies are needed to clarify whether IH represents a distinct entity or belongs within the spectrum of GPP.

EADV CONGRESS
VIENNA
30 SEP - 3 OCT 2026

Abstract N°: 2572

Treatment sequencing and drug survival in pustulosis palmoplantaris: a real-world cohort study

Sina Winkler[1], Ulrich Mrowietz[1], Sascha Gerdes*[1]

[1] UKSH, Campus Kiel, Kiel, Germany

Introduction

Pustulosis palmoplantaris (PPP) is a chronic inflammatory dermatosis with limited therapeutic options and no established treatment algorithm. Real-world data on treatment sequencing and comparative drug survival across systemic therapies in PPP remain scarce.

Our objective was to characterize real-world treatment pathways and evaluate drug survival across systemic therapies in PPP.

Materials and Methods

We conducted a retrospective cohort study of PPP patients receiving systemic therapy over a 15-year period. Patient characteristics, comorbidities and treatment histories were collected. Drug survival was assessed using Kaplan–Meier analysis, with therapy episodes analyzed individually. Treatment sequences were visualized using alluvial diagrams. Analyses were restricted to therapies with at least five treatment episodes ($n \geq 5$).

Results

A total of 130 patients were included (80.8% female, median age 54 years), with high rates of smoking and comorbidities. Overall, 297 therapy episodes across 20 systemic agents were analyzed, with a median of 2 therapies per patient.

Among therapies with $n \geq 5$, the most frequently used were apremilast (n=52), acitretin (n=41), ciclosporin (n=33), guselkumab (n=28), methotrexate (n=27), dimethylfumarate (n=19), fumaric acid esters (n=17), deucravacitinib (n=16), ixekizumab (n=10), bimekizumab (n=8), alitretinoin (n=7), and ustekinumab (n=5).

Treatment pathways demonstrated a heterogeneous, stepwise escalation pattern, with conventional systemic therapies predominating in first-line treatment and increasing use of small molecules and biologics in later lines. Frequent therapy switches were observed.

Drug survival differed significantly across therapies (Kruskal–Wallis p=0.0056), indicating heterogeneity in treatment persistence. Median treatment duration ranged from 2.5 months for dimethylfumarate (n=19) to 6.3 months for acitretin (n=41) and 7.0 months for ciclosporin (n=33). Longer treatment persistence was observed for targeted therapies, including 10.0 months for apremilast (n=52), 10.9 months for guselkumab (n=28), and 15.1 months for ixekizumab (n=10), with substantial variability among biologics (e.g., ustekinumab, n=5, 62.7 months).

Kaplan–Meier analysis confirmed more sustained drug survival for biologics and targeted therapies compared to conventional systemic treatments, consistent with class-dependent differences in treatment persistence.

Conclusions

Real-world management of PPP is characterized by heterogeneous treatment pathways and frequent therapy switching. Drug survival varies significantly across therapies, with conventional systemics showing shorter treatment persistence compared to targeted therapies and biologics. These findings support a class-based approach to treatment sequencing in PPP.

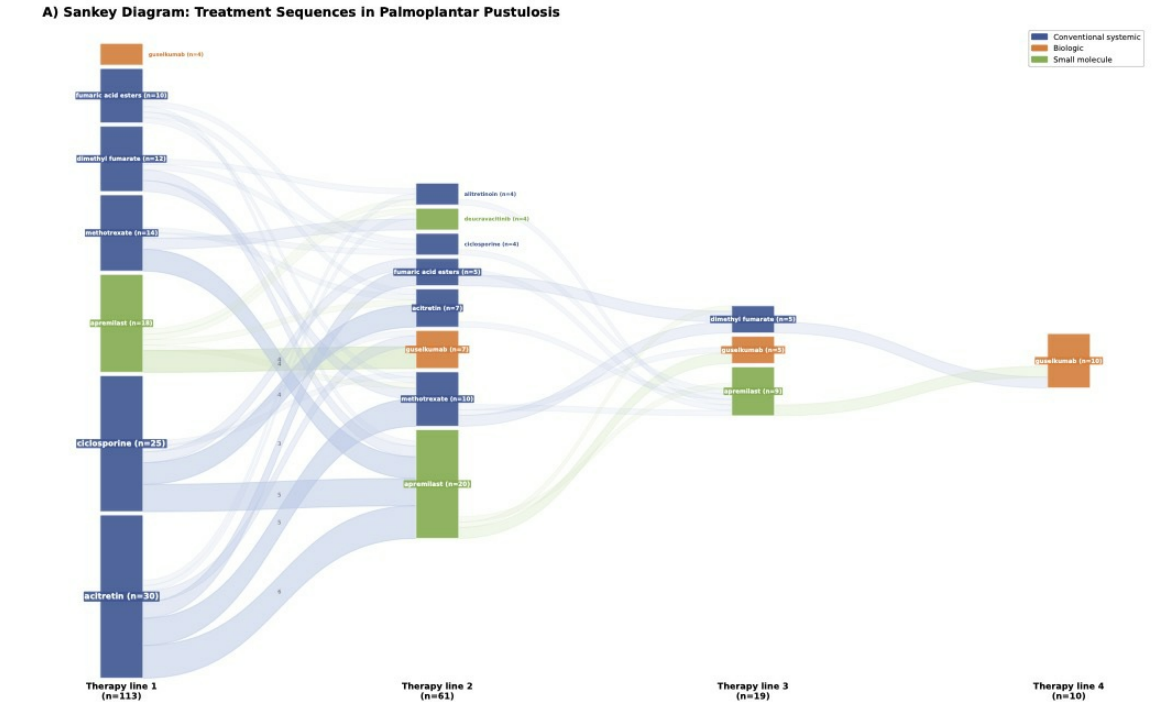

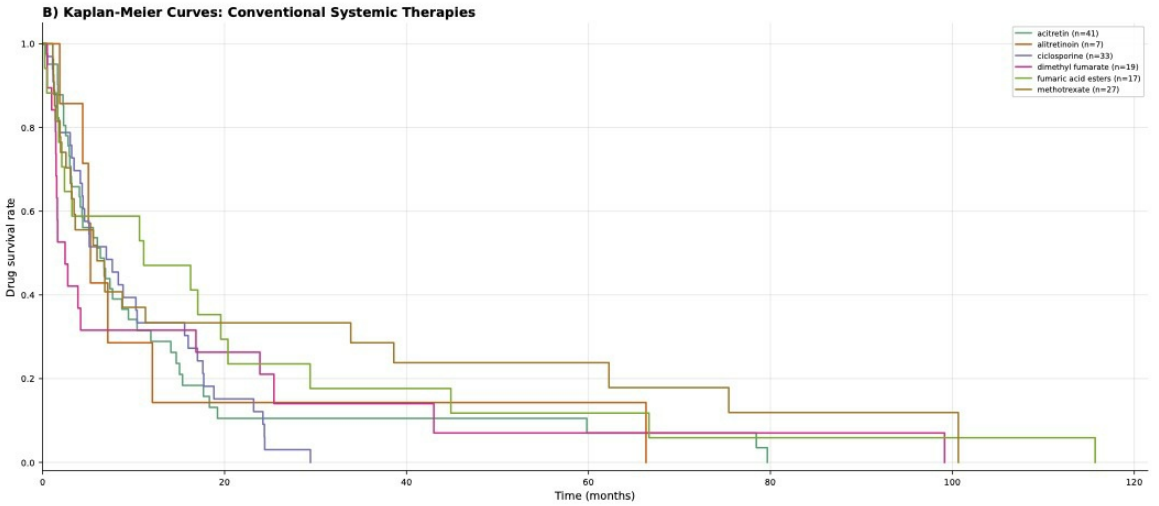

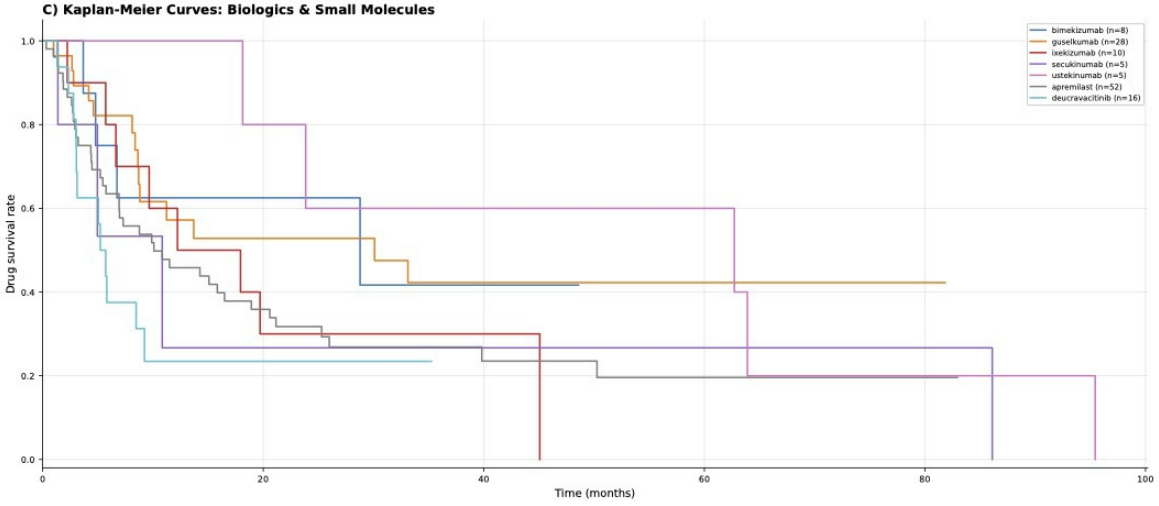

Figure 1 (A-C): Real-world treatment pathways and class-specific drug survival in pustulosis palmoplantaris. Figure showing (A) treatment pathways and (B–C) class-specific drug survival in patients with pustulosis palmoplantaris. (A) Sankey diagram illustrating treatment sequences across consecutive therapy lines (L1–L4), demonstrating stepwise escalation from conventional systemic therapies to small molecules and biologics. Therapies with ≥4 treatment episodes are depicted. (B) Kaplan–Meier curves depicting drug survival of biologics and small molecules. (C) Kaplan–Meier curves depicting drug survival of conventional systemic therapies. Kaplan–Meier analyses include therapies with ≥5 treatment episodes. Biologics and targeted therapies demonstrate more sustained treatment persistence compared to conventional systemic therapies.

EADV CONGRESS
VIENNA
30 SEP - 3 OCT 2026

Abstract N°: 2574

When Annular Lichen Planus Masquerades as Disseminated Superficial Actinic Porokeratosis

Imene Mahiou*[1], Samira Zobiri[1]

[1] mustapha bacha hospital center, algiers, Algeria

Introduction

Annular lichen planus is a rare variant of lichen planus characterized by annular lesions with variable clinical morphology. Its atypical presentation may mimic several annular keratotic dermatoses, particularly Disseminated superficial actinic porokeratosis, leading to diagnostic delay and therapeutic challenges.

Case Presentation

A 53-year-old woman with a history of Rheumatoid arthritis treated with methylprednisolone 4 mg/day and methotrexate 15 mg/week presented with a 2-year history of a mildly pruritic eruption resistant to topical corticosteroids.

Dermatological examination revealed multiple annular erythematous-violaceous lesions ranging from 0.5 to 2 cm in diameter, with slightly raised keratotic borders, symmetrically distributed on the upper and lower limbs, with a few scattered lesions on the trunk. Clinical examination initially suggested Disseminated superficial actinic porokeratosis.

Dermoscopy demonstrated an irregular peripheral whitish hyperkeratotic rim associated with subtle reticular whitish structures suggestive of Wickham striae on a violaceous background.

Two skin biopsies revealed a lichenoid dermatitis pattern characterized by wedge-shaped hypergranulosis, basal vacuolar degeneration and a band-like lymphocytic infiltrate without evidence of cornoid lamella, supporting the diagnosis of Annular lichen planus.

The patient was treated with acitretin 25 mg/day with partial clinical



Multiple annular erythematous-violaceous keratotic plaques

Conclusion

Annular lichen planus is an uncommon subtype of lichen planus that may closely simulate porokeratosis both clinically and dermoscopically. In our patient, the annular morphology, disseminated distribution and peripheral keratotic rim strongly suggested DSAP. Dermoscopy further contributed to the diagnostic confusion by revealing a pseudo “white-track” appearance.

However, histopathological examination failed to demonstrate cornoid lamella and instead showed characteristic lichenoid changes, allowing exclusion of porokeratosis. This observation highlights the importance of clinicopathological correlation in atypical annular keratotic dermatoses.

The unusual morphology observed in our case may have been influenced by the patient’s underlying immune dysregulation and long-term immunomodulatory therapy.

Annular lichen planus should be considered among the differential diagnoses of disseminated annular keratotic dermatoses mimicking DSAP. Histopathological examination remains essential for accurate diagnosis in misleading clinical presentations.

EADV CONGRESS
VIENNA
30 SEP - 3 OCT 2026

Abstract N°: 2605

Follicular Mucinosis Presenting as a Sclerodermiform Dermatosis Mimicking Plaque Morphea: Diagnostic Pitfalls, Histopathological Reappraisal and the Importance of Clinicopathological Correlation

Bianca Beatrice Carausu*[1], Mădălina Mocanu[1], Laura Gheucă Solovăstru[1]

[1] "Sf. Spiridon" Emergency Clinical Hospital, Iasi, Romania

Introduction

Follicular mucinosis (FM) represents an uncommon inflammatory dermatosis characterized histopathologically by mucin accumulation within the follicular epithelium and pilosebaceous unit. Current evidence supports the concept of FM as a clinicopathological reaction pattern rather than a distinct nosological entity, encompassing both primary idiopathic forms and secondary variants associated with inflammatory, autoimmune or lymphoproliferative disorders, particularly mycosis fungoides. Clinically, FM usually manifests through follicular papules, infiltrated erythematous plaques and varying degrees of alopecia. Nevertheless, atypical morphologic variants, especially sclerodermiform presentations, remain rare and may closely simulate localized scleroderma or other infiltrative connective tissue disorders, thereby generating substantial diagnostic uncertainty and therapeutic dilemmas.

Case Presentation

We report the case of a 41-year-old female patient admitted in February 2025 for the evaluation of persistent infiltrative plaques with progressive evolution over approximately six months. Dermatological examination identified multiple erythematous-violaceous plaques involving the left arm and bilateral thighs, displaying irregular yet sharply demarcated borders, central dyschromia, dermal induration and tenderness on palpation. The patient additionally described diffuse xerosis and a subjective sensation of cutaneous tightening. Owing to the infiltrative pseudo-sclerotic morphology, the initial clinical impression strongly favored plaque morphea. Laboratory investigations demonstrated mild leukopenia, minimally elevated erythrocyte sedimentation rate and increased serum IgE levels, while acute-phase inflammatory markers, hepatic and renal function tests, calcium metabolism and viral serologies remained within normal limits. Histopathological evaluation of a punch biopsy specimen revealed discrete epidermal atrophy with rectilinear rete ridges, preservation of dermal collagen architecture and focal interstitial mucinous degeneration involving the dermis. A mild perifollicular and perivascular lymphocytic inflammatory infiltrate was identified, in the absence of dermal sclerosis, adnexal atrophy or collagen bundle homogenization typically associated with morphea. Integration of the clinicopathological findings established the diagnosis of follicular mucinosis. Initial therapeutic management included oral antihistamines, topical corticosteroids and urea-based emollients. Dapsone 25 mg twice daily was subsequently initiated for a three-month period, resulting in favorable clinical evolution with partial remission of the pre-existing lesions and absence of newly emerging elements. Progressive tapering and eventual discontinuation of Dapsone became necessary because of significant gastrointestinal adverse effects. A notable therapeutic particularity of the case was the decision to avoid minocycline administration, despite its inclusion among first-line therapeutic options in several protocols, owing to the patient's history of two previous anaphylactic shocks triggered by an antibiotic and an anesthetic agents. During 12 months of follow-up, no additional lesions developed. Furthermore, associated alopecia demonstrated complete resolution following topical corticosteroid therapy combined with anti-hair loss and regenerative dermatocosmetic products.

Conclusion

This case illustrates a diagnostically challenging and clinically deceptive presentation of follicular mucinosis with prominent sclerodermiform features mimicking plaque morphea. The discordance between the initial clinical diagnosis and the definitive histopathological interpretation underscores the pivotal importance of meticulous clinicopathological correlation in atypical infiltrative dermatoses. Recognition of FM as a potential morphologic simulator of localized scleroderma is essential for preventing diagnostic misclassification, inappropriate therapeutic escalation and inaccurate prognostic assessment.

EADV CONGRESS
VIENNA
30 SEP - 3 OCT 2026

Abstract N°: 2617

Unilateral Laterothoracic Exanthem in an Adult: A Rare and Misdiagnosed Entity

Ahd Jday*[1], mariem tabka[1], Feryel Amri[1], Houda Abdelwahed[1], Asmahane Souissi[1], Mourad Mokni[1]

[1] Dermatology Department, Rabta Hospital, Tunis, Tunisia

Introduction

Unilateral laterothoracic exanthem (ULE), also known as asymmetric periflexural exanthem of childhood, is a self-limiting dermatosis characterized by a unilateral maculopapular eruption. It typically begins in the axillary or inguinal regions and extends centrifugally. Although its exact etiology remains unclear, a viral trigger has been proposed. While well-documented in pediatric populations, cases in adults are rare, posing a significant diagnostic challenge. We report an unusual case of ULE in a 30-year-old woman, highlighting its clinical presentation and diagnostic features.

Case Presentation

A 30-year-old woman with no significant medical history presented with a five-day history of a right laterothoracic maculopapular exanthem. The eruption had a sudden onset in the mid-thoracic region before rapidly extending to the right axillary fold and the dorsal area. The patient reported pruritus and a burning sensation. Clinical examination revealed well-demarcated erythematous infiltrated plaques with a papular surface and scattered vesicles. Over time, the lesions showed a markedly asymmetric extension to the contralateral side, involving the inguinal folds and popliteal fossae. No fever, lymphadenopathy, or enanthem was observed. Laboratory investigations revealed mild hepatic cytolysis, while serological tests for hepatitis B, C, HIV, CMV, EBV, and COVID-19 were negative. The patient was treated with oral antihistamines and topical corticosteroids. The eruption resolved completely within three weeks without residual scarring.

Conclusion

ULE is increasingly recognized in adults, although it remains rare. In this age group, the condition may present with more pronounced pruritus and a greater likelihood of bilateral, yet still asymmetric, involvement. The etiology is often linked to viral infections such as parvovirus B19, HHV-6, or Epstein–Barr virus, or to immune-mediated responses, including post-vaccination reactions. ULE is generally a self-limiting condition with a favorable prognosis, and symptomatic treatment is usually sufficient to achieve complete resolution within a few weeks. The diagnosis is primarily clinical and unnecessary investigations should be avoided.
This case illustrates the importance of recognizing ULE in adults. While its presentation is similar to the pediatric form, variations such as pronounced pruritus and potential bilateral extension can complicate the diagnosis.

EADV CONGRESS
VIENNA
30 SEP - 3 OCT 2026

Abstract N°: 2619

Paraneoplastic Sweet Syndrome Revealing Recurrence of Vulvar Squamous Cell Carcinoma: An Unusual Diagnostic Challenge

MOHAMED HOUBAYELI*[1], layla bendaoud[2], Nouhaila Bourht[2], Mariem Aboudourib[2], Ouafa Hocar[2], Amal Said[2]

[1] Mohammed VI University Hospital of Marrakech, Bioscience and Health Laboratory, Department of Dermatology Venerology, Marrakech, Morocco, marrakech, Morocco

[2] Mohammed VI University Hospital of Marrakech, Bioscience and Health Laboratory, Department of Dermatology Venerology, marrakech, Morocco

Introduction

Sweet syndrome, also known as acute febrile neutrophilic dermatosis, is an uncommon inflammatory disorder characterized by the abrupt onset of painful erythematous plaques or nodules associated with dense neutrophilic dermal infiltration on histopathology. Malignancy-associated Sweet syndrome accounts for approximately 15–20% of cases and is predominantly associated with hematologic malignancies, whereas associations with solid tumors remain uncommon. We report a rare case of paraneoplastic Sweet syndrome occurring in the setting of recurrent vulvar squamous cell carcinoma.

Case Presentation

A 60-year-old woman with a history of surgically treated vulvar squamous cell carcinoma was admitted for tumor recurrence. A dermatology consultation was requested for rapidly progressive skin lesions of the right hand evolving over six days, associated with asthenia without fever.

Dermatological examination revealed multiple erythematous-violaceous annular nodules and plaques located on the dorsal aspect of the right hand, some displaying a pseudo-vesicular surface with central clearing. The lesions were infiltrated and non-tender on palpation. No mucosal involvement was observed. General examination showed a hemodynamically and respiratory stable patient.

Differential diagnoses included cutaneous leishmaniasis and neutrophilic dermatosis. Laboratory investigations revealed inflammatory syndrome without evidence of infection. Skin biopsy demonstrated a dense dermal neutrophilic infiltrate without vasculitis, consistent with Sweet syndrome. Direct parasitological examination was negative. In the context of concomitant recurrence of vulvar carcinoma, the diagnosis of paraneoplastic Sweet syndrome associated with recurrent vulvar squamous cell carcinoma was retained.

Systemic corticosteroid therapy was initiated, leading to rapid and marked clinical improvement of the cutaneous lesions.

Conclusion

Malignancy-associated Sweet syndrome is most frequently linked to hematologic neoplasms, while associations with gynecologic solid tumors are exceptionally rare. The underlying pathophysiology remains incompletely understood but is thought to involve cytokine dysregulation and tumor-induced neutrophilic activation.

This observation highlights the importance of recognizing atypical neutrophilic dermatoses as potential cutaneous markers of underlying or recurrent malignancy. Histopathological confirmation is essential to exclude infectious mimickers, particularly in endemic regions for cutaneous leishmaniasis. The rapid response to corticosteroid

therapy further supported the diagnosis.

Paraneoplastic Sweet syndrome may represent an early cutaneous indicator of recurrence in patients with solid malignancies. Recognition of this entity is essential to avoid diagnostic delay and to promptly initiate both oncologic assessment and corticosteroid therapy, resulting in rapid clinical improvement and earlier detection of tumor progression.

EA DV CONGRESS
VIENNA
30 SEP - 3 OCT 2026

Abstract N°: 2645

Prognostic value of corneometry in assessing the course of rosacea and correlation with the intensity of erythema.

Khrystyna Nykolaichuk*[1]

[1] Ivano-Frankivsk National Medical University, Ivano-Frankivsk, Ukraine

Introduction

Rosacea is a chronic dermatosis characterized by a complex interaction among vascular disorders, neurogenic inflammation, and epidermal barrier dysfunction. One of the key indicators of the state of the stratum corneum is the level of its hydration. Violation of the skin's moisture-retaining properties not only intensifies the patient's subjective sensations (burning, tightness, tingling, and itching) but also triggers exacerbation of the inflammatory process.

Despite extensive study of the clinical forms of rosacea, the search for objective biophysical markers that would allow predicting the further development of the disease and assessing the effectiveness of therapy remains a priority in dermatology. Corneometry, a non-invasive method for assessing skin electrical conductivity, enables the quantitative determination of epidermal hydration in real time.

Objective: to assess the skin condition of patients with rosacea, considering the severity of centrofacial erythema and skin hydration, to develop prognostic criteria for the course of the disease, and to optimize treatment.

Materials and Methods

During 2024-2026, we examined 89 patients aged 28-68 years with rosacea (53 with erythematotelangiectatic and 36 with papulopustular phenotypes). The duration of dermatosis ranged from 0 to 17 years.

For the assessment of the skin condition, we used:

1. The CEA scale (Clinician Erythema Assessment) – to determine the intensity of erythema.
2. The corneometry using the BT-Analyzer at standardized facial points of cheeks under controlled environmental conditions for the evaluation of the stratum corneum hydration state.
3. Non-contact (polarized) dermoscopy by the Heine Delta 30 dermatoscope to find out the specific patterns.
4. Statistical analysis of the obtained data using Spearman's correlation and multivariate ordinal logistic regression analyses.

Results

In 35,96% of participants (32 patients), we observed grade 2 erythema, and in 55,05% (49 patients), grade 3. Corneometry values indicated significant xerosis in all patients with rosacea. Critically low skin moisture - less than 30 % (Me=14%, $[Q_1\text{-}Q_3]$=12-17 %) corresponded to dermatoscopic findings of skin dehydration in 70.79 %of participants (diffuse white scales that obscure the underlying vascular structures, blurred looped vessels, exaggerated skin furrows, and fine lines). Correlation analysis revealed a moderate negative association (r = -0.548; p = 0.001) between the degree of erythema and skin hydration level. The more severe the erythema, the lower the hydration level. The regression model showed that a 1% increase in skin moisture level reduces the risk

of severe erythema by 47%.

Conclusions

In patients with rosacea, reduced stratum corneum hydration indicates transepidermal water loss, leading to systemic impairment of the skin barrier and the release of pro-inflammatory cytokines, which, in turn, support vasodilation and enhance erythema. We found a correlation between the degree of dehydration and the severity of erythema: the lower the corneometry score, the more intense the facial redness. Therefore, it emphasizes the need to restore the skin barrier as a priority therapeutic strategy in the management of rosacea.

Regarding corneometry in rosacea, it is not just a method for measuring moisture. It is a predictive analysis tool that allows assessment of the epidermal barrier before clinical symptoms become critical, determining the exacerbation risk in the early stages. In addition, its results can be used to assess treatment efficacy. The lack of dynamics to increase the level of moisture against the background of rosacea therapy is a harbinger of rapid relapse or resistance to treatment.

EADV CONGRESS
VIENNA
30 SEP - 3 OCT 2026

Abstract N°: 2648

STIGMATIZATION IN PATIENTS WITH CHRONIC SKIN DISEASES: HIDRADENITIS SUPPURATIVA, PSORIASIS AND ATOPIC DERMATITIS

Mateja Dolenc Voljc*[1, 2], Manca Škulj[2], Bor Hrvatin Stančič[1, 2]

[1] Department of Dermatovenereology, University Medical Centre Ljubljana, Ljubljana, Slovenia
[2] Faculty of Medicine, University of Ljubljana, Ljubljana, Slovenia

Introduction

Chronic skin diseases impose a significant psychosocial burden, frequently accompanied by stigmatization, an impact often regarded as even more distressing than the physical symptoms. Patients with hidradenitis suppurativa (HS), psoriasis and atopic dermatitis (AD) report substantially higher stigmatization compared to healthy controls, leading to increased rates of depression, anxiety, social isolation, and diminished quality of life (QoL).

Materials and Methods

This prospective clinical study aimed to investigate internal and external stigmatization using the PUSH-D tool in a cohort of 64 patients with HS, 54 patients with psoriasis and 49 patients with AD, and to analyse its correlation with disease severity, gender, and QoL as measured by the Dermatology Life Quality Index (DLQI). Disease severity was assessed using standardized scores (IHS4 for HS, PASI for psoriasis and EASI for AD). Patients were categorized into three severity groups according to internationally accepted standards. For HS, mild disease was defined as IHS4 $\leq$ 3, moderate as IHS4 4-10, and severe as IHS4 $\geq$ 11. For psoriasis, mild disease corresponded to PASI < 10, moderate to PASI 10-20, and severe to PASI > 21. For AD, mild disease was defined as EASI < 7, moderate as EASI 7.1-21, and severe as EASI 21.1-50. All clinical and questionnaire data were systematically recorded in a structured spreadsheet. Statistical analyses were performed in Excel and R-Studio.

Results

We included a total of 167 patients (77 males, 90 females). Student's t-test for independent samples revealed significant inter-disease age differences: psoriasis patients were significantly older than both HS (p=0.020) and AD (p=0.000) patients, while HS patients were significantly older than those with AD (p=0.001). No statistically significant age differences were found between genders within any of the three disease groups (p=0.491 for AD, p=0.179 for psoriasis, p=0.206 for HS).

In HS, PUSH-D scores varied significantly according to disease severity (p=0.046, Kruskal–Wallis), with the highest median score observed in patients with severe disease. PUSH-D scores did not differ significantly across severity categories in either psoriasis (p=0.313) or AD (p=0.527). Although internal stigmatisation tended to be lower than external across all cohorts, no significant correlation was observed when analysing PUSH-D subscales for external stigmatisation (HS p=0.424; psoriasis p=0.465; AD p=0.280) and internal stigmatization (HS p=0.068; psoriasis p=0.132; AD p=0.128). Women reported higher median PUSH-D scores across all three diseases, but differences were not statistically significant (HS p=0.148; psoriasis p=0.446; AD p=0.082; Mann-Whitney U).

A significant positive association between PUSH-D and DLQI was demonstrated across all three conditions, with Spearman's correlation coefficients of r=0.63 ($p=2.44 \times 10^{-8}$) in HS, r=0.76 ($p=2.66 \times 10^{-11}$) in psoriasis and r=0.42 (p=0.003) in AD. QoL was significantly worse for women in the psoriasis cohort (p=0.037) and showed a similar non-significant trend in HS (p=0.316) and AD (p=0.231). Overall, HS patients experienced the poorest QoL among the three conditions. In HS patients, higher median PUSH-D scores were observed with longer disease

duration (p=0.026, Kruskal–Wallis).

Conclusions

This study highlights the complex nature of stigmatization in HS, psoriasis and AD. The highest levels were observed in patients with severe HS, whereas this pattern was not evident in psoriasis or AD. Stigmatization was consistently associated with poorer QoL. Notably, in HS, stigmatization increased significantly with longer disease duration.

These findings underscore the absolute necessity of routine screening for stigmatization and psychosocial distress in all patients with HS, psoriasis and AD, independent of their objective disease severity, to facilitate targeted psychosocial interventions and to improve holistic patient care.

EA DV CONGRESS
VIENNA
30 SEP - 3 OCT 2026

Abstract N°: 2650

Severe Generalized Pustular Psoriasis in a pediatric patient triggered by systemic corticosteroid therapy: diagnostic challenge with Acute Generalized Exanthematous Pustulosis

Alícia Mendes*[1], Angela Mendes[1], Cassiano Gomes[1], Carolina Okada[1], Maria Laura Malzoni[1], Maria Fernanda Addor[1]

[1] Pontifícia Universidade Católica de São Paulo- campus Sorocaba, Sorocaba, Brazil

Introduction

Generalized Pustular Psoriasis (GPP) is a rare and potentially life-threatening variant of psoriasis, associated with the dysregulation of the interleukin-36 (IL-36) pathway and a significant systemic neutrophilic inflammatory response. It is characterized by the abrupt onset of diffuse erythema, sterile pustules, and severe systemic inflammation. Systemic corticosteroid therapy is recognized as a potential trigger for severe forms due to the inflammatory rebound effect. The differential diagnosis with Acute Generalized Exanthematous Pustulosis (AGEP) remains challenging due to the clinical and histopathological overlap between the two entities. We report a severe case of pediatric GPP triggered by systemic corticosteroids, initially interpreted as AGEP.

Case Presentation

A 14-year-old female patient with a history of inverse psoriasis developed a diffuse pustular eruption following systemic corticosteroid therapy. The eruption began in the inguinal region and progressed rapidly over eight days to involve the entire integument, associated with fever, intense pain, and disabling arthralgia. Upon dermatological examination, she presented with erythematous plaques and macules with multiple sterile pustules, subsequently involving the face, palms, soles, and mucosa, along with significant facial edema and exulcerated areas.

Laboratory tests revealed marked leukocytosis (26,600/mm^3) and elevated liver enzymes. The initial histopathology showed intraepidermal pustules, spongiosis, and a neutrophilic infiltrate with eosinophils, suggesting AGEP. However, given the sustained clinical progression, the absence of exposure to classically related drugs, and the prior history of psoriasis, a histopathological review was performed, confirming the diagnosis of Generalized Pustular Psoriasis.

The patient's systemic condition progressively worsened, requiring admission to a Pediatric Intensive Care Unit (PICU). Initially treated with methotrexate and corticosteroids, she developed hepatotoxicity and showed insufficient response. Cyclosporine was then introduced with partial improvement. Following a clinical relapse and the onset of adverse effects related to immunosuppressive treatment, adalimumab was initiated. This resulted in a rapid and sustained clinical response, allowing for the progressive withdrawal of previous therapies.

Conclusion

The present case highlights the potential of systemic corticosteroid therapy as a trigger for severe and potentially fatal forms of Generalized Pustular Psoriasis, especially in pediatric patients. Furthermore, it reinforces the diagnostic complexity regarding AGEP, emphasizing the importance of clinicopathological correlation and histopathological review in challenging cases. The favorable outcome after escalating to biological therapy also underscores the growing role of immunobiologics in managing severe and refractory forms of the disease, contributing to reduced morbidity and the possibility of therapeutic de-escalation in highly complex patients.

EADV Congress 2026, VIENNA
30 SEPTEMBER - 03 OCTOBER 2026
POWERED BY M-ANAGE.COM

EA DV CONGRESS
VIENNA
30 SEP - 3 OCT 2026

Abstract N°: 2668

Cardiovascular Risk and Mortality In Patients with Hidradenitis Suppurativa: A Systematic Review and Meta-Analysis of Observational Studies

Sümeyye Aktaş*[1], Athanasios Stefanis[2], Laura Ghanem[3], Hasan Emre İlgenli[1], Victoria Zecchin Ferrara[4], İlkay Özer[1], Recep Dursun[1], Selami Aykut Temiz[1], Amor Khachemoune[5]

[1] Necmettin Erbakan University Faculty of Medicine Dermatology Department, Konya, Türkiye

[2] Third Faculty of Medicine, Charles University, Prague, Czechia. Czech Republic, Prague, Czech Republic

[3] Faculty of Medical Sciences, Lebanese University, Beirut, Lebanon, Beirut, Lebanon

[4] Faculty of Medicine and Surgery, University of Padua, Padua, Italy, Padua, Italy

[5] Department of Dermatology, International School of Medicine, Istanbul Medipol University, Istanbul, Turkey, Istanbul, Türkiye

Introduction

Hidradenitis suppurativa (HS) is a chronic inflammatory dermatosis characterized by painful, deep-seated nodules, abscesses, and sinus tract formation. HS is associated with multiple comorbidities that substantially impair quality of life. Inflammatory dermatoses, such as psoriasis, are well established as conditions associated with increased cardiovascular risk; similarly, HS may confer an elevated risk of mortality and cardiovascular events. This study aims to elucidate the burden of cardiovascular events and all-cause mortality (ACM) among patients with HS.

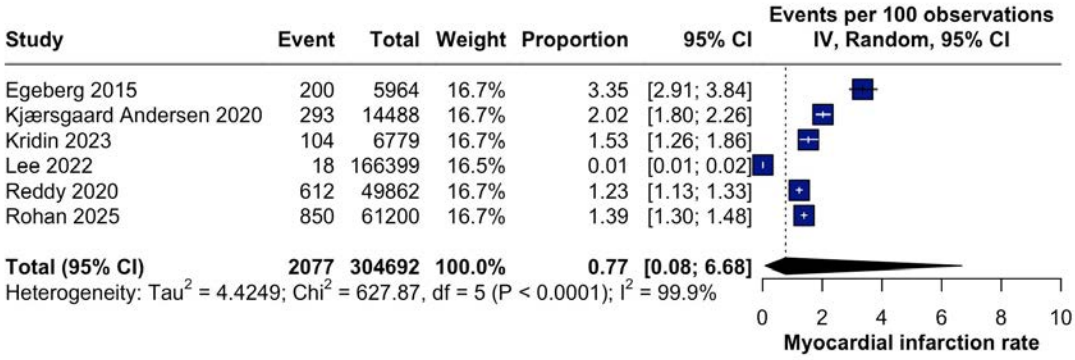

Figure 1: Myocardial infarction incidence was found 0.77% (95% CI= 0.08–6.68; I2= 99.9).

Materials and Methods

A comprehensive literature search was conducted across PubMed, Embase, Cochrane Library, and Web of Sience databases. This study adhered to the Preferred Reporting Items for Systematic Reviews and Meta-Analyses (PRISMA) and the Meta-analysis of Observational Studies in Epidemiology (MOOSE) guidelines. Statistical analyses were performed using RStudio software, applying a proportional meta-analytic approach. Leave-one-out sensitivity analyses were conducted to assess the source of heterogeneity when it was high. The primary outcomes included ACM, 5-year mortality, and cardiovascular events, including myocardial infarction (MI), major adverse cardiovascular events (MACE), coronary artery disease (CAD), and cerebrovascular events (including ischemic and hemorrhagic stroke).

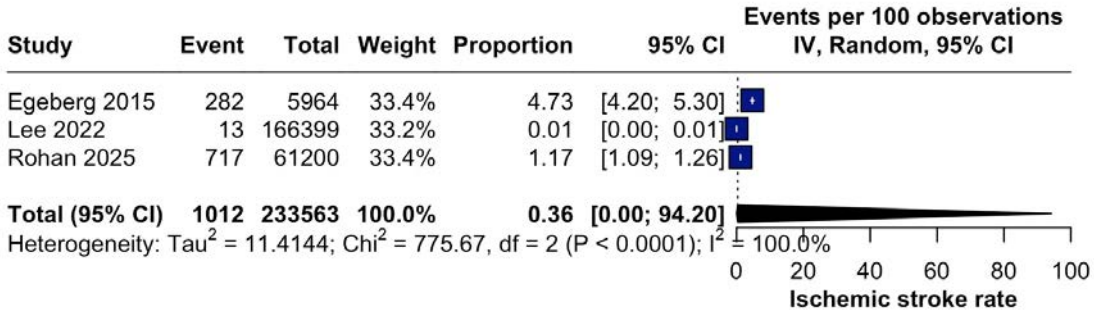

Figure 2:Ischemic stroke incidence was found %0.36 (95% CI= 0.00-94.20; I2= 100.0)

Results

13 studies comprising 340,629 patients met the predefined eligibility criteria, of which 10 were included in the meta-analysis. Considerable variability in mortality and cardiovascular outcomes was observed across studies. The pooled incidence of ACM among patients with HS was 4.44% (95% CI= 0.56–27.87; I^2= 99.9). The estimated 5-year mortality was 1.84%(95% CI= 0.95-3.54; I^2=92.9).The pooled incidence of CAD was 3.97% (95% CI= 0.41-29.17; I^2= 69.2),while the cardiac mortality rate was 0.98% (95% CI: 0.05-16.72; I^2= 99.7).The incidence of cerebrovascular events was 0.97% (95% CI= 0.46-2.03; I^2= 91.8); with ischemic stroke at %0.36 (95% CI= 0.00-94.20; I^2= 100.0) and hemorrhagic stroke at%0.06 (95% CI= 0.00-100.0; I^2= 99.5).MACEs occurred in 6.80% of patients (95% CI= 0.08-87.53; I^2= 99.6), and the pooled incidence of MI was 0.77% (95% CI= 0.08–6.68; I^2= 99.9).

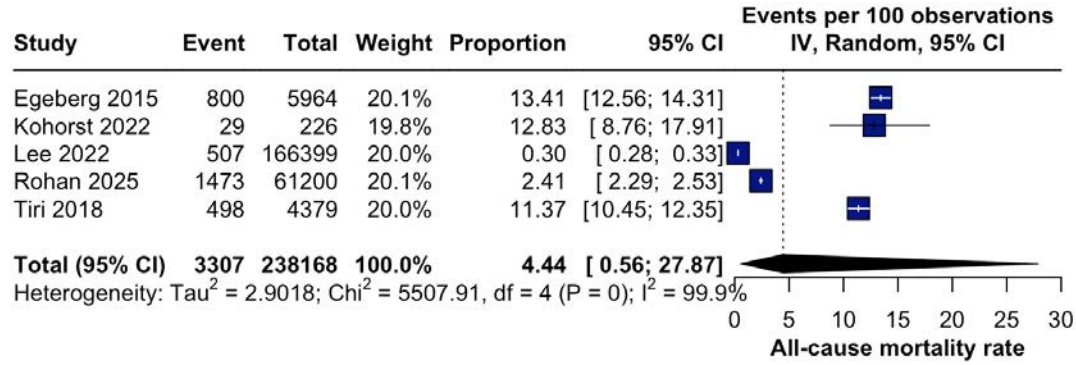

Figure 3:Incidence of ACM among patients with HS was found 4.44% (95% CI= 0.56–27.87; I2= 99.9).

Conclusions

Patients with HS appear to have a burden of cardiovascular events and mortality. These findings support the need for cardiovascular risk assessment and appropriate screening in this population.

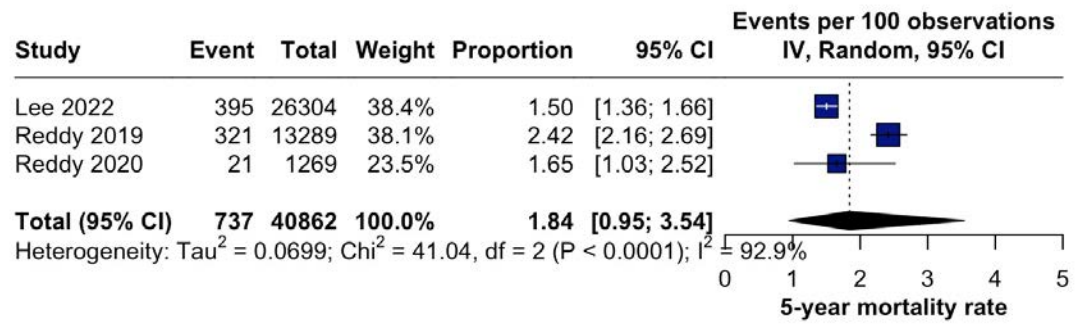

Figure 4:The estimated 5-year mortality was found 1.84%(95% CI= 0.95-3.54; I2=92.9).

EADV CONGRESS
VIENNA
30 SEP - 3 OCT 2026

Abstract N°: 2682

Enoxaparin in Recalcitrant Disseminated Lichen Planus: Complete and Sustained Clinical Response in a Patient with Contraindications to Standard Therapy

Doménica Cerón Chimarro*[1], Mayara Araújo Brilhante[1], Maria Fernanda Rangel de Vasconcellos Guerra[1], Julia de Oliveira Barcaui[1], Arles Martins Brotas[1]

[1] Pedro Ernesto University Hospital, State University of Rio de Janeiro (UERJ), Rio de Janeiro, Brazil

Introduction

Lichen planus (LP) is a T cell-mediated inflammatory dermatosis with a well-established immunopathological mechanism involving heparanase overexpression, CD8+ lymphocyte infiltration, and basal layer damage. Standard systemic therapy relies on corticosteroids, which carry significant risks in patients with comorbidities. Enoxaparin, a low molecular weight heparin (LMWH), has emerged as an alternative with anti-inflammatory properties independent of its anticoagulant effect, representing a viable option when conventional therapies are contraindicated. We report a case of recalcitrant disseminated LP with complete and sustained clinical response to enoxaparin in a patient with multiple contraindications to conventional systemic therapies, discussing the mechanistic rationale for this therapeutic choice.

Case Presentation

A 60-year-old female nurse presented with a 3-month history of disseminated pruritic erythematous-violaceous polygonal papules involving the trunk and limbs, sparing the face. She had a prior biopsy-confirmed diagnosis of LP. Current diagnosis was established clinically based on characteristic morphology and distribution. Hepatitis C serology was non-reactive. She had failed topical corticosteroids and antihistamines, and had used oral corticosteroids for approximately 2 years in an attempt to control prior LP flares, without sustained response. Relevant comorbidities included type 2 diabetes mellitus, dyslipidemia, cataract, and non-alcoholic fatty liver disease confirmed by abdominal ultrasound showing moderate hepatic steatosis with chronically elevated ALT at 83 U/L (reference: up to 41 U/L). This comorbidity profile precluded prolonged corticosteroid use, and hepatic steatosis with elevated liver enzymes additionally excluded methotrexate as a therapeutic option. Phototherapy was not feasible given the patient's residence approximately two hours from the treatment center. Current medications included simvastatin, metformin, omeprazole, and propranolol, which were maintained throughout treatment. Given the lack of viable systemic alternatives, enoxaparin 5 mg/week subcutaneously was initiated. After one month, lesions stabilized with persistent pruritus, prompting antihistamine optimization. By month three, approximately 80% reduction in pruritus was achieved alongside significant improvement of papular lesions. At month eight, only residual hyperpigmented macules remained and enoxaparin was discontinued. Modified Kligman formula was introduced for post-inflammatory dyschromia. No adverse events related to enoxaparin were recorded. The patient presented no new flares after 6 years of follow-up, demonstrating a sustained response.

Conclusion

This case demonstrates a complete and sustained clinical response to enoxaparin 5 mg/week in recalcitrant disseminated LP, supporting its role as a viable alternative in patients where standard systemic therapy is limited by comorbidities. The mechanistic basis involves competitive inhibition of heparanase by enoxaparin fragments,

preserving heparan sulfate integrity at the basement membrane and reducing CD8+ lymphocyte infiltration and pro-inflammatory cytokine release. These findings reinforce that pathophysiological knowledge should guide therapeutic decisions in complex dermatological cases. Low-dose weekly intermittent heparin may represent an additional option in the therapeutic arsenal, with a favorable safety profile and low cost. The potentially lichenoid medications (statins and beta-blockers) were maintained throughout treatment, as the clinical and histopathological features were consistent with idiopathic LP.

EA DV CONGRESS
VIENNA
30 SEP - 3 OCT 2026

Abstract N°: 2696

Repurposing Low-Dose Enoxaparin in Chronic Plaque Psoriasis: A Prospective Study Demonstrating Clinical Improvement and IL-17 Modulation

Hagar AL-Sharnoby*[1], Dalia Shaaban[1]

[1] Faculty of Medicine, Tanta, Egypt

Introduction
Psoriasis is a chronic immune-mediated inflammatory dermatosis driven by the IL-23/Th17 axis, with interleukin-17 (IL-17) playing a central pathogenic role. Despite advances in biologic therapies, accessibility remains limited in resource-constrained settings. Enoxaparin has demonstrated anti-inflammatory and immunomodulatory effects; however, its therapeutic role in psoriasis remains insufficiently explored.

Materials and Methods
In this prospective pilot study, 30 patients with chronic plaque psoriasis received subcutaneous enoxaparin 5 mg weekly for 6 weeks. Psoriasis severity was assessed by the Psoriasis Area and Severity Index (PASI) before and after treatment. Serum IL-17 was measured by ELISA at the same time points. Patients were followed up at 1 and 3 months. Safety was monitored clinically and by laboratory testing.

Results
Mean baseline PASI was 12.8 ± 5.7 (range 6.2–31.1). After 6 weeks, mean PASI declined to 7.4 ± 4.1 ($p<0.001$), corresponding to a 40.9% ± 21.8% reduction. At baseline, 43.3% of patients had moderate psoriasis (PASI 5–10), whereas 56.7% had severe disease (PASI >10). By the end of treatment, 30% of patients had mild psoriasis, 53.3% had moderate disease, and only 16.7% remained in the severe category. Clinical response was graded as excellent in 10%, moderate in 16.7%, mild in 50%, and poor in 20% of patients, while 3.3% showed no improvement. No patient demonstrated disease worsening following treatment.

Serum IL-17 levels declined from 18.6 ± 8.3 ng/mL to 17.0 ± 6.8 ng/mL ($p<0.001$), with a mean reduction of 1.6 ng/mL, paralleling clinical improvement. Post-treatment PASI scores positively correlated with serum IL-17 levels. In addition, PASI reduction positively correlated with IL-17 reduction ($r = 0.79$, $p<0.001$), indicating a parallel clinical and immunological response (Fig. 1).

Treatment was well tolerated, with no systemic adverse effects or laboratory abnormalities detected. Reported adverse events were limited to mild local injection-site reactions. At 3-month follow-up, mean PASI scores remained significantly lower than baseline values ($p<0.01$).

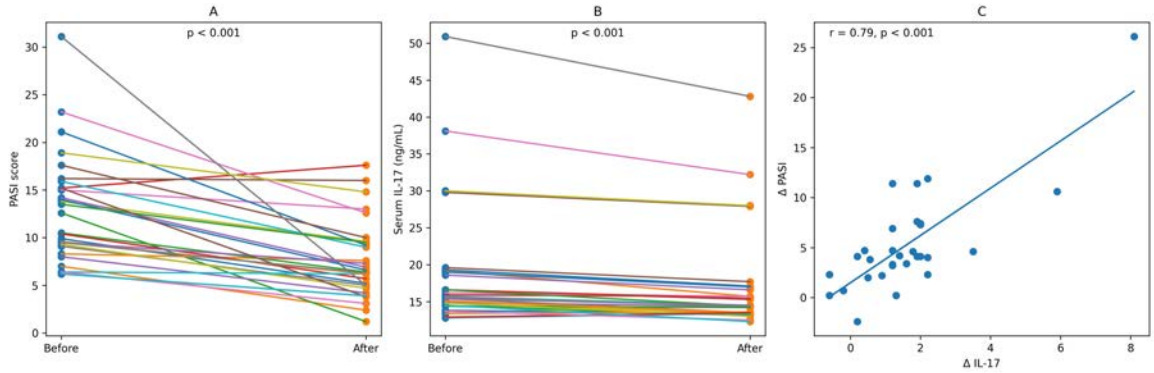

Figure 1. Clinical and immunological response to low-dose enoxaparin in psoriasis patients. (A) Significant reduction in PASI scores after 6 weeks of treatment ($p < 0.001$). (B) Significant decrease in serum IL-17 levels following therapy ($p < 0.001$). (C) Strong positive correlation between reduction in PASI score and IL-17 levels ($r = 0.79$, $p < 0.001$), supporting an immunomodulatory mechanism.

Conclusions

Low-dose enoxaparin produced significant clinical improvement and concomitant IL-17 reduction in chronic plaque psoriasis. These pilot data suggest that enoxaparin may be a cost-effective adjunctive therapy targeting the IL-17 pathway, especially where biologics are unavailable. Larger controlled trials are warranted to confirm efficacy and long-term safety.

EADV CONGRESS
VIENNA
30 SEP - 3 OCT 2026

Abstract N°: 2711

Successful Treatment of Cheilitis Granulomatosa with Upadacitinib in a 14-Year-Old Female with Mild Atopic Dermatitis

Rika Kluck*[1], Nikolaos Patsinakidis[1], Ulrike Raap[1]

[1] Universitätsklinik für Dermatologie, Klinikum Oldenburg, Oldenburg, Germany

Introduction

Cheilitis granulomatosa (CG) is a rare, chronic inflammatory condition of unknown etiology and represents a diagnostic and therapeutic challenge. The condition significantly impairs quality of life, and visible symptoms such as lip swelling may lead to teasing and social stigmatization. It may present as an isolated form or in association with systemic diseases such a Melkersson–Rosenthal syndrome, sarcoidosis or Crohn's disease. Conventional treatment options—such as corticosteroids, antibiotics, and immunosuppressive agents—often provide only partial or temporary relief and can be associated with significant adverse events.

Case Presentation

A 14-year-old female patient presented with a 1.5-year history of painful, persistent swelling of the lips accompanied by perioral dermatitis, causing significant social withdrawal and emotional distress. Previous treatments with various antibiotic and corticosteroid-containing topical agents had not been effective. The patient denied any other systemic complaints, and her personal and family history were negative for autoimmune diseases. Histopathological examination of a lip biopsy revealed granulomatous inflammation consistent with cheilitis granulomatosa. In addition, the patient had an atopic dermatitis since early childhood.

Upadacitinib, a selective Janus kinase 1 (JAK1) inhibitor, has been shown to be effective in several chronic inflammatory skin disorders, including atopic dermatitis and other granulomatous dermatoses. Given the refractory course and concomitant atopic dermatitis, therapy with upadacitinib 15 mg daily was initiated. Within approximately three months of treatment, a marked clinical improvement was observed, with significant reduction in lip swelling and resolution of discomfort. The therapy was well tolerated, and no adverse events occurred during follow-up. After tapering the dose to 15 mg every other day, mild worsening occurred, which resolved after re-escalation to 15 mg daily.

Conclusion

This case highlights the potential role of JAK1 inhibition as a targeted therapeutic approach for cheilitis granulomatosa, especially in patients unresponsive to conventional treatment. Further studies are warranted to better define its efficacy and safety in this rare condition.

EADV CONGRESS
VIENNA
30 SEP - 3 OCT 2026

Abstract N°: 2738

Late-onset PAPA syndrome with atypical clinical presentation: a case report

Eszter Jankovics*[1], Karolina Polgár[1], Anna Bátor[1], Katalin Lőcsei[1], Noémi Burkus[1], Éva Nagy[1], Nóra Megyes[2], Zsuzsanna Szakály[2], Eszter Varga[2], Csaba Gyömörei[3], Petra Görög[4], Csaba Tóth[4], Bernadette Kálmán[5], Enikő Telegdy[1]

[1] Department of Dermatology, Markusovszky University Teaching Hospital, Szombathely, Hungary
[2] Department of Reumatology, Markusovszky University Teaching Hospital, Szombathely, Hungary
[3] Department of Pathology, University of Pécs Clinical Centre, Pécs, Hungary
[4] Department of Pathology, Markusovszky University Teaching Hospital, Szombathely, Hungary
[5] János Szentágothai Research Centre, University of Pécs, Pécs, Hungary

Introduction

PAPA syndrome (pyogenic arthritis, pyoderma gangrenosum, acne) is a rare autosomal dominant autoinflammatory disease associated with mutations in the PSTPIP1 gene on chromosome 15. It typically presents in childhood or early adulthood. To present a case of PAPA syndrome with an unusually late onset and atypical clinical features.

Case Presentation

The case study is of a 49-year-old female patient under long-term rheumatological care. Clinical evaluation was supplemented by immunological, serological, and routine laboratory investigations, as well as histopathological examination (hematoxylin–eosin staining), direct immunofluorescence, and molecular genetic testing. In contrast to the typical course of the disease, symptoms appeared at the age of 45. The late onset and atypical presentation posed significant differential diagnosis
challenges. Due to the lack of a standardized treatment protocol, the patient received several systemic therapies, including methotrexate, methylprednisolone, hydroxychloroquine, and upadacitinib, without any satisfactory response. Biological therapies targeting TNF-α, IL-1, and IL-6 were subsequently initiated. Topical corticosteroids and tacrolimus were also applied. Following treatment, joint symptoms improved significantly, and cutaneous manifestations achieved remission.

Conclusion

This case is noteworthy due to the rarity of the disease, its atypical course, and the associated diagnostic difficulties. Early recognition, multidisciplinary collaboration, and individualized therapy are essential for improving patient quality of life.

EA DV CONGRESS
VIENNA
30 SEP - 3 OCT 2026

Abstract N°: 2757

Shared autoreactive T-cell responses across inflammatory skin diseases revealed by integrated humoral and cellular profiling

Yigit Köseoglu*[1], Christina Hillig[2, 3], Martin Meinel[2, 4], Felix Lauffer[5], Tilo Biedermann[1], Stefanie Eyerich[6, 7], Kilian Eyerich[6], Manja Jargosch[1], Natalie Garzorz-Stark[6]

[1] Department of Dermatology and Allergology, Technical University of Munich, Munich, Germany

[2] Department of Computational Health, Institute of Computational Biology, Helmholtz Munich, Neuherberg, Germany

[3] Department of Mathematics, Technical University of Munich, Munich, Germany

[4] Department of Biology, Ludwig-Maximilians University Munich, Martinsried, Germany

[5] Department of Dermatology and Allergy, LMU Hospital, Munich, Germany 6 Department of Dermatology and Venereology, University of Freiburg, Freibur, Munich, Germany

[6] Department of Dermatology and Venereology, Faculty of Medicine, University of Freiburg; Freiburg, Germany, Freiburg, Germany

[7] Institute for Immunodeficiency, Center for Chronic Immunodeficiency, Medical Center- University of Freiburg, Faculty of Medicine, University of Freiburg, Freiburg, Germany

Introduction

Inflammatory skin diseases (ISD), including psoriasis (Pso), atopic dermatitis (AD), and lichen planus (LP), are driven by dysregulated immune responses shaped by genetic and environmental factors. While these diseases are characterized by distinct immune polarization patterns, accumulating evidence suggests that autoreactive immune mechanisms contribute to their pathogenesis. In particular, T-cell responses against skin-derived autoantigens have been implicated across different ISD, although their distribution and disease specificity remain unclear.

Materials and Methods

To systematically investigate autoreactivity, we analyzed both humoral and cellular immune responses to a panel of known skin autoantigens in patients with Pso (n=15), AD (n=9), LP (n=10), and healthy donors (n=8). Circulating autoantibodies were assessed by ELISA, while antigen-specific T-cell responses were evaluated using CFSE-based proliferation assays. In addition, spatial transcriptomic data were examined to explore associations between autoantigen expression and disease-specific cytokine environments.

Results

Humoral autoreactivity against classical structural skin antigens was largely absent across all groups, with only minimal and non-diagnostic antibody levels detected. In contrast, antigen-specific T-cell proliferation was observed across all disease entities and also in healthy donors. The most frequent responses targeted KRT17 and ADAMTSL5, followed by BP180, DSG3, and α-NAC, with overlapping reactivity patterns across diseases. Individual patients, particularly in Pso and LP, frequently exhibited responses to multiple autoantigens, whereas AD patients and healthy donors showed fewer concurrent responses. Despite this broad autoreactivity, neither the number of recognized autoantigens nor proliferation rates showed consistent correlations with disease duration or clinical severity. Spatial transcriptomic analyses revealed that candidate autoantigens are predominantly expressed in epidermal compartments and their expression correlates with disease-specific cytokine signatures, suggesting that inflammatory microenvironments may enhance antigen availability and promote T-cell activation.

Conclusions

In conclusion, inflammatory skin diseases are not characterized by disease-specific humoral autoreactivity but rather by shared and overlapping T-cell responses against multiple skin autoantigens. These findings support a model of antigen spreading driven by chronic inflammation rather than the presence of distinct disease-defining autoantigens, highlighting autoreactive T cells as a

common feature across ISD.

EADV CONGRESS
VIENNA
30 SEP - 3 OCT 2026

Abstract N°: 2776

Early and Sustained Dual Disease Control With Bimekizumab in Psoriasis and Hidradenitis Suppurativa Overlap Syndrome: A Real-Life Case

Merve Akay*[1], Gülhan Aksoy Saraç[1], Merve Kaya[1]

[1] Ankara Bilkent Şehir Hastanesi, Ankara, Türkiye

Introduction

Psoriasis and hidradenitis suppurativa (HS) are chronic, immune-mediated inflammatory skin diseases that may substantially impair quality of life and are frequently associated with systemic comorbidities, including obesity and metabolic syndrome. Although they are traditionally considered distinct entities, both conditions share overlapping inflammatory pathways involving innate immune activation, neutrophilic inflammation, keratinocyte dysregulation, and the interleukin-17 (IL-17) axis. Their coexistence may represent a difficult-to-treat phenotype, particularly in patients with extensive skin involvement, metabolic comorbidity, and previous exposure to conventional systemic therapies. Bimekizumab, a monoclonal antibody selectively inhibiting IL-17A and IL-17F, may provide broad suppression of IL-17-mediated inflammation. Real-life evidence regarding its use in patients with concomitant psoriasis and HS remains limited.

Case Presentation

A 30-year-old male patient with an 8-year history of biopsy-confirmed psoriasis, concomitant HS, and metabolic syndrome was evaluated for systemic treatment. Previous therapies included topical corticosteroids, acitretin, and methotrexate; however, disease control was insufficient and treatment continuity had been limited by access-related issues. At baseline, the Psoriasis Area and Severity Index score was 10.8. Physical examination revealed widespread erythematous scaly papules and plaques involving the scalp, ears, face, trunk, upper and lower extremities, with predominantly guttate morphology and thicker plaques on extensor surfaces. Inflammatory nodules, scars, and postinflammatory changes consistent with HS were also present in the axillary and truncal regions. Before biologic therapy, routine laboratory screening and infectious disease evaluation were performed. Because previous laboratory testing showed elevated hemoglobin and hematocrit values suggestive of possible secondary polycythemia, the patient was evaluated by internal medicine and treatment approval was obtained. Bimekizumab was initiated according to the approved loading regimen.

Marked clinical improvement was observed as early as the first month of therapy, with flattening of plaques and regression of erythema and scaling. By week 12, near-complete clearance of active psoriatic lesions was achieved, with only residual postinflammatory hyperpigmentation in previously involved areas. Scalp and auricular lesions showed marked resolution, and diffuse truncal and lower extremity lesions were no longer clinically active. HS-related inflammatory activity also decreased, while residual scars and postinflammatory changes persisted. Laboratory monitoring supported the clinical improvement: C-reactive protein decreased from 26.3 mg/L to <0.5 mg/L, and erythrocyte sedimentation rate remained within the normal range, decreasing from 7 mm/h to 5 mm/h. Renal and hepatic parameters remained within normal limits, and no treatment-limiting laboratory abnormality was observed.

Conclusion

This case highlights the potential role of bimekizumab as an effective therapeutic option in patients with concomitant psoriasis and HS, particularly in difficult-to-treat phenotypes with high inflammatory burden,

metabolic comorbidity, and previous systemic treatment exposure. Dual inhibition of IL-17A and IL-17F may provide rapid and sustained control of both psoriatic and HS-related inflammatory lesions. Real-life cases may contribute to the growing evidence supporting IL-17A/F blockade in overlapping inflammatory dermatoses.

EADV CONGRESS
VIENNA
30 SEP - 3 OCT 2026

Abstract N°: 2777

Molecular Transcriptomics-Guided Treatment Selection in a Case of Palmar Psoriasis

Alexandra Junge*[1], Nikhil Yawalkar[1], Simone Cazzaniga[1, 2], Antoine Girardin[3], Jeremy Di Domizio[3], Michel Gilliet[3], Christoph Schlapbach[1]

[1] Department of Dermatology, Inselspital, Bern University Hospital, Bern, Switzerland

[2] Centro Studi GISED, Bergamo, Italy

[3] Department of Dermatology, CHUV, Lausanne University Hospital, Lausanne, Switzerland

Introduction

Palmoplantar inflammatory dermatoses are often difficult to classify, as eczema and psoriasis of the palms and soles may present with substantial clinical and histological overlap. This diagnostic uncertainty is clinically relevant, since for biologic treatment selection identifying the dominant inflammatory pathway is essential for treatment success.

Case Presentation

We report of a 25-year-old male electrician, who was referred to our center with a two-year history of pruritic, sharply demarcated erythematous plaques with coarse lamellar scaling isolated on the left hand. There was no sustained improvement with topical corticosteroids. Fungal infection was excluded by polymerase chain reaction (PCR) of skin scrapings and patch testing revealed no type-IV sensitization. The patient had a history of allergic rhinoconjunctivitis. Clinically, the differential diagnosis included hyperkeratotic hand eczema, palmoplantar psoriasis, or an eczema–psoriasis overlap phenotype.

Several different therapeutic approaches were attempted. Oral alitretinoin did not lead to relevant improvement. Oral ciclosporin resulted in a partial regression of the skin lesions, but no sustained complete remission. Additionally, topical delgocitinib cream as an add-on therapy also failed to achieve full symptom control.

To identify the underlying inflammatory pattern, NanoString-based transcriptomic profiling was performed on a skin biopsy (Figure 1). In the heatmap analysis, the sample clustered with psoriasis sentinel profiles. Similarly, UMAP visualization showed clear proximity to psoriasis samples and module-score analysis demonstrated a strong Th17-dominant immune signature. Based on this molecular profile, treatment with the IL-17A/F inhibitor bimekizumab was initiated subcutaneously. After five months of treatment, the patient achieved complete and sustained clearance of symptoms.

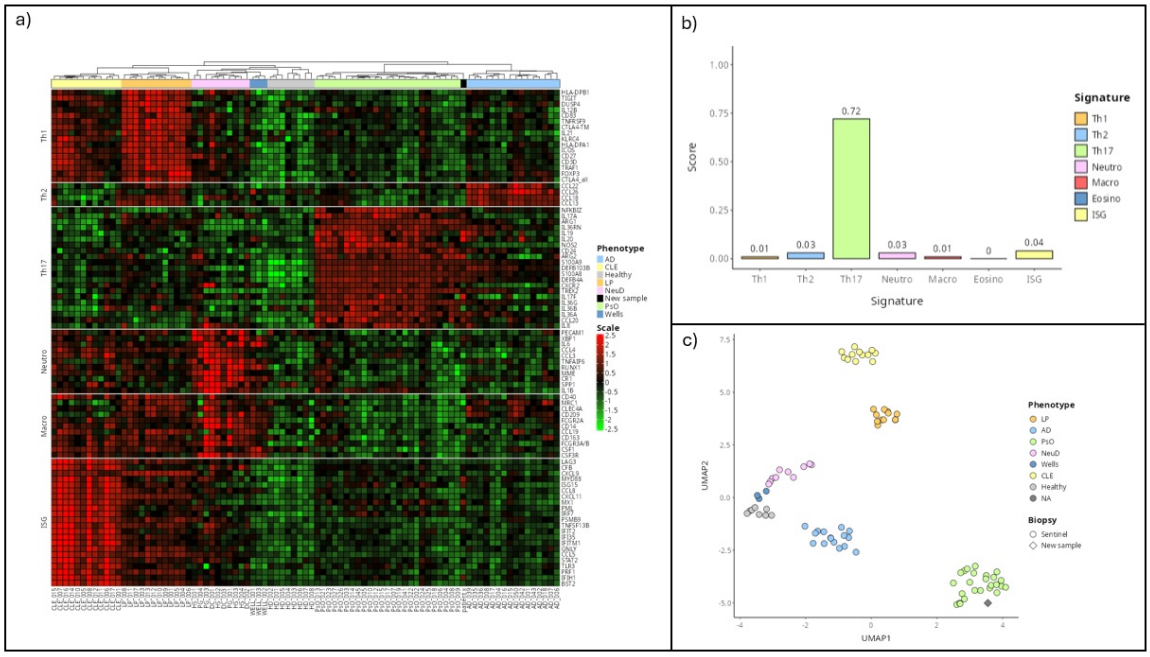

Figure 1. a) Unsupervised hierarchical clustering heatmap of predefined inflammatory gene signatures across reference samples and the patient sample. The patient sample clusters with the psoriasis sentinels. b) Module-score analysis demonstrating a dominant Th17 signature in the patient sample. c) UMAP visualization of transcriptomic profiles from sentinel reference samples and the patient sample. The patient sample clusters with the psoriasis sentinels.

Conclusion

Palmoplantar inflammatory dermatoses may be difficult do differentiate clinically and histologically, yet differ substantially at the molecular immune level. This is increasingly important, as targeted therapies are most likely to be effective when matched to the dominant inflammatory pathway. In this case, NanoString-based molecular profiling identified a Th17-dominant signature in a patient with diagnostically challenging chronic palmar inflammatory dermatosis and successfully guided treatment selection with IL-17A/F inhibition. This case supports the potential value of transcriptomic profiling as a practical decision-support tool in difficult to treat palmoplantar inflammatory dermatoses cases.

EA DV CONGRESS
VIENNA
30 SEP - 3 OCT 2026

Abstract N°: 2828

Unilateral Facial Cutaneous Sarcoidosis in a Female Professional Cook: Occupational Heat Exposure as a Potential Trigger

Shushan Kettsyan*[1], Hovhannes Hovhannisyan[2], Artyom Kharazyan[3], Anna Aghajanyan[2]

[1] Yerevan State Medical University after Mkhitar Heratsi, Yerevan, Armenia

[2] NATIONAL CENTER FOR BURNS AND DERMATOLOGY OF MOH OF RA CJSC,, Yerevan, Armenia

[3] DAVIDYANTS LABORATORIES, Yerevan, Armenia

Introduction

Sarcoidosis is a chronic multi-system granulomatous disease of uncertain etiology characterized by the formation of non-caseating epithelioid granulomas. Cutaneous manifestations are observed in approximately one-third of patients and exhibit considerable clinical heterogeneity, often representing a diagnostic challenge because of their resemblance to numerous inflammatory, infectious, and granulomatous dermatoses. Unilateral or strictly hemifacial involvement constitutes an exceptionally uncommon presentation. Although environmental and occupational factors have been implicated in disease induction and exacerbation, the contribution of chronic thermal and infrared exposure remains insufficiently investigated.

Case Presentation

A 55-year-old female professional cook presented with a nine-month history of persistent recurrent erythema and edema localized exclusively to the right hemiface, involving the nasal, malar, and lower labial regions. The lesions initially developed during the summer of 2025 and demonstrated consistent exacerbation during occupational activity associated with prolonged exposure to elevated temperatures, steam, and aerosolized cooking oils. The patient denied constitutional symptoms, pain, or pruritus. Empirical antiviral therapy with oral acyclovir administered for one month yielded no clinical improvement.

Dermatological examination revealed diffuse erythema with mild infiltrative edema sharply confined to the right side of the face. Dermoscopic assessment demonstrated a pink-to-reddish background accompanied by linear and arborizing vessels, orange-brown structureless areas, and prominent shiny white streaks, findings highly suggestive of an underlying granulomatous infiltrative process. Histopathological evaluation of two 4-mm punch biopsy specimens identified multiple well-formed non-caseating granulomas distributed within the superficial and mid-dermis, composed predominantly of epithelioid histiocytes with abundant eosinophilic cytoplasm, in association with mild epidermal hyperkeratosis and acanthosis. Clinicopathological correlation supported the diagnosis of cutaneous sarcoidosis.

The strictly unilateral distribution together with the evident occupational association rendered this case particularly distinctive. The differential diagnosis included granulomatous rosacea, lupus vulgaris, cutaneous leishmaniasis, and sarcoidal granulomatous reactions. The close temporal relationship between occupational thermal exposure and lesion exacerbation raises the possibility of a heat-induced koebnerization-like phenomenon contributing to disease expression in a predisposed individual.

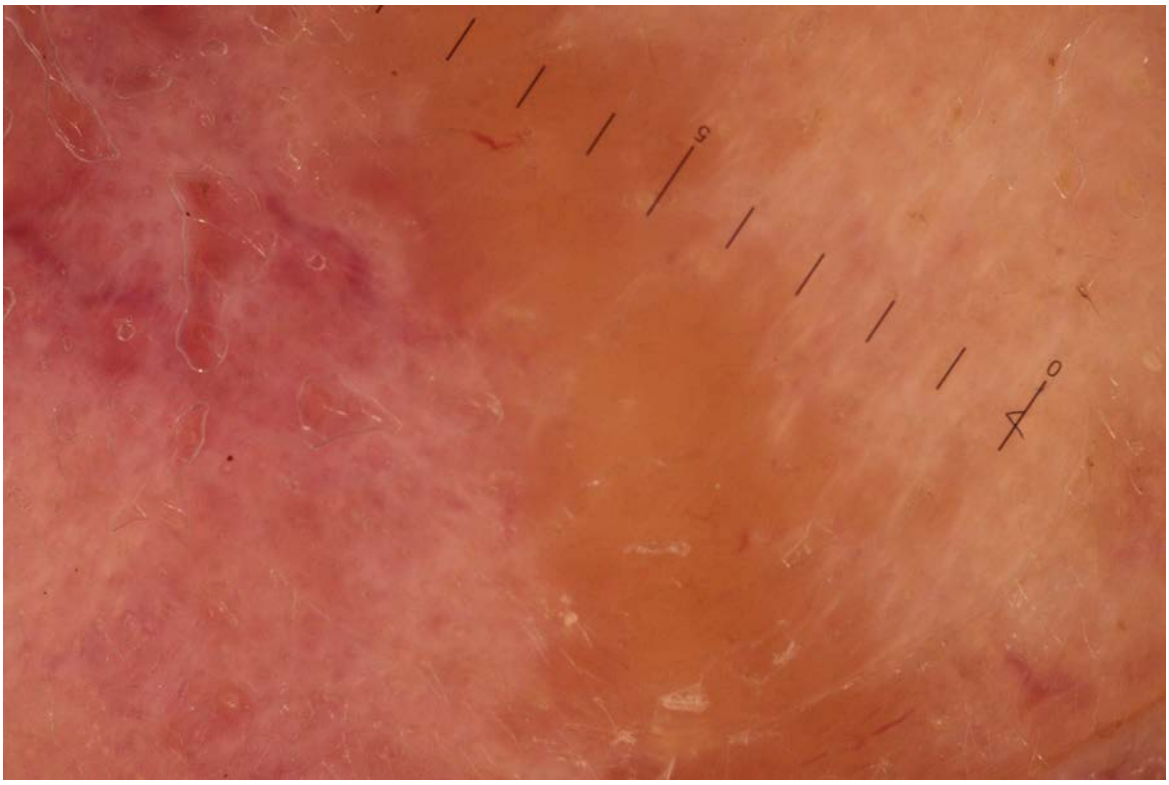

Fig. 1 - Dermoscopy revealed a diffuse pink-orange structureless background with prominent linear and branching vessels, focal shiny white streaks, and translucent orange-brown areas consistent with a granulomatous infiltrative process suggestive of cutaneous sarcoidosis.

Conclusion

This report describes an uncommon unilateral facial presentation of cutaneous sarcoidosis in a professional cook and underscores the importance of integrating dermoscopic and histopathological findings in the diagnostic evaluation of granulomatous facial dermatoses. The observed association with chronic occupational heat exposure may suggest a contributory triggering or aggravating role of thermal and infrared stimuli in susceptible patients. Prompt recognition of atypical cutaneous sarcoidosis is essential to prevent diagnostic delay, avoid inappropriate therapeutic interventions, and facilitate appropriate systemic assessment and occupational counseling.

EADV CONGRESS
VIENNA
30 SEP - 3 OCT 2026

Abstract N°: 2829

Acquired perforating dermatosis in a diabetic patient: partial improvement with phototherapy

hajar Elbokhari*[1], Bouchra Baghad[1], hanane Rachadi[1], farida Mernissi[2], soumiya Chiheb[1]

[1] Dermatology and Venerology departement, Ibn Rochd University Hospital, casablanca, Morocco
[2] Anatomopathology departement, Ibn Roch University hospital, casablanca, Morocco

Introduction
Acquired perforating dermatoses represent a rare group of skin disorders characterized by transepidermal elimination of altered dermal material. They are most commonly associated with metabolic comorbidities, particularly diabetes and chronic renal failure.

Case Presentation
We report the case of a 58-year-old man with type 2 diabetes treated with dual oral antidiabetic therapy, who presented with a chronic, mildly pruritic skin eruption evolving over two years. Clinical examination revealed excoriated papules associated with hyperpigmented, atrophic, brownish lesions distributed over the trunk and limbs. Histopathological examination of a skin biopsy showed epidermal ulceration with transepidermal elimination of basophilic material containing altered collagen bundles and neutrophils. Laboratory investigations were unremarkable, except for an HbA1c level of 7.3%.
The patient was treated with topical corticosteroids combined with PUVA therapy, resulting in partial improvement of the lesions.

Conclusion
Acquired perforating dermatosis is a rare condition, frequently associated with diabetes and/or chronic renal failure. It usually presents with umbilicated papules or nodules, often pruritic, mainly involving the trunk and extremities. Diagnosis relies on clinicopathological correlation, with histology showing transepidermal elimination of altered dermal material.

Management remains poorly standardized. Although control of associated comorbidities is essential, it usually does not lead to significant improvement of skin lesions when used alone. Therefore, specific dermatological treatments are often required. Phototherapy, particularly PUVA therapy or narrowband UVB, may be a useful option in chronic or extensive forms. In our case, topical corticosteroids combined with PUVA therapy resulted in partial clinical improvement.

This case highlights the importance of considering acquired perforating dermatosis in diabetic patients presenting with chronic papulonodular lesions, even in the absence of renal impairment. Histopathological confirmation remains essential. Management is challenging and should be individualized, as control of associated comorbidities is necessary but rarely sufficient alone. Phototherapy may represent a valuable therapeutic option in persistent or extensive forms.

EA DV CONGRESS
VIENNA
30 SEP - 3 OCT 2026

Abstract N°: 2836

Subcutaneous Sweet's Syndrome presenting as recurrent panniculitis: A diagnostic challenge

Laura Martínez Alcalde*[1], Carolina Corral Cuadrado[2], María Dolores Vélez Velázquez[3], Jose Campos Esteban[2], Elena Lucía Pinto Pulido[1]

[1] Servicio Dermatología, Hospital Universitario Príncipe de Asturias, Alcalá de Henares, Madrid, Spain
[2] Servicio Reumatología, Hospital Universitario Príncipe de Asturias, Alcalá de Henares, Madrid, Spain
[3] Servicio Anatomía Patológica, Hospital Universitario Príncipe de Asturias, Alcalá de Henares, Madrid, Spain

Introduction

Subcutaneous Sweet's syndrome, also known as febrile neutrophilic panniculitis, is a rare variant of acute febrile neutrophilic dermatosis. It is characterised by fever, systemic symptoms and painful cutaneous lesions, with histopathological evidence of neutrophilic infiltration involving not only the dermis but also the subcutaneous tissue. Although classic Sweet's syndrome primarily affects the dermis, subcutaneous involvement has been increasingly recognised, posing diagnostic challenges due to its overlap with other forms of neutrophilic panniculitis. Herein, we present a case of subcutaneous Sweet's syndrome and highlight the importance of considering this entity in the differential diagnosis of panniculitis.

Case Presentation

A 48-year-old woman with no significant past medical history was evaluated for recurrent episodes over a 10-year period, characterised by fever, arthromyalgia and a painful lesion on the left pretibial
region, recurring approximately every six months. Physical examination revealed an erythematous-violaceous plaque on the lower left pretibial area, with associated ipsilateral edema and tenderness on palpation, without overt signs of local infection or systemic involvement. Laboratory tests showed mild leukocytosis and elevated acute-phase reactants, along with elevated IgG levels. Autoimmune markers, cryoglobulins and infectious workup (including Mantoux test and serologies) were negative.

Histopathological examination demonstrated a dense neutrophilic infiltrate in the dermis, predominantly perivascular and without evidence of vasculitis, extending into the subcutaneous tissue with mainly septal and focal lobular involvement. Microbiological cultures were negative.

The patient was treated with systemic corticosteroids combined with colchicine, achieving rapid clinical improvement. Based on the recurrent clinical pattern, laboratory findings, histopathological
features and response to therapy, a diagnosis of subcutaneous Sweet's syndrome was established.

Conclusion

Subcutaneous Sweet's syndrome is an uncommon entity that should be considered in patients presenting with recurrent febrile episodes and neutrophilic panniculitis. Its main diagnostic challenge lies in distinguishing it from other causes, particularly early-stage erythema nodosum, which shares similar clinical, laboratory and histological features. However, Sweet's syndrome typically shows a more intense inflammatory response, persistent neutrophilic infiltrate, and rapid response to corticosteroids. In contrast, erythema nodosum evolves towards a lymphohistiocytic infiltrate with predominantly septal involvement. The differential diagnosis should also include infectious, pancreatic, drug-induced panniculitis and panniculitis associated with systemic diseases such as Behçet's syndrome or Crohn's disease.

This case highlights subcutaneous Sweet’s syndrome as an under-recognised cause of recurrent panniculitis and underscores the importance of its inclusion in the diagnostic workup.

EA DV CONGRESS
VIENNA
30 SEP - 3 OCT 2026

Abstract N°: 2885

Combination Biologic and JAK Inhibitor Therapy for Inflammatory Skin Diseases: A Systematic Review

Marina Shaker*[1], Meghna Varambally[1], Katya Peri[2], Eric McMullen[3], David Croitoru[3], Vincent Piguet[3]

[1] Western University, London, Canada
[2] Mcgill University, Montreal, Canada
[3] University of Toronto, Toronto, Canada

Introduction

Inflammatory skin diseases such as atopic dermatitis (AD), psoriasis, and hidradenitis suppurativa (HS) carry substantial disease burden, especially in patients refractory to standard biologic or small-molecule therapy. Some patients with comorbid inflammatory disease may attempt concurrent (dual) biologic and janus kinase inhibitor (JAKi) therapy for adequate disease control. This systematic review synthesizes and critically appraises the current literature on dual biologic/JAKi therapy in inflammatory dermatoses.

Materials and Methods

MEDLINE, Embase, CENTRAL, and Scopus were searched from inception to November 2025 following PRISMA guidelines (Table S1; Supplemental File 1; PROSPERO: CRD420251234919). Eligible studies included those reporting the safety and efficacy of dual biologic/JAKi therapy in inflammatory dermatoses, with exclusions for abstracts, reviews, non-English texts, non-concurrent dual therapy, or melanoma diagnoses. Two reviewers independently screened and extracted data, assessing risk of bias using the Joanna Briggs Institute Critical Appraisal Checklists.

Results

Among 128 reported patients receiving concurrent biologic/JAKi therapy, dual therapy was most commonly initiated because of inadequate response to prior biologic or JAKi monotherapy (91.0%), while discordant disease control accounted for 5.5% of cases. Atopic dermatitis was the predominant indication (70.3%), followed by psoriasis (25.0%), frequently with concomitant psoriatic arthritis. The most frequently reported combinations were dupilumab with baricitinib or tofacitinib (22.8%) and dupilumab with baricitinib alone (20.5%) (Table 1). All patients had previously received systemic therapy; 73.2% had failed at least one biologic, 43.7% had failed two or more biologics, and 49.3% had failed a prior JAKi.

Among published reports, which likely overrepresent successful outcomes, 98.4% (126/128) of patients demonstrated clinical improvement and 63.4% (81/128) achieved clinical remission over a mean dual-therapy duration of 6.7 months and mean follow-up of 9.3 months. Most patients (81.1%) experienced no adverse events, and no serious adverse events were reported. Laboratory abnormalities were the most common adverse events (6.3%), including dyslipidaemia, transaminitis, thrombocytopenia, and mild neutropenia. Infections were uncommon (5.3%) and included herpes zoster, eczema herpeticum, folliculitis, Clostridioides difficile infection, bronchitis, and upper respiratory tract infection, without clear trends. Increased blood pressure was only reported with pan-JAKis (tofacitinib/baricitinib; 2/95, 2.1%), whereas infections were more frequently reported with selective JAKis (upadacitinib; 4/95, 4.2%), though subgroup sample sizes were small. Mean patient age was 37.5 years (range: 13–83), with a male predominance (56.0%).

Category	Characteristic/Indication	N (years) (%)
Patient Characteristics		
Patient Age (n=83)	Mean Age ± Std (years)	37.5 ± 17.3
Patient Sex (n=84)	Female	37 (44)
Skin Conditions Requiring Dual Biologic/JAKi Therapy (n=128)	Atopic dermatitis	90 (70.3)
	Psoriasis	32 (25.0)
	Hidradenitis suppurativa	5 (3.9)
	Other inflammatory dermatoses (i.e., pyoderma gangrenosum, dissecting cellulitis of the scalp, alopecia areata)	8 (6.3)
Reported Comorbidities Among Included Patients (n=71)	Psoriatic arthritis	20 (28.2)
	Crohn's disease	3 (4.2)
	Other comorbidities (i.e., ulcerative colitis, asthma; rhinoconjunctivitis, Hashimoto's thyroiditis, environmental allergies)	21 (29.6)
	Not reported	26 (36.6)
	None	1 (1.4)
Previous Biologic Therapy (n=71)	≥1 prior biologic failure	52 (73.2)
	≥2 prior biologic failure	31 (43.7)
	≥3 prior biologic failure	16 (22.5)
	No prior biologic failure or not reported	19 (26.8)
Previous JAKi Therapy (n=71)	≥1 prior JAKi failure	35 (49.3)
	≥2 prior JAKi failure	7 (9.9)
	No prior JAKi failure or not reported	36 (50.7)
Indication for Combination Therapy (n=128)	Inadequate response/refractory disease	117 (91.0)
	Discordant disease domains	7 (5.5)
	Unclear indication	4 (3.3)
Adverse Events (n=94)	None	77 (81.05)
	Blood test abnormalities	6 (6.3)
	Infections	5 (5.3)
	Other minor events(i.e. fatigue, nausea, hyperhidrosis)	5 (5.3)
	Increased blood pressure	2 (2.1)
	Serious adverse events	0
Dual Biologic/JAKi Therapy (26 Combinations in 128 Patients)	Dupilumab + (Tofacitinib or Baricitinib)	29 (22.8%)
	Dupilumab + Baricitinib	26 (20.5%)
	Dupilumab + Upadacitinib	18 (14.2%)
	Dupilumab + Abrocitinib	8 (6.3%)
	Tralokinumab + Upadacitinib	5 (3.9%)
	Risankizumab + Tofacitinib	5 (3.9%)
	Infliximab + Upadacitinib	4 (3.1%)
	Ixekizumab + Tofacitinib	4 (3.1%)
	Guselkumab + Upadacitinib	3 (2.4%)
	Dupilumab + Tofacitinib	3 (2.4%)
	Secukinumab + Upadacitinib	3 (2.4%)
	Guselkumab + Tofacitinib	3 (2.4%)
	Ixekizumab + Upadacitinib	2 (1.6%)
	Ixekizumab + Deucravacitinib	2 (1.6%)
	Adalimumab + Baricitinib	1 (0.8%)
	Lebrikizumab + Upadacitinib	1 (0.8%)
	Infliximab + Tofacitinib	1 (0.8%)
	Adalimumab + Upadacitinib	1 (0.8%)
	Infliximab + Ustekinumab + Tofacitinib	1 (0.8%)
	Bimekizumab + Tofacitinib	1 (0.8%)
	Ustekinumab + Tofacitinib	1 (0.8%)
	Secukinumab + Tofacitinib	1 (0.8%)
	Secukinumab + Abrocitinib	1 (0.8%)
	Risankizumab + Upadacitinib	1 (0.8%)
	Brodalumab + Upadacitinib	1 (0.8%)
	Omalizumab + Upadacitinib	1 (0.8%)

Conclusions

Dual biologic/JAKi therapy may benefit patients with refractory inflammatory dermatoses, particularly atopic dermatitis and psoriasis, with high reported response rates and no serious adverse events identified in published reports. However, potential additive immunosuppression remains a concern. Findings are limited by short follow-up, small sample sizes, and likely publication bias, highlighting the need for larger prospective studies with standardized safety reporting.

EA DV CONGRESS
VIENNA
30 SEP - 3 OCT 2026

Abstract N°: 2886

Sustained Disease Control in Refractory Hailey-Hailey Disease with Low-Dose Naltrexone and Adjunctive CO_2 Laser Ablation

Jonas Rüth*[1], Vasileios Dervenis[1], Nikolaos Stavropoulos[1]

[1] Department of Dermatology, Venereology and Allergology, St. Josef Hospital, Ruhr University Bochum,, Bochum, Germany

Introduction

Hailey-Hailey disease (benign familial pemphigus) is a rare autosomal dominant acantholytic genodermatosis characterized by a chronic relapsing course associated with considerable morbidity and impaired quality of life. Management remains challenging, particularly in patients with long-standing refractory disease. We report a case of highly refractory Hailey-Hailey disease achieving sustained disease control under low-dose naltrexone and adjunctive CO_2 laser ablation.

Case Presentation

A 56-year-old male patient with a more than 25-year history of Hailey-Hailey disease presented with involvement of the axillary, inguinal and genital regions, as well as the trunk and flexural surfaces of the extremities. Clinical examination demonstrated recurrent painful erosions, maceration and hyperkeratotic partly annular plaques with flaccid blistering. The clinical course was further complicated by recurrent bacterial superinfections requiring repeated systemic antibiotic treatment.

Repeated skin biopsies revealed epidermal acantholysis with dyskeratosis consistent with Hailey-Hailey disease. Direct and indirect immunofluorescence studies showed no evidence of autoimmune bullous dermatosis. Repeated internal, infectious disease and malignancy work-up remained without relevant pathological findings.

Previous treatments included topical and systemic corticosteroids, dapsone, acitretin, methotrexate, ciclosporin, mycophenolate mofetil, azathioprine, apremilast, etanercept, rituximab, botulinum toxin injections and multiple topical anti-inflammatory and antiseptic regimens, resulting only in transient or insufficient clinical responses.

In October 2023, low-dose naltrexone was initiated at 3mg daily and subsequently increased to 4.5mg daily. During continued treatment, prednisolone was gradually tapered from an initial dose of 50mg daily over approximately 12 months and eventually discontinued completely. This resulted in substantial clinical improvement of the cutaneous lesions. However, persistent erosive and macerated inguinal lesions remained locally treatment-refractory, prompting targeted CO_2 laser ablation of the affected areas in October 2024.

Following this sequential multimodal therapeutic approach, sustained disease control was achieved. At latest follow-up, no new erosive lesions occurred under continued low-dose naltrexone therapy (4.5mg daily). Residual erythema was controlled with intermittent topical mometasone treatment. The patient reported high treatment satisfaction, significant improvement in daily functioning and no relevant adverse effects related to low-dose naltrexone therapy.

Conclusion

This case highlights the therapeutic potential of low-dose naltrexone as a steroid-sparing treatment option in highly refractory Hailey-Hailey disease after failure of multiple conventional, immunomodulatory and procedural

therapies. In persistent intertriginous lesions, adjunctive CO_2 laser ablation may further contribute to durable local disease control. Sequential multimodal treatment approaches may therefore represent a promising therapeutic strategy in selected patients with severe refractory Hailey-Hailey disease.

EADV CONGRESS
VIENNA
30 SEP - 3 OCT 2026

Abstract N°: 2894

Nanocarrier-Enhanced Alpha Hydroxy Acid Formulation as a Steroid-Sparing Topical Strategy for Plaque Psoriasis: A Double-Blind Comparative Clinical Study

Ahmed Nouh*[1]

[1] Al-Azhar university, Cairo, Egypt

Introduction
Topical treatment of plaque psoriasis remains limited by poor penetration through hyperkeratotic plaques, local irritation, and concerns related to prolonged corticosteroid use. Nanocarrier-based delivery may improve the therapeutic performance of alpha hydroxy acids (AHAs) by enhancing epidermal penetration while preserving their keratolytic and anti-inflammatory potential.
Objectives:
To compare the efficacy and safety of conventional AHA, nanocarrier-enhanced AHA, placebo, and standard fixed-combination topical therapy in patients with plaque psoriasis.

Materials and Methods
This double-blind comparative clinical study included 80 patients with plaque psoriasis, equally allocated into four groups of 20 patients each: standard fixed-combination topical therapy, conventional AHA formulation, nanocarrier-enhanced AHA formulation, and placebo. Patients were assessed at baseline, week 4, and week 8 using Psoriasis Area and Severity Index (PASI). Dermatology Life Quality Index (DLQI), dermoscopic changes, and local tolerability were also evaluated.

Results
Baseline PASI differed significantly among groups, with the nanocarrier-enhanced AHA group showing the highest initial disease severity. At week 8, a statistically significant difference in PASI was observed among treatment arms. The standard fixed-combination group achieved the lowest mean PASI score at week 8 (1.44 ± 1.00), while the nanocarrier-enhanced AHA group showed marked clinical improvement despite higher baseline severity. Conventional AHA and placebo demonstrated less pronounced improvement. Post-treatment DLQI also differed significantly among groups, with the standard therapy and nanocarrier-enhanced AHA groups showing the most favorable quality-of-life outcomes. Local tolerability was acceptable across groups.

Conclusions
Nanocarrier-enhanced AHA demonstrated clinically meaningful improvement in plaque psoriasis and showed superiority over conventional AHA, supporting the added value of nanotechnology in topical drug delivery. Although standard fixed-combination therapy remained the most effective comparator, nanocarrier-enhanced AHA may represent a promising steroid-sparing topical option for mild-to-moderate plaque psoriasis and warrants larger, longer-term controlled trials.

EADV CONGRESS
VIENNA
30 SEP - 3 OCT 2026

Abstract N°: 2919

Extragenital Lichen Sclerosus in a Child with Anaplastic Large T-Cell Lymphoma: A Probable Paraneoplastic Manifestation

Kenza Benothmane*[1], Yasmine Zekraoui[1], Fatima Ez-zahraa Sassine[1], Narjess Errachdy[1], Najoua Ammar[1], Syrine Hamada[1], Mariame Meziane[1], Laila Benzekri[1], Nadia Ismaili[1]

[1] Department of Dermatology, Ibn Sina University Hospital, Rabat, Morocco

Introduction

Lichen sclerosus is a chronic inflammatory dermatosis of multifactorial etiology, predominantly driven by autoimmune mechanisms.
In children, it primarily affects the anogenital region, whereas extragenital forms are considerably rarer.
The coexistence of lichen sclerosus with hematologic malignancies, particularly T-cell lymphomas, is exceptional, especially in pediatric patients.
This association raises questions regarding the role of immune dysregulation related to lymphoid proliferation in the development of certain autoimmune dermatoses.

We report the case of a child with anaplastic large T-cell lymphoma who simultaneously developed extragenital lichen sclerosus prior to any chemotherapy, suggesting a possible paraneoplastic origin.

Case Presentation

A 6-year-old girl, followed for three years for ALK-positive anaplastic large T-cell lymphoma, developed cutaneous lesions on the lower limbs concomitantly with the diagnosis of lymphoma, before initiation of chemotherapy or any specific treatment.

Clinical examination revealed hypopigmented macules and plaques of variable size with poorly defined borders, localized on the legs. The lesions were pruritic, smooth-surfaced, slightly sclerotic, and focally pearly in appearance. There was no mucosal involvement, nail or hair abnormalities, nor any other cutaneous lesions.

Dermoscopy demonstrated homogeneous structureless white areas with absence of pigment network, associated with fine linear and dotted peripheral vessels and scattered brown dots.

Skin biopsy showed orthokeratotic hyperkeratosis, epidermal atrophy, apoptotic bodies above the basal epidermal layer, and a dense diffuse lymphocytic inflammatory infiltrate filling the dermal papillae, associated with scattered melanophages and reduction of pilosebaceous appendages. These findings were consistent with lichen sclerosus.



Conclusion

We describe a case of hypopigmented extragenital lichen sclerosus occurring in a child with anaplastic large T-cell lymphoma prior to any treatment.

The temporal relationship and the immunological context strongly suggest a paraneoplastic manifestation related to lymphocytic dysregulation.

Close collaboration between dermatologists and pediatric hemato-oncologists is essential to recognize these atypical presentations and better understand their underlying mechanisms.

EADV CONGRESS
VIENNA
30 SEP - 3 OCT 2026

Abstract N°: 2922

Rapid remission of long-standing recalcitrant subcorneal pustular dermatosis with adalimumab

Jakob Najeeb[1], Maria Najeeb*[2]

[1] Department of Dermatology, Örebro University Hospital, Örebro, Sweden

[2] Department of Medicine (Solna), Division of Dermatology and Venereology, Karolinska Institutet, Stockholm, Sweden

Introduction

Subcorneal pustular dermatosis (SPD), also known as Sneddon-Wilkinson disease, is a rare neutrophilic dermatosis characterized by recurrent flaccid pustules arranged in annular or serpiginous patterns, typically involving the trunk, flexural, and intertriginous areas. Although its pathogenesis remains unclear, SPD has been associated with IgA monoclonal gammopathy, hematologic malignancies, and other neutrophilic disorders. Therapeutic management can be challenging, particularly in refractory disease. Tumor necrosis factor-alpha inhibitors have emerged as potential treatment options in selected recalcitrant cases. We report a case of long-standing, treatment-refractory SPD associated with chronic lymphocytic leukemia achieving rapid and complete remission with adalimumab.

Case Presentation

A 71-year-old man with a history of B-cell non-Hodgkin lymphoma, later reclassified as chronic lymphocytic leukemia and treated with chlorambucil and rituximab, as well as post-stroke hemiparesis, had suffered from SPD since 1997. The diagnosis had been repeatedly confirmed by skin biopsies showing characteristic subcorneal pustules.

Over more than two decades, he had received multiple systemic therapies, including acitretin, sulfasalazine, hydroxychloroquine, systemic corticosteroids, and long-term dapsone, with only partial and transient responses. Topical corticosteroids and potassium permanganate baths were used as adjunctive treatments. Phototherapy was not feasible because of limited mobility. Despite treatment, he experienced frequent severe flares requiring hospitalization, with extensive pustulation, pain, pruritus, sleep disturbance, and marked impairment in quality of life.

Given the refractory disease course and substantial clinical burden, adalimumab was initiated after multidisciplinary discussion with hematology and infectious disease specialists. Treatment was administered as an 80 mg loading dose at week 0, followed by 40 mg at week 1 and then 40 mg every other week.

Within four weeks, the patient achieved complete clinical remission, with resolution of pustules, erythema, pain, and pruritus. Dapsone was tapered and discontinued. At follow-up after one and two months, he remained in remission, with normalization of inflammatory laboratory parameters. The patient reported a marked improvement in quality of life, including restored sleep and the ability to resume normal daily activities.

Conclusion

This case highlights the potential efficacy and tolerability of adalimumab in severe, long-standing, treatment-refractory SPD in a medically complex patient with underlying chronic lymphocytic leukemia. It adds to the limited evidence supporting TNF-α inhibition as a rapidly effective therapeutic option in recalcitrant SPD. Longer follow-

up and additional cases are needed to better define the durability of response and safety of biologic therapy in this rare disease.

EADV CONGRESS
VIENNA
30 SEP - 3 OCT 2026

Abstract N°: 2929

Lichen Planus Pigmentosus Inversus: A Diagnostic and Therapeutic Challenge

Dunja Kisić*[1], Jelena Peric[2, 3], Dubravka Zivanovic[2, 3], Aleksandra Pucanovic[4], Katarina Nikolic[2], Vesna Reljic[2, 3]

[1] Clinic of Dermatology and Venereology, University Clinical Center of Serbia, Belgrade, Serbia

[2] Polyclinic Imedic, Belgrade, Serbia

[3] University of Belgrade - Faculty of Medicine, Department of Dermatology and Venereology, Belgrade, Serbia

[4] Department of Dermatology and Venereology, Clinical Hospital Center Zemun, Belgrade, Serbia

Introduction

Lichen planus pigmentosus inversus (LPPI) is a rare variant of lichen planus that typically presents with hyperpigmented macules, papules, and plaques in intertriginous areas such as the axillae, inguinal and submammary folds. Due to the rarity of LPPI, both diagnosis and therapeutic management remain challenging. We describe a case with initial involvement of the face and lower leg - an atypical presentation that delayed diagnosis - followed by characteristic intertriginous lesions, with a subsequent favorable response to isotretinoin.

Case Presentation

A 57-year-old female patient initially presented with erythematous and hyperpigmented macules and papules on her face and right shin persisting for more than three years. An initial biopsy from the shin was nonspecific. Over the following 12 months, new grey to dark brown macules and plane papules appeared on the forehead, axillae, inguinal region and thighs, accompanied by a subtle reticular pattern on buccal mucosa. This clinical presentation together with repeated skin biopsies from the face and inguinal region, led to diagnosis of lichen planus pigmentosus inversus. The patient's occupational history was considered clinically relevant: she had been employed in a weapons and military equipment factory, with documented exposure to heavy metals. Following a review of the available literature, this exposure was considered as one of the potential etiological factors in the pathogenesis of LPPI. Regarding the treatment, after insufficient response to topical corticosteroids and due to extensive body surface area involvement systemic therapy with isotretinoin was initiated. The patient retired during treatment, thereby eliminating further occupational exposure to heavy metals. Sustained treatment with isotretinoin at 30 mg/day, combined with topical corticosteroids, resulted in significant improvement, with complete regression of the intertriginous lesions and partial clearance of the facial lesions after 12 months of therapy.

Conclusion

Our case underscores the importance of considering LPPI in the differential diagnosis even in the presence of atypical, extra-intertriginous lesions. Occupational exposure to heavy metals may represent an underrecognized environmental trigger worthy of further investigation. Isotretinoin may be considered an effective systemic therapeutic option in patients refractory to topical treatment.

EADV CONGRESS
VIENNA
30 SEP - 3 OCT 2026

Abstract N°: 2930

Evaluation of trichoscopic features in Connective tissue diseases at a tertiary care centre - A cross sectional observational study

Shalini Malik*[1]

[1] Lady hardinge medical college, Delhi, India

Introduction
Background: Hair loss and scalp involvement is commonly present in Connective tissue diseases (CTDs) and these changes can denote signs of disease activity and systemic involvement. Several hair diseases are encountered in the CTDs namely telogen effluvium, diffuse thinning or fragility of hair and scarring alopecia/non- scarring alopecia. Skin biopsy and Direct immunofluorescence are needed for confirmation of the diagnosis but they are invasive procedures. Trichoscopy is a non-invasive handy-tool which aids in making early diagnosis of CTDs based on various trichoscopic features of scalp and hair. Various trichoscopic features include- changes in follicular openings, hair shaft, perifollicular and interfollicular surface, and vessel morphology. Trichoscopic findings/features help to identify disease activity and prognosis in various CTDs. There is a paucity of studies on trichoscopic features in CTD patients from India. We undertook this study to evaluate the various trichoscopic features in patients of CTDs who attended CTD clinic at a tertiary care hospital.
Objectives: To study trichoscopic features in various CTDs and compare with age and sex matched healthy controls

Materials and Methods
This cross-sectional observational study was conducted from November 2022 to February 2024 over 16 months in the CTD clinic of the Dermatology OPD at a tertiary care hospital in North India. Trichoscopy was performed using a polarized videodermatoscope (20X–70X magnification), and images were captured and stored for analysis. A total of 120 participants were included, comprising 60 patients with various connective tissue diseases (CTDs) aged 18–60 years and 60 age- and sex-matched healthy controls.

Results
total of 60 CTD cases and 60 age- and sex-matched healthy controls were enrolled. Mean age of cases and controls was 37.95 ± 9.89 and 38.10 ± 10.05 years, respectively, with female predominance in both groups. Systemic Sclerosis was the most common CTD (35%), followed by Systemic Lupus Erythematosus (33.3%), Discoid Lupus Erythematosus (20%), Dermatomyositis (6.66%), and Mixed Connective Tissue Disease (5%). Mean age of disease onset was 32.65 ± 9.95 years, while mean disease duration was 5.31 ± 5.57 years.Significant trichoscopic findings in CTD cases compared to controls included reduced hair density, hair diameter variability, hair shaft hypopigmentation, follicular plugging, coiled hair, and fine vellus hair ($p<0.05$). Follicular dots, including white, red, and black dots, were also significantly increased. Perifollicular and interfollicular changes such as scaling, erythema, brown pigmentation, white areas, background erythema, and interfollicular scales showed significant association with CTDs. Vascular abnormalities including arborizing vessels, polymorphic vessels, avascular areas, linear vessels, branching capillaries, loop capillaries, and coiled capillaries were significantly higher in cases. Patients on treatment showed significantly lesser positivity of hair pull test, white dots, salt and pepper pigmentation, and arborizing vessels. CTD-wise comparison showed significant differences in hair diameter variability, salt and pepper pigmentation, and avascular areas.

Conclusions

Trichoscopy revealed significant hair shaft, follicular, pigmentary, scalp surface, and vascular changes in patients with connective tissue diseases compared to healthy controls. Findings such as reduced hair density, hair diameter variability, perifollicular scaling, background erythema, and polymorphic vessels were commonly observed. Certain trichoscopic features also differed according to treatment status and specific CTD subtype. Thus, trichoscopy serves as a valuable non-invasive diagnostic and monitoring tool for early detection and assessment of scalp involvement in connective tissue diseases

EA DV CONGRESS
VIENNA
30 SEP - 3 OCT 2026

Abstract N°: 3016

Bidirectional Association Between Rosacea and Irritable Bowel Syndrome: A Systematic Review and Meta-Analysis

Fares Alammari*[1], Leena Alotaibi[2], Hana AlKhalifah[3], Maram Alanazi[4], Amnah Alrashdi[5], Hana Fatani[6], Manar Alshahrani[7], Khulud Alshammari[8], Abdullah AlBarrak[9]

[1] College of Medicine, Almaarefa university, Riyadh, Saudi Arabia
[2] East Jeddah General Hospital, Jeddah, Saudi Arabia
[3] College of Medicine, Jouf University, Al-Jouf, Saudi Arabia
[4] College of Medicine, Sulaiman Alrajhi University, Al Bukayriyah, Saudi Arabia
[5] Faculty of Medicine, Umm AlQura University, Al-Qunfudah, Saudi Arabia
[6] College of Medicine, King Abdulaziz University, Jeddah, Saudi Arabia
[7] College of Medicine, Princess Nourah bint Abdulrahman University, Riyadh, Saudi Arabia
[8] College of Medicine, Northern Border University, Arar, Saudi Arabia
[9] King Fahad Medical City, Riyadh, Saudi Arabia

Introduction
Rosacea is a chronic inflammatory dermatosis affecting 5-10% of adults worldwide and is increasingly recognized as a systemic condition with extracutaneous comorbidities, particularly gastrointestinal disorders. Irritable bowel syndrome (IBS), a disorder of gut-brain interaction, similarly affects 5-10% of adults globally. Both conditions have been linked through the gut-skin axis, with shared features including microbiota dysbiosis, increased intestinal permeability, low-grade systemic inflammation, and immune dysregulation.

Epidemiological studies suggest a bidirectional relationship, with rosacea patients showing a 20-70% higher risk of IBS and IBS patients a 30-80% higher risk of rosacea, though effect estimates vary widely across studies. To date, no comprehensive meta-analysis has synthesized this evidence. We therefore conducted a systematic review and meta-analysis to evaluate the bidirectional association between rosacea and IBS.

Materials and Methods
A systematic review and meta-analysis were conducted according to PRISMA guidelines. PubMed, Scopus, and Web of Science were searched up to January 2026. Observational studies assessing the association between rosacea and IBS were included. Random-effects models were used to calculate pooled effect estimates with 95% confidence intervals (CIs).

Results
Ten studies, including 5,555,641 participants, were analyzed. Eight studies assessing rosacea preceding IBS showed a significant association (OR 1.38, 95% CI 1.14-1.66; I^2 = 97.5%), consistent with pooled risk ratios (RR 1.36, 95% CI 1.15-1.60; I^2 = 94.2%). Subgroup analyses confirmed significance in case-control (OR 1.60) and cohort studies (OR 1.24), with smaller effects in cross-sectional data (OR 1.11). Results were consistent across effect measures and publication types, while sex-based analyses were non-significant. In the reverse direction, two studies showed that IBS was associated with an increased risk of rosacea (RR 1.10, 95% CI 1.03-1.18; I^2 = 0%).

Conclusions

This meta-analysis demonstrates a significant bidirectional association between rosacea and IBS, with stronger evidence in the rosacea-to-IBS direction. These findings support shared pathophysiological mechanisms along the gut-skin axis and highlight the need for integrated clinical awareness and further mechanistic research.

EA DV CONGRESS
VIENNA
30 SEP - 3 OCT 2026

Abstract N°: 3016

Granulomatous cheilitis: a rare disease characterized by persistent lip swelling

Barbara de Galvao e Brito Medeiros[1], Andrea Fernandes Eloy da Costa França[1], Lorraine Souza Santos[1], Laís Arroyo Lopes Anjo[1], Katariny Parreira de Oliveira Alves[1], Márcio Fellipe Menezes Viana[1], Elisa Nunes Secamilli*[1], Juliana Yumi Massuda Serrano[1]

[1] Universidade Estadual de Campinas - UNICAMP, Dermatologia, Dermatologia, Campinas, Brazil

Introduction

Orofacial granulomatosis (OFG) is a rare inflammatory condition characterized by recurrent or persistent swelling of the orofacial region associated with the histological presence of non-caseating granulomas. It encompasses manifestations such as granulomatous cheilitis and Melkersson–Rosenthal syndrome. Its etiology remains uncertain, with immunological, genetic, infectious, and allergic factors suggested as possible triggers. Lip swelling is the most frequent clinical manifestation and may progress from intermittent episodes to persistent edema, resulting in significant functional and aesthetic impact. Diagnosis requires exclusion of infectious and systemic granulomatous diseases, in addition to histopathological confirmation.

Case Presentation

A 22-year-old previously healthy male patient presented with persistent swelling of the upper lip, with sudden onset approximately 18 months earlier. He reported periods of improvement and exacerbation, followed by persistent lip swelling. He had previously undergone treatment with high-dose antihistamines and systemic corticosteroid therapy with prednisone, achieving only a partial response. Physical examination revealed isolated swelling of the upper lip associated with gingival friability, without facial asymmetry or fissured tongue. The patient denied systemic symptoms, gastrointestinal, respiratory, or cutaneous lesions, as well as previous facial paralysis, use of topical lip products, or aesthetic procedures. Laboratory and radiological investigations showed no significant abnormalities. Given the diagnostic suspicion of granulomatous cheilitis, a biopsy of the upper lip was performed. Histopathological examination revealed superficial and deep perivascular inflammatory infiltrate with non-caseating granulomas composed of epithelioid histiocytes and multinucleated giant cells, associated with a lymphoplasmacytic infiltrate. Special stains for fungi (PAS) and acid-fast bacilli (Ziehl–Neelsen) were negative. Based on the clinical and histopathological findings, a diagnosis of OFG presenting as isolated granulomatous cheilitis was established. Treatment was initiated with doxycycline 100 mg twice daily, with plans for intralesional corticosteroid injections depending on the clinical response. Screening tests were also requested in preparation for possible anti-TNF therapy.





Figure 1: Persistent upper lip swelling, with preserved facial expression and tongue appearance.



Figure 2: Gingival involvement associated with mucosal friability.

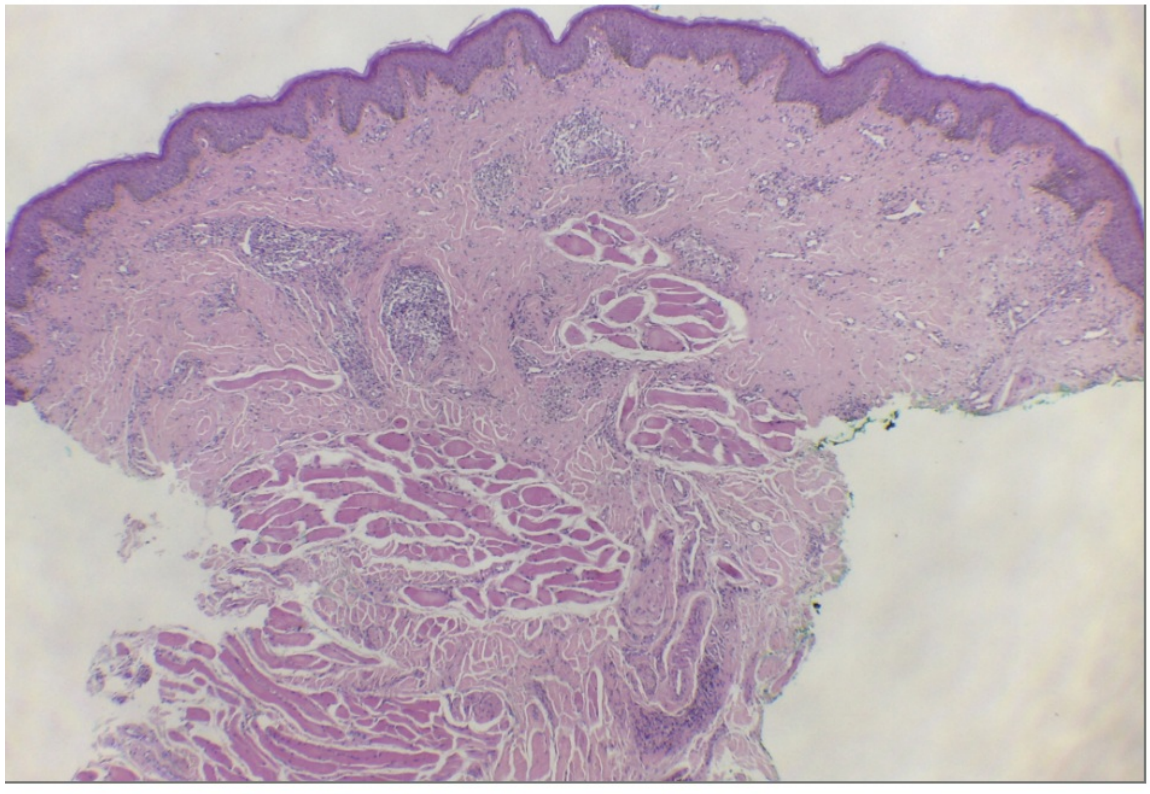

Figure 3: Superficial and deep perivascular inflammation, with the presence of some granulomas.

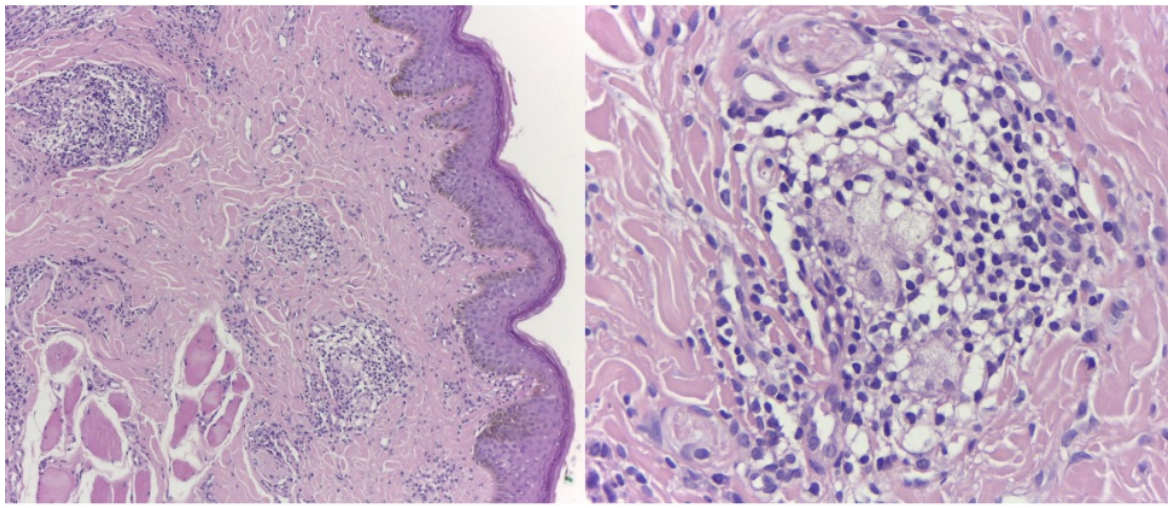

Figure 4: Granulomas are non-caseating, composed of epithelioid cells and multinucleated giant cells. Lymphomononuclear inflammatory infiltrate associated with plasma cells is observed.

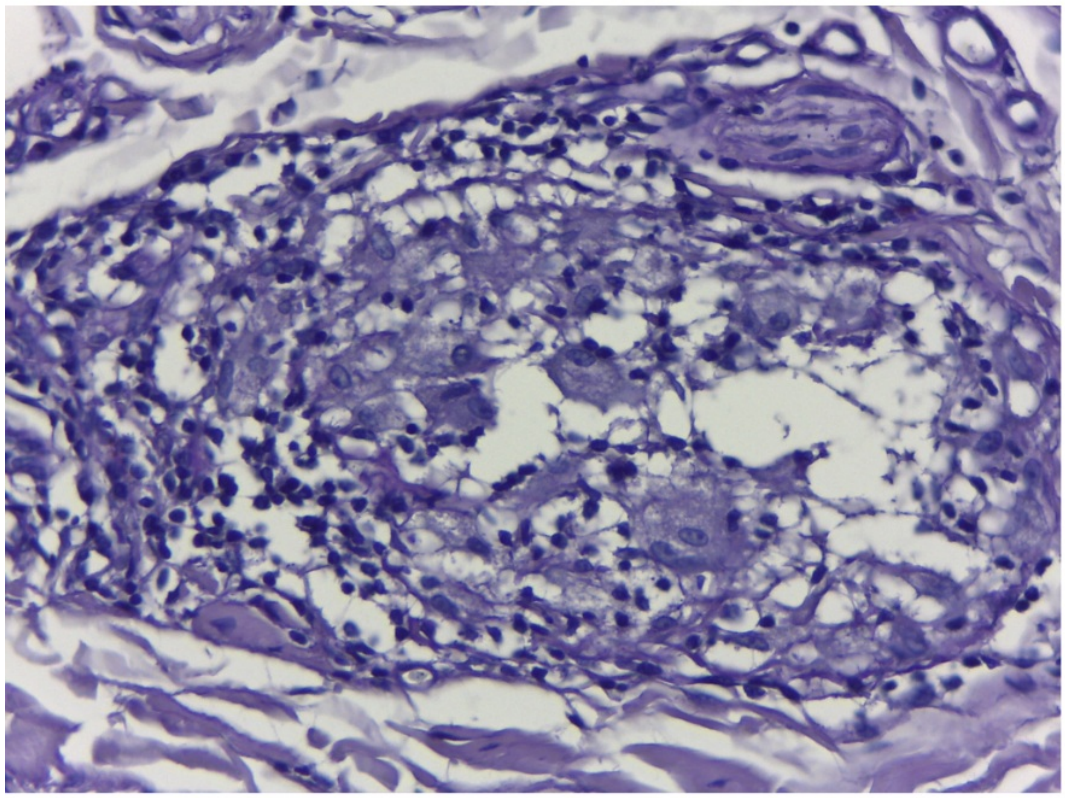

Figure 5: Fungal investigation was negative (PAS method).

Conclusion

Granulomatous cheilitis represents the most common manifestation of OFG and is characterized by chronic, recurrent, and progressively persistent lip swelling. When associated with recurrent facial paralysis and fissured tongue, it constitutes Melkersson–Rosenthal syndrome. The present case demonstrates an isolated form of the disease, without associated neurological manifestations to date.The differential diagnosis includes angioedema, sarcoidosis, Crohn's disease, granulomatosis with polyangiitis, foreign body reactions, infections, contact dermatitis, and periodontal disease. Exclusion of these conditions is essential, especially Crohn's disease, the main

systemic disorder associated with OFG, which may develop after the onset of the orofacial manifestations. Histopathologically, the presence of non-caseating granulomas, lymphoplasmacytic infiltrate, and tissue edema supports the diagnosis, although granulomas may be absent in some biopsies. No standardized treatment guidelines for OFG are currently available. Topical, intralesional, and systemic corticosteroids are considered first-line therapies, although they often provide only partial or temporary control. Other therapeutic options include tetracyclines, immunosuppressants, anti-TNF-α agents, topical tacrolimus, and dietary modifications. Refractory cases may require surgical intervention. This case highlights the importance of including OFG in the differential diagnosis of persistent lip swelling and reinforces the need for long-term follow-up due to the unpredictable course of the disease and its potential association with systemic conditions.

EADV CONGRESS
VIENNA
30 SEP - 3 OCT 2026

Abstract N°: 3032

Therapeutic Challenge in the Overlap of Immune-Mediated Inflammatory Diseases: Psoriasis, Atopic Dermatitis, and Psoriatic Arthritis

Verônica Franco[1], Bianca Fuser[1], Mariana Santos Lopes Da Conceição*[1], Emilia Peralta Ulerio[1], Sophia Benatti[1], Mariana Santos[1], Mariana Lesqueves[1], Thayane Zanineli[1], Fabricio Lamy[1]

[1] Policlínica Geral do Rio de Janeiro, Rio de Janeiro, Brazil

Introduction

Psoriasis is a chronic immune-mediated inflammatory disease frequently associated with systemic manifestations, including psoriatic arthritis. Although classically considered distinct entities from an etiopathogenic perspective, overlap with atopic dermatitis has been increasingly recognized, representing a diagnostic and therapeutic challenge.

Case Presentation

A 33-year-old female patient with a history of scaly skin lesions since adolescence, later compatible with psoriasis, had previously been treated with topical therapies and phototherapy without satisfactory response, in addition to intolerance to methotrexate and cyclosporine. Following extensive disease recurrence, including scalp involvement, guselkumab was initiated, resulting in excellent clinical response after induction.

Subsequently, the patient developed a change in cutaneous pattern, presenting exudative lesions and intense pruritus associated with eosinophilia and elevated serum IgE levels, compatible with atopic dermatitis. Given the new inflammatory profile, guselkumab was discontinued and dupilumab was initiated, resulting in complete remission and sustained cutaneous disease control.

During follow-up, the patient developed hand arthralgia, and an ultrasonographic evaluation was performed, demonstrating inflammatory tenosynovitis compatible with psoriatic arthritis. Risankizumab was initiated, followed by combined therapy with both biologics, with significant clinical improvement.

Conclusion

This case highlights the diagnostic and therapeutic complexity of overlapping immune-mediated inflammatory diseases, demonstrated by the phenotypic transition between psoriasis, atopic dermatitis, and subsequent progression to psoriatic arthritis. Continuous clinical reassessment is essential in the setting of changes in inflammatory patterns, which may require therapeutic redirection. Sequential and combined biologic therapy may represent a valuable strategy in selected refractory or atypical cases.

EADV CONGRESS
VIENNA
30 SEP - 3 OCT 2026

Abstract N°: 3032

IDO1+ Neutrophil-Mediated Immunosuppression Drives Chronicity in Hidradenitis Suppurativa: A Longitudinal Single-Cell Landscape of a Consistent Patient Cohort

Xinyuan Zhang*[1], Wu Chao[1], Hongzhong Jin[1]

[1] Peking union medical college hospital, Beijing, China

Introduction
Hidradenitis suppurativa (HS) is a debilitating chronic inflammatory skin disease characterized by recurrent abscesses and tunnels. While neutrophil infiltration is a hallmark of HS lesions, the functional heterogeneity of these cells and their contribution to disease chronicity remain poorly understood. This study aims to characterize the evolution of specific neutrophil subsets and their roles in maintaining chronic inflammation.

Materials and Methods
We utilized a longitudinal study design involving a consistent cohort of HS patients, collecting paired skin lesions and peripheral blood samples before and after systemic treatment. Through single-cell RNA sequencing (scRNA-seq), we initially identified a unique neutrophil population and characterized its dynamic evolution during therapy. These findings were validated using immunohistochemistry (IHC) on paired tissue sections and multi-color flow cytometry on an independent set of samples to assess the frequency and spatial distribution of IDO1+neutrophils. Furthermore, in vitroco-culture assays and computational metabolic modeling were employed to verify the impact of these cells on T-cell functions and tryptophan metabolism.

Results
Our scRNA-seq analysis identified a unique IDO1+neutrophil population that was significantly enriched in active lesions but underwent a marked depletion following clinical response. IHC and flow cytometry validated the presence of these IDO1+ neutrophils in both the tissue microenvironment, with IHC specifically revealing their localization near T-cell aggregates in chronic lesions. Mechanistically, computational modeling indicated an accelerated tryptophan-to-kynurenine flux in these cells, leading to localized tryptophan exhaustion. In vitro assays functionally confirmed that these neutrophils directly suppress T-cell activation and proliferation, a phenotype partially reversed by IDO1 inhibition.

Conclusions
This study identifies IDO1+ neutrophils as a primary driver of immune suppression and chronicity in HS. The dynamic reduction of this subset following treatment underscores its potential as both a biomarker for therapeutic monitoring and a novel target for breaking the cycle of chronic inflammation in HS.

EA DV CONGRESS
VIENNA
30 SEP - 3 OCT 2026

Abstract N°: 3035

Beyond Iodine Exposure: The Role of Hydralazine, Renal Dysfunction, and ANCA Positivity in Iododerma

Naga P. Grandhe[1], Nikifor K. Konstantinov*[1]

[1] University of New Mexico School of Medicine, Department of Dermatology, Albuquerque, United States

Introduction

Iododerma is a rare halogenoderma caused by iodine-containing compounds, occurring predominantly in patients with chronic kidney disease (CKD) due to impaired iodine clearance [1]. Hydralazine is a well-established cause of anti-neutrophil cytoplasmic antibody (ANCA)-associated vasculitis (AAV) and drug-induced lupus (DIL), driven by covalent hydrazone adduct formation on myeloperoxidase (MPO) that generates a neoantigen eliciting pathogenic anti-MPO autoantibodies – a haptenization mechanism producing type III hypersensitivity [2,3]. Hydralazine-associated ANCA-GN accounts for 4.3% of all ANCA-GN, with 98% demonstrating p-ANCA/MPO positivity [4]. Hydralazine has also been independently linked to Sweet syndrome and histologically may also produce a neutrophilic dermatosis with basophilic ovoid structures, resembling cryptococcus (also known as cryptococcoid Sweets syndrome) [5,6]. Iododerma may also produce cryptococcoid-like neutrophilic dermatosis and vasculitic changes as well [7]. Despite the convergence of hydralazine use, renal dysfunction, and ANCA positivity in the population at risk for iododerma, this relationship has not been systematically examined. We present a case series and literature review identifying a striking association with the combination of hydralazine use, ANCA positivity and renal dysfunction, in patients ultimately diagnosed with iododerma.

Materials and Methods

Three cases from our institution are described in patients with iododerma who had renal dysfunction, iodinated contrast exposure, history of hydralazine use, and positive p-ANCA reactivity. Additional cases of iododerma with ANCA testing were also identified through systematic literature search of PubMed and conference proceedings. Data extracted included renal function, hydralazine use, iodine exposure, ANCA status, autoimmune serologies, and cutaneous findings.

Results

Ten iododerma cases were identified with hydralazine exposure. ANCA was tested in 9 patients, all of whom were positive. p-ANCA predominated (7/9), with MPO positivity confirmed in 6 patients; 1 patient demonstrated a c-ANCA pattern. All patients had renal dysfunction. Cutaneous findings included hemorrhagic bullae, retiform purpura, and vegetating plaques favoring the face, hands, and upper trunk. Additional autoimmune serologies included ANA (n=2), anti-histone antibodies (n=1), hypocomplementemia (n=1), and Scl-70 positivity (n=1). Although not reported in our cohort, a 10-case series by Kilgore et al. describing cryptococcoid Sweet syndrome did not include iodine testing despite clinical suspicion for iododerma [8]. Lim et al. similarly emphasized considering iododerma in patients with renal dysfunction or hydralazine exposure presenting with acute vegetative or acneiform facial dermatoses [9].

Patient	Diagnosis	Renal Status	Iodine Exposure	Hydralazine Exposure	ANCA Status	Other Autoimmune Serologies	Skin Findings	Reference
1	Iododerma	ESRD on HD	CT angiogram with contrast 2 days before skin eruption	+ (chronic medication)	p-ANCA (-MPO/-PR3)	Negative	Retiform purpura, hemorrhagic bullae: hands, arms, face, scalp (Fig 1)	Vigil SR et al, *JAAD Case Rep.* 2025
2	Iododerma	AKI	CT with contrast 4 days before skin eruption	+ (chronic medication)	p-ANCA (+MPO/+PR 3)	+ANA, +anti-histone	Hemorrhagic/ulcerated plaques: trunk, lips, face (Fig 2)	Konstantinov, NK; unpublished
3	Iododerma	AKI	CT with contrast and angiogram 3-4 days before. Skin eruption	+ (chronic medication)	p-ANCA (+MPO/-PR3)	+Lupus-like inhibitor	Hemorrhagic/ulcerated plaques and nodules: face, scalp, bilateral forearms/hands, left leg (Fig 3)	Konstantinov, NK; unpublished
4	Iododerma	ESRD on HD	CT with contrast 2 days before skin eruption	+ (unknown chronicity)	p-ANCA (+MPO)	+ANA, +anti-histone, low C3/C4, elevated RF	Hemorrhagic bullae: neck, chest, periorbital, tongue, arms, hands, gluteal	Chen EL et al, *JAAD Case Rep.* 2026
5	Iododerma	Stage 3B CKD	CT with contrast 10 days before skin eruption	+ (unknown chronicity)	p-ANCA (+ MPO/-PR3)	+Anti-histone, scl-70+	Vesicles/bullae with hemorrhagic crusting: face, hand, neck, chest	Chen EL et al, JAAD Case Rep. 2026
6	Iododerma	Stage 3 CKD	CT angiogram with contrast 5 days before skin eruption	+ (unknown chronicity)	p-ANCA (+MPO)	Not reported	Tense bullae with purpura: forehead, eyes, neck, thigh	Chen EL et al, *JAAD Case Rep.* 2026
7	Iododerma	CKD stage 4	CT with contrast 2 days before skin eruption	+ (chronic medication)	+ANCA (unknown pattern or MPO/PR3 status)	Not reported	Violaceous papules with crusting: face, chest, dorsal hands	Runge M et al. *JAAD Case Rep.* 2020
8	Iododerma	CKD (unknown stage)	CT with contrast 4 days before skin eruption	+ (unknown chronicity of medication)	Unknown	Not reported	Vegetative plaques with purulent bullae: scalp, face, neck, chest	Chang MW et al, *JAAD.* 1997
9	Iododerma	CKD 4–5	CT with contrast 6 days before skin eruption	+ (unknown chronicity of medication)	p-ANCA (+MPO)	Not reported	Periocular/perioral hemorrhagic plaques; violaceous papules: trunk/extremities	Subhadarshani S et al. *JEADV.* 2024
10	Iododerma	CKD (unknown stage)	CT w/ contrast shortly before skin eruption	+ (shortly before skin eruption)	c-ANCA (unknown MPO/PR3)	Not reported	Papulonodular lesions: bilateral cheeks	Yanko et al. *ASDP* abstract. 2025

Table 1. Characteristics of patients diagnosed with iododerma who had a history of hydralazine use and degree of renal dysfunction

Conclusions

Universal ANCA positivity among tested iododerma patients, with a serologic profile mirroring hydralazine-induced autoimmunity, suggests hydralazine may be a critical underrecognized cofactor. CKD/ESRD patients are uniquely vulnerable due to convergence of three risk factors: (1) hydralazine use driving ANCA/MPO formation; (2) iodinated contrast imaging; and (3) impaired iodine clearance prolonging iodinated compound exposure. Hydralazine use should be systematically documented in future iododerma reports, and ANCA testing with MPO/PR3 specificity should be considered. The combination of hydralazine, iodinated contrast exposure, renal insufficiency, and ANCA positivity is a high-risk scenario for a diagnosis of iododerma. The mechanism of the "double-hit" of hydralazine with iodinated contrast leading to iododerma needs to be further elucidated. Prospective studies are needed to determine whether ANCA-positive iododerma is a distinct entity and whether hydralazine discontinuation alters disease course.

References:

1. Tervaert JWC. Drug- and vaccine-induced ANCA-associated vasculitis: An overview. Autoimmun Rev. 2025.
2. Xi G, McInnis EA, Lardinois O, et al. Sequential carbonyl derivatives and hydrazone adduct formation on myeloperoxidase contribute to development of ANCA vasculitis. J Clin Invest. 2025.
3. Santambrogio L. Haptenization as the missing link between vasculitis and myeloperoxidase. J Clin Invest. 2025 Apr 15;135(8):e191587.
4. Santoriello D, Bomback AS, Kudose S, et al. Anti-neutrophil cytoplasmic antibody associated glomerulonephritis complicating treatment with hydralazine. Kidney Int. 2021.
5. Ramsey-Goldman R, Franz T, Solano FX, Medsger TA. Hydralazine-induced lupus and Sweet's syndrome: Report and review of the literature. J Rheumatol. 1990.
6. Vroman J, Sagut P, Lynam K, Ederle A, Winterfield L. Cryptococcoid Sweet syndrome in the setting of hydralazine-induced ANCA vasculitis: A case report. J Cutan Pathol. 2026 Apr;53(4):356-361.
7. Vigil SR, Chiu LW, Cortez JL, Stepenaskie SA, Konstantinov NK. Retiform purpura in a patient with iododerma and atypical perinuclear antineutrophil cytoplasmic antibody. JAAD Case Rep. 2025 Dec 11;68:124-126.
8. Kilgore JR, Joseph JM, Walker A, Snider W, Culotta N, Bogatto C, Coulon A. Cryptococcoid Sweet syndrome or halogenoderma? Highlighting the crucial need for serum iodine testing. JAAD Case Rep. 2025 Aug 20;65:120-125.
9. Lim JH, Lee JS. Acute iododerma presenting as cryptococcoid neutrophilic dermatosis: A clinicopathological pitfall and interesting findings gleaned from a review of the literature. J Cutan Pathol. 2023 Jan;50(1):29-34.

EA DV CONGRESS
VIENNA
30 SEP - 3 OCT 2026

Abstract N°: 3073

Generalized annular lichen planus

Tarek Mansoul*[1], Mehdi Rouidi[1], Ahmed Samaouel Chehad[1]

[1] Department of Dermatology, Benbadis University Hospital Center, University of Constantine 3, Constantine, Algeria

Introduction

Lichen Planus is a chronic inflammatory dermatosis characterized by recurrent flares and remissions. The annular form is uncommon and may occur in association with more classical lesions of lichen planus. Clinically, it is characterized by pruritic violaceous papules with non-atrophic hyperpigmented centers and elevated, non-scaly borders. This particular morphology is thought to result from elastolysis secondary to inflammation, with elastic fibers being more fragmented and less numerous in the center of the lesion than at the periphery. We report a new case of generalized annular lichen planus in a 29-year-old woman.

Case Presentation

A 29-year-old woman presented with pruritic annular violaceous papules with hyperpigmented and slightly depressed centers. The lesions were isolated, with no mucosal or adnexal involvement, and were distributed over the limbs and trunk. They had been evolving for 9 months and were resistant to several topical and systemic corticosteroid treatments taken irregularly.

Dermoscopy revealed annular borders composed of confluent yellowish dots surrounded by dotted and linear vessels, a hyperpigmented center, and whitish streaks.

A skin biopsy demonstrated an acanthotic epidermis with hypergranulosis and orthokeratotic hyperkeratosis. A dense inflammatory infiltrate involving the dermoepidermal junction was observed, obscuring the basal layer and producing a characteristic saw-tooth appearance of the rete ridges. Focal pigmentary incontinence and elastolysis were also noted.

The diagnosis of annular lichen planus was established, and the patient was treated with intralesional triamcinolone acetonide injections every 21 days, resulting in complete remission after 3 months.

Conclusion

Generalized annular lichen planus is a rare variant of lichen planus. Its diagnosis may be challenging in the absence of typical papular lesions or classical mucosal and adnexal involvement. Dermoscopy remains a valuable diagnostic clue in such cases while awaiting histopathological confirmation. Typically, it demonstrates yellowish dots, dotted and linear vessels at the periphery of the lesion, pigmented dots, and whitish streaks corresponding to Wickham striae.

The treatment of annular lichen planus is similar to that of classic lichen planus and includes topical corticosteroids, topical calcineurin inhibitors, calcipotriol, and phototherapy. In resistant cases, systemic corticosteroids, retinoids, immunosuppressive agents, and dapsone may be considered.

EADV CONGRESS
VIENNA
30 SEP - 3 OCT 2026

Abstract N°: 3074

Single-Cell Atlas of Chronic Inflammatory Skin Diseases

Sabina Gansberger*[1], Inigo Oyarzun[1], Martin Simon[1], Shawn Santos[1], Wolfgang Bauer[1], Philipp Tschandl[1], Wolfgang Weninger[1], Johanna Strobl[1], Sophie Frech[1], Hao Yuan[2], Maksim V. Plikus[3, 4], Maria Kasper[2], Johannes Griss[1]

[1] Department of Dermatology, Medical University of Vienna, Vienna, Austria, Vienna, Austria
[2] Department of Cell and Molecular Biology, Karolinska Institutet, Stockholm, Sweden
[3] Department of Developmental and Cell Biology, University of California, Irvine, Irvine CA, United States
[4] ASTAR Skin Research Labs (ASRL), Singapore, Singapore

Introduction
Inflammatory skin diseases (ISDs) affect approximately 25% of the global population, yet differential diagnoses and the lack of targeted therapies still pose challenges. While single-cell RNA sequencing (scRNA-seq) has transformed the study of individual diseases, the molecular heterogeneity and shared pathogenic mechanisms across ISDs are still poorly understood. To date, scRNA-seq studies have primarily focused on intra-disease comparisons (lesional vs. non-lesional/healthy), with few studies comparing multiple skin diseases at once.

Materials and Methods
We integrated in-house and public scRNA-seq datasets spanning 27 ISDs from 50 studies, comprising over 2 million cells across 441 samples. Downstream analyses included differential abundance testing, cell-cell communication analysis, and the identification of shared and disease-specific gene programs.

Results
This ISD atlas enables the distinction between universal inflammatory signatures and disease-specific mechanisms. We validated the robustness of our integration by replicating established findings. Additionally, our analysis revealed novel insights, such as shared features between acne and granulomatous diseases, yet unrecognized roles of mural cells across ISDs, a shared gene expression signature between keratinocytes in atopic dermatitis and parapsoriasis as well as an upregulation of CXCL13 - a chemokine classically linked to B cell recruitment - in T cells across nearly all ISDs while increased B cell infiltration is only present in a few.

Conclusions
These examples highlight the power of the ISD atlas to resolve unique and shared immune mechanisms, providing a robust foundation for analyzing skin disease pathogenesis at single-cell resolution. The complete data are available through an interactive online portal at https://isd-atlas.derma.meduniwien.ac.at.

EA DV CONGRESS
VIENNA
30 SEP - 3 OCT 2026

Abstract N°: 3119

Frontal Fibrosing Alopecia and Lichen Planus Pigmentosus: Association with Biological Thyroid Dysfunction — A Comparative Study of 302 Patients

Yosra Ben Kraiem*[1], Hyba Taounza[1], Syrine hamada[1], Nadia Ismaili[1], Laila Benzekri[1], Mariame Meziane[1]

[1] Ibn Sina University Hospital Center, Rabat, Morocco

Introduction
Frontal fibrosing alopecia (FFA) and lichen planus pigmentosus (LPP) frequently coexist in dark-skinned populations. Although thyroid comorbidities in FFA are well documented, the impact of FFA–LPP coexistence on thyroid dysfunction has not yet been investigated.

The objectives of our study is to evaluate and compare the prevalence of biological thyroid dysfunction across four groups: FFA alone, LPP alone, FFA + LPP coexistence, and a reference group.

Materials and Methods
We conducted a retrospective and prospective cross-sectional study from February 2023 to February 2026 in the Dermatology Department of Ibn Sina University Hospital, Rabat, Morocco. A total of 302 patients with lichen disorders underwent systematic thyroid assessment. Patients were classified into four groups: FFA alone (n=79), LPP alone (n=67), FFA + LPP coexistence (n=49), and a reference group without FFA or LPP (n=107). Associations were analyzed using Chi-square tests, odds ratios (ORs) with 95% confidence intervals, and multivariate logistic regression adjusted for age and menopausal status.

Results
The prevalence of biological thyroid dysfunction was 19.0% in the FFA group, 3.0% in the LPP group, 22.4% in the FFA + LPP group, and 15.0% in the reference group. LPP alone was associated with a significantly lower prevalence of thyroid dysfunction compared with the reference group (OR=0.17; 95% CI [0.04–0.79], p=0.012). Hyperthyroidism was the most notable finding: it was absent in the reference and isolated LPP groups, but detected in 3.8% of patients with isolated FFA and 16.3% of patients with FFA + LPP coexistence. The coexistence of FFA and LPP increased the risk of hyperthyroidism nearly fivefold compared with isolated FFA (OR=4.94; 95% CI [1.24–19.65], p=0.014). In multivariate analysis, LPP remained an independent predictor of hyperthyroidism (adjusted OR=6.90; 95% CI [1.48–32.30], p=0.014), independently of age and menopausal status, whereas FFA remained independently associated with overall thyroid dysfunction (adjusted OR=2.12; 95% CI [1.05–4.28], p=0.037).

Conclusions
The coexistence of FFA and LPP appears to define a distinct dermatological phenotype associated with a high risk of biological hyperthyroidism in dark-skinned populations. This previously unreported finding suggests a possible synergistic autoimmune activation between both lichenoid conditions and thyroid disease. Systematic thyroid screening using TSH and free T4 should be considered in patients presenting this association.

EADV Congress 2026, VIENNA
30 SEPTEMBER - 03 OCTOBER 2026
POWERED BY M-ANAGE.COM

EA DV CONGRESS
VIENNA
30 SEP - 3 OCT 2026

Abstract N°: 3120

CONTROL OF CHRONIC AND SEVERE PRURITUS WITH UPADACITINIB IN A PATIENT WITH ATOPIC DERMATITIS AND LICHEN AMYLOIDOSIS

Ederson Lopes de Oliveira*[1]

[1] Ribeirão Preto Medical School, University of São Paulo, Ribeirão Preto, Brazil

Introduction

Lichen amyloidosis (LA), the most common form of primary localized cutaneous amyloidosis, presents as intensely pruritic lichenoid or verrucous papules, which are disseminated and tend to form plaques. It preferentially affects the distal portions of the legs, the dorsum of the feet, the upper arms, and the upper back region[1-3].

In turn, atopic dermatitis (AD) is a chronic inflammatory dermatosis characterized by xerosis, as well as eczematous and pruritic lesions[1].

The coexistence of LA and AD likely reflects shared mechanisms: immune dysregulation, chronic pruritus, and interleukin (IL)-31-mediated JAK-STAT pathway signaling[1,4].

We report a case of a 55-year-old male with long-standing, disruptive pruritus resulting from the association between extensive LA and AD lesions. Satisfactory improvement was observed following treatment with upadacitinib, a Janus kinase 1 (JAK1) inhibitor.

Case Presentation

A 55-year-old male presented with skin lesions and severe, generalized pruritus lasting approximately 40 years. During this long period, various treatments were attempted, none of which yielded a sustained response.

Upon dermatological examination, areas of xerosis and lichenification were noted (Figures 1 and 2). Multiple brownish papules were present on the anterior legs, arms, lower thorax, abdominal region, and back (Figures 3 and 4). On the back, numerous brownish-gray papules were observed, forming extensive plaques on a lichenified base (Figure 5). There was no mucosal involvement. Severity indices were: DLQI (Dermatology Life Quality Index) = 25 and SCORAD (Severity Scoring of Atopic Dermatitis) = 61.3.

Laboratory tests: Blood count was unremarkable, except for a relative eosinophilia of 6.3% (normal range: 1–5%); IgE was 322.7 UI/mL (1–183 UI/mL). Blood glucose, glycated hemoglobin, creatinine, creatine phosphokinase, liver transaminases, canalicular enzymes, thyroid function, prostate-specific antigen, and levels of calcium, iron, and ferritin were all within normal limits. Serologies for Hepatitis B, C, and HIV were negative/non-reactive. IGRA (Interferon-Gamma Release Assay) was negative. Protein electrophoresis showed no monoclonal spike.

Histopathology: Hyperkeratosis and mild acanthosis without atypia. Amyloid substance deposits and melanophagy were observed in the papillary dermis. Foci of non-specific chronic inflammatory infiltrate, predominantly lymphocytic with some eosinophils, were present.

Proposed Treatment: Upadacitinib 15 mg/day (oral) was prescribed. Regression of lesions and significant improvement in pruritus were observed. Six weeks after starting treatment, DLQI was 8 and SCORAD was 26.3; at 87 weeks post-treatment initiation, DLQI was 4 and SCORAD was 17.45.

Conclusion

In the case reported here, involving long-standing disseminated skin lesions with a negative impact on quality of life, upadacitinib successfully achieved control of the disruptive pruritus. It is noteworthy that the chronic pruritus itself in this patient is an amyloidogenic condition[1].

The achieved improvement can be justified by the effects of this medication on both inflammatory pathways and the neurosensory system. The effects of JAK1 inhibitors on the neurosensory system occur not only by blocking IL-31 signaling but also by blocking IL-4 and IL-13 signaling in primary afferent sensory neurons, which possess receptors for both cytokines[2,4-5].

Thus, provided there is careful monitoring, upadacitinib stands as a compelling therapeutic option for challenging cases of severe pruritus resulting from AD and LA[1-4].

EA DV CONGRESS
VIENNA
30 SEP - 3 OCT 2026

Abstract N°: 3124

Characterization of a Large Real-World Hidradenitis Suppurativa Patient Cohort with Physician-Evaluated Hurley Stage from U.S. Dermatology Practices

John R. Ingram*[1], Yizhou Ye[2], Lawrence Rasouliyan[3], Beth Rycroft[2], Bethanee J. Schlosser[2], Jayesh Patel[2], Martina L. Porter[4], Alexa B. Kimball[4], Amit Garg[5], Lukasz Matusiak[6]

[1] Division of Infection and Immunity, Cardiff University, Cardiff, United Kingdom

[2] AbbVie Inc., North Chicago, IL, United States

[3] OMNY Health, Atlanta, United States

[4] Harvard Medical School and Clinical Laboratory for Epidemiology and Applied Research in Skin, Department of Dermatology, Beth Israel Deaconess Medical Center, Boston, Massachusetts, United States

[5] Department of Dermatology, Northwell Health, New Hyde Park, United States

[6] Division of Dermatology, Venereology and Clinical Immunology, Faculty of Medicine, Wroclaw University of Science and Technology, Wroclaw, Poland

Introduction

Hidradenitis suppurativa (HS) is a chronic, debilitating inflammatory skin disorder that is not well characterized in real-world settings by Hurley stage. This population-based epidemiological study aims to describe the clinical burden and treatment landscape of HS within a large real-world cohort from the United States (US).

Materials and Methods

A US nationwide electronic health records (EHR) database (OMNY Health, January 2018–May 2025) was utilized to identify patients aged ≥ 12 years with a diagnosis of HS by dermatologists or from dermatology specialty centers and documented physician-evaluated Hurley stage at the same visit(index). Inclusion criteria required ≥ 365 days of pre-index data to facilitate assessment of demographics and comorbidities using EHR and linked open claims data on or prior to index visit. Complete treatment history including conventional therapies (antibiotics and antiseptics, corticosteroids, hormonal therapies, retinoids, and immunomodulators) and targeted therapies (biologics, JAK inhibitors, and PDE4 inhibitors) was evaluated using all available written prescriptions in EHR and reimbursed medication dispensation in open claims before and after index date. Anatomical lesion location was described among the subset of patients with lesion location documented on index date.

Results

A total of 16,154 patients with HS met inclusion criteria (mean age ± SD: 36.5 ± 14.3, 78% female; 66% White and 25% Black, mean body mass index ± SD: 32.6 ± 8.4 kg/m^2). At index visit, 50% (n=8,093) were at Hurley stage I, 40% (n=6,434) were at Hurley stage II, and 10% (n=1,627) were at Hurley Stage III. Lesion location was recorded for 91% of the cohort with involvement of the arms and legs, trunk, genitals, and/or head/neck occurring frequently; ectopic involvement of the face or hands was extremely rare, , and no patient reported feet involvement. Seventy-four percent of patients presented with lesions in two or more locations.

A substantial psychiatric burden was observed in this HS cohort, with 30% of patients having a documented diagnosis of anxiety, 26% with depression, 22% with chronic fatigue, 20% with sleep disorders, and 19% with

alcohol or substance use disorders. Furthermore, 18% of this HS cohort had at least one comorbid immune-mediated inflammatory diseases (IMIDs) with atopic dermatitis and psoriasis reported in 8.4% and 5.4% of patients with HS, respectively. Other IMIDs reported in this population include rheumatoid arthritis, Crohn's disease, ulcerative colitis, systemic lupus erythematosus, psoriatic arthritis, uveitis, alopecia areata, vitiligo, and ankylosing spondylitis.

Use of conventional therapies for HS was reported in 89% of patients across all Hurley stages, including oral corticosteroids (31%), and topical antibiotics or antiseptics (73%). A higher proportion of patients with systemic antibiotic use was observed in patients with Hurley Stage II or III (45%) than those with Hurley Stage I (39%). In addition, 7.5% of patients with Hurley Stage I had been treated with targeted therapies and 27.9% of patients with Hurley Stage II or III had been treated with targeted therapies despite recent approvals of biologic therapies.

Conclusions

This study evaluated patient characteristics and Hurley Stage assessed by dermatologists in a large, real-world HS population from the US. In this nationwide population-based cohort, 50% of this HS population were at Hurley stage I, 40% were at Hurley Stage II, and 10% were at Hurley Stage III at index visit. The use of biologics remained low despite recent regulatory approvals. Substantial psychiatric comorbidity and significant prevalence of concomitant IMIDs were observed, documenting the extensive burden of HS These findings highlight a persistent unmet need for novel and effective therapies with broader therapeutic reach to enable patients and clinicians to pursue individualized treatment strategies.

EADV CONGRESS
VIENNA
30 SEP - 3 OCT 2026

Abstract N°: 3135

Paradoxical psoriasis and cutaneous Crohn's disease coexisting within a single lesion during tumor necrosis factor alpha blockade

Andrea Fernández Carrillo[1], Mariana Santos Lopes Da Conceição*[1], Daniela Martinez[1], Antonio Correa Villela Neto[1], Bernard Kac[1], Fabricio Lamy[1]

[1] Policlinica Geral do Rio de Janeiro, Rio de Janeiro, Brazil

Introduction

Paradoxical psoriasis is a well-recognized complication of tumor necrosis factor alpha (TNF alpha) blockade in patients with Crohn's disease. However, the coexistence within a single lesion of psoriasiform and granulomatous inflammatory patterns consistent with cutaneous Crohn's disease represents an exceptional phenomenon. To our knowledge, this association has not previously been described during TNF alpha inhibitor therapy. We report the first known case of this dual histopathological phenotype documented through sequential biopsies of the same lesion.

Case Presentation

A 45-year-old woman with long-standing Crohn's disease in intestinal remission during infliximab therapy following prior adalimumab failure, as well as ankylosing spondylitis and type 2 diabetes mellitus, presented with a bilateral plantar dermatosis characterized by keratotic, erythematous, and scaly plaques with deep fissures, bleeding, and significant pain, predominantly affecting both heels. An initial biopsy demonstrated chronic granulomatous dermatitis with non-necrotizing granulomas and negative PAS and Ziehl–Neelsen stains, findings consistent with cutaneous Crohn's disease in the appropriate clinical context. Because the psoriasiform morphology persisted despite the granulomatous histology, a second biopsy was obtained from the same lesion, which revealed focal parakeratosis, regular acanthosis with elongation of the rete ridges, focal spongiosis, dermal edema, and a lymphocytic infiltrate. Clinicopathological correlation in the setting of prolonged TNF alpha inhibitor exposure supported the additional diagnosis of paradoxical psoriasis. Infliximab was discontinued and risankizumab was initiated, resulting in approximately 80% clearance at 16 weeks, complete resolution of pain, and no intestinal recurrence.

Conclusion

This case documents the topographic coexistence of paradoxical psoriasis and cutaneous Crohn's disease, an association previously undescribed during tumor necrosis factor alpha blockade and exceptionally rare in any biologic setting. The proposed immunological hypothesis integrates two parallel processes. Paradoxical psoriasis differs from classical psoriasis in being predominantly innate-mediated: TNF alpha blockade inhibits plasmacytoid dendritic cell maturation, prolonging type I interferon production and triggering an innate-driven psoriasiform phenotype, particularly in its early phase. Simultaneously, the Th1/Th17 granulomatous response intrinsic to Crohn's disease, mediated by IL-12 and IL-23, manifests cutaneously as the granulomatous component, consistent with the recognized overlap between paradoxical psoriasis and Crohn's disease at the IL-23/Th17 axis and shared susceptibility loci. The coexistence within a single lesion may reflect convergence of both inflammatory pathways on the IL-23/Th17 axis, with the local inflammatory microenvironment of one process potentially facilitating the cutaneous expression of the other. The favorable clinical response to selective IL-23 blockade with risankizumab further supports this shared inflammatory mechanism. Recognition of this dual phenotype may refine the diagnostic approach to persistent psoriasiform lesions in patients with inflammatory bowel disease receiving biologic therapy and supports selective IL-23 inhibition as a rational therapeutic strategy when both entities coexist.

EADV CONGRESS
VIENNA
30 SEP - 3 OCT 2026

Abstract N°: 3137

Orofacial Granulomatosis Initially Misdiagnosed as Angioedema: The Importance of Multidisciplinary Care and Psychosocial Support

Ericka Aguiar Mühlhaus*[1]

[1] Clínica Ericka Aguiar, Rio de Janeiro, Brazil

Introduction

Orofacial granulomatosis (OFG) is a rare chronic inflammatory disorder characterized by recurrent or persistent swelling of the oral and facial tissues associated with noncaseating granulomatous inflammation. The condition may clinically mimic angioedema, allergic reactions, infections, and systemic granulomatous diseases such as Crohn's disease and sarcoidosis, making diagnosis challenging. The disease often has a chronic relapsing course and may significantly affect patients' quality of life because of facial disfigurement and psychosocial distress. Histopathological examination and exclusion of systemic diseases are essential for diagnosis. We report a case of isolated OFG with important emotional impact and highlight the challenges of treatment and the relevance of multidisciplinary management.



Case Presentation

A 44-year-old man presented with a 2-year history of recurrent swelling of the lower lip. Initially intermittent, the edema progressively became persistent over time. The patient had previously been treated with antihistamines for

presumed angioedema, with only partial and temporary improvement.

Physical examination revealed diffuse edema of the lower lip. Intraoral examination demonstrated buccal mucosal ulcerations and gingival edema. No facial nerve palsy or fissured tongue was observed.

Histopathological examination of an incisional biopsy from the lower lip revealed chronic granulomatous inflammation with noncaseating granulomas composed of macrophages, multinucleated giant cells, lymphocytes, and plasma cells, findings compatible with orofacial granulomatosis.

Further investigation was performed to exclude systemic granulomatous disorders. Videocolonoscopy showed preserved colonic and terminal ileal mucosa without abnormalities. Chest computed tomography demonstrated no mediastinal or hilar lymphadenopathy or pulmonary findings suggestive of sarcoidosis. Allergy evaluation through prick testing showed sensitization to dust mites and airborne fungi, while food allergens tested negative.

The patient underwent intralesional corticosteroid injections with partial clinical improvement. Despite treatment, the chronic facial swelling had a substantial psychosocial impact. The patient reported embarrassment regarding his appearance, distress related to social judgment, and impaired quality of life.

Management involved close collaboration between dermatology, psychologist and stomatology specialists, which proved essential for diagnostic investigation, therapeutic planning, and emotional support.

Conclusion

Orofacial granulomatosis remains a diagnostic and therapeutic challenge because of its rarity, chronic course, and clinical overlap with other inflammatory disorders. This case emphasizes the importance of biopsy and exclusion of systemic diseases in patients with persistent lip swelling. It also highlights the psychosocial burden associated with facial disfigurement and the value of multidisciplinary care in providing comprehensive management and patient support. After partial response to intralesional corticosteroid therapy, the patient was treated with oral methotrexate. Methotrexate has been reported as a steroid-sparing therapeutic option in refractory cases of orofacial granulomatosis, with some case reports and small series describing significant clinical improvement and occasional complete remission. However, treatment responses remain variable, and standardized therapeutic guidelines are still lacking.



EA DV CONGRESS
VIENNA
30 SEP - 3 OCT 2026

Abstract N°: 3138

Rapidly progressive pansclerotic morphea with thrombocytopenia: a mimicker of systemic disease

Miguel Angel Nieto Bayona*[1], Hector Perez[1], Harold Farit Arenas Torrado[1], Juan Sebastian Sanchez Solarte[1]

[1] Universidad Nacional de Colombia, Bogotá, Colombia

Introduction

Pansclerotic morphea is a rare scleroderma-like disorder characterized by extensive, deep, progressive sclerosis of the dermis and subcutis. Although it may resemble systemic sclerosis, it lacks visceral and serologic involvement and mainly affects skin and deep soft tissues. Overlap with inflammatory or neoplastic disease requires careful diagnosis, especially with constitutional symptoms or hematologic abnormalities. We report an adult woman with this diagnosis presenting with extensive sclerotic plaques and thrombocytopenia after excluding major mimickers.

Case Presentation

A 48-year-old woman presented with thrombocytopenia, fever, and asthenia. Examination revealed indurated sclerotic plaques with violaceous borders on the proximal lower limbs, similar trunk lesions, and circumferential arm and forearm involvement, suggesting extensive disease. Panniculitis-like T-cell lymphoma was initially suspected.

Biopsy excluded infiltrative or neoplastic disease. Histopathology showed acellular sclerosis, compatible with scleroderma; the case was assessed as scleroderma-like. Differential diagnosis where considered (Table 1). Systemic sclerosis was unlikely because Raynaud phenomenon, sclerodactyly, acral disease, visceral involvement, capillaroscopic changes, and positive serology were absent. Eosinophilic fasciitis can produce diffuse induration, but absence of groove sign and tissue eosinophils argued against it. Scleredema was considered due to cytopenia, but serum protein electrophoresis was normal. Drug- or toxin-induced forms, diabetes-related disease, and advanced kidney disease were unlikely due to the absent compatible context. Scleromyxedema was ruled out because generalized papules were absent and histology lacked mucin or fibroblast proliferation. Panniculitis-like T-cell lymphoma was excluded because no deep lobular infiltrate with lymphoid atypia was found; dermal sclerosis and acellularity supported a scleroderma-like process.

Clinicopathologic correlation supported pansclerotic morphea: extensive, deep, circumferential, rapidly progressive plaques without systemic involvement. Oral methotrexate 10 mg weekly was started, with marked improvement at four months; due to residual activity, the dose was increased to 20 mg/week. Thrombocytopenia was managed as immune thrombocytopenic purpura (ITP), without recurrence.

Pansclerotic morphea accounts for less than 1% of morphea cases and has substantial burden. It may start on the trunk and then generalize, involving large body surface areas, and may cause restricted range of motion, ulceration, and functional disability. Extracutaneous manifestations, including restrictive respiratory impairment or dysphagia from extrinsic compression, support close follow-up. Here, thrombocytopenia initially suggested hematologic disease, but was ultimately attributed to ITP. Although pansclerotic morphea with ITP is exceptional, their coexistence should be considered and does not exclude the diagnosis when clinicohistologic findings are concordant.

Characteristic	Systemic sclerosis	Shulman fasciitis	Sclero-myxedema	Scleredema	Pan-sclerotic morphea
Raynaud's phenomenon	✓	X	X	X	X
ANA	✓	X	X	X	✓/X
Mucin	X	X	✓	✓	X
Anti Scl70, centromere, RNA pol III	✓	X	X	X	X
Gammopathy	X	✓/X	✓/X	✓	X
Eosinophilia	X	✓	X	X	X
Systemic involvement	✓	✓	✓	X	X
Note/Special Feature	Capillaroscopy	Groove sign	Papules	DM, infection	No organ damage

Table 1: Differential diagnosis.

Conclusion

In conclusion pansclerotic morphea is rare and potentially disabling, and may mimic systemic or neoplastic disease, particularly when constitutional symptoms or hematologic abnormalities coexist. This case highlights systematic work-up and clinicopathologic correlation. Methotrexate was effective, with early improvement and dose adjustment according to residual activity. Early recognition and treatment are essential to limit progression and sequelae.

EA DV CONGRESS
VIENNA
30 SEP - 3 OCT 2026

Abstract N°: 3148

Efficacy and safety of abdakibart, a selective anti-IL-1β agent for treatment of moderate to severe hidradenitis suppurativa; primary results of the placebo-controlled Phase 2 LOTUS Trial

Martina L. Porter*[1], Mittie Doyle[2], Leann Gasink[2], Lisa Goldberg[2], John W. Frew[3], Falk G. Bechara[4], Afsaneh Alavi[5], Youyi Shu[2], Alexa B. Kimball[1]

[1] Harvard Medical School, Cambridge, United States
[2] Avalo Therapeutics, Wayne, United States
[3] Liverpool Hospital, Sydney, Australia
[4] Universitätsklinikum St. Josef-Hospital, Bochum, Germany
[5] Mayo Clinic, Rochester, United States

Introduction

Hidradenitis suppurativa (HS) is a chronic inflammatory skin disease of the pilosebaceous unit characterized by nodules, abscesses, and draining tunnels. Three biologics (e.g., adalimumab, secukinumab, bimekizumab) are currently approved for the treatment of patients (pts) with moderate to severe HS; however, response to treatment in HS is often suboptimal with high rates of loss of efficacy. IL-1β has been demonstrated to be a key upstream inducer for TNF and Th17 cells in HS. In this analysis, we present the primary and major secondary efficacy and safety results from the LOTUS trial, a global Phase 2, double-blind, placebo- controlled trial comparing the efficacy and safety of abdakibart, a humanized, IgG4 selective anti IL-1β immunoglobin, to placebo in pts with moderate to severe HS.

Materials and Methods

The LOTUS trial evaluated 2 dosing regimens of abdakibart (600 mg loading dose, followed by 300 mg every 4 weeks [Q4W], or 300 mg loading dose, followed by 150 mg every 2 weeks [Q2W]) to placebo (1:1:1 randomization) in pts with moderate-severe HS. Eligible pts were ≥18 years old with symptoms of HS for ≥6 months, Hurley Stage II/III, a total abscess and/or inflammatory nodule (AN) count ≥5, and presence of HS lesions in ≥2 distinct anatomical areas. Pts with and without prior biologics experience were eligible. The primary endpoint was the proportion of pts achieving HiSCR75 at Week 16 defined as ≥ 75% reduction in the total AN count with no increase in abscess count and no increase in draining tunnel (DT) count relative to baseline. Pts who received systemic rescue therapy before Week 16, or discontinued study treatment due to an adverse event or lack of efficacy were treated as non-responders and pts with missing data were imputed as non-responders. The primary endpoint analysis compared both abdakibart groups to placebo using a closed testing procedure which controlled overall Type 1 error at a 0.05 significance level (2-sided). Key secondary endpoints included HiSCR50, and HiSCR90, change from baseline in International Hidradenitis Suppurativa Severity Score (IHS4), AN count, and draining fistula count. Pts were followed for safety through Week 20.

Results

A total of 253 pts were randomized to either placebo, abdakibart 150mg Q2W, **or** abdakibart 300mg Q4W; 86% of pts completed study treatment. Baseline characteristics were generally balanced although the abdakibart groups had a longer mean duration of HS, were more often female, and more frequently had

previously been treated with an approved biologic. At Week 16, a greater proportion of pts in both abdakibart groups achieved the primary endpoint of HiSCR75 versus placebo (Table 1). Similarly, both abdakibart groups showed statistically significant differences in the proportion of pts achieving HiSCR50, and in the mean change from baseline in both IHS4 and DT count. There were numerically higher rates of achieving HiSCR90 and a numerically greater decrease from baseline in AN count in both abdakibart groups vs placebo, with results in the 300 mg group showing statistical significance in AN count reduction. Abdakibart was well tolerated in both treatment groups. Rates of treatment emergent adverse events (AE) were similar between abdakibart and placebo groups (AEs: 51.8% [150 mg]; 55.4% [300 mg]); 53.5%[placebo]) with no unexpected safety findings. There were no adverse events of neutropenia, malignancy, hypersensitivity reactions, or serious or opportunistic infections, and there were no deaths.

Table 1

	Placebo N=86	Abdakibart 150 mg Q2W N=83	Abdakibart 300 mg Q4W N=84
Baseline Characteristics			
Age (mean, yrs)	37.7	38.4	39.0
Female (%)	52.3	66.3	63.1
BMI (mean, kg/m^2)	33.9	36.4	34.9
Duration of HS (mean, yrs)	6.9	9.1	7.8
Prior approved biologic use for HS (%)	30.2	39.8	39.3
Hurley Stage III (%)	40.7	42.2	44.0
AN count (mean)	13.8	13.5	14.0
DT count (mean)	2.8	2.7	3.2
IHS4 (mean)	27.5	26.7	29.0
Efficacy Results at Week 16			
HiSCR75 (NRI) (%)	25.6	42.2 p=0.018	42.9 p=0.015
HiSCR50 (NRI) (%)	40.7	59.0 p=0.013	64.3 p=0.001
HiSCR90 (NRI) (%)	14.0	22.9 p=0.116	23.8 p=0.100
LS mean change from Baseline, IHS4	-8.2	-14.5 p=0.012	-15.9 p=0.002
LS mean change from Baseline, AN count	-5.8	-7.8 p=0.111	-9.1 p=0.008
LS Mean change from Baseline, DT count	-0.6	-1.8 p=0.006	-1.8 p=0.008
Safety Results			
Any treatment emergent AE (n, %)	46 (53.5)	43 (51.8)	46 (55.4)
Any AE leading to study drug discontinuation (n, %)	2(2.3)	2 (2.4)	1 (1.2)

AN: inflammatory nodules + abscesses; DT: draining tunnels; IHS4: international hidradenitis suppurativa severity score; AE: Adverse Event

Conclusions

In the LOTUS trial, both abdakibart doses demonstrated statistically significantly higher rates of achieving HiSCR75 compared to placebo. Benefits were demonstrated in key secondary endpoints. Both doses of abdakibart were generally safe and well tolerated.

EADV CONGRESS
VIENNA
30 SEP - 3 OCT 2026

Abstract N°: 3167

Paradoxical Psoriasis Induced by Anakinra in a Child with Systemic Juvenile Idiopathic Arthritis

MOHAMED HOUBAYELI*[1], layla bendaoud[1], Mariem Aboudourib[1, 1], Amal Said[1], Ouafa Hocar[1]

[1] Mohammed VI University Hospital of Marrakech, Bioscience and Health Laboratory, Department of Dermatology Venerology, marrakech, Morocco

Introduction

Paradoxical psoriasis is a well-recognized adverse event associated with biologic therapies, particularly anti-TNF agents. However, psoriasiform eruptions induced by IL-1 inhibitors remain exceptionally rare, especially in pediatric patients.

Materials and Methods

We report the case of a 12-year-old girl followed for systemic juvenile idiopathic arthritis (sJIA). She was initially treated with tocilizumab (Actemra®) associated with low-dose corticosteroid therapy (prednisone 5 mg/day). Due to persistent disease activity, treatment was switched to Anakinra.

Two months after initiation of Anakinra, the patient developed a generalized erythematous and scaly eruption involving the trunk, abdomen, axillary folds, scalp, and both upper and lower limbs. Dermatological examination revealed multiple well-demarcated erythematous-squamous plaques, including inverse and peri-umbilical involvement, highly suggestive of psoriasis. The general condition remained preserved.

Skin biopsy was scheduled for histopathological confirmation. Immunological investigations including ANA and anti-dsDNA antibodies were requested to exclude drug-induced lupus. Anakinra was discontinued while awaiting further investigations, and topical symptomatic treatment was maintained.

Results

Paradoxical psoriasis has been extensively described with anti-TNF therapies but remains rarely reported with IL-1 blockade. The underlying mechanisms are not fully understood and may involve cytokine imbalance and dysregulated innate immunity. Differential diagnoses in our patient included paradoxical psoriasis and drug-induced lupus.

Conclusions

This case highlights a rare cutaneous adverse event induced by Anakinra in a pediatric patient with systemic JIA. Early recognition of paradoxical psoriasiform reactions during biologic therapy is important to optimize therapeutic management and prevent disease progression.

EADV CONGRESS
VIENNA
30 SEP - 3 OCT 2026

Abstract N°: 3174

From Aesthetics to an Aesthetic Problem: Red Pigment as a Trigger of a Granulomatous Reaction –A Case Report

Filip Bosnić*[1], Nika Filipović Mioč[1], Ivana Starčević[1], Mislav Mokos[1], Mirela Krišto[1, 1], Nikola Ferara[1, 1], Leo Košuta[2]

[1] Sestre milosrdnice University Hospital Center, Department of Dermatology and Venereology, Zagreb, Croatia
[2] School of Medicine, University of Zagreb, Zagreb, Croatia

Introduction

Reactions to tattoo pigments, particularly red pigment, may present with a wide range of clinical and histological patterns and can mimic granulomatous dermatoses such as granuloma annulare, necrobiosis lipoidica, or sarcoidosis. Lichenoid, eczematous, and pseudolymphomatous patterns have also been described, as well as the occurrence of perforating dermatoses and even neoplastic changes. Due to this variability, diagnosis can be challenging and requires careful clinicopathological correlation.

Case Presentation

A 49-year-old female patient presented with pruritic, indurated nodules and papules on the distal part of the right lower leg. The lesions had developed over the past year within the red-colored portion of a tattoo that had been made 8 years earlier. The patient had a known history of atopic diathesis, including asthma and allergic rhinitis. As part of an extensive diagnostic workup (chest X-ray, angiotensin-converting enzyme levels, and serum calcium), systemic sarcoidosis was excluded. Histopathological examination revealed interstitial granulomatous dermatitis with collagen necrobiosis, a diffuse lymphohistiocytic infiltrate, and focal hyalinization of the dermis, without well-formed granulomas. Sparse exogenous red pigment was identified in the superficial dermis. Morphologically, the findings were closer to a necrobiosis lipoidica-like pattern, although granuloma annulare could not be definitively ruled out. In the context of lesion localization and the presence of exogenous pigment, the findings were consistent with a reactive granulomatous response to tattoo pigment. Tattoo-related granulomatous reactions are thought to represent delayed-type hypersensitivity responses, often occurring years after pigment deposition. Red pigments, in particular, have been associated with a higher risk of adverse reactions, possibly due to their chemical composition. The chronic inflammatory response may lead to tissue remodeling and necrobiotic changes, further complicating histological interpretation.

Conclusion

Granulomatous reactions to red tattoo pigment may histologically mimic necrobiotic dermatoses, especially in the absence of well-formed granulomas. Accurate diagnosis relies on thorough clinicopathological correlation and identification of exogenous pigment, which helps avoid unnecessary investigations and misdiagnosis. Although rare, granulomatous reactions in tattoos can also represent a cutaneous manifestation of sarcoidosis, which must be excluded through appropriate clinical evaluation, as was done in this case. Therapeutically, topical and intralesional corticosteroids are most commonly used and often effective in reducing inflammation and lesion size. Cryotherapy may be considered in selected cases. Laser removal remains controversial, as it carries a potential risk of systemic reactions due to pigment fragmentation and dissemination. Careful follow-up is recommended to monitor treatment response and detect possible recurrence

POWERED BY M-ANAGE.COM

EA DV CONGRESS
VIENNA
30 SEP - 3 OCT 2026

Abstract N°: 3209

A spatially defined SPRR2F^{+} keratinocyte state underlies inflammatory activity and therapeutic response in psoriasis

Tatiana Sezin*[1], Nadia Prayitno[1], Yask Gupta[1], Henner Zirpel[1], Lena Pommerien[1], Sascha Ständer[1], Sadegh Mousavi[1], Diamant Thaçi[1]

[1] Institute and Comprehensive Center for Inflammation Medicine, University of Lübeck, Germany, Lübeck, Germany

Introduction
Psoriasis is a chronic immune-mediated skin disease driven by dysregulation of the IL-17/IL-23 axis. While biologic therapies targeting this pathway are highly effective, IL-17 inhibitors induce faster clinical responses than IL-23 inhibitors, suggesting distinct tissue-level mechanisms that remain incompletely understood.

Materials and Methods
We performed high-definition spatial transcriptomics (10x Genomics Visium HD, 2 µm resolution) on 42 skin sections from 11 patients with moderate-to-severe plaque psoriasis. Lesional and non-lesional biopsies were collected at baseline, week 2, and week 16 during treatment with IL-17 inhibitors (ixekizumab, brodalumab) or IL-23 (guselkumab, risankizumab) inhibitors. Spatial data were integrated with a single-cell RNA-seq atlas using ENACT for cell-level deconvolution and spatial mapping.

Results
We identified a previously uncharacterized SPRR2F^{+} keratinocyte population localized to the upper spinous layers of the lesional epidermis and characterized by a strong antimicrobial and innate immune transcriptional program, indicating a specialized role at the epidermal barrier interface. Notably, SPRR2F^{+} cells constituted ~8% of keratinocytes in psoriatic skin and declined more rapidly and to a greater extent under IL-17 than IL-23 inhibition. Under IL-17 inhibition, this population decreased approximately threefold by week 2 and was virtually absent by week 16, whereas IL-23 inhibition resulted in a more modest ~2-fold and ~6-fold reduction at 2 and 16 weeks, respectively. Re-emergence of this population was associated with disease relapses.
Protein-level validation confirmed SPRR2F expression in the spinous epidermis, identifying these cells as a major source of antimicrobial peptides. Consistently, minimally invasive skin-rinse measurements of S100A8/A9 mirrored SPRR2F dynamics, showing a ~3-fold reduction at week 2 and ~20-fold reduction by week 16 under IL-17 inhibition, compared to a more modest decline with IL-23 blockade. These findings support a potential non-invasive biomarker axis reflecting epidermal inflammation. Furthermore, SPRR2F^{+} cells co-localized with peptidase inhibitor 3 (PI3), a known antimicrobial protein and marker of disease severity in plaque psoriasis. Functional knockdown of SPRR2F attenuated IL-17–induced inflammatory gene programs in primary keratinocytes, indicating an active role in amplifying epidermal inflammation.

Conclusions
Together, these findings identify SPRR2F^{+} keratinocytes represent a spatially defined effector population that links IL-17 signaling to epidermal inflammation and provides mechanistic insight into the differential response kinetics

of IL-17 versus IL-23 inhibition in psoriasis.

EADV CONGRESS
VIENNA
30 SEP - 3 OCT 2026

Abstract N°: 3255

Blaschkoid Lichen Planus Mimicking Striae Distensae: An Unusual Clinical Presentation

Derya Yayla[1], Leyla Büşra Öztürkmen*[1], Mustafa Ciner[1], Ayça Ataş[1], Gülşen Akoğlu[1]

[1] Gülhane Eğitim Ve Araştırma Hastanesi, Ankara, Türkiye

Introduction

Lichen planus (LP) is a common inflammatory dermatosis that typically presents with pruritic, polygonal, purple papules. However, its clinical morphology can vary significantly. Linear LP following the **Lines of Blaschko** (Blaschkoid LP) is a rare variant that can mimic other linear conditions. We present a case where Blaschkoid LP clinically resembled **striae distensae** in the axillary region, posing a diagnostic challenge.

Case Presentation

A 46-year-old female presented with a history of linear, reddish lesions in her right axilla. Upon dermatological examination, erythematous, striae-like plaques were observed extending along the axillary fold. The initial clinical impression included striae distensae or linear morphea.

To confirm the diagnosis, a **punch biopsy** was performed. The histopathological analysis revealed:

- Hyperkeratosis and "saw-tooth" appearance of rete ridges.
- A dense, band-like lymphocytic infiltrate at the dermo-epidermal junction.
- Vacuolar degeneration of the basal layer.

Based on the clinicopathological correlation, the patient was diagnosed with**Blaschkoid Lichen Planus**. Treatment was initiated with topical **mometasone furoate** and emollients, which led to a significant reduction in erythema and pruritus.

Conclusion

This case emphasizes that LP should be considered in the differential diagnosis of linear erythematous lesions, even in atypical locations like the axilla. When LP follows Blaschko's lines, it can closely mimic the appearance of striae distensae. Histopathological examination remains the gold standard for avoiding misdiagnosis and ensuring appropriate anti-inflammatory treatment.

EA DV CONGRESS
VIENNA
30 SEP - 3 OCT 2026

Abstract N°: 3262

Erythema gyratum repens-like eruption in a patient with coexisting pemphigus foliaceus and psoriasis

Roxana-Mihaela Florescu*[1], Simona-Roxana Georgescu[1, 2], Mădălina-Ioana Mârza[1], Ilinca Doria Costescu[2], Monica Costescu[1, 2]

[1] Clinical Hospital of Infectious and Tropical Diseases Dr. Victor Babeş, Bucharest, Romania

[2] Carol Davila University of Medicine and Pharmacy, Bucharest, Romania

Introduction

Erythema gyratum repens is a rare, distinctive dermatosis characterized by rapidly migrating concentric erythematous bands with wood-like appearance caused by advancing serpiginous plaques and trailing scale. The eruption typically progresses quickly and usually involves the trunk and proximal extremities while sparing the face, hands, and feet.

It is considered a classic paraneoplastic dermatosis, most commonly associated with lung carcinoma. Although the number of non-neoplastic associations is increasing.

Associations between erythema gyratum repens-like eruptions and autoimmune dermatoses, particularly concomitant psoriasis and pemphigus foliaceus, are exceptionally uncommon.

Case Presentation

We report the case of a 61-year-old man admitted to our Dermatology Department for extensive erythematous and scaly lesions. The skin eruption had started one month prior to presentation, initially involving the scalp, with subsequent extension to the face and upper trunk. The upper and lower extremities were less severely affected. Mucosal involvement was absent. The patient reported significant xerosis without pruritus or pain.

At the initial hospitalization, clinical examination revealed diffuse erythematous-squamous plaques. Laboratory investigations performed at admission demonstrated mildly elevated inflammatory markers, including erythrocyte sedimentation rate and C-reactive protein levels. Bacteriological cultures revealed superinfection with *Staphylococcus aureus* and *Streptococcus agalactiae*, a complication frequently encountered in pemphigus foliaceus due to epidermal barrier disruption.

The patient was started on topical and systemic corticosteroid therapy, associated with intravenous amoxicillin-clavulanic acid and topical treatment containing neomycin, metronidazole, and hydrocortisone, resulting in rapid improvement and marked reduction of scaling within several days. He was discharged with continuation of corticosteroid treatment.

However, one to two weeks later, the patient returned for follow-up with recurrence of scaling lesions and reported significant discomfort and pain during topical corticosteroid application, resulting in poor adherence to topical treatment and subsequent aggravation of the cutaneous lesions. The patient was advised to continue topical corticosteroid therapy in combination with a soothing emollient cream. Two weeks later, he required readmission due to aggravation of the

cutaneous eruption, which had evolved into annular and concentric erythematous plaques with centrifugal extension and superficial scaling, resembling an erythema gyratum repens-like pattern.

Histopathological examination of two separate skin biopsies demonstrated similar features consistent with both psoriasis and pemphigus foliaceus, including superficial acantholysis involving the granular layer, hyperkeratosis with parakeratosis, focal spongiosis with neutrophils, and acanthosis. Serological testing revealed strongly positive anti-desmoglein 1 antibodies with a titer of 1:1280, supporting the diagnosis of pemphigus foliaceus. The patient had no personal history of psoriasis or other autoimmune dermatoses.

Although erythema gyratum repens is classically associated with malignancy, no clinical findings suggestive of an underlying neoplastic process were identified during hospitalization, supporting the possibility of a non-paraneoplastic erythema gyratum repens-like eruption.

Given the progressive evolution and recurrence of lesions despite corticosteroid therapy, cyclosporine treatment was initiated, resulting in progressive improvement of the cutaneous eruption.

Conclusion

This case highlights a rare erythema gyratum repens-like presentation associated with overlapping psoriasis and pemphigus foliaceus. Our report supports the concept that erythema gyratum repens-like eruptions may occur in the setting of autoimmune inflammatory dermatoses and should be considered in the differential diagnosis of rapidly evolving figurate erythematous lesions.

EA DV CONGRESS
VIENNA
30 SEP - 3 OCT 2026

Abstract N°: 3268

Clinical Features and Treatment Outcomes of Cutaneous Plasmacytosis: A Systematic Review

Meghna Varambally*[1], Jennifer Tran[1], Nima Karimi[1], Ruzeng Xue[2], Harry Chaocheng Liu[3, 4]

[1] Schulich School of Medicine and Dentistry, Western University, London, Ontario, Canada

[2] Dermatology Hospital, Southern Medical University, Guangzhou, China

[3] Department of Dermatology and Skin Science, University of British Columbia, Vancouver, British Columbia, Canada

[4] School of Medicine, Simon Fraser University, Surrey, British Columbia, Canada

Introduction

Cutaneous plasmacytosis (CP) is a rare benign proliferation of mature plasma cells in the skin that may progress to systemic involvement and has associated systemic diseases. This review aims to provide an overview on the epidemiology, clinical manifestations, and treatment outcomes of CP and cutaneous and systemic plasmacytosis (CSP).

Materials and Methods

Databases MEDLINE, Embase, and Scopus were searched from inception to January 2026 in accordance with PRISMA guidelines. Primary studies describing clinically diagnosed or histologically confirmed CP or CSP were eligible for inclusion. Two reviewers independently conducted screening and data extraction; conflicts were resolved by a third reviewer. Study quality was evaluated using the Oxford Centre for Evidence-Based Medicine criteria.

Results

Eighty-nine studies involving 149 patients were included, consisting of CP (n=94), CSP (n=50), and secondary CP (n=5). The mean age was 49.2 and 36.9% were female. Most patients were East Asian, most commonly Chinese (32.2%) and Japanese (21.5%). Common cutaneous findings included plaques (91/136; 67%), papules (53/136; 39%), and macules (42/136; 31%), predominantly affecting the trunk (91.9%) and head and neck (40.9%). Associated systemic conditions included concurrent hematologic disorders (16.1%), Castleman's disease (6.7%), and IgG4 disease (4.0%). Laboratory abnormalities included polyclonal hypergammaglobulinemia (43.6%), elevated CRP/ESR (23.5%), elevated IL-6 (18.1%; range 89.4-208 mg/dL), and elevated IgG4 (12.8%). Reported treatments included topical corticosteroids (20.6%), oral steroids (30.9%), interventional (including surgical excision, intralesional therapies, cryotherapy, and phototherapy;12.5%), topical calcineurin inhibitors (11.0%), and oral antibiotics (11.0%). Treatment duration ranged from 1 week to 3.5 years. Among 76 patients with documented outcomes, 21.6% achieved complete resolution and 28.8% experienced partial resolution, while others demonstrated progression or relapse (16.2%), or no change (24.3%). Five deaths (4.5%) were reported due to pulmonary edema, neoplastic progression, bilateral interstitial pneumonitis, cryptococcosis of the lung, and one etiology unknown.

Conclusions

CP should be considered in Asian patients presenting with red/violaceous-brown dermal papules or plaques involving the trunk and/or face. Evaluation for IL-6 and IgG4 abnormalities are crucial, and clinicians should screen and monitor for associated anemia, Castleman disease, and IgG4-related disease.

EA DV CONGRESS
VIENNA
30 SEP - 3 OCT 2026

Abstract N°: 3301

Refractory granulomatous cheilitis successfully treated with upadacitinib

Hugo Leme*[1], Margarida Pereira[1], António Magarreiro-Silva[1], Joana Nogueira[1], Ana Gouveia[1]

[1] Unidade Local de Saúde de Almada-Seixal, Almada, Portugal

Introduction

Granulomatous cheilitis is a rare chronic inflammatory disorder characterized by recurrent or persistent lip swelling characterized histologically by non-necrotizing granulomatous inflammation. Management remains challenging due to the absence of standardized treatment and limited evidence supporting systemic therapies in refractory cases.

Case Presentation

A 23-year-old woman presented with a 7-year history of recurrent lip edema, initially interpreted as angioedema due to spontaneous partial resolution of early episodes. During the preceding 18 months, persistent painless swelling of the lower lip developed, associated with inflammatory-type arthralgia of the left wrist. No facial palsy, fissured tongue, respiratory symptoms or initial gastrointestinal complaints were reported. Previous multidisciplinary evaluations failed to establish a definitive diagnosis.

Histopathological examination revealed chronic inflammatory infiltrate with non-necrotizing epithelioid granulomas extending into the soft tissues, while Periodic acid–Schiff, Grocott, Ziehl–Neelsen and Giemsa stains were negative for microorganisms. Extensive autoimmune, infectious and granulomatous disease work-up was unremarkable. Fecal calprotectin, chest radiography, interferon-gamma release assay and colonoscopy were also normal.

A diagnosis of granulomatous cheilitis was established. Topical clobetasol showed no significant benefit. Adalimumab was subsequently initiated following latent tuberculosis exclusion, resulting in only partial clinical improvement after 3 months. Due to persistent disease activity, dapsone 50 mg/day was introduced and later increased to 75 mg/day, with insufficient clinical response.

Upadacitinib 30 mg/day was initiated after inadequate response to previous therapies, leading to substantial clinical improvement, with approximately 60% reduction of lip swelling after 3 months and sustained improvement of nearly 80% at 6-month follow-up. Treatment was well tolerated apart from mild acneiform eruption and discrete hypercholesterolemia.

Conclusion

Granulomatous cheilitis may represent a significant diagnostic and therapeutic challenge due to its chronic relapsing course, rarity, and clinical overlap with conditions such as angioedema, frequently leading to delayed diagnosis. This case also highlights the absence of standardized treatment strategies and the difficulty in managing refractory disease. Upadacitinib may represent a promising therapeutic option in patients with inadequate response to conventional systemic therapies and anti-TNF agents.

EA DV CONGRESS
VIENNA
30 SEP - 3 OCT 2026

Abstract N°: 3328

Scurvy: Not so Historical After All – A Case Report

Salma Abid*[1], Hasnae Zerhouni[1], Narjess Er-rachdy[1], Najoua Ammar[1], Syrine Hamada[1], Nadia Ismaili[1], Laila Benzekri[1], Mariame Meziane[1]

[1] Dermatology Department of University Hospital Ibn Sina, Rabat, Morocco

Introduction

Scurvy is a severe vitamin C deficiency, described as early as the 15th century during long maritime expeditions. Once dreaded, it nearly vanished with industrialization, persisting only in contexts of extreme malnutrition and isolation. However, a recent resurgence has been reported, particularly in children with restrictive diets or neuropsychiatric disorders, which combined with the rare and often overlooked nature of the disease, frequently leads to diagnostic delays that can be fatal. Simple and widely available therapy typically results in a rapid resolution of clinical manifestations.

Case Presentation

We report the case of a 15-year-old female patient with no prior medical history, hospitalized for chronic abdominal pain, diarrhea, and weight loss over a 4-month period, raising suspicion of Crohn's disease. One month later, the patient developed a mucocutaneous hemorrhagic syndrome characterized by petechial and ecchymotic purpura, gingival bleeding, loosening of teeth, and significant rectal bleeding.

Physical examination revealed non-palpable purpura with several bullae, associated with severe deterioration of the general health status. Dermoscopy of the ecchymotic lesions did not show follicular hyperkeratosis, perifollicular purpura, or corkscrew hairs. Laboratory investigations revealed normochromic normocytic anemia and normal platelet counts, with no inflammatory syndrome. Viral serologies were negative. A skin biopsy confirmed a purpuric lesion without signs of vasculitis. A diagnosis of scurvy was established, and vitamin C supplementation was initiated, leading to rapid clinical improvement within days.

DISCUSSION

Scurvy is considered rare in industrialized nations; however, several reports in the literature suggest it remains underdiagnosed. A British study based on the Low-Income Diet and Nutrition Survey showed that 46% of men and 35% of women living in precarious conditions suffer from vitamin C deficiency or depletion.
Scurvy results from a deficiency in ascorbic acid, an essential cofactor for collagen synthesis, which is responsible for the stability of connective tissues and vascular walls. This deficiency explains the hallmark clinical manifestations: non-palpable purpura, mucosal hemorrhage, gingival disorders, musculoskeletal pain, and impaired wound healing. Nevertheless, the presentation can be atypical, leading to diagnostic wandering and unnecessary investigations.
The diagnosis is primarily clinical, supported by serum vitamin C levels. It should be suspected in any patient presenting with a combination of constitutional symptoms, non-palpable purpura, and a context of malnutrition.

Conclusion

The primary objective of this case is to serve as a reminder that even in the era of modern medicine, scurvy remains a reality. Early replacement therapy rapidly transforms the prognosis.

EA DV CONGRESS
VIENNA
30 SEP - 3 OCT 2026

Abstract N°: 3337

Ofuji Disease: A Rare Pustular Dermatosis Not to Be Overlooked

Hafsa Laouni*[1], Sara Elloudi[1], Majda Kadi[1], Ikram Bejja[1], Saadia Boughaleb[1], Zakia Douhi[1], Meryem Soughi[1], Hanane Baybay[1], Fatima Zohra Mernissi[1]

[1] Dermatology Department, HASSAN II University hospital, Fès, Morocco

Introduction

Eosinophilic pustular folliculitis (EPF), formerly known as Ofuji disease, is a rare idiopathic pruritic papulopustular dermatosis comprising three distinct subtypes: infantile EPF (iEPF), classic adult EPF, and immunosuppression-associated EPF (IS-EPF). These three subtypes are characterized by a non-infectious pruritic pustular eruption and histological eosinophilic infiltrates.

Case Presentation

A 57-year-old man with a history of thrombocytosis, followed in internal medicine and treated with antiplatelet therapy, presented to our department with fluid-filled lesions on the limbs evolving in relapsing–remitting flares for one year, without a history of bipolar aphthosis, digestive symptoms, or other associated complaints. The patient had previously been treated with topical corticosteroids and reported receiving several courses of antibiotics without improvement. Dermatological examination showed multiple milky follicular pustules on both lower and upper limbs, arising on large circinate erythematous plaques. Given the clinical presentation and lack of response to prior treatments, EPF was suspected, and a skin biopsy was performed. Histopathological examination confirmed EPF, showing skin tissue lined by an epidermis with variable acanthosis and focal spongiosis. An infundibular eosinophilic pustule was observed in relation to a hair follicle, surrounded by a dense inflammatory infiltrate composed of lymphocytes, macrophages, and eosinophils. The eosinophils exhibited exocytosis through the spongiotic epidermis, forming the superficial pustule described above.
Following this confirmation, HIV serological testing was performed and was negative. The complete blood count showed no peripheral eosinophilia. Treatment with dapsone was initiated, with good clinical improvement.



Multiple circinate erythematous plaques with follicular pustules on both lower limbs

Conclusion

EPF is a rare condition with a wide geographic distribution. Lesions are characterized by recurrent flares of sterile follicular pustules and papules forming circinate plaques with centrifugal expansion. The classic distribution of EPF lesions includes the face, back and trunk, and other seborrheic areas. Lesions may also occur on the extremities, palms, and soles, despite the absence of hair follicles in the latter sites. Leukocytosis and eosinophilia have been reported in up to 35% of patients. Therapeutic options for EPF include topical corticosteroids, indomethacin, dapsone, prednisolone, retinoids, colchicine, itraconazole, cyclosporine, minocycline, PUVA, UVB, and infliximab. Among systemic treatments, indomethacin is considered the most effective first-line therapy. Although indomethacin is regarded as the first-line oral treatment for EPF, our observation highlights the effectiveness of dapsone in this condition. The mechanism of action of dapsone is based on inhibition of eosinophil peroxidase activity and chemotactic signal transduction.

EADV CONGRESS
VIENNA
30 SEP - 3 OCT 2026

Abstract N°: 3353

Two cutaneous manifestations of cocaine use in the same patient. Case study and literature review.

Marta Folcra Gonzalez*[1], Ricardo Valverde Garrido[1], Jaime Mejías Bielsa[2], Alberto Sáez Vicente[1], Paola Maldonado Cid[1], Iolanda Prats Caelles[1]

[1] Department of Dermatology, Hospital Universitario Infanta Sofia, Madrid, Spain
[2] Department of Pathology, Hospital Universitario Infanta Sofia, Madrid, Spain

Introduction

Cocaine is a well known drug to dermatologists, since its use is often manifested in the skin. Clinical signs of cocaine use can be caused by either local or systemic action of the drug, and by various physiopathological mechanisms. They are often classified as secondary to: ischemia, adulterants (also known as cutting agents) and/or neutrophil activation.

Case Presentation

We present the case of a 51 year-old male, who had no prior relevant medical history except the use of cocaine almost daily for more than 10 years. When he was first referred to our consult, he presented with an ulcerated lesion in his nose which had been steadily growing in size for the last 4 years, despite medical and surgical treatment. In that first moment it was deemed as ischemic and treated topically, with no major changes, so a biopsy was performed. The biopsy was consistent with cocaine-induced plasma cell orificial dermatomucositis (CID). Furthermore, during treatment, he also developed cribriform, ulcerated lesions in his lower extremities, clinically and histologically consistent with pyoderma gangrenosum. Finally, with a strong recommendation to stop cocaine use, adalimumab was prescribed and both types of lesions improved significantly. During monitoring he experienced relapses, which consequently worsened both skin conditions.

Conclusion

When consulting similar manifestations of cocaine use in the skin, both CID and pyoderma have been reported in this context, but never in the same patient at the same time. CID is a recently described condition, only reported in Spanish patients who use cocaine. Thus, it is believed to be caused by an unknown adulterant present only in Spain. On the other hand, neutrophil activation can also occur and could be the cause of pyoderma gangrenosum in our patient. In both cases, CID and pyoderma, management is varied, but it rests upon the discontinuation of cocaine use. Other possible treatments include classic immunosuppressant therapy and TNF inhibitors, but results are diverse since they are seldom reported and these patients often leave monitoring.
Therefore, we present a case of coexistence of two manifestations of prolonged cocaine use in the same patient, in which evolution is linked to the use of the drug, so it is essential that we help our patients stop abusing cocaine in order to help them heal their skin and overall improve their lives.

EADV CONGRESS
VIENNA
30 SEP - 3 OCT 2026

Abstract N°: 3378

Acitretin versus Isotretinoin in Pustular Psoriasis: A Real-World Comparative Study

MOHAMED HOUBAYELI*[1], Bendaoud Layla[1], Mariem Aboudourib[1], Ouafa Hocar[1], Amal Said[1]

[1] Mohammed VI University Hospital of Marrakech, Bioscience and Health Laboratory, Department of Dermatology Venerology, marrakech, Morocco

Introduction
Pustular psoriasis (PP), including generalized and localized forms, is a severe inflammatory variant of psoriasis requiring rapid systemic treatment. Acitretin is considered the reference systemic retinoid in PP; however, its intermittent unavailability in Morocco significantly limits its use. Isotretinoin, more readily accessible and associated with a shorter post-treatment contraceptive period, remains insufficiently studied in this indication.

Objective

To compare the efficacy and tolerability of acitretin and isotretinoin in patients with pustular psoriasis managed in a tertiary-care setting.

Materials and Methods
We conducted a retrospective comparative study including patients with pustular psoriasis treated with either acitretin or isotretinoin at the Dermatology Department of Mohammed VI University Hospital, Marrakech. Baseline severity was assessed using the Generalized Pustular Psoriasis Area and Severity Index (GPPASI). Clinical response at 1 and 3 months, hospitalization duration, relapse rates, and treatment-related adverse events were analyzed. Statistical comparisons were performed using appropriate parametric tests, with $p < 0.05$ considered significant.

Results
Fifty-four patients were included (32 acitretin; 22 isotretinoin). Baseline demographic characteristics and initial GPPASI scores were comparable between groups (mean 40–42), confirming severe disease activity.

At 1 month, both treatments induced clinical improvement, with a greater reduction in GPPASI under acitretin (≈50%) compared with isotretinoin (≈30%).

At 3 months, mean GPPASI was significantly lower in the acitretin group compared with the isotretinoin group (8 vs 15; **p = 0.003**), demonstrating superior sustained efficacy.

Relapse rates ranged from 20–25% and were slightly higher in the isotretinoin group, particularly at lower maintenance doses. Under acitretin, relapses mainly occurred following dose reduction. Metabolic adverse events and mucocutaneous dryness were more frequent in the acitretin group, suggesting a slightly more favorable metabolic tolerance profile with isotretinoin. Hospitalization duration was comparable between groups.

Conclusions
In this real-world comparative study, acitretin demonstrated significantly faster and more durable disease control

compared with isotretinoin in pustular psoriasis. Nevertheless, isotretinoin represents a valuable therapeutic alternative in contexts of drug unavailability or near-term pregnancy planning, with an acceptable safety profile. Treatment decisions should integrate efficacy, tolerability, and contextual constraints.

EADV CONGRESS
VIENNA
30 SEP - 3 OCT 2026

Abstract N°: 3396

Role of Azathioprine in Vulvar Crohn's:A case series

Pratik Gajbe*[1], Swagata Tambe[1]

[1] Seth V C Gandhi & M A Vora Municipal General Hospital, Mumbai, India

Introduction

Introduction:
Vulvar Crohn’s disease (VCD) is a rare extraintestinal manifestation of Crohn’s Disease characterized by granulomatous inflammation of the vulva, with or without gastrointestinal involvement. It commonly presents with vulvar edema, ulceration, fissuring, and discharge, often leading to delayed diagnosis because of its nonspecific presentation. Management remains challenging, and immunomodulators such as azathioprine play an important role in long-term disease control.

Case Presentation

Case 1: A 13-year-old female presented with vulvar perianal swelling and ulceration.Further evaluation with colonoscopy revealed ileal erosions with and on colon biopsy was suggestive of mild active ileitis and colitis . On skin biopsy showed dermal edema with mixed granulomatous inflammatory infiltrate of neutrophil, epitheliod cells,lymphocytes and giant cell in superior and deep dermis were seen.Based on clinicopathological correlation and supportive investigation diagnosis of vulvar crohn's disease was established .Treatment with azathioprine was initiated, following which marked clinical improvement was observed in vulvar swelling and ulceration.
Case 2:A 44-year-old married female presented with foul smelling discharge in the groins with deep ulcers in groins between gluteal area and lower abdomen for 4 months.She had nodular growth on vulva which was previously excised as vulvar papilloma.There was history of choroidal granuloma for which she took intravitral injections. Skin biopsy findings suggestive of vulvar crohn's disease.Based on clinicopathological correlation and supportive investigations diagnosis of vulvar crohs disease was established.Treatment with Azathioprine 2mg/kg was initiated.Following Azathioprine therapy marked clinical improvement and complete healing of ulcer was observed.

Conclusion

Conclusion:
Vulvar Crohn’s disease is an uncommon condition that may occur with or without gastrointestinal manifestations. A high index of suspicion is required for early diagnosis, particularly in young females presenting with persistent vulvar swelling and ulceration. Azathioprine appears to be an effective therapeutic option in managing vulvar Crohn’s disease. It may help achieve significant clinical improvement in both cutaneous and systemic manifestations.

EADV CONGRESS
VIENNA
30 SEP - 3 OCT 2026

Abstract N°: 3405

Impact of Disease Severity and Episode Duration on the Efficacy of Upadacitinib in Adults and Adolescents With Severe Alopecia Areata: A Subgroup Analysis of the UP-AA Phase 3 Clinical Trial Program

Brett King*[1], Rocco Serrao[2], Justin Ko[3], Matthew Harries[4, 5], Vimal H. Prajapati[6, 7, 8, 9, 10, 11], Michela Starace[12, 13], Steven Bhathal[14], Xianwei Bu[14], Chenyang Duan[14], Tianshuang Wu[14], Henrique Teixeira[14], Andreas Lazar[15], Arash Mostaghimi[16]

[1] Dermatology Physicians of Connecticut, Fairfield, United States
[2] Dermatologists of Southwest Ohio, Mason, United States
[3] Department of Dermatology, Stanford University School of Medicine, Redwood City, United States
[4] Salford Royal Hospital, Northern Care Alliance NHS Foundation Trust, Manchester Academic Health Science Centre, Manchester, United Kingdom
[5] Centre for Dermatology Research, Faculty of Biology, Medicine and Health, University of Manchester & NIHR Biomedical Research Centre, Manchester, United Kingdom
[6] Probity Medical Research, Calgary, Canada
[7] Division of Dermatology, Department of Medicine, University of Calgary, Calgary, Canada
[8] Section of Community Pediatrics, Department of Pediatrics, University of Calgary, Calgary, Canada
[9] Section of Pediatric Rheumatology, Department of Pediatrics, University of Calgary, Calgary, Canada
[10] Skin Health & Wellness Centre, Calgary, Canada
[11] Dermatology Research Institute, Calgary, Canada
[12] Dermatology Unit, IRCCS Azienda Ospedaliero-Universitaria di Bologna, Bologna, Italy
[13] Department of Medical and Surgical Sciences, Alma Mater Studiorum University of Bologna, Bologna, Italy
[14] AbbVie Inc., North Chicago, IL, United States
[15] AbbVie Deutschland GmbH & Co. KG, Ludwigshafen, Germany
[16] Department of Dermatology, Brigham and Women's Hospital, Boston, United States

Introduction

Alopecia areata (AA) is a chronic immune-mediated inflammatory disease, characterized by nonscarring hair loss ranging from isolated patches on the scalp to complete scalp and body hair loss. In the ongoing UP-AA phase 3 clinical trial program (NCT06012240), once-daily upadacitinib 15 mg (UPA15) and 30 mg (UPA30) demonstrated superior efficacy over placebo for the treatment of severe AA in adults and adolescents at week 24, with a safety profile that is consistent with approved indications. Here, we evaluate whether the efficacy of UPA is affected by disease severity and episode duration at baseline.

Materials and Methods

In 2 parallel replicate studies (UP-AA1 and UP-AA2), patients aged 12-63 years with severe AA (defined as a Severity of Alopecia Tool [SALT] score ≥50) were randomized 2:2:1 to UPA15, UPA30, or placebo once daily for 24 weeks (period A). Randomization was stratified by baseline age groups (adults ≥18 years vs adolescents ≥12 to <18 years), baseline SALT score of severe AA (SALT score 50 to 94) vs very severe AA (SALT score 95 to 100) and AA episode duration at baseline (<3 years vs ≥3 years). The primary endpoint was SALT score ≤20 achievement at week 24. Prespecified demographic and disease characteristics subgroups included disease severity and current episode duration; these were analyzed separately using the Cochran-Mantel-Haenszel model with nonresponder imputation to handle missing data and intercurrent events. Integrated data from both studies were used for this

analysis.

Results

A total of 1399 patients were enrolled across both clinical trials, with balanced demographics and baseline disease characteristics (mean [SD] SALT score: 83.9 [18.9]; mean [SD] episode duration: 3.1 [2.2] years). At baseline, 48.8% and 51.2% of patients had severe and very severe AA, respectively, while 56.8% and 43.2% had AA episode duration <3 years and ≥3 years, respectively. At week 24, SALT score ≤20 was achieved by 44.9% (UPA15), 54.6% (UPA30), and 2.5% (placebo) of the overall patient population. Across all subgroups of disease severity and episode duration, UPA15 and UPA30 had higher response rates than placebo, and UPA30 outperformed UPA15, especially in patients with very severe AA. Among patients with severe/very severe AA at baseline, SALT score ≤20 was achieved by 55.8%/34.4% (UPA15), 56.9%/52.6% (UPA30), and 5.0%/0% (placebo), respectively (**Figure 1A**). In patients with AA episode duration <3 years/≥3 years at baseline, SALT score ≤20 was achieved by 53.1%/34.0% (UPA15), 63.6%/42.7% (UPA30), and 3.9%/0.8% (placebo), respectively (**Figure 1B**). SALT score ≤10 was achieved by 35.6% (UPA15), 46.4% (UPA30), and 1.1% (placebo) of the overall population, with response rates being 46.4%/25.3% (UPA15), 46.5%/46.4% (UPA30), and 2.1%/0% (placebo) for severe/very severe AA, respectively, and 45.0%/23.2% (UPA15), 52.6%/38.1% (UPA30), 1.9%/0% (placebo) for episode duration <3/≥3 years, respectively. SALT score 0 was achieved by 13.6% (UPA15), 21.4% (UPA30), and 0.4% (placebo) of the overall population, with response rates being 18.2%/9.1% (UPA15), 24.2%/18.9% (UPA30), 0.7%/0% (placebo) for severe/very severe AA, respectively, and 18.9%/6.6% (UPA15), 24.0%/18.0% (UPA30), and 0.6%/0% (placebo) for episode duration <3/≥3 years, respectively. Similar patterns of efficacy were observed for endpoints related to improvements in measures of eyebrow and eyelash hair loss.

Figure 1. Proportion of Patients Achieving Primary Endpoint of SALT ≤ 20 at Week 24

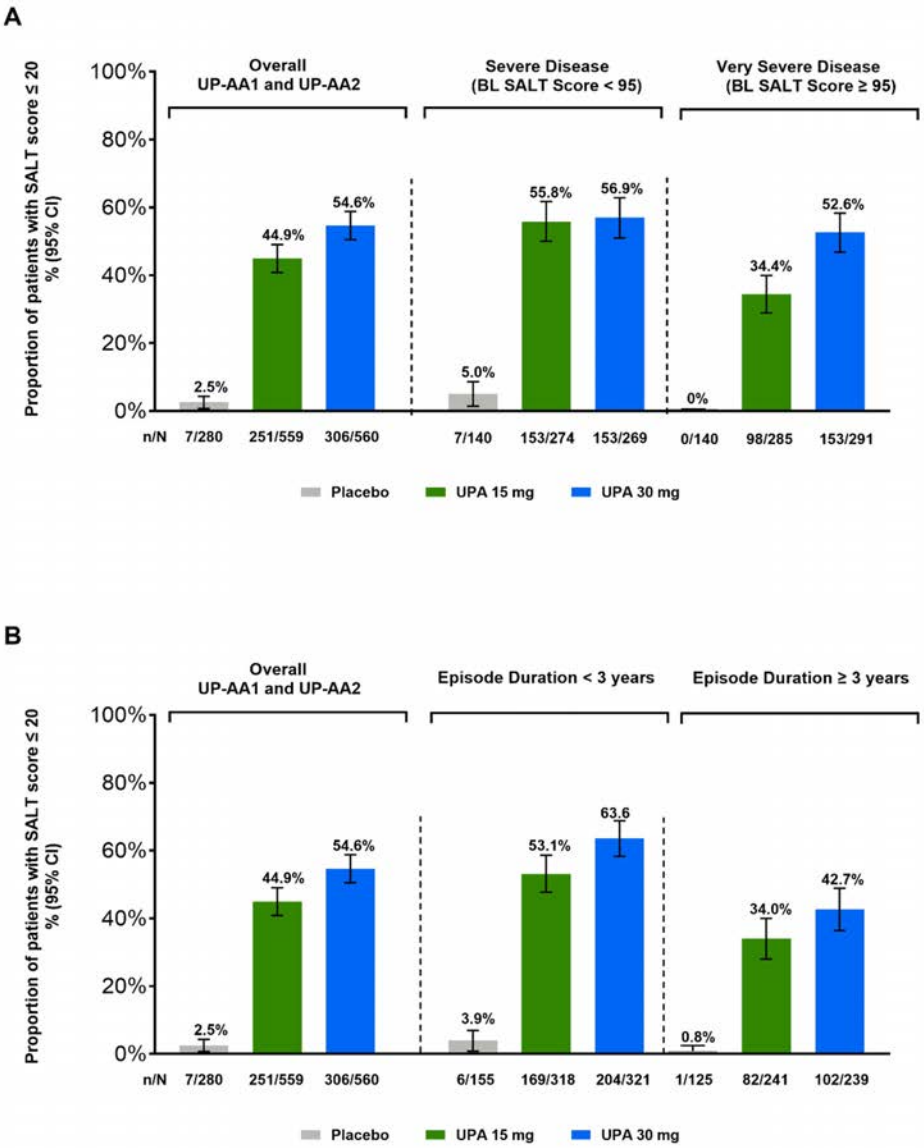

SALT score ≤ 20 is defined as less than or equal to 20% scalp hair loss.
Missing data and intercurrent events were handled using the NRI approach.

AA, alopecia areata; BL, baseline; NRI, nonresponder imputation; SALT, Severity of Alopecia Tool; UPA, upadacitinib.

Conclusions

At week 24, treatment with UPA15 and UPA30 showed higher SALT score ≤20 response rates than placebo across all clinical trial patients and the disease severity and AA episode duration subgroups; numerically better results were observed in patients with baseline SALT score <95 and current episode duration <3 years, indicating the importance of early intervention. Patients with very severe AA or a longer episode duration receiving UPA still achieved substantial hair regrowth, including SALT 0.

EA DV CONGRESS
VIENNA
30 SEP - 3 OCT 2026

Abstract N°: 3406

Rapid Response of Treatment-Refractory Generalized Granuloma Annulare to Upadacitinib 15 mg Daily

Ayberk Aktaran*[1], Ilknur Altunay[1]

[1] University of Health Sciences, Department of Dermatology and Venereology, Seyrantepe Hamidiye Etfal Training and Research Hospital, Istanbul, Türkiye

Introduction

Generalized granuloma annulare (GGA), conventionally defined by the presence of ≥10 widespread annular plaques, accounts for approximately 15% of granuloma annulare cases and frequently follows a chronic, treatment-refractory course. It demonstrates epidemiological associations with type 2 diabetes mellitus and dyslipidemia, both of which constrain therapeutic selection. Skin-profiling studies have demonstrated activation of Th1/Th2 cytokine signatures with downstream JAK-STAT signaling in granuloma annulare lesions, providing the biological rationale for targeted JAK inhibition. Conventional systemic options include hydroxychloroquine, retinoids, dapsone, methotrexate, and phototherapy, with variable efficacy; biologic agents and Janus kinase (JAK) inhibitors are reserved for refractory disease.

Case Presentation

A 55-year-old woman with biopsy-confirmed GGA presented with a 5-year history of more than ten erythematous, annular plaques across the dorsal hands, extensor forearms, and neck (total BSA ≈3%). Comorbidities included type 2 diabetes mellitus, dyslipidemia, and concomitant plaque psoriasis vulgaris. Sequential therapeutic failures over approximately 24 months comprised topical clobetasol propionate and tacrolimus 0.1%, repeated intralesional triamcinolone acetonide, cryotherapy, doxycycline, hydroxychloroquine 400 mg/day, methotrexate 15 mg/week, adalimumab 40 mg every two weeks for 9 months (yielding PASI 0 for concurrent psoriasis but no GA response), and cyclosporine 150 mg/day. Following off-label ministerial approval, upadacitinib was initiated at 15 mg once daily, the dose reported in the majority of published GGA case reports. A conservative dosing strategy was maintained in view of the patient's age (≥50 years) and cumulative metabolic-cardiovascular risk profile, balancing therapeutic intent against documented JAK1-inhibitor–associated risks of dyslipidemia, thromboembolism, major adverse cardiovascular events, and serious infection. Marked clinical regression of annular plaques was observed within approximately 4 weeks, with no adverse events at follow-up.

Conclusion

This case contributes to the growing primary literature documenting the rapid response of refractory GGA to oral JAK1 inhibition, with the onset of improvement reported within two to eight weeks across published cases. Response was achieved at the 15 mg once-daily regimen, the dose used in essentially all published GGA case reports to date, supporting its appropriateness as starting therapy in patients with metabolic-cardiovascular comorbidities. Given the recognized JAK inhibitor safety signals in patients ≥50 years with cardiovascular risk factors, individualized risk stratification remains essential. Prospective controlled studies are required to define optimal duration, tapering strategy, and long-term safety of upadacitinib in this indication.

EA DV CONGRESS
VIENNA
30 SEP - 3 OCT 2026

Abstract N°: 3409

Interstitial granulomatous dermatitis : a case with favorable response to methotrexate

Afli Donia*[1], Mariem Tabka[1], Feryel Amri[1], Zineb Mazzi[1], Asmahane Souissi[1], Ines Chelly[2], Mourad Mokni[1]

[1] Dermatology department, La Rabta Hospital, Tunis, Tunisia
[2] Anatomopathology department, La Rabta Hospital, Tunis, Tunisia

Introduction

Interstitial granulomatous dermatitis (IGD) is a rare reactive granulomatous dermatosis, most commonly associated with connective tissue diseases, particularly rheumatologic disorders. Diagnosis relies on clinicopathological correlation, while optimal management remains poorly defined. We report a case of IGD associated with arthralgia successfully treated with methotrexate.

Case Presentation

A 62-year-old woman with a history of hypertension, diabetes mellitus complicated by moderate-to-severe non-proliferative diabetic retinopathy and coronary artery disease, was referred for evaluation of a 3-month history of asymptomatic plaques involving the lower abdomen upper arms, and inner thighs. She had been followed in rheumatology for chronic arthralgia without evidence of defined inflammatory rheumatic disease. Dermatological examination showed large, well-defined, symmetrically distributed erythematous plaques with characteristic indurated, oedematous cords at the periphery, involving the lower abdomen, proximal upper limbs, and inner thighs.

Laboratory investigations, including complete blood count, inflammatory markers, immunological workup, serum protein electrophoresis, and viral serologies, were within normal limits. Computed tomography of the chest, abdomen, and pelvis showed no abnormalities. Histopathological examination showed a superficial and deep interstitial inflammatory infiltrate composed predominantly of histiocytes, associated with collagen degeneration, without significant mucin deposition. The clinical and histologic findings were supportive for interstitial granulomatous dermatitis.

Initial treatment with celecoxib and topical corticosteroids failed to improve the condition. Hydroxychloroquine was not initiated due to underlying diabetic retinopathy. Methotrexate was subsequently introduced at a weekly dose of 15 mg, resulting in complete resolution of the cutaneous lesions within 3 months, with significant improvement in joint pain. Treatment was later discontinued due to abnormal liver stiffness findings on FibroScan. There was no re-occurrence of the skin condition at follow-up.

Conclusion

IGD is a rare and poorly understood dermatosis, considered a reactive pattern often associated with systemic inflammatory conditions, particularly rheumatoid arthritis. However, it may also occur in patients without clearly defined autoimmune disease, as illustrated in our case, suggesting a broader spectrum of immune dysregulation. Clinically, IGD displays a polymorphic presentation, most commonly characterized by symmetrical erythematous to violaceous papules and plaques involving the trunk and proximal extremities, while skin-coloured papules, annular configurations and the characteristic linear cord-like lesions may occur less frequently. Histologically, IGD is characterized by an interstitial infiltrate of histiocytes with focal palisading and collagen alteration, helping to distinguish it from other granulomatous dermatoses.

Therapeutic management remains challenging and is not standardized. First-line treatments include topical corticosteroids and antimalarials such as hydroxychloroquine. In our patient, hydroxychloroquine was contraindicated due to diabetic retinopathy, limiting therapeutic options. Methotrexate has been reported as an effective alternative in refractory cases. However, its use requires careful monitoring due to potential hepatic adverse effects, as highlighted in our patient.

Our observation supports the efficacy of methotrexate in achieving both cutaneous and articular improvement, even in the absence of a well-defined inflammatory rheumatic disease.

EADV CONGRESS
VIENNA
30 SEP - 3 OCT 2026

Abstract N°: 3433

Multifocal Pyoderma Gangrenosum Associated with Antiphospholipid Syndrome: A Diagnostic and Therapeutic Challenge

Rim ZEROUATI*[1], Hajar AMMARI[1], Youssef ZEMMEZ[1], Mohamed EL AMRAOUI[1], Jawad EL AZHARI[1], Meryem KHALIDI[1], Rachid FRIKH[1], Naoufal HJIRA[1]

[1] Departement of Dermatology, Mohammed V Military Teaching Hospital, Rabat, Morocco

Introduction

Pyoderma gangrenosum is a rare neutrophilic dermatosis frequently associated with systemic diseases. Its association with antiphospholipid syndrome (APS) remains exceptional and represents both a diagnostic and therapeutic challenge. We report a case of multifocal pyoderma gangrenosum occurring in a patient with APS.

Case Presentation

A 39-year-old woman with a history of antiphospholipid syndrome, complicated by deep vein thrombosis and full-term fetal loss, presented with chronic lower limb ulcerations.

The disease initially began 16 months earlier with a post-traumatic ulceration of the right leg that recurred after skin grafting. Histopathological examination confirmed the diagnosis of pyoderma gangrenosum, and oral corticosteroid therapy was initiated.

Eight months later, the patient developed clinical worsening with the appearance of contralateral ulcerations associated with corticosteroid-related adverse effects, including cushingoid facies and extensive striae. Physical examination revealed a large ulceration on the right leg associated with four additional ulcerations on the left leg.

Laboratory investigations showed neutrophilic leukocytosis and secondary adrenal insufficiency, without associated vascular abnormalities. Management included local wound care, hyperbaric oxygen therapy, progressive corticosteroid tapering, and initiation of methotrexate, resulting in favorable clinical evolution with progressive healing.

Conclusion

Although uncommon, the association between pyoderma gangrenosum and antiphospholipid syndrome represents a major diagnostic and therapeutic challenge.

In patients with antiphospholipid syndrome presenting with atypical cutaneous ulcerations, pyoderma gangrenosum should be considered after exclusion of vascular and infectious causes. This case also highlights the potential severity of multifocal disease, the limitations of prolonged corticosteroid therapy, and the importance of early introduction of steroid-sparing treatment in cases of insufficient response or treatment-related toxicity.

EA DV CONGRESS
VIENNA
30 SEP - 3 OCT 2026

Abstract N°: 3434

Successful treatment of refractory genital lichen sclerosus with stromal vascular fraction, nanofat, and platelet-rich fibrin

Dudu Melike Keçeci*[1], Gulsen Akoglu[1]

[1] Department of Dermatology and Venereology, University of Health Sciences, Gülhane Training and Research Hospital, Ankara, Türkiye

Introduction

Lichen sclerosus is a chronic inflammatory dermatosis that predominantly affects the anogenital region. Although potent topical corticosteroids remain the first-line therapy, a substantial proportion of patients fail to achieve an adequate clinical response. Accordingly, regenerative therapies targeting tissue remodeling, including platelet-derived products and adipose-derived interventions such as stromal vascular fraction (SVF) and nanofat grafting, have emerged as promising treatment options for refractory disease.

Case Presentation

A 48-year-old woman presented with a 20-year history of chronic genital pruritus and vulvar pain, unresponsive to high-potency topical corticosteroids and emollients. A vulvar skin biopsy confirmed the diagnosis of lichen sclerosus. The patient underwent one session of autologous SVF injection followed, six months later, by one session of autologous nanofat injection. Subsequently, seven sessions of platelet-rich fibrin (PRF) injections were administered at approximately 20-day intervals.

Throughout the follow-up period, the patient's need for daily topical corticosteroid application progressively decreased to twice-weekly use. The pruritus severity score, assessed by Visual Analogue Scale (VAS; 0 = no symptom, 10 = most severe symptom), declined from 8 to 2. Clinical examination demonstrated near-complete resolution of vulvar atrophy, hyperkeratosis, and fibrotic changes compared with baseline findings, with residual postinflammatory hypopigmentation.

Conclusion

This case illustrates a severe, treatment-resistant form of genital lichen sclerosus in which regenerative medicine approaches were employed. The combination of adipose-derived regenerative therapies (SVF and autologous nanofat) with platelet-rich products has been shown to promote tissue regeneration, reduce inflammation, and improve fibrosis in genital lichen sclerosus. Previous studies have demonstrated that the combination of SVF and platelet-rich plasma (PRP) provides significant improvement in clinical severity and quality of life, while lipofilling combined with PRP has been associated with both morphological and functional recovery. Our findings are consistent with previous reports supporting the efficacy of regenerative approaches in refractory genital lichen sclerosus.

The combination of autologous nanofat, stromal vascular fraction, and platelet-rich fibrin may represent a safe and effective therapeutic strategy for refractory genital lichen sclerosus.

EA DV CONGRESS
VIENNA
30 SEP - 3 OCT 2026

Abstract N°: 3448

A silent pretibial nodule in childhood: an uncommon presentation of subcutaneous granuloma annulare

Ivana Starčević*[1], Dajana Smoljan Filipović[1], Mislav Mokos[1], Filip Bosnić[1], Iva Blajić[1, 2]

[1] University Hospital Center Sisters of Charity, Zagreb, Croatia
[2] Catholic University of Croatia, Zagreb, Croatia

Introduction

Granuloma annulare is a benign granulomatous dermatosis of unknown etiology that most commonly occurs in children and young adults. Several clinical variants have been described, including localized, generalized, perforating, and subcutaneous forms. Subcutaneous granuloma annulare represents a rare variant that occurs almost exclusively in childhood and clinically presents as painless, firm subcutaneous nodules with normal overlying skin color. Due to its nonspecific clinical presentation, it may represent a diagnostic challenge and mimic other benign and malignant subcutaneous lesions.

Case Presentation

We present the case of a seven-year-old girl with a lesion localized pretibially on the lower leg. The lesion had been present for two years, was completely asymptomatic, and represented an aesthetic concern. Clinical examination revealed a solitary, well-circumscribed, soft subcutaneous nodular lesion with normal overlying skin color. The girl's parents were not inclined toward any therapeutic option.A deep biopsy was performed, and histopathological analysis demonstrated granulomatous inflammation with histiocytes arranged in a palisading pattern surrounding areas of degenerated collagen, along with mucin deposits in the dermis and subcutaneous tissue, consistent with the subcutaneous form of granuloma annulare.

Conclusion

Numerous differential diagnoses should be considered, including rheumatoid nodules and benign and malignant subcutaneous tumors. Subcutaneous granuloma annulare may therefore represent a diagnostic challenge and often requires histopathological confirmation. This case highlights the importance of including this rare variant of granuloma annulare in the differential diagnosis of subcutaneous nodules in childhood, as well as the need for additional communication with parents in order to determine further therapeutic management.



Left pretibial subcutaneous nodule

EA DV CONGRESS
VIENNA
30 SEP - 3 OCT 2026

Abstract N°: 3454

The Itchy Coins Trap: Nummular Psoriasis Unmasked

Hiba Et-Taghy*[1], ikram lahmouch[1], Zaineb Kettani[1], Narjess Errachdy[1], Najoua Ammar[1], Syrine Hamada[1], Meriem Meziane[1], Nadia Ismaili[1], Laila Benzekri[1]

[1] Department of Dermatology, CHU Ibn Sina, Rabat, Morocco

Introduction

Nummular psoriasis is a rare clinical variant of plaque psoriasis, characterized by round, erythematosquamous plaques measuring 1 to 5 cm in diameter. Because of its atypical morphology, it is frequently misdiagnosed as tinea corporis or nummular eczema. We report a case of nummular psoriasis highlighting the importance of rigorous clinicopathological correlation to avoid diagnostic pitfalls.

Case Presentation

A 31-year-old man with no significant medical history presented with a mildly pruritic abdominal rash that had progressively worsened over three weeks. Physical examination revealed multiple sharply demarcated, round, nummular erythematosquamous plaques, 2 to 4 cm in diameter, located on the abdomen and flanks.(Fig1) The remainder of the examination was unremarkable, with no nail, scalp, or joint involvement. Laboratory workup, including inflammatory markers (CRP < 5 mg/L), was normal. A mycological culture was negative, ruling out tinea corporis. To differentiate from nummular eczema, a skin biopsy was performed. Histopathology revealed regular acanthosis, focal parakeratosis, hypogranulosis, and a perivascular lymphocytic infiltrate, confirming the diagnosis of psoriasis. First-line treatment with potent topical corticosteroids (clobetasol 0.05%) combined with narrowband UVB phototherapy was initiated, resulting in significant clinical improvement and clearance of the plaques within four weeks.



Figure 1. Clinical presentation of nummular psoriasis on the abdomen. Multiple sharply demarcated, erythematosquamous nummular plaques demonstrating a classic coin-like morphology with focal confluence.

Conclusion

Nummular psoriasis must be systematically considered in the differential diagnosis of pruritic nummular plaques, even in the absence of classic psoriatic topographic involvement (e.g., scalp, nails). The main differential diagnoses include tinea corporis, characterized by a peripheral active scaling collarette, and nummular eczema, which typically presents with oozing and spongiosis. Early mycological testing and skin biopsy are crucial to prevent diagnostic errors and inappropriate treatments. Prompt and accurate management optimizes outcomes and minimizes post-inflammatory pigmentary sequelae.

EADV CONGRESS
VIENNA
30 SEP - 3 OCT 2026

Abstract N°: 3483

Severe chronic hand eczema successfully treated with lebrikizumab in a patient with moderate-to-severe atopic dermatitis

Guiovana Fernanda Osorio Gomez[1], Juan Carlos Hernández Rodríguez*[1], Jose Juan Pereyra Rodriguez[1]

[1] Department of Dermatology. Virgen del Rocío University Hospital, Seville, Spain

Introduction

Chronic hand eczema (CHE) is a highly disabling condition that can substantially impair daily activities, occupational performance and quality of life. In patients with moderate-to-severe atopic dermatitis, hand involvement may be particularly persistent and difficult to treat, especially when atopic inflammation coexists with allergic contact sensitisation. Lebrikizumab, a monoclonal antibody targeting interleukin-13, represents a new therapeutic option for moderate-to-severe atopic dermatitis, but real-world data on its effect on severe chronic hand eczema remain limited.

Case Presentation

We report the case of a 44-year-old woman with a long-standing history of moderate-to-severe atopic dermatitis and severe CHE. The patient presented bilateral hand involvement characterised by erythema, scaling, lichenification and painful fissures affecting both palmar and dorsal surfaces. Patch testing showed clinically relevant sensitisation to nickel sulphate, methylchloroisothiazolinone and methylisothiazolinone. Previous systemic treatments included methotrexate and ciclosporin, with insufficient or only partial and transient response. At baseline, disease burden was high, with EASI 22.9, pruritus PP-NRS 9, pain PP-NRS 9, IGA-CHE 4, HECSI 134, DLQI 23 and POEM 21.

Lebrikizumab was initiated according to the approved dosing regimen for moderate-to-severe atopic dermatitis. After 16 weeks of treatment, the patient showed marked clinical improvement, with near-complete resolution of inflammatory signs on the hands and substantial reduction of fissuring, pain and pruritus. Clinical scores improved to EASI 3.4, pruritus PP-NRS 2, pain PP-NRS 1, IGA-CHE 1, HECSI 8, DLQI 5 and POEM 6. No adverse events were reported during follow-up.

Conclusion

This case illustrates a marked response of severe CHE to lebrikizumab in a patient with moderate-to-severe atopic dermatitis refractory to conventional systemic therapy. Selective IL-13 inhibition may provide meaningful clinical and quality-of-life benefits in difficult-to-treat atopic dermatitis phenotypes with severe hand involvement.

EA DV CONGRESS
VIENNA
30 SEP - 3 OCT 2026

Abstract N°: 3495

Efficacy of Minocycline in Refractory Hidradenitis Suppurativa: A Case Report

Billal Alibakir*[1], SOUMIA HAMZAOUI[1], chikhbled nadjet[1], Serradj Amina[1]

[1] Ehu oran, Oran, Algeria

Introduction

Hidradenitis suppurativa (HS) is a chronic inflammatory dermatosis affecting apocrine gland–bearing areas.[1,2] It is characterized by painful nodules, abscesses, and sinus tracts. Some forms remain refractory to conventional treatments, representing a major therapeutic challenge.[3]
We report a case of refractory hidradenitis suppurativa successfully treated with minocycline.

Case Presentation

A 35-year-old woman, B.R., followed since 2024 for hidradenitis suppurativa, with a history of cardiopathy, was referred to our department.
She had previously received several therapeutic lines without significant improvement, including antibiotics (metronidazole, cephalosporins, amoxicillin–clavulanic acid, pristinamycin) and tetracyclines (doxycycline and lymecycline).
Initial clinical examination revealed multiple papules and nodules, partially fistulized, associated with axillary sinus tracts and hypertrophic scars. The patient was classified as Hurley stage II with a moderate IHS4 score, showing a stationary course with frequent flares.
Treatment with minocycline 105 mg/day was initiated. After 6 months, a highly favorable outcome was observed, with complete healing of lesions, absence of new flares, and complete remission. A major improvement in quality of life was also noted, with the DLQI score decreasing from 21 to 6.



Before minocycline

Conclusion

Tetracyclines are considered first-line therapy in moderate HS because of their anti-inflammatory properties.[1,2] However, efficacy may vary between molecules. Owing to its specific pharmacological properties, minocycline may be effective in forms resistant to other tetracyclines.[4]

Several studies have demonstrated significant improvement with minocycline, either as monotherapy or in combination therapy.[2,4] Our observation highlights its efficacy even after failure of multiple antibiotic regimens, emphasizing its value in refractory forms. A notable impact was observed not only on cutaneous lesions but also on quality of life, as reflected by the marked reduction in DLQI score.

Minocycline appears to be an effective therapeutic option in hidradenitis suppurativa, including cases resistant to other tetracyclines. This case highlights its potential benefit in refractory forms, with prolonged remission and significant improvement in quality of life



EADV Congress 2026, VIENNA
30 SEPTEMBER - 03 OCTOBER 2026
POWERED BY M-ANAGE.COM

EA DV CONGRESS
VIENNA
30 SEP - 3 OCT 2026

Abstract N°: 3518

Effective treatment of vulvar lichen sclerosus with MC2-25 PAD Technology-cream with and without a dipeptide

Gudula Kirtschig[1], Louise Arenholt[2, 3, 4], Anja Snel-Prentø*[5], Thorkil Menné[5], Johan Selmer[5], Lars Iversen[5, 6]

[1] Medbase Health Centre, Frauenfeld, Switzerland
[2] Dept. of obstetrics and gynecology, North Denmark Regional hospital, Hjørring, Denmark
[3] Center for Clinical Research, North Denmark Regional Hospital, Hjørring, Denmark
[4] Department of Clinical Medicine, Aalborg University, Aalborg, Denmark
[5] MC2 Therapeutics, Hørsholm, Denmark
[6] Aarhus University, Aarhus, Denmark

Introduction

Vulvar Lichen Sclerosus (VLS) is an inflammatory, potentially scarring dermatosis that primarily affects the genital skin. In adult women with VLS, itch is the predominant symptom. It affects otherwise healthy individuals with a major impact on quality of life.

There are currently no treatments specifically approved for VLS in Europe or the UK. However, British and European guidelines recommend 3-month regimens with high potency topical corticosteroids daily, followed by maintenance treatment with high potency topical corticosteroids once or twice weekly and supported by moisturizers or emollients to maintain symptom relief.

The aetiology of VLS remains unclear, but evidence suggests two main pathogenic mechanisms; immunological dysreactivity and chronic inflammation, and abnormal collagen synthesis, which act on a susceptible genetic background and triggered by factors such as irritation from urine exposure. Urea, a degradation product excreted in urine, is a source of isocyanate through slow equilibrium. The reaction between isocyanate and amino groups, known as “carbamylation”, is irreversible and may contribute to the pathogenic mechanisms in VLS. Based on in-vitro data, the active dipeptide drug substance (Alanyl-Glutamine) in MC2-25 dipeptide PAD Technology cream (PAD-cream) appears to be an efficient isocyanate scavenger and MC2-25 dipeptide PAD-cream is therefore hypothesised to counteract the effects of carbamylation and potentially alleviate VLS.

Materials and Methods

This phase 2, double-blinded trial explored the efficacy and safety of MC2-25 dipeptide PAD-cream versus MC2-25 PAD-cream in 33 women with VLS randomized in a 1:1 ratio across six centres in Denmark. Approximately one fingertip-unit, roughly corresponding to 0.5 g of the assigned investigational product was applied by the participants after each toilet visit during the 12-week treatment period.

The primary endpoint was mean change in weekly mean Worst Itch - Numeric Rating Score (WI-NRS) recorded in the patient’s diary from Baseline to Week 12 for dipeptide PAD-cream compared to PAD-cream, which was analysed using a mixed model of repeated measures.

Results

The primary efficacy endpoint did not show statistically significant difference in treatment effect between the two treatment groups. A mean reduction in WI-NRS of 4 and 3,5 points were seen in the dipeptide PAD-cream and the PAD-cream group, respectively. The results from secondary and exploratory efficacy endpoints were in line with this showing reduction of itch and pain as well as improvement of health-related quality of life during the 12 weeks treatment period, but with similar effects between the treatment groups. Overall, no safety concerns were identified for the treatment with MC2-25 dipeptide PAD-cream or MC2-25 PAD-cream.

Conclusions

Both creams investigated in this trial, utilises PAD Technology, an oil-in-water formulation technology that readily enables high oil content with minimal emulsifier which could explain the unexpectedly large symptomatic improvement in the PAD-cream group. This is the first study to demonstrate clinically meaningful efficacy of an emollient on key symptoms such as itch and function in patients with VLS in a clinical trial. Whereas European guidelines estimate symptom improvement in only 10% of patients using moisturizers, the PAD-cream showed efficacy on itch reduction comparable to the results from a clinical trial investigating 3 months topical treatment with either the super potent corticosteroid, clobetasol propionate 0,05% or the calcineurin inhibitor, tacrolimus for VLS associated itch. These findings suggest that PAD-based emollients may represent a new class of symptomatic treatment for VLS, where therapeutic options remain limited.

EA DV CONGRESS
VIENNA
30 SEP - 3 OCT 2026

Abstract N°: 3531

Blaschkoid Psoriasiform Plaques With Nail Pitting: A Diagnostic Challenge Between Inflammatory Linear Verrucous Epidermal Nevus and Linear Psoriasis

Ela Gazal*[1], yasemin karabulut[2]

[1] Department of Dermatology, Mersin University Hospital, Mersin, Türkiye
[2] Department of Pathology, Mersin University Hospital, Mersin, Türkiye

Introduction

Inflammatory linear verrucous epidermal nevus (ILVEN) is an uncommon variant of epidermal nevus that usually appears in early childhood as persistent, pruritic, erythematous, hyperkeratotic plaques following the lines of Blaschko. Its psoriasiform appearance may closely mimic linear psoriasis, while its blaschkoid distribution in a pediatric patient may also raise the possibility of lichen striatus. Histopathologic evaluation is therefore essential for diagnosis. Herein, we describe a case of ILVEN with overlapping clinical features of linear psoriasis, emphasizing the importance of clinicopathologic correlation in blaschkoid psoriasiform eruptions.

Case Presentation

A 15-year-old female presented with long-standing, linear, hyperkeratotic, scaly plaques that had first appeared in early childhood. The lesions followed a blaschkoid distribution and predominantly involved the right side of the body, including the anterior and posterior trunk, right arm, and right retroauricular region. Interestingly, additional involvement was also present on the contralateral left neck, indicating a more complex, non-strictly unilateral blaschkoid pattern. Nail pitting was observed on the fingernails of the affected right arm.

The patient had received intermittent topical corticosteroid therapy several times over the past years, without significant improvement. More recently, she was treated with a continuous 4-week course of topical corticosteroids in our clinic, again with minimal clinical response. Based on the childhood onset, blaschkoid distribution, psoriasiform morphology, nail involvement, and poor response to topical corticosteroids, the main clinical differential diagnoses included inflammatory linear verrucous epidermal nevus, linear psoriasis, and lichen striatus. A skin biopsy was performed, and histopathologic findings supported the diagnosis of ILVEN.

Conclusion

ILVEN is a mosaic inflammatory epidermal nevus presenting in early life with persistent hyperkeratotic plaques along Blaschko lines. Its distinction from linear psoriasis remains controversial because both may show linear psoriasiform plaques and overlapping histopathology, requiring careful clinicopathologic correlation.

In our case, early childhood onset, chronic persistence, blaschkoid distribution, and poor response to topical corticosteroids favored ILVEN. Histopathologically, ILVEN classically shows psoriasiform epidermal hyperplasia with alternating orthokeratosis/hypergranulosis and parakeratosis/hypogranulosis, whereas psoriasis more typically shows regular psoriasiform acanthosis, confluent parakeratosis, suprapapillary thinning, dilated papillary vessels, and neutrophilic collections. This distinction is clinically relevant because linear psoriasis is generally more responsive to standard antipsoriatic therapy, while ILVEN is usually chronic and treatment-resistant, although therapeutic options may overlap.

Lichen striatus was also considered due to pediatric onset and blaschkoid distribution; however, it is usually acute, self-limited, and histologically characterized by lichenoid/interface and spongiotic changes with adnexal

lymphocytic inflammation.

Notable features of our case included segmental nail pitting, which suggested psoriasis, and a predominantly right-sided distribution with contralateral left-neck involvement. These findings highlight that nail changes and non-strictly unilateral involvement do not exclude ILVEN.

EADV CONGRESS
VIENNA
30 SEP - 3 OCT 2026

Abstract N°: 3536

An atypical presentation of lupus miliaris disseminatus faciei with early axillary involvement

Dilara Boztepe*[1], Sedef Şahin[1], Cüyan Demirkesen[1]

[1] Department of Dermatology and Venereology, Acibadem Mehmet Ali Aydinlar University, Istanbul, Türkiye, İstanbul, Türkiye

Introduction

Lupus miliaris disseminatus faciei (LMDF) is a rare, chronic granulomatous dermatosis of unknown etiopathogenesis, typically affecting the central facial regions. Extrafacial involvement is rare and may lead to diagnostic difficulty, particularly when lesions precede facial involvement.

Case Presentation

A 50-year-old woman presented with bilateral axillary papulonodular lesions associated with deep folliculitis-like induration on palpation. Several months later, erythematous papules and pitted atrophic scars developed on the right malar region and lateral canthus. Histopathological examination of a 4-mm punch biopsy obtained from an axillary papule demonstrated epithelioid histiocytes and multinucleated giant cells forming granulomatous structures with central caseification necrosis, consistent with necrotizing granulomatous dermatitis. Periodic acid–Schiff and Ziehl–Neelsen stains were negative for infectious organisms.

Granulomatous rosacea was considered less likely because of the absence of flushing and diffuse centrofacial erythema, together with the presence of caseification necrosis on histopathology. Infectious granulomatous diseases, including tuberculosis and deep fungal infections, as well as sarcoidosis, were excluded by clinicopathological, microbiological, and radiological evaluation. Based on the clinical and histopathological findings, a diagnosis of LMDF with atypical axillary involvement was established.

Treatment with oral isotretinoin (20 mg/day) and low-dose systemic corticosteroid therapy resulted in marked regression of facial papules and gradual improvement of axillary lesions with residual post-inflammatory hyperpigmentation at two-month follow-up.

Conclusion

LMDF may rarely present with axillary involvement preceding facial lesions, creating a significant diagnostic challenge. Although the disease predominantly affects the face, atypical extrafacial involvement should be considered in patients presenting with granulomatous axillary eruptions. In such cases, the term “faciei” may be clinically misleading. Early clinicopathological correlation is essential for accurate diagnosis and prevention of permanent atrophic scarring.

EADV CONGRESS
VIENNA
30 SEP - 3 OCT 2026

Abstract N°: 3539

Pityriasis Lichenoides As A Model For Paraviral Immunology: A Novel Long-Term Outcome Analysis Using A "Benign Lymphoma Phenotype" Framework To Redefine Treatment Endpoints

Chanul Thennekoon*[1], Randa Abdelhamid[1], Krish Lightwala[1], Zeel Lightwala[1]

[1] Belarusian state medical university, Minsk, Belarus

Introduction
Pityriasis lichenoides (PL) is a chronic, relapsing skin condition of unknown cause. Most treatments focus on clearing rashes, but relapse rates remain high because true remission is poorly defined. No open-source, immunology-based framework exists to determine when a patient is actually cured. Existing models ignore that PL behaves like a self-limited, clonal T-cell process, a "benign lymphoma." This study tested the Benign Lymphoma Phenotype (BLP) framework, which uses immune and genetic markers instead of only skin clearance to define real remission and predict long-term outcomes.

Materials and Methods
A retrospective-prospective cohort study was conducted using data from four academic centers (Italy, USA, Japan, Germany; 2008–2025). Inclusion required biopsy-proven PL (PLEVA or PLC) with ≥36 months of follow-up. A total of 568 patients (mean age 31.2 years, 52% male) with 1,847 disease episodes were analyzed. BLP remission required three criteria: (1) no lesions ≥6 months off all therapy, (2) no clonal TCRG rearrangement by high-sensitivity PCR, (3) normal lesional CD4/CD8 ratio (0.9–1.7). Traditional endpoints required only lesion clearance. Using Python, scikit-learn, and XGBoost with nested cross-validation, a predictor was trained on 70% of episodes (n=1,293) and validated on 30% (n=554). Ground truth was 24-month relapse-free survival off treatment. SHAP analysis identified key immune drivers.

Results
The BLP endpoint predicted 24-month relapse-free survival with ROC AUC 0.91 (95% CI, 0.88–0.94), accuracy 88%, precision 0.86, recall 0.90. Traditional clearance endpoints achieved only AUC 0.64 (95% CI, 0.59–0.69). Among patients meeting all three BLP criteria, 93% remained relapse-free at 24 months versus 49% of those meeting traditional endpoints. Strongest predictors of durable remission: normalized lesional CD4/CD8 ratio (HR 0.18, 95% CI 0.11–0.29, $p<0.001$), loss of TCRG clonal bands (HR 0.29, 95% CI 0.17–0.48, $p<0.001$), absence of parakeratotic foci on follow-up biopsy (HR 0.42, 95% CI 0.27–0.65, $p=0.002$). Higher paraviral serum markers (CXCL9, CXCL10, IL-27) at onset correlated inversely with BLP achievement ($r=-0.71$, $p<0.001$), indicating a viral trigger threshold. Over 5 years, BLP-negative patients on conventional therapy showed 22% progression to lymphomatoid papulosis (LyP) or early CTCL, versus 2% in the BLP-positive group ($p<0.001$, log-rank).

Conclusions
Pityriasis lichenoides can be reliably modeled as a paraviral, benign clonal T-cell disorder. The BLP framework redefines treatment endpoints from simple rash clearance to combined clinical, clonal, and immune normalization, dramatically improving long-term prediction. Patients meeting all BLP criteria can safely stop therapy; those who do not need prolonged surveillance and possible repeat biopsy for early LyP/CTCL detection. The full de-identified dataset, analysis code, and BLP scoring tool are publicly available for independent validation and clinical use.

EADV CONGRESS
VIENNA
30 SEP - 3 OCT 2026

Abstract N°: 3549

Upadacitinib in granulomatous vulvitis: learning from a challenging case

Cecilia Iborra García-Trevijano*[1], Vicente Márquez Garrido[1], Pablo Díaz-Calvillo[1], Marta Cortés Pérez[1], Irene Valencia[1], MERCEDES PICO VALIMAÑA[1]

[1] Hospital Universitario Puerto Real, Cádiz, Spain

Introduction

Granulomatous vulvitis is a rare chronic inflammatory disorder characterized by vulvar inflammation with significant functional impairment and reduced quality of life. Therapeutic evidence is limited and management remains challenging.

Case Presentation

A 36-year-old woman presented with a 6-year history of granulomatous vulvitis. After Crohn's disease had been excluded, she received multiple treatments including azithromycin, minocycline, methotrexate, infliximab, adalimumab, ustekinumab, vedolizumab, hyperbaric oxygen therapy, systemic corticosteroids and metronidazole, with only partial improvement. Disease progression eventually required urgent reconstructive surgery. The patient reported severe pain (VAS 9/10) and marked impairment in quality of life (VAS 10/10).

Treatment with upadacitinib 30 mg/day was initiated, leading to a rapid reduction in inflammation and pain (VAS 3/10), as well as improvement in quality of life (VAS 2/10) from the first month of therapy. However, the decrease in inflammation was associated with worsening synechiae, requiring surgical management. Therefore, the dose was reduced to 15 mg/day, maintaining a sustained partial response with adjunctive intralesional corticosteroid therapy.

Conclusion

The JAK-STAT signaling pathway plays a key role in granuloma formation. Consequently, Janus kinase inhibitors have been used in granulomatous dermatoses, with reports describing significant clinical improvement. At least two cases of their use in orofacial granulomatosis associated with Crohn's disease have been reported, showing resolution of oral ulcerations. Despite the similarities between these conditions, evidence regarding their use in granulomatous vulvitis is lacking.

In our case, upadacitinib at a dose of 30 mg/day proved effective in controlling lesions and improving pain and quality of life in severe granulomatous vulvitis, suggesting that it may represent a therapeutic option worth exploring. However, the development of synechiae following inflammation reduction required dose adjustment and highlighted the importance of multidisciplinary management in this condition.

EA DV CONGRESS
VIENNA
30 SEP - 3 OCT 2026

Abstract N°: 3551

SITRAME syndrome: A diagnostic challenge mimicking recurrent cellulitis

Andrés Ederra Galé*[1], Tamara Gracia-Cazaña[1], Juan Jose Garcia Alfonso[1], Clara Ruiz-Ullate[1], Itziar Muelas Rives[1, 1], laura Bernal Masferrer[1], Iranzu Barandika Urrutia[1], Yolanda Gilaberte[1], Emilio Abecia Martinez[1], Andrea Carilla Sanromán[1]

[1] Hospital Universitario Miguel Servet, Zaragoza, Spain

Introduction
Systemic inflammatory trunk recurrent acute macular eruption (SITRAME) is a recently proposed autoinflammatory syndrome in adults, with only 16 cases published in the literature.

Results
A 70-year-old male presented with a 9-year history of recurrent, large erythematous-violaceous macules on the trunk. The episodes were bilateral, asymmetrical, and always recurred in the same anatomical locations within a few hours. Flares were sometimes triggered by respiratory infections and were often accompanied by high fever (up to 39ºC) and malaise. Each episode resolved spontaneously within 7–9 days without residual lesions.

Laboratory tests during flares showed mild leucocytosis (10,100/mm^3), neutrophilia (8,400/mm^3), and elevated C-reactive protein (1.99 mg/dL), all of which normalized during remission. Extensive workup, including autoimmunity, serology, and CT scans, was unremarkable.

Two skin biopsies were performed. The second biopsy revealed a neutrophilic urticarial pattern: a moderate dermal inflammatory infiltrate (perivascular and interstitial) with mild edema and focal epidermal permeation by neutrophils. No signs of vasculitis or eosinophilia were found. The patient met all major diagnostic criteria (truncal location, recurrence, duration < 8 days, elevated CRP) and several minor criteria (fever, malaise, infectious trigger). Treatment with oral prednisone led to rapid remission of symptoms.

Discussion

Provisional diagnostic criteria for SITRAME were published in 2025. Our patient met the 4 major criteria (more than 3 outbreaks of macular eruption in the same area of the trunk associated with CRP > 5 mg/L lasting less than 8 days) and 2 minor criteria (fever and asthenia during outbreaks).Therefore, a diagnosis of exclusion was made after ruling out monogenic autoinflammatory disease, active neoplasm, and autoimmune disease.

The clinical similarity to the giant cellulitis-like variant of Sweet syndrome suggests that both may form part of a possible common spectrum of autoinflammatory neutrophilic dermatoses. Although both share a neutrophilic basis, GCLSS typically presents as edematous plaques rather than macules, and is classically associated with underlying malignancies, obesity, or trauma. In contrast, SITRAME is characterized by a strictly truncal distribution, shorter flare duration (less than 8 days), and triggers such as respiratory infections. These findings suggest that both entities might represent different points on the same clinico-pathological spectrum of adult-onset neutrophilic dermatoses.

Conclusions

This case of SITRAME, characterized by a dermal neutrophilic infiltrate, reinforces the proposed link between this entity and the broader spectrum of autoinflammatory neutrophilic dermatoses. The recognition of its clinical and histological features is essential for clinicians to avoid misdiagnosing these recurrent episodes as infectious cellulitis, thereby preventing the unnecessary use of systemic antibiotics and carrying out an appropriate treatment.

EA DV CONGRESS
VIENNA
30 SEP - 3 OCT 2026

Abstract N°: 3556

Schnitzler syndrome: A diagnostic challenge mimicking systemic lupus erythematosus with elevated VEGF as a potential activity marker.

Emilio Bert Mangino*[1], Linda Garcia Hidalgo[1], Karel Melchor[1]

[1] Instituto Nacional de Ciencias Médicas y Nutrición Salvador Zubirán, Ciudad de México, Mexico

Introduction

Schnitzler syndrome is a rare acquired autoinflammatory disorder characterized by chronic urticarial rash and monoclonal gammopathy (typically IgM). Due to its low prevalence and clinical overlap with other conditions, it is frequently underdiagnosed, with an average diagnostic delay of over five years. We present a case initially diagnosed as cutaneous lupus erythematosus but was eventually identified as Schnitzler syndrome, highlighting the utility of vascular endothelial growth factor (VEGF) and as a potential biomarker for disease activity and lymphoproliferative risk.

Case Presentation

Report: A 76-year-old female presented with a 10-year history of a recurrent, pruritic wheals on the trunk and extremities. The episodes were accompanied by severe bone pain, myalgia, arthralgia, and chronic fatigue. Previous evaluations suggested systemic lupus erythematosus based on positive antinuclear antibodies (1:640, speckled pattern) and skin biopsies showing vacuolar interface dermatitis. Consequently, the patient was treated with hydroxychloroquine and conventional antihistamines without clinical response.

Upon specialized re-evaluation, physical examination confirmed non-confluent urticarial plaques. Laboratory findings revealed an IgM-kappa monoclonal gammopathy (1237 mg/dL), elevated inflammatory markers (ESR 33 mm/h; leukocytosis 13,200/µL). Normal complement levels (C3: 105 mg/dL, C4: 21.3 mg/dL) helped exclude hypocomplementemic urticarial vasculitis. FDG-PET/CT demonstrated diffuse and homogeneous bone marrow hypermetabolism of reactive appearance, along with sclerotic changes and increased bone density in the axial skeleton. Bone marrow aspiration with <2% plasma cells, ruling out Waldenström macroglobulinemia. Notably, serum VEGF levels were significantly elevated (501.9 pg/mL; normal <115). A revised skin biopsy demonstrated neutrophilic urticarial dermatosis.

Following the Strasbourg criteria, a diagnosis of definite Schnitzler syndrome was established with two obligatory criteria (recurrent urticarial rash and IgM-kappa monoclonal gammopathy) plus four minor criteria (recurrent fever, bone remodeling changes with bone pain, neutrophilic dermatosis, and leucocytosis). The presence of ANAs was interpreted as a possible incidental finding or IgM autoreactivity to nuclear proteins, previously described in this syndrome. The patient was started on an interleukin-1 (IL-1) receptor antagonist (anakinra), resulting in a dramatic and complete clinical remission of all symptoms within 48 hours. However, consistent with the known risk of lymphoproliferative disorders in this syndrome, the patient subsequently developed a Grade 2B Stage IV follicular lymphoma.

Conclusion

This case illustrates the complexity of diagnosing Schnitzler syndrome, which can mimic lupus erythematosus due to shared clinical and serological features. Clinicians should maintain a high index of suspicion in patients with refractory urticaria and monoclonal gammopathy. Furthermore, the elevation of VEGF in this patient is consistent

with reports suggesting its potential utility as a biomarker in Schnitzler syndrome for both disease activity monitoring and potentially as an early indicator of lymphoproliferative risk, although further research is needed to validate its role. Furthermore, the development of follicular lymphoma emphasizes the necessity for long-term oncologic surveillance, including clinical evaluation and monitoring of the monoclonal component every 3 months.

EA DV CONGRESS
VIENNA
30 SEP - 3 OCT 2026

Abstract N°: 3562

Granulomatous Reaction in Unilateral Favre–Racouchot Syndrome: A Diagnostic Pitfall

Maissa Abid*[1], Kmar Turki[1], Sonda Yaich[1], Rim Chaabouni[1], Abderahmen Masmoudi[1], Hamida Turki[1]

[1] Dermatology Department, Hedi Chaker Hospital, Sfax, Tunisia, Sfax, Tunisia

Introduction

Favre–Racouchot syndrome (FRS), or nodular elastosis with cysts and comedones, is a chronic actinically induced dermatosis characterized by open comedones, cysts, and solar elastosis on sun-exposed facial skin, predominantly in elderly men. Chronic ultraviolet exposure and smoking are the main etiological factors. Histopathology typically shows epidermal atrophy, dilated keratin-filled follicular infundibula, solar elastosis, and sebaceous gland atrophy.

Case Presentation

A 62-year-old non-smoking phototype III patient with a history of right cataract surgery presented with a slowly progressive lesion of the right zygomatic region evolving over several months. The eruption began as pinpoint black and white lesions progressively becoming erythematous papules forming a plaque. Dermatological examination revealed a unilateral erythematous finely scaly plaque of the right zygomatic region, composed of confluent follicular papules initially appearing as tiny black and white dots. The lesion showed multiple open comedones, whitish microcysts, and prominent keratotic follicular plugs, giving a a rough granular texture on palpation. Dermoscopy demonstrated enlarged follicular openings containing yellowish-white keratotic plugs, open comedones, and milia-like cysts on an erythematous scaly background. Histopathological examination demonstrated a striking perifollicular granulomatous infiltrate composed of epithelioid granulomas without caseous necrosis, closely surrounding altered follicular structures. Differential diagnoses included cutaneous sarcoidosis, infectious granulomatosis (tuberculosis and leishmaniasis), comedonal lupus, and granuloma faciale. Ziehl–Neelsen staining, Mycobacterium tuberculosis PCR, Leishmania PCR on skin smear, chest radiography, serum angiotensin-converting enzyme, antinuclear antibodies, and routine infectious workup were all negative.

Topical adapalene was initiated, leading to marked clinical improvement, supporting the diagnosis of unilateral Favre–Racouchot syndrome with granulomatous reaction.



Figure : (A) Unilateral erythematous scaly plaque of the right zygomatic region with confluent follicular papules, open comedones, whitish microcysts, and prominent keratotic follicular plugs. (B) : Enlarged follicular openings filled with yellowish-white keratotic plugs, open comedones, and milia-like cysts on an erythematous scaly background

Conclusion

FRS typically presents bilaterally in the periorbital and temporal regions; unilateral forms are rare and suggest asymmetric chronic actinic exposure, as reported in drivers and outdoor workers. Notably, significant actinic damage can occur even in phototype III individuals with prolonged cumulative UV exposure, underlining that FRS is not restricted to fair-skinned phototypes. The present case is of additional interest in that it occurred in a non-smoker, suggesting that chronic UV exposure alone may be sufficient to trigger the condition, even in the absence of the synergistic oxidative effect of tobacco.

The associated granulomatous reaction is an uncommon histopathological finding in FRS, likely resulting from rupture of follicular cysts with extrusion of keratinous material into the dermis, triggering a foreign-body response. This may cause diagnostic confusion with granulomatous rosacea, milia en plaque, or colloid milium, making clinicopathological correlation essential. Treatment options include topical retinoids, comedone extraction, dermabrasion, and CO_2 laser, alongside sun protection.

Unilateral FRS with granulomatous inflammation is exceptionally rare. This case underscores the primacy of chronic actinic damage in FRS pathogenesis, even in the absence of smoking, and highlights the importance of recognizing atypical histological presentations to avoid misdiagnosis.

EADV CONGRESS
VIENNA
30 SEP - 3 OCT 2026

Abstract N°: 3606

Blaschkoid Lichen Planus: An atypical expression or a true variant?

AYA TADLAOUI*[1], Ikrame Bejja[1], Saadia Boughaleb[1], Zakia Douhi[1], Meryem Soughi[1], Sara Elloudi[1], Hanane Baybay[1], Fatima Zahra Mernissi[1]

[1] Dermatology department, University Hospital center of Fez, Sidi Mohamed Ben Abdellah university of Fez, Fez, Morocco

Introduction

lichen planus (LP) is a chronic inflammatory dermatosis characterized by pruritic violaceous polygonal papules. The blaschkoid variant is rare (<0,5% of cases) and is defined by lesions strictly following the lines of Blaschko, which represent embryonic keratinocyte migration pathways. This unusual segmental distribution may lead to diagnostic confusion with other acquired linear dermatoses.

Case Presentation

a 47-year-old woman, followed for coutaneous and ocular rosacea, presented with recently developed skin lesions evolving in less than 1month. Clinical examination revealed mildly pruritic erythematous papules, partially confluent into slightly infiltrated erythematous-squamous plaques, distributed along the lines of Blaschko on the left abdomen and ipsilateral leg. Dermoscopy showed a granular pattern in some areas, whitish scales and dotted vessels. Differential diagnoses included linear lichen planus, adult blashkitis, blashkoid psoriasis, and lichenoid keratosis. Histopathology demonstrated acanthosis, thickening of the granular layer, orthokeratotic hyperkeratosis, Civatte bodies, basal layer vacuolar alteration, and a band-like mononuclear inflammatory infiltrate at the dermoepidermal junction with pigmentary incontinence in the papillary dermis, consistent with the diagnosis of Lichen planus. An associated condition assessment was performed. Topical corticosteroids were initiated. Blaschkoid LP is clinically distinct from linear LP, which usually follows dermatomes or may occur via the Koebner phenomenon. In contrast, blashkoid LP strictly follows the lines of Blaschko and is not trauma-induced. Its pathogenesis is thought to involve postzygotic mosaicism with loss of heterozygosity, leading to a keratinocyte clone predisposed to developing LP after exposure to a triggering factor later in life. Main differential diagnoses include adult blaschkitis (spongiotic dermatitis without interface dermatitis), lichen striatus (spongiosis without marked epidermal hyperplasia), psoriasis (psoriasiform acanthosis, confluent parakeratosis and Munro microabcesses), and lichenoid keratosis (compact hyperkeratosis with focal lichenoid infiltrate). Dermoscopy is a valuable non-invasive diagnostic tool, typically revealing brown-gray dots and globules corresponding to pigmentary incontinence. Wickham striae may be absent in very early lesions before full development of hypergranulosis. The course is usually benign and self-limited, often leaving residual pigmentary changes. Topical corticosteoides remain first-line therapy.

Conclusion

This case illustrates a rare presentation of blaschkoid lichen planus, characterized by an atypical, minimally pruritic onset, which may obscure clinical suspicion. Although lichen planus classically presents with intensely pruritic violaceous papules, segmental and Blaschko-linear distributions can present with subtle or misleading features.

EADV CONGRESS
VIENNA
30 SEP - 3 OCT 2026

Abstract N°: 3634

Lichenoid reaction following illicit use of alpha-melanocyte-stimulating- hormone

Emily Orr*[1], Donal O'Kane[1]

[1] Royal Victoria Hospital, belfast, United Kingdom

Introduction

Illicit use of Alpha-melanocyte stimulating hormone remains an issue pertinent to the dermatology community. These compounds are frequently sold illegally in the UK for the purposes of inducing tanning and are often used in conjunction with sunbeds. When purchased for this use, they are unregulated, unlicensed and may pose a significant risk to health. Alpha-melanocyte-stimulating-hormone stimulates melanocytes and has been associated with pigmentary changes in existing naevi and eruptive naevi, making their assessment in dermatology challenging. There are numerous case reports detailing illicit use of alpha-melanocyte-stimulating- hormone associated with melanoma and melanoma in situ. Here we describe a case of a, previously unreported, cutaneous eruption secondary to alpha-melanocyte-stimulating- hormone.

Case Presentation

A 42 year old female was referred to the dermatology clinic for assessment of two lesions on her right arm. She had attended her general practitioner due to recent scaling of the lesions which has been present for several months and had no other recent changes. The patient had an extensive UV history, with frequent sun bed use since adolescence, and use of alpha-melanocyte-stimulating-hormone in the months leading up to review. Her regular medications included fluoxetine and amitriptyline, commenced in August 2025 and May 2024, respectively. On review in clinic the referral lesions were in keeping with benign seborrhoeic keratoses. In addition, the patient was noted to have numerous blue/ grey macules across her neck, arms and torso, predominantly in photo distributed areas. The patient reported that these had developed in the preceding months. On dermoscopy the macules appeared blue-grey with peppering of pigmentation. A 4mm punch biopsy was taken for histology from the area macular rash, this was reported to be in keeping with a lichenoid process with patchy chronic inflammation and melanin incontinence. In view of the use of alpha-melanocyte-stimulating- hormone, and no other new recent medications, the macular eruption may be attributed to use of alpha-melanocyte-stimulating- hormone. The patient was strongly advised to discontinue its use and she was reviewed back in clinic 3 months later.

Conclusion

The unregulated nature of these compounds, when purchased illegally, means that the constituent products are unknown, untested and may be adulterated with other products or potentially with microbial contaminants. For this reason, an awareness of this practice amongst patients attending dermatology clinics is vital to ensure that clinicians may counsel their patients on the associated risks and discourage further use of illicit compounds.

Alpha-melanocyte-stimulating- hormone continues to present a challenge for clinicians in dermatology. In this case, we present a patient who presented with an unusual eruption following

its illicit use. In view of the photo distributed nature, dermoscopic and histological findings this case was ultimately felt to be in keeping with a lichenoid process

EA DV CONGRESS
VIENNA
30 SEP - 3 OCT 2026

Abstract N°: 3651

Pellagra in a 40-Year-Old Patient: A Multifaceted Presentation

Maissa Abid*[1], Rim Chaabouni[1], Sonda Yaich[1], Kmar Turki[1], Hamida Turki[1]

[1] Dermatology Department, Hedi Chaker Hospital, Sfax, Tunisia, Sfax, Tunisia

Introduction

Pellagra, caused by niacin (vitamin B3) deficiency, is classically characterized by the triad of dermatitis, diarrhea, and dementia. Once considered a disease of the past, it persists today in specific clinical contexts, most notably chronic alcohol use disorder, where poor nutritional intake, impaired intestinal absorption, and altered tryptophan metabolism converge to precipitate niacin deficiency. Despite its treatability, pellagra is frequently overlooked due to its clinical polymorphism and declining familiarity among clinicians, resulting in delayed diagnosis and preventable complications.

Case Presentation

A middle-aged man with a longstanding history of chronic alcoholism presented with a progressive eruption evolving over several months, associated with mucosal and gastrointestinal symptoms. Dermatological examination revealed multiple well-demarcated plaques on photo-exposed areas, predominantly the forearms, ankles and the posterior neck. The plaques had a lichenified aspect; on the posterior neck, these lesions coalesced into a broad, symmetrical band encircling the lower cervical region like a collar.

Mucosal assessment revealed angular cheilitis with bilateral hemorrhagic and crusted fissuring at the oral commissures, alongside a smooth, erythematous, oedematous and depapillated tongue.

The patient additionally presented with atypical scalp and beard involvement characterized by sharply demarcated papulo-squamous plaques with greasy adherent scales, an unusual finding that initially evoked seborrheic dermatitis or sebopsoriasis.

Further clinical assessment disclosed chronic diarrhea associated with mild neuropsychiatric symptoms. In the setting of severe nutritional deficiency related to chronic alcoholism, the combination of photosensitive dermatitis, mucosal involvement, digestive manifestations, and neuropsychiatric signs strongly supported the diagnosis of pellagra — further reinforced by the characteristic collar-like distribution of the cervical lesions consistent with Casal's necklace, and the rapid, marked improvement following oral nicotinamide supplementation within two to three weeks. Histopathological examination was not performed, as the diagnosis was considered clinically evident.



Figure. (A,B) Multiple well-demarcated dyschromic and lichenified plaques involving photo-exposed areas, predominantly the posterior neck and forearms. On the posterior neck, the lesions coalesced into a broad symmetrical band encircling the lower cervical region, forming a “Casal’s collar”. (C) Angular cheilitis with bilateral hemorrhagic crusted fissures at the oral commissures and a smooth, erythematous, depapillated tongue. (D) Atypical scalp and beard involvement showing sharply demarcated papulo-squamous plaques covered with greasy adherent scales.

Conclusion

This observation highlights the polymorphic clinical presentation of pellagra and the diagnostic challenge posed by atypical cutaneous manifestations. While pellagra classically affects sun-exposed areas, scalp involvement with hyperkeratotic papulo-squamous plaques is uncommon and may mimic inflammatory dermatoses such as seborrheic dermatitis or sebopsoriasis. The coexistence of lichenified plaques, glossitis, angular cheilitis, diarrhea, and neuropsychiatric symptoms in a malnourished alcoholic patient constituted a highly suggestive clinical constellation. Chronic alcoholism promotes niacin deficiency through inadequate nutritional intake, impaired intestinal absorption, altered tryptophan metabolism, and increased metabolic consumption. The diagnosis remains primarily clinical and is reinforced by the rapid therapeutic response to nicotinamide. Early recognition is essential to prevent severe neurological and systemic complications. Thus, pellagra should be suspected in patients with chronic alcohol use presenting with photosensitive dermatitis, mucosal lesions, digestive symptoms, and neuropsychiatric manifestations. Prompt nicotinamide supplementation is both diagnostic and curative.

EA DV CONGRESS
VIENNA
30 SEP - 3 OCT 2026

Abstract N°: 3672

Between sun and silence ; A cellulitis you didn't expect

AYA TADLAOUI*[1], Meryem Soughi[1], Khawla Moufid[1], Ikrame Bejja[1], Saadia Boughaleb[1], Zakia Douhi[1], Sara Elloudi[1], Hanane Baybay[1], Fatima Zahra Mernissi[1]

[1] Dermatology department, University Hospital center of Fez, Sidi Mohamed Ben Abdellah university of Fez, Fez, Morocco

Introduction

Cutaneous lupus erythematosus (CLE) encompasses a broad spectrum of dermatologic manifestations. Among its subtypes, lupus erythematosus tumidus (LET) is a rare form characterized by erythematous, edematous plaques located predominantly on sun-exposed areas. Isolated periorbital involvement is exceptionally uncommon and may mimic inflammatory or infectious conditions, leading to diagnostic delay. We report a case of a 45year-old female, admitted to our department for the management of LET.

Case Presentation

A 45-year-old woman with a history of anxiety and poorly observed discoid lupus erythematosus of the scalp without systemic involvement presented for one year a progressive erythematous swelling of the left upper eyelid causing partial eye opening impairment. The lesion was asymptomatic but associated with marked photosensitivity. Before dermatologic evaluation, the patient had been treated repeatedly for presumed periorbital cellulitis with systemic antibiotics, without improvement. Clinical examination revealed a well-demarcated erythematous edematous plaque of the upper left eyelid, firm on palpation with deep dermal infiltration and a smooth surface with minimal scaling. Conjunctival involvement was absent. Dermoscopy showed an erythematous base, eccrine openings, orange areas and some meliceric crusts. Skin biopsy demonstrated findings consistent with lupus erythematosus tumidus, including a dermal lymphocytic infiltrate with mucin deposition and minimal epidermal involvement. Direct immunofluorescence revealed granular deposition of IgG, IgM and IgA along the dermo-epidermal junction. Significant improvement was observed after starting treatment with hydroxychloroquine and systemic corticosteroids without residual scarring or dyspigmentation.

LET is considered an uncommon subtype of cutaneous lupus erythematosus and is clinically characterized by succulent erythematous plaques with minimal epidermal changes, typically affecting photo-exposed areas. Periorbital localization is particularly rare. Only a limited number of cases have been reported describing unilateral eyelid edema as the main or sole manifestation of LET. Because of its inflammatory appearance, periorbital LET may be misdiagnosed as cellulitis, which was the case of our patient, contact dermatitis, dermatomyositis, angioedema, or other ophtalmological conditions, often leading to inappropriate treatments and delayed diagnosis. Skin biopsy remains essential to establish the diagnosis.

Conclusion

Isolated unilateral periorbital involvement of lupus erythematosus tumidus is extremely uncommon and may mimic infectious cellulitis, leading to repeated ineffective antibiotic treatments. Persistent eyelid edema or erythema unresponsive to antibiotics should prompt consideration of cutaneous lupus and histopathological confirmation to ensure appropriate management.

EADV CONGRESS
VIENNA
30 SEP - 3 OCT 2026

Abstract N°: 3680

Immunogenetic overlap between lichen planus pemphigoides and pemphigoid-spectrum disease: a retrospective case series

Anushka Sharma*[1], Thomas Tull[1]

[1] St John's Institute of Dermatology, London, United Kingdom

Introduction

Lichen planus pemphigoides (LPP) is a rare autoimmune blistering disorder characterised by overlapping clinical and immunopathological features of lichen planus (LP) and bullous pemphigoid (BP). Although BP180 autoantibodies are recognised in LPP, the immunogenetic basis of the disease remains poorly understood. We retrospectively reviewed patients evaluated for suspected LPP within a tertiary dermatology centre to assess clinical, serological and HLA associations.

Case Presentation

Patients initially considered to have LPP underwent multidisciplinary clinicopathological review and were classified as likely LPP (n=7) or unlikely LPP (n=4). BP180 positivity was observed in 5/7 likely LPP cases, with titres declining following treatment. Roof-binding indirect immunofluorescence on salt-split skin was demonstrated in all tested likely LPP patients, while BP230 antibodies were largely absent.

Four likely LPP patients underwent HLA phenotyping. Two patients carried HLA-DRB110, an allele previously described in a historical lichenoid pemphigoid phenotype. Additional patients demonstrated overlap with recognised BP-associated HLA class II alleles including HLA-DQB103 and HLA-DRB1*04. In contrast, patients classified as unlikely LPP lacked supportive serological or immunogenetic findings.

These findings support overlap between LPP and pemphigoid-spectrum disease and suggest that lichenoid inflammation in genetically susceptible individuals may promote secondary autoimmunity through epitope spreading.

Conclusion

This retrospective case series highlights the clinical and immunological heterogeneity of LPP while supporting a potential immunogenetic overlap with pemphigoid-spectrum disease. The recurrence of HLA-DRB1*10 in two patients is notable given previous limited reports of this association in lichenoid pemphigoid phenotypes. Integrated clinicopathological and immunological assessment remains essential in diagnostically heterogeneous presentations. Larger collaborative studies are required to further define the immunogenetic basis of LPP.

EA DV CONGRESS
VIENNA
30 SEP - 3 OCT 2026

Abstract N°: 3691

Multidimensional disease burden in vulvar lichen sclerosus: a single-centre real-world cohort study

Bianca Cei*[1], Giammarco Granieri[1], Alessandra Michelucci[1], Valentina Dini[1], Marco Romanelli[1]

[1] University of Pisa, Pisa, Italy

Introduction
Vulvar lichen sclerosus (VLS) is a chronic inflammatory disease associated with symptoms, scarring, sexual dysfunction, malignancy risk and impaired quality of life. As clinical signs and patient-reported burden may not overlap, multidimensional assessment is essential. This study aimed to describe baseline characteristics of women with VLS and explore associations between clinical severity scores, symptoms, quality of life, and sexual function.

Materials and Methods
A single-centre observational analysis of a dedicated VLS database was conducted. Demographic and clinical variables, diagnostic delay, comorbidities, potential triggers, and baseline scores were collected. Disease severity and burden were assessed using VASS, CSS, CLISSCO, VQLI, FSFI, and SDS. Continuous variables are reported as median and interquartile range (IQR). Associations were explored via Spearman's correlation; group comparisons were performed using non-parametric tests.

Results
Seventy-six women were included. Median age at diagnosis was 58.6 years (IQR 47.5–65.0); median age at symptom onset was 55.4 years (IQR 47.2–63.0). Median diagnostic delay was 2 years (IQR 0.4–5.0; range 0–20), with initial misdiagnosis in 55.3% (42/76). Post-menopausal onset was reported in 69.3% (52/75). Phototype I–II was observed in 86.5% (64/74), familial VLS in 18.4% (14/76), and extragenital involvement in 11.8% (9/76). Autoimmune or inflammatory comorbidities were present in 52.6% (40/76), including autoimmune thyroid disease (22.4%) and mucocutaneous disorders (27.6%). The most common symptom was vulvar pruritus (68.4%), followed by burning (27.6%). Frequent urogenital infections were reported in 52.6%, Candida infection in 46.1%, local trauma/friction in 35.5%, and stress-related worsening in 47.4%.

Baseline median scores were as follows: VASS 6 (IQR 4–8.25), CSS symptoms 8 (IQR 4–19.75), CSS clinical 4 (IQR 2–5), total CSS 12 (IQR 8–22), CLISSCO 11 (IQR 7.5–14), VQLI 16 (IQR 7–25), FSFI 22.4 (IQR 17.25–25.83), and SDS 27.5 (IQR 16–35.5). VASS correlated strongly with CLISSCO architectural changes ($\rho=0.916$, $p<0.001$) and CSS clinical score ($\rho=0.837$, $p<0.001$); symptom-based scores also correlated strongly (CSS symptoms vs CLISSCO symptoms: $\rho=0.897$, $p<0.001$). Conversely, objective architectural damage did not correlate with symptom burden or VQLI. CSS symptoms and total CSS correlated negatively with FSFI ($\rho=-0.632$, $p=0.002$ and $\rho=-0.649$, $p=0.001$, respectively); VQLI correlated negatively with FSFI ($\rho=-0.525$, $p=0.004$) and positively with SDS ($\rho=0.881$, $p<0.001$). Longer diagnostic delay was weakly associated with greater architectural involvement ($\rho=0.313$, $p=0.032$). Stress-related worsening was associated with higher VQLI (median 20 vs 10, $p=0.002$), higher CSS symptom score (12 vs 6.5, $p=0.018$), and lower FSFI (19.1 vs 24.8, $p=0.049$).

Conclusions

This real-world cohort confirms that VLS is associated with a substantial baseline burden across multiple domains, including diagnostic delay, structural damage, symptom severity, sexual dysfunction, and psychosocial impairment. A key finding of this study is that clinician-assessed architectural severity, while strongly consistent across objective scoring tools, did not correlate with symptom intensity, sexual function, or quality-of-life impairment. This indicates that the degree of structural damage alone cannot predict the subjective burden experienced by the patient, and that physical examination may substantially underestimate disease impact. Higher symptom burden scores were negatively correlated with FSFI, indicating worse sexual function in women with greater symptom severity. These results support the routine use of both clinician-reported and patient-reported outcome measures in the baseline evaluation of VLS, as structural assessment alone is insufficient to capture the full extent of disease impact.

EA DV CONGRESS
VIENNA
30 SEP - 3 OCT 2026

Abstract N°: 3692

Under the Mask of Erythema Nodosum: An Eight-Year Diagnostic Challenge of Bazin's Disease

ikram lahmouch*[1]

[1] Department of Dermatology, Ibn Sina University Hospital, Rabat, Morocco, rabat, Morocco

Introduction

Erythema nodosum is the most common form of panniculitis and is usually characterized by an acute, self-limited course. However, chronic or recurrent nodular panniculitis should raise suspicion for alternative diagnoses, particularly when evolution is atypical or refractory to conventional management.

Among these entities, erythema induratum of Bazin is a rare tuberculid regarded as a hypersensitivity reaction to *Mycobacterium tuberculosis*, histologically characterized by predominantly lobular panniculitis with vasculitic features. Owing to its marked clinicopathological overlap with erythema nodosum, diagnosis may remain unrecognized for years, resulting in prolonged diagnostic wandering and delayed appropriate therapy.

Through this case, we aim to highlight erythema induratum of Bazin as an important yet underrecognized differential diagnosis of chronic recurrent erythema nodosum–like panniculitis, emphasizing the crucial role of repeated clinicopathological reassessment in persistent or atypical presentations.

Case Presentation

We report the case of a 57-year-old woman with type 2 diabetes mellitus who had experienced recurrent episodes of painful nodular panniculitis over an eight-year period, repeatedly diagnosed and treated as erythema nodosum in different dermatology settings.

The disease initially manifested as recurrent, painful, deep-seated nodules involving the lower limbs, associated with ankle edema and migratory arthralgia of large joints, evolving in an afebrile context with preserved general condition. Despite multiple relapses, management remained essentially symptomatic.

She denied any history of tuberculosis exposure or previous tuberculosis infection. Sputum examination for *Mycobacterium tuberculosis* was negative.

The patient was referred to our department after a recent flare marked by extension of lesions to the upper limbs, accompanied by chills and non-quantified fever, without response to empirical antibiotic therapy and local care.

Dermatological examination revealed multiple bilateral and symmetrical deep erythematous-violaceous tender nodules involving the extensor aspects of both upper and lower extremities, suggestive of chronic nodular panniculitis.

Histopathological analysis of two successive skin biopsies demonstrated mixed septal and lobular panniculitis, with additional vasculitic changes identified on repeat sampling. Tuberculin skin testing was strongly positive (+++), whereas chest radiography remained unremarkable.

In light of the clinicopathological and immunological findings, a diagnosis of erythema induratum of Bazin was retained. Anti-tuberculous therapy combined with colchicine (1mg/day), rest, and local care resulted in marked clinical improvement within one month, leaving only residual post-inflammatory hyperpigmentation at follow-up.

Conclusion

This observation highlights erythema induratum of Bazin as a subtle yet important diagnostic pitfall in chronic recurrent panniculitis. The striking clinical overlap with erythema nodosum may lead to years of diagnostic delay, particularly when microbiological investigations remain negative. Our case emphasizes the importance of re-evaluating persistent “erythema nodosum” through rigorous clinicopathological correlation and considering tuberculids in endemic contexts. Ultimately, the dramatic response to anti-tuberculous therapy reinforces its dual diagnostic and therapeutic value in this underrecognized entity.

EADV CONGRESS
VIENNA
30 SEP - 3 OCT 2026

Abstract N°: 3695

Title: Pediatric Peri-orificial Sarcoidosis: A Diagnostic Challenge Masked by Steroid-Induced Flare

ghita bouzoubaa*[1], Barbri Kenza[1], Baghad Bouchra[1], Benhayoun Fatima-zohra[1], rachadi hanane[1], Chiheb Soumya[1]

[1] university hospital center ibn rochd, casablanca, Morocco

Introduction
Sarcoidosis is a rare multisystem granulomatous disease in the pediatric population. Cutaneous involvement is highly polymorphic and frequently mimics common conditions such as acne vulgaris or peri-oral dermatitis, often leading to significant diagnostic delays.

Case Presentation
A 15-year-old male presented with a 7-month history of persistent papulopustular lesions in the peri-oral and peri-nasal areas. Initially misdiagnosed as inflammatory acne, the use of topical corticosteroids (cleniderm) led to a paradoxical clinical worsening. Physical examination revealed erythematous papulo-pustules with characteristic sparing of the vermilion border. Dermoscopic evaluation was decisive, showing diffuse orange-yellowish globular structures (granulomas), linear branched vessels, and small whitish punctiform structures. Skin biopsy confirmed non-necrotizing granulomatous dermatitis consistent with sarcoidosis. The patient achieved complete clinical resolution after 3 months of oral doxycycline (100mg/day).

Conclusion
Pediatric sarcoidosis requires a high index of clinical suspicion. Clinicians should be wary of peri-facial lesions resistant to conventional acne therapy. Integrating dermoscopy into routine examinations can significantly reduce diagnostic delay and prevent the morbidity associated with inappropriate steroid use.

EA DV CONGRESS
VIENNA
30 SEP - 3 OCT 2026

Abstract N°: 3701

Longitudinal UHFUS, Doppler and LC-OCT assessment in vulvar lichen sclerosus

Bianca Cei*[1], Giammarco Granieri[1], Alessandra Michelucci[1], Marco Romanelli[1], Valentina Dini[1]

[1] University of Pisa, Pisa, Italy

Introduction
Vulvar Lichen Sclerosus (VLS) is a chronic inflammatory dermatosis in which clinical severity, architectural damage and patient-reported burden represent distinct disease dimensions. Ultra-high-frequency ultrasound (UHFUS), Doppler assessment and line-field confocal optical coherence tomography (LC-OCT) may provide complementary objective information on inflammatory and structural changes. This exploratory study evaluated instrumental parameters in women with VLS and their association with clinical severity scores and patient-reported outcomes.

Materials and Methods
A single-centre exploratory analysis was conducted among women with VLS who were treated with topical corticosteroids and underwent non-invasive instrumental follow-up assessment. UHFUS parameters included presence and echogenicity of a hypoechoic dermal band; Doppler activity was graded using an ordinal score. LC-OCT parameters included thickness of the hyperreflective band, residual epidermal thickness and dermo-epidermal junction morphology. Disease burden was assessed with VASS, CSS and CLISSCO as clinician-assessed measures, and VQLI, FSFI and SDS as patient-reported outcomes (PROs). Continuous variables are reported as median (IQR). Associations between instrumental parameters and clinical scores were explored with Spearman's rho; group comparisons were performed using non-parametric tests.

Results
Fourteen patients underwent non-invasive instrumental follow-up assessment. Median LC-OCT hyperreflective band thickness was 20.5 µm (IQR 16.0–28.5) and median residual epidermal thickness was 78.0 µm (IQR 70.25–97.0). A flattened dermo-epidermal junction was observed in 9/14 patients (64.3%). UHFUS identified a hypoechoic dermal band in 7/14 patients (50.0%), heterogeneous in 5/7 (71.4%) and homogeneous in 2/7 (28.6%). Median Doppler score was 1 (IQR 1–1.75). Doppler score showed moderate positive correlations with total CSS (ρ=0.554, p=0.040) and CLISSCO signs (ρ=0.543, p=0.045), with a borderline association with total CLISSCO (ρ=0.526, p=0.053) and a weaker non-significant trend with VASS (ρ=0.460, p=0.098). LC-OCT thickness parameters showed no significant associations with clinical severity scores or PROs. UHFUS hypoechoic dermal band presence showed a non-significant trend toward higher objective severity, including VASS, CSS, CLISSCO signs and total CLISSCO. No consistent associations were observed between instrumental parameters and PROs.

Conclusions
In this exploratory study, Doppler activity showed the most consistent association with clinician-assessed severity, particularly total CSS and CLISSCO signs. UHFUS hypoechoic dermal band and LC-OCT thickness parameters appeared to reflect structural tissue involvement without a consistent relationship with PROs, suggesting that imaging and PROs may capture distinct disease dimensions. These findings support the potential role of non-

invasive imaging as a source of complementary objective information on inflammatory and structural domains of VLS, rather than a replacement for clinical or PRO measures. Larger prospective studies are needed to define the role of UHFUS, Doppler and LC-OCT in VLS severity assessment and treatment monitoring.

EA DV CONGRESS
VIENNA
30 SEP - 3 OCT 2026

Abstract N°: 3718

Double Trouble: Morphea & Graham-Little-Piccardi-Lassieur Syndrome

AYA TADLAOUI*[1], Hanane Baybay[1], Khawla Moufid[1], Ikrame Bejja[1], Saadia Boughaleb[1], Zakia Douhi[1], Meryem Soughi[1], Sara Elloudi[1], Fatima Zahra Mernissi[1]

[1] Dermatology department, University Hospital center of Fez, Sidi Mohamed Ben Abdellah university of Fez, Fez, Morocco

Introduction

Graham-Little-Piccardi-Lassueur Syndrome (GLPLS) is a rare variant of lichen planopilaris, characterized by the classical triad of cicatricial alopecia of the scalp, non-cicatricial alopecia of the axillary and pubic regions, and disseminated keratotic follicular papules on the body. It occurs predominantly in middle-aged women and is thought to be related to an autoimmune mechanism directed against the hair follicles. Morphea is a localized form of scleroderma of inflammatory and autoimmune origin, which may be associated with other dysimmune diseases. The association between morphea and GLPLS is exceptional and has been very rarely reported. We report an original case of generalized morphea associated with Graham-Little-Piccardi-Lassueur syndrome in order to highlight the importance of careful clinico-histological evaluation and to discuss the possible shared pathophysiological mechanisms.

Case Presentation

A 57-year-old female patient, followed for chronic knee pain, with a past serological history of a resolved hepatitis B infection, presented with cutaneous lesions evolving for 9 months. Dermatological examination revealed diffuse pigmented and sclerotic plaques associated with multiple pigmented macules and plaques with a rough surface, showing a pseudo-comedonal appearance on dermoscopy over the trunk. A large cicatricial alopecia plaque on the scalp was also noted, arranged in a crown-like pattern involving the frontal, temporal, and occipital regions. Dermoscopy of these areas showed follicular plugging, whitish areas, erythema, and perifollicular scaling, with hair regrowth in different directions, pili torti, dystrophic hairs, and fine vellus hairs. This was associated with non-cicatricial alopecia of the axillary and pubic regions, with preservation of eccrine openings on dermoscopy. Histopathological examination of the sclerotic plaques on the body showed thickened dermal collagen bundles consistent with morphea, while follicular biopsies revealed a perifollicular lichenoid lymphocytic infiltrate with destruction of hair follicles, supporting the diagnosis of lichen planopilaris consistent with Graham-Little-Piccardi-Lassueur syndrome. The diagnosis of generalized morphea associated with GLPLS was retained. A marked clinical improvement was observed after initiation of systemic treatment (intravenous corticosteroid pulses and methotrexate) combined with topical therapy (topical corticosteroids and vitamin D analogues). Graham-Little-Piccardi-Lassueur syndrome is a rare variant of lichen planopilaris, characterized by the classical triad of cicatricial alopecia of the scalp, non-cicatricial alopecia of the axillary and pubic regions, and disseminated keratotic follicular papules. Histopathology typically shows a perifollicular lichenoid lymphocytic infiltrate with progressive destruction of the hair follicle, suggesting a T-cell-mediated autoimmune mechanism. Morphea is a localized form of scleroderma characterized by dermal inflammation followed by progressive fibrosis. Its autoimmune origin is supported by its frequent association with other dysimmune diseases and by the presence of autoantibodies in some patients. The association observed in our patient between generalized morphea and Graham-Little-Piccardi-Lassueur syndrome is

exceptional and rarely reported. These two conditions may share common pathophysiological mechanisms related to abnormal immune activation, chronic inflammation, and involvement of deep cutaneous structures, which could explain their coexistence. This
observation highlights the importance of clinicopathological correlation in cases of cicatricial alopecia or atypical follicular dermatoses and contributes to a better understanding of rare associations between autoimmune skin disorders.

Conclusion

Reporting such rare associations helps to broaden current knowledge about the possible links between autoimmune dermatoses and assists clinicians in recognizing atypical presenatations of uncommon diseases.

EA DV CONGRESS
VIENNA
30 SEP - 3 OCT 2026

Abstract N°: 3734

Sweet syndrome revealing acute myeloid leukemia

Lamia Nebia Moumen*[1], Serradj Amina[1]

[1] Établissement hospitalier universitaire d'Oran, Oran, Algeria

Introduction

Sweet syndrome (SS), also known as acute febrile neutrophilic dermatosis, is characterized by tender erythematous plaques, papules, or nodules most commonly involving the extremities, neck, and head. (1)

Sweet syndrome can be further classified into three subgroups as classic, malignancy associated, and drug induced. (2)

We describe a case of a refractory form of SS revealing Acute Myeloid Leukemia. (AML)



erythematous plaques and papules on the dorsal surface of the upper extremities

Materials and Methods

Observation :

A 61 year old male patient was referred to our department for erythematous, painful plaques, and nodules on the dorsal surface of the upper extremities evolving for 1 month. The patient was febrile, with leucopenia, Erythrocyte Sedimentation Rate >30mm/hour and positive CRP protein. A skin biopsy was performed, showing a dense neutrophilic infiltrate of the superficial and mid dermis without vasculitis. The patient was started on 1 mg/kg/day of prednisilone. Upon dose reduction, the lesions reappeared. An ultrasound of the lymph node areas revealed a left axillary lymph node with an eccentric hilum and thickened cortex measuring 33 x 15 mm. Given this appearance and the persistent leucopenia (3000/mm^3), the patient was referred to hematology where a diagnosis of AML was made. The patient was started on cytarabine (200 mg daily for seven days) and epirubicin (75 mg

daily for three days). After the first cycle, lesions of his SS disappeared. He is currently in remission from his AML.



erythematous plaques and papules on the dorsal surface of the upper extremities

Results

Discussion :

Sweet's syndrome was originally described by Robert Douglas Sweet in 1964 as an 'acute febrile neutrophilic dermatosis. (3) It is characterized by the abrupt development of painful, tender, erythematous plaques, fever greater than 38°C, and a perivascular neutrophilic dermal infiltrate without evidence of vasculitis on histologic

examination. (4) Few studies have systematically elaborated on this disorder and its features related with hematologic malignancy. (1) AML was reported to be the most common hematologic malignancy associated with SS (5), the case of our patient. Sweet syndrome in patients with AML may show atypical clinical forms with an aggressive course (1). A retrospective case series of 83 Sweet syndrome patients with and without malignancy corroborated that leukopenia was associated with malignancy. (6) as was found in our patient. Notably, SS occurred after the development of hematologic malignancy in most of the patients with hematologic malignancy. In our case, it was SS that revealed the AML which suggests the importance of screening for potential hematologic malignancy when treating patients with this syndrome.



erythematous nodules on the forearm

Conclusions
It is imperative that the dermatologist recognize the sentinel nature of this skin condition, as Sweet’s syndrome can alert the physician to the diagnosis of cancer or the recurrence of malignancy. (3)

References :

1 - Insights Into the Characteristics of Sweet Syndrome in Patients With and Without Hematologic Malignancy ; Zheng S. et al. ; Front. Med. 7:20 (2020)\

2 - Neutrophilic dermatoses: pathogenesis, sweet syndrome, neutrophilic eccrine hidradenitis, and behcet disease ; Nelson CA et al ; J Am Acad Dermatol. (2018)

3 - Insight into Sweet's syndrome and associated-malignancy: A review of the current literature ; Shahzad Raza et al. ; International Journal of Oncology Volume 42 Issue 5 (2013)

4- Sweet's Syndrome (SS) in the Course of Acute Myeloid Leukaemia (AML) ; Guarneri C et al. ; Open Access Maced J Med Sci. (2018)

5 - Sweet’s syndrome—a comprehensive review of an acute febrile neutrophilic dermatosis. ; Cohen PR. ; Orphanet J Rare Dis. (2007)

6 - Sweet syndrome in patients with and without malignancy: a retrospective analysis of 83 patients from a tertiary academic referral center. ; Nelson CA et al. ; J Am Acad Dermatol. (2018



erythematous nodules on the forearm

EADV CONGRESS
VIENNA
30 SEP - 3 OCT 2026

Abstract N°: 3747

Recurrent bilateral lower-limb cellulitis-like inflammation as the presenting sign of late-onset silicone and polymethylmethacrylate granulomatous reaction: diagnostic clues from duplex ultrasound interference and colchicine response

Millena de Freitas Ribeiro*[1], Letícia Silva Andrade[1], Isabella Freire Pedrini[1], Isabel Anuda Brum de Andrade[1], Daniel Pereira[1], Isabela Garibaldi Cucolicchio[1], Raquel Buosi[1], Isadora Prado Juliani[1], Anna Oliveira[1], Tiago Arouche[1], Ana Gabriela Lopes[1], Flávia Colares[1], Patrick Wanderson dos Santos[1], Marcelo Lyra[1]

[1] Hospital Central do Exército, Rio de Janeiro, Brazil

Introduction

Siliconoma is a chronic foreign-body granulomatous reaction to injected silicone or related non-medical filler substances, and may appear from months to decades after injection. Illicit cosmetic augmentation is frequently performed with mixtures of liquid silicone and polymethylmethacrylate (PMMA), which behave as permanent fillers with unpredictable long-term behaviour. Late-onset forms may mimic infectious or inflammatory conditions far from classical filler complications, and the causative history is often concealed. We report a patient in whom recurrent bilateral lower-limb cellulitis-like inflammation, unresponsive to antibiotics, was the presenting sign of a late granulomatous reaction to silicone/PMMA, with duplex ultrasound artefact as an early diagnostic clue and colchicine providing sustained response.

Case Presentation

Siliconoma is a chronic foreign-body granulomatous reaction to injected silicone or related non-medical filler substances, and may appear from months to decades after injection. Illicit cosmetic augmentation is frequently performed with mixtures of liquid silicone and polymethylmethacrylate (PMMA), which behave as permanent fillers with unpredictable long-term behaviour. Late-onset forms may mimic infectious or inflammatory conditions far from classical filler complications, and the causative history is often concealed. We report a patient in whom recurrent bilateral lower-limb cellulitis-like inflammation, unresponsive to antibiotics, was the presenting sign of a late granulomatous reaction to silicone/PMMA, with duplex ultrasound artefact as an early diagnostic clue and colchicine providing sustained response.

Duplex ultrasound of the lower limbs excluded deep and superficial venous thrombosis; notably, examination was explicitly described as technically impaired by "methacrylate and/or silicone" within the subcutaneous and muscular planes, providing the first objective clue to a foreign-body substrate. Incisional biopsy disclosed a granulomatous reaction with variably sized empty vacuoles within the reticular dermis, producing the classic "Swiss-cheese" pattern, surrounded by histiocytes, multinucleated foreign-body giant cells and a mixed inflammatory infiltrate, consistent with exogenous silicone compatible with combined silicone/PMMA deposits. Following initial symptomatic control with antibiotics, colchicine 0.5 mg daily was initiated, with clear reduction of erythema and oedema and sustained clinical improvement.

Three features of this case deserve particular attention. First, a recurrent bilateral cellulitis-like picture, rather than classical indurated filler nodules, may be the dominant presentation of late-onset silicone/PMMA reaction, and should prompt early reconsideration when standard antibiotic therapy fails. Second, duplex ultrasound may not only rule out thrombosis but also provide a diagnostic clue through the acoustic interference produced by intratissular silicone and PMMA, alerting clinicians to an otherwise undisclosed exposure. Third, although corticosteroids and tetracyclines remain first-line options, our patient reported corticosteroid allergy; colchicine 0.5 mg daily produced a favourable response, in line with emerging evidence in granulomatous filler-related inflammation and in the silicone-associated ASIA spectrum. Key differential diagnoses include bacterial and

atypical mycobacterial cellulitis, panniculitis, deep venous thrombosis and hypodermatitis; biopsy remains decisive.

Conclusion

Late-onset silicone/PMMA granulomatous reaction should be considered in patients with recurrent bilateral lower-limb cellulitis-like inflammation unresponsive to antibiotics, especially when clandestine cosmetic augmentation is elicited. Duplex ultrasound interference patterns may serve as an early objective clue, biopsy remains the diagnostic cornerstone, and colchicine represents a safe and effective therapeutic alternative when corticosteroids are contraindicated.

EADV CONGRESS
VIENNA
30 SEP - 3 OCT 2026

Abstract N°: 3759

A Rare Clinicopathological Association of Elastosis Perforans Serpiginosa and Morphea

Jana Dimitrova*[1], Lyubomir Dourmishev[2], Malena Gergovska[1]

[1] SBAL Polimed, Sofia, Bulgaria

[2] Department of Dermatology and Venerology, Sofia, Bulgaria

Introduction

Elastosis perforans serpiginosa is a rare perforating dermatosis defined by transepidermal elimination of abnormal elastic fibers. It may occur idiopathically or in association with connective tissue disorders, genetic syndromes, and certain medications. Morphea,also known as localized scleroderma, is a chronic inflammatory connective tissue disorder characterized by fibrosis of the skin and underlying soft tissues due to excessive collagen deposition. Its etiology remains unknown, with an estimated incidence of 2 per 100,000. The association between these two entities is exceptionally rare, with only isolated cases reported. We present a case of EPS arising in a patient with morphea and discuss diagnostic and therapeutic considerations.

Materials and Methods

A 62-year-old woman presented with a 5-year history of progressive pruritic plaques involving the trunk, gluteal region, and upper and lower extremities. She also reported a painful erosion on the right gluteal region appearing several weeks prior to presentation. Dermatological examination revealed well-demarcated, oval, indurated plaques with central hypopigmentation and atrophy and peripheral violaceous borders, consistent with morphea. Multiple hyperkeratotic papules arranged in a serpiginous pattern were observed at the margins of a gluteal plaque, along with a central erosion covered by hemorrhagic crusts.

Histopathological findings demonstrated epidermal basophilic debris and transepidermal elimination of abnormal elastic fibers. Biopsy from an indurated plaque showed thickened collagen bundles and dermal sclerosis consistent with morphea. Laboratory investigations revealed positive antinuclear antibodies (ANA) at a titer of 1:320.



Erosive lesion with hyperkeratotic papules in a serpiginous pattern

Results

Clinicopathological correlation confirmed the diagnosis of elastosis perforans serpiginosa associated with morphea. The patient was treated with systemic Methylprednisolone 4mg/24h, Ceftriaxone 2g/24h., topical clobetasol propionate 0.05%, emollients, and UVA phototherapy, along with topical mupirocin for the erosive lesion followed by a reparative cream. Partial improvement in inflammatory activity and progressive epithelialisation of the erosion were observed after 7 days of consistent therapy. At one-month follow-up, residual hyperpigmented plaques and a well-formed cicatrix were noted.



Well-formed cicatrix after therapy

Conclusions

EPS associated with morphea represents a rare dermatological entity reflecting altered elastic fiber degradation within sclerotic skin. Recognition of this association is important to avoid misdiagnosis with other perforating dermatoses and to ensure appropriate histopathological evaluation and management. Therapeutic response may be variable, reflecting the chronic and progressive nature of both conditions. Further research and reports are needed to better pathogenesis, clinical behavior, and optimal treatment strategies for this uncommon association.

EA DV CONGRESS
VIENNA
30 SEP - 3 OCT 2026

Abstract N°: 3770

PLEVA Triggered by Upper Respiratory Tract Infection: A Clinicopathological Approach

Isabel Anuda Brum de Andrade*[1], Letícia Silva Andrade[1], Millena de Freitas Ribeiro[1], Isabella Freire Pedrini[1], Daniel Pereira[1], Isabela Garibaldi Cucolicchio[1], Isadora Prado Juliani[1], Anna Oliveira[1], Raquel Buosi[1], Tiago Arouche[1], Ana Gabriela Lopes[1], Flávia Colares[1], Patrick Wanderson dos Santos[1]

[1] Hospital Central do Exército (HCE), Rio de Janeiro, Brazil

Introduction
Pityriasis lichenoides et varioliformis acuta (PLEVA) is an uncommon inflammatory dermatosis within the pityriasis lichenoides spectrum, characterized by an acute eruption of erythematous papules that may progress to necrosis and hemorrhagic crusts. It predominantly affects children and young adults, with a slight male predominance. Pathogenesis remains uncertain, with evidence implicating infectious, immunological, and lymphoproliferative mechanisms, frequently triggered by infections or drug exposure. Diagnosis relies on clinicopathological correlation, with dermoscopy serving as a useful adjunct. Narrow-band UVB (NB-UVB) phototherapy and antibiotics with anti-inflammatory properties are established first-line treatments. We report a case of PLEVA with a probable infectious trigger, highlighting its clinical, histopathological, and therapeutic features.

Case Presentation
A 20-year-old male, Fitzpatrick phototype II, presented with a polymorphous eruption comprising erythematous papules, hemorrhagic crusts, and scattered pustules. Lesions began on the abdomen and extended to the trunk, neck, and limbs, sparing the face and distal extremities. Onset occurred three weeks following an upper respiratory tract infection treated with amoxicillin. The patient reported mild pruritus without systemic symptoms.

Laboratory investigations revealed no significant abnormalities or evidence of active infection. Histopathological examination showed psoriasiform acanthosis, spongiosis, lymphocytic exocytosis, vacuolar degeneration of the basal layer, perivascular mononuclear infiltrate, and erythrocyte extravasation — findings consistent with PLEVA. Treatment was initiated with oral tetracycline and systemic corticosteroids, yielding partial improvement. NB-UVB phototherapy was subsequently introduced with gradual corticosteroid tapering, resulting in marked clinical resolution.

PLEVA is a rare inflammatory condition frequently associated with hypersensitivity responses to infectious agents or medications. In this case, the preceding respiratory infection and amoxicillin use likely served as immunological triggers. The polymorphous eruption with erythematous papules evolving into hemorrhagic crusts and varioliform lesions is characteristic, although histopathological confirmation is essential to exclude lymphoproliferative disorders. Key histological findings — lymphocytic exocytosis, keratinocyte necrosis, and superficial dermal infiltrate — support the diagnosis. Therapeutic management remains largely empirical; however, tetracyclines and NB-UVB phototherapy have demonstrated consistent efficacy in controlling inflammatory activity and promoting lesion resolution.

Conclusion
This case reinforces the value of an integrated clinicopathological approach in diagnosing PLEVA and highlights the role of infectious and pharmacological triggers in its pathogenesis. A multimodal strategy combining systemic antibiotics and NB-UVB phototherapy proved effective, supporting its use as a reliable option for achieving clinical

remission.

EA DV CONGRESS
VIENNA
30 SEP - 3 OCT 2026

Abstract N°: 3772

Largest Case Series of Red Scrotum Syndrome to Date : Clinical Features and Therapeutic Responses

Charbel Skayem*[1], Romain Salle[1], Tu-Anh Duong[1], Jean Noel Dauendorffer[1]

[1] Hopitaux de Paris, Paris, France

Introduction

Red scrotum syndrome(RSS) is a condition characterized by erythema of the scrotum, associated with pain(mainly burning sensation) and inconsistent pruritus, with a significant impact on patients' daily lives.[1] It is underreported, with fewer than 50 cases described in the literature. Our objective was to conduct a retrospective study to assess its clinical characteristics and treatment responses.

Materials and Methods

We extracted medical files of patients consulting a specialized clinic dedicated to male genital disorders, from January 2014 until May 2024, with a clinically confirmed diagnosis of RSS. The following data were collected: age, time of onset, history of rosacea or other vascular conditions, topical corticosteroid(TCS) application, triggering, aggravating, and relieving factors, frequency (persistent/flushes), presence oferythema, itch, xerosis, and response to treatments.

Results

In total, we included 38 patients(median age of 54[20-71]). The median duration of symptoms was 24.1 months[1 month-12 years]. Ten patients had facial rosacea (26.3%), and 1 patient had red ear syndrome. Prior to RSS, TCS application was found in 15 patients (39.4%), tight clothing and pudendal nerve decompression surgery in 1 patient each. After disease onset, 4 patients(10.5%) stated that tight clothing aggravated their symptoms. Additionally, 4 patients(10.5%) found relief with cold water, and 2 patients(5.2%) with warm water. Twenty-four patients(63%) experienced persistent symptoms vs 14 patients (37%) with flush. Burning sensation was found in all patients, and itch in 6 patients (16%). Erythema was diffuse and symmetrical in 35 patients(92.1%), and it spared the scrotal raphe in 3 patients (8%). In four patients (10.5%), the erythema extended to involve the perineum(n=2), inner thighs(n=1), groin(n=1), and proximal shaft of the of the penis (n=1). Scrotal xerosis was observed in 3 patients (8%). The median duration for all treatments was 3 months[1-6 months] (Figure1 below and Figure 2 at the end).

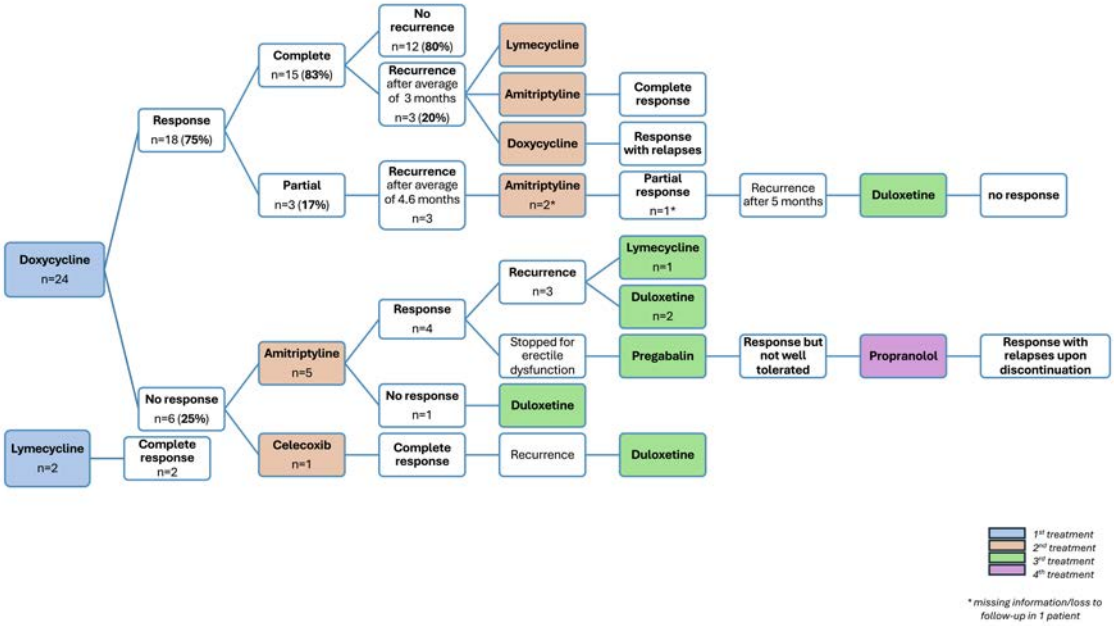

Conclusions

To our knowledge, this is the largest series of RSS. Facial rosacea was found in >1/4 of patients, highlighting that in some cases, RSS might be an extra-facial manifestation of rosacea[2]. While persistent erythema is often part of the definition of RSS[3], >1/3 rather reported flushes. Moreover, contrary to popular belief that RSS is a complication of TCS, over 60% of our patients had no history of TCS application. Scrotal xerosis was observed in 8% of patients. This condition can mislead physicians unfamiliar with male genital disorders into mistakenly diagnosing psoriasis, eczema, or fungal infections, potentially resulting in the prescription of TCS, which may exacerbate the symptoms. Doxycycline was the most prescribed treatment as first line and amitriptyline as second line. 50% of patients on doxycycline had complete response with no recurrence and 25% did not respond at all. If there was a failure to respond or a recurrence after doxycycline treatment, amitriptyline proved effective in 80% of cases, although frequent recurrences were observed(50% of those cases). In certain instances, combination therapy was a successful option. The heterogeneity of treatment prescriptions[3-5] and responses underscores the need for future comparative studies to standardize treatment approach. Doxycycline as 1st line and amitriptyline as 2nd line Limitations include unknown responses for 10/62 treatments prescribed(16%) due to missing data or pending follow-up.

Figure 1: Outcomes of treatment with tetracyclines d*oxycycline 100mg/day, lymecycline 300mg/day, amitriptyline 5mg per day with progressive increase up to 30 mg, pregabalin 50-150mg/day, gabapentin 300mg/day, propranolol 40mg/day, duloxetine 60mg/day , diosmin/hesperidin 500mg twice/day, topical metronidazole, brimonidine, and tacrolimus once/day. If no outcome is mentioned after a treatment, the patient was either lost to follow-up or the data was missing.*

Figure 2*:* Other treatments

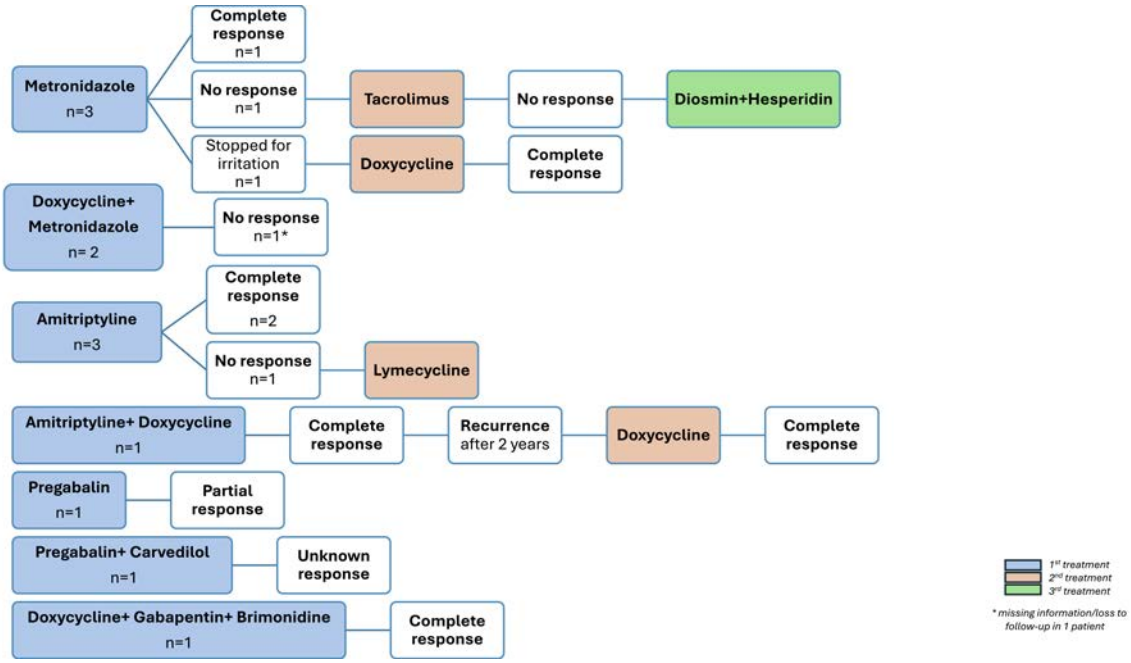
Metronidazole n=3
Complete response n=1
No response n=1
Stopped for irritation n=1
Tacrolimus
No response
Diosmin+Hesperidin
Doxycycline
Complete response
Doxycycline+ Metronidazole n= 2
No response n=1*
Amitriptyline n=3
Complete response n=2
No response n=1
Lymecycline
Amitriptyline+ Doxycycline n=1
Complete response
Recurrence after 2 years
Doxycycline
Complete response
Pregabalin n=1
Partial response
Pregabalin+ Carvedilol n=1
Unknown response
Doxycycline+ Gabapentin+ Brimonidine n=1
Complete response
1st treatment
2nd treatment
3rd treatment
* missing information/loss to follow-up in 1 patient

EADV CONGRESS
VIENNA
30 SEP - 3 OCT 2026

Abstract N°: 3788

When the Diagnosis Changes: Lupus Miliaris Disseminatus Faciei in a Hemato-Oncologic Patient

Madalena Correia*[1, 2], Inês Tribolet de Abreu[1, 2], Inês Pereira Amaral[1, 2], Ivânia Soares[1, 2], Sonia Fernandes[1, 2], Pedro de Vasconcelos[1], JOANA ANTUNES[1, 2]

[1] Unidade Local de Saúde de Santa Maria, Lisbon, Portugal
[2] University of Lisbon - Faculty of Medicine, Lisbon, Portugal

Introduction
Lupus miliaris disseminatus faciei (LMDF) is a rare granulomatous dermatosis of unclear etiology. Its clinical and histological overlap with other inflammatory conditions, mainly granulomatous rosacea and periorifical dermatitism may pose a diagnostic challenge, particularly in patients with complex medical histories.

Case Presentation
An 82-year-old woman with a history of acute myeloid leukemia in remission was followed in dermatology for Sweet syndrome, previously confirmed by histopathology and attributed to her hematologic malignancy.
Two years after the initial diagnosis, she developed multiple firm, erythematous, infiltrated, non-tender papules on the frontal, malar, and cervical regions, without associated systemic symptoms or improvment with topical steroids. Given the clinical suspicion of recurrence of Sweet syndrome or possible leukemia cutis, two skin biopsies were performed.
Histopathological examination revealed epithelioid cell granulomas with central caseous necrosis, predominantly in perifollicular areas. Microbiological cultures and polymerase chain reaction testing for mycobacteria were negative. These findings supported the diagnosis of lupus miliaris disseminatus faciei.

Conclusion
This case highlights the importance of reassessing established dermatological diagnoses when new or evolving lesions arise, particularly in patients with underlying hematologic malignancies. Repeat skin biopsy was crucial not only to exclude leukemia cutis and recurrence of Sweet syndrome but also to establish an alternative diagnosis with distinct therapeutic implications. The identification of LMDF in this context underscores the broad differential diagnosis of facial papular eruptions and the pivotal role of histopathology in guiding management. Furthermore, this case emphasizes the need for close dermatological follow-up and multidisciplinary collaboration in hemato-oncological patients, in whom cutaneous manifestations may reflect a wide spectrum of reactive, infectious, or neoplastic processes with significant diagnostic and therapeutic consequences.

EADV CONGRESS
VIENNA
30 SEP - 3 OCT 2026

Abstract N°: 3798

Can High-Frequency Ultrasound Reflect Histopathological Severity in Vulvar Lichen Sclerosus? A Preliminary Prospective Study

Nina Łabędź*[1], Monika Bowszyc-Dmochowska[2], Anna Slian[3], Joanna Czajkowska[3], Aleksandra Dańczak-Pazdrowska[1], Adriana Polańska[4]

[1] Department of Dermatology, Poznan University of Medical Sciences, Doctoral School, Poznan University of Medical Sciences, Poznań, Poland
[2] Cutaneous Histopathology and Immunopathology Section, Department of Dermatology, Poznan University of Medical Sciences, Poznań, Poland
[3] Department of Biomedical Informatics and Artificial Intelligence, Silesian University of Technology, Zabrze, Poland
[4] Department of Dermatology and Venereology, Poznan University of Medical Sciences, Poznań, Poland

Introduction
Vulvar Lichen Sclerosus is a chronic inflammatory dermatosis characterized by progressive architectural changes and fibrosis. Although VLS is primarily diagnosed clinically, histopathological examination provides detailed information regarding inflammatory activity, sclerosis, and tissue remodeling. However, a biopsy is an invasive procedure and therefore not suitable for repeated monitoring. High-frequency ultrasound (HFUS) has emerged as a promising non-invasive imaging technique for visualizing structural alterations in the skin in inflammatory and sclerotic dermatoses. However, the correlation between HFUS findings and histopathological severity in VLS remains poorly understood.

Materials and Methods
This preliminary prospective study included 40 women with histopathologically confirmed VLS. HFUS examination was performed using a 20 MHz probe. The probe was applied directly over clinically representative lesions whenever visible, or over areas showing labial shortening suggestive of active disease. Biopsies were subsequently obtained from the same examined area to enable direct imaging-histopathology correlation. Histopathological assessment included evaluation of epidermal atrophy, hyperkeratosis, dermal hyalinization/sclerosis, inflammatory infiltrate, and degree of tissue remodeling. HFUS parameters included epidermal and dermal echogenicity, skin thickness, hypoechogenic bands, and architectural disruption.

Results
Preliminary analysis demonstrated visible differences in HFUS morphology corresponding to varying histopathological stages of VLS. Advanced sclerotic lesions showed increased dermal echogenicity, loss of normal layered architecture, and marked tissue heterogeneity, whereas inflammatory lesions demonstrated more localized hypoechogenic changes with partially preserved architecture. Areas of pronounced histological sclerosis appeared to correlate with altered echogenic patterns and reduced structural differentiation on HFUS.

Conclusions

HFUS may represent a valuable non-invasive tool for assessing disease severity and tissue remodeling in VLS. The observed correlation between ultrasonographic and histopathological findings suggests the potential utility of HFUS in objective disease monitoring and longitudinal follow-up. Further studies with larger cohorts are warranted to validate these preliminary findings and to develop standardized imaging criteria for assessing VLS severity.

EA DV CONGRESS
VIENNA
30 SEP - 3 OCT 2026

Abstract N°: 3799

Tape-strip proteomic profiling and biopsy validation highlight inflammatory pathogenesis in seborrheic dermatitis

Benjamin Ungar*[1], Meredith Manson[1], Jessica Beaziz Tordjman[1], Ester Del Duca[1], Gianluca Avallone[1], Anudeep Golla[1], Inna Cueto[1], Yeriel Estrada[1], Jesus Gay-Mimbrera[2], Pedro Gomez Arias[2], Juan Ruano-Ruiz[2], Avner Shemer[3], Diane Hanna[4], Patrick Burnett[4], Emma Guttman-Yassky[1]

[1] Department of Dermatology, Icahn School of Medicine at Mount Sinai, New York, NY, United States
[2] Department of Dermatology, IMIBIC/Reina Sofía University Hospital/University of Córdoba, Córdoba, Spain
[3] Department of Dermatology, Sheba Medical Center, Tel-HaShomer, Ramat-Gan, Israel
[4] Arcutis Biotherapeutics, Inc., Westlake Village, CA, United States

Introduction

Seborrheic dermatitis (SD) is a common, chronic inflammatory skin disease characterized by erythema, pruritus, and scaling of sebum-rich areas including the face, scalp, chest, and skin folds. Transcriptomic profiling using tape strips has revealed a complex immunoinflammatory environment, predominantly involving the IL-23/Th17 and Th22 pathways, and distinct barrier impairment, characterized by dysregulation of lipid metabolism and tight junctional integrity. This study aims to validate the cutaneous molecular signature of SD via proteomics measured on both minimally-invasive tape strips and full-thickness skin biopsies.

Materials and Methods

Tape-strips were collected from lesional and nonlesional facial skin of 26 adult patients with mild-to-severe SD (Investigator's Global Assessment/IGA 2-4) and 12 healthy facial controls. Proteomic analysis was performed on tape strips using OLink and compared to a previously published cutaneous atopic dermatitis (AD) proteome (n=23); RT-PCR was also performed for validation. Lesional and nonlesional biopsies were collected from a subset of 8 patients and analyzed using immunofluorescence (IF) and immunohistochemistry (IHC).

Results

Using differentially expressed proteins/DEP criteria of fold change/FCH>1.5 and false discover rate/FDR<0.05, we identified 198 (197 Up, 1 Down) and 195 DEPs (194 Up, 1 Down) in lesional versus healthy skin and nonlesional skin respectively. The lesional SD proteome demonstrated strong and significant global inflammation, including significant Th1 (*TNF, IL8, IL12B, CCL3/4/5, CXCL9/11*) and Th17/22 activation (*CCL20, CXCL1, IL6/6R, IL17A/R*). Slight Th2-axis involvement (*IL4R, IL7R, CCL17/18/24*) was also observed compared to nonlesional and healthy skin. SD and AD shared significant enrichment of the Th1, IL12/23, IL17/TNFa-related pathways; however, significantly lower Th2 involvement was observed in SD compared to AD. Conversely, upregulation of Th17-associated biomarkers (*IL6R, IL17A/R*) was significantly greater in SD compared to AD. Using immunohistochemistry, we observed significant increases in epidermal thickness, cytotoxic T-cells (CD8+) and cellular proliferation markers (Ki-67) in lesional compared to nonlesional skin. Basal layer inconsistency and qualitative downregulation of Claudin-8 was visible using IF and IHC in lesional skin respectively. Downregulation of Claudin-23 was also noted via RT-PCR, highlighting an observable impairment in tight junctional function in lesional skin.

Conclusions

These data serve to further elucidate and validate the inflammatory pathomechanisms of SD. Consistent Th17/Th22 skewing with minimal Th2 involvement reinforces the characteristic differences between SD and AD, while highlighting SD as a primarily Th17-mediated disease. Furthermore, barrier impairment evident at the protein level further supports the multifaceted pathophysiology of SD, which may help to inform therapeutic targeting to ultimately address both inflammation and barrier function.

EA DV CONGRESS
VIENNA
30 SEP - 3 OCT 2026

Abstract N°: 3825

Primary Cutaneous Rosai–Dorfman Disease of the Scalp: A Rare Diagnostic Challenge

Fatma zahra Lefghih*[1], Mariem Tabka[1], Feryel Amri[1], Asmahane Souissi[1], Chelly Ines[2], Mourad Mokni[1]

[1] Dermatology department, La Rabta Hospital, Tunis, Tunisia, Tunis, Tunisia

[2] Departement of Pathology, Hospital La Rabta, Tunis, Tunisia, Departement of Pathology, Hospital La Rabta, Tunis, Tunisia, Tunis, Tunisia

Introduction

Rosai–Dorfman disease (RDD) is a reactive histioproliferative disorder of unknown etiology. It classically presents with bilateral cervical lymphadenopathy associated with systemic symptoms. Cutaneous Rosai–Dorfman disease (CRDD) is a rare variant limited to the skin without nodal involvement. Although facial localization is relatively frequent, primary scalp involvement remains exceptionally rare. We report a case of primary cutaneous Rosai–Dorfman disease of the scalp.

Case Presentation

A 50-year-old man with no significant past medical history presented to our department with a 4-cm nodular plaque involving the vertex, evolving over 8 months. Clinical examination revealed an alopecic telangiectatic plaque with a central ulcerocrusted area and focal pustules. Dermoscopic examination demonstrated milky-red areas and multiple yellowish homogeneous areas surrounded by large telangiectatic vessels on a red-orange background. Histopathological examination revealed numerous large histiocytes arranged in a nodular and diffuse infiltrative pattern. Emperipolesis was also observed. Immunohistochemical staining showed that the histiocytes expressed S100 and CD68 but were negative for CD1a, supporting the diagnosis of cutaneous Rosai–Dorfman disease. Bacterial and fungal stains were negative. The patient reported no systemic symptoms, including fever, night sweats, or weight loss. Comprehensive clinical and radiological investigations revealed no lymphadenopathy or extracutaneous involvement. Treatment with intralesional corticosteroid injections was initiated.

Conclusion

CRDD is a rare variant accounting for approximately one-third of extranodal cases. It typically presents as yellow-red to brownish papules, nodules, or plaques in the absence of lymphadenopathy. The face and trunk are the most commonly affected sites. Primary scalp involvement is exceedingly rare and may represent a significant diagnostic challenge. Clinical presentations may mimic cysts, cutaneous leishmaniasis, sarcoidosis, juvenile xanthogranuloma, malignant histiocytosis, lymphomas, or even angiosarcoma. Histopathological and immunohistochemical findings are essential for diagnosis. The combination of histiocytic infiltration, emperipolesis, S100 positivity, CD68 positivity, and CD1a negativity strongly supports the diagnosis and helps distinguish CRDD from Langerhans cell histiocytosis and malignant vascular tumors. CRDD generally follows a benign clinical course, although lesions may be cosmetically or functionally troublesome. Management is not standardized and depends on lesion extent, localization, and patient symptoms. Reported therapeutic options include corticosteroids (topical, intralesional, or systemic), surgical excision, radiotherapy, retinoids, methotrexate, and dapsone. Despite the diversity of therapeutic approaches, the prognosis is usually excellent, and spontaneous regression may occur within a few years.

Primary cutaneous Rosai–Dorfman disease of the scalp is an exceptionally rare presentation. Histopathological and immunohistochemical analyses remain essential for establishing the diagnosis. Dermatologists should consider CRDD in the differential diagnosis of chronic atypical scalp lesions in order to avoid misdiagnosis and unnecessary aggressive
management.

EA DV CONGRESS
VIENNA
30 SEP - 3 OCT 2026

Abstract N°: 3827

Artificial Intelligence-Driven Identification of Stress, Overscheduling, and Younger Age as High-Risk Factors for Sensitive Skin

Mina Farah*[1], Nikkia Zarabian[1], Savanna Vidal[1], Nikita Menta[1], Julien Dauriat[2], Guillame Bourdon[2], Krzysztof Piotrowski[3], Nadège Lachmann[3], Adam Friedman[1]

[1] Department of Dermatology, George Washington University School of Medicine and Health Sciences, Washington, District of Columbia,, United States

[2] Quinten Health, Paris, France

[3] Galderma Sensitive Skincare Faculty, Zug, Switzerland

Introduction

Sensitive skin (SS) is an independent dermatologic condition characterized by various cutaneous sensations, including stinging, tingling, burning, tightness, pain, and/or pruritus, that occur in response to ordinarily innocuous stimuli. SS affects a significant proportion of the global population, with an estimated self-reported prevalence of 71%. Previous studies have identified associations between sensitive skin, environmental stressors, and demographic characteristics; however, these factors have not been systematically categorized. While emerging research has improved understanding of the prevalence, diagnostic criteria, and pathophysiology of SS, significant gaps remain in identifying and characterizing its specific risk factors. Thus, this study aimed to identify high-risk factors for SS using artificial intelligence (AI)-based analytics.

Materials and Methods

Q-Finder, an AI-driven analytical algorithm, was applied to a global dataset of 16,619 individuals who participated in an international profiling survey disseminated across 12 countries: the United States, Australia, Brazil, China, India, the Philippines, Germany, Nigeria, Kenya, Egypt, Tunisia, and South Africa, to detect high-risk subgroups for SS. The data were stratified into two cohorts. Cohort 1 included all patients with self-reported 'not sensitive,' 'sensitive,' and 'very sensitive' skin (N = 11,338). Cohort 2 applied the same criteria but excluded patients with a history of prior skin conditions (N = 6,118). Subgroups were validated using odds ratio (OR) and confidence interval (CI), with statistical significance defined as OR ≥ 1.2 and a Bonferroni-corrected p-value < 0.05.

Results

In cohort 1, high-risk subgroups for SS included those who were frequently overscheduled (36%, OR 3.0, 95% CI [2.7–3.3]), highly stressed (30%, OR 2.7, 95% CI [2.4–3.0]), and aged 18 to 24 years old (17%, OR 2.4, 95% CI [2.1–2.7]. These high-risk subgroups remained consistent in cohort 2, including individuals who were frequently overscheduled (28%, OR 2.4, 95% CI [2.1–2.8]), highly stressed (22%, OR 2.2, 95% CI [1.9–2.6]), and aged 18 to 24 (15%, OR 2.7, 95% CI [2.3–3.3]).

Conclusions

This global, cross-sectional study uncovered associations between SS and frequent overscheduling, high stress levels, and younger age. Associations with behavioral factors such as overscheduling and stress suggest a

connection between SS and dysregulation of the hypothalamic-pituitary-adrenal axis and peripheral nervous system sensitization. The association with younger age may suggest hormonal variations and sleep deprivation as potential contributing factors. In addition to highlighting the utility of a novel AI algorithm in advanced identification of SS risk factors, these findings may inform more refined risk assessment and identification of individuals at greater risk for developing SS.

EA DV CONGRESS
VIENNA
30 SEP - 3 OCT 2026

Abstract N°: 3830

Innovative injectable therapies for inflammatory acne vulgaris: Platelet-rich plasma versus microbotox

Marwa El-Samongy*[1, 1], Asmaa Taha[2], Hanan El-Shenawy[3], Amal El-Ashmawy[1]

[1] Dermatology & Venereology department, Faculty of Medicine, Tanta University, Tanta, Egypt
[2] faculty of medicine, Tanta, Egypt
[3] Pathology department, Tanta, Egypt

Introduction

Acne vulgaris is a common disorder of the pilosebaceous unit. Despite various treatment options for acne, challenges like poor patient compliance, significant side effects, and high recurrence rates persist. Platelet-rich plasma has shown promise in treating active acne lesions, indicating its anti-inflammatory and antimicrobial properties and suggesting it as a potential alternative therapy. Additionally, botulinum toxin may reduce sebum production by inhibiting acetylcholine release in sebocytes and causing temporary paralysis of the arrector pili muscle, which may be used in the treatment of acne vulgaris. The work aimed to compare the clinical efficacy and safety of intradermal PRP injection versus intradermal microbotox injection in the treatment of inflammatory AV.

Materials and Methods

This study included 20 patients with inflammatory acne vulgaris. Each patient received 4 sessions of intradermal platelet-rich plasma injections on the right side of the face and a single session of intradermal microbotox injections on the left side of the face. Patients were monitored monthly for three months post-treatment. Histopathological changes were assessed before treatment and one month after the end of treatment

Results

On the right side (intradermal injection of platelet-rich plasma), the inflammatory lesions showed a statistically significant decrease after treatment as compared to before treatment. Also, on the left side (intradermal injection of microbotox), the inflammatory lesions showed a statistically significant decrease after treatment as compared to before treatment. However, there was a statistically significant improvement on the right side compared with the left side in the change in inflammatory lesions and in the recurrence rate after 3 months. There was a statistically negative correlation between the degree of improvement and the age of patients, as the younger the patient, the better the results.

- Regarding the histopathology: before treatment, the active AV showed opened comedone of cyst-like cavities filled with a compact mass of keratinous material and numerous bacteria, besides the numerous inflammatory infiltrate in the dermis, while after treatment with PRP, there was minimal inflammatory infiltrate seen in the dermis with intact epidermis with marked collagen deposition. After treatment with mesobotox, there were still a large number of inflammatory infiltrate with decreased number of sebaceous units, and collagen deposition.

Table (1): Comparison between right and left side according to 3 blinded physicians' opinion

	Right side		Left side		MH	p
	No.	%	No.	%		
Evaluation						
Poor	0	0.0	6	30.0		
Fair	1	5.0	1	5.0	MH= 31.500*	0.002*
Good	6	30.0	11	55.0		
Excellent	13	65.0	2	10.0		
Doctor satisfaction						
Min. – Max.	5.0 – 9.0		4.0 – 9.0			
Mean ± SD.	8.25 ± 1.21		6.0 ± 1.84		t= 4.265*	<0.001*
Median (IQR)	9.0 (7.5 – 9.0)		5.5 (4.0 – 8.0)			

IQR: **Inter quartile range** SD: **Standard deviation** **t: Student t-test**
MH: Marginal Homogeneity Test
p: p value for comparing between **right side** and **left side**
*: Statistically significant at $p \leq 0.05$

Conclusions

- Both PRP and mesobotox are effective treatments for inflammatory AV.
- All grades of inflammatory acne have been improved with both PRP and mesobotox, but skin texture and scars improved more with PRP.
- Platelet-rich plasma has better improvement at one month after completion of the treatment protocol compared to mesobotox, and has higher satisfaction with a delayed or minimal recurrence rate.
- Mesobotox has rapid action starting after 2 weeks, but with a higher recurrence rate after one to 2 months.
- Both PRP and mesobotox have no side effects like post-inflammatory hyperpigmentation, but all patients had slight pain during injection and erythema more with mesobotox than PRP.

EA DV CONGRESS
VIENNA
30 SEP - 3 OCT 2026

Abstract N°: 3860

Management of Erythrodermic Psoriasis and Axial Psoriatic Arthritis With Secukinumab Following Sequential Treatment of Latent Tuberculosis Infection: A Case Report

Ana Carolina Salomão*[1], Mariana Diniz[1], Raphael Pereira[1]

[1] Universidade Estadual do Rio de Janeiro, Hospital Universitário Pedro Ernesto, Rio de Janeiro, Brazil

Introduction

Erythrodermic psoriasis is a severe and potentially life-threatening form of psoriasis frequently associated with systemic complications and psoriatic arthritis. Axial involvement further increases therapeutic complexity, requiring effective control of both cutaneous and musculoskeletal inflammation while minimizing the risk of infectious complications in patients with latent infections.

Case Presentation

We report the case of a 64-year-old man presenting with universal erythroderma and inflammatory low back pain, with a Psoriasis Area and Severity Index (PASI) score of 52. Diagnostic evaluation revealed reactive interferon-gamma release assay (IGRA) and positive VDRL serology (1:16). Histopathological examination confirmed psoriasis, and imaging studies demonstrated axial involvement affecting the spine and sacroiliac joints.

Management followed a sequential therapeutic strategy. Syphilis treatment was initiated first, followed by chemoprophylaxis for latent tuberculosis infection with rifapentine and isoniazid. After 30 days of antituberculous therapy, secukinumab at a dose of 300 mg was introduced.

The patient subsequently achieved complete remission of erythroderma with marked improvement in axial pain and functional status. No evidence of tuberculosis reactivation or significant adverse events was observed during follow-up.

The therapeutic rationale for secukinumab was based on the central pathogenic role of interleukin-17A in both psoriasis and axial psoriatic arthritis. Compared with IL-23 inhibitors, IL-17A blockade demonstrates superior efficacy in axial disease control. In addition, sequential treatment of latent tuberculosis prior to biologic initiation was considered essential to reduce bacillary burden and stabilize granulomatous immune responses before immunomodulation. Although IL-17 inhibitors appear to carry lower tuberculosis reactivation risk than TNF-α inhibitors, careful temporal sequencing remains important to optimize safety.



Figures 1–3. Extensive erythematous-desquamative plaques consistent with erythrodermic psoriasis, involving the trunk, lower limbs, and feet, associated with diffuse scaling, marked cutaneous inflammation, nail dystrophy, and acral involvement prior to biologic therapy initiation.

Conclusion

This case highlights secukinumab as an effective therapeutic option for concomitant erythrodermic psoriasis and axial psoriatic arthritis. Sequential management of latent tuberculosis infection before biologic initiation allowed safe treatment administration and successful disease control without infectious reactivation.

EA DV CONGRESS
VIENNA
30 SEP - 3 OCT 2026

Abstract N°: 3867

Erythema Induratum of Bazin: Clinicopathological Features and Therapeutic Outcomes in a 15-Year Retrospective Study

Ines Atoui*[1], Litaiem Noureddine[1], Soumaya Gara[1], Meriem Jones[1], Faten Zeglaoui[1], rammeh soumaya[1]

[1] Dermatology department -Charles Nicolle Hospital, Tunis, Tunisia

Introduction
Erythema induratum of Bazin is an uncommon chronic nodular panniculitis, considered within the spectrum of nodular vasculitis and classically associated with a hypersensitivity reaction to *Mycobacterium tuberculosis*. Its diagnosis relies on clinico-pathological correlation, particularly in the absence of microbiological confirmation.

Materials and Methods
This was a retrospective study conducted between January 2011 and January 2026, including only histologically confirmed cases of erythema induratum of Bazin. It was defined by the presence of chronic nodular panniculitis of the lower limbs, with or without cutaneous fistulization, and a histopathological pattern consistent with a tuberculoid granulomatous infiltrate.

Results
Eight patients were included in this study, seven of whom were female, with a mean age of 54.6 years. No history of familial tuberculosis exposure was reported. The mean disease duration was 12.3 months. Clinically, all patients presented with chronic nodular hypodermitis of the lower limbs, which was fistulized in two cases and left post-inflammatory hyperpigmented scars in all patients. Subcutaneous nodules were observed in two patients, involving the thighs and buttocks in one case and the forearms in another. Histopathological examination consistently showed lobular necrotizing granulomatous panniculitis, associated with vasculitis in four cases. PCR testing on skin biopsies, performed in four patients, was negative for *Mycobacterium tuberculosis* DNA. Tuberculin skin testing was phlyctenular in five cases. No evidence of extracutaneous tuberculosis was found, with normal chest radiographs, negative sputum and urine acid-fast bacilli examinations, and no lymph node involvement. Regarding treatment, dapsone (100 mg/day) was prescribed in seven patients, with good clinical response and no recurrence. One patient received systemic corticosteroid therapy at a dose of 0.5 mg/kg/day. Colchicine (1 mg/day) was considered as second-line therapy when deemed necessary. A short course of antituberculous therapy was initiated in one patient but discontinued after seven days due to a maculopapular drug eruption, following pharmacovigilance advice, and subsequently replaced by dapsone.

Conclusions
Erythema induratum of Bazin remains a rare chronic nodular panniculitis with characteristic clinico-histological features. The frequent negativity of microbiological investigations despite strongly positive tuberculin skin tests supports a hypersensitivity reaction to *Mycobacterium tuberculosis* rather than active infection. Dapsone showed good therapeutic efficacy and may represent an effective first-line treatment, whereas antituberculous therapy should be considered selectively according to the clinical context.

EADV CONGRESS
VIENNA
30 SEP - 3 OCT 2026

Abstract N°: 3890

Medicolegal and Regulatory Considerations for Off-Label Use of Metabolic Therapies in Dermatology

Anna Delay*[1], Kasey Smith[2], Jacqueline Boyle[3], Kaylahn Jones[4], Alina Bridges[5]

[1] Touro University California College of Osteopathic Medicine, Vallejo, CA, United States
[2] HCA Florida Blake Hospital, Bradenton, FL, United States
[3] NYIT College of Osteopathic Medicine, Old Westbury, NY, United States
[4] Kansas City University College of Osteopathic Medicine, Kansas City, MO, United States
[5] Northwell, New Hyde Park, NY, United States

Introduction
Glucagon-like peptide-1 receptor agonists (GLP-1 RAs) have rapidly expanded in clinical use for obesity and type 2 diabetes, with recent FDA approvals extending to obstructive sleep apnea (OSA) and metabolic dysfunction-associated steatohepatitis (MASH). Despite growing evidence of anti-inflammatory properties relevant to dermatologic conditions, no GLP-1 RA currently carries an FDA-approved dermatologic indication, creating a complex regulatory and medicolegal landscape for dermatologists.

Materials and Methods
A narrative review was conducted synthesizing peer-reviewed literature, clinical trials, FDA regulatory communications, professional society guidelines, and medicolegal publications. Studies addressing off-label prescribing practices, adverse event profiles, and legal and regulatory considerations relevant to metabolic therapies in dermatologic practice were analyzed.

Results
GLP-1 RAs have demonstrated promising dermatologic results, including PASI reductions in psoriasis cohorts and reduced disease activity in hidradenitis suppurativa, with the TOGETHER-PsA trial providing the first randomized evidence supporting dual incretin and biologic therapy. However, rising off-label prescribing and patient demand have raised concerns regarding informed consent, scope of practice, and liability exposure. Regulatory scrutiny surrounding compounded GLP-1 formulations and ongoing medication shortages further complicate clinical practice. Notably, off-label prescribing is associated with higher adverse event rates when unsupported by strong evidence, and liability shifts from the manufacturer to the prescriber in the absence of an approved indication.

Conclusions
The TOGETHER trials have been promising and will be pivotal in transitioning GLP-1-based therapies from off-label adjuncts to evidence-based dermatologic standard of care. Until such evidence matures, dermatologists prescribing these agents must adopt appropriate safeguards, including informed consent that explicitly addresses off-label status, anticipated adverse effects, and therapeutic alternatives. Baseline metabolic and dermatologic monitoring, avoidance of compounded incretin formulations, and multidisciplinary co-management with endocrinology or primary care are recommended.

EADV CONGRESS
VIENNA
30 SEP - 3 OCT 2026

Abstract N°: 3893

Lupus miliaris disseminatus faciei - what do we know about it? A systematic review

Aleksandra Frątczak*[1], Michał Porada[2], Gabriela Skórska[2], Wiktor Kruczek[2, 3], Bartosz Miziołek[1], Beata Bergler-Czop[1]

[1] Department of Dermatology, School of Medicine in Katowice, Medical University of Silesia, Katowice, Poland
[2] Students' Scientific Association at the Department of Dermatology, School of Medicine in Katowice, Medical University of Silesia, Katowice, Poland
[3] Doctoral School, Medical University of Silesia, Katowice, Poland

Introduction
Lupus miliaris disseminatus faciei (LMDF) is a rare chronic granulomatous dermatosis predominantly affecting the central face and eyelid region. Due to substantial clinical and histopathological overlap with granulomatous rosacea, sarcoidosis and other granulomatous facial disorders, accurate diagnosis remains challenging and frequently delayed, increasing the risk of permanent scarring. Recent studies have highlighted the growing role of dermatoscopy, artificial intelligence-assisted diagnostics and immunologic pathways in improving understanding of LMDF. This study aimed to summarize current evidence regarding the clinical presentation, histopathological features, diagnostic approaches and emerging pathogenetic insights associated with LMDF.

Materials and Methods
The authors conducted research in PubMed, EMBASE and Cochrane databases to identify studies concerning LMDF. The search was performed from database inception to May 2026 and included MeSH and EMTREE terms in accordance with the PRISMA 2020 guidelines. The search strategy included the following terms and combinations: "Lupus miliaris disseminatus faciei", "LMDF", "acne agminata". After duplicate removal, title and abstract screening, eligible full-text articles were assessed for inclusion. Ultimately, 14 studies met the inclusion criteria and were analysed.

Results
The analysis of all 14 studies meeting the inclusion criteria revealed that LMDF most commonly affects young adults, with predominant involvement of the periorbital and centrofacial regions. Histopathological examination consistently revealed epithelioid granulomatous infiltrates within the superficial dermis, frequently accompanied by caseous necrosis and perifollicular involvement. Dermatoscopic findings included orange structureless areas, follicular plugs, perifollicular white scar-like areas and linear vascular structures, supporting its value as a non-invasive diagnostic tool. Diagnostic overlap with granulomatous rosacea was identified as a major clinical challenge. AI-assisted diagnostic models achieved high diagnostic accuracy and significantly improved clinician performance and diagnostic efficiency in differentiating LMDF from granulomatous rosacea. Additionally, immunologic studies demonstrated increased IL-17 and IL-23-positive cell infiltration within granulomatous lesions, suggesting a potential role of the IL-23/IL-17 axis in LMDF pathogenesis.

Conclusions

LMDF remains a diagnostically challenging granulomatosis facial dermatosis with incompletely understood pathogenesis. Histopathology continues to represent the diagnostic gold standard. However, dermatoscopy and emerging AI-assisted diagnostic tools may substantially improve non-invasive differentiation from other granulomatous facial diseases. Recent immunologic findings suggest that possible involvement of the IL-23/IL-17 pathway, providing new insights into disease mechanisms and potential future therapeutic targets.

EA DV CONGRESS
VIENNA
30 SEP - 3 OCT 2026

Abstract N°: 3918

Skin Tone and Sensitive Skin: An Artificial Intelligence-Driven Cross-Sectional Analysis

Mina Farah*[1], Nikkia Zarabian[1], Savanna Vidal[1], Nikita Menta[1], Julien Dauriat[2], Guillame Bourdon[2], Krzysztof Piotrowski[3], Nadege Lachmann[3], Adam Friedman[1]

[1] Department of Dermatology, George Washington University School of Medicine and Health Sciences, Washington, District of Columbia,, United States

[2] Quinten Health, Paris, France

[3] Galderma Sensitive Skincare Faculty, Zug, Switzerland

Introduction

Sensitive skin (SS) is characterized by stinging, tingling, burning, tightness, pain, or pruritus in response to typically innocuous stimuli, occurring indepdendently of other skin conditions. While literature on SS is predominantly derived from individuals with lighter skin types, emerging data suggest that SS may be prevalent in darker skin tones, though the underlying mechanisms are poorly understood. This study assessed whether skin type is a high risk factor for SS using artificial intelligence (AI).

Materials and Methods

An online survey was distributed across 12 countries. Skin sensitivity was assessed using a 4-point Likert scale ("not sensitive," "slightly sensitive," "sensitive," and "very sensitive"), and participants self-selected skin tones corresponding to their complexion. Selected tones were mapped to Fitzpatrick phototypes, and an expanded alphanumeric skin tone scale ranging from A1 (lightest) to C3 (darkest) was implemented (Figure 1). Participants were stratified into two cohorts: Cohort 1 included individuals with self-reported "not sensitive," "sensitive," or "very sensitive" skin (N = 11,338), while Cohort 2 applied the same criteria but excluded participants with prior skin conditions (N = 6,118). Both cohorts were analyzed using Q-Finder, AI-driven algorithm, with statistical significance defined as OR $\geq$1.2 and Bonferroni-corrected $p < 0.05$.



Figure 1. Alphanumeric skin tone scale (A1-C3) used in the survey for participant self-assessment of skin tone.

Results

In cohort 1, 13% (N = 1,508) had self-identified dark skin types, and 85.3% of these patients (N = 1,287) reported SS. In cohort 2, 13% (N = 802) comprised the dark skin type subgroup, and 75.8% of these patients (N = 608) reported SS. Dark skin phototype (Fitzpatrick VI + C2, C3) was identified as a high-risk factor for SS with identical OR and 95% confidence interval (CI) in both groups (OR 1.9; 95% CI [1.6-2.2]).

Conclusions

In this global analysis, an AI-based algorithm identified darker skin tones as a high risk factor for SS, expanding upon prior studies that have primarily focused on SS in lighter skin tones and highlighting the utility of AI in SS risk assessment. Proposed mechanistic links between darker skin tone and SS include differences in stratum corneum structure and lipid composition, such as altered ceramide and cholesterol levels, which may impair barrier stability and increase irritant penetration. Genetic polymorphisms associated with upregulation of transient receptor potential (TRP) channels, namely TRP Vanilloid (TRPV)1 and TRPV4, involved in pain, itch, and heat transduction, may also contribute to SS in this population. Beyond highlighting potential mechanisms, this study increases awareness of a previously underrecognized SS risk factor and underscores the need for future studies to

strengthen mechanistic understanding and support targeted management in high risk individuals.

EA DV CONGRESS
VIENNA
30 SEP - 3 OCT 2026

Abstract N°: 4010

Redefining Flares in Hidradenitis Suppurativa: Evidence from Prospective Daily Monitoring Across Two Cohorts

Emma Carroll*[1], Maria-Alexandra Visan[1, 2, 3], Emily Pender[1], Lisa Killion[1], Bruna Wafae[4], Rosalind Hughes[1, 5], Martina L. Porter[4], Brian Kirby[1, 5]

[1] St. Vincent's University Hospital, Dublin, Ireland
[2] Carol Davila Emergency University Central Military Hospital, Bucharest, Romania
[3] Carol Davila University of Medicine and Pharmacy, Bucharest, Romania
[4] Beth Israel Deaconess Medical Center, Boston, United States
[5] University College Dublin, Dublin, Ireland

Introduction
Inflammatory flares contribute substantially to disease burden in hidradenitis suppurativa (HS), yet remain poorly defined. Current consensus definitions rely primarily on increases in abscess and nodule counts, which may not adequately capture the multidimensional nature of disease activity.

The objectives of this study were to characterise flare dynamics, evaluate the adequacy of lesion-based flare definitions and identify symptom predictors of imminent flare in HS.

Materials and Methods
We conducted a prospective observational study in which patients with HS completed daily symptom monitoring over 30 days using a REDCap-based electronic diary. Flare states (quiet, imminent, peak, resolving), symptoms (pain, itch, odour), and lesion activity (new, pre-existing, or both) were recorded. A flare state was defined as either the development of a new inflammatory lesion or worsening of a pre-existing lesion.

Demographic and clinical characteristics, including Hurley stage, IHS4, and treatment status, were collected. The proportion of flares captured by a traditional lesion-based definition (new lesions only) was assessed, with sensitivity analyses accounting for recurrent-site activity. Logistic regression was used to evaluate symptom predictors of flare on the following day.

Findings were compared with an independent prospective cohort from the United States, which used a similar patient-reported monitoring approach to characterise flare dynamics.

Results
Thirty-eight patients were enrolled in the Irish cohort, with 25 completing 30-day monitoring. Patients had Hurley stages I–III (5, 14, 3), a mean baseline IHS4 of 3.64 (SD 5.94), and 44% were receiving biologic therapy. Despite systemic treatment, flares were frequent, with 35 flares identified (mean duration 2.2 days). “Soreness/swelling” was the most prominent symptom, and rescue therapy was commonly required.

Among 400 flare days, 47.6% occurred in pre-existing lesions only and would have been missed by a lesion-based definition relying on new lesion development. When recurrent-site activity was variably classified, the proportion

of missed flares ranged from 36.9% to 59.3%. At the patient level, the median proportion of flare days occurring in pre-existing lesions was 33.3% (IQR 12.5–62.5%), demonstrating substantial inter-individual variability.

In predictive analyses, mean odour scores were higher on days preceding a flare compared with non-flare days (2.55 vs 1.72), whereas pain showed only a modest increase and itch showed no positive association. In logistic regression, higher odour scores were independently associated with increased odds of flare the following day (OR 1.33, 95% CI 1.10–1.60, p=0.003). Itch demonstrated an inverse association (OR 0.81, p=0.013), while pain was not predictive (OR 1.01, p=0.947).

These findings were supported by the independent United States cohort (n=25), in which >50% of symptoms occurred in pre-existing lesions and most flares involved existing sites rather than new lesion formation. Common symptoms included pressure/discomfort, soreness/swelling, itching, pain, and drainage.

Conclusions

Flares in hidradenitis suppurativa frequently arise from pre-existing lesions and are not captured by current lesion count–based definitions. Consistent findings across Irish and United States cohorts highlight a fundamental limitation of existing flare definitions. Odour appears to be an early clinical marker of impending flare. These findings support the development of patient-centred definitions of HS flare that incorporate symptom dynamics alongside lesion counts.

EADV CONGRESS
VIENNA
30 SEP - 3 OCT 2026

Abstract N°: 4054

Panniculitis and psoriasis in individuals with alpha-1 antitrypsin deficiency:a Swedish nationwide register-based cohort study of 307 768 patients

Aleksandra Kanina*[1], Hannes Hagström[1], Axel Svedom[1]

[1] Karolinska Institutet, Stockholm, Sweden

Introduction
Alpha-1 antitrypsin deficiency (AATD) is a hereditary disorder characterized by reduced levels or misfolding of alpha-1 antitrypsin, leading to protease–antiprotease imbalance and systemic inflammation. While the clinical manifestations of AATD are well established in the lungs and liver, dermatologic involvement is less well characterized. Panniculitis is a recognized but rare complication of AATD, often described in case series, whereas the relationship between AATD and other inflammatory skin diseases, such as psoriasis, remains unclear. Existing evidence is limited to small studies and lacks population-based estimates. Improved understanding of the burden and timing of dermatologic manifestations in AATD may provide insights into disease mechanisms and support clinical awareness.

Materials and Methods
We aimed to estimate the occurrence, incidence rates, and cumulative incidence of panniculitis and psoriasis in individuals with AATD. We conducted a nationwide register-based cohort study including 3,106 individuals with AATD identified through healthcare registers between 2001 and 2022. The adult individuals were followed from the time of the first recorded AATD diagnosis. Incident panniculitis and psoriasis were defined using diagnostic codes occurring after the index date. Follow-up continued until outcome occurrence, death, emigration, or end of study (31 December 2022). Incidence rates per 1,000 person-years (PY) were estimated using time-to-event methods. Cumulative incidence functions (CIF) accounting for competing risk of all-cause mortality were calculated at 3, 5, and 10 years.

Results
Out of 307 768 patients with liver diseases, we identified 3106 AATD patients. Among 2,993 eligible individuals (median follow-up ~7.4 years), panniculitis occurred in 6 individuals, corresponding to an incidence rate of 0.27 per 1,000 PY (95% CI 0.12–0.60). Psoriasis was identified in 26 individuals after AATD diagnosis, yielding an incidence rate of 1.18 per 1,000 PY (95% CI 0.80–1.73). The cumulative incidence of psoriasis was 0.33% at 3 years, 0.65% at 5 years, and 1.01% at 10 years. Panniculitis remained rare throughout follow-up. All-cause mortality was a substantial competing event, affecting approximately one-fifth of the cohort.

Conclusions
This is the first nationwide register-based study on dermatological manifestations in AATD patients. In this cohort of individuals with AATD, panniculitis was a rare manifestation, while psoriasis occurred infrequently but at measurable rates over time. These findings provide population-based estimates of dermatologic outcomes in AATD and highlight that panniculitis is an underrepresented condition in register-based data.

EA DV CONGRESS
VIENNA
30 SEP - 3 OCT 2026

Abstract N°: 4059

Are We Asking The Right Questions? A Pilot Project of GSM Screening and Adjunct Local Oestrogen Use in Peri-/Postmenopausal Vulval Lichen Sclerosus

Paul Cooper*[1], Bairbre Wynne[1]

[1] St. James's Hospital, Department of Dermatology, Dublin, Ireland

Introduction
Vulval lichen sclerosus (VLS) is a chronic inflammatory dermatosis commonly affecting peri- and postmenopausal women. Genitourinary syndrome of menopause (GSM), including vulvovaginal atrophy (VVA), can cause dryness, soreness and dyspareunia and may coexist with VLS, creating diagnostic and therapeutic overlap that may contribute to persistent symptoms if not identified.

Objectives

To audit (i) documentation of GSM symptom screening and patient-centred outcomes and (ii) the provision of adjunct local oestrogen in peri-/postmenopausal patients with VLS, against guideline standards.

Materials and Methods
A retrospective audit of 23 clinical encounters over a 3-year period was performed. The cohort age range was 49–81 years (median 65) and included 22 postmenopausal and 1 perimenopausal patient. Records were reviewed for documentation of: GSM symptoms (explicit enquiry/recording of vaginal dryness and/or dyspareunia, plus urinary symptoms where documented), vulvovaginal atrophic findings on examination, VLS treatment with topical corticosteroids, whether adjunct local oestrogen was offered/prescribed, sexual health assessment (sexual activity/function), and quality-of-life/functional impact (including DLQI).

Results
Documentation of primary VLS management was high, with topical corticosteroid therapy recorded in 78.3% (18/23) encounters. GSM symptom screening was infrequently documented: explicit recording of vaginal dryness and/or dyspareunia occurred in 8.7% (2/23) encounters. Atrophic vulvovaginal findings were documented in 39.1% (9/23) encounters, yet adjunct local oestrogen was offered/prescribed in 21.7% (5/23). Sexual function was proactively discussed in 8.7% (2/23) encounters and DLQI was documented in 4.3% (1/23). Overall, there was a marked discrepancy between documentation of VLS-directed therapy and documentation of GSM screening and patient-centred outcomes.

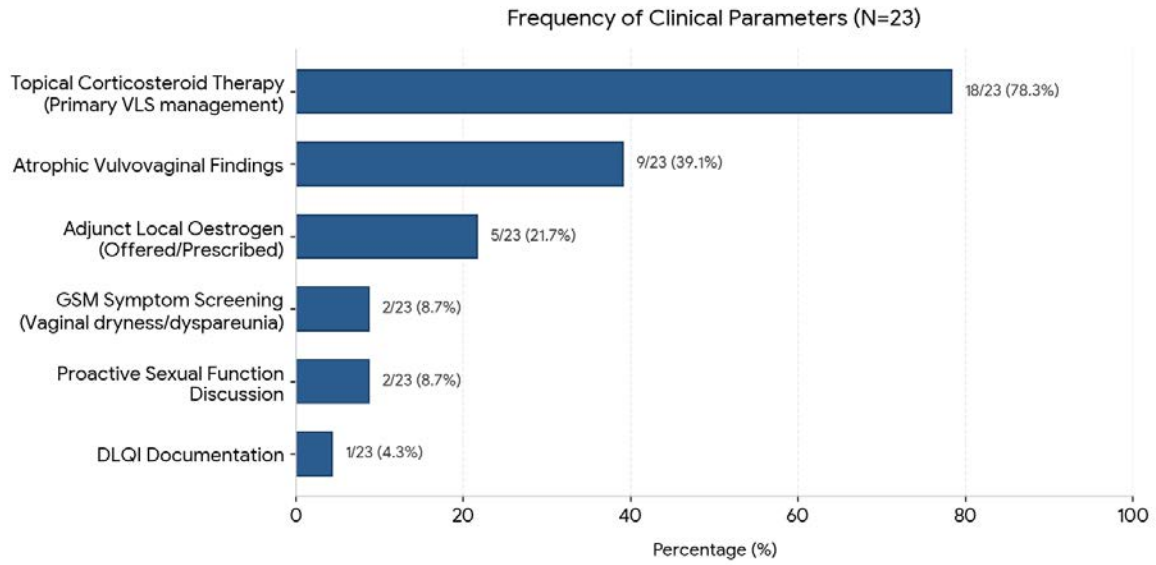

Conclusions

This audit demonstrates low documentation of GSM symptom screening, sexual function, and quality-of-life impact in peri-/postmenopausal VLS, with adjunct local oestrogen offered/prescribed less frequently than suggested by documented atrophic findings. We propose a quality-improvement approach focused on (1) implementing structured GSM symptom screening (a validated questionnaire e.g. VSQ), (2) considering adjunct local oestrogen when GSM is identified or suspected (symptoms ± signs) using shared decision-making, and (3) introducing clinic proformas to ensure consistent assessment of VLS activity, GSM symptoms, and functional outcomes.

EA DV CONGRESS
VIENNA
30 SEP - 3 OCT 2026

Abstract N°: 4068

Dissecting Molecular and JAK/STAT Signaling Heterogeneity in Chronic Hand Eczema

Georgio Chidiac[1], Eudeline Alix[2], Charlène Champin[2], Mallaury Epinat[2], Axel Villani[1], Audrey Nosbaum[1], Marie Tauber[1], Marie Donzel[2], Marc Vocanson*[1]

[1] Centre International de Recherche en Infectiologie, University of Lyon 1 and Ecole Nationale Supérieure de Lyon; Inserm U1111, Lyon, France

[2] Institut de pathologie multisite, Hospices Civils de Lyon, Hôpital Lyon Sud, Pierre Bénite, France

Introduction

Chronic hand eczema (CHE) is a common and disabling inflammatory skin disease characterized by marked clinical heterogeneity and limited therapeutic options. Current clinical and histopathological classifications often fail to capture its underlying biological diversity, limiting patient stratification and precision treatment. The molecular mechanisms driving CHE, particularly the involvement of intracellular signaling pathways such as JAK/STAT remain poorly defined.

Materials and Methods

We performed an integrated molecular and signaling analysis of lesional and control skin biopsies from patients with CHE (n=16), atopic dermatitis (AD, n=6), psoriasis (PSO, n=7), and healthy donors (n=6). Targeted transcriptomic profiling of 100 immune-related genes was conducted using Nanostring technology. In parallel, phosphorylation of JAK1-3, TYK2, and STAT1-6 proteins was quantified by immunohistochemistry combined with AI-assisted image analysis. Differential expression, immune module scoring, unsupervised clustering, principal component, and correlation analyses were performed to link gene expression programs with intracellular signaling activity.

Results

CHE lesions displayed a distinct molecular profile that partially overlapped with AD and PSO but remained clearly separable from both. Transcriptomic analyses revealed a predominant type-2 inflammatory signature, with substantial interpatient heterogeneity. Subgroup analyses identified additional activation of IFN-driven, IL-17/neutrophil-associated, or IL-36-related pathways. Phospho-protein profiling demonstrated heterogeneous but structured activation of the JAK/TYK2/STAT axis, with increased pTYK2, pSTAT1, pSTAT5, and pSTAT6 signals. Integration of transcriptomic and signaling data revealed coherent associations between immune modules and pathway activation states at the patient level.

Conclusions

These findings demonstrate that CHE comprises distinct molecular and signaling endotypes not captured by clinical classification alone. Integrated profiling of immune programs and JAK/STAT activity provides a framework for pathway-based stratification and supports the development of precision therapeutic approaches targeting dominant inflammatory axes in CHE.

EADV Congress 2026, VIENNA
30 SEPTEMBER - 03 OCTOBER 2026
POWERED BY M-ANAGE.COM

EA DV CONGRESS
VIENNA
30 SEP - 3 OCT 2026

Abstract N°: 4119

Composite Inflammatory Indices Identify Psoriasis Patients Likely to Achieve PASI 100 with IL-17 Inhibition

Yuxiong Jiang*[1], Yuling Shi[1]

[1] Department of Dermatology, Shanghai Skin Disease Hospital, Tongji University School of Medicine, Shanghai, China, shanghai, China

Introduction
Treatment responses to interleukin-17 (IL-17) inhibitors in psoriasis are highly heterogeneous. While some patients achieve rapid and complete skin clearance, reliable predictors of "super response" remain poorly defined. Composite inflammatory indices derived from routine blood tests may reflect systemic inflammatory burden and provide clinically accessible biomarkers for treatment stratification.

Materials and Methods
We conducted a prospective multicenter cohort study including 377 patients with moderate-to-severe psoriasis receiving ixekizumab therapy across 26 centers in China. Super response was defined as achieving PASI 100 at 3 months. Twelve baseline composite inflammatory indices, including neutrophil-to-lymphocyte ratio (NLR) and neutrophil-monocyte-to-lymphocyte ratio (NMLR), were calculated from routine laboratory parameters. Logistic regression and restricted cubic spline analyses were performed to evaluate associations between inflammatory indices and super response after adjustment for demographic and clinical confounders. A predictive nomogram model was further developed.

Results
Among 377 patients, 163 (43.2%) achieved super response. Super responders showed significantly lower baseline inflammatory burden, including lower NLR, NMLR, SII, SIRI, and PIV levels. In fully adjusted logistic regression analyses, elevated baseline NLR (OR 0.33, 95% CI 0.13–0.84, P = 0.021) and NMLR (OR 0.28, 95% CI 0.11–0.74, P = 0.010) independently predicted a lower likelihood of achieving PASI 100 at 3 months. Restricted cubic spline analyses demonstrated significant linear inverse dose–response relationships between NLR/NMLR and super response probability. An individualized prediction model integrating NLR with clinical variables achieved good predictive performance, with an area under the receiver operating characteristic curve of 0.77.

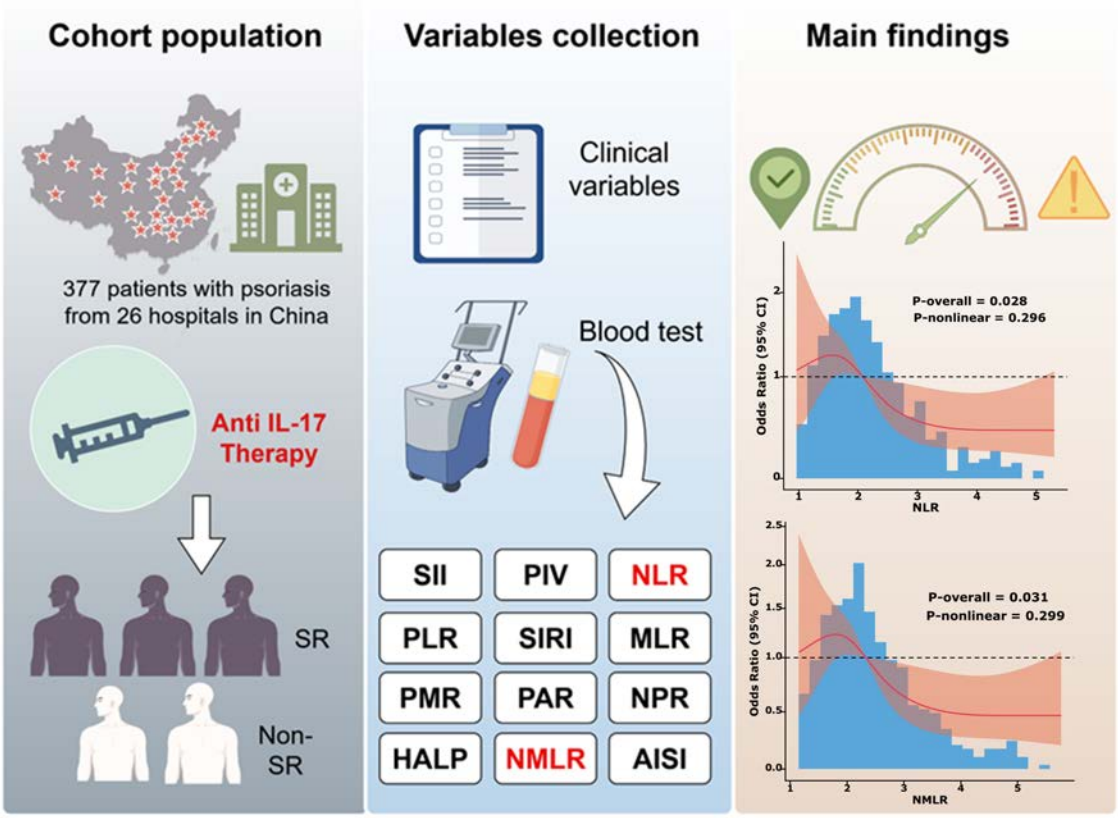

Graphical summary of the study design and key findings.

Conclusions

Lower neutrophil-dominant inflammatory signatures are associated with superior early response to IL-17 blockade in psoriasis. Baseline NLR and NMLR may serve as simple and accessible biomarkers for identifying patients likely to achieve complete skin clearance with IL-17 inhibitors, supporting more personalized treatment strategies in clinical practice.

EADV CONGRESS
VIENNA
30 SEP - 3 OCT 2026

Abstract N°: 4190

Retrospective Evaluation of Clinical Characteristics, Epidemiological Features, and Treatment Responses of Patients with Pityriasis Lichenoides in a Tertiary Health Care Center Between 2010–2025

Anıl Inan*[1], İlgen Ertam Sağduyu[1]

[1] Department of Dermatology, Ege University Faculty of Medicine, İzmir, Türkiye

Introduction

Pityriasis lichenoides (PL) is an uncommon inflammatory dermatosis that includes two clinical subtypes: pityriasis lichenoides et varioliformis acuta (PLEVA) and pityriasis lichenoides chronica (PLC). Owing to its rarity and highly variable clinical course, the optimal management of PL remains challenging. The present study aimed to retrospectively evaluate the clinical characteristics, treatment responses, adverse effects, and recurrence patterns of patients diagnosed with PL and followed in our tertiary referral center.

Materials and Methods

Medical records of patients diagnosed with PL between 2010 and 2025 in our dermatology department were retrospectively reviewed. Demographic characteristics, clinical findings, histopathological results, previous treatments, therapies initiated in our center, phototherapy parameters, treatment responses, and recurrence status were analyzed.

Recurrence was defined as the need for re-initiation of systemic treatment after achieving clinical response. Management strategies used for recurrent disease were also evaluated. Statistical analyses were performed using SPSS version 25.0, and a p-value below 0.05 was considered statistically significant.

Results

Of the 35 included patients, 22 (62.9%) were female and 13 (37.1%) were male. The mean age was 36.63 ± 16.74 years.

Comorbidities were present in 9 patients, with hypertension being the most common.

Patients were classified as:

- PLC: 31 patients (88.6%)
- PLEVA: 4 patients (11.4%)

Biopsy findings were reported as:

- Compatible with PL in 29 patients (82.9%)
- Suspicious in 6 patients (17.1%)

Fourteen patients had received systemic treatment before presentation, most commonly systemic antibiotics (25.7%).

Among the 35 patients:

- 18 patients (51.4%) received narrowband UVB (nbUVB) phototherapy
- 15 patients (42.9%) received non-phototherapy systemic treatment
- 2 patients (5.7%) received only topical corticosteroids

Non-phototherapy systemic treatments included:

- Azithromycin (n=9)
- Doxycycline (n=4)
- Acitretin (n=1)
- Isotretinoin (n=1)

The mean number of phototherapy sessions was 49.6 ± 23.6, and the mean cumulative dose was calculated as 47.1 ± 21.5 J/cm^2.

Phototherapy-related adverse effects were observed in 6 patients:

- Marked erythema in 3 patients
- Mild erythema in 2 patients
- Pruritus in 1 patient

Treatment response was achieved in:

- All 18 patients receiving phototherapy
- 9 of 13 patients receiving systemic antibiotics
- The single patients receiving isotretinoin and acitretin
- 1 of 2 patients receiving topical corticosteroids

When treatment responses between phototherapy-treated patients and systemic antibiotic-treated patients were compared, phototherapy was found to be significantly superior ($p < 0.05$).

Recurrence was observed in 11 of the 30 patients who responded to treatment.

Treatments administered for recurrence included:

- Phototherapy in 3 patients
- Systemic antibiotics in 5 patients
- Methotrexate in 1 patient
- Topical corticosteroids in 2 patients who refused systemic therapy

No significant association was found between recurrence and the evaluated phototherapy parameters in patients who developed recurrence after phototherapy.

Conclusions

The clinical course, treatment responses, and recurrence rates of PL patients demonstrate considerable heterogeneity.

nbUVB treatment showed a higher treatment response rate compared with systemic antibiotics.

No significant association was identified between recurrence development and the investigated clinical or phototherapy-related parameters.

Due to the rarity of the disease, individualized treatment approaches are important, and nbUVB was found to be an effective and safe treatment modality.

EA DV CONGRESS
VIENNA
30 SEP - 3 OCT 2026

Abstract N°: 4205

Comparative Efficacy of Treatments for Rosacea: A Systematic Review and Network Meta-Analysis of Randomized Controlled Trials

YUXIAO ZENG*[1]

[1] Department of Dermatology & Venerology, West China Hospital, Sichuan University, Chengdu, China

Introduction
Rosacea is a chronic inflammatory facial dermatosis characterized by heterogeneous clinical phenotypes, including erythema, telangiectasia, papules, and pustules, as well as diverse outcome measures across clinical trials. Although multiple topical, oral, and device-based treatments are available, comparative evidence remains fragmented. We conducted a systematic review and network meta-analysis (NMA) to compare current rosacea treatments and rank their efficacy and quality-of-life outcomes.

Materials and Methods
We searched PubMed, Embase, Cochrane Library, Web of Science, and ClinicalTrials.gov for randomized controlled trials (RCTs) of rosacea interventions. From 2,618 screened records, 165 rosacea RCTs were included in the systematic review and evidence mapping, with eligible studies subsequently incorporated into outcome-specific NMAs. Outcomes extracted for NMA included Investigator's Global Assessment (IGA), Clinical Erythema Assessment (CEA), inflammatory lesion counts, and Rosacea Quality of Life (RosaQoL). A frequentist NMA was performed in R using risk ratios (RR) for binary outcomes and mean differences (MD) or standardized mean differences (SMD) for continuous outcomes. Treatment ranking was based on P-scores.

Results
The evidence base was dominated by drug trials, whereas device- and light-based studies were more heterogeneous with limited network connectivity. For inflammatory lesion counts, ivermectin, metronidazole, azelaic acid, doxycycline, and minocycline showed favorable effects, in line with commonly recommended therapies. Supramolecular salicylic acid, encapsulated benzoyl peroxide, and adapalene also showed favorable ranking signals in selected analyses. For IGA success, topical ivermectin 1% plus oral doxycycline 40 mg showed the highest ranking estimate, while ivermectin, metronidazole, azelaic acid, doxycycline, and minocycline consistently showed favorable effects. For CEA, minocycline improved success outcomes, and several non-conventional interventions (e.g., paroxetine and botulinum toxin) showed exploratory signals. Ivermectin 1% showed the most favorable RosaQoL improvement.

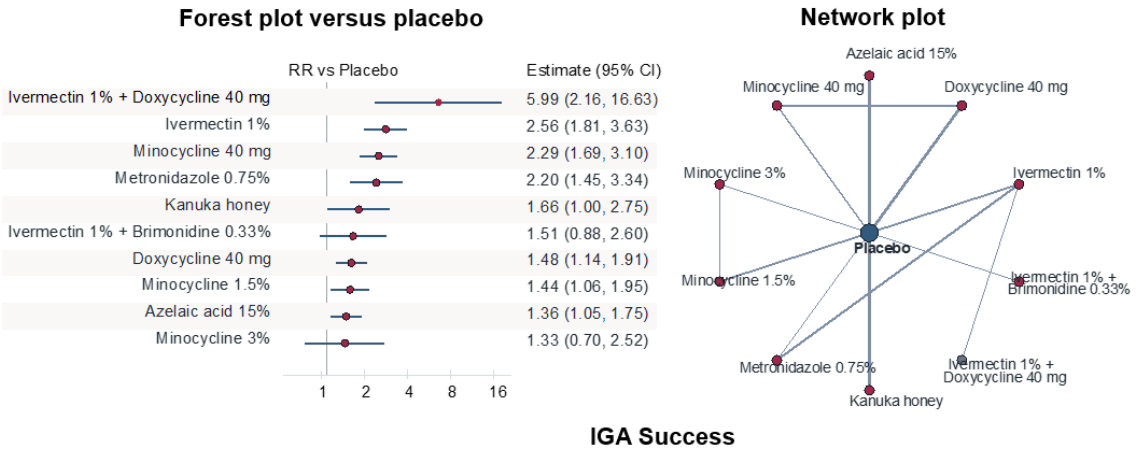

Network geometry and forest plot of relative efficacy versus placebo for IGA success.

Conclusions

Our NMA supports guideline-recommended therapies for rosacea and highlights several emerging treatment signals that may warrant further study in selected phenotypes. However, outcome heterogeneity, inconsistent scales, and incomplete numerical reporting hinder evidence synthesis. Future rosacea RCTs should adopt standardized core outcomes, unified reporting scales, and complete numerical data to improve evidence synthesis and clinical interpretation.

EA DV CONGRESS
VIENNA
30 SEP - 3 OCT 2026

Abstract N°: 4230

Exosome induced interleukin changes in hidradenitis suppurativa: a pilot 3D-SeboSkin co-culture study

Vaiva Jariene*[1], Paulius Valiukevicius[2], Justinas Maciulaitis[3], Romaldas Maciulaitis[4], Christos C. Zouboulis[5], Skaidra Valiukevičienė[1]

[1] Department of Skin and Venereal Diseases, Lithuanian University of Health Sciences, Department of Skin and Venereal Diseases, Hospital of Lithuanian University of Health Sciences Kauno Klinikos, European Reference Network for Rare and Complex Diseases of the Skin (ERN Skin) member, Kaunas, Lithuania

[2] Department of Neurology, Lithuanian University of Health Sciences, Department of Neurology, Hospital of Lithuanian University of Health Sciences Kauno Klinikos, Kaunas, Lithuania

[3] Institute of Cardiology, Lithuanian University of Health Sciences, Kaunas, Lithuania

[4] Institute of Physiology and Pharmacology, Lithuanian University of Health Sciences, Kaunas, Lithuania

[5] Departments of Dermatology, Venereology and Immunology, Universitaetsklinikum Ruppin-Brandenburg, Brandenburg Medical School Theodor Fontane and Faculty of Health Sciences Brandenburg, Neuruppin, Germany

Introduction

Mesenchymal stromal cells (MSCs) derived exosomes are potent immunomodulatory agents capable of regulating complex inflammatory microenvironments. The 3D-SeboSkin model is an ex vivo skin co-culture system, combining human skin explants with human SZ95 sebocytes as a feeder layer. It helps to prevent rapid degeneration of human skin *in vitro* and has been validated for preclinical studies of hidradenitis suppurativa (HS). In this pilot study, we investigated the immunomodulatory effects of placenta-derived MSCs exosomes in HS lesional skin using the 3D-SeboSkin model, focusing on changes in cytokine and chemokine secretion on different dosage and time conditions. To our knowledge, this is the first study evaluating exosome-based modulation in HS skin explants.

Materials and Methods

Experiment were conducted using 5mm skin punch biopsies obtained from three HS patients after wide regional excisions (five biopsies per patient). Skin samples were co-cultured with immortalized SZ95 sebocytes as described by Nikolakis et al. 2015 and were exposed to placental MSCs exosomes at two concentrations: standard (1×) and tenfold higher (10×). Results were evaluated at 24-hour and 48-hour time points. Secreted protein profiles in conditioned media were assessed using multiplex cytokine immunoassay. Buffer only conditions provided baseline reference values, and SZ95 sebocytes cultured without biopsy tissue served as feeder layer controls. Results were normalized to buffer controls.

Results

Baseline analysis confirmed that HS skin specimens exhibited elevated secretion of multiple inflammatory mediators compared to the SZ95 sebocyte feeder layer (CXCL1/GROα, ICAM-1/CD54, IL-6, IL-8, IL-13, IL-16, IL-18, IL-21, and IL-27), consistent with the established pro-inflammatory environment of HS lesional tissue.

After 24 hours of incubation with the standard exosome concentration (×1), a numerical reduction in CXCL1/GROα levels was observed across all samples. Additionally, IL-8 levels showed a numerical decrease in two out of three samples. The increase was observed across the IL-6, IL-16, and IL-18 cytokine groups at the same conditions.

After 48 hours of incubation with the standard exosome concentration (×1), a numerical reduction in CXCL1/GROα and IL-18 levels was observed in two out of three samples. The numerical increase in IL-6, IL-16 and IL-8 levels was observed in two out of three samples as well.

Following 24 hours of incubation with the high exosome concentration (×10), a pronounced numerical increase was observed across the majority of cytokines, including IL-6, IL-8, IL-16, and IL-18, with especially strong elevations detectable in ICAM-1/CD54 for one patient. Only isolated reductions were observed, most notably for IL-13 and IL-21 in individual samples. Overall, this condition showed the strongest early cytokine response among all tested settings.

After 48 hours of exposure to the ×10 exosome concentration, cytokine responses remained elevated for most analytes, with sustained numerical increases in CXCL1/GROα, ICAM-1/CD54, IL-6, IL-8, and IL-16. However, IL-21 and selected IL-6 and IL-8 measurements showed numerical reductions, particularly in one sample, suggesting a potential late-phase attenuation or adaptation of the response under prolonged high-dose conditions.

Conclusions

The data demonstrate that the immunomodulatory effects of exosomes are both dose-dependent and time-dependent. Low-dose exposure induced modest and variable cytokine shifts. High-dose conditions, particularly at the 24-hour time point, triggered robust upregulation of multiple pro-inflammatory mediators, including IL-6, IL-8, IL-16, and IL-18. By 48 hours, several cytokines show partial attenuation, suggesting the possibility of adaptive or regulatory feedback mechanisms under prolonged stimulation. Marked cytokine variability between patients highlights individualized responsiveness, suggesting potential relevance for personalized therapeutic approaches or dose optimization.

EADV CONGRESS
VIENNA
30 SEP - 3 OCT 2026

Abstract N°: 4246

Erosive pustular dermatosis of the scalp: a case series highlighting the Koebner phenomenon

Christophe Kharrat*[1], Juliette Fontaine[1], Hester Colboc[1]

[1] Department of Geriatrics — Wound Healing Unit, Rothschild Hospital, AP-HP, Sorbonne University, Paris, France

Introduction

Erosive pustular dermatosis of the scalp (EPDS) is a rare chronic inflammatory disorder of the elderly, with sterile pustules, erosions and crusts on photo-damaged or scarred scalp skin, leading to scarring alopecia. It is often misdiagnosed as bacterial folliculitis or squamous cell carcinoma, with repeated antibiotics and biopsies whose pathergic effect may worsen the disease. EPDS is closely linked to a Koebner phenomenon. The potential perpetuating role of silicone-based dressings, recently raised for the lower-leg variant (erosive pustular dermatosis of the leg, EPDL), remains unexplored on the scalp. We report a single-centre series focusing on dermoscopy, triggers, dressings, and outcomes.

Materials and Methods

Seven patients with EPDS were diagnosed between January 2022 and December 2025. Diagnosis combined clinical, dermoscopic and, when available, histopathological criteria. Data collected included demographics, scalp history, extra-scalp involvement, clinical presentation, dermoscopic patterns, skin biopsy, treatments, dressings used before and during specialised care, response and relapses. Patients gave informed consent for anonymised use of their data.

Results

Seven patients were included (3 women, 4 men; age 33–94 years, median 79). Five had advanced alopecia. All had at least one local triggering factor: 3 had cutaneous carcinoma excision with skin graft; 2 had previous neurosurgery; 1 cochlear-implant removal; 1 actinic keratoses; 1 scalp psoriasis. The estimated delay between initial trauma and EPDS onset was 1 to 3 months. Two patients had EPDL illustrating the EPDS–EPDL continuum. Dermoscopy consistently showed the hallmark features: orange structureless background, yellow scales and crusts, linear vessels of small calibre, peripheral fourchette vessels, and the peripheral horizontal hair sign — useful to differentiate EPDS from squamous cell carcinoma. Skin biopsy was performed in 5/7 patients to rule out carcinoma recurrence at graft sites; histology showed non-specific findings (granulation tissue, mixed inflammatory infiltrate, no malignancy).

Six of seven patients had been exposed to silicone-interface dressings (foam dressings with silicone adhesive, silicone-coated wound contact layers) for several months before referral. After diagnosis, all 7 received high-potency topical corticosteroids (clobetasol or betamethasone, ± salicylic acid). Topical tacrolimus 0.1% was used in 3 patients as second-line or maintenance therapy. Adjuncts included oral zinc (4 patients), topical antimicrobials when superinfection was suspected, and silver sulfadiazine in selected patients. Topical tacrolimus achieved sustained remission in patients refractory to first-line corticosteroids, with full clearance after 4 to 6 months in 3 patients. Most patients had at least one relapse during follow-up, often upon tapering, requiring long-term maintenance.

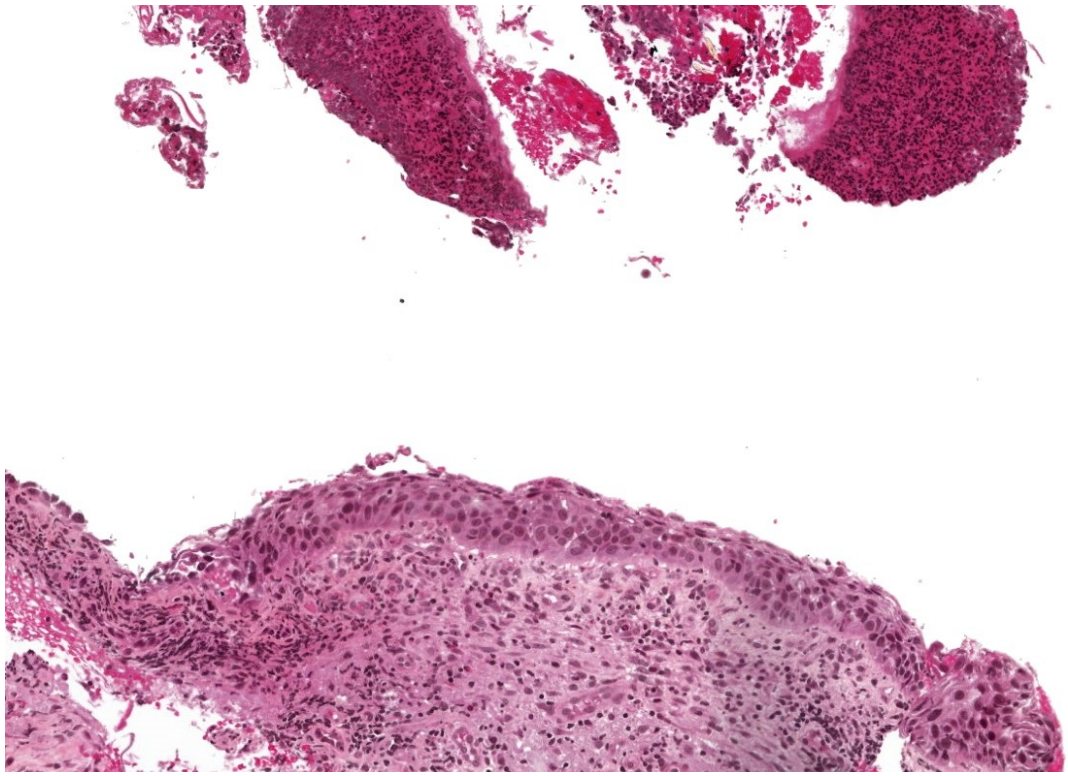

Histopathological appearance of a scalp skin biopsy from our series (H&E staining). Mixed inflammatory infiltrate within the superficial dermis and ulceration with granulation tissue, with no signs of malignancy.

Conclusions

This case series confirms the central role of the Koebner phenomenon in EPDS, particularly after scalp surgery and skin grafting, and illustrates the continuum with EPDL). It highlights two practical issues: the diagnostic dilemma of biopsy in patients with prior cutaneous carcinoma, often unavoidable despite its pathergic risk; and the systematic prior exposure to silicone-interface dressings, suggesting a possible entretaining role. Dermoscopy stands out as a key non-invasive diagnostic tool, and topical tacrolimus appears as a valuable second-line option achieving durable remission. A wound-care–oriented approach is essential to improve outcomes in this overlooked chronic wound.

EADV CONGRESS
VIENNA
30 SEP - 3 OCT 2026

Abstract N°: 4272

Incomplete Kawasaki Disease: A Diagnostic Challenge with Major Dermatologic and Cardiovascular Implications

fikri ouissal[1], Bichra Amina*[1], ahmed bouhamidi[1]

[1] Avicenne Military University Hospital Center of Marrakech, marrakech, Morocco

Introduction
Kawasaki disease (KD) is an acute systemic vasculitis predominantly affecting medium-sized vessels, particularly the coronary arteries. Although mucocutaneous manifestations are central to diagnosis, incomplete forms remain difficult to recognize due to the absence of full classical criteria, potentially delaying treatment and increasing the risk of cardiac complications. This study aimed to describe the clinical, biological, dermatologic and echocardiographic characteristics of incomplete Kawasaki disease in a tertiary pediatric center.

Materials and Methods
We conducted a retrospective observational study at Mohammed VI University Hospital of Marrakech between 2016 and 2025. Among 53 children diagnosed with Kawasaki disease, 14 patients fulfilled criteria for incomplete KD. Clinical, laboratory, echocardiographic and therapeutic data were collected from medical records using a standardized data sheet.

Results
Incomplete forms represented 26.4% of all Kawasaki disease cases. The mean age was 6.4 years with a male predominance (71%). Mucocutaneous involvement was highly prevalent, including oral mucosal changes in 86%, bilateral conjunctivitis in 79%, and polymorphous exanthema in 64% of patients. Extremity changes were less frequent (29%), while cervical lymphadenopathy ≥1.5 cm was observed in only 36% of cases. Elevated C-reactive protein levels were found in 86% of patients. Initial echocardiography was normal in 79% of cases, whereas 21% already presented coronary abnormalities, including aneurysms ranging from 3 to 11 mm. All patients received aspirin therapy, 71% intravenous immunoglobulins (IVIG), and 21% adjunctive corticosteroids. Clinical outcome was favorable in 79% of cases with complete symptom regression.

Conclusions
Incomplete Kawasaki disease requires a high index of suspicion in children with persistent fever and suggestive mucocutaneous manifestations. Combining dermatologic assessment with inflammatory markers and echocardiographic findings may improve early diagnosis and help prevent potentially life-threatening coronary complications

EADV CONGRESS
VIENNA
30 SEP - 3 OCT 2026

Abstract N°: 4285

Burden and clinical profile of pruritus among hepatitis B and C patients in Douala, Cameroon: a multicentric cross-sectional study

Martine Nida[1], Lynda Noufack*[1], Catherine Dominique Menanzou Ngamoe[2]

[1] Faculty of Medecine and Pharmaceutical Sciences, Douala, Cameroon
[2] ISSS - UDM, Bangangte, Cameroon

Introduction
Chronic pruritus is a disabling symptom whose systemic determinants remain underexplored in sub-Saharan Africa. Viral hepatitis B (HBV) and C (HCV) represent major public health concerns in this region, yet their dermatological burden — particularly pruritus — has received little attention in prospective multicenter studies. This study aimed to determine the prevalence, clinical features, dermatological lesions, and factors associated with pruritus in HBV and HCV carriers in 4 hospitals of Douala.

Materials and Methods
A retrospective-prospective cross-sectional study was conducted over five months (January–May 2024) across four referral hospitals in Douala, recruiting all consenting HBV or HCV carriers with complete records, excluding HIV coinfection, cirrhosis, hepatocellular carcinoma, chronic kidney disease, and biliary obstruction. All participants with pruritus underwent a standardized full-body dermatological examination. Logistic regression analyses (univariate then multivariate) identified associated factors ($p \leq 0.05$, 95% CI).

Results
Among the 1,101 participants with a mean age of 36 ± 11.5 years; 56.7% male, pruritus was identified in 261 patients, yielding a global prevalence of 23.7% (23.1% in HBV, 25.2% in HCV). Pruritus was predominantly chronic, generalized (94.6%) and permanent (87.4%). The most frequent primary dermatological lesions were lichen planus, urticaria and prurigo; excoriations were the dominant secondary lesion. On multivariate analysis in HBV carriers, independent factors associated with pruritus were hypertension (OR=1.753; 95% CI [1.222–3.102]; p=0.016), drug allergy history (OR=4.141; 95% CI [1.517–11.306]; p=0.006), elevated AST (OR=1.203; 95% CI [1.108–6.382]; p<0.001) and elevated ALT (OR=0.150; 95% CI [0.078–0.289]; p<0.001).

Conclusions
In sub-Saharan Africa, pruritus affects nearly one in four HBV and HCV carriers and follows a progressive epidemiological trend in Cameroon. Its dermatological expression and associated factors call for closer collaboration between dermatologists and hepatologists in the management of chronic viral hepatitis.

EADV CONGRESS
VIENNA
30 SEP - 3 OCT 2026

Abstract N°: 4309

Photodynamic therapy reduces bacterial growth in hidradenitis suppurativa fistula biofilm: an ex vivo study

JUAN ESCALAS TABERNER[1], Laura Moreno-Hernández*[1], INES GRACIA DARDER[1], Antonio Ramirez-Rosales[1], Juan Garcias-Ladaria[1]

[1] Hospital Universitario Son Espases, Palma de Mallorca, Spain

Introduction
Hidradenitis suppurativa (HS) is a chronic inflammatory disease characterized by recurrent nodules, abscesses, and fistulous tracts. Chronic fistulas may develop epithelialized tunnels containing bacterial biofilm, which has been associated with persistent inflammation, delayed healing, and reduced response to antibiotic therapy. Photodynamic therapy (PDT) has immunomodulatory, ablative, and antimicrobial properties, although its bactericidal activity against HS-associated biofilm has been scarcely investigated. The aim of this study was to evaluate the ex vivo bactericidal activity of PDT using methylene blue (MB) and 5-aminolevulinic acid (ALA) on bacterial populations obtained from HS fistulas.

Materials and Methods
This prospective single-center experimental study included patients with HS undergoing surgical deroofing. Biofilm samples obtained from fistulous tracts were divided into three groups: saline solution (control), MB, and ALA. Samples were incubated for 2 hours in darkness and subsequently irradiated according to the institutional PDT protocol. Microbiological cultures were then performed. The primary outcome was complete absence of bacterial growth after treatment. Secondary objectives included characterization of isolated bacterial species according to fistula type and lesion location.

Results
Twenty patients were included (mean age 36.2 ± 10.0 years; 65% female). Most patients presented Hurley stage II disease (65%), and inguinal involvement was the most frequent localization (45%). Predominantly anaerobic bacterial populations were identified in most samples. Complete absence of bacterial growth was observed in 8 treated samples: 6 in the MB group and 2 in the ALA group. Complete inhibition of bacterial growth was observed in 30% of MB-treated samples and 10% of ALA-treated samples, compared with 5% in controls. MB demonstrated greater bactericidal activity than ALA under the evaluated conditions.

Conclusions
PDT demonstrated ex vivo bactericidal activity against bacterial populations associated with HS fistulas, particularly with MB. Although the observed effect was moderate, these findings support a potential adjuvant role of PDT targeting bacterial biofilm in HS. Further quantitative analyses are needed to better define its antimicrobial effect.

EA DV CONGRESS
VIENNA
30 SEP - 3 OCT 2026

Abstract N°: 4328

Ixekizumab With Tirzepatide Was Associated With Reduced CV Risk Factors and Calculated CV Risk Beyond Ixekizumab Alone in Psoriatic Disease and Obesity

Brittany Weber*[1], Joel Gelfand[2], Elaine Husni[3], Wolf-Henning Boehncke[4], Michael Garshick[5], Naveed Sattar[6], Lihi Eder[7], Lluís Puig[8], Laura Coates[9], Laure Gossec[10], Andris Kronbergs[11], Marcus Ngantcha[11], Hong Liu-Seifert[11], Louis-Paul Sanden[11], Sarah Stevens[11], Susan Ball[11], Cynthia E. Kartman[11], Alexis Ogdie[12]

[1] Cardio-Dermatology Program, Division of Cardiology, Department of Internal Medicine and Dermatology, University of Texas Southwestern Medical Center, Dallas, Texas, United States
[2] Department of Dermatology and Center for Clinical Sciences in Dermatology, University of Pennsylvania Perelman School of Medicine, Pennsylvania, United States
[3] Cleveland Clinic, 9500 Euclid Avenue, Ohio, United States
[4] Division of Dermatology and Venereology, Geneva University Hospitals, Geneva, Switzerland
[5] New York University Langone Health, New York, United States
[6] School of Cardiovascular and Metabolic Health, University of Glasgow, Glasgow, United Kingdom
[7] Women's College Hospital, 76 Grenville Street, University of Toronto, Ontario, Canada
[8] Hospital de la Santa Creu I Sant Pau, Barcelona, Spain
[9] Nuffield Department of Orthopaedics, Rheumatology, and Musculoskeletal Sciences, University of Oxford, Oxford, United Kingdom
[10] Sorbonne University, Pitie-Salpetriere Hospital, Paris, France
[11] Eli Lilly and Company, Indianapolis, Indiana, United States
[12] Perelman School of Medicine, University of Pennsylvania, Philadelphia, Pennsylvania, United States

Introduction

Psoriasis (PsO) and Psoriatic Arthritis (PsA) are chronic inflammatory conditions in which systemic inflammation elevates cardiovascular (CV) disease risk beyond traditional risk factors (1, 2). Overweight or obesity affects 60–82% of patients and amplifies CV risk via established factors and inflammation (3, 4). Tirzepatide (TZP) reduces weight, CV outcomes and reduced CV events in a diabetes population (5). This analysis assessed whether concomitant IXE+TZP or ixekizumab (IXE) alone was associated with greater improvement in cardiometabolic outcomes (including hsCRP). Furthermore, post-hoc analysis assessed the predicted CV risk with IXE+TZP compared with IXE alone in moderate-to-severe PsO and active PsA with overweight or obesity from baseline to Week 36 (W36).

Materials and Methods

TOGETHER-PsA (NCT06588296) and TOGETHER-PsO (NCT06588283) are phase 3b, randomised, 52-week, multicentre, assessor-blinded, open-label trials conducted in the United States (3, 4). Patients with moderate-to-severe PsO or active PsA and obesity (BMI ≥30 kg/m^2) or overweight (BMI ≥27 - < 30 kg/m^2 with ≥1 weight-related comorbidity) were randomised 1:1 to IXE+TZP or IXE alone per US FDA-approved labelling. All participants received individualised diet and exercise counselling. At the primary timepoint W36, differences in weight characteristics, blood pressure, lipids, glucose, HbA1c, and hsCRP were assessed. Post-hoc analyses over time were performed for IXE+TZP versus IXE alone using mixed-model repeated-measures with treatment-by-baseline-by-visit interaction and unstructured within-subject covariance. Predicted 10-year CVD risk was

calculated using Framingham equations in patients without pre-existing CV events (6). Predicted hazard ratios (HR) were calculated as the ratio of negative logarithms of group-level predicted survival probabilities, under the proportional hazards assumption (7). P-values are nominal and not adjusted for multiplicity.

Results

Baseline demographics were balanced across treatment arms within TOGETHER-PsO and -PsA trials (3, 4). CV-related demographics include age, sex, smoking status, Type 2 Diabetes diagnosis and current lipid-lowering/anti-hypertensive medication use (Table 1). At W36, IXE+TZP was associated with greater improvements versus IXE across cardiometabolic outcomes in PsO and PsA, including weight, blood pressure (Systolic [SBP], diastolic [DBP]), triglycerides, glucose, HbA1c and hsCRP (Table 2). IXE+TZP was associated with reduced SBP versus IXE alone in both trials. IXE+TZP demonstrated a greater shift to lower waist-to-height ratio categories at W36, compared to IXE alone (Table 3). The Framingham predicted 10-year CVD risk scores were 15.38 and 15.25 at baseline for IXE+TZP and IXE, respectively in PsO, and 17.46 and 18.25 in PsA. After 36 weeks of treatment, IXE+TZP was associated with approximately 30% relative reduction in predicted CVD risk compared to IXE. HR [95% CI] = 0.70 [0.63–0.78] and 0.69 [0.62-0.78] in PsO and PsA, respectively (Table 4).

Table 1. CV-related baseline demographics in TOGETHER trials, without pre-existing CV Events

	TOGETHER-PsO		TOGETHER-PsA	
Characteristic	**IXE (N=136)**	**IXE + TZP (N=138)**	**IXE (N=133)**	**IXE + TZP (N=138)**
Mean Age	45.7	45.6	54.8	55.3
Female, %	44.9	44.9	69.2	70.3
Mean BMI (kg/m^2)	39.3	39.3	38.4	37.2
Smoking status Current, %	17.6	21.0	14.3	8.7
Former, %	22.8	18.1	24.8	29.7
Never, %	59.6	60.9	60.9	61.6
Type 2 Diabetes diagnosis, %	7.4	14.5	12.0	10.1
**Baseline lipid-lowering medication use, %*	15.4	17.4	38.3	39.1
**Baseline anti-hypertensive medication use, %*	39.0	41.3	53.4	63.0

Table 2. Baseline, and Change from Baseline in Cardiometabolic and Inflammatory Outcomes at Week 36, without pre-existing CV Events

	TOGETHER-PsO		TOGETHER-PsA	
Parameter	**IXE**	**IXE + TZP**	**IXE**	**IXE + TZP**
Weight (Kg)	BL: 115.5	BL: 112.1	BL: 107.6	BL: 104.6
	†CFB: -1.1	†CFB: -16.5 (-17.5, -13.1)	†CFB: -1.1	†CFB: -18.5 (-19.2, -15.7)

		(p<.001)		(p<.001)
Systolic blood pressure, (mmHg)	BL: 131.3 §CFB: -1.4 (-3.7, 0.8)	BL: 133.8 §CFB: -9.9 (-12.0, -7.7) (p<.001)	BL: 132.8 §CFB: -3.93 (-6.48, -1.38)	BL: 130.6 §CFB: -10.81 (-13.09, -8.54) (p<.001)
Diastolic blood pressure, (mmHg)	BL: 82.9 §CFB: 0.3 (-1.3, 2.0)	BL: 84.9 §CFB: -3.6 (-5.1, -2.0) (p<.001)	BL: 83 §CFB: -2.84 (-4.56, -1.12)	BL: 82.3 §CFB: -4.69 (-6.22, -3.16) (p=.114)
Serum cholesterol, (mmol/L)	BL: 5.08 §CFB: -0.03 (-0.18, 0.11)	BL: 4.86 §CFB: -0.26 (-0.39, -0.13) (p<.05)	BL: 4.84 †CFB: -0.021 (-0.19, 0.15)	BL: 4.69 †CFB: -0.29 (-0.43, -0.14) (p<.05)
LDLc, (mmol/L)	BL: 3.01 §CFB: -0.08 (-0.21, 0.05)	BL: 2.81 §CFB: -0.10 (-0.22, 0.02) (p=.824)	BL: 2.69 †CFB: -0.065 (-0.26, 0.13)	BL: 2.49 †CFB: -0.070 (-0.24, 0.096) (p=.970)
HDLc, (mmol/L)	BL: 1.13 §CFB: 0.01 (-0.02, 0.04)	BL: 1.16 §CFB: 0.04 (0.01, 0.07) (p=.256)	BL: 1.25 †CFB: -0.007 (-0.041, 0.026)	BL: 1.26 †CFB: -0.001 (-0.031, 0.029) (p=.777)
Non-HDLc (mmol/L)	BL: 3.89 §CFB: -0.04 (-0.18, 0.10)	BL: 3.64 §CFB: -0.29 (-0.41, -0.16) (p<.05)	BL: 3.52 §CFB: -0.02 (-0.19, 0.15)	BL: 3.35 §CFB: -0.30 (-0.44, -0.16) (p<.05)
Triglycerides, (mmol/L)	BL: 1.80 §CFB: -0.00 (-0.14, 0.14)	BL: 1.59 §CFB: -0.36 (-0.47, -0.26) (p<.001)	BL: 1.64 †CFB: 0.029 (-0.095, 0.15)	BL: 1.61 †CFB: -0.41 (-0.49, -0.33) (p<.001)
Glucose, (mmol/L)	BL: 5.62 §CFB: 0.34 (0.06, 0.62)	BL: 5.65 §CFB: -0.61 (-0.88, -0.35) (p<.001)	BL: 5.62 §CFB: 0.47 (0.18, 0.76)	BL: 5.93 §CFB: -0.85 (-1.11, -0.58) (p<.001)
HbA1c, (Fraction of 1)	BL: 0.057 §CFB: 0.001 (-0.000, 0.002)	BL: 0.058 §CFB: -0.005 (-0.006, -0.004) (p<.001)	BL: 0.058 §CFB: 0.001 (0.000, 0.003)	BL: 0.058 §CFB: -0.006 (-0.007, -0.005) (p<.001)
hsCRP, mean (mg/L)	BL: 4.12 §CFB: -0.41 (-0.95, 0.13)	BL: 4.06 §CFB: -1.42 (-1.80, -1.05) (p<.01)	BL: 4.01 †CFB: -0.50 (-1.18, 0.18)	BL: 3.87 †CFB: -1.94 (-2.32, -1.56) (p<.001)

Table 3. Waist-to-Height Ratio (WHtR) Category Shifts in a Population of Participants with Baseline Ratio ≥0.6, at Week 36

	TOGETHER-PsO		TOGETHER-PsA	
WHtR Shift	**IXE**	**IXE + TZP**	**IXE**	**IXE + TZP**
≥0.6 (%)	84.6	53.6	83.5	47.1
0.5–0.59 (%)	5.1	25.4	6.8	40.6
<0.5 (%)	0.7	3.6	0.8	4.3

Table 4. Predicted Hazard Ratio For CV Risk Over Time for IXE+TZP vs IXE

	TOGETHER-PsO	TOGETHER-PsA
Visit	**Overall HR [95% CI], p-value**	**Overall HR [95% CI], p-value**
Week 4	0.94 [0.88, 1.00], p<.05	0.92 [0.86, 0.99], p<.05
Week 12	0.78 [0.70, 0.86], p<.001	0.81 [0.73, 0.90], p<.001
Week 24	0.70 [0.64, 0.78], p<.001	0.78 [0.71, 0.86], p<.001
Week 36	0.70 [0.63, 0.78], p<.001	0.69 [0.62, 0.78], p<.001

Table 1. Subjects excluded if diagnosed with Type 1 Diabetes Mellitus (T1DM), have insulin-treated Type 2 Diabetes Mellitus (T2DM), or if HbA1c ≥9.5% at screening. *Subjects with ≥1 Medication. Lipid-lowering medications: HMG COA reductase inhibitors, other lipid-modifying agents, fibrates, bile acid sequestrants. Anti-hypertensive medications: angiotensin II receptor blockers, ace inhibitors, beta blocking agents (selective), dihydropyridine derivatives, thiazides, sulfonamides, alpha and beta blocking agents, aldosterone antagonists, imidazoline receptor agonists, ace inhibitors and diuretics, angiotensin II receptor blockers and diuretics, benzothiazepine derivatives, beta blocking agents (non-selective), hydrazinophthalazine derivatives, alpha-adrenoreceptor antagonists, low-ceiling diuretics and potassium-sparing agents, other potassium-sparing agents. Table 2. §Change from baseline at W36, MBE (95% CI). Glucose and lipid values were non-fasting. †Change from baseline at W36, Estimate (95% CI). Table 3. IXE+TZP treatment reduced the percentage of patients in the ≥0.6 group, shifting a proportion of patients to lower WHtR categories (i.e. 0.5-0.59 or <0.5), thus reducing CV risk. These values represent participants with a baseline ratio ≥0.6. Percentages may not sum to 100% due to exclusion of population subgroups with baseline of <0.5 and 0.5-0.59. Table 4. The 10-year cardiovascular disease (CVD) risk for each subject at each visit was estimated using the sex-specific D'Agostino BMI-based model (5). Treatment comparisons used a joint mixed-model repeated-measures (MMRM) on absolute predicted risk (%) fitted once across all post-baseline visits: Risk_t ~ Treatment × $Risk_0$ × Visit + sex + BMI category + diabetes at baseline + age + (Visit | Subject) The model uses unstructured within-subject covariance (REML, Satterthwaite degrees of freedom). Per-visit marginal means (LSMs) were extracted from the single joint model via emmeans (proportional weights), representing the predicted mean absolute risk for each treatment group at each visit, adjusted for all model covariates. Predicted hazard ratios (HR) were derived from the per-visit LSMs under the proportional hazards assumption: HR = −log(1 − p_Ixe_Tzp) / −log(1 − p_Ixe), where p = LSM / 100 95% CIs were computed via the delta method (z = 1.96) applied to log(HR); p-values use the standard normal distribution. A HR < 1 indicates a lower predicted 10-year CVD risk in the IXE+TZP arm versus IXE alone.

Conclusions

In patients with psoriatic disease (PsO or PsA) and overweight or obesity, concomitant IXE+TZP therapy was associated with clinically meaningful improvements in cardiometabolic outcomes in both treatment arms, corresponding to approximately 30% lower predicted 10-year CVD risk compared to patients in the IXE

monotherapy arm with diet and exercise counselling. These findings suggest that targeting both inflammatory and metabolic pathways may improve cardiovascular benefit and potentially reduce long-term cardiovascular burden in this high-risk population.

1. Ogdie A et al. Ann Rheum Dis. 2015;74(2):326-32
2. Boehncke WH et al. Exp Dermatol. 2011;20(4):303-7
3. Merola JF et al. Arthritis Rheumatol. 2026
4. Lebwohl M et al. JAMA Derm. 2026; Accepted
5. Jastreboff AM et al. N Engl J Med. 2022;387(3):205-16
6. D'Agostino RB et al. Circulation. 2008;117(6):743-53
7. Perneger TV. Contemp Clin Trials. 2008;29(5):762-6

EA DV CONGRESS
VIENNA
30 SEP - 3 OCT 2026

Abstract N°: 4397

Infrared thermography in inflammatory skin diseases: A scoping review of clinical applications, acquisition methodology, and reported outcomes

Tahirih Nasseri*[1], Samantha Bestavros[1], Rachel Tyli[2], Atif Cader[3], Erin Lou[1], Samia Rahman[4], Evan Chan[5], Sheila Wang[6, 7]

[1] Temerty Faculty of Medicine, University of Toronto, Toronto, Canada
[2] Laboratory Medicine & Pathobiology, Temerty Faculty of Medicine, University of Toronto, Toronto, Canada
[3] Dalla Lana School of Public Health, University of Toronto, Toronto, Canada
[4] Faculty of Medicine & Dentistry, University of Alberta, Edmonton, Canada
[5] Massey College, University of Toronto, Toronto, Canada
[6] Division of Dermatology, Department of Medicine, Women's College Hospital, Toronto, Canada
[7] Swift Medical, Toronto, Canada

Introduction
Infrared thermography (IRT) is a non-invasive imaging modality that detects surface temperature differences arising from cutaneous inflammation and altered blood flow. Its use in inflammatory skin diseases has grown, yet no review has characterized the scope of its clinical applications, acquisition methodology, or reported outcomes. The objective of this study was to map the existing evidence on IRT use across inflammatory skin diseases, including study designs, patient populations, acquisition protocols, image analysis methods, and outcomes.

Materials and Methods
A scoping review was conducted across three electronic databases from inception to 2025. Studies were eligible if they reported the use of IRT in patients with an inflammatory skin condition. The scoping review was conducted and reported in accordance with the PRISMA extension for scoping reviews (PRISMA-ScR).

Results
Thirty-five studies published between 2003 and 2024 were included, spanning twelve inflammatory skin conditions. Localized scleroderma was the most studied condition (n=17), followed by psoriasis (n=7) and hidradenitis suppurativa (n=5). Remaining studies addressed atopic dermatitis, vitiligo, palmoplantar pustulosis, oral lichen planus, and vulvar lichen sclerosus, among others. Study designs were predominantly observational; one randomized controlled trial was identified. IRT was most commonly used to assess disease activity or monitor treatment response. Temperature difference between lesional and contralateral skin (ΔT) was the most frequently reported outcome metric. Marked heterogeneity was identified across device specifications, acclimatization periods, environmental controls, region-of-interest selection, and image analysis approaches. Few studies reported how accurately IRT could distinguish active from inactive disease, such as sensitivity or specificity metrics.

Conclusions
IRT is an emerging adjunct in inflammatory dermatology with applications spanning disease activity assessment,

treatment monitoring, and surgical planning. However, because studies used widely different devices, protocols, and outcome measures, it is not possible to directly compare or pool findings across studies. Standardization of acquisition protocols and outcome reporting is urgently needed.

EADV CONGRESS
VIENNA
30 SEP - 3 OCT 2026

Abstract N°: 4438

Erythema Nodosum as a Marker of Underlying Systemic Disease: Insights from 54 Cases

mariem maaref*[1], Amira Atig[1], Hanin Krima[2], Nadia Ghariani[2], Sana Mokni[2], Amina Aounallah[2], najet ghariani[2]

[1] Internal Medicine Department, Farhat Hached hospital, Sousse, Tunisia
[2] Dermatology Department, Farhat Hached Hospital, Sousse, Tunisia

Introduction
Erythema nodosum (EN) is a common inflammatory septal panniculitis with a wide range of etiologies, predominantly infectious, inflammatory, and granulomatous. The aim of this study was to investigate the epidemiological, clinical, and etiological profile of EN in our tertiary care center.

Materials and Methods
We conducted a retrospective, single-center study including 54 patients managed for EN over an 8-year period (January 2019–January 2026).

Results
Fifty-four patients were included, with a mean age of 45.8 years (range: 26–69 years) and a marked female predominance (female-to-male ratio = 5.8). EN was recurrent in 31.5% of cases, with a mean disease duration of 29 days. Nodules were painful in all patients and predominantly located on the lower legs (94.4%).

Associated functional manifestations included inflammatory arthralgia (24.1%), exertional dyspnea (5.6%), asthenia and chronic cough (1.9% each). General and physical signs comprised fever (16.7%), oral aphthosis (11.1%), pseudofolliculitis (7.4%), arthritis, episcleritis, and deep vein thrombosis (3.7% each). A flu-like syndrome preceded EN in 39% of cases, and recent drug intake was reported in 5.6%.

Laboratory investigations revealed neutrophilic leukocytosis in 11.1% of cases, normocytic normochromic anemia in 7.4%, a biological inflammatory syndrome in 27.8%, and calcium–phosphate metabolism abnormalities in 3.7%. An infectious origin was identified in several cases, predominantly post-streptococcal EN (35.2%), followed by post-COVID-19 and rickettsial infections (1.9% each).

Etiological investigations identified pulmonary Sarcoidosis in 16.7% of cases, characterized by elevated angiotensin-converting enzyme levels in eight patients and mediastinal–hilar lymphadenopathy on chest computed tomography in 16.7%. Other associated conditions included Behçet disease (9.3%), pulmonary tuberculosis (5.6%) and lymph node tuberculosis (1.9%), granulomatous mastitis (5.6%), Rheumatoid arthritis (1.9%), and Takayasu arteritis (1.9%). A drug-induced origin related to nonsteroidal anti-inflammatory drugs was retained in two cases, while EN was considered idiopathic in eight patients.

The outcome was favorable in all cases, with complete resolution of lesions following initiation of various treatments, including potassium iodide (29.6%), colchicine (14.8%), and specific therapy targeting the underlying etiology (31.5%).

Conclusions

Erythema nodosum represents an important clinical marker of diverse underlying conditions. Comprehensive clinical, biological, and radiological evaluation is essential to establish etiological diagnosis and optimize patient management.

EA DV CONGRESS
VIENNA
30 SEP - 3 OCT 2026

Abstract N°: 4571

Therapeutic Impact and Immunometabolic Mechanisms of Tirzepatide in Chronic Inflammatory Dermatoses: A Systematic Review

Ana Carolina Salomão*[1], Mariana Diniz[1]

[1] Universidade Estadual do Rio de Janeiro, Hospital Universitário Pedro Ernesto, Rio de Janeiro, Brazil

Introduction
Tirzepatide, a dual glucose-dependent insulinotropic polypeptide (GIP) and glucagon-like peptide-1 (GLP-1) receptor agonist, has become an important therapeutic option for obesity and type 2 diabetes mellitus. Beyond its metabolic effects, increasing evidence suggests a potential role in inflammatory skin diseases due to the close relationship between adipose tissue, systemic inflammation, and cutaneous immune dysregulation. Conditions such as psoriasis and hidradenitis suppurativa are now recognized as systemic inflammatory disorders strongly associated with metabolic dysfunction and obesity.

Materials and Methods
A systematic review was conducted according to PRISMA guidelines using PubMed, MEDLINE, and Cochrane Library databases. Publications from 2024 to 2026 evaluating tirzepatide in inflammatory dermatoses were included, encompassing clinical trials, observational studies, and case reports. Data regarding immunologic pathways, clinical outcomes, and adverse events were analyzed to explore the emerging role of incretin-based therapies in dermatology.

Conclusions
Current evidence suggests that tirzepatide may improve inflammatory dermatoses through combined metabolic and immunomodulatory mechanisms. Activation of GLP-1 and GIP receptors expressed in keratinocytes and immune cells appears to inhibit NF-κB signaling pathways, leading to downregulation of proinflammatory cytokines including TNF-α, IL-17, and IL-23. These pathways are central to the pathogenesis of psoriasis and hidradenitis suppurativa.

In addition, significant visceral fat reduction contributes to attenuation of chronic low-grade inflammation by decreasing adipokine production and inflammasome activation. In hidradenitis suppurativa, this effect may reduce follicular occlusion, mechanical friction, and inflammatory burden within adipose-rich intertriginous regions. Preliminary reports have also suggested possible benefit in neutrophilic dermatoses and chronic follicular inflammatory disorders, including folliculitis decalvans.

Despite promising therapeutic potential, recent publications have described occasional paradoxical inflammatory reactions, including psoriasiform eruptions, possibly related to rapid immunometabolic shifts affecting the IL-23/IL-17 axis in genetically predisposed individuals. These findings reinforce the importance of careful dermatologic monitoring during treatment.

Tirzepatide may represent a novel immunometabolic therapeutic strategy for chronic inflammatory dermatoses, extending beyond weight reduction alone. Its potential direct effects on inflammatory pathways highlight a promising intersection between endocrinology and dermatology, although further controlled studies are required to establish long-term efficacy, safety, and optimal clinical indications.

EADV Congress 2026, VIENNA
30 SEPTEMBER - 03 OCTOBER 2026
POWERED BY M-ANAGE.COM