EADV CONGRESS
VIENNA
30 SEP - 3 OCT 2026

Abstract N°: 24

Determinants of delayed diagnosis of leprosy in Nepal

Rabindra Baskota*[1], Rashmi Baral[1]

[1] Ministry of Health and Population, Kathmandu, Nepal

Introduction
Leprosy continues to pose a public health challenge in Nepal despite significant progress toward elimination. Early diagnosis and prompt treatment are essential to prevent disease progression, reduce transmission, and minimize disability. However, delayed diagnosis remains a common problem, often resulting in advanced disease and visible deformities at the time of detection. Understanding the determinants that influence delayed diagnosis is crucial for designing effective interventions aimed at improving early detection and reducing disability associated with leprosy. This study aimed to identify the key socio-demographic, behavioral, and health system factors associated with delayed diagnosis of leprosy among patients in selected districts of Nepal.

Materials and Methods
A cross-sectional study was conducted among confirmed leprosy patients registered at government health facilities in Jhapa, Dhanusha, Bake and Kapilbastu districts of Nepal between 2024 and 2025. A total of 300 patients diagnosed with leprosy were included in the study using purposive sampling. Data were collected through structured interviews using a pretested questionnaire that captured information on socio-demographic characteristics, knowledge about leprosy, health-seeking behavior, stigma experiences, and access to healthcare services. Clinical information and disability grading, was obtained from patient records. Delayed diagnosis was defined as a period of more than 12 months between the onset of initial symptoms and confirmed diagnosis at a health facility. Data were analyzed using descriptive and inferential statistics to identify factors associated with delayed diagnosis.

Results
Among the 300 patients included in the study, 174 individuals (58%) experienced delayed diagnosis of leprosy. The median delay between the onset of symptoms and diagnosis was eight months. Delayed diagnosis was more common among individuals living in rural areas, those with lower levels of education, and those belonging to low-income households. Approximately 46% of patients initially ignored early symptoms such as numbness or skin patches, assuming they were minor skin conditions. In addition, 38% of respondents reported first seeking care from local pharmacies before visiting formal health facilities. Stigma-related concerns were reported by nearly one-third of participants, with some patients delaying care due to fear of discrimination or social exclusion. Patients who lived more than one hour away from the nearest health facility were more likely to experience delayed diagnosis. Furthermore, a higher proportion of patients with delayed diagnosis presented with Grade 1 or Grade 2 disabilities compared to those diagnosed earlier.

Conclusions
Delayed diagnosis of leprosy remains a significant challenge in Nepal and is influenced by multiple socio-demographic, behavioral, and health system factors. Limited awareness, stigma, reliance on traditional healers, and barriers to healthcare access contribute to delayed health-seeking behavior and late diagnosis. Addressing these determinants through community education, stigma reduction initiatives, and improved accessibility of leprosy services is essential for promoting early detection and preventing disability. Strengthening public health interventions targeting high-risk populations could significantly support ongoing efforts to control and eventually

eliminate leprosy in Nepal.

Abstract N°: 34

A Case of Nocardial Actinomycotic Mycetoma – Unmasking a rare mimic.

Anupama Manohar Prasad*[1]

[1] THE OXFORD MEDICAL COLLEGE HOSPITAL AND RESEARCH CENTRE., Bengaluru, India

Introduction

Actinomycotic Mycetoma is a chronic infection due to Actinomyces spp. characterized by swelling, formation of sinuses and alteration of the affected region, frequently seen in tropical and sub-tropical countries. Actinomycotic mycetoma caused by Nocardia spp. are very rare with prevalence of about 5%. Nocardiosis is a gram-positive bacterial infection, having the ability to cause chronic localized or systemic suppurative disease in both immunocompetent and frequently in immunosuppressed individuals. The actinomycotic mycetoma caused by Nocardia spp is highly uncommon, one must have high index of suspicion and requires multiple biopsies for isolation of the organism.

Herewith we present rare case of actinomycotic mycetoma caused by nocardia, treated with oral antibiotic linezolid with excellent outcome

Case Presentation

A 37yrold male presented with chief complaint of large swelling over the upper back associated with sero-sanguineous discharge since one and half yar. On examination, a large diffuse swelling over the upper back extending from the nape of neck to inter-scapular area vertically about 15cm, and horizontally up-to shoulder joints bilaterally of about 21cm ith numerous elevated, well-demarcated small to large nodular lesions with few discharging sinuses were seen ithout any apparent granules. investigations showed mild leucocytosis, elevated erythrocyte sedimentation rate. The biopsy from the discharging nodule,revealed chronic suppurative, granulomatous inflammation, with few irregular lobulated light basophilic granules, with minimum peripheral eosinophilic material, the filaments in the granules was weakly acid fast suggestive of Nocardia species.

The patient was diagnosed as a case of actinomycotic mycetoma and was started on, tablet Linezolid 600mg twice daily, the patient improved symptomatically and Lesions showed complete resolution within 2 months of therapy with scarring and hyperpigmentation.

Conclusion

Actinomycotic mycetoma has the propensity to mimic many other diseases with its wide variety of symptoms, and difficulty in isolating the organism. Clinicians should be aware of its varied presentations and its ability to be a great pretender. A high index of clinical suspicion is needed for the diagnosis of this condition along with the stringent efforts to isolate the organism. Our case responded well to linezolid, which can be considered as safe alternative agent in treatment of actinomycotic mycetoma.

EA DV CONGRESS
VIENNA
30 SEP - 3 OCT 2026

Abstract N°: 36

In Vitro Activity of Omadacycline and Eravacycline against Nocardia brasiliensis Isolates

Hassiel Ramírez-Marín*[1], Jorge Ocampo-Candiani[1], Lucio Vera-Cabrera[1]

[1] Hospital Universitario Doctor José Eleuterio González, Monterrey, Mexico

Introduction
Actinomycetoma is a chronic, progressive, and debilitating neglected tropical disease (NTD) that disproportionately affects low-income populations in tropical and subtropical regions. Nocardia brasiliensis remains the primary etiologic agent. For decades, the "gold standard" therapy has relied on trimethoprim-sulfamethoxazole (SXT), often in combination with aminoglycosides. However, this regimen is frequently complicated by significant systemic toxicity (including nephrotoxicity and myelosuppression), prolonged treatment durations, and poor adherence. There is a critical global need for potent, oral, and better-tolerated alternatives to transform the clinical management of this neglected condition and prevent long-term disability.

Materials and Methods
The in vitro susceptibility of 50 clinical isolates of N. brasiliensis obtained from human actinomycetoma cases was evaluated. Minimum Inhibitory Concentrations (MICs) were determined using the E-test method for eravacycline and omadacycline. These next-generation tetracyclines were compared against the current standard of care and earlier generation agents, including tigecycline, minocycline, and SXT. MIC50 and MIC90 values, along with the range of inhibition, were calculated for all tested antimicrobials. 5 reference strains were used for quality control (Nocardia NCTC 10300, S. aureus ATCC 29213, Nocardia transvalensis ATCC 6865, Nocardia farcinica ATCC 3318 and Nocardia asteroides NCTC 6761).

Results
Eravacycline demonstrated extraordinary potency, yielding an MIC50 of 0.047 µg/ml and an MIC90 of 0.094 µg/ml (range: 0.004–1.0 µg/ml). This activity was significantly superior to the current standard agent, SXT, which showed an MIC90 of 1.0 µg/ml. Notably, 100% of the isolates were inhibited by eravacycline at concentrations of ≤1.0 µg/ml. Omadacycline displayed an MIC50/MIC90 of 1.0/1.5 µg/ml (range: 0.064–3 µg/ml), while the older-generation minocycline had an MIC90 of 1.5 µg/ml but a wider range of up to 4 µg/ml. Tigecycline remained the most potent agent overall MIC90: 0.064 µg/ml), but eravacycline emerged as the most promising next-generation candidate due to its exceptional inhibitory profile and pharmacological potential.

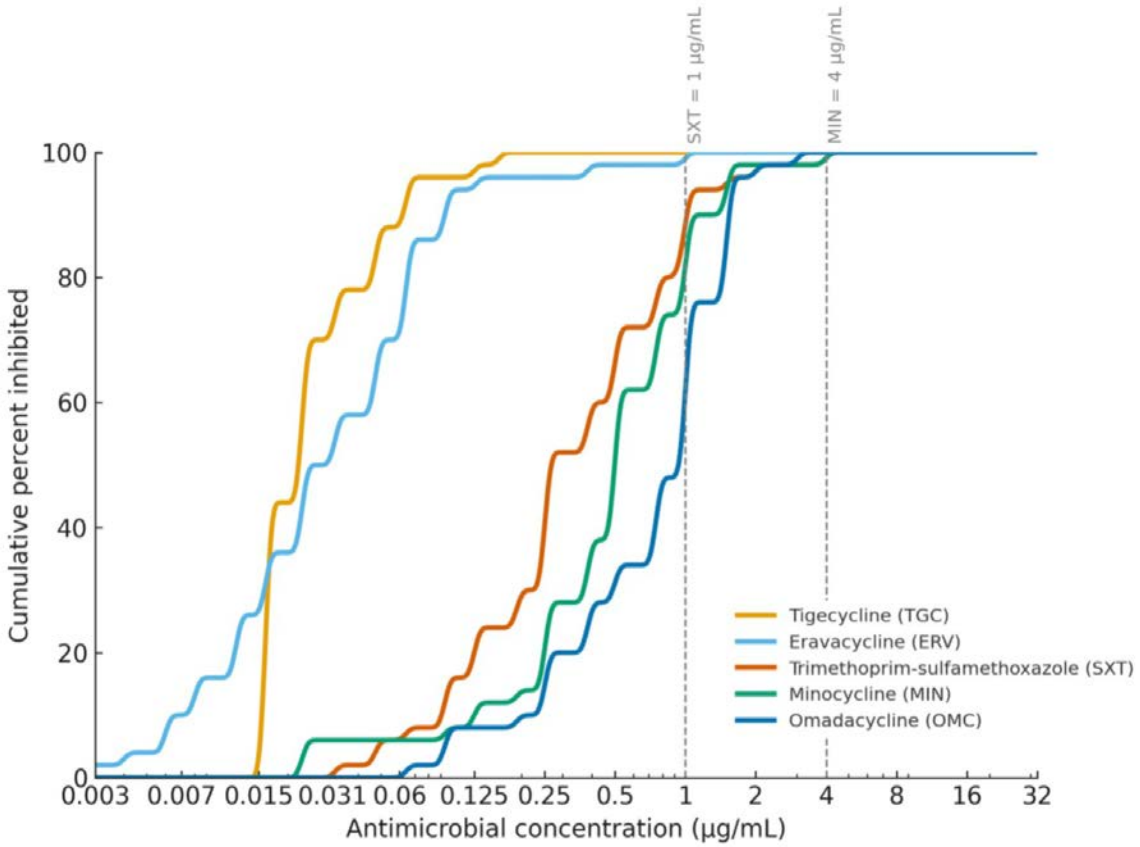

Figure 1: Cumulative percentages of Nocardia brasiliensis clinical isolates (n = 50) inhibited by tigecycline (TGC), eravacycline (ERV), trimethoprim-sulfamethoxazole (SXT), minocycline (MIN), and omadacycline (OMC). Vertical dashed lines indicate CLSI susceptibility breakpoints for SXT (1 µg/mL) and MIN (4 µg/mL).

Conclusions

These findings represent a potential paradigm shift in the global strategy against actinomycetoma. The superior in vitro activity of eravacycline—approximately 10 times more potent than SXT—suggests that next-generation tetracyclines could redefine the therapeutic landscape from a toxicity-laden, multi-drug approach to a highly targeted oral regimen. This is particularly relevant for the management of NTDs in resource-limited settings, where outpatient feasibility and treatment adherence are paramount for success. The significance of this study lies in its challenge to the current reliance on sulfonamide-based regimens and toxic aminoglycoside cycles that often require hospital monitoring. By identifying eravacycline and omadacycline as highly active agents, we provide the scientific foundation for transitioning toward a "next-generation tetracycline-first" paradigm. Such a shift could drastically reduce treatment cycles, minimize the risk of permanent disability or amputation, and improve the quality of life for vulnerable populations by offering a safer, more effective oral pathway to cure.

Next-generation tetracyclines, specifically eravacycline and omadacycline, represent a major conceptual advance in the treatment of N. brasiliensis. These agents offer a potent and feasible oral alternative to current toxic standards. Transitioning to these therapies could transform actinomycetoma from a disabling, difficult-to-manage condition into one with a streamlined, outpatient-friendly cure, addressing a major gap in the global management of neglected tropical diseases.

EADV CONGRESS
VIENNA
30 SEP - 3 OCT 2026

Abstract N°: 67

Cutaneous leishmaniasis in military population

Rym Zmiti*[1]

[1] Principal Military Hospital of Tunisia, Tunis, Tunisia

Introduction

Cutaneous leishmaniasis (CL) is a parasitosis transmitted to humans by female sandflies. The military population is particularly at risk due to their travels and the nature the nature of their missions. Our aim was to describe the epidemio-clinical and therapeutic aspects of CL in the military population, and to study its occupational repercussions.

Materials and Methods

We conducted a single-center retrospective study collecting all cases of LC confirmed either by dermal smear or PCR over a 13-year period from January 2008 to March 2021.

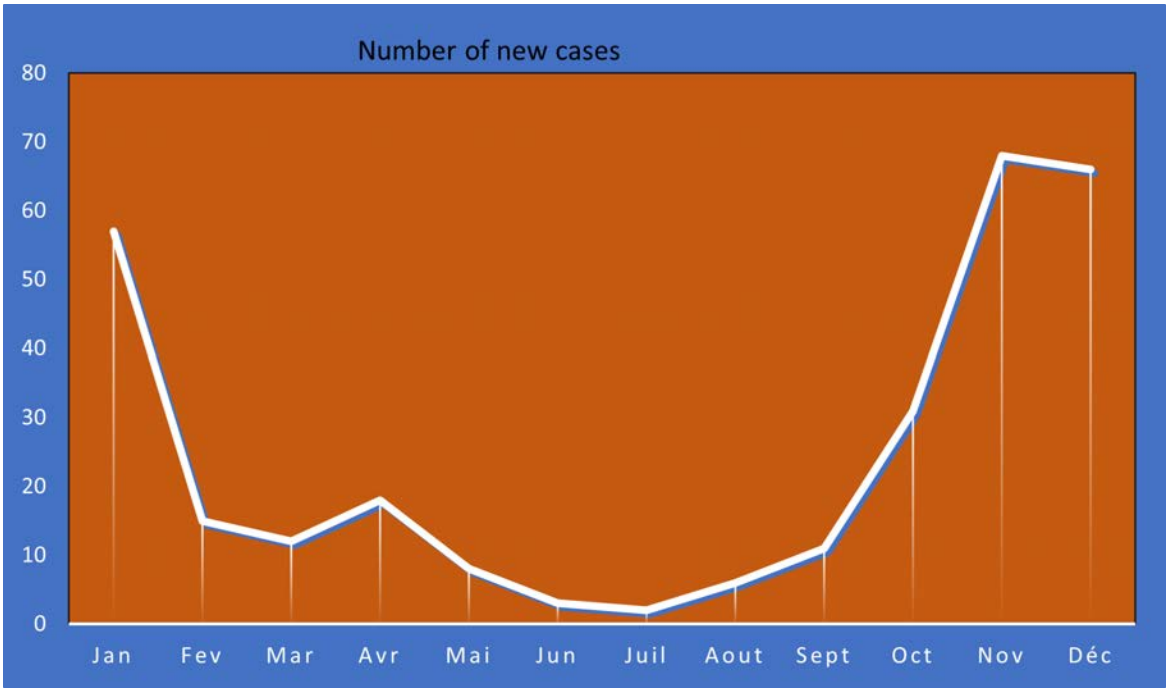

Distribution of patients with Cutaneous leishmaniasis according to the month of lesion onset

Results

We included 437 patients with 436 men and one woman. The hospital incidence was 31.2 new cases/year. Sixty percent of cases were non-commissioned officers and 29% were non-commissioned officers. The average age was 28. The average duration was 2.4 months. The predominant clinical aspect was the ulcerative-crust nodule (80%), followed by infiltrated plaques (18.4%). The lower limbs were the location (58.9%), followed by the upper limbs (42.6%). Over 60% of patients had lesions less than or equal to 2cm in size. Glucantime® was used intramuscularly intramuscular route in 35.7% of cases, and as an intra-lesional infiltration in 45% of cases. The stibio-intolerance was noted in 4.1% of cases, and stibiotoxicity in 3.8%. The cryotherapy was used in 8.4% of cases. A study of the

occupational impact of LC showed that 109 patients (24.9%) were off work for between 2 and 15 days. Hospitalization was indicated in 49.6% of cases (mean duration: 7.9days). Home convalescence was prescribed in 24.9% of cases (mean duration: 6.5days) and exemptions from wearing boots (15 days) in 7.7% of cases. Absenteeism and exemptions were significantly more frequent in patients with lower limb lesions treated with intramuscular injections of Glucantime®.



Cutaneous Leishmaniasis of the upper Lip

Conclusions

The ulcerative-crust nodule in the lower limbs is the most common in our population. Given the nature of the military activity, this leaded to absenteeism and temporary inability to work.

EADV CONGRESS
VIENNA
30 SEP - 3 OCT 2026

Abstract N°: 68

Diagnostic Clues in Alopecia: The Significance of Corkscrew and Comma Hairs.

Lula María Nieto Benito*[1], Loreto Carrasco-Santos[1]

[1] Hospital Central De La Defensa Gómez Ulla, Madrid, Spain

Introduction

Tinea capitis is a dermatophyte infection that predominantly affects children but may also occur in adults, particularly in postmenopausal women. Although relatively uncommon in this age group, its incidence in adults appears to be increasing. In adult patients, the clinical presentation may be atypical and can mimic several inflammatory or cicatricial alopecia, which may delay the correct diagnosis.

Case Presentation

A 43-year-old woman presented with a scalp lesion of more than 3 months' duration. The condition began as a patch of alopecia in the vertex region that progressively enlarged and was accompanied by increasing hair loss. The patient had initially been evaluated elsewhere and treated with a topical corticosteroid. Due to the absence of improvement, oral doxycycline and topical clindamycin were subsequently prescribed because of a suspected diagnosis of central centrifugal cicatricial alopecia. Despite this therapeutic approach, no clinical response was observed and the lesion continued to progress. For this reason, the patient sought a second opinion and was referred to our clinic. On physical examination, the patient exhibited an alopecic plaque composed of two clearly differentiated areas. The first consisted of an erythematous plaque with focal areas of scarring, absence of follicular openings, and scattered pustules. Inferior to this region, a second area displayed abnormal hair shafts that were visible even macroscopically. Dermoscopic examination revealed characteristic "corkscrew" and "comma" hairs, findings that strongly suggested the presence of tinea capitis. Microbiological studies were therefore performed. Both cultures obtained from pustular content and from scales grew Trichophyton verrucosum. The patient was treated with oral terbinafine for three months, which led to complete resolution of the "corkscrew" and "comma" hairs and the inflammatory component. However, areas corresponding to the scarring component persisted with permanent alopecia.

Conclusion

Dermoscopy has emerged as a useful non-invasive tool in the evaluation of scalp disorders, allowing the identification of characteristic signs such as comma hairs, corkscrew hairs, broken hairs, and black dots. These features are highly suggestive of dermatophyte infection and may help clinicians rapidly orient the diagnosis before mycological confirmation. In some cases, particularly when diagnosis and treatment are delayed, inflammatory variants of tinea capitis may develop. These forms may lead to significant follicular damage due to intense perifollicular inflammation. Severe inflammatory presentations such as kerion can ultimately destroy hair follicles and result in permanent cicatricial alopecia. Clinically, these advanced forms may resemble primary cicatricial alopecia, including central centrifugal cicatricial alopecia or folliculitis decalvans, which can further complicate the diagnostic process. Once fibrosis and follicular loss occur, hair regrowth is no longer possible, leaving irreversible alopecia. This case highlights the importance of including tinea capitis in the differential diagnosis of alopecic plaques with inflammatory or pustular features in adults. Early recognition through careful clinical examination, dermoscopy, and appropriate mycological testing is essential. Prompt initiation of systemic antifungal therapy can lead to complete resolution of the infection and prevent progression toward permanent follicular destruction. Therefore, maintaining a high index of suspicion and establishing an early diagnosis are key steps in avoiding long-term sequelae such as cicatricial alopecia.

EADV CONGRESS
VIENNA
30 SEP - 3 OCT 2026

Abstract N°: 95

Varied Misdiagnoses of Scabies—A Case Series Report

MENGMENG LI*[1]

[1] Department of Dermatology and Venereology, West China Hospital, Sichuan University, Chengdu, China

Introduction

Scabies is a common and highly contagious parasitic skin disease that is often misdiagnosed because of its clinical similarity to other pruritic and eczematous dermatoses. Delayed or incorrect diagnosis may result in prolonged symptoms, inappropriate treatment, and continued transmission. We report a series of scabies cases initially misdiagnosed as other inflammatory skin disorders, highlighting the diagnostic value of dermoscopy in routine clinical practice.

Case Presentation

We retrospectively reviewed five patients with confirmed scabies, including three children and two adults. All patients presented with persistent pruritic eruptions and had initially been diagnosed with other inflammatory dermatoses, including eczema, atopic dermatitis, allergic dermatitis, and papular urticaria. Prior treatments included topical corticosteroids and systemic therapy such as upadacitinib, with limited or no clinical improvement. Because of refractory symptoms and atypical presentation, further evaluation with dermoscopy was performed. In all cases, dermoscopy demonstrated characteristic white burrow structures consistent with scabies, leading to the correct diagnosis. After appropriate anti-scabietic treatment, all patients showed marked clinical improvement.

Conclusion

Scabies can be easily overlooked and misdiagnosed as other itchy and eczematous skin disorders in daily dermatology practice, especially when clinical manifestations are atypical. This case series emphasizes the importance of considering scabies in the differential diagnosis of refractory pruritic dermatoses. Dermoscopy is a practical, noninvasive, and cost-effective diagnostic tool that can improve diagnostic accuracy by identifying pathognomonic features of scabies. Greater clinical awareness and routine dermoscopic examination may help reduce misdiagnosis and improve patient outcomes.

EADV CONGRESS
VIENNA
30 SEP - 3 OCT 2026

Abstract N°: 104

Urban epidemiology and statistical analysis of American cutaneous leishmaniasis in one of the largest Latin American cities: a 20-year study (2003-2023)

Diogo dos Santos Serpa*[1], Italo Henrique Pereira da Silva[1], Renata Gonçalves Bueno Brandão Bertino[1]

[1] Institute of Medical Education of Estácio de Sá University, Rio de Janeiro, Brazil

Introduction
American cutaneous leishmaniasis is a neglected tropical disease that remains a persistent public health concern in endemic regions. In large urban centers, environmental changes, urban expansion, and socio-spatial inequalities may influence transmission dynamics and disease outcomes, highlighting the need for long-term epidemiological analyses.

Materials and Methods
An analytical retrospective epidemiological study was conducted using secondary data from a national notifiable diseases surveillance system in Brazil. Cases of American cutaneous leishmaniasis reported between 2003 and 2023 among residents of the city of Rio de Janeiro, one of the largest metropolitan areas in Latin America, were included. Bivariate statistical analysis compared two time periods (2007-2012 and 2018-2023). The association between diagnostic period and clinical outcome was estimated using odds ratios (OR) with 95% confidence intervals (95% CI), and statistical significance was assessed using Pearson's chi-square test.

Results
A total of 514 cases were identified during the study period, with cure being the most frequent outcome (339 cases). Bivariate analysis comparing the historical and recent periods revealed an odds ratio of 0.82 (95% CI: 0.35-1.92; $p > 0.05$). This result indicates no statistically significant difference in the probability of cure between the two periods, suggesting stability in therapeutic response and treatment adherence despite a reduction in the total number of reported cases. Treatment abandonment (27 cases) remained the main unfavorable outcome, while disease-specific lethality was extremely low, with only one death recorded during the 20-year period (0.19%).

Conclusions
The absence of statistically significant differences in cure probability across the analyzed periods suggests stability in treatment effectiveness over time. However, the persistence of treatment abandonment highlights the need for strengthened surveillance and follow-up strategies to ensure completion of the therapeutic regimen in endemic urban settings.

Abstract N°: 113

When the face reveals the diagnosis: two cases of advanced lepromatous leprosy from an endemic region in South America

Jimena Miranda*[1], María Burgesser[2]

[1] Clínica Privada Miranda V, Clínica Dra Agostina Miranda- Medicina dermatológica y láser, Jujuy, Argentina
[2] Laboratorio MVB, Jujuy, Argentina

Introduction

Leprosy, or Hansen's disease, is a chronic granulomatous infection caused by Mycobacterium leprae, an acid-fast, obligate intracellular pathogen with tropism for the skin and peripheral nerves. The lepromatous multibacillary form represents the most severe end of the clinical spectrum and is associated with impaired cellular immunity and high bacillary load. Despite a global decline in prevalence, advanced cases are still observed in endemic regions.
We report two cases of advanced lepromatous leprosy presenting with leonine facies from an endemic region in South America.

Case Presentation

Case 1: A 39-year-old male prison officer presented with a 6-year history of a diffuse erythematous and infiltrated dermatosis involving approximately 90% of the body surface area. Examination revealed indurated facial nodules causing leonine facies, madarosis, ptosis of the earlobes, and extensive infiltrated plaques on the trunk and extremities, with marked edema of the hands and feet. Neurological examination showed acral hypoesthesia.
Case 2: A 64-year-old male rural worker presented with a similar clinical picture, including nasal septum perforation with obstruction and recurrent epistaxis. Leonine facies, madarosis, extensive infiltrated lesions, and distal edema were also observed. Neurological examination revealed acral hypoesthesia.
Laboratory tests (complete blood count, liver function tests, renal function, HIV/HBV/HCV serologies, and tuberculin test) were within normal limits.
Skin biopsies showed a thinned epidermis and dermis occupied by a dense diffuse infiltrate of foamy histiocytes (Virchow cells) with interstitial, perineural, and periadnexal distribution, and a preserved Grenz zone. Ziehl–Neelsen staining demonstrated numerous intracellular acid-fast bacilli, confirming multibacillary leprosy.
Both patients were treated with standard multidrug therapy (rifampicin, clofazimine, and dapsone) with good initial tolerance.

Conclusion

These cases illustrate advanced lepromatous leprosy with high bacillary load and severe cutaneous involvement. Their persistence highlights the need for early diagnosis, improved access to care, and strengthened epidemiological surveillance in endemic areas to prevent transmission and disability.

EA DV CONGRESS
VIENNA
30 SEP - 3 OCT 2026

Abstract N°: 127

How many cases of scabies require a dermatologist to diagnosis? A retrospective review of scabies cases managed by the dermatology department in a North Queensland Australian Hospital over a 10-month period.

Madeleine Kelly*[1], Crystal Williams[1]

[1] Townsville University Hospital, Townsville, Australia

Introduction
Scabies is caused by the Sarcoptes scabiei mite. Scabies is most prevalent in low socioeconomic areas and has a high prevalence in First Nations communities and is often misdiagnosed as other skin conditions such as eczema. The International Alliance for the Control of Scabies published a guideline for the diagnosis of scabies, including 3 tiers: “Confirmed scabies (level A) requires direct visualization of the mite or its products, clinical scabies (level B) and suspected scabies (level C) rely on clinical assessment of signs and symptoms.

Materials and Methods
A retrospective review of electronic records was conducted over a 10-month period from 1st February 2025 until 1st December 2025 in a large tertiary hospital in North Queensland, Australia. Key search terms included 'scabies', 'ivermectin', 'permethrin' and 'crusted scabies'.

Results
25 cases of scabies required Dermatology input to establish diagnosis. 17 were diagnosed after an inpatient review. Eight were diagnosed after General Practitioner referral. 15 patients were ICAS A, 4 were ICAS B and 6 were ICAS C. The average duration of symptoms was 3 months. 40% of cases were recorded in First Nations patients. Treatment varied with 9 patients receiving combination therapy and the remainder receiving either permethrin or ivermectin. 38% of patients required further treatment to gain clearance.

Conclusions
A small number of cases required Dermatology input to diagnose. A high percentage were in First Nations patients suggesting some difficulty in the diagnosis of scabies in darker skin phenotypes as they can present with non-classical signs. It is important to follow up as 38% of individuals required further treatment furthering disease spread. Prolonged duration of symptoms is concerning as this can lead to secondary complications including acute rheumatic fever and kidney disease. Further research is required to develop diagnostic criteria for darker skin phenotypes.

EA DV CONGRESS
VIENNA
30 SEP - 3 OCT 2026

Abstract N°: 158

Role of Acyclovir in Severe Adult Hand, Foot, and Mouth Disease: A Case Report

Shama Naaz*[1]

[1] Ck Birla Hospital, Gurugram, India

Introduction

Hand, Foot, and Mouth Disease (HFMD) is an acute viral exanthem that commonly affects children, particularly those under ten years of age. The infection is frequently caused by Coxsackievirus A16 and Enterovirus 71, members of the Picornaviridae family. The disease is self-limiting, resolving spontaneously within a week to ten days. Adult-onset HFMD, however, remains an uncommon and underreported condition. It may present atypically and with increased severity, including extensive oral ulcerations, painful eruptions, and systemic symptoms. Currently, management remains largely supportive, and no standard antiviral therapy has been established. Certain antiviral agents have been empirically used in severe cases. Acyclovir, a guanine analogue, has occasionally shown clinical benefit in adult HFMD. While enteroviruses lack the thymidine kinase enzyme required for acyclovir activation, a few published case reports have suggested that acyclovir may hasten recovery. This report describes a case of severe adult-onset HFMD with extensive oral involvement that responded dramatically to oral acyclovir.

Case Presentation

A 34-year-old female presented with a two-day history of fever, painful oral ulcers, and swelling of lips and oral mucosa. She noted painful red spots on both hands and a few lesions on the right foot. Her four-year-old child had been diagnosed with HFMD one week earlier. On examination, the patient was dehydrated, hypotensive and febrile (101°F). Oral examination revealed multiple shallow, tender erosions on the buccal mucosa, tongue, and palate. Cutaneous examination showed multiple erythematous macules and vesicular lesions over the palmar surfaces of both hands and lateral aspect of the right foot. Given her symptoms, epidemiological link, and clinical presentation, a diagnosis of HFMD was made. The patient was admitted, and intravenous fluids were started to correct dehydration. Acetaminophen was given for fever. Oral care included the modification of Pandyas regimen to soothe mucosal lesions. Considering the severity of her mucosal involvement, oral acyclovir 400 mg three times daily was started for seven days. Within 48 hours of therapy, the patient reported significant reduction in oral pain and swelling. Fever subsided by the second day, and pharyngitis showed marked improvement. She was discharged in stable condition and followed up after one week, showing complete recovery.

Conclusion

Adult-onset HFMD is an emerging phenomenon.. Adults often experience a more severe course than children, particularly in the presence of extensive mucocutaneous lesions. The differential diagnosis includes herpetic stomatitis, Stevens–Johnson syndrome, aphthous ulcers, erythema multiforme, and fixed drug eruption. Several reports support the possible benefit of acyclovir in adult HFMD. Patil et al. (Indian J Dermatol, 2015) described a similar case of adult-onset HFMD treated successfully with acyclovir, showing complete resolution within four days. Kim et al. (J Korean Med Sci, 2012) also noted accelerated lesion healing in an adult patient following acyclovir initiation. In another case by Lee et al. (Singapore Med J, 2018), severe adult HFMD with painful mucosal involvement improved significantly within two days of acyclovir therapy. Although these are isolated reports, they suggest a reproducible pattern of faster recovery in acyclovir-treated patients. In our case, acyclovir therapy led to remarkable improvement within 48 hours, allowing early resumption of oral intake and discharge within four days. Similar findings in previously reported cases suggest that acyclovir may have a beneficial role, either through antiviral or anti-inflammatory mechanisms. Given its safety and availability, acyclovir could be considered as an

adjunctive treatment in selected adult HFMD cases with significant morbidity. Further research is warranted to elucidate its mechanism of action, establish treatment protocols, and determine efficacy.

EADV CONGRESS
VIENNA
30 SEP - 3 OCT 2026

Abstract N°: 175

Furuncular Myiasis by Dermatobia hominis: The Challenge of Differential Diagnosis in Recalcitrant Scalp Abscesses

Sebastian Bustos Segura*[1], Luz Maria Ramirez Faure[1], Sofia Rojas Escobar[1], Carla Zamboni De Los Rios[1], Ignacio Hurtado Arrau[2]

[1] Facultad de Medicina, Universidad Diego Portales, Santiago, Chile
[2] Servicio de Dermatología, Hospital del Salvador, Santiago, Chile

Introduction

Myiasis is the infestation of live or necrotic vertebrate tissue by dipterous larvae. Among its clinical forms, furuncular cutaneous myiasis is characterized by a painful nodular lesion with a central pore, which can be misidentified as bacterial abscesses or other inflammatory dermatoses. Historically, Chile has maintained a low-endemicity sanitary profile; however, the sustained increase in migratory mobility from tropical South American regions, combined with the growth of populations in informal settlements—often associated with poor hygiene and poverty—has altered the local epidemiological landscape.

Case Presentation

A 15-month-old female from Chile, with a history of recent travel to Bolivia and residence in an overcrowded informal settlement, presented with a one-month history of a progressive occipital scalp mass. Prior treatment with an 11-day course of amoxicillin for suspected bacterial cellulitis had failed. Upon admission, the lesion had evolved into a purulent, exudative nodule associated with fever and cervical lymphadenopathy. On physical examination, a larva was observed emerging from a central punctum within the lesion. Initial laboratory findings showed leukocytosis with a left shift and an elevated C-reactive protein (27 mg/L). The patient was hospitalized, and intravenous antibiotics (penicilin and cloxacilin) were initiated. Following larval asphyxiation with a transparent film dressing, mechanical extraction was performed under sedation. The specimen was morphologically confirmed as Dermatobia hominis by the Infectious Disease Department. Post-extraction, the patient remained afebrile, with a clean, not-secreting wound. She was discharged with a 10-day course of oral amoxicillin to treat secondary infection. Follow-up examinations confirmed complete wound healing and surgical resolution.

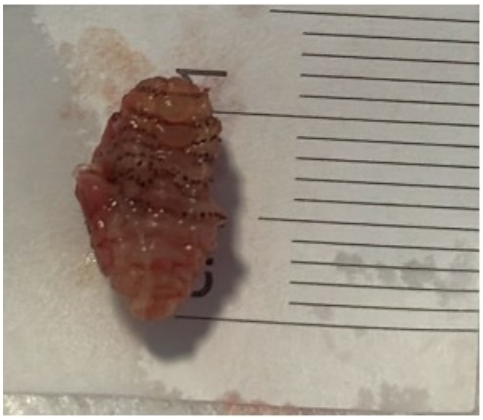

Figure 1. Dermatobia hominis larva removed during surgery

Conclusion

Myiasis is a parasitic infestation caused by dipteran larvae, classified by the species involved or the affected anatomical site. Cutaneous myiasis typically presents as an open lesion with direct inoculation, early symptom onset, and intense pruritus. While furuncular myiasis is infrequent in Chile, recent migratory shifts from tropical South American regions and the growth of informal settlements with poor sanitation have altered local epidemiology. International travel to endemic zones remains the primary risk factor.

Dermatobia hominis is a "great imitator," often misdiagnosed as bacterial furunculosis or abscesses. The hallmark differentiator is a visible central respiratory pore and a lack of response to conventional antibiotics. Differential diagnoses include infected epidermal cysts, cutaneous leishmaniasis, and cat-scratch disease. The complex transmission involves hematophagous insect vectors (e.g., mosquitoes) that carry the eggs; host body heat triggers hatching, allowing larvae to penetrate the dermis via the bite site or hair follicles. This explains why the initial lesion often resembles a simple insect bite before evolving into a furuncular lesion.

Diagnosis is primarily clinical but can be supported by Doppler ultrasound to detect larval "wriggling" or dermoscopy to identify hook-shaped cuticular spines. In this case, identification was confirmed by the cylindrical body with concentric rows of spines and caudal spiracles. The 1.3 cm size indicated a five-week developmental stage.

Definitive treatment requires complete larval extraction, ideally within seven weeks. While methods include pore occlusion or punch biopsy, standardized protocols for pediatric populations are limited. In this context, mechanical extraction under sedation represents a safe and effective option for pediatric scalp lesions. This approach minimizes neurosurgical risks, reduce the patient's discomfort and ensures complete removal. Recognizing this entity is crucial for early diagnosis and avoiding unnecessary prolonged antibiotic therapy.

EA DV CONGRESS
VIENNA
30 SEP - 3 OCT 2026

Abstract N°: 177

Long standing verrucous growth

Dr Smita Shinde*[1]

[1] Divine Skin Clinic, Santulan family wellness clinic, Mumbai, India

Introduction

Chromoblastomycosis is a chronic fungal infection of the skin and subcutaneous tissues; caused by pigmented fungi producing sclerotic bodies; characterized by slow growing exophytic lesions; usually on the lower extremities.

Case Presentation

A73 yrs old male presented with multiple asymptomatic, gradually progressive growths on medial aspect of left knee since 16 year .There was no history of fever, weight loss, trauma or any systemic complaints. Patient had received anti-tubercular treatment in the past. Patient had also received treatment for chromoblastomycosis in past .

Cutaneous examination revealed well-defined erythematous plaque with verrucous surface and satellite lesions. Differential diagnosis considered were Lupus vulgaris, Tuberculosis verrucous cutis, Chromoblastomycosis and Verrucous carcinoma. Histopathology showed irregular epithelial hyperplasia; dermis showed intraepithelial micro-abscesses, a dense lichenoid granulomatous infiltrate and several sclerotic bodies (copper pennies bodies). Unstained sections also showed copper penny bodies. Culture on Sabouraud's dextrose agar showed minimal growth of dematiaceous fungus spp; confirming the diagnosis of Chromoblastomycosis. Patient was treated in past in(2012)with Tab. Terbinafine 250 mg once daily for first 2 month and twice daily for next 16 months along with cryotherapy for localized lesions. Patient was continuously screened for adverse effects of prolonged antifungal therapy. Mass gradually regressed in size and satellite lesions markedly reduced during the treatment period. He was asymptomatic with no new grown for around 12 years.Then, since last 2 year (2024) he started same verrucous growth on the same site which gradually increased in size and started pain and bleeding on touch . Histopathology and culture on sabouraud's agar findings were consistent with Chromoblastomycosis. Started treatment with Terbinafine 250 mg twice daily for 18 months with excision of few lesions. Pain and bleeding on touch subsided within one month, and the growth regressed completely over one year. Excision of localized lesions improved patient compliance due to rapid relief, while oral terbinafine helped regress the remaining lesions.

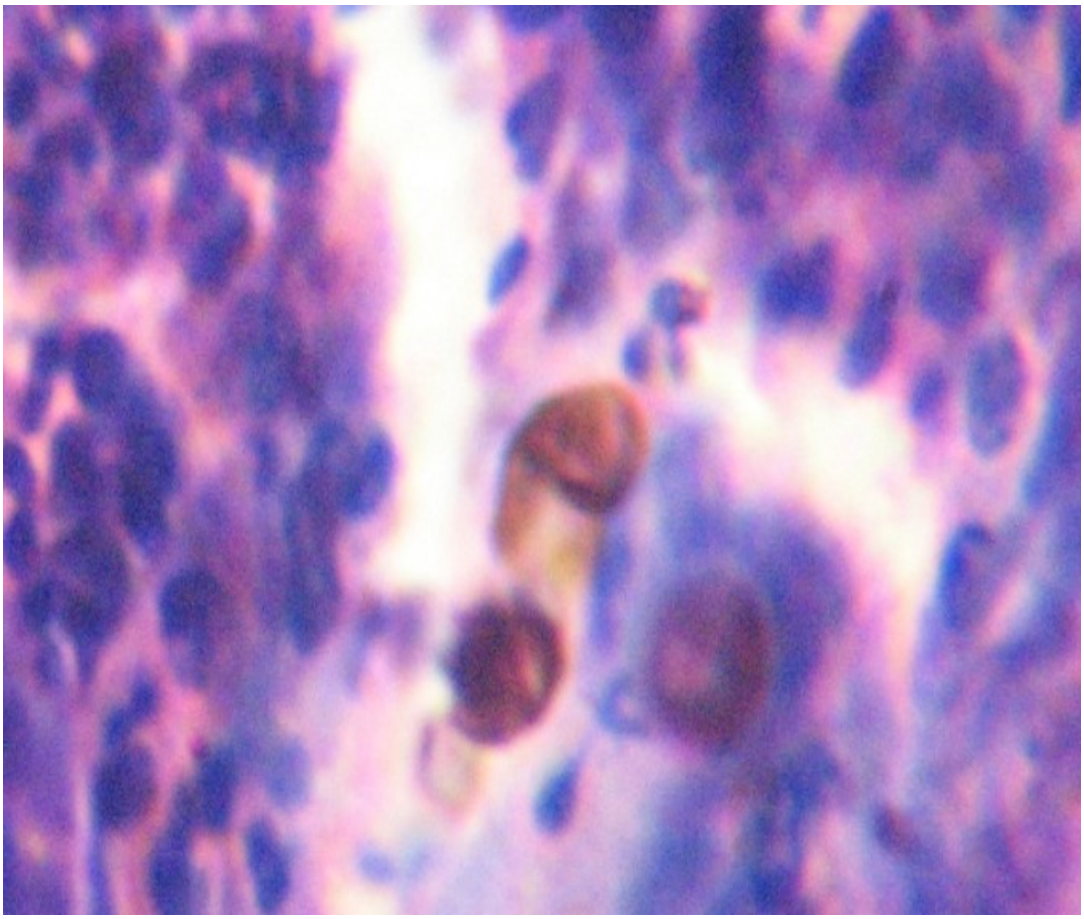

The cells divided by fission and may form septa in more than one plane of division, copper penies bodies

Conclusion

Chromoblastomycosis, a chronic fungal infection with prolonged indolent course, difficult to diagnose and resistant to treatment. Prolonged treatment with oral terbinafine is uncommonly reported. Good clinical response was seen with terbinafine.

EADV CONGRESS
VIENNA
30 SEP - 3 OCT 2026

Abstract N°: 178

Cutaneous polyarteritis nodosa in a child, precipitated by Mycobacterium tuberculosis

Mohamed Karideen Fathima Benazir*[1], Sriyani Samaraweera[1], Thuvaraha GUNASEGARAN[2]

[1] Lady Ridgeway hospital for Children, Lady Ridgeway hospital for Children, Lady Ridgeway hospital for Children, Colombo, Sri Lanka

[2] National Hospital of Srilanka, Lady Ridgeway hospital for Children, Lady Ridgeway hospital for Children, Colombo, Sri Lanka

Introduction

Cutaneous polyarteritis nodosa is a rare condition limited to the skin, without systemic symptoms. It's a vasculitis involving small to medium-sized arteries. It presents with painful nodules, ulcers, and livedo reticularis-like skin lesions.

Case Presentation

Previously healthy, four years old girl presented with two weeks history of fever and painful erythematous nodules in bilateral lower limbs. While the child was being investigated, she developed ulceration over nodules and developed new lesions over the upper limbs, and no associated joint pain. Further, the child had a cough. There was a strong contact history of tuberculosis recently with a family member. The full blood count with differentials was normal. Inflammatory markers are high. The blood picture is suggestive of ongoing bacterial infection. Chest X-ray was normal. Mycoplasma antibody was negative. The 2D echocardiogram and ultrasound scan abdomen were normal. The Deep punch biopsy done from the ulcer showed small to medium vessel vasculitis with panniculitis. The Mantoux test was strongly positive with 15 mm. The respiratory opinion was taken, and the diagnosis of cutaneous polyarteritis nodosa stimulated by Mycobacterium tuberculosis was made. Following Anti-tuberculosis treatment, the child's cutaneous lesions healed in 2 weeks.

Conclusion

Cutaneous polyarteritis nodosa can be triggered by autoimmune diseases, infections, and certain drugs. It commonly occurs due to various infections, such as streptococcus, hepatitis B, C, and parvovirus. Very rarely, polyarteritis nodosa can be induced by Mycobacterium tuberculosis. Histopathology is the principal investigation of choice in diagnosing polyarteritis nodosa. Cutaneous polyarteritis nodosa should be considered as a differential diagnosis in a patient presenting with painful ulcerated nodules. Therefore, this case emphasizes the need to consider polyarteritis nodosa in association with tuberculosis infection.

EADV CONGRESS
VIENNA
30 SEP - 3 OCT 2026

Abstract N°: 207

Deep cutaneous fungal infection in an immunocompetent individual caused by Purpureocillium lilacinum biopesticide exposure: a rare case report

Chunjiao Zheng*[1], Lianjuan Yang[1]

[1] Shanghai Skin Disease Hospital, Shanghai, China

Introduction

Purpureocillium lilacinum (P. lilacinum) is a saprophytic filamentous fungus widely used as a biocontrol agent against plant-parasitic nematodes and insects. While it rarely causes infection in immunocompetent hosts, it can lead to severe disease in immunocompromised individuals. We report a rare case of deep cutaneous fungal infection associated with occupational exposure to a P. lilacinum-based biopesticide, highlighting an emerging occupational health concern.

Case Presentation

A 66-year-old immunocompetent female farmer presented with a 10-year history of recurrent erythematous lesions on her face and arms. Each episode occurred following pesticide application on her farm, with spontaneous healing leaving atrophic scars. Physical examination revealed a 1.4×1.6 cm painless erythematous plaque on the left thumb base (near the wrist) and multiple atrophic scars on the face and arms. Medical history was unremarkable, with no evidence of immunocompromised disorders, diabetes, or HIV infection. Comprehensive immune marker analyses, including lymphocyte subsets, were normal. Histopathology of a skin biopsy showed septate hyphae in the dermis on periodic acid-Schiff (PAS) staining. Fungal culture of skin tissue yielded pale violet, fluffy colonies, and microscopy revealed transparent septate hyphae. Sequencing of the internal transcribed spacer (ITS) region identified the isolate as Purpureocillium lilacinum. Further inquiry confirmed that the pesticide used by the patient contained P. lilacinum as the active ingredient. The patient was treated with oral itraconazole 400 mg daily for three months, resulting in complete healing of skin lesions with no recurrence during follow-up.

Conclusion

This is a rare case of deep cutaneous fungal infection directly linked to occupational exposure to a P. lilacinum-based biopesticide in an immunocompetent individual. The case highlights the potential infectious risks of biopesticides, especially for agricultural workers, and underscores the need for safety precautions, personal protective measures, and heightened clinical awareness of emerging fungal pathogens in agricultural settings.

Abstract N°: 211

Mycobacterium haemophilum infection with cutaneous involvement: a case report

Keke Huang*[1], Degang Yang[1]

[1] Department of Infectious Dermatosis, Shanghai, China

Introduction

Mycobacterium haemophilum infection typically occurs in immunocompromised individuals. This article reports a case of an immunocompetent female presenting with cutaneous nodules, plaques, and ulcers, in which the infection was ultimately confirmed as *M. haemophilum* by polymerase chain reaction (PCR) assay and DNA sequencing.

Case Presentation

A 67-year-old woman presented with nodules and plaques on the left upper extremity for 8 months and ulceration for 3 months. Examination showed a 5 cm × 3 cm dark red plaque with a central ulcer measuring 1 cm in diameter, an irregular base covered by bright red granulation tissue, yellowish purulent discharge, and no bloody exudate. Routine laboratory tests, including complete blood count, liver and kidney function, tumor markers, and T-Spot assay, were all within normal limits. Histopathological of the skin lesion revealed parakeratosis and focal epidermal necrosis. Multiple epithelioid cell aggregates were noted in the dermis, surrounded by inflammatory infiltrates mainly composed of lymphocytes, histiocytes and plasma cells. Central necrosis was present in partial lesions. Acid-fast staining was negative. The pathological changes were suggestive of infectious granuloma. *Mycobacterial* DNA and *Mycobacterium leprae* DNA were detected in skin lesion tissue and pus by PCR. Further DNA sequencing ultimately confirmed the pathogen as *M. haemophilum*. The patient was finally diagnosed with *M. haemophilum* infection and treated with trimethoprim-sulfamethoxazole, rifampicin, and clarithromycin for 15 weeks, after which the plaque gradually regressed, the ulcer healed, and scarring formed on the surface.

Conclusion

1. *M.haemophilum*is a type of nontuberculous mycobacteria that mainly affects immunocompromised individuals. Infection in immunocompetent patients, as presented in this case, is clinically rare. In this case, both *mycobacterial* DNA and *M. leprae* DNA were simultaneously detected in skin lesions by PCR. Previous phylogenetic analysis based on limited sequence data has revealed that *M. haemophilum* shares a close evolutionary relationship and high genetic homology with *M. leprae*, which tends to cause cross-reactivity and interfere with molecular detection results. Further DNA sequencing ultimately confirmed the infection caused by *M. haemophilum*. The infection exhibits non-specific clinical and histopathological features, making early diagnosis challenging. Etiological examination remains the cornerstone of definitive diagnosis. PCR combined with DNA sequencing enables accurate identification of pathogens, providing reliable evidence for the clinical diagnosis of such rare nontuberculous mycobacteria infections.

EADV CONGRESS
VIENNA
30 SEP - 3 OCT 2026

Abstract N°: 226

Efficacy and safety of combination treatment of oral terbinafin and itraconazole in patients with extensive superficial dermatophytes

Mohammad Enamul Hoque*[1], Suraiya Akhter[2], Quazi Yazdi[3], Mohammad Hoque[4]

[1] Army Medical College Chattogram, Combined Military Hospital Chattogram, Chattogram, Bangladesh
[2] Army Medical college cumilla, Cumilla, Bangladesh
[3] Combined Military Hospital Dhaka, Dhaka, Bangladesh
[4] Department of Agricultural Extention, Dhaka, Bangladesh

Introduction
Dermatophytosis, a prevalent fungal infection, is instigated by species like Trichophyton, Epidermophyton and Microsporum. The current approach for treating dermatophytosis involves a blend of systemic and topical antifungal therapies, applicable to all patients except those with localized, untreated Tinea. Notably, there is a growing incidence of inadequate response to the standard treatment regimen in recent times.

Materials and Methods
This research comprised a randomized clinical trial involving 50 individuals diagnosed with extensive superficial dermatophytosis. Study conducted at the Department of Dermatology and Venereology, Combined Military Hospital Cumilla, the study spanned from July 2022 to June 2023. During the six-week duration, patients underwent treatment with terbinafine and itraconazole, with follow-up examinations every two weeks, including relevant investigations. Evaluation of treatment outcomes occurred at both four and six weeks. Statistical analysis was performed using version 25 of the Statistical Package for the Social Sciences (SPSS).

Results
This study shows the majority of the participants within the age range of 16-30 years (56.0%) and the average age of the participants is 31.74±11.77 years. In terms of gender, the majority are male (78.0%). The most prevalent diagnosis is Tinea corporis (68.0%), followed by Tinea cruris (36.0%), Tinea faciei (28.0%), and Tinea incognito (12.0%). The majority of participants (85.0%) have had the disease for 12 months or less. The most common sites are the trunk (35.0%), whole body (26.0%), and crural area (24.0%). The majority of participants experience severe itching (56.0%), followed by moderate itching (34.0%), and a smaller percentage report mild itching (10.0%). The majority of participants showed improvement, with percentages increasing from 66.0% after 2 weeks to 84.0% after 4 weeks.The percentage of cured individuals also increased over time, reaching a substantial 90.0% after 6 weeks.

Conclusions
The amalgamation of terbinafine and itraconazole demonstrates a superior clinical cure rate compared to use of single systemic antifungals. However, the observed clinical cure rate percentage is lower when juxtaposed with findings from previous studies. Notably, neither combination of systemic antifungals has exhibited efficacy against tinea infections previously treated with formulations containing topical steroids.

EA DV CONGRESS
VIENNA
30 SEP - 3 OCT 2026

Abstract N°: 232

Facial deformities associated with Leprosy: a case series of 9 Patients

Herin'Ny Fitiavana Princia Andriatahina*[1], Tsiory Iarintsoa Razafimaharo[1], Malalaniaina Andrianarison[1], Fenohasina Rakotonandrasana[1], Samson Leophonte Ramily[1], Moril Sata[2], Onivola Raharolahy[1], Lala Soavina Ramarozatovo[1], Rapelanoro Fahafahantsoa Rabenja[1], Irina Mamisoa Ranaivo[3]

[1] Dermatology Departement, Joseph Raseta Befelatanana University Hospital, Antananarivo, Madagascar
[2] Dermatology Departement, Morafeno Univesity Hospital, Toamasina, Madagascar
[3] Dermatology Department, Place Kabary University Hospital, Antsiranana, Madagascar

Introduction
Leprosy is a chronic infectious disease caused by Mycobacterium leprae, which may lead to visible deformities,particularly involving the face. The nasal mucosa is recognized as a major site of bacillary infection and replication, explaining the high frequency of nasal involvement and nasal bridge collapse in advanced forms. Facial manifestations are reported in approximately 40–45% of patients and may be associated with facial nerve involvement. This study reports patients presenting facial manifestations and facial nerve involvement in leprosy.

Materials and Methods
We conducted a retrospective case series over a three-year period in dermatology departments and leprosy referral centers. Collected data included age, gender, clinical classification, diagnostic delay, facial manifestations, neurological involvement, and functional complications.

Results
Nine patients with leprosy presenting significant facial deformities were identified among 200 patients with leprosy. The mean age at diagnosis was 45.4 ± 14.7 years, with a male-to-female ratio of 1.25. All patients had a diagnostic delay exceeding two years. Major facial deformities accounted for 4.5% (9/200) of leprosy cases during the study period.The main facial manifestations included collapse of the nasal bridge in 5/9 patients (55.6%), madarosis (loss of eyelashes and/or eyebrows) in 5/9 patients (55.6%), and leonine facies in 1/9 patients (11.1%). Facial neurological involvement was observed, with lagophthalmos in 4/9 patients (44.4%) and facial paralysis in 2/9 patients (22.2%). Partial amputation of the auricular helix was noted in one patient. Type 1 (reversal) lepra reactions were present in 7 patients (77.8%).

Conclusions
This case series highlights the occurrence of facial deformities and neurological complications associated with prolonged diagnostic delay of leprosy. The high frequency of nasal bridge collapse and lagophthalmos observed in our series emphasizes the importance of early detection to prevent irreversible sequelae.



Case 1: Nasal bridge collapse and lagophthalmos

EA DV CONGRESS
VIENNA
30 SEP - 3 OCT 2026

Abstract N°: 241

Extensive Kaposi Varicelliform Eruption in a Previously Healthy Adult: An Atypical Presentation

Tudor-Alex Rus*[1], Sabina Tăpălagă[1], Tania Maria Prainer[1], Florina-Adriana Ursu[2], Teodora-Larisa Timis[3]

[1] Faculty of Medicine, „Iuliu Haţieganu" University of Medicine and Pharmacy, Cluj-Napoca, Romania
[2] Dermatology Clinic, County Emergency Hospital, Cluj-Napoca, Romania
[3] Physiology Department, „Iuliu Haţieganu" University of Medicine and Pharmacy, Cluj-Napoca, Romania

Introduction

Kaposi Varicelliform Eruption (KVE), also known as eczema herpeticum, is a severe, disseminated skin infection caused by the herpes-simplex virus (HSV) that usually occurs in immunocompromised patients or individuals with pre-existing dermatoses, especially atopic dermatitis. It rarely affects immunocompetent adults without underlying skin disease.

Case Presentation

We report the case of a 50-year-old male who presented to the emergency room with a generalized erythematous eruption with erosions and confluent crusting, resting dyspnea, a low-grade fever and epigastric pain. A suspicion of thrombocytopenic purpura in the context of vasculitis was initially raised, and the patient was admitted to internal medicine, where subsequent treatment with antibiotics and corticosteroids lead to no improvement in his clinical status. Thus, he was admitted to the dermatology clinic two days later. Dermatological examination revealed confluent hemorrhagic crusts, scattered umbilicated vesicles, pustules, and multiple painful punched-out erosions predominantly involving the lower extremities and palmar-plantar surfaces. Physical examination also revealed lymphadenopathy with enlarged, palpable subclavicular, axillar and inguinal lymphatic nodules, that were mobile and painless. Pulmonary auscultation revealed bilateral crackles at the base of the lungs, and pulsoximetry showed decreased blood oxygen levels (90% SaO2). Initial laboratory tests revealed elevated total IgE levels, alongside elevated LDH (lactate dehydrogenase) and CRP (C-reactive protein) levels. Blood counts revealed leukocytosis with neutrophilia. Bacteriological examination of vesicle liquid showed the absence of any pathogen. HIV (human immunodeficiency virus) and syphilis were also excluded. Histological examination revealed epidermal ulceration and keratinocyte necrosis associated with neutrophilic microabscesses, alongside dermal focal vasculitis characterized by thickened vessel walls, leukocytic infiltrates and perivascular hemorrhage. Further lab tests revealed positive serology for both IgM and IgG antibodies specific to HSV-1.

A diagnosis of eczema herpeticum was made. Differential diagnosis included impetigo, primary varicella, disseminated herpes zoster and disseminated herpes simplex. Treatment included 1.5 grams of intravenous Acyclovir, divided into three daily doses for five days, followed by 2 grams of oral Acyclovir per day for an additional nine days, split into five daily doses. Intravenous corticosteroids and antibiotics were also administered, along with topical emollients.

The patient showed great improvement, with complete lesion resolution and remission of systemic symptoms.

Conclusion

Eczema herpeticum is a rare clinical entity usually associated with immunodeficiency or atopic dermatitis and has

a significant recurrence and complication rate. This case highlights an atypical presentation of eczema herpeticum in a previously healthy adult without identifiable risk factors. Early recognition and prompt antiviral treatment are essential in order to reduce morbidity and prevent potentially severe complications.

EADV CONGRESS
VIENNA
30 SEP - 3 OCT 2026

Abstract N°: 266

Chalklike White Plaque on the Scrotum

Hui Sun*[1], Wei Shen[1], Qiying Zhang[2], Shun-Li Tang[1], Yuan Wu[1], Hua-Jie Zhong[1]

[1] Huzhou Central Hospital, Huzhou, China
[2] Jinhua Municipal Central Hospital, Jinhua, China

Introduction

Tinea of the scrotum is uncommon and can present with atypical features when caused by geophilic dermatophytes such as Microsporum gypseum. This case highlights a striking pseudomembranous, chalklike plaque resulting from rapid fungal proliferation, which clinically mimicked other dermatoses but was readily diagnosed by microscopy and culture. Such presentations underscore the importance of considering dermatophytosis in acute genital lesions, even in immunocompetent adolescents.

Case Presentation

A 14-year-old boy presented with a 1-day history of a pruritic white plaque on the scrotum after swimming in a public pool. Physical examination showed a well-circumscribed, 5-cm circular plaque with peripheral miliary papules (Panel A). The lesion was covered by a thick, white, pseudomembranous material that was partially removable by washing but reaccumulated rapidly. Tests for HIV and syphilis were negative. Fluorescence microscopy of skin scrapings revealed a dense network of branching fungal hyphae (Panel B), and fungal culture grew Microsporum gypseum. M. gypseum is a geophilic dermatophyte that typically causes inflammatory tinea corporis. In this case, the rapid proliferation and surface accumulation of fungal elements created a striking, chalklike appearance, echoing the species designation (gypseum, meaning "gypsum-like").

Conclusion

After two weeks of topical antifungal therapy, the lesion resolved completely. This case illustrates an unusual pseudomembranous variant of tinea cruris corporis caused by M. gypseum, emphasizing the value of prompt microscopic examination and culture in atypical genital dermatoses.

EA DV CONGRESS
VIENNA
30 SEP - 3 OCT 2026

Abstract N°: 275

Tricyclazole alleviates Fonsecaea pedrosoi-induced immune suppression of neutrophils by inhibiting DHN-melanin biosynthesis

Chunjiao Zheng*[1], Qian Yu[1]

[1] Shanghai Skin Disease Hospital, Shanghai, China

Introduction
Chromoblastomycosis (CBM) is a chronic cutaneous infection caused by dematiaceous fungi, with Fonsecaea pedrosoi being the most common etiological agent. Therapeutic challenges include difficulty in pathogen clearance and high recurrence rates. DHN-melanin, a key virulence factor, enables fungal immune evasion by suppressing neutrophil function. Tricyclazole (TCZ), a melanin biosynthesis inhibitor used in agriculture, may offer a novel therapeutic approach by targeting both fungal virulence and host immune regulation.

Materials and Methods
In vitro assays assessed TCZ effects on F. pedrosoi melanin content, antioxidant enzyme activities (SOD, CAT), and human neutrophil functions including ROS production and NET formation. A murine footpad infection model evaluated TCZ therapeutic efficacy through histopathology, fungal clearance, and neutrophil activation markers.

Results
TCZ dose-dependently inhibited DHN-melanin synthesis and disrupted fungal antioxidant enzyme balance, reducing fungal resistance to oxidative stress. In co-culture models, TCZ significantly enhanced neutrophil ROS production and NETosis without affecting phagocytosis. In vivo, TCZ treatment alleviated footpad inflammation, reduced neutrophil hyperactivation markers (MPO, citrullinated histone H3), and achieved complete fungal eradication.

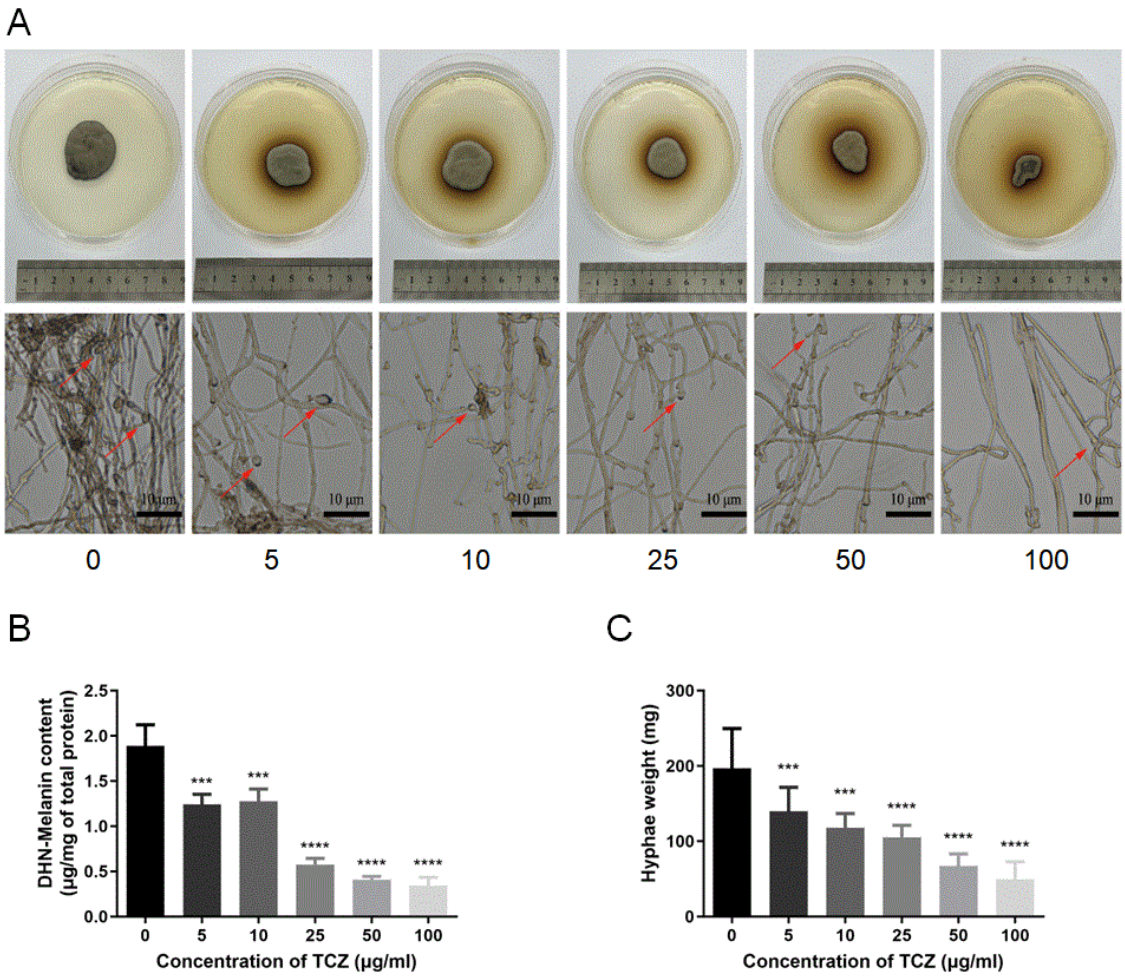

FIGURE 1 (A) Gross morphology of F. pedrosoi under different concentrations of TCZ; (B) DHN-melanin concentration in F. pedrosoi under different concentrations of TCZ (n=3); (C) Mycelial dry weight of F. pedrosoi under different concentrations of TCZ (n=3). Scale bar, 10mm. TCZ, tricyclazole; F. pedrosoi, Fonsecaea pedrosoi. ***p < 0.001, **** p < 0.0001.

Conclusions

This study reveals a novel dual mechanism by which TCZ combats F. pedrosoi infection: inhibiting melanin synthesis to weaken fungal defenses while restoring neutrophil oxidative killing functions. These findings support TCZ as a promising immunomodulatory adjuvant therapy for chromoblastomycosis, potentially addressing the challenges of refractory infection and high recurrence rates.

EA DV CONGRESS
VIENNA
30 SEP - 3 OCT 2026

Abstract N°: 279

Vellus Hair Involvement in Recurrent and Recalcitrant Tinea Corporis Compared with Newly Diagnosed Cases: A Cross-Sectional Study

Prashansa Jaiswal*[1], Youngdenla Lepcha[1]

[1] All India Institute of Medical Science Hospital, Bhopal, India

Introduction
Dermatophytosis is a superficial fungal infection of keratinized tissues including skin, hair and nails. India has seen a rise in chronic, recurrent and treatment-refractory cases. One proposed mechanism for persistence is invasion of vellus hair follicles, which may act as reservoirs. Due to their fine and often inapparent nature, vellus hair involvement is frequently overlooked, contributing to diagnostic and therapeutic challenges. Dermoscopy, microscopy and histopathology can aid in detecting follicular invasion. However, data on vellus hair involvement in recurrent and recalcitrant dermatophytosis remain limited, particularly from Central India.
Aim:To evaluate vellus hair involvement in recurrent and recalcitrant tinea corporis compared with newly diagnosed cases using clinical, dermoscopic, microbiological and histopathological assessment.

Materials and Methods
This single-centre cross-sectional study was conducted over 18 months in a tertiary care dermatology outpatient department in Central India. Patients aged >12 years were categorized into newly diagnosed, recurrent and recalcitrant tinea corporis involving vellus hair-bearing areas. Scalp, groin, beard, palms and nail involvement were excluded. Clinical and dermoscopic evaluation was performed. Skin scrapings with vellus hair were examined by potassium hydroxide (KOH) microscopy and cultured on Sabouraud dextrose agar and dermatophyte test medium. A subset underwent 4-mm punch biopsy with hematoxylin–eosin (H&E), periodic acid–Schiff (PAS) and Gomori methenamine silver (GMS) staining. Demographic, microbiological and histopathological parameters were analyzed.

Results
A total of 180 patients were included: newly diagnosed (n=53), recurrent (n=53) and recalcitrant (n=74). Males constituted 66.1%, with peak incidence in 21–40 years. Recalcitrant cases were most common (41.4%). Diabetes mellitus was present in 12.4% and 19.4% were on systemic immunosuppressants. Mean disease duration was 11.4 months. Topical therapy was used by 68.3%, most commonly antifungal–steroid combinations. Family history was present in 32.8% and 25% reported pet contact.KOH positivity was 63.8% (p=0.001), while culture positivity was 47.2%. Trichophyton tonsurans was the predominant isolate (54.1%), followed by T. mentagrophytes (28.2%) and T. rubrum (5.8%). PAS and GMS showed significantly higher detection rates than H&E (p<0.001). Most cases showed mild to moderate fungal load.Hair follicles were identified in 129 biopsies, with fungal elements detected in 53 cases, most commonly in recurrent disease. Follicular positivity was significantly associated with PAS (88.7%, p=0.03) and GMS (100%, p=0.01), but not KOH (Table 1). Among follicular-positive patients, 51% reported prior use of topical steroid combinations.Dermoscopy showed red globules and dotted vessels in early lesions, while chronic lesions demonstrated dark globules. Recalcitrant cases showed perifollicular scaling, hypopigmented hair, telangiectasia and micropustules.

	Hair follicle FE		P value
GMS stain	**Negative (n=76)**	**Positive (n=53)**	
Negative	9(11.8%)	0	**0.01**
Positive	67(88.2%)	53(100%)	

Table 1: Association Of Vellus Hair Involvement With GMS Staining Study Subjects (N=129)

Conclusions

Vellus hair follicular involvement may act as a reservoir contributing to chronicity, recurrence and treatment resistance in dermatophytosis. It is associated with prior topical steroid use. Dermoscopy and histopathology are valuable adjuncts for detecting follicular involvement. Identification of fungal species and modifiable risk factors such as steroid misuse, animal contact and occlusion may improve management and reduce recurrence.

EADV CONGRESS
VIENNA
30 SEP - 3 OCT 2026

Abstract N°: 297

Neglected Yet Persistent: Clinical Insights into Mycetoma through a case series

Diksha Garg*[1], Anuj Bhatnagar[1], Choudhary Sampoorna Raj[1]

[1] Armed Forces Medical College, Pune, India

Introduction

Mycetoma is a chronic, granulomatous infection of the skin and subcutaneous tissues, primarily affecting the foot and caused by true fungi (eumycetoma) or filamentous bacteria (actinomycetoma). It presents with a classical triad of swelling, sinus tracts, and discharge containing grains. Diagnosis is often delayed due to its indolent course, and management remains challenging due to varied etiological agents and limited therapeutic response.

Case Presentation

Case 1: 48-year-old male with history of swelling and discharging sinuses on left foot releasing black coloured grains for last 10 years. With history of trauma in fields prior to onset of lesions. With localised swelling over bilateral malleoli and sole with few discharging sinuses. KOH mount and culture of grains confirmed Madurella mycetomatis. He was treated with Itraconazole 200 mg twice daily, with clinical improvement over 12 months.
Case 2: 34-year-old male, with history of swelling in left foot for 4 yrs associated with multiple pale coloured grains discharging sinuses. Gram stain and Modified ZN stain showed non- acid fast, gram positive filamentous bacteria suggestive of Actinomycetoma. Patient was treated with Welsch regimen for 6 months showed satisfying response.
Case 3: 51-year-old male, with complaints of swelling and discharging sinuses over right foot for 5 yrs. With history of RTA prior to onset of lesion. On examination - involvement of bilateral malleoli in the form of hard swelling and multiple sinuses releasing pale coloured grains on probing. He was initially managed as a case of osteomyelitis with oral and injectable antibiotics with no response. Microscopy showed non-acid fast, gram positive filamentous bacteria suggestive of Actinomycetoma. He was managed with Modified Welsch regime with clinical improvement in swelling and discharging sinuses.
Case 4: 64-year-old male with history of swelling and discharging sinuses on the right foot, releasing black coloured grains for last 5 years. On examination - Localised swelling over 5th metatarsal with few discharging sinuses. KOH mount and culture of grains confirmed Madurella mycetomatis. He was treated with Itraconazole 200 mg twice daily, with clinical improvement over 12 months.
Case 5: 50-year-old male with a history of swelling and discharging sinuses on left foot releasing pale coloured grains for last 3 years. With history of trauma while walking barefoot in fields prior to onset of lesions. On examination - Localised swelling over bilateral malleoli and sole with few discharging sinuses. KOH mount and culture of grains confirmed Madurella mycetomatis. He was treated with Itraconazole 200 mg twice daily, with clinical improvement over 6 months.
Case 6: 48-year-old female, with a history of swelling in right forefoot for 7 yrs associated with multiple discharging sinuses . On examination, multiple sinuses on right forefoot discharging pale coloured grains. Gram stain and Modified ZN stain showed non- acid fast, gram positive filamentous bacteria suggestive of Actinomycetoma. She was managed with Modified Welsch regime with significant improvement.

Conclusion

Differentiating eumycetoma from actinomycetoma is essential, as the two differ in their etiology, response to treatment, and prognosis. Actinomycetoma, caused by filamentous bacteria such as Nocardia and Streptomyces, tends to respond well to antibacterial regimens, whereas eumycetoma, caused by fungi such as Madurella and

Fusarium, usually requires prolonged antifungal therapy, often with surgical excision for optimal results. Microscopy, culture, histopathology, and increasingly used molecular diagnostic methods (PCR, MALDI-TOF mass spectrometry and DNA sequencing) are employed for species identification, which can directly impact therapeutic strategy. This series highlights the diverse clinical presentations, microbial etiologies in mycetoma, emphasizing the need for early diagnosis, multidisciplinary care, and improved access to diagnostic tools in endemic settings.

EA DV CONGRESS
VIENNA
30 SEP - 3 OCT 2026

Abstract N°: 303

An Analysis of Chemotherapeutic & Local Treatment Avenues for Cutaneous and Mucocutaneous Leishmaniasis: A Systematic Review & Meta-Analysis

Joy Xu*[1], Sophia Salazar[2], Aashita Doshi[3], Tasniah Jahan[4], Kayla Wang[5], Daphne Simo[6], Salah Abboushi[7], Mrunal Munshi[8], Angela Hong[7], Hassan Tariq[9], Sanskriti Thapak[10], Aaron Yim[7]

[1] David Geffen School of Medicine at UCLA, Los Angeles, United States
[2] University of Toronto, Toronto, Canada
[3] University of Texas at Dallas, Richardson, United States
[4] Hunter College, New York, United States
[5] Stuyvesant High School, New York, United States
[6] Meharry Medical College, Nashville, United States
[7] McMaster University, Hamilton, Canada
[8] University of North Carolina at Chapel Hill, Chapel Hill, United States
[9] UCLA, Los Angeles, United States
[10] Levine Middle College High School, Matthews, United States

Introduction

Cutaneous and mucocutaneous leishmaniasis are protozoan parasitic diseases that cause skin and mucosal lesions. Despite pediatric cases accounting for 50% of the global disease burden, less than 10% of leishmaniasis clinical trials focus on pediatric patients. This significant underrepresentation in treatment development underscores the need to standardize pediatric treatment protocols. Amphotericin B, while achieving a high efficacy rate of 74%, is associated with severe adverse effects, particularly organ toxicities.

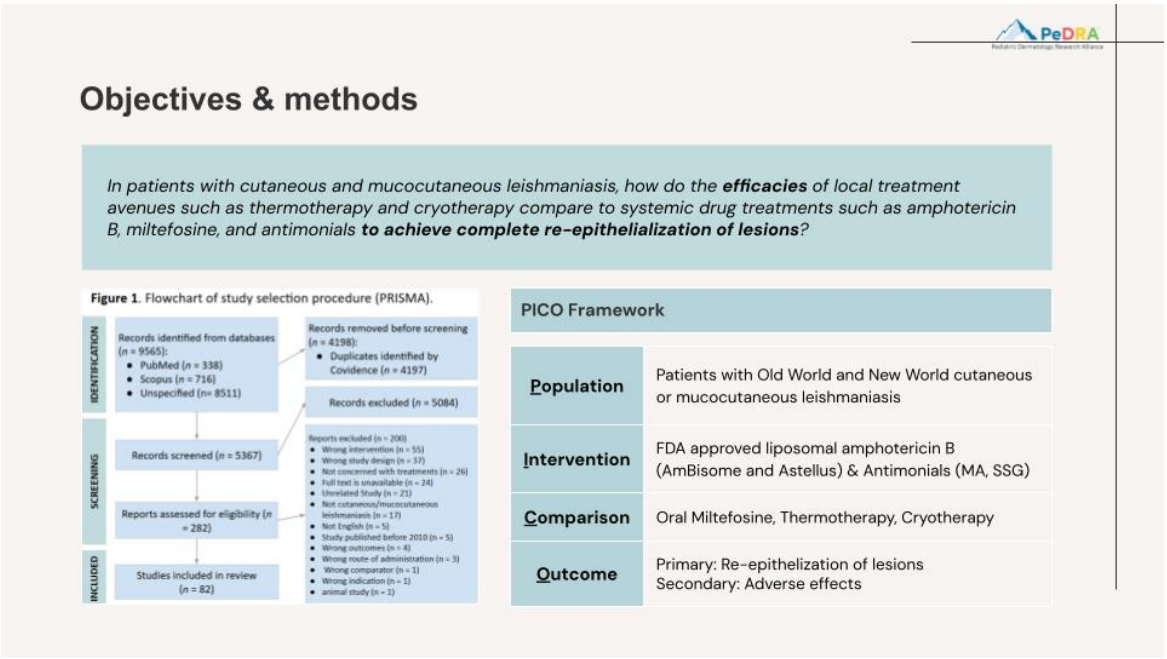

Materials and Methods

To counter these systemic toxicities, the WHO and the PAHO endorse localized treatments like heat therapy and cryotherapy for pediatric patients. This systematic review and meta-analysis compare the efficacy of amphotericin B with thermotherapy and cryotherapy in treating pediatric cutaneous and mucocutaneous leishmaniasis. The primary outcome assessed is the complete re-epithelialization of lesions, categorized into complete response, partial response, and failure. Secondary outcome measuring adverse effects. A comprehensive search was conducted across PubMed, Medline, Scopus, LILACS, and Cochrane Library for studies from 2010 to 2024. Screening, extraction, and quality appraisal using GRADE were performed by blinded reviewers with a third independent reconciler. Both peer-reviewed and gray literature in English were included, covering studies from the Old and New Worlds to minimize publication bias.

Interventions

Intervention	Pediatric dose/administration	Species use
Liposomal Amphotericin B	IV in divided 10–15 mg/kg total infusions	*L. donovani* & *L. infantum*
Miltefosine	PO, weight-based dosing (50mg for 15–29 kg, 100mg for 30–45 kg)	*L. braziliensis*
Antimonials (Sodium stibogluconate, Meglumine antimoniate)	IV or IM 20 mg/kg/day of Sb^{5+} for 20–30 days	*L. tropica*, *L. major*, *L. mexicana*, & *L. braziliensis*
Thermotherapy	Local lesion radiofrequency/heat device to ~50 °C for 30–60 seconds, usually 1–3 sessions	*L. tropica*, *L. major*, and *L. mexicana*
Cryotherapy	2 cycles of local liquid nitrogen for 10–30 seconds per lesion	L. *tropica*, *L, infantum*, and *L. major*

Results

The findings of this review indicate that thermotherapy and amphotericin achieve roughly comparable cure rates with around 80% across cohorts. Cryotherapy performed lower in mucocutaneous leishmaniasis with a cure rate of 60%, demonstrating its limitations as a monotherapy.

Results: Cost effectiveness & efficacy

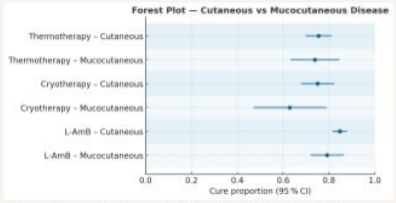

Figure 1. Comparing cure rates from thermotherapy, cryotherapy and liposomal amphotericin B. CL shows higher cure proportion across modalities than ML.

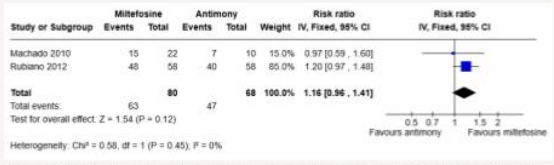

Figure 3a. Miltefosine versus antimonials cure rates in CL pediatric patients (n=2). RR 1.16 (95% CI 0.96–1.41); no significant difference, I^2=0%

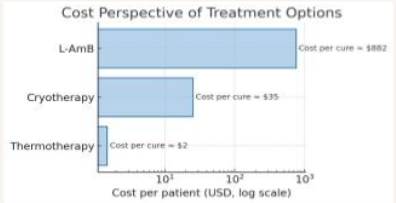

Figure 2. Comparing cost per cure (USD, Log) of treatment between liposomal amphotericin B, cryotherapy and thermotherapy

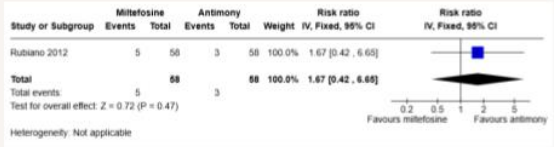

Figure 3b. Miltefosine versus antimonials number of AEs in CL pediatric patients (n=2). RR 1.67 (95% CI 0.42–6.65); trend favors miltefosine, low precision

Conclusions

Overall, this study aims to enhance clinical practice and guide future treatment guidelines for managing this disease in pediatric populations, especially as cases emerge in North America.

Conclusions & future directions

Local therapies:

- Thermotherapy and Amphotericin B shows ~80% cure rates in CL/ML cases
- Cryotherapy shows ~60% cure rates in ML cases

Systemic treatment:

- Miltefosine shows 16% higher cure rates but was not statistically significant to antimonials
- Adverse events for miltefosine and antimonials were not statistically significant

Cost effectiveness:
Local therapies are 90% cheaper than intravenous L-Amb

Future directions:
A network meta-analysis on the adverse events and side effects of local therapeutics versus chemotherapeutics

Call to Action:
Investing in research today will transform the care of children tomorrow: bridging gaps, improving cure rates, and reducing treatment burdens for vulnerable communities.

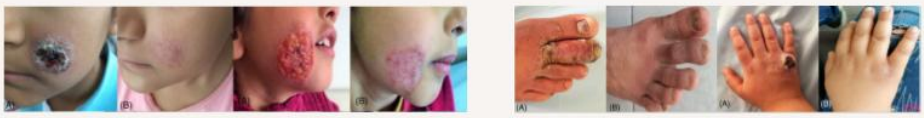

Figure 4. 31% (n=16) pediatric patients with complete clinical recovery in a case series (n = 54) after IV liposomal amphotericin B in 6 doses of 3mg/kg/day for 5 consecutive days and slow infusion over 60 mins on the 10th day.

EADV CONGRESS
VIENNA
30 SEP - 3 OCT 2026

Abstract N°: 307

Acute Unmasking of Disseminated Mycobacterium haemophilum Infection Presenting with Facial Lesions and Pulmonary Involvement in Advanced HIV: A Case Report

Thanyathorn Nuchanatanon*[1], Tanat Yongpisarn[2], Jackrapong Bruminhent[3], Teerapong Rattananukrom[2]

[1] Department of Community Medicine, Charoenkrung Pracharak Hospital, Medical Service Department, Bangkok Metropolitan Administration, Bangkok, Thailand

[2] Division of Dermatology, Department of Medicine, Faculty of Medicine Ramathibodi Hospital, Mahidol University, Bangkok, Thailand

[3] Division of Infectious Diseases, Department of Medicine, Faculty of Medicine Ramathibodi Hospital, Mahidol University, Bangkok, Thailand

Introduction
Mycobacterium haemophilum is a slow-growing nontuberculous mycobacterium (NTM) causing cutaneous and systemic infections predominantly in immunocompromised hosts. The infection is rare, and diagnosis is often delayed due to its fastidious growth requirements and non-specific clinical manifestations.

Case Presentation
A 49-year-old man with newly diagnosed HIV infection (CD4 8 cells/μL) presented with non-blanchable erythematous to purplish scaly plaques on the face, progressive over four weeks. He had recently been treated for presumed Pneumocystis pneumonia and syphilis. Chest CT showed multiple cavitary and ground-glass nodules in both lungs. Skin biopsy revealed negative stains for bacteria, fungi, and mycobacteria; however, mycobacterial culture later grew M. haemophilum. After initiation of antiretroviral therapy (TAF/FTC/DTG), his facial lesions worsened, consistent with unmasking immune reconstitution inflammatory syndrome (IRIS). The regimen was modified to ABC/3TC/DTG, and combination therapy with clarithromycin, rifampicin, ciprofloxacin, and tapering corticosteroids was started, leading to gradual clinical improvement.

Discussion:
This case illustrates disseminated M. haemophilum infection with both cutaneous and pulmonary involvement, unmasked by ART-associated IRIS. Due to its rarity and special culture requirements, M. haemophilum may be underdiagnosed in HIV-infected patients with atypical skin lesions. Early recognition and combination antimicrobial therapy are essential for favorable outcomes.

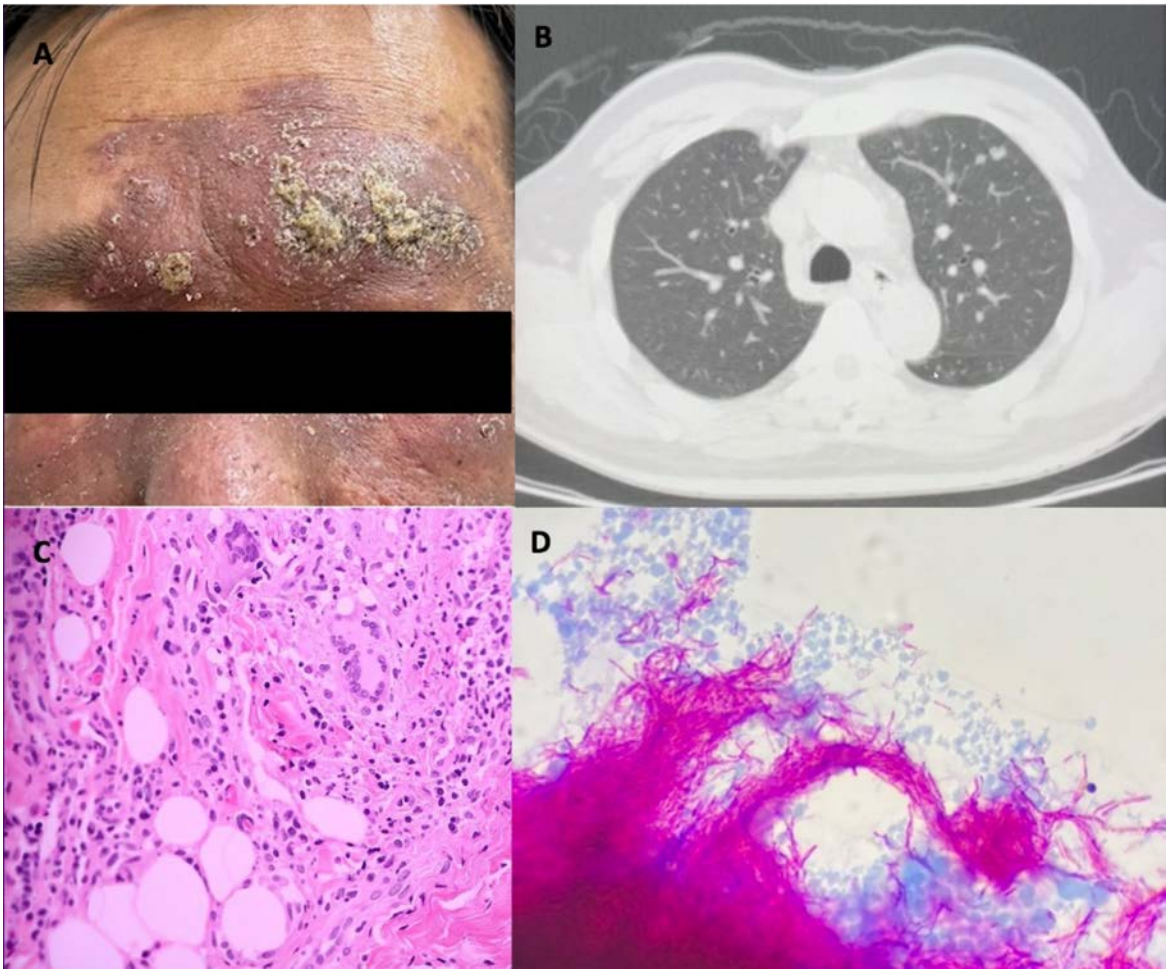

Figure 1. (A) Ill-defined, non-blanchable erythematous-to-purplish scaly plaques on the face. (B) Chest CT revealing multiple cavitary lesions and ground-glass nodules in both lungs. (C) Tuberculoid granuloma identified in an incisional biopsy specimen from the left cheek. (D) Acid-fast staining demonstrating the causative organism.

Conclusion

Clinicians should consider M. haemophilum in the differential diagnosis of chronic skin and pulmonary lesions in advanced HIV, particularly when IRIS is suspected after ART initiation.

EA DV CONGRESS
VIENNA
30 SEP - 3 OCT 2026

Abstract N°: 320

Loxosceles envenomation: Cutaneous findings as a window to systemic toxicity

Carla Villanueva Ochoa*[1], Rosa Maria Guevara Castillo[1], Erika Stephania Alvarado Arana[1], Marissa de Jesus Quintal[1]

[1] Centro Médico la Raza, instituto mexicano del seguro social, Ciudad de México, Mexico

Introduction
Loxoscelism is the medical condition caused by envenomation by one of several species of the Loxosceles genus of spider; the brown recluse spider. Envenomations most commonly occur in the warm months of late spring to early fall. The bite is initially painless and then develops into a painful single dark purple/slowly necrotizing lesion. While some brown recluse spider envenomations result in only the necrotic lesion, some patients can develop a rapid, massive hemolytic anemia leading to profound cardiovascular collapse and death without aggressive medical therapies. Close monitoring for the development of rapid hemolysis is needed and immediate medical treatment with rapid large-volume blood transfusions are required for a patient suspected of the fulminant hemolysis pathognomonic of systemic loxoscelism. Patients suspected of systemic loxoscelism from a brown recluse spider bite should be immediately referred to a facility capable of frequent monitoring/transfusions until stable and reported to the state Poison Control Center for urgent discussion with a medical toxicologist.

Materials and Methods
We report the case of a 55 year old male patient with no significant past medical history who presented to a tertiary care hospital with a 8 day history of a painful necrotic skin lesion on the right lower extremity associated with edema, erythema of the whole extremity and also malaise and fever. Symptoms started after a recent travel history to a coastal area in Acapulco, México. Three days after initial presentation, the patient developed progression of cutaneous findings with formation of bullae and blisters, subsequently sudden neurological deterioration occurred with seizures requiring advanced airway management, vasopressor support and intensive care unit admission. Due to suspicion of systemic loxocelism, four vials of anti-loxosceles fab antivenom were administered. Clinical course, laboratory parameters, treatment intervetions and histopathological evaluation were documented.

Results
Histopathological examination revealed epidermal necrosis associated with dermal vascular damage and inflammatory infiltrate, findings consistent with necrotic arachnidism. Laboratory evaluation showed evidence of systemic involvement including hemolysis, acute kidney injury, rhabdomyolysis and elevated inflammatory markers. Despite administration of four vials of anti-loxosceles fab antivenom and intensive support management, the patient showed no clinical improvement. The clinical course lead to progressive multiorgan failure including renal, hematologic, cardiovascular and gastrointestinal failure. The patient developed refractory shock requiring dual vasopressor resulting in a fatal outcome.

Conclusions
Systemic loxocelism is a rare but potentially fatal condition that represents a diagnostic challenge due to the initially nonspecific cutaneous manifestations, which may delay timely recognition and treatment. Early skin findings may mimic other inflammatory or infectious dermatoses, making clinical suspicion essential, particularly in patients with relevant epidemiological exposure. Although anti-loxosceles Fab antivenom remains an important therapeutic option, its effectiveness appears to depend largely on early administration. This case highlights the

critical importance of early diagnosis, recognition of subtle dermatological findings and prompt antivenom therapy, ideally during the initial stages of envenomation, to potentially improve outcomes and reduce mortality. To our knowledge, few reports describe systemic loxocelism with multiorganic involvement including rhabdomyolysis and subtle dermatologic findings, emphasizing the importance of clinical suspicion

EADV CONGRESS
VIENNA
30 SEP - 3 OCT 2026

Abstract N°: 321

Phaeoacremonium subcutaneous fungal infection in a post kidney transplant patient – A case report

Madhumekhala Rupasinghe Jayawardhana*[1], Navami Samaranayaka[2], Mazeera Abdul azees[3], Premini Rajendran[3]

[1] District General Hospital Matara, Matara, Sri Lanka
[2] Colombo North Teaching Hospital Ragama, Colombo, Sri Lanka
[3] National Hospital of Sri Lanka, Colombo, Sri Lanka

Introduction

Phaeoaremonium parasiticum is a rare heterogenous group of fungi that have wide distribution in environment.It can cause phaeohyphomycosis commonly in post kidney transplant patients with immunosuppression.It can cause subcutaneous abscesses,cysts eumycetomas, osteomyelitis, arthritis ,myositis and disseminated disease like fungemia and endocarditis.

Case Presentation

A 63 years old post kidney transplant patient on multiple immunosuppressive medications for 8 years presented with multiple asymptomatic nodules and ulcers over left leg, feet and dorsum of hands for 3 months duration without preceding history of trauma.On examination there were multiple ulcerated exophytic nodules over left leg ,feet and dorsum of hands without regional lymphadenopathy and hepatosplenomegaly.His histopathology revealed dense neutrophilic infiltrate in dermis with negative Grocott's Methenamine silver stain.His skin tissue for direct microscopy revealed sclerotic cells and fungal filaments and fungal culture was positive for Phaeoacremonium species which is sensitive for Itraconazole and Voriconazole.He was started on oral Itraconazole 100mg twice daily in combination with surgical debridement of larger nodules over left leg ,dorsum of hands with good clinical response.

Conclusion

Multiple asymptomatic nodular ulcerated growths in a post kidney transplant patient on immunosuppressive therapy together with neutrophil predominant inflammation in dermis raise the suspicion of deep fungal infection of skin which needs to be confirmed by further fungal studies and it need to be treated with systemic antifungal therapy to prevent dissemination.

EADV CONGRESS
VIENNA
30 SEP - 3 OCT 2026

Abstract N°: 421

Beyond the Surface: Erythroderma in the setting of Hansen's Disease

Lana Matti*[1], Lisa Townsend[1], Steven Capen[1], Ryan Apgar[1]

[1] Tripler Army Medical Center, Honolulu, United States

Introduction

Erythroderma, also known as exfoliative dermatitis, is a clinical sign that is potentially life-threatening condition characterized by diffuse erythema and scaling affecting ≥90 percent of skin surface area and can be secondary to a wide range of cutaneous and systemic diseases. Hansen's disease, also known as Leprosy, is a bacterial infection caused by Mycobacterium Leprae and Mycobacterium Lepromatosis, primarily affecting the skin and peripheral nerves. In this report, we present an unusual case of Hansen's Disease exhibiting erythroderma. We explore the underlying pathophysiological mechanism presenting as erythroderma and emphasize the critical importance of early diagnosis and treatment in patients presenting from endemic regions.

Case Presentation

We present a case of a 49-year-old male presenting from Micronesia to the emergency department with full body diffuse rash spreading over the course of several months. Physical exam revealed significant for diffuse indurated blanching erythema with overlying scale affecting the face, back, bilateral upper and lower extremities including the palms and soles, trunk, with conspicuous sparing of the abdominal creases, a phenomenon known as deck-chair sign and generalized swelling. Initially, the diagnosis initially favored to be psoriasis with differentials including pityriasis rubra pilaris. The patient was started on a prednisone taper to mitigate the inflammatory reaction which controlled the immune response. Histopathologic evaluation of skin shave biopsy showed noncaseating granulomatous dermatitis with acid fast organisms identified by Fite special stain, AFB culture demonstrated 4-36 acid-fast bacilli per 100 fields at 400X (1+ per bacteriologic index). The case was sent to the Joint Pathology Center for expert consultation, and a diagnosis of borderline lepromatous leprosy was rendered. Infectious disease was consulted, and they recommended the patient start on multidrug therapy consisting of rifampin, dapsone, and clofazimine daily for 24 months. Given his symptoms, a type 2 reversal reaction was also diagnosed, and he was started on high dose steroid taper as well.

Conclusion

This case report emphasizes the critical clinical signs and symptoms associated with erythroderma in patients diagnosed with Hansen's Disease, which is not initially considered in the differential diagnosis. The pathophysiological mechanisms underlying erythroderma in Hansen's Disease are multifaceted and these include intense reversal reaction, generalized immune response, cutaneous infiltration and cell-mediated immunity. Given the potential for significant morbidity, we recommend patients presenting from endemic regions with clinical signs of erythroderma to be further investigated for Hansen's Disease.

Abstract N°: 447

PLEVA – like secondary syphilis

Valeri Malev*[1], Lyubomir Durmishev[1], Elena Petrova[1], Valeriya Mateeva[1], Mina Saleva-Stateva[1]

[1] Alexandrovska Hospital, Derma-Act, Sofia, Bulgaria

Introduction

Because of its highly variable clinical manifestations, syphilis is known as “the great imitator”. Unusual variants of secondary syphilis may show striking clinical and histopathological overlap with other dermatoses. We present a case illustrating the resemblance between pustular secondary syphilis and pityriasis lichenoides et varioliformis acuta (PLEVA).

Case Presentation

A 36-year-old previously healthy man presented with a 2-month history of a pruritic rash progressively involving trunk, face, extremities, and genitalia. He denied similar complaints in close contacts, high-risk sexual behaviour, or recent drug intake. Examination revealed disseminated erythematous, oval papules with central pustulation and necrosis. On the arms and palms, lesions showed peripheral scaling compatible with Biett collarettes and hyperkeratotic plaques (clavi syphilitici). Flat, violaceous papules and mild phimosis were present on the genitalia. Mucosae, nails, and lymph nodes were normal. Laboratory tests showed elevated CRP (68.8 mg/L), negative serology for viral hepatitis, HIV, CMV and VZV, and a high EBV viral load (21,393 copies/mL). RPR was positive (1:64) and TPHA was strongly positive. Skin biopsy demonstrated spongiosis, a dense lymphocytic infiltrate with numerous plasma cells, perivascular inflammation, and erythrocyte extravasation. Spirochetes were not demonstrated. The overall findings were interpreted as secondary syphilis with a pustular presentation. The patient was treated with ceftriaxone 2 g/day for 7 days, with rapid improvement and fading of the eruption. During therapy, the RPR titre rose to 1:128, consistent with a serological Jarisch–Herxheimer reaction without clinical deterioration. At day 30, only postinflammatory erythematous macules remained, while RPR and TPHA remained reactive. At month 5, RPR had reverted to non-reactive and TPHA titres had declined; the patient was clinically disease-free and no further treatment was required.

Conclusion

Secondary syphilis typically presents with a generalized papulosquamous eruption but may also manifest as macular, papular, annular, palmo-plantar, nodular, pustular, or malignant forms, sometimes mimicking acne vulgaris or varicella. Pustular variants are classically associated with systemic impairment or HIV co-infection. In this case, the acute, necrotic, and exudative papules closely mimicked PLEVA. This impression was reinforced by the elevated EBV load, as viral infections are considered potential PLEVA triggers. Other differential diagnoses included lymphomatoid papulosis, vasculitis, varicella, drug eruption, and primary HIV infection. Histopathological features of pustular syphilis and PLEVA can be highly similar, including spongiosis and a lymphoplasmacytic infiltrate. Serological testing (RPR, TPHA) and the evolution of both the clinical picture and serology under appropriate therapy were decisive for establishing the diagnosis. This case underscores the importance of considering secondary syphilis in PLEVA-like eruptions and of relying on serology to avoid misdiagnosis.

EADV CONGRESS
VIENNA
30 SEP - 3 OCT 2026

Abstract N°: 464

Clinical Characteristics and Microbiological Factors of Patients with Cutaneous Mycobacterium haemophilum Infection

Sirikorn Densrisereekul*[1], Tanat Eittidachachote[1], Kunlawat Thadanipon[1], Teerapong Rattananukrom[1], Siriorn Watcharananan[2], Suthan Srisangkaew[3], Sanchawan Wittayakornrerk[4]

[1] Division of Dermatology, Faculty of Medicine Ramathibodi Hospital Mahidol University, Department of Clinical Epidemiology and Biostatistics, Faculty of Medicine, Ramathibodi Hospital, Mahidol University, Thailand, Bangkok, Thailand

[2] Division of Infectious Diseases, Department of Medicine, Faculty of Medicine Ramathibodi Hospital, Mahidol University, bangkok, Thailand

[3] 4Microbiology Unit, Department of Pathology, Faculty of Medicine Ramathibodi Hospital, Mahidol University, Bangkok, Thailand

[4] Division of Ambulatory Pediatrics and Adolescent Medicine, Department of Pediatrics, Faculty of Medicine Ramathibodi Hospital, Mahidol University, Bangkok, Thailand

Introduction
Mycobacterium haemophilum is emerging nontuberculous mycobacterium that predominantly causes cutaneous infections in immunocompromised individuals. However, its risk factors have not been well established. This study aimed to evaluate the clinical characteristics and microbiological factors associated with cutaneous M. haemophilum infection and to compare the time to diagnosis between different identification methods.

Materials and Methods
A retrospective case–control study was conducted at a tertiary care hospital between 2018 and 2025. We included outpatients who underwent incisional biopsy. Cases were defined as patients with confirmed cutaneous M. haemophilum infection while controls presented with similar cutaneous lesions but were diagnosed with other conditions. Clinical characteristics, underlying diseases, immunosuppressive therapies, and microbiological identification methods were analyzed. Conditional logistic regression was performed to identify associated risk factors.

Results
The study included 29 cases and 116 controls. The mean age of cases was 57.7 years and 65.5% were female. Common presentations included multiple lesion morphologies (55.2%), nodules (48.3%) and plaques (44.8%). Immunosuppressive use was observed in 75% of cases , with corticosteroids (58.6%) and mycophenolate mofetil (37.9%) being the most frequently used agents. Multivariate analysis revealed high-dose corticosteroids combined with steroid sparing agents were associated with the highest risk of infection (OR 106.73; 95% CI 5.98–1904.22; p=0.001). Regarding diagnostic methods, the median time to diagnosis using mycobacterial culture was 76.5 days (IQR 55.0–91.5), compared with 11 days (IQR 10.0–13.0) using molecular techniques.

Conclusions
Cutaneous M. haemophilum infection should be suspected in immunocompromised patients, particularly those receiving high-dose corticosteroids with additional immunosuppressive agents. Molecular diagnostic methods may significantly reduce diagnostic delay compared with conventional culture and facilitate earlier diagnosis.

EADV CONGRESS
VIENNA
30 SEP - 3 OCT 2026

Abstract N°: 492

Pediatric facial sporotrichosis misdiagnosed as bacterial infection: delayed diagnosis and successful treatment with saturated solution of potassium iodide

Thiago Lenoir*[1]

[1] Desenvolver Clínica Médica, Florianópolis, Brazil

Introduction

Sporotrichosis is a subcutaneous mycosis caused by fungi of the genus Sporothrix, increasingly associated with zoonotic transmission, particularly from infected cats. In endemic areas, atypical presentations may lead to misdiagnosis and delayed treatment, especially in the pediatric population.



Active erythematous nodular lesion with ulceration and crusting on the right malar region at presentation.

Case Presentation

A 6-year-old boy presented with a progressive facial lesion of five months' duration. Prior to dermatological evaluation, he had been treated with multiple systemic antibiotics, including cephalexin, amoxicillin–clavulanate, and trimethoprim–sulfamethoxazole, in addition to surgical drainage, without clinical improvement. Physical examination revealed an erythematous nodular lesion with central ulceration and crusting on the right malar region. When specifically questioned about animal contact at home, the family reported a domestic cat with an untreated cutaneous lesion, raising suspicion for zoonotic sporotrichosis. Direct mycological examination revealed compatible findings, and the diagnosis was established based on clinical presentation, epidemiological context, and treatment response. Oral saturated solution of potassium iodide (SSKI) was initiated at a starting dose of two drops three times daily, gradually increased to ten drops three times daily as tolerated. Complete resolution of the lesion was achieved after four months of treatment, which was maintained for an additional four weeks following clinical cure.



Ulcerated cutaneous lesion on the household cat, identified as the likely source of zoonotic transmission.

Conclusion

Sporotrichosis remains a diagnostic challenge, particularly in pediatric patients, due to its ability to mimic bacterial infections, abscesses, or other inflammatory dermatoses. Delayed diagnosis often results in unnecessary antibiotic courses and invasive procedures, as illustrated in this case. Facial involvement in children carries additional concern given the potential for scarring and cosmetic sequelae, further underscoring the importance of early recognition. Zoonotic transmission from infected cats has become a major route of infection in endemic regions, and a thorough epidemiological history is essential in establishing the diagnosis. Although itraconazole is currently considered first-line therapy, SSKI remains an effective, accessible, and well-tolerated alternative, particularly in resource-limited settings. Its use in pediatric patients requires careful dose titration to minimize adverse effects. This case highlights the importance of considering sporotrichosis in chronic nodular or ulcerated facial lesions unresponsive to antibiotics, particularly in children with possible zoonotic exposure. Early recognition prevents unnecessary treatments and ensures prompt, effective therapy with minimal sequelae.

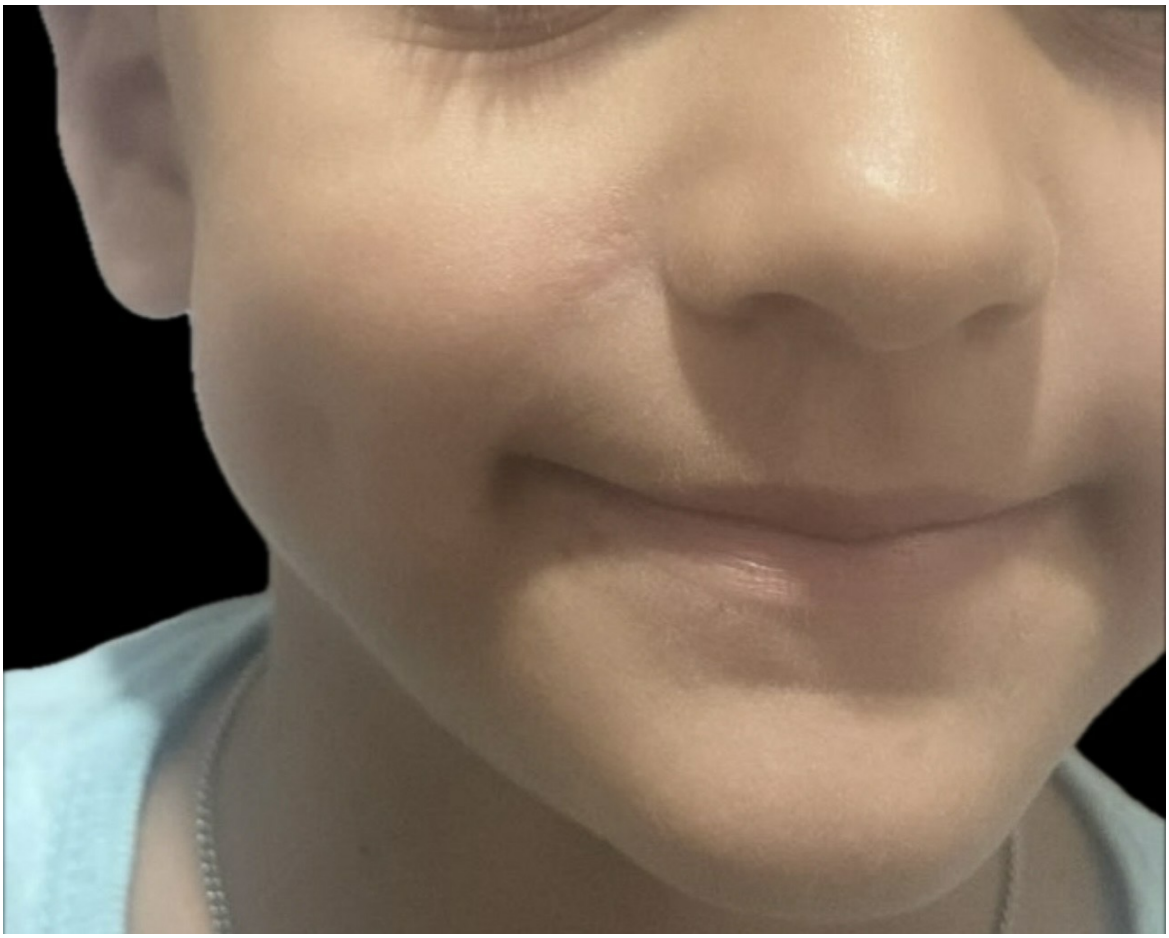

Complete resolution of the lesion after four months of SSKI treatment, with no residual scarring.

EADV CONGRESS
VIENNA
30 SEP - 3 OCT 2026

Abstract N°: 517

Erythema nodosum leprosum presenting as Sweet's syndrome

Fida Anjum*[1]

[1] Yenepoya Medical College, Mangalore, India

Introduction

Sweet's syndrome also known as acute febrile neutrophilic dermatosis, is defined by typical cutaneous lesions and neutrophilic dermal infiltrates. Most reports have described erythema nodosum leprosum (ENL) only as a mimicker of Sweet's syndrome. Through this case, we emphasize that ENL may present not merely as a mimicker of Sweet's syndrome, but as Sweet's syndrome itself, fully satisfying its diagnostic criteria.

Case Presentation

A 41-year-old male with a prior history of multibacillary Hansen's disease presented with fever and painful erythematous nodules of one week's duration. Examination revealed multiple tender plaques and nodules with vesiculation distributed over the face, trunk, and extremities, accompanied by systemic symptoms. Neurological findings included sensory loss and partial clawing of the left hand. Investigations showed leukocytosis with neutrophilia (TLC 15.1×10^3/µL; neutrophils 87%), elevated ESR (96 mm/hr) and CRP (310 mg/L). Histopathology of a nodular lesion revealed dense neutrophilic infiltrate with dermal edema, consistent with ENL. The case fulfilled both major and all four minor diagnostic criteria of Sweet's syndrome: (1) fever >38 °C, (2) leukocytosis, (3) neutrophilic dermal infiltrate without vasculitis, and (4) excellent response to systemic corticosteroids. The patient improved with systemic steroids and thalidomide, with resolution of fever and cutaneous lesions.

Conclusion

This case demonstrates that ENL can present as true Sweet's syndrome rather than only as a clinical mimicker. Recognizing such convergence is important, as it expands the spectrum of Sweet's syndrome associations and emphasizes the neutrophilic basis of ENL.

EADV CONGRESS
VIENNA
30 SEP - 3 OCT 2026

Abstract N°: 520

Erythema Nodosum Leprosum as A Clinical Marker of Multibacillary Leprosy Relapse After Multidrug Therapy

Benedikta Anandita*[1], Nurrachmat Mulianto[1]

[1] Universitas Sebelas Maret, Sukaharjo, Indonesia

Introduction
In the post-elimination era of leprosy, long-term complications and diagnostic uncertainty have emerged as major clinical challenges. One of the most critical dilemmas is differentiating true bacteriological relapse from late-onset Erythema Nodosum Leprosum (ENL) in patients who have completed multidrug therapy (MDT). ENL is classically regarded as an immune-mediated reaction triggered by residual antigens from non-viable bacilli; however, misclassification may result in inappropriate immunosuppressive treatment without addressing ongoing infection, leading to progressive disease activity and irreversible nerve damage.

Materials and Methods
We present a detailed clinicopathological case of a patient with a prior history of multibacillary leprosy who developed severe systemic inflammatory manifestations two years after completing standard MDT. Comprehensive clinical assessment was performed, followed by slit-skin smear examination from representative sites. A skin biopsy from an active erythematous nodule was obtained for histopathological evaluation using hematoxylin–eosin staining to assess tissue architecture and inflammatory patterns, as well as specific mycobacterial staining to determine bacillary burden and viability.

Results
Clinically, the patient presented with recurrent crops of painful erythematous subcutaneous nodules associated with fever, arthralgia, and constitutional symptoms, strongly suggestive of severe ENL. Slit-skin smear examination revealed a markedly elevated bacterial index (BI +5) despite a morphological index of 0%, creating diagnostic ambiguity in the post-treatment setting. Histopathological analysis demonstrated diffuse dermal infiltration by foamy macrophages consistent with lepromatous leprosy, accompanied by neutrophilic lobular panniculitis and vasculitis, confirming a concurrent ENL reaction. Crucially, mycobacterial staining revealed numerous intact, solid-staining acid-fast bacilli within macrophages, providing unequivocal evidence of viable Mycobacterium leprae and active bacteriological relapse.

Conclusions
This case highlights the limitations of relying solely on clinical features or slit-skin smear indices when evaluating inflammatory episodes after MDT completion. ENL in the post-treatment period should not be assumed to represent a delayed immune reaction alone, as it may serve as an early clinical manifestation of relapse driven by renewed bacterial proliferation. Comprehensive bacteriological and histopathological evaluation is essential to establish the correct diagnosis. Recognition of ENL as a potential harbinger of relapse supports the need for a dual therapeutic strategy combining prompt re-initiation of MDT with appropriate anti-inflammatory treatment to prevent disease progression and long-term disability.

EADV CONGRESS
VIENNA
30 SEP - 3 OCT 2026

Abstract N°: 521

Auricular cutaneous lesions as the first clue to fatal disseminated coccidioidomycosis: a diagnostic challenge

Karen Lizeth Hernández Jaime*[1], Giovanna Ríos López[1], Luisa Fernanda Betancourt Galvis[1], Shaúl Ariel Navarro Lara[1], Felipe de Jesús Bustos Rodríguez[1], Aida S. Ramírez González[1], Marisol Ramírez Padilla[1]

[1] Hospital Civil de Guadalajara "Fray Antonio Alcalde", Guadalajara, Mexico

Introduction

Coccidioidomycosis is an endemic fungal infection caused by Coccidioides species, acquired through inhalation of arthroconidia. It is also known as San Joaquin Valley fever and is endemic to the arid regions of the southwestern United States, Mexico, and parts of Central and South America. While most infections are asymptomatic or limited to the lungs, less than 2% of cases develop extrapulmonary dissemination. Cutaneous involvement may mimic infectious, inflammatory, or neoplastic conditions, often leading to diagnostic delays.

Case Presentation

A 52-year-old male with a history of temporary residence in an endemic region presented with progressive, painful lesions on the external ear and scalp. Initial evaluation elsewhere reported chronic granulomatous inflammation interpreted as granuloma annulare, and the patient received multiple topical and systemic treatments including corticosteroids and antibiotics without improvement. On further progression, he developed fever, severe pain, hearing impairment, dyspnea, and neurological symptoms. Physical examination revealed a polymorphic dermatosis involving the head and neck, predominantly affecting the auricular regions, occipital scalp, and posterior neck. Lesions consisted of verrucous plaques with excoriations, honey-colored and hemorrhagic crusts, and areas of necrosis, associated with bilateral otitis externa and purulent discharge. Microbiological and histopathological evaluation, including Grocott staining, revealed fungal spherules consistent with Coccidioides spp. Imaging studies demonstrated pulmonary involvement with a pattern suggestive of fungal infection. The patient’s condition deteriorated with severe respiratory distress requiring intensive care support. A diagnosis of disseminated coccidioidomycosis with cutaneous, pulmonary, and neurological involvement was established. Treatment with liposomal amphotericin B and high-dose fluconazole was initiated; however, the patient had an unfavorable outcome.

Conclusion

This case underscores the skin as a critical diagnostic window in systemic mycoses. Atypical cutaneous presentations of coccidioidomycosis may closely resemble benign granulomatous disorders, delaying diagnosis and enabling rapid systemic dissemination. Early recognition, repeat biopsy when clinicopathological correlation is incongruent, and consideration of epidemiological exposure are essential to avoid fatal outcomes. Dermatologists must maintain a high index of suspicion when evaluating chronic, atypical, or treatment-refractory dermatoses, as early recognition may be life-saving.

EADV CONGRESS
VIENNA
30 SEP - 3 OCT 2026

Abstract N°: 547

European expert consensus recommendations on the management of Trichophyton indotineae infection

David J Chandler*[1, 2, 3], Michael Arabatzis[1, 4], Carmen Rodríguez-Cerdeira[1, 5, 6, 7], Alexey Sergeev[1, 8, 9], Bianca Maria Piraccini[1, 10], Valeska Padovese[1, 11], Georgios Gaitanis[1, 12], Markus V Starink[1, 13, 14], Shyam B Verma[1, 15], Emmanuella Guenova[1, 16, 17], Tiina Toomson[1, 18, 19], Arnaud Jabet[1, 20, 21], Roderick J Hay[1, 22], Ditte M L Saunte[1, 23, 24]

[1] European Academy of Dermatology and Venerology TASK Force on Mycology, Lugano, Switzerland
[2] Department of Global Health & Infection, Brighton and Sussex Medical School, Brighton, United Kingdom
[3] Dermatology Department, University Hospitals Sussex NHS Foundation Trust, Brighton, United Kingdom
[4] First Department of Dermatology, School of Medicine, Aristotle University of Thessaloniki, Thessaloniki, Greece
[5] Fundación Vithas, Grupo Hospitalario Vithas, Madrid, Spain
[6] Department of Dermatology, Grupo Hospitalario (CMQ Concheiro), Vigo, Spain
[7] Department of Health Sciences, University of Vigo, Vigo, Spain
[8] Novosibirsk State University, Novosibirsk, Russian Federation
[9] All-Russian National Academy of Mycology, Moscow, Russian Federation
[10] Private Dermatology Practice, Bologna, Italy
[11] Genitourinary Clinic, Department of Dermatology and Venereology, Mater Dei Hospital, Msida, Malta
[12] Department of Skin and Venereal Diseases, Faculty of Medicine, University of Ioannina, Ioannina, Greece
[13] Amsterdam University Medical Centre, Amsterdam, Netherlands
[14] Fundashon Mariadal, Bonaire, Bonaire, Sint Eustatius and Saba
[15] Nirvan Skin Clinic, Vadodara, India
[16] Department of Immunodermatology, Kepler University Hospital, Johannes Kepler University, Linz, Austria
[17] Clinical Research Institute for Inflammatory Medicine, Johannes Kepler University, Linz, Austria
[18] Parnu Central Hospital, Parnu, Estonia
[19] Herthe Derm Skin Clinic, Parnu, Estonia
[20] Laboratoire de Parasitologie-Mycologie, Hôpital de La Pitié-Salpêtrière, APHP, Paris, France
[21] IPLESP, Institut Pierre Louis d'Epidémiologie et de Santé Publique, INSERM, Sorbonne Université, Paris, France
[22] King's College London, London, United Kingdom
[23] PHOENIX Research Center, Dept. of Dermatology & Allergy, Copenhagen University Hospitals, Herlev and Gentofte, Copenhagen, Denmark
[24] Department of Clinical Medicine, Faculty of Health & Medical Sciences, University of Copenhagen, Copenhagen, Denmark

Introduction

Chronic, treatment-resistant dermatophytosis caused by Trichophyton indotineae is an emerging problem in Europe. Increasing numbers of cases are being reported throughout Europe, most of which are travel-associated although autochthonous transmission has been documented. Consensus guidance on the management of T. indotineae infection has been developed by groups in India and China, however European recommendations are lacking.

Materials and Methods

A modified Delphi method was used to develop consensus recommendations on the management of T. indotineae infection in Europe. Study participants were members of the European Academy of Dermatology and Venereology (EADV) mycology task force, all dermatologists and/or mycologists with expertise in the management of dermatophytosis. Feedback was collected anonymously over three survey rounds.

Results

Recommendations were grouped into four sections to address the key issues faced by the clinician in managing a patient with T. indotineae infection: clinical presentation, diagnosis, treatment, and wider considerations including the treatment of contacts and fomites. Consensus was achieved for all recommendations. T. indotineae cannot be reliably distinguished from T. interdigitale and T. mentagrophytes based on routine culture; molecular methods are required for definitive identification. Terbinafine resistance is common in T. indotineae, therefore the recommended first-line treatment is oral itraconazole for a minimum duration of 8 weeks. Screening of family members and close contacts is recommended if there is clinical suspicion of infection. Survey of the study participants highlighted significant variation in diagnostic and treatment capacity at regional level. Only 36% of participants stated they were able to identify T. indotineae and perform antifungal susceptibility testing at their institution or place of work, however 91% had access to these tests within their country. The presence of generic forms of itraconazole, often of unknown efficacy, is a concern in some countries.

Conclusions

These recommendations will provide guidance for dermatologists in Europe in the management of suspected and confirmed cases of T. indotineae infection. Treatment experience to date is largely limited to terbinafine and itraconazole, and antifungal susceptibility testing is not routinely performed. Further work is needed to encourage standardised data collection for cases in Europe, and to correlate clinical outcomes and microbiological data. These consensus recommendations will facilitate the collection of such data.

EADV CONGRESS
VIENNA
30 SEP - 3 OCT 2026

Abstract N°: 550

Cutaneous leishmaniasis cluster in Southern Brazil: clinical variability and treatment outcomes in eight patients

Davi Leitner Carboni*[1], Dina Alves[2]

[1] Dermatology and Nutrology Clinic - Dr. Davi Leitner, Curitiba, Brazil
[2] Prefeitura Municipal de Itaperuçu, Itaperuçu, Brazil

Introduction

Cutaneous leishmaniasis is a parasitic infection caused by Leishmania species transmitted by sandflies, characterised by a wide spectrum of clinical manifestations. Polymorphic presentations may mimic other dermatological conditions, leading to diagnostic delays, particularly in areas with variable endemicity. The identification of temporal clusters with heterogeneous clinical features is clinically relevant and may indicate active local transmission.

Case Presentation

Eight patients presenting with cutaneous leishmaniasis were identified within a six-week period in a rural area of Southern Brazil, suggesting an emerging local cluster. The cohort included one child, one adolescent male, five adult men, and one elderly woman aged 74 years, demonstrating a wide age distribution. Clinical presentations were markedly heterogeneous, ranging from small ulcerated papules to large ulcerated plaques with raised indurated borders. Additional morphologies included nodular ulcerations, annular lesions, crusted plaques, and infiltrated lesions, predominantly affecting exposed areas, particularly the lower limbs. Lesions frequently demonstrated well-defined elevated borders with central ulceration and variable degrees of crusting and necrosis. Different stages of lesion evolution were observed within the same time frame, further supporting ongoing transmission. The polymorphic presentation contributed to diagnostic challenges, with initial differential diagnoses including bacterial infection, chronic ulcers and inflammatory dermatoses.

Diagnosis of cutaneous leishmaniasis was based on clinical suspicion supported by dermoscopy and confirmed by direct parasitological examination and culture. Species identification was not performed; however, Leishmania (Viannia) braziliensis is the most likely species based on regional epidemiology. Treatment decisions were individualised according to lesion size, number, anatomical location and patient characteristics. Most patients were treated with oral miltefosine, while selected cases received meglumine antimoniate according to individual clinical characteristics, including intralesional therapy in the elderly patient due to advanced age and to minimise systemic toxicity. Six patients achieved complete clinical resolution, one patient discontinued miltefosine due to gastrointestinal intolerance and subsequently responded to systemic meglumine antimoniate, and one patient remains under treatment with progressive improvement. Treatment was generally well tolerated, with gradual clinical improvement characterised by reduction in ulceration, inflammation and crusting. Patients were followed until clinical resolution or progressive improvement.

Conclusion

This case series describes an emerging cluster of cutaneous leishmaniasis with marked clinical polymorphism occurring within a short time frame. The identification of multiple patients across different age groups, combined with heterogeneous lesion morphology and varying stages of evolution, supports ongoing local transmission and highlights the diagnostic challenges associated with atypical presentations. These findings emphasise the

importance of maintaining clinical suspicion, particularly in areas with variable endemicity, where polymorphic lesions may mimic other dermatological conditions. Early recognition of such presentations may facilitate timely diagnosis, guide individualised therapeutic decisions and improve clinical outcomes.

EADV CONGRESS
VIENNA
30 SEP - 3 OCT 2026

Abstract N°: 563

Primary Herpes Simplex Virus Type 1 Infection in a Free Flap: A Rare Case Report

Gökberk Uyar*[1], Elif Kaya[1], Selda Pelin Kartal[1]

[1] Ankara Etlik City Hospital, Ankara, Türkiye

Introduction

Herpes simplex virus type 1 is a common pathogen typically causing orofacial infections; however, its occurrence in free flap tissue is extremely rare. In this study, we present a case of primary HSV-1 infection developing in a free flap, representing the second such case reported in the literature.

Case Presentation

A 63-year-old male patient underwent tumor excision of the floor of the mouth, left hemiglossectomy, and neck dissection for squamous cell carcinoma of the tongue and floor of the mouth. The resulting tissue defect was reconstructed using an anterolateral thigh (ALT) free flap. The patient was immunocompetent and had no history of preoperative chemotherapy or radiotherapy. The postoperative course was initially uneventful; however, erythematous lesions appeared on the flap on postoperative day 10, followed by vesicular eruptions on day 16. Although flap perfusion remained clinically normal, a Tzanck smear and swab samples for polymerase chain reaction (PCR) were obtained for differential diagnosis. The Tzanck smear revealed multinucleated giant cells accompanied by acantholytic cells. Based on clinical suspicion of herpes infection, topical (5% acyclovir cream, eight times daily) and intravenous acyclovir (5 mg/kg, three times daily) treatments were initiated. PCR analysis of the lesion swab confirmed HSV-1 positivity. The lesions showed rapid regression with antiviral therapy and completely resolved by day 10 of treatment.

Conclusion

Although erythema and edema in free flaps during the postoperative period primarily suggest vascular compromise, rare herpetic infections should also be considered in the differential diagnosis. Early recognition and prompt antiviral treatment can reduce disease severity and duration, prevent unnecessary surgical interventions, and ultimately improve patient outcomes.

EADV CONGRESS
VIENNA
30 SEP - 3 OCT 2026

Abstract N°: 619

An unusual granulomatous tinea due to Nannizzia incurvata in Germany without evidence of an acquisition from outside Europe and reduced itraconazole susceptibility

Elisabeth Schuldt*[1]

[1] UKSH, Kiel, Germany

Introduction

Nannizzia (N.) incurvata is a geo- and zoophilic fungus. It can infect animals but can cause skin infections in humans on rare occasions as well. Human N. incurvata-infections have been reported from Asia but only very few infections with N. incurvata have been communicated from Europe. To our knowledge, all previously published European cases had a connection to Asian countries. Our case is noteworthy because, firstly, it showed atypical clinical features with a granulomatous tissue reaction; secondly, a German woman with no relation to a non-European country was affected; and, thirdly, the isolated N. incurvata-strain unexpectedly had a reduced itraconazole susceptibility.



a) Culture on dermatophytes agar, obverse.

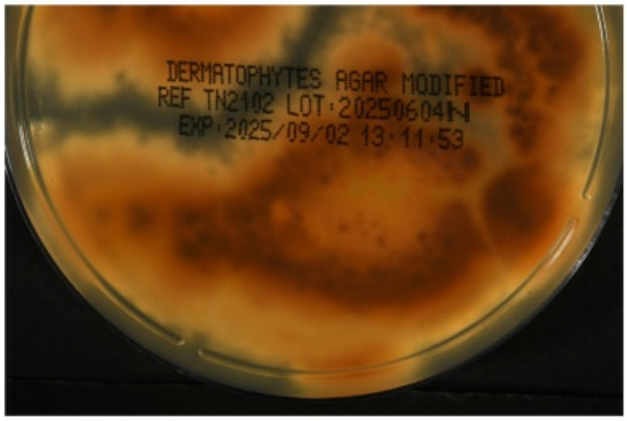

b) Culture on dermatophytes agar, reverse.



c) Culture on human stratum corneum *in vitro*.

Case Presentation

A 54-year-old woman was referred to our clinic by her internist to verify a diagnosis of chronic discoid lupus erythematosus. The patient complained of progressive itching macules on her face and arms that had been present for approximately two months. At the time these lesions had emerged, she had been on vacation on Sardinia, Italy. She also reported that about one year earlier, she had noted similar skin lesions which had healed after several weeks of topical antimycotic treatment. Her husband had recently developed two similar skin lesions, which had healed spontaneously. The patient kept cats on her property with no obvious abnormalities of fur.

Skin findings: On the right cheek and on both lower arms and thighs there were distinctly outlined violaceous-erythematous plaques with diameters of 1–3 cm, elevated borders and very little scaling.

The histopathology revealed dense granulomatous aggregates of mononuclear cells with small neutrophilic abscesses in the deep stratum reticulare. Periodic acid Schiff (PAS)-stains demonstrated intracorneal hyphal elements and rounded PAS-positive structures compatible with fungal elements within these granulomas. These findings proved a superficial fungal skin associated with a granulomatous dermal mycotic component. Formalin-fixed slides were subsequently used for PCR. N. incurvata was identified in the biopsied tissue. Lesional scales were

collected for mycological diagnostics. KOH-mounts showed short, hyaline, septate hyphal fragments and destructed hairs enveloped and presumably interspersed with small spores. On dermatophytes agar and on Sabouraud agar white colonies grew within days, later developing a brown pigmentation towards the edges. The reverse was yellowish to brown-orange.The urease test was positive, likewise the hair perforation test.

A semi-quantitative antifungal susceptibility testing showed no growth of the isolate with 0.15 mg/L terbinafine in RPMI-agar (Gibco RPMI Medium 1650, Life Technologies Ltd., Paisley, UK) within 14 days. However, with 1.0 mg/L itraconazole in RPMI-agar its growth was only partially suppressed with culture diameters still reaching as much as 20 mm after 14 days - as compared to 60 mm in controls without itraconazole. Our strain is preserved in the public German Collection of Microorganisms and Cell Cultures; DSM No. 121183.

Treatment was started with ciclopiroxolamine cream, terbinafine 250 mg/day p. o. was added. The skin lesions improved rapidly. Four weeks after start of oral terbinafine only a postinflammatory hyperpigmentation had remained. Terbinafine was discontinued and we only recommended to apply ciclopiroxolamine cream for an additional four weeks.The patient’s cat had been considered for a fungal reservoir and was preventively treated topically with an antifungal agent by a veterinarian.

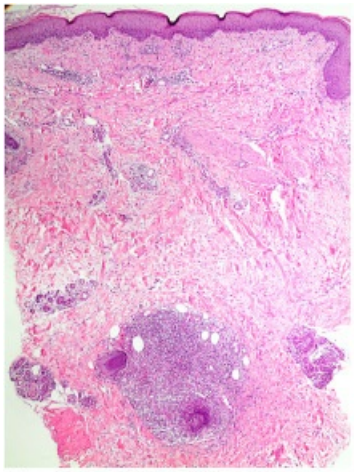

a) Histopathology of punch biopsy from lesion on the lower arm, hematoxylin-eosin-stain, overview. Conspicuous granulomatous infiltrate in the deep dermis.

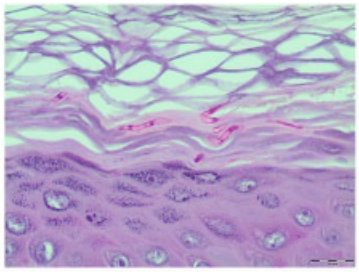

b) Lower stratum corneum with parakeratotic keratinization and periodic acid Schiff-positive hyphae.

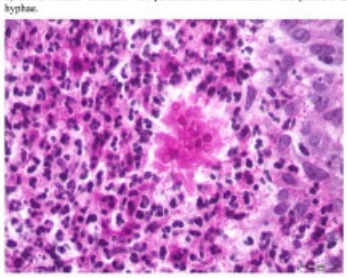

c) Periodic acid Schiff-positive fungal elements within granulomatous infiltrate in the deep stratum reticulare.

Conclusion

Our case demonstrates that N. incurvata should be considered as a possible cause of dermatomycosis not only in Asia but also in Europe. It also reveals that a N. incurvata-infection can present with an atypical clinical picture including a granulomatous tissue reaction and that reduced susceptibility to itraconazole may occur in this species. We suggest to check mammals with soil contact for colonization with N. incurvata in the surroundings of a N. incurvata-infection.

Abstract N°: 624

An ulcerated palque on the knee

Soumaya Gara*[1], Faten Zeglaoui[1]

[1] Department of dermatology Charles Nicolle Hospital, Tunis, Tunisia

Introduction

Cutaneous tuberculosis is a rare and polymorphic form of extrapulmonary tuberculosis that can mimic several chronic inflammatory, infectious or malignant conditions. Scrofuloderma, caused by contiguous spread from an underlying tuberculous focus, may exceptionally reveal osteoarticular tuberculosis and delay diagnosis in patients with apparently degenerative joint disease.

Case Presentation

A 69-year-old woman with a seven-year history of right knee osteoarthritis, scheduled for total knee arthroplasty, presented with a cutaneous painless lesion evolving over three months. Clinical examination revealed a painless, ulcerated plaque measuring 2 centimeters in diameter, with violaceous and retracted borders, located on the anterior aspect of the right knee. Radiography showed a narrowing of the femorotibial joint space associated with irregular bony destruction. Magnetic resonance imaging demonstrated extensive osteoarticular destruction of the femorotibial joint with intra articular fluid collections and multiple fistulous tracts extending toward the skin. Histopathological examination of cutaneous and synovial biopsies revealed granulomatous inflammation with epithelioid histiocytes and multinucleated giant cells and a central, eosinophilic necrotic area. Molecular analysis by polymerase chain reaction of the synovial biopsy confirmed the infection with Mycobacterium tuberculosis. The diagnosis of tuberculous osteoarthritis with associated scrofuloderma was confirmed. The patient received first line antituberculous drugs. Cutaneous tuberculosis is a rare manifestation of extrapulmonary tuberculosis, characterized by marked clinical polymorphism frequently leading to delayed diagnosis. Scrofuloderma is the most common form and results from the contiguous spread of a deep-seated tuberculous focus, most often lymph nodes or bone, to the overlying skin. In our case, a chronic, ulcerated plaque with retractile borders raised suspicion of mycobacterial infections and cutaneous malignancy. MRI findings showed lytic bone lesions, fluid collections, and fistulous tracts suggesting an underlying infectious osteoarticular process. Histopathology of lesional skin and synovium showed necrotizing granulomatous inflammation highly suggestive of osteoarticular and cutaneous tuberculosis, subsequently confirmed by molecular analysis. The management of osteoarticular tuberculosis with associated scrofuloderma requires a prolonged course of antituberculous therapy, usually ranging from 9 to 12 months. Surgical intervention may be considered after infection control, depending on the extent of osteoarticular involvement. Prognosis depends on the timeliness of diagnosis, the initiation of appropriate antituberculous therapy, and rigorous clinical and radiological monitoring.

Conclusion

To conclude, this case highlights several key points: the clinical polymorphism of cutaneous tuberculosis, the importance of considering tuberculosis in the differential diagnosis even in an apparently degenerative context and the necessity of a multidisciplinary approach before prosthetic procedure in cases of associated chronic cutaneous lesions of unclear etiology.

EADV CONGRESS
VIENNA
30 SEP - 3 OCT 2026

Abstract N°: 644

Precision Dermatology in Cutaneous Leishmaniasis: High-Frequency Ultrasound-Guided Intralesional Therapy and Imaging Follow-up

Barbara Brunca*[1], Sofia Mitidieri[1], Ana Weber[1], Leticia Nunes Tajra[1], Paula Tavares Colpas[1]

[1] Hospital PUC Campinas, Campinas, Brazil

Introduction

Cutaneous leishmaniasis (CL) is the most common presentation of tegumentary leishmaniasis, a parasitic disease caused by protozoa of the genus *Leishmania* and transmitted by infected sandflies. It remains endemic in tropical and subtropical regions and represents an important public health challenge. Clinically, CL may begin as a papule or plaque and progress to chronic ulcerated, infiltrated, verrucous, or atypical lesions, often leading to delayed diagnosis.

High-frequency ultrasound (HFUS) has emerged as a useful complementary imaging tool, allowing real-time evaluation of epidermal, dermal, and subcutaneous involvement, as well as supporting therapeutic planning and follow-up.

We report a chronic case of CL treated with HFUS-guided intralesional meglumine antimoniate.

Case Presentation

A 62-year-old woman presented with a progressive lesion on the left thigh with six years of evolution. Initially described as an erythematous area, it later developed crusting, pruritus, burning sensation, progressive enlargement, and central ulceration. Previous topical therapies and cryotherapy were unsuccessful, with subsequent worsening of inflammation. Histopathological examination revealed chronic lichenoid dermatitis, while microbiological cultures were negative. Due to persistent clinical suspicion, polymerase chain reaction (PCR) testing was performed and confirmed CL.

Dermatologic examination showed a well-defined erythematous plaque measuring approximately 3 cm, with mild scaling, central atrophy, and elevated brownish-violaceous borders. Pre-treatment HFUS demonstrated a linear lesion with hypoechoic areas, posterior acoustic shadowing, and a depth of 0.3 cm. Increased echogenicity of the subcutaneous tissue was also observed, suggesting active inflammatory panniculitis and deeper extension (Figure 1).

The patient underwent three weekly sessions of HFUS-guided intralesional meglumine antimoniate. Ultrasound guidance enabled accurate needle placement and optimized delivery of the medication into the most inflamed portions of the lesion, potentially improving drug distribution and reducing blind infiltration failure.

At post-treatment follow-up, marked clinical improvement was observed, with reduction in lesion size, erythema, and infiltration. Repeat HFUS demonstrated a thin subepidermal anechoic band (0.5 mm) associated with adjacent scar tissue, findings consistent with regression of inflammatory activity and tissue remodeling. Progressive resolution was maintained during outpatient follow-up (Figure 2).

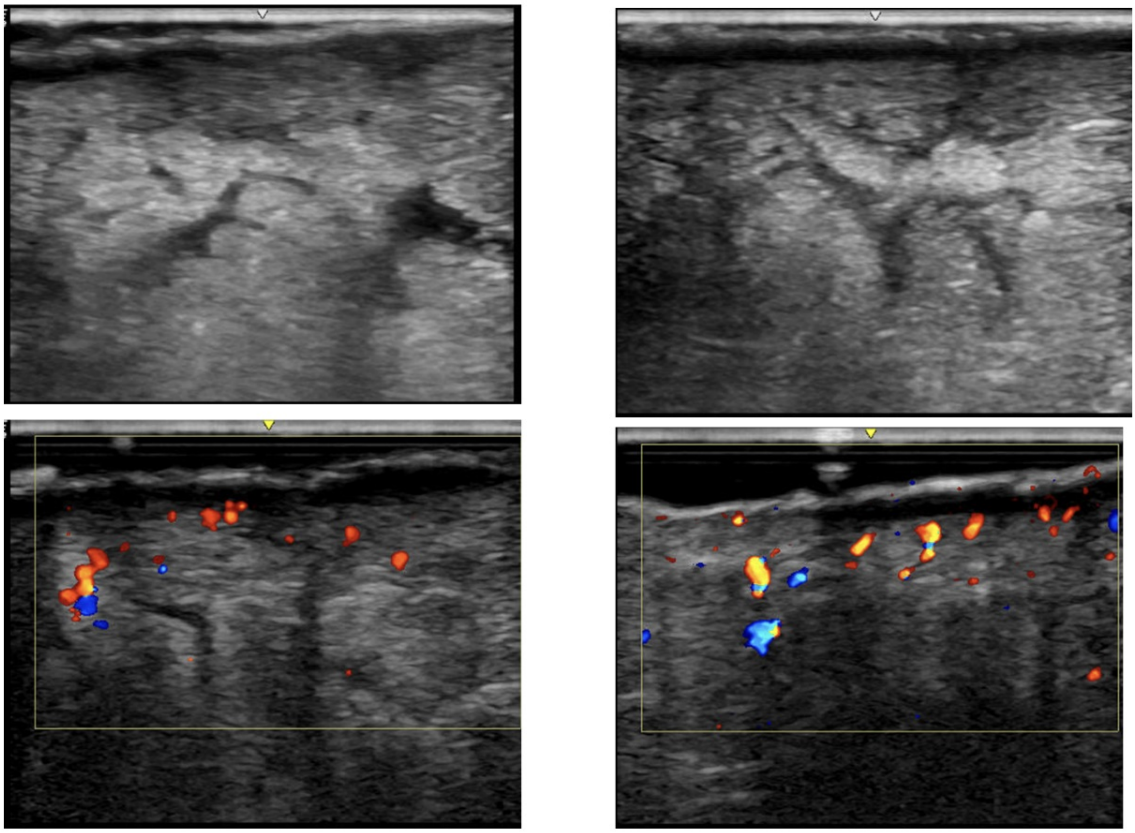

Figure 1: Baseline high-frequency ultrasound (22 MHz) of cutaneous leishmaniasis lesion. Gray-scale images demonstrate superficial dermal-subcutaneous architectural distortion with irregular hypoechoic areas and posterior acoustic shadowing. Color Doppler examination reveals increased intralesional and perilesional vascular signals, consistent with active inflammatory disease. Findings support dermal involvement with extension to the superficial subcutaneous tissue.

Conclusion

CL may be diagnostically challenging, particularly in chronic lesions or when histopathology is nonspecific. In such cases, molecular methods such as PCR are valuable. HFUS can identify inflammatory activity, evaluate lesion depth, detect subclinical extension, and help differentiate active disease from post-treatment fibrosis or scarring. In the present case, ultrasound was useful not only for assessment, but also as a procedural guide, supporting a more precise and individualized therapeutic approach. In addition, serial imaging allowed objective monitoring of response after treatment.

HFUS proved to be a valuable noninvasive adjunctive tool in localized CL, enabling evaluation of inflammatory activity, monitoring of therapeutic response, and guidance of intralesional meglumine antimoniate treatment. Its ability to direct medication into active areas, distinguish inflammation from fibrosis, and support individualized management may improve clinical decision-making and optimize outcomes. Further prospective studies are needed to validate and standardize this approach in routine dermatologic practice.

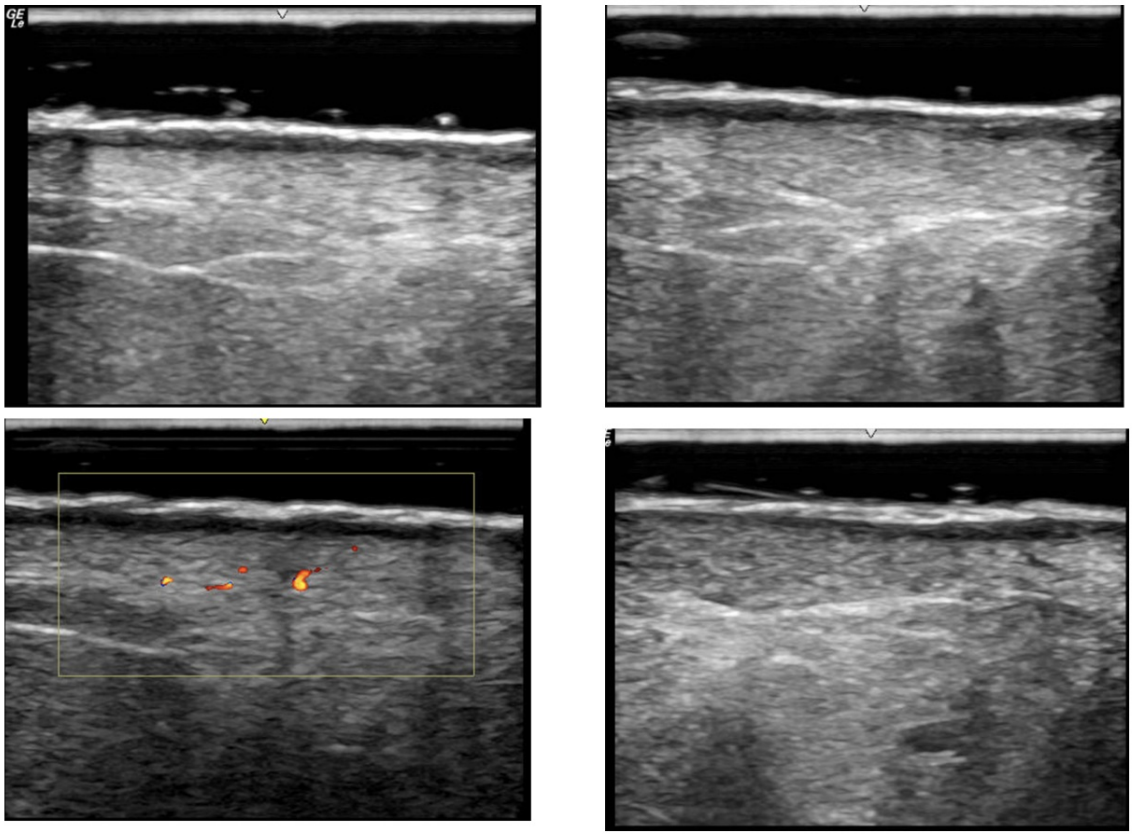

Figure 2: Five-month follow-up high-frequency ultrasound (22 MHz) after ultrasound-guided intralesional meglumine antimoniate treatment. Gray-scale images demonstrate restoration of normal dermal-subcutaneous architecture, with marked reduction of previously observed hypoechoic inflammatory areas and residual superficial fibrotic/scar-related changes. Color Doppler reveals minimal residual vascular flow, indicating near-complete resolution of active inflammation and favorable post-treatment tissue remodeling. References: Sadeghian G, Nilforoushzadeh MA, Ansari N, Sadoughi A, Goldust M, Ibrahimi OA, et al. Ultrasound patterns of localized cutaneous leishmaniasis and clinical correlations. Skin Res Technol. 2022;28(4):537-544. doi:10.1111/srt.13153. PMCID: PMC9148356. Vergara-de-la-Campa L, Cembrero-Saralegui H, Luna-Bastante L, Martínez-Lorenzo ER, Alfageme-Roldán F. Usefulness of ultrasound for treatment and follow-up of cutaneous leishmaniasis. J Ultrasound. 2021;24(4):573-576. doi:10.1007/s40477-020-00540-0. PMCID: PMC8572289. PMID: 33247813. Serrano-Coll H, Aristizábal-Parra LK, Olarte G, Salamanca-Leguizamón C. Cutaneous leishmaniasis: immunological insights and clinical challenges. Colomb Med (Cali). 2025 Sep 15;56(3):e3006750. doi: 10.25100/cm.v56i3.6750. PMID: 41306921; PMCID: PMC12646367. Koussayer Z, Koussayer J, Tyring SK. An Update on the Clinical Management of Cutaneous Leishmaniasis. Skin Therapy Lett. 2025 Jan;30(1):5-9. PMID: 39814367.

EADV CONGRESS
VIENNA
30 SEP - 3 OCT 2026

Abstract N°: 646

An analytical study on the mRNA expression of inflammatory cytokines in chronic dermatophytosis

Swathi A R[1], Manjunath Mala Shenoy[2], Amina Asfiya M Iqbal*[2]

[1] Cutis Academy Of Sciences, Bengaluru, India

[2] Yenepoya Medical College, Mangaluru Taluka, India

Introduction

Dermatophytosis is a fungal infection of the keratinized structures like stratum corneum of skin, hair and nails. The optimal resolution of dermatophytosis is associated with effective contributions of Th1 and Th17 responses involving IFN-γ and IL-17A respectively. Deviated response towards Th2 humoral arm may be associated with chronicity. The study aims to understand the events occurring at the molecular level by determining the mRNA expression of various inflammatory cytokines in chronic dermatophytosis as compared to healthy subjects.

Materials and Methods

The aim of the study was to analyse the mRNA expression of inflammatory cytokines in chronic dermatophytosis as compared to the healthy individuals.

A case-control study conducted on 40 patients with chronic dermatophytosis. Apart from history and dermatological examination, all patients underwent a 4 mm punch biopsy procedure. The sample was stored in RNAlater solution at -80 degrees Celsius for isolation of mRNA by Trizol method, followed by cDNA synthesis and RT-PCR. The mRNA expression of cytokines such as IL-1β, IL-17A, IL-23, IL-4, IL-10 and TNF-α was calculated. The values obtained were compared with those of age- and sex-matched healthy controls. Wilcoxon t-test was used as a test of significance, and the values were considered significant if the p-value was <0.05.

Results

The relative expression of mRNA levels of IL-17A, IL-1β, and TNF-α was increased in cases as compared to controls and found to be statistically significant with a p-value of <0.0001. While the levels of IL-4 and IL-23 showed a slight elevation, the result was statistically significant with p-values of <0.001 and <0.012. Although IL-10 also showed a slight elevation of mRNA levels in cases compared to controls, it was not statistically significant with a p-value of <0.124.

As this was a hospital-based, cross-sectional study, the findings may not represent the actual scenario of the disease in the general population, and only six cytokines were analysed in the study.

Conclusions

The current Indian epidemic of chronic dermatophytosis is unique due to several poorly understood aspects, including atypical presentations and recalcitrant nature. Immunological aspects of the current dermatophytosis epidemic in India have not been studied well. This study aimed to acquire a deeper understanding of the events occurring at the molecular level in the affected keratinocytes.

EADV CONGRESS
VIENNA
30 SEP - 3 OCT 2026

Abstract N°: 672

Bullous Dermatosis in a Young Adult: A Diagnostic Challenge Revealing Bed Bug Infestation

Nika Jutraž*[1], Bor Hrvatin Stančič[1, 2], Špela Šuler Baglama[1]

[1] University Medical Centre Ljubljana, Department of Dermatovenerology, Ljubljana, Slovenia
[2] Faculty of Medicine, University of Ljubljana, Ljubljana, Slovenia

Introduction
Bullous skin eruptions in young adults often raise suspicion for autoimmune blistering diseases or severe drug reactions. However, arthropod assaults can occasionally mimic these conditions. Our objective is to present an unusual case of extensive bullous eruption ultimately attributed to infestation with bed bugs (Cimex lectularius), highlighting important diagnostic pitfalls.

Materials and Methods
We present a 25-year-old male with generalized bullous and urticarial dermatosis. The clinical presentation raised suspicion for autoimmune or inflammatory dermatoses; however, despite extensive evaluation, findings remained inconclusive. A detailed history and environmental assessment ultimately identified bed bug infestation as the underlying cause, consistent with an exaggerated cutaneous hypersensitivity reaction to arthropod bites.

Results
A 25-year-old male with a known allergy to inhalant allergens, otherwise healthy, presented twice to our Dermatovenerology Department within a one-week interval. At the initial presentation, he reported a one-week history of pruritic skin lesions that had begun on the upper limbs and subsequently spread to the trunk and lower extremities. At the second visit, the eruption had further progressed with the development of additional bullous lesions. He denied recent insect bites, contact with plants, systemic symptoms, or introduction of new medications. No one else in the household had any problems.

Clinical examination revealed multiple serous bullae on distal extremities, accompanied by erythematous papules, plaques, and urticarial lesions on the back and shoulders. The face and oral mucosa were spared, and no signs of secondary infection were observed.

Upon admission, the patient underwent extensive laboratory, microbiological, imaging and endoscopic investigations to exclude autoimmune, autoinflammatory, and paraneoplastic etiologies. Results were largely unremarkable except for mild hepatopathy, elevated lactate dehydrogenase, eosinophilia, and positive ANA (1:160). Gastroscopic findings revealed erosions and reflux esophagitis. Specific IgE testing confirmed sensitization to multiple inhalant allergens.

Skin biopsy was performed twice. The first biopsy demonstrated a subepidermal bulla with a prominent eosinophilic infiltrate. The second biopsy revealed mild superficial and deep perivascular mixed-cell dermatitis with predominance of neutrophils, with evidence of nuclear debris deposition and focal erythrocyte extravasation, suggestive of early leukocytoclastic vasculitis or neutrophilic dermatosis. Direct immunofluorescence was non-specific on both occasions.

Treatment with topical corticosteroids and oral antihistamines initially led to complete regression of the lesions, and no new lesions were observed. The patient was discharged; however, he returned the following day with new

urticarial plaques. Systemic corticosteroid therapy was therefore initiated (oral methylprednisolone, starting dose 48 mg with gradual tapering), resulting in marked clinical improvement without further lesion development.

After discharge, the patient experienced several similar episodes; however, at follow-up, he reported the presence of insects in his living environment and brought specimens for evaluation, which were identified as bed bugs. Notably, lesions did not occur when he was away from home. Cimicosis was diagnosed retrospectively, and eradication measures were recommended, after which the condition resolved.

Conclusions

Bed bug bites can rarely present with extensive bullous eruptions and histopathological features mimicking autoimmune or vasculitic processes. This case highlights the importance of considering arthropod-related reactions in the differential diagnosis of atypical blistering dermatoses and of obtaining a thorough environmental history to guide appropriate management.

EADV CONGRESS
VIENNA
30 SEP - 3 OCT 2026

Abstract N°: 672

Isolated Auricular Cutaneous Tuberculosis in a Patient on Adalimumab: An Unusual Presentation of Latent Infection Reactivation

Laisa Goulart Saviatto Picasky*[1], Vitória Radichewski[1], Leandro Bispo de Oliveira[1], Gabriella Funchal[1], Bárbara Hartung Lovato[1]

[1] Santa Tereza Sanitary Dermatology Hospital, São Pedro de Alcântara, Brazil

Introduction

Cutaneous tuberculosis is a rare manifestation of *Mycobacterium tuberculosis* infection, accounting for a small proportion of extrapulmonary cases, with lupus vulgaris representing the most frequent clinical form. Auricular involvement is particularly uncommon, with few cases reported in the literature, and may present as an isolated lesion, often leading to delayed diagnosis due to its resemblance to other inflammatory, infectious, or neoplastic conditions. In patients receiving tumor necrosis factor-alpha (TNF-α) inhibitors such as adalimumab, there is a well-established increased risk of tuberculosis, primarily related to reactivation of latent infection, as TNF-α plays a critical role in granuloma formation and maintenance. In this context, tuberculosis more frequently presents with extrapulmonary and atypical manifestations, including cutaneous involvement. Therefore, chronic, treatment-refractory lesions in immunosuppressed patients should prompt consideration of cutaneous tuberculosis.

Case Presentation

A 52-year-old woman with Crohn's disease, under treatment with adalimumab for four years with good disease control, presented with a four-month history of edema and an ulcerated lesion with yellowish exudate on the right ear (Figure 1.A). Previous treatment with topical corticosteroids and systemic antibiotics had resulted in no clinical improvement. The patient denied any systemic symptoms. She had a history of latent tuberculosis treated for nine months prior to the initiation of adalimumab, complicated by severe isoniazid-related hepatotoxicity.
Histopathological examination revealed granulomatous inflammatory infiltrate with multinucleated giant cells, with a negative Ziehl–Neelsen stain (Figure 1.B and C). However, bacilloscopy demonstrated acid-fast bacilli, and molecular testing confirmed the presence of *Mycobacterium tuberculosis* complex DNA. Sputum examinations were negative across three samples, and chest radiography showed no abnormalities.
Based on these findings, a diagnosis of isolated cutaneous tuberculosis was established. The absence of pulmonary involvement and the unusual auricular location are consistent with previously reported atypical presentations in immunosuppressed patients. The clinical picture, combined with delayed response to conventional therapies and the need for molecular confirmation, underscores the diagnostic challenge described in the literature.



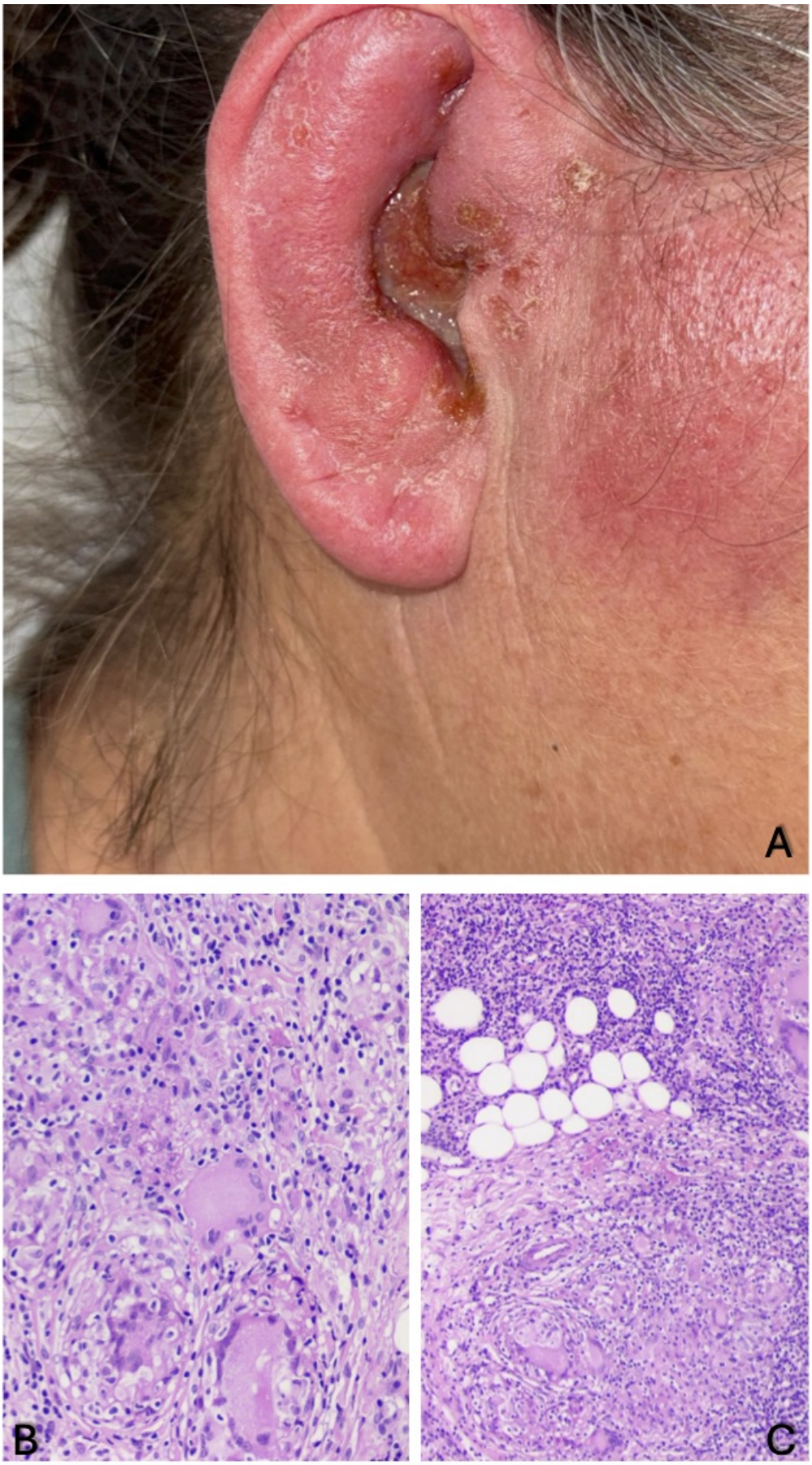

Figure 1: A. Clinical presentation. ; B and C. Histologic findings show sections of skin with hypergranulosis, parakeratosis and a granulomatous inflammatory infiltrate in the dermis with multinucleated giant cells. Hematoxylin and eosin stain (H&E) x400 (B) and x100(C).

Conclusion

This case highlights a rare presentation of cutaneous tuberculosis involving the auricle in a patient receiving anti-TNF therapy. The association with adalimumab, prior latent tuberculosis, and the absence of systemic involvement emphasize the importance of maintaining a high index of suspicion for atypical and extrapulmonary forms of tuberculosis in immunosuppressed individuals. Early recognition and thorough investigation, including histopathological and molecular methods, are essential to establish the diagnosis and initiate timely treatment.

References

1. Wallis RS, et al. Tumor necrosis factor inhibitors and tuberculosis risk. *Clin Immunol.* 2014;153(2):177–182. doi:10.1016/j.clim.2014.05.005
2. Kim EJ, et al. Cutaneous tuberculosis induced by adalimumab. *Dermatol Ther.* doi:10.1111/dth.15503
3. Patra AC, et al. Lupus vulgaris of the pinna – a case report. *Indian Dermatol Online J.* doi:10.4103/idoj.IDOJ_52_19
4. Wesołowska M, et al. Lupus vulgaris of the auricle. *Adv Dermatol Allergol.* doi:10.5114/ada.2020.93836

EADV CONGRESS
VIENNA
30 SEP - 3 OCT 2026

Abstract N°: 681

Study of methicillin-resistant Staphylococcus aureus (MRSA) in patients with atopic dermatitis

Makhliyokhon Zokhidova*[1]

[1] Republican Specialized center of Dermatovenerology and Cosmetology, Tashkent, Uzbekistan

Introduction

There are often golden and epidermal staphylococci are colonized in pathological skin lesions in patients with atopic dermatitis. Recent studies have shown that Staphylococcus aureus is present on the skin of newborns with atopic dermatitis in more than 90% of cases (in 78% - with dermatitis without damage and in 10% - on healthy skin). It is noted that the concentration of Staphylococcus aureus correlates with the severity of the disease. In addition, bacterial virulence, such as methicillin-resistant S. aureus (MRSA) produce significantly more superantigens, which increase their ability to cause infection and more severe skin inflammation in patients with atopic dermatitis.

Materials and Methods

There were examined 53 patients with various clinical forms of atopic dermatitis aged from 5 to 73 years. All patients underwent clinical, microbiological and molecular genetic studies to determine methicillin-resistant Staph. aureus (MRSA). According to clinical forms, patients with atopic dermatitis are distributed as follows: 28 (52.8%) patients were diagnosed with erythematous-squamose form, 11 (20.7%) – lichenization clinical form of atopic dermatitis and 14 (26.4%) patients were diagnosed with pruruginouse form of atopic dermatitis.

Results

The results of a microbiological study of the species identification of microorganisms showed a high incidence of S. Aureus - 38 (71.7%) in patients with pruruginouse form of atopic dermatitis, while S.Epidermidis was detected in 10 (18.8%) and S.Haemolyticus was detected in 5 (9.4%) patients with lichenization clinical form of atopic dermatitis. Contaminants of Stph. aureus strains were detected in 40 patients with atopic dermatitis, which accounted for 75.4% of cases. Such contaminants as MRSA were detected in 55% of cases, MSSA – 25% and MRCoNS in 20% of cases of atopic dermatitis. All carriers of methicillin-resistant Staphylococcus spp. they were distributed depending on the severity of the disease. Thus, the largest number were patients with severe MRSA contaminant disease – in 32.5% of cases, patients with moderate MRSA contaminant severity accounted for 17.5% of cases.

Conclusions

The data obtained indicate that, the genotypes of Staphylococcus spp. they play a certain role in the development of atopic dermatitis. Prolonged colonization of these microorganisms contributes to the development of persistent forms of atopic dermatitis.

EADV CONGRESS
VIENNA
30 SEP - 3 OCT 2026

Abstract N°: 685

Chronic Dermatophytosis: A Real-World Study Highlighting Corticosteroid Misuse and the Impact of Prolonged Itraconazole Therapy

Ali Hamieh[1], Ali Fakih*[2]

[1] Dermatology Department, Baabda University Hospital, Lebanese University, Beirut, Lebanon
[2] Dermatology Department, Hammoud Hospital University Medical Center, Lebanese University, Beirut, Lebanon

Introduction
Chronic and recurrent dermatophytosis is increasingly encountered in clinical practice, with frequent reports of treatment failure and relapse. This study aimed to evaluate the clinical characteristics and treatment outcomes of patients with chronic or recurrent dermatophytosis in a real-world setting.

Materials and Methods
A multicenter retrospective observational study was conducted in two university hospital dermatology clinics and one private practice between May 2024 and February 2026. Thtirty-five patients with chronic (duration >6 months) or recurrent dermatophytosis were included. Data collected included demographics, body mass index (BMI), clinical presentation, and prior treatments. Patients were primarily treated with oral Itraconazole (4–12 weeks). Clinical outcomes and recurrence were assessed during follow-up.

Results
The mean age was 36.4 years, with a female predominance (63%, n=22). The mean BMI was 27.2 kg/m^2, with 70.6% (n=24) of patients classified as overweight or obese. The most frequent clinical forms were tinea corporis (74.3%, n=26) and tinea cruris (65.7%, n=23), with multisite involvement in 63% (n=22). Prior use of topical corticosteroids was reported in 91.4% (n=32) of patients, and 68.6% (n=24) had previously received systemic antifungal therapy. Among 28 patients treated with itraconazole, longer treatment durations (10–12 weeks) were associated with higher complete remission rates (90%) compared to shorter regimens. Sixteen patients completed follow-up and were evaluable for recurrence; relapse occurred in 25% (n=4), typically within 2–4 weeks after treatment discontinuation.

Conclusions
Chronic dermatophytosis in this study was characterized by frequent corticosteroid misuse, high rates of prior antifungal exposure, and extensive disease involvement. Prolonged itraconazole therapy appeared more effective than shorter regimens, although early recurrence remains a concern, suggesting possible incomplete eradication or reinfection. These findings highlight the need for optimized management strategies and stricter regulation of corticosteroid use in real-world practice.

EADV CONGRESS
VIENNA
30 SEP - 3 OCT 2026

Abstract N°: 702

Unexpected Diagnosis in a Non-Endemic Region: A Case of Facial Cutaneous Leishmaniasis in the Thrace Region of Türkiye

Sezgi Sarıkaya Solak*[1], Gülsen Dilek Esmer[1]

[1] Trakya University, Faculty of Medicine, Department of Dermatology and Venereology, Edirne, Türkiye

Introduction

Cutaneous leishmaniasis (CL) is a parasitic infection that is endemic in only selected regions of Türkiye. The Thrace Region is not endemic for CL, and diagnosis may be delayed in non-endemic areas. However, it is important to consider CL in clinically compatible skin lesions regardless of geographic location. Herein, a case of facially localized CL is presented to emphasize that CL should be considered in the differential diagnosis even in non-endemic regions such as the Thrace Region, and that in appropriate patients, lesions near mucosal areas can also be effectively treated with local therapy.

Case Presentation

A 61-year-old female patient was referred to our clinic by the infectious diseases department with a preliminary diagnosis of furuncle due to a lesion on the nasal root that had been present for approximately two months. It was learned that the patient had previously received amoxicillin-clavulanate, doxycycline, clindamycin, and topical antibiotics without benefit, and the lesion had progressively enlarged. There was no history of systemic disease or trauma. The patient had not travelled outside the Thrace region for more than two years. Dermatological examination revealed an approximately 2×3 cm erythematous, firm, infiltrated nodule with mildly increased temperature on the nasal root. Dermoscopic examination showed branching vessels, predominantly at the periphery, central tear-drop–like structures, hyperkeratosis, crusting, and orange areas. In the differential diagnosis, squamous or basal cell carcinoma, cutaneous lymphoma, cutaneous metastasis, cutaneous tuberculosis, and atypical mycobacterial infection were considered, and a punch biopsy with further investigations was planned. Quantiferon testing and tissue cultures were negative for bacterial, fungal, and mycobacterial pathogens.Histopathological findings were suspicious for CL. A detailed re-evaluation confirmed that the patient had no travel history outside the province. Due to the consistency between clinical and histopathological findings, repeat sampling was performed. Dermal smear examination revealed amastigotes. PCR analysis performed at the National Parasitology Reference Laboratory in Ankara confirmed Leishmania spp. positivity. Following definitive diagnosis, intralesional meglumine antimoniate therapy was initiated. After a total of five doses administered at 10-day intervals, marked clinical regression was observed. At follow-up two months after the final dose, complete resolution of infiltration was noted, with only scar tissue and minimal erythema remaining. No recurrence was observed during 6 months of follow-up.

Conclusion

In non-endemic regions, CL should be considered in the differential diagnosis of chronic, treatment-resistant nodular and ulcerative skin lesions. Delayed diagnosis may lead to inappropriate antibiotic use and unnecessary surgical interventions. Therefore, clinical suspicion should be maintained even in the absence of travel history to endemic areas. According to national and international CL guidelines, systemic treatment is generally recommended for lesions located near mucosal areas (such as the eyelids and lips) due to the risk of functional impairment, particularly in patients under 60 years of age without systemic disease. In our case, the lesion extended to the medial aspects of both eyelids. However, due to the age and the potential adverse effects of systemic therapy, local treatment was preferred, resulting in complete response. This highlights the importance of

individualised treatment decisions based on patient and lesion characteristics. In conclusion, this case emphasises that CL should be considered in clinically compatible lesions even in non-endemic regions such as Thrace, and successful outcomes can be achieved with appropriate, individualised treatment selection.

EADV CONGRESS
VIENNA
30 SEP - 3 OCT 2026

Abstract N°: 705

Rare primary cutaneous nocardiosis infection caused by Nocardia acidovorans in a patient receiving Zanubrutinib for B-cell lymphoma

Fiza Noor*[1], McKenzie Van Eaton[1], Kirsten Walker[1]

[1] University of Saskatchewan, Saskatoon, Canada

Introduction

Cutaneous infection caused by Nocardia acidovorans is an uncommon manifestation of nocardial disease. Pulmonary nocardiosis, the most common presentation, and disseminated nocardiosis predominantly occur in immunocompromised hosts, whereas primary cutaneous nocardiosis more often affects immunocompetent individuals following direct inoculation into the skin. The clinical presentation of cutaneous nocaria is variable and can range from nodules, cellulitis, abscesses, to sporotrichoid lesions. Because these findings overlap with other infectious and inflammatory dermatoses, including atypical mycobacterial and deep fungal infections, diagnosis is often delayed. Definitive diagnosis requires tissue culture and microbiologic identification. With the increasing use of targeted oncologic therapies, opportunistic infections are increasingly recognized in patients receiving immunomodulatory agents such as the Bruton tyrosine kinase (BTK) inhibitor Zanubrutinib. Reports describing primary cutaneous nocardiosis in patients receiving BTK inhibitor therapy remain rare. Here, we report a case of primary cutaneous nocardiosis caused by Nocardia acidovorans presenting as chronic nodular lesions of the dorsal hand in a patient with B-cell lymphoma receiving Zanubrutinib.

Case Presentation

An 89-year-old woman with a history of B-cell lymphoma (2021) complicated by intra-abdominal and retroperitoneal lymphadenopathy, receiving the BTK inhibitor Zanubrutinib, presented with persistent nodular lesions to her dorsal right hand. Her medical history was significant for end-stage renal disease, hypertension, atrial fibrillation, obstructive sleep apnea, osteoarthritis, and thrombocytopenia. During her admission secondary to mechanical falls, dermatology was consulted for assessment of her ongoing cutaneous lesions. The patient reported a several month history of violaceous nodules to the right dorsal hand with intermittent serous drainage. She denied previous trauma, associated pain, fevers, chills, or other constitutional symptoms and remained vitally stable throughout admission. The patient previously received multiple courses of antibiotics including ceftriaxone and Amoxicillin/clavulanic acid over a six-month period with minimal improvement. Differential diagnoses included atypical bacterial, fungal, and mycobacterial infections, drug-associated cutaneous reactions related to BTK inhibition, neutrophilic dermatoses of the hand, eosinophilic dermatosis of hematologic malignancy, erythema elevatum diutinum, pseudomonas folliculitis, palisaded neutrophilic and granulomatous dermatitis, and calcinosis cutis. During admission the patient underwent a biopsy, which demonstrated mixed inflammatory infiltrate of neutrophils, lymphocytes, and histiocytes. The Gram stain and Grocott-Gomori Methenamine Silver stain highlighted bacterial cocci and filamentous broad-like structures in the upper dermis, and wound cultures demonstrated 1+ gram-positive bacilli. Given concern for an atypical infectious process in the setting of immunosuppression, repeat punch biopsy was performed for bacterial, fungal, and mycobacterial tissue cultures. Returning positive for Nocardia acidovorans. Subsequently her BTK inhibitor was held and a CT of the brain and chest were done to exclude systemic disease given nocardia most commonly presents as a pulmonary or CNS infection. Once systemic infection was ruled out, she was started on IV ceftriaxone in hospital then switched to double-strength trimethoprim(160mg)-sulfamethoxazole (800mg) for three months with maintained improvement.

Conclusion

Chronic nodular skin lesions that do not respond to conventional antimicrobial therapy should raise suspicion of nocardial infection. Early biopsy and microbiologic examination are critical for establishing the diagnosis and guiding proper treatment. Healthcare providers should be aware of these atypical opportunistic infections, and their metamorphous presentations as immunomodulatory therapy becomes more common.

EA DV CONGRESS
VIENNA
30 SEP - 3 OCT 2026

Abstract N°: 712

Evaluating the Role of Tinea Unguium and Other Risk Factors in Chronic and Recurrent Dermatophytosis: A Comparative Cross-Sectional Study

Amina Asfiya M Iqbal*[1], Faizan Kalekhan[2], Manjunath Mala Shenoy[1]

[1] Yenepoya Medical College, Mangaluru Taluka, India

[2] Shifa Al Jazeera Medical Centre, Kuwait, Kuwait

Introduction

In recent years, there has been a notable rise in chronic and recurrent dermatophytosis (CRD) in India, accounting for approximately 5–10% of new cases, although a standardized definition remains lacking. Environmental factors such as climate, social practices, and migration, along with host factors like immune status, diabetes, poor hygiene, and nail abnormalities, contribute to its epidemiology and the development of onychomycosis. Factors such as poor drug penetration in nail keratin, drug resistance, immunosuppression, noncompliance, reinfection from contacts, and inadequate hygiene contribute to chronicity and recurrence. Limited studies have evaluated these associations, though evidence suggests a significant link between onychomycosis and chronic dermatophytosis. This study aims to assess epidemiological and clinical factors, particularly the role of tinea unguium, in CRD.

Materials and Methods

The study was conducted among patients with clinically diagnosed dermatophytosis attending the dermatology outpatient department of a tertiary care hospital following ethics committee approval. A total of 80 consecutive cases and controls were enrolled based on predefined criteria. Chronic dermatophytosis was defined as glabrous tinea persisting for more than 6 months despite treatment, while recurrent dermatophytosis referred to recurrence within 6 weeks of clinical cure after adequate antifungal therapy. Cases included patients with chronic and/or recurrent dermatophytosis confirmed by potassium hydroxide (KOH) microscopy, whereas controls comprised non-chronic, non-recurrent dermatophytosis cases with positive KOH findings. Tinea unguium was diagnosed clinically and confirmed by KOH examination of nail samples. Detailed sociodemographic and clinical data, including comorbidities, hygiene practices, treatment history, and family history, were recorded. All patients underwent thorough cutaneous and nail examination, supplemented by dermoscopy and KOH microscopy (20%) of nail scrapings, with Chicago sky blue staining used to enhance diagnostic sensitivity. Patients with other nail disorders such as psoriasis, lichen planus, erythroderma, and those with paronychia-associated onychomycosis were excluded. Data were analyzed using SPSS version 22, with categorical variables expressed as frequencies and percentages and continuous variables as mean ± standard deviation; Chi-square or Fisher's exact test was applied, and a p-value <0.05 was considered statistically significant.

Results

A total of 80 cases and 80 controls were included, with 55% of cases having chronic and 45% having recurrent dermatophytosis. The most affected age group in both groups was 21–40 years, with a higher mean age in cases (41.1 ± 15.5 years) compared to controls (29.4 ± 16.4 years). Females predominated in both groups, and most participants were engaged in indoor occupations, while a larger proportion of controls were students. Sharing of linen (71.3% vs 37.5%, P = 0.001) and positive family history (72.5% vs 57.5%, P = 0.047) were significantly higher among cases. Comorbidities such as hypertension and diabetes were noted in both groups, and topical steroid use was common but not statistically significant. The most frequent clinical presentation was combined tinea corporis and tinea cruris. Tinea unguium was observed in 7.5% of cases and 2.5% of controls (P = 0.27), more commonly in recurrent cases and predominantly affecting fingernails, with all cases confirmed by KOH examination.

Conclusions

Chronic and recurrent dermatophytosis (CRD) remains a complex and evolving entity with limited evidence guiding its epidemiology and pathogenesis. Factors such as increasing age, fomite transmission (especially via linen), topical corticosteroid abuse, and host immunity appear to contribute to persistence and recurrence. Although the predominant pathogen shows greater skin affinity, hair and nail evaluation remains important.

EA DV CONGRESS
VIENNA
30 SEP - 3 OCT 2026

Abstract N°: 724

Histoid Leprosy: an unusual case

Maria Clara Linhares*[1], Bruno Soares[1], Isabella Dossin[1], Maria Castro[1], João Avelleira[1]

[1] Lagoa Federal Hospital, Rio de Janeiro, Brazil

Introduction

The terminology 'Histoid' was established in 1963 by Wade as a histological term describing tumors that develop from spindle-shaped cells, lacking the granulomatous and inflammatory evidence typically found in classical Lepromatous Leprosy (LL). Wade characterized this finding as a rare variant of LL, occurring in previously treated and cured patients who experienced relapse and subsequently developed lesions resistant to sulfone therapy, termed histoid lesions.

However, as early as 1947, Brazilian researchers Portugal and Mota had already observed spindle-cell patterns when analyzing biopsies from leprosy patients. In 1985, Sehgal reported histoid lesions in patients without a prior history of LL or sulfone treatment. Furthermore, a 2009 retrospective study of 40 cases evidenced histoid lesions not only in the Lepromatous pole but also across the borderline spectrum. The present case portrays a presentation of Multibacillary Leprosy with multiple lesions in the Histoid variant.

Case Presentation

A 49-year-old male presented with an 11-month history of papules, nodules, and plaques. The lesions were normochromic or erythematous, some ulcerated and slightly infiltrated, featuring a shiny surface with telangiectasias, distributed across the face, trunk, back, and both upper and lower extremities. Furthermore, physical examination revealed madarosis, accentuated facial lines, and infiltration of the ears. No thickening of peripheral nerve trunks or other physical abnormalities were noted. The patient reported that two coworkers presented with similar lesions.

Slit-skin smear (SSS) examination was performed, revealing numerous acid-fast bacilli (AFB). An incisional biopsy of a nodule demonstrated spindle-shaped histiocytes and a high bacillary load on Ziehl-Neelsen staining. The diagnosis of Histoid Leprosy was confirmed based on clinical presentation, bacilloscopy, and histopathology. Treatment for Multibacillary Leprosy was initiated using the Unified Multi-Drug Therapy (U-MDT) regimen, alongside screening and guidance for close contacts.

Discussion:

Histoid leprosy is a rare variant characterized by distinct immunological, clinical, histological, and bacteriological features. There is a predominance in males, particularly between the third and fourth decades of life. Clinically, patients exhibit lesional polymorphism, including papules, plaques, and subcutaneous nodules that are generally normochromic and painless, predominantly located on the upper limbs, trunk, and over bony prominences. These lesions may present a keloid-like appearance and central ulceration. In advanced cases, the oral and genital mucosae may be involved. Regarding peripheral nerve involvement, the ulnar nerve is most frequently affected, followed by the lateral popliteal nerve.

The histopathology of histoid leprosy involves three patterns: fusocellular, fusocellular with an epithelioid component, and fusocellular with vacuolated cells. The skin smear examination reveals abundant acid-fast bacilli in clusters or as isolated cells. These bacilli appear longer than typical leprosy bacilli. They exhibit a high bacillary and

morphological index. Diagnosis can be challenging, as it may mimic various conditions, such as xanthomatosis, neurofibromatosis, dermatofibroma, cutaneous metastasis, acute sarcoidosis, keloid, molluscum contagiosum, and the papulonodular variant of secondary syphilis. Multidrug therapy is the first-line treatment regimen for leprosy, recommended by the WHO since 1982. In 2018, the WHO began recommending three medications (rifampicin, clofazimine and dapsone) for the treatment of all cases of leprosy, regardless of operational classification. Histoid cases are treated with 12 courses of MDT.

Conclusion

Recognizing Histoid variant is crucial to avoid diagnostic errors. This case reinforces the need for U-MDT protocols to ensure cure and control transmission.

EADV CONGRESS
VIENNA
30 SEP - 3 OCT 2026

Abstract N°: 763

Retrospective Clinical Analysis of 14 Cases of Cutaneous Non-tuberculous Mycobacterial Infections

Xiaojiao Zhao*[1], Jianjian Zhu[1], Xin Li[1], Jing Xu[1], Xiaoxiao Chen[1]

[1] Changde Hospital, Xiangya School of Medicine, Central South University, Changde, China

Introduction
To analyze the clinical characteristics, diagnostic methods and treatment outcomes of cutaneous non-tuberculous mycobacterial (NTM) infections, and to improve the clinical identification, diagnosis and treatment level of the disease.

Materials and Methods
A retrospective analysis was conducted on the clinical data of 14 patients with etiologically confirmed cutaneous NTM infections admitted from March 2022 to January 2026. The demographic features, clinical phenotypes, etiology, imaging findings, underlying diseases and treatment prognosis of the patients were summarized.

Results
Among the 14 patients, 5 were male and 9 were female, with a mean age of (58.9±12.7) years and a mean course of disease of (9.50±21.80) months. Most skin lesions were limited to exposed parts such as the face and upper extremities, distributed in the unilateral upper extremity (6 cases, 42.9%) and face (4 cases, 28.6%), and the rest in the unilateral lower extremity, bilateral lower extremities, scattered limbs and generalized distribution (1 case each). The clinical manifestations included nodules (10 cases, 71.4%), plaques (4 cases, 28.6%), erythema (3 cases, 21.4%), papules (2 cases, 14.3%) and ulcers (1 case, 7.1%). The common predisposing factors were medical aesthetic procedures (injection rhytidectomy, 2 cases) and trauma/occupational exposure (fishery contact, plant stab wound, 2 cases), accounting for 28.6%. A total of 8 NTM species were detected, with Mycobacterium abscessus (4 cases, 28.6%), Mycobacterium marinum (3 cases, 21.4%) and Mycobacterium haemophilum (3 cases, 21.4%) being the most common. Pulmonary CT was performed in 8 patients, all of whom had abnormal pulmonary imaging findings. Eight patients (57.1%) had at least one important underlying disease or immunosuppressive state. Initial treatment was mainly based on the combination of macrolides (clarithromycin) and fluoroquinolones (moxifloxacin). The treatment regimen was adjusted in 4 patients due to poor initial efficacy. The 11 patients with available follow-up had a good prognosis, and 3 patients were lost to follow-up.

Conclusions
The clinical manifestations of cutaneous NTM infections are non-specific and prone to misdiagnosis. Different species have species-specific characteristics in infection routes, high-risk groups and treatment responses. Molecular diagnostic techniques such as PCR and high-throughput sequencing are the key to identifying the species accurately. Individualized combined medication based on species identification is required for treatment. Especially for drug-resistant species such as Mycobacterium abscessus, effective drugs should be selected according to drug sensitivity results or surgical intervention should be performed. Meanwhile, a comprehensive systemic evaluation of patients is necessary.

EA DV CONGRESS
VIENNA
30 SEP - 3 OCT 2026

Abstract N°: 780

Outbreak of Cutaneous Larva Migrans in a Training Academy in Zanzibar: A Case Series of Ten Patients

Hafidh Hassan*[1]

[1] Mnazi Mmoja Hospital, Mnazi Mmoja Hospital, Mnazi Mmoja Hospital, Zanzibar, Tanzania

Introduction

Cutaneous larva migrans (CLM) is a parasitic dermatosis caused by the epidermal migration of hookworm larvae, most commonly Ancylostoma braziliense and Ancylostoma caninum. It is endemic in tropical and subtropical regions with prevalence up to 15% in children, where exposure to contaminated soil or sand is common, especially those sitting or barefoot walking in places contaminated with faeces of infected dogs or cats. While CLM is typically seen in dogs and cats, humans can serve as accidental hosts.

The condition usually presents as serpiginous, erythematous, pruritic tracks on the ankles and feet, although other areas of the body in contact with infected soil or sand may also be affected. Although CLM is self-limiting, its dermatitis-like appearance can lead to misdiagnosis, prolonged morbidity, and inappropriate treatment.

Case Presentation

We present a case series of young female patients, aged 26 to 35 years, who attended the dermatology clinic with intense pruritus localised to the extremities, buttocks, and back, causing significant concern at the local training academy. Symptoms developed gradually, with all ten patients experiencing severe itching followed by serpiginous, raised, and slowly migrating lesions on the posterior thighs, legs, and buttocks, as shown in the image (1-5). Some also presented with nodules on the back, consistent with CLM. Most of them had attempted topical medications without improvement. All patients reported sitting on or contacting grass and sand during exercises in the rainy season, suggesting exposure to contaminated soil. No systemic symptoms were observed. The patient was treated with oral albendazole (400 mg daily for three days) and permethrin cream. Pruritus subsided within 48 hours, and the lesions regressed completely within two weeks. Follow-up at two weeks showed no recurrence in all patients except the one with back involvement, who remained with a few papules and PIH on the back.

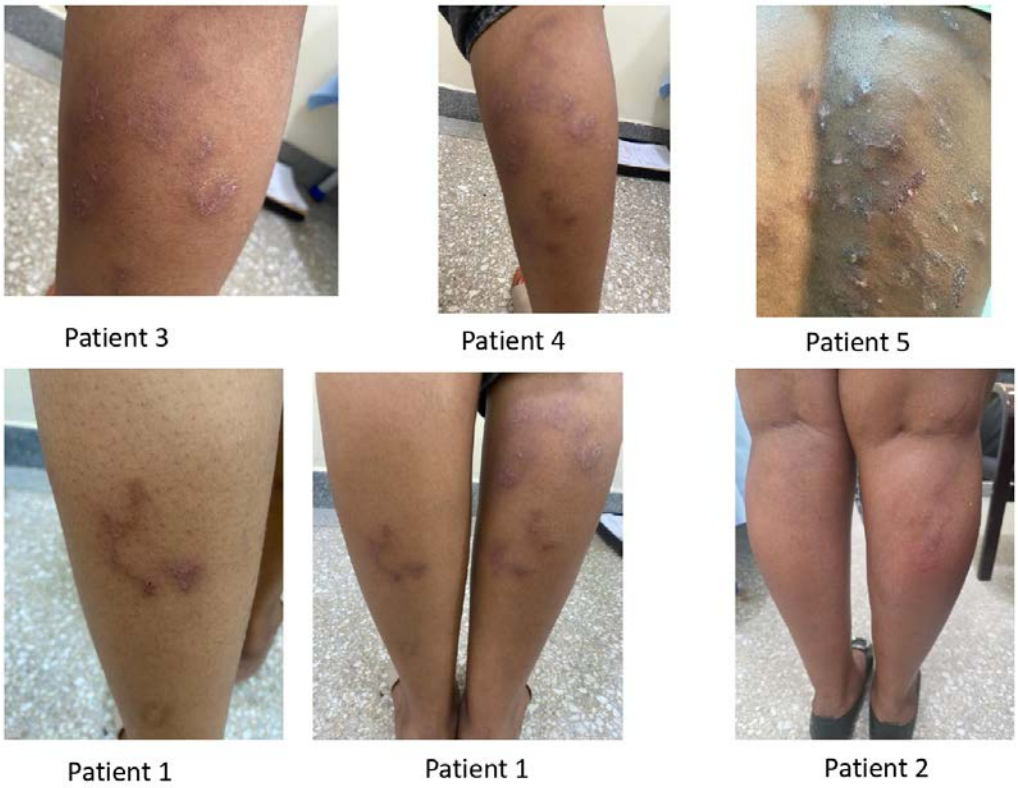

Image 1-4 represent patient with serpiginous, erythematous, pruritic tracks on the posterior legs and thigh while image 5 shows nodules, excoriation and serpeginous lesion on the back

Conclusion

This case illustrates the need to raise awareness among primary healthcare providers about CLM and the associated risk factors, as it is often misdiagnosed. The serpiginous nature of the eruption and the patient's exposure history can lead to timely diagnosis and appropriate treatment as well as reducing prolonged morbidity, and minimising economic impact and associated stigma.

Considering the zoonotic and touristic nature of the island, a One Health approach with integrated surveillance and response systems among humans, animals, and the environment is needed for an effective prevention and control strategy.

EA DV CONGRESS
VIENNA
30 SEP - 3 OCT 2026

Abstract N°: 798

Imported Human Tungiasis in Greece with Secondary Household Transmission

Thomas Fotas*[1], Ioannis Pappas[2], Menelaos Lefkaditis[3], George Christodoulopoulos[4]

[1] General Hospital "Asklepieion Voulas", Department of Dermatology and Venereology, Athens, Greece

[2] Laboratory of Pharmacology and Toxicology, Faculty of Veterinary Science, University of Thessaly, Karditsa, Greece

[3] Laboratory of Microbiology and Parasitology, Faculty of Veterinary Science, University of Thessaly, Karditsa, Greece

[4] Department of Animal Science, Agricultural University of Athens, Athens, Greece

Introduction

Tungiasis is a cutaneous ectoparasitosis caused by the penetration of gravid female fleas of *Tunga penetrans* into the epidermis. The parasite undergoes marked hypertrophy within the host's skin and releases eggs into the environment, thereby completing its life cycle under suitable ecological conditions. The disease is highly endemic in tropical and subtropical regions, particularly in resource-limited settings, where environmental contamination and close human-soil contact facilitate transmission. In contrast, tungiasis is rare in Europe and, to date, has been reported exclusively in travelers returning from endemic areas. To our knowledge, there is no previously documented, molecularly confirmed evidence of secondary household transmission or full life cycle completion of *T. penetrans* in Mediterranean countries.

Case Presentation

We report a cluster of imported tungiasis cases in eleven Greek men following travel to Tanzania, one of whom was associated with subsequent transmission to his non-traveling cohabiting partner. All affected individuals presented with painful plantar and/or subungual nodular lesions. Dermoscopic examination revealed characteristic features, including a central crateriform opening, a peripheral pigmented ring, and whitish ovoid structures consistent with parasite eggs. Notably, parasite eggs were detected on the plantar skin in the majority of patients.

In the case involving secondary household transmission, this occurred shortly after the traveler's return in June 2023, when his female partner developed a similar lesion on the foot despite no history of travel abroad, strongly suggesting local transmission. In all eleven patients, as well as in the secondary case, embedded parasites were surgically extracted under sterile conditions.

Molecular identification was performed by PCR amplification and sequencing of the mitochondrial cytochrome oxidase II (COII) gene. Identical nucleotide sequences were obtained from the index patient and his partner. Phylogenetic analysis using the Maximum Likelihood method demonstrated clustering within the *T. penetrans* clade with strong bootstrap support, confirming species-level identification and indicating a shared genotype among all twelve cases.

Following complete surgical extraction, treatment included local wound care and systemic administration of ivermectin, resulting in full clinical resolution without recurrence. In addition, environmental control measures were implemented to reduce

the risk of reinfestation, including application of phoxim spray in the household environment, targeting potential off-host developmental stages of the parasite.

Conclusion

This report documents imported tungiasis with secondary household transmission in Greece, molecularly confirmed in both cases. Infestation in a non-traveling contact, together with viable, egg-producing parasites, demonstrates that Tunga penetrans completed its life cycle under local environmental conditions. To our knowledge, this is the first molecularly supported report of such transmission in a Mediterranean country.

Transmission occurred in June, when high ambient temperatures in Greece favor parasite development. In coastal areas of Attica, habitual barefoot walking in domestic outdoor environments (e.g., gardens and yards) likely increases exposure to contaminated soil. These climatic and behavioral factors likely facilitated both life cycle completion and secondary transmission.

These findings highlight the potential for focal autochthonous transmission in non-endemic regions under suitable conditions. Clinicians should consider tungiasis in travelers with compatible plantar or subungual lesions and examine close contacts when appropriate. Molecular characterization remains important for confirming diagnosis and clarifying transmission pathways in imported cases.

EA DV CONGRESS
VIENNA
30 SEP - 3 OCT 2026

Abstract N°: 828

A systematic review of ecthyma gangrenosum: Pathogen diversity,septicaemia status, and a call for redefinition

Lenah AlMarzouk*[1]

[1] Dammam Medical Complex, Dammam, Saudi Arabia

Introduction
Ecthyma gangrenosum (EG) is considered an emergency dermatological condition and classically defined as a Pseudomonas aeruginosa infection-associated necrotic skin lesion in immunocompromised patients with septicemia. However, emerging evidence suggests a broader spectrum of causative pathogens and cases without concurrent septicemia.

Materials and Methods
This review aimed to reassess the pathogen diversity and septicemia status in EG, advocating for a more inclusive clinical definition. To this end, a systematic review compliant with Preferred Reporting Items for Systematic reviews and Meta-Analyses was conducted using screening databases, such as PubMed, EMBASE, Scopus, and Web of Science. Overall, 162 literature reports (311 patients) that described EG with confirmed pathogen identification were included. Data on pathogen types, septicemia, immune status, lesion location, and management were extracted and analyzed.

Results
Our findings revealed pathogen diversity, with P. aeruginosabeing the most common pathogen (72.2%), and other organismsaccounted for the remaining 27.8% of the cases (methicillin-resistant Staphylococcus aureus: 4.9%, fungi: 3.7%, andEscherichia coli: 4.3%). Septicemia was present in 61.7% of patients, and 71.0% were immunocompromised. Recovery rates varied by pathogen type, with P. aeruginosa cases having an 81.1% recovery rate, and fungal infections having a significantly lower recovery rate (47.4%). Mortality was the highest in fungal infection cases (52.6% vs. P. aeruginosa: 15.1%).

Conclusions
In conclusion, this review highlights the diverse microbial etiologies of EG and challenges the traditional view that the condition is solely linked to P. aeruginosa bacteremia. It advocates redefining EG as a pathogen-agnostic necrosis-driven entity to improve its diagnosis and management.

EADV CONGRESS
VIENNA
30 SEP - 3 OCT 2026

Abstract N°: 832

Rhinocerebral Mucormycosis in a Patient with Myelofibrosis: Clinical Significance of the Black Eschar

Juan BAI*[1], Xinyi CHEN[1], Jianjun QIAO[1], Hong FANG[1, 1]

[1] The first affiliated hospital of Zhejiang university school of medicine, Hangzhou, China

Introduction

Mucormycosis is an opportunistic, angioinvasive fungal infection that occurs primarily in immunocompromised individuals. Given its rapid progression and high mortality rate, early identification of cutaneous manifestations is essential. We report a case of rhinocerebral mucormycosis in a patient with myelofibrosis, focusing on the diagnostic value of necrotic skin lesions.

Case Presentation

A 59-year-old female with a history of chronic kidney disease and myelofibrosis presented with a one-month history of painful nasal sores, progressive facial swelling, fever, and headache. Physical examination revealed erythematous to violaceous plaques and deep ulcerations on the face. Distinct necrotic black eschars were observed involving the midface, periorbital region, nasal passages, and hard palate.Histopathological examination of a biopsy specimen demonstrated extensive tissue necrosis and granulomatous inflammation, with the presence of broad, pauciseptate, ribbon-like hyphae showing right-angle (90°) branching. A diagnosis of rhinocerebral mucormycosis was established. Management included urgent surgical debridement and systemic treatment with liposomal amphotericin B.

Conclusion

This case highlights the importance of maintaining a high index of suspicion for mucormycosis in patients with hematological systemic diseases who present with facial necrosis. The "black eschar" is a characteristic clinical sign that necessitates immediate histopathological confirmation and multidisciplinary intervention. Early recognition remains a critical factor in managing this severe infection.

EADV CONGRESS
VIENNA
30 SEP - 3 OCT 2026

Abstract N°: 833

Majocchi's Granuloma Mimicking Subcutaneous Nodules in a Patient with Acute Myeloid Leukemia

Juan BAI*[1], Xinyi CHEN[1], Qiqi Wang[1], Jianjun QIAO[1]

[1] The first affiliated hospital of Zhejiang university school of medicine, Hangzhou, China

Introduction

Majocchi's granuloma (MG) is a deep-seated inflammatory dermatophytosis resulting from fungal invasion into the dermis or subcutaneous tissue. In immunocompromised hosts, particularly those with hematological malignancies, MG can present atypically and progress aggressively. We report a significant case of MG in a patient with acute myeloid leukemia (AML), emphasizing the critical role of molecular diagnostics in identifying opportunistic fungal pathogens.

Case Presentation

A 61-year-old male with a 2-year history of AML presented with a one-week history of multiple, painless, subcutaneous nodules on the right thigh. No prior trauma was reported. Physical examination revealed several dusky-red, firm nodules (0.5~1.5 cm) on the right thigh, accompanied by erythematous patches on bilateral thighs.Soft-tissue ultrasound identified well-defined hypoechoic nodules in the dermis without internal vascularity. Histopathology of a nodule biopsy demonstrated a diffuse dermal infiltrate of histiocytes, neutrophils, and multinucleated giant cells. Characteristic cystic structures contained fungal hyphae and spores, confirmed by strongly positive PAS, GMS, and fungal immunofluorescence stains. While fungal culture was performed, metagenomic next-generation sequencing (mNGS) of the tissue provided rapid and definitive identification of Trichophyton rubrum.The patient was treated with oral terbinafine (250 mg/day). Following six months of therapy, the subcutaneous nodules resolved completely. No recurrence was observed during the 12-month follow-up.

Conclusion

This case highlights that in the context of AML-related immunosuppression, common superficial dermatophytes can lead to deep-seated invasion, mimicking primary subcutaneous tumors or panniculitis. Clinicians must maintain a high index of clinical suspicion for MG when subcutaneous nodules appear at sites prone to dermatophytosis in immunocompromised patients. The integration of mNGS with traditional histopathology facilitates early diagnosis and targeted antifungal management in complex hematological cases.

EA DV CONGRESS
VIENNA
30 SEP - 3 OCT 2026

Abstract N°: 834

A Sight-Threatening Masquerader: Type II Periorbital Craniofacial Necrotizing Fasciitis Complicating Uncontrolled Type 2 Diabetes

Dini Daniaty Imam*[1, 2], Eliza Miranda[1, 2], Sri Menaldi[1, 2]

[1] Department of Dermatology and Venereology, Dr. Cipto Mangunkusumo National Hospital, Jakarta, Indonesia
[2] Faculty of Medicine, Universitas Indonesia, Jakarta, Indonesia

Introduction

Necrotizing fasciitis (NF) is a rare but rapidly progressive, life-threatening infection spreading along fascial planes, with a rising incidence of ~4 cases per 100,000 persons/year and mortality of 12.1–76%. Periorbital craniofacial NF is an uncommon subtype that often mimics cellulitis, and delayed intervention risks blindness, intracranial extension, and death. Diabetes mellitus, the most prevalent comorbidity (44.5–72.3%), impairs immunity, endothelial function, and wound healing.

We report a case of type II periorbital craniofacial NF in a patient with uncontrolled type 2 DM to highlight the diagnostic pitfalls and the importance of multidisciplinary management.

Case Presentation

A 58-year-old female presented with a 2-week history of a painful (VAS 5/10) erythematous plaque with periorbital swelling around the right eye, initially arising from pruritus-induced excoriation, which progressed to a furuncle before evolving into an ulcerative lesion.

She had uncontrolled type 2 DM (HbA1c 11.1%) with irregular metformin use and severe periodontitis with gangrenous dental roots. On examination, she appeared acutely ill and tachycardic (129 bpm), with an erythematous, indurated, diffuse plaque bearing multiple ulcers (size of 0.5×0.5×0.1 cm to 2×0.5×0.3 cm) over the right orbit, periorbital region, and cheek. The wound bases were covered with purulent discharge, slough, and yellowish-brown crusts. Laboratory findings revealed leukocytosis (21,810/µL), elevated C-reactive protein (300.4 mg/L), hyponatremia (131 mEq/L), hyperglycemia (392 mg/dL), and elevated procalcitonin (0.09 ng/mL). The Laboratory Risk Indicator for Necrotizing Fasciitis (LRINEC) score was 8, consistent with high- risk NF. CT demonstrated preseptal and postseptal orbital cellulitis with destruction of the lateral wall of the ethmoid sinus, and maxillary sinusitis. Initial wound culture grew *Klebsiella pneumoniae* and *Enterobacter sp.*

Our multidisciplinary team (dermatology, plastic surgery, ophthalmology, internal medicine, dentistry,and ENT) initiated empirical intravenous piperacillin–tazobactam 4.5 g every 6 hours and clindamycin 600 mg every 8 hours with saline compresses twice daily. Hyperglycemia was managed with insulin infusion followed by subcutaneous insulin (3×12 IU). Surgical debridement on day 3 revealed necrotic tissue, fragile fascia, and approximately 10 mL of pus extending to subcutaneous tissue, muscle, and bone of the upper eyelid. Intraoperative tissue culture yielded Staphylococcus aureus susceptible to clindamycin and levofloxacin, with no anaerobes or fungi, confirming type II (monomicrobial) NF. Histopathology showed extensive dermal, subcutaneous, and muscular necrosis with nerve fiber necrosis, lymphocytic and neutrophilic infiltration, and damaged vessel walls — consistent with NF.

Post-debridement, we used a dialkylcarbamoyl chloride (DACC) dressing for daily wound care. By day 7, the wound was clean with early granulation and the LRINEC score had decreased to 1. The patient was discharged on oral levofloxacin and clindamycin, with outpatient follow-up showing progressive healing. Local flap

reconstruction was planned once the wound bed and glycemic control were optimized.

Conclusion

This case underscores the diagnostic challenge of periorbital craniofacial NF, which may initially mimic cellulitis, particularly in patients with uncontrolled DM. An LRINEC score ≥8, rapidly progressive lesion, and systemic signs should prompt urgent surgical exploration. Multidisciplinary collaboration, alongside timely debridement and broad-spectrum antibiotic therapy, is essential to prevent vision loss and reduce mortality. Clinicians must maintain a high index of suspicion for NF in immunocompromised patients presenting with periorbital infections.

EADV CONGRESS
VIENNA
30 SEP - 3 OCT 2026

Abstract N°: 837

Symmetrical midfacial erythema and nasal necrotic eschar in an elderly patient with CLL: mNGS solves the mystery

Zihan Zhao*[1, 2, 3], Ying Huang[2], Xin Ran[2], Yu-Ping Ran[2]

[1] West China School of Medicine, Sichuan University, Chengdu, China

[2] West China Hospital, Chengdu, China

[3] Department of Dermatology and Venerology, Peking University First Hospital, Peking University, Beijing, China

Introduction

Necrotic nasal lesions in immunocompromised elderly patients present a significant diagnostic challenge because invasive mucormycosis and neoplastic lesions may also share overlapping clinical features. We report an unusual case of severe HSV-1 infection with secondary streptococcal superinfection in an elderly patient with chronic lymphocytic leukaemia (CLL) receiving zanubrutinib, highlighting the diagnostic value of multimodal pathogen-directed investigation.

Case Presentation

An 82-year-old woman with CLL receiving a Bruton's tyrosine kinase inhibitor (zanubrutinib 80 mg bid) presented with a 7-day history of a rapidly progressive necrotic lesion on the nasal ala, clinically mimicking rhino-orbito-cerebral mucormycosis. Examination revealed a centrally located black necrotic crust involving the nasal ala and vestibule, accompanied by striking bilateral violaceous erythema extending across the perinasal region and nasolabial folds.

Nasal endoscopy showed no sinus invasion, while fungal microscopy and cultures were negative. Due to frailty and concern for delayed wound healing, skin biopsy was deferred.

Metagenomic next-generation sequencing identified herpes simplex virus type 1 (HSV-1) and Streptococcus spp., and transmission/scanning electron microscopy (TEM/SEM) demonstrated herpesvirus-like particles within the necrotic crust (Figure 1). A final diagnosis of atypical HSV-1 infection with secondary streptococcal erysipelas was established.

The patient responded well to antiviral and antibacterial therapy. Marked clinical improvement was observed, with only mild residual hyperpigmentation at 1-month follow-up and complete clinical recovery.

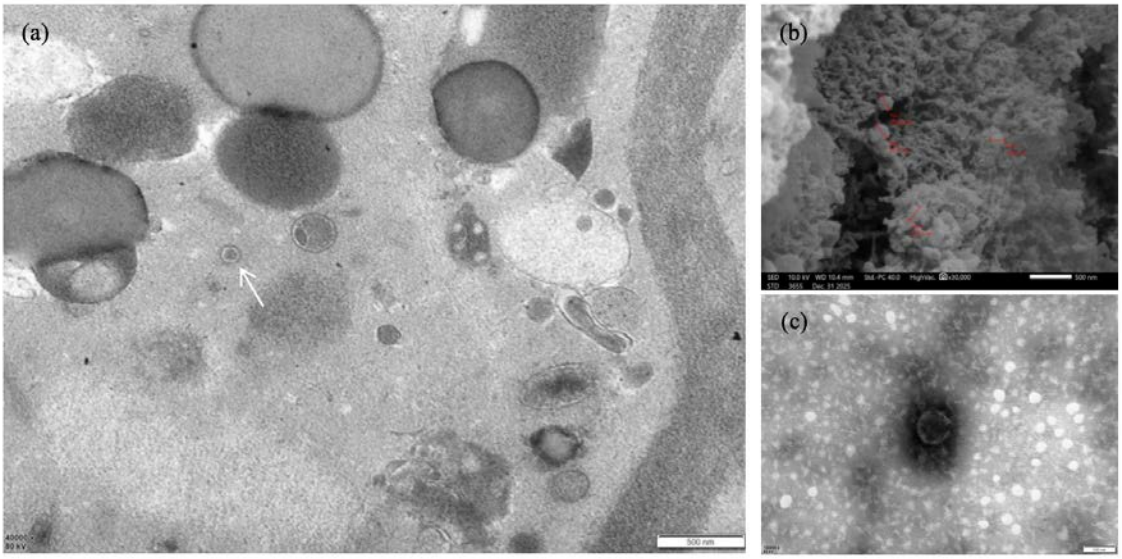

Figure 1: Ultrastructural findings. (a) TEM showing virus-like particles (arrow); (b) SEM revealing spherical particles ~150–200 nm; (c) negative-stain TEM demonstrating virus-like particles.

Conclusion

This case highlights key diagnostic challenges and expands the limited literature on atypical HSV-1 infection in elderly East Asian patients with haematological malignancies.

In immunocompromised individuals, HSV-1 may present with necrotic, tumour-like facial lesions closely mimicking invasive fungal infection. Concurrent viral and bacterial infection may further exacerbate inflammation and alter lesion morphology, while interconnected superficial facial lymphatics may contribute to symmetrical midfacial erythema.

This case also underscores the value of multimodal diagnostics, particularly mNGS combined with ultrastructural examination, for rapid pathogen identification when conventional investigations are inconclusive or when biopsy is high-risk, enabling timely targeted therapy.

EADV CONGRESS
VIENNA
30 SEP - 3 OCT 2026

Abstract N°: 837

Survival Outcomes and Treatment Response in Disseminated versus Localized Cutaneous Leishmaniasis: A 10-Year Retrospective Cohort Study

Caio César Silva[1], Maria Beatriz Nascimento[1], José Fabrício Leal[1], Milena Neves Sampaio*[1], Aridne Campos[1], Renata Trindade Gonçalves[1], Lúcia Helena Fernandes[1], Raimunda Sampaio[1], Daniel Barroso[1, 1]

[1] University of Brasília, University Hospital of Brasília, Brasília, Brazil

Introduction
American Tegumentary Leishmaniasis (ATL) encompasses a broad clinical spectrum, with disseminated leishmaniasis (DL) emerging as a severe and increasingly recognized phenotype characterized by multiple polymorphic lesions and reduced responsiveness to standard therapies. Compared to localized cutaneous leishmaniasis (LCL), DL is consistently associated with higher therapeutic complexity, increased treatment failure, and worse clinical outcomes. However, robust longitudinal data quantifying differences in healing trajectories remain limited. This study aimed to compare time to clinical cure between DL and LCL and to identify predictors of delayed healing.

Materials and Methods
A retrospective cohort study was conducted including patients diagnosed between 2014 and 2024. From 366 screened individuals, 123 met inclusion criteria, defined by parasitological or histopathological confirmation of leishmaniasis: 115 (93.4%) with LCL and 8 (6.5%) with DL. Exclusions included isolated mucosal disease (n=54), alternative diagnoses (n=61), and loss to follow-up prior to treatment initiation (n=128). The primary endpoint was time to clinical cure, defined as complete re-epithelialization of all lesions without signs of active inflammation. Kaplan–Meier curves were used to estimate time to clinical cure, and comparisons were performed using the log-rank test. Multivariable Cox proportional hazards models were applied to estimate hazard ratios (HRs), adjusted for age, sex, and lesion duration. All tests were two-sided, with $p<0.05$ considered significant.

Results
Baseline characteristics were comparable between groups, including mean age (44.6 years). Median lesion duration was 4 months in LCL and 5 months in DL. All DL patients were male, compared to 64.3% in LCL (p=0.05). DL patients required more frequent use of second-line therapies, including amphotericin B (50% vs. 10.4%, p=0.01) and pentamidine (25% vs. 3.5%, p=0.04), reflecting greater clinical severity and therapeutic escalation. Meglumine antimoniate remained the most commonly used treatment in both groups. In survival analysis, DL showed a significantly reduced probability of clinical cure over time (HR=0.35; p=0.024), persisting after adjustment (HR=0.29; p=0.021). Most importantly, median time to clinical cure was more than doubled in DL compared to LCL (784 vs. 350 days), demonstrating a marked divergence in healing trajectories between clinical phenotypes.

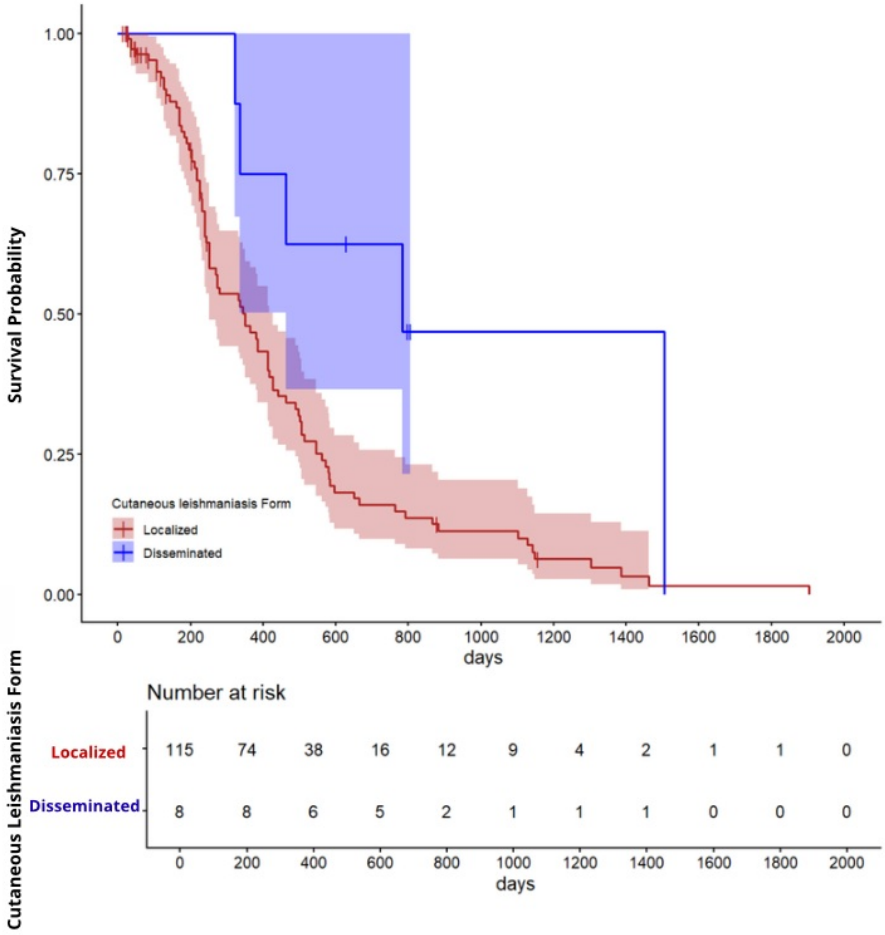

Time-to-Cure Analysis in American Tegumentary Leishmaniasis (ATL) Phenotypes. Kaplan-Meier survival curves comparing the therapeutic response between Localized Cutaneous Leishmaniasis (LCL, red line; n=115) and Disseminated Leishmaniasis (DL, blue line; n=8). The vertical axis represents the probability of remaining uncured, with complete re-epithelialization of all lesions as the primary endpoint. Shaded areas indicate 95% Confidence Intervals (95% CI), and vertical ticks represent censored observations. Median time to clinical cure was significantly longer for the disseminated phenotype (784 days vs. 350 days in LCL). The marked divergence between the cohorts underscores the prolonged time-to-healing and the refractory clinical course associated with the disseminated phenotype (Log-rank p=0.024)

Conclusions

Disseminated leishmaniasis represents a distinct high-risk clinical phenotype associated with significantly delayed healing, increased therapeutic complexity, and reduced treatment responsiveness. The more than two-fold prolongation in median time to clinical cure, together with a significantly reduced hazard of healing, supports DL as a biologically and clinically distinct entity rather than a simple extension of localized disease. These findings quantify a substantial therapeutic gap between clinical forms and underscore the importance of early recognition and phenotype-driven management strategies. They also suggest underlying differences in host–pathogen interaction that may contribute to divergent clinical evolution. Further prospective studies are warranted to optimize management and evaluate alternative or adjunctive therapies in disseminated disease.

EADV CONGRESS
VIENNA
30 SEP - 3 OCT 2026

Abstract N°: 856

Postherpetic Abdominal Pseudohernia: Report of Two Cases

Kubra Akdemir Yucel*[1], Sumeyye Altinkas Kaksi[1], Ozan Erdem[1], Humeyra Ozger Abdullahoglu[1], Mehmet Salih Gurel[1]

[1] Department of Dermatology, Istanbul Medeniyet University Faculty of Medicine, Goztepe Prof. Dr. Suleyman Yalcin Training and Research Hospital, Istanbul, Türkiye

Introduction

Herpes zoster usually presents with a painful vesicular eruption in a dermatomal distribution. Although sensory complications are common, motor involvement is rare. Postherpetic abdominal pseudohernia is an uncommon motor complication caused by segmental weakness of the abdominal wall muscles and may mimic a true abdominal hernia.

Case Presentation

A 73-year-old man presented with herpes zoster involving the right lower trunk. His medical history was notable for diabetes mellitus and hypertension. At presentation, he complained of skin lesions, constipation, and swelling on the right side of the abdomen. Dermatological examination revealed grouped vesicular lesions involving the right T11–T12 dermatomes. He was treated with oral valacyclovir 1,000 mg three times daily for 7 days. During follow-up, the lesions gradually regressed and became crusted, while the right lower abdominal bulging persisted. The patient reported that the swelling had started together with the zoster eruption. Abdominal ultrasonography revealed no pathology, and postherpetic abdominal pseudohernia was diagnosed. The pseudohernia later resolved completely without postherpetic neuralgia.

A 70-year-old woman presented with severe herpes zoster involving the left lumbar region. Her medical history was notable for diabetes mellitus, hypertension, and hypothyroidism. Dermatological examination revealed grouped vesicles involving the left L1–L2 dermatomes. She was treated with intravenous acyclovir for one week. During follow-up, the lesions gradually crusted and healed; however, neuropathic pain persisted. Because of postherpetic neuralgia, pregabalin was started and later increased to 150 mg twice daily. The lesions healed with postinflammatory hyperpigmentation. At the fourth month of follow-up, swelling developed on the left side of the abdomen. Physical examination revealed abdominal wall bulging extending over the left lower thoracic to upper lumbar dermatomal area (T12–L2), consistent with postherpetic abdominal pseudohernia.

Conclusion

Postherpetic abdominal pseudohernia is a rare manifestation of segmental zoster paresis. It may appear during the acute eruption or later during follow-up and may or may not be accompanied by persistent neuropathic pain. Recognition of this entity is important to avoid misdiagnosis and unnecessary surgical referral. These two cases highlight the variable timing and clinical course of this rare motor complication.

EADV CONGRESS
VIENNA
30 SEP - 3 OCT 2026

Abstract N°: 892

Real-World Comparison of 5% Permethrin Cream Alone versus Combination with Oral Ivermectin for the Treatment of Scabies: A Retrospective Study

Pantaree Kobkurkul*[1], Sumanas Bunyaratavej[1], Pattriya Jirawattanadon[1], Lalita Matthapan[1], Waranyoo Prasong[1], Akkarapong Plengpanich[1], Chatisa Panyawong[1], Wittawat Turakit[1], Charussri Leeyaphan[1]

[1] Department of Dermatology, Faculty of Medicine Siriraj Hospital, Mahidol University, Bangkok, Thailand

Introduction

Scabies is caused by *Sarcoptes scabiei* var. *hominis*, an ectoparasitic mite. Transmission occurs through close person-to-person contact or via contaminated fomites. Outbreaks commonly occur in crowded settings and have been increasingly reported in nursing homes for older adults. Topical scabicides, such as 5% permethrin cream, are the standard treatment for classic scabies and have a favorable safety profile. However, combination therapy with oral ivermectin is increasingly used because it is presumed to be more effective than monotherapy, although comparative evidence remains limited. This study aimed to compare the real-world effectiveness of 5% permethrin cream monotherapy versus combination therapy with oral ivermectin for the treatment of scabies.

Materials and Methods

This retrospective study included patients aged ≥18 years who were diagnosed with scabies confirmed by skin scraping demonstrating mites, eggs, or feces between January 2020 and December 2024. Patients received either 5% permethrin cream applied twice at a 7-day interval or combination therapy with oral ivermectin (200 mcg/kg/dose), administered as two doses 7 days apart. Cure was defined as negative skin scraping or clinical resolution based on physician assessment. Treatment-related adverse effects were also recorded.

Results

A total of 82 patients with scabies were included in the study. Of these, 57 received combination therapy and 25 were treated with 5% permethrin cream alone. Baseline characteristics are shown in **Table.** There were no significant differences between the two groups in baseline age, underlying diseases, disease severity, or treatment compliance. However, the proportion of patients with chronic kidney disease was higher in the monotherapy group than in the combination group (36% vs. 14%, $P = .024$).The cure rates were 84.2% in the combination therapy group and 84.0% in the monotherapy group, with no statistically significant difference between the groups ($P = 1.000$). Two patients (3.5%) in the combination group developed contact dermatitis related to 5% permethrin cream. No ivermectin-related adverse effects, including neurological events, were observed.

Table: Baseline characteristics

	5% Permethrin cream (N=25)	5%Permethrin cream & oral ivermectin (N=57)	P-value
	N (%)	N (%)	
Sex			
• Male	11 (44)	18 (31.6)	0.279
• Female	14 (56)	39 (68.4)	
Age (y) median (P25, P75)	75 (66,84)	76 (68,83)	0.891
Body mass index (kg/m²) mean ± SD	23.45 ± 5.20 [N=13]	23.00 ± 4.85 [N=42]	0.775
Underlying diseases			
• Diabetes mellitus	12 (48)	22 (38.6)	0.426
• Essential hypertension	15 (60)	36 (63.2)	0.786
• Dyslipidemia	10 (40)	34 (59.6)	0.100
• Chronic kidney disease	9 (36)	8 (14)	0.024*
• Neurological diseases	14 (56)	33 (57.9)	0.873
• Other concomitant cutaneous diseases	6 (24)	4 (7)	0.060
• HIV infection	0	1 (1.8)	1.000
• Other immunocompromised states	2 (8)	1 (1.8)	0.219
• Malignancy	6 (24)	4 (7)	0.060
• Limited mobility	17 (68)	42 (73.7)	0.598
Residence			
• Nursing home	11 (44)	30 (52.6)	
• Home	13 (52)	27 (47.4)	0.296
• Others	1 (4)	0	
History of contact with a scabies case	4 (16)	13 (22.8)	0.484
Diagnosis			
• Classic scabies	24 (96)	53 (93)	1.000
• Crusted scabies	1 (4)	4 (7)	
Location of the lesion			
• Head and neck	3 (12)	11 (19.3)	0.534
• Hand	13 (52)	42 (73.7)	0.054
• Finger web spaces	13 (52)	38 (66.7)	0.207
• Upper extremities	11 (44)	34 (59.6)	0.190
• Trunk	22 (88)	50 (87.7)	1.000
• Axilla	8 (32)	16 (28.1)	0.719
• Genitalia and buttock	13 (52)	14 (24.6)	0.015*
• Lower extremities	12 (48)	32 (56.1)	0.496
• Feet	5 (20)	17 (29.8)	0.355
• Toe web spaces	3 (12)	13 (22.8)	0.368
Symptom			
• Pruritus	24 (96)	55 (96.5)	1.000
Lesion morphology			
• Papule	18 (72)	42 (73.7)	0.874
• Plaque	5 (20)	22 (38.6)	0.099
• Patch	6 (24)	11 (19.3)	0.629
• Pustule	0	2 (3.5)	1.000
• Burrow	2 (8)	5 (8.8)	1.000
• Hyperkeratotic plaque	2 (8)	4 (7)	1.000
Skin scraping			
• Mites	20 (80)	51 (89.5)	0.297
• Eggs	21 (84)	45 (78.9)	0.765
• Feces	15 (60)	31 (54.4)	0.637
Good compliance	25 (100)	54 (98.2)	1.000

Table: Baseline characteristics

Conclusions

In this real-world study, combination therapy did not demonstrate significant superiority over 5% permethrin cream monotherapy. Permethrin alone remains an effective and well-tolerated treatment for scabies.

EADV CONGRESS
VIENNA
30 SEP - 3 OCT 2026

Abstract N°: 905

Disseminated Cutaneous Mycobacterium abscessus Infection in Adult-Onset Immunodeficiency with Anti–Interferon-γ Autoantibodies

Yu-Ching Wang*[1], Yu Hsiang Lin[1], Sheng-Hsiang Ma[1]

[1] Taipei Veterans General Hospital Department of Dermatology, Taipei, Taiwan

Introduction

Adult-onset immunodeficiency associated with anti–interferon-γ autoantibodies is an acquired immune disorder characterized by impaired interferon-γ–mediated immunity. It predominantly affects individuals of Asian ancestry and predisposes patients to severe, recurrent, or disseminated infections caused by intracellular pathogens, particularly nontuberculous mycobacteria (NTM). Cutaneous manifestations are heterogeneous and may mimic reactive dermatoses, leading to diagnostic challenges.

Case Presentation

A 56-year-old man with a history of recurrent infections presented with progressive ulcerative plaques involving the face, neck, and anterior chest wall for over six months. His medical history included recurrent cervical lymphadenitis, herpes zoster, and Salmonella bacteraemia. Physical examination revealed ulcerative and crusted plaques on the chin, neck, and anterior chest wall, along with multiple indurated papules and nodules in the axillary regions. Initial skin biopsies demonstrated dense neutrophilic and histiocytic infiltrates with occasional emperipolesis, raising consideration of neutrophilic dermatosis and Rosai–Dorfman disease. Immunosuppressive therapy was initiated; however, the lesions continued to progress. Subsequent biopsies from the anterior chest wall and axillary nodules revealed suppurative granulomatous inflammation with multinucleated giant cells. Tissue cultures consistently yielded Mycobacterium abscessus complex. Whole-body 18F-FDG PET demonstrated disseminated hypermetabolic lesions involving the skin and multiple lymph node regions, consistent with disseminated cutaneous and nodal infection. Given the disseminated NTM infection and prior history of opportunistic infections, testing for anti–interferon-γ autoantibodies was performed and revealed high titers, confirming adult-onset immunodeficiency.

Conclusion

This case highlights the diagnostic challenge of disseminated NTM infection presenting with neutrophilic dermatosis–like features. Early histopathologic findings may be misleading, and reliance on histology alone can result in inappropriate immunosuppressive therapy and disease progression. Microbiologic culture and molecular diagnostics are essential for accurate diagnosis. Clinicians should maintain a high index of suspicion for anti–interferon-γ autoantibody–associated immunodeficiency in adults with atypical, refractory, or disseminated cutaneous eruptions, particularly in the presence of recurrent opportunistic infections. Early recognition is critical to guide appropriate antimicrobial and immunomodulatory therapy.

EA DV CONGRESS
VIENNA
30 SEP - 3 OCT 2026

Abstract N°: 908

Expert curation of dermatologic image datasets for leprosy detection using an AI-based tool: standardizing diverse clinical presentations for algorithm training.

Bianca Barros Canhamaque Amorim[1], Douglas Almonfrey[2], Taynah Repsold[1], Thiago Zanetti[2], Rafael Loureiro[3], José Postigo[4], Nkechi Anne Enechukwu[5], João Nunes[1], Livya Soares[1], Rachel do Espirito Santo[1], Patricia Deps*[1]

[1] Department of Public Health, Postgraduate Programme of Infectious Diseases, Federal University of Espírito Santo (UFES), Vitória, Brazil

[2] Federal Institute of Espírito Santo (IFES), Vitória, Brazil

[3] Albert Einstein Hospital, São Paulo, Brazil

[4] World Health Organization, Global Neglected Tropical Disease Programme, Skin NTD, Geneve, Switzerland

[5] Dermatology & Infectious Disease Unit, Department of Internal Medicine, Nnamdi. Azikiwe University., Nnewi, Nigeria

Introduction

Leprosy remains a significant public health challenge characterized by complex diagnostic requirements and potential for severe disability. A major obstacle in developing reliable artificial intelligence (AI) for detection is the extraordinary morphological diversity of the disease. Dermatologic image datasets for leprosy must capture a wide spectrum of clinical presentations, including early hypopigmented lesions, infiltrated plaques, reactional states, and late-stage sequelae. This variability is further increased by nerve involvement, particularly autonomic and peripheral nerve damage, which leads to secondary changes such as xerosis, fissures, neuropathic changes, and facial alterations. AI is a transformative tool for image-based leprosy detection; however, its reliability is often compromised by heterogeneous labeling and inconsistent terminology. To ensure the development of robust and generalizable algorithms, dermatologic image datasets must therefore be paired with standardized clinical metadata derived from rigorous expert image analysis. The objective of this study is to develop a standardized dermatologic morphology classification for AI-based leprosy detection and evaluate the feasibility of extracting comprehensive clinical metadata through independent expert curatorship of image datasets. By analyzing specialist-confirmed cases across global training and external testing cohorts, we aim to ensure that algorithm development captures a broad range of clinical presentations, ultimately enhancing the reliability and generalizability of diagnostic support tools like the WHO Skin NTDs application.

Materials and Methods

Clinical images of confirmed leprosy cases were curated into two datasets: a training dataset (Dataset 1: n=306), used to train the algorithm for the WHO Skin NTDs application, and an external testing dataset (Dataset 2: n=418). While the initial diagnosis for all cases was established by leprosy specialists, a group of independent dermatologists subsequently performed a blinded analysis of the images to extract standardized metadata. Table 1 summarizes the data domains and variables derived from image analysis.

Table 1. Data aspects included in training and validation datasets

Data domain	Variables derived from image analysis
Clinical classification	Ridley–Jopling spectrum (TT, BT, BB, BL, LL, histoid), Madrid classification, operational classification (MB/PB)
Seven-category system	Macule/patch, plaque, nodule/papule, ulcer/erosion, scar/atrophy, neuropathy-related deformities, other skin changes
Lesion characteristics	Hypopigmentation, erythema, infiltration, scaling, nodularity, ulceration, atrophy, mixed lesions
Anatomical location	Face, upper limbs, lower limbs, trunk, hands, feet, ears, neck, multiple regions
Skin phototype	Fitzpatrick phototypes
Demographic inference	Adult, adolescent, child; gender estimation
Reactional states	Type 1 and 2 reaction, ENL, necrotic ENL, Lucio phenomenon
Neuropathy-related signs	Claw hand, foot drop, bone resorption, muscle wasting, other visual physical deformities
Facial alterations	Madarosis, saddle nose, sunken nose, facies leonina, lagophthalmos, RMS
Chronic sequelae	Scars, atrophy, ulcer scars, disabilities-related changes
Image-level variables	Single lesion vs multiple lesions, body region extent, localized vs disseminated

R-JC, Ridley–Jopling classification; LR, leprosy reactions; LF, Lucio phenomenon; I, indeterminate; TT, tuberculoid leprosy; BT, borderline tuberculoid leprosy; BB, borderline borderline leprosy; LL, lepromatous leprosy; LLh, histoid lepromatous leprosy; T1R, type 1 reaction; T2R, type 2 reaction; ENL, erythema nodosum leprosum; N ENL, necrotic erythema nodosum leprosum.

Results

A total of 724 clinical images were analyzed across both datasets, demonstrating substantial clinical heterogeneity. The expert-led consolidation of over 40 descriptive labels into a seven-category system successfully reduced label redundancy while preserving pathognomonic and clinically significant features. Table 2 shows the distribution of clinical skin lesions and leprosy classification, gender and age groups across both datasets. While the training dataset provided robust representation of Type 1 Reactions, the independent analysis of the testing dataset identified critical representation gaps, such as the Lucio phenomenon, which was absent in the training dataset. This expert-led characterization also confirmed a visual predominance of multibacillary cases in the testing dataset cohort, reflecting the clinical complexity of the disease in endemic settings.

Table 2: Distribution of leprosy reactions and Ridley-Joplin Classification

Category	Clinical aspects	Dataset 2	%	Dataset 1	%
LR	T1R	50	12.0	39	12.7
	N ENL (T2R)	13	3.1	0	0.0
	ENL (T2R)	17	4.1	10	3.3
	LF	7	1.7	0	0.0
	N/A	329	78.7	253	82.7
R-JC	I	22	5.3	11	3.6
	TT	48	11.5	32	10.5
	BT	96	23.0	15	4.9
	BB	61	14.6	57	18.6
	BL	43	10.3	20	6.5
	LL	98	23.4	50	16.3
	LLh	24	5.7	4	1.3
	N/A	0	0.0	113	36.9

R-JC, Ridley–Jopling classification; LR, leprosy reactions; LF, Lucio phenomenon; I, indeterminate; TT, tuberculoid leprosy; BT, borderline tuberculoid leprosy; BB, borderline borderline leprosy; LL, lepromatous leprosy; LLh, histoid lepromatous leprosy; T1R, type 1 reaction; T2R, type 2 reaction; ENL,

erythema nodosum leprosum; N ENL, necrotic erythema nodosum leprosum.

Conclusions

The curatorship of datasets by dermatologists is essential for improving algorithm training under a broad range of clinical presentations. This study demonstrates that high-quality metadata can be accurately extracted from clinical images of confirmed cases to guide the development, testing and validation of the WHO Skin NTDs app. Importantly, the creation of robust, equitable, and generalizable algorithms relies on the synergy of a multiprofessional team, integrating the expertise of clinicians, dermatologists and data scientists. This collaborative approach provides a roadmap for developing fairer and more effective diagnostic support tools to facilitate early leprosy detection across diverse global populations.

EADV CONGRESS
VIENNA
30 SEP - 3 OCT 2026

Abstract N°: 919

Immunological Impact of Dermatomycoses Gender-Associated Systemic Sensitization Independent of Clinical Severity

Artizana Dushi*[1], Artina Pajaziti[2], Fatime Kokollari[2]

[1] Faculty of Medical Sciences, Goce Delcev University, Stip, North Macedonia

[2] University Clinical Center of Kosovo, Prishtine, Kosovo

Introduction

Various immunological responses are triggered as a result of dermatomycoses. Even though a Th1-mediated cell response is necessary for clearing of fungal infections, a shift toward a Th2 response, which is branded by elevated specific and total IgE levels is linked to recalcitrant and chronic cases. This study aims to provide a thorough analysis of the immunological profile of patients with dermatomycosis with an emphasis on the IgE levels as a marker of systemic sensitization and its relation to gender and clinical severity.

Materials and Methods

A study was carried out on 60 patients which had been diagnosed with dermatomycosis by clinical medical examination, Wood's lamp, dermatoscopy and KOH microscopic examination. Whilst the identification of the fungal species was conducted through the usage of Sabouraud Dextrose Agar (SDA) cultures. On the other hand the total serum IgE levels were assessed using Enzyme-Linked Immunosorbent Assay (ELISA). And the statistical analysis included T-tests and Cohen's d to evaluate the significance and effect size of gender differences.

Results

In 80% of the patients the systemic sensitization (IgE>100 IU/ml) was observed. Furthermore, a strong correlation was detected between the male gender and the significantly higher IgE levels with a Mean of 1107.36 IU/ml) as opposed to females with a Mean of 255.51 UI/ml, that presents a high statistical significance with a p=0.009 and a large effect size presented by Cohen's d = 0.774. Notably, 88.4% of male patients exhibited high IgE levels. The immune response of the patients presented to be independent of the infection duration with a 81.3% in chronic ad 78.6% in the acute cases as well as the clinical lesion size

Conclusions

This study demonstrated that the systemic immune activation is induced significantly by dermatomycoses. The intensity of this sensitization is critically influenced by gender rather than visible clinical extent. These results present a strong necessity for a personalized therapeutic approach that take into consideration the systemic immunological profile, with an emphasis on male patients with high sensitization

EA DV CONGRESS
VIENNA
30 SEP - 3 OCT 2026

Abstract N°: 926

Isolated Lip swelling as the sole manifestation of hansens disease: A case series

Anisha Biswal*[1]

[1] Kalinga institute of medical science, bhubaneswar, India

Introduction

Hansen's disease is a chronic granulomatous infection caused by Mycobacterium leprae with classical involvement of skin and peripheral nerves. Oral and labial involvement is usually described in advanced multibacillary disease and commonly occurs along with cutaneous lesions.The usual clinical presentation of Hansen's disease includes hypopigmented or erythematous anesthetic patches, infiltrated plaques, nodules, peripheral nerve thickening, sensory loss, and, in multibacillary disease, diffuse infiltration of the skin. Mucosal involvement is more commonly reported in advanced lepromatous disease and typically affects the nasal mucosa, followed by the oral cavity. Within the oral cavity, lesions may involve the hard palate, soft palate, uvula, gingiva, tongue, and lips. Such manifestations generally occur in association with widespread cutaneous disease and high bacillary load rather than as an isolated finding.Lip involvement in Hansen's disease is uncommon, and isolated lip swelling as the sole manifestation is exceedingly rare. When enlargement of the lip occurs without accompanying skin lesions or peripheral neuropathy, the diagnosis is often overlooked. These patients are frequently labeled as having granulomatous cheilitis, cheilitis glandularis, chronic angioedema, Melkersson–Rosenthal syndrome, sarcoidosis, Crohn disease, or nonspecific inflammatory cheilitis. As a result, many receive repeated courses of corticosteroids, antihistamines, or antibiotics before the correct diagnosis is established.
Early diagnosis is crucial to prevent nerve damage, deformity, disability, and ongoing transmission.
Objective-To describe the clinical profile, diagnostic features, and early therapeutic outcomes of patients presenting with isolated lip swelling ultimately diagnosed as Hansen's disease.

Case Presentation

Of the 13 patients, nine were male and four female, with a mean age of 39.6 years (range: 22–64 years). Six patients had isolated upper-lip swelling, four had lower-lip involvement, and three had bilateral lip enlargement. The mean duration of symptoms prior to diagnosis was seven months. Common presenting features included diffuse non-tender enlargement, firmness, mild erythema, and occasional fissuring. No patient had visible skin patches or clinically significant peripheral nerve thickening at presentation. Initial diagnoses before referral included granulomatous cheilitis (n=5), cheilitis glandularis (n=3), chronic angioedema (n=3), and nonspecific inflammatory cheilitis (n=2). Slit-skin smear from the lip was positive for acid-fast bacilli in seven patients (53.8%). Fite-Faraco staining demonstrated bacilli in ten patients (76.9%). Histopathology revealed epithelioid granulomas with perineural/periadnexal inflammation in borderline-spectrum disease, while sheets of foamy macrophages containing bacilli were observed in lepromatous-spectrum cases. Eleven patients (84.6%) showed marked reduction in swelling within six months of multidrug therapy, with improvement beginning as early as 8–12 weeks in several cases. Two patients had partial residual edema but continued clinical response.

Conclusion

Isolated persistent lip swelling may represent the earliest and only manifestation of Hansen's disease, particularly in endemic regions. In patients with unexplained chronic cheilitis or granulomatous lip enlargement, clinicians should maintain a high index of suspicion even in the absence of classical skin or nerve signs. Combined use of slit-skin smear and deep biopsy with Fite-Faraco staining substantially improves diagnostic yield. Early recognition enables prompt multidrug therapy, prevents progression, and avoids prolonged misdiagnosis and inappropriate

treatment.

EADV CONGRESS
VIENNA
30 SEP - 3 OCT 2026

Abstract N°: 975

Comparative efficacy of Voriconazole versus High-Dose Terbinafine in Recalcitrant Tinea Corporis and Cruris.

Toioba Akter*[1]

[1] Dhaka Medical College Hospital, Dhaka, Bangladesh

Introduction
Dermatophytosis has emerged as a therapeutic challenge in recent years due to increasing resistance to conventional antifungal agents, particularly terbinafine. Recurrent and treatment-resistant cases are increasingly reported in South Asia, necessitating evaluation of alternative systemic therapies.

Materials and Methods
This cross-sectional comparative study was conducted at a tertiary care hospital in Dhaka, Bangladesh. A total of 100 patients with recurrent or treatment-resistant dermatophytosis were enrolled and divided into two equal groups. Group A received oral Voriconazole (200 mg twice daily), while Group B received oral terbinafine (250 mg twice daily) for 4 weeks. Patients were evaluated at 2 and 4 weeks for clinical responses and adverse effects. Clinical cure was defined as complete resolution of erythema and scaling with or without post-inflammatory hyperpigmentation. Statistical analysis was performed using SPSS, with p value ≤ 0.05 considered significant.

Results
The mean age of participants was comparable between groups (32.4±5.7 vs 31.9±5.9 years). Clinical cure was achieved in 82% of patients treated with voriconazole compared to 64% in the terbinafine group (p=0.043). Treatment failure was lower in the voriconazole group (6%) than in the terbinafine group (16%). In both cases, treatments were well tolerated, with no significant difference in adverse effects between groups.

Conclusions
Voriconazole demonstrated superior efficacy compared to high-dose terbinafine in the management of recalcitrant tinea corporis and cruris, with a comparable safety profile. It may serve as an effective alternative in resistant dermatophytosis.

EADV CONGRESS
VIENNA
30 SEP - 3 OCT 2026

Abstract N°: 980

Intralesional quadrivalent versus bivalent human papilloma virus vaccine for treatment of recalcitrant warts

Mohamed ElGhareeb*[1], Ahmad Nofal[2], Hagar Nofal[3], Esam Alwirshiffani[4]

[1] Assistant Professor of Dermatology and Venereology at Zagazig University Faculty of Medicine, Zagazig, Egypt
[2] Professor of Dermatology and Venereology at Zagazig University Faculty of Medicine, Zagazig, Egypt
[3] Assistant Professor of Dermatology and Venereology at Zagazig University faculty of medicine, Zagazig, Egypt
[4] Faculty of Medicine, University of Tripoli, Tripoli, Libya

Introduction
Management of verrucae poses a persistent challenge despite the existence of numerous destructive and immunotherapeutic modalities.Traditional destructive maneuvers are limited to the targeted lesions without distant therapeutic effect,might be uncomfortable for patients, and can be associated with significant adverse effects.2 For multiple, widely disseminated or highly resistant lesions, immunotherapy represents a better approach that allows clearance of both treated and untreated warts as well as helps to prevent recurrences.Human papillomavirus (HPV) vaccines, either in the intramuscular or intralesional routes, have recently shown promise in the treatment of common warts. Aim of the work: we compared the efficacy and tolerability of intralesional quadrivalent vaccine versus intralesional bivalent vaccine in the treatment of multiple recalcitrant warts.Management of verrucae poses a persistent challenge despite the existence of numerous destructive and immunotherapeutic modalities.Traditional destructive maneuvers are limited to the targeted lesions without distant therapeutic effect,might be uncomfortable for patients, and can be associated with significant adverse effects.2 For multiple, widely disseminated or highly resistant lesions, immunotherapy represents a better approach that allows clearance of both treated and untreated warts as well as helps to prevent recurrences.Human papillomavirus (HPV) vaccines, either in the intramuscular or intralesional routes, have recently shown promise in the treatment of common warts.The aim of this work was to compare the efficacy and tolerability of intralesional quadrivalent vaccine versus intralesional bivalent vaccine in the treatment of multiple recalcitrant warts.

Materials and Methods
A total of 50 patients with multiple recalcitrant warts of different types were randomly assigned into 3 groups; group 1 (quadrivalent vaccine, 20 patients), group 2 (bivalent vaccine, 20 patients), and group 3 (saline control, 10 patients). All participants received 0.1 mL of the respective treatment intralesional into the largest wart at 2-week intervals until complete clearance or for a maximum of 5 sessions.

Results
In our study, complete clearance of warts was observed in 18 patients of the quadrivalent vaccine (90%). in 6 patients of the bivalent vaccine (30%), whereas none of the saline control group showed response. There was statistically significant difference in the therapeutic response between the quadrivalent vaccine group and the other 2 groups

Conclusions
bivalent and quadrivalent HPVvaccines seem to be promising, well-tolerated therapeuticoptions for the treatment of warts, with statistically significant superiority of the quadrivalent vaccine over the bivalent one.

EA DV CONGRESS
VIENNA
30 SEP - 3 OCT 2026

Abstract N°: 983

How One Rash Concealed Another: Syphilis and Rickettsial Co-infection in an Immunocompetent Individual

Faiza Boukhobza*[1], Zakia Douhi[1], ikram bejja[1], Saadia Boughaleb[1], Meryem Soughi[1], Sara Elloudi[1, 1], Hanane Baybay[1], fatima zahra mernissi[1]

[1] Dermatology departement HASSAN II University Hospital, FES, Morocco

Introduction

Fever-associated rash pose a significant diagnostic challenge. A myriad of pathogens may cause them and reaching a correct diagnosis is often challenging.
While rickettsiosis and syphilis are distinct entities, their dermatological manifestations may overlap, complicating clinical recognition. Here, we report the first documented case of concurrent Mediterranean Spotted Fever (MSF) and primo-secondary syphilis in an immunocompetent individual.

Case Presentation

A 46-year-old man with no significant medical history presented with a one week history of febrile rash, preceded by headache, arthralgia, and diarrhea.
Notably, he denied recent travel, insect bites, or unprotected sexual intercourse.
Examination revealed a generalized non-pruritic discrete maculopapular exanthem involving the trunk, palms, and soles. Mucosal assessment disclosed a balano-preputial indurated ulceration with painless inguinal lymphadenopathy. Scalp examination revealed partially alopecic plaques in the occipital region with a characteristic moth-eaten pattern.
Laboratory investigations demonstrated thrombocytopenia and markedly elevated inflammatory markers.
At this stage, although an infectious etiology was suspected, the overlapping dermatological signatures of the rash raised the possibility that more than one pathogen was simultaneously at play. Serological workup confirmed this hypothesis, identifying two unrelated diagnoses: a recent Rickettsia conorii infection and a syphilitic profile consistent with primo-secondary syphilis. HIV serology returned negative, confirming an immunocompetent host. The fortuitous co-infection itself is exceptional, made further noteworthy by the simultaneous primo-secondary syphilis presentation. Contact tracing revealed syphilis seropositivity in the patient's partner. Combined therapy with doxycycline and benzathine penicillin G led to complete resolution within three weeks.



A solitary, well-defined, clean-based, indurated and painless ulcer located on the balanopreputial region

Conclusion

This case carries a double interest: the rarity of this fortuitous co-infection presenting atypically in an immunocompetent individual, and the reminder that when two rashes share the same signature; one should never be allowed to eclipse the other.

The implications are both therapeutic and epidermiological, as missing either diagnosis carries public health consequences.

Finally, a thourouh history, and meticulous skin and mucosal examination remains the clinician’s most decisive diagnostic tool.

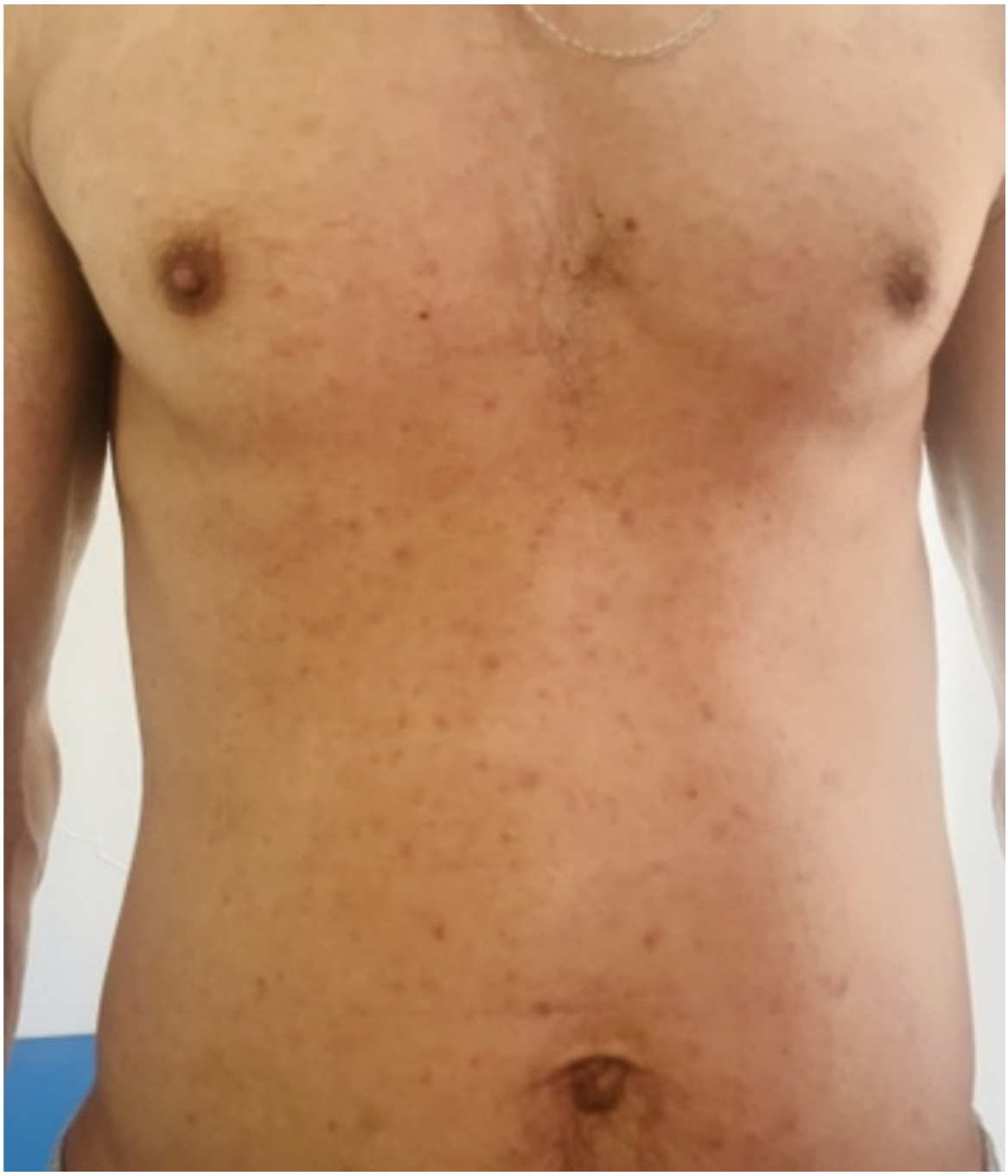

discrete maculo-papular exanthem of the trunk

EADV CONGRESS
VIENNA
30 SEP - 3 OCT 2026

Abstract N°: 1001

Pseudotumoral Cutaneous Leishmaniasis: A Rare Documented Form

salah eddin awawde*[1], Loubna ZREIK[1], Samira Zobiri[1]

[1] Mustapha University Hospital Center, Dermatology and venereology, Sidi M'Hamed - alger, Algeria

Introduction

Cutaneous Leishmaniasis (CL) is a parasitic infection characterized by significant clinical polymorphism. While it typically presents as localized ulcerated plaques, atypical "pseudotumoral" forms can occur, particularly in highly vascularized regions such as the ear lobe. In pediatric patients, these rare presentations pose a diagnostic challenge, often mimicking chronic bacterial infections, keloids, or malignancies. The chronic, painless nature of the lesion is a diagnostic hallmark, yet it is frequently overlooked. We report a rare case of an isolated, 6-month-old pseudotumoral tumefaction of the left ear lobe in a 13-year-old child, where a multimodal diagnostic approach led to a tailored, conservative therapeutic strategy.

Case Presentation

A 13-year-old female presented with a persistent, slowly enlarging, painless tumefaction of the left ear lobe that had been evolving for six months. Physical examination revealed a marked, firm, and non-tender swelling encompassing the entire left ear lobe. The surface exhibited a superficial erosion with mild serous discharge and peripheral scaling. Notably, there was an absence of local warmth, fever, or regional lymphadenopathy.

Examination under Wood's light showed a characteristic dull greenish fluorescence over the eroded area. Dermoscopy identified highly suggestive patterns, specifically:

- **"Yellow tears" (follicular plugs)**
- **A "white starburst" pattern (perifollicular white halos)**
- **Fine, linear irregular vessels**

Based on the six-month chronicity and specific dermoscopic signatures, bacterial perichondritis, lupus vulgaris, and keloids were systematically excluded.

A dermal smear with Giemsa stain was performed at the edge of the erosion, definitively identifying numerous Leishman-Donovan bodies (amastigotes) within the macrophages, confirming the diagnosis.

Treatment was initiated with a combination of oral Clarithromycin and Metronidazole. This regimen was selected to utilize their immunomodulatory and anti-parasitic effects, offering a non-invasive first-line option for a pediatric patient. Due to the anatomical sensitivity of the ear lobe—a terminal vascular zone with proximity to cartilage—the use of intralesional Meglumine Antimoniate (Glucantime) is currently under consideration. While Glucantime remains the gold standard, its use in this specific region requires a careful risk-benefit analysis regarding potential local necrosis or pain-related distress. The patient remains

under close clinical surveillance to monitor the response to oral therapy.

Conclusion

This case highlights the status of leishmaniasis as a "Great Mimicker," especially in its rare pseudotumoral form on the ear lobe. The six-month, painless evolution is a fundamental clinical clue that distinguishes CL from acute bacterial infections.

The integration of Wood's light and dermoscopy provided essential non-invasive evidence; the "yellow tears" and "white starburst" patterns are highly sensitive markers that guide clinicians toward the diagnosis prior to parasitological confirmation. Furthermore, the therapeutic strategy reflects a cautious pediatric approach. While intralesional Glucantime is highly effective, the decision-making process must weigh its efficacy against the risks of treating a sensitive anatomical site. Oral antibiotics serve as a valuable initial bridge in management. Early recognition through these multimodal tools is vital to prevent permanent destruction of the auricular architecture and to ensure optimal aesthetic outcomes.

EA DV CONGRESS
VIENNA
30 SEP - 3 OCT 2026

Abstract N°: 1015

From the Tropics to the Hair Shaft: Diagnostic Clues to White Piedra in a Child

Liz Beltrán Medina*[1], María Muñoz Mc Causland[2], Alvaro Tovar Cock[3]

[1] Pontificia Universidad Javeriana, Bogotá, Colombia
[2] Fundación Universitaria Sanitas, Bogotá, Colombia
[3] Centro Dermatológico Federico Lleras Acosta, Bogotá, Colombia

Introduction

White piedra is an uncommon superficial fungal infection of the hair shaft caused by Trichosporon species, presenting as soft whitish nodules adherent to the hair. Although globally distributed, it is more frequently reported in warm and humid climates and in girls younger than 15 years. Because it may mimic hair debris, pediculosis, or other shaft disorders, diagnosis is often delayed or inappropriate treatment initiated. We report the case of a 4-year-old girl living in a high-altitude urban setting who developed characteristic hair shaft concretions after travel to a tropical Caribbean region. This case highlights the importance of trichoscopy and direct mycological examination for accurate diagnosis and appropriate management of this rare pediatric infection.

Case Presentation

A 4-year-old girl presented with a 6-month history of asymptomatic white nodules on the scalp hair, initially mistaken for “dirt” by her caregiver, beginning after travel to a tropical Caribbean region. Hair was frequently tied while still wet. Examination revealed multiple soft, white, easily detachable concretions along the hairs. Trichoscopy showed translucent white-yellow nodules circumferentially encasing the shafts. Potassium hydroxide (KOH) microscopy demonstrated septate hyphae, blastoconidia, and arthroconidia, confirming white piedra. Topical ketoconazole shampoo was prescribed.

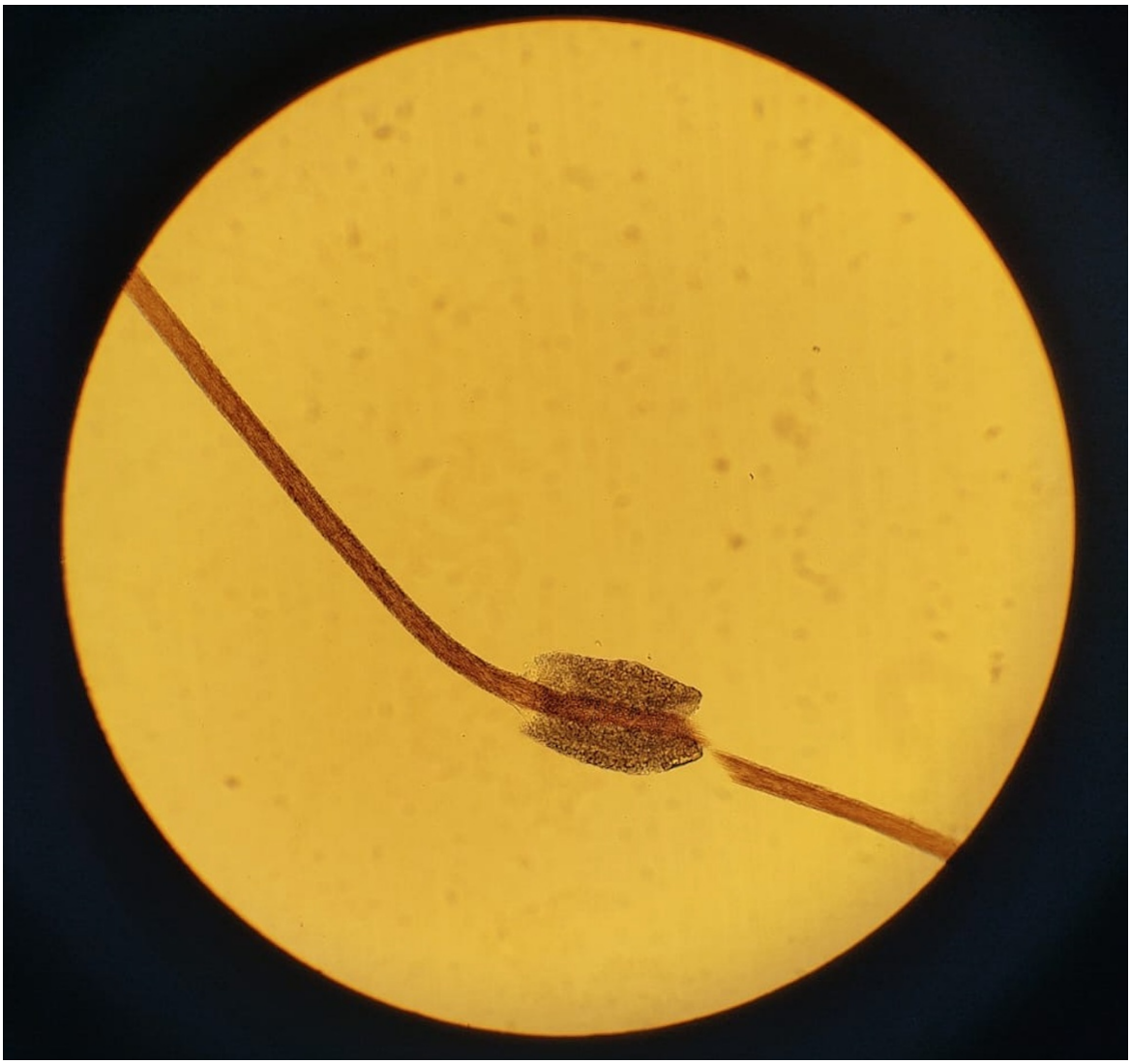

Direct potassium hydroxide (KOH) examination revealing a dense mass of septate hyphae, blastoconidia, and arthroconidia encasing the hair shaft, consistent with white piedra.

Conclusion

White piedra should be considered in children with persistent hair concretions mistaken for debris or pediculosis. Integration of clinical findings, hair-care habits, and epidemiological context, supported by trichoscopy and direct mycological examination, enables timely diagnosis and avoids unnecessary treatment.

EA DV CONGRESS
VIENNA
30 SEP - 3 OCT 2026

Abstract N°: 1032

Shifting Mycological Trends in Dermatophytosis: A Cross-Sectional Study in a Tertiary Care Centre

Afsana Nahid*[1], Sharmin Jahan[2], Toioba Akter[2]

[1] Dhaka Medical College, Dhaka, Bangladesh

[2] Dhaka Medical College Hospital, Dhaka, Bangladesh

Introduction

Dermatophytosis is a public health problem globally, affecting 20–25% of the world's population with varying geographic distribution. The hot and humid climate in tropical and subtropical countries makes dermatophytosis a prevalent superficial fungal infection. During the last decade, there has been an unrestrained increase of dermatophytosis with atypical clinical presentations in these areas with an increase in the occurrence of difficult-to-treat dermatophytosis. Surveillance studies are required to understand the changing epidemiology and prevalence of causative agents to decide an appropriate therapy. This study aims to evaluate the clinical types and current mycological profile of dermatophytosis in a tertiary care setting and identify emerging trends in causative organisms.

Materials and Methods

This cross-sectional study was conducted at the Department of Dermatology and Venereology of a government tertiary care hospital from December 2024 to May 2025 per the Ethical Review Committee of that hospital. The sample size was 226 and a consecutive sampling method was used for the inclusion of the study participants. Patients with tinea corporis, tinea cruris or tinea faciei, or any combination of these conditions from 15 to 60 years of age were included in this study. Written informed consent was obtained in Bangla. A detailed history of disease onset, duration, course, family history, and previous treatments was recorded. Socio-demographic characteristics, including age, gender, religion, marital status, occupation, and educational qualification, were also recorded. Examinations regarding clinical characteristics, affected area, clinical type, and percentage of body surface area (BSA) involved were done. Patients were thoroughly examined and Samples were taken from the erythematous, peripheral and actively growing margins of the skin lesions by scraping and sent for direct microscopic examination using 10% potassium hydroxide (KOH) mount and culture on Sabouraud dextrose agar performed at the Microbiology Department of that hospital. Dermatophyte species were identified based on colony morphology, biochemical tests and microscopic characteristics.

Results

A total of 226 participants were included in the present study. The median age was 33 years(15-60). Females constituted a slightly higher proportion (51%). The genital and inguinal region was the most frequently affected anatomical site, with over three-quarters of participants presenting lesions in this region (75%). More than one anatomical sites involvement was found in about 85% cases and tinea corporis with tinea cruris was the predominant clinical diagnosis, documented in 68% of cases. Nearly half of the participants (48%) had dermatophytosis involving 5% or more of their body surface area and majority of cases had a disease duration between 3 to 6 months (41%). 75% of cases presenting during the summer months. Nearly half of the participants (48%) had a history of steroid use for dermatophytosis, and skin atrophy (27%) and dyspigmentation (23%) were the most common adverse effects. Among 226 clinically diagnosed cases, KOH positivity was observed

in 77%, while fungal culture was positive in 32% of cases. A notable shift in the mycological pattern was observed, with Trichophyton mentagrophytes emerging as the predominant species, accounting for 72% of culture-positive isolates. In contrast, Trichophyton rubrum, historically the most common dermatophyte, constituted only 28% of isolates.

Conclusions

This study demonstrates a significant shift in the etiological spectrum of dermatophytosis, with *Trichophyton mentagrophytes* emerging as the major pathogen replacing *T. rubrum* as the dominant species. Continuous surveillance of dermatophyte species is essential to guide effective antifungal therapy and address evolving disease patterns.

EA DV CONGRESS
VIENNA
30 SEP - 3 OCT 2026

Abstract N°: 1038

Varicella Gangrenosa in an Immunocompetent Child: A Rare Complication of Varicella

Akshay Sankar P*[1], Prasun Mishra[1], Satyaki Ganguly[1]

[1] ALL INDIA INSTITUTE OF MEDICAL SCIENCES, RAIPUR, RAIPUR, CHHATTISGARH, India

Introduction

Varicella (chickenpox) is a highly contagious illness caused by primary infection with the varicella–zoster virus, typically characterized by a generalized vesicular eruption with fever and constitutional symptoms. Although most cases in children are self-limited, clinically significant complications occur, including pneumonia, encephalitis, invasive skin and soft-tissue secondary bacterial infections, and sepsis. Population studies have documented hospitalization and complication burdens attributable to varicella. Secondary bacterial infection of varicella lesions is one of the most common cutaneous complications and, in rare cases, can progress to varicella gangrenosa, a life-threatening necrotizing soft-tissue infection historically regarded as a severe form of necrotizing fasciitis following varicella. In children, invasive group A Streptococcus (GAS) necrotizing fasciitis following varicella has been repeatedly reported, emphasizing the need for early recognition and aggressive management. We report a 1-year-old immunocompetent child with varicella complicated by varicella gangrenosa presenting predominantly with multiple necrotic punched-out ulcers over the trunk.

Case Presentation

A 1-year-old presented with high-grade fever and painful progressive truncal ulcers. Seven days earlier, he developed generalized vesicular lesions consistent with chickenpox after household exposure, with malaise and poor intake. Despite symptomatic treatment, including ibuprofen, lesions became painful over 48–72 hours, coalesced, ruptured, and formed purulent ulcers. Progressive lethargy and fever prompted referral.

On examination, he was toxic and irritable, with fever (39.4°C), pulse 124/min, BP 96/60 mmHg, and mildly prolonged capillary refill. Multiple deep, punched-out ulcers (1–3 cm) with necrotic slough and disproportionate tenderness were noted over the trunk and extremities. Crusted papules and healing scars were present; the oral mucosa was normal.

Laboratory tests showed anemia (Hb 7.6 g/dL), leukocytosis (20.8 × 10^9/L), thrombocytosis (549 × 10^3/L), and elevated CRP (19.9 mg/L). Renal function and coagulation were normal, with mild transaminitis. Pus culture grew *Streptococcus pyogenes* and *Staphylococcus aureus*; blood cultures were sterile. Varicella IgM was positive.

With suspected varicella gangrenosa, the child was admitted to the PICU and started on IV fluids and monitoring. He received IV antibiotics (vancomycin 10 mg/kg/dose, QID for 14 days) and IV acyclovir (20 mg/kg every 8 hours for 7 days). Over 10–14 days, fever and pain subsided, inflammatory markers improved, no new lesions appeared, and ulcers healed with atrophic scarring.

Conclusion

Varicella gangrenosa, first described by Hutchinson in 1881, is a rare but potentially fatal complication of primary varicella. Though varicella is usually self-limiting in children, severe complications like necrotizing fasciitis can occur in healthy individuals. Three forms exist—moist (infective), dry (thrombotic), and purpura fulminans (DIC)—

with moist gangrene most commonly linked to GAS and S. aureus

Varicella gangrenosa should be suspected in patients with recent varicella presenting with disproportionate pain, swelling, gangrenous ulcers, and systemic symptoms, typically 4–7 days after onset. Lesions evolve from erythematous to violaceous within 24–48 hours, progressing to necrosis. Viral-induced epidermal damage predisposes to bacterial superinfection, commonly *Streptococcus pyogenes* or rarely *Staphylococcus aureus*. Management requires early diagnosis, broad-spectrum antibiotics with streptococcal coverage, antivirals, supportive care, and prompt surgical debridement when necrotizing infection is suspected. This case highlights the need to suspect varicella gangrenosa in painful, rapidly ulcerating or necrotic varicella lesions, even in immunocompetent children, and to start prompt intravenous antiviral therapy

EADV CONGRESS
VIENNA
30 SEP - 3 OCT 2026

Abstract N°: 1064

Giant Eyelid Molluscum Contagiosum Mimicking a Trichofolliculoma: A Diagnostic Pitfall

Mehmet Gökalp Karasu*[1], Serap Öztürkcan[1], Peyker Temiz[2]

[1] Manisa Celal Bayar University Faculty of Medicine, Department of Dermatology and Venereology, Yunusemre, Türkiye
[2] Manisa Celal Bayar University Faculty of Medicine, Department of Pathology, Yunusemre, Türkiye

Introduction

Molluscum contagiosum (MC) is a common benign viral infection in children, typically presenting as small, dome-shaped papules with central umbilication. However, atypical presentations, particularly in uncommon locations such as the eyelids, may mimic adnexal tumors and pose a diagnostic challenge.

Case Presentation

A 3-year-old girl presented with a slowly enlarging nodular lesion on the left upper eyelid, persisting for approximately 18 months. The lesion was dome-shaped, skin-colored, mobile, and measured about 1 cm in diameter, without evident central umbilication. A single smaller satellite papule was located 1 cm away from the main lesion. In addition, a smaller solitary lesion was observed on the contralateral lower eyelid; according to the history, this lesion had partially regressed following minor trauma during play 6 days prior, indicating bilateral involvement.

On clinical evaluation, the lesion exhibited a tumor-like morphology, raising suspicion for a benign adnexal neoplasm, particularly trichofolliculoma. Dermoscopic examination showed a well-circumscribed, structureless white area with scattered fine linear vessels, lacking a radial vascular arrangement. The presence of a central hair shaft further mimicked follicular differentiation and contributed to this impression.

Although the presence of an additional lesion raised the possibility of an infectious etiology, the tumor-like morphology and dermoscopic features mimicking trichofolliculoma led us to perform an excisional biopsy for definitive diagnosis.

Histopathological evaluation revealed epidermal hyperplasia with numerous large intracytoplasmic inclusion bodies (Henderson-Patterson bodies) within keratinocytes confirming molluscum contagiosum. Immunohistochemical studies excluded adnexal neoplasms and malignancy.



Dermoscopic image showing a structureless white area with scattered fine linear vessels lacking a radial vascular pattern

Conclusion

This case highlights that molluscum contagiosum should be considered in the differatial diagnosis of eyelid nodular lesions in children, even in the absence of classical umblication. Although additional lesions and bilateral involvement may suggest a possible infectious process, these clues can be overshadowed by tumor-like features. The absence of a typical crown like vascular pattern, together with misleading features such as a central hair shaft, may further contribute to diagnostic difficulty.Dermoscopic and histopathological evaluation remain essential to avoid misdiagnosis.

EADV CONGRESS
VIENNA
30 SEP - 3 OCT 2026

Abstract N°: 1074

Comparative evaluation of clinical features, bacteriological profile, drug resistance, histopathology, and therapeutic outcomes in upgrading and downgrading Type 1 reactions in leprosy

Savitha Bathula*[1], Surabhi Sinha[2], Arvind Ahuja[1], Kabir Sardana[1]

[1] Atal Bihari Vajpayee Institute of Medical Sciences and Dr Ram Manohar Lohia Hospital, New Delhi, India
[2] Lady Harding Medical College and associated hospitals, New Delhi, India

Introduction
Type 1 leprosy reactions (T1R), traditionally termed "reversal reactions," comprise a heterogeneous immunological spectrum comprising upgrading and downgrading, subtypes, along with a static category. They differ in immunopathogenesis, clinical behavior, bacteriological profile, and therapeutic response, yet remain poorly delineated. We compared the clinical, bacteriological, drug resistance, and histopathological characteristics of upgrading versus downgrading T1R and evaluated the differences in corticosteroid requirement and outcomes.

Materials and Methods
In this 2-year prospective study conducted at tertiary care center, 26 clinically diagnosed T1R patients underwent clinical evaluation, slit-skin smear, and skin biopsy for drug resistance studies (qPCR-HRM targeting rpoB, folP, and gyrA genes) and histopathology during the reaction. Treatment was tailored to severity, using non-steroidal anti-inflammatory drugs or systemic corticosteroids. Biopsy was repeated post resolution of reaction. Subtype of T1R (upgrading or downgrading) was established based on integrated clinical, bacteriological, and serial histopathological findings, with post-reactional biopsy considered the reference standard. Concordance between clinical, combined clinical-bacteriological, and histopathological diagnoses was analysed. Treatment details and side effects were compared between the subtypes.

Results
Of the 26 patients, 9 (34.6%) had upgrading and 17 (65.4%) had downgrading T1R. New lesion formation was significantly more frequent in downgrading T1R (88% vs 22%, $p<0.001$), while neuritis was more common in upgrading T1R (66% vs 23%, $p=0.008$). Most downgrading T1R patients were treatment-naïve (82.3%), while 44.4% of upgrading T1R occurred after release from therapy. Initial BI values were comparable; however, post-reactional BI differed significantly, with most upgrading T1R showing BI 0 (77.8%) and downgrading T1R demonstrating higher bacillary load (BI ≥3+ in 41.1%).Drug resistance occurred in 11% (1/9) upgrading and 35.2% (6/17) downgrading T1R, with rifampicin resistance observed exclusively in the latter subtype. Upgrading T1R histopathology showed dermal and intra-granuloma edema (88% and 77.7%, respectively with dense lymphocytic infiltrate, whereas downgrading T1R showed milder edema and relatively sparse lymphocytes. Post-reactional histology confirmed subtype in all cases and demonstrated strong concordance with clinical-bacteriological diagnosis (89.7%), while concordance with initial biopsy alone was low (51.7%). Post-reactional histology demonstrated a clear directional shift in disease spectrum, with 82.4% of downgrading T1R progressing toward the lepromatous pole, while 55.6% of upgrading T1R shifted toward the tuberculoid spectrum. Neuritis showed significant correlation with both clinical and post-reactional histopathological subtype classification (concordance 79.3%; $p=0.005$).Corticosteroids were required in all upgrading T1R but 35% of downgrading T1R, with longer treatment in former (mean 13months vs 4months; $p<0.0001$), with higher peak doses (45.6 mg vs 32.3 mg; $p=0.035$). Major steroid-related adverse events were more frequent in upgrading T1R (44.4% vs 5.8%).

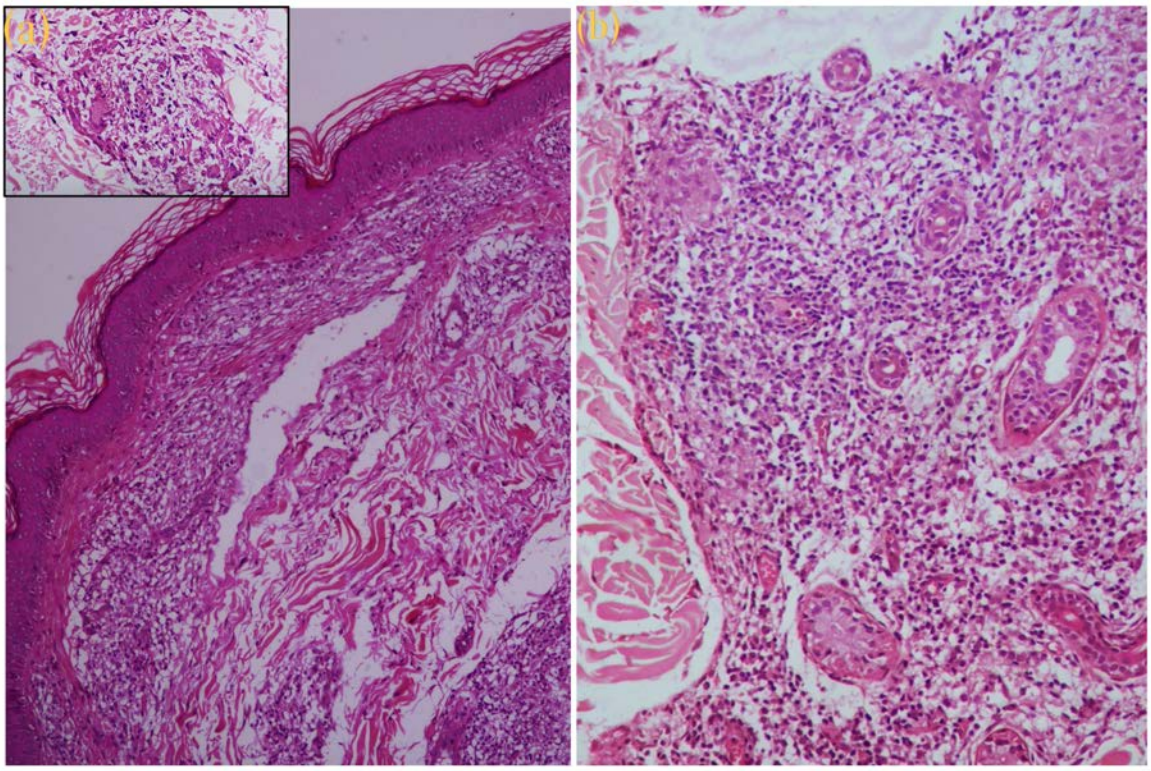

Fig 3: (a) Biopsy from reactional skin lesion showed intense dermal edema, dense lymphocytes and epithelioid cells, suggestive of borderline tuberculoid leprosy in T1R (H & E, ×200). Inset shows severe intragranuloma edema (H & E, ×400). (b) Post reactional biopsy (10weeks) from the same plaque showed resolution of edema, compact granulomas. Increase in the number of lymphocytes and epithelioid cells with few areas showing giant cell formation (black arrow), suggestive of upgrading to secondary tuberculoid spectrum (H & E, ×400). (BI-4+)

Conclusions

Downgrading T1R are more common and clinically milder, often associated with higher bacillary load and drug resistance, whereas upgrading T1R demonstrate greater neuritis and require prolonged corticosteroid therapy. Integrated clinic-bacteriological and serial histopathological assessment optimises treatment and reduces steroid-related morbidity.

EA DV CONGRESS
VIENNA
30 SEP - 3 OCT 2026

Abstract N°: 1080

Disseminated Herpes Virus Infection Clinically Consistent With Herpes Simplex Virus in an Immunosuppressed Adult With Vogt–Koyanagi–Harada Disease: A Case Report

Sasha Yzabel Reyes*[1]

[1] Rizal Medical Center Dermatology, Pasig City, Philippines

Introduction

Herpes simplex virus (HSV) infection typically manifests as localized mucocutaneous disease in immunocompetent individuals; however, in immunocompromised hosts, impaired cell-mediated immunity may permit uncontrolled viral replication and dissemination. Disseminated HSV is an uncommon but potentially severe condition characterized by widespread vesiculobullous or erosive lesions with possible mucosal and systemic involvement. Its presentation may mimic other conditions, particularly varicella-zoster virus (VZV) infection, as well as bullous impetigo and other vesiculobullous disorders, posing diagnostic challenges. Polymerase chain reaction (PCR) testing remains the gold standard for diagnosis but requires intact vesicular fluid and may not always be feasible. In such cases, adjunctive modalities including dermoscopy, Tzanck smear, and histopathology become essential. Patients with Vogt–Koyanagi–Harada (VKH) disease often require prolonged systemic corticosteroid therapy, predisposing them to opportunistic infections. We report a case of disseminated herpesvirus infection clinically most consistent with HSV in an immunosuppressed patient with VKH disease, emphasizing clinicopathologic correlation in the absence of PCR confirmation.

Case Presentation

A 22-year-old male with a two-year history of VKH disease on systemic corticosteroids presented with acute fever and rapidly progressive cutaneous eruptions. Initially appearing on the face, lesions spread to the trunk and extremities over several days, evolving from grouped vesicles into erosions and crusted plaques. The lesions were monomorphic, non-dermatomal, and largely asymptomatic. Mucosal involvement was present, including an oral ulcer, dysphagia, and conjunctival irritation. There was no prior history of herpes infection, varicella, or chronic dermatologic disease.

On examination, numerous grouped vesicles and crusted erosions on an erythematous base were observed over the face and trunk. Dermoscopy revealed cloudy white globules corresponding to intraepidermal vesicles and necrotic keratinocytes, with surrounding erythema and erosions. A Tzanck smear from an intact vesicle demonstrated multinucleated giant cells with nuclear molding and chromatin margination, consistent with herpesvirus infection. Histopathologic examination showed intraepidermal vesiculation, ballooning degeneration, necrotic keratinocytes, and multinucleated epithelial cells with viral cytopathic changes involving follicular epithelium, consistent with herpetic folliculitis. PCR testing was not feasible due to paucity of intact vesicles. Serologic testing for HSV and VZV IgM and IgG was negative, likely reflecting early infection or impaired antibody response due to immunosuppression.

A diagnosis of disseminated herpesvirus infection clinically most consistent with HSV was made based on clinical morphology and supportive dermoscopic, cytologic, and histopathologic findings. The patient was treated with intravenous acyclovir (10 mg/kg every 8 hours) and supportive care. Clinical improvement was observed with cessation of new lesion formation and progressive healing of existing lesions. No systemic dissemination occurred.

Conclusion

Disseminated HSV should be strongly considered in immunosuppressed patients presenting with widespread, non-dermatomal vesiculocrusted eruptions with mucosal involvement. This case highlights the diagnostic value of dermoscopy, Tzanck smear, and histopathology when PCR is not feasible. Early recognition and prompt initiation of antiviral therapy are critical to prevent progression and reduce morbidity. In patients requiring ongoing immunosuppression, consideration of antiviral prophylaxis is warranted to minimize recurrence risk.

EA DV CONGRESS
VIENNA
30 SEP - 3 OCT 2026

Abstract N°: 1113

Sixty Years of Topical Fusidic Acid: From Discovery to Modern Evidence-Based Dermatology

Mayra Ianhez*[1], Aline M F Magalhaes[2], Pedro Mendes-Bastos[3]

[1] Universidade Federal de Goiás, Goiânia, Brazil

[2] LEO Pharma Ltda, Sao Paulo, Brazil

[3] Cuf Descobertas Hospital, Lisboa, Portugal

Introduction

In 1962, Mary Barber and Pamela Waterworth first reported in The Lancet the potent in vitro activity of fusidic acid, a novel antibiotic derived from the fungus Fusidium coccineum. Now, marking six decades of global topical use, this milestone provides an opportunity to review its enduring role in dermatological practice. Despite this extensive history, fusidic acid remains a valuable agent in managing skin and soft tissue infections (SSTIs) due to its unique pharmacological profile as the only marketed fusidane-class antibiotic, and its robust clinical evidence base. Far from being a historical relic, fusidic acid's enduring relevance is underscored by its status as a first-line therapy in multiple current international clinical guidelines for the management of bacterial skin infections.

Materials and Methods

Pharmacological Profile: Fusidic acid belongs to the fusidanes, a distinct antibiotic class with a unique steroid-like structure that lacks hormonal activity. This stereochemical distinction (configuration) is responsible for its favorable skin penetration, reaching therapeutic concentrations in deep layers of both intact and damaged skin, as demonstrated in skin permeation studies (Figure 1). Fusidic acid inhibits bacterial protein synthesis by binding to elongation factor G (EF-G), blocking both mRNA translocation and ribosome disassembly (Figure 2). As the only marketed member of the fusidane class with a unique structure and mode of action, it exhibits little cross-resistance with other antibiotics.

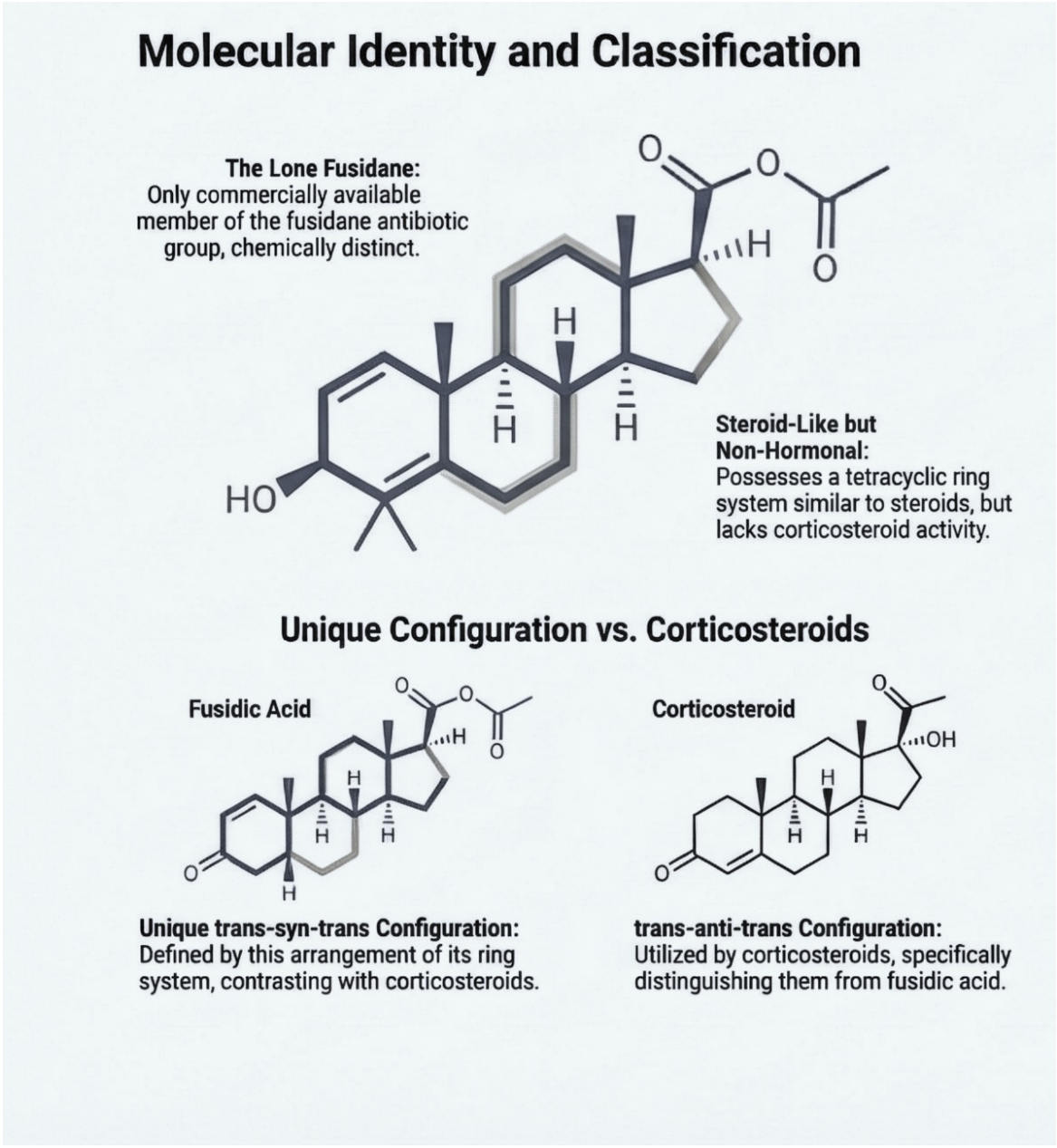

Figure 1. While fusidic acid structure is steroid-like, its stereochemical configuration is trans-syn-trans, which differs fundamentally from the trans-anti-trans arrangement of corticosteroids.

Results

Clinical Evidence and Applications: Historically, fusidic acid has demonstrated high potency against Staphylococcus aureus, including penicillinase-producing strains. In 2002, a landmark placebo-controlled trial confirmed its efficacy in treating impetigo, showing a clinical cure rate of 55% within one week compared to 13% for placebo (OR 12.6, 95% CI 5.0–31.5). Beyond primary infections, fusidic acid plays a role in atopic eczema management. S. aureus colonization and superantigen production are associated with increased disease severity, and combination formulations of fusidic acid with corticosteroids address both infection and inflammation. Studies suggest that these fixed combinations may provide additional benefit over corticosteroids alone in infected eczema. The clinical authority of fusidic acid is cemented by its status as a first-line in modern evidence-based medicine. Current NICE guidelines (2020/2021) designate topical fusidic acid 2% as the first-choice antibiotic for both impetigo and localized secondary infections in eczema for adults and children. This global standard is reinforced by national protocols across Belgium, France, Germany, Canada, and the Netherlands, which consistently position the molecule as the useful tool for staphylococcal management. Safety and Resistance Stewardship: Over 60 years of extensive use, fusidic acid has maintained a distinctively low allergenic potential, with patch test reactivity reported from 0.3% to 1.45% in general and higher risk populations, respectively. On a global level, resistance prevalence remains relatively low (approximately 0.5% overall), though rates may be higher

in specific populations such as atopic dermatitis patients. Judicious use is recommended, as topical monotherapy has been associated with resistance emergence.

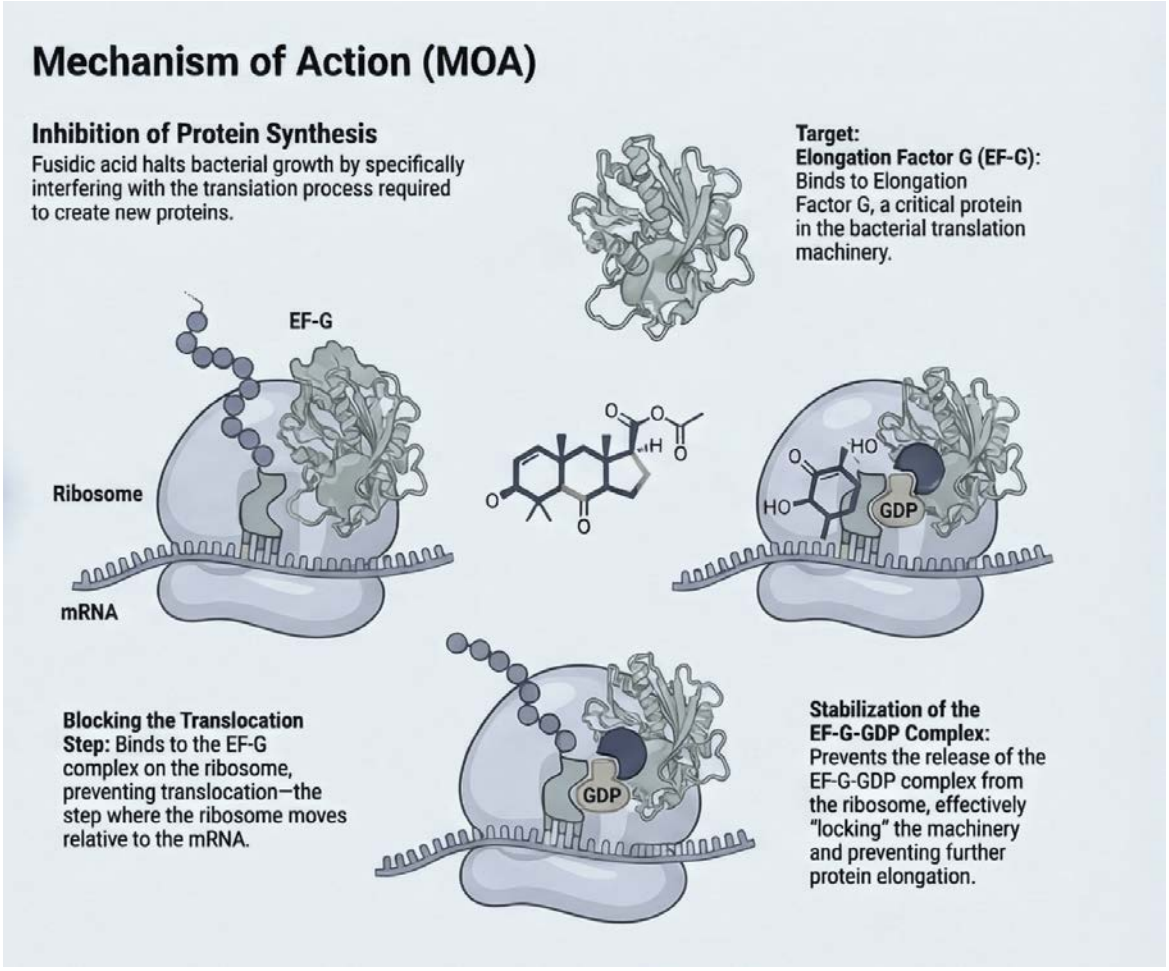

Figure 2. Fusidic acid inhibits bacterial protein synthesis by binding to Elongation Factor G (EF-G), specifically blocking the translocation step where the ribosome moves relative to the mRNA.

Conclusions

Sixty years since its introduction, topical fusidic acid continues to fulfill several criteria for an ideal dermatological antibiotic: high potency, enhance skin penetration relative to other topical antibiotics, and low sensitization. While global resistance prevalence remains relatively low, judicious use is warranted given increasing resistance trends in some populations. Its legacy, from the initial laboratory discoveries in 1962, the topical presentation available in 2025, to its presence in global guidelines for the management of bacterial skin infections, underscores its enduring role in global dermatology.

EA DV CONGRESS
VIENNA
30 SEP - 3 OCT 2026

Abstract N°: 1133

Chromoblastomycosis: Favorable evolution with combined treatment and review of therapeutic modalities

Isabella Dossin[1], Maria Clara Linhares*[1], Bruno Soares[1], Flávia Cassia[1], Rachel Grynszpan[1], João Avelleira[1]

[1] Lagoa Federal Hospital, Rio de Janeiro, Brazil

Introduction

Chromoblastomycosis (CMB) is a chronic granulomatous fungal infection of the skin and the subcutaneous tissue caused by a transcutaneous traumatic inoculation of dematiaceous fungi, found in soil, plants, anddecaying wood. It is an occupational disease that predominates in tropical and subtropical regions, more common in adult males and typically presents on the lower limbs. Spread occurs through contiguity or self-implantation, and the disease is more common in tropical and subtropical climates, with the majority of cases occurring in Brazil, Madagascar, and Venezuela. It is recognized as a neglected tropical disease.

Case Presentation

Male, 76 years old, carpenter, presenting with multiple circumscribed plaques with a verrucous surface on the legs for 2 years, associated with lymphedema, with no prior treatments, and did not recall any local trauma. We observed muriform cells on direct mycological examination as well as on skin biopsy, along with granulomas containing Langerhans giant cells. Fungal culture was positive for *Fonsecaea* sp., confirming the diagnosis of chromoblastomycosis. Treatment was initiated with itraconazole 200 mg daily, with partial improvement, and was optimized with cryotherapy, administered in monthly sessions of two 90-second open-spray cycles per lesion. Significant clinical response followed the therapeutic association, with partial regression of lesions, resolution of others, and a decrease in lymphedema. The patient continues follow-up in our dermatology department.

Discussion

The management of CBM is challenging due to low cure rates and high recurrence rates. Treatment typically involves systemic antifungals, with or without adjunctive physical modalities. The most frequently utilized agents are itraconazole and terbinafine, administered over months to years. While cure rates vary, these agents may be combined in refractory cases.

Surgical excision may be the treatment of choice for mild disease, with margins of at least 0.5 centimeters extending to the subcutaneous tissue. Electrodissection and curettage of the lesions are not recommended due to the risk of lymphatic spread. Cryotherapy is primarily indicated for small lesions, although a fragmented approach may be employed for larger areas. However, there is a lack of standardization regarding freeze time and tissue depth. Thermotherapy via direct heat application is indicated for isolated and circumscribed lesions.Other adjunctive therapeutic modalities include photodynamic therapy, CO_2 laser therapy, and imiquimod.

The highest success rates involve combining systemic antifungals with cryotherapy. The duration of treatment ranges from 10 months to 6 years, but is significantly reduced when surgical excision or cryotherapy is utilized. Remission is defined by clinical, histopathological, and mycological criteria. Observed complications include lymphedema, carcinomatous degeneration, and secondary infection.

Conclusion

This case highlights a neglected tropical disease with severe clinical features. Although therapeutically challenging, favorable clinical evolution was achieved through a multimodal approach consisting of itraconazole and

cryotherapy.

EADV CONGRESS
VIENNA
30 SEP - 3 OCT 2026

Abstract N°: 1212

Catastrophic Autoinoculation of Orf Virus after Surgical Intervention: High-Volume, Low-Concentration Intralesional Cidofovir as a Life-Saving Salvage Therapy

Alperen Ozmen*[1], Ceylan Avcı[1], Sevgi Akarsu[1]

[1] Dokuz Eylul University Hospital, Department of Dermatology and Venereology, Izmir, Türkiye

Introduction

Orf virus (ecthyma contagiosum), a zoonotic parapoxvirus, typically follows a self-limiting course in immunocompetent hosts. However, in the setting of profound immunosuppression—such as Chronic Lymphocytic Leukemia (CLL) or the use of targeted agents like Venetoclax—the virus can exhibit aggressive behavior. In such patients, Orf may progress into giant, recalcitrant, and vegetative lesions that mimic malignancy or severe pyoderma gangrenosum. There is currently no established gold standard for managing these complex cases. This report highlights a catastrophic case of surgical autoinoculation and discusses the clinical superiority of a novel high-volume, low-concentration intralesional (IL) cidofovir protocol over conventional surgical and high-dose therapeutic interventions.

Case Presentation

A 67-year-old female patient with a history of CLL (actively treated with Venetoclax and IVIG) presented in June 2025 with a recalcitrant papular Orf lesion on her 5th digit subsequent to livestock contact. Following the failure of initial cryotherapy, a simple surgical excision was performed, which quickly resulted in local recurrence. Seeking a definitive cure, a more aggressive secondary intervention involving wide excision and a split-thickness skin graft (STSG) from the right thigh was attempted.

Paradoxically, this procedure triggered a "catastrophic autoinoculation" event. Not only did the digital lesion recur with greater intensity, but the donor site on the thigh developed a massive, fungating, and vegetative 10x10 cm mass due to viral seeding during surgery. The patient was initially managed with systemic intravenous acyclovir and topical imiquimod (5%), but the lesions showed no clinical response and continued to expand, causing significant morbidity.

In January 2026, we initiated a salvage protocol using IL cidofovir. Diverging from previous literature, we utilized a lower concentration of 7.5 mg/ml (total dose of 10 ml per session) administered bi-weekly to ensure wide distribution within the giant vegetative mass. After six sessions, the digital lesion achieved complete clinical resolution. The massive thigh lesion demonstrated a 90% reduction in its vegetative component, shrinking to 4x3.5 cm, with healthy re-epithelialization at the margins and no systemic toxicity.

Conclusion

The management of giant Orf in immunocompromised patients remains a clinical challenge. While surgical excision is often the first instinct, this case demonstrates that surgery can act as a vehicle for viral dissemination, leading to "surgical seeding" and catastrophic outcomes.

A critical takeaway from our case is the dosing of IL cidofovir. Previous case reports have documented the use of intralesional cidofovir at concentrations as high as 30 mg/ml, often with limited success, significant local tissue

irritation, or failure to halt the progression of giant lesions. We hypothesize that the failure of high-concentration protocols may be due to inadequate drug distribution within large, hyperkeratotic masses. Our protocol emphasizes a high-volume, low-concentration approach (7.5 mg/ml), which allows for more thorough infiltration of the viral reservoir.

This case serves as a potent reminder that aggressive surgery should be avoided in the setting of active viral replication in IC patients. High-volume IL cidofovir should be considered an essential, definitive salvage option for recalcitrant Orf to prevent extensive surgical morbidity and achieve limb-sparing outcomes.

EADV CONGRESS
VIENNA
30 SEP - 3 OCT 2026

Abstract N°: 1245

Atypical Varicella-like presentation of an imported Mpox case in Austria confirmed to be infected with Clade Ib

Amelie Hampel*[1], David Springer[2], Jeremy Camp[2], Stephan Aberle[2], Maximilian Egg[1], Luigi Segagni Lusignani[3], Robert Strassl[4], Judith Wendt[1], Tamar Kinaciyan[1], Alessandra Handisurya[1]

[1] Department of Dermatology, Medical University of Vienna, Vienna, Austria

[2] Center for Virology, Medical University of Vienna, Vienna, Austria

[3] Vienna Regional Health Authority; Department of Epidemic and Pandemic Preparedness, Vienna, Austria

[4] Division of Clinical Virology, Department of Laboratory Medicine, Medical University of Vienna, Vienna, Austria

Introduction
The recent upsurge of cases caused by the newly identified Clade Ib monkeypox virus (MPXV) in the Democratic Republic of the Congo and other countries has emerged as a significant public health concern.

Case Presentation
A 34-year-old male tourist from Venezuela presented in Vienna, Austria, during traveling through Europe with fever, pharyngitis and an evolving rash. Cutaneous lesions were sparse and consisted of papules, pustules and a few partially ulcerated lesions of different stages of evolution, localized primarily on the trunk and extremities, clinically resembling chickenpox. In addition, prominent yellow-coated erosions with erythematous borders and ulcerative papules were present on the labial mucosa. While varicella-zoster virus and herpes simplex virus type 1 and 2 DNA were not detected by PCR, Orthopoxvirus DNA was identified in the patient´s oral lesions. Subsequent metagenomic sequencing from primary samples confirmed the infection with MPXV Clade Ib.

Conclusion
This case shows that, first, mpox Clade Ib is circulating across Europe; second, that the clinical presentation of Clade Ib-related mpox may differ from that observed during the previous Clade IIb-driven outbreak, potentially including atypical rash morphology and distribution; and third, as the patient explicitly denied prior sexual contacts, non-sexual close-contact transmission or environmental exposure may play an important transmission route for this specific clade. Heightened awareness of clinicians, diagnostic evaluations for mpox even in the absence of classical rash morphology or reported sexual exposure and establishment of Clade Ib-specific diagnostics, which are reliable, accessible and easy to perform, are crucial to enable early identification of infected individuals in order to limit further transmission. Continued genomic surveillance of MPXV remains critical for monitoring of virus spread beyond the traditional endemic regions and for the early detection of new variants. Finally, the effectiveness of mpox vaccination and antiviral therapeutics against Clade Ib MPXV requires further evaluation.

EA DV CONGRESS
VIENNA
30 SEP - 3 OCT 2026

Abstract N°: 1262

Sporotrichoid Cutaneous Leishmaniasis and Pentavalent Antimonial-Induced Pancreatic Toxicity

Meriem Mhiri*[1], Nadia Ghariani[1], Sarra Saad[1], Sana Mokni[1], Ghariani Nejet[1]

[1] Dermatology Department, Farhat Hached University Hospital, Sousse, Tunisia, sousse, Tunisia

Introduction

Cutaneous leishmaniasis is a protozoal parasitosis caused by anthroponotic and zoonotic species of Leishmania. It is characterized by high clinical polymorphism, often mimicking other infectious dermatoses and misleading clinical diagnostic suspicions. Furthermore, managing the systemic toxicity of pentavalent antimonials remains a critical challenge for clinicians.

Case Presentation

A 73-year-old Tunisian woman with no significant medical history presented with a four-month history of a progressively enlarging, painless lesion on the back of her right ankle. Physical examination revealed a well-circumscribed, papulo-nodular, verrucous plaque with central ulceration. Notably, a linear series of firm, violaceous nodules followed an ascending lymphatic trajectory from the primary lesion along her lower limb, characteristic of a sporotrichoid distribution (Figure 1).

Given the regional endemicity, cutaneous leishmaniasis was suspected and confirmed by a dermal smear identifying Leishmania amastigotes after May-Grünwald Giemsa staining. Systemic therapy was initiated with intramuscular meglumine antimoniate at 60 mg/kg/day alongside adjuvant cryotherapy. On the sixth day of treatment, laboratory monitoring detected a significant elevation in serum lipase levels, reaching 10 times the upper limit of normal (ULN). Despite the biochemical severity, the patient remained entirely asymptomatic. To prevent progression to clinical pancreatitis while maintaining therapeutic efficacy, the dosage was reduced to 40 mg/kg/day. This led to the rapid normalization of pancreatic enzymes. The revised regimen was well-tolerated, resulting in complete regression of all lesions over a four-month follow-up period.



Figure 1: Verrucous cutaneous leishmaniasis with multiple firm, violaceous-to-erythematous nodules distributed in a linear, ascending "sporotrichoid" pattern, following lymphatic trajectory.

Conclusion

The clinical presentation of sporotrichoid cutaneous leishmaniasis is a classic "great mimicker," characterized by the intralymphatic dissemination of the parasite. Differential diagnoses include sporotrichosis, nocardiosis, atypical mycobacteriosis, and deep fungal infections. This case highlights the pertinence of the epidemiological context and regional endemicity in narrowing diagnostic suspicions. While pentavalent antimonials remain a recommended first-line therapy, pancreatic toxicity is a common and predictable adverse event, typically manifesting as an increase in pancreatic enzyme levels between days 5 and 10 of treatment. Although treatment discontinuation is recommended for lipase elevations beyond 12-15x ULN or symptomatic pancreatitis, this observation demonstrates that for significant asymptomatic biochemical elevations, a pragmatic dose-reduction

strategy can be safe and effective under strict monitoring.

EADV CONGRESS
VIENNA
30 SEP - 3 OCT 2026

Abstract N°: 1274

Lucio's Phenomenon Preceding Diagnosis: Diffuse Lepromatous Leprosy Presenting as Vasculitis with Fatal Systemic Progression

Azalea Guadalupe Altamirano De La Cruz*[1]

[1] Imss Hgzmf 8 Ensenada, Ensenada, Mexico

Introduction

Lucio’s leprosy, also known as Latapí’s disease, is a rare and aggressive variant of diffuse lepromatous leprosy (DLL) historically described in Mexico and Central America. Unlike the more common nodular lepromatous leprosy, DLL presents with diffuse, smooth skin infiltration and madarosis, often without the presence of nodules, which makes clinical recognition exceptionally challenging. The most severe manifestation of this variant is Lucio’s Phenomenon (LP), a necrotizing cutaneous reaction triggered by direct endovascular invasion of *Mycobacterium leprae*. This invasion leads to complement activation, extensive thrombosis, and hemorrhagic ischemic ulceration. LP carries a high mortality rate when unrecognized, primarily because it is systematically misdiagnosed as primary vasculitides, such as leukocytoclastic vasculitis, or other conditions like antiphospholipid syndrome and pyoderma gangrenosum. Such diagnostic errors result in significant treatment delays and allow for life-threatening systemic dissemination.

Case Presentation

A 26-year-old Mexican male was admitted presenting with pancytopenia, jaundice, and progressive hepatosplenomegaly. The patient had a 14-month diagnosis of lepromatous leprosy and had been under the standard WHO multidrug therapy (rifampicin 600 mg/month, dapsone 100 mg/day, and clofazimine 50 mg/day). Critically, his clinical history revealed that 14 months prior to this admission, he presented with bilateral hemorrhagic ulcerations and black eschars on his extremities. At that time, the lesions were misinterpreted as leukocytoclastic vasculitis, delaying the formal diagnosis of leprosy.

Despite over a year of continuous treatment, there was a complete lack of clinical and bacteriological response; the bacilloscopy index (BI) remained at a sustained 4+. Upon the current admission, total bilirubin reached 12.02 mg/dL. While drug-induced liver injury (DILI) was initially considered, the patient's bilirubin levels responded to systemic corticosteroids, and a bone marrow aspiration revealed an overwhelming presence of acid-fast bacilli. This confirmed that the primary etiology was systemic mycobacterial infiltration of the marrow rather than isolated drug toxicity. Abdominal imaging further demonstrated massive hepatosplenomegaly and gallbladder wall thickening consistent with direct bacillary infiltration. A punch biopsy of the left forearm confirmed the diagnosis through Fite-Faraco staining, which demonstrated foamy epithelioid histiocytes (Virchow cells) and, most importantly, the presence of *M. leprae* within the vascular endotheliumm, the pathognomonic histopathological hallmark of Lucio’s Phenomenon. Molecular analysis via PCR for the RLEP gene and *M. lepromatosis* is currently underway to investigate potential rifampicin resistance or co-infection given the therapeutic failure.

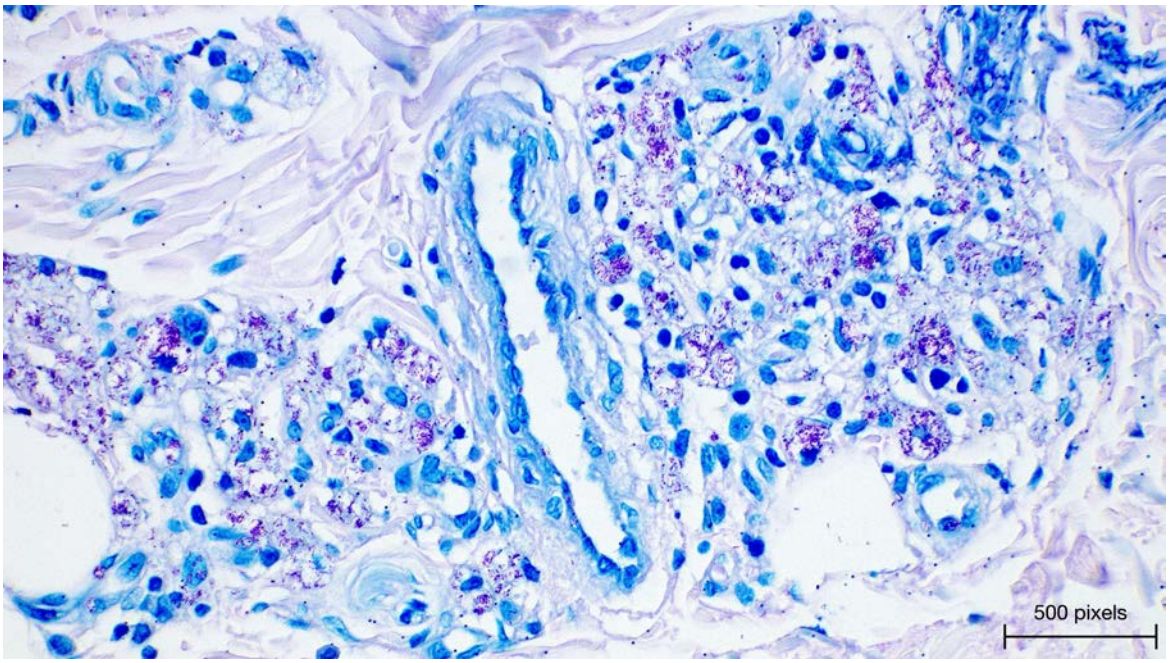

Punch biopsy of the left forearm (5 mm). Fite-Faraco staining demonstrates foamy epithelioid histiocytes (Virchow cells) with intracytoplasmic globi and abundant acid-fast bacilli. Critically, bacilli are identified within the vascular endothelium — the pathognomonic histopathological finding of Lucio's Phenomenon, distinguishing it from type 2 leprosy reactions and primary vasculitides. Granulomatous infiltrate extends from the papillary dermis to the adipose tissue in a perivascular, perineural, and periappendageal distribution.

Conclusion

This case highlights critical and underrecognized scenarios in the management of leprosy. First, Lucio's Phenomenon can be the inaugural manifestation of DLL, mimicking primary vasculitis and leading to fatal diagnostic delays. Second, the absolute lack of response to 14 months of standard WHO multidrug therapy, evidenced by a sustained BI of 4+, underscores the need to monitor for drug resistance or non-conventional species in endemic regions. Third, the development of pancytopenia in these patients must prompt immediate bone marrow evaluation to distinguish between drug toxicity and direct bacillary infiltration, as these conditions require fundamentally different management strategies. The endovascular localization of *M. leprae* remains the definitive diagnostic finding to distinguish LP from type 2 leprosy reactions and other vasculitides. Given global migration patterns, early dermatopathological recognition of this Mexican endemic variant is essential and life-saving.

EA DV CONGRESS
VIENNA
30 SEP - 3 OCT 2026

Abstract N°: 1275

A HARMFUL CURE: PRIMARY CUTANEOUS CRYPTOCOCCOSIS FOLLOWING TRADITIONAL PIGEON EXCRETA APPLICATION

Karthi Kishore*[1], Siva Senapathi[1]

[1] MILITARY HOSPITAL SHILLONG, SHILLONG, India

Introduction

Primary cutaneous cryptococcosis is a rare but important localized fungal infection that results from direct inoculation of *Cryptococcus* into the skin. Clinically, it may present as a papule, nodule, ulcer, cellulitis-like lesion, or abscess, making it easy to mistake for a routine bacterial skin infection.[1,2] Timely diagnosis is essential because delayed recognition can lead to progression of local disease and, in some cases, dissemination. This report describes a case of PCC that developed after application of pigeon excreta to a neck lesion, underscoring the hazards of traditional topical remedies and the importance of counseling patients against such practices.

Case Presentation

A 50-yr-old female with no comorbidities presented to our OPD with c/o a painful non-healing ulcer with pus discharge over the right side of the neck x 15 days. She gave h/o developing a pea-sized red raised lesion over the rt neck 3 weeks ago for which she had applied topical antibiotic cream with partial relief. However, with the urge to get the condition cured fast, she applied pigeon excreta over the lesion as advised by a Unani practitioner in her village. She started developing an increase in the size of the lesions after application of the pigeon excreta, resulting in the development of a pus-filled lesion over the neck, which ruptured after a period of 5 days to form an ulcer over the right side of the neck, following which she developed fever, pain, and swelling over the area. On general examination she was febrile and tachycardic. Local examination revealed a well-defined ulcer of size 6 cm x 4 cm with irregular erythematous margins with frank, foul-smelling pus discharge. **(Figure 1)** There was also a boggy soft tissue swelling present beside the ulcer involving the rt. clavicular and sternal regions. The skin over the adjoining neck region appeared erythematous and lichenified due to the intense itching done by the patient. Laboratory investigation revealed leukocytosis, and the pus swab on microscopic examination and culture showed the presence of gram-positive Cryptococcus sp. Hence, a diagnosis of primary cutaneous cryptococcosis with no systemic symptoms was made, and the patient was managed with local debridement of ulcer debris and oral antifungals (Cap itraconazole 200 mg once daily for 3 months).

Conclusion

Primary cutaneous cryptococcosis (PCC) refers to the fungal infection caused by the transcutaneous inoculation of the agent. The contributing factors are trauma, immunosuppression, advanced age and contact with avian excreta. The peculiarity of our case is that pigeon excreta was advised as a mode of topical therapy to the patient by an alternative medicine practitioner, which resulted in the cutaneous cryptococcus infection. In literature research it was noticed that in Unani practice, pigeon excreta has traditionally been used as a component in certain medicinal preparations due to its believed therapeutic properties. The rationale behind the use of pigeon excreta was its high acidic composition, which helps the “maturation” of acute abscesses and promotes their drainage.[3] However, it is to be noted that pigeon excreta is a harbor for many microorganisms such as E. coli, Salmonella, Histoplasma species, and Cryptococcus sp., and hence the use of the substance for medicinal

purposes should be strictly avoided. The treatment of PCC is the administration of oral antifungals (Fluconazole, Itraconazole) for a period of 3-6 months.[2] There is also a risk of dissemination of infection through the skin route into the bloodstream, causing disseminated or systemic cryptococcosis. Hence, this case report aims to highlight the dangers associated with unscientific alternative practices and the need of awareness among the clinicians while handling such cases, which may help them in counseling the patients to seek proper medical care from trained medical personnel.

EADV Congress 2026, VIENNA
30 SEPTEMBER - 03 OCTOBER 2026
POWERED BY M-ANAGE.COM

EA DV CONGRESS
VIENNA
30 SEP - 3 OCT 2026

Abstract N°: 1292

Scalp Strongholds: Mastering Microsporum canis Tinea Capitis via Precision Antifungal Profiling

Majd Abu Taleb*[1], Nesrine Ben Salah[1], Sameh Belgacem[2], Youssef Monia[1], Hichem Belhadjali[1], Maha Mastouri[2], Jameleddine Zili[1]

[1] Dermatology Department, Fattouma Bourguiba University Hospital, Monastir, Tunisia
[2] Microbiology Department, Fattouma Bourguiba University Hospital, Monastir, Tunisia

Introduction
Tinea capitis (TC) is a frequent superficial dermatophyte infection in children. Management commonly relies on empirical antifungal therapy without prior assessment of pathogen susceptibility. However, increasing rates of therapeutic failure, particularly in TC caused by *Microsporum canis*, raise concerns regarding the adequacy of this empirical approach. This study aimed to evaluate the antifungal susceptibility profile of local *M. canis* isolates and to assess the clinical relevance of antifungal susceptibility testing (AFST) for optimizing treatment strategies.

Materials and Methods
We conducted a retrospective clinical study including 419 pediatric cases of *M. canis*–related TC diagnosed between 2021 and 2025. In vitro antifungal susceptibility testing was performed using the EUCAST E.Def 11.0 reference method with antifungal agents commonly prescribed in empirical practice.

Results
In vitro, terbinafine, econazole, and griseofulvin demonstrated the highest antifungal activity, with MIC_{90} values of 0.03 µg/mL, 0.25 µg/mL, and 1 µg/mL, respectively. In contrast, 83.8% of isolates showed MIC_{90} values >16 µg/mL for fluconazole, and 50% exhibited MIC_{90} values of 8 µg/mL for itraconazole, indicating reduced susceptibility profiles. Clinically, terbinafine monotherapy achieved cure in only eight patients. Salvage therapy with itraconazole resulted in successful outcomes in 24 cases. In the remaining patients, combination therapy with oral terbinafine and topical econazole achieved complete clinical and mycological remission within four weeks. These findings highlight a marked discrepancy between the strong in vitro activity of terbinafine and its limited clinical effectiveness.

Conclusions
Our findings reveal a critical disconnect between current empirical prescribing and actual antifungal susceptibility patterns in *Microsporum canis*–related tinea capitis. The frequent clinical failure of terbinafine monotherapy likely stems from its limited hair shaft penetration despite favorable in vitro activity, while itraconazole-though pharmacologically advantageous-demonstrated emerging susceptibility reduction, aligning with recent Asian reports of acquired resistance to terbinafine and fluconazole. Conversely, sustained European clinical efficacy with griseofulvin despite higher MICs underscores the complex in vitro/in vivo relationship in dermatophytosis. In this evolving landscape, standardized empirical regimens are increasingly inadequate. Systematic integration of antifungal susceptibility testing into clinical pathways, particularly for refractory or atypical presentations, is

essential to guide individualized therapy and mitigate resistant strain dissemination. These results advocate for a paradigm shift toward susceptibility-driven management, supported by strengthened clinician–microbiology collaboration. Ultimately, routine AFST implementation will optimize treatment outcomes, preserve first-line antifungal efficacy, and position dermatology at the forefront of antifungal stewardship.

EADV CONGRESS
VIENNA
30 SEP - 3 OCT 2026

Abstract N°: 1298

When chronic ulcers are not graft-versus-host disease: HSV infection diagnosed by direct immunofluorescence in a pediatric transplant recipient

Maria Victória Figueiredo Rebolho*[1], Leticia Fogagnolo[1], Joana Teresa[1], Carlos Eduardo Grecco[1], Roberto Bueno Filho[1]

[1] Ribeirão Preto Medical School - University of São Paulo, Ribeirão Preto, Brazil

Introduction

Herpes simplex virus (HSV) infection is highly prevalent and typically presents as vesicular or erosive lesions on an erythematous base. However, in immunocompromised patients, HSV may exhibit atypical and polymorphic features, including chronic ulcerations that can closely mimic other dermatoses. This diagnostic challenge is particularly relevant in post-transplant patients with graft-versus-host disease (GVHD), in whom new ulcerative lesions may be misattributed to the underlying condition. We report a case of HSV infection presenting as chronic ulcers on GVHD-affected skin in a pediatric hematopoietic stem cell transplant recipient, highlighting the importance of maintaining a high index of suspicion for timely diagnosis and appropriate management.

Case Presentation

A 4-year-old girl with high-risk acute lymphoblastic leukemia, diagnosed at age 3, underwent chemotherapy followed by allogeneic hematopoietic stem cell transplantation (HSCT) from an unrelated donor one year after diagnosis. In the following months, she developed disseminated erythematous maculopapular lesions, vesicles, and exulcerations involving the trunk and extremities, including the palms and soles (Figures 1A and 1B), associated with diarrhea and nonspecific systemic symptoms. Graft-versus-host disease (GVHD) with cutaneous and gastrointestinal involvement was confirmed by skin and colon biopsy. Treatment included high-dose corticosteroids, etanercept, and mesenchymal stem cell infusions, along with management of secondary infections.

Approximately eleven months after HSCT, while on prednisolone, sirolimus, and tacrolimus, and undergoing ultraviolet A and B phototherapy for chronic GVHD, the patient developed new painful ulcers over previously affected, desquamated, xerotic skin with post-inflammatory hyperpigmentation. The lesions progressed with worsening ulceration of the extremities, accompanied by surrounding erythema and superficial erosions, as well as maceration, seropurulent discharge, intense pain, fever, and general malaise (Figures 1C and 1D). The patient was hospitalized and started on intravenous antibiotic therapy with ciprofloxacin and clindamycin.

A Tzanck cytology specimen was obtained by gently scraping the lesion with a spatula, with the freshly collected material immediately placed onto a glass slide and sent for direct immunofluorescence using anti-HSV antibodies, which yielded a positive result (Figure 1E). Treatment with acyclovir was initiated, resulting in marked clinical improvement and complete resolution of the ulcerative lesions.

Conclusion

HSV infection may mimic graft-versus-host disease in immunocompromised patients, particularly when arising on

chronically affected skin, leading to potential diagnostic delay. This case highlights the importance of considering HSV in the differential diagnosis of new or worsening ulcerative lesions in post-transplant patients, even when they occur in areas previously affected by GVHD. It also reinforces the concept that HSV may preferentially occur on previously damaged or diseased skin, with atypical presentations in the setting of immunosuppression. Direct immunofluorescence proved to be a rapid and valuable diagnostic tool in this setting, allowing prompt diagnosis despite its known limitations in sensitivity compared with molecular methods. Early recognition and prompt antiviral therapy are essential to reduce morbidity and improve clinical outcomes.

EADV CONGRESS
VIENNA
30 SEP - 3 OCT 2026

Abstract N°: 1332

Beyond the Flare: Mycobacterium tuberculosis as an Opportunistic Threat in VEXAS Syndrome

Hilmi Kilgin*[1], Muazzez Cigdem Oba[1], Tugba Kevser Ustunbas Uzuncakmak[1], Serdal Ugurlu[2]

[1] Istanbul University-Cerrahpasa, Cerrahpasa Faculty of Medicine, Department of Dermatology and Venereology, Istanbul, Türkiye
[2] Istanbul University-Cerrahpasa, Cerrahpasa Faculty of Medicine, Department of Internal Medicine, Division of Rheumatology, Istanbul, Türkiye

Introduction

VEXAS (Vacuoles, E1 enzyme, X-linked, Autoinflammatory, Somatic) syndrome is a UBA1-driven autoinflammatory disease characterised by bone marrow failure, systemic inflammation, and prominent cutaneous involvement, with skin manifestations frequently following a relapsing-remitting course. Infections occur in 40–60% of patients, with severe episodes accounting for 6–15% mortality. Frequently implicated opportunistic pathogens include Pneumocystis jirovecii, non-tuberculous mycobacteria (NTM), Legionella pneumophila, and herpesviruses. Susceptibility is driven by corticosteroid exposure, innate immune dysfunction, and haematological disorders. The frequent occurrence of atypical infections even in untreated patients supports an intrinsic immunodeficiency. However, in tuberculosis-endemic regions, Mycobacterium tuberculosis (MTB) — distinct from NTM — represents an underrecognised opportunistic pathogen capable of mimicking inflammatory flares. We report two VEXAS patients who developed active tuberculosis under immunosuppressive therapy, aiming to highlight MTB as a clinically significant infectious threat in endemic settings.

Case Presentation

Case 1: A 65-year-old male presented with recurrent fever, night sweats, weight loss, and leukocytoclastic vasculitis-like eruptions following cellulitis; erythematous-to-violaceous papules and nodules recurred with each flare. After UBA1 mutation confirmed VEXAS, he received anakinra (discontinued due to allergic reaction), tocilizumab, and pulse corticosteroids. Admitted with septic shock and left knee arthritis (warmth, swelling, restricted flexion), imaging revealed pulmonary nodules, splenic hypodense lesions, pleural effusion, and paraspinal collections consistent with miliary tuberculosis. MTB complex DNA was detected by PCR in synovial fluid and bronchoalveolar lavage; culture confirmed isoniazid-resistant MTB and quadruple therapy (rifampicin, ethambutol, pyrazinamide, moxifloxacin) was initiated. Co-infections with Kluyveromyces marxianus and Magnuciomyces capitatus required voriconazole. New pustular and papulovesicular lesions initially suspected as disseminated zoster were revised to acute generalised exanthematous pustulosis (AGEP) after biopsy.
Case 2: A 65-year-old male with a prior diagnosis of Sweet syndrome who was subsequently diagnosed with VEXAS upon UBA1 mutation detection, presenting with relapsing erythematous papulonodular lesions. Under anakinra and corticosteroids, he developed constitutional symptoms, bilateral hypermetabolic lymphadenopathy on PET-CT, and pleural effusion. Axillary lymph node biopsy revealed necrotising granulomatous lymphadenitis. Despite a negative interferon-gamma release assay (IGRA), extrapulmonary tuberculosis (tuberculous pleuritis with lymphadenopathy) was confirmed by pleural fluid MTB PCR, and four-drug anti-tuberculosis therapy was commenced.

Conclusion

Both cases highlighted the diagnostic overlap between VEXAS flares and tuberculosis: miliary TB with isoniazid resistance in Case 1, and tuberculous pleuritis with necrotising granulomatous lymphadenitis despite a negative IGRA in Case 2, underscoring the need for direct microbiological sampling in immunosuppressed patients. While NTM has been the principal mycobacterial concern in VEXAS literature, MTB must also be considered in endemic regions. Prophylactic strategies targeting Pneumocystis jirovecii pneumonia (PJP) and varicella zoster virus (VZV) have proven effective; analogous vigilance for MTB, including latent tuberculosis screening and prophylaxis where indicated, should be implemented in endemic settings. Cutaneous manifestations may represent the earliest findings in VEXAS; however, concurrent opportunistic infections — including MTB — may complicate the disease course and must be recognised and managed promptly.

EADV CONGRESS
VIENNA
30 SEP - 3 OCT 2026

Abstract N°: 1351

A Cross-Sectional Study to Determine the Prevalence of Bony Changes in Hands and Feet of Leprosy Patients using radiographs

Diksha Garg*[1], Anuj Bhatnagar[1], Smriti Sharma[1]

[1] Armed Forces Medical College, Pune, India

Introduction
Leprosy is a chronic granulomatous disease known to involve skin, peripheral nerves, and musculoskeletal structures. Bone changes, particularly in hands and feet, have been widely reported, especially in patients with deformities.However, there is limited data evaluating bony changes across all spectrums of Hansen's disease, including patients without visible deformities and those with pure neuritic involvement.

Materials and Methods
Aim
To determine the prevalence of radiological bony changes in hands and feet among leprosy patients across all clinical types, irrespective of deformity status using radiographs.
Methods
This cross-sectional study included clinically and microbiologically diagnosed cases of Hansen's disease attending a tertiary care center. Patients were enrolled irrespective of type (TT, BT, BB, BL, LL, and pure neuritic) and disability status. All patients had received or were receiving multidrug therapy (MDT).
Detailed clinical evaluation was performed, followed by radiography of hands and feet. Bony changes were categorized as specific and non-specific based on established radiological criteria. Descriptive statistical analysis was applied.

Results
The study included a heterogeneous cohort comprising patients across the leprosy spectrum, including pure neuritic cases and those without deformities.
Radiological bony changes were observed predominantly in patients with clinical deformities, consistent with prior studies where deformity cohorts showed high prevalence of bone involvement . In contrast, patients without deformities did not demonstrate any radiological bony changes.
Among patients with bony involvement, non-specific changes were more common than specific changes, aligning with previous literature . No significant association was observed between type of Hansen's disease and occurrence of bone changes, suggesting that deformity status rather than disease spectrum plays a more critical role.

Conclusions
Bony changes in leprosy are closely associated with the presence of deformities rather than the clinical type of disease. Patients without deformities, including pure neuritic cases, may not exhibit radiological bone involvement despite confirmed disease.
These findings emphasize the importance of early diagnosis and prevention of deformities to avoid secondary skeletal complications, rather than relying solely on disease classification to predict bone involvement.

EADV CONGRESS
VIENNA
30 SEP - 3 OCT 2026

Abstract N°: 1360

Erythema Nodosum Leprosum under observation

Dima Ghandour*[1], Monica Costescu[1]

[1] Spitalul de boli infectioase si tropicale "Dr. Victor Babes", Bucuresti, Bucharest, Romania

Introduction

Introduction

Leprosy (Hansen's disease), is a chronic infectious disease with a long incubation period, on average 5 years, primarily affecting the skin, peripheral nerves, and mucous membranes. It is caused by the bacteria *Mycobacterium leprae* and is known for its slow progression, often leading to nerve damage, skin lesions, and muscle weakness if left untreated.

Leprosy is a curable disease, treated with World Health Organization (WHO)-recommended multidrug therapy for multibacillary disease (MDT-MB).

We report this case of a patient who underwent the MDT-MB therapy but had recurrences of lesions and symptomatology with a focus on clinical evaluation, safety and multidisciplinary management.

Case Presentation

Clinic presentation

A 26-year-old female of Nepalese origin, Fitzpatrick phototype IV, with no relevant medical history, received a diagnosis of leprosy in Nepal in 2024 and was initiated on the multidrug therapy for multibacillary disease (MDT-MB). She was referred to our service for reassessment in the context of recurrent lesions observed during the course of treatment, including fever and fatigue.

The MDT-MB regimen is composed of:

- Rifampicin 600mg monthly, per os
- Clofazimine 300mg monthly + 50mg daily dose, per os
- Dapsone 100mg daily, per os

The patient however, developed a hypersensitivity reaction to dapsone, which was replaced with daily Ofloxacin 200mg, per os.

Initial treatment duration was 1 year, after which therapy was discontinued.

Treatment was later reinitiated based on recommendations from her provider in Nepal and is currently taking Ofloxacin, methylprednisolone, antihistamines, and MDT-MB.

Dermatological findings:

- Papules, plaques, and indurated erythematous-edematous patches on trunk and limbs
- Post-inflammatory hyperpigmentation
- Round-to-oval hypopigmentated macules with impaired tactile sensation and paresthesia (plantar region)

- Nerve tenderness: ulnar and posterior tibial nerves

The patient was transferred to the Infectious Diseases Department for further investigations.

Investigations

Laboratory investigations were largely unremarkable, with the exception of a mildly elevated C-reactive protein (CRP), consistent with a systemic inflammatory state.

A punch biopsy was performed; however, histopathological findings were non-specific and did not show active granulomatous inflammation.

Microbiological evaluation was negative for acid-fast bacilli via Ziehl-Neelsen staining and PCR for Mycobacterium leprae. Cultures on Löwenstein-Jensen medium showed no growth, effectively ruling out a mycobacterial co-infection or relapse.

Treatment

During hospitalization, the patient received :

- Intravenous hydrocortisone (100 mg/day)
- Analgesics and antihistamines
- Topical emollient therapy

This therapeutic approach resulted in significant clinical improvement.

Conclusion

Conclusion

The patient presented with new skin lesions and neuropathic pain after completing treatment for leprosy. Because her tests showed no active bacteria but high inflammatory markers, we confirmed a diagnosis of Type 2 Lepra Reaction (Erythema Nodosum Leprosum).

This is an immune response, not a sign that the infection is active again. The infectious disease department confirmed that the patient was not contagious and did not require isolation. Her positive response to anti-inflammatory therapy further supported the diagnosis. This case shows how important it is to distinguish between an immune reaction and a disease relapse in patients who have finished leprosy treatment.

EA DV CONGRESS
VIENNA
30 SEP - 3 OCT 2026

Abstract N°: 1384

Toxic Shock Syndrome originating from a Tattoo: A case Report

Sarah Østergaard Holm*[1]

[1] Department of Dermatology and Venereology, Aarhus University Hospital, Aarhus N, Denmark

Introduction

Tattooing is common and generally considered safe; however, it carries a risk of infection ranging from local infection to severe systemic illness. Among these complications, toxic shock syndrome (TSS) is a rare but potentially fatal condition, most often caused by toxin-producing *Staphylococcus aureus* or *Streptococcus pyogenes.* TSS is an acute, progressive, multisystem illness that may lead to multiorgan failure. Early identification and prompt multidisciplinary management are crucial, yet tattoo-associated TSS remains rarely described and may be underrecognized in clinical practice.

Case Presentation

A previously healthy 21-year-old male presented to the emergency department with mild erythema, warmth and swelling at the site of a recent tattoo, accompanied by fever, gastrointestinal symptoms, and malaise. These symptoms occurred following extensive tattooing of the arm over a three-day period. His condition rapidly progressed to profound hypotension, multiorgan dysfunction, declining consciousness, and respiratory distress necessitating intubation and intensive care. Extensive microbiological testing was negative, and a multidisciplinary team concluded that the clinical course was most consistent with TSS, most likely caused by *Staphylococcus aureus* according to diagnostic criteria. The patient was treated with hemodialysis, vasopressor therapy, antimicrobial and immunomodulating agents, alongside supportive treatment of disseminated intravascular coagulation (DIC)-associated coagulopathy. He gradually recovered, with normalization of organ function, and was discharged in full health after ten days of hospitalization.

Conclusion

This case highlights that TSS can occur as a rare complication of tattooing. Clinicians should consider TSS when acute hypotension, multiorgan dysfunction, and cutaneous symptoms develop shortly after tattooing, even in the absence of an identifiable pathogen. Early recognition, multidisciplinary evaluation, and prompt treatment are crucial for survival and patient outcomes.

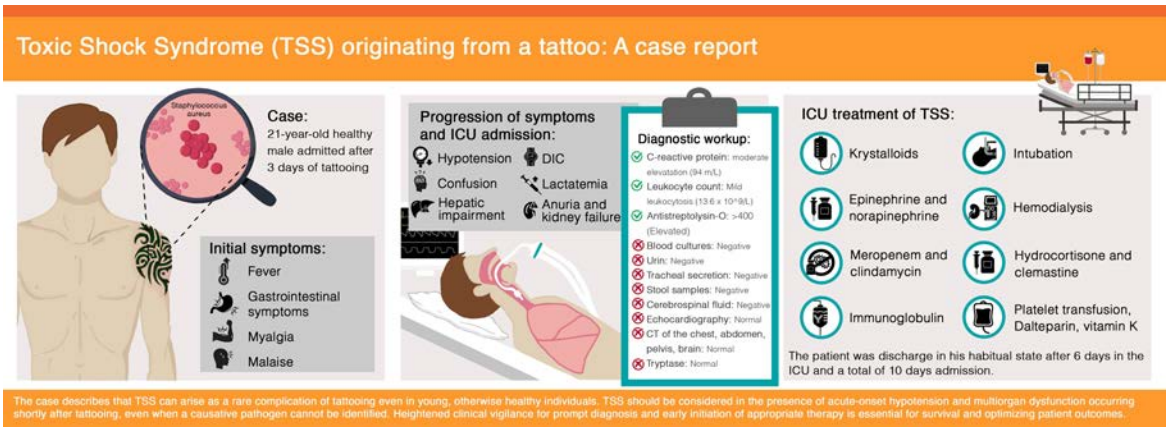

Graphical Abstract

EADV Congress 2026, VIENNA
30 SEPTEMBER - 03 OCTOBER 2026
POWERED BY M-ANAGE.COM

EADV CONGRESS
VIENNA
30 SEP - 3 OCT 2026

Abstract N°: 1398

Hyalohyphomycotic cyst on the hand caused by Sarocladium kiliense: A case report

Fida Anjum*[1]

[1] Yenepoya Medical College, Mangalore, India

Introduction

Hyalohyphomycoses are rare cutaneous or systemic infections caused by a heterogeneous group of non-pigmented fungi. Unlike cutaneous phaeohyphomycosis, which usually presents as subcutaneous cysts, cutaneous hyalohyphomycosis has a more varied clinical presentation, ranging from keratotic masses to subcutaneous cysts or nodules to diffuse erythema and ulcerations. We report a case of a hyalohyphomycotic cyst caused by *Sarocladium kiliense* in a diabetic patient.

Case Presentation

A 48-year-old diabetic male farmer was referred to dermatology during admission for an unrelated surgical site infection. He presented with an asymptomatic swelling on the dorsum of his right hand, which had developed insidiously over time. Examination revealed a lobulated, cystic swelling measuring 5 × 4 cm, with a 3 × 2 cm extension into the proximal middle finger. Differential diagnoses included bacterial abscess and phaeohyphomycotic cyst. Gram staining of the aspirate was non-contributory, while potassium hydroxide mount revealed long, non-pigmented hyphae with acute-angle branching. Culture confirmed *Sarocladium kiliense*. A diagnosis of hyalohyphomycotic cyst was made. The subcutaneous cyst was surgically excised, and the patient was initiated on long-term itraconazole therapy.

Conclusion

The term 'hyalohyphomycosis' refers to a group of opportunistic infections caused by non-pigmented fungi. These fungi may belong to various genera, such as *Fusarium, Penicilium, Scedosporium, Scopulariopsis, Acremonium/Sarocladium* etc. Clinical presentation of hyalohyphomycosis can be categorized into three - namely, superficial, subcutaneous and systemic hyalohyphomycosis.

Sarocladium kiliense, formerly *Acremonium kiliense*, is a soil saprophyte more commonly implicated in cutaneous hyalohyphomycosis. It is often caused by traumatic implantation and may manifest as a subcutaneous cyst or abscess. The diagnosis may easily be missed unless a fungal etiology is specifically investigated. Early recognition of a hyalohyphomycotic cyst is essential, allowing complete excision and infection clearance. Additionally, a chronic focus of this infection carries the risk of potentially fatal opportunistic dissemination, particularly in patients with comorbidities.

EA DV CONGRESS
VIENNA
30 SEP - 3 OCT 2026

Abstract N°: 1423

Molluscum contagiosum, warts and condylomas during JAK inhibitor therapy for dermatologic conditions: a retrospective series of 21 cases

Giuseppe Russo*[1], Emmanuel Mahe[2], Florence TETART[3], Audrey Loretan[1], Audrey Nosbaum[4], Marie Tauber[4], Raison-Peyron Nadia[5], Estelle Burle[6], Angèle Soria[7], Emilie Brenaut[8], Anne Saussine[9], Thibault Mahevas[9], Jean David Bouaziz[9], Emmanuel Laffitte[1], Marie Jachiet[9]

[1] Hôpitaux Universitaires de Genève, Genève, Switzerland
[2] Centre Hospitalier Victor Dupouy d'Argenteuil, Argenteuil, France
[3] CHU de Rouen, Rouen, France
[4] Centre Hospitalier Lyon Sud, Pierre-Bénite, France
[5] Hôpital Saint-Éloi, Montpellier, France
[6] Hôpitaux de Toulouse, Toulouse, France
[7] Hôpital Tenon APHP, Paris, France
[8] CHU Brest, Brest, France
[9] Hôpital Saint-Louis, Paris, France

Introduction

Janus kinase inhibitors (JAK-i) are increasingly used for inflammatory dermatoses. By blocking intracellular signal transduction of multiple cytokines, including type I and II interferons, they exert potent anti-inflammatory effects but may also impair antiviral immune defense. This effect may increase susceptibility to viral skin infections beyond herpesvirus reactivation. Data on molluscum contagiosum, warts and condylomas remain limited.

Materials and Methods

We report a multicenter retrospective case series of 21 patients who developed cutaneous viral infections (molluscum contagiosum, warts or condylomas) during JAK-i treatment. Our cohort comprised 21 patients (16 males, 5 females; mean age 34.7 ± 12.2 years, median 35 years, range 13-63) treated with JAK-i in nine dermatology centers in France and Switzerland. The primary indication was atopic dermatitis in 81% (n=17) of cases, with other conditions including vitiligo (n=1), alopecia areata (n=1), sarcoidosis (n=1), and Still disease (n=1). Upadacitinib was the most prescribed agent (85.7%, n=18; 15 patients at 30 mg/day, 3 patients at 15 mg/day). Eleven patients had received previous immunosuppressive therapy, most commonly ciclosporine (n=5) and prior JAK-i (n=5). Among the cohort, six patients (28.6%) had a documented history of molluscum contagiosum, warts or condylomas prior to JAK-i initiation.

Results

Cutaneous viral infections developed at a median of 6 months (range: 1-28 months, mean 10.1 ± 8.4 months) after JAK-i initiation. The predominant infection type were condylomas (71.4%, n=15), followed by warts (52.4%, n=11) and molluscum contagiosum (33.3%, n=7), with 23.8% (n=5) of patients exhibiting multiple concurrent infections (Table 1). Lesion burden varied considerably according to infection type, with most patients presenting either 10-50 lesions (n=7) or fewer than 10 lesions; however extensive disease (>50 lesions) occurred in 4 patients, predominantly in those with condylomas or molluscum contagiosum.

JAK-i therapy was modified in 57.1% (n=12) of cases, including discontinuation (n=6, 28.6%), dose reduction (n=3, 14.3%) or switching for another JAK-i (n=3, 14.3%) in response to viral infections. Therapeutic interventions included cryotherapy, topical imiquimod, topical keratolytic agents and surgical excision. Among the 6 patients in whom JAK-i were discontinued, cutaneous viral lesions completely regressed in 4 cases, including 3 patients with disseminated molluscum contagiosum and 1 with condylomas.



Figure 1: Cutaneous viral infections arising during treatment with upadacitinib in patients with atopic dermatitis. Giant plantar warts (left); extensive molluscum contagiosum eruption (right).

Conclusions

JAK-i may increase susceptibility to viral infections through suppression of type I interferon signaling in epidermal and mucosal tissues, a pathway critical for keratinocyte antiviral responses and cytotoxic lymphocyte activation.

A cohort study of 1793 atopic dermatitis patients reported higher overall infection rates with JAK-i treatment compared to biologic treatment, particularly for herpes infections. Beyond herpesviruses, isolated cases reports have described molluscum contagiosum and human papillomavirus (HPV)-related warts arising during JAK-i therapy. Notably, a case of disseminated molluscum contagiosum was reported in a patient receiving ruxolitinib, a JAK1/2 inhibitor, highlighting the role of interferon pathway blockade in impaired viral clearance.

Most recently, several reports documented the occurrence of HPV-related warts following JAK-i initiation. Collectively, these observations support a mechanistic link between JAK inhibition and reduced cutaneous antiviral immunity beyond herpesvirus reactivation.

Our retrospective series suggests that JAK-i may predispose patients to opportunistic cutaneous viral infections particularly HPV-related condylomas, warts, and molluscum contagiosum. Patients with atopic dermatitis and/or a prior history of viral skin infections may represent a population at increased risk. Clinicians should therefore remain alert to the development of new or progressive viral skin lesions during JAK-i therapy.

Patient	Age/Sex	Primary Indication	Prior Immunosuppression	Prior Viral Infection	JAKi (Dose, mg/day)	Time to Infection (months)	Infection Type	Lesion Count	JAKi Management
1	32/M	Atopic dermatitis	CsA, BARI, ABRO	No	UPA (30)	6	Molluscum contagiosum	Unknown	Switched JAKi
2	63/M	Atopic dermatitis	None	Molluscum contagiosum	UPA (30)	3	Molluscum contagiosum	Unknown	Continued
3	30/F	Atopic dermatitis	None	No	UPA (30)	15	Molluscum contagiosum	>50	Stopped
4	44/M	Atopic dermatitis	None	Molluscum contagiosum, condyloma, warts	UPA (30)	6	Condyloma, warts	Unknown	Stopped
5	36/M	Atopic dermatitis	None	Herpes zoster, warts	UPA (30)	6	Molluscum contagiosum, warts	10–50	Reduced
6	39/M	Atopic dermatitis	None	No	UPA (30)	9	Condyloma	10–50	Reduced
7	18/M	Vitiligo	None	No	UPA (30)	28	Warts	<10	Continued
8	15/F	Alopecia areata	None	No	UPA (15)	2	Warts	<10	Continued
9	41/M	Sarcoidosis	MTX	No	BARI (4)	3	Condyloma	>50	Stopped
10	28/M	Atopic dermatitis	None	No	UPA (15)	2	Molluscum contagiosum	>50	Continued
11	44/M	Atopic dermatitis	BARI, ABRO	No	UPA (30)	11	Condyloma	>50	Stopped
12	35/M	Atopic dermatitis	CsA, BARI, ABRO	No	ABRO (200)	24	Condyloma, warts	<10	Stopped
13	31/M	Atopic dermatitis	CsA	Condyloma	UPA (30)	1	Condyloma	<10	Continued
14	53/M	Atopic dermatitis	CsA, MTX	Herpes zoster, Condyloma	UPA (30)	1	Condyloma, warts	10–50	Switched JAKi
15	22/F	Atopic dermatitis	CsA	No	UPA (30)	15	Condyloma	10–50	Stopped
16	13/F	Atopic dermatitis	MTX, OCS	Warts	UPA (15)	12	Warts	<10	Continued
17	49/M	Still disease	OCS, ADA, LEF	Herpes zoster	TOFA (10-20)	23	Warts	10–50	Continued
18	31/M	Atopic dermatitis	BARI	No	UPA (30)	9	Molluscum contagiosum	10–50	Switched JAKi
19	31/F	Atopic dermatitis	BARI	No	UPA (30)	6	Warts	<10	Reduced
20	35/M	Atopic dermatitis	None	No	UPA (30)	6	Warts	<10	Continued
21	38/M	Atopic dermatitis	None	No	UPA (30)	24	Molluscum contagiosum, condyloma, warts	10–50	Continued

Table 1: Clinical characteristics and outcomes of 21 patients with cutaneous viral infections during JAK inhibitor therapy. Abbreviations: ABRO, abrocitinib; ADA, adalimumab; BARI, baricitinib; CsA, ciclosporine; HSV, herpes simplex virus; LEF, leflunomide; MTX, methotrexate; OCS, oral corticosteroids; TOFA, tofacitinib; UPA, upadacitinib. a Time to infection represents the interval from JAK-i initiation to viral infection onset. Reduced: Upadacitinib switched to 15 mg/day

EA DV CONGRESS
VIENNA
30 SEP - 3 OCT 2026

Abstract N°: 1463

Comparison of Relapse Rate and Disease Severity among patients with Type 2 Lepra Reaction receiving Tofacitinib and Thalidomide separately as an adjuvant to systemic steroids: A Longitudinal Analytical Study

Swetalina Pradhan*[1], Rishav Sanghai[1]

[1] All India Institute of Medical Sciences Patna, India, Patna, India

Introduction

Erythema nodosum leprosum (ENL) is a severe immune-mediated complication of multibacillary leprosy requiring prolonged immunosuppression. Steroid-sparing agents are essential to reduce relapse and treatment-related morbidity

Materials and Methods

This longitudinal analytical observational study compared outcomes in patients with ENL treated with prednisolone plus thalidomide (Group A; n=30) and prednisolone plus tofacitinib (Group B; n=31). Patients were followed for 6 months. Primary outcomes included relapse rate and ENLIST ENL Severity Score (EESS). Secondary outcomes were neutrophil–lymphocyte ratio (NLR), Dermatology Life Quality Index (DLQI), steroid dependency, and adverse events. Inter-group comparisons and longitudinal analyses were performed using non-parametric tests. Correlations between NLR, EESS, and DLQI were assessed using Spearman's rank correlation.

Results

Relapse occurred in 36.7% of patients in Group A and 71.0% in Group B ($p=0.007$). The mean number of relapses was significantly lower in Group A (0.70±1.06 vs 1.84±1.51; $p=0.002$)(Figure 1). At 3 and 6 months, Group A demonstrated significantly lower NLR values ($p=0.017$ and $p<0.001$, respectively). DLQI and EESS scores improved in both groups; however, sustained improvement was more consistent in Group A. Steroid-free status at 6 months was achieved in 93.3% of Group A compared with 58.1% of Group B ($p<0.001$). NLR showed a positive correlation with EESS ($\rho=0.269$, $p=0.018$) and DLQI ($\rho=0.604$, $p<0.001$) at 6 months. Adverse events were predominantly mild to moderate, with differing safety profiles between groups.

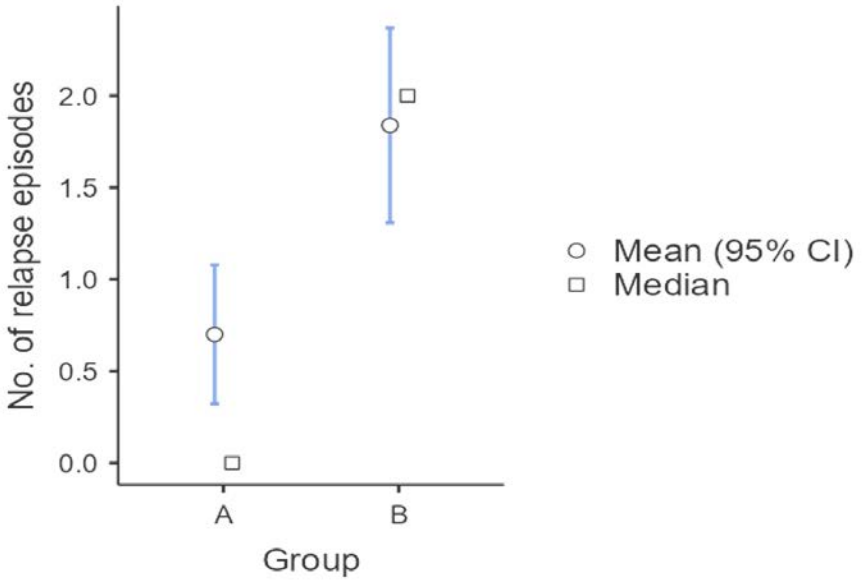

Comparison of mean number of relapse episodes between Group A and Group B during the follow-up period

Conclusions

Thalidomide demonstrated superior relapse prevention and steroid-sparing efficacy compared with tofacitinib in ENL. NLR correlated with disease severity and quality of life, supporting its role as a useful biomarker for monitoring disease activity during follow-up.

EA DV CONGRESS
VIENNA
30 SEP - 3 OCT 2026

Abstract N°: 1482

Management of Cutaneous Warts in Immunocompromised Patients: A Systematic Review Highlighting the Emerging Role of Immunotherapy

Abdullah Almeziny*[1], fares Alkhayal[2]

[1] College of Medicine, Imam Mohammad Ibn Saud Islamic University, Riyadh, Saudi Arabia, Riyadah, Saudi Arabia
[2] Prince Sultan Military Medical City, Riyadh, Saudi Arabia, Riyadah, Saudi Arabia

Introduction
Cutaneous warts are common viral infections caused by human papillomavirus (HPV) and are frequently more severe, persistent, and resistant to treatment in immunocompromised individuals. In this population, impaired immune responses contribute to chronic infection, recurrence, and therapeutic failure. Conventional treatment modalities, including cryotherapy, salicylic acid, and destructive procedures, often yield suboptimal outcomes, emphasizing the need for more effective and targeted therapeutic approaches.

Materials and Methods
A systematic review was conducted in accordance with PRISMA guidelines. PubMed, Scopus, and Cochrane databases were searched for studies published between January 2015 and May 2024. Eligible studies included randomized controlled trials, observational studies, case series, and case reports involving immunocompromised patients with cutaneous warts. Data extraction and screening were independently performed by two reviewers. Risk of bias was assessed using the ROBINS-E tool for non-randomized studies and the Cochrane RoB 2.0 tool for randomized trials.

Results
Sixteen studies were included, comprising one randomized controlled trial, eleven case reports, and four observational studies, involving a total of 100 immunocompromised patients. The most common causes of immunosuppression were organ transplantation and HIV infection. Warts were predominantly located on the feet, hands, and periungual regions and were frequently recalcitrant to prior therapies. Immunotherapeutic approaches —including intralesional antigen injections and human papillomavirus vaccination—demonstrated the most consistent clinical benefit, with high rates of complete or partial lesion clearance, even in patients unresponsive to multiple previous treatments. Notably, several studies reported regression of untreated distant lesions following intralesional therapy, supporting a systemic immune-mediated effect. In the included randomized trial, intralesional Candida antigen achieved significantly higher clearance rates compared to control (up to 80% complete response). Conventional therapies such as cryotherapy, laser therapy, photodynamic therapy, and systemic retinoids showed variable and less predictable outcomes. Adverse events were generally mild and localized, including injection-site pain, erythema, and edema, with rare systemic effects. Most studies were assessed as low to moderate risk of bias, although heterogeneity and small sample sizes were common limitations.

Conclusions
Sixteen studies were included, comprising one randomized controlled trial, eleven case reports, and four observational studies, involving a total of 100 immunocompromised patients. The most common causes of immunosuppression were organ transplantation and HIV infection. Warts were predominantly located on the feet, hands, and periungual regions and were frequently recalcitrant to prior therapies. Immunotherapeutic approaches —including intralesional antigen injections and human papillomavirus vaccination—demonstrated the most

consistent clinical benefit, with high rates of complete or partial lesion clearance, even in patients unresponsive to multiple previous treatments. Notably, several studies reported regression of untreated distant lesions following intralesional therapy, supporting a systemic immune-mediated effect. In the included randomized trial, intralesional Candida antigen achieved significantly higher clearance rates compared to control (up to 80% complete response). Conventional therapies such as cryotherapy, laser therapy, photodynamic therapy, and systemic retinoids showed variable and less predictable outcomes. Adverse events were generally mild and localized, including injection-site pain, erythema, and edema, with rare systemic effects. Most studies were assessed as low to moderate risk of bias, although heterogeneity and small sample sizes were common limitations.

EADV CONGRESS
VIENNA
30 SEP - 3 OCT 2026

Abstract N°: 1489

Ecthyma gangrenosum associated with Pseudomonas aeruginosa panniculitis in an immunocompetent infant

Lamia Ould Iddir*[1], Saliha Takheroubt[1], Issam TABLIT[1], Lemya Mezdour[1], Asma Haciane[1], Samira Zobiri[1]

[1] Dermatology department, Mustapha university hospital, Algiers, Algeria

Introduction

Ecthyma gangrenosum (EG) is a rare and severe necrotizing cutaneous infection, classically associated with Pseudomonas aeruginosa septicemia and usually occurring in immunocompromised patients. However, non bacteremic forms have also been described, including in immunocompetent individuals. We report a case of severe multifocal EG associated with panniculitis in an immunocompetent infant.

Case Presentation

A 6 month old female infant, born to a diabetic mother, was hospitalized for ulceronecrotic lesions evolving for 13 days. The lesions were initially pustular and then bullous before progressing to extensive ulcerations involving the buttocks, vagina, and anal region, later complicated by the appearance of violaceous subcutaneous nodules.

Laboratory investigations showed leukocytosis at 34,500/mm^3 (neutrophils 21,600/mm^3) and a C reactive protein level of 109 mg/L. Two pus cultures isolated Pseudomonas aeruginosa.

Mechanical necrosectomy was performed, combined with antibiotic therapy consisting of gentamicin for 5 days and ciprofloxacin for 21 days. The clinical course was favorable, with normalization of biological parameters, negative follow-up cultures, regression of the nodules, and complete re-epithelialization of the lesions. Etiological investigations, including screening for an underlying immunodeficiency, were negative.



Ulceronecrotic lesions of the buttocks, vulva, and inguinal region

Conclusion

Ecthyma gangrenosum results from vascular invasion by pathogens, most commonly Pseudomonas aeruginosa, leading to secondary cutaneous necrosis. It is usually associated with severe immunosuppression, particularly neutropenia. Nevertheless, cases in immunocompetent patients have been reported in the literature.

To our knowledge, our patient represents the second reported case of typical ecthyma gangrenosum associated with disseminated panniculitis. The latter is most often secondary to septicemia, which was not documented in our patient.

Pseudomonas aeruginosa panniculitis occurs predominantly in immunocompromised adults. Our observation represents the third pediatric case reported, with the particular feature of the absence of immunodeficiency, which may explain the favorable response to treatment despite the severity of the clinical presentation.

Cutaneous infection due to *Pseudomonas aeruginosa* most commonly presents as ecthyma gangrenosum, but it should also be considered in cases of panniculitis occurring in an infectious setting, even when no immunosuppression is identified. Early microbiological diagnosis and prompt initiation of appropriate antipseudomonal antibiotic therapy are key determinants of prognosis. A complete immunological assessment remains essential to identify any underlying immune deficiency.

EADV CONGRESS
VIENNA
30 SEP - 3 OCT 2026

Abstract N°: 1494

Tuberculosis Verrucosa Cutis: A Delayed Diagnosis Behind a Chronic Plaque

Ahmet TARAÇ*[1], Elif Bal Avcı[1], Sezgi Sarıkaya Solak[1], Yusuf Mert Döş[2], Nuray Can[3], Fatma Şeyda Direkel[3]

[1] Trakya University Faculty of Medicine , Department of Dermatology, Edirne, Türkiye
[2] Keşan State Hospital, Depertmant of Dermatology, Edirne, Türkiye
[3] Trakya University Faculty of Medicine , Department of Pathology, Edirne, Türkiye

Introduction

Cutaneous tuberculosis is a rare form of extrapulmonary tuberculosis caused by the *Mycobacterium tuberculosis complex*. Because of its polymorphic clinical presentation, it can mimic a wide spectrum of inflammatory and neoplastic dermatoses, often leading to diagnostic delay. Tuberculosis verrucosa cutis (TVC) is a slowly progressive form that occurs in previously sensitized individuals with preserved cell-mediated immunity. Owing to its paucibacillary nature, microbiological tests are frequently negative; therefore, the diagnosis relies on the correlation of clinical, histopathological, and immunological findings. Furthermore, cutaneous tuberculosis accounts for less than 1% of all tuberculosis cases, and delayed diagnosis is well documented, with lesions reported to persist for years. In TVC, the average time to diagnosis may approach 10 years, with extreme cases lasting several decades. Herein, we present a patient with a chronic verrucous lesion who underwent multiple treatments for presumed diagnoses before being ultimately diagnosed with TVC.

Case Presentation

A 42-year-old man presented with a progressively enlarging lesion on the left thumb of approximately two years' duration. He was engaged in animal husbandry. The patient had previously received topical corticosteroids, antifungal agents, and antibiotics for presumed eczema, fungal and bacterial infections, without clinical improvement. Dermatological examination revealed an indurated, erythematous, verrucous plaque. Microbiological investigations were inconclusive; both mycobacterial culture and polymerase chain reaction for *Mycobacterium tuberculosis* were negative. Dermoscopic evaluation showed dirty-white scales and yellow-orange structureless areas. The tuberculin skin test (TST) showed an induration of 20 mm. Histopathological examination revealed pseudoepitheliomatous hyperplasia and granulomatous inflammation. The diagnosis of TVC was established based on the combined evaluation of clinical findings, patient history, TST, and histopathological findings. No pulmonary or other extrapulmonary involvement was identified. Treatment was initiated with daily oral multidrug antituberculosis therapy consisting of isoniazid (300 mg), rifampicin (600 mg), pyrazinamide (2000 mg), and ethambutol (1500 mg) for 2 months, followed by isoniazid (300 mg) and rifampicin (600 mg) for 4 months. No drug-related adverse effects were observed, and complete clinical resolution was achieved at one-year follow-up.

Conclusion

TVC should be considered in the differential diagnosis of chronic, treatment-refractory verrucous lesions. Its paucibacillary nature frequently results in negative microbiological findings, potentially complicating the diagnostic process. In such cases, diagnosis relies on the integration of clinical presentation, histopathological findings, and immunological tests such as TST or interferon-gamma release assays. A high index of clinical suspicion is therefore essential for establishing the diagnosis. Early recognition and appropriate treatment are key to avoiding unnecessary interventions and achieving favorable outcomes.

EADV Congress 2026, VIENNA
30 SEPTEMBER - 03 OCTOBER 2026
POWERED BY M-ANAGE.COM

EADV CONGRESS
VIENNA
30 SEP - 3 OCT 2026

Abstract N°: 1515

Midline Destructive Lesions in Tropical Settings: Mucocutaneous Leishmaniasis vs Extranodal NK/T-Cell Lymphoma

Melissa Garcia Alvarez*[1], Liseth Losada Rodriguez[1], Camila Diaz[2], Oscar Mora[1]

[1] Fucs-Fundación Universitaria de Ciencias de La Salud, Hospital San José, Bogotá, Colombia

[2] Hospital San José, Bogotá, Colombia

Introduction

Midline destructive lesions of the face represent a significant diagnostic challenge due to the broad spectrum of infectious, inflammatory, and neoplastic conditions that may present with overlapping clinical features (1). In tropical regions, mucocutaneous leishmaniasis is often considered the leading diagnosis in patients presenting with nasal ulceration, septal perforation, or palatal destruction (2). However, other aggressive entities, such as extranodal NK/T-cell lymphoma, nasal type, must also be considered given their rapid progression and high morbidity and mortality (3).

Case Presentation

We report the case of a 45-year-old man with a six-month history of purulent rhinorrhea, postnasal drip, and progressively worsening frontal pain. Two weeks prior to presentation, he experienced clinical deterioration, with increased nasal discharge, severe pain, and swelling of the nasal and paranasal regions. This was associated with the development of yellowish vesiculobullous lesions in the same area.

The patient reported a history of travel to a tropical rural area within the previous two years. Physical examination and rhinoscopy revealed a septal perforation involving the mid portion of the nasal septum, along with a destructive lesion of the hard palate with mucosal discontinuity. Imaging studies demonstrated extensive destruction of the hard palate, with involvement of adjacent bony and cartilaginous structures.

Given the epidemiological context and the presence of midline destructive lesions, mucocutaneous leishmaniasis was initially suspected. However, nasal biopsy showed no amastigotes; instead, it revealed an aggressive NK/T-cell lymphoid neoplasm consistent with extranodal NK/T-cell lymphoma, nasal type (Figure 1.)Serological studies were positive for Epstein–Barr virus.

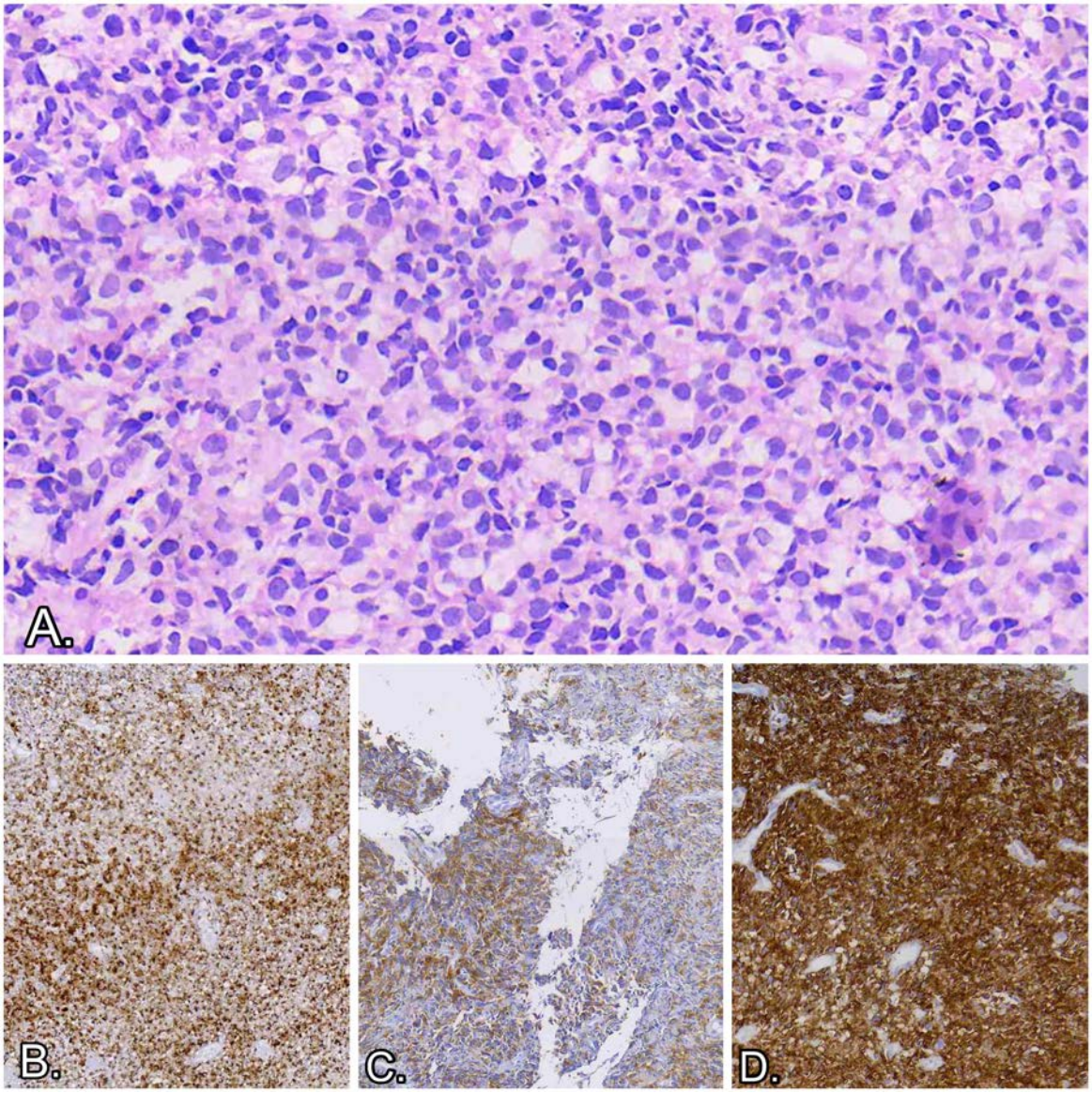

Figure 1. Biopsy of a nasal cavity lesion involving bone and soft tissue. A(H&E, 50×): Fragments of devitalized bone and soft tissue with necrosis and cellular debris; a focal infiltrate of a lymphoid neoplasm composed of small- to medium-sized cells with irregular nuclei, coarse chromatin, scant cytoplasm, and rare mitoses is identified. B(Granzyme B, 16.27×): Positivity in neoplastic cells. C (CD30, 20×): Focal expression (30%) in tumor cells. D(CD45, 28×): Positivity in neoplastic cells.

Conclusion

Midline destructive lesions in tropical settings should not be automatically attributed to mucocutaneous leishmaniasis, as a wide range of infectious, inflammatory, and malignant conditions may present with similar features (1–3). While epidemiological context may guide the initial diagnostic approach, it can also introduce bias and delay the recognition of aggressive neoplastic processes (2,4). The presence of rapidly progressive tissue destruction, palatal involvement, necrosis, and Epstein–Barr virus association should prompt consideration of lymphoma (3,5). In this context, early biopsy and histopathological evaluation are essential to establish an accurate diagnosis and avoid delays in the management of potentially life-threatening conditions such as extranodal NK/T-cell lymphoma (1,5).

EADV CONGRESS
VIENNA
30 SEP - 3 OCT 2026

Abstract N°: 1519

Single-cell transcriptome atlas reveals that JNK/AP-1 signalling modulates type 17 immune responses in Microsporum canis skin infection

Xin Zhou*[1], Wentao Liu[2], Peiying Feng[2], de Hoog Sybren[1, 3, 4], Chongxiang Xiong[5]

[1] Radboudumc/CWZ Center of Expertise for Mycology, Nijmegen, Netherlands
[2] the third Affiliated Hospital of Sun Yat-Sen University, Guangzhou, China
[3] Foundation Atlas of Clinical Fungi, Hilversum, Netherlands
[4] Westerdijk Fungal Biodiversity Institute, Utrecht, Netherlands
[5] the First Dongguan Affiliated Hospital of Guangdong Medical University, Dongguan, China

Introduction
Microsporum canis is one of the most common zoonotic dermatophytes and a leading cause of tinea capitis worldwide. Clinically, *M. canis* infection shows marked heterogeneity, ranging from highly inflammatory lesions to relatively mild chronic presentations, suggesting an important role for host immune regulation in determining disease outcome. Although type 17 immunity has been implicated in dermatophyte defense, the cellular basis of this response and its relationship with JNK/AP-1 signaling during *M. canis* skin infection remain poorly understood.

Materials and Methods
A murine epicutaneous *M. canis* infection model was established with three groups: control, infection, and infection plus the JNK inhibitor SP600125 (Fig1A). Skin lesions were monitored longitudinally, and infected skin tissues collected at day 7 were subjected to single-cell RNA sequencing. Integrated analyses included cell clustering and annotation, pseudotime trajectory analysis, pathway enrichment, cell-cell communication analysis, and focused re-clustering of ILC and T-cell compartments. Key signaling and epithelial response molecules were further examined by western blotting, GSVA, and co-immunoprecipitation.

Results
Single-cell profiling identified 30 cell clusters spanning epithelial, stromal, vascular, and immune compartments (Fig1B). *M. canis* infection reduced basal keratinocytes and hair follicle stem cell-associated populations, while increasing stress-associated keratinocytes, companion layer cells, extracellular matrix-remodeling fibroblasts, macrophages, and T cells. Pseudotime analysis indicated a shift of hair follicle cells toward companion layer states and keratinocytes toward stress-associated terminal differentiation. Immune re-analysis showed expansion of ILC3, Th17, and γδT17 populations after infection (Fig1C-E), together with enhanced IL-17-centered communication directed mainly toward epithelial and follicular compartments. These epithelial responder populations upregulated IL-17 receptors, inflammatory chemokines, antimicrobial peptides, and barrier-remodeling genes. JNK inhibition alleviated clinical lesions, reduced type 17-skewed immune states (Fig1F), attenuated IL-17-related intercellular communication, and suppressed epithelial inflammatory outputs. At the molecular level, infection was associated with activation of JNK/AP-1 signaling, induction of ATF3 in Th17-related states, increased JNK and c-Jun phosphorylation, and enhanced ATF3-Jun complex formation, all of which were weakened by JNK inhibition (FigG-I).

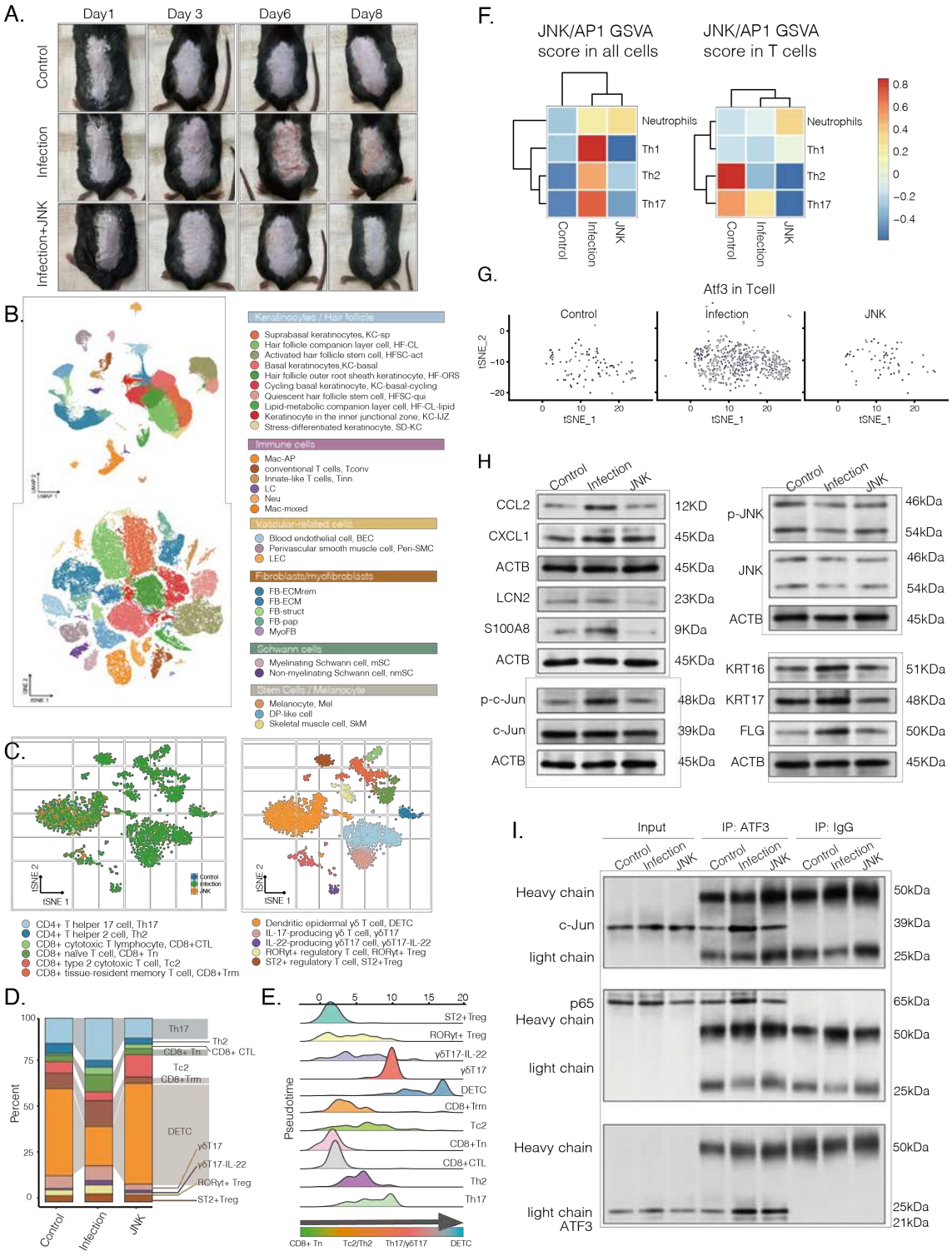

Figure 1. Single-cell transcriptomic analysis reveals the compositional changes of skin cell populations to Microsporum canis infection. (A) Representative images of dorsal skin lesions from Control, Infection, and JNK groups at days 1, 3, 6, and 8 post infection. Microsporum canis infection induced prominent hair loss, erythema, and scaling, whereas JNK intervention markedly alleviated skin damage and promoted lesion resolution. (B) UMAP visualization of scRNA-seq data. The left panels show the distribution of cells across the experimental groups (Control, Infection, and JNK). Right panels depict clustering results colored by cell type, illustrating infection-induced cellular heterogeneity and the modulatory effects of JNK signaling on the skin microenvironment during M. canis infection. (C) t-SNE representation of skin-derived T cells from Control, Infection, and JNK groups, colored according to experimental group or annotated T cell subsets. (D) Composition of T cell subsets in Control, Infection, and JNK groups presented as relative proportions. (E) Pseudotime ordering of T cell subsets along inferred trajectories, including CD8+T cells, helper T cell subsets, γδ T cells, and regulatory T cells. (F) Heatmaps showing GSVA scores of JNK/AP-1-related gene sets in all cells (left) and in T cells only

(right) across control, infection, and JNK inhibitor conditions (G) t-SNE feature plots showing ATF3 expression within Th17 cells under control, infection, and JNK inhibitor-treated conditions. (H) Western blot analysis. (I) Co-immunoprecipitation (Co-IP) analysis showing interactions between ATF3 and c-Jun or p65 under control, infection, and JNK inhibitor conditions. Whole-cell lysates (Input), ATF3 immunoprecipitates (IP: ATF3), and IgG immunoprecipitation controls (IP: IgG) were immunoblotted for c-Jun, p65, and ATF3. Heavy and light chains are indicated.

Conclusions

This study provides a single-cell atlas of the cutaneous response to *M. canis* infection and identifies JNK/AP-1 signaling as an important amplifier of type 17 immunity and epithelial inflammation (Fig2). The JNK-Jun-AP-1 axis, including ATF3-Jun complex formation, may represent a mechanistic link between immune activation and tissue pathology in dermatophytosis and a potential therapeutic target for inflammatory *M. canis* infection.

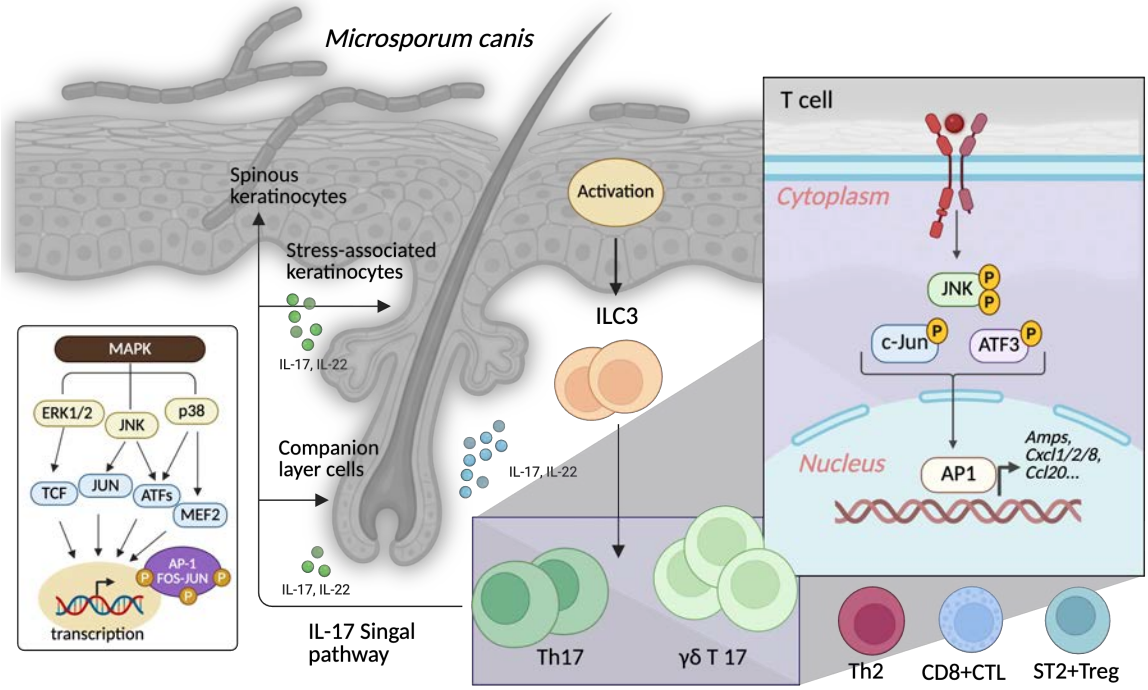

Figure 2. Proposed model of JNK/AP-1-driven type 17 immune responses during Microsporum canis skin infection

EA DV CONGRESS
VIENNA
30 SEP - 3 OCT 2026

Abstract N°: 1546

Extrapulmonary Nontuberculous Mycobacteria (EP-NTM) Infection in a 66-year-old patient - A Case Report

Alexander Löw*[1], Lev Volkov[1], Jörg Reichrath[1], Thomas Vogt[1], Roman Saternus[1]

[1] Clinic for Dermatology, Venerology and Allergology, Saarland University, Homburg, Germany

Introduction

Nontuberculous mycobacteria (NTM) comprise a diverse group of mycobacterial species distinct from the Mycobacterium tuberculosis complex and Mycobacterium leprae. Over 200 species and subspecies have been identified, with the Mycobacterium avium complex being the most prevalent. NTM are widely distributed in the environment, including soil and water systems, and primarily affect immunocompromised individuals. Recently, the prevalence and clinical relevance of NTM infections have increased globally, especially in regions with low tuberculosis rates.

Case Presentation

A 66-year-old university lecturer presented with a six-month history of progressive skin lesions. The disease initially manifested as nodules on the right calf and rapidly spread to the lower extremities, trunk, and upper extremities.

The patient also reported having experienced B symptoms for several months, including night sweats and unintentional weight loss, as well as persistent fatigue. During this time, he had an increased susceptibility to infections, including recurrent Epstein-Barr virus infections and prolonged genital herpes outbreaks.

Upon examination, multiple erythematous to livid macules and nodules, some measuring several centimeters, were observed on the lower extremities, trunk, and upper extremities less frequently.

Laboratory findings showed a decreased CD4/CD8 ratio, B-cell lymphopenia, CD8 lymphocytosis, NK-cell lymphopenia, and IgG hypogammaglobulinemia (675 mg/dL), while the complete blood count was unremarkable. Serology showed no evidence of acute Epstein-Barr virus or cytomegalovirus infection. An interferon-gamma release assay was positive, and sputum analysis repeatedly detected high levels of Mycobacterium avium by microscopy and culture.

Computed tomography scans of neck, thorax, and abdomen revealed a small subcapsular liver lesion without evidence of pulmonary involvement. To confirm the diagnosis, a representative skin lesion was excised for histopathological and immunohistochemical analysis.

Histopathology revealed a suppurative granuloma at the dermal-subcutaneous junction, which is consistent with an infectious process. Ziehl-Neelsen staining revealed acid-fast bacilli, raising suspicion of mycobacterial infection. Further testing was performed on paraffin-embedded tissue. Initial PCR testing was negative. Although Mycobacterium avium was detected in sputum, imaging showed no pulmonary involvement, so treatment was deferred initially. After 25 days, culture positivity of the skin biopsy confirmed the diagnosis of an EP-NTM infection, allowing the initiation of targeted therapy.

In the absence of robust randomized data, treatment followed current guideline recommendations. Combination therapy with azithromycin (250 mg/day), rifampicin (600 mg/day), and ethambutol (15 mg/kg/day) was initiated. Over the following months, the cutaneous lesions gradually regressed, resulting in an unremarkable skin examination at present. However, due to persistently positive sputum cultures throughout the treatment course, an extension of the antimicrobial regimen with amikacin and clofazimine is currently being considered.

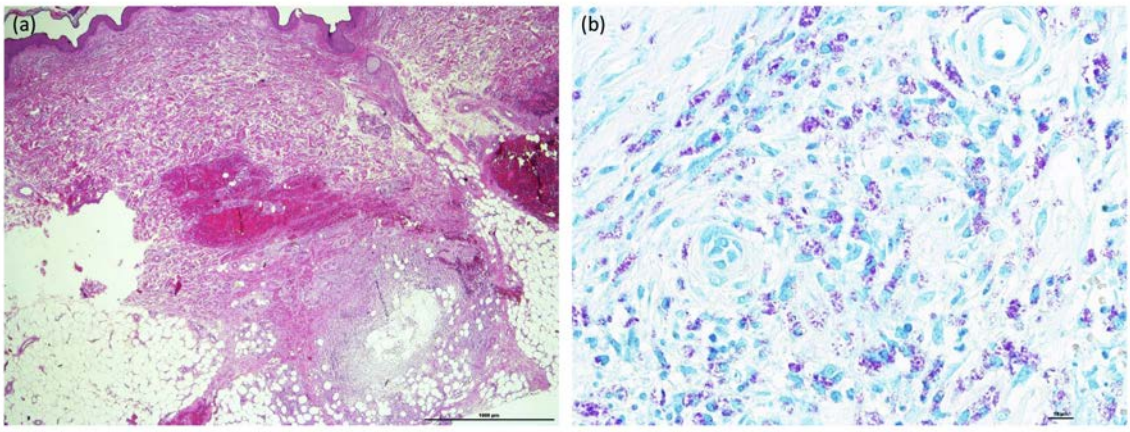

(a) Hematoxylin-eosin staining reveals an unremarkable epidermis and superficial to mid-dermis. A suppurative granuloma is present in the deep dermis at the dermal-subcutaneous junction, extending into the subcutis. It is characterized by a central accumulation of neutrophils and a peripheral rim of epithelioid macrophages, with only occasional multinucleated giant cells. (b) Ziehl-Neelsen staining reveals numerous densely packed acid-fast bacilli within macrophages.

Conclusion

The global prevalence of nontuberculous mycobacterial infections is rising, representing an increasing clinical challenge. Primary cutaneous manifestations may occur in the complete absence of pulmonary symptoms and may also present with a disseminated distribution pattern, in contrast to the sporotrichoid distribution typically observed in other nontuberculous mycobacteria infections. This case highlights the crucial role of dermatology in diagnosing extrapulmonary nontuberculous mycobacteria infections.

EADV CONGRESS
VIENNA
30 SEP - 3 OCT 2026

Abstract N°: 1552

delayed diagnosis of chromoblastomycosis in a chronic verrucous plaque with discordant histopathology

Laura Rodríguez Suárez*[1], Ana Jiménez Segura[1], Camilo Morales Cardona[2]

[1] Fundación Universitaria Sanitas, Bogotá, Colombia

[2] Centro Dermatológico Federico Lleras Acosta, Bogotá, Colombia

Introduction

Chromoblastomycosis is a chronic subcutaneous implantation mycosis caused by dematiaceous fungi, typically present as slowly progressive verrucous plaques or nodules on exposed areas. Its indolent course, along with the presence of pseudoepitheliomatous hyperplasia on skin biopsy may lead to repeated misdiagnosis, particularly in the absence of adequate clinicopathological correlation. This case aims to highlight the diagnostic value of integrating clinical morphology with histopathological findings in long-standing verrucous lesions, thereby preventing further delays and inappropriate management.

Case Presentation

We report the case of an 80-year-old patient with a 13-year history of a persistent, slowly enlarging lesion on his right wrist. Two previous biopsies had been interpreted as actinic keratosis and, more recently, cutaneous leishmaniasis. On physical examination, the lesion appeared as an erythematous verrucous plaque with black dots, a finding that, together with the prolonged clinical course, raised suspicion for chromoblastomycosis. A third skin biopsy was therefore performed to enable clinicopathological reassessment. Histopathological examination showed pseudoepitheliomatous hyperplasia characterized by hyperkeratosis, parakeratosis, irregular acanthosis, accompanied by a dense acute suppurative and chronic granulomatous lymphohistioplasmacytic inflammatory infiltrate. Scattered pigmented fungal structures consistent with Medlar bodies were identified, confirming the diagnosis of chromoblastomycosis. No evidence of malignancy was observed. Treatment with oral itraconazole was initiated, resulting in significant clinical improvement of the lesion.

Conclusion

This case underscores the importance of considering chromoblastomycosis in the differential diagnosis of chronic verrucous plaques, especially when previous histopathological interpretations are discordant or misleading. Recognition of key clinical clues, such as black dots and prolonged clinical course, combined with careful histopathological examination for Medlar bodies, is essential for establishing an accurate diagnosis and guiding appropriate antifungal treatment.

EADV CONGRESS
VIENNA
30 SEP - 3 OCT 2026

Abstract N°: 1564

Species Distribution, Antifungal Susceptibility, and Clinical Outcomes of Osteoarticular Fungal Infections: A Retrospective Study of 60 Cases

Jie Liu*[1], Kaiming Zhang[2], Rui Yu[1], Haozhi Han[1], Peng Zhao[1]

[1] Shanxi Provincial People's Hospital, Taiyuan, China

[2] Changsha Hospital of Traditional Chinese Medicine,, Changsha, China

Introduction

Osteoarticular fungal infections (OAFIs) are rare but disabling. Diagnosis and treatment remain challenging due to nonspecific presentations and limited antifungal guidance. To characterize the epidemiological patterns, clinical features, and antifungal susceptibility profiles of OAFIs, with emphasis on the role of *in vitro* susceptibility testing in guiding therapy.

Materials and Methods

A retrospective study was conducted on 60 patients with OAFIs diagnosed between January 2020 and February 2024. Fungal identification was performed using MALDI-TOF MS. Broth microdilution antifungal susceptibility testing was performed for amphotericin B (AMB), fluconazole (FLC), voriconazole (VRC), and posaconazole (POS) according to CLSI guidelines.

Results

Among 60 isolates, *Candida* spp. (66.7%) and *Aspergillus* spp. (23.3%) predominated. Rare pathogens included *Cryptococcus neoformans* (n=2), *Trichophyton rubrum* (n=2), *Lomentospora prolificans* (n=1), and *Cryptococcus laurentii* (n=1). Systemic comorbidities were present in 73.3% of patients. FLC showed the highest MIC values, while VRC and POS demonstrated favorable *in vitro* activity. Significant differences in VRC and POS activity were observed among *Candida*, *Aspergillus*, and *Cryptococcus* spp. ($P<0.01$). Overall treatment success rate was 95% (57/60). Two clinical failures occurred despite *in vitro* susceptibility, highlighting a discordance between MIC results and clinical response.

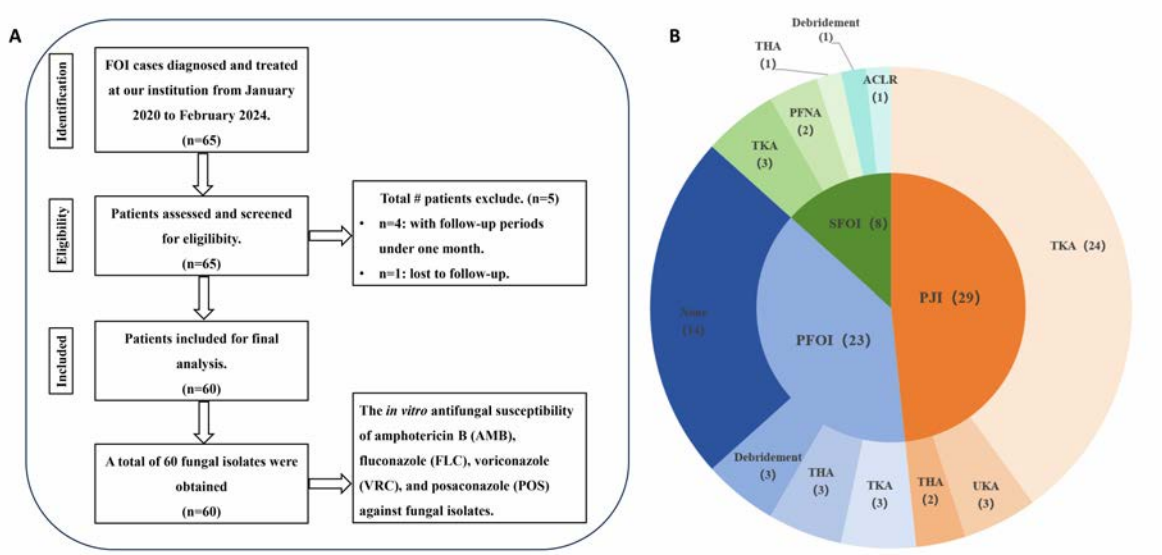

(A) Study flowchart. A retrospective analysis was conducted on 60 patients with OAFIs (January 2020 to February 2024). Following fungal isolation and in vitro susceptibility testing, patients underwent antifungal therapy. Outcomes included 54 successes, 3 cases with spacer retention, 2 failures, and 1 non-treatment-related death (heart disease). (B) A total of 60 patients with OAFIs, comprising 8 with secondary fungal osteoarticular infections (SFOI), 23 with primary fungal osteoarticular infections (PFOI), and 29 with periprosthetic joint infections (PJI). Surgical management following various types of osteoarticular fungal infections. The outer ring of the pie chart indicates the types of subsequent surgical procedures received, which included: total knee arthroplasty (TKA), unicompartmental knee arthroplasty (UKA), total hip arthroplasty (THA), proximal femoral nail antirotation (PFNA), anterior cruciate ligament reconstruction (ACLR), and debridement.

Conclusions

Candida albicans and *Aspergillus fumigatus* are the leading pathogens, but rare fungi including *Lomentospora prolificans*, *Cryptococcus laurentii*, and invasive *Trichophyton rubrum* are emerging causes of OAFIs. VRC and POS are potentially effective therapeutic options, but the discordance between *in vitro* susceptibility and clinical response warrants caution. Early detection of rare pathogens and susceptibility-guided therapy are crucial.

EADV CONGRESS
VIENNA
30 SEP - 3 OCT 2026

Abstract N°: 1571

Unilateral recurrent erythema and edema revealing demodicosis

Kmar Turki*[1], Rim Chaabouni[1], Dora Zghal[1], Hamida Turki[1]

[1] Dermatology department, Hedi Chaker university hospital, Sfax, TUNISIA, Sfax, Tunisia

Introduction

Demodicosis is an inflammatory dermatosis related to the proliferation of *Demodex folliculorum* within pilosebaceous follicles, most commonly mimicking rosacea. Its unilateral edematous presentation is rare and probably underdiagnosed.

Case Presentation

A 50-year-old man, with a history of deep vein thrombosis of the leg due to protein S deficiency and receiving rivaroxaban, presented with recurrent mildly pruritic erythematous edema of the right cheek, evolving for 1 year.

Several investigations, including antinuclear antibodies and C1 inhibitor testing, were negative. Patch testing showed sensitization to potassium dichromate, but this was considered clinically irrelevant in the present case. The patient was treated with topical corticosteroids and antihistamines, with worsening of symptoms.

Clinical examination revealed finely scaly erythema of the right cheek on a background of firm unilateral edema, sparing the upper eyelid. Dermoscopic examination showed Demodex tails, and parasitological examination confirmed the presence of *Demodex*. The patient was treated with metronidazole and topical ivermectin, with complete resolution of symptoms.

Conclusion

A similar case of unilateral facial demodicosis has been reported and was initially mistaken for Hansen disease. The literature on “unilateral rosacea” and “unilateral demodicosis” remains scarce, and there is a current tendency to group both entities under a single designation. As illustrated by our case, this presentation remains responsive to conventional anti-demodectic therapies, unlike Morbihan disease, which is mainly characterized by persistent facial edema with lymphatic ectasia and may be far more refractory to treatment, including systemic corticosteroids and immunosuppressive agents.
Demodicosis should be considered in cases of recurrent unilateral facial edema or atypical rosacea-like dermatitis, in order to reduce diagnostic errors and avoid inappropriate treatments. Dermoscopy and the identification of Demodex tails can rapidly orient the diagnosis and prompt initiation of appropriate, often effective, therapy, while helping to discuss the differential diagnosis with chronic facial edema, particularly Morbihan disease.

EADV CONGRESS
VIENNA
30 SEP - 3 OCT 2026

Abstract N°: 1574

Cutaneous Lesions as a Diagnostic Clue in Chronic Meningococcemia: A Case Series from a Tertiary Care Hospital

Ariadna Casamitjana-Casabó*[1], Gloria Aparicio Español[1], Patricia Bassas-Freixas[1], Alvaro Guerra Amor[1], Eugenia Hernández-Ruiz[1], Daniel Prades Almolda[1], Pablo Marino Castro García[1], Sergi Puajdas Vilà[1], Aina Estany Becares[1], Berta Ferrer Fabrega[2], Vicente García-Patos Briones[1]

[1] Hospital Universitari Vall d'Hebron, Dermatology Department, Barcelona, Spain

[2] Hospital Universitari Vall d'Hebron, Pathology Department, Barcelona, Spain

Introduction

Chronic meningococcemia is an uncommon and likely underdiagnosed form of invasive infection caused by Neisseria meningitidis. Unlike acute presentations, it is characterized by a subacute or chronic course (>1 week), with intermittent or persistent fever, flu-like syndrome, polymorphic cutaneous lesions, and osteoarticular involvement, in the absence of meningitis or septic shock. Diagnostic delay is common and may lead to inappropriate treatments, prolonged symptoms, and increased morbidity. The aim of this study is to describe the clinical features, management, and outcomes of patients with chronic meningococcemia, with particular emphasis on the diagnostic role of cutaneous manifestations.

Materials and Methods

A retrospective descriptive case series of chronic meningococcemia was conducted at a tertiary care hospital. Medical records were reviewed to collect demographic data, clinical features, microbiological findings, treatments, and outcomes.

Results

Four adult patients with chronic meningococcemia were included.

All patients had a subacute course (>1 week) with fever, flu-like syndrome, and cutaneous involvement; in some cases, lesions appeared at the same time as febrile episodes. Skin lesions were polymorphic and tender; however, the most consistent and diagnostically relevant finding was the presence of purpuric papules. Lesions predominantly involved the trunk and the lower and upper extremities. Most patients had palmoplantar involvement, and none had mucosal involvement. Arthralgia was frequent.

Diagnosis was established by repeated detection of Neisseria meningitidis using microbiological and/or molecular techniques. In one case, identification was achieved exclusively by polymerase chain reaction (PCR) from a skin biopsy, with negative blood cultures. Skin biopsy mostly showed features consistent with vasculitis with intravascular thrombi. No complement pathway abnormalities were identified.

Systemic antibiotic therapy was associated with a favorable clinical course, with progressive resolution of fever and skin lesions.

Conclusions

Chronic meningococcemia should be considered in the differential diagnosis of patients presenting

with intermittent fever and cutaneous lesions. Cutaneous manifestations, particularly purpuric papules, represent a key diagnostic clue that may raise suspicion of the disease. Early recognition enables prompt initiation of appropriate antibiotic therapy, improving clinical outcomes, and reducing associated morbidity.

EA DV CONGRESS
VIENNA
30 SEP - 3 OCT 2026

Abstract N°: 1575

Cutaneous Leishmaniasis in Central Sri Lanka: Epidemiology, Clinical Spectrum, Diagnosis and Management at a Tertiary Care Hospital

Hasini Jayasundara*[1], Sachithra Samarakoon[1], Chandani Udagedara[1]

[1] Postgraduate Institute of Medicine, University of Colomo, Sri lanka, Colombo, Sri Lanka

Introduction
Cutaneous leishmaniasis (CL) is a re-emerging parasitic dermatosis in Sri Lanka. Understanding regional epidemiological patterns, clinical morphology, and diagnostic yield is essential for optimizing early diagnosis, management strategies, and disease control.

Materials and Methods
A retrospective observational study was conducted at the Dermatology Unit, National Hospital Kandy, including 80 patients diagnosed with cutaneous leishmaniasis from June 2023 to June 2025. Demographic data, lesion characteristics, duration of disease, diagnostic investigations, and treatment modalities were extracted from medical records and analyzed descriptively using SPSS.

Results
Eighty patients were included in the analysis. The cohort comprised 54% males and 46% females, with ages ranging from 10 to 87 years (mean 42.5 years). The most affected age group was 41–60 years (35%). Most patients were Sinhalese (95%), with the highest proportion residing in the Galagedara Medical Officer of Health area (26%).

Lesions predominantly involved the head and neck region (41%), followed by the upper limbs (30%) and lower limbs (20%). Plaques were the most common clinical morphology (80%), followed by papules (12.5%) and ulcers (7.5%). Lesion duration ranged from 0.5 to 48 months, demonstrating a positively skewed distribution (skewness 3.39). Most patients presented within 3–6 months of onset (35%), while 17% presented after more than 12 months. The mean lesion duration was 6.2 months, with a median of 4 months.

Slit skin smear microscopy was positive in 30% of patients, while histopathological confirmation was obtained in 50% of cases. Among biopsied lesions, Donovan bodies were identified in 34%, granulomatous inflammation in 25%, and plasma cell infiltrates in 86%. Polymerase chain reaction testing was performed selectively and was positive in 13.8% of patients.

Treatment modalities included intralesional sodium stibogluconate (45%), topical metronidazole (16%), intralesional metronidazole (8%), cryotherapy (4%), and combination regimens incorporating sodium stibogluconate or itraconazole. Most patients achieved satisfactory clinical resolution, with no major adverse effects documented.

Conclusions
Cutaneous leishmaniasis remains endemic in Central Sri Lanka, predominantly affecting middle-aged individuals. Plaque-type lesions involving exposed sites, particularly the head, neck, and upper limbs,were the most frequent presentation. Delayed presentation beyond six months was common. Intralesional therapies, especially sodium stibogluconate and metronidazole, were effective and well tolerated. Strengthening regional surveillance,

improving access to early diagnosis, and promoting timely local treatment may reduce disease morbidity and transmission.

EA DV CONGRESS
VIENNA
30 SEP - 3 OCT 2026

Abstract N°: 1599

A Novel Surgical Approach for Condyloma Acuminata: The ECCHE Procedure for Improved Hemostatic Control in Highly Vascular Perianal Lesions

Idrianti Idrus Paturusi*[1], Lezdyana Islami[1], Muhlis Muhlis[1], Muji Iswanty[1], Rasiha Rasiha[2]

[1] Department of Dermatology and Venereology, Faculty of Medicine, Hasanuddin University, Makassar, Indonesia
[2] Faculty of Medicine, Hasanuddin University, Makassar, Indonesia

Introduction

Condyloma acuminata (CA) is a common sexually transmitted infection caused by human papillomavirus. In HIV-infected patients, lesions are often larger, recurrent, and more difficult to manage. Conventional surgical excision may be particularly challenging due to the highly vascular anatomy of the region, increasing the risk of intraoperative bleeding and impaired operative control. The ECCHE procedure (electrocauterization cutting and coagulation, hemostatic stabilization through infiltration and ligation, and excision) was developed to improve hemostatic control during excision.

Case Presentation

Materials and Methods:

We report three HIV-positive male patients (20–39 years) presenting with perianal CA. All patients underwent wide excision using the ECCHE technique, incorporating perioperative hemostatic optimization and electrocautery-based vessel control.

Results:

Lesions ranged from 3 × 0.5 cm to 7 × 2 cm, with one case presenting multiple verrucous nodules. Histopathological examination confirmed CA, demonstrating koilocytosis, acanthosis, papillomatosis, and hyperkeratosis. All procedures achieved adequate intraoperative hemostasis with minimal bleeding and no major complications. Postoperative wound healing was satisfactory in all cases.

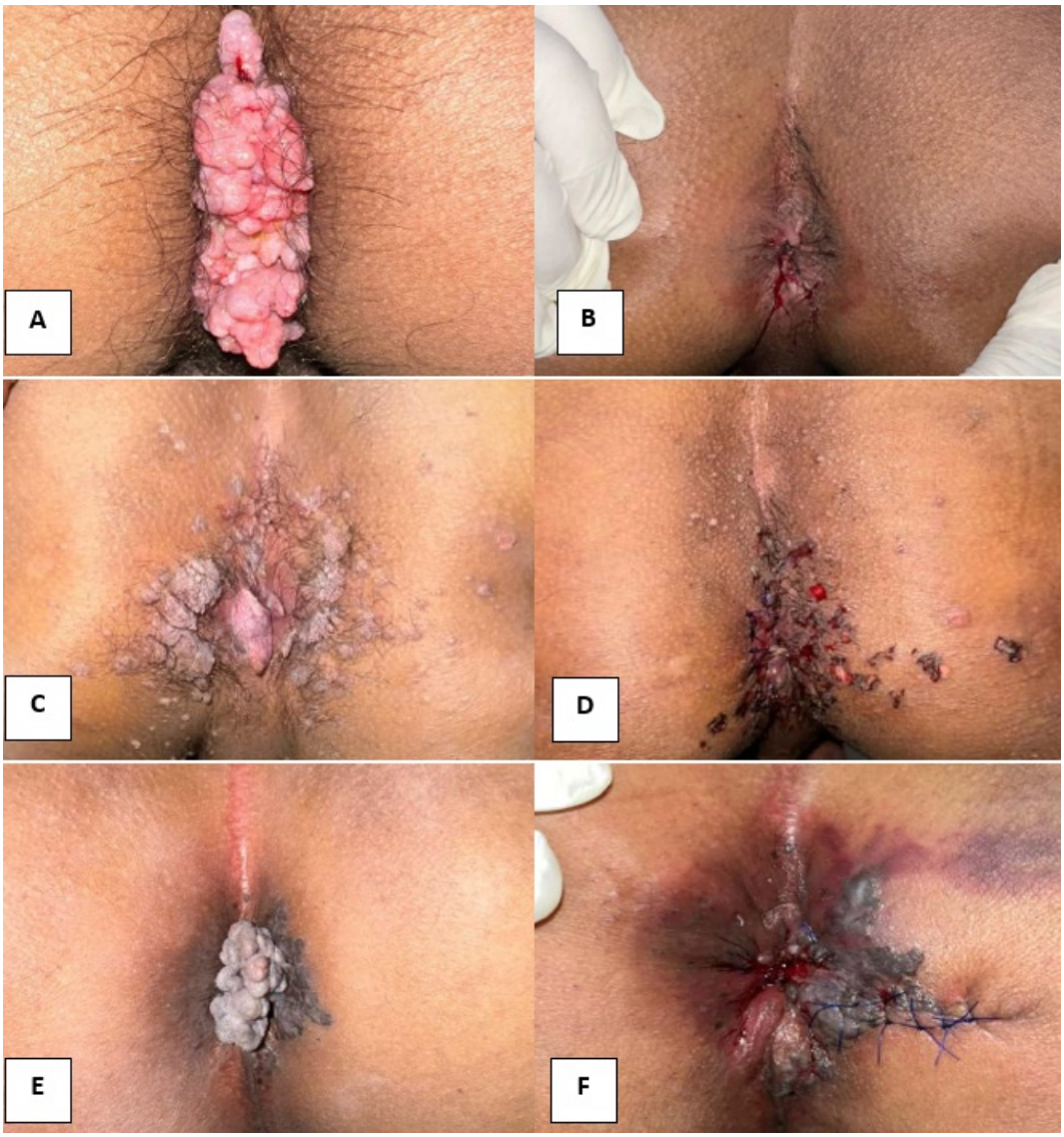

Figure 1. Clinical presentation and postoperative outcomes following the ECCHE procedure in three HIV-positive patients with perianal condyloma acuminata. (A,B) Case 1 preoperative and postoperative findings; (C,D) Case 2 preoperative and postoperative findings; (E,F) Case 3 preoperative and postoperative findings

Conclusion
Conclusion:

The ECCHE procedure addresses key limitations of conventional excision by improving hemostatic control and operative field visibility. It may represent a safe and reproducible approach for managing CA in HIV-infected patients.

EA DV CONGRESS
VIENNA
30 SEP - 3 OCT 2026

Abstract N°: 1605

Atypical and Giant Molluscum Contagiosum as the Initial Clinical Manifestation in an HIV-Positive Patient: A Case Report

Başak Sena Özhan*[1], Harbiye Dilek Canat[2]

[1] Başakşehir Çam and Sakura City Hospital, Dermatology Clinic, ISTANBUL, Türkiye

[2] Başakşehir Çam and Sakura City Hospital, Dermatology Clinic, istanbul, Türkiye

Introduction

Molluscum contagiosum (MC) is a benign cutaneous infection caused by a DNA virus belonging to the Poxviridae family. While it typically presents in immunocompetent individuals as self-limited lesions characterized by umbilicated papules measuring 3–5 mm in diameter, in conditions associated with suppressed cellular immunity, such as HIV infection, it may present as atypical, widespread, and “giant” (larger than 0.5 cm) lesions. (1,2) In this case, the clinical and dermoscopic features as well as the treatment response of atypical giant MC lesions presenting as the initial manifestation of HIV infection are presented.

Case Presentation

A 40-year-old male patient presented to our clinic with complaints of eruptions on the scalp and facial region persisting for approximately one year. No known systemic disease or regular medication use was identified in his medical history. On dermatological examination, giant papules and nodules, yellow in color, forming plaques by coalescing in some areas, and reaching sizes up to 2–2.5 cm, were observed on the frontal and temporal regions of the scalp, as well as on the forehead and both cheeks. Dermoscopic examination of the lesions revealed central white-yellow lobules and surrounding polymorphic, linear, and branching vascular structures (crown-like vascular pattern). This appearance was considered characteristic for MC. It was learned that the patient had previously been treated at an external center with topical isotretinoin under the diagnosis of “extensive verruca plana,” without clinical response. In order to confirm the diagnosis, a 4 mm punch biopsy was obtained from the lesion on the right cheek. Due to the presence of atypical and giant lesions, immunodeficiency was investigated. Laboratory examinations revealed positive HIV antigen and antibody; HIV-1 RNA PCR was measured at 91,2 copies/mL, and the CD4+ T lymphocyte count was 32 cells/µL. Histopathological examination demonstrated intraepidermal lobular proliferation and characteristic Henderson–Patterson bodies within keratinocytes, confirming the diagnosis. The case was evaluated as Stage 3 acquired immunodeficiency syndrome based on clinical and laboratory findings. A multidisciplinary approach was planned in collaboration with the infectious diseases department, and antiretroviral therapy (ART) consisting of a combination of bictegravir + emtricitabine + tenofovir alafenamide, along with trimethoprim-sulfamethoxazole prophylaxis for opportunistic infections, was initiated. Cryotherapy was applied every three weeks for the cutaneous lesions. In the later stages of follow-up, a dramatic regression of the lesions was observed with immune reconstitution and the effect of local treatments.

Conclusion

This case emphasizes that molluscum contagiosum (MC) may represent the first clinical sign of HIV infection and may serve as a marker reflecting different clinical manifestations of the immune system. In the differential diagnosis of giant MC, particularly in atypical localizations such as the face and eyelids, conditions such as cutaneous cryptococcosis, histoplasmosis, and basal cell carcinoma must be excluded. (3) Although data regarding the dermoscopic findings of giant MC lesions are limited in the literature, features such as central lobulated yellow-white amorphous structures, peripheral erythematous halo, polymorphic vascular structures, and hyperkeratosis/crust in some areas have been described. (4) These findings were observed in our case. Treatment options include destructive methods such as curettage, electrodesiccation, cryotherapy, and laser therapies. In cases where destructive therapies alone are insufficient, good responses have been achieved when combined with ART. (2,3) In conclusion, in the presence of widespread, coalescing, treatment-resistant atypical papules and nodules on the face and scalp, an underlying immunodeficiency (specially HIV) must be investigated, and treatment management should be conducted within a multidisciplinary framework.

EA DV CONGRESS
VIENNA
30 SEP - 3 OCT 2026

Abstract N°: 1617

Rare manifestations of facial cutaneous tuberculosis

Yu Lan*[1], Xuechen Ai[1], Peimei Zhou[1]

[1] The Eighth Affiliated Hospital, Sun Yat-Sen University, Guangdong,shenzhen, China

Introduction

Cutaneous tuberculosis (CTB) is an uncommon chronic infectious disease caused by *Mycobacterium tuberculosis*, with diverse clinical manifestations linked to mycobacterial pathogenicity, infection routes, and host immune status. Diagnosis remains challenging due to paucibacillary lesions and low sensitivity of conventional methods. We report an unusual case of facial CTB in an immunocompetent patient, potentially associated with minimally invasive aesthetic procedures, highlighting the diagnostic utility of metagenomic capture sequencing (MetaCAP™).

Case Presentation

A 23-year-old Chinese female had a persistent lesion on her right cheek for more than one year, which developed a few weeks after she underwent comedone extraction and facial therapy at a beauty clinic, during which local micro-trauma was induced by comedone extraction. According to the patient, only isolated, painless non-swollen papules were present pre-procedure. Rather than resolving, the lesion evolved from multiple papules into a 2×3 cm indurated orange-red plaque with central pustulation and an erythematous halo (*figure 1A)*. The patient had no history of tuberculosis, immunosuppression, or known TB contacts. Systemic investigations, including chest radiography, abdominal ultrasound and routine blood tests were unremarkable. Skin biopsy revealed epithelioid granulomas with fibrinoid necrosis, accompanied by lymphocytes, plasma cells, and multinucleated giant cells (*figure 1B*). Acid-fast and periodic acid-Schiff (PAS) stains were negative. Interferon-gamma release assay (IGRA) via T-SPOT.TB was positive.

To achieve a definitive diagnosis, MetaCAP sequencing was performed on lesional tissue, which detected *Mycobacterium tuberculosis complex* with 99% confidence, ruling out *non-tuberculous mycobacterial* (NTM), fungal and syphilitic infection. The lesion was diagnosed as lupus vulgaris via combined clinical, histopathological, T-SPOT and MetaCAP testing.Subsequently, the patient was referred to an infectious disease hospital and initiated on a 6-month guideline-concordant first-line anti-tuberculous combination regimen. At the end of treatment, a second telephone follow-up revealed excellent treatment adherence, no drug-related adverse events, and sustained complete resolution of the facial lesions.

Conclusion

CTB is a rare disease with diverse clinical manifestations and a high risk of misdiagnosis, accounting for approximately 1% to 1.5% of all extrapulmonary manifestations of tuberculosis. Furthermore, exogenous inoculation of *Mycobacterium tuberculosis* via direct penetration of the skin or mucous membranes during invasive aesthetic procedures is an even rarer occurrence. In this case, inadequate sterilization of instruments or contaminated topical products likely served as the source. Routine diagnostic tools have inherent limitations, with acid-fast staining and culture showing low sensitivity, histopathology being merely suggestive, and IGRA unable to distinguish active from latent M. tuberculosis infection or localize the infection site. MetaCAP (Metagenomics Capture) is a high-throughput sequencing method that combines probe capture technology with NGS technology.

It is used to detect microbiomes in various sample types without relying on clinical culture, and features a broad spectrum, high sensitivity, and coverage of pathogen resistance loci, among other characteristics. To our knowledge, this is the first case of using MetaCAP™ to diagnose *Mycobacterium tuberculosis* in skin tissue. Importantly, it provides an innovative technical paradigm and a reliable detection method for the rapid diagnosis of atypical cutaneous tuberculosis in the future. In summary, this case underscores the potential for iatrogenic CTB following facial cosmetic interventions and demonstrates the evolving role of metagenomic sequencing in diagnosing challenging cutaneous infections.

EADV CONGRESS
VIENNA
30 SEP - 3 OCT 2026

Abstract N°: 1619

Head lice infestation with Id reaction: a series of 6 cases

Kmar Turki*[1], Malek Cherif[1], Rim Chaabouni[1], ikram gassara[1], Sonia Boudaya[1], Hamida Turki[1]

[1] Dermatology department, Hedi Chaker university hospital, Sfax, TUNISIA, Sfax, Tunisia

Introduction

Head lice infestation (HLI) is a parasitic infestation caused by *Pediculus humanus capitis*. The autosensitization reaction, or id reaction (IR), is a secondary immunologic response to an underlying trigger, whether infectious or parasitic.

Through this case series, we aimed to describe the epidemiological, clinical, and therapeutic characteristics of IR to HLLI or pediculids.

Materials and Methods

We retrospectively collected all cases of pediculids diagnosed between January 2010 and June 2025.

Results

Six female patients were included. The mean age was 14.8 years (ranging from 5–32 years). A family history of atopy was found in one patient, while another had xeroderma pigmentosum. The mean disease duration was 34 days (ranging from 7 days to 3 months). The IR was generalized in 4 cases and localized to the auricles, nape of the neck, and face in 2 cases. HLI had not been previously diagnosed in any case. Clinical presentation included vesicles (5 cases), eczematous plaques (6 cases), with impetiginization in 1 case, psoriasiform plaques (1 case), pustules (1 case), dyshidrosis (1 case), and weeping eczematous plaques involving the folds (3 cases). Treatment consisted of systemic corticosteroid therapy at 1 mg/kg/day for 3 days in 4 cases, topical corticosteroids, anti-pediculosis treatment (lindane, dimethicone, benzyl benzoate) in all cases, and systemic antibiotic therapy in 1 case. The outcome was favorable in all cases, with symptom resolution after a mean of 1 week.

Conclusions

The prevalence of IR is estimated at approximately 4% to 5% among patients with *P. capitis* infestation. The term “pediculid” was introduced in 1984 by Brenner et al., who also proposed diagnostic criteria. Pediculid is an autosensitization reaction characterized by secondary lesions that do not correspond to any classic type of dermatosis. These lesions appear abruptly as a generalized eruption involving the trunk and both upper and lower limbs, in the absence of direct external contact or a localized infectious agent. Clinically, this reaction most often presents as erythematous maculopapular plaques located at a distance from the primary focus and associated with excoriations due to intense pruritus. Mobile cervical lymphadenopathy may also be observed. This clinical picture may be mistaken for atopic dermatitis, bullous pemphigoid, or dermatitis herpetiformis, thus delaying diagnosis. Id eruptions localized to the cephalic extremities are possible but less common.

EADV CONGRESS
VIENNA
30 SEP - 3 OCT 2026

Abstract N°: 1620

Bullous Erythrodermic Scabies: A Rare Clinical Variant Mimicking Autoimmune Blistering Disease

Selen Taner Akbay*[1], Tümay Özgür[2]

[1] Hatay Mustafa Kemal University Tayfur Ata Sökmen Medical Faculty, Dermatology Department, Hatay, Türkiye
[2] Hatay Mustafa Kemal University Tayfur Ata Sökmen Medical Faculty, Pathology Department, Hatay, Türkiye

Introduction

Scabies remains a major global parasitic skin infestation and is frequently complicated by bacterial superinfection. Bullous scabies is rare, and crusted scabies with erythrodermic presentation is even more uncommon. These atypical forms may obscure the diagnosis and mimic autoimmune blistering diseases, leading to delayed recognition and treatment.

Case Presentation

A 54-year-old man was referred from an outside center with a 6-month history of bullous eruptions and widespread erosive dermatitis, initially suspected to represent an autoimmune bullous disorder. Further history revealed prior cerebrovascular disease with marked immobility, previously treated but currently neglected diabetes mellitus, social isolation, and psychiatric symptoms. Dermatologic examination demonstrated diffuse erythema, extensive erosions covered with yellow and necrotic exudative crusts, scattered bullous lesions, maceration of the toe webs, inguinal folds, and axillae, as well as multiple pressure ulcers over the back and gluteal region. Histopathologic examination identified a parasitic structure consistent with scabies within the superficial parakeratotic layer, accompanied by ulceration, pustule formation, irregular epidermal hyperplasia, and a mixed eosinophilic and neutrophilic inflammatory infiltrate. Based on these findings, the patient was diagnosed with crusted scabies presenting with bullous and erythrodermic features. Treatment consisted of oral ivermectin on days 1 and 7, adjunctive topical scabicidal therapy, wound care, and culture-directed antibiotic treatment. Near-complete clinical improvement was achieved within 10 days.

Conclusion

This case highlights that crusted and bullous scabies should be included in the differential diagnosis of generalized erythematous and blistering eruptions, particularly in patients with neurologic disability, social neglect, or psychiatric vulnerability. Early recognition of these uncommon clinical variants is essential to avoid misdiagnosis and to ensure prompt, appropriate treatment.

EA DV CONGRESS
VIENNA
30 SEP - 3 OCT 2026

Abstract N°: 1670

Cutaneous Overlap Between Lepromatous Leprosy and Syphilis: A Diagnostic Pitfall in a Rural Patient

Letícia Mendes Gomes de Matos Lima*[1], Maria Vitoria Rocha de Morais[2], Lucas Prestes Delgado[3], Pietra Diniz Pereira[4], Raul Cartagena Rossi[5], Diogo Pazzini Bomfim[6]

[1] Faculdade de Medicina de Olinda, Olinda - PE, Brazil
[2] Universidade Anhembi Morumbi (Mooca), São Paulo - SP, Brazil
[3] Universidade Nove de Julho, São Paulo - SP, Brazil
[4] Universidade Mogi das Cruzes, Mogi das Cruzes - SP, Brazil
[5] Faculdade de Medicina de Taubaté, Taubaté - SP, Brazil
[6] Universidade Federal de São Paulo - UNIFESP, São Paulo, Brazil

Introduction

A 47-year-old male from a rural area presented with insidious nodular lesions on both auricles and the left hand. He denied hypopigmented lesions, sensory loss, and known contact with leprosy. Examination revealed coalescent lepromas with bilateral auricular infiltration, fibroelastic nodules on the dorsal left hand, and painless thickening of the great auricular nerve. Slit-skin smear demonstrated a high bacillary index, confirming multibacillary leprosy. VDRL was reactive (1:8), suggestive of active or previous syphilis infection, requiring clinical correlation. Treatment with multibacillary multidrug therapy and benzathine penicillin (7.2 million IU, administered in three weekly doses) was initiated.

Case Presentation

A 47-year-old male from a rural area presented with insidious nodular lesions on both auricles and the left hand. He denied hypopigmented lesions, sensory loss, and known contact with leprosy. Examination revealed coalescent lepromas with bilateral auricular infiltration, fibroelastic nodules on the dorsal left hand, and painless thickening of the great auricular nerve. Slit-skin smear demonstrated a high bacillary index, confirming multibacillary leprosy. VDRL was reactive (1:8), suggestive of active or previous syphilis infection, requiring clinical correlation. Treatment with multibacillary multidrug therapy and benzathine penicillin (7.2 million IU, administered in three weekly doses) was initiated. In the absence of classical features, diagnosis relied on the recognition of lepromatous infiltration, peripheral nerve thickening, and bacilloscopy. *M. leprae* exhibits tropism for cooler anatomical sites, explaining the preferential involvement of the auricles and the dorsal hand. Differential diagnosis with syphilis remains challenging: secondary disease may present with papules and diffuse infiltration, whereas tertiary forms may produce gummas that mimic granulomatous lesions. Borderline leprosy may resemble syphilides. The coexistence of both infections further increases diagnostic complexity and the risk of misinterpretation.

Conclusion

Cutaneous overlap between leprosy and syphilis constitutes a relevant diagnostic pitfall, particularly in endemic settings. This case underscores the need for heightened clinical suspicion in atypical presentations and highlights that failure to recognize overlapping features may lead to misdiagnosis and delayed treatment.

EADV CONGRESS
VIENNA
30 SEP - 3 OCT 2026

Abstract N°: 1674

Cutaneous-Lymphatic Sporotrichosis Associated with Hypersensitivity Reaction in an Adolescent

Anna Carolina Barcellos*[1], Luna Azulay-Abulafia[1], Guilherme Seith[1], sarah fadel[1], Regina C Schechtman[1], David Rubem Azulay[1], Vitoria Azulay[1]

[1] Instituto de Dermatologia Professor Rubem David Azulay, Rio de Janeiro, Brazil

Introduction

Sporotrichosis is a subacute or chronic mycosis caused by fungi of the genus *Sporothrix*, more frequently observed in tropical and subtropical regions. In Brazil, particularly in Rio de Janeiro, a hyperendemic scenario has been described, mainly related to transmission by cats. This case was selected for illustrating a lymphocutaneous presentation associated with a hypersensitivity reaction, emphasizing the importance of clinical suspicion and early therapeutic management.

Case Presentation

A 14-year-old male patient presented with a three-month history of an initially painless ulcer on the right arm, with well-defined and moisturing borders. The patient subsequently developed a nodule near the ulcer, with local fluctuation, edema, warmth, and tenderness on palpation, and underwent abscess drainage with partial improvement. One month later, a new ulcer appeared in the right epitrochlear region. Two months later, pruritic erythematous-edematous lesions developed on the abdomen. He sought medical care multiple times and received several antimicrobial treatments without improvement. He lived in a rural area, with frequent exposure to soil and cats.

On examination, there was an ulcerated lesion measuring approximately 2 cm on the right forearm, a scar on the posterior right arm, and a palpable lymphatic cord along the right upper limb. Although not reported by the patient, multiple erythematous-edematous macules and papules were also observed on the thigh, gluteal, and right inguinal regions. Direct mycological examination and culture from the ulcer were positive for *Sporothrix* spp. Skin biopsy of the thigh lesion showed superficial perivascular dermatitis with predominance of lymphocytes and no granulomas. A diagnosis of lymphocutaneous Sporotrichosis associated with a probable distant hypersensitivity reaction was established. Treatment with Itraconazole 100 mg twice daily was initiated, with clinical and laboratory follow-up.

Conclusion

This case highlights the importance of considering Sporotrichosis in patients presenting with ulcers and ascending lymphatic spread, especially those with rural exposure or contact with soil and animals such as cats. It also emphasizes that, even in endemic areas such as Rio de Janeiro, transmission may not necessarily be feline-related. Although histopathology did not allow definitive classification of the hypersensitivity reaction, regression of the eruption after treatment strongly suggests an association between the cutaneous eruption and lymphocutaneous sporotrichosis. Early recognition may prevent inappropriate treatments and therapeutic delay.

EADV CONGRESS
VIENNA
30 SEP - 3 OCT 2026

Abstract N°: 1679

Steroid-Modified Majocchi's Granuloma: A Diagnostic Pitfall in Pediatric Dermatology

GAYATIRI RAVEENTHERAN*[1], Lynn Chua[1], Mark Koh[1]

[1] KK Women's and Children's Hospital, Singapore, Singapore

Introduction

Majocchi's granuloma is an uncommon deep dermatophyte infection that may be diagnostically challenging, particularly when modified by prior corticosteroid therapy.

Case Presentation

We report an 8-year-old immunocompetent girl who presented with a progressive pruritic scalp lesion unresponsive to topical and intralesional corticosteroids and oral antibiotics. The lesion evolved into a well-demarcated pustular, scaly plaque, raising concern for an alternative diagnosis.

Initial fungal microscopy and culture were negative. In view of the atypical clinical course and treatment resistance, all therapies were discontinued for two weeks prior to skin biopsy. Histopathology demonstrated fungal elements within hair follicles associated with a neutrophilic and granulomatous inflammatory infiltrate, confirming Majocchi's granuloma. The patient showed rapid clinical improvement following initiation of systemic antifungal therapy.

Conclusion

This case highlights a key diagnostic pitfall in dermatology practice. Corticosteroids can suppress local immune responses and alter lesion morphology, leading to "steroid-modified" dermatophytosis and false-negative mycological investigations. Such modification may delay diagnosis and result in inappropriate treatment escalation.

Clinicians should maintain a high index of suspicion for deep fungal infections in patients with atypical, progressive, or treatment-resistant dermatoses, even in the absence of positive initial mycological tests. Temporary withdrawal of corticosteroids prior to biopsy may be essential to unmask underlying pathology. Early recognition is critical to avoid unnecessary immunosuppression and to enable timely, targeted antifungal therapy.

EADV CONGRESS
VIENNA
30 SEP - 3 OCT 2026

Abstract N°: 1682

The Forgotten Clinical Entity: Serpentine Supravenous Hyperpigmentation in Inactive Hansen's Disease

Swathi Nagabushan*[1]

[1] Father Muller Medical College, Mangaluru, India

Introduction

Hansen's disease, caused by *Mycobacterium leprae*, predominantly affects the skin and peripheral nerves, often leaving lasting sequelae despite effective therapy. Among its myriad sequelae, post-inflammatory hyperpigmentation is well-documented but underexplored and is primarily attributed to venous phlebitis or treatment-related side effects. Serpentine supra-venous hyperpigmentation is a particularly rare manifestation characterized by linear hyperpigmented streaks following the underlying superficial veins. Here, we present a series of three cases of Inactive Hansen's disease with Serpentine Supravenous Hyperpigmentation (SSH) associated with trophic ulcers, presenting exclusively on the limb affected by the ulcer. The phenomenon highlights an overlooked dermatological manifestation of a disease that continues to leave its mark decades after resolution.

Case Presentation

Case 1:

A 48-year-old male, diagnosed with Hansen's disease 30 years ago and classified as inactive following successful completion of multidrug therapy and release from treatment, presented with a long-standing wound on his left sole for 3 months and sensory loss in both hands and feet. No recent history of drug intake, trauma, or systemic symptoms were reported. On examination, the patient had a solitary ulcer on the left sole measuring approximately 5 × 7 cm. Multiple linear hyperpigmented streaks aligned with the superficial veins were noted over the affected limb. Dermoscopy showed a typical brown-black pigment network showing a honeycomb pattern, with interspersed white dots and perifollicular pigmentation. A deep skin biopsy was performed, and the underlying superficial vessel was also biopsied. The superficial vein identified was thrombosed and collapsed. The skin biopsy specimen revealed increased basal melanin pigmentation in the epidermis and sparse perivascular lymphocytic infiltrate in the dermis. Histopathological examination of the superficial vein showed focal hemosiderin deposition, indicative of prior venous inflammation. The pigmentation, while striking, required no specific intervention but was documented as a rare sequela of Hansen's disease.

Cases 2 and 3:

Two additional patients with a history of inactive Hansen's disease exhibited similar SSH associated with trophic ulcers. Both patients reported chronic sensory loss in the extremities and recurrent trophic ulcers. Dermoscopic and histopathological findings mirrored those of Case 1, with evidence of basal melanin hyperpigmentation and hemosiderin deposition.



Conclusion

SSH is a benign, self-limiting entity most often linked to chemotherapeutic infusions. To our knowledge, non–drug-induced SSH in Hansen's disease has not been previously documented.

Post-inflammatory hyperpigmentation in Hansen's disease may result from multiple mechanisms, including disease-related phlebitis causing hemosiderin deposition and chronic inflammation inducing basal melanin pigmentation. The serpentine pattern observed in our cases corresponds closely to superficial venous anatomy, suggesting sustained venous stasis and inflammation. Notably, pigmentation was confined to the limb bearing the trophic ulcer, raising the possibility of an association between venous insufficiency and impaired wound healing. Trophic ulcers in Hansen's disease, reported in up to 34% of patients, are traditionally linked to sensory loss, repeated trauma, abnormal weight bearing, and intrinsic muscle paralysis. However, autonomic neuropathy may additionally impair vascular tone, promote oxidative stress, and induce endothelial dysfunction. Combined with chronic immobility, this may predispose to superficial venous thrombosis and chronic venous insufficiency.

SSH may therefore represent a rare but clinically meaningful cutaneous marker in inactive Hansen's disease, potentially offering new insight into vascular contributions to chronic non-healing trophic ulcers.

EA DV CONGRESS
VIENNA
30 SEP - 3 OCT 2026

Abstract N°: 1722

Urease-Negative Recalcitrant Dermatophytosis as a Clinical Surrogate for Trichophyton indotineae: Prevalence, Clinical Characteristics, and Treatment Outcomes from a 318-Case Real-World Study in Thailand

Sutsarun Prunglumpoo*[1], Klaichan Intarachaieua[1], Oranat Tanprasertkul[1], Lakshmi Cheeva-akrapan[1], Kunyanat Krongboon[1], Jeerapa damrongpokkaphan[1], Anzawa Kazushi[2]

[1] Institute of Dermatology, Bangkok, Thailand
[2] Kanazawa Medical University Hospital, Ishikawa, Japan

Introduction

Recalcitrant dermatophytosis caused by the *Trichophyton mentagrophytes* complex is an increasing therapeutic challenge. *Trichophyton indotineae*, an emerging species within this complex, is frequently associated with chronic, extensive, and treatment-refractory disease. However, molecular confirmation is not always available in routine practice. A urease-negative phenotype among isolates reported as *T. mentagrophytes* complex may serve as a practical surrogate marker for suspected *T. indotineae* infection.

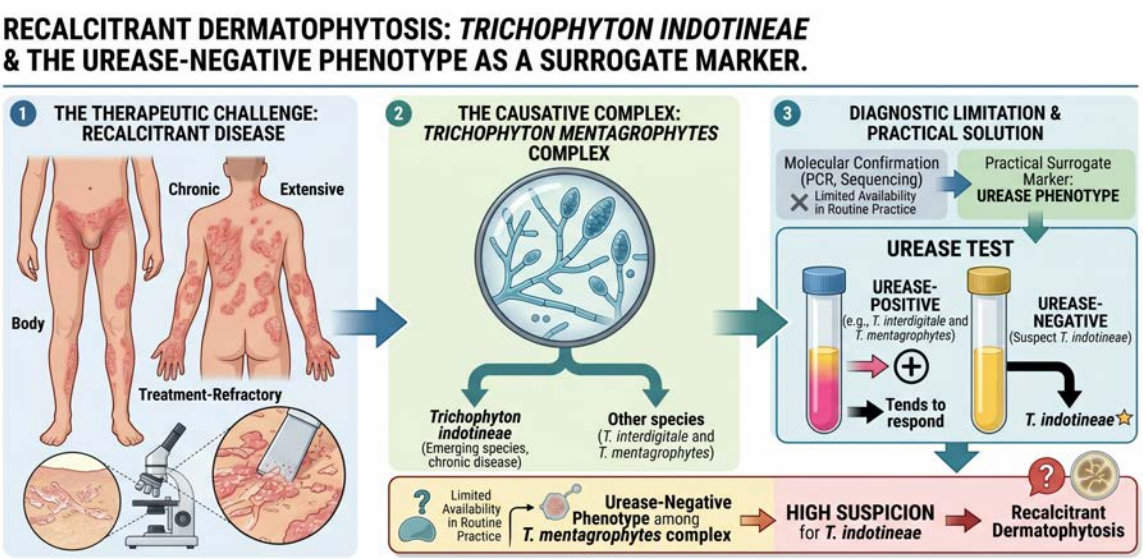

Urease-negative phenotype within the Trichophyton mentagrophytes complex may serve as a practical surrogate marker for suspected T. indotineae in recalcitrant dermatophytosis.

Materials and Methods

To compare clinical characteristics, antifungal treatment patterns, and outcomes between urease-negative and urease-positive *T. mentagrophytes* complex dermatophytosis.

We conducted a retrospective cohort study of patients with recalcitrant dermatophytosis whose fungal cultures were consistent with the *T. mentagrophytes* complex and who underwent urease testing. Patients were classified into urease-negative and urease-positive groups. Demographic data, disease duration, lesion number and distribution, lesion morphology, prior antifungal exposure, treatment regimens, dose escalation, clinical cure, mycological cure, and recurrence within 90 days were analyzed. Univariate logistic regression was used to identify factors associated with urease-negative status.

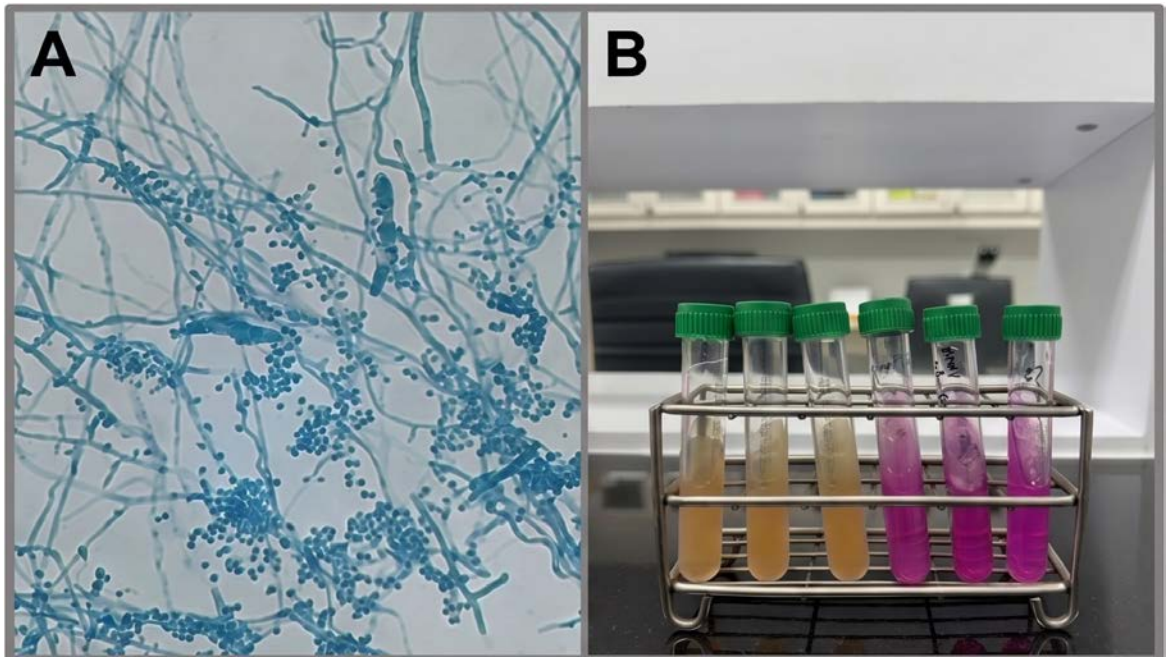

Figure. (A) Microscopic morphology of the T. mentagrophytes complex. (B) Urease test showing negative (suspected T. indotineae) yellow/orange and positive pink/magenta reactions.

Results

A total of 389 patients were included: 318 in the urease-negative group and 71 in the urease-positive group. The urease-negative group had a significantly longer onset duration than the urease-positive group [median onset 6.0 vs. 3.0 months, p<0.001]. Extensive disease was more frequent in the urease-negative group, particularly involvement of 3–5 lesion sites (60.4% vs. 12.7%, p<0.001). Trunk, groin, buttock, face, and arm involvement were also significantly more common.

In univariate logistic regression, urease-negative status was associated with longer disease duration (OR 1.23, 95% CI 1.14–1.33), two lesion sites (OR 4.61, 95% CI 2.33–9.11), 3–5 lesion sites (OR 19.66, 95% CI 9.04–42.76), face involvement (OR 5.94, 95% CI 1.81–19.47), trunk involvement (OR 4.57, 95% CI 2.61–7.99), groin involvement (OR 3.89, 95% CI 2.27–6.66), buttock involvement (OR 4.25, 95% CI 2.36–7.66), prior terbinafine exposure (OR 2.89, 95% CI 1.20–6.96), prior itraconazole exposure for less than two weeks (OR 3.33, 95% CI 1.29–8.60), and prior topical treatment (OR 8.06, 95% CI 4.51–14.40). Prolonged itraconazole treatment was strongly associated with urease-negative status (OR 12.13, 95% CI 6.60–22.29).

Patients in the urease-negative group more frequently required longer courses of itraconazole 200 mg/day, particularly for 1 month (17.0% vs. 5.6%, p=0.016), 2 months (21.4% vs. 1.4%, p<0.001), and 3 months (17.9% vs. 5.6%, p=0.010). Several urease-negative cases failed to achieve cure with itraconazole 200 mg/day and required escalation to 400 mg/day. In selected cases, itraconazole 400 mg/day was associated with earlier clinical improvement. A small number of highly refractory urease-negative cases achieved cure after oral voriconazole, suggesting a potential salvage option when itraconazole therapy fails.

Clinical cure rates were high in both groups and did not differ significantly (94.7% vs. 97.2%, p=0.546). Mycological cure was also comparable among those with available follow-up data (81.8% vs. 88.8%, p=0.732). Recurrence within 90 days was uncommon and did not differ significantly between groups (3.1% vs. 1.4%, p=0.697).



Figure. Key clinical and treatment differences by urease test result in recalcitrant T. mentagrophytes complex dermatophytosis.

Conclusions

Urease-negative *T. mentagrophytes* complex dermatophytosis was associated with longer disease duration, more extensive multi-site involvement, prior antifungal exposure, and a greater need for prolonged or escalated itraconazole therapy. The urease-negative phenotype is associated with a more treatment-refractory clinical course. Urease testing may provide a useful, accessible surrogate marker for suspected *T. indotineae*-associated recalcitrant dermatophytosis, while higher-dose itraconazole or oral voriconazole may be considered in selected refractory cases.

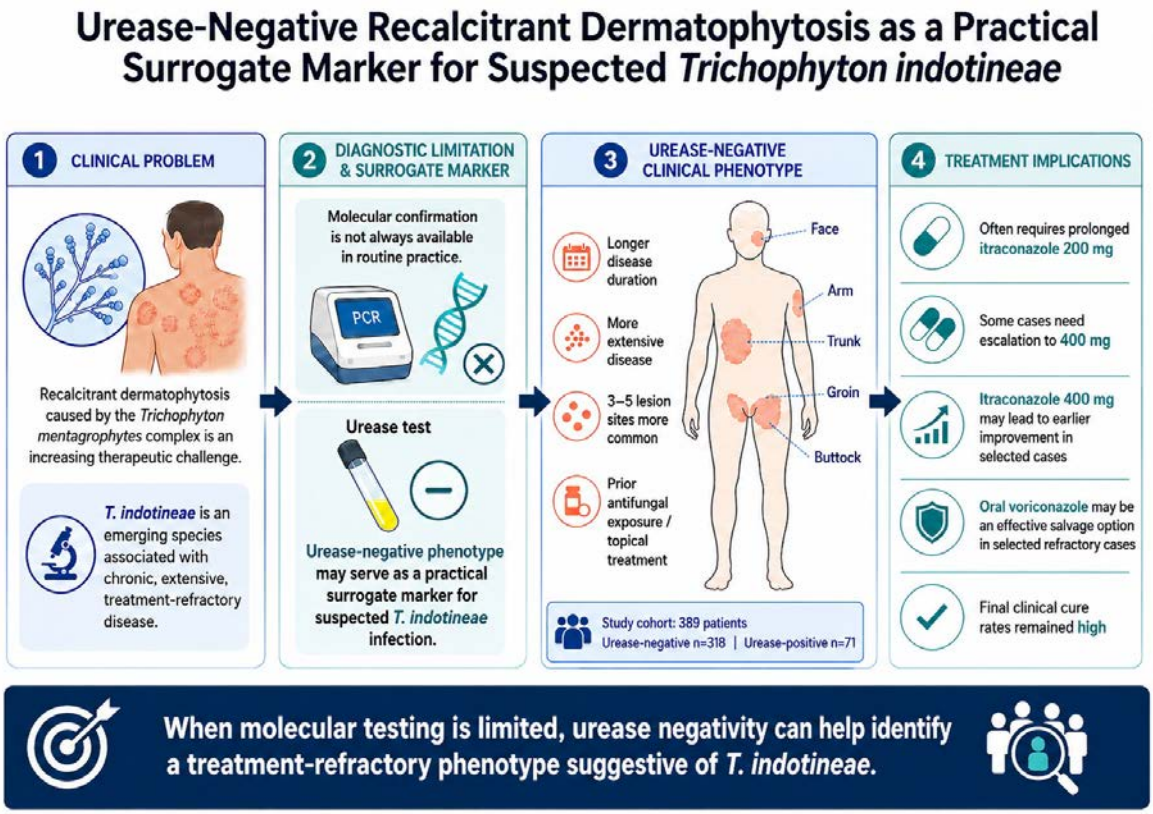

Figure. Urease-negative T. mentagrophytes complex dermatophytosis may represent a treatment-refractory phenotype suggestive of T. indotineae, particularly when molecular testing is unavailable.

EADV CONGRESS
VIENNA
30 SEP - 3 OCT 2026

Abstract N°: 1724

Unusual Presentation of Cutaneous Leishmaniasis on the Face in an Elderly Male

Deepti Dsouza*[1]

[1] Kasturba Medical College Mangalore, Manipal Academy of Higher Education, Manipal, India

Introduction

Cutaneous leishmaniasis is a vector-borne parasitic infection caused by *Leishmania* species and transmitted by infected sandflies. It typically presents as papules, nodules, or ulcerative lesions; however, a wide spectrum of atypical variants has been described, often mimicking other granulomatous dermatoses and posing diagnostic challenges. Although the disease is more commonly associated with certain endemic regions of the subcontinent, sporadic cases with atypical presentations are increasingly recognized outside classical settings, contributing to delayed diagnosis and management.

Case Presentation

We report a case of an elderly male presenting with asymptomatic erythematous papules and nodules with crusting over the nose and forehead for a duration of three months. There was no history of insect bite, recent travel or photosensitivity. Clinical examination revealed multiple erythematous papules with scaling and crusting lesions over the nose and forehead. The clinical differentials were lupus vulgaris, sarcoidosis and leishmaniasis. Histopathological evaluation of a skin biopsy demonstrated granulomatous inflammation and intracytoplasmic bodies which was suggestive of leishmaniasis. Special stains for fungal elements and acid-fast bacilli were negative. Given anecdotal reports of antifungal efficacy, the patient was initially treated with oral itraconazole 100 mg twice daily for 4 weeks, resulting in only minimal clinical improvement. Due to the suboptimal response, the patient was referred to an infectious disease specialist and subsequently initiated oral miltefosine 50mg twice a day for 1 month. This led to a remarkable clinical response with significant resolution of lesions.

Conclusion

This case underscores the importance of considering cutaneous leishmaniasis in the differential diagnosis of chronic facial dermatoses, even in the absence of classical exposure history. The increasing recognition of atypical presentations from both endemic and previously underreported regions highlights the need for heightened clinical suspicion. Early diagnosis through histopathological confirmation and prompt initiation of appropriate therapy are crucial for optimal outcomes. Miltefosine, as an effective oral agent, has shown good efficacy and tolerability in the treatment of cutaneous leishmaniasis, as demonstrated by the favourable clinical response in this case, and represents a valuable therapeutic option in such scenarios.

EA DV CONGRESS
VIENNA
30 SEP - 3 OCT 2026

Abstract N°: 1753

Pathological PCR Amplification and Sequencing Assisted in the Diagnosis of Bacille Calmette-Guérin Infection: A Case Report

Huaibo Zhao*[1], Degang Yang[1]

[1] Shanghai Skin Disease Hospital,Tongji University School of Medicine Shanghai, Shanghai, China

Introduction

This report describes a case of cutaneous Bacille Calmette-Guérin (BCG) infection definitively diagnosed using polymerase chain reaction (PCR) amplification and sequencing of lesional skin tissue.

Case Presentation

A 55-year-old female presented with a 40-year history of a rash on the lateral aspect of her left upper arm, which had enlarged over the preceding two years. Physical examination revealed a large, orange-red plaque on the left shoulder and arm with well-defined, raised borders, central scarring, and satellite lesions. The surface showed mild scaling without ulceration or exudation, and the lesion was non-tender. Auxiliary examinations, including complete blood count, tumor markers, anti-nuclear antibody panel, Mycobacterium tuberculosis-specific T-cell immune response assay, and interferon-gamma release assay, were negative or within normal limits. Molecular testing via the Xpert assay was negative for Mycobacterium tuberculosis and rifampin resistance gene mutations. Chest computed tomography revealed a small, solid nodule in the lower lobe of the right lung, considered benign, and follow-up was recommended. Repeated mycobacterial cultures showed mycobacterial growth. Pathological examination of a lesional skin biopsy revealed irregular epidermal hyperplasia and numerous epithelioid granulomas throughout the entire dermis, surrounded by a dense inflammatory infiltrate composed predominantly of lymphocytes. Both PAS and acid-fast staining were negative. A tentative diagnosis of verrucous cutaneous tuberculosis was considered. PCR analysis of cultured colonies detected the presence of BCG. Whole-exome sequencing identified a heterozygous duplication variant, c.851_852dup.
The patient was diagnosed with a mycobacterial infection (Bacillus Calmette-Guérin infection). After six weeks of treatment with ethambutol hydrochloride tablets combined with rifampicin capsules, the condition improved markedly, with skin lesions shrinking, turning dark red, and showing slight desquamation. Following another four weeks of therapy with ethambutol hydrochloride tablets, rifampicin capsules, and isoniazid tablets, only a localized atrophic scar with a dark red rash and mild crusting remained.

Conclusion

BCG is a live, attenuated vaccine derived from Mycobacterium bovis, widely used for tuberculosis prevention, particularly in endemic regions. Although generally safe, in rare instances—especially in immunocompromised individuals or when vaccination procedures are not aseptic—BCG can cause localized or disseminated mycobacterial infections involving the skin. Early recognition and targeted therapy can improve prognosis. For persistent lesions at the vaccination site or systemic symptoms, the possibility of disseminated infection should be considered, prompting timely etiological confirmation and systemic evaluation. In this case, whole-exome sequencing identified a heterozygous frameshift variant (c.851_852dup) in the TNFRSF13B gene. Abnormalities in TNFRSF13B can cause autosomal dominant or recessive immunodeficiency. This variant is predicted to result in an altered protein length, is not recorded in East Asian normal population databases, and has not been previously

reported. PCR amplification and sequencing performed on initial pathological paraffin-embedded tissue sections provided a characteristic etiological basis. This highly sensitive and specific PCR-based molecular diagnostic method proved effective in resolving the heterogeneity of infectious granulomatous lesions of mycobacterial origin.

EADV CONGRESS
VIENNA
30 SEP - 3 OCT 2026

Abstract N°: 1756

From Pediculosis to Septic Shock: Catastrophic Progression of a Common Ectoparasitosis in Childhood

Yocelin Nallely Lozano Figueroa*[1], Rocío Concepción Albores Arguijo[1], Valeria Noemi Rizo Hernández[1], Laura Sifuentes [1], Alan Octavio Muro Davalos[1], Karen Gonzalez[1]

[1] Hospital Civil de Guadalajara Fray Antonio Alcalde, Universidad de Guadalajara, Guadalajara, Mexico

Introduction
Pediculosis capitis (PC) remains a neglected yet persistent worldwide public health problem, disproportionately affecting children, especially those of school age, across all socioeconomic groups. Its high transmissibility, recurrent nature, and associated stigma sustain its global burden despite being widely regarded as a benign ectoparasitosis. However, this perception may underestimate its potential consequences. Severe pruritus and repetitive scratching can compromise the skin barrier, creating an entry point for secondary bacterial infection. While fatal outcomes are exceptionally uncommon, in contexts of healthcare disparity, social vulnerability, and delayed medical attention, PC may evolve beyond a simple infestation into a source of serious and even life-threatening complications.

Case Presentation
A 6-year-old girl patient from a rural community, speaker of the Huichol language, with a history of severe malnutrition, was hospitalized to the emergency department with a diagnosis of septic shock and scalp dermatosis. A family member reported that one week prior to admission, the patient developed a pustular lesion in the left retroauricular region, with progressively increased in size, associated with fever, arthralgias, and deterioration of her general condition. Pediatric Dermatology was consulted due to suspicion of inflammatory tinea capitis. Dermatological examination revealed, a single, polymorphic dermatosis was observed, localized to the left parieto-occipital region, consisting of an extensive erythematous plaque with well-defined borders, honey-colored crusting, a deep central ulcer (grade III), purulent discharge, and a hemorrhagic base. Wood's light fluorescence was negative. Dermoscopy and trichoscopy with non-polarized light revealed a pink structureless area, punctate hemorrhages, granulation tissue, and scant fine whitish scale on the surface. Active ectoparasitosis was identified, with multiple nits adherent to the hair shafts in adjacent areas and in the contralateral retroauricular region, with formation of *plica polonica*. Directed questioning confirmed a history of chronic pruritus and scratching. Laboratory tests showed anemia, thrombocytopenia, and elevated acute-phase reactants. She was transferred to the pediatric intensive care unit, where she required invasive mechanical ventilation, vasopressor support, and broad-spectrum intravenous antibiotic therapy, with a favorable clinical response. She was also evaluated by the wound care team, who applied a hydrocolloid dressing and silver nitrate, resulting in significant improvement of the lesion. The patient was discharged home with favorable clinical evolution.

Conclusion
Persistent scratching favors the development of excoriations, disruption of the skin barrier, and secondary impetiginization. In the presence of predisposing factors such as chronic infestation, severe malnutrition, and limited access to healthcare services, these lesions may progress to deep bacterial infections, including cellulitis. In the present case, the coexistence of nutritional immunocompromise, delay in medical care, and sociocultural barriers contributed to a torpid course, deep ulceration, and the development of septic shock. Although PC is

frequently considered a benign condition, it may be associated with severe infectious complications. Prompt recognition of warning signs, comprehensive patient assessment, and a multidisciplinary approach are essential, particularly in vulnerable populations.

EADV CONGRESS
VIENNA
30 SEP - 3 OCT 2026

Abstract N°: 1782

The Beautiful Disease that Disables: Diffuse Multibacillary Leprosy with Lepra Bonita Phenotype Masquerading as Mixed Connective Tissue Disease

Swathi Nagabushan*[1]

[1] Father Muller Medical College, Mangaluru, India

Introduction

Leprosy remains one of medicine's most enduring mimics. While classical Hansen's disease presents with anaesthetic patches and palpable nerve thickening, uncommon variants may lack these hallmark findings. Lepra bonita ("beautiful leprosy") is a rare clinicomorphological phenotype of diffuse multibacillary leprosy characterised by smooth diffuse infiltration, madarosis, appendageal loss, and deceptively preserved skin contours. Historically described predominantly in Mexico and Central America, it is only rarely reported from India and other endemic regions. Such atypical presentations may closely resemble connective tissue disorders, resulting in delayed diagnosis and preventable disability. We report a striking case initially investigated as mixed connective tissue disease (MCTD), ultimately diagnosed as diffuse multibacillary leprosy with lepra bonita phenotype.

Case Presentation

A 42-year-old woman undergoing evaluation for progressive neuromuscular decline, diagnosed as mononeuritis multiplex, presented with severe pain in the extremities and joints, hand deformities, and marked functional disability. Proximal muscle weakness suggested inflammatory myopathy, while shiny oedematous skin with appendageal loss, fusiform swelling of digits, and digital pitting raised concern for scleroderma-spectrum disease. The combination of inflammatory arthropathy, myopathic weakness, and sclerodermoid change led to an initial working diagnosis of MCTD.

Autoimmune serology, including ANA, was negative. Further examination revealed anterior tibial bowing and hyperpigmented macules over the palms and soles, prompting consideration of sequelae of congenital or secondary syphilis; however, VDRL was negative. Persistent unexplained neuropathic involvement led to further reassessment. Notably, no peripheral nerves were palpable or thickened.

Given unexplained neuropathy in an endemic setting, slit-skin smear was performed and revealed bacillary positivity from the forehead (3+, BI 0.75, MI 50%). Skin biopsy showed only subtle non-specific inflammation, and repeated Fite staining was negative. On revisiting the patient, subtle madarosis, generalized appendageal loss, smooth shiny infiltrated skin, diffuse symmetric involvement without discrete plaques, and neuropathy were appreciated. Together with multibacillary smear positivity, the patient fulfilled the characteristic clinicomicrobiological profile of diffuse lepromatous leprosy with lepra bonita phenotype.

The patient was started on prednisolone 40 mg daily for neuritis, along with WHO multibacillary multidrug therapy. At one-month follow-up, she reported approximately 70% symptomatic improvement and had regained the ability to perform routine daily activities independently.

Conclusion

This case highlights the extraordinary mimicry of diffuse multibacillary leprosy with lepra bonita phenotype, presenting simultaneously with rheumatologic, myopathic, neural, and syphilis-like features. It underscores the

exceptionally high index of suspicion required to diagnose Hansen’s disease when classical lesions and nerve thickening are absent. Although global leprosy control has approached elimination thresholds, the disease continues to challenge endemic regions through delayed diagnosis, hidden transmission, and preventable disability. Early recognition of atypical multibacillary forms such as this is essential not only to prevent irreversible morbidity but also to interrupt transmission chains, strengthen surveillance, and reduce the continuing public health burden of leprosy worldwide.

EA DV CONGRESS
VIENNA
30 SEP - 3 OCT 2026

Abstract N°: 1785

TITLE- AN UNSUAL PRESENTATION OF CUTANEOUS MYCOBACTERIA ABSCESSUS AS SPOROTRICHOSIS AND RESPONSE TO LINEZOLID

Payal Choithani*[1]

[1] RGMC THANE, GSMC AND KEM HOSPITAL MUMBAI, MUMBAI, India

Introduction

TITLE- AN UNSUAL PRESENTATION OF CUTANEOUS MYCOBACTERIA ABSCESSUS AS SPOROTRICHOSIS AND RESPONSE TO LINEZOLID

INTRODUCTION

Cutaneous mycobacterial disease may take many guises and may appear benign in nature. Atypical mycobacterial infections are among the main causes of infectious lesions with sporotrichoid distribution in Europe. Among cutaneous NTM infections, 20-30% of these infections are associated with a sporotrichoid pattern.
Mycobacterium abscessus are part of the rapidly growing mycobacteria group and have also been known to present with skin lesions that may follow a sporotrichoid pattern. We present one such interesting case that came out to be Nontubercular mycobacterial (NTM) infection.

Case Presentation

CASE REPORT

A 38-year-old male came with painful reddish swellings arranged in linear fashion on left upper extremity since 2 months. Lesions started from dorsum of left middle finger and extended upto posterior aspect of forearm.Lesions over forearm ruptured to release pus discharge, healing with atrophic scars. On examination, there were erythematous nodules on extensor aspect of left forearm, soft to firm in consistency, tender to touch, with few areas showing purulent material. Lymphnodes were not palpable. We suspected a diagnosis of Sporotrichosis and botryomycosis. 4 mm deep biopsies were done which revealed granulomatous inflammation in one biopsy and neutrophilic microabscesses extending upto the subcutaneous tissue in other biopsy. Pus culture for Acid fast bacilli and fungal culture was negative. It showed Methicillin resistant staphylococcus aureus sensitive to Linezolid. Ultrasonography of left wrist nodules suggested multiple draining sinuses with extensive edema and prominent veins. MRI left wrist suggested chronic tenosynovitis with rice bodies in the synovial fluid. Tissue culture for NTM revealed M.abscessus. Rest cultures were negative. Our patient was started on Tab linezolid 600 mg BD till drug susceptibility for NTM awaited. Patient resonded well to Linezolid in a span of 6 months.

Conclusion

CONCLUSION

The presentation of a sporotrichoid pattern with NTM may be misdiagnosed as fungal infection (e.g., sporotrichosis), as the pattern closely resembles fungal infections. So a thorough workup is necessary. M.abscessus is usullay a difficult to treat organism. The treatment consist of Macrolide and a parenteral agent such as amikacin, cefoxitin, imipenem or tigecycline, or combination of parenteral agents. Response to Linezolid is

very poor (48%). Our patient responded well to monotherapy of Linezolid.

EADV CONGRESS
VIENNA
30 SEP - 3 OCT 2026

Abstract N°: 1792

Leprosy Revisited: The First Diagnosis in Croatia After Three Decades

Matea Tramontana*[1], Maja Pavic[1], Dubravka Vuković[1], Toni Čeprnja[1], Mirela Pavičić Ivelja[1], Ana Sanader Vučemilović[1]

[1] University hospital of Split, Split, Croatia

Introduction

Leprosy is a chronic granulomatous infection caused by Mycobacterium leprae, with a broad and often deceptive clinical spectrum that frequently leads to diagnostic delay in non-endemic settings. Although considered eliminated as an autochthonous disease in Europe, leprosy continues to occur as an imported infection in the context of global migration. The aim of this report is to present newly diagnosed leprosy cases in Croatia after more than three decades, highlighting diagnostic pitfalls, decisive histopathological findings, and therapeutic implications relevant to dermatological practice in non-endemic European countries.

Case Presentation

A 42-year-old man originally from Nepal, residing in Croatia for six years, presented with chronic lumbosacral pain with radicular distribution, polyarthralgia, intermittent peripheral and periorbital edema, and mild, clinically nonspecific cutaneous lesions on the trunk and thighs. Extensive rheumatologic, neurologic, and infectious investigations failed to establish a diagnosis. Dermatological evaluation revealed discreet erythematous-brown macules, and skin biopsy was performed. Histopathological examination demonstrated a dense dermal histiocytic infiltrate with numerous intracellular acid-fast bacilli, which were also identified in an excised axillary lymph node, without necrosis or granuloma formation. The diagnosis of leprosy was established by microbiological confirmation of Mycobacterium leprae using fluorescence microscopy. Molecular resistance testing revealed heteroresistance to dapsone, with preserved susceptibility to rifampicin and clofazimine. An individualized multidrug regimen consisting of rifampicin 600 mg monthly, clofazimine 300 mg monthly followed by 100 mg daily, and clarithromycin 500 mg daily was initiated with a planned duration of at least 12 months. Treatment was well tolerated and resulted in early clinical stabilization, without progression of cutaneous or systemic manifestations. Epidemiological evaluation of a close household contact did not confirm active disease but indicated the need for structured clinical follow-up.

Conclusion

This case represents the first documented diagnosis of leprosy in Croatia in over 30 years and serves as a reminder that leprosy has not disappeared from Europe. Subtle or atypical skin findings, especially when accompanied by systemic or rheumatologic symptoms, may conceal advanced disease in patients with relevant epidemiological exposure. Histopathology remains pivotal for early diagnostic orientation, while resistance-guided, individualized therapy is essential for optimal management. In an era of increasing global mobility, sustained clinical awareness among dermatologists is crucial to prevent diagnostic delay, irreversible complications, and missed opportunities for timely treatment of this rare but still present disease.

EADV CONGRESS
VIENNA
30 SEP - 3 OCT 2026

Abstract N°: 1817

Efficacy of Intralesional Acyclovir versus Quadrivalent Human Papillomavirus Vaccine for Treatment of Recalcitrant Cutaneous Warts: A Clinical Trial

Ibrahim Fouda*[1, 1, 1], Zakaria obaid[1, 1, 1], Mona Alyamany[2, 2, 2]

[1] Al-Azhar University, egypt, Al-Azhar University, egypt, Al-Azhar University, egypt, cairo, Egypt
[2] damietta university, Damietta, Egypt

Introduction
Warts are the cutaneous manifestations of human papilloma virus infection. Immunotherapy with human papillomavirus (HPV) vaccines has been tried with promising outcomes. Acyclovir is an antiviral with established efficacy against DNA viruses, could become a possible revolutionary therapeutic option for warts

Materials and Methods
A total of 60 patients with recalcitrant warts were assigned into 3 groups: group I, 20 patients received Intralesional injection of acyclovir, group II ,20 patient received intralesional quadrivalent HPV vaccine, and group III, 20 patients received intralesional injection of normal saline. The patients were followed up monthly for 3 months after the last injection to detect any recurrence.

Results
Complete clearance was observed in 8 patients (40%) in group I,16 patients (80%) in group II and no response in group III. The most common side effects were pain (100%) among all groups, hemorrhagic eschars in group I(100%) ,edema in group II(30%) while the least was flu like symptoms (5%) in group II.

Conclusions
both intralesional quadrivalent HPV vaccine and intralesional acyclovir seem to be promising, well-tolerated therapeutic options for the treatment of warts, with statistically significant superiority of the quadrivalent vaccine over acyclovir

EADV CONGRESS
VIENNA
30 SEP - 3 OCT 2026

Abstract N°: 1821

A great imitator unveiled: multifocal scrofuloderma secondary to tuberculous peripleuritis and Pott's disease in an immunocompetent patient

Camila Bendahan*[1], Jorge Tiscornia[1]

[1] Hospital General de Agudos J. M. Ramos Mejía, Buenos Aires, Argentina

Introduction
Cutaneous tuberculosis is a great imitator, accounting for 2% of extrapulmonary forms, re-emerging in the context of multidrug resistance, HIV co-infection, solid organ transplantation, immunosuppressive therapies, and malnutrition.

Case Presentation
A 48-year-old woman with no known medical history presented with a four-year history of dull low back pain radiating to the lower limbs, accompanied by a 20-kilogram weight loss. Two years after symptom onset, she progressively developed multiple erythematous, fluctuant, mobile, and tender nodules over the presternal region, right scapular, axillary, and ipsilateral lumbar areas.

Physical examination revealed a 4-cm presternal nodule with irregular borders, painful on inspiration, a right axillary nodule, and a 3-cm erythematous lumbar scar on the right side.

Admission laboratory findings showed anemia of chronic disease (hemoglobin 9.5 g/dL), elevated acute-phase reactants, thrombocytosis (platelets 525,000/µL), and an ESR of 68 mm/h.

Excisional biopsy of the sternal lesion showed histological findings consistent with neutrophilic lobular panniculitis with suppurative foci; no granulomas were identified. Mycobacterial culture was performed on spontaneous discharge from the lumbar lesion. Chest CT revealed peripleuritis with cutaneous fistulization at the sternal level. MRI demonstrated lytic and blastic involvement of the sternum, cervical, thoracic, and lumbar spine, sacrum, and iliac bones, with retrospinal soft tissue involvement.

Upon identification of *Mycobacterium tuberculosis* complex in culture from the lumbar discharge, and using polymerase chain reaction to confirm rifampicin susceptibility, we diagnosed sternal scrofuloderma secondary to tuberculous peripleuritis and lumbar scrofuloderma associated with tuberculous spondylodiscitis or Pott's disease.

Antituberculous therapy, consisting of isoniazid, rifampicin, pyrazinamide, and ethambutol, was supervised by the pulmonology department, with a complete clinical response.

Conclusion
Scrofuloderma results from contiguous spread to the skin from an adjacent infected focus, most commonly a lymph node, osteoarticular, or testicular focus, and rarely a peripleural focus.

Tuberculous peripleuritis is an inflammatory process between the parietal pleura and the chest wall, and is frequently underdiagnosed. Infection spreads via lymphatic chains, forming cold abscesses that drain externally as caseous and purulent material

Regarding diagnosis, cutaneous tuberculosis poses a challenge given the nonspecific histopathological findings, which may include absent granulomas and variable caseous necrosis. Culture is considered the gold standard. In our case, microbiological identification by culture was fundamental, while nucleic acid amplification methods such as GeneXpert and BD MAX enabled rapid rifampicin susceptibility testing and early therapeutic adjustment.

We report an unusual presentation of extrapulmonary tuberculosis with simultaneous cutaneous involvement in two distinct locations, peripleural and osteoarticular, in an immunocompetent patient. To our knowledge, the coexistence of sternal scrofuloderma secondary to tuberculous peripleuritis, lumbar scrofuloderma associated with spondylodiscitis, and multifocal spinal involvement has not been previously reported in the literature. The insidious course and diverse manifestations reflect the disease's nature as a great imitator, contributing to diagnostic delay. Dermatological findings were key to diagnosing deep systemic involvement, underlining the importance of a high level of suspicion, a multidisciplinary approach, and combined use of microbiological and radiological methods to prevent irreversible neurological injury.

EADV CONGRESS
VIENNA
30 SEP - 3 OCT 2026

Abstract N°: 1872

Chronic centrofacial infiltrated plaque with central ulceration: a diagnostic challenge of lupoid cutaneous leishmaniasis

María Paula Muñoz Mc Causland*[1], Liz Daniela Beltrán[2], Maria Camila García Vasquez[3], Alvaro Tovar cock[4]

[1] Fundación Universitaria Sanitas, Bogotá, Colombia

[2] Pontificia Universidad Javeriana, Bogotá, Colombia

[3] Universidad de la Sabana, Bogotá, Colombia

[4] Federico Lleras Acosta, Bogotá, Colombia

Introduction

Lupoid cutaneous leishmaniasis is a rare chronic variant of cutaneous leishmaniasis characterized by a granulomatous inflammatory response with a low parasitic burden. It typically presents as a chronic infiltrated plaque and may closely mimic other granulomatous or inflammatory dermatoses, often resulting in diagnostic delay.

Case Presentation

A 60-year-old woman presented with a 6-week history of progressive pruritic erythema and edema involving the nasal bridge, with extension to the glabellar and periorbital regions. The initial clinical impression was compatible with a bacterial skin infection (cellulitis), and she received empirical systemic and topical antibiotic therapy as well as topical corticosteroids, with only partial and transient improvement, followed by persistence and slow progression.

On physical examination, there was a well-demarcated, infiltrated erythematous-edematous plaque on the nasal dorsum and glabella measuring 3.9 × 2.2 cm, with a central ulceration of approximately 1.2 × 0.3 cm covered by yellowish crust. No mucosal involvement or lymphadenopathy was observed.

Given the chronic evolution and morphology, a skin smear and biopsy were performed. Direct microscopic examination demonstrated Leishmania spp., confirming the diagnosis of cutaneous leishmaniasis. The clinical features were consistent with a chronic plaque-like granulomatous form compatible with lupoid cutaneous leishmaniasis. Systemic antileishmanial therapy was initiated, with subsequent clinical improvement.

Conclusion

This case illustrates an atypical centrofacial presentation of lupoid cutaneous leishmaniasis mimicking inflammatory dermatoses. It underscores the importance of considering infectious etiologies in chronic infiltrated facial plaques, particularly when is refractory to standard anti-inflammatory or antibacterial therapy, and highlights that leishmaniasis should always be included in the differential diagnosis in endemic areas to avoid diagnostic delay and mismanagement.

EADV CONGRESS
VIENNA
30 SEP - 3 OCT 2026

Abstract N°: 1878

A Mysterious Perioral Eruption in a Child: The Misleading Mouth

Gabriela Reginata*[1], Radyn Muhamad[2]

[1] Department of Dermatology and Venereology, Cililin Regional General Hospital, Kabupaten Bandung Barat, Jawa Barat, Indonesia

[2] Department of Dermatology and Venereology, Cililin Regional General Hospital, Kabupaten Bandung Barat, Indonesia

Introduction

Perioral erythema in children is a common yet diagnostically challenging condition with a broad spectrum of inflammatory and infectious etiologies. Common differential diagnoses include perioral dermatitis, irritant contact dermatitis, and lip-licking dermatitis. However, fungal infections such as candidiasis are often overlooked, particularly when clinical features are modified by prior corticosteroid use. Misdiagnosis may lead to inappropriate treatment and prolonged disease duration. This report highlights a steroid-masked presentation of perioral candidiasis and emphasizes key diagnostic clues for accurate recognition.

Case Presentation

A 5-year-old child presented with a 2-month history of persistent perioral erythema. The eruption initially appeared as mild redness and progressively evolved into well-demarcated, symmetrically distributed erythematous plaques surrounding the mouth. The lesions showed a slightly moist surface with fine scaling and were not associated with significant pruritus or pain. The patient had previously been treated with topical corticosteroids without improvement; instead, the lesions progressively worsened. There was no history of systemic symptoms or similar lesions elsewhere. Dermatological examination revealed bright erythema with mild maceration in the perioral region, accompanied by subtle peripheral scaling. Multiple small satellite papules were observed at the margins of the plaques, with partial sparing of the vermilion border. These findings raised suspicion for a fungal etiology rather than an inflammatory dermatosis. Direct microscopic examination using potassium hydroxide preparation demonstrated yeast forms consistent with *Candida* species, supporting the clinical diagnosis of steroid-modified perioral candidiasis. Topical antifungal therapy with miconazole 2% cream applied twice daily was initiated, along with discontinuation of topical corticosteroids. Marked clinical improvement was observed within 1 week, followed by near-complete resolution after 2 weeks of treatment.

Conclusion

Steroid-masked perioral candidiasis should be considered in children presenting with persistent or atypical perioral erythema, particularly when unresponsive to topical corticosteroids. Recognition of characteristic clinical features, including well-demarcated erythema, a moist surface, and satellite lesions, together with simple mycological confirmation, is essential for accurate diagnosis. Early identification is crucial to avoid misdiagnosis, prevent inappropriate corticosteroid use, and enable prompt and effective antifungal therapy.

EA DV CONGRESS
VIENNA
30 SEP - 3 OCT 2026

Abstract N°: 1892

Non-tuberculous mycobacteria after tattooing: a possible first case from Bulgaria

Lidiya Todorova*[1, 2], Nicolas Kluger[3, 4]

[1] Medical University Plovdiv, Plovdiv, Bulgaria
[2] Follica: Hair & Scalp Clinic, Plovdiv, Bulgaria
[3] Tampere University Hospital, Tampere, Finland
[4] Hôpital Bichat-Claude Bernard, Paris, France

Introduction

About 20% of adults have currently one tattoo or more worldwide. The figures are similar in Bulgaria according to a recent survey (19% of the population) and the number of tattoo shops is estimated around 107 in Bulgaria, mainly in Sofia and Plovdiv according to Poidata.io(3). To our knowledge, there is no formal legislation specific to tattooing, regarding minimum age or licensing in Bulgaria. Tattooing can result in a wide variety of complications including the potential inoculation of microorganisms in the dermis. Cutaneous infections usually develop within days to weeks after the procedure and may include: pyogenic infections (staphylococcus, streptococcus, Pseudomonas aeruginosa, etc.), atypical bacteria (commensal mycobacteria, tuberculosis, leprosy, etc.), viral infections (molluscum contagiosum, verruca vulgaris, herpes, etc.), fungal and parasitic infections. We report what we think to be the first non-tuberculous mycobacterial (NTM) infection reported in Bulgaria.

Case Presentation

A 23-year-old healthy young man presented in consultation for a rash that had been evolving for the past two weeks on a recent black tattoo of the right leg. The rash appeared 48 hours after tattooing in a professional tattoo parlor, in early June 2025. The rash was asymptomatic. Upon examination, the rash consisted of dark red-to-violaceous, non-scaly and non-follicular papules strikingly distributed only on the gray parts of the tattoo. All the black lines and fillings were normal. The physical examination was otherwise normal; he had no inguinal lymph nodes enlarged. He had previously applied clobetasol propionate for a week and dexanpanthenol ointment, without any effect. The delay of onset of the rash and its distribution strictly to the “gray washed” areas raised suspicion for a possible NTM infection. The tattooist confirmed he had used both distilled water for dilution of black ink to obtain a gray shade and the cup had been cleaned with tap water. The patient refused punch skin biopsies for microscopic analysis and culture for mycobacterial. Empiric monotherapy by oral doxycycline 200 mg daily for 3 months has been initiated alongside with application of moisturizers and sunscreens. Local corticosteroids were withdrawn. The rash had already subsided after one month and a half. The patient did not present for follow up consultation and is considered to have fully healed.



Image depicts the skin before the treatment.

Conclusion

Occurrence of environmental NTM after tattooing has been reported since early 2000s. The first outbreaks in tattoo parlors have been reported in France. Since then, numerous cases and outbreaks have been reported worldwide, mainly with M.chelonae and M.abscessus. NTM are most likely under looked in Bulgaria. Our case acts as a reminder of the necessity of proper training and education to rules of hygiene and asepsis during tattooing of Bulgarian tattoo artists.



Image depicts the skin after treatment.

EADV CONGRESS
VIENNA
30 SEP - 3 OCT 2026

Abstract N°: 1908

Coexistence of Hansen's Disease and Lymphatic Filariasis: Diagnostic Challenges in Overlapping Neglected Tropical Diseases

Mrudula Reddy Bathula*[1], Akash Agarwal[1], Maitreyee Panda[1], Ajaya Jena[1]

[1] IMS & SUM Hospital, Bhubaneswar, India

Introduction

Neglected tropical diseases frequently coexist in endemic regions; however, their combined impact on cutaneous morphology and disease classification remains under-recognised. Overlapping inflammatory, neuropathic, and lymphatic pathology may obscure classical clinical features, resulting in delayed diagnosis and preventable morbidity.

Case Presentation

A middle-aged woman presented with acute erythema, oedema, and tenderness of pre-existing lesions of one week duration, clinically suggestive of a lepra reaction. Detailed retrospective history revealed a four-year evolution of symptoms consistent with previously undiagnosed Hansen's disease, including progressive sensory loss, dry hypopigmented patches, ichthyosis-like changes, recurrent burn injuries, trophic ulcers, and progressive impairment in hand grip and daily activities.

The patient also had a 15-year history of treated lymphatic filariasis with chronic unilateral lower-limb lymphoedema. Cutaneous examination showed marked limb enlargement with verrucous hyperkeratotic plaques and chronic ulceration consistent with elephantiasis nostras verrucosa. Superimposed acute inflammatory changes over a chronically lymphoedematous limb created significant diagnostic difficulty.

Clinicopathological correlation, including slit-skin smear and histopathology, confirmed borderline lepromatous Hansen's disease with Type 1 lepra reaction, suggestive of immunological downgrading. Chronic filarial lymphoedema was considered a contributory factor to morphological distortion and delayed diagnosis.

Conclusion

This case highlights the diagnostic complexity created by coexisting neglected tropical diseases and demonstrates how chronic filarial lymphoedema may mask classical manifestations of Hansen's disease, leading to delayed recognition and irreversible disability. Careful neurological examination, detailed history-taking, and integrated clinicopathological evaluation are essential for early diagnosis and prevention of long-term morbidity in endemic settings.

EADV CONGRESS
VIENNA
30 SEP - 3 OCT 2026

Abstract N°: 1920

Extensive Cervicofacial Actinomycosis with Mediastinal Extension in an Elderly Patient with Psoriasis and Prior Biologic Therapy

Göksu Dalgıç Demirtaş*[1], Kamer Gündüz[1], Peyker Temiz[2], Gülgün Yılmaz Ovalı[3]

[1] Manisa Celal Bayar University Medical Faculty, Department of Dermatology, Manisa, Türkiye
[2] Manisa Celal Bayar University Medical Faculty, Department of Pathology, Manisa, Türkiye
[3] Manisa Celal Bayar University Medical Faculty, Department of Radiodiagnostics, Manisa, Türkiye

Introduction

Cervicofacial actinomycosis, caused by Actinomyces species, is a rare chronic granulomatous infection accounting for approximately 50–55% of all actinomycosis cases. Known as a clinical "masquerader," it frequently mimics malignancy, tuberculosis, or bacterial cellulitis. In patients with chronic inflammatory skin diseases receiving systemic immunomodulatory therapies, atypical and severe presentations may pose significant diagnostic challenges.

Case Presentation

A 74-year-old male with biopsy-confirmed erythrodermic psoriasis, previously treated with methotrexate and the IL-23 inhibitor risankizumab, presented with fever and rapidly progressive painful swelling of the right hemiface. Two months earlier, he had been misdiagnosed with preseptal cellulitis and treated with systemic antibiotics for one month. Clinical examination revealed ulcerated nodules, deep-seated abscesses, and draining sinus tracts involving the right temporal, periorbital, mandibular, cervical, and supraclavicular regions. Skin biopsy demonstrated a squamous epithelium-lined fistulous tract with dense mixed inflammatory infiltration; no microorganisms or sulfur granules were identified on routine staining, and mycological and mycobacteriological cultures yielded no growth. Contrast-enhanced CT showed extensive inflammatory involvement extending from the right temporal region through the cervical fascial planes to the superior mediastinal inlet. Despite culture-negative findings—likely attributable to prior antimicrobial exposure—the clinical presentation, histopathologic pattern, and characteristic radiologic spread along fascial planes supported a diagnosis of cervicofacial actinomycosis. Prolonged intravenous therapy including ertapenem and tigecycline resulted in marked clinical and radiologic improvement, with no recurrence at one-year follow-up.

Conclusion

This case illustrates that in elderly patients with psoriasis receiving systemic immunomodulatory therapy, a compromised skin barrier combined with immunosuppression may predispose to severe invasive infections. Cervicofacial actinomycosis should be included in the differential diagnosis of chronic, fistulizing cervicofacial soft tissue infections refractory to standard antibiotic regimens, even in the absence of microbiological confirmation. Early clinical suspicion and prolonged targeted antimicrobial therapy are essential to prevent life-threatening complications.

EADV CONGRESS
VIENNA
30 SEP - 3 OCT 2026

Abstract N°: 1923

CHRONIC FACIAL PUSTULOSIS AND STEROID-DEPENDENCE

salah eddin awawde*[1], Saliha Takheroubt[1], Issam TABLIT[1], Lemya Mezdour[1], SAMIA DJOUDI[1], Asma Haciane[1], Tasnime Bouaziz[1], Samira Zobiri[1]

[1] Mustapha University Hospital Center, Dermatology and venereology, Sidi M'Hamed - alger, Algeria

Introduction
Demodicosis is a skin condition caused by the abnormal proliferation of the commensal skin mite *Demodex*. Frequently misdiagnosed as acne or rosacea, it can be exacerbated by inappropriate treatments—particularly topical corticosteroids—leading to severe clinical manifestations and topical steroid withdrawal syndrome (steroid-dependence).

Case Presentation
Case History We report the case of a 37-year-old female with no significant personal medical history who presented with a facial pustulosis evolving with flare-ups and remissions since the age of 14 (2003). Initially treated for acne with topical therapies and hormone therapy, she experienced transient improvements. In 2022, treatment with isotretinoin and zinc proved effective but was discontinued due to photosensitivity, leading to a relapse. In March 2024, peeling sessions combined with PRP injections cleared the pustules but resulted in major skin fragilization. In August 2025, sun exposure triggered a severe flare-up. By late 2025, the failure and poor tolerance of topical antibiotics led to repeated courses of oral corticosteroids to control the inflammation. The introduction of a topical corticosteroid in February 2026 resulted in severe steroid-dependence; any attempt to withdraw the treatment provoked an immediate rebound flare-up with confluent lesions and crusting.

Clinical Examination and Investigations On clinical examination, the patient was in good general condition, afebrile, with a BMI of 25.88 kg/m^2. Dermatological assessment revealed pustular and crusted lesions resting on an erythematous and telangiectatic background on the cheeks and chin, sparing the perioral region, nose, forehead, and periorbital area. The pustules were non-follicular, flat, and yellowish. The patient reported extreme sensitivity to touch, burning sensations, and tingling, with no ophthalmological symptoms. Laboratory tests revealed moderate hyperprolactinemia (37 ng/mL), prompting a scheduled brain MRI, and severe hypovitaminosis D (6.5 ng/mL). All other blood parameters were within normal limits. Dermoscopy and Wood's lamp examination were highly suggestive, and the direct parasitological examination was strongly positive for *Demodex* on two separate occasions.

Management and Outcome Based on the diagnosis of severe facial demodicosis complicated by steroid-dependence, strict withdrawal of topical corticosteroids was enforced. Treatment was initiated on April 13, 2026, comprising systemic therapy (metronidazole 1.5 g/day and doxycycline 200 mg/day for 14 days) and topical ivermectin cream applied nightly, along with gentle skin care and sun protection. After 15 days of treatment, the clinical evolution was highly favorable, characterized by progressive crust detachment, an absence of new pustules, and the resolution of burning sensations. However, the follow-up parasitological test remained positive, indicating the need for continued therapy.

Conclusion
This case highlights the critical importance of suspecting demodicosis in patients with facial dermatoses that are

refractory to conventional acne or rosacea treatments and that worsen under corticosteroid therapy. Facial steroid-dependence is a severe complication that masks the underlying infection. Direct parasitological diagnosis is essential to implement targeted acaricidal therapy combined with strict corticosteroid withdrawal.

EA DV CONGRESS
VIENNA
30 SEP - 3 OCT 2026

Abstract N°: 1969

Extensive familial dermatophytosis due to Epidermophyton floccosum: therapeutic approach

Sihame Alaoui*[1]

[1] Ibn Sina University Hospital, Rabat, Morocco

Introduction

Dermatophytosis is a common fungal infection, usually limited and responsive to standard antifungal therapy. However, extensive and persistent forms may occur, particularly in the context of intrafamilial transmission, posing therapeutic challenges.



Multiple erythematous scaly plaques with circinate borders, associated with excoriated papules, diffusely involving the trunk.

Case Presentation

We report three familial cases involving a 9-year-old girl, her 30-year-old mother, and her 21-year-old aunt, all without significant past medical history.

The lesions had been evolving for 6 months and were characterized by pruritic, well-demarcated erythematous plaques with circinate and occasionally polycyclic borders, covered with whitish scaling and associated with

excoriated papules. The involvement was diffuse, affecting the trunk and limbs, with progressive extension to the entire body surface.

Clinical examination revealed no mucosal or adnexal involvement. The general condition was preserved in all three patients, with no associated systemic symptoms.

A mycological examination performed prior to treatment identified *Epidermophyton floccosum* as the causative agent.

Initial treatment with oral terbinafine at a dose of 250 mg/day did not result in significant clinical improvement.

A therapeutic switch to itraconazole at a dose of 100 mg twice daily led to rapid clinical improvement in all three patients within the first two weeks.



Multiple well-demarcated erythematous scaly plaques, round to oval in shape, with circinate borders, associated with excoriated papules, located on the back.

Conclusion

This case highlights an extensive familial dermatophytosis requiring adaptation of antifungal therapy. It underscores the importance of mycological identification and appropriate therapeutic adjustment in cases of inadequate response to initial treatment.

EADV CONGRESS
VIENNA
30 SEP - 3 OCT 2026

Abstract N°: 1977

Pediatric facial sporotrichosis with delayed diagnosis: a case report from an endemic region

Carolina Cruz*[1], Rubia Lury Hanada Marialva[1], Amanda Tanaka Iasbeck Gonçalves[2], Ana Clara Maia Palhano[2], Elizabeth Drullis[1]

[1] Universidade de Mogi das Cruzes, Mogi das Cruzes, Brazil

[2] Universidade de São Paulo, São Paulo, Brazil

Introduction

Sporotrichosis is a subcutaneous mycosis caused by fungi of the genus Sporothrix, most prevalent in Latin America and Asia. In Brazil, Sporothrix schenckii and Sporothrix brasiliensis predominate, with domestic cats as the main transmission reservoir. Clinical presentations include cutaneous, lymphocutaneous, mucosal, osteoarticular, and systemic forms. Children are disproportionately affected due to frequent feline contact, with the face being the most commonly involved site in this age group. We report a case in which diagnosis was delayed for several months despite the patient's residence in an endemic region, resulting in prolonged morbidity and significant impairment of quality of life.

Case Presentation

An 8-year-old female presented with facial lesions persisting for four months. Prior evaluations by other dermatologists prescribed only topical treatments. Dermatological examination revealed multiple soft, erythematous nodules with honey-colored crusts on the left hemiface — some isolated, others confluent — with expressible discharge. Crusted plaques were also noted on the left arm and right leg.

At the initial consultation, the patient had been on cephalexin 500 mg every 6 hours for four days. Following antibiotic completion, partial improvement was noted. Skin biopsy and culture were requested given the history of cat contact, residence in a neighborhood with documented feline sporotrichosis, and a prior histopathological report demonstrating mild granuloma formation.

The initial culture yielded only bacterial growth. Given the epidemiological context and after thorough discussion with the family, itraconazole 300 mg/day (10 mg/kg/day) was initiated empirically while awaiting the definitive culture result. The final culture proved negative; however, the patient showed clinical improvement and antifungal therapy was maintained. After eight months, complete remission was achieved. Itraconazole was discontinued and silicone gel prescribed for residual scarring.

Conclusion

The absence of laboratory confirmation did not prevent treatment. The decision to proceed empirically was made jointly with the family, grounded in the chronic disease course, characteristic lesion morphology, and strong epidemiological exposure. Facial involvement caused considerable psychosocial distress: the patient withdrew from school due to bullying and abandoned her hobby of recording online videos. These impacts resolved progressively alongside clinical improvement.

Fungal culture for Sporothrix spp. uses biopsy or swab specimens inoculated on Sabouraud agar; visible growth may appear within 5–8 days, although definitive confirmation can take up to 30 days. Histopathology is non-pathognomonic; granuloma formation may be observed, while direct fungal visualization is uncommon. Per Brazilian Ministry of Health Surveillance Guidelines, diagnosis may be established on compatible clinical and epidemiological findings, even in the absence of laboratory confirmation.

First-line treatment is itraconazole; alternatives include terbinafine, potassium iodide solution, posaconazole, and amphotericin B. Increasing itraconazole resistance in Brazil underscores the importance of monitoring therapeutic response. Cat-scratch disease, caused by Bartonella henselae, must also be considered as a differential diagnosis in similar epidemiological contexts, although its course is typically self-limited and primarily lymph-node–based.

EADV CONGRESS
VIENNA
30 SEP - 3 OCT 2026

Abstract N°: 1996

Disseminated Cutaneous Larva Migrans Mimicking Herpes Zoster: A Diagnostic Challenge

MARCIA GALVÃO TEIXEIRA*[1], ISABEL SOUZA[1], LARA FAUSTINO[1], ANDRÉ LUIZ DOS SANTOS[1], AMÉLIA MARTINS[1], GIOVANA CUBITS[1], RENATA MONTEIRO[21]

[1] Universidade de Pernambuco, Recife, Brazil

Introduction

Cutaneous larva migrans (CLM) is a parasitic skin disease endemic to tropical and subtropical regions, caused by the penetration of hookworm larvae (e.g., Ancylostoma spp.) into the skin. The clinical presentation typically includes highly pruritic, erythematous, linear, or serpiginous lesions, located primarily on the lower extremities. We report an atypical case of CLM, this time disseminated across the patient's back, a finding that accounts for approximately 7.1% of cases reported in the literature. The lesions, distributed mostly on the right half of the back, crossing the midline and extending to the left half, were characterized by multiple erythematous plaques connected by tortuous, desquamative tunnels. Their borders were well-defined, with brownish areas, associated with reports of intense pruritus and moderate pain.

Case Presentation

A 22-year-old woman presented with multiple painful and pruritic skin lesions on her back, causing insomnia. The symptoms began 10 days after she had lain on a terrace where cats frequently rested. Physical examination revealed multiple erythematous and scaly plaques, connected by tortuous lines, with brownish areas and well-defined borders. The lesions were widely distributed across the right half of the back.The patient initially sought care at the emergency department, where she was mistakenly clinically diagnosed with herpes zoster and treated with oral acyclovir (200 mg every 4 hours for 5 days), with no improvement. Subsequently, she was referred to a public dermatology clinic, where a correct clinical diagnosis of disseminated CLM was made. Treatment was initiated with oral ivermectin at 6 mg, 2 tablets once daily for 2 days (approximately 200 µg/kg based on the patient's weight of ~60 kg), with the regimen repeated after one week. Upon reevaluation, the patient showed complete regression of the skin lesions and total resolution of the clinical picture, with cessation of complaints of pruritus and pain.

Conclusion

This case illustrates two clinically relevant points. First, cutaneous larva migrans can present with extensive dissemination in atypical locations, such as the back, but remains consistent with its infectious-contagious transmission mechanism, mediated by direct skin contact with the soil. Second, the presence of significant pain—uncommon in CLM—combined with a hemidorsal distribution mimicked herpes zoster, a well-known diagnostic pitfall. Unlike herpes zoster, which follows a dermatomal nerve distribution and presents with vesicular lesions, CLM produces serpiginous tracks that progress independently of dermatomes. This case underscores the critical role of a detailed medical history, including environmental exposure, and a thorough dermatological examination in distinguishing atypical presentations of CLM from other skin conditions. Furthermore, ivermectin remains the treatment of choice for Larva Migrans, even in disseminated cases such as this one, with cure rates ranging from 77% to 100% after a single dose.

POWERED BY M-ANAGE.COM

EADV CONGRESS
VIENNA
30 SEP - 3 OCT 2026

Abstract N°: 1999

Unilateral Madarosis Revealing Lepromatous Leprosy: An Atypical Presentation Mimicking Alopecia Areata

Ana Lígia Scotti Alérico*[1], Hudson Rezende[1], João Henrique Aurich[1], Juliana Santos Rodrigues[1], Letícia Ferreira de Hybi Cerqueira[2]

[1] Centro Universitário Lusíada - UNILUS, Santos, Brazil

[2] Centro Universitário CESMAC, maceio, Brazil

Introduction

Leprosy is a chronic infectious disease caused by *Mycobacterium leprae*, with a broad clinical spectrum determined by host immune response. In lepromatous leprosy, diffuse cutaneous involvement and adnexal damage are common, often leading to madarosis, typically bilateral and symmetric. In contrast, unilateral madarosis is classically associated with tuberculoid forms and is rarely described in multibacillary disease, posing a diagnostic challenge, particularly when presenting in isolation.

Case Presentation

A two-year history of isolated alopecia of the right eyebrow was presented in a 13-year-old boy. He had previously been diagnosed with alopecia areata and treated with three sessions of intralesional triamcinolone hexacetonide (2.5 mg/mL), without improvement.On examination, unilateral madarosis was observed over a palpable nodular lesion with fibrous consistency. Additional findings included hypopigmented macules on the dorsal region and glabella, both demonstrating altered thermal sensitivity. These findings raised suspicion of a neuropathic and infiltrative process. A 2-mm punch biopsy of the eyebrow lesion revealed a dense dermal infiltrate composed predominantly of foamy histiocytes, with involvement of neural structures and destruction of the pilosebaceous units. Special staining confirmed the presence of acid-fast bacilli, establishing the diagnosis of lepromatous leprosy with a localized hansenoma.

Conclusion

This case highlights an unusual presentation of lepromatous leprosy manifesting as unilateral madarosis, mimicking alopecia areata and leading to delayed diagnosis. It expands the clinical spectrum of multibacillary disease, demonstrating that asymmetrical adnexal involvement may occur even in advanced forms. In endemic regions, leprosy should be considered in cases of treatment-resistant madarosis, particularly when associated with subtle sensory changes or nodular lesions. Early recognition is essential to prevent progression and irreversible complications, and to avoid misdiagnosis of potentially treatable infectious conditions.

EA DV CONGRESS
VIENNA
30 SEP - 3 OCT 2026

Abstract N°: 2000

Disseminated Varicella in an Adult Patient: A Reminder of a Well-Known Entity

Elisandra Barbara Pontes Carlos*[1], Anna Carolina Miola[1]

[1] UNESP, Botucatu, Brazil

Introduction

Primary infection with Varicella-zoster virus in adults is associated with a higher risk of severe disease compared to childhood, with increased incidence of systemic complications, including pneumonia, neurological involvement, and atypical visceral manifestations that may mimic an acute abdomen. Lower rates of pre-existing immunity and a more exuberant inflammatory response contribute to higher morbidity and mortality in this population, underscoring the importance of early recognition and prevention through immunization.

Case Presentation

A 51-year-old woman with multiple comorbidities (systemic arterial hypertension, pulmonary emphysema, long-standing tobacco use, fibromyalgia, chronic constipation, and psychiatric disorders), on regular use of psychotropic and antihypertensive medications, was admitted on July 6, 2025, to the emergency department of a tertiary care hospital with severe abdominal pain and distension that began the previous day, initially raising suspicion of an acute abdomen of unclear etiology. Abdominal computed tomography performed on July 7, 2025, ruled out a surgical cause. On July 8, 2025, during extended investigation, polymorphic facial lesions (papules, vesicles, ulcers, and crusts) were noted, with onset two days earlier and cranio-caudal progression, associated with mild respiratory symptoms. A relevant epidemiological history of household contact with a case of herpes zoster was reported. Given the suspicion of infection by a virus of the Herpesviridae family, particularly varicella, intravenous acyclovir (750 mg every 8 hours) was initiated. Tzanck cytology (July 10, 2025), performed after antiviral initiation, was inconclusive. Histopathological analysis (July 8, 2025) with immunohistochemistry demonstrated positivity for HSV-2, CD163, and myeloperoxidase, with negativity for AE1/AE3, CD20, CD3, CD1a, and S100, supporting a viral infection of the Herpes group. HSV-2 positivity was interpreted as possible cross-reactivity due to the unavailability of a specific marker for Varicella-zoster virus. Clinical, epidemiological, and morphological correlation—particularly the presence of polymorphic vesiculobullous exanthema in different evolutionary stages with typical distribution—supported the diagnosis of adult varicella. The patient showed progressive improvement after 14 days of intravenous acyclovir, with resolution of skin lesions and clinical stabilization, and was discharged on July 23, 2025.

Conclusion

Viruses of the Herpesviridae family are enveloped DNA viruses with tropism for epithelial tissues and the ability to establish latency in sensory ganglia, including the Varicella-zoster virus, which causes varicella (primary infection) and herpes zoster (reactivation). Cell-mediated immunity plays a central role in controlling infection, and its impairment is associated with more severe and disseminated presentations. From a diagnostic perspective, clinicopathological and epidemiological correlation remains essential, particularly in settings with limited laboratory resources, as methods such as Tzanck cytology have low sensitivity and specificity, and immunohistochemistry may exhibit cross-reactivity among viral subtypes. In this context, varicella vaccination is a highly effective strategy to reduce incidence, severe disease, and hospitalizations. Widespread immunization

programs have demonstrated a substantial reduction in disease burden in countries adopting universal vaccination, reinforcing its role as a key public health measure.

EADV CONGRESS
VIENNA
30 SEP - 3 OCT 2026

Abstract N°: 2017

The Great Imitator in Dark Skin: An Elegant Presentation of Secondary Syphilis in a Melanodermic Patient

Guilherme Gonçalves Nascimento*[1], Brian Vicente[1], Renata Bezerra[1], Claudio Lelis Souza[2]

[1] Intituto da Pele da Faculdade de Medicina do ABC - FMABC, Santo André, Brazil

[2] Universidade Prof.Edson Antônio Velano - UNIFENAS, Alfenas, Brazil

Introduction

Syphilis remains a major public health concern worldwide, with increasing incidence observed in recent years. Known as "the great imitator," the disease may present with a wide spectrum of dermatologic manifestations, often leading to delayed diagnosis. In melanodermic patients, clinical recognition can be even more challenging due to variations in lesion morphology, pigmentation patterns, and underrepresentation of darker skin phototypes in medical literature and dermatologic education. "Elegant syphilis" refers to subtle, refined, and sometimes aesthetically deceptive cutaneous manifestations of secondary syphilis, which may mimic inflammatory, pigmentary, or papulosquamous dermatoses.

Case Presentation

A 29-year-old melanodermic male patient presented with asymptomatic hyperpigmented papules and plaques distributed symmetrically over the trunk, upper limbs, neck, and palms, evolving progressively over six weeks. The patient denied pruritus, pain, fever, or constitutional symptoms. Dermatologic examination revealed well-defined copper-brown papules with smooth surface and discreet scaling, associated with palmar lesions and generalized micropolyadenopathy. Mucosal examination demonstrated subtle erythematous plaques on the oral mucosa.

The initial differential diagnoses included lichen planus pigmentosus, pityriasis lichenoides, sarcoidosis, and post-inflammatory dyschromia. Dermoscopy demonstrated diffuse coppery pigmentation with a discreet peripheral scaling pattern. Histopathological examination revealed psoriasiform epidermal hyperplasia associated with superficial and deep perivascular infiltrate rich in plasma cells. Serologic tests showed positive VDRL at 1:128 titration and reactive treponemal testing, confirming secondary syphilis.

Treatment with intramuscular benzathine penicillin G resulted in complete clinical resolution with residual post-inflammatory hyperpigmentation during follow-up.

Conclusion

This case highlights the diagnostic challenges of secondary syphilis in melanodermic patients, in whom clinical manifestations may appear more subtle or predominantly pigmentary. Recognition of atypical and "elegant" presentations is essential to avoid delayed diagnosis and inappropriate treatment. Greater representation of skin of color in dermatologic education and scientific literature is fundamental for improving recognition of sexually transmitted infections and inflammatory dermatoses across diverse phototypes.

EADV CONGRESS
VIENNA
30 SEP - 3 OCT 2026

Abstract N°: 2044

Tinea: A SQLE alteration in a terbinafine-susceptible isolate

Julia Jiarui Shen*[1, 2, 3], Karen Marie Thyssen Astvad[4], Nissrine Abou-Chakra[4], Gregor Borut Jemec[2], Ditte Marie L. Saunte[1, 2, 3, 4]

[1] Department of Dermatology, Zealand University Hospital, Roskilde, Roskilde, Denmark

[2] PHOENIX Research Center, Depatment of Dermatology and Allergy, Copenhagen University Hospital, Gentofte Hospital, Hellerup, Denmark

[3] University of Copenhagen, Copenhagen, Denmark

[4] Unit of Mycology, Bacteria, Parasites and Fungi, Statens Serum Institute, Copenhagen, Denmark

Introduction

Majocchi's granuloma is a rare fungal granulomatous folliculitis, mostly caused by *Trichophyton (T.)* species (spp.). The first-line treatment for *Trichophyton* spp. is terbinafine. It targets squalene epoxidase (SQLE), thereby inhibiting a critical step in the synthesis of ergosterol, an essential component of the fungal cell membrane. In the past 20 years an epidemic of terbinafine resistant dermatophytosis have emerged globally with several SQLE mutations described. However, do SQLE mutations always confer terbinafine resistance?

We present a terbinafine susceptible case of Majocchi's granuloma caused by *T. mentagrophytes* genotype III* harboring 2 SQLE polymorphisms.

Case Presentation

A well-managed HIV-positive man in his 30s presented with an indistinctly demarcated red, scaly rash in the right side of the groin. The rash began after a spa retreat 2 months earlier. The patient initially self-medicated with an over-the-counter miconazole cream. As the rash persisted, the patient consulted his general practitioner (GP), who initially prescribed hydrocortisone cream, and then betamethasone cream and ketoconazole shampoo. The rash progressed into abscess-like elements and bacterial infection was suspected. Oral dicloxacillin was initiated and the patient was referred to our clinic.

At the visit, the rash had progressed to painful pustules, nodules and abscesses. The bacterial swab was negative and dicloxacillin had no effect. The antibiotics were switched to amoxicillin (500 mg)/clavulanic acid (125 mg) 3 times daily for 10 days and a new swab for bacteria, and direct microscopy, culture and dermatophyte polymerase chain reaction (PCR) was performed. In the following 2 weeks, the rash extended to the thighs and abdomen, presenting as four large inflammatory plaques. No bacteria were cultured. However, direct microscopy revealed spores and hyphae and the PCR test detected *T. interdigitale*. Antifungal susceptibility testing (AFST) and *sqle* mutation analysis was requested. Oral terbinafine (250 mg) daily combined with terbinafine cream once daily for 6 weeks and ketoconazole shampoo twice weekly were initiated. Potassium permanganate baths for three days were also prescribed because of severe suppuration. A skin biopsy of the lesion was also performed due to suspected pyoderma gangraenosum.

The histology (Periodic Acid-Schiff) revealed perifollicular inflammation and hair follicle destruction with fungal spores, compatible with Majocchi's granuloma. Sequencing identified 2 SQLE alterations (L419F/K276N). The isolate was confirmed as *T. mentagrophytes* by internal transcriber sequencing (ITS) and classified as genotype III*.

Terbinafine minimal inhibitory concentration (MIC) was 0.03 mg/L, interpreted as susceptible. The infection cured mycologically after 6 weeks of oral terbinafine, but hyperpigmentation and red scar-like papules remained even 16 months after treatment.

Conclusion

Both K276N and L419F SQLE mutations have previously been detected. However, terbinafine MICs have varied; some studies categorized the mutations as terbinafine resistant and other as susceptible. Data on the clinical response is lacking.

We performed a Pubmed review on terbinafine MIC of SQLE mutations in *Trichophyton* spp. and found that most (n = 27/44, 61.4%) are associated with high terbinafine MIC (Table 1). However, 7 (15.9%) mutations were identified with low MIC, while 10 (22.7%) mutations including K276N/L419F were identified with varying MIC, highlighting the fact that a SQLE mutation does not always result in terbinafine resistance. This may reflect natural polymorphisms in the *sqle* gene in various subspecies, species differences in susceptibility, or alterations that do not affect terbinafine binding. AFST in these cases are recommended as MIC determination differentiates between susceptible isolates harboring neutral polymorphisms and those with clinically relevant resistance, thereby preventing both unnecessary treatment changes and ineffective terbinafine therapy.

Resistant	Variable association	Susceptible	No MIC reported
S392	I121M/V237I	L335F/A448T	Y414C/L438C
L393F	K276N**	S395P	F397L/F415S
L393F/Y394del	K276N/L419F**	Q417H/D460G	
L393F/F397L	F415V	V444I/A448T	
L393S	L419F	I479V	
L393S/A448T	H440Y	N429D	
L393S/F397L	S436A	D460G	
L393S/V444L	L437P		
F397L	S443P		
F397L/Y394N	A448T**		
F397L/A448T			
F397L/Y414H			
F397L/F311L			
F397L/K276N			
F397L/Q417H/D460G			
F397I			
F397I/F415S			
F397I/G418R			
F397V			
S395P/A448T			
Q408L			
Q408L/A448T			
Q408K			
F415I			
F415S			
F415C			
H440Y/F484Y			

Table 1: Overview of reported squalene epoxidase mutations in Trichophyton species by mycological terbinafine susceptibility based on the tentative epidemiological cut off values*. MIC = Minimum inhibitory concentration. *Tentative epidemiological cut off values of EUCAST: file:///Users/juliashen/Downloads/AFST_BP-ECOFF_v6.0_non-protected_Final_26_Jun_2025_MaCA.pdf. **Probably irrelevant to MIC elevation

EA DV CONGRESS
VIENNA
30 SEP - 3 OCT 2026

Abstract N°: 2067

Dermoscopy of extra-genital lichen sclerosus: A series of 7 cases

Kmar Turki*[1], Cheikh Elkadhi[1], Maissa Abid[1], ikram gassara[1, 1], Rim Chaabouni[1], Hamida Turki[1]

[1] Dermatology department, Hedi Chaker university hospital, Sfax, TUNISIA, Sfax, Tunisia

Introduction
Extragenital lichen sclerosus (EGLS) is an uncommon inflammatory dermatosis. However, its clinical differentiation from vitiligo and morphea can be challenging, often requiring histological confirmation. Dermoscopy is a non-invasive tool that may provide valuable diagnostic support.

Materials and Methods
We conducted a monocentric retrospective study, including all histologically confirmed cases of EGLS diagnosed between 2011 and 2025. Only patients with available dermoscopic images were included.

Results
Twenty-eight patients with EGLS were collected (20 women, 8 men), with a mean age of 45.7 years (range: 4–83 years) and a mean disease duration before diagnosis of 2 years. Seven patients underwent dermoscopic examination.

EGLS presented in all cases as shiny macules, with an erythematous border in 4 cases, late atrophy in 2 cases, and comedones overlying the lesions in 5 cases. The clinical presentation consisted of plaques in 5 cases, guttate lesions in 1 case, and a combination of both in 1 case. The mean disease duration was 20 months (range: 3 months–5 years).

Dermoscopy revealed structureless white areas (6 cases), follicular plugs (4 cases), appearing as comedo-like openings in 1 case, rainbow pattern (3 cases), rosettes (2 cases), chrysalis structures (1 case), linear scales (1 case), peripheral erythema (2 cases), and perifollicular erythema (1 case). The vascular pattern included dotted vessels (3 cases), linear vessels (1 case), and telangiectatic vessels arranged in a reticular network (1 case).

Analytical assessment suggested a trend towards different distribution of dermoscopic signs according to disease duration (greater or less than 6 months): linear vessels were noted only in early lesions, follicular plugs and rainbow pattern were observed in both early and late stages, whereas rosettes, perifollicular erythema, dotted vessels, and telangiectasias were exclusively seen in long-standing lesions. However, statistical comparisons using Fisher’s exact test did not demonstrate significant differences between groups ($p > 0.05$ for all signs), due to the limited sample size.

Conclusions
EGLS accounts for only 2.5–6% of all cases of lichen sclerosus and occurs predominantly in postmenopausal women. Clinically, it presents as white, polygonal, atrophic papules that tend to merge into plaques, often scattered with follicular plugs. Dermoscopic features of EGLS are rarely reported in the literature. The most

frequent are structureless white areas (66–100% of cases), keratotic follicular plugs (33–80%), chrysalis structures (26–84%), as well as peppering and rainbow pattern. In a comparative dermoscopic study of EGLS and morphea, structureless white areas were observed only in EGLS.

In our series, certain we suggest that dermoscopic features may vary according to disease duration: early lesions may present with linear vessels reflecting active inflammation, whereas late lesions tend to display more sclerotic structures such as rosettes, and vascular patterns consisting of dotted or telangiectatic vessels, likely explained by atrophy. These findings, however, should be interpreted with caution given the small sample size.

EADV CONGRESS
VIENNA
30 SEP - 3 OCT 2026

Abstract N°: 2078

Juvenile-Type Paracoccidioidomycosis in an Immunocompetent Adult: A Severe Fatal Case Report

Marcus Studart Frota*[1], Beatriz Trope[1]

[1] HUCFF-UFRJ, Rio de Janeiro, Brazil

Introduction

Paracoccidioidomycosis (PCM) is an endemic systemic mycosis in Latin America caused by dimorphic fungi of the genus *Paracoccidioides*. The acute/subacute juvenile form is uncommon, accounting for approximately 3–5% of PCM cases, and is usually associated with children, adolescents, or immunocompromised individuals. It is characterized by rapid progression, lymphatic dissemination, hepatosplenomegaly, and extensive cutaneous involvement. We report an atypical severe juvenile-type PCM in an immunocompetent adult with fatal outcome.

Case Presentation

A 35-year-old previously healthy male rural worker presented with progressive weight loss and abdominal pain. Computed tomography demonstrated extensive mesenteric and peripancreatic lymphadenopathy, initially raising suspicion for lymphoproliferative disease. Four months later, he developed intermittent fever and disseminated ulcerative papulopustular and ulcerovegetative skin lesions involving the face, scalp, trunk, and limbs. On admission, he presented with jaundice secondary to extrinsic lymph node compression, splenomegaly, peripheral edema, normocytic normochromic anemia, leukocytosis with eosinophilia, hypoalbuminemia, hyponatremia, hyperbilirubinemia, and elevated inflammatory markers. Direct mycological examination, swab, and skin biopsy revealed multibudding birefringent yeast forms compatible with *Paracoccidioides brasiliensis*. Treatment with amphotericin B was initiated, resulting in partial improvement of skin lesions. However, the patient progressed with anasarca, infected thrombophlebitis caused by *Staphylococcus aureus*, subsegmental pulmonary embolism, respiratory failure requiring intensive care admission and mechanical ventilation, followed by bronchoaspiration, septic shock, multiple organ dysfunction, and death.

Conclusion

Juvenile-type PCM is an aggressive form of the disease characterized by lymphatic and hematogenous dissemination. Although predominantly described in younger or immunocompromised patients, this case highlights that immunocompetent adults with occupational exposure in endemic rural areas may also develop severe disseminated disease. The initial presentation mimicking lymphoma contributed to delayed diagnosis. Direct mycological examination and histopathology remain essential diagnostic tools, particularly in endemic settings. Early recognition and prompt antifungal therapy are crucial, as severe PCM is associated with high morbidity and mortality despite adequate treatment.

EA DV CONGRESS
VIENNA
30 SEP - 3 OCT 2026

Abstract N°: 2085

Primary cutaneous actinomycosis of the trunk mimicking squamous cell carcinoma: a diagnostic challenge

Emy Kusumaningsih*[1], Pamela Thaib[1], Erika Santoso[1]

[1] Bhayangkara Kediri Hospital, Kediri, Indonesia, Kediri, Indonesia

Introduction

Actinomycosis is a chronic granulomatous infection caused by Actinomyces species, normal commensals of the oral cavity, gastrointestinal tract, and female genital tract. Primary cutaneous involvement without identifiable predisposing factors is exceptionally rare. The condition's slow progression and infiltrative appearance may clinically mimic malignant neoplasms, frequently resulting in diagnostic delay. Cervicofacial involvement accounts for approximately 55% of cases, while primary cutaneous actinomycosis confined to the skin without an identifiable deeper focus is unusual. We present a case of primary truncal actinomycosis mimicking squamous cell carcinoma in an immunocompetent host without risk factors.

Case Presentation

A 42-year-old immunocompetent woman presented with a five-year history of progressively enlarging lesions on the posterior trunk. The condition began as a small, painless subcutaneous nodule without preceding trauma. Over time, additional nodules developed and coalesced into an indurated plaque with recurrent suppuration, sinus tract formation, and scarring. She had no history of dental infection, thoracic or abdominal symptoms, prior surgery in the affected area, or immunosuppression. At initial evaluation, the lesion measured approximately 8 × 7 cm with focal ulceration. Fine-needle aspiration biopsy revealed atypical squamous epithelial cells with suppurative inflammation, interpreted as suggestive of well-differentiated squamous cell carcinoma. Chest radiography was normal. Incisional biopsy demonstrated extensive non-caseating necrosis with dense inflammatory infiltrates. Multiple basophilic bacterial aggregates surrounded by radiating eosinophilic clubs – sulfur granules – were identified, confirming actinomycosis. Periodic acid-Schiff staining highlighted magenta-staining filamentous branching colonies. Microbiological cultures isolated Streptococcus pyogenes, interpreted as secondary colonization. The lesion had progressed to 23 × 22 cm with woody induration, multiple sinus tracts, and scarring. Following diagnosis, the patient underwent wide surgical excision extending to muscular fascia. Postoperatively, she completed six weeks of oral amoxicillin. At three-month follow-up, no recurrence was observed.

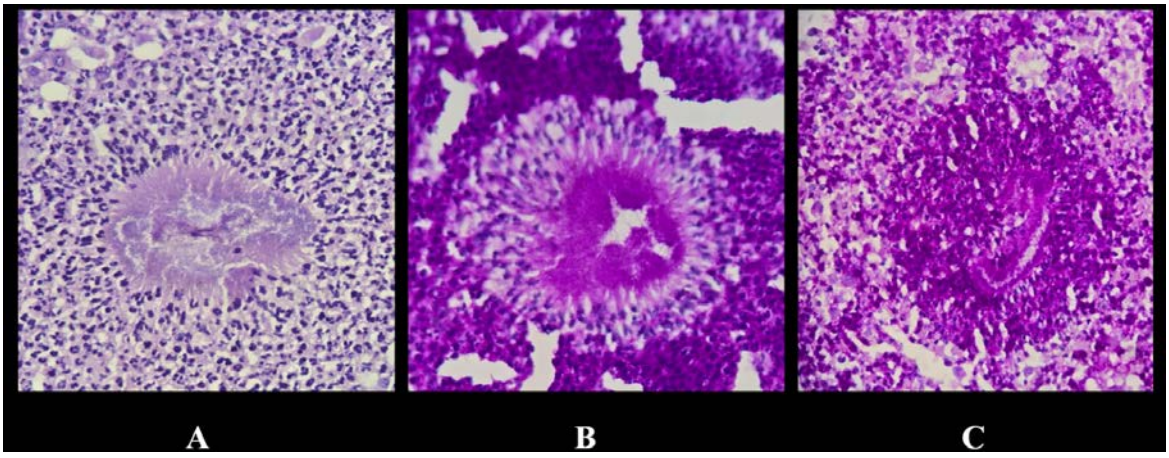

Histopathological findings confirming actinomycosis. (A) Low-power magnification (hematoxylin and eosin, ×100) showing a sulfur granule. (B) High-power magnification (H&E, ×400) demonstrating the

characteristic basophilic bacterial colony with peripheral radiating eosinophilic clubs (Splendore-Hoeppli phenomenon). (C) Periodic acid-Schiff stain (×400) highlighting magenta-staining filamentous branching bacterial colonies, confirming the diagnosis of Actinomyces infection.

Conclusion

Primary cutaneous actinomycosis should be considered in the differential diagnosis of chronic infiltrative lesions with sinus tract formation, even in immunocompetent individuals without apparent risk factors. This case demonstrates unusual truncal involvement clinically and cytologically mimicking squamous cell carcinoma. Histopathologic identification of sulfur granules remains the diagnostic gold standard, particularly when cultures are negative. Early histopathologic evaluation is essential to prevent misdiagnosis and guide appropriate management. Combined surgical and medical therapy is effective for extensive disease.

EA DV CONGRESS
VIENNA
30 SEP - 3 OCT 2026

Abstract N°: 2088

Oral Isotretinoin as a Potent Adjuvant to Azole Antifungals in Recalcitrant Dermatophytosis: A Case Series of 7 Patients

Mehmet Yeral*[1], Ceyda Tetik Aydoğdu[1], suzan demir pektas[1], Emine Tugba Alatas[1], Yunus özcan[1], Ekin Altinbas[1]

[1] Department of Dermatology and Venereology, Mugla Sıtkı Koçman University Faculty of Medicine, Training and Research Hospital, Muğla, Türkiye

Introduction

The global emergence of recalcitrant dermatophytosis, particularly driven by the spread of Trichophyton indotineae and other resistant strains, has created a significant therapeutic gap. Conventional systemic antifungal monotherapies, including terbinafine and high-dose azoles, frequently fail to achieve mycological clearance in these chronic cases. The recalcitrant nature of these infections is often attributed to biofilm formation, deep follicular involvement, and altered host immune responses. Oral isotretinoin (OIT), primarily known for its role in acne therapy, possesses unique properties that influence follicular keratinization, reduce sebum production, and modulate innate immunity. We hypothesized that low-dose OIT could act as a "treatment accelerator" by altering the skin microenvironment and enhancing the penetration or efficacy of systemic azoles in otherwise unresponsive patients.

Case Presentation

This study retrospectively evaluated 7 patients (4 females, 3 males; mean age 41 years) with biopsy-confirmed or KOH-positive chronic dermatophytosis that had persisted for a mean of 8.4 months (range: 3–16 months). Inclusion criteria required a demonstrated failure to respond to at least 12 weeks of continuous systemic azole therapy (fluconazole 200 mg/day or itraconazole 200 mg/day). In our clinical observation, all patients were started on an adjuvant regimen of ultra-low-dose oral isotretinoin (20 mg, twice weekly) added to their ongoing fluconazole (200 mg/day) treatment. Patients weighing less than 60 kg received a modified dose of 10 mg once weekly to ensure safety. Baseline laboratory tests (liver function and lipid profile) were performed, and patients were monitored every two weeks for clinical progress and potential adverse effects.The addition of low-dose OIT led to rapid clinical and mycological improvements across the entire cohort. Initial clinical response (defined as >50% reduction in inflammatory plaques and pruritus) was achieved at a mean of 3.1 weeks. Complete clinical regression was observed at a mean of 4.6 weeks (range: 2–6 weeks). Mycological clearance, confirmed by negative KOH microscopy, was reached at a mean of 3.7 weeks. Notably, even the most chronic case (16 months duration) achieved clearance within 6 weeks of starting the combined therapy. Regarding safety, the regimen was remarkably well-tolerated. Observed side effects were limited to mild cheilitis/xerosis (n=2), a transient, clinically insignificant elevation in serum triglycerides (n=1), and a minor flare of pre-existing eczema (n=1). No patient required dose reduction or discontinuation of the therapy due to adverse events

TABLE 1 **Demographic and clinical characteristics of seven patients with recalcitrant dermatophytosis treated with low-dose oral isotretinoin added to azole therapy.**

Case	Sex / Age	Comorbidities	Duration	Localization	Previously failed antifungal therapy	Pre-Tx KOH	KOH (−) (weeks)	Clinical regression (weeks)	Side effects
1	F / 41	Urticaria	5 mo	Hip, groin, chest	Itraconazole 200 mg/day — 3 months Fluconazole 200 mg/day — 2 months	Positive	3	2	Mild xerosis
2	F / 15	*None*	6 mo	Distal arm	Itraconazole 200 mg/day — 3 months Fluconazole 200 mg/day — 3 months	Positive	6	4	*None*
3	M / 58	DM, HT, CAD	6 mo	Hip	Itraconazole 200 mg/day — 3 months Fluconazole 200 mg/day — 3 months	Positive	2	3	Mild ↑ TG / LFT
4	M / 26	Hashimoto thyroiditis	16 mo	Abdomen, back	Itraconazole 200 mg/day — 4 months Fluconazole 200 mg/day — 6 months	Positive	N/A	2	Eczema flare
5	F / 51	*None*	16 mo	Thigh, arm	Itraconazole 200 mg/day — 6 months Fluconazole 200 mg/day — 4 months	Positive	6	3	*None*
6	M / 52	Solitary kidney	7 mo	Genital region	Itraconazole 200 mg/day — 4 months Fluconazole 200 mg/day — 3 months	Positive	3	3	*None*
7	F / 44	Hyperthyroidism	3 mo	Hip, thigh	Fluconazole 200 mg/day — 3 months	Positive	N/A	4	*None*

Abbreviations: CAD, coronary artery disease; DM, diabetes mellitus; F, female; HT, hypertension; KOH, potassium hydroxide microscopy; LFT, liver function tests; M, male; mo, months; N/A, not available; TG, triglycerides; Tx, treatment.

Table 1. Demographic and clinical characteristics of seven patients with recalcitrant dermatophytosis treated with adjunctive low-dose oral isotretinoin

Conclusion

Our observations suggest that ultra-low-dose oral isotretinoin serves as a potent and safe adjuvant to azole antifungals in the management of recalcitrant dermatophytosis. By potentially modifying the epidermal barrier and host-parasite interface, OIT significantly shortens the time to clinical recovery and mycological cure in patients failing conventional systemic treatments. While this case series provides promising evidence of OIT's role as a treatment accelerator, randomized controlled trials are warranted to define the optimal dosing and long-term durability of this synergistic approach in the era of escalating antifungal resistance

EADV CONGRESS
VIENNA
30 SEP - 3 OCT 2026

Abstract N°: 2092

Prevalence of leukonychia and plantar hyperkeratosis in TB patients

Darya Nalobina[1], Ksenia Stavriyani[1], Anastasiia Kolerova[1], Nataliya Stavitskaya[2], Irina Sergeeva*[1]

[1] Novosibirsk State University, Novosibirsk, Russian Federation

[2] Tuberculosis Research Institute, Novosibirsk, Russian Federation

Introduction

Tuberculosis remains one of the most significant infectious diseases worldwide. However, data on skin comorbidities associated with pulmonary tuberculosis are currently limited. This study aimed to characterize the spectrum of this conditions and their prevalence among patients with pulmonary tuberculosis.

Materials and Methods

We concluded retrospective descriptive study, enrolling 101 patients who developed cutaneous comorbidities due tuberculosis. Data collected included age, gender, type and history of TB, history of associated conditions, laboratory test results. Statistical analyses included descriptive statistics, Mann-Whitney test, chi-square, Fisher test, correlation assessment, multivariate logistic regression analyse.

Results

The cohort included 102 patients with pulmonary tuberculosis, leukonychia was detected in 47 patients (46,1%) and plantar hyperkeratosis in 90 patients (88,2%).The analysis of combination identified three main clusters: a combination of hyperkeratosis of the soles and leukonychia- 40 (39,2%), isolated plantar hyperkeratosis-50 patients 9 (49%), isolated leukonychia -7 patients (6,9%). Patients with hyperkeratosis and leukonychia had mean of age of 47±12,3 years (compared with 44,7±10,1 years in those without hyperkeratosis), a higher prevalence of hypertension (25,5% vs. 16,4%). Multivariate logistic regression analyses showed a trend toward an independent association of leukonychia with hypertension (OR 2,12; 95% 0,95-4,73; p=0,067). Combination of hyperkeratosis and leukonychia are statistically significantly associated with higher prevalence of hypertension in patients (OR 2,31; 95% CI 1.12-4.78; p-0,023), the MDT regimen of antituberculosis therapy (OR 1,89; 95% CI 1,03-3,47; p=0,04) and age (OR 1,04 per year; 95% CI 1.01-1,07; p=0,018). Isolated leukonychia was significantly associated with obesity (OR 3,85; 95% CI 1,05-14,1;p=0,042). Isolated hyperkeratosis of the feet was less common in patients with obesity (OR 0,22;p=0,041).

Conclusions

Leukonychia of the nail plates and plantar hyperkeratosis are common manifestation in patients with pulmonary tuberculosis. Hyperkeratosis is detected in nearly 9 out of 10 patients (88,2%) and leukonychia in a one out of every two (46,1%). Th e combination of them is observed in 39,2% patients and independently associated with hypertension, MDR-TB regimens and older age. Isolated leukonychia is significantly associated with obesity, indicating a contribution of metabolic disorders. Isolated plantar hyperkeratosis is predominant is virtually independent of metabolic factors. The data obtained indicate that changes in the skin of the feet and nails reflect systemic disorders in tuberculosis- chronic inflammation, trophic disorders, nutritional deficiency and the toxic effects of antituberculosis drugs. Hyperkeratosis is predominantly nonspecific in nature, while leukonychia may serve as marker of concomitant vascular and metabolic pathology.

Including a regular skin examination will allow for the timely detection of comorbidity conditions, correction of nutritional status and improved compliance with long-term therapy.

EADV CONGRESS
VIENNA
30 SEP - 3 OCT 2026

Abstract N°: 2132

Lymphocutaneous Sporotrichosis of the Scalp: A Diagnostic Challenge in an Immunocompetent Patient.

Raphael Pereira[1], João Barreto[1], Luiza Sena[1], Ana Clara Boareto Costa[1], Maria Eduarda Cesar Garcez*[1], Julia Cascardo Géo de Siqueira[1], Amanda Quintaes[1], Yasmin Mohamed[1], Rafaela Lopes[1], Karine Domingues Tavares[1], Mariana Diniz[1], Ana Carolina Salomão[1], David Souza[1], Regina C Schechtman[1], Alexandre Gripp[1]

[1] UERJ Hospital Universitário Pedro Ernesto, Rio de Janeiro, Brazil

Introduction

Brazil currently represents the largest urban zoonotic outbreak of sporotrichosis worldwide. This subcutaneous mycosis is caused by dimorphic fungi of the *Sporothrix* complex, with *Sporothrix brasiliensis* being the predominant species, known for its increased virulence and dissemination potential. Transmission occurs primarily through traumatic inoculation of fungal elements from contaminated organic material or via zoonotic transmission, especially through scratches or bites from infected cats.

Case Presentation

A 65-year-old immunocompetent woman, presented with a pruritic nodular lesion on the left temporal scalp. The lesion evolved over four months, with progressive extension to the frontoparietal region and the development of multiple ulcerated lesions, some covered with thick yellow-green crusts.

During the initial course, the patient was evaluated by several professionals and received multiple empirical treatments, including antibiotics, antifungals, antivirals, and systemic corticosteroids, without clinical improvement. Initially, she denied any history of local trauma or relevant epidemiological exposure.

Due to disease progression, hospitalization was required for further diagnostic investigation. Computed tomography of the skull and facial bones revealed no evidence of deep tissue involvement. Direct mycological examination was negative; however, after seven days, fungal culture yielded *Sporothrix* spp., establishing the diagnosis. Molecular identification by RT-PCR confirmed *Sporothrix brasiliensis*, a species associated with more severe clinical presentations.

Given the extent and severity of the lesions, treatment with lipid complex amphotericin B (3 mg/kg/day) was initiated for 15 days, resulting in marked clinical improvement and reduction of the inflammatory process. During hospitalization, the patient revised her initial history and reported prior contact with a cat in the affected scalp region before the onset of lesions.

Following clinical stabilization, she was discharged for outpatient follow-up on oral itraconazole (200 mg/day). The patient showed favorable evolution, with gradual healing.

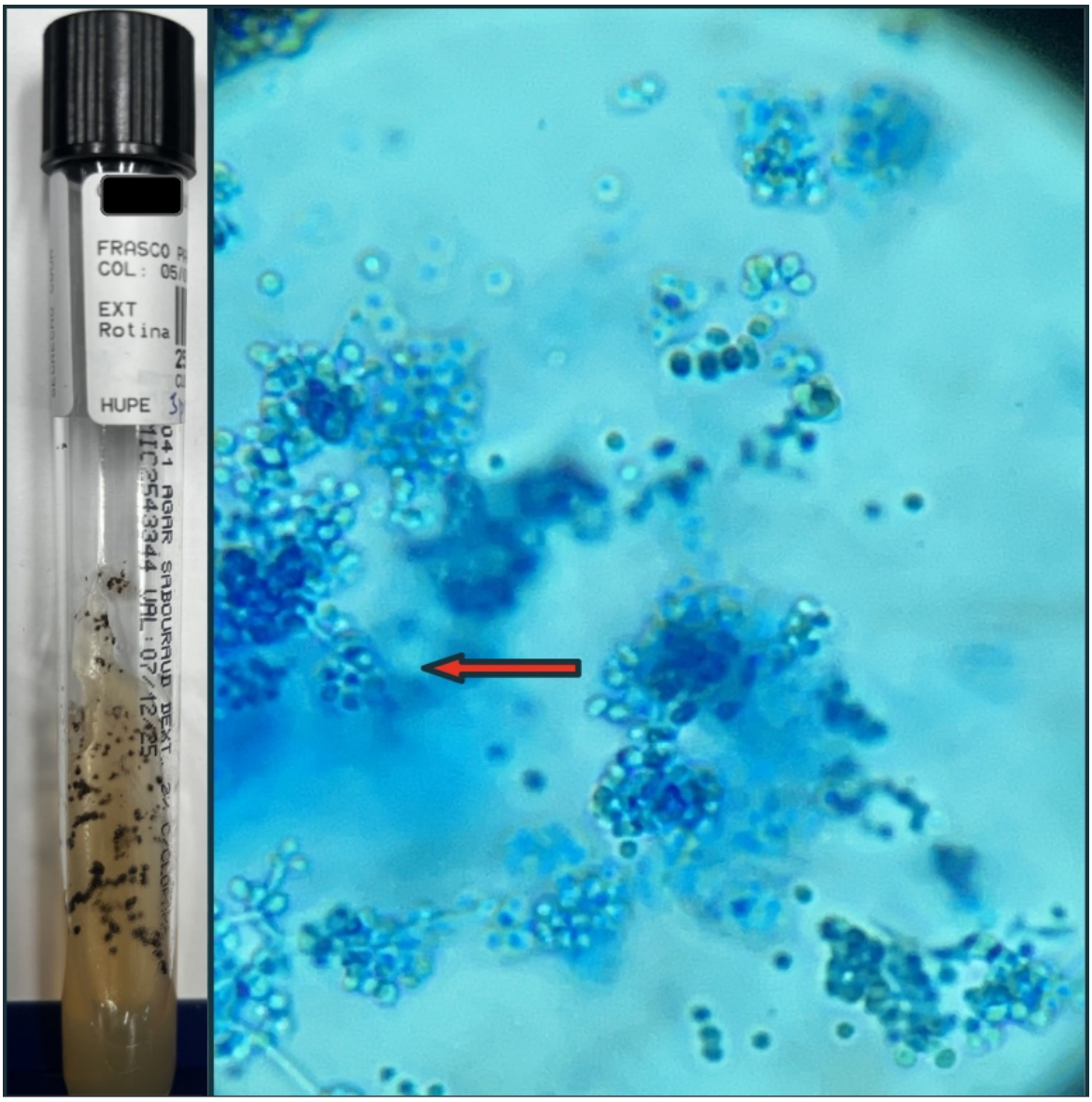

Conclusion

In this case, the combination of an atypical anatomical location and the initial absence of a suggestive epidemiological history resulted in multiple ineffective empirical treatments. This highlights the importance of early inclusion of subcutaneous mycoses in the differential diagnosis of chronic granulomatous dermatoses, especially in hyperendemic regions.

An important aspect was the reassessment of the patient's history during hospitalization, when she reported prior contact with a cat. This finding underscores a common limitation in clinical practice, in which relevant epidemiological exposures may initially be omitted or underestimated. Given the central role of zoonotic transmission in Brazil—particularly associated with *Sporothrix brasiliensis*—active and systematic investigation of animal contact should always be pursued.

Histopathological examination revealed a granulomatous inflammatory pattern, a nonspecific finding in sporotrichosis. A negative direct mycological examination does not exclude the diagnosis, reinforcing the importance of fungal culture as the diagnostic gold standard. Furthermore, molecular methods such as RT-PCR allow precise species identification, contributing to a better understanding of disease behavior and virulence.

The therapeutic approach lipid complex amphotericin B followed by itraconazole was appropriate considering the severity and extent of the disease, resulting in a favorable clinical outcome.

This case illustrates an atypical presentation of lymphocutaneous sporotrichosis involving the scalp in an immunocompetent patient, emphasizing the diagnostic pitfalls associated with unusual topographies. It reinforces the importance of a thorough and dynamic epidemiological history, appropriate interpretation of complementary examinations, and a systematic diagnostic approach in hyperendemic areas.

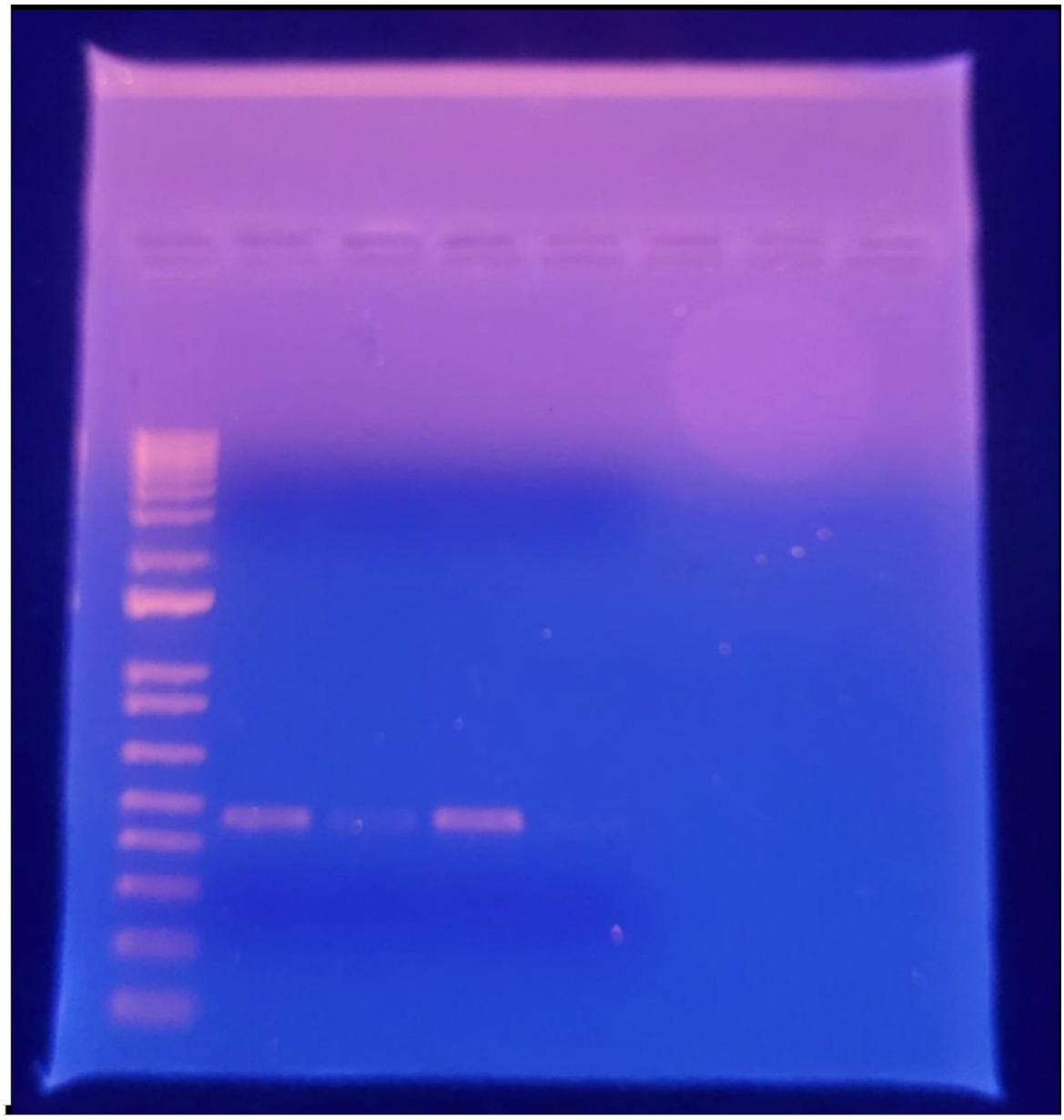

RT-PCR positive for Sporothrix brasiliensis.

EA DV CONGRESS
VIENNA
30 SEP - 3 OCT 2026

Abstract N°: 2184

Unravelling Single-Lesion Hansen's Disease: A Holistic 10-Year Retrospective Tripartite Study

Swathi Nagabushan*[1], Michelle Fernandes[1], Ramesh Bhat[1]

[1] Father Muller Medical College, Mangaluru, India

Introduction

Leprosy, caused by *Mycobacterium leprae*, remains a latent global health concern and continues to pose significant diagnostic and public health challenges, particularly in endemic regions where delayed recognition sustains transmission and disability, with a high potential for global spread. Single-lesion Hansen's disease (HD), usually classified under paucibacillary disease, often presents subtly and mimics several benign dermatoses. Such subtle presentations can delay diagnosis, prolong transmission risk, and increase the likelihood of preventable neuropathy and disability. Recognising these early forms is especially critical in endemic settings. Although seemingly limited cutaneous disease, these patients may already harbour neural involvement with risk of permanent disability. We evaluated the clinical, histopathological, and therapeutic profile of single-lesion HD over a decade at a tertiary care centre.

Materials and Methods

A retrospective observational study was conducted over 10 years at a tertiary care hospital. Medical records of 44 patients diagnosed with Hansen's disease presenting with a solitary skin lesion were reviewed. Demographic details, lesion morphology, anatomical site, sensory changes, nerve involvement, histopathology, treatment outcomes, and adverse effects were analysed.

Results

The cohort was predominantly adult (84%), with four childhood cases, and showed a subtle male predominance. Hypopigmented macules were the commonest presentation (56.8%), followed by erythematous plaques (38.6%). Lesions most frequently involved exposed areas, especially the upper limbs (52%) and the face (27%). Among erythematous plaques, granuloma annulare was the leading clinical differential diagnosis (44.4%), followed by lupus vulgaris, emphasizing the protean presentation of solitary HD. Mean symptom duration before diagnosis was 15 months, indicating a persistent diagnostic delay. Hypoaesthesia was present in 88.6% of patients and emerged as the most valuable clinical clue. Nerve involvement was identified in 25% of cases, including three borderline tuberculoid patients with multiple nerve involvement despite having only one visible lesion. All slit-skin smears were negative. Histopathology most commonly demonstrated borderline tuberculoid HD (45.45%), followed by tuberculoid HD (34%), while seven patients had indeterminate HD. Paucibacillary multidrug therapy was the preferred treatment regimen, with 63.63% completing therapy. Loss to follow-up occurred in 13.6% of patients. Adverse drug reactions were documented, most commonly dapsone-induced haemolysis (60% of reactions), along with one case of Type 1 lepra reaction.

Conclusions

In an era of re-emerging leprosy and persistent transmission in several parts of the world, early recognition of subtle presentations such as single-lesion Hansen’s disease has renewed global relevance. This study highlights that seemingly innocuous solitary lesions may represent active disease, often accompanied by sensory impairment and early neural involvement despite negative slit-skin smears. By defining the common clinical patterns, diagnostic pitfalls, and histopathological spectrum of single-lesion HD, our findings provide practical evidence to aid earlier detection and timely treatment. Strengthening awareness of these minimal forms can help reduce diagnostic delay, interrupt transmission chains, prevent irreversible disability, and support ongoing global leprosy elimination efforts. Recognising one lesion in time may protect many lives thereafter.

EADV CONGRESS
VIENNA
30 SEP - 3 OCT 2026

Abstract N°: 2217

Orf and Tuberculosis Verrucosa Cutis: A Rare Cutaneous Coinfection

Tolga Büyükkaya*[1], Mervenur Kanat[2], Banu Yaman[3], İdil Ünal[4]

[1] Department of Dermatology and Venereology, Ege University Faculty of Medicine, Izmir, Türkiye, Department of Medical Pathology, Ege University Faculty of Medicine, Izmir, Türkiye, Department of Medical Microbiology, Ege University Faculty of Medicine, Izmir, Türkiye, Izmir, Türkiye

[2] Department of Medical Microbiology, Ege University Faculty of Medicine, Izmir, Türkiye, Izmir, Türkiye

[3] Department of Medical Pathology, Ege University Faculty of Medicine, Izmir, Türkiye, Izmir, Türkiye

[4] Department of Dermatology and Venereology, Ege University Faculty of Medicine, Izmir, Türkiye, Izmir, Türkiye

Introduction

Orf is a viral zoonotic infection caused by Parapoxvirus and is usually transmitted to humans through contact with infected sheep and goats. Tuberculosis verrucosa cutis (TVC) is a rare form of cutaneous tuberculosis that develops following the inoculation of *Mycobacterium tuberculosis* into the skin after trauma in previously sensitized individuals. Both diseases are more commonly observed in individuals with close contact with animals, and their simultaneous occurrence in the same patient is extremely rare.

Case Presentation

A 20-year-old male butcher presented with ulcerative lesions on the second fingers of both hands and a chronic verrucous plaque over the third metacarpophalangeal (MCP) joint on the dorsum of the left hand. Clinically, a preliminary diagnosis of Orf was considered for the acute lesions. Histopathological examination of a biopsy taken from the chronic lesion over the left MCP joint revealed non-caseating granulomatous inflammation; the diagnosis of TVC was confirmed by detection of the *Mycobacterium tuberculosis* complex on mycobacterial PCR. The IGRA test was also positive. Supportive treatment was recommended for the Orf lesions, while a two-month quadruple and four-month dual antituberculous treatment regimen was initiated for TVC. Marked improvement was observed in both lesions during follow-up.

Conclusion

This case highlights the importance of considering infectious etiologies in the differential diagnosis of chronic verrucous or ulcerative skin lesions in individuals with close contact with animals, and emphasizes that early biopsy and microbiological confirmation are critical for accurate diagnosis.

EA DV CONGRESS
VIENNA
30 SEP - 3 OCT 2026

Abstract N°: 2232

Necrotic Cutaneous EnvenomationThe Determinant Role of Local Wound Care in Scar Outcome: A Case Report

Halima Abdelouhab*[1]

[1] University hospital center of ORAN, Oran, Algeria

Introduction
Cutaneous envenomation secondary to insect or arachnid bites may lead to severe inflammatory lesions that can progress to skin necrosis. Management relies on a multidisciplinary approach in which early local wound care plays a crucial role in limiting the extension of tissue necrosis, promoting wound healing, and potentially avoiding surgical necrosectomy.

Case Presentation

Case Report
We report the case of a 73-year-old hypertensive man presenting with a necrotic lesion on the dorsum of the hand, evolving over two days following a suspected insect bite, most likely caused by a spider.
The clinical course was characterized by a painful inflammatory plaque, the development of a central necrotic area, and progressive skin ulceration.
Management was primarily based on:
Daily local wound care: cleansing with normal saline, debridement of necrotic tissue, and calcium alginate dressings.
Adjunctive treatment: analgesics and antibiotic therapy for secondary cutaneous Staphylococcus aureus infection.
Results
Clinical outcome was favorable, with:
Regression of inflammation
Progressive reduction of necrotic tissue
Development of healthy granulation tissue
Gradual wound healing.
Discussion
Cutaneous envenomation may cause necrotic lesions through several pathophysiological mechanisms, including:
Direct cytotoxic effects of venom
Vasoconstriction and microvascular thrombosis.
Intense local inflammatory response
These mechanisms may ultimately lead to tissue ischemia and skin necrosis.
In this context, early local wound care plays a major role by enabling:
Debridement of necrotic tissue
Reduction of bacterial burden
Stimulation of granulation tissue formation
Optimization of the healing process
Several studies emphasize that early local management reduces complications and the need for surgical intervention.

Conclusion

Local wound care is a key component in the management of necrotic cutaneous envenomation. Early intervention helps limit the extension of necrosis and optimize wound healing.

EA DV CONGRESS
VIENNA
30 SEP - 3 OCT 2026

Abstract N°: 2242

Cutaneous Aspergillosis Due to Aspergillus flavus in a Neutropenic Child with Relapsed B-ALL

Fatih Boynueğrioğlu*[1], Nilay Duman[1], Süleyman Emre Karaüzüm[2]

[1] Department of Dermatology and Venereology, Faculty of Medicine, Ege University, Izmir, Türkiye
[2] Department of Pediatrics, Faculty of Medicine, Ege University, Izmir, Türkiye

Introduction

Aspergillus species are ubiquitous environmental molds responsible for life-threatening opportunistic infections in immunocompromised hosts. Among the recognized manifestations, cutaneous aspergillosis is rare, occurring in approximately 1% of invasive aspergillosis cases. It presents as either primary cutaneous aspergillosis (PCA), resulting from direct inoculation via intravenous catheter sites, burns, or trauma, or secondary cutaneous aspergillosis (SCA), arising from hematogenous dissemination originating from a pulmonary focus. Children with hematologic malignancies undergoing intensive cytotoxic chemotherapy are at elevated risk due to prolonged severe neutropenia. Hospital construction and renovation activities further increase environmental conidial burden, amplifying infection risk. Diagnosis is guided by the 2020 EORTC/MSG consensus criteria (proven, probable, possible), incorporating host risk factors, clinical and radiological findings, and mycological evidence.

Case Presentation

A 5-year-old male with pre-B ALL, initially diagnosed at age three and treated with the ALLIC-BFM 2009 protocol, was admitted with neutropenic fever during the maintenance phase of therapy. Investigations confirmed relapsed ALL, and salvage chemotherapy was initiated with fludarabine, cytarabine, idarubicin, and inotuzumab. Despite escalating broad-spectrum antibacterial coverage with piperacillin-tazobactam and meropenem, fever persisted, prompting the addition of empiric liposomal amphotericin B. Shortly thereafter, necrotizing skin lesions developed on the left hand and right arm; lesions on the right arm followed the trajectory of a prior intravenous access site, raising suspicion for primary cutaneous inoculation. Dermatology was consulted for further evaluation. Risk stratification identified several host factors: relapsed hematologic malignancy, prolonged severe neutropenia (>10 days, ANC <500/mm^3), intensive reinduction chemotherapy, and active hospital renovation works. Mycological cultures from two sequential wound specimens both yielded *Aspergillus flavus* growth. Serum galactomannan, initially negative, turned positive within one week of symptom onset and remained elevated across seven consecutive measurements over the following five weeks. Blood cultures showed no clinically significant growth during this period. HRCT of the thorax revealed nodular infiltrations with surrounding ground-glass opacities in the right upper lobe, suggestive of a halo sign consistent with angioinvasive fungal infection. Applying the 2020 EORTC/MSG criteria, the patient fulfilled all three diagnostic pillars: host risk factors, clinical/radiological findings, and mycological evidence, yielding a classification of probable invasive aspergillosis. Voriconazole was introduced as targeted therapy; caspofungin was added one week later. Dermal invasion of lesions was observed during the second week. As the patient demonstrated clinical improvement, caspofungin and amphotericin B were discontinued, and voriconazole monotherapy was continued for a planned three-month course. Progressive lesion healing was documented at follow-up.

Conclusion

This case highlights the critical importance of early recognition of cutaneous lesions as a potential manifestation

of invasive aspergillosis in neutropenic pediatric oncology patients. Structured diagnostic evaluation using EORTC/MSG 2020 criteria facilitated timely classification and prompt escalation of antifungal therapy. Voriconazole-based treatment achieved a favorable clinical response with progressive resolution of cutaneous and pulmonary findings. A high index of suspicion for invasive fungal infection should be maintained in severely immunocompromised children with persistent fever and atypical skin lesions, particularly in settings with elevated environmental fungal exposure.

EA DV CONGRESS
VIENNA
30 SEP - 3 OCT 2026

Abstract N°: 2247

A Case of Primary Oral Localised Histoplasmosis in an Immunocompetent Host

Niharika Singh*[1], Sonika Garg[2], Deepika Yadav[2], Zoya Hasan[3], Shramana Mandal[3], Ravi Meher[4]

[1] Maulana Azad Medical College, Delhi, India
[2] Department of Dermatology, Maulana Azad Medical College & Associated Hospitals, Delhi, India
[3] Department of Pathology, Maulana Azad Medical College, Delhi, India
[4] Department of Otorhinolaryngology, Maulana Azad Medical College & Associated Hospitals, Delhi, India

Introduction

Histoplasmosis is a soil fungal infection endemic in Latin America, India, Africa, East Asia, Australia, and the Northeast and Central United States. Conventionally associated with immunocompromised individuals; emerging studies have shown prevalence among immunocompetent hosts. Mucocutaneous manifestations appear in only 20% of cases; however, in Asia, immunocompetent hosts show higher mucocutaneous involvement. Primary oral histoplasmosis is even rarer, with few cases in literature.

Case Presentation

We present a case of a 57-year-old man with a progressively enlarging swelling on his posterior tongue for 5 months. He denied systemic symptoms, travel history or agricultural occupational history.He had no known comorbidities or evidence of immunodeficiency. Examination revealed a 4cm x 2.5cm erythematous firm non-tender nodular plaque on the dorsum of the posterior tongue. No regional lymphadenopathy or systemic abormalities were noted. Differentials included chronic hyperplastic candidiasis, oral tuberculosis, syphiliticgumma and histoplasmosis. KOH mount was negative for fungal elements. Serology for syphilis, HIV, Hepatitis B and C and anti-nuclear antibodies were negative. Mantoux test and chest x-ray were normal. Routine blood tests including serum calcium, liver and renal functions tests were within normal limits. Biopsyfrom the lesion showed histiocytes and occasional plasma cells in the dermis along with fungal elements morphologically characteristic of Histoplasma capsulatum; confirmed on PAS and GMS stain. Bacterial, mycobacterial and fungal cultures showed no growth. Contrast enhanced CT of chest, abdomen and pelvis revealed no abnormality.Diagnosis of localised oral histoplasmosis was made. Itraconazole 200 mg twice daily was initiatedwith improvement seen over 4 weeks.

Conclusion

This case illustrates an unusual presentation of primary histoplasmosis without dissemination in immunocompetent hosts.Histoplasmosis has both pulmonary and extrapulmonary presentations. About 20% of presentations are mucocutaneous with ulcers, nodules or plaques. Literature suggests that while pulmonary manifestations are more common in American population, Asian immunocompetent patients show a higher mucocutaneous involvement, commonly on the tongue, palate and gingiva. Many lesions are asymptomatic like this case, leading to delay in seeking medical attention. A 2023 European study found higher mortality among immunocompetent patients than immunocompromised hosts, likely due to delayed diagnosis and treatment initiation. Another reported patient with cutaneous histoplasmosis was misdiagnosed for 16 years as autoimmune disease and eventually succumbed to the illness. Oral histoplasmosis is underrecognized due to low awareness of the disease and frequent misdiagnosis as tuberculosis or leishmaniasis with limited cases reported from Asian subcontinent. Oral tuberculosis typically presents as chronic indurated ulcer with rolled borders and a yellow-grey membrane. Syphilis presents as painless oral ulcers or indurated plaques while oral candidiasis presents as chronic

non-scrapable white plaques**.** Leishmaniasis presents as chronic painful ulcerated or nodular lesions involving the palate, tongue, or lips. Importantly, fungal culture are often negative because Histoplasma is slow growing and may take more than 8-12 weeks to show significant growth.Delayed diagnosis and treatment may lead to dissemination involving the liver, spleen, bone marrow,lungs, skin and adrenal gland presenting with hepatosplenomegaly, respiratory failure, adrenal enlargement or rarely insufficiency. Adrenal involvement has been reported in 30–40% of cases. Delayed diagnosis increases the risk of life-threatening .This highlights the importance of biopsy in such oral mucosal lesions and considering histoplasmosis as a differential even in the absence of systemic symptoms, aiding prompt diagnosis, preventing complications and avoiding mortality.

EADV CONGRESS
VIENNA
30 SEP - 3 OCT 2026

Abstract N°: 2262

When infection complicates autoimmunity: Kaposi–Juliusberg eruption on superficial pemphigus

NOUSSAIBA CHEMLAL[1], BOUMEDIENE DAHMANI[1], KAMILA BOUCHENAK KHALADI*[1]

[1] Department of Dermatology, CHU Tlemcen, Aboubakr Belkaid, Faculty of Medicine, Tlemcen, Dermatology Association of the Wilaya of Tlemcen (ADWIT), TLEMCEN, Algeria

Introduction
Pemphigus foliaceus is an autoimmune bullous disease caused by IgG antibodies against desmoglein-1, leading to superficial acantholysis and scaly, crusted erosions mainly on the trunk, face, and scalp.

Kaposi–Juliusberg eruption is a disseminated herpes simplex virus infection occurring on compromised skin, often in inflammatory dermatoses, presenting with monomorphic vesicular lesions and systemic symptoms.

Association of pemphigus foliaceus with Kaposi–Juliusberg eruption is rare, and concomitant herpetic keratitis is exceptionally uncommon but potentially severe. We report a rare case combining these three conditions.

Case Presentation
We report a 50-year-old man diagnosed with pemphigus foliaceus confirmed clinically and histologically. He was treated with dapsone and topical corticosteroids.

One month later, he developed an acute febrile eruption with widespread erosions and clustered umbilicated vesicles, rapidly extending from the periorbital region to the trunk and limbs. Ophthalmologic examination revealed bilateral dendritic corneal ulcers consistent with herpetic keratitis, suggesting Kaposi–Juliusberg eruption complicating pemphigus foliaceus.

Intravenous acyclovir was initiated, leading to rapid improvement of both cutaneous and ocular lesions. The diagnosis of pemphigus foliaceus complicated by Kaposi varicelliform eruption was confirmed based on clinical evolution and therapeutic response.

DISCUSSION

Kaposi–Juliusberg eruption is a disseminated viral infection caused by herpes simplex virus, preferentially occurring on compromised skin. It is classically described in atopic dermatitis but remains rarer in autoimmune bullous dermatoses such as superficial pemphigus.

This complication is favored by a dual impairment: a compromised skin barrier due to acantholysis and immunosuppression induced by the disease and/or its treatments (corticosteroids, immunosuppressants).

Herpetic superinfection mimicking erosive dermatoses such as pemphigus has already been reported. Thus, the overlap of cutaneous manifestations of pemphigus foliaceus (PF) and Kaposi–Juliusberg eruption in certain areas may make their distinction difficult.

In our patient, the worsening of periorbital lesions was initially interpreted as an exacerbation of pemphigus foliaceus. However, ophthalmological findings, particularly the presence of herpetic keratitis, redirected the

diagnosis toward Kaposi–Juliusberg eruption.

We believe that, in this patient, herpes simplex virus initially infected the pemphigus lesions on the face, before secondarily spreading to both eyes. It should be noted that bilateral herpetic keratitis is rare, with only a few cases reported.

From a therapeutic perspective, the literature emphasizes the importance of early antiviral treatment with acyclovir, which significantly reduces morbidity and mortality. The favorable outcome observed in our patient, with rapid regression of cutaneous lesions and improvement of keratitis, is consistent with published data, where response to treatment is generally rapid when management is initiated early.

Finally, several authors highlight the risk of diagnostic delay due to possible confusion with a flare of pemphigus or bacterial superinfection. Therefore, the appearance of monomorphic, painful vesicular lesions associated with fever should systematically raise suspicion of herpetic superinfection.

Conclusion

This case illustrates that Kaposi–Juliusberg eruption is an extremely rare but potentially serious complication of pemphigus and highlights the importance of early diagnosis and prompt antiviral treatment, particularly in the presence of severity signs such as ocular involvement.

Kaposi–Juliusberg eruption should be systematically considered in any sudden worsening of pemphigus, especially in the presence of fever and atypical vesicular lesions.

EADV CONGRESS
VIENNA
30 SEP - 3 OCT 2026

Abstract N°: 2274

High-Frequency Ultrasonography in Sporotrichosis: Novel Insights from a Case Series

Barbara Brunca*[1], Sofia Mitidieri[1], Giulia Goedert[1], Paula Tavares Colpas[1]

[1] Hospital PUC Campinas, Campinas, Brazil

Introduction

Sporotrichosis is a subcutaneous mycosis caused by fungi of the *Sporothrix* complex, acquired through traumatic inoculation, often associated with contact with plant material or zoonotic transmission by cats.[1,4] It is an endemic disease in Brazil, with an increasing number of cases related to urban transmission.[2,3]

The lymphocutaneous form is the most common, characterized by an initial lesion at the site of inoculation, followed by the appearance of nodules along the lymphatic pathway in an ascending pattern.[1] It mainly affects individuals exposed to occupational risk factors or in contact with infected felines and may present more severe forms in immunosuppressed patients.[1]

Although diagnosis is based on clinical-epidemiological correlation and laboratory confirmation, dermatologic ultrasonography has emerged as a complementary tool in the evaluation of lesions and lymphatic involvement.[1]

In this context, we report a series of five cases with the aim of describing the ultrasonographic findings in cutaneous-lymphatic sporotrichosis.
High-frequency dermatologic ultrasound (HFUS) may assist in characterizing and assessing the extent of cutaneous sporotrichosis, serving as a complementary tool to clinical diagnosis, as well as contributing to patient treatment follow-up.

Materials and Methods

The table below describes the clinical and ultrasonographic findings of five patients with sporotrichosis (Table 1).

Case	Sex/Age	Epidemiological History	Clinical Findings	Ultrasonographic Findings
1	F/46	Contact with infected cat	Nodules along lymphatic pathway	Heterogeneous dermal/subcutaneous nodules, ↑ Doppler signal, dilated lymphatics, necrosis
2	F/61	Cat scratch	Nodules along lymphatic pathway	Heterogeneous dermal lesions, ↑ Doppler signal, no necrosis
3	F/80	Cat bite	Digital lesion + sporotrichoid pattern	Hypoechoic nodules, ↑ Doppler signal, necrosis, evident lymphatic pathway
4	M/60	Indirect contact with cat	Plaque + ascending nodules	Dermal/subcutaneous lesions, ↑ Doppler signal, necrosis, dilated lymphatics
5	M/59	Plant-related trauma	Nodules along lymphatic pathway	Heterogeneous lesions, ↑ Doppler signal, necrosis, linear pattern

Table 1: Clinical cases

Results

Cutaneous-lymphatic sporotrichosis presents a characteristic clinical pattern; however, it may pose diagnostic challenges, especially in early or atypical presentations. High-frequency dermatologic ultrasound has emerged as a relevant complementary tool, allowing noninvasive evaluation of lesion extent and inflammatory activity.

In this series, the main ultrasonographic findings included hypoechoic and/or heterogeneous nodular lesions, predominantly dermal, often extending into the subcutaneous tissue, suggesting panniculitis. Increased vascularization on Doppler was observed in all cases, reflecting inflammatory activity, as well as anechoic areas compatible with necrosis or microabscesses in some patients. Identification of the affected lymphatic pathway, through the linear distribution of lesions and dilation of lymphatic vessels, was a consistent finding of great diagnostic value.

The absence of significant lymphadenomegaly reinforces the classic pattern of the cutaneous-lymphatic form. It is also noteworthy that ultrasound allowed differentiation between lesions with and without necrosis, which may have implications for severity assessment.

During therapeutic follow-up, a reduction in Doppler vascularization was observed after one month of treatment with itraconazole, suggesting that the method may also be useful as an early marker of therapeutic response. These findings support the role of ultrasound not only in morphological characterization but also in disease monitoring.

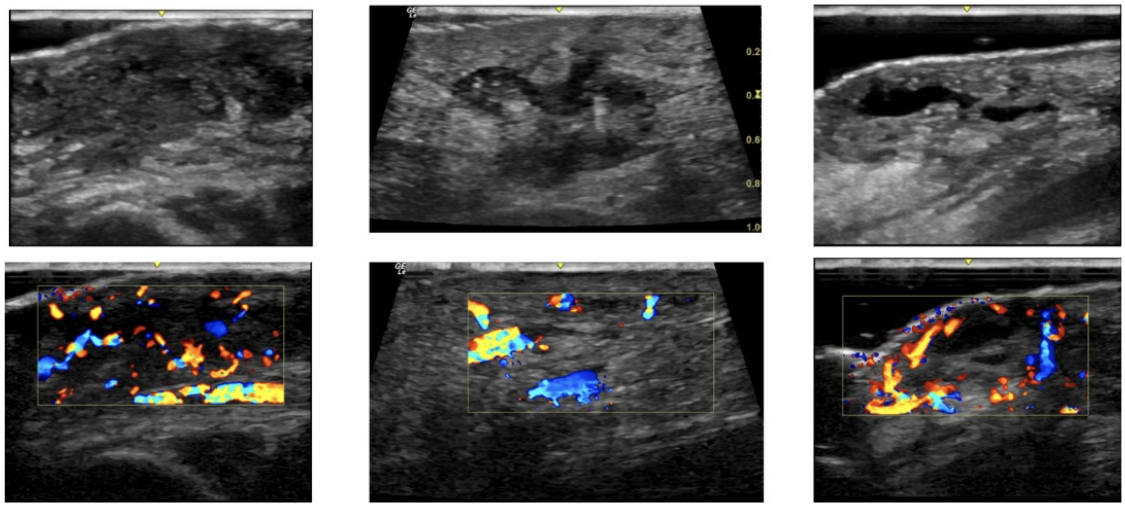

Figure 1: Pre treatment - 22MHz - Heterogeneous nodular lesions, predominantly dermal, with extension into the subcutaneous tissue (suggestive of panniculitis), increased vascularization on Doppler, dilation of lymphatic vessels, and anechoic areas compatible with necrosis, distributed along the lymphatic pathway.

Conclusions

High-frequency dermatologic ultrasound with Doppler proved to be a useful tool in the evaluation of cutaneous-lymphatic sporotrichosis, allowing characterization of lesions, identification of lymphatic involvement, and assessment of inflammatory activity. Despite the limited number of cases, it showed promise in therapeutic follow-up, particularly through the reduction of Doppler vascularization. Its use may contribute to greater diagnostic accuracy and improved clinical management of patients.

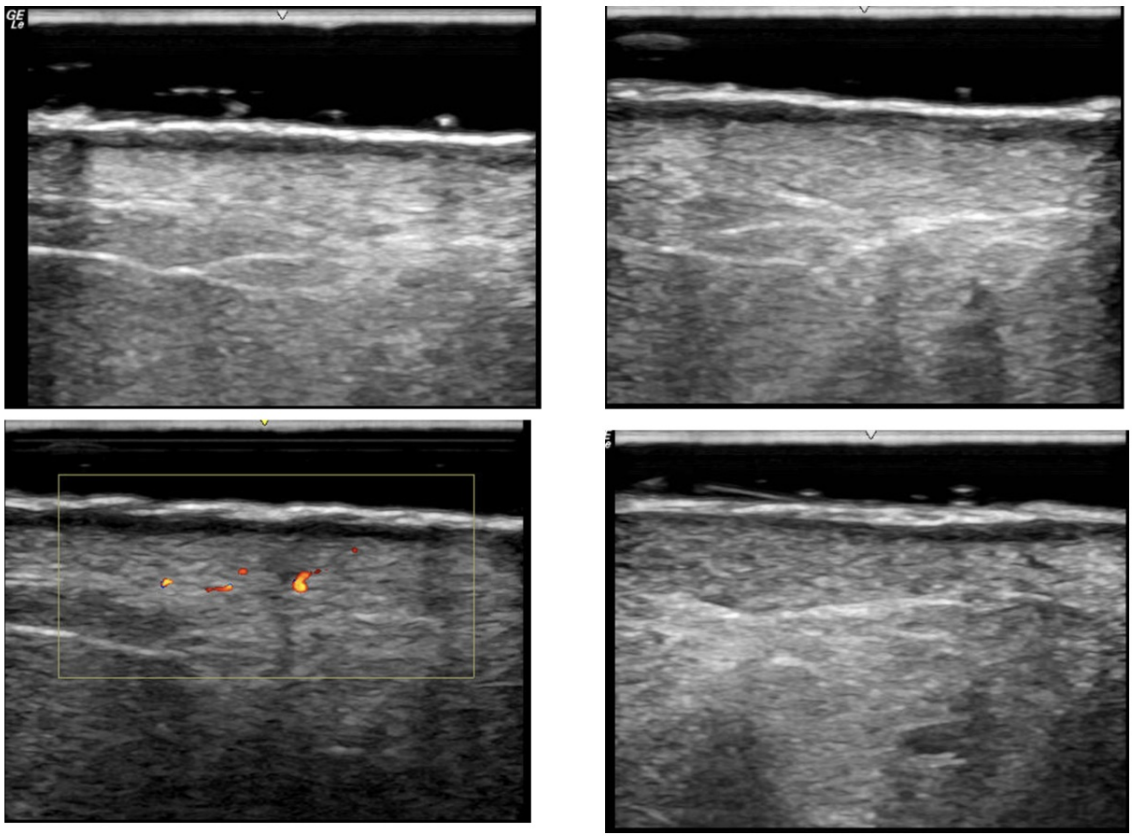

Figure 2: After 1month of treatment - 22MHz - Improvement of the lesions, with reduced infiltration, absence of increased vascularization on Doppler, and decreased dilation of lymphatic vessels.

References: Orofino-Costa R, Freitas DFS, Bernardes-Engemann AR, Rodrigues AM, Talhari C, Ferraz CE, et al. Human sporotrichosis: recommendations from the Brazilian Society of Dermatology for the

clinical, diagnostic and therapeutic management. An Bras Dermatol. 2022;97(6):757–777. de Lima Barros MB, Schubach AO, do Valle ACF, Gutierrez-Galhardo MC, Conceição-Silva F, Schubach TMP. Distribuição epidemiológica e geográfica da esporotricose no Brasil. An Bras Dermatol. 2022. Sanchotene KO, Madrid IM, Klafke GB, Bergamashi M, Della Terra PP, Rodrigues AM, de Camargo ZP, Xavier MO. Sporothrix brasiliensis outbreaks and the rapid emergence of feline sporotrichosis. Mycoses. 2015 Nov;58(11):652-8. doi: 10.1111/myc.12414. Epub 2015 Sep 25. PMID: 26404561. Veasey JV, Carvalho GSM, Ruiz LRB, Neves Neto MF, Zaitz C. Distribuição epidemiológica e geográfica da esporotricose urbana na cidade de São Paulo. An Bras Dermatol. 2022;97(2):228-230. doi:10.1016/j.abdp.2022.01.002.

EADV Congress 2026, VIENNA
30 SEPTEMBER - 03 OCTOBER 2026
POWERED BY M-ANAGE.COM

EADV CONGRESS
VIENNA
30 SEP - 3 OCT 2026

Abstract N°: 2297

Erythema Induratum of Bazin: A Retrospective Study of 11 Cases

Yosr Daoud*[1], Anissa Zaouak[1], Chaima Zammel[1], Ehsen Ben Brahim[1], Talel Badri[1], Houda Hammami[1]

[1] Habib Thameur Hospital, Tunis, Tunisia

Introduction

Erythema induratum of Bazin (EIB) is a rare nodular cutaneous vasculitis, characterized by type IV delayed hypersensitivity reaction to an infectious agent, most commonly Mycobacterium tuberculosis.
The aim of our study was to describe the epidemiological and clinico-pathological characteristics of EIB.

Case Presentation

Eleven patients were included: ten women and one man. The mean age was 42 years (range: 17–67 years). Three patients had a history of tuberculosis, including one with pulmonary involvement and two with lymph node tuberculosis. The mean disease duration was 51 months. Seven patients presented with erythematous-violaceous indurated subcutaneous nodules, while four patients presented with bilateral erythematous indurated plaques. Ulceration was observed in four cases. Lesions were multiple in eight cases and solitary in three cases. Hyperpigmentation was noted in two cases. Skin biopsy revealed epithelioid and multinucleated giant cell granulomas in all cases, caseous necrosis in three cases, lobular panniculitis in five cases, and septal panniculitis in four cases. Microbiological documentation was obtained in six cases: interferon-gamma release assay (Quantiferon) was positive in four cases, and the tuberculin skin test was positive in six cases. PCR for Mycobacterium tuberculosis performed on skin biopsy specimens (four cases) was negative in all cases. Extracutaneous tuberculosis involvement was observed in five cases: pulmonary in one case, lymph node involvement in three cases, and both in one case. All patients received anti-tuberculous therapy, with favorable outcomes in all cases.

Conclusion

Cutaneous involvement occurs in 1–2% of tuberculosis cases, with EIB representing one of its manifestations. It is characterized by indurated subcutaneous nodules, with ulceration being uncommon. The main differential diagnosis is erythema nodosum. A key concern is its association with active tuberculosis. Bacteriological confirmation is not always achieved despite multiple investigations. PCR for Mycobacterium tuberculosis on skin biopsy is positive in only about 77% of cases in large series. The prognosis is generally favorable under anti-tuberculous treatment. Alternative therapies such as dapsone and colchicine may also be considered.

EA DV CONGRESS
VIENNA
30 SEP - 3 OCT 2026

Abstract N°: 2304

Lucio's Phenomenon and Erythema Nodosum Leprosum : An unusual overlap revealing a non nodular form of lepromatous leprosy

Hiba Essolaymany*[1], Sara Elloudi[1]

[1] CHU HASSAN II, FES, Morocco

Introduction

Two serious life-threatening reactive conditions can occur in patients with multibacillary leprosy: Lucio's phenomenon (LP) and Erythema Nodosum Leprosum (ENL). We report a case of a female patient with a diffuse non-nodular form of lepromatous leprosy presenting with simultaneous LP and ENL.

Case Presentation

58 years old female patient, presented with complaints of joint pain, subcutaneous nodules and necrotic lesions on chest, back, and limbs that were painless. The patient had never been treated for Hansen's disease in the past. She had history of recurrent epistaxis, tingling of hands and feet, and deformity of distal joints for which she was mistakenly diagnosed with rheumatoid arthritis and put on chronic high doses of corticosteroids and Methotrexate. The patient had normal vital signs. Clinical examination revealed diffuse non nodular infiltration of the skin with smooth rosy skin, leonine face, saddle nose deformity, alopecia of eyelashes and eyebrows, partial destruction of ears, in addition to multiple tender ulcerative subcutaneous nodules with a purulent discharge and diffuse extensive necrotic ulcers of varying size in upper and lower limbs. Hemogram revieled hemoglobin level of 6.8g/dL, neutrophilic leukocytosis (15000G/l). Liver, renal function tests were normal. Smears taken from the skin lesions and earlobes revealed a bacillary index at +6. Skin biopsies were taken from a subcutaneous nodule of the back that revealed dermal edema, diffuse infiltration of foamy histiocytes admixed with neutrophils and nuclear debris, with perineural inflammation and focal panniculitis, in addition to evidence of leukocytoclastic vasculitis with presence of plump endothelial cells and nuclear debris in the vessel wall. There were numerous acid fast bacilli that were present within endothelial cells confirming the diagnosis of ENL. An other biopsy was taken from a necrotic ulcer of the limb and revieled numerous acid-fast bacilli in macrophages and necrotizing vasculitis of superficial dermal vessels with thrombosis confirming the diagnosis of LP. Based on these findings, the patient was diagnosed with multibacillary leprosy with an overlap of LP and ENL reactions. The patient was started on antileprosy treatment (multibacillary regimen) and was kept on oral prednisolone with progressive tapering. She responded favorably to treatment and is currently under follow-up.

Conclusion

ENL is a type III hypersensitivity reaction that is usually seen after initiating treatment, which leads to bacterial destruction and release of large quantities of antigen, resulting in formation of antigen–antibody complexes. These immune complex deposition in the skin and other organs, causes fever, malaise, arthralgia, peripheral nerve thickening, and other systemic symptoms and visceral involvement. Besides the sudden appearance of red tender erythematous edematous subcutanous nodules, unusual presentations of ENL have also been reported as vesiculobullous, pustular, ulcero-necrotic, hemorrhagic, erythema multiforme, and Sweet syndrome like. Histopathological features of ENL are increased vascularity with dilated capillaries in the upper and lower dermis, intense infiltration with neutrophils that surround and invade the walls of blood vessels. Bacilli are few and are

mostly fragmented.
LP, seen in untreated cases, is a rare reaction pattern in Lucio leprosy, a diffuse shiny non nodular form of the disease. In contrast to ENL, fever, constitutional symptoms, visceral involvement, leukocytosis are absent. It manifestsas as purpuric areas progressing to necrotic ulcers. The denomination of LP should be employed only under clinico-pathological correlation. Histopathologically, vascular changes are critical. We find endothelial cell proliferation, thrombosis, and ischemic necrosis with mild mononuclear cell infiltrate. This vascular damage is due to direct invasion and heavy colonization of bacilli in the vessel's walls leading to vascular occlusion and hemorrhagic infarcts.

EA DV CONGRESS
VIENNA
30 SEP - 3 OCT 2026

Abstract N°: 2313

Two diseases association that can create a therapeutic dilemma

Sarah Akram Kamal Hussein Orabi*[1]

[1] Cairo University, Dermatology Department, Cairo, Egypt

Introduction
Tuberculosis and Sarcoidosis are both chronic granulomatous diseases that present with clinical, radiological and histological similarities.

Case Presentation
a 25 years old female presented with 2 painless hand lumps of 1 year duration. She also complained of dyspnea and multiple neck swellings. Examination showed 2 non tender circumscribed nodules son the dorsum of both hands and multiple discrete bilateral firm cervical lymph nodes. Histopathology showed discrete sarcoidal granulomas formed mainly of histiocytes and giant cells ith minimal lymphocytic infiltrate and without caseation. Serum calcium and angiotensin converting enzyme level were normal. CT chest showe multiple enlarged mediastinal and hilar lymph nodes and multiple pulmonary nodules. Excisional lymph node biopsy showed Tuberculous Lymphadenitis hich was confirmed with positive Quantiferon test. The patient started antituberculosis regimen for 6 months. After completion of tuberculous treatment, dyspnea improved and neck lmph nodes resolved completely, but the hand lesions worsened. Another biosy as taken from hand's nodule and shoed discrete granulomas with no caseation and Tuberculosis culture on skin biopsy was negative. The final diagnosis was skin sarcoidosis and chest tuberculosis. Her treatment was upgraded to manage the sarcoidosis, to include Methotrexate 7.5 mg/week, folic acid, and systemic daily steroids (prednisolone) 20 mg daily. Complete resolution of hand nodules was acheived in one month.

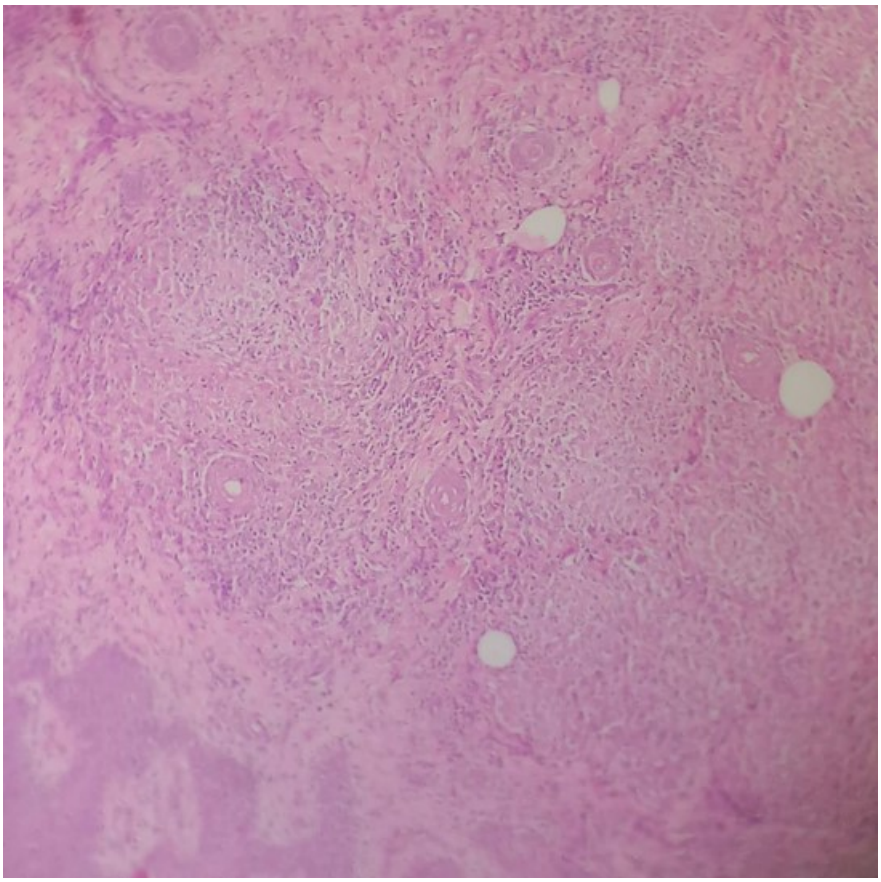

Histopathology of hand nodule showing discrete granuloma with no caseation

Conclusion

- If you suspect SARCOIDOSIS, exclude infectious causes especially TB in endemic areas
- Treatment of sarcoidosis can cause serious worsening of TB due to immune suppression.
- Confirmed cases of **TB** that shows **no** improvement or worsening on ttt, sarcoidosis should be considered.
- In such cases starting **prednisolone** 0.5-1 mg/kg/day under cover of antituberculosis drugs.
-

EA DV CONGRESS
VIENNA
30 SEP - 3 OCT 2026

Abstract N°: 2326

Hyperkeratotic Scabies Presenting as Erythroderma Mimicking Autoimmune Bullous Disease

Dorra Medhaffar*[1], Gara Soumaya[1], Litaiem Noureddine[1], Jones Meriam[1], Zeglaoui Faten[1]

[1] Charles Nicolle Hospital, Tunis, Tunisia

Introduction

Scabies is a common cosmopolitan ectoparasitic infestation caused by *Sarcoptes scabiei*. In its classical form, patients usually present with nocturnal pruritus associated with excoriated papules and characteristic burrows in typical locations. However, atypical presentations may mimic other inflammatory dermatoses. We report a case of hyperkeratotic scabies in an elderly woman presenting as a pruritic erythroderma initially misdiagnosed as an autoimmune bullous disease.

Case Presentation

A 66-year-old woman had been followed for one year for a chronic pruritic inflammatory dermatosis. Bullous pemphigoid was initially suspected because skin biopsy showed a dermal infiltrate rich in eosinophils, while direct immunofluorescence revealed linear deposits of IgG and C3 along the dermoepidermal junction. The patient was treated with very potent topical corticosteroids, antihistamines, and methotrexate. Subsequently, she reported persistent pruritus with worsening and extension of the skin lesions. Physical examination revealed multiple excoriated erythematous papulo-nodules, some centered by keratotic plugs, involving the trunk and proximal limbs, associated with honey-colored crusts and purulent vesiculo-pustules. A perforating dermatosis complicated by bacterial superinfection was initially suspected, and systemic antibiotic therapy was prescribed. A second skin biopsy showed no evidence of transepithelial elimination, ruling out perforating dermatosis. Topical corticosteroids were maintained.

One month later, the patient was re-admitted with erythroderma involving the trunk, limbs, and cervicofacial area, associated with severe refractory pruritus and a history of nocturnal familial itching. Examination revealed extensive hyperkeratotic and crusted plaques, predominantly affecting the axillary, intergluteal, and inframammary folds. Dermoscopy demonstrated the “delta-wing jet” sign and multiple interdigital burrows, leading to the diagnosis of hyperkeratotic scabies. The outcome was favorable following antiscabietic treatment.

Conclusion

Scabies incognito, often worsened by corticosteroid therapy, represents a misleading clinical entity. It may present with macules, papules, nodules, or even bullous lesions, and should be considered in any chronic pruritic dermatosis unresponsive to conventional treatment. This case is noteworthy because of the significant diagnostic delay related to its atypical polymorphic and nodular presentation, which initially led to confusion with perforating dermatosis and autoimmune bullous disease. Eosinophilic infiltrates and positive direct immunofluorescence findings have previously been reported in scabies. In our patient, prolonged and inappropriate use of topical corticosteroids and methotrexate likely contributed to the profuse hyperkeratotic and erythrodermic presentation. Dermoscopy played a crucial role by identifying burrows and the characteristic delta-wing sign, allowing rapid confirmation of the diagnosis. In cases of chronic diffuse pruritus, scabies should always be considered. Hyperkeratotic forms mainly occur in elderly or immunosuppressed patients and reflect prolonged progression of undiagnosed common scabies. Dermoscopy remains a simple, rapid, and non-invasive diagnostic tool that can strongly support the diagnosis.

EADV CONGRESS
VIENNA
30 SEP - 3 OCT 2026

Abstract N°: 2337

Primary Cutaneous Cryptococcus laurentii Infection in an Immunocompetent Host: An Emerging Diagnostic Challenge

Laisa Goulart Saviatto Picasky*[1], Vitória Radichewski[1], Gabriela Pedroso Mrozinski[1], Gabriella Funchal[1, 2], Bárbara Hartung Lovato[1], Carla Lorena de Azevedo Maia[3]

[1] Santa Tereza Sanitary Dermatology Hospital, São Pedro de Alcântara, Brazil

[2] Ufsc, Florianópolis, Brazil

[3] Public Health Central Laboratory of the state of Santa Catarina (LACEN), Florianópolis, Brazil

Introduction

Cryptococcus laurentii is an encapsulated non-neoformans yeast historically regarded as nonpathogenic to humans. Increasing reports, however, have implicated this organism in opportunistic infections involving the bloodstream, lungs, central nervous system, peritoneum, and skin, mostly in immunocompromised hosts. [1,5] Most cases occur in patients with malignancies, corticosteroid exposure, dialysis, indwelling catheters, transplantation, or advanced immunosuppression. [4,5] Cutaneous involvement is rare and usually associated with disseminated disease. Among immunocompetent individuals, primary cutaneous cryptococcosis caused by C. laurentii remains exceedingly uncommon, with only isolated cases reported. [1] Clinical manifestations are heterogeneous and may mimic inflammatory, granulomatous, or fungal dermatoses, posing a diagnostic challenge. We report a rare case of cutaneous cryptococcosis caused by C.laurentii in an immunocompetent agricultural worker presenting with disseminated papulopustular lesions and negative histochemical fungal stains, highlighting the diagnostic complexity of this emerging pathogen.

Case Presentation

A 47-year-old immunocompetent female agricultural worker presented with a one-year history of papules involving the cervical region, face, and limbs, progressing to painful pustular and ulcerated lesions exacerbated by sun exposure. Previous treatments with systemic antibiotics, topical agents, antifungals, and prednisone had produced no improvement. Dermatological examination revealed disseminated erythematous-to-violaceous papules, some ulcerated, with trunk sparing. An intact tense bulla with serous content was observed on the ulnar side of the left hand. Facial examination revealed an infiltrated erythematous-violaceous plaque with ill-defined borders and telangiectasias (Figure 1A - D). Laboratory workup demonstrated leukocytosis with neutrophilia; serologies for sexually transmitted infections were negative. Histopathology revealed chronic granulomatous dermatitis and panniculitis with epithelioid macrophages, multinucleated giant cells, focal caseous necrosis, and perineural involvement. Ziehl–Neelsen, PAS, Grocott, and Giemsa stains were all negative. Fungal culture from skin tissue isolated *Cryptococcus laurentii* (Figure 1E and F). The histopathological findings mimicked atypical granulomatous infections (Figure 1 G - I), underscoring the importance of fungal culture even in the setting of negative special stains. Most reported cases of cutaneous *C. laurentii* infection have occurred in immunocompromised patients with disseminated disease or fungemia.[4,5] Park et al. described disseminated papulobullous lesions in a patient with acute myeloid leukemia.[3] In contrast, infections in immunocompetent hosts are exceedingly rare and typically localized.[1,2] Rural occupational exposure may represent a source of environmental inoculation, consistent with previous reports of primary cutaneous cryptococcosis.[2]



Figure 1 - Erythematous-to-violaceous papules involving the face, upper limbs, showing a tense bulla on the ulnar side of the left hand (A); Infiltrated erythematous-violaceous plaque with ill-defined borders on the left side of the face (B); Lower limbs with similar papules (C and D); (E) Yellowish-orange, mucoid colonies of C. laurentii on incubation at 25°C (F) India ink preparation of C. laurentii demonstrating spherical to oval encapsulated yeast cells with a prominent polysaccharide capsule appearing as a clear halo surrounding the cells; G) Skin biopsy showing preserved epidermis with a dense inflammatory infiltrate throughout the dermis in a granulomatous pattern(×[100]). (H) Higher magnification demonstrating chronic inflammatory infiltrate with necrosis(×[200]). (I) Subcutaneous tissue with a focal inflammatory aggregate composed of lymphocytes, histiocytes, and multinucleated giant cells (×[200]).

Conclusion

This case highlights the diagnostic challenge posed by cutaneous *C. laurentii* infection in immunocompetent patients. The absence of systemic immunosuppression, combined with negative fungal stains and a granulomatous histological pattern with focal caseous necrosis, initially favored alternative diagnoses such as cutaneous tuberculosis or atypical mycobacterial infection. Nevertheless, fungal culture established the definitive diagnosis. Cano et al. demonstrated that non-neoformans/*gattii Cryptococcus* species are infrequently pathogenic

in humans, emphasizing the rarity of this condition.[6] This report expands the literature on primary cutaneous manifestations of *C. laurentii* in immunocompetent hosts and underscores the importance of including uncommon fungal pathogens in the differential diagnosis of chronic granulomatous dermatoses, particularly in patients with environmental exposure and refractory disease. Early microbiological investigation is essential to prevent diagnostic delay and avoid inappropriate treatment.

EA DV CONGRESS
VIENNA
30 SEP - 3 OCT 2026

Abstract N°: 2352

Cutaneous Tuberculosis Mimicking Papulonecrotic Tuberculid: A Diagnostic Pitfall in an Immunocompetent Patient

salma larabi*[1]

[1] Department of dermatology, Ibn Sina University Hospital ,Rabat , Morocco, rabat, Morocco

Introduction

Papulonecrotic tuberculid (PNT) is a rare cutaneous manifestation associated with *Mycobacterium tuberculosis*, classically considered a hypersensitivity reaction occurring in immunocompetent individuals, typically characterized by sterile, necrotizing papules with negative microbiological studies.

However, overlap between tuberculids and true cutaneous tuberculosis may occur, leading to diagnostic uncertainty, particularly in endemic areas.

We report a case of cutaneous tuberculosis presenting with a papulonecrotic tuberculid–like clinical pattern, highlighting an important diagnostic pitfall.

Case Presentation

A 26-year-old immunocompetent woman with no relevant medical history presented with a 2-year history of recurrent pruritic papular eruptions involving the extensor surfaces of both forearms.

Clinical examination revealed multiple symmetric papules with central ulceronecrotic crusts distributed bilaterally over the forearms. No mucosal involvement, systemic symptoms, or other cutaneous lesions were observed.

Initial differential diagnoses included prurigo nodularis, sarcoidosis, and secondary syphilis.

Histopathological examination demonstrated a granulomatous infiltrate with central necrosis. Ziehl–Neelsen staining revealed acid-fast bacilli. In addition, mycobacterial culture performed on biopsy material showed numerous acid-alcohol–resistant bacilli. HIV serology was negative, confirming the immunocompetent status of the patient.Systemic evaluation, including chest imaging and GeneXpert testing, showed no evidence of extracutaneous tuberculosis.

The patient received standard anti-tuberculous therapy for 6 months, with marked clinical improvement and near-complete resolution of lesions.

Conclusion

This case highlights a papulonecrotic tuberculid–like presentation revealing true cutaneous tuberculosis in an immunocompetent patient, emphasizing a key diagnostic pitfall.

Although PNT is traditionally regarded as a paucibacillary hypersensitivity reaction, the detection of abundant acid-fast bacilli in lesional tissue in this case supports active cutaneous mycobacterial infection and challenges strict separation between tuberculid and true cutaneous tuberculosis.

These findings suggest that, particularly in endemic areas, papulonecrotic tuberculid–like eruptions may fall within

a broader clinicopathological spectrum of cutaneous tuberculosis rather than representing a purely immunologic entity.

Therefore, histopathology combined with direct microbiological evidence remains crucial in chronic necrotizing papular dermatoses. Failure to integrate these data may lead to misclassification and delayed appropriate treatment.

EA DV CONGRESS
VIENNA
30 SEP - 3 OCT 2026

Abstract N°: 2362

Erythema induratum of Bazin confirmed by PCR for Mycobacterium tuberculosis: a diagnostic challenge beyond the tuberculid paradigm

Julia Cascardo Géo de Siqueira*[1], Maria Eduarda Cesar Garcez[1], Amanda Quintaes[1], Priscila Siqueira[1], Ana VARGAS[1], Maria de Fátima Guimarães Scotellaro Alves[1], Luna Azulay-Abulafia[1]

[1] Pedro Ernesto University Hospital, Rio de Janeiro State University (UERJ), Rio de Janeiro, Brazil

Introduction

Erythema induratum of Bazin (EIB) is a rare form of cutaneous tuberculosis classically regarded as a tuberculid: a hypersensitivity reaction to *Mycobacterium tuberculosis* in which the pathogen is not expected to be isolated at the site of the lesion. However, the advent of molecular diagnostic techniques has challenged this concept, as the mycobacteria has been detected by polymerase chain reaction (PCR) for *Mycobacterium tuberculosis* in a subset of biopsy specimens.

EIB, the tuberculosis-associated form of nodular vasculitis, is particularly relevant in endemic regions such as Brazil, where tuberculosis incidence remains among the highest globally and exceeds 40 cases per 100,000 inhabitants.

This report describes a case highlighting the role of PCR for *Mycobacterium tuberculosis* as an additional diagnostic tool applied in confirming the diagnosis of EIB.

Case Presentation

A 46-year-old woman presented with a chronic, relapsing course of painful ulcerated nodules and plaques on the posterior lower extremities extending over four years. Multiple skin biopsies performed over this period yielded non-specific or inconclusive findings. Autoimmune workup was entirely negative. Chest CT revealed fibrocalcific changes in the upper left lobe, consistent with prior pulmonary tuberculosis and tuberculin skin test (TST) was non-reactive.

Given the persistence and clinical morphology of the lesions, a new biopsy was performed. Histopathological examination revealed lobular panniculitis with granulomatous infiltrate, focal necrosis, and vasculitis consistent with EIB. PCR-based testing of the biopsy for tuberculosis subsequently returned positive for *Mycobacterium tuberculosis*. Direct smear microscopy for acid-fast bacilli and mycobacterial culture were negative, reinforcing that in EIB, the pathogen is typically undetectable by conventional methods, and molecular tools can play a key role in establishing the diagnosis.

The patient was referred to a dedicated tuberculosis outpatient clinic, where standard four-drug antituberculous therapy (rifampicin, isoniazid, pyrazinamide, ethambutol) was initiated. Complete healing of the cutaneous lesions was achieved with treatment.

Conclusion

This case illustrates two paradigm-challenging aspects of EIB. It challenges the classical tuberculid concept – the positive PCR for *Mycobacterium tuberculosis* from a cutaneous biopsy suggests that *Mycobacterium tuberculosis* DNA is present at the lesion site, rather than EIB representing a purely remote hypersensitivity phenomenon.

It also highlights a critical epidemiological dimension: in tuberculosis-endemic regions such as Brazil, EIB must be actively considered in the differential diagnosis of chronic ulceronodular panniculitis of the lower extremities, even when TST, a technique-dependent method, is negative and active pulmonary disease is absent. In high-income countries, awareness of this entity is increasingly relevant given growing migration from endemic regions.

Thus, PCR for *Mycobacterium tuberculosis*, already widely used in pulmonary tuberculosis diagnosis, emerges as a valuable and accessible tool in the diagnostic workup of suspected cutaneous tuberculosis, including tuberculids such as EID.

EADV CONGRESS
VIENNA
30 SEP - 3 OCT 2026

Abstract N°: 2404

The Skin as a Diagnostic Clue: Disseminated Histoplasmosis in an Immunocompetent Host

Catalina Valencia Marín*[1], Natalia Vélez López[2], Gabriel Jaime Varela Aguirre[2]

[1] Universidad Pontificia Bolivariana, Medellin, Colombia
[2] Clínica Aurora, Medellin, Colombia

Introduction

Disseminated histoplasmosis is a systemic fungal infection that rarely presents with cutaneous lesions in immunocompetent individuals. We report a rare case of an 82-year-old woman initially diagnosed with squamous cell carcinoma, whose persistent cutaneous lesions led to the eventual identification of *H. capsulatum*.

Case Presentation

An 82-year-old immunocompetent woman was referred to a skin cancer clinic for a two-year history of an asymptomatic, erythematous, hyperkeratotic plaque on the lateral right leg, diagnosed as well-differentiated invasive squamous cell carcinoma. Mohs surgery was performed with clear margins.

Three months later, the lesion recurred, along with new, smaller lesions on both legs. Initial histopathological analysis of multiple biopsies revealed benign lichenoid keratoses and seborrheic keratosis, with focal features suggestive of verruca vulgaris. Despite this, the number of lesions increased and the main plaque progressed.

Repeated biopsies again revealed lichenoid dermatitis. A histopathological review of the intial biopsy of the main plaque revealed pseudoepitheliomatous hyperplasia and a dense mixed inflammatory infiltrate. PAS and methenamine silver stains were negative. A universal fungal PCR identified *Histoplasma capsulatum*.

KOH and fungal cultures were negative, likely affected by prior topical treatments. A urinary antigen test for *Histoplasma* was positive. No pulmonary involvement or immunosuppression was identified. The patient reported no history of occupational or recreational exposure to environments typically associated with *Histoplasma capsulatum*.

The patient was diagnosed with disseminated histoplasmosis and treated with oral itraconazole, leading to complete resolution of all hyperkeratotic lesions. She remains under dermatology and infectious disease follow-up with favorable evolution.

Conclusion

This case underscores the diagnostic complexity of persistent cutaneous lesions in immunocompetent elderly patients, where disseminated histoplasmosis may clinically mimic neoplastic or inflammatory dermatoses. The use of molecular tools was crucial in achieving an accurate diagnosis. Early recognition and appropriate antifungal treatment are essential to avoid systemic involvement and ensure favorable outcomes.

EADV CONGRESS
VIENNA
30 SEP - 3 OCT 2026

Abstract N°: 2439

Eosinophilic Folliculitis Revealing HIV Infection in a Young Adult

fikri ouissal*[1]

[1] Avicenne Military University Hospital Center of Marrakech, marrakech, Morocco

Introduction

Eosinophilic Folliculitis is an uncommon inflammatory dermatosis most frequently associated with immunosuppression, particularly in the context of HIV infection. It typically presents with intensely pruritic follicular papules and pustules and may represent an early or initial cutaneous manifestation of HIV infection. Recognition of this entity is essential for prompt diagnostic evaluation.

Case Presentation

We report the case of a 27-year-old man presenting with a several-week history of generalized, intensely pruritic follicular papules and pustules involving the trunk, neck, and upper extremities. Initial treatments with topical corticosteroids and systemic antibiotics were ineffective.
Dermatological examination revealed monomorphic follicular erythematous papules with excoriations. Histopathological examination demonstrated perifollicular inflammatory infiltrates rich in eosinophils, consistent with eosinophilic folliculitis.
Given the clinical and histological findings, HIV serology was performed and returned positive. Further investigations revealed a CD4 lymphocyte count of 456 cells/mm^3 and an HIV viral load of 169,000 copies/mL. Antiretroviral therapy was initiated in association with symptomatic dermatological management, resulting in significant clinical improvement.
Clinical and histopathological images are presented.

Conclusion

This case highlights eosinophilic folliculitis as an important cutaneous marker of HIV infection in young adults. Persistent pruritic follicular eruptions refractory to standard therapies should prompt HIV testing. Cutaneous manifestations should never be underestimated, as they may constitute the first clinical clue to an underlying systemic disease, allowing earlier diagnosis and management.

EA DV CONGRESS
VIENNA
30 SEP - 3 OCT 2026

Abstract N°: 2467

Elephantiasis as a Mirror of Neglect: Severe Cutaneous Sequelaeof Lymphatic Filariasis After Three Decades — A Case Report

Letícia Mendes Gomes de Matos Lima*[1], Nicole Araújo Moura[2], Lunna Ruane Moura Luz[2], Mariana Rodrigues Luna de Araújo[2]

[1] Faculdade de Medicina de Olinda, Olinda - PE, Brazil

[2] Faculdade Paraíso - FAP, Araripina - PE, Brazil

Introduction

Lymphatic filariasis, caused by Wuchereria bancrofti and transmitted by mosquito vectors, is a neglected tropical disease responsible for significant morbidity. Chronic lymphatic obstruction leads to progressive cutaneous and subcutaneous changes, including elephantiasis, hyperkeratosis, hyperpigmentation, and verrucous transformation, representing severe dermatological sequelae. Cases with advanced chronic sequelae continue to be encountered in endemic regions of Brazil, particularly along the northeastern coast. Recognition of these cutaneous manifestations is essential for dermatologists, as affected individuals often present with profound functional impairment and psychosocial impact.

Case Presentation

A 74-year-old male, originally from an endemic coastal region of northeastern Brazil where lymphatic filariasis is historically prevalent, presented with a 30-year history of progressive unilateral lower limb lymphedema and its cutaneous sequelae. The patient reported having received antiparasitic treatment decades prior, though unable to specify the regimen. Physical examination revealed massive unilateral elephantiasis of the right lower limb with striking volumetric asymmetry compared to the contralateral limb. Cutaneous findings were extensive and severe: the entire surface of the affected leg presented diffuse verrucous hyperkeratosis with multiple confluent papules and nodules of varying sizes. Irregular hyperpigmentation in a reticular pattern was distributed throughout the leg, with darker areas concentrated in the medial and posterior regions. Deep fissures were visible between the verrucous nodules. A pronounced skin fold at the ankle-foot transition was observed, characteristic of advanced elephantiasis. The plantar region and toes presented significant hyperkeratosis and dystrophic nail changes. The contralateral limb was unaffected. The patient also reported recurrent episodes of erysipelas, a known complication that perpetuates lymphatic damage and accelerates disease progression. Comorbid obesity was noted, contributing to lymphatic insufficiency. Despite preserved ambulation, the patient reported significant impairment in self-esteem and quality of life. Diagnosis was established on clinical and epidemiological grounds. Current management focuses on lymphatic drainage, compression therapy, skin hygiene, and prophylaxis against recurrent bacterial infection.

Conclusion

This case serves as a powerful reminder of the irreversible nature of chronic lymphatic sequelae in lymphatic filariasis, a disease that, despite being treatable in its early stages,

continues to cause lifelong disfigurement when neglected. The 30-year evolution of unilateral elephantiasis with severe verrucous hyperkeratosis, reticular hyperpigmentation, deep fissuring, and dystrophic nail changes reflects not only the biological progression of the disease, but also the failure of healthcare systems to ensure timely diagnosis and sustained treatment in endemic regions. Recurrent erysipelas further accelerated lymphatic destructionin this patient. Beyond the physical sequelae, the profound impact on self-esteem and quality of life highlights that lymphatic filariasis is not merely a clinical condition — it is a social disease, carrying the burden of stigma and isolation. Dermatologists and primary care physicians in endemic regions must maintain heightened clinical awareness, as early intervention remains the only opportunity to prevent the severe sequelae witnessed in this case.

EADV CONGRESS
VIENNA
30 SEP - 3 OCT 2026

Abstract N°: 2479

Atypical hand-foot-mouth disease in a pediatric patient: the importance of early recognition.

Milena de Oliveira*[1], Thiago de Souza[1], Lais Acioli Lins[1], Vanessa Marcato[1], Daniele de Marqui[1], Elisandra Barbara Pontes Carlos[1], Luciana Patrícia Fernandes Abbade[1]

[1] UNESP, Botucatu, Brazil

Introduction

Hand-foot-mouth disease (HFMD), an enterovirus infection, remains a global public health concern. It classically presents with vesicular lesions on the palms, soles, and oral mucosa. However, atypical forms have been increasingly recognized and may mimic other vesiculobullous dermatoses, particularly in the early stages.

Case Presentation

A 16-month-old female patient with a one-day history of rapidly progressive cutaneous lesions, initially with a predominantly intertriginous distribution, particularly in the inguinal region, with subsequent involvement of the axillary regions, dorsum of the hands, and feet. The lesions presented as vesicles, some of which progressed to bullae with central umbilication.

The condition was preceded by two days of gastrointestinal symptoms, including watery diarrhea, approximately five episodes per day, and hyporexia. There was no fever or other systemic symptoms. On admission, the patient was in good general condition, although irritable.

Despite the atypical presentation and the prominent cutaneous involvement without initial involvement of the palms, soles, or oral mucosa, HFMD was suspected. RT-PCR testing was performed on a nasopharyngeal swab, and early clinical reassessment was planned. Differential diagnoses included eczema herpeticum and varicella.

At reassessment after 24 hours, vesicular lesions were observed on the palate, palms, and soles, supporting the diagnosis of HFMD. RT-PCR was positive for enterovirus, and the lesions gradually regressed over the following 7 days.

Conclusion

Atypical HFMD is an increasingly recognized variant of enterovirus infection. Unlike the classical form, atypical HFMD may present with more extensive and polymorphic cutaneous involvement, including vesiculobullous and erosive lesions beyond the typical acral distribution.

Lesions may involve intertriginous and gluteal areas and may mimic other vesiculobullous or viral dermatoses, including eczema herpeticum, herpes simplex infection, varicella, or bullous impetigo. This overlap can lead to diagnostic uncertainty, especially in the early stages. Atypical forms are more frequently observed in children under five years of age and are commonly associated with specific enterovirus serotypes, notably Coxsackievirus A6.

Although the diagnosis is primarily clinical, PCR may be useful in atypical cases. Early recognition is essential to avoid misdiagnosis, unnecessary antiviral therapy, and avoidable hospital admission, since HFMD is self-limited and requires only supportive care.

The disease usually resolves within one to two weeks, and late manifestations such as acral desquamation or nail changes may occur. Due to the high transmissibility of enterovirus infections, strict hygiene measures and temporary exclusion from group settings should be advised.

EADV Congress 2026, VIENNA
30 SEPTEMBER - 03 OCTOBER 2026
POWERED BY M-ANAGE.COM

EADV CONGRESS
VIENNA
30 SEP - 3 OCT 2026

Abstract N°: 2482

Solitary Facial Cutaneous Lesion as a Sentinel Sign of Disseminated Cryptococcosis in a Renal Transplant Recipient

Thiago de Souza[1], Milena de Oliveira[1], Lais Acioli Lins[1], Mateus Char[1], Elisandra Barbara Pontes Carlos*[1], Luciana Patrícia Fernandes Abbade[1]

[1] UNESP, Botucatu, Brazil

Introduction

Cryptococcosis is an opportunistic systemic fungal infection caused by species of the*Cryptococcus neoformans/C. gattii* complex. It may manifest with primary cutaneous lesions through direct inoculation or secondary lesions through hematogenous dissemination from a pulmonary focus, predominantly affecting immunocompromised individuals. Cutaneous involvement may mimic several dermatoses, but its recognition contributes to early diagnosis.

Case Presentation

A 34-year-old male renal transplant recipient on chronic immunosuppressive therapy (tacrolimus, mycophenolate, and prednisone) was admitted with neurological symptoms characterized by headache, vertigo, psychomotor agitation, and a recent seizure episode, raising suspicion for meningitis. Dermatology consultation was requested for evaluation of a facial skin lesion evolving over two months. Dermatological examination revealed a solitary ulcerated nodule on the left zygomatic region, without associated pain or pruritus.

The clinical context of immunosuppression, associated neurological manifestations, and the appearance of the cutaneous lesion raised strong suspicion of disseminated cryptococcosis. Direct mycological examination revealed numerous encapsulated yeasts suggestive of *Cryptococcus* spp. Histopathological analysis with hematoxylin and eosin staining demonstrated dermal infiltration by rounded yeast-like structures with a clear perilesional halo corresponding to the polysaccharide capsule, conferring the classic “soap-bubble” appearance and corroborating the diagnosis of cutaneous cryptococcosis. Laboratory investigations demonstrated inflammatory syndrome and renal dysfunction. Cerebrospinal fluid analysis and cryptococcal antigen testing were requested.

Cerebrospinal fluid analysis confirmed central nervous system involvement by cryptococcosis, establishing the diagnosis of disseminated cryptococcosis. Additional investigation also demonstrated associated pulmonary involvement. Systemic antifungal therapy with amphotericin B was initiated. Despite the instituted measures, the patient progressed with progressive neurological deterioration, intracranial hypertension, acute respiratory failure, and the need for orotracheal intubation, culminating in brain death and subsequent death.

Conclusion

Secondary cutaneous cryptococcosis most commonly presents as papular, nodular, ulcerated, or molluscum contagiosum-like lesions, frequently involving the cephalic region. In immunocompromised patients, especially transplant recipients, skin lesions may represent the first visible sign of dissemination.

Diagnosis is based on clinical findings, histopathology, culture, and cryptococcal antigen detection. Early recognition is essential considering the high morbidity and mortality associated with central nervous system involvement. Amphotericin B remains the treatment of choice during the induction phase.

This case reinforces the importance of dermatological evaluation in the early identification of atypical cutaneous lesions as markers of systemic fungal infection, contributing to the prompt diagnosis of disseminated

cryptococcosis.

EA DV CONGRESS
VIENNA
30 SEP - 3 OCT 2026

Abstract N°: 2484

Sacral Herpes Zoster Mimicking Herpes Simplex in an Immunocompetent Patient: A Diagnostic Challenge

Mariane Araujo*[1], Nurimar Fernandes[1]

[1] Sector of Dermatology and Post Graduation Course, University Hospital and School of Medicine, Federal University of Rio de Janeiro, Rio de Janeiro, Brazil

Introduction

Varicella-zoster virus (VZV), a member of the *Herpesviridae* family, causes varicella as the primary infection and herpes zoster (HZ), following viral reactivation after latency in dorsal root ganglia. In immunocompetent individuals, HZ typically manifests as a unilateral vesicular eruption limited to a single dermatome, most commonly in thoracic segments (T3–L3).

The classic presentation includes a prodrome of fever, malaise and dysesthesia in the affected dermatome, followed by painful grouped vesicles on an erythematous base that characteristically do not cross the midline. In immunocompromised patients, involvement of multiple dermatomes or disseminated disease may occur, defined by the presence of more than 20 vesicles outside the primary or adjacent dermatomes.

We report an unusual case of HZ with extensive sacral involvement in an apparently immunocompetent patient, clinically mimicking herpes simplex infection and posing a diagnostic challenge.

Case Presentation

A 65-year-old male with peripheral arterial disease and bilateral suprapatellar amputations, heart failure, diabetes mellitus, hypertension and heavy smoking history was admitted to the intensive care unit due to a painful ulcerated lesion involving the anal margin, associated with serohemorrhagic lesions on the gluteal region. Traumatic ecchymosis was also present on the right lower-limb stump. HIV and viral hepatitis tests were negative, and complement levels were within normal range.

During proctologic evaluation, surgical debridement of necrotic perianal tissue was performed due to suspected ischemic proctitis. Subsequent dermatological examination revealed multiple ruptured vesicles forming well-demarcated round erosions, some confluent with crusting and necrotic centers, involving the perianal, coccygeal and gluteal regions. Ulcerated purpuric lesions with necrotic centers were also observed on both lower-limb stumps.

Given the atypical morphology and distribution, empirical intravenous acyclovir therapy was initiated and lesion samples were collected for virological investigation. Polymerase chain reaction (PCR) testing was negative for HSV-1 and HSV-2 and positive for VZV.

Cutaneous involvement corresponded to sacral dermatomes, predominantly affecting the gluteal, perianal and perineal regions, suggesting multisegmental sacral involvement (S1–S4). Lesions improved after antiviral therapy.

Conclusion

Herpes zoster classically presents as a unilateral dermatomal eruption and diagnosis is usually clinical. However, atypical presentations involving unusual anatomical sites or extensive disease may obscure the diagnosis and

require laboratory confirmation.

Sacral involvement is uncommon, accounting for approximately 4–8% of cases and may be associated with anorectal or genitourinary manifestations depending on the dermatomes affected. In the present case, the extensive distribution across multiple sacral dermatomes and the presence of ulcerated lesions complicated the clinical interpretation and initially raised suspicion for herpes simplex infection.

Anogenital VZV infection may mimic other vesiculoulcerative dermatoses, particularly herpes simplex, most commonly caused by HSV-2, the leading etiology of lesions in this region. Such overlap increases diagnostic complexity, especially when lesions present with bilateral distribution, absence of dermatomal restriction or dysesthesia.

In such scenarios, molecular testing becomes crucial. PCR is currently considered the most sensitive and rapid method for distinguishing VZV from HSV infections, particularly in atypical or extensive presentations.

This case highlights a rare presentation of sacral herpes zoster mimicking herpes simplex in an apparently immunocompetent patient. Awareness of such atypical manifestations is crucial to ensure prompt antiviral therapy and avoid diagnostic delays, especially in patients presenting with ulcerative anogenital lesions.

EADV CONGRESS
VIENNA
30 SEP - 3 OCT 2026

Abstract N°: 2506

Thoracic scrofuloderma with cold subcutaneous abscesses: an unusual presentation in an immunocompetent patient

Émélie Simone Okouango*[1], Aiicha Chehab[1], Bouchra Baghad[1], Hanane Rachadi[1], Soumiya Chiheb[1]

[1] Department of Dermatology, Ibn Rochd University Hospital, Casablanca, Morocco, Faculty of Medicine and Pharmacy of Casablanca, Hassan II University, Morocco, Casablanca, Morocco

Introduction

Cutaneous tuberculosis (TB) is a rare form of extrapulmonary tuberculosis, accounting for approximately 2.1% of cases. Scrofulodermie is a multibacillary form resulting from the contiguous spread of an underlying tuberculous focus, most commonly lymph node or osteoarticular. Localization to the chest wall with cold subcutaneous abscesses (CSA) is rare (<5%) and poses diagnostic challenges due to clinical polymorphism and the difficulty in isolating the causative agent. We report a case of scrofuloderma-type TB with CSAs of the chest wall in a 37-year-old immunocompetent patient.

Case Presentation

This is a 37-year-old male patient with a history of recurrent right-sided pneumonia. For the past 6 months, he has presented with nodules in the right lateral chest and axilla, which have progressed to softening, fistula formation, and subsequently ulceration. The course of the disease was complicated by the appearance of a lateral thoracic mass associated with a dry cough, night sweats, evening and nighttime fever, and weight loss. Physical examination revealed two fluctuant, tender masses measuring approximately 2 and 25 cm in longest axis in the right lateral thoracic and suprasternal regions, as well as three ulcerations with infiltrated margins and purulent bases, associated with right axillary lymphadenopathy. Chest X-ray showed alveolar opacity in the lower two-thirds of the right lung. Ultrasound revealed a heterogeneous, vascularized hypoechoic lesion. Computed tomography revealed large anterior parietal collections without intrathoracic extension, the largest measuring 136 × 46 mm. Histopathology demonstrated a tuberculoid granuloma with epithelioid cells and Langhans giant cells, without caseous necrosis. Direct examination and culture were negative, while PCR (GeneXpert) and culture of the skin biopsy specimen confirmed Mycobacterium tuberculosis hominis. A diagnosis of multifocal scrofuloderma-type tuberculosis with cold subcutaneous abscesses was made. The patient was treated with antituberculosis drugs in combination with surgical drainage, with a partially favorable outcome at 3 months.

Conclusion

Scrofulodermatite results from the direct spread of a deep tuberculous focus and is more common in endemic areas. Tuberculosis of the chest wall is rare and can mimic a tumor, particularly in immunocompetent individuals. Diagnosis relies on histopathology, microbiology, and molecular techniques such as PCR. Imaging allows for the assessment of lesion extent. Management combines antituberculosis therapy with surgical drainage. Early diagnosis is essential to prevent complications and recurrence. Scrofuloderma of the chest wall with a cold abscess is a rare form of TB. It requires a high clinical suspicion and multidisciplinary management. Early combination therapy leads to a favorable prognosis.

EADV CONGRESS
VIENNA
30 SEP - 3 OCT 2026

Abstract N°: 2567

Importance of Dermatologic Clinical Assessment in Systemic Diseases: Papulonecrotic Tuberculid in an Immunocompetent Patient

Mariana Elguezabal Riojas*[1], Josefina Navarrete Solis[1], Irasema Romero González[1]

[1] Hospital de Especialidades No. 25 - Instituto Mexicano del Seguro Social, Monterrey, Mexico

Introduction

Tuberculosis remains a major public health concern in the world; however, its cutaneous manifestations are uncommon and often represent a diagnostic challenge, particularly in immunocompetent patients without identifiable risk factors. Tuberculids, such as papulonecrotic tuberculid, constitute a hypersensitivity reaction to *Mycobacterium tuberculosis* and may represent the only clinical clue to an underlying infection. Given the diagnostic difficulty posed by this condition, we report the case of a young patient without underlying disease who developed papulonecrotic tuberculid, along with a brief literature review aimed at highlighting the importance of dermatologic findings in systemic diseases.

Case Presentation

A 29-year-old male patient with no significant past medical history presented with a skin disorder that began in December 2024, characterized by the appearance of pruritic erythematous papules on both elbows. The lesions progressed into pustules with subsequent crust formation, leaving varioliform scars. In May 2025, he sought dermatologic evaluation. Physical examination revealed a disseminated, bilateral, and symmetrical dermatosis involving the dorsal and inner aspects of the forearms, arms, dorsal hands, abdomen, back, waistline, buttocks, thighs, legs, and dorsal feet. The lesions consisted of varioliform scars, erythematous-brown papules, nodules, and hemorrhagic crusts.

Initially, prurigo nodularis versus pityriasis lichenoides et varioliformis acuta was suspected; therefore, a skin biopsy was performed and treatment with oral doxycycline 100 mg once daily for one month was initiated. Histopathological examination revealed a foreign body-type granulomatous reaction (figure 1), prompting tuberculin skin testing with purified protein derivative (PPD), which was strongly positive with 24 mm induration. Chest radiography as well as contrast-enhanced and non-contrast chest computed tomography showed no abnormalities.

Based on clinicopathological correlation and the hyperergic PPD reaction, a diagnosis of papulonecrotic tuberculid was established. Treatment with oral levofloxacin 750 mg once daily was initiated, and the patient was referred to the Infectious Diseases Department for antituberculous therapy consisting of isoniazid, rifampin, pyrazinamide, and ethambutol for two months, followed by isoniazid and rifampin for four additional months, showing improvement of the dermatosis.

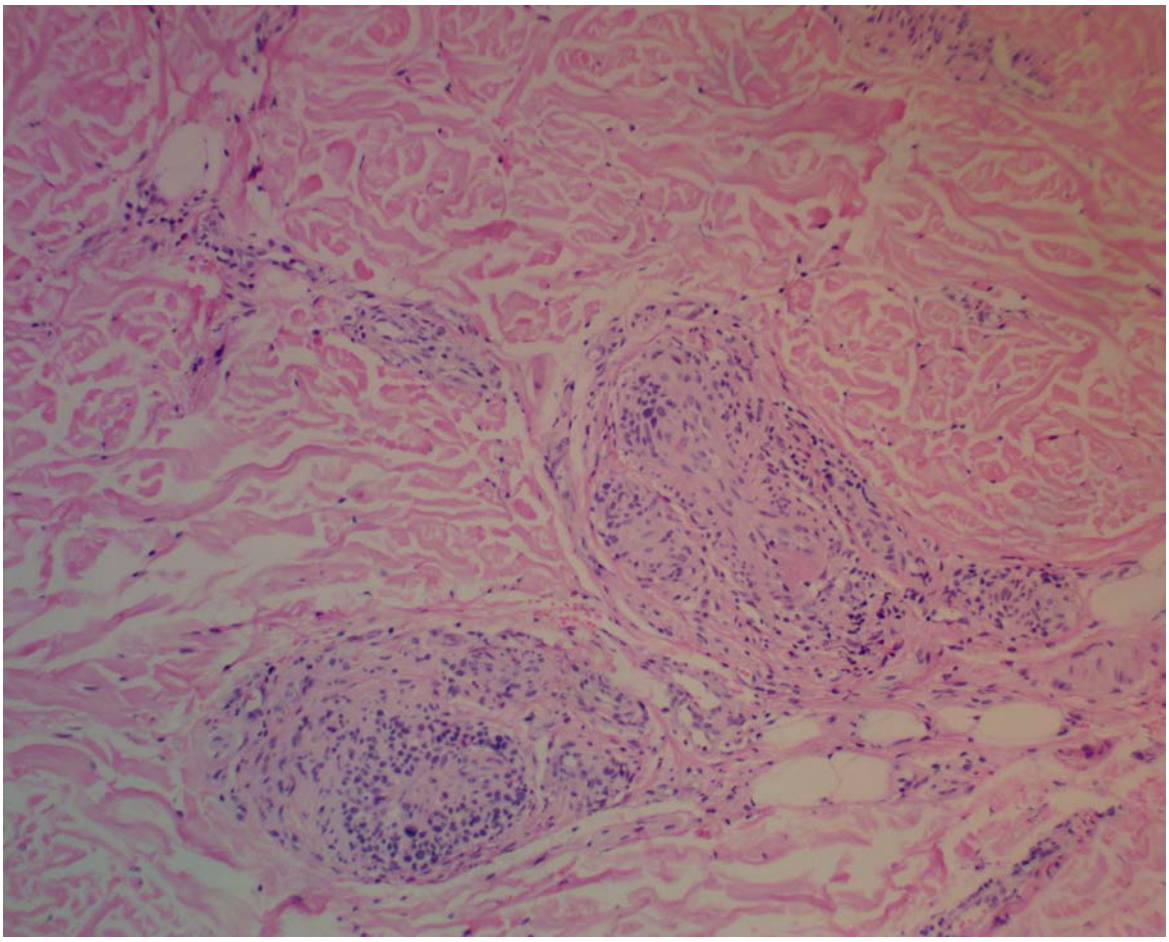

Granulomatous reaction

Conclusion

Papulonecrotic tuberculid (PNT) is an uncommon form of cutaneous tuberculosis, accounting for approximately 0.46–2.87% of cases, and predominantly affects children and young adults. It presents as recurrent symmetrical papules on extensor surfaces that evolve into necrotic lesions and ultimately leave varioliform scars. PNT represents a hypersensitivity reaction to *Mycobacterium tuberculosis*, and its diagnosis relies on the correlation of clinical findings, histopathological features, positive tuberculin skin testing, absence of detectable bacilli in direct studies, and response to antituberculous therapy.

This case is noteworthy because it initially mimicked more common inflammatory dermatoses, particularly prurigo nodularis and pityriasis lichenoides et varioliformis acuta, highlighting its potential for diagnostic confusion. Furthermore, the absence of systemic manifestations and normal imaging studies emphasize that the skin may represent the sole manifestation of underlying tuberculous infection.

Although uncommon, papulonecrotic tuberculid should be considered among the differential diagnoses of chronic papulonecrotic dermatoses, even in immunocompetent patients without evidence of systemic tuberculosis. This case demonstrates that the skin may be the only manifestation of *M. tuberculosis* infection, underscoring its value as a diagnostic window to underlying disease. Early recognition of this entity allows propper initiation of antituberculous therapy, which not only resolves the cutaneous manifestations but also prevents disease progression.

EADV CONGRESS
VIENNA
30 SEP - 3 OCT 2026

Abstract N°: 2587

Urticarial id reaction associated with tinea corporis infection

Robert Rosival*[1], Karolína Vorčáková[1]

[1] Department of Dermatovenerology, Martin University Hospital, Martin, Slovakia

Introduction

Dermatophytid (id) reactions are secondary hypersensitivity responses to a primary fungal infection. While they most commonly present as vesicular or papular eruptions, urticarial manifestations are rare. Such presentations may pose a diagnostic challenge and lead to inappropriate therapeutic management.

Case Presentation

A 25-year-old lactating woman presented with a persistent, highly pruritic 10 cm livid plaque on the right lower leg with a 2-month history. Several weeks after onset, disseminated urticarial lesions developed on the trunk and extremities, with the highest density surrounding the primary plaque. The condition was initially treated as acute urticaria with antihistamines and systemic corticosteroids, which were ineffective.

Clinical examination revealed an erythematous plaque with an accentuated border and fine scaling. A 10% potassium hydroxide (KOH) preparation demonstrated multiple septate hyphae, confirming tinea corporis. Given lactation, treatment was selected in consultation with a clinical pharmacologist. Topical terbinafine once daily and oral loratadine were initiated. After 14 days, the primary lesion showed partial resolution and the development of new urticarial lesions significantly decreased. Complete resolution of both the fungal infection and urticarial eruption was achieved after 8 weeks of topical therapy, leaving post-inflammatory hyperpigmentation.

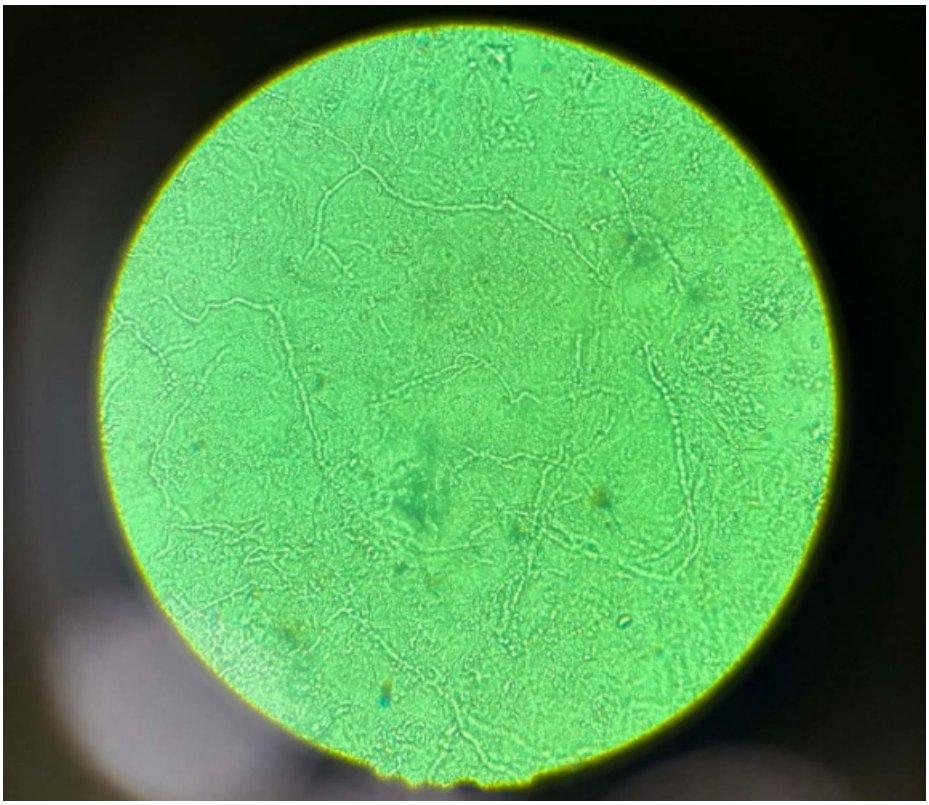

10% KOH mount showing septate hyphae from the peripheral margin of the primary plaque.

Conclusion

The diagnosis of an urticarial dermatophytid reaction was supported by clustering of lesions around the fungal focus and lack of response to systemic corticosteroids, suggesting a secondary immunological response to tinea infection. Urticarial manifestations of dermatophytid reactions are rare but clinically relevant. Identification of an underlying fungal infection is essential in patients with atypical or corticosteroid-resistant urticarial eruptions. Antifungal therapy remains the cornerstone of treatment, leading to resolution of both the infection and the associated id reaction.

EADV CONGRESS
VIENNA
30 SEP - 3 OCT 2026

Abstract N°: 2649

Pseudo-Koebner Phenomenon in Tinea Corporis: Linear Inoculation Pattern Following Traumatic Exposure

Thiago Lenoir*[1], Humberto Jimenez-Moreno[2]

[1] Desenvolver Clínica Médica, Florianópolis, Brazil

[2] Universidad Autónoma de Nuevo León, Monterrey, Mexico

Introduction

The pseudo-Koebner phenomenon refers to the appearance of skin lesions at sites of prior trauma and is most commonly described in viral infections such as verruga vulgaris and molluscum contagiosum. It differs from the true Koebner phenomenon, which is classically seen in inflammatory dermatoses such as psoriasis.

Its occurrence in dermatophytosis is uncommon and may represent a diagnostic pitfall, as linear lesion distribution following trauma can mimic inflammatory linear dermatoses or contact dermatitis.

We report a case of a 14-year-old female with Tinea corporis following exposure to a stray cat, in which scratching trauma was temporally and topographically associated with linear cutaneous lesions, suggesting a trauma related inoculation pattern.

Case Presentation

A 14-year-old female presented with multiple erythematous, annular and scaly plaques distributed over the trunk, extremities, and face, evolving over a 3-week period. The onset of lesions was temporally associated with the patient's rescue of a stray cat, during which she sustained superficial scratches.

Dermatological examination revealed multiple lesions consistent with Tinea corporis, predominantly annular with fine peripheral scaling and central clearing. In addition, a distinct linear lesion was observed on the anterolateral aspect of the left thigh, corresponding to the area of prior trauma, with surrounding skin appearing clinically unaffected.

Direct KOH examination demonstrated branching hyaline septate hyphae, consistent with a diagnosis of tinea corporis. The patient was treated with oral terbingfine (250 mg daily) as monotherapy for 14 days, achieving complete clinical and microbiological resolution.

Conclusion

This case highlights how trauma associated linear dermatophytosis may clinically mimic inflammatory linear dermatoses, creating a potential diagnostic pitfall.

Recognition of atypical distribution patterns in Tinea corporis is essential to avoid delayed diagnosis and inappropriate treatment of infectious dermatoses as non-infectious inflammatory conditions. Clinicians should remain aware of the pseudo-Koebner phenomenon's implications for management of similar cases in practice.

EADV CONGRESS
VIENNA
30 SEP - 3 OCT 2026

Abstract N°: 2653

MALIGNANT STAPHYLOCOCCAL INFECTION OF THE FACE: AN ATYPICAL PORT OF ENTRY

Hajar Haj Khlifa*[1], Fouzia Hali[1], Soumiya Chiheb[1]

[1] CHU Ibn Rochd, Casablanca, Morocco

Introduction

Malignant staphylococcal infection of the face (MSF) is a severe and rapidly progressive dermatological condition that constitutes a diagnostic and therapeutic emergency. This life-threatening infection is primarily characterized by its high risk of septic thrombophlebitis of the cerebral venous system.

MSF most commonly arises following the manipulation of a centrofacial furuncle; however, other potential entry points for infection may also be implicated.
The objective of our study is to highlight an unusual port of entry for MSF: nasal mucosal lesions induced by the use of snuff tobacco. The chronic irritation and microtrauma caused by this practice may facilitate bacterial invasion, leading to the rapid and severe progression of the infection.

Case Presentation

It was a case of a 45-years-old man, with a history of consumption of dry snuff, who presented to the emergency department with a 48 hours history of the appearance of a crusted lesion in the right nostril caused by tobacco consumption. The clinical course was marked, 24 hours later, by the onset of a warm, painful swelling of the nasal region, with secondary extension to the cheeks. This was associated with the use of nonsteroidal anti-inflammatory drugs (NSAIDs) and a high-grade fever reaching 40°C.
Dermatological examination revealed the presence of an extensive, warm, and tender erythematous plaque involving the nasal, malar, and periorbital regions, with well-demarcated borders, bilateral eyelid edema, erosion covered with scab, without fluctuation, necrosis, or crepitus. The cerebral CT scan, performed for the evaluation of suspected cerebral thrombophlebitis, revealed no abnormalities, for the facial CT scan a diffuse non-collecting facial cellulitis associated with bilateral cervical lymphadenopathy, laboratory tests revealed neutrophilic leukocytosis, increased C-reactive protein levels.
A therapeutic protocol was instituted, including amoxicillin clavulanate, third-generation cephalosporins, anticoagulant and local care.
The clinical and biological evolution was favorable within a defined timeframe marked regression of cellulitis.

Conclusion

MSF remains a serious and relatively common condition requiring prompt and targeted antibiotic therapy to mitigate the risk of severe complications and safeguard both functional and vital prognosis. The distinct aspect of our study lies in the etiological implication of microtrauma induced by nasal snuff tobacco use as a precipitating factor for infection.

Understanding this specific risk factor could enhance early diagnosis and contribute to more effective prevention strategies.

POWERED BY M-ANAGE.COM

EADV CONGRESS
VIENNA
30 SEP - 3 OCT 2026

Abstract N°: 2656

A neglected fungal disease behind refractory cutaneous lesions: an atypical presentation of paracoccidioidomycosis

Karine Domingues Tavares*[1], Luiz Rei[1], Luciana Lima[1], Raphael Pereira[1], Rafaela Lopes[1], Vivian Fichman[1], Paula Figueiredo de Marsillac[1], David Souza[1], Maria de Fátima Guimarães Scotellaro Alves[1], Alexandre Gripp[1]

[1] Universidade Estadual do Rio de Janeiro, Hospital Universitário Pedro Ernesto, Rio de Janeiro, Brazil

Introduction
Paracoccidioidomycosis is a systemic endemic mycosis with highly polymorphic cutaneous manifestations that may mimic inflammatory, autoimmune, and neoplastic dermatoses. Misdiagnosis is frequent and may lead to inappropriate immunosuppressive therapy and disease progression. We report a severe case of disseminated paracoccidioidomycosis presenting as refractory inflammatory scalp lesions, initially managed as autoimmune dermatosis.

Case Presentation
A 62-year-old woman from Rio de Janeiro presented with an erythematous-desquamative plaque on the frontal scalp, which progressed to ulceration and extension to the preauricular and occipital regions. The lesions were refractory to potent topical corticosteroids, antibiotics, and systemic prednisone (1 mg/kg/day), with continuous clinical worsening.

Given rapid progression and treatment failure, she was referred to tertiary care. At admission, she had significant unintentional weight loss (20 kg over 8 months) and a heavy smoking history (71 pack-years). Due to extensive disease and secondary infection, hospitalization was required. Initial differential diagnoses included cutaneous lupus erythematosus, sarcoidosis, pemphigus foliaceus, paraneoplastic dermatosis, and infectious etiologies.

Laboratory tests revealed normocytic normochromic anemia and elevated C-reactive protein. Antinuclear antibody was positive (1:320, homogeneous nucleolar pattern), without additional specific autoimmune markers. Chest CT demonstrated multiple pulmonary nodules, the largest measuring 1.9 cm with cavitation. Transbronchial biopsy revealed granulomatous inflammation, with negative stains and cultures for bacteria, mycobacteria, and fungi.

Definitive diagnosis was established by skin biopsy, which revealed a granulomatous dermal infiltrate with Langhans-type giant cells and multiple budding yeast forms in a characteristic “pilot wheel” configuration, highlighted by Grocott and PAS staining. Given the clinical suspicion and to strengthen diagnostic certainty, direct mycological examination and fungal cultures were repeated, both of which consistently demonstrated the presence of *Paracoccidioides* spp., thereby confirming the diagnosis.

The case was classified as severe chronic paracoccidioidomycosis according to the Brazilian Consensus (2017). Treatment with liposomal amphotericin B (5 mg/kg/day for 14 days) followed by itraconazole (200 mg/day) was initiated, with progressive clinical and serological improvement, including a 50% reduction in antibody titers after two months.

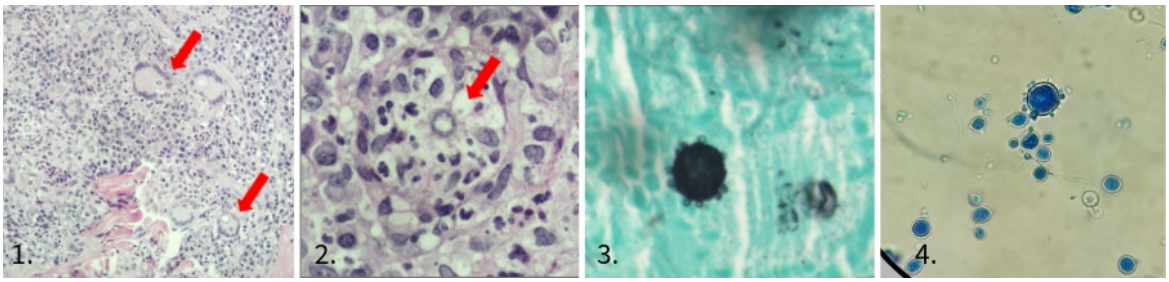

Figure 1: H&E, 400×: Langhans-type giant cells containing intracytoplasmic fungal organisms. Figure 2: H&E: Multiple budding yeast forms with the classic “pilot wheel” morphology. Figure 3. Grocott methenamine silver stain, 400×. Fungal organisms with classic “pilot wheel” configuration.. Figure 4. Culture micromorphology confirming the presence of identical fungal organisms consistent with Paracoccidioides spp.

Conclusion

This case highlights disseminated paracoccidioidomycosis as a critical diagnostic mimic of autoimmune and inflammatory dermatoses. Failure to recognize endemic systemic mycoses may result in inappropriate immunosuppression and disease progression. Early histopathological evaluation should be strongly considered in refractory cutaneous disease, particularly in endemic regions, to avoid diagnostic delay and therapeutic escalation.

EADV CONGRESS
VIENNA
30 SEP - 3 OCT 2026

Abstract N°: 2663

Herpes Simplex Virus Infection Following Hijama (Cupping Therapy)

Khadija Essekakri*[1], Bouchra Baghad[1], Soumiya Chiheb[1]

[1] University hospital Ibn Rochd, CASABLANCA, Morocco

Introduction

Hijama (cupping therapy) is a traditional therapeutic practice widely used for the management of musculoskeletal pain and is generally considered safe. Nevertheless, cutaneous trauma induced by acupuncture or cupping may facilitate infectious complications, including herpes simplex virus (HSV) reactivation. Reports of HSV infection following cupping therapy remain exceptionally rare.

Case Presentation

A 71-year-old man presented with painful vesicular lesions on the dorsal aspect of the right foot occurring three days after acupuncture and cupping therapy performed for chronic sciatica. Physical examination revealed grouped vesicles on an erythematous base arranged in a herpetiform pattern corresponding to the treated areas. Cytological examination using a Tzanck smear demonstrated multinucleated giant cells with ballooning degeneration of keratinocytes, consistent with HSV infection. The patient was treated with oral acyclovir, leading to rapid clinical improvement and progressive resolution of the lesions.

Conclusion

This case highlights a rare infectious complication of Hijama and underlines the importance of strict aseptic measures during traditional therapeutic procedures. HSV infection should be considered in patients presenting with vesicular eruptions after cupping therapy, as early recognition allows prompt antiviral treatment and favorable outcomes.

EA DV CONGRESS
VIENNA
30 SEP - 3 OCT 2026

Abstract N°: 2678

Cutaneous Scedosporium Infection Presenting with Disseminated Cutaneous Lesions in a Young Immunocompetent Male

Agbai Kalu[1], Camille Strackbein[2], Vivian Wong*[1, 2]

[1] Rosalind Franklin University the Chicago Medical School, Chicago, United States
[2] Skin Wellness Physicians, Naples, United States

Introduction

Cutaneous infection caused by *Scedosporium* species, including *Scedosporium apiospermum*, *Pseudallescheria boydii*, and *Lomentospora prolificans*, is a rare but increasingly recognized opportunistic fungal infection. These organisms are commonly found in soil, polluted water, sewage, and decaying organic material and are typically introduced through traumatic inoculation or inhalation. While pulmonary and central nervous system involvement are more commonly described in the literature, cutaneous manifestations remain underrecognized despite their important diagnostic implications.

Case Presentation

We present the case of a 22-year-old Hispanic male with pulmonary *Scedosporium* infection who developed multiple asymptomatic erythematous papules coalescing into plaques involving the left dorsal forearm, left hand, and right lower cutaneous lip over one month. Eight months prior, the patient developed chronic pneumonia and a right upper lobe pulmonary lesion, with bronchoscopic biopsy confirming fungal infection consistent with *Scedosporium*. The patient had no significant prior medical history and was otherwise immunocompetent. Due to concern for disseminated fungal infection, he was referred to Dermatology while receiving oral voriconazole therapy initiated by Infectious Disease.

Punch biopsies were performed from the right lower cutaneous lip and left dorsal forearm for histopathologic evaluation with PAS and GMS staining. Additional tissue culture from the forearm was submitted for fungal, bacterial, and mycobacterial studies. Histopathology demonstrated granulomatous dermatitis without evidence of malignancy. All tissue cultures were negative, likely secondary to ongoing antifungal therapy, as the patient had been receiving voriconazole for greater than one week prior to biopsy. Given the patient's known pulmonary fungal infection, compatible clinical presentation, and granulomatous histopathology, the lesions were favored to represent partially treated disseminated cutaneous fungal infection or a reactive granulomatous response.

The patient continued systemic voriconazole therapy with Infectious Disease and Pulmonology follow-up. At three-month follow-up, the cutaneous lesions had completely resolved without recurrence.



Erythematous nodule on right lower cutaneous lip

Conclusion

Cutaneous manifestations of *Scedosporium* infection are highly variable and may present as papules, nodules, ulcers, abscesses, verrucous plaques, or cellulitis-like lesions. Because of this broad clinical spectrum, lesions may mimic bacterial cellulitis, atypical mycobacterial infection, sporotrichosis, vasculitis, or cutaneous malignancy, often leading to delayed diagnosis. Existing case reports and literature reviews predominantly emphasize pulmonary and systemic disease manifestations, while comparatively fewer reports focus on cutaneous findings and their dermatologic evaluation.

Histopathologic diagnosis may be challenging. *Scedosporium* species can resemble other hyaline molds such as *Aspergillus* on microscopy, and fungal organisms may be sparse, particularly in partially treated infections. As demonstrated in this case, tissue cultures may be negative following initiation of systemic antifungal therapy despite ongoing clinical suspicion. Granulomatous dermatitis may therefore serve as an important histopathologic clue in the appropriate clinical setting.

Although *Scedosporium* infections classically occur in immunocompromised patients, including those with hematologic malignancies, organ transplantation, corticosteroid exposure, biologic therapy, or other immunosuppressive conditions, this case highlights that disseminated cutaneous involvement may also occur in immunocompetent individuals. Early recognition remains critical because these organisms may exhibit intrinsic resistance to several antifungal agents and delayed treatment can result in significant morbidity and mortality.



Erythematous nodule on left dorsal forearm

EADV CONGRESS
VIENNA
30 SEP - 3 OCT 2026

Abstract N°: 2681

Type 1 leprosy reaction as immune reconstitution inflammatory syndrome in a patient living with HIV: a diagnostic challenge

Amanda Quintaes*[1], João Barreto[1], Rafaela Lopes[1], Julia de Oliveira Barcaui[1], Anna Maria Andrade Barbosa[1], Maria Fernanda Rangel de Vasconcellos Guerra[1], Julia Cascardo Géo de Siqueira[1], Doménica Cerón Chimarro[1], Arles Martins Brotas[1], Alexandre Gripp[1], Daniel Obadia[1], Regina C Schechtman[1]

[1] Department of Dermatology, Universidade do Estado do Rio de Janeiro (UERJ), Rio de Janeiro, Brazil, Rio de Janeiro, Brazil

Introduction

Brazil stands out in the global epidemiological scenario of leprosy, representing an area of major relevance to international public health. HIV coinfection may favor the development of type 1 leprosy reaction as a manifestation of Immune Reconstitution Inflammatory Syndrome (IRIS). The introduction of antiretroviral therapy restores cellular immunity, intensifying the Th1 response against *Mycobacterium leprae* and triggering inflammation in previously quiescent cutaneous lesions and peripheral nerves. The literature demonstrates that leprosy may emerge or worsen in this context, particularly in the borderline tuberculoid (BT) form, imposing significant diagnostic and therapeutic challenges in endemic regions and reinforcing the need for early recognition and appropriate management.

Case Presentation

A 41-year-old female with a recent diagnosis of HIV infection, identified during investigation of a consumptive syndrome with significant weight loss (approximately 25% of baseline body weight), initiated antiretroviral therapy (HAART). Two weeks after HAART initiation, she developed progressive cutaneous lesions characterized by erythematous, infiltrated macules and plaques, initially affecting the lower limbs and subsequently spreading to the gluteal region, trunk, and face. Dermatological examination revealed infiltrated erythematous plaques in different stages of evolution, associated with palpable thickening of peripheral nerves, predominantly the right ulnar and radial nerves, and sensory deficits in thermal and tactile modalities. Extensive investigation was performed. Skin biopsy revealed superficial and deep granulomatous dermatitis with lymphocytes, plasmocytes, histiocytes, and multinucleated giant cells forming non-caseating granulomas. Histopathological findings favored borderline tuberculoid leprosy with type 1 reaction. Rapid leprosy testing was negative; however, this finding did not exclude the diagnosis, as negative results may occur in paucibacillary forms. Cranial, thoracic, and abdominal computed tomography scans showed no abnormalities. Cerebrospinal fluid analysis, VDRL, cryptococcal antigen testing, and FilmArray panel were negative. Ultrasound of the right elbow demonstrated focal thickening of the ulnar nerve (14 mm^2) without abnormal vascular flow. Special stains for acid-fast bacilli and fungi were negative. The combination of compatible dermatoneurological findings and complementary investigations strongly supported the diagnosis of borderline tuberculoid leprosy presenting as a type 1 reaction associated with IRIS.

Conclusion

Leprosy in patients living with HIV remains a diagnostic challenge due to the overlap of dermatological, neurological, and systemic manifestations with autoimmune and inflammatory diseases. Following the introduction of highly active antiretroviral therapy (HAART), several cases have been described as manifestations

of immune reconstitution inflammatory syndrome (IRIS), frequently associated with rising CD4 counts and reduction in viral load, supporting the role of immune restoration in triggering clinical disease expression, particularly in endemic regions such as Brazil. Paucibacillary forms, especially borderline tuberculoid leprosy, as well as type 1 leprosy reaction, represent the most frequent clinical presentations and are associated with restoration of Th1-mediated cellular immunity. Our case corroborates these findings, with cutaneous and neurological manifestations arising after initiation of antiretroviral therapy and histopathological findings compatible with borderline tuberculoid leprosy associated with type 1 reaction. This report reinforces the importance of including leprosy in the differential diagnosis of granulomatous dermatoses in patients living with HIV, particularly after initiation of antiretroviral therapy, allowing early diagnosis and treatment to prevent permanent neurological sequelae and reduce morbidity.

EADV CONGRESS
VIENNA
30 SEP - 3 OCT 2026

Abstract N°: 2683

The Great Mimicker Revisited: A Chronic Facial Paracoccidioidomycosis Masquerading as Granulomatous Disease and Cutaneous Malignancy

Karine Domingues Tavares*[1], Maria Fernanda Rangel de Vasconcellos Guerra[1], Elianis Gonzalez Perez[1], Mario Chaves Loureiro do Carmo[1], Thiago Jeunon[2], David Souza[1]

[1] Universidade Estadual do Rio de Janeiro, Hospital Universitário Pedro Ernesto, Rio de Janeiro, Brazil
[2] Investigação em Dermatologia, Rio de Janeiro, Brazil

Introduction
Paracoccidioidomycosis (PCM) is a systemic endemic mycosis caused by *Paracoccidioides* spp., with highly variable clinical and histopathological presentations, predominantly affecting pulmonary and mucocutaneous sites. In endemic regions, PCM represents a major diagnostic pitfall due to its ability to mimic inflammatory, granulomatous, and neoplastic dermatoses, including sclerodermiform cutaneous neoplasms.

Case Presentation
A 65-year-old woman from southeastern Brazil presented with a two-year history of a progressively enlarging crusted plaque in the right preauricular region. The lesion began as an erythematous macule in January 2023 and evolved into a keratotic, atrophic plaque. No history of local trauma was reported.

An initial skin biopsy performed elsewhere revealed ill-formed granulomas. Fungal and mycobacterial studies, including special stains, were negative, and the findings were interpreted as compatible with sarcoidosis. Systemic corticosteroid therapy was initiated at immunosuppressive doses, with no clinical response, followed by recurrent secondary bacterial infections requiring hospitalization.

During disease evolution, the patient developed ipsilateral hearing loss. Comorbidities included systemic arterial hypertension, type 2 diabetes mellitus, and prior neurocysticercosis. Family history was positive for systemic lupus erythematosus.

On examination, a well-demarcated erythematous sclerodermiform plaque with adherent crust, central atrophy, and peripheral telangiectasias was observed in the preauricular region. There was no oral mucosal involvement or lymphadenopathy.

Given the clinical differential diagnosis of sclerodermiform basal cell carcinoma, sarcoidosis, and atypical mycobacterial infection, imaging (CT and MRI) demonstrated subcutaneous edema with compression of the external auditory canal, without deep or osseous invasion.

A repeat biopsy was performed. Direct mycological examination, fungal culture, Ziehl-Neelsen staining, GeneXpert assay, and mycobacterial cultures were all negative. However, histopathology demonstrated multiple round, thick-walled fungal structures highlighted by Grocott methenamine silver staining, confirming *Paracoccidioides* spp.

Systemic workup excluded pulmonary and adrenal involvement. Based on the 2017 Brazilian consensus guidelines for paracoccidioidomycosis, the case was classified as chronic adult-type PCM of moderate severity.
Itraconazole (200 mg/day) was initiated, resulting in marked clinical improvement with near-complete resolution of the lesion after six months and significant recovery of auditory function.

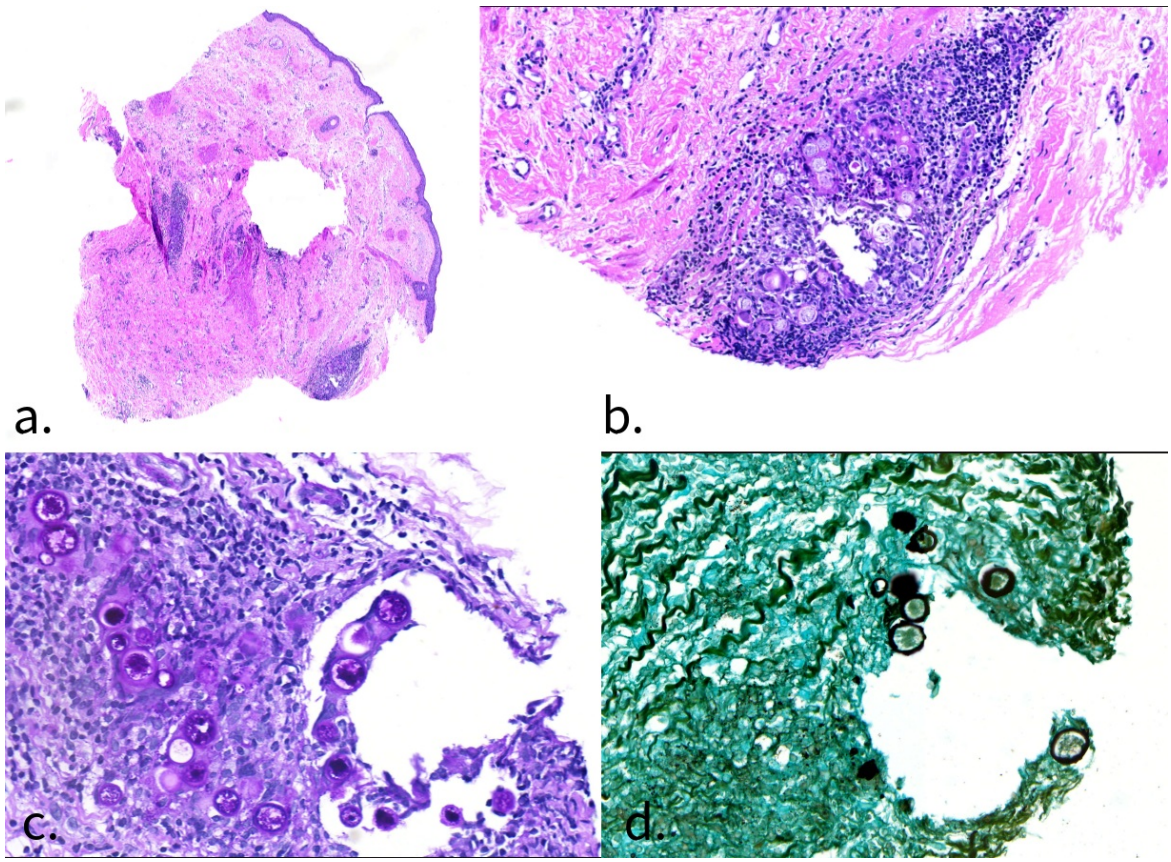

Figures a. H&E, chronic granulomatous dermal inflammatory infiltrate with multinucleated giant cells containing round fungal structures. b. Fungal structures surrounded by a chronic inflammatory infiltrate. c. PAS staining and d. Grocott methenamine silver staining highlighting yeast-like fungal structures with sparse budding, consistent with paracoccidioidomycosis.

Conclusion

This case highlights paracoccidioidomycosis as a major dermatologic and dermatopathologic great mimicker, capable of simulating a broad spectrum of dermatoses, particularly granulomatous inflammatory diseases and cutaneous neoplasms. Initial non-specific granulomatous histology associated with negative microbiological studies may lead to misdiagnosis and inappropriate immunosuppression, potentially exacerbating disease progression.

It emphasizes the need for high clinical suspicion in endemic regions and reinforces the central role of dermatopathology and repeat biopsy in granulomatous or sclerodermiform diseases unresponsive to standard therapies. Definitive diagnosis relies on histopathological demonstration and/or fungal culture, highlighting their complementary diagnostic value in endemic mycoses.

Paracoccidioidomycosis should remain a key differential diagnosis in persistent facial granulomatous or sclerodermiform plaques in endemic regions, even when initial microbiological investigations are negative.

EADV CONGRESS
VIENNA
30 SEP - 3 OCT 2026

Abstract N°: 2685

Parinaud Oculoglandular Syndrome Due to Ocular Sporotrichosis in a 13-Year-Old Girl: A Case Report

Juliana Mathias Bertonha[1], John Veasey[1], Beatriz Farias*[1], Iona Moreira[1], Luiza Zetone[1], Mariana Risso[1], Tifany Ito[1], João Pedro Carrijo Cunha Camara[1], Amanda Ferrari[1]

[1] Irmandade Santa Casa de Misericordia de São Paulo, São Paulo, Brazil

Introduction

Sporotrichosis is a subcutaneous and occasionally systemic mycosis caused by thermodimorphic fungi of the genus *Sporothrix*. Since the 1990s, the epidemiological profile of the disease in Latin America has markedly changed due to the emergence of zoonotic transmission by infected cats in Brazil, mainly associated with *Sporothrix brasiliensis*, leading sporotrichosis to become the most frequent subcutaneous mycosis on the continent. Although the lymphocutaneous form remains the predominant clinical presentation, the ongoing zoonotic epidemic has been accompanied by a substantial increase in clinical presentations previously considered atypical, particularly mucosal involvement. Ocular sporotrichosis is usually associated with direct inoculation of fungal elements into the conjunctival mucosa through contact with respiratory secretions from infected felines. Parinaud oculoglandular syndrome (POGS) is characterized by unilateral granulomatous conjunctivitis associated with ipsilateral preauricular or submandibular lymphadenopathy and represents a frequently underrecognized manifestation, especially in the absence of classic cutaneous lesions. We report the case of a 13-year-old girl presenting with this uncommon clinical manifestation.

Case Presentation

A 13-year-old girl was referred to the Dermatology Clinic of a tertiary referral center in São Paulo, Brazil, with a 17-day history of unilateral eyelid edema, ocular pain, and ipsilateral lymphadenopathy. She had previously been diagnosed with viral conjunctivitis at an emergency care visit; however, the condition progressed without clinical improvement, leading to referral for specialist evaluation. Dermatological examination revealed left upper eyelid edema, conjunctival hyperemia, and an erythematous granulomatous lesion affecting the lower tarsal conjunctiva, associated with painful ipsilateral preauricular (1.5 cm) and submandibular (1.0 cm) lymphadenopathy. No additional cutaneous lesions were observed. Given the suggestive clinical presentation and the current hyperendemic scenario of zoonotic sporotrichosis in Brazil, epidemiological investigation for contact with infected animals was performed. The patient reported that, one month before symptom onset, her household cat had developed multiple progressive ulcerated skin lesions. Biopsy specimen from the conjunctival lesion was collected for fungal culture, which yielded isolation of *Sporothrix spp*. The diagnosis of Parinaud oculoglandular syndrome secondary to ocular sporotrichosis was established, and oral itraconazole 100 mg/day was initiated, resulting in complete clinical resolution after three months of therapy.

Conclusion

This case highlights the importance of considering sporotrichosis as an etiological diagnosis in patients presenting with Parinaud oculoglandular syndrome, particularly in those with a history of contact with cats or exposure to endemic areas. In the context of the expanding zoonotic epidemic in Latin America, ocular involvement represents an increasingly relevant atypical manifestation and may occur in the absence of classic lymphocutaneous lesions. A detailed epidemiological history is therefore essential to avoid diagnostic delay. Once ocular sporotrichosis is

suspected or confirmed, systemic antifungal therapy, particularly with itraconazole, should be promptly initiated to achieve clinical resolution and prevent disease progression.

EA DV CONGRESS
VIENNA
30 SEP - 3 OCT 2026

Abstract N°: 2686

Beyond the Main Complaint: Complete Skin Examination as the Key to the Diagnosis of Leprosy

Bruna Marques Bilia[1], Renata Rodrigues*[1], Sandra e Dinato[1], Hudson Dutrra[1], Ana Lígia Scotti Alérico[1], Ingrid Oliveira[1, 1]

[1] Centro Universitário Lusíada (UNILUS), Santos, Brazil

Introduction

Leprosy is a chronic infectious disease that, although curable, remains endemic in several regions worldwide, including Brazil. Early diagnosis is essential, since transmission occurs mainly through untreated multibacillary forms. Complete dermatological examination plays a crucial role in recognizing its diverse clinical presentations.

Case Presentation

A 78-year-old male patient, Fitzpatrick phototype III, with a history of hypertension treated with losartan and plaque psoriasis affecting the scalp and elbows controlled with topical clobetasol, presented for dermatological evaluation of photodamage.

Dermatological examination also revealed bilateral infiltration of the earlobes and madarosis affecting the distal thirds of the eyebrows, more evident on the right side.

Given the diagnostic hypothesis of lepromatous leprosy, sensory testing with cotton and ether and superficial cutaneous reflex evaluation were performed and were within normal limits. Peripheral nerve palpation demonstrated mild thickening of the left ulnar nerve. Bacilloscopy revealed the following results: right earlobe 2+, left earlobe 4+, right elbow 1+, left elbow 0+, with a bacilloscopic index of 1.75.

The diagnosis of lepromatous leprosy was confirmed, and multidrug therapy was initiated with rifampicin 600 mg/month, dapsone 100 mg/day, and clofazimine 300 mg/month. The case was officially reported, and the patient was referred for multidisciplinary follow-up with ophthalmology, neurology, and physiotherapy teams.

Conclusion

Leprosy presents with variable clinical manifestations and may mimic several dermatological conditions. In the present case, madarosis could resemble frontal fibrosing alopecia, atopic dermatitis (Hertoghe sign), secondary syphilis, hypothyroidism, alopecia areata, or trichotillomania.

A thorough dermatological examination of the entire integument is a valuable tool for identifying subtle alterations that may go unnoticed by the patient, as observed in this case, in which discreet infiltrative lesions and madarosis were clinically subtle. Systematic full-body examination is essential, allowing diagnostic suspicion and subsequent confirmation through dermato-neurological examination and bacilloscopy.

Treatment aims to reduce disease transmissibility and prevent sequelae and physical disabilities. This report highlights a multibacillary lepromatous patient, emphasizing the importance of prompt recognition and immediate treatment initiation to prevent transmission and complications.

This case reinforces that leprosy should always be considered in patients presenting with madarosis and highlights the importance of meticulous dermatological examination for the early diagnosis of a disease with major social and public health impact.

EA DV CONGRESS
VIENNA
30 SEP - 3 OCT 2026

Abstract N°: 2687

Scrofuloderma secondary to sternal tuberculosis in a young immunocompetent adult: a rare extrapulmonary manifestation

Julia Cascardo Géo de Siqueira*[1], Maria Eduarda Cesar Garcez[1], Amanda Quintaes[1], Estêvão Vargas[2], Flavia Cassia[1], Mario Chaves Loureiro do Carmo[1]

[1] Pedro Ernesto University Hospital, Rio de Janeiro State University (UERJ), Rio de Janeiro, Brazil

[2] Professor Rubem David Azulay Institute of Dermatology, Rio de Janeiro, Brazil

Introduction

Extrapulmonary tuberculosis (TB) accounts for a significant proportion of TB cases worldwide, yet cutaneous and osteoarticular manifestations remain underdiagnosed due to their polymorphic presentation. Scrofuloderma resulting from contiguous spread of mycobacterial infection from underlying structures to the skin represents one of the most recognised forms of cutaneous TB. Sternal TB is exceedingly rare, particularly in immunocompetent patients, and may mimic soft tissue tumours, pyogenic infections, inflammatory conditions or neoplastic disease, leading to diagnostic delays and inappropriate interventions. Brazil ranks among the 30 high-burden TB countries globally, according to the WHO, and in this context, florid extrapulmonary presentations remain a diagnostic reality.

Case Presentation

A 23-year-old immunocompetent woman (Fitzpatrick phototype IV) presented with a 2-year history of a painful, indurated, erythematous nodular lesion in the left inframammary region, progressing to ulceration with copious purulent drainage. Multiple antibiotic courses failed to produce improvement. The lesion had been previously managed under a presumptive diagnosis of hidradenitis suppurativa, leading to surgical excision without histopathological analysis, which resulted in hypertrophic scarring, wound dehiscence, and ulcer recurrence. Systemic symptoms included fatigue, weight loss, and exertional dyspnoea. Epidemiological history was significant: close household contacts with confirmed pulmonary TB, including a fatal case.

Examination revealed a 2 cm ulcero-gummatous lesion with a necrotic base adjacent to a hypertrophic scar in the left lower parasternal region. Dermatological ultrasound identified a fistulous tract extending from the epidermis through the subcutaneous tissue to the left sternocostal space, in proximity to deep pleural and pericardial structures. Chest computed tomography confirmed a left lower sternal lesion with cutaneous extension; pulmonary parenchyma was unremarkable, with no mediastinal lymphadenopathy or pleural effusion. Tuberculin skin test was anergic (0 mm). Skin biopsy demonstrated suppurative granulomatous inflammation with Langhans multinucleated giant cells and central caseous necrosis. PCR for Mycobacterium tuberculosis performed on biopsy material was positive; mycobacterial culture confirmed the diagnosis.

Sternal bone tuberculosis with secondary scrofuloderma was diagnosed. The patient was referred to a specialised extrapulmonary TB outpatient clinic and initiated on standard four-drug therapy (rifampicin, isoniazid, pyrazinamide, and ethambutol) – planned duration of twelve months. Favourable clinical evolution was observed, with complete wound healing achieved under treatment.

Conclusion

This case illustrates the diagnostic pitfalls of cutaneous TB presenting as a chronic non-healing wound in a young immunocompetent adult. A misdiagnosis of hidradenitis suppurativa led to surgical intervention without tissue analysis – a critical missed opportunity that prolonged the diagnostic delay to nearly two years. A negative tuberculin skin test and absent pulmonary involvement further obscured the diagnosis, underscoring the risk of anchoring bias toward more common aetiologies. The complete response to antituberculous therapy confirmed the diagnosis and reinforced the importance of early targeted treatment. Dermatologists are uniquely positioned not only to recognise cutaneous manifestations of systemic disease, but to initiate the diagnostic workup that prevents irreversible morbidity. Histopathological examination combined with molecular workup is mandatory in any non-healing ulcerated lesion unresponsive to conventional antibiotics. In an era of global mobility, TB must remain on the differential as the great imitator.

EA DV CONGRESS
VIENNA
30 SEP - 3 OCT 2026

Abstract N°: 2691

Postherpetic Abdominal Pseudohernia - Case Report

Isabella Nobre[1], Ruan Cleuson da Costa[2], Dâmmarys Nascimento*[1], Camilla Pereira[1], Airton da Costa[1], José Carlos Sardinha[1]

[1] Fundação Hospitalar de Dermatologia Tropical e Venereologia 'Alfredo da Matta', Manaus, Brazil
[2] Universidade Federal do Acre, Rio Branco, Brazil

Introduction

Herpes zoster is a viral infection resulting from the reactivation of the varicella-zoster virus, classically characterized by a painful vesicular eruption distributed along sensory dermatomes. Although sensory manifestations predominate, motor neurological complications may occur, including the rare postherpetic abdominal pseudohernia. This condition is characterized by a localized protrusion of the abdominal wall without a true fascial defect, secondary to segmental motor involvement of the abdominal muscles caused by the virus. It usually develops days or weeks after the onset of cutaneous lesions and may mimic true abdominal hernias, potentially leading to unnecessary investigations and surgical interventions. Due to its low incidence and unusual clinical presentation, diagnosis may be challenging and requires appropriate clinicoradiological correlation. This study reports a case of abdominal pseudohernia secondary to herpes zoster, highlighting its clinical, diagnostic, and therapeutic aspects.

Case Presentation

A 62-year-old male patient with diabetes mellitus, from Ceará state, Brazil, presented with vesicular lesions on an erythematous base distributed along a dermatome on the left flank. A diagnosis of herpes zoster was established, and treatment with Acyclovir 800 mg every four hours for seven days was initiated, combined with analgesic management. The patient showed clinical improvement of the cutaneous lesions, while residual postherpetic neuralgia was controlled with Pregabalin. Approximately two weeks after treatment, the patient developed a localized protrusion in the area previously affected by herpes zoster. Abdominal wall ultrasonography excluded a true abdominal hernia despite the evident local protrusion, with findings compatible with inflammatory changes involving the epidermis/dermis. Abdominal computed tomography did not reveal a true hernia in the affected area. Based on the association between clinical history, physical examination, and complementary imaging studies, a diagnosis of postherpetic abdominal pseudohernia was established. Conservative management was adopted, with regular outpatient follow-up and reassessment.

Conclusion

Abdominal pseudohernia associated with herpes zoster represents a rare and underrecognized neurological complication capable of mimicking surgical conditions of the abdominal wall. This case highlights the importance of early recognition of this manifestation in patients with recent herpes zoster and subsequent development of segmental abdominal protrusion. Awareness of this entity may prevent unnecessary invasive investigations and surgical procedures, while contributing to appropriate clinical management. Therefore, this report has scientific and educational relevance by expanding the discussion on atypical motor manifestations of varicella-zoster virus infection and assisting dermatologists and other healthcare professionals in the differential diagnosis of this condition.

EADV Congress 2026, VIENNA
30 SEPTEMBER - 03 OCTOBER 2026
POWERED BY M-ANAGE.COM

EADV CONGRESS
VIENNA
30 SEP - 3 OCT 2026

Abstract N°: 2694

Penile Kaposi Sarcoma in an HIV-Negative Patient

Camilla Pereira[1], Dâmmarys Nascimento*[1], Airton da Costa[1], Rafhael Toschi[2], Matheus Pereira[3], José Carlos Sardinha[1]

[1] Fundação Hospitalar de Dermatologia Tropical e Venereologia 'Alfredo da Matta', Manaus, Brazil

[2] Universidade Nilton Lins, Manaus, Brazil

[3] Faculdade Metropolitana de Manaus, Manaus, Brazil

Introduction

Kaposi's sarcoma (KS) is a vascular neoplasm linked to human herpesvirus 8 (HHV-8). It became especially prevalent during the AIDS epidemic in the 1980s, particularly among HIV-positive individuals and other immunosuppressed patients, such as organ transplant recipients. KS can involve the skin, mucous membranes, and internal organs. However, isolated penile involvement, especially in HIV-negative patients, is exceedingly rare. Due to its rarity, penile KS may be misdiagnosed, most commonly as pyogenic granuloma.

Case Presentation

We report the case of a 68-year-old HIV-negative male presenting with a slow-growing, painless nodule on the glans penis and urethral meatus, which developed over a two-year period. The lesion had originated in an area previously treated with cryosurgery for what was diagnosed clinically as condyloma acuminatum. Initial clinical evaluation showed no systemic comorbidities, and all serological tests for HIV, syphilis, and hepatitis B and C were negative. Physical examination revealed a shiny, friable 2.5 x 2.5 cm nodular lesion. No lymphadenopathy was detected in the inguinal region. The initial diagnosis was pyogenic granuloma, and the lesion was surgically excised. Histopathology demonstrated an exophytic tumor with proliferating capillaries, extravasated red blood cells, spindle cells, and mononuclear infiltrates. Immunohistochemistry was positive for HHV-8, confirming the diagnosis of Kaposi's sarcoma. Penile KS is particularly rare in HIV-negative individuals, with literature reporting only a few such cases over the past decades. The patient's lesion was likely an early manifestation of KS that had been misdiagnosed and treated incorrectly for two years.

Conclusion

Penile Kaposi's sarcoma, although rare in HIV-negative individuals, should be considered in the differential diagnosis of vascular or tumorous penile lesions. Proper early diagnosis through histopathology and immunohistochemistry for HHV-8 is crucial to ensure appropriate and timely treatment. Surgical excision is effective, and recurrence is rare when the primary tumor is fully removed.

EA DV CONGRESS
VIENNA
30 SEP - 3 OCT 2026

Abstract N°: 2716

Leprosy and Cutaneous Tuberculosis within the same household: A rare diagnostic challenge

Dr. Smriti Venkatesh*[1], Dr. Meghana Phiske[1], Dr. Shylaja Someshwar[1, 2]

[1] Mgm Institute of Health Sciences, Panvel, India
[2] Kasturba Medical College, Mangaluru, India

Introduction

Hansen's disease and Lupus vulgaris are chronic granulomatous disorders that may present with overlapping clinical features, especially in endemic regions like India. Differentiating between these entities is critical, as management and prognosis differ significantly.

Prevalence rate of Hansens disease in India is 0.57 per 10,000, with high-burden areas like Chhattisgarh, Bihar, Maharashtra, and Uttar Pradesh. Lupus vulgaris is most common form of cutaneous tuberculosis in India, accounting for approximately 59%–75%. It often affects individuals with moderate immunity, presenting as chronic plaque-type, often on limbs or face, and is frequently more common in females.

In household contacts of Hansen's disease, there is a tendency toward diagnostic anchoring, which may lead to misdiagnosis of other granulomatous conditions.

Co-occurrence of leprosy in mother and lupus vulgaris in her child is rare. While both diseases are caused by related mycobacteria: M. leprae and M. tuberculosis, they are distinct conditions that can rarely present within same household due to shared environmental factors or inherent host susceptibility.

Exact nature of relationship between leprosy and tuberculosis remains unclear. They share similarities like both diseases being caused by gram-positive, acid-fast mycobacteria that are characterized by chronic granulomatous reaction and host-specific cell-mediated immune response plays vital role in defining clinical spectrum. Both depend on exposure in endemic settings, socioeconomic conditions, and close household contact. In addition, they share common antigens as evidenced by conversion of tuberculin and lepromin intradermal tests after administration of BCG vaccine. Cross-immunity and immune spectrum theories have made this association particularly interesting.

Case Presentation

Mother: A 26/F presented with multiple well-defined discrete skin-coloured nodules on B/L UL, LL, 0.5X0.5 to 01x0.5 cm, with ear infiltration and oedema of B/L hands and feet. She had tingling and numbness over B/L UL, LL. Slit Skin smear was positive (4+). Biopsy suggested borderline tuberculoid Hansen's.

Son: A 7/M fully vaccinated child with normal developmental milestones, presented with a single, well-defined erythematous scaly plaque (5 × 2 cm) over left leg since 1 year, gradually progressing in size. Apart from tingling, there was no sensory loss or nerve thickening.

Biopsy showed acanthosis, well-formed periappendageal epithelioid granulomas with giant cells and lymphocytes in upper and mid dermis, confirming diagnosis of Lupus vulgaris.

Conclusion

Rare intrafamilial occurrence of two distinct granulomatous disease causes initial misdiagnosis due to epidemiological bias. Diagnostic overlap can exist between leprosy and cutaneous tuberculosis highlighting the importance of biopsy in confirming diagnosis.

EADV CONGRESS
VIENNA
30 SEP - 3 OCT 2026

Abstract N°: 2725

Cutaneous Candidiasis with Secondary Infection in a Patient with Diabetes Mellitus and History of Stroke: A Case Report

Lezdyana Islami*[1], Anni Adriani[1], Sitti Rahmah[1], Safruddin Amin[1], Dirmawati Kadir[1], Widyawati Djamaluddin[1], Andi Nurhaerani[1], Asnawi Madjid[1]

[1] Dermatology, Venereology and Aesthetic Departement in Faculty of Medicine Hassanudin University, Makassar, Indonesia

Introduction

Cutaneous candidiasis is an opportunistic infection caused by Candida species, most commonly Candida albicans. The infection is endogenous in nature and predominantly affects moist, occluded cutaneous sites such as skin folds. Predisposing factors include diabetes mellitus (DM), prolonged immobilisation, obesity, broad-spectrum antibiotic use, and immunosuppression. Chronic hyperglycaemia in DM enhances fungal virulence through increased biofilm formation and secreted aspartyl proteinase (SAP) activity, while impairing neutrophil-mediated host defence via disruption of the interleukin-17 pathway. The combination of uncontrolled DM and prolonged bed rest represents a high-risk clinical scenario for the development of decubital candidiasis with secondary bacterial co-infection.

Case Presentation

We report a 63-year-old woman with a history of stroke and newly diagnosed Diabetes melitus type 2 (HbA1c 11%; fasting plasma glucose 250 mg/dL; random glucose 554 mg/dL) admitted with a 3-week history of erythematous patches on the bilateral gluteal region that progressively deteriorated into ulcerated lesions over 10 days. The patient had been bedridden for an extended period and used incontinence pads continuously. Dermatological examination revealed erythematous macules and patches with erosions, scaling, crusting, and peripheral satellite papulopustules over the bilateral gluteal region. Laboratory findings showed leukocytosis (WBC 17.76 × 10^3/µL) with neutrophilia (93.4%). KOH 10% preparation of skin scrapings demonstrated pseudohyphae and spores. Fungal culture on Sabouraud Dextrose Agar (SDA) yielded creamy-white, smooth colonies at day 5; Gram stain revealed conidia and budding yeast cells (blastoconidia). VITEK 2 automated identification confirmed Candida tropicalis (99.9% probability). A diagnosis of cutaneous candidiasis with secondary infection was established. Treatment comprised oral ketoconazole 200 mg once daily for 14 days combined with topical ketoconazole 2% cream, betamethasone 17-valerate cream, and fusidic acid cream applied twice daily to lesions. Cetirizine 10 mg once daily was added for symptomatic pruritus relief. Patient education on hygiene, diaper management, and moisture reduction was provided. Clinical improvement was observed by day 4 of hospitalisation, with complete resolution of erythema and pruritus by day 18, leaving only post-inflammatory hyperpigmentation

Conclusion

Cutaneous candidiasis caused by C. tropicalis should be considered in bedridden patients with poorly controlled DM. Early mycological confirmation with KOH preparation and culture, including species identification by VITEK 2, is essential for targeted antifungal therapy. Combined oral and topical antifungal regimens, supplemented by adjunctive anti-inflammatory and antibacterial topical agents, yield favourable outcomes. Optimisation of glycaemic control and meticulous skin-care education are fundamental to preventing recurrence in this high-risk population.

EADV Congress 2026, VIENNA
30 SEPTEMBER - 03 OCTOBER 2026
POWERED BY M-ANAGE.COM

EADV CONGRESS
VIENNA
30 SEP - 3 OCT 2026

Abstract N°: 2731

CUTANEOUS LEISHMANIASIS IN CHILDREN: ABOUT TWO CASES

Fatima Zahra Sassine*[1], Chourouq Mustapha Eid[1], Kenza Benothmane[1], Yasmine Zekraoui[1], Mariame Meziane[1], Laila Benzekri[1]

[1] Ibn Sina University Hospital, Dermatology Derpartment, Rabat, Morocco

Introduction

Cutaneous leishmaniasis (CL) is a parasitic disease caused by protozoa of the genus Leishmania, transmitted through the bite of infected sandflies. With an estimated 0.7–1 million new cases annually worldwide, CL represents a significant global health burden. In children, facial lesions are particularly concerning due to the risk of permanent scarring and long-lasting psychosocial consequences. Treatment in the pediatric population remains challenging, as conventional therapies such as intralesional pentavalent antimonials are painful and often require sedation. Oral clarithromycin has emerged as a promising, non-invasive alternative in pediatric CL. We report two cases of childhood CL successfully treated with oral clarithromycin combined with topical chlortetracycline.

Case Presentation

CASE 1

A 2-year-old girl presented with a chronic lesion on the chin evolving over 4 months, with a history of travel to an endemic area. Clinical examination revealed an erythematous, painless, crusted plaque on the chin with ipsilateral cervical lymphadenopathy. Dermoscopy showed a yellowish crust overlying an erythematous background with salmon-colored (orange-tinted) structures. Direct microscopic examination of a dermal smear revealed Leishmania amastigotes, confirming the diagnosis of CL.

CASE 2

A 3-year-old boy presented with two lesions, one on the cheek and one on the chin, evolving over 2 years, with a history of prior travel to an endemic area. The lesions initially appeared as erythematous papules that progressively became crusted plaques. Direct microscopic examination confirmed the presence of Leishmania amastigotes.

TREATMENT AND OUTCOME

Both patients were treated with oral clarithromycin 15 mg/kg/day for 10 days per month over 3 consecutive months, combined with topical chlortetracycline ointment applied twice daily. A satisfactory clinical response was observed at 3 months, with significant reduction in lesion size, resolution of crusting, and progressive healing with minimal residual scarring. No adverse effects were reported during treatment.

Conclusion

Cutaneous leishmaniasis should be considered in any child presenting with chronic, painless, crusted facial lesions and a history of travel to endemic areas. Dermoscopy and direct smear examination are valuable diagnostic tools. Oral clarithromycin combined with topical chlortetracycline represents a promising, child-friendly therapeutic approach, as supported by a recent series of 64 Moroccan children treated with the same protocol demonstrating favorable outcomes. Further controlled clinical trials are warranted to confirm these findings.

EADV CONGRESS
VIENNA
30 SEP - 3 OCT 2026

Abstract N°: 2770

The Treatment of Acute Cutaneous Leishmaniasis With Oral Zinc Bisglycinate and Oral Hydroxychloroquine Sulfate

Maryam AL Lami*[1], Adil A. Noaimi[1]

[1] The Scientific Committee of the Scientific Council of Dermatology and Venereology of the Iraqi Board for Medical Specializations, Baghdad, Iraq

Introduction

Cutaneous leishmaniasis (CL) is one of the most significant and endemic parasitic infections in many regions around the world, and it is caused by several species of the Leishmania parasite. It is a morbid condition that leads to stigmatization and disfiguring scars. Numerous methods have been tried to treat leishmaniasis with variable cure rates and side effects. This study aimed to compare the effects of oral zinc bisglycinate (ZnGly) and oral hydroxychloroquine sulfate (HCQ), alone and in combination, in treating acute CL.

Case Presentation

This comparative therapeutic study was conducted at the Center of Dermatology and Venereology, Medical City, Baghdad, Iraq, during the period from December 2021 to February 2023. All participants had been diagnosed through history and clinical examination, which involved skin smear in all patients and skin biopsy for some suspicious cases. Patients were classified into three groups based on the type of treatment: Group A was treated with oral ZnGly capsules 50 mg twice daily for eight weeks; Group B was administered oral HCQ tablets 200 mg twice daily for eight weeks; and Group C received a combination of both drugs for eight weeks. All patients were examined every four weeks for eight weeks, followed by every month for two months after stopping therapy. The treatment's impact on the lesions was assessed using Sharquie`s modified Leishmania score.

Results

A total of 40 patients with acute CL were included in this study, which spanned eight weeks. The total number of lesions was 144, and their duration ranged from five to 12 weeks. Group A included 14 patients, and the cure rate was 78.6% (11); Group B included 13 patients, and the cure rate was 84.7 % (11), while Group C included 13 patients, and the cure rate was 92.3% (12). We observed a statistically significant difference in the cure rate in Group C when compared to Group A and Group B at the end of the study (p=0.034).

Conclusion

While both oral ZnGly and HCQ as monotherapy were effective in the treatment of acute CL, the combination regimen of both drugs led to higher effectiveness without any increase in the frequency of adverse effects

EADV CONGRESS
VIENNA
30 SEP - 3 OCT 2026

Abstract N°: 2775

Intralesional Normal Saline as an Adjunctive Therapy for Recalcitrant Tinea Corporis: A Pilot Case Series

Dalia Abdelaziz*[1]

[1] Egyptian Ministry Of Health, Cairo, Egypt

Introduction

The increasing prevalence of recalcitrant dermatophytosis, particularly infections associated with emerging antifungal resistance, has complicated the management of tinea corporis and often necessitates prolonged systemic antifungal therapy. Extended use of systemic antifungals may increase the risk of drug interactions and drug-induced liver injury. Consequently, interest has grown in localized, adjunctive therapeutic approaches that may enhance treatment response while reducing dependence on long-term systemic therapy. The aim of this case series is to evaluate the clinical response and tolerability of adjunctive intralesional normal saline injection in patients with recalcitrant tinea corporis.

Case Presentation

We present a pilot case series of 10 patients with clinically and mycologically suspected recalcitrant tinea corporis who demonstrated inadequate response to standard topical therapy and/or short courses of systemic antifungals. Patients received single or serial sessions of intralesional sterile normal saline (0.9% NaCl) injected into the active border of the lesions in combination with topical antifungal therapy, including luliconazole or ciclopirox cream. Clinical assessment included evaluation of erythema, scaling, induration, pruritus, and lesion progression during follow-up (up to 6 months).

Results: Patients demonstrated marked clinical improvement during the treatment course, including reduction in pruritus, erythema, scaling, and induration, with progressive flattening of the active lesion border. Clinical clearance was achieved without the need for prolonged systemic antifungal therapy in the observed cases. Treatment was well tolerated, with only transient localized edema and mild injection-site discomfort reported. No significant adverse effects were observed during follow-up.

Conclusion

Intralesional normal saline may represent a simple, low-cost adjunctive option for selected cases of recalcitrant tinea corporis. The observed clinical response suggests a possible role for localized mechanical hydrodissection in improving topical treatment penetration and modifying the inflammatory microenvironment. Although the precise mechanism remains uncertain, this approach may have potential systemic-sparing implications in resistant dermatophytosis management. Larger controlled studies are required to validate efficacy, clarify mechanisms, and assess long-term outcomes.

EA DV CONGRESS
VIENNA
30 SEP - 3 OCT 2026

Abstract N°: 2797

Disseminated Gonococcal Infection Masquerading as Adult-Onset Still's Disease: A Diagnostic Pitfall

Fatima Zahra Sassine*[1], Meria Saci[2], Sandra Aloui[1], Michele Sanchez[2]

[1] Ibn Sina University Hospital, Dermatology Derpartment, Rabat, Morocco

[2] Hopital Henri Duffaut, Dermatology Department, Avignon, France

Introduction

Adult-onset Still's disease (AOSD) is a systemic autoinflammatory disorder characterized by high spiking fever, evanescent salmon-colored rash, arthralgias, and neutrophilic leukocytosis. Diagnosis relies on the Yamaguchi criteria, which require the exclusion of infections. Disseminated gonococcal infection (DGI) classically presents with fever, migratory polyarthralgia, tenosynovitis, and acral pustular skin lesions. However, atypical cutaneous presentations, including purpuric and vasculitic lesions, have been reported and may further obscure the diagnosis. We report a case of chronic DGI with purpuric skin lesions initially misdiagnosed as AOSD.

Case Presentation

A young woman presented with intermittent high-grade fever associated with marked asthenia, migratory polyarthralgia, and recurrent skin lesions. Cutaneous examination revealed purpuric macules and papules, some of which were infiltrated and tender, without any pustular or vesicular component. Lesions resolved spontaneously within 24–48 hours and recurred in temporal association with febrile episodes. No classic necrotic pustules on an erythematous base were observed. The patient denied any history of sexually transmitted infections, and her partner reported no prior STI history or genitourinary symptoms. No genitourinary complaints were elicited. Laboratory workup showed neutrophilic leukocytosis and elevated inflammatory markers. Initial blood cultures were negative.

The patient fulfilled the Yamaguchi criteria for AOSD, and this diagnosis was initially retained. The absence of pustules was a key factor leading to this misdiagnosis: the evanescent, painful, purpuric lesions recurring with febrile episodes closely mimicked the rash of AOSD, which is typically described as salmon-colored, macular or maculopapular, and evanescent. Furthermore, the complete absence of STI history in both the patient and her partner significantly lowered clinical suspicion for gonococcal infection. However, 86–93% of urogenital gonococcal infections in women are asymptomatic, and asymptomatic carriage can persist for months before dissemination.

Repeat blood cultures subsequently grew Neisseria gonorrhoeae, and NAAT confirmed mucosal gonococcal infection. A diagnosis of chronic DGI was established. While DGI skin lesions are classically described as hemorrhagic pustules on an erythematous base, atypical presentations including purpuric rash and vasculitic lesions have been documented. Histopathologically, DGI skin lesions demonstrate neutrophilic infiltration with leukocytoclasis and fibrin deposition in dermal vessels, a pattern of leukocytoclastic vasculitis, which explains the purpuric and infiltrated clinical appearance observed in our patient. Blood cultures are positive in only 43% of DGI cases

presenting with the arthritis-dermatitis syndrome, making initial negative cultures unreliable for exclusion.

Parenteral ceftriaxone led to rapid and complete resolution of fever, skin lesions, arthralgias, and asthenia within 24 hours, confirming the infectious etiology and serving as a valuable diagnostic clue in itself.

Conclusion

DGI can present with purpuric, infiltrated, painful skin lesions without pustules, closely mimicking AOSD. A negative STI history and initially negative blood cultures should not rule out gonococcal infection. Systematic NAAT-based STI screening at all exposed mucosal sites should be performed in any patient presenting with fever, evanescent rash, and polyarthralgia before retaining a diagnosis of AOSD.

EADV CONGRESS
VIENNA
30 SEP - 3 OCT 2026

Abstract N°: 2806

Glove-and-Sock Desquamation Following Streptococcal Pharyngitis in a 63-Year-Old Man: A Reminder of Scarlet Fever in the Elderly Introduction

Fatima Zahra Sassine*[1], Meria Saci[2], Chourouq Mustapha Eid[1], Michele Sanchez[2]

[1] Ibn Sina University Hospital, Dermatology Derpartment, Rabat, Morocco

[2] Hopital Henri Duffaut, Dermatology Department, Avignon, France

Introduction

Scarlet fever is a toxin-mediated disease caused by group A Streptococcus (GAS) superantigens, predominantly affecting children aged 5–15 years. A global resurgence of GAS infections has been observed since 2014, with a further post-pandemic upsurge in 2022–2023 attributed to waning population immunity and the emergence of hypervirulent clones such as M1UK. While adult cases have been increasingly reported, scarlet fever in elderly patients remains exceptionally rare, with population-based incidence rates below 0.01 per 100,000 in individuals over 65. We report a case of post-streptococcal glove-and-sock desquamation in a 63-year-old man.

Case Presentation

A 63-year-old man with no significant past medical history presented with extensive, symmetric desquamation of the hands and feet in a glove-and-sock distribution. He reported recurrent episodes of sore throat over the preceding weeks. He denied any drug intake, fever at presentation, or mucosal involvement.

Physical examination revealed large sheets of peeling skin on the palms, fingers, soles, and toes, without purpura. No residual sandpaper-like rash was noted on the trunk. There was no lymphadenopathy, strawberry tongue, or Pastia lines.

Laboratory workup revealed elevated anti-streptolysin O (ASO) titers, confirming recent streptococcal infection. Complete blood count, C-reactive protein, renal function, and urinalysis were unremarkable, ruling out post-streptococcal glomerulonephritis. The patient was treated with oral amoxicillin. The desquamation resolved spontaneously within two weeks without sequelae.

The glove-and-sock desquamation observed in this patient is the hallmark of the convalescent phase of scarlet fever. This late-phase peeling results from a delayed-type hypersensitivity reaction to GAS superantigens, including streptococcal pyrogenic exotoxins (SpeA, SpeC, SSA), which activate up to 20–30% of host T cells through non-conventional binding to MHC class II molecules and T-cell receptor Vβ regions. The resulting massive cytokine release leads to epidermal damage and subsequent desquamation, typically occurring 1–3 weeks after the initial exanthem.

In this elderly patient, the initial scarlatiniform rash was likely mild or subclinical, a phenomenon well recognized in adults where the exanthem may go unnoticed while the late desquamation phase becomes the presenting complaint.

The differential diagnosis of acral desquamation in a glove-and-sock pattern includes: (1) papular-purpuric gloves and socks syndrome (PPGSS), most commonly associated with parvovirus B19, characterized by edema, petechiae, and pruritus rather than sheet-like desquamation; (2) Kawasaki

disease , typically presenting in children with prolonged fever and periungual peeling; (3) toxic shock syndrome, associated with systemic toxicity and multiorgan failure; and (4) drug-induced desquamation. In our patient, the temporal relationship with pharyngitis, positive ASO titers, absence of purpura, and absence of drug exposure strongly supported post-scarlatinal desquamation.

The post-pandemic resurgence of GAS infections has been well documented, with a significant increase in both non-invasive and invasive disease in adults since 2022. A recent case report highlighted the importance of recognizing scarlet fever in adults presenting to the emergency department. However, cases in patients over 60 remain anecdotal. This case underscores the need for dermatologists to consider post-streptococcal desquamation in elderly patients presenting with unexplained acral peeling, particularly in the current epidemiological context.

Conclusion

Post-streptococcal desquamation can occur in elderly patients without a clinically apparent preceding rash. ASO titers should be obtained in any patient with unexplained acral desquamation following pharyngitis, regardless of age.

EADV CONGRESS
VIENNA
30 SEP - 3 OCT 2026

Abstract N°: 2835

Intralesional Measles–Mumps–Rubella Vaccine as Immunotherapy in Molluscum Contagiosum: Therapeutic Outcomes from a Prospective Study

Kavita Poonia*[1], sushama singh[2], Vishal Thakur[1], Dr Shivani Bansal[1]

[1] All India Institute of Medical Sciences, Bathinda, India

[2] Pragma Hospital, Bathinda, India

Introduction

Molluscum contagiosum is a mucocutaneous viral infection transmitted through direct contact or autoinoculation caused by the molluscum contagiosum virus. Management of molluscum contagiosum is quiet challenging, as conventional treatment are destructive modalities often shows variable efficacy, painful, cause scarring and are associated with recurrence. Immunotherapeutic approaches aim to enhance the host's cell-mediated immune response to enhance viral clearance.

Materials and Methods

This study was done to assess the efficacy and safety of intralesional MMR immunotherapy in MC patients. Forty two patients of MC were enrolled and received
0.2 ml dose of MMR vaccine was into the largest lesion every two weeks

Results

Out of 42 patients, complete clearance was observed in 26 (61.90%) patients, partial clearance in 10 (23.80%), and 6 (14.28%) exhibited minimal response. Mild swelling at the injection site was observed in 11 patients (26.19%) and 4 patients developed post inflammatory hyperpigmentation. Patients were followed up for 52 weeks and recurrence was noted only in one patient (2.3%). According to the patients' global assessment perceptions scoring system at week 22, 88% (37/42) of participants reported that their MC lesions either very much improved or much improved.

Conclusions

Intralesional MMR immunotherapy is an effective treatment modality in the management of molluscum contagiosum

EADV CONGRESS
VIENNA
30 SEP - 3 OCT 2026

Abstract N°: 2851

Asymptomatic isolated palmar bulla in a child: a deceptive presentation of HSV-1 Herpes Manuum

Lamiae Berrada*[1], Yassine Berrada[1], Syrine Hamada[1], Leila Benzekri[1]

[1] Ibn Sina University Hospital, Rabat, Morocco

Introduction

Herpetic infection of the hand (herpetic whitlow or herpetic manuum) typically presents as grouped, intensely painful vesicles on an erythematous base, most commonly affecting the distal phalanx. Solitary, strictly palmar, and entirely asymptomatic bullous presentations are exceptionally rare. This deceptive "single blister" appearance poses a significant diagnostic challenge, often mimicking benign friction blister or bullous impetigo, and carry a high risk of viral dissemination or auto-inoculation if mistakenly punctured.

Case Presentation

A 5-year-old otherwise healthy girl presented with a 5-day history of a solitary bullous lesion on her left (non-dominant) palm. There was no history of atopy, local trauma, friction, or contact with irritants. The mother had a history of recurrent herpes labialis. Remarkably, the child's lesion was completely asymptomatic, lacking the classical pain, burning sensation, or pruritus. Systemic symptoms and lymphadenopathy were absent. Physical examination revealed a tense, irregularly shaped, isolated bulla located on the thenar eminence, resting on an erythematous base. The lesion was cold and painless upon palpation. Dermoscopy showed multiple confluent, deep-seated vesicles firmly embedded within the dermis, creating a honeycomb pattern.

To rule out a mechanical blister or bullous impetigo,a sterile fine-needle aspiration of the serosanguinous fluid was carefully performed for polymerase chain reaction (PCR) analysis, which returned positive for Herpes Simplex Virus type 1 (HSV-1), confirming the diagnosis of palmar herpetic manuum due to hetero-inoculation.

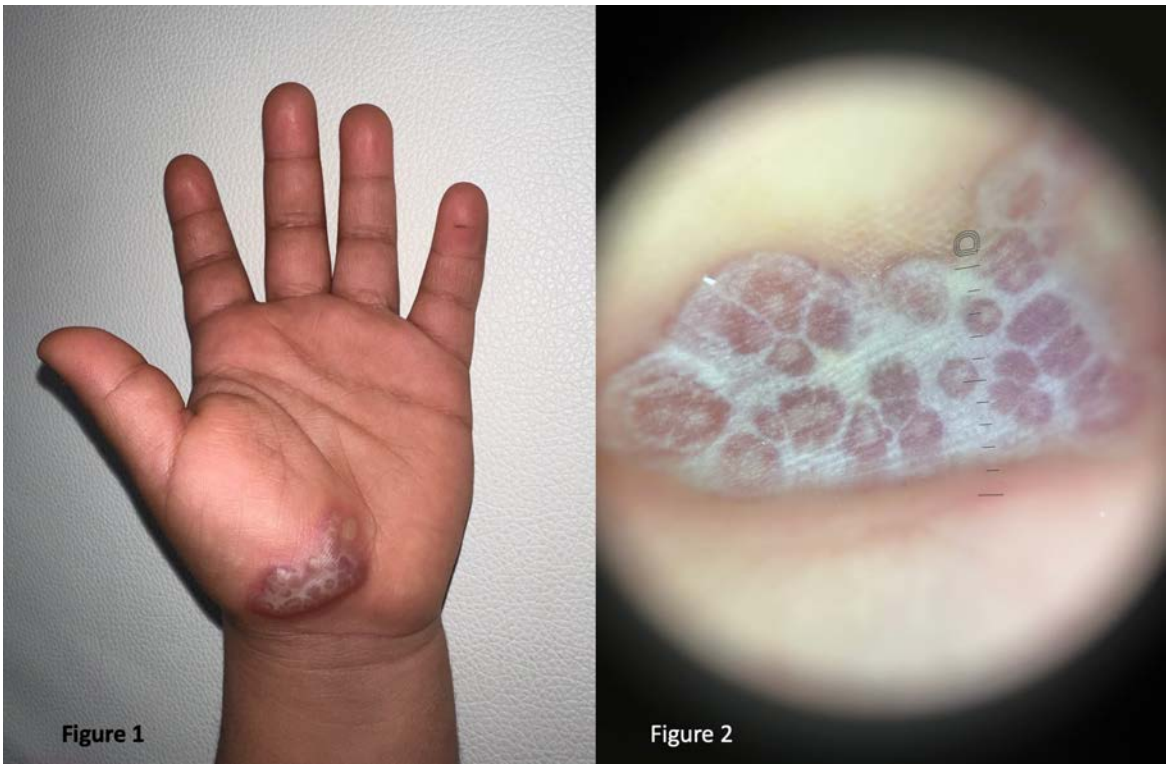

Solitary, asymptomatic palmar bulla (Figure 1) and its dermoscopic "honeycomb" pattern of deep vesicles (Figure 2).

Conclusion

This case underscores the phenotypic variability of HSV-1 infections on thick palmar skin. The stratum corneum can drastically alter the viral clinical expression, transforming a classically painful vesicular cluster into a deceptive, solitary, and entirely asymptomatic bulla. The differential diagnosis must carefully consider friction blisters, bullous impetigo, dyshidrotic eczema, and insect bite reactions. Recognizing the subtle clinical clue of "deep-seated" confluent vesicles is paramount to prevent misdiagnosis, avoid unnecessary antibiotics, and preclude contraindicated interventions such as surgical incision or blister deroofing, which carry a high risk of severe viral dissemination.

EADV CONGRESS
VIENNA
30 SEP - 3 OCT 2026

Abstract N°: 2853

Morbilliform Exanthem: A Rare Etiology Not to Be Missed

Fatima-Ezzahraa Zeroual*[1], Maha Habibi[1], Florent Grange[1]

[1] Department of Dermatology, Valence Hospital Center, Valence, France

Introduction

Morbilliform eruptions are a common reason for dermatological. Their clinical presentation is often non-specific and encompasses a broad spectrum of etiologies, ranging from benign viral infections to more severe systemic diseases. We report the case of a patient referred for a febrile morbilliform rash occurring in the context of sepsis and recent antibiotic exposure, associated with purpuric and vasculitic features, revealing an unusual etiology.

Case Presentation

A 41-year-old woman with no significant past medical history presented to the emergency department with sepsis syndrome, occurring four weeks after initiation of cefixime for symptoms including fever, chills, headache, and pollakiuria, and five days after initiation of amoxicillin–clavulanic acid prescribed for suspected cholecystitis following the onset of abdominal pain associated with hepatic cytolysis.

On clinical examination, the patient was confused and hemodynamically and respiratory unstable. Physical examination revealed facial edema (Figure), bilateral cervical lymphadenopathy, and left axillary lymphadenopathy. Dermatological examination demonstrated a morbilliform maculopapular exanthem involving the trunk and upper limbs (Figure), associated with infiltrated petechial purpura predominantly affecting the lower extremities (Figure). Oral examination showed vesicular lesions on the palate without enanthem.

Laboratory investigations revealed an inflammatory syndrome without eosinophilia, hepatic cytolysis, or other significant abnormalities. Skin biopsy demonstrated leukocytoclastic vasculitis without specific features.

Given the clinical and laboratory findings, the main differential diagnoses included drug-induced hypersensitivity reaction, as well as infectious etiologies, mainly viral or bacterial. Investigation for superficial or deep infectious foci remained negative, notably with no evidence of pneumonia or intra-abdominal infection. Blood cultures, urine culture, viral PCR assays for EBV, CMV, HSV, HHV-6, HHV-8, parvovirus B19, and Mycoplasma, as well as serologies for viral hepatitis, HIV, CMV, toxoplasmosis, syphilis, Bartonella, and Brucella, were negative. However, Q fever serology demonstrated high titers of both IgG and IgM antibodies.

Treatment with doxycycline at a daily dose of 200 mg was initiated for a duration of three weeks, resulting in rapid and marked clinical improvement, with resolution of fever and complete clearance of skin lesions, as well as normalization of inflammatory markers.

Discussion :

Q fever is a zoonosis caused by *Coxiella burnetii*, an obligate intracellular bacterium transmitted mainly by inhalation of contaminated aerosols from livestock. Acute infection typically presents as isolated fever, atypical pneumonia, or hepatitis, while chronic forms are mainly represented by culture-negative endocarditis (1).

Cutaneous involvement is rare and non-specific. In a Croatian series of 155 cases, skin manifestations were exceptional compared to hepatic or pulmonary involvement (2). However, isolated reports highlight that Q fever

may present with polymorphous exanthems mimicking other diagnoses. Boele van Hensbroek et al. described a pediatric case with febrile maculopapular exanthem and petechiae without visceral involvement (3). Unlike rickettsial infections, *C. burnetii* does not typically cause direct endothelial injury, suggesting an immune-mediated mechanism. Similarly, Koh et al. reported leukocytoclastic vasculitis associated with Q fever, likely immune complex-mediated (4).

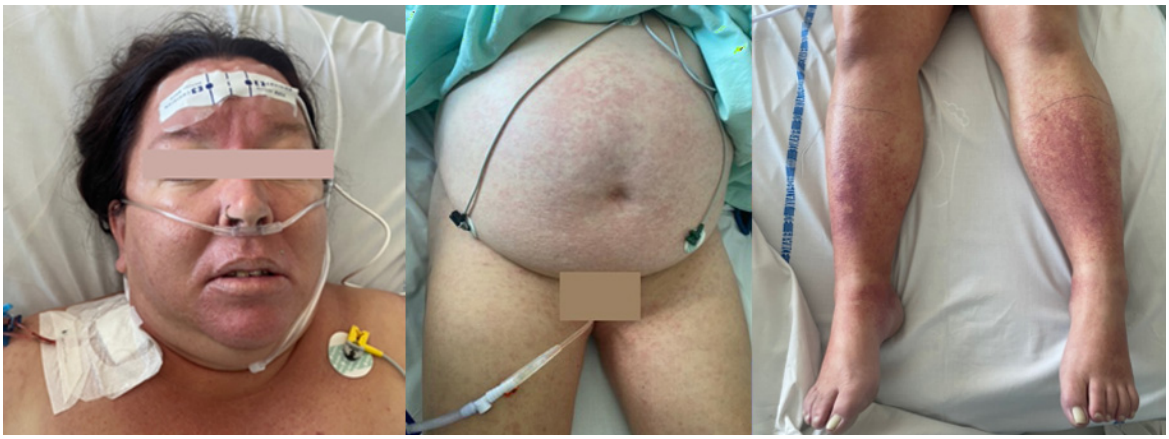

Figure. Clinical presentation of the rash

Conclusion

Although exceedingly rare, Q fever should be considered in the differential diagnosis of febrile morbilliform eruptions when no conventional etiology is identified, particularly in the presence of atypical clinical features and/or associated purpura. Recognition of this diagnosis allows prompt initiation of effective doxycycline therapy and may prevent unnecessary investigations for drug-induced reactions or autoimmune vasculitis.

EADV CONGRESS
VIENNA
30 SEP - 3 OCT 2026

Abstract N°: 2868

Bullous erysipelas mimicking carcinomatous lymphangitis

Afafe JEI*[1], bouchra baghad[1], Hanane Rachadi[1], Soumiya Chiheb[1]

[1] Dermatology departement, Ibn Rochd University Center, casablanca, Morocco

Introduction

Erysipelas is a common acute bacterial dermohypodermitis typically characterized by a painful erythematous plaque with distinct border associated with fever and inflammatory syndrome. However, atypical presentations may occur, particularly in elderly patients with multiple comorbidities and underlying lymphatic impairment, leading to important diagnostic challenges. We report an unusual case of bullous erysipelas with pseudo-neoplastic lymphedematous presentation in a patient with a history of urothelial carcinoma, highlighting the diagnostic difficulties, broad differential diagnoses, and the importance of clinicopathological correlation in excluding carcinomatous lymphangitis and neutrophilic dermatosis.

Case Presentation

A 74-year-old man with hypertension treated with amlodipine, type 2 diabetes, chronic smoking, prior surgery for cervical spondylotic myelopathy complicated by spastic paralysis (2022), high-grade papillary urothelial carcinoma operated in September 2025, and two previous episodes of erysipelas, was admitted for a swollen, warm, red, painless left leg evolving for 22 days over pre-existing lower limb edema progressing for 6 weeks. Oral antibiotics had been ineffective.

Examination showed an infiltrated erythematous plaque of the left leg with multiple bullous lesions, some purulent and others erosive, mainly involving the lower two-thirds of the leg. The lesions had irregular but well-defined borders and overlaid diffuse lymphedema of the entire limb with a peau d'orange and sclerodermiform appearance. Diffuse desquamation gave an eczematous aspect. Plantar dyshidrosis and interdigital intertrigo were present without necrosis, sensory loss, or crepitus. A fixed, painless left inguinal lymph node measuring 2.5 cm was palpable.

Deep vein thrombosis was excluded by venous Doppler ultrasound. Soft tissue ultrasound showed diffuse infiltration without collection. In view of the oncological history, carcinomatous lymphangitis and paraneoplastic Sweet syndrome were considered. Blood count and CRP were normal. Urinary assessment and renal-bladder ultrasound showed no abnormalities. Lymph node ultrasound revealed a 22 mm inguinal lymph node without suspicious features. Skin biopsy excluded both Sweet syndrome and carcinomatous lymphangitis.

The patient was treated with amoxicillin-clavulanic acid (50 mg/kg/day), local care, and limb elevation, with marked improvement by day 4. Antibiotics were continued for 21 days, and antifungal treatment was initiated for onychomycosis and interdigital intertrigo. Secondary antibiotic prophylaxis was indicated, and the patient was referred for oncological follow-up.

Conclusion

This case illustrates an atypical presentation of erysipelas mimicking carcinomatous lymphangitis in a high-risk oncological patient. The originality of this report lies in the coexistence of chronic infiltrated lymphedema with

peau d’orange appearance, fixed inguinal lymphadenopathy, normal inflammatory markers, and poor initial response to oral antibiotics, which raised suspicion of carcinomatous lymphangitis and paraneoplastic dermatosis. Favorable evolution under appropriate antibiotic therapy and exclusion of malignant and inflammatory differential diagnoses by imaging and histopathology confirmed the infectious origin. This observation underlines the importance of considering atypical erysipelas in the differential diagnosis of unilateral inflammatory lymphedema, particularly in elderly patients with cancer history and lymphatic fragility.

EADV CONGRESS
VIENNA
30 SEP - 3 OCT 2026

Abstract N°: 2877

Exuberant Lymphadenopathy in Multibacillary Leprosy: An Uncommon Presentation

Mariane Araujo*[1], Fernando Lima[1], Beatriz dos Reis[1], Danielle Quintella[2], Tullia Cuzzi[2], Cecília Sequeira[1]

[1] Sector of Dermatology and Post Graduation Course, University Hospital and School of Medicine, Federal University of Rio de Janeiro, Rio de Janeiro, Brazil
[2] Department of Pathology, School of Medicine, Federal University of Rio de Janeiro, Rio de Janeiro, Brazil

Introduction
Despite advances in science and the implementation of multidrug therapy (MDT), countries such as India, Brazil and Indonesia still account for most reported leprosy cases, reflecting persistent socioeconomic inequalities and challenges in early diagnosis. Leprosy has a broad clinical spectrum, ranging from paucibacillary to multibacillary forms, with cutaneous, neurological and systemic involvement. Classic features include hypopigmented or erythematous macules with sensory loss, peripheral nerve thickening and muscle weakness. Atypical presentations may delay diagnosis.

Leprosy reactions can occur at any stage, most often during MDT and are classified as type 1 (reversal reaction) or type 2 (erythema nodosum leprosum). Rarely, they represent the initial manifestation. We report a rare and diagnostically challenging case of borderline multibacillary leprosy with a type 2 reaction and atypical onset, masked by chronic corticosteroid use.

Case Presentation
A 32-year-old man with type 2 diabetes mellitus secondary to chronic self-medicated with corticosteroid was admitted for investigation of weight loss and intermittent lymphadenopathy, which partially regressing with corticosteroids use. He reported recurrent macules on the face and trunk that with corticosteroid. At admission, he was in use of prednisone 80 mg/day.

Physical examination revealed bilateral violaceous axillary striae, cervical lymphadenopathy, painful suppurative and fistulizing lymphadenopathy in the left inguinal region, right inguinal lymphadenopathy, and a nonspecific erythematous papule on the right elbow.

Corticosteroid tapering was initiated. Laboratory tests revealed leukocytosis; serologies for syphilis, HIV and viral hepatitis were negative, as were tests for gonorrhea and chlamydia. Computed tomography showed diffuse lymphadenopathy and splenomegaly, without pulmonary findings suggestive of tuberculosis. Swab of suppurative lymph node exudate revealed acid-fast bacilli forming globi, while GeneXpert testing was negative.

After corticosteroid reduction, the patient developed fever and new erythematous-infiltrated papules and plaques, some with pseudovesiculation and central clearing, on the face, neck and trunk, along with auricular infiltration. Neurological evaluation revealed bilateral sensory impairment in the feet.

Bacillary index of 3+ was assessed from skin biopsy and slit-skin smear and histopathological exam revealed perivascular and periadnexial dermatitis extending focally to the hypodermis, composed of Virchow cells, epithelioid macrophages and neutrophils, with acid-fast bacilli easily detected.

A diagnosis of borderline multibacillary leprosy associated with a type 2 reaction with Sweet syndrome–like clinical features was established. MDT-MB and corticosteroids were initiated, with progressive improvement and

resolution of lesions and lymphadenopathy.

Conclusion

Leprosy remains a diagnostic challenge due to its variable presentation. This case highlights an unusual initial manifestation in which prominent and fistulized lymphadenopathy predominated, overshadowing typical dermatological signs. Sweet-like syndrome reactions in leprosy are rare, and the predominance of lymph node involvement is even less frequently reported, often mimicking infectious or lymphoproliferative diseases, posing a significant diagnostic challenge.

Chronic corticosteroid use further masked classical findings and delayed diagnosis. Its reduction was essential to reveal the underlying condition, although it temporarily exacerbated symptoms. This case underscores that leprosy reactions may represent the initial manifestation of the disease.

Overall, this case emphasizes the importance of including leprosy in the differential diagnosis of unexplained lymphadenopathy in endemic regions, especially when atypical features are present, to ensure timely diagnosis and reduce the risk of complications.

EADV CONGRESS
VIENNA
30 SEP - 3 OCT 2026

Abstract N°: 2882

Facial Erythema in Children - Is It Always Atopic Dermatitis?

Dora Madiraca Glasović*[1], Dajana Smoljan Filipović[1, 2], Renata Tomašević[1, 2], Nika Franceschi[1], Iva Blajić[1], Mirna Situm[1, 2]

[1] Sestre Milosrdnice University Hospital Centre, Department of Dermatology and Venerology, Zagreb, Croatia
[2] School of Dental Medicine, Zagreb, Croatia

Introduction

Facial erythema in children is a common clinical finding that is frequently atributed to atopic dermatitis in everyday practice. However, a similar clinical presentation may occur in a variety of other dermatoses, including infectious diseases, which can represent a diagnostic challlenge. In addition, empirical use of topical corticosteroids may alter ther clinical appearance and delay the correct diagnosis.The aim of this report is to present the diagnostic challenge of pediatric facial erythema and to emphasize the importance of a thorough differential diagnostic approach, particulary in cases with poor response to standard therapy for atopic dermatitis.

Case Presentation

We present the case of a six-year-old boy referred by an ophthalmologist because of erythema of the left periocular region accompanied by a burning sensation. The child had previously been healthy and was not receiving chronic therapy. Clinical examination revealed a sharply demarcated erythematous plaque with marginal scaling localized in the left periocular area, involving the upper and lower eyelid and supraorbital region, with extension toward the nasal dorsum. Initial treatment prescribed by the ophthalmologist consisted of topical corticosteroid therapy (alclometasone dipopionate) twice daily for seven days, without clinical improvement. The patient was subsequently referred to the Department of Dermatology and Venerology at Sestre Milosrdnice University Hospial Centre, where mycological examination identified Trichophyton mentagrophytes. Following confirmation of the dermatophyte infection, topical terbinafine therapy was initiated twice daily for three weeks, resulting in complete regression of the skin lesions.

Conclusion

This case highlights that facial erythema in childhood does not necessarily represent atopic dermatitis. In the presence of atypical clinical features, unilateral localization, or lack of response to standard therapy, the differential diagnosis should be broadened to include infectious causes, particularly dermatophyte infections. Early recognition and mycological evaluation are essential for establishing the correct diagnosis, initiating appropriate treatment, and preventing unnecessary use of topical corticosteroids.

EADV CONGRESS
VIENNA
30 SEP - 3 OCT 2026

Abstract N°: 2913

When a tumor is not a tumor: cutaneous pheohyphomycosis mimicking soft tissue malignancy

Joana Margarida Reis*[1], José Ramos[1], Joana Nogueira[2], Rita Pimenta[1], João Alves[1], Adelina Costin[1]

[1] Serviço de Dermatovenereologia, Unidade Local de Saúde Almada-Seixal, Almada, Portugal
[2] Serviço de Anatomia Patológica, Unidade Local de Saúde Almada-Seixal, Almada, Portugal

Introduction

Pheohyphomycosis is a rare opportunistic fungal infection caused by melanized (dematiaceous) fungi, typically affecting immunocompromised hosts. *Exophiala dermatitidis*, a black yeast belonging to the order Chaetothyriales, is an uncommon etiological agent capable of causing a wide spectrum of disease, ranging from superficial to life-threatening systemic infections. These infections are often chronic, difficult to diagnose, and may mimic neoplastic processes. We report a case of localized cutaneous pheohyphomycosis due to *Exophiala dermatitidis*, initially suspected to represent a soft tissue malignancy based on clinical and metabolic imaging findings.

Case Presentation

A 49-year-old man with a history of systemic sarcoidosis involving the lymph nodes, lungs, and peripheral nervous system, as well as rheumatoid arthritis, presented with a one-week history of fever, dyspnea, and productive cough while receiving immunosuppressive therapy with methotrexate (25 mg/week), prednisolone (20 mg/day), and hydroxychloroquine (400 mg/day). He was admitted to the Pneumology Department with presumed pneumonia in an immunosuppressed host and started on piperacillin/tazobactam. Due to lack of clinical improvement and the identification of multiple new pulmonary nodules on chest computed tomography, a positron emission tomography scan was performed, revealing intense hypermetabolic activity (SUVmax 24.8), corresponding to a subcutaneous lesion on the lateral aspect of the left thigh and representing the highest uptake in the entire examination. Physical examination identified a well-circumscribed, firm subcutaneous nodule adherent to deep planes but mobile over superficial tissues, without pain, erythema, or overt inflammatory signs, although mild overlying scaling was present. Given the marked FDG uptake and clinical presentation, soft tissue sarcoma was initially considered, with lipoma deemed less likely. An excisional biopsy was performed and grayish purulent material was drained intraoperatively and sent for microbiological analysis. Histopathological examination demonstrated an extensive granulomatous inflammatory infiltrate involving the deep dermis and hypodermis, composed of numerous multinucleated giant cells and focal areas of necrosis. Periodic acid–Schiff staining revealed abundant fungal spores and short hyphal elements, consistent with fungal infection, while the epidermis and superficial dermis were unremarkable. Microbiological culture identified Exophiala dermatitidis, a slow-growing dematiaceous fungus characterized by black yeast-like colonies with polymorphic filamentous transformation. A diagnosis of localized cutaneous pheohyphomycosis was established. The patient was treated with oral itraconazole 200 mg/day for six weeks, with complete clinical resolution and no evidence of recurrence.

Conclusion

This case illustrates the significant diagnostic overlap between infectious and neoplastic processes, particularly in immunocompromised patients. The lesion's firm consistency, deep fixation, and intense FDG uptake on PET imaging strongly suggested malignancy, highlighting that fungal infections such as pheohyphomycosis may closely mimic soft tissue tumors both clinically and metabolically. *Exophiala dermatitidis* infections, although rare, should be considered in the differential diagnosis of atypical subcutaneous nodules in immunosuppressed individuals. Early recognition is crucial, as appropriate antifungal therapy can lead to complete resolution, avoiding unnecessary aggressive interventions.

EADV Congress 2026, VIENNA
30 SEPTEMBER - 03 OCTOBER 2026
POWERED BY M-ANAGE.COM

EA DV CONGRESS
VIENNA
30 SEP - 3 OCT 2026

Abstract N°: 2914

QUALITY OF LIFE IN PATIENTS WITH LEPROSY: correlation of the Dermatology Life Quality Index with clinical and epidemiological variables related to the disease

Carolina Julieta Postai de Araujo Santos[1], Karina Miroski[2], Ana Garcia[2], Ana Vitória Coppoli Siva[1], Laisa Goulart Saviatto Picasky*[1], Roberto Amorim Filho[1], Gustavo Amorim[1], Bárbara Hartung Lovato[1]

[1] Santa Tereza Sanitary Dermatology Hospital, São Pedro de Alcântara, Brazil

[2] University of Southern Santa Catarina (UNISUL), São José, Brazil

Introduction

Leprosy is a chronic infectious disease caused by *Mycobacterium leprae*, with a variable clinical spectrum and potential to cause permanent physical disabilities. Its psychosocial repercussions and the stigma associated with the disease significantly affect patients' quality of life (1,2). The **Dermatology Life Quality Index (DLQI)** is a validated instrument used to assess the impact of dermatologic diseases on quality of life and has also been applied to leprosy (3). This study aimed to evaluate the quality of life of patients with leprosy using the DLQI and correlate the scores with clinical and epidemiological variables, including disease classification, occurrence of leprosy reactions during treatment, disability grade (DG), and neurological symptoms.

Materials and Methods

This cross-sectional observational study applied the DLQI to patients followed at a State Reference Outpatient Clinic for Leprosy. Clinical and epidemiological data were collected from 53 patients currently receiving or who had previously received multidrug therapy (MDT). Data were obtained through medical record review and recorded on a standardized form. Patients who agreed to participate completed the DLQI during routine consultations. Data were analyzed using SPSS version 31 with the Chi-square test and a significance level of 5%.

Results

Among the 53 participants, 69.8% were male and 30.2% female, with a mean age of 44.92 ± 15 years and a mean age at diagnosis of 40.57 ± 15.62 years. Most patients were multibacillary (83%) and 45.3% were classified as lepromatous. At the time of data collection, 49.1% were undergoing MDT, 58.5% had experienced leprosy reactions at some point, and 58.5% reported neurological symptoms. Most patients had disability grade 1 (56.6%), and the mean eye-hand-feet (EHF) score was 3.92 ± 2.41. Most individuals (54.7%) were not originally from Santa Catarina, 58.5% had lived in other Brazilian states, and 39.6% reported previous residence in endemic areas. Additional epidemiological data are summarized in Table 1.

Approximately one-third of patients, regardless of sex, presented severe impairment in quality of life (Graph 1). Among paucibacillary cases, moderate impairment predominated (44.4%), whereas 50% of multibacillary patients presented severe to very severe impact (Graph 2). Patients without previous reactions mostly showed absent to moderate impact on quality of life (63.6%), while more than half of those with reactions (51.6%) presented severe to very severe impairment (Graph 3). Patients with neurological symptoms tended to present worse DLQI scores (Graph 4), and lower disability grades were associated with a trend toward less impairment in quality of life (Graph 5 and Table 2).



Table 1. Clinical, epidemiological, and quality-of-life variables of patients with leprosy. Table 2. Correlation of clinical and epidemiological variables with quality-of-life impact in patients with leprosy. Graph 1: Correlation between the Dermatology Life Quality Index and sex. Graph 2: Correlation between the Dermatology Life Quality Index and WHO classification. Graph 3: Correlation between Dermatology Life Quality Index and history of leprosy reactions. Graph 4: Correlation between Dermatology Life Quality Index (DLQI) and history of neurological symptoms. Graph 5: Correlation between Dermatology Life Quality Index and Degree of Physical Disability.

Conclusions

Leprosy had a significant impact on patients' quality of life, with possible effects that may persist beyond the treatment period. The mean DLQI score (10.34) was similar to that reported by Martins et al. (1) and higher than those observed in dermatoses such as alopecia areata, vitiligo, and urticaria (4). Chronic dermatoses generally have a greater impact on quality of life than acute conditions (5). Although leprosy is infectious, its sequelae may become chronic, which may explain the high DLQI scores observed. Previous studies have shown that sequelae are associated with worse quality-of-life outcomes (2). In our sample, worse DLQI scores were more frequent among multibacillary patients, those with reactions, and those with irreversible sequelae, reinforcing the importance of early diagnosis and appropriate management to prevent complications.

EADV CONGRESS
VIENNA
30 SEP - 3 OCT 2026

Abstract N°: 2915

Nontuberculous Mycobacterial Infection After Cosmetic Procedures: an Emerging Reality Following the Popularization of Aesthetic Interventions

Alessandra Krykhtine[1], Érica França[1, 1], Evelyn Rubin[2], Beatriz Moritz Trope[1], Marcia Ramos-e-Silva[1], Giselle Seabra*[1]

[1] FEDERAL UNIVERSITY OF RIO DE JANEIRO, Rio de Janeiro, Brazil

[2] Oswaldo Cruz Foundation, Rio de Janeiro, Brazil

Introduction

The increasing demand for invasive aesthetic procedures in contemporary society has led to the widespread use of techniques such as fillers, mesotherapy, and liposuction. The accessibility of these procedures, often performed by non-medical professionals, increases patient exposure to improper sterilization and contaminated substances. Consequently, complications have risen, including skin and soft tissue infections caused by nontuberculous mycobacteria.

These microorganisms are commonly found in non-sterile water sources, soil, and dust. The most frequently identified species in skin infections are the *Mycobacterium abscessus* complex, followed by *M. fortuitum*. Diagnosis is often delayed and requires specific investigation. Without accurate identification, these infections are frequently inadequately treated, leading to delayed resolution.

Complications related to those bacterias are commonly associated with mesotherapy, followed by abdominoplasty, breast implants, fat grafting, mastopexy, liposuction, and injectable procedures. Antibiotic therapy is employed with or without surgical resection of the focus. It typically involves a combination of macrolides with one or two additional agents, depending on disease extent and culture results. However, clinical guidelines remain poorly established. Treatment duration usually begins at six months and may extend to 12–24 months.

Surgical management plays a crucial role alongside medical therapy. It allows for mycobacterial culture sampling and removal of affected tissue, contributing to a shorter duration of antibiotic treatment and, consequently, fewer side effects.

Case Presentation

A 40-year-old female patient, with no comorbidities, developed nodular lesions in the anterior cervical region and face in July 2024 after submental liposuction performed by a dentist. An initial skin biopsy was nonspecific, and aspirated material had negative culture tests. Dermatologic ultrasonography was performed using linear transducers with a maximum frequency of 22 MHz, including Doppler evaluation, and revealed dermo-hypodermal fistulous tracts with hypoechoic content and increased vascularization, suggestive of active infection.

The patient had not received prior antibiotic therapy. Physical examination showed hyperchromic macules and scar tissue in the cervical and mandibular regions. Surgical excision of infectious foci was performed in two stages. In the first one, collected samples yielded negative culture results. After two months, there was reactivation of the infectious focus. During the second stage, hardened scar tissue, fistulous tracts, and abundant purulent discharge —in the left mandibular region—were observed intraoperatively.

Samples from excised tissue and aspirated material were sent for histopathology, acid-fast bacilli (AFB) testing, and cultures. AFB positivity was identified, and mycobacterial culture was positive for *Mycobacterium abscessus* complex. To date, the patient has not initiated antibiotic therapy and remains with excellent disease control.

Conclusion

Nontuberculous mycobacterial infections of the skin and subcutaneous tissue following invasive cosmetic procedures are becoming increasingly common due to the growing popularity of aesthetic interventions, often performed under suboptimal conditions and by non-medical professionals. Diagnosis is challenging and frequently delayed, particularly because the culture positivity rate for nontuberculous mycobacteria is only approximately 45%, contributing to prolonged treatment and increased healthcare costs.

This case highlights the importance of recognizing this entity as a potential cause of late skin infections after invasive aesthetic procedures.

EA DV CONGRESS
VIENNA
30 SEP - 3 OCT 2026

Abstract N°: 2930

A retractile scar with a hidden diagnosis: multifocal cutaneous tuberculosis

Kenza Benothmane*[1], Yasmine Zekraoui[1], Fatima Ez-zahraa Sassine[1], Narjess Errachdy[1], Najoua Ammar[1], Syrine Hamada[1], Mariame Meziane[1], Laila Benzekri[1], Nadia Ismaili[1]

[1] Department of Dermatology, Ibn Sina University Hospital, Rabat, Morocco

Introduction

Cutaneous tuberculosis is a rare form of extrapulmonary tuberculosis, characterized by marked clinical polymorphism and frequent diagnostic delay due to its paucibacillary nature. Scrofuloderma, also known as *tuberculosis cutis colliquativa*, classically results from contiguous extension of an underlying tuberculous focus, most often lymph node, bone, or joint involvement, toward the skin. It usually presents as chronic nodules, cold abscesses, sinus tracts, or ulcers, but may also evolve into misleading retractile scars.

Case Presentation

We report the case of a 64-year-old woman with no significant medical history, presenting with a chronic sternal skin lesion evolving for one year with a gummatous course. On examination, the sternal lesion had evolved into an erythematous retractile scar. A second lesion had appeared on the buttock a few weeks earlier, presenting as a 4-cm ulcer with undermined violaceous borders and a yellowish fibrinous base.

A skin biopsy performed from the sternal lesion revealed multiple epithelioid and giant-cell granulomas without caseous necrosis, associated with a fibrino-leukocytic epidermal exudate, acanthosis, and orthokeratotic hyperkeratosis. GeneXpert testing was positive for *Mycobacterium tuberculosis*. Sputum acid-fast bacilli smears performed on three consecutive days were negative.

The extension work-up, including chest X-ray, lymph node assessment, abdominal ultrasound, and urine culture, was unremarkable. A sternal X-ray showed no underlying bone involvement. Based on the chronic gummatous evolution, granulomatous histology, and positive GeneXpert result, the diagnosis of multifocal scrofuloderma was retained. The patient was started on standard anti-tuberculous therapy with ERIP-K4.



Conclusion

Scrofuloderma should be considered in any chronic gummatous skin lesion, retractile scar, or persistent ulcer, even in the absence of systemic or bone involvement. Granulomatous histology without caseous necrosis does not exclude cutaneous tuberculosis. GeneXpert is a valuable diagnostic tool in atypical or paucibacillary forms, allowing rapid confirmation and early initiation of anti-tuberculous therapy.

EADV CONGRESS
VIENNA
30 SEP - 3 OCT 2026

Abstract N°: 2948

Tinea caused by Trichophyton mentagrophytes genotype VII: a new sexually transmitted infection?

Valentina Honorati*[1], Elisabetta Rizzo[1], Aurora Pini[1], Michelangelo La Placa[1], Federico Bardazzi[1]

[1] DIMEC, Università di Bologna, Italia Unità di Dermatologia, IRCCS, Azienda Ospedaliero-Universitaria di Bologna, Bologna, Italia, Bologna, Italy

Introduction
Trichophyton mentagrophytes genotype VII (TMVII) is an emerging dermatophyte increasingly recognized as a sexually transmitted infection, particularly among men who have sex with men, presenting with inflammatory, pruritic, annular lesions on the face or genital areas. We describe two young MSM patients on PrEP with recent-onset beard lesions, both positive for fungal elements on microscopy and later confirmed as TMVII by culture. Initial treatment with oral terbinafine and topical ciclopirox led to only partial improvement; one case required prolonged terbinafine, while the other responded to itraconazole after terbinafine failure. Both patients achieved complete resolution with adjusted therapy. TMVII infections may be persistent and require tailored or prolonged antifungal treatment, highlighting the need for increased clinical awareness, appropriate management, and screening to prevent transmission.

Case Presentation
We report two young male patients presenting with recent-onset (5 and 8 days) inflammatory lesions in the beard area. Both had unremarkable medical histories, were on HIV pre-exposure prophylaxis (PrEP), and reported high-risk MSM sexual behavior with negative routine STI screening. The first patient showed erythematous, scaly patches with honey-colored crusts in the nasolabial area and a similar lesion in the axilla, partially modified by prior topical corticosteroid-antibiotic treatment. The second patient presented with a well-defined annular scaly lesion in the beard region. Direct microscopy was positive for fungal elements in both cases. Initial treatment with oral terbinafine (250 mg/day) plus topical ciclopiroxolamine led to only partial improvement after four weeks, and one patient reported similar lesions in his partner. Culture confirmed TMVII infection. Treatment was subsequently adjusted: terbinafine was extended to 8 weeks in one case, while the other was switched to oral itraconazole (200 mg/day) for 4 weeks. Both patients achieved complete clinical resolution.

Conclusion
TMVII should be considered an emerging STI, particularly in MSM patients presenting with inflammatory tinea in the beard or genital areas. Diagnosis may be delayed or masked by inappropriate topical therapies, and standard antifungal regimens may require prolongation or modification. Terbinafine remains first-line, but alternative agents such as itraconazole may be necessary in persistent cases. Increased clinical suspicion, appropriate mycological testing, and tailored treatment strategies are essential to ensure effective management and limit transmission.

EADV CONGRESS
VIENNA
30 SEP - 3 OCT 2026

Abstract N°: 2953

Inflammatory exacerbation of microsporic tinea under itraconazole: treatment failure or immune reaction?

assia zenagui*[1], K Bouchenak[1]

[1] CHU Dr Tidjani Damerdji of Tlemcen, Faculty of Medicine, Tlemcen, Algeria

Introduction

Dermatophytoses are common superficial fungal infections. Itraconazole is widely used in their management; however, cases of therapeutic failure or clinical exacerbation may occasionally occur. We report the case of a patient with microsporic tinea capitis treated with itraconazole, whose course was marked by the development, two weeks after treatment initiation, of a superinfected inflammatory form.

Case Presentation

We report the case of a 5-year-old child treated for microsporic tinea capitis initially managed with itraconazole.

Two weeks after treatment initiation, the patient developed a painful, infiltrated, suppurative and extensive inflammatory lesion consistent with a superinfected inflammatory tinea capitis.

Given this clinical worsening, treatment was switched to Terbinafine, along with appropriate management of bacterial superinfection.

The clinical outcome was favorable, with marked regression of inflammation and progressive improvement, although residual areas of cicatricial alopecia persisted.

Discussion :

The occurrence of inflammatory tinea during antifungal therapy does not correspond to a direct adverse effect of treatment, but may be explained by several mechanisms:

- An inflammatory reaction secondary to fungal antigen release following fungal lysis
- Relative inefficacy of itraconazole, particularly in resistant or less susceptible strains
- Primary infection by a highly inflammatory dermatophyte species

Terbinafine, a fungicidal agent, demonstrates superior efficacy in certain dermatophytic infections, allowing rapid reduction of fungal burden and inflammatory response.

Bacterial superinfection is a well-recognized complication of inflammatory forms and requires appropriate management.

Conclusion

This case illustrates the possibility of inflammatory exacerbation of dermatophytosis under itraconazole therapy. It highlights the importance of early therapeutic adjustment, particularly switching to terbinafine, in cases of unfavorable evolution in order to prevent scarring sequelae.

EA DV CONGRESS
VIENNA
30 SEP - 3 OCT 2026

Abstract N°: 2967

When the Joint Speaks to the Skin : Scrofuloderma Secondary to Tuberculous Arthritis in an Immunocompetent Adult

Bounneche Houda*[1], Amel Gherfi[1], Tarek Mansoul[1], esma bouhila[1], RIADH BOUSSAID[1], khadidja bouarroudj[1], kaghouche lilia[1], safa djebbas[1], Ahmed Samaouel Chehad[1]

[1] Department of Dermatology, University Hospital, Constantine, Algeria

Introduction

Scrofuloderma is a rare cutaneous form of tuberculosis resulting from contiguous spread from an underlying deep focus, most commonly lymph nodes or bone. In immunocompetent adults, it represents a diagnostic challenge, particularly when associated with tuberculous arthritis. We report a case of scrofuloderma secondary to tuberculous arthritis, highlighting the importance of early recognition of cutaneous lesions to ensure accurate diagnosis and appropriate management.

Case Presentation

A 28-year-old immunocompetent patient, with no known tuberculosis exposure, presented with painful right knee arthritis and functional impairment for 18 months, associated with fever and night sweats, refractory to conventional antibiotics. Three months before admission, a subcutaneous swelling developed on the supero-posteromedial right leg, progressing to ulceration with purulent and bloody discharge. Synovial fluid was negative for acid-fast bacilli, but culture on Löwenstein–Jensen medium grew *Mycobacterium tuberculosis* at day 28. Skin biopsy showed epithelioid and giant cell granulomas with necrosis. Standard antituberculous therapy (RHZE) led to marked improvement of both joint and skin lesions.

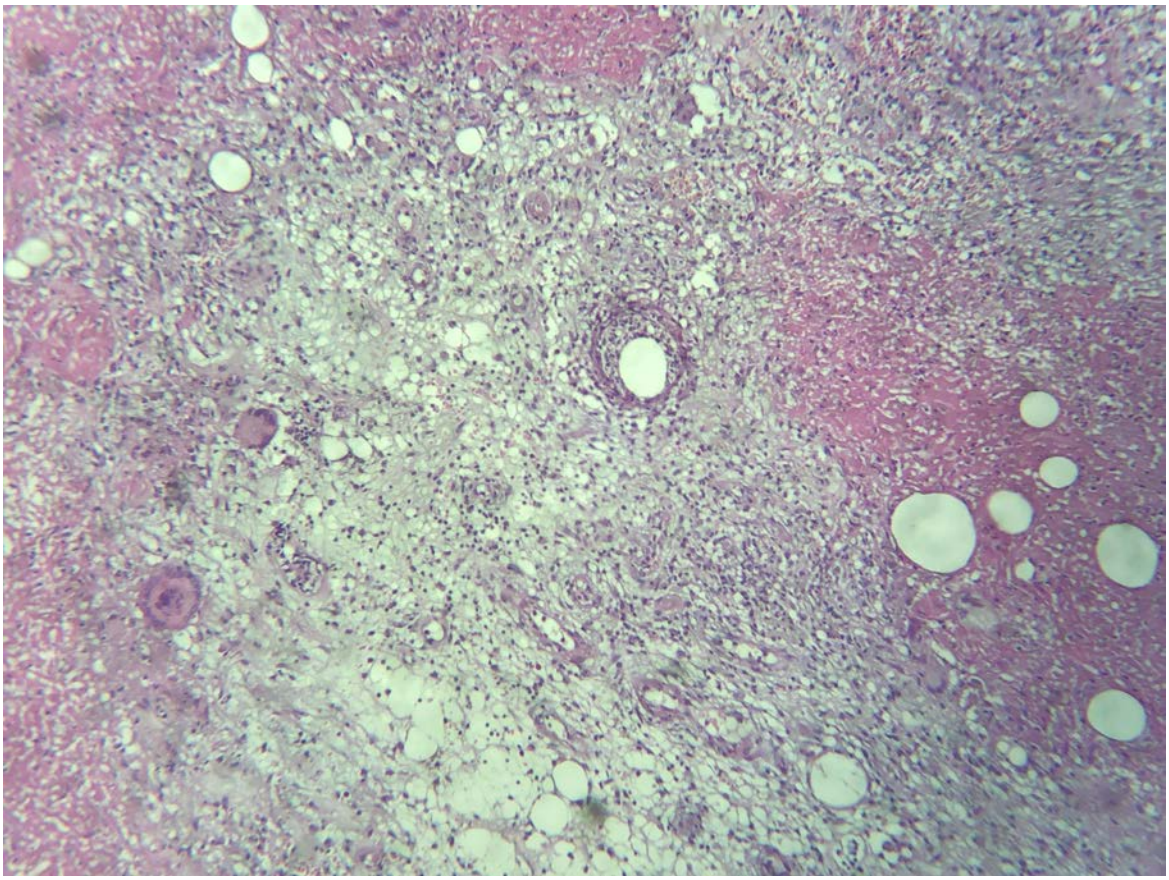

epithelioid and giant cell granulomas with necrosis

Conclusion

Scrofuloderma in this patient resulted from direct extension of tuberculous arthritis. Though rare, cutaneous tuberculosis can occur in immunocompetent adults without known exposure. The 18-month antibiotic-resistant course reflects diagnostic delays, especially with subtle or atypical skin lesions. Negative bacilloscopy highlights diagnostic challenges, whereas culture and granulomatous histology confirm the diagnosis. This case underscores the need to include tuberculosis in chronic arthritis and persistent cutaneous lesions, combine microbiological and histopathological investigations, and initiate prompt therapy. Multidisciplinary vigilance improves outcomes and prevents delays in rare extrapulmonary tuberculosis.

Scrofuloderma secondary to tuberculous arthritis, even in immunocompetent adults, underscores the importance of early diagnosis and a multidisciplinary approach integrating microbiology, histopathology, and appropriate antituberculous therapy to achieve a favorable cutaneous and articular prognosis.

EADV CONGRESS
VIENNA
30 SEP - 3 OCT 2026

Abstract N°: 2990

Extensive tinea corporis associated with high-dose inhaled corticosteroid use in a patient with chronic pulmonary disease

Daniela Martinez[1], Mariana Santos Lopes Da Conceição*[1], Andrea Fernández Carrillo[1], Rodolfo Santos[1], Sophia Benatti[1], Mariana Santos[1], Verônica Franco[1], Bianca Fuser[1], Emilia Peralta Ulerio[1], Carolina Claudino dos Santos[1], Marianella Paz[1]

[1] Policlínica Geral do Rio de Janeiro, Rio De Janeiro, Brazil

Introduction

Tinea corporis associated with immunosuppression may present with atypical or extensive manifestations, including tinea incognito. Prolonged corticosteroid therapy, particularly systemic corticosteroids, is associated with impaired immune response and dissemination of opportunistic infections. Although inhaled corticosteroids are generally considered safer, recent evidence suggests that high-dose regimens may also induce systemic immunosuppressive effects, especially when different administration routes are combined.

Case Presentation

A 71-year-old male, former smoker, with a history of rhinitis, asthma, and chronic bronchitis, presented with chronic pruritic erythematous lesions on the chest and inguinal region, with recent progression to the limbs. He had previously received long-term oral corticosteroids and remained on high-dose inhaled corticosteroids, including beclomethasone 100 µg/day, budesonide 800 µg/day, and intranasal budesonide 512 µg/day.

The lesions worsened after topical clobetasol use. Dermatological examination revealed extensive erythematous-violaceous scaly plaques with papules and pustules, well-defined borders, involving the cervical region, chest, inguinal folds, and proximal limbs. Differential diagnoses included tinea corporis, mycosis fungoides, and psoriasis vulgaris.

Laboratory tests showed mild eosinophilia and negative serologies. Fungal culture was negative; however, histopathological examination was suggestive of dermatophytosis. Oral terbinafine was prescribed for one month, and adjustment of corticosteroid therapy by the pulmonology team resulted in significant clinical improvement.

Extensive or atypical dermatophytosis should raise suspicion for underlying immunosuppression. In this case, the unusual presentation was likely related to cumulative corticosteroid exposure from previous systemic therapy and continued high-dose inhaled and intranasal corticosteroid use.

Conclusion

Tinea corporis should be considered in patients presenting with extensive or atypical cutaneous lesions during prolonged corticosteroid therapy, including high-dose inhaled corticosteroids. Recognition of cumulative corticosteroid exposure, early diagnosis of tinea incognito, and multidisciplinary management are essential for successful treatment and clinical resolution.

EADV CONGRESS
VIENNA
30 SEP - 3 OCT 2026

Abstract N°: 3015

Cutaneous leishmaniasis: experience of a Spanish tertiary hospital

Adrián Lario-González*[1], Claudia Guilarte-Cadavide[1], María-Elena Gimeno-Ribes[1], Natalia Rodríguez-Valero[2, 3], Aroa Silgado Gimenez[4, 5], Marina Alguacil[2, 6], Miriam José Álvarez-Martínez[2, 6], Maria Eugenia Valls[2, 6], Raquel Albero[7], Natalia Castrejon[7], Adriana Garcia-Herrera[7], Marta Bodro[8], Irene Fuertes[1]

[1] Dermatology Department, Hospital Clínic de Barcelona, Barcelona, Spain
[2] Barcelona Institute for Global Health (ISGlobal), Hospital Clínic – Universitat de Barcelona, Barcelona, Spain
[3] International Health Department, Hospital Clínic de Barcelona, Barcelona, Spain
[4] Microbiology Department, Vall d'Hebron Institut de Recerca (VHIR), Vall d'Hebron Hospital Campus, Barcelona, Spain
[5] Centro de Investigación Biomédica en Red de Enfermedades Infecciosas (CIBERINFEC), Instituto de Salud Carlos III, Madrid, Spain
[6] Microbiology Department, Hospital Clínic de Barcelona, Barcelona, Spain
[7] Pathology Department, Hospital Clínic de Barcelona, Barcelona, Spain
[8] Infectious Diseases Department, Hospital Clínic de Barcelona, Barcelona, Spain

Introduction

Leishmaniasis is an infectious disease caused by protozoa of the Leishmania genus. *L. (L.) infantum* is endemic in Spain, where cutaneous leishmaniasis (CL) is the most common form of the disease. The aim of this study is to describe the clinical and epidemiological characteristics, diagnostic methods and treatments used in confirmed-CL cases.

Materials and Methods

A retrospective case series of non-paediatric patients with CL at a Spanish tertiary hospital (2019-2026) was conducted. Epidemiological, clinical, diagnostic and therapeutic variables were described, including efficacy and safety data for the different treatments.

Results

A total of 33 cases were included, all of which were diagnosed between 2019 and 2026. The patients' median age was 45 years (range: 19-89); 21 were male (63.6%), and 12 were older than 65 years (36.4%). Six patients (18.2%) were immunocompromised, four of whom were receiving tumour necrosis factor-α inhibitors. Fourteen patients (42.4%) were imported cases, with Costa Rica (5/14; 35.7%) and Morocco (3/14; 21.4%) being the most common countries of origin. Twenty cases were classified as complex CL (60.6%) and 13 as simple CL (39,4%). The most common skin manifestation was papule/nodule (42.4%), followed by plaque (30.3%) and, third, ulcerative lesions (27.3%). The most common location of the lesions was the upper limbs (48.5%), followed by the head and neck (42.4%), lower limbs (27.3%), and trunk (0.1%). In 5 patients (15.2%), nodular lymphangitis was identified through cutaneous ultrasound (CUS). Imported cases, compared to autochthonous cases, had a lower median age of patients (34 vs 73 years, respectively), a greater number of cases with nodular lymphangitis on CUS (28.6% vs 0.5%) and a greater tendency to present as ulcerative lesions (64.3% vs 0%).

Histopathological study was performed in all patients, and amastigotes were identified in 24 cases (72.7%). Real-time polymerase chain reaction (qPCR) was performed in 22 patients, and it was positive in all cases. Of the 11 cases in which the species were typed, 8 were *L. (L.) infantum*, 2 were *L. (V.) panamensis* and 1 was *L. (L.) major*. In

10 cases (30.3%), the definitive diagnosis was only possible through qPCR, as amastigotes could not be identified.

Intralesional meglumine antimoniate (MGA), combined or not with prior cryotherapy, was the most used treatment (17/33; 51.5%) and achieved healing in 14 of the 17 cases (82.4%). Systemic treatment was used in 15 patients (45.5%), with intravenous liposomal amphotericin B (LAB) and MGA being the most used. LAB was used in 14/15 (93.3%) with a healing rate of 71.4%, while intravenous MGA was used in 4/15 (26.7%) with a healing rate of 100% (one of them requiring monthly maintenance doses). Among those treated with LAB, five experienced mild infusion reactions, three had reversible decrease in glomerular filtration rate (GFR), and two had mild hypokalaemia. In contrast, among those treated with intravenous MGA, one patient had reversible decrease in GFR. Other treatments used included: miltefosine (n=2), topical paromomycin (n=2), imiquimod (n=1), fluconazole (n=1), surgery (n=1) and photodynamic therapy (n=1). All patients were cured, and no relapses were reported.

Conclusions

In our series, a notable proportion of imported cases was observed, highlighting the impact of migration and travel. However, most cases were autochthonous, likely caused by *L. (L.) infantum*, which may explain the predominance of papular/nodular and plaque presentations, given the lower tendency of this species to ulcerate.

Diagnosis often required molecular techniques, as qPCR proved essential in a significant number of cases with inconclusive histology. Intralesional MGA remains an effective and well-tolerated first-line treatment for many patients, while systemic therapies (mainly intravenous ABL and MGA) are reserved for more complex cases and show acceptable safety profiles. In conclusion, outcomes were favourable, with high cure rates and no relapses.

EA DV CONGRESS
VIENNA
30 SEP - 3 OCT 2026

Abstract N°: 3029

Recurrent facial nodule: atypical presentation of tuberculous chancre

Nathaly Liliana Castro Barreto*[1], Miguel Angel Nieto Bayona[1], Harold Farit Arenas Torrado[1], Juan Raúl Castro Ayarza[1]

[1] Universidad Nacional de Colombia, Bogotá, Colombia

Introduction

Cutaneous tuberculosis is an uncommon manifestation of extrapulmonary tuberculosis, representing 1–2% of extrapulmonary tuberculosis.

Case Presentation

This is the case of a 32-year-old woman from Cúcuta (Colombia) with a one-year history of recurrent painful masses in the glabellar region, who received multiple courses of antibiotics (linezolid and piperacillin-tazobactam) and surgical drainage without initial microbiological isolation of the pathogen. Upon questioning, the patient denied undergoing any procedures in the described area or having a history of facial trauma.

Initial laboratory tests revealed leukocytosis with neutrophils and thrombocytosis, while ultrasound revealed frontal-glabellar subcutaneous thickening with no defined collection. Facial CT tomography revealed a 9cc hyperdense lesion in the frontal-glabellar area, suggestive of a hematoma.

Given the duration of evolution, with suspicion of mycobacterial infection, foreign body granuloma, or Morbihan syndrome, a skin biopsy was performed, showing evidence of exogenous eosinophilic material with histiocytic infiltrate and multinucleated giant cells at the periphery consistent with foreign body reaction. In addition, mycobacterial culture and RT-PCR detected Mycobacterium tuberculosis. Subsequent imaging revealed no pulmonary involvement.

Cutaneous tuberculosis is a form of extrapulmonary tuberculosis, accounting for 8.4-13.7% of all cases of tuberculosis. It remains a significant problem in countries with a high tuberculosis burden, such as India, Brazil, China, and Indonesia, with incidence varying by region and affecting both children and adults. It has multiple clinical manifestations depending on its main pathophysiological mechanism, whether by direct inoculation (primary) or hematogenous or contiguous spread.

Primary forms include tuberculous chancre, which occurs by direct inoculation of the bacillus into intact or injured skin, manifesting as a painless ulcer with localized lymphadenopathy, and primary verrucous tuberculosis. Among the clinical manifestations of dissemination, lupus vulgaris stands out, manifesting as chronic, indurated, erythematous plaques. Miliary tuberculosis, orificial tuberculosis, tuberculous gumma, and scrofuloderma (lymph node tuberculosis) were also noted. The clinical picture in this patient is considered compatible with a tuberculous chancre due to the initial solitary glabellar lesion, recurrent course without evidence of systemic dissemination, and absence of an obvious pulmonary focus.

Recurrence after multiple drainages and transient response to broad-spectrum antibiotics should suggest infection by pathogens such as MTB, among other non-tuberculous mycobacteria, with the former being common in endemic immunocompetent individuals. The broad differential diagnosis leads to delays in diagnosis, with an average of approximately 15.3 months, resulting in increased surgical morbidity.

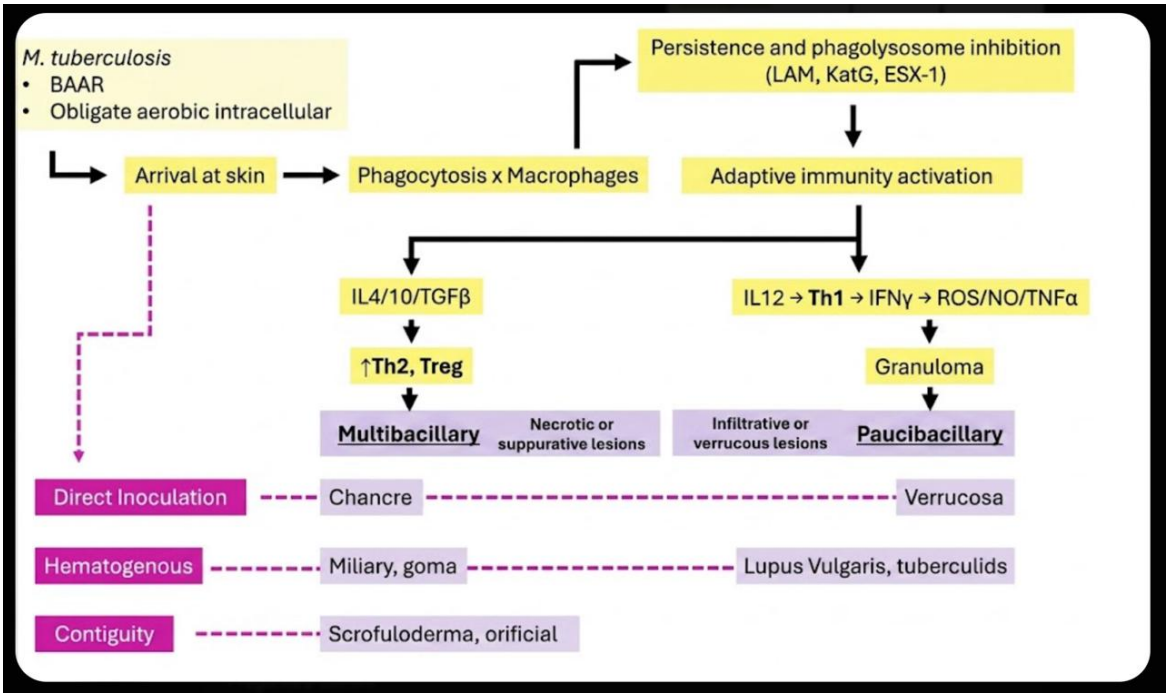

Pathophysiology and clinical spectrum of cutaneous tuberculosis

Conclusion

This case illustrates an atypical presentation of recurrent frontal cutaneous tuberculosis mimicking recurrent abscesses, probably corresponding to a tuberculous chancre due to its primary facial location and possible entry through an orbital scar.

EADV CONGRESS
VIENNA
30 SEP - 3 OCT 2026

Abstract N°: 3087

Sporotrichosis: a series of 02 cases with atypical presentation in São Paulo, Brazil

Marina Barrionuevo Mathias*[1], Giovanna Almeida[1], Inara Pereira[1], Kaique Arriel[1], Livia Vieira Almeida[2], Amanda Azevedo Bittencourt[2], José Ângelo Lindoso[2]

[1] Universidade Santo Amaro (UNISA), São Paulo, Brazil
[2] Instituto de Infectologia Emílio Ribas (IIER), São Paulo, Brazil

Introduction

Sporotrichosis is a subacute fungal infection caused by thermo-dimorphic fungi of the genus*Sporothrix*. Historically, it was associated with traumatic inoculation of contaminated soil and plants. However, in the last two decades, the disease has undergone an epidemiological shift due to zoonotic transmission by infected cats in Brazil and other countries of South America.

Brazil currently represents one of the main endemic areas worldwide, especially in the states of São Paulo and Rio de Janeiro. The most frequent etiologic agent related to zoonotic sporotrichosis is S*porothrix brasiliensis.* Clinical manifestations are classically divided into cutaneous and extracutaneous forms. The cutaneous ones include localized, lymphocutaneous, multiple inoculation and disseminated sporotrichosis. Disseminated disease is uncommon and usually associated with immunosuppression. We report two atypical cases with extensive lesions, in immunocompetent patients, highlighting the importance of epidemiological investigation, histopathological examination and mycological confirmation in challenging presentations.

Case Presentation

Case 1: A 51-year-old woman, previously healthy, presented with a persistent erythematous plaque on the dorsal region with an 11-month evolution. She had previously received an unspecified systemic treatment for two months without clinical improvement. Six months later, she was bitten by a domestic cat she cared for, which had previously been diagnosed with sporotrichosis. One month later, the patient reported worsening of the dorsal plaque associated with the appearance of disseminated lesions on other body sites. She was referred to an Infectious Diseases reference center in January 2026. Dermatological examination demonstrated crusted erythematous papules on the face and extremities, with a large erythematous plaque measuring more than 30 cm on the upper back. Differential diagnoses included sporotrichosis, paracoccidioidomycosis and histoplasmosis. Histopathological examination of the dorsal lesion revealed elastolytic giant cell granuloma, while fungal culture was positive for *Sporothrix spp*. The patient was treated with oral itraconazole 400 mg/day, with clinical remission.

Case 2: A 28-year-old woman, previously healthy, presented at the Emergency Department with a two-month history of two ulcerated lesions on the dorsal region. Fifteen days before symptom onset, her domestic cat developed lesions involving the ear and ocular region. The patient denied previous trauma or scratches. She initially sought medical care at another healthcare facility and received a presumptive diagnosis of sporotrichosis, being treated with itraconazole and cephalexin without clinical improvement. One month later, she was referred to an Infectious Diseases reference center because of persistent lesions associated with secondary bacterial infection and pain. Intravenous ceftriaxone and clindamycin were initiated. Skin biopsy demonstrated chronic granulomatous inflammation with suppuration, while immunohistochemical analyses were positive for *Sporothrix spp*.. During hospitalization, the patient evolved with progressive improvement of pain and partial regression of the lesions. She was discharged on oral itraconazole, achieving complete remission during outpatient follow-up.

Conclusion

Sporotrichosis was historically associated with traumatic inoculation of contaminated organic material into the skin. However, zoonotic transmission currently represents the main route of infection in endemic areas such as Brazil. Disseminated forms and extensive lesions are uncommon in immunocompetent individuals and usually present with papulonodular or ulcerated lesions. Both patients described here were immunocompetent and presented atypical extensive crusted plaques, making diagnosis challenging. These cases reinforce the importance of detailed epidemiological history and histopathological and mycological investigation for accurate diagnosis, particularly in endemic regions.

EADV CONGRESS
VIENNA
30 SEP - 3 OCT 2026

Abstract N°: 3099

Beyond Furunculosis: High-Frequency Ultrasonography as a Diagnostic Tool for Furuncular Myiasis

Matheus Gondim*[1], Pietra Diniz Pereira[1], Bianca Parreiras[1], Vivian Marques[1]

[1] Universidade de Mogi das Cruzes (UMC), Mogi das Cruzes, Brazil

Introduction

Furuncular myiasis is a parasitic infestation caused by fly larvae and may clinically mimic inflammatory or infectious dermatoses such as furunculosis, inflamed cysts, and abscesses. High-frequency ultrasonography (HFUS) has emerged as a valuable non-invasive imaging modality in dermatology, enabling real-time evaluation of cutaneous and subcutaneous lesions and improving diagnostic assessment in inflammatory, neoplastic, and infectious skin diseases.

Case Presentation

A 3-year-old female patient presented with painful lesions on the scalp and lateral aspect of the left thigh for approximately 10 days, associated with intermittent serous discharge. Dermatological examination revealed erythematous furunculoid nodules with a small central punctum.

HFUS examination demonstrated a hypoechoic dermal cavity containing an echogenic tubular structure associated with marked posterior acoustic shadowing. Color Doppler imaging revealed internal Doppler flow within the structure itself, corresponding to the larval body, in addition to increased peripheral vascularization compatible with adjacent inflammatory reaction (Fig. 1). These ultrasonographic findings strongly suggested furuncular myiasis.

Mechanical extraction of the larva was subsequently performed, confirming the diagnosis, followed by complete clinical resolution.

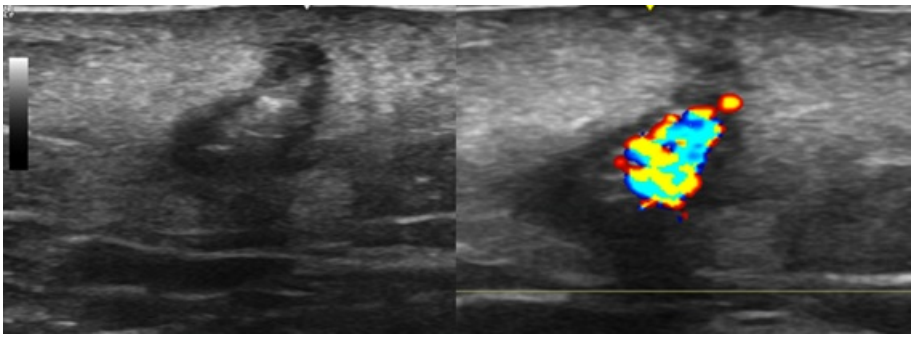

Fig. 1 - echogenic tubular structure associated with marked posterior acoustic shadowing. Color Doppler imaging revealed internal Doppler flow within the structure itself, corresponding to the larval body.

Conclusion

HFUS has become an increasingly important complementary tool in dermatology because of its ability to provide

dynamic, non-invasive, real-time evaluation of cutaneous and subcutaneous lesions. Recent literature highlights its expanding role in skin tumors, inflammatory dermatoses, aesthetic procedures, and infectious skin diseases.

In furuncular myiasis, ultrasonography may demonstrate characteristic findings such as a hypoechoic dermal cavity, echogenic tubular structures, posterior acoustic shadowing, and increased vascularization on color Doppler imaging. The presence of Doppler flow within the larval structure itself, as observed in this case, may represent an additional imaging clue supporting the diagnosis.

These findings may assist in differentiating furuncular myiasis from bacterial furunculosis, abscesses, and inflamed cysts, particularly in clinically nonspecific presentations.

This case highlights the potential role of dermatologic ultrasonography as a rapid and accessible bedside diagnostic tool in furunculoid lesions, especially in pediatric patients.

High-frequency dermatologic ultrasonography represents a promising diagnostic tool for furuncular myiasis, improving diagnostic accuracy and contributing to the early recognition of parasitic dermatoses that mimic common infectious skin conditions. The incorporation of Doppler evaluation may further enhance lesion characterization and support diagnostic suspicion in challenging cases.

EADV CONGRESS
VIENNA
30 SEP - 3 OCT 2026

Abstract N°: 3146

Acral Clues to a Fatal Mimicker: Janeway Lesions in ANCA-Vasculitis

Miguel Angel Nieto Bayona*[1], Hector Perez[1], Nathaly Liliana Castro Barreto[1], Harold Farit Arenas Torrado[1]

[1] Universidad Nacional de Colombia, Bogotá, Colombia

Introduction

Infective endocarditis may closely mimic autoimmune vasculitis, particularly in patients with prior ANCA-associated disease. Cutaneous findings can provide a key diagnostic clue, especially when histology reveals septic embolic phenomena rather than true vasculitic relapse.

Case Presentation

A 51-year-old man with stage V chronic kidney disease on hemodialysis due to ANCA-associated vasculitis was admitted for dyspnea at rest, with pulmonary nodular lesions on evaluation. He later developed painless acral hemorrhagic papules and vesicles. Given his autoimmune history and multiorgan involvement, cutaneous vasculitis activity was suspected and a skin biopsy was performed. The patient then developed catheter-associated septic shock. Histopathology showed intravascular bacterial colonies with a dense polymorphonuclear infiltrate, consistent with Janeway lesions, redirecting the diagnosis toward septic embolization. In the setting of methicillin-susceptible Staphylococcus aureus bacteremia, hemodialysis catheter exposure, fever, cutaneous vascular phenomena, and septic pulmonary emboli, he fulfilled modified Duke criteria for definite infective endocarditis. Targeted oxacillin therapy was started, with complete recovery.

Infective endocarditis is uncommon in the general population, with an estimated incidence of 5–7 cases per 100,000 person-years, yet it may be life-threatening because of embolic, valvular, and systemic complications. Diagnosis is often challenging; therefore, the modified Duke criteria remain essential for integrating microbiological, echocardiographic, and clinical findings. This challenge is amplified in patients with autoimmune comorbidities, such as ANCA-associated vasculitis, in whom infection risk may rise because of immunosuppression and invasive devices. Moreover, infective endocarditis may mimic vasculitic activity, presenting with purpuric or acral lesions, multiorgan involvement, and even autoantibody positivity, including ANCA.

Our case highlights the dermatologist's role in evaluating multisystem rheumatologic and infectious disease. Given the autoimmune background, plus renal, pulmonary, and cutaneous involvement, the teams initially suspected disease reactivation. However, dermatologic assessment and skin histology redirected the diagnosis, preventing unnecessary, potentially fatal immunosuppression in a severe infection.

Cutaneous manifestations occur in only 11.9% of infective endocarditis cases, but when present they are associated with more extracardiac complications. These findings include classic lesions such as Osler nodes in 2.7% of cases, splinter hemorrhages in 2.5%, and Janeway lesions in 1.6%. Janeway lesions are painless macules or papules, predominantly acral, caused by microembolization. Histologically, they show microabscesses, septic thrombi, and intravascular or intralesional bacteria.

Distinguishing active vasculitis from infectious pseudovasculitis has direct therapeutic implications. In ANCA-

vasculitis relapse, treatment usually requires escalation of immunosuppression; in infective endocarditis, the same approach may worsen bacteremia and delay source control. Thus, in patients with acral purpuric or hemorrhagic lesions, fever, bacteremia, or factors such as vascular catheters and hemodialysis, endocarditis should be considered before attributing skin findings to autoimmune activity.

Conclusion

This case underscores the skin as a diagnostic window into systemic disease. In patients with previous ANCA-associated vasculitis, acral hemorrhagic lesions should not automatically be interpreted as vasculitic relapse. A skin biopsy can differentiate true vasculitis from infectious pseudovasculitis, avoid harmful immunosuppression, and guide early diagnosis.

EA DV CONGRESS
VIENNA
30 SEP - 3 OCT 2026

Abstract N°: 3155

Lupus vulgaris developing at the site of BCG vaccination: a case report

Mouna Frikha*[1], Noureddine Litaiem[1], Arij Ben youssef[1], Hbib Dridi[2], Soumaya Gara[1], Meriem Jones[1], Faten Zeglaoui[1]

[1] Dermatology department, Charles nicolle Hospital, Tunis, Tunisia
[2] Private dermatology practice, Tunis, Tunisia

Introduction
Lupus vulgaris is a chronic paucibacillary form of cutaneous tuberculosis. BCG vaccination may cause local ulceration, abscesses, lymphadenitis or BCGitis, whereas lupus vulgaris at the vaccination site is rarely reported. We report a probable atypical lupus vulgaris developing several decades after a single neonatal BCG dose.

Case Presentation
Observation:

A 45-year-old woman with no medical history and no known tuberculosis contact presented with a chronic lesion of the left arm. She had received a single BCG vaccine dose shortly after birth. The lesion started in childhood as an erythematous papule precisely at the vaccination site on the lateral aspect of the left arm. It slowly enlarged over decades, with accelerated progression during the last 3 years, becoming a pruritic, well-demarcated, infiltrated erythematous-squamous plaque with central ulceration.

An initial biopsy showed epithelioid and giant-cell granulomatous inflammation with caseous necrosis, favoring BCGitis. The tuberculin skin test was positive at 18 mm, and chest radiography was normal. On examination, the plaque measured 8 × 6 cm, with no lymphadenopathy or systemic symptoms.

Repeat biopsy showed ulcerated epidermis and a dense dermal inflammatory infiltrate rich in plasma cells, with multiple epithelioid and giant-cell granulomas without necrosis. Mycobacterial PCR was inconclusive with a very low signal. Tests for acid-fast bacilli in sputum and urine were negative, as was direct examination for Leishmania. HIV, hepatitis B and hepatitis C serologies were negative.

Given the chronic evolution on a BCG vaccination site, granulomatous histology, positive tuberculin skin test, exclusion of mimickers and inconclusive microbiology, weight-adjusted isoniazid, rifampicin, pyrazinamide and ethambutol were initiated. After 2 months, the plaque decreased from 8 × 6 cm to 4 × 2 cm, with healing of the ulceration.

Discussion:

This case is most consistent with probable atypical lupus vulgaris occurring at a previous BCG vaccination site. Several BCG-related cutaneous complications are recognized, including ulceration, abscesses, lymphadenitis and BCGitis. However, lupus vulgaris arising at the vaccination site years later remains uncommon. The main originality of our case is the unusually long delay after neonatal BCG vaccination, contrasting with the shorter latencies generally reported in post-BCG lupus vulgaris.

The pathogenesis remains uncertain. It may represent late BCG-related cutaneous tuberculosis due to persistence of attenuated bacilli, or localization of another organism of the Mycobacterium tuberculosis complex on a BCG

scar after unrecognized exposure. Negative acid-fast bacilli testing and inconclusive PCR are compatible with the paucibacillary nature of lupus vulgaris. Diagnosis was supported by the vaccination-site location, granulomatous inflammation with caseous necrosis, positive tuberculin skin test, exclusion of mimickers and response to antituberculous therapy.

Conclusion

Lupus vulgaris should be considered in chronic progressive plaques developing on a BCG vaccination site, even decades later. Clinicopathological correlation, repeated biopsy and exclusion of differential diagnoses remain essential when microbiological confirmation is lacking.

EADV CONGRESS
VIENNA
30 SEP - 3 OCT 2026

Abstract N°: 3161

A Rare Case of Sporotrichoid Cutaneous Leishmaniasis Caused by Leishmania tropica

Selen Aydın*[1], Asena Çiğdem Doğramacı[1], Fatih Kızılkaya[1], Tuğba Kaya[2], Ceren Ünal[2]

[1] Hatay Mustafa Kemal University, Faculty of Medicine, Department of Dermatology and Venereology, Hatay, Türkiye
[2] Hatay Mustafa Kemal University, Faculty of Medicine, Department of Parasitology, Hatay, Türkiye

Introduction

Leishmaniasis is a parasitic disease transmitted to humans through the bite of infected phlebotomine sandflies and may present with cutaneous or visceral forms. Approximately 1.5 million new cases of cutaneous leishmaniasis are reported annually worldwide, and the disease is endemic in countries such as Türkiye, Syria, Afghanistan, and Brazil. Clinical manifestations of cutaneous leishmaniasis vary considerably depending on the causative species and host immune response. Although the classical presentation consists of localized ulcerative papules or plaques, atypical and rare variants such as the sporotrichoid form have also been described. Sporotrichoid cutaneous leishmaniasis has been reported predominantly in Brazil and Panama, with *Leishmania braziliensis* being the most frequently implicated species. This variant is characterized by lymphatic spread with multiple subcutaneous nodules distributed along the lymphatic drainage pathway. Such clinical findings may mimic deep fungal infections, nocardiosis, and cutaneous tuberculosis, leading to diagnostic difficulties. Herein, we present a leishmania smear and RT-PCR-confirmed case of extensive sporotrichoid cutaneous leishmaniasis in an elderly patient with multiple comorbidities.

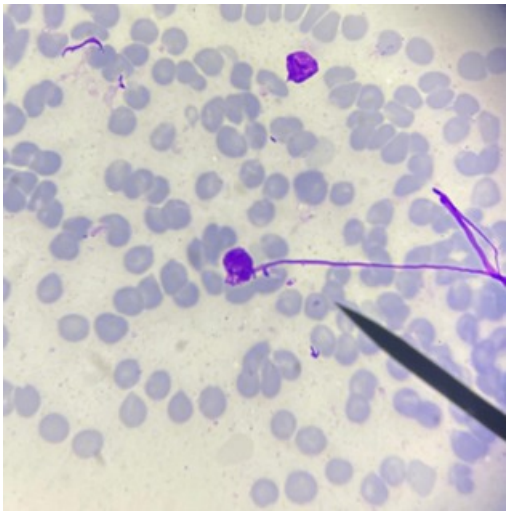

Figure 1. Microscopic examination of Giemsa stained smear revealing amastigote forms

Case Presentation

A 60-year-old female patient presented with progressively increasing painless ulcerative and nodular lesions on the left upper extremity for several months. Dermatological examination revealed multiple erythematous papules, nodules, and infiltrated plaques involving the left hand and forearm. A large plaque on the dorsum of the hand showed central black ulceration with yellowish crusting and surrounding papulonodular lesions. Additional

subcutaneous nodules along the forearm demonstrated a sporotrichoid distribution pattern following the lymphatic drainage pathway. Some nodules displayed violaceous discoloration, crateriform morphology, and central hyperkeratotic crusting. No regional lymphadenopathy was detected. The patient had a history of diabetes mellitus and congestive heart failure and was receiving multiple medications for these comorbid conditions. Laboratory investigations revealed elevated CRP (12 mg/L) and ESR (47 mm/h) with mildly impaired renal function, while complete blood count and liver function tests were normal. Detailed history revealed regular travel to Syria and an insect bite on the affected extremity before lesion onset. No history of animal exposure, gardening activities, or constitutional symptoms was present. Based on the endemic travel history and sporotrichoid noduloulcerative presentation, sporotrichoid cutaneous leishmaniasis was considered primarily. Differential diagnoses included sporotrichosis, nocardiosis, cutaneous aspergillosis, cutaneous tuberculosis, and atypical mycobacterial infections. Leishmania smear sample obtained from the patient's lesion was stained with Giemsa, and microscopic examination revealed amastigote forms, confirming a positive smear result. RT-PCR melting curve analysis identified the isolate as *Leishmania tropica*.

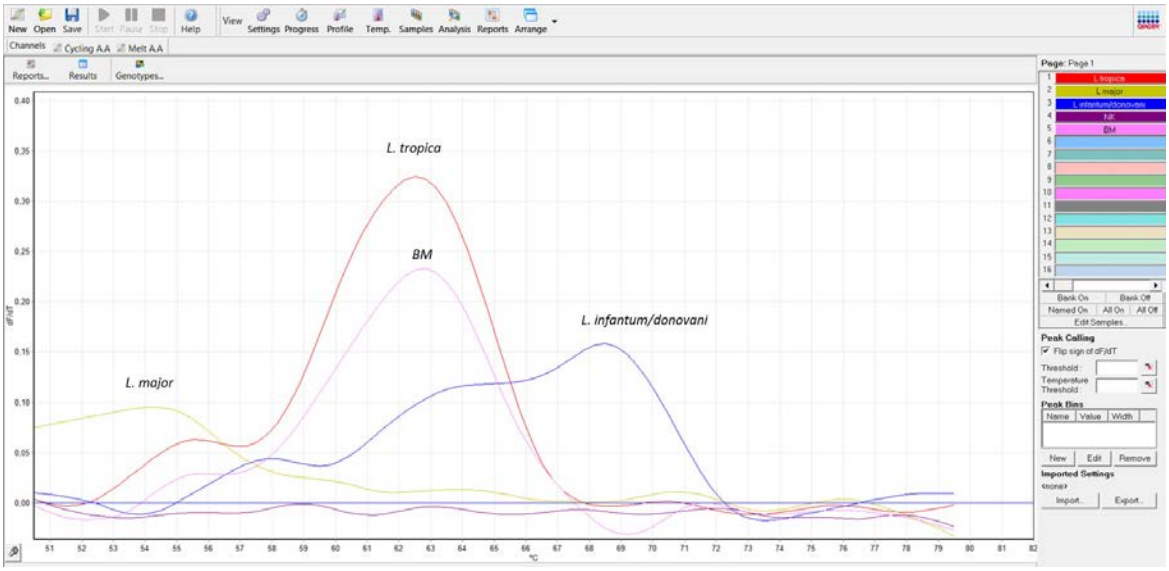

Figure 2. RT-PCR melting curve analysis confirming Leishmania tropica

Conclusion

Sporotrichoid cutaneous leishmaniasis is a rare clinical variant that may closely mimic deep fungal and atypical infectious diseases, resulting in delayed diagnosis and treatment. Careful evaluation of travel history to endemic regions is essential in patients presenting with chronic noduloulcerative lesions showing sporotrichoid spread. Advanced age, multiple comorbidities, and possible impairment of immune response may contribute to atypical and extensive clinical presentations. Although sporotrichoid leishmaniasis is most commonly associated with *Leishmania braziliensis*, our case demonstrates that *Leishmania tropica* may also present with this uncommon morphology. This case highlights the importance of considering atypical cutaneous leishmaniasis in the differential diagnosis of sporotrichoid lesions.

EADV CONGRESS
VIENNA
30 SEP - 3 OCT 2026

Abstract N°: 3190

Serum Cathelicidin LL-37 Levels and Nasal PCR Positivity among Leprosy Patients and Their Contacts in an Endemic Island Community

Putri Chaerunnisya*[1], Nur Mustakim[1], Asnawi Madjid[1], Widya Widita[1]

[1] Hasanuddin University, Makassar, Indonesia

Introduction
Cathelicidin LL-37 is an antimicrobial peptide crucial for innate immunity against *Mycobacterium leprae* and has been proposed as a biomarker in leprosy. Evidence on circulating LL-37 levels among patients and their contacts in endemic island settings remains limited. This study aimed to compare serum cathelicidin LL-37 levels between leprosy patients and contacts, and to evaluate the association of LL-37 and nasal PCR positivity for *M. leprae* with patient status, diagnostic status, and disease type.

Materials and Methods
In this analytical cross-sectional study, 75 participants were enrolled, including 20 clinically confirmed leprosy patients and 55 contacts. Serum LL-37 concentrations were measured using enzyme-linked immunosorbent assay, and nasal swabs were examined for *M. leprae* DNA by real-time PCR targeting the RLEP region. Demographic and clinical data, including diagnostic status (new case vs under treatment) and operational classification (paucibacillary vs multibacillary), were collected. Group comparisons and categorical associations were analysed with appropriate statistical tests, and receiver operating characteristic analysis was performed to identify an optimal LL-37 cut-off.

Results
Median LL-37 levels did not differ significantly between patients and contacts, and an LL-37 cut-off of 32.44 ng/mL showed limited discriminatory performance. However, LL-37 ≥32.44 ng/mL and nasal PCR positivity were both significantly associated with patient status and more frequent in new cases than in patients under treatment, while not clearly differentiating paucibacillary from multibacillary disease.

Conclusions
Serum LL-37 alone is not a reliable stand-alone screening biomarker for leprosy, but higher LL-37 levels and nasal PCR positivity are associated with clinical disease and may reflect infection activity and host immune activation.

EADV CONGRESS
VIENNA
30 SEP - 3 OCT 2026

Abstract N°: 3202

Crusted Scabies During JAK Inhibitor Therapy in a Patient with Atopic Dermatitis: A Diagnostic Challenge

Vasiliki Sidiropoulou*[1], Vasileios Dervenis[1], Nikolaos Stavropoulos[1]

[1] Department of Dermatology and Venereology, Catholic Hospital Bochum, University Hospital of Ruhr University Bochum, Bochum, Germany, Bochum, Germany

Introduction

Crusted scabies (*Scabies crustosa*) is a rare but highly contagious manifestation of *Sarcoptes scabiei* infestation, predominantly occurring in immunocompromised individuals. The increasing use of targeted immunomodulatory therapies, including Janus kinase (JAK) inhibitors, may predispose patients to atypical and severe infectious complications. In these cases, the clinical presentation may mimic exacerbations of chronic inflammatory dermatoses, potentially leading to delayed diagnosis and treatment.

Case Presentation

We report the case of a 42-year-old man with severe atopic dermatitis who had been receiving upadacitinib therapy since June 2023. In February 2024, he presented with rapidly progressive generalized scaling, extensive crusting, and severe pruritus. Dermatological examination revealed marked xerosis, widespread scaly plaques, hyperkeratotic lesions affecting the feet, and incipient suberythroderma.

Laboratory investigations demonstrated leukocytosis, anemia, thrombocytosis, and elevated inflammatory markers. Due to the clinical suspicion of Scabies crustosa, multiple skin biopsies were performed.

Histopathological analysis demonstrated compact orthohyperkeratosis and parakeratosis containing numerous mite fragments and ova within the stratum corneum, thereby confirming the diagnosis of Scabies crustosa.

Upadacitinib therapy was discontinued immediately. The patient was treated with a multidose regimen of systemic ivermectin in combination with topical permethrin and adjunctive keratolytic therapy using salicylic acid. Symptomatic antipruritic therapy was additionally initiated.

Following treatment initiation, rapid clinical improvement was observed, including marked reduction of pruritus, scaling, and hyperkeratotic skin lesions.

Conclusion

This case highlights the risk of severe parasitic infections such as crusted scabies during JAK inhibitor therapy. The clinical presentation may mimic exacerbations of underlying inflammatory dermatoses, potentially leading to diagnostic delay. Early recognition and histopathological confirmation are essential to initiate appropriate treatment and prevent further transmission.

EADV CONGRESS
VIENNA
30 SEP - 3 OCT 2026

Abstract N°: 3208

Haemoglobin Dynamics and Haemolysis During Multi-Drug Therapy for Leprosy: A Retrospective Cohort Study

Udhishtran Arudchelvam*[1], Sanath Thubellage[2], Ama Pathirage[2], Shamila Lasanthi[2], Dorothy Premkumar[2], Priyashantha Fernando[2], Sajith De Silva[3], Amaratunga Dissanayake[4], Nelum Wickramasinghe[5], Supun Wijesinghe[6], Indira Kahawita[1]

[1] Dermatology Unit, National Hospital of Sri Lanka, Colombo, Sri Lanka
[2] Central Leprosy Clinic, National Hospital of Sri Lanka, Colombo, Sri Lanka
[3] Faculty of Medicine, University of Sri Jayewardenepura, Sri Lanka, Sri Jayewardenepura Kotte, Sri Lanka
[4] Dermatology Unit, Colombo North Teaching Hospital, Sri Lanka, Ragama, Sri Lanka
[5] Dermatology Unit, Colombo South Teaching Hospital, Sri Lanka, Colombo, Sri Lanka
[6] Family Health Bureau, Ministry of Health, Sri Lanka, Colombo, Sri Lanka

Introduction

Adverse effects related to multi-drug therapy (MDT) remain an important challenge in the management of leprosy. Dapsone-associated haemolysis is among the most frequently encountered haematological adverse drug reactions during MDT, yet prospective haemoglobin (Hb) monitoring protocols in routine practice remain poorly defined.

This study characterized haemoglobin dynamics during standard MDT, quantified the magnitude and timing of Hb nadir, compared these parameters between patients who did and did not develop clinically confirmed haemolysis, and identified predictors of haemolysis and haemoglobin reduction.

Materials and Methods

A retrospective review of clinic records from the Central Leprosy Clinic, Sri Lanka, was conducted over a period of eight years (January 2016 to December 2023). Data were cleaned and analyzed using independent and paired t-tests, chi-square tests, logistic regression, and multiple linear regression analyses. Statistical Significance was set at $p < 0.05$.

Results

The records of 540 patients were included (mean age 39.5 ± 16.4 years). The mean baseline Hb for the cohort was 13.6g/dL. Paired t-test analysis demonstrated a statistically significant mean Hb reduction of 2.31g/dL from baseline to nadir ($p<0.001$). The maximum Hb decline occurred at a mean of 6.05 weeks. ADRs were documented in 19.3% of patients, with haemolysis confirmed in 14.1%.

Patients with haemolysis had a lower mean baseline Hb (13.2g/dL vs. 13.7g/dL) and a greater mean Hb reduction (3.0g/dL vs. 2.2g/dL) compared to those without. Female sex was associated with higher rates of haemolysis (19.1% vs 12%; $p = 0.03$). On logistic regression, lower baseline Hb was an independent predictor of haemolysis (OR 0.844, 95% CI, $p<0.05$), corresponding to a 15.6% reduction in odds for every 1g/dL increase in baseline Hb. Multiple linear regression identified both

age and baseline Hb as independent predictors of Hb decline ($p<0.05$); each 10-year increment in age was associated with an additional 0.11 g/dL Hb reduction. Notably, the timing of Hb nadir did not differ by haemolysis status. Both groups reached maximum decline at a median of 4 weeks, though 7% (n=36) demonstrated a nadir as early as 2 weeks.

Conclusions

Dapsone at standard MDT dosing results in a significant mean Hb fall of 2.31g/dL, typically peaking at approximately four weeks. These findings support mandatory Hb monitoring within the first two to four weeks of therapy, when the greatest Hb decline occurs. Repeat blood counts should be prioritized no later than 4 weeks from treatment initiation, with consideration of an interval check at weeks in patients with lower baseline Hb. Lower baseline Hb increases vulnerability to haemolysis, while older age and higher baseline Hb predict a greater overall Hb reduction, supporting intensified monitoring in these groups.

EADV CONGRESS
VIENNA
30 SEP - 3 OCT 2026

Abstract N°: 3220

When scabies does not look like scabies: a focused review of atypical phenotypes and diagnostic pitfalls

Rebecca Tweddell*[1], Katherine Farquhar[1], Rachel Gardner[1], Amrita Randhawa[1], Gordon Hale[1]

[1] Queen Elizabeth University Hospital, Glasgow, United Kingdom

Introduction

Scabies is classically recognized by nocturnal pruritus, burrows, and involvement of the interdigital spaces, wrists, genitalia, and trunk. However, it may present with atypical morphology, unusual distribution, or minimal itch, leading to misdiagnosis and inappropriate treatment.

Objectives

To review when scabies does not resemble classical scabies, focusing on atypical phenotypes, diagnostic pitfalls, and useful adjunctive diagnostic techniques.

Materials and Methods

Targeted literature review of published atypical scabies case reports. 7 reports were reviewed, featuring 7 phenotypic patterns: bullous, nodular, malar erythematous, nail, plantar/acral, gingival/oral, and crusted hyperkeratotic variants.

Results

Atypical scabies mimicked bullous pemphigoid and other blistering disorders, prurigo nodularis, systemic lupus erythematosus, nail dystrophy/onychomycosis, plantar blistering, gingival inflammatory disease, and diffuse hyperkeratotic dermatoses. Several cases described delayed diagnosis after treatment for eczema, autoimmune blistering disease, infection, DRESS syndrome with immunosuppression, or other inflammatory dermatoses, with corticosteroid exposure potentially obscuring the diagnosis further. Although immunosuppression was a frequent risk factor, severe atypical or crusted disease also occurred in apparently immunocompetent patients. Diagnosis in the reviewed reports was confirmed by skin scraping, microscopy, histopathology, or identification of mites. In addition to bedside scraping and dermoscopy, UV/ultraviolet dermoscopy is an emerging adjunctive technique that may improve visualization in equivocal or atypical cases.

Conclusions

This focused review highlights the breadth of atypical scabies phenotypes and the recurrent diagnostic pitfall of excluding scabies because the eruption is off-pattern, minimally pruritic, site-restricted, or steroid-modified. Scabies should remain in the differential diagnosis of treatment-resistant, bullous, nodular, hyperkeratotic, nail, mucosal, or acral eruptions. Early use of bedside confirmation techniques, with dermoscopy and emerging ultraviolet dermoscopic adjuncts where available, may reduce diagnostic delay, transmission, and avoidable mismanagement.

POWERED BY M-ANAGE.COM

EADV CONGRESS
VIENNA
30 SEP - 3 OCT 2026

Abstract N°: 3245

A Case of Tuberculosis Verrucosa Cutis Clinically and Histopathologically Mimicking Sporotrichosis: Successfully Treated with Standard Antituberculosis Drugs

Abdullah Kutay Masat*[1], Tubanur Cetinarslan[1], Peyker Temiz[2], Aylin Türel Ermertcan[1]

[1] Manisa Celal Bayar University, Department of Dermatology and Venereology, Manisa, Türkiye

[2] Manisa Celal Bayar University, Department of Medical Pathology, Manisa, Türkiye

Introduction

Cutaneous tuberculosis accounts for approximately 1–2% of all tuberculosis cases and is an uncommon clinical manifestation of tuberculosis (1). Tuberculosis verrucosa cutis typically develops following endogenous reinfection or exogenous inoculation and is characterized by localized verrucous hyperkeratotic plaques on the extremities (2). Clinically, it may mimic sporotrichosis, cutaneous leishmaniasis, and other granulomatous skin disorders (3). Herein, we present a case initially treated with antifungal therapy based on a presumed diagnosis of sporotrichosis, in whom the definitive diagnosis was established by isolation of Mycobacterium tuberculosis in mycobacterial culture and who was successfully managed with standard antituberculosis therapy.

Case Presentation

A 50-year-old male patient presented with a two-year history of persistent cutaneous lesions on his left arm and hand. The patient's medical history revealed lesions extending from the left second finger to the left elbow, and the patient had a history of occupational exposure as a gardener. He had received multiple courses of antibiotics without clinical improvement over the past two years. Dermatological examination revealed verrucous plaques and nodules with hyperkeratotic, sometimes hemorrhagic crusts, on an erythematous background, originating from the dorsal aspect of the left first finger and extending proximally, along the dorsal aspect of the left forearm and left elbow, suggestive of lymphocutaneous spread. A skin biopsy was perfomed with sporotrichosis and tuberculous verrucosa cutis considered in the differential diagnosis. Histopathological examination showed non-caseifying granulomatous dermatitis, multinuclear giant cells, and spore-like structures, with findings were considered primarily consistent with sporotrichosis. Acid-resistant bacilli testing showed no evidence of mycobacteria, and the patient was started on itraconazole treatment. Due to the absence of clinical response after 6 weeks of itraconazole treatment, the treatment was discontinued, and liposomal amphotericin B was initiated. Although a partial response was obtained with liposomal amphotericin B treatment, pancytopenia developed on day 29, and the medication was discontinued. Mycobacteria culture yielded growth of M. tuberculosis after 3 months. The patient received two months of quadruple tuberculosis therapy (rifampicin, isoniazid, ethambutol, pyrazinamide) followed by four months of dual tuberculosis therapy (isoniazid, rifampicin). Marked clinical improvement was observed

Conclusion

Cutaneous tuberculosis may frequently be mistaken for granulomatous dermatoses, particularly in endemic regions, potentially leading to delayed diagnosis (1,2). The partial regression of lesions and even limited clinical improvement observed with amphotericin B treatment is noteworthy and may lead to diagnostic confusion. It should be noted that histopathological findings may overlap among granulomatous disorders and may not always be characteristic. This case underscores the importance of clinicopathological and microbiological correlation for establishing an accurate diagnosis.

EADV CONGRESS
VIENNA
30 SEP - 3 OCT 2026

Abstract N°: 3246

A Preventable Source of Cutaneous Mycobacterium abscessus Infection: Contaminated Insulin Syringes in a Patient with Diabetes Mellitus

Daniela Mares-Custodio*[1], Jorge Valdespino-Valdes[1], Mariana García-Leal[1], Sonia Chavez-Alvarez[1], Jorge Ocampo-Candiani[1]

[1] Servicio de Dermatología del Hospital Universitario "Dr. José Eleuterio González", Monterrey, Nuevo León, Mexico

Introduction

Rapidly growing nontuberculous mycobacteria are increasingly recognized as causes of chronic skin and soft tissue infections following direct inoculation. Although increasingly reported, cutaneous *Mycobacterium abscessus* infection remains uncommon and poses significant diagnostic and therapeutic challenges because of its intrinsic antimicrobial resistance, biofilm formation, and ability to persist in aqueous environments. Cutaneous *M. abscessus* infection has been increasingly reported after trauma, injections, and medical or cosmetic procedures. We present a case of cutaneous *M. abscessus* infection associated with contaminated insulin syringes in a patient with diabetes mellitus.

Case Presentation

A 48-year-old woman with type 2 diabetes mellitus treated with insulin glargine, metformin, and weekly semaglutide presented with a two-month history of painful inflammatory lesions involving both upper extremities. Physical examination revealed bilateral, symmetric, erythematous, soft infiltrated nodules with a central necrotic eschar for two months. The patient reported accidental contamination of insulin syringes after they fell into water used to rinse paintbrushes, followed by repeated reuse of the contaminated syringes for insulin administration.

She subsequently developed pain at the injection sites, followed by abscess formation. Multiple empirical antibiotic regimens, including dicloxacillin, clindamycin, and ciprofloxacin, were ineffective. Histopathologic examination demonstrated chronic granulomatous inflammation involving the reticular dermis and subcutaneous tissue. The wound exudate was sent for gram stain and cultivation of microorganisms, which were negative. Skin biopsy specimens were also evaluated with gram stain, potassium hydroxide preparation, acid-fast stains, routine cultures, and mycobacterial PCR, all of which were initially negative.

A rapidly growing mycobacterium was isolated on Lowenstein–Jensen medium and identified as*Mycobacterium abscessus* by matrix-assisted laser desorption/ionization time-of-flight mass spectrometry (MALDI-TOF MS). Broth microdilution susceptibility testing according to Clinical and Laboratory Standards Institute guidelines demonstrated susceptibility to amikacin, clarithromycin, azithromycin, tigecycline, omadacycline, and tedizolid; intermediate susceptibility to imipenem and cefoxitin; and resistance to fluoroquinolones and linezolid. These results guided referral for targeted multidrug therapy.

Conclusion

Cutaneous *Mycobacterium abscessus* infection should be suspected in chronic nodular lesions or abscesses that fail to respond to conventional antibiotics, particularly when repeated skin punctures and exposure to contaminated water are documented. Negative stains and molecular assays do not exclude the diagnosis, and

prolonged mycobacterial culture remains essential. This case highlights the importance of species identification and antimicrobial susceptibility testing to guide targeted multidrug therapy.

EA CONGRESS DV
VIENNA
30 SEP - 3 OCT 2026

Abstract N°: 3292

Successful Treatment of Nocardia Infection Presenting As Tumor-Like Skin Lesions for 17 Years: A Case Report

Guomin Li*[1], Zhenmou Xie[1], Ruzeng Xue[1], Hongfang Liu[1]

[1] Dermatology Hospital, Southern Medical University, Guangzhou, China

Introduction

Nocardiosis is an infectious disease caused by Nocardia species in soil. It may involve multiple organs, including the lungs, central nervous system, and skin. Since the 1940s, sulfonamides have remained the cornerstone therapy for nocardiosis. Common therapeutic regimens include trimethoprim-sulfamethoxazole (TMP-SMX), amikacin, and imipenem. Most cutaneous and soft tissue nocardial infections can be cured, whereas a considerable proportion tends to relapse and responds poorly to empirical treatment. Herein, we report an case of long-standing tumor-like cutaneous nocardiosis with no recurrence after combined treatment with amikacin, TMP-SMX and surgical intervention.

Case Presentation

A 68-year-old male farmer presented with 17-year painless, non-pruritic right foot nodules that progressed to tumor-like masses. He underwent five surgical resections at external institutions due to suspected cutaneous neoplasm, but lesions relapsed and enlarged. Prior to consultation, puncture biopsy suggested inflammatory granuloma (cutaneous malignancy not ruled out); he had no local trauma but a history of pulmonary tuberculosis. Physical examination revealed two well-demarcated, irregular lesions on the right foot dorsum, with dark red to yellowish-brown discoloration, uneven pigmentation, rough surface, superficial erosion and crusting. Three 0.6cm dark red peripheral nodules were noted, with purulent discharge but no subcutaneous abscess; lesions were firm, non-fluctuant and non-tender.

Gram staining of skin lesion smears showed a few Gram-positive cocci (Acid-Fast Stain negative). Pathological biopsy demonstrated hyperkeratosis, acanthosis, pseudoepitheliomatous hyperplasia, diffuse dermal infiltration, neutrophilic abscesses and greyish-blue granular foci. Gram staining of biopsy tissue confirmed Gram-positive cocci and bacilli (D-PAS and Acid-fast Stain negative), with Nocardia species identified by MetaCAP sequencing. Skin lesion microbial culture yielded strains forming dry, wrinkled pink colonies after 14-day incubation (weak acid-fast positive). 16S rDNA sequencing (27F/1492R primers) showed 99.85% similarity with Nocardia africana; drug susceptibility testing confirmed sensitivity to amikacin, clarithromycin, linezolid and cotrimoxazole. Anti-γ-interferon antibody was normal; right foot MRI showed abnormal signals in the first phalanx base, medial cuneiform bone and soft tissues.

Initial treatment with itraconazole (0.2g daily for 2 weeks) was ineffective. He was hospitalized and treated with intravenous amikacin (1g daily) plus oral TMP-SMX and clarithromycin, with slight mass reduction. Subsequent local excision combined with 2-month oral antimicrobial therapy resulted in significant flattening of nodules; no recurrence was observed 8 months after drug discontinuation.

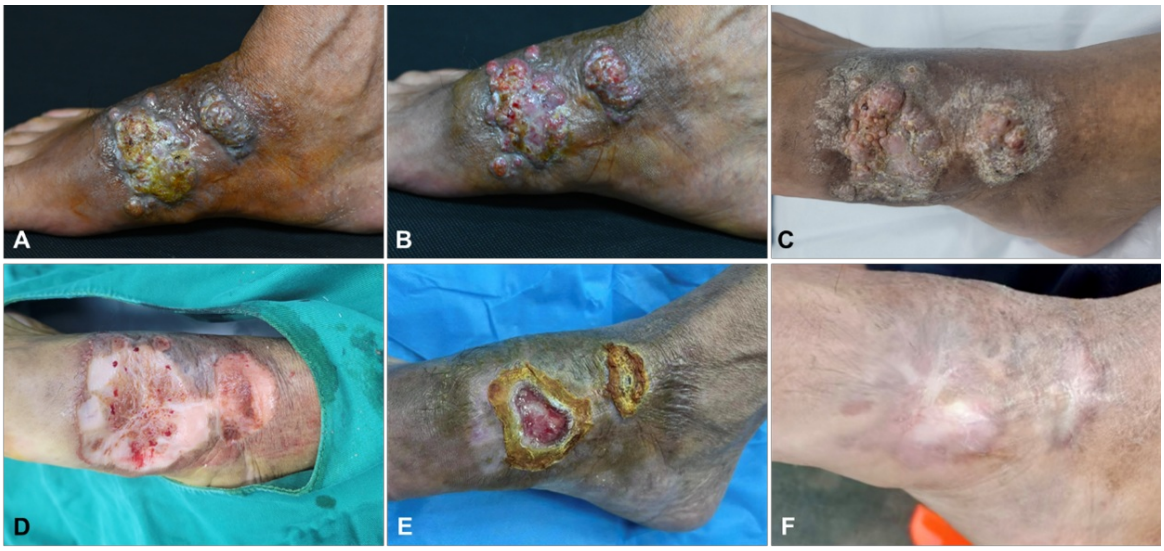

Fig 1. A, Right foot dorsum tumor-like lesions before treatment. B, After the amikacin combined with TMP-SMX treatment for 2 weeks. C, Tumor before surgical resection (TMP-SMX 2 tablets bid and clarithromycin 0.25g bid for 1 month). D, Tumor-like skin lesion after surgical resection. E, 4 weeks after surgical resection. F, 2 months after self-medication withdrawal.

Conclusion

Cutaneous nocardiosis caused by Nocardia africana is extremely rare, especially when presenting as long-standing tumor-like lesions, which easily leads to misdiagnosis as cutaneous neoplasm and ineffective treatment. This case highlights that atypical clinical manifestations and negative traditional microbiological tests do not exclude nocardial infection; when clinical suspicion exists, advanced detection methods such as MetaCAP, 16S rDNA sequencing, and microbial culture should be performed promptly to confirm the diagnosis. Single surgical excision is insufficient for the treatment of such long-standing cutaneous nocardiosis, and combined systemic antimicrobial therapy (amikacin, TMP-SMX, clarithromycin) with surgical intervention can significantly improve the therapeutic effect and reduce recurrence. This case provides valuable clinical experience for the diagnosis and treatment of atypical cutaneous nocardiosis, especially for rare Nocardia africana infections.

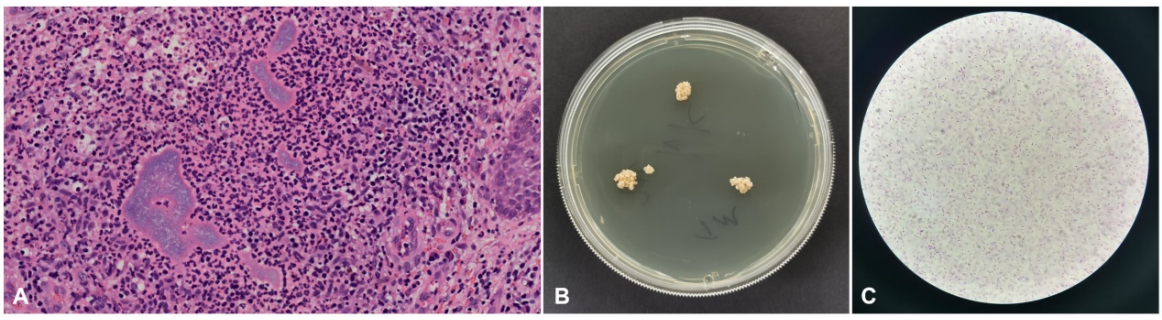

Fig 2. A, H & E stain, ◊200. B, Dry wrinkled pink colonies were observed in yeast submerged medium after seven days of culturing. C, The colonies were picked for weak acid-fast staining, and short red bacilli were observed (×1000).

EADV CONGRESS
VIENNA
30 SEP - 3 OCT 2026

Abstract N°: 3323

Emergence of difficult-to-treat lymphocutaneous sporotrichosis? Analysis based on two cases with Sporothrix brasiliensis isolates with high itraconazole and terbinafine MICs

Juliana Carreiro Avila*[1], Ana Paula Carvalho Reis[1], Kaique Arriel[2], Amanda Azevedo Bittencourt[2], Livia Vieira Almeida[2], Rita de Cassia Soler[2], Giovanna Azevedo Celestrino[1], Ana Paula Cordeiro Lima[1], Maria Gloria Teixeira Sousa[1], José Angelo Lauletta Lindoso[2], Gil Benard[1]

[1] Laboratory of Medical Mycology LIM-53, Division of Clinical Dermatology, Institute of Tropical Medicine, Hospital das Clínicas, Faculty of Medicine, Universidade de São Paulo,, São Paulo, Brazil
[2] Institute of Infectious Diseases Emilio Ribas, São Paulo, Brazil

Introduction

Sporotrichosis is traditionally considered an easily treatable subcutaneous mycosis. However, the ongoing zoonotic epidemic caused by *Sporothrix brasiliensis* in Brazil has been associated with more severe and atypical clinical presentations. In parallel, increasing reports of elevated antifungal minimum inhibitory concentrations (MICs) raise concern regarding the emergence of difficult-to-treat disease. We describe two non-immunocompromised patients with lymphocutaneous sporotrichosis caused by *S. brasiliensis* isolates showing high MICs to itraconazole and terbinafine, both requiring prolonged and complex therapeutic management.

Case Presentation

Case 1: A 24-year-old woman developed a finger abscess after a cat bite from an infected cat. Initial treatment with itraconazole 200 mg/day failed, with progression to lymphocutaneous disease characterized by ulceration of the primary lesion, forearm nodules, and fever. Escalation to itraconazole 400 mg/day resulted in partial improvement; however, after dose reduction and treatment interruption, the patient experienced multiple relapses. Subsequent treatment with terbinafine 500 mg/day also failed, with progression to chronic hyperkeratotic granulomatous plaques involving both finger lesions. Apart from a combined therapy with itraconazole 200 mg/day and terbinafine 250 mg/day, repeated cryosurgery sessions were required, ultimately leading to clinical resolution. Culture isolated *Sporothrix spp.*, molecularly identified as *S. brasiliensis*. Antifungal susceptibility testing demonstrated high MICs to itraconazole and terbinafine.

Case 2: A 65-year-old woman presented with a 9-month history of facial and oral lesions involving the nose, lips, palate, and perioral region. Initial treatment with amphotericin B deoxycholate followed by itraconazole 200 mg/day led to partial improvement, but repeated relapses occurred during prolonged therapy, including recurrence of granulomatous nasal and palatal lesions. Histopathology demonstrated chronic granulomatous inflammation with rare fungal structures. Due to progression despite prolonged itraconazole therapy, the patient required rehospitalization for three months of amphotericin B deoxycholate, with interruptions due to nephrotoxicity, followed by high-dose itraconazole 400 mg/day for an additional two months, ultimately achieving sustained clinical resolution without further relapses. Culture yielded *S. brasiliensis,* molecularly identified as *S. brasiliensis*. Antifungal susceptibility testing revealed high MICs to itraconazole and terbinafine, but low MIC to amphotericin B.

	MIC (mg/L)		
Antifungal	Case 1	Case 2	ECV*
Amphotericin B	2	2	4
Itraconazole	> 8	> 8	2
Terbinafine	4	2	0.12
Fluconazole	> 64	> 64	≥ 32

*Epidemiological cutoff points (ECV) for *Sporothrix brasiliensis* according to Espinel-Ingroff *et al.* (2017) (13).

Minimum inhibitory concentrations (MICs) for antifungals regarding Case 01 and Case 02 isolates

Conclusion

These cases challenge the traditional perception of sporotrichosis as a uniformly uncomplicated and readily treatable mycosis. Both immunocompetent patients developed refractory disease requiring prolonged treatment, dose escalation, therapeutic switching, and, in one case, hospitalization for amphotericin B therapy. The identification of *S. brasiliensis* isolates with elevated MICs to itraconazole and terbinafine raises concern regarding the emergence of reduced antifungal susceptibility during the Brazilian zoonotic epidemic. In parallel, the increasing frequency of severe and atypical presentations may reflect the enhanced virulence of *S. brasiliensis* and the high fungal burden associated with cat-transmitted infection. Current guidelines provide limited recommendations for refractory cases, and standardized definitions of treatment failure remain lacking. These findings highlight the importance of epidemiological surveillance, routine fungal isolation with antifungal susceptibility testing, and development of standardized management strategies for difficult-to-treat sporotrichosis.

EADV CONGRESS
VIENNA
30 SEP - 3 OCT 2026

Abstract N°: 3345

When a Nipple Eschar Reveals the Diagnosis: Rickettsial Vasculitis mimicking Purpura Fulminans

fatima zahrae EL Abidi*[1], Meryem Soughi[1], IKRAME BEJJA[1], Saadia Boughaleb[1], Zakia Douhi[1], Sara Elloudi[1], Hanane Baybay[1], Fatima Zohra Mernissi[1]

[1] dermatology departement, FEZ, Morocco

Introduction

Severe rickettsioses are endothelial-tropic infections in which small-vessel injury can lead to thrombocytopenia, coagulation abnormalities, necrotic purpura, and multiorgan dysfunction—thereby it can closely mimic fulminant bacterial sepsis and even purpura fulminans.

Case Presentation

A 67-year-old woman living in a rural area, with type 2 diabetes and treated hypertension, presented to the emergency department with acute fever, severe headache, and rapidly progressive skin lesions. Neurological examination revealed confusion and febrile meningeal syndrome. Purpuric lesions initially involved the lower limbs, prompting empiric treatment for suspected meningococcemia (two intravenous doses of a third-generation cephalosporin at meningeal dosage). Brain CT and cerebrospinal fluid analysis were normal.

Dermatological assessment showed purpura plaques affecting the lower abdomen, upper limbs, and lower limbs. A necrotic eschar on the left areolar–nipple, consistent with an inoculation eschar, strongly suggested severe rickettsial infection. Skin biopsy demonstrated leukocytoclastic vasculitis.

Laboratory tests showed hemoglobin 9.4 g/dL, hyperleukocytosis at 19.1 × 10^9/L with neutrophil predominance, severe thrombocytopenia 55 × 10^9/L, CRP 175 mg/L, procalcitonin 11 ng/mL, acute kidney failure (urea 2.3 g/L ≈ 38 mmol/L; creatinine 36 mg/L ≈ 318 µmol/L), and AST/ALT approximately twice the upper limit of normal. The administration of Doxycycline (200 mg/day) in addition to ciprofloxacin was correlated with a rapid clinical improvement, particularly neurological recovery. Rickettsial serology subsequently returned positive, confirming severe rickettsiosis.

Conclusion

Severe rickettsial infections may closely resemble meningococcemia in their clinical presentation. In any febrile patient presenting with rapidly progressive purpura, a meticulous search for an inoculation eschar should be systematically performed. Early initiation of doxycycline in combination with ciprofloxacin is recommended, as emerging clinical evidence suggests that this therapeutic approach may improve patient outcomes.

EADV CONGRESS
VIENNA
30 SEP - 3 OCT 2026

Abstract N°: 3354

Mycetoma: Clinicopathological Features, Therapeutic Management and Long-Term Outcomes in a 48-Year Retrospective Study

Ines Atoui*[1], Litaiem Noureddine[1], Soumaya Gara[1], Meriem Jones[1], Faten Zeglaoui[1], rammeh soumaya[1]

[1] Dermatology department -Charles Nicolle Hospital, Tunis, Tunisia

Introduction
Mycetoma is a chronic, progressively destructive infectious disease characterized by tumefaction, sinus formation, and discharge of grains. It remains a major diagnostic and therapeutic challenge in endemic regions due to its long evolution and frequent late presentation.

Case Presentation
Materials and methods

We conducted a retrospective study including all patients presenting with fistulized tumefactions with grain discharge, seen in the Dermatology Department of Charles Nicolle Hospital, Tunis, over a 48 year period (January 1976 to March 2024).

Results

Mycetoma was diagnosed in 16 patients based on clinical, histological, and biological criteria. The mean age was 31.7 years, and the mean disease duration was 11.5 years, reflecting a long-evolving condition. The causative organism was identified in 10 cases (4 actinomycetomas and 6 eumycetomas). Clinically, lesions were predominantly located on the feet in all patients, with a rural origin in 12 cases and a history of prior microtrauma in 4. One patient presented an uncommon bifocal involvement affecting the face and perineum. Bone involvement was observed in 11 cases, including osteitis, demineralization, and osteolysis. Grain color varied according to the etiological agent: white (n=7), black (n=5), and yellow (n=3). Identified actinomycetes included *Actinomadura madurae* (n=2) and *Streptomyces somaliensis* (n=2), while fungal agents were *Madurella mycetomatis* (n=4) and *Pseudallescheria boydii* (n=2). Treatment consisted of targeted antimicrobial therapy in actinomycetoma cases and antifungal agents for eumycetoma, including ketoconazole (200 mg/day), itraconazole (400 mg/day), and terbinafine (500 mg/day). Surgical management was required in 7 of the 11 patients with bone involvement. Overall, clinical improvement was achieved in 9 patients, while 3 were lost to follow-up.

Conclusion
Mycetoma remains a chronic and debilitating infection, predominantly affecting young adults from rural areas and frequently diagnosed at an advanced stage with exclusive foot involvement and possible bone extension. Histopathology played a central role in etiological diagnosis, particularly when microbiological identification was limited, allowing differentiation between actinomycetoma and eumycetoma and guiding therapy. Early diagnosis is essential to reduce destructive complications and sequelae. Combined medical and surgical management provided favorable outcomes in most patients.

EADV CONGRESS
VIENNA
30 SEP - 3 OCT 2026

Abstract N°: 3354

Comparative study to evaluate efficacy of Intralesional Vitamin D and MMR vaccine in palmo-plantar warts

Shashank Bhargava*[1]

[1] R.D. Gardi Medical College, Ujjain, India

Introduction

Warts are the viral infection of the skin caused by Human Papilloma Virus occurring in form of verrucous growth over the surface of the skin. Incomplete removal or local recurrence of the infection especially in palms and soles is the disadvantage with the currently available local tissue destructive therapies. Newer therapy i.e. intralesional immunotherapy offers the advantage of taking care of viral infection not only at treatment site but also at the remote site, and also offers life long immunity.

Materials and Methods

The study was conducted on 56 patients with palmar, plantar, and periungual warts of all ages. They were divided in 2 groups, group A patients were given 0.1-0.2 ml of Vitamin D intralesionally in the largest wart at an interval of 3 weeks for 3 sessions. whereas group B was given MMR vaccine. Patient assessment in follow-up visits was done with clinical photographs and by filling proforma for effects and side effects.

Results

Complete clearance was seen in 25(89%) and 22(78%) patients in group A and B respectively. Partial clearance in 2 and 5 patients in group A and B. 1 patient in each group did not respond, hence they were given 1 more session of treatment later. it was surprising to see that 12/28 and 9/28 in group A and B responded completely just after session. partial responders were mostly periungual warts patients.

Conclusions

Intralesional vitamin D is slightly superior to intralesional MMR vaccine in treating all types of warts; it can be used as a valuable first line treatment in difficult to treat sites like palmoplantar wart and periungual warts.

EADV CONGRESS
VIENNA
30 SEP - 3 OCT 2026

Abstract N°: 3362

An Indian study of various unusual presentations of Cutaneous Tuberculosis: Challenges in its diagnosis and management

Shashank Bhargava*[1], Ujjwal Kumar[1]

[1] R.D. Gardi Medical College, Ujjain, India

Introduction

Extrapulmonary tuberculosis (EPTB) is a serious health problem in both developing and developed countries. In India, cutaneous TB constitutes about 0.1% to 2% of the total skin diseases attending outpatients. We were surprised to see many cases of tuberculosis with unusual presentations, which led to diagnostic dilemma.

Materials and Methods

All suspected cases of cutaneous tuberculosis were studied over a period of 5 years (2020-2025) after taking their written consent. Thorough dermatological examinations and later skin biopsy, mantoux test, chest x-ray and other supporting tests were performed to confirm the diagnosis of tuberculosis. Their treatment outcome was also analysed.

Results

A total of 88 patients were confirmed to have cutaneous tuberculosis. Females (58/88) were more compared to males. Lupus vulgaris (46/88) was most common presentation followed by Tuberculosis verrucosa cutis (TBVC). Lupus vulgaris had head and neck involvement in majority of the cases. Mantoux positivity was observed in 79.5% (70/88) of patients while raised ESR in 88.6% (78/88) of patients. Few cases of lupus vulgaris were very confusing and presented similar to deep fungal infections, hypertrophic lichen planus, mycetoma, subacute lupus cutaneous lupus erythematosus to name a few. Other variants of EPTB also had very close differentials and were managed with Anti-tubercular therapy (ATT). 7 patients had serology positive for HIV. Histopathology was conclusive in 93.1% (82/88) cases. All the variants of cutaneous tuberculosis such as lupus vulgaris, scrofuloderma, and tuberculosis verrucosa cutis responded excellently to ATT.

Conclusions

The present study emphasizes the importance of clinicopathological correlation and therapeutic response in cutaneous TB. Although positive results of ESR, Mantoux reactivity, and TB cultures facilitate the clinical diagnosis, negative results should not exclude the diagnosis of cutaneous TB. Also cutaneous Tuberculosis is a great mimicker in dermatology especially in a tropical country like India.

EA DV CONGRESS
VIENNA
30 SEP - 3 OCT 2026

Abstract N°: 3381

Cutaneous cryptococcosis as the first manifestation of disseminated infection

Beatriz Córcoles Jannone*[1], Diego Perez Rodríguez[1], Javier Lorenz Dolz[1], Ruggero Moro[1], Fátima Mayo Martínez[1], Beatriz Llombart Cussac[1], Celia Requena Caballero[1], Carlos Serra Guillén[1], María Pilar Pérez García[1], Victor Traves Zapata[1], Eduardo Nagore Enguidanos[1]

[1] Fundacion Instituto Valenciano de Oncología, Valencia, Spain

Introduction

Cutaneous cryptococcosis is an uncommon fungal infection caused by encapsulated yeasts, most often affecting immunocompromised hosts, particularly patients with AIDS. Skin involvement usually reflects haematogenous dissemination from a pulmonary focus, although primary cutaneous inoculation may also occur. Its clinical spectrum is broad and may mimic bacterial, inflammatory or neoplastic dermatoses, delaying diagnosis. We report a case of disseminated cryptococcosis initially revealed by chronic ulcerated skin lesions in a patient receiving lenalidomide.

Case Presentation

A 58-year-old man with multiple myeloma in remission, receiving maintenance therapy with lenalidomide, was referred for a 6-month history of progressive cutaneous lesions. Examination showed multiple isolated plaques and nodules with central ulceration and raised borders, some with haemorrhagic crusts, located on the trunk and scalp. The initial differential diagnosis included ecthyma gangrenosum and cutaneous involvement of multiple myeloma.

Two partial skin biopsies were obtained for histopathological and microbiological studies. Haematoxylin-eosin staining demonstrated a granulomatous histiocytic infiltrate within the dermis, with multinucleated giant cells engulfing multiple round encapsulated yeast forms. PAS and Grocott stains were positive, and Alcian blue highlighted the mucopolysaccharide nature of the capsule (Figure). Microbiological culture demonstrated abundant growth of *Cryptococcus neoformans*, confirming cutaneous cryptococcosis.

Further history revealed daily exposure to birds, including pigeons and poultry. Because the patient also reported a 1-month history of persistent cough, he was admitted for systemic evaluation. Serum cryptococcal antigen was positive, while thoracic imaging and bronchoalveolar lavage confirmed pulmonary involvement. Cerebrospinal fluid studies were negative.

With the diagnosis of disseminated cryptococcosis, lenalidomide was discontinued and the patient received induction therapy with liposomal amphotericin B, flucytosine and high-dose fluconazole for 14 days, followed by oral fluconazole maintenance therapy. Cutaneous lesions and respiratory symptoms progressively improved.

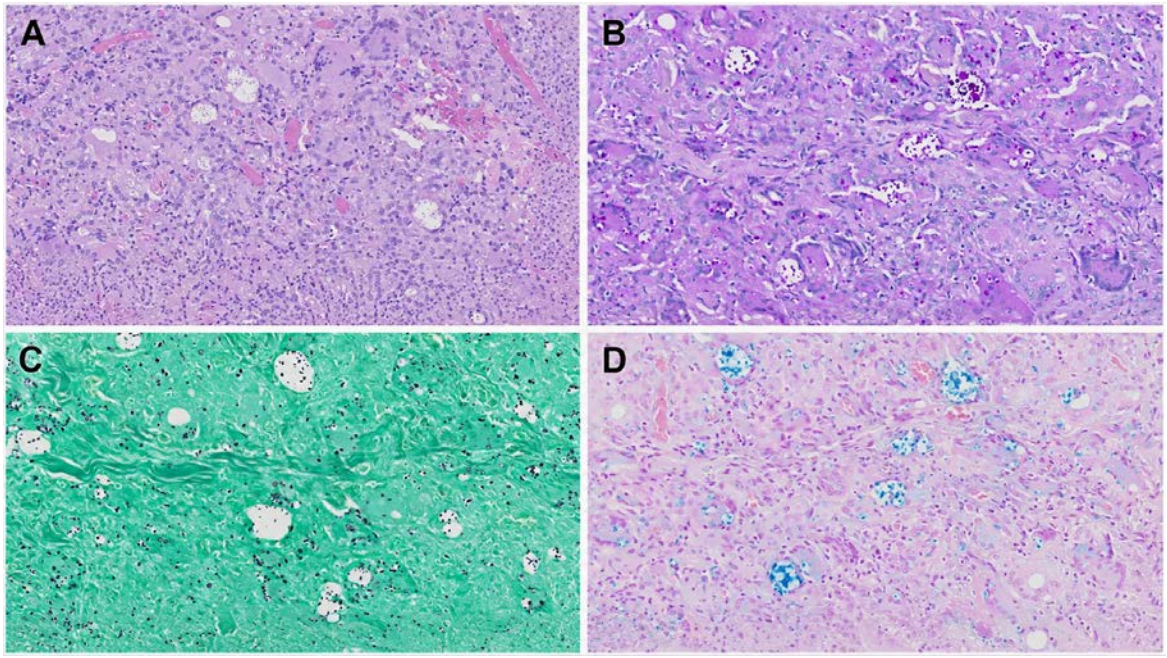

A. Hematoxylin-eosin (H&E) stain x20. B. Periodic acid–Schiff (PAS) stain x20. C. Grocott methenamine silver stain x20. D. Alcian blue stain x20.

Conclusion

Cutaneous cryptococcosis is a great clinical mimicker. This case highlights the highly variable presentation of cutaneous cryptococcosis that may delay diagnosis. Reported morphologies include papules, nodules, ulcers, molluscum contagiosum-like lesions and cellulitis-like plaques. In this case, the nodules with necrotic centres resembled ecthyma gangrenosum or neoplastic infiltration, illustrating the importance of early biopsy and tissue culture in atypical or persistent ulcerated lesions, particularly in immunosuppressed patients.

In our patient, the skin findings were the diagnostic clue to reveal disseminated infection. Evendirect inoculation of *Cryptococcus* species into the skin via trauma is possible; multiple lesions in immunocompromised patients should prompt investigation for pulmonary and central nervous system involvement. In this context, the dermatologist plays a key role in the early recognition of a potentially life-threatening infection.

Finally, although cryptococcosis is strongly related to AIDS patients, it can develop under other conditions as well. Lenalidomide is not a direct anti-TNF agent but it has complex immunomodulatory effects modulating cytokine responses, particularly TNF-α. Moreover, underlying multiple myeloma with hypogammaglobulinaemia and lymphopenia could contribute to infection after ambiental exposure to bird droppings.

EA DV CONGRESS
VIENNA
30 SEP - 3 OCT 2026

Abstract N°: 3384

Sporotrichosis Sequelae: An Underrecognized Burden of Disfiguring Scars in a Hyperendemic Region

Carolina Pires Lellis*[1], John Veasey[1], Karina Baruel de Camargo Votto Calbucci[1], Elisete Crocco[1]

[1] Irmandade Santa Casa de Misericórdia de São Paulo, São Paulo, Brazil

Introduction

Sporotrichosis is a subcutaneous mycosis caused by fungi of the genus *Sporothrix*. *S. brasiliensis* is particularly relevant due to its high virulence and zoonotic transmission, primarily via felines (1). Currently hyperendemic in Brazil, it is the most frequent subcutaneous mycosis in Latin America. Clinical forms include cutaneous, mucosal, systemic, and immunoreactive. The cutaneous form—the most prevalent—is subdivided into lymphocutaneous (sporotrichoid), fixed cutaneous, and multiple inoculations (2,3)

Treatment persists until complete lesion involution, utilizing oral antifungals, immunomodulators, and procedures such as cryotherapy (4) Post-infection scars are clinical markers of resolution but carry significant functional, aesthetic, and psychosocial weight. The "epidemic of scars" resulting from the lymphocutaneous form often produces linear patterns that patients associate with self-inflicted injuries ("self-cutting"), intensifying social stigma. Studies show that self-mutilation-like scars significantly impair the Dermatology Life Quality Index (DLQI) (5)

Scars are classified by trophic status: atrophic, normotrophic, and hypertrophic (6). In sporotrichosis, specific morphologies are described: "linear" (independent of skin tension lines) (Figure 1) and "candle-dripping" (coexistence of atrophic and hypertrophic areas) (figure 2) (7) Despite their relevance, these sequelae remain under-explored in medical literature.



Fig 1. Patients treated for sporotrichosis at the Tropical Dermatology Outpatient Clinic of the Dermatology Department at Santa Casa de São Paulo – evidencing the trend toward scar linearity regardless of the initial clinical presentation.



Fig 2. Patients treated for sporotrichosis at the Tropical Dermatology Outpatient Clinic of the Dermatology Department at Santa Casa de São Paulo – highlighting the 'guttering candle' (pingo de vela) scarring pattern.

Materials and Methods

To analyze scarring patterns in patients treated for sporotrichosis at a reference center in São Paulo, correlating morphological outcomes with clinical and therapeutic variables to identify ways to mitigate high-morbidity sequelae.
A retrospective, descriptive-analytical study was conducted using medical records from a sporotrichosis reference center in São Paulo - Brazil (January 2017 to June 2024). Variables included age, sex, phototype, clinical form, treatment duration, and number of lesions. Morphological analysis categorized scars by trophic status and specific patterns (candle-dripping, linear, or non-specific)

Results

The study analyzed 45 patients and 202 scars. Clinical forms were: lymphocutaneous (49%), multiple inoculation (29%), fixed cutaneous (20%), and systemic (2%). Anatomical distribution: upper limbs (80%), cephalic pole (8%), lower limbs (5%), and trunk (7%).
Trophic classification revealed 51% atrophic, 45% hypertrophic, and 4% normotrophic scars. Specific morphology was 60% non-specific, 22% linear, and 18% "candle-dripping." Among 38 lesions treated with adjuvant cryotherapy, 74% were atrophic and 26% hypertrophic; no normotrophic scars were observed.
Mean treatment time was significantly shorter for the cryotherapy group (23 ± 20.1 weeks) compared to oral monotherapy (25.5 ± 14.5 weeks; p= 0.004). This suggests cryotherapy not only acts as a tissue repair modulator, accelerating the transition from the inflammatory to the proliferative phase, but also promotes a better scarring outcome by reducing pro-inflammatory mediators (8)

Conclusions

The scarring impact of sporotrichosis is a significant clinical burden, with an average of four to five scars per patient. The predominance in upper limbs (80%) reflects zoonotic transmission but also intensifies social stigma and negative self-perception. Understanding these patterns is essential, as disfiguring scars limit social and occupational integration and cause physical symptoms like pruritus and pain, aggravating the overall disease burden.

EA DV CONGRESS
VIENNA
30 SEP - 3 OCT 2026

Abstract N°: 3390

Disseminated Herpes Zoster as the Sentinel Manifestation of Previously Unrecognized HIV Infection in a Pediatric Patient: A Case Report

Brilianti Viapita*[1], Elvira Lesmana[2], Fifa Argentina[3], Ferdinand Ferdinand[4], Hanny Nilasari[2]

[1] Faculty Of Medicine, Universitas Jambi, Jambi, Indonesia

[2] Department of Dermatology and Venereology, Faculty of Medicine Universitas Indonesia, Dr. Cipto Mangunkusumo National Central General Hospital, Jakarta, Indonesia

[3] Department of Dermatology and Venereology, Faculty of Medicine Universitas Sriwijaya, Dr. Mohammad Hoesin General Academic Hospital, Palembang, Indonesia

[4] Department of Dermatology and Venereology, Besemah Regional Hospital, Pagar Alam, Indonesia

Introduction

Herpes zoster (HZ) in children is rare, with an estimated incidence of 0.2–0.74 per 1,000 person-years, yet in pediatric HIV infection, this rises sharply to 9.3–141 per 1,000 patient-years, a 100-fold increase that renders HZ a powerful clinical signal. Disseminated herpes zoster (DHZ), defined as >20 vesicles beyond the primary and adjacent dermatomes, complicates 2–10% of immunocompromised pediatric cases and carries significant morbidity. Despite established links to immunodeficiency, DHZ as the index presentation of undiagnosed HIV in a child lacking conventional risk factors remains exceptionally and documentably rare. We report such a case and highlight DHZ as a critical sentinel for HIV screening even in pediatric patients lacking conventional risk factors.

Case Presentation

A 14-year-old Indonesian boy presented with a 10-day illness: 5 days of fever and myalgia, followed by rapidly progressive, painful vesiculobullous eruptions (VAS 5/10) originating on the right thigh and disseminating to the trunk, bilateral upper extremities, and face. He had a documented history of primary varicella at 9 months of age and had not received varicella vaccination. He denied sexual contact, intravenous drug use, blood transfusion, or tattooing, both parents and all siblings tested HIV-seronegative, excluding vertical or household transmission as the obvious source.

Dermatologic examination demonstrated multiple vesicles, pustules, and coalescent bullae in the right inguinal, pubic, scrotal, and femoral regions, alongside scattered extra-dermatomal vesicles and hemorrhagic crusts on the abdomen, frontal region, glabella, and right supraciliary area. Tzanck smear confirmed multinucleated giant cells (Figure 1). The profoundly atypical dissemination pattern prompted immunodeficiency evaluation.

Three sequential HIV rapid tests using different kits were reactive, fulfilling national diagnostic criteria. Immunological profiling revealed a CD4+ absolute count of 355 cells/μL (12.00%), a CD8+ count of 2,250 cells/μL (75.99%), and an inverted CD4/CD8 ratio of 0.16, consistent with severe immunosuppression. Syphilis serology (TPHA, VDRL), hepatitis B surface antigen, and chest radiography were unremarkable. Disseminated HZ with newly diagnosed HIV infection was confirmed.

Multidisciplinary management comprised isolation nursing, oral valacyclovir 1000 mg q8h for 7 days, 0.9% saline compresses, topical fusidic acid 2% cream, antihistamine and analgesic support, cotrimoxazole prophylaxis, followed by initiation of tenofovir/lamivudine/efavirenz fixed-dose combination per Indonesian National HIV Guideline. At the 26-day follow-up, the patient demonstrated marked clinical improvement, with no new lesions,

pain reduced to VAS 1/10, and resolution of vesiculobullous lesions, with residual hemorrhagic crusting persisting at the primary dermatomal site and scattered post-inflammatory hypopigmented patches at sites of prior lesions. No ophthalmological, neurological, or post-herpetic sequelae were identified.

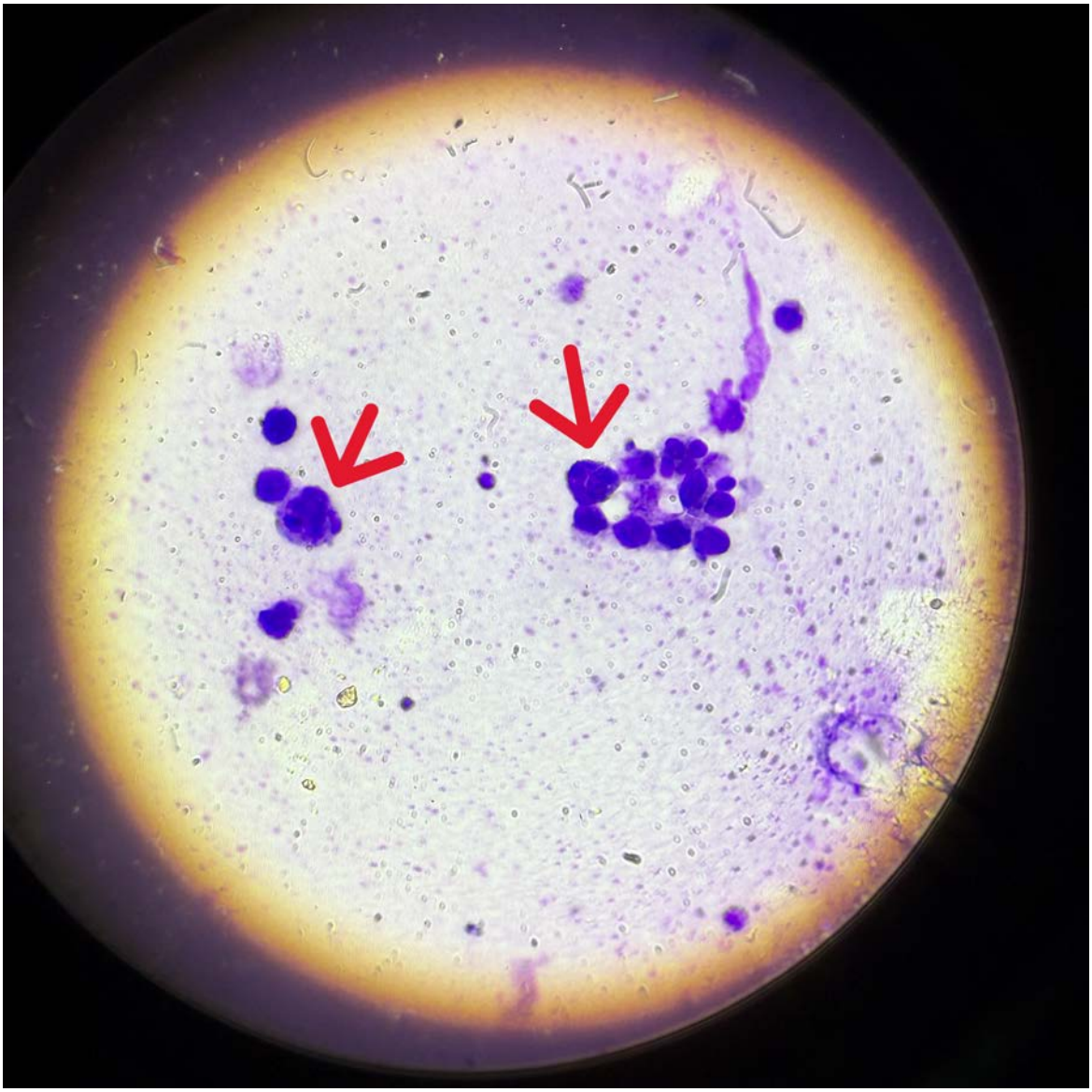

Figure 1. Tzanck smear demonstrated multinucleated giant cells

Conclusion

This case highlights disseminated herpes zoster as a potential sentinel manifestation of undiagnosed HIV infection in children, even in the absence of conventional risk factors. Dermatologists should maintain a high index of suspicion for underlying immunodeficiency when encountering atypical or disseminated HZ in pediatric patients, and HIV screening should be considered as part of the routine workup. Early recognition may facilitate the timely initiation of antiretroviral therapy and prevent long-term complications.

EADV CONGRESS
VIENNA
30 SEP - 3 OCT 2026

Abstract N°: 3391

Defining a Dermoscopic Inflammatory Gradient in Cutaneous Leishmaniasis

MOHAMED HOUBAYELI*[1], layla bendaoud[1], Mariem Aboudourib[1], Ouafa Hocar[1], Amal Said[1]

[1] Mohammed VI University Hospital of Marrakech, Bioscience and Health Laboratory, Department of Dermatology Venerology, marrakech, Morocco

Introduction
Cutaneous leishmaniasis (CL) remains highly prevalent in North Africa, where overlapping endemic foci contribute to marked clinical heterogeneity. While dermoscopy has been increasingly reported as a diagnostic aid, its potential role in defining inflammatory activity and lesion evolution has not been clearly established in endemic settings.

Objectives

To characterize clinicodermoscopic correlations in CL and to explore whether dermoscopic patterns reflect inflammatory dynamics and lesion stage.

Materials and Methods
We conducted a prospective study (January–June 2025) including 48 consecutive patients with parasitologically confirmed CL at a tertiary referral center in Marrakech. Epidemiological and clinical data were recorded. Standardized dermoscopic assessment evaluated erythematous background, hyperkeratosis/crusts, white starburst pattern, ulceration, yellow tears, and vascular morphology. Associations between clinical presentation and dermoscopic findings were analyzed using Fisher's exact test ($p < 0.05$).

Results
Patients originated from central-southern (58.3%) and southeastern (41.7%) endemic regions. Impetigoid forms predominated (52.1%), followed by Oriental sore (22.9%) and sporotrichoid variants (14.6%); atypical erysipeloid and cutaneous-mucosal forms were also observed.

Dermoscopy revealed erythematous background and atypical vascularization (79.2% each), hyperkeratosis/crusts (66.7%), white starburst pattern (60.4%), ulceration (54.2%) and yellow tears (35.4%). Clinical and dermoscopic ulceration were strongly associated ($p = 0.000144$).

Wet forms demonstrated predominant exudative features (ulceration, yellow tears), whereas dry forms showed keratotic and starburst patterns. Importantly, dermoscopic findings suggested a reproducible inflammatory gradient: exudative vascular patterns characterized active lesions, while keratotic/starburst features predominated in more organized stages.

Conclusions
CL in endemic Moroccan areas exhibits reproducible clinicodermoscopic profiles. Dermoscopy not only enhances diagnostic accuracy but may serve as a non-invasive indicator of inflammatory activity and lesion evolution. These

findings support systematic dermoscopic integration in endemic clinical practice and open perspectives for staging-oriented therapeutic strategies.

EA DV CONGRESS
VIENNA
30 SEP - 3 OCT 2026

Abstract N°: 3414

Atypical Presentations of Scrofuloderma Beyond Cervical Involvement: A Retrospective Case Series from a Tuberculosis-Endemic Region

Akshita Singh*[1], Swadhinata Sahoo[1], Subhashree Madhual[1], Maitreyee Panda[1], Ajaya Jena[1]

[1] Institute of Medical Sciences and SUM Hospital, Siksha ' O ' Anusandhan Deemed University, Bhubaneswar, India

Introduction

Extra-cervical presentation of Scrofuloderma is an exceedingly uncommon manifestation of cutaneous tuberculosis, with limited literature on its incidence. Here we present 4 cases of Scrofuloderma involving unusual anatomical sites, highlighting the diverse clinical spectrum and diagnostic complexity of this entity.

Case Presentation

Case 1

A 40- year-old male, resident of Odisha, presented with a 2-month history of multiple nodules with discharging sinus in the left axilla, associated with dry cough and weight loss. On examination, three tender fluctuant nodules were present, with puckering of skin. A single sinus tract with foul-smelling pus discharge was present. Differential diagnoses included hidradenitis suppurativa and bacterial abscesses. Ultrasonography showed a heterogeneously hyperechoic lesion with a sinus tract and necrotic lymphadenopathy. Mantoux test was strongly positive, and histopathology showed necrotizing epitheloid granulomatous lesions. Chest X-ray revealed bilateral fibrocavitatory lesion , while CBNAAT from pus aspirate detected *Mycobacterium tuberculosis complex*. The patient was then initiated on standard anti-tubercular therapy (ATT), with marked clinical improvement within 8 weeks.

Case 2

An 11-year-old female presented with a 3-month history of painful swelling in the left groin. History of intermittent fever, weight loss, and generalised malaise was present. She was a known case of chronic myeloid leukaemia(CML) on treatment. On examination, there was a nonmobile, tender, firm erythematous globular swelling of size 7 cm × 6 cm in the left inguinal region studded with multiple sinuses. The surrounding skin showed hyperpigmentation, with local rise of temperature present. Significant seropurulent discharge from the sinuses was seen. Bilateral axillary and inguinal lymph nodes were enlarged and matted. Radiological evaluation excluded pulmonary tuberculosis and underlying osteoarticular involvement. CBNAAT testing confirmed *Mycobacterium tuberculosis,* following which a diagnosis of inguinal scrofuloderma with underlying CML was established. The patient demonstrated significant clinical improvement following initiation of standard anti-tubercular therapy.

Case 3

A 32-year-old female presented with a gradually enlarging swelling over the arm since 5 months. On Examination, there was a single fluctuant tender erythematous swelling with a discharging sinus. Associated regional lymphadenopathy was present. Histopathology revealed dense granulomatous infiltrates with caseous necrosis. Chest radiography and systemic evaluation were unremarkable. The patient was then started on ATT, with clinical improvement.

Case 4

A 45 -year-old female presented with a chronic non-healing lesion over the flexor aspect of the forearm. No constitutional symptoms present. On examination, a violaceous plaque with multiple discharging sinuses was present. The atypical site and morphology initially raised suspicion of deep fungal infection and atypical mycobacterial infection. Histopathology showed tuberculoid granulomas with caseous necrosis, confirming our diagnosis. The patient was then started on conventional ATT, showing significant clinical improvement.

Case	Age/Sex	Site	Initial Differential Diagnosis	Key Clue	Diagnostic Modality	Outcome
1	40/M	Left axilla	Hidradenitis suppurativa, bacterial abscess	Discharging sinus with necrotic lymphadenopathy and constitutional symptoms	Ultrasonography, Mantoux test, histopathology, CBNAAT from pus aspirate	Marked clinical improvement after initiation of ATT within 8 weeks
2	11/F	Left inguinal region	Suppurative lymphadenitis, bacterial abscess	Matted lymph nodes with multiple sinuses in a patient with underlying CML	CBNAAT, radiological evaluation excluding pulmonary and osteoarticular TB	Significant clinical improvement on ATT
3	32/F	Flexor aspect of arm	Pyogenic abscess, soft tissue infection	Chronic fluctuant swelling with discharging sinus and regional lymphadenopathy	Histopathology showing granulomatous infiltrates with caseous necrosis	Complete resolution following ATT
4	45/F	Flexor aspect of forearm	Deep fungal infection, atypical mycobacterial infection	Violaceous plaque with multiple tiny discharging sinuses	Histopathology showing tuberculoid granulomas with caseous necrosis	Significant clinical improvement following conventional ATT

Table 1 : Summary of four cases of atypical extra-cervical scrofuloderma. ATT: anti-tubercular therapy; CBNAAT: cartridge-based nucleic acid amplification test; CML: chronic myeloid leukaemia; TB: tuberculosis.

Conclusion

Atypical extra-cervical scrofuloderma may mimic hidradenitis suppurativa, bacterial abscesses, deep fungal infections, or atypical mycobacterial infections, resulting in delayed diagnosis and treatment. Although scrofuloderma remains more frequently encountered in TB-endemic regions, atypical presentations are underreported and may pose substantial diagnostic challenges. Clinicians should maintain a high index of suspicion for cutaneous tuberculosis in chronic noduloulcerative lesions with discharging sinuses, unresponsive to conventional antibiotic therapy. In an era of increasing migration and international mobility, recognition of these atypical manifestations remains clinically relevant even in low-incidence regions.

POWERED BY M-ANAGE.COM

EADV CONGRESS
VIENNA
30 SEP - 3 OCT 2026

Abstract N°: 3419

Cutaneous Leishmaniasis Epidemiology in Mexico: A 40-Year Trend Analysis (1985–2024)

Alejandra Brown-Herrera*[1], Lucia Fernández[1], Jorge Ocampo-Candiani[1]

[1] Hospital Universitario Doctor José Eleuterio González, Monterrey, Mexico

Introduction

CL is a neglected tropical disease endemic in 99 countries, causing disfiguring skin lesions with permanent scarring that contribute to social stigma and economic loss.[1,2] In Mexico, transmission is predominantly zoonotic, with Leishmania mexicana as the principal species in southern states.[3] Environmental modifications, human mobility, and migratory flows have increasingly driven cases beyond traditional endemic boundaries.[2,4] A comprehensive trend analysis spanning recent decades is lacking, hence the present study aims to characterize the epidemiological trends of CL in Mexico over a 40-year period (1985–2024).

Materials and Methods

Observational, longitudinal, retrospective study of all newly reported CL cases in Mexico (1985–2024). Annual incidence rates per 100,000 inhabitants (95% CIs) were retrieved from Mexico's Morbidity Yearbook. Joinpoint regression analysis was used to identify statistically significant trend changes and calculate the Annual Percent Change (APC) per segment. Analyses were performed using SPSS v.22 and Joinpoint Trend Analysis Software v.4.9.0.0. Significance level: $p < 0.05$.

Results

A total of 27,747 cases were reported (mean: 694 ± 369/year). Incidence rose from 0.017/100,000 in 1985 to a peak of 1.794/100,000 in 1997. One significant joinpoint was identified in 1994 (95% CI: 1991–1998), yielding two segments: APC +27.97% (95% CI: 14.02–88.96; $p = 0.0016$) from 1985–1994, and APC −2.92% (95% CI: −5.03 to −1.52; $p = 0.0004$) from 1994–2024. The lowest counts occurred in 2020–2021 (439 and 242 cases; 0.343 and 0.188/100,000), followed by a rebound in 2022–2023 (1,026 and 1,126 cases; 0.791 and 0.861/100,000), and a subsequent decline in 2024 (351 cases; 0.266/100,000). These results are illustrated in Figure 1.

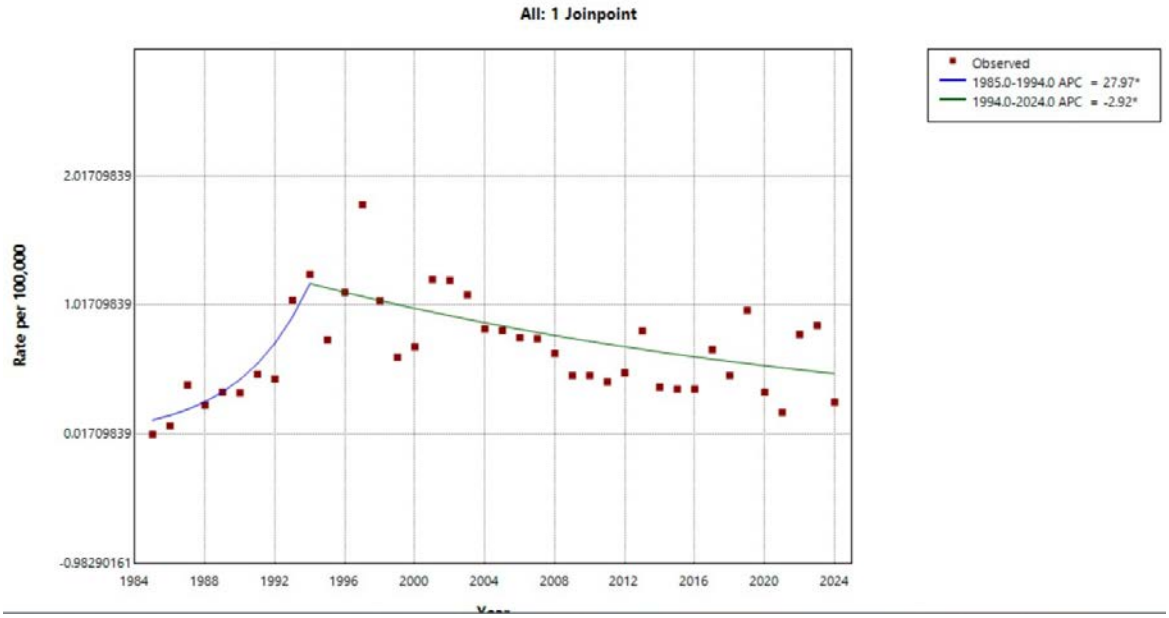

Figure 1. Joinpoint regression analysis of cutaneous leishmaniasis incidence rates in Mexico, 1985–2024. The blue line represents the first segment (1985–1994, APC = +27.97%*) and the green line the second segment (1994–2024, APC = −2.92%*). Red squares denote observed annual incidence rates per 100,000 inhabitants. *p < 0.05.

Conclusions

Between 1985 and 2024, the epidemiology of CL in Mexico has been characterized by two clearly distinct phases, with 1994 serving as a critical inflection point. The initial steep rise in incidence (APC +27.97%) during 1985–1994 likely reflects a combination of expanding disease surveillance infrastructure, increased diagnostic capacity, and progressive encroachment of human populations into endemic forested areas in southern Mexico. The subsequent and sustained decline (APC −2.92%) from 1994 onward is consistent with findings from other endemic countries.[2,5]

However, the overall declining trend of the second period was punctuated by notable and epidemiologically informative fluctuations. The 2020–2021 nadir likely reflects COVID-19-related underreporting rather than true transmission reduction. In contrast, a marked rebound was observed in 2022 and 2023, with case counts reaching levels not seen since the late 1990s. We propose that this resurgence reflects the convergence of at least three epidemiological drivers: (1) increased migratory flows from CL-endemic Central and South American countries through southern jungle corridors which introduced new cases and expanded the geographic distribution; (2) deforestation driven by the Tren Maya infrastructure project in the Yucatán Peninsula, disrupting established ecosystems and increasing human-vector contact among construction workers; and (3) post-pandemic diagnostic recovery of diagnostic and surveillance activities. The 2024 decline may reflect reduced migratory transit following policy interventions, though sustainability remains uncertain.

CL trends in Mexico reflect dynamic interactions between public health interventions, environmental change, and human mobility. Strengthening surveillance, ensuring equitable diagnostic and treatment access, and integrating epidemiological data into policy are critical for sustained disease control.

EA DV CONGRESS
VIENNA
30 SEP - 3 OCT 2026

Abstract N°: 3421

Epidemiological Profile of Leprosy in the State of Acre from 2012 to 2021

Isabella Nobre[1], Dâmmarys Nascimento*[1], Emílio de Albuquerque[2], Camilla Pereira[1], Ruan Cleuson da Costa[2], Maria de Fátima Fagundes[3]

[1] Fundação Hospitalar de Dermatologia Tropical e Venereologia 'Alfredo da Matta', Manaus, Brazil

[2] Universidade Federal do Acre, Rio Branco, Brazil

[3] Fundação Hospital Estadual do Acre, Rio Branco, Brazil

Introduction

Leprosy is a chronic infectious disease caused by *Mycobacterium leprae*, primarily transmitted through the upper respiratory tract during prolonged and close contact with untreated bacilliferous individuals. Despite advances in diagnosis and multidrug therapy, leprosy remains a significant public health challenge in Brazil, particularly in the Northern region. The state of Acre presents persistently high detection rates, highlighting the need for epidemiological assessments to support effective surveillance and control strategies. This study aimed to analyze the epidemiological profile of leprosy in Acre between 2012 and 2021 through the evaluation of the main health indicators related to the disease.

Materials and Methods

An observational, descriptive, retrospective epidemiological study was conducted using secondary data obtained from the Informatics Department of the Brazilian Unified Health System (DATASUS/SINAN), regarding the state of Acre and Brazil, from 2012 to 2021. Sociodemographic and clinical variables were analyzed, including sex, age group, operational classification, clinical form, bacilloscopy, number of skin lesions, degree of physical disability at diagnosis and cure, therapeutic regimen, and percentage of examined contacts. The epidemiological indicators evaluated included leprosy incidence and prevalence rates, as well as incidence in individuals under 15 years of age. Data were organized into tables and analyzed descriptively using absolute frequencies and percentages.

Results

During the analyzed period, Acre demonstrated a predominance of cases among males (66.7%), similarly to the national scenario. Multibacillary cases predominated (81.7%), with borderline and lepromatous clinical forms being the most frequent, suggesting diagnosis at more advanced stages of the disease. The most commonly adopted therapeutic regimen was 12-dose multidrug therapy. Most patients presented grade 0 physical disability both at diagnosis and at discharge. The incidence of leprosy in Acre remained consistently higher than the national average throughout the study period, with a marked increase observed in 2021. Furthermore, the incidence rate among individuals under 15 years of age was classified as high in virtually all years analyzed, indicating active and persistent transmission of the disease.

Conclusions

Leprosy remains a major public health concern in the state of Acre, with epidemiological indicators exceeding the national average and a high proportion of multibacillary cases, suggesting delayed diagnosis and ongoing transmission. These findings reinforce the importance of strengthening surveillance strategies, early diagnosis, and

systematic contact tracing, particularly within Primary Health Care services. In addition, accurate notification records and expanded educational initiatives targeting both healthcare professionals and the general population are essential. Further post–COVID-19 pandemic studies are recommended to assess the impact of the pandemic on leprosy indicators and to support more effective control measures.

EA DV CONGRESS
VIENNA
30 SEP - 3 OCT 2026

Abstract N°: 3428

Leprosy in Northern Brazil: Statistics from 2015 to 2025

Dâmmarys Nascimento*[1], Camilla Pereira[1], Airton da Costa[1], Yaçanã Costa[1], Daiane Silva[1], Paula Rebello[1], Manoel Costa[2], Isabella Nobre[1]

[1] Fundação Hospitalar de Dermatologia Tropical e Venereologia 'Alfredo da Matta', Manaus, Brazil
[2] Amazonas State University, Manaus, Brazil

Introduction

Leprosy is a chronic infectious disease caused by *Mycobacterium leprae*, with significant potential for physical disability and stigma, remaining an important public health issue in emerging countries. Despite advances in diagnosis and treatment, Brazil continues to rank among the countries with the highest number of leprosy cases worldwide, second only to India. Within Brazil, the Northern region stands out for its persistently high detection rates, associated with socioeconomic factors, limited access to healthcare services, and structural vulnerabilities. In this context, longitudinal epidemiological analyses are essential to better understand the disease profile, identify the most affected populations, and support more effective control strategies.

Materials and Methods

This was an observational, retrospective, and descriptive study using secondary data obtained from the Informatics Department of the Brazilian Unified Health System (DATASUS/SINAN), regarding Northern Brazil and the country as a whole, from 2015 to 2025. Sociodemographic and clinical variables were analyzed, including sex, age group, race/color, educational level, operational classification, and degree of physical disability at diagnosis. Collected data were organized into a database and submitted to descriptive statistical analysis using JAMOVI software.

Results

A total of 338.663 leprosy cases were reported in Brazil between 2015 and 2025, of which 61.254 (18.0%) occurred in the Northern region, second only to the Northeast region, which accounted for 141.281 notifications (41.7%). The state of Pará concentrated the highest number of cases in Northern Brazil, counting 30.059 notifications (49.0%). A predominance of male patients was observed, corresponding to 37.371 cases (61.0%), while females accounted for 23.881 notifications (38.9%). Regarding educational level, 30.041 individuals (49.0%) had completed primary education or less, and 4.929 (8.0%) were illiterate. Concerning race/color, most patients self-identified as mixed-race (“pardo”), totaling 43.271 cases (70.6%). The most affected age group was between 30 and 59 years, with 33.529 cases (54.7%). At diagnosis, 49.553 cases (80.0%) were classified as multibacillary. Regarding physical disability grading, 31.994 patients (55.2%) presented Grade 0 disability, 18.792 (30.6%) Grade I disability, and 6.132 (10.0%) Grade II disability at diagnosis.

Conclusions

The findings demonstrate that leprosy remains a major public health challenge in Northern Brazil despite advances in therapy and disease control policies. Between 2015 and 2025, the region accounted for 18.0% of all reported cases in the country, reflecting sustained transmission levels in historically vulnerable areas. Previous studies

suggest that social, economic, and structural factors—including poverty, low educational attainment, and limited access to healthcare services—contribute to the persistence of endemicity.

Male predominance among affected individuals was observed, a pattern frequently described in the literature and possibly associated with lower healthcare-seeking behavior, greater occupational exposure, and delayed recognition of early disease manifestations. The high proportion of multibacillary cases reinforces the hypothesis of delayed diagnosis, since these patients carry a higher bacillary load and greater transmission potential of *Mycobacterium leprae*.

Furthermore, the proportion of patients diagnosed with Grade II physical disability represents an important indirect marker of failures in early case detection. The presence of disabilities at diagnosis suggests ongoing active transmission and increased risks of stigma and functional impairment. Therefore, these results reinforce the need to strengthen primary healthcare services, professional training, active contact tracing, and targeted strategies aimed at vulnerable populations.

EA DV CONGRESS
VIENNA
30 SEP - 3 OCT 2026

Abstract N°: 3443

Dermatologic Care in Remote Areas of the Amazonas State: Experience of a Multidisciplinary Program Between 2023 and 2025

Camilla Pereira*[1], Dâmmarys Nascimento[1], Valderiza Pedrosa[1], Carlos Chirano[1], Isabella Nobre[1], Airton da Costa[1], Yaçanã Costa[1], Daiane Silva[1]

[1] Fundação Hospitalar de Dermatologia Tropical e Venereologia 'Alfredo da Matta', Manaus, Brazil

Introduction

Access to dermatologic care in remote regions of the Amazon represents a major public health challenge due to vast geographic distances, shortage of specialists, and logistical difficulties in accessing remote settings. In many locations, access is exclusively by river, with travel times exceeding 24 hours by boat. These limitations contribute to delayed diagnosis and treatment of leprosy, skin cancer, sexually transmitted infections (STIs), and infectious dermatoses. A multidisciplinary program was developed to expand access to specialized care for the population, including Indigenous communities, in addition to early diagnosis, surgical treatment, screening, and professional training for local healthcare teams.



Figure 1: Aerial survey over the Amazon Basin (Source: Authors' personal archive).

Materials and Methods

A retrospective descriptive study was conducted of activities carried out between 2023 and 2025 in approximately 12 remote municipalities per year. Multidisciplinary teams traveled by river and land to provide specialized dermatologic care, perform dermatologic surgeries, conduct STI screening, collect preventive samples with PCR and HPV genotyping, perform slit-skin smear collection, disability assessments, active case finding for leprosy, biopsies and educational activities. Visits to Indigenous communities were also conducted, including dermatologic consultations and active case finding for leprosy. In parallel, local healthcare professionals received training focused on diagnosis, therapeutic management, and recognition of leprosy complications, aiming to improve greater local healthcare autonomy within the municipalities. Primary care physicians participated in the field visits, gaining practical experience in tropical diseases and remote-area medicine.

Results

Between 2023 and 2025, a total of 38 municipalities were visited and 135.115 procedures were performed. These included 35.757 dermatologic examinations and 14.227 dermatology consultations. The program carried out 701 surgeries for skin cancer and other lesions, as well as 692 biopsies. Active case finding identified 220 new cases of leprosy, including in municipalities with previously negative case notification. A total of 225 slit-skin smears, 346 disability assessments, and 828 contact examinations were performed, expanding diagnostic capacity and transmission control.

The teams managed 14.139 cases of general dermatoses, in addition to STI-related activities, including 6.466 rapid tests for syphilis, HIV, and viral hepatitis, 798 cervical cancer screening tests, and PCR/genotyping procedures. The program also promoted training and awareness activities for 3.119 local healthcare professionals. Despite the logistical difficulties imposed by the absence of roads and prolonged river travel, dermatology teams maintained continuous and specialized care for vulnerable populations.

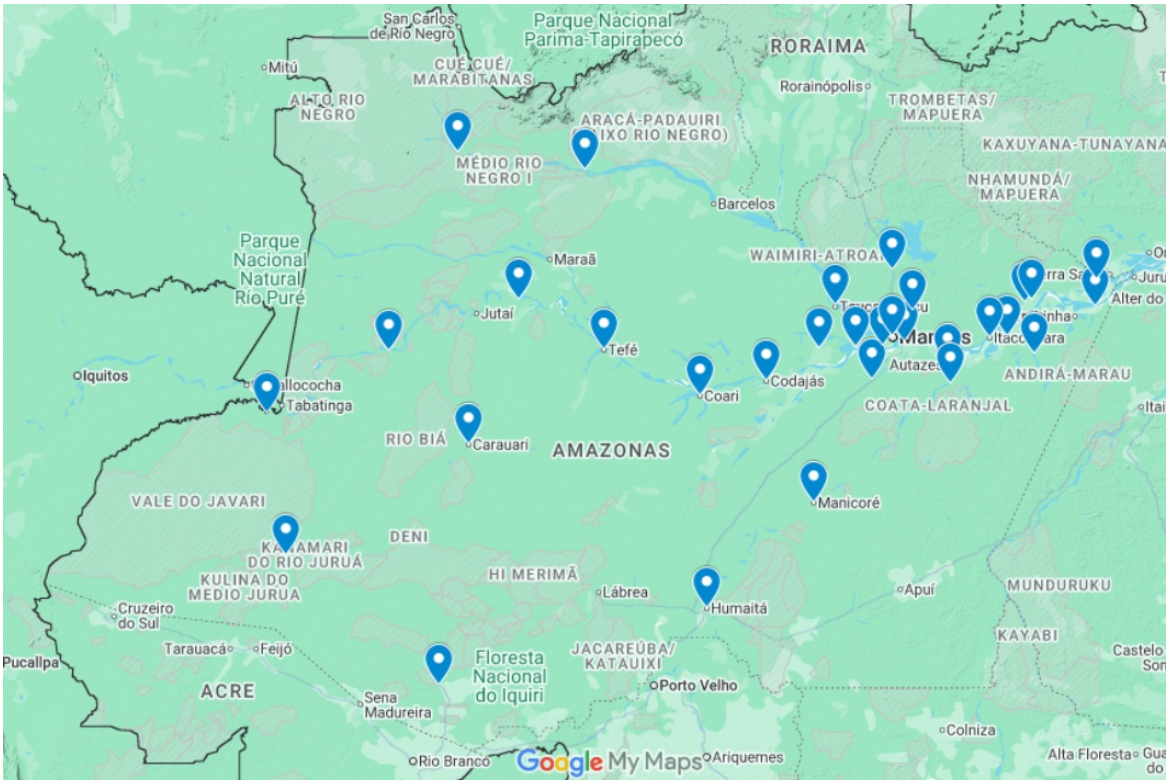

Figure 2: Political map of Amazonas: municipalities visited by the dermatological assistance project (Source: Authors' personal archive).

Conclusions

Dermatologic care in remote settings in the State of Amazonas proved to be feasible and highly impactful for

public health, promoting early diagnosis, specialized treatment, and strengthening epidemiologic surveillance. The identification of leprosy cases in previously silent areas reinforces the importance of active case finding in vulnerable populations. In addition to direct patient care, training local teams contributed to greater diagnostic and therapeutic autonomy in the assisted municipalities. The program also provided a unique educational experience for local dermatology residents and international visiting dermatology residents, highlighting the logistical and epidemiological challenges involved in healthcare delivery in isolated territories.



Figure 3: Small boats as an important means of transportation in remote areas of the Amazon (Source: Authors' personal archive).

EA DV CONGRESS
VIENNA
30 SEP - 3 OCT 2026

Abstract N°: 3450

Epidemiological Analysis of New Leprosy Cases Between 2023 and 2025

Camilla Pereira[1], Dâmmarys Nascimento*[1], Valderiza Pedrosa[1], Carlos Chirano[1], Yaçanã Costa[1], Rafhael Toschi[2], Airton da Costa[1]

[1] Fundação Hospitalar de Dermatologia Tropical e Venereologia 'Alfredo da Matta', Manaus, Brazil
[2] Universidade Nilton Lins, Manaus, Brazil

Introduction

Leprosy remains an important public health challenge in Brazil, especially in remote areas of the Amazon region, where geographic barriers, social vulnerability, and limited access to healthcare services contribute to delayed diagnosis and maintenance of disease transmission. In this context, multidisciplinary outreach initiatives play a key role in identifying hidden cases among vulnerable populations. Epidemiological analyses conducted during these healthcare activities allow better understanding of the demographic and clinical profile of affected individuals and help evaluate the effectiveness of active case-finding strategies in underserved territories.

Materials and Methods

A descriptive and retrospective study was conducted using secondary data obtained from a multidisciplinary healthcare program carried out between 2023 and 2025 in municipalities of Amazonas state. The analyzed variables included year of diagnosis, sex, age group, race/ethnicity, educational level, clinical form of leprosy, and municipality of occurrence. Data were analyzed using absolute and relative frequencies. In addition, the municipalities visited varied across the evaluated years, limiting direct temporal comparisons of the absolute number of cases. Therefore, the mean number of diagnosed cases per municipality visited was also used as a complementary indicator of diagnostic performance.

Results

Between 2023 and 2025, 221 new leprosy cases were identified during multidisciplinary healthcare actions in remote municipalities of Amazonas state. In 2023, 69 cases were diagnosed in 11 municipalities, with higher numbers observed in Carauari (14 cases) and Manaus (11 cases). In 2024, 56 cases were identified across 13 municipalities, mainly in Autazes and Careiro (six cases each). In 2025, 96 new cases were diagnosed in 14 municipalities, with higher concentrations in Codajás (20 cases) and Atalaia do Norte (10 cases). The mean number of cases per municipality was 6.27 in 2023, 4.3 in 2024, and 6.86 in 2025.

Although a 71.4% increase in the absolute number of cases was observed between 2024 and 2025, this finding should be interpreted cautiously because different municipalities were evaluated each year. Therefore, the increase may reflect territorial expansion of the program and intensification of active case-finding strategies rather than a true increase in disease incidence.

Females accounted for most diagnosed cases (56.6%), and individuals aged 15 years or older represented 89.6% of the sample. However, the identification of 23 cases in individuals younger than 15 years indicates persistent active transmission in the evaluated territories. Mixed-race individuals predominated, followed by Indigenous populations, especially among the Baré and Ticuna ethnic groups. Incomplete elementary education was the most frequent educational category, reinforcing the association between leprosy and socioeconomic vulnerability.

Regarding the clinical profile, the indeterminate form predominated, followed by borderline, tuberculoid, and

lepromatous forms. The coexistence of paucibacillary and multibacillary cases suggests both early and delayed diagnoses. Increased diagnostic yield during the 2025 interventions also suggests a significant hidden burden of disease in the visited municipalities.

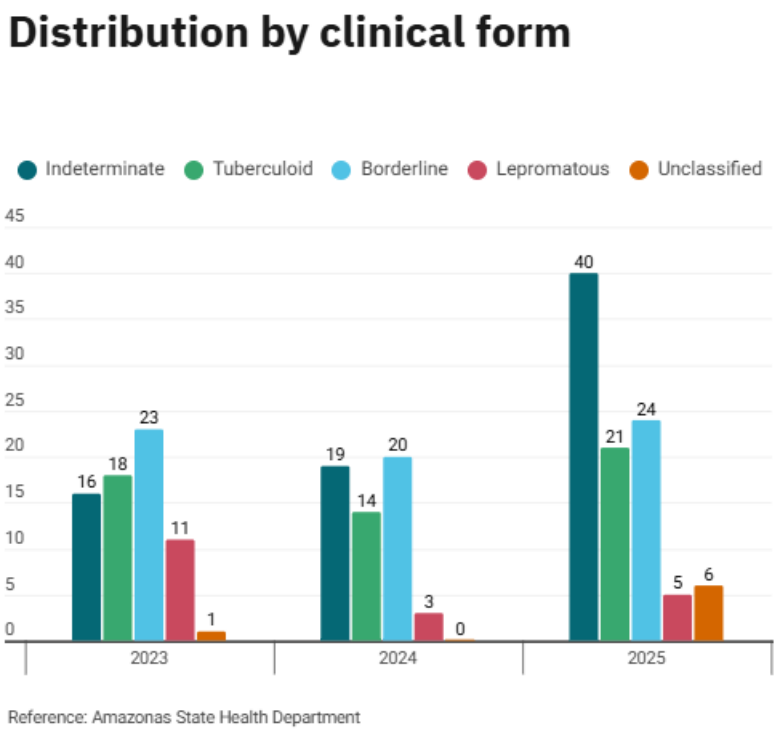

Source: Authors' personal archive

Conclusions

The findings reinforce the epidemiological importance of multidisciplinary outreach initiatives for detecting hidden leprosy cases in remote municipalities of the Amazon region. The occurrence of cases among individuals younger than 15 years and among Indigenous populations demonstrates persistent active transmission and highlights the need to strengthen surveillance, active case-finding, contact tracing, and early diagnosis strategies. Despite differences in the municipalities evaluated each year, the results demonstrate the relevance of decentralizing healthcare interventions to expand diagnostic access in vulnerable territories.

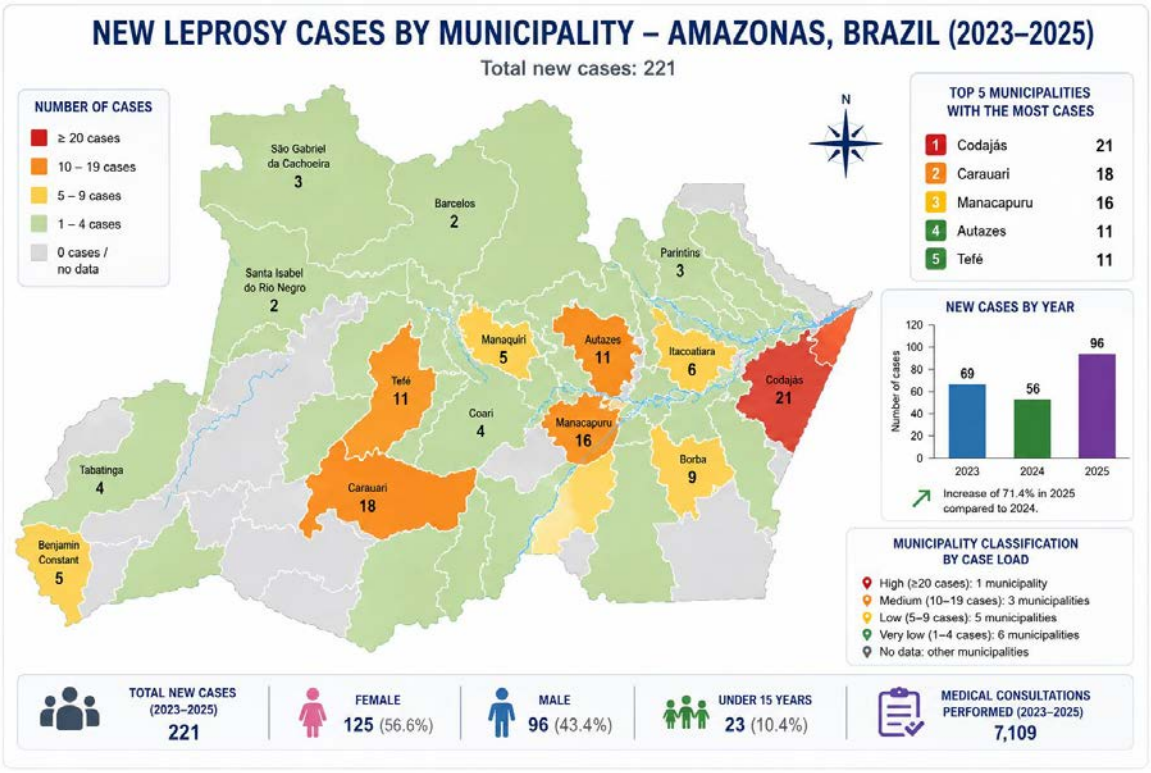

Source: Authors' personal archive

EA DV CONGRESS
VIENNA
30 SEP - 3 OCT 2026

Abstract N°: 3452

Quantitative Analysis of Dermatologic Surgeries and Biopsies Performed in Remote Regions of the Amazon (2023–2025)

Camilla Pereira[1], Dâmmarys Nascimento*[1], Carlos Chirano[1], Renato Cândido[1], Valderiza Pedrosa[1], Isabella Nobre[1], Daiane Silva[1]

[1] Fundação Hospitalar de Dermatologia Tropical e Venereologia 'Alfredo da Matta', Manaus, Brazil

Introduction

Dermatologic care in remote regions of the Amazon faces major challenges related to large geographic distances, logistical limitations, transportation difficulties, and shortage of specialists. In this context, neoplastic, infectious, and inflammatory skin diseases often present delayed diagnosis and treatment, contributing to increased morbidity and reduced quality of life among vulnerable populations. Skin cancer represents one of the main dermatologic conditions requiring specialized care, especially in individuals exposed to chronic occupational sun exposure. Therefore, dermatologic care provided in hard-to-reach municipalities represents an important strategy to expand access to diagnosis, skin biopsies, and specialized surgical treatment.

Materials and Methods

This is a quantitative, observational, descriptive, and retrospective study based on the analysis of dermatologic procedures performed in remote municipalities of the Amazon between 2023 and 2025. Dermatologic surgeries and skin biopsies were evaluated. Surgeries were categorized into procedures related to skin cancer and other dermatologic surgeries, including benign dermatologic lesions. Biopsies were analyzed separately because they represented diagnostic procedures performed for the investigation of inflammatory, infectious, autoimmune, and neoplastic dermatoses. Data were organized according to year of procedure, type of procedure, and patient sex, and were submitted to descriptive analysis.

Results

Between 2023 and 2025, a total of 717 dermatologic surgeries were performed in remote regions of the Amazon. Of these, 466 corresponded to skin cancer surgeries, representing approximately 65% of the total, while 251 were classified as other dermatologic surgeries.

In 2023, 213 surgeries were performed, including 175 related to skin cancer and 38 other dermatologic surgeries. In 2024, a reduction in the number of procedures was observed, totaling 139 surgeries, of which 73 corresponded to skin cancer treatment and 66 to other dermatoses. In 2025, there was a significant increase in surgical activity, with 365 procedures performed, including 218 oncologic surgeries and 147 other dermatologic surgeries.

Skin biopsies were analyzed separately, totaling 692 procedures during the study period. In 2023, 261 biopsies were performed, while 162 procedures were recorded in 2024 and 269 in 2025. These procedures were related not only to the investigation of cutaneous neoplasms, but also to the diagnostic evaluation of inflammatory, infectious, and autoimmune dermatoses observed during dermatologic care.

Regarding dermatologic surgeries, a predominance of male patients was observed in 2023, with 124 procedures performed in men and 89 in women. In contrast, female predominance was observed in both 2024 and 2025, with 61 versus 41 procedures and 159 versus 118 procedures, respectively. Overall, female patients accounted for the highest number of surgical procedures during the analyzed period.

The findings demonstrate an important unmet diagnostic and therapeutic demand in the assisted regions, especially related to suspected skin cancer lesions. Geographic factors, including dependence on river transportation, long distances between municipalities, and structural limitations of local healthcare services, contributed to delayed diagnosis and difficulties in outpatient follow-up.

Conclusions

Dermatologic care provided in remote regions of the Amazon between 2023 and 2025 demonstrated an important healthcare impact by expanding access to specialized diagnosis and treatment. The high number of skin cancer surgeries and biopsies highlights a significant unmet demand for dermatologic care in the Amazon region, reinforcing the need to strengthen specialized healthcare strategies for populations living in remote underserved populations.

EADV CONGRESS
VIENNA
30 SEP - 3 OCT 2026

Abstract N°: 3456

Liver Injury and ALT dynamics During Multi-Drug Therapy for Leprosy: A Retrospective Cohort Study

Udhishtran Arudchelvam*[1], Sanath Thubellage[2], Ama Pathirage[2], Shamila Lasanthi[2], Dorothy Premkumar[2], Priyashantha Fernando[2], Sajith De Silva[3], Amaratunga Dissanayake[4], Nelum Wickramasinghe[5], Supun Wijesinghe[6], Indira Kahawita[1]

[1] Dermatology Unit, National Hospital of Sri Lanka, Colombo, Sri Lanka
[2] Central Leprosy Clinic, National Hospital of Sri Lanka, Colombo, Sri Lanka
[3] Faculty of Medicine, University of Sri Jayewardenepura, Sri Lanka, Sri Jayewardenepura Kotte, Sri Lanka
[4] Dermatology Unit, Colombo North Teaching Hospital, Sri Lanka, Ragama, Sri Lanka
[5] Dermatology Unit, Colombo South Teaching Hospital, Sri Lanka, Colombo, Sri Lanka
[6] Family Health Bureau, Ministry of Health, Sri Lanka, Colombo, Sri Lanka

Introduction
Hepatotoxicity is a recognized adverse effect of multidrug therapy (MDT) for leprosy, attributable to rifampicin, dapsone, and clofazimine. Clinically significant alanine aminotransferase (ALT) elevation and drug-induced liver injury (DILI) represent important treatment-limiting toxicities, yet prospective comparative data between patients who develop hepatitis and those who do not remain scarce.
This study aimed to characterize ALT kinetics during MDT, determine the incidence of DILI-associated hepatitis, identify associated clinical factors, and compare baseline ALT and the magnitude of ALT rise between affected and unaffected patients.

Materials and Methods
A single-centre retrospective cohort analysis was performed at the Central Leprosy Clinic, Sri Lanka, on MDT-treated leprosy patients from January 2016 to December 2023 using prospectively maintained clinic records. Hepatitis was confirmed using a combination of clinical assessment, liver function tests, and abdominal ultrasonography where indicated. Given the non-parametric data distribution, Mann-Whitney U and Spearman rank correlation tests were applied throughout.

Results
A total of 493 patients were included (mean age 40.2 ± 16.8 years; 69.2% male), of whom 160 received PB-MDT and 333 received MB-MDT. Median baseline ALT was 26 U/L (IQR 17.25–42.45), with a median on-treatment ALT rise of 6.9 U/L (IQR –1.05 to 16.8). Peak ALT elevation occurred at a median of 4 weeks (IQR: 4–8 weeks).
Adverse drug reactions were recorded in 19.3% of patients, of whom 5.5% developed hepatitis. Hepatitis was significantly associated with MB regimen use (6.9% vs. 2.5% in PB), higher baseline ALT (median 31 U/L vs. 26 U/L), and greater absolute ALT rise (median 114 U/L vs. 6 U/L). Age and sex were not independently associated with hepatitis. All patients who developed hepatitis underwent a regimen change. Baseline ALT correlated inversely with the magnitude of ALT rise (p = 0,004), while time to peak ALT correlated positively (p = 0.019). Both groups reached peak ALT at a

median of 4 weeks, though 12% (n=58) demonstrated an earlier nadir at 2 weeks. All patients who developed hepatitis were promptly switched to an alternative regimen with reduced hepatotoxic potential.

Conclusions

ALT elevation and drug-induced hepatitis are clinically important toxicities during leprosy-MDT. Elevated baseline ALT and multibacillary regimens independently increase hepatitis risk. These findings support a risk-stratified monitoring protocol with intensified early surveillance in higher-risk patients.

EADV CONGRESS
VIENNA
30 SEP - 3 OCT 2026

Abstract N°: 3465

DISSEMINATED HISTOPLASMOSIS IN THE CONTEXT OF SEVERE IMMUNOSUPPRESSION: REPORT OF TWO CASES

Karoline Rodrigues Crevelim[1], Barbara Messias Pereira[1], Amanda Alencar dos Anjos*[1], Joao Marcos de Souza[1], Bianca Miyazawa[1], Marcos Vinícius Borges Martins[1], Rogerio Kondo[1], Cássio Moreira[1, 1]

[1] State University of Londrina, Londrina, Brazil

Introduction

Histoplasmosis, caused by the dimorphic fungus *Histoplasma capsulatum*, frequently presents in a disseminated form in patients with CD4+ T-lymphocyte counts below 150 cells/mm³. Cutaneous lesions are important markers of hematogenous dissemination and represent a diagnostic challenge due to their ability to mimic several other disease presentations.

Case Presentation

Case 1: A 37-year-old male patient with a recent diagnosis of AIDS (CD4 count: 108 cells/mm³ and viral load: 63,900 copies/mL), associated with disseminated tuberculosis, presented with pruriginous skin lesions for six months. Physical examination revealed diffuse umbilicated papules distributed on the torso and limbs, sparing the palms, soles, and mucosa. Skin biopsy demonstrated histiocytic proliferation with phagocytosis of PAS-positive oval microorganisms, confirming cutaneous histoplasmosis. Treatment consisted of liposomal Amphotericin B for 14 days, followed by maintenance therapy with Itraconazole.

Case 2: A 29-year-old male patient with AIDS (CD4 count: 25 cells/mm³ and viral load: 833,000 copies/mL) and a history of poor adherence to antiretroviral therapy presented with fever, weight loss, abdominal pain, and dysphagia, associated with erythematous scaly papules on the face, violaceous lesions on the limbs, and petechiae on the palate. Biopsy of the nasal septum and nasal cavity revealed ulcerated mucosa with extensive necrosis and intracytoplasmic corpuscles compatible with *Histoplasma* sp. Skin biopsy confirmed the diagnosis through the observation of superficial histiocytic proliferation with extensive phagocytosis of microorganisms compatible with the fungus in question. The patient was also treated with liposomal Amphotericin B followed by Itraconazole.

Conclusion

As observed in both cases, skin lesions may range from umbilicated papules (resembling molluscum contagiosum or cryptococcosis) to erythematous scaly lesions. According to the literature, skin biopsy with special stains (such as Grocott-Gomori or PAS) is essential for definitive diagnosis, since clinical presentation alone is nonspecific and represents a major diagnostic challenge in medical practice.

Furthermore, it is important to emphasize that therapeutic success depends not only on antifungal therapy with Amphotericin B and Itraconazole, but also on the careful management of drug interactions, toxicities, and immune restoration.

EA DV CONGRESS
VIENNA
30 SEP - 3 OCT 2026

Abstract N°: 3467

Disulfiram-Based Treatment for Scabies: Anti-Inflammatory and Antibacterial Benefits in Topical Combination Therapy

Carmen Maria Salavastru[1], Aymée Robainas[2], Laura Fernàndez Fajardo[3], Maria Lajarin-Reinares*[4]

[1] Carol Davila University, Department of Dermatology, Colentina Clinical Hospital, Bucharest, Romania

[2] Global Medical, Reig Jofre Laboratories, Sant Joan Despí, Spain

[3] Faculty of Sciences and Biosciences, Autonomous University of Barcelona, Bellaterra, Spain

[4] Translational research and value creation, Reig Jofre Laboratories, Sant Joan Despí, Spain

Introduction

Scabies is a skin condition caused by the mite *Sarcoptes scabiei*, leading to intense itching and rash that can disrupt daily life and cause secondary bacterial infections (*Staphylococcus aureus* and *Streptococcus pyogenes)*. In Sweden, Iceland and Finland an emulsion with benzyl benzoate (BB, 22.5%) and disulfiram (D, 2.0%) is used to treat scabies and lice in adults and children. This combination leverages two different mechanisms, with disulfiram disrupting mite metabolism by chelating metal ions and affecting key enzymes, which kills the parasite. Besides its antiparasitic effects, disulfiram may also offer antibacterial, antioxidant, and anti-inflammatory benefits, potentially reducing scabies-related complications.

This study aims to evaluate the additional therapeutic contributions of D 2%, beyond its antiparasitic activity, within a fixed-dose topical combination used for scabies treatment, focusing on its antibacterial, antioxidant, and anti-inflammatory properties relevant to scabies pathophysiology.

Materials and Methods

Antibacterial activity of disulfiram was assessed *in vitro* against *S. aureus* and *S. pyogenes* using both microdilution assays in accordance with CLSI guidelines. In parallel, transcriptomic profiling was performed in human keratinocyte (HEK001) cells exposed to the fixed-dose combination (D at 6.59 µM and BB] = 99.77 µM), enabling the identification of molecular pathways modulated at therapeutically relevant concentrations.

Results

Disulfiram demonstrated direct antibacterial activity against Gram-positive pathogens commonly implicated in scabies-associated secondary infections (Figure 1).

Transcriptomic analysis revealed a robust and coordinated cellular response characterized by activation of Nrf2-driven antioxidant pathways, including upregulation of genes involved in glutathione synthesis and reactive carbonyl detoxification (AKR1C1, AKR1C2, GCLC, SLC7A11, CAT), alongside downregulation of AOX1, limiting endogenous reactive oxygen species production. Concomitantly, key pro-inflammatory mediators such as PTGS2 (COX-2), IL-24, IL-33, and the neutrophil-recruiting chemokine CXCL5 were significantly suppressed ($p<0.05$). Comparative analysis confirmed that disulfiram contributes directly to this antioxidant and anti-inflammatory molecular signature (Figure 2).

Species	MIC (µg/mL)		
	Disulfiram	Clindamycin	Gentamicin
Streptococcus pyogenes	32	0.125	
Staphylococcus aureus	8		0.125

Figure 1: In Vitro Activity of Antimicrobials Against Gram-Positive Skin Pathogens. Minimum Inhibitory Concentration (MIC)Values for Disulfiram.

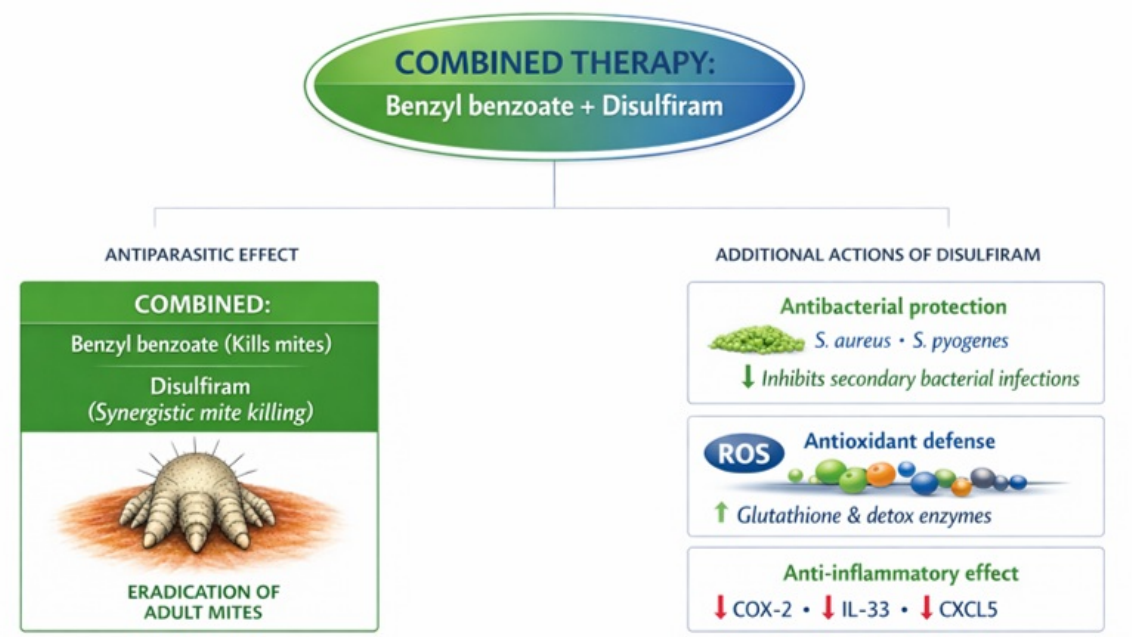

Figure 2: Role of disulfiram in combined scabies treatment. This schematic illustrates the dual antiparasitic effect of benzyl benzoate and disulfiram, together with the additional antibacterial, antioxidant, and anti-inflammatory properties of disulfiram that may contribute to improved management of scabies

Conclusions

Disulfiram is a key differentiating and value-driving component of the evaluated combination topical therapy, delivering benefits that extend well beyond antiparasitic activity. Through its pooled antibacterial, antioxidant, and anti-inflammatory actions, disulfiram actively supports skin recovery, reduces infection risk, and targets the biological drivers of scabies persistence. This multi-level activity redefines the product from a simple scabicide into a differentiated, skin-active solution that addresses both eradication and holistic skin repair, strengthening its clinical value.

EADV CONGRESS
VIENNA
30 SEP - 3 OCT 2026

Abstract N°: 3505

Enigmatic Eruption on Secondary Lymphedema: A Diagnostic and Therapeutic Challenge

Mejri Nawres*[1], Noureddine Litaiem[1], Soumaya Gara[1], Meriem Jones[1], Faten Zeglaoui[1]

[1] Dermatology department, Charles nicolle Hospital, Tunis, Tunisia

Introduction

Breast cancer treatment is one of the most common causes of secondary lymphedema. Dissemination of cutaneous leishmaniasis (CL) on lymphedema is exceptional and has only been reported twice in the literature.

Case Presentation

A 74-year-old woman had a history of right breast cancer treated with lumpectomy and lymph node dissection, complicated by lymphedema of the right upper limb. She presented with a circumferential erythematous plaque that was warm and painful, topped with multiple violaceous papulo-nodules occurring on the lymphedematous limb and complicating the superinfection of an ulcerated nodule on the dorsum of the right hand. Two painless ulcerocrusted plaques were also present, one on the face and the other on the contralateral arm.

Dermal smears from the right arm and facial lesions showed Leishman bodies. A biopsy of a papule from the right arm revealed a polymorphous inflammatory infiltrate composed of lymphocytes and plasma cells, rich in epithelioid histiocytes.
Two cycles of Glucantime® (40 mg/kg/day intramuscularly for 15 days), spaced 15 days apart, combined with amoxicillin-clavulanic acid, were prescribed. Flattening of the papulo-nodules occurred within two months.

Dissemination of CL may occur through several mechanisms. Lymphatic dissemination and intradermal spread lead to satellite lesions and parasitic lymphangitis. Hematogenous dissemination is responsible for the "disseminated CL" described in Brazil, characterized by more than ten lesions in two noncontiguous body regions. It should not be confused with diffuse CL, which results from anergy to leishmanial antigens.

The reported cases of disseminated CL on lymphedema correspond to locoregional dissemination on a limb. In our patient, multiple infective bites caused localized CL lesions on the face, left arm, and dorsum of the right hand. Ulceration of the right-hand nodule represented a bacterial entry site leading to erysipelas. Impaired lymphatic drainage, regional immunosuppression, and vasodilation caused by erysipelas resulted in hemolymphatic dissemination.

The role of lymphedema is further supported by the absence of CL dissemination from the previously healthy contralateral arm. CL itself is also a documented cause of secondary lymphedema. To avoid worsening preexisting lymphedema, despite its contraindication in elderly patients (>50 years), systemic meglumine antimoniate was prescribed at a slightly reduced dose compared with the recommended dose (60 mg/kg/day).

Conclusion

CL should be considered in cases of atypical evolution of erysipelas occurring on secondary lymphedema. Systemic treatment under strict clinical and biological monitoring may be justified in elderly patients when functional prognosis is compromised.

EA DV CONGRESS
VIENNA
30 SEP - 3 OCT 2026

Abstract N°: 3520

Comparative genomic analysis of clinically relevant human skin-associated fungi

Sofie Agerbæk[1], Knud Nor Nielsen[2], Julie Sølberg[3], Ying Zhang[1], Zahra Akil Meften Al-Badran[3], Marc Stegger[4, 5], Sonja Kabatnik[1, 6], Matthias Mann[6], Rachel Clark[7], Ditte Marie L. Saunte[3, 8], Alberto Santos[2], Marianne Løvendorf[1, 3, 9], Beatrice Dyring-Andersen*[1, 6, 7, 8, 9]

[1] Department of Dermatology, Zealand University Hospital, Roskilde, Denmark
[2] Novo Nordisk Foundation Center for Biosustainability, Technical University of Denmark, Copenhagen, Denmark
[3] Department of Dermatology and Allergy, Copenhagen University Hospital, Herlev and Gentofte Hospital, Copenhagen, Denmark
[4] Department of Sequencing and Bioinformatics, Statens Serum Institut, Copenhagen, Denmark
[5] Antimicrobial Resistance and Infectious Diseases Laboratory, Harry Butler Institute, Murdoch University, Perth, Australia
[6] Novo Nordisk Foundation Center for Protein Research, Faculty of Health and Medical Sciences, University of Copenhagen, Copenhagen, Denmark
[7] Department of Dermatology, Mass General Brigham, Harvard Medical School, Boston, United States
[8] Department of Clinical Medicine, Faculty of Health and Medical Sciences, University of Copenhagen, Copenhagen, Denmark
[9] LEO Foundation Skin Immunology Research Center, Department of Immunology and Microbiology, Faculty of Health and Medical Sciences, University of Copenhagen, Copenhagen, Denmark

Introduction

Fungal skin infections represent a significant global health burden, affecting approximately one billion people annually. Despite their prevalence and major global health impact, the molecular mechanisms underlying pathogenicity remain largely uncharacterized.

Materials and Methods

Here we present the genomes of 66 fungal strains, representing highly prevalent and clinically relevant species associated with human skin infections. Using comparative genomics, we investigate whether the taxonomic groups in this collection of skin fungi differ in their genome architecture, metabolic capacity, secreted enzyme repertoires, adhesin content, and predicted virulence determinants.

Results

These analyses reveal substantial variation in genome size and gene contents, indicating genome compaction occurred as the fungi transitioned from free-living to host-associated lifestyles. We report two non-hybrid strains of *Trichosporon ovoides*, the causative agent of white piedra. Our analyses reveal substantial differences in metabolic adaptations across skin-associated fungi, corresponding to body-site and nutrient niches. Significant differences are also observed in the distribution of virulence factors and adhesins, which are imperative for biofilm formation and antifungal resistance. We discuss metabolic adaptation and virulence mechanisms revealed by our data in the context of clinical presentations, highlighting shared and lineage-specific signatures of adaptations.

Conclusions

Together, these insights advance our understanding of skin-associated fungi and their mechanisms of infection.

EA DV CONGRESS
VIENNA
30 SEP - 3 OCT 2026

Abstract N°: 3530

Evaluating the therapeutic efficacy of add on intra-lesional immunotherapy against recalcitrant tinea cruris & corporis: a pilot study

Abeir Elkhouli*[1], Abeer Elkholy

[1] approved by IRB of Mansoura University Faculty of Medicine (R.25.11.3446), registered on Clinical Trials.gov (NCT07312604)., Mansoura, Egypt

Introduction

In 2018, an alarming rise in chronic, treatment-resistant dermatophytosis emerged in India. This strain has since spread worldwide, including to the US, and frequently resists first-line terbinafine, causing persistent and recurrent infections. Immunologically, cell-mediated immunity (CMI) is key to defense against dermatophytes; impaired CMI leads to chronic infection. Given that intralesional immunotherapy (e.g., MMR vaccine) enhances CMI and successfully treats viral warts, the same approach may benefit recalcitrant tinea.
Thus, this study is considered -up to our knowledge - the first trial to evaluate the efficacy and tolerability of add-on intralesional immunotherapy for tinea treatment at different body sites.

Materials and Methods

This prospective study included 30 patients with recalcitrant tinea diagnosed clinically and by KOH (culture or pathology in selected cases). The study was approved by IRB of Mansoura University Faculty of Medicine (R.25.11.3446) and registered on (NCT07312604). Written informed consent was obtained.

Inclusion criteria: age 10–60 years, failure of ≥2 sequential systemic antifungal courses (terbinafine and itraconazole for ≥6 weeks each within the last 3 months), and evidence of recalcitrant disease. Exclusion criteria: pregnancy, immunocompromise, hepatic disease, and no prior systemic antifungal treatment.

Patients were scheduled to receive 3 intralesional immunotherapy mainly MMR injections at 2-week intervals for 4–6 weeks (max 1 mL/session), with a repeat course if partial improvement occurred. Concomitant pulse itraconazole (400 mg/day for 2 weeks) and topical antifungal were given.

Efficacy was assessed by clinical and mycological (KOH) cure. Treatment failure was defined as <50% improvement at 4 weeks or lesion extension. Follow-up lasted ≥3 months post-treatment for recurrence and adverse events.

Results

Among the 30 patients studied**,** positive family history (66.7%) suggests intrafamilial spread and possible genetic susceptibility. Tinea corporis and cruris each affected 29 patients (96.7%) with a near-perfect correlation between them, followed by tinea faciei (26.7%), axillaris (13.3%), and manuum (3.3%). Most patients had multiple infected sites (mean 2.43), making localized infection the exception for this strain. Four patients (13.3%) lost to follow-up during the treatment phase and did not complete scheduled injections. Among the remaining 26 patients (86.7%) who completed the full treatment and follow-up protocol, recurrence occurred in 3 patients (11.5%), complete healing was achieved in 17 (65.4%), marked improvement in 4 (15.4%), considerable residual lesions (~50%) in 3 (11.5%), and no response in 2 (7.7%). Patient satisfaction levels were as follows: extremely satisfied in 17 patients

(65.4%), mostly satisfied in 5 (19.2%), somewhat satisfied in 1 (3.8%), and not satisfied in 3 (11.5%). In 30 patients with tinea resistant to standard therapy, the addition of immunetherapy yielded a per-protocol complete response rate of 80.8% (21/26) . Using intention-to-treat analysis (n=30), the complete response rate was 70.0% (21/30). Under a conservative worst-case imputation assuming all four lost patients as treatment failures, the complete response rate remained 56.7% (17/30). The addition of immunotherapy resulted in a significantly higher durable response ($p<0.001$, Fisher's exact test; number needed to treat = 1.4).

Conclusions

The addition — rather than substitution — of a new agent in the present study achieved a three- to four fold higher response rate, suggesting synergistic rather than redundant therapeutic effects. No patients reported treatment side effect (only mild injection site pain) so the treatment was well tolerated & showed superior efficacy compared to systemic antifungal alone.

EADV CONGRESS
VIENNA
30 SEP - 3 OCT 2026

Abstract N°: 3567

Evaluation of Efficacy and Safety of Intralesional Vitamin D3 in recalcitrant warts

Dilip Kumar*[1]

[1] Dr.B.R.Ambedkar Medical College and Hospital, Bangalore Medical College and Research Institute, Bengaluru, India

Introduction

Warts are the cutaneous infections caused by Human Papilloma virus (HPV), commonly seen in children and young adults. Clinically, warts present as common warts, planar warts, plantar warts, digitate warts, condyloma accuminata, oral and laryngeal papillomas and epidermodysplasia verruciformis. They are usually treated with conventional methods like topical salicylic acid, cryotherapy, electrosurgery and laser therapy, but none of them are considered gold standard. However, warts treated by these methods can reoccur and are recalcitrant in nature. Recalcitrant warts are resistant to conventional treatment and despite treatment, continue to increase in size and number. In this study, our aim was to evaluate efficacy of intralesional Vitamin D3 in recalcitrant warts

Case Presentation

In this case series, 70 patients with recalcitrant skin warts, previously treated with topical salicylic acid, Cryotherapy and intralesional MMR, but had recurrences were treated with intralesional Vitamin D3(15mg/ml) at an interval of two weeks for a period of two months i.e., a total of four doses and they were followed up for another two months. About 81.8% of them responded well to this immunotherapy and were cleared of the skin lesions, even those at distant sites, partial response was noted in 10.6% however 7.6% patient reported no improvement.. Local adverse effects were pain, swelling at the site of injection.

Conclusion

Recalcitrant warts are difficult to treat as conventional modalities of treatment fail to improve. Intralesional Vitamin D3 is a safe, inexpensive and effective treatment for recurrent, recalcitrant warts.

EA DV CONGRESS
VIENNA
30 SEP - 3 OCT 2026

Abstract N°: 3570

Mansonella ozzardi Infection Beyond the Amazon: A Neglected Diagnosis With Cutaneous and Ocular Manifestations

Brian Vicente[1], Guilherme Gonçalves Nascimento*[1], Renata Bezerra[1], Claudio Lelis Souza[2]

[1] Intituto da Pele da Faculdade de Medicina do ABC - FMABC, Santo André, Brazil

[2] Universidade Prof.Edson Antônio Velano - UNIFENAS, Alfenas, Brazil

Introduction

Mansonelliasis is a neglected filarial infection caused by *Mansonella ozzardi*, endemic in several regions of Latin America, particularly the Amazon Basin. Transmission occurs through hematophagous dipterans, mainly in rural and riverside populations. Although infection is highly prevalent in some endemic areas, it remains underdiagnosed because clinical manifestations are often nonspecific or absent. Reported symptoms include low-grade fever, headache, arthralgia, adenopathy, pruritus, and cutaneous lesions. In recent years, ocular involvement, especially keratitis and corneal lesions, has also gained attention. Awareness of the disease is particularly important in non-endemic regions, where diagnosis may be delayed due to low clinical suspicion.

Case Presentation

A 35-year-old female patient residing in a rural area of Alfenas, Minas Gerais, Brazil, sought medical attention after presenting with fatigue, intermittent low-grade fever, headache, migratory arthralgia, cold sensations in the lower limbs, and cutaneous pruritus that began approximately three months after an extended trip to the middle Purus River region in Amazonas State. During her stay in an Amazonian riverside community, she reported intense exposure to hematophagous insects without regular use of personal protective measures. Physical examination revealed discrete maculopapular lesions, posterior cervical lymphadenopathy, and mild conjunctival hyperemia associated with a foreign-body sensation in both eyes.

Laboratory investigation demonstrated mild eosinophilia, and parasitological examination using thick blood smear confirmed the presence of microfilariae morphologically compatible with *Mansonella ozzardi*. Ophthalmologic evaluation revealed mild bilateral superficial punctate keratitis. Following diagnostic confirmation, treatment with ivermectin (0.15 mg/kg as a single dose) was administered, in association with symptomatic management, resulting in favorable clinical evolution and significant improvement of systemic, cutaneous, and ocular manifestations during outpatient follow-up.

This case highlights the importance of considering *Mansonella ozzardi* infection in the differential diagnosis of patients presenting with nonspecific symptoms and an epidemiological history compatible with exposure in endemic areas of the Amazon region. Diagnostic confirmation through thick blood smear examination and the favorable clinical response to ivermectin reinforce the importance of early recognition of the disease, particularly in non-endemic regions where the infection remains frequently neglected and underdiagnosed.

Conclusion

This case emphasizes the need to consider *Mansonella ozzardi* infection in patients presenting with nonspecific systemic symptoms, pruritic cutaneous lesions, eosinophilia, and ocular complaints after exposure to endemic areas, particularly the Brazilian Amazon. Although mansonelliasis remains neglected and frequently underdiagnosed, early recognition through epidemiological history and thick blood smear examination is essential. The favorable response to ivermectin observed in this case reinforces the importance of timely diagnosis

and appropriate treatment, especially in non-endemic regions where clinical suspicion may be low.

EADV CONGRESS
VIENNA
30 SEP - 3 OCT 2026

Abstract N°: 3574

RECURRENT LOWER-LIMB ERYSIPELAS REVEALING UNDERLYING CHRONIC OSTEOMYELITIS: TWO CASE REPORTS.

Hasnae Zerhouni*[1], Salma Abid[1], Lina Mouline[1], narjess errachdy[1], najoua ammar[1], syrine hamada[1], nadia ismaili[1], laila benzekri[1], Mariame Meziane[1]

[1] Ibn Sina University Hospital, rabat, Morocco

Introduction

Erysipelas is a common reason for emergency dermatology consultation for an acute "red, hot, painful leg". Chronic osteomyelitis is a particularly deceptive mimicker. The reactivation of chronic osteomyelitis secondary to bone trauma can be delayed by several decades after the primary injury, with cutaneous inflammatory signs predominating over osseous ones, leading to repeated misdiagnosis as erysipelas and delayed management. We report two cases of young women in whom an apparent erysipelas revealed underlying chronic osteomyelitis.

Case Presentation

Case 1

A 28-year-old woman with a history of post-fracture tibial osteitis at age 7 presented with a one-week history of an erythematous, hot, tender, confluent plaque of the right ankle, with complete functional impairment, low-grade fever and altered general status. No recent trauma, portal of entry or preceding infection was found. CRP was 12 mg/L. Soft-tissue ultrasound showed no collection. Empirical amoxicillin–clavulanic acid failed after 72 hours, with extension of the plaque, blistering and persistent invalidating pain. CT revealed peri-ankle soft-tissue infiltration without collection, with bone remodelling and small tibial sequestra, leading to the diagnosis of reactivated chronic osteomyelitis on a previously affected bone.

Case 2

An 18-year-old woman, with a history of an open fracture of the left leg treated by external fixation and skin grafting, developed one year before admission a chronic ulceration on the surgical scar with progressive enlargement and purulent discharge. She also reported several "red leg" episodes treated as recurrent erysipelas with amoxicillin–clavulanate, each time with transient improvement. She was admitted for a 3-day history of a well-demarcated, warm, oedematous erythematous plaque extending up to the upper two-thirds of the left leg, and an 8–9 cm ulcer with melicerous crusts. CRP was 264 mg/L. Direct examination of the pus showed 90 % neutrophils with Gram-positive cocci in clusters; culture confirmed *S. aureus*. CT showed soft-tissue infiltration and extensive osteomuscular remodelling consistent with Brodie's abscess sequelae on chronic osteomyelitis with multiple bone sequestra. Intravenous third-generation cephalosporin led to rapid improvement.

Both patients were transferred to orthopedic surgery for further management.

Discussion

Both cases illustrate an under-recalled pitfall: chronic osteomyelitis can present as recurrent or treatment-resistant erysipelas-like cellulitis, especially in patients with previous open fractures, post-surgical scars, chronic ulcers or remote bone infection. Cutaneous signs frequently dominate over osseous ones. Key clues include a history of lower-limb trauma, fracture, surgery or chronic ulcer; recurrence of "erysipelas" with only transient response to

short antibiotic courses; pain disproportionate to skin findings; sensory anaesthesia over a scar; and *S. aureus* rather than streptococci. Inflammatory markers may be discordant, striking in active reactivation, mildly elevated in indolent forms, and should not reassure when imaging is suggestive. Plain radiography or CT showing sequestra, cortical thickening or periosteal reaction is highly suggestive; MRI and bone biopsy remain the gold standard. Management combines surgical debridement/sequestrectomy and prolonged targeted antibiotic therapy.

Conclusion

Chronic osteomyelitis should be considered in any "erysipelas-like" leg that is recurrent, fails first-line antibiotics, or occurs on a limb with previous trauma, fracture, surgery or chronic ulceration. Bone imaging should be part of the initial work-up of every atypical or treatment-resistant red leg.

EADV CONGRESS
VIENNA
30 SEP - 3 OCT 2026

Abstract N°: 3596

Hundreds of Fleas, One Forgotten Disease: A Case of Severe Disseminated Tungiasis

Guilherme Gonçalves Nascimento*[1], Brian Vicente[1], Renata Bezerra[1], Claudio Lelis Souza[2]

[1] Intituto da Pele da Faculdade de Medicina do ABC - FMABC, Santo André, Brazil
[2] Universidade Prof.Edson Antônio Velano - UNIFENAS, Alfenas, Brazil

Introduction

Tungiasis is a neglected ectoparasitic skin infestation caused by the penetration of the female flea *Tunga penetrans* into the epidermis. The disease is endemic in tropical and subtropical regions, particularly in areas with poor sanitation and limited socioeconomic resources. Although most cases are localized and self-limited, severe disseminated tungiasis may occur in vulnerable individuals, leading to significant morbidity, secondary bacterial infection, functional impairment, and social stigma. Despite being considered a neglected tropical disease, tungiasis remains underrecognized in dermatological practice, especially outside endemic regions

Case Presentation

A 63-year-old male patient from a rural area in northeastern Brazil presented with intense pruritus, pain, difficulty walking, and progressive development of multiple hyperkeratotic and crusted lesions affecting both feet, periungual regions, heels, toes, and plantar surfaces over several months. The patient reported poor housing conditions, walking barefoot daily, and limited access to medical care. Physical examination revealed hundreds of papular and nodular keratotic lesions with central black dots, confluent hyperkeratosis, fissures, nail dystrophy, and signs of secondary bacterial infection. Several lesions were found in different evolutionary stages, consistent with disseminated tungiasis.

Dermoscopy demonstrated characteristic central brown-black openings surrounded by whitish halos, compatible with embedded *Tunga penetrans*. Laboratory tests showed mild anemia and elevated inflammatory markers. Due to the extensive involvement and functional limitation, treatment with oral ivermectin associated with topical keratolytics, antiseptic measures, manual extraction of selected lesions, systemic antibiotics, and environmental hygiene recommendations was initiated. Progressive clinical improvement was observed during follow-up, with reduction of inflammation, pain, and parasite burden.

Conclusion

Severe disseminated tungiasis remains an important neglected dermatologic condition associated with poverty, inadequate sanitation, and limited healthcare access. Early recognition is essential to prevent complications such as bacterial superinfection, chronic pain, deformities, and impaired mobility. This case highlights the importance of dermatological awareness regarding tropical dermatoses and reinforces the role of combined therapeutic and preventive strategies in the management of advanced tungiasis.

EADV CONGRESS
VIENNA
30 SEP - 3 OCT 2026

Abstract N°: 3629

Buruli ulcer with prolonged evolution: diagnostic challenges in a non-endemic setting

Wanessa Rolando Roselli*[1], Silmara Cestari[1], Barbara Bueno[2], Isabela da Cruz[2], Marcela Cestari[1], Amanda Cochlar[1], Rodrigo Scabora[1], Reinaldo Tovo Filho[1]

[1] Hospital Sírio-Libanês-Bela Vista, São Paulo, Brazil
[2] Instituto de Infectologia Emílio Ribas, São Paulo, Brazil

Introduction

Buruli ulcer is a chronic cutaneous mycobacterial disease caused by *Mycobacterium ulcerans*, associated with the production of mycolactone, a toxin responsible for tissue necrosis and local immunosuppression. The disease is endemic in tropical regions, particularly in West Africa, and is considered a neglected tropical disease.

Clinically, it initially presents as painless nodules, papules, or plaques that progressively evolve into extensive and deep ulcers, potentially involving underlying structures and leading to functional disability.

Diagnosis is mainly based on clinico-epidemiological correlation, as laboratory methods have important limitations. Acid-fast bacilli smear microscopy has low sensitivity, culture is slow, and histopathology findings may be nonspecific. PCR is the most sensitive method, although its accuracy depends on adequate specimen collection.

The present case highlights an atypical and prolonged clinical course, emphasizing the diagnostic challenges in a non-endemic setting.

Case Presentation

A previously healthy 24-year-old man from West Africa, with a history of residence in a rural endemic area, presented with lower-limb ulcers evolving over approximately six years.

The lesions initially appeared as papules and gradually progressed to extensive, deep, bilateral ulcers, without spontaneous resolution(Figure 1). The patient had undergone multiple empirical treatments without diagnostic definition or clinical improvement.

At evaluation in a tertiary care center, skin biopsy for histopathological examination, culture, and PCR testing were performed, including investigation for *Leishmania* spp. and *Mycobacterium ulcerans*.

Due to the strong clinico-epidemiological suspicion of Buruli ulcer, treatment with rifampicin combined with clarithromycin was initiated, along with local wound care. The patient evolved with significant clinical improvement and progressive healing.

Conclusion

Buruli ulcer should be considered in the differential diagnosis of chronic ulcers in patients originating from endemic regions, even in non-endemic settings. This case highlights the importance of maintaining clinical suspicion despite negative or inconclusive laboratory findings, particularly in prolonged disease, where PCR sensitivity may be reduced. Early recognition and timely treatment are essential to reduce morbidity and prevent

long-term sequelae.

EADV CONGRESS
VIENNA
30 SEP - 3 OCT 2026

Abstract N°: 3630

Tumor-like nodular lesions revealing histoid leprosy with high bacillary load

Joao Marcos de Souza*[1], Barbara Messias Pereira[1], Bianca Miyazawa[1], Marcos Vinícius Borges Martins[1], Karoline Rodrigues Crevelim[1], Bruna Tuma[1], Rogerio Kondo[1], Mariana Collete[1], Amanda Alencar dos Anjos[1]

[1] State University of Londrina, Londrina, Brazil

Introduction
Histoid leprosy is an uncommon variant of lepromatous leprosy characterized by nodular lesions, high bacillary load, and distinctive histopathological findings. Its clinical presentation may mimic neoplastic and inflammatory dermatoses, leading to delayed diagnosis and continued transmission.

Case Presentation
An 84-year-old man was evaluated during hospital admission for unrelated clinical conditions. Dermatological examination revealed multiple erythematous-violaceous nodules on the trunk and extremities, associated with ulcerative lesions on the right foot and ankle. Additional findings included madarosis, infiltrated earlobes, saddle nose deformity, and nasal septum perforation. Peripheral nerve examination demonstrated bilaterally thickened and painful ulnar nerves, as well as a thickened painful right radial nerve.

Differential diagnoses included multibacillary leprosy, sarcoidosis, cutaneous lymphoma, and other nodular dermatoses. Slit-skin smear was positive, with a bacilloscopic index of 5+. Histopathological examination demonstrated a Grenz zone and a dermal spindle-cell infiltrate arranged in a storiform pattern. Fite-Faraco staining revealed numerous acid-fast bacilli, confirming the diagnosis of histoid leprosy. Multidrug therapy for multibacillary leprosy and systemic corticosteroids were initiated, with clinical improvement during hospitalization.

Conclusion
Histoid leprosy remains a relevant diagnostic challenge because of its tumor-like appearance and characteristic spindle-cell histopathology, which may resemble fibrohistiocytic and other cutaneous neoplasms. Recognition of classic clinicopathological findings, including Grenz zone, storiform spindle-cell infiltrate, peripheral nerve involvement, and high bacillary load, is essential for prompt diagnosis and treatment.
This case highlights the importance of clinicopathological correlation in patients presenting with nodular tumor-like lesions in endemic settings. Early recognition of histoid leprosy is critical to reduce diagnostic delay, prevent disability, and limit disease transmission.

EA DV CONGRESS
VIENNA
30 SEP - 3 OCT 2026

Abstract N°: 3665

Comparison of intralesional injection of vitamin D and MMR (Measles, Mumps, Rubella) vaccine in the treatment of extra-genital warts: A systematic review and meta-analysis of randomized controlled trials

Laura Ghanem*[1], Martin Cevallos-Cueva[2], Stanislav Tsvetanov[3], Victor Barreiros Pungirum[4], Devanie Martani[5], Daniela Lucía Mendoza-Millán[6, 7], Camila Almeida Sardinha[8], Virginia Velasco-Tamariz[9], Peter Chien[6, 7]

[1] Faculty of Medical Sciences, Lebanese University, Beirut, Lebanon
[2] School of Medicine, Universidad Central del Ecuador, Quito, Ecuador
[3] Burgas State University, "Prof. d-r Asen Zlatarov", Burgas, Bulgaria
[4] Faculty of Medical Sciences, University of Buenos Aires, Buenos Aires, Argentina
[5] Faculty of Medicine, Universitas Tarumanagara, Jakarta, Indonesia
[6] Department of Dermatology, Harvard Medical School, Boston, Massachusetts, United States
[7] Department of Dermatology, Beth Israel Deaconess Medical Center, Boston, Massachusetts, United States
[8] Faculty of Medical Sciences, Faculty of Minas (FAMINAS-BH), Belo Horizonte, Brazil
[9] Dermatology Department, Hospital Universitario 12 de Octubre, I+12 Research Institute, Universidad Complutense, Madrid, Spain

Introduction
Extra-genital warts caused by the Human Papillomavirus (HPV) are often persistent and difficult to treat. Intralesional vitamin D is thought to work by modulating local immune responses and enhancing cell-mediated clearance of HPV. The MMR (measles, mumps, rubella) vaccine acts as a nonspecific immunotherapy, stimulating a local immune reaction and T-cell–mediated antiviral activity against infected cells. Both treatments aim to promote immune clearance rather than directly destroy lesions. The aim is to conduct a systematic review and meta-analysis comparing their efficacy and safety in extra-genital warts.

Materials and Methods
PubMed, Embase, and Cochrane Library were searched for randomized controlled trials (RCTs) following PRISMA and Cochrane guidelines. Eligible studies compared intralesional injection of vitamin D and MMR vaccine in the treatment of extra-genital warts. Data were pooled using inverse-variance random-effects meta-analysis with restricted maximum likelihood (REML). The Hartung-Knapp-Sidik-Jonkman (HKSJ) correction was applied when $\tau^2 > 0$ and more than two studies were available. Trial sequential analysis (TSA) was performed. For outcomes with ≥10 studies, funnel plots, Egger's test, and meta-regression based on age, male proportion, and follow-up duration were performed. All statistical analyses were performed using RStudio.

Results
744 patients (aged 12.8-32.35 years) from 10 RCTs were included. Follow-up periods ranged between 3 and 6 months. Intralesional injection of MMR vaccine and vitamin D performed similarly in achieving complete clearance with no significant difference between groups (RR 1.06; 95% CI 0.90-1.25; p=0.456). Intralesional injection of MMR was significantly more effective for distant warts (RR 1.13; 95% CI 1.02-1.25; p=0.017) and showed lower no-response rates (RR 0.49; 95% CI 0.26-

0.91; p=0.025). There were no statistically significant differences in recurrence rates between the MMR vaccine and vitamin D (RR 0.71; 95% CI 0.33-1.51; p=0.372).
TSA showed that the required information size was not reached and the cumulative Z-curve did not cross the monitoring boundaries, indicating insufficient evidence for definitive conclusions. Overall, this suggests that further adequately powered trials are needed, and that current data may reflect comparable efficacy between the two treatments.
No small-study effects were detected (Egger's test p=0.77). Meta-regression showed consistent efficacy across age, sex, and follow-up, with non-significant trends toward lower effects in male-dominant studies and higher effects with longer follow-up.
Overall, both intralesional MMR vaccine and vitamin D3 showed comparable safety profiles. The incidence of pain (RR 0.94; p=0.563), erythema (RR 0.79; p=0.358), and pruritus (RR 0.42; p=0.511) did not differ significantly between groups. In contrast, swelling was significantly less frequent in the MMR group compared with vitamin D3 (RR 0.54; 95% CI 0.33–0.88; p=0.007), suggesting a potential tolerability advantage for MMR in terms of local post-injection edema.

Study	No. of patients, n	Male, n (%)	Age (years), mean ± SD	Duration of disease (months), mean ± SD	Types of warts	Follow-up (months)	Vitamin D3 regimen	MMR vaccine regimen
Baaniya 2025	61	31 (50.81)	NR	NR	PP; PU; VV	3	0.5 mL (600,000 IU/mL)	0.5 mL
Sallam 2025	112	31 (27.68)	24.47 ± 13.5	19.28 ± 9.56	VV; PP; VP	6	0.3 mL (15,000 IU)	0.3 mL
Singh 2025	36	20 (55.56)	25.63 ± 5.83	6.30 ± 3.77	NR	3	0.5 mL	0.5 mL
Ahmed 2024	100	63 (63)	24.40 ± 4.11	7.60 ± 3.40	NR	3	0.2 ml (15 mg/mL)	0.5 mL
Chaudhary 2023	50	NR	NR	NR	NR	3	0.2 to 0.5 mL (15 mg/ml)	0.3 mL
Joshi 2023	96	66 (68.75)	29.39	NR	VV; PP; VF; VP; PU	3	6 lac IU (15 mg/mL)	0.5 mL
Lahoria 2022	99	75 (75.76)	24.75 ± 8	11.67 ± 18.94	VV; PP; VP; VF; PU	NR	0.2 mL	0.5 mL
Jartarkar 2021	66	NR	29 ± 7.89	NR	VV	3	0.5 mL (6 lakh IU, 15 mg/mL)	0.5 mL
Mohta 2021	64	37 (57.81)	32.35 ± 7.35	8.73 ± 5.91	VV; VP; PP; PU	6	0.2 to 0.3 mL (15 mg/mL; 600,000 IU)	0.1 mL
Mohta 2020	60	40 (66.67)	12.80 ± 2.33	6.8 ± 4.5	NR	6	0.1 mL (15 mg/mL; 600,000 IU)	0.1 mL

Table 1. Baseline characteristics of included studies. IU: international units; mg: milligrams; mL: milliliters; MIP: Mycobacterium indicus pranii; MMR: measles, mumps, and rubella; NR: not reported; PP: palmoplantar; PU: periungual; SD: standard deviation; SS: saline solution; VF: verruca filiformis; VP: verruca plana; VV: verruca vulgaris.

Conclusions

In conclusion, this systematic review and meta-analysis indicates that intralesional immunotherapies, particularly with the MMR vaccine and Vitamin D3, are both effective for treating cutaneous warts. Intralesional injection of MMR vaccine may be preferred for the simultaneous targeting of distant lesions and when minimizing non-response and swelling is desired, whereas no significant differences were observed in recurrence, pruritus, or pain. Further research is needed to clarify long-term outcomes, standardize treatment regimens, and identify patient subgroups most likely to benefit.

EADV CONGRESS
VIENNA
30 SEP - 3 OCT 2026

Abstract N°: 3666

Type 2 Leprosy Reaction with Sweet Syndrome-like Features: Report of Two Cases

Luísa da Costa Garcia*[1], Maria Katia Gomes[1], Mariane Araujo[1], Bianca Amelio[1], Bruna Araújo[1], Marcia Ramos-E-Silva[1]

[1] Sector of Dermatology and Post Graduation Course, University Hospital and School of Medicine, Federal University of Rio de Janeiro, Rio de Janeiro, Brazil

Introduction

Leprosy remains an important public health concern, particularly in India, Brazil, and Indonesia. Reactional episodes may occur before, during, or after standard multidrug therapy (WHO-MDT), representing an important cause of neural damage and disability. Immunopathologically, these reactions are classified into two groups: type 1 reaction, or reversal reaction, characterized by exacerbation of Th1-mediated cellular immunity; and type 2 reaction, or erythema nodosum leprosum (ENL), associated with a predominant Th2 immune profile, immunoregulatory cytokine production, relative suppression of Th1 cellular immunity, and immune complex deposition, often accompanied by systemic manifestations, multiorgan involvement, and neural damage.
We report two cases of type 2 leprosy reaction with Sweet syndrome-like features in patients with multibacillary leprosy undergoing WHO-MDT.

Case Presentation

We describe a 69-year-old man and a 53-year-old woman, both receiving WHO-MDT for borderline lepromatous leprosy, who developed progressive polymorphic cutaneous lesions after initial improvement. Lesions consisted of infiltrated erythematous-edematous plaques, some with overlying scaling, associated with erythematous-violaceous papules and nodules, as well as normochromic to hyperpigmented nodules, distributed over the trunk and limbs. In both patients, the marked inflammatory and infiltrative cutaneous manifestations, together with previous leprosy diagnosis, were consistent with a Sweet-like variant of type 2 leprosy reaction, an uncommon manifestation of multibacillary leprosy. Compatible histopathological findings were observed in one case, while clinical and epidemiological correlation supported the diagnosis in both cases. Both patients presented peripheral nerve involvement, and the male patient exhibited right-sided steppage gait secondary to common peroneal neuropathy.
Based on the clinical findings, treatment with thalidomide 200 mg/day combined with prednisone 60 mg/day was initiated and maintained until clinical improvement, followed by gradual prednisone tapering by 10 mg every two weeks according to clinical response.

Conclusion

Leprosy reactions reflect the interaction between *Mycobacterium leprae* and the host immune system and may present with heterogeneous clinical manifestations. Sweet syndrome is an acute neutrophilic dermatosis associated with infectious, inflammatory, and neoplastic conditions and usually responds well to corticosteroid therapy.
In 1987, Kuo and Chan described a variant of type 2 leprosy reaction with clinical features resembling Sweet syndrome, reinforcing the overlap between infections and neutrophilic dermatoses. Histopathologically, Sweet syndrome-like leprosy reactions usually demonstrate papillary dermal edema and neutrophilic infiltration

associated with foamy histiocytes on hematoxylin-eosin sections, as well as intracellular acid-fast bacilli on Fite-Faraco staining, supporting the diagnosis of a Sweet syndrome-like type 2 leprosy reaction. Nevertheless, particularly in endemic regions, diagnosis should not rely solely on histopathological findings, and clinical and epidemiological correlation remains essential.

Although histopathological confirmation was available in only one patient, both cases shared similar clinical, epidemiological, and therapeutic features, including previous multibacillary leprosy diagnosis, polymorphic infiltrative cutaneous lesions, peripheral neuropathy, and favorable response to thalidomide and corticosteroids, supporting a Sweet-like type 2 leprosy reaction.

These reports highlight the need to include leprosy in the differential diagnosis of dermatoses resembling Sweet syndrome, especially in endemic areas, where clinical and epidemiological correlation and careful characterization of reactional cutaneous lesions may support the diagnosis even in the absence of complete histopathological documentation, contributing to early diagnosis and prevention of disability.

EADV CONGRESS
VIENNA
30 SEP - 3 OCT 2026

Abstract N°: 3694

Severe Erysipelas Associated with Pasteurella multocida Infection in an Immunosuppressed Patient with Pemphigus Vulgaris

Emircan İnce*[1], Berfin Ece Akbulut[1], Ayda Acar[2]

[1] Ege University Faculty of Medicine Department of Dermatology, Izmir, Türkiye

[2] Special office, Izmir, Türkiye

Introduction

Pasteurella multocida is a gram-negative coccobacillus that colonizes the upper respiratory tract of domestic animals, particularly cats and dogs. It commonly causes skin and soft tissue infections following animal bites or scratches; however, severe invasive infections may occur in elderly or immunocompromised individuals. We present a case of severe *P. multocida*-associated erysipelas developing after a cat bite in a patient with refractory pemphigus vulgaris receiving rituximab therapy.

Case Presentation

A 73-year-old woman with a 14-year history of pemphigus vulgaris presented with fever, hypotension, tachycardia, somnolence, urinary incontinence, and painful swelling of the left leg two days after a stray cat bite. Her medical history included diabetes mellitus, hypertension, venous insufficiency, hyperlipidemia, and asthma. She had previously received systemic corticosteroids, azathioprine, and maintenance rituximab therapy for refractory pemphigus vulgaris. Due to rituximab-associated hypogammaglobulinemia, intravenous immunoglobulin replacement had been recommended. The last rituximab dose had been administered five months before presentation.

Dermatological examination revealed sharply demarcated erythema extending from the medial and lateral malleoli to the knee, a violaceous indurated plaque with a visible bite mark on the anterior tibial region, purpuric lesions on the medial malleolus, and edema with erythema around the inguinal-femoral lymph nodes. Laboratory investigations demonstrated leukocytosis and markedly elevated inflammatory markers (CRP: 229 mg/L, procalcitonin: 54 µg/L, leukocyte count: 20.33 × 10^3/µL) together with low IgG levels (4.7 g/L). Blood cultures were sterile; however, tissue culture yielded *Pasteurella multocida* and *Staphylococcus aureus*.

The patient was treated with intravenous ampicillin-sulbactam (4 × 2 g/day) for 14 days together with topical antiseptic dressings. Intravenous immunoglobulin (2 g/kg) was administered because of concomitant pemphigus activation and hypogammaglobulinemia. Marked clinical improvement was achieved and the patient was discharged without complications.

Conclusion

Pasteurella multocida infection should be considered in the differential diagnosis of severe soft tissue infections in immunocompromised patients with a history of animal exposure. Early recognition, appropriate antimicrobial therapy, and multidisciplinary management are crucial to prevent severe systemic complications, particularly in patients receiving rituximab-associated immunosuppressive treatment.

EADV CONGRESS
VIENNA
30 SEP - 3 OCT 2026

Abstract N°: 3695

Cutaneous sporotrichoid leishmaniasis: a series of seven cases

hajar Elbokhari*[1], Bouchra Baghad[1], fadoua Chemsy[1], Keltoum Lamkhayar[2], Maha Soussi Abdellaoui[3], Myriam Riyad[2], soumiya Chiheb[1]

[1] Dermatology and Venerology departement, Ibn Rochd University Hospital, casablanca, Morocco
[2] Laboratory of cellular and Mollecular pathology, Faculty of medecine and pharmacy, Hassan 2 University, casablanca, Morocco
[3] Laboratory of Parasitology and Mycology, Ibn Rochd university hospital, Faculty of medecine and pharmacy, Hassan 2 university, casablanca, Morocco

Introduction
Cutaneous leishmaniasis (CL) is a parasitic endemic infection in Morocco. The sporotrichoid form is less frequent and constitutes a differential diagnosis for other causes of nodular lymphangitis. We report a series of 7 cases.

Materials and Methods
We conducted a prospective descriptive study between December 2024 and December 2025, including patients with CL confirmed by direct examination and/or PCR presenting with nodules arranged along a limb.

The data collected included clinical, dermoscopic, parasitological, therapeutic and evolutionary elements.

Results
Seven patients (four women and three men), aged 37 to 64 years, were included. Two patients were being treated for heart disease, and one patient was in her first trimester of pregnancy. The mean time to onset of skin lesions was 5.2 months (range, 1–10 months). All patients presented with non-pruritic, painless, nodular dermoepidermal lesions arranged in a bead-like pattern along one limb. The nodules were moist in two cases and dry in five cases. Dermoscopy revealed generalized erythema, central ulceration, and white star-shaped patterns. PCR (performed in six patients) identified *Leishmania tropica* (n=3), *Leishmania major* (n=2), and *Leishmania infantum* (n=1). Several treatment options were used : meglumine antimoniate for two pateints, fluconazole for three patients, and metronidazole was used for the pregnant women, with a favorable outcome in all patients.

Conclusions
Our series highlights the sporotrichoid form of cutaneous leishmaniasis as an uncommon but important clinical presentation in Morocco. PCR allowed identification of the three *Leishmania* species endemic in Morocco, including *L. infantum*, supporting its emerging role in cutaneous forms in North Africa. Dermoscopy was helpful, showing generalized erythema, star-shaped white patterns and central ulceration, which are suggestive features of cutaneous leishmaniasis. Treatment was individualized according to species, lesion characteristics and comorbidities. Because antimonials may be limited by cardiotoxicity or pregnancy-related contraindications, alternative regimens such as fluconazole or metronidazole may be considered in selected patients, although further studies are needed.

Although rare, the sporotrichoid form of CL must be recognized in clinical practice. Dermoscopy and PCR are key elements for diagnostic guidance and confirmation. Finally, management must be individualized, taking into account comorbidities and the patient's overall health.

EA DV CONGRESS
VIENNA
30 SEP - 3 OCT 2026

Abstract N°: 3701

Bilateral Thumb Nail Candidiasis Induced by Thumb Sucking in a Young Child: A Case Report

FATIMA ZAYOUN*[1], bouchra baghad[1], fatima zahra benhayoun[1], hanane rachadi[1], soumiya chiheb[1]

[1] Ibn Rochd University Hospital Center, CASABLANCA, Morocco

Introduction

Ungual candidiasis is a rare fungal infection in infants and young children, most commonly observed in predisposing settings such as chronic maceration, chronic periungual inflammation, or immunosuppression. Prolonged thumb sucking may represent a local predisposing factor through chronic salivary maceration, although cases of nail candidiasis strictly limited to the thumbs in association with this habit are rarely individualized in the literature.

We report the case of a 2-year-old child presenting isolated bilateral thumb nail candidiasis secondary to chronic thumb sucking.

Case Presentation

A 2-year-old child with no significant past medical history was referred to our department for bilateral thumbnail dystrophy evolving over one month. History-taking revealed a daily habit of thumb sucking since early infancy, predominantly involving both thumbs.

Clinical examination showed moderate xanthopachyonychia of both thumbnails associated with mild chronic paronychia. The remaining fingernails and toenails were unaffected, with no associated cutaneous or mucosal lesions. General examination was unremarkable.

Mycological nail sampling isolated *Candida albicans*.

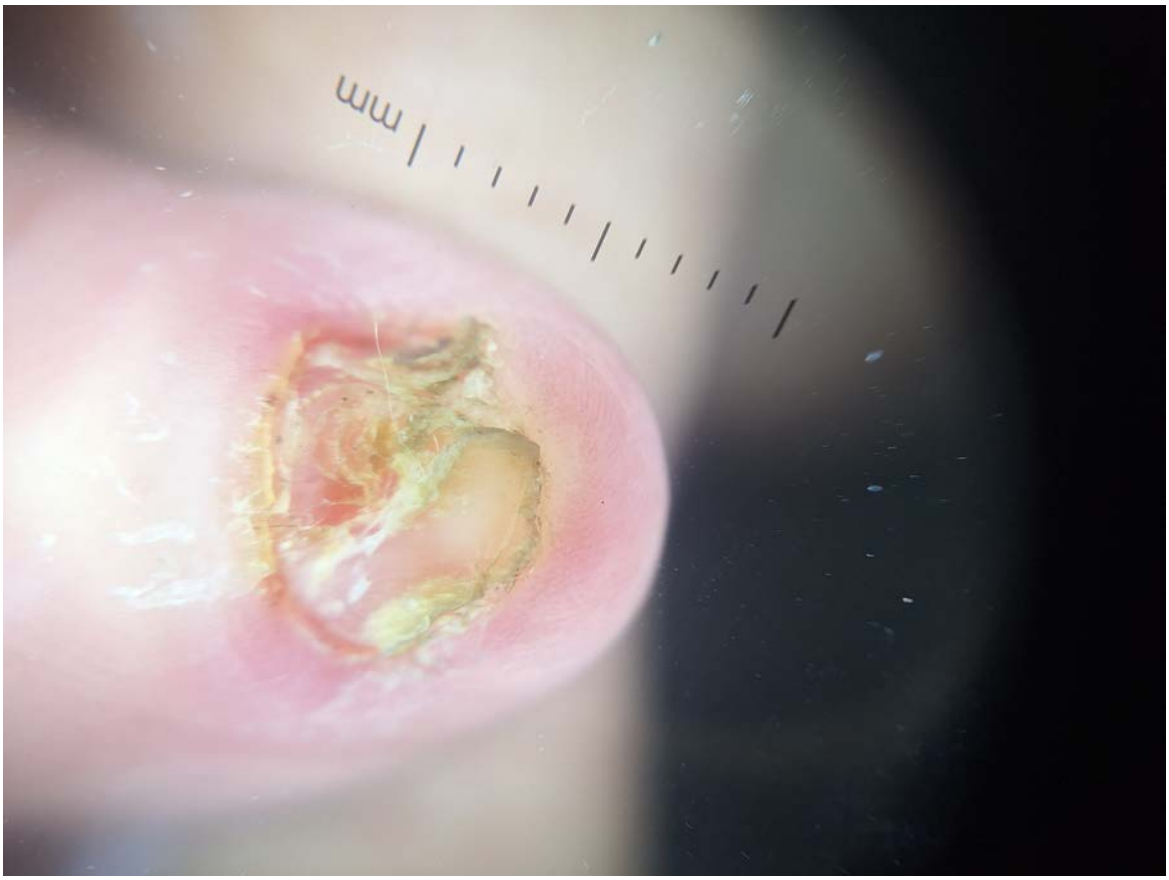

xanthopachyonychia of the thumbnail

Conclusion

Ungual candidiasis in children is an uncommon entity, most often described in predisposing contexts such as chronic maceration, recurrent paronychia, immunosuppression, repeated thumb sucking, or habitual licking.

In our case, the involvement strictly limited to both thumbs, associated with persistent thumb sucking, suggests a local pathogenic mechanism rather than an underlying systemic condition.

Saliva constitutes a moist environment rich in yeast organisms, leading to prolonged maceration of the nail plate and periungual folds, thereby creating favorable conditions for *Candida* proliferation.

It is important to emphasize that, in this context, the association relies on a plausible pathophysiological hypothesis without suggesting an underlying immune deficiency in the absence of supporting clinical findings, thus avoiding unnecessary investigations.

Management is based on topical antifungal therapy, with or without systemic treatment depending on disease extent, along with correction of the behavioral habit, which represents a key factor for therapeutic success.

Isolated bilateral thumb nail candidiasis in young children represents a rare clinical presentation. Thumb sucking should be considered a major local predisposing factor capable of inducing *Candida*-related nail involvement in the absence of underlying immunological disorders.

This observation highlights the importance of careful behavioral history-taking, prudent clinical reasoning avoiding overdiagnosis of immunodeficiency, and appropriate management combining antifungal therapy with correction of the predisposing factor.

EA DV CONGRESS
VIENNA
30 SEP - 3 OCT 2026

Abstract N°: 3717

One Collarette to Rule Them All: PRG in Dark Phototypes

Faiza Boukhobza*[1], Hanane Baybay[1], kenza Amrani Mesbahi[1], Ikram Bejja[1], Boughaleb Pr[1], Zakia Douhi[1], Meryem Soughi[1], Sara Elloudi[1], Fatima zahra Mernissi[1]

[1] Dermatology departement HASSAN II University Hospital, FES, Morocco

Introduction

Pityriasis Rosea of Gibert (PRG) is a self-limiting inflammatory dermatosis that can pose significant diagnostic challenges, particularly in patients with dark skin phototypes, where the classic erythematous presentation may be masked or altered by background pigmentation.

Case Presentation

We report the case of a 25-year-old woman with a known history of psoriasis (in remission for several years), who presented with erythematous-pigmented lesions evolving over 12 days. The onset sequence of lesions was not clearly recalled by the patient. Lesions were neither painful nor pruritic, and no fever was reported. Notably, she had taken NSAIDs three days prior to the eruption and had self-applied ketoconazole cream (Ketoderm) on two occasions after the rash appeared.

Given the clinical presentation, the following diagnoses were initially entertained:Psoriasis, Plaque parapsoriasis, Pityriasis Rosea of Gibert, Acute Generalized Exanthematous Pustulosis (AGEP) at the desquamation stage, and Syphilitic roseola.

Dermoscopy proved decisive in narrowing the diagnosis. Key features identified included: a characteristic double white collarette (peripheral fine scaling located internally to the lesion border — also described as "inverse Wickham's striae"), brown dots, crusts, and an erythematous background. Early lesions typically show dotted vessels on a pink-red background, while older lesions display the peripheral collarette and diffuse pigmentation replacing the dots, wich is a feature that allows dermoscopy to help date the lesions.



Left: Clinical presentation of Pityriasis Rosea of Gibert on a dark skin phototype, showing multiple erythematous-pigmented scaly plaques distributed over the trunk. Right: Dermoscopic clue ; the

characteristic double white collarette (peripheral fine scaling), brown pigmentation, and erythematous background, consistent with the diagnosis of Pityriasis Rosea of Gibert.

Conclusion

Dermoscopy established the diagnosis of Pityriasis Rosea of Gibert without additional investigations, highlighting its critical value in atypical presentations on dark skin phototypes, where clinical diagnosis alone is insufficient. Management with emollients led to complete resolution. Beyond its classic dermatological role, this case underscores the growing importance of dermoscopy in infectious dermatology, offering arapid, non-invasive bedside tool to orient the diagnosis and guide patient management before any workup, regardless of skin phototype.

EA DV CONGRESS
VIENNA
30 SEP - 3 OCT 2026

Abstract N°: 3723

HAND-FOOT-MOUTH DISEASE IN ADULTS: A CLINICOEPIDEMIOLOGICAL STUDY

Bikash Ranjan Kar[1], Liza Mohapatra[1], Manoj Kumar Nayak[1], Dr. Nibedita Dixit[1], Riddhi Sable*[1]

[1] Department of Dermatology, Institute of Medical Sciences and SUM hospitals,, Bhubaneshwar, India

Introduction

Hand-foot-mouth disease (HFMD) is an acute viral exanthem caused predominantly by Coxsackievirus A16 and Enterovirus 71, classically affecting children under 5 years of age. However, an increasing number of adult cases with atypical mucocutaneous manifestations have been reported in recent years, often leading to diagnostic difficulty. This study aimed to evaluate the clinical and epidemiological profile of HFMD in adults presenting to a tertiary care dermatology centre.

Materials and Methods

A prospective observational study was conducted between March 2023 and October 2023 to evaluate the clinical and epidemiological profile of HFMD in adults presenting to a tertiary care dermatology department. Forty-five patients aged ≥18 years fulfilling the inclusion criteria were enrolled. Detailed clinical history including onset, prodromal symptoms, systemic features, recurrence, and atopic background was recorded using a semi-structured questionnaire. Demographic characteristics and monthly incidence trends were analysed.

Results

Forty adults completed evaluation. A seasonal clustering of cases was observed, with peak incidence during May (35%) followed by July (20%). There was a male predominance (65%), with a mean age of 23.8±5.8 years. The most common prodromal manifestations were sore throat (57.5%) and fever with malaise (50%). Characteristic clinical manifestations are summarized in Table 1. Adult HFMD showed varied and atypical patterns of involvement, predominantly affecting acral and oral sites with additional flexural, gluteal, and periumbilical involvement. Oral lesions predominantly involved the soft palate, lower lip, tongue, and pharyngeal mucosa, with aphthous-like ulceration observed in 20% of patients. Painful plantar lesions and oral discomfort causing difficulty in food intake were frequently reported. Secondary bacterial infection developed in 32.5% of patients, particularly among those with an atopic background. Most patients responded favourably to symptomatic treatment without significant systemic complications.

Clinical characteristics of lesions	No. of cases	Percentage
Purpuric lesions on palms and soles	38	95%
Vesiculopapular lesions on palms and soles	24	60%
Vesiculopapular lesions on buttocks	8	20%
Vesiculopapular lesions in periumbilical area	6	15%
Flexural involvement	10	25%
Oral mucosal involvement	25	62.5%

Table 1. Clinical characteristics of lesions in adult HFMD

Conclusions

HFMD in adults may present with atypical, painful, and extensive mucocutaneous manifestations, frequently resulting in diagnostic delay or misdiagnosis. Recognition of these evolving clinical patterns is important for early diagnosis, appropriate management, and avoidance of unnecessary interventions.

EADV CONGRESS
VIENNA
30 SEP - 3 OCT 2026

Abstract N°: 3728

Tunnel window sign: A novel dermoscopic pattern of scabies under polarized and UV light.

Mateusz Mateuszczyk*[1]

[1] Clinical Department of General and Oncologic Dermatology, Wrocław, Poland

Introduction

Scabies remains a prevalent parasitic dermatosis caused by *Sarcoptes scabiei* var. *hominis*. Classic dermoscopic findings include the identification of burrows, the "delta sign" representing the mite along the tunnels. The role of UV-induced fluorescence dermoscopy (UVFD) has expanded diagnostic capabilities, especially in distinguishing features in fair and dark skin types. Here, we describe a new dermoscopic phenomenon observed consistently across multiple cases: the visualization of discrete scabies exit holes distributed along the burrow path, more apparent under UV dermoscopy. It can also be very helpful in distinguishing the burrows from the excoriations present in any patients with pruritus.

Materials and Methods

Ten patients (4 females, 6 males; aged 16-81 years) clinically diagnosed with scabies underwent dermoscopic examination using both polarized dermoscopy and UVFD (magnification x10). High-resolution images were captured and analyzed for burrow integrity, presence of mites, eggs, and the appearance of additional structural details along the burrow course. Particular attention was paid to small, round interruptions in the burrow wall.

Results

In all examined cases, conventional dermoscopy showed classic burrow structures and mites, with some irregularities noted along the tunnel path. However, under UVFD, numerous small, bright blue, round exit holes were visible along the burrow, which were not as readily detectable with conventional dermoscopy. These holes lacked associated crusting or signs of secondary trauma, and were aligned longitudinally with the burrow structure. The observation of scabies exit holes represents a potentially novel dermoscopic marker of active scabies infestation. The differential visualization under UVFD versus conventional dermoscopy suggests that UV light enhances the contrast between disrupted stratum corneum and intact skin, making such micro-perforations more detectable. We propose the term "tunnel window sign" to describe the appearance of blue fluorescent exit holes along scabies burrows observed under conventional and UVFD.



Left: Polarised light dermoscopy: Scabies burrow with surrounding epidermal disruption. Scabies exit points are poorly distinguishable from background skin texture. Red arrows indicate assumed sites of scabies exits. Right: Ultraviolet (UV) dermoscopy: Under UV light, multiple round bright blue structures along the burrow become evident - “tunnel window sign” (highlighted by red arrows), clearly demarcating active scabies emergence points and enhancing diagnostic accuracy.

Conclusions

Recognizing these exit holes could improve the assessment of infestation, aid in early detection of extensive mite reproduction, and guide therapeutic decisions. To our knowledge, such a dermoscopic pattern has not been reported in other dermatological diseases, supporting its potential specificity for active scabies infestation.

EA DV CONGRESS
VIENNA
30 SEP - 3 OCT 2026

Abstract N°: 3753

Health Disparities in Skin Neglected Tropical Disease Endemic Countries - Findings from the Global Skin Observatory Study

Simon Westby*[1, 2], Joseph Michael Yardman-Frank[1, 3], Jennifer Kilmer[4], Kathy Su[2], Christine Li[5], Ann Pacheco[2, 6], Sarah Anwar[7], Tebyan Khalfalla[1, 8], Parisa Shamaei Zadeh[1, 9], Devon McMahon[10], Ramesh Bhat[11], Mahira El Sayed[12], Wendemagegn Yeshaneh[13, 14], Cristina Galvan-Casas[15], Xing-Hua Gao[16], Srie Gondokaryono[17], Abdul-Ghani Kibbi[18], Adriene Lee[19], Fatimata Ly[20, 21], Jorge Ocampo-Candiani[22], Marie-Aleth Richard[23], Ricardo Romiti[24], Alexis Strahan[1], Junko Takeshita[25], Henry W. Lim[26], Bertrand Chuberre[27], Delphine Kerob[28], Lucinda Claire Fuller[29], Christopher E. M. Griffiths[30], Guénolée De Lambert[27], Ncoza Dlova[31], Esther Freeman[1, 2]

[1] Department of Dermatology, Massachusetts General Hospital, Boston, United States
[2] Medical Practice Evaluation Center, Mongan Institute, Massachusetts General Hospital, Boston, United States
[3] Department of Dermatology, Beth Israel Deaconess Medical Centre, Boston, United States
[4] The International League of Dermatological Societies, London, United Kingdom
[5] University of Massachusetts Chan Medical School, Worchester, United States
[6] University of Toledo College of Life Sciences, Toledo, United States
[7] Tufts University School of Medicine,, Boston, United States
[8] University of Rochester School of Medicine and Dentistry, Rochester, United States
[9] University of Kentucky College of Medicine, Lexington, United States
[10] Department of Dermatology, Hospital of the University of Pennsylvania, Philadelphia, United States
[11] Department of Dermatology, Venereology and Leprosy, Father Muller Medical College, Mangalore, India
[12] Ain Shams University, Cairo, Egypt
[13] Bahir Dar University, College of Medicine and Health Sciences, Bahir Dar, Ethiopia
[14] Collaborative Research and Training Center for Neglected Tropical Diseases, Arba Minch University, Arba Minch, Ethiopia
[15] Hospital Universitario de Móstoles, Madrid, Spain
[16] The First Hospital of China Medical University, Shenyang, China
[17] Department of Dermatology and Venereology, Dr. Hasan Sadikin General Hospital, Universitas Padjadjaran, Badung, Indonesia
[18] Department of Dermatology, American University of Beirut Medical Center, Beirut, Lebanon
[19] Department of Dermatology, St Vincent's Hospital, Melbourne, Australia
[20] Department of Dermatology, STI EPS Institut D'Hygiène Sociale de Dakar, Dakar, Senegal
[21] Faculty of Medicine, Pharmacy, and Odontostomatology, University Cheikh Anta Diop of Dakar, Dakar, Senegal
[22] Department of Dermatology, Hospital Universitario "Dr. José E. González", Universidad Autónoma de Nuevo León, Monterrey, Mexico
[23] Research Centre in Health Services and Quality of Life, Aix Marseille University Dermatology Department, University Hospital Timone, Assistance Publique Hôpitaux de Marseille, Marseille, France
[24] Department of Dermatology, University of São Paulo, São Paulo, Brazil
[25] Department of Biostatistics, Epidemiology and Informatics, Perelman School of Medicine at the University of Pennsylvania, Philadelphia, United States
[26] Department of Dermatology, Henry Ford Health, Detroit, United States

[27] L'Oréal Dermatological Beauty, Global Medical Team, Levallois-Perret, France
[28] La Roche-Posay Laboratoire Dermatologique,, Levallois-Perret, France
[29] London Bridge Hospital, London, United Kingdom
[30] Centre for Dermatology Research, NIHR Manchester Biomedical Research Centre, Manchester Academic Health Science Centre, University of Manchester, Manchester, United Kingdom
[31] Department of Dermatology, University of KwaZulu-Natal, Durban, South Africa

Introduction
Skin-related neglected tropical diseases (SNTD) affect approximately 1 billion people worldwide, causing suffering, disfigurement and stigma. The 2022 World Health Organization (WHO) SNTD strategic framework calls for national prioritisation and integration of services to best achieve disease control, with the availability of key diagnostic facilities and trained staff essential to these efforts. We use data from the Skin Observatory Study to explore access to skin care in SNTD endemic countries, highlighting potential barriers to the success of these global strategies.

Materials and Methods
The Skin Observatory Study is a cross-sectional, Delphi-derived survey study of national dermatologic leaders from 194 WHO member states. Data relevant to access to dermatologic care were extracted for analysis. Country SNTD endemicity status was determined for eight SNTD using the WHO Global Health Observatory data repository and the WHO Global Report on Neglected Tropical Diseases 2025. A country was deemed scabies endemic if it reported scabies among its five most common skin diseases in the survey.

Variation was tested across SNTD endemicity categories using chi-square and Fisher's exact tests for categorical variables and Kruskal-Wallis test for continuous variables.

Results
There were 158 respondent countries, 118 (74.6%) of which were endemic for at least one SNTD and 27 (17.1%) for three or more SNTDs. SNTD endemicity was associated with insufficient access to general dermatological care ($p=0.001$), poor healthcare infrastructure ($p=0.042$), inability to access dermatopathological review ($p=0.005$) and a shortage of healthcare workers providing dermatologic care ($p=0.047$).

Dermatologist density was associated with SNTD endemicity ($p<0.001$). When densities were weighted to account for urban/rural distribution, density in non-endemic countries was 3.08 per 100,000 compared to 2.52 in countries endemic for one SNTD, 1.41 in countries endemic for two and 0.66 in countries endemic for three or more (Figure 1). Density of dermatopathologists was also associated with SNTD endemicity ($p<0.0001$), with density decreasing as endemicity increased. Skin biopsies in rural areas were available in 44.1% of non-endemic compared to 16.5% of endemic countries.

Endemic countries had an increased reliance on traditional healers, health extension officers and physician assistants for dermatologic care. Only 14.7% of non-endemic countries reported patients accessed dermatologic care from traditional healers, compared to 29.4% in countries endemic for one SNTD, 34.5% in those with two and 66.7% in those with three or more. Almost half of endemic countries reported having access to teledermatology store and forward consultations compared to 38.2% of non-endemic countries.

Conclusions
This study highlights several barriers preventing the achievement of SNTD integrated control as set out in 2022 WHO SNTD strategic framework. SNTD endemic countries are disproportionately affected by skin care access disparities, with fewer skin specialists limited to urban centres and a lack of key infrastructure such as biopsy availability. Allied healthcare staff including traditional healers play a significant care role in endemic nations and, with existing telehealth capabilities, strategic efforts must incorporate their opinions and ensure they are included

in training and resource provision. SNTD care equity will hinge on political will, with skin health prioritisation being essential for the success of integration efforts.

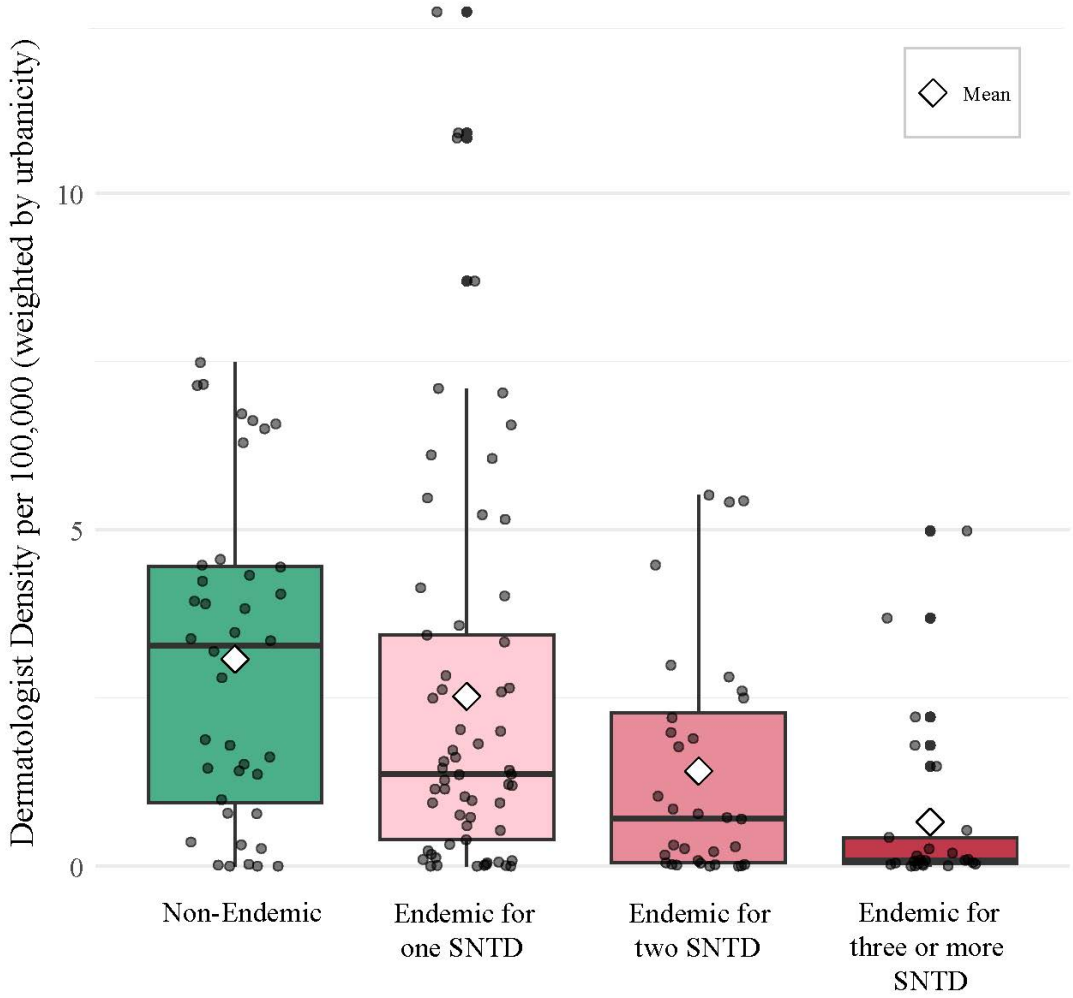

Figure 1. Dermatologist Density by Skin Neglected Tropical Disease Endemicity, Adjusted for Urban/Rural Distribution

EADV CONGRESS
VIENNA
30 SEP - 3 OCT 2026

Abstract N°: 3755

The Many Faces of Scabies: Comparative Insights into Typical and Atypical Presentations

Dilara Tuzcu*[1], Ilknur Altunay[1], pınar özdemir çetinkaya[1]

[1] Clinic of Dermatology, University of Health Sciences Türkiye, Şişli Hamidiye Etfal Training and Research Hospital, Istanbul, Türkiye

Introduction
Scabies is a highly contagious dermatosis caused by *Sarcoptes scabiei* var. *hominis*, typically characterized by nocturnal pruritus and typical skin lesions. Cases presenting with atypical or non-classical clinical features that mimic other dermatoses have been described as "scabies surrepticius". Due to the broad and variable clinical spectrum of scabies, diagnostic challenges may arise, particularly when classical findings are not prominent. The aim of this study was to describe atypical scabies cases and to compare the clinical and sociodemographic characteristics of typical and atypical scabies in order to determine the distinguishing features of atypical presentations.

Materials and Methods

This prospective comparative study included a total of 200 patients diagnosed with scabies according to the 2020 International Alliance for the Control of Scabies (IACS) criteria. The study population consisted of two groups: 100 patients with typical (classical) clinical presentations and 100 patients with atypical (non-classical) clinical presentations mimicking other dermatoses and consistent with the concept of "scabies surrepticius." Sociodemographic characteristics, clinical findings, pruritus features, previous diagnoses and treatment histories, comorbidities, IACS 2020 diagnostic classification, and treatment outcomes were recorded and compared between the typical and atypical scabies groups. Pruritus severity was additionally assessed using the Visual Analog Scale (VAS).

Results
The median age was significantly higher in the atypical scabies group compared to the typical group (43.0 vs 20.5 years; p=0.001). Analysis of age-group distribution revealed that the proportion of children was higher in the typical scabies group, whereas the proportion of geriatric patients was higher in the atypical scabies group. The presence of comorbidities was higher in the atypical group (54% vs 31%; p=0.001). In contrast, the presence of pruritic household members (63% vs 35%; p<0.001) and a history of scabies in household contacts (31% vs 17%; p=0.020) were more frequent in the typical group. The interval between symptom onset and diagnosis (median 1.5 vs 1.0 months) and the total duration of complaints (median 2.0 vs 1.5 months) were longer in the atypical group (p=0.035 and p=0.023, respectively). Additionally, prior misdiagnosis was more common in atypical cases (67% vs 35%; p<0.001), and skin biopsy was performed only in this group (12% vs 0%; p<0.001). According to the IACS diagnostic levels, clinical and suspected scabies were more frequent in the atypical group, whereas confirmed scabies was less common compared to the typical group (p<0.001). Regarding treatment, the number of treatment courses and hospitalization rates were higher in the atypical group compared to the typical group (p<0.001 and p=0.002, respectively). Furthermore, persistent lesions and the need for additional treatment following therapy were more frequently observed in the atypical group (13% vs 1% and 27% vs 1%, respectively; p<0.001).

Conclusions

Patients with atypical scabies were older, had more comorbidities, experienced longer diagnostic and treatment processes, and required more intensive treatment compared to those with typical scabies. In addition, prior misdiagnosis was more frequent in atypical cases, and skin biopsy was performed exclusively in this group. These findings suggest that atypical scabies may present with more complex and distinct clinical features compared to typical scabies. Therefore, early recognition of atypical clinical presentations and increased clinician awareness are important for preventing diagnostic delay and ensuring timely initiation of appropriate treatment.

EA DV CONGRESS
VIENNA
30 SEP - 3 OCT 2026

Abstract N°: 3781

Pooled Effectiveness of Terbinafine Versus Griseofulvin in the Management of Tinea Capitis: A Systematic Review and Meta-Analysis.

Haneen Abanmi*[1], Rayan Asiree[1], Sulaiman Almarshoud[2], Nouf Albogami[1], Abdulmajed Alghamdi[3], Khadejah sindi[4], Al-Jouhara Alaasmi[5], Mohammed abosabaah[6]

[1] Medical Student, Medicine and Surgery, Majmaah University, Al-Majmaah, Saudi Arabia

[2] Department of Dermatology, King Fahad Specialist Hospital, Buraidah, Saudi Arabia

[3] College of Medicine, Al-Imam Mohammad Ibn Saud Islamic University, Riyadh, Saudi Arabia

[4] college of medicine , Umm Al-Qura University, Makkah, Saudi Arabia

[5] College of medicine , Princess Nourah Bint Abdulrahman University, Riyadh, Saudi Arabia

[6] College of medicine , King Saud bin Abdulaziz University for Health Sciences, Riyadh, Saudi Arabia

Introduction
Tinea capitis is the common superficial fungi infection that mostly affects children all over the world. Effective management of it is done through oral antifungal therapy with griseofulvin traditionally being regarded as the standard treatment. Nevertheless, terbinafine is a substitute because it is fungicidal and the treatment period is shorter. Comparison of the efficacy and safety of terbinafine and griseofulvin, especially based on causative dermatophyte species, is still heterogeneous.

Materials and Methods
A meta-analysis and systematic review were carried out to compare the effectiveness and safety of oral terbinafine and griseofulvin in tinea capitus treatment. An extensive electronic database search was conducted on the publication of comparative clinical studies between 2001 and 2024. Some of the outcomes evaluated were clinical cure, mycological cure, species-specific response (Trichophyton and Microsporum), and adverse events. A random-effects model was used to obtain pooled effect estimates.

Results
A total of 2,155 patients in 6 comparative studies were included of which 1,358 patients were treated with terbinafine and 797 patients were treated with griseofulvin. Terbinafine showed a much greater rate of clinical cure in Trichophyton infected patients at four weeks (odds ratio [OR] = 4.63, 95% CI: 1.4015.25) but not at later follow-up periods. In general, terbinafine was linked to the increased pooled odds of clinical cure in Trichophyton infections (OR = 1.95, 95% CI: 1.113.41). There were no appreciable treatment differences between treatments in mycological cure rates of Trichophyton infections. Conversely, griseofulvin compared to terbinafine was much more effective in patients with Microsporum infections in terms of clinical and mycological cure. The two groups of treatments had a similar incidence of adverse events.

Conclusions
Terbinafine offers a quicker clinical action and equivalent long-term effectiveness as griseofulvin in the management of Trichophyton-related tinea capitis, and has the benefit of a reduced treatment period. Nonetheless, griseofulvin is still better in the case of infection by Microsporum species. The safety profiles of the two agents are similar. These results underpin the idea of species-oriented treatment of tinea capitis to achieve the best therapeutic results.

EA DV CONGRESS
VIENNA
30 SEP - 3 OCT 2026

Abstract N°: 3785

Cutaneous Loxoscelism: A Varied Clinical Spectrum

amir yahya bourbia*[1], Tarek Mansoul[1], RIADH BOUSSAID[1], Ahmed Samaouel Chehad[1]

[1] Department of Dermatology, CHU Constantine, Faculty of Medicine, University of Constantine 3, Constantine, Algeria

Introduction
Loxoscelism, defined as envenomation following a spider bite from the *Loxosceles* genus, may present with a wide spectrum of dermatological manifestations. While localized cutaneous necrosis is the most classical presentation, atypical and even systemic forms may also occur. We report three clinical cases of cutaneous loxoscelism illustrating the diversity of possible cutaneous manifestations.

Materials and Methods

Case 1: Acute Generalized Exanthematous Pustulosis (AGEP)

A 27-year-old woman presented with an acute febrile pustular eruption without any identified drug-related or infectious cause. Clinical examination revealed generalized pustulosis composed of superficial milky-white pustules associated with an inflammatory plaque centered by a necrotic area on the trunk, corresponding to the site of a spider bite that had occurred a few days earlier. The diagnosis of AGEP secondary to loxoscelism was retained based on clinical and histopathological findings. Systemic corticosteroid therapy led to rapid regression of the lesions.

Case 2: Progressive Necrotic Lesion

A 32-year-old woman developed, 24 hours after a spider bite on the left arm, a painful erythematous lesion that rapidly evolved toward central necrosis surrounded by a peripheral inflammatory halo. The course was marked by progressive extension of the necrosis, requiring surgical management. The clinical context and capture of the spider confirmed the diagnosis of typical necrotic loxoscelism.

Case 3: Maculopapular Exanthem

A 36-year-old woman was hospitalized for an erythematous maculopapular eruption evolving for 9 days after a spider bite on the right arm. The initial lesion at the bite site consisted of an inflammatory plaque centered by necrosis and surrounded by an erythematous halo. In the absence of any medication intake, the progression toward a diffuse eruption suggested a systemic immunological reaction secondary to



Case 1: Acute Generalized Exanthematous Pustulosis (AGEP)

Results

These three observations illustrate the diversity of cutaneous manifestations induced by *Loxosceles* venom. The necrotic form is the most common and characteristic presentation, related to the direct cytotoxic effect of the venom. The AGEP observed in the first case may reflect a systemic hypersensitivity reaction. The third case suggests a generalized immune response manifested by a maculopapular exanthem occurring outside any drug-related context.

These atypical clinical presentations highlight the importance of thorough history-taking and careful clinical examination in order to promptly recognize and appropriately manage unusual forms of loxoscelism.



Case 2: Progressive Necrotic Lesion

Conclusions

Cutaneous loxoscelism exhibits a broad clinical polymorphism extending beyond the classic necrotic presentation. Atypical forms such as AGEP or maculopapular eruptions should be recognized in order to ensure rapid and appropriate management.



Case 3: Maculopapular Exanthem

EADV Congress 2026, VIENNA
30 SEPTEMBER - 03 OCTOBER 2026
POWERED BY M-ANAGE.COM

EA DV CONGRESS
VIENNA
30 SEP - 3 OCT 2026

Abstract N°: 3800

When Infection Meets Infestation: A Rare Case of Coexisting Erysipelas and Cutaneous Myiasis

ikram lahmouch*[1]

[1] Department of Dermatology, Ibn Sina University Hospital, Rabat, Morocco, rabat, Morocco

Introduction
Cutaneous myiasis is an uncommon parasitic infestation caused by dipterous larvae invading necrotic or chronically damaged skin. It typically occurs in patients with poor hygiene, social deprivation, or underlying chronic skin conditions predisposing to tissue breakdown.

Erysipelas is an acute bacterial dermohypodermitis that usually presents with a well-defined erythematous and painful plaque, and generally responds rapidly to appropriate antibiotic therapy.

The simultaneous occurrence of erysipelas and cutaneous myiasis is exceptionally rare and may significantly modify the clinical presentation, leading to diagnostic complexity and therapeutic challenges. Such association is often favored by chronic skin disruption and neglect, providing a suitable environment for both bacterial infection and larval infestation.

We report a rare case of true coexistence of erysipelas complicated by cutaneous myiasis of the lower limb in a socially vulnerable patient, highlighting diagnostic and therapeutic implications.

Case Presentation
A 67-year-old man from a rural area, with a 30 pack-year smoking history and no relevant comorbidities, living in social isolation with poor self-care, was referred to our dermatology department for an acute painful erythematous swelling of the right lower limb initially suggestive of erysipelas.

He reported a chronic ulcerative lesion of the same limb evolving for 3 months, initially managed in primary care with a short course of antibiotics without improvement. The lesion progressively deteriorated, followed two months later by the onset of a rapidly spreading erythematous, warm and painful plaque, in the absence of fever or systemic signs, prompting referral.

On admission, the patient was apyretic and in good general condition. Dermatological examination of the right lower limb revealed a well-demarcated erythematous and oedematous plaque extending over the proximal two-thirds of the leg, associated with multiple ulcerations, erosions, and hemorrhagic crusts, on a background suggestive of chronic venous insufficiency.

Careful examination demonstrated a **true coexistence of erysipelas and cutaneous myiasis**, characterized by the presence of multiple motile larvae within ulcerated lesions and interdigital spaces of the right foot.

Examination of the contralateral limb revealed milder inflammatory changes with dorsal foot ulceration and interdigital maceration. Peripheral pulses were preserved and no neurological deficit was noted.

Laboratory investigations showed marked inflammatory response with leukocytosis (15,600/mm^3) and elevated C-reactive protein (161.5 mg/L), while renal and hepatic functions were within normal limits.

Outpatient treatment was initiated due to patient refusal of hospitalization, including local wound care, systemic

antibiotic therapy with ciprofloxacin, and management of interdigital intertrigo. **Immediate management consisted of mechanical debridement of necrotic tissue and manual extraction of larvae, combined with local antiseptic wound care and limb elevation.** Clinical evolution was favorable with significant regression after two weeks.

Conclusion

This case highlights the uncommon coexistence of erysipelas and cutaneous myiasis, a rare but clinically significant association that may complicate the clinical presentation and delay appropriate management. It also underlines the role of social vulnerability and self-neglect as major contributing factors to disease severity.

Early recognition of both the infectious process and the superimposed infestation, together with prompt mechanical debridement and larval extraction, is essential for optimal therapeutic outcomes.

EADV CONGRESS
VIENNA
30 SEP - 3 OCT 2026

Abstract N°: 3808

Cutaneous Tuberculosis (Lupus Vulgaris): A 10-Year Diagnostic Challenge

Mohamed Aymen Benachour*[1], esma bouhila[1], Tarek Mansoul[1], RIADH BOUSSAID[1], Amel Gherfi[1], khadidja bouarroudj[1], Safa Djebbas[1], kaghouche lilia[1], Ahmed Samaouel Chehad[1]

[1] Constantine university hospital, Constantine, Algeria

Introduction
Lupus vulgaris (LV) constitutes the most frequent form of cutaneous tuberculosis. It is characterized by marked clinical polymorphism, including papular, nodular, ulcerated, or tumor-like forms. This clinical heterogeneity is often the cause of diagnostic and therapeutic delays.

Case Presentation
This concerns a 20-year-old patient, with no notable pathological history, consulting for lesions on the face and right arm, evolving for 10 years. In the anamnesis, he reports no particular personal or family history nor any notion of tuberculosis contact. The clinical examination revealed a slightly infiltrated red scaly-crusted plaque affecting the nose and right cheek, and papular lesions on the left cheek associated with atrophic and pigmented sequellar lesions in the palpebral, periorbital, and right temporal areas. A plaque with an atrophic and pigmented center surrounded by erythematous-violaceous ulcerated-crusted lesions on the right arm. Diascopy (vitropression) highlights a yellowish lupoid infiltrate. The rest of the extra-dermatological examination is without anomalies.

Strongly positive tuberculin skin test (25 mm). The skin biopsy revealed an epithelioid and giant cell granuloma without caseous necrosis. The chest X-ray is unremarkable. Parasitological examination looking for Leishmania bodies returned negative. The rest of the biological assessment is without anomaly.

Given these clinical and paraclinical arguments, the diagnosis of tuberculous lupus was retained and a standard antitubercular treatment (2RHZE/4RH) was initiated, with a clear clinical improvement, thus confirming the diagnosis.

Conclusion
In Algeria, although cutaneous tuberculosis is rare, lupus vulgaris (LV) is its most common form. It remains a diagnostic challenge due to its clinical polymorphism and similarity to other granulomatous dermatoses like cutaneous leishmaniasis and sarcoidosis. Our case illustrates the significant chronicity of LV, where diagnostic delays often stem from its paucibacillary nature. Histopathologically, the frequent absence of caseous necrosis and negative bacteriology often preclude formal confirmation. Consequently, diagnosis relies on a combination of clinical findings, a positive tuberculin skin test, and a favorable response to antitubercular therapy. Differential diagnoses include chronic granulomatous infections and infiltrated skin tumors, necessitating an integrated clinicopathological approach. Finally, long-term surveillance is vital due to the rare risk of neoplastic transformation into squamous cell carcinoma within old scars.
Standard antitubercular treatment remains the only effective alternative for Lupus Vulgaris, for which early diagnosis in Algeria is essential to prevent mutilating sequelae and the risk of malignant transformation.

EADV CONGRESS
VIENNA
30 SEP - 3 OCT 2026

Abstract N°: 3813

Pseudo-sporotrichoid presentation of cutaneous leishmaniasis : an unusual clinical pattern

Tasnime Bouaziz*[1], Lemya Mezdour[1], Lamia Ould Iddir[1], Issam TABLIT[1], Saliha Takheroubt[1], Asma Haciane[1], Samira Zobiri[1]

[1] Dermatology departement mustapha hospital center, Algiers, Algeria

Introduction

Cutaneous leishmaniasis, caused by protozoa of the genus Leishmania, typically presents as a single lesion at the inoculation site. Sporotrichoid dissemination is rare and reflects lymphatic spread, clinically mimicking sporotrichosis. However, multiple sandfly inoculations may reproduce a similar pattern, creating a diagnostic challenge in endemic regions.

Case Presentation

We report a 39-year-old woman with no relevant medical history, living in an endemic area, presenting with a 3-month history of evolving cutaneous lesions.
Clinical examination revealed seven ulcerated crusted nodules ranging from 0.5 to 4 cm, with infiltrated borders and granular bases. Lesions predominantly involved the left upper limb with an ascending distribution and were associated with a single contralateral lesion. The clinical course began with a single lesion followed by progressive appearance of new lesions in a sequential pattern suggestive of spatial extension.
Direct parasitological examination of all lesions demonstrated abundant amastigotes of Leishmania in every sample, confirming cutaneous Leishmaniose cutanée. The patient was treated with intramuscular meglumine antimoniate combined with cryotherapy, with favorable clinical evolution.
Differentiating true sporotrichoid spread from pseudo-sporotrichoid patterns remains challenging in endemic settings. True sporotrichoid leishmaniasis reflects lymphatic dissemination characterized by nodular lesions arranged in a linear pattern, sometimes associated with lymphangitis.
Conversely, repeated sandfly bites may lead to multiple independent inoculation sites that clinically mimic lymphatic spread. In this case, the ascending distribution and temporal sequence of lesions were suggestive of lymphatic dissemination. However, the absence of lymphangitis and the superficial nature of lesions argued against true lymphatic spread. Uniform parasitological positivity across all lesions confirmed their leishmanial origin but did not allow differentiation of the underlying dissemination mechanism.

Conclusion

Multiple cutaneous lesions of leishmaniasis may mimic sporotrichoid spread without true lymphatic dissemination. In endemic areas, multiple inoculations should be considered in atypical sporotrichoid presentations to avoid misinterpretation of disease spread.

EA DV CONGRESS
VIENNA
30 SEP - 3 OCT 2026

Abstract N°: 3822

The New Threat: Widespread Dermatophytosis by Resistant T. indotineae

Anejjar Fatima*[1], Hanane Rachadi[1], Chiheb Soumiya[1]

[1] Hôpital Ibn Rochd, Casablanca, Morocco

Introduction

Superficial fungal infections affect approximately 20 to 25 % of the global population. They can result in a large of dermatologic clinical presentations depending on both the organism involved and the area of the body affected. Factors such as age, gender, and geographical location play an important role in the prevalence of these infections. The worldwide increased incidence of fungal infections and growing trend of resistant organisms have attracted global concern.

We report the case of a resistant dermatophytosis in a young immunocompetent Moroccan female following a stay in Thailand.

Materials and Methods

A 27-year-old Moroccan woman, with no significant medical history, presented with widespread annular lesions that had been evolving for nearly one year following a recent stay in Thailand. The patient reported intense pruritus that severely impaired her quality of life.

Dermatological examination revealed multiple erythematous squamous annular lesions with a circinate border, papular in some areas and confluent in others. The lesions varied in size and demonstrated a centrifugal spread. They were distributed across the trunk, back, limbs, face, and major folds. Several excoriated lesions were noted, consistent with scratching due to severe pruritus.

The clinical aspect strongly suggested a superficial fungal infection. Mycological culture identified *Trichophyton mentagrophytes*, later confirmed as *Trichophyton indotineae*, a newly recognized resistant strain. Based on these findings, the patient was started on oral terbinafine for two months. However, the absence of any clinical improvement prompted a switch to combined therapy with fluconazole and griseofulvin for one month, which also failed to yield benefits.

Given the known resistance of *T. indotineae* to conventional antifungals, oral itraconazole was introduced, reinforced by topical ketoconazole and antihistamine therapy. This revised regimen led to a favorable outcome, with marked regression of lesions and resolution of pruritus.

Results

Resistance to terbinafine is now increasingly recognized worldwide. First described in India, it has since been reported in Europe, Asia, and more recently in the United States. This global spread reflects the emergence of *Trichophyton indotineae*, a variant within the *T. mentagrophytes* complex, which is strongly associated with antifungal resistance.

The mechanism of resistance is linked to mutations in the **squalene epoxidase (SQLE) gene**, the target of terbinafine. These genetic changes render conventional therapy ineffective and explain the therapeutic failures observed in many patients.

Itraconazole has become the drug of choice for infections caused by resistant strains. Clinical cure is generally achieved with daily doses ranging from **200 to 800 mg**, administered for up to **8 weeks**. Despite its efficacy,

careful monitoring is required, as relapses remain possible.

Conclusions

This case highlights the emergence of *Trichophyton indotineae* as an imported resistant pathogen, responsible for widespread dermatophytosis unresponsive to conventional antifungals. Itraconazole remains the most effective therapeutic option, underscoring the need for vigilance in recognizing resistant strains in refractory infections.

EADV CONGRESS
VIENNA
30 SEP - 3 OCT 2026

Abstract N°: 3838

Chronic Unilateral Superficial Mycosis Mimicking Inflammatory Dermatoses for 20 Years: Importance of Clinicopathological Correlation

Elaine Shizue Novalo-Goto*[1], Mônica Linhares Sachett[1], Luísa Homem de Mello Maciel Campilongo[1], Nobuo Matsunaga[1], Mauro Cintra Giudice[1], Carlos D´Apparecida Santos Machado Filho[1]

[1] FMABC University Center, Santo André, Brazil

Introduction

Superficial fungal infections are usually easily diagnosed and respond well to conventional antifungal therapy. However, atypical and localized presentations may resemble chronic inflammatory dermatoses, leading to prolonged misdiagnosis and inappropriate treatment with topical corticosteroids. We report a case of chronic unilateral superficial mycosis with a 20-year evolution that clinically mimicked different inflammatory skin diseases before the correct diagnosis was established through histopathological and mycological investigation.

Case Presentation

A 59-year-old woman presented with a pruritic and painful lesion restricted to the right arm for approximately 20 years. Dermatological examination revealed coalescent erythematous papules forming poorly demarcated erythematous-scaling plaques with irregular borders, surmounted by a few pinpoint pustules. Symptoms fluctuated over time, with worsening during summer months and partial improvement during colder periods. Throughout the disease course, the patient was evaluated by several dermatologists and received different diagnostic hypotheses, including contact dermatitis, polymorphous light eruption, and psoriasis, without clinical improvement. Multiple topical treatments were prescribed over the years, especially topical corticosteroids. The patient reported transient relief of pruritus after corticosteroid application; however, lesions progressively worsened over time, frequently associated with local burning sensation after use. Skin biopsy demonstrated superficial perivascular lymphocytic inflammatory infiltrate with eosinophils, in addition to subcorneal pustules and crust formation. Periodic acid–Schiff staining revealed fungal hyphae and conidia within the stratum corneum. Direct mycological examination confirmed numerous hyaline septate hyphae and arthroconidia, establishing the diagnosis of superficial mycosis with subcorneal pustules. Treatment with oral fluconazole 150 mg weekly was initiated, resulting in partial clinical improvement after four weeks. Due to the long-standing disease course and residual lesions, therapy was maintained for an additional eight weeks, leading to progressive clinical improvement.

Conclusion

This case highlights an unusual presentation of chronic unilateral superficial mycosis persisting for two decades while mimicking inflammatory dermatoses. The prolonged evolution, localized distribution, subtle pustular component, and temporary symptomatic improvement with topical corticosteroids contributed to repeated diagnostic errors, while chronic corticosteroid use may also have favored fungal proliferation. Histopathological and mycological evaluation were essential for establishing the correct diagnosis. Dermatologists should consider fungal infection in chronic localized eruptions refractory to corticosteroids, particularly in cases with atypical clinical features and long-standing evolution.

EADV CONGRESS
VIENNA
30 SEP - 3 OCT 2026

Abstract N°: 3841

Beyond Rash: A Descriptive Evidence Map of Visible Vascular Mucocutaneous, Ocular, and Periocular Findings in Human Hantavirus Disease

Mohammed shanshal[1], George Karanasios*[1]

[1] Imperial College Healthcare NHS Trust, London, United Kingdom

Introduction

Hantavirus disease, causing hemorrhagic fever with renal syndrome (HFRS) and hantavirus pulmonary/cardiopulmonary syndrome (HPS/HCPS), is a systemic vascular-leak illness driven by endothelial barrier dysfunction, increased vascular permeability, thrombocytopenia, and host inflammatory dysregulation. The skin, conjunctiva, and visible mucosae are clinically accessible surfaces where this vascular biology may be directly observable, yet visible mucocutaneous findings remain fragmented across outbreak reports, nephrology cohorts, and ophthalmology series. The term "rash" conflates non-petechial exanthem with petechial, hemorrhagic, ocular, and mucosal signs, creating a critical reporting gap. In May 2026, a fatal multi-country Andes virus cluster linked to cruise-ship travel underscored that hantavirus may now be encountered in international, non-endemic clinical settings where bedside recognition of visible surface signs is essential. Rather than asking whether hantavirus causes "rash," we asked which visible surface findings are reproducibly reported across the literature, how they distribute across prespecified anatomical domains, and whether available evidence supports a broader visible mucocutaneous spectrum beyond non-petechial skin rash.

Materials and Methods

PubMed/MEDLINE and Embase/Ovid were searched from inception to 8 May 2026. Of 488 retrieved records, 211 duplicates were removed; 60 of 277 unique records met eligibility. Eligible records were cohort studies, case series, or outbreak/surveillance reports including at least 2 hantavirus patients with extractable denominator-bearing data for at least one visible finding. Findings were mapped into six prespecified domains: (1) ocular/conjunctival involvement; (2) petechial, purpuric, or visible bleeding; (3) flushing or erythematous vascular-congestive signs; (4) oropharyngeal/visible mucosal congestion; (5) edema, swelling, or chemosis; and (6) non-petechial rash or exanthem. Results are reported as study-level medians, IQR, ranges, and denominator-weighted descriptive signals. No meta-analysis was performed.

Results

Ocular/conjunctival involvement: 42/60 records, all positive; median 30.1% (IQR 20.1 to 57.8); signal 1374/4219 (32.6%). **Petechial/purpuric/bleeding:** 48/60 records, 45/48 positive; median 21.5% (IQR 8.7 to 38.9); signal 922/5051 (18.3%). **Flushing/erythematous vascular-congestive signs:** 16/60 records, all positive; median 33.7% (IQR 23.5 to 44.0); signal 779/2602 (29.9%). **Oropharyngeal/mucosal congestion:** 11/60 records, all positive; median 34.5% (IQR 27.4 to 51.1); signal 510/1370 (37.2%), the highest across all domains. **Edema/swelling/chemosis:** 17/60 records, 15/17 positive; median 32.0% (IQR 13.6 to 46.2); signal 416/1643 (25.3%). **Non-petechial rash/exanthem:** 15/60 records, 13/15 positive; median 6.3% (IQR 2.0 to 25.4); signal 88/886 (9.9%), the weakest domain. A broader rash sensitivity analysis yielded a similarly low signal (100/962; 10.4%). Severity-enriched HFRS cohorts suggested conjunctival congestion, pharyngeal congestion, and petechiae tracked with more severe disease, though data were unadjusted and hypothesis-generating.

Domain	Records with denominator-bearing data, n/N	Positive records, n/N	Study-level frequency, median % (IQR; range)	Denominator-weighted descriptive signal, n/N (%)
Ocular/conjunctival involvementa	42/60	42/42	30.1 (20.1–57.8; 5.6–100)	1374/4219 (32.6)
Petechial, purpuric, or visible bleeding manifestationsb	48/60	45/48	21.5 (8.7–38.9; 0–100)	922/5051 (18.3)
Flushing or erythematous vascular-congestive signs	16/60	16/16	33.7 (23.5–44.0; 4.7–100)	779/2602 (29.9)
Oropharyngeal or visible mucosal erythema, injection, or congestionc	11/60	11/11	34.5 (27.4–51.1; 8.3–90.7)	510/1370 (37.2)
Edema, swelling, or chemosisd	17/60	15/17	32.0 (13.6–46.2; 0–100)	416/1643 (25.3)
Non-petechial rash or exanthem-type findings	15/60	13/15	6.3 (2.0–25.4; 0–74.1)	88/886 (9.9)

Table 1. Report-level descriptive mapping of visible mucocutaneous, ocular, and periocular domains in human hantavirus disease (60 eligible records). Estimates are study-level descriptive signals, not pooled prevalence. Domains are not mutually exclusive and should not be summed.

Conclusions

Visible findings in human hantavirus disease extend well beyond non-petechial rash. Ocular/conjunctival involvement was the most consistently reported domain; oropharyngeal mucosal congestion yielded the highest denominator-weighted signal, likely reflecting ascertainment bias rather than rarity. Flushing, edema/chemosis, and petechial or bleeding signs formed a recurrent heterogeneous vascular-surface pattern, most clearly represented in HFRS. Non-petechial rash had the lowest signal across all domains. Absence of rash should not lower clinical suspicion when epidemiologic context is compatible; active inspection of the conjunctiva, visible mucosa, facial/neck erythema, and petechial sites is warranted. Standardized patient-level reporting is needed before these signs can serve as diagnostic, severity, or prognostic markers.

EADV CONGRESS
VIENNA
30 SEP - 3 OCT 2026

Abstract N°: 3870

Between grains and pain: Therapeutic challenges in six cases of mycetoma

Asmae Dahmani*[1], Sara Elloudi[1], Hanane Baybay[1], Meryem Soughi[1], Zakia Douhi[1], Saadia Boughaleb[1], IKRAME BEJJA[1], Fatima Zohra Mernissi[1]

[1] CHU HASSAN II,Dermatology department, FEZ, Morocco

Introduction

Mycetoma is a chronic granulomatous infection involving the skin, subcutaneous tissues, and occasionally the underlying bone. It is classified into two main forms according to the causative organism: actinomycetoma, of bacterial origin, and eumycetoma, of fungal origin. This disease mainly occurs in tropical and subtropical regions and remains a significant cause of morbidity in rural populations.

Materials and Methods

A retro-prospective descriptive study was conducted on six patients diagnosed with foot mycetoma between 2016 and 2026. Clinical features, type of mycetoma, treatment regimens, and outcomes were analyzed.

Results

Six cases were included, comprising five actinomycetomas and one eumycetoma.Among actinomycetoma cases, three patients received Cotrimoxazole monotherapy (40 mg/kg/day), with favorable outcomes in two cases with almost complete clinical regression and no relapse after two years of follow up.In the third patient, treatment had to be discontinued due to a maculopapular drug eruption.An alternative therapeutic regimen was therefore initiated, consisting of an intensive phase with intramuscular Amikacin (15 mg/kg/day) administered for three weeks per month combined with Ciprofloxacin (500 mg twice daily) for three months. This was followed by a maintenance phase with Ciprofloxacin alone for nine months, resulting in a favorable clinical outcome during six months of follow-up. The remaining two patients, who presented with bone involvement, were treated with triple antibiotic therapy consisting of Cotrimoxazole (10 mg/kg/day), Amoxicillin–clavulanic acid (1 g three times daily) and Amikacin (15 mg/kg/day administered in cyclical regimens), resulting in progressive clinical improvement over a two years follow up period.In contrast, the eumycetoma case demonstrated extensive bone invasion of the lower limb, ultimately necessitating limb amputation.

Conclusions

Mycetoma remains a therapeutic challenge, particularly in resource limited settings and advanced stages. While actinomycetoma generally responds well to antibiotic therapy, treatment may be complicated by adverse drug reactions requiring alternative regimens. In contrast, eumycetoma is associated with a more aggressive course and poorer prognosis, often necessitating surgical intervention. Early diagnosis and individualized management are crucial to improve outcomes and prevent mutilating complications.

EADV CONGRESS
VIENNA
30 SEP - 3 OCT 2026

Abstract N°: 3897

Efficacy and safety of systemic treatments in American Cutaneous Leishmaniasis: a 8-year-experience in French Guiana

Philippe Picherit-Steinbrucker*[1], Geoffrey Grotta[1], Olivier Collinet[2], Franklin Samou-Fantcho[2], Laurence Lachaud[3], Christophe Ravel[3], Magalie Pierre Demar[4], Romain Blaizot[4]

[1] French Guiana University Hospital, Cayenne, French Guiana

[2] French Guiana University Hospital, Saint-Laurent-du-Maroni, French Guiana

[3] Montpellier University Hospital, French National Reference Centre for Leishmaniasis, Montpellier, France

[4] French Guiana University Hospital, University of French Guiana, French National Reference Centre for Leishmaniasis, associate laboratory, Cayenne, French Guiana

Introduction

American Cutaneous Leishmaniasis (ACL) is a skin Neglected Tropical Disease caused by the bite of infected sandflies. It represents a major public health problem in the Americas, with no ideal therapeutic option. Though useful when facing numerous lesions, systemic treatments are often unavailable due to financial, legal and logistical constraints. Data regarding their efficacy and safety are conflicting. Our objective was to compare all systemic treatments used in French Guiana since 2017.

Materials and Methods

All patients with confirmed ACL between 01/01/2017 and 31/12/2024 in French Guiana were included. Confirmation was defined by at least one positive test (smear/culture/PCR/histopathology). Patients without at least one follow-up consultation were excluded. Final cure was assessed by follow-up at 3-6 months. The different drugs used were pentamidine (intravenous 4mg/kd/d on days 1, 3 and 5 or intramuscular, single dose, 7mg/kg), amphotericin B (intravenous, 4mg/kg/d, 5 days), intramuscular meglumine antimoniate (MA) (75mg/kg/d, 21 days) and miltefosine (oral, 50mg, tid, 28 days). Complete response was defined as 100% re-epithelisation/flattening at M3-M6.

Results

679 patients were included (472 men, 207 women, median age 32 [25 ; 43]). The median duration of symptoms before diagnosis was 4 weeks [4 ; 8]. Species identification was available for 612 patients, including *Leishmania guyanensis* (478/612, 78%), *Leishmania braziliensis* (93/612, 15 %), *Leishmania amazonensis* (27/612, 4 %), *Leishmania lainsoni* (11/612, 2%) and *Leishmania naiffi* (3/612, 0,5%). 20 (3%) patients were HIV positive, 14 (2%) had diabetes. The median number of lesions was 3, 129 patients (26 %) had > 10 lesions. The most frequent type of lesions were ulcerations (460/491, 93%) and papules/nodules (85/491, 17%), with 10 mucosal involvements.

A total of 945 courses of antiparasitic drugs were administered, and 868 had at least one follow-up. The overall cure rate was 573/868 (66%). Pentamidine was the most frequent first-line drug, for all species excepting *L. braziliensis*. Amphotericin B was used for *L. braziliensis* and mucosal/facial involvements, miltefosine when amphotericin B was impossible and MA as first-line against *L. braziliensis* until 2018, then replaced by amphotericin B and used only as a third line.

722 cures of pentamidine were administered with at least one follow-up, including 120 IV and 602 IM, with respective response rates of 67% (80/120) and 66% (395/602). We reported the following response rates for amphotericin B (63%, 63/101 cures), miltefosine (75%, 21/28 cures) and MA (82%, 14/17).

With pentamidine, Adverse effects (AE) were observed in 4.3 % of cases (mostly CPK elevation fatigue, and IM injection site reaction) and grade ≥ 3 AE in only 1% of patients, always with the IM route.

With amphotericin B, AE were observed in 49.6% of cases (mostly hypokalaemia and kidney failure), grade ≥ 3 AE in 21.3% of cases.

With miltefosine, AE were observed in 42% of cases (nausea and vomiting), with no severe AE but 10% of treatment discontinuation.

With MA, AE were observed in 68.2% of cases (increased lipase and SGOT, conduction disorder, headache, myalgia, arthralgia).

Conclusions

The efficacy of pentamidine was similar between the IV and IM routes, while the former was safer. This drug is probably underused in South America, though its intermediary cost (35$/vial) makes it useful in a local ecology dominated by *L. guyanensis*. Despite conflicting data in the literature, amphotericin B proved efficacious. Premedication and inpatient care allowed safe management of hypokalaemia and kidney failure. Miltefosine proved useful in case of amphotericin B contra-indication or failure, though limited by digestive effects. Systemic MA was associated with the highest cure rate, but was dropped after 2020 due to poor tolerance.

EA DV CONGRESS
VIENNA
30 SEP - 3 OCT 2026

Abstract N°: 3927

c-Met–MAPK Signaling Drives Macrophage Migration in Mycobacterium marinum Skin Infection

Lu Yang*[1], Chikit Chao[1], Han Ma[1], Yanqing Chen[1]

[1] Fifth Affiliated Hospital, Sun Yat-sen University, Zhuhai, China

Introduction
Skin infections caused by Mycobacterium marinum are increasingly prevalent and challenging to treat. Although bacterial components can trigger macrophage migration, it remains unclear whether viable bacteria activate distinct and potentially more potent signaling programs compared to inactivated bacteria—a question critical for understanding infection-specific immune modulation. This study aimed to compare macrophage responses to live versus heat-killed M. marinum, with a focus on identifying viability-dependent pathways that may underlie early granuloma formation and disease progression.

Materials and Methods
Primary mouse bone marrow-derived macrophages (BMDMs) were stimulated with live or heat-killed M. marinum at an MOI of 5. Transcriptomic profiling via RNA-seq identified differentially expressed genes, followed by GO and KEGG pathway enrichment analyses. Macrophage migration was evaluated using Transwell and wound-healing assays. Activation of ERK and p38 was assessed by Western blot. The role of c-MET was examined using the inhibitor PHA-665752 and siRNA-mediated knockdown. Clinical relevance was supported by proteomic analysis of patient skin lesions.

Results
RNA-seq revealed that live, but not heat-killed, M. marinum significantly upregulated migration-related genes, including c-MET, and enriched MAPK signaling pathways. Phenotypic assays confirmed that live infection enhanced macrophage migration, accompanied by increased phosphorylation of ERK and p38. Pharmacological inhibition or genetic knockdown of c-MET reduced macrophage migration and suppressed ERK/p38 phosphorylation. Clinically, proteomic analysis of patient lesions further supported these findings by revealing a robust pro-migratory microenvironment enriched in cytoskeletal reorganization and migration control.

Conclusions
Our results demonstrate that live, but not heat-killed, Mycobacterium marinum specifically enhances macrophage migration through activation of the c-MET–MAPK signaling axis. Supported by clinical proteomic evidence, this study identifies a viability-dependent mechanism that regulates macrophage recruitment, providing new insights into granuloma formation and immune microenvironment modulation in cutaneous mycobacterial infection.

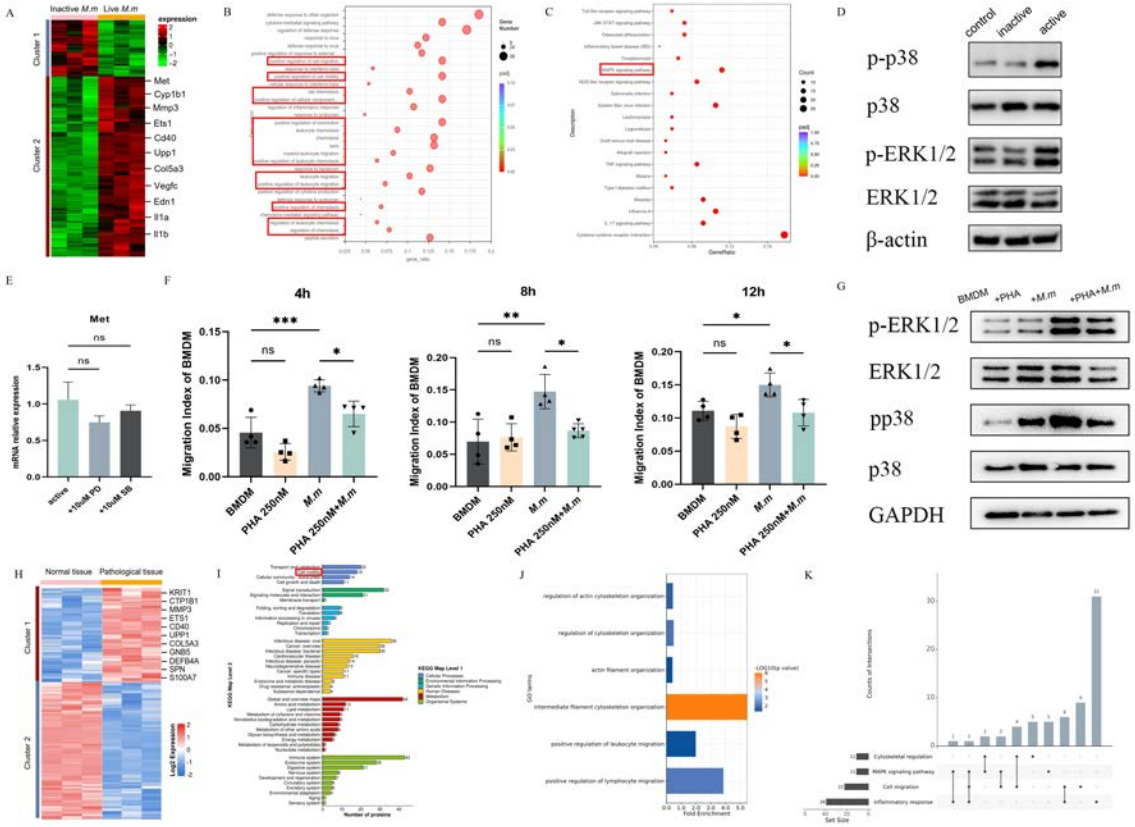

Live Mycobacterium marinum drives macrophage migration via a c-Met-MAPK signaling axis. (A) Clustering heatmap of transcriptome data. Selected upregulated migration-related genes in the live bacteria group are annotated. (B) GO enrichment analysis. The analysis demonstrates that the upregulated genes are significantly enriched in biological processes, including “positive regulation of cell migration,” “positive regulation of cell motility,” and “cell chemotaxis.” (C) KEGG pathway enrichment analysis. The upregulated genes are predominantly enriched in the cytokine-cytokine receptor interaction and MAPK signaling pathways. (D) Western blot analysis of p38 and ERK phosphorylation. Compared with heat-killed bacteria, infection with live Mycobacterium marinum significantly induces the phosphorylation of p38 and ERK. (E) Effect of MAPK inhibitors on Met expression. The expression of the upregulated migration-related gene Met remains unaffected by the ERK inhibitor (PD98059, 10 μM) or the p38 inhibitor (SB203580, 10 μM). (F-G) Inhibition of Met attenuates macrophage migration and MAPK signaling. Bone marrow-derived macrophages were pretreated with the selective c-Met inhibitor PHA-665752 for 1 h prior to M. marinum infection. Representative images captured at 4, 8, and 12 h post-infection reveal that Met inhibition significantly impairs the migratory capacity of infected cells, accompanied by decreased levels of p-p38 and p-ERK. (H) Clustering heatmap of differentially expressed proteins. Migration-related proteins that exhibit consistent upregulation with the transcriptomic data are highlighted. (I) KEGG pathway classification of DEPs. A total of 63 DEPs are categorized under the overarching category of "Cellular processes," among which 18 are enriched in the "Cell motility" subcategory. (J) GO enrichment analysis of DEPs. The analysis reveals significant enrichment in terms associated with cytoskeletal remodeling and the regulation of immune cell migration. (K) UpSet plot analysis. Proteins associated with the inflammatory response, MAPK signaling pathway, cytoskeletal regulation, and cell migration were filtered from the upregulated DEPs, illustrating the intersections and overlaps across distinct functional categories.

EA DV CONGRESS
VIENNA
30 SEP - 3 OCT 2026

Abstract N°: 3930

Unmasking severe lepra reactions: clinical insights, predictive risk factors and treatment outcomes

Ankita Tuknayat*[1], Kanika Dogar[2]

[1] Aster DM healthcare, dubai, United Arab Emirates

[2] GMCH, CHANDIGARH, India

Introduction

Introduction

Leprosy is a chronic granulomatous infection. Lepra reactionsare usually responsive to steroids, but can rarely be chronic, recurrent and recalcitrant. The aim of this study is to analyzethe clinical profile and predict risk factors for severe leprareactions requiring multiple drugs, treatment outcomes and clinical course.

Materials and Methods

Methods

A retrospective analysis was done. Records of 580 patients were reviewed from 2015-2023. The inclusion criteria wereany patient that had been prescribed any drug other than steroid for management of their reaction. 18 such patients were identified.

Results

Results

Out of18 patients, 72% were males (n=13) and 27% females (n=5). The mean follow up period was 22 months(range 12-72months). The mean number of reactions experienced by each patient was 3.6 (range 1-8). Bacillary index (BI) at baseline was 3.6 (range 3-6) and average BI after 1 year was 3. The drugs that were prescribed were clofazimine (n=11), thalidomide(n=11), hydroxychloroquine (n=3), methotrexate(n=2), minocycline(n=2) and cyclophosphamide(n=1). Each patient was prescribed at least 1 drug and 5 patients required use of 3 or more drugs due to nonresponse or side effects. Thalidomide and methotrexate showed the best response as assessed by ability to maintain a prolonged remission without steroid, all other drugs required moderate to low dose of steroid. Most side effects were experienced with thalidomide 36% (4/11), >clofazimine(2/11) and hydroxychloroquine(n=2), >methotrexate(n=1).
6 patients (3 males and 3 females) presented with extremely difficult to treat reactions. Use of upto 4 drugs was needed in them. Risk factors were identified as presence of granulomas in internal organs. All 3 males had testicular swelling ,investigations revealed granulomatous orchitis. 2 also had nerve abscesses. Among 3 females, 2 had severe lymphadenopathy and granulomas in lymph nodes and 1 had granulomatous inflammation in ovaries resulting in amenorrhea. 2 females and another study participant also had dapsone induced hemolysis. 4/6 patients were chronic smokers. All patients had BI >4 at baseline and average BI 2 at release from therapy. 1 patient died during therapy.

Conclusions

Conclusion

Risk factors that may predict a severe reaction are - ENL at time of presentation, necrotic ENL, high BI at release from therapy, removal of dapsone from therapy, smoking and presence of granulomas

in internal organs. Thalidomide and methotrexate promise the best steroid sparing effect in severe reactions but need to be closely monitored because of side effects.

EADV CONGRESS
VIENNA
30 SEP - 3 OCT 2026

Abstract N°: 3951

Efficacy of Benzyl Benzoate and Disulfiram Emulsion Versus Permethrin Against Macrocyclic Lactone-Resistant Scabies Mites in an Ex Vivo Bioassay

Carmen Maria Salavastru[1], Aymée Robainas[2], Maria Lajarin-Reinares*[3]

[1] Carol Davila University, Department of Dermatology, Colentina Clinical Hospital, Bucharest, Romania

[2] Global Medical, Reig Jofre Laboratories, Sant Joan Despí, Spain

[3] Translational research and value creation, Reig Jofre Laboratories, Sant Joan Despí, Spain

Introduction

Scabies, caused by the mite *Sarcoptes scabiei*, is a widespread skin disease affecting all income regions. Ivermectin has been the main treatment due to its ease and efficacy, but increasing resistance among scabies mites is leading to more treatment failures. This trend highlights the urgent need for new therapies or drug combinations to keep scabies manageable worldwide.

In this setting, a combination emulsion containing benzyl benzoate (BB, 22.5%) and disulfiram (D, 2.0%), which has been approved in Sweden, Iceland, and Finland, offers an intriguing alternative treatment option.

This study aims to assess the effectiveness of the BB+D emulsion, one permethrin-based product and two BB acaricides (commercial products), against macrocyclic lactone-resistant *Psoroptes ovis* (the scabies animal model) through an ex vivo direct contact bioassay.

Materials and Methods

An ex vivo bioassay was conducted with sheep skin sections (4 × 4 cm), retaining 1–2 mm of fleece, placed in Petri dishes. Test products were applied at 0.008 g/cm^2, followed by the introduction of 40–61 female mites per section. Samples incubated for 24 hours at 28°C and 75 ± 15% humidity. Acaricidal effects were assessed microscopically at set intervals by recording morbidity (knockdown) and mortality; after 24 hours, both measures were combined. All treatments, including controls, were tested in triplicate using 143–166 mites per condition, and effectiveness was calculated as the percentage of affected mites.

Results

All benzyl benzoate formulations rapidly killed mites, causing over 91% morbidity at 1 hour and more than 97% at 12 hours. The BB/D emulsion achieved 92.9% morbidity at 1 hour, exceeded 99% by 8–12 hours, and had 93.6% mortality at 24 hours. Permethrin was slower, with 94.1% mortality mainly from moribund mites (91.6%). The negative control showed minimal effect. BB treatments proved highly effective in this ex vivo model (Figure 1-2).

Treatment	% Moribund		
	1 h	**8 h**	**12 h**
Negative control (vehicle cream)	0.0	0.0	0.0
Formulation 1 (2% D + 22.5% BB)	92.9	99.2	99.2
Formulation 2 (10% BB)	91.3	97.7	97.7
Formulation 3 (25% BB)	97.0	99.3	99.3
Formulation 4 (5% permethrin)	95.3	84.9	84.9

Figure 1: Mean percentage of moribund ML-resistant *P. ovis* mites at 1, 8, and 12 hours after ex vivo exposure to the test compound, applied at 0.008 g/cm^2 (n=3).

Treatment	**% Mortality**	**% Moribund**	**% Dead**
Negative control (vehicle cream)	1.5	0.7	0.8
Formulation 1 (2% D + 22.5% BB)	93.6	0.0	93.6
Formulation 2 (10% BB)	99.3	0.0	99.3
Formulation 3 (25% BB)	98.0	0.0	98.0
Formulation 4 (5% permethrin)	94.1	91.6	2.5

Figure 2: Mean percentage mortality of ML-resistant *P. ovis* mites at 24 hours after direct exposure to the test compound ex vivo (0.008 g/cm^2). Mortality is defined as the proportion of moribund and dead mites (n=3).

Conclusions

The evaluated combination therapy demonstrated high acaricidal efficacy, including activity against mites with reduced susceptibility to standard treatments. The disulfiram–benzyl benzoate formulation showed superior performance compared with the permethrin-based comparator, achieving faster and more complete mite killing. This is particularly relevant in the context of emerging resistance to ivermectin and permethrin. Moreover, the multi-mechanistic nature of this combination is expected to reduce the likelihood of resistance development by increasing the barrier to selection of resistant populations.

EADV CONGRESS
VIENNA
30 SEP - 3 OCT 2026

Abstract N°: 3973

Multidimensional Psychosocial Burden of Scabies: Itch Severity, Quality of Life, Sleep Disturbance, and Cyberchondria

Yezdan İpek Davarcıoğlu*[1], eda karaismailoglu[2], Aslan Yürekli[1]

[1] Department of Dermatology and Venereology, Gülhane Training and Research Hospital, University of Health Sciences, Ankara, Türkiye

[2] Department of Biostatistics and Medical Informatics, University of Health Sciences, Gülhane Faculty of Medicine, Ankara, Turkey, Ankara, Türkiye

Introduction

Scabies is a contagious ectoparasitic infestation with a rising global and national incidence. Beyond its clinical features, scabies imposes a significant psychosocial burden through its transmissibility, social stigma, and frequent diagnostic delays. The interrelationships between itch severity, dermatology-specific quality of life, sleep disturbance, and cyberchondria — a pattern of repetitive, anxiety-amplifying online health information seeking — remain insufficiently characterised in this population. This study aimed to evaluate these domains comprehensively and identify their clinical and sociodemographic determinants.

Materials and Methods

A single-centre, prospective cross-sectional study was conducted at University of Health Sciences, Gülhane Training and Research Hospital. A total of 198 adults with a clinician-confirmed diagnosis of scabies were enrolled. Itch severity was assessed using a visual analogue scale (VAS; 0–10). Quality of life was measured with the Dermatology Life Quality Index (DLQI; 0–30). Sleep quality was evaluated using the Richards–Campbell Sleep Questionnaire (RCSQ; 0–100, higher = better). Cyberchondria was assessed with the validated Turkish short-form Cyberchondria Severity Scale (CSS). Spearman correlation and appropriate group-comparison tests were applied; significance was set at $p<0.05$.

Results

The mean age was 35.8±12.5 years; 53% were male. Mean scores were: VAS 6.11±2.44, DLQI 10.65±7.19, overall sleep quality 54.91±27.77, and CSS 31.35±9.20. The highest DLQI subdomain score was symptoms and feelings (3.06±1.59). VAS correlated strongly with DLQI ($r=0.834$, $p<0.001$) and inversely with sleep quality ($r=-0.794$, $p<0.001$). DLQI showed strong negative correlation with sleep quality ($r=-0.782$, $p<0.001$) and strong positive correlation with CSS ($r=0.715$, $p<0.001$). Sleep quality correlated moderately with CSS ($r=-0.694$, $p<0.001$). Disease duration, number of household contacts with itch, and number of prior treatments were independently associated with higher VAS, DLQI, and CSS scores and poorer sleep quality (all $p<0.001$). Household size >4 was associated with higher VAS ($p=0.020$), higher DLQI ($p=0.009$), and poorer sleep quality ($p=0.014$). Lower educational level was independently associated with higher DLQI ($p=0.004$) and CSS scores ($p=0.039$). Sex, age, marital status, and comorbidity did not significantly influence any scale score.

Conclusions

This study demonstrates that scabies extends well beyond a dermatological diagnosis, imposing a multidimensional psychosocial burden that profoundly affects patients' daily functioning, sleep, and mental well-being. Itch severity, quality of life impairment, sleep disturbance, and cyberchondria form a mutually reinforcing cycle, with this burden intensifying as disease duration prolongs and the number of treatment attempts increases. Household crowding emerged as a significant driver of both transmission and symptom load, while lower

educational attainment was an independent risk factor for greater quality of life impairment and cyberchondriac behaviour. Notably, demographic variables such as sex, age, and marital status did not significantly influence psychosocial outcomes, suggesting that the burden of scabies affects all patient groups with comparable severity.

These findings call for a management approach that goes beyond symptom control. Integrating validated patient-reported outcome measures into routine clinical assessment would enable a more accurate appreciation of the true disease burden. Incorporating psychosocially informed support strategies — particularly for patients living in crowded households or with lower educational backgrounds — has the potential to improve treatment adherence and overall clinical outcomes.

EA DV CONGRESS
VIENNA
30 SEP - 3 OCT 2026

Abstract N°: 4041

The changing face of dermatophytosis: lessons from a prospective case series

Hind Majdoul*[1], Fatima Anejjar[1], Fatimazahrae Benhayoun[1], Bouchra Baghad[1], Hanane Rachadi[1], Maha Soussi[2], Soumiya Chiheb[1]

[1] Dermatology and Venereology Department, Ibn Rochd University Hospital, Casablanca, Morocco
[2] Parasitology and Mycology Department, Ibn Rochd University Hospital, Casablanca, Morocco

Introduction
Dermatophytosis, superficial fungal infections affecting the skin and its appendages, remain among the most common reasons for dermatologic consultation. In recent years, antifungal resistance among *Trichophyton* species has become an increasing concern due to progressively difficult-to-treat presentations.

Through this case series, we aimed to characterize the profile of resistant superficial fungal infections encountered in routine practice.

Materials and Methods
We conducted a prospective descriptive case series over a 15-month period in our dermatology department, including patients presenting with clinically suspected superficial fungal infections showing persistence or progression despite conventional antifungal therapy. Demographic characteristics, risk factors, clinical presentation, mycological findings, treatment, and outcomes were analyzed.

Results
Fifteen patients were included, predominantly female (13/15, 86.7%), with a median age of 39 years (range: 20–64). Disease duration ranged from 1 month to 2 years, with prolonged evolution (≥6 months) observed in 6/15 patients (40%). Previous antifungal failure was observed in 9/15 patients (60%), all involving terbinafine, used as monotherapy in 5/9 cases and combined with or subsequently switched to griseofulvin in 4/9 cases. Inappropriate corticosteroid exposure (topical, injectable, or self-medication) was documented in 3/15 patients (20%) and was associated with lesion extension or delayed diagnosis. Epidemiological links were identified in 8/15 patients (53.3%). Familial clustering occurred in 4/15 cases (26.7%), whereas potential environmental or community acquisition was associated with occupational exposure (textile factory, hammam worker) or travel history in 4/15 cases (26.7%). Cutaneous involvement was extensive in 8/15 patients (53.3%), with predominantly pruritic annular erythematosquamous plaques showing centrifugal extension. Mycological identification was available in 11/15 patients (73.3%) and showed a predominance of *Trichophyton* species. T. *mentagrophytes* was the leading isolate, identified in 5/11 cases (45.5%), followed by *T. rubrum*, *T. tonsurans*, and *T. interdigitale* (2 isolates each, 18.2%). Itraconazole-based regimens were prescribed in 10/15 patients (66.7%) and achieved favorable outcomes in 8/10 (80%), while relapse occurred in one patient and incomplete remission due to poor adherence in another.

Conclusions
Our findings mirror recent reports showing an increasing burden of terbinafine-refractory dermatophytosis

associated with the *T. mentagrophytes/interdigitale* complex. The predominance of *T. mentagrophytes* in our cohort may reflect the ongoing epidemiological shift toward emerging resistant *Trichophyton* species. The high frequency of corticosteroid misuse and transmission clusters in our series further supports their role in difficult-to-treat infections. Current evidence supports itraconazole as the preferred systemic treatment in resistant cases, typically at doses ranging from 200 to 400 mg/day for 1–12 weeks, whereas terbinafine, griseofulvin, and fluconazole may show reduced efficacy. Taken together, these data highlight the importance of systematic mycological confirmation and therapeutic adaptation in difficult-to-treat fungal infections.

EADV CONGRESS
VIENNA
30 SEP - 3 OCT 2026

Abstract N°: 4106

The Epidemiology and Clinical features of 66 Cases of Balamuthia mandrillaris infection in mainland China

Tzuyi Yang[1], Yan Lei[1], Xiaobo Feng[1], Zhirong Yao[1], Zhen Zhang*[1]

[1] Xinhua Hospital, Shanghai Jiaotong University School of Medicine, Shanghai, China

Introduction

Balamuthia mandrillaris is a highly lethal free-living amoeba that primarily affects the skin and central nervous system, presenting clinically as chronic granulomatous lesions and granulomatous encephalitis. Once the central nervous system is involved, the mortality rate exceeds 90%. No standardized treatment regimen has yet been established.

Materials and Methods

To identify reported cases of *Balamuthia mandrillaris* infections in China, we conducted a comprehensive literature review. We included published articles in PubMed and the China National Knowledge Infrastructure (CNKI) up to September 2025 using the search terms: Free-living amoebae, *Balamuthia mandrillaris*, Infection, Encephalitis, Case Report, Diagnosis, Treatment, and China. We conducted searches in English and Chinese. Two authors (Tzuyi Yang and Yan Lei) independently reviewed the retrieved articles. Inclusion criteria were case reports or case series reporting ≥1 confirmed case of *Balamuthia mandrillaris* infection. Duplicate publications and studies not involving *Balamuthia mandrillaris* infection were excluded. Relevant data were extracted, including patient characteristics, epidemiologic features, clinical manifestations, treatment strategies, and clinical outcomes. We reviewed 39 publications through September 2025, and identified 66 confirmed cases of *Balamuthia mandrillaris* infection in China from 2002.

Results

The median patient age was 36 years (range, 10 months to 77 years), and males accounted for 62.12% of cases. 55 patients (83.33%) were immunocompetent. 42 patients (63.64%) initially presented with cutaneous manifestations, among whom 25 (59.52%) subsequently developed central nervous system involvement. 24 patients (36.36%) presented initially with encephalitis. Among the 63 patients with a known outcome, 43 (68.25%) succumbed to the infection. For patients with cutaneous-only disease, the survival rate was 93.75%, whereas once the central nervous system was affected, mortality reached 96.00%.

Conclusions

With advances in diagnostic technology and improved detection capacity, the number of confirmed cases of *Balamuthia mandrillaris* infection in China has gradually increased, underscoring the need for heightened clinical awareness. Whenever patients present with suspicious epidemiologic exposures or cutaneous manifestations, *B. mandrillaris* infection should be considered in the differential diagnosis. Given the exceedingly high mortality associated with this disease, further in-depth research is urgently needed to enable earlier prevention and more timely detection, with the ultimate goal of reducing both the incidence and mortality of this devastating infection.

EA DV CONGRESS
VIENNA
30 SEP - 3 OCT 2026

Abstract N°: 4116

Phase III Trial Results of Intralesional Purified Candida albicans Antigen (PCA) for Common Warts (Verruca vulgaris): Efficacy, Safety and Systemic Response

Sandra Johnson[1], Ted Lain*[1], Joel Schlessinger[2], Daniel Schlessinger[2], Akira Schimizu[3], Raja K. Sivamani[4], Bob Esch[5], Daisuke Watanabe[6]

[1] University of Arkansas for Medical Sciences, Little Rock, United States
[2] University of Nebraska, Omaha, United States
[3] Kanazawa, Uchinada, Japan
[4] Pacific skin institute, Sacremento, United States
[5] Nielsen, San Diego, United States
[6] Aichi Medical University, Nagakute, Japan

Introduction

Common warts, caused by human papillomavirus (HPV), represent a significant clinical challenge due to high recurrence rates and limitations of destructive therapies such as cryotherapy, which are frequently associated with pain, scarring, and pigmentation changes. Intralesional immunotherapy with a purified *Candida albicans* antigen (PCA) offers a targeted approach to stimulate cell-mediated immunity against the underlying viral infection. A post-hoc analysis of prior Phase II data indicated that traditional "clearance at any time" metrics may overestimate therapeutic success by failing to account for transient resolution; consequently, this Phase III trial was designed to evaluate the efficacy and safety of PCA using a novel, rigorous durable response framework.

Materials and Methods

In this multinational, multicenter, randomized, double-blind, placebo-controlled trial (CFW-3A; NCT05889845), 352 participants (aged ≥12 years) with 3–20 common warts were randomized 2:1 to receive up to 10 intralesional injections of PCA (0.5 mL) or saline placebo, administered every 2 weeks into a single wart (mITT population: N=325; 218 PCA, 107 placebo). The primary efficacy endpoint was the proportion of participants achieving complete resolution of the treated wart without recurrence through 12 weeks post-final injection, with completion of the 12-week follow-up visit required for success; participants who did not complete this visit were classified as treatment failures. Key secondary endpoints included time to clinical clearance of the treatment wart and the proportion achieving ≥50% or 100% clearance of measured non-injected warts at 12-week follow-up. Additional secondary endpoints included clearance of non-measured and non-common warts, the number of injections required to achieve resolution of distal lesions, and the proportion achieving clearance without scarring or pigmentation changes. Standardized longitudinal clinical photography supported all assessments.

Results

PCA demonstrated statistically significant superiority over placebo on the primary endpoint: durable complete resolution of the treated wart was achieved by 45.4% (99/218) of PCA participants versus 23.4% (25/107) in the placebo group (OR 2.78; $p<0.001$). Time-to-event analysis confirmed a significantly greater likelihood of clinical clearance with PCA (HR 2.5; $p<0.001$), with over 60% of responders achieving durable clearance in ≤ 4 injections.

PCA also induced a significant systemic response: 27.6% of participants achieved 100% clearance of all measured

warts at 12-week follow-up (vs. 16.0% placebo; p=0.023) and 35.3% achieved ≥50% clearance of measured warts (vs. 23.6% placebo; p=0.036).Among participants achieving durable treatment-wart clearance, 72% also achieved≥50% clearance of measured non-injected warts, consistent with a broad systemic immunotherapeutic effect. While primary and key secondary endpoints were met, significance was not reached for additional secondary endpoints.

Clearance was achieved with minimal cosmetic impact: scarring was absent in 95.3% and hypo/hyperpigmentation in 98.1% of resolved warts. PCA was well-tolerated; injection site reactions were more frequent with PCA than placebo (42.6% vs. 5.2%) but were predominantly mild-to-moderate and expected. No treatment-related serious adverse events were observed, and only 2 participants withdrew due to adverse events (1 PCA, 1 placebo).

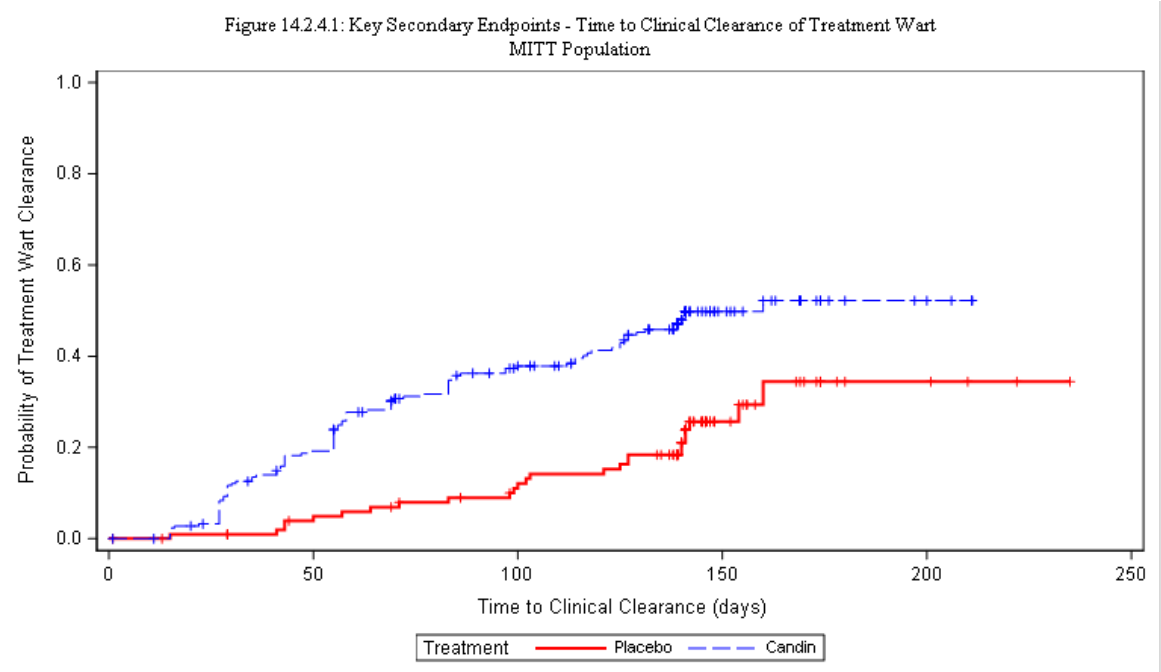

Conclusions

This Phase III trial establishes PCA as an effective, durable, non-destructive immunotherapy for common warts. The significant resolution of distal, non-injected warts is consistent with a systemic immunotherapeutic effect addressing HPV immune evasion. The efficient response profile, with the majority of responders achieving durable clearance within 4 injections, and favorable cosmetic outcomes differentiate PCA from current destructive approaches and support its potential as a first-line treatment option.

EA DV CONGRESS
VIENNA
30 SEP - 3 OCT 2026

Abstract N°: 4211

Scrubbing Off Scrub Typhus: A Cultural Exposé of Exposure in Japan

Jayalakshmi Alagar[1], Bisam-Ul Haq*[2]

[1] Temple University, Philadelphia, United States
[2] Oxford University Hospitals, Oxford, United Kingdom

Introduction

Scrub typhus is caused by one of the world's oldest known pathogens,*Orientia tsutsugamushi*, a Gram-negative intracellular bacteria in the Rickettsiaceae family that infects the larvae of "chigger" *Leptotrombidium* mites, enabling transmission to humans. Traditional risk factors include agriculture, flood-prone areas, and temperate climates in the Asia-Pacific "Tsutsugamushi Triangle," where the disease is endemic (Figure 1). However, recent years have seen an increase in cases, antibiotic resistance, and limited vaccine progress. Eschar formation at the site of bites and maculopapular rashes originating on the trunk are cutaneous manifestations that may provide vital early diagnostic clues. Unfortunately, these signs are not universally present. Delayed diagnosis and hospitalisation remain common.

Globalisation and ecological change contribute to the 1 billion people at risk for scrub typhus. Increasing awareness among dermatologists is therefore paramount, particularly in Japan, where the aetiological agent was first identified. Although early historical accounts suggest longstanding recognition of the disease, the potential role of cultural practices in shaping contemporary exposure risk, awareness, and health education has received limited attention.

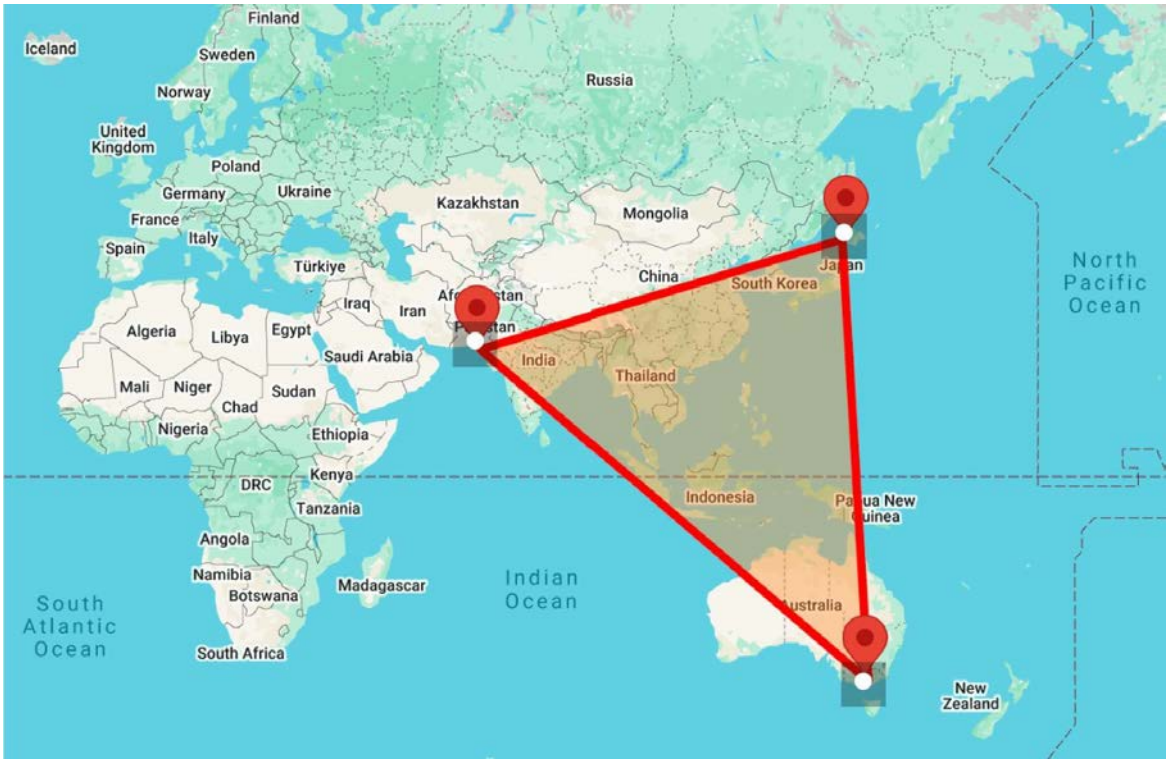

Figure 1. Traditional distribution of scrub typhus within the "Tsutsugamushi Triangle," spanning Pakistan, Japan, and Australia.

Materials and Methods

We conducted a narrative review of published literature to explore cultural factors and patient behaviours in association with scrub typhus in Japan.

Results

Early accounts describe physicians removing mites from at-risk and symptomatic patients, particularly farmers experiencing “prick-like” sensations. Prior to the scientific identification of scrub typhus, shrines and statues were constructed in the 19th century to pray for protection. Today, scrub typhus continues to shape tradition. During the Shoreisai Festival on Mount Haguro (Yamagata Prefecture), effigies of mites are burned on New Year’s Eve in hopes of a bountiful harvest. A similar summer festival is Mushi-okuri (literally, “sending off the bugs”), during which torches are carried to the sea to protect rice paddies from insects in Kagawa, Mie, Aomori, and Shimane prefectures.

Such practices appear to temporally align with known epidemiological patterns of scrub typhus in Japan. A total of 6 major serotypes have been identified nationally, with distinct regional and seasonal patterns suggesting heterogeneous ecological drivers. Contemporary surveillance data confirm widespread distribution across nearly all prefectures. Public health advisories in neighbouring countries have begun warning about the potential for mite transmission during “Tomb Cleaning” festivals, underscoring the need for further investigation and improved community awareness in Japan.

Conclusions

Scrub typhus remains an under-recognised, neglected infectious disease per the World Health Organization. Culturally-embedded risk factors may represent a consistently hidden, non-occupational diagnostic blind spot. Outdoor settings frequently involve prolonged contact with low-lying vegetation and soil, increasing the likelihood of mite exposure. Incorporating cultural context and travel history into dermatologic assessment may improve early recognition and expedite management.

EA DV CONGRESS
VIENNA
30 SEP - 3 OCT 2026

Abstract N°: 4237

Erysipeloid cutaneous leishmaniasis: a retrospective study of 8 cases

Arij Ben Youssef*[1], mariem fatnassi[1], Meriem Jones[1], Soumaya Gara[1], Litaiem Noureddine[1], Faten Zeglaoui[1]

[1] charles nicolle hospital, tunis, Tunisia

Introduction

Cutaneous leishmaniasis (CL) is endemic in Tunisia and exhibits a wide spectrum of clinical presentations. Among atypical forms, the erysipeloid variant is rare and may mimic infectious or inflammatory dermatoses, leading to diagnostic delay.
The aim of this study was to describe the epidemiological, clinical, paraclinical, and therapeutic features of erysipeloid CL in a Tunisian cohort.

Materials and Methods

We conducted a retrospective monocentric study in the Department of Dermatology, including all patients diagnosed with erysipeloid CL between January 2024 and April 2026. Diagnosis was confirmed by direct parasitological examination (smear) and/or polymerase chain reaction (PCR).

Results

Eight cases of erysipeloid CL were identified. The cohort included six women and two men (sex ratio M/F: 0.33), with a mean age of 54 years. Hypertension was present in 37% of patients. Two patients had a history of malignancy, and one patient was followed for Crohn's disease with lesion recurrence after each anti-TNF administration.

The diagnostic delay ranged from 1 month to 12 months (mean : 6 months). Clinically, lesions appeared as infiltrated erythematous-crusted plaques, mainly located on the face (75%), followed by the forearm (12.5%) and lower limb (12.5%). General condition was preserved in all cases, and pruritus was consistently reported.

Regarding lesion burden, two patients had a single lesion, three had three lesions, one had five lesions, and one had eight lesions. The initial diagnosis was incorrect in 62% of cases, and half of the patients received antibiotics without improvement.

Diagnosis was confirmed by smear in 62% of cases and by PCR in 38%. All patients received meglumine antimoniate (Glucantime), administered intralesionally in 25% and systemically in 75%. Treatment duration was 14 days in four cases and 21 days in two cases. Adjunctive therapies included cryotherapy in two cases and intralesional amphotericin B in one case.

Clinical outcome was favorable in all patients, with variable healing times.

Erysipeloid CL is a rare and misleading clinical variant of CL. A female predominance was observed in our series, consistent with previous reports. The underlying mechanisms remain unclear but may involve hormonal, immunological, or behavioral factors. One patient experienced lesion recurrence after anti-TNF therapy, suggesting a role of immune modulation in disease expression or persistence.

The mean age was relatively high compared to classical CL, suggesting that atypical forms may preferentially affect older patients.

Facial involvement was predominant (75%), in line with the literature describing a preference

for centrofacial areas. The preserved general condition despite an erysipelas-like appearance represents an important diagnostic clue.

Diagnostic delay was significant, with more than half of patients initially misdiagnosed and treated with antibiotics without response. This highlights the frequent confusion with erysipelas, rosacea, lupus erythematosus, sarcoidosis, or bacterial cellulitis.

These findings underline the importance of considering CL in
the differential diagnosis of chronic infiltrated erythematous plaques in endemic areas.

Conclusions

Erysipeloid cutaneous leishmaniasis is a rare and misleading clinical variant that remains a diagnostic challenge due to its resemblance to infectious and inflammatory dermatoses . That’s why it should be systematically considered in patients presenting with chronic erythematous infiltrated plaques resistant to conventional antibiotic therapy. Early recognition may help avoid unnecessary treatments and reduce diagnostic delay.

EA DV CONGRESS
VIENNA
30 SEP - 3 OCT 2026

Abstract N°: 4265

Population pharmacokinetics, subcutaneous tissue penetration, and host determinants of antibiotic exposure in critically ill patients: implications for the treatment of skin and soft tissue infections

Maria Sanz Codina*[1]

[1] Department of Dermatology, Medical University of Vienna, Vienna, Austria

Introduction
In critically ill patients, pathophysiological changes alter antibiotic pharmacokinetics (PK), increasing the risk of subtherapeutic concentrations in subcutaneous tissue and treatment failure in skin and soft tissue infections (SSTIs). Understanding both the magnitude and the host determinants of tissue penetration is essential for optimising antibiotic dosing in this population. The objective of this study is to characterise population PK and subcutaneous tissue penetration of linezolid and meropenem in septic patients, identify host clinical and biomarker predictors of tissue penetration, and determine the probability of target attainment (PTA) for clinically relevant dosing regimens.

Materials and Methods
Plasma and subcutaneous tissue free-drug concentrations were measured simultaneously using microdialysis and ultrafiltration in critically ill patients receiving linezolid (n=10) or meropenem (n=14). Population PK models were developed using nonlinear mixed-effects modelling. Monte Carlo simulations (n=500) determined PTA across dosing regimens. A panel of 28 multiplex biomarkers and 16 clinical variables, selected a priori based on a literature review, were assessed as markers of subcutaneous penetration with Spearman correlation.

Results
Linezolid showed high subcutaneous tissue penetration (91.8±29.6%), with similar free drug exposure in plasma (AUC0-12h 67.6±26.7 h·mg/L) and subcutaneous tissue (64.2±38.4 h·mg/L). Standard dosing (600 mg q12h) achieved ≥90% PTA for MIC ≤0.5 mg/L; dose escalation to 1200 mg q12h extended coverage to MIC ≤1 mg/L. Meropenem subcutaneous tissue concentrations exceeded plasma (subcutaneous penetration of 133%). For the conventional target (40% fT>MIC), 1000 mg q8h extended infusion achieved ≥90% PTA for MIC ≤8 mg/L; achieving 100% fT>4×MIC required ≥2000 mg q8h, particularly for Pseudomonas aeruginosa. Substantial interindividual variability (IIV) was observed for both drugs (IIV on clearance: linezolid 59.5%, meropenem 84.5%). Biomarker analysis revealed drug-specific host determinants of subcutaneous penetration: for linezolid, total proteins (rs=-0.81, p=0.008), GGT (rs=-0.77, p=0.009), and alkaline phosphatase (rs=-0.71, p=0.022) showed the strongest inverse associations, implicating protein binding and hepatobiliary dysfunction. For meropenem, Angiopoietin-1 (rs=-0.53, p=0.054) and GGT (rs=-0.51, p=0.061) were the strongest predictors, implicating endothelial integrity.

Conclusions
Both antibiotics achieved subcutaneous tissue exposure comparable to plasma, supporting plasma-based PK/PD targets for SSTI management in critically ill patients. However, substantial interindividual variability and drug-specific host determinants of tissue penetration were identified. Clinicians treating severe SSTIs in patients with elevated GGT, hypoalbuminaemia, or raised alkaline phosphatase should consider early therapeutic drug monitoring, as these markers were associated with impaired subcutaneous antibiotic exposure. Endothelial dysfunction, reflected by reduced Angiopoietin-1, highlights microvascular integrity as a novel pharmacological consideration in SSTI management.

EA DV CONGRESS
VIENNA
30 SEP - 3 OCT 2026

Abstract N°: 4277

The Crisis of Topical Steroid Misuse in Superficial Fungal Infections: A Cross-Sectional Study from a Tertiary Care Centre in Pakistan

Gohar Aftab*[1], Saadia Tabassum[1], Adeel Khoja[1]

[1] Aga Khan University Hospital, Karachi, Karachi, Pakistan

Introduction
Superficial fungal infections affect approximately 20–25% of the global population. In South Asia, the widespread misuse of topical corticosteroids (TCS) has led to a surge in steroid-modified, recalcitrant dermatoses, including tinea incognito. This study aims to evaluate the prevalence, sources, and clinical outcomes of steroid use in patients with superficial fungal infections in Pakistan.

Materials and Methods
A cross-sectional observational study was conducted at a tertiary care hospital in Pakistan over eight months (October 2024–May 2025). A total of 253 patients clinically diagnosed with superficial fungal infections (excluding nail involvement) were enrolled. Data on demographics, steroid preparations, prescription sources, and adverse effects were collected via a structured questionnaire.

Results
The cohort had a median age of 35 years (IQR 25–50) with a female predominance (63.64%). Dermatophytosis was the most common diagnosis (76.28%), followed by candidiasis (12.65%) and pityriasis versicolor (11.07%).

Overall, 66.8% of patients (n=169) reported prior corticosteroid use, primarily through the topical route (61.26%). The most common source of steroid prescription was non-dermatologist physicians (39.05%), followed by self-prescription (26.03%). Betamethasone (24.8%) and diflucortolone (15.76%) were the most frequently used agents.

Notably, 37.3% of patients in the dermatophytosis group presented with tinea incognito. Steroid-related adverse effects included striae and skin atrophy (5.53%), lichenification (4.74%), and cushingoid facies (n=2). Only 5.14% of patients were aware that corticosteroids could adversely affect their infection.

Conclusions
The high prevalence of steroid misuse (66.8%) reflects a significant public health challenge consistent with regional trends. Frequent prescribing by non-specialist clinicians and easy over-the-counter access point to gaps in seeking specialist dermatologic care and pharmaceutical regulation. The substantial rate of tinea incognito (37.3%) further highlights how topical corticosteroids alter the natural morphology of fungal infections, contributing to delayed diagnosis, atypical presentations, and treatment resistance. Collectively, these findings identify topical steroid misuse as a key contributor to morbidity in superficial fungal infections and emphasize the need for stricter regulation of topical corticosteroid availability, enhanced dermatologic training for general physicians, and targeted patient awareness initiatives to reduce the burden of steroid-modified disease.

EA DV CONGRESS
VIENNA
30 SEP - 3 OCT 2026

Abstract N°: 4279

Dermatological signs in Infective Endocarditis: An Underrecognized Diagnostic Window

fikri ouissal*[1], ahmed bouhamidi[1]

[1] Avicenne Military University Hospital Center of Marrakech, marrakech, Morocco

Introduction
Infective endocarditis (IE) is a severe systemic infection associated with high morbidity and mortality. Although cardiac manifestations predominate, dermatologic and mucocutaneous signs may represent important diagnostic clues, particularly in subacute forms. However, these manifestations are often underrecognized despite their contribution to the modified Duke criteria. The aim of this study was to analyze the frequency and spectrum of cutaneous and extracardiac manifestations of IE in a Moroccan tertiary care center, with a focus on their dermatologic relevance.

Materials and Methods
We conducted a retrospective descriptive study including 128 patients hospitalized for infective endocarditis between January 2022 and May 2025 at Mohammed VI University Hospital. Clinical, biological, microbiological, echocardiographic and extracardiac manifestations were collected using a standardized data sheet and analyzed using SPSS software.

Results
The mean age was 46.7 years with a male predominance (sex ratio 2.05). Native valvular disease, mainly of rheumatic origin, was the most common predisposing condition. The clinical presentation was predominantly subacute (75%), with a mean diagnostic delay of 44 days.

Cutaneous and mucosal manifestations were observed in 22.7% of patients and represented the most frequent extracardiac signs. Purpura was the predominant lesion (14.8%), followed by Janeway lesions (4.7%) and Osler nodes (2.3%). Subungual hemorrhages were rare (0.8%). Digital clubbing was identified in 7% of cases. Ophthalmologic examination revealed Roth spots in 4.7% and subconjunctival hemorrhages in 3.1% of patients. Splenomegaly was present in 11.6% of cases.

Biological investigations revealed a marked inflammatory syndrome. Anemia was present in 81.1% of patients, while leukocytosis was observed in nearly half of the cases. CRP elevation was found in 98.1% of patients, with values >100 mg/L in 50.9%. Erythrocyte sedimentation rate was elevated in 89.6% of cases. Hyperferritinemia and elevated procalcitonin levels were frequently observed, supporting the intense inflammatory and infectious process. Rheumatoid factor positivity was detected in 13.2% of patients, highlighting the immunologic activation associated with infective endocarditis. Proteinuria was present in 36.8% of cases.

Blood cultures were positive in 40.6% of patients, predominantly isolating Staphylococcus and Streptococcus species. Echocardiography detected vegetations in 96% of cases, mainly involving the aortic and mitral valves. The most frequent complications were heart failure (36.7%), neurologic

events (31%) and renal impairment (25%).

Conclusions

Cutaneous and mucosal manifestations remain important but underappreciated diagnostic clues in infective endocarditis. Increased awareness among dermatologists and clinicians may facilitate earlier diagnosis and improve patient outcomes, particularly in subacute presentations with delayed recognition.

EA DV CONGRESS
VIENNA
30 SEP - 3 OCT 2026

Abstract N°: 4430

Seven Boys, One Pattern: An Age-Dependent Genital Presentation of Pediatric Scabies

Rihem Godcha*[1], Maha Lahouel[1], Jacem Rouatbi[1], Nadia Ghariani Fetoui[1], Sana Mokni[1], Najet Ghariani[1]

[1] Farhat Hached Hospital Sousse, sousse, Tunisia

Introduction

Scabies, an infestation caused by *Sarcoptes scabiei* var. *hominis*, is common in pediatric populations. In boys, genital involvement may be the predominant manifestation and can mimic infectious balanitis or inflammatory dermatitis, potentially leading to diagnostic delay. A history of familial pruritus is a key diagnostic clue. We report a series of seven cases of circumscribed genital scabies.

Materials and Methods

Seven boys presenting with predominant genital involvement were included. The analyzed data included age, duration of symptoms before consultation, presence of familial pruritus, morphology and topography of lesions, the presence of penile or testicular edema, and any associated extragenital localizations.
All patients were treated with topical benzyl benzoate applied on days 1, 2, and 8, combined with local care in cases of marked inflammation. Clinical evolution was assessed during follow-up.

Results

The patients' ages ranged from 4 to 7 years. All presented with pruritus associated with balanitis, and familial pruritus was consistently reported. The median delay before consultation was 2 months (range: 1–4 months).

Nodules or scabietic chancres were observed in three children (43%), while four (57%) presented isolated inflammatory papules. Penile edema and testicular inflammation were each noted in two patients (28.6%).

Involvement was strictly genital in five children (71%), while three (43%) also had associated extragenital lesions. An initial inflammatory exacerbation after treatment occurred in four patients (57%), followed by favorable outcomes with complete resolution under continued therapy.

Conclusions

Circumscribed genital scabies in boys may present as isolated inflammatory balanitis, with nodules and scabietic chancres reflecting a hypersensitivity reaction to parasitic antigens. The initial worsening observed after treatment corresponds to a transient immune response and should not be mistaken for therapeutic failure.

The exclusive occurrence within the prepubertal age group (4–7 years) suggests a possible role of cutaneous or immunological factors specific to this developmental period. Recognition of this presentation and systematic investigation of familial pruritus are essential to avoid misdiagnosis and inappropriate treatments.

Circumscribed genital scabies represents a distinct clinical presentation in prepubertal boys. Targeted history taking and thorough dermatological examination allow early diagnosis. Benzyl benzoate remains an effective treatment, despite the possibility of a transient post-treatment inflammatory reaction.

EADV Congress 2026, VIENNA
30 SEPTEMBER - 03 OCTOBER 2026
POWERED BY M-ANAGE.COM

EADV CONGRESS
VIENNA
30 SEP - 3 OCT 2026

Abstract N°: 4443

Scabies and Quality of Life: Limitations of the DLQI in a Tunisian Population

Rihem Godcha*[1], Maha Lahouel[1], Jacem Rouatbi[1], Sana Mokni[1], Najet Ghariani[1]

[1] Farhat Hached Hospital Sousse, sousse, Tunisia

Introduction

Scabies is a common parasitic skin infestation responsible for intense pruritus and polymorphic lesions that can considerably impair patients' quality of life (QoL). The assessment of this impact using standardized tools such as the Dermatology Life Quality Index (DLQI) helps objectify the physical, psychological, and social burden of the disease. However, the DLQI was originally developed in Western populations, and some of its domains may be less relevant in different sociocultural contexts. This may be particularly true in Tunisia, where daily habits and social norms differ and could influence how patients perceive and report the impact of skin diseases.

Materials and Methods

We conducted a prospective study in the Dermatology Department of Farhat Hached University Hospital including 28 patients diagnosed with scabies. Sociodemographic data, medical history, symptom severity, and the distribution of cutaneous and mucosal lesions were collected. Quality of life was assessed using the DLQI questionnaire. A detailed item-by-item analysis was performed to identify domains that appeared less relevant or potentially underestimated in this population.

Results

The mean age of the patients was 42.7 ± 18.8 years (range: 19–88), with a slight female predominance (15 women, 13 men). Thirteen patients had a medical history, mainly diabetes (n = 4) and other dermatological conditions (n = 2). Pruritus was reported by 25 patients. Cutaneous and mucosal lesions were observed in 26 patients, mainly consisting of papules and nodules (n = 21), scabious chancres (n = 19), and vesicles (n = 18). The mean DLQI score was 10.6 ± 6.3, indicating a moderate impact on quality of life. However, this level appeared relatively low considering the clinical and psychological distress reported by the patients. Detailed analysis of the questionnaire items revealed minimal impairment in domains related to leisure activities, sports, social outings, and sexual life. This finding seems to reflect Tunisian sociocultural characteristics—such as limited participation in organized leisure activities and greater reserve regarding sexuality—rather than a true absence of impact. The most affected domains were symptoms and feelings (2.22 ± 0.94), embarrassment and social discomfort (1.50 ± 1.20), and daily activities (1.22 ± 1.21), highlighting a discrepancy between patients' lived experience and the global DLQI score.

Conclusions

This discrepancy suggests that the DLQI may underestimate the impact of scabies in non-Western populations. Responses to items related to leisure or sexuality are influenced by lifestyle, cultural norms, and modesty, while questions regarding work or study may not fully capture the emotional and social burden of the disease. In addition, factors such as family and

community support may modulate the perception of social disability. These findings highlight the importance of interpreting DLQI scores within their cultural context and suggest that complementary qualitative interviews may provide a more accurate understanding of the real burden experienced by patients.

EA DV CONGRESS
VIENNA
30 SEP - 3 OCT 2026

Abstract N°: 4451

Disseminated Cutaneous Leishmaniasis on Lymphedematous Limbs: A Retrospective Case Series

Maissa Abid[1], Rim Chaabouni[1], Kmar Turki[1], Massarra Ben Ayed[1], Abderrahmen Masmoudi*[1], Hamida Turki[1]

[1] Dermatology Department, Hedi Chaker Hospital, Sfax, Tunisia, Sfax, Tunisia

Introduction

Disseminated cutaneous leishmaniasis (DCL) is an uncommon clinical presentation characterized by multiple secondary lesions occurring after an initial inoculation lesion. Local lymphatic impairment and systemic comorbidities may contribute to parasite dissemination. Previous observations from our department highlighted the role of lymphoedema as a promoting factor for localized dissemination.

Materials and Methods

We conducted a retrospective descriptive study including patients diagnosed with disseminated cutaneous leishmaniasis in the Department of Dermatology over a 19-year period (2007-2026). Clinical, biological, histological, therapeutic, and outcome data were analyzed.

Results

Five patients presented with multiple disseminated papules localized to a single limb, including Four women and one man. Median age was 56 years (range: 45–71 years). Diabetes mellitus was present in 4 cases. All patients exhibited hundreds of erythematous papules scattered over one limb, associated with a primary ulcerocrusted nodular lesion corresponding to the inoculation site. Lesions involved the upper limb in two cases and the lower limb in two cases. Dermal smear identified amastigotes in one patient, whereas PCR confirmed the diagnosis in four cases; PCR performed on secondary papulonodular lesions was positive in all patients. Three patients had upper-limb lymphoedema secondary to mastectomy with axillary lymph node dissection for breast cancer, while the remaining two had lower-limb lymphoedema following recurrent erysipelas. Disseminated papules remained strictly confined to the lymphedematous area. Dissemination occurred 1–2 months after the primary lesion and followed erysipelas in three cases. Histopathological examination, performed in four patients, revealed epidermal hyperkeratosis (n=3), giant-cell granulomas (n=4), dermal inflammatory infiltrates (n=3), and lobular panniculitis (n=2). Species identification, available in two cases, demonstrated *Leishmania major*. Three patients received systemic meglumine antimoniate and two patient received systemic metronidazole, with favorable outcomes in all cases and regression of both primary and secondary lesions within a mean period of two months.



Figure : Cutaneous leishmaniasis presenting as disseminated papules associated with upper limb lymphedema.

Conclusions

Disseminated cutaneous leishmaniasis remains a rare but distinctive presentation of *Leishmania major* infection. Our findings support the role of lymphatic stasis, erysipelas, and diabetes mellitus as potential facilitating factors for local dissemination. Early recognition of this atypical form is essential to ensure prompt diagnosis and appropriate treatment. Inspired in part by previously reported cases from our institution describing dissemination on lymphedematous limbs, our study further emphasizes the importance of considering cutaneous leishmaniasis in any persistent papulonodular eruption occurring on chronic lymphoedema in endemic areas. Despite the impressive clinical presentation, therapeutic response was favorable in all patients, highlighting the value of early systemic treatment and molecular diagnostic techniques, particularly PCR, in confirming atypical disseminated forms.

EA DV CONGRESS
VIENNA
30 SEP - 3 OCT 2026

Abstract N°: 4517

Neuro-Rickettsiosis: From headache to fatal complications

Kenza Amrani Mesbahi*[1], Douhi Zakia[1, 2], Kawtar El fid[1], ikram bejja[1], Saadia Boughaleb[1], Meryem Soughi[1], Sara Elloudi[1], Hanane Baybay[1], Fatima Zohra Mernissi[1]

[1] Dermatology department CHU Hassan II FEZ, FEZ, Morocco
[2] Dermatology department CHU Hassan II FEZ, FES, Morocco

Introduction

Rickettsiosis is a re-emergent infection, responsible of vasculitis due to endothelial tropism. Among all the systemic manifestation, neurologic ones could be fatal, conditioning the prognosis.

The aim of our study is to describe and analyze neurological involvement in rickettsiosis, assess its severity, and identify other factors associated with severe cases.

Materials and Methods

We conducted a retro-prospective, descriptive and analytic study, from January 2020 to February 2026.We included patient with confirmed or highly suggestive rickettsiosis and divided them into two groups according to the presence or the absence of neurological manifestations, which were categorized as mild to moderate in cases of headaches and vertigo, and as severe in the presence of meningeal syndrome and altered consciousness.

Results

A total of 82 cases of rickettsiosis was included. All patients presented with fever and cutaneous rash. Among those patients, 67,1% had neurological manifestations, with a mean age of 54.2 years, older than those without neurological involvement.

Severe neurological involvement occurred in patients with a mean age of 67.3 years compared to 47.2 years in mild cases. High blood pressure was more frequent among severe cases (28.6% Vs 10.9 overall).

Headache was the prominent symptom, occurring in almost all patients. Other manifestations were found, such as vertigo (30.9%), meningeal syndrome (27.3%) and altered consciousness (16.4%).

All severe cases underwent lumbar punction and brain computed tomography scan. Cerebro-spinal fluid analysis showed an aseptic lymphocytic meningitis profile in all cases in this group, while vasculitis was identified in 30 % of cases, contrasting with mostly normal or non-specific findings.

Rickettsia Conori was the most frequently identified species in both groups. All patients were treated with doxycycline, along with ciprofloxacin.

The prognosis was favorable, with apyrexia, rash regression and the absence of sequelae.

The mortality rate was 5.5 %, occurring exclusively among patients with severe neurological involvement.

Conclusions

Neurological involvement in rickettsiosis appears to have a higher mortality rate ,especially if it occurs in older patients with comorbidities , highlighting the importance of early diagnosis and immediate care.

EADV CONGRESS
VIENNA
30 SEP - 3 OCT 2026

Abstract N°: 4524

Plasma and subcutaneous tissue pharmacokinetics of daptomycin in critically ill patients

Maria Sanz Codina*[1]

[1] Department of Dermatology, Medical University of Vienna, Vienna, Austria

Introduction
Daptomycin is a lipopeptide antibiotic approved for treating Gram-positive skin and soft tissue infections and bacteremia. This study investigated the pharmacokinetics (PK) and pharmacokinetic/pharmacodynamic (PK/PD) target attainment of daptomycin in plasma and interstitial subcutaneous tissue of critically ill patients.

Materials and Methods
We studied plasma and tissue daptomycin concentrations in five critically ill patients receiving daptomycin at doses of 9.0–11.3 mg/kg (700-1000 mg) administered every 24 or 48 hours. Free daptomycin concentrations in plasma and subcutaneous tissue were determined by ultrafiltration and microdialysis, respectively. PK parameters were determined by non-compartmental analysis, and daptomycin penetration ratios were assessed as the ratio of free (unbound) tissue to free (unbound) plasma area under the concentration-time curve from 0 to 24 hours ($fAUC_{0-24}$ Tissue/$fAUC_{0-24}$ Plasma).

Results
Median protein binding was 87.3% (range 85.7-94.3%). Based on free plasma concentrations, median volume of distribution was 10.2 L (range 8.6-23.4 L) and clearance was 0.57 L/h (range 0.45–1.00 L/h). Daptomycin showed moderate penetration into subcutaneous tissue, with a median $fAUC_{0-24}$ tissue/plasma ratio of 0.32 (range 0.21–0.50). The median plasma AUC_{0-24}/MIC ratio exceeded the efficacy target of 666 for MIC values ≤1 mg/L, covering the majority of wild-type *Staphylococcus aureus* isolates.

Conclusions
In critically ill patients receiving high-dose daptomycin (9-11 mg/kg), plasma PK/PD targets were achieved for pathogens with MIC ≤1 mg/L. Subcutaneous tissue penetration was moderate, with approximately one-third of free plasma exposure reaching the subcutaneous tissue compartment.

EADV CONGRESS
VIENNA
30 SEP - 3 OCT 2026

Abstract N°: 4531

Beyond rash: when Mediterranean spotted fever becomes systemic

Kenza Amrani Mesbahi*[1], Douhi Zakia[1], Kawtar El fid[1], ikram bejja[1], Saadia Boughaleb[1], Meryem Soughi[1], Sara Elloudi[1], Hanane Baybay[1], Fatima Zohra Mernissi[1]

[1] Dermatology department CHU Hassan II FEZ, FEZ, Morocco

Introduction

Mediterranean spotted fever, is a re-emerging infection transmitted to humans by arthropods. Cutaneous manifestations are very frequent. However, systemic manifestations may occur. The aim of this study was to establish the epidemiological and clinical profile if this group as well as its different extracutaneous manifestations.

Materials and Methods

We conducted a retro-prospective descriptive study, in Hassan II university hospital, between June 2016 and February 2026.

We included patients with a typical or highly suggestive clinical presentation of rickettsiosis, regardless of serological confirmation.

Results

A total of 82 patients were included, mainly aged 40-60 years, with a slight male predominance. The mean consultation delay was 8.2 days, with a hospitalization rate of 53.1% and a mean hospital stay of 5.8 days.

Cutaneous involvement included a maculopapular rash, present in all of our patients, with a purpuric component in 70.4% of cases. Less findings were noted, such as necrosis (5%) and livedo reticularis (3.7%), reflecting underlying vasculitis.

An inoculation eschar, was found in 51.9% of cases. It was commonly located in the lower limb (71.3%), followed by upper limbs (14.3%), trunk (11.9%), with atypical localization in the genital region (2.3%).

Fever occurred in nearly all patients, with frequent neurological involvement (headache 66.7%, vertigo 21.2%, meningeal signs 18.8%, altered consciousness 11.2%). Ocular involvement was observed in 51.9%, with 18.5% of cases of uveitis.

Other systemic manifestations were identified biologically, such as renal dysfunction and hepatic cytolysis, in 38% and 76.2% respectively.

Laboratory finding also noted, thrombocytopenia (68.4%), leukocytosis (64.4%), hyponatremia (69.6%) and hypokalemia (40.5%).

Serology confirmed the diagnosis in 70.3% of patients, with Rickettsia Conori being the predominant specie.

All patients were treated with doxycycline, with ciprofloxacin added in cases of neurological involvement.

Evolution was favorable in all patients, apart from 3 deaths, all related to neurological involvement.

Complications included pulmonary embolism, pancreatitis, stroke and hearing loss (one case each).

Conclusions

Rickettsiosis is a re-emerging infection with frequent systemic involvement . Early diagnosis and prompt doxycycline therapy are essential to improve outcomes and prevent complications that might be fatal .

EADV CONGRESS
VIENNA
30 SEP - 3 OCT 2026

Abstract N°: 4543

Topical Potassium Hydroxide for Common Warts: A Randomized Dose-Response Clinical Trial Comparing 10%, 15%, and 20% Concentrations

Sherihan Allam*[1]

[1] Dermatology Department, Mansoura University, Mansoura, Egypt

Introduction
Cutaneous warts caused by human papillomavirus (HPV) remain a therapeutic challenge due to variable response rates and frequent recurrence. Potassium hydroxide (KOH) is a low-cost topical agent with keratolytic and potential immunomodulatory effects. This study evaluated the dose-response efficacy and safety of three concentrations of topical KOH (10%, 15%, and 20%) in the treatment of common warts.

Materials and Methods
This randomized, parallel-group clinical trial included 60 patients aged 18–60 years with clinically diagnosed common warts. Participants were randomly assigned to three equal groups (n=20 each): KOH 10%, KOH 15%, and KOH 20%. A standardized topical application protocol was used. Clinical response was assessed using a Physician Global Assessment (PGA) scale (excellent: complete clearance; good: >50% reduction; fair: <50% reduction; poor: no response). Safety was evaluated through systematic recording of local adverse events. Statistical comparisons were performed between groups.

Results
Baseline demographic and clinical characteristics were comparable among the three groups ($p > 0.05$). A statistically significant dose-response relationship was observed ($p < 0.05$). The 20% KOH group achieved the highest rate of complete clearance and “excellent” response, followed by the 15% group, while the 10% group demonstrated the lowest efficacy. No statistically significant differences were observed in adverse effects between groups ($p > 0.05$), with only mild and transient local irritation reported. Lesions located on the ring finger were significantly associated with higher rates of complete response ($p < 0.05$)

Conclusions
Topical potassium hydroxide represents a safe, inexpensive, and effective treatment for common warts, with a significant dose-dependent improvement in clinical outcomes. The 20% formulation achieved the highest clearance rates without compromising safety, suggesting it may be the optimal concentration among those evaluated.