EADV CONGRESS
VIENNA
30 SEP - 3 OCT 2026

Abstract N°: 12

Pediatric Onychopathies: Clinical and Etiological Analysis of a Series of 112 Cases

Oumaima Markouk*[1], Layla Bendaoud[1], Maryem Aboudourib[1], Said Amal[1], Ouafa Hocar[1]

[1] Department of Dermatology, Arrazi Hospital, Mohammed VI University Hospital Center, Marrakech Biosciences Research Laboratory, Faculty of Medicine and Pharmacy of Marrakech, Cadi Ayyad University, Marrakech, Marrakesh, Morocco

Introduction
Pediatric onychopathies represent a frequent reason for consultation in pediatric dermatology. They encompass a heterogeneous group of disorders affecting the nail unit, whose clinical manifestations are often polymorphic. Their etiologies are multiple and mainly include inflammatory, infectious, and traumatic causes. Although rare in children, melanonychia often raises diagnostic concern. The objective of our study was to evaluate the clinical and etiological aspects of pediatric onychopathies.

Materials and Methods
This was a retrospective descriptive and analytical study conducted in a pediatric dermatology outpatient clinic over a 13-year period (January 2012 to November 2025). Demographic and clinicobiological data were extracted from consultation records, entered, and analyzed using SPSS software. Comparisons between qualitative variables were performed using the chi-square (χ^2) test. The level of statistical significance was set at 0.05.

Results
A total of 112 patients were included, comprising 55 girls and 57 boys (male-to-female ratio: 1.03). The mean age was 7.4 years, ranging from 1 month to 16 years. Parental consanguinity was identified in 18 patients (16% of cases), 66% of which were first-degree consanguinity.Predisposing factors, predominantly microtrauma and onychophagia, were identified in 36.6% of cases. Nail abnormalities were predominantly bilateral (73.2%) and preferentially involved fingernails, particularly in chronic inflammatory dermatoses.The nail manifestations observed in this series were varied and sometimes associated in the same patient. Ranked by frequency, surface and structural abnormalities were the most common and included nail pitting (24.1%), trachyonychia (14.3%), onychodystrophy (12.5%), onychomadesis (10.7%), onycholysis (9.8%), subungual hyperkeratosis (7.1%), and longitudinal ridging (6.3%).Color abnormalities included leukonychia (8.0%), longitudinal melanonychia (5.4%), and xanthonychia (3.6%). Regarding shape abnormalities, koilonychia was noted in 4.5% of cases and pachyonychia in 3.6%.The main etiologies identified were nail psoriasis (32.1%) and onychomycosis (23.2%), followed by hand-foot-mouth disease (10.7%), viral warts (9.8%), atopic dermatitis (7.1%), alopecia areata (6.3%), nail lichen planus (4.5%), and nail nevi (4.5%).Melanonychia was observed in six children, presenting as a dark brown to black longitudinal band of variable thickness, extending from the matrix to the free edge in half of the cases. The remaining three cases exhibited clinically suspicious features; two demonstrated Hutchinson's sign, while the third presented a wide melanonychia band associated with a pseudo-Hutchinson's sign. Nail biopsy was performed in these patients, and histopathological examination was consistent with nail nevus. No unfavorable evolution or signs of malignancy were observed during follow-up.Regarding statistical analysis, onychophagia was significantly associated with onychomycosis ($p = 0.018$). Nail pitting and trachyonychia were significantly associated with nail psoriasis ($p = 0.004$ and $p = 0.011$, respectively). Onychomadesis was systematically observed following hand-foot-mouth disease ($p < 0.001$). Onychodystrophy was more frequently observed in patients with atopic dermatitis ($p = 0.037$), whereas trachyonychia was significantly associated with nail lichen planus ($p = 0.029$).Onychomycosis occurred in significantly older children ($p = 0.015$), was frequently associated with

paronychia, and was predominantly caused by Candida species (65.4%).

Conclusions

This study highlights the clinical and etiological diversity of pediatric onychopathies and underscores the importance of a structured clinical approach to ensure accurate diagnosis and appropriate management. Nail melanonychia, although rare in this series, was most often of benign origin, emphasizing the importance of thorough clinical evaluation in order to avoid unnecessary invasive investigations.

Abstract N°: 32

Pityriasis amiantacea associated with acute telogen effluvium in a patient with androgenetic alopecia

Mariia Babushkina*[1]

[1] Innovative medical center “Lada Estet”, Izhevsk, Russian Federation

Introduction

Pityriasis amiantacea is an inflammatory scalp condition, characterised by excessive scaling with thick silvery-yellow scales encircling the hair shafts. It is often associated with underlying dermatoses and may be accompanied by increased hair shedding. In some cases, it may coexist with other hair disorders, which can complicate diagnosis and management.

Case Presentation

A 41-year-old female patient presented with complaints of increased hair shedding, scalp scaling, crusting and moderate itching. During the previous year she had noticed gradual hair thinning in the vertex with widening of the central parting. Intermittent dandruff had been present since adolescence, but during the last month scaling significantly worsened and was accompanied by marked hair shedding.

Because of hair loss, the patient began washing her hair less frequently and avoided touching the scalp. Yellow crusts appeared and bound down tafts of hair. Hair combing was also minimized, resulting in severe matting of hair on the right side of the scalp.The patient associated the deterioration with a period of significant emotional stress and a respiratory viral infection approximately three months earlier.

Clinical examination revealed decreased hair density and hair shaft miniaturization in the frontal and vertex areas. The entire scalp, particularly the vertex, demonstrated thick whitish-yellow adherent scales resembling asbestos wrapping around and binding down tufts of hair. The hair pull test was strongly positive across the scalp.

Trichoscopy of the frontal and vertex areas revealed mild anisotrichosis and an increased number of single follicular units. Abundant white-yellow greasy scale-crusts adherent to hair shafts were observed. Dilated arborizing vessels were visible at the base of the scales.

A diagnosis of severe seborrheic dermatitis, acute telogen effluvium, and concomitant androgenetic alopecia was established.

Treatment included a topical corticosteroid combined with salicylic acid applied overnight for 14 days, followed by morning hair washing with a keratolytic shampoo and gentle removal of scales using a soft brush.

After two weeks, itching resolved and most crusts detached from the scalp surface, although some remained attached to hair shafts. Continued treatment with 5% salicylic acid ointment applied overnight facilitated further scale removal.

After four weeks, complete resolution of crusts was achieved and hair shedding significantly decreased. Subsequently, therapy for androgenetic alopecia with topical minoxidil 2% solution was initiated.

Conclusion

This case highlights that pityriasis amiantacea may present with prominent scaling and reactive hair shedding, potentially masking underlying androgenetic alopecia. Anti -inflammatory and keratolytic therapy can effectively resolve scalp hyperkeratosis and reduce hair shedding, allowing accurate evaluation and subsequent management of concomitant hair disorders.

POWERED BY M-ANAGE.COM

EADV CONGRESS
VIENNA
30 SEP - 3 OCT 2026

Abstract N°: 59

Regenerative Potential of Autologous Nanofat Grafting in Androgenetic Alopecia: Clinical and Trichoscopic Evaluation

Shady Ibrahim*[1]

[1] Al-Azhar University ,, Cairo, Egypt

Introduction
Androgenetic alopecia (AGA) is the most common cause of progressive hair loss, characterized by follicular miniaturization and shortened anagen phase. Conventional therapies such as Minoxidil and Finasteride primarily slow disease progression rather than induce true follicular regeneration. Autologous nanofat, rich in adipose-derived stem cells and stromal vascular fraction, has emerged as a promising regenerative modality due to its pro-angiogenic, anti-inflammatory, and follicle-stimulating properties. To evaluate the clinical efficacy and safety of autologous nanofat grafting in patients with androgenetic alopecia using clinical and trichoscopic parameters.

Materials and Methods
This prospective interventional study included patients diagnosed with mild-to-moderate AGA (male and/or female pattern hair loss). Autologous fat was harvested under local anesthesia, mechanically emulsified, and filtered to obtain nanofat. The prepared nanofat was injected intradermally into affected scalp areas in a single session. Patients were evaluated at baseline and at 3- and 6-month follow-up visits. Outcome measures included hair density (hairs/cm^2), hair shaft thickness, anagen/telogen ratio assessed by trichoscopy, standardized global photographic assessment, and patient satisfaction scores. Adverse events were documented.

Results
Preliminary findings demonstrated a statistically significant increase in hair density and mean hair shaft diameter at 6 months compared to baseline ($p < 0.05$). Trichoscopic evaluation revealed reduction in hair miniaturization and improvement in perifollicular vascularity. Global photographic assessment showed visible cosmetic improvement in the majority of patients.

Conclusions
Autologous nanofat grafting appears to be a safe and promising regenerative approach for androgenetic alopecia, demonstrating measurable clinical and trichoscopic improvement.

EA DV CONGRESS
VIENNA
30 SEP - 3 OCT 2026

Abstract N°: 75

Sequential JAK Inhibition in Severe Alopecia Areata: Sustained Remission After Direct Switch from Tofacitinib to Ritlecitinib

Ludmila Porfirio*[1], Raimunda Ribeiro da Silva[2], Diana Peñaranda[3]

[1] IMS Dermatologia, Rio de Janeiro, Brazil

[2] Universidade Federal do Maranhão, São Luís, Brazil

[3] IMS Dermatologia, São Luís, Brazil

Introduction

Alopecia areata (AA) is a T cell–mediated autoimmune disorder characterized by non-scarring hair loss and significant psychosocial burden. Severe disease is frequently chronic and refractory to conventional therapies. Advances in the understanding of AA pathogenesis have highlighted the central role of the JAK–STAT pathway, leading to the development of Janus kinase inhibitors as targeted therapies for moderate-to-severe disease.

Case Presentation

A 38-year-old woman with long-standing severe alopecia areata since childhood presented with near-complete scalp hair loss (SALT 90). Previous treatments included topical corticosteroids, intralesional corticosteroids, systemic corticosteroids, and methotrexate without sustained response. Treatment with oral tofacitinib 5 mg twice daily was initiated in February 2024. Progressive hair regrowth was observed, achieving near-complete scalp repopulation within nine months (SALT <10). Laboratory monitoring performed every three months remained within normal limits and no adverse events were reported. In May 2025, therapy was transitioned directly to ritlecitinib 50 mg once daily without washout or overlap. No post-switch shedding occurred and complete remission was maintained through September 2025. Serial laboratory evaluations remained stable and no adverse effects were observed.

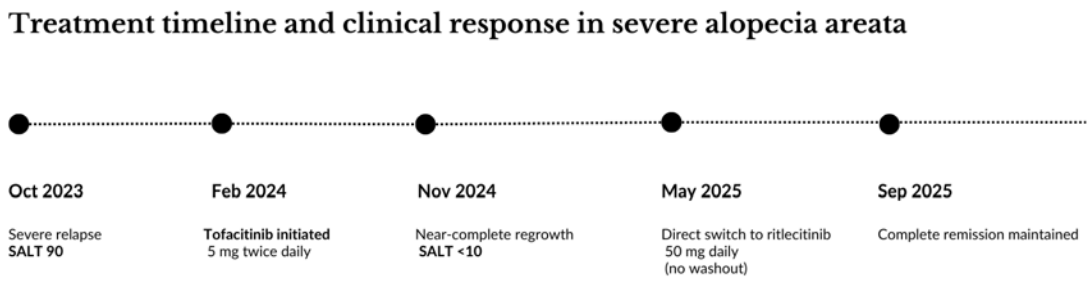

Figure 1. Treatment timeline and clinical response in severe alopecia areata. Timeline illustrating disease relapse, initiation of tofacitinib therapy, achievement of near-complete regrowth, and

subsequent direct transition to ritlecitinib with sustained remission.

Conclusion

This case highlights the effectiveness of JAK inhibition in severe treatment-refractory alopecia areata and suggests that sequential therapy with different JAK inhibitors may represent a promising strategy for maintaining disease remission.

EADV CONGRESS
VIENNA
30 SEP - 3 OCT 2026

Abstract N°: 90

Assessment of the effectiveness of apremilast in the treatment of nail psoriasis employing Nail Area Psoriasis Severity Index (NAPSI), and Dermatologic Life Quality Index (DLQI: an observational cross-sectional study.

Najam U Saqib*[1]

[1] RAK Hospital, North Ras Al Khaimah, United Arab Emirates

Introduction

Psoriasis is a chronic condition characterized by periods of remission and recurrence. Psoriasis involving the nails can cause severe discomfort, significantly lower quality of life, and possibly permanent impairment. Nail psoriasis can be treated with a variety of topical and systemic therapies. Nonetheless, patients frequently complain about them, pointing to unpleasant side effects or ineffectiveness. PDE4 inhibitors, like apremilast, are small molecular peptides that have lately shown promise as a treatment for psoriasis and psoriatic arthritis. In light of this, we conducted a 6-month real-world observational study to see how apremilast affected nail psoriasis.

Materials and Methods

Materials and methods: Thirty patients with nail psoriasis who visited the dermatology outpatient clinic at our tertiary care hospital were included in the study. All patients were put on a 30 mg of Apremilast orally twice daily dosage. The Dermatologic Life Quality Index (DLQI) and the Nail Area Psoriasis Severity Index (NAPSI) were used to evaluate the clinical status at weeks 0, 4, 8, 12, and 24. All patients had nail samples collected at week zero for culture in order to verify the existence of onychomycosis in suspected pateints.

Results

Results: Thirty patients with nail psoriasis were recruited. The mean percentage change in mNAPSIand DLQI at week 24 relative to baseline for all nails served as the main outcome. A per-protocol research found that while DLQI dropped from 12.2 to 4.66, mNAPSI dropped from 26.46 to 11.6. For NAPSI, the one-way ANOVA showed significant results: p-value < 0.002; F statistic 4.68 and DLQI: p-value < 0.001; F statistic = 18.32.

Conclusions

Apemilast showed quick and long-lasting relief from nail psoriasis. A notable decrease in DLQI. Unlike other drugs, including immunosuppressants, which may not be appropriate in the presence of comorbidities, it is safe to use for nail psoriasis.

EA DV CONGRESS
VIENNA
30 SEP - 3 OCT 2026

Abstract N°: 100

Effectiveness of 1% Topical Spironolactone in Management of Androgenetic Alopecia

Muheera Javaid*[1], Haroon Nabi[1]

[1] Ghurki Trust Teaching Hospital, Lahore Medical and Dental College, Lahore, Pakistan

Introduction
Androgenetic alopecia(AGA) is the leading cause of patterned hair loss and carries a substantial psychosocial burden,affecting self-esteem and quality of life.Early disease is frequently subtle and may be missed on clinical examination,particularly in females.Trichoscopy enables detailed visualization of follicular changes and objective assessment of treatment response.In resource-limited settings,it provides a practical alternative to invasive investigations like scalp biopsy.Spironolactone,an anti-androgen that blocks androgen receptors and mitigates follicular miniaturization,has emerged as a promising topical therapy.Evidence for topical spironolactone remains limited,especially in South Asian populations.The study therefore evaluates the effectiveness of 1% topical spironolactone using trichoscopy-guided assessment.

Materials and Methods
This prospective interventional study was conducted at a tertiary dermatology center in Lahore,Pakistan,with institutional ethical approval and informed consent.Forty adults with trichoscopically confirmed androgenetic alopecia were enrolled.Disease severity was graded using the Hamilton–Norwood scale(males)and Sinclair scale(females).Patients with scarring alopecia,inflammatory scalp disorders,pregnancy,lactation,or recent anti-androgen therapy were excluded.Trichoscopy documented hair shaft diameter diversity,peripilar signs,and yellow dots,and quantified baseline hair parameters.Participants applied 1% topical spironolactone daily for 16 weeks.The primary outcome was change in total hair count on trichoscopy;secondary outcomes included terminal and vellus hair counts,hair shaft thickness,terminal-to-vellus ratio,global photos,and patient outcomes($p<0.05$).

Results
At 16 weeks,1% topical spironolactone produced significant trichoscopic improvement in hair density and follicular parameters,with increased terminal hairs and reduced vellus hairs,suggesting partial reversal of follicular miniaturization.A total of 40 patients completed the study,representing a spectrum of disease severity.The terminal thick hair count increased significantly from 17.55 ± 6.88 to 22.78 ± 13.47 ($p < 0.001$),indicating stimulation of terminal hair growth.Similarly,total terminal hair count rose from 30.28 ± 8.79 to 39.15 ± 17.58.The overall total hair count increased from 41.95 ± 11.40 to 48.33 ± 17.42,demonstrating increased scalp hair density.Conversely,vellus hair count decreased from 11.68 ± 4.14 to 9.18 ± 3.50,indicating a favorable shift in the terminal-to-vellus ratio.These improvements were documented through serial trichoscopic assessment.Subgroup analysis revealed greater response among females with early-stage disease,including increased hair density and partial reversal of miniaturization,while male patients primarily showed stabilization of hair loss.Global photographic assessment correlated with trichoscopic findings,with visible improvement in scalp coverage in several participants.Treatment was well tolerated,with 82% reporting no adverse effects.Mild events included pruritus(10%) and transient dryness/peeling(8%),none requiring treatment discontinuation.

Conclusions
This study demonstrates that 1% topical spironolactone is a safe and potentially effective option for androgenetic alopecia,particularly in early disease.Significant increases in hair density and terminal hair counts,along with reduced vellus hairs,indicate a favorable shift in follicular dynamics.Treatment was well tolerated,with minimal and

transient adverse effects.Topical spironolactone may therefore serve as a useful alternative when conventional therapies are unsuitable or poorly tolerated,providing localized anti-androgenic effects with minimal systemic exposure.Importantly,trichoscopy enabled objective assessment of follicular changes and treatment response.In resource-limited settings such as Pakistan,it offers a cost-effective,non-invasive method for early diagnosis and longitudinal monitoring,supporting trichoscopy-guided management of androgenetic alopecia.

EADV CONGRESS
VIENNA
30 SEP - 3 OCT 2026

Abstract N°: 122

Dual Response of Atopic Dermatitis and Alopecia Areata to Upadacitinib

Ali Hamieh*[1], Aya Awwad[1], Ali Fakih[2], Fouad El Sayed[1, 3]

[1] Dermatology Department, Baabda University Hospital, Lebanese University, Beirut, Lebanon
[2] Dermatology Department, Hammoud Hospital University Medical Center, Lebanese University, Beirut, Lebanon
[3] Dermatology Department, Trad Hospital, Beirut, Lebanon

Introduction

Atopic dermatitis (AD) is a chronic inflammatory skin disease predominantly mediated by Th2 cytokines, particularly IL-4 and IL-13. In contrast, alopecia areata (AA) is an autoimmune non-scarring alopecia driven by CD8+ T-cell–mediated hair follicle destruction involving Th1 and Th17 cytokines. Janus kinase inhibitors, such as upadacitinib, target the JAK-STAT signaling pathway and inhibit multiple cytokines involved in both inflammatory and autoimmune processes, offering a potential therapeutic option for patients with concomitant AD and AA.

Case Presentation

A 29-year-old man with childhood-onset AD presented with extensive hair loss involving approximately 50% of the scalp and parts of the beard, consistent with AA (Severity of Alopecia Tool [SALT] score: 57%). Physical examination also revealed widespread erythematous, scaly plaques with an Eczema Area and Severity Index (EASI) score of 11. Previous treatment with topical and intralesional corticosteroids failed to control either condition. Considering the dual disease burden, oral upadacitinib 15 mg daily was initiated. After seven months of therapy, the patient achieved complete clearance of eczematous lesions and full hair regrowth.

Conclusion

JAK inhibitors are usually effective in AD and AA. A few cases have been reported with upadacitinib, a selective JAK1 inhibitor, demonstrating high efficacy in this disease association. In our case, a low dose of upadacitinib 15 mg daily was effective for both AD and AA. By targeting shared cytokine signaling pathways, JAK inhibitors may represent an effective strategy for managing complex inflammatory and autoimmune comorbidities. Larger studies are needed to evaluate long-term efficacy and safety in this population.

EA DV CONGRESS
VIENNA
30 SEP - 3 OCT 2026

Abstract N°: 131

Reduced Melanocyte-to-Keratinocyte Ratio: A Key Diagnostic Marker for Frontal Fibrosing Alopecia

Eylül Ceren Bal Bayazıtlı*[1], Seray Kulcu Cakmak[2], Esra Ucaryilmaz[3], Yıldız Hayran[2], Akin Aktas[2]

[1] Department of Dermatology, Akyurt State Hospital, Ankara, Türkiye
[2] Department of Dermatology, Ankara City Hospital,, Ankara, Türkiye
[3] Department of Pathology, Ankara City Hospital, Ankara, Türkiye

Introduction

Lichen planopilaris (LPP) and frontal fibrosing alopecia (FFA) are primary cicatricial alopecias characterized by a lymphocytic infiltrate targeting the hair follicle bulge. While historically considered a clinical variant of LPP, FFA presents with a distinct band-like recession of the frontal hairline and specific clinical associations. The etiopathogenesis involves immune-mediated destruction of hair follicle stem cells, yet the triggering antigens remain elusive. Recent findings suggest that FFA may share pathogenetic mechanisms with other autoimmune conditions like vitiligo and alopecia areata, where melanocytes or specific follicular antigens are targeted. This study aimed to quantitatively compare epidermal and follicular melanocyte parameters between LPP and FFA to evaluate their potential as diagnostic markers and their role in disease pathogenesis.

Materials and Methods

A retrospective study included biopsy specimens from patients diagnosed with LPP (n=33) and FFA (n=22) between 2018 and 2024. Demographic data and systemic comorbidities were retrieved from electronic records. Immunohistochemical analysis using Melan-A and SOX-10 antibodies evaluated melanocyte counts and the melanocyte-to-keratinocyte (M/K) ratio in the upper hair follicle epithelium. A ratio <1:10 was defined as decreased. Assessments were conducted by an experienced dermatopathologist blinded to clinical data.

Results

FFA patients had a significantly longer median time to diagnosis (24 vs. 12 months, p=0.004). Systemic comorbidities were prevalent in both groups, but FFA was significantly associated with a higher frequency of metabolic disorders including type 2 diabetes (40.9%), hypertension (36.4%), and hyperlipidemia (27.3%) compared to LPP ($p<0.05$) (Table 1). Immunohistochemical results showed that median epidermal (4 [IQR 3-6] vs. 8 [IQR 5.5-9], $p<0.001$) and follicular (2 [IQR 1-5] vs. 8 [IQR 5-10], $p<0.001$) melanocyte counts were significantly lower in FFA. A decreased M/K ratio was observed in 72.7% of FFA patients compared to only 6.1% in LPP ($p<0.001$). Representative immunohistochemical staining patterns highlighting these differences are provided in (Figure 1). In FFA, this decrease was significantly linked to postmenopausal status (p=0.032).

Characteristics	FFA (n=33)	LPP (n=22)	p
Age at diagnosis, median (IQR), years	54,5 (47,25-58,25)	50 (37,5-58)	0,12
Time from onset of symptoms to diagnosis, median (IQR), months	24 (12-36)	12 (6-24)	**0,004**
Presence of comorbidity, %	59,1	69,7	0,42
Comorbidities, %			
Thyroid disease	18,2	30,3	0,37
Type 2 DM	40,9	15,2	**0,032**
Hypertension	36,4	12,1	**0,033**
Hyperlipidemia	27,3	6,1	**0,029**
Coronary artery disease	13,6	0	**0,029**
Osteroporosis	13,6	6,1	0,33
Psychiatric disorder	13,5	18,2	0,62
Dry eye	13,6	15,2	0,87
Autoimmune disease	13,6	12,1	0,86
History of lichen planus	4,5	0	0,21
Allergic rhinitis	0	15,2	**0,076**
Reproductive status, %			**0,097**
Premenopausal	31,8	54,5	
Postmenopausal	68,2	45,5	

Table 1: Comparison of Demographic and Clinical Data of FFA and LPP Patients

Conclusions

A significant reduction in both epidermal and follicular melanocytes is a hallmark of FFA, distinguishing it from LPP, as demonstrated by the contrasting immunohistochemical staining patterns (Figure 1). The results suggest that FFA may involve an autoimmune response targeting melanocytes, similar to the mechanisms observed in vitiligo and alopecia areata, leading to the characteristic hypopigmentation and follicular destruction. These findings highlight the M/K ratio as a robust histopathological marker for differentiating FFA from LPP and support the hypothesis that melanocytes serve as key antigenic targets in FFA pathogenesis.

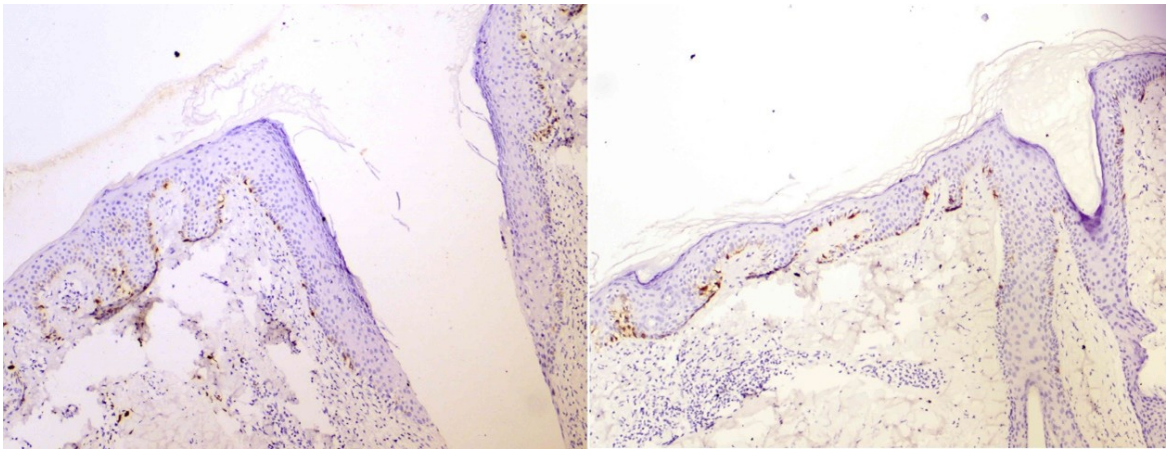

Preparations stained with MelanA, x100 magnification On the left, LPP tissue is observed, while on the right, FFA tissue is seen. In the FFA tissue, a decrease in the number of melanocytes at the upper part of the follicle is prominent

EADV CONGRESS
VIENNA
30 SEP - 3 OCT 2026

Abstract N°: 139

Management of periungual pyogenic granulomas due to EGFR inhibitors in real-world

Luca Rapparini*[1], Stephano Cedirian[1], Francesca Pampaloni[1], Francesca Bruni[1], Ginevra Martelli[1], Federico Quadrelli[1], Andrea Ardizzoni[2], Fabiola Lorena Rojas[2], Francesca Sperandi[2], Bianca Maria Piraccini[3], Michelangelo La Placa[1], Michela Starace[1]

[1] Dermatology Unit, IRCCS Azienda Ospedaliero-Universitaria di Bologna, Policlinico S. Orsola-Malpighi, Bologna, Italy, Bologna, Italy

[2] Oncology Unit, IRCCS Azienda Ospedaliero-Universitaria di Bologna, Bologna, Italy, Bologna, Italy

[3] Private Dermatology Practice, Bologna, Italy, Bologna, Italy

Introduction

Paronychia is a painful inflammatory condition of the periungual tissues frequently observed in oncological patients treated with epidermal growth factor receptor inhibitors (EGFRi), with a reported incidence of 6–25% and frequent involvement of multiple digits. Lesions usually appear after several weeks of therapy and commonly affect thumbs and great toes due to repeated microtrauma. EGFR blockade impairs keratinocyte proliferation, leading to epidermal thinning and secondary inflammation caused by nail plate penetration into surrounding tissues. Although not life-threatening, periungual pyogenic granulomas can be functionally disabling, causing pain and limiting daily activities. As no validated guidelines exist for their management, we conducted a retrospective study to compare the effectiveness of three commonly used topical treatments.

Materials and Methods

This retrospective single-center study evaluated the efficacy of three first-line topical regimens over 6 weeks (±5 days): (i) timolol 1 mg/g gel twice daily; (ii) clobetasol propionate 0.05% cream nightly under occlusion combined with mupirocin 20 mg/g ointment in the morning; (iii) fusidic acid 2% + betamethasone 0.1% cream twice daily. Response was classified as complete response (CR: disappearance of lesion with absence of pain and bleeding), partial response (PR: improvement in at least one parameter), or no response (NR). Secondary endpoints included pain reduction assessed by the Numeric Rating Scale (NRS), improvement in the Scoring System for Paronychia related to Oncologic Treatments (SPOT score), the effect of concomitant tetracyclines, and outcomes of second-line treatments.

Results

Eighty-two patients were included (46 males, 36 females; mean age 68 years). The mean time to onset of periungual pyogenic granulomas after initiation of EGFRi therapy was 11.6 weeks. Thirty-eight patients had involvement of both fingernails and toenails, 18 only hands, and 26 only feet. All treatments were effective for fingernail lesions, with CR rates of 80.2% for clobetasol + mupirocin, 75.0% for fusidic acid/betamethasone, and 74.1% for timolol, without significant differences. In toenail lesions, clobetasol + mupirocin showed the highest efficacy (CR 78.8%, NR 2.0%), followed by fusidic acid/betamethasone (CR 64.1%, NR 2.6%), while timolol was less effective (CR 36.1%, NR 36.1%). Differences between groups were statistically significant ($p<0.001$). Pain significantly decreased in all groups. In fingernails, mean NRS reduction was similar between treatments ($p=0.519$). In toenails, the reduction was greater with clobetasol + mupirocin and fusidic acid/betamethasone compared with timolol ($p=0.003$). SPOT scores improved in all groups, with significant differences for foot lesions ($p<0.001$), where clobetasol + mupirocin showed the greatest improvement. Concomitant tetracycline therapy was not associated with treatment response. Second-line management included alternative topical therapy, silver nitrate cauterization, and chemical removal of lateral nail horns.

Conclusions

Topical clobetasol propionate 0.05% under occlusion combined with mupirocin 20 mg/g appears to be the most effective first-line treatment for EGFRi-induced periungual pyogenic granulomas, particularly for lesions affecting the feet, whereas timolol gel showed lower efficacy in this anatomical site.

EA DV CONGRESS
VIENNA
30 SEP - 3 OCT 2026

Abstract N°: 158

S100A8 promotes cyclophosphamide-induced alopecia through NCF2/NOX2-mediated ferroptosis

Wen Xu*[1], Xiuzu Song[1]

[1] Hangzhou third people's hospital, Hangzhou, China

Introduction
Chemotherapy-induced alopecia (CIA) is one of the most distressing adverse effects of anticancer treatment and markedly impairs patients' quality of life. Although accumulating evidence suggests that oxidative stress contributes to CIA, the precise molecular mechanisms underlying chemotherapy-related hair follicle injury remain incompletely understood. Ferroptosis, an iron-dependent form of regulated cell death characterized by lipid peroxidation, has recently emerged as a potential mechanism in several hair disorders and may also participate in CIA. In parallel, S100A8 is a pro-inflammatory calcium-binding protein closely associated with oxidative stress and inflammatory signaling, yet its role in chemotherapy-induced hair follicle damage has not been clarified. Accordingly, this study aimed to investigate whether S100A8 contributes to cyclophosphamide-induced alopecia by promoting ferroptosis in outer root sheath keratinocytes (ORSKs), and to further explore the involvement of the NCF2/NOX2 signaling axis.

Materials and Methods
A cyclophosphamide-induced alopecia mouse model was established and evaluated by serial gross observation, histopathology, immunofluorescence, qRT-PCR, western blotting, ELISA, and oxidative stress assays. Paquinimod was administered to inhibit S100A8 in vivo. In vitro, primary human ORSKs were exposed to 4-hydroperoxycyclophosphamide or recombinant S100A8. Cell viability, reactive oxygen species generation, intracellular Fe^{2+} accumulation, lipid peroxidation, mitochondrial membrane potential, and ultrastructural mitochondrial changes were assessed using CCK-8, DCFH-DA staining, FerroOrange staining, TBARS assay, JC-1 assay, and transmission electron microscopy. To verify downstream signaling, NCF2 knockdown and NOX2 inhibition were performed in S100A8-treated ORSKs.

Results
Cyclophosphamide induced progressive follicular injury and overt alopecia in mice, accompanied by increased S100A8, NCF2, and NOX2 expression and decreased GPX4 expression in hair follicles, consistent with enhanced oxidative stress and ferroptosis in vivo. Pharmacological inhibition of S100A8 significantly alleviated hair loss, improved follicular morphology, reduced reactive oxygen species accumulation and lipid peroxidation, and partially restored ferroptosis-related molecular changes. S100A8 expression was also positively associated with oxidative and inflammatory mediators, including NOX2, IL-1β, TNF-α, and 8-OHdG.In primary human ORSKs, exposure to 4-hydroperoxycyclophosphamide increased S100A8 secretion and induced a ferroptotic phenotype characterized by reduced cell viability, increased reactive oxygen species generation, intracellular Fe^{2+} overload, elevated lipid peroxidation, mitochondrial membrane depolarization, and ultrastructural mitochondrial damage. These changes were accompanied by increased NCF2, NOX2, and ACSL4 expression and decreased GPX4, FTH1, and SLC7A11 expression. Inhibition of S100A8 attenuated these abnormalities, while exogenous S100A8 alone reproduced them in a dose-dependent manner. Mechanistically, NCF2 silencing or NOX2 inhibition significantly reversed S100A8-induced oxidative stress, iron overload, mitochondrial dysfunction, and ferroptosis-related protein alterations, while improving cell viability.

Conclusions

These findings identify ferroptosis as an important pathogenic mechanism in cyclophosphamide-induced alopecia and demonstrate that S100A8 promotes hair follicle keratinocyte injury through the NCF2/NOX2 signaling axis. Targeting the S100A8–NCF2/NOX2 pathway may therefore represent a promising therapeutic strategy for the prevention or mitigation of chemotherapy-induced alopecia.

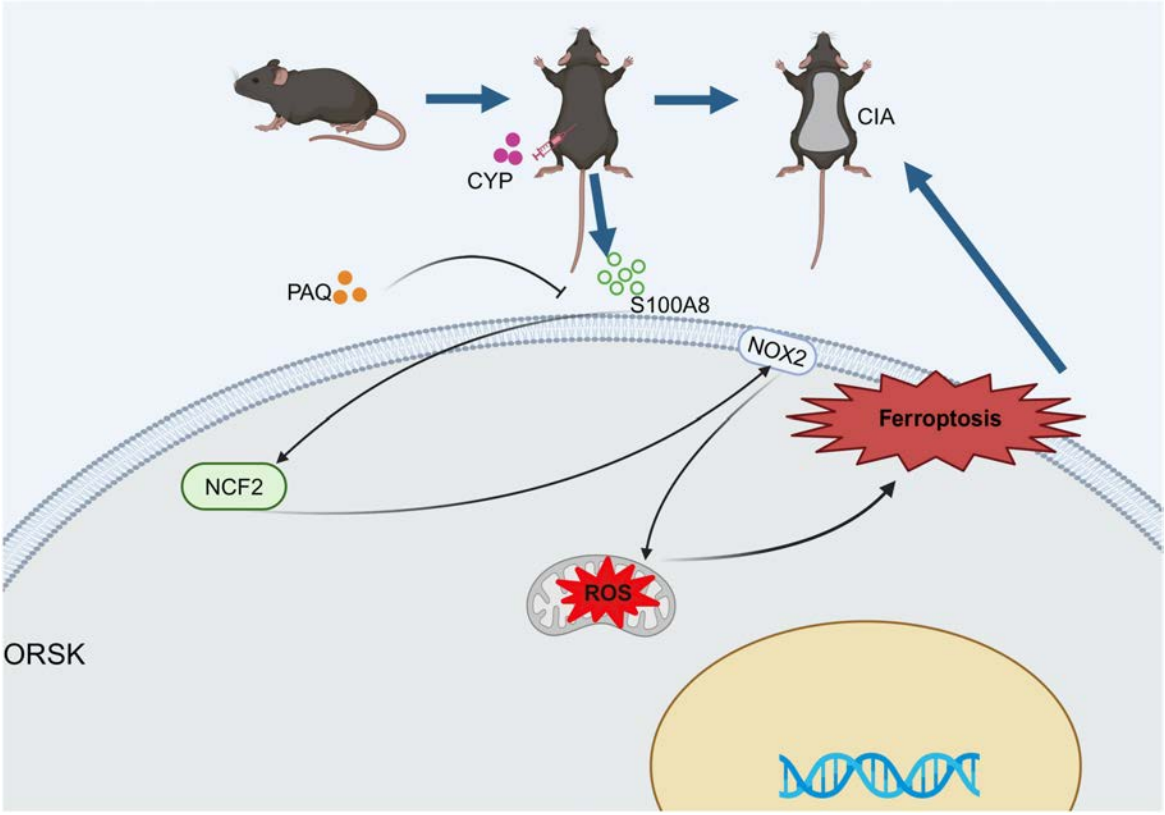

Proposed molecular mechanism by which S100A8 exacerbates CYP-induced alopecia S100A8 activates the NCF2/NOX2 axis, increasing reactive oxygen species (ROS) production and triggering ferroptosis in outer root sheath keratinocytes (ORSKs), thereby contributing to chemotherapy-induced alopecia (CIA). Paquinimod (PAQ) inhibits S100A8, reducing oxidative stress and ferroptosis and preserving hair follicle integrity (created by biorender).

EA DV CONGRESS
VIENNA
30 SEP - 3 OCT 2026

Abstract N°: 175

The significant role and high efficacy of podological procedures in the conservative management of acquired onychogryphosis and nail deformities.

Khatuna Nodia*[1]

[1] Head of Department Podiatry, Clinic Microderma, MD dermato- venereologist Clinic Microderma, Clinical Research Unit in Nevi. Tbilisi State Medical University Ph D - Student, Tbilisi, Georgia

Introduction

Surgical interventions involving the nail unit often provoke fear among patients, leading many to prefer conservative treatment options. Asquired onychogryphosis and nail deformities significantly effect function, comfort and quality of life. The aim of the study was to evaluate the effectiveness of podological procedures in achieving favourable clinical outcomes without surgical intervention, pain or postoperative rehabilitation.

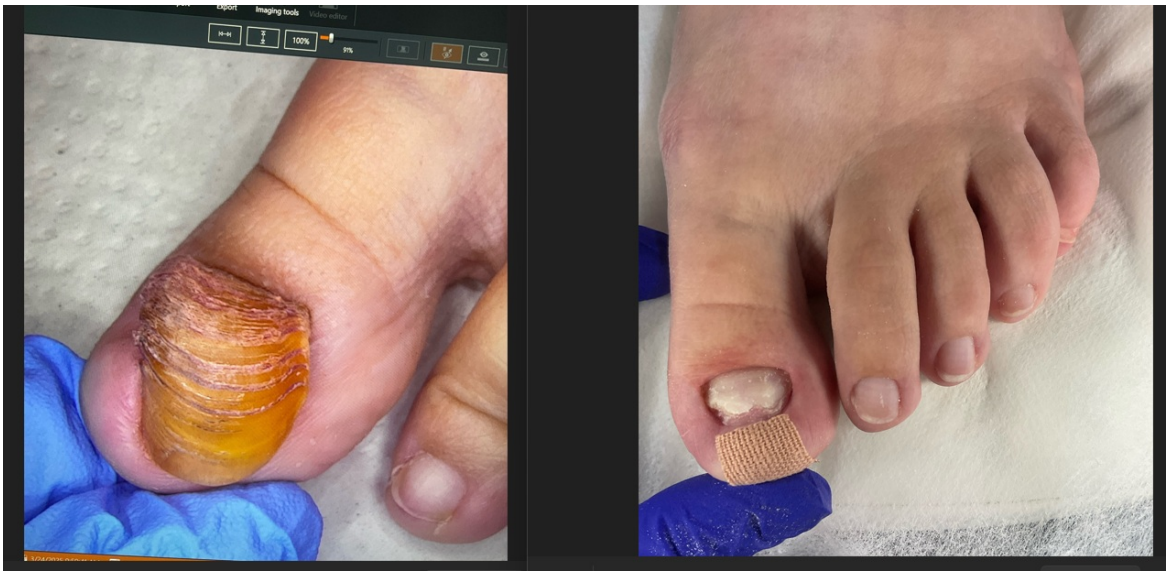

Acquired onychogryphosis after 5 months, was made 2 podological procedure.

Materials and Methods

The clinical evaluation included patients diagnosed with asquired onychogryphosis and various nail deformities. Conservative management consisted of specialised podological procedures. Topical therapy was prescribed to reduce the risk of secondary infections. Orthonyxia and taping techniques played a central role in deformity corection.

Twenty patients ages 20-50 years were diagnosed with onychopryphosis and underwent regular podological treatment. Additionally, 25 patients presented with nail deformities, including onychodystrophy and pincer nail. Clinical outcomes were assessed during follow-up, focusing on nail morphology, symptom relief and oatient satisfaction.



onychogryphosis after procedure and result after 4 months.

Results

In patients with onychogryphosis favourable clinical outcomes were acgieved in 90% of cases within 9-12 months. Among patients with other nail deformities satisfactory results were observed in 90-95% of cases within 7-9 months. Treatment led to significant improvement in nail shape, reduction of discomfort and high patient satisfaction. No complications or adverse effects were recorded and all patients avoided surgical intervention.

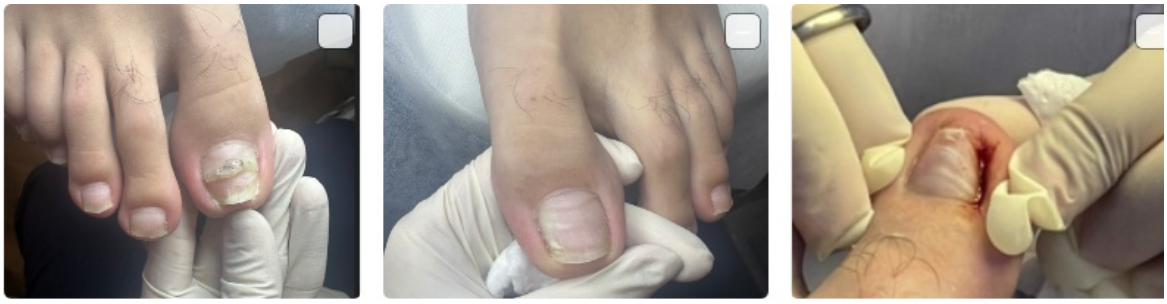

Pincer nail, was made adhesive nail brace and result after 8 months

Conclusions

Our finding demonstrate that podological procedures represent an effective , safe and well-tolerated conservative treatment otion for asquired onychopryphosis and nail deformities. This approach addresses patient concerns regarding surgery and recovery and shoul be considered a valuable firs-line therapeutic strategy in selected patients.

EADV CONGRESS
VIENNA
30 SEP - 3 OCT 2026

Abstract N°: 182

Dupilumab for the treatment of pediatric alopecia areata: a case report and review of literature

Elias Marquart*[1], Wolfgang Weninger[1], Tamar Kinaciyan[1]

[1] Medical University of Vienna, Department of Dermatology,, Vienna, Austria

Introduction

A 3-year-old girl of Indian-Pakistani descent presented with a 4-month history of generalized diffuse hair loss following an infection 6 months earlier, with a fluctuating course refractory to glucocorticoid therapy. The subsequent disease trajectory was characterized by the emergence of a chronic, recurrent pruritic dermatitis. Family history was non-contributory. Notably, the patient had a history of reproducible immediate-type reactions to eggs and nuts, manifesting as gastrointestinal and cutaneous symptoms.

Case Presentation

The patient was in good general condition with an age-appropriate nutritional status. Dermatological examination showed diffuse effluvium with exclamation mark hairs and yellow and black dots on trichoscopy, highly suggestive of alopecia areata diffusa, along with scaling eczematous plaques in a distribution typical of atopic dermatitis. Serological evaluation demonstrated significantly elevated total IgE levels (816 kU/L) and strong sensitization, with specific IgE positivity to timothy grass, multiple nuts (peanut, almond, Brazil nut, hazelnut), and egg components (egg white and yolk). The parents were already avoiding nuts and eggs that we advocated.Given diffuse alopecia areata in association with atopic dermatitis and markedly elevated total IgE levels, treatment with dupilumab (300 mg subcutaneously every 4 weeks), adjusted for age and body weight, was initiated. Within 3 months, clinical response was observed with progressive resolution of cutaneous lesions and simultaneous hair growth, which resulted in complete hair regrowth after 12 months of therapy.

Conclusion

This subtype of alopecia areata is clinically characterized by diffuse effluvium and may pose a diagnostic challenge. If left untreated, the disease may progress and lead to substantial impairment of quality-of-life. Early diagnosis and timely initiation of effective therapy are therefore critical. Dupilumab treatment is associated with rapid improvement of both atopic dermatitis and alopecia areata, underscoring its potential as a steroid-sparing and well-tolerated systemic treatment option, particularly in young children. So far, available evidence supports the efficacy of dupilumab in pediatric alopecia areata, particularly in association with atopic dermatitis. While JAK inhibitors have demonstrated efficacy, their use in this age group remains limited, making dupilumab a promising alternative with a favorable safety profile. However, larger studies are needed to further define its role in pediatric alopecia areata.

EA DV CONGRESS
VIENNA
30 SEP - 3 OCT 2026

Abstract N°: 184

Multiple Onychomatricomas as a Rare Clinical Presentation with BAP1 mutation

Guldehan Atis*[1, 1], Ayşenur Şam Sarı[1, 2], Gaye Guldiken Dogruel[3], Pembegül Güneş[3], filiz özen[4]

[1] Üsküdar University, Faculty of Medicine, Department of Dermatology, Ataşehir Memorial Hospital, İstanbul, Türkiye

[2] Üsküdar University, Faculty of Medicine, Department of Dermatology, İstanbul, Türkiye

[3] Ataşehir Memorial Hospital, İstanbul, Türkiye

[4] Department of Medical Genetics, Prof. Dr. Süleyman Yalçın City Hospital, İstanbul, Türkiye

Introduction

Onychomatricoma (OM), is a rare benign fibroepithelial tumor of nail that originated from nail matrix and nail bed . Thickening of nail plate, yellowish longitudinal bands, leukoxanthonchia, transverse overcurvature and splinter hemorrhages are common clinical features of OM. Surgical excision should be performed for certain diagnosis and curative treatment. This case highlights the exceptional nature of multiple onychomatricomas. Nearly all reported onychomatricomas involve a single nail. Herein we report a 50-year- old woman with multiple OM on her fingers with BAP1 mutation.

Case Presentation

The patient applied to our dermatology out-patient clinic with the complaint of some changes in the shape and colour of her thumb nails for one year. On her dermatologic examination, leukoxanthonchia extending from the distal nail to the lunula, irregularity on the lunula, and erythematous and whitish bands on the lunula were found on her both left and right thumb nail. Subungual hyperkeratotic papular lesions were seen on the free edge of nail plate. Both lesions were operated. Papillary structures formed by edematous stroma lined with matrix epithelium were seen on the nail bed on histopathological evaulation. The histopathological evaluation of both lesions were consistent with OM. Genomic DNA was isolated from peripheral blood, followed by single-gene sequencing analysis of the BAP1 gene. Variant classification was based on ACMG guidelines, and the heterozygous frameshift variant NM_004656.4:c.322_324delCTGinsT p.(Leu108TrpfsTer17) in the BAP1 gene was reported as likely pathogenic, This variant is novel, as it has not been previously reported in the literature. The patient underwent genetic counseling and was enrolled in a surveillance program for the early detection of potential malignancies

Conclusion

Onychomatricoma is a benign rare nail tumor that should be distinguished from onychomycosis, onychopapilloma, Bowen’s disease, subungual melanoma, and squamous cell carcinoma. Involvement of multiple nails is exceptionally uncommon. Patients with multiple lesions may be misdiagnosed with onychomycosis. BRCA1-associated protein (BAP1) tumor predisposition syndrome is an autosomal dominant cancer syndrome characterized by an increased susceptibility to both cutaneous and internal malignancies. Individuals harboring BAP1 mutations exhibit elevated risks for cutaneous melanoma (17–36%), uveal melanoma (24%), malignant mesothelioma (14–24%), renal cell carcinoma (11%), basal cell carcinoma, breast carcinoma, meningioma, bladder carcinoma, cholangiocarcinoma, and hepatocellular carcinoma. When examining the relationship between nail tumors and BAP1 mutations, an association has been identified specifically between multiple onychopapillomas and BAP1 mutations. Our case is the firt case in the literature with multiple OM with BAP1 mutation. Considering the exceptional rarity of multiple OM cases, evaluation for underlying BAP1 mutations appears to be clinically justified. Onychomatricoma is a rare, benign neoplasm originating from the nail matrix. Although it commonly

affects a single nail, the involvement of multiple nails should not be considered a reason to exclude the diagnosis of OM. This case highlights that OM can, in fact, involve more than one nail.These type of presentations should be included in the differential diagnosis multi-nail dystrophies. Patients with multiple OMs should be evaluated for the presence of an accompanying BAP1 mutation

EA DV CONGRESS
VIENNA
30 SEP - 3 OCT 2026

Abstract N°: 192

Early Intervention of 5% Minoxidil Usage Yields Improved Hair Regrowth in Male Androgenetic Alopecia: The Effects of Age and Stage

Ramond J Waide*[1], James A McGuire[1], Paul LaTerra[1], Asha Patel Shah[1]

[1] JJCI, part of Kenvue, Skillman, United States

Introduction

A total of 80 million Americans suffer from hair loss; 50 million are men, which accounts for about 85% of all men in America. In a survey completed in 2023, 322 male topical minoxidil users were surveyed to inquire how old they were when they started treatment. On average, men started at age 38.2 y/o and on average wished they had started at age 34 y/o. It is often assumed that starting an intervention earlier in any disease process helps mitigate progression of disease. There is a paucity of data in androgenetic alopecia regarding earlier intervention resulting in better outcomes. The objective of this research is to investigate change from baseline non-vellus hair counts within different age groups and different hair loss severity stages, as classified by the Norwood-Hamilton scale.

Materials and Methods

To explore the relationship between hair regrowth and some covariates, subject's age and stage of hair loss, the change from baseline at Week 16 in target area hair count (TAHC) were summarized by the covariates in a men's 5% Minoxidil Topical Foam (MTF) study. A 2019 post-hoc analysis probed effects in the change from baseline at the end of treatment (16 weeks) in hair count based on age: considering younger millennials (20-30 years), older millennials (31-40 years), and generation X (41-50 years) for men enrolled in a phase III trial of commercially available 5% Minoxidil Topical Foam (MTF). Difference in hair regrowth in the stages of hair loss was assessed by the mean change from baseline hair count at week 16 in stages of hair loss based on the Norwood-Hamilton scale. Men enrolled in the study were in Type III (vertex), Type IV, and Type V classification of hair loss.

Results

Subjects using 5% MTF twice daily regrew more non-vellus hairs from baseline in younger millennials than in older millennials and generation X. Change in TAHC from baseline at 16 weeks showed hair count for younger millennials (26.25), older millennials (19.22), and generation X (20.41). Subjects using 5% MTF showed statistically significant improvement in hair regrowth compared with placebo for each of the three age categories ($p<0.005$). Subjects using 5% MTF twice daily regrew more non-vellus hairs from baseline for Type III hair loss pattern than for Type IV and Type V. Subjects in Type III classification showed an increase in hair count (23.06) compared to Type IV (15.83) and Type V (21.57) classifications. Subjects using 5% MTF showed statistically significant improvement in hair regrowth compared with placebo for each of the three hair loss classifications ($p<0.002$).

Conclusions

This study has proven that there is objective improvement of hair regrowth when intervening earlier in age and stage of hair loss severity with topical minoxidil. We believe that this data will appropriately and objectively inform health care providers with evidence to provide best practices in shaping the treatment paradigm for male androgenetic alopecia.

EA DV CONGRESS
VIENNA
30 SEP - 3 OCT 2026

Abstract N°: 208

Long-term efficacy and safety of ritlecitinib in patients with alopecia areata and ≥25% scalp hair loss by severity: results from the phase 3 long-term ALLEGRO-LT study through 5 years

Brett King*[1], Rodney Sinclair[2], Xingqi Zhang[3], Bianca Maria Piraccini[4], Christos Tziotzios[5], Dalia Wajsbrot[6], Robert Wolk[6], Mojgan Sadrarhami[7], Alexandre Lejeune[8], Helen Tran[7]

[1] Dermatology Physicians of Connecticut, Fairfield, United States
[2] Sinclair Dermatology, Melbourne, Victoria, Australia
[3] Dermatology Hospital, Southern Medical University, Guangzhou, China
[4] Piraccini Medical Center, Bologna, Italy
[5] St John's Institute of Dermatology, King's College London, London, United Kingdom
[6] Pfizer Inc, Groton, CT, United States
[7] Pfizer Inc, New York, NY, United States
[8] Pfizer Inc, Paris, France

Introduction
The oral JAK3/TEC family kinase inhibitor ritlecitinib demonstrated efficacy and safety in patients aged ≥12 years with alopecia areata (AA) with ≥50% hair loss in the ALLEGRO phase 2b/3 and ALLEGRO-LT studies. ALLEGRO-LT is the only clinical trial among the approved treatments for severe AA to include patients with ≥25% scalp hair loss. This post hoc analysis of de novo patients from ALLEGRO-LT (end of study) evaluated the efficacy and safety of ritlecitinib up to 5 years in patients with AA and ≥25% scalp hair loss at baseline.

Materials and Methods
The open-label, multicenter, long-term ALLEGRO-LT study (NCT04006457) enrolled patients into 2 cohorts. This post hoc analysis only included patients in the de novo cohort who were aged ≥12 years with AA with ≥25% scalp hair loss at baseline and had no previous ritlecitinib treatment. De novo patients received an initial 4-week loading dose of ritlecitinib 200 mg once daily (QD) followed by ritlecitinib 50 mg QD (200/50 mg). Outcomes included the proportions of patients with Severity of Alopecia Tool (SALT) score ≤20 and SALT score ≤10 up to Months 58-60. Patients were stratified by SALT score at baseline: 25 to <50, 50 to <95, and 95 to 100. Observed and last observation carried forward (LOCF) data are reported.

Results
In ALLEGRO-LT, 447 patients received ritlecitinib in the de novo cohort. Of these, 26.4% (n=118), 28.9% (n=129), and 44.7% (n=200) had baseline SALT scores 25 to <50, 50 to <95, and 95 to 100**,** respectively. Patients with baseline SALT score ≥95 generally had longer mean duration of current AA episode (3.5 vs 2.5 years) and disease duration (10.8 vs 8.8 years) than patients with baseline SALT score <50. Observed SALT ≤20 responder rates generally increased and remained stable over time up to Months 36-38, reaching 96.2% in baseline SALT 25 to <50, 92.6% in baseline SALT 50 to <95, and 57.4% in baseline SALT 95-100 (**Figure 1A**). Observed rates fluctuated after Months 36-38, ranging from 92.3%-100.0% in baseline SALT 25 to <50, 95.2%-100.0% in SALT 50-<95, and 66.7%-81.6% in SALT 95-100, reflecting patient discontinuations for various reasons and decreasing patient numbers, which may limit data interpretability at later visits. LOCF response rates increased and remained stable

from Month 18-Months 58-60 in baseline SALT 25 to <50 (84.8%-87.3%) baseline SALT 50-<95 (76.0%-79.1%), and baseline SALT 95-100 (36.0%-39.0%) (**Figure 1B**). SALT≤10 response rates followed a similar trend across severity groups. The most frequently reported treatment-emergent adverse events were SARS-CoV-2 test positive (24.2%), headache (21.7%), and nasopharyngitis (14.1%). Safety events, including adverse events of special interest, were consistent with previously reported data.

Figure 1. Proportion of patients achieving SALT score ≤20 response by AA severity at baseline **A**) as Observed and **B**) LOCF. The de novo cohort of ALLEGRO-LT was treated with an initial 4-week loading dose of ritlecitinib 200 mg QD followed by ritlecitinib 50 mg QD (200/50 mg).

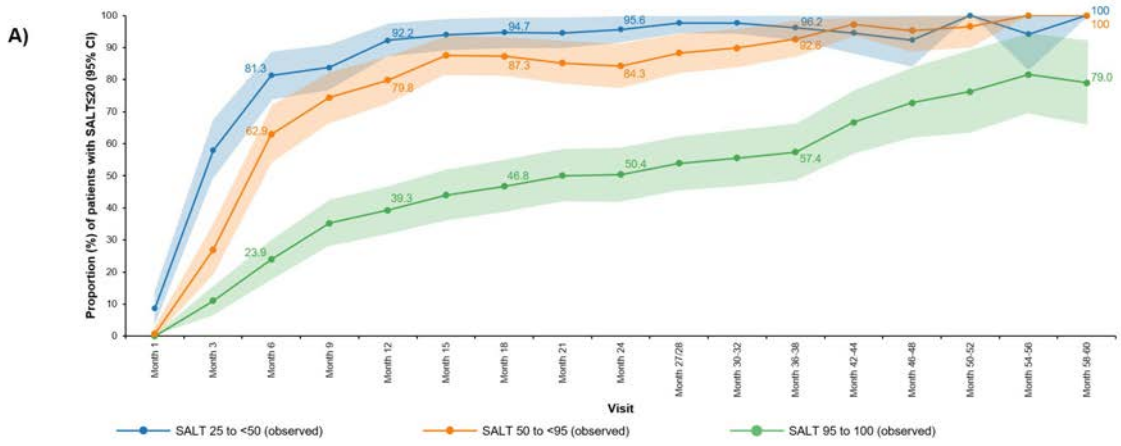

n/N	1	3	6	9	12	15	18	21	24	27/28	30-32	36-38	42-44	46-48	50-52	54-56	58-60
SALT 25 to <50 (observed)	10/116	62/107	87/107	88/105	95/103	93/99	89/94	86/91	87/91	85/87	83/85	76/79	52/55	36/36	22/22	16/17	15/15
SALT 25 to <50 (LOCF)	10/118	62/118	90/118	94/118	102/118	103/118	103/118	102/118	102/118	102/118	102/118	101/118	101/118	100/118	102/118	101/118	101/118
SALT 50 to <95 (observed)	1/129	34/126	78/124	87/117	91/114	98/112	98/110	92/108	91/108	90/102	88/98	88/95	69/71	40/42	28/29	23/23	20/20
SALT 50 to <95 (LOCF)	1/129	34/129	79/129	90/129	94/129	102/129	101/129	90/129	90/129	100/129	100/129	102/129	102/129	102/129	102/129	102/129	102/129
SALT 95 to 100 (observed)	0/193	21/190	45/188	62/176	66/168	69/157	72/154	73/146	69/137	70/130	70/126	70/122	62/93	48/66	32/42	31/38	30/38
SALT 95 to 100 (LOCF)	0/200	21/200	45/200	63/200	68/200	71/200	74/200	75/200	72/200	75/200	76/200	77/200	78/200	77/200	76/200	76/200	75/200

AA, alopecia areata; LOCF, last observation carried forward; QD, once-daily; SALT, Severity of Alopecia Tool.
Shaded areas represent 95% CIs.

Conclusion

Clinically meaningful SALT ≤20 and SALT ≤10 response rates were observed through the end of study in de novo patients receiving ritlecitinib 200/50 mg. Patients with baseline SALT 25-<50 and SALT 50-<95 had higher SALT response rates. The safety profile of ritlecitinib supports its long-term use in adults and adolescents with no new safety risks through 5 years.

EADV CONGRESS
VIENNA
30 SEP - 3 OCT 2026

Abstract N°: 218

Changing Trends in Hair Transplantation: A Comparative Analysis Between 2018 and 2025

Shama Naaz*[1]

[1] Ck Birla Hospital, Gurugram, India

Introduction
Hair transplantation has evolved significantly over the past decade with advances in surgical techniques, instrumentation, and patient expectations. Changes in demographic profiles and procedural preferences may reflect broader shifts in aesthetic awareness, early intervention, and refinement of minimally invasive methods. However, comparative real-world data demonstrating these evolving trends remain limited.

Materials and Methods
A retrospective comparative observational study was conducted including 300 patients who underwent hair transplantation, with 150 patients each from the years 2018 and 2025. Data were analyzed for age, sex distribution, type of hair loss pattern, surgical technique (follicular unit transplantation or follicular unit extraction), and number of grafts implanted. Categorical variables were compared using the chi-square test, and continuous variables using the independent t-test. A p-value <0.05 was considered statistically significant.

Results
The mean age of patients undergoing hair transplantation was significantly lower in 2025 compared to 2018 (32.4 vs 36.9 years; $p < 0.001$), indicating a trend toward earlier surgical intervention. The proportion of female patients increased from 4.0% in 2018 to 8.0% in 2025, although this difference did not reach statistical significance ($p = 0.22$). A marked and statistically significant shift in surgical technique was observed, with follicular unit extraction–based procedures increasing from 18% in 2018 to 60% in 2025 ($p < 0.001$). The mean number of grafts implanted per procedure also increased significantly over time (1844 vs 2375 grafts; $p < 0.001$).

Conclusions
Between 2018 and 2025, hair transplantation practice demonstrated a clear evolution characterized by younger patient presentation, increased female participation, and a strong shift toward minimally invasive extraction-based techniques. These findings highlight changing patient expectations and advancements in surgical practice, underscoring the need for continued adaptation of hair restoration strategies in modern dermatologic surgery.

EADV CONGRESS
VIENNA
30 SEP - 3 OCT 2026

Abstract N°: 245

A Multi-Centre Real-World Evaluation of Ritlecitinib in Severe Alopecia Areata: Safety and Treatment Persistence: Efficacy in Skin of Colour

Sonika Nayyar[1], Danning Li*[2], Radhika Bhanot[3], Vidette Wong[3], Kareem Hassanin[4], Graciaa Singhal[5], Sarah Elhabrouk[1], Donna Thompson[1], James Halpern[4], Simon Tso[2], Tang Ngee Shim[3], Kashini Andrew[6]

[1] Sandwell and West Birmingham NHS Trust, Birmingham, United Kingdom
[2] South Warwickshire University NHS Foundation Trust, Warwick, United Kingdom
[3] University Hospitals Coventry and Warwickshire NHS Trust, Coventry, United Kingdom
[4] Walsall Manor Hospital, Walsall, United Kingdom
[5] New Cross Hospital, Wolverhampton, United Kingdom
[6] Worcestershire Acute Hospitals NHS Trust, Worcester, United Kingdom

Introduction
Ritlecitinib, a selective oral Janus kinase 3 and TEC family kinase inhibitor, was approved in the UK in March 2024 for patients aged ≥12 years with severe alopecia areata (AA). Limited real-world data exist regarding treatment outcomes in patients with skin of colour.

Materials and Methods
A retrospective multi-centre analysis was conducted across five ethnically diverse dermatology centres in the West Midlands. Patients with severe AA receiving oral ritlecitinib were identified. Due to small numbers within individual ethnic subgroups, patients were categorised as White or non-White. Baseline disease severity (SALT), quality of life (DLQI), treatment response, prior therapies, and adverse events were analysed.

Results
Fifty-four patients were included: 15 non-White and 39 White. Non-White patients demonstrated significantly more severe disease at baseline, with a higher mean SALT score compared with White patients (94.5 vs 83.4; p = 0.036). Median baseline DLQI was higher in non-White patients (16.5 [IQR 6.5]) compared with White patients (11.5 [IQR 15.5]), although this difference was not statistically significant (p = 0.53). Mean age did not differ significantly between groups (31.5 vs 36.9 years; p = 0.24). Treatment success was observed in 13.3% (2/15) of non-White patients compared with 33.3% (13/39) of White patients; however, this difference did not reach statistical significance (odds ratio 0.31, 95% CI 0.03–1.73; p = 0.19). Non-White patients were more likely to have received prior diphenylcyclopropenone or systemic immunosuppressive therapy (9/15 vs 18/39), suggesting greater disease refractoriness. Adverse events occurred in both groups without an apparent ethnic predilection.

Conclusions
Non-White patients presented with more severe and treatment-refractory AA and demonstrated lower response rates to ritlecitinib, although differences were not statistically significant. Larger, adequately powered studies, with an estimated 72 patients per group, are required to better evaluate ethnic disparities in treatment outcomes.

EA DV CONGRESS
VIENNA
30 SEP - 3 OCT 2026

Abstract N°: 248

Common Causes of Eyebrow Loss in Light of Trichoscopic Findings

Guldehan Atis*[1], Ayşenur Şam Sarı[2], Esra Nur İpek[3]

[1] Üsküdar University Medicine Faculty, Department of Dermatology, Ataşehir Memorial Hospital, İstanbul, Türkiye
[2] Üsküdar Medicine Faculty, Department of Dermatology, İstanbul, Türkiye
[3] Üsküdar University, Faculty of Medicine, Department of Dermatology, Ataşehir Memorial Hospital, İstanbul, Türkiye

Introduction
Eyebrows are anatomically and functionally specialized hair-bearing structures that contribute significantly to facial aesthetics and nonverbal expression. Loss of eyebrow hair can lead to considerable cosmetic and psychosocial distress. Despite these effects, eyebrow hair loss has not been extensively studied in the literature. Eyebrow loss may present with heterogeneous clinical patterns, making the diagnostic process can be challenging. Trichoscopy, a non-invasive, rapid, and reproducible diagnostic method, has gained increasing interest in the evaluation of eyebrow disorders. However, studies systematically describing trichoscopic findings specific to eyebrow loss are limited. The aim of this study is to evaluate diseases causing eyebrow loss in light of trichoscopic findings and to identify the most common trichoscopic features.

Materials and Methods
Patients with eyebrow hair loss between January 2023 and November 2025 were retrospectively included in the study. Ethical committee approval was obtained (Ethics Committee Number: 61351342/020-47). Patients' diagnoses, available histopathological findings, and trichoscopic features were recorded and analyzed.

Results
A total of 36 patients were included in the study. Of these, 23 (63.8%) were female and 13 (36.2%) were male. Isolated eyebrow loss was observed in 7 patients (19.4%), while 29 patients (80.6%) also exhibited hair loss in other body areas. Diagnostic distribution revealed that 18 patients (51.4%) had alopecia areata (AA), 13 patients (35.1%) had frontal fibrosing alopecia (FFA), 3 patients (8.1%) had trichotillomania (TTM), and 2 patients (5.4%) had lichen planopilaris (LPP). Among patients with isolated eyebrow loss, histopathological confirmation was obtained in 4 cases (57.1%). In contrast, among the remaining 29 patients, 10 (34.4%) underwent histopathological confirmation, all from scalp biopsy specimens. There was no statistically significant difference between the two groups in terms of biopsy rates ($p = 0.33$). The most common trichoscopic findings were vellus hairs in 32 patients (88.8%), diffuse empty follicles in 31 patients (86.1%), yellow dots in 27 patients (75%), black dots in 18 patients (50%), and hairs growing in different directions in 13 patients (35.1%). In patients with AA, the most frequent trichoscopic findings were vellus hairs (93.5%), yellow dots (88%), and diffuse empty follicles (82.5%). In patients with FFA, the most common findings were diffuse empty follicles (92.4%), vellus hairs (92.4%), and yellow dots (63.9%). In LPP patients, the most frequent findings were yellow dots (100%), vellus hairs (100%), and diffuse erythema (100%). In TTM patients, the most common trichoscopic findings were black dots (100%), broken hairs (100%), and comma hairs (100%).

Conclusions
In our study, AA was the most common cause of eyebrow loss. Vellus hairs, diffuse empty follicles, and yellow dots were the most frequently observed trichoscopic findings. Although no statistically significant difference was found in biopsy rates between patients with isolated eyebrow loss and those with more widespread involvement, yet

biopsy rates were higher in the isolated eyebrow loss group. Recognizing the diseases that cause eyebrow loss and understanding their trichoscopic features may reduce the need for biopsies from cosmetically sensitive areas such as the eyebrows, particularly in cases of isolated eyebrow loss. This approach may facilitate rapid diagnosis and enable timely treatment planning.

EADV CONGRESS
VIENNA
30 SEP - 3 OCT 2026

Abstract N°: 259

Pseudopelade of Brocq: A Case of Misdiagnosed Scarring Alopecia

Alesja Palaj*[1], Arlin Kokomani[2], Ina Sotiri[1], Lejdis Zeneli[1], Oljeda Kaçani[3], Monika Fida[1]

[1] Department of Dermatology, University Hospital Centre "Mother Theresa", University of Medicine of Tirana, Tirana, Albania
[2] Department of Othorhinolaryngology, University Hospital Centre "Mother Theresa", University of Medicine of Tirana, Tirana, Albania
[3] Private Clinic "A-derma", Tirana, Albania

Introduction
Pseudopelade of Brocq is a rare lymphocytic cicatricial alopecia that may present either as a distinct entity or as the late stage of other primary scarring alopecias. Its clinical features often lead to misdiagnosis as non scarring hair loss, delaying proper management. Trichoscopy and histopathology are essential for accurate diagnosis. We present a case illustrating the role of these diagnostic tools in a patient initially misdiagnosed with alopecia areata.

Case Presentation
A 36 year old woman with a four year history of slowly progressive scalp hair loss and mild pruritus was evaluated. Clinically it was observed a single, diffuse cicatricial alopecia patch in the frontal scalp region without associated symptoms. Trichoscopic evaluation revealed fibrotic white areas within the alopecic patch, and most surrounding follicles showed only a single emerging hair. A punch biopsy was performed in the affected area. Histopathology showed a mild lymphocytic inflammatory infiltrate around the infundibulum and absence of sebaceous glands.

Conclusion
Pseudopelade of Brocq (PB) remains a rare and challenging cicatricial alopecia that lacks specific trichoscopic features, making it essentially a diagnosis of exclusion. On trichoscopic examination, the hallmark findings include absence of follicular openings, porcelain white areas, and occasional dystrophic hairs at the periphery of the lesions. Most follicles surrounding the alopecic patch contain only a single hair, and characteristic features of other scarring alopecias are absent. Histopathology confirms the diagnosis, showing follicular dropout, absence of sebaceous glands, concentric lamellar fibroplasia around remaining follicles, and eventual replacement by fibrous tracts. PB does not have a standardized treatment. For localized lesions, potent topical corticosteroids or intralesional triamcinolone may be used. In advanced cases, systemic therapies such as prednisolone, hydroxychloroquine, isotretinoin, or mycophenolate mofetil have been reported, although evidence remains limited.

This case emphasizes the importance of careful correlation between clinical, trichoscopic, and histopathologic findings. Early recognition is essential to avoid inappropriate treatments, minimize irreversible hair loss, and guide management in this diagnostically challenging condition.

EADV CONGRESS
VIENNA
30 SEP - 3 OCT 2026

Abstract N°: 260

Pigmented Giant Onychomatricoma of the Great Toenail: An Atypical Presentation Supported by Ultrasound

Thais Barros Felippe Jabour*[1], Maisa Nagao[1], Alessandra Moraes Barros Vieira[2], Alexandre Michalany[1], Carolina Malavassi Murari[1]

[1] University of Santo Amaro, São Paulo, Brazil

[2] Instituto de Infectologia Emílio Ribas, São Paulo, Brazil

Introduction

Onychomatricoma is a rare benign fibroepithelial tumor of the nail matrix that classically presents with xanthonychia, nail plate thickening, splinter hemorrhages, increased transverse curvature, and distal honeycomb-like cavities. However, atypical variants, including pigmented and giant onychomatricoma, may mask these classic clues and mimic more common disorders such as onychomycosis. Recent reviews also highlight the growing utility of nail ultrasound as a non-invasive adjunct for the preoperative assessment of nail tumors.

Case Presentation

A 64-year-old man presented with an 18-year history of progressive nail dystrophy affecting the right great toenail, previously treated irregularly and, more recently, with oral and topical antifungal therapy without improvement. He denied preceding trauma and reported mild pain on compression, especially at the lateral nail fold. Examination showed marked nail plate thickening, brownish chromonychia, and lateral paronychia of the right hallux.Point-of-care ultrasound of the nail unit was performed using a 20-MHz transducer and revealed an irregular subungual tumor with mild posterior acoustic enhancement, measuring 2.88 mm in transverse diameter and 7.54 mm longitudinally. Because of persistent dystrophy and the imaging findings, nail plate avulsion and complete tumor excision were performed.Histopathological examination showed a markedly thickened nail plate with variable epithelial invaginations and onycholemmal keratinization, associated with parakeratosis and focal bacterial colonization. The deeper portion of the lesion was composed of elongated and irregular epithelial projections extending toward the onychodermis, focally anastomosing, with scattered cells containing melanin pigment. The stroma was loose fibromyxoid and richly vascularized, with numerous mast cells and melanophages. No cytologic atypia or malignancy was identified. The final diagnosis was pigmented onychomatricoma. The deep surgical margin coincided with the lesion.

Conclusion

Persistent nail dystrophy refractory to antifungal treatment should prompt investigation for nail unit tumors. In this setting, ultrasound may improve preoperative suspicion and contribute to timely diagnosis and appropriate management, while histopathological examination remains the gold standard for definitive diagnosis and confirmation of benignity.

EADV CONGRESS
VIENNA
30 SEP - 3 OCT 2026

Abstract N°: 263

A Unique Blend of Alopecia Areata And Monilethrix Concurrently Presenting In A Child: Trichoscopy's Revelation

Aishwarya Muddebihal*[1], Abhinav Bansal[2], Pooja Arora[2]

[1] Sharda Narayan SIPS Hospital, Lucknow, India

[2] Atal Bihari Vajpayee Institute of Medical Sciences & Dr Ram Manohar Lohia Hospital, New Delhi, India

Introduction

Alopecia areata (AA) is an autoimmune disorder commonly seen in adults of 25 to 40 years age.1 Monilethrix is a rare genetic hair shaft disorder with increased fragility. Herein, we describe a unique presentation of concomitant alopecia areata and monilethrix in an eleven-year-old child.

Case Presentation

A 11-year-old girl presented with decreased hair growth and easy pluckability since one year of age. Parent reported inability of hair to grow long. There was no history of similar complaints in family members. On examination, visible scalp hair sparsening with diffuse non-scarring alopecia was seen, predominately in fronto-temporal-occipital region. Multiple grouped keratotic follicular papules were present over the nape of neck and frontal hair line. Eyebrows and eyelashes were intact. Hair, teeth, nail examination was unremarkable. There was no sweating abnormality. Trichoscopy revealed multiple uniformly beaded short hair shafts along with black dots, few exclamation mark hair, coudability hair, broken hairs and few yellow dots. Trichogram of hair shafts revealed alternating constrictions and nodes suggestive of monilethrix. Based on clinical, trichoscopic and trichogram evaluation, a diagnosis of diffuse alopecia areata with monilethrix was made. Genetic testing could not be done as the patient was non-affordable. Patient was started on topical minoxidil and oral tofacitinib 2.5mg twice daily. After weeks of therapy, there was visible hair regrowth and improvement in hair density. Patient is currently under follow-up.

Conclusion

Monilethrix is a rare hereditary hair shaft disorder and needs to be differentiated from pseudomonelithrix. Monilethrix has been treated successfully with topical minoxidil and oral retinoids (acitretin). Oral JAK inhibitor is given to our patient to manage alopecia areata. Tofacitinib is known to be effective in alopecia areata and its role in monilethrix is yet to be established. The coexistence of alopecia areata and monilethrix present as a rare clinical occurrence. To the best of our knowledge no case has yet been reported in literature. Our case exemplifies the significance of thorough clinical examination and underscores the clinical value of trichoscopy in diagnosing concurrent hair disorders.

EADV CONGRESS
VIENNA
30 SEP - 3 OCT 2026

Abstract N°: 269

Assessment of Serum Micronutrient Levels in Children with Alopecia Areata: A Case–Control Study

Prashansa Jaiswal*[1], Shiwangi Rana[2], Kanchan Taneja[3]

[1] All India Institute of Medical Science Hospital, Bhopal, India
[2] All India Institute of Medical Science Hospital, GORAKHPUR, India
[3] Chacha Nehru Bal Chikitsalaya, New Delhi, India

Introduction
Alopecia areata (AA) is a chronic inflammatory disorder causing non-scarring hair loss. Micronutrients such as zinc, copper, magnesium, iron, vitamin D, and vitamin B12 are essential for hair follicle growth, and deficiencies may play a role in AA pathogenesis. Most evidence comes from adult populations, and pediatric data are limited. This study aimed to evaluate serum micronutrient levels in children with AA and age- and sex-matched healthy controls and to assess their association with disease severity.

Materials and Methods
Aim: To evaluate serum levels of micronutrients like zinc, copper, magnesium, iron, vitamin D, and vitamin B12 in pediatric patients with alopecia areata compared to healthy controls, and to assess their association with disease severity.

Materials and Methods:A case–control study was conducted including 50 pediatric AA cases and 50 age- and sex-matched controls. Disease severity was assessed using the Pediatric Severity of Alopecia Tool (pSALT) score. Blood samples were analyzed for serum zinc, copper, magnesium, iron, vitamin D, and vitamin B12 using standard spectrophotometric and chemiluminescence methods.

Results
The mean age of cases and controls was 7.2 ± 3.2 and 6.2 ± 3.0 years, respectively. Circumscribed patchy alopecia was the most common pattern (62%), with a mean pSALT score of 11.8. No significant differences were observed between cases and controls for serum vitamin B12, iron, magnesium, copper, or vitamin D levels. Serum zinc deficiency was more prevalent in controls than cases ($p = 0.04$). Positive family history was noted in 14% of cases, and earlier onset was observed in males.

Conclusions
Micronutrient deficiencies, including vitamin B12, iron, magnesium, copper, and vitamin D, were not significantly associated with pediatric AA in this study. Serum zinc results were inconclusive. Routine measurement and supplementation of micronutrients in pediatric AA cannot be recommended based on current evidence. Larger studies are needed to clarify their potential role in disease pathogenesis and management.

EADV CONGRESS
VIENNA
30 SEP - 3 OCT 2026

Abstract N°: 309

"EVALUATION OF CLINICAL, DERMATOSCOPIC AND ETIOLOGICAL FEATURES OF MELANONYCHIA"

Chayashree S*[1]

[1] Vardhman Mahavir Medical college and Safdarjung Hospital, New Delhi, India

Introduction

Melanonychia, presenting as brown-black nail pigmentation, may occur in longitudinal, transverse, or diffuse patterns and arise from diverse benign, infectious, and malignant causes. Few Indian studies have comprehensively evaluated all three patterns using both clinical and dermoscopic correlation.

Case Presentation

Aims & Objectives:To evaluate the clinical, dermoscopic, and etiological features of melanonychia.To correlate clinical and dermoscopic findings with underlying causes.
Materials & Methods:A cross-sectional study was conducted on 120 patients with melanonychia at tertiary care centre over 18 months. All underwent detailed history, clinical and dermoscopic examination of the nail plate, matrix, bed, and fold. Investigations included KOH mount, fungal culture, nail clippings, biopsy, and serum vitamin B12 estimation.

Results:Mean age was 34.5 years; males 78, females 42. Brown pigmentation predominated (104 cases). Patterns: longitudinal 61, diffuse 48, transverse 17. On clinical examination, melanonychia bands/abnormal pigmentation were seen in 31; irregular borders 12, homogeneous color bands 15, longitudinal ridges 7, thinning 6, thickening 4, dystrophy 3, hemorrhage 2, splitting 2, trachyonychia 1, and subungual growth 1. On dermoscopy, normal nail plate in 90; brown-black bands 31; irregular borders 12; color variegation 15; faint streaks and satellite globules better visualized. Regular parallel lines indicated benign lesions; multicolor irregular bands indicated fungal causes; crisscross/blurred lines with periungual pigment (Hutchinson's sign) suggested melanoma. Additional findings: nail matrix normal in 118, pitting in 2; nail bed normal in 112, onycholysis 6, subungual hyperkeratosis 4; nail fold normal in 119, Hutchinson's sign 1. KOH positive in 38/54, nail clippings positive in 4/6. Fungal culture: Trichophyton (2), Aspergillus niger (1), A. fumigatus (1); 2 negative. Biopsy (14 cases): fungal 6, melanoma 2, nevus 2, psoriasis 2, negative 2.

Conclusion

Conclusion:This study highlights the rarity of comprehensive Indian data evaluating clinical, dermoscopic, and etiological correlations of melanonychia across all patterns. Dermoscopy emerged as a vital, non-invasive diagnostic tool that enhances visualization of subtle pigmentary features, enabling early differentiation between benign, infectious, and malignant causes. Recognizing the wide spectrum of etiologies—from common racial and fungal melanonychia to rare melanoma and systemic associations—is crucial for accurate diagnosis, timely management, and prevention of unnecessary interventions.

EADV CONGRESS
VIENNA
30 SEP - 3 OCT 2026

Abstract N°: 315

Predictors of Treatment Response in Pediatric Alopecia Areata: A Retrospective Cohort Study

Shanti Mehta*[1], Jenna Mistry[1], Michal Moshkovich[1], Cinthiya Sugumar[1], Amy Buros Stein[2], Cathryn Sibbald[3]

[1] Temerty Faculty of Medicine, University of Toronto, Toronto, ON, Canada, Toronto, Canada
[2] Pediatric Dermatology Research Alliance, Portland, OR, USA, Portland, United States
[3] Division of Pediatric Dermatology, The Hospital for Sick Children, University of Toronto, Toronto, Canada

Introduction
Pediatric alopecia areata (AA) is an autoimmune, non-scarring hair loss disorder with an unpredictable clinical course. While systemic and targeted therapies, including methotrexate and Janus kinase (JAK) inhibitors, are increasingly used in pediatric populations, treatment response remains heterogeneous and predictors of response are poorly defined. The aim of this study was to identify clinical, demographic, and laboratory predictors of treatment response in pediatric AA across multiple therapeutic classes.

Materials and Methods
We conducted a retrospective longitudinal cohort study of 93 pediatric patients with AA, comprising 626 treatment observations. Patients under 18 years receiving systemic therapy were included. Demographic, clinical, and laboratory data collected encompassed disease pattern, anatomic involvement, comorbidities, and inflammatory markers. Systemic treatments evaluated included methotrexate, oral minoxidil, and JAK inhibitors. Adjunct therapies, including systemic corticosteroids and topical agents, were also recorded. The primary outcomes were treatment response and change in Severity of Alopecia Tool (SALT) score. Mixed-effects logistic and linear regression models were used to evaluate predictors of response and SALT score change while accounting for repeated measures. Subgroup analyses were performed by treatment class.

Results
The mean age of disease onset was 6.7 years, with a mean disease duration of 21.9 months, and 52% of patients were male. The most common phenotype was patchy AA (54%), followed by alopecia totalis (33%). Eyebrow, eyelash, and body hair involvement were present in 46%, 36%, and 32% of patients, respectively, and were associated with greater baseline disease severity. Overall, 88% of patients experienced a treatment response, with a median response time of 3-4 months. Response occurred earlier with methotrexate (3 months) and JAK inhibitors (3.5 months) compared to oral minoxidil (5 months).

A lower baseline SALT score was the most consistent predictor of response across all treatment classes (OR range 0.79-0.83 per 10-point increase). Clinical phenotype strongly influenced outcomes: eyebrow, eyelash, and body hair involvement, as well as complete scalp alopecia, were associated with higher baseline SALT scores and reduced odds of response. Longer disease duration was associated with increased baseline severity but did not preclude treatment response.

Methotrexate response was more likely in female patients and those with sisaipho pattern or elevated CRP, and less likely with complete scalp alopecia or eyelash involvement. JAK inhibitors demonstrated high response rates even in severe disease, although higher IgE was associated with reduced response. Oral minoxidil was less effective in extensive disease, particularly in patients with alopecia totalis or eyebrow involvement. No consistent predictors of SALT score change were identified across therapies, and laboratory biomarkers showed limited predictive value overall.

Conclusions

In pediatric AA, baseline disease severity and hair distribution were the strongest predictors of treatment response. JAK inhibitors appear effective across a broad severity spectrum, including more extensive disease. Methotrexate may be better suited to patients with moderate disease, particularly those with inflammatory features, while oral minoxidil appears to have limited efficacy as monotherapy and may be more appropriate as an adjunct or in less extensive involvement. These findings support a phenotype-driven approach to treatment selection in pediatric alopecia areata and highlight the limited role of routine laboratory biomarkers in predicting outcomes. Further prospective studies are needed to validate these findings and refine individualized, phenotype-guided treatment strategies.

EADV CONGRESS
VIENNA
30 SEP - 3 OCT 2026

Abstract N°: 318

Safety of low dose oral minoxidil in healthy South Asian adult population

Rahul Nagar*[1]

[1] Skin Solutions, Malviya Nagar, New Delhi, India

Introduction

Hair loss in all it's myriad forms constitute a significant proportion of dermatology patients. Patterned alopecia is the most common type of hair loss. Minoxidil is the gold standard treatment for treating hair loss. Of late, off-label low dose oral minoxidil (LDOM) is being increasingly prescribed all around the world by dermatologists. The popularity of LDOM is mainly due to better ease of administration as compared to the topical formulation, which improves compliance. The efficacy is same as topical medication without any adverse effects seen with the topical formulation, such as irritation, rash, poor hair texture, etc. Also, LDOM is useful for patients who do not respond to the topical formulation because of the lack of the enzyme SULT1A1 (minoxidil sulfotransferase) in hair follicles. But concerns remain regarding the systemic safety of LDOM especially it's effect on cardiovascular health, since minoxidil is a vasodilator.

Materials and Methods

A retrospective, single centre, observational study of patients, suffering with any type of alopecia, who were treated with LDOM for 9 months, was performed. Inclusion criteria included healthy adult patients aged between 18-60 years of age, affected with any type of hair loss for the last 3 months or more and treatment naive. Exclusion criteria included presence of cardiac disorders such as ischemic heart disease, valvular heart disease and heart failure, diabetic patients with uncontrolled blood glucose levels (HbA1c > 8). Hypertensive patients on medications were not excluded. A total of 50 patients were included in the study, 35 males and 15 females. Female patients were started on a dose of 0.625mg, while men were started at 1.25mg. In the absence of any adverse effects, the dose was subsequently increased to 1.25mg and 2.5mg, respectively, after 3 months. The total duration of the study was 9 months, starting from 1 April to 31 December 2025. The patients were seen once a month for first three months and later, once in three months for a total of 3 visits. Patients were asked to report earlier in case of any major adverse effect. Blood pressure and weight was checked at each visit.

Results

45 patients completed the study, 32 males and 13 females. The most common side effect was hypertrichosis (5 patients-10%), leading to treatment withdrawal in 3 patients. 2 patients continued despite this. Ankle edema was seen in 3 patients. One patient had an episode of a non serious supraventicular tachycardia, which was treated by the cardiologist. However, he also reported to have been involved in a fight with his neighbours on the same day. He was withdrawn from the treatment. No significant reduction was seen in blood pressure measurements. 4 patients had an increase in weight of 1-3kg. No one reported giddiness (lightheadedness), headache or any other side effect.

Conclusions

Despite a small series of patients, this study demonstrates that LDOM has a good safety profile in the treatment of hair loss in healthy adults. No major adverse effects were seen and the side effects were infrequent and easily manageable.

EADV CONGRESS
VIENNA
30 SEP - 3 OCT 2026

Abstract N°: 363

Reversing Greying Hair with Exosome Therapy: A Novel Regenerative Approach with Multicenter Clinical Evidence

Suparuj Lueangarun*[1]

[1] Department of Aesthetic Medicine, College of Integrative Medicine, Dhurakij Pundit University, Bangkok, Thailand

Introduction

Hair graying remains one of the most visible and difficult-to-treat manifestations of aging. Current options are largely cosmetic and do not address the underlying follicular dysfunction. Exosome therapy offers an innovative regenerative strategy with the potential to restore pigmentation by modulating melanocyte activity, follicular signaling, and tissue repair.

Materials and Methods

In this multicenter cross-sectional observational study, 10 patients with gray or white hair were treated with rose stem cell-derived exosomes (RSCEs) using various delivery procedures. Repigmentation outcomes were assessed using a standardized grading scale, and correlations between clinical variables and treatment response were analyzed. This study aimed to assess the clinical efficacy of exosome-based therapy for hair repigmentation and to identify predictors of treatment response in patients with greying hair.

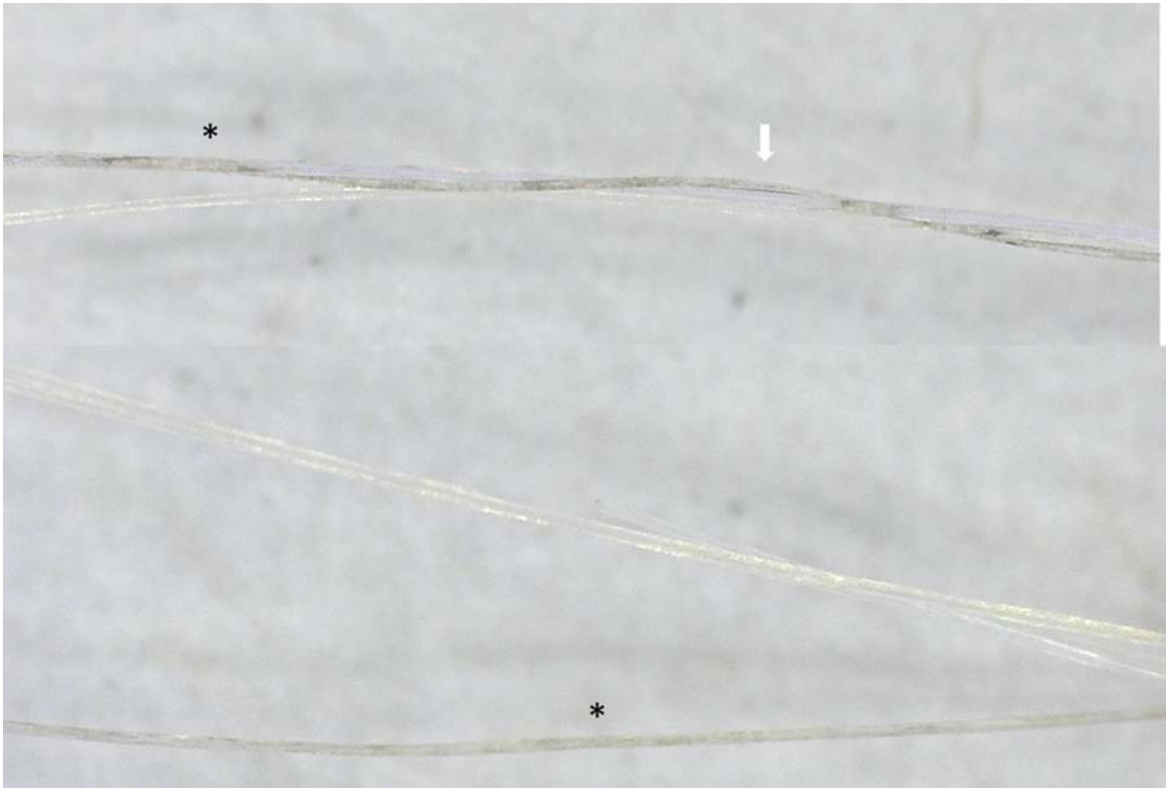

After six sessions of treatment, the whitish hair turned yellowish. Repigmentation is also visible as blackish granules (*) and lines (Arrow) within the yellowish hair (200x, Dino-Lite Digital Microscope, AnMo Electronics Corporation, Taiwan).

Results

Patients received a mean of 4.6 ± 1.3 sessions. Hair repigmentation became visible after 2.4 ± 0.7 sessions and lasted 4.7 ± 1.9 months. Treatment also provided concurrent benefits in hair regrowth. The mean outcome score was 2.8 ± 0.78, with 60% of patients achieving at least 50% improvement. Better outcomes were significantly associated with shorter duration of graying ($p = 0.0363$), concomitant androgenetic alopecia ($p = 0.0332$), and moderate baseline severity (Stage 2) ($p = 0.0133$).



Hair repigmentation after 6 treatment sessions at 4-week intervals using fractional 1064-nm Nd: YAG picosecond laser combined with electroporated exosome delivery. Vertex views at baseline (A), 4 weeks after 2 sessions (B), 4 weeks after 6 sessions (C), and 24 weeks after completing 6 sessions (D) show progressive darkening of hair shafts. Lateral views of the left scalp at baseline (E), 4 weeks after 2 sessions (F), after 6 sessions (G), and 24 weeks post-treatment (H) demonstrate visible pigment restoration and hair regrowth.

Conclusions

Exosome therapy may represent a breakthrough regenerative option for greying hair by promoting both repigmentation and hair restoration. This study supports the concept that age-related hair graying may be biologically modifiable rather than purely irreversible. Further controlled studies are warranted to validate these findings and optimize candidate selection and treatment protocols.

EA CONGRESS
VIENNA
30 SEP - 3 OCT 2026

Abstract N°: 364

Targeting hair-follicle regulatory mechanisms beyond established approaches: a translational evaluation of MEV-miRNAs/iSFRP1 gel

Apostolos Pappas*[1], Daniela Pinto[1], Laetitia LIEGARD[2], Piero TESAURO[3], Maria Caterina FORTUNA[4], Marco Andrea TOMASSINI[5], Federico QUADRELLI[6], Bianca Maria Piraccini[7], Giammaria GIULIANI[1], Fabio RINALDI[1]

[1] Human Microbiome Advanced Project Lab, Milan, Italy
[2] Laboratoires Bailleul International - Giuliani Group, Geneva, Switzerland
[3] Studio Tesauro, Milan, Italy
[4] Sapienza University of Rome, Rome, Italy
[5] Studio Medico Estetimedica, Foligno, Italy
[6] Alma Mater Studiorum University of Bologna, Bologna, Italy
[7] Piraccini Medical Center, Bologna, Italy

Introduction
Advances in hair-follicle biology are opening new avenues beyond conventional approaches by revealing mechanisms that regulate follicular activity and hair-cycle transitions, including miRNA-mediated post-transcriptional regulation and cyclosporine A-like modulation of the SFRP1/Wnt signaling axis. A patented isolation and purification process was developed to obtain standardized milk-derived exosomes (MEV-miRNAs). Characterization of their miRNA cargo identified 25 miRNAs of interest for hair-follicle biology. In parallel, mechanistic studies of cyclosporine A-induced hypertrichosis identified SFRP1 suppression and subsequent Wnt activation as a potential hair-growth mechanism, leading to the development of the non-drug SFRP1 inhibitor iSFRP1. An integrated program evaluated the combination of MEV-miRNAs and iSFRP1 from *in vitro* and *ex vivo* models to controlled and exploratory clinical studies.

Materials and Methods
The objective was to characterize the complementary effects of MEV-miRNAs and iSFRP1 on hair-follicle biology and to assess the efficacy and tolerability of their combination in a once-weekly topical gel vs placebo and as an adjunct to topical minoxidil. MEV-miRNAs were evaluated in human hair-follicle dermal papilla (HFDP) cells for effects on viability, and in organ-cultured human hair follicles for hair-shaft elongation and Wnt-pathway gene expression. iSFRP1 was evaluated in organ-cultured human scalp follicles for effects on hair-cycle staging and Wnt activity. Clinically, 39 adults with androgenetic alopecia (AGA) and/or chronic telogen effluvium were randomized in a multicenter, double-blind study to once-weekly MEV-miRNAs/iSFRP1 gel or placebo for 12 weeks. Anagen hair percentage, anagen/telogen (A/T) ratio and hair-shaft diameter were assessed. An exploratory proof-of-concept series evaluated patients with AGA receiving topical minoxidil (5%, twice daily) at baseline and Month 3. Patients either added MEV-miRNAs/iSFRP1 gel once weekly or continued topical minoxidil alone. Hair density and terminal/vellus hair proportions were assessed in frontal, vertex and occipital regions.

Results
MEV-miRNAs significantly increased HFDP cell viability and upregulated key Wnt-pathway components vs untreated controls. Hair-shaft elongation in human hair follicles cultured in MEV-miRNA-enriched medium showed a trend toward growth promotion. *Ex vivo*, iSFRP1 significantly increased transcription of the Wnt target gene LEF1 and inhibited catagen development, with more follicles remaining in anagen VI than with vehicle. In the randomized clinical study, relative changes with MEV-miRNAs/iSFRP1 gel vs placebo were +23% vs +4% at Week

8 and +36% vs +3% at Week 12 for anagen hair percentage; +80% vs +6% and +173% vs +11% for A/T ratio; and +50% vs +3% and +62% vs +7% for hair-shaft diameter. All three parameters improved significantly from baseline in the MEV-miRNAs group, with significant differences vs placebo, at both time points (all $p \leq 0.001$). In the exploratory series, mean Month-3 increases in hair density with adjunctive gel vs minoxidil alone were +16.1% vs +7.5% frontally, +18.3% vs +8.8% at the vertex and +9.6% vs +4.3% occipitally. Absolute increases in terminal hair proportion were +13.3 vs +6.0, +14.3 vs +6.7 and +9.7 vs +4.3 percentage points, respectively. No product-related clinical signs, discomfort, or adverse events were reported in either study.

Conclusion

MEV-miRNAs and iSFRP1 demonstrated convergent biological effects relevant to follicular activity, Wnt signaling and hair-cycle transitions. Their combination in a once-weekly topical gel significantly improved key trichoscopic outcomes versus placebo, while preliminary adjunctive observations suggested numerically greater improvements than topical minoxidil alone. These findings provide translational support for further controlled evaluation of this dual-component, non-drug approach alongside established hair-loss management.

EA DV CONGRESS
VIENNA
30 SEP - 3 OCT 2026

Abstract N°: 382

The impact of hormone therapy-induced hair changes on the quality of life among the transgender population: a cross-sectional study

Chaninan Kositkuljorn*[1], Napapat Pongbangpho[2], Poonkiat Suchonwanit[1]

[1] Division of Dermatology, Department of Medicine, Faculty of Medicine Ramathibodi Hospital, Mahidol University, Bangkok, Thailand

[2] Division of Dermatology, Department of Medicine, Faculty of Medicine, Chulalongkorn University, Bangkok, Thailand

Introduction

There is limited data on the impact of hair changes on Quality of Life (QoL) among transgender individuals receiving gender-affirming hormone therapies (GAHT).

Materials and Methods

We conducted a questionnaire-based, cross-sectional study among transgender individuals. Hair changes were assessed at baseline and survey date. Hair loss patterns were examined using the Hamilton-Norwood (H-N) scale and Ludwig scale; hirsutism was assessed using the modified Ferriman–Gallwey (mFG) score. The impact of hair changes on QoL was evaluated using the Dermatology Life Quality Index (DLQI).

Results

The study included 168 participants (129 transgender men [TM] and 39 transgender women [TW]) with a median GAHT duration of 2 years. For scalp hair, the median H-N scale scores of TM increased from 1 to 2 after treatment, while TW showed no significant change (Ludwig scale remained at 1). Regarding body hair, mFG scores in TM increased to 15, while TW's scores decreased to 9 after therapy. These changes had minimal impact on QoL. Median DLQI scores for scalp hair changes were 1 for both groups, while body hair changes scored 0 for TM and 1 for TW. Multivariable linear regression analysis in both groups showed that scalp hair loss has the strongest impact on DLQI score, while body hair growth does not significantly affect QoL. Additionally, a positive correlation was observed between the duration of GAHT and both the H-N scale and mFG scores in TM, whereas a negative correlation was found in TW between the duration of GAHT and both DLQI hair scores and mFG scores.

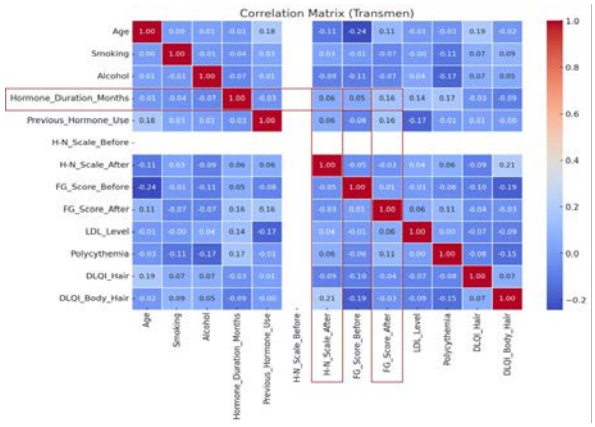

Figure 2. Correlation Matrix between Variables in Transgender Men. R values are shown as different degree of color intensity (red, positive correlations; blue, negative correlation). R values are reported in

the plot only for statistically significant correlations (p-value <0.05 after FDR correction

Conclusions

While GAHT leads to hair changes in transgender individuals, these changes do not substantially affect QoL for most participants. However, clinicians should identify and provide targeted support for the subset of participants who experience significant QoL impacts from these changes.

EADV CONGRESS
VIENNA
30 SEP - 3 OCT 2026

Abstract N°: 408

Analysis of the health status of patients suffering from ingrowing nail plate – data from clinical studies.

Michalina Jakubowska[1], Dominika Wcislo-Dziadecka*[1], Elżbieta Chełmecka[1], Dawid Heczko[1]

[1] Department of Practical Cosmetology and Skin Diagnostics, Faculty of Pharmaceutical Sciences in Sosnowiec, Medical University of Silesia, Sosnowiec, Poland

Introduction

Ingrown toenails are a common condition that can occur at any age. The overall health of affected patients also plays a significant role in treatment. One way to classify the severity of the condition is the Mozen classification. It divides the condition into three stages: I - Characterized by mild swelling, redness, and pain around the nail fold. In this stage, infection is not yet present, and the nail plate merely presses against soft tissue. II - Inflammation worsens, with purulent discharge and increased pain. The nail fold is significantly swollen and red. III - Chronic inflammation occurs, with the formation of granulation tissue that grows beyond the nail fold. The pain is severe, and the hypergranulation tissue bleeds easily. The aim of the study was to determine the influence of the patient's health condition on the conservative treatment of ingrowing toenail. Establishing a correlation may be useful in recommending first-line treatment.

Case Presentation

Materials & Methods:The study included 233 cases of ingrowing toenails in individuals of varying ages and health status. Conservative treatment techniques included tamponade, active dressing, taping, wedge undercutting, local disinfection, and orthonyx braces. Treatment outcomes were collected, along with other data regarding the patients' health, lifestyle, and functioning. An analysis was conducted to identify the most common health correlations among the study volunteers.
Results:Among the studied patients, the duration of conservative treatment of ingrowing nails differed significantly in statistical terms among patients suffering from diabetes and cancer, compared to healthy patients.

Conclusion

Conclusion:1) Health status significantly influences the conservative treatment of ingrown toenails.2) The severity of the condition was most often moderate – Mozen classification level II – among the study participants.3) Ingrown toenails affect patients of all ages.4) Comorbidities constitute a significant risk factor when treating ingrown toenails.5) Obesity and being overweight can be significant risk factors leading to the development of many conditions, including ingrown toenails.6) Genetic factors associated with the occurrence of ingrown toenails were observed in approximately 39% of the study participants.7) Diabetes and cancer may delay conservative treatment of ingrown toenails.

EA DV CONGRESS
VIENNA
30 SEP - 3 OCT 2026

Abstract N°: 449

Topical onychomycosis treatment with once-daily acidifying peelable nail lacquers – A multicentric randomized clinical trial

Stef Robijn*[1], Nejib Doss[2], Laurens De Schepper[1], Bart Rossel[1]

[1] Oystershell Laboratories, Merelbeke-Melle, Belgium

[2] Dermatology Clinic N. Doss, Tunis, Tunisia

Introduction

Onychomycosis is a prevalent fungal nail infection of the fingernails and toenails, frequently caused by dermatophytes but also attributable to non-dermatophyte molds and yeasts such as Candida species. Effective treatment remains challenging because of inherent slow nail growth, the nail's composition and poor patient compliance.

This study evaluated the efficacy and safety of two peelable acetic acid based nail lacquers (FORTE and ACTIVE COVER LIGHT) as topical treatment for superficial or light to moderate distolateral onychomycosis. Both formulations are designed to acidify the nail environment and form a peelable, water and physical stress resistant film (transparent for FORTE and neutral tone coloured for ACTIVE COVER LIGHT). By acidifying the nail environment, the infection is prevented from expanding and allows the infected part of the nail to grow out.

Materials and Methods

In this multicentric, evaluator-blinded clinical trial (NCT06254027), 132 adults were randomized diagnosed with onychomycosis in at least one great toenail or fingernail, confirmed by a positive KOH staining. For 270 days, subjects applied either FORTE or ACTIVE COVER LIGHT once daily, or a 5% amorolfine lacquer once weekly.

The primary objective was to assess efficacy by blinded evaluation of the increase in the percentage of healthy nail surface compared to baseline. The secondary objectives were to evaluate efficacy in terms of microbiological cure, improvements in nail appearance (onychomycosis evolution, onycholysis, nail dystrophy, nail discoloration and nail thickening). Safety and tolerability of the products were also assessed. Objectives were evaluated at baseline and on days 30, 90, 180, and 270.

Results

Subjects were 18–75 years old, and 58% were female. Onychomycosis most frequently involved the great toenail (94%), followed by the thumbnail (3.8%).

The percentage of healthy nail surface increased significantly over time in all treatment groups ($p<0.001$). After 270 days, the mean increase in the percentage of healthy nail surface was 24.0% (95% CI: 19.0 - 29.0, $p<0.001$) in the FORTE group, 29.5% (95% CI: 23.4 - 35.7, $p<0.001$) in the ACTIVE COVER LIGHT group, and 24.1% (95% CI: 19.4 - 28.8, $p < 0.001$) in the amorolfine group. KOH staining was positive in all subjects at baseline. By day 270, negative KOH results were observed in 86% of subjects treated with FORTE and in 75% treated with ACTIVE COVER LIGHT, compared with 68% in the amorolfine group.

Across all treatment groups, onychomycosis evolution, onycholysis, nail dystrophy, nail discoloration, and nail thickening showed progressive improvement. For onychomycosis improvement and treatment success (completely cured), both FORTE and ACTIVE COVER LIGHT showed earlier shifts toward improvement (notably from day 30) and achieved higher success rates by day 270. At day 30, onychomycosis improvement was substantially higher with FORTE (79.5%) and ACTIVE COVER LIGHT (70.5%) than with amorolfine (41.9%). By day 270, both FORTE and ACTIVE COVER LIGHT also demonstrated greater success rates than amorolfine (FORTE 32.6%, ACTIVE COVER LIGHT 27.3% and amorolfine 14.6%, respectively). After 270 days, improvement or

treatment success was observed in 93.1% of subjects in the FORTE group and 90.9% in the ACTIVE COVER LIGHT group, compared with 82.9% in the amorolfine group. Overall, all treatments were very well tolerated.

Conclusions

This randomized clinical trial confirmed that both acidifying peelable nail lacquers, FORTE and ACTIVE COVER LIGHT, are safe and effective topical treatments for onychomycosis.

EA DV CONGRESS
VIENNA
30 SEP - 3 OCT 2026

Abstract N°: 472

Artificial Intelligence–Assisted Trichoscopic Density Mapping for Donor Area Evaluation and Surgical Planning in Hair Transplantation

Sandeep Mahapatra*[1]

[1] Neo Follicle Hair Transplant Clinic, Bangalore, India

Introduction

Background

Accurate evaluation of donor density, follicular unit distribution, and hair shaft characteristics is essential for optimal hair transplant (HT) planning. Conventional trichoscopic assessment relies on manual counting and visual estimation, which can be time-consuming and subject to inter-observer variability. Advances in artificial intelligence (AI) and computer vision enable automated analysis of scalp images, offering the potential for standardized and reproducible follicular measurements.

Objective

To evaluate the clinical utility of an AI-assisted trichoscopic analysis system (AI ScalpScan) for automated follicular density estimation and donor area assessment during hair transplant consultations.

Materials and Methods

Methods

High-resolution trichoscopic images from [45] hair transplant patients undergoing consultation were analyzed using an AI-driven image analysis platform (AI ScalpScan). A total of [180] trichoscopic images from donor and recipient scalp regions were processed. The system automatically detected follicular units and generated structured reports including follicular unit density (FU/cm^2), estimated follicle counts, hair shaft thickness measurements, and calculating the total Donor area availability . Serial image analysis allowed comparison of scalp characteristics across time points.

Results

Results

AI-assisted analysis generated automated follicular density measurements ranging from [60–95 FU/cm^2] in donor regions. The platform produced region-specific follicular density insights and visual scalp maps within [8–10 seconds per image], compared with approximately 3–5 minutes per image required for manual trichoscopic counting. Automated reporting enabled consistent documentation of donor capacity, regional density variation, and scalp characteristics relevant to graft planning.

Conclusions

Conclusion

AI-assisted trichoscopic analysis using AI ScalpScan provides a comprehensive, standardized, and efficient approach for donor area evaluation and follicular density assessment in hair transplant practice. Unlike conventional analysis tools in market that demand extensive setup, technical expertise, or prolonged workflows, AI ScalpScan is designed to be intuitive and minimally disruptive to clinical routines and is device agnostic—delivering detailed, actionable scalp assessments without adding operational burden to the consultation process. This technology supports more data-driven surgical planning, improves consultation efficiency, and enhances patient communication through objective and reproducible scalp measurements.

EA DV CONGRESS
VIENNA
30 SEP - 3 OCT 2026

Abstract N°: 495

The impact of unconscious bias in diagnosing hair disorders: the role of trichoscopy and clinicopathological correlation

Salwa Owasil*[1], Leila Asfour[1]

[1] Chelsea Westminster Hospital NHS Foundation Trust, London, United Kingdom

Introduction

Diagnosis of hair disorders relies on pattern recognition and distribution. However, this can lead to unconscious bias and misdiagnosis. A review of referrals to a tertiary hair service found an incorrect diagnosis was given to 24% of patients before being seen, with certain cases being mislabelled as scarring alopecia, which has a tremendous impact on prognosis and treatments.

We present a case series demonstrating the potential pitfalls in clinicians' unconscious bias in the diagnostic process. We report two cases where a misdiagnosis of central centrifugal cicatricial alopecia (CCCA) or traction alopecia were made in women with afro-textured hair. After clinicopathological correlation (CPC), their diagnoses were revised to Alopecia Areata (AA) and Fibrosing Alopecia in a Pattern Distribution (FAPD). Finally, a South Asian woman with parietal hair loss initially diagnosed as traction whose diagnosis was revised to alopecia areata.

Case Presentation

A 30-year old female was referred with circular areas of hair loss over the vertex. Scalp biopsy showed trichomalacia and pigment casts in keeping with trichotillomania. In addition, concentric perifollicular fibrosis was noted around the upper segments of hair follicles raising the differential of CCCA. Through our CPC review we were able to revise her diagnosis from a scarring process of CCCA to that of AA with associated trichotillomania. The fibrosis seen on biopsy was felt to be in keeping with chronic traction/trichotillomania. Patient was subsequently treated successfully with triamcinolone injections.

A 35-year-old female was referred with suspected traction alopecia with bi-temple hair recession and diffuse trichodynia. Biopsy showed follicular scarring, extensive miniaturisation and presence of patchy perifollicular inflammation and raised the question of CCCA. No features of traction were seen. No perifollicular scale or erythema was noted and the crown showed good follicular growth with no scarring which would be expected with CCCA. Given the unclear diagnosis, the case was discussed at a multidisciplinary specialist hair meeting. The meeting confirmed inflammation in keeping with 'lichenoid process' and fibrosis in isthmus/infundibulum levels. These findings combined lead to a revised diagnosis of FAPD. Oral lymecycline was commenced and topical clobetasol propionate 0.05% continued for the LPP component. Oral minodixil was prescribed for the female pattern hair loss component.

A 50-year-old South Asian woman presented with several years of reduced hair density on the parietal lower portions of her scalp. She was initially diagnosed as potential traction alopecia and androgenetic alopecia. On trichoscopy there was evidence of yellow dots which led to performing a biopsy. This enabled, following CPC review, a revised diagnosis of alopecia areata. She has been commenced on steroid injections and immunosuppressive therapy with evidence of regrowth.

Conclusion

Certain hair disorders are more prevalent in certain hair types/ patient groups. CCCA has solely been described in afro-textured hair. Traction alopecia is also commonly seen in other patient groups including South Asian patients, use of certain headgear and hair styles. Closing the knowledge gaps in skin of colour is vital; however, it is equally important to avoid generalisations as this may lead to diagnostic delays and suboptimal management. Unconscious bias can lead to over-diagnosis of these conditions. CPC is therefore vital for accurate and timely diagnosis rather than relying on trichoscopy or biopsy findings alone.

EA DV CONGRESS
VIENNA
30 SEP - 3 OCT 2026

Abstract N°: 498

Oral minoxidil enhances early response to baricitinib in moderate-to-severe alopecia areata. A retrospective study of 59 patients.

Juan Jimenez Cauhe*[1], Diego Buendia-Castaño[2], David Saceda-Corralo[2], Sergio Vaño-Galvan[2], Angela Hermosa-Gelbard[2]

[1] Hair Disorders Unit, Grupo Pedro Jaen, Madrid, Spain

[2] Dermatology, Hospital Universitario Ramon y Cajal, Hair Disorders Unit, Grupo Pedro Jaen, Madrid, Spain

Introduction

Preliminary reports suggest that combining baricitinib with oral minoxidil (OM) may offer synergistic benefits in alopecia areata (AA). However, the lack of comparative studies including baricitinib monotherapy limits the understanding of OM's true clinical contribution. We aimed to evaluate whether the combination of OM improves the outcomes of baricitinib treatment for AA in a real-world setting.

Materials and Methods

We conducted a retrospective study including adults with AA treated with baricitinib 4 mg alone or combined with OM (0.5–10 mg daily) for ≥ 6 months. Patients receiving other treatments for AA were excluded. Response rate (achieving SALT score ≤20) and evolution of SALT score were analyzed.

Results

A total of 59 patients were included (64.4% women), with a mean age of 41.8 years (range 18 – 66). Mean duration of the current episode of AA was 3.2 years (0.1 – 14), and mean baseline SALT score was 79.3 (21 – 100), with 36 patients (61%) presenting SALT ³ 95. Mean duration of baricitinib treatment was 16.2 months (7 – 22). A total of 46 patients (77.9%) received concomitant OM at different points of the follow-up: 24 patients (40.7%) at baseline, 33 (55.9%) at month 3, 43 (72.9%) at month 6.Patients initiating concomitant OM at baseline achieved a significantly higher response rate compared to those on baricitinib monotherapy, at month 3 (41.7% vs. 17.1%; p=0.03) and 6 (66.7% vs. 34.3%; p=0.01). No statistically significant differences were found at month 9 and 12. Also, the reduction in SALT score at month 3 was significantly greater in the combination group, compared with baricitinib monotherapy (p=0.02) (Figure 1).Among patients not responding to baricitinib monotherapy at month 3, those who subsequently initiated OM achieved a significantly higher response rate at month 9, compared to those remaining on monotherapy (77.8% vs 33.3%; p=0.04). In patients with baseline SALT 95–100, adding OM at month 3 resulted in a 71.4% response rate at month 6, 9 or 12, compared to 26.7% in the monotherapy group (p=0.01). Multivariate logistic regression showed no differences in the overall response rate at 3, 6, 9 or 12 months for age, gender, OM dose and duration of the current AA episode.

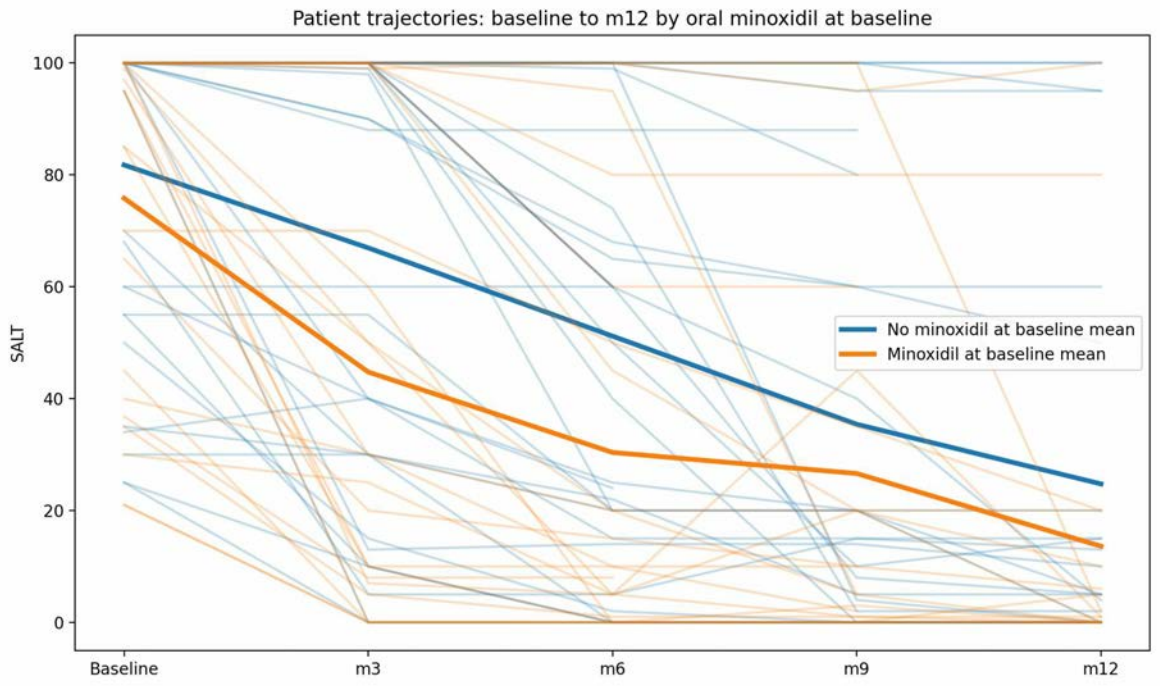

Temporal evolution of SALT score in patients with alopecia areata treated with baricitinib and oral minoxidil from baseline (orange line), compared to those with no oral minoxidil from baseline (blue line).

Conclusions

Although a time-lagged exposure approach was used, limitations include its retrospective design and potential confounding by indication and time-dependent biases. In conclusion, this real-world study provides preliminary evidence that OM may be associated with a faster clinical response when combined with baricitinib for AA.

EADV CONGRESS
VIENNA
30 SEP - 3 OCT 2026

Abstract N°: 547

Alopecia areata of the donor area following follicular unit extraction: a case series

Thiago Lenoir*[1], André Vieira Maciel[2]

[1] Desenvolver Clínica Médica, Florianópolis, Brazil

[2] Universidade Federal de Santa Catarina, Florianópolis, Brazil

Introduction

Alopecia areata (AA) is an autoimmune hair loss disorder rarely reported as a complication of hair transplantation surgery. While post-transplant autoimmune phenomena have been described, most notably lichen planopilaris, the occurrence of classic AA specifically in the donor area remains poorly characterized in the literature. We report a case series of three patients who developed AA exclusively in the donor area following follicular unit extraction (FUE).

Case Presentation

Among approximately 400 consecutive FUE procedures performed by a single surgeon, three patients aged 44, 55, and 58 years (incidence 0,75%) developed AA restricted to the donor area. AA onset occurred at 8, 12, and 18 weeks postoperatively, respectively. All cases were mild, with Severity of Alopecia Tool (SALT) scores of 10, 12, and 18. No recipient area involvement was observed in any patient.All three patients were treated with topical corticosteroids followed by oral minoxidil. Complete hair regrowth was confirmed by clinical and trichoscopic assessment within 12, 14, and 15 weeks of treatment initiation, respectively. The pathophysiology of post-transplant AA remains incompletely understood. Proposed mechanisms include immune privilege collapse triggered by surgical trauma, the Koebner phenomenon, and a post-surgical proinflammatory microenvironment targeting follicular antigens. The exclusive involvement of the donor area in all three cases may reflect the direct mechanical and inflammatory insult to follicular units at the harvest site, potentially unmasking latent autoimmune susceptibility in genetically predisposed individuals.Exposure to general anesthesia has been associated with an increased risk of AA in population-based studies, suggesting that systemic surgical stress may also play a role. The variable onset (8–18 weeks postoperatively) and the favorable, consistent treatment response observed in all patients are noteworthy. This complication warrants inclusion in pre-operative counseling for candidates undergoing FUE.



Donor-area alopecia areata following follicular unit extraction (FUE) hair transplantation. Well-demarcated, smooth patches of non-scarring alopecia are visible within the occipitoparietal donor zone, consistent with alopecia areata triggered in the post-surgical setting.

Conclusion

AA of the donor area is a rare but clinically relevant complication of FUE hair transplantation, with an estimated incidence of 0,75% in this series. All cases were mild and responded fully to topical corticosteroids and oral minoxidil within 15 weeks. Early recognition and prompt treatment are essential for favorable outcomes. Larger prospective studies are needed to better characterize risk factors and optimal management strategies.

EA DV CONGRESS
VIENNA
30 SEP - 3 OCT 2026

Abstract N°: 553

Diffuse Longitudinal Melanonychia Revealing Severe Vitamin B12 Deficiency on a Lupus Nail Background

Maria Charaa*[1]

[1] Mohamed V Military Instruction Hospital, Rabat, Morocco

Introduction

Melanonychia is defined as a brown-black pigmentation of the nail plate, most commonly resulting from melanocytic activation within the nail matrix. Its etiologies are diverse, ranging from benign racial variations to systemic inflammatory diseases and nutritional deficiencies. Although uncommon, vitamin B12 deficiency can trigger significant cutaneous and nail pigmentary abnormalities. In patients with systemic lupus erythematosus, interpreting nail findings is often challenging due to overlapping mechanisms, including disease-specific vasculopathy and drug-induced changes. We report a case of diffuse melanonychia revealing profound vitamin B12 deficiency in a patient with lupus, where the clinical timeline was crucial for the differential diagnosis.

Case Presentation

A 40-year-old woman with a history of systemic lupus erythematosus presented with progressive melanonychia involving all fingernails over the past year. This was associated with chronic fatigue, decreased hair density, and distal paresthesias. Notably, the patient had been started on hydroxychloroquine therapy only three months before her consultation. Clinical examination revealed brown-black longitudinal melanonychia affecting multiple nails, occasionally becoming confluent. This was accompanied by nail dystrophy, including yellowish subungual hyperkeratosis, distal onycholysis, and nail plate fragility, without Hutchinson's sign or periungual inflammation. Dermoscopy showed regular, parallel, and homogeneous longitudinal pigmented bands without features suggestive of malignant melanocytic proliferation, supporting a diagnosis of benign systemic melanocytic activation. Laboratory investigations revealed macrocytic megaloblastic anemia with markedly reduced vitamin B12 levels (50 pg/mL). While hydroxychloroquine can induce nail pigmentation, its recent introduction (3 months) made it an unlikely primary cause for such diffuse involvement. Given the association with SLE, an autoimmune etiology for the deficiency was suspected; consequently, anti-intrinsic factor antibody testing was initiated and is currently pending. A diagnosis of melanonychia secondary to severe vitamin B12 deficiency was retained, and parenteral supplementation was started.

Vitamin B12 deficiency may induce cutaneous hyperpigmentation and longitudinal melanonychia through increased melanogenesis, likely related to intracellular glutathione depletion, which normally inhibits tyrosinase. In this case, the short duration of hydroxychloroquine exposure (3 months) was insufficient to explain the extent of the pigmentation, as antimalarial-induced melanonychia typically requires longer cumulative doses. Furthermore, while lupus-related nail involvement usually manifests as periungual erythema or capillaroscopic abnormalities, the presence of megaloblastic anemia strongly pointed toward a nutritional or malabsorptive origin. The ongoing investigation for anti-intrinsic factor antibodies is essential, as the coexistence of SLE and Pernicious Anemia is well-documented in the context of polyautoimmunity.



Diffuse homogeneous longitudinal melanonychia affecting multiple fingernails

Conclusion

Diffuse longitudinal melanonychia can be a sentinel sign of severe vitamin B12 deficiency, even in patients already managed for systemic inflammatory diseases. This case highlights that clinicians should not automatically attribute nail changes to long-term medications like hydroxychloroquine, especially when the treatment duration is brief. Serum vitamin B12 assessment remains a fundamental, cost-effective step in the diagnostic workup of acquired multiple melanonychia, ensuring that reversible systemic conditions are not overlooked.

EA DV CONGRESS
VIENNA
30 SEP - 3 OCT 2026

Abstract N°: 561

Traction Folliculitis with Early Traction Alopecia in a Pediatric Male: An Underrecognized Entity

Ayushman Bindal*[1]

[1] Charak Hospital, Indore, Lady Hardinge Medical College, New Delhi, Indore, India

Introduction

Traction folliculitis (TF) is a rare, noninfectious inflammatory disorder caused by prolonged mechanical stress on hair follicles due to tight hairstyles. It presents with perifollicular erythema and pustules localized to areas of traction and may progress to traction alopecia (TA), which can become permanent if unrecognized. Although commonly described in females, TF is underreported in male children, especially in the Indian pediatric population where such grooming practices are prevalent.

Case Presentation

A 7-year-old boy presented with a 12-month history of progressive, asymptomatic hair loss over bilateral temporal regions, followed by the recent appearance of pustules. There was no history of chemical exposure or systemic symptoms. On evaluation, tightly tied ponytail since early childhood was identified as the precipitating factor. Examination revealed non-cicatricial alopecia with a positive fringe sign and follicular pustules over areas of maximum traction. Trichoscopy showed perifollicular erythema with preserved follicular openings and absence of fibrosis. Gram stain ruled out infection. A diagnosis of traction folliculitis with early traction alopecia was made. Management included cessation of tight hairstyles and short-term topical mupirocin. Marked clinical improvement with resolution of pustules and early hair regrowth was observed within one month.



Image shows tractional alopecia with multiple pustules suggestive of traction folliculitis

Conclusion

This case highlights an underrecognized presentation of TF with early TA in a male child. Early identification and simple behavioral modification can prevent progression to irreversible alopecia. Increased awareness among clinicians and caregivers is essential, particularly in regions where tight hairstyling practices are common.

EA DV CONGRESS
VIENNA
30 SEP - 3 OCT 2026

Abstract N°: 575

Efficacy of Hair Mesotherapy with Biomimetic Peptides and Micronutrients in Patients with Androgenetic Alopecia: A Retrospective Observational Study

Özlem Karadağ Köse*[1], Murat Borlu[2]

[1] İstanbul Aydın University Faculty of Medicine Department of Dermatology, İstanbul, Türkiye

[2] Erciyes University, Faculty of Medicine Department of Dermatology, Kayseri, Türkiye

Introduction

Androgenetic alopecia (AGA) is the most common form of hair loss, affecting approximately 50% of men and women during their lifetime. Current therapeutic options include topical minoxidil, oral finasteride, low-dose oral minoxidil, spironolactone, cyproterone acetate, platelet-rich plasma (PRP), microneedling, mesotherapy, and low-level laser therapy. Mesotherapy is a minimally invasive technique that delivers active agents directly into the dermis and has been used in dermatology for more than six decades. Commonly used mesotherapy agents for hair loss include minoxidil, dutasteride, growth factors, biomimetic peptides, vitamins, and micronutrients. Among these, biomimetic peptides have attracted attention because of their ability to mimic the activity of naturally occurring growth factors such as vascular endothelial growth factor (VEGF), insulin-like growth factor-1 (IGF-1), and fibroblast growth factor (FGF), all of which play critical roles in hair follicle cycling and angiogenesis. The present study aimed to evaluate the clinical efficacy and safety of a mesotherapy formulation containing biomimetic peptides, vitamins, and micronutrients in patients with AGA through a retrospective observational analysis.

Materials and Methods

This retrospective study included patients clinically diagnosed with AGA who presented to our dermatology department between April 2021 and June 2025. Ethical approval was obtained. Patient demographics, including age, sex, and skin phototype, were recorded, and AGA severity was classified using the Ludwig and Hamilton scales. Trichoscopic parameters included hair diameter variability, peripilar halo, empty follicles, and upright vellus hairs. Images were obtained at ×30 magnification from marked scalp regions. TrichoScan analysis was performed at baseline and four weeks after treatment completion. Total hair count, hair density, hair mass, mean hair thickness, terminal hair density, and terminal hair ratio were recorded before the first mesotherapy session. Each session involved 3 mL of solution, with injections spaced 0.5–1 cm apart. Treatments were administered using a mesogun with 30G, 13-mm needles at a depth of 2 mm. Multiple punctures were made in continuous mode over the entire alopecic area. Each session lasted 15–20 minutes. Patients were instructed not to wash their scalp for at least 24 hours after treatment. The treatment protocol consisted of four weekly sessions followed by four biweekly sessions, for a total of eight sessions over three months. After completing the 3-month treatment protocol, patients were evaluated both clinically and with trichoscopy four weeks after the last session.



Figure: Clinic photos before (a) and after (b) hair mesotherapy.

Results

Post-treatment, significant improvements were observed in trichoscopic parameters, including reduced hair diameter variability ($p<0.01$), decreased empty follicles ($p=0.012$), and increased upright vellus hairs ($p<0.01$). TrichoScan analysis demonstrated significant increases in total hair count, hair density, average hair thickness, terminal hair density, and terminal hair ratio (all $p<0.001$). Treatment was well tolerated, with only mild, transient pain reported.

Table. Trichoscan results before and after hair mesotherapy in patients with androgenetic alopecia.

	Patients with androgenetic alopecia (n=50)		
Trichoscan results	Before treatment	After treatment	p-values
Total hair count	72,9±24.8	87,5±27.9	p<0.001
Hair density	213.7±114.8 1/cm^2	236.6±77.8 1/cm^2	p<0.001
Average hair thickness	52.7±8.4 µm	55.5±8.9 µm	P<0.001
Terminal hair density	128.7±56.8 1/cm^2	159.2±58.6 1/cm^2	P<0.001
Terminal hair ratio	61±13.4 %	68.6±13.8 %	P<0.001

Table: Values expressed as mean ± standard deviation. Statistical significance was determined using paired tests; $p<0.05$ was considered significant.

Conclusions

In this retrospective study, hair mesotherapy with biomimetic peptides, vitamins, and micronutrients demonstrated significant improvements in both trichoscopic and TrichoScan parameters in patients with AGA. The protocol was safe and well tolerated. These findings suggest that biomimetic peptide-based mesotherapy may represent a promising therapeutic option for AGA; however, further large-scale randomized controlled studies are needed to validate its efficacy, establish standardized protocols, and assess long-term safety.

EADV CONGRESS
VIENNA
30 SEP - 3 OCT 2026

Abstract N°: 576

Subungual Metastasis of Colorectal Adenocarcinoma

Ceyda Çaytemel[1], Cuyan Demirkesen[2], Duygu Koskuoğlu*[1]

[1] Acıbadem Mehmet Ali Aydınlar University, Department of Dermatology, Istanbul, Türkiye

[2] Acıbadem Mehmet Ali Aydınlar University, Department of Pathology, Istanbul, Türkiye

Introduction

Nail unit metastases are exceedingly rare and may mimic benign inflammatory or infectious disorders, resulting in delayed diagnosis. Recognition of atypical nail lesions in patients with advanced malignancy is therefore essential.

Case Presentation

A 61-year-old man with metastatic colorectal adenocarcinoma presented with a two-week history of nail deformity involving the left thumb. His oncologic history included colon adenocarcinoma treated with surgery and adjuvant FOLFOX chemotherapy, followed by multiple liver, lung, and cerebellar metastases managed with metastasectomies and radiotherapy.

Clinical examination revealed a hemorrhagic, lobulated, fragile nail bed lesion with focal mucinous appearance following nail plate removal. The initial differential diagnosis included organized paronychia, hematoma, and metastasis. Shave biopsy demonstrated adenocarcinoma infiltration with partially papillary architecture within the nail bed. Immunohistochemical staining showed diffuse strong positivity for SATB2 and CDX2, focal CK20 positivity, and CK7 negativity, supporting metastatic colorectal adenocarcinoma. Although digital papillary adenocarcinoma was considered histopathologically, the overall findings were consistent with nail bed metastasis of colorectal origin.

Conclusion

Nail unit metastases represent a rare manifestation of internal malignancy and may clinically simulate benign nail disorders. Persistent or atypical nail bed lesions in oncology patients should prompt histopathological evaluation. Immunohistochemistry plays a critical role in distinguishing metastatic colorectal adenocarcinoma from primary adnexal neoplasms such as digital papillary adenocarcinoma.

EA DV CONGRESS
VIENNA
30 SEP - 3 OCT 2026

Abstract N°: 579

Automated Classification of Scalp Diseases and Detection of Alopecia Areata Features Using Dermoscopic Images

Juncheng Wang*[1], Jie Liu[2]

[1] Department of Dermatology, Fuzhou University Affiliated Provincial Hospital, Fuzhou University, Fuzhou, China
[2] Department of Dermatology, Peking Union Medical College Hospital, Chinese Academy of Medical Science and Peking Union Medical College, Beijing, China

Introduction
Accurate diagnosis of scalp diseases is essential for effective treatment but remains challenging due to hair coverage and overlapping clinical manifestations. Dermoscopy enables detailed visualization of scalp structures, making it particularly suitable for integration with artificial intelligence (AI) techniques.

Materials and Methods
Dermoscopic images of scalp diseases collected from five medical centers between 2022 and 2024 were used to establish a multicenter classification dataset comprising 8,664 images from 10 disease categories. In parallel, an AA feature detection dataset was constructed, including 1,699 images with 50,067 annotated features. For disease classification, a SpectFormer model integrating spectral layers and multi-head self-attention was adopted. For AA feature detection, a YOLOv8 model was used. Both models were initially trained on data from a single center, further fine-tuned with external multicenter data, and validated on an independent external test set to assess their generalizability.

Results
SpectFormer achieved strong overall performance in scalp disease classification, outperforming some comparator models despite having fewer parameters (Figure 1). After multicenter fine-tuning, the overall accuracy of the classification model on the external test set improved from 0.878 to 0.923, and the area under the curve increased from 0.831 to 0.938. For AA, the classification accuracy reached 0.931, with an area under the curve of 0.969. After fine-tuning, YOLOv8 improved its mAP@0.5 on the external AA feature detection test set from 0.453 to 0.514. Among the detected features, black dots and yellow dots showed particularly strong performance, with average precision values of 0.895 and 0.989, respectively. Visualization results further demonstrated that the models were able to focus on clinically meaningful dermoscopic features, including follicular openings and vascular patterns.



Figure 1. Classification performance and representative heatmaps of SpectFormer on dermoscopic images of scalp diseases. The ground-truth label and model prediction are shown below each image.

Conclusions

Artificial intelligence models based on dermoscopic images can accurately classify common scalp diseases and automatically localize and identify key dermoscopic features of AA. Multicenter fine-tuning substantially improves model generalizability. With both diagnostic performance and a degree of interpretability, this approach may serve as a useful tool for standardized diagnosis, disease severity assessment, and clinical decision-making in scalp disorders.

EADV CONGRESS
VIENNA
30 SEP - 3 OCT 2026

Abstract N°: 586

Efficacy and safety of a topical gel containing bovine milk-derived exosomes enriched in specific miRNAs (MEV-miRNAs) and an SFRP1 inhibitor (iSFRP1) in androgenetic alopecia and/or telogen effluvium: a multicentre randomised double-blind placebo-controlled study

Apostolos Pappas*[1], Laetitia LIEGARD[2], Maria Caterina FORTUNA[3], Marco Andrea TOMASSINI[4], Daniela PINTO[1], Giammaria GIULIANI[1], Fabio RINALDI[1]

[1] Human Microbiome Advanced Project Lab, Milan, Italy

[2] Laboratoires Bailleul by Giuliani, Geneva, Switzerland

[3] Sapienza University of Rome, Rome, Italy

[4] Studio Medico Estetimedica, Foligno, Italy

Introduction

Androgenetic alopecia and telogen effluvium are common hair loss disorders characterized by dysregulated hair follicle cycling and impaired dermal papilla cell function. iSFRP1, a novel non-drug antagonist of SFRP1 (secreted frizzled-related protein 1), has been shown *ex vivo* to inhibit catagen development in human hair follicles. MicroRNAs (miRNAs) are increasingly recognized as key post-transcriptional regulators of hair follicle biology, with effects on cell proliferation, differentiation, and pathways involved in follicular cycling, including Wnt/β-catenin signalling. Combined innovative strategies targeting follicular cycling and growth-related signalling may open new clinical perspectives in hair loss disorders.

Materials and Methods

This multicentre, randomised, double-blind, parallel-group clinical study aimed to assess the efficacy and safety of a topical gel containing MEV-miRNAs together with an SFRP1 inhibitor (iSFRP1), compared with placebo, in adult men and women aged 18–60 years with androgenetic alopecia and/or telogen effluvium, according to predefined inclusion and exclusion criteria. Subjects were assigned to MEV-miRNAs/iSFRP1 gel or placebo, applied once weekly for 12 consecutive weeks. 40 subjects were enrolled; 39 completed the study and were evaluable (MEV-miRNAs/iSFRP1 gel, n=19; placebo gel, n=20). Efficacy was assessed at baseline, Week 8 and Week 12 using digital phototrichogram analysis and epiluminescence microscopy. Primary endpoints included percentage of anagen hair follicles, anagen/telogen ratio and hair shaft diameter. Sample size was calculated to detect a 15% difference in anagen percentage with 80% power. Secondary assessments included trichoscopic features and subject self-assessment. Safety was evaluated through investigator examination and subject-reported tolerability.

Results

The MEV-miRNAs/iSFRP1 gel significantly increased the percentage of anagen hair follicles from 58.15±1.67 (mean ± SEM) at baseline to 70.37±1.05 at Week 8 and 77.73±0.86 at Week 12 (both $p<0.001$ vs baseline), whereas no significant change was observed with placebo. Compared with placebo, the between-group difference in change from baseline was significant at Week 8 (+23±4% vs +4±2%; $p<0.001$) and remained significant at Week 12 (+36±5% vs +3±2%; $p<0.001$). Between-group differences remained significant after adjustment for baseline values ($p<0.001$). The anagen/telogen ratio also increased significantly with the MEV-miRNAs/iSFRP1 gel, from 1.45±0.09 to 2.46±0.13 at Week 8 and 3.63±0.20 at Week 12, corresponding to relative increases of

+80±14% and +173±28%, versus +6±3% and +11±7% with placebo; between-group differences were significant at Week 8 and Week 12 (p<0.001). Hair shaft diameter increased from 47.54±2.64 µm at baseline to 65.26±3.10 µm at Week 8 and 70.63±2.27 µm at Week 12 with MEV-miRNAs/iSFRP1 gel, versus 46.00±2.11 µm, 47.00±1.74 µm and 48.44±2.52 µm with placebo. The relative increase from baseline was +50±12% and +62±10% with MEV-miRNAs/iSFRP1 gel versus +3±2% and +7±4% with placebo, with significant between-group differences at Week 8 (p=0.001) and Week 12 (p<0.001). Subject-reported outcomes at Week 12 favoured MEV-miRNAs/iSFRP1 gel, with 89.47% reporting stronger hair, 89.47% higher hair density, 94.74% improved hair quality, and 89.47% satisfaction with the product. No product-related clinical signs or discomfort were reported in either group.

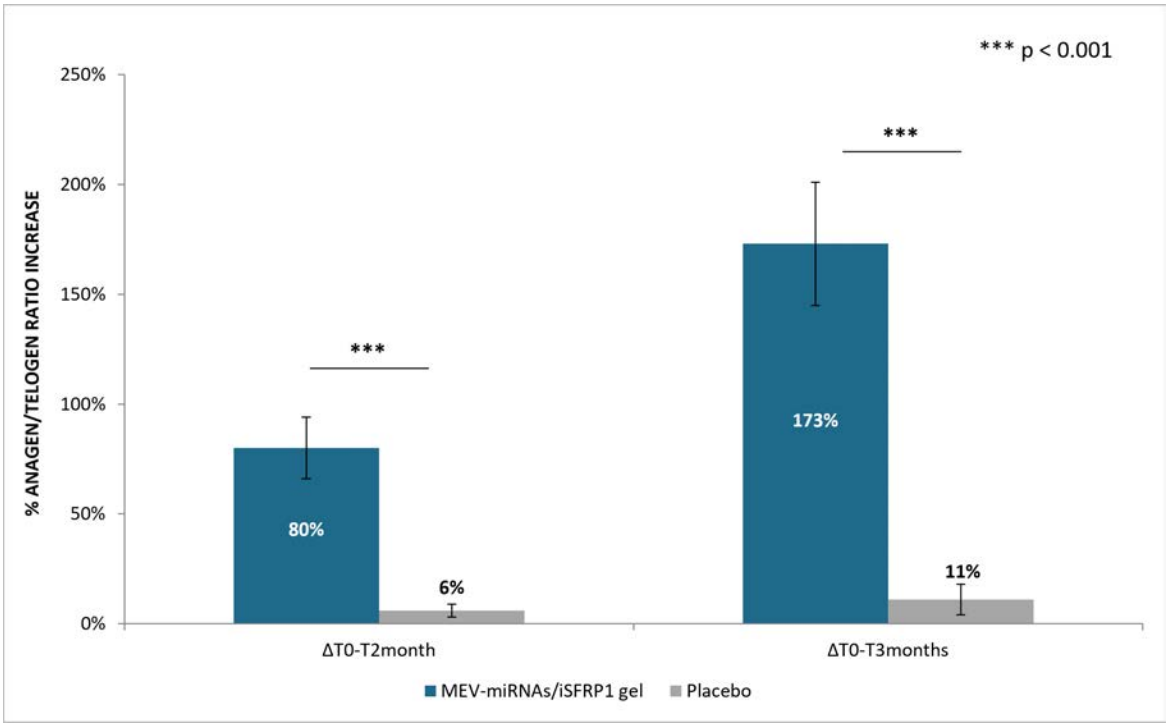

Mean percentage change from baseline (T0) in anagen/telogen ratio at T1 (2 months) and T2 (3 months) visits. Values are expressed as mean ± SEM. **p < 0.001 vs placebo at the corresponding time point.

Conclusions

Once-weekly application for 12 weeks of a topical gel containing bovine milk-derived exosomes enriched in specific miRNAs and an SFRP1 inhibitor significantly improved key objective hair-growth parameters and patient-perceived outcomes versus placebo in subjects with androgenetic alopecia and/or telogen effluvium, with excellent tolerability. These findings support further investigation of this non-pharmacological approach in larger and longer-term studies.

EA DV CONGRESS
VIENNA
30 SEP - 3 OCT 2026

Abstract N°: 616

The BEARD Score: A Practical Tool for Assessing Beard Involvement in Alopecia Areata

Giuseppe Gallo*[1, 2]

[1] University of Turin, Turin, Italy
[2] University of Bologna, Bologna, Italy

Introduction
Beard involvement in alopecia areata (AA) is a frequent and psychologically impactful manifestation in male patients. However, currently available clinician-reported outcome measures primarily focus on scalp involvement or rely on complex composite indices, leaving a gap for a simple, dedicated tool to assess beard disease severity. To propose a practical, rapid, and clinically applicable scoring system specifically designed to evaluate beard involvement in AA.

Materials and Methods
Based on clinical experience and anatomical considerations, we developed the BEARD score (Beard Evaluation Alopecia Rating Degree). The beard area is divided into six anatomically defined regions: bilateral mandibular branches, mustache area, and three cervical regions (left, medial/submental, right). Each region is assigned 1 point if any degree of hair loss is present, irrespective of extent or density. The total score ranges from 0 to 6. Severity categories were defined as mild (1–2 areas), moderate (3–4 areas), and severe (5–6 areas).

Results
The BEARD score provides a straightforward and reproducible method to quantify beard involvement in AA without requiring complex calculations. Its binary regional assessment enhances usability in both clinical practice and research settings. The score aligns with clinical observation and may better reflect patient-perceived disease burden compared to scalp-focused tools. It also offers potential utility as an outcome measure in clinical trials targeting facial hair regrowth.

Conclusions
The BEARD score represents a novel, simple, and beard-specific assessment tool for alopecia areata. Further studies are warranted to validate its interobserver reliability, sensitivity to change, and correlation with patient-reported outcomes.

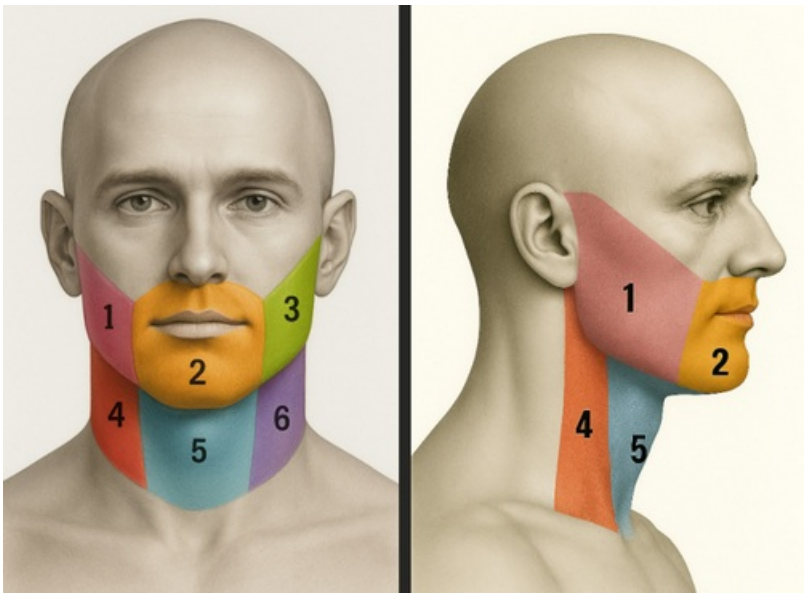
1
2
3
4
5
6
1
2
4
5

EADV CONGRESS
VIENNA
30 SEP - 3 OCT 2026

Abstract N°: 617

Comparative real-world effectiveness and safety of baricitinib and ritlecitinib in severe alopecia areata: a 52-week monocentric real-world cohort study

Giuseppe Gallo*[1, 2]

[1] University of Bologna, Bologna, Italy
[2] University of Turin, Turin, Italy

Introduction
Janus kinase (JAK) inhibitors represent a significant therapeutic advancement for moderate-to-severe alopecia areata (AA). While baricitinib and ritlecitinib have demonstrated robust efficacy in clinical trials, direct real-world comparative data between these two agents are currently lacking. This study evaluated the real-world effectiveness and safety of baricitinib and ritlecitinib in patients with moderate-to-severe AA over a 52-week treatment period.

Materials and Methods
This retrospective observational cohort study was conducted at the Dermatology Unit, University of Turin. The study included 243 patients aged ≥12 years with severe AA (baseline SALT score ≥50) who received treatment with baricitinib (2–4 mg/day) or ritlecitinib (50 mg/day) for at least 52 weeks. Data on clinical characteristics, SALT scores, and safety outcomes were collected. The primary endpoint was the change in SALT score at 52 weeks, while secondary endpoints evaluated the achievement of SALT ≤20, time-to-response, and treatment safety. Statistical evaluations included Kaplan–Meier survival curves and multivariable regression models.

Results
Patient Demographics: The cohort consisted of 154 patients treated with baricitinib and 89 with ritlecitinib, with an overall mean age of 41.1 years.
Efficacy Outcomes: Baseline disease severity was high, with a mean SALT score of 77.4. At 52 weeks, the mean SALT score decreased significantly to 24.7 ($p<0.001$).
Time-to-Response: The median time to achieve clinically meaningful hair regrowth (SALT ≤20) was 35.9 weeks. Kaplan–Meier analysis indicated no significant difference in the time to achieve SALT ≤20 between the two treatment groups (log-rank $p=0.166$).
Predictors of Response: Multivariable analysis showed that disease duration and clinical phenotype (e.g., patchy AA versus alopecia totalis/universalis) were the primary predictors of clinical improvement. The specific type of JAK inhibitor used was not independently associated with treatment outcomes.
Safety Profile: Both therapies were well tolerated. Adverse events occurred in approximately 24% of patients, were predominantly mild (such as headaches and upper respiratory tract infections), and did not result in permanent treatment discontinuation.

Conclusions
In this 52-week real-world cohort, baricitinib and ritlecitinib demonstrated comparable long-term clinical effectiveness and safety in treating severe alopecia areata. The findings emphasize that sustained treatment is required to achieve optimal therapeutic benefits. Furthermore, patient-specific disease characteristics appear to play a more substantial role in determining clinical outcomes than the selection of the specific JAK inhibitor, supporting a highly individualized approach to AA management.

Baricitinib vs. Ritlecitinib in Severe Alopecia Areata

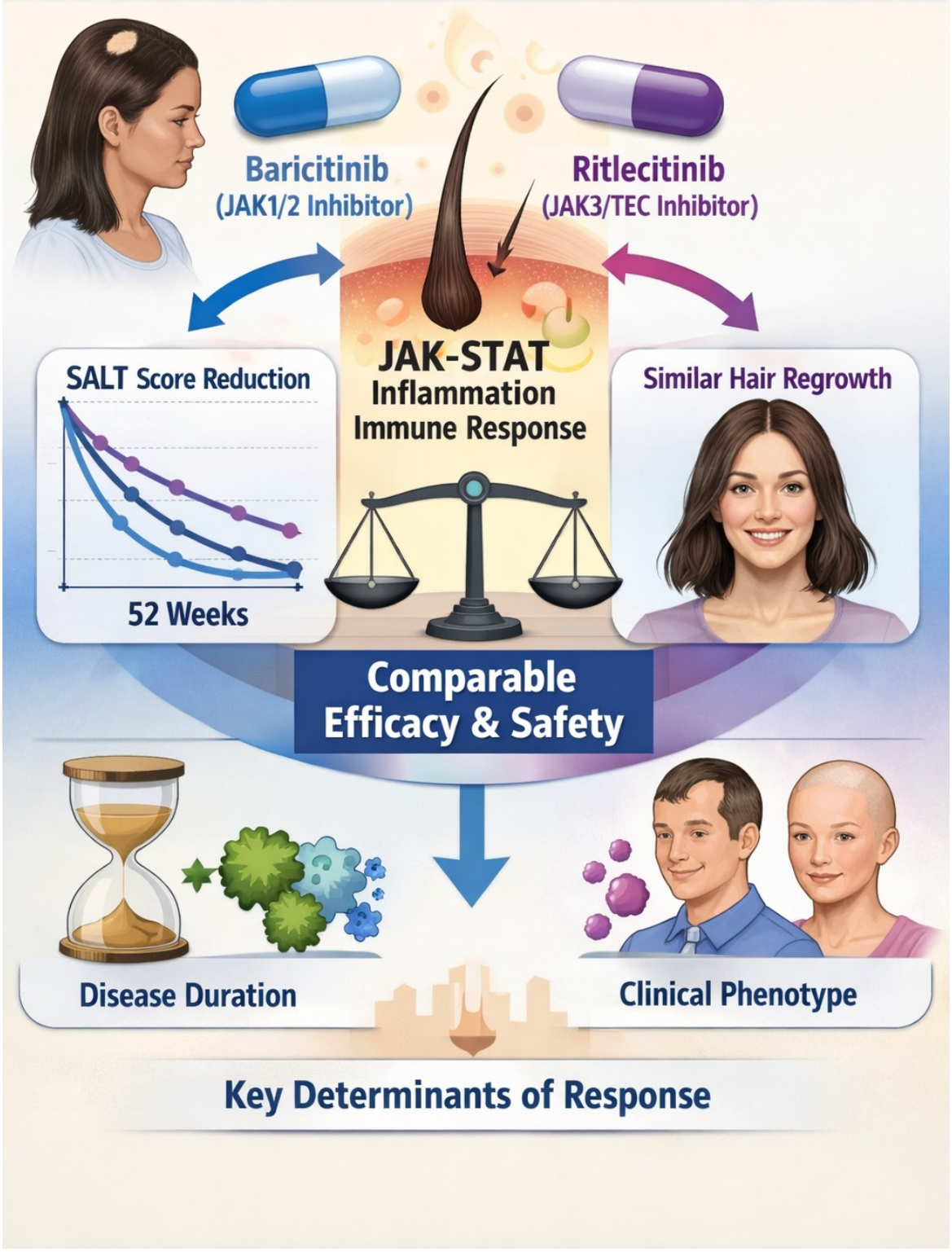

EADV Congress 2026, VIENNA
30 SEPTEMBER - 03 OCTOBER 2026
POWERED BY M-ANAGE.COM

EADV CONGRESS
VIENNA
30 SEP - 3 OCT 2026

Abstract N°: 627

Fractional 1570 nm Laser Therapy in Telogen Effluvium

Iva Stoilova*[1]

[1] Dermavist Clinic - Dermatology & Laser Therapy, Plovdiv, Bulgaria

Introduction

Telogen Effluvium (TE) is a non-scarring alopecia characterized by premature transition of hair follicles from the anagen to the telogen phase, commonly triggered by systemic stressors or post-viral conditions. Beyond visible shedding, TE reflects disruption in follicular signaling, microvascular support, and dermal homeostasis. Conventional therapies, including supplementation, topical agents, and platelet-based approaches, often demonstrate variable efficacy and limited influence on long-term follicular cycling.

I aim to evaluate the clinical efficacy and safety of a protocol-based, non-ablative 1570 nm fractional laser approach for follicular reactivation and modulation of the scalp microenvironment in patients with stress-related and post-viral Telogen Effluvium.

Materials and Methods

A total of 120 female patients with clinically and trichoscopically confirmed chronic or post-stress TE underwent a standardized protocol of three sessions of non-ablative fractional laser therapy at monthly intervals. The 1570 nm wavelength was used to induce controlled dermal heating and microthermal stimulation, targeting follicular structures and the surrounding tissue environment. The treatment aimed to enhance microcirculation, support extracellular matrix remodeling, and promote re-entry of follicles into the anagen phase. Clinical evaluation included trichoscopy, hair-pull test, and digital imaging, alongside patient-reported outcomes assessing scalp condition and perceived improvement. A follow-up was conducted three months after the final session.

Results

Clinical observations demonstrated improvement in hair density, follicular thickness, and overall scalp quality. Trichoscopic evaluation suggested a shift toward increased anagen activity and reduced shedding. Patients reported improved scalp comfort and reduced distress associated with hair loss. The protocol was well tolerated, with no significant adverse events observed. The treatment also showed potential as a supportive modality in patients undergoing hair transplantation, contributing to improved scalp condition and procedural outcomes.

Conclusions

Non-ablative 1570 nm fractional laser therapy represents a regenerative, energy-based approach to Telogen Effluvium, acting through modulation of the follicular microenvironment and restoration of physiological hair cycling. By addressing underlying biological dysfunction rather than isolated symptoms, this protocol may offer a safe and adaptable strategy in the management of stress-related and post-viral hair loss, with potential integration into multimodal hair restoration protocols.

EADV CONGRESS
VIENNA
30 SEP - 3 OCT 2026

Abstract N°: 642

Trichoscopic features of androgenetic alopecia according to the basic and specific (BASP) classification: a retrospective observational study in Korean patients

Jeewoo Choi*[1], Mina Song[2], So Hyun Ahn[3], Ji Yeon Byun[1]

[1] Department of Dermatology, Ewha Womans University Seoul Hospital, Seoul, Korea, Rep. of South

[2] Ewha Womans University College of Medicine, Seoul, Korea, Rep. of South

[3] Ewha Medical Research Institute, Ewha Womans University College of Medicine, Seoul, Korea, Rep. of South

Introduction

Androgenetic alopecia (AGA) is a common hair loss where early diagnosis is challenging. Trichoscopy offers a noninvasive method for evaluating AGA, but its relationship with disease severity is not well-established. Herein, we aimed to evaluate the correlation between qualitative and quantitative trichoscopic features and the severity of AGA graded by the Basic and Specific (BASP) classification.

Materials and Methods

This retrospective study analyzed 471 trichoscopic images from 157 Korean participants (99 with AGA, 58 controls). Qualitative and quantitative trichoscopic factors were compared between groups and assessed for trends across BASP stages.

Results

The prevalence of all qualitative scalp signs was significantly higher in the AGA group than in controls ($p < 0.05$ for all). As BASP stages advanced, there was a stepwise increase in all scalp signs and the proportion of single-hair follicular units, while total hair count and proportion of multi-hair follicular units decreased significantly ($p < 0.001$ for all). Notably, females showed a significantly higher 1FU% than males in the early stage.

Conclusions

In conclusion, a significant association existed between trichoscopic features and AGA severity. Vellus hairs can serve as an early indicator, while an increased 1FU% may serve as quantitative markers of follicular miniaturization. These findings support the use of trichoscopy as an objective tool for the early detection and monitoring of AGA.

EA DV CONGRESS
VIENNA
30 SEP - 3 OCT 2026

Abstract N°: 678

Marigold therapy for nail dystrophy in a patient with epidermolysis bullosa simplex

Aalia Syed*[1], Mohammed Tariq Khan[2], Dédée Murrell[1]

[1] Faculty of Medicine, University of New South Wales, Sydney, NSW, Australia, Department of Dermatology, St. George Hospital, Sydney, NSW, Australia, Sydney, Australia

[2] Faculty of Medicine, University of New South Wales, Sydney, NSW, Australia, Department of Dermatology, St. George Hospital, Sydney, NSW, Australia, EB Department, Great Ormond Street Hospital for Sick Children, London, U.K., Sydney, Australia

Introduction

Epidermolysis bullosa simplex (EBS), the most common subtype of EB, is characterised by intraepidermal mucocutaneous blistering in response to mechanical trauma, most frequently caused by dominant mutations in the keratin 5 (KRT5) or keratin 14 (KRT14) genes. Marigold therapy has a significant history in topical skin therapy of the lower extremities and is available as a paste, tincture, oil, ointment or cream. In particular, the safety, keratolytic and anti-inflammatory properties of the Tagetes species are supported by double-blind, placebo-controlled trials in hyperkeratotic plantar lesions, hallux valgus and verruca pedis ($p<0.001$). We report a case of an EBS patient whose nail dystrophy was treated with Tagetes-based marigold therapy.

Case Presentation

A 44-year-old female with genetically confirmed EBS (heterozygous likely pathogenic KRT14 variant c.1163G>A; p.Arg388His) presented with chronic blistering localised to the feet since adolescence, triggered by prolonged walking, heat and tight footwear. Examination revealed no active blisters, but minor residual damage from previous blisters. Management included 15% aluminium chloride anti-perspirant spray nocte to the soles to reduce sweating, sterile silicone adhesive wound dressings to reduce friction and trauma, and antimicrobial foam dressings and polymeric membrane dressings to manage active blisters, resulting in satisfactory blister control.

Subsequently, she developed an infection of the left hallux following rupture of a periungual blister, which resolved after three courses of oral cephalexin, though residual frosty-white nail discolouration and surface irregularity persisted. Podiatry assessment revealed nail dystrophy of the left hallux toenail. Initial treatment included keratolytic Tagetes-based marigold paste to the left hallux toenail and compressible felt pad coverage for one week. The patient then self-applied topical marigold tincture and oil twice daily, and wore gel toe protectors. By day seven, the nail surface appeared smoother and clearer, with visible new nail growth at the base of the nail bed. By 12 weeks, 70% of the nail had grown out and by six months the dystrophic nail had resolved completely. No pain or adverse effects were associated with the treatment.

Case reports exist on the use of marigold therapy in median canaliform nail dystrophy affecting both hallux toenails and in lichen striatus nail dystrophy of the right hallux toenail, with resolution achieved within four months and three months, respectively. Both cases used a similar regimen of a week-long Tagetes paste and an overlying pad, followed by self-application of a tincture and oil, without adverse effects. Similarly, we report the successful use of Tagetes-based marigold therapy in an EBS patient with nail dystrophy. This is likely due to the antikeratolytic, antiviral, antibacterial and antifungal flavonoids (quercetagetin, quercetagetrin, kaempferol and kaempferitrin) contained in Tagetes, facilitating gradual reduction in excess nail keratin. General measure may also have contributed to improvement of the nail dystrophy, including appropriate foot care and toe protection. Of note, Tagetes belongs to the Compositae (Asteraceae) family, which carries recognised allergenic potential; cross-

reactivity with other Compositae plants, including Arnica, should be considered.

Conclusion

To conclude, this case illustrates that Tagetes-based marigold therapy may support restoration of nail architecture in patients with EBS and underscores the need for larger studies to confirm its safety and effectiveness.

EADV CONGRESS
VIENNA
30 SEP - 3 OCT 2026

Abstract N°: 680

topical metformin copmared with clobetasol propionate for alopecia areata : clinical outcomes from clinical trial

nashwa saged[1], Zakaria obaid[2, 2], Ibrahim Fouda*[3]

[1] cairo university, Mansoura, Egypt
[2] Al-Azhar University, egypt, Al-Azhar University, egypt, Al-Azhar University, egypt, cairo, Egypt
[3] Al-Azhar University, egypt, Al-Azhar University, egypt, Al-Azhar University, egypt, Mansoura, Egypt

Introduction
alopecia areata is non scaring form of hair loss driven by autoimmune processes. although benign , AA significantly impairs health - related quality of life
(HRQoL), primarily affecting psychological and social well-being due to associated alterations in appearence.

Materials and Methods
thirty -four adult individuals with patchy alopecia areata partcipiated in a randomized clinical trial and were categorized into two groups: Group I(17 participants) with metformin 30% applied twice daily for 12 weeks and Group II (17 paricipants) with clobetasol propionate 0.05% administered twice daily for 12 weeks.the 5- point semiqauntitative regrowth score(RGS), SALT score and dermoscopic examination were done to evaluate the therapeutic response .

Results
At the week 12 , the median hair regrowth score for group I was 2, wheras for groupII it was 5. there was no difference of significant impotrance regarding hair regrowth between the two groups, with p=0.133. significant reduction in SALT score were observed in the two groups, and the reductions were mostly observed in groupII.

Conclusions
topical metformin 30% represents a promising and well-tolerated option in alopecia areata treatment. Although no statisticaly significant difference was observed between metformin 30% and clobetasol propionate 0.05% in primary endpoints,clobetasol demonstrated superior clinical efficacy in treating localized AA. Tthis positions metformin as a viable steroid sparing alternative for patients priortrizing tolerability.

EA DV CONGRESS
VIENNA
30 SEP - 3 OCT 2026

Abstract N°: 690

Feasibility of Stepwise Baricitinib Tapering After Complete Response in Alopecia Areata

Hye Rin Seo*[1], Doyoung Kim[1]

[1] Department of Dermatology and Cutaneous Biology Research Institute, Yonsei University College of Medicine, Seoul, Korea, Rep. of South

Introduction
Long-term maintenance strategies after complete hair regrowth on Janus kinase inhibitors for alopecia areata (AA) remain undefined. Although continued treatment is often recommended, evidence on dose tapering after complete response is limited. We evaluated the feasibility of stepwise baricitinib tapering in patients with AA who achieved complete response on baricitinib 4 mg daily in routine practice.

Materials and Methods
We conducted a real-world prospective observational cohort study in patients with AA receiving baricitinib 4 mg daily who had achieved complete response, defined as a Severity of Alopecia Tool (SALT) score of 0 or no clinical evidence of active disease. Between January 2023 and March 2026, eligible patients underwent individualized stepwise tapering in routine care. Tapering generally proceeded at approximately 2-month intervals, from 4 mg daily to alternating 4/2 mg dosing, 2 mg daily, 2 mg 5 times weekly, 2 mg every other day, and discontinuation. Recurrence was managed according to clinical severity with intralesional triamcinolone, topical corticosteroids, stepwise dose re-escalation to the prior tapering step, or return to baricitinib 4 mg daily. The primary outcome was tapering failure, defined as recurrence requiring re-escalation to baricitinib 4 mg daily. Major recurrence was defined as recurrence with a SALT score >5. Minor recurrence was defined as recurrence with a SALT score ≤5.

Results
Sixty-three patients were included. Median age at AA onset was 30.0 years, median baseline SALT score at baricitinib initiation was 25.0, median current episode duration was 11.0 months, median time from baricitinib initiation to tapering was 6.6 months, and median follow-up after taper initiation was 8.3 months. Tapering failure occurred in 18/63 patients (28.6%), whereas 45/63 (71.4%) avoided re-escalation to 4 mg. Median time to failure was 3.8 months, suggesting that most failures occurred early after taper initiation. Overall, 44/63 patients (69.8%) maintained response at a dose of 2 mg or lower during follow-up, including 12/63 (19.0%) who remained off treatment. Among failures, 15/18 (83.3%) were minor recurrences and 3/18 (16.7%) were major recurrences. All major recurrences occurred in patients who had progressed to alopecia totalis within 3 months of disease onset and had been refractory to prior immunomodulatory therapies. No baseline variable was significantly associated with the binary endpoint of tapering failure. However, in an exploratory analysis, current episode duration differed among the tapering failure, on-drug taper success, and off-drug success groups (median 19.5 vs 14.0 vs 4.5 months, respectively; P=0.037).

Conclusions
In real-world practice, gradual baricitinib tapering after complete response in AA appeared feasible, with most patients avoiding re-escalation to 4 mg and nearly one-fifth remaining off treatment during follow-up. Because most recurrences were early and minor, closer monitoring during the first months after taper initiation may be warranted. Shorter current episode duration may be associated with deeper tapering success and could help identify better candidates for dose reduction. These findings are clinically relevant because successful tapering may reduce long-term treatment burden, cumulative drug exposure, and treatment costs, with potential safety

advantages. Limitations include the single-center design and limited follow-up after discontinuation.

EADV CONGRESS
VIENNA
30 SEP - 3 OCT 2026

Abstract N°: 709

An unusual case of alopecia with Lupus erythematosus-Ashy dermatosis overlap syndrome

Edwin Tan*[1], Katherine Darch[2], Kiarash Khosrotehrani[2], Dominic Wood[1]

[1] IQ Pathology, Brisbane, Australia

[2] Queensland Institute of Dermatology, Brisbane, Australia

Introduction

Lupus erythematosus-Lichen planus overlap syndrome are unusual cases with clinical, histopathological, and immunopathological features of lupus erythematosus and lichen planus. Case reports of alopecia with features of Lupus erythematosus-Lichen planus overlap syndrome and Lupus erythematosus-Frontal fibrosing alopecia overlap syndrome have been previously described in the literature. However, to the best of our knowledge, Lupus erythematosus-Ashy dermatosis overlap syndrome has not been previously reported.

Case Presentation

We present a case of a 35-year-old man with Fitzpatrick skin type IV with a two-year history of gradual, patchy hair loss which started from bilateral sideburn areas extending to involve bitemporal scalp and forearms. On examination, there was perifollicular scale. There was no patchy loss of hair throughout the scalp, and there was no eyebrows, lashes, oral mucosa, nail or genital involvement. The face and neck showed ashy hyperpigmentation. He has a background of autoimmune thyroiditis. His ANA was negative and he had a low positive anti-SSA/Ro-60.

The biopsies from the scalp showed features of lupus erythematosus. There was a follicular lichenoid reaction pattern characterised by basal vacuolar change and occasional dyskeratotic keratinocytes. There was no involvement of the inter-follicular epidermis. There was a superficial and deep perivascular and periadenxal lymphoplasmacytic cell infiltrate and increased interstitial mucin deposition. Follicular plugging was present. Biopsy from the preauricular area showed features of ashy dermatosis. There was a interface reaction pattern and superficial dermal pigment incontinence. There was overlying basket weave stratum corneum and no significant hypergranulosis. There was also a mild superficial perivascular inflammatory cell infiltrate comprising lymphocytes and histiocytes. There was no deep inflammatory cell infiltrate and no increase in interstitial mucin deposition.

The patient was managed on weaning dose of oral prednisone which was changed to tofacitinib, hydroxychloroquine, methotrexate, folic acid, minoxidil and hydrocortisone. Over a period of nine months, there were some improvements in perifollicular inflammation and fading of hyperpigmentation. There were no new areas of hair loss.

Conclusion

This is an unusual case of alopecia with features of Lupus erythematosus-Ashy dermatosis overlap syndrome which responded well to tofacitinib, hydroxychloroquine, methotrexate, minoxidil and hydrocortisone. It is important to recognise these unusual cases as the disease course and optimal treatment may differ from Lupus erythematosus-Lichen planus overlap syndrome and Lupus erythematosus-Frontal fibrosing alopecia overlap syndrome.

EADV CONGRESS
VIENNA
30 SEP - 3 OCT 2026

Abstract N°: 715

When hair transplantation is deferred due to active inflammation: a case report of folliculitis decalvans-lichen planopilaris spectrum with concomitant androgenetic alopecia

Natia Sheklashvili*[1]

[1] Hair Transplant Clinic "DEAMED", Tbilisi, Georgia, , Tbilisi, Georgia

Introduction

Primary cicatricial alopecias may present with overlapping clinical and trichoscopic features, making diagnosis challenging. The folliculitis decalvans–lichen planopilaris spectrum (FDLPPPS) represents a proposed entity characterized by combined neutrophilic and lymphocytic inflammation. We report a diagnostically challenging case initially evaluated for hair transplantation.

Case Presentation

A 32-year-old male patient presented with progressive scalp hair thinning and requested hair transplantation. He reported intermittent scalp symptoms, including pruritus and pain. Clinical and trichoscopic examination revealed perifollicular erythema, hyperkeratosis, follicular tufts, and perifollicular milky-red areas. Trichoscopy also demonstrated features consistent with concomitant androgenetic alopecia. Due to suspicion of cicatricial alopecia, a scalp biopsy was performed.Histopathological examination demonstrated overlapping features of folliculitis decalvans and lichen planopilaris, including hyperkeratosis, mild epidermal hyperplasia, basal layer degeneration of the follicular epithelium, and a dense perifollicular lymphohistiocytic infiltrate with focal plasma cells. Horizontal sections showed partial follicular destruction with perifollicular fibrosis and preservation of the arrector pili muscle. Active inflammatory changes led to deferral of surgical intervention.The patient was treated with combined antibacterial and anti-inflammatory therapy, including doxycycline (100 mg twice daily for 1 month, followed by 100 mg once daily for an additional month), intralesional triamcinolone injections every 4-6 weeks, and topical betamethasone with gentamicin ointment. This regimen resulted in marked clinical improvement within 2 months, with stabilization of the condition and no further progression of hair loss.

Conclusion

This case highlights an important diagnostic pitfall, as patients seeking hair transplantation may present with underlying active cicatricial alopecia. FDLPPPS should be considered in cases with overlapping clinical and trichoscopic features. Early diagnosis using trichoscopy and histopathology is essential to prevent inappropriate surgical intervention and disease progression.

EA DV CONGRESS
VIENNA
30 SEP - 3 OCT 2026

Abstract N°: 730

The Efficacy of Growth Factor Injection in Androgenic Alopecia: A Systematic Review and Meta-Analysis

Azhar Alali[1], Mohammed Alahmadi*[1], Ghazal Alsisi[1], Sara Alghamdi[2], Ghaida Elmehallawy[3], Lama Albelowi[4], Haya Altouri[3], Layan Albejawi[5]

[1] Department of Dermatology, King Fahad General Hospital, Medina, Saudi Arabia
[2] Department of Dermatology, King Fahad Hospital, Al-Baha, Saudi Arabia
[3] College of Medicine, Taibah University, Medina, Saudi Arabia
[4] Department of Dermatology, King Salman bin Abdulaziz Medical City, Medina, Saudi Arabia
[5] College of Medicine, Alrayan Medical Colleges, Medina, Saudi Arabia

Introduction
Androgenetic alopecia (AGA) is the most common cause of hair loss, and current pharmacotherapies have limitations. Autologous platelet-derived therapies, including PRP, its standardized derivative PRGF, and other growth factor concentrates (GFC), have emerged as regenerative options, but differences in preparation and mixed clinical evidence remain. While individual studies have reported positive outcomes, the comparative effectiveness of different growth factor preparations remains unclear. Furthermore, no systematic review has comprehensively synthesized the evidence for GFC specifically, which may offer advantages over conventional PRP due to its higher growth factor concentration and fibrin scaffold properties. Therefore, a systematic evaluation of the available evidence is needed to clarify its therapeutic role in AGA.

Materials and Methods
This systematic review was carried out following the guidelines of the Preferred Reporting Items for Systematic Reviews and Meta-Analyses (PRISMA). To maintain a rigorous yet clinically relevant focus, this review included studies involving patients with AGA treated with injected GFC, PRP, or PRGF, encompassing randomized controlled trials and non-randomized trials, as well as case reports reporting extractable data on outcomes such as hair density, thickness, photographic scores, or adverse events. Quality assessed using RoB2, MINORS, and MMS tools.

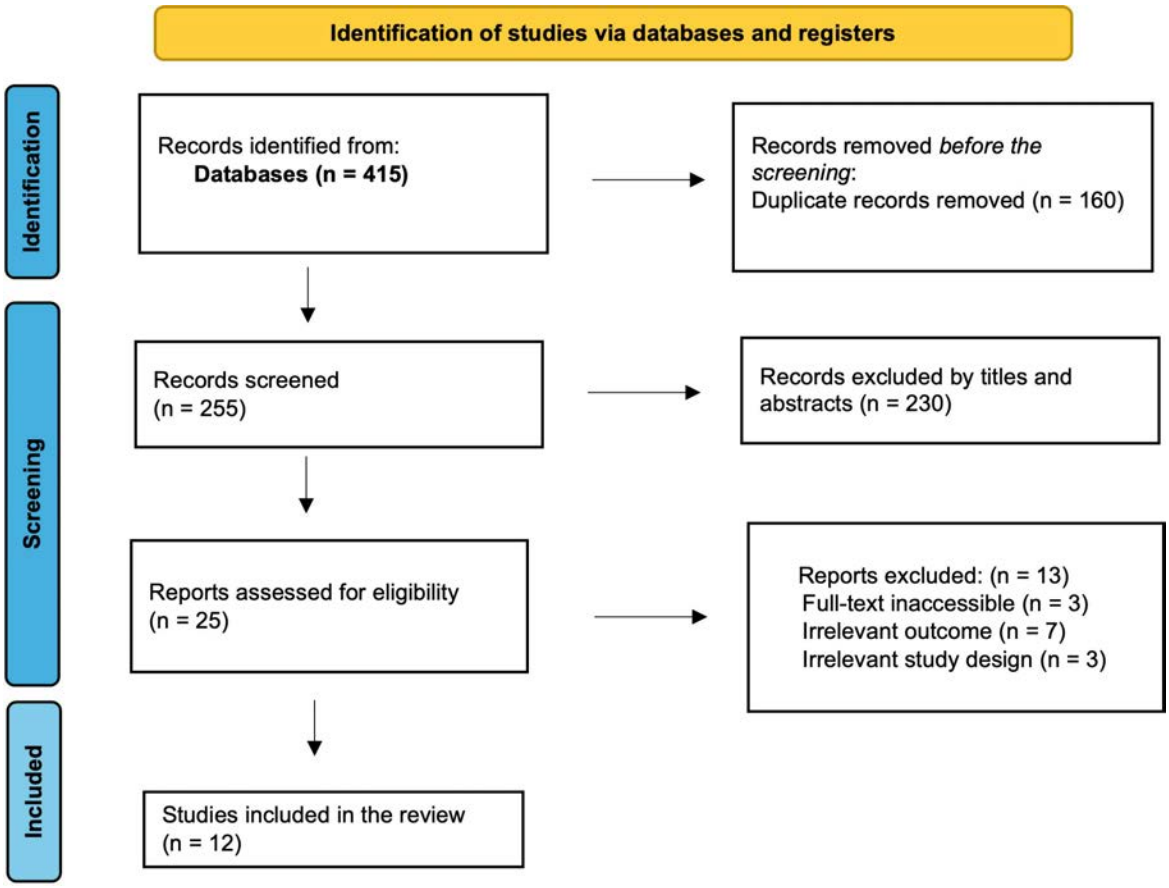

Figure 1 PRISMA Flowchart

Results

Twelve studies (745 patients) were included. GFC showed progressive hair density gains from 19.6 hairs/cm^2 at 1 month to 57.1 at 12 months, while PRP increased density by 34.4 at 6 months and 42.0 at 12 months. GFC also improved thickness (5.19 to 22.03 μm) with 94.3% patient satisfaction. Adverse events were mild, but RCTs had a high risk of bias, and non-randomized studies showed serious to critical bias. Autologous growth factor injections appear safe and improve hair density, thickness, and patient satisfaction over 12 months, especially with newer concentrates. However, high risk of bias, substantial heterogeneity (I^2 > 90%), and non-standardized protocols limit the evidence, making findings hypothesis-generating until larger, standardized, double-blind trials with long-term follow-up are conducted.

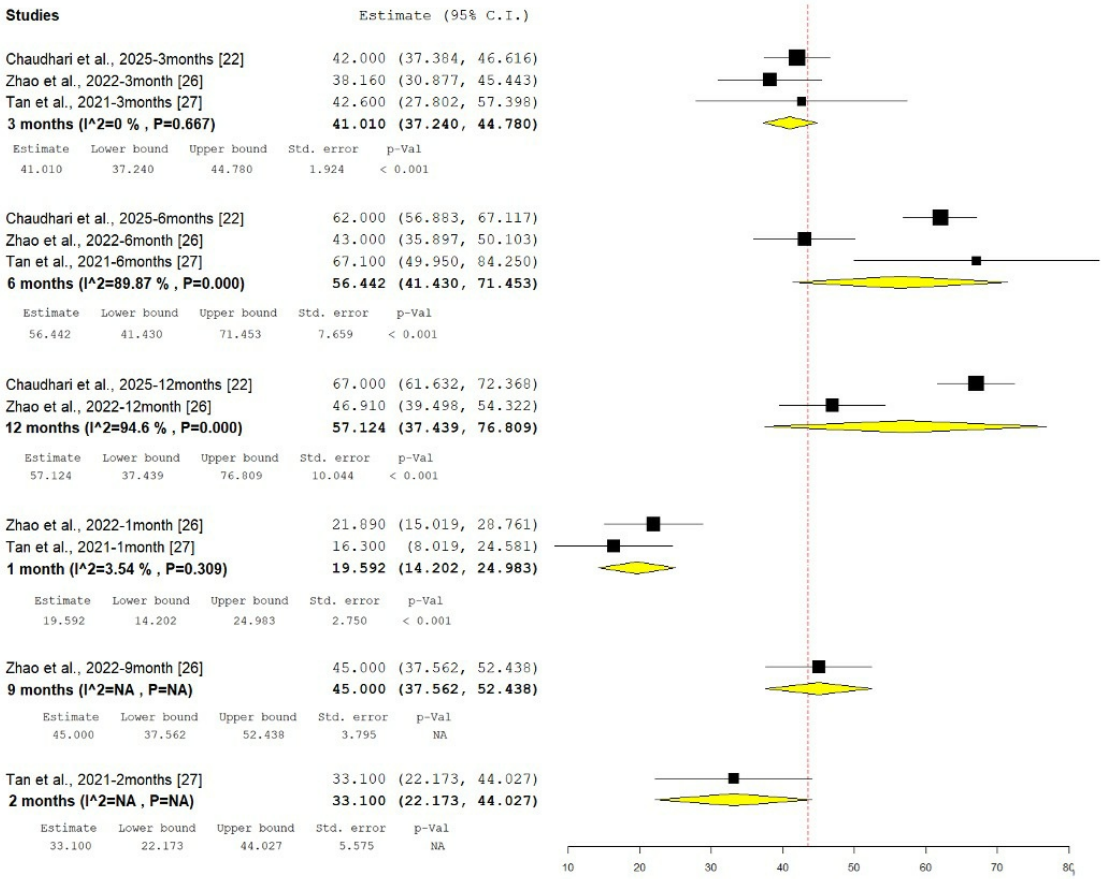

Forest Plot of Mean Change in Hair Density (hairs/cm^2) from Baseline Following Growth Factor Concentrate (GFC) at 1 to 12 Months Follow-up

Conclusions

This systematic review and meta-analysis suggest that intralesional autologous growth factor concentrates (PRGF and GFC) may be safe and potentially effective for AGA, with preliminary evidence of improved hair density, thickness, and patient satisfaction. GFC demonstrated progressive density increases from 19.59 hairs/cm^2 at 1 month to 57.12 at 12 months in pooled analyses, while PRP increased density by 34.43 hairs/cm^2 at 6 months and 42.00 at 12 months. Hair thickness with GFC rose from 5.19 µm to 22.03 µm over 12 months, and pooled satisfaction reached 94.3%. However, these estimates must be interpreted with extreme caution due to substantial methodological heterogeneity (I^2 > 90% for long-term outcomes), high or serious risk of bias in all included studies, and variability in preparation protocols. The current evidence does not support definitive clinical recommendations. Although results support growth factor therapy as a potentially promising alternative or adjunct, firm conclusions require larger, well-designed randomized trials with standardized methods, longer follow-up, and blinded outcome assessment

EA DV CONGRESS
VIENNA
30 SEP - 3 OCT 2026

Abstract N°: 753

Management of Chemotherapy-Induced Alopecia: A Systematic Review and Meta-Analysis

Azhar Ahmed[1], Mohammed Alahmadi*[2], Sara Alghamdi[3], Reenad Alharbi[4], Dalia Alanazi[5], Abdulsalam Humedi[6], Joud Alalawi[7]

[1] Department of Dermatology, King Faisal Specialist Hospital and Research Center, Medina, Saudi Arabia
[2] Department of Dermatology, King Fahad General Hospital, Medina, Saudi Arabia
[3] Department of Dermatology, King Fahad Hospital, Al-Baha, Saudi Arabia
[4] College of Medicine, Taibah University, Medina, Saudi Arabia
[5] College of Medicine, Al-Imam Muhammad ibn Saud Islamic University, Riyadh, Saudi Arabia
[6] College of Medicine, Jazan University, Jazan, Saudi Arabia
[7] College of Medicine, University of Jeddah, Jeddah, Saudi Arabia

Introduction
An estimated 65% of chemotherapy patients are predicted to experience chemotherapy-induced alopecia (CIA) and potential alterations in the color, texture, quantity, and growth of their hair. In addition to experiencing psychological distress, patients with CIA may refuse chemotherapy or stop taking it altogether. Our systematic review and meta-analysis were conducted to assess the current state of research on CIA treatment options and preventative strategies, compiling information on their effectiveness, safety, and effects on patient outcomes.

Materials and Methods
This systematic review was performed following the Preferred Reporting Items for Systematic Reviews and Meta-Analyses (PRISMA) guidelines. To identify relevant studies, a comprehensive literature search was performed across multiple electronic databases, including PubMed, EBSCO, Medline, Google Scholar, Wiley, and Web of Science.

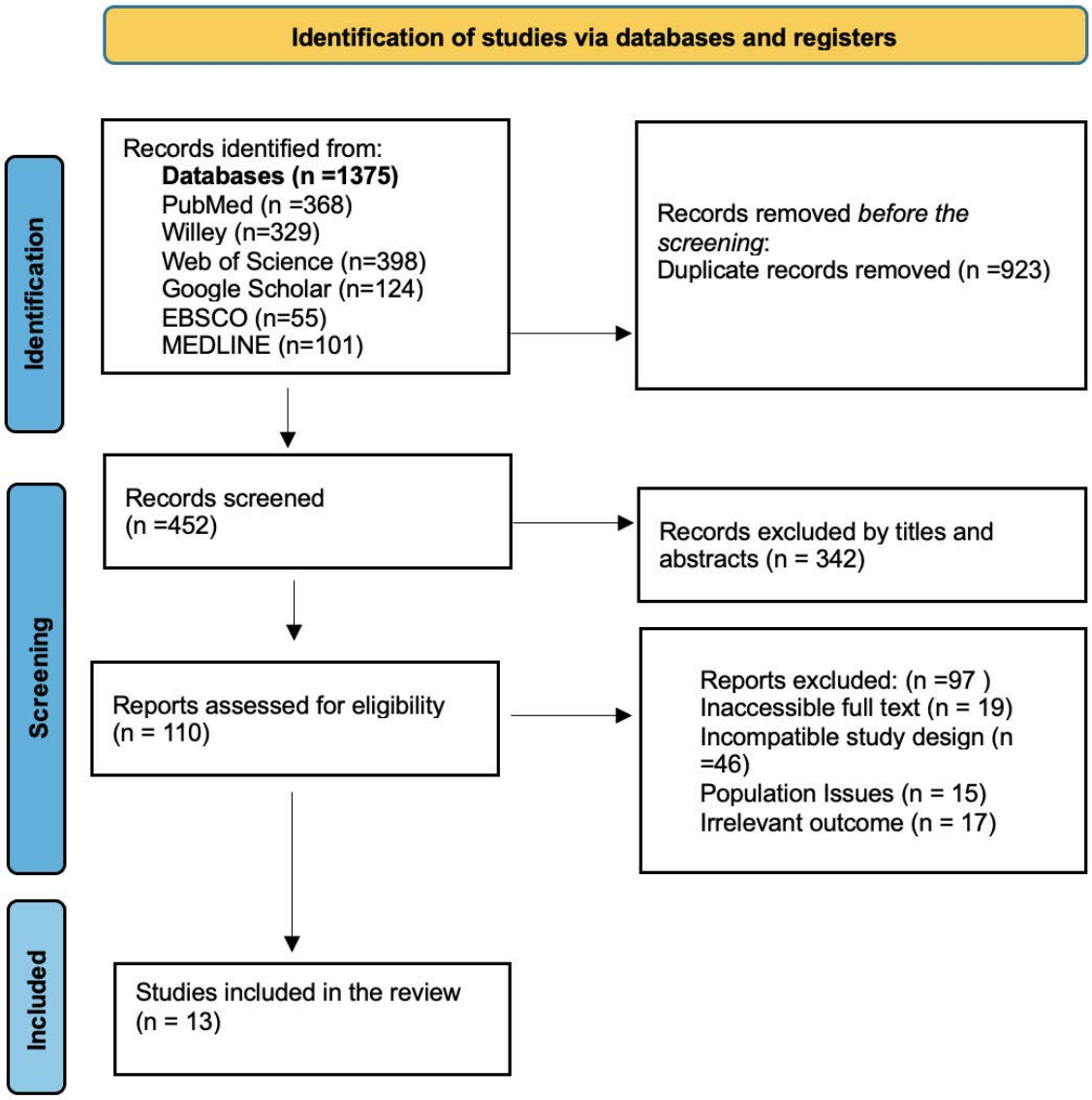

Figure 1 PRISMA

Results

Our review included 13 randomized and quasi-experimental trials that demonstrated that scalp cooling reduced moderate-to-severe chemotherapy-induced alopecia by more than half. Acceptable hair preservation rates in cooling arms ranged from 75% to 95%. In a meta-analysis of three trials, scalp cooling increased the odds of maintaining cosmetically acceptable hair by over fourteen times. In a separate meta-analysis of four trials (n = 262), scalp cooling reduced the odds of moderate-to-severe alopecia by 90%. Additionally, the patient-reported need for wigs or head coverings decreased from a control range of 45–84% to 5–33%. Adverse events were predominantly mild, including headaches, chills, and cold sensations. Treatment discontinuation due to side effects occurred in fewer than 30% of patients who received cooling. Across three RCTs, adverse events occurred in 62/150 cooled patients versus 0/95 controls, yielding a pooled OR of 86.63 for any event.

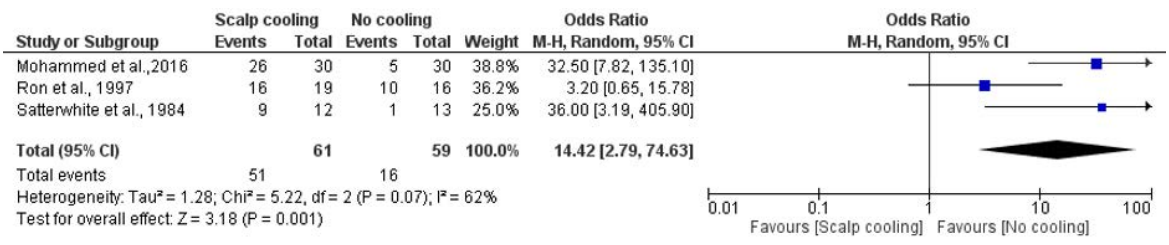

Forest Plot of Effectiveness of Scalp Cooling for Acceptable Hair Preservation

Conclusions

This review highlights that scalp cooling effectively reduces chemotherapy-induced hair loss, achieving hair preservation rates of 75–95%. Cooling should start 20–30 minutes before treatment, continue throughout the treatment, and last an additional 20–150 minutes afterward. Patients generally report high satisfaction, and side effects, such as mild headaches and chills, are rarely severe enough to stop treatment. Shorter post-infusion cooling times (20–45 minutes) are equally effective, allowing for improved workflow. These findings support the incorporation of scalp cooling into standard care for chemotherapy patients. Future research should focus on optimizing cooling schedules, assessing the cost-effectiveness of this treatment, and improving access to it.

EA DV CONGRESS
VIENNA
30 SEP - 3 OCT 2026

Abstract N°: 760

Symptom Relief and Disease Stabilization with Roflumilast Foam in LPP Spectrum Disorders: A Case Series

Elena Tay[1], Wei Jing Loo*[1, 2, 3]

[1] Western University, London, Canada
[2] DermEffects, London, Canada
[3] Probity Medical Research, Waterloo, Canada

Introduction

Lichen planopilaris (LPP) and its variants, including frontal fibrosing alopecia (FFA) and fibrosing alopecia in a pattern distribution (FAPD), are primary cicatricial alopecias characterized by lymphocytic inflammation targeting the follicular epithelium. Patients frequently experience pruritus, burning, and scalp dysesthesia, often preceding irreversible hair loss. Current treatments are limited by adverse effects, tolerability, and adherence challenges. Roflumilast 0.3% foam is a topical phosphodiesterase-4 (PDE4) inhibitor approved for inflammatory dermatoses, but its role in cicatricial alopecia has not been described.

Case Presentation

We report a retrospective case series of 5 patients with LPP-spectrum disease treated with topical roflumilast foam in a single-center dermatology practice.

Case 1: A 68-year-old woman with refractory FFA experienced marked reduction in pruritus and burning, with near-resolution of perifollicular erythema and scaling after 3 months of once-daily roflumilast foam.
Case 2: A 61-year-old man with biopsy-proven LPP treated with doxycycline and topical therapies demonstrated complete resolution of pruritus and erythema and disease stabilization at 3 months, transitioning to roflumilast maintenance.
Case 3: A 59-year-old woman with FAPD and longstanding treatment-refractory disease reported reduced shedding and clinical stabilization at 6 months, with improved adherence due to the foam vehicle.
Case 4: A 70-year-old woman with chronic LPP reported rapid symptomatic improvement within 24 hours of initiation, with sustained remission on maintenance therapy.
Case 5: A 47-year-old woman with diffuse LPP experienced resolution of scalp dysesthesia, eyebrow regrowth, and improved scalp findings with combination therapy including roflumilast, maintaining stability after discontinuation of intralesional corticosteroids.

Across all cases, patients demonstrated consistent improvement in pruritus, burning, and perifollicular inflammation, with good tolerability and high patient satisfaction.

Conclusion

Topical roflumilast foam may represent a promising steroid-sparing therapeutic option for LPP-spectrum disorders. Its mechanism of PDE4 inhibition increases intracellular cyclic AMP and downregulates pro-inflammatory cytokines implicated in lichenoid interface dermatitis, potentially attenuating the lymphocytic inflammation that drives follicular destruction. In this series, patients experienced rapid and sustained symptomatic relief, reduction in clinical inflammation, and disease stabilization across multiple LPP phenotypes, including refractory cases.

Importantly, roflumilast foam was well tolerated and cosmetically acceptable, supporting improved adherence compared to traditional topical therapies. Its utility as both an adjunctive and maintenance therapy highlights its versatility, particularly for patients who are intolerant of or unwilling to use systemic agents or long-term topical corticosteroids. While limited by small sample size and retrospective design, these findings support further investigation of roflumilast foam as a safe, effective, and patient-friendly treatment option in cicatricial alopecia.

EA DV CONGRESS
VIENNA
30 SEP - 3 OCT 2026

Abstract N°: 769

Dissecting cellulitis in a pediatric female

Karla Daniela Celis Vera*[1], Guadalupe Maldonado Colin[2]

[1] NA, MEXICO, Mexico
[2] Hospital 20 de Noviembre, Ciudad de México, Mexico

Introduction

Dissecting cellulitis of the scalp (DCS) is a disease that affects follicle hairs by chronic and recurrent inflammation tipically seen in Afro-American young men. Clinically is characterized by suppurative nodules, painful abscesses and scarring alopecia [1]. Tricoscophy findings are black dots, broken hair shafts and "yellow 3D- dots" which represent keratin accumulation and sebum inside infundibular follicle in active phase of the condition [2]. Histological test is necessary to confirm diagnosis distinguished by dermis infiltration of lymphocytes, monocytes, neutrophils in early-stages. Presence of lymphocytes granulomas, plasma cells and foreign-body cells revealed late-stages. End-stages manifest with follicle destruction and scarring changes [3].Treatment is focused on stop inflammation and prevent follicle destruction. Those are topical treatments: retinoids, antibiotics such as clindamycin, chlorhexidine washings, intralesional corticosteroids, oral isotretinoin, anti-TNF, anti-IL17; all of them based on clinical reports [4]. The most effective reported are oral tetracyclines not recommended under 8 years old; regarding of oral retinoids, they can be used in low-doses and short course because of risk of premature epipysheal closure [5].

Case Presentation

An 8-year-old hispanoamerican girl presented to the dermatology office with an history of recurrent fluctuant sterile, painless nodules on scalp and scarring. During interrogatory she had positive family history of African ethnicity in both parents. One year before, she emerged with total alopecia and treated as a tinea capitis. On examination was confirmed the presence of 3 nodules, skin colored, mobile and painless surrounded by scar tissue on the whole scalp. Trichoscopy revealed structureless white-red areas, and 3D-yellow dots. An ultrasound was performed reporting a fibrosing condition of the scalp. Skin biopsies were taken and reported with a dense mixed- inflammatory infiltration of lymphocytes, histocytes, multinucleated giant cells, plasma cells, and polymorphonuclears foci, also some eosinophiles around hair follicles with follicular destruction. The diagnosis of dissecting cellulitis scalp was confirmed. Three weeks later after biopsy nodules disappeared, with partially regrowth. Chlorhexidine hair washing was indicated twice a week and clobetasol 0.05% cream daily until 3 months.

Conclusion

This case reinforcs the importance of inquire into ethnicity when making an interrogatory of scalp diseases in children which could prevent delayed diagnosis. On the other hand, also highlights the need of developing clinical guidelines in pediatric population to standardize treatments. More evidence is needed for assuring security with isotretinoin in children.

EADV CONGRESS
VIENNA
30 SEP - 3 OCT 2026

Abstract N°: 775

Crowning Glory: Safety and efficacy of 1.25 mg versus 2.5 mg oral minoxidil in male androgenic alopecia

Shefa Karim*[1]

[1] Dr. D. Y. Patil Medical College, Navi Mumbai, India

Introduction
Androgenic alopecia (AGA) affects up to 80% of men and has a significant psychosocial impact. While oral minoxidil is emerging as a systemic alternative to topical therapy, its optimal dose remains undefined. This study aims to evaluate and compare the safety and efficacy of 1.25 mg vs. 2.5 mg oral minoxidil in male AGA patients.

Materials and Methods
This observational study enrolled 112 male patients with clinically diagnosed AGA. Patients were randomly selected to receive either 1.25 mg or 2.5 mg oral minoxidil daily for 6 months.Inclusion criteria: Males aged 18–45 years, Norwood-Hamilton grade II–V, normal baseline ECG and lab parameters, and no prior oral minoxidil use.Exclusion criteria: History of cardiovascular disease, uncontrolled hypertension, renal/hepatic dysfunction, hypersensitivity to minoxidil, concurrent use of other hair growth treatments, or poor follow-up compliance.Baseline and follow-up evaluations included:· Hair count (via dermoscopy)· Norwood-Hamilton scale grading· Hair pull test· Patient satisfaction and quality of life scoring· Safety profile investigations: CBC, ECG, RFT, LFT, serum electrolytes, lipid profile, and blood pressure monitoring.Adverse events were documented at each visit.

Results
Both groups showed significant hair count improvement. The 1.25 mg group increased from 170.54 ± 20.88 to 193.33 ± 24.61/cm^2 (14.75 ± 3.81%), while the 2.5 mg group improved from 160.50 ± 13.33 to 187.50 ± 14.68/cm^2 (16.96 ± 3.74%, p=0.004). Adverse events, including hair shedding, hypertrichosis, weight gain, and light-headedness, were more frequent in the 2.5 mg group but did not reach statistical significance. Patient satisfaction was higher in the 2.5 mg group (80.3%) compared to 1.25 mg (66.1%). No serious cardiovascular or metabolic adverse effects were observed.

Conclusions
Both 1.25 mg and 2.5 mg oral minoxidil are effective and safe for male AGA. The 2.5 mg dose offers superior efficacy with a slightly higher—but tolerable—adverse effect profile. Dose selection should be individualised based on clinical severity and patient tolerability.

EADV CONGRESS
VIENNA
30 SEP - 3 OCT 2026

Abstract N°: 795

From Tooth to Scalp: Alopecia Totalis Triggered by Chronic Apical Periodontitis

Irena Dezelak*[1], Špela Grilc[1]

[1] Department of Dermatovenerology, University Clinical Centre Ljubljana, General hospital Jesenice, Ljubljana, Slovenia

Introduction

Alopecia areata (AA) is an organ-specific autoimmune disorder mediated by T cells that target hair follicles during their growth phase, leading to non-scarring hair loss. While associations between AA and dental infections have been described, previously reported cases resolving after dental treatment have been limited to localized patches. This case report details a patient whose alopecia areata progressed to alopecia totalis (AT) despite local treatment, and fully resolved following treatment of an underlying dental infection. To our knowledge, no prior case report describes AA of this extent resolving after treatment of a confirmed dental infection.

Case Presentation

A 32-year-old male presented with a 10-month history of patchy hair loss on his scalp and beard. His medical history included mild atopic dermatitis, allergies, and a family history of androgenetic alopecia. Despite regular dental check-ups and a normal X-ray, he reported an unpleasant taste and bad breath. Clinical examination revealed several confluent alopecic patches on the scalp and a smaller patch on the chest. Scalp trichoscopy showed yellow dots, vellus hairs, black dots, and broken hairs at patch edges. Laboratory tests indicated Hashimoto's disease, though intervention was not required. The patient declined systemic treatments, opting for topical corticosteroids and local PUVA therapy, later discontinued due to pandemic restrictions, followed by topical mometasone and pimecrolimus. At a nine-month follow-up, the condition had worsened to total scalp hair loss with additional partial loss of eyebrow and eyelash hair. ENT evaluation and CT imaging identified chronic apical periodontitis around tooth number 25. The patient underwent surgical endodontic treatment and apicoectomy. Significant regrowth of scalp, beard, eyebrow, and eyelash hair was observed one to two months after dental treatment. A follow-up visit over a year later confirmed satisfactory scalp hair regrowth, with the patient expressing considerable satisfaction.

Conclusion

AA is often linked with autoimmune disorders and sometimes with infections, including dental infections, though the nature of this relationship remains debated. Our case showed complete AA recovery within five months of dental treatment, consistent with other reports of AA improvement following management of dental infections. Most such reports describe AA localized to patches, whereas our patient experienced total scalp hair loss. This more extensive presentation may be related to concurrent Hashimoto's disease, a known AA comorbidity not reported in other available case reports, which could amplify the autoimmune response. These findings suggest that treating local infections may significantly alter the course of AA, and that screening for infectious foci should be considered in AA patients based on their clinical history and symptoms.

EADV CONGRESS
VIENNA
30 SEP - 3 OCT 2026

Abstract N°: 804

When hair regrowth misleads: JAK inhibitor therapy unmasking lichen planopilaris in alopecia areata.

Anna Pirogova*[1]

[1] DocMed, Moscow, Russian Federation

Introduction

Alopecia areata (AA) and lichen planopilaris (LPP) are distinct forms of non-scarring and scarring alopecia, respectively; their rare coexistence presents a significant diagnostic and therapeutic challenge. The use of JAK inhibitors has significantly advanced the treatment of moderate-to-severe alopecia areata. Moreover, emerging evidence suggests their potential efficacy in various forms of lichen planus, including LPP. However, it remains uncertain whether JAK inhibitors could adversely affect the course of LPP.

Case Presentation

We report a patient with alopecia areata, initially presenting with patchy hair loss in 2022 and progressing to alopecia universalis within 3 months. Tofacitinib was initiated in 2023 at 10 mg daily. Hair regrowth was most prominent in the occipital and temporal regions, while remaining limited in the vertex area, resulting in an androgenetic alopecia–like pattern. Therefore, after 15 months, the dose was increased to 15 mg daily, with no laboratory abnormalities observed. Intralesional corticosteroid injections were administered; however, since 2024, new scarring patches have developed. On examination, multifocal LPP predominantly involving the vertex, along with isolated patches of AA, was observed. Based on the combination of clinical, trichoscopic, and histopathological findings, a diagnosis of LPP coexisting with AA universalis was established. Tofacitinib therapy was continued, and a short course of systemic prednisolone was initiated, followed by intralesional corticosteroid injections, along with hydroxychloroquine and minoxidil. At present, the disease is stable and monitored using fixed reference points.

Conclusion

This case underscores the critical role of trichoscopy in the early detection and monitoring of trichological diseases and highlights the complexity of coexisting alopecia types. Furthermore, it raises an important question regarding the role of JAK inhibitors: whether they are insufficient to halt an underlying scarring process such as LPP, or whether they might, in some cases, contribute to disease activation, resembling paradoxical reactions observed during biologic therapies.

EA DV CONGRESS
VIENNA
30 SEP - 3 OCT 2026

Abstract N°: 825

Bald and Bold: Female Characters with Alopecia and Buzzcuts in Film and TV

Nicolas Kluger*[1, 2, 3], Lidiya Todorova[4]

[1] Aava medical Centre, Dermatology, Kerava, Finland
[2] Tampere University Hospital, Dermatology, Tampere, Finland
[3] Société Francaise des Sciences Humaines sur la Peau, Paris, France
[4] Medical University of Plovdiv, Dermatology, Plovdiv, Bulgaria

Introduction

Visible modifications to the skin are commonly used as visual cues in movies and TV shows. However, certain features may be perceived negatively by audiences. Traits such as red hair, scars, alopecia, deep wrinkles, periorbital hyperpigmentation, rhinophyma, warts, extensive tattoos, albinism, or grayish complexions are often associated with villainous characters.Hair plays a significant role in defining a character's identity. For men, it can symbolize strength and seduction, while for women, it often represents femininity, allure, and secondary sexual characteristics. In this context, we examined the portrayal of alopecia and buzz cuts among female characters in films and series.

Materials and Methods

This narrative review focuses on female characters with alopecia or buzz cuts in movies and series. The search was based on the authors' personal experience, the Internet Movie Database (IMDb), and various newspaper articles available online. We reviewed 25 films and characters spanning the years 1928 to 2025. Documentaries, comics, and anime were excluded from this review

Results

Among female characters, alopecia or a buzz cut may be attributed to either main characters (85%) or secondary ones (15%). This trait can be a primary characteristic—present from the beginning of the film—or a secondary one—acquired during the course of the narrative. Hair loss is seldom the central focus of a movie. One notable exception is the Indian film Gone Kesh (2019), which explores the emotional and social impact of alopecia areata.Chemotherapy-induced hair loss due to cancer is another common cause of alopecia depicted in female characters. More often, however, hair loss is used as an indirect character trait, associated with fighters, villains, aliens, or individuals with superhuman abilities. In rarer cases, alopecia or a buzz cut serves a practical narrative function—such as imprisonment, escape, or financial necessity—or symbolizes transformation or personal change.Overall, we classified the depiction of alopecia in female characters into the following categories, noting that a character may belong to more than one group:i) fearsome fighters,ii) cancer fighters,iii) characters showing sacrifice or support,iv) punishment, imprisonment, or submission,v) cultural or religious motivations,vi) villains,vii) non-human or alien entities,viii) characters with supernatural powers,ix) comedic roles, andx) representation of hair disease.

Conclusions

Alopecia is not an uncommon feature among female characters in film. It is most frequently used to convey strength, as seen in the many portrayals of fearsome fighters in action and science fiction genres. This theme of strength also extends to characters "fighting" cancer. Unlike in male characters, where baldness is more often linked to villainy, the association of alopecia with evilness in female characters is less prevalent and typically tied to alien or non-human identities.It has been noted that the repeated depiction of disfiguring or visibly distinct traits

as markers of villainy can have a negative impact on real-life individuals with such conditions. However, in the case of female characters with alopecia, media coverage and public perception appear to be more positive. These portrayals encompass a wide range of roles and circumstances, suggesting that, unlike in men, alopecia in women is not strongly associated with negative character traits.

EA DV CONGRESS
VIENNA
30 SEP - 3 OCT 2026

Abstract N°: 845

Clinical Application of Diaminopyrimidine Oxide (Unodil) for Anti-Hair Loss and Hair Vitalization in Subjects with Mild to Moderate Hair Loss -A Self-Controlled Interventional Study of 31 Cases

Li Ye*[1], Qi Li[2], Minjia Yuan[2], Jinyin Liang[1], Si Wen[1], Linshan Wu[1], Xuesong Xian[1], Hongling Zhu[1]

[1] Cosmetics Testing Center, Dermatology Hospital of Southern Medical University, NMPA Center for Innovation and Research in Regulatory Science, Translational Medicine Center, Dermatology Hospital of Southern Medical University, GuangZhou, China

[2] Shanghai Qiran Biotechnology Co., Ltd, Shanghai Jincai Technology Co., Ltd, Shanghai, China

Introduction

To investigate the efficacy of diaminopyrimidine oxide (Unodil) in anti-hair loss and hair vitalization by improving hair diameter, follicular function, and anagen/telogen ratio in individuals with mild to moderate hair loss, and to clarify its regulatory effect on the hair follicle microenvironment and mildness profile. This study aims to provide a safe and effective anti-hair loss regimen and clinical evidence based on human efficacy data from the Dermatology Hospital of Southern Medical University.

Materials and Methods

This ethically approved study (Approval No.: HZP-2025-023) employed a single-group self-controlled interventional design. A total of 31 healthy Asian subjects aged 22–54 years (1 male, 30 females) with complaints of excessive hair shedding, thinning, and slow hair growth were enrolled. All subjects applied 3odice anti-hair loss and hair vitalizing shampoo containing diaminopyrimidine oxide (Unodil) topically once every two days for 28 consecutive days. Assessments were performed at baseline (Week 0) and Week 4 using professional instruments including DermoScan TrichoScan HD and SPOCS scalp positioning and imaging analysis system. Core indicators such as mean hair diameter, number of follicular units, distribution of follicle types, and anagen/telogen hair ratio in fixed scalp regions were measured. Changes and percentage variations of each parameter were analyzed statistically with SPSS 25.0.

Results

All 31 subjects completed the study with no product-related adverse events reported, demonstrating favorable skin and scalp tolerability of the Unodil-containing anti-hair loss shampoo. Positive improvements were observed in all core indicators post-intervention: mean hair diameter increased by 0.224% compared with baseline. Follicular function-related parameters were simultaneously optimized: follicular unit count increased by 2.682%, and mean hair strands per follicle rose by 0.538%. Notably, high-quality follicles with 3 or more hair strands (Type 3 follicles) showed a marked improvement of 9.913%. The hair growth cycle was favorably regulated: anagen hair ratio increased by 1.802%, while telogen hair ratio decreased by 5.890%. These improvements were consistent with the mechanism of diaminopyrimidine oxide in regulating the follicular microenvironment, prolonging anagen, and inhibiting telogen transition, further verifying its anti-hair loss and hair vitalization potential.

Conclusions

Shampoo formulations containing diaminopyrimidine oxide (Unodil) exhibit excellent safety and are milder than traditional anti-hair loss ingredients, making them suitable for long-term daily use. It exerts significant anti-hair loss and hair vitalization effects by positively regulating follicular function, optimizing the hair growth cycle, and increasing the proportion of high-quality follicles, thereby improving hair health in individuals with mild to moderate hair loss. Human efficacy data from the Dermatology Hospital of Southern Medical University provide

robust scientific support for the clinical application of diaminopyrimidine oxide in anti-hair loss management. As a safe and convenient daily care option, this ingredient demonstrates promising clinical translation value and application prospects.

EA DV CONGRESS
VIENNA
30 SEP - 3 OCT 2026

Abstract N°: 877

Dermatologic Implications of the Russian Manicure Trend

Michelle Kaminski[1], Madelyn Scarmack[1], Jonique Depina[2], Madison Sigler[3], Kelly Frasier[4], Pooja Shah*[4]

[1] Lake Erie College of Osteopathic Medicine, Erie, United States
[2] Kansas City College of Osteopathic Medicine, Kansas City, United States
[3] Orlando College of Osteopathic Medicine, Orlando, United States
[4] Northwell, New Hyde Park, United States

Introduction
"Russian manicure" (e-file–assisted dry manicure with cuticle and proximal nail fold manipulation and gel placement adjacent to the eponychium) has expanded through social media aesthetics emphasizing a seamless periungual margin and prolonged wear. Popularity intersects with dermatologic risk because the cuticle and proximal nail fold function as a barrier against microbial ingress and irritant or allergen penetration. Disruption converts a cosmetic technique into a repeated microtrauma model with inflammatory, infectious, and dystrophic sequelae. Dermatology guidance has cautioned against cuticle cutting or forceful manipulation due to infection risk, positioning this trend as a patient-safety priority.

Materials and Methods
A structured narrative review was conducted using PubMed, Google Scholar, and dermatology society guidance documents to identify English-language literature evaluating periungual barrier anatomy, nail biomechanics, e-file injury, salon-associated infections, and adverse effects of gel and acrylic systems. Search terms included "e-file manicure," "Russian manicure," "cuticle removal," "proximal nail fold trauma," "paronychia," "onycholysis," "acrylate allergic contact dermatitis," and "UV nail curing." Clinical studies, case series, outbreak investigations, patch-testing reports, and occupational exposure analyses were prioritized. Data were extracted on mechanisms of injury, microbiologic profiles, sensitizers, clinical presentation, and preventive strategies relevant to outpatient counseling.

Results
Four complication domains recur and map to core procedural steps. Barrier disruption follows cuticle removal and proximal fold trauma, reducing protection of the nail matrix and lateral folds and increasing susceptibility to acute bacterial paronychia and chronic periungual inflammation. Mechanical injury arises from repeated e-file abrasion near the proximal nail plate and folds, provoking irritant dermatitis, microfissuring, onychoschizia, onycholysis, and dystrophy; risk is amplified by technician variability, bit selection, pressure, and frictional heat. Allergic contact dermatitis and nail dystrophy occur with methacrylate-containing systems, with presentations ranging from periungual eczema to severe onychodystrophy; occupational sensitization among nail technicians is an added concern. Environmental risks include inadequate instrument sterilization and contaminated tools, with infection clusters underscoring the need for rigorous disinfection.

Conclusions
Russian manicure concentrates risk at the periungual barrier through cumulative mechanical trauma and concurrent exposure to potent sensitizers. A dermatologic perspective identifies the trend as a barrier-injury cascade in which proximal fold disruption increases infection vulnerability, high-speed instrumentation increases dystrophy risk, and acrylate exposure increases sensitization with potential long-term material intolerance. Clinical counseling emphasizing barrier preservation, early recognition of paronychia and dermatitis, structured nail-rest

intervals, and strict salon hygiene standards may reduce preventable morbidity associated with high-intensity cosmetic nail practices.

EADV CONGRESS
VIENNA
30 SEP - 3 OCT 2026

Abstract N°: 905

Hair Loss in Menopause: A Vulnerable Window for the Hair Follicle—A Unifying Hypothesis

Paradi Mirmirani*[1, 2]

[1] The Permanente Medical Group, Vallejo, United States
[2] University of California San Francisco, San Francisco, United States

Introduction
Background: Hair loss is a frequent and distressing complaint during the menopausal transition. While female pattern hair loss (FPHL), chronic telogen effluvium (CTE), and frontal fibrosing alopecia (FFA) are traditionally viewed as distinct entities, they often emerge or accelerate during perimenopause and early postmenopause. This temporal association suggests a shared biological vulnerability of the hair follicle during hormonal transition.

Materials and Methods
Hypothesis: We propose that menopause represents a critical window of vulnerability for the female hair follicle, driven by declining and fluctuating estrogen levels. Loss of estrogen's protective effects—coupled with relative androgen predominance—may destabilize follicular immune, metabolic, and cycling homeostasis. Depending on individual genetic susceptibility, metabolic health, environmental exposures, and immune programming, this disruption may manifest phenotypically as FPHL, CTE, or FFA.Rationale: Estrogen plays a key role in prolonging anagen, modulating perifollicular inflammation, enhancing microvascular support, and counterbalancing androgen signaling at the follicular level. Menopause is characterized not only by estrogen deficiency but also by hormonal variability and altered androgen-to-estrogen ratios. In genetically predisposed individuals, this shift may unmask androgen sensitivity leading to patterned miniaturization. In others, abrupt hormonal fluctuation and follicular cycling instability may precipitate chronic telogen effluvium. In susceptible immune environments, estrogen loss may impair immune privilege, facilitating inflammatory scarring alopecia such as frontal fibrosing alopecia.

Results
Implications: This framework reframes menopausal hair loss as a spectrum of follicular responses to a common hormonal insult rather than isolated diseases. Recognizing menopause as a high-risk period for follicular dysfunction may enable earlier identification, phenotype-specific intervention, and personalized therapeutic strategies integrating hormonal, metabolic, and inflammatory considerations.

Conclusions
Conclusion: Viewing menopause as a biologically vulnerable period for the hair follicle provides a unifying model to explain the heterogeneity of hair loss patterns observed in midlife women and highlights the need for proactive, mechanism-based approaches to prevention and treatment.

EA DV CONGRESS
VIENNA
30 SEP - 3 OCT 2026

Abstract N°: 938

Graham-Little Syndrome: A Rare Variant of Lichen Planopilaris. Case Report and Literature Review.

Cinthia Zambrano*[1], Karina Castro[1], Silvina Claudia Gonzalez[1], Carlos Delgado[1], Mariano Marini[1]

[1] Sanatorio Güemes, Buenos Aires, Argentina

Introduction

Graham-Little-Piccardi-Lassueur Syndrome (GLPLS) is an uncommon clinical variant of lichen planopilaris that presents a diagnostic challenge due to its multifaceted presentation. It is classically defined by a distinctive triad:

1. Multifocal cicatricial alopecia of the scalp.
2. Non-cicatricial alopecia of the axillary and pubic regions.
3. Disseminated follicular lichenoid papules (keratosis pilaris-like).

The exact pathogenesis remains elusive, though it is considered a T-cell mediated autoimmune process targeting the hair follicle. Given its rarity and the progressive nature of the cicatricial component, early recognition is vital to prevent permanent hair loss. Current therapeutic options are often limited and lack standardization, leading to the exploration of emerging treatments such as Janus kinase (JAK) inhibitors for refractory cases. This report describes a clinical case of GLPLS and reviews the current management strategies.

Case Presentation

A 25-year-old woman with a history of idiopathic laryngeal stenosis, tracheostomized since 2022, and no other significant comorbidities, was admitted for tracheostomy tube replacement. During hospitalization, a dermatology consultation was requested due to progressive alopecia.

Physical examination revealed a large alopecic plaque on the scalp with ill-defined borders, a smooth non-scaly surface, and absence of follicular openings, with few residual hairs and scattered perifollicular keratotic papules. Additionally, the patient exhibited generalized follicular hyperkeratosis involving the trunk and extremities, along with decreased axillary and pubic hair. These findings raised suspicion for Graham-Little syndrome, a rare variant of lichen planopilaris characterized by the classic triad of cicatricial scalp alopecia, follicular keratotic papules, and non-cicatricial hair loss in intertriginous areas.

Histopathological examination supported the diagnosis, demonstrating features of cicatricial alopecia, including dermal fibrosis, marked reduction and atrophy of pilosebaceous units, and a sparse inflammatory infiltrate.

The patient is currently undergoing treatment with systemic corticosteroids and minoxidil; however, she has shown poor clinical response. Given the extent of the disease and its progressive nature, the medical team is currently processing authorization with healthcare payers to initiate targeted therapy with a Janus kinase (JAK) inhibitor (tofacitinib).

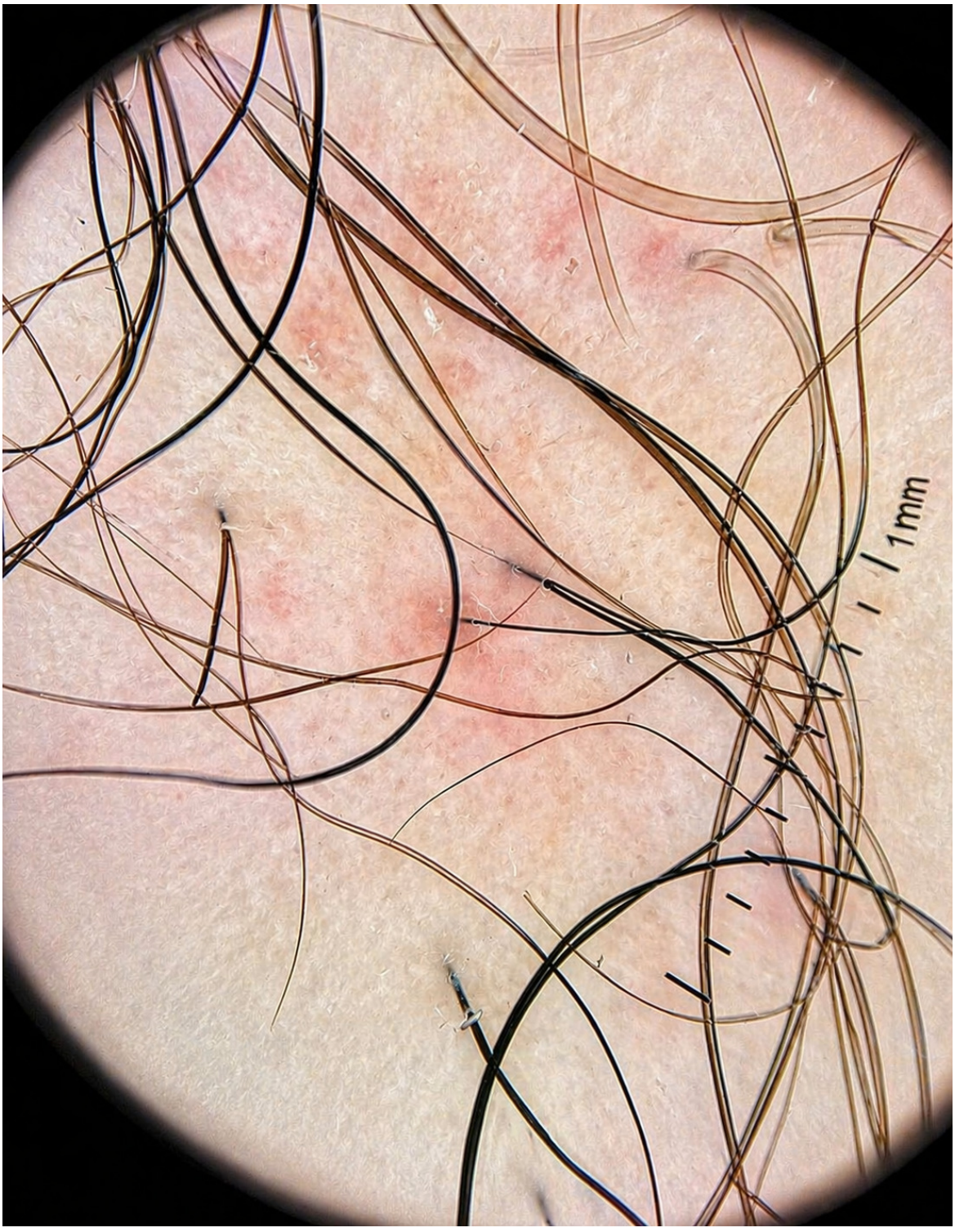

Figure 1. Scalp Dermoscopy. Dermoscopic image (showing 1mm scale) reveals absence of follicular ostia, indicating cicatricial involvement. Mild perifollicular erythema and delicate desquamation are visible, suggesting active, though sparse, lichenoid inflammation at the periphery of the alopecic plaque. Scattered residual hairs show diameter diversity.

Conclusion

Graham-Little-Piccardi-Lassueur syndrome is a rare and often underdiagnosed variant of lichen planopilaris. This case highlights the critical importance of recognizing the characteristic clinical triad—cicatricial scalp alopecia, follicular keratosis, and intertriginous hair loss—to ensure a timely diagnosis.

The limited response to conventional therapies, such as systemic corticosteroids, underscores the need for standardized management guidelines and the exploration of new therapeutic frontiers. The potential use of JAK inhibitors, like tofacitinib, represents a promising shift in the management of refractory cicatricial alopecia, aiming to halt disease progression and prevent irreversible follicular destruction. Clinicians must maintain a high index of

suspicion in patients with progressive hair loss and multisite involvement to improve long-term prognostic outcomes.

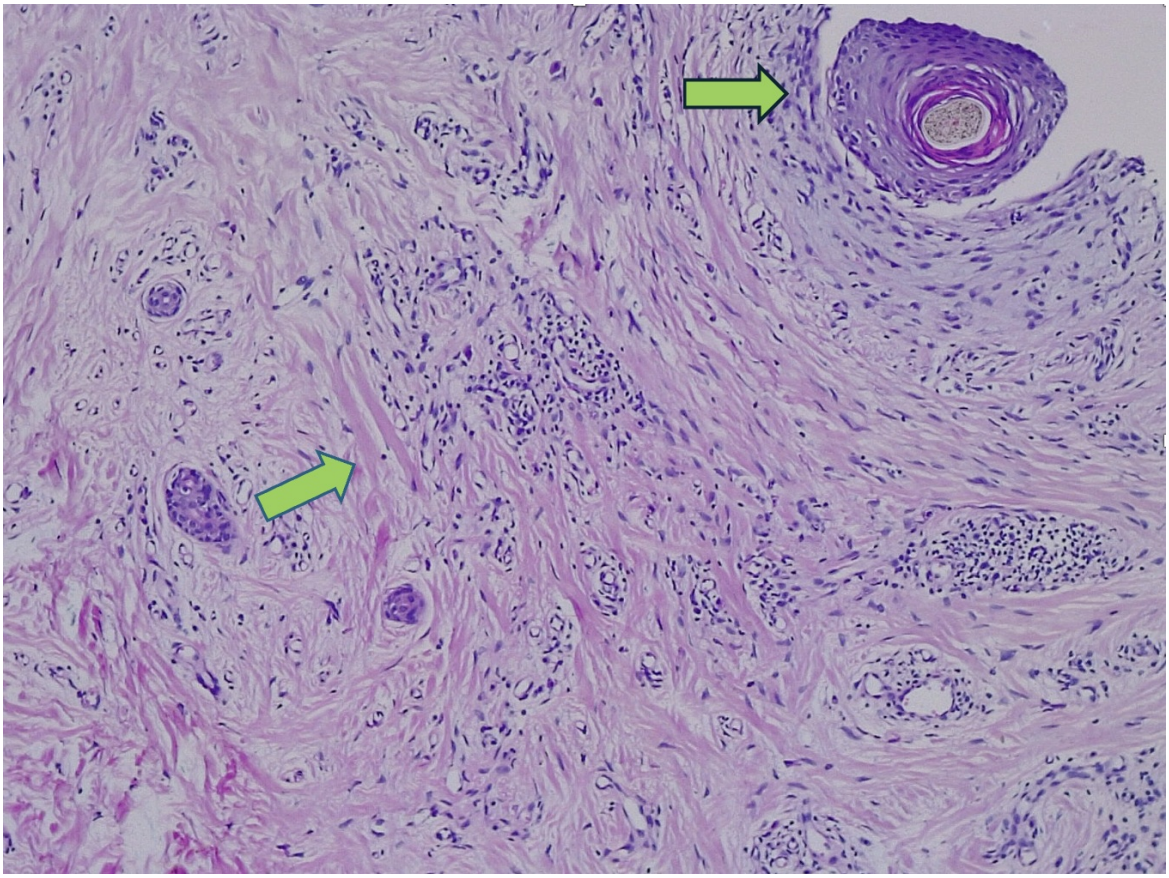

Figure 2. Histopathological correlation (H&E, 10x): Micrograph showcasing extensive dermal fibrosis and replacement of pilosebaceous units by fibrous tracts (lower green arrow). A single, remaining atrophic transverse hair follicle is present (upper green arrow), consistent with the final stage of cicatricial alopecia.

EADV CONGRESS
VIENNA
30 SEP - 3 OCT 2026

Abstract N°: 939

Drug-Induced Lichen Planopilaris in a Patient Undergoing Immunotherapy: a Case Report.

Christina Kordali*[1], Fiori Kousta[1], Sofia Papanikou[1], Vasiliki Chasapi[1]

[1] Department of Dermatology, Andreas Syggros Hospital of Venereal and Dermatological Diseases., Athens, Greece

Introduction

Treatment with immune checkpoint inhibitors (ICIs) for various malignancies is associated with a wide spectrum of immune-related adverse events (irAEs), with cutaneous manifestations being the most common. Among these, lichenoid reactions are increasingly recognized. While classic lichen planus has been repeatedly reported in patients undergoing immunotherapy, its follicular variant, lichen planopilaris (LPP), remains exceptionally rare.

Case Presentation

We describe the clinical, trichoscopic, and histopathological findings of a 61-year-old female who developed cicatricial alopecia during treatment with the PD-1 inhibitor pembrolizumab for breast cancer.
Clinically, the patient presented with plaques of scarring alopecia involving the parietal and temporal regions of the scalp, accompanied in the early stages of the disease by perifollicular hyperkeratosis, erythema, and intense pruritus. Trichoscopic and histopathological findings were consistent with the diagnosis of lichen planopilaris. The time of appearance only a few months after the initiation of immunotherapy supported the diagnosis of an immune-related adverse event.

Conclusion

Lichen planopilaris represents a rare but clinically important cutaneous immune-related adverse event associated with PD-1/PD-L1 inhibitor therapy. Early recognition and appropriate management are crucial to prevent irreversible scarring alopecia while allowing continuation of effective anticancer treatment.

EA DV CONGRESS
VIENNA
30 SEP - 3 OCT 2026

Abstract N°: 970

Topical pan-JAK inhibition with delgocitinib 20mg/g cream in inflammatory diseases of the nails: a real-life case series

Matilde Iorizzo*[1], Christin Pelzer[2]

[1] Private Dermatology Practice, Lugano / Bellinzona, Switzerland
[2] HOCH Health Ostschweiz, Cantonal Hospital St. Gallen, Clinic of Dermatology, Venereology and Allergology, St. Gallen, Switzerland

Introduction

Topical Janus kinase (JAK) inhibitors have emerged as a promising therapeutic option for several inflammatory dermatologic conditions, including those affecting the nails. While topical data exist for molecules such as tofacitinib and ruxolitinib, evidence on delgocitinib, the newest topical pan-JAK inhibitor, remains limited, particularly regarding its off-label use in nail disorders.

Case Presentation

The goal of this study is to report real-life clinical outcomes of topical delgocitinib 20mg/g cream in 4 patients affected by 4 distinct inflammatory nail conditions: lichen planopilaris, psoriasis, pustular psoriasis and trachyonychia. All patients were treated with topical delgocitinib 20mg/g cream, provided on a compassionate use basis, applied twice daily for a minimum of 6 months. Clinical evaluation was performed at baseline and at follow-up using disease-specific clinical scores, alongside a photographic documentation. No concomitant systemic therapies were introduced during the observation period.

All four patients showed clinically meaningful improvement after treatment, with progressive amelioration of nail signs.

- The patient with nail lichen planus demonstrated reduction in longitudinal ridging, fissuring, and nail plate thinning, with restoration of nail architecture.
- The patient with nail psoriasis exhibited improvement in onycholysis and subungual hyperkeratosis, with a more regular and homogeneous nail plate.
- The patient with pustular psoriasis showed reduction in pain, periungual inflammation and nail plate dystrophy.
- The patient with trachyonychia showed improvement in nail roughness and opacity, with smoother and more uniform nail surfaces.

Treatment was well tolerated, with no significant local or systemic adverse effects reported.

Conclusion

This small case series suggests that topical delgocitinib may represent a promising therapeutic option for localized inflammatory nail conditions. Its favorable cream vehicle formulation — non-greasy and rapidly absorbed — likely contributes to good patient adherence and tolerability, particularly in such a challenging anatomical site. In line with the shared pathogenic role of JAK-STAT signaling and existing evidence with other pan-JAK inhibitors such as tofacitinib, these findings further support the potential of this class of agents in improving inflammatory keratotic nail disorders and warrant confirmation in controlled clinical studies.

EADV Congress 2026, VIENNA
30 SEPTEMBER - 03 OCTOBER 2026
POWERED BY M-ANAGE.COM

EADV CONGRESS
VIENNA
30 SEP - 3 OCT 2026

Abstract N°: 1006

Successful Switching from Baricitinib to Tofacitinib in a Case of Refractory Alopecia Universalis: A Case Report

Adnan Semiz*[1], Hasan Emre İlgenli[1], Selami Aykut Temiz[1], İlkay Özer[1], Munise Daye[1], Recep Dursun[1]

[1] NECMETTİN ERBAKAN UNIVERSITY DERMATOLOGY DEPARTMENT, Konya, Türkiye

Introduction

Alopecia areata (AA) is a chronic, non-scatricial inflammatory disorder with a multifactorial etiopathogenesis, where the JAK/STAT signaling pathway plays an **important** role(1)(2).In this report, we present a patient with recalcitrant alopecia universalis who was **refractory** to conventional therapies and baricitinib (JAK1/2i), but subsequently achieved remarkable clinical and trichoscopic recovery following a transition to tofacitinib (JAK1/3i). This case underscores the potential of intra-class JAKi switching as a successful rescue strategy in resistant presentations.

Case Presentation

A 27-year-old male patient with no comorbidities has been followed in our clinic for a long period with a diagnosis of alopecia areata universalis. He presented with complete hair loss of the scalp, eyebrows, and eyelashes (baseline SALT score: 100). Previous treatments including topical corticosteroids, minoxidil, systemic methylprednisolone, cyclosporine, and diphenylcyclopropenone (DPCP) failed to achieve a clinical response.Treatment with baricitinib 4 mg/day was initiated, resulting in near-complete regrowth of eyebrows and eyelashes at week 24. SALT scores were 60 at week 12 and 42 at weeks 24 and 36, with no additional clinical improvement observed after the first 6 months.Due to a suboptimal response, therapy was switched to tofacitinib 5 mg twice daily. Screening tests for HIV, tuberculosis, hepatitis B and C, and syphilis were normal prior to treatment initiation. During follow-up, complete blood count, liver and renal function tests, and lipid profile remained within normal limits.Pre-tofacitinib trichoscopic examination revealed decreased terminal hairs, vellus hairs, yellow and black dots, and trichoptilosis. At 6 months of tofacitinib treatment, trichoscopy showed increased hair density, thickening of terminal hairs, reduction of yellow dots, and emergence of upright regrowing hair shafts.At 6 months, the SALT score decreased to 9, indicating a significant clinical response to tofacitinib therapy.

Conclusion

As observed in the literature, switching to a different JAK inhibitor offers significant clinical benefit, particularly in selected patients who have previously responded to oral JAKi therapy.(4) **In light of these data, the resolution of therapeutic resistance encountered with baricitinib (JAK1/2i) through tofacitinib (JAK1/3i) in our case confirms that an intra-class switch represents a potent therapeutic alternative for refractory patients.**

EA DV CONGRESS
VIENNA
30 SEP - 3 OCT 2026

Abstract N°: 1068

Comparison of effectiveness and safety of low-dose oral minoxidil (1.25 mg) versus topical 5% minoxidil in male androgenetic alopecia: a randomized open-label pilot study

Bikash Ranjan Kar[1], Liza Mohapatra[1], Riddhi Sable*[1]

[1] Department of Dermatology, Institute of Medical Sciences and SUM hospitals,, Bhubaneshwar, India

Introduction
Androgenetic alopecia (AGA) is a common progressive condition characterized by follicular miniaturization and patterned hair loss, significantly affecting quality of life. While topical minoxidil remains a standard treatment, its use is often limited by poor compliance and local side effects. Low-dose oral minoxidil has emerged as a potential alternative; however, direct comparative data between oral and topical formulations remain limited.
This study aimed to compare the effectiveness and safety of low-dose oral minoxidil (1.25 mg once daily) versus topical 5% minoxidil (twice daily) in male patients with AGA over 24 weeks.

Materials and Methods
This prospective, randomized, open-label pilot study included 60 male patients with Norwood–Hamilton Grade II–IV AGA. Participants were allocated to oral minoxidil (Group A) or topical minoxidil (Group B). Efficacy was assessed at baseline and every 4 weeks up to 24 weeks using trichoscopic parameters including hair density (hairs/cm^2), hair shaft diameter, interfollicular distance, and terminal-to-vellus (T/V) hair ratio. Patient satisfaction and standardized photographic documentation were also evaluated. Safety was assessed through clinical monitoring and documentation of adverse events.

Results
Baseline characteristics were comparable between groups. At 24 weeks, the oral minoxidil group demonstrated significantly greater improvement in hair density (132.67 ± 5.62 vs 127.73 ± 4.50 hairs/cm^2; mean difference 4.93; $p < 0.001$), with significant divergence from week 12 onward. The T/V hair ratio also improved significantly in the oral group (1.743 ± 0.165 vs 1.556 ± 0.106; $p < 0.001$), as summarized in Table 1. No statistically significant differences were observed in hair shaft diameter or interfollicular distance ($p > 0.05$). Both groups showed significant intragroup improvement across all parameters. Adverse effects were mild and infrequent. In the oral group, 1 patient (3.3%) developed transient hypotension and 1 patient (3.3%) developed mild hypertrichosis. In the topical group, 2 patients (6.7%) reported scalp irritation. Responder rates were higher in the oral group (28/30; 93.3%) compared to the topical group (26/30; 86.7%), although this difference was not statistically significant ($p = 0.389$)

Parameter	**Group A**-Oral Minoxidil 1.25 mg OD	**Group B**-Topical Minoxidil 5% BD	Key Outcome
Hair Density	increased from Week 12 onward; **132.67 hairs/cm² at Week 24**	127.73 hairs/cm² at Week 24	**Higher with oral minoxidil ($p < 0.001$)**
Terminal-to-Vellus Ratio (TV Ratio)	Increased to **1.743 ± 0.165 by Week 24**	1.556 ± 0.106 at Week 24	Oral minoxidil showed **better follicular remodelling ($p < 0.001$)**
Hair Shaft Diameter	0.061 mm at Week 24	0.063 mm at Week 24	No significant difference ($p = 0.159$)
Interfollicular Distance	Reduced to 1.29 mm	1.315 mm	No significant difference
Responders	93.3%	86.7%	Higher responders with oral minoxidil (NS)

Table 1: Comparative trichoscopic outcomes at 24 weeks between oral and topical minoxidil

Conclusions

Low-dose oral minoxidil demonstrated superior improvement in hair density and follicular terminalization compared to topical minoxidil, with a comparable safety profile. Its ease of administration and favourable tolerability make it a practical alternative, particularly in patients with poor adherence to topical therapy.

EA DV CONGRESS
VIENNA
30 SEP - 3 OCT 2026

Abstract N°: 1070

A multi-stage assessment of a novel shampoo for seborrheic dermatitis: clinical safety and efficacy and skin microbiota analysis

Monika Pasikowska-Piwko*[1], Anna Kuranc[1], Katarzyna Rogiewicz[1], Irena Eris[1]

[1] Dr Irena Eris S.A., Piaseczno, Poland

Introduction

Clinically, seborrheic dermatitis (SD) presents with erythema, pruritus, and characteristic flaking of the scalp and other seborrheic areas. Despite numerous therapeutic options, there is still a need for well-tolerated, topically acceptable formulations that combine antifungal efficacy with support for the skin barrier and microbiome balance. The aim of this study was to evaluate the efficacy scalp tolerance and skin microbiota analysis after usage of two shampoos containing ciclopirox olamine (0.1%), piroctone olamine (0.6%), *Ophiopogon japonicus* fruit extract (1%), *Juniperus communis* fruit oil (0.2%), and either lactic acid (0.32%) or citric acid (0.2%).

Materials and Methods

A multi-stage study design was applied. In a preliminary comparative in vivo study, 14 adults (aged 21–70) with SD symptoms, dandruff, or psoriasis used the lactic acid shampoo (A) daily or several times per week for 1 week, followed by the citric acid shampoo (B) in the second week. Self-assessment questionnaires and measurements of skin pH, transepidermal water loss (TEWL), and hydration were performed.

Antimicrobial activity of the shampoo (A) was evaluated according to EUCAST recommendations using the disc diffusion method, with fluconazole (25 µg) and amoxicillin/clavulanic acid (30 µg + 10 µg) as reference substances. The activity was tested against *Staphylococcus aureus* (ATCC 6538, NCTC 4135) and *Malassezia furfur* (ATCC 14521), with two independent experiments per strain.

In a microbiota analysis, 10 healthy adults (aged 21–51) used the shampoo (A) 2–3 times weekly for 4 weeks. Quantitative (swab method, CFU/cm^2) and qualitative microbiological analyses were performed at D0 and D28. Identification was based on colony and cell morphology and biochemical characteristics.

Ophthalmological safety was assessed in 10 participants (aged 28–70) with sensitive eyes using the shampoo (A) for 3 weeks under specialist supervision. Additionally, patch tests with 10% lactic acid were conducted in 30 subjects with sensitive skin, with evaluations at 48, 72, and 96 hours.

Results

Participants reported effective cleansing and reduced itching with the lactic acid shampoo (A), which was preferred over the citric acid variant (B). Skin pH remained within physiological range, hydration was unchanged, and TEWL decreased. The shampoo (A) showed antimicrobial activity against all tested strains, including *M. furfur* and *S. aureus*.

Microbiological analysis confirmed that the lactic acid shampoo (A) did not disrupt the overall number of microorganisms and supported the natural microbiome, while eliminating *S. aureus* and *E. coli*. Patch test results were negative in all subjects, indicating no irritation or allergic reactions. Ophthalmological evaluation revealed no

adverse effects.

Conclusions

The shampoo containing lactic acid demonstrated a favorable efficacy and safety profile in SD management. It provided symptom relief, antimicrobial activity, and microbiome support while maintaining high tolerability. These findings indicate that it is a safe and effective option for skin cleansing in patients with SD-prone scalp.

EADV CONGRESS
VIENNA
30 SEP - 3 OCT 2026

Abstract N°: 1079

Alopecia Areata: from challenge to control

Hanan Morsy*[1, 1]

[1] faculty of Medicine Assiut University Egypt, Assiut University, Faculty of Medicine, Dermatology Department, Faculty of Medicine, Assiut, Egypt

Introduction

Alopecia totalis/ universalis is the most serious and stressing type of alopecia areata, with loss of hair from total scalp and sometimes it affects eyebrows, eye lashes and total body hair. It has a marked effect on patient's quality of life. Patients usually suffer from anxiety, social isolation, depression, and bullying. Our study aimed to evaluate two modalities of treatment oral mini pulse steroids versus JAK inhibitors in management of cases with alopecia totalis.

Case Presentation

100 cases were presented in my clinic in Assuit, Upper Egypt with alopecia totalis/universalis. Patient evaluation was done by history, physical examination, dermoscopy, SALT score and quality of life using DLQI assessment. Thirty patients received systemic steroids as initial therapy to stimulate hair regrowth, monthly intramuscular triamcinolone injections, followed by pulsatile oral prednisone every week (OMP). Other group of patients(20 patients) received systemic JAK inhibitor (baricitinib). Follow up for patients was carried out every month by dermoscopy and clinical examination for at least 3-6 months after therapy started.
Age of participants ranged from 4-45 years, dermoscopic evaluation at presentation revealed empty hair follicles, or fine vellous hair. Hair started to grow 30-40 days after starting the therapy with OMP, but in JAK inhibitors more than 60 days for hair to appear. Recurrence was reported more with OMP group especially after reduction of dose. Many factors such as :age, previous failure of systemic therapies and the duration of alopecia areata did appear to influence the patient's response to therapy. The use of oral JAK inhibitors have shown good outcomes in treating alopecia totalis and universalis, but OMP were more potent and rapid with more side effects, combination between both therapies is much better.

Conclusion

Oral mini pulse therapy was superior to JAK inhibitors in stimulation of hair growth, many patients received OMP have a recurrence of hair loss after therapy discontinuation plus side effects of use of corticosteroids. Side effects of oral JAK were minimal, with less incidence of relapse.

EA DV CONGRESS
VIENNA
30 SEP - 3 OCT 2026

Abstract N°: 1149

Intraclass Switching of Janus Kinase Inhibitors in Severe Pediatric Alopecia Areata: Two Cases with Favorable Response to Ritlecitinib

Yocelin Nallely Lozano Figueroa*[1], Luis Sanchez[2], Rocío Concepción Albores Arguijo[1]

[1] Hospital Civil de Guadalajara Fray Antonio Alcalde, Universidad de Guadalajara, Guadalajara, Mexico

[2] Dermika Laser dermatology center, Guadalajara, Mexico

Introduction

Alopecia areata (AA) is an immune-mediated disorder driven by collapse of hair follicle immune privilege and activation of the JAK/STAT pathway. Beyond the remarkable complexity of its pathophysiology the burden of AA in childhood extends far beyond the physical loss of hair, with important repercussions on quality of life, emotional development, self-esteem, and social integration. JAK inhibitors have become an effective therapeutic option for severe AA, although approval varies by agent. Tofacitinib, JAK1/JAK3 inhibitor, is not approved for AA, while baricitinib, JAK1/JAK2 inhibitor, is approved for severe AA in adults and ritlecitinib, selective JAK3/TEC family kinase inhibitor, is approved for older than 12 years. Treatment response is variable, loss of efficacy may occur, and guidance on intraclass switching remains limited in children.

Case Presentation

We report two girls with severe long-standing AA who required an intraclass JAK inhibitor switch.

Case 1: 11-year-old mexican girl with hypothyroidism and AA since 5 years of age, previously received methotrexate for 5 years, followed by dexamethasone pulses, and intralesional corticosteroids, with baseline SALT S4A (90%). At age of 12 with SALT S4A (85%), started tofacitinib 5 mg BID. Decreased to SALT S2 (38%) at 2 months and achieving regrowth with reduction to SALT S0 (0%) at 8 months. After 15 months, relapse occurred with SALT S1 (5%), treated with oral minoxidil and topical lotion of clobetasol 0.05%. At 1 year and 10 months, persisted with activity of AA with SALT S1 (7.5%) and started with thyroid antibodies positives managed with endocrinology. At 2 years and 1 months, increase activity to SALT S1 (15.5%), so initiated to decrease tofacitinib 5mg OD for 5 months, then 5 times a week for 3 months. At 33 months, was switched to ritlecitinib 50mg OD for 6 months, and maintained low disease activity, with SALT S1 (6%) at follow-up and no adverse events.

Case 2: 10-year-old mexican girl with alopecia areata since 18 months of age and no relevant comorbidities progressed from patchy to alopecia totalis within 3 months, despite topical and systemic treatment. Baricitinib 4 mg OD, was initiated with a baseline SALT score of S5 (100%), and nail pitting was also present. After 2 months, her SALT score decreased to S4A (90%). At 6 months, SALT score improved to S3 (65%). At 9 months, SALT score decreased to S2 (28%), and after 1 year, it further improved to S1 (7%). However, at 1 year and 5 months, she relapsed to SALT S1 (16%) and was treated with topical crisaborole 2% on alternate days. After 2 years of treatment, at 12 years old, worsened to SALT S3 (50%), and was switched to ritlecitinib. She experienced 6 episodes of recurrent herpes labialis and 1 episode of urticaria during baricitinib therapy. After switching to ritlecitinib 50 mg OD, she had 1 episode of herpes labialis and was found to have insulin resistance at 2 months, although regrowth was already evident. By 7 months, she showed favorable hair regrowth and improvement to SALT S1 (16%), with no clinical signs of active disease and no further adverse events.

Conclusion

Intraclass switching between JAK inhibitors may be a useful strategy in patients with severe AA who show incomplete response, plateaued improvement, or loss of efficacy. In both patients, switching to ritlecitinib was associated with improved hair regrowth and acceptable short-term safety. Higher baseline SALT scores and longer disease duration may predict a lower likelihood of complete remission and a greater need for switching. A lower number of viral infections was observed after switching from baricitinib to ritlecitinib. Greater hair regrowth was observed after switching from tofacitinib or baricitinib to ritlecitinib. Although current evidence remains limited and no formal recommendations exist for pediatric intraclass JAK switch, this approach appears promising and deserves further prospective study.

EA DV CONGRESS
VIENNA
30 SEP - 3 OCT 2026

Abstract N°: 1164

Efficacy of Topical Finasteride 0.25% in HPCH Spray Across Baseline Subgroups: A Pooled Analysis of Two Phase 3 Trials in European and Chinese Populations

Bianca Maria Piraccini[1], Cheng Zhou[2], Francisco Hernandez[3], Aditya K. Gupta[4], Jianzhong Zhang[2], Wenyu Wu[5, 6], Huagao Zhang[7], Nuowen Xu[7], Aida Valmaseda*[8]

[1] Private Dermatology Practice, Bologna, Italy

[2] Peking University People's Hospital, Department of Dermatology, Beijing, China

[3] Global Statistics, Almirall SA, Sant Feliu de Llobregat, Spain

[4] Division of Dermatology, Department of Medicine, Temerty Faculty of Medicine, University of Toronto, Toronto, Ontario, Canada

[5] Department of Dermatology, Huashan Hospital, Shanghai Institute of Dermatology, State Key Laboratory of Molecular Engineering of Polymers, Fudan University, Shanghai, China

[6] Department of Dermatology, Jing'an District Central Hospital, Shanghai, China, 200040; Academy for Engineering and Technology, Fudan University, Shanghai, China

[7] Cutia Therapeutics Co., Ltd, Shanghai, China

[8] Global Medical Affairs, Almirall SA, Barcelona, Spain

Introduction

Androgenetic alopecia (AGA) represents the most common form of hair loss in men. Despite the proven efficacy of oral finasteride, worries about systemic side effects have increased attention toward topical alternatives. Topical finasteride 0.25% formulated in a hydroxypropyl-chitosan (HPCH) vehicle has shown efficacy in androgenetic alopecia (AGA), yet the consistency of treatment effects across diverse demographic and clinical subgroups has not been reported so far.

Materials and Methods

This pooled analysis evaluated the efficacy of topical finasteride 0.25% in HPCH spray versus placebo at week 24 across baseline characteristics using data from two multicenter, double-blind, placebo-controlled Phase 3 trials conducted in Europe and China. Patients from the intention-to-treat population were included. A total of 283 patients received topical finasteride and 184 received placebo. Efficacy was assessed at week 24 based on changes in target area hair count (TAHC) and terminal-to-vellus hair ratio (TVR). Subgroup analyses for TAHC were performed according to age, baseline AGA severity, baseline hair counts (total and terminal), body mass index (BMI), and smoking history. Treatment effects were estimated as adjusted mean differences with 95% confidence intervals derived from a mixed model for repeated measures (MMRM).

Results

At week 24, the overall between-group difference in TAHC was 9.5 hairs (95% CI 5.1–14.0). Superiority of topical finasteride versus placebo for TAHC was consistently observed across all baseline demographic and clinical subgroups, including age (≥ or <30 years), disease severity (mild and moderate), baseline hair count (≥median population value), baseline BMI (≥25 or <25 kg/m^2), and smoking history. For TVR, a statistically significant increase from baseline to week 24 was observed in patients treated with topical finasteride 0.25% in HPCH

($p<0.05$), whereas no significant change was observed in the placebo group. Despite the between-treatment difference not reaching statistical significance for TVR, numerical trends across most analyzed subgroups favored topical finasteride over placebo.

Conclusions

These findings demonstrate that topical finasteride 0.25% in HPCH spray provides robust and clinically meaningful improvements in hair growth irrespective of baseline demographic or clinical characteristics, supporting the broad applicability of topical finasteride 0.25% in HPCH spray in the management of AGA.

EA DV CONGRESS
VIENNA
30 SEP - 3 OCT 2026

Abstract N°: 1199

Evolving longitudinal melanonychia revealing atypical melanocytic proliferation in a young adult

Bugra Burc Dagtas*[1], Ozan Erdem[1], Fatih Göktay[2], Cem Leblebici[3], Pembegül Güneş[4], Eckart Haneke[5, 6, 7]

[1] Department of Dermatology, Faculty of Medicine, Istanbul Medeniyet University., Istanbul, Türkiye
[2] Private Clinic, İstanbul, Türkiye
[3] Department of Pathology, Istanbul Training and Reseach Hospital, Istanbul, Türkiye
[4] Pathology Department, Memorial Healthcare Group Hospital, İstanbul, Türkiye
[5] Private Dermatology Practice Dermaticum, Freiburg, Germany
[6] Department of Dermatology, Inselspital, Bern, Switzerland
[7] Centro deDermatología Epidermis, CUF Institute, Porto, Portugal

Introduction
Longitudinal melanonychia in young individuals is usually benign; however, evolving lesions may indicate atypical melanocytic proliferation requiring further evaluation.

Case Presentation
A 20-year-old female presented with a 5-year history of longitudinal melanonychia affecting the right thumb. The lesion had been stable for several years but recently showed enlargement and mild asymmetry.

Clinical examination revealed a solitary longitudinal pigmented band extending from the proximal nail fold to the distal nail plate. Dermoscopic evaluation demonstrated a brown band composed of longitudinal parallel lines with mild irregularity in color and spacing, accompanied by scattered dots and globules. End-on dermoscopy revealed a full-thickness melanonychia focus involving the entire nail plate.

Due to these changes, a tangential matrix excision was performed. Intraoperative dermoscopy of the exposed matrix revealed irregularly distributed pigmented lines with focal dots and globules.

Histopathological examination demonstrated increased melanocytic proliferation with cytological atypia, asymmetric distribution, focal nesting, and partial loss of polarity. Immunohistochemical analysis showed positivity for SOX10, Melan-A, HMB45, and PRAME.

Based on these findings, the lesion was diagnosed as atypical melanocytic proliferation, and total nail unit excision was performed.

At the 4-month follow-up, the surgical site had healed uneventfully, with no complications or recurrence.

Conclusion
Evolving longitudinal melanonychia should be carefully evaluated, and dermoscopic and intraoperative findings may support the decision for biopsy and definitive surgical management even in young patients.

EA DV CONGRESS
VIENNA
30 SEP - 3 OCT 2026

Abstract N°: 1217

Onychomatricoma: a rare neoplasia of the nail apparatus

Júlia Bittencourt*[1], Isadora Schmidt[1], Julia Loureiro Fontana Bolsoni[1], elisandre maria camelo gomes natario Natario[1], gabriela amaral[1], Yasmin Duran[1], Mariana Ferreira da Silva silva[1], Samara Rabay[1], Beatriz Tavares[1], Nilton Di Chiacchio[2], Flávia Regina Ferreira[1]

[1] TAUBATE UNIVERSITY MUNICIPAL HOSPITAL, TAUBATÉ, Brazil
[2] Municipal Public Servant Hospital of São Paulo, sao paulo, Brazil

Introduction

The incidence of onychomatricoma is higher in caucasian women around the age of 50. Fingers are more frequently affected than toes with a prevalence of 63% and 36%, respectively. Despite presenting characteristic clinical and intraoperative signs the lack of knowledge about this condition and its tendency to be asymptomatic contribute to misdiagnosis and late diagnosis. We report a rare case of onychomatricoma on the hallux of a 65-year-old man, illustrating its clinical, intraoperative, and histopathological presentation.

Case Presentation

A 65-year-old male gardener of mixed race presented to a dermatology clinic with a 5-year history of an asymptomatic lesion affecting the left first toe. Asymptomatic and reported an initial phase of progressive growth followed by stabilization. On examination, the medial aspect of the nail plate showed thickening with yellowish and brownish longitudinal streaks. Dermoscopy revealed distal nail plate perforations and longitudinal white and yellow bands. Nail clipping and radiography of the left hallux were performed.

Histological examination of the clipping demonstrated serous material, foci of parakeratosis, and focal intracorneal hemorrhage, with negative periodic acid–Schiff (PAS) and Fontana–Masson stains. Radiographic findings showed no evidence of malignancy, with preserved bone structure, normal joint alignment, regular articular surfaces, and no periarticular abnormalities. The initial differential diagnosis included fibroma and fibrokeratoma. Complete surgical excision of the lesion was subsequently performed. Histopathological analysis revealed epithelial projections extending into the superficial dermis within a hyalinized collagenous stroma and associated vascular dilation (Fig. 1). Clinicopathological correlation, supported by dermoscopic and imaging findings, established the diagnosis of onychomatricoma.
Onychomatricoma is a rare tumor specific to the nail unit, of uncertain etiology. Diagnosis is based on the classic tetrad of clinical signs and supported by additional modalities, including dermoscopy, ultrasonography, and histopathology, the latter being the gold standard. Based on histopathological features, alternative terms have been proposed, such as onychoblastoma, onychoblastic fibroma, and atypical onychoblastic fibroma. Nevertheless, the term *onychomatricoma* remains the most widely used in the current literature.

Dermoscopy typically reveals distal nail plate perforations, splinter hemorrhages, and longitudinal white grooves corresponding to channels within the nail plate, consistent with the findings observed in this patient. Radiologic evaluation is useful to exclude associated underlying osseous involvement.

Following nail plate avulsion, cavities and openings can be observed at the proximal portion. These orifices are associated with villous tumor formations that give rise to digitiform projections within the nail matrix (Fig. 2), representing characteristic intraoperative findings.

Histologically, onychomatricoma is a fibroepithelial neoplasm composed of two distinct zones. The proximal zone, located beneath the posterior nail fold, is characterized by deep epithelial invaginations containing V-shaped overlying nail plate projections. The second zone, also proximal and corresponding to the lunula, contains epithelial digitations originating from the nail matrix epithelium. These projections proliferate and result in perforations of the nail plate, as observed in the present case.

The treatment of choice is complete surgical excision, including the entire proximal matrix, to prevent local recurrence. Adequate surgical technique is essential to minimize the risk of recurrence and subsequent nail dystrophy.

IMAGES

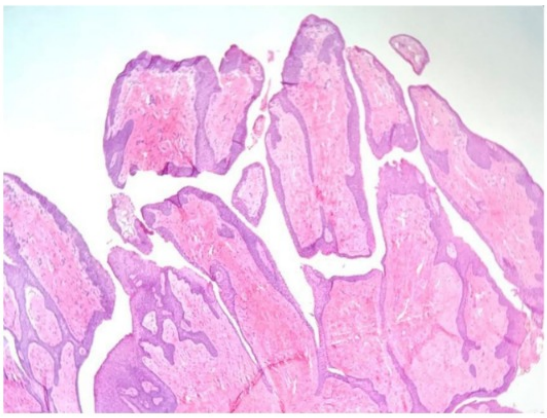

Figure 1: Projections of epithelial cones in the superficial dermis within hyalinized collagen and vascular dilation (H&E)



Figure 2: Cavitations and openings at the proximal end associated with villous tumor formations, which generate finger-like projections in the nail matrix

Figure 1: Projections of epithelial cones in the superficial dermis within hyalinized collagen and vascular dilation (H&E) / Figure 2: Cavitations and openings at the proximal end associated with villous tumor formations, which generate finger-like projections in the nail matrix

Conclusion

Therefore, we present a case of onychomatricoma a rare tumor arising from the nail matrix contributing to its knowledge and recognition by dermatologists and future dermatologists, favoring the early and correct diagnosis of this condition.

EADV CONGRESS
VIENNA
30 SEP - 3 OCT 2026

Abstract N°: 1249

PATCHY ANAGEN EFFLUVIUM SECONDARY TO SUBMENTAL LIPOSUCTION: SHOULD WE BE CAREFUL WITH AESTHETIC PROCEDURES?

Emilly Neves Souza*[1, 2], Helena Vallandro[2]

[1] Hospital Universitário Cassiano Antônio Moraes, Ambulatório de Dermatologia, Vitória, Brazil
[2] Enseada Clínica - Dermatologia e Tricologia, Vitória, Brazil

Introduction

Secondary alopecia due to aesthetic surgeries is a rare complication. Telogen effluvium is the most common postoperative non cicatricial hair loss and can be triggered by various factors, such as surgical trauma, anesthesia, use of drugs, and emotional stress. Beard alopecia has already been described as induced by deoxycholic acid for the treatment of submental fat, but still there isn't any report of localized hair loss after liposuction.

We report a case of anagen effluvium in patches secondary to neck liposuction.

Case Presentation

A previously healthy 32-year-old man presented to dermatological consultation with a complaint of beard hair loss. He underwent submental liposuction for the treatment of neck fat accumulation performed by a non-physician in 2025. Following the procedure, he used a compression garment for 7 days. Three weeks later, he developed beard alopecia. Dermatological examination revealed submental fan-shaped patches of non-scarring alopecia in the post-procedural areas. Trichoscopy findings showed multiple broken hairs, yellow dots and black dots.

Based on the clinical history and physical examination, non-cicatricial alopecia secondary to liposuction was suspected. Treatment was initiated with 5% topical minoxidil twice daily, clobetasol 0.05% solution once daily, and mini pulse corticosteroid therapy with dexamethasone 8 mg twice weekly. After this therapeutic approach, the patches showed satisfactory improvement and hair regrowth within 1 month.

Conclusion

Liposuction is one of the most frequently performed aesthetic surgeries worldwide. Postoperative complications are rare, such as hematoma, submental edema, cervico-facial dystonia, hypertrophic scar formation, scar contracture, cervical necrotizing fasciitis, and transient facial nerve paralysis. Anatomical knowledge and adequate surgical techniques are essential requirements for surgeons who deal with cosmetic procedures in the face.

Unfortunately, in Brazil, non-physician professionals have ventured into performing aesthetic surgeries without sufficient technical knowledge to carry out such complex procedures or the necessary expertise to manage complications. In the present case, alopecia appeared in the same areas where the surgery was performed, with fan-shaped patches resembling the trajectory of the liposuction cannula. Trichoscopy findings were suggestive of anagen effluvium, such as black dots, yellow dots, and broken hairs. It is possible that postoperative edema, ischemia, and external compression from the dressing triggered hair loss.

The prescribed treatment focused on anti-inflammatory therapy with topical and oral corticosteroids, as well as

stimulation of healthy hair regrowth with topical minoxidil lotion. After one month of follow-up, beard regrowth was observed. With the growing demand for aesthetic procedures driven by the pursuit of the “perfect body”, the risk of secondary alopecia should be considered, and clinicians should remain vigilant, especially in patients who wear a beard.

EADV CONGRESS
VIENNA
30 SEP - 3 OCT 2026

Abstract N°: 1252

Enhanced hair regrowth in postmenopausal female pattern hair loss with multimodal therapy: a case series

Emilly Neves Souza*[1, 2]

[1] Hospital Universitário Cassiano Antônio Moraes, Ambulatório de Dermatologia, Vitória, Brazil
[2] Enseada Clínica - Dermatologia e Tricologia, Vitória, Brazil

Introduction
FPHL is the most common cause of hair loss and thinning in women. It appears as a diffuse non-scarring alopecia and increases with age. FPHL typically manifests during reproductive years, with a second peak incidence at menopause. Almost 70% of women over 60 years experience this disease. Genetic, hormonal and environmental factors can influence the progression of follicle miniaturization. Although the role of androgens is not yet elucidated in this alopecia, the use of 5ARIs plus topical or oral minoxidil can increase hair thickness and may be considered the most effective treatment for postmenopausal women. Scalp microneedling with drug delivery is a popular procedure in Brazil and has been performed as adjunctive therapy to enhance hair regrowth. This case series reports three postmenopausal women with successful hair recovery due to the combination of oral treatment and monthly sessions of scalp microneedling with drug delivery.

Case Presentation
Case 1: A 67-year-old woman with a medical history of hypertension and dyslipidemia presented with long-standing hair thinning, classified as Sinclair grade 4. Menopause had occurred at 48 years of age. She was treated with oral dutasteride 0.5 mg three times per week, oral minoxidil 2 mg/day, and topical minoxidil 5% once daily. In addition, she underwent six monthly scalp microneedling sessions. After 8 months of follow-up, a marked clinical improvement was observed, with reduction to Sinclair grade 2.

Case 2: A 58-year-old woman with hypertension presented with severe, progressive hair thinning since the age of 48. FPHL was classified as Sinclair grade 2 at baseline. Treatment consisted of oral dutasteride 0.5 mg three times per week, oral minoxidil 1.5 mg/day, and three initial monthly scalp microneedling sessions. After 15 months of follow-up, significant improvement in hair pigmentation, density, and thickness was documented.

Case 3: A 63-year-old woman with hypothyroidism presented with progressive hair loss and thinning corresponding to Sinclair grade 2. Menopause had occurred at 57 years of age. She was treated with oral dutasteride 0.5 mg twice per week, oral minoxidil 1.5 mg/day, and six monthly scalp microneedling sessions. After 7 months of follow-up, an excellent therapeutic response was identified.

Scalp microneedling procedure: all patients underwent scalp microneedling using the same standardized protocol. Procedures were performed with a Smart Pen device after 20 minutes of topical anesthesia with a 20% lidocaine solution (figure 4). Prior to microneedling, the scalp was cleansed with aqueous chlorhexidine and gauze. Microneedling was applied uniformly across the entire scalp using a cartridge containing 12 needles at a depth of 1.25 mm. This was followed by transdermal drug delivery of 5 ml of a sterile compounded solution containing minoxidil 0.5%, dutasteride 0.1%, biotin 0.5%, and silicium 3% (figure 5). The clinical endpoint was mild scalp erythema. Patients were instructed to wash their hair 24 hours after the procedure.

Conclusion

FPHL has a high prevalence in postmenopausal women and comes with a negative impact on quality of life. Low self-esteem, sadness and discomfort with hair loss are frequently reported. Treatment remains a challenge, as topical minoxidil is the only FDA-approved medication. Antiandrogen therapy is off-label, but 5AIRs have been recommended for elderly females in combination to topical or oral low-dose minoxidil. Scalp microneedling is an effective and well-tolerated adjunct option to stimulate hair recovery. The drug delivery technique enhances transdermal penetration of topical agents such as minoxidil, dutasteride, and nutrients, potentiating hair regrowth through dual mechanisms: direct follicular stimulation via growth factor release and improved medication bioavailability. This combined approach represents an excellent therapeutic alternative for patients with moderate to advanced alopecia as adjuvant therapy to home-based medical treatment.

EA DV CONGRESS
VIENNA
30 SEP - 3 OCT 2026

Abstract N°: 1281

Metformin as a Therapeutic Option for central centrifugal cicatricial alopecia: A Systematic Review of Clinical Outcomes and Safety

Ana Clara Felix de Farias Santos[1], Fernanda Valeriano Zamora[2], Ana Beatriz Nardelli Da Silva[3], Ana Carolina Putini Vieira[4], Ana Carolina Ventura de Santana de Jesus[5], Gustavo Fernandes Braga[5], Deivyd Vieira Silva Cavalcante[6], Andres Villca Zamora[7], Guilherme Kuceki[8], Thais Barros Felippe Jabour*[4]

[1] City University of São Paulo, São Paulo, Brazil
[2] Rio de Janeiro State University, Rio de Janeiro, Brazil
[3] Federal University of Pará, Pará, Brazil
[4] University of Santo Amaro, São Paulo, Brazil
[5] Escola Bahiana de Medicina e Saúde Pública, Salvador, Brazil
[6] University of North Texas Health Science Center, North Worth, United States
[7] Federal University of Minas Gerais, Belo Horizonte, Brazil
[8] Ohiohealth Riverside Methodist Hospital, Columbus, United States

Introduction
Central centrifugal cicatricial alopecia (CCCA) is a form of scarring alopecia that predominantly affects women of African descent, leading to progressive permanent hair loss, inflammation, scalp pain, pruritus, and burning. Available treatments, including corticosteroids, minoxidil, and immunomodulatory agents, often provide incomplete or inconsistent benefit. Metformin has recently emerged as a potential therapeutic option because of its anti-inflammatory and antifibrotic properties. We systematically reviewed the available evidence on metformin for CCCA, focusing on symptom improvement, hair regrowth, and safety.

Materials and Methods
This systematic review followed Cochrane methods and PRISMA recommendations and was prospectively registered in PROSPERO (CRD420251101578). PubMed, Embase, and Web of Science were searched from inception through July 9, 2025. Eligible studies included adults with clinically and/or histologically confirmed CCCA treated with topical or oral metformin, either as monotherapy or adjunctive therapy, and reporting at least one relevant clinical, histological, or safety outcome. Two reviewers independently screened studies, extracted data, and assessed risk of bias using Joanna Briggs Institute critical appraisal tools. Because of heterogeneity in study design, treatment regimens, and outcome measures, results were synthesized qualitatively.

Results
The search identified 519 records. After duplicate removal and screening, 6 full-text articles were assessed and 5 studies met the inclusion criteria, comprising 19 patients with CCCA. Four studies were case series and one was a case report. Most patients were women aged 30 to 60 years, and most studies were conducted in the United States. Metformin was administered predominantly as topical 10% formulations, whereas one study evaluated oral metformin at 500 mg/day.
Across studies, metformin was associated with improvement in both symptoms and hair outcomes. Reported benefits included reduction in scalp pain, pruritus, inflammation, and scalp tenderness, together with increased hair density and visible regrowth. Clinical response was generally observed after 4 to 10 months. In the largest

included series, 9 of 12 patients treated with oral metformin reported symptomatic improvement and 6 showed clinical hair regrowth after at least 6 months. Additional reports using topical metformin, either alone or combined with minoxidil and/or corticosteroids, described substantial vertex repopulation and improved hair density.
Topical metformin was generally well tolerated. Adverse effects were mild and limited to local dryness or irritation, with no systemic adverse events reported. One included study also demonstrated transcriptomic changes consistent with reduced inflammation and fibrosis, supporting a biologically plausible therapeutic effect. Risk of bias was low in 3 studies and moderate in 2, with no study classified as high risk.

Table 1. Summary of included studies evaluating metformin for CCCA

Study	n	Route	Regimen	Main result	Follow-up
Araoye 2020	2	Topical	10% cream	Regrowth / improvement	4-6 mo
Bao 2024	12	Oral	500 mg/day	9 improved symptoms; 6 showed regrowth	≥6 mo
Granja 2024	1	Topical	10% cream	Substantial vertex regrowth	8 mo
Lubov 2023*	3	Topical	Used in 1 case	Limited interpretation	NA
Williams 2025	3	Topical	10% cream	Improved density and regrowth	6-10 mo

* Only 1 of 3 patients received metformin.

Table 1. Summary of included studies evaluating metformin for CCCA, including route, regimen, main outcomes, and follow-up. NA: not available.

Conclusions

The currently available evidence suggests that metformin, particularly as a topical 10% formulation, is a promising and well-tolerated therapeutic option for CCCA, with recurrent signals of benefit in symptom control, hair density, and regrowth. Oral metformin also showed encouraging results in the largest available series. Its potential anti-inflammatory and antifibrotic effects make metformin especially relevant in a disease characterized by progressive follicular destruction and scarring. However, the certainty of evidence remains very low because the current literature is limited to small observational studies with heterogeneous protocols. Randomized controlled trials are needed to confirm efficacy, define the optimal formulation and dosing strategy, and clarify the role of metformin in CCCA management.

EA DV CONGRESS
VIENNA
30 SEP - 3 OCT 2026

Abstract N°: 1295

Fresh Prunus speciosa Flower Extract as a Low-Irritation Botanical Strategy for Sensitive Scalp and Hair Loss: Mechanistic and Clinical Validation

Li Ye*[1], Peng Huang[2], Xiaoyan Fu[1], Jian He[2], Ping He[2], Linshan Wu[1], Suqi Lu[2], Shaojie Gu[2], Hongling Zhu[1], Jianfang Luo[2], Dongcui Li[2], Naisheng Jiang[3]

[1] Cosmetics Testing Center, Dermatology Hospital of Southern Medical University, NMPA Center for Innovation and Research in Regulatory Science, Translational Medicine Center, Dermatology Hospital of Southern Medical University, GuangZhou, China

[2] Research and Development, Hua An Tang Biotech Group Co., Ltd, Guangzhou, China

[3] School of Materials Science and Engineering, University of Science and Technology Beijing, Key Laboratory of Advanced Materials and Devices for Post-Moore Chips, Ministry of Education, Beijing, China

Introduction

Hair loss and scalp sensitivity are increasingly prevalent conditions with limited solutions tailored for sensitive scalp populations, as most current interventions rely on high concentrations of bioactive compounds. This study aimed to evaluate the mechanistic and clinical efficacy of Fresh Prunus speciosa Flower Extract (FPSFE), obtained via a solvent-free mobile Good Manufacturing Practice (GMP) extraction system designed to preserve bioactivity, for sensitive scalp care and hair loss–related conditions.

Materials and Methods

FPSFE was produced using an on-site solvent-free GMP-compliant extraction platform and formulated into a topical scalp serum. In vitro assays were conducted to assess antioxidant capacity (DPPH, ABTS), oxidative stress modulation (ROS generation and apoptosis), anti-inflammatory activity (TNF-α, IL-1β), and 5α-reductase inhibition. A 12-week clinical study was conducted in 30 participants to evaluate the effects of FPSFE-containing serum on scalp sensitivity, sebum production, and hair loss–related outcomes.

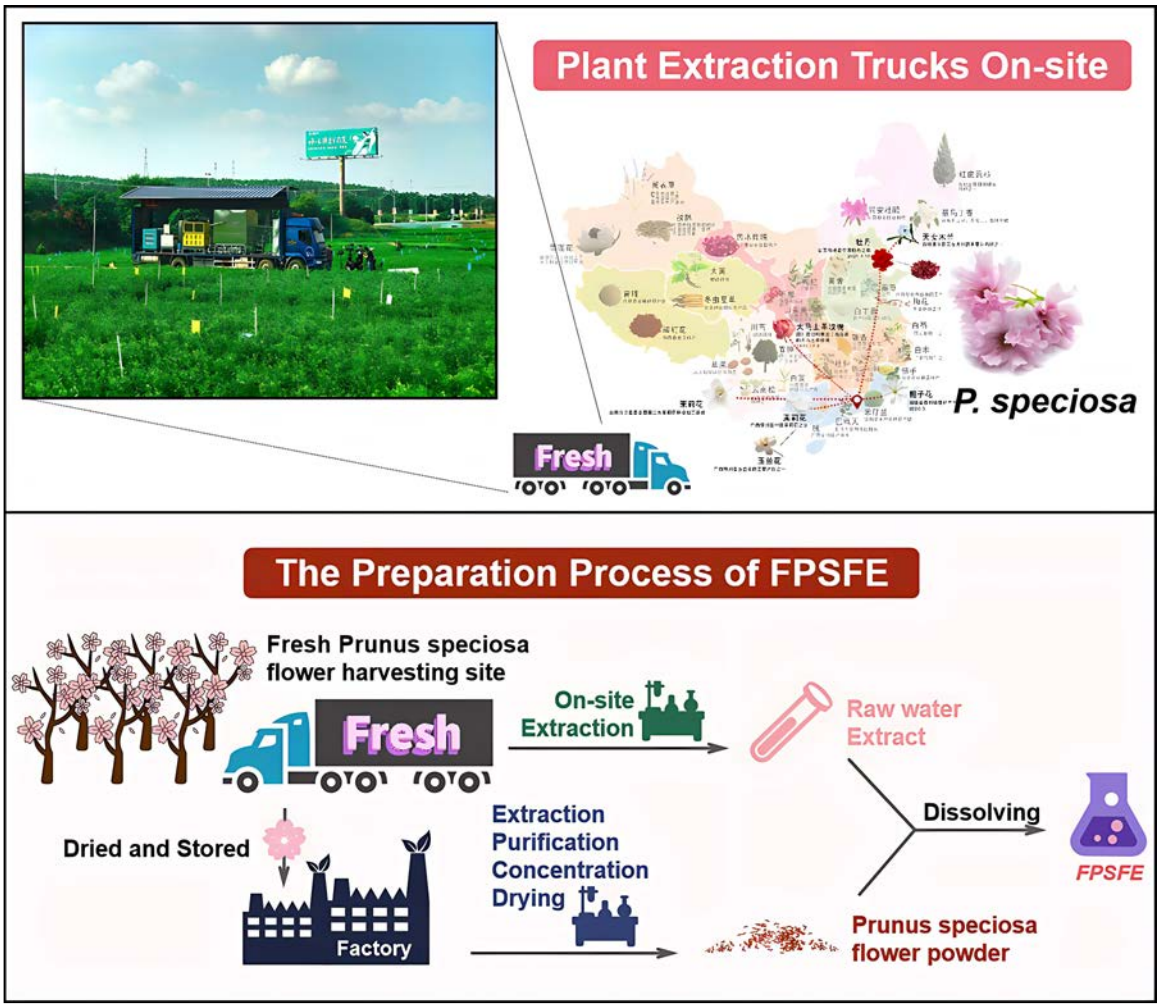

Results

FPSFE demonstrated strong antioxidant activity, with DPPH radical scavenging activity >80% and ABTS activity >90%. It significantly reduced blue-light–induced ROS accumulation and apoptosis. The formulation exhibited anti-inflammatory effects, with reductions in TNF-α (30.7%) and IL-1β (44.4%). In addition, 5α-reductase activity was inhibited by 42.6%, accompanied by a 37.5% reduction in sebum-related activity in vitro. Clinically, after 12 weeks of use, participants showed significant reductions in hair shedding, increased hair density, decreased scalp sebum levels (>80% reduction), and improvements in scalp sensitivity and discomfort scores, indicating overall improvement in scalp health.

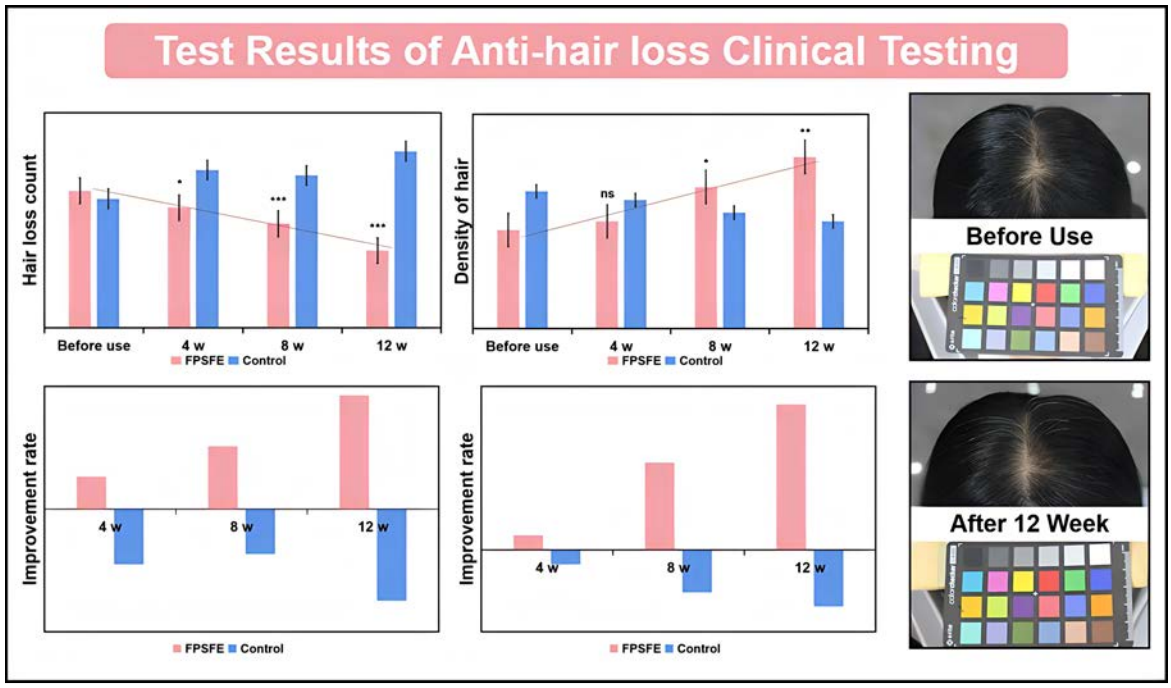

Conclusions

This study demonstrates that solvent-free GMP-based extraction enables the production of a high-bioactivity Prunus speciosa flower extract with preserved functional properties. FPSFE exhibited antioxidant, anti-inflammatory, photoprotective, and 5α-reductase inhibitory activities in vitro, which translated into clinically observable improvements in scalp condition and hair loss–related parameters. These findings suggest that FPSFE may represent a gentle and effective option for managing sensitive scalp conditions associated with hair loss.

EA DV CONGRESS
VIENNA
30 SEP - 3 OCT 2026

Abstract N°: 1299

Pediatric Patients with Alopecia Universalis and Severe Alopecia Areata Successfully Treated with Upadacitinib: A Case Series

Jun Hyeong Jeong*[1], Gwang Seong Choi[1]

[1] Department of Dermatology, Inha University School of Medicine, Incheon, Korea, Rep. of South

Introduction

Alopecia areata (AA) is a common autoimmune hair disorder that ranges from patchy alopecia to more severe forms like alopecia universalis (AU). Severe forms of the disease often start during childhood While increasing evidence suggests that Janus kinase (JAK) inhibitors may be effective in treating AA, data regarding their use in pediatric populations remain limited. Upadacitinib is an oral selective inhibitor of JAK1, currently approved for the treatment of moderate to severe atopic dermatitis in adults and pediatric patients 12 years of age and older. This study aims to evaluate the real-world efficacy and safety of upadacitinib in pediatric patients with severe, refractory AA or AU.

Materials and Methods

A cohort of 11 pediatric patients diagnosed with severe AA or AU was treated with upadacitinibThe age of the patients at upadacitinib initiation ranged from 7 to 17 years old. All patients had a history of previous treatment failures, which included therapies such as diphenylcyclopropenone (DPCP), cyclosporine, methotrexate, oral minoxidil, dupilumab, and baricitinib. Efficacy was assessed using the Severity of Alopecia Tool (SALT) score, with evaluations conducted at weeks 0, 8, 16, and 24. Clinical improvements were defined by the achievement of SALT 75, 90, and 100, representing at least 75%, 90%, and 100% improvement from the baseline condition, respectively. Safety was monitored by evaluating adverse events and laboratory abnormalities

Results

The baseline characteristics of the 11 patients included 4 males (36.3%) and 7 females (63.6%), with a mean disease duration of 54.5 months. Comorbidities included atopic dermatitis (n=3) and prurigo nodularis (n=1). Notably, 6 patients (54.5%) had a previous treatment history with baricitinib. Upadacitinib was administered at doses of 15 mg per day (n=7) or 30 mg per day (n=4). Regarding clinical efficacy within 6 months of treatment, SALT 75 was achieved in 10 patients (90.9%). Furthermore, SALT 90 was achieved in 9 patients (81.8%), and SALT 100 was achieved in 5 patients (45.4%). The treatment was generally well-tolerated, with hyperlipidemia reported as an adverse event in 2 patients.

Case	Sex/Age	Age at Upadacitinib Initiation	Upadacitinib Treatment dose	Prior Treatments	Comorbidities	Disease Duration (months)	SALT Scores				Adverse Events
							0 week	8 week	16 week	24 week	
#1.	F/16	12	15mg per day	DPCP, MTX	Atopic dermatitis	28	100	60	10	0	Hyperlipidemia
#2.	F/19	15	15mg per day	Dupilumab	Atopic dermatitis	36	100	50	0	0	-
#3.	F/18	17	30mg per day	Baricitinib, MTX	-	60	95	20	0	0	-
#4	M/18	16	30mg per day	CsA, MTX, oMNX	Atopic dermatitis	62	100	97	50	0	-
#5.	F/15	13	30mg per day	Baricitinib	-	13	100	99	55	10	-
#6.	M/13	11	30mg per day	Baricitinib, oMNX	-	89	100	100	35	8	Hyperlipidemia
#7.	F/13	10	15mg per day	MTX, CsA, oMNX	-	48	100	100	50	15	-
#8.	M/10	9	15mg per day	Baricitinib, CsA oMNX	-	73	65	30	25	15	-
#9.	F/8	7	15mg per day	DPCP, CsA, Baricitinib	-	69	100	90	50	10	-
#10.	F/8	7	15mg per day	DPCP, CsA	-	74	100	95	10	0	-
#11.	M/11	8	15mg per day	DPCP, CsA MTX	Prurigo nodularis	48	100	80	25	7	-

Table 1. Baseline Demographics, Prior Treatments, Comorbidities, and Clinical Responses to Upadacitinib in Pediatric Patients with Severe Alopecia Areata and Alopecia Universalis (DPCP: Diphenylcyclopropenone, CsA: Cyclosporine, MTX: Methotrexate, oMNX: Oral Minoxidil, SALT: Severity of Alopecia Tool)

Conclusions

This case series presents 11 pediatric patients with recalcitrant AU who were successfully treated with upadacitinib Upadacitinib demonstrated profound anti-inflammatory effects and emerged as a viable therapeutic option for the pediatric population suffering from refractory AA or AU. Importantly, recent clinical evidence in this series demonstrates that selective JAK1 inhibition may offer a distinct therapeutic benefit, achieving substantial hair regrowth even in non-responders to previous JAK1/2 inhibitors like baricitinib. Large, comparative studies are needed to further confirm these results.

EA DV CONGRESS
VIENNA
30 SEP - 3 OCT 2026

Abstract N°: 1359

The Efficacy of Saw Palmetto in the Management of Androgenetic Alopecia: A Comprehensive Review of the Current Evidence

Marie Line Chedid[1], Sheeda Jabeen[2], Carine Nassif[1], Shabbeer Imtiaz Ahamed[2], Annabelle Diaz[3], Lara Ghazzaoui[4], Ana Franco[3], Nancy Emmanuel*[5]

[1] Medical University of Łódź, Łódź, Poland

[2] Tbilisi State Medical University, Faculty of Medicine, Tbilisi, Georgia

[3] Facultad de Ciencias Médicas Enrique Ortega Moreira, Universidad de Especialidades Espíritu Santo, Samborondon, Ecuador

[4] Universidade de Santo Amaro, UNISA, São Paulo, Brazil

[5] Department of Dermatology, Hospital das Clínicas da Faculdade de Medicina da Universidade de São Paulo, São Paulo, Brazil

Introduction

Androgenetic alopecia (AGA) is a progressive condition affecting up to 80% of aging men and 40% of women, characterized by follicular miniaturization. While synthetic 5-alpha-reductase inhibitors (5-ARIs) are established treatments, patient concerns regarding systemic side effects and teratogenicity in females have driven interest in botanical alternatives. *Serenoa repens*, or Saw Palmetto, has emerged as a prominent non-pharmacological option for both male pattern hair loss (MPHL) and female pattern hair loss (FPHL). This review aims to synthesize current evidence regarding the mechanism of action, clinical efficacy, and safety profile of *Serenoa repens* in treating AGA across both sexes.

Materials and Methods

A systematic literature search was conducted using the terms: ("Alopecia"[MeSH Terms] OR "Androgenetic Alopecia"[MeSH Terms] OR androgenetic alopecia OR androgenic alopecia OR male pattern baldness OR female pattern hair loss OR pattern hair loss OR AGA) AND ("Serenoa repens" [MeSH Terms] OR saw palmetto OR Serenoa repens OR sabal serrulata). PubMed, Embase, and Web of Science searches yielded 120 records. Two reviewers independently screened English-language studies (including randomized controlled trials, clinical and comparative studies, cohort studies, and case series) and a third resolved conflicts. No date restrictions were applied.

Results

Mechanistically, *Serenoa repens* acts as a competitive, non-selective inhibitor of 5-alpha-reductase types I and II, blocking the conversion of testosterone to dihydrotestosterone (DHT). It further reduces DHT uptake and binding to androgen receptors. In vivo models suggest it promotes hair regeneration by activating transforming growth factor-β (TGF-β) and mitochondrial signaling pathways. Clinical evidence indicates significant efficacy in both men and women. A 180-day RCT involving a balanced cohort of men and women reported a 283% greater improvement in total terminal hair count compared to placebo. Subgroup analysis of menopausal women in this trial showed a significant mean increase in terminal hair counts (7.7%) and total hair density (11.2%) over 90 days. By day 180, menopausal women treated with the botanical extract achieved a 4-fold

increase in terminal hairs and a 3-fold growth in total hair density compared to placebo. Another multicenter trial of 225 subjects (including 60 women) found that adding *Serenoa repens* to standard pharmacological therapy significantly increased the rate of "great improvement" from 25% to 36.5%. In women with chronic telogen effluvium and AGA, oral supplementation significantly increased hair density and the percentage of anagen hairs over six months. Safety assessments show *Serenoa repens* is generally well-tolerated. However, female-specific concerns have been identified, including potential menstrual effects, changes in libido, and hormonal disruptions that may impact fertility in fertile women. A case report also detailed persistent anxiety, dyspareunia, and diffuse mucosal dryness in a 36-year-old woman using topical *Serenoa repens*. In pediatric populations, a case of an 11-year-old girl described hot flashes and possible early menarche linked to a *Serenoa repens* supplement. Urological data supports its efficacy in reducing DHT, though urological outcomes in BPH remain debated.

Conclusions

Current evidence suggests *Serenoa repens* is an effective alternative for managing mild-to-moderate MPHL and FPHL. Its dual action on enzyme activity and receptor binding provides measurable clinical benefits, with particularly strong outcomes observed in menopausal women. While generally safe, practitioners should remain vigilant regarding rare persistent sexual or psychiatric symptoms and potential antiestrogenic effects in female and pediatric populations. Further large-scale trials are required to establish standardized dosages and long-term safety profiles.

EADV CONGRESS
VIENNA
30 SEP - 3 OCT 2026

Abstract N°: 1365

Clinical Trial Eligibility in Real-World Alopecia Areata Patients Treated With Baricitinib

Daniel Muñoz Barba*[1], Miguel Limeres de la Rosa[1], Carmen García Moronta[1], Manuel Sanchez-Diaz[1], Salvador Arias-Santiago[1]

[1] Hospital Universitario Virgen de las Nieves, Granada, Spain

Introduction
The eligibility criteria applied in baricitinib randomized clinical trials (RCTs) for alopecia areata (AA) may not fully capture the spectrum of patients encountered in routine clinical practice. The aim of this study was to determine the proportion of AA patients treated with baricitinib in a real-world setting who would meet RCTs eligibility criteria.

Materials and Methods
A prospective, observational, single-center study was conducted. Patients receiving baricitinib were classified according to whether they fulfilled BRAVE AA´s RCTs eligibility criteria. Variables collected were compared between groups.

Results
Forty-eight patients were included, with a mean age of 36.9 years and a female:male ratio of 2:1. Overall, only 20.8% of patients fulfilled RCTs eligibility criteria, most commonly due to disease duration (43.8%), recent use of corticosteroids (62.5%), and baseline SALT (29.17%). Non-eligible patients more frequently had long-standing disease, whereas eligible patients exhibited higher baseline SALT and more frequent eyebrow/eyelash involvement ($p < 0.05$). Despite these differences, both groups showed comparable efficacy and safety profiles ($p > 0.10$).

Conclusions
This study highlights the need to broaden eligibility criteria in RCTs, as overly strict requirements reduce their applicability and fail to reflect the diverse patient population seen in real-world dermatological practice.

EADV CONGRESS
VIENNA
30 SEP - 3 OCT 2026

Abstract N°: 1366

Early-onset androgenetic alopecia mimicking alopecia areata in an adolescent girl: a diagnostic pitfall

Maja Mitrovic*[1]

[1] General Hospital Pancevo, Department of Dermatology and Venereology, Pancevo, Serbia

Introduction

Androgenetic alopecia (AGA) in the paediatric population remains underrecognized in clinical practice.
It may present with atypical features and mimic other forms of non-scarring alopecia, particularly alopecia areata, representing a diagnostic pitfall with potential for misdiagnosis and inappropriate treatment.

Case Presentation

A 13-year-old girl was referred by her paediatrician for localized hair loss over the vertex, progressing over several months. Clinical examination revealed a well-demarcated, predominantly circular alopecic patch in the frontoparietal region, with diffuse thinning of the surrounding hair, particularly over the vertex. The frontal hairline was preserved, and the scalp appeared normal.

Family history was positive for androgenetic alopecia. Laboratory investigations, including hormonal assessment, were within normal limits. Gynaecological evaluation was unremarkable, and no associated systemic or cutaneous symptoms were reported.

Trichoscopy showed marked hair shaft diameter variability (anisotrichosis) and follicular miniaturization, with a mixture of terminal, intermediate, and vellus hairs. Although the clinical presentation suggested alopecia areata, the absence of characteristic trichoscopic features argued against this diagnosis and supported early-onset AGA.

Treatment with topical minoxidil was initiated.

Conclusion

Early-onset AGA may present with an atypical patchy pattern and mimic alopecia areata, representing a diagnostic pitfall in paediatric patients.
Recognition of key trichoscopic features, particularly anisotrichosis and follicular miniaturization, is essential for accurate diagnosis.
Although considered uncommon, AGA in the paediatric population is likely underdiagnosed and should be included in the differential diagnosis of patchy non-scarring alopecia to ensure appropriate management.

EA DV CONGRESS
VIENNA
30 SEP - 3 OCT 2026

Abstract N°: 1372

Can Acrodermatitis Continua of Hallopeau with Moderate-to-Severe Nail Involvement Be Effectively Controlled? A Real-World, 24-Week Study of 17 Cases Treated via Periungual Injection of the Novel IL-17A Inhibitor Xeligekimab Combined with Tofacitinib

Anqi Liu*[1], Zhiying Yu[1], Meng Wang[1], Shaohui Geng[2], Ying Yang[1], Chen Li[1]

[1] Shenzhen People's Hospital(The First Affiliated Hospital, Southern University of Science and Technology;The Second Clinical Medical College,Jinan University), Department of Dermatology, Shenzhen, China
[2] Beijing University of Chinese Medicine, School of Life Science, Beijing, China

Introduction

Acrodermatitis continua of Hallopeau (ACH) is a localized clinical variant of pustular psoriasis that predominantly affects the distal phalanges of the fingers and toes. It is characterized by sterile periungual and subungual pustulation, paronychia, and onychodystrophy, which may progress to osteolysis, pain, and atrophy of the distal phalanx. Due to the rarity of the disease, standardized therapeutic guidelines are currently lacking, rendering the management of ACH a significant clinical challenge.

Materials and Methods

This 24-week, single-center study enrolled 17 adults with ACH, focusing on patients with moderate-to-severe nail involvement (≥3 affected nails) and inadequate responses to prior therapies. Exclusion criteria included contraindications to xeligekimab or any ACH-directed treatment within the 4-week washout period before enrollment, including topical and systemic therapies. Participants received periungual xeligekimab injections (0.1 mL per affected nail, biweekly) plus oral tofacitinib (5 mg twice daily). Clinical response and safety were assessed at baseline and every 2 weeks during the study. Baseline cohort characteristics are shown in Table 1 (n = 17). The protocol was approved by the local Institutional Review Board, and written informed consent was obtained from all participants.

Treatment-emergent adverse events (TEAEs) were documented throughout the study. At each visit, standardized clinical photography was performed to document morphological changes and assess nail damage severity. Clinical scoring was independently conducted using the Nail Psoriasis Severity Index (NAPSI) and the Physician's Global Assessment for ACH (ACHPGA). The ACHPGA scale ranges from 0 (clear) to 4 (very severe), with scores of 0 or 1 defined as "clear" or "almost clear." Clinical improvement was calculated as follows: Improvement Rate = (Baseline NAPSI − Current NAPSI)/Baseline NAPSI. Concomitant topical or systemic therapies were prohibited during the study. Efficacy endpoints included the proportions of patients achieving ≥75% (NAPSI 75) and ≥90% (NAPSI 90) reductions in NAPSI scores at Week 24, as well as changes in ACHPGA scores from baseline.

Table 1. Baseline Patient Characteristics

Patient No./sex/age of onset,y	Disease Duration,mo	Previous treatments	Comorbidities	Concomitant Psoriasis	No. of Affected Nails	NAPSI	ACHPGA	Smoking	Drinking
1/F/22	36	Topical ointments/creams; Tofacitinib; Upadacitinib	Pustulosis	No	10	80	4	No	No
2/F/35	9	Topical ointments/creams	Thyroid disease	No	4	24	3	No	No
3/F/33	9	Acitretin; Topical ointments/creams	Rhinosinusitis	Yes	7	54	4	No	No
4/M/33	40	Acitretin; Topical ointments/creams	None	No	3	22	3	Yes	No
5/F /22	144	Acitretin; Cyclosporine; Topical ointments/creams; Apremilast; Secukinumab	None	No	4	15	3	No	No
6/F/27	24	Acitretin; Topical ointments/creams; Apremilast; Upadacitinib	Pustulosis	No	3	24	4	No	No
7/M/33	48	Topical ointments/creams	None	No	3	12	3	Yes	No
8/F/35	9	Methotrexate; Topical ointments/creams; Tofacitinib	None	Yes	6	42	4	No	No
9/F/28	24	Topical ointments/creams	Pustulosis; Rhinosinusitis; Tonsillitis	No	4	24	4	No	No
10/F/39	12	Topical ointments/creams; Apremilast	Pustulosis; Dermatitis/Eczema	Yes	10	76	4	No	No
11/F/44	24	Acitretin; Topical ointments/creams; Apremilast	Otitis media	No	7	44	4	No	No
12/F/33	12	Topical ointments/creams	Pustulosis	No	3	20	3	Yes	No
13/M/42	36	Topical ointments/creams; Tofacitinib; Upadacitinib	Diabetes mellitus; Pustulosis	No	8	62	3	Yes	No
14/F/30	12	Topical ointments/creams	Rhinosinusitis	No	6	34	3	No	Yes
15/F/34	10	Acitretin; Cyclosporine; Topical ointments/creams; NB-UVB; Tofacitinib; Secukinumab	Otitis media	Yes	10	80	4	No	No
16/F/29	24	Topical ointments/creams	None	No	4	18	3	No	No
17/M/20	120	Topical ointments/creams	None	No	6	48	4	No	No

Results

A total of 17 patients were enrolled, including 13 females and 4 males. The mean age at disease onset was 31.5 years, and the median number of affected nails was 6. All participants had confirmed ACH. Regarding comorbidities, 4 patients had concomitant psoriasis, and 6 had localized chronic inflammatory diseases, including rhinitis, sinusitis, eczema, otitis media, or tonsillitis. 3 patients were active smokers, and only 1 reported alcohol consumption. Regarding treatment history, 9 patients were biologic-naïve, whereas 8 had previously received biologics or small-molecule inhibitors. All patients had persistent ACH-associated nail damage lasting months to years and refractory to prior therapies.

In this real-world study, all enrolled patients (n = 17) completed the 24-week follow-up. At week 12, 58.8% of patients (n = 10) achieved NAPSI 50, and 17.6% (n = 3) achieved NAPSI 75. At week 24, 94.1% of patients (n = 16) achieved NAPSI 50, 76.5% (n = 13) achieved NAPSI 75, 47.1% (n = 8) achieved NAPSI 90, and 11.8% (n = 2) achieved NAPSI 100. Furthermore, 82.4% (n = 14) achieved an ACHPGA score of “clear” or “almost clear.” Longitudinal clinical improvement is shown in Figures 1A and 1B. No serious adverse events (SAEs) were reported. Adverse events included upper respiratory tract infections in 3 patients and injection-site pain in 1 patient. Most participants reported no or mild injection-site discomfort, and all showed good adherence to the injection protocol.

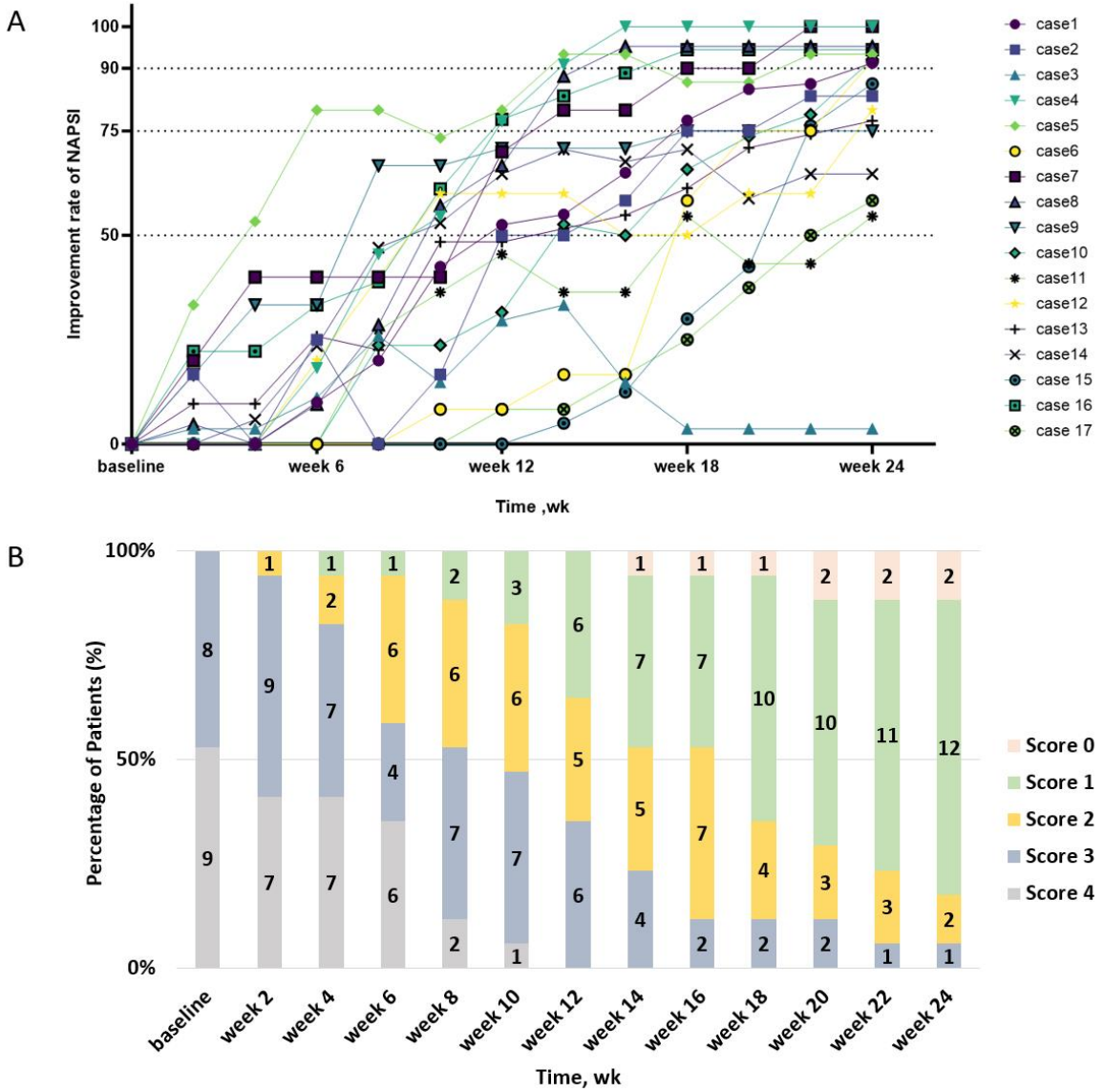

(A) Improvement rate from baseline in Nail Psoriasis Severity Index(NAPSI) scores through weeks. (B) Change from baseline in ACH Physician Global Assessment (ACHPGA) scores through weeks.

Conclusions

This real-world study demonstrates that ACH with moderate-to-severe nail involvement can be effectively controlled through periungual xeligekimab combined with tofacitinib. It is a well-tolerated therapeutic strategy offering significant improvement in nail lesions.

EADV CONGRESS
VIENNA
30 SEP - 3 OCT 2026

Abstract N°: 1394

A Novel Azelaic Acid-Aminexil Eutectic Mixture Promotes Hair Regeneration via Wnt/β-catenin Pathway Activation

Qian Yu*[1], yue wang[1], Ce Zhang[2], Yanyan Zhang[2], Beilei Cai[1], Xiaolei Ding[2]

[1] Zhiyan Biotechnology Co., Wuxi, China

[2] Shanghai Engineering Research Center of Organ Repair, School of Medicine, Shanghai University, Shanghai, China

Introduction

Androgenetic alopecia (AGA) accounts for more than 90% of alopecia cases, with reported prevalence in China of 21.3% in men and 6.0% in women. Conventional therapeutic interventions, notably oral finasteride and topical minoxidil, are profoundly limited by systemic endocrine adverse reactions, frustratingly low individual response rates, and high relapse frequencies upon cessation of therapy. Consequently, an urgent clinical demand exists for multi-target topical agents combining high efficacy with localized safety profiles to improve patient compliance. Azelaic acid has been reported to inhibit 5α-reductase and modulate perifollicular inflammation, whereas diaminopyrimidine oxide may improve the perifollicular microenvironment and support follicular activity. We investigated whether a eutectic combination of these agents exerts synergistic capacity to reverse dihydrotestosterone (DHT)-induced follicular miniaturization across human dermal papilla cell (hDPC) models.

Materials and Methods

Human dermal papilla cell (hDPC) assays were used to compare azelaic acid, diaminopyrimidine oxide, and their eutectic mixture for effects on cell proliferation, β-catenin protein expression, and VERSICAN mRNA. In a dihydrotestosterone (DHT)-injured hDPC model, VEGF expression was quantified by ELISA after treatment with the eutectic mixture or diaminopyrimidine oxide alone. Type II 5α-reductase inhibition was also evaluated in an enzyme assay. Minoxidil and finasteride served as positive controls in the cell-based and enzyme assays, respectively.

Results

In hDPCs, the eutectic mixture enhanced cell proliferation, with the greatest effect observed at 0.01%–0.02%, and showed the highest β-catenin/GAPDH ratio and VERSICAN mRNA level among the test groups. In the DHT model, the eutectic mixture increased VEGF to 145.26±2.86 pg/mL at 0.1%, 114.41±1.37 pg/mL at 0.05%, and 96.98±0.66 pg/mL at 0.0006%, corresponding to increases of 57.2%, 23.8%, and 4.9% versus model control, respectively. At 0.1%, VEGF induction by the eutectic mixture was not significantly different from minoxidil and was 16.9% higher than that of diaminopyrimidine oxide alone (145.26±2.86 vs 129.70±0.38 pg/mL; $p<0.05$). In the enzyme assay, the eutectic mixture showed 47.93±4.94% inhibition of type II 5α-reductase at 2.72%, significantly higher than diaminopyrimidine oxide alone at 1.5% (33.89±6.28%; $p<0.05$), although lower than finasteride (73.26±2.41%).

Conclusions

The azelaic acid/diaminopyrimidine oxide eutectic demonstrated multitarget activity relevant to AGA, including promotion of dermal papilla cell proliferation, activation of Wnt/β-catenin pathway, upregulation of VERSICAN and VEGF, and inhibition of type II 5α-reductase. These preclinical findings support further in vivo and clinical

evaluation of this topical strategy for AGA.

EADV CONGRESS
VIENNA
30 SEP - 3 OCT 2026

Abstract N°: 1399

A novel framework for integrative hair longevity management

Hema Sundaram[1], Jing Zhou[2], Miguel Marti[3], Sebastien Thibaut[4], Stéphane Commo[5], Georges El Haddad[6], Natalia Kovylkina*[6], Diala Haykal[7]

[1] Cosmetic & Laser Surgery, Rockville, United States
[2] Shanghai General Hospital, Shanghai Jiao Tong University School of Medicine, Shanghai, China
[3] Centro de Tricologia y Transplante Capilar Dr Miguel Marti, Buenos Aires, Argentina
[4] L'Oreal R&I, Aulnay sous Bois, France
[5] L'Oreal R&I, Aulany sous Bois, France
[6] Vichy Laboratoires, Levallois-Perret, France
[7] Centre Médical Laser Palaiseau, Palaiseau, France

Introduction
Hair ageing is a multifactorial process involving progressive deterioration of hair follicle structure and function, leading to reduced density, diameter, and overall hair quality. Inspired by advances in longevity science, the emerging concept of hair longevity shifts focus from reactive treatment of visible hair loss to proactive preservation of follicular health. Androgenetic alopecia (AGA), the most common form of non-scarring alopecia, illustrates hair ageing through mechanisms including follicular miniaturization, microinflammation, oxidative stress, and intrinsic cellular senescence. Despite the prevalence and psychological burden of age-related hair thinning, especially among women, preventive approaches remain underdeveloped.

Materials and Methods
An analysis of 102 articles published between 2003 and October 2025 synthesized by an international expert working group and a comprehensive literature analysis allowed to establish a conceptual framework for hair longevity.

Results
The proposed model identifies nine hallmarks of hair ageing, grouped into structural, metabolic, and signalling dysfunctions influenced by genetic, hormonal, environmental, and lifestyle factors. Building on this framework, this work proposes an integrative approach to AGA management that incorporates pharmacological treatments, cosmetic formulations, nutritional supplementation, medical devices, and lifestyle-based strategies

Conclusions
Emphasizing prevention as well as treatment, the concept of hair longevity introduces opportunities for earlier intervention, improved patient education, and development of innovative, multi-targeted formulations to support lifelong scalp and hair health

EADV CONGRESS
VIENNA
30 SEP - 3 OCT 2026

Abstract N°: 1412

Real-World Comparison of Ritlecitinib 50 mg and Baricitinib 4 mg in Alopecia Areata: A Retrospective Cohort Study

Raffaele Dante Caposiena Caro*[1], Camilla Brunello[1], Bianca Bonessi[1], Caterina Aceti[1], Nicola di Meo[1], Iris Zalaudek[1]

[1] Dermatology Clinic, Hospital Maggiore of Trieste, University of Trieste, Trieste, Italy

Introduction
Alopecia areata is a chronic immune-mediated disorder with a significant psychosocial impact. JAK inhibitors have revolutionized its management, with baricitinib (JAK1/2) approved for moderate-to-severe disease and ritlecitinib (JAK3/TEC) emerging as a promising alternative. However, direct comparative data are lacking, and differences in selectivity may influence efficacy, safety, and speed of response. This study aims to compare ritlecitinib 50 mg and baricitinib 4 mg in terms of clinical outcomes, hair regrowth, and tolerability in patients with alopecia areata.

Materials and Methods
We conducted a retrospective study. Clinical scores, including SALT (Severity of Alopecia Tool) and Clinician-Reported Outcomes (ClinRO) for eyebrows (EB) and eyelashes (EL), as well as quality of life (QoL), assessed using Skindex-16 and the Hospital Anxiety and Depression Scale (HADS), were collected at baseline and after 12 (T12) and 24 (T24) weeks of treatment. Demographic characteristics were recorded at baseline. Patients were divided into two groups: those treated with baricitinib 4 mg (Group A) and those treated with ritlecitinib 50 mg (Group B). Descriptive statistics (mean ± standard deviation) were used for demographic and clinical data. Clinical outcomes at different time points were analyzed using paired t-tests, while outcomes between the two groups were compared using ANCOVA (analysis of covariance). Statistical significance was set at $p < 0.05$.

Results
A total of 42 patients were enrolled (32 females and 10 males). In Group A, 20 patients (14 females and 6 males) were included, with a mean age of 40.3 ± 9.7 years. Baseline mean scores were: SALT 72.4 ± 32.4, ClinRO EB 1.7 ± 1.3, and ClinRO EL 1.6 ± 1.3. At week 12 (T12), scores were SALT 58.0 ± 39.1, ClinRO EB 1.2 ± 1.2, and ClinRO EL 1.2 ± 1.1; at week 24 (T24), SALT 49.0 ± 40.8, ClinRO EB 0.8 ± 1.0, and ClinRO EL 0.8 ± 1.2. Paired t-tests showed significant improvements from baseline to T12 ($p = 0.011$) and to T24 ($p = 0.002$). No statistically significant changes in QoL were observed during the study period. In Group B, 22 patients (18 females and 4 males) were included, with a mean age of 40.5 ± 18.8 years. Baseline mean scores were: SALT 73.9 ± 22.6, ClinRO EB 1.2 ± 1.3, and ClinRO EL 0.9 ± 1.2. At T12, scores were SALT 56.6 ± 37.3, ClinRO EB 1.1 ± 1.2, and ClinRO EL 0.6 ± 1.1; at T24, SALT 33.4 ± 40.1, ClinRO EB 0.5 ± 0.9, and ClinRO EL 0.3 ± 0.8. Paired t-tests showed significant improvements from baseline to both T12 and T24 (both $p < 0.001$). A statistically significant improvement in QoL (Skindex-16) was observed between baseline and T12. ANCOVA analysis showed no statistically significant differences between Group A and Group B at T24 for SALT ($p = 0.088$), ClinRO EB ($p = 0.375$), and ClinRO EL ($p = 0.747$).

Conclusions
This study compared baricitinib and ritlecitinib in alopecia areata, showing that both treatments significantly

improve hair regrowth and disease severity over 24 weeks. Both groups demonstrated reductions in SALT scores and improvement in eyebrow and eyelash involvement, confirming the efficacy of JAK inhibition across different selectivity profiles. Although ritlecitinib showed a numerically greater reduction in SALT at T24, particularly in more advanced regrowth, ANCOVA analysis did not reveal statistically significant differences between treatments at week 24, suggesting comparable overall efficacy after adjustment for baseline values. Quality of life improved earlier in the ritlecitinib group but remained overall variable, with no consistent between-group differences. Overall, results suggest similar clinical effectiveness despite mechanistic differences between JAK1/2 and JAK3/TEC inhibition. These findings are limited by the retrospective design, small sample size, and short follow-up. Larger prospective head-to-head studies are needed to confirm potential differences in onset and magnitude of response between these agents.

EADV CONGRESS
VIENNA
30 SEP - 3 OCT 2026

Abstract N°: 1415

Short-, medium-, and long-term effects of curcumin-mediated photodynamic therapy for the treatment of severe toenail onychomycosis

Enrique Alberdi Jeronimo*[1], Marta Alberdi[1], Clara Gómez Hernández[2]

[1] Terapéutica Dermatológica Alberdi S L, Madrid, Spain
[2] Instituto de Química Física Blas Cabrera, Madrid, Spain

Introduction
Curcumin has long been recognized for its anti-inflammatory, antioxidant, and antimicrobial properties. However, its clinical application remains limited due to its low aqueous solubility. For the treatment of fungal nail infections, incorporation into delivery systems such as emulsions may enhance its bioavailability and, consequently, its therapeutic efficacy. The aim of this study was to evaluate the short-, medium-, and long-term efficacy of curcumin-mediated photodynamic therapy, formulated in an oil-in-water emulsion, in patients with severe toenail onychomycosis.

Materials and Methods
A controlled trial was conducted including 20 patients diagnosed with severe distal lateral subungual onychomycosis affecting the great toenail. Affected nails were treated with an oil-in-water emulsion containing 40% urea and 0.1% curcumin, applied under occlusion for 12 hours daily throughout the intervention period. Nails were irradiated with blue light (λ = 450 nm, 20.6 mW/cm^2) for 30 minutes per session, completing a total of 10 sessions at weekly intervals. Clinical progression was assessed by direct examination and photographic documentation, enabling quantification using the Onychomycosis Severity Index (OSI). Mycological outcomes were determined through histopathological analysis of the affected nail plate at different time points during follow-up.

Results
Favorable clinical and mycological outcomes were observed throughout follow-up, with a mean clinical improvement of 58.5%, a mycological cure rate of 60.0%, and a complete cure rate of 55.0% at 64 weeks after treatment completion—promising results given the initial severity of the condition. No patient reported pain or side effects at any time.

Conclusions
The findings of this study support the short-, medium-, and long-term efficacy and safety of curcumin formulated in an oil-in-water emulsion as a photosensitizer in photodynamic therapy for the treatment of toenail onychomycosis.

EA DV CONGRESS
VIENNA
30 SEP - 3 OCT 2026

Abstract N°: 1468

Treatment Resistant Scalp Folliculitis, Why Demodex Folliculitis is a Diagnostic Challenge

Divas Mappa*[1]

[1] Wrightington, Wigan and Leigh Hospital NHS Foundation Trust, Wigan, United Kingdom

Introduction

Demodex folliculitis is an under recognised inflammatory condition caused by proliferation of *Demodex folliculorum*, a commensal external parasite of pilosebaceous units. While commonly associated with facial dermatoses such as rosacea, scalp involvement is rare and may mimic other causes of folliculitis and alopecia, contributing to misdiagnosis and delayed treatment.

Case Presentation

A 25-year-old man presented with a 1–2 year history of a pruritic, inflamed scalp with associated scaling and focal hair thinning over the right parietal region. Initial presentation included pruritus and cervical lymphadenopathy, and he was treated empirically for suspected tinea capitis with oral terbinafine, with partial response. Subsequent treatment with ketoconazole shampoo, topical antifungals and antibiotics failed to resolve persistent follicular papules and inflammation. Examination demonstrated reduced hair density with perifollicular scaling and inflammatory papules. Dermoscopy revealed broken hairs and black dots, raising suspicion of ongoing dermatophyte infection. There was no clear evidence of scarring or tufting. Differential diagnoses included lichen planopilaris, folliculitis decalvans, chronic folliculitis, and persistent tinea infection.

Investigations:

Punch biopsy illustrated acute-on-chronic folliculitis with the presence of *Demodex folliculorum*. DPAS staining was negative for fungal elements. No significant scarring was identified.

Management:

A trial of topical ivermectin was initiated, the patient subsequently reported clinical improvement in symptoms and scalp inflammation.

Conclusion

This case highlights how *Demodex folliculorum* can be associated with persistent scalp folliculitis and should be considered in patients with chronic, treatment-resistant scalp inflammation. Early biopsy and consideration of anti-Demodex therapy may facilitate accurate diagnosis, reduce diagnostic delay and prevent prolonged ineffective treatment.

EADV CONGRESS
VIENNA
30 SEP - 3 OCT 2026

Abstract N°: 1479

Intralesional Dutasteride for Androgenetic Alopecia: A Systematic Review and Meta-Analysis Revealing High Response Rates with Minimal Systemic Risk

Abdullah Almeziny*[1], Saad Altalhab Altalhab[1], Abdullah alkhalifah[1, 2]

[1] College of Medicine, Imam Mohammad Ibn Saud Islamic University, Riyadh, Saudi Arabia, Riyadah, Saudi Arabia
[2] Prince Sultan Military Medical City, Riyadh, Saudi Arabia, Riyadah, Saudi Arabia

Introduction
Androgenetic alopecia (AGA) is the most common cause of hair loss, characterized by progressive follicular miniaturization in androgen-sensitive scalp regions, leading to reduced hair density and significant psychosocial burden. The process is driven by dihydrotestosterone (DHT), formed from testosterone via 5-α-reductase, which shortens the anagen phase and promotes follicular regression. Dutasteride, a dual inhibitor of type I and II 5-α-reductase, effectively suppresses DHT but is limited by systemic adverse effects. Intralesional delivery via mesotherapy has emerged as a targeted approach to enhance local efficacy while minimizing systemic exposure.

Materials and Methods
comprehensive search of PubMed, Scopus, Embase, Web of Science, Cochrane Library, and ClinicalTrials.gov was performed to identify studies involving adults (≥18 years) with AGA treated with intralesional dutasteride. Eligible studies included randomized controlled trials, cohort studies, and observational studies. Outcomes assessed included hair density, terminal and vellus hair counts, and safety profiles. Data extraction was performed independently, and a random-effects model was applied. Subgroup and sensitivity analyses were conducted to explore heterogeneity.

Results
Eight studies were included. Intralesional dutasteride demonstrated significant improvement in hair growth outcomes, with an increase in terminal hair count (mean difference [MD] = 8.73) and a reduction in vellus hair count (MD = −6.04). The pooled improvement rate was 75%, indicating substantial clinical benefit. The treatment exhibited a manageable safety profile, with an overall adverse event rate of 37%, predominantly mild and localized. Combination therapy showed higher efficacy but was associated with increased adverse effects. Importantly, no systemic side effects were reported.

Conclusions
Intralesional dutasteride is a promising targeted therapy for AGA, demonstrating meaningful improvements in hair growth with a favorable safety profile and minimal systemic risk. Combination regimens may enhance efficacy but increase local adverse events. However, current evidence is limited Large, well-designed randomized trials are required to establish standardized protocols and confirm long-term efficacy and safety.

EA DV CONGRESS
VIENNA
30 SEP - 3 OCT 2026

Abstract N°: 1480

Advanced Hair Transplantation: A Comprehensive Review of Long Hair No-Shave FUE vs. Traditional FUE

Talia El Chaer[1], Carine Nassif[2], Jean Paule Joumaa[3], Elias Abboud[4], Malak Mohamed Ahmed Ragaie[5], Mariam Walaa Elkomy[5], Nancy Emmanuel*[6]

[1] University of Balamand, Koura, Lebanon

[2] Medical University of Łódź, Łódź, Poland

[3] University of Balamand, Beirut, Lebanon

[4] Saint Joseph University, Beirut, Lebanon

[5] Ain Shams University, Cairo, Egypt

[6] Department of Dermatology, Hospital das Clínicas da Faculdade de Medicina da Universidade de São Paulo, São Paulo, Brazil

Introduction

Follicular unit excision (FUE) has evolved into the predominant minimally invasive restorative technique, surpassing traditional strip harvesting due to the absence of linear scarring and reduced postoperative discomfort. Despite these benefits, the requirement for donor-area shaving in traditional FUE remains a significant aesthetic and psychosocial barrier for patients who prioritize procedural discretion. Consequently, a long hair no-shave FUE (LH-FUE) variation was developed to eliminate donor-area trimming while preserving graft integrity. This review synthesizes clinical evidence comparing the efficacy, safety, and patient outcomes of these two approaches.

Materials and Methods

A comprehensive review of Scopus, PubMed, and the Cochrane Library was conducted using the following search string: ("hair transplantation" OR "follicular unit extraction" OR FUE) AND ("no shave FUE" OR "no-shave FUE" OR "long hair FUE" OR "unshaven FUE") AND (outcomes OR complications OR "patient satisfaction" OR efficacy). Following the initial search, 42 articles were pooled on Rayyan software, and 17 were selected for qualitative synthesis based on clinical relevance and study quality.

Results

Traditional FUE involves harvesting grafts from a completely shaven donor region, whereas Long-Hair FUE (LH-FUE) utilizes direct methods to punch hair shafts without any pre-trimming. To ensure axial stability and protect these long shafts during excision, advanced instrumentation, such as trumpet-shaped flared or asymmetric punches, is frequently required. While implantation for both techniques can be performed via manual forceps or specialized devices, LH-FUE allows for meticulous hair curl matching, providing a significant aesthetic "preview" where the 12-month outcome is visualized immediately postoperatively. This "look-back" result facilitates immediate social reintegration by camouflaging surgical signs; furthermore, because long shafts provide immediate volume, LH-FUE may require up to 24% fewer grafts than shaved batches to achieve ideal perceived coverage. However, the technique is technically demanding, requires a higher degree of expertise, and nearly doubles operative time. In terms of efficacy, while Total Transection Rates (TTR) are comparable between techniques (2.2% to 5.1%), LH-FUE can be associated with partial transection rates approximately 8% higher than shaved FUE due to hair shaft interference.

Postoperative recovery remains rapid for both, with common minor complications including transient edema (40-50%) and pruritus. Ultimately, LH-FUE is the ideal technique for patients requiring maximal discretion, such as celebrities and professionals, or for hairline and eyebrow restorations where curl orientation is critical, while traditional FUE remains the gold standard for large-volume restorations (>3,000 grafts) where cost-efficiency and technical simplicity are prioritized.

Conclusions

Both LH-FUE and traditional FUE are safe and effective methods for hair restoration. While LH-FUE offers superior immediate aesthetic outcomes and social discretion, it involves greater technical complexity and time consumption. Proper patient selection and specialized instrumentation are vital for optimizing follicle survival and procedural efficiency in no-shave techniques.

EA DV CONGRESS
VIENNA
30 SEP - 3 OCT 2026

Abstract N°: 1485

Hair Pigmentary Changes Associated with Rosemary-Containing Products: A Cross-Sectional Study

Abdullah Almeziny*[1], Abrar Bukhari[1]

[1] College of Medicine, Imam Mohammad Ibn Saud Islamic University, Riyadh, Saudi Arabia, Riyadah, Saudi Arabia

Introduction
Rosemary (Rosmarinus officinalis) is widely incorporated into hair care products due to its reported benefits in promoting hair growth, improving scalp microcirculation, and enhancing overall hair health. While its therapeutic effects have been increasingly supported by experimental and clinical data, its potential influence on hair pigmentation remains insufficiently explored. Emerging anecdotal and observational evidence suggests that rosemary-containing formulations may be associated with hair color changes, warranting further investigation.

Materials and Methods
A cross-sectional study was conducted using a structured, self-administered online questionnaire distributed among adults (≥18 years) in Saudi Arabia who were current or previous users of rosemary-containing hair products. Data collected included demographic characteristics, type of product used, frequency and duration of use, and self-reported changes in hair parameters, including pigmentation. Statistical analysis was performed using descriptive statistics, chi-square testing, and multivariate logistic regression to identify associated factors, with significance set at $P<0.05$.

Results
A total of 360 participants were included, predominantly female (78.6%), with the majority aged between 26–45 years. Overall, 90.6% of participants reported noticeable changes in hair characteristics following rosemary use. The most frequently reported benefits included increased hair shine or improved texture (49.7%), reduced hair shedding (46.4%), enhanced hair growth (39.2%), and improved scalp health (38.1%).

Importantly, **11.7% of participants reported hair pigmentary changes**, including darkening, lightening, or graying. These changes were significantly associated with increasing age ($P=0.005$), with the highest prevalence observed among individuals older than 45 years, and with marital status ($P=0.003$). Frequency of use was also significantly associated with pigmentary changes ($P=0.018$), particularly among individuals using rosemary products 2–3 times per week. No significant associations were observed with gender, product type, or duration of use. Multivariate logistic regression did not identify independent predictors of overall hair change, suggesting a multifactorial influence.

Conclusions
While rosemary-containing products are widely perceived as beneficial for hair growth and scalp health,**a clinically meaningful proportion of users report pigmentary alterations**, highlighting a potentially underrecognized effect. These findings raise the possibility that rosemary's bioactive compounds may influence follicular melanogenesis or oxidative pathways involved in hair pigmentation.

From a clinical perspective, this underscores the importance of counseling patients regarding possible cosmetic changes, particularly in older individuals and frequent users. Although causality cannot be established due to the cross-sectional design and reliance on self-reported data, this study provides important preliminary evidence

supporting a link between rosemary use and hair color changes.

Further prospective and mechanistic studies are warranted to confirm these findings, identify at-risk populations, and elucidate the underlying biological pathways, ultimately guiding safer and more informed use of herbal-based hair products.

EADV CONGRESS
VIENNA
30 SEP - 3 OCT 2026

Abstract N°: 1495

Switching to ritlecitinib in alopecia areata: Real-world outcomes according to prior JAK inhibitor exposure

Xinxin Li*[1], Wenhan Zhang[1], Cheng Zhou[1]

[1] Peking University People's Hospital, Beijing, China

Introduction
Ritlecitinib is effective for alopecia areata (AA), but its role after prior exposure to oral Janus kinase (JAK) inhibitors remains uncertain in routine practice, particularly with respect to response depth, time to regrowth, and whether post-switch outcomes vary according to the specific prior JAK inhibitor and prior response history. We therefore examined whether prior oral JAK inhibitor exposure influenced post-switch outcomes after ritlecitinib initiation, whether the specific prior JAK inhibitor and prior response history further refined those outcomes, and characterized safety.

Materials and Methods
This single-center retrospective cohort included 72 patients with AA who initiated oral ritlecitinib 50 mg/day between December 2023 and December 2025 and had evaluable follow-up through approximately 24 weeks. Patients were classified as JAKi-naïve (n = 33) or JAKi-experienced (n = 39). The primary outcome was achievement of SALT50 at week 24. Secondary outcomes included SALT75, achievement of SALT ≤20 among patients with baseline SALT score ≥50, time to SALT50, and safety. Among JAKi-experienced patients, post-switch outcomes were further described according to the most recent prior JAK inhibitor and prior response history. Multivariable logistic and Cox regression analyses were performed, with sensitivity analyses to test robustness.

Results
By week 24, JAKi-experienced patients were less likely than JAKi-naïve patients to achieve SALT50 (66.7% vs 87.9%; P = .051) and SALT75 (48.7% vs 81.8%; P = .006). Among patients with baseline SALT score ≥50, achievement of SALT ≤20 was also less frequent in the JAKi-experienced group (30.0% vs 75.0%; P = .018). In multivariable analyses, prior JAK exposure was associated with reduced odds of achieving SALT50 (OR, 0.23; 95% CI, 0.06-0.97; P = .045) and delayed achievement of SALT50 (HR, 0.48; 95% CI, 0.28-0.82; P = .008). In exploratory analyses, week-24 SALT50 was achieved in 9 of 12 patients (75.0%) after prior tofacitinib and in 14 of 21 (66.7%) after prior baricitinib. Deeper responses appeared more likely in patients with prior partial or complete response to the most recent JAK inhibitor than in those with no prior response. The most common adverse event was folliculitis (18.1%).

Conclusions
Ritlecitinib remained clinically useful after prior systemic therapy, including prior oral JAK inhibitor exposure, although responses were slower and less deep in JAKi-experienced patients. The specific prior JAK inhibitor and response history to the most recent JAK inhibitor may further help frame expectations after switching.

EADV CONGRESS
VIENNA
30 SEP - 3 OCT 2026

Abstract N°: 1507

Ivarmacitinib Response Trajectories in Severe Alopecia Areata: A Post Hoc Analysis of Early, Gradual, Late, and Non-Responder Subgroups Over 52 Weeks

Cheng Zhou*[1], Jianzhong Zhang[1]

[1] Peking University People's Hospital, Beijing, China

Introduction

Alopecia areata (AA) is a chronic autoimmune disorder characterized by non-scarring hair loss. Severe phenotypes rarely resolve spontaneously and are associated with substantial impairment in quality of life. Ivarmacitinib, a highly selective oral Janus kinase 1 (JAK1) inhibitor, demonstrated clinically meaningful hair regrowth in a phase 3 trial in patients with severe AA.[1] However, temporal patterns of clinical response remain incompletely characterized. This post hoc analysis aimed to identify distinct response patterns to ivarmacitinib and describe hair-regrowth trajectories over 52 weeks.

Materials and Methods

Methods

This post hoc analysis used data from a randomized, double-blind, phase 3 trial in which patients with severe AA (Severity of Alopecia Tool [SALT] score ≥50) received ivarmacitinib 4 mg, ivarmacitinib 8 mg, or placebo once daily for 24 weeks, followed by a 28-week extension. The present analysis included patients assigned to ivarmacitinib. Patients were classified into four response subgroups based on time to first achievement of $SALT_{30}$ (≥30% reduction from baseline in SALT score): Early responders (≤12 weeks), Gradual responders (>12 to 36 weeks), Late responders (>36 to 52 weeks), and Non-responders (did not achieve $SALT_{30}$ by week 52). Outcomes included percent change from baseline in SALT score and proportions achieving $SALT_{50}$, SALT ≤20, and SALT ≤10 through week 52.

Results

In the ivarmacitinib 4 mg group (n=109), 41 (37.6%) patients were early responders, 32 (29.4%) gradual responders, 8 (7.3%) late responders, and 28 (25.7%) non-responders. In the ivarmacitinib 8 mg group (n=111), 49 (44.1%) patients were early responders, 37 (33.3%) gradual responders, 7 (6.3%) late responders, and 18 (16.2%) non-responders, indicating a higher overall responder proportion with 8 mg. Across both doses, early and gradual responders constituted the majority, with early responders being the largest subgroup. Early responders were more likely to have a shorter duration of the current AA episode and severe disease (SALT 50 to <95), whereas late responders and non-responders tended to have longer current episode durations and very severe disease (SALT 95–100) (Table 1).

Over 52 weeks, early responders in both the ivarmacitinib 4 mg and 8 mg groups exhibited rapid and pronounced reductions in SALT score, followed by gradual responders and then late responders (Figure 1). Across SALT-based endpoints ($SALT_{50}$, SALT ≤20, and SALT ≤10), early responders showed rapid increases in the proportions achieving these outcomes within the first 24 weeks, followed by a plateau; gradual responders showed steady,

time-dependent increases through week 52, whereas late responders showed delayed increases in attainment, mainly for $SALT_{50}$ and SALT ≤20. By week 52, early responders had the highest proportions achieving SALT-based endpoints, followed by gradual and late responders. Notably, ivarmacitinib 8 mg was associated with higher proportions achieving SALT-based endpoints across responder categories and a lower overall non-responder proportion than 4 mg (Figure 2).

Table 1 Baseline characteristics of patients

	Ivarmacitinib 4 mg				Ivarmacitinib 8 mg			
	Early responder (n=41)	Gradual responder (n=32)	Late responder (n=8)	Non-responders (n=28)	Early responder (n=49)	Gradual responder (n=37)	Late responder (n=7)	Non-responders (n=18)
Age, years								
Mean (SD)	33.9 (9.22)	31.6 (8.90)	25.3 (8.73)	30.5 (7.82)	32.0 (10.43)	30.9 (9.36)	30.7 (10.64)	32.6 (10.60)
Median (range)	35 (18, 54)	31.5 (18, 56)	23.5 (19, 46)	29 (18, 48)	30 (18, 61)	30 (18, 55)	27 (20, 49)	30 (20, 57)
Sex, n (%)								
Female	18 (43.9)	20 (62.5)	5 (62.5)	15 (53.6)	25 (51.0)	23 (62.2)	6 (85.7)	8 (44.4)
Disease duration since diagnosis, years								
Mean (SD)	5.06 (6.059)	4.75 (5.457)	7.30 (6.156)	6.00 (5.292)	4.77 (4.952)	6.45 (6.646)	6.54 (1.864)	7.99 (6.183)
Median (range)	3.3 (0.7, 32.4)	2.55 (0.7, 23.9)	4.95 (1.8, 20.6)	4.55 (0.7, 29.0)	3.2 (0.5, 22.6)	4.6 (0.5, 26.8)	6.2 (4.2, 9.1)	6.4 (1.1, 22.1)
Duration of current AA episode, years								
Mean (SD)	2.93 (2.232)	2.88 (2.093)	4.55 (1.790)	3.87 (1.909)	2.78 (1.965)	3.51 (2.313)	4.30 (2.322)	4.68 (2.338)
Median (range)	1.7 (0.7, 7.7)	2.4 (0.7, 7.4)	4.6 (1.6, 7.3)	4.05 (0.7, 7.6)	2.2 (0.5, 7.2)	2.9 (0.6, 7.7)	5.1 (0.9, 7.0)	5.1 (0.9, 8.0)
Baseline AA severity, n (%)								
Severe (SALT score 50 to < 95)	35 (85.4)	23 (71.9)	5 (62.5)	10 (35.7)	38 (77.6)	25 (67.6)	4 (57.1)	7 (38.9)
Very severe (SALT score 95–100)	6 (14.6)	9 (28.1)	3 (37.5)	18 (64.3)	11 (22.4)	12 (32.4)	3 (42.9)	11 (61.1)

Figure 1 Percentage change in Severity of Alopecia Tool (SALT) score from baseline

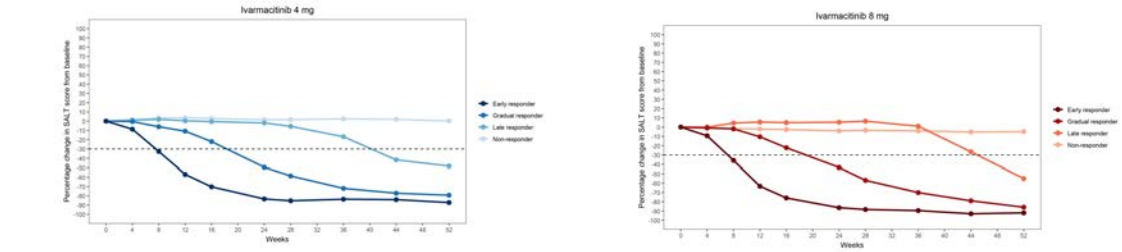

Figure 2 Severity of Alopecia Tool (SALT) scores ≤10 and ≤20 and $SALT_{50}$ responses tracked over time across four responder subgroups

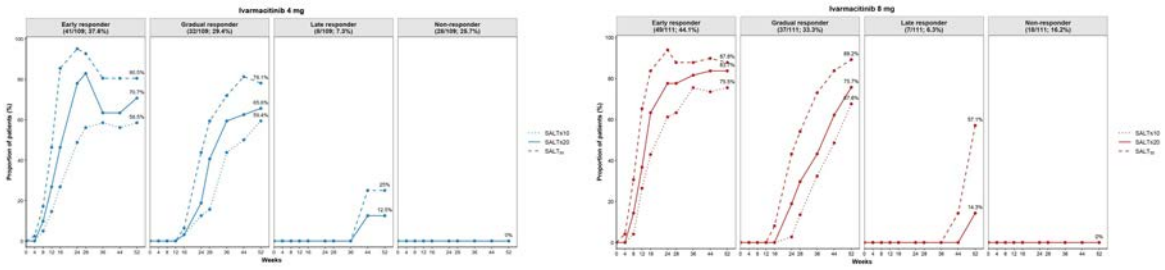

Conclusions

Ivarmacitinib produced rapid, robust hair regrowth in patients with severe AA, with the vast majority of patients demonstrating early or gradual response patterns, indicating that most achieved a treatment response before Week 36. A shorter duration of the current AA episode and less-extreme baseline severity were associated with a higher likelihood of early response. Compared with 4 mg, the 8 mg dose increased the proportions of early and gradual responders, supporting 8 mg as the more effective dose to optimize clinical outcomes in severe AA.

Reference

1. Zhou C, et al. J Am Acad Dermatol. 2026;94(1):161-171.

EADV CONGRESS
VIENNA
30 SEP - 3 OCT 2026

Abstract N°: 1515

Scalp morphology alterations under menopause and Female Pattern Hair Loss using line-field confocal optical coherence tomography.

Clementine ALVAREZ*[1, 2, 3], Heiva Le Blay[1], Nastassia Pricoupenko[4], Edouard Raynaud[1, 3], Geraldine Rolland[1, 3], Aline Van Der Lee[1, 3], Jennifer Bourland[1], Mira Pavlovic Ganascia[5], Laurence Michel[2], Sebastien Thibaut[1]

[1] L'Oréal Advanced Research, Aulnay-Sous-Bois, INSERM U1342, Hôp.St-Louis, Univ.Paris Cité, CRB L'Oréal, Hôp.St-Louis, Paris, France
[2] INSERM U1342, Hôp.St-Louis, Univ.Paris Cité, Paris, France
[3] CRB L'Oréal Advanced Research, St Louis Hospital, Paris, France
[4] DAMAE Medical, Paris, France
[5] Sabouraud center, Paris, France

Introduction
Menopause is well-known to impact hair quality and hair loss, yet the structural evolution of the scalp tissue itself remains poorly characterized. Historically, imaging has focused on facial skin, leaving the scalp's histological environment underexplored. This study uses line-field confocal optical coherence tomography (LC-OCT) to assess the impact of menopause as well as Female Pattern Hair Loss (FPHL) on scalp internal structure.

Materials and Methods
A cohort of 77 women was categorized into four groups: pre-menopausal (mean age 46.8; N=20 no FPHL, N=18 with FPHL) and post-menopausal (mean age 55.2; N=20 no FPHL, N=19 with FPHL). Vertex measurements were compared against a facial skin reference database (temple, N=100).

Results
Results reveal that the scalp possesses a distinct histological signature: the stratum corneum (SC) (17±4µm *vs* 13±1µm) and epidermis (87±18µm *vs* 51±4µm) were 31% and 71% thicker respectively than facial skin in age-matched groups. In menopausal women *vs* non-menopausal, a decrease in SC (15±2µm *vs* 17±4µm, $p \leq 0.005$) and epidermal thickness (76±17µm *vs* 87±18µm, $p \leq 0.005$) was observed. Interestingly, we show that menopause predominated over chronological age in driving structural change. FPHL also induced a significant decrease in SC and epidermal thickness ($p \leq 0.05$).

Dermal fiber reorganization was analyzed and showed FPHL and menopause deteriorated network integrity, with decreased bundle length and higher fragmentation in papillary dermis. This suggests that dermal fibers remodeling occurs under FPHL before any menopause characteristics are present yet.

Conclusions
By using LC-OCT, this study highlights the impact of menopause modulations on scalp integrity. FPHL might induce similar morphological alterations, even before menopause, suggesting that premature hair loss acts as a driver of anticipated scalp aging.

EADV Congress 2026, VIENNA
30 SEPTEMBER - 03 OCTOBER 2026
POWERED BY M-ANAGE.COM

EA DV CONGRESS
VIENNA
30 SEP - 3 OCT 2026

Abstract N°: 1528

Evaluation of the continued benefit of a shampoo containing Selenium Disulphide on subjects with moderate to severe dandruff after a 12-week treatment-free phase following a 4-week treatment period

Julie Faure[1], Corinne Chagnoleau[1], Natalia Kovylkina*[1], Georges El Haddad[1], CABERLOTTO ELISA[1]

[1] Vichy Laboratoires, Levallois-Perret, France

Introduction

Scalp seborrheic dermatitis (SSD) or its milder form, dandruff, is a chronic, relapsing scalp condition characterized by flakes, sometimes erythema, and pruritus. It is observed in all photo- and hair type populations.

The treatment benefit of selenium disulphide shampoo (SeS_2) in dandruff has been demonstrated through several clinical studies and various populations.

Materials and Methods

This open-label, observational, single-centre study was conducted in 39 adult subjects with clinically confirmed moderate to severe dandruff. Subjects washed 3 times per week for 4 weeks SeS_2 their hair and scalp. After these 4 weeks, subjects entered a 12-week observational period to assess the anti-relapse effect of SeS_2 using 3 times per week a neutral shampoo to wash their hair and scalp.

Clinical evaluation included the seborrheic dermatitis and dandruff score, quality of life (QoL), auto-evaluation of discomfort (itching, burning, stinging), pruritus, cosmeticity at Day 0, 3, 7, 14, 21, 28/week 4 during the treatment phase and at Week 5, 8, 10 and 12 during the observational period.

Standardised photos were made at all visits.

Results

At the end of the treatment phase at Day 28, the total dandruff score had decreased by 3.22 points (-57%). It increased by 1.3 points (-37%) until Week 5 and then continuously decreased until Week 12 (-54%). The decrease was statistically significant ($p<0.001$). According to the subjects, 4 weeks after the treatment, the dandruff score had improved by 4.56 points and 12 weeks after SeS2 use had been stopped, the auto-evaluated discomfort remained improved by 51% compared to baseline (-3.49 points at Week 12 post-treatment).

Adherent and non-adherent dandruff scores remained stable between Day 28 and Week 12 with a percent decrease of 54% and 60% for the adherent and non-adherent dandruff score, respectively at Day 28 and of 53% and 54% for the adherent and non-adherent dandruff score at Week 12, respectively.

Individual discomfort symptoms had significantly ($p<0.001$) improved at Day 28 and Week 12 from Day 0 and remained unchanged during the observational period, except for itching, for which the score significantly worsened ($p<0.001$) between Day 28 and Week 12 and greasy scalp for which the score significantly improved during the observational period.

The subjects' QoL had improved by 78% Day 28 and by 91% at Week 12. Subjects highly appreciated the cosmeticity of SeS_2 shampoo, local tolerance was good.

Figure 1 provides visual results from Day 0 to Week 12.

Conclusions

SeS_2 is highly beneficial in improving moderate to severe dandruff after 4 weeks of use and significantly reduces dandruff relapse after a 12-week treatment free observational period.

EA DV CONGRESS
VIENNA
30 SEP - 3 OCT 2026

Abstract N°: 1529

Evaluation of the continued benefit of a combination treatment of a shampoo and a conditioner both containing Selenium Disulphide on subjects with moderate to severe dandruff after a 12-week treatment-free phase following a 4-week treatment period

Julie Faure[1], Corinne Chagnoleau[1], Natalia Kovylkina*[1], Georges El Haddad[1], CABERLOTTO ELISA[1]

[1] Vichy Laboratoires, Levallois-Perret, France

Introduction

Scalp seborrheic dermatitis (SSD) or its milder form, dandruff, is a chronic, relapsing scalp condition characterized by flakes, sometimes erythema, and pruritus. It is observed in all photo- and hair type populations. The treatment benefit of selenium disulphide (SeS_2) in dandruff has been demonstrated through several clinical studies and various populations.

This study assessed the anti-relapse benefit during an observational, treatment-free period of 12 weeks in subjects with moderate to severe dandruff having received a combination of SeS_2 shampoo and piroctone olamine (PO) conditioner (SeS_2/PO combination) for 4 weeks.

Materials and Methods

This open-label, observational, single-centre study was conducted in 41 adult subjects (mean age 30±8 years) with clinically confirmed moderate to severe dandruff. Subjects used 3 times per week for 4 weeks SeS_2/PO combination on their hair and scalp. After these 4 weeks, subjects entered a 12-week observational period to assess the anti-relapse effect of the SeS_2/PO combination using 3 times per week a neutral shampoo to wash their hair and scalp.

Clinical evaluation included the seborrheic dermatitis and dandruff score, quality of life (QoL), auto-evaluation of discomfort (itching, burning, stinging), pruritus, cosmeticity at Day 0, 3, 7, 14, 21, 28/week 4 during the treatment phase and at Week 5, 8, 10 and 12 during the observational period.

Standardised photos were made at all visits.

Results

At the end of the treatment phase at Day 28, the total dandruff score had decreased by 56% and by 51% after 12 weeks of no application. The decrease was statistically significant ($p<0.001$). All subjects had their dandruff improved after 28 days.

Global investigator efficacy and overall satisfaction reached 73% after 28 days and still 19% after 12 weeks.

Adherent and non-adherent dandruff scores remained stable between Day 28 and Week 12 with a percent decrease of 55% and 58% for the adherent and non-adherent dandruff score, respectively at Day 28 and of 43% and 58% for the adherent and non-adherent dandruff score at Week 12, respectively. Subject observations paralleled these results.

Individual discomfort symptoms had significantly (all $p<0.05$) improved at Day 28 and Week 12 from Day 0 and

remained unchanged during the observational period.

The subjects' QoL had improved by 74% Day 28 and by 89% at Week 12.

Subjects highly appreciated the cosmeticity of SeS_2 shampoo, local tolerance was good.

Figure 1 provides visual results for a mean case after 28 days of 3/week treatment and Figure 2 shows a mean case after 12 weeks of no treatment with SeS_2/PO combination.

Figure 1 Mean case with moderate dandruff at Day 0 and after 28 days of 3/week use of SeS_2/PO combination



Figure 2 Mean case after 28 days of 3/week use of the SeS_2/PO combination and at the during the treatment free observational phase



Conclusions

SeS_2/PO combination is highly beneficial in improving moderate to severe dandruff after 4 weeks of use and significantly reduces dandruff relapse after a 12-week treatment free observational period

EA DV CONGRESS
VIENNA
30 SEP - 3 OCT 2026

Abstract N°: 1530

Evaluation of the maintenance effect over a period of 6 months of a shampoo containing Selenium Disulphide after a 4-week treatment period on subjects with moderate to severe dandruff

Julie Faure[1], Corinne Chagnoleau[1], Natalia Kovylkina*[1], Georges El Haddad[1], CABERLOTTO ELISA[1]

[1] Vichy Laboratoires, Levallois-Perret, France

Introduction

Scalp seborrheic dermatitis (SSD) or its milder form, dandruff, is a chronic, relapsing scalp condition characterized by flakes, sometimes erythema, and pruritus. It is observed in all photo- and hair type populations.

The active treatment benefit of selenium disulfide shampoo (SeS_2) in dandruff has been demonstrated through several clinical studies and various populations. However, no data exist about its maintenance activity after an initial treatment phase.

This study assessed the maintenance benefit of SeS_2 in moderate to severe dandruff and moderate itching over a period of 6 months.

Materials and Methods

This open-label, observational, single-centre study was conducted in 47 adult subjects with clinically confirmed moderate to severe dandruff and an itching score of at least 7 on a scale from 0=none to 10=very much. Subjects used 3 times per week for 4 weeks SeS2 to wash their hair and scalp. After these 4 weeks, subjects entered a 6 months observational period to assess the maintenance benefit effect of SeS_2. During this period subjects used SeS_2 once a week and a neutral shampoo twice a week to wash their hair and scalp.

Clinical evaluation included the total, adherent and non-adherent dandruff score, the score of scalp seborrheic dermatitis (SSSD), quality of life (QoL), auto-evaluation of discomfort (itching, burning, stinging), pruritus, cosmeticity at Week 0 and Week 4 during the treatment phase and at week 5, Month 2, 2.5, 3, 4, 5 and 6 during the observational period.

Standardised photos were made at all visits.

Results

At the end of the treatment phase at Day 28, the total dandruff score had decreased by 41.4% ($p<0.001$). After 6 months the relative change from baseline was –79.8% ($p<0.001$).

The adherent dandruff score had significantly ($p<0.001$) decreased at Day 28 and Month 6 (-41.4% and –81.6%, respectively). The non-adherent dandruff score significantly decreased by 41.2% at Day 28 and by –77.9% at Month 6 from baseline (both $p<0.001$)

The global irritation score had decreased by 29.1% at Day 28 and by 73.4% at Month 6 (both $p<0.001$). The SSSD score continuously and significantly ($p<0.001$) decreased by up to 83.1% at Month 6. Subject evaluations paralleled these findings, with itching, burning, stinging, global irritation greasy aspect being significantly ($p<0.001$) reduced after 6 months from Day 0, starting Day 28.

Subjects had their QoL significantly ($p<0.001$) improved and were highly satisfied with SeS_2. The shampoo was very well tolerated.

Figure 1 provides visual results of the evolution of severe dandruff during the treatment and maintenance phase.

Conclusions

SeS_2 is highly beneficial in maintaining over 6 months the 4-week intensive treatment outcome in subjects with moderate to severe dandruff while greatly improving QoL, being well tolerated and highly appreciated by the subjects.

EA DV CONGRESS
VIENNA
30 SEP - 3 OCT 2026

Abstract N°: 1543

Subungual intraneural glomus tumor evolving from longitudinal erythronychia over two decades: a rare clinicopathological presentation

Yomna A. Metwally[1], Doaa Borham[1], Yousef Husseiny*[2], Yousra Azzazi[1]

[1] Faculty of Medicine, Cairo University, Cairo, Egypt

[2] Faculty of Medicine, NewGiza University, Giza, Egypt

Introduction

Glomus tumors are rare benign vascular neoplasms arising from modified smooth muscle cells of the glomus body, most commonly in subungual locations. Intraneural glomus tumors are extremely uncommon, with only isolated cases reported in the literature, and cutaneous involvement is particularly rare. The pathogenesis is unknown. It has been suggested that they are caused by ectopic migration of glomus cells into neural tissue or by the differentiation of perivascular cells. Clinical presentation can resemble other subungual lesions and delay diagnosis.

Case Presentation

A 68-year-old male presented with a painful subungual mass of the right ring finger, progressively enlarging over two years with marked worsening during the last six months. The lesion had a history of long-standing longitudinal erythronychia following blunt trauma to the distal phalanx approximately 20 years earlier.

Clinical examination revealed a tender violaceous subungual nodule that was approximately 7 mm in diameter and associated with onycholysis. Dermoscopy showed a violaceous subungual structureless area with ramified vessels, accompanied by separation of the overlying nail plate, consistent with one of the dermoscopic patterns (bed subungual spot with onycholysis) described for nail bed glomus tumors.

An excisional biopsy was performed after nail plate elevation to allow full visualization of the lesion, achieving complete excision. Histopathological examination demonstrated a well-circumscribed deep dermal tumor with no connection to the overlying epidermis, composed of dilated vascular channels lined by endothelial cells and surrounded by uniform round glomus cells arranged in nests and trabeculae. The glomus cells were round with sharply defined, punched-out nuclei.

Notably, the tumor showed close association with neural tissue composed of S-shaped slender spindle cells within a pale myxoid stroma, accompanied by mast cells. The expanded nerve featured a bland proliferation of small oval cells forming a ribbon-like pattern distributed between the nests of glomus cells. Immunohistochemical staining showed strong Alpha-Smooth Muscle Actin (SMA) positivity highlighting the glomus cells, surrounded by S100-positive Schwann cells.

Dermoscopy



Biopsy

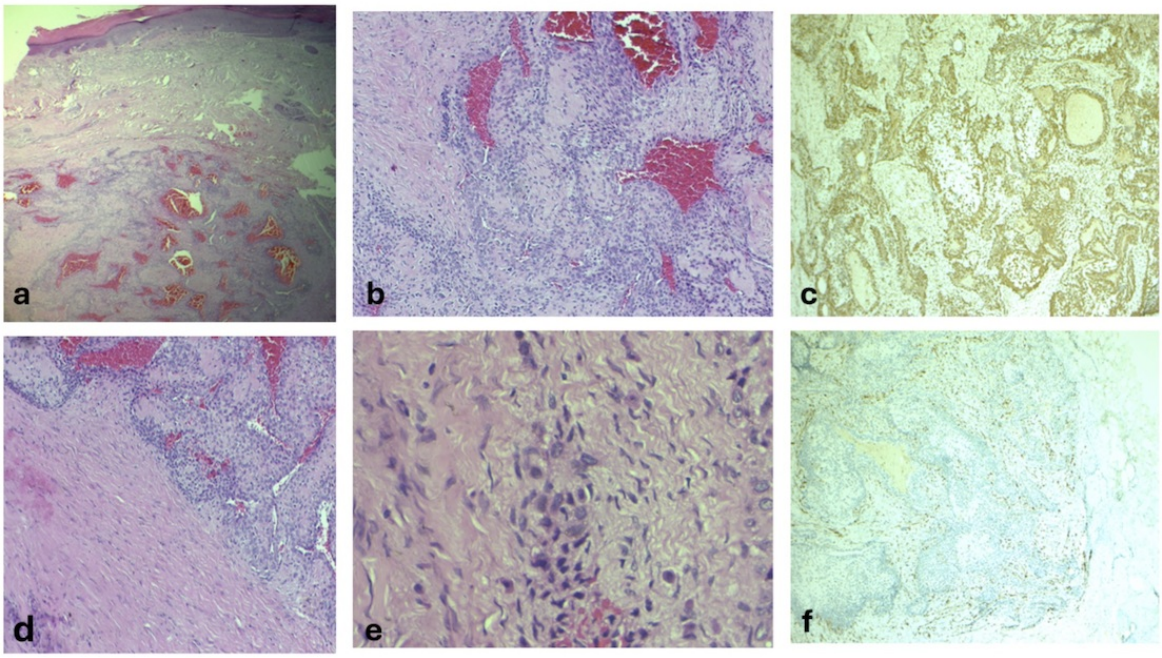

Figure 1: Dermoscopy showed a violaceous sub-ungual structureless area with ramified vessels, accompanied by onycholysis of overlying nail plate. Figure 2: a: Histopathological micrograph showing a deep dermal vascular tumor with no connection to the overlying epidermis (H&E ×25). b: The tumor was formed of dilated vessels lined by endothelial cells surrounded by uniform glomus cells which are round in shape, with rounded, sharply punched out nuclei (H&E ×200). c: Immunohistochemical staining showing strong Alpha-Smooth Muscle Actin (SMA) positivity highlighting the glomus cells (SMA ×200). d: The tumor was encased by neural tissue formed of s-shaped spindle cells in a pale myxoid stroma (H&E ×200). e: Higher magnification revealed the S-shaped slender spindle Schwann cells in a pale myxoid stroma, together with mast cells (H&E ×400). f: Immunohistochemical staining showing S100 positivity of Schwan cells surrounding the nests of glomus cells (S100 ×100).

Conclusion

To the best of our knowledge, this is the fourth reported cutaneous intraneural glomus tumor and the first

reported subungual intraneural glomus tumor, presenting with a long-standing evolution from longitudinal erythronychia to a painful subungual nodule over the course of two decades. The post-traumatic onset is consistent with the proposed mechanism of ectopic glomus cell migration into neural tissue, although the exact pathogenesis remains to be determined. This case further broadens the clinical spectrum of intraneural glomus tumor and should be included in the differential diagnosis of long-standing longitudinal erythronychia and chronic painful nail lesions. Diagnosis is dependent on clinicopathologic correlation and immunohistochemistry.

EA DV CONGRESS
VIENNA
30 SEP - 3 OCT 2026

Abstract N°: 1577

REDUCTION OF DISEASE BURDEN AND IMPROVEMENT IN PATIENT PERCEPTION DURING SELENIUM DISULFIDE SHAMPOO USE IN DANDRUFF AND SEBORRHOEIC DERMATITIS: REAL WORLD DATA

Marta Sar-Pomian*[1]

[1] Department of Dermatology, Medical University of Warsaw, Poland, Warsaw, Poland

Introduction

Dandruff and seborrhoeic dermatitis (SD) are common chronic scalp disorders that impose a substantial disease burden, affecting patients' quality of life, comfort and daily functioning. The aim of the study was to assess changes in disease burden and patient perception during treatment with selenium disulfide shampoo (Dercos DS, Laboratoires Vichy, France) in a real-world setting.

Materials and Methods

This multicenter observational study included 696 patients aged ≥12 years with dandruff or SD. Evaluations were performed at baseline, after 4 weeks and after 8 weeks, combining physician-assessed clinical signs with patient-reported outcomes, including perceived disease burden, pruritus, treatment satisfaction and willingness to continue therapy.

Results

At baseline, disease burden was high, with nearly all patients reporting a negative impact of scalp condition on daily life. Clinically, scaling was present in 99% of patients and erythema in 83%, with a mean pruritus score of 4.65/10.

After 4 weeks, a marked reduction in disease burden was observed: 84% of patients reported decreased impact of the disease on daily life, and 90% experienced improvement in pruritus. The proportion of patients reporting no pruritus increased from 3% to 20%, reflecting early improvement in patient comfort and perception.

After 8 weeks, these effects were sustained and further enhanced. Overall, 93% of patients reported improvement in disease burden, and the proportion of patients declaring no impact of the disease increased from 0.3% at baseline to over 50%. Half of patients reported complete resolution of pruritus.

Patient perception of treatment was highly positive, with 89% rating satisfaction ≥7/10 and 93% expressing willingness to continue therapy, highlighting strong acceptance and perceived effectiveness.

Conclusions

In real-world conditions, selenium disulfide shampoo leads to a rapid and sustained reduction of disease burden and significant improvement in patient perception in dandruff and SD, supporting its role as a patient-centered therapeutic approach.

EADV CONGRESS
VIENNA
30 SEP - 3 OCT 2026

Abstract N°: 1585

Transient Bilateral Temporal Alopecia After Deep Plane Rhytidoplasty: A Reversible Phenomenon

Renata Rodrigues*[1], Hudson Rezende[1], João Henrique Aurich[1], Nara Cristina Tasso Almeida Carvalho[1], Mariana Menezes de Mauro[1]

[1] Centro Universitário Lusíada (UNILUS) – Santos, SP, Santos, Brazil

Introduction

Hair loss following rhytidoplasty tends to receive less attention than other postoperative events, although it may be particularly distressing for patients. When it occurs in the temporal region, the mechanism is not always immediately apparent and may involve a combination of traction, vascular compromise, and local tissue stress rather than primary follicular damage.

Case Presentation

The first sign was not the hair loss itself, but the discomfort. In the days following a deep plane rhytidoplasty with cervical dissection, a 63-year-old woman experienced unusually intense pain along the temporal scalp. The surgery had been prolonged, exceeding five hours, and involved extensive dissection. Hair shedding became noticeable around the third postoperative week, confined to areas bordering the surgical incisions. What stood out was the symmetry: bilateral, sharply localized, and entirely restricted to the temporal scalp. Closer examination revealed smooth alopecic patches without erythema or scaling. There was no clinical suggestion of inflammation or scarring. Dermoscopy added another layer: black dots, dystrophic shafts, and early regrowth, suggesting an active but reversible process. Histology, obtained through small punch samples, did not point to destruction. Follicular structures were preserved, cycling appeared ongoing, and there was no perifollicular fibrosis or inflammatory infiltrate. In other words, the follicles were still there, temporarily impaired, not lost. Topical minoxidil was introduced more as support than as a definitive treatment. Regrowth began within weeks and was complete by the third month, following a pattern consistent with recovery after transient follicular stress.

Conclusion

Rather than a true alopecia in the classic sense, this presentation is better understood as a temporary shutdown of follicular activity in response to local surgical stress. The symmetry, timing, and full recovery all support a reversible mechanism, likely combining mechanical tension and microvascular compromise. For clinicians, the key lies less in treating and more in recognizing. Distinguishing this entity from scarring alopecia early on changes the entire conversation: from concern about permanence to reassurance about recovery

EADV CONGRESS
VIENNA
30 SEP - 3 OCT 2026

Abstract N°: 1586

Inflammatory Destruction of Transplanted Hair Follicles Mimicking Poor Surgical Outcome: A Case of Lichenoid Scalp Disease After Hair Transplantation

Renata Rodrigues*[1], Hudson Rezende[1], João Henrique Aurich[1], Juliana Santos Rodrigues[1], Letícia Ferreira de Hybi Cerqueira[2]

[1] Centro Universitário Lusíada (UNILUS) – Santos, SP, Santos, Brazil

[2] Centro Universitário CESMAC – Maceió, AL, Maceió, Brazil

Introduction

Hair transplantation outcomes may be compromised by unrecognized inflammatory scalp disorders. Lichenoid and lymphocytic cicatricial alopecias can lead to progressive follicular destruction, including transplanted grafts, clinically mimicking suboptimal surgical results and causing patient dissatisfaction.

Case Presentation

A male adult patient with a history of two follicular unit extraction procedures in 2021 and 2022 presented with persistent dissatisfaction due to low hair density in the frontal region. Despite regular use of dutasteride and oral minoxidil, he reported progressive thinning and increased hair shedding over recent months. Initial clinical and trichoscopic evaluation showed no clear signs of active inflammatory disease, and the patient was initially managed with maintenance therapy and mesotherapy sessions. Due to persistent symptoms and diagnostic uncertainty, a 4-mm punch biopsy of the scalp was performed. Histopathological examination revealed perifollicular lymphocytic inflammation predominantly involving the isthmus and infundibular regions, interface changes with vacuolar degeneration of the follicular epithelium, focal neutrophilic activity, and concentric perifollicular fibrosis. Sebaceous glands were reduced in size and number. These findings were consistent with an active lichenoid inflammatory process leading to progressive destruction of both native and transplanted follicles. Imaging provided by the pathologist demonstrated structural damage to transplanted follicles associated with acute inflammatory activity.

Conclusion

This case highlights that inflammatory scalp diseases may be clinically subtle and not always detected on initial trichoscopic evaluation, even in patients undergoing hair transplantation. Misinterpretation as poor surgical outcome may delay appropriate diagnosis and treatment. Early histopathological investigation is essential in cases of unexpected hair loss after transplantation. Recognition of underlying inflammatory disease is critical to prevent further graft loss, guide appropriate medical therapy, and avoid additional surgical intervention in an active disease setting.

EADV CONGRESS
VIENNA
30 SEP - 3 OCT 2026

Abstract N°: 1587

Lichen Planopilaris–Folliculitis Decalvans Spectrum: Recognizing Overlap in Cicatricial Alopecia

Renata Rodrigues*[1], Hudson Rezende[1], João Henrique Aurich[1], Juliana Santos Rodrigues[1], Letícia Ferreira de Hybi Cerqueira[2]

[1] Centro Universitário Lusíada (UNILUS) – Santos, SP, Santos, Brazil
[2] Centro Universitário CESMAC – Maceió, AL, Maceió, Brazil

Introduction
Lichen planopilaris (LPP) and folliculitis decalvans (FD) are classically described as distinct forms of primary cicatricial alopecia. Increasingly, however, cases have been recognized in which clinical, trichoscopic, and histopathological findings do not fit neatly into either category. This overlapping presentation, referred to as the LPP–FD phenotypic spectrum, remains insufficiently recognized and may complicate both diagnosis and therapeutic decisions.

Case Presentation
Progressive scalp symptoms initially limited to the vertex raised concern for an inflammatory alopecia with atypical features. In a 58-year-old woman, localized pruritus evolved into a linear alopecic area over time, prompting further evaluation. Clinical examination revealed a well-defined alopecic plaque with perifollicular erythema, pustules, and crusting. Trichoscopy showed a combination of findings, including polytrichia, perifollicular scaling, and a diffuse erythematous background, suggesting overlapping inflammatory patterns. Given this presentation, two scalp biopsies were obtained. Histopathological examination demonstrated a predominantly lymphocytic perifollicular infiltrate, alongside areas of mixed inflammatory activity, supporting a diagnosis within the LPP–FD phenotypic spectrum. Treatment was initiated with oral doxycycline (100 mg twice daily) combined with intralesional triamcinolone acetonide (5 mg/mL) at six-week intervals. Over follow-up, there was a clear reduction in inflammatory signs and stabilization of hair loss.

Conclusion
This case highlights the importance of recognizing overlap presentations within cicatricial alopecias, where rigid classification may not fully capture the underlying process. The coexistence of lymphocytic and neutrophilic features should prompt consideration of the LPP–FD spectrum.
From a practical standpoint, identifying this pattern has therapeutic implications, as combined or tailored approaches may be required. Greater awareness of this entity may improve diagnostic accuracy and contribute to more effective, individualized management.

EA DV CONGRESS
VIENNA
30 SEP - 3 OCT 2026

Abstract N°: 1604

Associations Between GLP-1 Receptor Agonists and Alopecia: A Multi-Center Retrospective Analysis and Public Interest Trends

Lauren Guirguis*[1], Christopher Guirguis[1], Joe Tung[2]

[1] Georgetown University School of Medicine, Washington, D.C., United States

[2] University of Pittsburgh Medical Center, Department of Dermatology, Pittsburgh, United States

Introduction

There is a growing body of literature suggesting that GLP-1 receptor agonists (GLP-1RAs) may be associated with hair loss; however, primary literature is sparse. Additionally, it is not well-established which types of hair loss may be associated with GLP-1RA use.

This study aims to assess associations between GLP-1RAs and hair loss, specifically androgenetic alopecia (AGA), alopecia areata (AA), and telogen effluvium (TE) using a multi-center retrospective database, to augment existing single-institution and adverse event reporting system data. Additionally, this study assesses trends in public perception of GLP-1RAs and hair loss using a publicly available dataset.

Materials and Methods

The All of Us Database (AoUDB) was queried for GLP-1RA prescriptions as well as alopecia diagnoses with subanalysis of AGA, AA, and TE. Multivariate regression adjusted for demographics, metabolic factors, and socioeconomic factors. Google Trends data was used to track aggregate search records worldwide for hair loss and GLP-1RAs.

Results

Patients with any GLP-1RA use had a significantly higher odds ratio (OR) for diagnosis of any alopecia. Subanalysis for individual GLP-1RAs revealed significant increases in OR for any alopecia and AGA but not AA for patients on liraglutide and dulaglutide. Patients on semaglutide had a significantly increased OR for AGA. Patients on exenatide had a significantly increased OR for AGA and TE. Tirzepatide revealed no significant changes across all outcomes. Analysis of Google Trends data showed a significant increase in searches for hair loss and subcutaneous semaglutide and tirzepatide over the studied period.

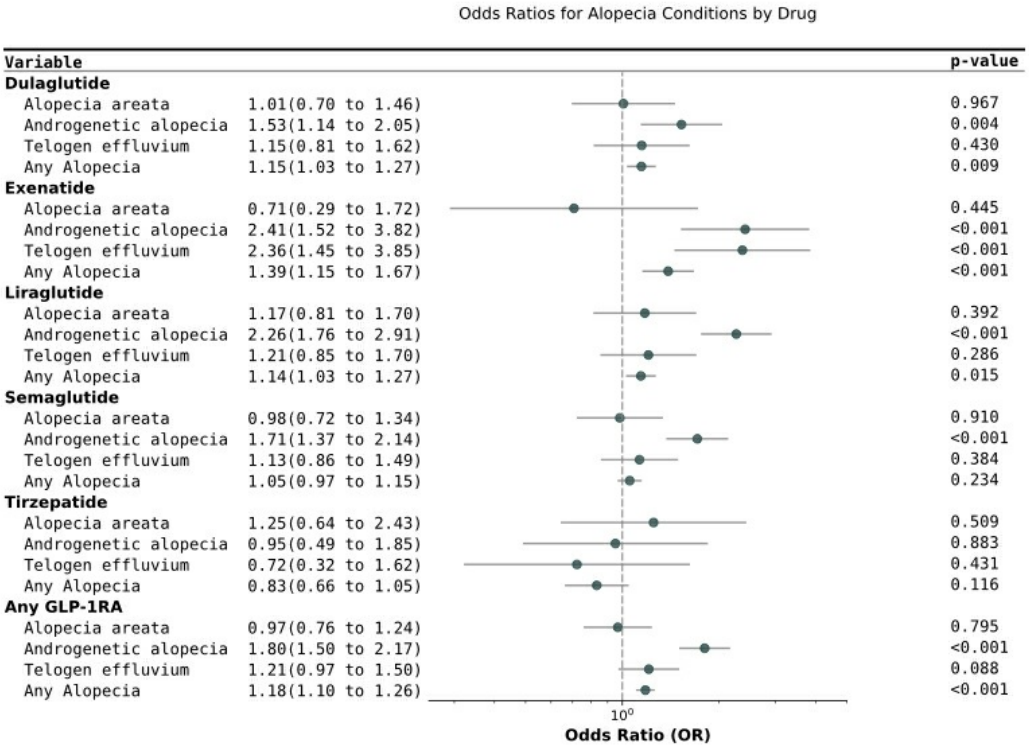

Conclusions

The effect of GLP-1RAs on hair loss may not be universal across all types of hair loss. The underlying mechanism is not yet entirely understood and may be attributed to many factors. As public interest in this association continues to rise, clinicians should consider counseling patients on these associations when discussing the risks and benefits of GLP-1RAs.

EA DV CONGRESS
VIENNA
30 SEP - 3 OCT 2026

Abstract N°: 1615

Efficacy and Safety of Low-Dose Oral versus Topical Minoxidil in Androgenetic Alopecia: A Double-Blind, Double-Dummy Randomized Controlled Trial in a South Asian Population

Muhammad Asad Ejaz Chaudhry*[1]

[1] Shaikh Zayed Hospital, Lahore, Pakistan

Introduction

Androgenetic alopecia (AGA) is the most prevalent cause of hair loss, affecting over 50% of men and 40% of women over their lifetime, causing a significant psychological burden. Topical minoxidil (TM) remains the only FDA-approved topical therapy for AGA; however, non-compliance is a major limitation due to difficult application, cutaneous side effects, and cosmetically unacceptable formulations. Low-dose oral minoxidil (LDOM) has surfaced as a valid off-label solution, boasting once-daily dosing, improved compliance, and increased systemic bioavailability via hepatic sulfotransferase-mediated activation. Importantly, sulfotransferase enzyme activity can vary across ethnicities, but a comparative randomized controlled trial (RCT) remains in paucity in South Asian populations. This study aimed to compare the efficacy and safety of LDOM versus TM in male and female AGA in this understudied population.

Table 1: Demographic and Assessment

			Group		p-value
			Topical	Oral	
			Median (p25-p75)	Median (p25-p75)	
Age			28.0 (23.0 -37.0)	28.0 (23.0 – 37.0)	0.852
Hair Loss Grade	Gender	Male	3.0 (2.5-3.5)	3.0 (3.0-4.0)	0.258
		Female	2.5 (2.0 -3.5)	3.0 (2.0-4.0)	
Dermatology Assessment Score at 24 weeks (DAS24)			1.0 (.0-2.0)	1.0 (.0 – 2.0)	0.684
Patient Satisfaction Score at 24 weeks (PSS24)			1.0 (.0-2.0)	2 (1.0 – 2.0)	0.195
Heart Rate Baseline (HR0)			74.0 (72.0 – 76.0)	75.0 (71.0 – 81.0)	0.127
Heart Rate at 24 weeks (HR24)			73.5 (72.0 – 77.0)	74.0 (71.0 -78.0)	0.903
Change in systolic BP (mmHg) at 24 weeks vs baseline (ΔSBP)			0.0 (−6.3 to 8.5)	−1.5 (−8.5 to 5.0)	0.669
Change in diastolic BP (mmHg) at 24 weeks vs baseline (ΔDBP)			2.0 (−6.0 to 7.0)	0.5 (−5.0 to 8.0)	0.948

Materials and Methods

A double-blind, double-dummy RCT was conducted at a tertiary dermatology center from August 2025 to February 2026. The trial was registered at ClinicalTrials.gov with identifier NCT07273799. One hundred patients aged 18–50 years with AGA in Norwood class 2-6 and Sinclair class 2-5 in females were randomly assigned to receive sequentially numbered opaque sealed envelopes. Group A received twice-daily topical minoxidil (5% in males, 2% in females) plus an oral placebo; Group B received once-daily LDOM (2.5 mg in males, 1.25 mg in females) plus a topical placebo. Co-primary outcomes included the proportion of patients achieving ≥+1 improvement in (1) dermatologist assessment scores at 24 weeks (DAS24), using a validated 7-point global photographic scale by two blinded dermatologists and (2) patient satisfaction score at 24 weeks (PSS24), which was measured using a 7-point self-assessment scale. Secondary outcomes included adverse effects and cardiovascular parameters (blood pressure, heart rate). Data were analyzed using SPSS v26 with $p \leq 0.05$ as significant.

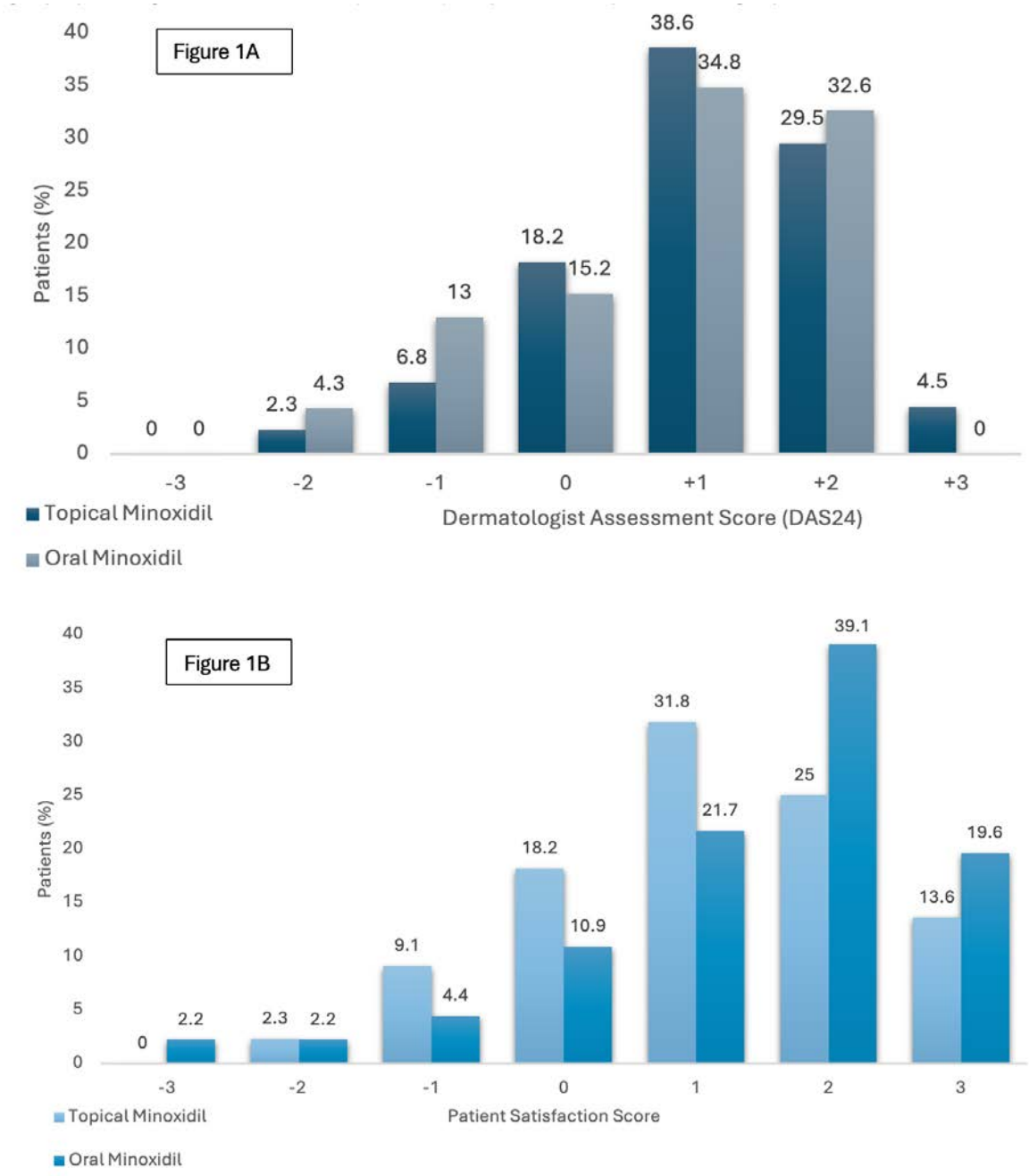

Figure 1A shows Dermatologist Assessment Scores over 24 weeks (DAS24). Scores are measured on a 7-point scale, ranging from -3 (severe worsening) to +3 (excellent improvement). Figure 1B denotes Patient Satisfaction Scores (PSS24). A higher proportion of patients in the oral minoxidil group reported higher satisfaction scores (+2 and +3) compared to the topical minoxidil group.

Results

Ninety patients (54 males, 36 females; mean age 30.3 +/- 9.19 years) completed 24 weeks of follow-up (TM: n=44, LDOM: n=46). Groups were well-matched at baseline across demographic and clinical parameters ($p > 0.05$). Both treatments demonstrated significant improvement from baseline in DAS24 and PSS24 ($p < 0.001$). Median change in DAS24 was 1(IQR 0-2) for both groups. (Table 1). After 24 weeks, the proportion of patients achieving a ≥+1 (mild-to-excellent improvement) in DAS24 was comparable between LDOM (67.4%) and TM (72.7%) (p=0.684) (Figure 1 A, B). Although median PSS24 was higher in the LDOM group [2 (IQR 1-2)], compared to TM [1 (IQR 0-2)], overall satisfaction (PSS ≥+1) did not reach statistical significance (80.4% vs 70.4%; p=0.26). Trends favouring LDOM were seen for both PSS24 ≥+2 (moderately satisfied, 58.7% vs. 38.6%, p = 0.057) and ≥+3 (highly satisfied, 19.6% vs 13.6%) categories (Figure 2). No serious adverse events occurred. Hypertrichosis was significantly more frequent with oral minoxidil (30% vs 9%, p = 0.011), whereas allergic contact dermatitis was exclusive to TM (11% vs. 0%, p = 0.025) (Table 2). Cardiovascular parameters remained within physiological limits throughout, and discontinuation due to adverse effects was rare and comparable between groups (oral 4%, topical 5%; p = 0.92).

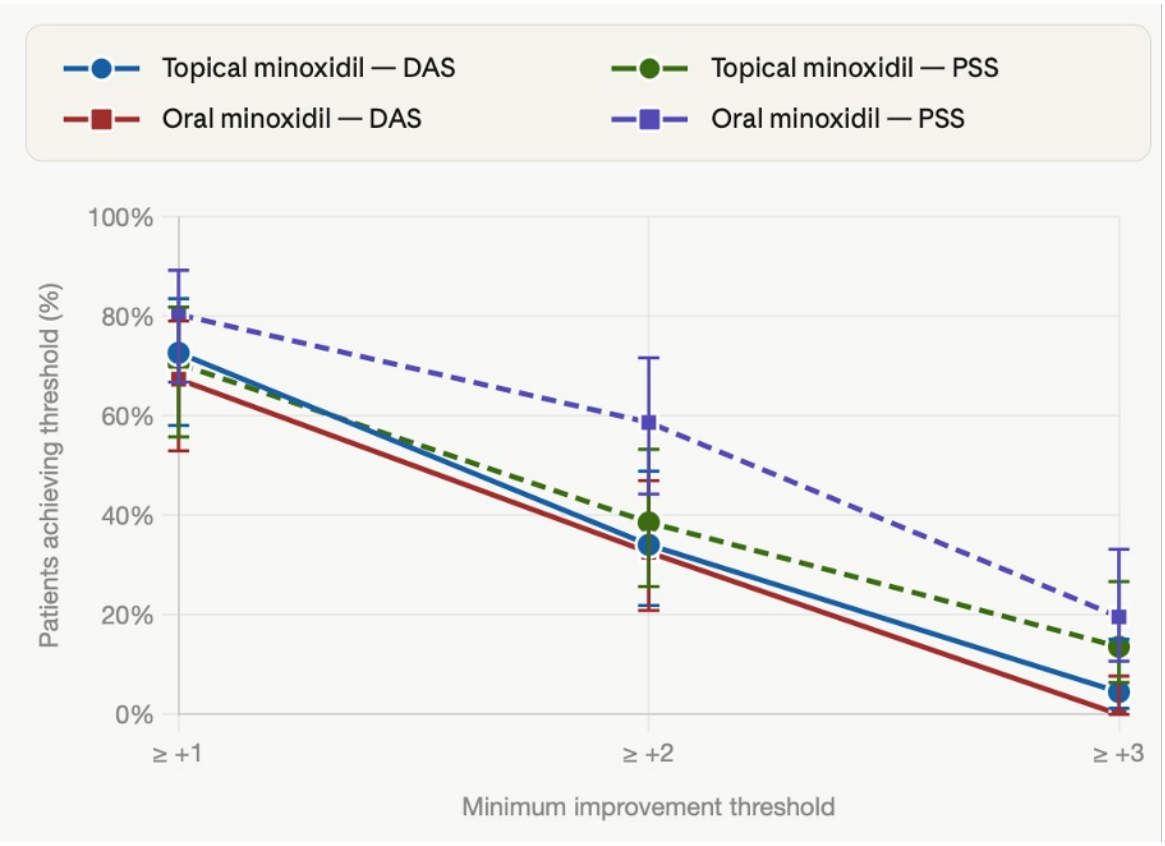

Figure 2: Cumulative Responder analysis curves. PSS24 curve for OM showed a shallower decline, indicating higher patient-reported satisfaction with oral therapy.

Conclusions

Both TM and LDOM demonstrated clinically meaningful improvement in androgenetic alopecia with no significant intergroup differences and a distinct but well-tolerated adverse effect profile. LDOM demonstrated higher patient satisfaction and simpler dosing, but a higher rate of hypertrichosis. This supports low-dose oral minoxidil as a practical alternative to standard topical minoxidil in male and female pattern hair loss and provides population-specific evidence informing prescribing decisions for the large and underrepresented South Asian patient population.

Table 2: Clinical Characteristics and Adverse Effects

Variable	Topical N (%)	Oral N (%)	P-value
Baseline Characteristics			
Gender (Male)	28 (63.6%)	26 (56.5%)	0.491
Gender (Female)	16 (36.4%)	20 (43.5%)	
Family History	19 (43.2%)	13 (28.3%)	0.140
History of Seborrheic Dermatitis	12 (27.3%)	11 (23.9%)	0.715
Adverse Effects			
Hypertrichosis	4 (9.1%)	14 (30.0%)	**0.011**
Allergic Dermatitis	5 (11.4%)	0 (0.0%)	**0.025**
Seborrheic Dermatitis	3 (6.8%)	0 (0.0%)	0.113
Telogen Effluvium	4 (9.1%)	3 (6.5%)	0.711
Orthostatic Hypotension	1 (2.3%)	4 (8.7%)	0.361
Fluid Retention	0 (0.0%)	2 (4.3%)	0.495
Tachycardia	0 (0.0%)	4 (8.7%)	0.117
Headache / Light-headedness	2 (4.5%)	2 (4.3%)	1.000

p-values were calculated using chi-square or Fisher's exact test, as appropriate

EA DV CONGRESS
VIENNA
30 SEP - 3 OCT 2026

Abstract N°: 1628

Microcrystalline Honeycomb Carbon-based VEGF Delivery System for Hair Regeneration: From In Vitro Validation to Clinical Assessment

Li Ye*[1], Yizhou Hao[2], Peng Zhang[2], Zhen Yi[1], Jinyin Liang[1], Xiaoyan Fu[1], Hongling Zhu[1], Jianhao Chen[3]

[1] Cosmetics Testing Center, Dermatology Hospital of Southern Medical University, NMPA Center for Innovation and Research in Regulatory Science, Translational Medicine Center, Dermatology Hospital of Southern Medical University, GuangZhou, China

[2] Guangzhou Moxi Technology Co., Ltd., Guangzhou, China

[3] Peking University, Beijing, China

Introduction

Hair loss represents a global health challenge, with current therapies often limited by inconsistent efficacy and adverse effects. The core challenge in hair follicle regeneration lies in delivering key bioactive molecules such as Vascular Endothelial Growth Factor (VEGF) to target sites with high bioavailability and controlled release. Therefore, developing an efficient delivery system capable of stable loading, protection, and sustained release of growth factors is crucial. This study aimed to design and construct a Microcrystalline Honeycomb Carbon-based delivery system for efficient VEGF loading and sustained release, providing a novel strategy for hair loss treatment.

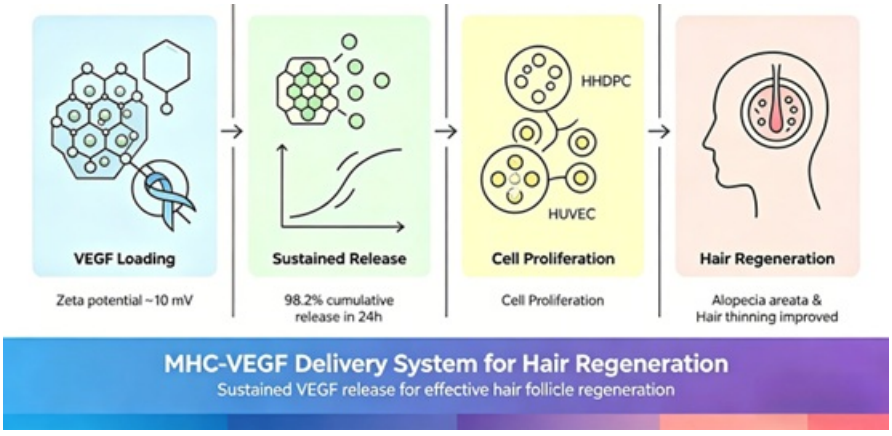

Materials and Methods

The Microcrystalline Honeycomb Carbon carrier was successfully synthesized and characterized. VEGF was then loaded onto the carrier to form the MHC-VEGF composite delivery system, with stability evaluated through zeta potential measurements and in vitro release kinetics. In vitro experiments investigated the effects of the MHC-VEGF system on proliferation of Human Hair Dermal Papilla Cells (HHDPC) and Human Umbilical Vein Endothelial Cells (HUVEC) to verify bioactivity. In vivo animal models were used to evaluate the effects on hair follicle regeneration, focusing on cell proliferation at the hair bulb base, hair bulb morphology, and hair follicle cycle. Preliminary human clinical trials were conducted with volunteers to assess the actual improvement in alopecia areata and vertex hair thinning.

Results

Characterization showed that after successful VEGF loading, the MHC carrier maintained a stable zeta potential of approximately 10 mV. In vitro release curves demonstrated that VEGF was continuously released from the carrier within 24 hours, achieving a cumulative release of 98.2%, followed by a sustained release plateau, confirming the system's excellent sustained-release properties. In vitro cell experiments confirmed that the MHC-VEGF composite significantly promoted HHDPC and HUVEC proliferation compared to free VEGF, indicating that the MHC carrier effectively enhanced VEGF stability and bioavailability. Animal experiments further demonstrated that the MHC-VEGF delivery system effectively stimulated cell proliferation at the hair bulb base, induced hair bulb enlargement, and promoted synchronous progression of the hair follicle cycle into early anagen phase. The therapeutic potential of MHC-VEGF was further validated in human subjects with alopecia. Macroscopic and microscopic observations demonstrated that after 56 days of continuous use, the number of hair follicles with newly emerging hairs was significantly increased compared to baseline. Representative clinical photographs of the scalp showed marked improvement in the sparse hair area at the vertex, with reduced scalp visibility and improved hair coverage. Quantitatively, hair loss was monitored continuously over the 56-day treatment period using the 60-combing test. The mean number of shed hairs decreased progressively over time, with statistically significant reductions observed at day 28 and day 56 compared to baseline (both $p < 0.0001$). These data collectively demonstrate that MHC-VEGF promotes hair follicle activation, induces anagen entry, and effectively reduces hair loss in both preclinical and clinical settings.

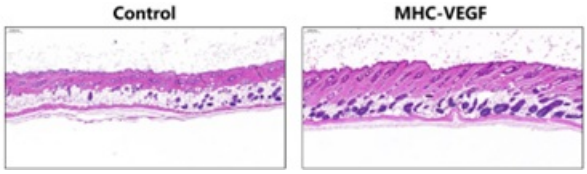

Conclusions

This study successfully constructed and systematically evaluated a Microcrystalline Honeycomb Carbon-based VEGF delivery system. The carrier demonstrated stable structure with effective VEGF loading and sustained release capability. Both in vitro and animal experiments proved that the MHC-VEGF system exhibited significant effects in promoting hair follicle-related cell proliferation, inducing hair follicle regeneration, and regulating hair follicle cycle. Preliminary clinical volunteer trials also demonstrated improvement potential for hair loss symptoms. In summary, the MHC-VEGF delivery system developed in this study provides a promising novel strategy.

EADV CONGRESS
VIENNA
30 SEP - 3 OCT 2026

Abstract N°: 1636

Ritlecitinib as Salvage Therapy in Long-Standing Alopecia Areata With Prior JAK Inhibitor Failure

Abhishek De*[1], Disha Chakraborty[2]

[1] Dermatology, Calcutta National Medical College, Dermatology, Wizderm Hair and Skin Specialty Clinic, Kolkata, India
[2] Dermatology, Mayo Clinic, Rochester, Rochester, United States

Introduction

Alopecia areata (AA) is a chronic autoimmune disorder, and long-term therapy is often required for adequate disease control. However, effective systemic treatment options remain limited for some patients. Ritlecitinib, a selective dual inhibitor of JAK3 and TEC family kinases, has recently been approved for the treatment of AA in adolescents aged ≥12 years.

Case Presentation

A 40-year-old woman presented with a longstanding history of AA for 18 years, with significant impairment in quality of life and associated depressive symptoms. She had previously received multiple systemic therapies, including cyclosporine for approximately 17 months, methotrexate for 3–4 years, and intermittent intralesional corticosteroids, either alone or in combination. At presentation, she had >50% scalp hair loss. She was initiated on oral tofacitinib 5 mg twice daily along with intralesional platelet-rich plasma and exosomes, which was continued for 17 months with minimal clinical improvement. Given the suboptimal response, treatment was switched to oral ritlecitinib 50 mg once daily. At 3-month follow-up, significant hair regrowth was observed in most scalp patches, although eyebrow regrowth was not noted. The patient continues to be followed. No treatment-related adverse events were observed during therapy.

Conclusion

In the pivotal randomized, double-blind, placebo-controlled phase 2b/3 ALLEGRO trial involving adults and adolescents with alopecia areata and ≥ 50% scalp hair loss, once-daily oral ritlecitinib 50 mg was shown to significantly increase the proportion of patients achieving ≤ 20% scalp hair loss at 24 weeks. Treatment with ritlecitinib was also associated with eyebrow and eyelash regrowth. Response rates for key efficacy outcomes were observed to continue to increase with ongoing treatment up to 48 weeks. Ritlecitinib may represent a viable therapeutic option for patients with moderate-to-severe AA who have had an inadequate response to other systemic therapies, including prior JAK inhibitors such as tofacitinib or baricitinib.

EA DV CONGRESS
VIENNA
30 SEP - 3 OCT 2026

Abstract N°: 1678

Role of 1% Selenium Disulfide-based Shampoo in Seborrheic Dermatitis and Dandruff Management: A Real-world, Multicenter, Observational Study

Maiada Magdi*[1], Fadi Al Sabbagh[2], Abrar Bukhari[3], Husain Ali Juma[4], Almontaser Bellah Almodeimegh[5], Badreya ALSHEHHI[6], Najah Sinno[7], Heba Mohamed[7], Eman Almukhadeb[5], Samir Hantirah[8], Chadan Naji[9], Salman Bin Dayel[10], Natalia Kovylkina[11]

[1] Prime Medical Center, Dubai, United Arab Emirates
[2] Novomed Marina, Dubai, United Arab Emirates
[3] Symphony Clinic, Riyadh, Saudi Arabia
[4] Global Dermatology Dr Husain Juma Centre, Manama, Bahrain
[5] King Saud University, Riyadh, Saudi Arabia
[6] Emirates Hospital, Dubai, United Arab Emirates
[7] L'Oréal Middle East, Dubai, United Arab Emirates
[8] American Hospital, Dubai, United Arab Emirates
[9] Novomed Shamma, Dubai, United Arab Emirates
[10] Prince Sattam Bin Abdulaziz University, Al Kharj, Saudi Arabia
[11] Vichy Laboratoires, Levallois Perret, France

Introduction
Scalp seborrheic dermatitis (SD) and dandruff are chronic, relapsing scalp disorders affecting sebum-rich areas and characterized by erythema, scaling, greasiness, flakiness, and pruritus. These conditions are associated with disbalanced scalp microbiome and Malassezia proliferation, altered keratinocyte turnover, and sebaceous activity, often leading to significant psychosocial burden. Selenium disulfide, an antifungal and keratolytic agent, is widely used in anti-dandruff formulations due to its ability to reduce fungal load, sebum production, and epidermal turnover. This study aimed to evaluate the real-world efficacy, tolerability, satisfaction, and cosmeticity of a 1% selenium disulfide-based shampoo in the management of SD and dandruff across the Middle East.

Materials and Methods
This prospective, open-label, multicenter observational study was conducted across 86 clinics in Bahrain, Jordan, Kuwait, Lebanon, Oman, Qatar, Saudi Arabia, and the United Arab Emirates between July 2022 and June 2023. A total of 822 patients aged ≥12 years with mild-to-severe SD and/or dandruff were enrolled, with 767 patients included in the efficacy analysis. Patients were prescribed a proprietary 1% selenium disulfide-based shampoo (with salicylic acid) and assessed at baseline, Week 4, and Week 8. Clinical evaluations included scalp desquamation, erythema, irritation, affected surface area, and pruritus, alongside hair fiber quality. Patient-reported outcomes captured efficacy, tolerability, cosmeticity, and satisfaction using structured questionnaires. Statistical analyses were performed using two-sided tests at a 5% significance level.

Results
The mean age of participants was 32.3 years, with a predominance of females (57.9%) and a diverse ethnic

distribution. SD was diagnosed in 74.1% of patients and dandruff in 25.9%, with a high prevalence of concomitant hair and scalp conditions. Prescription compliance was high (93.3%), and most patients had prior treatment exposure, including antifungals and topical corticosteroids.

Significant improvements in all clinical parameters were observed at Weeks 4 and 8 ($p<0.0001$ for all comparisons). At Week 4, improvements were noted in desquamation (75.3%), erythema (61.7%), irritation (74.1%), affected area (77.1%), and pruritus (85.8%). These outcomes further improved by Week 8, with recovery rates reaching 91.9% for desquamation, 76.8% for erythema, 90.9% for irritation, 88.9% for affected area, and 94.2% for itching. Overall, more than 90% of patients demonstrated noticeable scalp improvement.

Hair-related outcomes also improved, with dermatologists reporting enhanced hair fiber quality and integrity in 78.4% of patients, and 58.6% of patients perceiving improvements in hair appearance and texture. Patient-reported efficacy was high, with >90% agreement across most efficacy measures and strong positive ratings for organoleptic and cosmetic properties, including ease of application, texture, and cleansing performance.

Tolerability was excellent, with 98.3% of patients reporting good tolerance and over 97% considering the shampoo gentle and suitable for their hair type. Satisfaction increased over time, with dermatologist satisfaction rising from 92.6% at Week 4 to 96.2% at Week 8, alongside significant improvements in patient satisfaction ($p<0.0001$). Additionally, over 90% of patients preferred the 1% selenium disulfide shampoo over their previous products and expressed willingness to continue its use.

Conclusions

The 1% selenium disulfide-based shampoo demonstrated significant and progressive reductions in clinical signs and symptoms of SD and dandruff over 8 weeks of use, with concurrent improvements in hair quality, patient satisfaction, and cosmetic acceptability. High compliance and excellent tolerability further support its utility as an effective real-world therapeutic option for SD and dandruff management across diverse Middle Eastern populations.

EADV CONGRESS
VIENNA
30 SEP - 3 OCT 2026

Abstract N°: 1749

Efficacy of Ivarmacitinib in Severe Alopecia Areata by Prior Treatment History: A Post-Hoc Analysis of a Phase 3 Trial

Feng Wang*[1], Xin Du[1], Chunjun Yang[1]

[1] Second Affiliated Hospital of Anhui Medical University, Hefei, China

Introduction

In clinical practice, patients often undergo a variety of treatments, including systemic corticosteroids, immunosuppressants, and various topical therapies. However, these options are frequently hampered by limited efficacy, high relapse rates, and potential systemic toxicities that preclude long-term use. Given the diverse treatment backgrounds of patients, evaluating whether prior therapy influences the efficacy of JAK inhibitors is essential. Ivarmacitinib, a selective JAK1 inhibitor, has demonstrated significant efficacy in phase 3 trials for severe AA.[1] Therefore, this post-hoc analysis investigated the impact of prior AA treatment history on the efficacy of ivarmacitinib to provide valuable guidance for clinical practice and personalized management.

Materials and Methods

Data were derived from a randomized, double-blind, phase 3 trial (NCT05470413) in patients with severe AA (baseline Severity of Alopecia Tool [SALT]≥50). This 52-week study comprised a 24-week double-blind treatment period, where patients were assigned to ivarmacitinib (4 mg or 8 mg once daily) or placebo, followed by a 28-week extension phase during which patients initially receiving placebo were re-randomized to receive ivarmacitinib (4 mg or 8 mg). The efficacy outcome for this post-hoc analysis was the achievement of SALT≤20 at week 24. Clinical responses were compared based on three different aspects of prior treatment history: the use of systemic corticosteroids or immunosuppressants (yes vs no), the use of other AA therapies (yes vs no), and treatment-naïve versus previously treated status. Multivariable logistic regression was employed to assess the association between these prior treatment factors and clinical response, adjusting for baseline age, sex, body mass index (BMI), disease duration since diagnosis, duration of current AA episode, and disease severity. Missing data were handled using non-responder imputation.

Results

A total of 220 patients were included (n=109 in the ivarmacitinib 4 mg group and n=111 in the 8 mg group). Of the total population, 138 patients (62.7%) had prior AA treatment history. This included 44 (20.0%) treated with systemic corticosteroids or immunosuppressants and 94 (42.7%) who received other therapies, primarily traditional herbal medicines, topical corticosteroids/immunosuppressants, and other dermatological preparations (e.g., topical minoxidil).

In the 4 mg group, the proportion of patients achieving SALT≤20 was 47.6% (10/21) among those with prior systemic corticosteroids or immunosuppressants versus 31.8% (28/88) in those without (odds ratio [OR] 1.449, 95% CI 0.483–4.345; p=0.5083). Response rates were 30.6% (15/49) in patients with prior use of other therapies compared to 38.3% (23/60) in those without (OR 0.565, 95% CI 0.221–1.449; p=0.2349). Among treatment-naïve patients, the response rate was 33.3% (13/39) versus 35.7% (25/70) in the previously treated population (OR 0.687, 95% CI 0.243–1.940; p=0.4786) (Figure 1). Findings in the ivarmacitinib 8 mg group were consistent with those observed in the 4 mg group, showing no significant association between prior treatment history and clinical response at week 24 (all p>0.05) (Figure 2).

Figure 1. Efficacy of ivarmacitinib 4 mg at week 24 by prior AA treatment history



Figure 2. Efficacy of ivarmacitinib 8 mg at week 24 by prior AA treatment history



AA, alopecia areata; CI, confidence interval; OR, odds ratio; SALT, Severity of Alopecia Tool.

Conclusions

Ivarmacitinib demonstrates consistent efficacy in patients with severe AA, irrespective of their prior treatment history. With rapid and significant hair regrowth achieved within 24 weeks, ivarmacitinib represents a robust therapeutic option for a broad spectrum of patients, regardless of their previous intervention history.

Reference

1. Zhou C, et al. J Am Acad Dermatol. 2026;94(1):161-171.

EADV CONGRESS
VIENNA
30 SEP - 3 OCT 2026

Abstract N°: 1753

Efficacy of Ivarmacitinib in Adults with Severe Alopecia Areata Across Baseline Characteristics: A Post-hoc Analysis of a Phase 3 Trial

Jianji Wan*[1], Zhu Shen[1]

[1] Department of Dermatology, Guangdong Provincial People's Hospital, Guangdong Academy of Medical Sciences, Southern Medical University, Guangzhou, China

Introduction

Systemic Janus kinase (JAK) inhibitors are currently the only approved targeted therapies for alopecia areata (AA). Expert consensus emphasizes that AA management should integrate factors such as age, disease duration, and baseline severity. Previous studies suggest that response rates may vary based on these demographic and clinical characteristics. While the pivotal phase 3 trial of ivarmacitinib demonstrated overall efficacy and safety,[1] the consistency of response across subgroups stratified by baseline disease severity and patient characteristics remains to be fully elucidated.

Materials and Methods

Data were analyzed from a phase 3, randomized, double-blind, placebo-controlled trial of ivarmacitinib in patients with severe AA (Severity of Alopecia Tool [SALT] score≥50) (NCT05470413). Patients received ivarmacitinib 4 mg, 8 mg, or placebo once daily for 24 weeks, followed by a 28-week extension phase during which placebo-treated patients were re-randomized to receive either ivarmacitinib 4 mg or 8 mg. The primary endpoints for this post-hoc analysis were the proportions of patients achieving SALT≤20 and SALT≤10 at week 24. Missing data were handled using non-responder imputation. Subgroup factors evaluated included age, sex, body weight, body mass index (BMI), age at AA onset, duration of current AA episode, baseline disease severity, prior treatment history, and alcohol consumption history.

Results

The analysis included 109, 111, and 110 patients in the ivarmacitinib 4 mg, 8 mg, and placebo groups, respectively. At week 24, 34.9% and 40.5% of patients receiving ivarmacitinib 4 mg and 8 mg, respectively, achieved SALT≤20, compared with 8.2% in the placebo group. SALT≤10 was achieved by 22.0% and 27.9% of patients in the 4 mg and 8 mg groups, respectively, versus 5.5% with placebo. Across nearly all subgroups, both ivarmacitinib doses consistently achieved significantly higher SALT≤20 and SALT≤10 response rates compared to placebo (most $p<0.05$). Notably, treatment effects were maintained in clinically challenging populations, including patients with longer disease duration (≥3 years) and those with more severe disease, such as alopecia totalis/universalis (AT/AU) (Figures 1-2).

Additionally, the 8 mg dose generally yielded numerically higher response rates than 4 mg in several subgroups, including males (SALT≤20: 44.9% vs 33.3%; SALT≤10: 28.6% vs 15.7%), BMI≥25 kg/m² (SALT≤20: 44.8% vs 34.5%; SALT≤10: 27.6% vs 20.7%), and age at AA onset<18 years (SALT≤20: 35.5% vs 15.0%; SALT≤10: 25.8% vs 10.0%). Importantly, for SALT≤10, patients with AT/AU also showed a numerically higher response with 8 mg versus 4 mg (10.8% vs 5.6%) (Figures 1-2). These findings suggest that certain subgroups may derive additional benefit from

the higher dose.

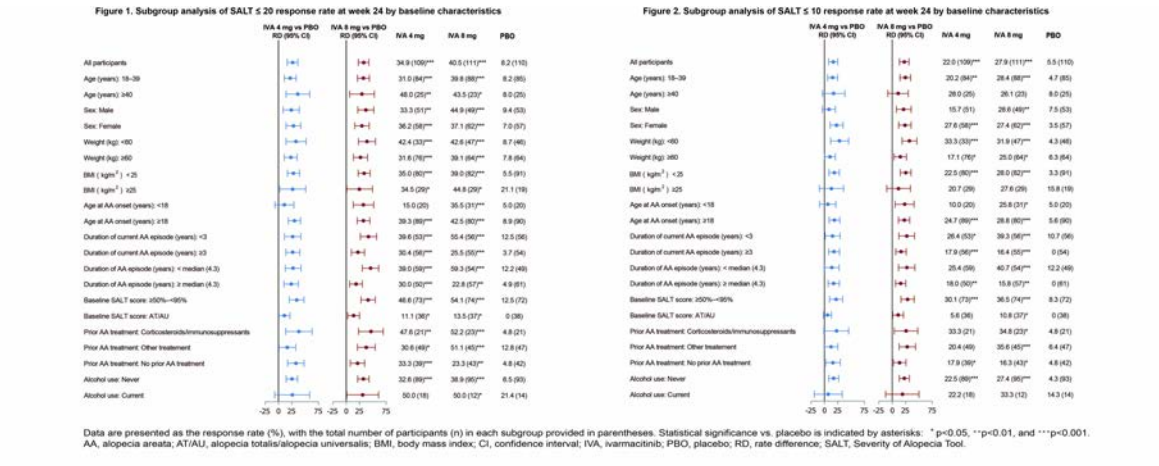

Data are presented as the response rate (%), with the total number of participants (n) in each subgroup provided in parentheses. Statistical significance vs. placebo is indicated by asterisks: *p<0.05, **p<0.01, and ***p<0.001.
AA, alopecia areata; AT/AU, alopecia totalis/alopecia universalis; BMI, body mass index; CI, confidence interval; IVA, ivarmacitinib; PBO, placebo; RD, rate difference; SALT, Severity of Alopecia Tool.

Conclusions

Ivarmacitinib provides consistent and robust efficacy at both 4 mg and 8 mg doses across a wide range of baseline characteristics in patients with severe AA, supporting its efficacy across a broad spectrum of patients. In several subgroups, responses were numerically higher with 8 mg than with 4 mg, warranting further study to identify patients most likely to derive additional benefit from the higher dose and to inform individualized dosing.

Reference

1. Zhou C, et al. J Am Acad Dermatol. 2026;94(1):161-171.

EADV CONGRESS
VIENNA
30 SEP - 3 OCT 2026

Abstract N°: 1755

Real-world Effectiveness of Baricitinib in Chinese Patients with Alopecia Areata: A Multicenter Prospective Study

Xiangqian Li[1], Yuxin Wang[1], Dingquan Yang[2], Aihua Wei[3], Cheng Zhou*[1]

[1] Peking University People's Hospital, Beijing, China
[2] Department of Dermatology, China-Japan Friendship Hospital, Beijing, China
[3] Department of Dermatology, Beijing Tongren Hospital, Capital Medical University, Beijing, China

Introduction
this study aimed to evaluate the real-world effectiveness of Baricitinib in Chinese adult patients with alopecia areata (AA).

Materials and Methods
This is a multicenter prospective observational study across 3 tertiary hospitals in Beijing, China from Nov 2023 to Dec 2025. Eligible adult patients (≥18 years) with a confirmed diagnosis of AA and receiving Baricitinib for the first time were enrolled. At baseline, demographic characteristics, disease severity (assessed by Severity of Alopecia Tool, SALT), and treatment details were collected. Patients were followed up in weeks 12, 24, and 36, where clinical outcomes and patient-reported outcomes (Dermatology Life Quality Index, DLQI; Skindex-16) were evaluated. Descriptive analyses were performed to assess changes from baseline to each follow-up time point.

Results
A total of 104 patients were enrolled in the study. Of these, 91, 72, and 61 patients completed the 12-week, 24-week, and 36-week follow-up visits, respectively. The mean (standard deviation, SD hereafter) age of the patients was 34.8 (11.7) years, and 37.5% were male. Thirty-one patients (29.8%) had other comorbidities. The mean disease duration was 8.4 (9.2) years, with 43.3% of patients in the active phase. The predominant types of alopecia areata were patch-type (34.6%) and diffuse-type (28.8%). In addition to scalp hair involvement, 54.8%, 29.8%, 21.2%, and 20.2% of patients had eyebrow, eyelash, body hair, and nail (finger/toe) involvement, respectively. A history of at least one prior treatment for alopecia areata was reported by 80.8% of patients, with minoxidil being the most common previous therapy (39.3%). At baseline, 65.4% of patients received 4mg of baricitinib, while the remaining patients received 2mg. Additionally, 84.6% of patients had concomitant treatments at baseline, such as minoxidil (53.4%).

At baseline, the mean SALT score of patients was 59.3 (26.8). After 12 weeks of treatment, 40.7% of patients achieved a SALT score ≤20. This proportion increased to 56.9% and 70.5% in weeks 24 and 36, respectively. The mean SALT score decreased by 19.4 (26.4), 33 (30.8), and 39.2 (29.4) in weeks 12, 24, and 36, respectively. Additionally, at week 12, the proportions of patients achieving SALT30, SALT50, SALT75, SALT90, and SALT100 were 54.4%, 43.3%, 25.6%, 14.4%, and 7.8%, respectively. These rates further increased at weeks 24 (76.1%, 64.8%, 54.9%, 38.0%, 18.3%) and 36 (83.3%, 73.3%, 63.3%, 45.0%, 25.0%).

At baseline, the mean Dermatology Life Quality Index (DLQI) score was 8.6 (6.5). After 12, 24, and 36 weeks of treatment, the mean DLQI score decreased by 1.8 (7.1), 2.8 (6.7), and 3.1 (7.3), respectively. Additionally, the

baseline mean Skindex-16 scores for symptoms, emotions, and functioning were 17.6 (21.7), 68.2 (25.5), and 45.1 (32.6), respectively. After 12 weeks, the mean changes in these three dimensions were -5.88 (18.2), -18.7 (29.4), and -7.1 (29.3). After 24 and 36 weeks, the mean changes were -1.52 (27.1), -28 (34.1), -13.72 (33.4), and -0.9 (24.5), -27.4 (36.4), -16.4 (37.6), respectively. No serious adverse events were reported.

Conclusions

This real-world study demonstrates that Baricitinib treatment leads to significant improvements in scalp hair regrowth and patient-reported quality of life in Chinese adult AA patients, with progressive benefits observed up to 36 weeks. These findings support the effectiveness of Baricitinib in real-world clinical practice and highlight its positive impact on both clinical outcomes and patient-reported quality of life in the Chinese AA population. Further long-term follow-up is needed to confirm the durability of these effects.

EADV CONGRESS
VIENNA
30 SEP - 3 OCT 2026

Abstract N°: 1767

An Innovative Plant Exosome-like Nanovesicles Derived from Leontopodium Alpinum Callus for Excellent Treatment of Androgenetic Alopecia (AGA)

Xiaoyi Ma*[1], Min Yu[2]

[1] Tongji University, Shanghai Dongfang Hospital, Shanghai, China

[2] Xi'an Jiaotong-Liverpool University, Suzhou, China

Introduction

Plant Exosome-like Nanovesicles have emerged as promising bioactive nanoparticles rich in effective target-regulating factors. However, traditional plant cultivation is limited by geography, seasonality, and pesticide residues, posing significant challenges to impurity removal and batch-to-batch standardization during extraction.

Materials and Methods

To address the limitations of traditional extraction, we collaborated with Swiss partners to employ biomanufacturing techniques for inducing hairy roots from Alpine wild Edelweiss calluses. This approach enables the laboratory-directed enrichment of bioactive components and standardized mass production, facilitating the successful isolation of highly purified nanovesicles characterized by exceptional batch-to-batch uniformity and compositional stability. We comprehensively characterized the physicochemical properties of these nanovesicles and unequivocally demonstrated their efficient internalization by dermal papilla cells. Furthermore, their therapeutic efficacy was systematically evaluated through in vitro cell culture models utilizing dermal papilla cells and hair follicle stem cells, androgenetic alopecia (AGA) mouse models, and ethically compliant human volunteer trials.

Results

Physicochemical characterization confirmed the canonical vesicular morphology of the isolated nanovesicles and a precisely defined particle size of 170 nm. In vitro results demonstrated that the nanovesicles significantly promote dermal papilla cell proliferation and regulate the hair follicle cycle, alongside critically mitigating the inflammatory cytokine burden within the scalp microenvironment. In AGA animal models, treatment induced noticeable follicular changes within 14 days, with hair regeneration effects at 28 days significantly surpassing those of Minoxidil. Furthermore, human trials confirmed high safety profiles and received unanimous positive feedback from volunteers. Clinical observations substantiated that these Edelweiss hairy root derived nanovesicles effectively confer robust anti-hair loss efficacy in the hair parting, hairline, and temporal regions among cohorts aged 20 to 50 years, whilst significantly enhancing overall hair texture and quality.

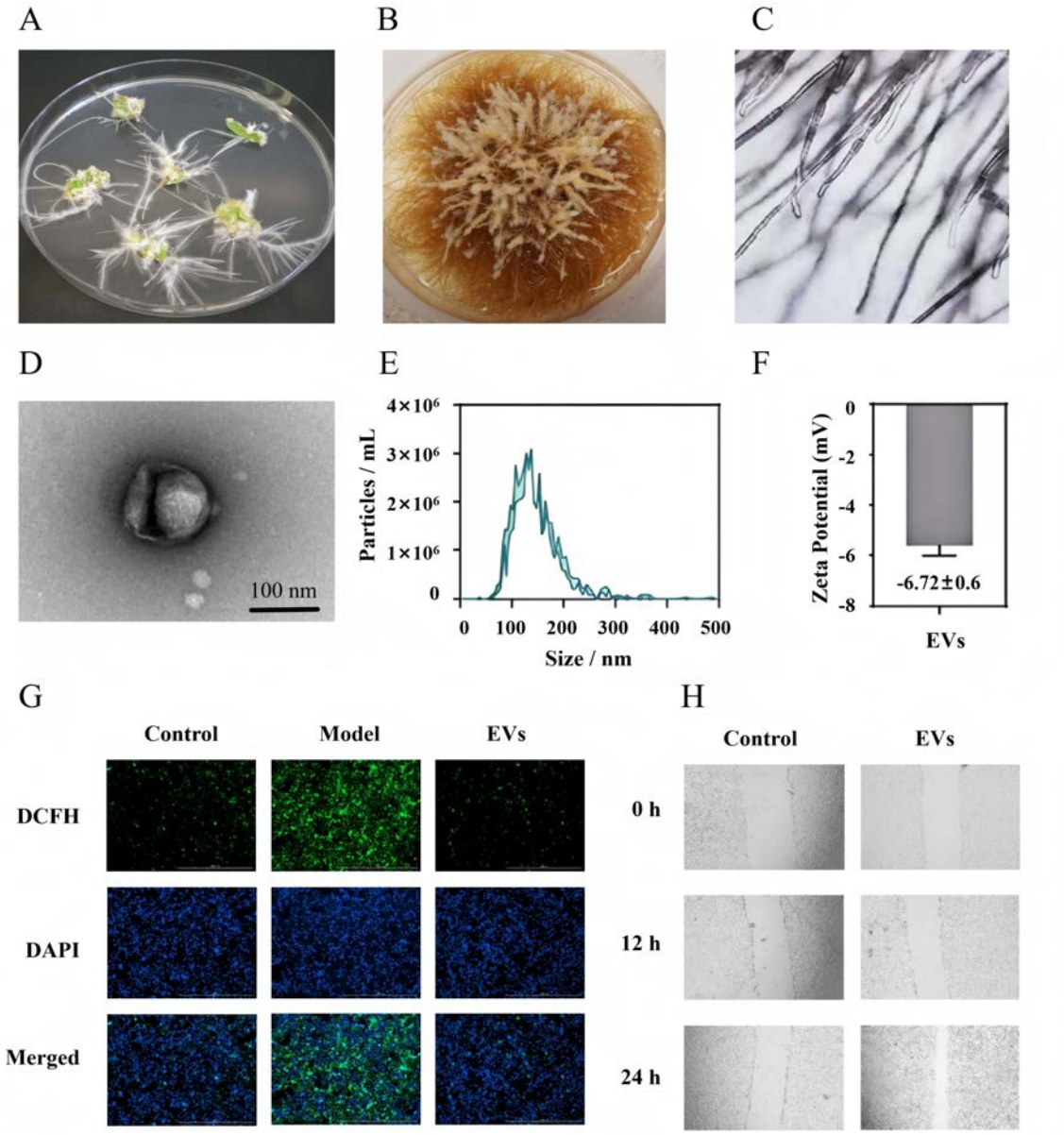

Fig. 1. Characterization and biological evaluation of Edelweiss hairy root-derived nanovesicles. (A) Edelweiss callus tissues. (B) Edelweiss hairy roots induced by biomanufacturing techniques. (C) Microscopic morphology of Edelweiss hairy roots. (D) Edelweiss hairy root-derived nanovesicles observed under transmission electron microscopy (scale bar = 100 nm). (E) Nanoparticle tracking analysis (NTA) of nanovesicle size distribution. (F) Zeta potential measurement of nanovesicles. (G) Cellular antioxidant evaluation of nanovesicles using DCFH-DA staining (Control: untreated cells; Model: oxidative stress-induced cells; EVs: nanovesicle-treated cells). (H) Cellular migration repair evaluation of nanovesicles at 0 h, 12 h, and 24 h post-treatment (Control: untreated cells; EVs: nanovesicle-treated cells).

Conclusions

This study overcomes the critical bottlenecks of standardization and mass production associated with plant Exosome-like Nanovesicles. By successfully utilizing biomanufactured Alpine wild Edelweiss hairy roots, we have identified a novel, highly effective, and safe therapy for androgenetic alopecia with substantial potential for translational clinical application.

EA DV CONGRESS
VIENNA
30 SEP - 3 OCT 2026

Abstract N°: 1791

Real World Effectiveness of Ritlecitinib in Alopecia Areata: Interim Findings from the PRESTO Prospective Non Interventional Study

Wenyu Wu[1], Taisuke Ito[2], Leila Asfour[3], Vivien Hébert[4], Giuseppe Micali[5], Chesahna Kindred[6], Mojgan Sadrarhami[7], Griffith Bell[7], Ernest Law[7], David Barnes[7], Genevieve Gauthier[8], Doina Doroftei[9], Gregor Shaefer*[10]

[1] Huashan Hospital, Fudan University, Shanghai, China
[2] Hamamatsu University School of Medicine, Hamamatsu, Japan
[3] Chelsea and Westminster NHS Foundation Trust, London, United Kingdom
[4] Department of Dermatology, PANTHER UMR 1234, Rouen University Hospital, Rouen, France
[5] Dermatology Clinic, University of Catania, Catania, Italy
[6] Kindred Hair and Skin Center, Marriottsville, United States
[7] Pfizer Inc, New York, United States
[8] Pfizer Inc., Kirkland, Canada
[9] Pfizer Romania SRL, Bucharest, Romania
[10] Pfizer Pharma GmbH, Berlin, Germany

Introduction

Ritlecitinib, an oral JAK3/TEC family kinase inhibitor, was approved in the USA in June 2023 for the treatment of severe alopecia areata (AA) in patients aged ≥12 years, and then in additional countries globally. The efficacy and safety of ritlecitinib have been demonstrated in the ALLEGRO phase 2b/3 and ongoing, phase 3, open-label ALLEGRO-LT studies.

Materials and Methods

PRESTO (NCT06531109) is an ongoing, multinational, prospective, cohort study evaluating patient and disease characteristics, treatment patterns, and clinical and patient-reported outcomes among adults and adolescents with AA who are receiving ritlecitinib 50 mg daily in routine clinical practice. We present interim findings from this study in six countries (China, UK, Japan, Italy, France, USA), describing the baseline population and evaluating change from baseline SALT score in patients who completed the baseline and week 24 visits. Eyelash Assessment (ELA) and Eyebrow Assessment (EBA) data are also described.

Results

For this interim analysis, 221 patients had initiated ritlecitinib treatment (index date) 14 days before to 30 days after study enrollment. Mean age at index was 34.0 years (SD: 16.6 years, range: 12-89 years). Of these participants, 42.5% were Asian, 26.7% White, 12.7% Other, and 7.2% Black or African American. Mean time since first diagnosis was 7.3 years (median: 3.1 years). Mean duration of last AA episode was 3.3 years and median (range) was 1.0 years (0-45.6 years). Mean number of pre-baseline AA episodes was 1.5 (SD: 1.9; median: 1.0). Most recent (not necessarily prior) episode phenotype was patchy in 76 cases (34.4%), alopecia totalis/universalis (AT/AU) in 81 (36.7%), diffuse in 33 (14.9%), and ophiasis in 10 (4.5%). Mean SALT score at index was 63.0; 37.5%; of patients had SALT score 50-94, and 26.2% had SALT score 95-100.

Among the 26 patients who reached the week-24 timepoint for this interim analysis and had two SALT scores documented, mean SALT score improved from 70.2 to 22.5 and median SALT score improved from 75.1 to 6.6. Similar improvements were seen in adolescent, adult, male, and female subgroups. Among the 29 patients with

documented ELA and EBA data at index and week 24,15 and 18 had abnormal ELA and EBA scores (<3) at index, respectively. Of these, 73.3% and 72.2% had improved by at least one grade in ELA and EBA, respectively, at week 24. Of the 24 patients with Patient Global Impression of Change (PGI-C) data at week 24, 83.3% reported moderate or great improvement. All 24 patients with Patient Satisfaction with Hair Growth (P-Sat) data at week 24 reported being satisfied with their hair growth (50.0% greatly, 29.2% moderately, and 20.8% slightly).

Conclusions

This interim analysis of a real-world, multinational, prospective cohort study demonstrates improved clinical- and patient-reported outcomes among adults and adolescents with severe AA after receiving 24 weeks of ritlecitinib. Subsequent analysis with additional longitudinal follow-up will allow further evaluation of ritlecitinib effectiveness.

EA DV CONGRESS
VIENNA
30 SEP - 3 OCT 2026

Abstract N°: 1800

Association between GLP-1 receptor agonists and scalp involvement: results from a multinational case-control study

Bruno Halioua*[1], Charles Taieb[2], Alexandre COUTTET[3, 3], Nuria PEREZ CULLELL[3], Virginie Ribet[4], Valérie MENGEAUD[4], Bianca Maria Piraccini[5]

[1] Société Française des Sciences Humaines de la Peau, Paris, France
[2] European Market Maintenance Assessment, FONTENAY SOUS BOIS, France
[3] Pierre Fabre, Toulouse, France
[4] Laboratoire Dermatologique Ducray, Lavaur, France
[5] Dermatology Unit, Department of Experimental, Diagnostic and Specialty Medicine, University of Bologna,, Bologna, Italy

Introduction
GLP-1 receptor agonists (GLP-1 RA) have revolutionized the management of type 2 diabetes (T2D) and obesity, and their worldwide use is growing exponentially. Several recent publications (FAERS analysis, TriNetX cohort study, case series) have reported an association between these treatments and the occurrence of alopecia, but without an appropriate control group, leaving unresolved the share attributable to telogen effluvium related to rapid weight loss versus a specific pharmacological effect. The objective of this study was to characterize scalp involvement with an appropriate control group and to determine whether these effects persist after stratification by weight loss.

Materials and Methods
A multinational cross-sectional study (France, United States, Brazil, Mexico) including 575 GLP-1 RA users and 1,329 controls (type 2 diabetes and/or obesity, BMI >30) with no exposure to GLP-1 RA, recruited from a representative sample in each country. Targeted assessment: unusual hair loss, loss of hair volume/density, dandruff and scalp erythema, nail fragility, dyschromia, changes in thickness, onycholysis and ridges/grooves. Weight loss was measured over a 3-month period, and a stratified analysis was performed to distinguish the drug effect from the weight loss effect.

Results
GLP-1 RA users (mean treatment duration 18.5 months; median 9 months) users reported weight loss over 3 months more frequently than controls (76.3% vs 47.3%; $p<0.001$). Prevalences of hair and scalp involvement were significantly higher in the exposed group. Unusual hair loss was reported in 50.4% of cases versus 33.5% of controls (OR = 4.49 [3.62-5.56], $p<0.001$), with new onset hair loss in 26.1% versus 11.6% (OR = 2.67 [2.03-3.50], $p<0.001$). Loss of hair volume/density affected 42.4% of cases versus 19.3% of controls (OR = 3.23 [2.61-4.00], $p<0.001$). Scalp erythema was also more frequent (OR = 3.05 [2.34-3.99], $p<0.001$).

Conclusions
This multinational case-control study confirms, with enhanced statistical power and an appropriate control group,

the risk of alopecia associated with GLP-1 RA and demonstrates that it cannot be reduced to the effect of weight loss alone. The persistence of the signal after stratification supports a specific pharmacological mechanism. The underlying mechanisms are probably multiple and intertwined (telogen effluvium, nutritional deficiencies, hormonal fluctuations); the expression of GLP-1 receptors around hair follicles and the activation of the MAPK/ERK pathway represent a mechanistic avenue to be explored. Systematic dermatological screening including scalp examination should be integrated into the follow-up of patients treated with GLP-1 RA.

EADV CONGRESS
VIENNA
30 SEP - 3 OCT 2026

Abstract N°: 1872

Rezpegaldesleukin, a Novel Regulatory T Cell-Inducing Biologic, Demonstrates Efficacy and Safety in Severe-to-Very-Severe Alopecia Areata: 52-Week Results from the Phase 2b REZOLVE-AA Study

David Rosmarin*[1], Benjamin Ungar[2], Natasha Mesinkovska[3], Jonathan I. Silverberg[4], Beata Imko-Walczuk[5], Ewa Ring[6], Tadeusz Debniak[7], Hubert Arasiewicz[8], Jacek Szepietowski[9], Agnieszka Owczarczyk-Saczonek[10], Wojciech Baran[11], Bartlomiej Kwiek[12], Michal Torz[13], Jacek Zdybski[14], Neil Sadick[15], Evelyn Chinchilla[16], Mary Veremis-Ley[17], Edward Lain[18], Lawrence Osman[19], Lorne Albrecht[20], Charles Lynde[21], Maria Hannaway[22], Haq Nawaz[22], Zachary Lee[22], Soratree Charoenthongtrakul[22], Christie Fanton[22], Heng Xu[22], Yi Liu[22], Sohail Chaudhry[22], Mary Tagliaferri[22], Jonathan Zalevsky[22], Brett King[23]

[1] Indiana University School of Medicine, Indianapolis, United States
[2] Department of Dermatology, Icahn School of Medicine at Mount Sinai, New York, United States
[3] Department of Dermatology, University of California, Irvine, United States
[4] Department Of Dermatology, George Washington University School Of Medicine, Washington, DC, United States
[5] Centrum Badań Klinicznych PI-House, Gdansk, Poland
[6] Prywatna Praktyka Lekarska Ewa Ring, Warsaw, Poland
[7] Twoja Przychodnia SCM – Wyzwolenia, Szczecin, Poland
[8] Clinical Department of Pediatric Dermatology and Vascular Anomalies,Faculty of Medical Sciences in Katowice, Medical University of Silesia, John Paul II Children's and Family Health Center, Wrocław, Poland
[9] City Clinic, Medical and Psychological Center, Wrocław, Poland
[10] Department of Dermatology, Sexually Transmitted Diseases and Clinical Immunology, Municipal Hospital in Olsztyn, Olsztyn, Poland
[11] Department of Dermatology, Venereology, and Allergology, Wroclaw Medical University, Wroclaw, Poland
[12] Klinika Ambroziak Dermatologia, Lazarski University, Warsaw, Poland
[13] Dermaceum Centrum Badań Klinicznych, Wroclaw, Poland
[14] Dermedic Jacek Zdybski, Ostrowiec Świętokrzyski, Poland
[15] Department Of Dermatology, Weill Cornell Medicine, Sadick Research Group, New York, United States
[16] Centre De Recherche, Sherbrooke, Canada
[17] Midwest Center for Dermatology, dba Michigan Center for Skin Care Research, Clinton Township, United States
[18] Austin Institute for Clinical Research, Austin, United States
[19] Quest Dermatology Research, Northridge, United States
[20] Enverus Medical Research, University of British Columbia and Probity Medical Research, Surrey, BC, Canada
[21] Division of Dermatology, Department of Medicine, University of Toronto, Lynde Institute for Dermatology, Toronto, ON, Canada
[22] Nektar Therapeutics, San Francisco, United States
[23] Dermatology Physicians of Connecticut-Fairfield, Fairfield, CT, United States

Introduction

Alopecia areata (AA) involves dysfunction of regulatory T cells (Tregs) and loss of hair follicle immune privilege, leading to hair loss and a debilitating quality of life. Currently, only Janus kinase (JAK) inhibitors are approved to treat severe AA, with limited clinical adoption due to safety concerns. There are no targeted biologic therapies approved or in late-stage development for AA. Rezpegaldesleukin is an investigational IL-2 receptor agonist

biologic that increases the number and function of Tregs, a novel therapeutic strategy for multiple autoimmune and inflammatory diseases. REZOLVE-AA topline Week 36 primary and key secondary endpoint data have been previously presented. Here, we report new results from REZOLVE-AA evaluating up-to 52 weeks of therapy with rezpegaldesleukin in patients with severe-to very-severe AA.

Materials and Methods

REZOLVE-AA (NCT06340360) is a randomized, double-blind, placebo-controlled Phase 2b monotherapy trial evaluating adult patients (males: 18-60 years, females: 18-70 years) with AA Severity of Alopecia Tool (SALT) score ≥50. Patients were randomized 3:3:2 to receive subcutaneous Rezpegaldesleukin 24 µg/kg every 2 weeks (Q2W) (n=35), rezpegaldesleukin 18 µg/kg Q2W (n=37), or placebo (n=20) for 36 weeks and were stratified by baseline SALT score ≥50–<95 vs ≥95–100. Key eligibility criteria included: JAK inhibitor-naïve, diagnosis of AA, stable hair loss for ≥6 months, current episode ≤8 years, washout of prior AA therapies and no hair loss from causes other than AA. Patients with SALT score >20 at Week 36 were eligible for the blinded 16-week treatment extension through to Week 52. A total of 31 patients continued into the 16-week treatment extension: rezpegaldesleukin 24 µg/kg Q2W (n=13), rezpegaldesleukin 18 µg/kg Q2W (n=14), and placebo Q2W (n=4). The primary endpoint for the study was mean percent change from baseline in SALT score at Week 36. Key secondary endpoints included, proportions of patients achieving absolute SALT scores ≤20 and ≤30 at end of treatment; proportions achieving ≥50% and ≥75% SALT reduction at end of treatment; and safety/tolerability. Similar exploratory efficacy endpoints were included to assess 52 weeks of treatment. Data for patients in the non-treatment extension Set after Week 36 are carried over from Week 36 and missing data for patients in the treatment extension Set after Week 36 are imputed using Multiple Imputation for the overall efficacy results at Week 52.

Results

The new SALT ≤20 responders in the blinded 16-week treatment extension included rezpegaldesleukin 24 µg/kg 4/13 (31%), rezpegaldesleukin 18 µg/kg 4/14 (29%), and placebo 0/4 (0%). From Week 36 to Week 52, the overall proportion of patients with SALT ≤20 improved from 15.6%, 14.8%, and 6.7% to 27.6%, 25.8%, and 6.7% for rezpegaldesleukin 24 µg/kg, rezpegaldesleukin 18 µg/kg, and placebo, respectively. At Week 52, rezpegaldesleukin 24 µg/kg, rezpegaldesleukin 18 µg/kg and placebo had the following results: SALT score ≤30 was observed in 35.0%, 30.2% and 8.4%; and $SALT_{50}$ was 38.8%, 37.7% and 13.6%, respectively. 94% of patients completed the 16-week treatment extension period. No increased risk of conjunctivitis, oral herpes, or malignancy was observed in a combined database of over 1,000 treated patients.

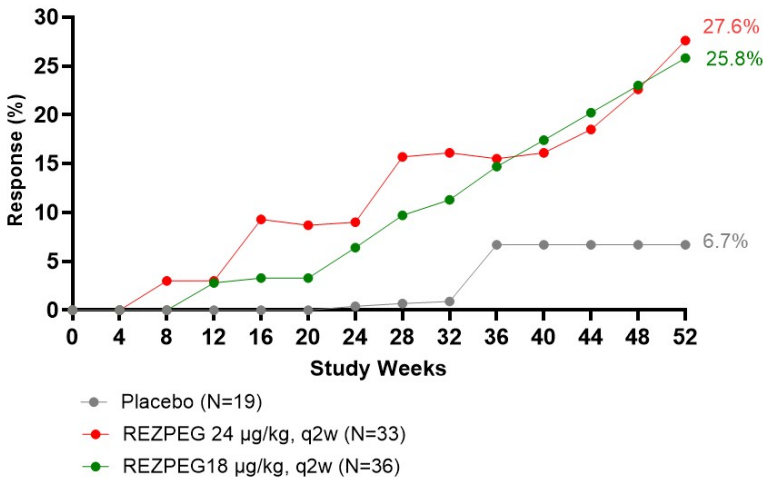

Conclusions

The Phase 2b REZOLVE-AA study provides proof-of-concept for rezpegaldesleukin as a potential first-in-class, Treg-targeted, twice-monthly biologic for severe-to-very-severe alopecia areata. At Week 52, both doses of rezpegaldesleukin achieved clinically meaningful SALT score reductions versus placebo, with consistent dose-response relationships and a differentiated safety profile from the currently available JAK inhibitors. Continued treatment for 52 weeks yielded further hair regrowth. The favorable efficacy and safety findings support the advancement of rezpegaldesleukin into Phase 3 development in patients with severe-to-very-severe AA.

EADV CONGRESS
VIENNA
30 SEP - 3 OCT 2026

Abstract N°: 1873

Folliculitis decalvans, cicatricial alopecia.

Tatiana Shmidt*[1], Irina Smirnova[1], Natalia Shin[1], Polina Ptashnikova[1], Valeria Vasilieva[1]

[1] Saint-Petersburg State University, Saint-Petersburg, Russian Federation

Introduction

Folliculitis decalvans is a rare chronic inflammatory disease of the scalp that belongs to the group of primary scarring alopecias. The disease is characterized by a persistent, recurrent course, progressive destruction of hair follicles, and the development of irreversible scarring alopecia. The clinical picture is dominated by follicular pustules, erythema, crusts, and areas of hair loss.

Case Presentation

A 55-year-old woman presented with complaints of hair loss, itching, and tenderness of the scalp in April 2025. She has been ill since 2013, when she first noticed a coin-sized patch of alopecia; she had no complaints at that time. The patient consulted dermatologists and was diagnosed with lichen planus? Discoid lupus erythematosus? She received hydroxychloroquine 400 mg/day in courses for over a year, with no improvement. In 2015, a biopsy was performed and the diagnosis was established: decalcifying folliculitis. Treatment was prescribed — topical corticosteroids, topical antibiotics, with plans to prescribe isotretinoin. From 2015 to 2025, the patient was not followed up. Upon re-examination 10 years later, the patient complained of itching of the scalp and trichodynia. On examination: the area of alopecia had significantly increased; there was extensive scarring alopecia in the parietal region with marked scar density, isolated pustules, perifollicular erythema, and polytrichia.
Discoid lupus erythematosus was ruled out: antinuclear antibody titer 1:320; other markers of systemic diseases were negative; a repeat biopsy was performed. Diagnosis: Folliculitis decalvans, late stages of the pathological process. Bacteriological examination of pustule contents was performed—moderate growth of S. epidermidis.
The patient received 6 intradermal injections of betamethasone. Since April 2025, she has been taking isotretinoin at a dose of 32 mg/day. She has been applying a fusidic acid cream topically twice daily to the affected area for 2 months. Since October 2025, she has been undergoing a course of photodynamic therapy, with 6 procedures completed. Trichodynia and itching have decreased during treatment. Hair is actively falling out.

Conclusion

This clinical case demonstrates the challenges of early diagnosis of folliculitis decalvans. The nonspecific nature of clinical manifestations and limited awareness of this disease contribute to diagnostic errors and delays in establishing the correct diagnosis. The disease is characterized by a persistent, progressive course. It highlights the complexity of treating progressive scalp alopecia and the need for a multidisciplinary approach.

EADV CONGRESS
VIENNA
30 SEP - 3 OCT 2026

Abstract N°: 1901

SYSTEMIC TREATMENT OF PEDIATRIC MODERATE-TO-SEVERE ALOPECIA AREATA IN PORTUGAL: A RETROSPECTIVE MULTICENTER STUDY

Nuno Miguel Preto Gomes*[1], Ana Cristina Brandao Nogueira[2], Ana Paula Vieira[3], Carolina Gouveia[4], Cristina Amaro[5], MARIA CRISTINA TAPADINHAS[6], Felicidade Santiago[7], Maria Francisca Jácome Morgado[8], Isabel Freitas[9], Leonor Castendo Ramos[7], Maria João Cruz[2], Mariana Sousa Batista[7], Rafael Santos[2], Sonia Fernandes[6], Susana Machado[10], Rita Pimenta[11]

[1] ULS Alto Minho, Viana do Castelo, Portugal
[2] ULS São João, Porto, Portugal
[3] ULS Braga, Braga, Portugal
[4] ULS São José, Lisboa, Portugal
[5] Hospital de Cascais, Cascais, Portugal
[6] ULS Santa Maria, Lisboa, Portugal
[7] ULS Coimbra, Coimbra, Portugal
[8] ULS Leiria, Leiria, Portugal
[9] ULS Loures-Odivelas, Loures, Portugal
[10] ULS Santo António, Porto, Portugal
[11] ULS Almada-Seixal, Almada, Portugal

Introduction

Alopecia areata is a non-scarring alopecia that can present with various clinical forms and affect individuals throughout their lifetime. A significant percentage of alopecia areata cases begin in childhood, and there is currently no approved treatment for moderate-to-severe disease, apart from ritlecitinib in patients aged 12 years and older. Although they constitute a minority of alopecia areata cases, these forms of the disease have a considerable impact on the quality of life of children and adolescents and may be associated with various comorbidities, making effective systemic treatment essential.

Materials and Methods

The authors present a retrospective multicenter study of twelve Portuguese hospitals, developed on behalf of the Portuguese Pediatric Dermatology Group. The main objective was to evaluate systemic treatments for alopecia areata with a SALT score of 21 or higher in patients aged 18 years or younger, initiated between January 2015 and June 2025 and with a minimum treatment duration of 3 months. Exclusion criteria were the diagnosis of two or more concomitant forms of alopecia and the absence of at least three months of follow-up. Secondary outcomes included treatment response, safety profile and treatment persistence. Treatment outcomes were assessed based on changes in SALT score and clinical response rate, providing an objective measure of therapeutic efficacy.

Results

Sixty-two patients were identified, who completed 113 therapeutic courses. The majority of patients were female, had no comorbidities, and had a mean age at the start of the first therapeutic course of 10.25 years. Most patients

completed two therapeutic courses. Alopecia areata was, in most cases, chronic, of multifocal or universal type, and with a mean pre-treatment SALT score of 70.55 points. The most commonly used drugs were corticosteroids, followed by ritlecitinib, cyclosporine, and tofacitinib (28, 15, 13, and 13 therapeutic courses, respectively). The mean duration of medication was 14 months. Most patients remained on some form of systemic treatment at the last follow-up.

Most patients with moderate-to-severe alopecia areata undergo multiple lines of therapy, corroborating the chronic nature of the disease and its refractoriness to different treatments. Over the ten years evaluated in this retrospective study, the treatment paradigm has changed, and Janus kinase (JAK) inhibitors are currently emerging as the most safe and effective option in patients with chronic alopecia areata. However, systemic corticosteroids are still the most widely used drugs, despite heterogeneous treatment protocols, significant side effects, and frequent relapse following dose tapering.

Conclusions

In Portugal, systemic treatment of severe forms of alopecia areata in children is primarily based on corticosteroids and JAK inhibitors, whether approved for this indication or used off-label. The approach to alopecia areata is heterogeneous and requires standardization; therefore, reimbursement of the available on-label medications by the competent authorities is urgently needed to improve equitable access to effective treatments.

EA DV CONGRESS
VIENNA
30 SEP - 3 OCT 2026

Abstract N°: 1919

Stigma, quality of life, and disease burden of people living with alopecia areata

Jana Koch[1], Sabine Steinke*[1], Jana Stucke[1], Alina Wacker[1]

[1] University Bielefeld, Bielefeld, Germany

Introduction
Hair disorders affect not only physical health but also emotional well-being, identity, and social bonds. Among them, alopecia areata (AA) stands out as a common inflammatory disease that significantly affects daily life and mental health. However, the interplay between disease burden, perceived stigma, and psychological distress remains insufficiently understood.

Materials and Methods
In a cross-sectional study in a German dermatology clinic, data from 172 patients with hair disorders were analysed in order to illustrate the burdens and care aspects of those affected. Patients with AA were compared with patients with other diagnosed hair disorders; AA was given priority in cases of coexisting diagnoses. Hair-specific quality of life (Hairdex), psychological distress (PHQ-4), and perceived stigmatisation (PSQ) were assessed. Depending on distributional properties and measurement level, we applied parametric tests (e.g., t-tests, Pearson correlations, linear regression, mediation models) or non-parametric procedures (e.g., Mann–Whitney U tests, chi-square tests) to examine associations between clinical characteristics, treatment patterns, and psychosocial burden. Exploratory mediation analyses were conducted using PROCESS Model 4 with 5,000 bootstrap samples.

Results
Patients with AA did not report greater hair-specific quality-of-life impairment than those with other hair disorders (Hairdex: M = 70.51, SD = 33.83, n = 37 vs. M = 70.39, SD = 34.81, n = 51; t(86) = 0.02, p = 0.987).
Psychological distress was numerically higher among patients with AA but did not differ significantly between groups (PHQ-4: M = 3.98, SD = 3.14, n = 66 vs. M = 3.56, SD = 3.40, n = 71; t(135) = 0.75, p = 0.453).
Patients with AA reported significantly higher perceived stigmatisation than patients with other hair disorders (PSQ total score: M = 2.05, SD = 0.75, n = 64 vs. M = 1.80, SD = 0.54, n = 72; t(134) = 2.23, p = 0.028).
Exploratory mediation analysis indicated a significant indirect association between AA status and psychological distress through perceived stigma (indirect effect: B = 0.459, 95% bootstrap CI [0.062, 0.961]; n = 133). AA status was associated with higher perceived stigma (B = 0.253, p = 0.026), and perceived stigma was associated with higher psychological distress (B = 1.812, p < 0.001). The total association between AA status and psychological distress was not statistically significant (B = 0.321, p = 0.575).
Self-reported healthcare burden was also increased. In analyses comparing participants with and without AA, patients with AA attended significantly more dermatology visits on average (M = 4.44 vs. 3.18; t(165) = −4.20, p < 0.001). They were also more likely to report out-of-pocket costs above €1,000 (16.9% vs. 3.0%; $\chi^2(3) = 9.73$, p = 0.021).

Conclusions
Beyond visible hair loss, AA was associated with greater perceived stigma, more frequent dermatology consultations, and higher out-of-pocket costs. In contrast, AA was not associated with significantly greater hair-specific quality-of-life impairment or psychological distress compared with other diagnosed hair disorders.

Exploratory analyses suggest that perceived stigma may represent an important pathway linking AA status with psychological distress. These cross-sectional findings underline the need for psychosocially informed dermatologic care that considers perceived stigma, psychological distress, quality of life, and healthcare burden in addition to diagnostic subtype.

EA DV CONGRESS
VIENNA
30 SEP - 3 OCT 2026

Abstract N°: 1978

Understanding the Disease Burden of Alopecia Areata: A Comparative Analysis of Patient Profiles and Disease Characteristics Between Europe and Japan

Alice Beckley*[1], Hamizah Hamdan[2], Atikah Kamaruddin[2]

[1] Ipsos, London, United Kingdom
[2] Ipsos, Kuala Lumpur, Malaysia

Introduction

Alopecia Areata (AA) is a chronic, immune-mediated condition causing non-scarring hair loss, affecting approximately 2% of the global population. Beyond its physical manifestations, AA imposes substantial psychological burden, significantly impacting quality of life and mental health[1,2]. While AA occurs globally, regional variations in patient characteristics, disease presentation, and associated comorbidities remain underexplored, yet are critical for informing region-specific management strategies. This study aimed to characterize and compare the disease burden of moderate-to-severe AA patients between European regions (UK, France, Italy) and Japan, examining patient demographics, disease severity patterns, and psychological impact.

Materials and Methods

An online physician-reported chart review was conducted January-March 2026 among 227 dermatologists actively managing AA from the UK, France, Italy (EU3: n=121) and Japan (n=106), who provided data on 843 patients with moderate-to-severe AA (SALT score ≥30). Participating physicians were primary treaters and saw a minium number of AA patients per month. Patient psychological distress was categorized (mild/moderate/severe) based on documented clinical assessments in patient charts. Statistical comparisons were performed using two-proportion z-test, with significance set at $p<0.01$.

Results

Among reported moderate-severe AA patients, Japanese patients were significantly more likely to have presented with severe disease at initial diagnosis (56% vs 37% in EU3, $p<0.01$), while initial mild-stage diagnosis was uncommon in Japan (4% vs 15% in EU3, $p<0.01$).

AA disease burden extends beyond the scalp with high non-scalp involvement for both EU3 and Japan cohorts, particularly eyebrows and eyelashes, demonstrating frequent multi-site presentation. EU3 patients showed higher rates of extensive disease patterns (AA Totalis: 13% vs 8%; AA Universalis: 8% vs 3%, $p<0.01$) and greater non-scalp involvement, particularly beard and nail. Japanese patients more commonly presented with diffuse scalp patterns (26% vs 15%, $p<0.01$).

The most pronounced regional difference was psychological impact: 41% of EU3 patients exhibited severe psychological distress versus 26% in Japan ($p<0.01$). Depression/anxiety comorbidity was markedly higher in EU3 (19% vs 4%, $p<0.01$), as was thyroid disease (13% vs 2%, $p<0.01$). Conversely, atopic dermatitis was more

prevalent in Japan (18% vs 11%, p<0.01), and Japanese patients more frequently had no comorbidities.

Conclusions

This comparative analysis reveals distinct regional phenotypes in moderate-severe AA. Japanese patients present with more severe disease at diagnosis but lower psychological distress, while EU3 patients show more extensive disease patterns and substantially higher psychological burden and related comorbidities. These differences may reflect cultural factors in psychological distress expression and physician recognition, healthcare access affecting diagnostic timing, or genuine phenotypic variations. These findings underscore the need for region-specific management approaches: psychological support integration is particularly critical in EU3 settings given the higher distress burden, while Japanese settings might benefit from structured psychological assessment to ensure distress is not under-recognized regardless of expression style. Further investigation using matched cohorts is warranted.

EADV CONGRESS
VIENNA
30 SEP - 3 OCT 2026

Abstract N°: 1980

Testosterone Therapy and Risk of Nonscarring Alopecia in Men With Testicular Hypofunction

Robert Adler*[1], Michael Kozlov[1], Derek Maas[2], Archie Spindler[2], Kristen Lo Sicco[2], Jerry Shapiro[2], Jeffrey Weiss[1]

[1] SUNY Downstate College of Medicine, Brooklyn, United States

[2] The Ronald O. Perelman Department of Dermatology, New York University Grossman School of Medicine,, New York, United States

Introduction

Testosterone replacement therapy (TRT) is widely used for hypogonadism, but its relationship with nonscarring alopecia is not well established. Androgen signaling, particularly via dihydrotestosterone (DHT), plays a central role in hair follicle miniaturization and androgen-sensitive hair loss. We sought to evaluate the association between TRT and incident nonscarring alopecia in men with testicular hypofunction.

Materials and Methods

We conducted a retrospective cohort study using the TriNetX Research Network. Adult men with testicular hypofunction (ICD-10-CM: E29.1) were included. The exposed cohort received TRT, while the control cohort had no testosterone exposure. Patients with prior androgenic alopecia or nonscarring hair loss were excluded. One-to-one propensity score matching was performed to balance demographics, comorbidities, medications, laboratory values, and healthcare utilization. The primary outcome was incident nonscarring alopecia (ICD-10-CM: L64, L65.9). Risk ratios and hazard ratios were calculated.

Results

After matching, 197,763 patients were included in each cohort with balanced baseline characteristics. Mean follow-up was approximately 2.3 years. Nonscarring alopecia occurred in 0.55% of the TRT group versus 0.43% of controls (risk ratio 1.29, 95% CI 1.18-1.41). Time-to-event analysis showed an increased hazard in the TRT group (HR 1.18, 95% CI 1.08-1.30; $p < 0.0001$).

Conclusions

TRT was associated with a modest but statistically significant increase in incident nonscarring alopecia. Elevated DHT levels may contribute to this effect. Although causality cannot be inferred, these findings support informed counseling. Limitations include residual confounding and reliance on diagnostic coding.

EADV CONGRESS
VIENNA
30 SEP - 3 OCT 2026

Abstract N°: 1998

Misdiagnosed Temporal Triangular Alopecia as Alopecia Areata Delaying Hair Transplantation: A Diagnostic Pitfall with Therapeutic Implications

Ana Lígia Scotti Alérico*[1], Hudson Rezende[1], João Henrique Aurich[1], Antonio Moraes Madeira Quindos[2], Juliana Santos Rodrigues[1]

[1] Centro Universitário Lusíada - UNILUS, Santos, Brazil

[2] Universidade de Taubaté (UNITAU), Taubate, Brazil

Introduction

Temporal triangular alopecia (TTA) is a non-scarring, localized form of alopecia characterized by follicular miniaturization in the absence of inflammation. Although typically present since childhood, it often remains unrecognized in adults, particularly when associated with androgenetic alopecia (AGA). This overlap may obscure clinical recognition and lead to misdiagnosis, most commonly as alopecia areata, with direct implications for management and therapeutic decision-making.

Case Presentation

A 48-year-old man was referred for evaluation prior to hair transplantation due to progressive androgenetic alopecia. He had been previously diagnosed with bilateral alopecia areata and treated for approximately 18 months with topical clobetasol and intralesional triamcinolone, without significant improvement. Hair transplantation had been deferred due to the assumption of active alopecia areata, considered a relative contraindication for surgical intervention. Clinical examination revealed AGA (grade III) associated with two well-defined, non-progressive alopecic patches in the bilateral temporal regions. The lesions were reportedly present since childhood, although this historical detail had not been previously integrated into the diagnostic reasoning. Trichoscopic evaluation demonstrated preserved follicular openings with predominance of vellus hairs, arranged in a characteristic carpet-like pattern raising strong suspicion of temporal triangular alopecia. This hypothesis was subsequently confirmed by a 4-mm punch biopsy with horizontal sectioning, which revealed normal follicular density with marked follicular miniaturization, absence of inflammation, and no evidence of fibrosis.

Conclusion

This case illustrates a clinically significant diagnostic pitfall in which temporal triangular alopecia was misinterpreted as alopecia areata, resulting in unnecessary and ineffective treatment and delayed eligibility for hair transplantation. Recognition of key features such as lifelong stability, typical localization, and characteristic trichoscopic findings is essential for accurate diagnosis. While trichoscopy alone may strongly suggest the diagnosis in most cases, histopathology confirmation remains valuable in uncertain cases. Early identification of TTA prevents inappropriate therapies and allows appropriate surgical planning when indicated.

EA DV CONGRESS
VIENNA
30 SEP - 3 OCT 2026

Abstract N°: 2012

Folliculitis decalvans: challenges in the differential diagnosis of scarring alopecia

Bianca Ignatescu*[1], Daciana Elena Branisteanu[1]

[1] Clinical Railway Hospital Iasi, Iasi, Romania

Introduction

Folliculitis decalvans is a chronic neutrophilic cicatricial alopecia characterized by recurrent follicular pustules, tufted hair (polytrichia), and progressive scarring. Due to its overlapping clinical features with infectious, inflammatory, and other forms of cicatricial alopecia, diagnosis remains challenging and is often delayed.

Case Presentation

We report the case of a 51-year-old male with moderate intellectual disability, presenting with a 7-year history of persistent scalp lesions. Clinical examination revealed papulo-pustular lesions on an erythematous background, follicular pustules, and characteristic tufting (multiple hair shafts emerging from a single follicular opening), associated with a cicatricial alopecic plaque on the vertex. The patient reported pain and pruritus.

The disease had a chronic relapsing course, with periods of partial remission but no complete resolution, despite multiple prior treatments including antifungal and antibacterial therapies, prescribed under different suspected diagnoses such as kerion celsi, bacterial folliculitis, and cicatricial alopecia of unclear etiology.
Given the clinical presentation, several differential diagnoses were considered. Kerion celsi was initially suspected due to the inflammatory aspect; however, the long-standing evolution, lack of response to antifungal therapy, and absence of typical boggy plaques or lymphadenopathy argued against dermatophytic infection. Dissecting cellulitis of the scalp was excluded based on the absence of nodules, sinus tracts, and purulent drainage. Acne keloidalis nuchae was ruled out due to lesion localization outside the occipital region and lack of keloidal papules.

Other primary cicatricial alopecias were also evaluated. Lichen planopilaris was considered unlikely due to the absence of perifollicular scaling and violaceous erythema, along with the predominance of pustular lesions. Discoid lupus erythematosus was excluded based on the absence of atrophy, dyspigmentation, follicular plugging, and systemic features. Central centrifugal cicatricial alopecia was considered less likely given the clinical context and the prominent pustular inflammatory component.

The presence of follicular pustules, chronic relapsing course, and especially tufting strongly suggested a neutrophilic cicatricial alopecia, with folliculitis decalvans as the leading diagnosis. A scalp biopsy from the vertex revealed a neutrophilic infiltrate targeting hair follicles, supporting the diagnosis.

The patient received multiple treatments over the years, including systemic isotretinoin and systemic and topical antibiotics, with a fluctuating course marked by partial improvement and recurrent relapses.

Conclusion

This case highlights the diagnostic complexity of chronic inflammatory scalp disorders and emphasizes the importance of a structured differential diagnosis in cicatricial alopecia. Clinical features such as follicular pustules, tufting, and a chronic relapsing course are key elements in distinguishing folliculitis decalvans from infectious conditions and other forms of scarring alopecia. Early recognition is essential to prevent irreversible hair loss.

EADV Congress 2026, VIENNA
30 SEPTEMBER - 03 OCTOBER 2026
POWERED BY M-ANAGE.COM

EADV CONGRESS
VIENNA
30 SEP - 3 OCT 2026

Abstract N°: 2028

Dermoscopy as a Quick Clinical Tool for the Assessment of Monilethrix

Nouf Mohammed Aleid*[1]

[1] Prince Sultan Military Medical City, Riyadh, Saudi Arabia

Introduction

Hair shaft disorders are structural abnormalities of the hair, either genetic or acquired, categorized by increased fragility (leading to breakage) or structural changes without breakage. Common types include Trichorrhexis nodosa (breaking/splitting), Monilethrix (beaded hair), and Pili torti (twisted hair). They are diagnosed via trichoscopy. We report a case of monilthrix diagnosed by dermoscopy in a young female.

Case Presentation

A 30-year-old medically free female presented with a lifelong history of hair fragility and poor hair growth since infancy. Her hair remained short, thin, and unable to reach significant length due to frequent breakage. Family history was notable for similar findings in three siblings, and she was born to consanguineous parents. On examination, the hair appeared sparse, short, rough, and dull. Multiple tiny violaceous follicular papules were observed over the occipital scalp and nape of the neck, with no associated nail or dental abnormalities. Dermoscopic evaluation using a handheld ×10 contact dermoscope (FotoFinder) revealed characteristic beaded hair shafts with alternating normal nodes and constricted internodes. Perifollicular hyperkeratosis was also noted in the affected areas. These findings confirmed the diagnosis of monilethrix.

Conclusion

Monilethrix is a rare inherited hair shaft disorder characterized by beaded hair with alternating nodes and constricted internodes, leading to fragility and patchy hair loss. It typically appears in infancy with short, brittle scalp hair and is most often caused by autosomal dominant mutations in keratin genes (KRT81, KRT83, KRT86), with rare autosomal recessive forms linked to DSG4. Diagnosis is mainly clinical and supported by dermoscopy or microscopy showing the characteristic beaded pattern. Dermoscopy (trichoscopy) is a quick, noninvasive tool that also helps differentiate it from other hair shaft disorders.

EADV CONGRESS
VIENNA
30 SEP - 3 OCT 2026

Abstract N°: 2065

Trichoscopic characteristics of discoid lupus erythematosus alopecia: a systematic review and meta-analysis

Gianna Carolinne Graff Caletti*[1], Maria Antônia Costa Cruz Akabane[2], Natã Alegransi Ribeiro[1], Sara Filippini[3], Ana Clara Felix de Farias Santos[4], Amanda Tauana Oliveira e Silva[5]

[1] University of Passo Fundo, Passo Fundo, Brazil
[2] Federal University of Juiz de Fora, Juiz de Fora, Brazil
[3] University of Bologna, Bologna, Italy
[4] City University of São Paulo, São Paulo, Brazil
[5] Federal University of Piauí, Teresina, Brazil

Introduction

Discoid lupus erythematosus (DLE) is a primary scarring alopecia that leads to irreversible hair loss, requiring prompt identification and treatment. Trichoscopy is an accessible and non-invasive diagnostic tool, but evidence on characteristic patterns associated with DLE is limited. Therefore, we aimed to perform a systematic review and meta-analysis to evaluate trichoscopic features of DLE alopecia and compare them with those of other types of scarring alopecia.

Materials and Methods

We conducted a systematic review and meta-analysis by searching PubMed, Embase, Cochrane Central and Web of Science for studies evaluating trichoscopic findings in patients with DLE scalp lesions. We used R software, version 4.4.2, for all statistical analyses. Heterogeneity was evaluated through I^2 statistics.

Results

We included 23 studies, comprising 1,733 patients with alopecia, of whom 301 (17,39%) had DLE scalp involvement. The most prevalent trichoscopic findings in patients with DLE alopecia were absent follicular openings (91.35%; 95% CI 72.20, 97.72; I^2 = 4.6%), structureless white areas (72.41%; 95% CI 54.08, 90.73; I^2 = 96.5%), follicular keratotic plugs (62.79%; 95% CI 50.00, 75.58; I^2 = 90.2%) and arborizing vessels (53.17%; 95% CI 38.46, 67.87; I^2 = 91.2%). DLE alopecia was significantly more likely to present follicular keratotic plugs compared with lichen planopilaris (LP) (OR 12.75; 95% CI 5.23, 31.10; P < 0.001; I^2 = 0%; Figure 1.a), frontal fibrosing alopecia (FFA) (OR 10.40; 95% CI 2.15, 50.39; P = 0.004; I^2 = 0%; Figure 1.b), dissecting cellulitis (DC) (OR 15.54; 95% CI 2.56, 94.22; P = 0.003; I^2 = 18.3%) and folliculitis decalvans (FD) (OR 6.48; 95% CI 1.46, 28.71; P = 0.014; I^2 = 37.9%). DLE also presented higher odds of arborizing vessels than LP (OR 5.90; 95% CI 1.81, 19.25; P = 0.003; I^2 = 61.2%; Figure 1.a), FFA (OR 6.09; 95% CI 1.57, 23.53; P = 0.009; I^2 = 41%; Figure 1.b) and DC (OR 11.08; 95% CI 2.21, 55.61; P = 0.003; I^2 = 27.2%). Other features more strongly associated with DLE compared to LP include yellow dots (OR 7.29; 95% CI 2.17, 24.52; P = 0.001; I^2 = 3.5%) and red dots (OR 2.77; 95% CI 1.09, 7.00; P = 0.032; I^2 = 0%).

Fig1.a: Forest plot comparing the association of follicular keratotic plugs and arborizing vessels between discoid lupus erythematosus (DLE) and lichen planopilaris (LP)

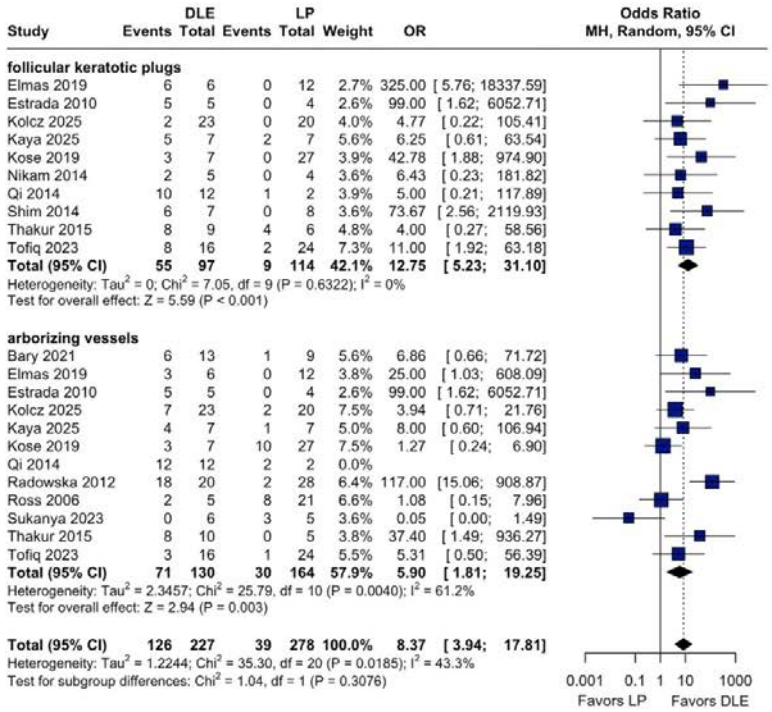

Fig1.b: Forest plot comparing the association of follicular keratotic plugs and arborizing vessels between discoid lupus erythematosus (DLE) and frontal fibrosing alopecia (FFA)

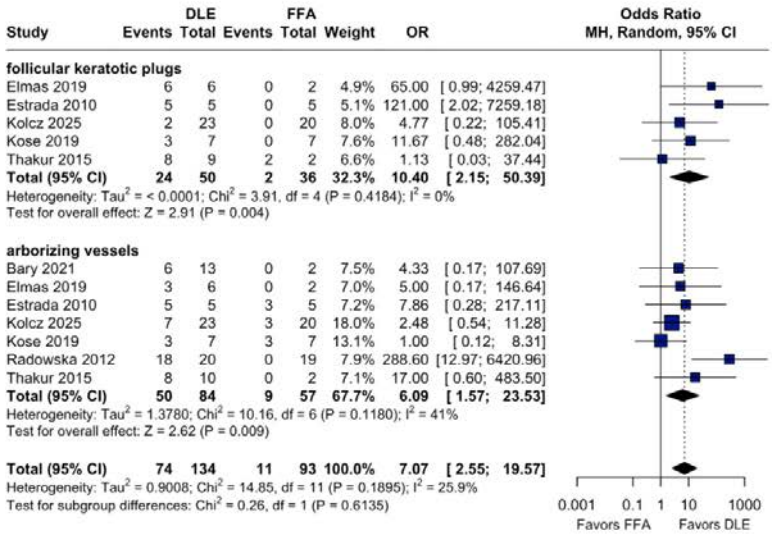

Fig1.a: Forest plot comparing the association of follicular keratotic plugs and arborizing vessels between discoid lupus erythematosus (DLE) and lichen planopilaris (LP). Fig1.b: Forest plot comparing the association of follicular keratotic plugs and arborizing vessels between discoid lupus erythematosus (DLE) and frontal fibrosing alopecia (FFA).

Conclusions

The most prevalent trichoscopic findings in DLE alopecia include absent follicular openings, structureless white areas, follicular keratotic plugs and arborizing vessels. Among these, follicular keratotic plugs and arborizing vessels showed a stronger association with DLE than with other scarring alopecias. Yellow and red dots were also

more likely to be observed in DLE than in LP.

EADV CONGRESS
VIENNA
30 SEP - 3 OCT 2026

Abstract N°: 2076

Occipital involvement in frontal fibrosing alopecia: clinical features and association with increased disease severity

Chourouq Mustapha Eid*[1], Fatima Zahra Sassine[1], Fatima Zahra Hammoud[1], Laila Benzekri[1], Mariame Meziane[1]

[1] Centre Hospitalier Ibn Sina, Dermatology Department, Rabat, Morocco

Introduction
Frontal fibrosing alopecia is a primary lymphocytic cicatricial alopecia typically affecting the frontotemporal hairline. Occipital involvement remains insufficiently characterized, with limited data available in the literature. This study aimed to describe the clinical and trichoscopic characteristics of occipital involvement in frontal fibrosing alopecia and to assess its association with disease severity and progression.

Materials and Methods
We conducted a retrospective study including patients diagnosed with frontal fibrosing alopecia according to International Frontal Fibrosing Alopecia Cooperative Group criteria between September 2023 and October 2025. Among 110 patients, 17 presented with occipital involvement. Occipital recession was measured as the distance between the occipital hairline and the cervical vertebral prominence (C7). Comparative analysis was performed between patients with occipital involvement and those with isolated frontal disease. Longitudinal assessment included patients with at least 12 months of follow-up.

Results
Occipital involvement was identified in 17 patients (15.45%), most commonly associated with frontotemporal involvement (16/17), while isolated occipital disease was rare (1/17). The median age was 52 years (range: 14–70 years), including one adolescent patient aged 14 years.

Among the 12 patients with ≥12 months follow-up, progressive occipital recession was observed, with a mean increase of 0.32 cm ($p = 0.065$). Comparative analysis including 40 patients demonstrated significantly greater hairline recession in patients with occipital involvement compared with those with frontal-only disease (5.67 ± 3.24 cm vs 2.75 ± 1.54 cm; $p = 0.001$). This finding supports an association between occipital involvement and increased disease severity and progression.

Conclusions
Occipital involvement in frontal fibrosing alopecia is not rare and appears associated with greater disease severity and progression. Systematic examination of the occipital scalp should be performed routinely to improve early detection and optimize clinical management.

EA DV CONGRESS
VIENNA
30 SEP - 3 OCT 2026

Abstract N°: 2079

Quality of life in hair disorders: a prospective study using a validated dermatology-specific questionnaire

Chourouq Mustapha Eid*[1], Fatima Zahra Sassine[1], Fatima Zahra Hammoud[1], Najoua Ammar[1], Syrine hamada[1], Nadia Ismaili[1], Laila Benzekri[1], Mariame Meziane[1]

[1] Centre Hospitalier Ibn Sina, Dermatology Department, Rabat, Morocco

Introduction
Hair disorders are common and often considered benign conditions; however, they encompass a wide range of diseases that can profoundly affect patients' quality of life. This study aimed to evaluate the impact of hair disorders on patients by assessing their emotional burden, the severity of physical symptoms, and their influence on daily activities. A secondary objective was to compare the findings with previously published data and to assess changes in quality-of-life impairment after six months of treatment.

Materials and Methods
A prospective observational analytical cross-sectional study was conducted over a 10-month period (October 2023 to July 2024). Adult patients presenting with hair disorders were invited to complete a validated dialectal Arabic version of the Dermatology Life Quality Index (DLQI), designed to assess the impact of dermatological conditions on quality of life.

Pregnant or breastfeeding women, patients undergoing chemotherapy, and those with known psychiatric disorders were excluded. Epidemiological parameters analyzed included age, sex, marital status, educational level, disease duration, and consultation delay. These variables were selected to allow comparison with previously published studies.

Results
A total of 318 patients were included (median age: 43 years; range: 18–85 years), with a marked female predominance (81.8%). More than half of the participants were married (52.5%). The median delay before the first consultation was 24 months, and only 12.9% of patients sought medical attention within the first 6 months.

Frontal fibrosing alopecia was the most frequent diagnosis, followed by androgenetic alopecia and alopecia areata. The highest DLQI scores were observed in patients with folliculitis decalvans, whereas the lowest scores were recorded in patients with benign scalp tumors.

The mean DLQI score was 9.54, indicating a moderate impact on quality of life. A severe impact on quality of life was observed in 36.5% of patients. Among DLQI domains, aesthetic concern was identified as the most impactful factor.

Significant associations were identified between higher DLQI scores and age under 30 years ($p = 0.04$), rural residence ($p = 0.04$), and single marital status ($p < 0.001$). Lower DLQI scores were observed in patients who sought consultation within the first 6 months ($p < 0.01$). No statistically significant associations were found with sex, disease duration, or educational level.

After 6 months of treatment, a significant improvement in mean DLQI score was observed ($p < 0.001$), with comparable benefits noted across frontal fibrosing alopecia, androgenetic alopecia, and alopecia areata.

Conclusions

This study is among the first to evaluate the Dermatology Life Quality Index (DLQI) across a wide spectrum of hair disorders and to include a 6-month follow-up after treatment. It highlights a substantial impact on quality of life, affecting 87.2% of patients, particularly among younger individuals, single patients, those living in rural areas, and patients with folliculitis decalvans.

The DLQI proved to be a valuable tool for identifying the most affected patients. Beyond medical treatment, psychological or psychiatric support may be beneficial in improving overall patient care.

EA DV CONGRESS
VIENNA
30 SEP - 3 OCT 2026

Abstract N°: 2087

Serum Vitamin D Levels in Patients with Lichen Planopilaris Before and After Systemic Treatment with Hydroxychloroquine or Pioglitazone

Sanja Momčilović*[1, 2], Snežana Minić[1, 3], Nataša Maksimović[4], Dubravka Živanović[1, 3], Danilo Mićanović[1], Tijana Orlić[1], Olivera Drulović[1], Igor Kapetanović[1]

[1] Clinic of Dermatovenereology, University Clinical Center of Serbia, Belgrade, Serbia

[2] Group for Neuroendocrinology, Institute for Medical Research, National Institute of the Republic of Serbia, University of Belgrade, Belgrade, Serbia

[3] Faculty of Medicine, University of Belgrade, Belgrade, Serbia

[4] Institute of Epidemiology, Faculty of Medicine, University of Belgrade, Belgrade, Serbia

Introduction

Lichen planopilaris (LPP) is a chronic inflammatory cicatricial alopecia characterized by immune-mediated destruction of hair follicles. LPP is considered a T-cell–mediated autoimmune disorder, with a cytotoxic lymphocytic infiltrate targeting the follicular epithelium and leading to irreversible follicular damage and scarring. Vitamin D has been shown to have important immunomodulatory properties and has been implicated in various inflammatory and autoimmune dermatological diseases. In a small number of retrospective studies, scarring alopecias (only two specifically for LPP) have been linked to a higher likelihood of vitamin D deficiency. However, no data or prospective study are available regarding vitamin D status in patients with LPP and its changes during systemic treatment. Therefore, the aim of this study was to evaluate serum vitamin D levels in patients with LPP before initiation of systemic therapy and after six months of treatment, and to compare changes in vitamin D levels between patients treated with hydroxychloroquine (HCQ) and pioglitazone (PG).

Materials and Methods

This prospective study included 46 patients diagnosed with LPP. Patients were treated with either HCQ (dosage: 5 mg/kg) (n = 25) or PG (dosage: 15 mg daily) (n = 21). Patients on vitamin D supplementation were excluded. Serum 25-hydroxyvitamin D levels were measured at baseline and after six months of therapy. The cohorts were categorized into ‘‘sufficient" (>75 nmol/L), "insufficient" (50-75 nmol/L), ‘‘deficient’’ (25-50 nmol/L), and "severe deficiency" (<25 nmol/L) according to baseline serum 25-hydroxyvitamin D levels. Data were analyzed using repeated measures analysis of variance, with time as the within-subject factor and treatment group as the between-subject factor. Statistical significance was defined as $p < 0.05$.

Results

Mean age was 51.7 ± 15.4. Vitamin D deficiency was present in 86.9% of patients, with 15.2% having severe deficiency, 41.3% deficient and 30.4% insufficient at baseline. Mean baseline serum 25-hydroxyvitamin D levels were 44.4 and 51.4 nmol/L in the PG and HCQ cohort (overall: 48.2 nmol/L). Values after therapy were 56.6 and 63.2 nmol/L in the PG and HCQ cohort (overall: 60.1 nmol/L). A statistically significant increase in serum 25-hydroxyvitamin D levels was observed over time in the overall study population ($p = 0.001$). No statistically significant differences were found between treatment groups. Furthermore, the interaction between time and treatment group was not significant, indicating that changes in serum 25-hydroxyvitamin D levels over time were

comparable in patients treated with HCQ and those treated with PG.

Conclusions

Serum 25-hydroxyvitamin D levels significantly increased after six months of systemic treatment in patients with LPP, independent of the therapeutic agent used. The absence of significant differences between treatment groups suggests that changes in serum 25-hydroxyvitamin D levels are not drug-specific. These findings support the relevance of monitoring serum 25-hydroxyvitamin D levels in patients with LPP and highlight the need for further studies to clarify its role in disease mechanisms and treatment outcomes.

EADV CONGRESS
VIENNA
30 SEP - 3 OCT 2026

Abstract N°: 2102

A Novel Paronychia-like Mouse Model Induced by Epidermal Growth Factor Receptor-Tyrosine Kinase Inhibitor (EGFR-TKI)

Xuelin Wu*[1], Yanqing Chen[1], Jianjian Li[1], Tailong He[1], Mengwen He[1], Han Ma[1]

[1] Department of Dermatology, The Fifth Affiliated Hospital, Sun Yat-sen University, Zhuhai, China

Introduction

Anti-tumor drugs-associated paronychia, also known as periungual inflammation, is a common skin toxicity that severely impairs the patient's quality of life. It occurs in up to 58% patients using EGFR-TKIs. The precise mechanism remains unclear, and effective treatments are limited. Sometimes it may even be necessary to interrupt anti-tumor therapy. A major obstacle hindering research on paronychia is the lack of suitable animal models. Here, we established an appropriate paronychia-like mouse model induced by EGFR-TKIs to serve as an animal research tool for antitumor drug-related paronychia.

Materials and Methods

Female BALB/c mice in the model group received erlotinib solution (280 mg/kg; solvent: sterile distilled water) by oral gavage once daily for 26 days, while the control group received an equal volume of sterile distilled water. The clinical and histopathological characteristics of their forepaws were evaluated. Clinical signs involved four aspects: redness, edema, burning sensation, and pain. Specifically, the degree of periungual skin redness was measured with a spectrophotometer (Konica Minolta, CM-2600d, Japan); erythematous swelling of the forepaws was photographed with a handheld dermoscope (BEINING, BN-FDJ-I, China); skin temperature of the forepaws was measured with an infrared thermometer; and the pain threshold on the nail fold was assessed with the Von Frey test. The skin barrier function of forepaws was evaluated by measuring transepidermal water loss (TEWL) with the professional meter VAPOSCAN. The pathological results using HE staining of mouse forepaws were compared with those of the nail fold in patients with EGFR-TKI-induced paronychia. Furthermore, skin samples from the mouse forepaws were collected for RNA sequencing. The main differentially expressed genes and pathways were preliminarily validated in the mouse model and in patients using immunohistochemical staining. In addition, *in vitro* experiments were conducted with erlotinib to treat HaCaT cells, thereby further verifying the RNA-seq results.

Results

Clinical and histological analyses in paronychia-like mice confirmed hallmark features consistent with those observed in patients with EGFR-TKI-induced paronychia. Compared to mice in the control group, the paronychia-like mice exhibited a higher degree of redness ($P < 0.0001$), edema, skin temperature ($P = 0.0084$), and TEWL ($P < 0.0001$), as well as a lower pain threshold ($P < 0.0001$) in their forepaws. Histopathological changes included thinned stratum corneum, thickened stratum spinosum, extensive inflammatory cell infiltration in the dermis, and dilated small blood vessels in the dermis, indicating successful modeling. RNA-seq revealed that 196 genes were downregulated in the paronychia model group compared to the control group, primarily among extracellular matrix (ECM)-related genes, including collagen XVII (Col17A1), Col4a6, and Col4a5, while the IL-17 pathway was upregulated. Immunohistochemical results indicated that Col17A1 was downregulated in both the paronychia mouse model and patient specimens. An *in vitro* experiment showed that when HaCaT cells were exposed to erlotinib, there was a significant decrease in Col17A1 mRNA and protein expression, along with reductions in proteins related to the skin tight-junction barrier, indicating barrier disruption, accompanied by upregulation of the IL-17 pathway. Exogenous supplementation of Col17A1 could reverse these trends.

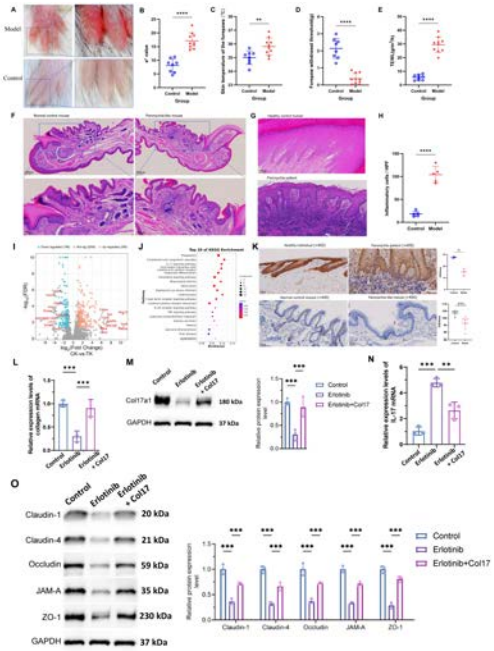

Fig. Establishment of a paronychia-like mouse model induced by Erlotinib. (A) Comparison of clinical findings of nail fold in forepaws in the control mouse and the model mouse treated with Erlotinib. The low-magnification images are at 20×, and the localized magnified images are at 50×. (B) Measurement of skin redness of forepaws in the two groups using a spectrophotometer. The larger the a* value, the more obvious the erythema. (C) Measurement of local skin temperature of forepaws in the control and model mice. (D) Forepaw-withdrawal threshold, as measured by the Von Frey test. (E) Assessment of skin barrier function in the forepaws with the transepidermal water loss (TEWL) indicator. (F) Representative H&E-stained skin sections from the forepaws of the control mouse and model mouse (low magnification ×100, high magnification ×200). (G) Histopathological H&E-stained skin sections of the lateral nail fold from a healthy individual and a patient with paronychia caused by the EGFR inhibitor (original magnification ×200). (H) Quantification of inflammatory cells per high-power field (HPF) from histopathological images in animal groups. (I) Volcano plots comparing gene expression on forepaws in control mice and paronychia-like mice. (J) KEGG pathway enrichment analysis of upregulated genes, showing involvement in IL-17 signaling and immune pathways. (K) Immunohistochemical staining results of COL17A1 in normal nail fold tissue and paronychia lesion from clinic patients and the mouse model. The integrated option density (IOD) value / the area of the target protein distribution region (Area) = the average option density (AOD) value. For the in vitro experiments, expression levels of COL17A1 mRNA (L) and protein (M), IL-17 mRNA (N), as well as the expression of tight-junction barrier-related proteins (O) in HaCaT cells subjected to different treatments. (Control group: HaCaT cells treated with 0.4% DMSO solvent without erlotinib for 4 hours; Erlotinib group: HaCaT cells treated with erlotinib at a concentration of 1000 nM for 4 hours; Erlotinib + Collagen XVII Group: After treating HaCaT cells with erlotinib at a concentration of 1000 nM for 4 hours, 2 mg/ml collagen XVII was added and incubated for 48 hours.) Animal number: N = 8 in the control group and N = 10 in the model group. Results are representative of three independent experiments. Statistical significance: ** $P < 0.01$, *** $P < 0.001$, **** $P < 0.0001$. A Student's t-test or one-way ANOVA with a Tukey post hoc test was used.

Conclusions

A novel EGFR-TKI-induced paronychia-like mouse model is successfully established. It provides a new platform for dissecting pathogenic mechanisms and exploring strategies for managing adverse events. Extracellular matrix-related genes may be involved in the development of EGFR-TKI-associated paronychia.

EA DV CONGRESS
VIENNA
30 SEP - 3 OCT 2026

Abstract N°: 2112

Upadacitinib Outperforms Other JAK Inhibitors as First-Line and Switch Therapy in Alopecia Areata: A Multicenter Real-World Study

Ömer Karakoyun*[1], Kadir Kaya[2], Bahadır Aslancan[3], İsa An[3], Erhan Ayhan[4]

[1] TC Sağlık Bakanlığı Sbü Diyarbakır Gazi Yaşargil Eğitim Ve Araştırma Hastanesi, Diyarbakır, Türkiye

[2] Istinye University Çekmeköy Campus, Çekmeköy, Türkiye

[3] Şanlıurfa Eyubiye Eğitim ve Araştırma Hastanesi, Şanlıurfa, Türkiye

[4] Dicle University, Sur, Türkiye

Introduction

Alopecia areata(AA) is a chronic immune-mediated disorder affecting ~2% of the global population.JAK inhibitors have transformed management of severe AA since baricitinib's approval in 2022, yet head-to-head real-world comparisons remain lacking, predictors of response are poorly defined across agents, and optimal switching strategies after first JAK inhibitor failure are unknown.We conducted a three-centre retrospective study of 139 patients to compare upadacitinib, baricitinib, and tofacitinib, identify predictors of response, and evaluate sequential JAK inhibitor outcomes.

Materials and Methods

Retrospective multicenter cohort study at three tertiary dermatology centres in Turkey(January 2020–December 2024).Patients aged ≥12 years with severe AA(SALT ≥50) receiving upadacitinib, baricitinib, or tofacitinib were included;those with follow-up <3 months or incomplete data were excluded.Primary outcome was SALT50; secondary outcomes included SALT75, SALT90, and SALT≤20 at 3, 6, 9, and 12 months. Patients receiving ≥2 JAK inhibitors were classified as the switch group.Predictors of response were identified by univariable logistic regression($p<0.05$).Study design is summarised in Figure 1.

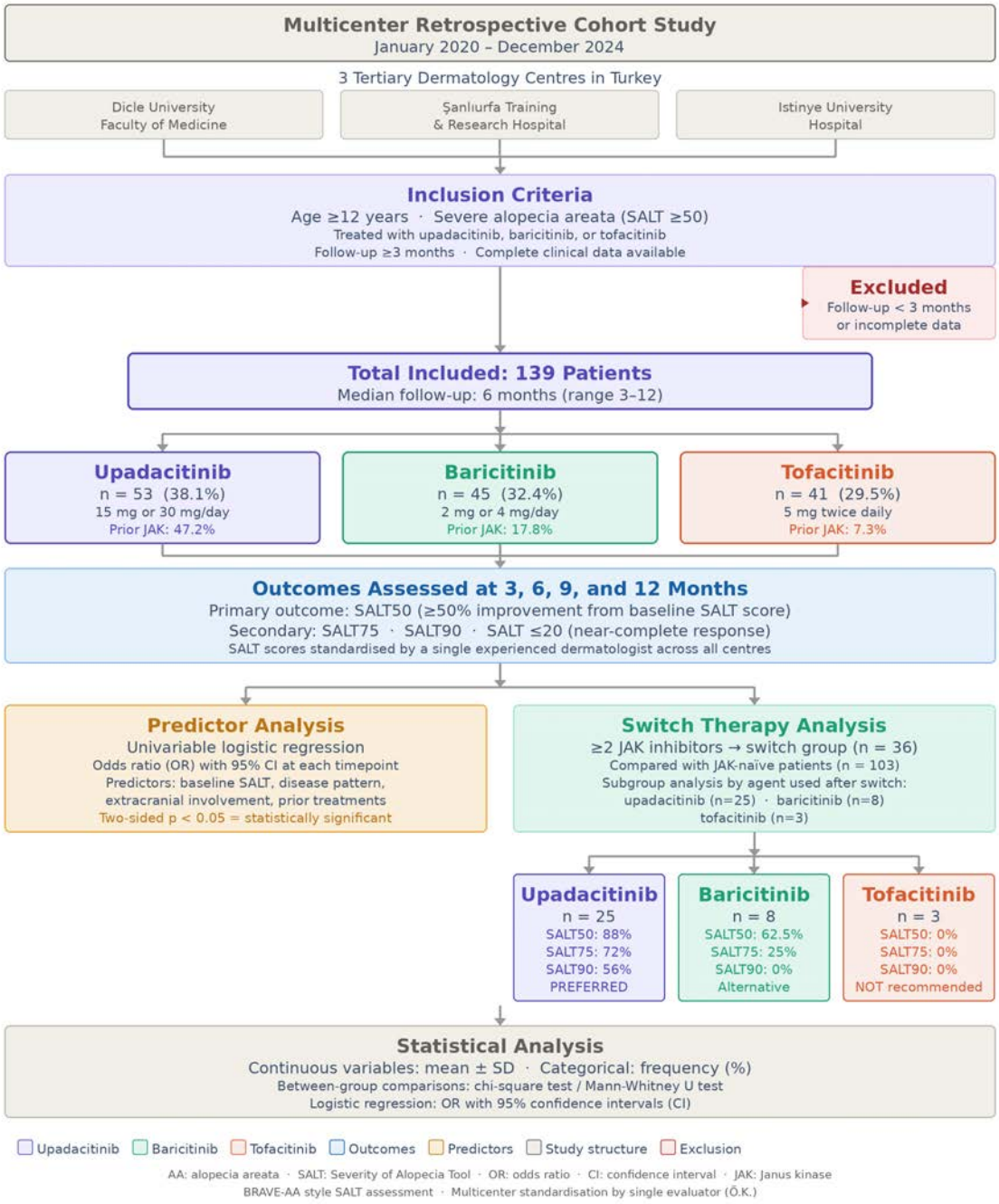

Results

A total of 139 patients were included:upadacitinib(n=53, 38.1%), baricitinib(n=45, 32.4%), and tofacitinib(n=41, 29.5%); median follow-up was 6 months(range 3–12).Tofacitinib-treated patients had significantly higher baseline SALT scores(94.4 vs 83.7 vs 72.3, p<0.001), more extensive disease(87.8% vs 71.1% vs 58.5%, p=0.008) and greater extracranial involvement including eyebrow,eyelash,body hair and nail changes.Prior JAK inhibitor exposure was more prevalent in the upadacitinib group(47.2%).

Upadacitinib demonstrated superior efficacy across all endpoints:SALT50 90.6% vs 60.0% vs 58.5%; SALT75 75.5% vs 37.8% vs 43.9%; SALT90 43.4% vs 17.8% vs 29.3%; SALT≤20 77.4% vs 40.0% vs 53.7%.Mean SALT improvement was greatest with upadacitinib(−56.5 vs −42.9 vs −49.6).Onset was significantly faster at 3 months(SALT50: 80% vs 29% vs 10%, p=0.003; SALT75: 70% vs 14% vs 10%, p=0.004).At 9 months, SALT90 remained highest with upadacitinib(64.3% vs 10.0% vs 30.0%, p=0.021).Monthly comparisons across all thresholds are shown in Figure 2.

Significant negative predictors of SALT50 included high baseline SALT score(p=0.001),extensive disease(OR=0.26, p=0.007),ophiasis pattern(OR=0.31, p=0.009) and eyelash,nail,body hair involvement.Prior systemic corticosteroid use was the only positive predictor across all thresholds(SALT50: OR=7.71,p<0.001; SALT75: OR=4.26,p<0.001;

SALT90: OR=3.12,p=0.012).Age, sex, BMI, and prior JAK use were not significant. Predictor effects are summarised in Figure 3.

Prior JAK exposure did not reduce subsequent efficacy(SALT50: 75.0% vs 69.9%, p=0.671).Post-switch SALT50 was highest with upadacitinib (88%),moderate with baricitinib (62.5%) and zero with tofacitinib (0%).Switch outcomes are illustrated in Figure 4.

No serious adverse events occurred.Acne was the most common event(22–36%);no VTE, malignancy, herpes zoster or opportunistic infections were reported.

Figure 2. Monthly SALT Response Rates: Upadacitinib vs Baricitinib vs Tofacitinib

SALT50, SALT75, and SALT90 response rates at 3, 6, 9, and 12 months

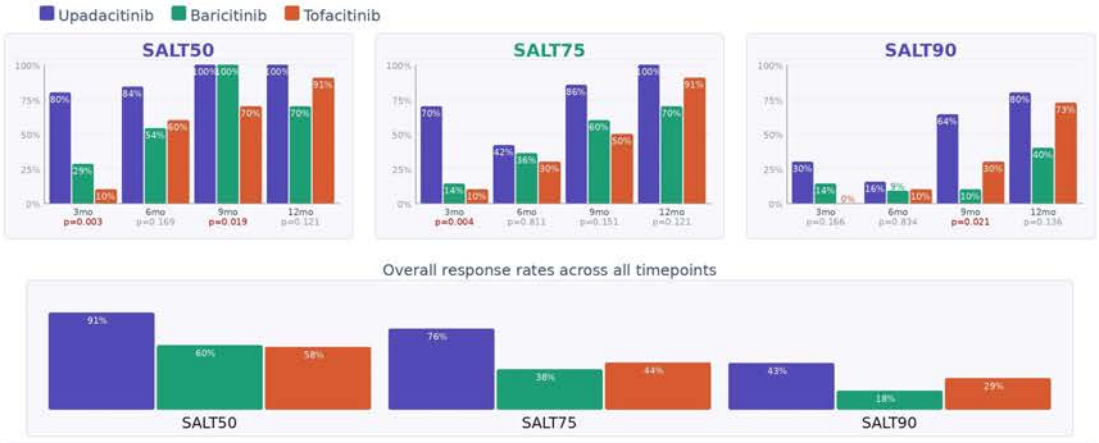

SALT≤20 (near-complete response): Upadacitinib 77.4% · Tofacitinib 53.7% · Baricitinib 40.0% | Mean ΔSALT: Upadacitinib −56.5 · Tofacitinib −49.6 · Baricitinib −42.9

SALT: Severity of Alopecia Tool. p values from chi-square test. Red p = statistically significant (p<0.05).

Figure 3. Predictors of JAK Inhibitor Response in Alopecia Areata

Odds ratios (OR) with p values for SALT50, SALT75, and SALT90 — univariable logistic regression

Predictor	SALT50 OR (p)	SALT75 OR (p)	SALT90 OR (p)
Positive predictor			
Prior systemic corticosteroids	7.71 p<0.001	4.26 p<0.001	3.12 p=0.012
Negative predictors			
High baseline SALT score	0.26 p=0.001	0.38 p=0.017	0.55 p=0.071
Extensive disease	0.26 p=0.007	0.53 p=0.132	0.77 p=0.546
Ophiasis pattern	0.31 p=0.009	0.39 p=0.035	0.69 p=0.501
Eyelash involvement	0.28 p=0.025	0.52 p=0.157	0.83 p=0.668
Nail involvement	0.39 p=0.024	0.69 p=0.358	0.61 p=0.318
Body hair involvement	0.43 p=0.039	0.64 p=0.235	0.7 p=0.363
Genetic trigger	0.3 p=0.036	0.72 p=0.592	1.13 p=0.777
Non-significant predictors			
Prior JAK inhibitor	1.29 p=0.671	1.09 p=0.848	1.62 p=0.295
Family history	0.4 p=0.050	0.83 p=0.822	0.7 p=0.629
Atopy / Autoimmune disease	0.8 p=0.664	0.81 p=0.693	1.3 p=0.529
Smoking status	1.43 p=0.447	1.31 p=0.491	0.69 p=0.356

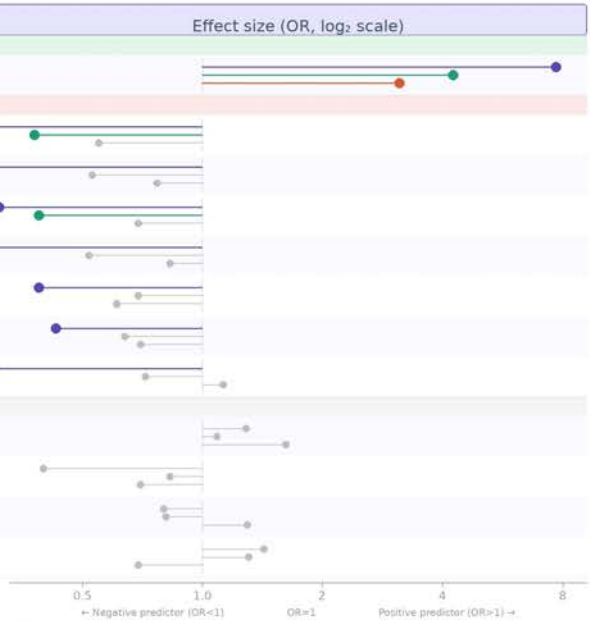

OR: odds ratio. Significant = p<0.05 (two-sided). Log₂ scale used for forest plot display.

Figure 4. Sequential JAK Inhibitor Therapy: Switch vs JAK-Naive Patients

Overall outcomes (n=139) and post-switch response by agent used after switching (n=36)



Upadacitinib post-switch	Baricitinib post-switch	Tofacitinib post-switch	Prior JAK exposure
88% SALT50 72% SALT75 56% SALT90	62.5% SALT50 25% SALT75 0% SALT90	0% SALT50 0% SALT75 0% SALT90	SALT50: p=0.671 SALT75: p=0.848 SALT90: p=0.295
PREFERRED	Alternative	NOT recommended	Does NOT reduce efficacy

OR: odds ratio. p values from chi-square test. JAK: Janus kinase inhibitor.

Conclusions

This multicenter real-world study demonstrates that upadacitinib provides the fastest onset and highest overall efficacy among JAK inhibitors in severe alopecia areata,achieving SALT50 in 90.6% of patients — significantly superior to baricitinib and tofacitinib at every timepoint.Critically, prior JAK inhibitor exposure does not impair subsequent response, validating sequential therapy as a viable and effective strategy.Among switch agents, upadacitinib is the clear preferred choice, while tofacitinib showed 0% response and should be avoided in this setting.Disease severity markers — ophiasis, nail involvement and high baseline SALT — predict poorer outcomes, whereas prior systemic corticosteroid use strongly predicts response.These findings provide actionable, evidence-based guidance: treat early, switch to upadacitinib on failure, and maintain therapy for at least 9–12 months before concluding non-response.

EA DV CONGRESS
VIENNA
30 SEP - 3 OCT 2026

Abstract N°: 2112

Subungual osteochondroma of the big toe

Salma Kozmane*[1], Zakia Douhi[1], IKRAME BEJJA[1], Saadia Boughaleb[1], Meryem Soughi[1], Sara Elloudi[1], Hanane Baybay[1], Fatima Zohra Mernissi[1]

[1] Department of Dermatology, University Hospital Hassan II, Faculty of Medicine, Pharmacy and Dental Medicine, Sidi Mohamed Ben Abdellah University, fez, Morocco

Introduction

Subungual osteochondroma is a rare benign bony tumor that typically affects the phalanges of the fingers or toes, most frequently the distal phalanx of the hallux. The appearance as ulcerative tumors is uncommon and can mimic other benign or malignant conditions, such as squamous cell carcinoma (SCC) and achromic melanoma (AM). We present a case that highlights an unusual presentation.

Case Presentation

A 15-year-old female presented with a mass of the right great toe beneath the nail, evolving for seven months. The mass was slowly progressive in size, to the extent that it had lifted the nail plate, causing anonychia and pain. Clinical examination found an erythematous ulcerating tumor measuring 30 mm in size, situated beneath the nail. The mass was nontender, firm in consistency, and ulcerated with no restriction of movements of proximal and distal interphalangeal joints. Dermoscopy shows an erythematous background with irregular linear vessels and crusts. Pyogenic granuloma, osteochondroma, SCC, and AM were considered. X-ray of the foot revealed a bony growth on the dorsal aspect of the distal phalanx of the big toe. An excisional biopsy was performed, confirming the diagnosis of osteochondroma. Then the tumor was excised under digital block using a ring tourniquet, and a hydrocolloid dressing was applied. The patient was closely monitored for her care. She received light-emitting diode (LED) therapy sessions to optimize healing. The patient was evaluated at one month, the clinical examination showed complete regression of the tumor.

Conclusion

Subungual osteochondroma is a rare benign osteocartilaginous tumor usually affecting the distal phalanx of the great toe. Clinically, it appears as a firm, small, pink colored nodule or tumor projecting beneath or beyond the nail plate. It may be painful and cause nail deformation, onycholysis, or anonychia, as we see in our case. The exact etiology remains unclear, although heredity, long-term infection, chronic irritation, and trauma have been suggested. Diagnosis is based on clinical, radiological, and histopathological findings. Radiography typically shows a sessile or pedunculated bony outgrowth continuous with the cortex and medullary cavity of the distal phalanx. Histologically, the osteochondroma is made up of hyaline cartilage with cells arranged similarly to a normal growing epiphysis. Our patient was young and presented with an ulcerated, budding tumor with anonychia, an unusual form of ostecochondroma, that can be confused with a pyogenic granuloma. It presents as a rapidly growing friable papule that bleeds easily, with dermoscopic features including homogeneous reddish areas, white collarette, and ulceration. It is important to rule out SCC and AM, although the patient’s age was not suggestive of these diagnoses. Indeed, SCC occurs frequently in men after the fifth decade of life. It is painful, bleeding, and causes nail plate dyschromia, nail deformity, and ulceration. In dermoscopy, keratin accumulations, scaling, blood spots, white circles, and perivascular white halos are found, but are not pathognomonic. As for AM, it can also

mimic subungual osteochondroma, but it manifests as a rapidly growing, ulcerated nodule. Dermoscopy of AM is nonspecific, showing diffuse milky-red areas, atypical vessels, and ulceration. Surgical excision is the gold standard for treating osteochondroma. Excision usually involves the use of digital block anesthesia. A recurrence rate of 5–11% may result from incomplete surgical excision. However, no cases of malignant change have been reported. Subungual osteochondroma should remain an important consideration when assessing slowly progressive ulcerated nail-unit masses in adolescents. This case underscores the importance of integrating clinical, dermoscopic, and radiologic evaluations to refine the differential diagnosis and guide appropriate management.

EA DV CONGRESS
VIENNA
30 SEP - 3 OCT 2026

Abstract N°: 2122

Artificial intelligence in trichoscopy: a systematic review of diagnostic accuracy and clinical applications in hair and scalp disorders

Letícia Mendes Gomes de Matos Lima*[1]

[1] ESF VILA SANTA MARIA I, Araripina - PE, Brazil

Introduction
Trichoscopy is a non-invasive dermoscopic technique widely used for the evaluation of hair and scalp disorders. Despite its diagnostic value, its interpretation remains largely subjective and highly dependent on the examiner's expertise and training level. Interobserver variability and the steep learning curve associated with trichoscopic pattern recognition represent relevant limitations in clinical practice. In recent years, artificial intelligence (AI) has emerged as a promising tool to support automated image analysis and overcome these barriers in dermatology.

Materials and Methods
A systematic search was conducted in PubMed, Scopus, and Web of Science databases, covering publications from January 2018 to April 2026. Search terms combined "artificial intelligence", "deep learning", "machine learning", and "neural network" with "trichoscopy", "hair dermoscopy", and "scalp dermoscopy". Studies were included if they reported the use of AI algorithms applied to trichoscopic images for diagnosis, staging, or treatment monitoring of hair or scalp conditions. Case reports, conference abstracts without full data, and studies based exclusively on clinical (non-trichoscopic) photographs were excluded.

Results
Fourteen studies met the inclusion criteria. The most frequently studied conditions were androgenetic alopecia (AGA) and alopecia areata (AA). Convolutional neural networks (CNNs) were the predominant AI architecture employed. For AGA, deep learning models demonstrated the ability to automatically quantify hair density, shaft diameter, and follicular unit distribution, enabling objective staging and treatment response monitoring. For AA, AI frameworks showed high accuracy in distinguishing active from inactive disease based on trichoscopic pattern recognition. One study evaluated AI performance in differentiating scarring from non-scarring alopecias. Reported diagnostic accuracy ranged from 80% to 97% across studies, though direct comparison was limited by methodological heterogeneity and variability in dataset size and image acquisition protocols. Notably, most datasets were derived from single institutions, raising questions about generalizability.

Conclusions
Current evidence supports the potential of AI as a complementary tool in trichoscopic analysis, particularly for standardizing diagnostic criteria, reducing interobserver variability, and enabling objective longitudinal monitoring. Existing models show promising accuracy for AGA and AA. However, the field still lacks large multicentric validation studies and standardized image acquisition protocols. Future research should focus on developing generalizable, externally validated models applicable across diverse patient populations and clinical settings, including phototypes underrepresented in current datasets.

EA DV CONGRESS
VIENNA
30 SEP - 3 OCT 2026

Abstract N°: 2124

The Trichoceutical Paradox: a Systematic Review of Oral Nutraceuticals in Alopecia

Christine Rachelle Prescendo Chaves*[1], Michele Kreuz[2], Nicolle Gollo Mazzotti[1]

[1] Federal University of Rio Grande do Sul, Porto Alegre, Brazil

[2] Lutheran University of Brazil, Canoas, Brazil

Introduction

Oral nutraceuticals are increasingly used in patients with alopecia, largely driven by patient demand and the appeal of "natural" therapies. However, their clinical role remains controversial due to heterogeneous evidence and widespread empirical supplementation. This study aimed to systematically evaluate the clinical evidence supporting oral nutraceuticals in alopecia and define their appropriate role in practice.

Materials and Methods

A systematic review was conducted following PRISMA principles. PubMed, Embase, and Cochrane databases were searched for human studies evaluating oral nutraceuticals in alopecia, including androgenetic alopecia and telogen effluvium. Eligible studies included randomized controlled trials, cohort studies, and controlled clinical trials. Outcomes assessed included hair count, density, shedding, hair shaft parameters, and patient-reported outcomes. Interventions were grouped by mechanism: antiandrogenic botanicals, nutritional correction, structural substrates, and emerging bioactive compounds.

Results

A total of 23 studies with 1,662 patients, including 9 randomized controlled trials, were included. Moderate evidence supported saw palmetto, which demonstrated improvements in hair density and stabilization of androgenetic alopecia, although consistently inferior to pharmacologic therapies. Pumpkin seed extract showed a 40% increase in hair count compared to 10% in placebo at 24 weeks. Sulfur-containing amino acids improved anagen/telogen ratios and reduced shedding in telogen effluvium. Bioactive collagen peptides increased hair shaft thickness without affecting density. Conditional benefit was observed for iron, zinc, and vitamin D supplementation only in patients with documented deficiencies. Limited or inconsistent evidence was found for tocotrienols, spermidine, and omega fatty acids. No consistent clinical benefit was demonstrated for biotin in non-deficient individuals. Across studies, limitations included small sample sizes, short follow-up, subjective endpoints, and frequent industry sponsorship.

Conclusions

Oral nutraceuticals may play a targeted adjunctive role in alopecia, particularly in telogen effluvium, nutritional deficiency states, and hair shaft fragility. However, their use as standalone therapy is not supported by current evidence. A clinically relevant paradox emerges: while deficiency impairs hair growth, empirical or excessive supplementation does not improve outcomes and may be harmful. Nutraceutical prescribing should therefore be evidence-based, indication-specific, and integrated into a multimodal treatment strategy.

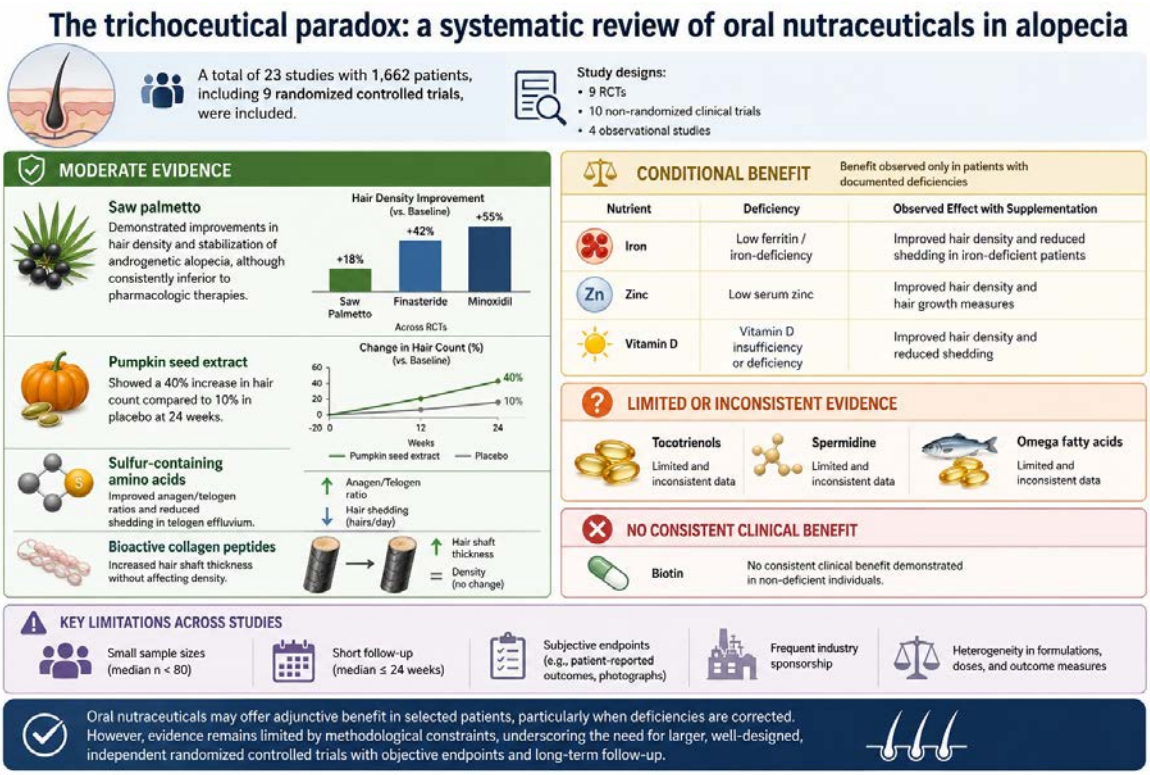

Graphic Abstract

EADV CONGRESS
VIENNA
30 SEP - 3 OCT 2026

Abstract N°: 2126

Efficacy and Safety of Oral Tofacitinib in Severe Alopecia Areata: A Real-World Experience in 64 Patients

MD. Shah Alam*[1], Ayesha Siddika[1]

[1] Dhaka Medical College Hospital, Dhaka, Bangladesh

Introduction

Alopecia areata (AA) is a common autoimmune disease that can have a significant psychological impact, especially in its more severe forms. Currently, there is no consistently effective treatment for AA. However, recent advancements in understanding the disease's underlying mechanisms suggest that JAK inhibitors, such as Tofacitinib, may offer a promising therapeutic option.

Materials and Methods

This non-randomized clinical trial was conducted at the Department of Dermatology, Dhaka Medical College Hospital, Dhaka, from 1st January 2023 to 31st December 2024. This study included adult patients of both genders having AA with ≥50% scalp hair loss, Alopecia Totalis (AT), and Alopecia Universalis (AU). All patients were treated with 5 mg of tofacitinib twice daily. The efficacy evaluated based on the percent change in severity of alopecia tool (SALT) score, and Adverse events were assessed by physical examinations and laboratory tests after 4 weeks, at the end of 4th and 6th months of treatment initiation. Statistical analysis was performed using the software SPSS version 25.0. A two-tailed $p < 0.05$ was considered statistically significant.

Results

A total of 64 patients were included in this study. Among them, there were 30 males and 34 females with a mean age 29.6 ± 11.4 years (range:18-55 years). The mean percentage of the baseline SALT score was 80.1 ± 18.6% (range: 52.8%-100%). After 4 months, it was 40.51 ± 26.7% (range: 8%-100%), and after 6 months, 14.17 ± 30.4% (range: 0%-100%). The mean change in SALT score after 4 months was 40.17% (p-value = .000), and after 6 months it was 66.51% (p-value = .000), both of which were highly significant statistically. Importantly, no serious side effects were observed in any of the patients.

Conclusions

Tofacitinib shows promise as a therapy for severe alopecia areata (AA) at the studied dose and duration. Larger randomized controlled trials with longer follow-up are necessary to establish its long-term efficacy and safety for treating severe AA.

EA DV CONGRESS
VIENNA
30 SEP - 3 OCT 2026

Abstract N°: 2158

HAIR IQ Study: Hair Attitudes, Ideology & Representation – Identity & Qualitative Study on Afro Textured Hair

Divas Mappa*[1], Somto Okoli[2], Jasmine Chevolleau[3], Honey Brandy Frimpong-Manso[4], Folashade Oyewole[5], Oluwadamilare Haastrup[6], Emma Amoafo[7]

[1] Wrightington, Wigan and Leigh Hospital NHS Foundation Trust, Wigan, United Kingdom
[2] Bristol Medical School, University of Bristol, Bristol, United Kingdom
[3] London North West University Healthcare NHS Trust, London, United Kingdom
[4] Basildon University Hospital, Mid and South Essex NHS Trust, Essex, United Kingdom
[5] Lewisham And Greenwich NHS Trust, London, United Kingdom
[6] Aston Medical School, Aston University, Birmingham, United Kingdom
[7] Kingston and Richmond NHS Foundation Trust, London, United Kingdom

Introduction
Hair is central to identity, culture, and self-expression for many Black women. Despite protection under the Equality Act 2010, discrimination and texturism (discrimination based on hair texture) persists in the UK, influencing the use of concealing hairstyles. While socially adaptive, these styles may involve prolonged tension, increase the risk of traction alopecia and contribute to conditions such as central centrifugal cicatricial alopecia (CCCA). However, UK based, healthcare-focused research examining how Black women perceive their hair, and how these perceptions translate into behaviour and wellbeing remains limited. This study explores the relationship between hair perceptions, sociocultural pressures, and self-esteem among Black women in the UK

Materials and Methods
A cross-sectional mixed-methods survey of Black women aged ≥18 years in the UK was conducted using online recruitment (social media, community networks, universities, hair salons). The questionnaire combined Likert-scale and open-ended items. Quantitative data were analysed using descriptive statistics, Pearson's correlation, and multiple regression (Excel, Jamovi). Qualitative data underwent reflexive thematic analysis.

Results
196 Black women participated, predominantly identifying as Black African (80.6%), based in Greater London (44.9%), and educated to degree level or above (85.7%). Most reported natural hair (86.5%), with 4C hair texture being the most common. Hair styling practices and protective style usage varied widely across participants.

Braun and Clake thematic analysis identified five key themes (Table 3), highlighting a consistent tension between personal identity and external influences. Confidence positively correlated with liking natural hair, yet this did not translate into higher self-esteem. Adherence to straighter, more socially accepted hairstyles was a significant predictor of hair satisfaction ($p = 0.003$), whereas perceived discrimination was not ($p = 0.464$). Despite overall positive perceptions of natural hair, self-esteem was significantly higher among participants with relaxed (permanently chemically straightened) hair (mean = 16.73, SD = 1.93) compared to natural hair (mean = 15.86, SD = 2.49; $p = 0.03$). This finding aligned with theme 3: racialised beauty hierarchies, in which participants

described how factors such as hair length, texture, and proximity to Eurocentric beauty standards influenced perceptions of hair within the Black community.

Furthermore, a perceived lack of knowledge regarding the care of Afro-textured hair was reported to negatively impact feelings of empowerment. Additional factors influencing perceptions and expression included the infantilisation of Afro-textured hair, limited representation on social media, and a disconnect between personal perceptions of Afro-textured hair and broader societal attitudes.

Themes				
Theme 1	Theme 2	Theme 3	Theme 4	Theme 5
Internalised conflict Many Black women feel torn between embracing their natural hair and conforming to European beauty standards	**Knowledge and access as the pathway to positive perception** Learning the basics about caring for ones' hair and having access to the right salons or products. These help to shape confidence and pride in wearing natural hair	**Racialised beauty hierarchies** Society often praises hair closer to European standards which may leave those with tighter coils / hair feeling marginalised	**Representation and community as drivers of shifting perception** The natural hair movement on social media has allowed diversity of hair to be more visible and allows others to find support within the community, a space to celebrate black hair	**The infantilisation of natural hair** Many black women feel they look young or less professional wearing their natural hair which leads to feeling undervalued in certain spaces

Conclusions

The finding that relaxed hair is associated with higher self-esteem despite strong identification with natural hair highlights a critical disconnect between identity and lived experience, driven by persistent Eurocentric beauty standards. For dermatology, this has direct clinical relevance: hair-related decisions are deeply psychosocial and may influence presentation, management, and adherence. Clinicians working with Black patients should develop greater awareness of the psychosocial dimensions of Afro-textured hair, recognising that hair-related decisions are rarely purely aesthetic. Embedding this cultural competence into dermatology training curricula and trichology services would support more inclusive, patient-centred care, and may meaningfully improve both patient engagement and treatment adherence.

EADV CONGRESS
VIENNA
30 SEP - 3 OCT 2026

Abstract N°: 2192

Adalimumab in Refractory Folliculitis Decalvans: Clinical Experience at Our Center

Mathilde Christine Ramirez Cassagne*[1], Andrea Berrueta Navascues[1], Jone López Martínez[1], Amaia Saenz Aguirre[1], Amaia Urtaran Ibarzabal[1], Irene García Río[1], Amaia Barrutia Etxebarria[1], Ricardo Gonzalez Pérez[1]

[1] Hospital Universitario de Álava, Vitoria-Gasteiz, Spain

Introduction

Foliculitis decalvans is a chronic, inflammatory primary scarring alopecia that, in a subgroup of patients, is refractory to multiple treatment lines.

Case Presentation

Three female patients aged 42, 57, and 70 years with a clinical and histopathological diagnosis of folliculitis decalvans are presented. All had previously received multiple treatments, including intralesional triamcinolone acetonide injections, oral prednisone, systemic antibiotics (doxycycline, clindamycin–rifampicin, amoxicillin/clavulanate, and ciprofloxacin), cyclosporine, and isotretinoin, with limited response. Due to the refractory nature of the condition, off-label treatment with adalimumab was initiated, aiming to control inflammation, halt the progression of alopecia, and improve symptoms. The standard dosing regimen was used, consisting of an initial dose of 80 mg followed by 40 mg every two weeks.
All three patients exhibited an acceptable clinical response following initiation of adalimumab, with improvement in inflammatory signs. In one case, it was necessary to intensify the regimen to weekly administration after seven months due to persistent inflammatory activity within the alopecic plaque; intralesional triamcinolone acetonide injections were also added to achieve adequate disease control. Treatment was well tolerated in all three cases, with no significant adverse effects observed during follow-up.

Conclusion

In our experience, Adalimumab represents a well-tolerated therapeutic option associated with a moderate clinical response in patients with refractory folliculitis decalvans who have failed conventional treatments. In selected cases, treatment intensification or combination with local therapies may be required to optimize the clinical response

EA DV CONGRESS
VIENNA
30 SEP - 3 OCT 2026

Abstract N°: 2230

Disease Duration Among Patients Recruited to Alopecia Areata Clinical Trials: A Systematic Review

Mayeesha Khan*[1], Miranda Branyiczky[1], Sarah Aly[2], Eric McMullen[3], Jeffrey Donovan[4, 5], Cathryn Sibbald[6]

[1] Michael G. DeGroote School of Medicine, McMaster University, Hamilton, Canada

[2] Faculty of Medicine and Health Sciences, McGill University, Montreal, Canada

[3] Division of Dermatology, Department of Medicine, University of Toronto, Toronto, Canada

[4] Donovan Hair Clinic, Whistler, Canada

[5] Department of Dermatology and Skin Science, University of British Columbia, Vancouver, Canada

[6] Division of Paediatric Dermatology, The Hospital for Sick Children, University of Toronto, Toronto, Canada

Introduction

Alopecia areata (AA) is an immune-mediated hair disorder. A challenge in AA management is deciding when to initiate systemic treatment, as spontaneous regrowth is possible and future disease course remains uncertain. However, accumulating evidence suggests that disease duration (DD) is an underrecognized predictor of treatment response. This review examines DD among participants in phase II/III AA trials and evaluates associations with treatment response.

Materials and Methods

MEDLINE and Embase were searched from January 2015 to August 2025 for phase II/III AA clinical trials by two reviewers adhering to PRISMA guidelines. Eligible studies included completed adult trials evaluating emerging AA therapies. Data were extracted on patient characteristics, DD, flare duration, and treatment outcomes. Risk of bias was assessed using Joanna Briggs Institute tools.

Results

Seven studies comprising eight trials (n=2,815 patients) were included. Participants were predominantly female (63.1%) with a mean age of 36.8 ± 2.4. Mean baseline Severity of Alopecia Tool (SALT) score was 82.7 ± 7.0. Mean DD was 11.2 ± 1.9 years; DD was reported in only five out of eight trials. Trials enrolling patients with shorter DD (<5 years or <2 years) were uncommon compared to longer DD. Mean flare duration was 3.3 ± 0.7 years. Eligibility criteria emphasized flare duration, whereas total DD was infrequently reported or analyzed. DD was rarely reported in post-hoc analyses.

Table 1. Demographic and clinical characteristics of patients with AA included in phase II/III clinical trials.

Characteristic	N (%)
Total population	2815 (100)
Female sex	1775 (63.1)
Mean age, years (SD)	36.8 (2.4)
Mean BMI, kg/m^2 (SD)[a]	28.2 (1.4)
Mean disease duration, years (SD)[b]	11.2 (1.9)
Mean baseline flare duration, years (SD)	3.3 (0.7)
Mean baseline AA severity, SALT score (SD)	82.7 (7.0)
Ethnoracial group[c]	
White	1777 (63.1)
Asian	608 (21.6)
Black	243 (8.6)
Other/unknown	187 (6.6)
Drug class evaluated	
JAK1/2 inhibitor	1577 (56.0)
JAK3 inhibitor	48 (1.7)
JAK1/TYK2 inhibitor	47 (1.7)
JAK3/TEC inhibitor	449 (16.0)
S1P1,4,5 modulator	56 (2.0)

Legend: SD, standard deviation; AA, alopecia areata; BMI, body mass index; SALT, Severity of Alopecia Tool; JAK, janus kinase; TYK2, tyrosine kinase 2; S1P, sphingosine-1-phosphate.

[a]BMI only reported for 79 out of 2815 patients

[b]Disease duration only reported by 5 out of 8 clinical trials (1870 out of 2815 patients)

Conclusions

Current AA trials disproportionately enroll patients with long-standing disease and underreport DD as a prognostic factor. Evidence suggests that shorter DD is associated with improved treatment response. To define if there is an ideal “window of opportunity” for disease-modifying treatment, future trials should recruit short-DD patients, stratify outcomes by DD, and assess DD-related predictors or confounders (e.g., age, sex). This may clarify whether an early “top-down” approach, such as earlier initiation of systemic disease-modifying therapies, is more effective.

EA DV CONGRESS
VIENNA
30 SEP - 3 OCT 2026

Abstract N°: 2235

Alopecia areata disease burden among adults in the EU and US: Results from the 2025 National Health and Wellness Survey

David Barnes*[1], Noha Elshimy[2], Carolyn Goh[3], Justin Ko[4], Michela Starace[5, 6], Sergio Vañó-Galvan[7], Gregor Shaefer[8], Fred Kasraei[9], Helen Tran[1], Genevieve Gauthier[10], Griffith Bell[9], Nikoletta Sternbach[11], Mojgan Sadrarhami[1]

[1] Pfizer Inc, New York, United States
[2] Imperial College Healthcare NHS Trust, London, United Kingdom
[3] University of California Los Angeles, Los Angeles, United States
[4] Stanford University School of Medicine, Stanford, United States
[5] Dermatology Unit, IRCCS Azienda Ospedaliero-Universitaria di Bologna, Bologna, Italy
[6] Department of Medical and Surgical Sciences, Alma Mater Studiorum University of Bologna, Bologna, Italy
[7] Hair Disorders Unit at Ramón y Cajal University, Hospital and Pedro Jaén Group Clinic, University of Alcalá, Madrid, Spain
[8] Pfizer Pharma GmbH, Berlin, Germany
[9] Pfizer Inc, Cambridge, United States
[10] Pfizer Canada ULC, Kirkland, Canada
[11] Oracle Life Sciences, Austin, United States

Introduction
Alopecia areata (AA) is an autoimmune disease characterized by nonscarring hair loss on the scalp of variable extent, with or without additional loss of facial and/or body hair. Individuals with AA often experience psychological distress and stigma that can impact their quality of life (QOL). This study, based on self-report data, aimed to describe AA prevalence, socio-demographics, and psychological and behavioural health burdens in adults in 5 European countries (EU5: France, Germany, Italy, Spain, UK) and the US.

Materials and Methods
Data were obtained from the National Health and Wellness Survey (NHWS), a general population-based, self-report cross-sectional survey of adults aged ≥18 years in the EU5 and US. Adults with AA were identified using self-reported history of physician-diagnosed AA and were classified into extent of hair loss categories at the time of the survey (i.e., 0%, 1-20%, 21-49%, 50-94%, and 95-100%) based on their response to the Scalp Hair Assessment patient-reported outcome (PRO). EU5 and US study samples were weighted to better reflect demographic distributions of the adult population in the EU5 and US, respectively.

Results
62,020 NHWS participants from the EU5 and 75,005 from the US were included, with 614 (weighted lifetime prevalence: 1.07%) and 1187 (1.36%) reporting a physician diagnosis of AA, respectively. Among EU5 and US participants, respectively: 130 and 182 reported 0% scalp hair loss (weighted population prevalence: 0.23% and 0.22%); 230 and 444 reported 1-20% (0.41% and 0.54%); 136 and 291 reported 21-49% (0.23% and 0.31%); 81

and 195 reported 50-94% (0.14% and 0.21%); and 37 and 75 reported 95-100% (0.07% and 0.08%). In the EU5 and US, compared to adults reporting no AA diagnosis, those with AA on average were (all results weighted) younger (EU5: mean age 48.5 vs 50.3 years; US: mean age 46.1 vs 48.4 years), more likely to be married (EU5: 53.1% vs 50.7%; US: 57.6% vs 48.2%), more likely to have completed college/university (EU5: 50.0% vs 44.3%; US: 44.4% vs 36.4%), and more likely to be employed (EU5: 65.4% vs 60.7%; US: 68.9% vs 59.5%) (**Table 1**). In both locations, adults with AA were more likely than those without AA to report alcohol consumption (EU5: 76.8% vs 70.9%; US: 78.4% vs 61.7%), alcohol consumption ≥4 times per week (EU5: 18.9% vs 15.9%; US: 27.1% vs 18.8%), and smoking (EU5: 34.1% vs 22.8%; US: 44.9% vs 22.6%). In both locations, adults with AA reported higher levels than adults without AA of depression and general anxiety symptoms in the past 2 weeks (measured by the Patient Health Questionnaire-9 [PHQ-9] and Generalized Anxiety Disorder-7 [GAD-7], respectively; **Table 1**). In both locations, the proportions of adults reporting both ever being diagnosed with specified anxiety disorders and experiencing related symptoms in the past 12 months were higher among those with vs without AA. Among adults with AA in both locations, those reporting >20% vs ≤20% scalp hair loss were more likely to report receiving psychological counselling or prescription medication for depression, anxiety, and sleep disorders related to AA, dissatisfaction with their current hair growth, and perceptions of stigma (shame, anger, discrimination) related to their AA. In both locations, >20% vs ≤20% scalp hair loss was associated with worse QOL scores (Dermatology Life Quality Index) and reporting more symptoms of depression and general anxiety in the past 2 weeks (PHQ-9 and GAD-7).

Conclusions

In the EU5 and US, adults with AA may experience greater psychological and behavioural health burdens vs those without AA, and these burdens may be greater in those with >20% vs ≤ 20% scalp hair loss. These patterns were directionally consistent across locations, supporting their generalizability; however, the usual limitations of self-report data apply. Our results suggest a complementary role for psychological support among adults with AA, alongside medical therapies.

Table 1. Demographics and behavioural and mental health in participants with and without AA

Characteristic	EU5 (N=270.3M)		US (N=260.3 M)	
	Participants Without AA	Participants With AA	Participants Without AA	Participants With AA
Age, mean (years)	50.3	48.5	48.4	46.1
Married, %	50.7	53.1	48.2	57.6
College/university degree, %	44.3	50.0	36.4	44.4
Employed full time, part time, or self-employed, %	60.7	65.4	59.5	68.9
Currently drink alcohol, %	70.9	76.8	61.7	78.4
Drink alcohol ≥ 4 times/week, %	15.9	18.9	18.8	27.1
Current smoker, %	22.8	34.1	22.6	44.9
Symptoms of diagnosed depression experienced in the prior 12 months, %	10.0	10.2	18.6	23.3
Symptoms of diagnosed GAD experienced in the prior 12 months, %	3.5	6.9	7.8	13.9
Symptoms of diagnosed social anxiety disorder experienced in the prior 12 months, %	2.5	4.8	5.5	9.0
Symptoms of diagnosed anxiety disorder (any) experienced in the prior 12-months, %	9.5	15.3	18.2	26.6
PHQ-9 (depression symptoms) last 2 weeks, mean	6.2	8.9	6.1	10.8
PHQ impact, mean	1.7	2.0	1.9	2.4
GAD-7 (anxiety symptoms) last 2 weeks, mean	4.8	7.6	4.9	9.0

All results weighted.

AA, alopecia areata; GAD, generalized anxiety disorder; M, million; PHQ, patient health questionnaire; PRO, patient-reported outcome.

EADV CONGRESS
VIENNA
30 SEP - 3 OCT 2026

Abstract N°: 2311

Lymphocytic Cicatricial Alopecia: An Overlap Between Lichen Planopilaris and Discoid Lupus Erythematosus

Olena Tymkiv*[1, 2], Olga Busko[3]

[1] Kyiv Medical University, Kyiv, Ukraine
[2] Dermline Centre, Lviv, Ukraine
[3] OlgaBuskoClinic, Zaporizhia, Ukraine

Introduction

Differentiating lichen planopilaris (LPP) from discoid lupus erythematosus (DLE) can be challenging because both conditions are primary lymphocyte-mediated cicatricial alopecias that share overlapping clinical, trichoscopic, and histopathological features. This similarity can complicate accurate diagnosis. However, establishing the correct diagnosis is crucial, as the prognosis, disease progression, and treatment strategies vary significantly between these two conditions.

Case Presentation

A 33-year-old female presented with progressive hair loss accompanied by pruritus and scalp scaling. Clinical examination revealed recession of the frontal hairline and patchy alopecia. Trichoscopy demonstrated perifollicular erythema, scaling, scarring, and a characteristic “strawberry ice cream” appearance.

A punch biopsy was performed, and histopathological findings were consistent with lichen planopilaris.

The patient had a history of Marfan syndrome, a hereditary connective tissue disorder associated with aortic dilation, lens dislocation, and skeletal abnormalities, and was receiving beta-blocker therapy. Treatment with oral doxycycline and topical clobetasol propionate solution resulted in only mild improvement. Hydroxychloroquine was contraindicated due to pre-existing retinal pathology.

Following cardiology consultation, beta-blocker therapy was discontinued. A marked clinical improvement was observed thereafter. Intralesional triamcinolone acetonide injections were also administered, leading to further disease control.

After combined topical and systemic anti-inflammatory treatment, almost complete hair regrowth was noted in previously affected areas. This finding is unusual for LPP and prompted reconsideration of the initial diagnosis.

Trichoscopy was repeated at follow-up visits. Over time, a reduction in scarring features was observed, along with the appearance of findings suggestive of discoid lupus erythematosus of the scalp, including erythema, arborizing vessels, and follicular plugging.

In the early stages of lupus-associated cicatricial alopecia, hair regrowth may still occur due to incomplete follicular destruction. This prompted a diagnostic re-evaluation and a repeat punch biopsy.

Histopathological examination of the second biopsy confirmed discoid lupus erythematosus.

Systemic involvement consistent with systemic lupus erythematosus was excluded.

Conclusion

A drug-induced lichenoid reaction related to beta-blocker therapy cannot be ruled out. These findings may represent an overlap, as both conditions belong to the spectrum of primary lymphocytic cicatricial alopecias. The patient remains under regular follow-up and close clinical monitoring. Further observation is required to understand the disease course better. Additional studies are needed to clarify underlying mechanisms and improve diagnostic and therapeutic approaches in overlap cases.

EADV CONGRESS
VIENNA
30 SEP - 3 OCT 2026

Abstract N°: 2336

From paronychia to nail matrix arrest: dermatillomania as a perpetuating factor of inflammatory nail matrix arrest

salma larabi*[1]

[1] Department of dermatology, Ibn Sina University Hospital ,Rabat , Morocco, rabat, Morocco

Introduction

Onychomadesis is characterized by a proximal detachment of the nail plate secondary to a temporary arrest of nail matrix activity. It may result from trauma, infections, systemic disease, drugs, or inflammatory conditions. Among infectious causes, paronychia is rarely reported as a trigger. We report a case highlighting the role of dermatillomania as an aggravating factor in inflammatory nail matrix dysfunction.

Case Presentation

A 26-year-old woman with no relevant medical history presented with acute paronychia of the left middle finger. She had a long-standing history of dermatillomania since childhood, with repeated periungual manipulation.

The patient was initially treated with a 7-day course of oral and topical antibiotics, with partial clinical improvement. Six weeks later, she developed proximal nail shedding consistent with onychomadesis of the same digit.

Microbiological analysis confirmed secondary infection with *Pseudomonas aeruginosa*, consistent with chloronychia.

She was managed with local care, including daily acetic acid soaks (1–2%) for 30 minutes. A rapid clinical improvement was observed within two weeks.

Conclusion

This case illustrates that even localized paronychia can induce a reversible arrest of nail matrix activity leading to onychomadesis when inflammation is sustained. Dermatillomania likely acted as a key perpetuating factor by repeatedly traumatizing the periungual tissue, maintaining inflammation and favoring secondary infection.

Although rare, this mechanism highlights an underrecognized interaction between infectious, inflammatory, and behavioral factors in nail pathology. Management remains conservative, based on local antiseptic care and strict avoidance of trauma, while early identification of underlying compulsive skin-picking behavior is essential to prevent recurrence and complications.

EADV CONGRESS
VIENNA
30 SEP - 3 OCT 2026

Abstract N°: 2377

Pseudo-lichenoid Onychodystrophy in AL Amyloidosis: A Case Report

Kawtar Diaa*[1]

[1] CHU IBN SINA Rabat, Rabat, Morocco

Introduction

Cutaneous amyloidosis is a rare disease characterized by extracellular deposition of amyloid proteins in the skin and skin appendages. Cutaneous and mucosal manifestations occur in one-third of patients with systemic AL amyloidosis; however, nail involvement is uncommon and may represent the **only** cutaneous sign, mimicking inflammatory onychopathies (particularly lichen planus), infectious, or tumoral conditions.

Case Presentation

A 64-year-old woman, followed in internal medicine for AL amyloidosis with cardiac and renal involvement treated with VCD protocol (Velcade + cyclophosphamide + dexamethasone), was referred to dermatology for onychodystrophy affecting all 20 nails evolving for over 4 years. Clinical examination revealed longitudinal striations, onychorrhexis, longitudinal melanonychia, trachyonychia, and koilonychia involving all fingernails and toenails, along with xanthopachyonychia of the toenails. The fingers showed infiltration and sausage-like swelling. The remainder of the skin examination was normal. Given this lichenoid appearance, a latero-longitudinal biopsy confirmed dermal amyloid deposits (Congo red positive, apple-green birefringence under polarized light) associated with a subepidermal lympho-histiocytic infiltrate. Mycological examination of the toenails revealed onychomycosis due to *Trichophyton rubrum*. The diagnosis of nail amyloidosis was established.

Conclusion

Discussion:

Nail amyloidosis is a rare manifestation of systemic AL amyloidosis that may precede systemic signs by several years, sometimes representing the **only** dermatological manifestation. Clinically, it closely resembles lichen planus of the nails, which is the main differential diagnosis. Nail involvement is nonspecific and may include longitudinal striations, onycholysis, splinter hemorrhages, trachyonychia, pterygium, chronic paronychia, nail atrophy, and anonychia in late stages. Fungal co-infection, as in our case, may worsen the dystrophy. Nail biopsy is diagnostic, demonstrating amyloid deposits confirmed by Congo red staining. Systemic amyloidosis treatment generally improves onychodystrophy.

Conclusion:

This case underscores the importance of nail biopsy in any chronic pseudo-lichenoid onychodystrophy in older adults, potentially revealing underlying systemic amyloidosis.

EADV CONGRESS
VIENNA
30 SEP - 3 OCT 2026

Abstract N°: 2397

Lichen planopilaris in a 6-year-old child exacerbated after a hair straightening treatment

Chaima Ezzaki*[1], sokaina chhiti[1], Imane Mouabbir[1], mhaimer soukaina[1], chaouche mohammed[1], Radia Chakiri[1]

[1] Department of Dermatology, Faculty of Medicine and Pharmacy, Ibn Zohr University, Agadir, Morocco, agadir, Morocco

Introduction

Lichen planopilaris (LPP) is an inflammatory disorder affecting hair follicles that often leads to permanent damage and scarring alopecia. Due to its potential for rapid progression and irreversible outcomes, it is regarded as a 'trichologic emergency', requiring prompt diagnosis and management .

LPP is the most common cause of primary cicatricial alopecia in adults, but it is only rarely described in the pediatric population.

Case Presentation

We report the case of a 6-year-old girl with a history of chemical hair straightening performed 6 months earlier. She presented to the dermatology departement with hair loss evolving over 1 year, with worsening during the past 6 months and the appearance of mildly pruritic alopecic patches. Clinical examination revealed poorly demarcated alopecic plaques with a scarring appearance, without erythema or scaling, located on the vertex, along with eyebrow loss. Dermoscopic examination showed perifollicular scaling, perifollicular pigmentation, and absence of follicular ostium. An auto-immune workup was performed and returned negative. A scalp biopsy was performed, demonstrating cicatricial alopecia characterized by a reduction in follicular units replaced by vertical fibrous tracts, associated with lamellar perifollicular fibrosis, consistent with lichen planopilaris at the fibrotic stage. As for treatment, high-potency topical corticosteroid in combination with topical minoxidil was initiated, with the aim of halting disease progression. The prognosis and the risk of irreversible hair loss were clearly explained to the parents.

Conclusion

LPP is an uncommon condition in children and poses both diagnosis and therapeutic challenges. It is a lymphocyte-mediated alopecia presumed to have an autoimmune pathogenesis and may therefore be associated with other autoimmune conditions. Several triggering factors for LPP have been reported, including exposure to chemicals and medications.

In adults, LPP predominantly affects females between 40 and 60 years-old, whereas in children it typically presents around 11 years of age and appears to be more common in males. Pediatric LPP typically presents as a slowly progressive patchy scarring alopecia, that can be asymptomatic or present with pruritus or a burning sensation, located most commonly in the vertex. Trichoscopic findings include perifollicular erythema and desquamation, blue-gray dots, and absence of the follicular ostium. The differential diagnosis includes other causes of patchy alopecia, such as tinea capitis, trichotillomania, aplasia cutis congenita, alopecia areata, and congenital triangular alopecia.

Scalp biopsy is the standard exam for definitive diagnosis, histopathology reveals perifollicular fibrosis,

perifollicular lymphohistiocytic infiltrate, pigment incontinence, cytoid bodies, and scarring in the dermis. In terms of management, topical and intralesional corticosteroids are the most commonly used options in children. Other therapies reported in the literature may involve calcineurin inhibitors, topical minoxidil, and tocilizumab. In refractory cases, systemic treatments can be considered, including oral corticosteroids, methotrexate, cyclosporine, tetracyclines, mycophenolate mofetil, and Janus kinase inhibitors.

LPP is a rare condition in children, but it should be considered in any cicatricial alopecic patch in order to ensure early diagnosis and appropriate management.

EADV Congress 2026, VIENNA
30 SEPTEMBER - 03 OCTOBER 2026
POWERED BY M-ANAGE.COM

EA DV CONGRESS
VIENNA
30 SEP - 3 OCT 2026

Abstract N°: 2412

Adjunctive Non-Ablative Fractional 1550-nm Diode Laser With 2% Topical Minoxidil for Female Pattern Hair Loss: A Split-Scalp Case Series in Asian Women With Fitzpatrick Skin Types IV–V

Hafiza Fathan Rasyid*[1]

[1] ONELIFE+ Integrated Health Center, South Jakarta, Indonesia

Introduction

Female pattern hair loss (FPHL) in Fitzpatrick skin types IV–V remains therapeutically challenging, and evidence supporting energy-based devices as adjunctive treatment is still limited. Non-ablative fractional 1550-nm diode laser has emerged as a potential complementary modality through the creation of dermal microthermal zones, which may promote perifollicular remodelling, neoangiogenesis, and wound-healing pathways involved in hair follicle cycling and regrowth. Previous reports in Asian populations have shown encouraging findings; however, these studies have largely focused on laser monotherapy or comparisons with topical agents rather than combination strategies. Evidence in women with darker phototypes remains particularly scarce. To our knowledge, no report has evaluated non-ablative fractional 1550-nm diode laser as an adjunct to topical 2% minoxidil using a split-scalp design in Asian women with Fitzpatrick skin types IV–V.

Case Presentation

We present two adult Asian women with Fitzpatrick skin types IV–V and clinically diagnosed FPHL (Sinclair grade 2–4), managed using a prospective split-scalp design. Both patients applied 2% topical minoxidil solution twice daily to the entire affected scalp throughout the study period, with temporary interruption on laser treatment days and resumption the following day. In each case, one randomly assigned scalp half received adjunctive non-ablative fractional 1550-nm diode laser at 4-week intervals for three sessions, while the contralateral half was maintained on topical minoxidil alone. Standardised global photography and dermoscopic documentation of predefined target areas were obtained at baseline and during follow-up at Weeks 4, 8, and 12. In both cases, the laser-treated side demonstrated earlier and more noticeable improvement in hair density and overall scalp coverage compared with the minoxidil-only side. Dermoscopic assessment suggested increased terminal hair density and improvement in hair shaft calibre on the combination-treated side. Treatment was well tolerated, with only mild and transient erythema observed after laser sessions and no unexpected adverse events.

Conclusion

This split-scalp case series suggests that non-ablative fractional 1550-nm diode laser may provide additive benefit when combined with topical 2% minoxidil in Asian women with FPHL and Fitzpatrick skin types IV–V. The combination was well tolerated and showed favourable early clinical improvement compared with minoxidil alone. These preliminary observations support further controlled studies evaluating fractional laser therapy as a complementary regenerative strategy for hair restoration in darker phototypes.

EA DV CONGRESS
VIENNA
30 SEP - 3 OCT 2026

Abstract N°: 2415

Low-temperature argon plasma as a promising therapeutic approach for androgenetic alopecia

Viktoriia Sysoeva*[1], Anfisa Lepekhova[1], Olga Olisova[1]

[1] Sechenov University, Department of Dermatology and Venereology, Moscow, Russian Federation

Introduction
Androgenetic alopecia is the most common form of chronic hair loss and is associated with progressive miniaturization of hair follicles, reduction of hair density, and a substantial negative impact on patients' quality of life. Although standard therapeutic options are available, their efficacy may be limited, and long-term treatment is often required to maintain the achieved effect. This supports the search for new safe and well-tolerated methods that may enhance follicular activity and improve treatment outcomes. Low-temperature argon plasma is an ionized flow of the inert gas argon generated at relatively low temperature, allowing tissue exposure without pronounced thermal damage. Its biological effects are thought to be related to reactive oxygen and nitrogen species, improvement of microcirculation, modulation of local inflammation, and stimulation of reparative processes. Therefore, low-temperature argon plasma may represent a promising non-invasive therapeutic approach for patients with androgenetic alopecia. The aim of this pilot study was to evaluate the tolerability, safety, and early clinical and instrumental outcomes of low-temperature argon plasma therapy in patients with androgenetic alopecia.

Materials and Methods
This pilot study included 20 patients with clinically confirmed mild to moderate androgenetic alopecia. All patients received a course of low-temperature argon plasma therapy consisting of 10 procedures performed at intervals of 7 to 10 days. Treatment tolerability, technical feasibility of the procedure, adverse events, clinical dynamics, and changes in phototrichogram parameters after completion of the treatment course were assessed. Clinical evaluation included patients' reports of hair shedding intensity and overall perception of hair condition. Instrumental assessment was based on phototrichogram parameters reflecting hair density and hair shaft characteristics.

Results
All 20 patients completed the full treatment course, which indicated good adherence and feasibility of the method in routine clinical practice. Low-temperature argon plasma therapy was well tolerated. No adverse events, local complications, or treatment discontinuations were reported. All patients demonstrated positive clinical dynamics after completion of the course, including reduced hair shedding and improvement in the overall perception of hair condition. According to phototrichogram assessment, positive changes were also observed in all participants. These changes included increased hair density and terminal hair proportion, as well as a reduction in the proportion of vellus hair. Taken together, the clinical and instrumental findings suggested a potential stimulating effect of low-temperature argon plasma on the hair follicle and supported the biological rationale for further investigation of this method in androgenetic alopecia.

Conclusions
The results of this pilot study showed that low-temperature argon plasma therapy in patients with

mild to moderate androgenetic alopecia was well tolerated, technically feasible, and not associated with adverse events. Positive clinical dynamics and improvement of phototrichogram parameters in all patients suggest that this method may be considered a promising therapeutic approach. Further studies with larger patient cohorts, standardized assessment criteria, and longer follow-up are needed to confirm its efficacy and determine the durability of the observed effect.

EADV CONGRESS
VIENNA
30 SEP - 3 OCT 2026

Abstract N°: 2428

Polydioxanone alone or with injection Platelet Rich Fibrin or with injection Platelet Rich Plasma in the Treatment of Androgenetic Alopecia

Khaled Gharib*[1]

[1] Zagazig University Faculty of Medicine, Zagazig, Egypt

Introduction

- Androgenetic alopecia is the most common form of hair lose that genetically predetermined disorder due to an excessive response to androgens.
- This condition affects up to 50 percent of males and females and is characterized by progressive loss of terminal hair of the scalp any time after puberty.
- The physical examination of a person with androgenetic alopecia involves assessing the pattern and extent of hair loss, also look for signs of increased hair shedding, miniaturized hair follicles, and the overall condition of the scalp.
- It follows a characteristic distribution in both males and females.
- The aim of the work was to compare efficacy of injection of PRF with PDO threads Versus injection of PRP with PDO threads or PDO threads alone in the treatment of AGA patients.
-

Materials and Methods

- This randomized controlled clinical study was conducted in outpatient clinics of Dermatology, Venerology and Andrology Department, Faculty of Medicine, Zagazig University hospitals in the period from Jun 2024 till Jun 2025.
-
- Thirty-three patients of different ages, sex, duration, and grades of AGA were included in our study. The diagnosis was clinically established by Norward Hamilton scale for male and Sinclair scale for female. Also, it was dermoscopically established by the characteristic number of vellus and terminal hair.

Results

Regarding the Hamilton-Norwood Scale before and after intervention in male patients, no significant differences were found between the groups. For the "before" intervention stage, the mean values were 3.000 ± 1.414 for Group A, 3.500 ± 1.732 for Group B, and 3.714 ± 0.951 for Group C. After intervention, the means were 2.500 ± 2.121 for Group A, 2.750 ± 1.500 for Group B, and 2.857 ± 0.900 for Group C. Intragroup comparisons revealed significant changes in Group C with a p-value of 0.017, while Groups A and B had p-values of 0.500 and 0.058, respectively, showing no significant changes within those groups

Conclusions

- Polydioxanone threads, whether used alone or in combination with PRP or PRF, are effective and safe for enhancing hair growth in patients with androgenetic alopecia.
- However, the combination of PDO threads with PRF produced superior clinical outcomes, greater patient satisfaction, and less injection pain. This combined approach may represent a promising, minimally invasive therapeutic option as a synergistic treatment for AGA.
-

EA DV CONGRESS
VIENNA
30 SEP - 3 OCT 2026

Abstract N°: 2429

Evaluation of the Efficacy of Exosome versus Platelet-Rich Plasma or Minoxidil in Treatment of Androgenetic Alopecia

Khaled Gharib*[1]

[1] Zagazig University Faculty of Medicine, Zagazig, Egypt

Introduction

Androgenetic alopecia (AGA) is the most common cause of chronic progressive hair loss in men and also affect women. It is believed to have a worldwide prevalence of about 50,000 per 100,000 men and 15,000 per 100,000 women with post-menopausal women making up the majority

Exosomes, or extracellular vehicles, are nanoscale vesicles secreted by various cell types with a diameter approximately 30-150 nm. They have a wide variety of therapeutically active substances and potential in treating dermatological conditions such as hair regeneration, wound healing, and oxidative stress. They own particular advantages in repairing damaged hair follicles and promoting follicular regrowth. The treatment with exosomes provides a solid theoretical base for future clinical research.

Previously, platelet-rich plasma (PRP) had been reported as an effective treatment in AGA. PRP is an autologous concentration of platelets in plasma with numerous growth factors that contribute to hair regeneration. The growth factors contained within the alpha granules of platelets act on stem cells in the bulge area of the hair follicles and stimulate the development of new follicles along with neovascularization The aim of the present study was to find new effective alternatives for treatment of androgenetic alopecia other than traditional therapies with high efficacy such as PRP and minoxidil.

Materials and Methods

Treatment groups: Patients were divided into three groups

- Group A: included 13 patients (9 females and 4 males) aged from 17 to 48 years. They were injected with exosomes (Elysee Dermafirm, South Korea 4 ml vial) 0.5 ml per session, intradermally diluted with 1 ml saline for each patient at a dose of 0.1 ml/cm2 of scalp, a session per month for three successive months.

- Group B: included 13 patients (9 females and 4 males) aged from 16 to 50 years. They were injected sub or intradermally with PRP into the affected scalp.

- Group C: included 13 patients (6 females and 7 males) aged from 26 to 51 years. Intradermal injections were administered to the affected area of the scalp with 1 ml minoxidil 5% mesotherapy (Global for cosmeceuticals 5 ml vial), using point-to-point technique, a session per month for 3 successive months.

Results

In females; significant improvement occurred in group A ($p=0.025$) and group C ($p=0.025$), whereas group B showed no significant change ($p=0.317$). Improvement percentages differed significantly across groups

(p=0.021)
Vellus hair count significantly decreased in group A (p=0.009) and group C (p=0.001), with no significant change in group B (p=0.310). Post treatment differences between groups were significant (p=0.013)

Conclusions

This comparative clinical investigation revealed that all three treatment modalities: exosome injection, PRP and minoxidil mesotherapy resulted in quantifiable enhancements in androgenetic alopecia, but with variable efficacy. The most reliable and significant improvements in alopecia grade, hair counts and follicular characteristics were shown by minoxidil mesotherapy which was followed by exosome therapy. PRP showed the least improvement.

Exosomes have demonstrated promising outcomes particularly in increasing hair density and increasing terminal and multiple-hair follicular units suggesting that they could be a good substitute for people who are intolerant to or unresponsive to traditional therapies.

Adverse effects were predominantly mild and varied by treatment methods with pain occurring more frequently in PRP, itching associated with minoxidil, and minimal adverse effects observed in exosome therapy. Exosome therapy seems to be a safe and effective developing alternative, nevertheless larger studies with extended follow-up are necessary to confirm its long-term efficacy relative to existing treatments.

EADV CONGRESS
VIENNA
30 SEP - 3 OCT 2026

Abstract N°: 2516

Quality of life and psychological outcomes in men with androgenetic alopecia before and after hair transplantation

Anargyros Kouris*[1], Vasiliki Efstathiou[2], Revekka Tsatovidou[3], Stamatis Gregoriou[4]

[1] Private Hair Clinic, Athens, Greece

[2] Department of Psychology, National and Kapodistrian University of Athens, Athens, Greece

[3] Aspropyrgos Primary Health Care Center, Athens, Greece

[4] Faculty of Medicine, Andreas Sygros Hospital, National and Kapodistrian University of Athens, Athens, Greece

Introduction

Androgenetic alopecia (AGA) is the most common form of nonscarring alopecia, characterized by progressive patterned hair loss. Beyond its physical manifestations, AGA has been associated with significant impairment in quality of life and psychological well-being, including reduced self-esteem, anxiety, and depressive symptoms.

Case Presentation

Materials-Methods: We conducted a prospective controlled longitudinal study to evaluate psychological outcomes and dermatology-related quality of life in men undergoing hair transplantation for AGA. A total of 150 male participants were enrolled, including 75 patients in the hair transplantation group and 75 age-matched controls. Participants in the intervention group were assessed before and after the procedure, while controls were evaluated at corresponding time points. Outcomes included dermatology-related quality of life, anxiety, depression, loneliness and self-esteem, measured using validated instruments.

Results:

Patients undergoing hair transplantation demonstrated a significant improvement in dermatology-related quality of life over time, with mean DLQI scores decreasing from 10.99 (SD = 4.29) at baseline to 0.60 (SD = 1.70) at follow-up ($p < 0.001$). Anxiety levels also decreased significantly following the procedure ($p = 0.004$). At baseline, the transplantation group exhibited significantly lower self-esteem compared with controls ($p < 0.001$). However, a marked improvement in self-esteem was observed post-treatment ($p < 0.001$).

Conclusion

Men with AGA seeking hair transplantation experience a substantial psychological burden. Hair transplantation is associated with significant improvements in quality of life, anxiety, depression and self-esteem, highlighting its potential psychological as well as aesthetic benefits.

EADV CONGRESS
VIENNA
30 SEP - 3 OCT 2026

Abstract N°: 2517

Efficacy of deuruxolitinib in patients with severe alopecia areata by baseline alopecia areata episode duration: Pooled analysis of the THRIVE-AA1 and THRIVE-AA2 Phase 3 trials

Brett King*[1], Arash Mostaghimi[2], Maryanne M. Senna[3], Natasha Mesinkovska[4], Heidi Goldstein[5], Yasmin Mathlin[5], Kizito Kyerematenng[5], Nicholas Squittieri[5]

[1] Dermatology Physicians of Connecticut, Fairfield, United States
[2] Department of Dermatology, Brigham and Women's Hospital, Boston, United States
[3] Lahey Hair Loss Center of Excellence, Lahey Hospital and Medical Center, Burlington, United States
[4] Department of Dermatology, School of Medicine, University of California Irvine, Irvine, United States
[5] Sun Pharmaceutical Industries, Inc., Princeton, United States

Introduction
Alopecia areata (AA) is a common cause of nonscarring hair loss, and the duration of AA is inversely correlated with hair regrowth. Deuruxolitinib is approved in the US for adults with severe AA. This pooled post hoc analysis examined scalp hair regrowth with deuruxolitinib by baseline duration of AA episode in the Phase 3 trials THRIVE-AA1 (NCT04518995) and THRIVE-AA2 (NCT04797650).

Materials and Methods
Patients 18 to 65 years of age with AA and ≥50% scalp hair loss received deuruxolitinib 8 mg twice daily (BID) or placebo for up to 24 weeks. Scalp hair loss was assessed in patients using Severity of Alopecia Tool (SALT). The percentage of patients achieving SALT scores ≤20 or ≤10 at Week 24 was assessed in the pooled population by baseline duration of AA episode <4 and ≥4 years.

Results
Patients receiving deuruxolitinib 8 mg BID (n=600) or placebo (n=267) had a mean baseline duration of AA episode of 3.7 and 3.9 years, respectively. The percentage of patients achieving SALT scores ≤20 and ≤10 at Week 24 was significantly higher with deuruxolitinib 8 mg BID vs placebo regardless of baseline AA duration (P<0.0001 for all). The percentage of patients with a baseline duration of AA episode <4 years achieving SALT scores ≤20 and ≤10 with deuruxolitinib 8 mg BID was significantly greater than those with a baseline AA duration ≥4 years (P=0.0024 and P=0.0236, respectively) at Week 24.

Conclusions
A significantly higher proportion of patients receiving deuruxolitinib achieved clinically meaningful scalp hair regrowth by Week 24 vs placebo-treated patients regardless of the baseline duration of their AA episode. Further, a significantly higher proportion of patients with a shorter vs longer baseline AA duration achieved ≥80% and ≥90% scalp hair regrowth by Week 24 with deuruxolitinib.

EA DV CONGRESS
VIENNA
30 SEP - 3 OCT 2026

Abstract N°: 2521

Subungual Osteochondroma of the Great Toe: A Surgical Case Report.

Lejdis Zeneli*[1], Gentian Zikaj[1], Virxhinia Çuka[1], Oljeda Oljeda Kaçani[1], Alesja Palaj[1], Ina Sotiri[1], Monika Fida[1]

[1] University Hospital Center “ Mother Teresa", Tirana, Albania, Tirana, Albania

Introduction

Subungual osteochondroma is a benign osteocartilaginous lesion that most commonly develops on the distal phalanx of the toe, particularly the hallux. Although considered a variant of classical osteochondroma, the subungual localization presents unique diagnostic and surgical challenges due to the involvement of the nail bed and its functional and aesthetic impact. The aim of this presentation is to highlight the importance of accurate diagnosis and appropriate surgical technique in order to minimize recurrence and permanent nail deformity.

Case Presentation

We report the case of a 30-year-old female patient who presented with progressive pain and nail deformity of the right great toe for nearly 3 years. Initially, the patient had been treated conservatively with a clinical diagnosis of onychocryptosis (ingrown toenail), without sustained improvement of symptoms. Clinical examination revealed a firm subungual mass associated with elevation of the nail plate and local inflammation.Due to persistent pain and progressive enlargement of the subungual lesion, radiographic evaluation was performed, demonstrating an exophytic bony lesion arising from the distal phalanx. Surgical intervention was undertaken, including nail plate removal and complete excision of the lesion down to its base. Histopathological examination confirmed the diagnosis of benign subungual osteochondroma.



Figure 1. (a) Preoperative clinical appearance showing subungual hyperkeratotic mass with nail plate elevation, distal nail dystrophy, and periungual inflammation of the right great toe. (b) Intraoperative view following nail plate removal, revealing the underlying subungual lesion. (c) Postoperative appearance after complete surgical excision of the lesion with primary closure of the surgical site.

Conclusion

Subungual osteochondroma may clinically mimic more common nail disorders, such as

onychocryptosis, leading to delayed diagnosis and inappropriate treatment. Persistent pain, progressive nail deformity, and the presence of a firm subungual mass should raise suspicion for an underlying bony lesion and prompt radiologic evaluation. Complete surgical excision remains the treatment of choice and is essential to prevent recurrence and permanent nail dystrophy. This case highlights the importance of early recognition and appropriate surgical management of subungual osteochondroma to achieve favorable functional and cosmetic outcomes.

EADV CONGRESS
VIENNA
30 SEP - 3 OCT 2026

Abstract N°: 2538

Microneedling-delivered phytoactive compounds in pattern hair loss: preliminary clinical outcomes

Lidiya Todorova*[1, 2]

[1] Medical University Plovdiv, Plovdiv, Bulgaria
[2] Follica: Hair & Scalp Clinic, Plovdiv, Bulgaria

Introduction

Androgenetic alopecia (AGA) or pattern hair loss is the most common form of hair loss in both men and women, significantly affecting quality of life. The present study aims to assess treatment outcomes using objective trichoscopic parameters and standardized photographic documentation in a clinical setting, evaluating a solution of anti-hair loss phytotherapy ingredients, administered through microneedling to patients with mild to moderate AGA.

Materials and Methods

Five patients with AGA were treated (3 females, 2 males; age range 26–63 years) diagnosed with AGA (Hamilton–Norwood III and III + vertex in males; Ludwig I–II in females). Clinical history was recorded, and standardized high-quality macro-photography (frontal, top, vertex, lateral, occipital) and trichoscopic images (×20 and ×40 magnification) were obtained at baseline and follow-up. Hair density (hairs/cm^2) was measured in frontal, vertex, and occipital regions. Hair shaft thickness (mm) was assessed where available. General scalp health (inflammation, erythema) was documented. The treatment followed a standardized protocol: 5 sessions every 2 weeks, each consisting of microneedling application of 5 mL of anti hair loss phytosolution over the affected scalp area. Patients were evaluated at baseline and at 3 months using macroscopic photographs, trichoscopy analysis, and satisfaction questionnaires.

Results

In a 26-year-old male (AGA III), vertex density increased from approximately 35 ± 5 to 38 ± 5 hairs/cm^2, and frontal density from 30 ± 4 to 31 ± 4 hairs/cm^2. In a 45-year-old male (AGA III + vertex), frontal density increased from 33 ± 5 to 49 ± 7 hairs/cm^2, and occipital density from 51 ± 7 to 67 ± 9 hairs/cm^2, while vertex density remained relatively stable (46 ± 6 to 44 ± 6 hairs/cm^2). In a 63-year-old female (AGA II, Ludwig scale), vertex density improved from 37 ± 5 to 39 ± 5 hairs/cm^2, while frontal and occipital densities remained stable (42 ± 6 and 58 ± 8 hairs/cm^2, respectively). In a 27-year-old female (AGA I, Ludwig scale), vertex density changed from approximately 50 ± 10 to 40 ± 5 hairs/cm^2, while occipital density markedly increased from 35 ± 5 to 70 ± 10 hairs/cm^2. Hair thickness improved in the frontal region (50 ± 12 µm to 55 ± 10 µm) and significantly in the vertex area (45 ± 15 µm to 68 ± 15 µm). For patient five, at baseline, vertex hair density was approximately 33–38 hairs/cm^2 and increased at follow-up to ≈ 53 ± 7 hairs/cm^2. Frontal hair density improved from approximately 35–48 hairs/cm^2 at baseline to ≈ 45–50 hairs/cm^2 at follow-up. Occipital hair density increased from approximately 33–42 hairs/cm^2 to ≈ 62 ± 8 hairs/cm^2.

Overall, improvements were most notable in frontal density and hair shaft thickness in selected patients, with stable or mildly increased vertex density in others. Scalp health remained normal in all documented cases, with no reported inflammation or adverse effects. Based on the available patient data (n = 5) from the study, the overall

results demonstrate stabilization or improvement in most trichoscopic parameters, with regional variability.

Conclusions

This case series demonstrates variable but generally positive effects on hair density and thickness in patients with mild to moderate AGA treated with anti-hair loss phytotherapy ingredients, administered through microneedling. The most consistent improvements were observed in frontal hair density and hair shaft thickness. The treatment was well tolerated, with no reported scalp adverse events. Larger controlled studies are warranted to further validate these findings.

EA DV CONGRESS
VIENNA
30 SEP - 3 OCT 2026

Abstract N°: 2548

Variable Response to JAK Inhibitors in Severe Alopecia Areata

Alesja Palaj*[1], Arlin Kokomani[2], Ina Sotiri[1], Lejdis Zeneli[1], Oljeda Kaçani[3], Monika Fida[1]

[1] Department of Dermatology, University Hospital Centre "Mother Theresa", University of Medicine of Tirana, Tirana, Albania
[2] Department of Othorhinolaryngology, University Hospital Centre "Mother Theresa", University of Medicine of Tirana, Tirana, Albania
[3] Private Clinic "A-derma", Tirana, Albania

Introduction

Alopecia areata is an autoimmune, T-cell-mediated, non-scarring alopecia with variable clinical presentation ranging from well-defined patches to complete scalp and body hair loss. In recent years, Janus kinase inhibitors have emerged as promising therapeutic options for severe and refractory disease. Variability in treatment response and persistent resistant areas remain important clinical challenges. We present two cases of severe alopecia areata demonstrating heterogeneous clinical response to different JAK inhibitors and the role of individualized therapeutic strategies.

Case Presentation

Case 1

A 29-year-old female flight attendant, initially developed a small patch of Alopecia Areata in 2024. She had previously been treated with topical and intralesional corticosteroids, topical minoxidil and platelet-rich plasma therapy, without improvement, followed by progressive extension of the alopecic areas. The patient presented to our clinic after five months of treatment with Baricitinib 4 mg once daily, during which the disease had progressed to alopecia universalis with complete loss of scalp hair, eyebrows, eyelashes, and body hair. Treatment was switched to Tofacitinib 5 mg twice daily combined with oral minoxidil 2.5 mg daily. No local treatment was used during follow-up. Laboratory investigations were within normal limits except for vitamin D deficiency, for which supplementation was recommended. After seven months of treatment, significant scalp hair regrowth was observed, with improvement in eyebrow and eyelash involvement. Residual resistant areas persisted predominantly in the ophiasis distribution. Serial clinical photographs demonstrated objective clinical improvement.

Case 2

A 17-year-old female with a history of Alopecia Areata since the age of 11 , presented with long-standing extensive disease consistent with alopecia totalis. She had been previously treated with Tofacitinib 5 mg once daily, which led to partial stabilization of the disease but incomplete hair regrowth. Because of reimbursement limitations, treatment was switched to Ritlecitinib 50 mg once daily. In addition, the patient continued with topical minoxidil, intralesional corticosteroid injections , microneedling with PRP and exosomes. The patient was followed up every 2–3 months. Clinical evaluation during follow-up showed disease stability without progression. Partial regrowth was observed in selected areas, while other alopecic patches demonstrated limited response.

Conclusion

These cases demonstrate that response to JAK inhibitors in severe Alopecia Areata is highly variable and may differ substantially even within the same patient across agents. Therapeutic switching can lead to significant regrowth in otherwise progressive disease, while in other cases it may primarily achieve stabilization without full restoration of hair density. Refractory involvement, particularly in the ophiasis pattern, remains a consistent unmet need. These observations reinforce the importance of early therapeutic reassessment and individualized sequencing strategies when managing severe alopecia areata in routine clinical practice.

EA DV CONGRESS
VIENNA
30 SEP - 3 OCT 2026

Abstract N°: 2561

Real-World Clinical Experience on the Effectiveness and Safety of Topical Finasteride 0.25% in HPCH spray in Patients with Androgenetic Alopecia: A Retrospective Study

Fares Alkhayal*[1], Abdullah Almeziny[2]

[1] Department of Dermatology, Prince Sultan Military Medical City, Riyadh, Saudi Arabia, Riyadh, Saudi Arabia
[2] College of Medicine, Imam Mohammad Ibn Saud Islamic University, Riyadh, Saudi Arabia, Riyadah, Saudi Arabia

Introduction
Androgenetic alopecia (AGA) is the most common cause of hair loss in both men and women. While oral finasteride is effective, its use is often limited by concerns regarding systemic adverse effects. Topical finasteride has emerged as a promising alternative aimed at reducing systemic exposure while maintaining efficacy; however, real-world evidence remains limited.

Materials and Methods
This retrospective cohort study evaluated adult patients with AGA treated with topical finasteride 0.25% in hydroxypropyl chitosan (HPCH) spray at a tertiary medical center between April and October 2025. Patients completing at least 6 months of therapy with available baseline and follow-up data were included. Outcomes included patient-reported hair regrowth, investigator-assessed improvement scores, safety profile, adherence, and subgroup analyses by age and sex.

Results
A total of 59 patients were included (mean age 32.1 ± 8.5 years; 64.4% female). All patients reported subjective hair regrowth, indicating a high perceived treatment benefit. Investigator-assessed improvement demonstrated consistent outcomes across two independent reviewers (mean score 2 ± 1), corresponding to mild-to-moderate clinical improvement.

Persistent hair shedding was reported in 8.5% of patients. Local adverse events were infrequent (3.4%) and mild, with no reported systemic adverse effects or treatment discontinuations. Treatment adherence was notably high, with all patients completing at least 6 months of therapy.

No significant associations were identified between treatment response and age or sex, suggesting consistent effectiveness across patient subgroups.

Conclusions
Topical finasteride 0.25% in HPCH spray demonstrates **favorable real-world effectiveness, excellent tolerability, and high adherence** in patients with AGA. The absence of systemic adverse effects highlights its potential as a **safer long-term alternative to oral therapy**.

These findings support the growing role of topical finasteride in routine clinical practice and underscore the need for larger, controlled studies to confirm long-term efficacy and optimize patient selection.

EADV CONGRESS
VIENNA
30 SEP - 3 OCT 2026

Abstract N°: 2562

A Case Report: A 14-Year-Old Patient with Severe Alopecia Areata, Vitiligo, and Atopic Dermatitis Undergoing Ivarmacitinib Treatment

XIN GUAN*[1]

[1] Department of Dermatology, Peking University Third Hospital, Beijing, China

Introduction
Immune-mediated inflammatory diseases (IMIDs) constitute a heterogeneous group of disorders. For patients presenting with more than one IMID, the use of Janus kinase (JAK) inhibitors may be considered a therapeutic option. Ivarmacitinib, a highly selective JAK1 inhibitor, has been approved in China for the treatment of severe alopecia areata and moderate-to-severe atopic dermatitis in adults. Real-world evidence regarding its efficacy and safety is accumulating through clinical case reports.

Case Presentation
A 14-year-old female patient with a three-year history of vitiligo and a three-month history of hair loss presented concurrently with skin lesions and pruritus. Her prior medical history was unremarkable. Physical examination revealed well-demarcated depigmented patches extending from the left chest and neck to the oral commissure. Scalp examination showed complete hair loss on the vertex, with sparse residual hairs at the periphery, along with depigmented patches and poliosis within the affected areas. The Severity of Alopecia Tool (SALT) score was 90. The diagnoses were severe alopecia areata, vitiligo, and moderate-to-severe atopic dermatitis.
The patient was subjected to treatment with ivarmacitinib at a dose of 4 mg administered orally once daily. At week 8 of treatment, scalp hair regrowth was observed, and the SALT score decreased to 70. By week 16, substantial hair regrowth was noted, with the SALT score improving to 0, indicating complete recovery. Symptoms of vitiligo and moderate-to-severe atopic dermatitis also showed varying degrees of improvement. No serious adverse events were reported during ivarmacitinib treatment, and the patient tolerated the therapy well.

Conclusion
This case demonstrates that, in a real-world setting, ivarmacitinib exhibits significant efficacy and a reliable safety profile in a pediatric patient with severe alopecia areata. It also represents a suitable therapeutic option for patients with multiple concurrent IMIDs.

EADV CONGRESS
VIENNA
30 SEP - 3 OCT 2026

Abstract N°: 2565

From descriptive to quantitative trichoscopy: current applications and limitations of artificial intelligence in hair and scalp disorders

Corrado Zengarini*[1, 2, 3], Nico Curti[4], Stephano Cedirian[1, 2], Luca Rapparini[1, 2], Francesca Pampaloni[1, 2], Alessandro Pileri[1, 2], Francesco Durazzi[4], Martina Mussi[1, 2, 3], Francesca Bruni[1, 2, 3], Federico Quadrelli[1, 2], Michelangelo La Placa[1, 2], Bianca Maria Piraccini[5], Michela Starace[1, 2]

[1] Department of Medical and Surgical Sciences, University of Bologna, Bologna, Italy

[2] Dermatology Unit, IRCCS Azienda Ospedaliero-Universitaria di Bologna, Dermatology Unit, IRCCS Azienda Ospedaliero-Universitaria di Bologna, Bologna, Italy

[3] Dermatology Unit, AUSL Bologna, Bologna, Italy

[4] Department of Physics and Astronomy "Augusto Righi", University of Bologna, Bologna, Italy

[5] Ambulatorio Piraccini, Bologna, Italy

Introduction

Trichoscopy has evolved from a qualitative diagnostic tool to a quantitative method for assessing hair and scalp disorders. The integration of computational image analysis and artificial intelligence (AI) is driving this transition, enabling objective and reproducible evaluation of follicular parameters. However, the extent of clinical validation and real-world applicability of these technologies remains uncertain.

Materials and Methods

A scoping review was conducted using a structured PubMed search based on MeSH terms related to trichoscopy, diagnostic imaging, and computational methods, including artificial intelligence and image processing. A citation network–based approach was applied to identify the most relevant and interconnected studies. Articles were screened according to PRISMA principles, and graph-based analysis was used to explore thematic clustering and research trends

Results

Out of 1,261 identified records, 58 studies were included: the most developed AI applications in trichoscopy focus on follicular unit quantification, including hair density, shaft diameter distribution, vellus-to-terminal ratio, and severity mapping, mainly using convolutional neural networks with object detection and instance segmentation architectures. Reported performances in controlled settings are promising, with high diagnostic accuracy in classification tasks and reliable automated morphometric measurements.

However, translation into clinical practice remains limited, and applications beyond basic follicular metrics such as hair count and shaft diameter are still scarce: most studies rely on small, single-center datasets with expert-annotated ground truth and lack external validation. In parallel, several AI-assisted trichoscopy platforms are commercially available, integrating image acquisition, cloud-based analysis, and automated reporting. Nevertheless, their validation methods and underlying datasets are typically proprietary and not publicly accessible, limiting independent verification and cross-platform comparability.

Finally, significant heterogeneity exists in image acquisition protocols, annotation standards, and evaluation metrics across studies, further reducing reproducibility. The collected citation network analysis highlighted fragmentation into distinct methodological and clinical clusters, with limited integration between technological development and real-world clinical validation.

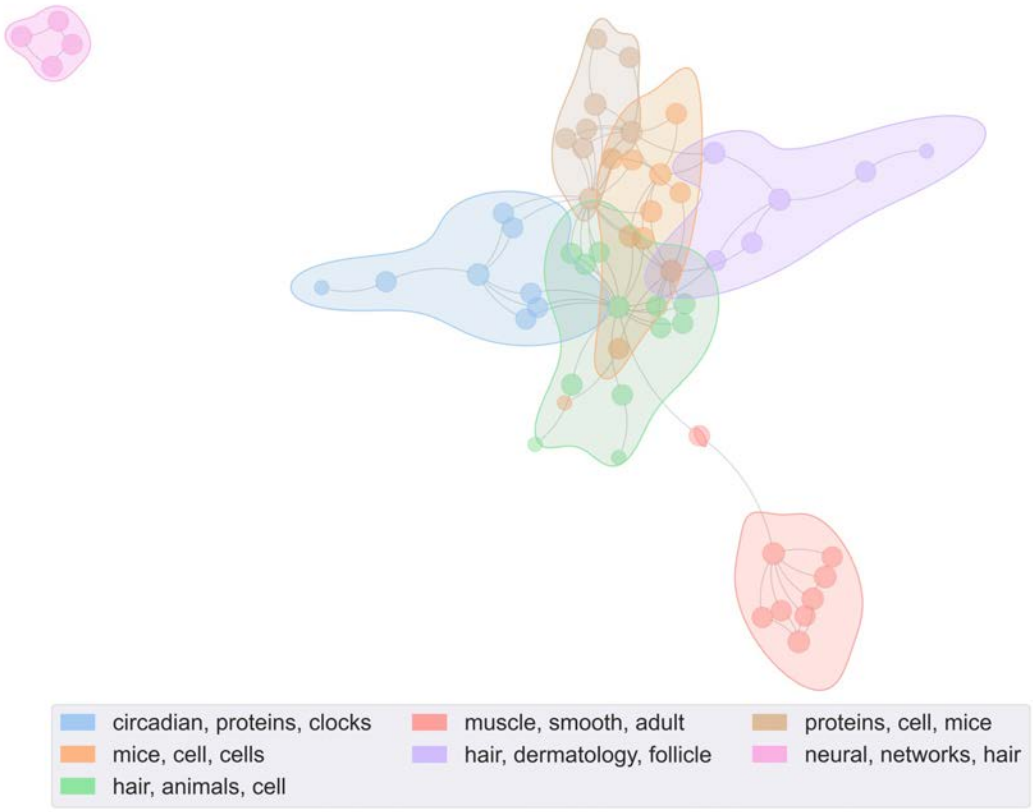

Pruned keyword co-occurrence network showing thematic clusters. Nodes represent keywords, edges indicate co-occurrence, and colored areas highlight communities, including circadian biology, smooth muscle, murine studies, hair follicle dermatology, neural networks, and animal cell research.

Conclusions

AI-assisted trichoscopy represents a promising step toward standardized and operator-independent evaluation of hair disorders but clinical translation is still constrained by limited dataset transparency, lack of shared benchmarking frameworks, and scarce prospective validation. Future developments should focus on standardized acquisition protocols, open and interoperable datasets, and real-world clinical studies to enable reliable integration into dermatological practice.

EA DV CONGRESS
VIENNA
30 SEP - 3 OCT 2026

Abstract N°: 2606

Lipedematous alopecia in a patient with systemic lupus erythematosus: A new case report

Ahd Jday*[1], Asmahane Souissi[1], Feryel Amri[1], mariem tabka[1], Imed Ben Ghorbel[2], Monia Khanfir[2], Mourad Mokni[1]

[1] Dermatology Department, Rabta Hospital, Tunis, Tunisia

[2] Department of Internal Medicine, Rabta Hospital, Tunis, Tunisia

Introduction

Lipedematous alopecia (LA) is a rare cutaneous entity characterized by an increase in the thickness of the subcutaneous adipose tissue of the scalp associated with hair thinning. While its etiology remains unknown, reported cases suggest possible associations with chronic inflammatory processes. We report the case of a patient presenting with LA that appeared concomitantly with the diagnosis of systemic lupus erythematosus (SLE).

Case Presentation

A 31-year-old female, with a 3-year history of primary infertility, was referred for a photosensitive erythematous facial eruption evolving for 10 days. Physical examination revealed a bilateral erosive and crusty malar rash, as well as generalized erythemato-squamous plaques on sun-exposed areas. Scalp examination showed two well-demarcated, non-scarring alopecia plaques (3 and 6 cm in diameter) located on the frontal area and the vertex. Palpation of these plaques revealed a soft, spongy, and painless thickening. The hair pull test was negative. Dermoscopic examination showed only vellus hairs, with no signs of alopecia areata (absence of yellow dots, black dots, or exclamation mark hairs).Histopathological examination of an alopecic plaque revealed a marked expansion of the hypodermic adipose tissue associated with a discrete perivascular lymphocytic infiltrate in the dermis. Direct immunofluorescence (DIF) showed intense deposits of IgG, IgM, C3, and C1q at the dermo-epidermal junction. Laboratory investigations revealed hemolytic anemia, lymphopenia, proteinuria (2g/day), and positive antinuclear antibodies (1/1600), confirming the diagnosis of SLE according to EULAR/ACR criteria. Treatment combining hydroxychloroquine and oral corticosteroids was initiated. After three months, the skin rash regressed and complete hair regrowth was achieved; dermoscopy confirmed normal hair density, length, and diameter.

Conclusion

LA is a rare entity, with only about fifty cases reported in the literature. Its pathogenesis remains debated. Some authors suggest that the thickening of adipose tissue may exert mechanical pressure on hair follicles, altering their microenvironment and shortening the hair cycle. The main differential diagnosis is alopecia areata; however, the spongy nature of the scalp on palpation and the absence of characteristic dermoscopic signs help guide the diagnosis. LA has been described in association with various conditions, including chronic renal failure, diabetes, and breast cancer. Associations with discoid lupus erythematosus of the scalp or systemic lupus flares, as seen in our patient, have also been reported. It has been hypothesized that the adipose tissue reacts to chronic inflammatory insult or follicular apoptosis. The favorable outcome following SLE-specific treatment in our patient suggests that adipose tissue remodeling may be reversible if systemic inflammation is controlled early.
Our observation highlights the importance of systematic scalp palpation in all cases of alopecia: identifying a spongy and compressible texture is a key clinical sign for the diagnosis of LA. In our patient, the initiation of SLE treatment led to complete hair regrowth, demonstrating the potential reversibility of lipedematous alopecia.

EADV CONGRESS
VIENNA
30 SEP - 3 OCT 2026

Abstract N°: 2618

An Overlap of Cutis Verticis Gyrata and Traction Alopecia Secondary to Chronic Scalp Tension: The Contribution of Inflammation

Ana Lígia Scotti Alérico*[1], Sandra e Dinato[1], Hudson Rezende[1], Ingrid Palloma Vieira de Melo[1]

[1] Centro Universitário Lusíada - UNILUS, Santos, Brazil

Introduction

Cutis Verticis Gyrata (CVG) is a rare disorder characterized by thickened folds and furrows of the scalp, resulting in a cerebriform appearance. CVG may be classified as primary or secondary, the latter being associated with inflammatory, neoplastic, endocrine, or mechanical conditions. Traction alopecia results from prolonged tension applied to the hair shafts, most commonly related to hairstyles that exert continuous traction on the scalp, leading to perifollicular inflammation, fibrosis, and progressive hair loss. Although rare, the coexistence of CVG and traction alopecia has been previously described, suggesting that chronic mechanical stress and inflammation-induced fibrotic remodeling may contribute to the development of both conditions.

Case Presentation

A 55-year-old black woman presented to the dermatology department with progressive alopecia associated with scalp allodynia and pruritus. She reported a lifelong history of tightly braided hairstyles and noted the onset of hair thinning at 18 years of age, with gradual progression thereafter.

Dermatological examination revealed extensive cicatricial alopecia with marked reduction in follicular density, predominantly affecting the frontoparietal regions, with relative preservation of terminal hairs at the periphery of the lesions. The scalp also exhibited thickened skin with convoluted folds and furrows showing a cerebriform pattern, predominantly involving the vertex region, consistent with Cutis Verticis Gyrata.

Dermoscopy of the vertex demonstrated scattered pustules, perifollicular scaling, and focal areas of polytrichia (“tufted hairs”). Additional investigations for conditions associated with secondary CVG were performed, with no significant abnormalities identified.

Conclusion

Chronic and prolonged scalp traction may induce repetitive microtrauma and sustain a persistent inflammatory response. Ongoing perifollicular inflammation can progressively damage the follicular unit, leading to follicular miniaturization and permanent hair loss, which are key mechanisms in traction alopecia. Simultaneously, the release of pro-inflammatory and profibrotic cytokines may stimulate dermal fibroblasts and excessive collagen deposition, contributing to dermal thickening, fibrosis, and the formation of the cerebriform folds characteristic of CVG.

Secondary CVG associated with chronic scalp traction is rare, and its concomitant occurrence with traction alopecia is even more uncommon. Cultural and cosmetic hair practices involving persistent traction may represent important predisposing factors for both conditions, particularly in genetically susceptible individuals.

POWERED BY M-ANAGE.COM

EA DV CONGRESS
VIENNA
30 SEP - 3 OCT 2026

Abstract N°: 2626

Upadacitinib for acute diffuse alopecia areata: rapid and substantial improvement

Wenyu Wu*[1], Ke Tao[1], Xinyi Zhang[1], Jinran Lin[1]

[1] Department of Dermatology, Huashan Hospital, Fudan University, Shanghai, China

Introduction

Diffuse alopecia areata (AA) is a form of AA characterized by diffuse hair thinning and shedding involving the entire scalp or a large scalp area. Acute diffuse AA typically presents with sudden onset and rapid disease progression, and may approach alopecia totalis in some patients. Corticosteroid therapy remains the recommended mainstay for acute-phase AA, with clinical improvement generally becoming evident over several months. JAK inhibitors have been recommended as first-line treatment for severe non-acute AA. Nevertheless, evidence regarding the use of JAK inhibitors, especially upadacitinib, in acute diffuse AA is still lacking.

Materials and Methods

This study included 15 patients with acute diffuse AA. All patients had a disease duration of less than 6 months and presented with diffuse hair loss. Demographic data, baseline clinical characteristics, and prior treatments are collected. All 15 patients received upadacitinib 15 mg/day for 16 weeks. During the 16-week follow-up, changes in SALT scores and adverse events were recorded.

Results

The median baseline SALT score was 62.0 (55.0–69.5), decreasing to 5 (3.0–12.5) at week 12 and to 0 (0–5.0) at week 16.

At week 12, 13 patients (86.67%) achieved SALT ≤20, 3 (20.00%) achieved SALT=0, 13 (86.67%) achieved $SALT_{50}$, and 9 (60.00%) achieved $SALT_{90}$.

At week 16, all patients achieved SALT ≤20, 8 achieved SALT=0, all achieved $SALT_{50}$, and 12 achieved $SALT_{90}$.

During 16 weeks of observation, only 1 patient developed acne, which improved after symptomatic treatment, and no serious adverse events occurred.

	Week 12	Week 16
SALT≤20, n (%)	13 (86.67)	15 (100.00)
SALT=0, n (%)	3 (20.00)	8 (53.33)
$SALT_{50}$, n (%)	13 (86.67)	15 (100.00)
$SALT_{90}$, n (%)	9 (60.00)	12 (80.00)

Conclusions

Our study found that upadacitinib induced rapid responses within 12 weeks in patients with acute diffuse AA and showed a favorable safety profile, suggesting that upadacitinib may represent a treatment option for acute-phase diffuse AA.

EA DV CONGRESS
VIENNA
30 SEP - 3 OCT 2026

Abstract N°: 2647

Pili Torti in a Patient with Porphyria Cutanea Tarda – A Case Report

Martyna Kiołbasa*[1], Marta Pośpiech[1], Maciej Pastuszczak[1]

[1] Medical University of Silesia, Katowice, Szpital Specjalistyczny w Zabrzu, Zabrze, Poland

Introduction

Porphyria Cutanea Tarda is the most common type of porphyria and results from decreased activity of uroporphyrinogen decarboxylase, leading to accumulation and increased urinary excretion of porphyrins. Typical clinical manifestations include skin fragility, blistering lesions on sun-exposed areas, and photosensitivity. Hair abnormalities are rarely reported.

Case Presentation

A 68-year-old woman presented with a 6-month history of progressive hair loss and lack of improvement after topical treatment. The patient additionally reported hair twisting and a previous diagnosis of Porphyria Cutanea Tarda established 8 years earlier based on elevated delta-aminolevulinic acid (ALA) levels after the occurrence of recurrent blistering lesions on the dorsal hands.

Physical examination revealed twisted hair shafts consistent with acquired pili torti, vertex hair thinning, hypertrichosis involving the temporal regions, eyebrows, and upper lip, as well as brown perifollicular papules on the scalp and upper back. Videodermoscopy confirmed characteristic twisting of the hair shafts. Although pili torti is most commonly associated with congenital disorders, detailed history revealed that the patient's hair had become progressively twisted approximately 2 years earlier. Archival photographs confirmed previously straight hair.

Further diagnostic work-up included Wood's lamp examination of urine, which demonstrated characteristic pink fluorescence. Laboratory investigations showed elevated liver enzymes, increased ferritin levels, high-normal serum iron, markedly elevated urinary porphyrins with predominance of uroporphyrin in 24-hour urine collection, and increased urinary coproporphyrin levels. Due to inconclusive abdominal ultrasonography, computed tomography was performed and raised suspicion of liver cirrhosis. The patient was referred for further hepatologic and hematologic evaluation.



Macroscopic and videodermoscopic appearance of pili torti hair in a patient with Porphyria Cutanea Tarda.

Conclusion

This case suggests that acquired pili torti may represent an underrecognized manifestation of Porphyria Cutanea Tarda. Recognition of unusual hair abnormalities in patients with porphyria may facilitate earlier diagnosis and broader understanding of the disease phenotype.

EA DV CONGRESS
VIENNA
30 SEP - 3 OCT 2026

Abstract N°: 2651

Scalp seborrheic keratosis with dermoscopic pattern mimicking melanoma following scalpmicroneedling: the critical role of pre-procedure trichoscopy

Luciana Valle*[1], MARIA EDUARDA BARBIERI ORTA[1], Sofia Leal[1], Debora Barbosa Ribas[1], Gisele Viana de Oliveira[1]

[1] Faculdade Ciências Médicas de Minas Gerais Fcmmg, Belo Horizonte, Brazil

Introduction

Brazil ranks second worldwide in aesthetic procedures, with 3.1 million performed in 2024 (ISAPS), and scalp microneedling (MMP) is among the fastest-growing treatments for alopecia. Despite its broadly promoted safety profile, the effects of repetitive mechanical trauma on pre-existing pigmented scalp lesions constitute an insufficiently investigated clinical gap. The literature recognizes that irritated or traumatized seborrheic keratoses may acquire atypical dermoscopic patterns mimicking melanoma or squamous cell carcinoma (Braga et al., JAAD, 2008), and that invasive scalp procedures may induce pigmentary, inflammatory and structural alterations in pre-existing melanocytic lesions, impairing dermoscopic assessment and potentially delaying oncological diagnoses. Trichoscopy, with 98.1% sensitivity and 95.5% specificity for melanoma detection, constitutes an indispensable tool not only for diagnosing hair disorders, but equally for screening pigmented lesions at this high-risk site, where findings are frequently asymptomatic and incidental. The dermoscopic overlap between both entities, documented in 134 cases (Carrera et al., JAMA Dermatology, 2017), reinforces trichoscopic screening prior to any invasive scalp intervention.

Case Presentation

A 63-year-old woman presented for trichological evaluation with a complaint of diffuse hair shedding. She reported a previous history of treatment, including six sessions of microneedling with drug delivery (MMP). No prior trichoscopic examination had been performed. Dermatological examination incidentally revealed an asymptomatic melanocytic-appearing lesion on the left frontoparietal scalp. Macroscopically, the lesion was flat, measuring approximately 6 × 4 cm, with heterogeneous pigmentation ranging from light brown to black, irregular borders, and asymmetric distribution. Trichoscopic evaluation demonstrated marked multicomponent pigmentation, dense central hyperpigmentation with poorly defined margins, irregular peripheral radial projections in a starburst-like pattern, scattered pigmented dots, irregular pigment network, and pronounced structural asymmetry. These findings, although representing an indeterminate dermoscopic pattern, exhibited features associated with an increased risk of malignancy in a high-risk oncologic area that is inherently difficult to monitor clinically. An incisional biopsy targeting the most hyperpigmented area was performed. Concurrently, the patient was diagnosed with chronic telogen effluvium and initiated on low-dose oral minoxidil in an escalating regimen. Histopathological examination revealed acanthosis with proliferation of mature pigmented basaloid cells arranged in anastomosing cords, permeated by horn pseudocysts, associated with a dermal mononuclear inflammatory infiltrate, consistent with seborrheic keratosis. At six-month follow-up, without any additional intervention, near-complete regression was observed on both macroscopic and trichoscopic examination.

Conclusion

This case documents a possible association between successive microneedling sessions and dermoscopic modification of a pre-existing seborrheic keratosis, generating a pattern that mimicked melanoma on trichoscopy and was confirmed as benign only upon biopsy. The local inflammatory cascade and mediator release represent a biologically plausible mechanism for the observed changes; however, a causal relationship cannot be established from a single case. Spontaneous regression following treatment cessation supports, without confirming, a

procedure-related etiology. Scalp melanoma tends to be diagnosed at more advanced stages and carries worse prognosis compared to other cutaneous sites, a risk amplified when invasive procedures are performed without prior trichoscopic screening. Given the still incompletely understood consequences of repetitive scalp trauma on pre-existing pigmented lesions, systematic trichoscopic evaluation prior to any invasive scalp intervention is strongly advocated.

EADV CONGRESS
VIENNA
30 SEP - 3 OCT 2026

Abstract N°: 2657

Postoperative Folliculitis After FUE: The Role of Hormonal Therapy and Follicular Trauma

Ingrid Palloma Vieira de Melo*[1], Hudson Rezende[1], João Henrique Aurich[1], Mariana Menezes de Mauro[2], Antonio Moraes Madeira Quindos[3]

[1] Centro Universitário Lusíada, Santos, Brazil
[2] Universidade São Francisco, Bragança Paulista, Brazil
[3] Universidade de Taubaté (UNITAU), Taubaté, Brazil

Introduction
Folliculitis is the most common complication after follicular unit extraction (FUE), yet the factors driving its occurrence remain incompletely understood, particularly when considering donor and recipient areas separately. While follicular trauma is inherent to the procedure, the influence of systemic factors, such as exogenous testosterone use, has not been clearly established. Understanding these associations is essential, as folliculitis in the recipient area may compromise graft survival and final outcomes.

Materials and Methods
A retrospective analysis was conduced of 143 male patients who underwent FUE between December 2021 and January 2025 and presented at least one early postoperative complication. Clinical and surgical variables were reviewed, including age, number of procedures, graft characteristics, surgical duration, anesthesia type, antibiotic use, partial follicular transection rate (PTxR), and hormone therapy status.
Folliculitis was defined clinically by the presence of erythematous papules or pustules centered on follicular units during follow-up. Associations were analyzed using Student's t-test and Pearson's chi-square test, with $p < 0.05$ considered significant.

Results
Folliculitis was observed in 77.6% of patients, more frequently in the donor area (68.5%) than in the recipient area (49.6%). A strong association was found between folliculitis and higher partial follicular transection rates in both regions ($p < 0.001$). Hormonal therapy emerged as an additional relevant factor. Among patients receiving testosterone-based therapy, 90% developed folliculitis, compared to 56.6% of non-users ($p < 0.001$). No significant associations were observed with age, number of procedures, surgical duration, anesthesia type, or antibiotic use. Other complications, including infection and bleeding, were infrequent and not associated with folliculitis.

Conclusions
This study highlights two clinically relevant factors associated with postoperative folliculitis after FUE: follicular trauma, reflected by higher transection rates, and exogenous testosterone use. Both may contribute to a pro-inflammatory microenvironment, favoring follicular inflammation in the early postoperative period.
These findings suggest that careful surgical technique aimed at minimizing follicular injury, along with a more attentive evaluation of hormonal status, may help reduce postoperative complications. Further prospective studies are needed, but these results already support a more individualized risk assessment in patients undergoing hair transplantation.

EADV Congress 2026, VIENNA
30 SEPTEMBER - 03 OCTOBER 2026
POWERED BY M-ANAGE.COM

EA DV CONGRESS
VIENNA
30 SEP - 3 OCT 2026

Abstract N°: 2669

Efficacy of deuruxolitinib in patients with severe alopecia areata by baseline eyebrow involvement: Pooled post hoc analysis of the THRIVE-AA1 and THRIVE-AA2 Phase 3 trials

Arash Mostaghimi*[1], Maryanne M. Senna[2], Natasha Mesinkovska[3], Brett King[4], Heidi Goldstein[5], Yasmin Mathlin[5], Kizito Kyerematenng[5], Nicholas Squittieri[5]

[1] Department of Dermatology, Brigham and Women's Hospital, Boston, United States
[2] Lahey Hair Loss Center of Excellence, Lahey Hospital and Medical Center, Burlington, United States
[3] Department of Dermatology, School of Medicine, University of California Irvine, Irvine, United States
[4] Dermatology Physicians of Connecticut, Fairfield, United States
[5] Sun Pharmaceutical Industries, Inc., Princeton, United States

Introduction
Alopecia areata (AA) is an autoimmune disorder characterized by nonscarring scalp hair loss, with or without involvement of other hair-bearing areas of the body. Eyebrow involvement has been reported in AA with varying prevalence; patients with AA have indicated that eyebrow involvement is as important as scalp hair loss. The Janus kinase 1/2 inhibitor deuruxolitinib is approved for the treatment of adults with severe AA. This pooled post hoc analysis examined the efficacy of deuruxolitinib in patients with or without baseline eyebrow involvement in THRIVE-AA1 (NCT04518995) and THRIVE-AA2 (NCT04797650).

Materials and Methods
Adults 18 to 65 years of age with a diagnosis of AA and ≥50% scalp hair loss received deuruxolitinib 8 mg twice daily (BID) or placebo for 24 weeks. Eyebrow involvement was determined by the rater's "yes" or "no" response to the question, "Is there eyebrow involvement?" Scalp hair loss was assessed in patients with and without baseline eyebrow involvement using Severity of Alopecia Tool (SALT) scores at Week 24. Proportions of patients achieving SALT scores ≤20 or ≤10 at Week 24 were compared between treatment groups by baseline eyebrow involvement.

Results
For patients receiving deuruxolitinib 8 mg BID (n = 600) and placebo (n = 267), the mean age was 38.6 and 39.0 years, respectively; 35.8% and 34.8% were male; and 73.8% and 74.2% were White. In the pooled population, a comparable percentage of patients receiving deuruxolitinib 8 mg BID (431/600 [71.8%]) and placebo (197/267 [73.8%]) had baseline eyebrow involvement. At Week 24, among patients with baseline eyebrow involvement, a significantly higher percentage of patients receiving deuruxolitinib 8 mg BID achieved a SALT score ≤20 vs placebo (26.9% [109/405] vs 0% [0/184]; P <0.0001). Similarly, among patients without baseline eyebrow involvement, a significantly higher percentage of patients receiving deuruxolitinib 8 mg BID achieved a SALT score ≤20 vs placebo (45.6% [47/103] vs 4.2% [2/48]; P <0.0001). Further, among patients with baseline eyebrow involvement, 18.8% (76/405) of patients receiving deuruxolitinib 8 mg achieved a SALT score ≤10 at Week 24, compared with 0% (0/184) of patients receiving placebo (P <0.0001). Among those without baseline eyebrow involvement, 36.9% (38/103) of patients receiving deuruxolitinib 8 mg achieved a SALT score ≤10 at Week 24, compared with 0% (0/48) of patients receiving placebo (P <0.0001). There was no significant difference in the percentage of patients receiving deuruxolitinib 8 mg BID with vs without eyebrow involvement at baseline who achieved a SALT score ≤20 (P = 0.4084) or ≤10 (P = 0.1680) at Week 24.

Conclusions

In patients with and without baseline eyebrow involvement, a significantly greater proportion of patients receiving deuruxolitinib 8 mg BID achieved SALT scores ≤20 and ≤10 at Week 24, compared with patients who received placebo, indicating that baseline eyebrow involvement does not affect the efficacy of deuruxolitinib.

EA DV CONGRESS
VIENNA
30 SEP - 3 OCT 2026

Abstract N°: 2674

Efficacy of deuruxolitinib in patients with severe alopecia areata by baseline eyelash involvement: Pooled post hoc analysis of the THRIVE-AA1 and THRIVE-AA2 Phase 3 trials

Maryanne M. Senna*[1], Natasha Mesinkovska[2], Brett King[3], Arash Mostaghimi[4], Heidi Goldstein[5], Yasmin Mathlin[5], Kizito Kyerematenng[5], Nicholas Squittieri[5]

[1] Lahey Hair Loss Center of Excellence, Lahey Hospital and Medical Center, Burlington, United States
[2] Department of Dermatology, School of Medicine, University of California Irvine, Irvine, United States
[3] Dermatology Physicians of Connecticut, Fairfield, United States
[4] Department of Dermatology, Brigham and Women's Hospital, Boston, United States
[5] Sun Pharmaceutical Industries, Inc., Princeton, United States

Introduction
Alopecia areata (AA), an autoimmune disorder characterized by nonscarring scalp hair loss, may affect other areas of the body. Eyelash involvement has been reported in patients with AA and eyelash hair loss has been associated with reduced quality of life. The Janus kinase 1/2 inhibitor deuruxolitinib is indicated for the treatment of adults with severe AA. This pooled post hoc analysis examined the efficacy of deuruxolitinib in patients with AA with or without baseline eyelash involvement in THRIVE-AA1 (NCT04518995) and THRIVE-AA2 (NCT04797650).

Materials and Methods
In the two trials, patients 18 to 65 years of age with a diagnosis of AA and ≥50% scalp hair loss received deuruxolitinib 8 mg twice daily (BID) or placebo for 24 weeks. Eyelash involvement was determined by the rater's "yes" or "no" response to the question, "Is there eyelash involvement?" Scalp hair loss was assessed in patients with and without baseline eyelash involvement using Severity of Alopecia Tool (SALT) scores at Week 24. Proportions of patients achieving SALT scores ≤20 or ≤10 at Week 24 were compared between treatment groups.

Results
Patients in the pooled population (deuruxolitinib 8 mg BID [n=600]; placebo [n=267]) had a mean age of approximately 39 years, approximately one-third were male, and approximately 74% were White. In the pooled population, 421/600 (70.2%) and 182/267 (68.2%) patients receiving deuruxolitinib 8 mg BID or placebo, respectively, had baseline eyelash involvement. At Week 24, among patients with baseline eyelash involvement, a significantly higher percentage of patients receiving deuruxolitinib 8 mg BID achieved a SALT score ≤20 vs placebo (26.9% [105/391] vs 0% [0/170]; P <0.0001). Similarly, among patients without baseline eyelash involvement, a significantly higher percentage of patients receiving deuruxolitinib 8 mg BID achieved a SALT score ≤20 vs placebo (39.3% [57/145] vs 2.8% [2/72]; P <0.0001). Additionally, among patients with baseline eyelash involvement, a significantly greater percentage of patients receiving deuruxolitinib 8 mg vs placebo achieved a SALT score ≤10 at Week 24 (18.7% [73/391] vs 0% [0/170]; P <0.0001). Among those without baseline eyelash involvement, 30.3% (44/145) vs 0% (0/72) of patients receiving deuruxolitinib 8 mg or placebo achieved a SALT score ≤10 at Week 24 (P <0.0001). There was no significant difference in the percentage of patients receiving deuruxolitinib 8 mg BID with vs without eyelash involvement at baseline who achieved a SALT score ≤20 (P = 0.7965) or ≤10 (P = 0.4423) at Week 24.

Conclusions
Significantly greater proportions of patients receiving deuruxolitinib 8 mg BID achieved SALT scores of ≤20 and ≤10 at Week 24 versus placebo-treated patients, regardless of baseline eyelash involvement, indicating that this

baseline characteristic does not affect the efficacy of deuruxolitinib.

EA DV CONGRESS
VIENNA
30 SEP - 3 OCT 2026

Abstract N°: 2680

Efficacy of deuruxolitinib in patients with severe alopecia areata by baseline nail involvement: Pooled post hoc analysis of the THRIVE-AA1 and THRIVE-AA2 Phase 3 trials

Natasha Mesinkovska*[1], Brett King[2], Arash Mostaghimi[3], Maryanne M. Senna[4], Heidi Goldstein[5], Yasmin Mathlin[5], Kizito Kyerematenng[5], Nicholas Squittieri[5]

[1] Department of Dermatology, School of Medicine, University of California Irvine, Irvine, United States
[2] Dermatology Physicians of Connecticut, Fairfield, United States
[3] Department of Dermatology, Brigham and Women's Hospital, Boston, United States
[4] Lahey Hair Loss Center of Excellence, Lahey Hospital and Medical Center, Burlington, United States
[5] Sun Pharmaceutical Industries, Inc., Princeton, United States

Introduction
Alopecia areata (AA) is an inflammatory autoimmune disorder resulting in nonscarring hair loss of the scalp or other areas of the body. Some patients with AA present with nail changes, including pitting and trachyonychia. Nail involvement occurs more frequently in patients with severe forms of AA. Deuruxolitinib, a Janus kinase 1/2 inhibitor is approved for adults with severe AA. This pooled post hoc analysis evaluated the efficacy of deuruxolitinib in patients with AA with or without nail involvement at baseline in the THRIVE-AA1 (NCT04518995) and THRIVE-AA2 (NCT04797650) Phase 3 trials.

Materials and Methods
Adults aged 18 to 65 years with a diagnosis of AA and ≥50% scalp hair loss were treated with deuruxolitinib 8 mg twice daily (BID) or placebo for 24 weeks. Nail involvement was determined by the rater's "yes" or "no" response to the question, "Is there nail involvement?" Scalp hair loss was assessed by Severity of Alopecia Tool (SALT) scores at Week 24. Efficacy was based on patients who achieved a SALT score ≤20 or ≤10 at Week 24.

Results
Among the patients receiving deuruxolitinib 8 mg BID (n = 600) and placebo (n = 267), the mean age was approximately 39 years and approximately 64% were female and 74% were White. At baseline, 233/600 (38.8%) patients receiving deuruxolitinib 8 mg BID and 103/600 (38.6%) patients treated with placebo had nail involvement. Of the patients with baseline nail involvement, 64/217 (29.5%) patients receiving deuruxolitinib 8 mg BID and 0/95 patients treated with placebo achieved a SALT score ≤20 at Week 24 (P <0.0001 vs placebo). For patients without baseline nail involvement, 104/330 (31.5%) and 2/151 (1.3%) patients treated with deuruxolitinib 8 mg BID and placebo, respectively, achieved a SALT score ≤20 at Week 24 (P <0.0001 vs placebo). Additionally, among patients with baseline nail involvement, 45/217 (20.7%) patients receiving deuruxolitinib 8 mg BID and 0/95 patients treated with placebo achieved a SALT score ≤10 at Week 24 (P <0.0001 vs placebo). For those without baseline nail involvement, 76/330 (23.0%) and 0/151 patients treated with deuruxolitinib 8 mg BID and placebo, respectively, achieved a SALT score ≤10 at Week 24 (P <0.0001 vs placebo). There was no significant difference in the percentage of patients receiving deuruxolitinib 8 mg BID with vs without nail involvement at baseline who achieved a SALT score ≤20 (P = 0.9224) or ≤10 (P = 0.9004) at Week 24.

Conclusions
Similar proportions of patients with and without baseline nail involvement achieved a SALT score ≤20 or ≤10 at Week 24 with deuruxolitinib, demonstrating that baseline nail involvement does not impact the efficacy of deuruxolitinib.

EA DV CONGRESS
VIENNA
30 SEP - 3 OCT 2026

Abstract N°: 2682

Maintenance of hair regrowth following dose reduction or discontinuation of deuruxolitinib in patients with severe alopecia areata: A Phase 2 randomized study

Natasha Mesinkovska*[1], Paradi Mirmirani[2], Amy McMichael[3], Ted Lain[4], Bridget Daly[5], Heidi Goldstein[6], Kizito Kyerematenge[6], Nicholas Squittieri[6], Brett King[7]

[1] Department of Dermatology, School of Medicine, University of California Irvine, Irvine, United States
[2] Department of Dermatology, The Permanente Medical Group, Vallejo, United States
[3] Department of Dermatology, Wake Forest University School of Medicine, Winston-Salem, United States
[4] Sanova Dermatology, Austin, United States
[5] Rho, Inc., Durham, United States
[6] Sun Pharmaceutical Industries, Inc., Princeton, United States
[7] Dermatology Physicians of Connecticut, Fairfield, United States

Introduction
Deuruxolitinib, a Janus kinase 1/2 inhibitor is approved in the US for adults with severe alopecia areata. This Phase 2 study (NCT04784533) assessed the effect of deuruxolitinib dose reduction or discontinuation on scalp hair regrowth in patients with severe alopecia areata.

Materials and Methods
In Part A, Period 1 (PAP1), patients aged 18 to 65 years with AA and ≥50% scalp hair loss were randomized to deuruxolitinib 8 mg (DRX8) or 12 mg (DRX12) twice daily for 24 weeks. The results for the DRX8 group are presented herein. In Part A, Period 2 (PAP2), patients achieving a response (Severity of Alopecia Tool [SALT] score ≤20 in PAP1) were rerandomized to a lower deuruxolitinib dose or placebo (DRX8-deuruxolitinib 4 mg [DRX4], or DRX8-placebo) for up to 24 weeks or loss of maintenance (LOM; defined as SALT score >20). Patients with LOM entered Part B and received their original deuruxolitinib dose from PAP1 for 24 weeks. Scalp hair loss was assessed by SALT at baseline and every 4 weeks. Safety included treatment-emergent adverse events (TEAEs).

Results
In PAP1, response was achieved by 36/163 (22.1%) patients receiving DRX8 at Week 24. By the end of PAP2, LOM criteria were met by 5/18 (27.8%; DRX8-DRX4) patients in the dose-reduction group, and 15/18 (83.3%; DRX8-placebo) patients in the treatment-discontinuation group. Patients discontinuing treatment met LOM criteria faster compared with those who underwent dose reduction. In Part B, patients who underwent deuruxolitinib retreatment after dose reduction (n = 5) experienced faster scalp hair regrowth vs those who discontinued treatment (n = 13). Most TEAEs were mild or moderate in severity.

Conclusions
Following hair regrowth with deuruxolitinib, dose reduction or discontinuation resulted in loss of treatment response. Scalp hair regrowth was restored in most patients retreated with deuruxolitinib.

EA DV CONGRESS
VIENNA
30 SEP - 3 OCT 2026

Abstract N°: 2684

Deuruxolitinib improves scalp hair regrowth in adults with severe alopecia areata: Long-term efficacy results from an open-label extension study

Athanasios Tsianakas*[1], Thierry Passeron[2, 3], Pawel Brzewski[4], Ajith Cy[5, 6], Brett King[7], Nina Magnolo[8], Manabu Ohyama[9], Ricardo Romiti[10], Rodney Sinclair[11], Dmitri Wall[12, 13, 14, 15], Heidi Goldstein[16], Asif Shaikh[16], Kizito Kyerematenge[16], Arash Mostaghimi[17]

[1] Department of Dermatology, Fachklinik Bad Bentheim, Bad Bentheim, Germany
[2] Department of Dermatology, University Hospital of Nice, Côte d'Azur University, Nice, France
[3] INSERM U1065, C3M, Côte d'Azur University, Nice, France
[4] Department of Dermatology, Jagiellonian University, Krakow, Poland
[5] Alliance Clinical Trials and Probity Medical Research, Inc., Waterloo, Canada
[6] Faculty of Health Sciences Department of Medicine, McMaster University, Waterloo, Canada
[7] Dermatology Physicians of Connecticut, Fairfield, United States
[8] Department of Dermatology, University Hospital of Münster, Münster, Germany
[9] Department of Dermatology, Kyorin University School of Medicine, Tokyo, Japan
[10] Department of Dermatology, University of São Paulo, São Paulo, Brazil
[11] Sinclair Dermatology, Melbourne, Australia
[12] Hair Restoration Blackrock, Dublin, Ireland
[13] Charles Institute of Dermatology, UCD School of Medicine, University College Dublin, Dublin, Ireland
[14] Department of Dermatology, Mater Misericordiae University Hospital, Dublin, Ireland
[15] National and International Skin Registry Solutions, University College Dublin, Dublin, Ireland
[16] Sun Pharmaceutical Industries, Inc., Princeton, United States
[17] Department of Dermatology, Brigham and Women's Hospital, Boston, United States

Introduction

Alopecia areata (AA) is a chronic autoimmune disease causing reversible hair loss. Deuruxolitinib 8 mg twice daily (BID) is approved in the US and UK for the treatment of adults with severe AA based on results from the 24-week, Phase 3 THRIVE-AA1 and THRIVE-AA2 trials. Patients with severe AA often require prolonged treatment to maintain hair regrowth. Long-term efficacy of deuruxolitinib for the treatment of patients with severe AA has not yet been reported.

Materials and Methods

Patients aged 18 to 65 years with ≥50% hair loss completing 24 weeks of treatment in either THRIVE-AA1 or THRIVE-AA2 were included in 1 of 2 open-label extension (OLE) studies; we report results from the European OLE study (NCT05041803). Patients receiving deuruxolitinib 8 mg or 12 mg BID in the Phase 3 trials continued the same dose in the OLE study. Patients receiving placebo in Phase 3 trials were randomized 1:1 to either deuruxolitinib 8 mg or 12 mg BID in the OLE study. The deuruxolitinib 12 mg BID dose was discontinued after rare incidence of thrombosis with long-term administration and patients were switched to deuruxolitinib 8 mg BID. Data for deuruxolitinib 8 mg BID are presented. Scalp hair regrowth was assessed by Severity of Alopecia Tool (SALT) score every 4 weeks through the first 12 weeks, then every 8 weeks thereafter. At Week 52, patients with a SALT score ≤20 (responders) could continue in the OLE study for up to 56 additional weeks, while those with a SALT score >20 (nonresponders) completed the study. Efficacy outcomes included the percentage of responders

up to Week 108, the shift in treatment response from OLE baseline (the last assessment prior to receiving study drug in the OLE) up to Week 108, and changes in SALT scores over time. Missing SALT scores were not imputed.

Results

Overall, 407 patients (THRIVE-AA1, 114/407 [28.0%]; THRIVE-AA2, 293/407 [72.0%]) were enrolled in the OLE study. Of the 255 patients receiving deuruxolitinib 8 mg BID at OLE baseline, 201 (78.8%) patients completed the study. Patients in the deuruxolitinib 8 mg BID group had a mean age of 38.9 years, 71.0% were female, 75.7% were White, and the mean OLE baseline SALT score was 60.2. Among the 114 patients continually receiving deuruxolitinib 8 mg BID in the qualifying studies and the OLE study (DRX8-DRX8 group), 88 (77.2%) were responders at Week 52. Of the 22 patients receiving placebo in the qualifying studies and switching to deuruxolitinib 8 mg BID in the OLE study (placebo-DRX8 group), 19 (86.4%) were responders at Week 52. In the DRX8-DRX8 group, 36/47 (76.6%) nonresponders (SALT score >20) at OLE baseline that continued to Week 52 achieved response (SALT score ≤20) at Week 52; at Week 108, 30/31 (96.8%) shifted from nonresponse at OLE baseline to response. In the DRX8-DRX8 group, 52/52 (100%) patients with a SALT score ≤20 at OLE baseline maintained a response at Week 52; of the patients in this group, 46/49 (93.9%) were responders at Week 108. In the placebo-DRX8 group, similar trends were observed with increasing proportions of OLE baseline nonresponders shifting to response at Weeks 52 and 108. SALT scores decreased from OLE baseline through Week 108. In the DRX8-DRX8 group, the mean (standard deviation [SD]) changes in SALT scores from OLE baseline were -20.8 (27.98) at Week 52 and -20.4 (30.05) at Week 108, corresponding to relative increases of 68% and 30% , respectively, in mean scalp hair regrowth. In the placebo-DRX8 group, the mean (SD) changes from OLE baseline in SALT scores were -78.0 (23.20) at Week 52 and -88.0 (14.69) at Week 108, corresponding to relative increases of 90% and 97% in mean scalp hair regrowth.

Conclusions

Deuruxolitinib 8 mg BID resulted in clinically meaningful improvements in scalp hair regrowth for up to 108 weeks of treatment, with most patients maintaining response through Week 108. The results support the long-term efficacy of deuruxolitinib for severe AA.

EADV CONGRESS
VIENNA
30 SEP - 3 OCT 2026

Abstract N°: 2686

Predictors of Treatment Response to Ritlecitinib: The Impact of Prior Systemic Therapy and DCP Exposure in Severe Alopecia Areata

Kareem Hassanin*[1], Danning Li[2], Radhika Bhanot[3], Sonika Sethi Nayyar[4], Vidette Wong[3], Graciaa Singhal[5], Sarah Elhabrouk[4], Donna Thompson[4], James Halpern[1], Simon Tso[2], Tang Ngee Shim[3], Kashini Andrew[6]

[1] Walsall Manor Hospital, Walsall, United Kingdom
[2] South Warwickshire University NHS Foundation Trust, Warwick, United Kingdom
[3] University Hospitals Coventry and Warwickshire NHS Trust, Coventry, United Kingdom
[4] Sandwell and West Birmingham NHS Trust, Birmingham, United Kingdom
[5] New Cross Hospital, Wolverhampton, United Kingdom
[6] Worcestershire Acute Hospitals NHS Trust, Worcester, United Kingdom

Introduction

This multi-centre study, involving 4 dermatology centres in the UK, aimed to evaluate the early real-world outcomes of ritlecitinib 50 mg once daily in patients with severe AA. Fifty-four patients with severe alopecia areata were deemed eligible for inclusion, identified through locally maintained records. Patients were excluded if they did not have three months' worth of follow up data. Data was collated using OneDrive and analysed with R version 4.3.3.

Materials and Methods

Data were extracted on age, sex, ethnicity, date of ritlecitinib commencement, duration of alopecia onset, involvement of eyebrows and eyelashes, laboratory analyses, adverse events, Patient Global Impression of Change score (PGIC), and severity of alopecia tool (SALT) score at baseline, three months, and six months. Data on previous DCP or systemic utilisation was also collated. Treatment success was defined as a SALT score of 20 or less at three or six months.

Results

Among 54 patients, treatment success occurred in 15 cases. Further exploratory findings suggest that past diphencyprone (DCP) usage is inverse to treatment success; only 1/15 (6.67%; Fisher's exact, p = 0.043) patients with prior DCP exposure achieved treatment success compared with 14/39 patients without prior DCP exposure.

Across 15 patients treated with systemic therapy, oral prednisolone was the most common treatment (used in 9 patients), followed by methotrexate (6 patients), while ciclosporin was used in 2 patients, and oral betamethasone and guselkumab (for concurrent psoriatic arthritis) were each used in 1 patient.

The success rate in the systemic exposed group was 6/ 15 (40%) and non-systemic exposed group 9/ 39 (23.1%), although this finding was not statistically significant (chi-squared p value = 0.217, which may have been secondary to sparse data.

Conclusions

Although both DCP and systemic therapy may act as proxies for more severe or treatment-resistant disease, the differing trends observed raise the possibility of distinct biological effects. One hypothesis is that prior systemic immunosuppression may modulate immune pathways in a way that enhances responsiveness to JAK inhibition.

Overall, these findings support the use of ritlecitinib across a heterogeneous patient population, suggesting that prior systemic therapy does not necessarily limit the likelihood of treatment success with ritlecitinib. Further validation in larger studies is warranted to better characterise these observations.

EA DV CONGRESS
VIENNA
30 SEP - 3 OCT 2026

Abstract N°: 2688

Safety of deuruxolitinib with up to 2 years of treatment in adults with severe alopecia areata: Long-term results from an open-label extension study

Athanasios Tsianakas*[1], Thierry Passeron[2, 3], Pawel Brzewski[4], Ajith Cy[5, 6], Brett King[7], Nina Magnolo[8], Manabu Ohyama[9], Ricardo Romiti[10], Rodney Sinclair[11], Dmitri Wall[12, 13, 14, 15], Heidi Goldstein[16], Asif Shaikh[16], Kizito Kyerematenng[16], Arash Mostaghimi[17]

[1] Department of Dermatology, Fachklinik Bad Bentheim, Bad Bentheim, Germany
[2] Department of Dermatology, University Hospital of Nice, Côte d'Azur University, Nice, France
[3] INSERM U1065, C3M, Côte d'Azur University, Nice, France
[4] Department of Dermatology, Jagiellonian University, Krakow, Poland
[5] Alliance Clinical Trials and Probity Medical Research, Inc., Waterloo, Canada
[6] Faculty of Health Sciences Department of Medicine, McMaster University, Waterloo, Canada
[7] Dermatology Physicians of Connecticut, Fairfield, United States
[8] Department of Dermatology, University Hospital of Münster, Münster, Germany
[9] Department of Dermatology, Kyorin University School of Medicine, Tokyo, Japan
[10] Department of Dermatology, University of São Paulo, São Paulo, Brazil
[11] Sinclair Dermatology, Melbourne, Australia
[12] Hair Restoration Blackrock, Dublin, Ireland
[13] Charles Institute of Dermatology, UCD School of Medicine, University College Dublin, Dublin, Ireland
[14] Department of Dermatology, Mater Misericordiae University Hospital, Dublin, Ireland
[15] National and International Skin Registry Solutions, University College Dublin, Dublin, Ireland
[16] Sun Pharmaceutical Industries, Inc., Princeton, United States
[17] Department of Dermatology, Brigham and Women's Hospital, Boston, United States

Introduction

Alopecia areata (AA) is a chronic inflammatory condition characterized by nonscarring hair loss. Deuruxolitinib, an oral Janus kinase 1/2 inhibitor, is approved in the US and UK at a dose of 8 mg twice daily (BID) for the treatment of adults with severe AA based on results from the THRIVE-AA1 and THRIVE-AA2 Phase 3 trials. Long-term safety results of deuruxolitinib from 1 of 2 open-label extension (European OLE) studies are presented.

Materials and Methods

Adults aged 18 to 65 years with ≥50% hair loss who completed 24 weeks of treatment in either THRIVE-AA1 or THRIVE-AA2 were included in this OLE study (NCT05041803). Patients who received deuruxolitinib 8 mg or 12 mg BID in the qualifying trials continued the same dose in the OLE study; those who received placebo in the qualifying trials were randomized 1:1 to receive deuruxolitinib 8 mg or 12 mg BID in the OLE study. Dose adjustment was allowed at the discretion of the investigator. Safety was assessed by treatment-emergent adverse events (TEAEs; every 4 weeks through Week 108) and clinical laboratory assessments (every 8 weeks through Week 108). The deuruxolitinib 12-mg BID dose was discontinued after rare reports of thrombosis with long-term administration and patients were switched to deuruxolitinib 8 mg BID. Data for 3 populations are described here: patients receiving deuruxolitinib 8 mg BID at any time during OLE (n=367); those initiating deuruxolitinib 8 mg BID in the OLE (n=255); and those continually receiving deuruxolitinib 8 mg BID (n=137).

Results

A total of 367 of 407 (90.2%) enrolled patients received deuruxolitinib 8 mg BID at some point in the OLE study, including 255 (62.6%) who initiated OLE dosing with deuruxolitinib 8 mg BID. For those 255, the mean age was 38.9 years, 71.0% were female, 75.7% were White, and the mean Severity of Alopecia Tool score at OLE baseline (defined as the last assessment prior to receiving study drug in the OLE) was 60.2; 41 (16.1%) patients reported past or concomitant diseases, conditions, or serious infection, or past surgeries. A total of 1260 TEAEs were reported in 308 of 367 (83.9%) patients treated with deuruxolitinib 8 mg BID. TEAEs led to drug interruption in 89 of 367 (24.3%), dose reduction in 3 of 367 (0.8%), and discontinuation in 4 of 367 (1.1%) patients; there were no deaths among patients receiving deuruxolitinib 8 mg BID. Most TEAEs were mild (161 of 367 [43.9%]) or moderate (128 of 367 [34.9%]) in severity. The most common TEAEs included coronavirus disease 2019 (COVID-19; asymptomatic 22.6%; symptomatic, 21.3%), nasopharyngitis (20.7%), increased blood creatine phosphokinase levels (11.4%), and hypercholesterolemia (11.2%). A total of 19 serious TEAEs were reported in 16 of 367 (4.4%) patients. Of these, 6 events in 5 of 367 (1.4%) patients were considered related to the study drug: infectious mononucleosis and tonsilitis in the same patient, and Stage IV gastric cancer, spontaneous abortion, asthma, and anemia in 1 patient each. Serious infections were reported in 3 of 367 (0.8%; 4 events total) patients. Nine of 367 (2.5%) patients had herpes zoster infections. Malignancies were reported in 9 of 367 (2.5%; 10 events total) patients. There were no instances of thrombosis or major cardiovascular adverse events reported in this study. Of the 137 patients who were continuously treated with deuruxolitinib 8 mg BID throughout the entire OLE (no dose adjustment), some had potentially clinically significant changes in lymphocytes (4 of 137 [2.9%]), creatine kinase (14 of 137 [10.2%]), and triglycerides (3 of 137 [2.2%]). However, changes in other laboratory parameters were generally not considered clinically significant.

Conclusions

Long-term treatment of up to 2 years with deuruxolitinib 8 mg BID was well tolerated in patients with severe AA. The long-term safety profile was consistent with the known safety profile of deuruxolitinib and other drugs of the same class.

EA DV CONGRESS
VIENNA
30 SEP - 3 OCT 2026

Abstract N°: 2705

Hairy tales: A clinicotrichoscopic case series of unusual hair disorders

Dr. Smriti Venkatesh*[1], Dr. Sukhada Patankar[1], Dr. Meghana Phiske[1], Dr. Shylaja Someshwar[1, 2]

[1] Mgm Institute of Health Sciences, Panvel, India
[2] Kasturba Medical College, Mangaluru, India

Introduction
Hair disorders comprise a heterogeneous group of cicatricial and non-cicatricial alopecias that frequently demonstrate overlapping clinical features, making diagnosis challenging. Trichoscopy improves diagnostic accuracy and aids in differentiating scalp disorders. Lichen planopilaris (LPP), a form of scarring alopecia, presents with patches of alopecia on vertex/parietal region. Alopecia areata (AA), a common cause of noncicatricial alopecia, presents as patchy/diffuse hair loss. LPP is considered an irreversible process, AA is associated with partial/complete recovery. Coexistence of AA and LPP is rare. Folliculitis decalvans (FD) is rare, chronic inflammatory disorder primarily affecting scalp, leading to scarring alopecia. FD accounts for 11% of adult cases of primary cicatricial alopecia (PCA). In paediatric age group, PCA is very rare.Short anagen syndrome is a rare idiopathic disorder characterized by short hair and increased hair in telogen phase. It is unassociated with hair breakage and total hair loss. Most cases are Caucasian blond-haired girls. Only 4 Asian, 1 Hispanic, and 2 African patients have been reported; only 1 case is reported from India. Alopecia of eyelashes is rare, even rarer when presenting with unilateral eyelash and eyebrow alopecia. Varied prevalence of eyebrow and eyelash alopecia is reported in Japanese study (19.8% and 10.1% respectively), Danish study (62.8% and 56.4% respectively), and Asian females study (69% and 5.2% respectively).

Case Presentation
Case 1-A 15/F presented with multiple asymptomatic hyperpigmented to erythematous alopecic patches over frontoparietal scalp associated with progressive patchy hair loss. Trichoscopy demonstrated perifollicular scaling, follicular plugging, black dots, broken hairs, and exclamation mark hairs. Histopathology revealed follicular plugging overlying mildly acanthotic epidermis, orphaned arrector pili muscle, some showing infiltrate surrounding and within it, few catagen follicles, perifollicular fibrosis and infiltrate with fibrotic fibrous stella, and perivascular lymphocytes. Clinicopathological correlation confirmed an overlap of lichen planopilaris and alopecia areata.

Case 2-A 8/F presented with multiple erythematous to skin-coloured pustular scalp lesions associated with crusting, patchy hair loss, and scarring alopecia. Trichoscopy showed diffuse erythema, branching vessels, pustules, crusting, fibrosis, broken hairs, curved hairs, and tufted hair follicles. Clinical and trichoscopic findings were suggestive of folliculitis decalvans (FD).

Case 2a-A 7/F presented with recurrent erythematous scalp plaques associated with pustules, focal hair loss, and episodic pus discharge. Trichoscopy revealed ill-defined pink patches, sparsity of hair, pustules, crusting, scaling, coiled hair and tufted folliculitis (“doll’s hair appearance”).FD was established based on clinico-trichoscopic findings.

Case 3-30/F born of consanguineous marriage presented with lifelong inability to grow scalp hair beyond short length associated with diffuse hair sparsity, short, rough hair distributed in normal pattern. There were similar complaints in her parents and four siblings. Hair shaft examination demonstrated short hairs with tapered tips, while trichoscopy revealed sparse terminal and vellus hairs and white dots. Based on clinicotrichoscopic findings,

short anagen syndrome was diagnosed.

Case 4- 9/F presented with unilateral loss of eyebrow hair and upper eyelid eyelashes . Dermoscopy of upper eyelid shows complete loss of hair with telangiectatic vessels at edge and from eyebrow showed focal loss of hair with few vellus hair at periphery. Diagnosis of unilateral alopecia areata involving eyebrow and eyelashes was established.

Conclusion

Trichoscopy serves as valuable non-invasive diagnostic modality that facilitates early diagnosis, reducing need for invasive investigations.

EA DV CONGRESS
VIENNA
30 SEP - 3 OCT 2026

Abstract N°: 2726

Concomitant Improvement of Severe Alopecia Areata and Vitiligo with the Selective JAK1 Inhibitor Ivarmacitinib: A Case Report

Dexin Hu*[1], Aili Zhang[1], Jie Fang[1]

[1] Bijie Hospital of Zhejiang Provincial People's Hospital (Bijie First People's Hospital), Bijie, China

Introduction

Alopecia areata (AA) and vitiligo are immune-mediated disorders frequently associated with overlapping autoimmune comorbidities, indicating shared pathogenic pathways involving interferon-gamma (IFN-γ) signaling and cytotoxic CD8+ T-cell-mediated tissue damage. Janus kinase (JAK) inhibitors, which block this signaling cascade, have demonstrated efficacy in both diseases. This report describes the dual clinical response of severe AA and vitiligo to monotherapy with ivarmacitinib, a selective JAK1 inhibitor.

Case Presentation

A 21-year-old female with a 10-year history of severe recurrent AA presented with extensive patchy scalp alopecia, complete madarosis, and total eyebrow loss. Four years before presentation, she developed a vitiligo patch on the right parietal scalp, followed by irregular depigmented macules on the dorsal right hand two years later. Her medical history included papillary thyroid carcinoma status-post total thyroidectomy, with euthyroidism maintained by levothyroxine. Thyroid autoantibody screening (thyroglobulin antibody, thyroid peroxidase antibody) was within normal limits. The patient was treated with oral ivarmacitinib sulfate 4 mg once daily as monotherapy. Disease activity was assessed using the Severity of Alopecia Tool (SALT) score for AA , Eyebrow Assessment (EBA) score for Eyebrow loss and the Vitiligo Area Scoring Index (VASI) for vitiligo repigmentation. Safety was monitored by serial laboratory tests.

After 4 months of continuous treatment, a marked clinical response was observed. There was significant terminal hair regrowth over the vertex and entire scalp, as well as complete eyebrow regrowth. The vitiligo lesions on the right hand demonstrated prominent perifollicular repigmentation. The treatment was well-tolerated with no adverse events, and all routine laboratory parameters remained stable. Key clinical and laboratory data are summarized in Table1:

Assessment	Baseline	4 Months
SALT Score	90	2
EBA	0	3
VASI(Hand)	0.063	0.053
Thyroid Function	Euthyroid on replacement therapy	Euthyroid on replacement therapy
Liver/Renal Function	Normal	Normal

Table1:Key clinical and laboratory data

Conclusion

This case demonstrates the successful concomitant treatment of severe AA and vitiligo with the selective JAK1 inhibitor ivarmacitinib, leading to near-complete hair regrowth and significant vitiligo repigmentation within four months. The dual therapeutic response highlights the shared dependence of these two conditions on the JAK-STAT signaling pathway and suggests that targeted JAK1 inhibition may represent a novel therapeutic option for patients with coexisting autoimmune dermatoses.

EA DV CONGRESS
VIENNA
30 SEP - 3 OCT 2026

Abstract N°: 2747

Serial cryotherapy in refractory onychomycosis: a case series in medically complex patients

Alícia Mendes*[1], Angela Mendes[1], CASSIANO GOMES[1], Karem Silva[1], Maria Fernanda Sant'Anna[1], Eduarda Rodriguez[1], Leonardo Ribeiro[1]

[1] Pontifícia Universidade Católica de São Paulo- campus Sorocaba, Sorocaba, Brazil

Introduction
Onychomycosis is the leading cause of onychodystrophy, predominantly caused by dermatophytes of the genus *Trichophyton*. It is characterized by nail thickening, subungual hyperkeratosis, onycholysis, and progressive dystrophy, significantly impacting functional and psychosocial aspects. Treatment remains challenging due to limited antifungal penetration into the nail unit, high recurrence rates, and frequent therapeutic refractoriness. Although oral terbinafine remains the gold standard, clinical contraindications, polypharmacy, and treatment failure limit its use in a significant portion of patients. In this context, physical methods, such as cryotherapy, emerge as promising therapeutic alternatives, especially in refractory cases or patients with contraindications to systemic treatment. We report three cases of onychomycosis treated with serial cryotherapy.

Case Presentation
The first case involves a 44-year-old female with multiple autoimmune and metabolic comorbidities, including type 1 diabetes mellitus with chronic complications, Sjögren's syndrome, systemic sclerosis, vitiligo, celiac disease, and autoimmune hypothyroidism, on multiple continuous medications. She had been under dermatological follow-up since 2022 for refractory onychomycosis, with no response after more than one year of topical treatment.

The second case is a 66-year-old female patient presented with onychomycosis of the toenails with nail thickening, subungual hyperkeratosis, and significant dystrophy. She showed no satisfactory response following previous topical and systemic antifungal treatments.

The third case is a 50-year-old female with an ongoing investigation for a neuropathic disorder, presented with onychomycosis involving multiple toenails. She reported previous therapeutic failure with both topical and oral antifungals.

Serial direct mycological examinations confirmed the diagnosis in all patients.

We initiated serial cryotherapy using the spray technique on all affected nails, with 21-day intervals between sessions, until a single periungual whitening was achieved, without repeat cycles. The protocol required a minimum of 10 sessions or maintenance until satisfactory clinical improvement.

There was no association with nail debridement or concomitant antifungal therapies. Objective and subjective clinical improvement was observed in all patients, with a reduction in nail thickening, subungual hyperkeratosis, and onychodystrophy, alongside good treatment tolerability.

Conclusion
Refractory onychomycosis remains a relevant therapeutic challenge, particularly in patients with multiple comorbidities, polypharmacy, or contraindications to systemic antifungal use. The presented cases demonstrate

cryotherapy as a promising, safe, and easily applicable outpatient therapeutic alternative, even in scenarios of high clinical complexity and failure of conventional treatments. Beyond the clinical benefit observed in monotherapy, this report reinforces the potential of physical therapies in onychomycosis management and highlights the need for prospective studies to standardize protocols and better define their efficacy and clinical reproducibility.

EA DV CONGRESS
VIENNA
30 SEP - 3 OCT 2026

Abstract N°: 2786

In-House White Mallow Botanical Extraction (WMBE): an Efficient Way to Deliver Superior Fiber Shine by Replacing Formulation Water in Hair Care Products.

Nicolas Barriere*[1], Magali Favre-Mercuret[1], Patricia Manissier[1]

[1] PHYTO PARIS, Laboratoire Native, Levallois-Perret, France

Introduction

The appearance of hair plays a central role in physical attractiveness and social perception. Among hair characteristics, hair shine is emerging as a particularly outstanding visual attribute. These findings support increased hair shine as a key, functionally relevant target in cosmetic research and product development.
Hair care products largely use water, usually as 60–85% of the total composition, sometimes more, where it primarily serves as a solvent and formulation vehicle rather than an active ingredient. Aiming at maximal efficacy, white mallow (*Althaea officinalis*) was selected for its known high content in water-soluble mucilages, exhibiting strong film-forming and bioadhesive properties for functional performance in hair care treatments.

This study aimed to evaluate the benefit of incorporating in-house White Mallow Botanical Extraction (WMBE) instead of water as ingredient base in hair care products to improve hair shine.

Materials and Methods

WMBE is an in-house aqueous extract made by hot water maceration of dried and crushed organic white mallow roots originated from France. Composition of WMBE was evaluated by high pressure size exclusion chromatography (HPSEC) to determine molecular weight (MW) of main polysaccharides (Dextran equivalent).

In first *ex vivo* study focusing on hair surface damage, brown Caucasian hair strands were subjected to combined chemical and mechanical stress. WMBE was applied either once (protocol A simulating leave-on single application) or 12 times (protocol B simulating one month of rinse-off application). Hair strands were soaked in WMBE, wrung out, rinsed with water for 30 seconds (only for protocol B), dried, and combed. Hair surface morphology was examined by scanning electron microscopy (SEM, ZEISS DSM 982 GEMINI, Probe EDS NORAN). For each condition, 20 hair fibers were analyzed at the distal area and compared to untreated damaged strands as control. Fibers exhibiting cuticle uplift were quantified, and statistical analysis was performed using Mann–Whitney test.

In second *ex vivo* study evaluating hair shine, 10 hair strands were treated with WMBE or water according to protocol B. Hair shine was assessed by high-resolution photography (Nikkor 60 mm lens) under standardized lighting and temperature conditions, before (T0) and after treatment (T1), with two measurements per strand. Statistical analysis was performed using Student test.

Results

Presence of particular polysaccharides in WMBE was confirmed, Mp (molecular weight of the highest peak) was egal to 1.4MDa, and the lowest MW is about 147KDa.

In first study, 70% of fibers exhibited cuticle uplift in control hair strands. This proportion was markedly reduced following WMBE treatment, decreasing to 25% with rinse-off protocol B and 15% with leave-on protocol A. Overall, WMBE significantly reduced cuticle lifting by 2.8-fold and 4.6-fold, respectively, compared to the control ($p \leq 0.05$).

In second study, hair shine was significantly improved after WMBE application, with a 9.4% increase relative to T0 ($p \leq 0.05$). When compared to water, WMBE demonstrated 2.4-fold greater efficacy in enhancing hair shine ($p \leq 0.05$).

Conclusions

WMBE is characterized by presence of high–molecular weight polysaccharides, supporting film-forming properties.

WMBE application on damaged hair fibers significantly improved cuticle morphology, as evidenced by a marked reduction in cuticle uplift in both protocols, highlighting a smoothing effect on hair fiber surface.

Smoothing efficacy reflects in WMBE bringing twice as much shine to hair fiber in rinse-off products, outperforming water alone and demonstrating superior functional cosmetic benefit of this specific mucilaginous extraction.

Replacing water in hair care cosmetic formulations by WMBE is an effective strategy for improving hair shine. This innovative approach is either suitable in rinse-off or leave-on products for all hair types (dry, wavy, curly, colored) or styling.

EADV CONGRESS
VIENNA
30 SEP - 3 OCT 2026

Abstract N°: 2799

Unusual post-traumatic acquired fibrokeratoma in a child: a rare pediatric presentation

Catalina Valencia Marín*[1], Valentina Naranjo Tobón[2], María Camila Vélez Peláez[3], Gabriel Jaime Varela Aguirre[3], Daniel Noreña[3]

[1] Universidad Pontificia Bolivariana, Medellin, Colombia
[2] Universidad CES, Medellin, Colombia
[3] Clínica Aurora, Medellin, Colombia

Introduction

Acquired digital fibrokeratoma (ADFK) is an uncommon benign fibrous tumor that most commonly affects digits, although other anatomical locations have been reported. It predominantly affects adult males, whereas pediatric cases are exceedingly rare. Although trauma and repetitive irritation have been proposed as possible etiologic factors, most patients do not recall a preceding traumatic event. We present a pediatric case of ADFK of the left hallux developing after local trauma, with diagnosis confirmed by ultrasound and clinicopathologic correlation.

Case Presentation

A 15-year-old male with a history of local trauma during a taekwondo class presented to the Dermatology clinic with a 1 year history of an asymptomatic erythematous nodule located in the proximal portion of the left hallux nail unit, between the ventral and dorsal nail plates. Dermoscopy revealed focused vessels on a rainbow-pattern background, with linear vessels surrounded by a whitish halo. Associated proximal onycholysis and hyperkeratosis were observed.

Given the suspicion of adcquired digital fibrokeratoma and other connective tissue tumors, ultrasound evaluation was performed; it demonstrated a solid hypoechoic hypovascular lesion between the dorsal and ventral nail plates, causing extrinsic compression of the nail matrix with secondary canaliform dystrophy. The lesion was subsequently excised surgically. Histopathologic analysis showed an exophytic lesion with hyperkeratosis, epidermal collarette formation, and loose fibroconnective stroma containing dilated vascular channels and focal erythrocyte extravasation, likely related to previous trauma. It confirmed the diagnosis. The patient had a favorable clinical course, with no recurrence of the lesion after surgical intervention.

Conclusion

Adcquired digital fibrokeratoma should be considered in the differential diagnosis of pediatric nail unit tumors, particularly in patients with a history of local trauma. This case highlights the diagnostic value of clinicopathologic correlation and supports the potential role of trauma in the development of ADFK.

EADV CONGRESS
VIENNA
30 SEP - 3 OCT 2026

Abstract N°: 2800

Heterogeneous Acral Distribution of Acquired Digital Fibrokeratoma

Meriem Harrouchi*[1], Anissa Zaouak[1], Fatma Khanchel[2], Ehsen Ben Brahim[2], Selima Ben jennet[1], Talel Badri[1], Houda Hammami[1]

[1] Department of Dermatology, Habib Thamer Hospital, tunis, Tunisia

[2] Department of Anatomopathology, Habib Thameur Hospital, Tunis, Tunisia, tunis, Tunisia

Introduction

Acquired digital fibrokeratoma (ADFK) is a rare benign fibrous tumor that typically appears on the fingers and toes. It usually presents as a solitary, dome-shaped papule with a slightly raised collarette of skin around its base, which is considered a characteristic feature. Because it can resemble other periungual or digital lesions, careful pathological evaluation is needed to avoid misdiagnosis.

Materials and Methods

We conducted a retrospective descriptive study of eleven patients diagnosed with ADFK in the Dermatology Department of Habib Thameur Hospital between January 2020 and December 2025. We collected data on age, sex, history of trauma, duration of the lesion, location, clinical appearance, dermoscopic findings, treatment, histopathological features, and outcomes.

Results

The cohort included 10 males and 1 female, with a mean age of 51.3 years (range: 29–80 years). The most common location was the periungual region of the fingers (7/11), followed by the toes (4/11). Two patients reported a prior history of trauma. The time before seeking medical consultation ranged from 3 months to 20 years.

Clinically, all lesions presented as solitary, hyperkeratotic, flesh-colored papules measuring between 7 and 13 mm in diameter. Their distribution was varied, involving the periungual regions of both fingers and toes, the palmar and plantar surfaces, and the distal interphalangeal joints.

Dermoscopy revealed a well-defined central pale-yellow homogeneous area surrounded by a white scaly collarette. A peripheral whitish-yellow zone containing dotted vessels was also observed.

Histopathological examination consistently demonstrated a core of dense collagen bundles arranged perpendicular to the epidermis, covered by acanthotic epidermis with orthokeratotic hyperkeratosis. No signs of malignancy were identified.

All patients underwent complete surgical excision under local anesthesia. No recurrences were observed over a mean follow-up period of 12 months.

Herein we report eleven cases of acquired digital fibrokeratoma. In our series, the condition was most common in middle-aged men and predominantly affected the distal extremities. Consistent with the literature, fingers were affected more frequently than toes. Although the periungual region is the most commonly affected site, our series

demonstrated a wide distribution across various acral locations, emphasizing the importance of considering this diagnosis in any solitary hyperkeratotic acral lesion.

ADFK typically presents as a solitary lesion but can be multiple in tuberous sclerosis complex (TSC).

Its exact etiology remains unclear, but proposed mechanisms include trauma and post-inflammatory or post-streptococcal processes.

ADFK is frequently misdiagnosed, leading to diagnostic delay. Patients usually seek medical attention due to aesthetic concerns or functional discomfort.

The differential diagnosis is broad and includes supernumerary digit, superficial acral fibromyxoma, Koenen tumors, verruca vulgaris, cutaneous horn, and malignant lesions such as Bowen's disease, especially when atypical features are present.

Histopathology is essential for confirmation, typically showing a fibrocollagenous core with overlying hyperkeratotic and acanthotic epidermis. Surgical excision is the treatment of choice and is curative, with excellent cosmetic results and no reported recurrences.

Compared to previously reported isolated cases, our series highlights the dermoscopic and histopathological consistency of this entity across varied anatomical locations.

Conclusions

ADFK is a rare benign acral tumor with variable clinical presentation that is often misdiagnosed. Histopathology confirms the diagnosis. Surgical excision is curative, with an excellent prognosis and no recurrence observed in our series.

EA DV CONGRESS
VIENNA
30 SEP - 3 OCT 2026

Abstract N°: 2803

Acquired Ectopic Nail: Clinical, Dermoscopic, and Histopathological Findings in Three Cases

Meriem Harrouchi*[1], Anissa Zaouak[1], Imen Helel[2], Ehsen Ben Brahim[2], Selima Ben jennet[1], Talel Badri[1], Houda Hammami[1]

[1] Department of Dermatology, Habib Thamer Hospital, tunis, Tunisia
[2] Department of Anatomopathology, Habib Thameur Hospital, Tunis, Tunisia, tunis, Tunisia

Introduction

Ectopic nail is a rare benign condition characterized by nail tissue developing outside the normal nail unit. It may be congenital, often associated with digital malformations, or acquired, typically secondary to trauma or arising spontaneously. Due to its rarity and variable presentation, ectopic nail is frequently misdiagnosed as other hyperkeratotic or periungual lesions. Diagnosis requires clinical suspicion, dermoscopy, imaging, and histopathological confirmation.

Materials and Methods

We conducted a retrospective descriptive study of three patients diagnosed with ectopic nail in the Dermatology Department of Habib Thameur Hospital between January 2020 and December 2025. Clinical data included age, sex, medical history, lesion location, duration, and trauma history. Dermoscopy and radiological imaging were performed, and histopathological analysis confirmed the diagnosis in all patients.

Results

We present three cases of acquired ectopic nail in females aged 77, 52, and 70 years. Two cases were trauma-related, while one occurred spontaneously.

The first patient presented with a progressively enlarging keratotic plaque on the plantar surface of the right fifth toe. The second patient exhibited a recurrent lateral periungual keratotic mass on the left middle finger. The third patient, with underlying diabetes, displayed a painful, slow-growing brownish keratotic plaque on the right third toe that evolved over 18 months.

Dermoscopy revealed variable but characteristic findings, including an onychomatrix-like pattern with yellow-brown chromonychia and longitudinally oriented keratin lamellae in some cases, and a lamellar keratotic architecture surrounded by a whitish scaly collarette in others.

Plain radiography excluded underlying bony abnormalities in all cases. Histopathological examination consistently demonstrated ectopic nail tissue with well-differentiated nail matrix, nail bed, and mature nail plate formation.

Our cases exemplify the clinical heterogeneity and diagnostic complexity of acquired ectopic nail, a rare dermatological entity.

Direct traumatic displacement of nail matrix cells into surrounding tissue is the most accepted mechanism as reported in two of our patients. Chronic microtrauma may also contribute, particularly in diabetic neuropathy as in the third case where diminished pain perception permits cumulative tissue damage in acral sites. In the absence of

trauma, alternative mechanisms include ectopic persistence of embryologic germinal matrix tissue or metaplastic differentiation of pluripotent epithelial cells toward nail-forming lineages.

Clinically, ectopic nails present as flesh-colored to brownish keratotic papules, nodules, or plaques. The lateral periungual region is most frequently reported, though plantar and other acral locations occur.

Dermoscopic characterization remains sparse but demonstrates consistency. The hallmark includes an onychomatrix-like pattern with longitudinally arranged keratin lamellae, yellowish-brown structures reflecting nail plate keratinization.

Recognition of these features may obviate unnecessary biopsy and facilitates differentiation from verruca vulgaris, acquired digital fibrokeratoma, and cutaneous horn, which lack structured nail matrix architecture.

Radiological assessment excludes osseous pathology, particularly subungual exostosis. Histopathology remains the gold standard, revealing a fully differentiated ectopic nail apparatus with mature nail matrix, bed, and keratinized plate.

Complete surgical excision encompassing the entire ectopic matrix is curative. Prognosis is excellent with negligible recurrence when excision is complete.

Conclusions

These cases expand the clinical spectrum of ectopic nail and emphasize considering this entity in patients with progressive keratotic acral lesions. A multimodal approach integrating dermoscopy, imaging, and histopathology is essential for accurate diagnosis and optimal management.

EA DV CONGRESS
VIENNA
30 SEP - 3 OCT 2026

Abstract N°: 2814

Sisaipho alopecia areata: A reversal worth recognising

James Irvine*[1, 2], Sarah Digby[3], Susan Holmes[2, 4]

[1] Royal Alexandra Hospital, Paisley, Glasgow, United Kingdom
[2] University of Glasgow, Glasgow, United Kingdom
[3] Department of Pathology, Queen Elizabeth University Hospital, Glasgow, United Kingdom
[4] Department of Dermatology, Glasgow Royal Infirmary, Glasgow, United Kingdom

Introduction

Alopecia areata (AA) is a common autoimmune disease causing non-scarring hair loss. Several typical patterns of scalp hair loss are recognised namely patchy AA, alopecia totalis (AT) and alopecia universalis (AU). Loss of the hairline is termed ophiasis-pattern AA and is recognised as a difficult-to-treat variant. An inverse ophiasis pattern, termed sisaipho, is rarely encountered clinically and is characterised by hair loss from the central scalp with sparing of the peripheral scalp margins.

We report a case of sisaipho-variant alopecia areata (sAA) in whom an initial diagnosis of trichotillomania was considered. We review the literature on this rare variant of Alopecia Areata and present high-quality longitudinal clinical images documenting disease evolution over a two-year period. In addition, we provide detailed dermoscopic and histopathological images to further characterise the clinical and pathological features of this uncommon presentation.

Case Presentation

A 66-year-old woman developed an asymptomatic coin-sized patch of hair loss on her occipital scalp, identified by her hairdresser. Over the course of six months, the patch gradually enlarged. Her general practioner initiated treatment with betamethasone cream (0.1%w/w) BD however, the area of hair loss continued to extend and she was referred to Dermatology. On initial assessment, a large solitary patch of markedly reduced hair density was noted affecting the vertex and central scalp, with sparing of the hairline. The pattern of hair loss was felt to be unusual and the clinical differential diagnosis included trichotillomania due to the tonsure-like sparing of the hairline .

A scalp biopsy was undertaken. This showed a non-scarring alopecia with proportionally increased catagen/telogen: anagen follicles, some miniaturised follicles and multiple follicles with a lymphocytic infiltrate present around their bulbs and also within follicular stelae. The clinicopathological features were compatible with a diagnosis of alopecia areata. Treatment with intralesional triamcinolone (10mg/ml) was initiated and the patient was referred to the specialist Hair Clinic.

On review 2 months later, examination revealed further enlargement of the solitary patch of alopecia, with continued sparing of the hairline. Within the patch of alopecia, there was evidence of white terminal hairs of varying lengths as well as patches of short, pigmented hairs at sites of IL steroid injection. Estimated SALT score was 80. On close inspection / dermoscopy, easily extracted broken hairs (black dots and exclamation mark hairs) were noted at the margin of the patch. A diagnosis of sisaipho-pattern AA (sAA) was made. The patient was reluctant to consider systemic therapy, and, given the evidence of spontaneous regrowth and favourable response to ILT, further treatment with triamcinolone acetonide 5 mg/mL was undertaken. Follow up 4 months later showed continued significant regrowth of hair.

Conclusion

This case highlights a rare AA phenotype. The pattern of loss is reminiscent of a monk`s tonsure and mimics the pattern of loss seen with trichotillomania (TM), which was initially considered as a possible diagnosis in this case. Clinical and dermatoscopic features may suggest AA but if there is diagnostic doubt, scalp biopsy may be necessary to exclude TM.

EA DV CONGRESS
VIENNA
30 SEP - 3 OCT 2026

Abstract N°: 2820

Clascoterone 5% topical solution, an androgen receptor inhibitor in clinical development for male pattern hair loss, modulates androgen-driven inflammatory and fibrotic pathways in an ex vivo human affected scalp skin organ culture model

Luigi Longo[1], Gordon Alton[2], Prama Pallavi[3], Alizee Le Riche[3], David Broadley[3], Marta Bertolini[3], Janin Edelkamp[3], Mara Gerloni*[2]

[1] Cosmo NV, Dublin, Ireland

[2] Cosmo NV, SAN DIEGO, United States

[3] QIMA Life Sciences, QIMA Monasterium,, Muenster, Germany

Introduction

Clascoterone is an androgen receptor (AR) inhibitor currently under investigation in Phase 3 clinical trials for the topical treatment of male pattern hair loss (MPHL). Androgen-mediated dysfunction of dermal papilla (DP) cells is a key driver of disrupted hair cycle balance in the frontal and vertex scalp and consequently hair follicle (HF) miniaturization. Elevated AR signalling reduces DP inductive capacity and hair matrix keratinocyte proliferation, lowering the anagen/catagen-telogen ratio. In addition, inflammation and fibrosis are increasingly recognized as key contributors to MPHL. Chronic perifollicular microinflammation can activate fibroblasts and promote excessive extracellular matrix impairing follicle regeneration. These processes form a self-reinforcing loop, correlating with reduced responsiveness to standard treatments. Since *in vivo* animal models of androgenetic alopecia do not adequately reproduce hormone-driven responses, we have previously shown that topical application of clascoterone 5% solution results in enhanced DP inductivity and proliferation of hair matrix keratinocytes using the affected MPHL scalp skin organ culture model.
In this study we examine how clascoterone modulates the MPHL microenvironment by analysis of the secreted proteome *ex vivo*.

Materials and Methods

Scalp biopsies were obtained from affected regions of five MPHL patients (Hamilton–Norwood stages III–VI) who were not receiving any MPHL medications at the time of sampling and cultured *ex vivo* with 30 nM testosterone to reproduce physiological androgen exposure. After 24-hours, clascoterone 5% solution was applied topically for 4 hours every other day over 5 days. Tissue culture medium was collected on days 1, 3, and 5. The proteins secreted into the culture medium were evaluated using the Omni1000 nELISA platform from Nomic Bio.

Results

Of the 1000 protein analytes evaluated using the Omni1000 nELISA, 47% were detected (in-range) across all patients in the clascoterone-treated group. On day 5 numerous androgen-regulated proteins were differentially expressed in clascoterone-treated samples relative to testosterone-treated controls, along with proteins associated with MPHL through gene expression studies. The key androgen-regulated proteins Thrombospondin 1 (TSP1) and Matrix Metalloproteinase 9 (MMP9), also associated with MPHL, were both reduced by clascoterone treatment. Importantly, the TGF-β precursor, TGF-β LAP domain, which is activated by TSP1 and MMP9, was

significantly reduced. Concurrent modulation of TGF-β signalling and IGF-binding proteins further supports preservation of dermal papilla inductivity and maintenance of the anagen growth phase, in line with our previous data at the tissue level. Further, AR inhibition by clascoterone translated into robust suppression of secreted pro-inflammatory mediators (e.g. IL-6, IL-1b, CXCL9, CCL5, CCL18), along with downregulation of immune-activating receptors (e.g. CLEC5A), macrophage-associated inflammatory markers (e.g. TREM1), and broad inhibition of ECM-degrading enzymes, particularly multiple MMPs. These molecular changes are consistent with reduced perifollicular inflammation, stabilization of the follicular extracellular matrix, and mitigation of fibrotic remodelling that characterizes progressive MPHL. Concurrent modulation of TGF-β activation and IGF-binding proteins further supports preservation of dermal papilla inductivity and maintenance of the anagen growth phase.

Conclusions

Overall, these findings support clascoterone as a mechanistically targeted intervention in MPHL, addressing core AR-driven inflammatory and fibrotic pathways underlying follicular miniaturization. The present data provide a strong mechanistic support for the therapeutic potential of clascoterone for treatment of MPHL.

EA DV CONGRESS
VIENNA
30 SEP - 3 OCT 2026

Abstract N°: 2822

Impact of Eyebrow and Eyelash Regrowth on Patient-Reported Outcomes in Patients With Severe Alopecia Areata: Interim Results From the Phase 3 UP-AA Trial

Arash Mostaghimi*[1], Ahmed M Soliman[2], Carolyn Goh[3], Meena K Singh[4], Kent A Hanson[2], Kaili Ding[2], Sharanya Ford[2], Henrique Teixeira[2], Ramona Vladea[2], Nina Magnolo[5]

[1] Brigham and Women's Hospital, Harvard University, Boston, Massachusetts, United States
[2] AbbVie Inc., Chicago, Illinois, United States
[3] David Geffen School of Medicine at the University of California, Los Angeles, California, United States
[4] Skin and Hair Center, Kansas, United States
[5] University of Münster, Münster, Germany

Introduction

Alopecia areata (AA) is a chronic, immune-mediated disease characterized by nonscarring hair loss that can substantially impair quality of life. Loss of eyebrows (EB) and eyelashes (EL) is particularly distressing due to their role in facial identity, emotional expression, and ocular protection (Starace M, et al. *Dermatol Ther*. 2023;13:1244). In a phase 3 trial, patients with severe AA who were treated with upadacitinib (UPA), an oral, selective Janus kinase (JAK) inhibitor, experienced improved EB and EL regrowth (Mostaghimi et al. *J Skin*. 2025;9:s664). Although improved hair coverage is a key treatment goal for patients with AA, the relationship between EB and EL regrowth and patient-reported outcomes (PROs) is not well characterized. Here, we evaluate the relationship between EB and EL regrowth and patient-reported quality of life (QoL) and symptom burden in UP-AA.

Materials and Methods

UP-AA (NCT06012240) is an ongoing, phase 3, randomized, placebo-controlled, double-blind study evaluating once-daily UPA in adults and adolescents with severe AA (Severity of Alopecia Tool [SALT] score ≥50). Patients (aged 12–64 years) were randomly assigned to receive UPA 15mg, UPA 30mg, or placebo for 24 weeks (wk). We assessed the relationship between EB and EL regrowth and PROs at wk 24, based on clinician-reported outcome (ClinRO) responder status. EB and EL regrowth were each evaluated using 4-point ClinRO scales with higher scores indicating greater hair loss (0=no hair loss; 1=minimal hair loss; 2=significant hair loss; 3=no noticeable hair). This post hoc, treatment-agnostic analysis included patients who had available EB/EL scores and PRO data, and baseline EB/EL scores ≥2. Patients were classified as ClinRO responders (achieving a score of 0/1) or nonresponders (score of 2/3) for each measure. PROs were assessed using the Skindex-16 for AA and the Alopecia Areata Symptom Impact Scale (AASIS). The Skindex-16 AA evaluates the impact of AA on health-related QoL across 3 domains—emotions, symptoms (not included in this analysis), and daily functioning—over the past wk, with responses ranging from 0="never bothered" to 6 ="always bothered." The AASIS comprises 2 numerical rating subscales assessing AA-related symptom severity (7 items; 0="not present," 10="as bad as you can imagine") and functional interference (6 items; 0="did not interfere," 10="interfered completely"). PROs were analyzed at wk 24 using ANCOVA, adjusting for corresponding baseline score and prespecified covariates (baseline disease severity [SALT score <95 vs SALT score ≥95], age (adults vs adolescents), sex, and AA episode duration at baseline [<3 years vs ≥3 years]). Comparisons were made between ClinRO-defined responders (score of 0/1) and nonresponders (score of 2/3) for EB and EL regrowth.

Results

The study enrolled 1381 patients with a mean (SD) age of 35.9 (13.3) and baseline SALT score of 84.0 (18.9); of these, 41.4% were male, 51.3% had very severe AA (SALT score ≥95), and 43.3% had a disease duration ≥3 years. At wk 24, among patients with baseline EB/EL scores ≥2, those who met ClinRO responder criteria (score of 0/1) for EB or EL growth experienced significantly ($P \leq .001$ for all comparisons) greater improvements from baseline in Skindex-16 AA emotions and functioning domains compared with nonresponders (score of 2/3) (**Figure 1**). Similarly, patients who met ClinRO responder criteria for EB or EL growth experienced significantly ($P \leq .001$ for all comparisons) greater improvements from baseline at wk 24 in AASIS interference and symptom scores compared with nonresponders.

Figure 1. Health-Related Quality-of-Life Improvements in Patients With Eyebrow and Eyelash ClinRO Scores of 0/1 and 2/3 at Week 24

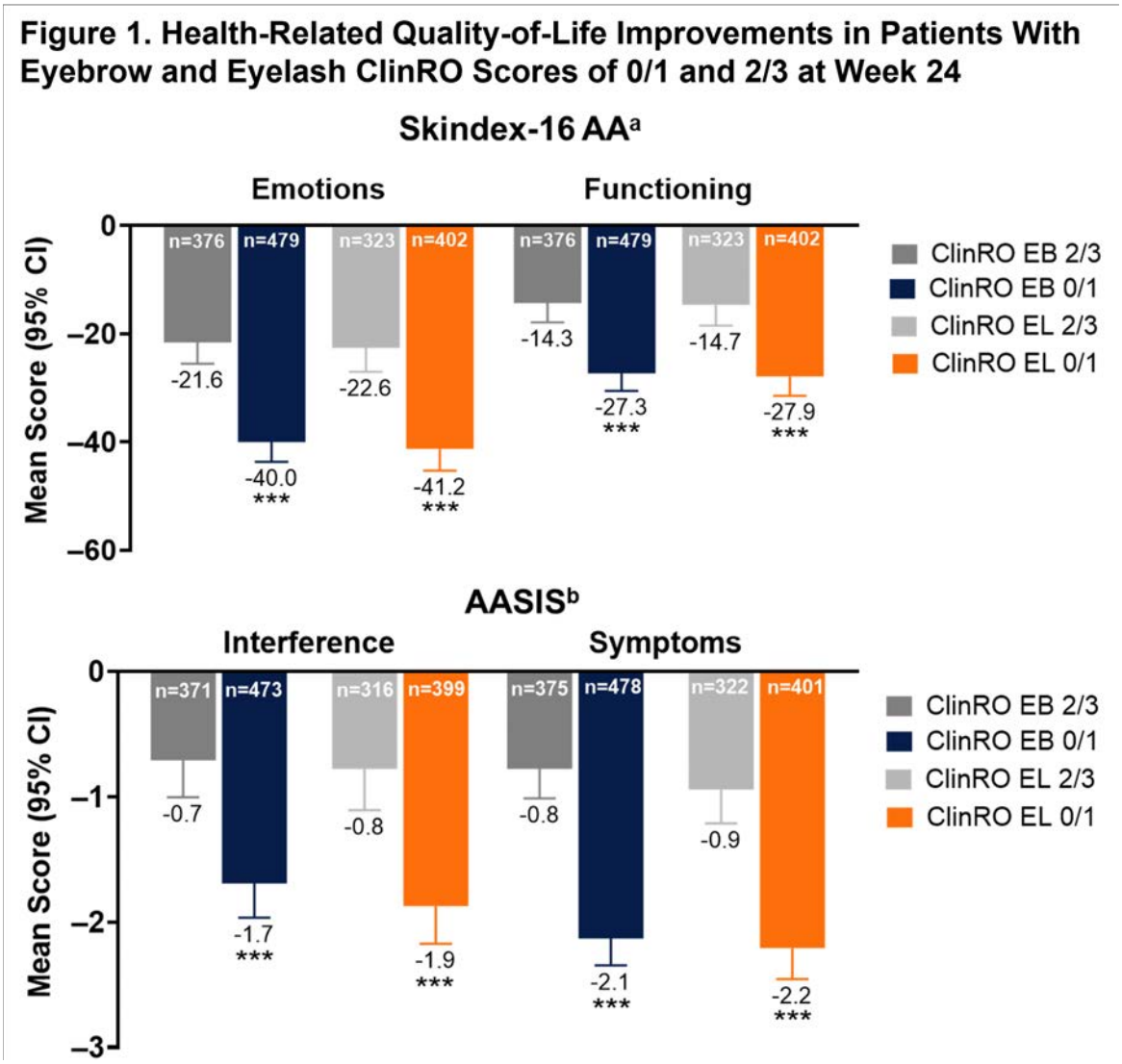

AA, alopecia areata; AASIS, Alopecia Areata Symptom Impact Scale; ClinRO, clinician-reported outcome; EB, eyebrow; EL, eyelash. aSkindex-16 AA domain-specific scores are calculated as the sum of all items in that domain and standardized to a 0-100 range, with higher scores indicating greater impact on health-related quality of life. bAASIS subscale scores are calculated as the sum of all items, ranging from 0–10, with higher scores indicating greater symptom severity and functional interference. ClinRO scores for EB hair loss: 0 = the eyebrows have full coverage and no areas of hair loss; 1 = there are minimal gaps in eyebrow hair, and distribution is even; 2 = there are significant gaps in eyebrow hair or distribution is not even; 3 = no notable eyebrows. ClinRO scores for EL Loss: 0 = the eyelashes form a continuous line along the eyelids on both eyes; 1 = there are minimal gaps and the eyelashes are evenly spaced along the eyelids on both eyes; 2 = there are significant gaps along the eyelids or the eyelashes are not evenly spaced along the eyelids; 3 = no notable eyelashes. Analysis included patients who had available EB/EL scores and PRO data, and baseline EB/EL scores ≥ 2. ***P ≤ .001 for ClinRO 0/1 compared with ClinRO 2/3 within each domain analyzed using ANCOVA, adjusting for the corresponding baseline score and prespecified covariates (baseline disease severity [SALT score < 95 vs SALT score ≥ 95], age (adults vs adolescents), sex, and AA episode duration at baseline [< 3 years vs ≥ 3 years]).

Conclusions

Patients with severe AA who achieved ClinRO-defined EB and EL responses also demonstrated greater health-related QoL improvements in symptoms and emotional and daily functioning. These results highlight the clinical relevance of EB and EL regrowth as criteria for treatment success in severe AA and further demonstrate that regrowth beyond the scalp contributed to meaningful improvements in QoL for patients with AA.

EA DV CONGRESS
VIENNA
30 SEP - 3 OCT 2026

Abstract N°: 2824

Facial Hair Regrowth and Health-Related Quality of Life in Males With Severe Alopecia Areata: First Report of Facial Hair Regrowth Outcomes Using Interim Results From the Phase 3 UP-AA Trial

Melinda Gooderham*[1, 2, 3], Ahmed M Soliman[4], Benjamin Ungar[5], Melissa Piliang[6], Kent A Hanson[4], Kaili Ding[4], Andreas Lazar[4], Cristina Sancho Sanchez[4], Brett King[7]

[1] SKiN Centre for Dermatology, Peterborough, Ontario, Canada
[2] Queen's University, Kingston, Ontario, Canada
[3] Probity Medical Research, Waterloo, Ontario, Canada
[4] AbbVie Inc., Chicago, Illinois, United States
[5] Kimberly and Eric J. Walman Department of Dermatology, Mount Sinai Hospital, New York, NY, United States
[6] Cleveland Clinic, Cleveland, Ohio, United States
[7] Dermatology Physicians of Connecticut, Fairfield, Connecticut, United States

Introduction
Alopecia areata (AA) is a chronic autoimmune disease resulting in nonscarring hair loss on the scalp, face, and/or body. Unpredictable facial hair loss among males can have a profound impact on a patient's health-related quality of life (HRQoL), particularly in psychosocial domains, including social anxiety, self-consciousness, and depression. We investigated the relationship between facial hair regrowth and improvement in patient-reported outcomes (PROs) in males with severe AA who were enrolled in a phase 3 clinical trial.

Materials and Methods
UP-AA (NCT06012240) is an ongoing, multicenter, phase 3, randomized, placebo-controlled, double-blind clinical trial evaluating the efficacy and safety of upadacitinib (UPA) in adults and adolescents (12–64 years) with severe AA (defined as a Severity of Alopecia Tool [SALT] score ≥50) who were randomized (2:2:1) to receive orally once-daily UPA 15 mg, UPA 30 mg, or placebo for 24 weeks in 2 replicate studies. This post hoc, treatment-agnostic analysis included males who had available beard scores and PRO data. Clinician-reported outcomes were evaluated using the Global Investigator Assessment for beard hair loss where 0 = no hair growth; 1 = mostly areas with hair loss, some areas of hair growth; 2 = mostly normal hair growth, some areas of hair loss; and 3 = normal hair growth. Patients were instructed to not shave their beard for ≥3 days before assessment. PROs included the Skindex-16 AA and the Alopecia Areata Symptom Impact Scale (AASIS). The Skindex-16 AA has 3 domains including emotions, functioning, and symptoms. Patients rated (range, 0 to 6) how much each impact or symptom bothered them during the past week, and the sum for each domain was standardized to a 0 to 100 scale with higher scores indicating greater impact on HRQoL. The 13-item AASIS has 2 subscales including symptom severity and interference of daily functioning; an average score of the items within each subscale was calculated, with higher scores indicating greater symptom severity and interference. To be included in the analysis patients had to have a beard hair loss score of 0 or 1. The mean change from baseline in Skindex-16 AA and AASIS scores at week 24 was assessed for responders (those who achieved a ≥2 point improvement from baseline in beard hair loss score) and compared with nonresponders (those failing to achieve a ≥2 point improvement from baseline in beard hair loss score). Continuous PROs were analyzed using ANCOVA, adjusting for corresponding baseline PRO score and prespecified covariates, including scalp hair loss as assessed by SALT. The effect of concurrent scalp, eyebrow, and eyelash hair regrowth at week 24 on PROs was not controlled for in this analysis.

Results

The study enrolled 561 males with a mean (SD) age of 33.5 (12.7) years and baseline SALT score of 84.8 (18.8); 53.7% had very severe AA (SALT score ≥95) and 41.0% had a disease duration of ≥3 years. Among those with a beard hair loss score of 0 or 1 at baseline, 370 patients had complete Skindex-16 AA and 366 had complete AASIS data and were included in this analysis. At week 24, responders (117/370, 31.6%) who achieved a beard hair loss score of 2 (mostly normal growth) or 3 (normal growth) experienced significantly greater improvement in Skindex-16 AA emotions (*P*<.05) and functioning (*P*<.001) scores than nonresponders (253/370, 68.4%) with a beard hair loss score of 0 (no hair growth) or 1 (mostly hair loss; **Figure 1**). Similarly, at week 24, responders with a beard hair loss score of 2 or 3 experienced significantly greater improvement in AASIS interference (*P*<.001) and symptom severity (*P*<.001) scores than nonresponders.

Health-Related Quality-of-Life Improvements at Week 24 By Beard Loss Scores Among Males With a Baseline Beard Loss Score of 0 or 1

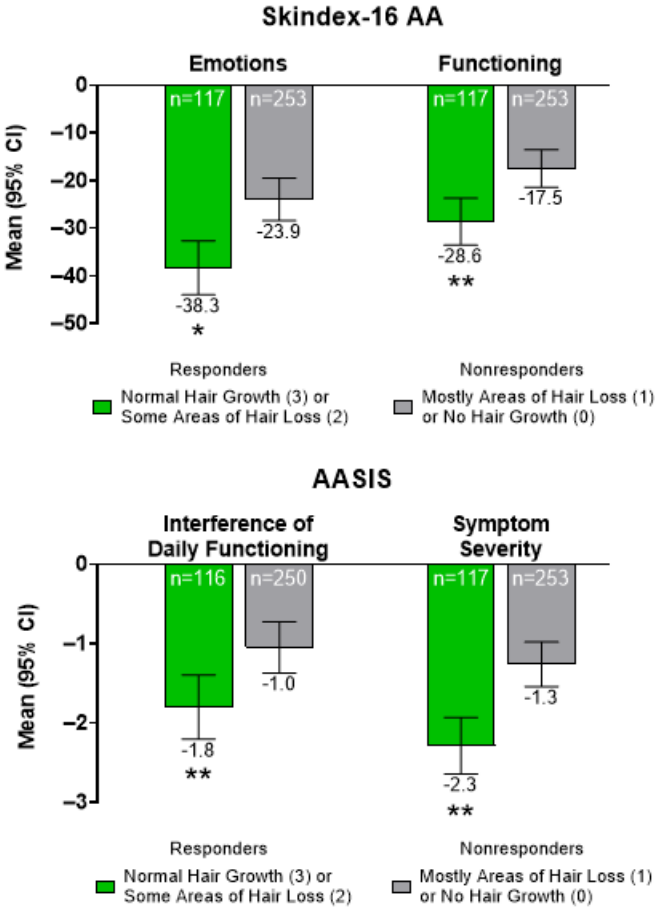

AA, alopecia areata; AASIS, Alopecia Areata Symptom Impact Scale; SALT, Severity of Alopecia Tool. Clinician-reported beard hair loss was evaluated using the Global Investigator Assessment for beard hair loss where 0 = no hair growth; 1= mostly areas with hair loss, some areas of hair growth; 2 = mostly normal hair growth, some areas of hair loss; and 3 = normal hair growth. Responders were those who achieved a ≥ 2 point improvement from baseline in beard hair loss score. *P ≤ 0.05; ** P ≤ 0.001 analyzed using ANCOVA, adjusting for the corresponding baseline score and the prespecified covariates (baseline disease severity [SALT score < 95 vs SALT score ≥ 95], age (adults vs adolescents), and AA episode duration at baseline [<3 years vs ≥ 3 years]). Completed cases and patients with baseline beard hair loss scores < 2 were included. Effects of concurrent scalp, eyebrow, and eyelash hair regrowth at week 24 on PROs was not controlled.

Conclusions

Males with severe AA who achieved clinician-assessed improvement in facial hair coverage experienced significant multidimensional HRQoL benefits including improvements in symptom severity, emotional well-being, and daily functioning.

EADV CONGRESS
VIENNA
30 SEP - 3 OCT 2026

Abstract N°: 2825

Determining Alopecia Areata Severity With the Severity of Alopecia Tool (SALT) vs Alopecia Areata Scale (AASc): Results From an International, Real-World Survey

Brett King*[1], Mark I. Kaldas[2], Ahmed M Soliman[2], Ramona Vladea[2], William Jones[3], Tiffany Mayo[4], Leila Asfour[5]

[1] Dermatology Physicians of Connecticut, Fairfield, Connecticut, United States

[2] AbbVie Inc., North Chicago, IL, United States

[3] Adelphi Communications, Bollington, Cheshire, United Kingdom

[4] School of Medicine Department of Dermatology, The University of Alabama at Birmingham, Birmingham, Alabama, United States

[5] Department of Dermatology, Chelsea and Westminster NHS Foundation Trust, London, United Kingdom

Introduction

Measures of alopecia areata (AA) severity in clinical studies currently rely on the extent of scalp hair loss (Severity of Alopecia Tool [SALT]). The Alopecia Areata Scale (AASc) is a scoring system that includes a more comprehensive assessment of severity based on scalp hair loss as well as eyebrow/eyelash involvement, response to prior therapy, the psychosocial impact of AA, and rapidly progressing disease (hair pull test). While clinical trials utilize SALT, AASc is mentioned in EU guidelines and recommended by US guidelines for severity assessment in clinical practice. This analysis compares the severity categorization of real-world patients with AA evaluated by SALT vs AASc.

Materials and Methods

This ongoing, real-world data was taken from the Adelphi AA Disease Specific Programme™, a cross-sectional survey of dermatologists and their adult patients in Canada, France, Italy, Spain, and the UK who were enrolled starting in October 2025. Eligible dermatologists were actively involved in AA management and consulted with ≥7 patients with AA monthly. Eligible patients were aged ≥18 years, had an AA diagnosis, and were not involved in any clinical trials. A targeted sampling approach was used to achieve an approximate ratio of 1:3:3 patients with mild, moderate, and severe disease, respectively. Physicians completed forms in which they rated each patient's AA severity using the Alopecia Areata Investigator Global Assessment scale (AA-IGA; a clinician-reported proxy for SALT severity categorization). AA severity among these patients was then reevaluated by applying criteria from AASc components extracted from patient record forms completed by physicians. Rates of AA severity evaluated by AA-IGA and AASc were compared and the proportion of patients meeting each of the secondary AASc criteria were reported descriptively.

Results

Of 925 patients, the mean age was 36.8 years, 51.8% were female, and the mean AA duration was 3.1 years. The proportion of patients with severe AA was lower when severity was evaluated using AA-IGA (SALT proxy; 32.4%) vs AASc (61.1%; **Figure**). In addition, application of AASc criteria resulted in shifts in severity categorization among those patients initially categorized as either mild or moderate by AA-IGA (**Figure**). Most patients (79.1%) with mild AA according to AA-IGA had moderate AA when evaluated by AASc and 80.8% of patients with moderate AA as assessed by AA-IGA were categorized as severe when using AASc. Across all severity categories, more than 70%

of participants had negative impacts on psychosocial well-being from AA. With increasing severity as evaluated by AA-IGA, the prevalence increased for the AASc secondary criteria of eyebrow/eyelash involvement (mild, 8.8%; moderate, 25.6%; severe, 50.3%), positive hair pull test (mild, 21.7%; moderate, 43.3%; severe, 52.5%), and prior treatment failure (mild, 7.4%; moderate, 11.0%; severe, 18.0%).

Figure. Estimation of AA Severity with AA-IGA and AASc

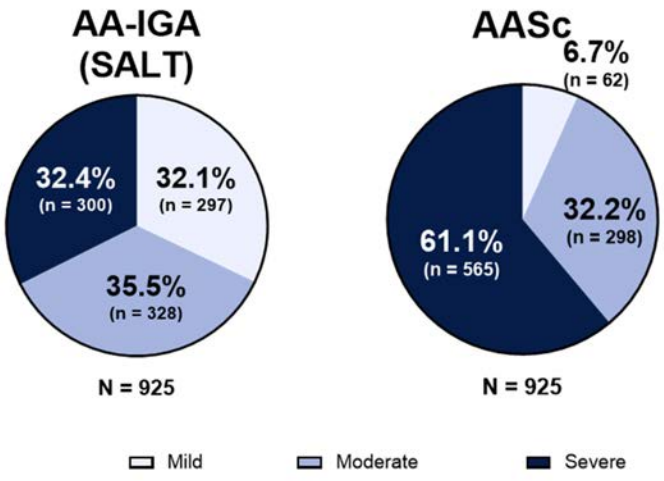

	AASc		
AA-IGA (SALT)	**Mild (n = 62)**	**Moderate (n = 298)**	**Severe (n = 565)**
Mild (n = 297)	20.9% (n = 62)	79.1% (n = 235)	0
Moderate (n = 328)	0	19.2% (n = 63)	80.8% (n = 265)
Severe (n = 300)	0	0	100% (n = 300)

AA, alopecia areata; AA-IGA, Alopecia Areata Investigator Global Assessment; AASc, Alopecia Areata Scale; SALT, Severity of Alopecia Tool.

Conclusions

This international real-world analysis confirms results from a US-based study [1] demonstrating an underestimation of AA severity when evaluated by SALT vs AASc. The increasing prevalence of AASc secondary criteria with increasing AA severity in this international population further support the results of the US study. Importantly, approximately three-quarters of patients had psychosocial impacts from AA, indicating a substantial burden of the disease to patients. Accurate AA severity assessment is critical to optimize treatment decisions and improve patient outcomes.

Reference:

1. King B, et al. Assessment of Alopecia Areata Severity Using the Alopecia Areata Scale (AASc) Compared With the Severity of Alopecia Tool (SALT): Results From a Real-World Survey. Poster presented at: 2026 American Academy of Dermatology (AAD) Annual Meeting; March 27–31, 2026; Denver, CO, USA. Poster 72822.

EA DV CONGRESS
VIENNA
30 SEP - 3 OCT 2026

Abstract N°: 2830

A safety review of JAK inhibitors for managing alopecia areata in adults

Kanchalit Thanomkitti[1], Sofia Spagnolini*[2], Antonella Tosti[3]

[1] Department of Dermatology, Faculty of Medicine Siriraj Hospital, Mahidol University, Bangkok,, Thailand
[2] Dermatology Resident Training Program, Department of Medicine and Surgery, University of Parma,, Parma, Italy
[3] 3Dr. Phillip Frost Department of Dermatology and Cutaneous Surgery, University of Miami School of Medicine, Miami, United States

Introduction

Alopecia areata (AA) is a chronic autoimmune hair loss disorder that can range from patchy scalp involvement to complete loss of scalp and body hair. JAK inhibitors such as baricitinib, ritlecitinib, and deuruxolitinib, have shown substantial efficacy in clinical trials and real-world studies. However, important safety concerns remain, including risks of infections, malignancy, cardiovascular events, thrombosis, and reproductive toxicity. This review summarizes current evidence on the safety of JAK inhibitors in adults with AA, focusing on clinical trials, real-world experience, and post-marketing data to support individualized treatment decisions.

Materials and Methods

expert opinion

Results

Alopecia areata (AA) is a chronic autoimmune disease that can cause significant psychological distress and impairment in quality of life. Traditional therapies often show limited long-term efficacy, leading to growing interest in targeted treatments such as Janus kinase (JAK) inhibitors. Currently approved agents for severe AA include baricitinib, ritlecitinib, and deuruxolitinib, while tofacitinib and ruxolitinib are commonly used off-label.

Overall, JAK inhibitors have demonstrated favorable efficacy and tolerability profiles in both clinical trials and real-world studies. The most common treatment-emergent adverse events are mild to moderate and include headache, acne, upper respiratory tract infections, nasopharyngitis, and urinary tract infections. Herpes zoster represents the most characteristic infection-related adverse event, although serious infections and opportunistic infections remain uncommon in AA populations.

Laboratory abnormalities are generally mild, dose-dependent, and manageable with monitoring. These include lipid elevations, mild anemia, neutropenia, lymphopenia, liver enzyme increases, and creatine kinase elevations. Weight gain and metabolic changes appear more frequent with JAK1/2 inhibitors such as baricitinib and deuruxolitinib, whereas newer selective JAK inhibitors may have a more limited metabolic impact.

Major concerns regarding malignancy, major adverse cardiovascular events (MACE), and venous thromboembolism (VTE) originate primarily from rheumatoid arthritis studies involving older patients with multiple cardiovascular risk factors. In contrast, available AA-specific data show very low rates of these complications, particularly in younger and healthier individuals. Current evidence therefore suggests that the safety profile of JAK inhibitors in AA is more favorable than in rheumatologic populations.

Overall, JAK inhibitors represent an important therapeutic advance for severe AA, with a generally acceptable safety profile when appropriate patient selection, baseline risk assessment, and long-term monitoring are applied.

Conclusions

Careful monitoring and risk stratification are essential. Baseline and periodic evaluation should include CBC, liver and renal function, lipid profile, and cardiovascular risk factors. Vaccination strategies are important: recombinant herpes zoster, pneumococcal, and annual influenza vaccines, while live vaccines should generally be avoided during treatment.

Special consideration is required in patients with active infections, HBV, HCV, HIV, latent TB, pregnancy, hepatic or renal impairment, prior malignancy, or increased cardiovascular and thromboembolic risk. Treatment decisions should be individualized, often involving multidisciplinary management and temporary treatment interruption when necessary. Although current evidence suggests that serious adverse events remain uncommon in AA populations, long-term vigilance is warranted given class-wide safety concerns derived mainly from rheumatologic diseases.

Drug–drug interactions differ among JAK inhibitors according to their metabolic pathways and may require dose adjustments. Overall, current evidence supports a favorable safety profile for JAK inhibitors in AA when appropriate patient selection, preventive measures, and ongoing monitoring are applied.

EA DV CONGRESS
VIENNA
30 SEP - 3 OCT 2026

Abstract N°: 2854

AI-based automated Ludwig scale assessment for female androgenetic alopecia: development of a segmentation-driven scoring system

Miguel Sánchez Viera*[1], Giuseppe Razzani[2], Alfonso Medela[3], Taig Mac Carthy[2], Gerardo Fernandez[2], Andy Aguilar[2], Antonio Martorell[4], Daniel Dagnino[3], María Ribagorda[2], Agustín Oyhamburú[2]

[1] Instituto de Dermatología Integral (IDEI), Madrid, Spain
[2] Clinical Endpoint Innovation - Legit.Health, Bilbao, Spain
[3] Medical Data Science - Legit.Health, Bilbao, Spain
[4] Manises Hospital, Manises, Spain

Introduction
Female androgenetic alopecia (FAA) is a common condition affecting between 3% and 38% of women worldwide, depending on age and population characteristics. Accurate and reproducible assessment of disease severity is essential for diagnosis, monitoring progression, and evaluating treatment response. However, current clinical scales, including the Ludwig scale, are subject to significant interobserver variability. This study aims to develop an automated, objective scoring system for FAA severity using artificial intelligence (AI), aligned with the Ludwig classification.

Materials and Methods
A dataset of 96 clinical images (62 retrospective and 34 prospective) of FAA cases was collected from a dermatology institute in Madrid, acquired using smartphone imaging. Two deep learning models were developed: one for automatic scalp localization and another for segmentation of hair-bearing and alopecic areas.

The models were trained using a larger annotated dataset from public dermatological atlases. Based on segmentation outputs, the percentage of hair loss was calculated and mapped to the three standard Ludwig scale grades. Model optimization was performed using Bayesian hyperparameter tuning on the retrospective dataset.

Results
Model performance was evaluated on the prospective cohort. The system correctly classified the Ludwig grade in 53% of cases. The estimated percentage of hair loss showed moderate correlation with expert estimations, while agreement with categorical Ludwig grading was lower.

Importantly, the model demonstrated high consistency in estimating continuous hair loss percentage, with most classification errors limited to a one-grade difference. Confusion matrix analysis confirmed that only a small number of cases were misclassified beyond adjacent severity levels.

Representative segmentation outputs across Ludwig grades are shown in Figure 1.



Figure 1: Results of the segmentation of the capillary zone and the areas of hair loss, illustrated for each of the three degrees of alopecia according to the Ludwig scale.

Conclusions

This study presents an automated, segmentation-based method for estimating Ludwig scale severity in the FAA. The proposed approach provides an objective and reproducible alternative to traditional visual scoring systems. By enabling quantitative assessment of hair loss from a single image, this tool may support standardized evaluation in both clinical practice and research settings.

EA DV CONGRESS
VIENNA
30 SEP - 3 OCT 2026

Abstract N°: 2874

Baricitinib in alopecia areata: real-world 52-week results

Patricia Bodas Gallego*[1], Victor Onecha Vallejo[2], Ana Fernández Vázquez[3], Sara Mateos Navarro[1], Jose Castiñeiras González[1]

[1] Department of Dermatology. Complejo Asistencial Universitario de León, León, Spain
[2] Department of Dermatology. Complejo Asistencial Universitario de Palencia, Palencia, Spain
[3] Department of Hospital Pharmacy. Complejo Asistencial Universitario de León, León, Spain

Introduction

Alopecia areata is an immune-mediated disorder targeting the hair follicle, with an estimated lifetime prevalence of approximately 2%. The disease can substantially impair patients' quality of life, and although no curative therapy is currently available, existing treatments are aimed at controlling disease activity and promoting hair regrowth. In 2022, Baricitinib became the first Janus kinase inhibitor (JAKi) approved for the treatment of alopecia areata. The aim of this study is to assess the efficacy and safety of Baricitinib in the treatment of alopecia areata in routine clinical practice after 52 weeks of follow-up.

Materials and Methods

A retrospective, two-centre cohort study was conducted including patients with alopecia areata treated with baricitinib and followed for at least 52 weeks. Eligible patients were aged ≥18 years, had a SALT score ≥50, a disease duration of ≥6 months, and had either failed systemic corticosteroid therapy or had a contraindication to its use. Exclusion criteria included other forms of alopecia and concomitant use of other systemic JAKi.

Results

The cohort included 32 patients, of whom 40.6% were women and 59.4% were men, with a mean age of 43.3 years. The mean age at disease onset was 31.5 years, with an average disease duration of 11.8 years. Regarding clinical phenotype, 50.0% presented with alopecia universalis, 15.6% with multiple patchy lesions, 21.9% with ophiasis, 9.4% with total alopecia, and 3.1% with other forms. All patients had received prior treatments, and only one had been previously exposed to another JAKi (tofacitinib). All patients were treated with 4 mg of Baricitinib. Additionally, 56.3% received concomitant therapies, most commonly oral minoxidil and topical corticosteroids. The mean baseline SALT score was 76.5. At 52 weeks, 62.5% of patients achieved a SALT score ≤20, 46.9% reached a SALT score ≤10, and 18.8% achieved a complete response (SALT = 0). Two patients discontinued treatment before 52 weeks due to lack of efficacy. Most patients achieved a SALT score <20 within the first 24 weeks of treatment; however, 6 patients reached a clinical response after more than 6 months of therapy. Regarding safety, 43.8% of patients experienced adverse events, most of which were mild in severity. The most frequently reported events were alterations in liver function tests and lipid profiles, as well as herpesvirus infections. Two additional discontinuations were attributed to adverse events: one case of herpes zoster and one case of pulmonary thromboembolism in a patient with previously undiagnosed May–Thurner syndrome.

Conclusions

Baricitinib demonstrates significant and progressively increasing efficacy over time, with a high overall clinical response rate and predominantly early responses, as most patients achieve a SALT score <20 within 24 weeks of treatment. However, it is noteworthy that nearly 20% of patients reach a clinical response after more than 6 months of therapy. The safety profile remains favourable, with predominantly mild adverse events, although careful patient selection is recommended due to the potential risk of thromboembolic events.

EADV CONGRESS
VIENNA
30 SEP - 3 OCT 2026

Abstract N°: 2880

Congénital Hypotrichosis: Consider The Diagnosis Of Monilethrix

amir yahya bourbia*[1], Tarek Mansoul[1], HAIDER BARKAT[2], RIADH BOUSSAID[1], Ahmed Samaouel Chehad[1]

[1] Department of Dermatology, CHU Constantine, Faculty of Medicine, University of Constantine 3, Constantine, Algeria
[2] Private Dermatology Practice, Dr Haider Barkat Clinic, Batna, Algeria

Introduction

Monilethrix is a rare hair shaft disorder, most often inherited, characterized by short, fragile, and brittle hair appearing during the first months of life. It is defined by a beaded appearance of the hair shaft, with regular alternation of elliptical nodes and constrictions, the latter corresponding to fracture-prone areas. Dermoscopy is a simple and highly useful examination that can rapidly orient the diagnosis.

Case Presentation

We report the case of a 2-year-old girl referred for congenital hypotrichosis. Since birth, her parents had noticed short, fragile hair that failed to grow, with no similar family history. Over the preceding 6 months, she had also developed a scaly scalp condition consisting of slightly adherent whitish scales, leading to several consultations during which tinea capitis was suspected despite the absence of mycological confirmation. The patient received multiple topical and systemic antifungal treatments without improvement.

At our department, a mycological examination performed more than 3 months after discontinuation of all antifungal therapies was negative. Dermoscopic examination revealed a characteristic beaded appearance of the hair shaft, highly suggestive of monilethrix. Symptomatic management with a gentle keratolytic shampoo was proposed, and the parents were informed about the benign chronic nature of the condition.

Monilethrix usually manifests during the first months of life with hypotrichosis and short, fragile hair. Hair fragility results from regular constrictions along the hair shaft, where fractures typically occur. Keratotic or scaly scalp lesions may also be associated. Dermoscopy classically demonstrates regularly spaced nodes separated by narrowed internodal segments, producing the typical beaded appearance.

The interest of our observation lies in the initial diagnostic wandering and the decisive contribution of dermoscopy. In children presenting with congenital hypotrichosis or brittle hair, monilethrix should be considered in order to avoid unnecessary treatments. In our case, the negative mycological examination further argued against tinea capitis.

The absence of a family history does not exclude the diagnosis. Although monilethrix is usually inherited, sporadic cases related to de novo mutations have been reported. There is no standardized curative treatment; management mainly relies on gentle hair care, avoidance of hair shaft trauma, and parental education

Conclusion

In cases of congenital hypotrichosis associated with short and fragile hair, monilethrix should be suspected. Dermoscopy provides a rapid and noninvasive diagnosis, helping to prevent diagnostic errors and inappropriate treatments

EA DV CONGRESS
VIENNA
30 SEP - 3 OCT 2026

Abstract N°: 2883

The Overlooked Target of Phototherapy: Hair Protection with Fabric Barriers During Narrowband UVB Treatment

Ana Raimundo*[1], Hudson Rezende[1], João Henrique Aurich[1], Letícia Ferreira de Hybi Cerqueira[2], Nara Cristina Tasso Almeida Carvalho[3]

[1] Centro Universitário Lusíada (UNILUS) – Santos, SP, Santos, Brazil

[2] Centro Universitário CESMAC – Maceió, AL, Maceio, Brazil

[3] Centro Universitário de Araraquara (UNIARA) – Araraquara, SP, Araraquara, Brazil

Introduction

Ultraviolet (UV) radiation is a cornerstone in the management of chronic inflammatory dermatoses, with well-established cutaneous adverse effects. In contrast, its impact on hair remains underrecognized, despite evidence of cumulative structural damage, including protein loss, cuticular disruption, and pigment degradation. Given the non-regenerative nature of the hair shaft, even subclinical injury may be permanent. Practical strategies for hair protection during phototherapy are not standardized, and the role of simple physical barriers has not been systematically evaluated in real-world settings.

Materials and Methods

We conducted a multicenter cross-sectional study across four dermatology centers, including female patients undergoing narrowband UVB phototherapy. All participants were instructed to tie their hair and fully cover it with a dark-colored cotton headscarf before each session, without the use of topical hair products. A total of 36 patients (mean age 38 years) were included. Psoriasis was the most frequent indication (53%), followed by other inflammatory dermatoses. Treatment frequency ranged from one to three sessions per week, with a mean of 15 sessions. Notably, 86% of patients reported prior chemical hair treatments, a factor associated with increased susceptibility to hair damage.

Results

Despite repeated UV exposure, no patients reported hair loss. Hair dryness was noted by 36%, while the majority (64%) did not perceive dryness. Changes in hair color and split ends were uncommon, reported by 17% and 33% of patients, respectively. No statistically significant association was found between the number of phototherapy sessions and hair-related complaints ($p > 0.05$ for all variables). In contrast, cutaneous adverse effects were frequent and exposure-dependent: 58% reported skin dryness, 36% hyperpigmentation, and 17% worsening of pre-existing lesions, with significant associations observed between treatment frequency and both dryness and pigmentation.

Conclusions

In this multicenter cohort, consistent hair coverage with a dense, dark cotton fabric during narrowband UVB phototherapy was associated with minimal self-reported hair damage, even in a population with high baseline susceptibility. The absence of a dose–response relationship between UV exposure and hair alterations, contrasted with clear cutaneous effects, supports a protective role of fabric barriers. These findings highlight a simple, low-cost, and immediately applicable intervention that may be incorporated into routine phototherapy protocols. More

broadly, they underscore the need to recognize hair as a relevant, yet often neglected, target of UV exposure in dermatologic practice.

EA DV CONGRESS
VIENNA
30 SEP - 3 OCT 2026

Abstract N°: 2897

Clinical patterns and perceived triggers of stress-related hair shedding among medical students

Artina Pajaziti*[1, 1], Fatlinda Sadiku[1], Donjeta Bajraktari[1], Fjona Hajrullahu[1], Erinda Hajdari[1], Ylleza Terstena[1], Afrora Krasniqi[1]

[1] University Clinical Center of Kosovo, Prishtine, Kosovo

Introduction
Hair shedding complaints are common among young adults and may be influenced by academic stress, lifestyle factors, and individual susceptibility. In medical students, perceived stress may not only be associated with the presence of hair shedding, but also with its perceived timing, severity, and worsening during stressful periods. This study aimed to describe the clinical patterns and perceived triggers of stress-related hair shedding among medical students.

Materials and Methods
A cross-sectional questionnaire-based study was conducted among students of the Faculty of Medicine. Data were collected using an anonymous self-administered questionnaire including demographic and clinical variables, the 10-item Perceived Stress Scale (PSS-10), and structured questions on hair shedding. Hair shedding characteristics included self-reported increased shedding during the previous 6 months, frequency of visible shedding on the comb/brush, pillow, shower, and clothes/floor, time since onset, self-rated hair density, concern about hair loss, stressful events within 3 months before onset, and perceived worsening during stressful periods.

Results
A total of 449 medical students were included in the analysis. Increased hair shedding during the previous 6 months was reported by 221 students (49.2%), while 150 (33.4%) reported no increased shedding and 78 (17.4%) were unsure. The mean PSS-10 score was 19.29 ± 6.84, and most participants had moderate perceived stress.

Visible hair shedding was most commonly reported as occurring “sometimes” in daily situations such as combing, showering, pillow shedding, or shedding on clothes/floor. Regarding onset, 89 students (19.8%) reported increased shedding beginning 6–12 months earlier, while 113 (25.2%) reported onset more than 12 months earlier. A strong stressful period within 3 months before the onset of increased hair shedding was reported by 241 students (53.7%). In addition, 122 students (27.2%) reported that hair shedding worsened “often” during stressful periods, while 66 students (14.7%) reported that this occurred “always”.

Conclusions
Nearly half of medical students reported increased hair shedding, and many perceived a temporal relationship with stressful periods. Stressful events before onset and worsening during stress were frequently reported, suggesting that psychosocial stress may play an important role in hair shedding complaints in this population. These findings highlight the importance of considering stress-related triggers when evaluating young adults with hair shedding, particularly in academically demanding environments.

EADV Congress 2026, VIENNA
30 SEPTEMBER - 03 OCTOBER 2026
POWERED BY M-ANAGE.COM

EADV CONGRESS
VIENNA
30 SEP - 3 OCT 2026

Abstract N°: 2942

Ungual Bowen Disease Revealed by Longitudinal Melanonychia: A Case Report

Afaf Ait Bilaou*[1], chaouche mohammed[1], mhaimer soukaina[1], hiba kherbach[1], Chaima Ezzaki[1], Hajar Lahmidi[1], Chaima El Assali[1], sokaina chhiti[1], radia chakiri[1]

[1] Department of Dermatology, Mohammed VI University Hospital, agadir, Morocco

Introduction

Ungual Bowen disease is a rare in situ squamous cell carcinoma of the nail unit, frequently underdiagnosed because of its polymorphic clinical presentation. Pigmented forms are uncommon and may mimic subungual melanoma, representing a significant diagnostic challenge. We report a case of ungual Bowen disease revealed by longitudinal melanonychia, emphasizing the importance of early biopsy in atypical nail pigmentation.

Case Presentation

A 67-year-old man was admitted for treatment of left leg erysipelas. His medical history was notable only for chronic smoking. Systematic examination of the toenails revealed longitudinal melanonychia involving the right great toenail, presenting as a brown longitudinal band occupying less than one-third of the nail plate width, without true periungual pigmentation.

Dermoscopy showed an irregular and inhomogeneous pigmented longitudinal band associated with distal notching and distal onycholysis. Pigmentation visible through the cuticle corresponded to a pseudo-Hutchinson sign. No lymphadenopathy was detected, and foot radiography showed no underlying bone involvement.
Given the suspicious clinical and dermoscopic findings, surgical exploration of the nail unit was performed and identified a 2-mm pigmented lesion arising from the distal nail matrix. Complete surgical excision with safety margins was achieved.
Histopathological examination demonstrated full-thickness atypical intraepithelial keratinocytic proliferation without basement membrane invasion, consistent with ungual Bowen disease (squamous cell carcinoma in situ). Histological analysis confirmed clear surgical margins, and no additional surgery was required.

Conclusion

Ungual Bowen disease is a rare and polymorphic nail tumor that may exceptionally present as longitudinal melanonychia mimicking nail melanoma. Early histopathological evaluation remains essential for accurate diagnosis and allows conservative management with an excellent prognosis.

EA DV CONGRESS
VIENNA
30 SEP - 3 OCT 2026

Abstract N°: 2974

Neonatal-Onset Alopecia Areata With Trachyonychia: A Rare Case Report.

Ramiro Alanis Ronquillo*[1], Guadalupe Maldonado Colin[1], Lucia Achell Nava[1], Dolores Maribel Arellano Vivero[1]

[1] Department of Dermatology, ISSSTE Centro Médico Nacional 20 de Noviembre, Ciudad de México, Mexico

Introduction
Neonatal-onset Alopecia Areata is an exceptionally rare form of autoimmune alopecia. Disease onset during the first months of life has been associated with severe clinical phenotypes, chronic progression, and increased treatment refractoriness, particularly in patients with concomitant nail involvement. Currently, it represents a major diagnostic and therapeutic challenge in pediatric dermatology.

Case Presentation
A 9-month-old female infant presented with progressive hair loss beginning during the first 2 months of life. Physical examination revealed diffuse nonscarring alopecia involving the entire scalp, eyebrows, and eyelashes, accompanied by trachyonychia affecting all fingernails. No associated systemic abnormalities were identified, and thyroid function tests were within normal limits. Given the differential diagnosis of alopecia areata versus ectodermal dysplasia, a punch biopsy from the occipital scalp was performed.

Histopathological examination demonstrated preserved epidermal architecture with mild regular acanthosis. Reduced follicular density with an abnormal terminal-to-vellus hair ratio was observed, in addition to decreased sebaceous gland size and a peribulbar lymphocytic inflammatory infiltrate, findings consistent with alopecia areata. Eccrine glands were preserved, and no histopathological features suggestive of aplasia cutis congenita were identified. Overall, clinicopathological findings supported the diagnosis of neonatal-onset Alopecia Areata.

Treatment included vitamin D supplementation, alternate-day 5% topical minoxidil, dexamethasone pulse therapy, intralesional triamcinolone, and topical betamethasone lotion, resulting in partial clinical improvement after 6 months of follow-up.

Conclusion
Severe forms of pediatric alopecia areata with onset during infancy are uncommon and frequently associated with poor prognosis, particularly in cases progressing to alopecia totalis or universalis and those accompanied by nail involvement such as trachyonychia. Early-onset disease has been linked to chronicity, recurrent activity, and limited therapeutic response.

The pathophysiology of severe alopecia areata involves the loss of follicular immune privilege mediated by CD8+ T lymphocytes and activation of the JAK-STAT signaling pathway through the IFN-γ/IL-15 axis, leading to inflammatory damage of both the hair follicle and nail matrix. The aggressive clinical course observed in neonatal presentations suggests an early and profound dysregulation of immune tolerance, likely influenced by genetic and epigenetic susceptibility factors.

Although corticosteroids remain the cornerstone of treatment in pediatric alopecia areata, therapeutic refractoriness is common in extensive disease. The partial response observed in this patient is consistent with

current literature describing persistence of resident memory T cells involved in disease recurrence and chronic inflammation.

Recently, Janus kinase inhibitors such as tofacitinib and ritlecitinib have emerged as promising therapeutic options for severe pediatric alopecia areata due to their ability to target key inflammatory pathways and improve both hair and nail involvement. However, their use in infants remains off-label, and safety data in this age group are still limited.

This case highlights the diagnostic and therapeutic challenges of neonatal-onset alopecia areata and emphasizes the need for further studies evaluating targeted therapies in early pediatric populations.

EA DV CONGRESS
VIENNA
30 SEP - 3 OCT 2026

Abstract N°: 2978

Deucravacitinib in highly pre-treated refractory lichen planopilaris

Guillaume Rouvet*[1, 2], Estelle Charvet[1, 2], Chloé Grolleau[1, 2, 3], Jeremie Delaleu[1, 2, 3], Marie Jachiet[1, 2], Jean David Bouaziz[1, 2, 3], Thibault Mahevas[1, 2], Charles Cassius[1, 2, 3, 4]

[1] Assistance Publique Hôpitaux de Paris, Paris, France
[2] Hôpital Saint-Louis, Paris, France
[3] Université Paris Cité - BU Villemin, Paris, France
[4] Karolinska Institutet Campus Solna, Solna, Sweden

Introduction

Lichen planopilaris (LPP) is a chronic primary cicatricial alopecia in which perifollicular lymphocytic inflammation leads to irreversible follicular destruction. Standard treatments often provide incomplete disease control and recent expert recommendations highlight the lack of effective options for refractory disease.[1] Deucravacitinib, an oral selective TYK2 inhibitor approved for plaque psoriasis, has shown efficacy in mucosal and cutaneous lichen planus (LP). We report three patients with severely refractory LPP who responded rapidly to deucravacitinib monotherapy.

Case Presentation

A 52-year-old woman with biopsy-proven LPP, oral LP and vulvar LP was refractory to intralesional triamcinolone followed by three months of prednisone (0.5 mg/kg/day) + acitretin (20 mg/day) + hydroxychloroquine (400 mg/day), with persistent scalp inflammation (LPPAI 8.3; Figure 1A). All systemic agents were withdrawn and deucravacitinib 6 mg/day initiated. Within 4 weeks, perifollicular erythema resolved with vertex regrowth (LPPAI 1.08; Figure 1B). Response was sustained at 4 months.

A 53-year-old woman with biopsy-proven scalp LPP, cutaneous LP and vulvar LP failed two months of prednisone (0.5 mg/kg/day) + acitretin (0.3 mg/kg/day) (LPPAI 5.83; Figure 2A,B). Deucravacitinib 6 mg/day was initiated and prednisone progressively tapered to 5 mg/day. At 6 weeks, scalp inflammation, vulvar pruritus and facial lesions had markedly improved (Figure 2C,D). Response was maintained at 4 months (LPPAI 2.17) with no laboratory abnormalities.

A 31-year-old man with biopsy-proven scalp and cutaneous LP/LPP involving scalp, eyebrows, face, neck and trunk failed twelve months of sequential therapy with prednisone (up to 1 mg/kg/day), methotrexate (15 mg/week), hydroxychloroquine (400 mg/day) and acitretin (0.3 mg/kg/day) (DLQI 11/30). All systemic agents were withdrawn and deucravacitinib 6 mg/day initiated. At 4 months, scalp and eyebrow regrowth was observed.

These three patients with severely refractory LPP achieved rapid clinical improvement under deucravacitinib. Whereas the previously reported series included patients with a median of one prior systemic therapy and none exposed to systemic corticosteroids, methotrexate or retinoids, our cohort had failed a median of three mechanistically distinct systemic classes. Two patients showed concurrent improvement of mucosal and cutaneous LP, supporting a broader role of TYK2 inhibition across the LP spectrum.

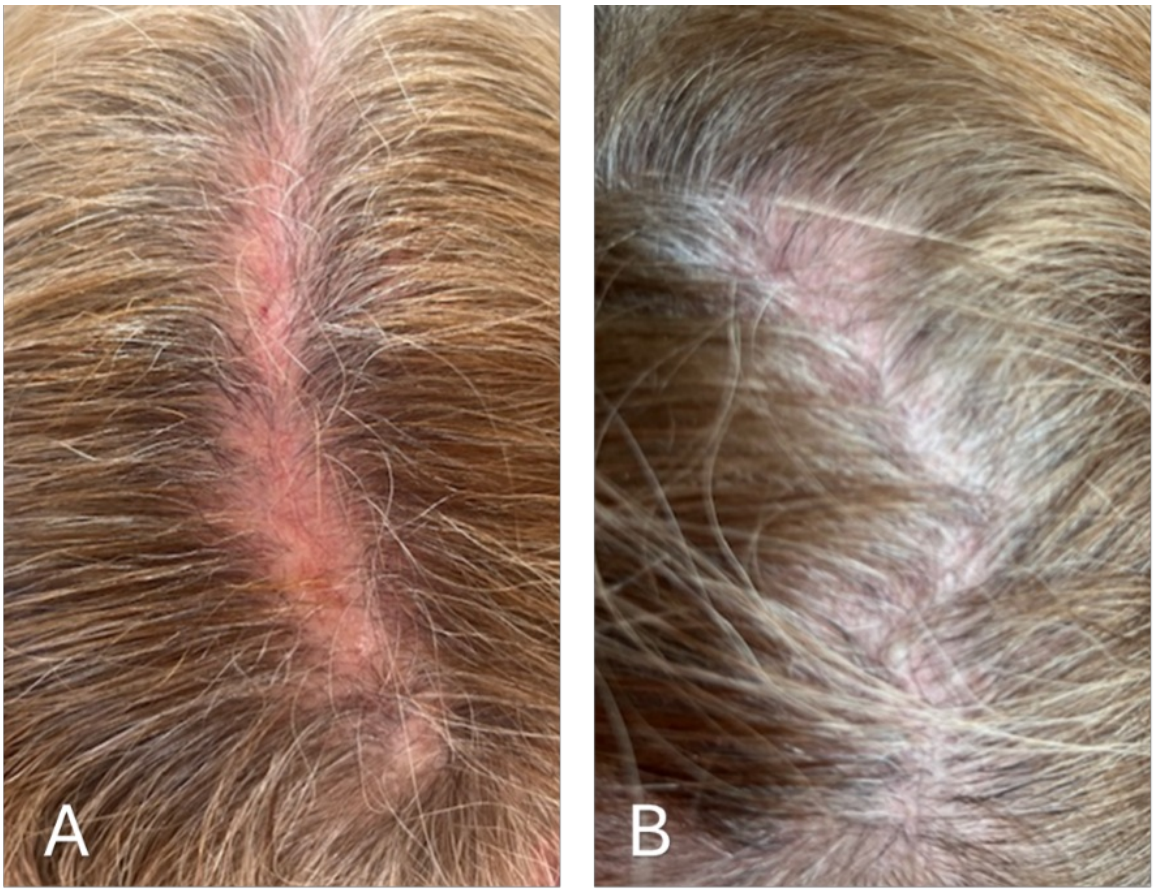

Conclusion

Type I IFN signaling, driven mainly by plasmacytoid dendritic cell-derived IFN-α, is the central pathogenic axis in LP and LPP. TYK2 mediates type I IFN receptor signal transduction. Deucravacitinib selectively binds the TYK2 pseudokinase domain through an allosteric mechanism, suppressing IFN-driven follicular inflammation without inhibiting JAK1–3—a profile potentially more favorable than non-selective JAK inhibitors for long-term management of chronic scalp disease.

Transient acneiform eruptions occurred in all three patients, consistent with the safety signal reported in psoriasis trials. Limitations include the small sample size, retrospective design, four-month follow-up, and absence of quantitative trichoscopy. Larger prospective studies are warranted to confirm efficacy and durability, particularly regarding hair regrowth in zones of active versus established cicatricial inflammation.

EA DV CONGRESS
VIENNA
30 SEP - 3 OCT 2026

Abstract N°: 2990

A Comparative Clinical and Trichoscopic study between Fractional Radiofrequency Microneedling (FRM) versus Intralesional Steroids in Treatment of Alopecia Areata

Sarah Akram Kamal Hussein Orabi*[1]

[1] Cairo University, Dermatology Department, Cairo, Egypt

Introduction
Alopecia areata (AA) is a common autoimmune disorder with significant psychosocial burden. Intralesional corticosteroid (ILCS) injection is considered the main line of management. More tolerable treatment methods with less side effects are needed. Fractional radiofrequency microneedling (FRM) can be used in the treatment of hair disorders. It was reported to stimulate hair regrowth in patients with androgenic alopecia.Our objective was to evaluate the efficacy and safety of FRM compared to ILCS as a potential therapeutic agent in AA.

Materials and Methods
24 patients with multifocal patchy AA were recruited. In each patient, 3 patches were randomly assigned to 3 different treatment modalities; FRM, ILCS and control patches not subjected to any treatment. Six sessions were done with 3 weeks intervals. Comparative assessment was conducted utilizing trichoscopic scaled scores of dystrophic and terminal hairs, SALT score, physician global assessment (PGA) score as well as the global patients' satisfaction score.

Results
Both treatment modalities showed comparable efficacy demonstrated by the non-significant difference in trichoscopic scaled scores of dystrophic and terminal hairs, nor in PGA and patients' satisfaction scores.

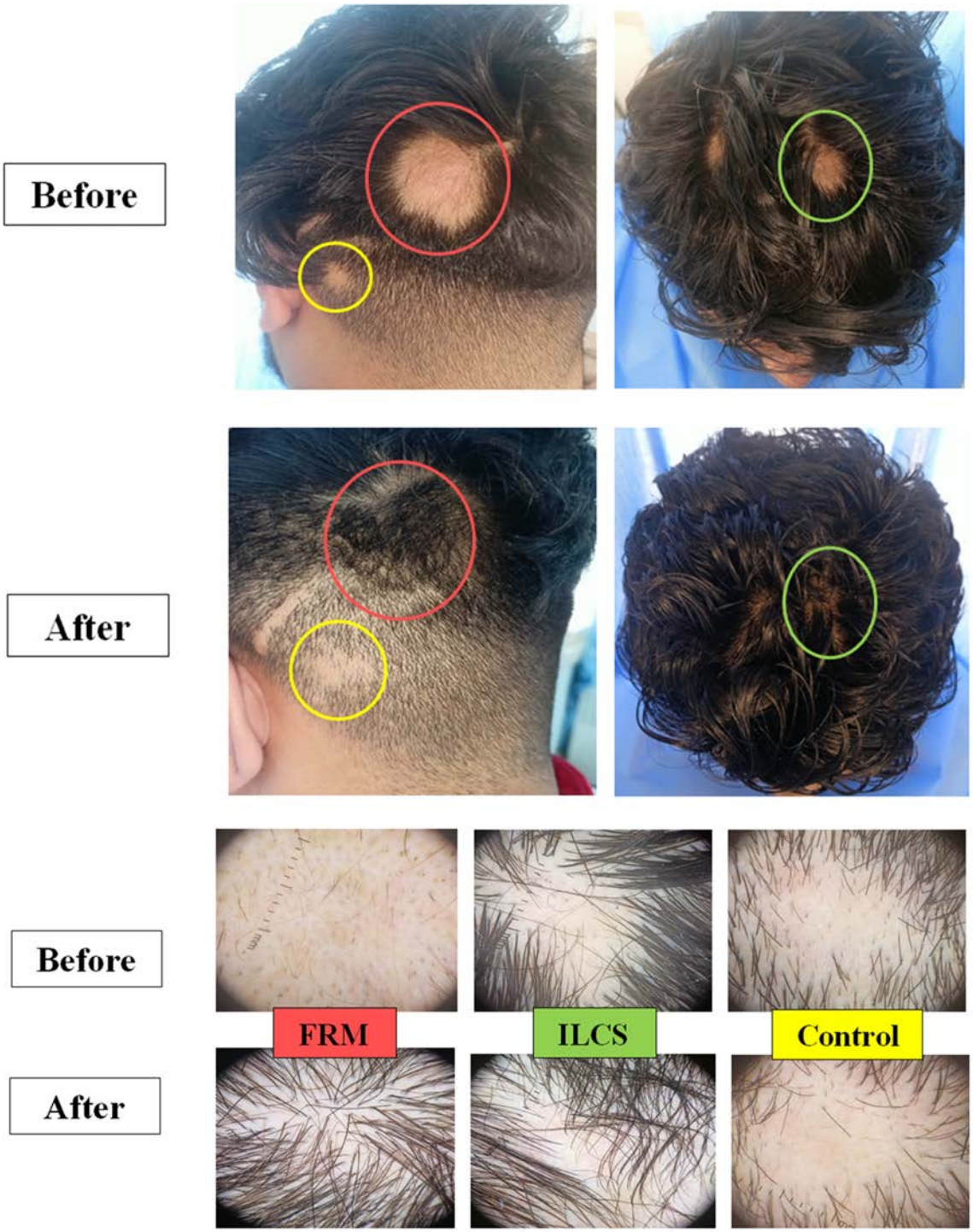

A 35 years old male patient with patchy AA (Red): Patch treated with FRM for 6 sessions with 3 weeks interval showing good response clinically & trichoscopically. (Green): Patch treated with ILCS for 6 sessions with 3 weeks interval showing good response clinically & trichoscopically. (Yellow): Control patch not subjected to any treatment modality showing no improvement.

Conclusions

FRM could be one of the effective and safe treatment modalities in patchy AA. It is a good alternative to ILCS with less side effects.

EA DV CONGRESS
VIENNA
30 SEP - 3 OCT 2026

Abstract N°: 2995

Distinct trichoscopic findings of the “Headspin Hole” phenomenon in Breakdancing

Lidiya Todorova*[1, 2], Nicolas Kluger[3, 4]

[1] Medical University Plovdiv, Plovdiv, Bulgaria
[2] Follica: Hair & Scalp Clinic, Plovdiv, Bulgaria
[3] Tampere University Hospital, Tampere, Finland
[4] Hôpital Bichat-Claude Bernard, Paris, France

Introduction

Lifestyle-associated mechanical factors may contribute to previously unrecognized patterns of localized alopecia. Breakdancing remains a popular acrobatic dance sport among adolescents and young adults worldwide. The “headspin,” a power move involving rotational spinning on the vertex of the head, subjects the scalp and skull to repetitive pressure, shear stress, and frictional forces, particularly at the primary point of ground contact. The combination of rotational acceleration, body weight loading, surface characteristics, and variable use of head protection may result in chronic microtrauma to the hair shafts and follicular units. Anecdotal reports among dancers have described localized hair loss, referred to as the “headspin hole.” We report one distinct presentation consisting of two patches of focal hair loss associated with repetitive mechanical trauma.

Case Presentation

One 15-year-old male patient presented with well-demarcated patchy alopecia localized to the vertex region and the right parietal part of the scalp. He reported frequent breakdancing involving repetitive spinning on the vertex and right side of the head over several years, without consistent use of protective headgear. There was no personal or family history of alopecia areata, autoimmune disease, or other dermatologic conditions. Clinical examination revealed localized hair loss mimicking long-standing alopecia areata for the parietal patch and, for the vertex, diffuse hair thinning with preservation of follicular ostia and no evidence of scarring. A gentle hair pull test was negative at the margins of both patches.

Trichoscopic findings for the vertex area included trichorexis nodosa, broom hairs, anisotrichosis, and hair shaft breakage at variable lengths, consistent with chronic mechanical damage. For the parietal patch, broken hairs were observed predominantly at the same level, along with peri- and interfollicular erythema, anisotrichosis, and trichorrhexis nodosa. No exclamation mark hairs, black dots typical of alopecia areata, or signs of cicatricial alopecia were identified. These findings support a diagnosis of friction-induced hair shaft fragility rather than an autoimmune or scarring process.

Conclusion

The case illustrates distinct forms of localized mechanical alopecia secondary to repetitive friction and sustained pressure. The coexistence of two clinically different patterns—one resembling alopecia areata and the other presenting as vertex thinning or male pattern hair loss - highlights the variability in presentation depending on the direction, intensity, and chronicity of mechanical stress. Recognition of such lifestyle-related etiologies is important to avoid unnecessary diagnostic interventions, including biopsy or systemic therapy, and to guide appropriate behavioral modification, such as reducing headspin frequency or improving scalp protection. In addition, we describe unique trichoscopic findings for this type of alopecia, which might aid the clinician and alleviate diagnostic uncertainty regarding the etiology of localized hair loss in young patients engaged in breakdancing or similar activities involving repetitive scalp trauma.

EADV Congress 2026, VIENNA
30 SEPTEMBER - 03 OCTOBER 2026
POWERED BY M-ANAGE.COM

EA DV CONGRESS
VIENNA
30 SEP - 3 OCT 2026

Abstract N°: 3006

Diagnostic Value of Hematological and Inflammatory Markers in Telogen Effluvium: Correlation with Ferritin and ROC Analysis

Simge Süel Eroğlu*[1], Meryem Çetin[2], Şirin Çetin[3]

[1] Amasya Sabuncuoğlu Şerefeddin Research and Training Hospital, Dermatology, Amasya, Türkiye

[2] Amasya University, Microbiology, Amasya, Türkiye

[3] Amasya University, Bioistatistics, Amasya, Türkiye

Introduction

Telogen effluvium (TE) is a form of diffuse hair loss that impairs quality of life, especially in women, and is closely linked to iron metabolism disorders. This study aimed to evaluate the diagnostic value of routine complete blood count parameters, ferritin levels, inflammatory ratios (NLR, PLR), and their derived combined indices (MCV/RDW, RDW/MCV, PLT/MCV, MCH/MCV, FER/MCV) in patients with TE.

Materials and Methods

This retrospective study included 200 TE patients who presented to the dermatology outpatient clinic and 99 healthy controls matched for age and gender. Complete blood count parameters, ferritin values, and calculated ratios of all participants were retrospectively reviewed. The normality of the data distribution was assessed using the Kolmogorov-Smirnov and Shapiro-Wilk tests. The Mann-Whitney U test and independent samples t-test were used for intergroup comparisons. The diagnostic performance of the parameters was evaluated using ROC curve analysis; cutoff points were determined using the Youden index ($p<0.05$).

Results

While no significant differences were found between the groups in terms of hemoglobin, hematocrit, MCV, MCH, and MCHC values ($p>0.05$), RDW was significantly higher in the patient group (13.61 vs. 12.95; $p<0.001$), and ferritin was significantly lower (30.24 vs. 40.67 ng/mL; $p=0.01$). Of the calculated ratios, MCV/RDW was significantly lower in the patient group ($p<0.001$); RDW/MCV ($p<0.001$), PLT/MCV ($p=0.001$), and PLR ($p=0.047$) were significantly higher. No difference was found between the groups in terms of NLR ($p=0.887$). In ROC analysis, MCV/RDW and RDW/MCV were obtained with AUC=0.628 (95% CI: 0.570–0.682; $p=0.0001$), indicating 50.25% sensitivity and 75.76% specificity; PLT/MCV was obtained with AUC=0.625 ($p=0.0002$), indicating 72.91% sensitivity.

Table 1. Comparison of demographic and hematological parameters of patient and control groups.

Parameters	Control(n=99)	Patient (n=200)	p value
Hgb (g/dL)	14,07 ± 1,53	13,82 ± 2,28	0,33
Hct (%)	41,99 ± 4,07	41,60 ± 6,54	0,58
RBC (×10⁶/µL)	4,85 ± 0,56	4,90 ± 0,80	0,60
MCV (fL)	86,90 ± 4,72	86,51 ± 11,85	0,75
MCH (pg)	29,13 ± 2,02	28,75 ± 4,25	0,40
MCHC (g/dL)	33,51 ± 1,15	33,69 ± 4,22	0,67
RDW-CV (%)	12,95 ± 1,06	13,61 ± 2,18	<0,001
PDW	12,24 ± 2,15	12,17 ± 2,55	0,82
MPV (fL)	11,29 ± 9,05	10,43 ± 1,58	0,20
Ferritin (ng/mL)	40,67 ± 33,20	30,24 ± 33,12	0,01

Table 2. Comparison of calculated hematological and inflammatory ratios by group.

Calculated Ratios	Control (n=99)	Patient(n=200)	p value
MCV/RDW	6,80 ± 0,60	6,44 ± 0,88	<0,001
RDW/MCV	0,148 ± 0,014	0,159 ± 0,028	<0,001
NLR	2,06 ± 1,92	1,82 ± 0,75	0,887
PLR	121,55 ± 36,69	129,35 ± 37,29	0,047
PLT/MCV	3,10 ± 0,73	3,48 ± 0,93	0,001
MCH/MCV	0,335 ± 0,011	0,332 ± 0,013	0,064

Table 3.ROC curve analysis results of the evaluated parameters in distinguishing patients with telogen effluvium.

Parameters	AUC	%95 CI	p value	Cut-off value	Sensitivity / Specificity (%)
MCV/RDW	0,628	0,570 – 0,682	0,0001	≤ 6,477	50,25 / 75,76
RDW/MCV	0,628	0,570 – 0,682	0,0001	> 0,154	50,25 / 75,76
PLT/MCV	0,625	0,568 – 0,680	0,0002	> 2,946	72,91 / 49,49
MCH/MCV	0,558	0,500 – 0,615	0,1005	≤ 0,337	66,50 / 46,46

AUC: Area Under the Curve , 95% Confidence Interval

Conclusions

In TE patients, elevated RDW combined with low ferritin, despite normal conventional anemia markers, may indicate early-stage iron deficiency. Hemogram-derived indices offer practical and cost-effective tools for clinical decision-making, with moderate-to-high sensitivity (~73%) and specificity (~76%). Further prospective, multicenter studies are needed to confirm these findings.

Figure 1: Receiver operating characteristic (ROC) curve analysis of the MCV/RDW ratio for the prediction of the study

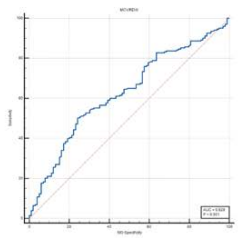

Figure 2: Receiver operating characteristic (ROC) curve analysis of the RDW/MCV ratio for the prediction of the study outcome

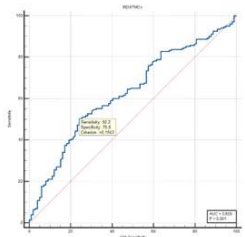

Figure 3: Receiver operating characteristic (ROC) curve analysis of the PLT/MCV ratio for the prediction of the study outcome

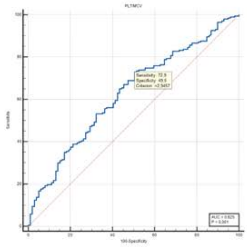

Figure 4: Receiver operating characteristic (ROC) curve analysis of the MCH/MCV ratio for the prediction of the study outcome

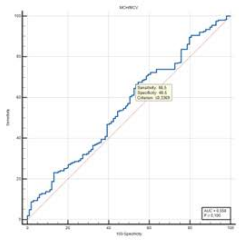

EA DV CONGRESS
VIENNA
30 SEP - 3 OCT 2026

Abstract N°: 3031

Emerging unconventional therapies in primary cicatricial alopecia: a systematic review

Mayeesha Khan*[1], Christopher Shenouda[1], Ikeade Adeyinka[1], Ilya Mukovozov[2, 3]

[1] Michael G. DeGroote School of Medicine, McMaster University, Hamilton, Canada
[2] Division of Dermatology, Department of Medicine, University of Toronto, Toronto, Canada
[3] Division of Dermatology, Women's College Hospital, Toronto, Canada

Introduction

Primary cicatricial alopecia (PCA) are inflammatory scalp disorders associated with irreversible hair loss. Many patients experience refractory disease despite conventional therapies such as corticosteroids, hydroxychloroquine, and minoxidil. Emerging unconventional therapies may offer benefit through antifibrotic, anti-inflammatory, regenerative, or metabolic mechanisms. This review evaluates the efficacy and safety of unconventional therapies in PCA.

Materials and Methods

MEDLINE and Embase were systematically searched for English-language studies reporting unconventional therapies in PCA. Studies were screened in accordance with PRISMA guidelines. Data extracted included demographics, PCA subtype, therapy type, treatment response, adjunctive therapy use, time to clinical response, and adverse events. Study quality was assessed using Joanna Briggs Institute quality appraisal tool.

Results

Twenty-nine studies describing 183 patients with PCA were included. Mean age was 49.1±9.8 years and mean disease duration at baseline was 2.0±5.3 years. Most patients were female (82.2%). Reported ethnoracial distribution included White (47.5%), Black (25.3%), Middle Eastern (20.2%), Asian (2.0%), and other backgrounds (5.1%). Most patients had lymphocytic PCA (97.3%), including lichen planopilaris (69.4%), central centrifugal cicatricial alopecia (CCCA) (13.7%), and frontal fibrosing alopecia (10.4%). Neutrophilic PCA included folliculitis decalvans and dissecting folliculitis of the scalp. Most patients had refractory disease despite prior therapies (87.4%).

Unconventional therapies included pioglitazone (60.7%), platelet-rich plasma (PRP) (19.7%), metformin (9.8%), adipose-derived and growth factor therapies (6.6%), botanical therapy (2.2%), and botulinum toxin (1.1%). Most patients receiving metformin, pioglitazone, PRP, and botanical therapy used one or more adjunctive therapies, whereas adipose-derived therapies and botulinum toxin were primarily used as monotherapy.

Pioglitazone demonstrated a response rate of 73.9%, including remission in 13.5% of patients, with a mean time to clinical response of 5.3±8.9 months. Reported adverse events included lower extremity edema and weight gain. PRP demonstrated efficacy in 88.9% of patients, with a mean response time of 5.0±4.4 months; injection-site pain was infrequently reported. Metformin demonstrated hair regrowth in 66.7% of patients with CCCA, with a mean response time of 6.3±1.9 months. Adverse events included scalp dryness and irritation.

Adipose-derived and growth factor therapies demonstrated the highest efficacy, with all patients responding and 58.3% achieving remission. Mean response time was 3.3±0.6 months. Botulinum toxin demonstrated hair regrowth

in both reported cases of dissecting folliculitis of the scalp. Botanical therapy demonstrated hair regrowth in all reported cases of CCCA, though all patients received concomitant therapies. Overall, adverse events across therapies were infrequent and generally mild.

Conclusions

Unconventional therapies demonstrated efficacy in refractory PCA and were well-tolerated in many patients, particularly regenerative therapies, PRP, and pioglitazone. However, evidence remains limited by small sample sizes, study heterogeneity, and frequent concomitant therapy use. Larger prospective studies and randomized controlled trials are needed to better establish the efficacy, safety, and optimal use of these emerging therapies in PCA.

EA DV CONGRESS
VIENNA
30 SEP - 3 OCT 2026

Abstract N°: 3036

Concomitant Alopecia Areata and Scalp Psoriasis Responsive to Ritlecitinib: A Case Supporting Shared JAK-Dependent Inflammatory Pathways

Daniele de Marqui[1], Carolina Kowalski[1], Ivanka Martins[1], Vanessa Marcato[1], Elisandra Barbara Pontes Carlos*[1], Milena de Oliveira[1], Hélio Miot[1]

[1] UNESP, Botucatu, Brazil

Introduction

Alopecia Areata (AA) is a T cell–mediated autoimmune disease, predominantly driven by CD8+ lymphocytes, characterized by non-scarring hair loss and associated with activation of the JAK-STAT signaling pathway. Ritlecitinib, a selective JAK3 and TEC inhibitor, was recently approved for severe alopecia areata. Although Psoriasis and alopecia areata have traditionally been regarded as distinct dermatoses, emerging evidence suggests shared immunologic mechanisms involving Th1/interferon signaling and cytotoxic immune activity. Reports of patients with concomitant AA and psoriasis treated with ritlecitinib remain scarce.

Case Presentation

A 34-year-old woman presented with severe scalp alopecia areata of approximately 1 year's duration, associated with scalp psoriasis for 10 years. She reported prior treatment with mesotherapy (five sessions at an outside clinic). At our institution, she was initially prescribed oral minoxidil combined with topical clobetasol, and a scalp biopsy was performed to confirm the diagnosis. However, adherence to topical therapy was poor, and she used only oral minoxidil for two months without satisfactory response.

Physical examination revealed a 12.5 × 8.5 cm alopecic plaque involving the vertex and frontoparietal scalp. Trichoscopy showed black dots, yellow dots, and exclamation mark hairs. Erythematous scaly plaques involving the occipital and temporal scalp were also present, consistent with active psoriasis.

Histopathological examination demonstrated miniaturized follicles associated with a bulbar and periadnexal lymphocytic infiltrate, confirming the diagnosis of alopecia areata.

Given the substantial psychosocial impact of the disease, oral ritlecitinib 50 mg once daily was initiated.

After 30 days, alopecia areata activity had ceased, and early hair regrowth was observed. Simultaneously, the psoriatic lesions improved, with reductions in erythema, scaling, and affected area.

After two months, the patient developed persistent diarrhea, which resolved following gradual dose reduction to 50 mg five times weekly and subsequently four times weekly. However, the improvement in psoriasis was not sustained after dose reduction, and recrudescence of the psoriatic lesions was noted after approximately four months. In contrast, the alopecia areata response was maintained. No clinically relevant laboratory abnormalities were observed.

Conclusion

Alopecia areata and psoriasis share inflammatory pathways involving Interferon Gamma signaling, Th1/CD8+ polarization, and JAK-dependent cytokines, particularly Interleukin 15. Recent studies have demonstrated clinical benefit of JAK inhibitors in refractory psoriasis phenotypes, supporting the concept of partially overlapping immunologic mechanisms.

The concurrent improvement of alopecia areata and psoriasis observed in this case reinforces the relevance of these shared pathways. The partial loss of psoriasis control after dose reduction, despite sustained alopecia areata

remission, may reflect differences in the threshold dependence on JAK/TEC-mediated signaling between the two conditions.

This case supports the hypothesis that alopecia areata and scalp psoriasis may share relevant inflammatory pathways and highlights the potential role of ritlecitinib in patients with overlapping inflammatory phenotypes. The differential response after dose adjustment also suggests that these disorders may exhibit distinct levels of dependence on JAK/TEC-mediated signaling.

EA DV CONGRESS
VIENNA
30 SEP - 3 OCT 2026

Abstract N°: 3037

Early massive alopecia in DRESS syndrome: beyond the classic telogen effluvium

Ahd Jday*[1], mariem tabka[1], Feryel Amri[1], Asmahane Souissi[1], Salma Nefzi[1], Mourad Mokni[1]

[1] Dermatology Department, Rabta Hospital, Tunis, Tunisia

Introduction

DRESS syndrome is a severe, potentially life-threatening drug-induced hypersensitivity reaction characterized by multisystem involvement. Although appendageal manifestations have been described, hair involvement is classically reported as a delayed telogen effluvium occurring several weeks to months after the acute phase. We report an unusual case of acute massive alopecia and synchronous onychomadesis occurring during the eruptive phase of DRESS syndrome, raising the hypothesis of an anagen effluvium-like mechanism.

Case Presentation

A 42-year-old woman with no significant past medical history was hospitalized for erythroderma associated with high-grade fever (40°C) and marked facial edema, occurring five weeks after the introduction of carbamazepine prescribed for trigeminal neuralgia. The diagnosis of DRESS syndrome was established based on the association of erythroderma, facial edema with cervical lymphadenopathy, hypereosinophilia (940/mm^3), atypical lymphocytes on peripheral blood smear, and hepatic cholestasis. During the acute phase, the patient developed marked appendageal involvement characterized by diffuse massive scalp alopecia, predominantly involving the frontal scalp, associated with a thick psoriasiform scaly scalp eruption. Trichoscopic examination revealed numerous dystrophic hairs, broken hair shafts, and marked perifollicular scaling. Simultaneous onychomadesis involving all ten fingernails was also observed.The suspected drug was discontinued, and the patient was treated with topical corticosteroids and emollients. At 4-month follow-up, the patient showed complete hair regrowth without residual dermoscopic hair shaft abnormalities, together with complete nail regrowth.

Conclusion

The originality of this observation lies primarily in the timing and presumed mechanism of the alopecia. Hair involvement in DRESS syndrome is usually described as a delayed telogen effluvium secondary to systemic inflammation and metabolic stress, typically occurring two to four months after the acute episode. In contrast, our patient developed abrupt, massive hair loss concurrent with the erythrodermic phase, suggesting that the hair follicle itself may have been a direct target of the acute inflammatory process. The coexistence of severe inflammatory scalp involvement, dystrophic hairs on trichoscopy, and simultaneous onychomadesis strongly supports an acute matrix injury affecting both hair and nail apparatuses. An anagen effluvium-like mechanism may therefore be hypothesized. The concomitant involvement of the hair and nail matrices suggests an abrupt interruption of mitotic activity in rapidly proliferating keratinocytes, possibly mediated by the intense cytokine storm associated with DRESS syndrome and/or direct toxic effects of carbamazepine.
To our knowledge, such an early and massive alopecia occurring during the acute phase of DRESS syndrome has rarely been reported. This observation broadens the clinical spectrum of appendageal manifestations associated with DRESS syndrome and suggests that scalp involvement may reflect more than a simple delayed reactive phenomenon.

EADV Congress 2026, VIENNA
30 SEPTEMBER - 03 OCTOBER 2026
POWERED BY M-ANAGE.COM

EADV CONGRESS
VIENNA
30 SEP - 3 OCT 2026

Abstract N°: 3062

Onychomatricoma of the hallux: a rare nail matrix tumor mimicking onychomycosis

Rania Bouabdallaoui*[1, 1], Mohammed Chaouche[1], Soukaina Mhaimer[1], Hiba Kharbach[1], Soukayna Chhiti[1], Achraf Miry[2], Radia Chakiri[1]

[1] Department of Dermatology and Venereology, Mohammed VI University Hospital, Agadir, Morocco, Agadir, Morocco
[2] Department of Anatomical Pathology , Mohammed VI University Hospital, Agadir, Morocco

Introduction
Onychomatricoma is a rare benign fibroepithelial tumor originating from the nail matrix. It remains an underdiagnosed entity because of its clinical resemblance to onychomycosis and chronic nail dystrophies.

The aim of this report is to highlight the value of clinical, dermoscopic, and histopathological findings in the diagnosis of this rare nail tumor.

Case Presentation
A 67-year-old woman with a history of rheumatoid arthritis receiving long-term treatment presented with a progressive asymptomatic dystrophy of the great toenail evolving over several years.

Clinical examination revealed xanthonychia associated with distal subungual hyperkeratosis and onycholysis, longitudinal striations, as well as localized overcurvature of the nail plate. No significant pain or periungual inflammation was observed. Dermoscopic examination showed parallel longitudinal white-yellow bands associated with proximal transverse erythronychia.

Following partial nail plate avulsion, macroscopic examination revealed a villous tumoral appearance characterized by several filiform projections emerging from the nail matrix. The ventral surface of the avulsed nail plate showed multiple regular cavities corresponding to matricial tumor projections perforating the nail plate. Post-avulsion dermoscopy demonstrated an erythematous background associated with fine whitish filiform projections.

A matrix biopsy was performed. Histopathological examination revealed squamous epithelial proliferation with marked acanthosis and a "saw-tooth" architecture, associated with matrix-type keratinization characterized by the absence of a granular layer and nuclear retention, without cytonuclear atypia or signs of malignancy, thereby confirming the diagnosis of onychomatricoma.

The interest of this observation lies in the recognition of clinical signs suggestive of onychomatricoma, particularly xanthonychia associated with chronic nail dystrophy, allowing early diagnostic orientation. The main differential diagnosis is onychomycosis, but traumatic nail dystrophies, Bowen disease, and subungual verrucae should also be considered. Dermoscopy highlighted characteristic findings, while histopathology confirmed the diagnosis definitively.

Conclusion
Onychomatricoma should be considered in any case of localized chronic nail dystrophy associated with

xanthonychia and subungual hyperkeratosis. Recognition of dermoscopic signs may help avoid prolonged inappropriate antifungal treatments and unnecessary diagnostic delay.

Finally, this report emphasizes the importance of an integrated clinico-dermoscopic and histopathological approach in the evaluation of nail apparatus tumors.

EADV CONGRESS
VIENNA
30 SEP - 3 OCT 2026

Abstract N°: 3095

Localized Acquired Trichorrhexis Nodosa Mimicking Scalp Mycosis: a Diagnostic Challenge

Claudio Lelis Souza[1], Ana Clara Freitas*[1], Guilherme Gonçalves Nascimento[2], Ana Laura Ritter[1], Julia Coffler[3], Mônica Linhares Sachett[2]

[1] unifenas, alfenas, Brazil
[2] FMABC, Santo Andre, Brazil
[3] EMESCAM, Vitória, Brazil

Introduction

Trichorrhexis Nodosa is a hair shaft abnormality characterized by nodular fractures and increased hair fragility. The acquired localized form may clinically mimic infectious and inflammatory scalp disorders, leading to delayed diagnosis and inappropriate treatment.

Case Presentation

A 22-year-old male presented with localized hair loss on the scalp refractory to multiple antifungal treatments prescribed for presumed scalp mycosis. Dermatological examination revealed a focal area of marked hair rarefaction with whitish pinpoint structures on the right parietofrontal scalp. The patient denied chemical hair treatments, heat exposure, or cosmetic trauma. Trichoscopy demonstrated characteristic whitish-gray nodules along the hair shaft, corresponding to cuticular disruption and cortical fiber exposure, producing the classic “two opposing brushes” appearance. Associated focal shaft breakage and trichoptilosis were also observed. After exclusion of common etiologies of localized acquired Trichorrhexis Nodosa, detailed anamnesis identified repetitive mechanical trauma caused by habitual scalp rubbing and scratching.

Conclusion

This case highlights the importance of trichoscopy and detailed behavioral history in the diagnosis of localized acquired trichorrhexis nodosa. Recognition of characteristic trichoscopic findings is essential to differentiate this condition from infectious alopecias and to avoid unnecessary treatments.

EADV CONGRESS
VIENNA
30 SEP - 3 OCT 2026

Abstract N°: 3097

Trichoscopic Evaluation of a Topical Formulation Containing Yerba Santa Extract and Lentil Sprouted Seed Extract in Subjects with Progressive and Reactive Hair Loss: A Prospective Open-Label Study

Maëla ABDUL*[1], Daphné GAUTIER[1], Stéphanie BREDIF[1], Virginie FERA[1]

[1] Groupe Rocher, Issy-les-Moulineaux, France

Introduction

Hair loss is a multifactorial condition characterized by alterations in hair cycle dynamics, including shortening of the anagen phase and increased telogen shedding. Progressive and reactive hair loss are frequently encountered in clinical practice, highlighting the need for well-tolerated topical approaches targeting both follicular activity and the scalp microenvironment.

We selected two botanical extracts for their complementary biological efficacy on regulation of hair cycle and follicle environment: Yerba Santa extract, rich in flavonoids with anti-oxidant properties, has demonstrated improved anchorage and protection of follicular stem cells, while Lentil sprouted seed extract contributes to protection against inflammatory stress, stimulation of microcirculation, and activation of the Wnt/β-catenin pathway.

This study aimed to evaluate the efficacy of a topical formulation containing Yerba Santa-derived extract and Lentil sprouted seed extract on hair growth parameters and hair loss.

Materials and Methods

This prospective, open-label study included 60 male and female subjects aged 36 to 56 years, presenting progressive or reactive hair loss.

Subjects applied the spray formulation once daily, part by part, over the entire scalp for 4 months. Clinical evaluations were performed at baseline (T0), 1 month (T1M), 3 months (T3M) and 4 months (T4M).

Efficacy was assessed using digital phototrichogram analysis to measure hair density (hairs/cm^2), hair growth rate, proportions of anagen and telogen hairs, and the anagen/telogen ratio. Hair loss was evaluated using the hair pull test. Hair diameter measurements, clinical scoring and self-scoring were also performed.

Results

After 1 month of application, a statistically significant improvement in hair growth and hair loss–related parameters were observed. The proportion of telogen hairs decreased by 9%, leading to a 19% increase in the anagen-to-telogen ratio ($p < 0.05$).

At T3M, hair growth rate showed a significant increase of 23% compared to baseline ($p < 0.05$).

The hair pull test indicated an 85% reduction in hair shedding at T3M ($p < 0.05$), corresponding to the preservation of 11 667 hairs across the entire scalp.

At T4M, hair diameter increased by 7.9% compared to baseline ($p < 0.05$).

Clinical assessment showed a 28% increase in hair thickness at T4M, while self-scoring indicated a 51% improvement in hair density and a 40% increase in hair growth.

The formulation was well tolerated, with no or only mild adverse events reported.

Conclusions

This study demonstrates that a topical formulation containing a combination of botanical extracts from Yerba santa and Lentil sprouted seed significantly improves hair growth parameters and reduces hair loss in subjects with progressive and reactive hair loss.

The observed increases in anagen hair proportion, hair density, and fiber diameter suggest a beneficial effect on hair cycle dynamics and follicular function. These findings, together with the ability of the active ingredients to modulate key mechanism regulating hair growth, support the relevance of this well-tolerated approach as a promising option for hair loss management.

EADV CONGRESS
VIENNA
30 SEP - 3 OCT 2026

Abstract N°: 3121

Patient perspective and satisfaction with JAK-inhibitor treatments for Alopecia Areata: Results from the 2025 VOICES-AA study by the National Alopecia Areata Foundation

Arash Mostaghimi[1], George Gondo*[2], Lisa Anderson[2]

[1] Harvard Medical School, Brigham and Women's Hospital, Boston, United States
[2] National Alopecia Areata Foundation, Novato, United States

Introduction

Alopecia areata (AA) is a chronic, immune-mediated inflammatory disease affecting approximately 2% of the global population. While characterized by visible hair loss, the condition is driven by a collapse of hair follicle immune privilege, triggering an inflammatory attack on the follicle itself. Beyond its physical manifestations, AA often has a profound impact on emotional well-being and overall quality of life.

Until recently, effective therapies for severe disease were nonexistent. However, since 2022, the treatment landscape has been transformed by the approval of several JAK inhibitors—including three by the U.S. Food and Drug Administration (FDA) and two by the European Medicines Agency (EMA). These therapies work by inhibiting the JAK-STAT pathway to restore follicular immune privilege, effectively allowing hair to regrow. Little research has been conducted to understand patient perspectives and satisfaction with these new treatments.

The Values, Outcomes, and Insights from Community Experiences Survey (VOICES-AA) was conducted by the National Alopecia Areata Foundation (NAAF) to better understand the lived experiences of individuals living with alopecia areata and parents of individuals living with AA, including impact of disease on quality of life, and health care utilization and treatment patterns. Using data from the VOICES-AA survey, this study explores patient perspectives on JAK inhibitors, including utilization of JAK inhibitors among patients with AA, their satisfaction with these treatments, and barriers to their uptake.

Materials and Methods

This study consisted of an online survey of individuals with AA 18 years of age or older, and parents of children living with AA. Potential participants were drawn from the National Alopecia Areata Foundation's constituent database and from a third-party recruiter. The survey was conducted from November 2025 to March 2026. The study was approved by the Genetic Alliance Institutional Review Board.

Results

A total of 852 people participated in the survey. Participants were mostly White (81%), Female (63%), 63% reported an annual income > $75,000 (USD), and 72% have attained at least a college education. All self-reported receiving a diagnosis of AA by a dermatologist. Complete loss of hair on the scalp was reported by 60% of participants with 81% of these individuals also experiencing complete loss of hair on their body. Nearly two-thirds (65%) of participants were diagnosed with AA before the age of 40.

Prescription treatment usage was high (67%), including 36% currently using a JAK inhibitor to treat their AA. Among all participants, 53% have been on their current treatment for more than 6 months, including 41% who have been on their current treatment for more than 12 months. Overall treatment satisfaction was low (27%),

though it nearly doubled to 50% for participants using a JAK inhibitor. Satisfaction with JAK-inhibitor treatment varied by duration of treatment. Satisfaction was highest among those who have been on their current treatment for 7 – 12 months (73%) and lowest among those on treatment < 6-months (37%).

Among participants not using a JAK inhibitor, the most common barriers to adoption were concern over side effects (45%), a lack of knowledge about the treatment (35%), and their healthcare provider had not recommended they use a JAK inhibitor (29%).

Conclusions

Utilization of JAK inhibitors remains low among individuals with alopecia areata. Despite lower utilization, individuals who use a JAK inhibitor to treat their alopecia areata report higher treatment satisfaction than those using other prescription treatments. Satisfaction with JAK inhibitor treatment is associated with duration on treatment, with treatment satisfaction peaking at 7 – 12 months and declining slightly after being on treatment for more than 12 months. Patient-reported barriers to using a JAK inhibitor suggest that increased patietnt education is needed, especially on the topic of safety and adverse treatment effects.

EADV CONGRESS
VIENNA
30 SEP - 3 OCT 2026

Abstract N°: 3123

Use of Terbinafine in pulse therapy for Onychomycosis: a multicenter study of 29 patients

Miguel Centeno Pons*[1], Luis Alonso Martínez de Salinas[1], Andrea Sechi[2], Paolo bortoluzzi[2], Juan Aramberri Araiz [1], Ana Barquín Ruiz[1], Jon Ignacio Uriarte[1], Juan Jiménez-Cauhe[1, 3]

[1] Hospital Universitario Ramón Y Cajal, Madrid, Spain

[2] Fondazione IRCCS Ca' Granda Ospedale Maggiore Policlinico, Milano, Italy

[3] Grupo de Dermatologia Pedro Jaén, Madrid, Spain

Introduction

Terbinafine is the oral treatment of choice for Onychomycosis. The continuous regimen for 3 months is the most commonly used, although the pulse regimen has emerged as an alternative due to its lower cumulative drug dose and greater convenience. The aim of this study was to evaluate the effectiveness and safety of pulse terbinafine therapy in real-world clinical practice

Materials and Methods

A multicenter retrospective study was conducted in patients with toenail onychomycosis treated with pulse terbinafine (500 mg/day, 1 week per month). Clinical and laboratory data were collected. Clinical response was assessed using the Onychomycosis Severity Index (OSI), with clinical cure defined as a final OSI ≤1.

Results

A total of 29 patients were included (51.7% women), with a mean age of 52.1 years (range 15–81). Fungal culture was positive in 21 patients (72.4%), with *T. rubrum* being the most frequent causative agent (n=15). The median number of affected nails was 2 (range 1–10). The median baseline OSI was 20 (range 9–35), with severe OSI (≥16) in 82.8% of patients. The median total treatment duration was 5 months (range 3–9), and the median final OSI was 0 (range 0–9), with a clinical cure rate (OSI ≤1) of 86.2% (25/29). No predictive variables for cure were identified. However, total treatment duration was significantly associated (p=0.003) with baseline OSI (median 5.5 months in patients with severe OSI [16–35] vs. 3 months in patients with moderate OSI [6–15]). Likewise, matrix involvement was associated with longer treatment duration (6 vs. 4 months; p=0.036). Concomitant use of topical antifungals did not significantly improve treatment duration or cure rate. Pre- and post-treatment laboratory tests were performed in 19 patients, with no relevant abnormalities detected, including in patients with pre-existing Hypercholesterolemia (34.5%, n=10). Four patients (13.8%) experienced mild adverse effects (gastrointestinal discomfort), without requiring treatment discontinuation.

Conclusions

Pulse terbinafine therapy showed good effectiveness in onychomycosis and a favorable safety profile, with mild and self-limited adverse effects. A severe baseline OSI (≥16) and nail matrix involvement may predict a longer treatment duration, making pulse therapy an effective alternative in these cases, with a lower cumulative drug dose

EA DV CONGRESS
VIENNA
30 SEP - 3 OCT 2026

Abstract N°: 3144

Baricitinib for alopecia universalis in a patient with HIV infection: A case report & therapeutic considerations

Varvara Vasalou[1], Georgia Pappa*[1], Stella Maria Michelaki[1], Evgenios-Nikolaos Ntovas[1], Electra Nicolaidou[1], Alexander Stratigos[1]

[1] 1st Department of Dermatology-Venereology, "Andreas Syggros" Hospital of Cutaneous and Venereal Diseases, National and Kapodistrian University of Athens, Medical School, Athens, Greece

Introduction

Alopecia areata (AA) is a chronic, relapsing, auto-inflammatory, non-scarring alopecia, causing significant psychosocial burden to affected individuals. The use of Janus kinase (JAK) inhibitors in patients living with HIV remains controversial because of concerns regarding immunosuppression and infectious complications. However, emerging evidence suggests that selected JAK inhibitors may have a more complex immunologic role, while certain agents have demonstrated selective inhibition of HIV-1 replication and potential effects on latent HIV reservoirs in vitro. We report a case of alopecia universalis successfully managed with baricitinib in a patient with well-controlled HIV infection.

Case Presentation

A 47-year-old man with well-controlled HIV infection receiving single-tablet antiretroviral therapy with emtricitabine, tenofovir alafenamide, elvitegravir, and cobicistat presented with scalp alopecia areata in March 2023, which progressively evolved into alopecia universalis. At presentation, HIV viral load was undetectable and immune status was preserved (CD4 cell count: 512 cells/μL). Although the patient tolerated scalp hair loss relatively well, the progressive loss of eyebrows, eyelashes, and beard hair caused substantial psychosocial and aesthetic distress and became the primary therapeutic concern.

Since disease onset in 2019, the patient had undergone multiple therapeutic interventions with limited or transient benefit, including platelet-rich plasma, intralesional corticosteroids, topical minoxidil, anthralin, latanoprost for eyebrows and eyelashes, and methylprednisolone per os. Due to ongoing disease progression and significant impairment in quality of life, baricitinib 4 mg daily was initiated in February 2025 following close monitoring by a specialist in our Sexually Transmitted Infections Unit. Follow-up demonstrated limited scalp regrowth, consisting mainly of a few non-pigmented terminal hairs along with scattered vellus hairs. In contrast, full eyelash regrowth and near-complete beard regrowth were observed, while the eyebrows demonstrated mild but noticeable improvement. These were the areas of greatest concern to the patient and the response resulted in marked satisfaction, with substantial improvement in self-image and social confidence. HIV infection remained stable throughout treatment, with persistent viral suppression and improvement of CD4 cell count to 716 cells/μL. No opportunistic infections or significant adverse events were observed during follow-up, apart from mild hyperlipidemia and a transient elevation of creatine phosphokinase levels.

Conclusion

This case highlights the importance of individualized therapeutic decision-making in patients with HIV and severe AA. In carefully selected patients with well-controlled HIV infection receiving stable antiretroviral therapy and close

infectious disease follow-up, JAK inhibitors may represent a reasonable therapeutic option. Moreover, the favorable clinical course observed in this patient, together with experimental evidence suggesting anti-HIV activity of certain JAK inhibitors, supports the need for further investigation into the safety and potential immunovirologic effects of these agents in patients living with HIV.

EA DV CONGRESS
VIENNA
30 SEP - 3 OCT 2026

Abstract N°: 3146

Efficacy and Safety of Janus Kinase Inhibitors in Refractory Nail Lichen Planus: A Systematic Review and Meta-analysis

Fares Alammari*[1], Mohammed Mojiri[2], Mohammed Akkam[2], Sultan Aqeel[3]

[1] College of Medicine, Almaarefa university, Riyadh, Saudi Arabia

[2] College of Medicine, Jazan University, Jazan, Saudi Arabia

[3] King Fahd Central Hospital, Jazan, Saudi Arabia

Introduction

Nail lichen planus (NLP) is an immune-mediated and chronic inflammatory disorder that can be considered one of the most difficult lichen planus types to treat. The traditional therapies, such as intralesional corticosteroids, systemic immunosuppressants, and topical agents have large failure rates and extensive side-effect profiles. JAK inhibitors (JAKIs) are now put forward as mechanologically rational targets due to the pivotal role of the IFN-γ/JAK-STAT pathway in lichenoid inflammation, but the efficacy and safety of JAKIs in NLP have not been synthesized in a systematic fashion.

Materials and Methods

The systematic search of PubMed, Scopus, and Web of Science (until March 2026) was performed in accordance with the PRISMA 2020. Biopsy-confirmed JAKI-treated NLP studies of any type that reported original patient-level data were eligible, even those that were not done by biopsy. The assessment of risk of bias was based on the JBI Critical Appraisal Checklist. An analysis of cumulative time to treatment success was modelled, and a random-effects meta-analysis of standardised mean change (SMC) in severity index score was undertaken where data were available.

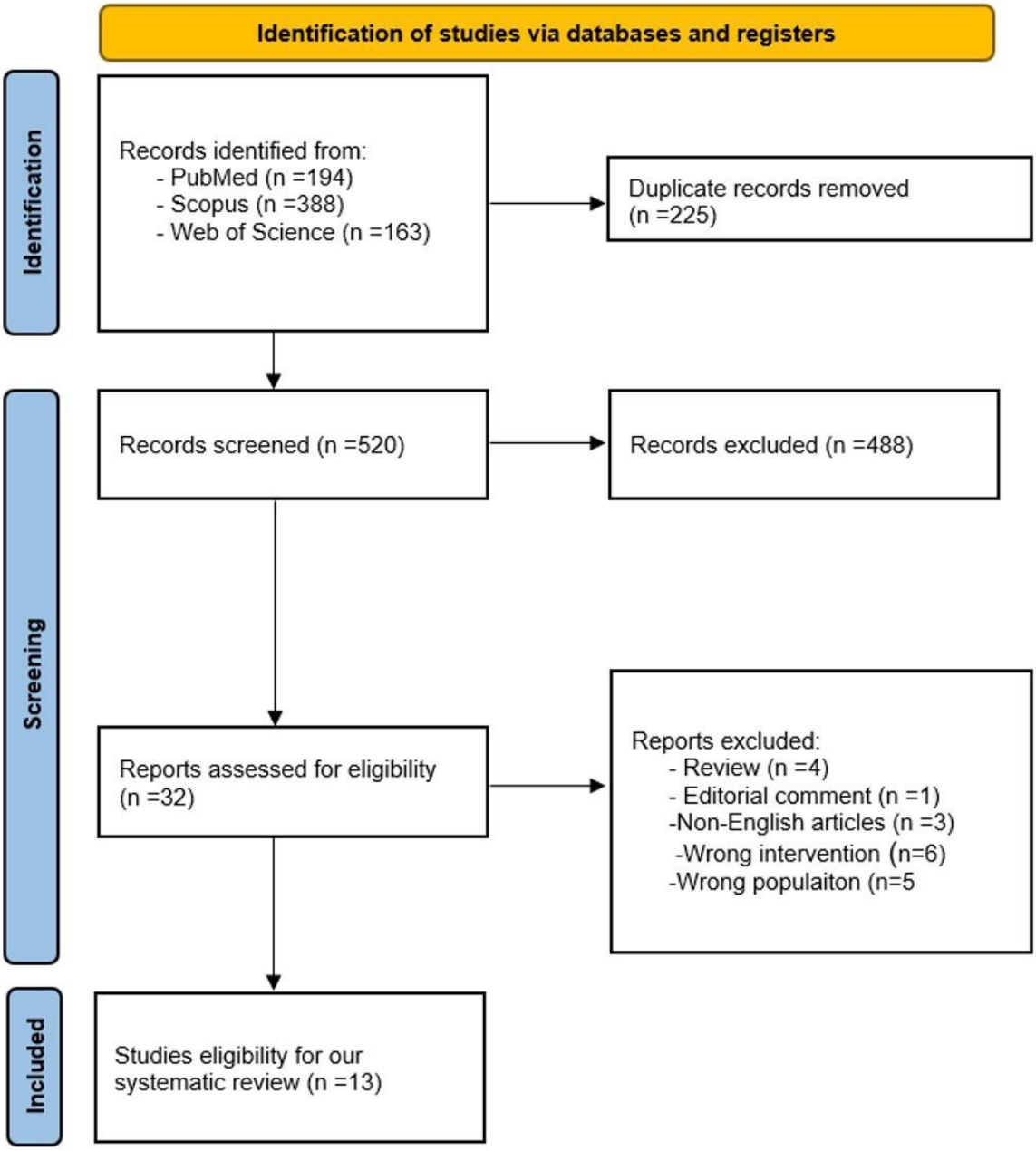

Results

A total of 13 articles that fit the criteria of case report (10), case series (1), retrospective cohort (2) were included (n = 25). Tofacitinib was assessed (orally and topically), baricitinib, abrocitinib, upadacitinib and topical ruxolitinib. Clinically meaningful responses were reported in all reporting studies and most of the improvements were realised after 3-7 months. The pooled SMC was 1.65 (95% CI: 0-3.59), and the heterogeneity is significant (I^2 = 87.6%). There were no serious adverse events reported in any of the included studies.

Conclusions

JAK inhibitors are effective, and well-tolerated in the short run in refractory NLP. Their application as a rescue therapeutic option is supported by this first systematic review and highlights the necessity of prospective randomised trials with standardised outcome measures.

POWERED BY M-ANAGE.COM

EADV CONGRESS
VIENNA
30 SEP - 3 OCT 2026

Abstract N°: 3186

Onychomycosis of the Hallux caused by Fusarium oxysporum: From Molecular Diagnosis to Targeted Therapy

João Carrola Costa*[1], Joel Reis[1]

[1] Serviço de Dermatologia, ULS Matosinhos, Matosinhos, Portugal

Introduction

Onychomycosis is the most frequent nail disorder in dermatological practice, with dermatophytes being the predominant etiological agents. However, non-dermatophytic fungi are under-recognised causes of onychomycosis, particularly in cases resistant to conventional therapy. Their recognition is essential, given that the antifungal susceptibility profile differs significantly from that of dermatophytes, requiring a targeted diagnostic approach. This case illustrates the importance of in-depth microbiological investigation, including molecular biology and susceptibility testing, in guiding the therapeutic management of recalcitrant onychomycoses.

Case Presentation

A 63-year-old woman, with no relevant medical history, presenting with bilateral hallux onychomycosis of 10 years' evolution, with no response to multiple treatment courses of ciclopirox, terbinafine, and itraconazole. Given the treatment resistance, molecular biology testing was requested, which returned positive for *Fusarium oxysporum* and negative for dermatophytes. Cultural examination confirmed the growth of*Fusarium oxysporum*. Antifungal susceptibility testing, performed by broth microdilution technique, demonstrated sensitivity to voriconazole. Treatment was initiated with voriconazole 200 mg twice daily and topical amphotericin B 2% once daily, with prior preparation using 50% urea cream.

Conclusion

This case underscores the need for rigorous aetiological investigation in onychomycoses resistant to first-line treatments. The identification of non-dermatophytic agents such as *Fusarium oxysporum*, through molecular biology and susceptibility testing, is critical for a targeted and effective therapeutic approach. The dermatologist plays a central role in this process, preventing repeated and unnecessary treatment cycles.

EADV CONGRESS
VIENNA
30 SEP - 3 OCT 2026

Abstract N°: 3200

Comparison Of Efficacy Between 5% Minoxidil And 5% Procapil In Patients With Androgenetic Alopecia

Uzma Sarwar*[1], munifa Noor[1]

[1] Shalamar institute of health sciences, Lahore, Pakistan

Introduction
Patients with androgenetic alopecia (AGA), a common form of non scarring hair loss, often experience significant psychosocial distress and reduced quality of life. The most popular treatment is topical minoxidil, but more modern options, such as procapil, have shown promise in terms of effectiveness and possibly fewer side effects.

Objective: To compare the efficacy of 5% minoxidil and 5% procapil in patients with androgenetic alopecia.

Materials and Methods
This randomized controlled trial was conducted at the Department of Dermatology, in a tertiary care hospital in Lahore, Pakistan over a period of six months. Two groups, Group A (5% minoxidil) and Group B (5% procapil), each consisting of 37 individuals, were randomly selected from a total of 74 patients. The Modified Global Photographic Assessment Score was used to evaluate efficacy at baseline, three months, and six months.

Results
The mean age of participants was 30.73 ± 5.03 years. At 6 months, efficacy was observed in 30 patients (81.1%) in the minoxidil group and 28 patients (75.7%) in the procapil group ($p > 0.05$). Stratified analysis demonstrated variation in response across gender and age groups. Minoxidil was more effective for males, whilst procapil was more effective for females. Minoxidil was more effective in the 31–50 age range, whereas procapil was more successful in the 25–30 age range. However, these results should be interpreted with caution due to the smaller subgroup sizes and potential limits in statistical power.

Conclusions
Both 5% minoxidil and 5% procapil were effective in the management of androgenetic alopecia, with comparable efficacy. Procapil may serve as a viable alternative to minoxidil, particularly in patients who are intolerant to conventional therapy. Further large scale studies are recommended to establish long term outcomes.

EA DV CONGRESS
VIENNA
30 SEP - 3 OCT 2026

Abstract N°: 3212

Efficacy and Safety of Upadacitinib in Chinese Adults and Adolescents with Severe Alopecia Areata: 24-Week Integrated Analysis from a Randomized, Placebo-Controlled, Double-Blind Phase 3 Program (UP-AA)

Wenyu Wu*[1], Bin Yang[2], Huiping WANG[3], Zhongrong Liu[4], Yayi Sun[5], Dingquan Yang[6]

[1] Huashan Hospital Fudan University, shanghai, China

[2] Dermatology Hospital of Southern Medical University, Guangzhou, China

[3] Tianjin Medical University General Hospital, Tianjin, China

[4] The First Affiliated Hospital of Guangzhou Medical University, Guangzhou, China

[5] AbbVie Inc., Shanghai, China

[6] China-Japan Friendship Hospital, Beijing, China

Introduction

Alopecia areata (AA) is a systemic immune-mediated disease, characterized by non-scarring hair loss ranging from isolated scalp patches to complete scalp and body hair loss. Upadacitinib (UPA), an oral selective Janus kinase inhibitor approved for several immune-related diseases in China, is investigated for efficacy, safety, and tolerability in severe AA through a phase 3 program (UP-AA; NCT06012240) in adults and adolescents.

Materials and Methods

The UP-AA program comprised two independent, pivotal, phase 3, randomized, double-blind, placebo-controlled, multicenter studies assessing upadacitinib in severe AA. Each study included a 35-day screening period, a 24-week placebo-controlled, double-blind treatment period (Period A), and a 28-week blinded extension period (Period B). Eligible participants were adults (<64 years) and adolescents (≥12 years) diagnosed with severe AA (SALT score ≥50), no spontaneous scalp hair regrowth for 6 months, current AA episode <8 years, and absence of other interfering alopecia types. Subjects were randomized (2:2:1) to UPA 15 mg QD, UPA 30 mg QD, or placebo. The primary endpoint was SALT score ≤20 at week 24 (≤20% scalp hair loss); secondary endpoints included improvements in scalp, eyebrow, and eyelash hair coverage, symptom reduction, and HRQoL. This analysis is to evaluate the effectiveness and safety profiles of UPA among Chinese population in the UP-AA program.

Results

A total of 184 adult and adolescent participants (38 in PBO, 66 in UPA 15 mg, and 80 in UPA 30 mg) were included in the integrated analysis of China population, and 97.8% of subjects completed Period A. The primary endpoint at week 24 was achieved by 56.1% (UPA 15 mg), 53.8% (UPA 30 mg) and 5.3% (placebo), with both nominal $p < 0.001$. Primary and most secondary endpoints of efficacy were showed in Table 1. TEAE rates during Period A were comparable across groups: UPA 15 mg (71.2%), UPA 30 mg (76.3%), and placebo (73.7%). Most TEAEs were mild/moderate, non-serious, and did not result in study drug discontinuation.

Table 1 Integrated 24-Week Efficacy Results in Chinese Population from UP-AA Program: Overview of Primary and Secondary Endpoints

Endpoints	PBO (N = 38)	UPA 15 mg QD (N = 66)	Nominal P-value (UPA 15mg)	UPA 30 mg QD (N = 80)	Nominal P-value (UPA 30mg)
Primary Endpoint					
Achievement of SALT score ≤ 20 at Wk 24, n (%)	2 (5.3)	37 (56.1)	<0.001***	43 (53.8)	<0.001***
Secondary Endpoints					
Achievement of SALT score ≤ 10 at Wk 24, n (%)	1 (2.6)	32 (48.5)	<0.001***	36 (45.0)	<0.001***
Achievement of SALT score ≤ 20 at Wk 12, n (%)	1 (2.6)	16 (24.2)	<0.001***	19 (23.8)	<0.001***
Achievement of ClinRO measure for Eyebrow Hair Loss of 0 or 1 at Wk 24 with a ≥ 2-point improvement (reduction) from Baseline among subjects with Baseline score ≥ 2, n/N (%)	1/27 (3.7)	19/39 (48.7)	<0.001***	35/54 (64.8)	<0.001***
Achievement of ClinRO measure for Eyelash Hair Loss of 0 or 1 at Wk 24 with a ≥ 2-point improvement (reduction) from Baseline among subjects with Baseline score ≥ 2, n/N (%)	1/19 (5.3)	20/29 (69.0)	<0.001***	20/35 (57.1)	<0.001***
Achievement of SALT 75 (at least a 75% improvement [decrease] from Baseline in SALT score) at Wk 24, n (%)	2 (5.3)	38 (57.6)	<0.001***	43 (53.8)	<0.001***
Achievement of SALT 90 (at least a 90% improvement [decrease] from Baseline in SALT score) at Wk 24, n (%)	0	30 (45.5)	<0.001***	35 (43.8)	<0.001***
Percent change from Baseline in SALT score at Wk 24, LS Mean (SE)	−11.153 (5.621)	−64.486 (4.542)	<0.001***	−65.977 (3.961)	<0.001***
Achievement of PaGIC-AA score of 1 "much better" or 2 "moderately better" at Wk 24, n (%)	4 (10.5)	46 (69.7)	<0.001***	64 (80.0)	<0.001***
Achievement of PRO for Scalp Hair Assessment 0 or 1 with ≥ 2-point improvement (reduction) from Baseline at Wk 24 among subjects with Baseline score ≥ 3, n/N (%)	2/35 (5.7)	35/63 (55.6)	<0.001***	39/77 (50.6)	<0.001***
Change from Baseline in AASIS Interference Subscale score at Wk 24, LS Mean (SE)	−0.286 (0.324)	−1.610 (0.258)	<0.001***	−1.275 (0.229)	0.011*
Change from Baseline in AASIS Symptoms Subscale score at Wk 24, LS Mean (SE)	−0.861 (0.227)	−1.694 (0.181)	0.003**	−1.892 (0.161)	<0.001***
Change from Baseline in Skindex-16 AA Emotions Domain scores at Wk 24, LS Mean (SE)	−18.772 (4.072)	−39.434 (3.253)	<0.001***	−34.965 (2.867)	<0.001***
Change from Baseline in Skindex-16 AA Functioning Domain scores at Wk 24, LS Mean (SE)	−11.679 (4.175)	−31.523 (3.361)	<0.001***	−24.849 (2.943)	0.008**
Achievement of SALT score 0 at Wk 24, n (%)	0	18 (27.3)	<0.001***	17 (21.3)	<0.001***
Achievement of SALT score ≤ 20 at Wk 8, n (%)	1 (2.6)	8 (12.1)	0.016*	8 (10.0)	0.050*

Point estimate is based on NRI approach for binary endpoints and RTB-MI approach for continuous endpoints.
* p value ≤ 0.05, ** p value ≤ 0.01, *** p value ≤ 0.001

Conclusions

In this integrated analysis of China population from UP-AA program, both UPA 15 mg and 30 mg demonstrated substantial therapeutic advantages in adults and adolescents with severe AA and were well-tolerated. No new safety signal was identified. The positive benefit-risk profile of upadacitinib for the treatment of severe AA in China is consistent with that of the global population.

EADV CONGRESS
VIENNA
30 SEP - 3 OCT 2026

Abstract N°: 3217

Disease burden and patient-reported outcomes in adolescents and adults with severe alopecia areata: results from SCALPOBS, a national longitudinal observational study

Ángela Hermosa-Gelbard[1], Pablo Fernández-Crehuet[2], Víctor Cabezas[3], Ana Martín-Santiago[4], Ignasi Figueras-Nart[5], Pablo De la Cueva Dobao[6], Andrea Combalia[7], Arantxa Torrijos-Aguilar[8], Alejandro Lobato-Berezo[9], Raúl De Lucas Laguna[10], Noelia Llevat[11], Irene Hernandez-Martin*[11], Maria del Pilar Fortes Soto[11], Sergio Vaño-Galván[12]

[1] Dermatology Service, Hospital Universitario Ramón y Cajal; Hair Disorders Unit, Grupo de Dermatología Pedro Jaén; Department of Systems Biology, Faculty of Medicine, Universidad de Alcalá, IRYCIS, Madrid, Spain
[2] Department of Dermatology, Hospital Universitario Reina Sofía, Instituto Maimónides de Investigación Biomédica (IMIBIC), Córdoba, Spain
[3] Department of Dermatology, Hospital Universitario Vall d'Hebron, Barcelona, Spain
[4] Department of Dermatology. Hospital Universitario Son Espases, Balearic Islands, Spain. Institut d'Investigació Sanitària Illes Balears (IdISBa), Balearic Islands, Spain
[5] Department of Dermatology, Hospital Universitario de Bellvitge, University of Barcelona, Barcelona, Spain
[6] Department of Dermatology, Hospital General Universitario Gregorio Marañón, Madrid, Spain
[7] Department of Dermatology, Hospital Clinic de Barcelona, Barcelona, Spain
[8] Department of Dermatology, Hospital Arnau de Vilanova, Valencia, Spain
[9] Department of Dermatology, Hospital Universitario Mútua de Terrassa, Barcelona, Spain
[10] Department of Dermatology, Hospital Universitario La Paz, Madrid, Spain
[11] PFIZER SLU, Madrid, Spain
[12] TricoHRC Research Group, Hair Disorders Unit, Dermatology Department, Ramón y Cajal University Hospital, Instituto Ramon y Cajal de Investigación Sanitaria, University of Alcala; Hair Disorders and Hair Transplantation Unit, Grupo Pedro Jaen Clinic, Madrid, Spain

Introduction

Alopecia areata is a chronic, immune-mediated inflammatory disease with an unpredictable course and a substantial impact on patients' quality of life, emotional well-being, productivity, and healthcare resource use. Real-world data describing disease burden and its evolution over time in patients with severe scalp involvement remain limited.

Materials and Methods

Objectives: To evaluate the longitudinal burden of alopecia areata in adolescents and adults with severe scalp hair loss, focusing on health-related quality of life, patient-reported outcomes, clinical severity, work productivity, and healthcare resource utilization.

Methods: This was a multicenter, national, observational, longitudinal study including adolescents and adults with ≥50% scalp hair loss. Patients were assessed at baseline and after 6 months of follow-up in specialized centers. Outcomes included clinical severity assessed by the Severity of Alopecia Tool (SALT), eyebrow, eyelash and nail involvement, and multiple patient-reported outcomes, including generic and disease-specific quality of life, emotional status, work productivity, and healthcare resource utilization. Descriptive analyses were performed to evaluate baseline characteristics and changes over time.

Table 1. Demographic and baseline characteristics of the study population

Characteristic	Total (N = 61)
Age, years	
Mean (range)	42.1 (13.0–71.0)
< 18 years, n (%)	4 (6.6)
≥ 18 years, n (%)	57 (93.4)
Sex, n (%)	
Female	33 (54.1)
Male	28 (45.9)
Ethnicity, n (%)	
White	59 (96.7)
Hispanic or Latino	2 (3.3)
Body mass index (kg/m^2)	
Mean (SD)*	24.7 (4.1)
Family history of alopecia areata, n (%)	
Yes	8 (13.8)
No	50 (86.2)
Family history of other autoimmune or allergic diseases, n (%)	
Yes	7 (12.3)
No	50 (87.7)
Most frequent comorbidities (current or past, last 4 years), n (%)	
Vitamin D deficiency	16 (26.2)
Thyroid disease	14 (23.0)
Atopic dermatitis	13 (21.3)
Depression	12 (19.7)
Anxiety disorder	12 (19.7)
Prior treatment history (previous and/or ongoing before baseline), n (%)	
Any prior treatment	59 (96.7)
Systemic corticosteroids	51 (83.6)
Topical corticosteroids	45 (73.8)
Topical minoxidil	40 (65.6)
Intralesional corticosteroids	39 (63.9)
Cosmetic treatments	32 (52.5)
Oral minoxidil	28 (45.9)
Immunosuppressants (any)	24 (39.3)
└ Methotrexate†	13 (54.2)
└ Ciclosporine†	7 (29.2)
└ Baricitinib†	3 (12.5)
└ Tofacitinib†	1 (4.2)
Topical immunotherapy	10 (16.4)
Other alopecia areata treatments	9 (14.8)
Topical prostaglandin analogues	6 (9.8)
Antihistamines	4 (6.6)
Anthralin (dithranol)	2 (3.3)

*Body mass index available for 50 patients. †Percentage calculated over patients previously treated with immunosuppressants (n = 24)

Results

A total of 61 evaluable patients were included (mean age 42.1 years; 54.1% female). Baseline demographic

characteristics are summarized in Table 1. At baseline, 39.3% of patients presented with SALT >90, and eyebrow, eyelash and nail involvement were reported in 73.8%, 50.0% and 19.3% of patients, respectively. As shown in Table 2, improvements were observed across both SALT scores and patient-reported outcomes over 6 months, with a trend toward greater relative improvements in patient-reported measures. A shift toward lower SALT severity categories was observed, including an increase in patients achieving SALT ≤30 and reductions in the most severe categories.

Improvements were observed across multiple quality-of-life domains, particularly in social functioning, emotional role, and mental health. Disease-specific patient-reported outcomes showed consistent reductions in hair loss-related emotional symptoms and activity limitations, together with increased patient satisfaction with hair regrowth and its impact on quality of life.

Work productivity impairment and daily activity limitations decreased at 6 months compared with baseline. A global reduction in healthcare resource utilization related to alopecia areata was observed during follow-up, including fewer medical visits and reduced use of cosmetic or camouflage therapies, accompanied by a decrease in associated monthly costs.

Table 2. Clinical characteristics and patient-reported outcomes at baseline and after 6 months in patients with severe alopecia areata

Domain	Variable / Scale	Baseline	Month 6	Change
Population	Evaluable patients, n	61	61	—
Clinical severity	SALT distribution, %			
	SALT ≤30	0.0	33.3	+33.3 pp
	SALT 30–50	0.0	14.6	+14.6 pp
	SALT 50–75	44.3	14.6	−29.7 pp
	SALT 75–90	16.4	10.4	−6.0 pp
	SALT >90	39.3	27.1	−12.2 pp
Hair involvement	Eyebrow involvement, %	73.8	66.0	−7.8 pp
	Eyelash involvement, %	59.0	52.8	−6.2 pp
	Nail involvement, %	19.3	10.4	−8.9 pp
PROs	**SF-36** (mean score)			
	Social functioning	65.0	78.8	+13.8
	Emotional role	71.4	79.2	+7.8
	Mental health	59.8	67.5	+7.7
	P-Sat (%)			
	Moderately/very satisfied, %	15.3	36,6	+21.3pp
	AAPO (mean score)			
	Emotional symptoms	2.36	1.81	−0.55
	Activity limitations	1.57	0.97	−0.60
	WPAI (%)			
	Overall work impairment, %	27.6	15.3	−12.3 pp
	Activity impairment, %	32.8	16.3	−16.5 pp
	AARU (mean score)			
	Visits to doctors for AA	4.8	3.1	−1.7
	HADS (mean score)			
	Anxiety	8.6	7.1	−1.5
	Depression	5.5	3.9	−1.6

Conclusions

In this real-world longitudinal study, adolescents and adults with severe alopecia areata experienced a high

baseline disease burden affecting quality of life, emotional well-being, productivity, and resource use. Over 6 months of follow-up in specialized care, improvements were observed across clinical severity, patient-reported outcomes, work productivity, and healthcare resource utilization. These findings highlight the multidimensional burden of alopecia areata and the importance of comprehensive, patient-centered management strategies in routine clinical practice.

Limitations: follow-up was short, limiting assessment of the long-term course of a chronic, fluctuating disease such as alopecia areata. The observational design and the relatively small sample size from specialized centers may also limit broader applicability of the findings.
Abbreviations: SALT, Severity of Alopecia Tool; PRO: Patient-Reported Outcome, SF-36, Short Form-36 Health Survey; P-SAT, Patient Satisfaction with Hair Growth; AAPO, Alopecia Areata Patient Priority Outcomes; WPAI, Work Productivity and Activity Impairment Questionnaire; AARU: Alopecia Areata Resource Utilization, HADS: Hospital Anxiety and Depression Scale, pp, percentage points

This non-interventional study was sponsored by Pfizer.

EADV CONGRESS
VIENNA
30 SEP - 3 OCT 2026

Abstract N°: 3224

Hair today, misinformed tomorrow: a pilot audit of generative AI chatbots advising patients on androgenetic alopecia and alopecia areata

Szymon Leonik*[1, 2], Mikołaj Łanocha[1, 2], Anna Tekielak[1, 2], Beata Bergler-Czop[1, 2]

[1] Medical University Of Silesia, Department of Dermatology, Katowice, Poland
[2] Szpital Kliniczny im. A. Mielęckiego, Department of Dermatology, Katowice, Poland

Introduction
Androgenetic alopecia (AGA) and alopecia areata (AA) are the two most common non-scarring causes of hair loss and together drive the majority of trichology consultations. Both carry a substantial psychosocial burden and are heavily targeted by online misinformation, unproven supplements and direct-to-consumer products. Patients increasingly bypass clinical assessment and turn to generative artificial intelligence (AI) chatbots, which deliver fluent, authoritative answers regardless of accuracy. No published audit has systematically evaluated chatbot performance specifically in AGA and AA. The aim of this study was to assess the safety and accuracy of three popular AI chatbots when answering misinformation-prone, patient-facing queries on these two disorders.

Materials and Methods
Three publicly available, free-tier consumer chatbots were queried via their official desktop web interfaces on 2 May 2026, between 14:00 and 16:00 CEST: ChatGPT (GPT-5.3 Instant; OpenAI), Gemini (2.5 Flash; Google) and Grok (Grok 3; xAI, accessed via X). For each model, a single new chat session was opened with default settings, no plug-ins or external retrieval, and a non-identifying account. Fifty adversarial prompts were drafted to mirror common misinformation tropes from clinical practice and social media: 25 targeted AGA and 25 targeted AA. Within each disease, prompts spanned five thematic domains — aetiology and risk factors, approved pharmacotherapy, procedural and regenerative interventions, supplements, recurrence and lifestyle myths. Two physicians with trichology experience independently rated every response using a predefined three-tier matrix as non-problematic (NP — accurate, evidence-based, no false balance), somewhat problematic (SP — partially inaccurate or hedging) or highly problematic (HP — clearly misleading or potentially unsafe).

Results
One hundred and fifty responses were analysed. Overall, 36% (54/150) were rated NP, 36% (54/150) SP and 28% (42/150) HP. Inter-model performance differed substantially. Gemini was the „safest" with 64% NP, 28% SP and 8% HP. ChatGPT delivered mid-range performance (24% NP, 50% SP, 26% HP). Grok was the weakest performer (20% NP, 30% SP, 50% HP).

Conclusions
This audit suggests that public-facing AI chatbots vary in their handling of common patient queries on AGA and AA, with high-risk misinformation present in roughly one in four responses overall. Chatbot choice may meaningfully influence the information patients encounter. Suggested actions include: 1. Enquiring about AI-sourced information during consultation and contextualising chatbot limitations; 2. Developing society-endorsed, plain-language patient resources targeting common misinformation themes; 3. Engaging developers to integrate dermatology-vetted content for hair-loss queries. Larger, multi-domain audits are warranted.

POWERED BY M-ANAGE.COM

EA DV CONGRESS
VIENNA
30 SEP - 3 OCT 2026

Abstract N°: 3231

Management of scalp seborrheic dermatitis: a combined ciclopirox olamine and selenium disulfide protocol

Patricia Burgos-Blasco*[1], David Saceda-Corralo[1], Jon Ignacio Uriarte Terán[1], Miguel Centeno Pons[1], Ana Barquín Ruiz[1], Juan Aramberri Araiz[1], Leonor Prieto-Cabezas[2], Mercedes Abarquero-Cerezo[2]

[1] Servicio de Dermatología, IRyCIS, Hospital Universitario Ramón y Cajal., Madrid, Spain

[2] L'Oréal España S.A.U., Madrid, Spain

Introduction

Seborrheic dermatitis (SD) is a chronic, recurrent inflammatory skin condition affecting 1–3% of the adult population. Current treatments aim not only to achieve lesion remission but also to reduce visible signs, alleviate itching, and prevent relapses. Previous studies have demonstrated the individual effectiveness of medicated shampoo containing ciclopirox olamine (CPO) and a cosmetic shampoo formulated with selenium disulfide (SeS_2) and salicylic acid in improving clinical outcomes in SD. This study aims to evaluate the added benefit of incorporating the cosmetic shampoo containing SeS_2 as part of an integrated therapeutic approach for scalp SD.

Materials and Methods

A randomized, double-blind, placebo-controlled clinical trial was conducted over one month, enrolling 37 adult patients with mild to moderate scalp SD. Participants were randomized into two groups: the active treatment group (n=18, mean age [range] = 28 [26–34]) and the placebo control group (n=19, mean age [range] = 28 [26–32]). The study comprised two phases: 1. Treatment phase (2 weeks):Both groups used 1.5% ciclopirox olamine (CPO) shampoo three times per week; the active group alternated with a 2–3 times per week SeS_2-based shampoo, while the control group alternated with a soft shampoo without active ingredients targeting SD. 2. Maintenance phase (2 weeks):Participants in the active group applied the SeS_2 cosmetic shampoo twice weekly, alternating with the same soft shampoo, whereas the control group used only the soft shampoo. Clinical evaluations were conducted at baseline and on days 7, 14, and 28, employing a 16-point severity scale (SSD), standardized scalp photography, and trichoscopic analysis. Additionally, patients assessed product tolerance, cosmetic acceptability, and satisfaction with the results.

Results

CPO with the cosmetic shampoo containing SeS_2 demonstrated a greater reduction in SD severity (SSD) during the treatment phase (-41% at day 7 and -67% at day 14, both $p < 0.05$) compared to the combined use of CPO and soft shampoo (0% at day 7 and -20% at day 14, $p<0.05$ at day 14). These findings were corroborated by representative clinical photographs. Additionally, significant improvements in pruritus and scaling were observed during the treatment phase compared with the placebo group: at day 14, scaling showed a 75% improvement in the active group versus 25% in the control group, and pruritus showed a 100% improvement in the active group versus 0% in the control group. During the maintenance phase, the shampoo containing SeS_2 helped sustain the reduction in SD severity (-79% at day 28, $p<0.05$). Patients reported good tolerability of the products included in the protocol, high cosmetic acceptability, and satisfaction with the results.

Conclusions

The combination of a cosmetic shampoo containing SeS_2 with a medicated shampoo containing 1.5% CPO demonstrated a synergistic effect in the treatment of scalp seborrheic dermatitis, significantly reducing disease severity from the first week of the treatment phase compared to a control group using CPO shampoo and a soft shampoo. The use of the SeS_2 shampoo during the maintenance phase contributed to sustained control of signs and symptoms. These results support this combination as an effective and well-tolerated strategy for the integrated management of seborrheic dermatitis of the scalp, with high patient satisfaction.

EA DV CONGRESS
VIENNA
30 SEP - 3 OCT 2026

Abstract N°: 3235

Real-world European digital insights into disease awareness, clinical guidance, and unmet needs in severe alopecia areata

Padma Mohandas*[1], Yousaf Aftab[2], Hana Alic[2], Georgia Cole[2]

[1] Barts Health NHS Trust, London, United Kingdom

[2] Pfizer, Tadworth, United Kingdom

Introduction

Alopecia areata (AA) is an autoimmune condition targeting hair follicles and can cause extensive scalp hair loss. Although new therapies (including Janus kinase inhibitors [JAKi]) are changing management, variability in awareness, clinical guidance and access may persist. We used real-world digital data from Europe to characterise online discourse around severe AA, compare patient and healthcare professional (HCP) perspectives, and identify unmet needs.

Materials and Methods

We conducted a retrospective social listening study using Brandwatch analytics with AI-enabled classification. Publicly available English language online conversations from Europe were collected across >100 million open web and social media sources from March 2024 to February 2026. Boolean search strings captured AA terms, treatments, and relevant hashtags; posts were segmented by audience (patients vs HCPs) and summarised descriptively.

Results

We identified 27,675 AA mentions. Overall conversation volume declined by ~29% over the study period, despite new treatment options, suggesting sustained gaps in awareness and engagement. Misclassification was common: 11% of mentions referred to androgenetic alopecia, indicating limited understanding of AA as an autoimmune condition. Patient and HCP narratives diverged (as shown in Figure 1). Patients primarily discussed psychosocial burden (loss of identity and confidence). Among emotion-labelled posts, sadness (23%) and anger (23%) were most frequent. Patients also highlighted frustration with trial-and-error care, side-effect burden, and variable efficacy. They also referenced a spectrum of approaches from JAKi to cosmetic and 'natural' options. HCP discussions emphasised disease mechanisms, efficacy, and safety of treatment options. They reflected movement towards individualised management alongside ongoing challenges (long-term outcomes, monitoring requirements, and lack of standardised care pathways). JAKi were referenced in ~5% of AA patient conversations; sentiment was mixed, dominated by safety skepticism (36.8%), anxious vigilance (32.6%), and cautious optimism (30.5%).

Figure 1: Patients vs. HCP perspectives in AA

Area	Patients	HCPs
Awareness	Confusion with other Alopecia (11%)	Diagnosis and autoimmune mechanism
Focus	Psychosocial burden (Sadness 23%; Anger 23%)	Clinical efficacy, safety, mechanisms
Treatment overview	Trial-and-error, side effects	Evidence based, individualised management
JAKi	Hope tempered by safety concerns	Therapeutic advances with monitoring needs

Figure 2: 'What concerns do patients and HCPs raise regarding current AA therapies?'

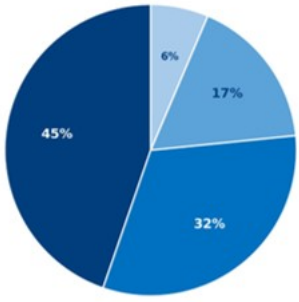

Color	Concern Category	% of Respondents (N=392)
	Treatment efficacy	45%
	Severe adverse reactions (e.g., myelosuppression, alopecia totalis)	32%
	Relapse & infection risks with JAK Inhibitors	17%
	Other concerns	6%

Figure 1 illustrates divergence in patient and HCP narratives. Figure 2 illustrates key concerns raised by patients and HCPs regarding current AA therapies, including trial-and-error management, durability and relapse concerns, and safety-related risks.

Conclusions

Social listening data reflects publicly available online conversations and may not be representative of the broader patient or HCP population. Demographic and clinical characteristics (e.g., diagnosis confirmation, disease severity, treatment history) cannot be fully validated. Silent populations (patients not active on social media) are not captured. Findings are observational and should not be interpreted as causal or generalizable to clinical outcomes.

Real-world European digital discourse highlights a persistent awareness gap and a clear mismatch between patient reported burden and clinically focused HCP discussion in severe AA. The reduction in overall conversation volume, alongside frequent confusion with androgenetic alopecia, supports the need for improved education and engagement. Standardised, patient-centred care pathways and clearer guidance on treatment selection, safety monitoring and expectations may help bridge the patient's HCP gap and improve real-world outcomes.

EA DV CONGRESS
VIENNA
30 SEP - 3 OCT 2026

Abstract N°: 3243

Combination Therapy versus Monotherapy in Androgenetic Alopecia: A Comparative Systematic Review and Meta-Analysis of Treatment Strategies

Laurentia Fidella Averina Setia Santoso*[1], Alyaa T. Sharshar[2], Marie Line Chedid[3], Jihad Mazloum[4], Hiba K. Abi Rizk[5], Baraa Saifi[6], Micaelly Samara Meneses Santos[7], Nancy Emmanuel[8]

[1] Faculty of Medicine, Universitas Padjadjaran, Sumedang, Indonesia
[2] Faculty of Medicine, Ain Shams University, Cairo, Egypt
[3] Faculty of Medicine, Medical University of Łódź, Łódź, Poland
[4] Faculty of Medicine, UNINOVE, Guarulhos, Brazil
[5] Faculty of Medicine, Lebanese University, Beirut, Lebanon
[6] Gilbert and Rose Marie Chagoury School of Medicine, Lebanese American University, Byblos, Lebanon
[7] Department of Dermatology, Complexo Hospitalar Padre Bento de Guarulhos, Guarulhos, Brazil
[8] Department of Dermatology, Hospital das Clínicas of the Faculty of Medicine, University of São Paulo, São Paulo, Brazil

Introduction
Androgenetic alopecia (AGA) is the most prevalent form of hair loss in adults and impacts quality of life. Standard treatments like topical minoxidil, oral finasteride, and low-level laser therapy have variable effectiveness. Combination therapies, encompassing pharmacologic and regenerative modalities, are being utilized more. Nonetheless, their relative efficacy and safety compared to monotherapies remain ambiguous, as the majority of reviews concentrate on individual treatments. This study offers a network meta-analysis that contrasts nonsurgical combination therapies with monotherapies for AGA, aiming to enhance clinical practice and guide future research.

Materials and Methods
A review of eight databases over the last decade identified studies comparing combination therapy to monotherapy for AGA in adults. The PICO framework comprised: participants being human adults with AGA, interventions involving various nonsurgical combination therapies (including topical/oral minoxidil, topical finasteride, topical 2% flutamide, oral vitamin D3, topical/oral spironolactone, oral bicalutamide 25 mg/d, fractional, low-level laser therapy, microneedling, platelet-rich plasma, basic fibroblast growth factor, secretome from adipose-derived stem cells, and thread therapy employing poly-L-lactic acid), comparisons with monotherapy or placebo, and outcomes measured in terms of hair density, diameter, global photographic assessment, and adverse events. The risk of bias was evaluated using Cochrane RoB2 for randomized trials and ROBINS-I V2 for observational studies, with data analyzed via Review Manager 5.4.

Results
43 studies (3174 patients) were analyzed out of 2171 records. In 27 studies (62.8%) and 11 comparisons, hair density was measured. Four studies (9.3%) with 2 comparisons reported mean hair thickness. Global photographic assessment (GPA) was examined in 7 studies (16.28%) across 4 comparisons, whereas hair shaft diameter was assessed in 8 studies (18.6%) across 4 comparisons. Across 7 comparisons, 16 studies (37.2%) reported adverse effects.

In general, combined treatments outperformed monotherapy in hair density improvement, although the comparisons were mostly not statistically significant. Minoxidil plus topical flutamide or PLLA threads performed better than minoxidil alone (SMD 0.85). Laser plus minoxidil outperformed both by themselves (SMD 1.40). PRP+minoxidil outperformed both PRP or minoxidil alone (SMD 1.55) and minoxidil alone (SMD 1.09). Microneedling+minoxidil outperformed both microneedling and minoxidil alone (SMD 2.69). Minoxidil+regenerative therapy worked better than either treatment alone (SMD 1.02).

Only minoxidil+topical finasteride significantly improved hair shaft diameter (SMD 0.68) compared to topical minoxidil only. Both laser+minoxidil (SMD 0.72) and minoxidil+microneedling (SMD 1.22) performed noticeably better than laser, microneedling, and minoxidil alone for hair thickness.

While other comparisons were not significant, laser+minoxidil (SMD 0.52) and microneedling+minoxidil (SMD 1.29) both increased GPA. There were no discernible variations in adverse events.

Pairwise comparisons were utilized instead since significant discrepancies between rankings and effect estimates indicated violations of important network meta-analysis assumptions, rendering the results untrustworthy. Large SMDs should be taken with caution since they probably represent limited samples, multi-arm designs, and varied methodologies; therefore, the direction and consistency of the results should be prioritized over their magnitude.

Conclusions

Combination therapy is reportedly more effective than monotherapy for AGA, exhibiting fewer side effects. However, limitations include short follow-ups (≤ 6 months) and inadequate ethnicity reporting in studies. Long-term safety and effectiveness require confirmation through randomized controlled trials with longer follow-up periods.

EADV CONGRESS
VIENNA
30 SEP - 3 OCT 2026

Abstract N°: 3275

IMG-007 a non-depleting OX40 mAb produces durable shift in TCR repertoire and T cell function: Early biomarker insights from a phase 1b/2a trial in immune-mediated alopecias

Julia Coronella[1], Jonatan Tuncel*[1], Chongtian Guo[2], Kurinji Pandiyan[1], Kristin Yarema[1]

[1] ImageneBio, 12526 High Bluff Drive, Suite 345, San Diego, United States

[2] Miragene, 4653 Carmel Mountain Road Suite 308, San Diego, United States

Introduction

Both OX40 and OX40L are upregulated in many dermatologic autoimmune diseases. In this exploratory biomarker study of four patients with immune-mediated alopecias (three alopecia areata, one scarring-type alopecia) from a Phase Ib/II trial of OX40 nondepleting mAb IMG-007 (NCT06060977), we show that OX40 inhibition by IMG-007 resulted in both short term and durable off-drug immunologic modulation.

Materials and Methods

We have previously reported progressive clinical improvement following adminstration of 3 IV doses of IMG-007 at Weeks 0, 2 and 4 up to 8 months after cessation of IMG-007 administration (Guttman-Yassky *et al*, Journal of Investigative Dermatology, 145:11:E72, 2025), and a reduction in inflammatory serum cytokines. In this study, we describe shifts in peripheral T cell repertoire and phenotype as well as recovery of scalp keratin expression that may be associated with the durability of clinical responses observed after cessation of IMG-007 dosing.

Results

By week 4 after treatment initiation, and before clinically measurable changes, scRNA-seq (10x Genomics; mean 7,376 cells/sample; median 1,092 genes/cell) of PBMCs showed a major shift in the peripheral T cell compartment. At baseline, the most abundantly expanded T cell clones (N>100 as determined by 10X Genomics Cell Ranger V(D)J analysis tool) were comprised primarily of activated CD8, and to a lesser degree, CD4 effector compartments. Although the relative frequency of T cells in samples was unchanged at week 4, the most highly expanded T cell clones present at baseline were notably absent or reduced. This was concurrent with a shift to a less activated state, as measured by lower enrichment in cell activation pathways (GSEA), indicative of a loss of the most highly activated and proliferative effector T cells. At 4 weeks, effector T cells also expressed lower levels of differentiation pathway genes and dermal trafficking / retention molecules.

Although last drug dose was administered at week 4, durable immunological changes were noted at weeks 16-24. While high-frequency T cell clones re-emerged in peripheral blood by week 16, the post-treatment clones showed a shift in both repertoire and phenotype. Clones were comprised largely of CD8 central memory/effector memory or effector cells with reduced expression of cytotoxic pathways, as opposed to the activated effector cells seen at baseline, with an ~6-fold average reduction in CD4 effector cells. These changes are consistent with the upstream role of OX40 in T cell activation and differentiation. Other shifts in serum biomarker proteins (measured by Olink Target 48 panels) were also observed.

Conclusions

Overall, these data suggest a potentially durable shift in immune biology rather than deletion of the effector compartment. Additionally, a marked increase in expression (~6-100-fold as measured by bulk RNAseq) of hair pathway genes including Keratin (KRT) 35 and KRT85 was observed in scalp biopsy samples for 3/3 patients (2 AA,

one scarring-type alopecia) for whom both baseline and week 16 scalp biopsies were available, indicating follicular recovery.

These intriguing preliminary results from this small sample of patients with immune-mediated alopecias treated with IMG-007 suggest potential for durable disease modification. This will be explored further in an upcoming Phase 2 clinical trial of IMG-007 in alopecia areata.

EADV CONGRESS
VIENNA
30 SEP - 3 OCT 2026

Abstract N°: 3282

Graham-Little-Piccardi-Lassueur Syndrome Treated with Baricitinib: A Case Report

Chiara Zangrando[1], Patrick Silvetti*[2], Leonardo Balestra[2], Giulio Gualdi[2]

[1] Dermatology Unit, Azienda Ospedaliero-Universitaria di Parma, Parma, Italy

[2] School of Dermatology, University of Parma, Parma, Italy

Introduction

Graham-Little-Piccardi-Lassueur syndrome is a rare variant of lichen planopilaris characterized by progressive cicatricial alopecia of the scalp, non-scarring alopecia of the axillary and/or pubic regions, and follicular keratotic papules involving the trunk or extremities. Due to its rarity and chronic inflammatory course, therapeutic management remains challenging, particularly in extensive or refractory disease.

Case Presentation

We report the case of a 51-year-old woman who had been misdiagnosed for several years and consequently remained undertreated despite progressive disease evolution. She had a long standing history of presumed alopecia areata and had undergone multiple topical therapies over the years with poor clinical benefit. Since August 2025, she had developed widespread lichen spinulosus-like follicular lesions involving the upper and lower limbs, associated with significant symptomatic folliculitis, which represented the most burdensome aspect of the disease.

In January 2026, she came to our clinic for worsening of the scalp alopecia. Clinical examination revealed active lichen planopilaris with an extensive cicatricial alopecic area of the vertex. Trichoscopy showed perifollicular hyperkeratosis and widespread fibrotic white areas. Follicular keratotic papules were diffusely present on the upper limbs, lower limbs and back, together with bilateral rarefaction of axillary hair. Histopathology confirmed lichen spinulosus on the right thigh and lichen planopilaris of the scalp. Laboratory investigations, including blood count, liver and renal function, lipid profile, antinuclear antibodies, and infectious screening for HBV, HCV and tuberculosis, were unremarkable.

Hydroxychloroquine was considered poorly indicated in this specific clinical setting, given the predominance of severe follicular inflammatory involvement and the extent of disease. After discussion of available therapeutic options, systemic treatment with the Janus kinase inhibitor baricitinib 4 mg once daily was initiated, together with topical clobetasol on symptomatic inflammatory areas.

Conclusion

This case highlights a rare presentation of Graham-Little-Piccardi-Lassueur syndrome and supports the potential role of JAK inhibition as a therapeutic option in selected patients with active inflammatory cicatricial alopecia and prominent follicular inflammatory involvement. Although longer follow-up is required to assess efficacy and safety, baricitinib may represent a promising strategy in difficult-to-treat cases within the lichen planopilaris spectrum.

POWERED BY M-ANAGE.COM

EADV CONGRESS
VIENNA
30 SEP - 3 OCT 2026

Abstract N°: 3315

Fibrosing alopecia in a pattern distribution in a patient with Sjögren's disease: a case report and review of shared pathogenic mechanisms

Iuliia Romanova*[1], Aida Gadzhigoroeva[2], Oksana Katunina[1]

[1] Moscow Scientific and Practical Center of Dermatovenerology and Cosmetology Moscow Health Department, Moscow, Russian Federation

[2] Moscow Scientific and Practical Center of Dermatovenerology and Cosmetology Moscow Health Department, Peoples' Friendship University of Russia, Moscow, Russian Federation

Introduction

Fibrosing alopecia in a pattern distribution (FAPD) is a primary lymphocytic cicatricial alopecia considered a clinical variant of lichen planopilaris (LPP) of presumably autoimmune origin. Sjögren's disease (SD) is one of the predominant autoimmune diseases in patients with LPP (PMID: **41123306)**. A large-scale analysis of over 4.4 million patients with autoimmune disorders found SD to be associated with the highest rate of oral lichen planus among all 17 studied autoimmune conditions, at 4.57% (PMID: **41456989)**. Both conditions share CD8+ T-cell-mediated cytotoxicity and polarization toward Th1/Th17 immune responses as key pathogenic mechanisms. A further diagnostic challenge lies in the delayed recognition of Sjögren's disease itself: the average diagnostic latency for primary SD is reported at nearly 6 years, with patients typically consulting multiple specialists before receiving an accurate diagnosis. UP to 30–50% of patients with SD have significant extraglandular manifestations (nephrological, neurological, etc.).

Case Presentation

A 35-year-old woman presented with a 3–4-year history of progressive hair shedding and thinning. The patient had previously been diagnosed with androgenic alopecia and had initiated topical minoxidil 5% one-month prior. Medical history included primary Sjögren's disease diagnosed in 2020, treated with rituximab since 2021. The patient's SD manifestations included salivary gland involvement (history of recurrent parotitis, parenchymatous parotitis, sialadenitis based on minor salivary gland biopsy FS > 3), ocular involvement (keratoconjunctivitis sicca, grade 1 lacrimal hyposecretion), reticuloendothelial system involvement (history of lymphadenopathy), hematologic disorders (leukopenia, polyclonal hypergammaglobulinemia, elevated IgG, history of hyperproteinemia), and immunological abnormalities (ANA+, Ro+). Family history was notable for Sjögren's disease and alopecia in patient's mother.

Trichoscopy of the vertex, parietal and temporal scalp revealed hair grouping up to 5 hairs per follicular unit, mild perifollicular erythema, follicular hyperkeratosis, anisotrichosis, and signs of scalp xerosis. A 4 mm punch biopsy under trichoscopic guidance was performed. The histopathological findings are consistent with fibrosing alopecia in a pattern distribution showing: dense lichenoid lymphohistiocytic infiltration in the infundibular region and hair follicles of varying diameters. Topical betamethasone dipropionate 0,05% lotion plus Minoxidil 5% foam once daily were initiated, along with a gentle shampoo.

Conclusion

The coexistence of LPP and autoimmune disorders such as SD may suggest a common pathogenic background.

This is the first report of an association between FAPD and SD. The prior misattribution of hair loss to androgenetic alopecia underscores the diagnostic difficulty in patients with FAPD. The present case report complements the dermatologic literature that highlights the importance of investigating of other autoimmune diseases associated with FAPD as an LPP variant. We propose that trichological assessment in FAPD patients should include targeted questioning to detect early signs of Sjögren's disease by routinely screening for sicca symptoms, including xerophthalmia and xerostomia. Interdisciplinary awareness between dermatologists/trichologists and rheumatologists is essential to reduce diagnostic delay and enable timely intervention in this vulnerable patient group.

EADV CONGRESS
VIENNA
30 SEP - 3 OCT 2026

Abstract N°: 3346

Trichoscopic differentiation between telogen effluvium and androgenetic alopecia: practical diagnostic clues in early hair loss

Ana Beatriz Gomes Cordovil*[1], Maria Eduarda da Silva Cunha Pinheiro[1], Giovana Bueno Fernandes[1], Maria Esperança Figueira de Mello Altberg[1], Renata da Gama Cruz Luz[1], Clara Brito Hegedüs[1], Caroline Teruszkin Wiedermann[1], Alice Klajman Agostino[1], Allen Becker[1], Maria Luiza Corrêa Sebba[1], Sofia Rase Chaves[2], Manuela Attianesi de Freitas Rocha[3], Julia Dionisio Lima[4]

[1] Universidade Estácio de Sá, Rio de Janeiro, Brazil

[2] Hospital Mário Kroeff, Rio de Janeiro, Brazil

[3] Faculdade São Leopoldo Mandic, São Paulo, Brazil

[4] Universidade do Oeste Paulista, São Paulo, Brazil

Introduction

Telogen effluvium (TE) and androgenetic alopecia (AGA) are among the most common causes of diffuse hair loss and may coexist or present with overlapping clinical manifestations, particularly in early disease stages. Accurate differentiation is essential for prognosis, therapeutic planning, and patient counseling. Trichoscopy has emerged as a non-invasive and highly valuable diagnostic tool capable of identifying characteristic scalp and hair shaft alterations. This review aims to summarize the main trichoscopic findings that assist in distinguishing TE from AGA in routine clinical practice.

Materials and Methods

A narrative literature review was conducted using PubMed, Scopus, and Embase databases, including studies published between 2010 and 2025. Search terms included “trichoscopy”, “telogen effluvium”, “androgenetic alopecia”, “hair loss”, and “scalp dermoscopy”. Original studies, review articles, and case series evaluating trichoscopic patterns in diffuse alopecias were included. Studies lacking dermoscopic correlation or clinical applicability were excluded. A qualitative synthesis of the findings was performed.

Results

AGA was consistently associated with marked hair shaft diameter variability (anisotrichosis), typically exceeding 20%, increased proportions of miniaturized/vellus hairs, variable-sized yellow dots, and the presence of the peripilar sign (perifollicular pigmentation), as well as a predominance of single-hair follicular units in the frontal scalp (Miteva et al., 2023; Kuczara et al., 2024). In contrast, TE demonstrated preserved follicular density with relatively homogeneous shaft diameter, reflecting its non-miniaturizing pattern (Miteva et al., 2023), and occasional yellow dots representing empty follicles during the shedding phase. The primary differentiating features identified in this review are synthesized in Table 1. Empty follicles, upright regrowing hairs, and diffuse short regrowing hairs were more frequently identified in TE, corresponding to synchronized shedding and regrowth cycles (Errichetti et al., 2024). Recent evidence also highlights the value of recognizing overlapping TE/AGA patterns, particularly in patients exposed to systemic stressors, viral infections, or nutritional deficiencies (Errichetti et al., 2024). Hair shaft diameter diversity involving frontotemporal regions remained one of the strongest indicators favoring AGA, whereas diffuse shedding with preserved shaft homogeneity supported a diagnosis of TE (Kuczara et al., 2024).

Trichoscopic Feature	Telogen Effluvium (TE)	Androgenetic Alopecia (AGA)
Hair Shaft Diversity	Homogeneous diameters (minimal variation)	Marked Anisotrichosis (>20% diversity)
Follicular Units	Preserved (mostly 2-3 hairs per unit)	Predominance of single-hair units
Vellus Hairs	Not significantly increased	Markedly increased (>20%)
Perifollicular Signs	Usually absent	Peripilar Sign (brownish halo)
Regrowing Hairs	Pigtail hairs and upright regrowing hairs	Short, thin, hypopigmented vellus hairs
Distribution	Diffuse (uniform across the scalp)	Localized (Frontal/Vertex > Occipital)
Yellow Dots	Occasional (representing empty follicles)	Numerous and variable-sized

Table 1. Differential trichoscopic features between Telogen Effluvium (TE) and Androgenetic Alopecia (AGA).

Conclusions

Trichoscopy represents an accessible and reliable method for differentiating TE from AGA, particularly in patients presenting with early or diffuse hair loss, providing greater diagnostic accuracy when clinical tests such as the pull test are inconclusive. Recognition of characteristic follicular and vascular patterns may facilitate prompt diagnosis, optimize therapeutic decisions, and improve patient counseling. Integrating trichoscopy into routine hair evaluation enhances diagnostic confidence and supports a more individualized management approach.

EA DV CONGRESS
VIENNA
30 SEP - 3 OCT 2026

Abstract N°: 3348

Inflammatory infiltrate precedes collapse of the immune privilege in human Alopecia areata

Sophie Frech*[1], Namrata Singh[1], Martin Simon[1], Inigo Oyarzun[1], Philipp Tschandl[1], Sabina Gansberger[1], Johannes Griss[1]

[1] Department of Dermatology, Medical University of Vienna, Vienna, Austria

Introduction

Alopecia areata (AA) is a common immune-mediated, non-scarring hair loss disorder with a highly variable clinical course and heterogeneous treatment responses. Although $CD8^+NKG2D^+$ T-cell–mediated cytotoxicity targeting the lower portion of the anagen hair follicle (HF) and collapse of HF immune privilege (IP) are widely regarded as central pathogenic mechanisms, the upstream drivers of AA remain poorly understood. In extensive disease, high-dose systemic corticosteroids or Janus kinase (JAK) inhibitors represent first-line therapies; however, only ~40% of patients respond. Moreover, treatment discontinuation frequently results in relapse.

Materials and Methods

Here, we performed single-cell RNA sequencing of lesional, perilesional, and control skin biopsies from patients with localized and generalized AA, totaling 42 samples and more than 180,000 analyzed cells.

Results

Our data reveal that perilesional skin samples (2–3 cm from active lesions) exhibit a cytotoxic T-cell infiltrate indistinguishable from that observed in active lesions, thereby capturing an early pathogenic state preceding manifest tissue destruction. This observation enables a precise dissection of the temporal dynamics underlying human AA progression. Notably, we demonstrate that $CD8^+$ T-cell infiltration precedes the collapse of HF IP. In samples obtained 4–6 weeks after therapy initiation, coinciding with clinical response, the HF IP defect persists despite resolution of the inflammatory infiltrate. Furthermore, our findings identify disease-specific inflammatory hair follicle fibroblast populations and dendritic cells that may collaboratively drive the breakdown of HF IP. Further validation of these findings could be achieved using Xenium-based spatial transcriptomic analysis of six additional samples.

Conclusions

For the first time, our data resolve a long-standing immunological paradox in human AA by demonstrating that immune cell infiltration precedes and likely drives the collapse of HF IP. While therapeutic suppression of inflammation successfully restores hair growth, we show that HF IP is not reconstituted - a critical insight that may mechanistically explain the high recurrence rates observed in AA.

Sampling & Methods

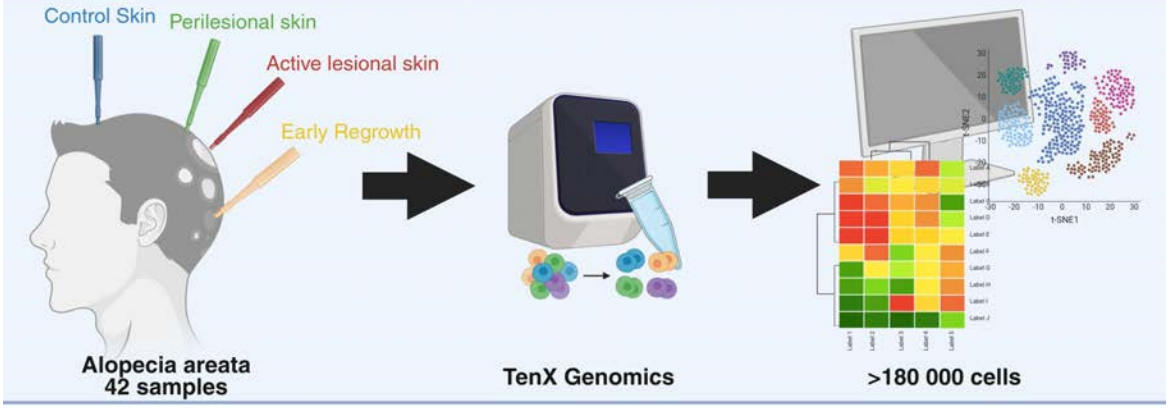

Results & Conclusion

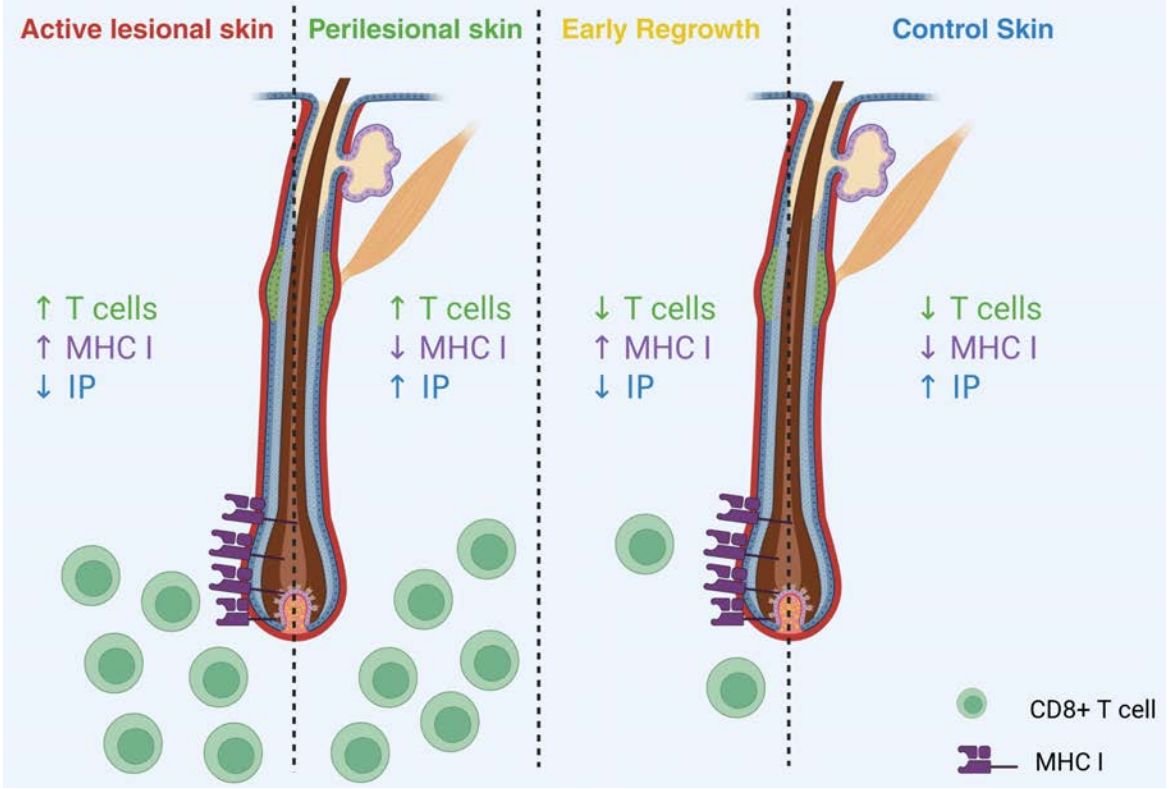

EA DV CONGRESS
VIENNA
30 SEP - 3 OCT 2026

Abstract N°: 3372

Surgery Alone Is Insufficient: Continuous Medical Stabilization Determines 5-Year Aesthetic Durability After Hair Transplantation in Progressive Androgenetic Alopecia — A Comparative Cohort Study

Nana Korkia*[1], Salome Vadachkoria[1]

[1] Talizi Hair Transplantation Clinic, Tbilisi, Georgia

Introduction

Follicular unit extraction (FUE) achieves high graft survival rates in androgenetic alopecia (AGA), typically 90–95%, with satisfactory early postoperative outcomes. However, AGA remains a progressive condition characterized by ongoing miniaturization of native follicles, which may alter long-term aesthetic outcomes despite stable transplanted grafts.

Long-term results are therefore increasingly dependent on disease control rather than surgical yield alone.

This study aimed to evaluate the impact of continuous postoperative medical stabilization on 5-year aesthetic durability, patient satisfaction, and secondary procedure rates following FUE in progressive AGA.

Case Presentation

This retrospective comparative cohort study included 100 male patients with AGA (Norwood II–V), aged 25–65 years, who underwent primary FUE and completed ≥5 years of follow-up.

Patients were stratified into a medical stabilization group (n = 68; continuous finasteride and/or topical minoxidil) and a non-stabilized/discontinued therapy group (n = 32). Baseline characteristics were comparable between groups, including mean age (39.2 ± 7.3 years), mean graft number (2,470 ± 520), and Norwood stage distribution.

Outcomes included global aesthetic stability score (0–10), patient satisfaction score (0–10), and secondary procedure rate at 5 years.

Early postoperative outcomes were comparable between cohorts, with graft survival rates of approximately 93–95% in both groups and similar 12-month satisfaction scores.

At 5 years, substantial divergence emerged. Global aesthetic stability was significantly higher in the stabilization group (8.5 ± 0.9 vs 6.1 ± 1.2), as was patient satisfaction (8.7 ± 0.8 vs 6.3 ± 1.3). Secondary procedures were required in 5.9% of stabilized patients compared with 46.9% of non-stabilized patients, corresponding to an approximately 8-fold increased risk.

In the non-stabilized cohort, long-term aesthetic deterioration was primarily associated with progressive native hair miniaturization, density mismatch between transplanted and native hair, and temporal recession progression. Importantly, graft survival remained preserved (>90%) in both groups, indicating that long-term decline was driven predominantly by disease progression rather than surgical failure.

Patients aged >50 years demonstrated lower progression burden and fewer secondary procedures, whereas patients aged ≤50 years exhibited higher progression rates and greater revision demand. Patients who discontinued therapy showed outcomes comparable to the non-stabilized cohort, with accelerated decline in aesthetic satisfaction over time.

Conclusion

Long-term outcomes after hair transplantation in androgenetic alopecia are strongly influenced by ongoing disease activity rather than surgical performance alone.

Across a 5-year follow-up, absence of continuous medical stabilization was associated with significantly reduced aesthetic stability, lower patient satisfaction, and an approximately 8-fold higher risk of secondary procedures.

These findings support a treatment paradigm in which hair transplantation should be conceptualized as part of a long-term disease-control strategy, where continuous medical stabilization is essential for maintaining aesthetic durability and reducing corrective surgical demand.

Keywords: Hair transplantation; androgenetic alopecia; follicular unit extraction; long-term outcomes.

POWERED BY M-ANAGE.COM

EA DV CONGRESS
VIENNA
30 SEP - 3 OCT 2026

Abstract N°: 3398

Coexistence of frontal fibrosing alopecia and fibrosing alopecia in a pattern distribution in a young man : Evidence for a shared disease spectrum

Afli Donia*[1], Mariem Tabka[1], Feryel Amri[1], Asmahane Souissi[1], Mourad Mokni[1]

[1] La Rabta Hospital, Tunis, Tunisia

Introduction

Frontal fibrosing alopecia (FFA) and fibrosing alopecia in a pattern distribution (FAPD) are two distinct forms of primary cicatricial alopecia belonging to the lichen planopilaris spectrum. Both entities share a patterned distribution of hair loss and histopathological features of perifollicular lichenoid inflammation associated with concentric fibrosis.

Their coexistence in a young male patient is exceptional and may support the hypothesis of a shared pathophysiological continuum between these two disorders.

Case Presentation

A 30-year-old man with no significant past medical history presented with progressively worsening frontotemporal alopecia associated with hair thinning of the vertex, evolving over several months. Dermatological examination revealed bilateral recession of the frontotemporal hairline associated with decreased hair density involving the frontal and vertex scalp regions. Trichoscopic examination demonstrated loss of follicular ostia, marked hair shaft diameter variability, perifollicular erythema and scaling, milky-red areas, and white cicatricial patches. Eyebrows and body hair were spared. Histopathological examination revealed a perifollicular lymphocytic infiltrate associated with lamellar perifollicular fibrosis, consistent with a lymphocytic cicatricial alopecia. The clinical, trichoscopic, and histopathological findings supported the diagnosis of overlapping frontal fibrosing alopecia and fibrosing alopecia in a pattern distribution. Intralesional triamcinolone acetonide injections were initiated, resulting in partial stabilization of the disease.

Conclusion

This case supports the concept that FFA and FAPD may represent phenotypic variants within a shared clinicopathological spectrum of lymphocytic cicatricial alopecia. FFA classically affects postmenopausal women and predominantly involves the frontal hairline, whereas FAPD presents as a cicatricial alopecia mimicking androgenetic alopecia, mainly affecting androgen-dependent scalp areas. The coexistence of FFA and FAPD has previously been reported within the same family, although affecting different individuals. However, such overlapping presentations remain exceptional, particularly in young male patients. Awareness of this rare overlap, particularly in young men, is important to avoid misdiagnosis as androgenetic alopecia and to ensure timely initiation of anti-inflammatory treatment.

EA DV CONGRESS
VIENNA
30 SEP - 3 OCT 2026

Abstract N°: 3416

Alopecia and GLP-1 Receptor Agonists : What is the real risk ? A Systematic Review and Bayesian Meta-analysis

Emiliano Arantes*[1], Pedro Paulo Arantes[2], Klivia Finzer[1]

[1] Clínica Menu, Rio verde, Brazil

[2] Faculdade de Medicina de São José do Rio Preto, São José do Rio Preto, Brazil

Introduction

GLP-1 receptor agonist agents have been widely used in type 2 diabetes, obesity management and weight loss, becoming some of the most prescribed medications in the world. Alopecia has recently been reported as a potential side effect associated with this treatment. Reports based on pharmacovigilance data and small cohort studies have raised concerns about its consequences on hair growth. However, report of alopecia as an adverse side effect of GLP-1 receptor agonists remain scarce. To address this gap, we conducted a systematic review and Bayesian meta-analysis to provide a more robust and comprehensive assessment of this association.

Materials and Methods

We conducted a systematic search across Pubmed, Embase and Cochrane through April 2026. Studies evaluating GLP-1 Receptor Agonists (GLP-1 RAs) and alopecia as side effect were included. Studies were eligible for inclusion if they (1) were randomized controlled trials (RCTs), and, (2) reported alopecia as a clinically relevant side effect of any GLP-1 receptor agonist. Bayesian random-effects models were fitted using the bayesmeta R package with vague priors for both the overall effect (μ: normal, mean 0, SD 2.7) and between-study heterogeneity (τ: half-normal, scale 1.0). Posterior distributions were summarized as medians with 95% credible intervals (CrIs). We computed posterior probabilities at pre-specified thresholds (OR >1, >1.5, >2.0, >3.0) and 95% prediction intervals. Sensitivity analyses were performed varying the τ prior (half-normal, scale 0.5 and 1.5). A Bayesian meta-analysis was then performed to pool the available evidence.

Results

Five studies including 4,496 patients, of whom 2,866 (63%) were treated with GLP-1 RA (semaglutide and tirzepatide) and 3,052 (68.2%) were female, were included. The posterior probability of a positive association (OR > 1) was 100%, of a moderate association (OR > 1.5) was 99.9%, of a strong association (OR > 2.0) was 99.1%, and a very strong association (OR>3) was 81.6%, yielding an OR of 3.71 (95% CI 2.24–6.14; Figure 1). The predictive posterior distribution demonstrated a probability of 99.7% of any association between GLP-1 RA and alopecia, and a probability of 96.6% of a strong association (OR>2) in future trials.

In the subgroup analysis restricted to GLP-1 RA only (semaglutide), the posterior probability of any benefit (OR > 1) was 97.5%, of a moderate association (OR > 1.5) was 87.7%, of a strong association (OR > 2.0) was 70%, and a very strong (OR >3) association was 34.2% (Figure 1B), with an OR of 2.50 (95% CI 1.01–6.19). However, when analyzing GLP-1 and GIP RAs (tirzepatide), the probability of any benefit (OR > 1) was 100%, of a moderate association (OR > 1.5) was 99.9%, of a strong association (OR > 2.0) was 99.2%, and a very strong association (OR>3) was 89.7%, resulting in an OR of 4.45 (95% CI 2.39–8.29).

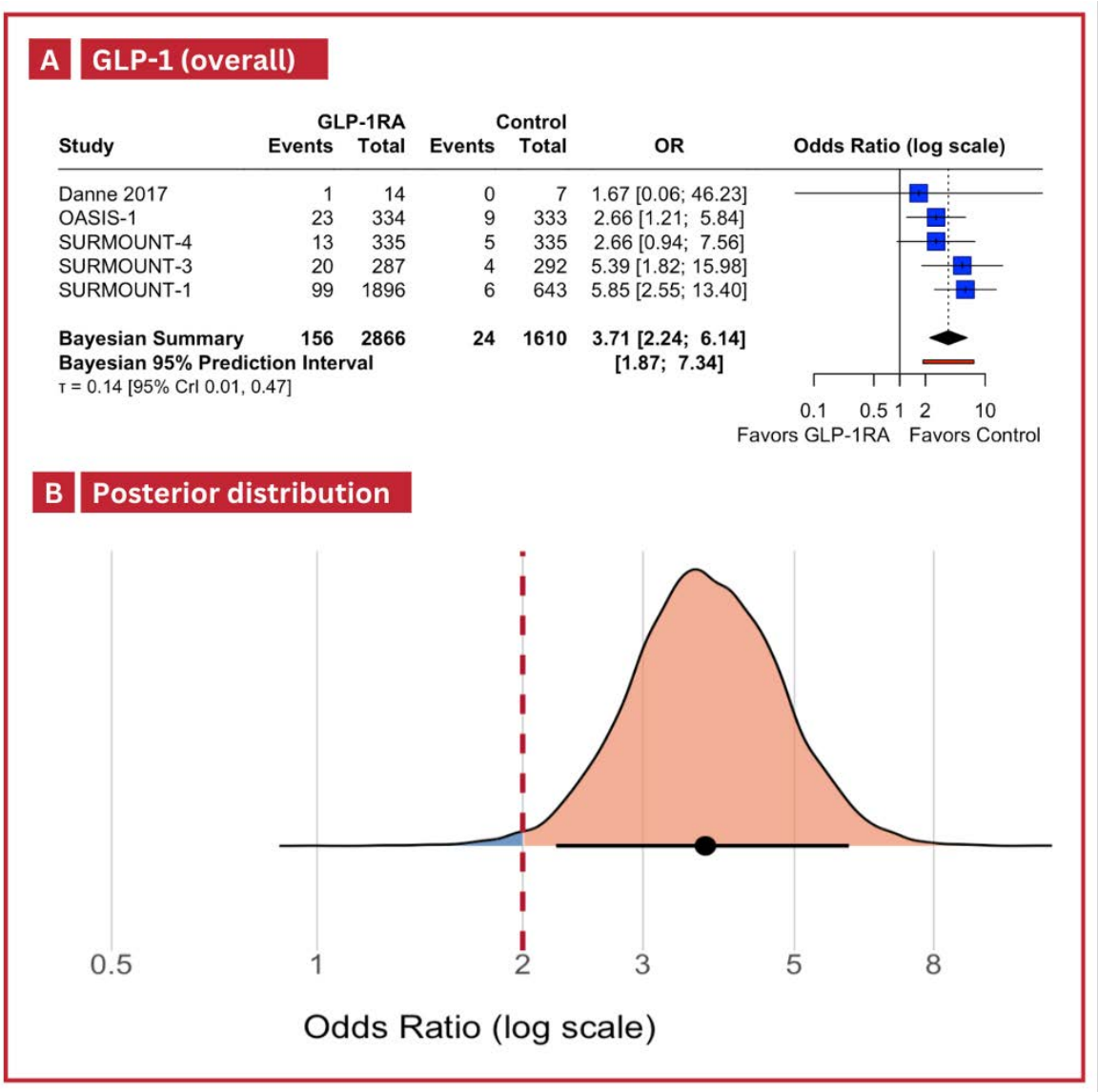

A. Bayesian random-effects forest plot for the association between GLP-1 RA (overall) use and alopecia. The diamond represents the pooled odds ratio with 95% credible interval, and the red bar represents the 95% prediction interval. τ = between-study heterogeneity standard deviation; CrI = credible interval. B. Bayesian posterior distribution for the association between tirzepatide use and alopecia. The panel shows the posterior density on a log scale, with the blue area representing the probability that the odds ratio is below 2 and the salmon area representing the probability that it exceeds 2. The right panel displays the cumulative distribution function, with the dashed red line indicating an odds ratio of 2 as a reference threshold.

Conclusions

This Bayesian meta-analysis of RCTs demonstrates a strong association between GLP-1 RA use and hair loss. This association was particularly strong for tirzepatide. Moreover, we found that future studies are very likely to find a strong association between the drug use and alopecia. This is essential to ensure informed clinical decision–making and adequate patient counseling .

POWERED BY M-ANAGE.COM

EADV CONGRESS
VIENNA
30 SEP - 3 OCT 2026

Abstract N°: 3435

Rapid Efficacy of Ivarmacitinib in Promoting Scalp Hair, Eyebrow, and Eyelash Regrowth in Alopecia Areata: Chinese Single-Center Real-World Experience in Adults and Minors

Yu-Ping Ran*[1], Xin Ran[1], Ying Huang[1], Zihan Zhao[2]

[1] WEST CHINA HOSPITAL, SICHUAN UNIVERSITY, CHENGDU, China
[2] West China School of Medicine, Sichuan University, West China Hospital, Sichuan University, CHENGDU, China

Introduction

Alopecia areata (AA) is a nonscarring, autoimmune-mediated hair loss disorder characterized by a chronic, relapsing clinical course. Ivarmacitinib, a selective Janus kinase 1 (JAK1) inhibitor, demonstrated efficacy in a phase 3 trial for moderate-to-severe AA. However, real-world data remain limited. This study aimed to assess the real-world effectiveness and safety of ivarmacitinib in patients with AA.

Materials and Methods

In this single-center, prospective observational study, 49 patients with AA received oral ivarmacitinib 4 mg once daily. Clinical responses were systematically evaluated using the Severity of Alopecia Tool (SALT), Clinician-Reported Outcome (ClinRO) Eyebrow (EB), and ClinRO Eyelash (EL) assessments.

Results

Of 49 enrolled patients aged from 8 to 53 years (mean [SD] age, 25.55 [14.15] years) adults (≥18 years) accounted for 59.2% (29/49) and minors (8–17 years) for 40.8% (20/49). 38.8% (19/49) were male and 61.2% (30/49) were female. Mean (SD) disease duration, 5.17 (4.45) years. At baseline, 30.6% (15/49) had mild AA (SALT score ≤ 20), 32.7% (16/49) moderate AA (SALT score 21–49), and 36.7% (18/49) severe AA (SALT score ≥50). Prior JAK inhibitor treatment was reported in 14.3% (7/49) of patients.

Mean baseline SALT score was 43.88 [95% confidence interval (CI), 35.38–52.39] overall and 44.02 (95% CI: 29.50–58.54) in minors, similar to adults. Subgroup analysis revealed similar treatment responses between adult and minor patients. Eyebrow involvement (ClinRO EB 1–3) was observed in 38.8% (19/49) and eyelash involvement (ClinRO EL 1–3) in 20.4% (10/49) of patients.

At a mean [SD] follow-up duration, 103.31 [71.57] days (range: 28–296), mean SALT score decreased to 27.62 (95% CI: 19.45–35.79, $p < 0.0001$; 37.1% improvement from baseline) overall and to 24.14 (95% CI: 11.20–37.08, $p < 0.0041$; 45.2% improvement) in minors. Eyebrow improvement (≥1-point improvement) was achieved in 47.4% (9/19) of eyebrow-affected patients and eyelash improvement (≥1-point improvement) was achieved in 40.0% (4/10) of eyelash-affected patients.

Among patients completing follow-up assessments, at week 4, SALT30 (30% improvement from baseline) and SALT50 (50% improvement from baseline) response rates were 21.4% (6/28) and 10.7% (3/28), respectively. At week 8, SALT30, SALT50, and SALT75 (≥75% improvement from baseline) response rates were 75.0% (12/16), 50.0% (8/16), and 25.0% (4/16). At week 12, SALT30, SALT50, SALT75, and SALT100 (complete hair regrowth) response rates were 71.4% (10/14), 50.0% (7/14), 42.9% (6/14), and 28.6% (4/14). No serious adverse events were reported during treatment.

Conclusions

In real-world clinical practice setting, ivarmacitinib demonstrated rapid onset and significant efficacy in promoting hair, eyebrow, and eyelash regrowth in patients with AA, including minors, with a favorable safety profile. Ivarmacitinib emerges as a promising therapeutic option for AA. Updated data will be presented at the congress.

EA DV CONGRESS
VIENNA
30 SEP - 3 OCT 2026

Abstract N°: 3453

Cardiovascular Safety of Oral Minoxidil Use in Dermatologic Patients: A Systematic Review and Meta-Analysis

Sana Gupta*[1], Daniel Wang[1], Vinesh Rao[2], Samiha Mohsen[3], Cathryn Sibbald[4]

[1] Faculty of Medicine, University of Ottawa, Ottawa, Canada

[2] Faculty of Medicine, University of Alberta, Edmonton, Canada

[3] Division of Dermatology, Cumming School of Medicine, University of Calgary, Calgary, Canada

[4] Division of Dermatology, Department of Paediatrics, SickKids Hospital, Toronto, Canada

Introduction

Oral minoxidil (OM) is increasingly used for hair loss disorders including androgenetic alopecia and alopecia areata. Despite observed efficacy, cardiovascular adverse events have been reported with growing use. While these effects are well characterized in hypertensive populations or those using higher doses of minoxidil, their incidence and potential sex-based variations in dermatologic patients remain incompletely understood. Accordingly, this study aimed to synthesize the evidence on cardiovascular safety of OM.

Materials and Methods

MEDLINE, Embase, CINAHL and PubMed were searched in February 2026 using keywords related to "minoxidil" and "cardiovascular." We included randomized controlled trials and observational studies reporting any cardiovascular adverse event following OM use for dermatologic indications, with no restrictions. Combination regimens involving OM were excluded unless adverse events were clearly attributed to OM use. Random-effects meta-analyses (R v4.5.1) were used to estimate odds ratios (ORs) and 95% confidence intervals (CIs) for comparisons of OM with other treatments and sex-stratified analyses. Endpoints were grouped into four categories: (1) overall cardiovascular outcomes, (2) edema or fluid retention, (3) hypotensive or orthostatic symptoms, and (4) tachycardia or palpitations. Certainty of evidence was assessed using the Grading of Recommendations Assessment, Development and Evaluation (GRADE) approach.

Results

Sixty-three studies comprising 1,646,631 participants (mean age: 39.6 years; 73.8% female) were included. Overall, 4.2% (n=69,494/1,646,631) received OM at a mean dose of 2.4mg and mean duration of 10.8 months. OM was discontinued in 2.3% (n=79/3,431), most commonly due to edema/fluid retention (29.1%, n=23/79). Compared to any control group (i.e. treatment-naïve patients, sublingual/topical minoxidil, antiandrogens, spironolactone), OM was not significantly associated with cardiovascular adverse outcomes (OR 1.44; 95% CI 0.88-2.35; low certainty). However, when compared specifically to topical minoxidil, OM users were significantly more likely to report cardiovascular effects (OR 2.80; 95% CI 1.42-5.54; moderate certainty). Regarding sex-stratified analyses, female OM users were significantly more likely to report cardiovascular events compared to male users (OR 1.49; 95% CI 1.04-2.14; moderate certainty). Female OM users particularly demonstrated significant associations with hypotensive/orthostatic symptoms (OR 1.70; 95% CI 1.01-2.85; moderate certainty), but not fluid retention/edema (OR 1.38; 95% CI 0.76-2.49; low certainty) or tachycardia/palpitations (OR 1.20; 95% CI

0.81-1.76; low certainty).

Table 1. Summary of meta-analyses of cardiovascular outcomes in oral minoxidil users.

OM outcomes versus any comparator	**OR (95% CI)**	***P* value**	**k***	**I^2**	**τ^2**	**GRADE**
All cardiovascular events	1.44 (0.88-2.35)	0.14	16	22.90	0.25	Low
Fluid retention/edema[a]	1.81 (0.95-3.46)	0.07	9	0.00	0.00	Low
Hypotensive/orthostatic symptoms[b]	1.79 (0.89-3.60)	0.09	11	0.00	0.00	Low
Tachycardia/palpitations	2.27 (0.12-43.53)	0.35	3	0.00	0.18	Low
OM outcomes versus TM	**OR (95% CI)**	***P* value**	**k***	**I^2**	**τ^2**	**GRADE**
All cardiovascular events	2.80 (1.42-5.54)	**0.01**	8	0.00	0.00	Moderate
OM outcomes by sex[c]	**OR (95% CI)**	***P* value**	**k***	**I^2**	**τ^2**	**GRADE**
All cardiovascular events	1.49 (1.04-2.14)	**0.03**	14	0.00	0.09	Moderate
Fluid retention/edema	1.38 (0.76-2.49)	0.25	9	24.60	0.26	Low
Hypotensive/orthostatic symptoms	1.70 (1.01-2.85)	**0.04**	7	0.00	0.00	Moderate
Tachycardia/palpitations	1.20 (0.81-1.76)	0.30	7	0.00	0.00	Low

Abbreviations: CI: confidence interval; GRADE: Grading of Recommendations, Assessment, Development, and Evaluation; OM: oral minoxidil; OR: odds ratio; TM: topical minoxidil a. Any report of edema (ankle, pedal, peripheral, preorbital, pretibial, generalized, localized) b. Any report of dizziness, lightheadedness, syncope, hypotension or orthostatic hypotension c. Male oral minoxidil users = reference group *Number of studies included per outcome

Conclusions

OM use in dermatologic populations was associated with increased cardiovascular effects, particularly compared with topical minoxidil; however, these events infrequently resulted in treatment discontinuation. Female OM users demonstrated higher likelihood of overall cardiovascular events, including hypotensive/orthostatic symptoms, suggesting potential sex-related differences in pharmacodynamic response, which highlights the need for individualized counseling. Limitations of this analysis include heterogeneity in study methodologies and exclusion of patients with pre-existing cardiovascular disease, thus impacting generalizability. Further prospective studies with dose and age stratification, long-term follow-up and standardized outcome reporting are needed to clarify the cardiovascular risk profile of OM and inform evidence-based prescribing practices in dermatologic settings.

EADV CONGRESS
VIENNA
30 SEP - 3 OCT 2026

Abstract N°: 3453

Glomus Tumor of the great toe: A rare case report

Afafe JEI*[1], Hanane Rachadi[1], Soumiya Chiheb[1]

[1] Dermatology departement, Ibn Rochd University Center, casablanca, Morocco

Introduction

Glomus tumors are uncommon begnin mesenchymal neoplasms originating from the neuromyoarterial glomus bodies. While they represent 1–5% of hand tumors, they are exceptionally rare in the lower extremities, with a limited number of cases reported in the toes. These tumors manifest a classical triad of paroxysmal pain, extreme cold sensitivity, and localized pinpoint tenderness (Love's Test). Herein, we presente a unique case based on its unusal location and clinical and dermoscopical appearance.

Case Presentation

A 70-year-old female with a history of hypertension presented with a one-year history of spontaneous and provoked pain, exacerbated by cold, localized to the nail bed of the right great toe (hallux). There was no history of prior trauma or underlying systemic disease. Physical examination revealed a normal-appearing nail plate (no dystrophy, erythronychia, longitudinal splitting, or onycholysis). However, the patient exhibited positive point tenderness (Love's test) upon palpation of the medio-distal subungual area. Onychoscopy was unremarkable, showing no bluish/erythematous spots, no onycholysis, and no onychorrhexis. Given the atypical location and normal appearance, MRI of the foot was ordered, revealing a 4.8x4.5mm well-defined soft tissue mass in the distal nail bed, causing scalloping of the anterior cortex of the distal phalanx of the hallux.
The patient underwent surgical excision via a direct approach following nail avulsion. Histological examination confirmed the diagnosis of a glomus tumor. At follow-up, the patient had an excellent outcome with complete resolution of symptoms.

Conclusion

Subungual glomus tumors are rare, but not exceptional, in the lower extremity; a high index of suspicion is required when encountering a painful, yet clinically unremarkable, digit. Our case demonstrates that this condition must be considered in any patient presenting with chronic painful conditions of the toenail, even in the absence of traditional clinical or dermoscopic findings.

EA DV CONGRESS
VIENNA
30 SEP - 3 OCT 2026

Abstract N°: 3466

Androgenetic alopecia revealing non-classical congenital adrenal hyperplasia

Afli Donia*[1], Asmahane Souissi[1], Mariem Tabka[1], Feryel Amri[1], Tayssir Ben Achour[2], Ines Kammoun[3], Mourad Mokni[1]

[1] Dermatology department, La Rabta Hospital, Tunis, Tunisia
[2] Internal medicine department, La Rabta Hospital, Tunis, Tunisia
[3] Endocrinology department, Institute of Nutrition and Food Technology, Tunis, Tunisia

Introduction

Androgenetic alopecia (AGA) is the most common form of hair loss. In women, it may reveal an underlying endocrine disorder. While polycystic ovary syndrome is the most frequent cause, AGA may more rarely uncover non-classical congenital adrenal hyperplasia (NCCAH), an often underdiagnosed entity

Case Presentation

A 20-year-old female with no significant past medical history presented with gradual hair loss over one year. Dermatological examination revealed hair thinning along the crown of the scalp. Dermoscopic evaluation of the frontal area showed hair shaft miniaturization with diversity in diameter, predominance of pilosebaceous units with only one hair, perifollicular hyperpigmentation and the presence of yellow dots, consistent with AGA. Physical examination revealed hirsutism (Ferriman–Gallwey score: 9), involving the beard area, chin, periareolar regions, and linea alba. Inflammatory acne affecting the face and neckline was also noted. The remainder of the physical examination was unremarkable, and the patient reported regular menstrual cycles. Given the clinical signs of hyperandrogenism, a hormonal workup was performed, showing normal total testosterone levels and elevated 17-hydroxyprogesterone (2.16 ng/mL). Other hormonal parameters, including dehydroepiandrosterone sulfate (DHEA-S), cortisol, follicle-stimulating hormone (FSH), luteinizing hormone (LH), progesterone, estradiol, thyroid-stimulating hormone (TSH), and prolactin, were within normal ranges. Pelvic ultrasound did not reveal polycystic ovaries. An ACTH stimulation test demonstrated significantly elevated 17-hydroxyprogesterone levels (30.8 ng/mL; reference <20 ng/mL), consistent with the diagnosis of NCCAH. Genetic analyse is currently ongoing.

Conclusion

Congenital adrenal hyperplasia (CAH) is a group of autosomal recessive disorders resulting from enzymatic defects in cortisol biosynthesis. In its non-classical, or late-onset form, aldosterone production is preserved and cortisol secretion is usually sufficient. NCCAH may present in adolescence or adulthood with isolated cutaneous manifestations of hyperandrogenism, including AGA, acne, and/or hirsutism, as observed in our patient. Dermatologists play a key role in the early recognition of this condition when faced with signs of cutaneous hyperandrogenism. Diagnosis relies on hormonal assessment demonstrating elevated 17-hydroxyprogesterone levels, often confirmed by ACTH stimulation testing. Genetic analysis identifying mutations in the CYP21A2 gene establishes the diagnosis in most cases, reflecting the predominant role of 21-hydroxylase deficiency. Patients with NCCAH require multidisciplinary management, including endocrine and gynecological follow-up, to optimize hormonal balance and reproductive outcomes.

This case highlights the importance of systematically assessing signs of hyperandrogenism in young women

presenting with AGA. Early identification of NCCAH allows appropriate multidisciplinary management and may improve both clinical and reproductive prognosis.

EADV CONGRESS
VIENNA
30 SEP - 3 OCT 2026

Abstract N°: 3467

A Case of Localized Alopecia at Traumatic Site: Beyond Cicatricial Alopecia

Jin-Yuan Ma*[1], Xi Chen[1], Ai-Hua Wei[1]

[1] Beijing Tongren Hospital, Capital Medical University, Beijing, China

Introduction

Localized alopecia with scalp lesions is a common clinical presentation, often initially diagnosed as cicatricial alopecia due to the formation of scar tissue. However, overlapping phenotypes such as Folliculitis Decalvans and Lichen Planopilaris Phenotypic Spectrum (FDLPPPS) are easily misdiagnosed because of their nonspecific early manifestations. Reporting such atypical cases is crucial for improving the accuracy of clinical diagnosis and providing valuable references for the differential diagnosis of scalp alopecic lesions.

Case Presentation

A 33-year-old male patient presented with a 4-year history of localized alopecia at a traumatic site, which gradually enlarged accompanied by severe scalp pruritus. Three years prior, he underwent a skin biopsy at another hospital, which showed scar tissue, and he was diagnosed with "cicatricial alopecia". Intermittent topical treatments, including selenium disulfide lotion, mupirocin ointment, and asiaticoside ointment, only partially relieved the pruritus. The patient visited our hospital due to aggravated scalp redness and itching for more than three months.

Comprehensive examinations were performed, including clinical examination, trichoscopy, and 4mm punch scalp biopsy (both vertical and horizontal sections). Physical examination revealed a single irregular alopecic patch on the vertex, with smooth atrophic scalp, scattered erythema, follicular papules, and clustered hairs. Trichoscopy showed several characteristic features: a starburst sign surrounding hair tufts, indicating epidermal hyperplasia around compound follicular infundibula; milky white scarred areas without follicular ostia; and concentric elongated perifollicular vessels in the regions affected by folliculitis decalvans. Pathological examination of the vertical section showed epidermal pustules, acanthosis, dermal scarring, and sebaceous gland loss. The horizontal section showed mixed inflammatory infiltration (predominantly lichenoid lymphocytes, histiocytes, and plasma cells) around infundibular follicles and compound follicles, as well as milder inflammation in the isthmus with multiple compound follicles. Based on these findings, the patient was finally diagnosed with FDLPPPS.

Conclusion

This case highlights that FDLPPPS, an overlapping phenotype of folliculitis decalvans and lichen planopilaris, is prone to misdiagnosis as cicatricial alopecia in the early clinical stage due to nonspecific manifestations and the presence of scar tissue. Comprehensive examinations, including trichoscopy and scalp biopsy (combining vertical and horizontal sections), are essential for the accurate diagnosis of FDLPPPS. This case report provides important clinical references for the differential diagnosis of localized scalp alopecia and helps reduce misdiagnosis of such atypical cases.

POWERED BY M-ANAGE.COM

EA DV CONGRESS
VIENNA
30 SEP - 3 OCT 2026

Abstract N°: 3481

Efficacy and safety of oral Janus kinase inhibitors in alopecia areata: A systematic review and meta-analysis of randomised controlled trials

Samuel Morriss*[1], Chuan Hui Foo[2, 3], Emily Lin[4, 5], Flavia Rodrigues-Dias[6], Daniella Kushnir-Grinbaum[6, 7], Holly FitzGerald[6], Shalem Leemaqz[8], Sharon Lee[3], Bevin Bhoyrul[6]

[1] The Royal Melbourne Hospital, Parkville, Australia
[2] Sultan Idris Education University, Tanjong Malim, Malaysia
[3] The University of Queensland, St Lucia, Australia
[4] Monash University, Clayton, Australia
[5] Monash Health, Clayton, Australia
[6] Sinclair Dermatology, East Melbourne, Australia
[7] Emek Medical Centre, Haifa, Israel
[8] Flinders University, Adelaide, Australia

Introduction
Alopecia areata (AA) is an autoimmune disorder characterised by T-cell-mediated damage of hair follicles, resulting in non-scarring hair loss that can progress to complete scalp (alopecia totalis) or body hair loss (alopecia universalis). While long-term systemic options were historically limited, the emergence of Janus kinase (JAK) inhibitors has revolutionised the treatment of AA, even in patients with moderate-to-severe disease. The objective of this systematic review and meta-analysis was to evaluate the efficacy and safety of oral JAK inhibitors compared with placebo in adults with moderate-to-severe AA.

Materials and Methods
MEDLINE, Embase and the Cochrane Central Register of Controlled Trials databases were searched from inception to 28 November 2025. Randomised controlled trials (RCTs) evaluating oral JAK inhibitors in adolescents and adults (≥12 years) with AA were included. Data extraction and risk of bias assessment were performed independently by multiple reviewers. Primary outcomes were the proportion of patients who achieved Severity of Alopecia Tool (SALT) scores of ≤10 and ≤20, and 50%, 75% and 90% reductions in SALT scores from baseline, as well as treatment-related adverse events (AEs). Data were synthesised using random-effects models to calculate odds ratios (ORs) and mean differences (MDs) with 95% confidence intervals (CIs).

Results
12 RCTs involving 4,141 participants (mean age 35.8 years, mean baseline SALT score 86.0) met the inclusion criteria. All trials enrolled adult participants, with the exception of one RCT in which adolescents comprised 15% of the study population. Six trials were rated as having a low risk of bias, while six had “some concerns” primarily due to missing outcome data. Oral JAK inhibitors were significantly more effective than placebo across all primary efficacy endpoints. At week 24, the odds of achieving SALT ≤10 were 5.69 times higher for JAK inhibitors than placebo (95% CI 3.58-9.03); by week 36, this effect increased to an OR of 9.40 (95% CI 4.58-19.29). For SALT ≤20, the OR was 7.99 (95% CI 5.13-12.44) at week 24. Significant improvements were also noted for SALT50 (OR 4.96; 95% CI 3.16-7.77 at weeks 12-16) and SALT90 (OR 10.11; 95% CI 4.91-20.81 at week 36). Regarding safety, JAK inhibitors were associated with a higher risk of total AEs (OR 1.60; 95% CI 1.33- 1.94), but no statistically significant difference was found for serious AEs (OR 1.04; 95% CI 0.69-1.57) or discontinuation due to AEs (OR 1.22; 95% CI 0.84-1.76).

Conclusions

Oral JAK inhibitors are effective in promoting scalp, eyebrow and eyelash hair regrowth in patients with moderate-to-severe AA, with efficacy increasing progressively over time. The favourable safety profile of these agents is reassuring. Future research should prioritise head-to-head RCTs and long-term pharmacovigilance to define comparative efficacy and safety.

EADV CONGRESS
VIENNA
30 SEP - 3 OCT 2026

Abstract N°: 3488

Successful treatment of coexisting alopecia areata and hidradenitis suppurativa with upadacitinib

Patrícia Moreira Gomes*[1], Ruben Nogueira Costa[1], Manuel Costa[1], Rafael Baptista Santos[1], Ana Pedrosa[1], Carmen Lisboa[1]

[1] Department of Dermatology and Venereology, São João Local Health Unit, Porto, Portugal

Introduction

Upadacitinib is a selective Janus kinase 1 (JAK1) inhibitor approved for the treatment of several immune-mediated diseases. However, evidence supporting its use in alopecia areata (AA) and hidradenitis suppurativa (HS) remains limited.

Case Presentation

A 25-year-old woman with Down syndrome, hypothyroidism, and overweight was followed in Dermatology for inguinal HS (Hurley stage II) and AA universalis, both beginning in adolescence. Regarding HS, she had previously undergone multiple courses of systemic antibiotics and surgical excision of lesions in the right groin and was currently on metformin. AA showed initial response to topical and intralesional corticosteroids, topical minoxidil, and diphencyprone, followed by relapse and progression to alopecia universalis. Given refractory disease in both conditions, treatment with upadacitinib 15 mg daily was initiated with regular clinical and laboratory monitoring. After 4 months, marked clinical improvement was observed in both diseases, with achievement of HiSCR (Hidradenitis Suppurativa Clinical Response)-90 and partial hair regrowth, SALT (Severity of Alopecia Tool) 37. At 9 months, sustained HS response and near-complete scalp hair regrowth were documented (SALT 5). No relevant adverse events or laboratory abnormalities occurred. The patient reported significant improvement in functional status and quality of life.

Conclusion

This case suggests that upadacitinib may represent an effective and safe therapeutic option for both AA and HS, with a favorable safety profile and rapid clinical response. The sustained clinical response in both diseases supports the role of selective JAK1 inhibition as a promising therapeutic strategy in refractory, overlapping immune-mediated dermatoses, reinforcing their shared immunopathogenic mechanisms.

EA DV CONGRESS
VIENNA
30 SEP - 3 OCT 2026

Abstract N°: 3494

White Piedra and Pediculosis Capitis Coinfection: A Rare Case Report

Maisa Nagao*[1], Liana Barros[1], Thais Barros Felippe Jabour[1], fernanda carlesso[1], camila trindade de almeida[1], Giovanna Almeida[1], Camila Scuotto[1], Kaique Arriel[1]

[1] University Santo Amaro, São Paulo, Brazil

Introduction

Coinfection between pediculosis and white piedra is an uncommon and potentially underdiagnosed scalp disorder characterized by the coexistence of *Pediculus humanus capitis* infestation and superficial fungal infection caused by *Trichosporon* species.

Pediculosis capitis is characterized by pruritus and nits attached to the hair shafts. White piedra, in turn, is a superficial fungal infection presenting as whitish or brownish nodules adherent to the hair shaft.

Both conditions may present as adherent structures on the hair shaft and share similar predisposing factors, including warm and humid climates, long hair, potentially delaying diagnosis when simultaneously present.

The present study reports a case of a patient treated at a dermatology outpatient clinic with concomitant diagnosis of white piedra and pediculosis capitis, emphasizing the importance of recognizing this association for accurate diagnosis and treatment.

Case Presentation

A 31-year-old female patient sought care at a dermatology outpatient clinic with hair loss for one month. She reported concomitant whitish nodulations adherent to the hair shafts.

Dermatological physical examination identified one nit laterally attached to the hair shaft and multiple whitish nodules surrounding the shafts. Wood's lamp examination showed whitish-green fluorescence, and direct mycological examination confirmed white piedra.

Coinfection by white piedra and pediculosis was diagnosed and treatment included shampoo containing ketoconazole 2%, salicylic acid 2% and panthenol 5% on alternative days, with permethrin 1% shampoo on D0 and D7 associated mechanical nit removal.

After six weeks, the patient reported significant hair cutting, in addition to adherence to the proposed treatment. On physical examination, no nits or whitish nodulations compatible with white piedra were observed.

Conclusion

Coinfection between pediculosis and white piedra is rarely reported in the literature.

Differential diagnosis may be challenging because both conditions present adherent structures on the hair shaft. Pediculosis capitis represents one of the most common infestations among school-aged children and, at physical examination, pediculosis capitis nits present unilateral implantation adhering laterally to the hair, maintaining an oval, regular, and eccentric arrangement in relation to the hair shaft. White piedra, in turn, is a superficial mycosis

characterized by irregular whitish to light-brown nodules surrounding the hair.

Although the literature does not specifically document risk populations for coinfection with white piedra and pediculosis, higher-risk groups for each condition individually, which, when overlapping, define the populations most vulnerable to coinfection. These populations include girls and young women with long hair in tropical and subtropical regions, female school-aged children (2–12 years old) in endemic areas for white piedra, populations with limited access to hygiene and healthcare, rural communities in tropical regions with high humidity, and groups with cultural practices favoring wet/damp hair or the use of hair oils.

Direct microscopic examination and fungal culture are essential to confirm the diagnosis of white piedra, whereas direct visualization of lice or viable nits confirms pediculosis. Therapeutic management of the coinfection should involve simultaneous treatment of both diseases. Pediculosis treatment includes topical pediculicides (1% permethrin as first-line therapy), wet combing, and oral therapies for resistant cases. White piedra treatment involves topical antifungals (miconazole or ketoconazole), oral antifungals (such as itraconazole), and in some cases, cutting the affected hair. Mechanical removal of the nodules may also be effective.

Recognition of this possible coinfection is important to avoid misdiagnosis and ensure appropriate treatment.

EA DV CONGRESS
VIENNA
30 SEP - 3 OCT 2026

Abstract N°: 3503

Graham-Little-Piccardi-Lassueur Syndrome Associated with Chronic Hepatitis C: Case Report and Literature Review

Huriye Aybüke Koç*[1], Cansu Altınöz Güney[2], İlkay Çınar Esenyel[3]

[1] Giresun University, Faculty of Medicine, Department of Dermatology, Giresun, Türkiye
[2] Dinar State Hospital, Department of Dermatology, Afyonkarahisar, Türkiye
[3] Giresun University, Faculty of Medicine, Department of Pathology, Giresun, Türkiye

Introduction

Graham-Little-Piccardi-Lassueur syndrome (GLPLS) represents an uncommon subtype of lichen planopilaris. Here, we present a case of GLPLS diagnosed in a patient under follow-up for chronic HCV (hepatitis C virus) infection.

Case Presentation

A 63-year-old female patient presented to the outpatient clinic with mildly itchy, spiky bumps on her lower back and the posterior surfaces of her upper arms, which had been present for 1.5 months. She has been followed for chronic hepatitis C for the past 10 years, and for the last 5 years, she has been managed without treatment. Dermatological examination revealed follicular hyperkeratotic papules in the bilateral lumbar areas and the extensor surfaces of the upper arms. A comprehensive skin examination also identified alopecia in both axillary and pubic regions. Upon examination of the scalp, multiple areas of scarring alopecia were noted in the vertex region, which the patient was unaware of. Trichoscopic evaluation of the vertex revealed perifollicular erythema, reddish-white areas with absent follicular ostia, and perifollicular silver-white scaling, while dermoscopic examination of the lumbar region showed slight perifollicular erythema along with keratotic follicular plugs. Anti-HCV and Anti-HBs were positive, while HCV RNA was negative. Other laboratory tests were within normal limits. A punch biopsy obtained from the lumbar region revealed keratotic plugs within the hair follicles and lymphocytic inflammation surrounding the follicles. No mucin deposition was observed with Alcian blue staining. The punch biopsy from the scalp showed skin tissue covered by stratified squamous epithelium with focal hyperkeratosis and irregular acanthosis. Two hair follicles were identified, one of which exhibited lymphoplasmacytic cell infiltration involving the isthmus region. Inflammation was also observed around the other follicle, with its isthmus replaced by fibrous tissue. Fibrotic areas were further highlighted using Masson's trichrome stain. Based on the clinical and histopathological findings, the patient was diagnosed with Graham-Little-Piccardi-Lassueur syndrome. Clobetasol propionate foam was prescribed for the scalp, and mometasone furoate ointment was initiated for the lesions on the trunk. The patient is currently under follow-up.

Conclusion

Lichen planopilaris is classified into three clinical subtypes: classic lichen planopilaris, frontal fibrosing alopecia, and GLPLS. Clinically, GLPLS is characterized by patchy scarring alopecia on the scalp, non-scarring alopecia in the axillary and pubic regions, and follicular keratotic papules on the trunk or extremities. While the exact etiology of GLPLS remains unclear, it is considered a variant of lichen planus and is thought to involve a T-cell-mediated autoimmune mechanism. The association between lichen planus and hepatitis B or C infection is well established, particularly in the oral erosive form of lichen planus. However, only two cases have linked GLPLS with hepatitis C infection. GLPLS is a rare and challenging variant of lichen planopilaris. Moreover, not all features of the classic triad may be noticeable to the patient, making a thorough skin examination crucial to avoid missing the diagnosis. Although the exact etiology remains unclear, it should be kept in mind that there may be an association with

hepatitis C infection.

EA DV CONGRESS
VIENNA
30 SEP - 3 OCT 2026

Abstract N°: 3503

Baricitinib provides sustained efficacy through 1.5 years and consistent safety up to a maximum of 2.5 years of treatment in adolescents with severe alopecia areata: BRAVE-AA-PEDS trial results

Brittany Craiglow[1], Manabu Ohyama[2], Jennifer Soung[3, 4], OHSANG KWON[5], David Saceda-Corralo[6, 7], Benjamin Ungar[8], Naiem T. Issa[9, 10, 11], Karen Denning[12], Tuhina Das[12], Kristin Meyers[12], Angelina Sontag[12], Thierry Passeron*[13]

[1] Yale University, New Haven, Connecticut, United States
[2] Kyorin University School of Medicine, Tokyo, Japan
[3] Southern California Dermatology, Santa Ana, California, United States
[4] Harbor University of California Los Angeles, Los Angeles, California, United States
[5] Seoul National University College of Medicine, Seoul, Korea, Rep. of South
[6] Hospital Universitario Ramon y Cajal, IRYCIS, Universidad de Alcala, Madrid, Spain
[7] Hair Disorders Unit, Pedro Jaen Group, Madrid, Spain
[8] Icahn School of Medicine at Mount Sinai, New York, New York, United States
[9] Forefront Dermatology, Vienna, Virginia, United States
[10] University of Miami Miller School of Medicine, Miami, Florida, United States
[11] Department of Dermatology at George Washington University, School of Medicine and Health Sciences, Washington, District of Columbia, United States
[12] Eli Lilly and Company, Indianapolis, Indiana, United States
[13] Cote d'Azur Universitée, CHU Nice, Department of Dermatology, Nice, France

Introduction
BRAVE-AA-PEDS (NCT05723198) is a randomised, double-blind, phase 3 trial of baricitinib (BARI) for children and adolescents with severe alopecia areata (AA). We assessed maintenance of efficacy through Week (W)76 and safety up to 2.5 years in adolescents (age 12 to <18 years).

Materials and Methods
Data were pooled by treatment arm from cohort 1 (randomised 1:1:1 to BARI 4mg, BARI 2mg, placebo) and cohort 2 (randomised 1:1 to BARI 4mg, BARI 2mg). Efficacy was assessed W52–W76 among patients meeting W52 response criteria and remaining on their same dose through W76. In the 4mg arm, this comprised patients with W52 Severity of Alopecia Tool (SALT) score $\leq$20. In the 2mg arm, SALT $\leq$10 AND clinician-reported outcome eyebrow AND eyelash scores [0,1]), termed "deep, multi-site response" (DMR), at W52 and W64. Safety is reported as incidence rates (IR) per 100 patient-years of exposure (PYE) in two datasets: All-BARI (N=415; any dose of BARI); Extended-BARI (continuously treated with 2mg [N=166] or 4mg [N=168]).

Results
In the BARI 4mg arm, 57.1% (n=96/168) achieved SALT ≤20 response at W52; 92.7% of responders maintained SALT ≤20 at W76. Most 4mg responders had deep scalp responses (SALT ≤10, 79.2%; ≤5, 68.8%; 0, 44.8%) at W52; rates were relatively steady through W76. DMR was achieved by 42.9% (n=72) in the BARI 4mg arm at W52; of those achieving DMR, 95.8% maintained DMR at W76.

In the BARI 2mg arm, 36.5% (n=61/167) achieved SALT <20 at W52; 25.1% (n=42) achieved DMR. 83.3% of 2mg DMR-responders maintained DMR at W76.

The most common adverse events in All-BARI (615.8 PYE; median/maximum exposure, 80.6 and 131.4 weeks) were acne (IR, 11.2) and nasopharyngitis (IR, 9.9). IRs for serious adverse events were 3.6 for BARI 4mg and 1.0 for 2mg. There were no VTE/PEs, MACE, or deaths.

Conclusions

In summary, nearly all BARI 4mg responders maintained SALT responses through W76 and >80% of BARI 2mg DMR-responders maintained DMR. Maintenance of DMR was >95% among BARI 4mg DMR-responders. No new safety signals were identified.

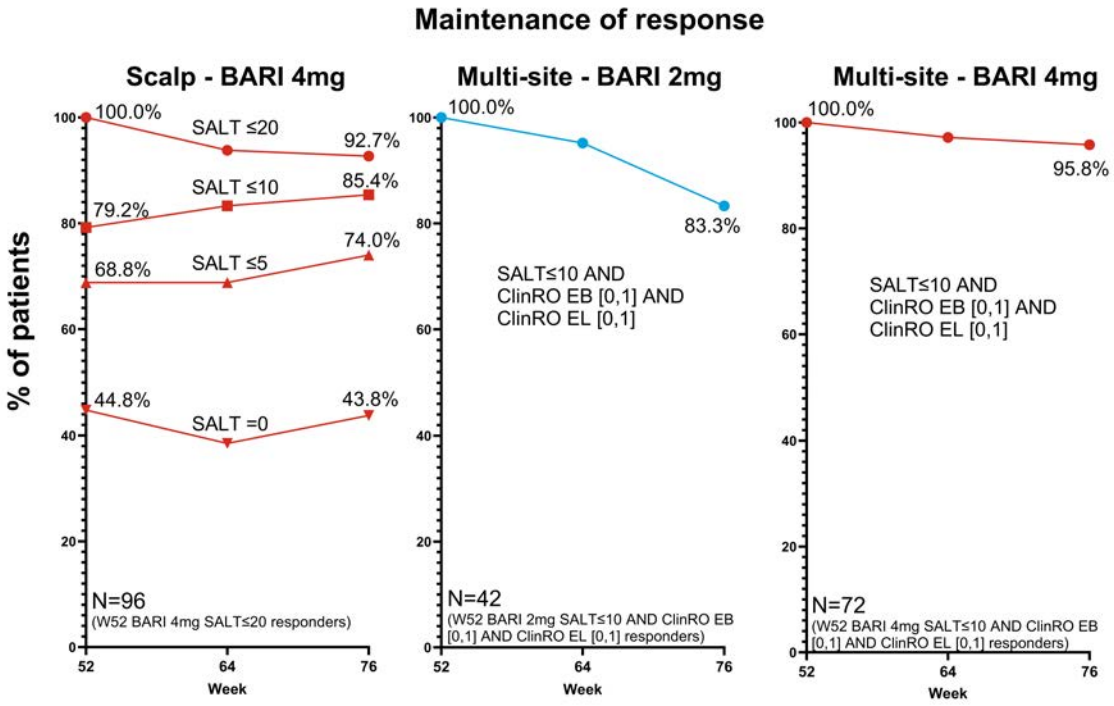

Maintenance of response with baricitinib. Response rates among adolescents in BRAVE-AA-PEDS randomised to BARI 2mg or 4mg who met W52 response criteria and continued their assigned dose through W76. In the BARI 4mg arm, this comprised patients with SALT score ≤20 at W52. In the BARI 2mg arm, this comprised patients with SALT score <10 AND ClinRO EB [0,1] AND ClinRO EL [0,1] at W52 and W64. Missing data were handled using modified last observation carried forward (mLOCF). Abbreviations: BARI, baricitinib; ClinRO, clinician-reported outcome; EB, eyebrow; EL, eyelash; SALT, severity of alopecia tool; W, week.

EADV CONGRESS
VIENNA
30 SEP - 3 OCT 2026

Abstract N°: 3516

Mapping Hair Restoration: Efficacy and Indications of Transplants in Various Hair Loss Forms

Salome Vadachkoria*[1]

[1] Talizi Hair Transplantation Institute, Tbilisi, Georgia

Introduction

Background

Hair transplantation is most commonly conceptualized within the paradigm of androgenetic alopecia (AGA), yet it is clinically indicated across a heterogeneous spectrum of disorders including traction alopecia, secondary scarring alopecia, frontal fibrosing alopecia (FFA), pseudopelade of Brocq, aplasia cutis congenita, and aesthetic restoration of eyebrows and beard. Each indication presents distinct biological substrates, disease trajectories, and surgical considerations that fundamentally alter patient selection, timing relative to disease activity, technique choice, and the requirement for sustained medical therapy. Existing literature addresses these entities individually, but a unified decision framework that maps these dimensions across indications has not been formalized — contributing to inconsistent candidacy assessment, suboptimal timing, and incomplete preoperative counseling.

Objectives

To derive, from structured clinical observation across the principal alopecia indications, a unified four-dimensional decision framework — comprising candidacy criteria, timing relative to disease activity, technique selection, and post-transplant medical management — and to apply it consistently across the spectrum of hair-loss disorders.

Methods

Structured retrospective clinical observation of patients undergoing hair transplantation with the principal indications: AGA, traction alopecia, secondary scarring alopecia, FFA, pseudopelade of Brocq, aplasia cutis congenita, and facial hair restoration. For each indication, four parameters were systematically characterized: (1) candidacy criteria including demographic, dermatologic, and disease-activity considerations; (2) optimal timing relative to disease stability; (3) preferred surgical technique and procedural considerations; (4) requirement for adjunct or sustained medical therapy.

Results

Application of the framework revealed indication-specific patterns. In AGA, candidacy is age- and stability-dependent: patients under 25 typically require a conservative medical treatment first due to ongoing progression; patients over 60 generally reach stable disease and may not require lifelong pharmacotherapy; between these extremes, sustained medical stabilization (5α-reductase inhibitor and/or topical minoxidil) is necessary to preserve long-term integration between transplanted and native hair. Traction alopecia requires definitive elimination of the causative hairstyle practice prior to surgery; lifelong medical therapy is not required. Secondary scarring alopecia from burns, surgical scars, or trauma is feasible after 12–18 months of scar stabilization and typically requires two procedures for adequate density due to compromised graft survival in fibrotic tissue. FFA requires 12–18 months of demonstrated disease inactivity and mandatory ongoing anti-inflammatory or immunomodulatory therapy to protect grafts. Pseudopelade of Brocq follows similar post-stabilization timing with continued management. Aplasia cutis congenita is feasible for stable superficial lesions, with FUE preferred to minimize additional scarring; multiple sessions are typically required. Eyebrow and beard restoration are pattern-dependent and do not require lifelong post-procedural medication.

Conclusions

The proposed indication-specific decision framework provides a unified structure for candidacy assessment, timing, technique selection, and ongoing medical management across the heterogeneous spectrum of alopecia subtypes. A unified surgical paradigm is inadequate for this diversity; an indication-stratified approach supports more rigorous patient selection, improved long-term aesthetic outcomes, and clearer preoperative counseling — particularly regarding sustained medical stabilization in androgenetic and inflammatory or scarring alopecias. The framework is proposed as a structured clinical tool for routine integration into the hair restoration consultation.

Conclusion

EADV CONGRESS
VIENNA
30 SEP - 3 OCT 2026

Abstract N°: 3531

Standardized enzymatic stromal vascular fraction therapy in androgenetic alopecia: longitudinal trichoscopic outcomes from a single-center cohort

Assel Markabayeva*[1, 2]

[1] Department of Aesthetic and Regenerative Medicine, AL Clinic of Plastic and Aesthetic Surgery, Almaty, Kazakhstan, Kazakhstan Society of Dermatologists, Cosmetologists and Leprologists, Kazakhstan, Almaty, Kazakhstan

[2] Department of Aesthetic and Regenerative Medicine, "AL-Clinic" of Plastic and Aesthetic Surgery, Almaty, Kazakhstan, Kazakhstan Society of Dermatology, Cosmetology and Leprology, Almaty, Kazakhstan, Almaty, Kazakhstan

Introduction

Androgenetic alopecia (AGA) remains one of the most prevalent hair disorders worldwide, while regenerative therapies continue to demonstrate considerable heterogeneity in processing, injection techniques, and follow-up protocols. Although multiple regenerative approaches, including platelet-rich plasma, micrografts, nanofat, and stromal vascular fraction (SVF)-based therapies, have been evaluated, no standardized treatment protocol currently exists. The lack of procedural standardization limits reproducibility and long-term comparison of outcomes. Therefore, evaluation of a single standardized methodology performed by one operator within one center may provide clinically relevant longitudinal data regarding regenerative treatment outcomes in AGA.

Materials and Methods

This retrospective longitudinal observational single-center study included 22 patients with androgenetic alopecia treated between 2023 and 2026 using a standardized enzymatic stromal vascular fraction processing and filtration protocol followed by intradermal scalp injections according to a uniform treatment workflow. The cohort included 16 males with Norwood stage III–V AGA and 6 females with Ludwig stage II–IV AGA, with a mean age of 40.2 years. All harvesting, processing, and injection procedures were performed by the same physician using identical methodology throughout the study period. Patients underwent one treatment session annually, while follow-up trichoscopic assessment was performed no earlier than 3 months after treatment using serial FotoFinder TRICHOSCALE analysis. Objective evaluation included hair density, shaft diameter, vellus hair proportion, terminal/vellus ratio, anagen/telogen distribution, follicular density, cumulative thickness, and global scalp comparison. Patients with scarring alopecia, active inflammatory scalp disease, recent hair transplantation, or inconsistent follow-up were excluded. Mean subgroup outcomes were summarized as mean ± standard deviation.

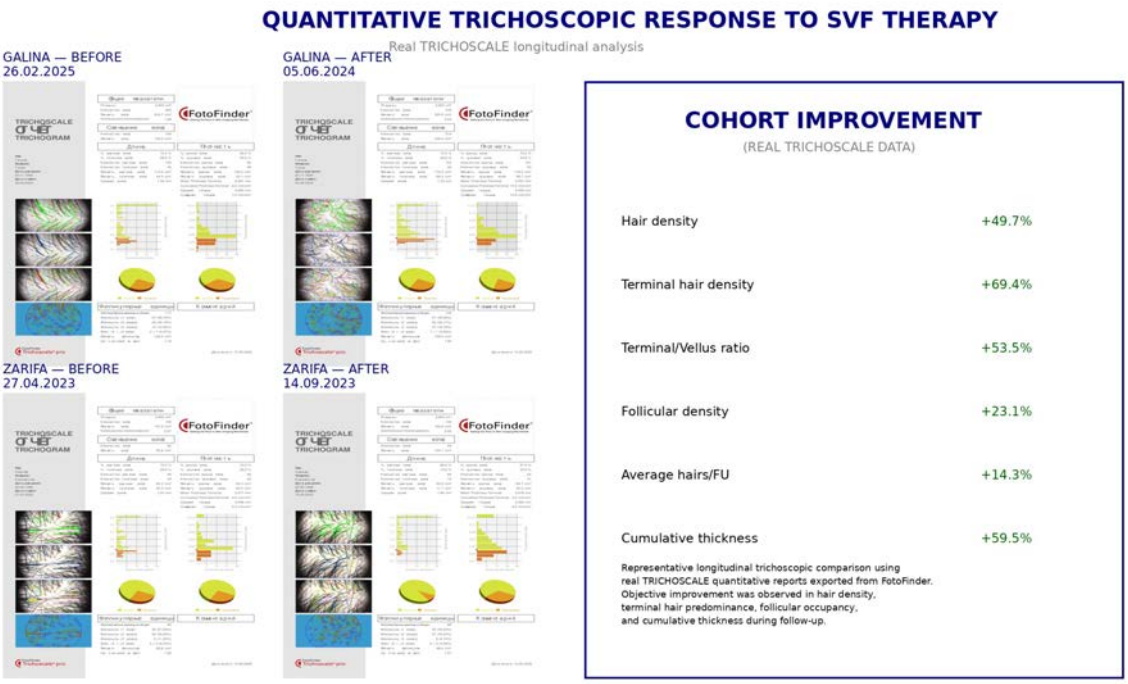

Representative longitudinal trichoscopic comparison of two patients with androgenetic alopecia treated using standardized stromal vascular fraction (SVF) therapy.

Results

Objective trichoscopic improvement was observed across all evaluated subgroups during longitudinal follow-up. In the total cohort, mean hair density increased from 116 ± 15 to 134 ± 16 hairs/cm^2, mean shaft diameter increased from 0.061 ± 0.006 mm to 0.070 ± 0.005 mm, vellus hair proportion decreased from 34 ± 7% to 22 ± 5%, terminal/vellus ratio increased from 1.9 ± 0.4 to 3.1 ± 0.5, anagen percentage increased from 71 ± 6% to 86 ± 5%, while telogen percentage decreased from 29 ± 6% to 14 ± 4%. The strongest regenerative response was observed in earlier-stage AGA, particularly Norwood III patients, who demonstrated mean hair density improvement from 124 ± 12 to 148 ± 14 hairs/cm^2 and terminal/vellus ratio increase from 2.2 ± 0.4 to 3.8 ± 0.5. Advanced Norwood V disease demonstrated more moderate improvement characterized predominantly by stabilization, reduction in miniaturization, and shaft thickening. Serial TRICHOSCALE analysis in representative cases demonstrated increased follicular occupancy, improved terminal hair predominance, reduction in scalp visibility, and increased cumulative thickness during follow-up. No major adverse events were observed during follow-up.

FIGURE 1. LONGITUDINAL SUBGROUP TRICHOSCOPIC OUTCOMES FOLLOWING STANDARDIZED SVF THERAPY

Cohort subgroup	n	Baseline Density	Follow-up Density	Shaft Diameter Baseline	Shaft Diameter Follow-up	Vellus Baseline	Vellus Follow-u	Terminal/Vellus Baseline	Terminal/Vellus Follow-up
Male Norwood III	5	124 ± 12	148 ± 14	0.064 ± 0.006	0.074 ± 0.005	29 ± 5	18 ± 4	2.2 ± 0.4	3.8 ± 0.5
Male Norwood IV	7	111 ± 10	129 ± 12	0.060 ± 0.005	0.069 ± 0.004	35 ± 6	23 ± 5	1.8 ± 0.3	3.0 ± 0.4
Male Norwood V	4	95 ± 11	108 ± 10	0.056 ± 0.004	0.063 ± 0.004	42 ± 7	31 ± 6	1.3 ± 0.2	2.1 ± 0.3
Female Ludwig II	4	132 ± 13	146 ± 12	0.066 ± 0.005	0.074 ± 0.004	27 ± 4	18 ± 3	2.5 ± 0.4	3.6 ± 0.5
Female Ludwig II-IV	2	118 ± 9	131 ± 10	0.061 ± 0.004	0.069 ± 0.004	33 ± 5	24 ± 4	2.0 ± 0.3	3.0 ± 0.4
Total cohort	22	116 ± 15	134 ± 16	0.061 ± 0.006	0.070 ± 0.005	34 ± 7	22 ± 5	1.9 ± 0.4	3.1 ± 0.5

Values are presented as mean ± SD. Longitudinal subgroup trichoscopic analysis demonstrated objective improvement across all evaluated androgenetic alopecia stages following standardized enzymatic SVF therapy. The most pronounced response was observed in earlier-stage AGA, particularly Norwood III patients.

Longitudinal subgroup trichoscopic analysis of 22 patients with androgenetic alopecia treated using a

standardized enzymatic stromal vascular fraction (SVF) protocol between 2023 and 2026.

Conclusions

Standardized enzymatic SVF treatment performed within a single-center, single-operator workflow demonstrated reproducible longitudinal trichoscopic improvement in patients with androgenetic alopecia. The most pronounced response was observed in earlier-stage AGA, particularly in Norwood III patients, while advanced stages demonstrated predominantly stabilization and partial reversal of follicular miniaturization. Objective improvements in hair density, shaft thickness, terminal/vellus ratio, anagen predominance, and cumulative thickness support the importance of procedural standardization in regenerative hair restoration and suggest that annual enzymatic SVF therapy may represent a clinically practical long-term treatment strategy for selected AGA patients.

EA DV CONGRESS
VIENNA
30 SEP - 3 OCT 2026

Abstract N°: 3551

Beyond conventional therapies: successful TYK2 inhibition in refractory lichen planopilaris

Hind Majdoul*[1], Christopher Cossart[1], Annie Vermersch Langlin[1]

[1] Dermatology and Venereology Department, Dr Jean Eric Techer Hospital, Calais, France

Introduction

Lichen planopilaris (LPP) is a chronic inflammatory cicatricial alopecia leading to irreversible follicular destruction and permanent hair loss. Management remains challenging, as conventional therapies frequently induce incomplete or transient responses.

Increasing evidence supports the involvement of the JAK/STAT pathway in LPP pathogenesis, opening new perspectives for targeted therapies. TYK2 inhibition has recently emerged as a promising therapeutic strategy in inflammatory dermatoses; however, evidence regarding its efficacy in LPP remains scarce.

We report a case of refractory LPP successfully treated with deucravacitinib.

Case Presentation

A 52-year-old woman consulted our department for progressive vertex alopecia associated with pruritus, burning sensations, and increased hair shedding. Clinical examination revealed an irregular confluent alopecic plaque of the vertex associated with perifollicular erythema and adherent perifollicular scaling. Trichoscopic examination demonstrated perifollicular erythema and hyperkeratosis, tubular scales, and reduced follicular openings, consistent with active LPP. Initial treatment consisted of repeated intralesional corticosteroid injections, leading only to temporary improvement. Subsequently, oral acitretin was introduced for several months but had to be discontinued because of poor efficacy and disabling palmar xerosis. Owing to persistent inflammatory activity and progressive enlargement of the alopecic plaque, intralesional corticosteroids were resumed over the following year, without achieving disease stabilization. Given this refractory course, treatment with the selective TYK2 inhibitor deucravacitinib was initiated. Progressive clinical improvement was observed during follow-up, with stabilization of the cicatricial alopecia and partial peripheral hair regrowth. Baseline laboratory investigations were unremarkable except for isolated elevation of gamma-glutamyl transferase. After 9 months of treatment, significant hair regrowth was achieved, without further disease progression or relevant adverse effects. Follow-up laboratory monitoring remained satisfactory, including normalization of liver enzymes.

Conclusion

LPP remains one of the most therapeutically challenging primary cicatricial alopecias because of its chronic relapsing course and the irreversible nature of follicular destruction. Conventional therapies, including corticosteroids, hydroxychloroquine, retinoids, tetracyclines, methotrexate, cyclosporine, and mycophenolate mofetil, often provide only partial or transient disease control, with frequent relapses after treatment withdrawal. Recent studies have implicated interferon-mediated inflammation and JAK/STAT pathway activation in the collapse of follicular immune privilege in LPP, providing a rationale for targeted kinase inhibition. Promising results have recently been reported with JAK inhibitors in refractory LPP, particularly tofacitinib and baricitinib. However, evidence regarding selective TYK2 inhibition remains extremely limited despite its targeted action on IL-12, IL-23, and type I interferon signaling pathways involved in T-cell-mediated inflammatory disorders. In our patient,

selective TYK2 inhibition with deucravacitinib led to marked reduction of inflammatory activity and substantial hair regrowth within 9 months, with favorable clinical and biological tolerance. Thus, this case suggests a promising therapeutic approach in refractory LPP and further supports the emerging role of targeted immunomodulation in cicatricial alopecias.

EADV CONGRESS
VIENNA
30 SEP - 3 OCT 2026

Abstract N°: 3553

Clinicodermoscopic–Histopathological Correlations and Long-Term Outcomes in Onychopapilloma: A Retrospective Longitudinal Study

Merve Alızada*[1], Baran Ozden[1], Aylin Okcu Heper[2], Ayca Kirmizi[2], Bengü Nisa Akay[1], Pelin Koçyiğit[1]

[1] Ankara Üniversitesi Tıp Fakültesi Hastaneleri, Department of Dermatology, Ankara University Faculty of Medicine, ankara, Türkiye

[2] Ankara Üniversitesi Tıp Fakültesi Hastaneleri, Department of Pathology, Ankara University Faculty of Medicine, ankara, Türkiye

Introduction

Onychopapilloma is a rare benign tumor of the nail unit that typically presents with longitudinal erythronychia, leukonychia, distal subungual hyperkeratosis, and distal nail plate changes. Despite increasingly recognized dermoscopic features, the condition may clinically mimic malignant nail tumors, often creating diagnostic uncertainty. Moreover, data regarding long-term outcomes, clinicopathologic correlations, and factors associated with postoperative recurrence remain limited. Therefore, we aimed to investigate the clinicodermoscopic–histopathological features and long-term outcomes of patients with onychopapilloma.

Materials and Methods

Thirty-seven patients diagnosed between 2016 and 2025 were retrospectively evaluated. Fourteen cases were histopathologically confirmed, whereas 23 were diagnosed based on stable clinical and dermoscopic findings. Demographic, clinical, dermoscopic, histopathological, and follow-up data (mean follow-up: 4.37 years) were analyzed.

Results

Mean age was 55.5 years, with slight male predominance; the thumb was the most commonly affected digit (56.7%). Major clinical findings included longitudinal erythronychia (51.3%) and distal subungual hyperkeratotic mass (43.7%). Dermoscopy revealed longitudinal erythronychia and leukonychia (62%), splinter hemorrhages (59.4%), distal V-shaped onycholysis (51.4%), and subungual hyperkeratosis (54.1%). Histopathology demonstrated acanthosis (78.6%), hyperkeratosis (71.4%), papillomatosis (50%), and parakeratosis (42.9%), showing close clinicopathologic concordance. Recurrence occurred in 28.5% and postoperative nail dystrophy in 42.8% of surgically treated patients; greater lesion width was associated with recurrence. No progression was observed in conservatively managed lesions during long-term follow-up.

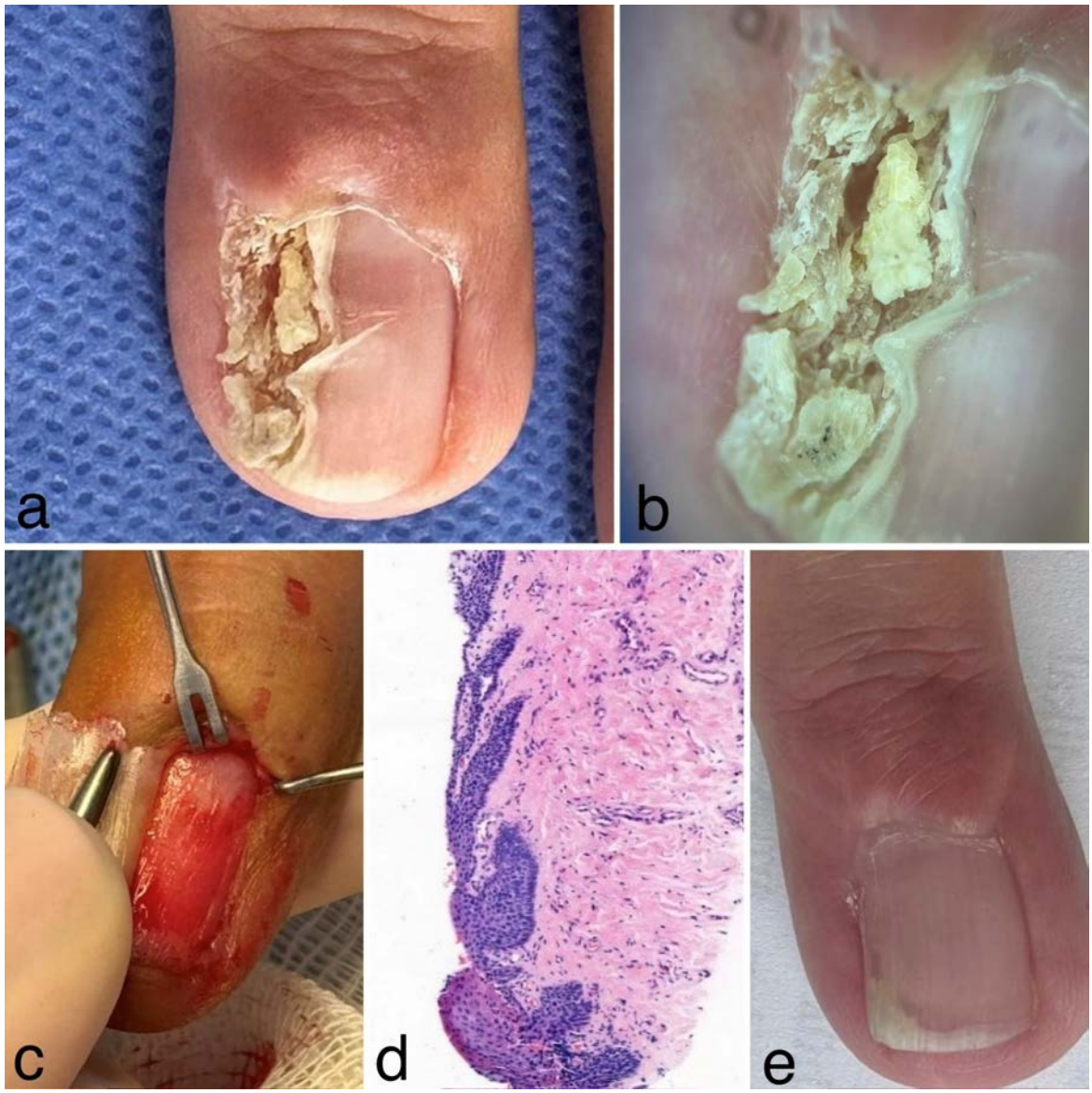

Conclusions

Onychopapilloma demonstrates distinctive clinicodermoscopic and histopathologic features together with a generally indolent long-term course. Careful recognition of characteristic clinicodermoscopic patterns may improve diagnostic accuracy and assist in individualized management decisions, particularly in clinically stable lesions. In addition, greater lesion width may represent a potential predictor of postoperative recurrence and progressive nail dystrophy following surgical excision.

EADV CONGRESS
VIENNA
30 SEP - 3 OCT 2026

Abstract N°: 3564

Efficacy and Safety of Ivarmacitinib in the Treatment of Severe Alopecia Areata: A Retrospective Study

Nan Jiang[1], Yuxin Zhang[1], Wenzhao Han[1], Jiaqi Li[1], Xiang Liu*[1]

[1] The First Affiliated Hospital of Hebei University of Traditional Chinese Medicine, Shijiazhuang, China

Introduction
Ivarmacitinib, a highly selective Janus kinase 1 (JAK1) inhibitor, has been approved in China for the treatment of alopecia areata. This retrospective study was conducted to further evaluate the real-world efficacy and safety of ivarmacitinib in patients with severe alopecia areata who were subjected to treatment at the hospital between June 2025 and April 2026.

Materials and Methods
A total of 9 patients with severe alopecia areata who had demonstrated an inadequate response to conventional therapies were enrolled. All patients were subjected to oral ivarmacitinib at a dose of 4 mg daily. The Severity of Alopecia Tool (SALT) score was used to assess the severity of hair loss, and the Dermatology Life Quality Index (DLQI) score was employed to evaluate quality of life. Efficacy assessments were performed at baseline, Week 12, and Week 24, and adverse events during the treatment period were recorded.

Results
The mean baseline age of the entire cohort was 25.9 years, including 4 adolescents (<18 years) and 5 adults. The mean baseline SALT score was 73.2 (range: 57.6–89.8), and the mean baseline DLQI score was 26.0 (range: 21–28). After 12 weeks of treatment, the mean SALT score decreased to 41.5, and the mean DLQI score decreased to 16.7. Among the 6 patients who completed the 24-week follow-up, the baseline SALT score was 71.1, which decreased to 22.0 after 24 weeks of treatment, representing a relative reduction of 70.7%. The DLQI score decreased from 25.8 to 10.3, corresponding to a relative reduction of 60.3%. At Week 24, the SALT50 response rate was 83.3% (5/6), and the SALT75 response rate was 50.0% (3/6), with one patient achieving SALT 100. A SALT score ≤20 was observed in 33.3% (2/6) of patients, and a SALT score ≤30 was observed in 83.3% (5/6) of patients. Varying degrees of hair regrowth were noted in all patients who completed the follow-up. Adverse effects during the treatment period were predominantly mild headache and dyspepsia, with no serious adverse events reported.

Table 1. Baseline Information of Patients and Efficacy Evaluation During Treatment

				Baseline		12W		24W	
Case No.	Age	Gender	Diagnosis	SALT Score	DLQI Score	SALT Score	DLQI Score	SALT Score	DLQI Score
01	16	Male	Severe AA	83.6	27	23.5	16	——	——
02	37	Male	Severe AA	65	24	54.4	18	——	——
03	13	Female	Severe AA	83	28	66.7	20	——	——
04	25	Female	Severe AA	89.8	28	47.4	14	21	6
05	36	Female	Alopecia Totalis	57.6	21	13.9	10	10	14
06	35	Female	Severe AA	58	22	7	6	1	0
07	13	Male	Severe AA	73	28	43	20	28	10
08	44	Female	Severe AA	85.4	28	75.8	24	45.8	18
09	14	Male	Severe AA	63	28	41.6	22	26	14

Conclusions

This single-center retrospective study demonstrates that ivarmacitinib, as a novel highly selective JAK1 inhibitor, exhibits favorable efficacy and safety in the real-world treatment of patients with severe alopecia areata, consistent with the results of Phase III studies. Furthermore, this study included 4 adolescent patients, in whom the efficacy and safety profiles were generally comparable to those observed in adults, suggesting that ivarmacitinib may offer a new therapeutic option for adolescents with severe alopecia areata. Future large-scale studies with long-term follow-up are warranted to further validate the long-term efficacy and safety of this agent.

EADV CONGRESS
VIENNA
30 SEP - 3 OCT 2026

Abstract N°: 3578

Interest of an anti-hair loss serum containing Silybum marianum extract, manganese pyrrolidone carboxylic acid and Lespedeza capitata extract in the management of chronic hair loss: an international real-world study

Valérie MENGEAUD*[1], Alexia Brocario[1], Eva Mantel[1], Virginie Ribet[1], Bianca Piraccini[2]

[1] Medical Department, Laboratoires Dermatologiques DUCRAY, Lavaur, France

[2] Dermatologist in private practice, Bologna, Italy

Introduction

Non-scarring hair disorders result in a decrease in visible hair and can significantly impair psychosocial wellbeing and quality of life. The most frequent forms of chronic hair loss (CHL) are androgenetic alopecia, chronic telogen effluvium, senescent alopecia, and post-cancer treatment alopecia. The objective of this real-world study was to evaluate the efficacy and tolerance of an anti-hair loss and anchorage serum containing *Silybum marianum* extract, manganese pyrrolidone carboxylic acid, and *Lespedeza capitata* extract in the management of these four types of CHL in daily dermatological practice.

Materials and Methods

This international, open label, prospective, post marketing and multicentric study was conducted in 13 countries across Europe, the Middle East, Africa, East Asia and South America. Adult subjects (18–93 years; mean age 40 years) with CHL of any phototype and hair type were included and followed for 3 months. The serum was applied once daily to the scalp and used either as:

- monotherapy,
- in combination with other treatments (including topical and oral agents, and emerging therapies), or
- as a follow-up after completion of treatments, including drugs and emerging therapies such as platelet-rich plasma and mesotherapy, according to routine dermatologist practice.

Efficacy was assessed by dermatologists using a hair pull test and a Numeric Rating Scale (NRS, 0–10) evaluating hair density and overall hair aspect. Subjects also rated hair appearance using an NRS. Tolerance was evaluated by dermatologists on a 4-point scale (very poor, poor, good, very good). Changes from baseline were analyzed for all endpoints.

Results

A total of 1676 adult subjects with CHL were included; 34% were men and 66% women, representing all phototypes. The serum was mainly prescribed as monotherapy (61.2%; n=1025). The distribution of CHL types was: androgenetic alopecia 61.8%, chronic telogen effluvium 31.7%, senescent alopecia 4.8%, and post-cancer treatment alopecia 1.7%.

After 3 months of once daily application, significant improvements were observed across all types of CHL. In monotherapy, mean hair density as assessed on the NRS by dermatologists increased by 32% ($p<0.001$) in both androgenetic alopecia and chronic telogen effluvium. When the anti-hair loss serum was combined with emerging therapies (such as platelet-rich plasma (PRP) and mesotherapy), the increase in hair volume assessed by

dermatologists was significantly greater than in monotherapy, at 52% ($p < 0.05$) and 68% ($p < 0.05$) respectively for androgenetic alopecia and chronic telogen effluvium. Tolerance was rated as good to very good in 95.1% of subjects. No specific safety signal was identified in any subgroup, regardless of CHL type, phototype, or mode of use (monotherapy, combination or follow-up).

Conclusions

This large international, real-world cohort of adults with chronic hair loss of various etiologies, demonstrates clinically relevant efficacy and very good tolerance of an anti-hair loss serum used as monotherapy and in combination with other anti-hair loss treatments. These results support its use as a convenient, once daily option in routine dermatology practice.

EA DV CONGRESS
VIENNA
30 SEP - 3 OCT 2026

Abstract N°: 3586

Enhanced effectiveness of an anti-hair loss serum containing Silybum marianum extract, manganese PCA and Lespedeza capitata extract when combined with emerging therapies in androgenetic alopecia and chronic telogen effluvium: an international real-life analysis

Valérie MENGEAUD*[1], Alexia Brocario[1], Eva Mantel[1], Virginie Ribet[1], Bianca Piraccini[2]

[1] Medical Department, Laboratoires Dermatologiques DUCRAY, Lavaur, France

[2] Dermatologist in private practice, Bologna, Italy

Introduction

Androgenetic alopecia and chronic telogen effluvium are the most frequent forms of chronic hair loss in adults and are commonly managed with topical, oral and procedural (such as platelet-rich plasma and mesotherapy) therapies. Combining topical anti-hair loss products with emerging therapies may optimise clinical outcomes. This analysis aimed to compare the effectiveness of a topical serum containing *Silybum marianum* extract, manganese pyrrolidone carboxylic acid (PCA) and *Lespedeza capitata* extract used as monotherapy *versus* in combination with topical minoxidil or emerging therapies such as platelet-rich plasma and mesotherapy in subjects with androgenetic alopecia and chronic telogen effluvium.

Materials and Methods

Data were derived from an international, post-marketing, prospective, open-label study conducted in 13 countries in adult subjects with chronic hair loss. The serum was applied once daily to the scalp for 3 months. For this analysis, subjects with androgenetic alopecia or chronic telogen effluvium were stratified according to use of the serum as monotherapy, in combination with topical minoxidil, or in combination with emerging therapies including platelet-rich plasma, mesotherapy and other procedures. Dermatologists evaluated hair density using a Numeric Rating Scale (NRS, 0–10). Percentage change from baseline was calculated, and differences between monotherapy and combination groups were analysed ($p < 0.05$ considered significant). Tolerance was assessed on a 4-point scale.

Results

Among the 1676 included subjects, androgenetic alopecia accounted for 61.8% and chronic telogen effluvium for 31.7% of cases. In subjects with androgenetic alopecia, mean hair density increased by 33% with serum monotherapy (n=575) and by 41% when combined with topical minoxidil (n=133). In subjects with chronic telogen effluvium, mean hair density increased by 32% with monotherapy (n=345). When the serum was combined with emerging therapies, the increase in hair density reached 50% in androgenetic alopecia and 67% in chronic telogen effluvium; these results were significantly superior to those obtained with monotherapy ($p<0.05$). Overall tolerance of the serum was rated as good to very good in 95% of subjects.

Conclusions

In real-life conditions, daily use of a topical serum containing *Silybum marianum* extract, manganese PCA and *Lespedeza capitata* extract improved hair density in androgenetic alopecia and chronic telogen effluvium. Its

effectiveness was further enhanced when combined with topical minoxidil or emerging therapies such as platelet-rich plasma and mesotherapy, while maintaining a favourable tolerance profile.

EA DV CONGRESS
VIENNA
30 SEP - 3 OCT 2026

Abstract N°: 3590

Interest of an anti-hair loss serum containing Silybum marianum extract, manganese pyrrolidone carboxylic acid and Lespedeza capitata extract in the management of androgenetic alopecia in men: an international real-world study

Valérie MENGEAUD*[1], Alexia Brocario[1], Eva Mantel[1], Virginie Ribet[1], Bianca Piraccini[2]

[1] Medical Department, Laboratoires Dermatologiques DUCRAY, Lavaur, France

[2] Dermatologist in private practice, Bologna, Italy

Introduction

Non-scarring hair disorders result in a decrease in visible hair and can significantly impair psychosocial well-being and quality of life. The most common form is androgenetic alopecia.

The objective of this real-world study was to evaluate the efficacy and tolerance of an anti-hair loss and anchorage serum containing *Silybum marianum* extract, manganese pyrrolidone carboxylic acid, and *Lespedeza capitata* extract in the management of androgenetic alopecia in men in daily dermatological practice.

Materials and Methods

Data were derived from an international, open-label, prospective, post-marketing and multicentric study conducted in 13 countries in adult subjects with chronic hair loss. The serum was applied once daily to the scalp for 3 months and used in monotherapy, in combination, or as a follow-up to treatments, including drugs and emerging therapies (such as platelet-rich plasma (PRP), mesotherapy...), according to usual practice of dermatologists.

Efficacy was assessed by dermatologists using a Numeric Rating Scale (NRS, 0–10) evaluating hair density and overall hair aspect. Subjects also rated hair appearance using an NRS. Tolerance was evaluated by dermatologists on a 4-point scale (very poor, poor, good, very good). Changes from baseline were analyzed for all endpoints.

Results

Among the 1676 included subjects, 522 men had androgenetic alopecia (31.1% of the subjects included). The serum was mainly prescribed in monotherapy (17.2%; n=289).

After 3 months of daily use as monotherapy, mean hair density and volume, as assessed on the NRS by dermatologists, increased by 31.7% ($p<0.001$) and by 32.2% ($p<0.001$) respectively. When the anti-hair loss serum was combined with other treatments, the increase in hair density and volume assessed by dermatologists was greater than that observed with monotherapy, reaching 39.3% ($p<0.001$ compared with baseline) and 40.7% ($p<0.001$ compared with baseline) respectively.

Tolerance was rated as good to very good in 94.4% of subjects.

Conclusions

In real-life conditions, daily use of a topical serum, containing *Silybum marianum* extract, manganese PCA and

Lespedeza capitata extract, demonstrated clinically relevant efficacy and very good tolerance used as monotherapy and in combination with other anti-hair loss treatments in men with androgenetic alopecia.

These results support its use as a convenient, once-daily option in routine dermatology practice.

EADV CONGRESS
VIENNA
30 SEP - 3 OCT 2026

Abstract N°: 3595

Stapokibart as Add-on Therapy for Moderate-to-Severe Alopecia Areata With Atopic Background During Upadacitinib Maintenance

Jinran Lin*[1], Qin Wang[1], Jui-Ming Lin[1], Wenyu Wu[1]

[1] Department of Dermatology, Huashan Hospital, Fudan University, Shanghai, China

Introduction

Alopecia areata (AA) is a chronic immune-mediated hair loss disorder with marked clinical heterogeneity. Although upadacitinib has shown promising efficacy in moderate-to-severe or refractory AA, some patients continue to experience unstable disease control during ongoing therapy. Atopic comorbidities and elevated IgE are common in a subset of patients with AA, suggesting that type 2 inflammation may contribute to disease heterogeneity. Stapokibart, an IL-4Rα-targeting monoclonal antibody, may provide additional modulation of type 2 inflammatory signals.

Materials and Methods

We retrospectively analyzed 12 patients with AA who received add-on stapokibart during ongoing upadacitinib therapy because of unstable disease control, defined as failure to achieve SALT ≤20 by week 24 of upadacitinib treatment or a SALT fluctuation of ≥10 points during treatment. Clinical characteristics, AA subtype, baseline disease severity, SALT scores, atopic comorbidities, serum IgE levels, and longitudinal disease courses were collected. Changes in SALT score from add-on W0 to W12 were evaluated in patients with W12 follow-up data. Paired changes in SALT score and serum IgE levels were analyzed using the Wilcoxon signed-rank test.

Results

The baseline characteristics of the patients are summarized in Table 1. The mean age was 21.3 years, and 3 patients were female. All patients had an atopic background, including atopic dermatitis in 11 patients, allergic rhinitis in 5, and chronic urticaria in 2. All patients had elevated pretreatment serum IgE levels, with a median level of 475.5 KUA/L (IQR, 174.5–765.3). The median total disease duration was 45.0 months, and the median current episode duration was 14.0 months. Alopecia subtypes included alopecia areata multiplex in 6 patients, alopecia totalis or alopecia universalis in 3, diffuse alopecia areata in 2, and ophiasis alopecia in 1. Baseline disease severity was moderate in 7 patients, severe in 3, and very severe in 2.

During ongoing upadacitinib therapy, stapokibart was added at different time points because of unstable disease control (Figure 1). Among the 12 patients with W12 follow-up data after stapokibart initiation, the median SALT score decreased from 15.0 (IQR, 14.0–22.0) at add-on W0 to 6.5 (IQR, 2.8–8.2) at W12, with a significant paired change (P = 0.004). Paired serum IgE data were available in 10 patients. Serum IgE levels significantly decreased from a median of 570.5 KUA/L (IQR, 222.0–789.8) before stapokibart treatment to 163.0 KUA/L (IQR, 83.6–209.0) after treatment (P = 0.0059).

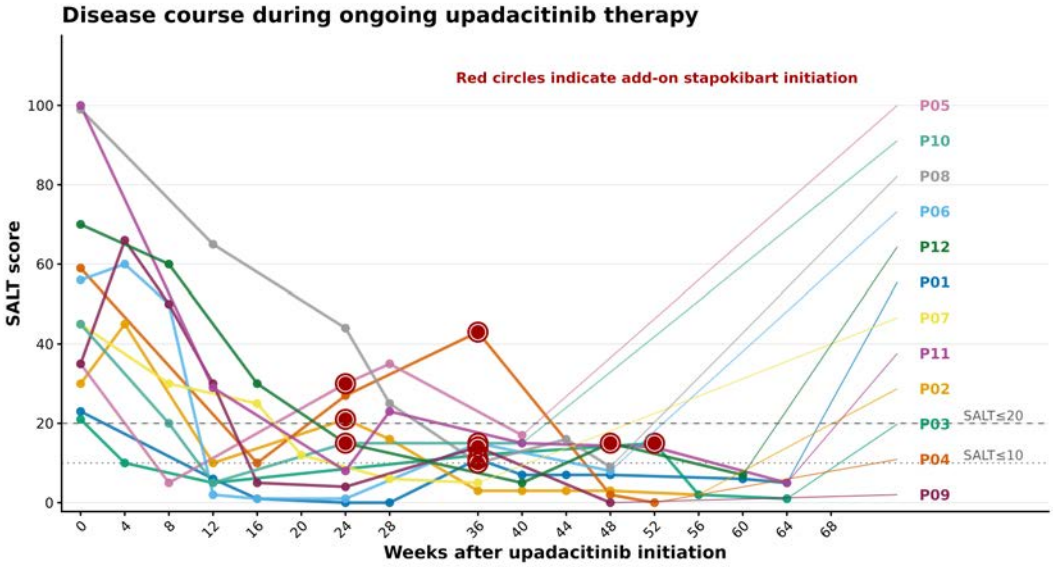

Figure 1. Longitudinal SALT trajectories before and after add-on stapokibart during ongoing upadacitinib therapy.

Conclusions

In this real-world case series, add-on stapokibart during ongoing upadacitinib therapy was associated with improved disease control or stabilization in patients with AA and atopic features who had residual or unstable disease activity. The reduction in SALT scores was accompanied by a significant decrease in serum IgE levels, suggesting that type 2 inflammatory signals may contribute to persistent or fluctuating disease activity in selected patients during JAK inhibitor therapy. These findings provide preliminary evidence that targeting IL-4Rα may be a useful adjunctive strategy for patients with incomplete or unstable responses to upadacitinib. Given the retrospective design, small sample size, lack of a control group, and limited follow-up, larger prospective studies are needed to validate these observations and define the patient subgroup most likely to benefit from this approach.

EA DV CONGRESS
VIENNA
30 SEP - 3 OCT 2026

Abstract N°: 3615

Patient Knowledge, Treatment Expectations, and Diagnostic Delay in Lichen Planopilaris: Insights from a Single Center

Giulia Bazzacco*[1], Giuseppe Stinco[1]

[1] Dermatology Unit, Department of Medicine (DMED), University of Udine, University Hospital Santa Maria della Misericordia, Udine, Italy, Udine, Italy

Introduction

Lichen planopilaris (LPP) is a primary scarring alopecia leading to permanent hair loss with a substantial impact on patients' psychosocial well-being. Despite its clinical relevance, limited data are available regarding patients' disease knowledge, illness perceptions, and factors contributing to diagnostic delay. The aim of this study is to characterize the psychosocial burden of LPP and explore patients' knowledge, perceptions, and care-seeking behaviors to better understand and reduce diagnostic delays.

Materials and Methods

Adult patients (>18 years) with histologically confirmed classic LPP patients attending a dermatology clinic in a tertiary care hospital between 2025 and 2026 were included. Disease activity was assessed using the Lichen Planopilaris Activity Index (LPPAI). QoL was evaluated with Hair-Specific Skindex-29 (HSS-29), composed of 29 items divided into three domains: Symptoms, Emotions, and Social and Daily Functioning. Disease knowledge, perceptions, and experiences along the diagnostic journey, including timing, healthcare contacts, and barriers to diagnosis, were assessed using a 15-item investigator-designed questionnaire. Statistical analysis was performed using non-parametric methods. Continuous variables are reported as mean ± SD, categorical variables as n (%). Correlations were assessed using Spearman's rank correlation coefficient; $p<0.05$ was considered statistically significant. The study was conducted in accordance with the Declaration of Helsinki.

Results

Forty-two patients were enrolled (38 female, 4 male; mean age 65.4 years). Mean disease duration was 46.3 months, and mean treatment duration was 10.5 months. Twenty-two (52%) received only topical therapy, while 20 (48%) received systemic therapy (95% of these combined with topicals); approximately two-thirds were treated with hydroxychloroquine, and the remaining patients received systemic corticosteroids or methotrexate. Education level was generally low to moderate (primary or less 54%, high school 21%, bachelor's degree 21%, PhD 2%; one patient (2%) was illiterate). LPPAI showed moderate disease activity (6.1 ± 1.6). HSS-29 showed minimal QoL impact in 40%, moderate impact in 48%, and marked impact in 12%. LPPAI did not correlate with knowledge, illness perception, or QoL ($p>0.05$). In the disease knowledge questionnaire, most patients (74%) knew that LPP is inflammatory and causes hair loss; only 29% recognized all signs of disease activity, while 5% recognized none. All patients identified the dermatologist as the responsible healthcare provider. The impact of the disease on QoL was rated as "very high" in 38%, "moderate" in 48%, and "low" in 14%. Most patients (64%) correctly understood that the disease can only be controlled; treatment expectations were stopping hair loss (64%), reducing itch/pain (19%), regrowing hair (12%), and minimizing long-term medication use (5%). Using the diagnostic journey questionnaire, 86% of patients first noticed symptoms more than one year prior; 40% waited over one year to consult a physician. Most initially consulted a dermatologist (47%) or general practitioner (19%), with a median of

two physicians seen before diagnosis. About 43% reported delaying seeking care, mainly due to self-initiated therapies (55%) or personal reasons (45%) related to lack of disease awareness, logistical difficulties, or mild/stabilized symptoms. Disease knowledge and the diagnostic journey were independent of age, sex, or education. QoL positively correlated with knowledge scores ($p<0.05$), and longer disease duration was associated with higher knowledge scores ($p<0.05$).

Conclusions

Patients' knowledge and illness perception appear to influence both care-seeking behavior and the diagnostic journey in LPP.Improving patient education and awareness, may help reduce diagnostic delay, optimize treatment expectations, and ultimately improve quality of life.

EADV CONGRESS
VIENNA
30 SEP - 3 OCT 2026

Abstract N°: 3654

Clinical evaluation of tolerance and efficacy of a non-rinsed spray used by subject with seborrheic dermatitis on scalp

Mélanie Froliger[1], Virginie Ribet[2], Valérie MENGEAUD*[2]

[1] R&D Department, Pierre Fabre Dermo-Cosmetics & Personal Care, Toulouse, France

[2] Medical Department, Laboratoires Dermatologiques DUCRAY, Lavaur, France

Introduction

A new spray containing an antifungal combination of Piroctone Olamine/Cyclopirox Olamine and soothing active ingredients was developed to treat Scalp Seborrheic Dermatitis (SSD) and relieved the undesirable discomfort sensations of the scalp. The objective of the clinical study is to evaluate the effectiveness and the tolerance of the new spray on moderate to severe dandruff scalp with intense itching and sensation of burning.

Materials and Methods

This study was conducted in teenager and adult subjects having mild to moderate recurrent squamous states (SD) associated to erythema assessed by dermatologist and pruritus and burning sensations assessed by subject according to a Numerical Rating Scale (0-10). The new spray was applied thrice a week on dry scalp areas concerned. Subjects used the same neutral shampoo for hair washing. Efficacy and tolerance were assessed after the first application, after 1 and 2 weeks of use depending on the criterion. The efficacy evaluation included scoring of the squamous state, and erythema, self-assessment of burning sensation and cosmetic acceptability.

Results

31 teenagers and adults were included in this clinical study. Results showed a significant decrease of squamous state and erythema clinical score and a significant decrease of pruritus and burning sensations immediately after the first application, after 1 and 2 weeks (*$p<0.01$ *versus* baseline). Global tolerance was judged very good by the Dermatologist.

The global score of acceptability cosmetics was around 100%, the product soothes the scalp (99% of satisfaction), reduces dandruff (97% satisfaction) reduces scalp discomfort (94% of satisfaction), eases itching (94% of satisfaction) and burning sensations (100% of satisfaction).

Conclusions

The study results show that the new leave-in calming spray displays a very good overall tolerance and confirms the rapid effectiveness at treating scalp seborrheic dermatitis and reduce scalp irritation. Cosmetic qualities and perceived efficacy were highly appreciated.

EA DV CONGRESS
VIENNA
30 SEP - 3 OCT 2026

Abstract N°: 3727

Prolactin Receptor Antagonism by ABS-201 Drives Hair Follicle Growth and Stem/Progenitor Cell Expansion in Human Male Scalp Skin

Vishal Kothari[1], Amer-Denis Akkad*[1], Ralf Paus[2]

[1] Absci, Vancouver, United States

[2] Miller School of Medicine, Miami, United States

Introduction

Background: Current FDA-approved therapies for androgenetic alopecia provide limited and often insufficiently durable clinical benefit, underscoring the need for therapeutic strategies beyond minoxidil and 5α-reductase inhibition. We previously showed that human male scalp hair follicles (HFs) express prolactin receptors (PRLR), produce prolactin (PRL) locally, and undergo premature catagen in response to PRL stimulation. These findings imply that blocking PRLR signaling could promote HF growth through a non-androgen-dependent mechanism.

Objective: This study examined whether ABS-201, a novel AI-designed, highly selective anti-PRLR antibody, can enhance HF growth in intact human male scalp skin ex vivo while preserving or improving the epithelial hair follicle stem cell (eHFSC) compartment.

Materials and Methods

Methods: Full-thickness, androgen-sensitive frontotemporal scalp skin from male donors was maintained in organ culture. Molecular and phenotypic responses of HFs were assessed using phototrichogram analysis together with quantitative immunohistomorphometry. Orthogonally, bulk RNA-seq of microdissected full length HFs (n=4 healthy donors) ex vivo treated with ABS-201 or control IgG in the presence or absence of exogenous PRL was performed to identify transcriptional changes in HFs in response to the treatment. These approaches were used to determine whether ABS-201 counteracts PRL-induced premature catagen and to evaluate its effects on eHFSC.

Results

Results: ABS-201 suppressed PRLR-dependent STAT5 activation induced by exogenous PRL. This inhibition was associated with maintenance of anagen and prevention of premature catagen entry. ABS-201 also increased hair matrix keratinocyte proliferation and promoted hair shaft production, including expression of the hair shaft keratin K85. In addition, follicles treated with ABS-201 showed increased expression of key hair growth-promoting factors, including IGF1 and FGF7. Bulk RNA-seq corroborated these phenotypes: PRL induced hair growth-inhibitory inflammation and catagen-associated HF remodeling, both transcriptional responses corrected by ABS-201. Beyond its effects on follicle growth, ABS-201 preserved and expanded the hair follicle stem/progenitor cell pool by reducing PRL-induced apoptosis of K15-positive stem cells, increasing their proliferation, and enhancing their ability to generate CD34-positive progeny. ABS-201 also exerted growth-promoting effects in the absence of exogenous PRL, consistent with neutralization of intrafollicular PRL activity.

Conclusions

Conclusion: These preclinical findings independently confirm the inhibitory role of PRL in human male scalp hair

follicle growth and provide the first direct evidence that antibody-mediated antagonism of PRLR signaling stimulates human HF growth ex vivo. The observed effects occur directly in androgen-sensitive male scalp skin and extend across multiple biological levels, including anagen maintenance, matrix keratinocyte activity, hair shaft production, growth factor expression, reduction in catagen-associated HF remodeling and epithelial hair follicle stem/progenitor cell support. Together, these data identify ABS-201 as a promising, first-in-class, non-androgen-targeting therapeutic candidate for androgenetic alopecia, with potential to promote vellus-to-terminal hair follicle reconversion and achieve more durable hair regrowth in male patients.

EADV CONGRESS
VIENNA
30 SEP - 3 OCT 2026

Abstract N°: 3735

Hair regrowth in female androgenetic alopecia combining microneedling-assisted delivery of minoxidil and dutasteride with topical minoxidil and oral spironolactone

MARCELE TRINDADE DOS SANTOS[1], Mariana Santos Lopes Da Conceição[1], Bianca Fuser[1], Verônica Franco[1], Ana Amelia Bezerra Milfont[1], Emilia Peralta Ulerio[1], Eduarda Gregório Arnaut Lima*[1]

[1] Policlínica Geral do Rio de Janeiro, Rio de Janeiro, Brazil

Introduction

Female androgenetic alopecia (AGA) is a common cause of progressive hair thinning characterized by follicular miniaturization and reduced hair density, frequently associated with significant psychosocial impact. Although topical minoxidil and antiandrogen therapy remain standard therapeutic approaches, microneedling-assisted drug delivery techniques may enhance follicular penetration and improve treatment response. We report a case of female AGA treated with microneedling-assisted medication delivery (MMP), topical minoxidil, and oral spironolactone, resulting in marked hair regrowth and improved scalp coverage.

Case Presentation

A 30-year-old woman presented to our clinic with progressive hair thinning affecting the vertex and central scalp, clinically and dermoscopically consistent with AGA. Baseline examination demonstrated diffuse reduction in hair density, increased scalp visibility, and hair shaft diameter variability compatible with follicular miniaturization. The patient underwent six monthly sessions of microneedling-assisted drug delivery (MMP) using a compounded solution containing minoxidil and dutasteride. The solution was applied after controlled microneedling using a 1.5 mm depth tip. Concurrently, the patient used topical minoxidil 5% once daily and oral spironolactone 200 mg/day throughout treatment. After three monthly sessions, serial clinical photographs demonstrated early improvement in hair density and reduced scalp visibility over the vertex and central scalp. Following completion of the six-session protocol, marked repilation and more homogeneous scalp coverage were observed, with visible reduction in alopecic areas compared with baseline photographs. The response remained stable during follow-up, without evidence of progression. The patient reported high satisfaction with treatment and improvement in quality of life. No relevant adverse effects, scalp irritation, or inflammatory complications were observed.

Conclusion

This case highlights the potential benefit of combining microneedling-assisted drug delivery with topical minoxidil and oral spironolactone in female AGA. Multimodal therapeutic strategies integrating procedural and pharmacological approaches may enhance hair regrowth and improve patient satisfaction in selected patients with cosmetically significant disease. Further studies are needed to better define the role of assisted drug delivery techniques in AGA management.

EA DV CONGRESS
VIENNA
30 SEP - 3 OCT 2026

Abstract N°: 3758

Female pattern hair loss: recommendations from a new Danish national clinical guideline

Anders Benjamin Rønsholdt*[1], Mathias Tiedemann Svendsen[1]

[1] Odense University Hospital, Department of Dermatology and Allergy Centre, University of Southern Denmark, Department of Clinical Research, Odense C, Denmark

Introduction

Female pattern hair loss (FPHL) is the most common cause of hair loss in women, with a prevalence rising from approximately 12% in women in their twenties to nearly 50% in women over 70 years of age. Despite its high prevalence, significant variation exists in diagnostic practice and treatment across Denmark.

To present the key recommendations from the first Danish national guideline on FPHL, developed by the Alopecia Committee of the Danish Dermatological Society (DDS), with a focus on diagnosis, treatment algorithms, and monitoring.

Materials and Methods

A review of the literature was conducted. Recommendations were developed through expert consensus within the DDS Alopecia Committee and subjected to a national hearing process prior to finalisation.

Results

FPHL is diagnosed clinically based on history, family history, and physical examination. Trichoscopy is a key non-invasive adjunct, with characteristic findings including anisotrichosis (>20% hair diameter variation), a reduced terminal-to-vellus ratio (<4:1), and preserved follicular ostia distinguishing FPHL from cicatricial alopecias. Classification follows the Ludwig (grade I-III) or Sinclair scale (grade I-V). Targeted blood testing is recommended only when early-onset FPHL, menstrual irregularities, or signs of hyperandrogenism are present.

First-line treatment is topical minoxidil 5% applied twice daily. Oral spironolactone 50-200 mg daily is recommended as adjunct therapy in selected cases, with particular efficacy in patients with signs of hyperandrogenism. Low-dose oral minoxidil (0.625-2.5 mg daily) represents an effective off-label alternative for patients with insufficient response or intolerance to topical application. Oral finasteride 2.5-5 mg daily may be considered in postmenopausal women with significant treatment desire and inadequate response to first-line therapies; finasteride 1 mg has not demonstrated sufficient efficacy in women. Combined oral contraceptives containing drospirenone or cyproterone may be considered, particularly in patients with concurrent polycystic ovary syndrome. Adjuvant treatments including microneedling, platelet-rich plasma, and low-level laser therapy may be considered to augment medical therapy.

Monitoring of treatment response should not be assessed before 6-12 months of therapy. Standardised photography and trichoscopy are recommended for follow-up. Routine laboratory monitoring is not required for topical minoxidil. Baseline blood pressure and electrolytes are recommended prior to initiation of spironolactone and oral minoxidil.

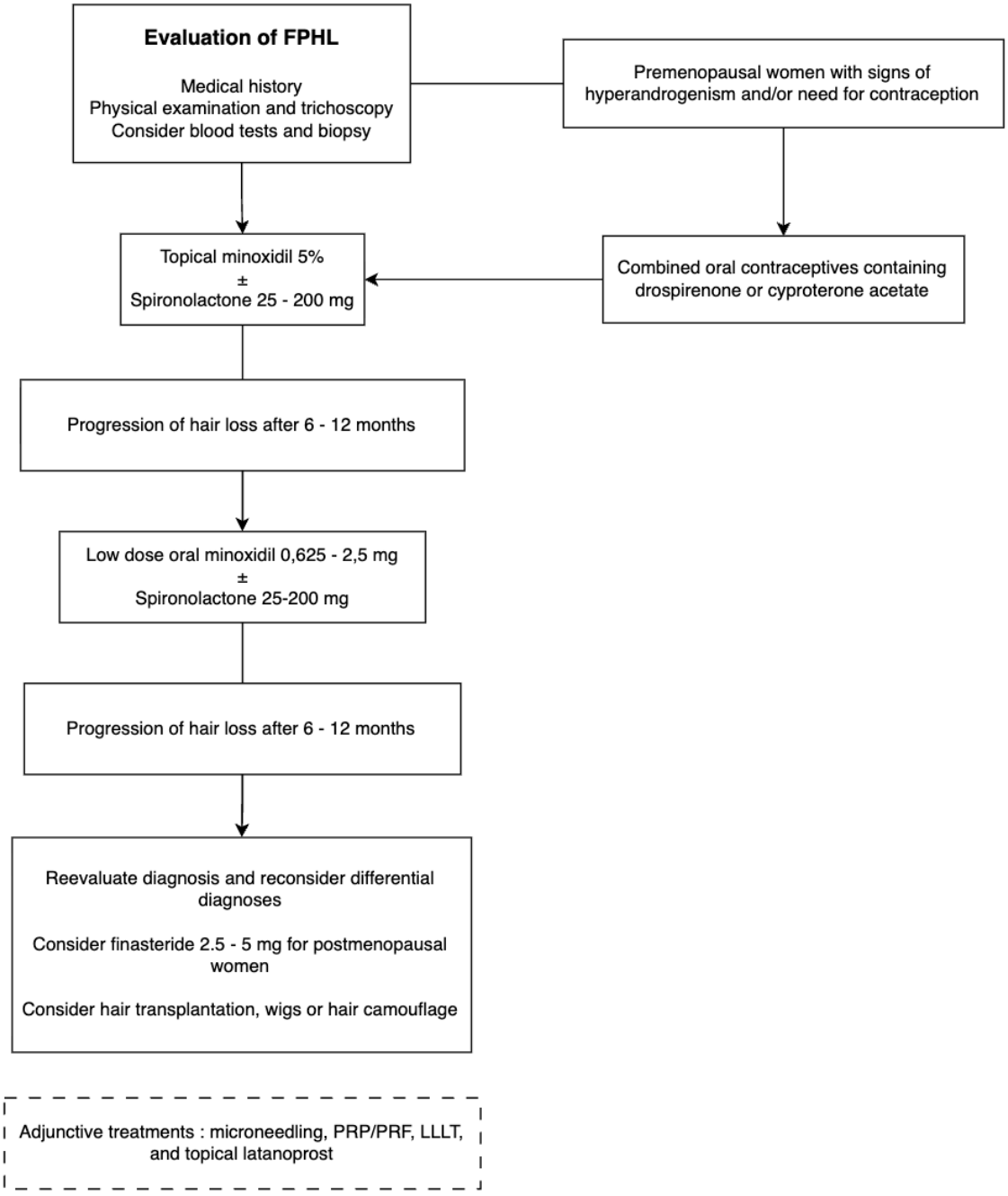

Figure 1. New Danish national treatment algorithm for female pattern hair loss (FPHL), including first-line therapy, escalation to low-dose oral minoxidil, adjunctive antiandrogen treatment, and consideration of procedural or cosmetic interventions in refractory cases. LLLT = low light laser therapy, PRP = platelet rich plasma, PRF = platelet rich fibrin

Conclusions

This new Danish national guideline on FPHL provides evidence-based, standardised recommendations for diagnosis and treatment. Early treatment initiation is essential, as preserving existing hair is far more achievable than regrowing lost hair. Topical minoxidil remains the cornerstone of treatment, with spironolactone and low-dose oral minoxidil expanding the therapeutic options. The guideline aims to ensure uniform, high-quality care for women with FPHL across Denmark.

POWERED BY M-ANAGE.COM

EADV CONGRESS
VIENNA
30 SEP - 3 OCT 2026

Abstract N°: 3761

Trichoscopic Patterns in Chemotherapy-Induced Alopecia: Dynamic Changes Across Treatment Stages and Comparison Between Patients Receiving and Not Receiving Preventive Scalp Cooling

Anna Lyakhovitsky*[1], lital brilant[1, 1], Aviv Barzilai[1, 1]

[1] Sheba Medical center, Dermatology, Ramat Gan, Israel

Introduction
Chemotherapy-induced alopecia (CIA), including transient and persistent CIA (pCIA), is a common and emotionally distressing adverse effect, particularly among women receiving taxane-based chemotherapy for breast cancer. Scalp cooling (SC) systems may reduce the incidence and severity of CIA; however, their use remains limited, partly because of insufficient awareness and knowledge among medical practitioners. Although trichoscopy is widely used for the diagnosis and monitoring of hair disorders, data on trichoscopic features of CIA are limited, and findings in patients receiving preventive SC are even scarcer. This study aimed to characterize dynamic trichoscopic features of CIA across different treatment stages and to compare trichoscopic findings between patients receiving preventive SC and those not receiving SC.

Materials and Methods
Female patients with breast cancer receiving taxane-based chemotherapy at the Oncology Department of Sheba Medical Center, Tel Hashomer,underwent serial trichoscopic assessment using the Canfield HairMetrix system at baseline, during chemotherapy, and during post-treatment follow-up. Trichoscopic findings were compared between patients receiving Paxman SC and those not receiving SC.

Results
In patients not receiving SC, CIA was trichoscopically characterized by progressive hair shaft thinning, marked hair shaft diameter diversity, broken hairs, short regrowing hairs, and distinctive three-dimensional yellow dots containing internal black dots. Exclamation mark hairs and typical yellow dots were not observed, supporting a trichoscopic distinction from alopecia areata. In patients receiving SC, most scalp hair was clinically preserved, and trichoscopy demonstrated preservation of normal hair shafts, with only few dystrophic and broken hairs. These findings suggest that SC attenuates chemotherapy-related follicular injury and reduces the severity of trichoscopic abnormalities.

Conclusions
CIA is associated with distinct and evolving trichoscopic features that may help monitor treatment-related follicular damage and distinguish CIA from alopecia areata. Paxman SC appears to attenuate chemotherapy-induced follicular injury, as reflected by better clinical hair preservation and milder trichoscopic changes. Trichoscopy may serve as a useful noninvasive tool for diagnosis, monitoring, and post-treatment evaluation of CIA and pCIA. These trichoscopic findings further support the use of SC as a preventive strategy for CIA.

EA DV CONGRESS
VIENNA
30 SEP - 3 OCT 2026

Abstract N°: 3767

Demodex folliculorum as a Histopathological Mimicker of Lichen Planopilaris: A Case Series with Therapeutic Implications

Celina Kazumi Iwasa[1], Uliana Nicholls[1], Carolina Kohn de Penhas[2], Gabriela César de Barros Abrantes[3], Milena Neves Sampaio*[4]

[1] Hair Loss Treatment -london, London, United Kingdom

[2] Centro Universitário São Camilo São Camilo, São Paulo, Brazil

[3] Faculdade Nova Esperança, João Pessoa, Brazil

[4] University of Brasília, University Hospital of Brasília, Brasília, Brazil

Introduction

Lichen planopilaris (LPP) is a primary lymphocytic cicatricial alopecia characterised by perifollicular erythema, scaling, and progressive scarring hair loss. Its diagnosis relies on clinical, trichoscopic, and histopathological convergence. *Demodex folliculorum*-associated chronic folliculitis is an increasingly recognised cause of scalp inflammation capable of mimicking LPP at all three diagnostic levels, potentially leading to diagnostic misclassification and inappropriate immunosuppressive therapy. We present a case series examining *Demodex folliculorum* as a histopathological confounder in patients with clinically suspected LPP, with direct therapeutic implications.

Case Presentation

Four female patients (38–43 years) with inflammatory scalp alopecia and clinical suspicion of LPP underwent trichoscopy and punch scalp biopsy (Alopecia Protocol). Trichoscopy was highly suggestive of LPP in all cases; histopathology revealed Demodex folliculorum chronic folliculitis as the primary or co-existing diagnosis in 100%.

Case 1 (38F): Perifollicular erythema, scaling, scalp tenderness. Trichoscopy: miniaturisation, telangiectasias. Histopathology: AGA with superimposed Demodex folliculorum chronic folliculitis. LPP excluded.

Case 2 (38F): Severe pruritus, >50% hair loss; background of telogen effluvium and corrected iron-deficiency. Trichoscopy: perifollicular halo, root transparency, cicatricial features. Histopathology (bilateral parietal): Demodex folliculorum chronic folliculitis ,no features of LPP.

Case 3 (43F): Cyclical inflammatory frontal hair loss, pruritus, burning; background of lichen sclerosus and seborrhoeic dermatitis. Trichoscopy: severe perifollicular inflammation, no FFA features. Histopathology (bilateral): Demodex folliculorum chronic folliculitis and no fibrosis for LPP. Treatment: oral ivermectin (x2), metronidazole 250 mg TID x14 days, topical corticosteroid. Resolving.

Case 4 (40F): Highly inflamed scalp, extreme pruritus, post-COVID hair loss. Trichoscopy: high-grade miniaturisation, severe perifollicular inflammation. Histopathology (bilateral): LPP confirmed lymphocytic infiltrate, perifollicular lamellar fibrosis, follicular fusion with superimposed Demodex folliculorum chronic folliculitis. Dual-pathology regimen: topical corticosteroid, ketoconazole shampoo, oral ivermectin x4 weeks, triamcinolone intralesional injections, photobiomodulation. Ongoing. In 75% of cases LPP was fully excluded Demodex folliculorum was the sole diagnosis. One case presented confirmed dual pathology. No patient had LPP without concurrent Demodex infestation

Conclusion

Chronic *Demodex folliculorum* folliculitis may convincingly simulate LPP at clinical, trichoscopic, and histopathological levels, representing an important diagnostic pitfall in inflammatory scalp alopecia. In this series, 75% of patients initially suspected of having LPP lacked histopathological confirmation of cicatricial alopecia, with inflammation instead driven exclusively by Demodex infestation. Histopathological confirmation remains essential before initiating LPP-directed immunosuppressive therapy. Investigation for Demodex infestation should be considered in all patients presenting with inflammatory scalp alopecia suspicious for LPP, as targeted anti-Demodex therapy may effectively resolve symptoms, prevent unnecessary immunosuppression, and address the true underlying pathology.

EA DV CONGRESS
VIENNA
30 SEP - 3 OCT 2026

Abstract N°: 3788

Impact of Upadacitinib on Clinician- and Patient-Reported Outcomes Assessing Visible Hair Loss at Key Sites in Patients With Severe Alopecia Areata: Results From Two Replicate Phase 3 Trials

Arash Mostaghimi*[1], Ahmed Soliman[2], Rodney Sinclair[3], Maria Hordinksy[4], Nina Magnolo[5], Xianwei Bu[2], Henrique Teixeira[2], Andreas Lazar[2], Elektra J Papadopoulos[2], Thierry Passeron[6]

[1] Department of Dermatology, Brigham and Women's Hospital, Boston, United States
[2] AbbVie Inc., North Chicago, United States
[3] Department of Medicine, University of Melbourne, Melbourne, Australia, Sinclair Dermatology, Melbourne, Australia
[4] Department of Dermatology, University of Minnesota Medical School, Minneapolis, United States
[5] Department of Dermatology and Venereology, University Hospital Münster, Münster, Germany
[6] Department of Dermatology, Centre Hospitalier Universitaire de Nice, Côte d'Azur University, Nice, France

Introduction

Upadacitinib (UPA) is being investigated in 2 replicate phase 3 studies for the treatment of severe alopecia areata (AA). In study 1, 45.2% and 55.0% of patients treated with UPA 15 mg (UPA15) and 30 mg (UPA30), respectively, met the primary endpoint, Severity of Alopecia Tool ≤ 20 (SALT ≤ 20) at week 24, compared with 1.5% ($P < .001$) of patients treated with placebo (PBO). In study 2, 44.6% and 54.3% of patients treated with UPA15 and UPA30, respectively, achieved SALT ≤ 20 at week 24, compared with 3.4% ($P < .001$) of patients treated with PBO (Mostaghimi et al. *J of Skin* 2025:9(6): s664). Here, we present the impact of UPA on clinician- (ClinRO) and patient-reported outcomes (PRO) using integrated data.

Materials and Methods

This is a phase 3 (NCT06012240), global, randomized, double-blind, PBO-controlled, multicenter trial with 2 replicate studies. Enrolled patients (12-< 64 years) had severe AA (SALT score ≥ 50 scalp hair loss) with no spontaneous scalp hair regrowth in the past 6 months. In period A, patients were randomized 2:2:1 to UPA15 once daily (QD), UPA30 QD, and PBO, respectively. Integrated results from studies 1 and 2 in the 24-week period A are reported. Endpoints reported include achievement of ClinRO measure for eyebrow hair loss of 0/1 and ClinRO measure for eyelash loss, both with ≥ 2-point improvement from baseline among patients with baseline score ≥ 2 (ClinRO eyebrow loss 0/1 and ClinRO eyelash loss 0/1, respectively), PRO for scalp hair assessment 0/1 with ≥ 2-point improvement from baseline among patients with baseline score ≥ 3 (PRO scalp hair 0/1), achievement of ClinRO measure for beard loss (I-ALFA) grade 2 or 3 with ≥ 2-point improvement from baseline among patients with baseline score < 2 (ClinRO beard loss 2/3), and PRO measure for eyebrow score of 0/1 and PRO measure for eyelash score of 0/1, both with ≥ 2-point improvement from baseline among patients with baseline score ≥ 2 (PRO eyebrow 0/1 and PRO eyelash 0/1, respectively). Non-responder imputation was used to handle missing data and intercurrent events. Nominal *P* values are presented.

Results

A total of 559 (UPA15), 560 (UPA30), and 280 (PBO) patients were included in this 24-week efficacy analysis. Baseline characteristics were similar between treatment groups.

Substantial differences were observed as early as week 8 in patients treated with UPA15 and UPA30 compared with PBO (Table). At week 24, the proportion of patients who achieved ClinRO eyebrow loss 0/1 was higher in the UPA15 (41.2%) and UPA30 (60.3%) groups than in the PBO (2.2%) group ($P < .001$). The proportion of patients who achieved ClinRO eyelash loss 0/1 was higher in the UPA15 (43.2%) and UPA30 (60.1%) groups than in the PBO (4.5%) group ($P < .001$). The proportion of patients who achieved ClinRO beard loss 2/3 was higher in the UPA15 (32.2%) and UPA30 (42.1%) groups than in the PBO (1.3%) group ($P < .001$).

At week 24, the proportion of patients who achieved PRO scalp hair loss 0/1 was higher in the UPA15 (40.9%) and UPA30 (52.8%) groups than in the PBO (3.5%) group ($P < .001$). The proportion of patients who achieved PRO eyebrow 0/1 was higher in the UPA15 (43.8%) and UPA30 (62.4%) groups than in the PBO (2.8%) group ($P < .001$). The proportion of patients who achieved PRO eyelash 0/1 was higher in the UPA15 (40.9%) and UPA30 (57.4%) groups than in the PBO (1.3%) group ($P < .001$). [a]

Table. Patient outcomes at week 8 and 24.

Endpoints[a]	Week 8			Week 24		
	UPA15	UPA30	PBO	UPA15	UPA30	PBO
Proportion of patients achieving ClinRO measure for eyebrow hair loss of 0 or 1 with a ≥ 2-point improvement from baseline among patients with baseline score ≥ 2 %, (95% CI) n/N	8.3 (5.4, 11.1)*** 30/362	12.8 (9.4, 16.2)*** 48/375	0 0/180	41.2 (36.1, 46.2)*** 149/362	60.3 (55.3, 65.2)*** 226/375	2.2 (0.1, 4.4) 4/180
Proportion of patients achieving ClinRO measure for eyelash hair loss of 0 or 1 with a ≥ 2-point improvement from baseline among patients with baseline score ≥ 2 %, (95% CI) n/N	7.9 (4.9, 10.9)** 25/317	13.5 (9.7, 17.4)*** 41/303	1.9 (0, 4.1) 3/154	43.2 (37.8, 48.7)*** 137/317	60.1 (54.6, 65.6)*** 182/303	4.5 (1.3, 7.8) 7/154
Proportion of patients achieving ClinRO measure for beard loss (I-ALFA) grade 2 or 3 with a ≥ 2-point improvement from baseline among patients with baseline score < 2 %, (95% CI) n/N	6.3 (2.3, 10.3)** 9/143	11.7 (6.5, 17.0)*** 17/145	0 0/78	32.2 (24.5, 39.8)*** 46/143	42.1 (34.0, 50.1)*** 61/145	1.3 (0, 3.8) 1/78
Proportion of patients achieving PRO for scalp hair assessment 0 or 1 with a ≥ 2-point improvement from baseline among patients with baseline score ≥ 3 %, (95% CI) n/N	6.6 (4.5, 8.8) 34/513	10.4 (7.7, 13.0)*** 53/513	4.3 (1.8, 6.8) 11/256	40.9 (36.7, 45.2)*** 210/513	52.8 (48.5, 57.2)*** 270/513	3.5 (1.3, 5.8) 9/256
Proportion of patients achieving PRO measure for eyebrows score of 0 or 1 with a ≥ 2-point improvement from baseline among patients with baseline score ≥ 2 %, (95% CI) n/N	9.1 (6.2, 12.0)*** 35/384	17.1 (13.3, 20.9)*** 66/386	1.1 (0, 2.7) 2/179	43.8 (38.8, 48.7)*** 168/384	62.4 (57.6, 67.3)*** 241/386	2.8 (0.4, 5.2) 5/179
Proportion of patients achieving PRO measure for eyelash score 0 or 1 with a ≥ 2-point improvement from baseline among patients with baseline score ≥ 2 %, (95% CI) n/N	7.2 (4.4, 9.9)** 24/335	16.6 (12.5, 20.7)*** 53/319	2.0 (0, 4.3) 3/149	40.9 (35.6, 46.2) 137/335	57.4 (51.9, 62.8) 183/319	1.3 (0, 3.2) 2/149

ClinRO, clinician-reported outcomes; PRO, patient-reported outcomes; UPA15, upadacitinib 15 milligrams; UPA30, upadacitinib 30 milligrams.** P < 0.005; ***P < 0.001. aNominal P values are presented for endpoints.

Conclusions

In this 24-week analysis, patients with severe AA treated with UPA demonstrated substantial and consistent improvements in ClinROs and PROs assessing visible hair loss at key sites in multiple locations beyond the scalp compared with PBO.

EA DV CONGRESS
VIENNA
30 SEP - 3 OCT 2026

Abstract N°: 3793

Evening Versus Morning Baricitinib Administration in Alopecia Areata: A Real-World Cohort Study

Luca Valtellini*[1, 2], Chiara Pruneri[1, 2], Mauro Barbareschi[2], Angelo Valerio Marzano[1, 2], Andrea Sechi[1]

[1] Dermatology Unit, Fondazione IRCCS Ca' Granda Ospedale Maggiore Policlinico, Milan, Italy., Milan, Italy
[2] Department of Pathophysiology and Transplantation, Università degli Studi di Milano, Milano, Italy

Introduction
Alopecia areata (AA) is an immune-mediated, non-scarring hair loss disorder with a substantial impact on quality of life. Janus kinase (JAK) inhibitors have emerged as the first effective systemic therapies capable of inducing clinically meaningful and often robust hair regrowth in patients with moderate-to-severe AA. Increasing attention has been devoted to the identification of predictors of treatment response, with shorter disease duration, lower baseline SALT score, and female sex emerging as factors associated with better clinical outcomes. Chronotherapy, defined as the optimization of drug administration according to biological rhythms, has been shown to influence treatment efficacy in several immune-mediated diseases. However, whether the timing of JAK inhibitor administration affects clinical outcomes in AA has not yet been investigated.

Materials and Methods
We performed a monocentric retrospective chart review of patients with AA treated with baricitinib. Patients with a follow-up period shorter than 48 weeks were excluded from the analysis.

Results
A total of 108 patients were included, of whom 58 received the medication in the morning and 50 in the evening. No significant differences were observed between the morning and evening groups in terms of female distribution (64% vs 66%, p=0.81), baseline SALT score [100 (IQR 86.25–100) vs 100 (IQR 70–100), p=0.33], or disease duration [10 (IQR 3–19.5) vs 9 years (IQR 3.25–19.75), p=0.75]. However, patients in the morning group were significantly older than those in the evening group [45 (IQR 35.25–52.75) vs 35.5 years (IQR 25.25–50.75), p=0.03]. At week 48, the median SALT score was 50 (IQR 10–80) in the morning group and 20 (IQR 0–78.75) in the evening group. The proportion of patients achieving SALT≤20 was 34.5% in the morning group and 54% in the evening group (p=0.058). In univariable analysis, evening administration of baricitinib was associated with higher odds of achieving SALT≤20 (OR 2.23, 95%CI 1.03–4.85; p=0.043). In multivariable analysis adjusted for baseline SALT score, disease duration, age, and sex, the association was attenuated and no longer reached statistical significance, although a similar effect size was maintained (OR 2.37, 95%CI 0.97–5.80; p=0.059). Higher baseline SALT scores (OR 0.96, 95%CI 0.93–0.98; p=0.001) and longer disease duration (OR 0.95, 95%CI 0.91–0.99; p=0.017) were independently associated with lower odds of achieving SALT20, whereas age and sex were not significantly associated with treatment response.

Conclusions
In this real-world cohort, evening administration of baricitinib was associated with better clinical outcomes compared with morning administration. This finding is consistent with a multicentre non-randomized controlled study in patients with rheumatoid arthritis, in which evening administration of baricitinib 4 mg was associated with greater clinical improvement compared with morning administration. A preclinical study in collagen-induced

arthritis mice further supported this chronotherapeutic rationale, showing that several cytokines involved in JAK/STAT3 pathway activation follow circadian rhythmicity, with inflammatory activity increasing during the nocturnal phase. In this model, baricitinib administration during periods of higher cytokine production resulted in lower arthritis scores. By analogy, it may be hypothesized that inflammatory pathways involved in alopecia areata also exhibit circadian fluctuations, with greater nocturnal activity potentially making evening administration of baricitinib more effective in targeting disease-related cytokine signalling. However, the association observed in multivariable analysis did not reach conventional statistical significance after adjustment for baseline disease severity, disease duration, age, and sex. Prospective randomized studies specifically designed to evaluate chronotherapeutic strategies in alopecia areata are warranted.

EA DV CONGRESS
VIENNA
30 SEP - 3 OCT 2026

Abstract N°: 3795

Diffuse Alopecia Areata in a Renal Transplant Recipient with Suspected B-cell Lymphoproliferative Disease

Pedro Barbosa*[1], Carla Trila[1], Corina Busso[1]

[1] Hospital Universitario Austral, Pilar, Buenos Aires, Argentina

Introduction

Hair loss in transplant recipients may have multiple contributing factors, including systemic disease, anemia, nutritional deficiencies, chronic immunosuppression, androgenetic alopecia and telogen effluvium. Alopecia areata may also present with a diffuse pattern, making the diagnosis less straightforward. We report a case of severe diffuse non-scarring alopecia in a renal transplant recipient with graft failure and suspected B-cell lymphoproliferative disease.

Case Presentation

A 71-year-old woman with a history of kidney transplantation in 2016 for chronic kidney disease was evaluated for progressive hair shedding since 2025, associated with scalp pruritus. She was receiving tacrolimus, mycophenolate mofetil and oral corticosteroids. Her medical history included post-transplant diabetes mellitus, hypertension, asthma and chronic obstructive pulmonary disease.

At the first dermatological evaluation, she presented diffuse hair loss involving more than 20% of the scalp, with a positive hair-pull test. Laboratory studies showed anemia. The initial clinical impression was telogen effluvium related to anemia and repeated hospitalizations, and topical minoxidil was started.

On follow-up in a specialized hair clinic, trichoscopy showed black dots, exclamation-mark hairs, short dystrophic hairs and perifollicular scaling. Laboratory tests showed persistent anemia and severe vitamin D deficiency. Because of the suspicion of diffuse alopecia areata, with possible associated androgenetic alopecia and acute telogen effluvium, a 4-mm scalp punch biopsy was performed.

Histopathology showed non-scarring alopecia, with perifollicular lymphocytic infiltrate at the isthmic and bulbar levels, associated with follicular miniaturization. Periodic acid–Schiff staining did not show fungal microorganisms. The findings supported diffuse alopecia areata, with concomitant follicular miniaturization.

Topical minoxidil was continued. After discussion with the nephrology team, topical mometasone lotion three times weekly and ketoconazole shampoo were added.

From a systemic perspective, the patient had progressive loss of renal graft function and was being evaluated for hemodialysis. She also had persistent lymphocytosis under hematological study. Bone marrow biopsy showed interstitial and intrasinusoidal infiltration by CD5-positive B lymphocytes, raising the possibility of mantle cell lymphoma versus post-transplant lymphoproliferative disorder. Hematological reassessment was pending at the time of dermatological discussion.

Conclusion

This case illustrates a severe diffuse non-scarring alopecia in a medically complex renal transplant recipient. Although anemia, graft failure, chronic disease and possible androgenetic alopecia could explain part of the hair

loss, trichoscopy and histopathology supported diffuse alopecia areata. In transplant recipients, diffuse alopecia should not be automatically attributed to telogen effluvium or medication exposure. Clinicopathological correlation is useful, particularly when alopecia develops in the context of graft failure, chronic immunosuppression and possible lymphoproliferative disease.

EADV CONGRESS
VIENNA
30 SEP - 3 OCT 2026

Abstract N°: 3803

Bilateral eyebrow alopecia: an atypical form of trichotillomania revealed by trichoscopy

imane denni*[1], Meryem Soughi[1], ikram bejja[1], Saadia Boughaleb[1], Zakia Douhi[1], Sara Elloudi[1], Hanane Baybay[1], Fatima Zohra Mernissi[1]

[1] Department of Dermatology, Hospital Hassan II University, FES, Morocco

Introduction

Trichotillomania is a behavioral disorder characterized by compulsive hair or hair shaft pulling, leading to localized or extensive non-scarring alopecia. Classified among obsessive-compulsive related disorders in the DSM-5, it may involve any hair-bearing area. However, isolated and bilateral eyebrow involvement is rare and often underdiagnosed.

We report a case of eyebrow trichotillomania in a young woman, highlighting the diagnostic value of trichoscopy in confirming the diagnosis and guiding management.

Case Presentation

A 20-year-old woman with no relevant medical or family history presented with progressive bilateral complete loss of the eyebrows over several months. Clinical history revealed repetitive eyebrow hair pulling mainly during periods of stress or inactivity, associated with a sense of relief after the behavior.

Clinical examination showed complete bilateral symmetric eyebrow alopecia. The scalp hair, eyelashes, and body hair were preserved. No nail abnormalities were observed.

Trichoscopic examination revealed hair shafts of varying length, broken hairs, trichoptilosis, V-sign hairs, flame hairs, hook hairs, and tulip hairs. These dermoscopic features were highly suggestive of trichotillomania and allowed differentiation from alopecia areata and other causes of non-scarring alopecia.

Laboratory investigations including hormonal, nutritional, and autoimmune workup were normal.

The patient was started on N-acetylcysteine and referred for cognitive behavioral therapy, with psychiatric follow-up to evaluate the need for additional pharmacological management targeting obsessive-compulsive features.

Conclusion

Trichotillomania should be suspected in cases of bilateral complete eyebrow alopecia, especially when scalp hair, eyelashes, and nails are preserved. Trichoscopy is a key diagnostic tool, and early psychological management is essential to improve therapeutic outcomes.

EADV CONGRESS
VIENNA
30 SEP - 3 OCT 2026

Abstract N°: 3808

Comparative study of the efficacy and safety of topical minoxidil 2% versus topical bimatoprost 0.01% versus topical bimatoprost 0.03% in treatment of eyebrow hypotrichosis: a randomized controlled trial

Mohamed Zaky*[1], Osama Hashem[1], Mohamed Elsaie[2], Sara Mahfouz[1]

[1] Department of Dermatology, Venereology and Andrology, Damietta Faculty of Medicine, Damietta, Egypt

[2] Department of Dermatology, Medical Research and Clinical Studies Institute, National Research Centre, Giza, Egypt

Introduction

Eyebrows are an important feature of facial identity and communications in human beings as well as an important eye defense shield from dust and foreign bodies. The study aims to compare the efficacy and safety between 0.01%, 0.03% bimatoprost and minoxidil 2% in gel formulations for eyebrow enhancement.

Materials and Methods

Sixty eligible subjects were female or male, aged 18 years or older with eyebrow hypotrichosis, defined as either a Grade 1 or 2 on the Global Eyebrow Assessment (GEBA) scale. Patients were randomized into 3 groups using block randomization. Group a (20 patients) applied topical 0.03% bimatoprost gel once daily onto both eyebrows, group b (20 patients) applied topical 0.01% bimatoprost gel once daily onto both eyebrows while group c (20 patients) applied topical minoxidil 2% gel once daily onto both eyebrows.



Clinical and dermoscopic image of a case of primary eyebrow hypotrichosis before (a, c) and 16 weeks after treatment with topical bimatoprost 0.01% (b, d)

Results

A significant improvement in GEBA score was reported in all the three groups after treatment ($F \leq 0.001$); however, there was no statistically significant difference between the three groups ($P1 = 0.091$; $P2 = 0.102$; $P3 = 0.663$).

Clinical and dermoscopic image of a case of primary eyebrow hypotrichosis before (a, c) and 16 weeks after treatment with topical minoxidil 2% (b, d)

Conclusions

Bimatoprost is equally efficacious as minoxidil in enhancement of eyebrows with a more favorable response produced by the 0.03% concentration.

EA DV CONGRESS
VIENNA
30 SEP - 3 OCT 2026

Abstract N°: 3816

The efficacy of Platelet-Rich Plasma (PRP) in the Treatment of Female Pattern HairLoss: A systematic review of Clinical Trials.

Haneen Abanmi[1], Ali Alqarni*[1], Hessah Almutairi[1], Rawan Alanazi[2]

[1] Medical Student, Medicine and Surgery, Majmaah University, Al-Majmaah, Saudi Arabia

[2] College of Medicine, Dar Al Uloom University, Riyadh, Saudi Arabia

Introduction

Female Pattern Hair Loss (FPHL) is a progressive condition which affects the women across all ages. There are limited, but the often-inconsistent treatment options are available like minoxidil and anti-androgens. Platelet-rich plasma (PRP) therapy, using autologous blood-derived growth
factors, has emerged as a promising regenerative approach. The early studies suggest improvements in hair density and thickness, though results vary due to differences in protocols.
This systematic review aims to assess the PRP's efficacy, safety, and the optimal delivery methods. It also explores patient-specific predictors and establishes standardized, evidence-based guidelines for effective FPHL management through PRP therapy.

Materials and Methods

This systematic review followed PRISMA and R-AMSTAR guidelines. We searched PubMed, and Google Scholar (2015–2023) for studies on PRP's therapy for FPHL. Two independent reviewers screened titles, abstracts, and full texts, with data extracted into Excel; disagreements resolved.

Results

This systematic review included 12 clinical trials with 450 participants (313 females, 69.6%; 137 males, 30.4%) conducted across eight countries, with the USA contributing the most (n=4). Most trials (75.0%) were randomized, placebo-controlled or double-blind. PRP monotherapy was used in 9 studies, while 2 combined it with topical minoxidil. Hair density improvements were consistent across studies, with PRP-treated patients gaining an average of +58.0 hairs/cm² versus a mean loss of –10.6 hairs/cm² in control arms. Thickness improvements averaged +0.0048 mm in PRP arms versus –0.0047 mm in controls. Follow-up ranged from 3 to 6 months. Safety profiles were favorable, with only 2 studies (16.7%) reporting minor adverse events (e.g., headache, redness). However, 58.3% of studies lacked formal safety reporting, and short durations limited long-term assessments. Patient satisfaction with PRP therapy was generally high across studies, with most participants reporting positive perceptions of treatment outcomes and willingness to undergo the procedure again

Conclusions

This systematic review shows that the PRP is a promising and the well-tolerated treatment option for the Female Pattern Hair Loss, which shows the consistent improvements in the hair density and the thickness. While minor adverse events were rare, the lack of long-term safety dataunderscores the need for standardized protocols and extended follow-up. High patient satisfaction further supports PRP's role as a viable therapeutic option

EA DV CONGRESS
VIENNA
30 SEP - 3 OCT 2026

Abstract N°: 3821

Impact of Upadacitinib on Health-Related Quality of Life in Patients With Severe Alopecia Areata: Results From Two Replicate Phase 3 Trials

Arash Mostaghimi*[1], Ahmed M Soliman[2], Rodney Sinclair[3], Maria Hordinksy[4], Xianwei Bu[2], Henrique Teixeira[2], Andreas Lazar[2], Ellie Julian[2], Thierry Passeron[5]

[1] Department of Dermatology, Brigham and Women's Hospital, Boston, United States

[2] AbbVie Inc., North Chicago, United States

[3] Department of Medicine, University of Melbourne, Melbourne, Australia, Sinclair Dermatology, Melbourne, Australia

[4] Department of Dermatology, University of Minnesota Medical School,, Minneapolis, United States

[5] Department of Dermatology, Centre Hospitalier Universitaire de Nice, Côte d'Azur University, Nice, France

Introduction

In a recent phase 3 trial (with 2 replicate studies) evaluating upadacitinib (UPA) for severe alopecia areata (AA), a significantly higher proportion (%) of patients (pts) treated with UPA 15 mg (UPA15; 45.2% and 44.6%) and UPA30 (55.0% and 54.3%) achieved the primary endpoint, Severity of ALopecia Tool score ≤ 20 (SALT ≤ 20), compared with pts on placebo (PBO; 1.5% and 3.4%, *P* < .001) at week 24. (Mostaghimi et al. J of Skin 2025:9(6): s664). As the burden of AA can be significant to pts, here, we report the health-related quality-of-life outcomes in pts with severe AA treated with UPA compared with PBO.

Materials and Methods

From the phase 3 (NCT06012240), global, randomized, double-blind, PBO-controlled, multicenter trial of 2 replicate studies, integrated data over the 24-week treatment period are reported. Enrolled pts (12-< 64 years) with severe AA (SALT score ≥ 50 scalp hair loss) were randomized 2:2:1 to UPA15 once daily (QD), UPA30 QD, or PBO. Outcomes included the % of pts whose Skindex-16 AA emotions and functioning domain scores improved by at least the minimum clinically important difference (MCID; 19 points and 13.3 points, respectively) from baseline limiting the analysis to pts whose baseline Skindex-16 AA emotions and functioning domain scores were greater than or equal to the respective MCID values. Similarly, we evaluated the % of pts achieving an improvement in AA Symptom Impact Scale (AASIS) symptoms and interference subscales scores ≥ MCID (1.3 points for both subscales) from baseline for pts with AASIS symptoms and interference subscale scores ≥ MCID at baseline, change from baseline in Hospital Anxiety and Depression Scale for Anxiety (HADS-A) and Depression (HADS-D), and the % of pts achieving HADS-A < 8 and HADS-D < 8 in pts with baseline HADS-A ≥ 8 or HADS-D ≥ 8. Non-responder imputation or multiple imputation incorporating return-to-baseline were used to handle missing data and intercurrent events. Nominal *P* values are reported.

Results

Among the enrolled 1399 pts, 559, 560, and 280 were randomized to UPA15, UPA30, and PBO, respectively. Baseline characteristics were similar between treatment groups.

At week 24, the % of pts achieving an improvement in Skindex-16 emotions domain score ≥ MCID were higher in the UPA15 (66.4%) and UPA30 (70.4%) groups than in the PBO (37.7%) group (*P* < *.001*) (Table). The % of pts achieving an improvement in Skindex-16 functioning domain score ≥ MCID was higher in the UPA15 (70.1%) and UPA30 (70.8%) groups than in the PBO (45.4%) group (*P* < *.001*).

The % of pts achieving an improvement in AASIS symptoms subscale scores ≥ MCID was higher in UPA15 (62.4%) and UPA30 (68.0%) groups than in the PBO (29.8%) group (*P* < *.001*). The % of pts achieving an improvement in AASIS interference subscale score ≥ MCID was higher in UPA15 (61.6%) and UPA30 (63.1%) than in the PBO (43.6%) group (*P* < *.001*).

The % of pts achieving HADS-A < 8 and HADS-D < 8 was higher in the UPA15 (35.1%, *P* = 0.008) and UPA30 (36.0%, *P* = 0.004) groups than in the PBO (23.7%) group. There was a greater improvement in HADS-A score in pts in the UPA15 (-1.2; *P* = .004) and UPA30 (-1.5; *P* < .001) groups compared with pts in the PBO (-0.5) group. Similarly, there was a greater improvement in HADS-D score in pts in the UPA15 (-0.9; *P* < .001) and UPA30 (-1.0; *P* < .001) groups compared with pts in the PBO (0.1) group.

Table. Patient reported outcomes of patients with AA at week 24.

Responses[a]	Week 24		
	UPA15	UPA30	PBO
Proportion of pts achieving an improvement in Skindex-16[b] AA ≥ MCID from baseline for pts with Skindex 16 AA ≥ MCID at baseline (NRI)			
Emotions domain (MCID = 19), % (95% CI)	66.4 (62.3, 70.5)***	70.4 (66.4, 74.5)***	37.7 (31.8, 43.7)
n/N	334/503	348/494	97/297
Functioning domain (MCID = 13.3), % (95% CI)	70.1 (65.8, 74.3)***	70.8 (66.7, 75.0)***	45.4 (38.9, 51.9)
n/N	316/451	328/463	103/207
Proportion of pts achieving an improvement in AASIS[c] subscale score ≥ MCID from baseline for pts with AASIS subscale score ≥ MCID at baseline (NRI)			
Symptoms subscale (MCID = 1.3) % (95% CI)	62.4 (57.9, 67.0)***	68.0 (63.7, 72.4)***	29.8 (23.7, 35.9)
n/N	276/442	298/438	65/218
Interference subscale (MCID = 1.3), % (95% CI)	61.6 (56.7, 66.5)***	63.1 (58.1, 68.1)***	43.6 (36.3, 50.8)
n/N	231/375	224/355	78/179
Proportion of pts achieving HADS-A[d] < 8 and HADS-D < 8 in pts with baseline HADS-A ≥ 8 and HADS-D ≥ 8 at baseline (NRI)			
% (95% CI)	35.1 (29.3, 40.9)**	36.0 (30.0, 42.0)**	23.7 (16.4, 30.9)
n/N	92/262	90/250	31/131
Change from baseline (RTB-MI)			
HADS-A, % (95% CI)	-1.2 (-1.5, -0.9)**	-1.5 (-1.8, -1.2)***	-0.5 (-0.9, -0.1)
HADS-D, % (95% CI)	-0.9 (-1.1, -0.6)***	-1.0 (-1.2, -0.8)***	-0.1 (-0.2, 0.4)

AA, Alopecia Areata; AASIS, Alopecia Areata Symptom Impact Scale; HADS-A, Hospital Anxiety and Depression Scale-Anxiety; HADS-D, Hospital Anxiety and Depression Scale-Depression; MCID, minimum clinically important difference NRI, Non-Responder Imputation; Pts, patients; RTB-MI, Multiple Imputation incorporating Return-To-Baseline; UPA15, upadacitinib 15 milligrams; UPA30, upadacitinib 30 milligrams. *P ≤ .05; **P ≤ .01;***P ≤ .001. aNominal P values are presented. bSkindex-16 for AA measures the effect of AA on patients' health-related quality of life (HR-QOL) with 3 domains (emotions, symptoms, and functioning). Patients rate how much each symptom has bothered them in the past week, ranging from "never bothered" (score of 0) to "always bothered" (score of 6). The sum of each domain is standardized to 0-100 where higher scores indicate worse impact on HRQOL. cAASIS is a disease-specific measure that asks about patients' AA symptoms and how these symptoms interfere with their daily functioning, with a recall period of the past week. AASIS is composed of 2 subscales (symptom and interference subscales). The 11-point numerical scale is anchored with "not present", with a score of 0, to "as bad as you can imagine" with a score of 10, for the symptom items, and "did not interfere", with a score of 0, to "interfered completely", with a score of 10, for the impact items. Global scores range from 0 to 10, with higher scores indicating greater symptoms and interference. dHADS is a self-administered scale that measures anxiety and depression. It contains 14 items (7 for anxiety and 7 for depression), which are scored separately and summed to

yield a total score. Item scores range from 0 (best) to 3 (worst), and total scores are categorized as normal (0-7), borderline abnormal (8-10), and abnormal (11-21).

Conclusions

With 24 weeks of treatment, pts on UPA achieved clinically meaningful improvements across several dimensions of quality of life, including reduced symptoms of anxiety and depression.

EADV CONGRESS
VIENNA
30 SEP - 3 OCT 2026

Abstract N°: 3838

Diagnostic Utility of Trichoscopy in Scalp Disorders: A 650-Case Series

Samah Boualem*[1], Ouiame El Jouari[1], Sabrina Oujdi[1], Salim Gallouj[1]

[1] Dermatology Department, University Hospital Center Mohammed VI, Tangier, Morocco, Tangier, Morocco

Introduction
Scalp disorders are common conditions that may significantly impair patients' quality of life. Accurate diagnosis remains essential for appropriate management. Trichoscopy, a non-invasive imaging technique used for the evaluation of the scalp and hair, has emerged as a valuable diagnostic tool in daily dermatological practice. The aim of this study was to assess the diagnostic utility of trichoscopy in scalp disorders.

Materials and Methods
We conducted a cross-sectional, descriptive, and analytical study including 650 patients presenting with various scalp disorders over a consecutive six-year period from June 2019 to November 2025.
Patients with scalp tumors, ulcerative lesions, or congenital hair dysplasias were excluded, as well as cases with non-interpretable trichoscopic images.
Trichoscopic examinations were performed using a handheld dermoscope attached to a smartphone.
Standardized photographs were systematically recorded for each patient. Clinical and trichoscopic data were analyzed for each case.
The final diagnosis was established based on clinical and trichoscopic findings, with histopathological and mycological investigations performed in selected cases when necessary for confirmation.

Results
This study included 650 patients with a mean age of 26.69 years and a sex ratio of 0.53. The most frequent diagnoses were psoriasis (35.1%), tinea capitis (18.3%), alopecia areata (17.9%), androgenetic alopecia (15%), and seborrheic dermatitis (5.9%).
The most common trichoscopic findings overall were white scales (39.8%), black dots (29.4%), and erythema (28.9%).
Psoriasis was characterized by thick white scales, red dots, glomerular and dotted vessels, and tortuous capillary loops ($p < 0.001$). Tinea capitis showed black dots, yellowish scales, erythema, broken hairs, comma hairs, corkscrew hairs, and barcode hairs ($p < 0.001$).
Alopecia areata was associated with yellow dots, black dots, exclamation mark hairs, vellus hairs, and circle hairs ($p < 0.001$ for all except circle hairs: $p = 0.02$). Androgenetic alopecia was mainly characterized by anisotrichia and peripilar signs ($p < 0.001$).
Seborrheic dermatitis presented with yellow scales, greasy intrafollicular material, erythema, and arborizing vessels ($p < 0.001$ to 0.022). Trichotillomania showed fractured hairs of variable length, split ends, V-sign, coiled hairs, and microhemorrhages ($p \leq 0.02$ to 0.001).
Overall, trichoscopy demonstrated consistent and reproducible patterns across different scalp disorders, supporting its diagnostic reliability in routine clinical practice.

Conclusions

Trichoscopy appears to be an essential tool for improving the diagnosis of common scalp disorders. Our study demonstrates its ability to reliably differentiate psoriasis, androgenetic alopecia, alopecia areata, tinea capitis, and seborrheic dermatitis based on specific trichoscopic criteria. It enhances diagnostic accuracy while reducing the need for invasive procedures. Despite certain limitations, its use should be further promoted and explored in routine dermatological practice.

EADV CONGRESS
VIENNA
30 SEP - 3 OCT 2026

Abstract N°: 3850

Pustular Lichen Planopilaris Mimicking Folliculitis Decalvans: Diagnostic and Histopathological Challenges in Cicatricial Alopecia

Elaine Shizue Novalo-Goto*[1], Bruna Minatel Alves de Souza[1], Lívia Gonçalves Gará[1], Lara Beatriz Prata Ribeiro[1], Francisco Le Voci[1], Carlos D´Apparecida Santos Machado Filho[1]

[1] FMABC University Center, Santo André, Brazil

Introduction

Lichen planopilaris (LPP) is a primary lymphocytic cicatricial alopecia that may occasionally present with pustules, resulting in significant clinicopathological overlap with neutrophilic scalp disorders, particularly folliculitis decalvans (FD). These atypical presentations may delay diagnosis and complicate histopathological interpretation. We report a case of pustular LPP initially interpreted as FD, highlighting the importance of clinicopathological correlation and repeat biopsy after control of secondary inflammation.

Case Presentation

A 39-year-old woman presented with a 7-year history of progressive scalp hair loss that began during pregnancy and persisted after delivery. Previous treatments, including hydroxychloroquine and antibiotic therapy, failed to achieve clinical improvement.

Dermatological examination revealed an extensive alopecic plaque involving the parietal scalp and vertex, characterized by atrophic shiny skin, perifollicular scaling, adherent crusts, tufted hairs, and scattered pustules. The clinical presentation initially suggested folliculitis decalvans.

The patient had previously undergone two scalp biopsies. The first demonstrated a predominantly neutrophilic inflammatory infiltrate consistent with FD, while the second revealed nonspecific cicatricial alopecia with atrophy. Due to persistent pustulation, doxycycline therapy was introduced, resulting in partial reduction of pustules and inflammatory activity. A subsequent biopsy demonstrated perifollicular lymphocytic infiltrate compatible with lichen planopilaris, establishing the final diagnosis.

Conclusion

This case highlights the diagnostic complexity of pustular LPP and its overlap with folliculitis decalvans. Secondary neutrophilic inflammation may obscure the underlying lymphocytic infiltrate and contribute to misleading histopathological findings. In selected cases, repeat biopsy after antibiotic therapy may be essential for accurate diagnosis. Recognition of overlap phenotypes between LPP and FD may help optimize diagnostic accuracy and therapeutic management in cicatricial alopecia.

EA DV CONGRESS
VIENNA
30 SEP - 3 OCT 2026

Abstract N°: 3859

Median Canaliform Nail Dystrophy of Heller as a Manifestation of Body-Focused Repetitive Behavior: Therapeutic Response to N-Acetylcysteine

Mariana Diniz*[1], Ana Carolina Salomão[1], Miguel Ceccarelli[1]

[1] Universidade Estadual do Rio de Janeiro, Hospital Universitário Pedro Ernesto, Rio de Janeiro, Brazil

Introduction

Median canaliform nail dystrophy of Heller is a rare and frequently underrecognized nail disorder characterized by a central longitudinal groove with oblique ridging, producing a characteristic "fir tree" appearance. Increasing evidence suggests an association between this condition and body-focused repetitive behaviors, particularly chronic manipulation of the proximal nail fold and cuticle.

Case Presentation

We report the case of a 27-year-old man presenting with nail dystrophy affecting the right thumb. Physical examination revealed a central longitudinal canal with multiple transverse and oblique ridges extending laterally from the midline, without signs of infection or inflammatory nail disease. The patient reported chronic manipulation of the cuticle associated with anxiety and repetitive self-induced trauma.

Based on the clinical findings and behavioral history, a diagnosis of median canaliform nail dystrophy associated with body-focused repetitive behavior was established. Treatment consisted of oral N-acetylcysteine at a dose of 600 mg/day combined with behavioral counseling and the use of bitter nail lacquer to discourage manipulation. Progressive clinical improvement of the nail plate and reduction of compulsive manipulation were observed during follow-up.

Body-focused repetitive behaviors are increasingly recognized within the spectrum of psychodermatologic disorders involving impaired impulse control and compulsive self-manipulation. In this context, repetitive trauma to the nail matrix may lead to characteristic dystrophic changes. N-acetylcysteine has emerged as a promising therapeutic option due to its modulatory effects on glutamatergic neurotransmission and compulsive behaviors, with growing evidence supporting its use in disorders such as trichotillomania, skin-picking disorder, and onychophagia.




Figures 1 and 2. Clinical findings consistent with median canaliform nail dystrophy of Heller associated with chronic self-induced manipulation. Figure 1 documents repetitive manipulation behavior, while Figure 2 demonstrates involvement of the left thumb with macrolunula, a yellow-brown central longitudinal groove extending from the nail matrix to the distal free edge, producing the characteristic “fir tree” pattern, associated with periungual atrophy, fissuring, and eponychial detachment.

Conclusion

This case highlights the importance of recognizing median canaliform nail dystrophy as a possible manifestation of psychodermatologic disease. Early identification of behavioral triggers allows targeted multidisciplinary management and may prevent unnecessary antifungal or invasive treatments. Combined pharmacologic and behavioral therapy may represent an effective strategy for long-term clinical improvement.

EA DV CONGRESS
VIENNA
30 SEP - 3 OCT 2026

Abstract N°: 3868

Beyond the Hairline: Facial and Extrafacial Cutaneous Involvement in Frontal Fibrosing Alopecia - A Systematic Review

Wiktor Kruczek*[1, 2, 3], Kinga Piksa[3], Iga Litwińska[3], Aleksandra Frątczak[2], Bartosz Miziołek[2], Beata Bergler-Czop[2]

[1] Doctoral School, Medical University of Silesia, Department of Dermatology, School of Medicine in Katowice, Medical University of Silesia, Students' Scientific Association at the Department of Dermatology, School of Medicine in Katowice, Medical University of Silesia, Katowice, Poland

[2] Department of Dermatology, School of Medicine in Katowice, Medical University of Silesia, Katowice, Poland

[3] Students' Scientific Association at the Department of Dermatology, School of Medicine in Katowice, Medical University of Silesia, Katowice, Poland

Introduction

Frontal fibrosing alopecia (FFA) is a form of progressive scarring alopecia affecting the frontal hairline and extending to the eyebrows, eyelashes, and facial regions. First described in 1994, FFA mainly affects postmenopausal women, with increasing cases in younger patients and men. FFA is considered an LPP variant, but its pathogenesis remains poorly understood. It is diagnosed late, especially when facial changes precede scalp involvement. Facial papules, pigmentation, erythema, and vascular changes are frequently overlooked or misdiagnosed as other dermatoses. This review assesses facial phenotypes in FFA, their histopathological characteristics, diagnostic value of trichoscopy, dermoscopy, and biopsy, and treatment outcomes, focusing on oral isotretinoin.

Materials and Methods

A systematic literature search was conducted in PubMed/MEDLINE, Scopus, and the Cochrane Library from inception to May 2026, in accordance with PRISMA 2020 recommendations. Search terms combined "frontal fibrosing alopecia" with facial lesions, papules, pigmentary and rosacea-like changes, glabellar and vascular signs, dermoscopy, trichoscopy, histopathology, and isotretinoin. Case reports, series, observational studies, and randomized controlled trials were eligible when facial manifestations in FFA and relevant clinical, diagnostic, histopathological, or therapeutic data were available. Non-human studies, reviews, editorials, and articles without facial-specific data were excluded. Titles, abstracts, and full texts were screened according to predefined criteria. Data on study design, patient characteristics, lesion morphology, distribution, diagnostic methods, histopathology, treatment, and outcomes were extracted. Quality was assessed using study-design-specific tools. Owing to heterogeneity, findings were synthesized narratively.

Results

The analysis revealed four distinct facial phenotypes associated with FFA. The papular phenotype was characterized by facial papules, rough skin, and vellus hair follicle involvement, commonly observed on the temples, zygomatic areas, and preauricular regions. The pigmentary phenotype presented as hyperpigmentation and lichenoid changes, mainly in the periorbital, neck, and chin regions, often associated with Lichen Planus Pigmentosus (LPPig). The inflammatory/rosacea-like phenotype displayed erythema, papules, and flushing, typically affecting the eyebrows and forehead, and was often

misdiagnosed as rosacea or Demodex folliculitis. The vascular phenotype was marked by glabellar red dots and visible frontal veins, with
perifollicular erythema and collagen thickening observed histopathologically. Histopathology confirmed lymphocytic infiltrates, fibrosis, and sebaceous gland changes. The papular phenotype showed inflammation around vellus hair follicles, with sebaceous gland involvement in some cases. Dermoscopy revealed perifollicular erythema, loss of follicular openings, and vellus hair abnormalities, providing diagnostic clues. Treatment responses varied, but oral isotretinoin was notably effective in papular and inflammatory facial lesions. Pigmentary and vascular lesions showed less favorable responses, indicating the need for targeted therapies.

Conclusions

This systematic review highlights the importance of recognizing facial lesions in FFA as early indicators of the disease. Early identification of facial papules, hyperpigmentation, and vascular changes can lead to better outcomes, as these lesions often precede scalp involvement. Trichoscopy and dermoscopy remain essential diagnostic tools in early-stage FFA, and oral isotretinoin shows promise in managing papular and inflammatory lesions. Further studies are required to develop effective treatment strategies for pigmentary and vascular phenotypes.

EADV CONGRESS
VIENNA
30 SEP - 3 OCT 2026

Abstract N°: 3884

Cardiovascular Safety and Efficacy of Low-Dose Oral Minoxidil 5 mg Daily in Men with Androgenetic Alopecia: An Open-Label, Prospective Pilot Study with Echocardiographic Evaluation (MAACD Study)

Shin Shen Yong*[1], Sheng Fei Wong[1], Winn Hui Han[1], Nik Aimee Azizah Faheem[1], Rebecca Kai Jan Choong[1], Ruban Nathan[2]

[1] University Malaya, Kuala Lumpur, Malaysia

[2] Nathan's Skin and Hair Laser Centre, Kuala Lumpur, Malaysia

Introduction

Androgenetic alopecia (AGA) is the most prevalent form of hair loss in men, affecting up to 80% of males by age 70. Low-dose oral minoxidil (LDOM) has recently emerged as a promising therapeutic alternative, but its clinical adoption remains constrained by concerns regarding potential cardiovascular adverse effects. Existing cardiovascular safety data, particularly echocardiographic assessment following LDOM administration, are limited, with no comprehensive local studies to guide clinical practice. We aimed to evaluate the cardiovascular safety profile of LDOM 5 mg daily in men with AGA, with particular emphasis on echocardiographic cardiac function assessment, alongside its clinical efficacy.

Materials and Methods

We conducted an open-label, prospective, single-arm outpatient pilot study at a tertiary dermatology clinic. Thirty-three adult males aged 18–60 years with AGA, without pre-existing hypertension, diabetes, ischaemic or congenital heart disease, phaeochromocytoma, or renal impairment (eGFR <60 mL/min/1.73m^2) were recruited by convenience sampling. Participants received oral minoxidil 5 mg once daily for 6 months. Standardised clinical (anthropometry, blood pressure, heart rate, peripheral oedema), biochemical (full blood count, renal and liver profile), and cardiovascular (12-lead ECG, transthoracic echocardiography including chamber dimensions, ejection fraction, fractional shortening, global longitudinal strain [GLS], TAPSE, diastolic indices, and pericardial/pleural effusion) assessments were performed at baseline and at 6 months. Treatment efficacy was assessed using the Norwood-Hamilton scale, Dermatology Life Quality Index (DLQI), standardised photography, and a self-developed satisfaction questionnaire. Paired t-tests, chi-square/Fisher's exact, and marginal homogeneity (Stuart-Maxwell) tests were performed; $p<0.05$ was considered significant.

Results

Mean age was 34.64 ± 5.38 years (Chinese 48.5%, Malay 39.4%, Indian 9.1%). No statistically significant changes occurred in weight (76.88→76.81 kg; p=0.870), BMI (p=0.853), SBP (126.33→124.06 mmHg; p=0.126), DBP (81.85→79.45 mmHg; p=0.084), or heart rate (77.88→78.36 bpm; p=0.809). No participant developed peripheral oedema, pericardial or pleural effusion. Haematological and hepatic parameters were stable; serum creatinine decreased significantly (81.45→78.18 µmol/L; p=0.028). ECG parameters (PR, QTc), axis deviation, and LV hypertrophy showed no significant change. Echocardiography revealed stable chamber dimensions, ejection fraction (69.78→70.67%; p=0.453), fractional shortening, TAPSE, and preserved diastolic indices (MV E/A, E/E'). Notably, GLS improved significantly from –19.28% to –20.00% (mean difference 0.72; 95% CI 0.10–1.33; p=0.024), suggesting enhanced myocardial contractility. Norwood-Hamilton classifications shifted towards lower-severity categories (χ^2=15.30; p=0.121). DLQI improved significantly, with the “no effect” category rising from 34.4% to

62.5% (χ^2=9.50; p=0.049). Photographic assessment demonstrated moderate-to-good frontal and vertex regrowth. Over 84% of participants reported positive treatment outcomes, with treatment-related satisfaction exceeding 93%.

Parameter	Mean baseline	Mean 6 months	Mean difference (95% CI)	p-value
Chamber sizes				
LVIDd (cm)	4.67 (0.50)	4.78 (0.42)	−0.11 (−0.27, 0.05)	0.177
LA dimension (cm)	3.22 (0.36)	3.21 (0.33)	0.01 (−0.12, 0.14)	0.887
RVDd (cm)	1.78 (0.38)	1.79 (0.40)	−0.01 (−0.14, 0.12)	0.865
Systolic function				
EF (%)	69.78 (6.46)	70.67 (6.33)	−0.89 (−3.27, 1.49)	0.453
FS (%)	39.62 (5.31)	40.60 (5.49)	−0.98 (−3.07, 1.10)	0.344
EDV (mL)	104.17 (19.70)	106.28 (22.14)	−2.11 (−9.82, 5.60)	0.582
GLS (%)	−19.28 (1.26)	−20.00 (1.85)	0.72 (0.10, 1.33)	0.024*
TAPSE (mm)	20.92 (3.08)	21.46 (3.54)	−0.54 (−2.15, 1.06)	0.497
RWMA, n (%)	0 (0)	0 (0)	—	—
Diastolic function				
MV E/A	1.38 (0.31)	1.47 (0.29)	−0.10 (−0.21, 0.02)	0.087
Average E/E'	6.33 (1.47)	6.29 (1.32)	0.04 (−0.35, 0.43)	0.831
Effusion				
Pericardial effusion, n (%)	0 (0)	0 (0)	—	—
Pleural effusion, n (%)	0 (0)	0 (0)	—	—

Table 1. Baseline and 6-month echocardiography (ECHO) parameters.

Conclusions

LDOM 5 mg daily demonstrated an excellent cardiovascular safety profile in healthy men with AGA over 6 months, with no adverse haemodynamic, electrocardiographic, or echocardiographic changes. Improvements in GLS and renal function suggest potential beneficial systemic effects warranting further evaluation. Combined with favourable hair regrowth and high patient-reported satisfaction, these findings support LDOM as a viable, well-tolerated therapeutic alternative for AGA. Larger randomised controlled trials with extended follow-up are warranted.

EADV CONGRESS
VIENNA
30 SEP - 3 OCT 2026

Abstract N°: 3886

Scarring Alopecia and Inflammatory Bowel Diseases – Comorbidity or an Inducing Factor?

Aleksandra Frątczak*[1], Anna Kożuch[2], Weronika Nowicka[2], Wiktor Kruczek[1, 2, 3], Karina Polak[1], Bartosz Miziołek[1], Beata Bergler-Czop[1]

[1] Department of Dermatology, School of Medicine in Katowice, Medical University of Silesia, Katowice, Poland
[2] Students' Scientific Association at the Department of Dermatology, School of Medicine in Katowice, Medical University of Silesia, Katowice, Poland
[3] Doctoral School, Medical University of Silesia, Katowice, Poland

Introduction
Scarring alopecia represents a heterogeneous group of inflammatory disorders leading to irreversible destruction of hair follicles and permanent hair loss. Increasing evidence suggests that immune-mediated mechanisms may play a significant role in the pathogenesis of both scarring alopecia and inflammatory bowel diseases (IBD), including Crohn's disease and ulcerative colitis. The coexistence of these conditions raises questions regarding shared pathogenic pathways, systemic inflammatory background, and the potential influence of IBD on the initiation or progression of cicatricial alopecia. The aim of this study was to evaluate the relationship between scarring alopecia and inflammatory bowel diseases, with particular emphasis on whether IBD may constitute a comorbid condition or a potential inducing factor.

Materials and Methods
A systematic literature review was conducted in accordance with the PRISMA guidelines. The PubMed, Embase, and Scopus databases were searched from their inception until April 2026 using combinations of the following keywords: "scarring alopecia", "cicatricial alopecia", "inflammatory bowel disease", "Crohn's disease", "ulcerative colitis". The literature search was conducted using both MeSH (Medical Subject Headings) and EMTREE terms. Eligible studies included 10 publications addressing adult patients diagnosed with scarring alopecia and concomitant inflammatory bowel diseases, including Crohn's disease and ulcerative colitis, with particular consideration of potential immunological and pathogenic associations between these conditions. Studies involving individuals under 18 years of age, non-scarring forms of alopecia, or patients without confirmed inflammatory bowel disease were excluded.

Results
The reviewed literature demonstrated a potential association between inflammatory bowel diseases and autoimmune-mediated hair disorders, including scarring alopecia and related inflammatory alopecias. Several studies and case reports described the coexistence of ulcerative colitis or Crohn's disease with lymphocyte-mediated alopecia, suggesting a shared immunopathogenic background involving T-cell dysregulation and chronic systemic inflammation. Hair loss in patients with inflammatory bowel disease was reported both as an extraintestinal manifestation and as a potential adverse effect of immunomodulatory therapies, particularly anti-TNF agents and thiopurines. Additionally, emerging evidence highlighted the role of cytokine signaling pathways, including JAK/STAT-mediated

inflammation, in the pathogenesis of both dermatological and gastrointestinal diseases. Some reports indicated clinical improvement of alopecia following treatment with JAK inhibitors, supporting the hypothesis of overlapping inflammatory mechanisms.

Conclusions

Current evidence suggests that scarring alopecia and inflammatory bowel diseases may share common immune-mediated and inflammatory pathways rather than representing an incidental coexistence. Chronic systemic inflammation, T-cell dysregulation, and cytokine-mediated immune responses appear to contribute to the development of both conditions. Furthermore, immunosuppressive and biologic therapies used in inflammatory bowel disease may influence the onset or progression of alopecia in susceptible individuals. Nevertheless, the currently available literature remains limited and heterogeneous, emphasizing the need for further prospective, multicenter studies to clarify the exact relationship between scarring alopecia and inflammatory bowel diseases and to optimize interdisciplinary diagnostic and therapeutic approaches.

EADV CONGRESS
VIENNA
30 SEP - 3 OCT 2026

Abstract N°: 3910

Hormonal profiles and trichoscopic features in Korean women younger than 30 with female pattern hair loss: An observational case-control study

Seong Min Hong*[1], Hee Weon Yun[1], Gyung Hwan Kwon[1], Seung Hee Jang[1], Jung Eun Seol[1], Hyojin Kim[1]

[1] Department of Dermatology, Busan Paik Hospital, College of Medicine, Inje University, Busan, Korea, Rep. of South

Introduction
Female pattern hair loss (FPHL) is a common cause of hair loss in women and characteristics of FPHL vary depending on the age group. In young age under 30 years old, FPHL is known as related to androgen excess, however its role is not fully understood. This study aimed to investigate the clinical characteristics and hormonal profiles of FPHL under 30 years old.

Materials and Methods
Clinical data, gross photographs, trichoscopic findings, and laboratory results (Dehydro-Epiandrosterone Sulfate (DHEA-S), anti-Müllerian hormone (AMH), total testosterone, free testosterone, hemoglobin, thyroid-stimulating hormone (TSH), ferritin) were reviewed in 51 FPHL patients under 30 years old and compared with those of 35 healthy control(HC) under 30 years.

Results
The mean age was 22.6 years over all, 21.7 years in the FPHL group, and 24.0 years in the HC group. The FPHL group had a higher mean body mass index (BMI) (22.6□/□) and a higher prevalence (13.04%) of BMI over 25, compared to those of HC (20.2□/□, 2.86%) (p<0.05). Menstrual irregularity was significantly more frequent in the FPHL group (52.9%) than in the normal group (14.3%) (p<0.05). In FPHL group, 30(58.8%) were compatible with polycystic ovarian syndrome(PCOS) and 78.6% of them showed BMI under 25. In hormonal profiles, mean DHEA-S (242.5±115.3 μg/dL vs. 203.1±96.2 μg/dL), AMH (9.87±12.3 ng/mL vs. 6.39±4.52 ng/mL), and TSH (2.45±1.9 mIU/L vs. 1.53±0.9 mIU/L) were significantly higher in the FPHL group (p<0.05). The FPHL group also showed a higher rate of abnormal AMH levels (45.1% vs. 8.57%). A higher proportion of vellus hairs on trichoscopy was associated with lower mean ferritin levels and a higher frequency of ferritin abnormality in HC groups (p<0.05).

Conclusions
Considering the younger age, higher prevalence of menstrual irregularity and significantly elevated DHEA-S and AMH levels, FPHL before 30 years old may be more influenced by hormonal factors and may reflect underlying hyperandrogenism. Androgen excess can be easily overlooked without targeted evaluation due to phenotypical heterogenicity. Also, ferritin may serve as a more sensitive indicator of hair miniaturization in healthy controls, rather than androgen-related factors.

EADV CONGRESS
VIENNA
30 SEP - 3 OCT 2026

Abstract N°: 3913

Ritlecitinib in middle to severe alopecia areata with eyebrow and eyelash involvement: a single-center, longitudinal real-world outcomes

Xin Ran*[1], Zihan Zhao[2], Ying Huang[1], Yu-Ping Ran[1]

[1] West China Hospital, Chengdu, China

[2] West China School of Medicine, Sichuan University, Chengdu, China

Introduction

Ritlecitinib, a selective JAK3/TEC inhibitor, has demonstrated efficacy in alopecia areata (AA) in randomized clinical trials. However, real-world evidence remains limited. We aimed to evaluate the longitudinal efficacy and safety of ritlecitinib in a real-world single-center cohort of middle to severe AA, including alopecia totalis (AT) and alopecia universalis (AU), with eyebrow and eyelash involvement.

Materials and Methods

This retrospective single-center observational study included 54 patients with AA treated with oral ritlecitinib 50 mg daily between December 2023 and May 2026. Patients with AA, AT, or AU and at least one post-baseline follow-up assessment were included.

Patients aged from 8 to 57, median age of 15 (12–22.5) years, and 54% of patients were female. Median baseline Severity of Alopecia Tool (SALT) score was 40.46 (15.55 – 95.61). AT/AU accounted for 35% of cases, while respectively 41% and 35% had baseline eyebrow and eyelash involvement. Mean follow-up duration was 38.6 weeks, with extended follow-up up to 108 weeks.

Follow-up visits were grouped into predefined windows: baseline (T0), T4 (≤8 weeks), T12 (≤16 weeks), T24 (≤28 weeks), T52 (≤52 weeks), and long-term (>52 weeks). The primary outcome was longitudinal SALT change. Secondary outcomes included SALT50/75/90 response rates, Clinician-Reported Outcome (ClinRO) Eyebrow (EB) Assessment/Eyelash (EL) assessments scores, and subgroup analyses according to disease subtype, baseline severity, disease duration, age, and eyebrow/eyelash involvement.

Longitudinal changes in SALT scores were analyzed using linear mixed-effects models (LMMs) with random intercepts for individual patients to account for repeated measurements, missing data, and unbalanced follow-up intervals inherent to real-world longitudinal studies.

Results

Progressive improvement in SALT score was observed throughout follow-up. Median SALT remained relatively stable during the early treatment phase, changing only minimally from 40.46 at baseline to 40.84 at T4. More substantial improvement emerged after T12, with median SALT decreasing to 26.64, followed by marked reductions to 2.80 at T24 and 2.28 at T52. Sustained responses were also observed during extended follow-up. Median ΔSALT also progressively improved from T4 to long-term follow-up. LMM analysis also demonstrated a significant overall effect of time on SALT score ($F=31.666$, $P<0.001$). This pattern suggests a delayed but accelerated therapeutic response after approximately 12 weeks of treatment, consistent with the characteristic response kinetics of JAK inhibitor therapy in AA.

As illustrated in Figure 1a, consistent with the longitudinal reductions observed in median SALT scores, clinical responses became more apparent after T12. By T24, responder rates increased substantially, reaching 81.25% for SALT50, 59.38% for SALT75, and 37.50% for SALT90. Continued improvement was observed during extended follow-up.

Eyebrow and eyelash involvement also improved progressively (Figure 1b). Patients with ClinRO 2-3 eyebrow

involvement decreased from 20 at baseline to 2 at T52, while ClinRO 2-3 eyelash involvement decreased from 15 to 2 patients.
Subgroup analyses demonstrated significantly more favorable longitudinal trajectories in patients with multiple-patch AA versus AT/AU (F=5.504, P<0.001), baseline SALT <50 versus ≥50 (F=12.171, P<0.001), and patients without baseline eyebrow involvement (F=4.129, P=0.002). No significant interaction was observed for disease duration, age group, or eyelash involvement. No clearly adverse events or treatment discontinuations were observed during follow-up.

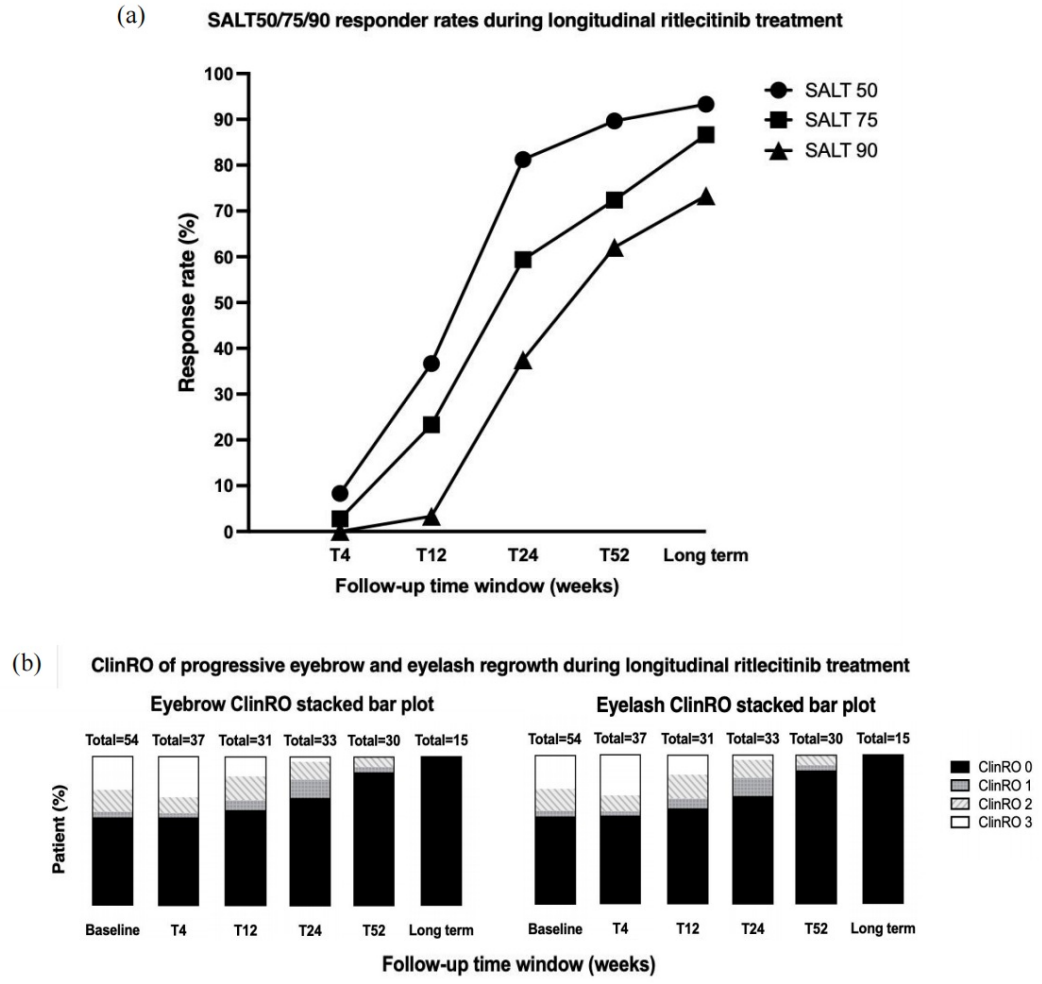

Figure 1. (a) Longitudinal SALT50, SALT75, and SALT90 responder rates during longitudinal ritlecitinib treatment. (b) Longitudinal changes in eyebrow and eyelash ClinRO scores during treatment. Stacked bar plots show the distribution of ClinRO categories across follow-up windows.

Conclusions

Ritlecitinib demonstrated substantial and sustained real-world efficacy in AA, including eyebrow/eyelash involvement. Analyses revealed a characteristic response pattern, with accelerated clinical improvement emerging after approximately 12 weeks. Multiple-patch AA, lower baseline SALT score, and absence of eyebrow involvement were associated with more favorable treatment trajectories.

EA DV CONGRESS
VIENNA
30 SEP - 3 OCT 2026

Abstract N°: 3965

Association Between TNF-α, IL-1β, IL-17A, and IL-6 Cytokine Levels and Depression in Patients with Alopecia Areata

Canan Dere*[1], İlknur Altunay[1], Aslı Aksu[1], Pınar Özdemir Çetinkaya[1], Birgül Özkesici Kurt[1]

[1] University of Health Sciences, Şişli Hamidiye Etfal Training and Research Hospital, Istanbul, Türkiye

Introduction
Alopecia areata is a common immune-mediated skin disease that typically causes patchy hair loss but may involve the entire scalp and body hair. Although its pathogenesis has not been fully elucidated, CD8+NKG2D+ T cells are thought to play a key role in disease development. In this process, altered proinflammatory cytokines may also be associated with disease-related comorbidities. This study aimed to compare serum TNF-α, IL-1β, IL-17A, and IL-6 levels in patients with alopecia areata and healthy controls, and to evaluate the relationship between these cytokines and depression. In addition, associations among clinical characteristics, cytokine levels, and psychosocial scale scores were investigated.

Materials and Methods
This prospective, cross-sectional, case-control study included a total of 88 participants: 44 patients with alopecia areata and 44 age- and sex-matched healthy volunteers. Disease severity in the patient group was assessed using the Severity of Alopecia Tool (SALT) score. Serum TNF-α, IL-1β, IL-17A, and IL-6 cytokine levels were measured using the enzyme-linked immunosorbent assay (ELISA) method. The Hospital Anxiety and Depression Scale (HADS) and the Social Appearance Anxiety Scale (SAAS) were administered to all participants; the Dermatology Life Quality Index (DLQI) was additionally used in the patient group. Group comparisons, Spearman correlation analysis, and linear regression analysis were performed for statistical evaluation.

Results
Among the patients, 79.5% had a SALT score <25, while 20.5% had a score ≥25. Serum IL-6 levels were significantly higher in the patient group than in the control group ($p=0.013$). No significant differences were observed between the groups in TNF-α and IL-17A levels ($p>0.05$). HADS depression, HADS anxiety, and SAAS scores were significantly higher in patients with alopecia areata than in controls [7 (4–9) vs. 3 (1–4.75); 6 (4–10) vs. 4 (1.25–6); 36.5 (21.25–46.75) vs. 19 (16–25), respectively; all $p<0.001$]. The median DLQI score was 3 (IQR: 1–6), indicating generally mild quality of life impairment; however, marked impairment was observed in approximately 11% of patients (n=5). In the patient group, TNF-α levels showed a weak positive correlation with HADS depression scores ($r=0.300$; $p=0.048$). In multiple linear regression analysis adjusted for age, sex, and active smoking, log-transformed IL-6 level was independently associated with HADS depression score ($B=3.598$; $\beta=0.352$; 95% CI: 0.598–6.599; $p=0.024$).

Conclusions
Patients with alopecia areata had higher serum IL-6 levels, HADS depression and anxiety scores, and SAAS scores than healthy controls. Findings regarding serum cytokine levels and depression scores, particularly IL-6 and TNF-α, support a possible relationship between systemic inflammation and psychiatric symptoms in alopecia areata. Alopecia areata should be considered a multifactorial clinical condition in which systemic inflammatory processes

and psychosocial factors may contribute beyond hair follicle involvement. Larger prospective studies are needed to further clarify these relationships.

EA DV CONGRESS
VIENNA
30 SEP - 3 OCT 2026

Abstract N°: 3976

Beyond approved therapies: off-label oral Janus kinase inhibitors for alopecia areata - a systematic review of efficacy and safety in adolescents and adults

Samuel Morriss*[1], Chuan Hui Foo[2, 3], Emily Lin[4, 5], Sharon Lee[3], Holly FitzGerald[6], Molly Greenwood[6], Bevin Bhoyrul

[1] The Royal Melbourne Hospital, Parkville, Australia
[2] Sultan Idris Education University, Tanjong Malim, Malaysia
[3] The University of Queensland, St Lucia, Australia
[4] Monash University, Clayton, Australia
[5] Monash Health, Clayton, Australia
[6] Sinclair Dermatology, East Melbourne, Australia

Introduction
Alopecia areata (AA) is a chronic, immune-mediated disorder characterised by non-scarring hair loss driven by a collapse of hair follicle immune privilege. While recent regulatory approvals of oral Janus kinase (JAK) inhibitors (such as baricitinib, ritlecitinib, and deuruxolitinib) have revolutionised the treatment of severe AA, access remains limited or cost-prohibitive in many regions. Consequently, off-label oral JAK inhibitors, including tofacitinib, upadacitinib, ruxolitinib, and abrocitinib, are frequently utilised. The objective of this systematic review and meta-analysis is to synthesise the efficacy and safety of off-label oral JAK inhibitors in adolescent and adult patients with AA.

Materials and Methods
MEDLINE, Embase, and the Cochrane Central Register of Controlled Trials (CENTRAL) databases were systematically searched from inception to 16 March 2026. Studies evaluating off-label oral JAK inhibitors as monotherapy in adolescents and adults (≥12 years) with AA were included. Efficacy outcomes focused on absolute regrowth (Severity of Alopecia Tool [SALT] scores ≤10 and ≤20) and relative regrowth thresholds (SALT50, SALT75, and SALT90) stratified by time intervals: <12 weeks, 12-36 weeks, and ≥36 weeks. Safety outcomes included any adverse event (AE), severe AEs, serious AEs, and discontinuations due to AEs. Data were synthesised using a random-effects generalised linear mixed model to calculate pooled proportions and 95% confidence intervals (CIs).

Results
A total of 28 studies (comprising RCTs, open-label trials, retrospective cohorts, and case series) involving 897 patients met the inclusion criteria. Rapid onset of therapeutic effect was observed at <12 weeks, with approximately 45-50% of patients achieving SALT50, though early absolute endpoints (SALT ≤10 and ≤20) remained imprecise. Efficacy strengthened rapidly between weeks 12 and 36: the overall pooled proportion for SALT50 was 0.70 (95% CI 0.60-0.78), SALT75 was 0.50 (95% CI 0.27-0.72), and SALT90 was 0.29 (95% CI 0.16-0.47). Notably, upadacitinib demonstrated significantly higher SALT90 achievement than tofacitinib during this window ($p \approx 0.007$). In terms of absolute scores, tofacitinib pooled estimates reached 0.08 (95% CI 0.04-0.14) for SALT ≤10 and 0.20 (95% CI 0.08-0.44) for SALT ≤20. Efficacy proved durable and stable beyond 36 weeks, with an overall pooled effect of 0.64 (95% CI 0.50-0.77) for SALT50 and 0.49 (95% CI 0.37-0.61) for SALT75. For tofacitinib beyond week 36, SALT ≤20 was achieved in 37% of patients (95% CI 0.16-0.64) and near-complete regrowth (SALT ≤10) in 31% (95% CI 0.15-0.53). Regarding safety, the pooled proportion experiencing any AE was 0.33 (95% CI 0.23-0.45). Severe and serious AEs were exceedingly rare in that only one severe AE (0.14%) and zero serious AEs (0.00%) were reported. Discontinuation due to AEs occurred in just 0.69% of patients, all within

tofacitinib cohorts.

Conclusions

Off-label oral JAK inhibitors demonstrate robust and durable efficacy in promoting hair regrowth for patients with AA. Efficacy increases progressively over time across all SALT thresholds, with selective agents like upadacitinib showing potential superiority in achieving high-threshold responses (SALT90) compared to tofacitinib. Supported by an exceedingly reassuring safety profile with negligible serious adverse events or discontinuation rates, off-label JAK inhibitors remain a viable therapeutic option for severe AA where approved alternatives are inaccessible.

EA DV CONGRESS
VIENNA
30 SEP - 3 OCT 2026

Abstract N°: 3994

Synthetic Data Generation for Automated Hair Instance Segmentation in Trichoscopy: A Multi-Strategy Evaluation

Mohamed Ali Ben Youssef[1], Khoi Dang[1], Duc Thang Nguyen[1], Yoon Kyoung Kim[2], Awatef Kelati[3], Hang Nguyen*[1]

[1] Belle.ai, Toulouse, France

[2] Faculty of Medicine, Imperial College London, London, United Kingdom

[3] Department of Dermatology. Cheikh Khalifa International University Hospital, Casablanca, Morocco

Introduction

Trichoscopy provides dermatologists with direct visualization of the scalp and hair shafts and is routinely used in the diagnosis and monitoring of alopecia. Quantitative analysis like hair density, shaft caliber, follicular unit counting currently relies on manual inspection, which is time-consuming and subject to inter-observer variability. Deep learning models for instance segmentation can automate these measurements but require large quantities of pixel-precise annotations that are prohibitively expensive to produce for hair shafts, given their number and morphological complexity. In this work, we develop and evaluate a synthetic data generation pipeline for trichoscopy hair instance segmentation, and to quantify the extent to which synthetic images can reduce the need for manual pixel-level annotation.

Materials and Methods

We created a system that generates labeled synthetic trichoscopy images using two reusable components (1) a scalp library, generated by removing hairs using an inpainting model and (2) a segment library: individual hair images cropped from manually annotated images. Hair segments are composited onto clean scalps at detected follicle positions, with per-instance rotation and edge feathering (Figure 1). Polygon annotations are derived automatically, requiring no additional labeling.

Two strategies were evaluated.

S1: 60/40 split of the 284 images; 60% as source to generate synthetic images, 40% as test set. For the training set, we have three scenarios: real images only, synthetic images only, and combined both.

S2: Scalps and follicle positions generated from a separate unannotated dataset (251 images), for which 174 were **sparsely** annotated for segment extraction only, with **few** visually valid hairs labelled per image, allowing scalp and hair identity to be decoupled for maximal variety.

All models used yolo26l-seg (28 M parameters). Primary metrics: Mask mAP50 (segmentation) and Box mAP50 (detection).

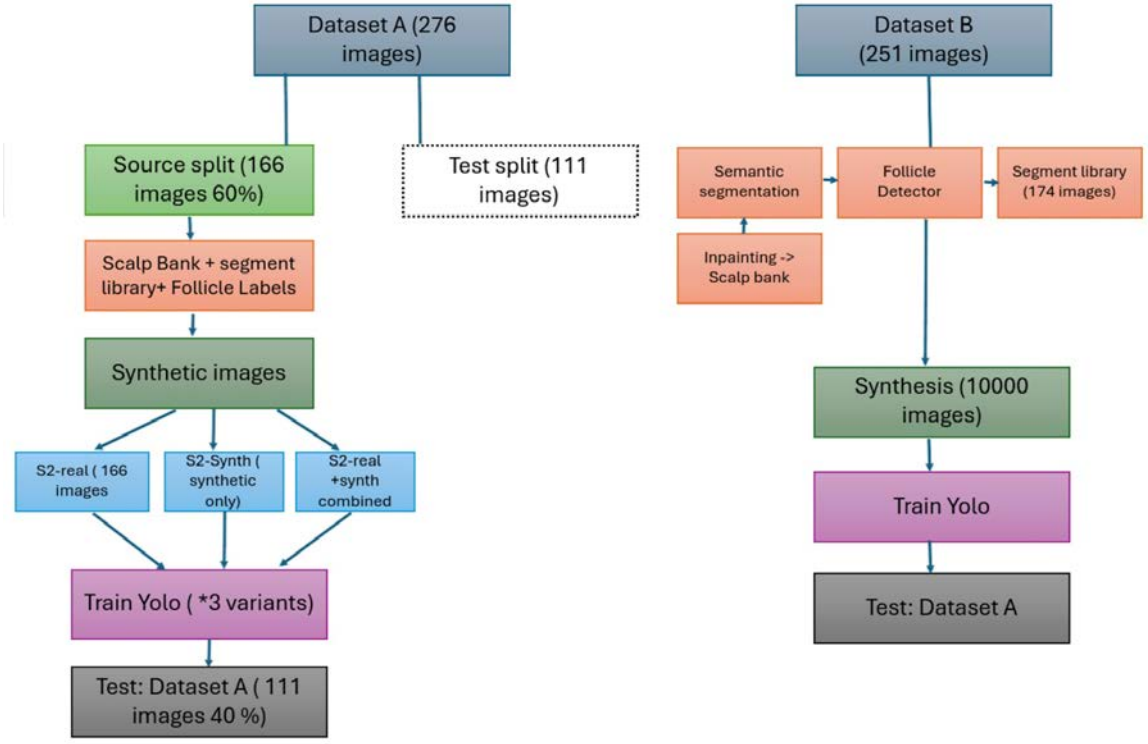

Figure 1. Data flow for the three experimental strategies

Results

The summary of the result is in Table 1.

Table 1. Instance segmentation performance across training strategies. S1 variants share the same 40 % held-out test set; S2 are tested on all 276 real annotated images.

Strategy	Training data	Test set	Mask mAP50	Box mAP50
S1-real	Real only	111 real	0.37	0.74
S1-synth	Synthetic only	111 real	0.35	0.66

For S2, white/vellus-hair annotations were excluded from the test ground truth before scoring — as these hairs were outside the models' training scope which raised both strategies' scores by approximately 2%.

S1: The synthetic-only model reached Mask mAP50 0.34 / Box mAP50 0.66, reaching 92% of the real-annotations baseline (0.37 / 0.74) without pixel-level annotation of the synthetic images themselves. Combining both sources yielded the best overall result (Mask mAP50 0.43 / Box mAP50 0.79, +3% over real data alone), confirming that synthetic images complement rather than duplicate real annotations.

S2 cross-dataset transfer. Trained on a separate dataset (251 images; 174 partially annotated for segment extraction), S2 reached Mask mAP50 0.22 / Box mAP50 0.52. The gap reflects cross-dataset domain shift and sets a practical lower bound for near-annotation-free deployment.

Detection vs. segmentation. Box mAP50 exceeded Mask mAP50 by 0.30–0.41 across all strategies: follicle localization is consistent, while precise mask delineation remains the main bottleneck.

Conclusions

Our pipeline generates an unlimited supply of precisely annotated trichoscopy images from a small real specimen pool. Synthetic-only training reached 92 % of supervised performance; augmenting real annotations with synthetic data yielded the best model. These findings support data synthesis as a practical strategy for scaling computational trichoscopy, especially where annotation resources are limited. Future work will address cross-dataset generalisation through follicle-size normalisation and domain adaptation.

EADV CONGRESS
VIENNA
30 SEP - 3 OCT 2026

Abstract N°: 4028

Association Between Domestic Water Quality and Hair and Scalp Health in Young Adults: A Cross-Sectional Comparative Study from Osh

Amegha Nair*[1]

[1] Osh State University, International Medical Faculty, Osh, Kyrgyzstan

Introduction
Hair and scalp health are influenced by several environmental factors, including climate, air pollution, and water quality. Hard water containing high concentrations of calcium and magnesium may contribute to scalp irritation, dryness, dandruff, and hair shaft damage. However, limited data are available from Central Asian countries regarding the association between domestic water quality and scalp and hair health. This study aimed to compare scalp and hair health among young adults using domestic tap water and purified filtered water in Osh.

Materials and Methods
A cross-sectional observational comparative study was designed among 60 participants aged 18–35 years. Participants were categorized into two groups based on their primary water source for hair washing: tap water users (n=30) and purified filtered water users (n=30). Data were assessed using structured questionnaires evaluating hair fall, scalp dryness, dandruff, scalp irritation, and overall hair satisfaction. Information regarding washing frequency, shampoo type, oil application, and other hair care practices was also collected. Parameters were graded using a 0–4 scoring scale and analyzed descriptively and comparativel

Results
Preliminary observations suggested that participants using domestic tap water reported higher frequencies of scalp dryness, dandruff, and hair fall compared to participants using purified filtered water. Variations in hair texture satisfaction and scalp comfort were also observed between the two groups

Conclusions
Domestic water quality may represent an important modifiable environmental factor influencing scalp and hair health among young adults. Further large-scale studies are recommended to better evaluate the dermatological impact of water mineral composition and household water quality.

EA DV CONGRESS
VIENNA
30 SEP - 3 OCT 2026

Abstract N°: 4032

Unmet needs in textured hair: Insights from a patient-based survey on shampoo satisfaction

Lina Mouline*[1], Fatima Zahra Hammoud[1], Bouchra Idrissi Rhenimi[1], Najoua Ammar[1], Syrine hamada[1], Nadia Ismaili[1], Laila Benzekri[1], Mariame Meziane[1]

[1] Dermatology Venereology Department, Ibn Sina University Hospital, Rabat, Morocco

Introduction
Hair care satisfaction is strongly influenced by hair structure and grooming practices. Despite the wide availability of cosmetic and dermocosmetic shampoos, real-world patient-reported outcomes remain insufficiently explored in textured hair populations. Understanding these practices is essential to guide dermatological counseling.

Materials and Methods
A cross-sectional survey was conducted between September and November 2025 among 100 Moroccan participants. Data collected included age, sex, hair type (Andre Walker classification), washing habits, product use, selection criteria, expectations, and satisfaction.

Results
The study included 100 participants, predominantly women in their third decade of life. Hair textures were mainly wavy to curly, with type 2C–3A accounting for 47%, followed by 3B–3C.

Hair washing was most commonly performed 2–3 times per week (61%), followed by once weekly (23%). Shampoo was used at each wash by 87.9% of participants, whereas only 57.4% systematically used conditioner.

Cosmetic shampoos were predominantly used (76.5%), compared to dermocosmetic products (23.5%). Hydration and nutrition ranges were the most frequently selected (38.8%), followed by repair (16.4%), anti-hair loss (13.9%), and straightening products (10.9%).

Regarding formulation preferences, 64% of participants reported no strict criteria, while 24% preferred sulfate-free products, 22% paraben-free, and 14% silicone-free formulations.

The main expectation from shampoos was the prevention of dryness and frizz (72%), followed by affordability (41%) and control of greasiness (38%). However, dryness and frizz were also the most frequently reported complaint (43%), followed by lack of efficacy for specific hair concerns (19.8%) and dandruff (11%).

Overall satisfaction was limited, with only 18.8% of participants reporting full satisfaction, while 53.5% were partially satisfied and 27.7% dissatisfied.

Traditional practices were frequently reported, including hair oiling (43%), henna use (19%), and rhassoul/clay application (19%).

Conclusions
This study highlights a significant gap between patient expectations and the performance of commonly used shampoos in individuals with textured hair. The fact that dryness and frizz represented both the primary expectation (72%) and the leading complaint (43%) underscores a persistent unmet need in this population.

Previous structural studies have shown that textured hair is characterized by increased porosity, shaft curvature, cuticular irregularities, and greater mechanical fragility, factors that may contribute to reduced moisture retention, frizz, and breakage. These intrinsic characteristics, combined with specific grooming habits and cultural practices, likely influence both product performance and patient satisfaction.

Traditional practices such as hair oiling, henna application, and clay use may therefore represent adaptive responses to the specific needs of textured hair rather than simple cultural habits.

These findings emphasize the importance of integrating hair texture, real-world behaviors, and culturally relevant practices into dermatological counseling. A more tailored approach, combining adapted formulations with better understanding of textured hair physiology, may improve patient satisfaction and optimize hair care outcomes in diverse hair populations.

EADV CONGRESS
VIENNA
30 SEP - 3 OCT 2026

Abstract N°: 4052

Cicatricial alopecia post hair transplant: a case series and literature review

Francesca Pampaloni*[1], Maria Theodora Sirtoli Marcondes[2], Michela Starace[1]

[1] Dermatology Unit, IRCCS Azienda Ospedaliero-Universitaria di Bologna, Bologna, Italy, Bologna, Italy

[2] Universidade Federal do Estado do Rio de Janeiro - UNIRIO, Rio de Janeiro, Brazil // Hospital Universitário dos Servidores do Estado (HUSE/ UNIRIO), Rio de Janeiro, Brazil

Introduction
Cicatricial alopecia (CA) comprises a heterogeneous group of inflammatory disorders leading to irreversible destruction of hair follicles and permanent hair loss. With the increasing popularity of hair transplantation techniques, including follicular unit extraction (FUE) and follicular unit transplantation (FUT), recognition of post-surgical scarring alopecia as a potential complication is becoming increasingly relevant.

The aim of this study is to describe the clinical and trichoscopic features of cicatricial alopecia occurring after hair transplantation through a case series and review of the literature.

Materials and Methods
We retrospectively reviewed adult patients presenting with cicatricial alopecia after hair transplantation at a tertiary dermatology center. Demographic, clinical, trichoscopic, histopathological, and therapeutic data were collected. In parallel, a narrative literature review was conducted in PubMed using predefined keywords related to cicatricial alopecia and hair transplantation.

Results
Four patients (3 males, 1 female; mean age 43.3 years) were identified. Alopecia onset ranged from 1 month to 10 years after transplantation. Clinical findings included cicatricial alopecic patches with erythema, scaling, crusting, pustules, and nodules. Trichoscopy showed perifollicular erythema and scaling, hemorrhagic crusts, broken hairs, yellow dots, perifollicular hyperkeratosis, and loss of follicular ostia. Three patients had erosive pustular dermatosis of the scalp and one had lichen planopilaris. Treatments included topical/systemic corticosteroids, doxycycline, oral minoxidil, and topical isotretinoin.

The literature review identified 12 studies comprising 51 patients. Lichen planopilaris was the most frequently reported diagnosis (80.3%), followed by erosive pustular dermatosis and other neutrophilic scarring alopecias. Disease onset varied widely, from 1 month to over 20 years after transplantation.

Conclusions
Cicatricial alopecia following hair transplantation is an uncommon but likely underrecognized

complication with variable latency and heterogeneous clinical presentations. Early recognition through clinical and trichoscopic assessment is essential to prevent irreversible follicular destruction and optimize management.

EA DV CONGRESS
VIENNA
30 SEP - 3 OCT 2026

Abstract N°: 4053

Immune-metabolic disorders in patients with alopecia areata.

Galyna Girnyk*[1], Marian Voloshynovych[1], Oleksa Bondarenko[1], Maria Matluk[1]

[1] Ivano-Frankivsk national medical university, Ivano-Frankivsk, Ukraine

Introduction

Alopecia areata is considered a chronic autoimmune pathology, characterized by frequent relapses and variable severity of the course. Violations of the body's supply of vitamin D, as well as imbalance of calcium-phosphate metabolism significantly affect the formation of the clinical severity of the disease. The study of these pathophysiological links makes it possible to identify markers predicting severe course and substantiate effective approaches to pathogenetic therapy. The study objective is to assess the impact of vitamin D deficiency and calcium-phosphate homeostasis disorders on the severity of alopecia areata, as well as to determine their significance as predictors of the chronicity of the process and response to therapy.

Materials and Methods

A systematic meta-analysis of 34 studies (n=17286) from PubMed, Scopus, Web of Science, and EMBASE was performed, and 20 patients (mean age 32.5 ± 7.8 years; 65% women) were prospectively followed up, divided into groups with 25(OH)D deficiency.

Results

A meta-analysis of 34 studies with a total sample of 17,286 patients showed that the mean 25(OH)D level in patients with alopecia areata (AA) was 14.2 ± 5.3 ng/mL, while in controls it was 27.1 ± 6.8 ng/mL ($p < 0.001$). 25(OH)D deficiency (<20 ng/mL) was observed in 61.7–88.4% of patients with AA, while in controls this figure ranged from 26 to 29.5% (95% CI: 26.2–33.8). It was found that 25(OH)D deficiency increases the risk of severe forms of AA by 4.2 times (OR = 4.23; 95% CI: 2.91–6.15; $p < 0.0001$), and at a level <15 ng/ml the risk of chronicity increases by 82%. Disturbance of calcium-phosphate homeostasis was noted in 58–68% of patients, manifested by a decrease in total calcium by 12–18%, ionized calcium by 9.7–14.5%, phosphate by 15–21% and an increase in parathyroid hormone by 25.6–41.2% ($p < 0.01$). A prospective cohort study included 20 patients (mean age 32.5 ± 7.8 years, 65% female), divided into a 25(OH)D deficiency group <20 ng/mL (n = 12) and a normal level group ≥20 ng/mL (n = 8). In the deficiency group, severe AA occurred in 67%, moderate in 25%, mild in 8%, relapses within 6 months in 66.7%, C-reactive protein (CRP) >5 mg/L in 58%, total calcium decreased in 60%, ionized calcium in 65%, phosphate in 45%, and PTH increased in 41.7%. In the normal 25(OH)D group, severe AA was 12%, moderate was 37.5%, mild was 50%, relapses were 25%, CRP >5 mg/L was 12.5%, total and ionized calcium were reduced by 12.5%, phosphate and PTH were increased in 12.5%. Hair growth restoration after correction of 25(OH)D calcium-phosphate balance was observed in 68% of patients within 12–16 weeks, while in the group without correction it was only in 24%. The average SALT index in the deficiency group was 54.3 ± 18.7%, in the normal 25(OH)D group it was 28.6 ± 14.2%.

Conclusions

Correlation analysis showed an inverse relationship between 25(OH)D levels and AA severity according to SALT ($r = -0.61$; $p = 0.003$), as well as a direct relationship between PTH and AA severity ($r = +0.54$; $p = 0.004$). Thus, the results of the meta-analysis and prospective study demonstrate that 25(OH)D deficiency and secondary hyperparathyroidism are key predictors of severe and chronic forms of AA, increase the risk of relapse by 41–44%, reduce the duration of remission by 40–41% and ensure the effectiveness of therapy with timely correction of metabolic imbalance.

EA DV CONGRESS
VIENNA
30 SEP - 3 OCT 2026

Abstract N°: 4065

Increased female representation in hair loss research: A bibliometric analysis of 1975-2025

Eric McMullen[1], Christopher Shenouda[2], Brendan Amoyaw*[3], Cathryn Sibbald[1], Jeffrey Donovan[3]

[1] University of Toronto, Toronto, Canada

[2] McMaster University, Hamilton, Canada

[3] University of British Columbia, Vancouver, Canada

Introduction

Dermatology research has evolved into an increasingly international and multidisciplinary field.Previous studies have identified key trends, including the underrepresentation of women in research. This study aims to evaluate trends in hair loss research over the past five decades.

Materials and Methods

Citations were collected from the WoS Core Collection (1975-October 2025), an online database that enables analysis of the most cited studies and researchers. Data were queried using the filter “Hair Disorders” combined with several hair loss keywords. English peer-reviewed work including meeting abstracts and editorial material were included. Author sex/gender identity was inferred based on first name. When this was unclear, a Google search using the author’s institutional affiliation was conducted and pronouns recorded.

Results

A total of 12,301 results were identified. Countries with the largest number of hair loss publications included the United States (32%, n=3,889), China (10%, n=1,288), Germany (8%, n=959), South Korea (8%, n=958), and England (8%, n=953). The top 20 cited articles are summarized in Table 1. The top five authors collectively had 31,421 citations (25.6%) and 865 publications. Of the 50 most cited publications, women comprised 24 of the 50 (48%) first authors and 8 of the 50 (16%) senior authors. Of the 50 most cited authors in hair loss research, 21 (42%) were female.

Table 1. Number of hair loss publications by country

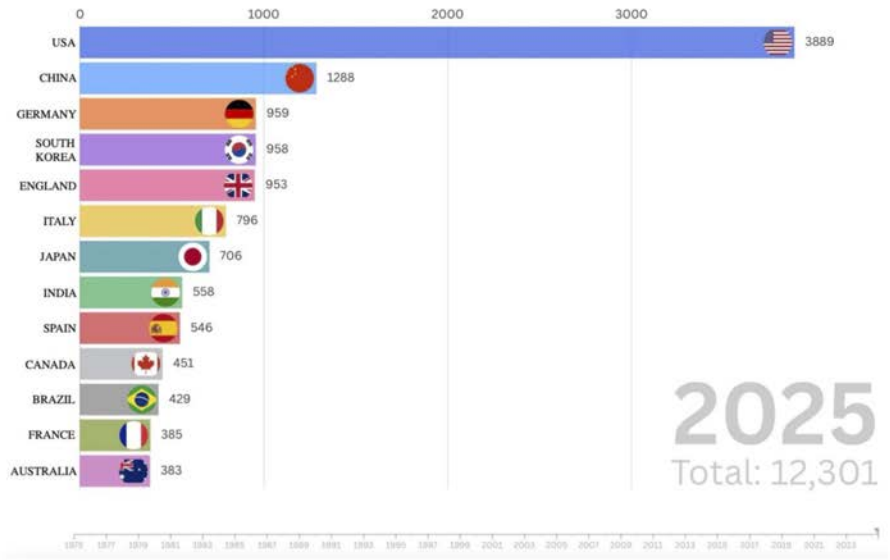

Conclusions

Limitations include reliance on first-name-based sex/gender identity classification, and author name changes. Article numbers for authors were limited to those relevant to hair loss disorders and to one database. Further study of the successes of drawing women into certain areas of dermatology research may prove valuable as a model for other disciplines. Research is needed to understand how gender, funding and geography influence dermatology research, to obtain an equitable and globally representative field.

EA DV CONGRESS
VIENNA
30 SEP - 3 OCT 2026

Abstract N°: 4070

Low-Level Light Therapy versus Sham Treatment for Hair Density in Androgenetic Alopecia: A Systematic Review and Meta-Analysis of Randomized Controlled Trials

Sharifah Almasoud*[1], Yazan Alalwani[2], Ahmed Bahattab[3], Abdullah AlHwiriny[4], Hussain Almarzoug[5], Yara Almutairi[6], Hajeer Alhadi[7], Sumoud AlQurashi[8], Abrar Altayeb[9], Raghad Alharbi[10], Taif Alshehri[11], Rahaf Alshehr[12], Saleh Bu Mozah[13], Reem Alqahtani[14], Ahmed Azzam[15]

[1] College of Medicine, Majmaah University, Majmaah, Riyadh, Saudi Arabia

[2] Imam Abdulrahman Bin Faisal University College of Medicine, Dammam, Saudi Arabia

[3] College of Medicine, King Saud bin Abdulaziz University for Health Sciences, Riyadh, Saudi Arabia

[4] Department of Dermatology, King Fahad Specialist Hospital, Buraydah, Saudi Arabia

[5] College of Medicine, King Faisal University, Al-Ahsa, Saudi Arabia

[6] College of Medicine, Imam Abdulrahman Bin Faisal University, Dammam, Saudi Arabia

[7] College of Medicine, Al Baha University, Al baha, Saudi Arabia

[8] Umm Al-Qura University, Saudi Arabia, MAKKAH, Saudi Arabia

[9] College of Medicine, Princess Nourah bint Abdulrahman University, Saudi Arabia, Riyadh, Saudi Arabia

[10] King Saud bin Abdulaziz University for Health Sciences College of Nursing, Riyadh, Saudi Arabia

[11] Al-Sulaimaniah Primary Health Care Center, Riyadh, Saudi Arabia, Riyadh, Saudi Arabia

[12] Al-Manar Primary Health Care Center, Riyadh, Saudi Arabia, Riyadh, Saudi Arabia

[13] College of Medicine, King Faisal University, Al-Ahsa, Saudi Arabia, Al-Ahsa, Saudi Arabia

[14] King Abdulaziz Hospital, Al-Jouf, Saudi Arabia, Al jouf, Saudi Arabia

[15] Division of Global Health and Public Health, School of Nursing, Midwifery and Public Health, University of Suffolk, Ipswich, United Kingdom, Ipswich, United Kingdom

Introduction
Low-level light therapy (LLLT) has demonstrated possible benefits for hair growth in androgenetic alopecia (AGA); however, the magnitude and consistency of treatment effects across different populations and device types remain incompletely characterized. This systematic review and meta-analysis aimed to evaluate the efficacy of LLLT compared to sham treatment for hair density improvement in patients with AGA.

Materials and Methods
Following PRISMA 2020 guidelines, we searched PubMed, Scopus, Cochrane Library, and Web of Science up to December 12, 2025. Randomized controlled trials (RCTs) comparing LLLT to sham devices in AGA patients were included. The primary outcome was change in hair density measured as hairs/cm². Random-effects meta-analysis, subgroup analyses, and sensitivity analyses were performed.

Results
Eleven RCTs enrolling 890 patients were included. LLLT significantly increased hair density compared to sham treatment (mean difference [MD]: 18.55 hairs/cm², 95% confidence interval [CI]: 13.07 to 24.04, P-value<0.00001). Significant heterogeneity was observed (I^2=89.1%). Subgroup analyses revealed significant differences by device type (P-value=0.016) and ethnicity (P-value=0.010), with helmet devices and Caucasian populations demonstrating greater benefits.

Leave-one-out sensitivity analysis identified Barikbin 2017 as the major heterogeneity contributor (46.0% of total Q). Trim-and-fill imputed two missing studies, with adjusted MD remaining significant (16.34 hairs/cm², 95% CI: 11.13 to 21.56).

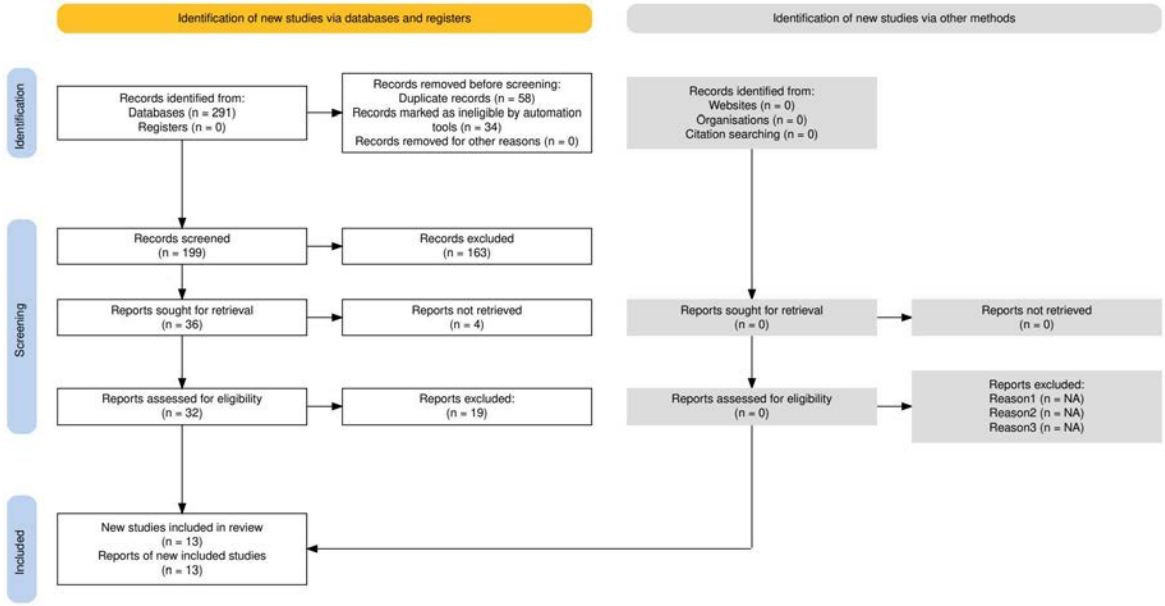

Fig 1. PRISMA Flowchart

Conclusions

LLLT was found to significantly improve hair density in AGA patients compared to sham treatment. Treatment effects varied by device type and ethnicity, highlighting the importance of individualized therapeutic approaches.

EA DV CONGRESS
VIENNA
30 SEP - 3 OCT 2026

Abstract N°: 4080

Central Centrifugal Cicatricial Alopecia in Male Patients: A Systematic Review

Brendan Amoyaw*[1], Eric McMullen[2], Chi Azurunwa[3], Narachai Julanon[4], Marissa Joseph[2]

[1] University of British Columbia, Vancouver, Canada
[2] University of Toronto, Toronto, Canada
[3] McMaster University, Hamilton, Canada
[4] Khon Kaen University, Khon Kaen, Thailand

Introduction
Central centrifugal cicatricial alopecia (CCCA) is an inflammatory scarring alopecia and is common in Black women. Rarely, men are diagnosed with CCCA, but little is known about the clinical features of CCCA in men. This systematic review aims to synthesize and critically appraise the current literature on CCCA in males.

Materials and Methods
MEDLINE, Embase, and CENTRAL were searched from inception to January 2026 using keywords relevant to CCCA and males. Backward citation chaining of articles was performed. This review followed PRISMA 2020 reporting guidelines and was registered on PROSPERO (CRD420261336390). Eligible studies included cases of males with CCCA diagnoses. Exclusions consisted of abstracts, reviews, and non-English texts. Two reviewers performed the risk of bias assessment using the Joanna Briggs Institute checklists, with conflicts resolved by a third reviewer. All included studies were rated as low (50.0%) or moderate (50.0%) risk of bias.

Results
Eight case series, one case report, and one retrospective multicenter study met eligibility criteriaincluding 51 male patients with a mean reported age, age of CCCA onset, of 36.4 years (range: 18–56 and 23.3 years. Mean time to diagnosis after disease onset was 1.9 years. Ethnoracial groups included Black (93.5%), White (3.2%), and other (3.2%). Complete clinical characteristics are outlined in **Table 1**.

A family history of any type of hair loss was common (47.2%). Two studies quantified CCCA severity with the Central Scalp Alopecia Photographic Scale, a 6-point scale that characterizes alopecia severity from 0 to 5. Most patients (78.6%) on this scale were 3B or more severe. Of patients where hair practices were reported (n=25), braids or cornrows (24.0%), relaxers or texturizers (8.0%), hot razors or combs (8.0%) and colouring (4.0%) were most common.

Symptoms and clinical findings were reported in 37 patients. Pruritus was the most common symptom (40.5%), followed by papules (24.3%), scale (21.6%), hair thinning (18.9%), scalp lesions (13.5%), tenderness (10.8%) and bleeding (10.8%). Hair loss distribution was reported, and the classic centrifugal distribution beginning at the vertex (72.2%) was most common. Other distributions included occipital (8.3%) and diffuse (8.3%). Concurrent hair loss disorders were reported in eight patients, including two patients with male pattern hair loss and lichen planopilaris, respectively, and one patient with lichen simplex chronicus of the scalp. Scalp biopsy to confirm diagnosis was performed in most patients (n=50/51). Trichoscopy was used to diagnose most patients (74.5%, n=38/51). Detailed histologic and trichoscopic findings for all patients were analyzed, with many patients

presenting with pustules, inflammatory or hyperpigmented follicular papules, scale, perifolluiclar fibrosis, lymphocytic inflammation, and premature desquamation, among other findings. Past treatments were inconsistently reported, and longitudinal treatment-response data were unavailable.

Table 1. Summary of clinical and epidemiological characteristics of male CCCA patients.

Patient characteristics	**n = 51**
Ethnoracial Group	**n = 31**
Black or African American, n (%)	29 (93.5)
White, n (%)	1 (3.2)
Other, n (%)	1 (3.2)
Clinical Features	
Mean (SD) age of CCCA onset (individually reported data), years	23.3 (10.2)
Mean (SD) time from CCCA onset to diagnosis (individually reported data), years	1.9 (1.7)
Mean (SD) patient age (all available data), years	36.4 (9.8)
Mean (SD) patient age (individually reported data), years	30.9 (10.4)
Family history reporting	**n = 36**
Positive family history of hair loss	17 (47.2)
High risk hair practices	**n = 11**
Permanent hair coloring	1 (9.1)
Locs, braids, or cornrows	6 (54.5)
Relaxer or texturizer	2 (18.2)
Hot razor use or frequent haircuts	2 (18.2)
Concurrent hair loss disorders	**n = 5**
Male pattern hair loss	2 (40.0)
Lichen planopilaris	2 (40.0)
Lichen simplex chronicus	1 (20.0)
Symptomatic and Clinical Events	**n = 58**
Pruritus	15 (25.9)
Bleeding	4 (6.9)
Erythema	2 (3.4)
Pain or tenderness	4 (6.9)
Hair thinning	7 (12.1)
Irritation	1 (1.7)
Scalp lesions	5 (8.6)
Scalp flakiness or scaliness	8 (13.8)
Dryness	1 (1.7)
Purulent drainage	1 (1.7)
Pustules	1 (1.7)
Papules	9 (15.5)
Hair Loss Distribution Patterns	**n = 36**
Occipital	3 (8.3)
Diffuse	3 (8.3)
Undetermined	1 (2.8)
Vertex	26 (72.2)
Concurrent Hair Loss Disorders	**n = 8**
Lichen planopilaris	2 (25.0)
Lichen simplex chronicus	1 (12.5)
Male pattern hair loss	2 (25.0)
Seborrheic dermatitis	1 (12.5)
Acne keloidalis nuchae	1 (12.5)
Dissecting cellulitis	1 (12.5)
Diagnostic tool usage	**n = 51**
Analysis by Trichoscopy	3 (5.9)
Scalp biopsy performed	51 (100.0)

Conclusions

Data is limited on CCCA in males, but it appears clinically and histologically the same as CCCA in females in the reported cases.

Limitations include low sample sizes and poor reporting of treatments. Cases consisted of mostly observational case reports/series. Future large-scale studies comparing diverse sexes and ethnoracial groups will allow for the continued understanding of the clinical and diagnostic outcomes in CCCA.

EADV Congress 2026, VIENNA
30 SEPTEMBER - 03 OCTOBER 2026
POWERED BY M-ANAGE.COM

EA DV CONGRESS
VIENNA
30 SEP - 3 OCT 2026

Abstract N°: 4114

Psychosocial impact of scarring alopecia: A cross-sectional analysis of social media posts

Brendan Amoyaw*[1], Sana Gupta[2], Eric McMullen[3], Elisabeth Jonah[4], Chi Azurunwa[4], Chinyere Iro[4], Lola Irelewuyi[4], Graziella Djuidje De Pandja[4], Marissa Joseph[3], Narachai Julanon[5], Jeffrey Donovan[1]

[1] University of British Columbia, Vancouver, Canada
[2] University of Ottawa, Ottawa, Canada
[3] University of Toronto, Toronto, Canada
[4] McMaster University, Hamilton, Canada
[5] Khon Kaen University, Khon Kaen, Thailand

Introduction

Scarring alopecias are frequently associated with significant psychological distress and impaired quality of life. Social media platforms provide unique opportunities to better understand patient experiences. This study aimed to characterize YouTube and TikTok videos related to scarring alopecia in order to better understand the psychological impact of these diseases and differences across platforms.

Materials and Methods

YouTube and TikTok were searched from inception to December 2025 using the format, "My [diagnosis] story" and specific keywords, "frontal fibrosing alopecia" (FFA), "lichen planopilaris" (LPP), "central centrifugal cicatricial alopecia" (CCCA), and "scarring alopecia." English-language videos describing individual patient experiences were included. Five independent reviewers rated videos using the modified DISCERN instrument and JAMA Benchmark criteria. Information related to video characteristics, clinical characteristics and psychological symptoms were collected (**Table 1**). Disease severity scores were rated independently by two authors and resolved by consensus. Mild disease was defined as non-cosmetically obvious hair loss, moderate as visible hair loss affecting hairstyle, and severe as cosmetically obvious hair loss difficult to conceal.

Results

Overall, 538 videos were included (314 YouTube videos and 224 TikTok videos), representing 22,632,625 views and 49 hours of content. The mean duration of YouTube videos (8.252 minutes) was longer than TikTok videos (1.660 minutes). Individuals in videos were mostly female (98.0%) (**Table 1**). YouTube videos had significantly higher JAMA scores than TikTok videos ($p<.001$). However both JAMA and DISCERN scores were overall low, suggesting that scarring alopecia-related social media content frequently contains poor-quality, low-reliability medical information with limited transparency, sourcing, and educational value.

Psychological symptoms were common across both platforms and included anxiety/embarrassment (64.4%), loss of confidence (49.1%), low/depressed mood (45.0%), anger/frustration (36.7%), and feelings of isolation (20.8%). Emotionally, TikTok videos conveyed a greater psychosocial burden of disease. Compared to YouTube videos, TikTok videos were more likely to depict patients describing feelings of isolation (20.1 % vs 4.8%, $p<0.001$), were significantly more likely to contain multiple negative psychological themes (24.1% vs 12.1%, $p<.001$) and were less likely to report treatment satisfaction (33.5% vs 64.7%, $p<0.001$) (**Table 2**).

When data from patients with scarring alopecia (FFA, LPP, and CCCA) were analyzed together, estimated disease severity was not associated with psychological symptom burden (p=0.34).

Table 1. Summary of disease, demographic and treatments characteristics of patients with scarring alopecia on YouTube and TikTok.

	LPP all videos N (%), (N= 159)	FFA all videos N (%), (N= 136)	CCCA all videos N (%), (N= 243)	Total videos for all scarring alopecia types N (%), (N= 538)
Sex				
Female	153 (96.2)	135 (99.3)	239 (98.4)	527 (98.0)
Male	6 (3.8)	1 (0.7)	4 (1.6)	11 (2.0)
Estimated Fitzpatrick type				
Lighter skin tones (1–3)	140 (88.1)	98 (72.1)	49 (20.2)	287 (53.3)
Darker skin tones (4–6)	19 (11.9)	38 (27.9)	194 (79.8)	251 (46.7)
Race/ethnicity				
White	79 (49.7)	86 (63.2)	1 (0.4)	166 (30.9)
Black	74 (46.5)	44 (32.4)	241 (99.2)	359 (66.7)
East Asian	0 (0.0)	2 (1.5)	0 (0.0)	2 (0.4)
Hispanic	3 (1.9)	0 (0.0)	1 (0.4)	4 (0.7)
South Asian	1 (0.6)	2 (1.5)	0 (0.0)	3 (0.6)
Other/Unknown	2 (1.3)	2 (1.5)	0 (0.0)	4 (0.7)
Disease Severity	n = 153	n = 135	n = 221	n = 509
Mild	33 (21.6)	19 (14.1)	34 (15.4)	86 (16.9)
Moderate	25 (16.3)	6 (4.4)	69 (31.2)	100 (19.6)
Severe	95 (62.1)	110 (81.5)	118 (53.4)	323 (63.5)
Clinical presentation and diagnosis	n = 48	n = 84	n = 149	n = 281
Individual responsible for diagnosis/treatment				
Dermatologist	45 (93.7)	40 (47.6)	134 (89.9)	219 (78.0)
Non-dermatologist physician	3 (6.3)	5 (6.0)	4 (2.7)	12 (4.3)
Non-physician	0 (0.0)	39 (46.4)	11 (7.4)	50 (17.7)
Treatments found useful	n = 83	n = 120	n = 255	n = 458
Cosmetic changes (e.g., shaving head or wearing a wig)	40 (48.2)	83 (69.2)	56 (22.0)	179 (39.1)
Stress management (e.g., therapy, exercise, and meditation)	2 (2.4)	0 (0.0)	21 (8.24)	23 (5.0)
Western medicine	24 (28.9)	28 (23.3)	58 (22.7)	110 (24.0)
Diet (e.g., autoimmune protocol)	6 (7.2)	4 (3.3)	30 (11.8)	40 (8.7)
Complementary alternative medicine (e.g., acupuncture and essential oils)	11 (13.3)	4 (3.3)	53 (20.8)	68 (14.8)
Over-the-counter supplements	0 (0.0)	1 (0.83)	37 (14.5)	38 (8.3)

Table 2: Comparison of TikTok and YouTube Videos Related to Scarring Alopecia

	TikTok (n=224)	YouTube (n=314)	P value
Mean Duration of video (minutes)	1.660 (SD 1.691)	8.252 (SD 9.767)	P<.001
Mean DISCERN Scores	1.415 (SD 0.864)	1.443 (SD 0.709)	0.6904
Mean JAMA Scores	1.000 (SD 0)	1.256 (SD 0.479)	P<.001
Proportion of videos made by healthcare workers	1/224 (0.45%)	21/314 (6.68%)	P<.001
Proportion of videos made by patients with severe disease.	150/224 (66.96%)	172/314 (54.78%)	0.006
Proportion of LPP videos	113/224 (50.45%)	46/314 (14.65%)	P<.001
Proportion of FFA videos	63/224 (28.13%)	73/314 (23.25%)	0.2371
Proportion of CCCA videos	48/224 (21.43%)	195/314 (62.10%)	P<.001
Proportion of patients feeling anxious/worried/embarrassed	87/224 (38.84%)	99/314 (31.53%)	0.0958
Proportion of patients feeling anger/frustration	51/224 (22.77%)	55/314 (17.52%)	0.1616
Proportion of patients feeling isolated	45/224 (20.10%)	15/314 (4.78%)	P<.001
Proportion of patients feeling not beautiful/loss of confidence	67/224 (29.91%)	75/314 (23.89%)	0.1432
Proportion of patients feeling sad/depressed/down	57/224 (25.45%)	73/314 (23.25%)	0.6277
Videos with 2 or more negative emotions	75/224 (33.48%)	91/314 (28.98%)	0.3079
Videos with 3 or more negative emotions	54/224 (24.11%)	38/314 (12.10%)	P<.001
Videos with 4 or more negative emotions	38/224 (16.96%)	14/314 (4.46%)	P<.001
Discussion of any treatment use present in video	161/224 (71.88%)	276/314 (87.90%)	P<.001
Proportion of patients who feel overall satisfied with treatment	75/224 (33.48%)	203/314 (64.65%)	P<.001

Conclusions

This study is among the largest analyses of patient-reported scarring alopecia content on social media. Limitations include selection bias, narrow search terms, inability to verify diagnoses, and the inherent limitations of using social media videos as proxies for in-person clinical assessments. This study was limited to LPP, FFA, and CCCA, which may limit generalizability to other types of scarring alopecias.

Collectively, these findings suggest that TikTok functions more as an emotionally driven platform emphasizing lived experiences and psychosocial distress, whereas YouTube appears to provide longer, somewhat more

educational and treatment-oriented content. Furthermore, this study reaffirms the view that the psychological burden that accompanies hair loss may not be directly proportional to visible disease severity. Given the low quality of information on social media, increasing the online presence of dermatologists and dermatology organizations may help counter misinformation and improve patient education regarding scarring alopecia.

EADV CONGRESS
VIENNA
30 SEP - 3 OCT 2026

Abstract N°: 4162

Two-year prospective longitudinal experience with intramuscular abobotulinum toxin A in female pattern hair loss

Ceyda Tetik Aydoğdu*[1], Ekin Altinbas[1], Gamze Çömlekçi[1], Emine Tugba Alatas[1], suzan demir pektas[1]

[1] Muğla Sıtkı Koçman University, Faculty of Medicine, Department of Dermatology, Muğla, Türkiye

Introduction
Female pattern hair loss (FPHL) is characterized by progressive follicular miniaturization and may be influenced not only by androgen-mediated pathways but also by scalp microenvironmental factors such as chronic muscle tension, reduced perfusion and perifollicular inflammation. Botulinum toxin has been proposed to improve hair growth by relaxing scalp muscles, enhancing microcirculation and modulating transforming growth factor-beta signaling. This study evaluated the clinical efficacy and safety of intramuscular abobotulinum toxin A in women with Ludwig stage I-II FPHL and explored clinical factors associated with response.

Materials and Methods
This prospective single-center case series included 24 women aged 18-65 years with clinically and trichoscopically diagnosed FPHL who had received no alopecia treatment during the preceding 3 months. Exclusion criteria included active scalp infection, pregnancy or lactation, neuromuscular disease, known botulinum toxin allergy and concomitant scarring alopecia. Abobotulinum toxin A was reconstituted as 100 U/2.5 mL saline and injected intramuscularly into frontal, temporal and occipital scalp muscle groups, with an administered total dose of 24-32 U per session. Eleven patients received one session and 13 received two or more sessions. Clinical response was assessed using standardized global photography, patient self-assessment on a 5-point Likert scale for reduction in hair shedding and new hair growth, and adverse-event monitoring. Baseline concomitant telogen effluvium was evaluated clinically and trichoscopically. A procedural video demonstrating our standardized intramuscular scalp injection technique will be included in the oral presentation to illustrate the practical application of the protocol.

Results
Of the 24 included patients, 14 (58.3%) had Ludwig stage I and 10 (41.7%) had Ludwig stage II disease. Patient-reported reduction in hair shedding was observed in 17/24 patients (70.8%), while new hair growth was reported in 10/24 patients (41.7%). Improvement was most evident after the first treatment session, with several patients also reporting decreased scalp sebum at the 1-month assessment. Patients with concomitant telogen effluvium showed a clearly weaker response than those with isolated FPHL, with insufficient reduction in shedding and no reported new hair growth. Among patients who underwent repeated sessions, the duration and magnitude of response appeared to decline after the second session, suggesting possible tachyphylaxis, suboptimal retreatment interval or need for individualized dosing. No serious adverse events occurred. Mild transient headache and local hematoma were reported in some patients and resolved spontaneously; no frontal asymmetry was observed.

Conclusions
Intramuscular abobotulinum toxin A was well tolerated and was associated with clinically meaningful patient-reported improvement in hair shedding in women with Ludwig stage I-II FPHL. The response appeared more pronounced in isolated FPHL and limited in the presence of concomitant telogen effluvium, highlighting the importance of careful etiological assessment before treatment. The reduced efficacy observed with repeated sessions suggests that fixed retreatment intervals may not be optimal. Larger randomized controlled studies with

objective trichoscopic endpoints are needed to confirm efficacy, define optimal dosing and identify predictors of response.

EA DV CONGRESS
VIENNA
30 SEP - 3 OCT 2026

Abstract N°: 4199

Clinical Characteristics, Subtype Classification and Prognostic Factors of Ophiasis

Fanshu Li*[1], Wenhan Zhang[1], Chen Wang[2], Jianzhong Zhang[1], Xiangqian Li[1], Cheng Zhou[1]

[1] Department of Dermatology, Peking University People's Hospital, Beijing, China

[2] Department of Dermatology, The First Affiliated Hospital, Zhejiang University School of Medicine, Hangzhou, China

Introduction

Ophiasis is an uncommon, clinical heterogeneous and therapeutically challenging presentation of alopecia areata (AA). Evidence guiding meaningful subtyping and its implications for management remains limited.

Materials and Methods

A retrospective study of 150 ophiasis patients was performed. Clinical, trichoscopic, and histopathologic data were collected and compared with patchy AA, acute diffuse and total alopecia, and alopecia universalis/alopecia totalis cohorts. A novel three-subtype classification of ophiasis based on scalp involvement patterns was proposed and evaluated its prognostic value.

Results

Ophiasis showed a female predominance, prolonged disease duration, and lower activity and regrowth rates than other AA subtypes. Trichoscopy demonstrated significant vellus hair involvement, abundant yellow dots, and minimal activity signs, while histopathology revealed minimal inflammation and increased telogen follicles, supporting chronicity. The three subtypes—typical ophiasis, ophiasis with patchy AA, and diffuse ophiasis—exhibited markedly different prognoses. Ophiasis with patchy AA showed comparatively favorable regrowth. Subtype classification independently predicted treatment response.



Images of pattern I (ophiasis with mono-hairline) (A), pattern Ⅱ (ophiasis with patchy AA□the red arrow points to patchy areas of alopecia) (B) and pattern Ⅲ (ophiasis with diffuse AA) (C). The blue arrow indicates recession of the hairline.

Conclusions

Ophiasis is chronic and refractory. Our proposed classification system can accurately identify patients with poorer prognosis, guiding early intervention and stratified treatment.

EADV CONGRESS
VIENNA
30 SEP - 3 OCT 2026

Abstract N°: 4234

Quantifying scalp microcirculatory response to a topical hair activation serum inandrogenetic alopecia: a proof-of-concept study using full-field laser perfusion imaging

Nabiah Malik*[1], Anders Reckendorff[2], Jasmine Pola[2], Sara Brace[2]

[1] Imperial College Healthcare NHS Trust, London, United Kingdom

[2] Scandinavian Biolabs, Copenhagen, Denmark

Introduction

Scalp microcirculation is essential for hair follicle health, supplying oxygen and nutrients through dermal vascular plexuses. In androgenetic alopecia (AGA), perfusion and vessel density are reduced in affected areas, with vascular regression and tissue hypoxia both implicated in follicle miniaturisation. Yet despite this, there is very little objective data on how topical hair products influence scalp microcirculation. The serum investigated here contains Vanillyl Butyl Ether (VBE), an ingredient with previously demonstrated microcirculatory properties, assessed using full-field laser perfusion imaging (FLPI). This is to determine whether FLPI can detect acute changes in scalp perfusion following a single application of a topical hair activation serum in men with AGA, and to describe the time course of any response observed

Materials and Methods

This single-centre proof-of-concept study was conducted in July 2025. Five male subjects aged 18-60 years with AGA (Hamilton-Norwood score 4-5) were enrolled. Scalp microcirculation was assessed non-invasively using FLPI, which measures light scatter from moving erythrocytes to produce quantitative perfusion maps. Flux Mean values (perfusion units, PU) were recorded at 1-second intervals throughout a 15-minute baseline period and for 90 minutes after a single application of the serum. Data from all five subjects were collated and analysed to characterise the temporal perfusion response.

Results

All five subjects showed an increase in scalp Flux Mean above baseline following application. Peak response occurred at approximately 10 minutes, with elevated perfusion maintained for up to around 40 minutes before returning toward baseline. These findings are consistent with previously published ingredient-level data for VBE, which demonstrated a perfusion increase of up to 30.24%, initial response at 10 minutes, peak effect at 23.5 minutes, and mean duration exceeding 30 minutes in over 80% of volunteers.

Conclusions

FLPI offers a practical and objective way to measure how topical formulations affect scalp blood flow. A single application of the hair activation serum produced a consistent, time-limited increase in perfusion in men with AGA, supporting a microcirculation-based mechanism of action. Larger controlled studies are needed to build on these findings and explore their implications for hair follicle health and growth.

EA DV CONGRESS
VIENNA
30 SEP - 3 OCT 2026

Abstract N°: 4242

Scalp Rosacea: Novel Clinical and Trichoscopic Insights into an Underdiagnosed Manifestation

Beata Zagórska*[1], Krzysztof Pastuszak[2], Daniel Nette[1], Carlos Peralta[3], Urszula Maińska[1, 1], Roman Nowicki[1, 1], Martyna Sławińska[1]

[1] Department and Clinic of Dermatology, Venereology and Allergology, Faculty of Medicine, Medical University of Gdańsk, Department of Dermatology, Venereology and Allergology, University Clinical Center of Gdańsk, Gdańsk, Poland

[2] Centre of Biostatistics and Bioinformatics, Medical University of Gdańsk, Laboratory of Translational Oncology, Intercollegiate Faculty of Biotechnology, Medical University of Gdańsk, Faculty of Electronics, Telecommunication and Informatics, Gdańsk University of Technology, Gdańsk, Poland

[3] Department of Dermatopathology, LABPAT Pathology Laboratory, Mar del Plata, Argentina, Mar del Plata, Argentina

Introduction

Scalp involvement in rosacea is insufficiently characterized, and data on its clinical and trichoscopic features remain limited. To prospectively evaluate scalp involvement in patients with facial rosacea, with particular emphasis on trichoscopic vascular patterns and their clinical correlates.

Materials and Methods

This prospective observational study included 104 adults with clinically confirmed facial rosacea. All participants underwent standardized scalp examination and trichoscopy using a videodermoscope. Vascular features were assessed by type and distribution across scalp regions, and associations with clinical symptoms, Rosacea Area and Severity Index (RASI) scores, and androgenetic alopecia (AGA) were analyzed.

Results

Subjective scalp symptoms were reported by 76.0% of patients and objective scalp findings by 80.8%; both were present in 63.5%. The most frequent symptoms were pruritus, hair loss, and painful papules or pustules, whereas erythema and telangiectasia were the most common objective signs. Pink structureless areas were the most prevalent trichoscopic finding across all scalp regions. Vascular structures were observed most often in the temporal scalp, with thin arborizing vessels and linear irregular vessels predominating. Higher facial rosacea severity was associated with more frequent subjective scalp symptoms and a greater number of objective scalp signs. AGA was associated with increased vascular burden in the frontal-parietal scalp, but not with the characteristic regional predominance of vascular findings in the temporal-occipital scalp.

Conclusions

Scalp involvement may represent a common but underrecognized manifestation of rosacea. Trichoscopy may support recognition of this phenotype, and routine scalp assessment may improve evaluation of overall disease burden.

EADV Congress 2026, VIENNA
30 SEPTEMBER - 03 OCTOBER 2026
POWERED BY M-ANAGE.COM

EA DV CONGRESS
VIENNA
30 SEP - 3 OCT 2026

Abstract N°: 4312

Alopecia Areata as a Systemic Inflammatory Disease: Can Inflammatory Biomarkers and EASIX Predict Treatment Response?

Ayşenur Demir*[1], Ilknur Altunay[1], pınar özdemir çetinkaya[1], Aslı Aksu[1]

[1] University of Health Sciences, Şişli Hamidiye Etfal Training and Research Hospital, Department of Dermatology and Venereology, Istanbul, Türkiye

Introduction

Alopecia areata (AA) is a chronic immune-mediated disorder characterized by non-scarring hair loss and increasingly recognized as a systemic inflammatory disease rather than a condition limited to the hair follicle. This study aimed to evaluate systemic inflammatory markers and the Endothelial Activation and Stress Index (EASIX), an indirect marker of endothelial dysfunction, in patients with AA compared with healthy controls; to investigate their associations with disease severity; to assess their changes following treatment; and to identify potential predictors of treatment response.

Materials and Methods

This prospective controlled observational study included 80 patients with alopecia areata presenting to the dermatology outpatient clinic between January and December 2025 and 80 age- and sex-matched healthy controls. Disease severity was assessed using the Severity of Alopecia Tool (SALT) score. Baseline laboratory evaluations included complete blood count, C-reactive protein (CRP), erythrocyte sedimentation rate (ESR), high-density lipoprotein (HDL), lactate dehydrogenase (LDH), and creatinine levels. Neutrophil-to-lymphocyte ratio (NLR), monocyte-to-lymphocyte ratio (MLR), platelet-to-lymphocyte ratio (PLR), monocyte-to-HDL ratio (MHR), systemic immune-inflammation index (SII), systemic inflammation response index (SIRI), pan-immune inflammation value (PIV), and EASIX were calculated. Patients received intralesional corticosteroids, systemic corticosteroids, or cyclosporine according to clinical characteristics and were followed for 3 months. Clinical and laboratory reassessments were performed after treatment, and treatment response was evaluated based on changes in SALT score.

Results

Compared with healthy controls, patients with AA had significantly higher levels of NLR, MLR, MHR, ESR, CRP, SII, SIRI, PIV, and EASIX (all $p<0,05$). Following treatment, significant reductions were observed in inflammatory markers, including NLR, MLR, PLR, MHR, ESR, CRP, SII, SIRI, PIV, and EASIX (all $p<0,05$). Linear regression analysis demonstrated a strong association between SII and disease severity ($p<0,001$). Analyses performed to identify predictors of treatment response demonstrated that higher baseline PLR levels (AUC≈0,605) and NLR values ≥2.38 (AUC≈0,564) were associated with better treatment response (Figure 1). In subgroup analyses, the reduction in SII was significantly greater in patients receiving cyclosporine compared with systemic corticosteroids ($p=0,011$).

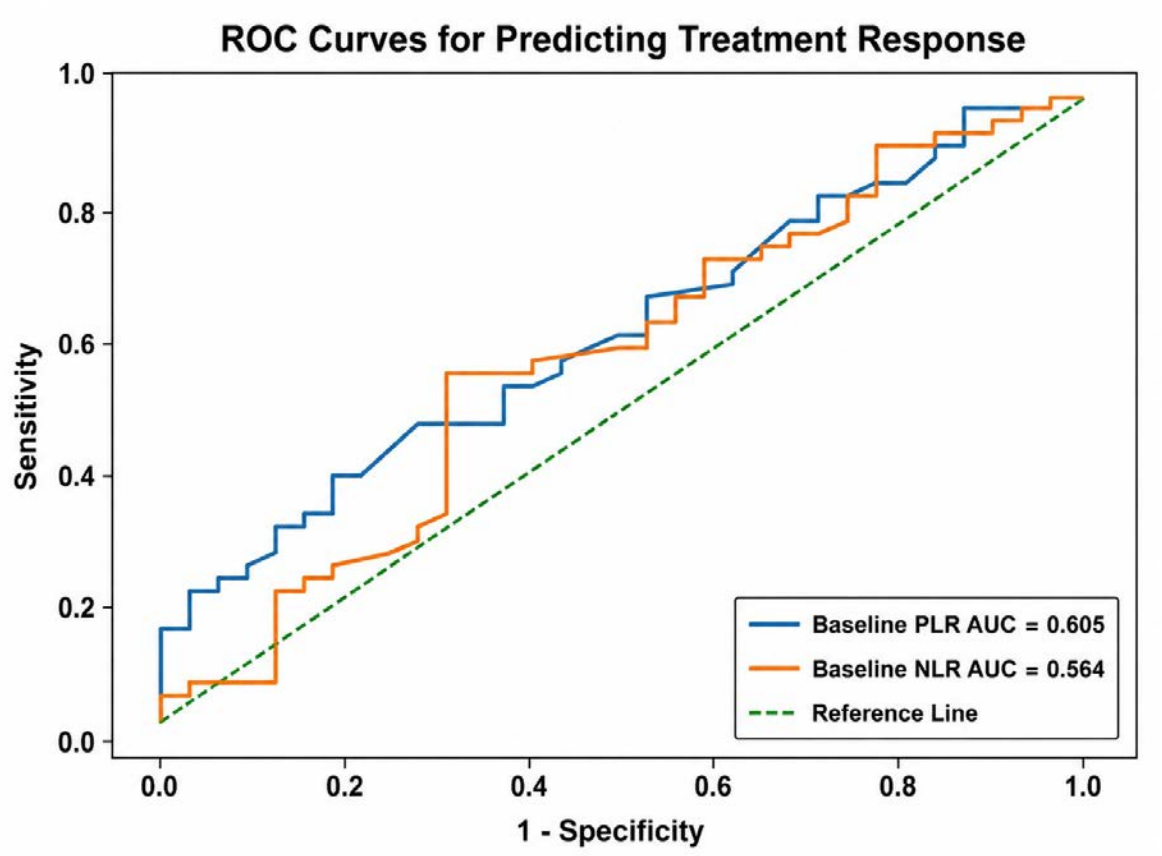

AUC: Area under the curve; PLR: Platelet-to-lymphocyte ratio; NLR: Neutrophil-to-lymphocyte ratio

Conclusions

Our findings further support the concept that alopecia areata is a systemic inflammatory disease extending beyond the hair follicle. The significant relationship between SII and disease severity suggests that inflammatory burden may reflect clinical activity in AA. In addition, baseline PLR and NLR may serve as potential predictors of treatment response in AA. The inclusion of EASIX provides novel insight into the possible link between endothelial dysfunction and systemic inflammation in AA. These findings may contribute to the identification of accessible biomarkers for disease monitoring and therapeutic stratification in alopecia areata.

EA DV CONGRESS
VIENNA
30 SEP - 3 OCT 2026

Abstract N°: 4315

Psychosocial impact of JAK inhibitors in the treatment of alopecia areata: a comparative analysis of patient-reported outcomes across clinical trials

Luísa Groba Bandeira*[1], María Paula Wang Lizarme[2], Natália Bigossi Aguiar[3], Lara Munhoz Melhado[4], Maykon Mendonça de Lima Azevedo[5], Luiza Kalil[6]

[1] Private Practice in Dermatology, Sao Paulo, Brazil
[2] Universidad de Costa Rica San Pedro, San Pedro, Costa Rica
[3] Private Practice, Santiago, Chile
[4] Private Practice in Dermatology, Cosmorama, SP, Brazil
[5] Fundação de Medicina Tropical Dr Heitor Vieira Dourado, Manaus, Brazil
[6] Yale Department of Dermatology, Yale School of Medicine, New Haven, CT, United States

Introduction

Alopecia areata (AA) is an autoimmune hair loss disorder that can cause significant psychosocial distress. Beyond the visible hair loss, patients frequently experience anxiety, depression, shame, and social withdrawal. A scoping review found signs of anxiety and/or depression in 30-68% of patients, with quality of life impairment in over 75% of cases.[1] While JAK inhibitors have revolutionized the treatment of severe AA, their impact on patients' emotional wellbeing remains incompletely reported. The objective of this study was to assess the impact of JAK inhibitors on psychosocial outcomes in patients with severe alopecia areata through a comparative analysis of patient-reported outcomes from clinical trials.

Materials and Methods

Comparative analysis of phase 2/3 clinical trials of JAK inhibitors in severe AA reporting psychosocial patient-reported outcome (PRO) data: the BRAVE-AA1 and BRAVE-AA2 trials of baricitinib (N=1,200, up to 104 weeks);[2,3] the ALLEGRO-2b/3 trial of ritlecitinib (N=718, 48 weeks);[4] and pooled data from the THRIVE-AA1 and THRIVE-AA2 trials of deuruxolitinib (N=1,220, 24 weeks).[5]

Results

All three approved JAK inhibitors demonstrated meaningful improvements in psychosocial outcomes, reflecting the profound emotional burden of this condition. In the BRAVE-AA1/AA2, patients treated with baricitinib reported baseline HADS-Anxiety scores of 6.1-6.4 and HADS-Depression of 3.8-4.2.[2] Among week-52 responders, anxiety improved by 1.4 points and depression by 0.9 points at week 52, sustained through week 104. Skindex-16 emotion scores improved by up to 47.1 points and functioning scores by up to 39.1 points at week 104, maintained in over 90% of responders.[3] In the ALLEGRO-2b/3 trial, treatment with ritlecitinib was associated with small mean changes in AAPPO emotional symptoms and activity limitations scores across all groups; however, patients achieving hair regrowth (SALT ≤20) reported greater improvements in emotional symptoms compared with non-responders (−1.1 vs −0.5 at week 24). [4] With deuruxolitinib (THRIVE-AA1/AA2), 22.5% of treated patients achieved a clinically meaningful improvement in total HADS score versus 11.8% on placebo (p=0.0003), with improvements also seen in anxiety (18.9% vs 10.2%) and depression (26.2% vs 14.2%) subscores.[5] Across all trials, patients who regrew hair felt better, emotionally and functionally.

Conclusions

Alopecia areata is a hair loss disorder with a substantial impact on patients' quality of life. JAK inhibitors produce significant and sustained psychosocial benefits in severe AA, confirmed across phase 2/3 clinical trials of all three approved agents. These findings support the full impact of treatment in addressing both hair regrowth and the psychological burden associated with severe AA.

EA DV CONGRESS
VIENNA
30 SEP - 3 OCT 2026

Abstract N°: 4321

The Hidden Impact of Hair Cosmetics on Scalp Health: Results from a Cross-Sectional Survey

Rehab Bellout*[1], Ouiame El Jouari[1], Sabrina Oujdi[1], Salim Gallouj[1]

[1] Dermatology Department, University Hospital Center Mohammed VI, Tangier, Morocco

Introduction
Scalp disorders, including dandruff, seborrheic dermatitis, pruritus, erythema, and hair loss, are highly prevalent and significantly affect quality of life. Recent studies have emphasized the role of exogenous triggers such as cosmetic products, hair dyes, conditioners, and thermal devices in scalp irritation and sensitive scalp syndrome.

Hair cosmetic products may induce both irritant and allergic contact dermatitis, especially products containing preservatives, fragrances, sulfates, and para-phenylenediamine (PPD) in hair dyes.

The objective of this study was to investigate the impact of cosmetic hair products and hair care habits on scalp symptoms and disorders

Materials and Methods
A cross-sectional questionnaire-based study was conducted among 305 participants and distrubuted via google forms on a period of 3 months from 15 january to 15 April 2026. Sociodemographic data, hair characteristics, cosmetic practices, and scalp symptoms were collected. Data were analyzed descriptively using percentages and frequencies. Associations between cosmetic practices and symptoms were explored using chi-square testing, with $p < 0.05$ considered statistically significant.

Results
Among the 305 participants : 72% were female, The most represented age group was 18–30 years (46%), followed by 31–45 years (34%).

The most frequently reported symptoms were: Pruritus was the most frequent symptom (62%), followed by dandruff (48%), hair loss (37%), and erythema (29%), scalp redness was observed in 29% of the patitns and burning sensation was felt by 18%.

Hair dye use was the most commonly reported trigger (34%), followed by shampoo (28%) and thermal tools (26%). Hair dye was significantly associated with scalp pruritus and erythema ($p = 0.02$).
Thermal tool use was significantly associated with excessive hair shedding ($p = 0.03$).

Among participants who reported symptoms, 41% developed symptoms after product use, 74% improved after discontinuing the product, 36% consulted a dermatologist, and 80% of the patients who consulted a dermatologist have noticed an improvement of the symptoms after treatment.

Conclusions
Despite the high burden of symptoms, dermatological consultation remained low, confirming that scalp disorders are often under-recognized and under-treated.

this study supports existing evidence that hair cosmetics—particularly hair dyes—are major contributors to scalp disorders. The consistency between our findings and published literature strengthens the validity of our results and highlights the importance of considering cosmetic exposure in the evaluation of scalp symptoms.

EA DV CONGRESS
VIENNA
30 SEP - 3 OCT 2026

Abstract N°: 4334

Real-World Treatment Decision-Making and Prescribing Behaviour in Alopecia Areata Among Dermatologists and Nurse Practitioner/Physician Assistants

Breanna Hudspeth*[1]

[1] RxY, Montreal, Canada

Introduction

The treatment landscape for alopecia areata has rapidly evolved with the approval of oral Janus kinase inhibitors (JAKis), baricitinib, ritlecitinib, and most recently, deuruxolitinib in 2024. Despite growing usage of these agents, little is known about how prescribing patterns differ across health care provider types, including dermatologists and nurse practitioner/physician assistant (NP/PA) providers. Understanding how treatment decisions are made in real-world practice, and how NP/PA prescribing behavior compares with that of dermatologists, may provide important insights into access, uptake, and shared decision-making surrounding newer therapies for alopecia areata.

Materials and Methods

We analyzed clinical chart information and physician verbatim rationale for treatment decisions with oral systemics and oral JAKis for 754 patients submitted by 107 US-based dermatologists and NP/PAs (82 dermatologists, 25 NP/PAs) through an online market research study. Sample composition includes 31 mild, 557 moderate, and 166 severe AA patients based on physician assessment. 646 of these patients are prescribed oral JAKis (509 managed by dermatologists, 137 managed by NP/PAs). This study was fielded from September 18th to October 30th, 2025.

Results

Dermatologists are significantly more likely to classify AA patients as having severe disease compared to NP/PAs (26% vs. 17%; $p<0.05$). Dermatologist-managed AA patients have directionally higher scalp body surface area (BSA) affected on average compared to NP/PA-managed patients (37% vs 31%). AA patient quality of life (QoL) and emotional impact metrics are similar across dermatologist and NP/PA-managed groups (high QoL 51% vs 52%; average emotional impact rating (4.6 vs 4.5).

Among JAKi-prescribed patients, dermatologists are significantly more likely to prescribe the newest novel JAKi, ritlecitinib, compared to NP/PAs (41% vs. 28%; $p<0.05$), while NP/PAs are significantly more likely to prescribe the first-to-market JAKi, baricitinib, compared to dermatologists (53% vs. 43%; $p<0.05$). This indicates that dermatologists may be more willing to adopt newer agents earlier in their treatment algorithms when there is a clinical need. Prescriber-cited AA treatment selection drivers also show that dermatologists are more likely than NP/PAs to mention familiarity with the treatment and strategic planning regarding line-of-therapy use when prescribing newer JAKis, ritlecitinib and deuruxolitinib.

When prescribing oral JAKis, dermatologists report making the final treatment decision without patient involvement more frequently compared to NP/PAs (54% vs 51%). When they do prescribe the newer JAKis, NP/PAs are more likely than dermatologists to cite patient profile and patient preference as selection drivers, suggesting that NP/PA prescribing may have more collaborative decision-making dynamics.

Oral JAKi-prescribed patients managed by NP/PAs are significantly less likely to have commercial health insurance compared to patients managed by dermatologists (79% vs. 90%; $p<0.05$), and are significantly more likely than patients managed by dermatologists to initiate their JAKi via free samples (27% vs. 17%; $p<0.05$).

Conclusions

Health care provider type is associated with meaningful differences in patient characteristics, treatment selection, and decision-making patterns among patients with alopecia areata receiving oral JAK inhibitors. Dermatologists are more likely to manage clinically severe AA cases and adopt newer JAKis, whereas NP/PAs appear to practice in more access-constrained settings with lower commercial insurance coverage, greater sample use, and more patient-driven treatment decisions. These findings show that health care provider type differences in oral JAKi prescribing appear to reflect distinct patient populations, access realities, and treatment decision frameworks rather than simple preference differences.

EADV CONGRESS
VIENNA
30 SEP - 3 OCT 2026

Abstract N°: 4348

Effectiveness and Safety of JAK Inhibitors in Alopecia Areata: A Real-World Study

Jose Fuentes Ros*[1], Vicente Márquez Garrido[1], Marta Cortés Pérez[1], Cecilia Iborra García-Trevijano[1], Pablo Díaz-Calvillo[1], MERCEDES PICO VALIMAÑA[1]

[1] University Hospital of Puerto Real, Dermatology, Pueto Real, Cádiz, Spain

Introduction
Alopecia areata (AA) is a chronic immune-mediated disorder that often requires systemic therapy in moderate-to-severe cases. JAK inhibitors (JAKi) have significantly expanded the therapeutic arsenal, although real-world evidence remains essential to refine clinical practice, particularly regarding maintenance and switching strategies. This study aimed to evaluate the effectiveness and safety of oral JAKi in routine clinical practice, including the assessment of clinical response, safety alignment with regulatory standards, and prognostic factors

Materials and Methods
We conducted a retrospective study of patients with patchy, total, or universal AA treated with JAKi at our center (October 2023 – April 2026). Effectiveness was measured by the Severity of Alopecia Tool (SALT) score. We also analyzed the neutrophil-to-lymphocyte ratio (NLR) as a potential biomarker and treatment-emergent adverse events (AEs)

Results
Nineteen patients were included (52.6% female; mean age 38 years). Clinical subtypes included AA universalis (57.9%), patchy AA (31.6%), and AA totalis (10.5%). The mean SALT score in patients with patchy AA was 66. Baricitinib 4 mg/day was the most frequent treatment (84.2%), while 15.8% received ritlecitinib 50 mg/day. Four patients had previously failed tofacitinib and only one (25%) achieved SALT ≤ 20 after switching to baricitinib. Overall, 63.2% of the total cohort achieved SALT50 and 47.4% reached SALT ≤ 20. The median time to initial clinical response was 4.25 months (IQR: 2.5–6.5). The mean NLR was 1.8; however, it showed no association with a shorter time to treatment response. Two relapses (10.5%) were documented, one following a dose reduction of baricitinib to 2 mg/day and another in a female patient receiving ritlecitinib. During the current 30-month follow-up period, AEs occurred in 21.1% of patients and consisted exclusively of mild LDL abnormalities.

Conclusions
JAK/STAT pathway inhibitors are a valuable therapeutic option for moderate-to-severe and treatment-refractory alopecia areata in real-world clinical practice, with a favorable tolerability profile. However, response heterogeneity remains a major clinical challenge, particularly regarding time to response, maintenance strategies, and outcomes after switching between JAK inhibitors. The observed time to response supports the clinical practice of maintaining treatment for at least 6–9 months before declaring primary failure. The lack of association between NLR and response timing suggests that baseline systemic inflammatory markers may not predict the speed of hair follicle recovery. In addition, relapse after dose reduction highlights that induction dose maintenance may be necessary to sustain remission in severe phenotypes. Future studies should focus on identifying predictive biomarkers and defining optimal long-term treatment algorithms for recalcitrant disease.

EADV Congress 2026, VIENNA
30 SEPTEMBER - 03 OCTOBER 2026
POWERED BY M-ANAGE.COM

EA DV CONGRESS
VIENNA
30 SEP - 3 OCT 2026

Abstract N°: 4378

Reducing the burden of chemotherapy-induced alopecia: real-world evaluation of scalp cooling in 468 breast cancer patients

Spyridon Kostaras*[1], Evgenia Makrantonaki[1, 2, 3], Athina Kostara[4]

[1] Derma Center Wildeshausen, Wildeshausen, Germany

[2] Brandenburg Medical School Theodor Fontane, Department of Dermatology, Venereology and Immunology, University Hospital, Ruppin-Brandenburg, Germany

[3] Ulm University Hospital, Department of Dermatology and Allergology, Ulm, Germany

[4] Center für Gynecologic Oncology, GynOnco Düsseldorf, MVZ Medical Center Düsseldorf, Düsseldorf, Germany

Introduction

Advances in individualized and targeted therapeutic approaches have significantly improved the long-term prognosis of oncology patients in recent years; nevertheless, chemotherapy remains an essential cornerstone in the treatment of many malignancies. Chemotherapy-induced alopecia (CIA) is among the most distressing adverse effects of systemic therapy, particularly in younger women, negatively affecting body image, self-esteem, and quality of life. Complete hair loss is frequently associated with stigmatization and considerable psychological burden and may even influence treatment acceptance. Scalp cooling represents the most effective strategy for reducing CIA. However, its implementation remains associated with substantial logistical and tolerability challenges for both patients and oncology staff and is therefore often not fully integrated into routine clinical practice.

Objectives

To evaluate acceptance, adherence, tolerability, and effectiveness of scalp cooling in breast cancer patients receiving chemotherapy in a real-world clinical setting.

Methods

A retrospective analysis of 468 patients receiving chemotherapy who were offered scalp cooling as supportive care was performed in a gynecologic oncology outpatient setting. Scalp cooling was performed using processor-controlled systems, continuously reducing scalp temperature to approximately 18–20°C before, during, and after each chemotherapy administration. The recommended cooling times varied depending on the administered substance. Data collected included patient acceptance rates, reasons for initial refusal, premature discontinuation rates and causes, tolerability as well as cosmetic outcomes. Cosmetic efficacy was assessed in a subgroup of 114 patients who completed scalp cooling as planned, using standardized photographic documentation and a structured 5-point cosmetic grading scale ranging from very good to poor. Associations between chemotherapy regimens and cosmetic outcomes were analyzed.

Results

Initial acceptance of scalp cooling was high, with 88.5%(n=414) of patients choosing treatment, and 11.5%(n=54) declining. The most common reasons for initial refusal were fear of cold intolerance or migraine 44.4%(n=24) and pre-existing alopecia due to previous treatment 18.5%(n=10). Among patients who initiated scalp cooling, 54.3% (n=225) completed treatment as planned, while 45.7%(n=189) discontinued prematurely. The leading causes of discontinuation were hair loss corresponding to grade I or II alopecia in 54.0%(n=102) and intolerance to cold in 22.2%(n=42), followed by headaches (6.9%, n=13). Among patients who discontinued scalp cooling due to hair loss, anthracycline-containing regimens were predominant, with the two leading anthracycline-based schedules

accounting for 27.5% (n=28) and 15.7% (n=16), respectively. Taxane-based regimens including docetaxel or paclitaxel followed, accounting for 23.5% (n=24).
Among the 114 patients who underwent documented cosmetic assessment, 64.9% (n=74) achieved good or very good hair preservation, while satisfactory, sufficient, and poor cosmetic outcomes were observed in 9.6% (n=11), 7.9% (n=9), and 17.5% (n=20), respectively. Scalp cooling demonstrated slightly higher efficacy in non-anthracycline-based regimens; however, good or very good cosmetic outcomes were still achieved in 64.5–65.8% of patients across both anthracycline-containing and non-anthracycline regimens.

Conclusions

Scalp cooling is a well-accepted and clinically effective supportive intervention for reducing CIA in breast cancer patients in routine clinical practice. With nearly 90% of patients accepting scalp cooling and approximately 65% achieving good or very good cosmetic outcomes, our data underline its clinical relevance. Despite relevant discontinuation rates and logistical challenges, meaningful hair preservation contributes to improved quality of life, body image, and well-being during chemotherapy.

EADV CONGRESS
VIENNA
30 SEP - 3 OCT 2026

Abstract N°: 4392

Real-World Effectiveness and Safety of Upadacitinib in Moderate-to-Severe Alopecia Areata: A Single-Center Retrospective Study

Muazzez Çiğdem Oba[1], Ege Uğur*[1], Tuğba Kevser Uzunçakmak[1], Burhan Engin[1], Zekayi Kutlubay[1], Server Serdaroğlu[1]

[1] Cerrahpaşa Faculty of Medicine, Department of Dermatology and Venereology, Istanbul, Türkiye

Introduction
Alopecia areata is a chronic immune-mediated disorder characterized by non-scarring hair loss that may significantly impair quality of life and psychosocial well-being. Management of moderate-to-severe alopecia areata remains challenging, particularly in extensive disease subtypes such as alopecia totalis and alopecia universalis. Increasing evidence regarding the role of the JAK–STAT pathway in alopecia areata pathogenesis has led to the emergence of Janus kinase inhibitors as promising therapeutic options. Upadacitinib, a selective JAK1 inhibitor targeting key inflammatory pathways involved in alopecia areata pathogenesis, has recently demonstrated encouraging efficacy; however, real-world data remain limited.

Materials and Methods
This retrospective single-center study included patients with moderate-to-severe Alopecia Areata treated with Upadacitinib between October 2023 and March 2026. Demographic characteristics, disease subtype, disease duration, previous JAK inhibitor exposure, concomitant Atopic Dermatitis, nail involvement, treatment duration, baseline and follow-up SALT (Severity of Alopecia Tool) scores, treatment discontinuation status, and adverse events were retrospectively reviewed from patient records.

Patients were categorized according to treatment duration as <24 weeks and ≥24 weeks. Treatment response was defined as achieving a SALT score ≤20 after at least 24 weeks of therapy. Baseline and follow-up SALT scores were compared using the Wilcoxon signed-rank test, with $p<0.05$ considered statistically significant.

Results
A total of 54 patients were included, comprising 28 females and 26 males. Clinical subtypes included alopecia areata, alopecia totalis, and alopecia universalis. Concomitant atopic dermatitis was present in 5 patients (9.3%), while nail involvement was observed in 9 patients (16.7%). Forty-four patients (81.5%) had previously received at least one JAK inhibitor before upadacitinib treatment.

Among patients completing at least 24 weeks of therapy (n=34), mean SALT score significantly decreased from 78.7 at baseline to 17.8 during follow-up ($p<0.001$). Treatment response, defined as SALT ≤20 after at least 24 weeks of therapy, was achieved in 29 of 34 patients (85.3%).

Patients treated for less than 24 weeks also demonstrated early clinical improvement with reductions in SALT scores observed during follow-up.

Treatment discontinuation occurred in 9 patients (16.7%) during follow-up. Reported adverse events included herpes zoster, herpes labialis, hypercholesterolemia, seborrheic dermatitis/seborrhea, headache, asthenia, myalgia/bone pain, elevated creatine kinase levels, and delayed recovery from infections. Most adverse events were mild and manageable, and no unexpected safety signals were observed.

Conclusions

Upadacitinib demonstrated high treatment response rates and significant reductions in SALT scores in patients with moderate-to-severe alopecia Areata, including heavily pretreated cases with prior JAK inhibitor exposure. Among patients completing at least 24 weeks of therapy, 85.3% achieved SALT ≤20, with mean SALT scores improving from 78.7 to 17.8 ($p<0.001$). Treatment discontinuation rates remained relatively low (16.7%), and no unexpected safety signals were identified, supporting upadacitinib as an effective and generally well-tolerated treatment option in real-world clinical practice.

EA DV CONGRESS
VIENNA
30 SEP - 3 OCT 2026

Abstract N°: 4404

Autoimmunity in frontal fibrosing alopecia

Valentina Balaguera-Orjuela*[1], David Saceda-Corralo[1], Ana Laura Melian Olivera[1], Javier Perez-Bootello[1], Hari Krishnan Krishnamurthy[2], Chithra Changalath[2], Vasanth Jayaraman[2], Karthik Krishna[2], Tianhao Wang[2], Kang Bei[2], John Rajasekaran[2]

[1] Grupo de Dermatologia Pedro Jaén, Madrid, Spain
[2] Vibrant Wellness, San Carlos, United States

Introduction
Frontal fibrosing alopecia (FFA) is a progressive scarring alopecia characterized by hair loss affecting the frontal hairline, temples, and eyebrows. Historically, FFA has been predominantly reported in postmenopausal women; however, its prevalence in men has increased over the past decade, although it is frequently underdiagnosed because of its resemblance to other forms of alopecia. Recent reports have also described cases in younger individuals. The exact etiology of FFA remains unclear, but proposed mechanisms include genetic predisposition, hormonal dysregulation, neurogenic inflammation, collapse of immune privilege, and environmental factors such as sunscreen use.

Materials and Methods

Materials and Methods

This study included adult patients with clinically and histologically confirmed frontal fibrosing alopecia (FFA) treated at a tertiary dermatology center between January 2015 and September 2020. Serum samples were obtained from an institutional biobank following approval by the Ethics and Scientific Committees and after informed consent from all participants.

A customizable multiplex microarray platform was used to identify autoantibodies against self-antigens in patients with FFA and to evaluate their potential association with disease pathogenesis. A total of 100 self-antigens associated with different autoimmune diseases were assessed. Recombinant antigens were immobilized onto silicon microchips assembled into high-throughput pillar plates, enabling simultaneous analysis in a single run.

Serum samples were analyzed using chemiluminescent immunoassays for the detection of IgG and IgM autoantibodies. Chemiluminescent signals were quantified using in-house software, and antigen-specific sensitivity, specificity, and diagnostic odds ratios were calculated to determine antibody reactivity profiles.

Results
A total of 282 alopecia samples were analyzed. Autoantibody reactivity was identified against multiple antigens, with the most frequently detected including human PMEL/SILV/gp100 protein, CYP21A2, zinc transporter 8, CYP1B1, tyrosinase, tropomyosin, HLA-related antigens, Pdx1, SS-B (La), and Ro (SS-A).

Among the evaluated self-antigens, 20 demonstrated significant reactivity in patients with FFA. Of these, 12

antigens showed moderately high sensitivity with high specificity, indicating a consistent and reproducible antibody response pattern.

In particular, tropomyosin, PMEL/SILV/gp100, tyrosinase, and zinc transporter 8 showed sensitivities of 0.58, 0.46, 0.38, and 0.39, respectively, with specificities ranging from 0.82 to 0.97. Overall, these findings suggest a reproducible pattern of autoantibody reactivity involving melanocytic, structural, endocrine, and immune-related antigens in FFA, supporting a potential autoimmune component in its pathogenesis.

Conclusions

This study identifies a broad autoantibody signature in patients with FFA, supporting the hypothesis that autoimmune mechanisms may contribute to its pathogenesis. The most relevant antigens involve melanocyte-associated (PMEL, tyrosinase), structural (tropomyosin), endocrine/metabolic (CYP21A2, zinc transporter 8, Pdx1, CYP1B1), and immune-related (HLA, SS-B, Ro) targets.

These findings reinforce the concept of FFA as a complex immune-mediated disorder with potential overlap with systemic autoimmunity. Further studies are required to validate these results and clarify their pathogenic relevance.

EA DV CONGRESS
VIENNA
30 SEP - 3 OCT 2026

Abstract N°: 4411

Is Hyperkeratosis of the First and Fifth Toenails a Neuropathic Manifestation Associated with L5–S1 Nerve Root Compression? A Case Series

Orhan Yilmaz*[1], Ceyda Tetik Aydoğdu[1], Miray Kendir[1], Ozan Aydoğdu[2]

[1] Muğla Sıtkı Koçman University, Faculty of Medicine, Department of Dermatology, Muğla, Türkiye
[2] Department of Neurosurgery, Muğla Training and Research Hospital, Muğla, Türkiye, Muğla, Türkiye

Introduction

The epidermis and nervous system share a common embryologic origin from the ectoderm, which may explain the coexistence of neurological and cutaneous findings in several conditions. Beyond genodermatoses, peripheral nerve disorders may influence skin appendages, including nails and hair follicles. Lumbar disc herniation, particularly at the L4–L5 and L5–S1 levels, may lead to chronic nerve root compression affecting sensory and trophic functions in the foot. Prolonged neuropathic involvement may therefore contribute to subtle but clinically meaningful nail changes.

Materials and Methods

This observational case series included 20 patients with radiologically confirmed L5–S1 disc herniation who presented with localized thickening, hyperkeratosis, and discoloration of the first and fifth toenails. All patients underwent dermatological and neurological examination. Onychomycosis was excluded through mycological testing. Patients with a history of significant local trauma or primary dermatological nail disease were not included.

Results

Nail changes were consistently localized to the hallux and fifth toenail. The most common findings were nail plate thickening, subungual hyperkeratosis, and discoloration. No trauma, fungal disease, or primary dermatological disorder was identified. The distribution of nail findings corresponded anatomically to regions potentially affected by the involved lumbosacral nerve roots.

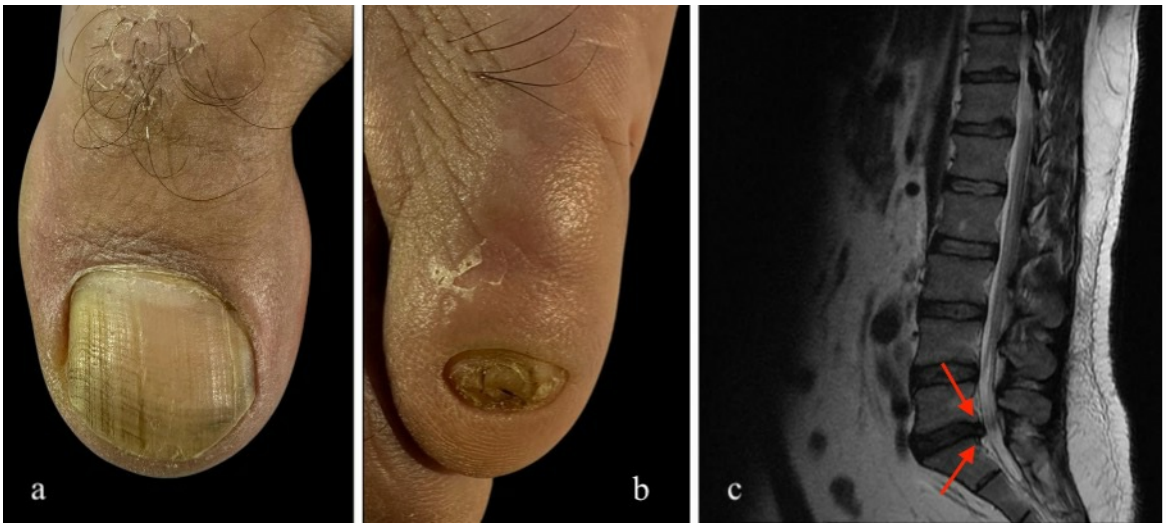

Figure 1. a) Marked discoloration and streaking of the first toenail. b) Ungual hyperkeratosis of the fifth toenail. c) MRI showing L5-S1 disc bulging with compressive effect

Conclusions

Hyperkeratosis and discoloration of the first and fifth toenails in patients with L5–S1 disc herniation may reflect a neuropathic influence on nail morphology. After common causes such as onychomycosis, trauma, and primary inflammatory nail diseases are excluded, localized involvement of the hallux and fifth toenail may serve as a clinical clue to underlying nerve root compression. Further controlled studies are needed to clarify the relationship between lumbosacral radiculopathy and nail unit changes.

EADV CONGRESS
VIENNA
30 SEP - 3 OCT 2026

Abstract N°: 4450

A topical medical device restores nail plate keratin through a novel biophysical mode of action in an ex vivo model of onychomycosis

Anthony Brown*[1], Adrià Ribes[1], Sang-Chie Lin[1], Monica Foyaca[1]

[1] Innovation & Development, ISDIN S.A., Barcelona, Spain

Introduction
Onychomycosis caused by dermatophytes like *Trichophyton rubrum* compromises the nail plate's structural and functional integrity. Fungal invasion degrades keratin, leading to oxidative damage, loss of barrier function, and altered mechanical properties. This study aimed to evaluate the protective and restorative biophysical efficacy of a topical nail-care medical device on human nails experimentally infected with *T. rubrum*.

Materials and Methods
An *ex vivo* experimental model was developed using clipped human nails. Fungal infection was induced by incubating nails on *T. rubrum*-inoculated agar plates. Following colonization, a comprehensive biophysical and biochemical evaluation was performed on treated-infected nails (prevention protocol) and infected-treated nails (curative protocol) , including: 1) Quantification of keratin carbonylation to assess oxidative keratin damage ; 2) Fluorescein dye penetration to evaluate barrier integrity and porosity; 3) Instrumental measurement of compressive resistance for firmness and rigidity; 4) X-polarized light microscopy to analyze keratin structural organization; and 5) Atomic Force Microscopy (AFM) for nanomechanical stiffness characterization.

Results
T. rubrum infection severely impacted nail integrity. Fluorescent dye penetration increased four-fold in infected nails, indicating severe barrier disruption; this was fully restored (100% efficacy) by the curative treatment and partially restored (60%) by the preventive protocol. Oxidative stress, measured by keratin carbonylation, showed a greater than 3-fold increase in infected controls; the medical device significantly reduced carbonylation in both treatment (58% reduction) and preventive (86% reduction) groups ($p < 0.001$). Pathological hardening was observed in infected nails, with firmness increasing from 251 N/mm to 533 N/mm. The treatment protocol normalized rigidity with a 63% recovery, while the preventive protocol preserved flexibility with a 47% recovery. Furthermore, AFM revealed that nanoscale stiffness decreased due to fungal keratin degradation; the application of the product partially restored the elastic modulus. Lastly, birefringence analysis confirmed that the infection caused severe keratin misalignment and disorganization, an effect significantly reversed by both treatment and preventive protocols ($p < 0.001$).

Conclusions
The tested nail-care medical device demonstrated a robust keratin-protective and regenerative mechanism against *T. rubrum* infection. It effectively counteracted oxidative damage, restored the keratin structural organization, normalized the mechanical properties of the nail matrix, and preserved barrier impermeability under infectious stress. These findings indicate that the medical device not only provides protective benefits against fungal invasion but also promotes functional biophysical repair of the nail plate.

EA DV CONGRESS
VIENNA
30 SEP - 3 OCT 2026

Abstract N°: 4481

Regenerative Versus Antiandrogen Therapy in Androgenetic Alopecia: Nanofat Compared with Intradermal Dutasteride

Marwa El-Samongy*[1], Nourhan El-Sheikh[1], Mohamed Khedr[2], Dalia Shaaban[1]

[1] Dermatology & Venereology department, Faculty of Medicine, Tanta University, Tanta, Egypt
[2] Plastic surgery department, Tanta, Egypt

Introduction
Androgenetic alopecia is the most common type of patterned hair loss in genetically predisposed individuals, particularly males. It is characterized by the progressive miniaturization of terminal hair follicles into vellus hairs, primarily affecting the frontal scalp and vertex. AGA is influenced by multiple genetic and hormonal factors, especially the action of DHT on susceptible hair follicles.

Recently, regenerative therapies such as nanofat have emerged as promising modalities in hair restoration. Nanofat is a mechanically emulsified form of fat rich in stromal vascular fraction, growth factors, and adipose-derived stem cells, all of which may enhance hair follicle regeneration and promote angiogenesis.

Dutasteride, a potent 5-alpha-reductase inhibitor, acts by blocking the conversion of testosterone to DHT. It has been used both systemically and intradermally to treat AGA. Intradermal injection allows for localized delivery with potentially fewer systemic side effects, making it a viable option for improving hair density and slowing hair loss progression.

The present randomized comparative study aimed to evaluate the efficacy of intradermal injection of nanofat versus dutasteride in the treatment of androgenetic alopecia.

Materials and Methods
Thirty male patients diagnosed clinically and dermoscopically with androgenic alopecia were enrolled in the study. Patients were randomly divided into two groups: Group I received a single session of nanofat intradermal injection, while Group II received six sessions of intradermal dutasteride injections at monthly intervals. All participants underwent complete history-taking, general and dermatological examinations, and photographic documentation at baseline and at 1, 3, and 6 months after treatment.

Efficacy assessment was conducted through clinical grading using the Norwood–Hamilton classification, patient satisfaction scores, and the global aesthetic improvement scale (GAIS). Trichoscopic evaluation was performed to assess changes in hair density, hair shaft diameter, and the ratio of terminal to vellus hairs.

Ethical consideration ensured informed consent, confidentiality, and participants' right to withdraw at any time.

Results
Both treatments showed significant clinical and trichoscopic improvement; however, statistically significant differences were observed in group II compared with group I in the percentage changes in hair density, hair width, and the percentage of terminal hair at 1 and 6 months after treatment. Clinical improvement was also significantly higher in the dutasteride group. This trend aligns with the greater pharmacologic potency of dutasteride. Patient

satisfaction showed significantly higher scores in the dutasteride group. Age was not significantly correlated with improvement in either group, suggesting that both therapies can be effective across a wide adult age range. However, longer disease duration negatively correlated with improvement in the dutasteride group, indicating that earlier intervention yields better outcomes. No such correlation was observed in the nanofat group, highlighting its potential utility even in chronic, longstanding cases. The maximum clinical and trichoscopic improvement was noted at one month post-treatment in the dutasteride group and at 3 months post-treatment in the nanofat group.

-

Conclusions

Intradermal injection of dutasteride and nanofat injections are both effective and safe for treatment of AGA. Dutasteride provided more rapid and significant improvement, while nanofat remains a valuable regenerative, non-hormonal option for chronic or advanced cases.

EA DV CONGRESS
VIENNA
30 SEP - 3 OCT 2026

Abstract N°: 4485

Nail Cosmetic-Induced Nail Disorders: Dermoscopic Patterns and Diagnostic Challenges

Hajar Dahmani*[1], Ouiame El Jouari[1], Salim Gallouj[1]

[1] University Hospital Center Mohammed VI of Tangier, Tangier, Morocco

Introduction

The growing popularity of nail cosmetic procedures, including gel polish, semi-permanent polish and artificial nails, has been accompanied by an increasing number of nail adverse events, which remain insufficiently recognized. These alterations may mimic inflammatory or infectious nail disorders, making diagnosis challenging. Dermoscopy may represent a valuable non-invasive diagnostic tool in this setting. This study aimed to describe the clinical and dermoscopic features of nail alterations associated with nail cosmetic procedures.

Materials and Methods

A prospective observational study was conducted in female patients presenting nail abnormalities after the use of nail cosmetic products, including gel polish, semi-permanent polish, acrylic resin and artificial nails. Clinical and dermoscopic examinations were performed to characterize nail alterations and identify recurrent dermoscopic patterns.

Results

Ninety female patients presenting nail alterations following cosmetic nail procedures were included. The most frequent dermoscopic findings were onycholysis (77.8%), keratin granulation (55.6%), splinter hemorrhages (55.6%), transverse leukonychia (44.4%), chromonychia (44.4%) and onychoschizia (33.3%). Subungual hyperkeratosis and psoriasiform nail dystrophy were observed in 22.2% of cases. A characteristic traumatic “roller coaster” onycholysis pattern was identified in several patients. Some nail alterations clinically mimicked onychomycosis or psoriatic nail dystrophy; however, mycological sampling was negative in certain cases. Infectious complications included acute paronychia and Pseudomonas-associated green chromonychia. More severe nail dystrophy was predominantly observed in patients with repeated or prolonged exposure to gel polish, semi-permanent polish or artificial nails.

Conclusions

Nail cosmetic procedures may induce a wide spectrum of mechanical, infectious and inflammatory nail alterations. Dermoscopy represents a useful non-invasive tool for early recognition, differential diagnosis and follow-up of post-cosmetic nail disorders. Increased awareness among dermatologists and consumers is essential to improve prevention and reduce cosmetic nail-related complications.

EADV CONGRESS
VIENNA
30 SEP - 3 OCT 2026

Abstract N°: 4494

TELOGEN EFFLUVIUM AND COMORBIDITIES

Houda El ABBADE*[1], Hanane Baybay[1], Rihame Alheyasat[1], Ikrame Bejja[1], Saadia Boughaleb[1], Zakia Douhi[1], Meryem Soughi[1], Sara Elloudi[1], Fatimazahra Mernissi[1]

[1] UHC HASSAN II, FEZ, Morocco

Introduction

Telogen effluvium is a non-scarring alopecia characterized by diffuse hair shedding resulting from the premature transition of a large number of hair follicles into the telogen (resting) phase of the hair cycle. It is a reactive process most commonly triggered by metabolic stress, hormonal changes, nutritional deficiencies, or certain medications. Its incidence has been increasing and it may be associated with numerous comorbidities as well as other inflammatory and autoimmune diseases. The main objective of our study was to describe the frequency of comorbidities associated with telogen effluvium among patients attending the dermatology department of Hassan II University Hospital in Fez.

Materials and Methods

This was a retrospective, monocentric observational study conducted among all patients attending the hair consultation clinic for hair loss over a four-year period, at the dermatology department of Hassan II University Hospital in Fez, from March 2021 to March 2025.

All patients presenting with telogen effluvium diagnosed clinically and dermoscopically were included. All patients underwent a complete dermatological examination including dermoscopy when necessary, performed by an experienced dermatologist.

A complete general examination and laboratory workup were requested, including complete blood count (CBC), serum iron, ferritin level, vitamin D, and thyroid-stimulating hormone (TSH). Hormonal investigations and additional explorations were performed according to clinical orientation based on the patient interview.

Results

Several comorbidities and medical histories were identified among patients with telogen effluvium. The most frequent was iron deficiency anemia, evidenced by low ferritin levels in 37 patients (37.4%), while vitamin D deficiency was found in 70% of patients. Thyroid disorders were identified in 3 patients (3%).

Among other associated conditions, certain dermatoses such as acne, lupus, and rosacea were found in 3 patients (3%). In addition, autoimmune diseases including psoriasis, lichen planus, diabetes mellitus, rheumatoid arthritis, systemic lupus erythematosus, multiple sclerosis, and Crohn’s disease were reported in a limited number of analyzed cases.

Regarding alopecic associations, coexistence with other forms of alopecia was observed in some cases, particularly androgenetic alopecia (AGA) and, more rarely, frontal fibrosing alopecia (FFA).

On dermatological clinical examination, decreased hair density was observed in 80 patients (80.8%), reflecting the diffuse pattern of hair loss in this population.

Among the identified triggering factors, medication intake was reported in 23 patients (23.2%), psychological stress in 10 patients (10.1%), and postpartum status in 10 female patients (10.1%), the latter representing a common triggering factor among women of childbearing age.

The outcome was favorable in 70% of cases, with progressive improvement in hair shedding following appropriate management according to the identified etiology.

Conclusions

Telogen effluvium is a common diffuse alopecia predominantly affecting young women and is often associated with triggering factors such as iron deficiency, stress, and hormonal variations. In our series, iron deficiency anemia was the most frequent comorbidity, and most patients presented with diffuse decreased hair density. Identifying and correcting etiological factors are essential components of management. The prognosis is generally favorable when diagnosis is made early and appropriate treatment is initiated.

EA DV CONGRESS
VIENNA
30 SEP - 3 OCT 2026

Abstract N°: 4556

Efficacy and safety of treatments for alopecia areata-associated nail involvement: A systematic review

Sanaz Lordfard*[1], Eric McMullen[2], Jaehyun Hwang[3], Katya Peri[4], Chiara Paolitto[4], Nandi Edwards[1], Jeffrey Donovan[5], Cathryn Sibbald[2]

[1] Temerty Faculty of Medicine, University of Toronto, Toronto, Canada
[2] Division of Dermatology, Department of Medicine, University of Toronto, Toronto, Canada
[3] Department of Medicine, University of British Columbia, Vancouver, Canada
[4] Faculty of Medicine and Health Sciences, McGill University, Montreal, Canada
[5] Department of Dermatology, University of British Columbia, Vancouver, Canada

Introduction
Nail involvement occurs in up to 64% of patients with alopecia areata (AA) and is more common in severe disease and paediatric populations. This systematic review evaluates the efficacy and safety of treatments for AA-associated nail changes.

Materials and Methods
MEDLINE, Embase, and Web of Science were searched from inception to December 2025 using key terms relevant to AA and nail changes. This review was registered on PROSPERO (CRD420261363996) and followed PRISMA 2020 reporting guidelines. Eligible studies reported on patients of any age with AA-associated nail changes receiving systemic or localised treatments for nail involvement. Abstracts, reviews, and non-English publications were excluded.

Results
The search identified 895 records, of which 37 studies met inclusion criteria. These consisted of 24 case reports, seven retrospective cohort studies, and six case series. Risk of bias assessment was conducted using adaptations of the Joanna Briggs Institute Critical Appraisal Checklist, finding the majority with moderate quality (48.6%) and others with good quality (35.1%) or poor quality (16.2%).

A total of 81 patients with AA-associated nail changes receiving treatment were identified. Patients had a slight male predominance (56.3%) and had a median age of 32.5 years. A large number of patients had AA universalis (53.1%) or totalis (15.6%).

The most frequently reported nail changes included nail dystrophy (38.3%), nail pitting (35.8%), trachyonychia (16.0%), longitudinal ridging (11.1%), brittle (9.9%) and onycholysis (8.6%). When reported, nail involvement often affected all fingernails and toenails in 56.0% (n=14/25) of patients, followed by involvement of only all fingernails in 28.0% (n=7/25). Limited involvement (≤3 digits) was reported in only 1 patient.

Treatment outcomes varied considerably across therapeutic categories (Table 1), with intralesional and systemic agents generally showing greater response rates than topical therapies. Intralesional corticosteroids into the proximal nail fold demonstrated the highest complete response rate, with 57.1% (n=4/7) achieving complete response, 14.3% (n=1/7) partial response, and 28.6% (n=2/7) no response after a mean of 3.5 injections. Oral

steroids were associated with a complete response in 45.5% (n=5/11) of patients, partial response in 27.3% (n=3/11), and no response in 27.3% (n=3/11). Topical corticosteroids (n=3) demonstrated limited efficacy, with 1 patient achieving partial response.

Systemic Janus kinase (JAK) inhibitors were used in 52 patients, with 9.6% (n=5/52) achieving complete response, 59.6% (n=31/52) partial response, and 30.8% (n=16/52) no response. Dupilumab resulted in partial response in two patients.

Among topical non-steroidal therapies, diphenylcyclopropenone achieved partial improvement (16.7%, n=1/6), whereas no improvement was seen with tacrolimus, ciclopirox, ketoconazole, urea, calcipotriene, and hydroxypropyl chitosan. Oral retinoids resulted in partial response in 1 patient, and no response in another. Topical retinoids (tazarotene) and phototherapy each resulted in partial response in 1 patient each.

Adverse events were reported in 3 patients, including acne with oral upadacitinib, grade 1 creatine kinase elevation with oral baricitinib, and local irritant contact dermatitis with topical tazarotene. Mean follow-up duration when specified, was 5.8 months (range: 1-22 months).

Treatment category[1]	Total patients (n)	Complete response	Partial response	No response
Oral JAK inhibitors	52	5 (9.6%)	31 (59.6%)	16 (30.8%)
Tofacitinib	24	5	19	-
Baricitinib	17	-	3	14
Ritlecitinib	9	-	9	-
Upadacitinib	1	-	-	1
Abrocitinib	1	-	-	1
Oral steroids +/- adjunct	11	5 (45.5%)	3 (27.3%)	3 (27.3%)
Betamethasone	5	4	1	-
Non-specified steroid	1	-	1	
Non-specified steroid + tacrolimus topical + topical corticosteroid	1	-	-	1
Prednisolone + azathioprine	1	-	-	1
Prednisolone + topical corticosteroid	1	1	-	-
Prednisone	1	-	1	-
Cortisone + corticotropin gel	1	-	-	1
Intralesional steroid into proximal nail fold (Triamcinolone acetonide)	7	4 (57.1%)	1 (14.3%)	2 (28.6%)
Topical non-steroid	6	-	1 (16.7%)	5 (83.3%)
Diphenylcyclopropenone	1	-	1	-
Ciclopirox	1	-	-	1
Ketoconazole	1	-	-	1
Urea	1	-	-	1
Calcipotriene	1	-	-	1
Hydroxypropyl-chitosan	1	-	-	1
Topical steroid	3	-	1 (33.3%)	2 (66.6%)
Fluocinonide	2	-	-	2
Mometasone furoate	1	-	1	-
Oral retinoids	2	-	1 (50.0%)	1 (50.0%)
Alitretinoin	1	-	-	1
Isotretinoin + topical corticosteroid	1	-	1	-
Biologics (Dupilumab)	2	-	2 (100%)	-
Topical retinoid (Tazarotene)	1	-	1 (100.0%)	-
Phototherapy (Psoralen + UVA)	1	-	1 (100.0%)	-
Other				
Methyl testosterone	1	1	-	-
Hydroxychloroquine	1	-	1	-
Thyroideum siccum	1	-	-	1
Intralesional steroid + betamethasone dipropionate 0.5% + dexamethasone iontophoresis	1	-	-	1

[1] Some patients tried more than one treatment regimen, therefore totals may exceed the number of patients.

Table 1. Treatment response to different interventions in patients with alopecia areata-related nail changes.

Conclusions

AA-associated nail involvement remains challenging to treat, with variable therapeutic responses and limited data on long-term outcomes. This review highlights a heterogeneous evidence base, largely composed of case reports and small series, with inconsistent reporting of treatment response, dosing, and safety. Future prospective, controlled studies with standardised outcome measures are needed to better define the efficacy and safety of treatments for nail involvement in AA.

EADV Congress 2026, VIENNA
30 SEPTEMBER - 03 OCTOBER 2026
POWERED BY M-ANAGE.COM

EADV CONGRESS
VIENNA
30 SEP - 3 OCT 2026

Abstract N°: 4579

Biologic therapies in dissecting cellulitis of the scalp: a literature review

Anabell Andrea Lima Galindo*[1], Diego Buendia-Castaño[2], David Saceda-Corralo[2]

[1] Dermatology Private Practice, San Andrés Cholula, Mexico

[2] Hospital Universitario Ramón y Cajal, Madrid, Spain

Introduction

Dissecting cellulitis of the scalp (DCS) is a chronic inflammatory follicular occlusion disorder characterized by painful nodules, abscesses, sinus tracts, and scarring alopecia. Current treatment options remain limited, and although isotretinoin is considered first-line therapy, response rates are suboptimal and relapses are frequent. Increasing evidence suggests that inflammatory pathways involving TNF-α, IL-17, and IL-23 play an important role in disease pathogenesis, supporting the use of biologic therapies in refractory cases.

Materials and Methods

A literature review was conducted including published case reports, case series, retrospective studies, and reviews evaluating biologic therapies in DCS. Data regarding biologic class, dosage, treatment duration, prior therapies, clinical outcomes, adverse events, and associated comorbidities were analyzed.

Results

The available evidence suggests that biologic therapies may represent an effective treatment option for refractory DCS. TNF-α inhibitors, particularly adalimumab and infliximab, are the most extensively studied agents and have demonstrated favorable clinical responses in most reported cases, with rapid improvement in inflammatory activity, pain, purulent discharge, and hair regrowth. IL-23 inhibitors, including risankizumab, guselkumab, and tildrakizumab, as well as IL-17 inhibitors such as secukinumab and ixekizumab, have also shown promising results in recalcitrant disease. Reported adverse events were generally infrequent and manageable.

Conclusions

Biologic therapies appear to be a promising therapeutic alternative for DCS, particularly in refractory or advanced disease. Early control of inflammation may help prevent irreversible scarring alopecia and chronic sequelae. However, current evidence remains limited to small observational studies and case reports, highlighting the need for prospective controlled studies to better establish efficacy, safety, and long-term outcomes.