EADV CONGRESS
VIENNA
30 SEP - 3 OCT 2026

**Abstract N°: 37**

# Efficacy and Safety of Stem Cell Therapy in the Management of Epidermolysis Bullosa: A Systematic Review and Meta-Analysis

Sarah Rafehi*[1], Tia Sarkis[2], Thalia El Chaer[2], Sophie Haidar[2], Frederic Harb[2]

[1] University of Balamand, Faculty of Medicine and Medical Science, Tripoli, Lebanon
[2] University of Balamand, Faculty of Medicine and Medical Sciences, Tripoli, Lebanon

## Introduction
Background: Epidermolysis bullosa (EB) comprises rare, inherited blistering disorders with severe morbidity, limited to supportive care and without curative treatments. Stem cell–based therapies have emerged as a promising strategy to enhance skin regeneration, reduce blistering, and improve quality of life, but their efficacy and safety remain uncertain due to small, heterogeneous studies.

## Materials and Methods
Methods: We are conducting a systematic review and meta-analysis of randomized and non-randomized clinical studies evaluating stem cell therapies (hematopoietic, mesenchymal, umbilical cord, and gene-corrected cell grafts) in patients with any EB subtype, compared with usual care, placebo, or other active treatments. Searches in MEDLINE, Embase, CENTRAL, CINAHL, PubMed, and Scopus, supplemented by citation tracking and trial registries, include studies in English without date restriction. Primary outcomes are wound healing, reduction in blistering, and adverse events; secondary outcomes include skin integrity and patient-reported quality of life. Random-effects meta-analyses are performed where appropriate, and non-randomized evidence is synthesized narratively with risk of bias assessed using RoB 2 and ROBINS-I, and certainty of evidence graded with GRADE.

## Results
Results: Data extraction and synthesis are ongoing. Preliminary quantitative results from the available randomized controlled trial suggest that systemic stem cell therapy may meaningfully reduce pain intensity and pruritus compared with placebo/usual care over short- to medium-term follow-up, with no major safety signals detected to date. Non-randomized studies, which are being synthesized qualitatively, generally report improvements in wound healing and symptom burden, but are limited by small sample sizes, heterogeneous protocols, and moderate-to-high risk of bias.

## Conclusions
Conclusions: Early evidence indicates that stem cell therapy could offer clinically relevant benefits for symptom control and wound outcomes in EB, with an acceptable short-term safety profile, but the overall certainty of evidence remains low and longer-term data are lacking. Completion of this review will provide a more robust estimate of treatment effects across study designs and help define priorities for future well-powered trials in this rare disease population.

EADV CONGRESS
VIENNA
30 SEP - 3 OCT 2026

**Abstract N°: 42**

# Multiple Cutaneous Leiomyomas Associated with Possible Hereditary Leiomyomatosis: A Case Report

Adalina Kozma*[1]

[1] Vash Likar Medical Center, Izmail, Ukraine

## Introduction

Cutaneous leiomyomas are benign smooth muscle tumors derived from the arrector pili muscle. They may occur sporadically or as part of Hereditary Leiomyomatosis and Renal Cell Cancer (HLRCC), also known as Reed syndrome, an autosomal dominant condition associated with uterine leiomyomas and an increased risk of aggressive renal cell carcinoma. Because cutaneous lesions may precede systemic manifestations, dermatologists play a crucial role in recognizing this syndrome. However, diagnosis is often delayed due to the rarity and nonspecific appearance of lesions.



## Case Presentation

A 43-year-old woman presented with multiple skin lesions persisting for more than six years. Clinical examination

revealed more than 15 firm papules distributed randomly across the back, flanks, and abdomen, with a few isolated elements on the shoulders. The lesions were partly skin-colored and partly flesh-to-pink, and were associated with pain, pruritus, and occasional burning sensations. The patient reported periodic development of new lesions over time.The medical history was significant for rapidly growing nodular uterine leiomyoma diagnosed in 2011. A family history of uterine leiomyomas was also reported. The patient did not report known adrenal or endocrine disorders.A punch biopsy from a lesion on the right lateral trunk was performed. Histopathological examination confirmed cutaneous leiomyoma.
The presence of multiple painful leiomyomas combined with a personal history of uterine leiomyoma and positive family history raised suspicion for Hereditary Leiomyomatosis and Renal Cell Cancer. The patient was referred for genetic counseling and consideration of testing for FH gene mutation.Treatment was initiated with intralesional triamcinolone acetonide injections together with pregabalin for pain control, resulting in noticeable improvement of pain symptoms.



**Conclusion**

Multiple painful cutaneous papules should prompt consideration of cutaneous leiomyomas and possible underlying HLRCC. Dermatologists play a key role in recognizing these lesions, which may serve as an early clinical marker of a potentially life-threatening hereditary syndrome and allow timely genetic evaluation and surveillance.

EADV CONGRESS
VIENNA
30 SEP - 3 OCT 2026

**Abstract N°: 67**

## Skewed X-chromosome inactivation causing X-linked hypohidrotic ectodermal dysplasia symptoms in a Caucasian girl

Tatevik Harutyunyan*[1], Armine Adilkhanyan[1], Inga Mkhitaryan[1]

[1] 1. Department of Pediatric Dermatology, Arabkir Medical Center, Yerevan, Armenia, Yerevan, Armenia

**Introduction**
X-linked hypohidrotic ectodermal dysplasia (XLHED) is caused by mutations of the gene for ectodysplasin A (EDA) , which encodes a protein belonging to the TNF family. The phenotype ranges from classic HED to non syndromic hypodontia. The objective of this abstract revealing the reason of severe eczema and XLHED symptoms in a female patient.

**Case Presentation**
6-year-old Caucasian girl presented with severe eczema . She is the second child of unrelated parents. Dysmorphic features were noted , including palmoplantar keratoderma, sparse hair , hypohidrosis, polysyndactyly , hypodontia, .The analysis by targeted Next- Generation of the genes , involved in genodermatoses revealed the presence of the c.467G>A (p. Arg156His) variant in exon 2 in the EDA gene at the heterozygous state and the c.9709A >T (p. Arg3237*) and c.1501C>T (p. Arg501*) variants in exon 3 in the FLG gene at the heterozygous composite state. The EDA variant is inherited from patient' s mother who has also mild teeth abnormalities consistent with a status of carrier. The first variant in the FLG gene is inherited from the patient's father. The second variant in FLG gene is inherited from mother.

**Conclusion**
Diagnosis of HED is confirmed at molecular level. It was interesting in our case that the marked EDA symptoms (teeth abnormalities, complete absence of sweating , sparse and thin hair) in a female patient could be due to skewed X- chromosome inactivation . FLG variants lead to premature stop codons and are likely to contribute to severe eczema seen in patient.

EA DV CONGRESS
VIENNA
30 SEP - 3 OCT 2026

**Abstract N°: 98**

# Health care utilization patterns among individuals with Neurofibromatosis type 1 and cutaneous neurofibromas, using administrative data, in Ontario, Canada

Hadiya Elahmar*[1], Alejandro Hernandez[2], Aaron Drucker[3], Patricia Parkin[4], Carolina Barnett-Tapia[5]

[1] Institute of Health Policy, Management and Evaluation, Dalla Lana School of Public Health, University of Toronto, Canada., Toronto, Canada

[2] Institute for Clinical Evaluative Sciences (ICES), Toronto, Canada

[3] Institute of Health Policy, Management and Evaluation, Dalla Lana School of Public Health, University of Toronto, Canada., Department of Medicine and Research and Innovation Institute, Women's College Hospital, Institute for Clinical Evaluative Sciences (ICES), Toronto, Canada

[4] Institute of Health Policy, Management and Evaluation, Dalla Lana School of Public Health, University of Toronto, Canada., Department of Paediatrics, Faculty of Medicine, University of Toronto., Toronto, Canada

[5] Institute of Health Policy, Management and Evaluation, Dalla Lana School of Public Health, University of Toronto, Canada., Elisabeth Raab Neurofibromatosis Clinic, Toronto General Hospital, University Health Network, Toronto, Canada, Toronto, Canada

**Introduction**

Neurofibromatosis type 1 (NF1) is a genetic condition characterized by cutaneous neurofibromas (cNFs), benign skin tumors affecting up to 95% of adults with NF1. Data on healthcare utilization for cNF management are limited. This study aimed to characterize healthcare utilization related to cNFs in Ontario by comparing rates of skin lesion resections and specialist consultations between individuals with NF1 and matched controls, and by identifying factors associated with higher use of these services among individuals with NF1.

**Materials and Methods**

We conducted a retrospective cohort study linking NF1 registries from two major NF1 clinics (paediatric and adult) in Toronto with administrative health data from Ontario, Canada. Adults (≥18 years) with confirmed NF1 and at least 2 years of Ontario Health Insurance Plan (OHIP) eligibility were included and matched 1:5 to controls by age, sex, income quintile, and geographic region. The index date was the later of the 18th birthday, July 1, 1992, or OHIP eligibility, with follow-up to December 31, 2024. We compared rates of skin lesion resections and specialist consultations (dermatology, plastic surgery, and general surgery) between adults with NF1 and matched controls using negative binomial regression. Factors associated with excision procedures within the NF1 cohort were assessed using logistic regression analysis. For secondary outcomes, we calculated the proportion of individuals who had ever undergone an excision or consultation and compared the mean number of excisions and consultations between individuals with NF1 and matched controls.

**Results**

The study included 727 individuals with NF1 matched to 3,635 controls; 54.2% were female, and the mean (SD) age at the index date was 21.4 (7.3) years. Overall, 52% of individuals with NF1 underwent at least one skin lesion excision compared with 23% of controls, with higher mean counts (3.87 vs. 0.71; $p < 0.0001$); skin biopsies were the most common procedure, with counts ranging up to 499 in the NF1 group and 151 in controls. Specialist consultations were also higher among individuals with NF1 (mean 13.49 vs. 2.97), with 78% versus 43% having at least one consultation; among skin-related specialties, general surgeons were the most frequently consulted. Adjusted analyses showed higher rates of excisions (RR = 2.31, 95% CI 1.91–2.78) and specialist consultations (RR = 2.81, 95% CI 2.45–3.23) among individuals with NF1. Within the NF1 group, older age and female sex were

associated with greater healthcare use; excision rates increased by 6% per additional year of age (RR = 1.06, 95% CI 1.04–1.07), and females had approximately twice the excision rate of males (RR = 2.10, 95% CI 1.59–2.77). Individuals with NF1 in income quintiles 2 and 3 had lower excision rates compared with those in the lowest-income quintile (RR = 0.51, 95% CI 0.31–0.84; RR = 0.45, 95% CI 0.26–0.79), whereas those in material resources quintiles 3 and 4 had higher excision rates compared with quintile 5 (RR = 2.55, 95% CI 1.41–4.60; RR = 4.63, 95% CI 2.84–7.57).

**Conclusions**

Individuals with NF1 had twofold higher rates of skin excisions and threefold higher rates of specialist consultations than matched controls. Older age and female sex were associated with higher excision rates, highlighting the need for age- and sex-responsive healthcare planning. Socioeconomic differences and the higher proportion of excisions performed by general surgeons may reflect variation in access to private insurance and the ability to pay out-of-pocket for cNF removal, which is often considered cosmetic and not publicly funded in Ontario; the low mean numbers of excisions and consultations per person may also reflect these healthcare system factors. Further research is needed to assess the role of private coverage and out-of-pocket costs in access to cNF care in Canada.

EA DV CONGRESS
VIENNA
30 SEP - 3 OCT 2026

**Abstract N°: 115**

## Lipoid Proteinosis (Urbach–Wiethe Disease): A Clinico-Pathological Correlation

Pranam Swapan Dash*[1], Mohammad Abu Hena[1], A.T.M Asaduzzaman[1], Tanzina Chowdhury[1]

[1] Bangladesh Medical University, Dhaka, Bangladesh

### Introduction

Lipoid proteinosis (LP), or Urbach–Wiethe disease, is a rare autosomal recessive genodermatosis characterized by deposition of Periodic acid–Schiff (PAS)–positive, Congo red–negative hyaline material within the skin, mucous membranes, and internal organs. Mutations in the extracellular matrix protein 1 (ECM1) gene on chromosome 1q21 disrupt dermal structure, basement membrane composition, and keratinocyte differentiation, leading to glycoprotein accumulation in the dermis and submucosa. Clinically, LP usually presents in childhood with hoarseness of voice, beaded papules on the eyelid margins (moniliform blepharosis), and waxy thickening or scarring of the skin. . Although the condition is rare worldwide, its prevalence is higher in regions with consanguineous marriages. Histopathological examination remains the cornerstone of diagnosis, distinguishing LP from amyloidosis and other mucocutaneous deposition disorders. This report describes a young male patient showing classic mucocutaneous and laryngeal features of LP, highlighting the correlation between clinical findings and histopathology for accurate diagnosis and management.



Beaded papules

**Case Presentation**

A 22-year-old male, born of consanguineous parents, presented with asymptomatic, skin-colored papules distributed over his eyelids, periorbital region. Over subsequent years, he developed pock-like scars over trunk. There was hoarseness of voice, and difficulty protruding the tongue. There was no history of seizures, headaches, or visual abnormalities. There were skin-colored papules on the upper eyelids, periorbital area, forehead, neck, and cheeks, giving the facial skin a waxy appearance. The elbows and knees showed rough hyperkeratotic plaques, and both axillary and inguinal folds had hyperkeratotic papules and plaques due to friction. The trunk showed multiple pock-like scars corresponding to healed bullae. Oral examination revealed macroglossia with dental indentations, a shortened frenulum, and multiple waxy papules on the buccal mucosa, labial mucosa, and undersurface of the tongue, extending to the uvula and fauces. Laryngoscopy demonstrated waxy papules over the vocal cords, consistent with his hoarse voice. Histopathology of a papular lesion revealed amorphous, eosinophilic hyaline deposits in the papillary dermis surrounding sweat glands and blood vessel which were PAS positive confirming non-amyloid glycoprotein deposition consistent with Lipoid Proteinosis, which was supported by a positive ECM 1 mutation. Based on the constellation of findings, a final diagnosis of Lipoid Proteinosis (Urbach–Wiethe disease) was made.

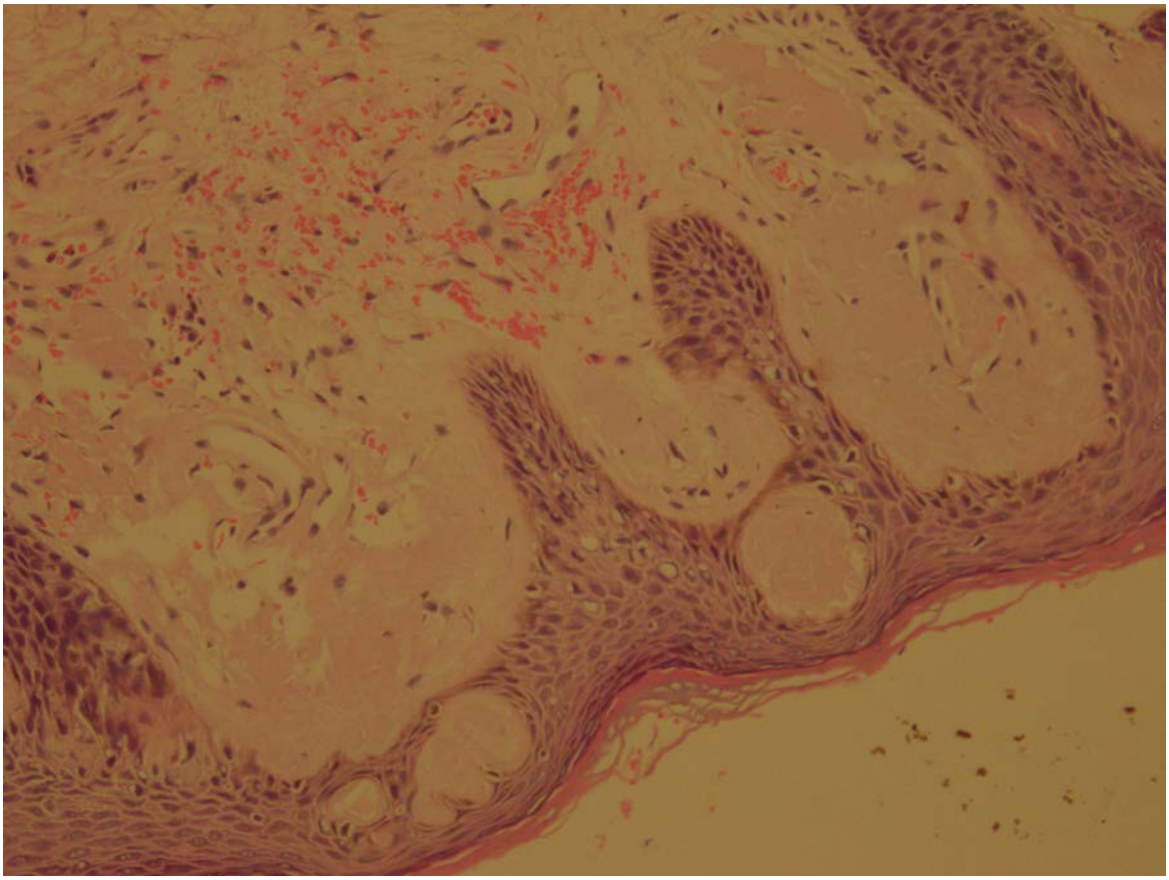

Positive skin biopsy

**Conclusion**

Lipoid proteinosis is a multisystem disorder caused by ECM1 gene mutations resulting in abnormal hyaline deposition within the skin and mucous membranes. Hoarseness due to vocal cord infiltration is usually the earliest manifestation, followed by moniliform blepharosis, mucocutaneous thickening, acneiform scarring, and hyperkeratotic plaques on pressure areas. Histopathologically, LP is characterized by deposition of eosinophilic PAS-positive, Congo red–negative material within the papillary dermis and around adnexal structures, distinguishing it from cutaneous amyloidosis.Management remains symptomatic and aims to improve functional and cosmetic outcomes. Voice therapy and microlaryngoscopic removal of laryngeal deposits may improve hoarseness, while dermabrasion, $CO_2$ laser therapy, and oral retinoids such as acitretin may reduce cutaneous lesions. Genetic counseling is important, particularly in families with consanguineous marriages. Early recognition of characteristic features, particularly childhood-onset hoarseness with eyelid papules, allows timely diagnosis and appropriate multidisciplinary care, improving patient quality of life.

EADV CONGRESS
VIENNA
30 SEP - 3 OCT 2026

**Abstract N°: 153**

## Familial acrodermatitis enteropathica in two siblings from Mongolia: A case report

Urangoo Ochirchuulgan*[1]

[1] National Dermatology Center of Mongolia, Ulaanbaatar, Mongolia

### Introduction

Acrodermatitis enteropathica (AE) is a rare autosomal recessive disorder caused by mutations in SLC39A4, encoding the ZIP4 zinc transporter, resulting in impaired intestinal zinc absorption. It affects approximately 1 in 500,000 children and typically presents with acral and periorificial dermatitis, diarrhea, alopecia, growth retardation, immune dysfunction, and neuropsychiatric disturbances. Reports from Mongolia remain limited.

### Case Presentation

We report two sisters aged 6 and 8 years from rural Mongolia with persistent acral and periorificial dermatitis and diffuse alopecia since early infancy. Two of four siblings were affected despite no previously known family history. Clinical and laboratory findings supported Acrodermatitis enteropathica. At presentation (April 2025), serum zinc levels were 5.3 µmol/L and 7.3 µmol/L (reference 9.8–16.8 µmol/L) in the 8- and 6-year-old, respectively. Oral elemental zinc (1 mg/kg/day) was initiated and adjusted to clinical response. Cutaneous lesions resolved within 10 days, and scalp hair and eyelashes regrew within five months. Clinical follow-up has continued for 11 months.




Figure 1. (A) Periorificial dermatitis characterized by erythema, erosions, and crusting in acrodermatitis enteropathica prior to treatment; (B) significant clinical improvement after initiation of oral zinc therapy

### Conclusion

AE is a rare but treatable condition that can lead to significant morbidity if not recognized early. Cases without a clear family history may pose diagnostic challenges, particularly in resource-limited settings. Early recognition and prompt lifelong zinc supplementation are essential to prevent complications and improve quality of life.

EA DV CONGRESS
VIENNA
30 SEP - 3 OCT 2026

**Abstract N°: 228**

# Homozygous familial hypercholesterolemia associated with aortic stenosis and ischemic heart disease revealed by multiple cutaneous xanthomas

almeghari widad*[1], Imene Mahiou[1], Samira Zobiri[1]

[1] CHU MUSTAPHA, Alger, Algeria

## Introduction

Homozygous familial hypercholesterolemia (HoFH) is a rare genetic disorder.It manifests itself from childhood by a very significant increase in LDL cholesterol, exposing early on to severe cardiovascular complications. Dermatological manifestations, in particular xanthomas, can constitute the first warning sign.



large xanthomas (tendinous)

**Case Presentation**

This is a 22-year-old patient, with no significant medical history, from a consanguineous marriage, who presented with unlabeled skin lesions since the age of 3. The clinical examination revealed the presence of three types of xanthomas: tuberous, tendinous and flat xanthomas. The biological assessment showed very high cholesterol and lipid profile. Dermoscopic examination revealed orange dermal globules on an erythematous background suggestive of the diagnosis.Histological study of the lesions confirmed the diagnosis, showing dense dermal infiltration by foamy histiocytes.Systemically, the patient presented with supravalvular aortic stenosis as well as ischemic heart disease, in heart failure. The family genetic investigation revealed a heterozygous profile in the parents and two sisters and a homozygous profile in the younger brother, whose examination revealed the presence of tendon xanthomas without systemic involvement.

Homozygous familial hypercholesterolemia (HoFH) is an extremely rare condition, estimated at between 1/160,000 and 1/1,000,000. This diagnosis is often overlooked and delayed, despite dermatological signs visible from childhood. In our case, the simultaneous coexistence of three forms of very large xanthomas (tuberous, tendinous and flat) constitutes an exceptional presentation, very rarely reported in the literature. This cutaneous polymorphism reflects a massive lipid overload, linked to the almost total absence of functional LDL receptors. But it is above all the severity of the cardiovascular involvement that gives this case a warning character. At only 22 years old, our patient presents with heart failure, a complication usually observed much later, following repeated MIs but also with supravalvular aortic stenosis which is rare, due to premature malignant atherogenesis.



very large xanthomas (tuberous) perineal

**Conclusion**

This case highlights the importance of early dermatological signs, particularly xanthomatous polymorphism, in the diagnosis of homozygous familial hypercholesterolemia. The severity of early cardiovascular complications requires systematic screening of relatives and urgent, specialized management.

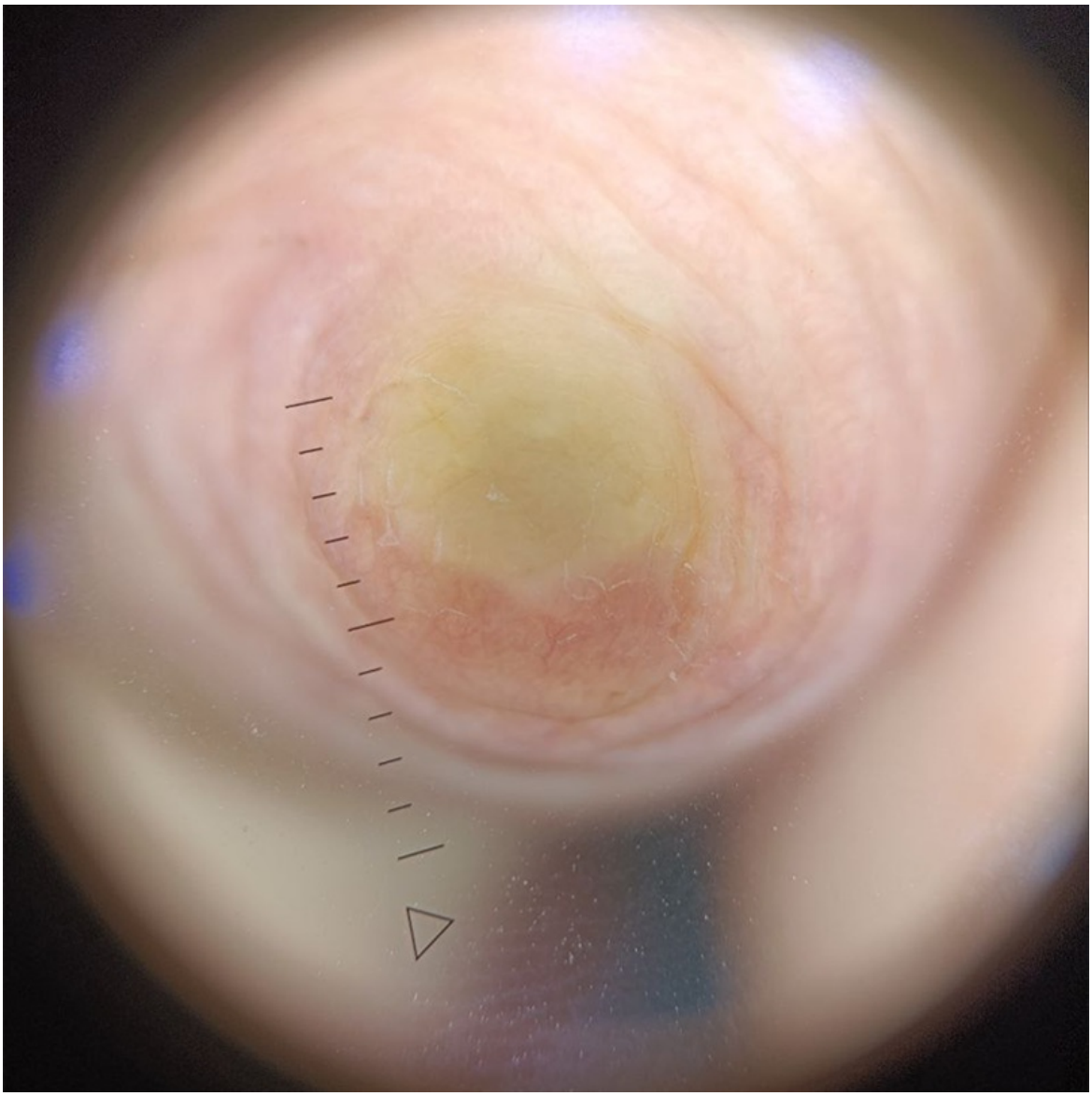

Dermoscopic examination revealed orange dermal globules on an erythematous background suggestive of the diagnosis

EADV CONGRESS
VIENNA
30 SEP - 3 OCT 2026

**Abstract N°: 248**

# Late segmental form of Darier's disease

Heorhi Ulasevich*[1], YULIYA ULASEVICH[1]

[1] OAO Center of medical cosmetology, Mogilev, Belarus

## Introduction

Darier disease, also known as Darier-White disease, or dyskeratosis follicularis, is a rare autosomal dominantgenodermatosis characterized by a persistent eruption of red-brown, keratotic papules scattered toconfluent in a seborrheic distribution, nail abnormalities, pitting of palms and soles, and mucosalchanges. The disease usually starts around puberty and runs a chronic course withexacerbations induced by sun exposure, heat, friction, or infections. Mutations in the ATP2A2 gene that encodes asarco/endoplasmic reticulum Ca -adenosine triphosphate (ATP)ase pump (SERCA2) lead to bothacantholysis and apoptosis, accounting for the characteristic pathologic finding of acantholyticdyskeratosis in Darier disease.

## Case Presentation

The patient is a 48 year old woman who presents with brown papules with a greasy texture. The initial lesions appeared 6 month ago. Groups of keratotic papules follow the Baschko lines on the left body side. On the anterior trunk, these lines tend to take the form of transverse bands, and V-shape in the middle of the back
No family history
Otherwise healthy
Histology: Acantholysis and dyskeratosis are the main histologic features. The epidermis with “Corps ronds” and “Grains” is thickened, shows focal parakeratosis, papillomatosis, and hyperkeratosis. The underlying dermal papillae are covered by a single layer of epithelium and forming villus-like structures.

## Conclusion

Several cases have been reported of acantholytic epidermal naevi comprising crusted keratotic papules, clinically and histologically resembling those seen in Darier’s disease. The suggestion that such naevi represent mosaicism for Darier’s disease has been confirmed by finding a mutation in the Darier’s disease gene ATP2A2 in the naevus, but not in unaffected skin. Linear or segmental forms of Darier disease may result from genetic mosaicism of ATP2A2. Type 1 mosaicism, reflecting a postzygotic somaticmutation in ATP2A2 early during embryogenesis, presents with one or more unilateral bands of keratotic papules following the Blaschko lines.  Darier disease usually starts around puberty, but such cases appear relatively late, even after the age of 20 years, in individuals who lack a family history of Darier’s disease.

EA DV CONGRESS
VIENNA
30 SEP - 3 OCT 2026

**Abstract N°: 279**

## Lost for Two Decades: Unmasking WILD Syndrome in a GATA2-Associated Genodermatosis

Alperen KIZILKAYA*[1], Burcu Tugrul[2], Akin Aktas[3]

[1] Ankara Bilkent Şehir Hastanesi, Ankara, Türkiye
[2] Doç Dr Burcu Tuğrul - Ankara Dermatolog, Ankara, Türkiye
[3] Ankara Yıldırım Beyazit Üniversitesi Tip Fakültesi, Ankara, Türkiye

### Introduction

WILD syndrome — an acronym for Warts, Immune deficiency, primary Lymphedema, and Anogenital Dysplasia — is one of the rarest genodermatoses ever described. Since its first characterization in 2008, only 21 cases have been documented in the world literature, making this condition extraordinarily rare even within the spectrum of primary lymphedema syndromes. The syndrome arises from germline mutations in the GATA2 gene, a transcription factor critical for hematopoietic and lymphatic development. GATA2 deficiency predisposes to recurrent viral infections, progressive immune deterioration, and hematologic malignancies. Due to its variable and asynchronous multi-system manifestations, diagnosis is frequently delayed by decades. Herein, we present a case diagnosed after approximately 20 years of symptomatic disease, supplemented by systemic inflammatory index analysis to characterize the subclinical immune-inflammatory profile.

### Case Presentation

A 36-year-old male presented with a two-decade history of unresolved complaints managed across multiple specialties without a unifying diagnosis. Beginning at age 20, he developed therapy-resistant plantar warts, followed by progressive unilateral lower limb lymphedema and bleeding nodular anogenital lesions — each addressed in isolation for nearly 20 years. This prolonged diagnostic odyssey imposed repeated cycles of ineffective therapy, profound psychosocial distress, social withdrawal, occupational impairment, and a severely diminished quality of life.Dermatological examination revealed hyperkeratotic plaques on the plantar surfaces, verrucous lesions on both palms, hemorrhagic nodules in the anogenital region, and marked lymphedema of the left lower extremity. Laboratory workup demonstrated leukopenia (2.68 $\times 10^9$/L), neutropenia (1.52 $\times 10^9$/L), persistent monocytopenia (0.08 $\times 10^9$/L), mild thrombocytopenia (111 $\times 10^9$/L), and anemia (Hgb: 10.5 g/dL). Flow cytometry revealed B cell dysregulation with otherwise preserved CD marker ratios. Systemic inflammatory indices (Table 1) revealed a complex immunosuppressive profile: a markedly elevated platelet-to-monocyte ratio (PMR: 1387.5) and a reduced monocyte-to-lymphocyte ratio (MLR: 0.08) reflected GATA2-related monocytopenia, while a low systemic immune-inflammation index (SII: 168.72) indicated an immunosuppressed rather than hyperinflammatory state.Genetic analysis confirmed a pathogenic germline GATA2 mutation, establishing the diagnosis of WILD syndrome. Treatment was initiated with systemic acitretin (50 mg/day) and topical imiquimod 5% on alternate days. After six months, 75% regression of wart lesions and 90% improvement in anogenital dysplasia were achieved.

**Table 1. Systemic Inflammatory Indices in a Patient with WILD Syndrome (GATA2 Mutation)**

| Index | Full Name | Formula | Patient Value | Interpretation |
|---|---|---|---|---|
| NLR | Neutrophil-to-Lymphocyte Ratio | Neutrophils / Lymphocytes | 1.52 | Low-normal; blunted inflammatory response |
| PLR | Platelet-to-Lymphocyte Ratio | Platelets / Lymphocytes | 111.0 | Low-normal; reflects mild thrombocytopenia |
| MLR | Monocyte-to-Lymphocyte Ratio | Monocytes / Lymphocytes | 0.08 | Markedly decreased; hallmark of GATA2 deficiency |
| SII | Systemic Immune-Inflammation Index | (Platelets × Neutrophils) / Lymphocytes | 168.72 | Low; indicates immunosuppressive state |
| HLR | Hemoglobin-to-Lymphocyte Ratio | Hemoglobin (g/dL) / Lymphocytes ($\times 10^9$/L) | 10.5 | Reflects co-existing anemia |
| PMR | Platelet-to-Monocyte Ratio | Platelets / Monocytes | 1387.5 | Markedly elevated; driven by monocytopenia |
| HPR | Hemoglobin-to-Platelet Ratio | Hemoglobin (g/dL) / Platelets ($\times 10^3$/L) | 0.0946 | Mildly elevated; combined cytopenia pattern |
| dNLR | Derived Neutrophil-to-Lymphocyte Ratio | Neutrophils / (WBC − Neutrophils) | 1.31 | Low-normal; consistent with global leukopenia |

Abbreviations: NLR, neutrophil-to-lymphocyte ratio; PLR, platelet-to-lymphocyte ratio; MLR, monocyte-to-lymphocyte ratio; SII, systemic immune-inflammation index; HLR, hemoglobin-to-lymphocyte ratio; PMR, platelet-to-monocyte ratio; HPR, hemoglobin-to-platelet ratio; dNLR, derived neutrophil-to-lymphocyte ratio; WBC, white blood cell count.

## Conclusion

With only 21 documented cases worldwide, WILD syndrome stands as one of the rarest genodermatoses ever reported. This case illustrates the profound human cost of diagnostic delay — a 20-year odyssey marked by misattributed symptoms, failed therapies, social isolation, and severely impaired quality of life. The asynchronous and non-simultaneous presentation of its cardinal features appears to be an intrinsic characteristic of the syndrome itself, rendering early recognition inherently challenging. Systemic inflammatory indices (NLR, PLR, SII, PMR) provided adjunctive insight into the subclinical immune dysregulation associated with GATA2 deficiency; although non-specific, they may complement clinical and genetic evaluation in similarly complex immunodermatological presentations. Given the extreme rarity of this condition, each new case contributes meaningfully to the evolving understanding of its natural history and management. In our patient, combined retinoid and immunomodulatory therapy yielded substantial clinical efficacy, adding to the sparse but growing therapeutic experience in WILD syndrome.

EA DV CONGRESS
VIENNA
30 SEP - 3 OCT 2026

**Abstract N°: 317**

# Hailey–Hailey Disease: Long-Standing Misdiagnosis and the Role of Botulinum Toxin in Modern Management

Vira Pavlova*[1], Lesia Henyk[2]

[1] Veselka Medical Center, Lviv, Ukraine

[2] Henyk Dermatology, Kolomyia, Ukraine

## Introduction

Hailey–Hailey disease (benign familial pemphigus) is a rare autosomal dominant genodermatosis characterized by chronic, recurrent erythematous plaques, erosions, and fissures predominantly affecting intertriginous areas.

## Case Presentation

We report a 68-year-old man with a 40-year history of recurrent rash in skin folds accompanied by unpleasant odor. Family history was unknown due to deceased parents. He had previously been misdiagnosed with lichen planus and treated with various topical corticosteroids without improvement. Symptoms worsened with heat and physical activity. Physical examination revealed well-demarcated erythematous macerated plaques with polycyclic borders on the lateral neck, axillary, and inguinal folds, with weeping erosions, yellow crusts, and deep fissures. Peripheral flaccid vesicles (phlyctenae) were present; Nikolsky sign was negative. Laboratory tests were within normal limits. Histopathology showed suprabasal acantholysis in a “dilapidated brick wall” pattern with dyskeratotic cells, acanthosis, and hyperkeratosis. Direct immunofluorescence was negative, confirming Hailey–Hailey disease. Treatment included cleansing with benzoyl peroxide foam, intradermal botulinum toxin type A (100 units) to reduce sweating, and a twice-daily topical combination of high-potency corticosteroid with antibacterial and antifungal agents, along with avoidance of heat and friction. After one month, the patient showed significant clinical improvement.

## Conclusion

Hailey–Hailey disease remains a diagnostic and therapeutic challenge, but modern management strategies, particularly botulinum toxin, provide rapid and meaningful improvement. Early recognition is essential to avoid ineffective treatments, and further research is needed to optimize long-term management and improve patients’ quality of life.



EADV CONGRESS
VIENNA
30 SEP - 3 OCT 2026

**Abstract N°: 322**

# Therapeutic Approach to Epidermodysplasia Verruciformis with Trichilemmoma: A Case Report

Samiksha Shankar Shetty*[1], Shireen Furtado[1]

[1] Aster CMI Hospital, Bengaluru, India

## Introduction

Epidermodysplasia Verruciformis(EV) with trichilemmoma are rare cutaneous presentations of human papilloma virus. The coexistence of these entities are treated with different modalities without benefit. We report a case of EV which was treated with acitretin and interferon Alpha 2b.

## Case Presentation

A 42 year old African male presented with multiple, hyperpigmented lesions over upper and lower limbs since the last 20 years. Predominant lesions over palms and soles in a circinate pattern was observed especially over soles. Patient was unable to walk as lesions over feet were extremely painful with overlying tiny ulcers which were secondarily infected. Routine blood tests and serology was negative. Initial biopsies showed tumour cells in dermis with epidermal connection showing follicular differentiation. Repeat biopsies were taken which confirmed viral cytopathic changes in the background – large keratinocytes with blue-gray cytoplasm and perinuclear halos. Immunohistochemistry showed low proliferative index as evidenced by low Ki67. After discussion with Hepatologist, patient was started on weekly injections of Pegylated Interferon alpha 2b with oral acitretin and zinc supplements. Patient reported improvement in symptoms and lesions started reducing and is currently still undergoing treatment.

## Conclusion

The treatment of Epidermodysplasia Verruciformis is challenging as there are limited reports and is a genetic condition. There are few cases of treating with Interferons especially when associated with benign tumours which aid in preventing maliganant transformation. As our patient had multiple tricholemmomas, we started on interferon while monitoring required blood tests. Awareness of such associations is important for long term surveillance and treatment approaches.

**Abstract N°: 329**

## A Patient with Coexistence of Darier's Disease and Lichen Simplex Chronicus:A Case Report

Hasan Emre İlgenli*[1], Selami Aykut Temiz[1], İlkay Özer[1], Pembe Oltulu[2]

[1] Necmettin Erbakan University Faculty of Medicine Dermatology Department, Konya, Türkiye
[2] Necmettin Erbakan University Faculty of Medicine Pathology Department, Konya, Türkiye

### Introduction

Darier's disease is a rare autosomal dominant genodermatosis characterized by a mutation in the ATP2A2 gene, which encodes a calcium channel involved in the intracellular calcium signaling pathway. This mutation results in hyperkeratotic papules or wart-like verrucous plaques, usually located in areas with high fat accumulation, such as the forehead, scalp, neck, back, and chest.For treatment,avoiding triggering factors, moisturizing, and sun protection are important. Clinically significant responses have been observed in the literature with treatment using systemic retinoids. Management of secondary bacterial and viral infections is a point of concern for both clinicians and patients(1,2).

### Case Presentation

A 53-year-old female patient presented to our clinic with a complaint of severe itching. Her medical history included diabetes and obsessive-compulsive disorder. Dermatological examination revealed lichenification and excoriations on the creases of her arms and legs (Figure 1), while hyperkeratotic papules were observed on her neck and under her breasts. She had a frequent handwashing habit and was receiving psychiatric treatment for sleep problems. Her mother also had similar hyperkeratotic papules on her neck (Figure 2). Based on this data, biopsies were taken from the papules under her breasts and on the backs of her hands. The biopsy under the breast was consistent with Darier's disease, and the biopsy from the back of the hand was consistent with lichen simplex chronicus. Treatment was initiated with systemic corticosteroids, starting at 40 mg and gradually decreasing, 25 mg acitretin, topical corticosteroids, and moisturizers. During the follow-up period, both the papules on the neck and under the chest regressed, and the lichenification on the hands and legs improved. Improvement was also observed in the eczematous areas. We would also like to mention our pathology preparations below. Acantholysis, dyskeratosis, and villus formation are observed(Figures 3, 4).

### Conclusion

Neurological abnormalities such as epilepsy and intellectual disability have been identified as being associated with Darier's disease(3). Depression and mood disorders have been found to occur at higher rates in patients with Darier's disease. This situation may be considered as the reason for the observation of lichen simplex chronicus accompanying our case(4). We also received an opinion from the psychiatry unit during the clinical follow-up of our patient. SSRI treatment was started. In the literature, neuropsychiatric evaluations were also performed in patients with Darier's disease in the studies of Gordon Smith K and colleagues, and as previously mentioned, mood disorders were detected in the vast majority of these patients. Therefore, the presence of psychodermatous conditions can also be expected in this patient group, and patients should be evaluated by dermatologists in this respect as well(1,4).

EA DV CONGRESS
VIENNA
30 SEP - 3 OCT 2026

**Abstract N°: 373**

# Variegate porphyria presenting as isolated cutaneous disease: importance of plasma porphyrin fluorescence scanning and PPOX genotyping

Fredo Da Silva*[1], Sian McGarel[1], Sarah Fleming[1], Rory Barry[1], Michael O'Connell[1]

[1] University Hospital Waterford, Waterford, Ireland

## Introduction

Variegate porphyria (VP) is a rare metabolic disorder characterised by deficient function of the protoporphyrinogen oxidase (PPOX). Its inheritance follows an autosomal dominant pattern with variable penetrance. This is an acute hepatic porphyria that classically presents with cutaneous photosensitivity and intermittent neurovisceral attacks. However, isolated cutaneous manifestations may be the only presentation of VP, resembling other types of porphyria. We emphasise the role of plasma porphyrin fluorescence scanning (PPFS), faecal porphyrin profile, and molecular genetic testing for accurate classification and confirmation of diagnosis.

## Case Presentation

We describe a 61-year-old male who initially presented to our clinic in 2017 with a 1-year history of recurrent episodes of photosensitive blistering and erosions affecting the dorsal hands and forearms. Over 9 years of follow-up, his symptoms worsened in the summer while engaged in outdoor manual labour and improved in the winter, indicating a clear seasonal tendency. There were no associated neurological or visceral symptoms reported, and his past medical history was unremarkable, as well as his family history.

No significant abnormalities were found on baseline investigations, namely complete blood count, liver function tests, iron studies, and autoimmune screen. Erythrocyte protoporphyrin analysis was negative. Histopathology showed only non-specific features of chronic photodamage. A presumptive diagnosis of porphyria cutanea tarda was established, and while treatment with hydroxychloroquine rendered initial improvement, it was ultimately not effective.

Further evaluations with PPFS revealed a characteristic emission peak at 628nm, consistent with VP. A mild increase in coproporphyrin and uroporphyrin excretion was demonstrated by urinary porphyrin analysis. Faecal porphyrin analysis showed marked elevation of both coproporphyrin and protoporphyrin, with a coproporphyrin III:I ratio estimated at 6.4. Molecular genetic testing identified that this patient is heterozygous for the splice donor site variant, c.807+2T>C, in intron 7 of the PPOX gene. This variant is located in a canonical GT+2 splice site, predicted to lead to deletion of exon 7.

Our case highlights that VP may present with isolated skin manifestations for a long period of time, potentially mimicking other cutaneous porphyrias, resulting in a challenging diagnosis. PPFS is a valuable biochemical test that can display distinctive spectral features, permitting rapid and accurate differentiation of VP from other porphyria types.

Molecular analysis of PPOX gene remains important for diagnostic confirmation. Current evidence appears limited for the genetic variant detected, c.807+2T>C, which is listed in the ClinVar database as likely pathogenic based on a single submission, and has also been reported in a recent clinical abstract.

## Conclusion

PPFS associated with faecal and molecular testing are crucial for accurate diagnosis and enabling appropriate

management, particularly in patients presenting with isolated skin features.
This variant is classified as likely pathogenic and is considered the probable cause of this patient's clinical manifestations, although further research is needed to confirm its pathogenicity conclusively.

EADV CONGRESS
VIENNA
30 SEP - 3 OCT 2026

**Abstract N°: 373**

# The Interferon Signaling Pathway Plays a Key Role in Hailey-Hailey Disease and is Effectively Targeted by Ruxolitinib

Sara Ceccacci *[1, 2], Hoang Duc Minh Pham *[1], Marion Dessaignes[1], Jasmin Mirzayan[1], Kevin Roger[2, 3], Lam Tsoi[4], Paul Harms[4], Johann Gudjonsson[4], Maria Puig Lombardi[3], Ida Guerrera[2], Alain Hovnanian*[1, 5]

[1] INSERM UMR 1163, Imagine Institute, Université Paris Cité Paris, France, Paris, France

[2] Proteomics platform Necker, Université Paris Cité - Structure Fédérative de Recherche (SFR) Necker Paris, France, Paris, France

[3] Bioinformatics Core Platform, Imagine Institute, INSERM UMR1163 and Structure Fédérative de Recherche Necker, INSERM US24/CNRS UAR3633, Paris, France

[4] University of Michigan, Ann Arbor, United States

[5] Department of Genomic Medicine of Rare Diseases, Necker hospital, AP-HP, Paris, France

## Introduction

The objectives of the study were to better understand the pathophysiology of Hailey-Hailey disease (HHD) and identify therapeutic targets. HHD, also known as familial benign chonic pemphigus, is a rare genetic skin disease caused by pathogenic variants in *ATP2C1* leading to loss of cell-to-cell adhesion of the epidermis (acantholysis). People with HHD develop recurrent vesicular lesions resulting in painful erosions with fissures which predominate in intertriginous areas. The lesions often become infected and progress in flare-ups leading to marked impairment in quality of life. There is no specific treatment and potent topical corticosteroids remain the classical treatment.

## Materials and Methods

We conducted a multiomics study to define the molecular and cellular landscape of HHD.Bulk transcriptomic and proteomic analyses of skin biopsies were performed from a cohort of 29 subjects with HHD. Single-cell and spatial transcriptomic analyses (Visium and Xenium) were conducted on 5 patients. The results of integrated multiomics analysis were used for *in silico* candidate drug repurposing and led to targeted therapy in 10 patients.

## Results

Integrated bulk transcriptomic and proteomic pathway analysis revealed a striking type I and type II interferon (IFN) signature in HHD skin lesions compared to non-lesional and healthy skin. Spatial transcriptomics (Visium HD) showed significantly increased IFN signaling pathway activity scores in lesional skin, with preferential localization in the epidermal layers. Single cell and high-resolution spatial transcriptomics (Xenium) identified inflammatory niches composed of keratinocytes, immune cells, vascular and stromal cells. These cells create an IFN-driven signaling network through multiple intercellular communications that sustain a self-amplifying loop. Immune module profiles generated from the bulk transcriptomic dataset confirmed the IFN signature to be the predominant axis and were used to identify candidate repurposed drugs through the Open Targets Platform. Ruxolitinib was identified as the best candidate based on its potent inhibition of IFN signaling and other JAK1 or JAK2-dependent pathways along with its suitability for topical delivery. Remarkably, in nine out of ten subjects with refractory HHD, topical treatment with the JAK1/2

inhibitor ruxolitinib led to rapid and sustained skin healing (over 10 months) with drastic reduction in pain, itching, weeping and skin inflammation; resulting in a significant improvement of quality of life (DLQI, Skindex16, NRS for pain and itch). One patient developed a bacterial infection and another a herpes infection in the treated areas, both of which resolved following specific local treatment. Post-treatment histological and immunostaining demonstrated reduced immune cell infiltration and rescued epidermal architecture. This clinical outcome falls in line with recent single case reports.

**Conclusion**

Collectively, our results identify IFN signaling as a key pathogenic driver in HHD and support JAK inhibition as an effective mechanism-based therapy for HHD.

*These authors contributed equally.

EA DV CONGRESS
VIENNA
30 SEP - 3 OCT 2026

**Abstract N°: 417**

## Isolated longitudinal leukonychia as an early clue to familial Hailey-Hailey disease

Assia El Bouhmadi*[1], Hanane Rachadi[1], Bouchra Baghad[1], Soumiya Chiheb[1]

[1] CHU Ibn Rochd, CASABLANCA, Morocco

### Introduction

Hailey-Hailey disease (HHD) is a rare autosomal dominant genodermatosis characterized by recurrent intraepidermal blistering and erosions, most often affecting flexural and intertriginous areas. Although its clinical presentation is distinctive, the disease exhibits considerable variability and is often misdiagnosed, particularly in early or atypical forms. Nail involvement, historically considered absent, has recently been recognized as an underappreciated feature that may provide valuable diagnostic clues.

### Case Presentation

We report a familial case of HHD spanning three generations, in which a single longitudinal leukonychia in the proband preceded the onset of typical skin lesions. The initial nail change, unassociated with trauma or systemic disease, prompted a detailed family history revealing recurrent erosive lesions in relatives. Months later, the proband developed painful, fissured, erythematous plaques in flexural regions, confirmed histologically as HHD. Treatment with topical calcineurin inhibitors, oral doxycycline, and ultraviolet B (UVB) phototherapy led to marked clinical improvement and reduced flare frequency, although the leukonychia remained unchanged.



Longitudinal leukonychia on the right thumbnail

**Conclusion**

This case highlights the diagnostic importance of subtle nail findings in HHD. Early-onset or isolated leukonychia, often asymptomatic and easily overlooked, may precede cutaneous involvement and thus represent a valuable marker for early detection in at-risk individuals. Recognition of such signs can facilitate timely diagnosis, genetic counseling, and preventive management within affected families. Nail alterations in HHD appear long-lasting and independent of disease activity, underscoring their potential role as a stable phenotypic manifestation of this disorder.Early identification of these subtle nail changes can therefore improve patient outcomes by guiding early therapeutic intervention and reducing the delay in diagnosis often associated with this underrecognized condition.

EA DV CONGRESS
VIENNA
30 SEP - 3 OCT 2026

**Abstract N°: 486**

# Analysis of genotype and clinical phenotype of SERPINA12-related hereditary palmoplantar keratoderma in Chinese population

Sheng Wang*[1], Xueqin Xu[1], Zhongtao Li[1]

[1] Department of Dermatology, West China Hospital, Sichuan University, Chengdu, China

**Introduction**
Nagashima-type palmoplantar keratosis (NPPK) is the most common type of hereditary palmoplantar keratoderma (hPPK) in East Asia, which exhibits symmetric palmoplantar erythema and hyperkeratosis caused by biallelic loss-of-function (LOF) mutations in SERPINB7. In 2020, Mohamad et al. first reported a novel form of autosomal recessive inherited hPPK caused by LOF mutations in SERPINA12, with clinical manifestations virtually indistinguishable from NPPK. Interestingly, recent studies have demonstrated a potential digenic inheritance model involving SERPINA12 and SERPINB7. Because of the rarity of SERPINA12-related hPPK, the precise clinical phenotype, genotype and correlations between them remain elusive.

**Materials and Methods**
Patients presenting with NPPK-like clinical features were recruited in our hospital. Sanger sequencing confirmed the existence of either homozygous or compound heterozygous SERPINA12 mutations, or at least one SERPINA12 variant combined with SERPINB7 variant(s). The patients' clinical manifestations, including lesion characteristics, distribution, comorbidities, quality of life and psychological status, were collected, and then the genotypic and phenotypic features were analyzed.

**Results**
A total of 16 Chinese patients with SERPINA12-related hPPK were enrolled. All patients presented with bilateral symmetric palmoplantar erythema and hyperkeratosis. Among them, 5 (31.25%) had atopic dermatitis (AD), 6 (37.5%) had superficial fungal infections, and 4 (25%) had generalized skin lesions. Hyperhidrosis and foul odor were common. Of the 16 patients, 68.75% (11/16) reported varying degrees of impairment in quality of life, 37.5% (6/16) exhibited anxiety, and 12.5% (2/16) showed mild depression. Genotyping revealed the following three groups: Group A (biallelic SERPINA12 mutations only, n=3), Group B (digenic mutations with two pathogenic alleles in SERPINA12 and SERPINB7, n=7), and Group C (digenic mutations with three or more pathogenic alleles, n=6). Three pathogenic SERPINA12 variants were identified: c.970_971del (allele frequency 40.6%), c.635-7A>G (28.1%), and c.656A>G (6.3%). Haplotype analysis confirmed c.635-7A>G as a founder mutation in the Chinese population. Disease severity followed a gradient of Group C > Group A > Group B.

**Conclusions**
The clinical features of all patients with SERPINA12-related hPPK were basically identical to those of NPPK. Genetic testing is therefore essential for definitive diagnosis. Of note, generalized lesions beyond the classic palmoplantar and adjacent regions were not uncommon. The high prevalence of AD and superficial fungal infections indicated a epidermal barrier impairment resulting from SERPINA12 loss of function. Hyperhidrosis and foul odor were accompanied with varying degrees of impairment in quality of life and anxiety, highlighting the importance of psychological assessment.Genetic analysis identified c.970_971del and c.635-7A>G as the two most prevalent SERPINA12 variants, and haplotype analysis further confirmed c.635-7A>G as a founder mutation in Chinese population. Digenic mutations involving both SERPINA12 and SERPINB7 were remarkably common in this cohort, indicating that concurrent SERPINB7 screening should be performed in SERPINA12-related hPPK. Furthermore,

this study provided evidence for a cumulative dose effect between SERPINA12 and SERPINB7, suggesting that these two genes may share intersecting or overlapping pathogenic pathways.

EADV CONGRESS
VIENNA
30 SEP - 3 OCT 2026

**Abstract N°: 505**

# Inherited Epidermodysplasia Verruciformis: Diagnostic and Therapeutic Challenges

Daniel Barquero-Orias*[1], Ruben Barrientos-Rivera[2]

[1] Department of Dermatology - Caja Costarricense del Seguro Social, San José, Costa Rica
[2] Department of Pathology - Caja Costarricense del Seguro Social, San José, Costa Rica

## Introduction

Inherited epidermodysplasia verruciformis (EV) is a rare genodermatosis characterized by an abnormal susceptibility to specific human papillomavirus (HPV) infections, leading to persistent cutaneous lesions and an increased risk of non-melanoma skin cancer. The condition is most commonly associated with mutations affecting cell-mediated immunity, particularly involving EVER1 (TMC6) and EVER2 (TMC8) genes. Clinically, EV presents with widespread flat warts, pityriasis versicolor–like macules, and seborrheic keratosis–like lesions, typically beginning in childhood. Given its rarity and variable presentation, diagnosis may be challenging and often requires clinicopathological correlation. We report a case of inherited EV, highlighting its clinical features, diagnostic workup, and management considerations.

## Case Presentation

A 50-year-old female patient with a history of consanguinity (parents who are first cousins and a father also born from a first-cousin union), without a family history of similar lesions, presented with a history of multiple previously treated basal cell carcinomas and numerous actinic keratoses. On physical examination, she exhibited lesions on the upper and lower extremities, as well as to a lesser extent on the trunk, consisting of plaques and papules, some brownish and others erythematous, without evident surface scaling.Skin biopsies demonstrated orthokeratotic hyperkeratosis and mild to moderate acanthosis, along with cytoplasmic vacuolization in the upper layers of the epidermis. Enlarged keratinocytes with pale cytoplasm (EV cells) were observed, as well as enlarged nuclei with basophilic chromatin. Focal changes consistent with chronic actinic damage were also noted.Based on clinicopathological correlation, a diagnosis of inherited epidermodysplasia verruciformis was established. Treatment was initiated with systemic acitretin, strict photoprotection, topical 5-fluorouracil, lesion-directed cryotherapy, and human papillomavirus (HPV) vaccination. The patient was scheduled for regular dermatologic follow-up to monitor treatment response and for early detection of malignant transformation.

## Conclusion

In conclusion, inherited epidermodysplasia verruciformis remains a challenging condition to manage due to its chronic course, recalcitrant lesions, and increased risk of malignant transformation. Diagnosis can also be difficult, given its rarity and the variability of clinical presentations, often requiring careful clinicopathological correlation. Therapeutic approaches are largely supportive and aimed at reducing lesion burden and preventing complications. Systemic and topical retinoids have shown benefit in improving keratinization and decreasing the extent of lesions, although relapses are common after discontinuation. Additional options include destructive modalities, such as cryotherapy and laser, as well as topical agents like imiquimod and 5-fluorouracil, with variable efficacy. Rigorous photoprotection and long-term surveillance are essential given the elevated risk of cutaneous malignancies. Further studies are needed to establish standardized and more effective treatment strategies.

EA DV CONGRESS
VIENNA
30 SEP - 3 OCT 2026

**Abstract N°: 520**

## Epidermolytic Hyperkeratosis: Report of a Rare Genodermatosis

Isadora Schmidt*[1], Julia Loureiro Fontana Bolsoni[1, 1], Júlia Bittencourt[1], elisandre maria camelo gomes natario Natario[1], Flávia Regina Ferreira[1]

[1] Municipal University Hospital of Taubaté, Taubaté, Brazil

### Introduction

Epidermolytic hyperkeratosis, or bullous ichthyosiform erythroderma, is a rare autosomal dominant genodermatosis caused by mutations in the KRT1 and KRT10 genes, which encode keratins 1 and 10. The condition manifests at birth with the presence of erythema, erosions, and blisters that evolve into hyperkeratotic plaques and intense skin desquamation. The blisters rupture easily, leaving painful areas susceptible to secondary infections. Over time, the skin becomes thickened, dry, and scaly, especially in friction areas, and there may be a characteristic odor, hyperkeratosis on the palms and soles, and alterations in nails and hair. In addition to cutaneous manifestations, systemic symptoms may arise due to the loss of skin integrity, such as dehydration, electrolyte imbalance, hypoalbuminemia, generalized infections, alterations in thermoregulation, nutritional deficiency, and growth delay. Histopathological examination shows orthohyperkeratosis, acanthosis, hypergranulosis with coarse keratohyalin granules, dyskeratosis, and suprabasal cytolysis, confirming the keratinopathic nature of the disease.Epidermolytic hyperkeratosis has a significant impact on quality of life and requires early diagnosis, genetic counseling, and individualized management aimed at preventing complications and improving clinical and functional prognosis. Thus, the rarity of this genodermatosis and the importance of its knowledge and early recognition motivated this report.



Figure 1: Malar erythema, intense and diffuse xerosis, ichthyosiform appearance, and marked keratosis on the knees, hands, and feet.

**Case Presentation**

A male patient, 1 year and 1 month old, White, and from the countryside of São Paulo, was seen at a Pediatric Dermatology outpatient clinic with a history of "dry and thick skin since birth." Dermatological examination revealed intense and diffuse cutaneous xerosis, more pronounced on the hands and feet, with the presence of fissures, ichthyosiform areas, and malar erythema (Figures 1 and 2). The patient has a history of prematurity, lactose intolerance, and intrauterine exposure to illicit drugs. He was abandoned by his mother, and the father is unknown.Histopathological examination (biopsy from the right upper back) showed an acanthotic epidermis and extensive orthokeratotic hyperkeratosis with a preserved granular layer. In addition, suprabasal intraepidermal cleavage associated with keratinocyte vacuolization, as well as the presence of dyskeratotic cells and a mild dermal lymphocytic inflammatory infiltrate, were observed, consistent with the clinical hypothesis of epidermolytic hyperkeratosis.The patient was started on treatment with low-potency topical corticosteroids, emollients, and Vasenol gel®, as well as oral hydroxyzine, with partial improvement. Laboratory tests are pending for the possible initiation of acitretin



Figure 1: Malar erythema, intense and diffuse xerosis, ichthyosiform appearance, and marked keratosis on the knees, hands, and feet. Figure 2: Back: greater detail of skin thickening and the ichthyosiform appearance.

**Conclusion**

Epidermolytic hyperkeratosis is rare, with an estimated incidence of 1:200,000–1:300,000 births. The mutations impair the integrity of the keratinocyte cytoskeleton, leading to suprabasal cytolysis and blister formation. Although hereditary, approximately 50% of cases arise from spontaneous mutations, explaining the absence of a family history in some cases.Clinically, it presents with diffuse erythema, erosions, and blisters that evolve into hyperkeratotic and desquamative lesions, predominantly affecting flexural areas, as well as the palms and soles. Palmoplantar involvement tends to be more severe in KRT1 mutations. Diagnosis is based on clinicopathological correlation and can be confirmed by genetic testing, which was not performed in this case but is suggested by the clinical and morphological findings.Treatment is symptomatic, aiming to reduce blistering, prevent infections, and improve the skin barrier, including the use of emollients, keratolytics, topical or oral retinoids, and antimicrobial measures. Knowledge and early recognition of epidermolytic hyperkeratosis allow for individualized interventions, genetic counseling, and improved quality of life. We emphasize the importance of clinical, histological, and genetic integration (whenever possible).

EADV CONGRESS
VIENNA
30 SEP - 3 OCT 2026

**Abstract N°: 525**

# Epidermolytic Hyperkeratosis Type 1 with a New Heterozygous Mutation in KRT1 Gene: A New Case Report

Maitha Aljuwaied*[1]

[1] Rashid hospital, Sharjah, United Arab Emirates

## Introduction

Epidermolytic hyperkeratosis (EHK) formerly known as bullous ichthyosiform erythroderma, is a rare autosomal dominant inheritance condition with a prevalence ranging from 1:200,000 to 1:300,000. The underlying etiology of which is a mutation in the genes responsible for keratin proteins synthesis, primarily in *KRT1* and *KRT10* genes, cataloged under OMIM number 113800. The clinicopathological presentations include blistering during the neonatal period, followed by ichthyotic hyperkeratosis in childhood and adolescence. This is characterized by hallmark features such as generalized dry skin, scaling, and hyperkeratosis, and is often associated with erythroderma. EHK may present with or without palmoplantar keratoderma involvement, depending on the keratin gene variant.

## Case Presentation

A 24-year-old male of Arab descent was born with diffuse skin hyperkeratotic plates featuring erythematous fissures, covering his entire body, resembling a collodion baby. His birth was full-term via cesarean section without complications, although he later developed developmental dysplasia of the hip. By the time he started primary school, he began experiencing severe thickening of the skin around his joints, reducing flexibility and leading to contractures and significant disfigurement. He is undergoing treatment with acitretin. Genetic testing using Next-Generation Sequencing (NGS) was performed to identify the responsible gene, revealing a novel heterozygous variant in the *KRT1* gene (OMIM 139350), while no variant was detected in the *KRT10* gene.

## Conclusion

EHK type 1 manifests with a new heterozygous mutation in the *KRT1* gene confirmed by genetic analysis. This variant has not been reported in the literature to the best of our knowledge. Epidermolytic hyperkeratosis is a rare disorder with a challenging differential diagnosis. Despite this, it is important for clinicians to be able to identify the disease in the earliest stages in order to reduce the risk of morbidity and mortality.

EA DV CONGRESS
VIENNA
30 SEP - 3 OCT 2026

**Abstract N°: 539**

# Punctate Palmoplantar Keratoderma Type 1 (Buschke–Fischer–Brauer Disease): An Autosomal Dominant Case Confirmed by AAGAB Mutation

Dila Çağla Durmuş*[1], Batuhan Guroz[2], ERALP KOPARAL[1], ÜMRAN ÇETİNÇELİK[3], Ilknur Altunay[2]

[1] University of Health Sciences, Seyrantepe Hamidiye Etfal Training and Research Hospital, Department of Dermatology and Venerology, ISTANBUL, Türkiye

[2] University of Health Sciences, Seyrantepe Hamidiye Etfal Training and Research Hospital, Department of Dermatology and Venerology, İstanbul, Türkiye

[3] Seyrantepe Hamidiye Etfal Training and Research Hospital, Department of Medical Genetics, İSTANBUL, Türkiye

## Introduction

Punctate palmoplantar keratoderma type 1 (Buschke–Fischer–Brauer disease) is a rare inherited subtype of palmoplantar keratoderma characterized by multiple punctate hyperkeratotic papules on the palms and soles. It follows an autosomal dominant pattern of inheritance[1]. Clinically, lesions tend to become more prominent and may coalesce in areas subjected to increased mechanical stress, and in some cases, may lead to pain and functional limitation[2].

## Case Presentation

A 62-year-old male patient presented with multiple verrucous hyperkeratotic lesions located on the bilateral palms and soles, which had been present for approximately 20 years and had shown gradual progression over time. A notable family history revealed similar findings in three of his seven brothers, while no lesions were reported in his sisters. The lesions had remained asymptomatic for many years; however, the patient sought medical attention due to recent cosmetic concerns. Following punch biopsy and differential diagnostic evaluation (including epidermodysplasia verruciformis and palmoplantar keratoderma), genetic analysis was performed considering the familial pattern. Genetic testing identified a mutation in the AAGAB gene, and the patient was diagnosed with punctate palmoplantar keratoderma type 1 (Buschke–Fischer–Brauer disease). This case is noteworthy due to the rarity of the condition and the presence of variable penetrance within the family, despite its autosomal dominant inheritance pattern.



Figure 1. Bilateral plantar involvement characterized by numerous hyperkeratotic, punctate and verrucous papules coalescing into plaques, predominantly over pressure-bearing areas, consistent with punctate palmoplantar keratoderma (Buschke–Fischer–Brauer type).

**Conclusion**

Palmoplantar keratodermas are a heterogeneous group of genetic or acquired disorders characterized by hyperkeratosis of the palms and soles. Punctate palmoplantar keratoderma (PPPK) is a subtype divided into three forms, with type 1 being the most common and typically associated with AAGAB mutations and autosomal dominant inheritance. Clinically, PPPK presents with multiple small hyperkeratotic papules with a “raindrop” appearance. Lesions are usually scattered on the palms and tend to coalesce on the soles, where they may appear more prominent, as observed in our case. The disease typically begins in adolescence or early adulthood and progresses with age. Although generally asymptomatic, cosmetic concerns are common. Keratolytic agents and systemic retinoids are effective treatment options, and combination therapy was preferred in our case. Differential diagnosis includes verruca vulgaris, clavus, and other forms of palmoplantar keratoderma.



Figure 2. Symmetrical distribution of multiple hyperkeratotic, punctate and verrucous papules on the palmar surfaces, with occasional coalescence into plaques, consistent with punctate palmoplantar keratoderma (Buschke–Fischer–Brauer type).

EADV CONGRESS
VIENNA
30 SEP - 3 OCT 2026

**Abstract N°: 569**

# Autosomal recessive congenital ichthyosis presenting as adult erythroderma: a delayed genetic diagnosis

Maja Pavic*[1], Ana Bubić[1], Ante Tavra[2], Dubravka Vukovic[1]

[1] Department of Dermatovenerology, University Hospital of Split, Split, Croatia
[2] Department of Pediatric Disease, University Hospital of Split, Split, Croatia

## Introduction

Autosomal recessive congenital ichthyoses (ARCI) are a heterogeneous group of genodermatoses, representing approximately 5–10% of inherited ichthyoses, and typically presenting at birth as a collodion baby phenotype. The clinical course is variable, and definitive classification often requires integration of clinical and genetic data. Here, we present a patient in whom a congenital keratinization disorder remained unrecognized until adulthood, when erythroderma prompted diagnostic reassessment.

## Case Presentation

A 34-year-old woman with a lifelong history of diffuse scaling skin disorder was referred for evaluation of generalized erythroderma. She was otherwise healthy, with no family history of skin disease, but was reported to have had a collodion baby phenotype at birth, although no medical documentation was available. Dermatological examination revealed generalized erythroderma with ichthyosiform scaling, facial erythema, and palmoplantar hyperlinearity, with superimposed erosive and crusted lesions. Laboratory findings revealed eosinophilia and markedly elevated total IgE levels, consistent with an inflammatory component. Histopathological examination demonstrated mild epidermal hyperplasia with focal parakeratosis and spongiosis, along with a superficial perivascular lymphocytic infiltrate. Initial treatment with systemic corticosteroids and antihistamines resulted in only a partial response, followed by initiation of acitretin therapy in accordance with current guidelines.I n view of the reported collodion baby phenotype, genetic analysis was performed. Genetic testing identified compound heterozygous pathogenic variants in the ALOX12B gene (c.1562A>G and c.754+2del), establishing the diagnosis of autosomal recessive congenital ichthyosis, most consistent with a lamellar ichthyosis phenotype.

## Conclusion

This case highlights that congenital ichthyoses may remain unrecognized into adulthood when inflammatory features obscure the underlying disorder. ARCI should be considered in the differential diagnosis of adult erythroderma, particularly in patients with a lifelong history of scaling. Genetic analysis is essential for establishing the diagnosis and guiding management.

EADV CONGRESS
VIENNA
30 SEP - 3 OCT 2026

**Abstract N°: 587**

# Critical Appraisal of the cNF-Skindex Questionnaire for Assessing Health-Related Quality of Life in Neurofibromatosis Type 1

hadiya elahmar*[1], Carolina Barnett Tapia[2], Patricia C. Parkin[3]

[1] Institute of Health Policy, Management and Evaluation, Dalla Lana School of Public Health, University of Toronto, Canada., Toronto, Canada

[2] Institute of Health Policy, Management and Evaluation, Dalla Lana School of Public Health, University of Toronto, Canada., Elisabeth Raab Neurofibromatosis Clinic, Toronto General Hospital, University Health Network, Toronto, Canada, Toronto, Canada

[3] Institute of Health Policy, Management and Evaluation, Dalla Lana School of Public Health, University of Toronto, Canada., Department of Paediatrics, Faculty of Medicine, University of Toronto., Toronto, Canada

**Introduction**

Objective:To evaluate the measurement properties of the cNF-Skindex questionnaire, a disease-specific instrument developed to discriminate varying levels of impact that cutaneous neurofibromas (cNFs) have on the health-related quality of life (HRQoL) of individuals with Neurofibromatosis type 1 (NF1).

**Materials and Methods**

Methods:A literature search was conducted to identify articles describing the development and validation of the cNF-Skindex questionnaire. Evidence supporting its sensibility, reliability, validity, and responsiveness was critically appraised. We used the COSMIN checklist to evaluate the measurement properties of the cNF-Skindex instrument.

**Results**

Results: 4 studies were identified from the literature search addressing the development and evaluation of the measurement properties of the cNF-Skindex, which was developed following current guidelines for instrument development, incorporating evidence from literature reviews together with substantial input from both patients and clinicians. Item generation and reduction were conducted through a meticulous process combining judgmental methods and mathematical approaches, including exploratory factor analysis. The questionnaire provides domain-specific scores reflecting the impact of cNFs on symptoms, emotional well-being, and functional limitations, as well as a global score representing the overall HRQoL burden of cNFs; higher scores indicate greater impact.Compared with available generic HRQoL instruments, the cNF-Skindex demonstrated incremental face, feasibility, and content validity by specifically capturing how much patients are bothered by their cNFs, rather than merely documenting lesion frequency or presence. The instrument also demonstrated good construct and convergent validity, as well as reproducibility, with strong intra-rater reliability. Furthermore, cNF-Skindex scores were associated with lesion burden, with individuals having more than 50 cNFs showing higher total and domain scores.Originally developed in French, the cNF-Skindex was later translated and validated into American English using a forward-backward translation process. However, responsiveness has not yet been formally assessed in either version.

**Conclusions**

Conclusion:The cNF-Skindex is a well-developed disease-specific HRQoL instrument with incremental face and content validity, excellent reliability, and demonstrated construct and convergent validity. However, further investigation of its responsiveness is needed before it can be established as a standardized responsive outcome measure for evaluating treatment benefit and longitudinal change in patients with cNFs.

EA DV CONGRESS
VIENNA
30 SEP - 3 OCT 2026

**Abstract N°: 589**

# Health care utilization patterns among individuals with Neurofibromatosis type 1 and cutaneousneurofibromas, using administrative data, in Ontario, Canada

hadiya elahmar*[1], Alejandro Hernandez[2], Aaron M Drucker[3], Patricia C. Parkin[4, 5], Carolina Barnett Tapia[6]

[1] Institute of Health Policy, Management and Evaluation, Dalla Lana School of Public Health, University of Toronto, Canada., Toronto, Canada

[2] Institute for Clinical Evaluative Sciences (ICES), Toronto, Canada

[3] Institute of Health Policy, Management and Evaluation, Dalla Lana School of Public Health, University of Toronto, Canada., Department of Medicine and Research and Innovation Institute, Women's College Hospital, Institute for Clinical Evaluative Sciences (ICES), Toronto, Canada

[4] Department of Paediatrics, Faculty of Medicine, University of Toronto., Toronto, Canada

[5] Institute of Health Policy, Management and Evaluation, Dalla Lana School of Public Health, University of Toronto, Canada., Department of Paediatrics, Faculty of Medicine, University of Toronto., toronto, Canada

[6] Institute of Health Policy, Management and Evaluation, Dalla Lana School of Public Health, University of Toronto, Canada., Elisabeth Raab Neurofibromatosis Clinic, Toronto General Hospital, University Health Network, Toronto, Canada, Toronto, Canada

**Introduction**

Neurofibromatosis type 1 (NF1) is a genetic condition characterized by cutaneous neurofibromas (cNFs),benign skin tumors affecting up to 95% of adults with NF1. Data on healthcare utilization for cNFmanagement are limited. This study aimed to characterize healthcare utilization related to cNFs in Ontario by comparing rates of skin lesion resections and specialist consultations between individuals with NF1 and matched controls, and by identifying factors associated with higher use of these servicesamong individuals with NF1.

**Materials and Methods**

We conducted a retrospective cohort study linking NF1 registries from two major pediatric and adult NF1 clinics in Toronto to Ontario administrative health data. Adults (≥18 years) with confirmed NF1 and at least 2 years of Ontario Health Insurance Plan (OHIP) eligibility were matched 1:5 to controls by birth year (±1 year), sex, income quintile, and geographic region. The NF1 index date was defined as the latest of the 18th birthday, July 1, 1992, or OHIP eligibility. Controls were assigned a pseudo index date to approximate the distribution of case index dates. Follow-up continued until death, loss of OHIP eligibility, or December 31, 2024. To account for differing follow-up times, crude rates of excisions and specialist consultations were calculated as events per person-year. Rates of skin lesion resections and specialist consultations (dermatology, plastic surgery, and general surgery) were compared between NF1 and controls using negative binomial regression. Factors associated with excision procedures within the NF1 cohort were assessed using logistic regression. Secondary outcomes included the proportion of individuals with at least one excision or consultation and the mean number of excisions and consultations.

**Results**

A total of 4,362 participants were included (727 NF1; 3,635 matched controls). Cohorts were balanced by sex, birth year, and age at end of follow-up, although follow-up was longer in NF1 (mean [SD] 18.4 [9.87] vs. 11.4 [8.21] years). At least one excision was recorded in 52% of NF1 versus 23% of controls, corresponding to crude rates of 0.21 vs. 0.06 excisions per person-year. Specialist consultations were also more frequent in NF1 (78% vs. 43%), with crude rates of 0.73 vs. 0.26 consultations per person-year; general surgeons were the most commonly consulted skin-related specialists. In adjusted analyses, individuals with NF1 had higher rates of excisions (RR 2.31,

95% CI 1.91–2.78) and specialist consultations (RR 2.81, 95% CI 2.45–3.23) than controls. Within NF1, older age and female sex were associated with greater healthcare use. Excision rates increased by 6% per year of age (RR 1.06, 95% CI 1.04–1.07), and females had approximately double the excision rate of males (RR 2.10, 95% CI 1.59–2.77). Lower excision rates were observed in income quintiles 2 and 3 versus the lowest-income quintile, while higher rates were observed in material resources quintiles 3 and 4 versus quintile 5.

**Conclusions**

Individuals with NF1 had twofold higher rates of skin excisions and threefold higher rates of specialist consultations than matched controls. Older age and female sex were associated with higher excision rates, highlighting the need for age- and sex-responsive healthcare planning. Socioeconomic differences and the higher proportion of excisions performed by general surgeons may reflect variation in access to private insurance and the ability to pay out-of-pocket for cNF removal, which is often considered cosmetic and not publicly funded in Ontario; the low mean numbers of excisions and consultations per person may also reflect these healthcare system factors. Further research is needed to assess the role of private coverage and out-of-pocket costs in access to cNF care in Canada

EA DV CONGRESS
VIENNA
30 SEP - 3 OCT 2026

**Abstract N°: 665**

# Bazex Dupré Christol Syndrome Presenting with Early-Onset Milia and Hypotrichosis Associated with a De Novo Xq26.1 Duplication: A Case Report and Systematic Review

Melika Motamedi*[1], Zack Perala[1], Luis Sanchez-Espino[1]

[1] University of Alberta, Edmonton, Canada

## Introduction

Bazex–Dupré–Christol syndrome (BDCS) is a rare X-linked genodermatosis classically characterized by follicular atrophoderma, congenital hypotrichosis, and early-onset basal cell carcinomas. Due to its rarity, existing knowledge is derived largely from isolated case reports and small familial series, and a comprehensive synthesis of the clinical and genetic features is lacking. In this report, we present a case along with a systematic review of this rare genodermatosis.

## Case Presentation

We report a case of a 4-year-old male presenting with early-onset facial milia and progressive hypotrichosis beginning in infancy. Initial genetic investigations, including chromosomal microarray analysis and whole-exome sequencing, were unremarkable. With time, additional features, including palmoplantar pits and café au lait macules, emerged. Whole genome sequencing ultimately identified a de novo Xq26.1 duplication consistent with BDCS.

To further characterize BDCS, a systematic literature search was conducted in PubMed, Embase and Medline in accordance with PRISMA guidelines using the terms “Bazex–Dupré–Christol syndrome,” “Bazex Dupre Christol,” and “BDC syndrome.” Original studies reporting clinical, genetic, or pathological data on individuals diagnosed with BDCS were included. Data were extracted on study characteristics, patient demographics, clinical features, basal cell carcinoma characteristics, and genetic findings. This search identified approximately 196 records, of which 25 studies met the inclusion criteria, comprising predominantly case reports and small familial series describing 65 affected individuals. Reports of de novo Xq26.1 duplications were limited. Due to heterogeneity of study design and reporting, a qualitative synthesis was performed.

Age at diagnosis ranged from infancy to adulthood, with many studies not reporting specific age. Among individuals for whom clinical features were reported, hypotrichosis was present in 56 of 58 patients (96.6%), follicular atrophoderma in 52 of 56 (92.9%), milia in 44 of 55 (80.0%), and hypohidrosis in 27 of 50 (54.0%). Basal cell carcinomas were frequently documented, most commonly arising during adolescence or early adulthood, with considerable variability in lesion burden and recurrence. Genetic testing was performed in 24 of 65 (36.9%) affected patients, with recent studies identifying pathogenic variation at Xq26.1 and implicating ARP-T1–related ciliary dysfunction in disease pathogenesis.

## Conclusion

Our case highlights the diagnostic challenges associated with BDCS and underscores the importance of longitudinal clinical assessment and advanced genetic testing in patients with evolving dermatologic phenotypes. This systematic review demonstrates that BDCS exhibits a consistent core phenotype, with hypotrichosis and follicular atrophoderma present in over 90% of assessable cases and milia in the majority of patients. Hypohidrosis is common but variably reported. Recognition of early cutaneous features is critical given the subsequent risk of basal cell carcinoma. Although advances in genetic characterization suggest a ciliopathy-related mechanism, many

cases remain clinically diagnosed. Early diagnosis and longitudinal dermatologic surveillance remain essential to optimizing patient outcomes.

EADV CONGRESS
VIENNA
30 SEP - 3 OCT 2026

**Abstract N°: 684**

# A Recurrent Pathogenic AAGAB Variant (p.R161*) in Punctate Palmoplantar Keratoderma Type IA with Concurrent Breast Carcinoma: A Case Report

Neriman Demirayak*[1], Ahmet Kağan Özdemir[1], Huban Sibel Orhun[2]

[1] Ankara Bilkent City Hospital, Dermatology Clinic, Ankara, Türkiye
[2] Ankara Bilkent City Hospital, Pathology Clinic, Ankara, Türkiye

## Introduction

Punctate palmoplantar keratoderma type IA is a rare autosomal dominant genodermatosis caused by loss-of-function variants in the *AAGAB* gene, encoding alpha and gamma-adaptin binding protein[1]. It is characterized by small, discrete hyperkeratotic papules on the palms and soles, with onset typically in the second or third decade of life.[1] The pathogenic mechanism involves haploinsufficiency of AAGAB, impairing clathrin-mediated endocytosis and receptor tyrosine kinase downregulation[2]. A potential association between PPKP1 and internal malignancy has been suggested, though case-level molecular evidence remains limited.

## Case Presentation

A 48-year-old woman presented with a 15–20 year history of asymptomatic punctate hyperkeratotic papules on the palms and soles, previously treated with intermittent topical corticosteroids and keratolytics without complete resolution. Family history was significant for similar cutaneous lesions in her brother and son. Two months prior to dermatological referral, she had been diagnosed with right breast invasive ductal carcinoma with ductal carcinoma in situ, ER/PR-positive, HER2-negative.

Dermatological examination revealed bilateral, symmetrically distributed discrete punctate hyperkeratotic papules over the palmar and plantar surfaces, with plantar fissuring and focal erosions. Skin punch biopsy demonstrated epidermal keratinization disorder consistent with punctate palmar keratoderma; no neoplastic transformation was identified.

Next-generation sequencing (NGS) panel identified a heterozygous pathogenic nonsense variant in *AAGAB*: c.481C>T (p.R161*), NM_024666.5, classified as pathogenic.[2]
This case presents a confirmed *AAGAB* truncating variant (p.R161*) in a patient with longstanding PPKP1 and concurrent hormone receptor-positive breast cancer. The cutaneous lesions preceded the malignancy by approximately 15-20 years. The co-occurrence raises the question of whether AAGAB haploinsufficiency through disrupted receptor tyrosine kinase downregulation may contribute to epithelial malignancy susceptibility.[3] Most recently, a 2025 case report described PPKP1A co-occurring with multiple primary melanomas in a patient with the p.Arg124* AAGAB variant, and highlighted AAGAB's potential role as an on-treatment biomarker in breast cancer[4].

The positive family history (brother and son affected) supports autosomal dominant inheritance consistent with PPKP1. The p.R161* variant introduces a premature stop codon in exon 5, predicted to result in nonsense-mediated mRNA decay and loss of function, consistent with the established haploinsufficiency mechanism of AAGAB-related PPKP1.

**Conclusion**

We report a molecularly confirmed PPKP1 case harbouring a pathogenic*AAGAB* nonsense variant (p.R161*) in association with ER/PR-positive breast carcinoma. This case highlights the importance of dermatological recognition of punctate palmoplantar keratoderma and the potential value of systematic oncological surveillance in affected individuals and their first-degree relatives. Larger studies are warranted to clarify the relationship between *AAGAB* variants and internal malignancy susceptibility.

EA DV CONGRESS
VIENNA
30 SEP - 3 OCT 2026

**Abstract N°: 692**

# Late-Onset Birt–Hogg–Dubé Syndrome Presenting with Cutaneous Lesions and Pulmonary Cysts: A Case Report

Serdar Can Aydın*[1], gizem özge öztürk aktaş[1], meltem türkmen[1], selcen kundak[1]

[1] izmir city hospital, izmir, Türkiye

## Introduction

Title: Late-Onset Birt–Hogg–Dubé Syndrome Presenting with Cutaneous Lesions and Pulmonary Cysts: A Case Report

Background: Birt–Hogg–Dubé (BHD) syndrome is a rare autosomal dominant disorder caused by mutations in the FLCN gene, characterized by cutaneous lesions, pulmonary cysts, and renal tumors (1,2). Cutaneous findings are often the initial manifestation and may guide early diagnosis (2,3).

Objective: To present a late-onset case of BHD syndrome with characteristic dermatological and pulmonary findings and to emphasize the importance of recognizing skin lesions in elderly patients (2,4).

## Case Presentation

A 72-year-old female patient presented with multiple asymptomatic papular lesions on the face and neck that had been present for approximately 3 years. Dermatological examination revealed multiple dome-shaped, skin-colored papules consistent with fibrofolliculomas . The patient had no history of smoking. Pulmonary evaluation demonstrated bilateral multiple lung cysts, predominantly located in the apical regions, with the largest measuring 7 mm. These cystic lesions had been present for 1 year . Abdominal computed tomography revealed a 3 cm nodular lesion in the left adrenal lodge . Genetic analysis performed by the medical genetics department identified a pathogenic mutation in the FLCN gene, confirming the diagnosis of BHD syndrome.

## Conclusion

The coexistence of fibrofolliculomas and bilateral pulmonary cysts raised suspicion for BHD syndrome, which was subsequently confirmed by genetic testing (1,2). The presence of an adrenal nodular lesion highlights the need for comprehensive systemic evaluation in such patients (4,5). This case underscores that BHD syndrome can present at an advanced age and that cutaneous findings may precede or accompany systemic involvement (2,4). Recognition of fibrofolliculomas is crucial for early diagnosis, genetic counseling, and appropriate surveillance for associated internal manifestations (2,3).

References: 1. Jensen DK et al. Birt-Hogg-Dubé syndrome: a case report and review  https://pmc.ncbi.nlm.nih.gov/articles/PMC5345590/
2. Tong Y et al. Birt-Hogg-Dubé syndrome: a review of the literature  https://pubmed.ncbi.nlm.nih.gov/28695430/
3. Schmidt LS et al. Molecular genetics and clinical features of BHD  https://pmc.ncbi.nlm.nih.gov/articles/PMC5119524/
4. Lodi G et al. Birt-Hogg-Dubé syndrome: case report and review  https://pmc.ncbi.nlm.nih.gov/articles/PMC12172425/
5. Stamatakis L et al. Renal and extrarenal manifestations of BHD  https://pubmed.ncbi.nlm.nih.gov/25007872/ı

EADV CONGRESS
VIENNA
30 SEP - 3 OCT 2026

**Abstract N°: 721**

# Case report of Bart syndrome due to aplasia cutis and junctional epidermolysis bullosa caused by a collagen XVII mutation

Daniel Robles Murcia*[1], Diego Gallego García[1], Jose Molina Espinosa[1], Pedro Ezomo Gervilla[1], Israel Pérez López[1], Ricardo Ruiz Villaverde[1]

[1] Hospital Universitario Clínico San Cecilio, Granada, Spain

## Introduction

We present the clinical case of a neonate treated in our department with the aim of describing the presentation, diagnostic process, and therapeutic approach to Bart syndrome, a condition characterized by the association of congenital aplasia cutis and epidermolysis bullosa.

## Case Presentation

A consultation was requested from the Dermatology Department by the Pediatric Intensive Care Unit for a newborn presenting with congenital ulceration on the right lower limb. After a detailed review of the medical history from both parents, including family dermatological history, obstetric data, and possible consanguinity, physical examination revealed an area of denuded skin approximately 4 cm in diameter, extending from the right knee to the toes, with slightly raised borders and a clean wound bed. Multiple blisters and erosions were also observed in areas subjected to friction or pressure, with a recurrent course. Additional investigations were performed, including biochemical, microbiological, and genetic studies. The initial clinical suspicion of Bart syndrome was confirmed by genetic testing, which demonstrated the homozygous presence of a pathogenic variant of the COL17A1 gene, responsible for junctional epidermolysis bullosa. Treatment consisted of minimizing mechanical trauma, daily moist wound care using Oleogel-S10 (topical birch triterpenes) and contact with the DEBRA-Butterfly Skin patient association. After three months of follow-up, the patient showed clinical improvement, with a decrease in the number of wounds and a faster healing rate, without any adverse effects reported.

## Conclusion

This case highlights the importance of integrated clinical and genetic evaluation for accurate diagnosis and suggests that incorporating emerging therapies into individualized approaches can improve functional outcomes and quality of life in severe congenital genodermatoses.

EADV CONGRESS
VIENNA
30 SEP - 3 OCT 2026

**Abstract N°: 727**

# Topical gentamicin 0.1% as a targeted therapy in hereditary epidermolysis bullosa: A prospective open-label study

Rajaa Bousmara*[1], Fouzia Hali[1], soumia Chiheb[1]

[1] Ibn Rochd University Hospital Center, Casablanca, Morocco

**Introduction**
Epidermolysis bullosa (EB) is a rare inherited disorder characterized by extreme skin fragility and chronic blistering, with no curative treatment currently available. A significant proportion of severe cases are caused by premature termination codons ( PTCs) leading to defective structural proteins. Gentamicin has been shown to induce read-through of these mutations and improve wound healing. This prospective open-label interventional study evaluates the efficacy and safety of topical gentamicin 0.1% as a targeted therapy in patients with EB carrying presumed nonsense mutations.

**Materials and Methods**
This prospective, open-label study evaluated the efficacy of 0.1% topical gentamicin applied twice daily for three weeks. Patients were followed twice weekly during the first month and once monthly during the following two months. Biological tests and audiometry were performed before and after treatment to ensure the absence of systemic toxicity.

**Results**
Five patients were included, two girls and three boys, aged 3 to 19 years, all from consanguineous families. Four patients had recessive dystrophic EB and one had junctional EB. A total of 22 lesions were treated, including acute wounds (n = 8) and chronic wounds (n = 14), located on the face (n = 2), elbow (n = 1), knee (n = 1), pubis (n = 4), trunk (n = 2), feet (n = 5), toes (n = 2), forearms (n = 3), shoulder (n = 1), and leg (n = 1). All treated lesions showed clear clinical improvement. Acute wounds achieved complete re-epithelialization in a mean of 7 days, while chronic wounds healed in an average of 15 days. Local and systemic tolerance was excellent, with no inflammatory reactions or adverse effects reported. However, the effect was temporary, with recurrence of blisters observed in 4 of the 22 previously treated sites (26.7%) after a mean of 67 days.

**Conclusions**
Compared with gene therapy or systemic agents such as ELX-02, topical gentamicin offers a low-cost, accessible, and non-invasive alternative, particularly valuable in resource-limited settings. Although its effects are temporary, these results support the potential benefit of repeated treatment cycles. Topical gentamicin 0.1% thus represents a promising and well-tolerated therapeutic option for selected EB patients with nonsense mutations

EA DV CONGRESS
VIENNA
30 SEP - 3 OCT 2026

**Abstract N°: 737**

## A New Mutation of FERMT1 Gene in a Chinese Patient with Kindler Syndrome

□□ □*[1]

[1] Southwest Hospital, Army Medical University, Department of Dermatology, Chongqing, China

### Introduction

Kindler syndrome (KS; OMIM 173650) is a rare autosomal recessive genodermatosis that is considered to be a subtype of epidermolysis bullosa, characterized by skin fragility, photosensitivity, and blisters that appear from birth[1]. Blisters and photosensitivity gradually improve with age, but most patients develop progressive dermatochromatism, skin atrophy, palmoplantar keratoderma and pseudosyndactyly[2]. Mucosal manifestations are also common, including periodontitis and mucosal leukoplakia[3]. Serious long-term complications include mucosal stenosis and squamous cell carcinoma (SCC)[2,4].

The determinant gene of KS is FERMT1 (also known as KIND1; MIM 607900)[5]which Is located on chromosome 20p12.3 contains 14 coding sequences of exons (2-15) and one non-coding exon 1, spanning 48.5 Kb of genomic DNA. FERMT1 gene encodes protein kindlin-1 (677 amino acids, molecular weight 77.3 kDa)which is specifically expressed in epidermal keratinocytes in tissues such as skin, periodontal tissues and colon ]. Kindlin-1 consists of the FERM domain (band 4.1/ ezrin/ radixin/ moesin), PH domain (pleckstrin homology), tarin-homologous C-terminal and filopodin-homologous N-terminal domains. Kindlin-1 plays the role of an adhesive spot connector protein and participates in the connection of filamentous actin cytoskeleton and the cell membrane[2,5]. In addition, kindlin-1 is also involved in the proliferation of stem cells regulated by Wnt and TGF-β, and in the migration of EGF-dependent keratinocytes[6]. Lack of kindlin-1 leads to decreased cell adhesion, reduced proliferation, increased apoptosis, and loss of cell polarity[7], and even carcinogenesis.

### Case Presentation

The patient's parents are cousins, and her parents and sisters are unaffected by KS. The patient had suffered from repeated facial blisters and blood blisters after trauma since the age of 1 year old, and no scars were left after healing. The symptoms alleviated with age. She no longer had blisters after 5 years old, but developed poikiloderma in her face and dorsal of the hands. Poikiloderma progressed with age from sun-expose areas to non-sun-exposed areas. This was followed by skin atrophy, which was with ‘cigarette paper’-like wrinkling.At the same time, she also suffered from diffuse erythema and hyperkeratosis on both hands and dorsal of feet, severe webbing of the fingers (toes), and nail dystrophy.When she was 12 years old, syndactyly of pair of hands except thumbs caused difficulty in grip a pen. The patient did not have photosensitivity, difficulty swallowing, oral ulcers, gingivitis, difficulty in defecation, skeletal or neuro developmental dysplasia. Physical examination found that dry skin, skin atrophy and extensive poikiloderma were revealed over the lip, face, neck, trunk andextremities. Erythema and hyperkeratosis with desquamation, a waxy appearance and dermatoglyphics flattened or lost could be seen on both hands and feet. Severe webbing of fingers (toes) and pseudosyndactyly with hands contractured like half-fisted were revealed. Nail dysplasia and dental plaque were also seen. There was no blisters and mucosal involvement.

### Conclusion

We reported a 13-year-old KS patient with blood-relative parents in China, whose clinical manifestations were mainly blisters on the face, hands and feet, poikiloderma, skin atrophy, palmoplantar keratoderma, as well as pseudosyndactyly, but no mucosal involvement. Skin histopathology and transmission electron microscopy supported the diagnosis of KS. New homozygous nonsense variant of FERMT1 gene (c.994C>T, p.Gln332Ter) was

assessed to be pathogenic. Combined with the previous two reports of variants at this site, we speculated that premature termination of codon at the 332nd glutamine might be related to no or minor mucosal involvement. At the same time, we reviewed the previous reports with gene mutation detection, and counted the clinical characteristics of KS and the mutations of FERMT1 gene, but unfortunately failed to find a connection.

EADV CONGRESS
VIENNA
30 SEP - 3 OCT 2026

**Abstract N°: 745**

# Localized Hyperkeratosis Lenticularis Perstans (Flegel Disease) Confined to the Lower Legs: A Case Report

Corina Ioana Cucu*[1]

[1] University of Medicine and Pharmacy "Carol Davila", Bucharest, Romania

## Introduction

Hyperkeratosis lenticularis perstans (Flegel disease) is a rare, chronic keratinization disorder characterized by multiple, small, hyperkeratotic papules, typically distributed on the lower extremities. The condition is often underdiagnosed due to its subtle clinical presentation and resemblance to other keratotic dermatoses.

## Case Presentation

I report the case of a 56-year-old female presenting with a several-year history of asymptomatic, persistent, erythematous to brownish hyperkeratotic papules localized exclusively on the lower legs. The lesions were non-confluent, measuring 1–5 mm in diameter, and showed no significant response to prior topical therapies, including emollients and corticosteroids. The patient denied systemic symptoms or family history of similar skin conditions.
Dermoscopic evaluation revealed central keratin plugs with surrounding erythema. Histopathological examination demonstrated compact orthokeratosis, focal parakeratosis, epidermal atrophy, and a band-like lymphocytic infiltrate in the superficial dermis, consistent with hyperkeratosis lenticularis perstans.
The patient was treated with topical keratolytics and retinoids, resulting in mild clinical improvement. Given the benign and chronic nature of the disease, management focused on symptomatic relief and cosmetic concerns.

## Conclusion

This case highlights a localized presentation of Flegel disease confined to the lower legs, emphasizing the importance of clinicopathological correlation for accurate diagnosis. Increased awareness of this rare entity may help differentiate it from other keratinization disorders and guide appropriate management strategies.

EA DV CONGRESS
VIENNA
30 SEP - 3 OCT 2026

**Abstract N°: 749**

## Inflammation in Scales: Cytokine Clues to Treating Inherited Ichthyosis

Ayushman Bindal*[1]

[1] Charak Hospital, Indore, Lady Hardinge Medical College, New Delhi, Indore, India

**Introduction**
Congenital ichthyosis is a group of rare genodermatoses with varied manifestations requiring a need for better understanding of pathophysiology for future therapeutics. There is role of pro-inflammatory cytokines in pathogenesis and hence use of specific IL-inhibitors in therapy of ichthyosis may have a role in upcoming treatment strategies. There is a paucity of data on the role of cytokines in pathophysiology of inherited ichthyosis.

**Materials and Methods**
Objectives: To compare the levels of cytokine profile (IL-17, IL-22 and TNF-α) in patients with inherited ichthyosis as compared to age and sex matched healthy controls. To study alteration in cytokine levels (IL-17, IL-22 and TNF-α) in different clinical types of ichthyoses. To study the correlation between cytokine levels with severity of ichthyosis measured by IASI score.

This was a hospital based cross-sectional study with 30 clinically diagnosed cases of inherited ichthyosis (2-18 years) and 30 age and sex- matched controls. 3-4 ml of blood samples drawn from patients and from controls for estimation of cytokines levels (TNF-alpha, IL-17 and IL-22) by ELISA. Detailed evaluation was done including determination of ichthyosis area severity index (IASI).

**Results**
Values of IL-17 and IL-22 had significant difference between cases and controls. There was even a significant difference between values of IL-17 and IL-22 among different groups of ichthyoses. IASI positively correlated with the values of TNF-α and IL-22.

**Conclusions**
IL-17, IL-22 and TNF-α play a role in pathophysiology of ichthyosis and their levels increase with the severity of the disease. IL-22 can be a potential molecule for targeted therapy in the treatment for Sjögren-larsson syndrome. However targeted therapy by IL-17/IL-22/TNF-alpha inhibitors in ichthyosis requires larger study and multicentric trials.

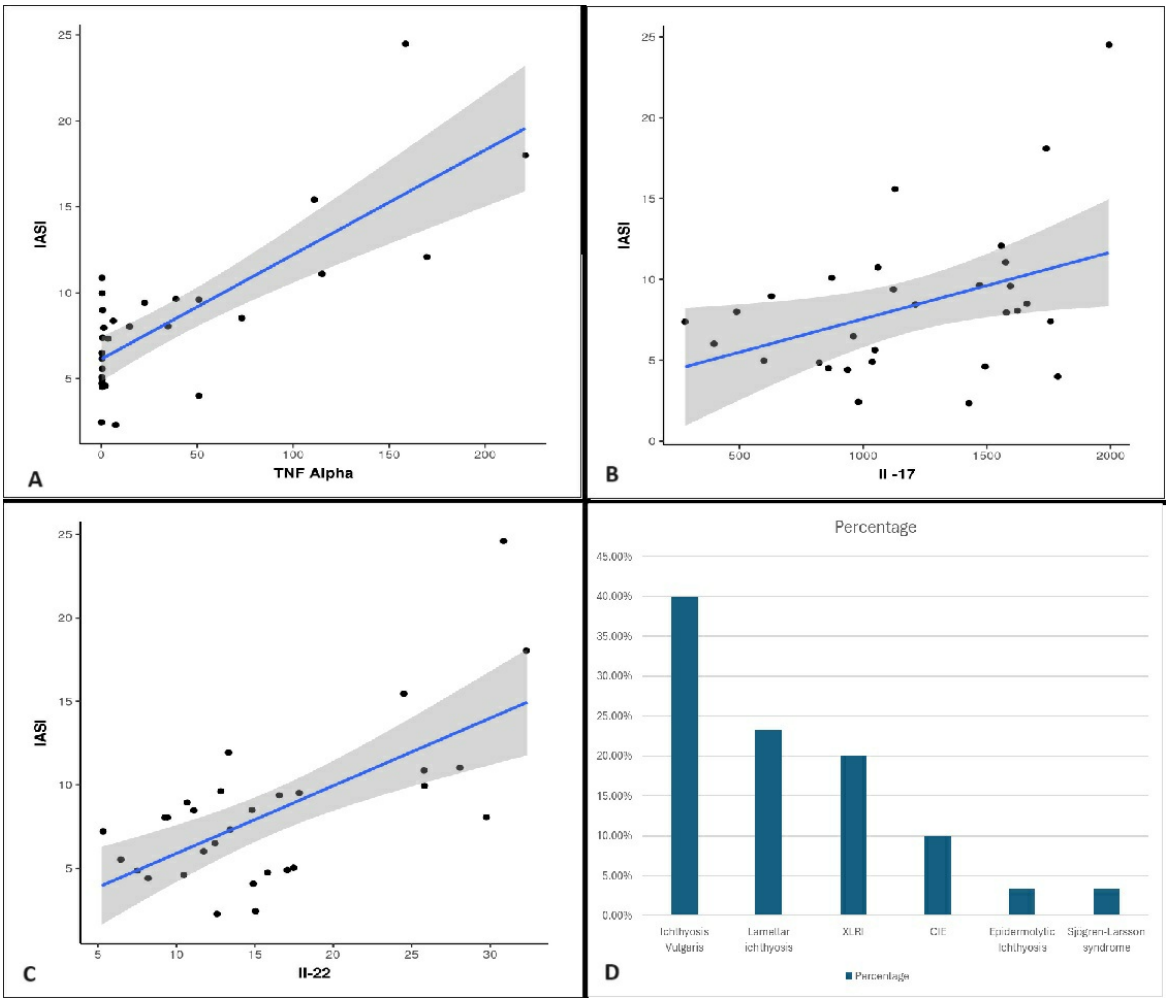


IASI positively correlated with the values of TNF-α and IL-22.

EADV CONGRESS
VIENNA
30 SEP - 3 OCT 2026

**Abstract N°: 761**

# Epidermal Nevus Syndrome: Recognizing a Rare Neurocutaneous Disorder Hidden Behind a Common Presentation

Carolina Cruz*[1], Ana Clara Maia Palhano[1], Amanda Tanaka Iasbeck Gonçalves[1], Bruna Polito Teixeira[1], Luciana de Paula Samorano[1], Maria Cecília Rivitti-MacHado[1], Zilda Najjar Oliveira[1]

[1] Universidade de São Paulo, São Paulo, Brazil

## Introduction

Epidermal nevus syndrome (ENS) designates epidermal nevi are associated with neurologic, ocular and/or musculoskeletal abnormalities.[1] Diseases included within the epidermal nevus syndromes are quite rare and incidence and prevalence are not well reported. [2]

The most common syndromes include Schimmelpenning syndrome, phakomatosis pigmentokeratotica, nevus comedonicus syndrome, Proteus syndrome, congenital hemidysplasia, ichthyosiform erythroderma and limb defects (CHILD) syndrome and Becker nevus syndrome. Given the rarity of this entity, which often leads to delayed diagnosis, we present this case to enchance awarness.[3]

## Case Presentation

A 34-year-old male presented since birth hypochromic macules along the lines of Blaschko on his left leg, a pre auricular plaque covered by a cluster of follicular openings filled with keratin since 20 years-old, refractory epilepsy since 1-year-old and intellectual disability. Magnetic resonance imaging scan revealed cortical dysplasia. Biopsies of the skin lesions were performed: hypochromic macules and the pre auricular lesion.

Histopathologic of for the hypochromic lesion showed hyperkeratosis and papillomatosis, indicating an epidermal nevus. Histopathologic of the pre auricular lesion described a group of follicular ostia in the epidermis filled with keratin plugs, suggesting nevus comedonicus.

Dermatological findings associated with the neurologic alterations that the patient presented stablished the diagnostic of epidermal nevus syndrome.

## Conclusion

In the last 10 years there has been genetic studies on ENS evidenciating somatic mosaicism with post zygotic mutations in the specified gene.[2] For example, for the nevus comedonicus syndrome is related to the Fibroblast growth factor receptor 2 (FGFR2) gene mutations. The clinical expression depends on the timing of the mutation, influencing the distribution of mosaicism.

Recognition of ENS requires a high index of suspicion and a multidisciplinary approach, as early identification of associated anomalies may significantly impact prognosis and management. Ongoing advances in molecular genetics continue to refine the classification and understanding of these disorders, highlighting the importance of integrating clinical and genetic data in patient evaluation.[3]

EADV Congress 2026, VIENNA
30 SEPTEMBER - 03 OCTOBER 2026
POWERED BY M-ANAGE.COM

EADV CONGRESS
VIENNA
30 SEP - 3 OCT 2026

**Abstract N°: 781**

# Dermatophytic Disease: Variable Evolution from One Case to Another — Should We Speak of a Disease Spectrum? Algerian Case Series and Literature Review

omar boudghene stambouli*[1]

[1] Medical Practice of Dermatology and Venereology Former Head of Dermatology at Tlemcen, Tlemcen, Algeria

## Introduction

Dermatophytic disease (DD) is a chronic cutaneo-visceral dermatophytosis caused by common dermatophytes that cross the cutaneous barrier. It is mainly observed in the Maghreb, where cases are regularly reported, particularly in Algeria.

## Materials and Methods

We report 5 cases of dermatophytic disease due to Trichophyton violaceum and Trichophyton rubrum in patients living in western Algeria (Tlemcen, Sidi Bel Abbès, Chlef).

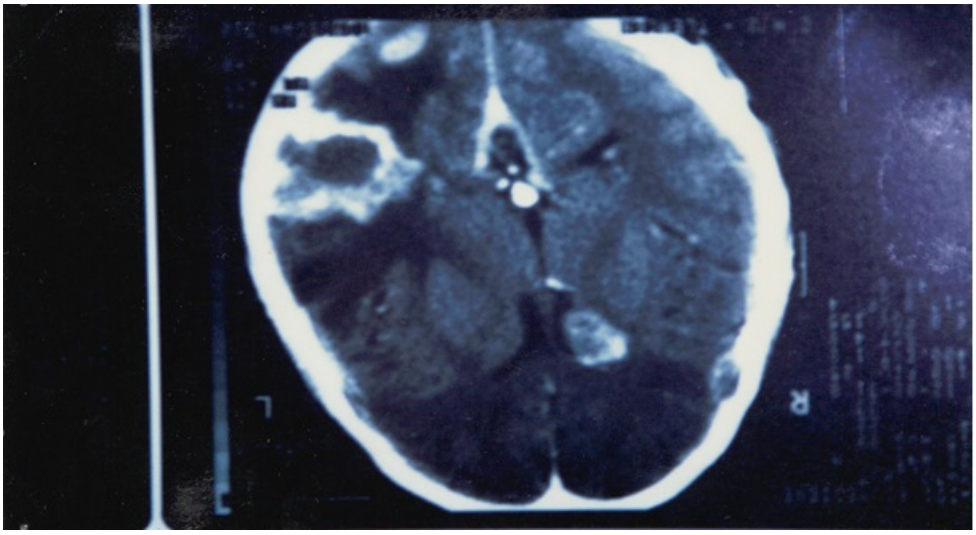

## Results

Five cases of DD (4 males and 1 female) were regularly followed in the dermatology department of the University Hospital of Tlemcen (western Algeria) over several years.The dermatological manifestations presented by the patients, along with histological and mycological examinations, paraclinical investigations (IgE levels), intradermal reaction (IDR) to trichophytin, as well as radiological, ultrasound, and CT scan examinations, confirmed the diagnosis of DD.Since its first description in 1959, dermatophytic disease has shown new clinical aspects. During its course, DD presents a polymorphism of lesions, probably related to immune deficiency associated with the more or less prolonged evolution of the disease: plaques, erythematous patches, papulo-nodules, ulcerations, vegetative lesions, plantar hyperkeratosis, etc. (Fig. 1).Should we consider or define a spectrum in dermatophytic disease, ranging from a long-standing form to a severe, rapidly fatal form (with cerebral involvement and/or septicemia), including intermediate forms? (Fig. 2)



**Conclusions**

Antifungal agents, whether old or recent, are unlikely to achieve definitive cure of dermatophytic disease (DD) until new advances are made in understanding the pathophysiology of this severe dermatophytosis

EADV CONGRESS
VIENNA
30 SEP - 3 OCT 2026

**Abstract N°: 790**

# A Novel Association of Lamellar Ichthyosis and Juvenile Macular Dystrophy with Dual CDH3 and ALOX12B Mutations: A Case Report.

Serap Öztürkcan*[1], Ege Nur Yıldız[1], Ayça Aykut[2], Asude Durmaz[2], Peyker Temiz[3]

[1] Manisa Celal Bayar University, Department of Dermatology and Venereology, Manisa, Türkiye
[2] Ege University Faculty of Medicine, Department of Medical Genetics, İzmir, Türkiye
[3] Manisa Celal Bayar University Faculty Of Medicine, Department of Pathology, Manisa, Türkiye

**Introduction**
Hypotrichosis with juvenile macular dystrophy (HJMD) and autosomal recessive congenital ichthyosis (ARCI) are rare genodermatoses caused by mutations in CDH3 and ALOX12B, respectively. To the best of our knowledge, the coexistence of these two mutations in a single patient has not been previously reported in the literature.

**Case Presentation**
We describe a 45-year-old woman with lifelong generalized xerosis, collodion baby history, progressive scalp alopecia, nail dystrophy, recurrent otitis externa, and juvenile-onset visual loss. Dermatologic examination revealed diffuse lamellar scaling, cicatricial alopecia with loss of follicular openings, and nail deformities. Ophthalmologic evaluation showed bilateral chorioretinal atrophy consistent with macular dystrophy. Genetic testing demonstrated homozygous pathogenic variants in both ALOX12B and CDH3, confirming ARCI and HJMD simultaneously. Treatments included emollients, topical keratolytics, lubricating eye drops, otic antibiotics, bilateral phenol matricectomy, liniment oleo-calcarine for hair scales and acitretin for ichthyosis. While lamellar ichthyosis improved, alopecia, nail changes, and macular dystrophy persisted.

**Conclusion**
To the best of our knowledge, this report presents the first documented case of concurrent homozygous ALOX12B and CDH3 mutations, resulting in a combined phenotype of lamellar ichthyosis, cicatricial alopecia, and juvenile macular dystrophy. Recognition of this rare overlap is important for prognosis, multidisciplinary management, and genetic counseling.

EA DV CONGRESS
VIENNA
30 SEP - 3 OCT 2026

**Abstract N°: 792**

# Rare synonymous JUP variant causing Naxos disease: clinical and genetic insights from a familial case

Marina de la Puente Alonso*[1], Luis Angel Zamarro Díaz[1], Javier Gómez-Herrero[2], Julia Suárez Gonzalez[1], María Angeles Espinosa Castro[1], Ana Isabel Fernández Ávila[1], Belén Rodríguez Sánchez[1], Jorge Martín-Nieto Gonzalez[1], Andrea Fuentes Bellas[1], Daniel de Ramón Rueda[1], Minia Campos[1]

[1] Hospital General Universitario Gregorio Marañón, Madrid, Spain
[2] Hospital General Universitario de Segovia, Segovia, Spain

## Introduction

Naxos disease and Carvajal syndrome are inherited disorders characterized by the association of arrhythmogenic cardiomyopathy with a cutaneous phenotype, including woolly hair and palmoplantar keratoderma.Desmosomes are adhesive junction proteins that play a crucial role in maintaining the structural integrity and mechanical resilience of cells in both the epidermis and the myocardium.Three desmosomal genes have been implicated in this type of cardiocutaneous syndrome: the plakoglobin gene (JUP), more commonly associated with Naxos disease (predominantly right ventricular involvement); the desmoplakin gene (DSP), associated with Carvajal syndrome (primarily left ventricular involvement); and the desmocollin-2 gene (DSC2).

## Case Presentation

A 62-year-old male with no significant past medical history was evaluated. His parents, originating from a small village of approximately 2,000 inhabitants, had no known history of cardiomyopathy or cutaneous disease.At the age of 42, he was diagnosed with arrhythmogenic right ventricular dysplasia/cardiomyopathy (ARVD/C) following presyncopal episodes. An implantable cardioverter-defibrillator (ICD) was placed for primary prevention.Regarding the cutaneous phenotype, the patient presented with severe dental enamel defects requiring comprehensive prosthetic rehabilitation. Since childhood, he has exhibited severe palmoplantar hyperkeratosis with fissuring, limited finger extension, and hyperkeratosis affecting both elbows. In addition, the hair is fine, thin, and tightly curled (woolly hair). No nail or sweating abnormalities were reported.He is currently receiving acitretin at a dose of 10 mg/day, with significant improvement in palmoplantar hyperkeratosis.Genetic analysis identified a homozygous synonymous mutation in JUP (c.468G>A, p.Pro156=), associated with abnormal splicing. This finding explains the patient's clinical phenotype, consistent with Naxos disease.Following diagnosis, the patient reported a sister without clinical manifestations and an older brother with a similar cutaneous phenotype.The brother, aged 72, presented with a neonatal-onset condition characterized by woolly hair from birth, generalized ulcerative skin lesions (involving the scalp, face, upper and lower extremities, as well as the gluteal and perianal regions), and severe nail dystrophy. Over time, he developed progressive palmoplantar keratoderma associated with resorption of the distal phalanges of the fingers and leading to impaired ambulation.Genetic testing confirmed the presence of the same pathogenic variant identified in his brother. He is currently undergoing comprehensive cardiological evaluation.

## Conclusion

Five cases associated with this mutation have been reported in the literature. Four of these involve young patients sharing a similar cutaneous phenotype, in whom the presence of associated cardiac involvement has been questioned.Additionally, this mutation has been described in a child in association with ARVD/C for the first time.These findings contribute to the understanding of the clinical and genetic heterogeneity associated with JUP mutations and highlight the importance of a multidisciplinary approach in the diagnosis and management of these patients. This approach should take into account phenotypic variability, potential systemic involvement, and

the need for appropriate family screening and follow-up.

EA DV CONGRESS
VIENNA
30 SEP - 3 OCT 2026

**Abstract N°: 801**

## Expanding the phenotype of mosaic trisomy 18: a case with phylloid pigmentary mosaicism

Marina de la Puente Alonso*[1], Luis Angel Zamarro Díaz[1], Belén Rodríguez Sánchez[1], Jorge Martín-Nieto Gonzalez[1], Daniel de Ramón Rueda[1], Andrea Fuentes Bellas[1], Raquel Horcajo Ortega[1], Victoria Robles Almazan[1], Alba Bergaz Alonso[1], Minia Campos[1]

[1] Hospital General Universitario Gregorio Marañón, Madrid, Spain

### Introduction

Mosaicism refers to the presence of two or more cell populations with different genetic expression, despite originating from a single zygote [1], [2]. It is slightly more frequent in females, and hypopigmented mosaicism is more common than hyperpigmented forms [2]. The most frequent distribution pattern is blaschkoid (following the Blaschko lines), observed in approximately 80% of cases. Less common patterns include phylloid, patchy, checkerboard, and band-like distributions. Extracutaneous manifestations have been described in approximately half of patients with pigmentary mosaicism, particularly in hypopigmented forms. The most commonly reported abnormalities include developmental delay, skeletal deformities, seizures, dysmorphic facial features, and psychomotor delay [2].In patients with pigmentary mosaicism, the most frequently involved chromosomes are 3, 5, 6, 9, 10, 13, 15, 18, 20, and X [3].

### Case Presentation

A 16-year-old female, with no relevant past medical history, presented with a two-month history of asymptomatic hypopigmented lesions on her lower extremities and left forearm.Two skin biopsies were performed: one for histopathological examination and another for chromosomal analysis of the hypopigmented lesions. Histopathological examination revealed mild acanthosis. HMB45 staining demonstrated a preserved number of melanocytes along the basal layer. No associated inflammatory infiltrate was observed in the underlying dermis. These findings were consistent with pigmentary mosaicism.Fluorescence in situ hybridization (FISH) for aneuploidy in skin revealed a mosaic trisomy 18 (47,XX,+18) [5].Peripheral blood karyotype and FISH analysis showed normal results.At one-year follow-up, the lesions remained stable.Clinically, the lesions exhibited a phylloid pattern characterized by oval, leaf-like hypopigmented macules. Notably, our case displayed features consistent with phylloid hypomelanosis. It has been specifically associated with abnormalities of chromosome 13 [1].Individuals with mosaic trisomy 18 represent approximately 5% of all trisomy 18 cases. These patients exhibit both trisomic and euploid cell lines, and their clinical presentation is highly variable, ranging from absence of dysmorphic features to the full trisomy 18 phenotype [4].Several cases of mosaic trisomy 18 associated with pigmentary abnormalities have been reported in the literature, although this is not a common feature. One patient with mosaic trisomy 18 (17%) presented with an irregular hypopigmented pattern on the right side of the abdomen that did not follow Blaschko lines [4]. Three additional cases with mosaic trisomy 18 and pigmentary alterations (one hypopigmented and two hyperpigmented), as well as one case with mosaic monosomy 18 and hypopigmentation, have been described; none of these followed a phylloid pattern [5]. Another case described multiple linear hypopigmented macules distributed along Blaschko lines on the back and upper extremities, associated with mosaic monosomy 18 detected in hypopigmented skin [3].Although the underlying mechanism of phylloid hypomelanosis remains unclear, mosaicism has long been proposed as the cause of cutaneous pigmentary variability [6].

### Conclusion

To the best of our knowledge, this is the first reported case in the literature describing the association of mosaic

trisomy 18 with a phylloid pattern of pigmentary mosaicism. While pigmentary abnormalities have been previously documented in patients with mosaic trisomy 18, none of the reported cases have demonstrated a phylloid distribution. This observation expands the phenotypic spectrum of mosaic trisomy 18 and highlights the importance of considering underlying chromosomal mosaicism in patients presenting with atypical patterns of cutaneous pigmentation.

EADV CONGRESS
VIENNA
30 SEP - 3 OCT 2026

**Abstract N°: 849**

## A Case of Atypical TP63 Mutation–Associated Rapp–Hodgkin Syndrome

Kun Zhan*[1], Sheng Wang[1], Wei Li[1]

[1] West China Hospital of Sichuan University, Sichuan, China

### Introduction

TP63-related ectodermal dysplasia comprises a group of autosomal dominant disorders affecting ectoderm-derived structures, often accompanied by orofacial clefting. Traditionally, mutations in the DNA-binding domain (DBD, exons 4–8) are associated with ectrodactyly–ectodermal dysplasia–clefting (EEC) syndrome, while mutations in the sterile alpha motif (SAM, exons 12–14) are linked to Rapp–Hodgkin syndrome (RHS) and ankyloblepharon–ectodermal defects–cleft lip/palate (AEC).However, increasing evidence suggests significant phenotypic overlap, indicating that TP63-related disorders form a clinical spectrum. Here, we report a patient with a DBD mutation presenting with an RHS-like phenotype.

### Case Presentation

A 14-year-old Chinese male presented with nail dystrophy and hair hypopigmentation since birth. He was born to non-consanguineous healthy parents after an uneventful pregnancy, with no reported exposure to radiation, chemicals, or teratogenic medications. He was delivered vaginally at 38 weeks of gestation without perinatal complications. At birth, the patient was noted to have a cleft lip and palate, which were surgically repaired during infancy, resulting in satisfactory cosmetic and functional outcomes. Since early childhood, he exhibited dental abnormalities, including enamel hypoplasia, multiple missing permanent teeth, and malocclusion, which affected both mastication and appearance. No specific dental treatment had been undertaken. Hair abnormalities were also evident from an early age, characterized by hypopigmented, yellowish hair that was coarse, brittle, and prone to breakage. Nail dystrophy was present, with fingernails described as rough, uneven, and fragile. The patient reported that toenails were also brittle, although their external appearance was relatively normal. Notably, he had no ectrodactyly, ankyloblepharon, or scalp erosions. Approximately 10 years prior to presentation, he developed bilateral ptosis and dry eyes, and was later found to have punctal agenesis, treated with punctoplasty. No family history of similar conditions was noted. Whole-exome sequencing identified a de novo heterozygous TP63 mutation, c.1028G>A (p.Arg343Gln) in exon 8, not previously reported in East Asian populations. Based on cleft lip/palate and multisystem ectodermal abnormalities, a diagnosis of Rapp–Hodgkin syndrome was made. The patient showed good outcomes after surgical interventions and was advised to undergo regular follow-up and genetic counseling.

### Conclusion

This case demonstrates that a TP63 mutation in the DNA-binding domain can present with an RHS-like phenotype, supporting the concept of a phenotypic spectrum rather than strict genotype–phenotype correlations. The variability of TP63-related disorders may result from mutation-specific effects, genetic background, and environmental factors. Clinically, TP63-related disorders should be considered in patients with cleft lip/palate and ectodermal abnormalities, even without limb defects. Early genetic testing is essential for accurate diagnosis, management, and genetic counseling.

EA DV CONGRESS
VIENNA
30 SEP - 3 OCT 2026

**Abstract N°: 887**

# Cutaneous Changes During Adjuvant Breast Radiotherapy in Recessive Dystrophic Epidermolysis Bullosa: A Prospective Photographic Case Report and Wound Care Considerations

Sarah Shareef*[1], Eleanor Walker[2], Andrea Matsumoto[2], Holly Kerr[1]

[1] Henry Ford Hospital, Department of Dermatology, Detroit, United States
[2] Henry Ford Hospital, Department of Radiation Oncology, Detroit, United States

## Introduction

Recessive dystrophic epidermolysis bullosa (RDEB) is a mechanobullous genodermatosis caused by pathogenic variants in *COL7A1*, encoding type VII collagen. Patients exhibit skin fragility, impaired wound healing, and an increased lifetime risk of aggressive cutaneous squamous cell carcinoma (SCC).[1] Reports of radiation therapy (RT) in RDEB are limited to SCC treatment, where increased normal tissue toxicity and impaired healing were observed.[2] Prospective data describing RT delivery in RDEB are lacking and existing acute radiation dermatitis grading systems may not be applicable to this population, limiting their utility in guiding clinical expectations.[3] To our knowledge, this is the first prospectively documented case of cutaneous changes (CC) during adjuvant chest wall RT in a patient with RDEB, with serial clinical photography throughout treatment and follow-up. We highlight our patient's clinical course, wound management, and considerations for patient counseling.

## Case Presentation

A 35-year-old female with RDEB due to a partial *COL7A1* deletion and a germline *BARD1* mutation presented with recurrent right-sided breast malignancies. Two years prior, she was diagnosed with right breast ductal carcinoma in situ (cTisN0M0, grade 2, ER+/PR+) and underwent bilateral mastectomies; final pathology revealed a concurrent mucinous carcinoma (pT1bN0M0, grade 1, ER+/PR+, HER2+, Ki-67 14%) with less than 1 mm margins. She declined adjuvant endocrine therapy.

She subsequently developed a second primary right chest wall invasive mammary carcinoma (pT1cN0M0, grade 2, ER+/PR+, HER2 1+) which was excised and treated with low-dose tamoxifen.

Excision of a new right chest wall nodule confirmed recurrent invasive carcinoma (rpT1cN0M0, grade 2, ER+/PR+, HER2 1+, Ki-67 15%). Following multidisciplinary discussion, adjuvant hypofractionated chest wall RT was pursued (42.72 Gy in 16 fractions).

The patient had a pre-existing right axillary erosion that demonstrated interval progression during treatment. By day 11 of RT, there was marked enlargement with severe pain and clothing adherence, limiting her mobility. This change was likely multifactorial, with contributions from bacterial colonization, local moisture and friction, and baseline impaired wound healing. Wound cultures grew *Staphylococcus aureus* and *Corynebacterium striatum*, and cephalexin was initiated. Wound care was started 7days post-RT, including daily pure hypochlorous acid cleansing, petrolatum, border gauze and non-adherent silicone tape. A lipocolloid dressing was trialed but discontinued due to poor tolerance in the axilla.[4] Pain improved within one week. By 61 days post-radiation, there was substantial peripheral re-epithelialization with a persistent central erosion at the skin fold.

**Conclusion**

This report provides prospectively documented insight into adjuvant chest wall RT in a patient with RDEB, an understudied clinical scenario. CC were characterized by progression of a pre-existing axillary erosion. Notably, only the inferior axilla was included in the radiation field, further supporting a multifactorial etiology, rather than radiation-induced dermatitis.

Wound care principles in RDEB, prioritizing atraumatic dressing removal, a moist healing environment, and antimicrobial management, must be maintained throughout RT to prevent associated skin injury.[5] This case emphasizes the importance of close monitoring of pre-existing wounds within the radiation field, as these areas may be more susceptible to interval change and may benefit from early, proactive intervention, and targeted wound care. Additionally, a chronic wound within an irradiated field may further increase SCC risk in an already high-risk population, necessitating close dermatologic surveillance.[2]

Importantly, RT was well tolerated without interruption or significant acute toxicity, suggesting that patients with RDEB may undergo RT with appropriate multidisciplinary support and monitoring.

EADV CONGRESS
VIENNA
30 SEP - 3 OCT 2026

**Abstract N°: 945**

## Disseminated Molluscum Contagiosum Associated with Dock 8 Deficiency

Beghdad Ikram*[1], Saliha Takheroubt[1], Issam TABLIT[1], Lemya Mezdour[1], Asma Haciane[1], Samira Zobiri[1]

[1] Mustapha University Hospital, Dermatology Departement, Algiers, Algeria

### Introduction

Dock8 deficiency is a rare autosomal recessive combined primary immunodeficiency, characterized by impaired cellular immunity and increased susceptibility to cutaneous viral infections. Among these, Molluscum Contagiosum may represent an early and revealing manifestation.

### Case Presentation

We report the case of a 10-year-old child presenting with disseminated Molluscum Contagiosum in context of a Dock8 Deficiency. The patient was born to consanguineous parents, with a family history of sibling's death. Symptoms began at the age of three years with a solitary facial lesion, followed by progressive dissemination to the etire tegument over seven-year-old. The Clinical course was marked by numerous, extensive, and persistanr umbilicated papules and nodules, consistent with generalized Molluscum Contagiousum. These lesions are associated with palmoplantar warts and perianal vegetations. Recurrent subcutaneous abscesses and repeated respiratory infections were also noted. These features prompted specialized pediatric evaluation, leading to the diagnosis of Dock8 deficiency. Laboratory investigations revealed hepatic cytolysis. The patient is currently managed with regular intravenous Immunoglobulin therapy 10 g every two weeks and Prophylactic antibiotics

### Conclusion

This case highlights the key role of dermatologists in recognizing atypical and severe viral dermatoses suggestive of underlying immunodeficiency. Early diagnosis is essential to enable genetic confirmation and timely referral for hematopoietic stem cell transplantation, which remains the only curative treatment.

EADV CONGRESS
VIENNA
30 SEP - 3 OCT 2026

**Abstract N°: 972**

# Between cylindromas and spiradenomas: insights into Brooke-Spiegler Syndrome

Judith Ivonne Fernández Tarradas*[1], Jorge Arandes Marcocci[1], Maribel Iglesias Sancho[1], Mònica Quintana Codina[1], María Teresa Fernández Figueras[2], Rosa Ballester Victoria[2], Mariona Pintiado Gámez[1], María Isabel Fernández Velasco[1], Montserrat Salleras Redonnet[1]

[1] Department of Dermatology, Hospital Universitari Sagrat Cor, Barcelona, Spain
[2] Department of Pathology, Hospital General De Catalunya, Sant Cugat del Vallès, Spain

## Introduction

Brooke-Spiegler syndrome (BSS) is a rare genodermatosis with autosomal dominant inheritance and variable penetrance.

## Case Presentation

32-year-old woman from Peru, with a past medical history of hepatitis during childhood. Since the age of 14, she reported progressive appearance of multiple skin lesions on the face, scalp, and extremities. In her country of origin, a diagnosis of Brooke-Spiegler syndrome had been suggested after a biopsy (not available). The patient was unaware of any family history.

On physical examination, lesions compatible with cysts were observed in the frontal region, trichoepitheliomas along the hairline and paranasal area, and spiradenomas on both upper and lower extremities, one of them markedly painful. Surgical excision of the painful lesion on the first digit of the right hand was performed, and histopathological examination confirmed spiradenoma.

Cutaneous ultrasound of two frontal lesions revealed well-defined dermo-hypodermal lesions, heterogeneous in echotexture and hypervascularization, suggestive of adnexal tumors. Subsequent excision of the largest frontal lesion again confirmed spiradenoma.

Genetic testing of the patient identified a heterozygous pathogenic variant in the CYLD gene (tumor suppressor).

## Conclusion

BSS is characterized by the development of multiple adnexal tumors, mainly cylindromas, trichoepitheliomas, and spiradenomas, with a predilection for the scalp and facial region. Lesions typically appear during puberty, show a slight female predominance, and progressively increase in number and size.

BSS is part of the CYLD cutaneous syndrome, together with familial cylindromatosis and multiple familial trichoepithelioma, which are considered phenotypic variants within the same clinical spectrum. There is marked intra- and interfamilial phenotypic variability, even among individuals carrying identical mutations.

Diagnosis is based on family history, clinical findings, histopathology, and genetic testing, although up to 20% of patients do not show detectable CYLD mutations. A minority of cases are attributed to de novo mutations, as may be the case in our patient.

Treatment is mainly palliative, consisting of surgical excision or ablative techniques depending on the case.

EADV CONGRESS
VIENNA
30 SEP - 3 OCT 2026

**Abstract N°: 979**

## Poikiloderma revealing Rothmund-Thomson Syndrome: A Case Report

Beghdad Ikram*[1], Saliha Takheroubt[1], Khaled Sawalha[1], Issam TABLIT[1], Lemya Mezdour[1], Asma Haciane[1], Samira Zobiri[1], Farid Ait Belkacem[1]

[1] Mustapha University Hospital, Dermatology Departement, Algiers, Algeria

### Introduction
Rothmund-Thomson Syndrome is a rare autosomal recessive genodermatosis, most commonly associated with mutations in the RECQL4 gene involved in genomic stability and DNA Repair. It presents in early childhood with characteristic poikiloderma and may involve multiple systems, with increased risk of malignancy.

### Case Presentation
We report the case of a 5-year-old child, born to consanguineous parenrs, hospitalized for congenital poikiloderma. Cutaneous manifestations began at 02 months of age with erythematous macules on the lower limbs, followed by recurrent blistering episodes evolving through phases of remission and exacerbation. Lesions progressively extended to the buttocks and face, leading to diffuse involvement. Dermatological examination revealed erythematous finely scaly plaques on the cheeks, blanchable on diaoscopy, associated to erythematous plaques on the buttocks and lower limbs, sometimes atrophic and covered with fine pityriasiform scaling. A flaccid blister with clear content was observed on the right leg. Diffuse onychodystrophy and Scalp hypotrichosis, spare eyebrows and eyelashes are found. Ocular involvement was noted arly and consisted of trichasis and conjunctival hypermia.
The overall clinical presentation is consistent with Rothmund-Thomson Syndrome. Mangement included Photoprotection, Surgical correction of trichiasis and endocrinological assessment for growth retardation.

### Conclusion
The diagnosis of Rothmund-Thomson relies on early recognition of characteristic cutaneous, Nail and Hair signs. This allows genetic confirmation and multidisciplinary management. Early identification is essential to prevent long-term complications, particularly osteosarcoma and cutaneous malignancies. This case highlights the key role of the dermatologists in the early detection of rare genodermatoses and specialized care.

EA DV CONGRESS
VIENNA
30 SEP - 3 OCT 2026

**Abstract N°: 1010**

## WHEN LENTIGINES RESPECT THE MIDLINE:A CASE OF SEGMENTAL LENTIGINOSIS

Israe El Ghazouli*[1], Ouiame El Jouari[1], Salim Gallouj[1]

[1] Dermatology department, Mohammed VI Hospital, faculty of medicine and pharmacy- ABdelMALek Essaadi University, Tangier, Morocco

**Introduction**

Agminated or segmental lentiginosis is a rare pigmentary disorder characterized by multiple lentigines clustered in a localized or segmental distribution, often with a sharp midline demarcation. It is considered a manifestation of cutaneous mosaicism.

However, its distinction from segmental neurofibromatosis (NF1 mosaicism) remains challenging, particularly in cases associated with café-au-lait macules (CALMs), raising the question of whether these entities belong to the same spectrum.



Figure 1: Multiple lentigines arranged in a strictly unilateral pattern, respecting the midline, consistent with segmental lentiginosis

**Case Presentation**

We report the case of a 26-year-old patient presenting with multiple asymptomatic pigmented macules localized to the [right/left] side of the body.

The lesions had been present since early childhood and progressively increased in number over time, with no history of excessive sun exposure.

Clinical examination revealed numerous small, well-defined brown macules consistent with lentigines, distributed in a strictly unilateral pattern with a sharp demarcation at the midline.

No neurofibromas, axillary freckling, mucosal involvement, or other systemic abnormalities were observed.

Dermoscopic examination showed a regular reticular pattern without atypical features.



**Conclusion**

Segmental lentiginosis (also referred to as agminated lentiginosis or partial unilateral lentiginosis) is thought to result from postzygotic somatic mutations leading to cutaneous mosaicism.

Clinically, it presents as grouped or segmentally distributed lentigines, often following dermatomal or mosaic patterns and typically respecting the midline.

The main differential diagnoses include:

- Segmental neurofibromatosis
- Speckled lentiginous nevus
- Other mosaic pigmentary disorders

The key diagnostic challenge lies in distinguishing segmental lentiginosis from segmental neurofibromatosis, particularly when café-au-lait macules are present.

Previous reports have suggested that agminated lentiginosis associated with CALMs may represent:

- either a coincidental association
- or a mosaic form of neurofibromatosis type 1

Some authors have even proposed that agminated lentiginosis could represent a forme fruste or incomplete expression of NF1, supported by cases with Lisch nodules or familial transmission.

However, in the absence of neurofibromas, intertriginous freckling, Lisch nodules, or systemic involvement, the diagnosis of segmental lentiginosis is favored.

Histopathology typically shows features of lentigo simplex, including basal hyperpigmentation and increased melanocytes without nesting.

Given the age-dependent expression of NF1 features, long-term follow-up is recommended.

Segmental lentiginosis is a benign mosaic pigmentary disorder presenting as unilateral lentigines since childhood.

Its distinction from segmental neurofibromatosis remains challenging, especially in the presence of café-au-lait macules.

Careful clinical evaluation and long-term follow-up are essential, as some cases may represent incomplete or mosaic forms within the neurofibromatosis spectrum.

Key learning points:

- Segmental lentiginosis presents as unilateral lentigines respecting the midline
- It is considered a manifestation of cutaneous mosaicism
- Differential diagnosis with segmental neurofibromatosis is critical
- Presence of café-au-lait macules does not confirm NF1
- Long-term follow-up is recommended due to possible delayed manifestations



Figure 2: Regular reticular pattern with homogeneous light-to-dark brown pigmentation. UV dermoscopy revealing accentuation of pigmented macules without fluorescence, supporting an epidermal melanin distribution

EADV CONGRESS
VIENNA
30 SEP - 3 OCT 2026

**Abstract N°: 1011**

# A Deep Intronic Splicing Mutation in LAMB3 Causes Systemic Inflammation in Herlitz Junctional Epidermolysis Bullosa Amenable to Targeted Therapy

Yue Li[1], Hua Wang[1], Xiaoyan Luo*[2]

[1] Children's Hospital of Chongqing Medical University, Chongqing, China
[2] Shanghai Skin Disease Hospital, Shanghai, China

## Introduction

Junctional epidermolysis bullosa (JEB) is a severe hereditary skin disease with high mortality in its Herlitz subtype (JEB-H). Most JEB-H cases result from nonsense mutations in LAMB3 exons, while the role of non-coding variants remains elusive. Though systemic inflammation has been described in some subtypes of epidermolysis bullosa, the nature and underlying mechanisms of this inflammation in JEB-H are unknown.

## Materials and Methods

Phenotypic characterization of the patient was integrated with whole-genome sequencing data to delineate the genotype–phenotype correlation. Lesional skin samples were collected for histopathological analysis by hematoxylin and eosin staining and ultrastructural assessment via transmission electron microscopy. RNA from skin biopsies was subjected to RT-PCR followed by Sanger sequencing to validate aberrant splicing isoforms, while qRT-PCR was employed to quantify nonsense-mediated mRNA decay (NMD). Protein expression and localization of the LM332 β3 chain were assessed by Western blotting and immunofluorescence on paraffin-embedded sections. In light of systemic inflammatory manifestations, RNA sequencing of skin tissue combined with Western blotting was performed to characterize the inflammatory microenvironment. Additionally, flow cytometry was applied to analyze peripheral blood immune cell subsets and inflammatory cytokines with longitudinal monitoring.

## Results

Here, we report a JEB-H patient with typical cutaneous fragility and systemic inflammatory activation. She had recurrent and widespread blistering and erosions beginning in infancy, accompanied by delayed wound healing. Histopathological examination of the lesional skin revealed epidermal necrosis and subepidermal blister formation with hemorrhage, along with dense mixed acute and chronic inflammatory infiltrates in the superficial dermis. Transmission electron microscopy demonstrated disruption of the basement membrane zone (BMZ) structure, with cleavage confined to the lamina lucida. Whole-genome sequencing (WGS) identified compound heterozygous mutations of *LAMB3*, including a novel deep intronic variant (c.3382+244G>A) and a splicing variant (c.2701+6C>A). Functional assays confirmed that both variants affected aberrant pre-mRNA splicing, created premature termination codons (PTCs), and markedly decreased laminin-332 β3 protein levels by inducing nonsense-mediated mRNA decay. With more comprehensive immunological profiling, we discovered a systemic inflammatory state dominated by Th1 and Th17 cellular responses, along with hyperactivation of inflammatory pathways such as TNF-α/NF-κB and JAK-STAT signaling pathways. However, based on these molecular insights, targeted therapy with the TNF-α inhibitor was initiated, leading to substantial clinical improvement, including nearly complete resolution of erythema, reduction of erosions and scaling, and expedited wound healing. Peripheral Th1 responses remained low, and Th17 frequencies remained constant, with most circulating pro-inflammatory cytokines nearly normalized during the course of treatment. Importantly, the resolution of systemic inflammation was associated with significant catch-up growth. In contrast, treatment with the JAK1/2 inhibitor conferred only a transient benefit, subsequently leading to relapse associated with sustained NF-κB activation.

**Conclusions**

Our findings identify a mechanistic link between a deep intronic *LAMB3* mutation and a severe JEB-H phenotype characterized by systemic inflammation, define the TNF-α/NF-κB axis as a principal pathogenic driver and highlight the potential efficacy of targeted anti-cytokine therapy. Our study broadens JEB genetics, highlights WGS in identifying potential pathogenic non-coding variants, and presents a promising approach towards precision medicine for inflammatory complications associated with JEB-H.

EA DV CONGRESS
VIENNA
30 SEP - 3 OCT 2026

**Abstract N°: 1033**

## Characterization of Psoriasis Epigenetic Differentially Methylated Regions and Overlapping Genes Expression

Leticia Vidotti Storti*[1], Austin Coppinger[1], Gerard Nau[2], Carlos Wambier[1, 3]

[1] Department of Dermatology, Warren Alpert Medical School, Brown University, Providence, United States
[2] Division of Infectious Diseases, Department of Medicine, The Warren Alpert Medical School of Brown University, Providence, United States
[3] University of Miami Leonard M. Miller School of Medicine, Miami, United States

**Introduction**
Psoriasis is a chronic inflammatory skin disease that affects skin and joints, with systemic metabolic consequences. Epigenetic mechanisms, such as DNA methylation (DNAm), are increasingly recognized as contributors to disease pathogenesis. Previous studies have identified differentially methylated regions (DMRs) in treated psoriasis patients, along with changes in DNAm-related aging. This study aimed to identify DMRs and overlapping diferentially expressed genes (DEGs) in peripheral blood leukocytes from moderate-to-severe psoriasis patients not receiving systemic therapy.

**Materials and Methods**
Baseline peripheral blood samples were collected from 20 psoriasis patients and 10 age-matched healthy controls enrolled in a clinical trial (ClinicalTrials.gov/NCT05110313). Genomic DNA was extracted and profiled using the Infinium MethylationEPIC v2.0 BeadChip (935,000 CpG sites). Data were processed and analyzed in R Studio using the Bioconductor packages minfi and DMRcate. DMRs were defined by FDR<0.05 and p<0.01. Gene overlap and CpG region classifications were assessed using GRCh38 genome annotations. For gene expression analysis, RNA was sequenced (Illumina NextGen, 2x150 bp, 100M reads), and DEGs were identified with p<0.05.

**Results**
A total of 26 significant DMRs were found, overlapping 35 genes, including 19 promoter regions. Most DMRs were hypomethylated in psoriasis, except LINC01877 and LRCOL1. The strongest signal involved MCRIP1, with CpG shore and shelf hypomethylation. Among the DMR-overlapping genes, HYAL2 and SCO2 were also significant upregulated in psoriasis. Gene ontology analysis indicated enrichment in processes related to viral life cycle, vitamin D signaling, and lipid metabolism.

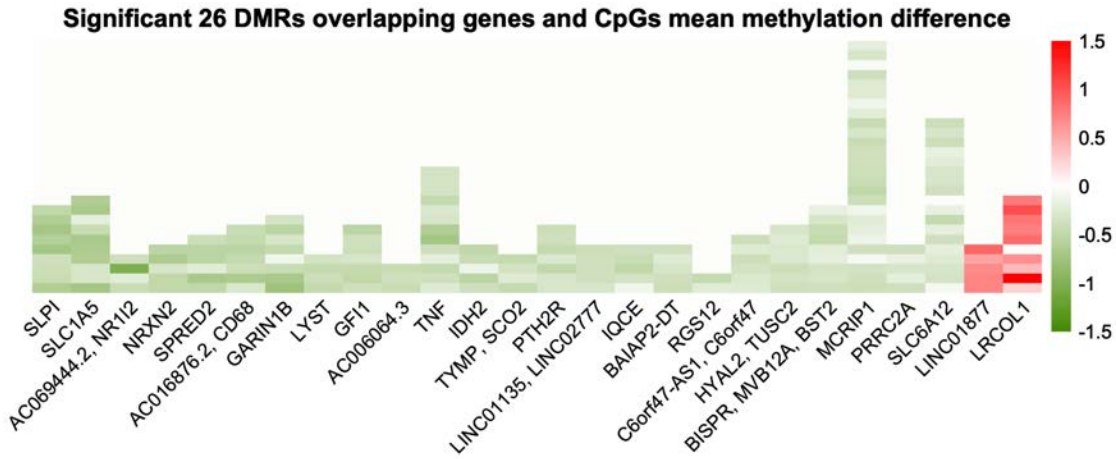


Figure 1. Heatmap of differentially methylated regions overlapping genes with more than three CpGs per DMR showing differences of methylation between psoriasis and controls. Each column represents each DMR with overlapping gene acronyms as labels, and each color block corresponds to an individually significant CpG, with the tallest column with 26 CpGs (MCRIP1). The red color indicates hypermethylation and green indicates hypomethylation (facility to transcribe).

**Conclusions**

Peripheral blood revealed distinct DNAm and gene expression patterns in untreated psoariasis patients. MCRIP1 emerged as a potential regulatory gene of interest. These findings support blood-based DNAm profiling as a non-invasive strategy for identifying epigenetic markers and therapeutic targets in psoriasis.

| *DMR* | *Smoothed FDR* | *Mean Difference* | *Chromosome* | *(Base Pair Range)* | *# CpGs* | *Type* | *Genes* | *DEG Log2Fold Change* | *DEG P value* |
|---|---|---|---|---|---|---|---|---|---|
| *1* | 2.36E-37 | -0.04 | **chr17** | (81821273–81822652) | 26 | shore; shelf | MCRIP1 | 0.01 | 0.820 |
| *2* | 6.07E-25 | -0.04 | **chr6** | (31575392–31575909) | 13 | inter | TNFp | 0.12 | 0.176 |
| *3* | 3.97E-19 | -0.05 | **chr19** | (46784521–46785658) | 8 | shore; shelf | SLC1A5p | 0.02 | 0.935 |
| *4* | 5.14E-19 | -0.07 | **chr20** | (45254349–45255105) | 7 | inter | SLPIp | 0.40 | 0.093 |
| *5* | 7.27E-19 | -0.07 | **chr1** | (92487084–92487722) | 7 | shore | GFI1p | 0.27 | 0.141 |

FDR: false discovery rate; p Overlapped Gene Promoter.

EADV CONGRESS
VIENNA
30 SEP - 3 OCT 2026

**Abstract N°: 1037**

# Dowling-Degos Disease Type 3 Associated With a Novel POGLUT1 Nonsense Variant: Clinicopathologic and Immunohistochemical Correlation

José González Fernández*[1], Paula Soto Revuelta[1], Karol Sabas Ortega[1], Lydia Corbalan Escortell[1], Javier Soro Miranda[1], José Asensio Gómez[1], Sonia De La Fuente[1], Lucía Prieto Torres[1], Victoria Lezcabo-Biosca[1], Ignacio Rivera Fuertes[1], Mar García-García[1], Andrea Montes-Torres[1], Mariano Ara Martín[1]

[1] Hospital Clínico Universitario Lozano Blesa, Zaragoza, Spain

## Introduction

Mutations in KRT5, POFUT1, POGLUT1, and PSENEN define four genetic subtypes of Dowling-Degos disease (DDD), with varied clinical and histologic expression including those previously reported as Galli-Galli disease. We report a case of DDD3 associated with a novel early nonsense variant in POGLUT1 (c.12G>A; p.Trp4*), representing, to our knowledge, the first documented case in Spain.

## Case Presentation

A 55-year-old man presented with recurrent pruritic erythematous scaly papules on the trunk and hyperkeratotic brown papules on the cervical and thoracic regions. Direct microscopic examination of scales from erythematous lesions revealed yeast cells and short hyphae compatible with Malassezia sp. Initial histopathologic evaluation of a pigmented papule was interpreted as simple lentigo. Subsequent biopsy demonstrated elongated rete ridges and focal suprabasal acantholysis without dyskeratosis, raising suspicion for DDD. Whole-exome sequencing identified a heterozygous nonsense variant in POGLUT1, confirming the diagnosis of DDD3.

## Conclusion

Previous studies have shown that diffuse cytokeratin 5 (CK5) expression throughout all epidermal layers may support the diagnosis of DDD3.

This case highlights diagnostic pitfalls related to subtle and focal acantholysis, emphasizes the importance of clinicopathologic correlation and serial sectioning.

EA DV CONGRESS
VIENNA
30 SEP - 3 OCT 2026

**Abstract N°: 1129**

# Sun Exposure-Dependent Skin Barrier Alterations in Xeroderma Pigmentosum Revealed by Electrical Impedance Spectroscopy

Nazmiye Selin Salici Akdemir*[1], Bengü Nisa Akay[2], Esra Adışen[3], Aysenur Botsali[4], Burhan Engin[5], Tugba Kevser Uzuncakmak[5], Savas Yayli[1], İrem Özdemir[3], Ahmet Ataş[6], Sena Tugana Ates[5], Funda Aktürk[7], Zeynep Topkarci[8], Tugba Atci[7], Ayse Deniz Yucelten[6], Can Baykal[7], Secil Saral[9]

[1] Koç University School of Medicine, Department of Dermatology and Venereology, Istanbul, Türkiye
[2] Ankara University Faculty of Medicine, Department of Dermatology and Venereology, Ankara, Türkiye
[3] Gazi University Faculty of Medicine, Department of Dermatology and Venereology, Ankara, Türkiye
[4] University of Health Sciences Faculty of Medicine, Gulhane Training and Research Hospital Department of Dermatology and Venereology, Ankara, Türkiye
[5] Istanbul University Cerrahpasa Faculty of Medicine, Department of Dermatology and Venereology, Istanbul, Türkiye
[6] Marmara University Faculty of Medicine, Department of Dermatology and Venereology, Istanbul, Türkiye
[7] Istanbul University Istanbul Faculty of Medicine, Department of Dermatology and Venereology, Istanbul, Türkiye
[8] Bakirkoy Dr. Sadi Konuk Training & Research Hospital, Istanbul, Türkiye
[9] Halic University Faculty of Medicine, Department of Dermatology and Venereology, Istanbul, Türkiye

## Introduction

Xeroderma pigmentosum (XP) is a rare genodermatosis characterized by defective repair of UV-induced DNA damage and a markedly increased risk of skin cancer. However, the biological consequences of chronic UV exposure in XP may extend beyond genomic instability, including impairment of skin barrier function. Electrical impedance spectroscopy (EIS) is a non-invasive technique that assesses tissue structure and barrier integrity across multiple frequencies.

This study aimed to compare EIS-derived barrier parameters in non-lesional XP skin across selected anatomical sites versus controls, with a particular focus on site-specific and UV exposure–related differences.

## Materials and Methods

This multicenter case–control study included 29 XP patients and 34 age- and sex-matched controls. EIS measurements were obtained from non-lesional skin at six anatomical sites, including sun-exposed areas (forehead, cheeks, nose), the forearm, and a non-exposed reference site (buttock). Non-lesional skin was defined as clinically normal-appearing skin without visible tumors, lentigines, actinic damage, or other XP-related lesions. Three repeated measurements per site were performed to enhance reliability. The primary parameters were Z1, MIX, and Max_Phase; Z1 mainly reflects superficial low-frequency epidermal impedance, whereas MIX and Max_Phase reflect relatively deeper frequency-dependent epidermal responses, with lower values indicating impaired barrier function. Linear mixed-effects models with subject-level random intercepts were used, including group, body site, and their interaction as fixed effects. Additional analyses were conducted based on UV exposure. Analyses were performed using R statistical software. Individuals with inflammatory dermatoses affecting skin barrier function, such as atopic dermatitis, were excluded.

**Results**

The XP cohort had a mean age of 28.7 ± 12.8 years, 58.6% were female, and the predominant subtype was Xeroderma pigmentosum C (48.3%); the median age at diagnosis was 9 years (IQR 6–19). In mixed-effects models adjusted for body site, XP patients exhibited significantly lower MIX (−0.62, 95% CI −0.93 to −0.31, p<0.01) and Max_Phase (−2.97, 95% CI −4.21 to −1.73, p<0.01) compared with controls, while Z1 was not different (p=0.40). However, these differences were strongly dependent on anatomical site. To evaluate whether differences varied by anatomical site, group × site interactions were fitted and significant for all parameters (p<0.01), with the largest reductions observed at sun-exposed facial sites (forehead, nose and cheeks) whereas no differences were detected at the buttock. Consistent with this, stratification by UV exposure revealed significant group × exposure interactions for MIX (p=0.02) and Max_Phase (p=0.01), but not for Z1 (p=0.26). In UV-exposed areas, XP patients showed marked reductions in both MIX and Max_Phase, while no differences were observed in non-exposed skin. To summarize regional variation within individuals, facial sites-to-buttock ratios were calculated, further supporting this pattern by demonstrating a greater relative impairment of exposed skin in XP compared with controls for both MIX and Max_Phase, whereas Z1 remained unchanged. Notably, within the XP group, EIS parameters were not associated with mutation subtype, treatment status, or prior skin cancer burden.

**Conclusions**

Non-lesional skin in XP demonstrates site-specific EIS alterations, predominantly in sun-exposed areas, supporting impaired barrier function in chronically UV-exposed skin, driven by reductions in MIX and Max_Phase, with differences across EIS parameters reflecting different skin depths. These findings provide functional support for the clinical concept of “xeroderma” and align with prior evidence linking cumulative UV damage to barrier disruption. Accordingly, approaches supporting skin barrier function may have a role in XP management.

EADV CONGRESS
VIENNA
30 SEP - 3 OCT 2026

**Abstract N°: 1219**

# Severe generalized Darier disease with leonine facies in a 35-year-old male: A 19-year untreated case report

Magda Gogilidze*[1], Ekaterine Beraia[1], Natia Khutsishvili[1], Lana Lomidze[1], Tatia Khatchapuridze[1]

[1] Kani Clinic, Tbilisi, Georgia

## Introduction

Darier disease (keratosis follicularis) is a rare autosomal dominant genodermatosis caused by mutations in the ATP2A2 gene, leading to impaired keratinization and acantholysis. It typically presents with keratotic papules in seborrheic areas; however, extensive and long-standing untreated cases with marked facial involvement are uncommon. We present a case of severe generalized Darier disease with leonine facies following a 19-year untreated course, aiming to highlight the diagnostic challenges and the clinical relevance of timely recognition and intervention.

## Case Presentation

A 35-year-old male with a positive family history presented with a 19-year history of progressive keratotic eruptions, first appearing at the age of 16 and never previously treated. The lesions involved the face, trunk, and extremities. Cutaneous examination revealed numerous hyperkeratotic yellowish-brown papules and confluent plaques, predominantly affecting seborrheic regions. Facial involvement was prominent, with thickened, coalescent plaques producing a leonine facies–like appearance. Dermoscopy demonstrated yellowish-brown structureless areas with adherent scales and crusts on an erythematous background.

Histopathological evaluation of a punch biopsy showed focal hyperkeratosis, suprabasal acantholysis with cleft formation, and dyskeratosis with corps ronds and grains. Routine laboratory investigations were unremarkable.

The constellation of clinical, dermoscopic, and histopathologic findings confirmed the diagnosis of Darier disease.

Differential diagnoses included seborrheic dermatitis, psoriasis, Hailey–Hailey disease, and pityriasis rubra pilaris, which were excluded based on the presence of suprabasal acantholysis and characteristic dyskeratosis.

Systemic treatment with oral acitretin (initiated at 25 mg/day and increased to 50 mg/day), in combination with topical betamethasone dipropionate and salicylic acid, resulted in significant clinical improvement, with reduction in hyperkeratosis and inflammation during follow-up.

## Conclusion

This case underscores that Darier disease may remain untreated for decades following adolescent onset, reflecting potential gaps in early recognition. The presence of leonine facies represents an uncommon and potentially misleading manifestation that may mimic other infiltrative or inflammatory dermatoses. Our findings highlight the utility of dermoscopy as a supportive non-invasive diagnostic tool and demonstrate that systemic retinoid therapy can achieve meaningful clinical improvement even in long-standing disease. Early diagnosis remains essential to prevent disease progression and reduce morbidity.

EA DV CONGRESS
VIENNA
30 SEP - 3 OCT 2026

**Abstract N°: 1257**

# SMARCAD1 splice-site duplication in Huriez syndrome with marked intrafamilial heterogeneity and high cutaneous squamous cell carcinoma burden

Brent Doolan*[1], Michelle Lee[1], Yiming Wang[2], Andrea Shugar[2], Irene Lara-Corrales[1], Elena Pope[1]

[1] The Hospital for Sick Children, Division of Dermatology, Toronto, Canada

[2] Division of Clinical and Metabolic Genetics, The Hospital for Sick Children,, Toronto, Canada

## Introduction

Huriez syndrome is a rare autosomal dominant genodermatosis characterised by congenital palmoplantar keratoderma, scleroatrophy, adermatoglyphia and a marked predisposition to aggressive acral cutaneous squamous cell carcinoma. Pathogenic variants cluster at the splice donor site of the skin-specific *SMARCAD1* isoform, resulting in haploinsufficiency. Despite this well-defined genetic locus, significant variability in clinical severity is observed, and genotype–phenotype correlations remain poorly understood.

## Case Presentation

A 7-year-old boy presented with early-onset diffuse palmoplantar keratoderma, adermatoglyphia, hypohidrosis, hypoplastic nails and progressive sclerodermoid thickening of the digits, resulting in pain and functional impairment. The clinical constellation, combined with a striking family history of acral cutaneous squamous cell carcinoma, raised suspicion for Huriez syndrome. Across four generations, affected relatives demonstrated marked phenotypic variability, ranging from mild keratoderma to severe disease complicated by multiple aggressive cutaneous squamous cell carcinomas requiring digital amputations in early adulthood. Trio whole-exome sequencing identified a heterozygous splice-site duplication in *SMARCAD1* (NM_001254949.1:c.-10+2dupT), affecting the canonical donor site of the skin-specific isoform. The variant segregated with disease and is absent from population databases, consistent with pathogenicity. This duplication affects a recognised mutational hotspot but differs structurally from previously reported deletions. We propose that partial preservation of splice-site function may permit “leaky” splicing, resulting in variable transcript output and providing a mechanistic explanation for the striking intrafamilial heterogeneity observed.

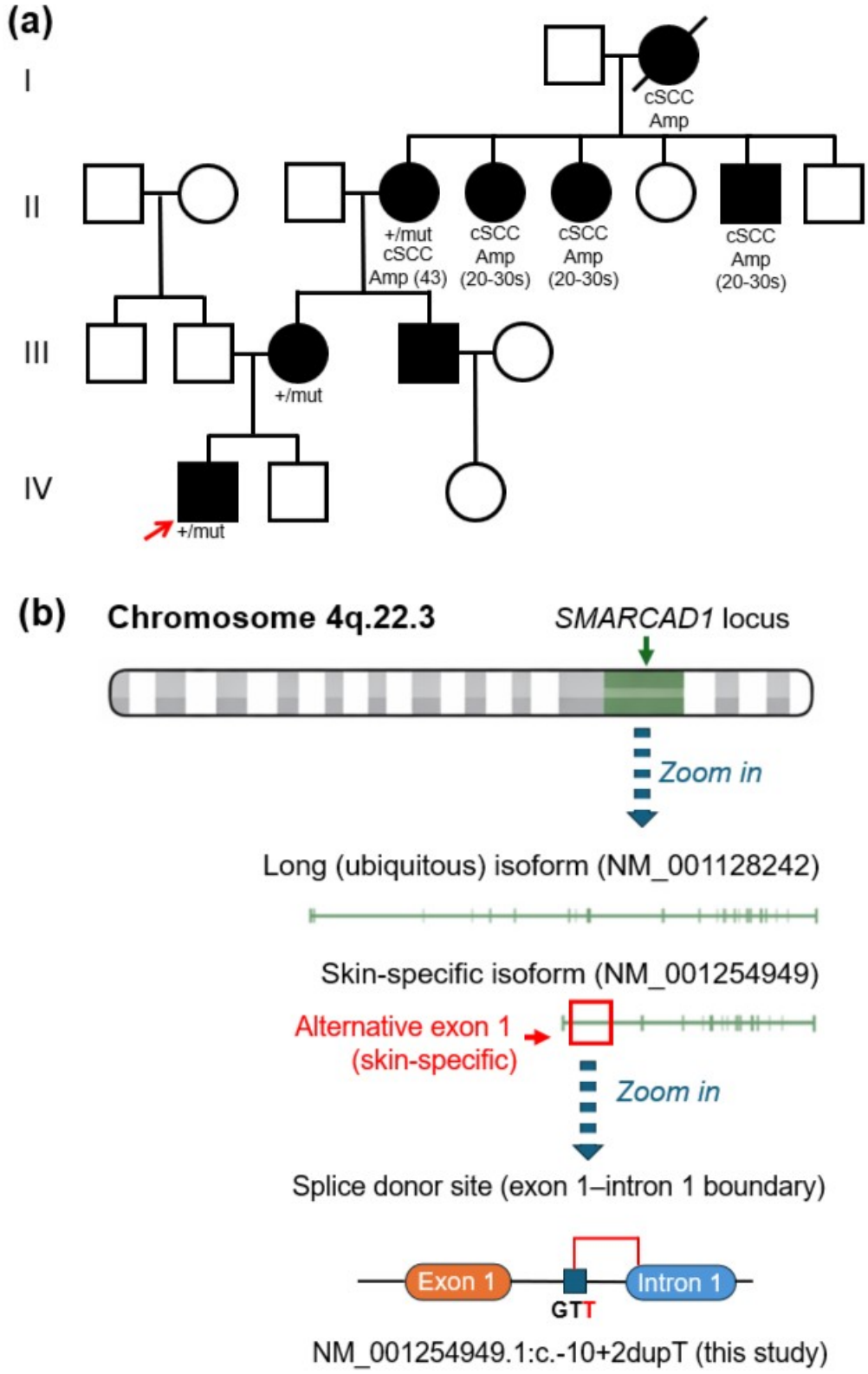


Figure 1: Multigenerational pedigree and SMARCAD1 splice-site variant in Huriez syndrome. (a) Family pedigree demonstrating autosomal dominant inheritance across four generations. Filled symbols indicate affected individuals. Multiple relatives developed acral cutaneous squamous cell carcinoma (cSCC), with several requiring amputations (Amp). The proband is indicated by a red arrow. Information given by mother of proband. (b) Schematic representation of the SMARCAD1 locus on chromosome 4q22.3, illustrating the long (ubiquitous) isoform (NM_001128242) and the alternative promoter giving rise to the skin-specific isoform (NM_001254949). The alternative exon 1 of the skin-specific transcript is highlighted. A zoomed view of the exon 1–intron 1 boundary demonstrates the canonical splice donor site and the location of the identified variant, NM_001254949.1:c.-10+2dupT, affecting the donor site and predicted to disrupt normal splice-site recognition.

**Conclusion**

This case highlights a structural mechanism at a known *SMARCAD1* splice-site hotspot and demonstrates that a single variant can drive extreme phenotypic variability within families. The substantial burden of early, aggressive cutaneous squamous cell carcinoma underscores the importance of early molecular diagnosis to enable targeted surveillance and cascade testing. Recognition of this phenotype is critical for dermatologists, as timely diagnosis may alter oncological outcomes.

EADV CONGRESS
VIENNA
30 SEP - 3 OCT 2026

**Abstract N°: 1297**

# From nodules to genes: whole exome sequencing reveals LZTR1-associated schwannomatosis in a child before the onset of neurological symptoms

Martyna Duda*[1], Michał Dec[1], Lilianna Leśniak-Jakubiec[1], Małgorzata Kowacka[1], Hubert Arasiewicz[1]

[1] Clinical Department of Pediatric Dermatology and Vascular Anomalies, Faculty of Medical Sciences in Katowice, Medical University of Silesia, John Paul II Children's and Family Health Center, Sosnowiec, Poland, Sosnowiec, Poland

## Introduction

Schwannomatosis is a rare tumour predisposition syndrome that typically presents in adulthood with neuropathic pain. Diagnosis in childhood is uncommon and may be delayed, particularly in the absence of neurological symptoms. In some patients, the disease may initially present with non-specific subcutaneous nodules, creating a diagnostic challenge in dermatological practice. Conventional diagnostic approaches, including imaging and histopathology, may be inconclusive in such cases, and genetic testing can be helpful in establishing the diagnosis.

## Case Presentation

A 5-year-old girl was referred for evaluation of multiple asymptomatic subcutaneous nodules initially confined to the axillary regions, with subsequent development of a lesion in the temporal area. The nodules were firm, mobile and arranged linearly, with normal overlying skin. No features suggestive of a neurocutaneous syndrome were observed. The patient had no pain or neurological symptoms, and her medical and family history was unremarkable.

Ultrasonography demonstrated well-defined hypoechoic subcutaneous nodules without detectable vascular flow. Histopathological examination of an excised lesion showed non-specific findings and did not establish a diagnosis. As the lesions persisted and conventional investigations remained inconclusive, whole exome sequencing (WES) was performed. This identified a pathogenic variant in the LZTR1 gene, confirming LZTR1-associated schwannomatosis. The diagnosis was established before the onset of neurological symptoms.

## Conclusion

This case highlights an atypical presentation of schwannomatosis in early childhood, limited to subcutaneous nodules in the absence of neurological symptoms. It also illustrates the limitations of conventional diagnostic approaches in patients with non-specific findings. In such cases, WES can play a key role in establishing the diagnosis and shortening the diagnostic process. Early identification is clinically important, as it enables appropriate surveillance, genetic counselling and avoidance of unnecessary or potentially harmful interventions.

EA DV CONGRESS
VIENNA
30 SEP - 3 OCT 2026

**Abstract N°: 1300**

# Global Molecular Epidemiology and Genotype-Phenotype Correlations in Keratinocytic Epidermal Nevus: A Systematic Review

Fang Zhang*[1], Sheng Wang[1]

[1] Department of Dermatology，West China Hospital，Sichuan University, Chengdu, China

## Introduction

Keratinocytic epidermal nevus (KEN) represents a heterogeneous group of mosaic skin disorders driven on diverse causative genes that converge on major pathways including the RAS/MAPK pathway, the PI3K/AKT pathway, and keratin structural integrity, among others, resulting in variable clinical presentations. This systematic review aims to delineate the global molecular epidemiological landscape of KEN, elucidate multi-layered genotype-phenotype correlations involving histopathological subtypes, lesion distribution, and systemic involvement, and establish a stratified framework for molecular diagnosis and targeted therapy.

## Materials and Methods

A systematic literature review was conducted in PubMed spanning January 1945 to 2025 to identify clinical cases of KEN with genetic testing data. The search strategy employed MeSH terms and keywords encompassing "keratinocytic epidermal nevus" and its related terms, as well as all established causative genes. No restrictions were imposed on language, publication date, patient age, ethnicity, or photographic documentation. Two independent reviewers conducted study selection, data extraction, and risk-of-bias assessment. Extracted data included demographics, clinical characteristics, and genetic testing data. Genotype-phenotype associations were analyzed with stratification on histopathological subtype (Figure 1), lesion distribution pattern, and systemic involvement.

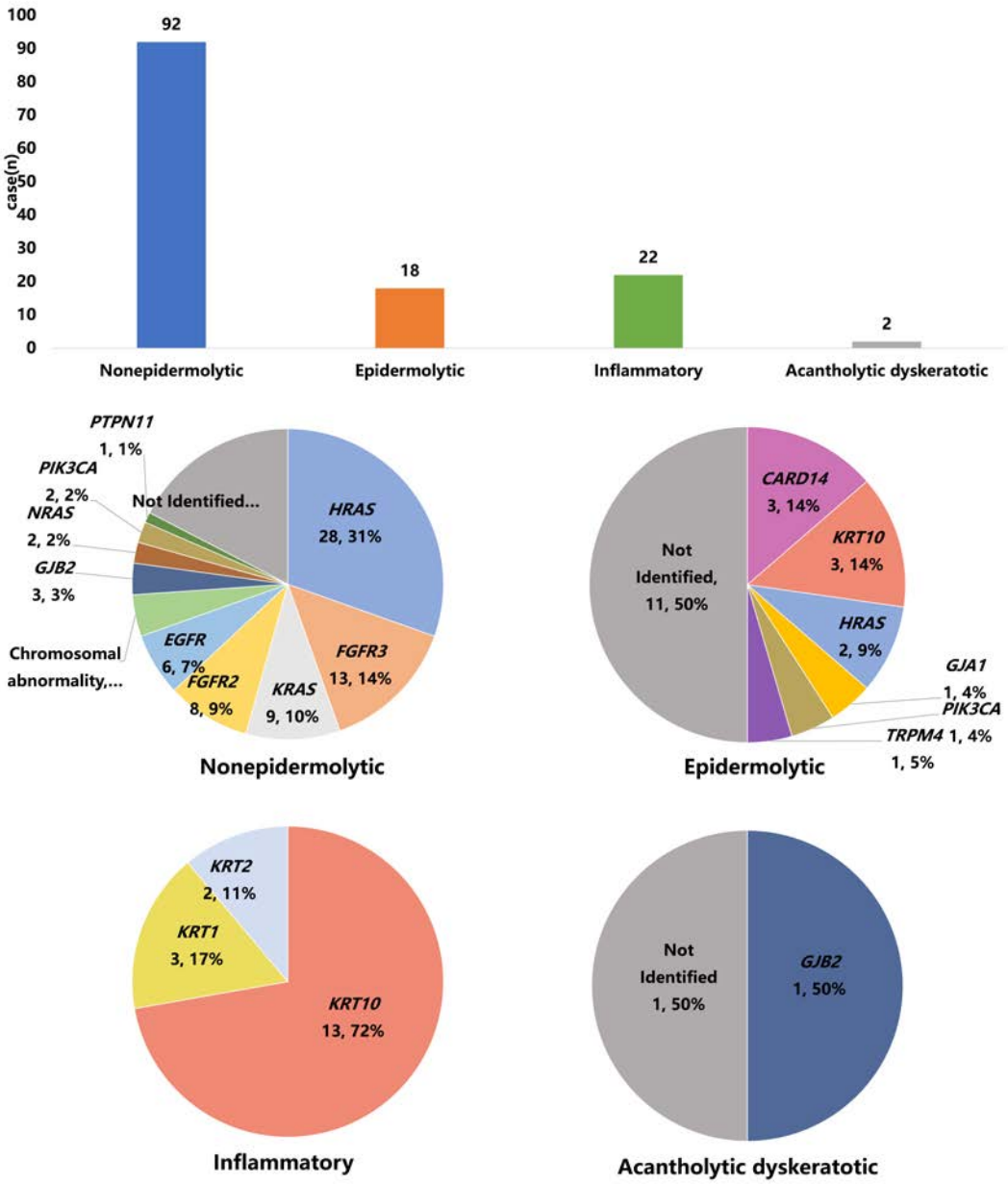


Genotype-phenotype correlations on histopathological subtype in KEN.

**Results**

A total of 72 articles comprising 134 patients were included. The cohort exhibited a balanced sex distribution, with 54.5% presenting generalized lesions and 36.6% localized disease, and a right-sided predominance of 33.6% compared to 17.9% on the left (Figure 2). Pathogenic mutations were detected in 79.1% of cases, with *HRAS* (n=30, 22.4%), *KRT10* (n=16, 11.9%), *FGFR3* (n=13, 9.7%), *KRAS* (n=9, 6.7%), and *FGFR2* (n=8, 6.0%) being the most frequently mutated genes. Genotype-phenotype analysis revealed that non-epidermolytic KEN was the predominant histopathological subtype (68.7%, n=92). Notably, epidermolytic KEN (n=18) exclusively harbored keratin gene mutations (*KRT1, KRT2, KRT10*), whereas inflammatory linear verrucous epidermal nevus (n=22) displayed heterogeneous genetic alterations. Mutation detection rates were significantly higher in lesional skin compared to peripheral blood (77.7% vs. 26.8%, P<0.001). Furthermore, among lesional skin samples, patients with systemic involvement showed higher detection rates than those with isolated KEN (90.9% vs. 72.2%, P=0.029). Extracutaneous manifestations occurred in 29.9% of patients (n=40), primarily associated with *HRAS*, *KRAS*, and *FGFR3* mutations. Intergenerational transmission was documented primarily in *KRT1*/*KRT10* mutation carriers, with rare cases involving *GJB2* or *HRAS*. A total of 32 patients from 17 studies received targeted therapies: ILVEN predominated and was treated with IL-17/IL-23 or TNF-α biologics, while other subtypes received MEK, mTOR, FGFR, or EGFR inhibitors matched to their genetic alterations.

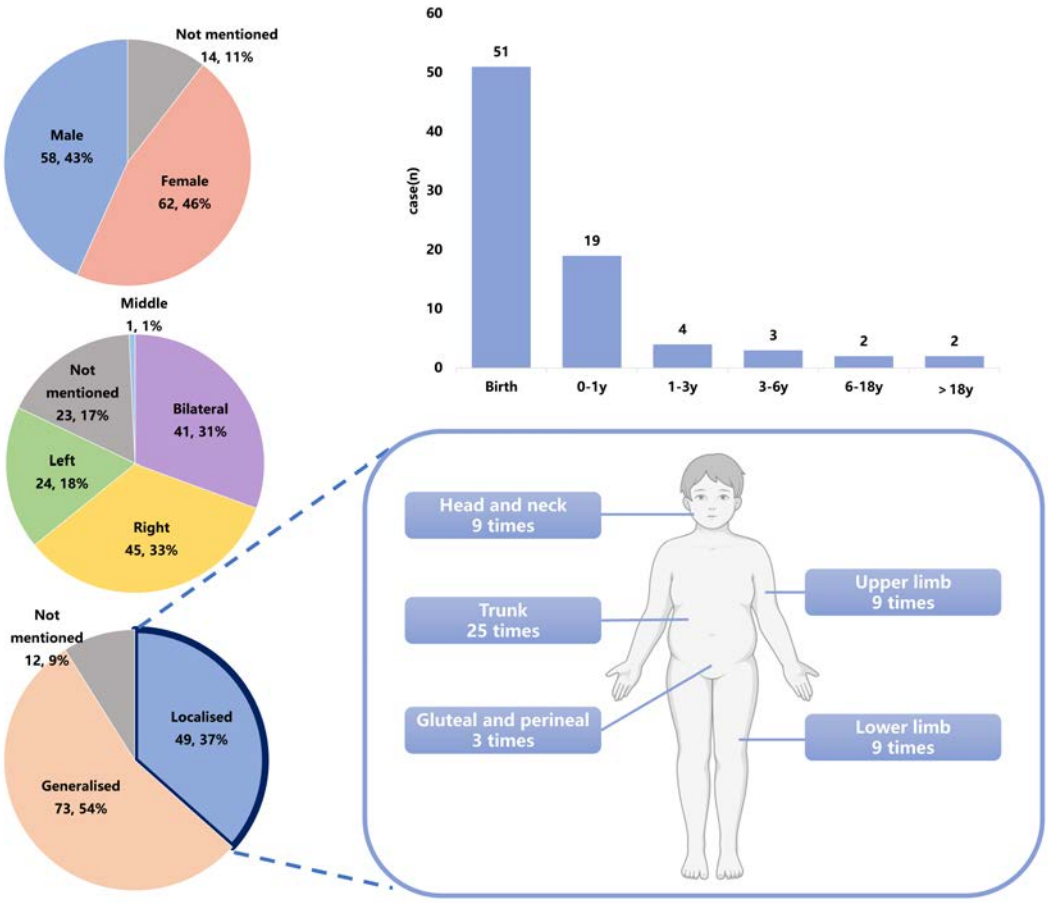


Demographic and clinical characteristics of 134 KEN patients.

**Conclusions**

This systematic review establishes the first comprehensive global molecular epidemiological landscape of KEN, delineating genotype-phenotype correlations across histopathological subtypes, lesion distribution, and systemic involvement. Our findings support a tiered molecular diagnostic approach prioritizing high-depth targeted panel sequencing of lesional tissue across all known causative genes, and identify mechanism-driven therapeutic targets amenable to pathway-specific inhibition (Figure 3). The recognition of germline mosaicism-mediated transmission, predominantly involving *KRT1* and *KRT10* mutations, underscores the necessity of systematic genetic counseling for reproductive-age patients. Future research should prioritize the standardization of high-depth targeted sequencing panels, elucidate the genetic basis of mutation-negative cases, and validate genotype-directed targeted therapies through prospective multicenter studies.

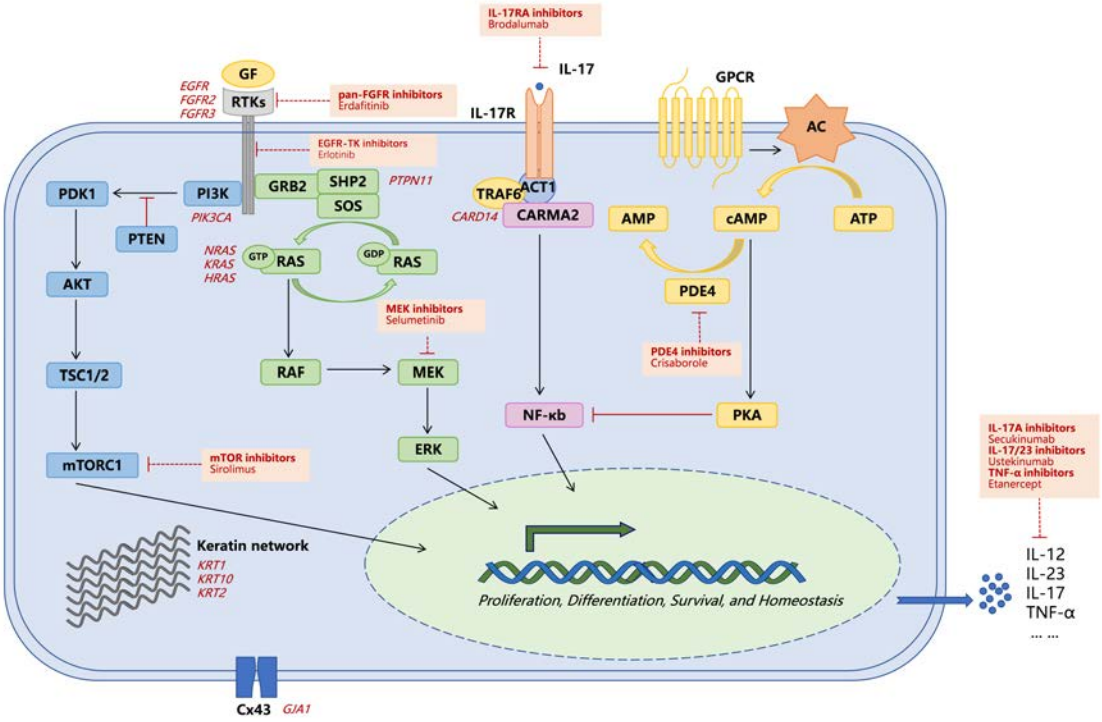


Molecular signaling pathways and mechanism-based therapeutic targets in KEN.

EA DV CONGRESS
VIENNA
30 SEP - 3 OCT 2026

**Abstract N°: 1344**

# Integrated Clinical, Genetic, and Imaging Analysis of Aggressive Multifocal Cutaneous Squamous Cell Carcinoma Associated with a Germline COL6A3 Truncating Variant

Bogdan Florea*[1], Stefan Cristian Vesa[2], Mircea Negrutiu[3], Diana Miclea[4], Mircea Razvan Bucur[5], Adrian Baican[3], Monica Focsan[6], Sorina Danescu[3]

[1] Clinical Hospital of Infectious Diseases, Cluj-Napoca, Romania
[2] Department of Functional Sciences, Discipline of Pharmacology, Toxicology and Clinical Pharmacology, Faculty of Medicine, "Iuliu Haţieganu" University of Medicine and Pharmacy, Cluj-Napoca, Romania
[3] Department of Dermatology, "Iuliu Hatieganu" University of Medicine and Pharmacy, Cluj-Napoca, Romania
[4] Mother and Child Department, "Iuliu Haţieganu" University of Medicine and Pharmacy, Medical Genetics Department, Clinical Emergency Hospital for Children, Cluj-Napoca, Romania
[5] Sanconfind Hospital, Poiana Câmpina, Romania
[6] Nanobiophotonics and Laser Microspectroscopy Center, Interdisciplinary Research Institute on Bio-Nano-Sciences, Babes-Bolyai University, Cluj-Napoca, Romania

**Introduction**

Cutaneous squamous cell carcinoma (cSCC) is commonly regarded as a sporadic malignancy primarily driven by ultraviolet exposure. However, the occurrence of multiple, aggressive tumors at a relatively young age suggests the presence of underlying genetic susceptibility. The role of germline variants affecting extracellular matrix organization, pigmentation pathways, and tumor metabolism in aggressive cSCC remains incompletely understood.

**Case Presentation**

We describe a 53-year-old patient with a long-standing history of multiple aggressive cutaneous squamous cell carcinomas involving the scalp and facial regions, characterized by recurrent and multifocal disease. A comprehensive diagnostic approach was undertaken, including histopathological examination, fluorescence confocal microscopy, high-frequency cutaneous ultrasound, and genetic analysis using whole exome sequencing (WES).

Histopathology confirmed high-risk features consistent with aggressive cSCC. Cutaneous ultrasound and fluorescence confocal microscopy provided complementary, non-invasive insights into tumor depth, architecture, and invasive patterns. Whole exome sequencing identified a heterozygous truncating variant in COL6A3 (NM_004369.4:c.5645C>A, p.Ser1882Ter), classified as likely pathogenic according to ACMG criteria. Additionally, two heterozygous variants of uncertain significance were detected in TYR (NM_000372.5:c.1569C>A, p.Ser523Arg) and FH (NM_000143.4:c.1237-5_1237-4insTCTCCCTCCCTC).

Although individually inconclusive, the combined germline genetic background may have contributed to the patient’s aggressive and multifocal cutaneous phenotype. A focused review of the literature supports a potential role of extracellular matrix remodeling, pigmentation-related susceptibility, and metabolic dysregulation in cutaneous carcinogenesis and tumor aggressiveness. This case illustrates how integrating WES with advanced non-invasive imaging techniques can enhance the understanding of biologically aggressive cSCC.

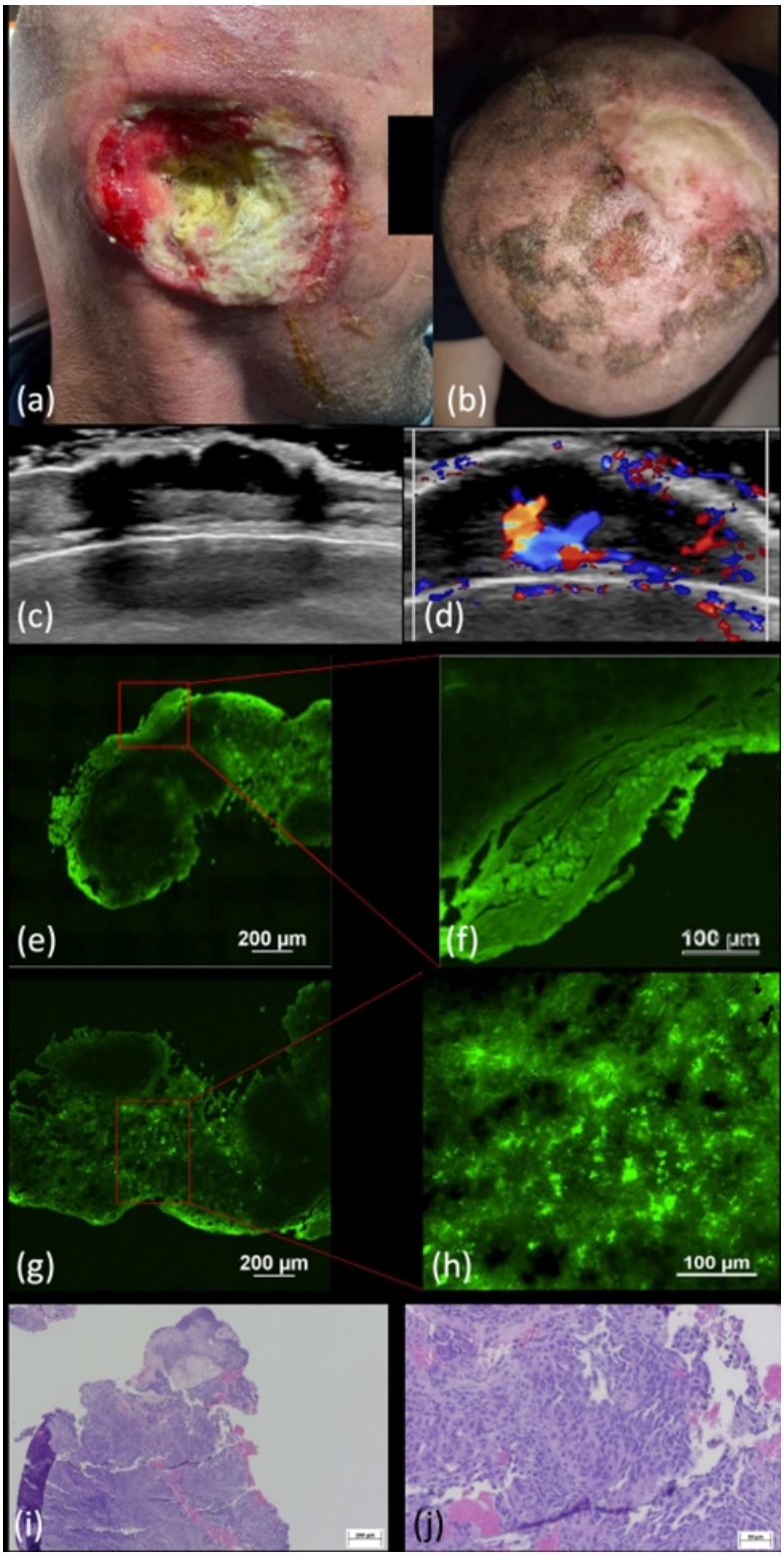


(a) The clinical picture shows a right temporoauricular ulceration, covered with fibrinous deposits and exhibiting exudation, with absence of the right auricular pavilion. (b) Multiple ulcerated tumors covered with yellowish crusts, on the scalp, a whitish, depressed area corresponding to a prior surgical excision of a tumor. (c) HFUS (20 MHz) reveals a poorly defined hypoechoic lesion with irregular contours and heterogeneous echogenicity, extending through the epidermis and dermis, associated with posterior acoustic shadowing. (d) Color Doppler mode shows a marked increase in local vascularization. (e), (f), (g) (h) Ex vivo fluorescence confocal microscopy reveals a tumor characterized by hyperkeratosis and parakeratosis of the stratum corneum, accompanied by marked architectural disorganization. Numerous plump, highly reflective (bright) and speckled cells are observed within the epidermis. (i) (j) The histopathological exam shows epidermis with marked hyperparakeratosis, associated with the formation of a neutrophilic abscess at this level, as well as moderate cytonuclear atypia of keratinocytes throughout the full thickness of the epidermis. The underlying dermis shows a moderately dense, diffusely distributed round-cell inflammatory infiltrate and focal hemorrhagic

extravasation.

**Conclusion**

This report highlights a unique case of multifocal aggressive cSCC characterized by a distinct germline genetic profile identified by WES and multimodal imaging assessment. Comprehensive molecular and imaging evaluation may be beneficial in selected patients with atypical or aggressive cutaneous squamous cell carcinoma, with implications for personalized surveillance and management.

EADV CONGRESS
VIENNA
30 SEP - 3 OCT 2026

**Abstract N°: 1352**

# Subtype-specific Inflammatory Signatures in Epidermolysis Bullosa reveal inflammation-associated endotypes: A Cross-Sectional Cytokine Profiling Study

Meropi Karakioulaki*[1], Theodora Sarantopoulou[2], Rui Zhang[1], Eleni Papakonstantinou[2], Daiana Stolz[2], Kilian Eyerich[1], Cristina Has[1]

[1] Department of Dermatology and Venereology, Faculty of Medicine and Medical Center, University Hospital Freiburg, Germany, Freiburg, Germany
[2] Department of Pneumology, Faculty of Medicine and Medical Center, University Hospital Freiburg, Germany, Freiburg, Germany

## Introduction

Epidermolysis bullosa (EB) is a rare group of inherited skin disorders characterized by mechanical fragility of the skin and mucosa, leading to chronic blistering, impaired wound healing, and progressive tissue damage. Beyond structural defects, inflammation is increasingly recognized as a key driver of disease severity. However, inflammation-associated disease endotypes remain insufficiently characterized. This study aims to elucidate subtype-specific inflammatory signatures across EB and explore their association with disease severity.

## Materials and Methods

Cytokine levels, including TNF-α, IL-1β, IL-13, IL-17A, IL-22, IL-31, and TGF-β3, were quantified in serum of 49 EB patients using a multiplex immunoassay (Meso Scale Discovery Assay).

## Results

TNF-α levels were significantly elevated in dominant and recessive dystrophic EB (DDEB and RDEB) compared to EB simplex (EBS) and junctional EB (JEB) (p=0.016). Severe RDEB patients demonstrated the highest TNF-α levels, whereas JEB patients the lowest, indicating a type I inflammation-associated endotype.

IL-31 levels were increased in RDEB (intermediate and severe) compared to other subtypes (p=0.045) with intermediate RDEB showing the highest IL-31 levels, while EBS the lowest, reflecting a Type II/III inflammation-associated endotype in intermediate RDED.

TGF-β3 levels, reflecting a type IV inflammation-endotype, were higher in DEB and EBS compared to JEB (p=0.015). EBS demonstrated the highest TGF-β3 levels, while JEB had the lowest.

Th17-associated inflammation was markedly elevated in RDEB, particularly in severe cases. IL-22 levels were significantly higher in severe versus intermediate RDEB (p=0.004) and in severe RDEB compared to all other EB subtypes (p=0.031). DDEB showed the lowest IL-22 levels. Similarly, IL-17A levels were higher in DEB compared to EBS and JEB (p=0.028), with the highest levels observed in RDEB, particularly severe RDEB, and the lowest in JEB.

Inflammatory cytokines, including IL-1β, IL-13, IL-17A, TNF-α, IL-22, and IL-31, showed significant positive correlations with wound body surface area. IL-13 was additionally significantly positively correlated with circulating autoantibodies (anti-BP180, anti-BP230, and anti-collagen VII). Furthermore, IL-22, TNF-α, and IL-17A were significantly higher in severe compared to intermediate EB.

**Conclusions**

This study demonstrates distinct, inflammation-associated endotypes across EB subtypes. DEB (DDEB and RDEB) is characterized by elevated TNF-α and IL-17A, reflecting a strong pro-inflammatory and Th17-driven profile. RDEB, particularly severe forms, shows the highest levels of TNF-α, IL-17A, IL-22, consistent with combined type I inflammation and Th17 activation. Intermediate RDEB is characterized by elevated IL-31, suggesting a type II/III, pruritus-associated immune activity. In contrast, EBS shows relatively lower pro-inflammatory cytokine levels and higher TGF-β3, indicating a more regenerative, scarless wound-healing and tissue-remodeling–associated profile. JEB consistently exhibits the lowest levels of most inflammatory markers, suggesting a comparatively attenuated systemic inflammatory response. The strong association between key cytokines (TNF-α, IL-17A, IL-22, and IL-31) and both disease severity and wound burden underscores their relevance as biomarkers and potential therapeutic targets.

These findings support the rationale for targeted anti-inflammatory therapies in EB, particularly modulation of TNF-α and the Th17 axis. In addition, IL-31 represents a potential target for anti-pruritic and anti-inflammatory strategies, while elevated TGF-β3 suggests a possible role for antifibrotic interventions. Overall, these results highlight the importance of personalized, cytokine-driven therapeutic approaches in EB.

EA DV CONGRESS
VIENNA
30 SEP - 3 OCT 2026

**Abstract N°: 1368**

# Familial Linear Steatocystoma Multiplex: A Multigenerational Case Report

Barbara Messias Pereira*[1], Bianca Miyazawa[1], Cássio Moreira[1], Joao Marcos de Souza[1], Milene Cripa Pizzato de Araújo[1], Rogerio Kondo[1]

[1] State University of Londrina, Londrina, Brazil

## Introduction

Steatocystoma multiplex (SM) is an uncommon dermatosis characterized by multiple benign dermal cysts filled with sebum, originating from sebaceous glands. The linear variant is extremely rare, with few cases described in the literature, in which cysts are arranged in a linear pattern, potentially following the lines of Blaschko.[1]

## Case Presentation

A 36-year-old female patient presented with normochromic papulonodular lesions distributed linearly, predominantly affecting the upper limbs and bilateral axillary regions, with an approximate 15-year history. She reported recurrent episodes of spontaneous drainage of secretion, as well as a positive family history of similar lesions affecting her father and two daughters, aged 10 and 15 years.

Dermatological examination revealed multiple normochromic, mobile, superficial, well-defined nodules measuring between 0.5 and 1.0 cm in diameter, located in the axillae, arms, medial thighs, bilateral inguinal regions, and trunk.

An excisional biopsy of one lesion was performed. During the procedure, encapsulated cystic structures containing thick yellowish material were observed. Histopathological examination confirmed the diagnosis of steatocystoma.

Considering the positive family history and clinical evaluation of affected relatives, a diagnosis of familial linear steatocystoma multiplex was established.

## Conclusion

DISCUSSION:

Steatocystoma multiplex is a hamartomatous condition derived from the pilosebaceous junction1,2 It typically manifests during adolescence, and may affect both sexes. Lesions most commonly involve the trunk, neck, proximal upper limbs, axillae, and thighs. 2,3

The development of steatocystomas involves mutations in the KRT17 gene, which alter the structure of keratin 17 and the functional cytoskeletal network, rendering cells of the pilosebaceous duct fragile and abnormal.1 This dysfunction of the ductal junction leads to sebum retention and abnormal proliferation of the ductal epithelium, forming dermal cysts lined by stratified squamous epithelium with a characteristic eosinophilic cuticle and flattened sebaceous lobules in the cyst wall.1,2

The linear distribution of steatocystomas represents the rarest presentation of this variant, and its pathophysiological interpretation requires an understanding of cutaneous mosaicism and Blaschko's lines.3,4 Type 1 segmental mosaicism results from a postzygotic mutation in a previously normal embryo. The individual is

heterozygous only in the mutant cell clone, which is distributed along Blaschko's lines, with no family history and disease limited to the affected segment, as described by Park et al. in a 5-year-old girl with congenital linear lesions on the nose (3,4). In type 2 segmental mosaicism, a second somatic mutation occurs in an embryo already heterozygous for a germline KRT17 mutation inherited from one parent, resulting in loss of heterozygosity and more pronounced expression in that region, as observed in the present case.4

Diagnosis may be supported by ultrasonography, which typically shows well-defined hypoechoic nodules with posterior acoustic enhancement and no calcifications (2). Histopathological evaluation and genetic testing can confirm the diagnosis and its molecular basis, especially in familial cases.1 Treatment remains challenging, with no universally effective modality.5 Available options include surgical excision, $CO_2$ laser therapy, cryotherapy, oral isotretinoin, and patient education regarding the benign nature of the condition.5

CONCLUSION:

Familial linear steatocystoma multiplex is a rare variant with atypical presentation and hereditary pattern. Clinicopathological and genetic correlation, along with understanding mosaicism, explains its distribution. Early recognition supports genetic counseling and individualized management, despite limited definitive treatment options.

EADV CONGRESS
VIENNA
30 SEP - 3 OCT 2026

**Abstract N°: 1372**

# A novel extraintestinal manifestation of BMPR1A-related juvenile polyposis syndrome: cutaneous arteriovenous malformation

Samuel Morriss*[1], Ingrid Winship[1]

[1] The Royal Melbourne Hospital, Parkville, Australia

## Introduction

Juvenile polyposis syndrome (JPS) is a rare autosomal dominant disorder characterised by multiple hamartomatous gastrointestinal polyps that predispose patients to an increased risk of gastric and colorectal cancers. JPS is caused by pathogenic variants in either *SMAD4* or *BMPR1A* genes, which both play a role in the transforming growth factor-β (TGF-β) signaling pathway. While SMAD4-related JPS is known to be associated with extraintestinal vascular anomalies, in particular the juvenile polyposis/hereditary haemorrhagic telangiectasia (JP-HHT) overlap phenotype in approximately 20% of affected individuals, vascular malformations have not previously been reported in association with BMPR1A-related JPS. The phenotypic expression of *BMPR1A* variants has traditionally been considered limited to gastrointestinal manifestations and malignancy risk. We present the case of a cutaneous arteriovenous malformation (AVM) in a patient with BMPR1A-related JPS, highlighting a novel extraintestinal manifestation.

## Case Presentation

A 17-year-old female presented with a history of a cutaneous AVM located at the nasal tip/columella junction. The lesion, appearing clinically as a well-defined erythematous nodule with overlying papules, was first noticed at six months of age. Over time it gradually enlarged, caused mild discomfort, and bled with minor trauma. The patient had no other cutaneous lesions and denied respiratory symptoms or recurrent epistaxis. An initial ultrasound of the nasal tip revealed a highly vascular 4x2x4 mm lesion composed of multiple closely packed vessels with flow velocities up to 43 cm/s, consistent with a high-flow AVM. The lesion was excised at 13 years of age, and histopathology confirmed an AVM with variably sized thin- and thick-walled ectatic vessels. Post-operative ultrasounds demonstrated no evidence of recurrence and a saline contrast echocardiogram showed no evidence of an intrapulmonary AVM.

There was no other known family history of AVMs. The patient did not meet the Curaçao criteria for a diagnosis of HHT. Due to her father's history of JPS and a familial *BMPR1A* variant which was present across three generations in the family in an autosomal dominant pattern, the patient at age 17 underwent predictive testing for this familial variant which identified a heterozygous pathogenic deletion of exon 3 in *BMPR1A* [g.(?88,635,775)_(88,635,843_88,649,818)del] involving the translation initiation codon. Although she was asymptomatic at the time of genetic diagnosis, a subsequent screening colonoscopy revealed 27 colonic polyps. Histopathology confirmed these as juvenile polyps, establishing the clinical phenotype of JPS.

## Conclusion

This case represents a novel case of a cutaneous AVM in a patient withBMPR1A-related JPS, expanding the recognised clinical spectrum of this genetic variant. Given the close functional interplay of BMPR1A and SMAD4 proteins within the TGF-β pathway, it is plausible that *BMPR1A* disruption could also contribute to vascular anomalies much like the recognised JP-HHT overlap seen in *SMAD4* mutations. This case suggests that vascular malformations may be an underappreciated extraintestinal feature of BMPR1A-related JPS. Recognition of these

cutaneous manifestations is important for dermatologists and geneticists, as it may prompt earlier genetic screening and have broader implications for multidisciplinary surveillance and management of affected individuals.

EADV CONGRESS
VIENNA
30 SEP - 3 OCT 2026

**Abstract N°: 1392**

# Comparative efficacy of topical pirfenidone versus sirolimus in facial cutaneous neurofibromas: a split-face clinical case study

Divya Madonna Dsouza*[1], Sucheta Chikodi[1]

[1] Father Muller Medical College Hospital, Mangalore, India

**Introduction**
Cutaneous neurofibromas (cNFs) in Neurofibromatosis Type 1 (NF1) represent a critical unmet therapeutic need, often leading to profound cosmetic disfigurement and psychological distress. While surgical and laser interventions exist, reliable topical therapies are limited. This study compares the efficacy and tolerability of topical sirolimus (an mTOR inhibitor) and topical pirfenidone (an antifibrotic agent) using an intra-individual split-face design. This methodology minimizes genetic and environmental variability, providing high-quality comparative data in this pilot setting.

**Case Presentation**
A 31-year-old male with NF1 (Riccardi Scale Grade 3) with no comorbidities presented with numerous symptomatic facial cNFs. A 12-week split-face protocol was implemented: topical sirolimus was applied to the right hemiface and topical pirfenidone to the left hemiface. Evaluation was performed at baseline and week 12. Assessment tools included the Patient and Observer Scar Assessment Scale (POSAS) and the disease-specific cNF-Skindex. Baseline POSAS (Observer) scores were identical for both hemifaces (7 vs 7), indicating comparable objective disease severity. Baseline POSAS (Patient) scores differed (42 vs 45), reflecting subjective variability. The baseline cNF-Skindex score was 70. By Week 12, both interventions resulted in clinical improvement. Subjective improvement (POSAS Patient) was greater on the pirfenidone-treated side (42 to 20) compared to the sirolimus-treated side (45 to 30). Objective assessment (POSAS Observer) showed a similar trend, improving from 7 to 4 and from 7 to 5, respectively. In addition, clinically relevant improvements were observed in lesion burden, including a reduction in lesion number, decrease in lesion size and prominence, and improved surface homogeneity. These changes were more pronounced on the pirfenidone-treated side compared to the sirolimus-treated side. Overall quality of life improved, with cNF-Skindex reducing to 30. A mild transient burning sensation was reported on the pirfenidone-treated side, which subsided within a few days. No other significant adverse events were observed.

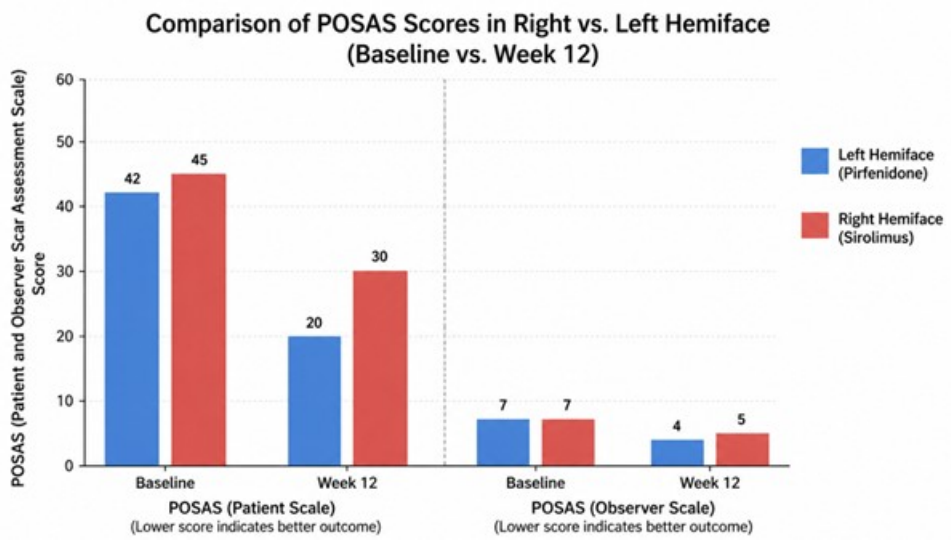


Figure 1. Comparison of Patient and Observer Scar Assessment Scale (POSAS) scores between hemifaces at baseline and Week 12. Bar graph illustrating changes in POSAS (Patient and Observer) scores for the left hemiface treated with pirfenidone and the right hemiface treated with sirolimus. Both treatments resulted in improvement at Week 12; however, a greater reduction in scores was observed on the pirfenidone-treated side. Lower POSAS scores indicate clinical improvement.

**Conclusion**

In this intra-individual, split-face comparison, topical pirfenidone demonstrated superior clinical efficacy compared to topical sirolimus in reducing lesion severity of facial cutaneous neurofibromas over 12 weeks. Greater improvements were observed in both subjective and objective POSAS scores, along with a reduction in overall quality-of-life burden as measured by cNF-Skindex. While both agents target relevant pathogenic pathways in neurofibromatosis type 1, modulation of fibrotic pathways with pirfenidone appeared to yield more consistent clinical benefit than mTOR inhibition. The split-face design strengthens internal validity by minimizing inter-individual variability. These findings suggest that topical pirfenidone may represent a promising non-invasive therapeutic option for facial cNFs and support the need for larger randomized controlled studies to validate its efficacy.

EADV CONGRESS
VIENNA
30 SEP - 3 OCT 2026

**Abstract N°: 1393**

# Multiple Pilar Leiomyomas as the Presenting Sign of Hereditary Leiomyomatosis and Renal Cell Cancer Syndrome: A Case Report

Faruk Emre Enikonu*[1], Ahmet Emre Avcı[1], Türkan Ekin Hız[1], Cem Leblebici[2], Ayşe Esra Koku Aksu[1]

[1] İstanbul Training and Research Hospital, Dermatology and Venereology, İstanbul, Türkiye
[2] İstanbul Training and Research Hospital, Pathology, İstanbul, Türkiye

## Introduction

Pilar leiomyomas are benign, often painful, smooth muscle tumors arising from the arrector pili muscle. While they may may occur sporadically, the presentation of multiple lesions is strongly associated with Hereditary Leiomyomatosis and Renal Cell Cancer (HLRCC) syndrome, historically known as Reed syndrome. HLRCC is an autosomal dominant condition characterized by cutaneous and uterine leiomyomas, along with a significantly increased risk of aggressive renal cell carcinoma (RCC). Recognition of its cutaneous manifestations is essential for early diagnosis and the implementation of life-saving renal surveillance.

## Case Presentation

A 64-year-old woman presented to our dermatology clinic with multiple, painful pink nodules. Physical examination revealed three tender, pink nodules, approximately 5 mm and 7 mm in diameter, on the left flank, and a similar nodule, approximately 8 mm in diameter, on the extensor surface of the left arm. Excisional biopsy of a representative lesion showed features consistent with pilar leiomyoma. A detailed medical history revealed that the patient had previously undergone a total abdominal hysterectomy and bilateral salpingo-oophorectomy (TAH+BSO) secondary to severe, multiple uterine myomas. The combination of multiple cutaneous leiomyomas and a history of uterine leiomyomas raised strong suspicion for HLRCC. The patient was referred for genetic evaluation. And molecular analysis identified a heterozygous mutation in the Fumarate Hydratase (*FH*) gene, confirming the diagnosis of HLRCC. Following diagnosis, urological and radiological assessment was initiated because of the associated risk of renal malignancy. Urinary system and abdominal ultrasonography showed no renal mass or other structural abnormality.

## Conclusion

Dermatologists play a key role in the early recognition of HLRCC. The identification of multiple pilar leiomyomas must immediately prompt a thorough gynecological history, genetic evaluation, Even in the absence of renal pathology at the time of diagnosis, identification of an FH mutation necessitates lifelong radiological screening for RCC and genetic counseling for at-risk family members.

EA DV CONGRESS
VIENNA
30 SEP - 3 OCT 2026

**Abstract N°: 1415**

# Multisystem Lipoid Proteinosis Confirmed by a Homozygous ECM1 Exon 9–10 Deletion in a Non-Consanguineous Family with Four Clinically Affected Members

Mustafa Altaş*[1], İbrahim İbiloğlu[2], Erhan Ayhan[1]

[1] Dicle University Faculty of Medicine, Department of Dermatology and Venereology, Diyarbakir, Türkiye
[2] Dicle University Faculty of Medicine, Department of Pathology, Diyarbakir, Türkiye

## Introduction

Lipoid proteinosis (LP, Urbach–Wiethe disease) is a rare autosomal recessive genodermatosis caused by biallelic loss-of-function variants in the extracellular matrix protein 1 gene (ECM1) on chromosome 1q21, with approximately 400 cases reported worldwide. Progressive deposition of hyaline material in the skin, mucous membranes and internal organs produces a clinical triad of lifelong hoarseness, infiltrative cutaneous lesions and bilateral intracranial calcifications. The disorder remains under-recognised, particularly when parents do not declare consanguinity. We report a young woman with the full multisystem phenotype, genetically confirmed by a previously reported homozygous ECM1 exon 9–10 deletion, and with striking familial aggregation despite denied parental consanguinity.

## Case Presentation

A 28-year-old woman presented with a two-month history of a non-healing ulcer on the dorsum of the tongue. She reported lifelong hoarseness from a neonatal hoarse cry, and from early childhood had developed yellowish, waxy papules and plaques on the face, eyelids, scalp, dorsa of the hands, elbows and knees, with atrophic varioliform scars and palmoplantar keratoderma-like changes. Examination revealed bilateral moniliform blepharosis (rows of beaded papules along the eyelid margins), a thickened sublingual frenulum with restricted tongue mobility, recurrent aphthous ulceration, periodontitis and xerostomia. Patchy alopecia and eyelash thinning were also noted. Flexible laryngoscopy revealed diffuse mucosal thickening with irregular nodular elevations along the free margins of both vocal cords, consistent with hyaline infiltration. Family history was notable for three relatives clinically affected with similar lifelong hoarseness and cutaneous changes — an adult sister, a maternal uncle and a niece — although the parents denied consanguinity. A 4 mm punch biopsy from a yellowish plaque on the elbow showed epidermal hyperkeratosis with acanthosis and amorphous, eosinophilic hyaline material deposited throughout the upper and reticular dermis, concentrically surrounding small blood vessels and eccrine secretory coils, with peri-adnexal atrophy. The hyaline material stained strongly positive with periodic acid–Schiff (PAS) within vascular walls, while alcian blue at pH 2.5 was negative, a pattern characteristic of LP. Cranial CT demonstrated bilateral 6–7 mm hyperdense amygdaloid calcifications, a near-pathognomonic neuroradiological feature. Cognitive testing showed a Mini-Mental State Examination (MMSE) score of 28/30 with borderline IQ (82). Targeted next-generation sequencing of an inherited skin disease panel identified a homozygous deletion of exons 9–10 of ECM1 (transcript ENST00000369047), classified as pathogenic according to ACMG criteria, and consistent with a 1163-bp intragenic founder deletion previously reported in the southeast region of Türkiye. The patient was referred for multidisciplinary follow-up including otolaryngology, ophthalmology, neurology and genetic counselling for at-risk relatives.

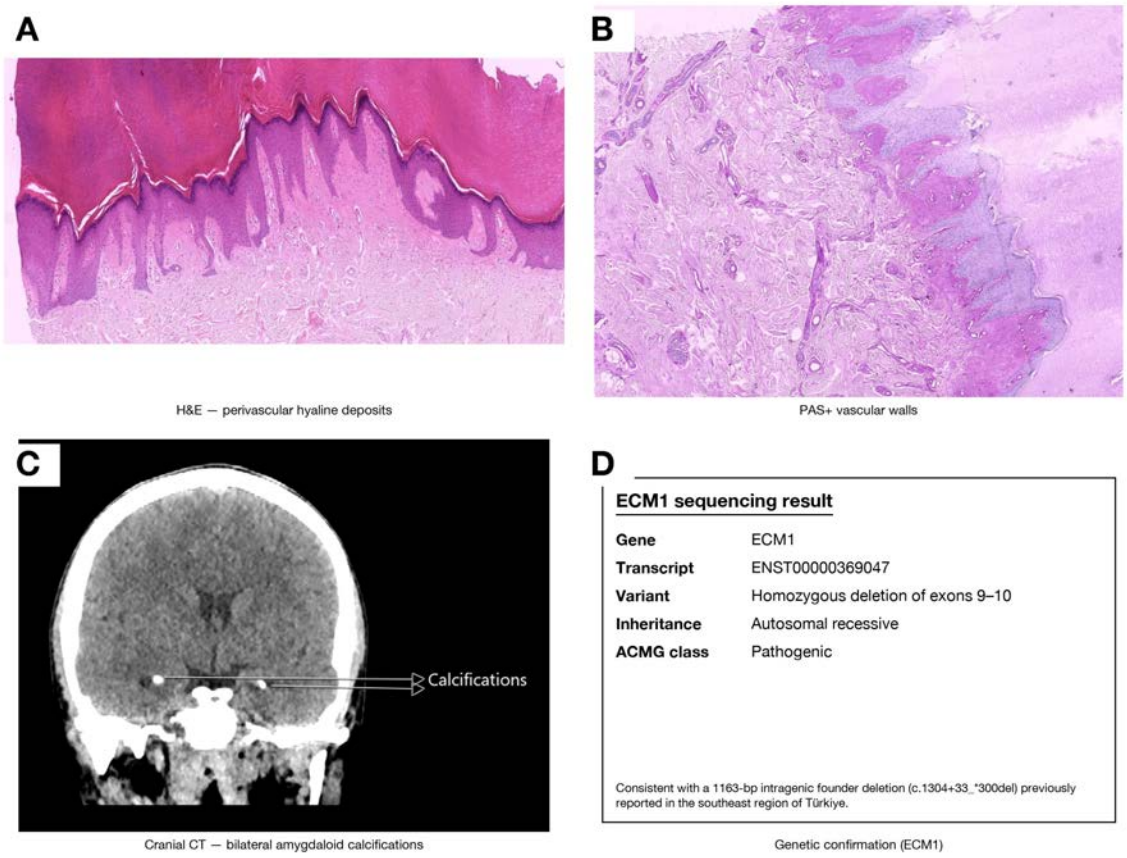


Clinico-pathological and genetic correlates of lipoid proteinosis. (A) H&E: epidermal hyperkeratosis with acanthosis and amorphous, eosinophilic hyaline material throughout the upper and reticular dermis. (B) PAS: strongly PAS-positive hyaline material, particularly in the papillary dermis and around perivascular and periadnexal structures; alcian blue (pH 2.5) negative. (C) Cranial CT: bilateral hyperdense amygdaloid calcifications (arrows). (D) Targeted next-generation sequencing identified a homozygous deletion of ECM1 exons 9–10 (ENST00000369047), classified as pathogenic by ACMG criteria, consistent with a 1163-bp intragenic founder deletion (c.1304+33_*300del) previously reported in the southeast region of Türkiye.

**Conclusion**

This case illustrates the full clinico-pathological and neuroradiological spectrum of lipoid proteinosis in a single patient and underlines that absence of declared consanguinity does not exclude autosomal recessive inheritance: a regional founder effect can produce homozygosity for previously reported pathogenic ECM1 variants even when parents do not recognise a shared ancestor. The constellation of moniliform blepharosis, lifelong hoarseness and amygdaloid calcifications should prompt directed PAS-stained skin biopsy and ECM1 sequencing — including copy-number analysis to detect large intragenic deletions — rather than empirical immunosuppressive therapy, which is ineffective. Reporting recurrent ECM1 variants from under-represented populations is essential for refining genotype–phenotype correlations and for population-based carrier screening.

EA DV CONGRESS
VIENNA
30 SEP - 3 OCT 2026

**Abstract N°: 1490**

# Constitutional Mismatch Repair Deficiency Syndrome Mimicking Neurofibromatosis Type 1: A Pediatric Case Recognized Through Clinicogenetic Correlation

Burak Erçoban*[1], Türkan Ekin Hız[1], Gamze Titiz Acur[1], Duygu Yamen[1], Ayşe Esra Koku Aksu[1]

[1] Department of Dermatology and Venereology, Istanbul Research and Training Hospital, İSTANBUL, Türkiye

## Introduction

Constitutional Mismatch Repair Deficiency (CMMRD) is an extremely rare autosomal recessive syndrome caused by biallelic germline mutations in mismatch repair genes. It is characterized by early-onset malignancy predisposition and a neurocutaneous phenotype that strikingly resembles Neurofibromatosis Type 1 (NF1). Dermatologists are often the first to encounter these patients, as café-au-lait macules (CALMs) and hypopigmented patches are frequently the earliest clinical indicators.

## Case Presentation

A pediatric male patient presented with multiple café-au-lait macules across the trunk and inner thigh, five hypopigmented macules on the back, and two subcutaneous soft nodules in the left axillary region. Ultrasonography and, more definitively, magnetic resonance imaging (MRI) of the axillary region demonstrated a 5 cm mixed-type lymphangioma with cystic components and additional solid and semisolid lesions suspicious for plexiform neurofibromas. Family history was notable for consanguinity, a sibling's death at age 10 due to a brain tumor, and colorectal cancer in another relative. Genetic testing had previously been performed because of the family history and had identified a homozygous MSH6 mutation. Based on the dermatologic findings, imaging features, family history, and prior molecular result, the diagnosis of CMMRD was established through clinicogenetic correlation. The patient was subsequently referred for multidisciplinary follow-up including oncology, neurology, cardiology, and ophthalmology.

## Conclusion

**Discussion:** The diagnostic value of dermatological findings in CMMRD is paramount, as NF1-like features occur in nearly 95% of cases. However, atypical features such as hypopigmented macules or a strong family history of early-onset malignancies should alert the clinician to CMMRD rather than NF1. Distinguishing these entities is critical because CMMRD is associated with a very high risk of childhood malignancy. This case underscores that even when molecular testing has already been performed, the diagnosis may remain clinically unrecognized until the genetic result is accurately interpreted in light of the patient's neurocutaneous phenotype and family history.

**Conclusion:** Dermatologists play a sentinel role in the early detection of CMMRD. Recognizing the neurocutaneous overlap between CMMRD and NF1 allows for early clinical confirmation and the implementation of intensive, multidisciplinary cancer surveillance programs, which are vital for improving survival outcomes in these high-risk pediatric patients.

**References:**

1.Anderson, S., et al. (2025). Constitutional Mismatch Repair Deficiency: Scoping Review of a Cancer-

Predisposition Syndrome With Distinctive Cutaneous Findings. *Pediatric Dermatology*, 42(4).
2.Wimmer, K., & Kratz, C. P. (2016). Connections between constitutional mismatch repair deficiency syndrome and neurofibromatosis type 1. *Clinical Genetics*, 91(4), 507-519.
3. Wimmer, K., & Kratz, C. P. (2016). Connections between constitutional mismatch repair deficiency syndrome and neurofibromatosis type 1. *Clinical Genetics*, 91(4), 507-519.

EA DV CONGRESS
VIENNA
30 SEP - 3 OCT 2026

**Abstract N°: 1495**

## Sebaceous Neoplasms as Early Cutaneous Clues to Muir-Torre Syndrome

Anna Clara Toledo de Azevedo*[1], Lara Melo de Souza[1], Maria Clara de Campos Sales[1], Alícia Mendes[1], Maria Fernanda Sant Anna Addor[1], Karem Christine Correa e Silva[1]

[1] Pontifícia Universidade Católica de São Paulo (PUC-SP), Faculdade de Ciências Médicas e da Saúde, Sorocaba, Brazil

### Introduction

Muir–Torre syndrome is a rare genodermatosis and a variant of Lynch syndrome caused by germline mutations in DNA mismatch repair genes. It is characterized by sebaceous neoplasms associated with internal malignancies, particularly colorectal and genitourinary cancers.
Cutaneous lesions may precede visceral malignancies and represent key clinical markers.
Recommended surveillance includes periodic colonoscopy every 3–5 years, upper gastrointestinal endoscopy when indicated, annual urinalysis, and regular dermatological and physical examinations.

### Case Presentation

A 75-year-old male presented with multiple erythematous nodular lesions on the scalp and right chest, with an eight-month history of asymptomatic and non-progressive lesions. He reported previous excisions of similar lesions on the cervical region and right upper limb, although prior histopathological diagnoses were not initially available.
His medical history was significant for myocardial infarction treated with coronary artery bypass grafting and aortic valve replacement. He was a former smoker and denied alcohol use.
Excision of the current lesions was performed. Histopathological examination revealed a sebaceoma on the scalp and sebaceous adenomas on the chest (Figure 1). Review of previous pathology reports later confirmed additional sebaceous adenomas in the upper limb, establishing a pattern of multiple and recurrent sebaceous neoplasms.
Given these findings, further investigation was undertaken due to suspicion of an underlying hereditary cancer syndrome. Colonoscopy identified tubular and tubulovillous adenomas with low-grade dysplasia in the cecum and ascending colon. Despite the indication for continued surveillance, the patient was lost to follow-up.
He returned later with new cutaneous lesions and a confirmed diagnosis of ureteral carcinoma, reinforcing the clinical suspicion of Muir-Torre syndrome and illustrating disease progression in the absence of early structured screening.
This outcome underscores the importance of adherence to surveillance protocols, as recommended screening might have enabled earlier detection of genitourinary malignancy.



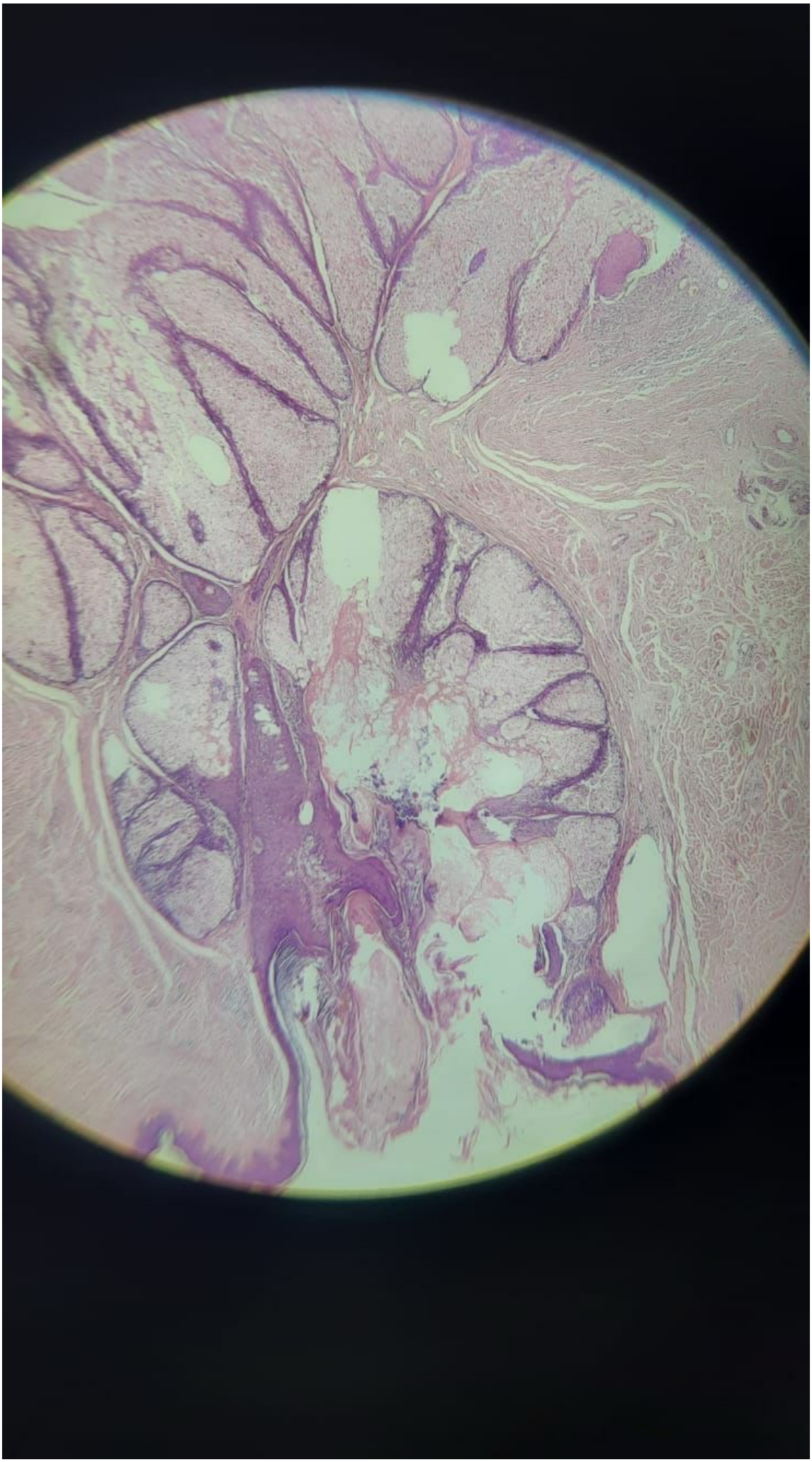

Figure 1. Sebaceous adenoma (chest), low-power view showing a lobulated proliferation of sebaceous glands with central differentiation and peripheral basaloid cells (H&E).

**Conclusion**

This case highlights the strong association between multiple sebaceous neoplasms and internal malignancies, strongly suggestive of Muir-Torre syndrome. Multiple and recurrent sebaceous neoplasms should be considered a clinical red flag, as illustrated by the characteristic sebaceous differentiation (Figure 2), warranting prompt investigation for DNA mismatch repair deficiency and possible underlying Lynch syndrome.

Dermatologists play a central role in recognizing these cutaneous markers and initiating appropriate multidisciplinary evaluation, including genetic assessment and oncologic screening. Early identification is essential, as it may precede the development of visceral malignancies and significantly impact patient prognosis through timely surveillance and intervention.

Structured surveillance protocols are essential to reduce morbidity and mortality associated with Lynch syndrome-related malignancies, and clear patient counseling on strict follow-up is crucial for early detection and improved outcomes.

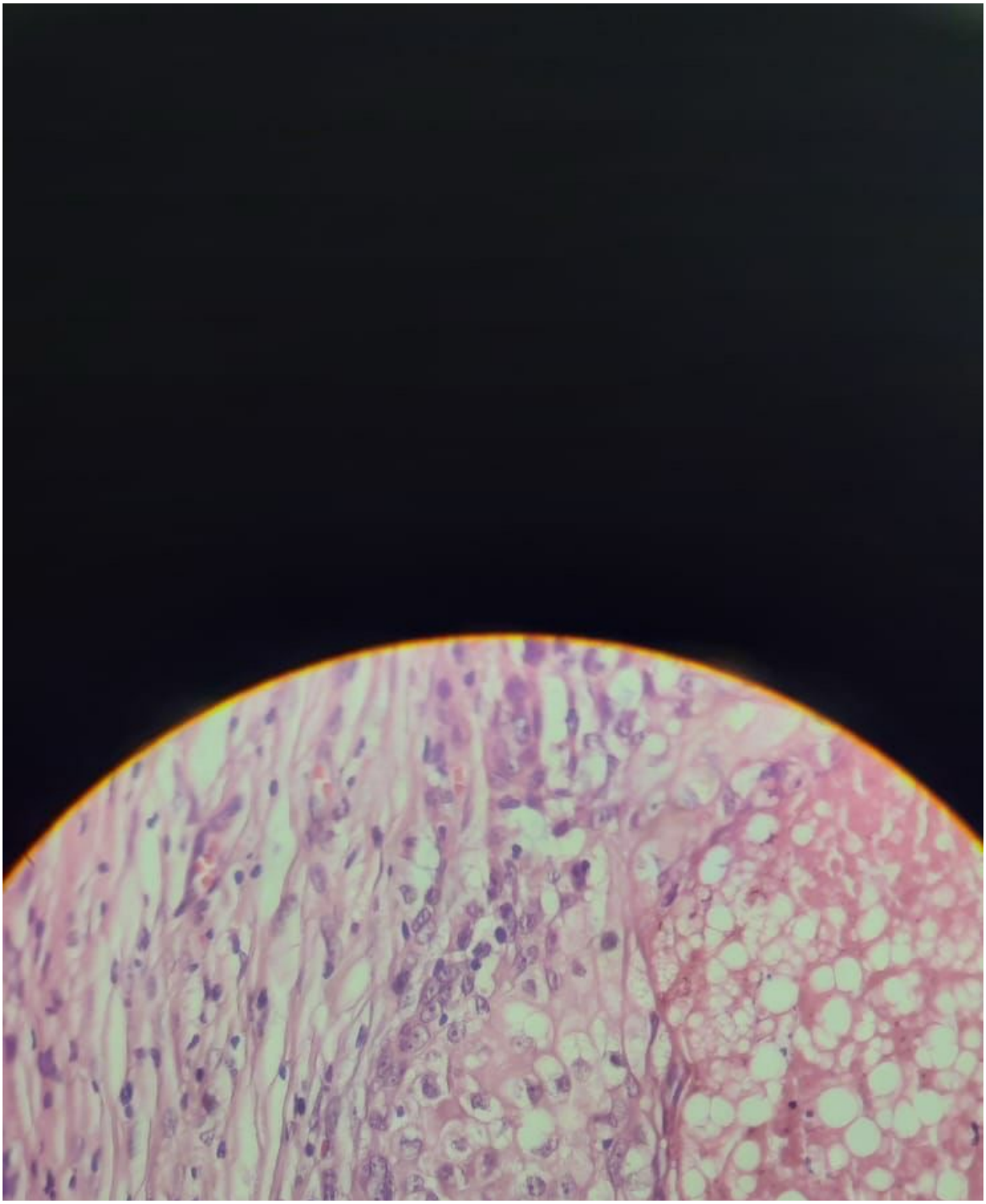

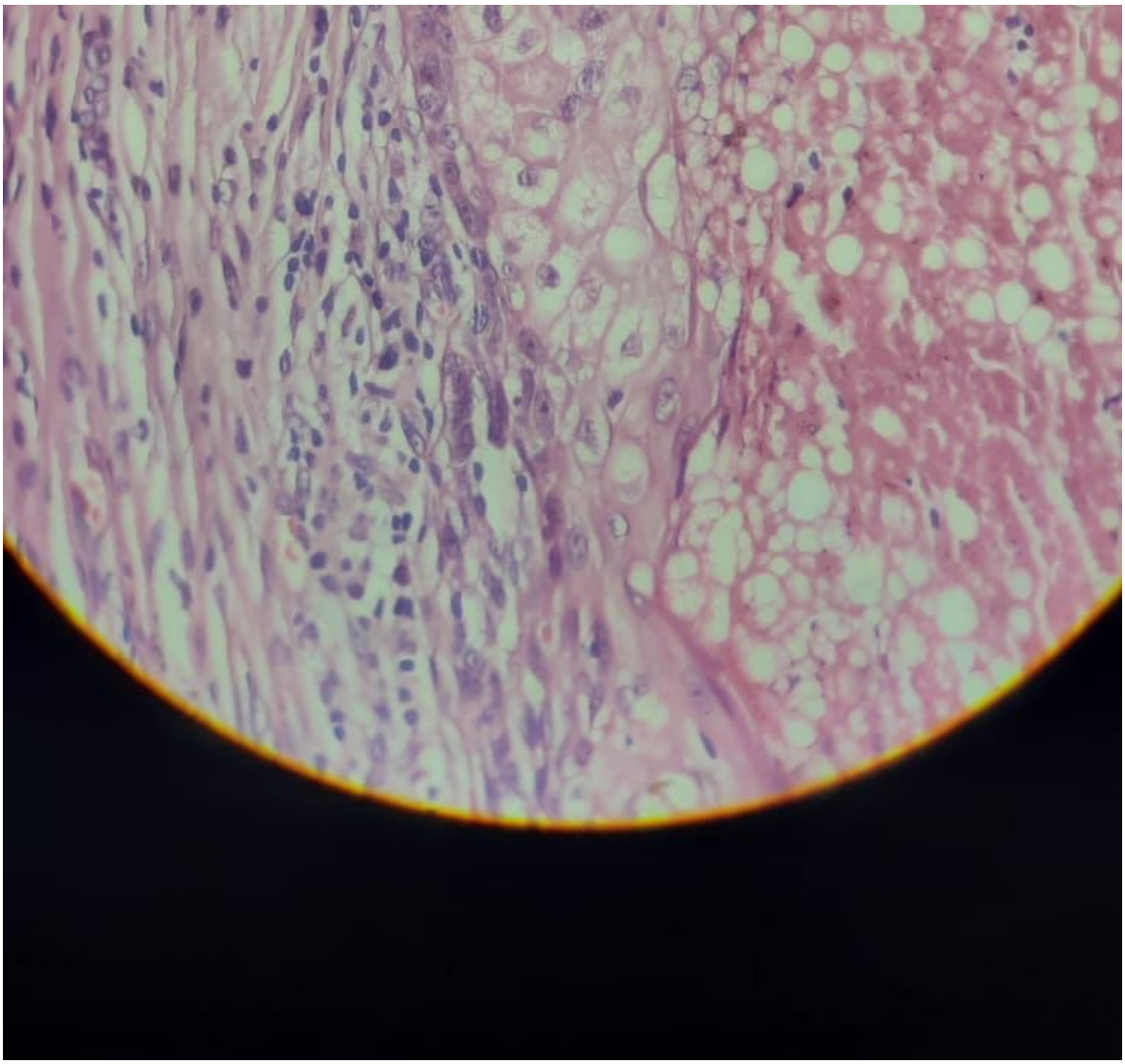

Figure 2. Sebaceoma (scalp), high-power view showing a proliferation of basaloid cells with focal sebaceous differentiation, including mature sebocytes with vacuolated cytoplasm (H&E).

EA DV CONGRESS
VIENNA
30 SEP - 3 OCT 2026

**Abstract N°: 1628**

# ATYPICAL HYPERPIGMENTED SHAGREEN PATCH MIMICKING A MELANOCYTIC LESION IN TUBEROUS SCLEROSIS COMPLEX: EXPANDING THE PHENOTYPIC SPECTRUM

Devina Gracia Pratama*[1], Reiva Farah Dwiyana[1], Srie Gondokaryono[1], Mohamad Rendy Ariezal Effendi[1], Rafithia Anandita[1]

[1] Department of Dermatology Venereology and Aesthetica, Faculty of Medicine, Universitas Padjadjaran, Bandung, Indonesia

## Introduction

Tuberous sclerosis complex (TSC) is a multisystem genetic disorder characterized by hamartoma formation in multiple organs, including the skin, brain, and eyes. Cutaneous manifestations often represent the earliest clinical clue and play a central role in diagnosis. Classic dermatologic features include facial angiofibromas, periungual fibromas, and shagreen patches, typically described as skin-colored connective tissue nevi with a leathery or “orange peel” surface. However, phenotypic variability may lead to atypical presentations that deviate from classical descriptions and create diagnostic challenges, particularly when lesions resemble common melanocytic conditions. Recognition of such variants is essential, as delayed diagnosis may postpone appropriate systemic evaluation and multidisciplinary management.

## Case Presentation

A 14-year-old girl, with a history of seizures during infancy, presented with long-standing asymptomatic facial papules and nodules that first appeared in early childhood and gradually increased in number (Figure 1D). These lesions were initially not evaluated as they were asymptomatic. Several years later, she developed additional skin changes on the left lower back, characterized by irregular, partly confluent hyperpigmented patches with adjacent skin-colored plaques, without obvious elevation or the typical texture of a shagreen patch (Figure 1A-B). The hyperpigmented areas gradually darkened and initially raised suspicion for melanocytic lesions, contributing to delayed recognition of the underlying condition. Approximately one year prior to presentation, a periungual lesion appeared on the toenail (Figure 1E). Further evaluation confirmed a periungual fibroma, which, together with multiple facial angiofibromas, fulfilled major diagnostic criteria for TSC. Given the initial suspicion of melanocytic lesions and limited access to advanced evaluation, further assessment was performed after referral to our center. Dermoscopy of the lesions demonstrated predominantly white structureless areas without a pigment network, suggesting a non-melanocytic process (Figure C). Histopathological examination of both lesions revealed dense, disorganized collagen bundles with adnexal atrophy, consistent with a shagreen patch. Systemic evaluation identified retinal hamartomas on fundoscopic examination (Figure 1F), further supporting the diagnosis of TSC with multisystem involvement.




Figure 1. Multisystem manifestations of tuberous sclerosis complex with atypical hyperpigmented shagreen patch. A. Clinical overview showing an irregular hyperpigmented patch on the left lower back (yellow arrow) interspersed with adjacent skin-colored plaques, lacking the typical elevated, leathery "orange peel" texture of a classical shagreen patch. B. Close-up view demonstrating a mottled, partly confluent hyperpigmented pattern admixed with subtle skin-colored plaques (red arrow) C. Dermoscopic examination revealing predominantly white structureless areas without a pigment network, supporting a non-melanocytic process. D. Multiple facial angiofibromas distributed over the centrofacial region. E. Periungual fibroma on the toenail (blue arrow). F. Fundoscopic image showing a retinal hamartoma (green arrow), consistent with systemic involvement in tuberous sclerosis complex

**Conclusion**

This case highlights an atypical hyperpigmented presentation of shagreen patch that may clinically mimic melanocytic lesions and contribute to diagnostic uncertainty. It underscores the importance of recognizing phenotypic variability in tuberous sclerosis complex to facilitate earlier diagnosis and appropriate evaluation of multisystem involvement.

EADV CONGRESS
VIENNA
30 SEP - 3 OCT 2026

**Abstract N°: 1640**

# Early Detection of Sebaceous Carcinoma and Colorectal Cancer in Muir–Torre Syndrome: Impact of Long-Term Dermatological Surveillance on Prognosis

Eduarda Gregório Arnaut Lima*[1], Mariana da Conceição[1], Mariana Treu[1], Curt Treu[1]

[1] Policlínica Geral do Rio de Janeiro, Rio de Janeiro, Brazil

## Introduction

Muir–Torre syndrome (MTS), a phenotypic variant of Lynch syndrome, is characterised by sebaceous neoplasms and internal malignancies due to germline DNA mismatch repair mutations. Among cutaneous manifestations, sebaceous carcinoma is clinically significant due to its potential for local invasion and metastasis. Early recognition of these lesions may directly impact patient prognosis.

## Case Presentation

A 44-year-old male presented with multiple sebaceous adenomas on the face, trunk, and upper limbs, associated with recurrent keratoacanthomas and a previous squamous cell carcinoma of the scalp. Clinical suspicion of MTS prompted colonoscopic evaluation and genetic testing. During a 10-year dermatological follow-up, more than 30 sebaceous neoplasms were documented and histologically confirmed. Continuous surveillance enabled the early detection of a low-grade sebaceous carcinoma in the epigastric region, which was promptly treated with wide local excision, with no evidence of recurrence to date. Genetic testing confirmed pathogenic mismatch repair gene mutations consistent with MTS. Family cascade screening identified the same mutation in the patient's daughter, son and sister, who subsequently developed colorectal carcinoma. Ongoing colonoscopic surveillance led to the detection of an early-stage colorectal adenocarcinoma, successfully managed with surgical resection without the need for adjuvant therapy. The patient remains under active multidisciplinary follow-up.

## Conclusion

This case demonstrates that long-term dermatological surveillance in MTS has a direct impact on prognosis by enabling early detection of both sebaceous carcinoma and colorectal cancer. Identification of sebaceous carcinoma as a high-risk cutaneous marker allows timely intervention before metastatic progression and facilitates systemic cancer screening at a curable stage. Dermatologists play a central role in recognising these patients and initiating genetic and oncological evaluation, with significant implications for patient and family outcomes.

EADV CONGRESS
VIENNA
30 SEP - 3 OCT 2026

**Abstract N°: 1664**

# Efficacy and Safety of Biologics and JAK Inhibitors in Epidermolysis Bullosa: A Real-World Retrospective Cohort Study

Han-Tang Wang*[1], Ping-Chen Hou[1], Hui-Ching Cheng[1], Wei-Ting Tu[1], John A McGrath[1, 2], Chao-Kai Hsu[1, 3]

[1] Department of Dermatology, National Cheng Kung University Hospital, Tainan, Taiwan
[2] St John's Institute of Dermatology, King's College London, London, United Kingdom
[3] Institute of Clinical Medicine, National Cheng Kung University, Tainan, Taiwan

**Introduction**
Epidermolysis bullosa (EB) is characterized not only by skin fragility but also by chronic inflammation contributing to impaired wound healing, fibrosis, and pruritus. We evaluated real-world outcomes of targeted immunomodulatory therapies, including dupilumab and Janus kinase (JAK) inhibitors, across EB subtypes.

**Materials and Methods**
We retrospectively reviewed 25 EB patients treated with biologics (dupilumab) and/or JAK inhibitors (abrocitinib, upadacitinib, and baricitinib) at National Cheng Kung University Hospital between 2021 and 2025. Subtypes included EB simplex (EBS, n=1), junctional EB (JEB, n=2), dominant dystrophic EB (DDEB, n=14), and recessive dystrophic EB (RDEB, n=8).

**Results**
Therapeutic responses varied by EB subtype. In patients with DDEB, abrocitinib and upadacitinib demonstrated superior efficacy over dupilumab, achieving sustained pruritus reduction (mean VAS decrease: 3.9) and lesion flattening in 11 of 13 subjects. Common adverse events included acneiform eruptions and dizziness. Transcriptomic analysis of lesional skin following JAK inhibition revealed the suppression of Th1/Th2 differentiation, JAK-STAT, and IL-17 signaling. For RDEB, dupilumab provided substantial and durable relief, with a significant reduction in itch (mean VAS decrease: 4.4) over a mean treatment duration of 23.6 months; notably, one patient saw a marked decrease in wound dressing requirements. In JEB, abrocitinib significantly improved itch, erythema, and exudate in one patient, while dupilumab proved ineffective in another.

**Conclusions**
These real-world outcomes demonstrate the clinical utility of subtype-directed immunomodulation in EB. While dupilumab provides durable relief in RDEB, JAK inhibitors offer superior pruritus control and lesion flattening in DDEB. Despite limitations like a small retrospective sample size, these findings support tailoring systemic therapies to subtype-specific inflammatory mechanisms and warrant further prospective studies.

POWERED BY M-ANAGE.COM

EADV CONGRESS
VIENNA
30 SEP - 3 OCT 2026

**Abstract N°: 1677**

# Eczema with Purpura and Infections: Wiskott–Aldrich Syndrome as a Critical Diagnostic Pitfall

Eduarda Gregório Arnaut Lima*[1, 2], Daniela Martinez[1, 2], Isabela Marinho[2], Omar Lupi[1, 2]

[1] Policlínica Geral do Rio de Janeiro, Rio de Janeiro, Brazil

[2] Universidade Federal do Rio de Janeiro (UFRJ), Rio de Janeiro, Brazil

## Introduction

Wiskott–Aldrich syndrome (WAS) is a rare X-linked primary immunodeficiency, characterised by microthrombocytopenia, recurrent infections, and eczema. Cutaneous manifestations are common and may be clinically indistinguishable from atopic dermatitis, which can delay diagnosis and lead to potentially fatal consequences. Awareness of WAS as a differential diagnosis in childhood eczema remains limited outside specialist settings. We report a genetically confirmed familial case of WAS, highlighting the role of dermatological recognition in early diagnosis and long-term outcome 13 years following haematopoietic stem cell transplantation (HSCT).

## Case Presentation

An 18-year-old male patient presented for transition follow-up from paediatric to adult dermatological care. WAS had been diagnosed at age 2 after recurrent infections, purpura, thrombocytopenia, and eczematous dermatitis beginning at 6 months of age, with multiple hospitalizations prior to diagnosis. Genetic testing confirmed a pathogenic WAS gene mutation, with maternal carrier status established. Intravenous immunoglobulin replacement was administered between ages 2 and 5. The family history was notable for an older sibling who died from an undiagnosed but similar presentation and a younger brother with the same mutation who underwent allogeneic HSCT one month after the index patient. The index patient underwent HSCT at age 5, followed by long-term dermatological surveillance. Following HSCT, complete and sustained remission of cutaneous manifestations, including eczema and purpura, was achieved, with no recurrence over 13 years of follow-up. The patient remains asymptomatic, requires no ongoing treatment, and is under regular multidisciplinary surveillance.

## Conclusion

Childhood eczema associated with petechiae or purpura and recurrent infections should prompt consideration of Wiskott–Aldrich syndrome and urgent immunological evaluation. Diagnostic delay can be fatal, as illustrated by the death of an affected sibling in this family. Early recognition enables molecular diagnosis, genetic counselling, and timely referral for HSCT, leading to favourable long-term outcomes. This case underscores the critical role of dermatologists in identifying primary immunodeficiency disorders presenting with cutaneous manifestations.

EADV CONGRESS
VIENNA
30 SEP - 3 OCT 2026

**Abstract N°: 1681**

# Think beyond milia: an attenuated Bazex–Dupré–Christol syndrome lacking classical cancer features

GAYATIRI RAVEENTHERAN*[1], Tan Ene Choo[1], Ang Yi Shan[1], Lynette Wee[1], Mark Koh[1]

[1] KK Women's and Children's Hospital, Singapore, Singapore

## Introduction

Bazex-Dupré-Christol syndrome (BDCS) is a rare X-linked dominant genodermatosis characterised by a triad of follicular atrophoderma, hypotrichosis, and early-onset basal cell carcinomas (BCCs). Pathogenic non-coding duplications in the Xq26.1 region will lead to overexpression of the ARHGAP36 gene. This has been identified as a key contributor to the syndrome's characteristic basal cell carcinomas. This index family presented with key features of BDCS except for no history of BCCs.

## Case Presentation

We evaluated a three-generation family with eight affected individuals presenting with early-onset generalised milia and follicular atrophoderma. Long-read whole genome sequencing (Oxford Nanopore) and breakpoint validation by Sanger sequencing were performed.

The index case, a 9-year-old girl, presented from infancy with extensive generalised milia and follicular atrophoderma involving the hands and knees. Family history revealed similar findings across multiple relatives, with milia often improving with age. Notably, hypotrichosis and BCCs were absent in all affected individuals. Genomic analysis identified a 218 kb tandem duplication at Xq26.1 (chrX:131,068,029–131,286,431), encompassing partial sequences of *ARHGAP36* and *IGSF1* and the entire intergenic region. This duplication segregated with disease and is substantially larger than previously reported BDCS-associated duplications, which are typically confined to intergenic regions.

## Conclusion

We report the largest Xq26.1 duplication to date associated with an atypical BDCS phenotype characterised by milia and follicular atrophoderma without BCC or hypotrichosis. Our findings suggest that duplication size and gene involvement may modulate phenotypic expression, potentially attenuating canonical features. Recognition of milia-predominant presentations is important for early diagnosis and surveillance and highlights the value of long-read sequencing in detecting complex structural variants in genodermatoses.

EADV CONGRESS
VIENNA
30 SEP - 3 OCT 2026

**Abstract N°: 1702**

# Clinical Heterogeneity in Pseudoxanthoma Elasticum: Two Case Reports

Fahamettin Can Birol*[1], Hülya Mürüvvet GÜVENDİ[1], Seda Nalça[2], Nuray Can[3], Elif Bal Avcı[1]

[1] Trakya University Faculty of Medicine Department of Dermatology and Venereology, Edirne, Türkiye
[2] Trakya University Faculty of Medicine Department of Ophthalmology, Edirne, Türkiye
[3] Trakya University Faculty of Medicine Department of Medical Pathology, Edirne, Türkiye

## Introduction

Pseudoxanthoma elasticum (PXE) is a rare genetic metabolic disorder inherited in an autosomal recessive manner, resulting from mutations in the ABCC6 gene. Dystrophic calcification leads to cutaneous, ocular, cardiovascular, and other systemic manifestations. The primary cutaneous findings of PXE are round, yellowish or skin-colored macules or papules. These lesions may coalesce, forming a cobblestone-like appearance, large plaques, or linear streaks. In ocular involvement, angioid streaks, peau d'orange appearance, and macular changes may be observed due to calcification of Bruch's membrane. The clinical course is variable, ranging from disease limited to cutaneous findings to the development of severe systemic complications. In this study, two PXE cases with different clinical features are presented to emphasize the clinical heterogeneity of the disease and the necessity of systemic evaluation.

## Case Presentation

### Case 1

A 31-year-old female patient presented with complaints of lesions on the neck for ten years and on the arm for one year. Her medical history was unremarkable except for a history of breast cancer. Dermatological examination revealed yellowish, hyperpigmented papules and plaques consistent with a cobblestone pattern on the bilateral lateral aspects of the neck, and an erythematous papule on the extensor surface of the right forearm. No mucosal involvement was observed. Histopathological examination of a punch biopsy obtained from the lesions demonstrated disorganization and hyalinization of elastic fibers in the reticular dermis, consistent with PXE. The patient was evaluated for possible accompanying systemic involvement, and no additional pathology was detected. The patient was informed about the risk of gastrointestinal bleeding and was placed under clinical follow-up.

### Case 2

A 47-year-old female patient presented with complaints of lesions on the neck for six years. Dermatological examination revealed yellowish papules and plaques consistent with a cobblestone pattern on the bilateral lateral aspects of the neck. Similar lesions were also present in the right axilla and on the medial aspect of the right thigh. No mucosal involvement was observed. It was learned that the patient had been diagnosed with PXE three years earlier due to the presence of angioid streaks and had received intravitreal injection therapy in the left eye for macular degeneration, and had been followed without treatment for the past two years. Her medical history was unremarkable except for a history of rhytidectomy and mastopexy. Her family history was notable for vision loss and PXE. Histopathological examination of a punch biopsy obtained from the lesion demonstrated degeneration of elastic fibers and calcification of elastic fibers in the dermis, consistent with PXE. Systemic evaluation revealed macular degeneration, angioid streaks, peau d'orange appearance, and mild tricuspid regurgitation, with no additional systemic involvement detected. The patient was informed about the risk of gastrointestinal bleeding and was placed under clinical follow-up.

**Conclusion**

The two cases followed in our clinic demonstrate that the clinical spectrum of PXE is heterogeneous and that the disease may vary from isolated cutaneous findings to multisystem involvement. There is no curative treatment for the disease, and regular follow-up of patients is recommended. In PXE, cutaneous lesions mostly lead to cosmetic concerns, whereas the morbidity and prognosis of the disease are primarily determined by ocular and cardiovascular involvement. Early diagnosis, systemic evaluation, and regular follow-up are of critical importance for the prevention of potential complications.

EA DV CONGRESS
VIENNA
30 SEP - 3 OCT 2026

**Abstract N°: 1706**

# Paradoxical eczematous reaction and clinical worsening in patients with Darier disease treated with Upadacitinib: a prospective case series

Georgia Skarafigka*[1], Eftichia Zouridaki[1], Vasiliki Vosynioti[1], Fiori Kousta[1], Eirini Merikas[1], Eleni Remountaki[1], Kalliopi Athanasoula[1], Vasiliki Chasapi[1], Alexander Stratigos[1]

[1] Andreas Syngros, Athina, Greece

## Introduction

Darier disease is a rare, autosomal dominant genetic skin disorder characterized by the development of greasy wart-like, yellowish, or brown papules. It is caused by mutations in the ATP2A2 which encodes the sarcoplasmic reticulum ATPase type two (SERCA2) calcium pump. Given the refractory nature of the disease and the limited efficacy of conventional therapies, a treatment protocol was developed and approved by the institutional scientific board, in accordance with ethical standards. Following this process, treatment with Upadacitinib was initiated. Upadacitinib is a selective and reversible JAK inhibitor with preferential activity against JAK1-mediated signaling pathways involved in inflammation, while sparing JAK2-dependent hematopoiesis and JAK3-mediated immune function.

## Objectives

To evaluate the efficacy, safety, and tolerability of oral Upadacitinib in patients with moderate-to-severe Darier disease.

## Case Presentation

We report a case series of three patients with severe Darier disease unresponsive to conventional therapies, including systemic retinoids like acitretin and topical corticosteroids. Patients underwent comprehensive baseline clinical, laboratory, and quality-of-life assessment (DLQI) prior to treatment initiation and were subsequently treated with oral Upadacitinib at a dose of 15 mg once daily. The primary outcomes were investigator-assessed clinical improvement at 1, 3, and 6 months relative to baseline, and evaluation of treatment safety and tolerability. Secondary outcomes included characterization of common and serious adverse events, duration of treatment response, and persistence of response after treatment discontinuation.

## Results

Three patients were enrolled. None of the patients completed the planned treatment period of 6 months. Treatment discontinuation occurred within the first two months in all cases (one patient at 2 months and two patients in less than 2 months). Two patients were followed during inpatient care

at our institution, whereas the third patient was managed in the Rare Skin Disease Clinic.
All patients developed a pronounced eczematous reaction characterized by intense erythema, burning sensation, pruritus, and marked discomfort, accompanied by clinical worsening and flare of dermatitis. No clinical improvement was observed during treatment.

**Conclusion**

In this small prospective case series, treatment with Upadacitinib in patients with Darier disease was associated with early intolerance and paradoxical eczematous exacerbation, leading to treatment discontinuation in all cases.
These findings highlight the need for caution when considering JAK inhibition in this patient population and underscore the importance of further studies to better understand the underlying mechanisms.

EADV CONGRESS
VIENNA
30 SEP - 3 OCT 2026

**Abstract N°: 1751**

# Five Pneumothoraces Before Diagnosis: Birt–Hogg–Dubé Syndrome Revealed by Dermatologic Recognition and Family Cascade Screening

Eduarda Gregório Arnaut Lima*[1], Mariana da Conceição[1], Mariana Treu[1], Curt Treu[1]

[1] Policlínica Geral do Rio de Janeiro, Rio de Janeiro, Brazil

## Introduction

Birt–Hogg–Dubé (BHD) syndrome is a rare autosomal dominant genodermatosis caused by germline pathogenic variants in the FLCN gene, encoding folliculin, a tumour suppressor protein. It is characterised by cutaneous fibrofolliculomas and trichodiscomas, pulmonary cysts with spontaneous pneumothorax, and renal neoplasia. Despite its potentially life-threatening systemic manifestations, BHD often remains unrecognised as the cutaneous lesions are frequently overlooked or misattributed to benign entities. This case aims to document a representative phenotypic spectrum of genetically confirmed BHD syndrome with an international family cascade, underscoring the central role of dermatological recognition in enabling timely systemic surveillance and cancer detection.

## Case Presentation

A 73-year-old male patient presented with multiple asymptomatic papules on the face and trunk, associated with a history of **five spontaneous pneumothoraces** and pleural bullae. Dermoscopic and histopathological examination identified **fibrofolliculomas and trichodiscomas**, raising suspicion for BHD syndrome. Genetic testing confirmed a pathogenic heterozygous variant in the FLCN gene: c.1285dup; p.(His429ProfsTer27), located in exon 11, a recognised mutational hot spot of FLCN insertions and deletions in BHD families. Dermatologist-indicated renal surveillance identified a renal malignant tumour, which was surgically treated. Family cascade testing detected the same FLCN variant in a relative in another country, a sister who was subsequently diagnosed with papillary renal carcinoma and died from the disease. The patient remains under active multidisciplinary follow-up encompassing dermatological, pulmonary, and urological surveillance.

## Conclusion

This case highlights the broad clinical spectrum of Birt–Hogg–Dubé syndrome and demonstrates how recognition of subtle cutaneous findings can uncover an inherited cancer syndrome. Early dermatologic suspicion enabled molecular diagnosis, family cascade screening, and targeted renal surveillance leading to the detection of renal malignancy at a treatable stage. Dermatologists play a critical role in identifying BHD syndrome and initiating potentially life-saving multidisciplinary surveillance.

EADV CONGRESS
VIENNA
30 SEP - 3 OCT 2026

**Abstract N°: 1760**

## Senotherapeutic potential against xeroderma pigmentosum

Xuebing Wang*[1]

[1] Institute for Genetic Medicine, Hokkaido University, Sapporo, Japan

### Introduction
Xeroderma pigmentosum (XP) is an inherited photoaging syndrome caused by mutations in genes involved in the nucleotide excision repair (NER) pathway. XP patients exhibit hypersensitivity to ultraviolet (UV) radiation, leading to accelerated skin aging and requiring lifelong sun avoidance. In this study, we aimed to investigate UV-induced cellular senescence in XP melanocytes and explore potential senotherapeutic strategies.

### Materials and Methods
Melanocytes differentiated from iPSCs derived from an XP-A patient and a healthy individual, respectively, were used to induce senescence. Senescence was assessed by SA-β-gal and γH2AX staining. The drug screening tested a panel of 12 senolytic agents and 15 senomorphic agents for their ability to target senescent XP-iMCs. The effects of these agents were evaluated through cell viability assays and SPiDER-βGal staining followed by flow cytometry. RNA sequencing was performed to analyze transcriptional changes induced by senomorphic treatments.

### Results
We demonstrate that UV-induced DNA damage triggers cellular senescence and up-regulates senescence-associated secretory phenotype (SASP) genes in melanocytes derived from an XP patient. The drug screening identified JAK inhibitors and curcuminoids as promising senomorphic agents. In addition, two classes of senolytic agents, BCL-2-like protein inhibitors and HSP90 inhibitors, effectively eliminate senescent melanocytes. Further analysis demonstrates that senomorphic treatment effectively counteracts senescence and reduces SASP gene expression in XP-derived melanocytes. Moreover, genes in senescence-related pathways, including the cytokine-cytokine receptor interaction, JAK/STAT, and PI3K/AKT pathways, which are activated in senescent cells, are down-regulated by senomorphic treatment.

### Conclusions
This study highlights a potential senotherapeutic strategy for XP, which may help alleviate photoaging symptoms in XP patients.

EADV CONGRESS
VIENNA
30 SEP - 3 OCT 2026

**Abstract N°: 1800**

## Papular clues to a hairless case: A diagnostic challenge

Rohan Barua*[1]

[1] IPGME&R and SSKM HOSPITAL Kolkata, Kolkata, India

### Introduction

Hair loss is one of the most distressing complaints we encounter in dermatological practice, especially if it is at a young age and non-responsive to treatments. Discussed below is a case of treatment refractory alopecia being diagnosed and treated as alopecia universalis until a connection was drawn between the overlooked keratotic papules and early onset of irreversible loss of hair.

### Case Presentation

A 2 year old female child was brought by her parents with chief complaint of loss of scalp and eyebrow hair which was not amenable to treatment by multiple physicians.

The child was born with normal appearing hair which began to shed when she was 2 months old and within a few months almost all hair on her scalp and eyebrows were shed. Concurrently she started developing papular lesions on her scalp, forehead and proximal upper limbs. She was examined by physicians and dermatologists who provisionally started treating for alopecia universalis but to no avail.

No developmental delay or growth retardation was noted. No family history of similar hair loss was present. There was history of consanguinity between parents.

On examination, presence of sparse hair over scalp and medial eyebrows was noted. The loss of hair was more prominent over fronto-parietal region and lateral eyebrows. Multiple keratotic papules dotted the scalp, upper back and proximal upper limbs. Teeth and nails were unremarkable.

Dermoscopic examination revealed presence of multiple white spots at regular intervals throughout the scalp creating characteristic "cluster of stars" appearance interspersed with irregular arrangement of black dots.

Histopathological examination from scalp revealed mildly acanthotic epidermis with dilated follicular ostia and infundibulum. Few functional hair follicles and multiple non-functional hair follicles with central keratin filled cysts were seen in the dermis. Adnexal structures were normal.

Biochemical examination: were all within normal limits

Based on clinical, dermoscopic and histopathological findings a diagnosis of atrichia congenita with papular lesions was made.

### Conclusion

Atrichia with papular lesions is a rare commonly misdiagnosed disease that is attributed to putative mutations in the hairless gene on chromosome 8p21.2.

The disease characteristically presents with irreversible loss of hair within one to two months of birth involving the scalp, eyebrows and eyelashes. Axillary and pubic hair is also affected after puberty. Keratotic papules, which are manifestations of non-functional hair follicles with mid-dermal keratin filled cyst formation abound extensively over the body.

The closest differential to this condition include alopecia universalis, vitamin D dependent rickets type 2A and ectodermal dysplasias. Presence of papular lesions and non response to therapy vouches against alopecia universalis and absence of hair, nail or dental anomalies rules out ectodermal dysplasias. Considering the more widespread presence of mutations in the hr gene it is likely that misdiagnosis is probably the cause for under-reporting and relative rarity of the disease.

EADV CONGRESS
VIENNA
30 SEP - 3 OCT 2026

**Abstract N°: 1844**

## Extensive Plexiform Neurofibroma in Neurofibromatosis Type 1

Bounneche Houda*[1], Tarek Mansoul[1], RIADH BOUSSAID[1], Amel Gherfi[1], esma bouhila[1], khadidja bouarroudj[1], kaghouche lilia[1], safa djebbas[1], Ahmed Samaouel Chehad[1]

[1] Department of Dermatology, University Hospital, Constantine, Algeria

### Introduction

Neurofibromatosis type 1 (NF1) is an autosomal dominant phakomatosis with variable cutaneous, neurological, and ophthalmological manifestations. Plexiform neurofibroma, often occurring early in life, is a characteristic lesion with progressive growth that may lead to significant aesthetic and functional impairment. Its management is challenging and relies on a multidisciplinary approach, mainly surgical. We report an illustrative case.

### Case Presentation

We report the case of a 17-year-old patient with a history of learning difficulties, presenting with a dermatosis evolving since the age of 1 year, initially marked by the appearance of café-au-lait macules, with a family history of similar lesions in the mother. Clinical examination revealed a large cutaneous and subcutaneous soft, poorly limited, mobile mass measuring approximately 25 cm in its greatest diameter, associated with hyperpigmentation and alopecia, located in the left fronto-parieto-temporo-occipital region, consistent with a plexiform neurofibroma; more than six disseminated café-au-lait macules measuring over 15 mm in diameter; and axillary freckling. Ophthalmologic examination revealed bilateral Lisch nodules, while the remainder of the clinical examination was unremarkable. The diagnosis of neurofibromatosis type 1 (NF1) was established according to the NIH clinical criteria (1988, revised in 2021). Brain and cervicofacial MRI demonstrated a plexiform neurofibroma infiltrating the parotid gland, parapharyngeal space, and ipsilateral cervical soft tissues. Following multidisciplinary team discussion involving maxillofacial surgery, contouring excision and reconstructive closure of the plexiform neurofibroma were indicated, along with genetic counseling

### Conclusion

In our patient, NF1 was diagnosed based on a combination of clinical findings fulfilling the NIH criteria (1988, revised in 2021), including early café-au-lait macules, axillary freckling, Lisch nodules, and extensive plexiform neurofibroma. The plexiform neurofibroma observed in our case involved the left fronto-parieto-temporo-occipital region, with deep infiltration demonstrated on MRI involving the parotid gland, parapharyngeal space, and ipsilateral cervical soft tissues. This extensive localization explains the cutaneous deformity and associated alopecia, resulting in major aesthetic impairment. In our observation, management was discussed during a multidisciplinary meeting, and surgical treatment was retained. Contouring excision and reconstructive closure were proposed in order to improve the aesthetic and functional burden, which represented the main therapeutic objective in this young patient, considering the potentially significant psychological and social impact. However, the infiltrative nature of these lesions often limits complete excision and exposes patients to a risk of recurrence.

This case illustrates the challenges associated with the management of plexiform neurofibromas. Although surgery is rarely curative, it remains a cornerstone of treatment aimed at improving aesthetic appearance and psychosocial well-being. Multidisciplinary management and long-term follow-up are essential.

EADV CONGRESS
VIENNA
30 SEP - 3 OCT 2026

**Abstract N°: 1927**

# Renal Amyloidosis as a Rare Extracutaneous Complication of Recessive Dystrophic Epidermolysis Bullosa

Teodora Toc*[1], Adela Chirita-Emandi[2, 3], Adrian-Ovidiu Vaduva[4], Flaviu Bob[5], Alina Gogulescu[1]

[1] Municipal Emergency Hospital-Clinic for Dermatology, "Victor Babeș" University of Medicine and Pharmacy, Timisoara, Romania

[2] Department of Microscopic Morphology, Genetics Discipline, Center of Genomic Medicine, "Victor Babeș" University of Medicine and Pharmacy, Timisoara, Romania

[3] Department of Microscopic Morphology, Genetics Discipline, Center of Genomic Medicine, "Victor Babeș" University of Medicine and Pharmacy, Clinical Geneticist Coordinator of Regional Center of Medical Genetics Timiș, part of ERN ITHACA, Clinical Emergency Hospital for Children "Louis Țurcanu", Timisoara, Romania

[4] Department of Microscopic Morphology—Anatomic Pathology,"Victor Babeș" University of Medicine and Pharmacy, Department of Pathology, "Pius Brinzeu" County Emergency Clinical Hospital, ANAPATMOL Research Center, Timisoara, Romania

[5] "Pius Brânzeu" Emergency County Hospital, Department of Nephrology, Timisoara, Romania

## Introduction

Epidermolysis bullosa (EB) is a rare inherited skin fragility disorder defined by blistering caused by mutations affecting the dermoepidermal junction. It can be classified into four main types: simplex, junctional, dystrophic (DEB), and Kindler EB. DEB is caused by mutations in the COL7A1 gene and can be dominant (DDEB) or recessive (RDEB). Secondary extracutaneous complications are common in the more severe forms of RDEB. Although potentially life-threatening, there are only a few case reports regarding secondary nephrological associations; one of these is renal amyloidosis.

## Case Presentation

A 19-year-old patient with a homozygous COL7A1 mutation (c.3140-2A>G), classified as likely pathogenic, was referred for facial, abdominal, scrotal, and lower limb oedema, as well as weight gain during a month of final exams. A skin biopsy performed at birth showed a subepidermal blister with inflammation. Cutaneous manifestations included multiple bullae, post-bullous erosions, crusts on the face, milia, scarring, and pseudosyndactyly, as well as mucosal involvement with oesophageal strictures and symblepharon. Extracutaneous associations included reduced mobility, hypocalcaemia, anaemia, and constipation. The patient was also known to have coeliac disease and lactose intolerance. He presented with nephrotic syndrome (2233 mg/m$^2$/1.73), hypoproteinaemia, hypoalbuminaemia, pleural effusion, a marked inflammatory syndrome, and lack of response to systemic corticosteroid therapy. Abdominal ultrasound showed increased echogenicity of the liver and bilateral kidneys.

A renal biopsy was performed, confirming amyloidosis, with positive Congo red staining observed under polarised light, and colchicine treatment was initiated. A central venous catheter was inserted due to the need for albumin administration. This led to more difficult wound management and persistent inflammation. Despite supportive management, the patient's condition progressively deteriorated, and he ultimately died from complications related to systemic disease.

**Conclusion**

**:** Sustained inflammation leads to increased serum amyloid A protein levels, which can result in progressive amyloid deposition in various organs. This highlights the importance of optimal wound care and careful monitoring of complications, including renal involvement, in patients with EB. In addition, amyloidosis should be actively investigated in patients with chronic inflammatory states such as EB, and may warrant consideration as a routine screening component in severe forms. Phenotype–genotype correlations may add value not only to prevention or early recognition, but also to management strategies.

EADV CONGRESS
VIENNA
30 SEP - 3 OCT 2026

**Abstract N°: 1936**

# Multifocal Neonatal Congenital Cutaneous Aplasia: A Revealing Presentation of Bart Syndrome

Ouissal Laadime*[1], Mariem Aboudourib[1], Bendaoud Layla[1], ouafa hocar[1], Amal Said[1]

[1] Department of Dermatology and Venereology, Arrazi Hospital, Mohammed VI University Hospital Center, Marrakech, Morocco

## Introduction

Congenital cutaneous aplasia (CCA) is a rare defect characterized by localized or extensive absence of skin at birth. It may occur as an isolated condition or be part of genetic syndromes, particularly Bart syndrome, which associates CCA with epidermolysis bullosa. Management and prognosis depend on the extent of skin involvement and associated anomalies.

## Case Presentation

We report the case of a male neonate examined at one hour of life, born at term from a first-degree consanguineous marriage and an uncomplicated pregnancy. A significant family history was noted, with neonatal death of a sibling on day 7 of life in a similar context. No maternal drug exposure, particularly to antithyroid medications, was reported.

On general examination, the newborn was in good condition (pink complexion, reactive, good axial and peripheral tone). Dermatological examination revealed multifocal congenital cutaneous aplasia involving 10 sites, including both hands, both elbows, both knees, the right leg, both feet, the nose, and the mouth. No blistering lesions or skin detachment were initially present. However, on day 2 of life, cutaneous detachment appeared on the dorsal aspect of the left hand, suggesting possible Bart syndrome.

Management included strict supportive care with prevention of hypothermia and dehydration, daily local wound care using sterile vaseline gauze, and avoidance of mechanical trauma. Malformative workup (transfontanellar ultrasound, echocardiography, abdominal ultrasound, ophthalmological examination, and limb radiographs) was unremarkable. The clinical course was unfavorable, with death occurring on day 5 of life.

## Conclusion

This case illustrates a severe form of multifocal congenital cutaneous aplasia, likely syndromic, occurring in a context of consanguinity and similar family history. The secondary appearance of skin detachment supports the diagnosis of Bart syndrome. Prognosis remains poor in extensive forms, highlighting the importance of early diagnosis, multidisciplinary management, and genetic counseling.

EA DV CONGRESS
VIENNA
30 SEP - 3 OCT 2026

**Abstract N°: 1951**

**Trichorrhexis Invaginata as a Diagnostic Clue in Early-Onset Netherton Syndrome**

Ina Sotiri*[1], Alesja Palaj[1], Oljeda Kaçani[1], Lejdis Zeneli[1], Monika Fida[1]

[1] University Hospital Center "Mother Teresa", Tirana, Albania

**Introduction**

Netherton syndrome is a rare autosomal recessive disorder characterized by the triad of congenital ichthyosiform erythroderma or severe atopic dermatitis–like skin involvement, atopic diathesis, and hair shaft abnormalities, most notably trichorrhexis invaginata. Early diagnosis is often challenging due to its clinical overlap with severe atopic dermatitis in infancy and the delayed appearance of hair shaft changes.

**Case Presentation**

We report a 2-year-old girl presenting with severe, persistent eczema since early infancy, poorly responsive to emollients and topical corticosteroids. The dermatitis was diffuse, intensely pruritic, and clinically consistent with severe atopic dermatitis. The patient also had multiple confirmed food allergies, indicating a marked atopic diathesis.

Given the early onset, refractory course, and prominent allergic manifestations, a syndromic condition was suspected. Clinical examination of the scalp revealed short, fragile hairs. Trichoscopic evaluation demonstrated trichorrhexis invaginata, characterized by invagination of the distal hair shaft into its proximal portion, producing the typical “ball-and-socket” or bamboo-like appearance. The presence of trichorrhexis invaginata, in association with severe eczema and atopic features, established the diagnosis of Netherton syndrome.

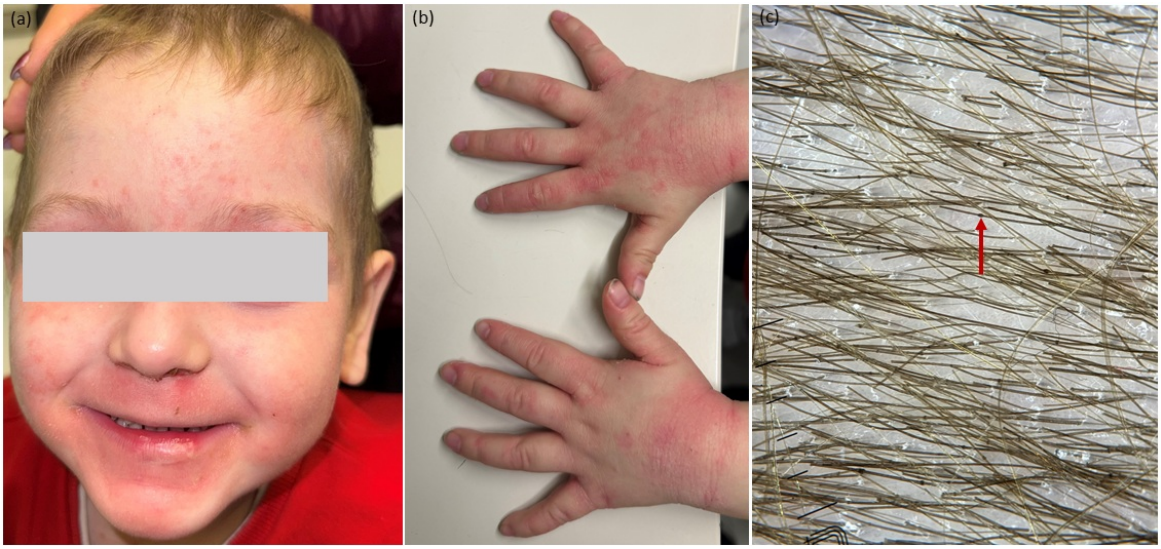


Figure 1. Clinical and trichoscopic features of Netherton syndrome. (a, b) Severe eczematous dermatitis involving the face and hands, characterized by diffuse erythema, xerosis, and excoriations. (c) Trichoscopic examination revealing trichorrhexis invaginata, with the characteristic “bamboo hair" appearance resulting from invagination of the distal hair shaft into its proximal portion.

**Conclusion**

Netherton syndrome may initially mimic severe atopic dermatitis, leading to delayed diagnosis in early childhood. Hair shaft abnormalities can be focal and easily overlooked, requiring careful and repeated examination. Identification of trichorrhexis invaginata, a pathognomonic feature, is crucial for confirming the diagnosis. This case highlights the importance of considering Netherton syndrome in children with early-onset, therapy-resistant eczema and pronounced atopy, enabling timely diagnosis, appropriate management, and genetic counseling.

EADV CONGRESS
VIENNA
30 SEP - 3 OCT 2026

**Abstract N°: 1956**

# The two faces of pseudoxanthoma elasticum: classic cutaneous presentation versus systemic manifestation without visible skin lesions — a report of two cases

Mariana Risso*[1], Iona Moreira[1], Luiza Zetone[1], Tifany Ito[1], João Pedro Carrijo Cunha Camara[1], Juliana Bertonha[1], Beatriz Farias[1], Amanda Ferrari[1], Giordanna Duarte[1], Thais Helena Proenca Freitas[1], Raynne Jozala[1]

[1] Irmandade de Misericórdia da Santa Casa de São Paulo, São Paulo, Brazil

## Introduction

Pseudoxanthoma elasticum (PXE) is a rare autosomal recessive genodermatosis caused by biallelic mutations in the ABCC6 gene, resulting in impaired secretion of inorganic pyrophosphate and subsequent progressive mineralization of elastic fibers. Its clinical triad involves the skin, eyes, and cardiovascular system, with a broad phenotypic spectrum that can challenge timely diagnosis.1,2 We report two cases with contrasting presentations, highlighting the importance of dermatological evaluation across the full clinical spectrum of the disease.

## Case Presentation

***Case 1***

A 22-year-old woman presented with asymptomatic whitish-yellowish papules on the neck since childhood, seeking evaluation due to concern about possible systemic associations. She had no personal or family history of relevant disease. Dermatological examination revealed multiple small, slightly elevated, smooth-surfaced papules, whitish-yellowish in color, confluent into reticulated plaques with mild cutaneous laxity over the entire cervical region. No flexural involvement or mucosal changes were noted. Skin biopsy with hematoxylin-eosin staining showed accumulations of swollen, irregularly aggregated fibers in the mid-dermis consistent with altered elastic fibers, and a discrete perivascular lymphocytic infiltrate, with preserved epidermis. Ophthalmological evaluation, including fundoscopy, and cardiological assessment were subsequently performed at our institution, with no abnormalities identified in either. The patient remains under multidisciplinary surveillance.

***Case 2***

A 46-year-old woman was referred to our service after PXE diagnosis confirmed at an external centre by whole-exome sequencing, identifying a pathogenic ABCC6 variant. Investigation had been triggered by an ischemic stroke eight years prior, refractory hypertension, and a positive maternal family history of PXE. Dermatological examination revealed no visible cutaneous lesions. External skin biopsies showed: posterior cervical skin (August 2019) with preserved epidermis and moderate elastic fiber disorganization and fragmentation throughout the full dermal thickness on hematoxylin-eosin, without evident calcification; and labial mucosa (February 2020) with intense collagen fiber fragmentation in the lamina propria on resorcin-fuchsin staining. Fundoscopic examination performed at our service showed no abnormalities, with no angioid streaks or other ocular manifestations identified. Cardiological assessment is currently pending. The patient will remain under ongoing multidisciplinary surveillance.

## Conclusion

These cases illustrate the phenotypic heterogeneity of PXE. While Case 1 followed the classic dermatological route — visible cutaneous lesions leading to diagnosis — Case 2 demonstrates that systemic events such as early stroke and refractory hypertension may be the presenting features, even in the absence of macroscopic skin changes. Histopathological examination of clinically normal skin and mucosal sites proved essential in Case 2, reinforcing the value of biopsy even when cutaneous signs are absent.3,4 Molecular genetic testing confirmed the diagnosis and enabled family screening, underscoring its role in atypical presentations.5 The complete absence of cutaneous lesions in a genetically confirmed PXE patient is a well-recognized but underappreciated phenomenon.6 Notably, both patients had normal fundoscopic findings at the time of evaluation, consistent with early or subclinical disease, and highlighting the need for periodic ophthalmological follow-up regardless of initial results.7,8 No disease-modifying therapy is currently available; management remains preventive and multidisciplinary.9,10 The dermatologist is central to the

diagnostic pathway of PXE — both in recognizing its classic cutaneous stigmata and in investigating systemic presentations through targeted skin biopsy.

EA DV CONGRESS
VIENNA
30 SEP - 3 OCT 2026

**Abstract N°: 1958**

## Dysregulation of the HOTAIR/miR-34a-3p/TNF-α Axis in Rosacea

Alp Eren Köroğlu*[1], Emine Tugba Alatas[1], Çilem Özdemir[2], Tuba Edgünlü[3]

[1] Muğla Sıtkı Koçman University, Faculty of Medicine, Department of Dermatology, Muğla, Türkiye
[2] Muğla Sıtkı Koçman University, Graduate School of Natural and Applied Sciences, Department of Bioinformatics, Muğla, Türkiye
[3] Muğla Sıtkı Koçman University, Faculty of Medicine, Department of Medical Biology, Muğla, Türkiye

### Introduction

Rosacea is a chronic inflammatory skin disease characterized by erythema, telangiectasia, papules, and pustules primarily affecting the central region of the face. This study aimed to investigate the molecular interactions between the pro-inflammatory cytokine TNF-α, a key mediator of the inflammatory response in rosacea, and the epigenetic regulators lncRNA HOTAIR and miR-34a-3p. In this context, the expression levels of these molecules were comparatively evaluated between rosacea patients and healthy control individuals.

### Materials and Methods

The study included 40 patients diagnosed with erythematotelangiectatic rosacea (ETR) and 44 healthy controls. Expression levels of TNF-α, HOTAIR, and miR-34a-3p were determined from peripheral blood samples using quantitative real-time PCR (qRT-PCR). Relative expression levels were calculated using the $2^{-\Delta\Delta Ct}$ method (Figure 1).

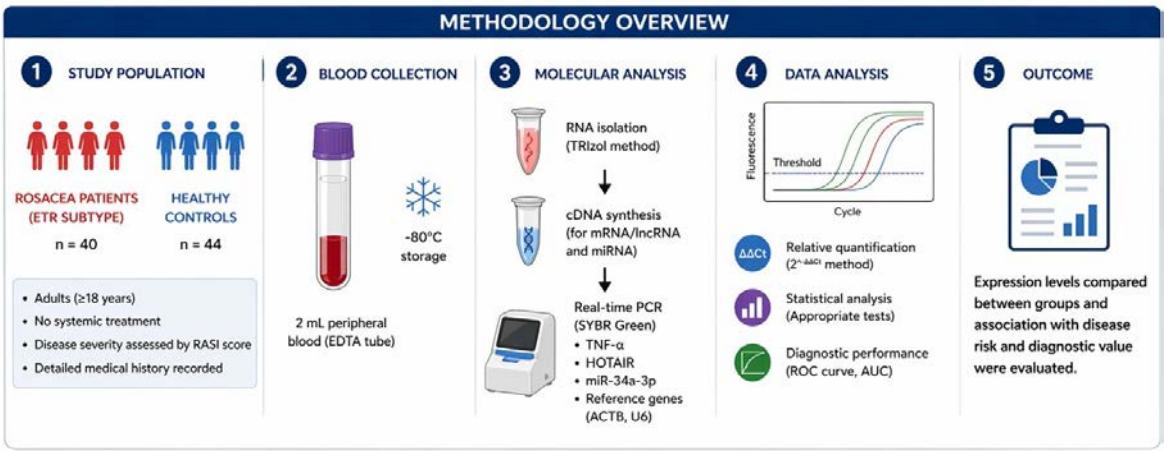


Figure 1. Schematic Overview of the Study Design and Methodology

### Results

According to the findings, TNF-α and HOTAIR expression levels were significantly increased in rosacea patients compared to the control group (2.91-fold, $p$= 0.022; and 1.43-fold, $p$= 0.025, respectively). In contrast, miR-34a-3p levels were lower in the patient group; however, this difference was not statistically significant ($p$= 0.096) (Figure

2A–C). In logistic regression analysis, miR-34a-3p showed a trend toward a protective effect against disease risk (OR= 0.921; *p*= 0.051). In diagnostic performance analysis, although individual biomarkers demonstrated moderate effectiveness, the combined model including all three molecules showed improved diagnostic performance, with an AUC value of 0.702 (Figure 2D). Correlation analyses revealed that the strong and statistically significant positive correlation between miR-34a-3p and TNF-α observed in the healthy control group (ρ= 0.718; *p*< 0.001) weakened and lost significance in the rosacea group (ρ= 0.32;*p*= 0.065). Additionally, while a positive trend was observed between HOTAIR and miR-34a-3p in the control group, this relationship shifted toward a negative direction in the patient group.

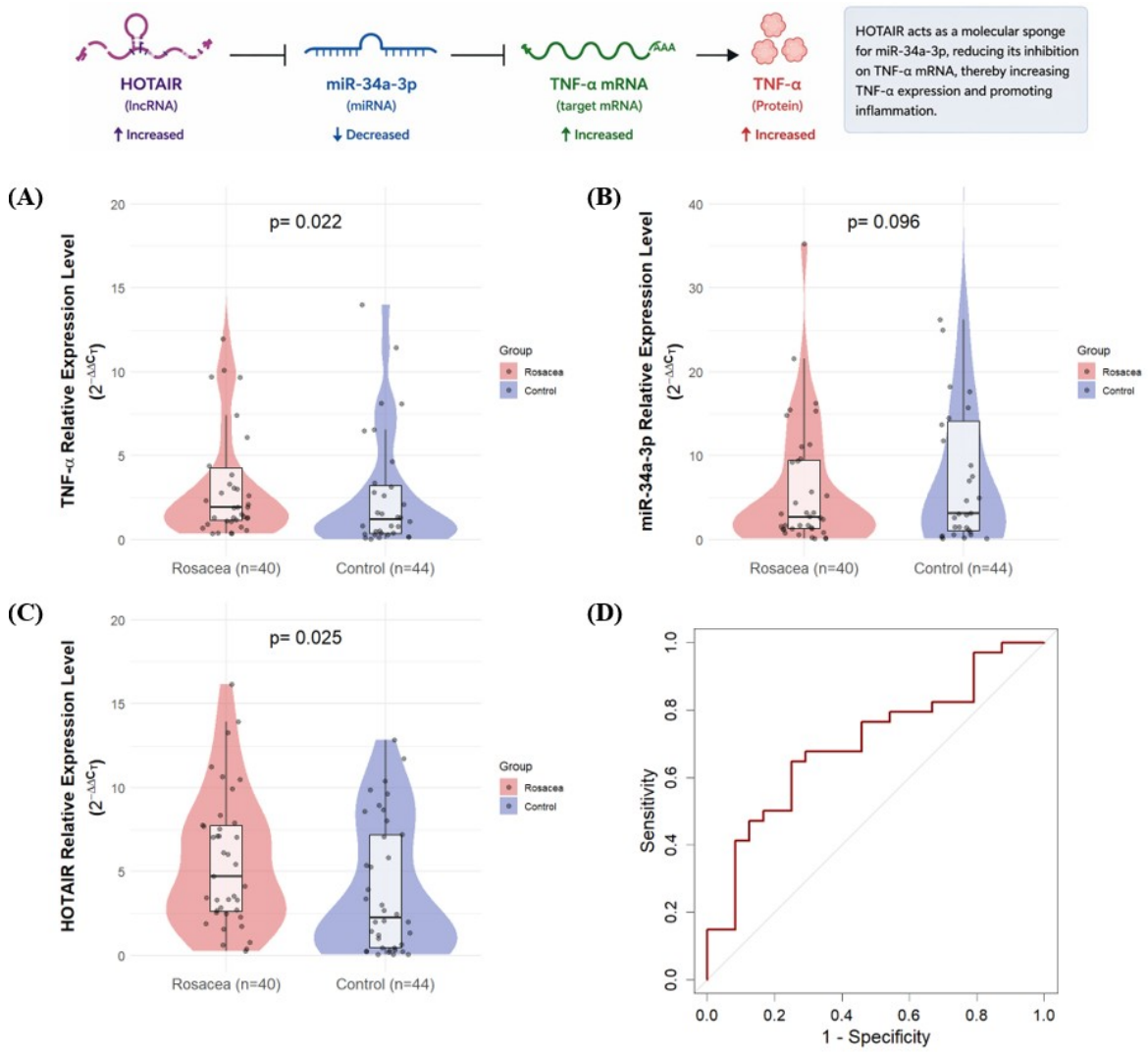


Figure 2. Expression levels of TNF-α, miR-34a-3p, and HOTAIR in rosacea and control groups, and diagnostic performance of the combined model. (A) TNF-α , (B) miR-34a-3p and (C) HOTAIR expression levels are significantly increased in rosacea patients compared to controls (p= 0.022, p= 0.096 and p= 0.025, respectively), (D) ROC curve of the combined model (AUC= 0.702)

**Conclusions**

In conclusion, this study demonstrates that TNF-α-associated inflammation in rosacea is not only related to cytokine-level alterations but also to the dysregulation of epigenetic regulators such as HOTAIR and miR-34a-3p. These findings highlight the regulatory role of lncRNA–miRNA interactions in rosacea pathogenesis and suggest that these molecules may serve as potential biomarkers and therapeutic targets in future studies.

**Funding:** The research was supported by Muğla Sıtkı Koçman University Research Support and Funding Office (Grant No: 25/43).

EADV Congress 2026, VIENNA
30 SEPTEMBER - 03 OCTOBER 2026
POWERED BY M-ANAGE.COM

EA DV CONGRESS
VIENNA
30 SEP - 3 OCT 2026

**Abstract N°: 1965**

# A Case of Methylmalonic Aciduria with Homocystinuria (CblJ type) Presenting as Generalized Hyperpigmentation of the Skin in a Filipino Adolescent Female

Krisha Lim*[1], Juan Antonio Poblador[1], Carmela Augusta Dayrit-Castro[1]

[1] University of the Philippines-Philippine General Hospital, Manila, Philippines

## Introduction

Methylmalonic aciduria with homocystinuria (MAH) is a rare autosomal recessive metabolic disorder that may be missed on newborn screening. The cblJ type, caused by mutations in the *ABCD4* gene, disrupts intracellular cobalamin transport, preventing its release from the lysosome to the cytoplasm and rendering it unavailable for metabolic processes. This defect impairs pathways involved in amino acid and lipid metabolism, leading to the accumulation of homocysteine and methylmalonic acid, with consequent haematologic and neurologic manifestations. Reduced intracellular glutathione levels may further contribute to dysregulated melanogenesis through loss of tyrosinase inhibition, resulting in cutaneous hyperpigmentation. We present a case of methylmalonic aciduria with homocystinuria, cblJ type (MAHCJ), representing the ninth reported case in the literature and, to our knowledge, the first documented case in a Filipino patient.

## Case Presentation

A 12-year-old Filipino female presented with generalized, mottled truncal hyperpigmentation interspersed with discrete, round hypomelanotic macules. Lesions were first noted on the bilateral distal extremities within the first two weeks of life, subsequently involving the proximal extremities, trunk, and face by one year of age. Premature greying of the scalp hair and hyperaccentuation of pigmentation over distal joints were also observed. There was no associated pruritus, scaling, skin tightening, Raynaud's phenomenon, arthralgia, microstomia, or dysphagia. Previous consultations with multiple dermatologists did not yield a definitive diagnosis. Birth history and newborn screening were unremarkable. The patient is the first of three children born to a healthy couple, with possible consanguinity reported (great-grandparents potentially being cousins), although this could not be confirmed.

Anthropometric parameters were within normal limits. Comprehensive physical examination revealed no craniofacial, thoracic, cardiovascular, abdominal, or musculoskeletal abnormalities. An initial working diagnosis of dyschromatosis universalis hereditaria was considered based on clinical features and skin biopsy findings.

To establish a definitive diagnosis, whole genome sequencing was performed, revealing a rare missense variant in the *ABCD4* gene, consistent with methylmalonic aciduria with homocystinuria, cblJ type (MAHCJ). This variant has been previously reported in a limited number of cases and is associated with a milder, predominantly cutaneous phenotype. Laboratory evaluation demonstrated markedly elevated serum homocysteine levels and low cobalamin levels, with trace urinary methylmalonate, supporting the revised diagnosis.

The patient was initiated on oral mecobalamin, folic acid, vitamin B6, and betaine which improved her laboratory parameters.

## Conclusion

This case represents, to our knowledge, the first reported Filipino patient and the ninth case worldwide of

methylmalonic aciduria with homocystinuria, cblJ type. Diagnosis may be challenging, particularly when newborn screening is unremarkable and systemic manifestations are absent, as this subtype can present predominantly with generalised cutaneous hyperpigmentation. This case underscores the importance of considering inherited metabolic disorders in the differential diagnosis of pigmentary abnormalities. Early recognition and confirmation through genetic and biochemical testing are essential to enable timely initiation of appropriate supplementation, which may improve clinical outcomes.

EA DV CONGRESS
VIENNA
30 SEP - 3 OCT 2026

**Abstract N°: 1976**

# Bannayan–Riley–Ruvalcaba Syndrome: An Uncommon PTEN Hamartoma Tumor Syndrome Phenotype

Amanda Tanaka Iasbeck Gonçalves*[1], Carolina Cruz[1], Ana Clara Maia Palhano[1], Bruna Polito Teixeira[1], Luciana de Paula Samorano[1], Maria Cecília Rivitti-MacHado[1], Zilda Najjar Oliveira[1]

[1] Universidade de São Paulo, São Paulo, Brazil

## Introduction

Bannayan–Riley–Ruvalcaba syndrome (BRRS) is a rare autosomal dominant overgrowth disorder associated with pathogenic variants in the *PTEN* gene located on chromosome 10q23.31, identified in up to 60% of affected individuals.[1] BRRS is part of the *PTEN* hamartoma tumor syndrome (PHTS) spectrum and is therefore associated with an increased risk of malignancy. Clinically, it is characterized by macrocephaly; hamartomatous, lipomatous, or vascular lesions; pigmented macules of the genitalia (most commonly involving the penile glans); intestinal polyposis; and neurodevelopmental manifestations, including developmental delay and autism spectrum disorder.[2] Management options are limited and primarily consist of longitudinal clinical surveillance, with particular emphasis on age-appropriate cancer screening.[3]

## Case Presentation

Two brothers, aged 12 and 23 years, presented with pigmented macules on the penile glans. Their head circumferences measured 61 cm and 62 cm, respectively, consistent with macrocephaly. The older brother (Patient 1) was found to carry a heterozygous mutation in exon 5 of the PTEN gene. Colonoscopic evaluation revealed hyperplastic polyps. He underwent total thyroidectomy at 17 years of age for suspected thyroid neoplasia; however, histopathological examination demonstrated multinodular non-toxic goiter. Other findings included a pilonidal cyst.The younger brother (Patient 2) underwent total thyroidectomy at 10 years of age, with histopathological confirmation of invasive follicular carcinoma (pT1a). He is currently undergoing evaluation for possible metastatic disease in the context of pulmonary nodules.

## Conclusion

Bannayan–Riley–Ruvalcaba syndrome (BRRS) is a rare autosomal dominant disorder typically diagnosed in childhood. It is associated with pathogenic variants in *PTEN*, a tumor suppressor gene that regulates cellular metabolism, growth, and proliferation primarily through negative regulation of the PI3K–AKT signaling pathway; such variants are identified in approximately 60% of cases.[2] Dysregulation of this pathway underlies a group of overgrowth conditions collectively referred to as *PTEN* hamartoma tumor syndrome (PHTS), which are characterized by multiple hamartomas, developmental abnormalities, and an increased risk of malignancy. The PHTS spectrum includes, among others, Cowden syndrome (CS), Proteus syndrome, Lhermitte–Duclos disease, and BRRS. Given their shared molecular basis—germline *PTEN* variants at 10q23.31—CS and BRRS are increasingly considered phenotypic variants along a single disease continuum, with variable expressivity and age-dependent penetrance.[4] Notably, approximately 8% of individuals without identifiable *PTEN* variants present pathogenic alterations in other cancer-predisposition genes, including *MUTYH, RET, TSC2, BRCA1, BRCA2, ERCC2,* and *HRAS*.[5] Macrocephaly, defined as a head circumference ≥97th percentile, is the most consistent clinical feature, reported in 80–100% of patients with BRRS.[2] Additional common findings include pigmented macules of the genitalia (particularly of the penile glans), lipomas, intestinal polyposis, thyroid abnormalities, and neurodevelopmental

manifestations such as developmental delay or autism spectrum disorder.[2] Vascular malformations and other cutaneous findings are less frequent. Although genital lentigines are often regarded as pathognomonic, they may emerge in childhood or only during adolescence; therefore, their absence does not exclude the diagnosis.[3] Given the underlying *PTEN* mutation and the associated increased risk of malignancy, management of BRRS is centered on long-term surveillance, including age- and risk-adjusted cancer screening strategies guided by family history and clinical findings (Table 1).[2,6,7] Early recognition, implementation of appropriate surveillance protocols, and multidisciplinary management are essential for timely diagnosis and treatment of malignancies, reducing morbidity and improving patient outcomes.

| System | Recommendation | Age at onset | Frequency | Patient 1 | Patient 2 |
|---|---|---|---|---|---|
| **General** | Clinical history, physical examination (including thyroid); patient education | 18 years or earlier based on family history | Annual / ongoing | Annual | Annual |
| **Breast (female)** | Breast self-awareness and self-examination | 18 years | Monthly | N/A | N/A |
| | Clinical breast examination | 25 years | Every 6–12 months | N/A | N/A |
| | Mammography ± breast MRI | 30–35 years or 5–10 years before earliest family case | Annually | N/A | N/A |
| **Thyroid** | Thyroid ultrasound | 7–12 years (or at diagnosis) | Every 2–5 years (shorter if nodules) | Nontoxic multinodular goiter with pseudopapillary colloid hyperplasia; largest nodule: follicular adenoma | Invasive follicular carcinoma involving the left lobe and isthmus |
| | TSH (optional) | 18 years | Consider annually | N/A | N/A |
| **Gastrointestinal** | Colonoscopy | 35–40 years | Every 5 years (1–3 years if high risk) | Hyperplastic polyps | N/A |
| **Endometrium** | Symptom awareness; evaluation of abnormal uterine bleeding | 30–35 years | Ongoing | N/A | N/A |
| | Transvaginal ultrasound ± biopsy if symptomatic | ≥30–35 years | As indicated | N/A | N/A |
| **Renal** | Renal ultrasound | 35–40 years | Every 2 years | N/A | N/A |
| **Skin** | Dermatologic examination | At diagnosis | Annually | Macrocephaly (62 cm); genital lentigines | Macrocephaly (61 cm); genital lentigines; pilonidal cyst |
| **CNS/Developmental** | Psychomotor assessment; brain MRI if symptomatic | At diagnosis | As indicated | No changes | No changes |
| **Genetic** | Genetic counseling | At diagnosis | Ongoing | PTEN exon 5 heterozygous mutation | Ongoing |

Table 1. Recommended screening for patients with BRRS and clinical data of the present patients. Abbreviations: N/A, not applicable; MRI, magnetic resonance imaging; TSH, thyroid-stimulating hormone; CNS, central nervous system.

**Abstract N°: 2006**

# Severe metabolic imbalance unveiled by eruptive xanthomas in Prader–Willi syndrome: a clinical case

Ingrid Palloma Vieira de Melo*[1], João Henrique Aurich[1], José de Almeida[1], Sandra e Dinato[1]

[1] Centro Universitário Lusíada, Santos, Brazil

## Introduction

Prader–Willi syndrome is a rare genetic disorder characterized by neonatal hypotonia, hyperphagia with progressive obesity, endocrine abnormalities, and neurodevelopmental impairment. The metabolic disturbances associated with obesity and insulin resistance frequently predispose these patients to complications such as severe dyslipidemia, which may remain unrecognized.

Eruptive xanthomas are characterized by the sudden onset of erythematous-yellow papules, most commonly located on extensor surfaces, and are strongly associated with marked hypertriglyceridemia. These lesions may serve as an important cutaneous indicator of underlying metabolic dysfunction. Reports describing this manifestation in patients with Prader–Willi syndrome are scarce, reinforcing the relevance of clinical recognition.

## Case Presentation

A 14-year-old girl with Prader–Willi syndrome was referred to a tertiary dermatology service due to the recent onset of multiple yellowish papules and papulo-nodules affecting the trunk, extremities, and gluteal region, evolving over approximately two weeks, without associated symptoms.

On examination, the distribution and morphology of the lesions were consistent with eruptive xanthomas. Histopathological analysis confirmed the diagnosis, revealing dermal infiltration by lipid-laden foamy histiocytes and extracellular lipid deposits.

Laboratory evaluation showed profound metabolic derangement, including severe hypertriglyceridemia (triglycerides >4000 mg/dL), markedly elevated total cholesterol (>900 mg/dL), significant hyperglycemia (glucose >300 mg/dL, HbA1c up to 15.2%), reduced HDL levels, and proteinuria, consistent with metabolic syndrome.

Therapeutic management included metformin and glibenclamide for glycemic control, along with ciprofibrate and atorvastatin for lipid reduction. The patient showed progressive clinical improvement, with regression of cutaneous lesions and residual post-inflammatory hyperpigmentation. She remains under multidisciplinary follow-up.

## Conclusion

Eruptive xanthomas may act as a visible marker of severe metabolic imbalance in individuals with Prader–Willi syndrome. Prompt recognition of these lesions allows early identification and treatment of potentially life-threatening metabolic disturbances. This case emphasizes the role of dermatological findings as a gateway to the diagnosis of systemic disease.

EA DV CONGRESS
VIENNA
30 SEP - 3 OCT 2026

**Abstract N°: 2013**

# Giant Congenital Melanocytic Nevus Covering 50% Body Surface Area with Multiple Satellite Lesions in a 4-Month-Old Infant: A Case Report

Marufa Shahrin*[1]

[1] Bangladesh Medical University, Dhaka, Bangladesh

## Introduction

This case highlights a rare presentation of extensive Giant Congenital Melanocytic Nevus with significant body surface involvement and satellite lesions. Early multidisciplinary evaluation, baseline neuroimaging, and long-term surveillance are essential to detect complications and guide management. Individualized treatment strategies, including surgical and laser modalities, should be considered based on lesion characteristics and risk profile.Giant Congenitl Melanocytic Nevus results from aberrant proliferation of melanocytes, potentially mediated via pathways such as the RAS–RAF–MAPK cascade. Risk factors for malignant transformation include large size, axial distribution, and presence of multiple satellite lesions. Early-life melanoma risk remains significant, necessitating vigilant monitoring.



A 4month infant of Giant Congenital Melanocytic Nevus.

## Case Presentation

A 4-month-old female infant, born at term via normal vaginal delivery to a primigravida mother from a non-consanguineous marriage, presented with extensive pigmented lesions since birth. There was no relevant family history. Cutaneous examination revealed a large, dark brown to black pigmented patch involving approximately 50% of the body surface area, affecting the scalp, neck, back, thighs, and legs. Multiple satellite lesions (4–5 cm) were distributed over the trunk and extremities. Areas of hypertrichosis with coarse hair were noted, particularly over the posterior neck and back. Systemic evaluation showed a small ostium secundum atrial septal defect and a small patent ductus arteriosus on echocardiography. CT scan of the head showed no intracranial involvement. Abdominal ultrasonography, spinal X-ray, and fundoscopic examination were unremarkable. Histopathology confirmed congenital melanocytic nevus without evidence of malignant transformation.



A 4month infant of Giant Congenital Melanocytic Nevus.

**Conclusion**

This case highlights a rare presentation of extensive Giant Congenital Melanocytic Nevus with significant body surface involvement and satellite lesions associated with congenital Heart disease. Early multidisciplinary evaluation, baseline neuroimaging, and long-term surveillance are essential to detect complications and guide management. Individualized treatment strategies, including surgical and laser modalities, should be considered based on lesion characteristics and risk profile.

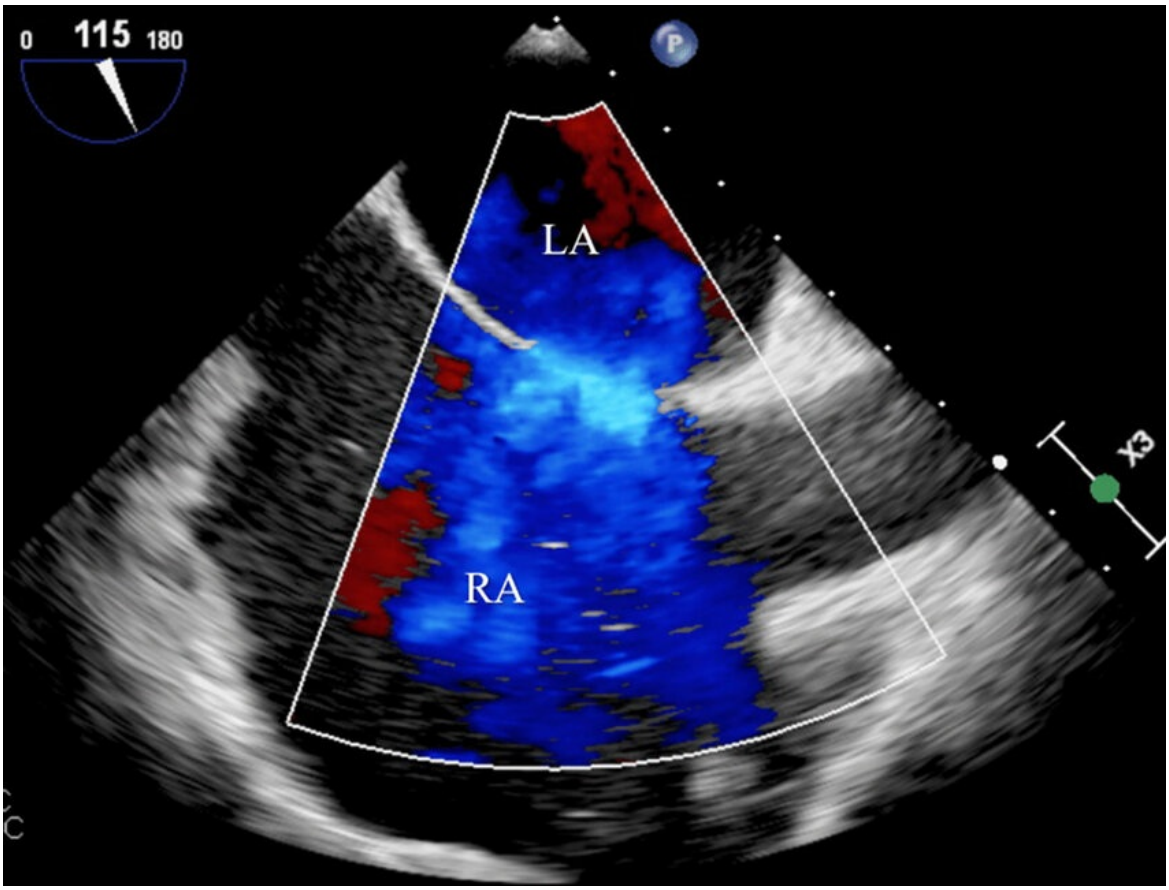


Color Doppler Echocardiography showed A small ostium secundum ASD (size: 2mm) with L-R shunt and a small Patent Ductus Arteriosus.

EA DV CONGRESS
VIENNA
30 SEP - 3 OCT 2026

**Abstract N°: 2032**

**Shadows and capillaries: An unusual dermatologic challenge**

Luisa Montenegro[1], mariana tamayo[2], Sara Catano*[3], Maribel Trujillo[1]

[1] Hospital de la Misericordia, Bogotá, Colombia
[2] Hospital Militar Central, Bogotá, Colombia
[3] Pontificia Universidad Javeriana, Bogotá, Colombia

**Introduction**
Phacomatosis pigmentovascularis (PPV) is a rare congenital mosaic disorder characterized by the coexistence of capillary vascular malformations and dermal melanocytosis, most commonly associated with postzygotic activating mutations in GNAQ and GNA11 affecting the Gαq signaling pathway. In contrast, the PIK3CA-related overgrowth spectrum (PROS) comprises mosaic disorders driven by activation of the PI3K/AKT/mTOR pathway, resulting in segmental overgrowth, vascular malformations, and frequent neurological involvement, including megalencephaly and cortical abnormalities. While both entities are well defined, their potential overlap remains poorly characterized and raises the possibility of complex or dual mosaicism involving distinct developmental pathways.

**Case Presentation**
An 8-year-old male presented with congenital cutaneous findings. Physical examination revealed a facial capillary malformation (nevus flammeus) associated with nevus of Ota, as well as extensive dermal melanocytosis involving the trunk and extremities, with areas of overlap between pigmentary and vascular lesions. Mild body asymmetry was also observed.

These findings supported a diagnosis of phacomatosis pigmentovascularis. Given the extent and distribution of lesions, further evaluation was performed. Brain magnetic resonance imaging demonstrated marked asymmetry of the right cerebral hemisphere due to hemispheric enlargement, associated with ipsilateral prominence of vascular structures, including the carotid artery and middle cerebral artery. Additionally, a developmental venous anomaly was identified in the right cerebellar hemisphere.

These imaging findings raised suspicion for hemimegalencephaly. However, neuropediatric evaluation did not reveal seizures, developmental delay, or focal neurological deficits.

The coexistence of classical PPV cutaneous features with cerebral overgrowth and vascular anomalies—findings more typically associated with PROS, particularly megalencephaly–capillary malformation—suggests an atypical and potentially overlapping phenotype.

**Conclusion**
This case highlights an unusual association between phacomatosis pigmentovascularis and cerebral structural abnormalities suggestive of the PIK3CA-related overgrowth spectrum. The presence of hemispheric enlargement and ipsilateral vascular prominence is not characteristic of classical PPV, in which neurological involvement is more commonly related to vascular malformations without significant parenchymal overgrowth, and instead aligns more closely with PI3K-driven overgrowth phenotypes characterized by tissue overgrowth rather than isolated vascular

anomalies.

These findings raise the possibility of underlying dual somatic mosaicism, in which independent postzygotic mutations affecting GNAQ/GNA11 and PIK3CA pathways coexist, leading to a blended clinical presentation involving both pigmentovascular and overgrowth features. Alternatively, this presentation may represent an expanded phenotypic spectrum of PPV with previously underrecognized neurological manifestations.

Although molecular confirmation was not available, this limitation is inherent to mosaic disorders, as low-level variants are frequently undetectable in peripheral blood and require high-sensitivity sequencing of affected tissue. Recognition of such phenotypic overlap is clinically relevant, as it may refine current classification frameworks, improve diagnostic accuracy, and guide targeted genetic testing strategies, with potential implications for pathway-directed therapies in complex vascular mosaic disorders.

EA DV CONGRESS
VIENNA
30 SEP - 3 OCT 2026

**Abstract N°: 2034**

## Gardner Syndrome -A case report

Elaine Alcalde*[1]

[1] Private Clinic Dra. Elaine Alcalde, Talara, Peru

### Introduction

Gardner's syndrome (GS) is a rare genetic disorder which is a variant of familial adenomatous polyposis (FAP). It is characterized by a coexistence of multiple intestinal polyps with bone and soft-tissue tumors, frequently impacted teeth or cutaneous and subcutaneous cystic lesions. The syndrome is caused by a mutation of the adenomatous polyposis coli gene (APC) located at chromosome 5q21. The majority of patients have a family history of this disorder [1, 2]. We demonstrate a male patient with this genetic syndrome, which had not been recognized for a long time.

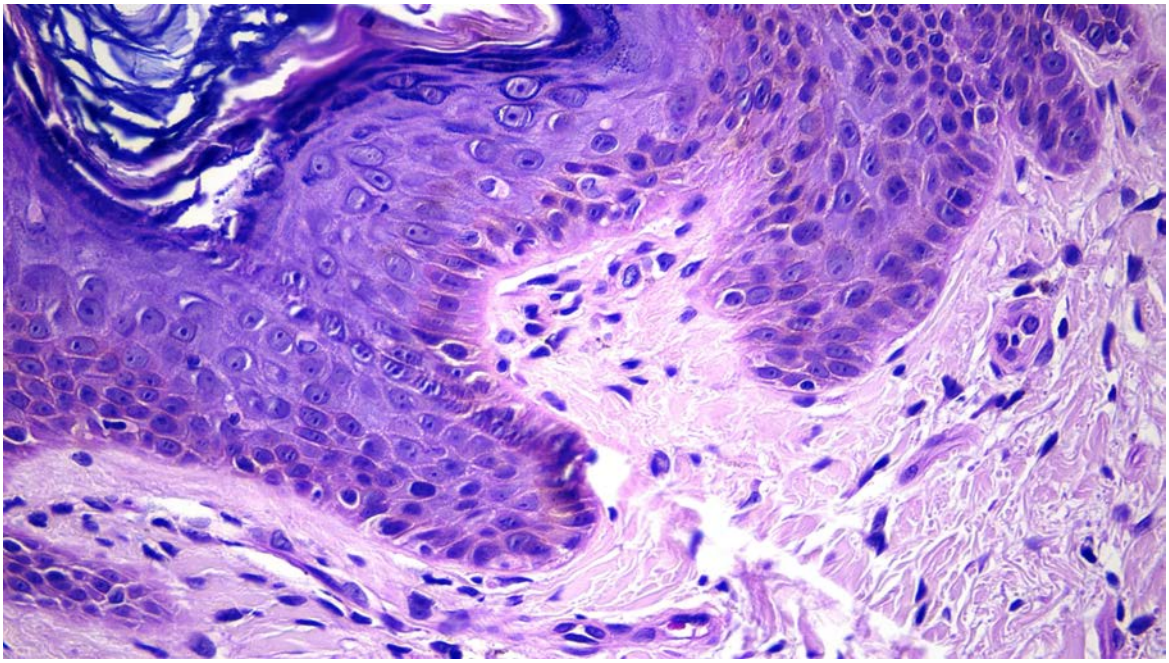

Infundibular dilation resembling an epidermal inclusion cyst, surrounded by fibrotic dermal stroma, with scant inflammatory lymphocytic infiltrate.

### Case Presentation

A 46-year-old female patient with multiple skin lesions on the neck, trunk and arms. Clinically, these cutaneous findings were giant nodules , 10–16 × 8-10 cm in size. All of them were palpable, soft and well circumscribed from the surrounding skin. An initial, clinical diagnosis of epidermoid cysts was further confirmed by histopathology (Figures 1, 2).

The first skin lesions appeared 12 years earlier . Since the beginning, the lesions have been localized predominately on the skin of the abdomen and gradually they started to spread over the trunk and into proximal surfaces of the neck and into proximal surfaces of the limbs. Presumptively, similar cutaneous findings were present in a father of our male patient. The man died 7 years earlier at the age of 54 due to a lung cancer and the skin lesions could not be investigated. The family

history also highlighted a stomach cancer in a grandmother (died 20 years earlier).

All these pathologies in the family motivated our male patient to examine herself for potential malignancies. Retrospectively, none abnormalities were detected in several diagnostic tests such as X-ray of the chest, ultrasound imaging (thyroid, abdominal and chest), as well as mammography. The most of laboratory blood measurements stayed within normal limits. CT scan did not reveal any pathologies, but >100 small polyps were detected at colonoscopy. Their histopathology provided a diagnosis of adenomatous polyps. Then, the patient was referred by a local surgeon to genetic tests towards mutations in the APC gene. All these cutaneous and colonic manifestations together with detected mutations in the APC gene provided a diagnosis of GS.

Due to the known extracolonic manifestations of GS, the patient was further referred to the otolaryngologist doctor, dentist and ophthalmologist. All of them, as well as dental X-ray, did not reveal any abnormalities

Further colonoscopy(repeated at 2 months) have still detected another polyps, however the patient has not agreed to preventive proctocolectomy suggested by surgeons. Fortunately, panendoscopy as well as other imaging tests have still remained free from pathologies

She was admitted to our Dermatology Clinic due to progressively appearing skin lesions to have them removed surgically, however for cosmetic reasons only.

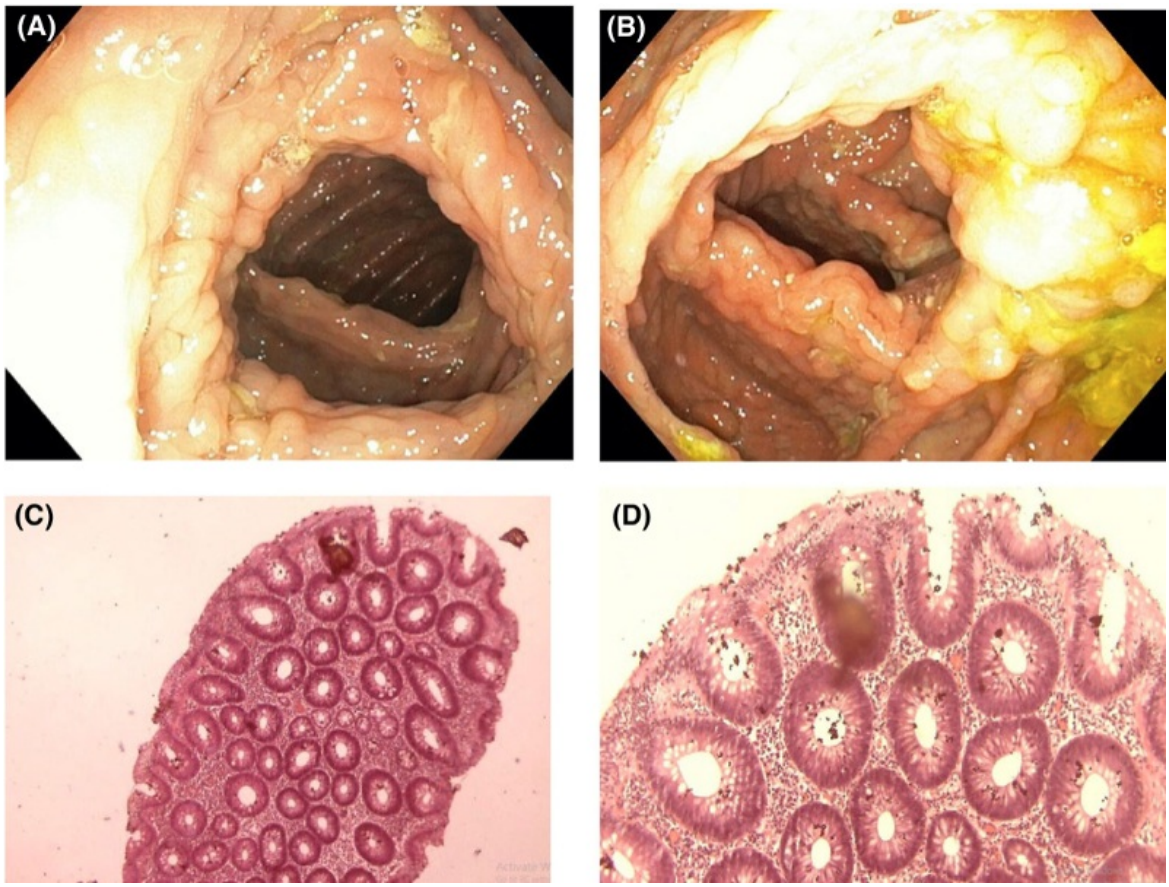


(A) and (B) are the endoscopic images of the transverse colon. (C) and (D) show the histological sections of the transverse colonic polyp at X40 and X100, respectively.

## Conclusion

This case represents a classical picture of Gardner's syndrome which is usually overlooked by many medical and dental professionals. This can be very unfortunate as intestinal polyps in this condition have 10% chance of malignant transformation. Our patient no have dental alteration, but he have a giant epidermoids cyst in neck , chest and arms and many colonic polips which are extirped in our clinic for cosmetical reason(Figure3). And colonic, and extracolonic manifestations may help in halting this dreaded disease from further progression. After the diagnosis of Gardner's

syndrome, the patients must be aggressively followed-up since there is a constant threat to their lives at any age.

EA DV CONGRESS
VIENNA
30 SEP - 3 OCT 2026

**Abstract N°: 2116**

**Brooke-Spiegler Syndrome: Case Report**

Paula de Oliveira Caetano Queiroz[1], Iollanda Nunes Faria[1], Mirian Lane de Oliveira Rodrigues Castilho*[1]

[1] IPM Pós, Goiânia, Goiás, Brazil

**Introduction**
Brooke-Spiegler syndrome (BSS) is a genodermatosis with autosomal dominant inheritance and variable penetrance, caused by mutations or loss of heterozygosity of the CYLD1 tumor suppressor gene located on chromosome 16q12-q13. It is a rare condition that frequently manifests during the second and third decades of life and is more commonly observed in females. It is characterized by a predisposition to the development of cutaneous adnexal neoplasms with different types of differentiation: eccrine, apocrine, follicular, and sebaceous. Lesions tend to appear progressively, with cylindromas of the scalp, facial trichoepitheliomas, and eccrine spiradenomas being particularly common. In addition to the classic adnexal tumors, patients with the syndrome may also present associated tumors, such as basal cell carcinomas, which increases the complexity of the clinical picture. The coexistence of different cutaneous neoplasms in this syndrome reinforces the importance of detailed and continuous dermatological evaluation for early recognition and treatment of lesions.

**Case Presentation**
A 64-year-old female patient with a history of hypertension and epilepsy reported the onset of multiple papulonodular, skin-colored or hyperpigmented, asymptomatic lesions of variable sizes on the face and scalp since the age of 21 years, with progressive increase in both number and size of the lesions between the second and third decades of life.

At the age of 26 years, she received her first diagnosis of skin cancer and underwent excision of approximately 10 suspicious lesions at that time. On physical examination, multiple papulonodular lesions and tumors were observed on the face, with fine surface telangiectasias, some multilobulated or with a pearly appearance. She also presented multiple pink papules and nodules on the scalp, with smooth and shiny surfaces, variable sizes, fibroelastic consistency, and surface telangiectasias.

Multiple excisional biopsies were performed, revealing cylindromas, basal cell carcinomas, and trichoepitheliomas. The patient returned after two months, and a new excisional biopsy was performed on the upper back, with diagnosis of cylindroma. Management included counseling on photoprotection measures using physical barriers and sunscreen containing photolyase, in addition to adjuvant therapy with oral nicotinamide. Clinical follow-up was chosen, with detailed dermoscopic examination every three months and surgical excision of new suspicious lesions. Genetic counseling was also provided, and the patient was referred to clinical oncology to evaluate the possibility of immunotherapy or targeted therapy.

**Conclusion**
As this is a rare genodermatosis, the importance of early recognition of Brooke-Spiegler syndrome should be emphasized. The typical clinical presentation, characterized by multiple progressively growing lesions predominantly affecting the cephalic region, associated with characteristic histopathological findings, is highly suggestive. Therapeutic management is challenging and should be individualized. Long-term clinical follow-up of

these patients is essential, both because of the aesthetic impact and the risk of new malignant lesions, as well as malignant transformation of initially benign lesions. In this context, multidisciplinary follow-up, especially involving dermatology and oncology, is fundamental for the early diagnosis of malignant and potentially malignant lesions, appropriate therapeutic decision-making, and improvement of quality of life. Lesions may be treated with electrosurgery, cryosurgery, or laser therapy; however, surgical excision is still considered the gold-standard treatment. Therefore, accurate diagnosis, early management, and continuous monitoring for possible complications are essential. Genetic counseling should also be recommended, considering the hereditary pattern of BSS.

EADV CONGRESS
VIENNA
30 SEP - 3 OCT 2026

**Abstract N°: 2137**

# A case report of primary erythromelalgia and exploration of misoprostol treatment

Fanny Gomarjoyo[1], Yanhua Liang*[1]

[1] Shenzhen Hospital of Southern Medical University, Shenzhen, China

## Introduction

Primary erythromelalgia (PEM) is a rare autosomal dominant neurovascular disorder characterised by the triad of burning pain, erythema and warmth of the extremities, typically triggered by heat and physical activity. The condition is caused by gain-of-function mutations in SCN9A, encoding the voltage-gated sodium channel Nav1.7. Approximately 30-40% of patients fail to respond to sodium channel blockers, representing a significant therapeutic challenge.

## Case Presentation

A 29-year-old woman presented with an 18-year history of recurrent severe burning pain, erythema and swelling affecting bilateral lower legs and hands. Symptoms were aggravated by heat and exercise, and partially relieved by cooling. Over the disease course, symptoms progressively worsened, complicated by severe skin ulcers with secondary MRSA and Candida parapsilosis infection. The patient's sister reported similar symptoms, suggesting autosomal dominant inheritance.

Genetic testing revealed a heterozygous SCN9A missense variant c.3947T>C (p.V1316A), previously associated with severe, early-onset, treatment-resistant PEM. Skin immunofluorescence demonstrated PGP9.5-positive nerve fibres but complete absence of Nav1.7, suggesting the mutation dramatically alters protein structure. Skin biopsy revealed thickened vascular basement membrane and endothelial cell proliferation, indicating chronic microvascular ischaemic changes.

Multiple pharmacological agents were trialed and failed, including mexiletine, carbamazepine, baclofen and nifedipine. Management initially focused on infection control with intravenous immunoglobulin, levofloxacin, topical potassium permanganate and oral voriconazole. Subsequently, oral misoprostol 200 microg once daily was initiated. Within 3 weeks, the burning sensation completely resolved, with VAS pain score decreasing from 7/10 to 0/10. Skin ulcers healed completely, erythema resolved, and the patient resumed normal daily activities with maintained improvement at follow-up.

## Conclusion

Misoprostol achieved complete remission in a patient with refractory PEM after 18 years of symptoms. Targeting secondary vascular pathology may be effective when sodium channel blockers fail. Prospective studies are warranted.

EADV CONGRESS
VIENNA
30 SEP - 3 OCT 2026

**Abstract N°: 2167**

# Fabry Disease in Two Egyptian Brothers: Angiokeratoma as a Diagnostic Clue and the Role of Family Screening

Nora Mohamed Abdelrazik*[1], Soheir Abdelgaber[2], Zahraa Abdelmonem[3], Mohammad Al-Haggar[3]

[1] Faculty of medicine, Mansoura University, Mansoura University Hospitals, Mansoura, Egypt
[2] Faculty of medicine, Mansoura University, , Mansoura University Hospitals, Mansoura, Egypt
[3] Faculty of medicine, Mansoura University, Mansoura University Children Hospital, Mansoura, Egypt

## Introduction

Fabry disease is an X-linked inborn error of metabolism due to deficient activity of α-galactosidase A (α-Gal A) enzyme, resulting in progressive multisystem involvement. The present report describes two Egyptian brothers with Fabry disease, confirmed by enzymatic and genetic testing, highlighting the diagnostic value of cutaneous findings and the importance of family screening, which identified both an asymptomatic carrier mother and an affected older brother. Following diagnosis, specific therapy was initiated.

## Case Presentation

A 14-year-old Egyptian boy presented to the dermatology clinic with a 7-year history of asymptomatic, progressive cutaneous lesions starting in the groin and spreading to the trunk and extremities. He also reported acroparesthesia and intolerance to heat and physical activity. Examination revealed coarse facies (broad nasal bridge, thickened lips, prominent earlobes) and numerous non-blanchable, dark red to blue-black papules over the trunk and extremities.

Dermoscopy showed multicolored lacunae with a bluish-white veil (Figure 1), and histopathology confirmed angiokeratoma (Figure 2). Additional findings included weight and height below the 5th percentile, delayed bone age (13.5 years), and microcytic hypochromic anemia. Systemic, ophthalmological, and hearing examinations were unremarkable. Given the constellation of these findings, Fabry disease was strongly suspected.

Family history was initially unremarkable with no early deaths. The patient was the fourth child of non-consanguineous parents and one of a dizygotic twin pair; his twin brother appeared unaffected. The patient was referred to the Genetics Unit for α-galactosidase enzyme assay and comprehensive diagnostic evaluation. Enzyme assay showed markedly decreased α-galactosidase A activity (0.1 µmol/L/h; normal >2.8). Genetic testing identified a missense mutation in a hemizygous state: c.467C>T, resulting in p.(Ala156Val) substitution, confirming Fabry disease.

## Family Screening

Genetic screening of all family members revealed that the older sister and dizygotic twin were normal. The mother and 2-year-older brother carried the same mutation. The older brother had undetectable enzyme activity (0.0 µmol/L/h) with minimal symptoms, including subtle angiokeratomas and mild heat intolerance that had never required medical attention. Slit lamp examination revealed bilateral cornea verticillata and tortuous retinal vessels without visual complaints; systemic evaluation was unremarkable. The mother was nearly asymptomatic despite slightly reduced enzyme activity (GLA 2.5 µmol/L/h; normal >2.8).

## Treatment

The patient and his brother were started on enzyme replacement therapy with agalsidase beta at a dose of 1 mg/kg intravenously every 2 weeks. The patient's pain crises were treated with carbamazepine 200 mg three times daily.

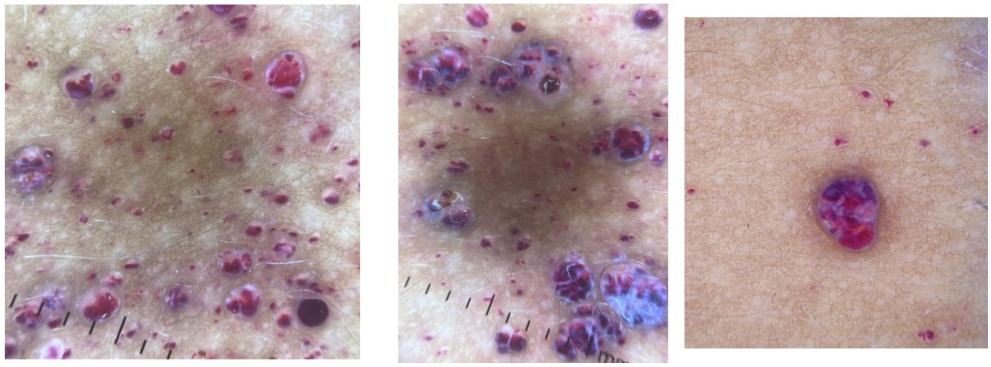

(Figure 1 ) Dermoscopy of angiokeratoma: Multicolored lacunae (red, purple & dark) with bluish white veil.

**Conclusion**

This report highlights the important role of careful dermatologic evaluation, combined with a high index of suspicion in the early recognition of Fabry disease. Cutaneous findings, such as angiokeratomas, may serve as important early diagnostic clues that prompt further investigation. When combined with family genetic screening, this approach enables the identification of affected family members at early or minimally symptomatic stages. The X-linked inheritance pattern was exemplified by the asymptomatic carrier mother and the variably affected brothers. Early diagnosis, in turn, supports timely initiation of disease-specific therapy and facilitates appropriate screening and counseling of at-risk relatives.

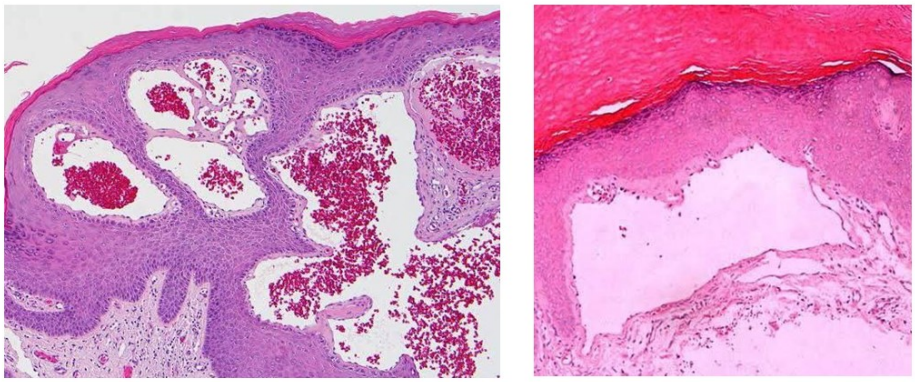

(Figure 2 ) Histopathology of Angiokeratoma : Multiple thin-walled dilated blood vessels containing erythrocytes ,Hyperkeratosis, Hypergranulosis, and Acanthosis.

EA DV CONGRESS
VIENNA
30 SEP - 3 OCT 2026

**Abstract N°: 2176**

# Low Prevalence of Hereditary Melanoma Among Patients Referred for Genetic Testing: A Multicentre Retrospective Cohort Study

Ethan Bendayan*[1], Santina Conte[2], Raquel Lazarowitz[1], Tania Cruz Marino[3], William Foulkes[3, 4, 5, 6, 7], Elena Netchiporouk[2, 4]

[1] Faculty of Medicine, McGill University, Montreal, Canada
[2] Division of Dermatology, McGill University Health Centre, Montreal, Canada
[3] Division of Medical Genetics, Department of Specialized Medicine, McGill University, Montreal, Canada
[4] Division of Experimental Medicine, Department of Medicine, McGill University, Montreal, Canada
[5] Department of Human Genetics, McGill University, Montreal, Canada
[6] Cancer Research Program, Research Institute of the McGill University Health Centre, Montreal, Canada
[7] Cancer Axis, Lady Davis Institute, Jewish General Hospital, Montreal, Canada

**Introduction**
Hereditary melanoma (HM) is associated with germline pathogenic variants (GPVs) in *CDKN2A*, *MITF*, and other genes. Historically, referral criteria to medical genetics clinics were developed around the probability of carrying a GPV in *CDKN2A*, including three or more invasive melanomas or pancreas cancers in a family. In research studies of highly selected cohorts, *CDKN2A* GPV frequency could reach up to ~60%. With the increasing availability of multigene panel testing, the prevalence of GPV carriage and variant spectrum among patients referred to medical genetics in routine practice remain unclear. We aimed to describe the frequency and spectrum of HM-associated variants among patients referred for genetic testing for suspected HM in routine care, and to explore the performance of *CDKN2A*-based referral criteria in this setting.

**Materials and Methods**
We conducted a retrospective chart review of consecutive patients referred for HM testing at two tertiary academic centres between 2014 and 2025. Referral required ≥1 primary melanoma plus at least one additional feature: (1) ≥3 primary melanomas; (2) melanoma with ≥2 first/second-degree relatives with melanoma and/or associated malignancies (e.g., pancreatic, brain, kidney, breast cancer); (3) melanoma before age 40 with ≥1 first/second-degree relative with melanoma or associated malignancy; (4) melanoma before age 18; or (5) uveal melanoma. Testing was performed using the Hereditary Melanoma and Skin Cancer Panel (Blueprint Genetics) or the Hereditary Skin Cancer Panel (Invitae/Labcorp). HM was defined as the presence of a GPV definitely or plausibly associated with melanoma predisposition. Descriptive statistics were used. An exploratory univariate logistic regression assessed the association between fulfilment of *CDKN2A*-based criteria and GPV detection.

**Results**
Eighty-one patients were included (64.2% female; 94.9% White). GPV-confirmed HM was identified in 7/81 patients (8.6%); variants of uncertain significance or risk factor alleles in HM-associated genes were identified in a further 5/81 (6.2%). Among the 7 GPV-positive patients, *CDKN2A* and *MITF* variants were each identified in 3 cases, and one *BRCA2* variant. Descriptively, GPV-positive patients had a younger median age at first melanoma (40.0 vs 48.0 years) and more frequently reported a family history of melanoma (71.4% vs 53.8%) compared with GPV-negative patients. *CDKN2A*-based criteria were met by 24/68 patients (35.3%), of whom 2/24 (8.3%) were GPV-positive. The exploratory association between criteria fulfilment and GPV detection was not statistically significant (OR 0.8; 95% CI 0.1–4.8), though the wide confidence interval reflects limited precision and does not

exclude a clinically meaningful effect in either direction.

**Conclusions**

In this single-region retrospective cohort, GPV-confirmed HM was identified in approximately 10% of patients referred for testing, with *CDKN2A*, *MITF*, and *BRCA2* variants each contributing. Diagnostic yield among those meeting *CDKN2A*-based criteria (8.3%) was lower than reported in selected research cohorts, though direct comparison is limited by differing enrolment populations. These descriptive, hypothesis-generating findings highlight the value of multigene panel testing in dermatologic practice and motivate larger prospective studies to refine referral criteria and better characterise the HM variant spectrum in unselected clinical populations.

EADV CONGRESS
VIENNA
30 SEP - 3 OCT 2026

**Abstract N°: 2182**

# What if the diagnosis was hanging by a hair? The role oftrichoscopy in Netherton Syndrome.

KHALDI HANANE FADOUA*[1, 2], BOUAYED GHIZLENE[1, 2], Abdelmoumene Latifa[1], Mahi Ilhem[1, 2], DAHMANI Boumediene[1, 2], Benhamed Nardjes[2]

[1] Department of Dermatology and Venereology, CHU Tlemcen, Tlemcen, Algeria
[2] Faculty of Medicine, Dr. Benzerdjeb Benaouda, Tlemcen, Faculty of Medicine, Dr. Benzerdjeb Benaouda, Tlemcen, Tlemcen, Algeria

## Introduction

Netherton Syndrome (NS) is a rare autosomal recessive genodermatosis caused by mutations in the **SPINK5** gene. It is classically defined by a pathognomonic triad: congenital ichthyosiform erythroderma (or ichthyosis linearis circumflexa), severe atopic predisposition, and a specific hair shaft abnormality known as **trichorrhexis invaginata (TI)**. We report the critical diagnostic role of trichoscopy in correcting a delayed diagnosis in a 7-year-old child.

## Case Presentation

A 7-year-old male with a history of unlabeled ichthyosiform erythroderma and failure to thrive was admitted with altered general status, febrile erythroderma, disseminated pustulosis, and bullous erosions suggesting severe impetiginization. Initially mismanaged as pustular psoriasis under exclusive topical treatment, the patient exhibited polymicrobial bacterial colonization and a systemic inflammatory response.

Systemic antibiotic therapy and fluid resuscitation stabilized the patient, revealing a dry ichthyosiform scaling state accompanied by cheilitis and conjunctivitis. The diagnostic breakthrough was achieved through an exhaustive **scanning trichoscopic examination**, which revealed pathognomonic lesions of trichorrhexis invaginata ("**bamboo hair**") presenting as multi-level nodules. This diagnostic rectification to Netherton Syndrome led to the initiation of **dupilumab** therapy, alongside rigorous therapeutic education and endocrine evaluation for growth retardation, resulting in rapid and significant cutaneous improvement.

Patients with Netherton Syndrome typically present with sparse, dry, short, spiky, and brittle hair. A definitive clinical diagnosis can be established by identifying at least one hair shaft featuring trichorrhexis invaginata. The term "trichorrhexis invaginata" derives from the Greek *trichos* (hair) and *rhexis* (rupture), referring to the invagination of the hair shaft into itself within the keratinization zone.

TI, or bamboo hair, is characterized by the telescoping of the distal hair shaft into the proximal portion. This results from an intermittent keratinization defect of the hair cortex. The incomplete conversion of **sulfhydryl groups (–SH)** into **disulfide bridges (S-S)** in cortical fiber proteins leads to cortical softening. Consequently, the normally keratinized distal shaft invaginates into the softer, abnormally keratinized proximal segment. Other morphological variants such as "**golf-tee hair**" or "**matchstick hair**" may also be observed.

While TI often improves or disappears with age, its identification is crucial for differential diagnosis. Dark nodules on the hair shaft must be distinguished from trichorrhexis nodosa, monilethrix, and black piedra. Differential diagnoses for the systemic presentation include Omenn syndrome, generalized seborrheic dermatitis, erythrodermic psoriasis, staphylococcal scalded skin syndrome (SSSS), and non-bullous ichthyosiform erythroderma. In our case, the initial misdiagnosis of erythrodermic psoriasis was corrected solely through

trichoscopic markers.

**Conclusion**

Although definitive diagnosis relies on molecular genetics or immunohistochemical studies, the identification of pathognomonic signs such as bamboo hair remains paramount. This case illustrates the vital role of trichoscopy as a primary diagnostic tool: it is simple, non-invasive, and cost-effective, facilitating immediate orientation, accelerating management, and significantly improving patient prognosis.

EA DV CONGRESS
VIENNA
30 SEP - 3 OCT 2026

**Abstract N°: 2208**

# Incontinentia Pigmenti in a Newborn: A Case Highlighting Rapid Progression from Stage 1 to Stage 3

Ahmed Yassine Righi*[1], Issam TABLIT[1], Saliha Takheroubt[1], Samira Zobiri[1]

[1] University of Health Sciences of Algiers, Algiers, Algeria

## Introduction

Incontinentia pigmenti (IP), also known as Bloch–Sulzberger syndrome, is a rare X-linked dominant genodermatosis that predominantly affects females. It is caused by mutations in the *IKBKG* (NEMO) gene located on chromosome Xq28 and is usually lethal in male fetuses. The disease is characterized by a typical cutaneous evolution through four stages: vesiculobullous, verrucous, hyperpigmented, and hypopigmented/atrophic. Lesions usually follow the lines of Blaschko. Extracutaneous manifestations may occur, particularly involving the nervous system, eyes, and teeth, requiring multidisciplinary monitoring. The estimated prevalence is approximately 1 in 40,000 female births.

## Case Presentation

We report the case of a 27-day-old female newborn, born at term by cesarean section to non-consanguineous parents, with no relevant personal or family history. At birth, erythematous vesicular lesions appeared on the left forearm and rapidly extended to the limbs. Within a few weeks, these lesions resolved and were replaced by hyperpigmented macules arranged along Blaschko's lines on the trunk and extremities.
Clinical examination revealed a good general condition and typical stage 3 hyperpigmented lesions with a blaschkolinear distribution. No mucosal, neurological, or ophthalmological abnormalities were detected at this stage. No complementary investigations have yet been performed. Emollient topical care was initiated.

This case is notable for the unusually rapid transition from the vesiculobullous stage (stage 1) to the hyperpigmented stage (stage 3) in less than four weeks. In most reported cases, the different stages of IP appear sequentially over several weeks to months and may even overlap. The accelerated progression observed in our patient highlights the variability in the clinical course of IP during the neonatal period.

The blaschkolinear distribution and asymmetric pattern of the hyperpigmented lesions strongly support the diagnosis. Although no extracutaneous involvement has been identified so far, the absence of early systemic manifestations does not exclude later complications. Neurological, ophthalmological, and dental follow-up is therefore recommended. This observation emphasizes that even typical cases of IP may show a markedly accelerated cutaneous evolution.



Clinical image showing hyperpigmented macules arranged along Blaschko’s lines on the extremities

**Conclusion**

This case illustrates a typical neonatal presentation of incontinentia pigmenti with an uncommon feature: a rapid progression from the vesiculobullous stage to the hyperpigmented stage within the first month of life. Early recognition of such rapid stage transition is important for diagnosis and for ensuring appropriate multidisciplinary monitoring to detect potential extracutaneous complications.



Clinical image showing hyperpigmented macules arranged along Blaschko’s lines on the trunk

**EADV Congress 2026, VIENNA**
**30 SEPTEMBER - 03 OCTOBER 2026**
**POWERED BY M-ANAGE.COM**

EA DV CONGRESS
VIENNA
30 SEP - 3 OCT 2026

**Abstract N°: 2209**

# KID Syndrome Associated with Inflammatory Tinea Capitis Misdiagnosed as Scalp Involvement of the Disease: Successful Treatment with Terbinafine

Ahmed Yassine Righi*[1], Issam TABLIT[1], Saliha Takheroubt[1], almeghari widad[1], Asma Haciane[1], Samira Zobiri[1]

[1] University of Health Sciences of Algiers, Algiers, Algeria

## Introduction

KID syndrome is a rare congenital ectodermal disorder caused mainly by mutations in the GJB2 gene encoding connexin 26. It is characterized by the triad of keratitis, ichthyosiform erythrokeratoderma, and sensorineural deafness. Cutaneous manifestations include follicular hyperkeratosis, palmoplantar keratoderma, xerosis, alopecia, and recurrent infections related to impaired epidermal barrier function. Scalp involvement may represent either a manifestation of the syndrome itself or a superimposed infectious process, making diagnosis challenging. We report a case of KID syndrome complicated by inflammatory tinea capitis initially mistaken for scalp involvement of the genodermatosis, with favorable outcome after terbinafine therapy.

## Case Presentation

A 15-year-old girl with no familial history of similar disease presented with diffuse follicular hyperkeratosis and inflammatory scalp alopecia evolving since infancy. The disease began at the age of 6 months with erythroderma followed by progressive hyperkeratotic and erythematous lesions involving the face, extremities, and trunk. A diagnosis of KID syndrome was established during childhood.

On admission, dermatological examination revealed diffuse follicular hyperkeratotic papules, xerosis, palmoplantar keratoderma, acral erythema, and hyperkeratotic facial plaques. Scalp examination showed painful inflammatory nodules of the vertex associated with purulent discharge and localized alopecia. Bilateral sensorineural hearing loss and ocular involvement with photophobia and corneal ulceration were also present.

Laboratory tests demonstrated inflammatory syndrome with leukocytosis and elevated CRP. Mycological examination of scalp samples isolated Trichophyton violaceum var. glabrum.

The patient was treated with oral terbinafine 250 mg/day associated with supportive therapy and short-course systemic corticosteroids. Rapid improvement was observed with regression of inflammatory nodules, cessation of purulent discharge, and stabilization of alopecia.

KID syndrome is associated with severe epithelial barrier dysfunction predisposing patients to recurrent bacterial and fungal infections. Scalp involvement is frequent and may manifest as alopecia, follicular hyperkeratosis, or inflammatory lesions, potentially masking superimposed infections.

The originality of our case lies in the diagnostic confusion between inflammatory tinea capitis and scalp manifestations of KID syndrome. The worsening under isotretinoin and the identification of Trichophyton violaceum confirmed the infectious origin of the scalp lesions. Dermatophyte infections have rarely been reported in KID syndrome, although susceptibility to infections is well recognized.

Our observation highlights the importance of systematic mycological evaluation in inflammatory scalp lesions occurring in genodermatoses with alopecia. Early recognition is essential because appropriate antifungal therapy

may significantly improve clinical outcome.

Terbinafine remains the treatment of choice for Trichophyton tinea capitis because of its fungicidal activity and excellent follicular penetration. The favorable response observed in our patient confirms the major role of fungal infection in the scalp presentation.



painful inflammatory nodules of the vertex associated with purulent discharge and localized alopecia

**Conclusion**

We report a rare case of KID syndrome complicated by inflammatory tinea capitis caused by Trichophyton violaceum, initially misinterpreted as scalp involvement of the underlying genodermatosis. This case underlines the diagnostic challenge of inflammatory alopecia in KID syndrome and emphasizes the importance of mycological investigations in atypical scalp lesions. Early treatment with terbinafine resulted in marked clinical improvement and prevented further progression of inflammatory scalp damage.



after treatement with Terbinafine for 6 weeks

EA DV CONGRESS
VIENNA
30 SEP - 3 OCT 2026

**Abstract N°: 2231**

# Palmar Acrokeratosis Verruciformis-Like Lesions in Darier Disease

Mustafa Bozkır*[1], Mehmet Salih Gürel[1]

[1] Department of Dermatology, Faculty of Medicine, Istanbul Medeniyet University, Istanbul, Türkiye, İstanbul, Türkiye

## Introduction

Darier disease (DD)is a autosomal dominant genodermatosis caused by mutations in the *ATP2A2* gene. The main clinical findings show a characteristic distribution; lesions consist of yellow-brown, crusted hyperkeratotic papules concentrated in seborrheic areas such as the scalp,forehead,chest,and back. Flat, wart-like papules resembling acrokeratosis verruciformis of Hopf (AKV) on the dorsum of the hands are an expected part of the classic picture. On the palmar surface of the hand, involvement is typically limited to punctate pits containing millimetric keratin plugs—palmar pits. Histopathologically, it is characterized by prominent hyperkeratosis, papillomatosis, and regular acanthosis.The absence of acantholysis and dyskeratosis (corps ronds/grains) is the clearest finding that confirms the diagnosis and distinguishes it from DD. In DD, the AKV-like hyperkeratotic papules seen on the hand dorsum are not seen in the palmar region. In this case series, 3 DD patients with AKV-like papules in the palmar region are presented.

## Case Presentation

**Case 1** A 52-year-old female patient had disease-specific classic hyperkeratotic, hyperpigmented follicular papules on her anterior chest, back,and inguinal regions, along with symmetrically distributed multiple purple lichenoid papules on her trunk. She had been receiving intermittent systemic acitretin therapy for a long time. Dermatological examination revealed asymptomatic, skin-colored hyperkeratotic papules on both palmar areas. Histopathological examination showed spongiosis and acanthosis in the epidermis, and perivascular lymphocytic infiltration in the superficial dermis.

**Case 2** A 61-year-old male patient followed in our clinic with a diagnosis of DD had disease-specific erythematous, scaly follicular keratoses on his neck, inside and behind the ears, nape, back, chest, axillary region, right arm, and pubic area, along with longitudinal striations on his nails.Simultaneous punch biopsies were taken for diagnostic purposes from the back and from 1 mm diameter yellowish papules on both palmar regions. While the histopathology of the back lesion was consistent with DD showing suprabasal separation, the palmar papule biopsy showed prominent hyperkeratosis, hypergranulosis, and acanthosis.

**Case 3** A 66-year-old female patient had DD-specific erythematous, hyperkeratotic papules on her neck, nape, back, axilla, and inframammary regions and a cobblestone-like appearance on her right buccal mucosa. Upon detecting skin-colored papules in both palmar regions during dermatological examination, histopathological evaluation of two biopsies from the neck and palmar area revealed suprabasal acantholysis in the neck lesion, proving DD; whereas the palmar papule biopsy showed hyperkeratosis, acanthosis, and spongiosis without specific acantholysis.

## Conclusion

In DD, flat, wart-like papules can be seen on the back of the hand. These lesions were first described by Hopf and named AKV. In this clinical variant of DD, dyskeratotic acantholysis may not always be observed histopathologically; however, the detection of the same genetic mutation in both DD and AKV cases suggests that these two conditions may share a common pathogenetic ground. Although palmar pitting can be seen in DD, in the three DD patients we observed, similar verrucous papular lesions were detected in the palmar region in addition to the AKV-like lesions observed on the back of the hands. No pathology was detected on the foot dorsums or plantar regions of all 3 patients. Biopsies from the palmar lesions showed common histopathological features of acanthosis and hypergranulosis, but no separation was observed. A literature review revealed no data regarding the presence of AKV-like lesions in the palmar region in DD. Recognizing these lesions in the palmar region, in addition to the classic clinical findings of DD, will contribute to the clinical diagnosis and spectrum of the disease.

EA DV CONGRESS
VIENNA
30 SEP - 3 OCT 2026

**Abstract N°: 2268**

# The approach to the diagnosis and follow-up of patients with mosaic genodermatoses with high cancer risk

Tatyana Belysheva*[1], EKATERINA Zelenova[2], Tatyana Nasedkina[3], Svetlana Varfolomeeva[4]

[1] N.N. Blokhin National Medical Research Center of Oncology, Ministry of Health of the Russian Federation, Central State Medical Academy, Moscow, Russian Federation

[2] N.N. Blokhin National Medical Research Center of Oncology, Ministry of Health of the Russian Federation, Engelhardt Institute of Molecular Biology, Russian Academy of Sciences, Moscow, Russian Federation

[3] Engelhardt Institute of Molecular Biology, Russian Academy of Sciences, Moscow, Russian Federation

[4] N.N. Blokhin National Medical Research Center of Oncology, Ministry of Health of the Russian Federation, Moscow, Russian Federation

## Introduction

Mosaic genodermatoses are a group of orphan diseases with skin lesions (various nevi, usually congenital) and a wide spectrum of extracutaneous manifestations, including the risk of malignancies. At the same time dermatological changes can be the first sign of the syndrome, which can be used for early diagnosis and starting of dynamic follow-up. The similarity and partial overlap of phenotypes is due to the intersection of RAS/RAF/MAPK, FGF/FGFR, and PIK3CA/AKT1/mTOR signaling pathways, whose role in carcinogenesis has been well studied. However, the mechanisms of the influence of these genes on the formation of tissues in embryogenesis have not been fully established.

The goal of this study was to determine the role of postzygotic mutations in the development of genodermatoses with high cancer risk, as well as to analyze the dependence of clinical manifestations on the genotype.

## Materials and Methods

A comprehensive physical examination of 24 patients with congenital nevus and extracutaneous abnormalities was performed. In all cases DNA testing included next-generation sequencing on the NextSeq 2000 Illumina platform using a targeted panel of genes (NimbleGen, Roche probes). Material for genetic study was DNA isolated from nevus, tumor, skin without lesion and blood lymphocytes.

Informed consent was obtained from patients involved in the study or their official representatives. The study was conducted according to the guidelines of the Declaration of Helsinki and approved by the Ethics Committee of leading institute (№ 4 from 26 February 2026).

## Results

From 24 patients (male – 15, female – 9) with age 0-21 years old postizygotic mutations have been identified in patients with Schimmelpenning-Feuerstein-Mims syndrome (SFMS) (N=8), phacomatosis pigmentokeratotica (PPK) (N=7), Garcia-Hafner-Happle syndrome (GHHS) (N=5), Proteus syndrome (N=3), and *PIK3CA*-related overgrowth spectrum (N=1) (Figure 1). Among them 3 patients with Proteus syndrome received PI3K-inhibitor, 2 patients with SFMS and 1 with PPK – monoclonal antibody to FGF23.
In a detailed analysis of patients with SFMS and PPK two genotype-phenotype groups were identified. In patients

with *KRAS* mutations (N=6), anomalies of the nervous and cardiovascular systems, organs of vision and kidneys predominate. At the same time, patients with *HRAS* mutations (N=8) had high risks of developing skeletal disorders (including hypophosphatemic rickets) and malignancy under the age of 1 year: inguinal rhabdomyosarcoma (N=2) and ectomesenchioma (N=1).

In patients with wide-spread nevus, a different variant allele frequency (VAF) was determined in different areas of the body. It is worth noting that the biggest VAF was detected in malignant neoplasms, but the correlation between VAF and the severity of the disease has not been confirmed.

Moreover, patients with great area of skin lesions suffer from more extracutaneous disorders. For instance, neurological involvement was diagnosed only in 1 patient with GHHS and the spread of a nevus over almost the entire upper body.

Based on the results of the study, we suggest the algorithm for diagnosing mosaic genodermatoses: testing 2-3 samples of affected skin to identify mutation, as well as 1 sample of healthy skin and/or blood DNA to exclude germline variants. Due to low VAF (especially in Proteus syndrome) we recommend preferring next-generation sequencing instead of Sanger sequencing despite on hot-spot mutation in most cases. Taking into account possible cancer risk, consultation with an oncologist should be included in the plan of regular examinations.

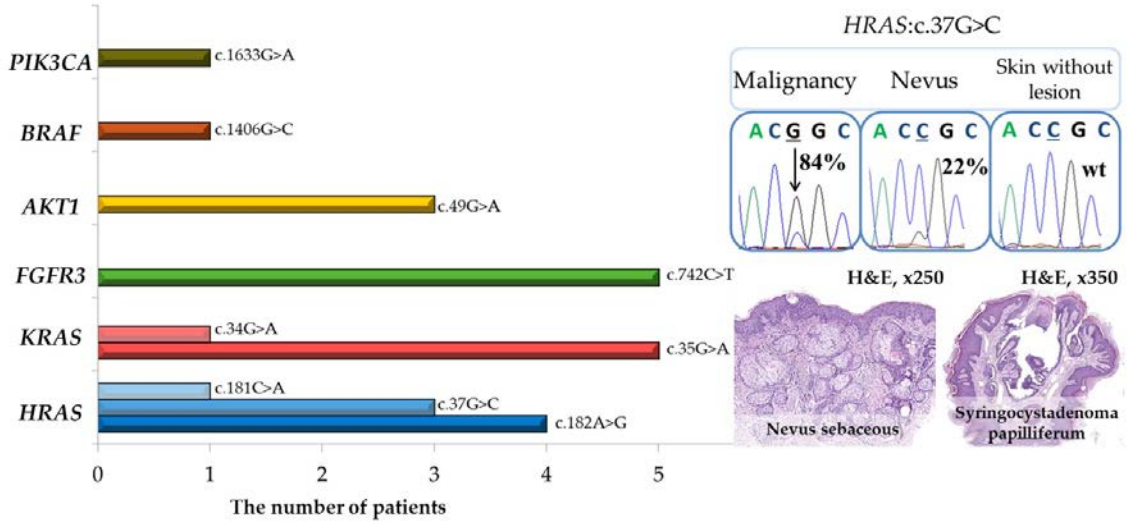


Figure 1. Spectrum of identified mutations, different VAF in one patient's samples; histology of congenital nevus and benign tumor in one patient from the study

**Conclusions**

Depending on the gene involved, the spectrum of extracutaneous pathology varies, which makes it possible, after genotyping the patient, to draw up an individual follow up and optimize treatment options.

EA DV CONGRESS
VIENNA
30 SEP - 3 OCT 2026

**Abstract N°: 2271**

# Genodermatoses with a high cancer risk: incidence of malignant tumors among the Russian pediatric population

Tatyana Belysheva*[1], EKATERINA Zelenova[2], Elena Sharapova[3], Tatyana Nasedkina[4], Svetlana Varfolomeeva[3]

[1] N.N. Blokhin National Medical Research Center of Oncology, Ministry of Health of the Russian Federation, Central State Medical Academy, Moscow, Russian Federation

[2] N.N. Blokhin National Medical Research Center of Oncology, Ministry of Health of the Russian Federation, Engelhardt Institute of Molecular Biology, Russian Academy of Sciences, Moscow, Russian Federation

[3] N.N. Blokhin National Medical Research Center of Oncology, Ministry of Health of the Russian Federation, Moscow, Russian Federation

[4] Engelhardt Institute of Molecular Biology, Russian Academy of Sciences, Moscow, Russian Federation

## Introduction

Genodermatoses with high cancer risk are a group of orphan genetic skin diseases with multiple extracutaneous abnormalities and malignant neoplasms of various localizations. Hereditary genodermatoses are characterized by a different type of inheritance and often incomplete penetrance, which determines the necessity of segregation analysis for patient relatives. The rarity of these syndromes and the low awareness of clinicians can lead to late detection of cancer and poor survival, including in pediatric cohort.

The goal of this study was to determine the incidence of childhood malignancies in patients with various genodermatoses, as well as the searching of an optimal diagnostic algorithm based on skin changes.

## Materials and Methods

A comprehensive examination of 165 pediatric patients with hereditary genodermatoses with high cancer risk was performed (Figure 1). Pathogenic variants in genes was identified by NGS sequencing on the NextSeq 2000 Illumina platform using a targeted panel of genes (NimbleGen, Roche probes) in all cases, DNA testing of relatives was made by Sanger sequencing. Material for genetic study was DNA isolated from peripheral venous blood lymphocytes.

Informed consent was obtained from official representatives of patients involved in the study. The study was conducted according to the guidelines of the Declaration of Helsinki and approved by the Ethics Committee of leading institute (№ 4 from 26 February 2026).

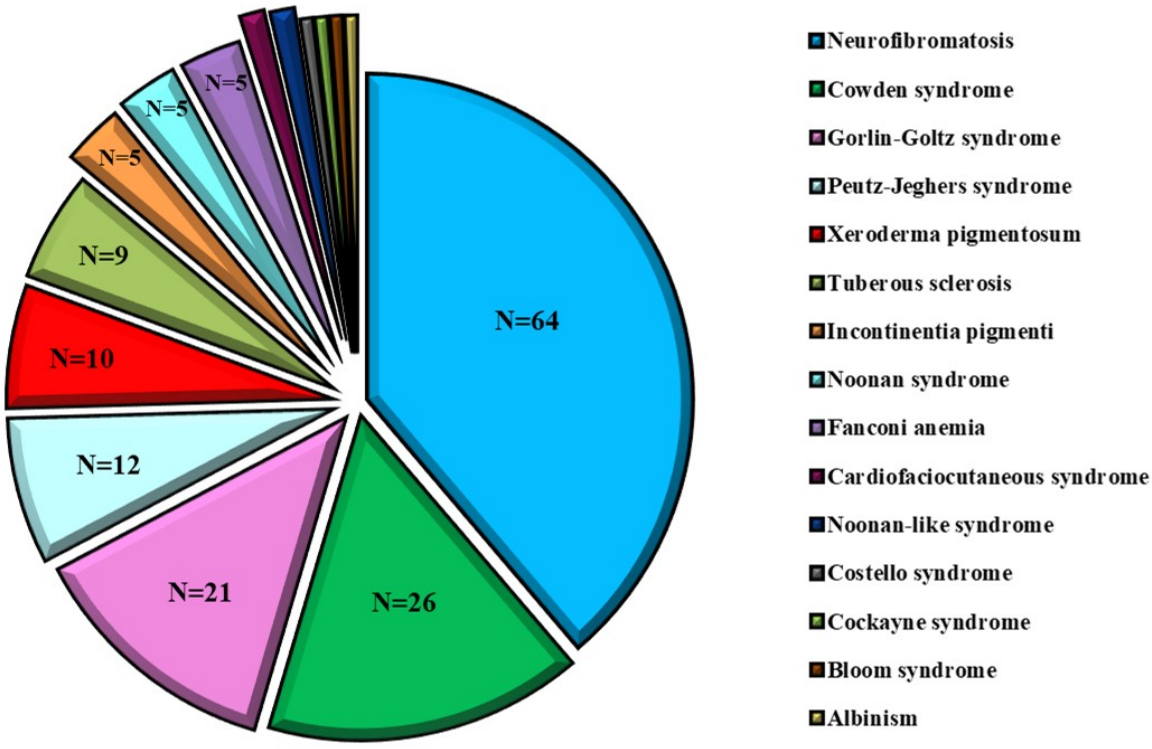


Figure 1. Frequency of genodermatoses in the study

**Results**

From 165 pediatric patients with hereditary genodermatoses the most group was diagnosed with neurofibromatosis 1 (N=64, 38,8%), Cowden syndrome (N=26, 15,8%) and Gorlin-Goltz syndrome (N=21, 12,8%). Among them 71 (43%) patients had at least one neoplasm. In 19 (11,5%) cases multiple malignant tumors were detected. There were 8 children with development of neoplasms under 1 year old: 2 cases of medulloblastoma, neuroblastoma and embryonal rhabdomyosarcoma associated with Gorlin-Goltz syndrome, 2 cases of subependymal giant cell astrocytoma combined with tuberous sclerosis and 1 patient with neuroblastoma and neurofibromatosis 1. The spectrum of extracutaneous malignancies (59 tumors from 53 patients) is shown on Figure 2.

Non-melanoma skin cancer were detected in 12 patients (7,3%) with Gorlin-Goltz syndrome (N=10), xeroderma pigmentosum (N=8), Fanconi anemia (N=1) and incontinentia pigmenti (N=1). Multiple carcinomas were identified in a group of Gorlin-Goltz syndrome (N=8) and xeroderma pigmentosum (N=8). Melanoma was diagnosed just in case of xeroderma pigmentosum (N=2) since 13 years old.

Our results demonstrated a new signs of syndromes (germ cell tumors in Cowden syndrome), and earlier age of individual manifestations (gastrointestinal polyposis since 1 years and renal cell carcinoma since 13 years associated with Cowden syndrome; squamous cell skin cancer in a teenager with Fanconi anemia). Also we described a high risk of basal cell carcinoma and medulloblasoma in children with Gorlin-Goltz syndrome, regardless of the involved gene.

After segregation analysis, mutations were detected in 95 (46.3%) relatives, which allowed us to form an additional cancer risk group and asses the possibility of having a healthy child in the family.




Figure 2. Spectrum of extracutaneous malignant tumors in patients with genodermatoses in the study

**Conclusions**

The accumulation of scientific data has allowed us to improve the diagnostic algorithm based on the time of appearance of the first tumor and spectrum of possible neoplasms. Also, not all patients met the approved diagnostic criteria due to the incomplete clinical picture. So we recommend genetic testing be performed in all susceptible cases, even in the absence of complete diagnostic criteria. The high incidence of cancer in pediatric patients with genodermatoses confirmed the necessity of dynamic follow up since early childhood.

EADV CONGRESS
VIENNA
30 SEP - 3 OCT 2026

**Abstract N°: 2334**

## Beyond Thick Nails: Clinical Spectrum of Pachyonychia Congenita

oumaima sabour*[1], Hanane Baybay[1], hanae lammini[1], ikram bejja[1], Saadia Boughaleb[1], Zakia Douhi[1], Meryem Soughi[1], elloudi sara[1], Fatima Zohra Mernissi[1]

[1] Department of Dermatology, Hassan II University Hospital, fes, Morocco

### Introduction

Pachyonychia congenita (PC) is a rare autosomal dominant genodermatosis, caused by pathogenic variants in keratin genes. These keratins are expressed in nail beds, palmoplantar epidermis, hair follicles, and sebaceous glands. Although hypertrophic nail dystrophy is the hallmark feature, the clinical spectrum extends beyond thickened nails and includes palmoplantar keratoderma, follicular hyperkeratosis, cyst formation, natal or congenital teeth, and pilosebaceous abnormalities. We report a case illustrating this broader phenotype, with prominent cystic lesions and severe nail involvement.




figure 1 : a. diffuse pachyonychia affecting all nails, with marked subungual hyperkeratosis, b and c : longitudinal spikes, disappearance of lunulae, trachyonychia, splinter hemorrhages, an “aurora borealis” pattern, and a few regular melanonychia bands.

### Case Presentation

A 22-year-old man presented with multiple cutaneous cysts. His history revealed congenital teeth and nail changes beginning at the age of three months, characterized by progressive thickening. he lately noted progressive

development of multiple cystic lesions on the scalp and trunk. examination revealed numerous subcutaneous nodules across the trunk, each topped with an opening, along with numerous open comedones distributed over the body. Examination of the scalp showed multiple subcutaneous nodules located on the frontal, vertex, and occipital regions; Nail examination demonstrated diffuse pachyonychia affecting all nails, with marked subungual hyperkeratosis and a "ruin-like" dystrophic appearance. Dermoscopy showed longitudinal spikes, disappearance of lunulae, trachyonychia, splinter hemorrhages, an "aurora borealis" pattern, and a few regular melanonychia bands. The patient was put on isotretinoin, with mild clinical improvement in cystic lesions.

Pachyonychia congenita is a keratin disorder resulting from dominant-negative mutations that disrupt intermediate filament assembly. The mutated keratins impair structural stability in tissues exposed to mechanical stress, particularly the nail unit and palmoplantar skin. Keratin 17 mutations are especially associated with cyst formation and natal teeth, features present in our patient. Hypertrophic nail dystrophy typically presents in infancy and remains one of the earliest signs. The marked subungual hyperkeratosis observed in our patient reflects excessive keratin accumulation secondary to altered keratinocyte differentiation. Dermoscopic findings such as longitudinal spikes and splinter hemorrhages correspond to disrupted nail plate architecture and vascular fragility. Beyond nail changes, follicular involvement is a defining but sometimes underrecognized aspect of the disease. Cyst formation—including epidermoid and trichilemmal cysts—results from abnormal keratinization within the pilosebaceous unit. The multiple scalp nodules observed in our case are consistent with trichilemmal cysts, a feature frequently associated with *KRT17* mutations. The presence of open comedones and residual linear scars suggests recurrent cyst inflammation and rupture. Natal or congenital teeth, reported in approximately 15–20% of cases, further support the diagnosis and point toward specific keratin subtypes. Although palmoplantar keratoderma is common in PC, its severity varies considerably, highlighting the phenotypic heterogeneity of the condition. Management remains symptomatic. Systemic retinoids such as isotretinoin may reduce cyst formation and hyperkeratosis but often provide limited benefit for nail dystrophy. Surgical excision is frequently required for symptomatic cysts. Emerging therapeutic approaches include allele-specific small interfering RNA therapies and mutation-targeted treatments currently under investigation.



figure 2 : multiple cysts and nodules with follicular openings all over the body, some are inflammed

**Conclusion**

Pachyonychia congenita is more than a nail disorder. This case highlights the extended clinical spectrum of the disease, encompassing severe nail dystrophy, congenital teeth, and prominent follicular cyst formation. Recognition of these associated features is essential for accurate diagnosis, genetic counseling, and appropriate multidisciplinary management. Ongoing genetic analysis will further clarify the molecular subtype and guide future therapeutic considerations.

EA DV CONGRESS
VIENNA
30 SEP - 3 OCT 2026

**Abstract N°: 2371**

## Acral Peeling Skin Syndrome in Two Siblings with Identified TGM5 Mutation

Preslav Vasilev*[1, 2], Zornitsa Kamburova[2, 3], Ivelina Yordanova[1]

[1] Department of Dermatology, Venereology and Allergology, Faculty of Medicine, Medical University Pleven, Bulgaria, Pleven, Bulgaria
[2] Centre of Competence in Personalized Medicine, 3D and Telemedicine, Robotic Assisted and Minimally Invasive Surgery „Leonardo da Vinci“, Pleven Bulgaria, Pleven, Bulgaria
[3] Department of Medical Genetics, Faculty of Pharmacy, Medical University Pleven, Bulgaria, Centre of Competence in Personalized Medicine, 3D and Telemedicine, Robotic Assisted and Minimally Invasive Surgery „Leonardo da Vinci“, Pleven Bulgaria, Pleven, Bulgaria

### Introduction

Acral peeling skin syndrome (APSS) is a rare autosomal recessive genodermatosis characterized by recurrent superficial desquamation affecting predominantly the acral skin of the limbs. The disease is associated with pathogenic variants in the *TGM5* gene, encoding transglutaminase 5, an enzyme essential for epidermal barrier formation and keratinocyte differentiation. Due to its rarity and clinical overlap with inherited blistering disorders, APSS is frequently underdiagnosed or misinterpreted as epidermolysis bullosa simplex. We present a familial case of APSS in a sister and brother with confirmed *TGM5* mutation and characteristic clinical manifestations.

### Case Presentation

A female and a male siblings born to clinically unaffected parents underwent detailed dermatological evaluation. The girl was born from first normal pregnancy without any pathological changes. When she was 2 months old peeling and formation of multiple small blisters on the skin of her palms and soles was initiated. Seven years later, after a second normal pregnancy from the same parents, a healthy boy was born. Two months later the same peeling and blistering started on the acral surfaces of his limbs. Clinical examination and molecular genetic testing were performed. Differential diagnosis included epidermolysis bullosa simplex and other inherited keratinization disorders.

Both brother and sister demonstrated symmetrical superficial desquamation localized predominantly to the plantar surfaces, with occasional extension to the dorsal aspects of the hands and feet. Lesions were aggravated by friction, humidity, sweating and mechanical trauma. The skin changes were characterized by painless superficial peeling with transient erythema, without significant inflammation, scarring, erosions or mucosal involvement. Nail growth and hair development were normal. Molecular genetic analysis using next-generation sequencing (NGS) identified a pathogenic missence mutation in the *TGM5* gene (p.337G>p.Gly113Cys), confirming the diagnosis of APSS. The genetic analysis also showed that the patient was homozigotous – meaning that both of the parents carry the same mutation in the same place and gene. The clinical presentation correlated with previously reported phenotypes associated with transglutaminase 5 deficiency, including recurrent acral peeling and exacerbation after environmental or mechanical triggers. Both of the children are constantly treated with topical emollients and epithelizing creams, with a very good overall effect.

### Conclusion

This report describes a rare familial presentation of APSS associated with *TGM5* mutation in two siblings born to clinically unaffected parents. The findings further support the central role of transglutaminase 5 in epidermal cohesion and skin barrier stability. Recognition of the characteristic clinical presentation is essential for accurate diagnosis and differentiation from inherited blistering diseases, particularly epidermolysis bullosa simplex. Early diagnosis may prevent unnecessary investigations and therapeutic interventions while allowing appropriate genetic counseling and long-term patient management. Increased awareness of APSS among dermatologists and pediatricians remains important due to the rarity of the condition and its potential diagnostic challenges.

EADV CONGRESS
VIENNA
30 SEP - 3 OCT 2026

**Abstract N°: 2373**

# Hailey-Hailey Disease in the anus of 30-year-old Filipino: A case report

Kyle Daniel Andal*[1], Clarisse Mendoza[1]

[1] Research Institute for Tropical Medicine, Muntinlupa, Philippines

## Introduction

Hailey-hailey disease (HHD), also known as familial benign chronic pemphigus is a rare acantholytic disorder that presents with erythematous, malodorous, vegetative, scaly plaques mainly on the flexural areas of the body. This is common between the second and fourth decades of life. Although, uncommon, the presence of longitudinal white lines in the nails is helpful in the diagnosis. This report aims to highlight the clinical presentation, diagnosis, and management of Hailey-hailey disease. Diagnosis is quite challenging as this patient has only one lesion on the anus. This can simulate common dermatoses such as eczema, fungal infection, and even extramammary paget's disease. Hence, we highlight the importance of histopathologic examination. By discussing a case of a 30-year-old girl diagnosed with Hailey-hailey disease, the report seeks to emphasize the importance of accurate diagnosis and the effectiveness of topical therapy in achieving successful treatment outcomes.

## Case Presentation

We report a case of a 30-year-old Filipino female with a 2-year history of persistent solitary well-defined erythematous plaque on the anus. Patient was previously treated with a topical combination of antifungal and corticosteroids with minimal improvement. Review of systems were unremarkable. Patient reported that her mother has similar lesions on the axillae, inframammary and inguinal areas. Physical examination revealed solitary, well-defined, irregularly-shaped erythematous scaly plaque some with excoriations on the anus. Hair and nail findings were normal. Sexual history was unremarkable.

A 4-mm skin punch biopsy was taken from the anal area. The microsections showed suprabasal acantholysis with a characteristic dilapidated brick wall appearance of the epidermis. The dermis shows a moderately dense superficial and deep perivascular and periadnexal inflammatory infiltrate of numerous lymphocytes, histiocytes, and few plasma cells with dilated blood vessels. Hematologic and biochemical tests were unremarkable. Direct immunofluorescence was negative. Desmoglein 1 and 3, and BP 180 were also negative. The patient was given antibacterial soap, mupirocin 2% +betamethasone dipropionate 0.05% ointment twice daily with noted improvement seen as flattening and decrease in erythema of lesion. The patient's blood was sent for genetic testing for detection of ATP2C1 mutation.

## Conclusion

The case shows an unusual location of HHD in a Filipino female. It presents as an erythematous scaly plaque with erosions which are also seen in common dermatoses. HHD can rarely appear on the anus. This presentation poses a diagnostic challenge to dermatologists, as other conditions like Paget's disease, fungal infection, and eczema exhibit similar signs and symptoms. Therefore, careful clinical and histopathological correlation is a crucial part of the diagnostic process. Hailey-hailey disease should be considered in cases of chronic lesions that respond

suboptimally to treatment.

EADV CONGRESS
VIENNA
30 SEP - 3 OCT 2026

**Abstract N°: 2391**

# Rapid response to oral minoxidil in ichthyosis-associated alopecia ABCA12-nTDE

Miquel Casals*[1], Anna Porta-Vilaro[1], Antonio Daviu[1], Rafael Garrido[1], Cristina Lopez[1]

[1] Parc Tauli Hospital Universitari, Institut investigació i innovació Parc Taulí (I3PT), Sabadell (Barcelona), Spain

## Introduction

ABCA12-nTDE ichthyosis, formerly known as malignant ichthyosis or harlequin fetus, is the rarest and most severe form of autosomal recessive congenital ichthyosis. It is caused by a mutation in the ABCA12 gene on chromosome 2q35, which leads to impaired keratinization with dysgenesis of the lamellar layer due to cutaneous lipid abnormalities, resulting in massive follicular hyperkeratosis. At birth, individuals present with large, thick scales affecting the entire body, associated with severe ectropion, eclabium, and flattened ears. Two distinct patterns of alopecia have been identified in autosomal recessive congenital ichthyosis. In the ABCA12-nTDE variant, a diffuse decrease in hair density and a vertex bald patch are observed, while in TGM1-nTDE, a pattern of alopecia is seen consisting of a recession of the hairline, leaving a band of atrophic, shiny skin. Minoxidil is a peripheral vasodilator that promotes hair growth both topically and orally, and is increasingly used orally for androgenetic alopecia, chronic effluvium, and other forms of hair loss. We present the case of a patient with ABCA12-nTDE ichthyosis exhibiting a pattern of diffuse, generalized hair thinning and a vertex bald patch who showed an excellent response to oral minoxidil.

## Case Presentation

A 24-year-old woman, diagnosed with ABCA12-nTDE, presented with diffuse generalized alopecia with marked eyebrow and eyelash loss and a long-standing area of baldness on the vertex of the scalp. Oral minoxidil was started at a dose of 1 mg/day. Four months after starting treatment, an excellent response was observed, with increased hair density in the affected areas and progressive growth of eyebrows and eyelashes. The minoxidil dosage was then increased to 2 mg/day. Ten months after starting treatment, the response and progressive increase in hair density were maintained, except for the central vertex region of the scalp, where scarring alopecia developed after birth. Currently, the patient continues with 2 mg/day of minoxidil without experiencing any side effects.

## Conclusion

Oral minoxidil is considered a safe and effective treatment option for autosomal recessive congenital ichthyosis, as is the case with our patient. However, it's important to remember that it can take several months to produce visible results and that the positive effect only lasts while the treatment is being administered.

EADV CONGRESS
VIENNA
30 SEP - 3 OCT 2026

**Abstract N°: 2410**

# A Case of Goltz Syndrome

Jingjing Liu*[1]

[1] The First Affiliated Hospital of Wenzhou Medical University, Wenzhou, China

## Introduction

Goltz syndrome is an X-linked dominant inherited disorder, a rare genetic disease caused by ectodermal and mesodermal dysplasia, which can involve multiple systems. This study reports a case of Goltz syndrome in a 24-year-old female patient who presented with generalized dry skin accompanied by atrophy. Whole-exome sequencing revealed a heterozygous mutation (c.1287dup:p.Y430Lfs*41) in the PORCN gene. This is a novel mutation that has not been previously reported.

## Case Presentation

A 24-year-old female presented with a 17-year history of dry and atrophic skin lesions. The patient first developed partial generalized hyperpigmentation, dry skin and cutaneous thinning in localized areas since early childhood. There was no obvious pruritus or pain, and she subsequently presented to the Department of Dermatology of our hospital. She had a past medical history of hearing loss and renal atrophy. Physical examination: The patient had normal intellectual development, short stature, slightly sparse hair, a small and asymmetrical face, mild exophthalmos, abnormal dental development, and loss of multiple teeth. Multiple cutaneous hyperpigmented lesions were observed over the whole body, distributed along the lines of Blaschko. There was dysplasia of both hands and feet, with syndactyly and deformity of multiple toes on both feet. Laboratory examinations: Elevated serum creatinine and uric acid levels were noted. Ophthalmic examination revealed abnormal meibomian gland development. Audiological testing indicated bilateral conductive hearing loss. Whole-exome sequencing identified a heterozygous variant mutation in the PORCN gene (c.1287dup:p.Y430Lfs*41).

## Conclusion

Cutaneous manifestations of Goltz syndrome are well-demarcated, thin atrophic depressed plaques, with formation of fatty herniation in some areas. Hypopigmented or hyperpigmented macules and telangiectatic erythema distributed along the lines of Blaschko may also be present. Papillomas frequently arise at the mucocutaneous junctions. Besides cutaneous involvement, the disorder may affect the skeleton, teeth, eyes, hair, digits and other organ systems.

EA DV CONGRESS
VIENNA
30 SEP - 3 OCT 2026

**Abstract N°: 2438**

# Collodion Baby Neonatal Phenotype in ALOX12B-Associated Non-Syndromic Autosomal Recessive Congenital Ichthyosis Type 2 (ALOX12B-nEDD): Clinical and Genetic Perspectives

Cătălina-Ioana Naum*[1], Mihaela Leventer[2], Adriana Diaconeasa[3]

[1] Spitalul Universitar de Urgență Elias București, București, Romania

[2] Dr. Leventer Centre, Bucharest, Romania

[3] Spitalul Clinic de Urgență Pentru Copii Grigore Alexandrescu București, București, Romania

## Introduction

Non-syndromic autosomal recessive congenital ichthyoses (ARCI), currently included within epidermal differentiation disorders (EDD), represent a clinically and genetically heterogeneous group of inherited keratinization disorders characterized by impaired epidermal barrier formation and defective cornification. Mutations in genes involved in epidermal lipid metabolism, including *ALOX12B*, are frequently associated with collodion membrane phenotype at birth and variable degrees of lamellar ichthyosis or congenital ichthyosiform erythroderma during later evolution.

## Case Presentation

We present the case of a term neonate with collodion baby phenotype. The newborn had Apgar scores of 8 at both 1 and 5 minutes, birth weight 2300 g, and length 46 cm. Clinical status was moderately impaired, with generalized cyanosis immediately after birth. Dermatological examination demonstrated diffuse infiltrated, tense, shiny skin with multiple erythematous fissures, findings consistent with a generalized collodion membrane. Associated dysmorphic features included nasal hypoplasia, narrow palpebral fissures, small low-set dysplastic ears, hypoplastic digits with abnormal morphology, micronychia, restricted limb mobility, and bilateral syndactyly involving toes III–IV. Molecular analysis by next-generation sequencing identified a homozygous pathogenic variant c.1562A>G (p.Tyr521Cys) in the *ALOX12B*gene, establishing the diagnosis of ARCI type 2. Pathogenic *ALOX12B* variants are commonly associated with mild or intermediate phenotypes of lamellar ichthyosis/congenital ichthyosiform erythroderma, frequently preceded by collodion membrane presentation during the neonatal period.

Initial therapeutic management consisted of intensive topical emollient therapy aimed at restoration of epidermal barrier function and reduction of transepidermal water loss. Diagnosis was established predominantly on clinical and molecular criteria, as histopathological findings in ARCI are generally non-specific. Differential diagnosis included lamellar ichthyosis, congenital ichthyosiform erythroderma, and self-improving collodion baby phenotype. Long-term management focuses on maintenance of epidermal hydration and regulation of abnormal keratinization. Systemic retinoids may be indicated in severe hyperkeratotic forms. Immunosuppressive agents, including ciclosporin, have not demonstrated therapeutic benefit and are not recommended. Biologic therapies such as secukinumab show limited efficacy, mainly in severe erythrodermic phenotypes, whereas Janus kinase inhibitors currently provide only transient clinical improvement.

## Conclusion

Early molecular confirmation of *ALOX12B*-associated ARCI is essential for establishing an accurate diagnosis, defining prognosis, and guiding individualized multidisciplinary management from the neonatal period onward. Identification of the pathogenic variant facilitates differentiation from other congenital ichthyoses and syndromic keratinization disorders with overlapping phenotypes, particularly in neonates presenting with collodion

membrane. Prompt recognition of this entity allows early implementation of supportive measures aimed at restoring epidermal barrier integrity, preventing infectious and metabolic complications, and improving overall neonatal outcomes.

EA DV CONGRESS
VIENNA
30 SEP - 3 OCT 2026

**Abstract N°: 2484**

## Familial CANDLE Syndrome in the Sétif Region: A Series of Six Cases Suggesting a Founder Effect

Bounneche Houda*[1], Rouba Medfouni[1], Ahmad Abuhammad[1], Tarek Mansoul[1], RIADH BOUSSAID[1], Amel Gherfi[1], esma bouhila[1], khadidja bouarroudj[1], kaghouche lilia[1], safa djebbas[1], Ahmed Samaouel Chehad[1]

[1] Department of Dermatology, University Hospital, Constantine, Algeria

### Introduction

CANDLE syndrome (Chronic Atypical Neutrophilic Dermatosis with Lipodystrophy and Elevated Temperature) is a rare childhood-onset interferonopathy related to proteasome dysfunction, characterized by chronic systemic inflammation, early-onset dermatosis, and progressive lipodystrophy. We report a series of six cases from three families originating from the same region, suggesting possible familial clustering with a suspected founder effect.

**CANDLE Syndrome: Six Cases in Three Families**

| Family | Case | Sex | Consanguinity | Current Age | Age at Onset | Dermatological Features | Systemic Manifestations | Laboratory Findings | Histology + Immunohistochemistry | Treatment |
|---|---|---|---|---|---|---|---|---|---|---|
| Family 1 (Sétif) | Case 1 | F | Yes | 39 years | 2 weeks | Annular erythematous plaques Palpebral edema Facial and truncal lipodystrophy Facial dysmorphism | Bilateral cataracts Lagophthalmos, limited mouth opening Arthralgia Restricted range of motion | Elevated CRP Anemia Leukopenia Lymphopenia Neutropenia Hyperferritinemia CPK and LDH: normal | Polymorphous interstitial infiltrate (PMN, lymphocytes, histiocytes) Leukocytoclasia MPO+, CD68+ | Corticosteroids: corticosteroid-dependent Then colchicine: partial improvement, discontinued due to gastrointestinal and hematological side effects |
| | Case 2 | M | Yes | 34 years | 2 weeks | Same as Case 1 plus: Nail involvement (anonychia, pterygium, onycholysis) Alopecia areata | Lagophthalmos, bilateral limited mouth opening Arthralgia Restricted range of motion | | | None |
| | Case 3 | M | Yes | 28 years | 2 weeks | Same as Case 1 | Same as Case 2 | | | |
| Family 2 (Sétif) | Case 4 | F | Yes | 10 years | Birth | Erythematous papulo-nodules with purpuric evolution Progressive lipodystrophy Facial dysmorphism | Growth retardation Splenomegaly Nephromegaly Arthralgia Myalgia Decreased muscle strength | Elevated CRP Anemia Leukocytosis with neutrophilia CPK/LDH: normal AST: elevated ALT: elevated | | Corticosteroids and IV polyvalent immunoglobulins: no improvement |
| | Case 5 | M | Yes | 2 years | Birth | | None | Elevated CRP Anemia | | Corticosteroids |
| Family 3 (Sétif) | Case 6 | M | No | 2 years | Birth | Annular erythematous lesions Panniculitis Lipodystrophy | Splenomegaly Growth retardation | Elevated CRP Anemia | Diffuse perivascular and interstitial mononuclear infiltrate, without neutrophils | Corticosteroids with corticosteroid dependence |

Table 1 :CANDLE syndrome: six cases in three families

### Materials and Methods

This series includes six cases distributed across three families from the same region of Algeria (Sétif province). The diagnosis of CANDLE syndrome was based on clinical features (recurrent fever starting within the first two weeks of life, poor general condition, erythematous annular plaques, inflammatory nodules and/or papules, lipodystrophy, and facial dysmorphism), laboratory findings (biological inflammatory syndrome), and

histopathological features, after exclusion of differential diagnoses, particularly normal thyroid function (normal TSH) and negative antinuclear antibodies (see Table 1).

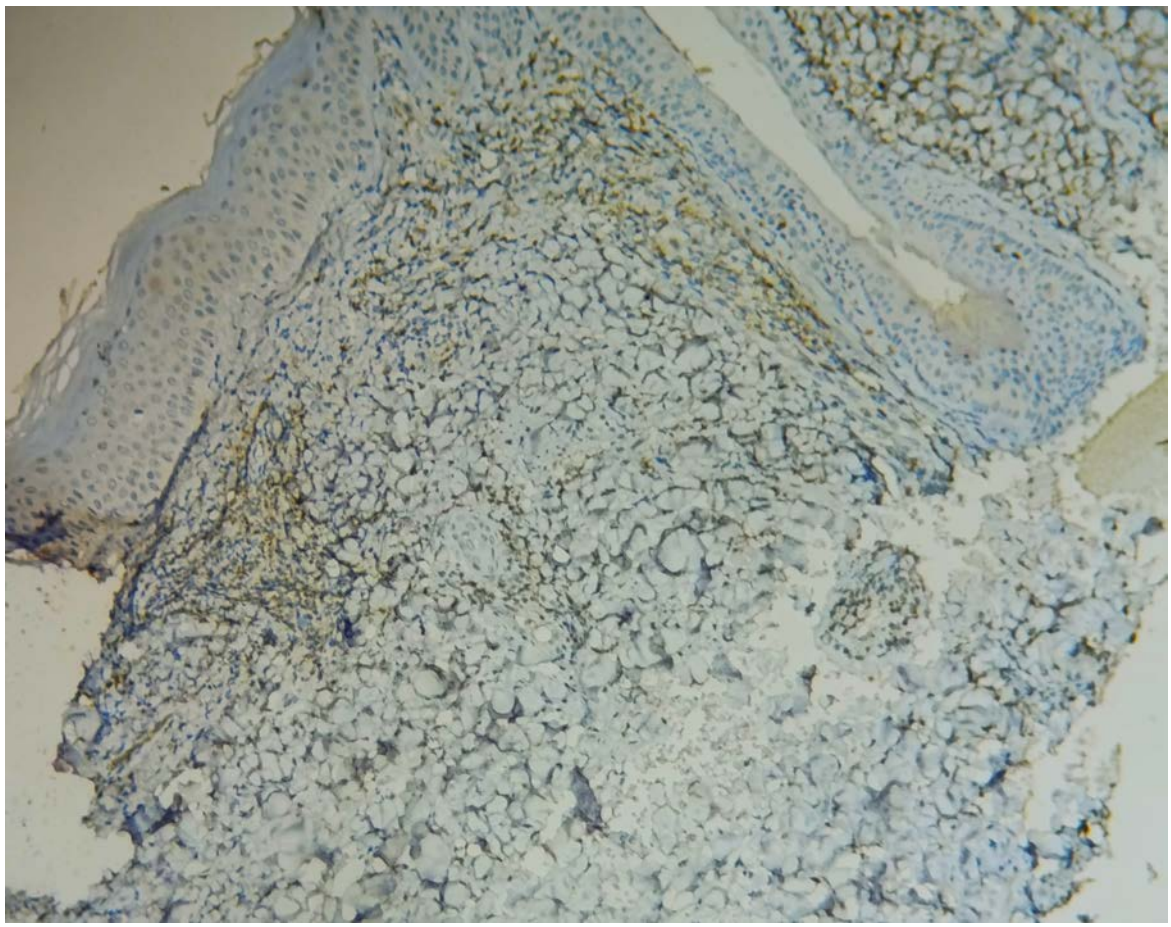

MPO :Granular cytoplasmic staining within the interstitial inflammatory infiltrate

**Results**

The clustering of six cases within three consanguineous families from the same geographic area strongly suggests a genetic origin with a possible founder effect. A male predominance (sex ratio = 2) was observed. Disease onset was consistently early, representing a key clue distinguishing CANDLE syndrome from other autoinflammatory disorders.

Initial manifestations were mainly systemic, dominated by recurrent fever and poor general condition. Arthralgia appeared later, mainly in adults, suggesting progression toward chronic inflammatory disease.

Cutaneous manifestations were constant and homogeneous, characterized by erythematous annular lesions involving the face, trunk, and upper limbs, associated with progressive lipodystrophy and facial dysmorphism. One patient presented nail dystrophy and alopecia areata with characteristic dermoscopic findings. This association may be explained by shared interferon-mediated immune pathways.

Systemic manifestations varied according to age. Pediatric patients showed growth retardation and splenomegaly in two cases. One patient presented nephromegaly associated with muscle weakness and elevated liver enzymes, suggesting a more severe phenotype. In adults, functional manifestations predominated, including lagophthalmos, reduced mouth opening, and restricted joint mobility. Bilateral cataracts were observed in one patient.

Biological abnormalities varied according to disease stage. Active pediatric forms showed neutrophil-predominant leukocytosis, whereas chronic adult forms were associated with leukopenia, neutropenia, and lymphopenia. Anemia and persistent CRP elevation were observed in all patients.

Histologically, skin lesions showed polymorphous dermal infiltrates composed of neutrophils, lymphocytes, and

histiocytes, sometimes with leukocytoclasia. Immunohistochemistry (MPO+, CD68+) confirmed myeloid involvement.

Management remains challenging and non-standardized. Corticosteroids provided transient improvement but were limited by steroid dependence. Colchicine showed partial efficacy but was discontinued because of adverse effects. Current data identify JAK inhibitors, particularly baricitinib, as the most promising targeted therapy through inhibition of type I interferon signaling

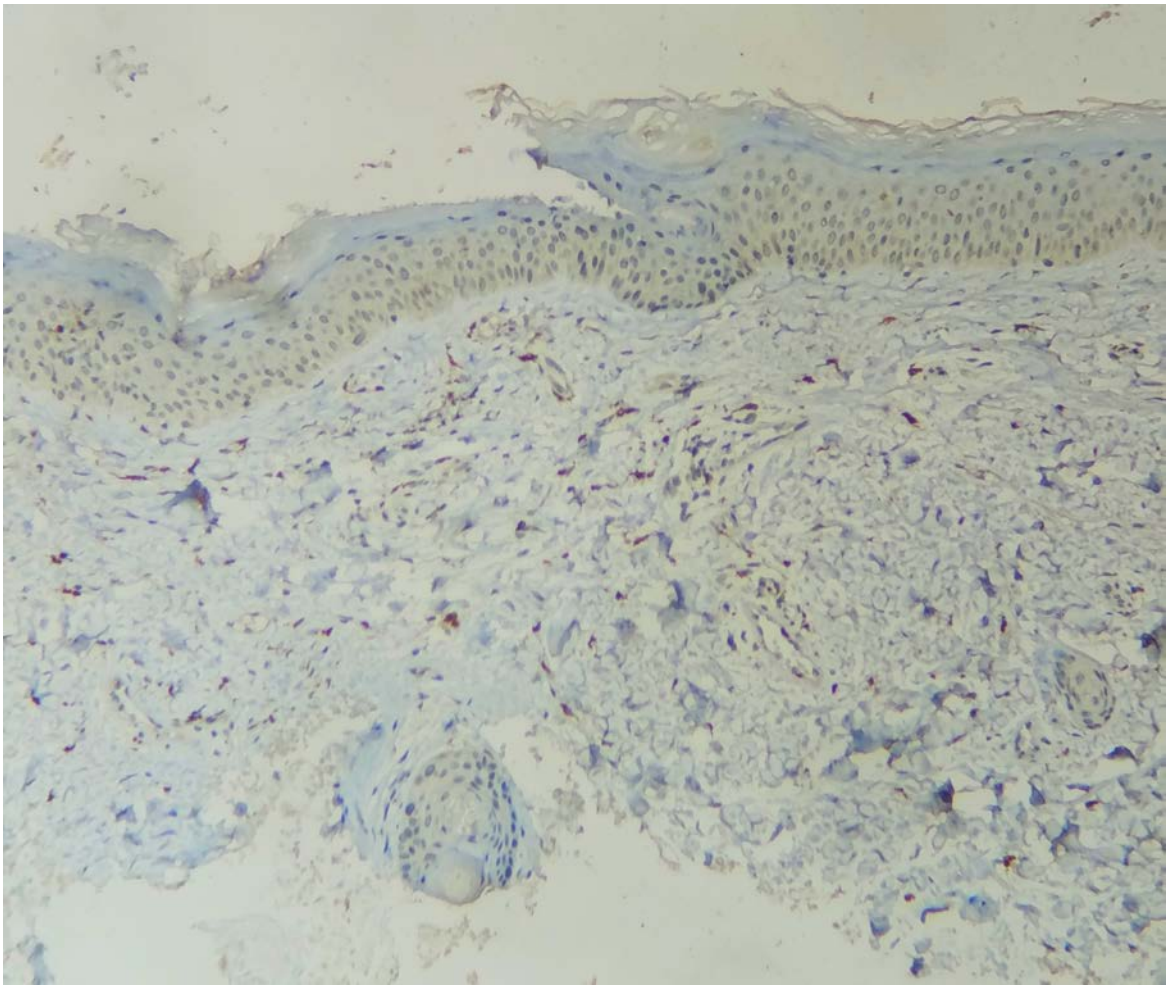

CD68 :Granular cytoplasmic staining within the interstitial inflammatory infiltrate

**Conclusions**

This series of six cases of CANDLE syndrome from three families in the Sétif region suggests a possible shared genetic origin with a founder effect. The homogeneous clinical presentation confirms the early-onset and severe nature of this type I interferonopathy. Conventional treatments remain limited, highlighting the potential of JAK inhibitors, particularly baricitinib, as a promising targeted therapeutic option.

EA DV CONGRESS
VIENNA
30 SEP - 3 OCT 2026

**Abstract N°: 2487**

# Papillon–Lefèvre Syndrome Associated with Sjögren's Syndrome: A First Reported Case in an 11-Year-Old Girl

Nouha Touhami*[1], Kenza Benothmane[1], Najoua Ammar[1], Leila Benzekri[1]

[1] Ibn Sina Hospital, rabat, Morocco

**Introduction**

**Papillon-Lefèvre syndrome (PLS) is a rare autosomal recessive genodermatosis caused mainly by mutations in the cathepsin C (CTSC) gene. It is characterized by diffuse palmoplantar keratoderma associated with early-onset aggressive periodontitis leading to premature loss of primary and permanent teeth. Cutaneous lesions usually appear within the first years of life and may be associated with recurrent pyogenic infections. Early diagnosis is essential to prevent severe functional, aesthetic, and psychosocial complications.Sjögren's syndrome is a systemic autoimmune disease mainly characterized by exocrine gland dysfunction, leading to ocular and oral dryness, and may be associated with systemic manifestations.We report the case of an 11-year-old girl presenting with palmoplantar keratoderma and severe periodontal involvement consistent with Papillon-Lefèvre syndrome, in whom features suggestive of Sjögren's syndrome were also identified, highlighting a rare association between both conditions**



Figure 1 : Missing permanent teeth in upper and lower arch

**Case Presentation**

**An 11-year-old girl born to non-consanguineous parents, with two brothers without notable medical history, who presented for evaluation of palmoplantar keratoderma, which had been present since the age of 1 year. Her past medical history included infantile asthma, as well as rheumatic fever with cardiac involvement, for which she was receiving Benzathine benzylpenicillin. A history of anxiety and panic attacks was also reported. Since the age of 2 years, she had presented with diffuse cutaneous dryness and was being followed for ocular and oral dryness under treatment. Psychomotor development was normal. The patient also reported oral involvement characterized by failure of eruption of several permanent teeth following the loss of primary teeth.Dermatological examination revealed diffuse xerosis associated with symmetrical, slightly yellowish palmoplantar keratoderma extending to the dorsal aspects of the fingers**

**and phalanges,with a few fissures on the palmar aspect of the right hand. Examination of the hair and nails was normal. Oral examination showed multiple missing teeth with persistence of several deciduous teeth and areas of erythematous gingivitis. Osteoarticular examination was normal.Laboratory investigations demonstrated a normal complete blood count, normal erythrocyte sedimentation rate, and negative 24-hour proteinuria. Immunological workup, including rheumatoid factor and extractable nuclear antigen antibodies, was negative. Minor salivary gland biopsy revealed grade III chronic lymphocytic sialadenitis according to the Chisholm and Mason classification, suggestive of Sjögren's syndrome. Skin biopsy showed orthokeratotic hyperkeratosis consistent with hereditary or acquired palmoplantar keratoderma. Panoramic dental radiography demonstrated permanent absence of several teeth, periodontal involvement, and persistence of some deciduous teeth.Genetic analysis for *CTSC* mutation was not performed due to technical and financial limitations, which represents a limitation in confirming the molecular diagnosis. However, the strong clinico-radiological and histopathological correlation supports the diagnosis of PLS.**



Figure 2 :Dermatological examination revealed diffuse xerosis associated with symmetrical, slightly yellowish palmoplantar keratoderma extending to the dorsal aspects of the fingers and phalanges,with a few fissures on the palmar aspect of the right hand.

**Conclusion**

**This case is, to our knowledge, the first reported association between Papillon-Lefèvre syndrome and Sjögren's syndrome. It highlights an atypical and exceptionally rare overlap of a genetic keratoderma with an autoimmune exocrinopathy. Although genetic confirmation was not performed, clinical, radiological, and histological findings strongly support the diagnosis.**




Figure 3 : Panoramic dental radiography demonstrated permanent absence of several teeth, periodontal involvement, and persistence of some deciduous teeth

EA DV CONGRESS
VIENNA
30 SEP - 3 OCT 2026

**Abstract N°: 2497**

# Pityriasis Rubra Pilaris-like Cutaneous Manifestations as the Initial Presentation of Carvajal Syndrome Associated with a DSP Gene Mutation

Sanghyun Park[1], Tae Wook Kim*[1], Kyung Eun Ha[2], Wook-Jin Chung[2], Ja Young Seo[3], Sangho Lee[4]

[1] Department of Dermatology, Gil Medical Center, Gachon University College of Medicine, Incheon, Korea, Rep. of South

[2] Department of Cardiology, Gil Medical Center, Gachon University College of Medicine, Incheon, Korea, Rep. of South

[3] Department of Laboratory Medicine, Gil Medical Center, Gachon University College of Medicine, Incheon, Korea, Rep. of South

[4] Department of Pathology, Gil Medical Center, Gachon University College of Medicine, Incheon, Korea, Rep. of South

## Introduction

Carvajal syndrome is a rare inherited cardiocutaneous syndrome caused by pathogenic variants in *Desmoplakin*(*DSP*) and characterized by woolly hair, palmoplantar keratoderma, and cardiomyopathy. Variable cutaneous manifestations may also be present. Although cutaneous manifestations often precede cardiac disease, diagnosis may be delayed when skin lesions are regarded as simple inflammatory dermatoses. We report an 18-year-old male with DSP-related cardiocutaneous syndrome who presented with refractory pityriasis rubra pilaris(PRP)-like dermatosis prior to the development of progressive, life-threatening cardiomyopathy.

## Case Presentation

The patient had a long-standing dermatologic history beginning in infancy and had previously been treated for presumed atopic dermatitis. At 12 years of age, he developed generalized erythematous scaly patches and follicular papules involving the face, trunk, and extremities, accompanied by palmoplantar keratoderma and hyperkeratotic nails. Skin biopsy showed hyperkeratosis with orthokeratosis and parakeratosis, mild acanthosis, and superficial perivascular lymphocytic infiltration. Initially diagnosed with PRP, he was sequentially treated with acitretin, phototherapy, and methotrexate, with only partial improvement and a refractory waxing-and-waning course. At 18 years of age, worsening dyspnea and edema prompted cardiac evaluation, revealing marked cardiomegaly and severe biventricular systolic dysfunction, with a left ventricular ejection fraction of <5%. Cardiac magnetic resonance imaging confirmed dilated cardiomyopathy with diffuse myocardial thinning and global hypokinesia. Despite intensive medical treatment, his condition progressed to cardiogenic shock, requiring mechanical circulatory support followed by left ventricular assist device implantation as a bridge to heart transplantation. Because of the unusual combination of severe cardiomyopathy and chronic keratinizing dermatosis, dermatologic re-evaluation was performed. Closer examination revealed woolly, coarse, and sparse scalp hair, focal plantar keratoderma, brownish scaly papuloplaques with islands of sparing, hypodontia, and hypohidrosis. Repeat skin biopsy demonstrated focal compact hyperkeratosis and dyskeratotic keratinocytes. Transmission electron microscopy revealed widening of intercellular spaces with reduced desmosome density, suggesting impaired cell-cell adhesion. Targeted exome sequencing identified a heterozygous *DSP* missense variant, c.1760A>C (p.Tyr587Ser), located in the spectrin repeat 6 domain. This variant is absent from major population databases. Based on the combined cardiac, cutaneous, histopathologic, ultrastructural, and genetic findings, a diagnosis of DSP-related cardiocutaneous syndrome consistent with the Carvajal phenotype was established. The patient is clinically stable on left ventricular assist device support while awaiting heart transplantation, and dermatologic treatment has remained conservative because of his systemic condition.

**Conclusion**

This case highlights that DSP-related cardiocutaneous syndrome may initially mimic inflammatory papulosquamous dermatoses such as pityriasis rubra pilaris, resulting in delayed diagnosis. In patients with refractory PRP-like eruptions, the presence of palmoplantar keratoderma, woolly or sparse hair, nail changes, dental anomalies, or hypohidrosis should prompt consideration of an underlying desmosomal disorder. Early recognition of these dermatologic and appendageal clues may lead to timely cardiac assessment and genetic testing, potentially preventing delayed detection of fatal cardiomyopathy.

EA DV CONGRESS
VIENNA
30 SEP - 3 OCT 2026

**Abstract N°: 2625**

## A rare cutaneous manifestation of Neurofibromatosis type 1

Maria Yankova*[1], Toma Tomov[1], Inna Popova[1], Valeria Mateeva[1], Grisha Mateev[1], Kossara Drenovska[1]

[1] Department of Dermatology and Venereology, Medical University – Sofia, Bulgaria, Sofia, Bulgaria

### Introduction

Neurofibromatosis type 1 (NF1, von Recklinghausen disease) is a rare autosomal dominant genetic disorder, occurring in1: 2500 - 3000 newborns. In approximately 50% of cases it arises from spontaneous mutation, while the remaining 50% exhibit familial inheritance. NF1 is a multisystem disease with neurological, ocular, skeletal and cardiovascular manifestations but it is the wide spectrum of cutaneous involvement including café-au-lait macules, intertriginous freckling, and multiple neurofibromas that helps its recognition. Occasionally, red-blue neurofibromas (RBNs) presenting as bluish to red-blue pseudo-macules have been described as a rare morphological subtype of cutaneous neurofibromas. Their atypical appearance may result in delay of NF1 diagnosis.

### Case Presentation

A 14-year-old boy presented with multiple soft, raised cutaneous lesions on the trunk and extremities of 3 years duration. The initial lesion has appeared on the lateral aspect of the abdomen and has gradually increased in size without any subjective complaints. The dermatological examination revealed barely elevated, oval shaped lesions of approximately 2–3 cm in diameter on the right abdominal flank and anterolateral surface of upper right arm. The lesions exhibited a smooth surface, and bluish coloration. Smaller lesions with similar morphology were distributed across other parts of the trunk and extremities. On palpation a positive buttonhole sign was demonstrated. Additionally, more than six café-au-lait macules with varying sizes along with inguinal freckling were observed. Family history revealed an 8-year-old brother with a single seizure episode and electroencephalographic abnormalities, while no other family members were known to have similar manifestations or confirmed NF1 diagnosis.

Routine laboratory results were within the normal limits. Histopathological analysis of a biopsy specimen from the abdominal lesion revealed normal epidermis with an underlying ‘grenz’ zone of uninvolved superficial and mid-dermis. Beneath, a non-encapsulated, dense tumor composed of delicate fascicles and scattered spindle-shaped cells with wavy nuclei, compatible with neurofibroma was detected. Thick-walled blood vessels were observed mainly in the papillary dermis and within the subcutaneous neurofibromatous tissue, possibly contributing to the bluish colour of the lesions.

Slit-lamp ophthalmological examination, revealed well-defined dome-shaped asymptomatic iris elevations consistent withLisch nodules (melanocytic hamartomas).

### Conclusion

The diagnosis of NF 1 in our patient had not been recognized previously and was established during our evaluation. It was based on the revised clinical criteria including café-au-lait macules, intertriginous freckling, multiple RBNs and Lisch nodules in the absence of typical neurofibromas. RBNs are regarded as a rare morphological variant clinically presenting as bluish macular lesions but histopathologically consistent with neurofibromas. Although reported in up to 29% of NF1 patients, their recognition is challenging as they may

mimic vascular or other dermal tumors and potentially delay diagnosis similarly to other NF1 atypical lesions such as juvenile xanthogranuloma, nevus anemicus, glomus tumor, etc. This case highlights the importance of careful clinicopathological assessment and expands the phenotypic spectrum of NF1.

EADV CONGRESS
VIENNA
30 SEP - 3 OCT 2026

**Abstract N°: 2693**

**Piebaldism-Waardenburg spectrum with multisystem involvement: a case report**

Julia Cascardo Géo de Siqueira*[1], Maria Eduarda Cesar Garcez[1], Mayara Araújo Brilhante[1], Doménica Cerón Chimarro[1], Amanda Quintaes[1], Luna Azulay-Abulafia[1]

[1] Pedro Ernesto University Hospital, Rio de Janeiro State University (UERJ), Rio de Janeiro, Brazil

**Introduction**
Piebaldism is a rare autosomal dominant disorder of melanocyte development, most commonly caused by mutations in the KIT proto-oncogene or, less frequently, SNAI2. It is characterized by congenital, stable achromic patches and a white forelock, typically involving the frontal scalp, forehead, and trunk midline.

Waardenburg syndrome comprises a group of auditory–pigmentary neurocristopathies with variable pigmentary abnormalities and congenital sensorineural hearing loss. Significant phenotypic overlap exists between piebaldism and Waardenburg syndrome and both are increasingly considered within a shared developmental spectrum affecting neural crest-derived tissues.

The concept of a piebaldism-Waardenburg spectrum has therefore been proposed to encompass overlapping cutaneous and extracutaneous phenotypes. In this context, the presence of extracutaneous manifestations should prompt evaluation for broader syndromic diagnoses within congenital pigmentary disorders.

**Case Presentation**
A 17-year-old male, Fitzpatrick phototype III, was referred to Dermatology for evaluation of hypopigmented skin lesions present since birth.

Physical examination revealed extensive, symmetrical achromic macules affecting the face, anterior trunk, extensor surfaces of the upper limbs and proximal lower limbs, with relative sparing of the distal extremities, associated with frontal poliosis and a well-defined triangular achromic macule extending to the anterior hairline. Hyperpigmented macules were observed within and at the borders of the depigmented areas. No progression or development of new lesions had occurred over time.

Family history was notable for approximately 11 relatives across multiple generations presenting similar pigmentary findings and poliosis, consistent with autosomal dominant inheritance.

Relevant medical history included chronic kidney disease secondary to a solitary left pelvic kidney – a subtype of congenital anomaly of the kidney and urinary tract (CAKUT), epilepsy, and hearing loss of unclear etiology. The patient was already under nephrology and neurology follow-up and was referred for otorhinolaryngological evaluation to further characterize the hearing deficit. A comprehensive genetic panel is currently pending.

**Conclusion**
Cutaneous phenotype characterized by congenital, stable, well-demarcated achromic patches, frontal poliosis, triangular forehead involvement and islands of hyperpigmented macules is highly suggestive of a disorder within

the piebaldism-Waardenburg spectrum. The marked familial aggregation across multiple generations further supports an autosomal dominant inheritance pattern.

The presence of sensorineural hearing loss significantly challenges the diagnosis of isolated piebaldism and is most consistent with an auditory-pigmentary neurocristopathy, particularly Waardenburg syndrome type 2. In contrast, piebaldism typically lacks extracutaneous manifestations, making a syndromic overlap or alternative diagnosis more likely in this case.

Coexistence of CAKUT and epilepsy adds an additional layer of complexity, as this combination has not been previously reported in association with the piebaldism phenotype, further expanding the differential diagnostic considerations. Whether these findings represent an atypical expansion of a known neurocristopathy spectrum or a distinct syndromic entity remains to be determined.

Genetic testing, including analysis of KIT and genes implicated in auditory-pigmentary disorders (PAX3, SOX10, MITF, EDNRB), will be essential to further delineate the underlying diagnosis. However, these tests are not widely available.

This case highlights the diagnostic challenges posed by congenital pigmentary disorders with multisystem involvement. Comprehensive genetic investigation, multi-institutional collaboration and multidisciplinary evaluation are essential to clarify the diagnosis and to better understand potential genotype-phenotype correlations.

EA DV CONGRESS
VIENNA
30 SEP - 3 OCT 2026

**Abstract N°: 2722**

## Pseudoxanthoma Elasticum with Ocular, Gastrointestinal and Neurological Involvement in a Young Woman

Seyma Seray Coban*[1]

[1] BLACK SEA TECHNIC UNIVERSITY, TRABZON, Türkiye

### Introduction

PXE is a rare hereditary connective tissue disorder characterized by progressive calcification and fragmentation of elastic fibers involving the skin, retina, and vascular system. Cutaneous findings may be subtle, delaying diagnosis for years.

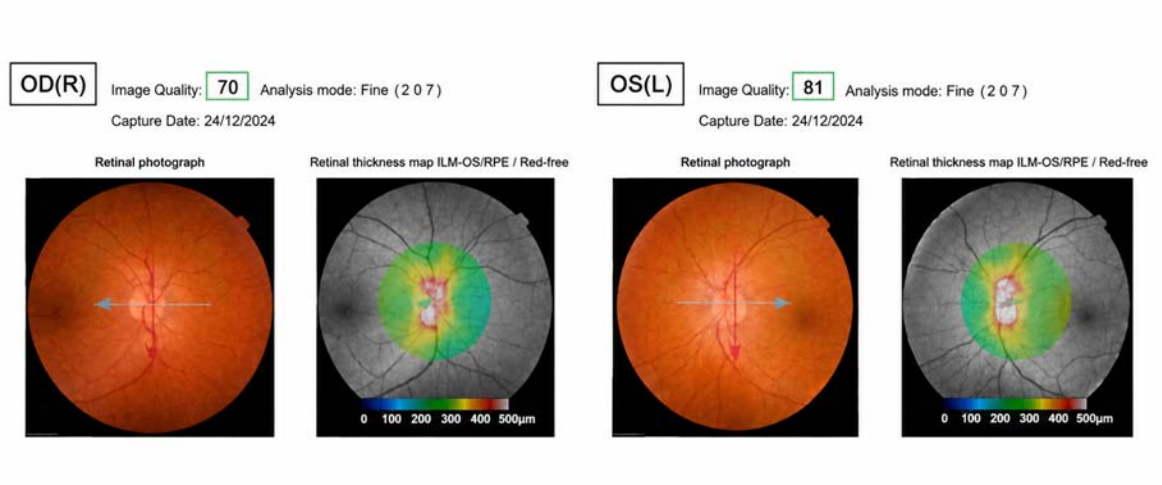


Fundus and OCT imaging findings

### Case Presentation

A 29-year-old female patient was referred to dermatology after incidental detection of angioid streaks during ophthalmologic evaluation prior to refractive surgery. The patient had no significant visual complaints.Dermatologic examination revealed bilateral yellowish papular plaques localized to both axillary regions. No lesions were detected on the neck, antecubital fossae, popliteal fossae, inguinal region, wrists, or ankles.

Detailed history revealed recurrent gastrointestinal bleeding attacks since childhood. The first episode occurred at age 4, with recurrent bleeding approximately every two years. During one hospitalization, four vascular clips were required.

The patient also described transient paresthesia involving upper and lower extremities. Brain MRI demonstrated bilateral deep white matter hyperintense lesions. Demyelinating disease was considered in the differential diagnosis.

Multidisciplinary evaluation including gastroenterology, neurology, cardiology, cardiovascular surgery,

ophthalmology, and medical genetics was initiated.

## OPHTHALMOLOGIC FINDINGS

Fundus examination and OCT imaging demonstrated retinal alterations compatible with PXE-associated angioid streak involvement. Retinal findings were incidentally identified and led to dermatologic referral. The patient denied severe visual impairment.

## PATHOLOGY & GENETICS

Punch biopsy from the right axillary region demonstrated findings compatible with pseudoxanthoma elasticum. PAS and EVG staining supported the diagnosis.

Genetic CNV analysis revealed a homozygous deletion involving exon 9 of the ABCC6 gene. Additional confirmatory testing was requested by the genetics department.



Yellowish papular plaques in left axillary region.

**Conclusion**

PXE is a multisystem hereditary disorder caused mainly by abnormalities in the ABCC6 gene. Although characteristic flexural yellow papules are considered hallmark findings, cutaneous lesions may remain subtle and localized for years.

Besides ocular and gastrointestinal involvement, increasing evidence suggests an association between PXE and cerebral microvascular abnormalities, including white matter lesions and ischemic changes. Neurological manifestations may therefore represent an underrecognized component of the disease spectrum.

In our patient, recurrent gastrointestinal hemorrhage since childhood, incidental angioid streaks, and nonspecific

cerebral white matter lesions accompanied subtle axillary papules, emphasizing the heterogeneous and multisystemic nature of PXE.

This case highlights the importance of thorough dermatologic examination and multidisciplinary evaluation in patients with unexplained systemic manifestations.

Careful dermatologic examination in patients presenting with angioid streaks or unexplained recurrent GI bleeding may facilitate earlier diagnosis of PXE.

EADV CONGRESS
VIENNA
30 SEP - 3 OCT 2026

**Abstract N°: 2748**

# Nemolizumab in dominant dystrophic epidermolysis bullosa pruriginosa

Eglė Janušonytė*[1], Emmanuel Laffitte[1]

[1] Department of Dermatoveneorology, Geneva University Hospitals, Geneva, Switzerland

## Introduction

Dominant dystrophic epidermolysis bullosa (DEB) pruriginosa is a rare COL7A1-associated genodermatosis characterised by chronic treatment-refractory pruritus, pretibial prurigo-like lesions, and skin fragility. Pruritus ranks above pain as the leading unmet therapeutic need, with Th2-skewed cytokine dysregulation and elevated IL-31 implicated in its pathogenesis. Despite emerging use of dupilumab and JAK inhibitors, a subset of patients remains refractory, representing a persistent therapeutic gap. Nemolizumab, a monoclonal antibody targeting IL-31 receptor alpha, is approved for atopic dermatitis and prurigo nodularis, but has not previously been reported in DEB pruriginosa.

## Case Presentation

A 22-year-old woman presented with genetically confirmed dominant DEB (COL7A1) and bilateral pretibial prurigo-like lesions with recurrent wound formation. Baseline Peak Pruritus Numerical Rating Scale (PP-NRS) was 8-9/10. Prior treatments included topical agents, systemic corticosteroids, doxycycline, gabapentin, prolonged penicillin courses, and approximately two years of dupilumab, discontinued due to loss of efficacy. Nemolizumab was initiated in July 2025 at a loading dose of 60 mg, followed by 30 mg subcutaneously monthly. Rapid reduction in pruritus and pain was reported within the initial weeks. At eight months of follow-up (March 2026), PP-NRS decreased to 1-2/10 with marked clinical improvement in pretibial lesions. No adverse effects were reported.

## Conclusion

The observed PP-NRS reduction of 7 points exceeds the clinically meaningful threshold defined in the OLYMPIA prurigo nodularis trial. The Th2/IL-31 axis, well characterised in DEB pruriginosa lesional skin, provides a biologically plausible mechanistic rationale for nemolizumab's efficacy in this setting. To our knowledge, this is the first reported case of nemolizumab in genetically confirmed dominant DEB pruriginosa, positioning IL-31 pathway blockade as a clinically promising strategy in this therapeutically orphan condition.

EA DV CONGRESS
VIENNA
30 SEP - 3 OCT 2026

**Abstract N°: 2756**

# GLP-1 agonist as an adjunct therapy in benign familial chronic pemphigus (Hailey–Hailey disease)

Christian Puttinger*[1], Nasim Niknezhad[2], Martin Laimer[1], Dédée Murrell[2]

[1] Department of Dermatology and Allergology and EB House Austria, University Hospital of the Paracelsus Medical University Salzburg, Austria, Salzburg, Austria
[2] Department of Dermatology, St George Hospital, Sydney, New South Wales, Australia, Sydney, Australia

## Introduction

Benign familial chronic pemphigus, also known as Hailey–Hailey disease, is a rare inherited blistering skin disorder caused by a heterozygous mutation in the ATP2C1 gene located on chromosome 3. This gene encodes the hSPA1C protein, a $Ca^{2+}$ and $Mn^{2+}$ transporting ATPase expressed in keratinocytes. Mutations in ATP2C1 impair this transport function, resulting in acantholysis and abnormal keratinocyte differentiation, which subsequently compromises the skin barrier. Clinically, symptoms typically start in adulthood and present as erosions and crusting within flexural and intertriginous regions. Patients commonly experience pain and pruritus, while disease flares are often triggered by humidity, friction, and secondary infections. With no definitive cure, treatments include topicals agents (e.g. corticosteroid, antibiotics, 5-fluorouracil, …) and systemic treatments (retinoids, immunosuppressive/immunomodulating drugs, antibiotics, …) as well as laser therapy, photodynamic therapy and surgical treatments.

## Case Presentation

We report a 66-year-old woman with HHD with a disease course over four decades. Initially the diagnosis was histologically confirmed with biopsies. The patient presented with erosions on the abdomen, chest, groin and painful lesions on the lower back. Over the disease course the patient underwent multiple treatments including oral prednisolone, dapsone, methotrexate, adalimumab, omalizumab, apremilast, acitretin, doxycycline, low-dose naltrexone as well as UV-B therapy; however, these therapies were either ineffective or resulted in adverse effects that necessitated discontinuation.

Because of the coexisting adipositas and diabetes mellitus type II, semaglutide, a GLP-1 agonist, was started in our patient. This resulted into 15kg weight loss within six months and improvement in her HHD. This trend continued with a 25kg weight reduction eight months after starting semaglutide with the patient stating that her skin appears much improved with significantly reduced pruritus compared to her previous severe presentation. One year after starting semaglutide this effect was still visible, and the patient was very satisfied with the treatment. (Figure 1)
The Pemphigus Disease Area Index (PDAI), was used quantify disease severity due to lack of a disease specific measurement tool. In our patient, the PDAI activity score decreased from 17 prior to initiation of semaglutide therapy to 3 after 5 months and further improved to near-complete resolution with a score of 1 at the final assessment after 14 months.




Fig 1: Serial clinical images of the patient's back illustrating the course of Hailey–Hailey disease over time, with substantial reduction of erythema and erosions following initiation of GLP-1 agonist.

Fig 1: Serial clinical images of the patient's back illustrating the course of Hailey–Hailey disease over time, with substantial reduction of erythema and erosions following initiation of GLP-1 agonist.

**Conclusion**

In our case improvement started after initiation of semaglutide and with weight loss of the patient. As shown in a previous report of a successful treated patient with HDD receiving liraglutide, the decrease of the proinflammatory cytokine IL-6 due to GLP-1 agonists, which has been shown to play an important role in the regulation of ATP2C1 expression in the skin, might have a causal and beneficial effect of the disease. In our case there is strong temporal correlation, with the initiation of semaglutide and improvement of the disease. This effect might not be direct but rather due to reduction of friction and occlusion and less sweating because of weight loss due to GLP-1 agonists. Additionally, GLP-1 agonists, such as semaglutide, reduce systemic inflammation and improve insulin resistance which may be indirectly beneficial for skin barrier function.

Taken together, this case further supports the evidence that GLP-1 receptor agonists, such as Semaglutide, may serve as highly effective adjunctive therapies by promoting weight loss and reducing important triggers of disease activity.

EA DV CONGRESS
VIENNA
30 SEP - 3 OCT 2026

**Abstract N°: 2795**

## A novel mucocutaneous syndrome associated with homozygous ZNF750 frameshift mutation

Ibrahim Akcay*[1], Elif Kubar[2], Asude Durmaz[2], Banu Yaman[3], Ayca Aykut[2], Nilay Duman[1]

[1] Department of Dermatology and Venereology, Ege University Faculty of Medicine, İzmir, Türkiye
[2] Department of Medical Genetics, Ege University Faculty of Medicine, İzmir, Türkiye
[3] Department of Medical Pathology, Ege University Faculty of Medicine, İzmir, Türkiye

**Introduction**
ZNF750 is a keratinocyte-specific transcription factor involved in epidermal terminal differentiation and epithelial barrier homeostasis. Heterozygous ZNF750 variants have previously been associated with seborrheic dermatitis-like psoriasiform eruptions in a limited number of families. To date, homozygous ZNF750 deficiency has not been described in humans. We report a consanguineous family carrying a homozygous ZNF750 frameshift mutation and compare the clinical, histopathological, and genetic findings between homozygous and heterozygous family members.

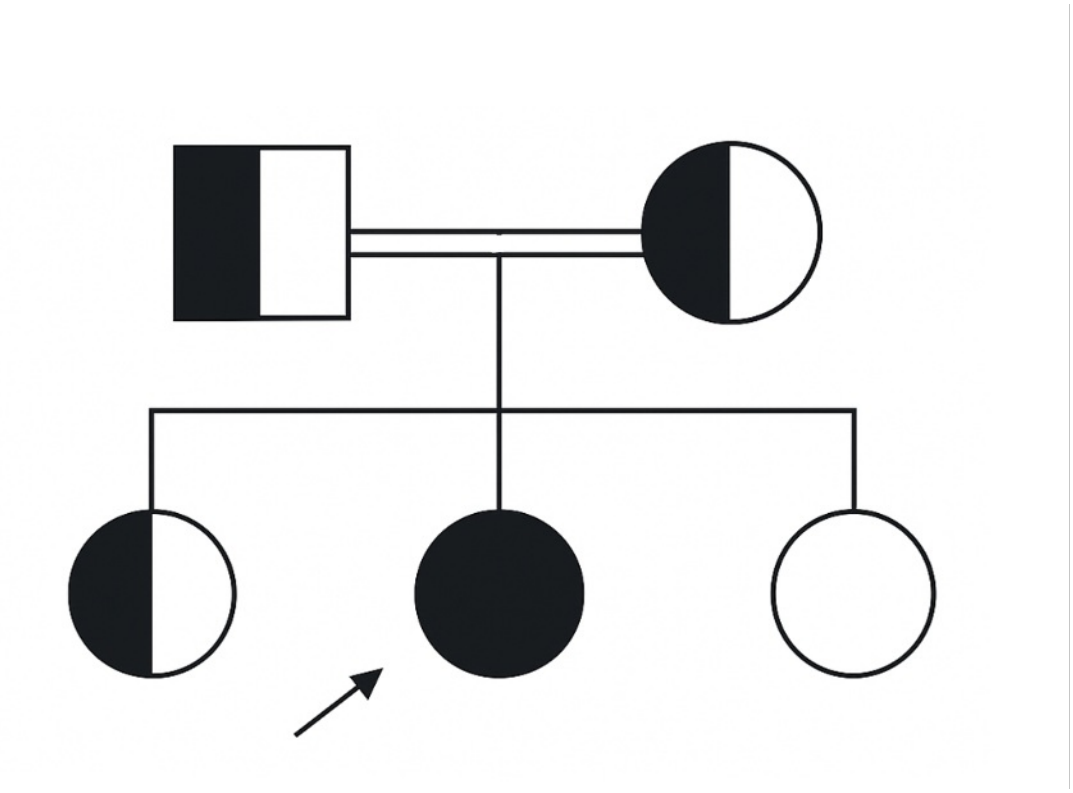

Pedigree of the family carrying the ZNF750 mutation: Both parents were heterozygous carriers. Among the offspring, one child was homozygously affected (indicated by the arrow), one sibling was a heterozygous carrier, and one sibling was unaffected. Phenotypic severity appeared to correlate with

allelic dosage. Heterozygous individuals exhibited mild psoriasiform cutaneous and mucosal manifestations, whereas the homozygous patient demonstrated severe epidermal differentiation defects and a markedly more severe phenotype.

**Case Presentation**

A 22-year-old woman presented with early-onset treatment-resistant seborrheic dermatitis-like eruptions, palmoplantar hyperkeratosis, follicular hyperkeratosis, nail dystrophy, recurrent mucosal infections, and progressive hair abnormalities. Dermatological examination, histopathological evaluation, trichoscopy, polarized light microscopy, family screening, and whole exome sequencing (WES) were performed. Clinical findings of heterozygous relatives were comparatively evaluated.

The patient demonstrated severe mucocutaneous manifestations beginning in early childhood, including diffuse erythematous-squamous lesions involving seborrheic areas, plantar hyperkeratosis, severe toenail dystrophy, digital clubbing of the fingernails, sparse fragile hair, folliculitis, and focal alopecic patches. Trichoscopic examination revealed marked hair shaft caliber variability and trichoschisis, while polarized light microscopy demonstrated a tiger-tail–like pattern consistent with an underlying keratinization disorder.

Histopathological examination showed psoriasiform epidermal hyperplasia with parakeratosis, irregular acanthosis, focal lymphocytic and polymorphonuclear exocytosis, and superficial perivascular inflammatory infiltrates. The patient also had recurrent vaginitis, otitis, bronchitis, and urinary tract infections despite normal immunoglobulin levels.

WES identified a homozygous frameshift mutation in ZNF750 located on chromosome 17q25.3. Family analysis demonstrated heterozygous carriage in both parents and one sibling, while another sibling was unaffected. Heterozygous individuals exhibited milder manifestations, including limited psoriasiform lesions, nail abnormalities, recurrent mucosal infections, and bladder wall thickening suggestive of chronic mucosal inflammation.

These findings support a dose-dependent phenotypic spectrum associated with ZNF750 dysfunction. The observed phenotype may reflect impaired epidermal differentiation, altered barrier integrity, and defective keratinocyte-mediated mucosal immunity.

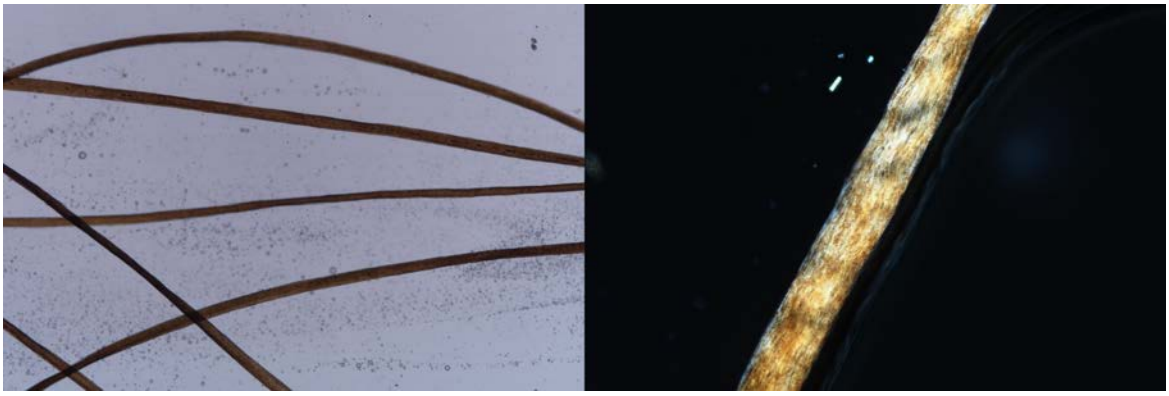

Hair shaft microscopy and polarized light microscopy findings: Marked variability in hair shaft diameter, surface irregularities, and focal trichoschisis were observed. Polarized light microscopy demonstrated a characteristic tiger-tail–like pattern within the hair shaft.

**Conclusion**

To our knowledge, this is the first reported human case of homozygous ZNF750 frameshift mutation. The combination of severe epidermal differentiation defects, hair shaft abnormalities, nail involvement, palmoplantar keratoderma, and recurrent mucosal infections suggests a previously unrecognized mucocutaneous syndrome

associated with ZNF750 deficiency. The milder manifestations observed in heterozygous relatives further support a dose-dependent phenotypic effect. The broad phenotypic spectrum may be related to disrupted regulatory pathways involved in keratinocyte differentiation, epithelial barrier integrity, and mucosal homeostasis. These findings further emphasize the critical role of ZNF750 in epithelial differentiation and epithelial barrier regulation.

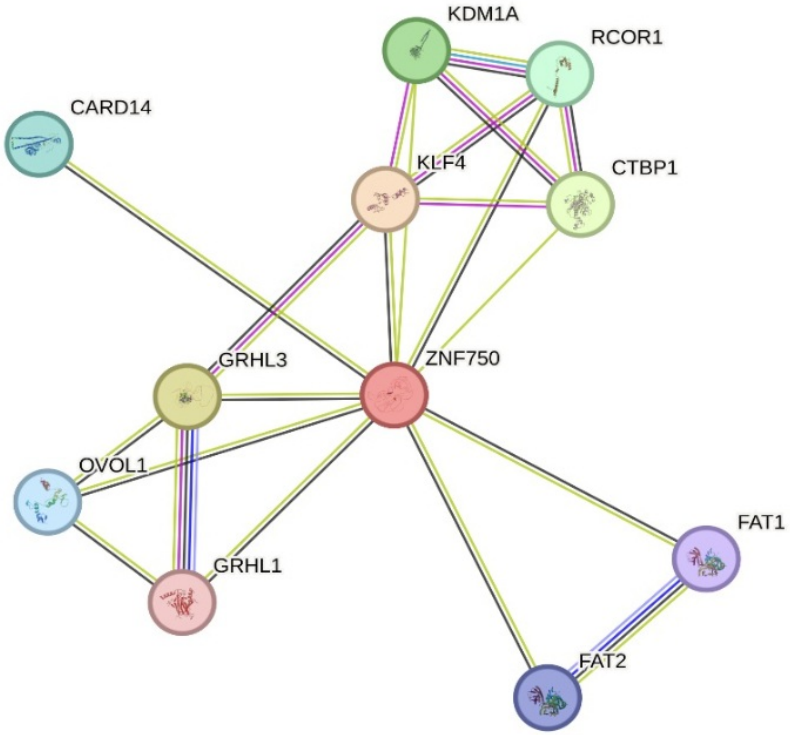


Previously reported regulatory network involved in ZNF750-mediated epidermal differentiation and epithelial barrier homeostasis. ZNF750 interacts with multiple regulatory proteins associated with keratinocyte differentiation and epithelial homeostasis, including KLF4, OVOL1, GRHL3, CARD14, FAT1/2, and KDM1A.

EA DV CONGRESS
VIENNA
30 SEP - 3 OCT 2026

**Abstract N°: 2802**

# Intrafamilial Phenotypic Variability in Recessive Dystrophic Epidermolysis Bullosa: First Philippine Case Series of Three Affected Siblings and Asymptomatic Carrier Mother with Comprehensive COL7A1 Testing

Rommela Angeli Quiampang*[1], Jamaine Melisse Regalado[1], Jasper Nuel Dayanan[2]

[1] Dr. Jose N. Rodriguez Memorial Hospital and Sanitarium, Caloocan City, Philippines
[2] The Mount Sinai Hospital, New York City, United States

## Introduction

Inherited epidermolysis bullosa is a rare group of genetic blistering disorders that manifests with widespread blistering and mucosal fragility caused by minor trauma.[1] Recessive dystrophic epidermolysis bullosa (RDEB) is a subtype that is caused by mutations in the COL7A1 gene, which encodes for the alpha-1 chain in Type VII collagen.[2] Dysfunction of COL7A1 gene results in skin fragility, scarring, nail changes, and variable extracutaneous involvement.[3] Clinical severity varies widely, even among affected members of the same family sharing the same COL7A1 variants.[4] This variability highlights the importance of combining careful clinical assessment with genetic testing to confirm the diagnosis, clarify inheritance patterns, improve prognostication, and guide genetic counseling. In the Philippines, published data on familial RDEB with full genetic work-up are limited, and to our knowledge, this represents the first intrafamilial case series with comprehensive COL7A1 genetic testing.

## Case Presentation

This case series includes four members of a Filipino family. Three siblings—a 9-year-old boy (proband), his 11-year-old brother, and 7-year-old sister—presented with generalized blistering, atrophic scarring, anonychia, and hand contractures consistent with recessive dystrophic epidermolysis bullosa (RDEB), while their mother was clinically unaffected. Targeted COL7A1 next-generation sequencing was performed, with variants interpreted using ACMG/AMP criteria and intrafamilial segregation. Disease severity of the siblings were documented using the Epidermolysis Bullosa Disease Activity and Scarring Index (EBDASI).

**Patient 1 (Proband):** A 9-year-old boy who presented at birth with a denuded leg lesion and later developed widespread trauma-induced blistering, slow-healing erosions, atrophic scarring, milia, anonychia, oral involvement, and dental caries. He had severe disease (EBDASI 141) requiring frequent wound care.

**Patient 2 (Older brother):** An 11-year-old male with onset of blistering in infancy, progressing to generalized erosions, scarring, and milia involving the skin and oral mucosa, with anonychia, finger contractures, and syndactyly of the right foot. Disease severity was moderate (EBDASI 108).

**Patient 3 (Younger sister):** A 7-year-old female with early-onset blistering, erosions, scarring, and milia affecting the neck, trunk, extremities, and oral mucosa, with anonychia and hand contractures. She had moderate disease (EBDASI 106).

**Patient 4 (Mother):** A 37-year-old female with no history of blistering, nail changes, or mucosal involvement, consistent with an asymptomatic carrier.

Initial genetic testing of the proband identified one pathogenic COL7A1 variant and one variant of uncertain significance (VUS). Cascade testing showed that all affected siblings carried both variants, supporting reclassification of the VUS as likely pathogenic. The mother carried only the reclassified variant, confirming carrier status. The father was unavailable for genetic testing; however, the presence of both variants in all affected siblings together with the maternal heterozygous state strongly supports autosomal recessive inheritance. Despite identical genotypes, the siblings demonstrated variable severity, highlighting intrafamilial phenotypic variability in

RDEB.

| Patient | Gene Variant | Variant Classification | EBDASI Score | Score Interpretation |
|---|---|---|---|---|
| Proband | c. 6091G>A (p. Gly2031Ser) | Pathogenic | 141 | Severe |
| | c. 1241-5G>A (Intronic) | | | |
| Patient 2 (older brother) | c. 6091G>A (p. Gly2031Ser) | | 108 | Moderate |
| | c. 1241-5G>A (Intronic) | | | |
| Patient 3 (younger sister) | c. 6091G>A (p. Gly2031Ser) | | 106 | Moderate |
| | c. 1241-5G>A (Intronic) | | | |
| Mother | c. 1241-5G>A (Intronic) | | asymptomatic | - |

This table summarizes the gene variants and their corresponding classification shown in the genetic test results of the patients. The three affected siblings share similar gene variants of COL7A1, while the mother carries one pathogenic variant of the gene. This table also shows the EBDASI score of the patients and their corresponding interpretation. The siblings, albeit sharing the same gene variants, show varying severity while the carrier mother is asymptomatic.

**Conclusion**

This first reported intrafamilial RDEB case series in the Philippines highlights the central role of genetic testing in evaluating suspected familial RDEB. In addition to confirming the diagnosis, genetic testing helped clarify the significance of an initially uncertain variant, establish the likely mode of inheritance, identify an asymptomatic carrier, and support counseling. The varying severity observed among the affected siblings despite sharing the same genetic variants further demonstrates that comprehensive genetic evaluation can provide substantial diagnostic, counseling value, and may also help prepare patients for future gene-based therapeutic opportunities.

References:

[1] *Soro L, Bartus C, Purcell S. Recessive dystrophic epidermolysis bullosa: a review of disease pathogenesis and update on future therapies. J Clin Aesthet Dermatol 2015; 8: 41–46.*

[2] *Fine JD, Eady RA, Bauer EA, et al. The classification of inherited epidermolysis bullosa (EB): report of the Third International Consensus Meeting on Diagnosis and Classification of EB. J Am Acad Dermatol 2008; 58: 931–950.*

[3] *Has C, Bauer JW, Bodemer C, et al. Consensus reclassification of inherited epidermolysis bullosa and other disorders with skin fragility. Br J Dermatol 2020; 183: 614–627.*

[4] *Zharylkap U, Ospanova S, Idrissova A. Dystrophic epidermolysis bullosa: case series of three related patients. Cent Asian J Med Hypotheses Ethics 2025; 6: 201–208.*

[5] *Thompson AJ, Tidman MJ, Murrell DF, et al. A comparison study of outcome measures for epidermolysis bullosa: Epidermolysis Bullosa Disease Activity and Scarring Index (EBDASI) and the Instrument for Scoring Clinical Outcomes of Research for Epidermolysis Bullosa (iscorEB). J Eur Acad Dermatol Venereol 2021; 35: 2193–2201.*

References for the introduction

EA DV CONGRESS
VIENNA
30 SEP - 3 OCT 2026

**Abstract N°: 2803**

# Intermediate-Dose Naltrexone for Refractory Hailey–Hailey Disease in an Elderly Patient with Multiple Comorbidities: A Case Report

Catherine Shin Huey Chen*[1], Cheng Yuan Li[2]

[1] Taipei Veterans General Hospital, Dermatology Department, Taipei, Taiwan
[2] Taipei Veterans General Hospital, Taipei, Taiwan

## Introduction

Hailey–Hailey disease (HHD) is a rare autosomal dominant acantholytic dermatosis caused by ATP2C1 mutation, leading to impaired keratinocyte adhesion and recurrent erosions in intertriginous areas. Disease course is chronic and relapsing, often exacerbated by friction, infection, and emotional stress. Management is challenging, particularly in elderly patients with multiple comorbidities. Naltrexone has emerged as a potential therapeutic option in refractory cases. We report an elderly patient with familial HHD successfully treated with intermediate dose Naltrexone.

## Case Presentation

A 76-year-old woman with underlying medical histories of Parkinson's disease, hypertension, arrhythmia, osteoporosis and adjustment disorder presented with recurrent painful scaly erosions over the groin region for 3 years. Upon physical examination, she had painful and pruritic erythematous plaques and erosions on bilateral crural folds, accompanied with yellow crusting. First-degree family history was positive for similar complaints. She had been treated in the past with topical and oral antibiotics, antifungals and topical steroids but was refractory to all kinds of treatment. Systemic examination was unremarkable. KOH smear was negative. Excisional biopsy of the right groin region was performed. After inadequate response to previous treatment, oral intermediate-dose Naltrexone was initiated at 12.5 mg daily. Clinical response was assessed over two months.

Histopathological analysis with hematoxylin and eosin (H&E) staining demonstrated parakeratosis, hyperkeratosis, and acanthosis with prominent suprabasal and intraepidermal acantholysis forming cleft-like spaces, compatible with the 'dilapidated brick wall' appearance . Elongated dermal papillae lined by basal keratinocytes projected into the acantholytic areas. Occasional dyskeratotic keratinocytes were noted. The upper dermis showed vascular proliferation with perivascular mononuclear infiltrates. Direct immunofluorescence revealed linear type IV collagen staining along the dermal–epidermal junction without blister formation. IgG, IgA, IgM, and C3 were negative. Findings were compatible with HHD. After two months of Naltrexone, marked reduction in erythema, erosion, and exudation was observed. Patient reported significant reduction of pain and pruritus with substantial improvement in quality of life. No adverse effects occurred.

## Conclusion

This case demonstrates efficacy of intermediate dose Naltrexone in refractory familial HHD in a medically complex elderly patient. At the intermediate dose of 12.5 mg daily used in this case, Naltrexone provides both the immunomodulatory effects seen at low dose and potentially enhanced anti-inflammatory activity. The excellent safety profile and absence of drug interactions make Naltrexone particularly valuable in elderly patients with polypharmacy and multiple comorbidities. While most published HHS cases utilize low dose Naltrexone (1.5-4.5 mg daily), higher doses (25-50mg ) have demonstrated efficacy in treating pruritus and other inflammatory dermatoses. This case adds to the growing evidence supporting intermediate-dose Naltrexone as a first-line option for refractory HHD, particularly in vulnerable populations.

EADV CONGRESS
VIENNA
30 SEP - 3 OCT 2026

**Abstract N°: 2906**

# When three acral keratinization disorders meet : A rare clinical triad

Khadija Essekakri*[1], Bouchra Baghad[1], Soumiya Chiheb[1]

[1] University hospital Ibn Rochd, CASABLANCA, Morocco

## Introduction

Acral keratinization disorders constitute a heterogeneous group of rare dermatological entities characterized by abnormal epidermal differentiation and hyperkeratosis predominantly affecting the palms and soles. Marginal acral hyperkeratosis is a rare condition presenting with hyperkeratotic papules along the borders of the hands and feet, whereas punctate palmar keratoderma is characterized by multiple discrete keratotic lesions involving the palmar surface or creases. Aquagenic keratoderma, an uncommon acquired or hereditary disorder, manifests as transient whitish papules or plaques triggered by water exposure and is thought to be related to eccrine sweat duct dysfunction or alterations in the stratum corneum. The coexistence of these conditions is exceptional and suggests a shared pathophysiological background involving keratinization abnormalities.

## Case Presentation

A 30-year-old Moroccan woman with no significant personal or familial medical history presented with a 10-year history of asymptomatic, non-pruritic hyperpigmented papular lesions involving the hands and feet. Four years after disease onset, whitish thickened plaques appeared on the feet, with marked accentuation after water exposure. Clinical examination revealed multiple monomorphic, closely clustered hyperpigmented micropapules, some flattened and others umbilicated, distributed bilaterally and symmetrically over the thenar eminences extending to the wrists and along the lateral borders of the feet. Small punctate keratotic lesions were observed on the distal palmar crease and the hypothenar area of the right hand. Whitish hyperkeratotic plaques were noted along the medial borders of both feet. Histopathological examination demonstrated acanthosis with marked hyperorthokeratosis. A topical treatment combining keratolytic agents and emollients was prescribed, leading to a partial but noticeable clinical improvement.

## Conclusion

This observation highlights a rare coexistence of three distinct acral keratinization disorders. The overlapping clinical and histological features support the hypothesis of a shared underlying defect of keratinization and stratum corneum barrier function. Aquagenic plantar keratoderma in this setting may reflect eccrine sweat duct involvement or increased water permeability of an altered stratum corneum. Awareness of such associations is crucial to avoid diagnostic confusion with other palmoplantar dermatoses and may contribute to a better understanding and classification of acral keratodermas

EA DV CONGRESS
VIENNA
30 SEP - 3 OCT 2026

**Abstract N°: 2985**

# From Candidate Gene Sequencing to Whole Exome Sequencing: A Thirteen-Year Diagnostic Journey finally reveals a COL7A1 Mutation in Epidermolysis Bullosa

Nicole Tomas*[1], Alfred Klausegger[2], Martin Laimer[2, 3], Dédée Murrell[4, 5]

[1] Paracelsus Medical University, Salzburg, Austria

[2] EB House Austria, Department of Dermatology and Allergology, University Hospital of the Paracelsus Medical University, Salzburg, Austria

[3] Department of Dermatology and Allergology, University Hospital of the Paracelsus Medical University, Salzburg, Austria

[4] Faculty of Medicine, University of New South Wales, Sydney, Australia

[5] Department of Dermatology, St George Hospital, Sydney, Australia

## Introduction

Epidermolysis Bullosa (EB) is a rare inherited skin condition that is caused by more than 4500 different mutations in at least 21 genes. Genetic testing is considered the gold standard for diagnosis and can be performed using a variety of methods, ranging from the traditional Sanger Sequencing (SS) technique to the more advanced Next Generation Sequencing (NGS) approach, which includes whole genome sequencing (WGS), whole exome sequencing (WES), and transcriptome sequencing (RNA-seq).

## Case Presentation

## Material and Methods:

All affected members presented with non-scarring blistering predominantly on the feet, hands, ankles, knees and elbows, as well as dysphagia and toenail dystrophy.

Between 2005 and 2018, the following genetic testing methods were applied sequentially to identify a causative mutation in the family with clinical suspicion of EBS or DEB.

- 2005: Immunofluorescence mapping (IFM) and SS of *KRT5* and *KRT14* in Brisbane (Australia)
- 2011: SS of the entire *PLEC1* gene in Salzburg (Austria), where further analyses were carried out.
- 2015: Targeted Panel Sequencing of the main EB genes (Table 1) using the Ion Torrent Personal Genome Machine (PGM)
- 2017: SS of exon 1 of the *KLHL24*
- 2018: WES analysing the main EB genes.

## Results:

The initial clinical suspicion was for EBS or DEB, but given the IFM findings, that were suggestive for EBS, showing blistering of the basal layer, it prompted genetic analysis of the *KRT5* and *KRT14* genes. Findings only showed a *KRT5*c.413G>A (p.Gly138Glu) variant, which is considered a benign single nucleotide polymorphism (SNP). No variants were detected on *KRT14*. Further SS analysis revealed a heterozygous intronic *PLEC1* splice variant in exon 30 (c.3922-18C>T).

Family analysis, however, revealed that one unaffected family member also carried this variant, indicating to represent a SNP rather than a disease-causing mutation.

Subsequent targeted panel sequencing revealed no pathogenic variants in any of the tested EB genes (Table 1). Thereafter, *KLHL24* was analyzed as it was not included in the initial panel, but results showed no molecular aberrations.

Finally, WES identified a heterozygous splice site variant in *COL7A1* exon 55 (c.5097+1G>A) as the disease-causing mutation, consistent with dominant dystrophic epidermolysis bullosa (DDEB).

Family segregation analysis of *COL7A1* confirmed sixteen affected and seventeen unaffected family members.

At the time of testing, the cost of a WES analysis for a family of three was approximately 2,000€, compared to around 750€ today.

**Conclusion**

This case highlights limitations of different genetic testing modalities but likewise the significant technological advancements in molecular diagnostics for EB over the past two decades.

SS is particularly useful when the candidate gene has already been identified through family history, IFM, or EM. In our case, the IFM diagnosis suggestive for EBS, prompted genetic analysis of the *KRT5* and *KRT14* genes. The IFM finding was rather misleading than helpful. Since no pathogenic mutations were identified, *PLEC1* was targeted next. However, only a SNP was identified.

Subsequently, a targeted panel sequencing of all the major EB genes was performed. Once again, this method also could not reveal a mutation.

Finally, WES revealed the *COL7A1* splice site mutation. Obviously, the exon 55 of *COL7A1* was not properly amplified to cover the +1-donor site, which made the mutation invisible to targeted panel sequencing. WES has a more uniform coverage and is an effective diagnostic approach when the candidate gene is unknown. However, it requires a high level of specialized expertise to interpret the data, and the higher costs limit its availability in low-resource settings.

EA DV CONGRESS
VIENNA
30 SEP - 3 OCT 2026

**Abstract N°: 3002**

**Incontinentia pigmenti: The value of early diagnosis : Report of two neonatal cases**

Nouha Touhami*[1], Kenza Benothmane[1], Assia Elharti[1], Lina Mouline[1], Laila Benzekri[1], Nadia Ismaili[1]

[1] Ibn Sina Hospital, rabat, Morocco

**Introduction**

Incontinentia pigmenti is a rare X-linked genodermatosis that affects almost exclusively females. It is characterized by an evolving cutaneous eruption distributed along the lines of Blaschko and is associated with a risk of neurological, ophthalmological, and dental involvement. Its diagnosis is particularly important during the neonatal period, when vesiculobullous lesions may mimic several infectious or genetic dermatoses. Through two case reports, we highlight the importance of early clinical recognition in order to guide the assessment of extracutaneous involvement and multidisciplinary follow-up.

**Case Presentation**

Case 1:  A 3-month-old female infant, born following a well-monitored pregnancy, with no parental consanguinity and no similar family history. The lesions began on day 10 of life as vesicles distributed along the lines of Blaschko, subsequently evolving into verrucous lesions and then into Blaschko-linear hyperpigmentation, predominantly affecting the back. The course was afebrile, with no impairment of general condition, no signs of infection, no mucosal involvement, no respiratory distress, and no feeding difficulties. There were no hair or nail abnormalities. Neurological and ophthalmological examinations were normal. No dental abnormalities could be assessed at this age.

Case 2:

A 15-day-old female neonate, born following a well-monitored pregnancy, with no parental consanguinity and a similar family history in a cousin.

The eruption began at birth with vesicles localized to the left hand, in an afebrile setting, and then gradually extended to the rest of the body. Examination revealed vesicles on an erythematous base, linear verrucous lesions, and whorled hyperpigmented lesions distributed along the lines of Blaschko. There was no mucosal involvement, no hair or nail abnormalities, no seizures, no infantile spasms, no hypotonia, and no other neurological abnormalities. The ophthalmological examination was normal. No dental involvement could be assessed at this age.




Figure : A/B/C/D/E :Clinical photographs of the first case. F/G/H/I: Clinical photographs oh the seconde case.

**Conclusion**

Incontinentia pigmenti should be considered in any female neonate presenting with a Blaschko-linear vesiculoverrucous eruption. Our two cases highlight that early diagnosis not only helps avoid diagnostic errors, but also allows prompt initiation of screening for extracutaneous involvement, particularly ophthalmological and neurological complications. Even when the initial evaluation is normal, prolonged follow-up remains essential.

EA DV CONGRESS
VIENNA
30 SEP - 3 OCT 2026

**Abstract N°: 3040**

## Extensive form of ulerythema ophryogenes

Tarek Mansoul*[1], Haoua Bensaad[1], Ahmed Samaouel Chehad[1]

[1] Department of Dermatology, Benbadis University Hospital Center, University of Constantine 3, Constantine, Algeria

### Introduction

Ulerythema ophryogenes (UO) is a rare dermatosis currently classified as an orphan disease (OMIM: 604093). Originally described by Tanzer in 1889, the term 'ulerythema ophryogenes' was first used by Unna in 1896. UO most commonly affects children and young adults of both sexes. With age, the condition tends not to extend further and may stabilize or even improve. Clinically, it is characterized by atrophying red keratosis pilaris, with the pathognomonic feature being the loss of the lateral third of the eyebrows. Along with Siemens' keratosis follicularis spinulosa decalvans and vermiculate atrophoderma, UO belongs to the group of red, atrophying keratosis pilaris.

### Case Presentation

A 16-year-old female patient, with no significant medical history, born to non-consanguineous parents, consulted for keratosis pilaris involving the face, trunk, and limbs, which had been present since childhood.

Clinical examination revealed inflammatory, keratotic, spinous follicular papules, on a background of pinkish erythema, with an alopecic course. The lesions were bilateral and symmetrical, predominating on the face, the extensor surfaces of the limbs, and the trunk.

The patient also presented photosensitivity and facial dysmorphism, including low-set ears, a broad forehead, and hypertelorism. No intellectual disability or growth retardation was observed.

### Conclusion

The diagnosis of UO is clinical, based on follicular keratotic papules and erythema appearing on the lateral parts of the eyebrows and the cheeks. Involvement is usually limited to the head; more extensive forms, as in our patient with the involvement of the extensor surfaces of the limbs, are infrequent. In extensive forms, lesions may spread to the scalp and the extensor surfaces of the arms and thighs.

UO may be associated with thyroid dysfunction or intellectual disability, or may reveal rare congenital disorders such as Noonan syndrome, Cornelia de Lange syndrome, or Rubinstein-Taybi syndrome. Our patient presents a particular dysmorphic syndrome resembling Noonan syndrome, but without the other cardinal features of that syndrome (cardiac involvement, postnatal growth retardation, and intellectual disability).

Although generally benign, the age of affected patients, the facial involvement, and the resulting permanent alopecia are responsible for significant impairment in quality of life and a major psychological impact. Genetically, this disease appears to be linked to chromosome 18 abnormalities.

Treatment includes topical corticosteroids, emollients, and exfoliating agents containing urea or salicylic acid. Effective photoprotection and psychological support are often necessary. Pulsed dye laser appears to be a

promising therapeutic option.

EA DV CONGRESS
VIENNA
30 SEP - 3 OCT 2026

**Abstract N°: 3041**

# Exploring the therapeutic effect of Er:YAG laser on Hailey-Hailey disease through transcriptomics

Marie-Eline Debeuf*[1, 2], Janou Roubroeks[3], Michel van Geel[1, 2, 3], Michiel Adriaens[4], Peter Steijlen[1, 2], Maria Bolling[5], Gerben van der Vries[6], Duco Kramer[5], Jeroen Bremer[5], Valerie Verstraeten[1, 2, 7]

[1] Department of Dermatology, Centre of Expertise for Genodermatoses, Maastricht University Medical Centre+, Maastricht, Netherlands

[2] GROW Research Institute for Oncology and Developmental Biology, Maastricht University, Maastricht, Netherlands

[3] Department of Clinical Genetics, Maastricht University Medical Centre+, Maastricht, Netherlands

[4] Maastricht Centre for Systems Biology and Bioinformatics (MaCSBio), Maastricht University, Maastricht, Netherlands

[5] University of Groningen, University Medical Center Groningen, UMCG Centre of Expertise for Genodermatoses and European Reference Network-Skin, Department of Dermatology, Groningen, Netherlands

[6] University of Groningen, University Medical Center Groningen, Department of Genetics, Groningen, Netherlands

[7] Dermadok Huidkliniek, Antwerp, Belgium

## Introduction

Hailey-Hailey disease (HHD) is a rare genodermatosis caused by pathogenic variants in the *ATP2C1* gene, encoding the Golgi-bound calcium pump hSPCA1. Although a variety of therapies exist, long-term remission is rare. We recently showed long-term remission following one single Er:YAG laser treatment, but the underlying biological mechanism is currently unknown. The aim of this study was to explore the biomolecular mechanisms leading to long-term remission of Hailey-Hailey disease by Er:YAG laser.

## Materials and Methods

Eight patients were included in this prospective study. Biopsies for RNA extraction were obtained from a HHD plaque in each patient (n=8) before and 6 weeks after one Er:YAG laser treatment. For control purposes, RNA was extracted from skin samples of patients' non-lesional skin. A transcriptomic analysis using RNA-sequencing was performed and mainly focused on enriched biological pathways induced by laser treatment. Immunofluorescence studies on the desmosomal proteins (Dsg1 and Dsg3) and pERK were conducted to evaluate desmosomal protein trafficking and ERK activation.

## Results

On a transcriptomic level, compensatory expression of two calcium permeable channels *TRPV4* and *TRPC1* was observed after one single ablative laser treatment. Downregulated genes in treated (vs affected) skin were associated with ERK1/2, Th1 and Th17 pathways. Ablative laser therapy also affected genes related to Protein Kinase C, Wnt, intermediate filament and actin filament organization. Immunofluorescence studies showed hyperactivation of ERK in lesional skin, which decreased after laser treatment and revealed an improved desmosomal protein trafficking, as shown by the plasma membrane localisation of Dsg1 and Dsg3 after laser treatment.

**Conclusions**

Er:YAG laser alters calcium- and cell-cell adhesion associated transcriptomic pathways, reduces ERK activation and enhances desmosomal protein trafficking to the plasma membrane. These observations support the long-term remission observed after laser treatment.

EA DV CONGRESS
VIENNA
30 SEP - 3 OCT 2026

**Abstract N°: 3084**

# Periorbital nodules in a 51-year-old woman

Yuxiong Jiang*[1], Yuling Shi[1]

[1] Department of Dermatology, Shanghai Skin Disease Hospital, Tongji University School of Medicine, shanghai, China

## Introduction

Sitosterolemia is a rare autosomal recessive lipid metabolism disorder caused by mutations in ABCG5 or ABCG8, resulting in abnormal accumulation of plant sterols in plasma and tissues. Although tendon xanthomas and premature cardiovascular disease are recognized manifestations, orbital xanthogranulomas are rarely reported and may lead to diagnostic delay. We report a patient with periorbital xanthogranulomatous lesions associated with hematologic abnormalities caused by sitosterolemia.

## Case Presentation

A 51-year-old woman presented with progressively enlarging bilateral periorbital nodules for four years, accompanied by intermittent pruritus. She had a history of splenectomy performed two decades earlier for presumed hypersplenism associated with severe thrombocytopenia. Family history revealed thrombocytopenia in several siblings born to consanguineous parents.

Clinical examination demonstrated yellow-to-violaceous periorbital nodules and plaques. Laboratory investigations showed thrombocytopenia, anemia, giant platelets, and stomatocytes on peripheral blood smear. Histopathology revealed diffuse histiocytic infiltration with focal vacuolated cells and fibrosis, consistent with xanthogranuloma. Orbital magnetic resonance imaging demonstrated bilateral granulomatous lesions.

Further metabolic evaluation identified markedly elevated plasma plant sterol levels, including sitosterol and campesterol. Whole-exome sequencing confirmed a homozygous splice-site mutation in ABCG5 (c.904+1G>A), establishing the diagnosis of sitosterolemia with orbital xanthogranulomas. The patient was treated with a low-plant-sterol diet and ezetimibe, resulting in gradual clinical improvement.

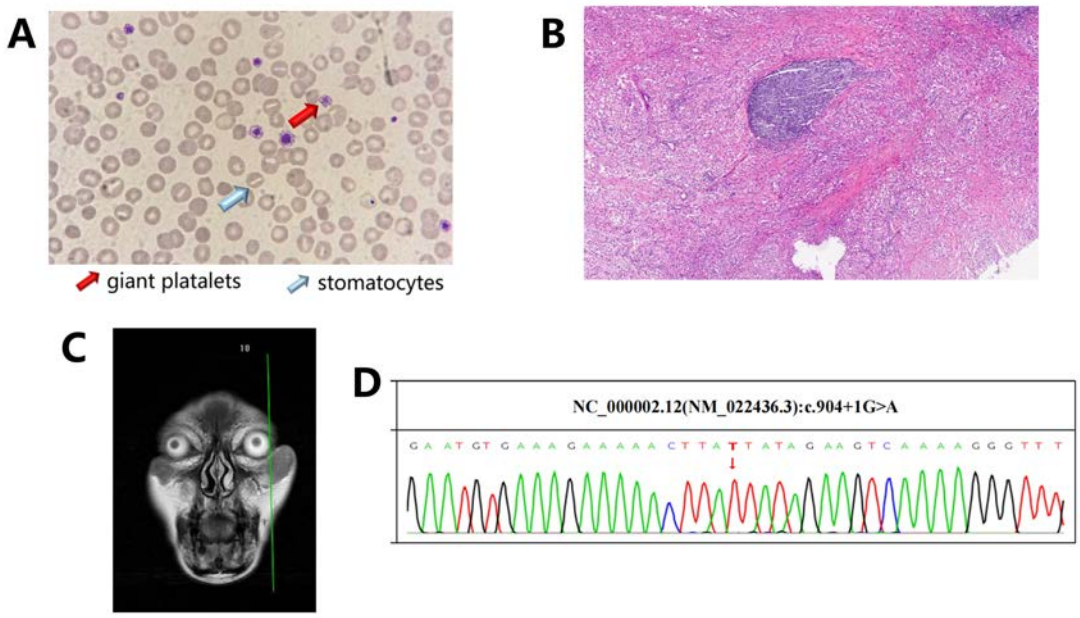


Overview of hematologic, histopathologic, imaging, and genetic findings in sitosterolemia with orbital xanthogranulomas. (A) Peripheral blood smear findings. (B) Histopathologic examination of skin biopsy. (C) Orbital magnetic resonance imaging (MRI). (D) Genetic analysis showing ABCG5 splice-site mutation.

**Conclusion**

Orbital xanthogranulomas may represent an important cutaneous clue to underlying sitosterolemia. The coexistence of xanthomatous lesions and unexplained cytopenias should prompt consideration of this rare metabolic disorder to avoid delayed diagnosis and unnecessary splenectomy. Early recognition combined with plasma sterol analysis and genetic testing enables timely targeted treatment.

EA DV CONGRESS
VIENNA
30 SEP - 3 OCT 2026

**Abstract N°: 3116**

# Real-World Therapeutic Response to Upadacitinib in Paediatric Netherton Syndrome: A Case Report

Akshita Singh*[1], Akash Agarwal[1], Maitreyee Panda[1], Ajaya Jena[1]

[1] Institute of Medical Sciences and SUM Hospital, Siksha ' O ' Anusandhan Deemed University, Bhubaneswar, India

## Introduction

Netherton syndrome is a rare autosomal recessive genodermatosis caused by mutations in the *SPINK5* gene. It presents as a triad of congenital ichthyosiform erythroderma, hair shaft abnormalities, and atopic diathesis. It is associated with pruritus, recurrent infections, sleep disturbance, psychosocial distress, and impairment in quality of life from early childhood. Management of Netherton syndrome remains challenging due to limited therapeutic options and no standardised therapy. Here, we report a child with Netherton syndrome demonstrating early clinical improvement with oral upadacitinib.

## Case Presentation

A 5-year-old boy presented with generalized erythema and scaling associated with intense pruritus since birth. Cutaneous examination revealed diffuse xerosis with fine scaling and lichenified hyperpigmented plaques over the flexures. Multiple erythematous to hyperpigmented annular and serpiginous plaques with characteristic double-edged scaling were seen over the back and dosrum of bilateral feet, suggestive of ichthyosis linearis circumflexa. Scalp hair was sparse, lustreless, and of short uneven length. Sparse eyebrows and eyelashes were also present alongwith angular cheilitis. Dermoscopic and trichoscopic examination of the hair shaft revealed characteristic nodular invaginations consistent with trichorrhexis invaginata (bamboo hair), along with matchstick hair and broken hair shaft. Histopathological examination showed psoriasiform hyperplasia with parakeratosis and hypogranulosis. Raised serum IgE levels (4521.40 kU/L), with elevated eosinophil count (7.0% ) was present. Subsequent genetic analysis revealed a pathognomic SPINK5 mutation, confirming our diagnosis of Netherton Syndrome. Considering financial constraints and limited access to biological therapy, the patient was then started on oral upadacitinib 15mg daily, along with topical emollients. Baseline liver and renal function tests, fasting lipid profile, and QuantiFERON-TB Gold assay were unremarkable.

Prior to treatment initiation, there was involvement of 90% of their body surface area (BSA) with diffuse xerosis and scaling. Baseline PP-NRS and cDLQI scores were 9 and 18 respectively, with significant sleep disturbance present. After 4 weeks of therapy, there was significant improvement in pruritus, with PP-NRS score reducing to 4, alongwith fading of erythematous plaques over back, reduced sleep disturbance and cDLQI score improving to 10. After 8 weeks, the BSA decreased to less than 20 %, with significant improvement in xerosis. The patient remains under regular follow-up for ongoing assessment of therapeutic response and disease activity.

## Conclusion

Netherton Syndrome is characterized by defective LEKTI expression and uncontrolled kallikrein-related peptidase activity. This results not only in epidermal barrier disruption and excessive desquamation, but also in protease-activated receptor 2 (PAR2)-mediated release of pro-inflammatory cytokines, driving a mixed Th2/Th17/IL-36 inflammatory dysregulation. These cytokines including IL-4, IL-13, IL-31, IL-22, and IL-36 signal through JAK1-receptor complexes, positioning selective JAK1 inhibition as a rational therapeutic target. Upadacitinib being a

selective JAK-1 Inhibitor, suppresses downstream inflammation while restoring epidermal differentiation markers (filaggrin, loricrin, involucrin).

Our case report highlights significant symptom alleviation over two months, demonstrating a therapeutic response comparable to that reported in adults. In settings with restricted biologic access, upadacitinib may represent promising therapeutic option. However, further research is warranted to validate its long-term efficacy and safety.

EADV CONGRESS
VIENNA
30 SEP - 3 OCT 2026

**Abstract N°: 3121**

# A Rare Case Report of Morphoea in Multicentric osteolysis nodulosis and arthropathy (MONA) syndrome

Shwetha Rahul*[1], Bhavani Kirubakaran[1]

[1] Hydra Dermatology, Chennai, India

## Introduction

Multicentric osteolysis, nodulosis and arthropathy (MONA) syndrome is an umbrella term for ultra-rare subtypes of primary skeletal dysplasia inherited in an autosomal recessive manner that results from homozygous or compound heterozygous mutations in the MMP2 gene. It is characterized by progressive osteolysis, arthropathy, and extra-skeletal manifestations such as facial dysmorphism, subcutaneous nodules, pigmented skin lesions, cardiac defects, corneal opacities. Disease onset is generally between ages six months to six years, with most affected children looking apparently normal at birth. Here we present a rare case of Morphea in a patient with MONA syndrome.

## Case Presentation

Here we present a case of a 25 year female who presented to us with multiple progressive erythematous hyperpigmented papules and plaques over both forearms, abdomen and thighs with features of short stature, joint deformities ,contractures and stiffness of both hands and feet, facial dysmorphism and high arched palate. She was born to parents out of a consanguineous marriage, and her older sibling died of a congenital cardiac disease six weeks after birth. At the age of 8 yrs, our patient was provisionally diagnosed as a form of juvenile idiopathic arthritis and was subjected to therapy with unsatisfactory results. When she turned 16 years old, she received genetic testing in the form of whole exome sequencing. It confirmed the presence of a homozygous pathogenic missense mutation in the Matrix Metalloproteinase 2 gene. In our present evaluation of her condition, skin biopsy from her forearm lesion revealed histopathological features consistent with a diagnosis of morphoea. In view of extensive progression of lesions , she was started on oral methotrexate (12.5 mg/ week). She continued to develop new lesions over the next eight months despite increasing the dose of methotrexate to 15 mg /week. At this point we had to conclude that she was not responding to the drug and shifted her over to oral Mycofenolate mofetil ( 1000mg/day) which was finally effective in controlling further progress. She is presently stable with no new morphea lesions.

## Conclusion

Recent studies suggest that mutation in matrix metalloproteinase-2 (MMP-2) may also result in scleroderma-like skin thickening in patients with MONA syndrome. To date 51 individuals of MONA syndrome with molecularly proven evidence have been reported across the world . This case is reported for its rarity and the correlation of MMP-2 gene involvement in morphoea and MONA syndrome.

EA DV CONGRESS
VIENNA
30 SEP - 3 OCT 2026

**Abstract N°: 3128**

# Following Blaschko's Lines Toward Diagnosis

María Teresa Berumen Murra*[1], Lucia Achell Nava[1], Guadalupe Maldonado Colin[1]

[1] Centro Médico Nacional 20 de Noviembre ISSSTE, Mexico City, Mexico

## Introduction

Conradi–Hünermann–Happle syndrome is a rare X-linked dominant genodermatosis caused by pathogenic variants in the EBP gene, which is involved in the distal pathway of cholesterol biosynthesis. The condition predominantly affects females and exhibits significant phenotypic variability, including cutaneous, skeletal, and ocular abnormalities.

We present the case of an infant with characteristic blaschkoid hyperpigmented lesions associated with congenital ocular and skeletal anomalies, in whom a variant in the EBP gene was identified. This case highlights the importance of recognizing cutaneous patterns as a diagnostic clue and emphasizes the role of clinical suspicion as a basis for genetic confirmation in rare genodermatoses.

## Case Presentation

A 10-month-old female was referred for evaluation due to a dermatosis localized on the anterior thorax, characterized by linear and reticular hyperchromic macules of light brown color following a Blaschkoid pattern, with well-defined borders.

The patient had the following medical history: preterm newborn at 38.2 corrected weeks of gestational age, appropriate weight for gestational age, with respiratory distress syndrome secondary to transient tachypnea of the newborn. Cause of prematurity: uterine activity. Delivered by cesarean section. APGAR score 8/9. Silverman-Anderson score 0. Presence of syndactyly of the 4th and 5th fingers of the right hand. Congenital bilateral cataract, total in the left eye, associated with microphthalmia and microcornea. Phacoaspiration with intraocular lens implantation was performed in the left eye.

In the Genetics Department, a mutation in the EBP gene was detected: heterozygous variant c.246>C. Based on this, the diagnosis of Conradi-Hünermann-Happle Syndrome was confirmed.

Literature Review:

Conradi-Hünermann-Happle syndrome is a rare X-linked genodermatosis caused by pathogenic variants in the EBP gene, which plays a role in the distal pathway of cholesterol synthesis. It predominantly affects females and is characterized by a wide phenotypic variability, including linear skin lesions following Blaschko's lines, skeletal abnormalities, cataracts, and body asymmetry.

Dermatological manifestations usually appear from the neonatal period as erythroderma or Blaschkoid hyperkeratosis, later evolving into areas of hyperpigmentation and skin atrophy. The most frequent ophthalmological alterations include congenital cataracts, microphthalmia, and other developmental eye defects.

Diagnosis is based on clinical, radiological, and molecular correlation, and is confirmed by identifying variants in the EBP gene through genetic sequencing. Management is multidisciplinary and includes follow-up by genetics, dermatology, ophthalmology, and orthopedics, focusing on clinical manifestations as well as monitoring

neurodevelopment and skeletal complications.



Dermatosis localized on the anterior thorax, characterized by linear and reticular hyperchromic macules of light brown color following a Blaschkoid pattern, with well-defined limits.

**Conclusion**

Conradi–Hünermann–Happle syndrome is a rare genodermatosis with highly variable clinical manifestations, which may pose a diagnostic challenge. The presence of cutaneous lesions following Blaschko's lines should raise clinical suspicion, particularly when associated with ocular and skeletal abnormalities.

This case emphasizes the importance of recognizing characteristic dermatological patterns as an early diagnostic clue, allowing timely genetic confirmation and multidisciplinary management. Increased awareness of this condition may contribute to earlier diagnosis and improved patient outcomes.

EA DV CONGRESS
VIENNA
30 SEP - 3 OCT 2026

**Abstract N°: 3160**

# Efficacy and safety of dupilumab in Hailey–Hailey disease: A multicentre cohort study

Naia Oillarburu*[1], Sébastien Barbarot[2], Christelle NICOL[2], Claire Abasq[3], Raphaël Janela[4], Anne-Claire Bursztejn[5], Aurore Brun[6], Claire Guedon[7], Camille Decaestecker[4], Céline Tournier[1], Juliette Mazereeuw-Hautier[1], Maella Severino-Freire[1]

[1] Larrey Hospital, University Hospital of Toulouse, Toulouse, France
[2] Nantes Université, Centre Hospitalier Universitaire de Nantes, Nantes, France
[3] Brest University Hospital, Brest, France
[4] Rouen University Hospital, Rouen, France
[5] Nancy Regional and University Hospital, Nancy, France
[6] Cahors General Hospital, Cahors, France
[7] Albi General Hospital, Albi, France

## Introduction

Hailey–Hailey disease (HHD), also known as *ATP2C1*-associated non-syndromic epidermal differentiation disorder, is a rare inherited acantholytic dermatosis characterized by recurrent inflammatory erosive lesions of intertriginous areas, leading to major impairment in quality of life. Current therapeutic options often provide limited and inconsistent efficacy. Recent case reports have suggested a potential benefit of dupilumab, an IL-4/IL-13 inhibitor, in refractory HHD. We aimed to evaluate the long-term efficacy and safety of dupilumab in a multicentre cohort of patients with severe HHD.

## Materials and Methods

We conducted a retrospective multicentre cohort study including patients with HHD treated with dupilumab for at least 6 months. The primary endpoint was treatment response at 6 months assessed using the Investigator Global Assessment change (IGA-C) score. Patients with IGA-C scores of −1, −2 or −3 were considered responders, while scores of −2 or −3 defined good responders. Secondary outcomes included changes in Dermatology Life Quality Index (DLQI), use of topical treatments and analgesics, hospital admissions, long-term efficacy, and safety.

## Results

Twenty patients (13 women, 7 men) with a median age of 59 years were included. Disease severity at baseline was severe or very severe in 95% of cases, with a median disease duration of 26.5 years. All patients had previously received multiple topical and/or systemic therapies.

At 6 months, 18/20 patients (90%) were responders, including 14/20 (70%) good responders. Mean DLQI improved from 24.1 to 8.6. Topical treatment use decreased or was discontinued in 80% of patients, while analgesics were discontinued in 78% of patients requiring them at baseline. Hospital admissions decreased from 30% to 5%.

Long-term efficacy beyond 6 months was maintained in 16/18 responders, after a mean treatment duration of 18.4 months, while two patients experienced relapses. Dupilumab demonstrated a favourable safety profile, with no major adverse events reported. Injection-site pain occurred in four patients and resolved after switching from pen to syringe administration. No ocular adverse events were observed.

We are currently collecting unprecedented 3-year follow-up data to further assess long-term efficacy and safety.



Skin lesions at baseline (a–d) and 6 months after initiation of dupilumab (e–h).

**Conclusions**

Dupilumab appears to be an effective and well-tolerated therapeutic option for severe refractory HHD, with sustained long-term efficacy in most patients and significant improvement in quality of life. These findings support further prospective randomized controlled studies to confirm the efficacy and safety of dupilumab in HHD.

EADV CONGRESS
VIENNA
30 SEP - 3 OCT 2026

**Abstract N°: 3170**

# Carney complex : a case report

Dali osmane Rima*[1]

[1] Hospital Mouhamed Lamine Debagine, Alger, Algeria

## Introduction

Carney complex (CC) is a rare autosomal dominant genetic disorder. It encompasses various systemic manifestations, predominantly endocrine, cardiac, and cutaneous. We report a new case.

## Case Presentation

A 38-year-old woman with a history of gastritis, hypertension, endometrial polyposis, and poorly monitored Cushing's syndrome (CS) presented with periorificial lentiginosis evolving over 14 years and resistant to multiple treatments. She also reported similar lesions in her sister. Clinical examination revealed periorificial lentiginosis; papulonodular lesions measuring 1–2 cm in diameter on the limbs, back, and abdomen; two café-au-lait macules on the abdomen and intergluteal fold; and keratosis pilaris affecting the arms and chest. In addition, there was faciotroncular fat distribution with wasting of the lower limbs. Laboratory investigations showed an ACTH level of 5 pg/mL (reference range: 10–60 pg/mL) and a serum cortisol level of 780 nmol/L (reference range: 140–690 nmol/L), consistent with Cushing's syndrome. Pituitary MRI was normal. Cardiac ultrasound and skin biopsy are ongoing. The patient was referred to the endocrinology department for management of her Cushing's syndrome. Discussion: Carney complex is a rare genetic disorder most commonly associated with mutations in the PRKAR1A gene, encoding the type I-alpha regulatory subunit of protein kinase A, located on chromosome 17. Diagnostic criteria were proposed in 1996 and revised in 2001. The diagnosis is established in the presence of at least two major criteria or one major criterion associated with one supplementary criterion. Our patient fulfilled two major criteria: periorificial lentiginosis and Cushing's syndrome; and one supplementary criterion: a similar condition in a sibling. Cutaneous lesions may be present from the first year of life. Their number increases during puberty and early adulthood, then tends to decrease around the fourth decade. Cardiac myxoma is one of the major manifestations and is diagnosed in more than one-third of patients. Adrenal Cushing's syndrome is the most frequent endocrine manifestation, diagnosed in more than 60% of patients with CC. It may be the sole manifestation in 10–15% of cases. Regular follow-up is essential for the detection and monitoring of disease manifestations. At least annual screening for cardiac myxoma is recommended. Treatment is directed toward visceral involvement. It is surgical for cardiac myxomas and for adrenal Cushing's syndrome. Family screening is recommended for relatives, and genetic counseling is necessary in case of pregnancy planning.

## Conclusion

We report a new case of Carney complex revealed by cutaneous involvement.

EADV CONGRESS
VIENNA
30 SEP - 3 OCT 2026

**Abstract N°: 3202**

## ACVI-Med, an open source variant interpretation tool for medical genomics

Moritz Stadler*[1], Sabina Gansberger[1], Liliane Borik-Heil[1], Johannes Griss[1], Ichiro Okamoto[1], Wolfgang Weninger[1], Matthias Wielscher[1]

[1] University Hospital Vienna, Vienna, Austria

### Introduction

The use of comprehensive genetic testing, such as whole genome and exome sequencing, has become a cornerstone in identifying the causes of rare and complex skin diseases. However, a significant information gap exists: while we can sequence a patient's DNA quickly, interpreting the millions of identified genetic variants to find the single cause of a disease remains an overwhelming task for most clinicians. Current analysis tools are often expensive, technically difficult to use, or require sending sensitive patient data to external companies. In the field of dermatology, where many conditions have a clear but rare genetic basis, there is an urgent need for a private, easy-to-use, and transparent tool that helps doctors bridge the gap between a blood sample and a clear diagnosis.

### Materials and Methods

To address this, we developed ACVI-Med (Accelerated Candidate Variant Interpretation in Medicine), a software platform designed specifically for use within a hospital or research institution's own secure network. Unlike many other tools, ACVI-Med is open-source, meaning its methods are transparent and accessible to the scientific community. The system was designed to take raw genetic data files and automatically cross-reference them against major global medical databases (such as ClinVar and the Human Phenotype Ontology). We simplified the complex rules for classifying mutations -set by the American College of Medical Genetics (ACMG) - into an automated system that flags the most likely harmful mutations for the clinician or researcher to review.

### Results

ACVI-Med provides an intuitive, visual dashboard that allows a dermatologist or researcher to filter through millions of genetic variants in seconds. A key feature is the ACMG-based tiering module, which allows the user to type in a patient’s specific symptoms (e.g., "blistering skin" or "abnormal hair growth"). The software then automatically prioritizes the genes most likely to be responsible for those specific clinical features. Beyond finding the primary cause of a skin condition, the platform also automatically screens for secondary findings, important health risks like predispositions to treatable conditions, and provides information on how a patient might react to specific medications (pharmacogenomics). The interface includes a built-in visualizer, allowing the clinician to see the raw evidence for a mutation without needing specialized bioinformatics training.

### Conclusions

ACVI-Med represents a significant step forward in making precision medicine a reality for everyday dermatology practice. By removing the technical and financial barriers to genetic analysis, the platform allows clinicians to maintain full control over their patient data while significantly speeding up the diagnostic process. This tool does

not just process data, it translates complex genomic information into actionable medical insights. While it is currently a powerful tool for clinical research, its ease of use and privacy-focused design provide a blueprint for how genetic diagnosis can be integrated into standard dermatological care, ultimately leading to faster diagnoses and more personalized treatment plans for patients with rare genetic skin disorders.

EA DV CONGRESS
VIENNA
30 SEP - 3 OCT 2026

**Abstract N°: 3243**

# A New Case of Phacomatosis Pigmentovascularis Type Phacomatosis Cesioflammeomarmorata Complexa: A Rare Model of Pigmentovascular Mosaicism

S Abadlia*[1], A BOUHILA[1], T MANSOUL[1], R BOUSSAID[1], A GHERFI[1], K BOUARROUDJ[1], L KAGHOUCHE[1], S DJEBBAS[1], A.S CHEHAD[1]

[1] Department of Dermatology, University Hospital of Constantine, Algeria, constantine, Algeria

## Introduction

Phacomatosis Pigmentovascularis (PPV) is a rare and complex congenital malformation belonging to the spectrum of postzygotic mosaic disorders affecting neuroectodermal derivatives, combining vascular and pigmentary abnormalities. It is characterized by the presence of capillary malformations (port-wine stains), cutaneous melanosis (Nevus of Ota, Mongolian spots, nevus spilus, etc.), and may be associated with systemic manifestations including ophthalmologic, cerebral, and soft tissue hypertrophy involvement, thus fitting within syndromic complexes.

Cesioflammeomarmorata-type PPV is an exceptionally rare form of PPV. Cases associated with ocular involvement such as ocular melanocytosis complicated by glaucoma are even rarer and have mainly been described as isolated case reports.

We report the case of a 13-year-old girl with cesioflammeomarmorata-type phacomatosis pigmentovascularis associated with ocular involvement and a segmental overgrowth syndrome with hypertrophy.

## Case Presentation

We report the case of a 13-year-old girl with no significant medical history, presenting since birth with an association of pigmentary and vascular skin lesions.

Clinical examination revealed:

- Diffuse livedo involving almost the entire body, sparing the palms and soles.
- A capillary malformation (port-wine stain) involving the face, neck, and right breast.
- Bluish discoloration of the sclerae.
- Limb asymmetry with upper limb length discrepancy and hypertrophy of the left lower limb.
- Thoracic scoliosis.
- Right hemifacial hypertrophy associated with hypertrophy of the lower lip.

Ophthalmologic examination revealed bilateral ocular melanocytosis associated with glaucoma.

Neurological examination was unremarkable except for isolated headaches, and brain MRI showed no abnormalities.

The clinical presentation was consistent with cesioflammeomarmorata-type phacomatosis pigmentovascularis associated with ocular melanocytosis complicated by glaucoma, scoliosis, right facial hemihypertrophy, and left lower limb hypertrophy.

**Conclusion**

Phacomatosis Pigmentovascularis combines vascular and melanocytic components. Its classification evolved toward the Happle classification proposed in 2005. The pathophysiology is based on genetic mosaicism involving mutations in *GNAQ* and *GNA11*.

Ocular involvement is frequent, with glaucoma representing the leading cause of blindness, thereby requiring early screening.

In addition to the cutaneous and ocular manifestations, the limb and facial hypertrophy as well as scoliosis observed in our patient suggest more extensive involvement, fitting within the spectrum of overgrowth syndromes associated with vascular mosaic disorders.

Phacomatosis Pigmentovascularis is a rare and heterogeneous entity. This case illustrates the clinical complexity of the cesioflammeomarmorata form, particularly through its association with glaucomatous ocular involvement and an overgrowth syndrome. Multidisciplinary management with close ophthalmologic follow-up is essential to prevent complications.

EADV CONGRESS
VIENNA
30 SEP - 3 OCT 2026

**Abstract N°: 3258**

# Diagnostic Challenges of Erythrokeratodermia Variabilis in a Resource-Limited Setting: A Case Series from Tajikistan

Mavzuna Zokiri*[1], Rustam Sultonov[1], Hayotjon Aliev[1]

[1] Avicenna Tajik State Medical University, Dushanbe, Tajikistan

## Introduction

Erythrokeratodermia variabilis (EKV) is a rare inherited disorder of keratinization characterized by transient erythematous patches and fixed hyperkeratotic plaques. Diagnosis is often difficult due to variable clinical presentation, nonspecific histopathological findings, and limited access to molecular testing, particularly in low-resource countries.

## Case Presentation

We present two clinically suspected cases of EKV from Tajikistan.

The first patient was a 15-year-old girl with pruritic sharply demarcated erythematous and hyperkeratotic plaques involving the face and extremities since birth. Seasonal improvement during summer months was reported. Examination revealed thickening of the dorsal hands and feet without palmoplantar keratoderma or involvement of hair, nails, and teeth. Family history was positive in two siblings with similar cutaneous lesions. Histopathology demonstrated moderate acanthosis, hyperkeratosis with focal parakeratosis, irregular granular layer thickening, and sparse perivascular lymphocytic infiltrate.

The second patient was a 7-year-old boy with a 6-year history of recurrent pruritic hyperkeratotic plaques affecting the shoulders, axillary regions, face, thighs, and gluteal area. Differential diagnoses included atopic dermatitis and Pityriasis Rubra Pilaris (Devergie’s disease). Histopathological analysis revealed moderate acanthosis and papillomatosis, with a stratum corneum thickened by diffuse orthokeratotic hyperkeratosis. Notably, there was an absence of dyskeratosis and significant dermal inflammation. PAS staining was negative for fungal organisms

In both cases, histopathological findings were nonspecific and did not allow definitive diagnosis. However, clinicopathological correlation strongly supported EKV. Genetic testing, including connexin gene analysis (GJB3/GJB4), was unavailable.

## Conclusion

These cases highlight the diagnostic challenges of EKV in resource-limited settings where molecular confirmation cannot be performed. Careful clinical evaluation, family history assessment, exclusion of mimicking dermatoses, and clinicopathological correlation remain essential for diagnosis. Increased recognition of rare genodermatoses in underserved regions may help reduce diagnostic delays and inappropriate treatment.

EADV CONGRESS
VIENNA
30 SEP - 3 OCT 2026

**Abstract N°: 3267**

# Laser Therapy for the Treatment of Hailey-Hailey Disease: An Updated Systematic Review

Meghna Varambally*[1], Jennifer Tran[1], Harry Chaocheng Liu[2, 3]

[1] Schulich School of Medicine and Dentistry, Western University, London, Ontario, Canada

[2] Department of Dermatology and Skin Science, University of British Columbia, Vancouver, British Columbia, Canada

[3] School of Medicine, Simon Fraser University, Surrey, British Columbia, Canada

**Introduction**

Benign familial chronic pemphigus, or Hailey–Hailey disease (HHD), is an inherited skin dermatosis that manifests as recurrent erosive plaques affecting intertriginous regions and often associated with severe quality-of-life impairment. Laser-based therapies have increasingly been explored as a treatment approach for refractory disease. This review aims to provide an updated synthesis of the efficacy and safety of laser therapies in HHD.

**Materials and Methods**

Following PRISMA guidelines, MEDLINE, Embase, and CINAHL were searched from inception through March 29, 2026. Original studies involving patients of any age with HHD treated using laser therapy were eligible for inclusion. Two reviewers independently completed screening and data extraction. Study quality was assessed using the Oxford Centre for Evidence-Based Medicine Levels of Evidence framework. Narrative synthesis was performed.

**Results**

Twenty-five studies comprising 100 patients were included. Patient ages ranged from 26-81 years, and 58% were female. Mean follow-up duration was 26.5 months. Five laser modalities were identified, most commonly carbon dioxide (CO2) laser (68%), followed by Er:YAG (20%), pulsed dye laser (PDL; 8%), diode laser (4%), and Alexandrite laser (4%). Among patients treated with CO2 laser, complete resolution was reported in 53% and partial resolution in 18%. Most patients treated with Er:YAG laser experienced partial or complete resolution. Data for non-ablative modalities were sparse but indicated potential benefit. Reported adverse events across modalities were generally minor, most commonly dyspigmentation and mild scarring.

**Conclusions**

Current evidence suggests that laser therapy may represent an effective and generally well-tolerated management option for HHD. However, interpretation is limited by small sample sizes, few comparator studies, inconsistent outcome measures, and limited long-term follow-up. Future prospective longitudinal studies and randomized controlled trials are needed to define optimal laser modalities and treatment protocols.

EA DV CONGRESS
VIENNA
30 SEP - 3 OCT 2026

**Abstract N°: 3307**

# Beyond bone marrow failure: dermatologic clues revealing dyskeratosis congenita in adulthood

lalla safia echarif*[1], layla bendaoud[1], maryem aboudourib[1], ouafa hocar[1], said amal[1]

[1] Department of Dermatology and Venerology, Mohammed VI University Hospital, Biosciences and Health Laboratory, Faculty of Medicine and Pharmacy of Marrakesh, MARRAKECH, Morocco

## Introduction

Dyskeratosis congenita (DC), or Zinsser–Cole–Engman syndrome, is an exceedingly rare genodermatosis (estimated prevalence of 1 in 1,000,000) resulting from defective telomere maintenance. It is classically defined by a clinical triad of reticulated skin pigmentation, nail dystrophy, and oral leukoplakia. Bone marrow failure (BMF) is the most severe complication, affecting approximately 80% of patients and representing the primary cause of mortality. While typically diagnosed in childhood, the significant clinical pleomorphism of DC can lead to delayed diagnosis in adulthood, often after years of unexplained hematological decline.



figure 1 :fine reticulated hyperpigmentation on the neck and trunk

**Case Presentation**

We report the case of a 35-year-old male with an unremarkable family history, followed in hematology for five years for chronic refractory bicytopenia of unknown etiology. The patient presented with pallor, significant weight loss, and severe transfusion-dependent cytopenia (thrombocytopenia of 5,000/µL and hemoglobin of 6 g/dL), requiring monthly platelet and packed red blood cell transfusions. Previous extensive investigations, including bone marrow biopsies, were inconclusive, and the patient showed no clinical improvement following treatment for

a presumed vitamin B deficiency.

The diagnosis was suspected following a referral to dermatology for mucocutaneous lesions that the patient reported had been appearing since age 19. Physical examination revealed the complete classic triad: fine reticulated hyperpigmentation on the neck and trunk, marked nail dystrophy with longitudinal ridging, and oral leukoplakia involving the tongue. Notably, the patient also exhibited mottled pigmentation on both palms with thinning of the palmar ridges. Pulmonary and hepatic evaluations were normal. The patient has been referred for telomere length analysis and molecular studies to confirm the diagnosis and guide potential reduced-intensity conditioning for hematopoietic stem cell transplantation (HSCT).



figure 2 : leukoplakia involving the tongue

**Conclusion**

Our case highlights the critical role of dermatological examination in the evaluation of idiopathic bone marrow failure. The five-year diagnostic latency demonstrates that the mucocutaneous triad may be overlooked in a purely hematological setting or misattributed to nutritional deficiencies. Dyskeratosis congenita (DC) must remain a key differential diagnosis in adults with unexplained bicytopenia, and early recognition is essential to initiate multidisciplinary surveillance for organ failure, including pulmonary fibrosis, and to ensure appropriate screening for possible malignancies.



figure 3 :mottled pigmentation on both palms

EA DV CONGRESS
VIENNA
30 SEP - 3 OCT 2026

**Abstract N°: 3312**

# Study Design and Baseline Characteristics of APOLLO: A Randomized, Double-Blind, Placebo-Controlled Confirmatory Trial of Bitopertin in Adults and Adolescents with Erythropoietic Protoporphyria or X-Linked Protoporphyria

Amy Yeung[1], Gayle Ross[2], Paula Aguilera[3], Luca Barbieri[4], Fiona Browne[5], Robert Stewart Dawe[6], Petra De Haes[7], Laurent Gouya[8], Liezel Griffin[9], Ilja Kubisch[10], Janneke Langendonk[11], MARIE LE MOIGNE[12], Bruce Ritchie[13], Manuel Pereira[14], Peter Stewart[15], Robert Sarkany[16], Staffan Wahlin[17], Will Savage*[18]

[1] Harvard Medical School, Massachusetts General Hospital, Boston, United States
[2] Royal Melbourne Hospital, Melbourne, Australia
[3] Hospital Clínic de Barcelona, Barcelona, Spain
[4] San Gallicano Dermatological Institute IRCCS UOSD Center for Porphyrias and Rare Diseases, Rome, Italy
[5] Children's Health Ireland, Dublin, Ireland
[6] Scottish Cutaneous Porphyria Service Ninewells Hospital, Dundee, United Kingdom
[7] Universitair Ziekenhuis Leuven, Leuven, Belgium
[8] University of Paris, Paris, France
[9] Salford Royal Hospital, Northern Care Alliance NHS Foundation Trust, Salford, United Kingdom
[10] Klinikum Chemnitz gGmbH, Chemnitz, Germany
[11] Erasmus MC, University Medical Center Rotterdam, Rotterdam, Netherlands
[12] CHU de Nantes, Nantes, France
[13] University of Alberta, Edmonton, Canada
[14] Charité Universitätsmedizin Berlin, Berlin, Germany
[15] Royal Prince Alfred Hospital, Camperdown, Australia
[16] Guy's and St Thomas' Hospitals, London, United Kingdom
[17] Karolinska Institutet/Karolinska University Hospital, Stockholm, Sweden
[18] Disc Medicine, Watertown, United States

## Introduction

Erythropoietic protoporphyria (EPP) and X-linked protoporphyria (XLP) result in the accumulation of photoreactive protoporphyrin IX (PPIX) in the skin and other organs. PPIX accumulation causes debilitating phototoxic skin reactions upon exposure to sunlight and, in some cases, life-threatening protoporphyric hepatopathy.

Glycine transporter 1 (GlyT1) supplies extracellular glycine for the initial step of heme biosynthesis in erythroid cells. Bitopertin is an investigational orally administered inhibitor of GlyT1 that has been shown to significantly decrease PPIX. Prior Phase 2 studies (AURORA [NCT05883748], BEACON [ACTRN12622000799752]) showed that PPIX reductions were associated with improvements in multiple measures of light tolerance, including significant reductions in phototoxic reactions and increased patient-reported quality of life.

APOLLO (NCT06910358) was designed to confirm safety, tolerability, and efficacy of bitopertin in adults and adolescents with EPP or XLP.

**Materials and Methods**

APOLLO is a global randomized, double-blind, placebo-controlled Phase 3 study that randomized participants (1:1) to receive oral, once-daily administration of 60 mg bitopertin or placebo for 24 weeks. Eligible participants were ≥12 years of age with a confirmed diagnosis of EPP or XLP by biochemical porphyrin analysis and/or genetic testing.

The co-primary efficacy endpoints include 1) percent change in whole blood metal-free PPIX in participants randomized to bitopertin compared to placebo and 2) average monthly total time in sunlight on days without pain from a phototoxic reaction between 10:00 and 18:00 (10:00 AM and 6:00 PM) after 6 months (24 weeks) of treatment. Secondary endpoints include the occurrence of phototoxic reactions, change from baseline in time to first prodromal symptoms, and cumulative total time in sunlight on days without pain from a phototoxic reaction. Other assessments will evaluate patient-reported quality of life measures.

After completion of the 6-month treatment period, including assessment of light tolerance, and the end-of-study visit, participants may be eligible to continue bitopertin in a separate open-label extension study (HELIOS).

**Results**

Between April 2025 and March 2026, 199 patients were screened at 28 study sites in the US, Canada, Europe, United Kingdom, and Australia. A total of 183 participants were randomized to receive bitopertin or placebo, including 82 (45%) in the US and 101 (55%) outside the US. The mean (SD) age was 37.1 ± 17.1 years, and a majority of participants were female (107/183 [59%]) and white (166/183 [91%]). Of the enrolled patients, 171 (93%) had EPP and 12 (7%) had XLP; 95 (52%) had biochemical testing and 88 (48%) had genetic testing to support their diagnosis of EPP or XLP. Most (60%) participants had not received prior treatment for their EPP, and 28% and 18% of participants reported having previously received afamelanotide or dersimelagon, respectively. Participants were evenly distributed across light tolerance categories of <30 minutes versus ≥30 minutes at baseline. The study enrolled a total of 34 (19%) adolescent participants (12 to <18 years of age), and, in contrast to the adult population, most (85%) of the adolescent participants had not received prior treatment with afamelanotide or dersimelagon. Other baseline characteristics were generally similar across the adolescent and adult subpopulations.

**Conclusions**

The APOLLO study is designed to confirm the safety and efficacy of bitopertin as a potential disease-modifying treatment for adults and adolescents with EPP or XLP. The demographic and baseline characteristics of participants enrolled in the APOLLO study are generally consistent with the characteristics of participants from other EPP and XLP clinical studies and representative of the EPP and XLP patient population. As a result, the APOLLO results will be relevant to the broader population of adults and adolescents with EPP and XLP.

EA DV CONGRESS
VIENNA
30 SEP - 3 OCT 2026

**Abstract N°: 3340**

# Phenotypic Heterogeneity within the PIK3CA-Related Overgrowth Spectrum: Three Pediatric Cases of MCAP, CLOVES Syndrome, and Klippel–Trenaunay Syndrome Managed with Multidisciplinary and Targeted Therapeutic Approaches

Zeina Tannous*[1, 2], Namir Saade[1], Jason El Jalkh[1], Yara Saad[1]

[1] Lebanese American University, Beirut, Lebanon

[2] Harvard School of Medicine, Cambridge, Boston, United States

**Introduction**

PIK3CA-related overgrowth spectrum (PROS) comprises a heterogeneous group of rare mosaic disorders caused by postzygotic activating variants in the PIK3CA gene, resulting in constitutive activation of the PI3K–AKT–mTOR pathway and subsequent segmental overgrowth, vascular malformations, adipose dysregulation, and neurodevelopmental abnormalities. Clinical manifestations vary according to mutation timing and tissue distribution, producing overlapping phenotypes including Macrocephaly-capillary malformation syndrome (MCAP), CLOVES syndrome, and Klippel-Trenaunay syndrome. Molecular confirmation is optimally achieved through deep next-generation sequencing of affected tissue due to low-level mosaicism. With the emergence of targeted therapies such as sirolimus and alpelisib, early recognition and molecular characterization have become increasingly important. We present three pediatric patients demonstrating distinct PROS phenotypes and evolving therapeutic approaches.

**Case Presentation**

## Case 1 – MCAP Phenotype

A 5-month-old male infant presented with congenital macrocephaly and extensive pink-to-purple capillary malformations involving the face, scalp, trunk, and upper extremities. Additional findings included frontal bossing, asymmetric upper limb overgrowth, developmental delay, joint hyperextensibility, moderate cerebral atrophy, and mild ventriculomegaly on brain MRI. Ophthalmologic evaluation demonstrated right-sided glaucoma secondary to abnormal ocular vasculature requiring diode cyclophotocoagulation. The presentation was most consistent with MCAP syndrome. Genetic testing remains pending. Pulsed dye laser (PDL) therapy was initiated at 8 months of age with visible improvement after two sessions.

## Case 2 – CLOVES Phenotype

A 1.5-month-old female demonstrated left-sided hemihypertrophy associated with a violaceous vascular plaque, right foot hypertrophy, and polydactyly/syndactyly, consistent with CLOVES syndrome. MRI revealed extensive soft tissue and vascular involvement, while laboratory investigations excluded consumptive coagulopathy. Genetic sequencing of affected tissue confirmed a pathogenic somatic PIK3CA variant. Systemic therapy with sirolimus (0.8 $mg/m^2$) resulted in early reduction in trunk mass volume, improved contour symmetry, and decreased vascular congestion without adverse effects. Transition to alpelisib was planned pending age eligibility.

## Case 3 – KTS Phenotype

A 14-month-old female presented with an extensive capillary malformation involving the right lower extremity associated with angiokeratoma-like papules, oligodactyly, and mild soft tissue hypertrophy causing gait

impairment. MRI demonstrated venous malformations including a persistent lateral marginal vein, while biopsy with genetic sequencing confirmed a pathogenic PIK3CA variant. Oral alpelisib therapy (50 mg daily) was initiated at 2 years of age with serial metabolic monitoring. The patient demonstrated marked regression of capillary malformation intensity, reduction in hypertrophy, improved mobility, and no treatment-related adverse effects.




**Clinical improvement after targeted PI3K-α inhibition**

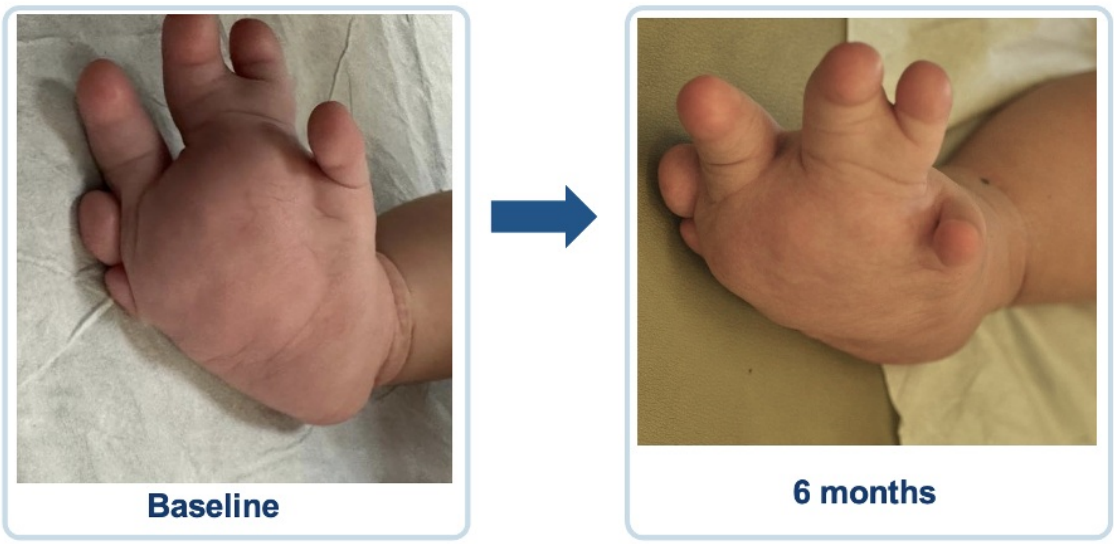


**Early stabilization after mTOR inhibition**

**Conclusion**

These cases illustrate the marked phenotypic heterogeneity of PROS and emphasize the importance of recognizing overlapping manifestations of somatic PIK3CA activation. MCAP demonstrated prominent neurocutaneous involvement, whereas CLOVES syndrome and KTS highlighted progressive vascular and musculoskeletal abnormalities. The cases further support the expanding role of targeted pathway inhibition, with sirolimus providing early disease stabilization and alpelisib producing meaningful regression of vascular and soft tissue manifestations. Concurrently, PDL therapy remained an important adjunctive modality for capillary malformation management. Early diagnosis through affected-tissue genetic sequencing, multidisciplinary collaboration, and individualized therapy are essential to optimize outcomes in patients with PIK3CA-related disorders.

EADV CONGRESS
VIENNA
30 SEP - 3 OCT 2026

**Abstract N°: 3436**

# A successful case report of the treatment of HRAS-mutant inflammatory linear verrucous nevus following Mycobacterium obuense infection with sequential therapy using secukinumab and guselkumab

Jia-yu Ye[1], Ye He[1], Ya-xuan Zhu[1], Changhua Zhu[2], Jincong Chen[1], Huichun Su*[1], Yang Chen[3]

[1] Department of Dermatology, Fujian Medical University Union Hospital, Fujian, China, Fuzhou, China

[2] Department of Dermatology, Fujian Cancer Hospital, Fuzhou, Fujian, China., Fuzhou, China

[3] Department of Fuzhou Dermatology Hospital, Fujian, China, Fuzhou, China

## Introduction

Inflammatory linear verrucous epidermal nevus (ILVEN) is a rare keratotic hyperplastic dermatosis distributed along the Blaschko line, often accompanied by intense pruritus. Histologically, it exhibits alternating psoriasis-like hyperplasia and abnormal keratinization. The condition shows poor response to conventional treatments, with the primary therapeutic goal being symptom relief. Recent studies have identified HRAS somatic mutations as associated with ILVEN pathogenesis. This case report presents the first documented case of HRAS-mutated ILVEN complicated by Mycobacterium obuense (M. obuense) infection. Following infection control, successful induction of remission and long-term maintenance therapy were achieved through sequential administration of secukinumab and guselkumab.

## Case Presentation

The patient presented with verrucous plaques distributed along the Blaschko line on the left lower limb accompanied by intense pruritus. Histopathological analysis of the skin biopsy revealed psoriatic features, while pathogenic microorganism culture and metagenomic testing of the skin lesions indicated a co-infection with M. obuense. After six months of combined antimicrobial therapy (amikacin, rifampicin, isoniazid, clarithromycin), the infection was controlled. However, the skin lesions remained widespread.

After failure of acitretin treatment, secukinumab was added. Pruritus significantly alleviated within 4 weeks, and skin lesions markedly resolved after 16 weeks. Evaluation using the Psoriasis Area and Severity Index (PASI) showed a reduction from 5.4 to 1.0, while the Dermatological Quality of Life Index (DLQI) decreased from 12 to 1, and the affected body surface area (BSA) decreased from 4 to 1.5. The therapeutic response remained stable during the 18-month follow-up.

Following treatment with secukinumab, characteristic large brown circles were observed via dermatoscopy. Additionally, reflective confocal microscopy (RCM) revealed spongiosis, hyperrefractive honeycomb-like keratinocyte gaps, and inflammatory cell infiltration. Comprehensive whole-exome sequencing (WES) and Sanger sequencing confirmed a heterozygous mutation (c.-53-13C>T) in the 5′UTR region of the HRAS gene. Based on the combined clinical, pathological, and diagnostic findings, the final diagnosis was ILVEN.

Due to slow resolution of some skin lesions, the patient switched to the IL-23 inhibitor (IL-23i) guselkumab after 19 months of treatment. Within 7 months post-switch, pruritus remained consistently relieved, the condition stabilized, and no new lesions developed. However, residual lesions showed no significant regression. Subsequently, the patient underwent staged surgical excision of the residual lesions while continuing maintenance therapy with guselkumab.

**Conclusion**

This case represents the first report of ILVEN driven by a somatic mutation (c.-53-13C>T) in the 5′ UTR region of the HRAS gene, accompanied by an infection with M. obuense. Although this mutation does not alter the protein sequence, it may contribute to disease pathogenesis by regulating gene expression. The HRAS mutation may amplify inflammatory responses through activation of the MAPK/ERK pathway, synergistically with the IL-17/IL-23 inflammatory axis.

Therapeutically, secukinumab rapidly induces remission by blocking the IL-17A pathway, and when combined with tretinoin, it further controls hyperkeratosis. Subsequent switching to guselkumab failed to completely eliminate refractory lesions but demonstrated significant efficacy in maintaining disease stability, controlling pruritus, and preventing new lesion development. Neither biologic agent induced reactivation of non-tuberculous mycobacteria, indicating their safety in settings of co-infection.

This case highlights the clinical value of sequential use of IL-17i and IL-23i in achieving the therapeutic goal of "induced response–long-term maintenance." Future research should focus on elucidating the molecular mechanisms underlying HRAS regulatory region mutations .

EA DV CONGRESS
VIENNA
30 SEP - 3 OCT 2026

**Abstract N°: 3440**

# A One-Sided Story that Broke the Skin Barrier: Segmental Darier Disease Complicated by Bullous Pemphigoid and an HPV-6-Associated Giant Acanthopapilloma with Identification of a Novel ATP2A2 Mutation

Ioannis Sagonas*[1, 2], Ulrike Hueffmeier[3], Michael Sticherling[1, 2]

[1] Department of Dermatology, Uniklinikum Erlangen, Friedrich-Alexander University Erlangen-Nürnberg,, Erlangen, Germany

[2] Deutsches Zentrum Immuntherapie (DZI), Uniklinikum Erlangen,, Erlangen, Germany

[3] Institute of Human Genetics, University Hospital Erlangen, Friedrich-Alexander-Universität Erlangen-Nürnberg (Friedich-Alexander University Erlangen-Nürnberg),, Erlangen, Germany

## Introduction

Segmental Darier disease is a rare localized variant of Darier disease, an autosomal dominant acantholytic dermatosis caused by pathogenic *ATP2A2* variants. Type 1 segmental disease usually reflects post-zygotic somatic mosaicism and may remain genetically elusive if only blood DNA or predefined mutation panels are analysed. In immunocompromised patients, segmental Darier disease may act as a *locus minoris resistentiae*, predisposing to infection, neoplasia and secondary inflammatory disease. We report an unusual five-year course in which segmental Darier disease was followed by severe bullous pemphigoid and an HPV-6-associated giant acanthopapilloma, with subsequent molecular confirmation of a novel mosaic *ATP2A2* mutation.

## Case Presentation

A middle-aged male with a history of HIV-1 infection, severe coronary artery disease, asbestosis, and heavy smoking presented to our dermatology department in August 2021 with grouped, brownish, keratotic papules strictly localized to the right hemithorax and abdomen. Histopathology revealed suprabasal clefting, acantholysis, and corps ronds/grains, supporting a diagnosis of segmental Darier disease. However, initial targeted genetic screening for known classical *ATP2A2* mutations was negative.

Six months later, in February 2022, the patient developed a sudden, severe, generalized vesiculobullous eruption. Diagnostics revealed negative infectious swabs. Strikingly, direct immunofluorescence showed linear IgG and C3 deposition at the basement membrane zone, and serum anti-BP180 antibodies were markedly elevated (1735.4 U/ml; normal 0-9), confirming bullous pemphigoid (BP). Treatment with systemic corticosteroids and dapsone was initiated; however, in May 2022 dapsone was discontinued because of dyspnoea due to dapsone-induced methaemoglobinemia. Disease control was subsequently achieved with azathioprine and gradual corticosteroid tapering.

In early 2025, the patient developed large indurated verrucous plaques on the right lower leg, confined to the original Darier segment, raising concern for malignant transformation (SCC) or Kaposi sarcoma. Deep biopsies and MRI ruled out deep infiltration and malignancy, instead revealing a giant HPV-6-associated acanthopapilloma.

In March 2026, comparative exome sequencing of lesional skin and blood resolved the initial genetic discrepancy. This revealed a previously undescribed post-zygotic somatic mosaicism: lesional skin DNA harboured a novel pathogenic *ATP2A2* stop mutation (c.1645C>T, p.Arg549Ter) in 18% of reads, alongside a missense variant. Both variants were entirely absent in blood-derived DNA, consistent with Type 1 segmental Darier disease.

**Conclusion**

This case illustrates the complex interplay between a mosaic genodermatosis, autoimmunity and opportunistic viral proliferation. First, chronic localized acantholytic dermatoses can disrupt basement membrane architecture, potentially facilitating secondary autoimmune blistering through epitope spreading. Second, what clinically mimics malignant transformation in chronic dermatoses of immunocompromised patients may be an extensive viral superinfection. Finally, clinical and histopathological correlation remains paramount. When classical genetic screening for Darier disease is negative, advanced comparative skin-blood exome sequencing may be required to identify novel post-zygotic *ATP2A2* mosaicism.

EA DV CONGRESS
VIENNA
30 SEP - 3 OCT 2026

**Abstract N°: 3451**

# Cutaneous clue to hereditary leiomyomatosis and renal cell cancer syndrome

Marina López de Dicastillo-Cía*[1], Clara Miguel-Miguel[1], Paula Rodríguez-Jiménez[1], Olatz Aristu Mañu[1], Juan Ignacio Yanguas Bayona[1]

[1] Hospital Universitario de Navarra, Pamplona, Spain

## Introduction

Hereditary leiomyomatosis and renal cell cancer syndrome (HLRCC), also known as Reed syndrome, is a rare autosomal dominant genodermatosis caused by pathogenic variants in the fumarate hydratase (FH) gene, which encodes an enzyme involved in the Krebs cycle with tumor suppressor activity. The syndrome is characterized by the development of multiple cutaneous leiomyomas, early-onset uterine leiomyomas and an increased risk of aggressive renal cell carcinoma, most commonly papillary type 2. Since cutaneous lesions may represent the first manifestation of the disease, dermatologists play a crucial role in its recognition and early diagnosis.

## Case Presentation

A 73-year-old man was referred to our dermatology department for evaluation of multiple asymptomatic erythematous-to-brown papules and nodules distributed over the left scapular region and upper extremity in a segmental pattern. The lesions had progressively developed over a period of 27 years. The patient reported a family history of similar cutaneous lesions and hysterectomy in female relatives.

Histopathological examination revealed poorly circumscribed dermal proliferations composed of interlacing fascicles of smooth muscle fibers embedded within collagen bundles. Immunohistochemical studies demonstrated positivity for smooth muscle actin, supporting the diagnosis of cutaneous piloleiomyoma.

Given the clinical presentation and family history, the patient was referred for genetic evaluation. Molecular analysis identified the pathogenic FH variant c.1118A>G, confirming the diagnosis of HLRCC/Reed syndrome. Following diagnosis, genetic counseling was offered to first-degree relatives. The patient was subsequently included in a multidisciplinary surveillance program, including annual urological follow-up with renal cancer screening and periodic dermatological assessments for clinical monitoring of cutaneous disease.

## Conclusion

HLRCC is an uncommon hereditary cancer syndrome with potentially severe systemic implications. Cutaneous leiomyomas may constitute the earliest and most accessible clinical sign, allowing prompt recognition of affected individuals and at-risk family members. Although renal involvement is less frequent than cutaneous or uterine manifestations, associated renal carcinomas may exhibit aggressive behavior and poor prognosis if not detected early.

This case highlights the importance of considering HLRCC in patients presenting with multiple or segmental cutaneous leiomyomas, particularly in the presence of a compatible family history. Early diagnosis through dermatological recognition enables appropriate genetic counseling, multidisciplinary management, and implementation of surveillance strategies aimed at reducing disease-associated morbidity and mortality.

EADV Congress 2026, VIENNA
30 SEPTEMBER - 03 OCTOBER 2026
POWERED BY M-ANAGE.COM

EA DV CONGRESS
VIENNA
30 SEP - 3 OCT 2026

**Abstract N°: 3458**

# Racial and Socioeconomic Disparities in Diagnosis and Outcomes of Neurocutaneous Disorders

Meagan King[1], Andrew Spires*[1], Aliu Opeyemi Yakubu[2], Haripriya Eadala[3], Olorungbami Kolade Anifalaje[3], Gregory Atafo[4], Tosin Fakiyesi[5], Moses Effiong[6], Hassan Almustapha[7], Xiang Fang[2]

[1] University of Texas Medical Branch, Galveston, United States
[2] Department of Neurology, University of Texas Medical Branch, Galveston, United States
[3] University Hospital Wishaw, Department of Surgery, Wishaw, United Kingdom
[4] Medical University of the Americas, Nevis, Saint Kitts and Nevis
[5] Shirley Oaks Hospital, Surrey, United Kingdom
[6] Clinical Research Centre, Dundee, United Kingdom
[7] Sokoto University Teaching Hospital, Sokoto, Nigeria

## Introduction

**Introduction:** Neurocutaneous disorders, including neurofibromatosis type 1, tuberous sclerosis complex, and Sturge–Weber syndrome, are multisystem genetic conditions requiring early diagnosis and coordinated multidisciplinary care to optimize outcomes. Despite advances in diagnostic criteria and targeted therapies, significant racial and socioeconomic disparities persist across diagnosis, management, and long-term outcomes. This review evaluates how these disparities affect disease recognition, access to care, treatment utilization, and clinical outcomes.

## Materials and Methods

**Materials and Methods:** A narrative review of the literature was conducted, focusing on studies evaluating diagnostic pathways, healthcare access, treatment utilization, and clinical outcomes in neurocutaneous disorders. Emphasis was placed on evidence describing racial, ethnic, and socioeconomic disparities across these domains.

## Results

**Results:** Disparities occur throughout the diagnostic pathway, beginning with under-recognition of dermatologic findings in skin of color and limitations in dermatologic training. These factors contribute to delayed or missed diagnoses, particularly in early disease stages when surveillance and intervention are most effective. Variability in referral practices and structural barriers further limit access to multidisciplinary evaluation and genetic testing. Inequities in healthcare access, including insurance status, geographic location, and financial constraints, reduce continuity of care and limit access to specialty services. Differences in treatment utilization, particularly for targeted therapies such as mTOR and MEK inhibitors, reflect systemic barriers including cost, provider experience, and healthcare infrastructure.

These disparities are associated with worse clinical outcomes, including increased neurologic morbidity, higher tumor burden, reduced quality of life, and potentially increased mortality. Broader structural determinants, including health literacy, institutional bias, and underrepresentation in research, further compound these inequities.

**Conclusions**

**Conclusion:** Racial and socioeconomic disparities significantly impact the diagnosis, management, and outcomes of neurocutaneous disorders. Addressing these gaps requires a multifaceted approach, including improved representation in medical education, standardized referral and surveillance pathways, expanded access to multidisciplinary and telehealth services, policy reform to improve treatment accessibility, and more inclusive research practices. Advancing equity is essential to ensure that emerging diagnostic and therapeutic advances benefit all patient populations.

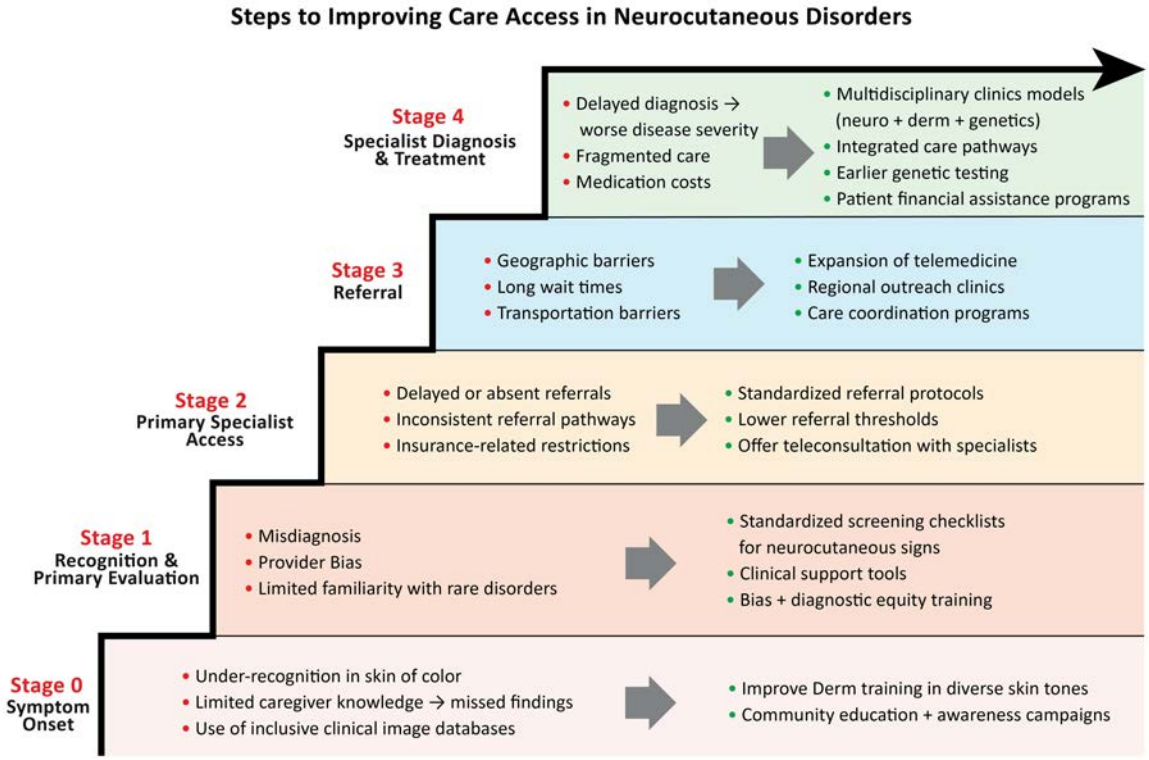

EADV CONGRESS
VIENNA
30 SEP - 3 OCT 2026

**Abstract N°: 3506**

# A Novel Homozygous HOXC13 Variant in a Case of Pure Hair and Nail Ectodermal Dysplasia

Jin-Yuan Ma*[1], Zhuo Fan[2], Can Cui[1], Xi Chen[1], Ai-Hua Wei[1]

[1] Beijing Tongren Hospital, Capital Medical University, Beijing, China
[2] The First Affiliated Hospital, Xi'an Medical College, Xi'an, China

## Introduction

Pure hair and nail ectodermal dysplasia (PHNED) is a rare congenital disorder characterized by selective impairment of hair and nail development, with no involvement of other ectodermal or non-ectodermal structures. *HOXC13*, a member of the evolutionarily conserved HOX gene family, encodes a homeobox-containing transcription factor that serves as a key regulator of hair follicle differentiation and nail morphogenesis. This protein is predominantly expressed in hair follicles and other skin appendages, exerting its function through transcriptional activation of downstream target genes, including those encoding keratins (e.g., *KRT35, KRT85, KRT74*), keratin-associated proteins, and additional transcription factors critical for maintaining the structural integrity of hair and nails. Animal models further validate this role: *HOXC13*-null mice exhibit complete absence of external hair, abnormal nails, and vertebral anomalies. However, in humans, pathogenic variations in the *HOXC13* gene are infrequently reported to be associated with congenital hypotrichosis accompanied by nail dysplasia, and the mutation spectrum of this gene remains inadequately characterized. Therefore, reporting novel *HOXC13* variants and their associated phenotypes is essential to expand the genetic etiology of PHNED and improve clinical genetic diagnosis.

## Case Presentation

The proband presented with congenital generalized alopecia and nail dysplasia, consistent with the clinical manifestations of PHNED. To identify the genetic cause of the patient's condition, whole exome sequencing (WES) was performed on the proband and his family members (trio-WES). The identified genetic variants were interpreted in accordance with the variant classification guidelines established by the American College of Medical Genetics and Genomics (ACMG) to determine their pathogenicity.
Sequencing results revealed a novel homozygous variant in the *HOXC13* gene, specifically at the site c.772delC (p.Arg258Glyfs*15), which is a frameshift mutation. Further analysis showed that this particular variant was not detected in the East Asian control population within the gnomAD database, supporting its potential pathogenicity.

## Conclusion

Trio-WES identified a novel homozygous frameshift mutation (c.772delC, p.Arg258Glyfs*15) in the *HOXC13* gene in the proband with congenital hair loss and nail dysplasia. According to ACMG guidelines, this variant is classified as likely pathogenic. To the best of our knowledge, this is the first report of this novel *HOXC13* variant associated with ectodermal dysplasia. This finding highlights the critical role of *HOXC13* in ectodermal development, expands the mutation spectrum of the *HOXC13* gene, and provides an important reference for clinical genetic diagnosis, counseling, and further research on similar PHNED cases.

POWERED BY M-ANAGE.COM

EADV CONGRESS
VIENNA
30 SEP - 3 OCT 2026

**Abstract N°: 3535**

# When Alopecia Reveals an Underlying Genetic Abnormality : a Rare Association in a Child

Rehab Bellout*[1], Ouiame El Jouari[1], Sabrina Oujdi[1], Salim Gallouj[1]

[1] Dermatology Department, University Hospital Center Mohammed VI, Tangier, Morocco

## Introduction

Alopecia areata is an autoimmune inflammatory disorder characterized by non-scarring hair loss. Alopecia totalis represents a severe form involving complete loss of scalp hair. Leukodystrophies are a heterogeneous group of genetic disorders affecting the cerebral white matter and often leading to progressive neurological impairment in children. The association between alopecia totalis and structural neurological abnormalities is rare and may suggest a shared neurocutaneous mechanism.

## Case Presentation

A 5-year-old girl born to non-consanguineous parents presented with progressive complete scalp hair loss since the age of 3 years, associated with growth retardation and delayed speech development. Dermatological examination revealed alopecia totalis with loss of eyelashes and eyebrows. Dermoscopy showed empty follicular openings, while the eyebrows exhibited erythema and leukotrichia. The remainder of the examination was unremarkable. Thyroid function tests were normal. Due to growth retardation, laboratory evaluation revealed iron deficiency (ferritin: 7 mg/L). Brain MRI demonstrated periventricular white matter signal abnormalities suggestive of leukodystrophy. In light of these findings, a genetic consultation was requested, and karyotyping revealed a deletion of the short arm of chromosome 18 (Monosomy 18p).

## Conclusion

Alopecia totalis in children should not be considered solely a dermatological condition when associated with developmental abnormalities. This case highlights the importance of neurological and genetic evaluation in children presenting with severe or atypical alopecia.

EA DV CONGRESS
VIENNA
30 SEP - 3 OCT 2026

**Abstract N°: 3616**

# A Father-Son Case of Epidermolytic Ichthyosis Associated With a KRT1 c.482T>C (p.Leu161Pro) Variant: NGS-Guided Diagnosis and Therapeutic Considerations

Muhammed Kerem Özkan*[1], Huseyin Karabat[1], Irem Ozcan[1], Asude Kara Polat[1], Savaş Yaylı[1]

[1] Koç University School of Medicine, Dermatology and Venereology Department, Istanbul, Türkiye

## Introduction

Epidermolytic ichthyosis (EI) is a rare keratinopathic disorder most commonly caused by heterozygous pathogenic variants in KRT1 or KRT10. Although EI is typically inherited in an autosomal dominant manner, sporadic cases due to de novo variants are well recognized. KRT1 mutations are frequently associated with prominent palmoplantar involvement, reflecting the expression pattern of keratin 1 in palmoplantar epidermis. Variants affecting the highly conserved H1 subdomain are of particular functional relevance, as leucine-to-proline substitutions in this region may severely disrupt keratin intermediate filament assembly.

Beyond classic KRT1-associated EI, the KRT1 mutation spectrum encompasses cyclic EI, ichthyosis hystrix Curth-Macklin, ichthyosis with confetti associated with KRT1, and palmoplantar keratoderma variants. Next-generation sequencing (NGS) with precise variant localization is valuable for accurate differential diagnosis across this clinically overlapping spectrum and for distinguishing KRT1- from KRT10-associated subtypes.

## Case Presentation

A 36-year-old male and his 11-year-old son were referred with a lifelong history of ichthyosis. Both carried a heterozygous KRT1 c.482T>C (p.Leu161Pro) variant confirmed by NGS and Sanger sequencing. The unaffected mother tested negative, confirming paternal transmission to the child and suggesting that the variant most likely arose de novo in the father, although this could not be definitively established without testing the father's parents.

The p.Leu161Pro substitution maps to the H1 subdomain, structurally analogous to the established L160P hotspot. This localization supports the pathogenic relevance of the variant and is consistent with the severe KRT1-associated EI phenotype with palmoplantar involvement. Both patients had neonatal-onset bullous erythroderma evolving into chronic hyperkeratosis. Examination of father revealed flexural hyperkeratotic plaques, intertriginous maceration with malodour, bilateral diffuse palmoplantar keratoderma with yellow discolouration, trachyonychia, and subungual hyperkeratosis. Periorbital and cervical lichenification in the son raised suspicion of comorbid atopic dermatitis.

The father had used acitretin for three years with partial improvement but increasing cutaneous fragility, necessitating irregular dosing. In the son, acitretin 10 mg every other day was discontinued after the development of painful plantar fissuring and vesiculation, consistent with the known limitation of systemic retinoids in patients with fragile hyperkeratotic skin.

## Conclusion

The confirmed absence of the variant in the mother is diagnostically pivotal, supporting paternal transmission and highlighting the diagnostic value of family-based molecular testing in EI. Precise H1 subdomain localization helps refine genotype–phenotype correlation, supports classification within the KRT1-associated EI spectrum, and may inform prognosis.

The concurrent atopic features in the son are clinically relevant, as EI-associated barrier dysfunction may contribute to type 2 inflammatory features; dupilumab, through IL-4/IL-13 pathway blockade, may therefore be considered when clinically significant atopic dermatitis is present, although its role in EI itself remains insufficiently established.

Beyond retinoids—still the therapeutic mainstay despite significant tolerability limitations—emerging options include anti-IL-17A agents such as secukinumab and other IL-17A inhibitors, which have been reported in selected cases of inflammatory ichthyosis, including KRT1-mutant EI; however, current evidence remains limited. Experimental gene-silencing and other genotype-directed strategies may offer future therapeutic potential but remain investigational. This case highlights the diagnostic value of NGS in KRT1-associated EI and underscores the need for well-tolerated, genotype-informed therapeutic strategies, particularly in paediatric patients.

EA DV CONGRESS
VIENNA
30 SEP - 3 OCT 2026

**Abstract N°: 3641**

# "Horse Collar" Sign and Pseudo-Athletic Appearance in Madelung Disease: A Classic Presentation of Multiple Symmetric Lipomatosis

Guilherme Gonçalves Nascimento*[1], Brian Vicente[1], Renata Bezerra[1], Claudio Lelis Souza[2]

[1] Intituto da Pele da Faculdade de Medicina do ABC - FMABC, Santo André, Brazil

[2] Universidade Prof.Edson Antônio Velano - UNIFENAS, Alfenas, Brazil

## Introduction

Madelung disease, also known as multiple symmetric lipomatosis or Launois–Bensaude syndrome, is a rare disorder characterized by progressive and symmetrical deposition of non-encapsulated adipose tissue, predominantly affecting the neck, upper trunk, shoulders, and proximal upper limbs. The disease is strongly associated with chronic alcohol consumption and metabolic disturbances, particularly in middle-aged men of Mediterranean ancestry. Characteristic clinical findings include the so-called "horse collar" sign, resulting from circumferential cervical fat accumulation, and a pseudo-athletic or "weightlifter" appearance caused by abnormal fat deposition over the shoulders and upper torso. Despite its distinctive phenotype, the disease is frequently underrecognized, leading to delayed diagnosis and psychosocial impairment.

## Case Presentation

A 48-year-old man presented with progressive enlargement of the neck, upper back, shoulders, and proximal upper limbs over the previous six years. The patient reported progressive aesthetic discomfort, limitation when wearing collared shirts, and mild cervical mobility restriction. He also described chronic alcohol consumption for more than 20 years.

Physical examination revealed extensive, symmetric, soft, non-tender, non-encapsulated adipose masses distributed around the cervical region, supraclavicular fossae, posterior neck, deltoid regions, and upper trunk. Marked circumferential cervical infiltration produced the characteristic "horse collar" sign, while prominent shoulder and upper thoracic fat accumulation resulted in a pseudo-athletic "weightlifter-like" appearance. No inflammatory signs or lymphadenopathy were observed.

Computed tomography demonstrated diffuse, symmetric, non-encapsulated fatty tissue proliferation without evidence of malignancy or significant airway compression. Laboratory evaluation revealed dyslipidemia and mild hepatic dysfunction associated with chronic alcohol use. Histopathological examination confirmed benign adipose tissue proliferation consistent with Madelung disease.

The patient was advised regarding alcohol cessation and underwent multidisciplinary follow-up. Surgical debulking was considered due to progressive cosmetic deformity and functional limitation.

## Conclusion

Madelung disease is a rare but clinically distinctive disorder whose recognition is essential for early diagnosis and management. The presence of the characteristic "horse collar" sign and pseudo-athletic appearance may provide important diagnostic clues. Dermatologists should be aware of this condition, particularly in patients with chronic alcohol consumption and symmetric cervical or upper trunk lipomatosis. Early recognition may help prevent functional complications and improve quality of life through appropriate multidisciplinary management.

EADV CONGRESS
VIENNA
30 SEP - 3 OCT 2026

**Abstract N°: 3647**

# Photodynamic therapy as a sustained therapeutic option in refractory Hailey-Hailey disease: a case report

Ibrahim El Awar*[1], Aleksandra Małolepsza[1], Aleksander Kostrzewa[1], Wiktoria Krzesłowska[1], Katarzyna Juczyńska[1], Agnieszka Żebrowska[1]

[1] Medical University of Łódź, Łódź, Poland

## Introduction

Hailey–Hailey disease (HHD; familial benign chronic pemphigus) is a rare autosomal dominant genodermatosis caused by ATP2C1 mutation, characterized by recurrent erosive and macerated plaques in skin fold areas. Its chronic course, frequent secondary infection, and the absence of standardized treatment guidelines make management particulary challenging, with topical corticosteroids, antibiotics, and systemic retinoids often providing only transient relief. Photodynamic therapy (PDT) has emerged as a potential therapeutic option, but evidence remains limited to small studies and individual case reports.

## Case Presentation

A 72-year-old woman with a long-standing history of biopsy-confirmed HHD presented for a planned admission to undergo her seventh session of PDT with topical 5-aminolevulinic acid (5-ALA). Skin involvement primarily affected the axillae, groins, and inframammary folds, with additional lesions in the lumbosacral region. Histopathology had previously confirmed HHD, with negative direct immunofluorescence and negative pemphigus/pemphigoid antibodies, ruling out autoimmune blistering disorders. Past treatments included acitretin 25 mg/day, which produced partial improvement but was discontinued due to intolerable side effects (alopecia, mucocutaneous dryness, low mood). Notably, she had a past history of breast carcinoma treated with surgery and adjuvant radiotherapy;. Two prior PDT sessions performed during a 2025 admission (right and left submammary folds) had stabilized the disease. On current admission, active erythema and erosions persisted under the right breast, while the left side and both axillae showed no active lesions. PDT with 5-ALA was applied to the affected right inframammary area at 37 J/cm$^2$. The session was complicated only by transient burning and post-procedural edema and erythema. After discharge the patient was treated with a topical vitamin D analogue and topicalcorticosteroid. Following the cumulative course of PDT, the axillae and lumbosacral region can be considered to have entered clinical remission, with no active lesions on the most recent dermatological examination.

## Conclusion

First, PDT delivered in a repeated, anatomically targeted areas can achieve durable control of skin fold flare ups where systemic retinoids have failed or been poorly tolerated. Third, integrating PDT with conservative measures like gentle cleansing, breathable clothing, sweat reduction, super-oxidized antiseptic solutions, and intermittent topical corticosteroid-vitamin D analogue therapy appears to extend remission intervals between procedures. PDT should be considered earlier in the algorithm for localized, treatment-resistant HHD, particularly in older patients or those with comorbidities limiting systemic options. Treating such patients remains a real challenge, as there are still no clear, widely accepted guidelines for the management of Hailey-Hailey disease, leaving clinicians to rely on individualized approaches. Larger studies are still needed to agree on the best light dose, photosensitizer concentration, and treatment intervals.

POWERED BY M-ANAGE.COM

EA DV CONGRESS
VIENNA
30 SEP - 3 OCT 2026

**Abstract N°: 3661**

# Targeting Proteostasis Through Autophagy Induction Reduces Keratin Aggregation and Blister Burden Across Keratinopathies

Karen McGuire*[1], Albert S. Chiou[2], Austin Johnson[2], Joyce Teng[2], Nihal Kaplan[3], Theresa Rowe[1], Laurie Broadwater[1], Aleesha McCormick[1], Amy Paller[3]

[1] BioMendics, LLC, Rootstown, United States

[2] Stanford School of Medicine Department of Dermatology, Palo Alto, United States

[3] Northwestern University Feinberg School of Medicine, Chicago, United States

## Introduction

Keratinopathies, including epidermolysis bullosa simplex (EBS), pachyonychia congenita (PC), and epidermolytic ichthyosis (EI), are characterized by cytoskeletal fragility and lack effective disease-modifying therapies. These disorders are characterized by recurrent blistering, pain, hyperkeratosis, and substantial impairment in quality of life. Despite well-defined genetic etiologies, therapeutic options remain limited. Emerging evidence implicates impaired proteostasis, including collapse of keratin intermediate filament (KIF) networks and accumulation of damaged keratin proteins, as a central driver of disease expression. This suggests a shared, targetable pathogenic axis across genetically distinct keratin disorders. We investigated the ability of pharmacologic induction of autophagy to restore keratin homeostasis. BM-3103 is a topical small-molecule modulator of the mTOR pathway that induces autophagy via a mechanism distinct from rapamycin-class inhibitors.

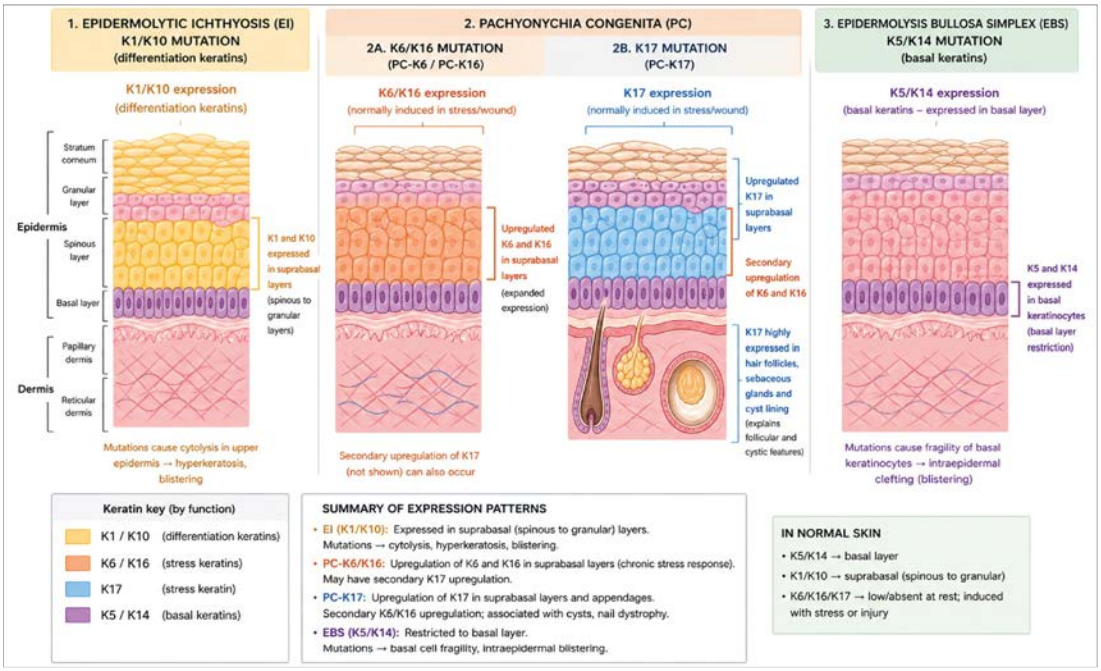


Keratin expression patterns across epidermal layers in keratinopathic disorders. This diagram compares keratin expression patterns across rare genetic skin disorders by mapping them onto epidermal layers. In EI (KRT1/KRT10 variants), suprabasal differentiation keratins are disrupted, leading to cytolysis, intraepidermal blistering, and hyperkeratosis. In PC (KRT6/KRT16 or KRT17 variants), stress-inducible

keratins are aberrantly expressed in suprabasal keratinocytes, with KRT17 variants also affecting hair follicles and sebaceous glands. In EBS (KRT5/KRT14 variants), basal keratins are disrupted, resulting in cytoskeletal instability and blistering within the basal layer. Overall, the figure highlights how keratin identity and epidermal localization determine the level of tissue fragility and clinical phenotype.

**Materials and Methods**

Primary and immortalized patient-derived keratinocytes were studied, including EBS (KRT5 p.E447K, KRT14 p.Y415H, KRT5 p.E475G), PC (KRT6A p.N171K, KRT16 p.N125D), and EI (KRT10 p.G467A). Autophagic flux was assessed by LC3-I to LC3-II conversion using Western blotting and immunofluorescence. A heat stress assay (43°C, 30 minutes) was used to induce KIF aggregation. Clinical relevance was evaluated using data from the EBS TAMES-01 Phase 1/2a study, including longitudinal blister surface area measurements in target lesion areas (TLAs) using a within-subject, vehicle-controlled design and transmission electron microscopy (TEM) of paired biopsies.

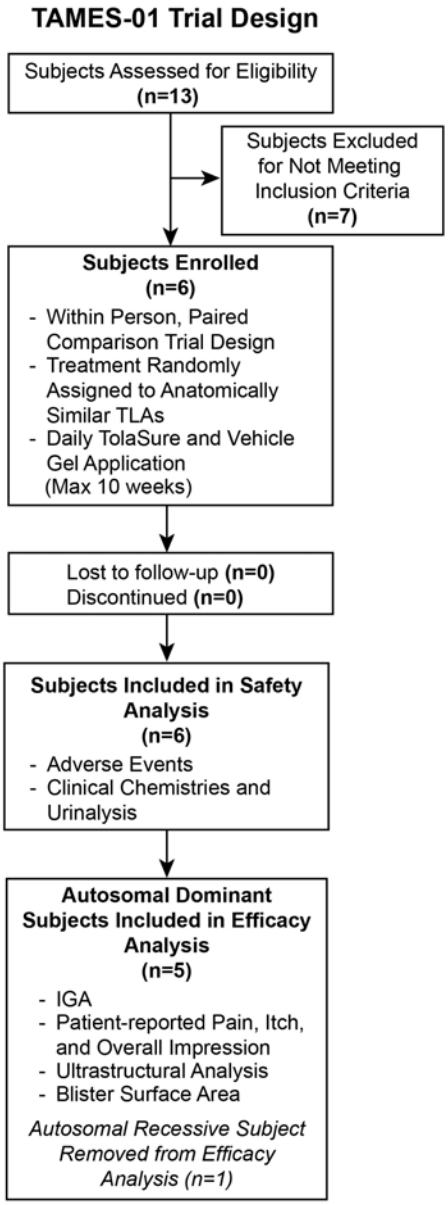

The TAMES-01 clinical trial was a parallel-group, double-blind, vehicle-controlled randomized clinical trial of once-daily topical TolaSure 5% w/w (BM-3103) for the treatment of EBS for up to 10 weeks at the discretion of the investigator. Thirteen (13) volunteers were screened with 6 patients enrolling in the TAMES-01 clinical study. The 7 screen failures were mostly attributed to patients not having the proper severe EBS diagnosis and/or insufficient flaring of clinical presentation to reach an Investigator's Global Assessment (IGA) score of ≥ 3. The 6 patients had confirmed severe EBS and two Target Lesional Areas (TLAs) totaling ~300-400 cm2/area with an IGA score ≥ 3/area on anatomically matched areas not including the palmar-plantar surfaces, head, neck or groin. Patients were monitored for safety, clinical efficacy (blister surface area), patient-reported outcomes (PROs for pain, itch, and impression scores), and beginning of study (BOS) and end of study (EOS) perilesional biopsy ultrastructural analysis was performed under TEM.

**Results**

BM-3103 robustly increased autophagic flux in EBS (~8-fold), PC (~5-fold), and EI (~3.5-fold) cells when compared to untreated controls. Rapamycin failed to induce autophagy at any dosage or duration tested. Bafilomycin was used as a positive control. Under stress conditions, BM-3103 reduced keratin aggregate-positive cells by approximately 60% compared with untreated controls ($p<0.001$), with concordant effects observed in primary EBS keratinocytes.

In the TAMES-01 study (n=5 genetically confirmed intermediate-to-severe autosomal dominant EBS subjects), a within-subject, vehicle-controlled design demonstrated rapid and sustained separation between treatment and control by Week 3. Baseline mean blister areas were 11.7 $cm^2$ (BM-3103) and 9.8 $cm^2$ (vehicle). By Week 3, BM-3103-treated areas decreased by 93% (to 0.8 $cm^2$) versus 52% with vehicle (to 4.7 $cm^2$; $p<0.05$). By Week 4, reductions reached 96% (to 0.4 $cm^2$) versus 45% with vehicle (to 5.4 $cm^2$; $p<0.01$). Consistent reductions were observed in all subjects with KRT5 or KRT14 mutations. Notably, treatment effects were localized, with continued blister formation in untreated skin, supporting a direct pharmacologic effect. TEM analysis demonstrated improved KIF organization and restoration of KIF ultrastructure.

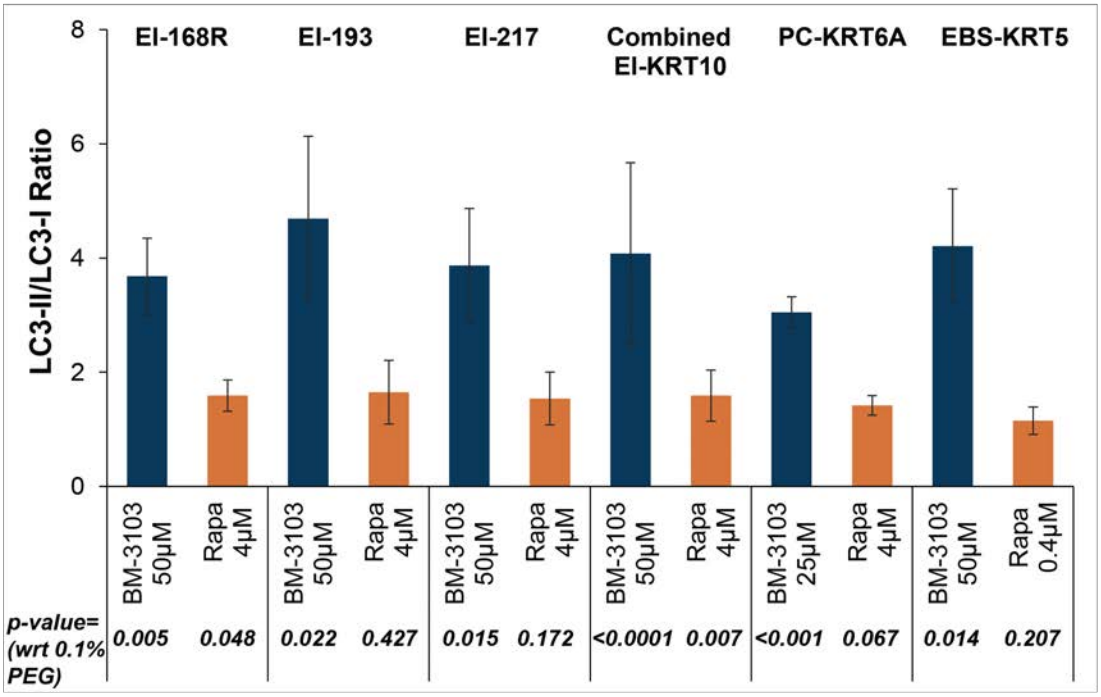


Rapamycin and BM-3103 Comparison- Statistical analysis of the mean fold change LC3-II/LC3-I ratios (±STDEV) across EI, PC, and EBS keratinopathies. P-values were calculated using two-tailed t-test ($\alpha$=0.05) with respect to 0.1% PEG control. Rapa = Rapamycin. All treatments were for 24hr. EI dose range, BM-3103=12.5μM -100μM, Rapa = 0.4μM and 4μM. PC dose range, BM-3103 = 12.5μM and 25μM, Rapa = 0.04μM-4μM. EBS dose range, BM-3103 = 50μM, Rapa = 0.04μM-4μM.

**Conclusions**

These findings establish proteostasis dysfunction as a convergent and targetable mechanism across keratinopathies and demonstrate that pharmacologic induction of autophagy can reduce keratin aggregation and restore filament architecture. Rapid, localized clinical effects observed in a within-subject controlled study, including substantial reductions in blister surface area by Week 3, provide strong translational support for this approach. Together, these data position autophagy modulation as a novel, mechanism-based therapeutic strategy for keratinopathies and support further clinical evaluation of BM-3103 as a potential disease-modifying treatment.

BM-3103 is currently being evaluated in a Phase 2 clinical trial in patients with EBS.

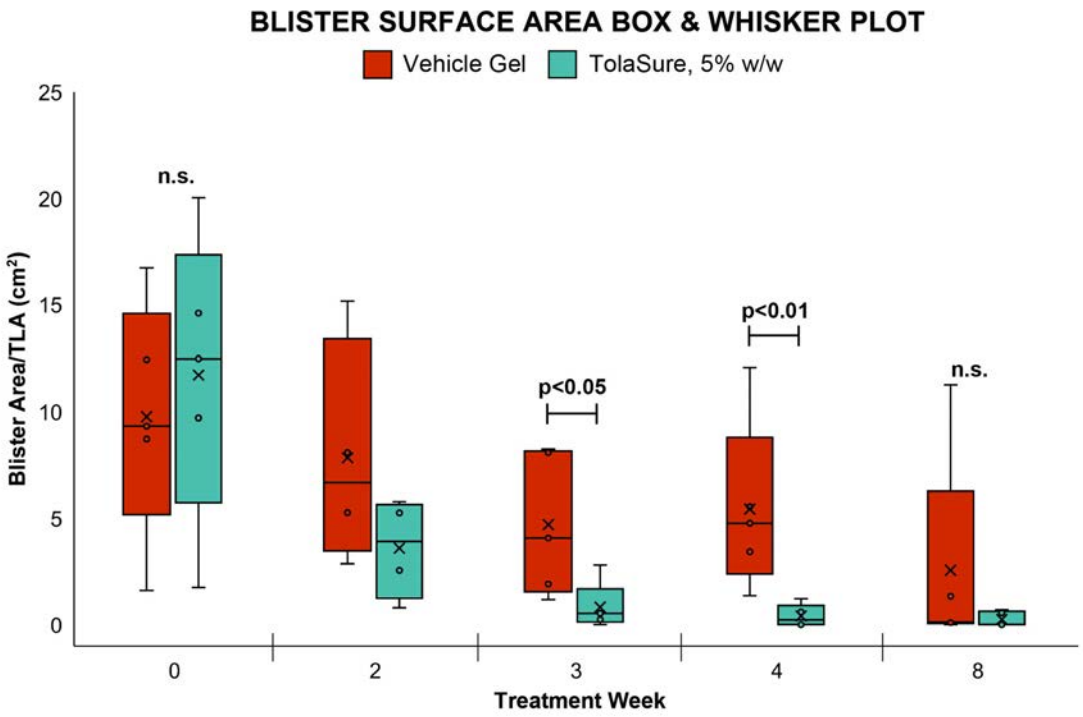


A box and whisker plot of TLA blister surface area of all subjects treated with either topical Vehicle Gel or TolaSure Gel, 5% w/w. By 3 and 4 weeks there is a statistically significant difference between treatment groups ($p<0.05$, $p<0.01$, respectively). There was no significance (n.s.) at Week 0, prior to treatment and at Week 8 between treatment groups.

EADV CONGRESS
VIENNA
30 SEP - 3 OCT 2026

**Abstract N°: 3669**

# Translating Genetic Findings into Care: COL7A1 Variant Spectrum as a Foundation for Personalized DEB Treatment in Germany

Johanna Zandanell*[1], Aleix de Vargas-Machuca Peydró[1], Cristina Has[1]

[1] Clinic of Dermatology and Venereology, Medical Center - University of Freiburg, Faculty of Medicine, University of Freiburg, Freiburg, Germany

## Introduction

Dystrophic epidermolysis bullosa (DEB) is a rare, severely disabling blistering disorder caused by pathogenic *COL7A1* variants that impair or abolish type VII collagen formation. Population-specific patterns of recurrent variants are highly relevant for the design of mutation-adapted therapies. Defining these variant landscapes is essential to bridge the gap between genetic diagnosis and emerging targeted treatment options.

## Materials and Methods

We retrospectively evaluated 506 individuals with DEB (198 dominant, 308 recessive) living or diagnosed in Germany and identified 808 pathogenic *COL7A1* alleles. Variants were grouped according to their predicted effect on the encoded protein and placed in the context of mutation-guided therapeutic strategies.

## Results

Glycine substitutions accounted for 35% of alleles, followed by splice-site variants (20%), frameshift variants (14.4%), premature termination codon (PTC) variants (14.2%), and other amino acid substitutions (11.5%). A pronounced clustering of variants was observed in exon 73, which contained 17.7% of all pathogenic alleles, the vast majority of them causing dominant DEB.

On the patient level, glycine substitutions were detected in 51.4% of patients, splice-site variants in 26.5%, frameshift variants in 18.6%, PTC variants in 18.4%, and other amino acid substitutions in 15.6%. Among those with recessive DEB, the splice-site variant c.425A>G in exon 3 was the most frequent (21.1% of patients), and 30.2% of patients carried nonsense mutations. In dominant DEB, the glycine substitution c.6127G>A in exon 73 represented the predominant variant (23.7% of patients).

## Conclusions

The identified mutation spectrum in Germany delineates distinct subgroups of DEB that are particularly amenable to RNA- and small-molecule–based interventions. Patients with nonsense variants constitute a sizeable fraction of recessive DEB and represent prime candidates for pharmacological stop-codon readthrough, with the prospect of targeting both cutaneous and extracutaneous disease. The accumulation of glycine substitutions in exon 73, including the recurrent c.6127G>A, highlights this region as a rational focus for antisense oligonucleotide–mediated exon skipping. By mapping these genotypes, our data provide a practical framework for selecting, prioritizing, and combining precision-tailored therapies, thereby complementing gene replacement approaches and supporting broader access to disease-modifying treatment for DEB.

EADV Congress 2026, VIENNA
30 SEPTEMBER - 03 OCTOBER 2026
POWERED BY M-ANAGE.COM

EADV CONGRESS
VIENNA
30 SEP - 3 OCT 2026

**Abstract N°: 3725**

# Hair Shaft Abnormalities in Acral Peeling Skin Syndrome

Aleksandra Kuźniak-Jodłowska*[1], Jakub Szewczyk[2], Magdalena Jałowska[1], Karolina Grochowska[3], Grzegorz Nowaczyk[2], Aleksandra Dańczak-Pazdrowska[1]

[1] Department of Dermatology, Poznan University of Medical Sciences, Poznan, Poland

[2] NanoBioMedical Centre, Adam Mickiewicz University, Poznan, Poland

[3] Department of Medical Genetics, Poznan University of Medical Sciences, Poznan, Poland

**Introduction**

Acral peeling skin syndrome (APSS) is a rare inherited disorder of keratinization characterized by painless superficial epidermal peeling resulting from impaired epidermal adhesion. Although the clinical manifestations primarily involve the skin, the potential involvement of other keratinized structures, including hair shafts, remains poorly understood. Advanced imaging techniques such as scanning electron microscopy (SEM) may provide additional insight into subtle ultrastructural abnormalities not visible during routine clinical examination. The aim of this study was to evaluate hair shaft surface morphology in pediatric patients with APSS using SEM.

**Materials and Methods**

Two pediatric female patients with clinically and genetically confirmed APSS were included in the study: patient A (6 years old) and patient B (2 years old), together with two healthy age- and sex-matched controls. Hair shafts collected from comparable scalp regions were examined using scanning electron microscopy (JEOL JSM-7001F) at 5 kV after gold sputter-coating. Six representative SEM images were obtained for each group. Hair shaft morphology was assessed using a standardized ultrastructural grading system. Statistical analysis was performed using IBM SPSS Statistics version 31.0.0, and categorical variables were analyzed using Fisher's exact test.

**Results**

SEM examination demonstrated visible alterations in hair shaft surface morphology in patients with APSS compared with healthy controls. Hair shafts from the control group showed preserved and regular cuticular architecture without significant structural abnormalities, corresponding predominantly to intact surface morphology. In contrast, hair samples obtained from APSS patients demonstrated irregular cuticle overlay and mild surface abnormalities without cortical exposure. A statistically significant difference in ultrastructural grading scores was observed between patient B and the healthy control group ($p = 0.015$). Although differences between patient A and the control group did not reach statistical significance, a clear tendency toward altered hair surface morphology was observed ($p = 0.08$). No significant differences were found between the two APSS patients ($p = 0.98$).




Figure 1. Scanning electron microscopy images of hair shaft surface morphology. (a) Control group hair showing grade 0 morphology with regular overlay of the cuticle; (b) Patient A showing grade 1 abnormalities with irregular cuticle overlay without cracks or holes; (c) Patient B showing grade 1 abnormalities with irregular cuticle overlay without cracks or holes. Scale bar: 10 µm; magnification ×1000; accelerating voltage 5 kV.

**Conclusions**

The present findings indicate that APSS may be associated with subtle ultrastructural abnormalities of the hair shaft detectable by SEM, suggesting that the disorder may involve keratinized structures beyond clinically visible epidermal lesions. SEM appears to be a useful complementary technique for the assessment of hair surface morphology in rare disorders of keratinization and may contribute to a better understanding of the structural manifestations of APSS.

EADV CONGRESS
VIENNA
30 SEP - 3 OCT 2026

**Abstract N°: 3743**

## A Therapeutic Alternative in Porphyria Cutanea Tarda: Alpha-Tocopherol

Madalena Correia*[1, 2], Inês Pereira Amaral[1, 2], Ivânia Soares[1, 2], Gustavo Silva[1, 2], Sonia Fernandes[1, 2], JOANA ANTUNES[1, 2]

[1] Unidade Local de Saúde de Santa Maria, Lisbon, Portugal
[2] University of Lisbon - Faculty of Medicine, Lisbon, Portugal

### Introduction

Porphyria cutanea tarda (PCT) is the most common porphyria and results from a qualitative deficiency of the enzyme uroporphyrinogen decarboxylase (UROD). Clinically, it is characterized by vesicles, bullae, and erosions in photoexposed areas and is associated with triggers such as alcohol consumption, chronic liver disease, and iron overload.

### Case Presentation

A 59-year-old man with no relevant past medical history reported recurrent vesicles and serous bullae on the dorsal hands over the past 10 years, progressing to erosions and worsening with sun exposure. Physical examination revealed diffuse hyperpigmentation of the face, hands, and forearms, as well as serous bullae, erosions, and hypo- and hyperpigmented scars on the hands. Laboratory evaluation showed an isolated elevation of gamma-glutamyl transferase (GGT). Porphyrin studies demonstrated positive plasma fluorescence and elevated urinary and fecal porphyrins. Genetic testing identified a heterozygous mutation in the UROD gene, confirming the diagnosis of type II (hereditary) PCT. A polymorphism in the HFE gene associated with iron overload was also detected; however, normal serum ferritin levels were considered a criterion for excluding phlebotomy.

Strict photoprotection measures and alcohol abstinence were recommended, and hydroxychloroquine was initiated but discontinued due to a morbilliform drug eruption. Given the inability to use first-line therapies, vitamin E supplementation (alpha-tocopherol, 300 mg/day) was started, resulting in complete resolution of lesions and no recurrences after one year of follow-up.

### Conclusion

This case shows that PCT may require individualized treatment when first-line therapies are contraindicated or poorly tolerated. In this setting, vitamin E emerged as a well-tolerated and effective alternative,likely through increasing UROD activity, leading to the reduction of circulating and excreted porphyrins.. The report supports considering vitamin E as a therapeutic option in selected patients, while emphasizing the importance of photoprotection, trigger avoidance, and careful clinical monitoring.



Clinical photograph of the dorsal hands showing hyperpigmented skin with scarring, erosions, and tense serous bullae on sun-exposed areas, consistent with porphyria cutanea tarda.

EADV CONGRESS
VIENNA
30 SEP - 3 OCT 2026

**Abstract N°: 3751**

# Disseminated Superficial Actinic Porokeratosis Treated with Topical Lovastatin and Cholesterol: A Case Report

Isabella Freire Pedrini*[1], Millena de Freitas Ribeiro[1], Letícia Silva Andrade[1], Isabel Anuda Brum de Andrade[1], Daniel Pereira[1], Flávia Colares[1], Isadora Prado Juliani[1], Anna Oliveira[1], Raquel Buosi[1], Isabela Garibaldi Cucolicchio[1], Tiago Arouche[1], Ana Gabriela Lopes[1], Patrick Wanderson dos Santos[1]

[1] Hospital Central do Exército (HCE), Rio de Janeiro, Brazil

## Introduction

Porokeratosis is a rare keratinization disorder, typically inherited in an autosomal dominant pattern. First described by Mibelli, disseminated superficial actinic porokeratosis (DSAP) is its most common subtype. It predominantly affects middle-aged to elderly women, involving sun-exposed areas and strongly associated with chronic ultraviolet radiation. Histopathologically, it is defined by the cornoid lamella, a column of parakeratosis with an absent or diminished granular layer. Recent studies have identified alterations in the mevalonate pathway, supporting a pathogenetic model based on impaired cholesterol synthesis and accumulation of toxic intermediates. These findings have provided a rationale for targeted therapies. We report a case of a patient with DSAP treated with a pathogenesis-directed therapy using topical lovastatin combined with cholesterol.

## Case Presentation

A 79-year-old female, Fitzpatrick phototype IV, presented with an 8-year history of hyperpigmented macules, initially on the left leg with subsequent spread to the right leg and proximal upper limbs. She reported mild pruritus. Medical history included hypertension and diabetes mellitus. Dermatological examination revealed multiple well-demarcated hyperpigmented macules with rough surface, scaly borders, and atrophic centers, distributed on the lower limbs, clavicular region, and upper back, sparing the face and acral areas.

Histopathological analysis demonstrated hypogranulosis, cornoid lamella formation, dermal lymphocytic infiltrate, and features of chronic dermatitis, consistent with porokeratosis. Treatment with emollients and topical lovastatin 2% combined with cholesterol 2% resulted in progressive clinical improvement.

DSAP is a chronic, progressive disorder affecting sun-exposed areas, frequently exacerbated by ultraviolet radiation in genetically predisposed individuals. Mutations in the mevalonate pathway lead to reduced cholesterol synthesis and accumulation of cytotoxic metabolites, resulting in premature keratinocyte apoptosis and abnormal epidermal differentiation, culminating in cornoid lamella formation.

Conventional therapies, including topical retinoids, vitamin D analogues, and 5-fluorouracil, often show limited efficacy and high recurrence rates, reflecting their inability to target the underlying metabolic defect. In contrast, pathogenesis-directed therapy has emerged as a rational and promising approach.

Topical lovastatin combined with cholesterol targets both components of the metabolic imbalance by inhibiting HMG-CoA reductase and restoring epidermal cholesterol levels, thereby improving barrier function and normalizing keratinocyte differentiation. Increasing evidence supports its efficacy and tolerability, including in refractory cases, although further controlled studies are required.

**Conclusion**

This case highlights the relevance of mechanism-based therapy in DSAP, particularly in elderly patients with extensive disease. Long-term follow-up remains essential due to the potential risk of malignant transformation. Advances in understanding DSAP pathophysiology support targeted treatments such as lovastatin and cholesterol as a promising therapeutic strategy.

EADV CONGRESS
VIENNA
30 SEP - 3 OCT 2026

**Abstract N°: 3769**

# Atypical Netherton Syndrome: A Case Report

Kholoud Afeissa*[1], Houria SAHEL[1]

[1] Faculty of medicine Algiers, Bab el oued hospital, Dermatology department, Algiers, Algeria

## Introduction

Ichthyoses are rare genodermatoses. They may occur as isolated forms, referred to as "ichthyosis vulgaris," or as part of syndromic conditions, the most common being Netherton syndrome. Clinically, Netherton syndrome is classically defined by a triad associating congenital erythroderma followed by characteristic ichthyosis linearis circumflexa, specific hair shaft abnormalities, and atopic manifestations, usually allowing straightforward diagnosis.

## Case Presentation

A 9-year-old girl born from a second-degree consanguineous marriage, with a history of collodion baby at birth followed by early-onset erythroderma, was initially diagnosed with ichthyosis vulgaris.

Due to the presence of facial erythema initially interpreted as photosensitivity, a diagnosis of trichothiodystrophy was subsequently considered. Hair examination under polarized light microscopy was performed in this context and did not reveal the alternating light and dark bands typical of trichothiodystrophy, nor features of trichorrhexis invaginata. However, pili annulati was observed in a large number of examined hairs, along with occasional pili torti.

During her most recent hospitalization for arthralgia and recurrent ENT infections, laboratory investigations revealed persistently elevated total IgE levels over several years (1860 IU/mL, approximately 18 times the upper normal limit). An immunodeficiency workup was subsequently performed and strongly suggested Comèl-Netherton syndrome.

The patient did not exhibit growth retardation or any history of atopy.

The diagnosis of atypical Netherton syndrome was therefore ultimately retained.

DISCUSSION

Netherton syndrome is a rare genodermatosis resulting from biallelic mutations in the SPINK5 gene, which encodes the serine protease inhibitor LEKTI. This defect leads to premature desquamation and impairment of the skin barrier.

Clinically, the syndrome is characterized by the classical triad of ichthyosiform erythroderma, hair shaft abnormalities, atopic manifestations, and elevated IgE levels.

Two major phenotypes of cutaneous desquamation have been described: ichthyosis linearis circumflexa, which is characteristic of Netherton syndrome, and desquamative erythroderma, as observed in our patient. In some cases, only an eczematous presentation may be present. However, significant phenotypic variability exists depending on the underlying genetic mutation, and isolated desquamative erythroderma forms have been reported.

Trichorrhexis invaginata is considered pathognomonic but may disappear with age. Other hair shaft abnormalities reported in Netherton syndrome include interrupted bands, pili torti, trichorrhexis nodosa, and helical hair shafts. To our knowledge, pili annulati has not previously been reported in association with Netherton syndrome and may represent a coincidental finding.

Facial erythema is characteristic of Netherton syndrome and may sometimes be associated with severe pruritus.

The severity of the syndrome is mainly related to its association with immune dysfunction. Although LEKTI deficiency itself suggests an underlying immunologic abnormality, the major impairment of the skin barrier is primarily responsible for recurrent infections and chronic allergic manifestations.

**Conclusion**

Our case highlights the importance of considering syndromic ichthyosis, particularly when associated with immune deficiency, before concluding to an isolated vulgar ichthyosis, even when the initial presentation appears limited to cutaneous manifestations alone.

EA DV CONGRESS
VIENNA
30 SEP - 3 OCT 2026

**Abstract N°: 3786**

# A Hypothesis of Blaschko line corresponding structures in the Central Nervous System

Snezana Minic*[1], Vladimir Peric[2], Olga Pantovic[1]

[1] University Clinical Center of Serbia, Clinic of Dermatovenereology, Belgrade, Serbia

[2] University Clinical Hospital Centre "Dr. Dragisa Misovic", Department of Gynecology and Obstetrics, Belgrade, Serbia

## Introduction

The distribution pattern of X-linked skin disorders follows the lines described by Blaschko. Blaschko lines represent pathways of epidermal cell clone migration during embryonic development. Disorders distributed along these lines arise from genetic mosaicism caused either by X-chromosome inactivation or early embryonic somatic mutations. Similar patterns corresponding to cutaneous Blaschko lines have also been described in other organs, including the eyes, teeth, and bones.

Incontinentia pigmenti (IP) is one of the best-studied X-linked disorders with a Blaschko-linear skin pattern. In this rare X-linked genodermatosis, caused by IKBKG (inhibitor of kappa B kinase gamma) gene mutations, typical skin changes are often combined with other organ anomalies, such as teeth, eyes, and central nervous system (CNS). The *IKBKG* gene product activates NF-kB, a transcription factor involved in the regulation ofalmost all cellular processes and has its highest expression level in CNS. Besides cutaneous manifestations, Blaschko line analogies have also been observed in ocular structures in IP. The aim of this study was to propose a hypothesis of Blaschko line corresponding structures within the CNS in IP.

## Materials and Methods

We reviewed available literature describing morphological CNS abnormalities in IP patients with neurological manifestations and analysed studies based on MRI and CT imaging findings

## Results

CNS abnormalities in IP usually occur at birth or during early infancy. The most commonly reported findings on MRI and CT include brain infarcts or necrosis, cerebral atrophy, corpus callosum hypoplasia or agenesis, and myelination disorders.

Some findings, particularly brain infarcts, suggest that a vascular mechanism is responsible for the pathogenesis of CNS lesions in IP. However, cerebral atrophy, corpus callosum abnormalities, myelination defects, and the absence of correspondence between lesions and vascular patterns suggest an alternative pathogenetic mechanism involving dysfunction of the NF-kB signaling pathway in neurons and glial cells.

Because the skin, eyes, and CNS share a common ectodermal origin, similar pathogenetic mechanisms maycause their anomalies in IP. Lesions are thought to result from apoptosis of cells carrying the mutated*IKBKG*gene, followed by replacement with cells in which the normal X chromosome remains active.

In one clinical study of IP patients with neurological manifestations, MRI demonstrated radially distributed CNS lesions extending from the ependyma to the cerebral cortex. The most severe parenchymal abnormalities were

observed in patients with extensive neonatal skin lesions, especially when located on the scalp. Notably, the affected areas were not vascularized by any determined artery.

The radial distribution of CNS lesions morphologically resembles the radial unit model of cortical development. According to this model, clonally related cells remain organized within radial columns during embryogenesis. Radial migration is the dominant mechanism of neuronal translocation in the developing CNS, and sister cells tend to remain closely grouped throughout development and adulthood.

**Conclusions**

Considering the common embryological origin of the skin, eyes, and CNS, together with the identical pathophysiological mechanisms of IP development with apoptosis as a key event in all affected tissues, the observed radially distributed cerebral lesions may represent CNS structures analogous to Blaschko lines. Their morphology, extension from ependyma to cortex, and association with severe neonatal cutaneous involvement further support the hypothesis that developmental clonal patterns similar to Blaschko lines may also exist within the CNS.

EA DV CONGRESS
VIENNA
30 SEP - 3 OCT 2026

**Abstract N°: 3791**

# The Diagnostic Challenge of Congenital Bullous Disorders in a Pediatric patient: a case report

Hamad El Hajj*[1], Dima Jeha[1], Andre Megarbane[2], Hala Abi Rached[1]

[1] Saint George University of Beirut, Beirut, Lebanon

[2] Lebanese American University, Institut Jérôme Lejeune, Byblos, Lebanon

## Introduction

Hereditary bullous disorders are rare and diverse group of skin conditions resulting from mutations in genes encoding structural proteins essential for skin cohesion and stability. The most prevalent of these conditions is epidermolysis bullosa, characterized by mucocutaneous fragility and the formation of bullae following minor trauma.

Epidermolytic ichthyosis (EI), previously known as epidermolytic hyperkeratosis and bullous congenital ichthyosiform erythroderma, is a rare, autosomal dominant genodermatosis, affecting 1 in over 200,000 newborns, with 50% are spontaneous mutations. The disease results from pathogenic variants in the genes encoding the suprabasal keratins 1 (KRT1) and 10 (KRT10), which disrupt the formation of keratin intermediate filaments within suprabasal keratinocytes.

We present a case of epidermolytic ichthyosis misdiagnosed as epidermolysis bullosa and review the clinical and genetic features of epidermolytic ichthyosis along with an overview of treatment.



Figure 1: Widespread areas of severe erythroderma and bullae and post-bullae erosion.

**Case Presentation**

An 18-month-old boy presented with persistently scaly, dry skin since birth. At birth, the patient presented with widespread erythroderma and erosions (figure 1). The family was advised to apply daily emollients. Upon presentation to our clinic, the child was afebrile and with no evidence of acute distress. Dermatological examination revealed mild erythroderma and diffuse white to gray scaling with hyperkeratosis, most prominent on the extensor surfaces of the extremities and the scalp (Figure 2). The palms and soles were not involved, and no ectropion was seen. There were no blisters, mucosal surfaces were intact, and both scalp hair and nails appeared normal. There were no parental consanguinity and no family history of skin disorders. A skin biopsy was recommended, but the family declined. Gene testing was carried out.

Whole Exome Sequencing was performed using the Agilent SureSelect kit and Illumina HiSeq 2500 system, followed by GATK variant calling and in-house annotation. A heterozygous pathogenic variant in *KRT10 (NM_000421.5:c.467G>A, p.(Arg156His)) was* identified in the proband.

The diagnosis was revised to **autosomal dominant epidermolytic ichthyosis**. The family was informed of the updated diagnosis and counseled on appropriate management.



Figure 2: Diffuse erythema with severe scaling and hyperkeratosis most prominent on the flexural surfaces of the extremities and the scalp.

**Conclusion**

In the present case, the detected KRT10 variant *(NM_000421.5:c.467G>A, p.(Arg156His))* has been previously reported in affected individuals, thereby confirming its pathogenicity and its association with the classical clinical

course of EI, characterized by early-life blistering followed by progressive hyperkeratosis.

Variants involving KRT1 are typically associated with palmoplantar involvement, reflecting the broader expression of this keratin in acral sites, whereas KRT10 demonstrates limited expression in these regions. This molecular variation aligns with our patient's lack of palmoplantar manifestations.

At birth, EI manifests with erythema, blisters, and superficial erosions, mostly involving the flexural regions. Blister formation is precipitated by minor trauma, friction and secondary infection. As the child grows, blister formation typically diminishes and is gradually replaced by epidermal thickening and scaling after the initial months of life.

There is no curative treatment for EI and management of is mainly supportive. In more severe cases, acitretin at a dosage of 0.5–1.0 mg/kg body weight has shown effectiveness in minimizing hyperkeratosis. However, systemic retinoids, while promoting desquamation, must be used cautiously due to their potential to worsen blistering.

This case highlights the importance of considering EI in the differential diagnosis of neonatal blistering disorders. Early differentiation between EI and EB not only prevents unnecessary interventions but helps implement accurate long-term management strategies.

EADV CONGRESS
VIENNA
30 SEP - 3 OCT 2026

**Abstract N°: 3792**

# Low-dose naltrexone in the treatment of Hailey–Hailey disease: a case report of refractory disease with significant clinical response

Kristina Miskovic*[1], Iva Blajic[2], Mirna Situm[2, 2]

[1] Helios Klinik Munchen West, Munchen, Germany

[2] Department of Dermatovenereology, Sestre Milosrdnice University Hospital Center, Zagreb, Zagreb, Croatia

## Introduction

**Introduction:**

Hailey–Hailey disease (HHD) is a rare autosomal dominant genodermatosis characterized by recurrent erosive and macerated plaques in intertriginous areas, often associated with a chronic relapsing course and therapeutic challenges. In recent years, low-dose naltrexone (LDN), an opioid receptor antagonist with immunomodulatory and anti-inflammatory properties, has emerged as a potential therapeutic option in dermatology. Several reports have demonstrated its benefit in HHD and other inflammatory dermatoses; however, its use remains off-label and not yet standardized.

## Case Presentation

We report a 54-year-old male patient with an 18-year history of HHD, presenting with recurrent exacerbations predominantly affecting the axillary, inguinal, intergluteal, and cervical regions. Over the years, numerous therapeutic approaches were implemented, including systemic corticosteroids, retinoids, methotrexate, prolonged courses of doxycycline, and topical antimicrobial and corticosteroid preparations, all yielding only partial and transient improvement, while some therapies were poorly tolerated or ineffective. One year earlier, the patient presented with a disease exacerbation involving approximately 10% BSA that was refractory to conventional therapy, at which point naltrexone therapy was initiated at 25 mg daily and subsequently adjusted to a low dose (5 mg daily). Within 7 weeks, a marked clinical response was observed, with almost complete regression of axillary lesions and significant improvement in inguinal and intergluteal involvement. At 5-month follow-up, the patient remained on low-dose naltrexone, with sustained disease control and no significant exudation, erythema, or crusting. Residual verrucous plaques persisted in the intergluteal and inguinal regions, without signs of active inflammation. At 8-month follow-up, sustained disease control was maintained. The therapy was well tolerated, with no reported adverse effects.

## Conclusion

This case supports the growing evidence for the efficacy of low-dose naltrexone in refractory Hailey–Hailey disease. Given its favorable safety profile, low cost, and immunomodulatory effects, naltrexone may represent a valuable therapeutic option in difficult-to-treat cases. Our findings further emphasize the need for larger controlled studies to establish the role and optimal dosing of naltrexone in HHD management.

POWERED BY M-ANAGE.COM

EA DV CONGRESS
VIENNA
30 SEP - 3 OCT 2026

**Abstract N°: 3811**

## Reticulate acropigmentation of Kitamura: a case report

Marcela López*[1]

[1] Hospital de Especialidades No. 25, Centro Médico Nacional del Noroeste, Monterrey, Mexico

### Introduction

Reticulate acropigmentation of Kitamura is an exceptionally rare genodermatosis, with an estimated worldwide prevalence of fewer than 1 case per 1,000,000 individuals. It is characterized by hyperpigmented, reticulated, and slightly depressed macules. Palmoplantar pits and interruption of dermatoglyphics are considered distinctive findings, while onset during infancy is unusual.

### Case Presentation

A 2-year-old female patient with a history of rhinitis and no family history of genodermatoses, pigmentary disorders, or endocrinopathies. Since the age of 3 months, she had developed brown reticulated pigmentation affecting the palms, soles, and dorsum of the hands and feet. Progressive dissemination to the forehead, neck, chest, axillae, hips, popliteal folds, and genital region was observed, without associated systemic symptoms. Dermatological examination revealed light brown to grayish hyperchromic reticulated macules, distributed bilaterally and symmetrically, predominantly in acral areas with accentuation in flexural regions. Multiple punctate palmar pits and distal interruption of dermatoglyphics, particularly evident on the fingertips, were identified. Laboratory studies, including ACTH, cortisol, and thyroid profile, were normal for age, with no evidence of adrenal insufficiency, endocrinopathy, failure to thrive, or growth abnormalities. Dermoscopy demonstrated a brown reticular pigment network and distal interruption of dermatoglyphics. Histopathological examination revealed a slight increase in intraepidermal melanocytes, elongation of rete ridges, hyperpigmentation at the tips of the rete ridges, and scattered melanophages within the superficial dermis. These clinicopathological findings were consistent with a reticulate pigmentary disorder compatible with reticulate acropigmentation of Kitamura.

Definitive diagnosis may be confirmed through genetic sequencing with identification of mutations in the ADAM10 gene; however, this diagnostic resource is not available in our location. Consequently, the integration of clinical, dermoscopic, and histopathological findings becomes particularly important. In this case, the age of onset, acral reticulated pattern, loss of dermatoglyphics, palmar pits, and histopathological features supported a highly suggestive clinicopathological diagnosis.



Light brown to grayish hyperchromic reticulated macules, distributed bilaterally and symmetrically, predominantly in acral areas with accentuation in flexural regions

**Conclusion**

The rarity of this disease, its early onset, and the absence of a family history make this case clinically relevant. In places where genetic sequencing is unavailable, diagnosis should rely on careful clinical, dermoscopic, and histopathological correlation. As this is a rare genodermatosis, reporting additional cases contributes to expanding the recognized clinical spectrum, particularly in patients with early-onset presentation.

EADV CONGRESS
VIENNA
30 SEP - 3 OCT 2026

**Abstract N°: 3819**

# Premature Ovarian Insufficiency in Xeroderma Pigmentosum: Therapeutic Challenges of Hormone Replacement Therapy

Meriem Emna Jones*[1], Imen Rojbi[1], Soumaya Gara[1], mariem fatnassi[1], Litaiem Noureddine[1], Faten Zeglaoui[1]

[1] Charles Nicolle Hospital, Faculté de médecine de Tunis, Tunis, Tunisia

## Introduction

Xeroderma pigmentosum is a rare inherited disease caused by defects in nucleotide excision repair, leading to extreme photosensitivity and increased cancer susceptibility. Beyond cutaneous manifestations, endocrine abnormalities including premature ovarian insufficiency (POI) may occur, exposing young patients to severe hypoestrogenism, osteoporosis, and impaired quality of life.

Hormone replacement therapy (HRT), usually recommended in young women with POI, remains challenging in xeroderma pigmentosum because of the underlying genomic instability and concerns regarding hormone-sensitive malignancies.

We report two young women with xeroderma pigmentosum presenting with early POI, severe vasomotor symptoms, and osteoporosis, highlighting the therapeutic dilemma surrounding HRT in this high-risk context.

## Case Presentation

We report two young women aged 26 and 28 years with genetically confirmed Xeroderma pigmentosum type C presenting with premature ovarian insufficiency diagnosed at the ages of 24 and 25 years, respectively. In both cases, hormonal investigations confirmed hypergonadotropic hypogonadism. The patients complained of severe and disabling vasomotor symptoms, predominantly hot flashes, significantly impairing quality of life. Bone mineral density assessment revealed early osteoporosis in both patients, highlighting the skeletal consequences of prolonged hypoestrogenism at a young age. Because of the underlying oncologic susceptibility, breast imaging surveillance was performed. Initial breast ultrasonography was normal in both patients. Given the severity of symptoms and osteoporotic involvement, hormone replacement therapy was initiated in both cases. During follow-up, breast ultrasonography remained unremarkable in the first patient, whereas follow-up imaging after two years in the second patient identified an ACR 4A lesion requiring further investigations and raising concerns regarding the long-term safety of HRT in this high-risk population.

## Conclusion

Although reported in the literature, premature ovarian insufficiency is an underrecognized extracutaneous manifestation of Xeroderma pigmentosum. In these very young patients, prolonged estrogen deprivation may lead to major skeletal, cardiovascular, and psychosocial consequences. Current recommendations for POI generally support hormone replacement therapy until the physiological age of menopause to prevent long-term complications. However, therapeutic management in xeroderma pigmentosum remains particularly challenging because of the underlying DNA repair defect and the increased lifetime risk of malignancies. In this context, the long-term safety of hormonal exposure remains uncertain, especially when suspicious breast imaging findings occur during follow-up, as illustrated in one of our patients. Evidence guiding HRT prescription in this rare population is extremely limited.

EA DV CONGRESS
VIENNA
30 SEP - 3 OCT 2026

**Abstract N°: 3843**

# Low-Dose Naltrexone for Refractory Hailey-Hailey Disease: A Case Report

Mariana Diniz*[1], Ana Carolina Salomão[1], Raphael Pereira[1]

[1] Universidade Estadual do Rio de Janeiro, Hospital Universitário Pedro Ernesto, Rio de Janeiro, Brazil

## Introduction

Hailey-Hailey disease (HHD), also known as familial benign pemphigus, is a rare autosomal dominant genodermatosis characterized by recurrent erosive plaques involving intertriginous areas. The disease is associated with impaired keratinocyte adhesion, leading to painful fissures, secondary infection, malodor, and significant quality-of-life impairment. Therapeutic management remains challenging, particularly in patients with refractory or recurrent disease. Recent studies have highlighted the potential role of low-dose naltrexone (LDN) as an emerging therapeutic option due to its anti-inflammatory and immunomodulatory properties.

## Case Presentation

We report the case of a 46-year-old woman with a 5-year history of recurrent painful erosive lesions affecting the axillary and inguinal folds. Initial differential diagnoses included inverse psoriasis and candidiasis. Histopathological examination revealed marked suprabasal acantholysis with the characteristic “dilapidated brick wall” pattern, confirming the diagnosis of HHD. Previous treatment with high-potency topical corticosteroids and topical calcineurin inhibitors resulted in only partial and temporary clinical improvement.

Due to persistent disease activity and frequent relapses, low-dose naltrexone at 4.5 mg/day was initiated. After 8 weeks of therapy, the patient demonstrated near-complete remission of erosive lesions, significant pain reduction, and marked improvement in daily activities and overall quality of life. Intermittent dose adjustments were required during periods of emotional stress and heat exposure, with maintenance of satisfactory long-term disease control and no relevant adverse effects.

Proposed mechanisms of LDN include opioid receptor modulation, anti-inflammatory effects, and restoration of intracellular calcium regulation, potentially contributing to improved keratinocyte adhesion and reduced acantholysis. Compared with conventional systemic immunosuppressive therapies, LDN appears to provide a favorable safety profile for long-term disease management.



Figures 1 and 2. Erythematous scaly plaques with superficial erosions involving intertriginous and truncal regions. Figure 1 demonstrates a well-demarcated erythematous-desquamative plaque with crusts and superficial erosions on the right supraescapular area, while Figure 2 shows an erythematous-violaceous plaque with mild scaling and erosions in the inguinal region.

**Conclusion**

This case supports low-dose naltrexone as a safe and effective therapeutic option for refractory Hailey-Hailey disease. The report also highlights the importance of emerging targeted therapies in the management of complex genodermatoses and reinforces the potential role of immunomodulatory strategies in achieving long-term disease control.

EADV CONGRESS
VIENNA
30 SEP - 3 OCT 2026

**Abstract N°: 3845**

# Treatment-Refractory Darier Disease Flare Responsive to Upadacitinib

Sanaz Lordfard*[1], Morvarid Hessami[2]

[1] Temerty Faculty of Medicine, University of Toronto, Toronto, Canada
[2] Division of Dermatology, Department of Medicine, University of Toronto, Toronto, Canada

## Introduction

Darier disease is a rare autosomal dominant disorder of keratinization caused by pathogenic variants in*ATP2A2*, which encodes a sarcoendoplasmic reticulum $Ca^{2+}$ ATPase (SERCA2) involved in intracellular calcium homeostasis. We describe a patient with long-standing Darier disease who presented with a treatment-refractory flare that showed improvement after starting Upadacitinib.

## Case Presentation

A 62-year-old white male with very severe Darier disease presented to a dermatology clinic due to a persistent flare for the past 10 days. The patient was diagnosed with Darier disease at 7 years of age. Red and brown hyperkeratotic papules and plaques initially appeared on the chest and gradually progressed to involve the majority of the scalp and ears, and parts of the back, lower abdomen, lower legs, and groin area. The patient had been followed by this clinic's dermatologist for the last 10 years.

The patient described persistent mild symptoms (3–4 out of 10) with intermittent moderate flares (6–7 out of 10) characterized by increased pruritus and pain. Triggers included mechanical friction from clothing, particularly non-cotton fabrics, humid weather, and sweating during summer months. The patient noted increased pruritus and discomfort on days when bathing was missed due to sweat accumulation. He also reported a consistent temporal association between ingestion of citrus fruits and worsening of symptoms. Measures that improved symptoms included wearing cotton clothing, limiting sun exposure, and maintaining skin hygiene. Minimizing scratching was particularly important in preventing worsening of lesions. Nail abnormalities had been present since adolescence, including brittleness, longitudinal ridging, and the sandwich sign.

Family history was notable for Darier disease in both of his children. His son (27 years old) and daughter (30 years old) were diagnosed during childhood between ages 8 and 10, though their disease excluded scalp involvement. The patient also reported that his mother and maternal grandfather had similar skin findings previously diagnosed as rosacea, which he suspected may have been undiagnosed Darier disease.

Past medical history included vitamin B12 deficiency, coronary artery disease, obesity, and a history of multiple fractures. Current medications included ticagrelor, atorvastatin, omega-3 supplements, vitamin B12, and occasional acetaminophen or ibuprofen. He reported no known drug or food allergies and did not smoke, consume alcohol, or use recreational drugs.

The patient had previously tried several treatments with limited benefit. Acitretin, which had been increased from 25 mg to 50 mg daily due to the current flare did not lead to a sufficient response. Additional treatments included topical tazarotene, pyrithione zinc shampoo, roflumilast foam, and halobetasol propionate/tazarotene combination lotion (0.01%/0.045%), which all improved pruritus but did not lead to a sufficient response.

He was subsequently started on cephalexin 500 mg four times daily for one week and topical ruxolitinib 1.5% once

daily. A trial of low-dose naltrexone and topical 5-fluorouracil also did not lead to improvement. Given the refractory nature of his disease, upadacitinib 30 mg once daily was initiated, leading to significant improvement and reduction in his flare. He is currently being monitored for maintenance of disease control and ongoing safety while on upadacitinib therapy.

**Conclusion**

This case highlights the therapeutic challenge of severe, long-standing Darier disease, particularly during flares that are refractory to topical therapies, systemic retinoids, and antibiotics. The significant clinical improvement observed after initiation of upadacitinib suggests that Janus Kinase (JAK) inhibition may represent a potential treatment option for recalcitrant Darier disease. Further studies are needed to demonstrate the efficacy and safety of upadacitinib and other JAK inhibitors in Darier disease.

EA DV CONGRESS
VIENNA
30 SEP - 3 OCT 2026

**Abstract N°: 3938**

# MOLECULAR GENETIC STUDIES OF ALLELIC VARIANTS AND GENOTYPE POLYMORPHISM ASSOCIATIONS OF THE CATECHOL-O-METHYLTRANSFERASE ( COMT) G/A GENE (VAL/MET; H/L) 116790 IN PATIENTS WITH ATOPIC DERMATITIS.

Shahnoza Mavlyanova*[1], Dilshod Hakimov[1]

[1] 1Republican Specialized Scientific and Practical Medical Center of Dermatovenereology and Cosmetology of the Ministry of Health of the Republic of Uzbekistan, Tashkent, Uzbekistan

## Introduction

Atopic dermatitis remains a pressing healthcare problem due to its genetic determination, continuing to increase among the population, and the development of complicated clinical forms of dermatosis. One of the provoking factors for the exacerbation of atopic dermatitis is nervous stress, increased anxiety, etc. In this regard, research into the genetic factors behind the formation of neurobiochemical disorders in patients with atopic dermatitis will reveal new mechanisms of dermatosis pathogenesis.

Catechol-O-methyltransferase (C O-T) is one of the main enzymes involved in the metabolic breakdown of catecholamines, such as dopamine, noradrenaline, or catecholestrogen in the prefrontal cortex, and is involved in the disruption of the catecholamine metabolic pathway - the neurobiochemical basis of attention deficit hyperactivity disorder (ADHD) and other mental disorders such as memory, attention impairment, increased anxiety, stress, etc.

**The purpose of our research** was to assess the identification of allelic variants and the association of genotype polymorphism of the COMT gene G/A (Val/Met; H/L) 116790 in patients with atopic dermatitis of the Uzbek population.

## Materials and Methods

Research materials and methods. 75 patients with atopic dermatitis aged from 7 to 61 years were examined. All patients underwent clinical laboratory, molecular genetic and statistical studies. The control group consisted of 40 healthy individuals at the appropriate age without any skin diseases.

## Results

Molecular genetic studies in patients with atopic dermatitis showed a high detectability of the mutant allele "A" rs116790 of the COMT G/A gene compared with the indicators of control individuals (42.6% and 2.5%, respectively; $\chi 2=41.14$; $p<0.00001$; OR=29.02; 95%CI 6.87-122.55). The frequency of the "wild" allele "G" in the control group was 1.7 times higher than in the main group and amounted to 97.5% versus 57.3% in patients with blood pressure, respectively; ( $\chi 2=41.14$; $p<0.00001$; OR=0.03; 95% CI 0.01-0.15). ( Tabl. 1.) Associations of "functionally unfavorable" G/A genotypes ($\chi 2=38.6$; $p<0.00004$; OR=15.76; 95%CI 3.54-70.11) and A/A ($\chi 2=38.6$; $p<0.00004$; OR=20.75; 95%CI 1.21-356.7) with the development of atopic dermatitis, which is 9.06 times higher than in the healthy control group. Moreover, frequent relapses were noted in the group of patients with the heterozygous variant G/A rs116790 of the COMT gene in 52.5% (32 out of 61) and the non–functional variant A/A in 24.6% (15), while with favorable G/G genotypes in 22.9% (14), respectively. The data obtained is of great practical interest in terms of the development of pathogenetic therapy.

Table 1. Distribution frequency of alleles and genotypes of the COMT G/A polymorphism (Val/Met; H/L) 116790, localization in chromosome 22q11.21. in the group of patients with AD and the control group.

| № | Group | Allele frequency | | | | Frequency of genotype distribution | | | | | |
|---|---|---|---|---|---|---|---|---|---|---|---|
| | | G | | A | | G/G | | G/A | | A/A | |
| | | *n | % | *n | % | *n | % | *n | % | *n | % |
| 1. | Main group n= 75 (150) | 86 | 57,3 | 64 | 42,6 | 26 | 34,6 | 34 | 45,3 | 15 | 20 |
| 2 | control group n= 40 (80) | 78 | 97,5 | 2 | 2,5 | 38 | 95 | 2 | 5 | | |

n - number of examined patients; *n - number of examined chromosomes

**Conclusions**

The A allele and the heterozygous/homozygous genotypes of the rs116790 polymorphism of the COMT G/A gene are significant markers of an increased risk of atopic dermatitis in the Uzbek population (P<0.0001). ($\chi2=38.6$; p<0.00004; OR=15.76; 95%CI 3.54-70.11; $\chi2=38.6$; $\chi2=38.6$; p<0.00004; OR=20.75; 95%CI 1.21-356.7) The G allele and the functionally favorable G/G genotype are reliable protective markers for the development of pathology ($\chi2=38.6$; p<0.00004;OR=0.03;95%CI 0.01-0.13).



Foto 1/ P. S. Atopik dermatitis

EADV CONGRESS
VIENNA
30 SEP - 3 OCT 2026

**Abstract N°: 4024**

# Genetic Variants and Phenotypic Spectrum in Neurofibromatosis Type 1: Insights from a Chinese Cohort

Jiali Liang[1, 2], Yifei Liu[1], Qiang Li[1], Changxing Li*[1]

[1] Department of Dermatology, the Tenth Affiliated Hospital, Southern Medical University (Dongguan People's Hospital), Dongguan, China

[2] Dermatology Hospital, Southern Medical University, Guangzhou, China

## Introduction

Neurofibromatosis type 1 (NF1) is an autosomal dominant tumor-predisposition syndrome with striking phenotypic heterogeneity. Genotype–phenotype correlations remain incompletely defined.

## Materials and Methods

A total of 117 patients meeting the National Institutes of Health (NIH) diagnostic criteria for NF1 were retrospectively enrolled. NF1 variants were identified by whole-exome sequencing (WES) and validated by Sanger sequencing. Tumor burden was assessed by whole-body MRI (WBMRI), recording the maximum tumor volume per patient and stratifying by predefined gradients.

## Results

The cohort included 59 males and 58 females. Pathogenic or likely pathogenic variants were identified in 106 patients, with 36 familial and 70 de novo cases. Among those with documented phenotypes, café-au-lait macules (CALMs) occurred in all cases (106/106), with 96.2% noted at birth; skinfold freckling in 92.4%; cutaneous neurofibromas (cNFs) in 85.6%; plexiform neurofibromas (pNFs) in 92.4%, including spinal pNFs in 2.8%; Lisch nodules in 51.8%; skeletal abnormalities in 36.7%; and no OPGs. Variant distribution showed truncating mutations as predominant (66.3%: nonsense 39.8%, frameshift 25.6%, initiation codon 0.8%), followed by splice-site (13.2%), missense (14.1%), CNVs, (4.4%), in-frame indels (0.8%), and one intronic variant. Domain analysis revealed frequent involvement of the GAP-related domain (GRD, 18.5%) and C-terminal domain (CTD, 15.9%). No significant associations were observed between variant categories or domains and tumor volume; however, patients with CTD variants exhibited larger mean tumor volumes (646.32 ± 1225.37 $cm^3$), including one case with a maximum volume of 5204.7 $cm^3$. Splice-site variants were associated with later age at onset compared with single amino acid variations (median 32.0 vs. 26.0 years, P = 0.042); CNV carriers were more likely to develop Lisch nodules (100.0% vs. 33.3%, P = 0.033); and CSRD variants were more often linked to congenital cNFs (42.9%), while CTD (77.8%, P = 0.028) and GRD variants (80.0%, P = 0.027) were associated with childhood-onset cNFs.

## Conclusions

This study defines the clinical and molecular landscape of NF1, with truncating mutations as the predominant class and GRD/CTD as frequently affected domains. Specific variant types may influence age at onset and clinical phenotype, providing insights for future mechanistic research and risk-adapted management.

EA DV CONGRESS
VIENNA
30 SEP - 3 OCT 2026

**Abstract N°: 4060**

# Distinct Pigmentary Patterns Identify Cancer-Resilient and Early-Onset High-Risk Phenotypes in Xeroderma Pigmentosum

Shafaque Imran*[1], Neetu Bhari[1], Rhea Ahuja[1], Devesh Kumar[1], Somesh Gupta[1], Sudheer Arava[1]

[1] All India Institute of Medical Sciences, New Delhi, India

## Introduction

Xeroderma Pigmentosum is a rare DNA repair disorder characterized by defective nucleotide excision repair, persistent UV-induced DNA damage, and increased risk of various malignancies. However, despite sharing a common defect in DNA repair pathways, XP patients exhibit marked heterogeneity in cancer susceptibility, tumor burden, and age of onset. While some individuals develop multiple aggressive malignancies early in life, others demonstrate relative resistance to tumor development despite having same pathogenic mutation and environmental stress. Pigmentary abnormalities are among the earliest features of XP, but they are typically considered descriptive and are not directly linked to disease severity. In this study we aim to identify distinct pigmentary patterns in xeroderma pigmentosum and determine their association with age and rate of tumor development and susceptibility to aggressiveness skin cancers.

## Materials and Methods

We conducted a prospective observational study of patients with xeroderma pigmentosum. Detailed clinical evaluation was performed to evaluate the morphology and distribution of pigmentary pattern. Tumor burden (tumors per year of life) was calculated for overall skin cancers for each patient. Kruskal Wallis test was used to find difference in age of first tumor and tumor burden across pigmentary group. Incidence rate ration was calculated as total number of tumors per person year life for each group. $p<0.05$ considered as statistically significant.

## Results

Based on clinical examination, patients were stratified into three distinct pigmentary phenotypes:

- Group 1 (n=8): generalized distribution of hyperpigmented macules throughout body.
- Group 2a (n=13): Relative sparing of photo-protected sites with idiopathic guttate hypomelanosis (IGH)-like hypopigmented macules predominantly on lower limbs.
- Group 2b (n=8): Relative sparing of photo-protected sites with confluent hypopigmented macules with overlying hyperpigmentation on extremities.

Cutaneous malignancies occurred in 7/8 (87.5%) patients in group 1, 3/13 (23.1%) in group 2a, and 6/8 (75.0%) in group 2b. Median age at first malignancy differed significantly across groups, occurring at 16.1 years in Group 1, 17.5 years in Group 2a, and 8.7 years in Group 2b (Kruskal Wallis test: overall $p=0.0067$).

Compared with group 2a, the incidence rate of cutaneous malignancy was significantly higher in group 1 (IRR: 4.93; 95% CI: 2.29-12.13; $p<0.0001$) and Group 2b (IRR: 8.99; 95% CI: 4.04-22.63; $p<0.0001$). Melanoma occurred in

2/8 (25.0%) patients in group 1 and 4/8 (50.0%) patients in group 2b but was not observed in Group 2a.

These findings defined three clinically distinct risk categories: group 2a as a low-risk, cancer-resilient phenotype; group 1 as a high-risk phenotype with higher cumulative tumor burden; and group 2b as a very high-risk, early-onset phenotype.

**Table 1: Pigmentary phenotype–based stratification of cutaneous malignancy risk in xeroderma pigmentosum.**

| *Clinical phenotype* | *Group1: Generalized hyperpigmentation* | *Group 2a: IGH-like hypopigmented macules (lower limbs)* | *Group 2b: Confluent hypopigmented macules with overlying hyperpigmentation* |
|---|---|---|---|
| *Number of patients* | 8 | 13 | 8 |
| *Age of presentation (Mean±SD)* | 24.25±15.18 | 13.38±6.1 | 9.37±2.38 |
| *Age of first tumor (Median (IQR))* | 16.14 (12-22.53) | 17.55 (16.92-22.92) | 8.68 (7.23-10.6) |
| *Total number of tumors* | 44 | 8 | 31 |
| *Number of patients with BCC* | 7/8 (87.5%) | 3/13 (23.07%) | 4/8 (50%) |
| *Number of patients with SCC* | 3/8 (37.5%) | 0/13 (0%) | 4/8 (50%) |
| *Number of patients with Melanoma* | 2/8 (25%) | 0/13 (0%) | 4/8 (50%) |
| *Incidence rate ratio (95% CI))* | 4.933 (2.2971-12.132) | Reference | 8.99 (4.0424-22.636) |
| *Risk category* | **High-risk** | **Low-risk (caner-resilient)** | **Very high-risk (Early-onset)** |

**Figure 1: Age of first cutaneous malignancy**

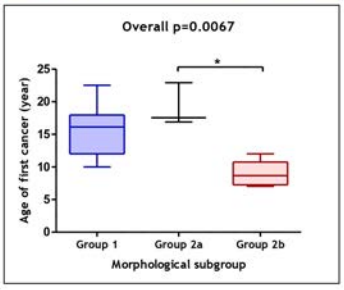


**Figure 2: Tumor burden by pigmentary group**

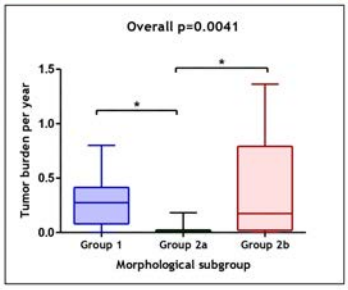


**Figure 3: Incidence rate ratio (IRR) for cutaneous malignancy**

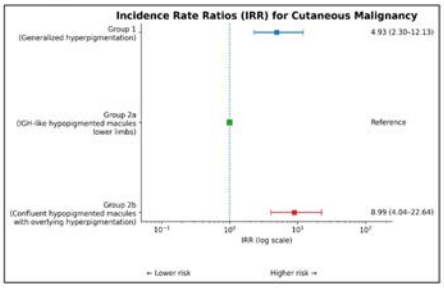


**Conclusions**

Distinct pigmentary patterns stratify cutaneous malignancy risk in XP and provide a simple clinical framework for personalized surveillance and risk-adapted management. Distinct pigmentary patterns in xeroderma pigmentosum are associated with differential disease severity, with some patterns representing a relatively protective phenotype and others identifying patients at higher risk of aggressive malignancies. These clinically identifiable patterns may serve as a practical tool for risk stratification and personalized surveillance

EADV CONGRESS
VIENNA
30 SEP - 3 OCT 2026

**Abstract N°: 4138**

## Clinical, biochemical and genetic characterization of familial porphyria cutanea tarda and hepatoerythropoietic porphyria

Pablo Balado-Simó*[1], Miriam Albéniz[2], Cèlia Badenas-Orquín[2], Jordi To-Figueras[2], Paula Aguilera[1]

[1] Dermatology Department, Hospital Clínic Barcelona, Barcelona, Spain, Melanoma Group, August Pi Sunyer Biomedical Research Institute (IDIBAPS), Barcelona, Spain, University of Barcelona, Barcelona, Spain., Barcelona, Spain
[2] Hospital Clínic, Barcelona, Spain

**Introduction**
Familial porphyria cutanea tarda (F-PCT) is an inherited metabolic disorder caused by pathogenic variants in the *UROD* gene. It is characterized by incomplete penetrance, variable biochemical expression and marked clinical heterogeneity, ranging from asymptomatic carriers to patients with overt blistering photosensitivity. In rare cases, biallelic *UROD* variants result in hepatoerythropoietic porphyria (HEP), a severe recessive phenotype usually presenting in early childhood. The relationship between urinary porphyrin excretion, iron metabolism abnormalities, genotype and clinical expression has not been systematically assessed in large genetically confirmed cohorts. We aimed to characterize the clinical, biochemical and genetic profile of a large single-centre cohort of patients with F-PCT, describe the *UROD* mutational spectrum, identify novel pathogenic variants, compare high and low porphyrin excretors and present the clinical and molecular features of patients with HEP.

**Materials and Methods**
We conducted a retrospective observational study of patients with genetically confirmed F-PCT evaluated at a tertiary referral centre between 1977 and 2025. Demographic and clinical data, cutaneous manifestations, age at onset, precipitating factors, iron metabolism parameters, urinary porphyrin levels and genetic findings were collected from clinical records and laboratory databases. Patients were classified as high or low excretors according to sustained urinary porphyrin excretion over time. Patients with biallelic *UROD* variants and a compatible severe phenotype were classified as HEP. Comparative analyses between excretion groups were performed, and correlations between porphyrin levels and iron metabolism parameters were assessed using R software.

**Results**
A total of 88 patients from 50 families were included. Thirty-six distinct *UROD* variants were identified, including four previously undescribed variants, expanding the known mutational spectrum of F-PCT. Eighteen patients were classified as high excretors. Compared with low excretors, high excretors showed more severe cutaneous involvement and higher transferrin saturation levels, supporting the clinical relevance of sustained porphyrin overproduction. A positive correlation was observed between urinary porphyrin excretion and serum ferritin, reinforcing the association between biochemical disease activity and iron overload.

Three patients were diagnosed with HEP. These patients showed a distinct and severe phenotype characterized by early-onset photosensitivity, marked cutaneous fragility and more extensive skin involvement than classical F-PCT. Their presentation was consistent with profound UROD deficiency caused by biallelic pathogenic variants. Compared with heterozygous F-PCT patients, HEP cases represented the extreme end of the clinical and biochemical spectrum, with earlier disease onset and greater clinical burden. The identification of these cases

within the cohort illustrates the phenotypic continuum associated with *UROD* deficiency and highlights the importance of genetic confirmation in patients with severe or unusually early presentations.

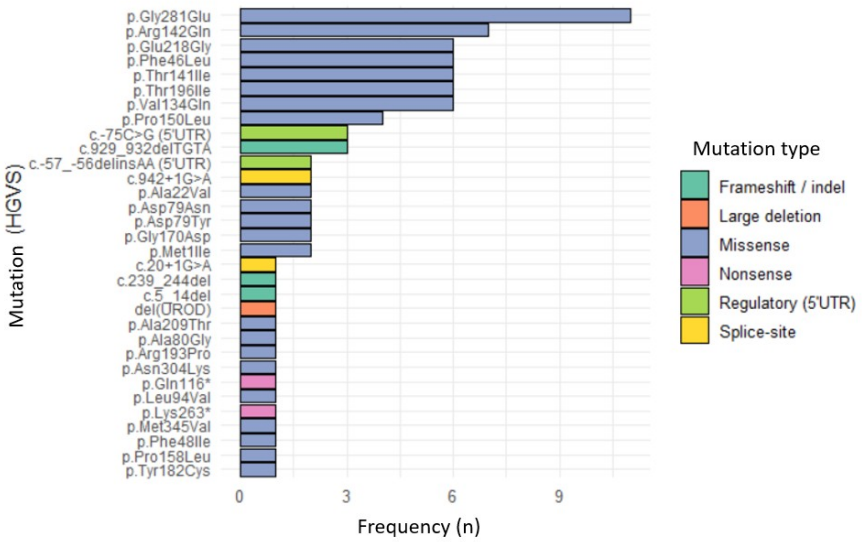


Distribution and frequency of UROD variants identified in the cohort. Horizontal bars represent the number of patients carrying each variant. Colours indicate mutation type, including missense, nonsense, splice-site, frameshift/insertion-deletion, regulatory 5′UTR variants and large deletions. HGVS nomenclature is shown for each variant.

**Conclusions**

This large single-centre cohort provides a comprehensive clinical, biochemical and genetic characterization of F-PCT and broadens the spectrum of pathogenic *UROD* variants. Stratification according to sustained urinary porphyrin excretion may provide additional insight into disease heterogeneity and suggests that residual UROD activity and iron metabolism could contribute to clinical expression. The detailed characterization of three HEP patients emphasizes that biallelic *UROD* variants are associated with a severe early-onset phenotype at the extreme of the PCT spectrum. Recognition of these subgroups may improve diagnostic accuracy, phenotypic classification, family counselling and individualized clinical management.

EADV CONGRESS
VIENNA
30 SEP - 3 OCT 2026

**Abstract N°: 4208**

# Clinical and epidemiological profile of Epidermolysis Bullosa in Tajikistan: A cross-sectional study

Mavzuna Zokiri*[1], Muzaffar Homidov[1], Robiya Salimova[1]

[1] Avicenna Tajik State Medical University, Dushanbe, Tajikistan

**Introduction**
Epidermolysis bullosa (EB) remains a challenging genodermatosis worldwide. In the Republic of Tajikistan, data regarding its prevalence and clinical manifestations are limited. This study aims to characterize the clinico-genetic features, subtype distribution, and comorbid status of EB patients within this region.

**Materials and Methods**
A cross-sectional observational study was conducted involving 53 patients. Data were collected via clinical examination and physician-led structured paper-based survey. Evaluation included demographic profiles, family history (with a focus on consanguinity), disability status, laboratory parameters (including IgE, Vitamin D, CRP), and genetic verification where accessible.

**Results**
The cohort showed a slight female predominance (54.7%) and was primarily pediatric. Genetic testing (available for 20.7% of the cohort) verified EB simplex (n=7), junctional EB (n=2), and autosomal recessive dystrophic EB (n=2). A significant finding was the high prevalence of consanguinity (67.9%). Disability was nearly universal (96.2%), and clinically, nail dystrophy was present in 16 cases (30.2%), while skin involvement was generalized in all cases.Systemic comorbidities were present in all patients (100%), including severe vitamin D deficiency, hypergamma-globulinemia E (elevated IgE), and anemia. Somatic impairments included gastrointestinal disorders (chronic constipation) and genitourinary pathologies (cystitis, dysuria). Notably, 90% of respondents exhibited a dietary sensitivity to rice, which consistently triggered the formation of new bullous lesions.

**Conclusions**
The link between dietary factors (rice consumption) and disease exacerbation warrants further investigation via allergological monitoring. Due to limited access to molecular diagnostics in the region, diagnosis currently relies predominantly on clinical presentation.

EA DV CONGRESS
VIENNA
30 SEP - 3 OCT 2026

**Abstract N°: 4231**

## Challenges and perspectives in the dermatological management of Epidermolysis Bullosa in Brazil

Natalia Gurgel do Carmo[1], Ana Isa Oliveira Azevedo[2], Maria Eduarda Lopes*[3], Ana Luiza Oliveira da Silva Fontes[4], Ana Vitória Gonçalves Minatti[5], Natália Jácomo Auad[6]

[1] Universidade de Brasília, Brasília, Brazil
[2] Universidade Alto Vale do Rio do Peixe, Caçador, Brazil
[3] Centro Universitario Ingá, Maringá, Brazil
[4] Universidade de Vassouras, Vassouras, Brazil
[5] Faculdade de Medicina de Presidente Prudente, Presidente Prudente, Brazil
[6] Centro Universitário Municipal de Franca, Franca, Brazil

### Introduction

Epidermolysis bullosa (EB) encompasses more than 30 phenotypically and genetically distinct disorders. Currently, it is categorized into four main subtypes: simplex, junctional, dystrophic, and Kindler syndrome. Generally, EB is characterized by severe epidermal ulcerations, which may progress to recurrent infections if management is suboptimal. In Brazil, EB is not included in the list of compulsory notifiable diseases, a factor that hinders epidemiological mapping. Nevertheless, it is estimated that approximately 2,300 Brazilians are affected, with 802 cases already registered by the DEBRA Brazil association. Regarding dermatological features, the condition presents with bullae and erosions of the epithelial tissue, as well as milia, alopecia, ocular scarring secondary to lesions, otorhinolaryngological complications, enamel hypoplasia, gastrointestinal and genitourinary tract injuries, and cutaneous neoplasms. The diagnosis of EB is established through clinical and laboratory evaluation; transmission electron microscopy (TEM) remains the gold standard for early diagnosis, as it identifies structural alterations within the skin layers. Treatment is inherently multidisciplinary. This study aims to review literature-based proposals for the dermatological management of these lesions.

### Materials and Methods

The methodology consisted of a literature review conducted across the SciELO and PubMed databases, utilizing the descriptors "Epidermolysis Bullosa", "treatment", and "Brazil", along with the Boolean operators 'AND' and 'OR'. Inclusion criteria comprised full-text articles published in Portuguese and available via open access.

### Results

The search yielded seven scientific papers, which emphasize that the therapeutic approach is predominantly multidisciplinary and it is fundamentally palliative, focusing on the avoidance of mechanical trauma, the prevention of secondary infections, and the promotion of wound healing through the systematic application of specialized dressings. Within the dermatological field, low-level laser therapy (LLLT) emerges as a promising tool, assisting in inflammatory modulation, analgesia, and the acceleration of wound healing. Furthermore, the efficacy of Photobiomodulation (PBM) has been demonstrated in reducing wound size ($P < 0.001$), alleviating pain and pruritus (itching), and enhancing both functional and psychosocial aspects of patients' lives.

### Conclusions

It is concluded that, despite recent advances, Brazilian literature still lacks robust clinical trials; clinical management is frequently guided by expert consensus and case reports. Nevertheless, the national landscape includes a Clinical Protocol and Therapeutic Guidelines (PCDT) established by the Ministry of Health. Furthermore, emerging therapies involving gentamicin and losartan have shown promising results in international literature.

EADV CONGRESS
VIENNA
30 SEP - 3 OCT 2026

**Abstract N°: 4297**

# Scanning Electron Microscopic Analysis of Ultrastructural Characteristics of Hair Shafts in Congenital Hypotrichosis with Different Genotypes

Jin-Yuan Ma*[1], Can Cui[1], Xi Chen[1], Ying-Zi Zhang[1], Ai-Hua Wei[1]

[1] Beijing Tongren Hospital, Capital Medical University, Beijing, China

## Introduction

Congenital hypotrichosis is a rare hereditary disorder characterized by abnormal hair development, presenting as sparse, fragile, and easily shed hair that impairs patients' appearance and mental health. It is highly heterogeneous, with different genotypes leading to varied clinical manifestations (e.g., congenital alopecia or progressive hair loss) and inheritance patterns (autosomal-dominant, autosomal-recessive, or X-linked), complicating diagnosis.

Scanning Electron Microscopy (SEM) is a powerful tool for biological ultrastructure research, enabling high-resolution visualization of sample surfaces unavailable via light microscopy. It generates 3D images of hair shaft topography, revealing details like scale structure, cuticle integrity, and surface texture.

## Materials and Methods

This study aimes to analyze ultrastructural abnormalities in hair shafts from patients with congenital hypotrichosis caused by mutations in genes such as *LIPH*, *KRT86*, *SREBF1*, *EBP*, *DSG4*, *CDSN*, and *HRURF* using SEM, and to explore correlations between cuticle morphology and genotype.Such SEM-based analysis of hair shaft ultrastructure in genotype-specific congenital hypotrichosis can deepen understanding of pathogenic mechanisms. Genotype-associated unique ultrastructural features may serve as diagnostic markers for early accurate diagnosis.

Hair samples were collected from ten genotypically confirmed patients. Following standard preparation, samples were examined via SEM to evaluate cuticle morphology, integrity, arrangement, and interval.

## Results

SEM revealed significant cuticular abnormalities in all samples, with features varying by genotype. Common findings included marginal curling, absence, erosion, and disorganization. *SREBF1* mutations were associated with the most severe damage, featuring longitudinal fissures and extensive cuticle lifting.

## Conclusions

Distinct gene mutations in congenital hypotrichosis correlate with specific ultrastructural hair shaft abnormalities, with *SREBF1* mutations causing significantly damage.

EADV CONGRESS
VIENNA
30 SEP - 3 OCT 2026

**Abstract N°: 4318**

# Nail pathology in COL7A1-related recessive dystrophic epidermolysis bullosa: a clinical and socioeconomic perspective

Teodora Toc*[1], Adela Chirita-Emandi[2], Alina Gogulescu[1]

[1] Municipal Emergency Hospital-Clinic for Dermatology, "Victor Babeș" University of Medicine and Pharmacy, Timisoara, Romania

[2] Department of Microscopic Morphology, Genetics Discipline, Center of Genomic Medicine, "Victor Babeș" University of Medicine and Pharmacy, Timisoara, Romania

**Introduction**

Recessive dystrophic epidermolysis bullosa (RDEB) is a genetic blistering disorder caused by mutations in *COL7A1*. Nail involvement is a consistent yet relatively underreported clinical aspect of RDEB. It may reflect underlying tissue fragility even before diagnosis and can contribute to caregiving demands. The aim of this study is to present the association of nail pathology in RDEB patients with *COL7A1* mutations, as well as to assess its relationship with caregiver burden and real-world care costs estimated by the families.

**Materials and Methods**

A retrospective review included a series of five patients with genetically confirmed pathogenic *COL7A1* variants followed in our center. Extracted variables included type of nail involvement, monthly direct care costs (home support, transport, total expenses), and maternal caregiver burden measured by the Zarit Burden Interview.

**Results**

Nail pathology occurred in all five cases. One patient already had anonychia at birth with rapid development towards mitten hands. Two patients presented partial anonychia with pseudosyndactilia. One patient had isolated toenail dystrophy and another one onychogryphosis, onychoschizia and onycholysis Of note, anonychia was associated with substantial functional limitation and increased reliance on maternal caregiving.

Caregiver Zarit scores ranged from 11 to 64**,** with the highest burden reported in families of patients with anonychia. Even in onychodystrophies, scores indicated moderate strain.

Monthly direct care costs were considerable, with a significant higher level in patients with anonychia. Nail severity appeared to parallel both caregiver burden and financial demand.

**Conclusions**

In *COL7A1*-related RDEB, nail involvement is a universal and clinically meaningful feature. Anonychia aligns with higher maternal caregiver burden and greater monthly care costs. Nail assessments may serve as a simple but powerful indicator of functional impairment and care dependency, supporting their integration into EB severity scoring and resource-planning tools.

EADV CONGRESS
VIENNA
30 SEP - 3 OCT 2026

**Abstract N°: 4515**

# Prevalence and severity of anemia in patients with Epidermolysis Bullosa: A retrospective study from Tajikistan

Mavzuna Zokiri*[1], Muzaffar Homidov[1]

[1] Avicenna Tajik State Medical University, Dushanbe, Tajikistan

**Introduction**
Anemia is a common chronic complication of epidermolysis bullosa (EB), particularly in patients with junctional EB and recessive dystrophic EB (RDEB). Contributing factors include poor nutritional intake due to painful mucosal involvement, chronic protein loss from non-healing wounds, and recurrent infections. To date, comprehensive data on the prevalence and characteristics of anemia among patients with EB in Tajikistan have been limited. The aim of this study was to evaluate the prevalence and clinical characteristics of anemia in the Tajik EB population through a retrospective cross-sectional analysis.

**Materials and Methods**
A retrospective review was conducted of 53 patients with EB registered in the Tajikistan Epidermolysis Bullosa Registry who received inpatient care between 2020 and 2025. Hematological parameters, including hemoglobin and ferritin levels, were analyzed to assess the presence and severity of anemia. Patients were categorized into pediatric (<18 years) and adult (≥18 years) groups and further stratified by sex. Anemia severity was classified according to World Health Organization (WHO) criteria.

**Results**
Among the 53 patients included in the analysis, 28 were female (52.8%) and 25 were male (47.2%). Patient age ranged from 1 to 61 years, with a mean age of 12.3 years.

The mean hemoglobin level in pediatric patients (<18 years, n = 45) was 116.4 ± 16.4 g/L. Among adult females (>18 years, n = 5), the mean hemoglobin level was 114.5 ± 10.2 g/L, while adult males (>18 years, n = 3) had a mean hemoglobin level of 129.0 ± 31.0 g/L.

In the revised age-stratified analysis presented in the poster (n = 45), 14 patients (31.1%) had anemia: mild in 4 (8.9%), moderate in 9 (20.0%), and severe in 1 (2.2%). The remaining 31 (68.9%) had normal hemoglobin.

Among patients aged 6–23 months (n = 4), 1 (25.0%) had moderate anemia and 3 (75.0%) had normal hemoglobin. Among those aged 24–59 months (n = 4), 2 (50.0%) had mild anemia, 1 (25.0%) had moderate anemia, and 1 (25.0%) had normal hemoglobin.

Among children aged 5–11 years (n = 21), 1 (4.8%) had mild anemia, 4 (19.0%) had moderate anemia, 1 (4.8%) had severe anemia, and 15 (71.4%) had normal hemoglobin.

In adolescents aged 12–14 years (n = 6), 1 (16.7%) had moderate anemia and 5 (83.3%) had normal hemoglobin.

Among females aged 15 years or older (n = 6), 2 (33.3%) had moderate anemia and 4 (66.7%) had normal

hemoglobin.

Among males aged 15 years or older (n = 4), 1 (25.0%) had mild anemia and 3 (75.0%) had normal hemoglobin.

Ferritin levels were available for 37 patients. The mean serum ferritin level in pediatric patients (<18 years, n = 31) was 31.8 ± 37.6 ng/mL. Among adult female patients (>18 years, n = 4), the mean ferritin level was 42.5 ± 28.4 ng/mL, while adult male patients (>18 years, n = 2) had a mean ferritin level of 78.0 ± 52.3 ng/mL.

Using a ferritin threshold of <15 ng/mL, 20 of 37 patients (54.1%) had low ferritin. Among these 20 patients, 8 (40.0%) had anemia and 12 (60.0%) had normal hemoglobin.

**Conclusions**

The study demonstrated reduced hemoglobin and ferritin levels across both pediatric and adult patient groups, with variations in severity according to age and sex. In the revised age-stratified subset, moderate anemia was the most common anemia category and the single severe case occurred in the 5–11-year age group. Low ferritin was also observed in patients with normal hemoglobin. These findings emphasize the importance of regular hematological assessment, nutritional support, and early management of iron deficiency in EB patients to improve long-term outcomes and quality of life.

EADV CONGRESS
VIENNA
30 SEP - 3 OCT 2026

**Abstract N°: 4527**

# Subungual glomus tumors in neurofibromatosis type 1: a national survey-based study

Natalia Chalupczak*[1], Nuran Golbasi[2], Kaya Curtis[3], Shari Lipner[2]

[1] Chicago Medical School, Rosalind Franklin University of Medicine and Science, Chicago, United States
[2] Weill Cornell Medicine, New York, United States
[3] memorial sloan kettering cancer center, New York, United States

**Introduction**
Glomus tumors are benign mesenchymal neoplasms arising from the glomus body, presenting with cold hypersensitivity, pinpoint tenderness, and paroxysmal subungual pain. Prior studies suggest an association with neurofibromatosis type 1 (NF1), attributed to biallelic NF1 inactivation and downstream RAS–MAPK pathway hyperactivation. However, glomus tumor prevalence in NF1 and its impact on quality of life (QoL) remain incompletely defined.

**Materials and Methods**
Following IRB exemption (Weill Cornell Medicine, #23-11026690), a voluntary online survey was distributed to NF1 patients registered in the Children's Tumor Foundation registry. Participants reported demographic information, prior subungual glomus tumor diagnosis, and nail signs and symptoms (pain with cold, pain with pressure, nocturnal pain, blue/red nail discoloration). Dermatology-related QoL was assessed using the Dermatology Life Quality Index (DLQI; range 0–30; higher scores indicate worse QoL). Group differences in DLQI were evaluated using the Mann-Whitney U test. Multivariable logistic regression assessed associations with moderate–severe QoL impairment (DLQI ≥6), adjusting for age and sex.

**Results**
Of 143 respondents, 120 (83.9%) provided complete responses. Mean age was 47.2±16.5 years; 72.1% were female and 87.1% were White. Overall, 8.9% (11/123) reported a prior subungual glomus tumor diagnosis. Glomus tumor–related symptoms were present in 43.4% (53/122) of participants: pain with cold (30.3%), pain with pressure (22.7%), blue/red nail discoloration (16.9%), and nocturnal pain (12.6%). Notably, 40.2% of undiagnosed participants reported ≥1 glomus-related symptom, and 84.9% of all symptomatic respondents had never received a diagnosis. Participants with ≥1 symptom had significantly worse QoL than asymptomatic participants (mean DLQI 8.1±6.8 vs. 5.2±4.8; p=0.009). In multivariable analysis, symptom presence was independently associated with moderate–severe QoL impairment (OR 2.28; 95% CI 1.05–4.96; p=0.038), with a graded effect per additional symptom (OR 1.54; 95% CI 1.06–2.22; p=0.022).

**Conclusions**
Subungual glomus tumors and related symptoms are highly prevalent in NF1, with the vast majority of symptomatic individuals undiagnosed, and symptom burden significantly predicts worse dermatologic QoL. Incorporating targeted nail-focused screening into routine NF1 surveillance may facilitate earlier recognition, prompt surgical excision, and reduce avoidable morbidity.

EADV CONGRESS
VIENNA
30 SEP - 3 OCT 2026

**Abstract N°: 4541**

# Clinical and Epidemiological Profile and Psychosocial Impact of Hereditary Ichthyoses in a Brazilian Tertiary Referral Center: A Pilot Study

Ana Clara Maia Palhano*[1], Carolina Cruz[1], Luciana de Paula Samorano[1], Maria Cecília Rivitti-MacHado[1], Zilda Najjar Oliveira[1]

[1] University of São Paulo, São Paulo, Brazil

## Introduction

Hereditary ichthyoses comprise a heterogeneous group of genodermatoses characterized by keratinization disorders and impaired skin barrier function. Beyond physical involvement, these conditions impose significant social stigma and emotional burden. Despite their severity, data regarding the psychosocial impact of ichthyoses in the Brazilian population remain scarce. This pilot study aimed to describe the clinical profile and evaluate quality of life and mental health in patients followed at a tertiary referral center.

## Materials and Methods

This is a pilot observational, cross-sectional, and prospective study, conducted as part of an ongoing research protocol. The sample included 77 patients with a clinical diagnosis of hereditary ichthyosis. Data collection was performed through structured anamnesis and direct application of validated instruments: the DLQI/CDLQI to assess quality of life and the DASS-21 scale to evaluate symptoms of depression, anxiety, and stress. Data were tabulated in an electronic spreadsheet and analyzed using descriptive and frequency statistics.

## Results

The sample demonstrated a predominance of severe and rare forms of ichthyosis, particularly lamellar ichthyosis and congenital ichthyosiform erythroderma, in addition to cases of Netherton syndrome, CHILD syndrome, and harlequin ichthyosis. Most patients presented manifestations since birth, including a history of collodion baby, as well as relevant extracutaneous findings such as ectropion and alopecia.

Regarding quality of life (n=49), the mean DLQI/CDLQI score was 9.7 (±7.5), with a maximum recorded value of 28 points. Overall, 53.1% of the sample showed moderate to extremely severe impairment in quality of life. The most affected domains were physical symptoms (pain and pruritus) and emotional impact/self-consciousness.

Mental health assessment using the DASS-21 (n=41) revealed critical findings:

- Anxiety affected 56.1% of patients, with 26.8% presenting extremely severe levels.
- Depression was present in 48.8% of individuals, with extremely severe impact in 14.6% of cases.
- Stress was identified in 46.3% of the sample.

A trend toward greater psychological distress was observed among patients with erythrodermic forms and greater lesion visibility.

**Conclusions**

The preliminary results of this pilot study confirm that hereditary ichthyoses in a tertiary care setting are associated with substantial impairment in quality of life and alarming levels of anxiety and depression. Disease visibility and chronic symptoms contribute to severe psychological vulnerability. As this is an ongoing study, expansion of the sample will allow deeper analysis of genotype–phenotype correlations; however, the current data already reinforce the urgent need for a multidisciplinary approach integrating psychological support into routine dermatological care.