EA DV CONGRESS
VIENNA
30 SEP - 3 OCT 2026

Abstract N°: 1

Dermoscopic Clues to Cutaneous Metastases: A Retrospective Analysis of 715 Lesions from Systemic and Cutaneous Malignancies

Olga Simionescu*[1, 2], Marian Petrica[3, 4], Alina Mariana Avram[1], Mariana Costache[5], Lucian Gheorghe Scurtu[1], Polixenia Iorga[6], Mariana Grigore[1]

[1] Department of Dermatology, "Carol Davila" University of Medicine and Pharmacy, Bucharest, Romania
[2] 1st Clinic of Dermatology, Colentina Clinical Hospital, Bucharest, Romania
[3] Department of Partial Differential Equations and Applications in Sciences, "Gheorghe Mihoc Caius Iacob" Institute of Mathematical Statitics and Applied Mathematics of the Romania Academy, Bucharest, Romania
[4] Faculty of Mathematics and Computer Science, University of Bucharest, Bucharest, Romania
[5] Department of Pathology, University Emergency Hospital, Bucharest, Romania
[6] Department of Medical Oncology, University Emergency Hospital, Bucharest, Romania

Introduction
Cutaneous metastases occur in up to 10% of cancer patients and usually indicate advanced disease and poor prognosis. They commonly present as painless papules or nodules in patients with a history of malignancy, yet dermoscopic diagnostic criteria remain poorly defined. This study aimed to identify dermoscopic clues associated with cutaneous metastases from systemic and cutaneous cancers.

Materials and Methods
We performed a retrospective analysis of 715 dermoscopic images of cutaneous metastases from 33 patients, including breast cancer, ovarian cancer, melanoma, non-melanoma skin cancer, and chronic leukemia, collected between 2013 and 2023 at two academic centers. Four independent blinded observers evaluated each lesion for dermoscopic patterns, colors, vascular morphology, and elementary structures using 30 predefined dermoscopic parameters.

Results
A white structureless pattern was the most frequent dermoscopic feature (81.26%, $p < 0.001$) and was observed across all tumor types. Overall, the predominant colors were pink, red, white, and tan, while elementary structures were uncommon except in melanoma metastases.Distinct tumor-specific dermoscopic patterns were identified.Melanoma metastases were characterized by blue coloration (85.71%) and a blue structureless pattern (79.37%).Breast cancer metastases frequently showed blue coloration and a blue-nevus–like pattern.Ovarian cancer metastases consistently displayed a white–tan structureless pattern with dotted vessels.Non-melanoma skin cancer metastases were predominantly associated with vascular and angioma-like patterns, often accompanied by irregular vessels.Chronic leukemia metastases most commonly exhibited a pink structureless pattern.

Conclusions
A white structureless dermoscopic pattern represents a key clue for recognizing cutaneous metastases, regardless of the primary tumor. Additional tumor-specific patterns may further guide clinical suspicion, including blue structureless lesions in melanoma metastases and vascular patterns with irregular vessels in non-melanoma skin cancer metastases. Dermoscopy may therefore assist in the early recognition of cutaneous metastases in oncologic patients and help guide prompt diagnostic biopsy.

Abstract N°: 16

Ochre Fluorescence a Marker of Invasive Melanoma under Ultraviolet-Induced Fluorescence Dermoscopy

Noureddine Litaiem*[1]

[1] University of Tunis El Manar, Tunis, Tunisia

Introduction
In 2022, Ultraviolet-induced fluorescence dermoscopy (UVFD) has been introduced into pocket-size commercial dermatoscopes. It works by exposing the skin to long-wave UV light (typically 365 nm), which excites specific endogenous or exogenous molecules called fluorophores. When these fluorophores absorb the UV energy, they transition to a higher energy state and then emit visible light of a longer wavelength, revealing unique colors and structures that are invisible under standard white-light dermoscopy. We present herein a case of invasive melanoma with ochre fluorescence under UVFD.

Case Presentation
A 59-year-old woman presented with biopsy-proven nodular melanoma of the left thigh . UVFD revealed focal ochre fluorescence (OF). Histopathology after tumor excision confirmed deep dermal invasion with a Breslow thickness of 2.5 mm. Thoraco-abdomino-pelvic and brain CT scans were unremarkable. A 2-cm re-excision of the surgical scars was performed.

Conclusion
OF was recently described as a specific sign of melanoma [1,2]. In a multicenter study conducted in 3 tertiary care clinics in Chile, France, and Poland including 551 cutaneous tumors, ‘‘Ochre color’ was only seen in melanomas. It was present in 21.4% of melanoma cases and 44% of invasive melanomas [1]. The specificity and positive predictive value of OF for melanoma were 0.97 and 0.852 respectively [2]. The inter-evaluator agreement was excellent 0.94 [2]. It was hypothecized that the responsible fluorophore may be lipofuscin or melanolipofuscin present in melanomas [2] OF is a readily identifiable feature in UVFD with high specificity for melanoma diagnosis, particularly in invasive lesions [1,2]. Its utility in guiding surgical excision margins warrants further investigation

References:
[1] Navarrete-Dechent C, Pietkiewicz P, Abarzua-Araya A, et al. Ultraviolet-induced fluorescent dermoscopy for the diagnosis of skin tumors: A multicenter study. J Am Acad Dermatol. 2026;94(3):835-842. doi:10.1016/j.jaad.2025.10.131
[2] Pietkiewicz P, Voloshynovych M, Anriot J, et al. Ochre fluorescence under ultraviolet-induced fluorescence dermatoscopy is a strong clue to melanoma: Results of an international retrospective cross-sectional study. J Am Acad Dermatol. Published online January 21, 2026. doi:10.1016/j.jaad.2026.01.018

EA DV CONGRESS
VIENNA
30 SEP - 3 OCT 2026

Abstract N°: 38

Multimodal Diagnostic Approach to Disseminated Superficial Actinic Porokeratosis: A Case Report

Meltem Cebeci*[1], Cem Leblebici[2], Ayşe Esra Koku Aksu[3]

[1] Istanbul Training and Research Hospital Department of Dermatology, İstanbul, Türkiye
[2] Istanbul Research And Training Hospital Department of Pathology, Istanbul, Türkiye
[3] Istanbul Research And Training Hospital Department of Dermatology, Istanbul, Türkiye

Introduction

Disseminated superficial porokeratosis (DSAP) is a rare variant of porokeratosis characterized by multiple, small, annular keratotic papules and macules widely distributed over the body. While the hallmark of the disease is the cornoid lamella, a column of parakeratotic cells seen on histopathology, the clinical presentation can be highly variable. Pigmented variants of DSAP are particularly challenging as they can closely mimic other pigmentary or inflammatory dermatoses. Accurate diagnosis requires a high index of clinical suspicion, supported by dermoscopic evaluation and confirmed by histopathological correlation to differentiate it from its mimickers and to monitor for potential malignant transformation.

Case Presentation

A 57-year-old male presented with a three-month history of widespread, evolving pigmented macules. Dermatological examination revealed multiple, well-demarcated, brownish to erythematous annular lesions with a distinct, slightly raised peripheral keratotic border. These lesions were disseminated across the bilateral lower extremities, particularly the dorsum of the feet and anterior crural regions, as well as the inguinal folds.
Dermoscopic evaluation of the lesions provided crucial supportive evidence, revealing a characteristic continuous, peripheral whitish-grey track with a distinct 'double-track' appearance. The central areas of the macules exhibited mild epidermal atrophy and subtle brownish-grey structureless pigmentation. Under polarized light, the peripheral keratotic rim was significantly accentuated, and fine dotted vessels were noted just inside the border, indicating a localized inflammatory component.
Histopathological examination demonstrated focal parakeratosis and a cornoid lamella in the epidermis. Additionally, widespread vacuolar degeneration of the basal layer and numerous pigment-laden histiocytes with lymphocytes in the superficial dermis were observed. The histopathological findings were consistent with porokeratosis.

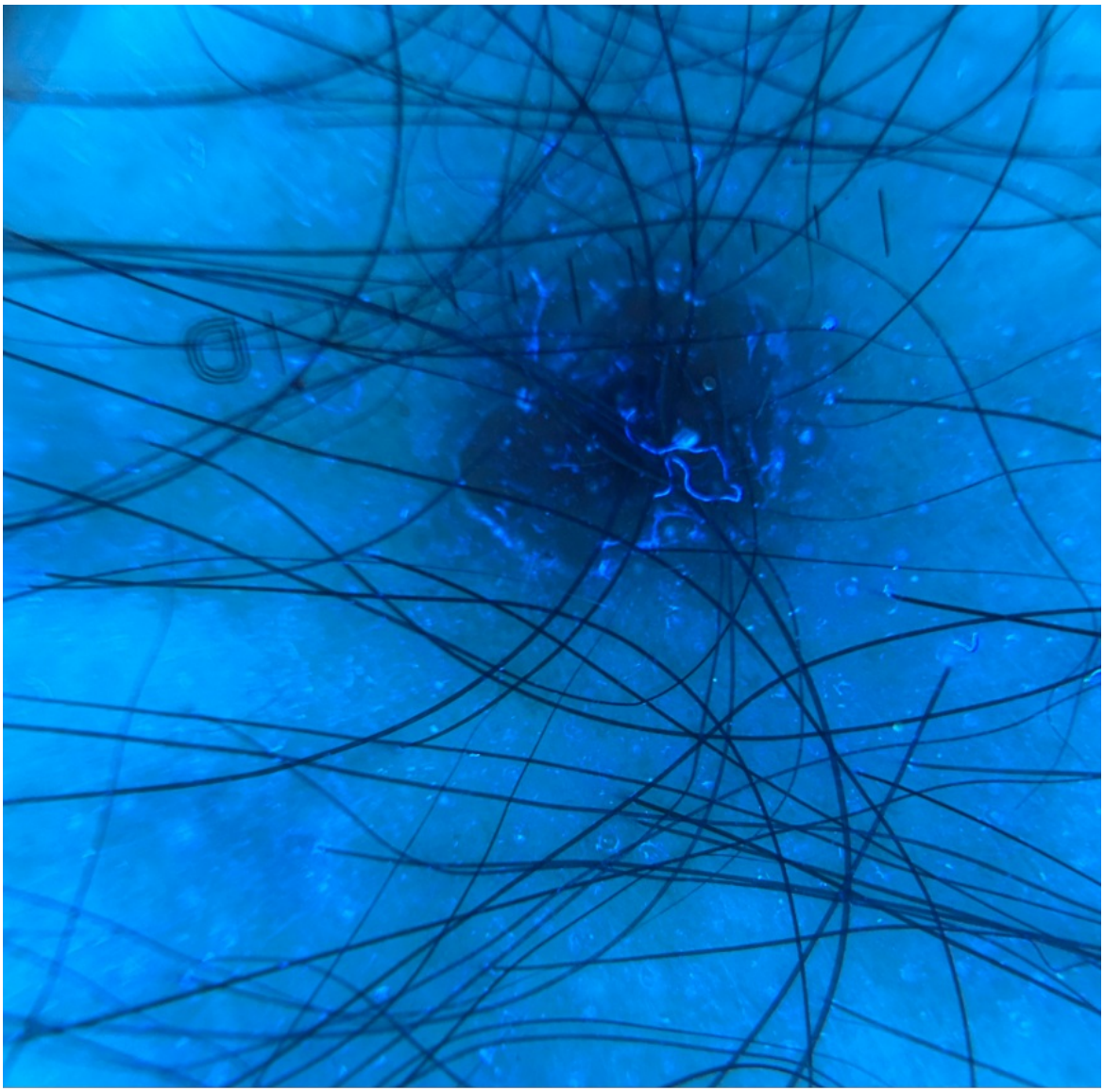

Dermoscopic imaging of the lesion showing the pathognomonic peripheral whitish-grey 'double-track' rim corresponding to the cornoid lamella, surrounding a central area of structureless pigmentation.

Conclusion

DSAP should be considered in the differential diagnosis of disseminated pigmented annular lesions. This case highlights that while histopathological identification of the cornoid lamella remains the definitive gold standard, dermoscopy serves as an indispensable, non-invasive bedside tool. The identification of the pathognomonic 'double-track' white rim reflects the underlying pathological architecture and facilitates the diagnostic process in atypical or disseminated clinical presentations.

EA DV CONGRESS
VIENNA
30 SEP - 3 OCT 2026

Abstract N°: 93

Rapidly growing nodular melanoma arising in a scar after laser treatment of a melanocytic lesion: dermoscopic clues and diagnostic pitfalls

Larysa Larionova*[1]

[1] St. Panteleimon Clinical hospital, Sumy, Ukraine

Introduction

Destructive treatment of melanocytic lesions remains controversial because it may delay melanoma diagnosis and lead to diagnostic difficulties. Careful evaluation of new or rapidly growing lesions in postoperative scars is therefore essential.



Erythematous nodular lesion measuring approximately 3 × 1.5 cm located on the left shoulder within a postoperative scar.

Case Presentation

A 22-year-old woman presented with a rapidly growing lesion on the left shoulder. Two years earlier, a melanocytic lesion at the same site had been treated with laser ablation. Histopathological examination performed at that time described a proliferating nevus measuring 0.3 × 0.3 cm.Approximately six months after the procedure, the patient noticed pigmentation within the postoperative scar followed by progressive nodular growth.Clinical examination revealed a firm erythematous nodule measuring approximately 3 × 1.5 cm located within the scar and covered with superficial hemorrhagic crusts.Dermoscopy demonstrated a predominantly structureless pink background with polymorphous vessels, focal pigmentation and hemorrhagic areas, raising strong suspicion for nodular melanoma.

Excisional biopsy and subsequent histopathological examination confirmed melanoma with invasive growth. Due to tangential orientation of the specimen, Breslow thickness could not be reliably assessed; however, the level of invasion corresponded at least to Clark level IV. Mitotic activity was 5 mitoses/mm^2. Sentinel lymph node biopsy revealed no evidence of metastatic involvement.

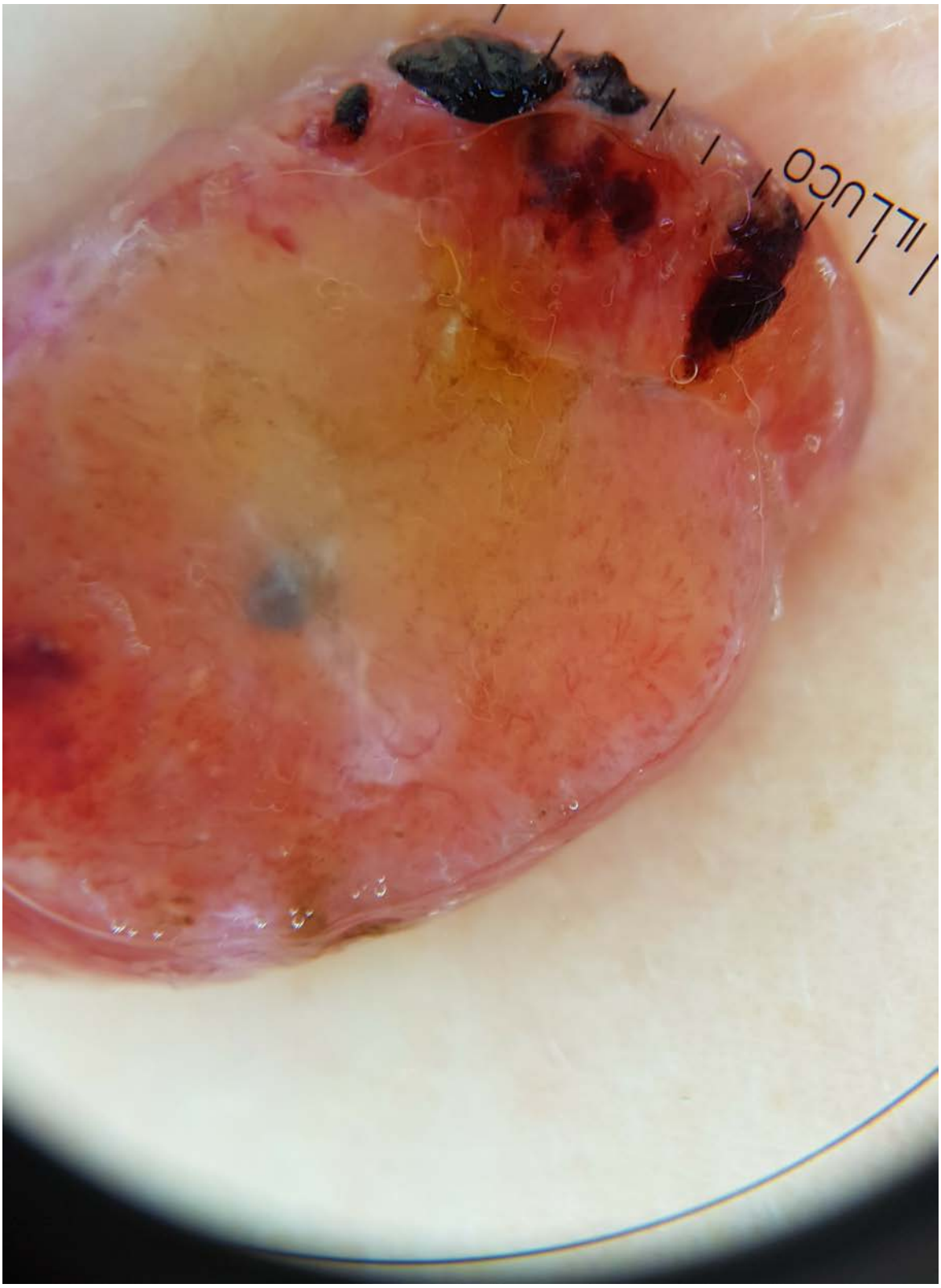

The vascular structures included: • irregular linear vessels • dotted vessels Additional features included: • hemorrhagic areas • superficial crusts • focal residual pigmentation

Conclusion

Rapid development of nodular lesions in postoperative scars should always raise suspicion for melanoma. This case highlights the potential diagnostic pitfalls associated with destructive treatment of melanocytic lesions and emphasizes the importance of dermoscopy and histopathological examination for accurate diagnosis.

EA DV CONGRESS
VIENNA
30 SEP - 3 OCT 2026

Abstract N°: 129

Reasoning Under Uncertainty: A Pediatric Congenital Nevus with New Nodularity

Lidija Petrovska*[1]

[1] Faculty of Medical Sciences, Goce Delcev University, Stip, North Macedonia, Department of Dermatovenerology, Clinical Hospital Stip, North Macedonia, Stip, North Macedonia

Introduction

Congenital melanocytic nevi (CMN) occasionally develop new features that can mimic malignant transformation. Differentiating proliferative nodules from melanoma in children remains diagnostically challenging.We present a pediatric case of a congenital nevus with a recently appeared blue-gray nodular area. The lesion had been stable since birth but showed asymmetric growth and new pigmentation within several months. Dermoscopy revealed an irregular structureless focus, leading to excision with a 1 cm margin. Histopathology confirmed a dysplastic congenital nevus without melanoma.This case illustrates reflective diagnostic reasoning in pediatric dermatology, emphasizing the importance of decisive clinical judgment when faced with ambiguous changes in long-standing congenital lesions. histologically with architectural disorder, supporting excision as a precautionary step. Across the literature, the common conclusion is that when a congenital nevus exhibits asymmetric nodularity, structureless pigmentation, or recent evolution, excision is justified even if the final histology is benign. The present case contributes to this body of evidence by reinforcing that clinical intuition supported by dermoscopic asymmetry remains a reliable safeguard in pediatric dermatology.

Case Presentation

A 9-year-old girl was evaluated for a congenital melanocytic nevus on the back. The lesion, present since birth, was reported by her parents to have developed a small nodular blue-gray area over the preceding few months. A brown plaque with a recently elevated, firm nodule, approximately 5 mm in diameter. Asymmetric structureless blue-gray pigmentation with irregular peripheral dots. Given the lesion’s evolution and dermoscopic asymmetry, melanoma could not be excluded. The decision was made to excise the entire lesion with a 1 cm safety margin. The postoperative course was uneventful; the child remains recurrence-free at 6 months. The overall dermoscopic impression was of a new, structureless, asymmetrically pigmented nodule within a congenital nevus, a finding that warranted complete excision to exclude melanoma arising in association with a congenital nevus. Histopathologic examination of the excised specimen revealed a compound congenital melanocytic nevus with areas of architectural disorder and focal cytologic atypia. The findings were consistent with a dysplastic congenital melanocytic nevus with recent reactive changes.

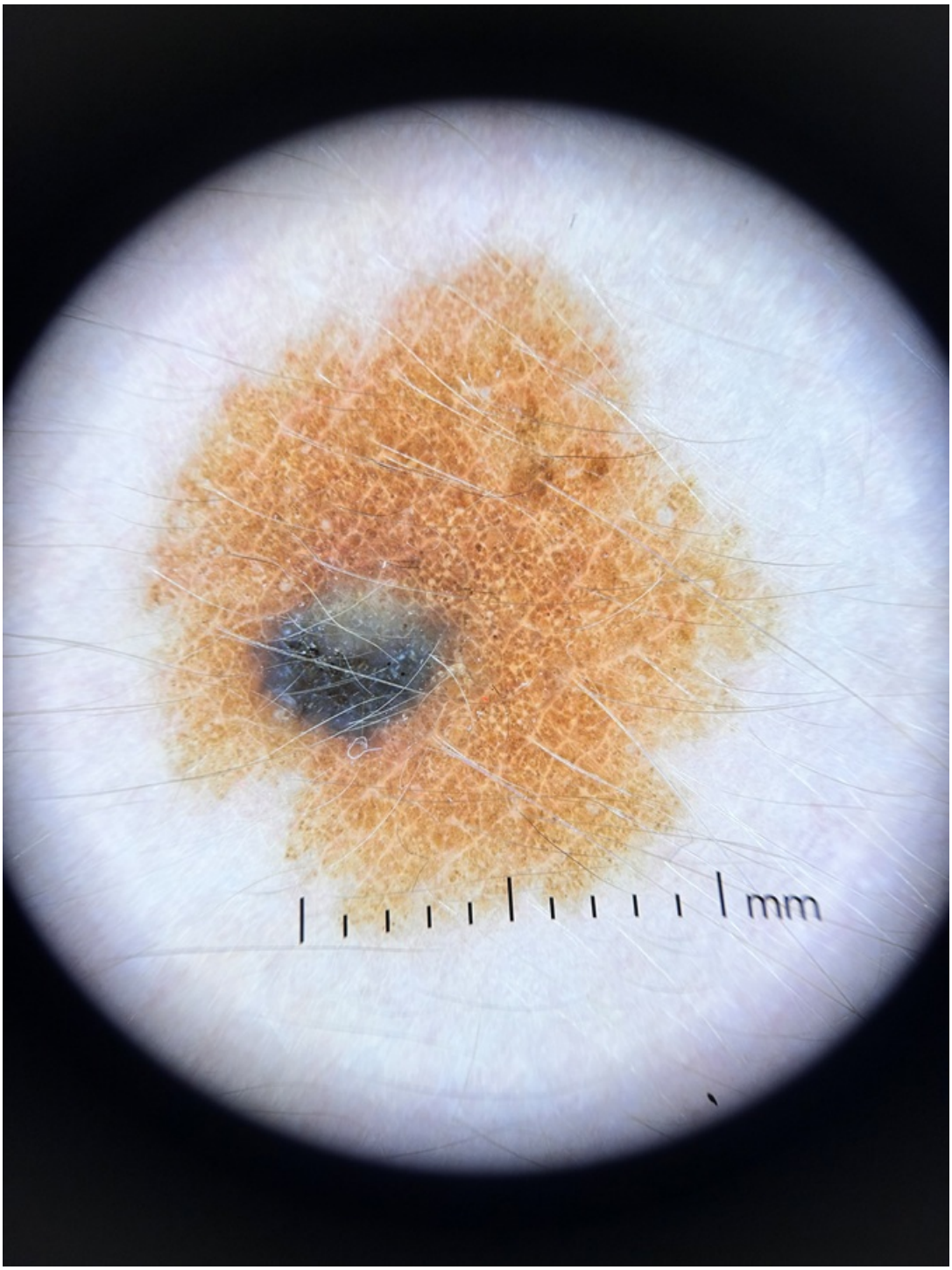

Figure 1. Dermoscopic image demonstrating a preserved reticular network with a new blue- gray structureless focus.

Conclusion

Congenital melanocytic nevi (CMN) may develop secondary changes over time, including color variation, surface elevation, or nodularity. While many of these alterations are benign, the appearance of a new, asymmetric, and structureless nodule within a long-standing lesion always raises concern for malignant transformation. Differentiating between proliferative nodules and melanoma in childhood remains one of the most demanding tasks in dermatologic practice, as both entities can exhibit overlapping clinical and dermoscopic features. In the present case, the newly appeared blue-gray, structureless nodule within an otherwise stable congenital nevus was considered an alarming sign. The decision to excise was therefore guided by principles of diagnostic safety, recognizing that pediatric melanoma, although rare, can arise in congenital nevi, and that delayed intervention may have severe consequences. Histopathology confirmed a dysplastic congenital nevus without melanoma, validating the excisional approach as precautionary rather than excessive. This case underscores the importance of reflective reasoning under uncertainty. In pediatric dermatology, decision-making often relies not on absolute

diagnostic certainty but on a synthesis of morphologic assessment, evolution history, and clinical intuition. The act of choosing excision, in this context, represents not an overreaction but an ethically grounded response to a potentially dangerous ambiguity.

EA DV CONGRESS
VIENNA
30 SEP - 3 OCT 2026

Abstract N°: 168

Primary Cutaneous Epithelioid Angiosarcoma Presenting as Periungual Nodules in the Lower Extremity: Dermoscopic Clues in an Unusual Case

Beyza Çolpan*[1], Tubanur Cetinarslan[1], Hakan Koray Tosyalı[2], Figen Yelmen Tosun[3], Ferhat Ekinci[4], Peyker Temiz[5], Aylin Türel Ermertcan[1]

[1] Manisa Celal Bayar University, Faculty of Medicine, Department of Dermatology and Venereology, Manisa, Türkiye
[2] Manisa Celal Bayar University, Faculty of Medicine, Department of Orthopedics and Traumatology, Manisa, Türkiye
[3] Manisa City Hospital, Department of Dermatology and Venereology, Manisa, Türkiye
[4] Manisa Celal Bayar University, Faculty of Medicine, Department of Internal Medicine, Division of Medical Oncology, Manisa, Türkiye
[5] Manisa Celal Bayar University, Faculty of Medicine, Department of Pathology, Manisa, Türkiye

Introduction

Primary cutaneous epithelioid angiosarcoma (EAS) is an exceptionally rare and aggressive malignant vascular neoplasm. In the literature, a limited number of primary cutaneous cases have been described, predominantly reported in the extremities, and distinct from classic cutaneous angiosarcoma of the head and neck region in older individuals. Dermoscopic characterization of this variant remains limited to case reports. We report a young female patient with primary cutaneous EAS, initially presenting as periungual verrucous nodules in the lower extremity, with distinctive dermoscopic features.

Case Presentation

A 32-year-old female with no history of chronic disease, immunosuppression, or prior malignancy presented with a one-year history of progressive nodules on the right foot, initially verrucous and subsequently hemorrhagic in nature.The lesions had initially manifested as verrucous periungual nodules on the fifth toe, for which electrocoagulation had been performed at another dermatology outpatient clinic. Subsequently, painful hemorrhagic nodules developed on the plantar area and disease extension to the proximal medial right thigh was also noted. Physical examination revealed erythematous-violaceous exophytic nodules with hemorrhagic crusts in the periungual and plantar regions, along with right inguinal lymphadenopathy. Dermoscopic evaluation demonstrated polymorphic vascular structures on a pinkish background, hemorrhagic areas, shiny white structureless zones, and violaceous hemorrhagic crusts at the periphery. Initial biopsy performed at another dermatology center yielded nonspecific findings; therefore, a new punch biopsy was performed, and histopathological examination was consistent with a malignant neoplasm of predominantly epithelioid morphology diffusely infiltrating the dermis. Immunohistochemical analysis confirmed endothelial differentiation via ERG positivity and CD31 expression. Expression of pan-cytokeratin (AE1/AE3), CK7, and CK19 was also detected. A core needle biopsy of the thigh lesion demonstrated ERG and CD31 positivity. The overall findings were consistent with a diagnosis of primary cutaneous epithelioid angiosarcoma. Imaging studies (ultrasonography, MRI, and PET/CT) revealed a subcutaneous soft tissue mass with surrounding satellite nodules in the proximal medial right thigh, multiple lytic bone lesions in the right femur and foot, right inguinal lymphadenopathy, and bilateral pulmonary nodules consistent with metastatic disease.Systemic treatment was initiated by the medical oncology department, with paclitaxel as first-line therapy; however, due to disease progression, treatment was changed to pazopanib.

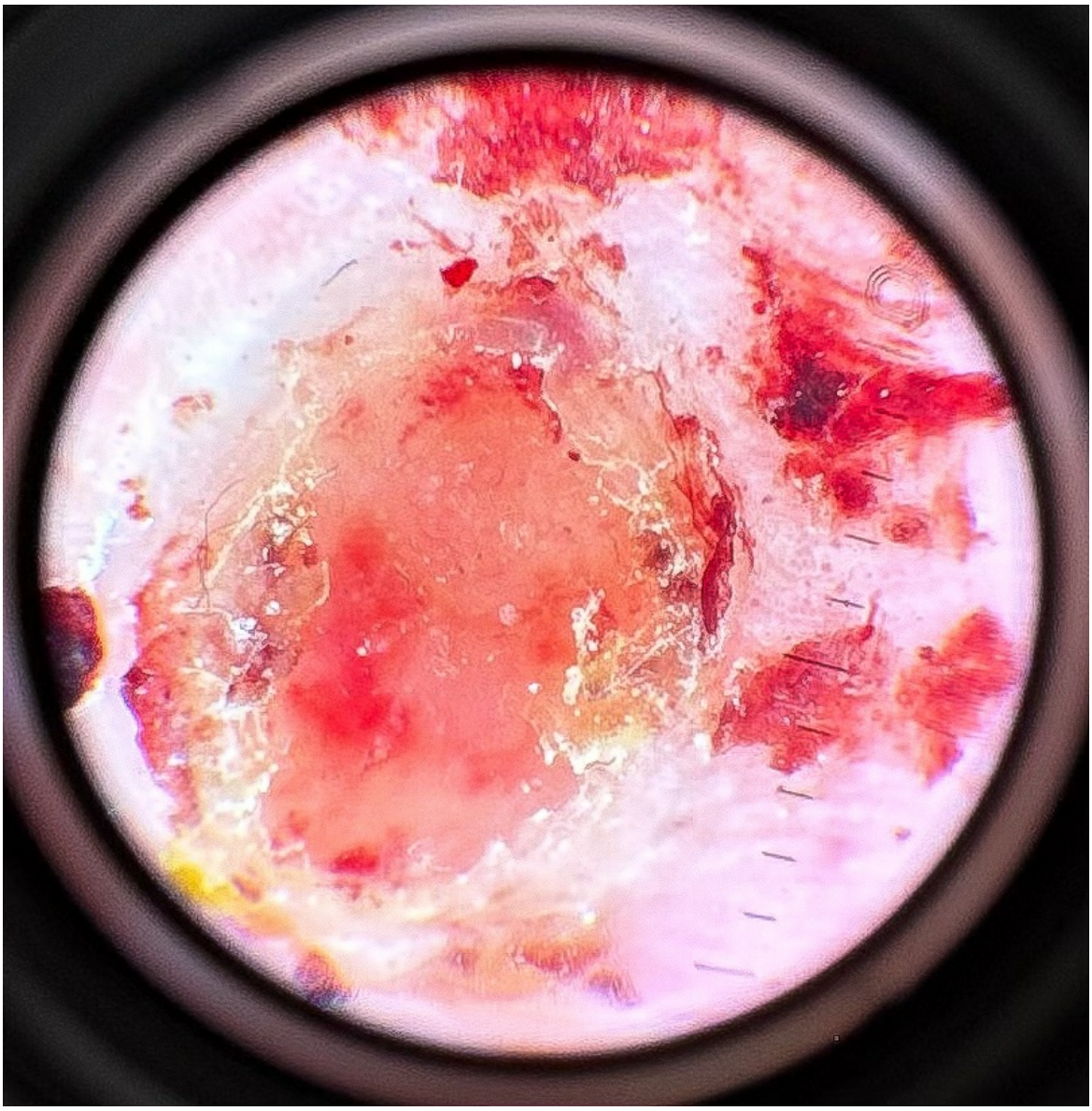

Fig. 1. Dermoscopy revealing polymorphic vascular structures on a pinkish background, hemorrhagic areas, shiny white structureless zones, and violaceous hemorrhagic crusts at the periphery.

Conclusion

This case is notable for several features: a young patient age, atypical lower extremity location with periungual onset, and an initially benign-appearing verrucous morphology. In our case, all these atypical findings resulted in a delayed diagnostic process prior to definitive diagnosis. Moreover, the cytokeratin co-expression underscores the risk of misclassifying EAS as carcinoma on histopathology, reinforcing the necessity of a comprehensive endothelial immunohistochemical panel anchored by ERG in epithelioid tumors of uncertain lineage. Dermoscopic detection of polymorphic vascular structures and hemorrhagic areas in progressively growing, bleeding cutaneous nodules may serve as a critical indicator of malignancy, prompting timely biopsy. This case adds to the limited body of dermoscopic data on primary cutaneous EAS in the literature and highlights that this diagnosis should also be considered in young patients with atypically located, benign-looking vascular or verrucous lesions resistant to therapies.

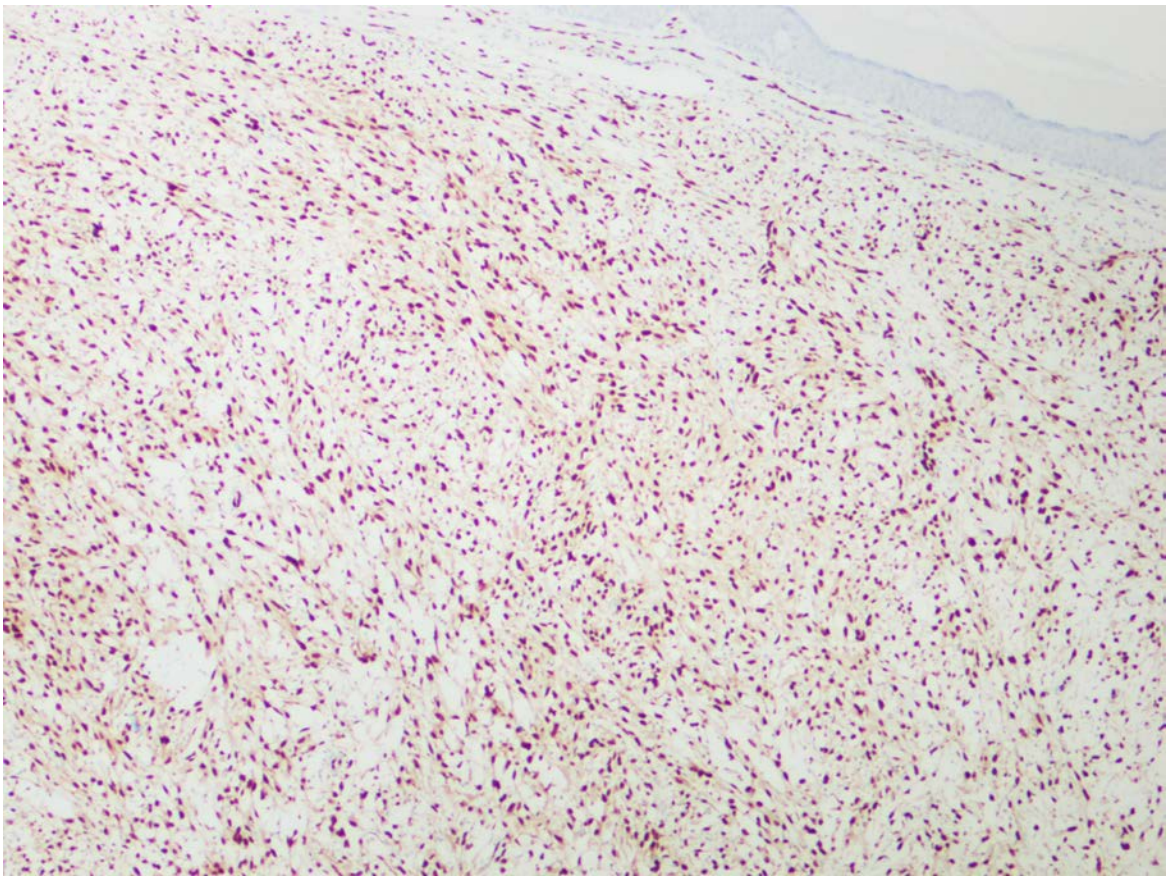

Fig. 2. Diffuse nuclear ERG immunostaining confirming endothelial differentiation (×40).

EA DV CONGRESS
VIENNA
30 SEP - 3 OCT 2026

Abstract N°: 201

Dermoscopic clues for the early diagnosis of mpox: a case series

Yanhong Shou*[1]

[1] Zhejiang university, Zhejiang Sheng, China

Introduction

Mpox is a zoonotic viral infection caused by the mpox virus belonging to the Orthopoxvirus genus. The disease is characterized by systemic symptoms followed by polymorphic cutaneous lesions, including papules, vesicles, pustules and crusts [1]. However, in the early stage, lesions may present as nonspecific papules or erosions, making clinical diagnosis challenging before the development of characteristic pustules. Recent outbreaks have highlighted mpox as an emerging global public health concern with increasing numbers of cases reported worldwide[2]. Although polymerase chain reaction (PCR) remains the gold standard for diagnosis, these laboratory-based tests require specialized facilities and are not always immediately available in routine clinical settings[3, 4]. Therefore, rapid recognition of suspicious lesions at the point of care is essential for early diagnosis and infection control[5].

Case Presentation

Dermoscopy is increasingly used in the evaluation of infectious and inflammatory dermatoses and may reveal characteristic morphological patterns that assist bedside diagnosis. Nevertheless, dermoscopic features of mpox lesions remain insufficiently described. Here, we report dermoscopic findings in six patients with PCR-confirmed mpox. Six patients with clinically suspected mpox were evaluated in our dermatology department, and all cases were confirmed by PCR testing for mpox virus(Figure1 A). Dermoscopic examination (×50 magnification) was performed using a handheld dermoscope on representative lesions. Across all cases, dermoscopy revealed relatively consistent features. Most lesions demonstrated a central round yellowish scale or brown crust, occasionally presenting as a central erythematous or brown structureless area. Surrounding the central component, a whitish annular halo was frequently observed, while lesion borders were generally well defined. Vascular structures were absent or inconspicuous in most lesions(Figure1 B). Several dermatoses may clinically resemble early mpox lesions. Molluscum contagiosum typically demonstrates central white or yellowish lobulated structures with peripheral crown vessels. Condyloma acuminatum often presents papillomatous or finger-like projections with regularly distributed dotted or linear vessels. Genital herpes usually shows clustered vesicles with a grayish multilocular appearance that may rupture and form erosions or crusts. In contrast, mpox lesions in our series were characterized by a central crust or structureless area surrounded by a whitish halo with minimal vascular structures. Recent reviews have highlighted the reliance of mpox diagnosis on nucleic acid detection technologies such as PCR[3, 4]. Although these approaches provide high diagnostic accuracy, they may not always be readily accessible in all clinical settings. Dermoscopy, as a rapid and non-invasive tool, may therefore provide useful visual clues for early recognition of suspicious lesions during routine dermatological examination. Based on our observations, we propose the term “central crust–white halo pattern” to describe this dermoscopic appearance(Figure2) . The central crust or structureless area may correspond to epidermal necrosis and viral-induced keratinocyte damage, whereas the surrounding whitish halo may reflect localized inflammatory edema or keratinocyte degeneration.

Conclusion

In conclusion, early mpox lesions may demonstrate a characteristic dermoscopic pattern consisting of a central crust or structureless zone surrounded by a whitish annular halo with minimal vascular structures. Recognition of

this pattern may assist clinicians in the early bedside identification and differential diagnosis of mpox, particularly in patients presenting with atypical genital or perianal lesions.

EADV CONGRESS
VIENNA
30 SEP - 3 OCT 2026

Abstract N°: 262

Diagnostic performance of dermoscopy in American tegumentary leishmaniasis: a prospective study of 101 lesions

Renata Trindade Gonçalves*[1], Camille da Silva[1], Marina Galvão[1], Fernando de Oliveira[1], Daniel Barroso[1], Raimunda Sampaio[1]

[1] University of Brasilia, Brasília, Brazil

Introduction
American tegumentary leishmaniasis (ATL) is a neglected tropical disease characterized by heterogeneous clinical manifestations and frequent diagnostic delays. Although dermoscopy enables visualization of subsurface vascular and structural patterns, prospective studies evaluating its diagnostic accuracy in ATL remain scarce.

Materials and Methods
This prospective diagnostic accuracy study included consecutive patients presenting with skin lesions clinically suspected for ATL between June 2023 and August 2025. Standardized macroscopic and dermoscopic images were obtained prior to treatment initiation. Final diagnosis was established using predefined composite clinical and laboratory criteria, including compatible clinical findings plus either two positive non-parasitological tests (e.g., indirect immunofluorescence or Montenegro skin test) or one positive parasitological test (polymerase chain reaction, culture, histopathology, or smear demonstrating amastigotes). Dermoscopic images were independently evaluated by a board-certified dermatologist blinded to clinical and laboratory data. Sensitivity, specificity, and overall diagnostic accuracy were calculated.

Results
A total of 69 patients with 101 lesions met the inclusion criteria. The cohort was predominantly male (62.7%), with a median age of 46 years. Lesions were mainly located on the lower limbs (63.4%). Forty-eight lesions were confirmed as ATL and 53 as alternative diagnoses. Dermoscopy suggested ATL in 46 lesions. A significant association was observed between dermoscopic assessment and confirmed diagnosis ($\chi^2 = 9.34$; $p = 0.0022$). Sensitivity was 62.5%, specificity 69.8%, and overall diagnostic accuracy 66.3%. Dermoscopic diagnosis was associated with a more than twofold increase in the probability of confirmed ATL (prevalence ratio 2.07; 95% CI: 1.30–3.29).

Conclusions
Dermoscopy demonstrated moderate diagnostic accuracy for ATL and showed a significant association with confirmed disease. As a rapid and non-invasive technique, it may represent a useful adjunct in structured diagnostic algorithms and facilitate earlier recognition of ATL, particularly in endemic regions where access to parasitological confirmation may be limited.

EADV CONGRESS
VIENNA
30 SEP - 3 OCT 2026

Abstract N°: 333

Detection of Demodex in Rosacea: Standardized Skin Surface Biopsy versus Ultraviolet Dermoscopy

Esranur Ünal*[1], Muhammed Burak Yücel[2], Meryem Yiğit[2], Ozan Yaman[3], Ragıp Ertaş[2], Bengü Nisa Akay[4]

[1] Ufuk University, Faculty of Medicine, Department of Dermatology, Ankara, Türkiye

[2] University of Health Sciences, Kayseri City Education and Research Hospital, Kayseri, Türkiye

[3] Department of Parazitology, University of Health Sciences, Kayseri City Education and Research Hospital, Kayseri, Turkey, Kayseri, Türkiye

[4] Ankara University, Faculty of Medicine, Department of Dermatology, Ankara, Türkiye

Introduction

Demodex mites are believed to contribute to the pathogenesis of both rosacea and demodicosis. While standardized skin surface biopsy (SSSB) remains the gold standard for detecting Demodex density, it is invasive and time-consuming. Ultraviolet (UV) dermoscopy, a non-invasive technique that visualizes fluorescent structures, may offer a rapid alternative for identifying Demodex proliferation. To investigate the relationship between Demodex folliculorum (D. folliculorum) and Demodex brevis (D.brevis) counts obtained by SSSB and fluorescent dots detected under UV dermoscopy, and to evaluate the diagnostic value of these findings in rosacea and demodicosis.

Materials and Methods

Fifty-four patients with rosacea or demodicosis were evaluated using both UV dermoscopy and SSSB from the same facial region. Orange and bright blue fluorescent dots were recorded dermoscopically, and mite density and species were quantified via SSSB. Correlation analyses and ROC curve analysis were performed to assess diagnostic performance.

Results

A significant positive correlation was found between total Demodex count and bright blue fluorescent dots ($r = 0.343$, $p = 0.013$), but not with orange dots ($r = -0.065$, $p = 0.649$). Only D. folliculorum showed significant correlation with blue and total fluorescent dots. ROC analysis identified >11 bright blue dots as the optimal threshold for predicting Demodex positivity, with a sensitivity of 82.1% and specificity of 71.4% (AUC = 0.793, $p = 0.003$).

Conclusions

Bright blue fluorescent dots observed under UV dermoscopy significantly correlate with Demodex density, particularly D. folliculorum. A threshold of >11 blue dots demonstrated good diagnostic accuracy and may serve as a practical, non-invasive alternative or adjunct to SSSB in clinical settings. Orange fluorescence was not associated with Demodex density and likely reflects unrelated sebaceous or microbial activity.

EADV CONGRESS
VIENNA
30 SEP - 3 OCT 2026

Abstract N°: 359

Nailfold Dermoscopy as a practical alternative to Capillaroscopy in Autoimmune Connective Tissue Diseases.

Ina Sotiri*[1], Alesja Palaj[1], Oljeda Kaçani[1], Lejdis Zeneli[1], Monika Fida[1]

[1] University Hospital Center "Mother Teresa", Tirana, Albania

Introduction
Nail and periungual changes are increasingly recognized as visible manifestations of microangiopathy in autoimmune connective tissue diseases (ACTDs). The pattern, distribution, and combination of nail and periungual changes may contribute to the clinical assessment and differentiation of autoimmune connective tissue diseases. Nailfold capillaroscopy is the gold standard for microvascular assessment; however, its limited availability has led to growing interest in handheld dermoscopy as a practical alternative for evaluating nailfold capillary abnormalities. The aim of this study is to evaluate nail and periungual changes in ACTDs and to determine whether dermoscopic nailfold findings can reliably reflect capillaroscopic patterns of microangiopathy.

Materials and Methods
A prospective observational study including 70 patients with systemic sclerosis, systemic lupus erythematosus, dermatomyositis, rheumatoid arthritis, and mixed connective tissue disease was conducted. All patients underwent detailed nail and periungual examination, followed by dermoscopic evaluation of nailfold capillaries using a handheld dermatoscope. Associations between clinical findings and capillaroscopic patterns were analyzed statistically.

Results
Periungual changes demonstrated significant disease-specific associations, including periungual telangiectasias ($p = 0.042$) and cuticular atrophy ($p < 0.001$), predominantly in systemic sclerosis, while cuticular hypertrophy ($p = 0.015$) and periungual hyperkeratosis ($p = 0.003$) were more frequent in dermatomyositis and rheumatoid arthritis. Nail plate abnormalities also differed significantly across diagnoses, particularly splinter hemorrhages, subungual hyperkeratosis, and leukonychia (all $p < 0.05$).
The most clinically relevant differences were observed in capillaroscopic findings. Reduced capillary density, giant capillaries, capillary loss, and avascular areas (all $p < 0.001$) were strongly associated with diagnosis, predominantly in systemic sclerosis and dermatomyositis. Capillary hemorrhages ($p = 0.035$), architectural disorganization ($p = 0.004$), and bushy capillaries ($p = 0.002$) further contributed to disease differentiation. Capillaroscopic patterns reinforced these findings, with scleroderma patterns predominantly observed in systemic sclerosis and dermatomyositis, while non-specific and normal patterns were more frequent in rheumatoid arthritis and systemic lupus erythematosus. Overall, capillaroscopic abnormalities demonstrated the highest discriminatory value among all evaluated parameters.

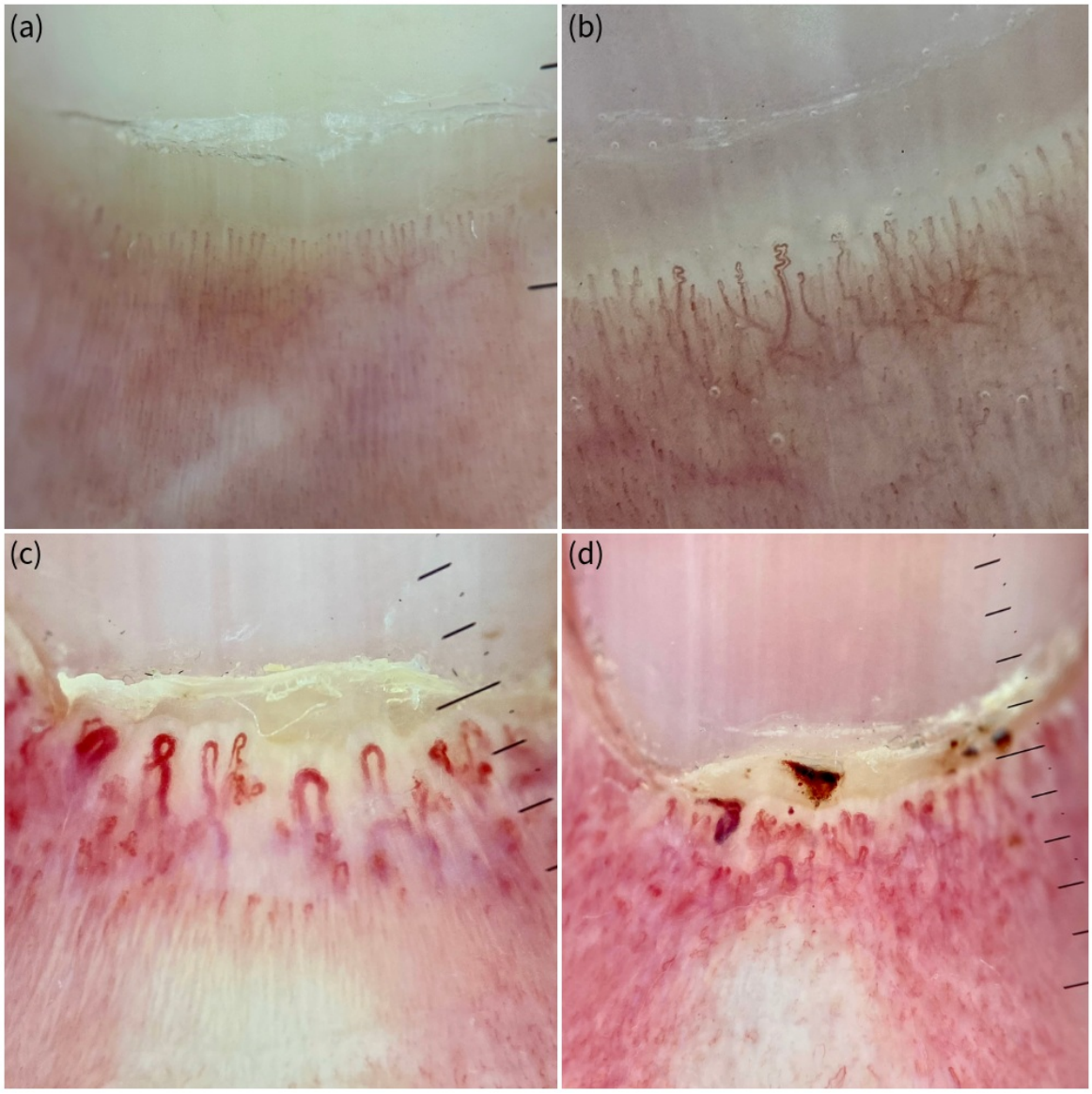

Representative dermoscopic nailfold findings corresponding to capillaroscopic patterns of microangiopathy in autoimmune connective tissue diseases. (a) Normal pattern with regular hairpin-shaped capillaries. (b) Non-specific pattern showing dilated and tortuous capillaries. (c) Scleroderma pattern with giant capillaries. (d) Advanced microangiopathy with microhemorrhages, avascular areas, and architectural disorganization.

Conclusions

Nail and periungual changes reflect underlying microvascular damage in autoimmune connective tissue diseases, although their specificity is limited. In contrast, dermoscopic nailfold evaluation reveals characteristic and statistically significant microangiopathic patterns, particularly in systemic sclerosis and dermatomyositis. Handheld dermoscopy represents a reliable, non-invasive, and accessible tool that can approximate capillaroscopy and enhance early detection and differentiation of microvascular involvement in clinical practice.

EA DV CONGRESS
VIENNA
30 SEP - 3 OCT 2026

Abstract N°: 440

Role of Dermoscopy in Nail Psoriasis: Assessing Correlation with NAPSI and Psoriatic Arthritis

Amina Asfiya M Iqbal*[1], Akbar Ali Shanavaz[2], Manjunath Mala Shenoy[1]

[1] Yenepoya Medical College, Mangaluru Taluka, India
[2] Karlovy Aesthetics, Thrissur, India

Introduction
It is estimated that nail changes are seen in 50% of cases of psoriasis and may be considered a reason for significant morbidity due to the pain and aesthetic appearance. In addition to this, nail psoriasis is seen in 87% of patients with psoriatic arthritis. Dermoscopy is a useful and feasible diagnostic technique which helps in in vivo evaluation of pigmentary skin lesions. Recently, dermoscopy has been considered a useful modality for the clinical assessment of nail disease. The aim of the present study was to evaluate the dermatoscopic findings in nail psoriasis

Materials and Methods
It was a hospital-based cross sectional descriptive study designed with the aim of evaluating the dermoscopic findings in nail psoriasis. A total of 110 clinically diagnosed psoriatic fingernails were included in the study. The Nail Psoriasis Severity Index (NAPSI) scores were recorded in all patients. Dermoscopic evaluation was conducted and the features were recorded. Comparison of features was done with mild, moderate and high NAPSI groups and arthritic and non-arthritic patients. Statistical analysis included percentages, frequency, chi square test and Fischer's exact test.

Results
The most common dermoscopic findings included subungual hyperkeratosis (90.9%), onycholysis (64.5%) and pitting (62.7%). Pitting, nail plate thickening, transverse grooves, trachyonychia, and onycholysis were associated with higher NAPSI scores ($p<0.05$). Nails of arthritis patients had significantly higher NAPSI scores ($p=0.004$). Corresponding dermoscopic evaluation revealed subungual hyperkeratosis, transverse grooves, pitting, onycholysis and trachyonychia to be more frequent in higher NAPSI groups and transverse grooves, nail plate thickening and trachyonychia in arthritic patients.

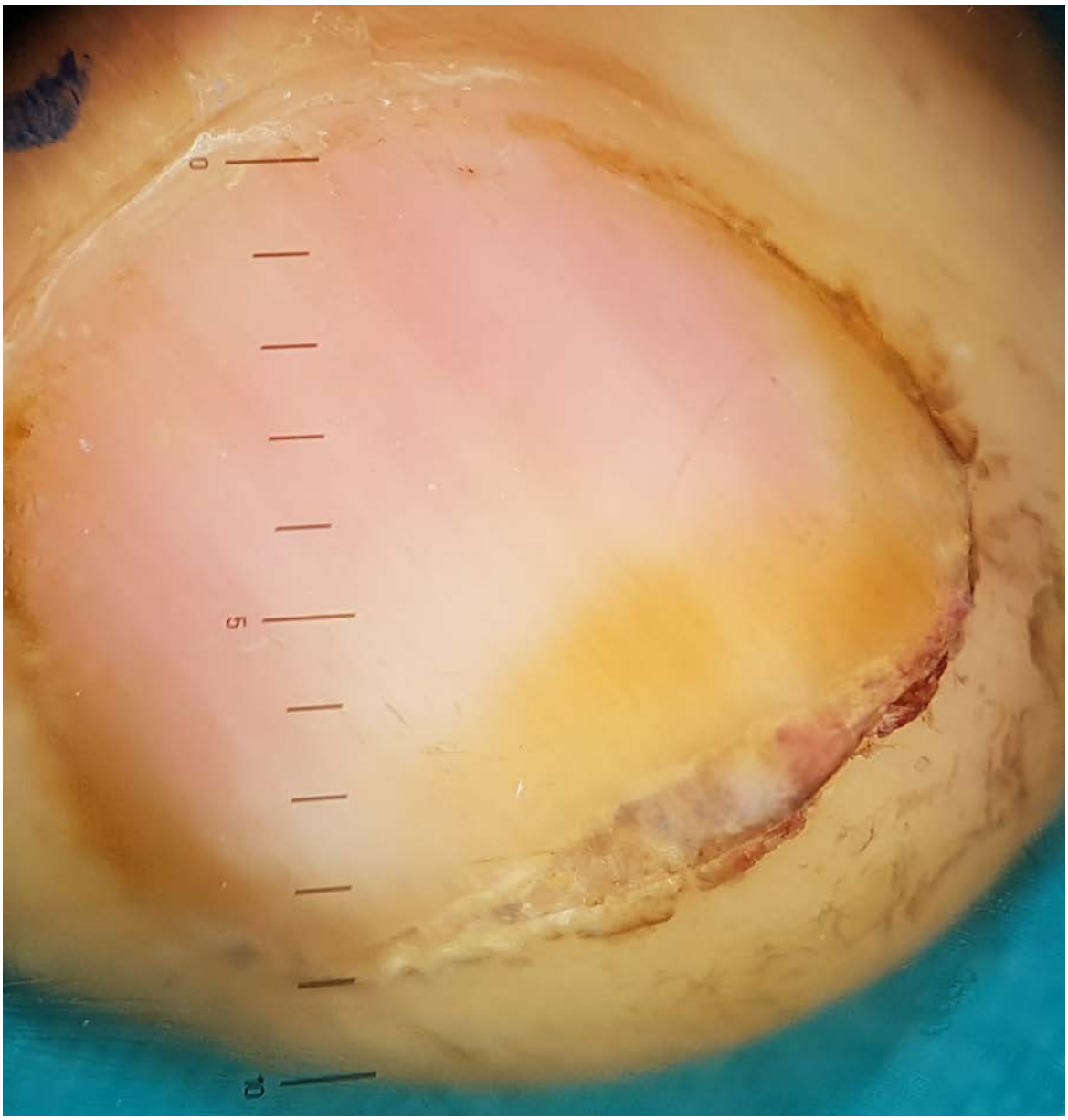

Image showing salmon patch on psoriatic nail

Conclusions

Dermoscopy coupled with NAPSI scoring in nail psoriasis can serve as a useful guide to assess nail, cutaneous and arthritic psoriasis.

EA DV CONGRESS
VIENNA
30 SEP - 3 OCT 2026

Abstract N°: 452

Dermoscopy of microcystic adnexal carcinoma: a case series

Orsolya Hengan*[1]

[1] Emergency Clinical County Hospital Targu Mures, Targu Mures, Romania

Introduction
Microcystic adnexal carcinoma (MAC) is an uncommon, locally aggressive sweat gland tumor that often poses a diagnostic challenge due to its non-specific, scar-like clinical presentation that may mimic basal cell carcinoma (BCC) or other benign adnexal lesions. Early detection and appropriate treatment are crucial in reducing locoregional spread and recurrence rates. Dermoscopy, therefore, plays a key role in revealing specific features that prompt timely biopsy and histopathological diagnosis. This case series aims to provide a comprehensive characterization of MAC from clinical, dermoscopic and histopathological perspectives to enhance diagnostic accuracy and improve differential diagnosis.

Case Presentation
Four histopathologically confirmed cases of MAC were included in this series. Patients ranged in age from 53 to 77 years (median age was 67.8 years) with an equal distribution of males and females. All of the lesions were localized on the facial region and presented as a whitish or skin-colored indurated plaque. Dermoscopy revealed polymorphous vessels in all cases mainly consisting of unfocused arborizing, short irregular and glomerular vessels. Distinct white structures were present: white clods (4/4), shiny white strands and blotches (2/4), white stuctureless area (2/4). Histopathological findings showed the presence of small, monomorphic, basaloid cells arranged in nests and cords, infiltrating the deep dermis or subcutaneous layer. Keratin-filled cysts containing lamellar keratin were observed in all lesions. Detailed description of clinical, dermoscopic and histopathologic features is summarized in Table 1.

	Case 1	Case 2	Case 3	Case 4
Age	53	72	77	69
Sex	Female	Male	Female	Male
Tumor location	Nasal	Upper lip	Cheek	Nasal
Lesion size	0.7x1 cm	1.2x2 cm	4x4 cm	3x3.5 cm
Other skin malignancies	No	BCC	No	Multiple BCCs
Clinical description	White indurated plaque with ill border	Skin-colored, scar-like plaque with central depression	Whitish-pink indurated plaque, pearly rolled borders, ulceration, white scales	Whitish-pink scar-like plaque with central ulceration, white scales
Dermoscopy	- White clods - Unfocused arborizing, short linear irregular and glomerular vessels	- White clod - Unfocused arborizing, short linear irregular and glomerular vessels - Central white structureless area	-White clods - Shiny white lines, strands and blotches - White stuctureless area - Arborizing vessels - Ulceration - Brown dots and blue-grey ovoid nest - White scales	- White clods - Shiny white lines, strands and blotches - Milky-red areas - Unfocused arborizing, short linear irregular, hairpin and glomerular vessels - Ulceration - White scales
Histopathology	- Nests and cords of small, monomorphic, basaloid cells infiltrating the deep dermis - Keratin-filled cysts containing lamellar keratin	- Nests and cords of small, monomorphic, basaloid cells infiltrating the subcutaneous tissue - Keratin-filled cysts containing lamellar keratin	- Nests and cords of small, monomorphic, basaloid cells infiltrating the deep dermis - Keratin-filled cysts containing lamellar keratin	- Nests and cords of small, monomorphic, basaloid cells infiltrating the subcutaneous tissue - Keratin-filled cysts containing lamellar keratin

Table 1. Detailed description of clinical, dermoscopic and histopathologic features

Conclusion

Microcystic adnexal carcinoma should be included in the differential diagnosis of non-distinctive, scar-like plaques on the face, especially when polymorphous vessels including arborizing, short linear irregular and glomerular vessels along with white clods or shiny white structures are detected on dermoscopy. Although these findings are not pathognomonic, dermoscopy may provide valuable clues that aid early detection and prompt histopathological confirmation.

EADV CONGRESS
VIENNA
30 SEP - 3 OCT 2026

Abstract N°: 478

Dermoscopic and Clinico-Mycological Study of KOH-Confirmed Tinea Corporis at a Tertiary Care Hospital

Noor-E Jannat*[1], Mohammed Saiful Islam Bhuiyan[2], Abida Sultana[2]

[1] Consultant Dermatologist, Aurora Skin and Aesthetics, Dhaka, Bangladesh

[2] Department of Dermatology and Venereology, Bangladesh Medical University, Dhaka, Bangladesh

Introduction

Tinea corporis is a common superficial fungal infection. Dermoscopy is a noninvasive tool that can enhance clinical diagnosis by revealing characteristic patterns. This study aimed to characterize dermoscopic patterns in KOH-confirmed tinea corporis and evaluate their clinicomycological diagnostic value.

Materials and Methods

A cross-sectional study was conducted at a tertiary care hospital in Bangladesh, including 46 potassium hydroxide (KOH) mount–positive patients with tinea corporis. Dermoscopic evaluation was performed using a third-generation hybrid dermoscope attached to a smartphone for image capture. Skin scrapings were examined by KOH microscopy, and cultures were grown on Sabouraud's dextrose agar. Dermoscopic patterns were recorded, and diagnostic performances (sensitivity, specificity, positive predictive value, and negative predictive value) were calculated. Data were analyzed using the 26th version of statistical software.

Results

The study showed a mean age of 29.7 years, with a female predominance (54.3%). The waist was the most affected site (71.7%), and multiple annular lesions were the most common presentation (78.3%). Dermoscopy revealed several scaling patterns; the "annular arrangement with inward free margin" was a consistent and novel finding across lesion types and sites ($p < 0.05$). "Translucent vellus hair" was associated with longer disease duration ($p = 0.017$), background color changes with comorbidities ($p = 0.038$), and scales along skin creases with fewer lesions ($p = 0.006$). Culture positivity was 84.8%, with diffuse erythema significantly associated with culture-positive cases ($p = 0.033$). Trichophyton mentagrophytes was the predominant isolate (53.8%) and showed a significant association with vascular changes such as "red dots and globules" ($p = 0.041$) and "translucent vellus hairs" ($p = 0.011$). The superficial scales with an "annular arrangement with inward free margin" demonstrated the highest diagnostic reliability (sensitivity 82%, specificity 100%, PPV 100%). For Trichophyton mentagrophytes, sensitivity and specificity were 81% and 80%, respectively, whereas for Trichophyton rubrum, sensitivity was 72% and specificity was 86%.

Conclusions

The "annular arrangement with inward free margin" emerges as a novel, consistent, and highly reliable dermoscopic marker, with potential for species-level differentiation. These findings support the role of dermoscopy in improving diagnostic accuracy and facilitating early, bedside evaluation in routine clinical practice.

EA DV CONGRESS
VIENNA
30 SEP - 3 OCT 2026

Abstract N°: 545

Ink Matters: The ink test significantly improves diagnostic confidence in seborrhoeic keratosis among non-dermatologists.

Husnaa Ali*[1, 2], Tugba Aydin[2], Iona Watts[2], Ryan Amer Syed[3, 4], Amy Prideaux[5], Kalina Bridgewater[6], Kyriaki Stefania Mitsaki[7], Daniel Keith[1, 2]

[1] North Bristol NHS Trust, Bristol, United Kingdom
[2] University of Bristol, Bristol, United Kingdom
[3] King's College London, London, United Kingdom
[4] University College London, London, United Kingdom
[5] Dermoscopea, Bristol, United Kingdom, Bristol, United Kingdom
[6] Cardiff & Vale University Health Board, Cardiff, United Kingdom
[7] Royal United Hospital Bath, Bath, United Kingdom

Introduction
Seborrhoeic keratosis (SK) is a common benign skin lesion but may present diagnostic challenges due to its variable clinical and dermoscopic appearance. Previous studies have reported that SK's are frequently misdiagnosed as malignant lesions, including basal cell carcinoma and squamous cell carcinomas, highlighting the need for improved diagnostic support, particularly for non-dermatologists. The ink test has been described as a simple bedside technique that enhances three-dimensional dermoscopic features such as fissures and comedo-like openings, potentially aiding lesion characterisation. However, its educational impact on diagnostic confidence among non-dermatologists has not been evaluated. This study aimed to assess whether the SK ink test improves diagnostic confidence in non-dermatologists interpreting images of suspected SKs.

Materials and Methods
An image-based, cross-sectional educational study was conducted using an online survey. Medical students and doctors below dermatology registrar level were recruited. Participants reviewed eight cases of suspected seborrhoeic keratoses presented as macroscopic and dermoscopic images. For each case, participants rated the change in diagnostic confidence after viewing images with the ink test applied compared to without ink, using a four-point Likert scale ("not at all", "a little", "a lot", "very much"). Responses were anonymised. Likert responses were coded numerically (0–3) and dichotomised into "no improvement" versus "any improvement".

Results
Thirty-two participants completed the survey. The use of dermoscopic images with ink resulted in a significant and substantial increase in diagnostic confidence (Median increase = 2.0 (95% CI[1.5,3.0]); Wilcoxon V=26335, $p<0.001$). The effect size was very large ($r = 0.84$), indicating that the images provided a robust and consistent improvement in clinician certainty.

Conclusions
The ink test significantly improves diagnostic confidence among non-dermatologists in an image-based educational setting. This low-cost diagnostic aid represents a valuable adjunct to undergraduate and early postgraduate dermatology teaching and may help reduce diagnostic uncertainty when assessing benign skin lesions.

EA DV CONGRESS
VIENNA
30 SEP - 3 OCT 2026

Abstract N°: 590

AI-Based Risk Stratification of Skin Lesions Using Clinical Images: A Pilot Study in Dermatology Practice

Gevorg Mkhitarian*[1]

[1] Dermatology Practice, Saint Petersburg, Russian Federation

Introduction
Evaluation of skin lesions represents a fundamental component of dermatological practice and dermato-oncology. Dermoscopy significantly improves diagnostic accuracy and allows identification of morphological structures associated with benign and malignant skin tumors. However, dermoscopic interpretation requires experience and systematic analytical approaches.Artificial intelligence (AI) technologies may support dermatologists by assisting in structured interpretation of dermoscopic images and integrating multiple diagnostic frameworks used in dermoscopy.The aim of this study was to evaluate the feasibility of an AI-assisted clinical decision-support system for risk stratification and structured dermoscopic interpretation of skin lesions.

Materials and Methods
A digital clinical decision-support system for evaluation of skin lesions was developed as part of a dermatology-oriented application (DERMAI). The physician module of the system allows dermatologists to upload dermoscopic images of skin lesions and perform structured analytical assessment.The analytical framework integrates several established dermoscopic diagnostic algorithms widely used in dermatology practice, including pattern analysis, Chaos and Clues, TADA, the 7-point checklist, BRAAFF, ABCD rule, and Menzies criteria.The system evaluates dermoscopic structures visible in the uploaded images and generates a structured analytical report. The report includes description of dermoscopic features, algorithm-guided interpretation, risk stratification, and suggested clinical management options.Based on integrated analysis of dermoscopic features and algorithm-based interpretation, lesions are stratified into three risk categories:low risk – dermoscopic features consistent with benign lesionsintermediate risk – atypical dermoscopic structures requiring monitoring or further evaluationhigh risk – dermoscopic features suspicious for malignancy requiring prompt clinical management.The system is designed as a clinical decision-support tool intended to assist dermatologists in dermoscopic interpretation and clinical decision-making rather than to replace physician evaluation.

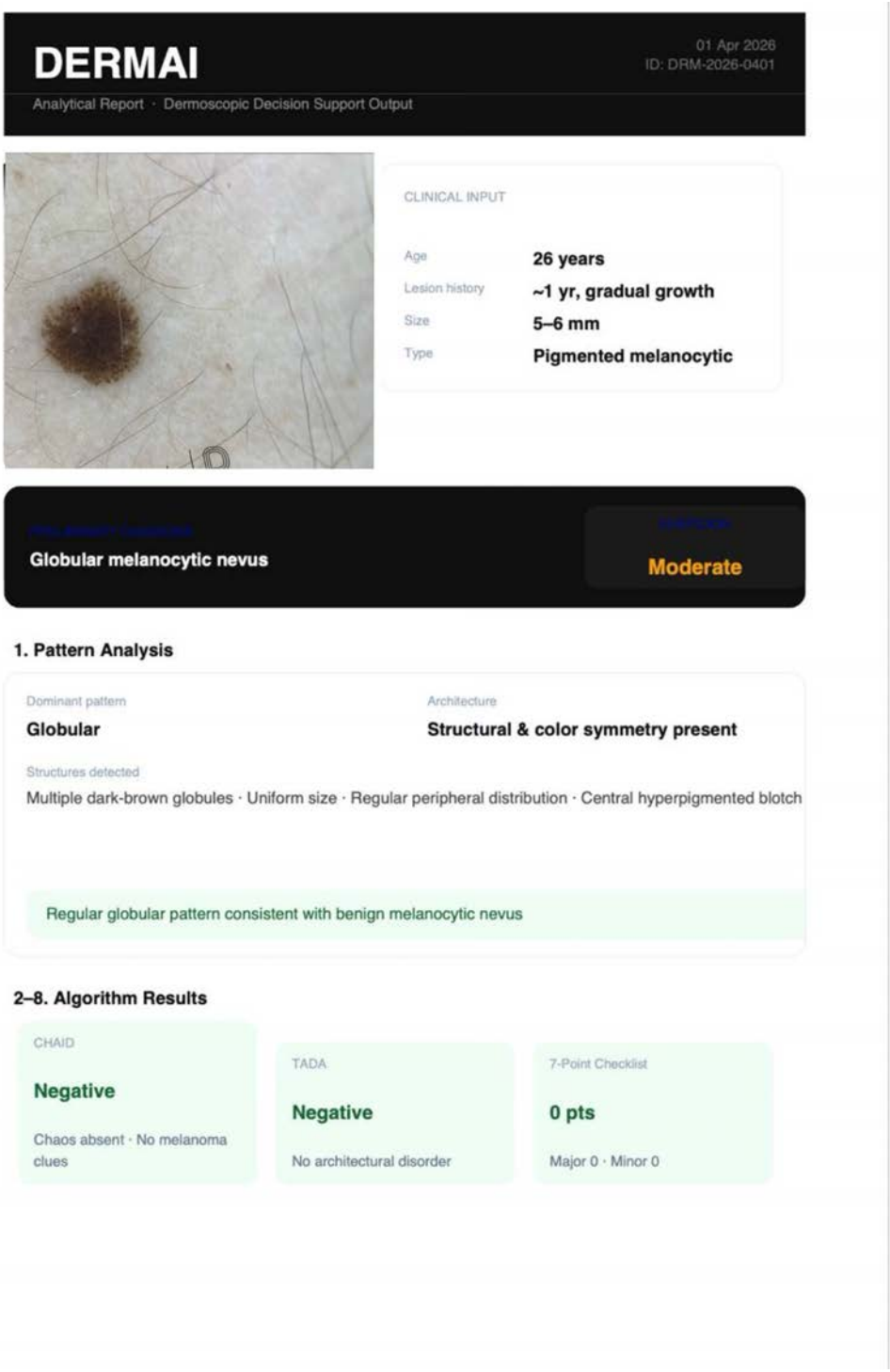

Results

The pilot implementation demonstrated that the AI-assisted analytical system was capable of generating structured dermoscopic assessments and stratifying lesions into clinically meaningful risk categories. The generated reports summarized dermoscopic structures identified in the image and provided algorithm-guided interpretation based on multiple diagnostic frameworks.In addition to risk stratification, the system provided structured clinical guidance by suggesting potential management strategies such as dermoscopic follow-up, clinical monitoring, biopsy, or excision depending on the detected dermoscopic features.The system demonstrated potential utility in supporting dermatologists during evaluation of dermoscopic images and assisting with structured clinical documentation.

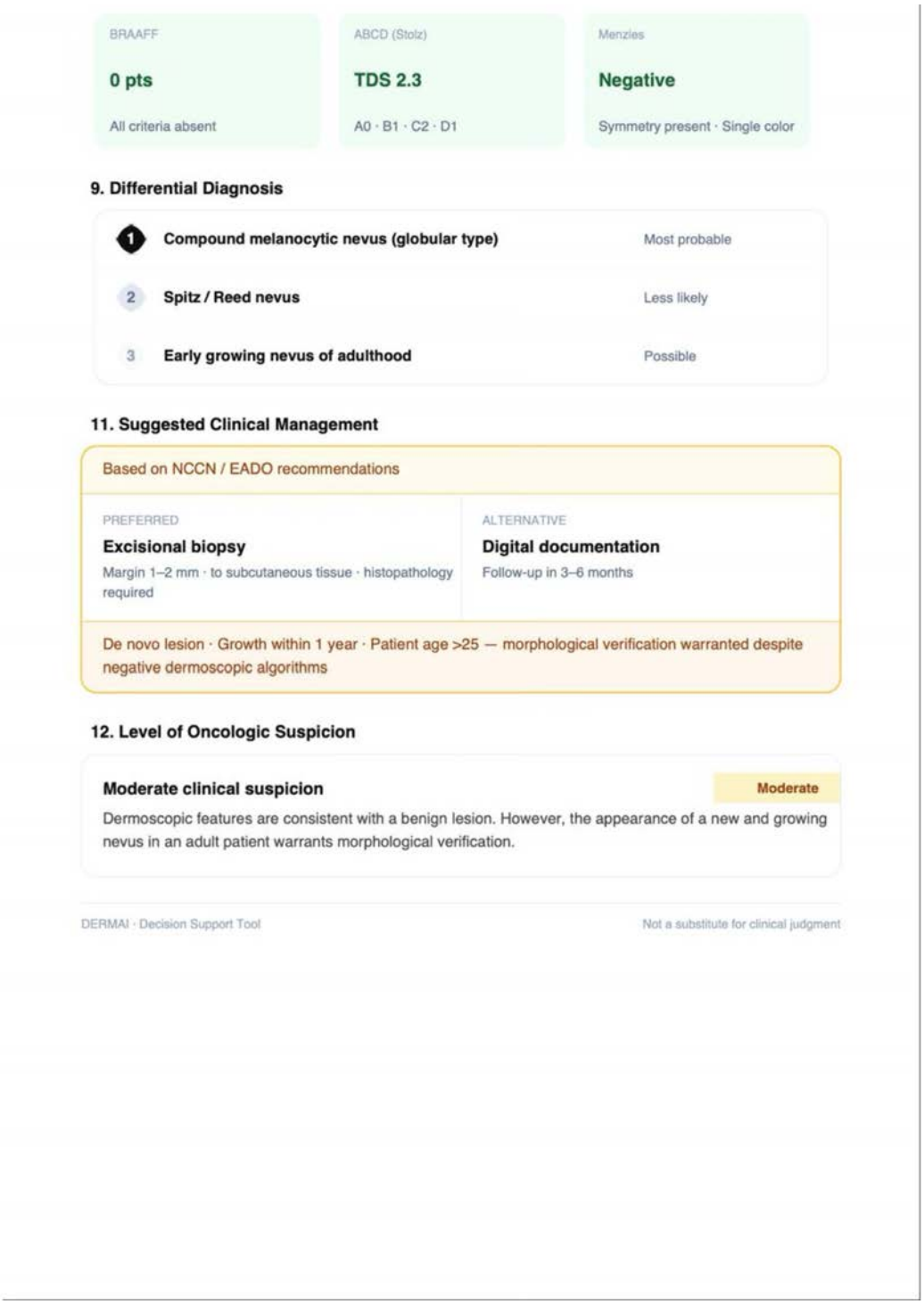

Conclusions

AI-assisted dermoscopic analysis integrating multiple established diagnostic algorithms may represent a promising approach for supporting dermatologists in evaluation of skin lesions. Digital clinical decision-support systems such as DERMAI may facilitate structured interpretation of dermoscopic images, support risk stratification, and assist clinicians in selecting appropriate management strategies.Further prospective studies are required to evaluate diagnostic performance and clinical impact of AI-assisted dermoscopic decision-support systems in dermatology practice.

EADV CONGRESS
VIENNA
30 SEP - 3 OCT 2026

Abstract N°: 638

HIGH PREVALENCE OF YELLOW DOTS IN ANDROGENETIC ALOPECIA AMONG ADULT MALES OF SKIN OF COLOUR: A TRICHOSCOPIC STUDY

Kevwie Becky Obasi*[1], Benson Okwara[1]

[1] University of Benin Teaching Hospital, Benin City, Nigeria

Introduction
Trichoscopy has emerged as a valuable non-invasive diagnostic tool in the evaluation of alopecia. Yellow dots (YDs) are a recognized trichoscopic feature, traditionally reported to be less common in individuals with skin of colour. However, evidence from African populations remains limited. This study aimed to determine the clinical patterns and trichoscopic features of androgenetic alopecia in adult males with skin of colour.

Materials and Methods
This was a descriptive cross-sectional study conducted at the Dermatology and General Practice Clinics of a tertiary hospital in Africa. A total of 118 adult males presenting with alopecia were consecutively recruited. Sociodemographic and clinical data were collected using a structured questionnaire. All participants had detailed clinical scalp examination, followed by trichoscopic assessment using a Firefly dermoscope (DE 370) in both polarized and non-polarized modes. Data were analyzed using IBM SPSS version 27.

Results
Sixty-one adult males with androgenetic alopecia (AGA) were evaluated, with a mean age of 43.9 ± 11.8 years. The predominant clinical pattern was focal hair loss (90.2%), while patchy and diffuse patterns each accounted for 4.9%.Trichoscopy demonstrated hair thinning in all participants (100%). Other common findings included honeycomb pigmentation (90.2%), peripheral brown halo (86.9%), white dots (81.9%), and empty follicles (81.9%). Notably, yellow dots were observed in 68.9% of cases, indicating a relatively high prevalence in this population of men with skin of colour.

Conclusions
This study demonstrates a high prevalence of yellow dots in androgenetic alopecia among adult males with skin of colour, contrasting previous reports of their rarity in this population. Trichoscopy remains a valuable tool in the evaluation of alopecia and may reveal population-specific variations. These findings highlight the need for further studies to refine trichoscopic criteria in diverse ethnic groups.

EADV CONGRESS
VIENNA
30 SEP - 3 OCT 2026

Abstract N°: 657

Evaluation of the contribution of repeat Total-Body Photography for the early diagnosis of melanoma

Amjad Zoabi[1], Itay Shavit[1], Tomer Mimouni[1], Hana Feuerman[2], Ofer Reiter Agar*[2]

[1] Universitat Tel Aviv, Tel Aviv-Yafo, Israel

[2] Rabin Medical Center, Beilinson Campus, Petah Tikva, Israel

Introduction

Early detection of cutaneous melanoma is crucial, as prognosis is strongly determined by Breslow thickness. Total-body photography (TBP) is increasingly used in high-risk populations, yet optimal surveillance strategies remain undefined. In our study, we aimed to evaluate how different follow-up approaches, including those incorporating TBP at varying frequencies, influence the early diagnosis of melanoma, as measured by Breslow thickness.

Materials and Methods

This retrospective cohort study included adult patients diagnosed with primary cutaneous melanoma at Rabin Medical Center between 2020 and 2025. Melanomas were classified into four groups according to the clinical setting at diagnosis: non–high-risk clinics; first visit to a high-risk clinic before TBP; high-risk follow-up with prior TBP only; and high-risk follow-up with both prior and repeat TBP on the day of diagnosis. Demographic, clinical, and histopathologic data were extracted. Differences in Breslow thickness were analyzed using analysis of covariance, and invasive versus in situ melanoma rates were assessed using multivariable logistic regression.

Results

A total of 282 melanomas from 249 patients were analyzed. Melanomas diagnosed in non–high-risk clinics were significantly thicker than those diagnosed in high-risk clinics (adjusted mean Breslow difference: 0.78 mm). Surveillance strategy was associated with invasiveness: invasive melanoma rates were highest in non–high-risk clinics (52%), followed by first-visit to high-risk clinic (39%), patients with prior TBP only (34%), and lowest in patients diagnosed during repeat TBP (20%; overall model $p = 0.03$). Overall Breslow thickness did not differ significantly between melanomas diagnosed during visits with prior TBP alone and those diagnosed during repeat TBP.

Conclusions

High-risk melanoma clinics incorporating TBP are associated with earlier melanoma detection and lower rates of invasive disease. Repeated TBP was associated with lower rate of invasive melanoma compared with baseline TBP and manual comparison on the day of diagnosis.

EA DV CONGRESS
VIENNA
30 SEP - 3 OCT 2026

Abstract N°: 770

Cutaneous Mixed Tumor on the Skin Area of the Lower Lip: Dermoscopic Features of A Rare Sweat Gland Neoplasm

Hülya Mürüvvet GÜVENDİ*[1], Ahmet Ölmez[1], Merve Bağış[2], Sezgi Sarıkaya Solak[1]

[1] Trakya University Faculty of Medicine Department of Dermatology and Venereology, Edirne, Türkiye
[2] Trakya University Faculty of Medicine Department of Medical Pathology, Edirne, Türkiye

Introduction

Cutaneous mixed tumor is a benign sweat gland neoplasm characterized by a biphasic architecture comprising epithelial and stromal components. The head and neck region is the primary site of involvement, with predominant involvement of the nose, cheeks, and upper lip. The lower lip skin is an extremely rare location for cutaneous mixed tumor. Herein, we present a case of cutaneous mixed tumor in the skin area of the lower lip in a patient with a history of cutaneous malignancy, highlighting its dermoscopic features.

Case Presentation

A 58-year-old male presented to our clinic with a 5-year history of painless swelling on the near left lower lip. He denied smoking, local trauma, or prior radiation exposure. His medical history was significant for multiple prior excisions of squamous cell carcinoma and basal cell carcinoma. Dermatological examination revealed a firm, mobile subcutaneous nodule in the lower left lateral aspect of the lip, with no associated mucosal involvement. Dermoscopy of the nodule showed a white structureless area with peripheral arborizing vessels, raising an initial suspicion for basal cell carcinoma. Ultrasonography identified a 6×5 mm heterogeneous lesion with echogenic contents and posterior acoustic enhancement in the subcutaneous tissue of the left lateral lower lip, without vascularization or deep tissue infiltration; the sonographic appearance was initially consistent with an epidermoid cyst. Despite these imaging features suggesting a cystic process, a 4-mm punch biopsy revealed a tumor composed of a chondromyxoid stromal component and a ductal epithelial component, confirming the diagnosis of cutaneous mixed tumor. The lesion was subsequently managed with surgical excision with clear margins. No cervical lymphadenopathy was detected. The patient has been followed up by dermatology and plastic surgery departments for 11 months without recurrence.

Conclusion

Cutaneous mixed tumor, also known as chondroid syringoma, typically affects men in the 3rd–6th decades; chronic irritation and trauma are recognized risk factors. Cutaneous mixed tumors are typically slow-growing, painless, firm nodules and are morphologically identical to pleomorphic adenoma of the salivary glands, which constitutes a key differential diagnosis — particularly in the perioral region where minor salivary glands are present. Distinction between the two relies on anatomical origin: in our case, the subcutaneous localization without mucosal involvement and the absence of connection to underlying salivary gland tissue supported the diagnosis of CMT over pleomorphic adenoma. Dermoscopic features of cutaneous mixed tumor are not well defined, with only five cases containing dermoscopic descriptions reported in the literature. Most of the reported cases demonstrated white structureless areas, the so-called “white-cotton” appearance, and telangiectatic vessels. In our case, dermoscopy revealed peripheral branching vessels and a white structureless area, initially mimicking basal cell carcinoma and representing a potential diagnostic pitfall, particularly in patients with a history of

cutaneous malignancy. These findings are consistent with the limited dermoscopic features previously reported in the literature. Differential diagnoses include epithelial cysts, basal cell carcinoma, cutaneous metastases, adnexal carcinomas. Definitive diagnosis relies on histopathology, with imaging serving a supportive role. Complete excision with clear margins is essential, given the risk of local recurrence and the risk of malignant transformation into malignant chondroid syringoma. This case expands the dermoscopic characterization of cutaneous mixed tumor and emphasizes its inclusion in the differential diagnosis of firm, painless lower lip nodules encountered in dermatological practice.

EA DV CONGRESS
VIENNA
30 SEP - 3 OCT 2026

Abstract N°: 797

Melanoacanthoma: A Perfect Melanoma Mimicker

Meryem El Moustaoui*[1], Hajar EL HASSANI TAIB[1]

[1] Ibn Sina University Hospital, Rabat, Morocco

Introduction

Melanoacanthoma is a rare benign variant of seborrheic keratosis characterized by a proliferation of both keratinocytes and melanocytes. Clinically and dermoscopically, it may closely mimic melanoma, particularly in elderly patients, leading to diagnostic uncertainty.

Case Presentation

We report the case of a 70-year-old man with a history of hypertension under treatment, who presented with chronic pruritus. Clinical examination revealed a highly pigmented black nodular lesion located on the forearm. The lesion had been evolving for approximately two months.Given the suspicious clinical appearance, dermoscopic evaluation was performed, showing a central black area surrounded by a blue-white veil obscuring underlying structures. The lesion had well-defined borders and surface scaling. As dermoscopy was inconclusive and could not rule out melanoma, an excisional biopsy was performed.Histopathological examination revealed a heavily pigmented seborrheic keratosis consistent with melanoacanthoma.

Seborrheic keratosis (SK) is one of the most common benign epidermal tumors in the elderly. However, it encompasses a wide spectrum of clinical and histopathological variants, some of which may closely mimic malignant lesions. Among these, irritated, regressive, and heavily pigmented forms are particularly challenging, as they may simulate melanoma or other skin tumors both clinically and dermoscopically.Melanoacanthoma represents a rare pigmented variant of SK, characterized histologically by a proliferation of keratinocytes intermingled with numerous dendritic melanocytes distributed throughout the lesion. Clinically, it often presents as a deeply pigmented plaque or nodule, which may raise concern for melanoma, especially in older patients.Dermoscopically, SK typically shows characteristic features such as milia-like cysts, comedo-like openings, and fissures. However, in atypical variants—including irritated or melanoacanthoma forms—these structures may be absent or obscured. Instead, misleading features such as a blue-white veil, irregular pigmentation, or structureless areas can be observed, making differentiation from melanoma difficult.In this context, dermoscopy may not always be sufficient to establish a definitive diagnosis. As illustrated in our case, the presence of a blue-white veil—classically associated with melanoma—led to diagnostic uncertainty. Therefore, histopathological examination remains the gold standard, allowing accurate differentiation between benign variants of SK and malignant tumors



Clinical image of the pigmented lesion

Conclusion

This case highlights that melanoacanthoma should be considered in the differential diagnosis of highly pigmented lesions. When dermoscopic findings are equivocal, excisional biopsy is essential to establish a definitive diagnosis and avoid misdiagnosis of melanoma.

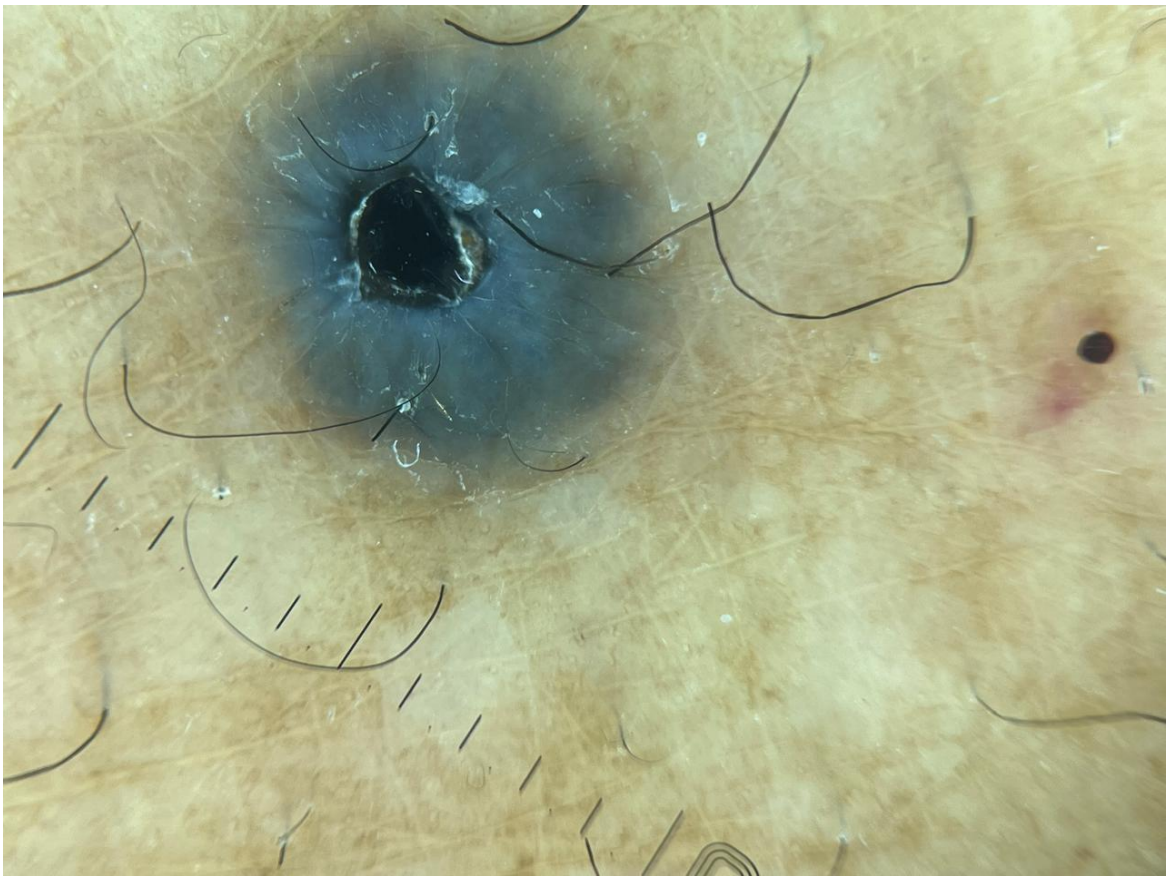

Dermoscopy of the pigmented lesion

EA DV CONGRESS
VIENNA
30 SEP - 3 OCT 2026

Abstract N°: 849

Development of a Multi-Modal AI Model for Precise Staging and Management of Androgenetic Alopecia and Alopecia Areata: A Dermoscopic Analysis of 2,000+ Cases

xun zhou*[1], yu sheng[1, 2]

[1] Chongqing Traditional Chinese Medicine Hospital, chongqing, China
[2] Chengdu University of Traditional Chinese Medicine, chengdu, China

Introduction

Precise staging of Androgenetic Alopecia (AGA) and Alopecia Areata (AA) is critical for determining prognosis and treatment protocols but often relies on subjective clinical assessment. This study aims to develop a multi-modal AI model correlating specific dermoscopic features with pathological stages to automate diagnosis and provide personalized management recommendations.

Materials and Methods

In this retrospective diagnostic study and algorithm development, we curated a dataset of over 2,000 dermoscopic images (1,000+ AGA, 1,000+ AA) with expert annotations of key signs (e.g., yellow dots, hair diameter diversity). A correlation analysis linked distinct dermoscopic patterns with specific pathological stages. These data trained a multi-modal deep learning model designed to identify disease stage and generate corresponding management workflows.

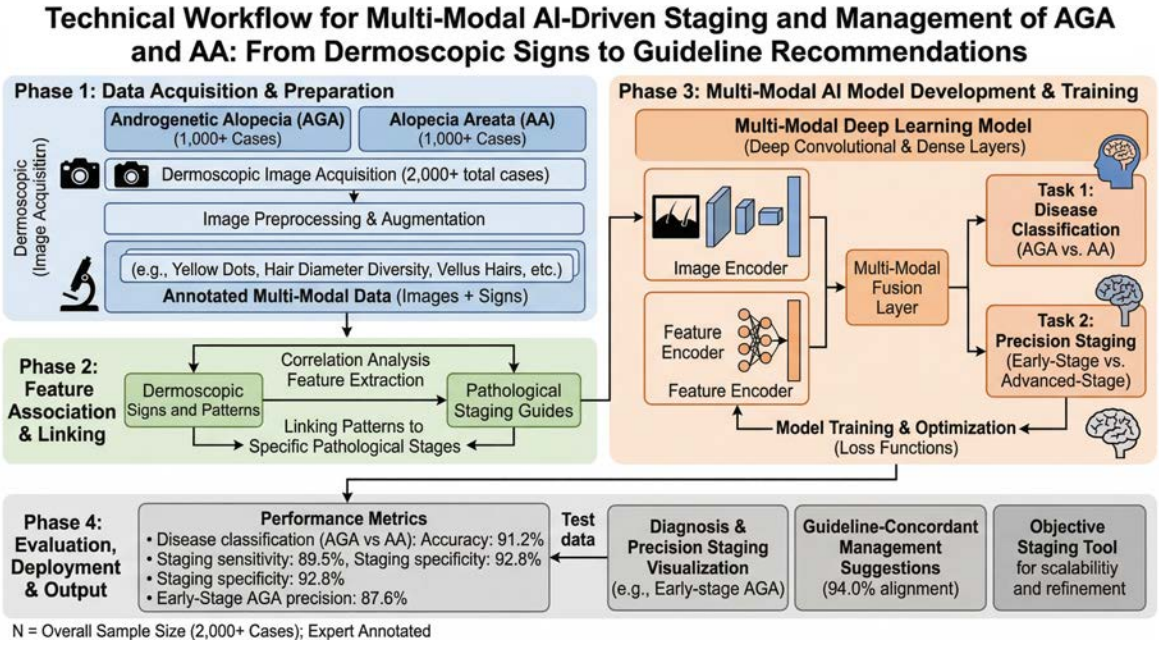

Results

The AI model achieved an overall diagnostic accuracy of 91.2% in distinguishing between AGA and AA. In staging analysis, the model correlated dermoscopic signs with pathological severity with a sensitivity of 89.5% and specificity of 92.8% ($p < 0.001$). Specifically, the recognition rate for early-stage versus advanced-stage AGA showed a precision of 87.6%. The system successfully generated guideline-concordant management suggestions

for 94.0% of the validation cases.

Conclusions

This study demonstrates that a large-scale, dermoscopy-trained AI model can accurately establish correlations between surface signs and pathological stages. This novel technology offers an objective, scalable tool for refining hair loss staging and optimizing clinical management workflows.

EADV CONGRESS
VIENNA
30 SEP - 3 OCT 2026

Abstract N°: 850

Dermoscopic clues in Reticular Mid-Dermal Elastolysis

Vincenzo Filastro*[1], Gregorio Baruffaldi[2], Alessandra Gelmetti[2, 3], Miriam Leuzzi[2, 3], Michelangelo La Placa[2, 3], Neri Iria[2]

[1] Dermatology Unit, Health Science Department, Magna Graecia University, Catanzaro, Italy

[2] Dermatology Unit, IRCCS Azienda Ospedaliero-Universitaria di Bologna, Policlinico S.Orsola Malpighi, Bologna, Italy, Bologna, Italy

[3] Department of Medicine and Surgery (DIMEC), Alma Mater Studiorum University of Bologna, Dermatology Unit, IRCCS Azienda Ospedaliero-Universitaria di Bologna, Policlinico S.Orsola Malpighi, Bologna, Italy, Bologna, Italy

Introduction

Mid-dermal elastolysis (MDE) is a rare acquired elastolytic disorder characterized by selective degeneration and loss of elastic fibers confined to the mid-dermis. The most recognized clinical patterns include diffuse fine wrinkling parallel to skin cleavage lines (type 1) or perifollicular papular protrusions (type 2), often affecting the trunk, neck, or arms of middle-aged women. A distinctly uncommon variant manifests as persistent reticular erythema with mild atrophic patches (type 3), which can mimic other reticular dermatoses such as reticular erythematous mucinosis (REM), granuloma annulare, annular elastolytic giant cell granuloma (AEGCG). Dermoscopy, though rarely described in this condition, can provide valuable supportive clues, while histopathology delivers the definitive diagnosis.

Case Presentation

A 49-year-old caucasian man was referred for an asymptomatic eruption on the bilateral anterior pectoral region, first noticed approximately 2 years earlier during a routine blood donation. The patient reported no pruritus, pain or burning. Family history was significant for Hashimoto thyroiditis in his mother and sister. His medical background included mild arterial hypertension controlled through lifestyle modifications and nasal polyposis managed with intranasal corticosteroid spray. No personal or familial history of dermatologic, rheumatologic, autoimmune, or oncologic conditions was reported, and he denied smoking, excessive sun exposure, relevant occupational exposures, accidental injuries or trauma related to diagnostic procedures. Physical examination disclosed well-demarcated bilateral reticular erythema on the anterior chest, comprising thin reddish interlacing meshes alternating with subtle whitish atrophic macules and patches. The pattern became more conspicuous upon forward bending of the trunk, suggesting tension-related accentuation, with no scale, papules, wheals, purpura, or mucosal involvement. The eruption spared the neck, abdomen, and extremities. Dermoscopic evaluation revealed distinctive features: patchy erythematous areas superimposed on a non-uniform red background, faint brownish pseudoreticular pigmentation outlining the reticular network, prominent yellow-brown follicular structures resembling "caramel-like" dots, and short, linear perifollicular capillaries. These follicular elements were more pronounced in the adjacent dorsolumbar region, where the reticular pattern subtly extended. A 3-mm punch biopsy from the chest lesion showed an unremarkable epidermis, with marked fragmentation and paucity of elastic fibers in the mid-dermis, better highlighted by Weigert staining, accompanied by focal elastophagocytosis with multinucleated cells. No solar elastosis, mucin deposition, granulomatous inflammation was evident, ruling out differentials like actinic damage, mucinoses, or granulomatous elastolysis. Based on clinicodermoscopicopathologic correlation, reticular MDE was diagnosed. Given its asymptomatic, idiopathic nature and lack of proven therapies, expectant management with follow-up was elected.

Conclusion

Reticular MDE is an exceedingly rare clinical variant, predominantly involving the trunk and characterized by persistent reticular erythema with variable atrophy, often in middle-aged adults without clear triggers. Dermoscopy emerges as a pivotal noninvasive tool, offering descriptive hallmarks like non-uniform erythema, pseudoreticular pigmentation, "caramel-like" follicular dots, and perifollicular vessels, features sparsely documented but instrumental in raising suspicion, as evidenced here. Nonetheless, histopathology remains confirmatory, demonstrating selective mid-dermal elastolysis. No effective treatments exist; conservative observation is standard for asymptomatic cases. This report advocates for dermoscopic scrutiny in unexplained reticular trunk eruptions to guide biopsy and avert misdiagnosis, enriching the limited dermoscopic literature on reticular MDE.

EA DV CONGRESS
VIENNA
30 SEP - 3 OCT 2026

Abstract N°: 989

Cutaneous Non-Langerhans Histiocytosis NOS as a Possible Paraneoplastic Manifestation in Metastatic Breast Cancer

Aimane Zaim*[1], Zakia Douhi[1], Ikram Bejja[1], Saadia Boughaleb[1], Meryem Soughi[1], Sara Elloudi[1], Hanane Baybay[1], Layla Tahiri El Ousrouti[2], Fatima Zahra Mernissi[1]

[1] Department of Dermatology, Hassan II University Hospital, Sidi Mohamed Ben Abdellah University, Fez, Morocco
[2] Department of Pathology, Hassan II University Hospital, Sidi Mohamed Ben Abdellah University, Fez, Morocco

Introduction

Histiocytoses comprise a heterogeneous group of disorders characterized by the abnormal accumulation and proliferation of histiocytes in various tissues. Their clinical spectrum ranges from benign, self-limited conditions to aggressive malignancies and systemic inflammatory syndromes. Diagnosis can be challenging because of overlapping clinical, histopathological, immunophenotypic, and genetic features. According to the revised classification, histiocytoses are divided into 5 groups: Langerhans cell histiocytosis (LCH, L group), cutaneous and mucocutaneous histiocytoses (C group), malignant histiocytoses (M group), Rosai–Dorfman disease (RDD, R group), and hemophagocytic lymphohistiocytosis (H group). Cutaneous non-LCH of the C group include juvenile and adult xanthogranulomas (XG), solitary reticulohistiocytoma, generalized eruptive histiocytosis, progressive nodular histiocytosis, xanthoma disseminatum, and cutaneous RDD. However, some cases remain unclassifiable despite thorough clinicopathological and immunohistochemical evaluation and are designated as cutaneous histiocytosis not otherwise specified (NOS). We report a rare case of cutaneous non-LCH, non-XG, NOS type occurring in a patient with metastatic breast carcinoma, raising the hypothesis of a reactive or paraneoplastic macrophagic phenomenon.

Case Presentation

A 44-year-old woman with metastatic HR-positive, HER2-negative invasive breast carcinoma, treated with ribociclib, letrozole, and ovarian suppression, developed multiple painful cutaneous nodules four months before presentation. Dermatological examination revealed six erythematous, firm-to-hard papulonodules, some with fine scaling or superficial erosion, located on the right lateral thoracic area, left inframammary region, left arm, pubic area, left anterior thigh, and left leg. No lymphadenopathy was detected. No lymphadenopathy was detected. Dermoscopy showed a “setting sun” pattern with polymorphous vessels, whitish scales, peripheral collarettes, white streaks, and structureless white areas. Differential diagnoses included cutaneous metastases of breast carcinoma, cutaneous sarcoidosis, and cutaneous histiocytosis. Excisional biopsy of one nodule revealed a normal epidermis and a well-circumscribed dermal nodular histiocytic infiltrate arranged in perivascular and peri-adnexal aggregates. Rare multinucleated giant cells were present. No emperipolesis, foamy histiocytes, cytologic atypia, or increased mitotic activity were observed. Special stains were negative for infectious agents. Immunohistochemical analysis showed strong CD163 expression in the histiocytic population. CD1a, S100 protein, factor XIIIa and CK 8/18 were negative. A diagnosis of cutaneous non-LCH, non-XG, NOS type, was made. Imaging excluded systemic involvement, and lesions regressed markedly with topical steroids.

Conclusion

An intriguing aspect of this case is its occurrence in a patient with metastatic breast carcinoma. The association between histiocytoses and malignancies is uncommon and has been mainly reported in multicentric reticulohistiocytosis, in which 20–30% of patients have an associated neoplasm, including breast carcinoma. Although our patient did not fulfill the criteria for this entity, the temporal relationship with active malignancy suggests a possible reactive macrophagic process triggered by tumor-related cytokines or immune dysregulation. Tumor-associated macrophages are known to play a central role in the tumor microenvironment, particularly in breast carcinoma. A systemic macrophage activation phenomenon could theoretically manifest as cutaneous histiocytic proliferation. The favorable response to topical corticosteroids and the absence of systemic progression further support a reactive, possibly paraneoplastic mechanism. Additional reports and molecular studies are needed to better clarify the relationship between histiocytic proliferations and solid tumors.

EADV Congress 2026, VIENNA
30 SEPTEMBER - 03 OCTOBER 2026
POWERED BY M-ANAGE.COM

EA DV CONGRESS
VIENNA
30 SEP - 3 OCT 2026

Abstract N°: 1067

Cutaneous Rosai-Dorfman-Destombes Disease: The Diagnostic Value of the Yellow Island Sign

Maha El Maati*[1], Laila Benzekri[1], Nadia Ismaili[1]

[1] Ibn Sina University Hospital Center of Rabat, Mohammed 5 University, Rabat, Morocco

Introduction

Rosai-Dorfman-Destombes (RDD) disease is a rare non-Langerhans cell histiocytosis, typically characterized by massive, painless cervical lymphadenopathy occurring mostly in young African male. While the systemic form is well-documented, the purely cutaneous subtype (CRDD) is an exceptional entity that clinicians must not overlook. CRDD often presents without the systemic symptoms or lymph node involvement characteristic of the classic form. Given its significant clinical polymorphism, it can mimic various inflammatory or neoplastic conditions, making its diagnosis a challenge. We report a case of a 25-year-old Moroccan female presenting with a localized, polylobed tumor on the thigh.

Case Presentation

A 25-year-old female of skin phototype IV without any medical history presented with a progressively enlarging tumor on her posterior thigh. Clinical examination revealed a 2.5 cm soft, polylobed, violaceous tumor with yellowish areas. The surface was smooth with focal scaling (Fig 1). Dermoscopy showed structureless yellow areas on a brownish-violaceous background, fine telangiectasias and a peripheral pigment network (Fig 2). Histological analysis of the lesion revealed a dense pseudo-tumoral dermal infiltrate composed of small lymphocytes, mature plasma cells, and neutrophils with large vacuolated histiocytes exhibiting significant emperipolesis. PAS and Gram stains were negative. Immunohistochemistry confirmed the diagnosis, with histiocytes staining positive for S100 and CD163, and negative for CD1a (Fig 3). A systemic workup, including a CT scan and long-bone X-rays, showed no abnormalities. The patient underwent complete surgical excision of the remaining lesion with a favorable outcome.

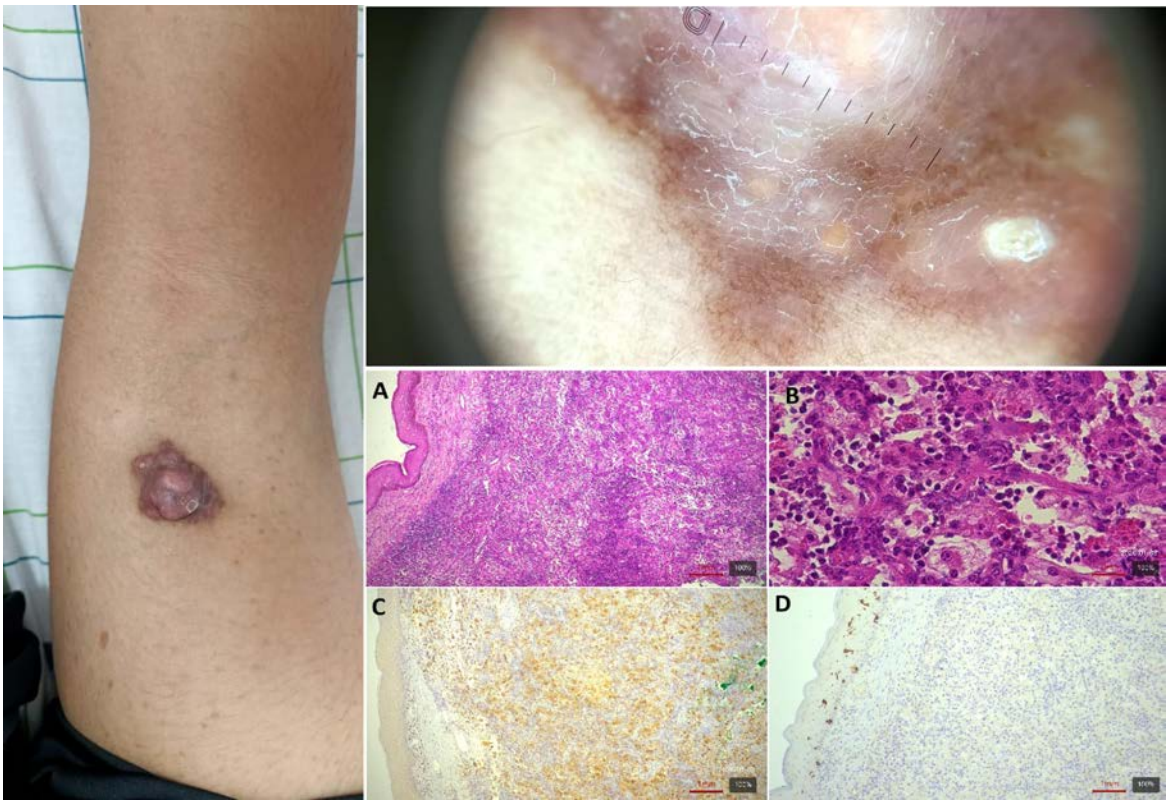

Figure 1: polylobed, brownish-violaceous tumor with focal yellowish areas on the posterior thigh.
Figure 2: Dermoscopy showing structureless yellow areas on a brownish-violaceous background, fine telangiectasias, and a peripheral pigment network Figure 3: (A) Dense and diffuse infiltration of the reticular dermis with clear areas corresponding to clusters of histiocytes mixed with lymphocytes and plasma cells. (B) Emperipolesis phenomenon. (C) CD163 (+) histiocytes. (D) CD1a (-) histiocytes, control of intraepidermal Langerhans cells (+)

Conclusion

Purely CRDD disease is a distinct clinical entity. Characterized by an average onset at 20.6 years, CRDD primarily involves children and young adults. Clinical data also reflect a higher incidence in African patients with a discrete male preponderance. Dermoscopic findings in this case are highly characteristic. The "structureless yellow areas" correlate histologically with the underlying dense histiocytic infiltration and lipid deposits within the dermis. These yellow zones, combined with fine telangiectasias, are valuable clues for orienting the diagnosis toward a granulomatous or histiocytic process, especially in patients with higher phototypes where the background may appear more violaceous.

While this sign is frequently described in granulomatous diseases, its association with fine, branching telangiectasias in a tumoral lesion should strongly orient the clinician toward a histiocytic disorder. The emperipolesis which was prominently observed within a background of mature plasma cells and lymphocytes in our patient, is consistent with the international consensus diagnostic criteria. The differential diagnosis must be done with the other Langerhans Cell Histiocytosis (LCH) that can present with cutaneous nodules, it is characterized histologically by "coffee-bean" shaped nuclei and, crucially, an immunohistochemical profile that is positive for CD1a and Langerin. In our case, the CD1a negativity was essential to exclude LCH. Imunohistochimy rules out the other diagnosis such as cutaneous sarcoidosis, infectious granuloma and juvenile xanthogranuloma that often presents with Touton giant cells typically S100 negative.

Consistent with international consensus recommendations, a thorough systemic workup is mandatory to ensure the disease is limited to the skin. The absence of lymphadenopathy and the negative systemic workup confirmed a purely cutaneous localized form, which carries a much more favorable prognosis than the systemic variants.

Management options range from observation to corticosteroids, radiotherapy, or surgery. In this case, complete surgical excision resulted in a favorable outcome with no recurrence, supporting the efficacy of surgery for

localized tumors.

EA DV CONGRESS
VIENNA
30 SEP - 3 OCT 2026

Abstract N°: 1250

Dermoscopy of erythema elevatum diutinum: a trizonal pattern

Kmar Turki*[1], Rim Chaabouni[1], Maissa Abid[1], chaari chiraz[2], Tahya Boudawara[2], Hamida Turki[1]

[1] Dermatology department, Hedi Chaker university hospital, Sfax, TUNISIA, Sfax, Tunisia
[2] Anatomopathology laboratory, Habib Bourguiba hospital, sfax, Tunisia

Introduction
Erythema elevatum diutinum (EED) is an uncommon, chronic dermatosis characterized by red–violet to red–brown papules, plaques, and nodules that favor extensor surfaces. Herein, we present an original case of vesiculobullous EED and we describe it dermatoscopic examination.

Case Presentation
A 22-year-old woman presented with progressively increasing asymptomatic lesions over elbows, knees, palms, soles, and trunk for 2 years. Dermatologic examination revealed multiple red-brown nodules and plaques symmetrically distributed over the extensor aspect of the elbows, knees, palms, soles, and trunk**.** Multiple tense vesicles were noticed on the elbows. The systemic workup of the patient was normal.

Dermatoscopic examination of the nodules revealed polymorphous vessels (dotted, linear, arborizing, and curved vessels) with a patchy, unspecific distribution over a reddish-purple background. White shiny lines and white structureless were observed. Sparse white rosettes, scales, and crust were noticed. A "trizonal concentric" pattern was noted in some lesions with a central erythematous area with prominent polymorphous vessels (I) surrounded by an orange-yellowish peripheral zone displaying mostly white lines and areas and few vessels (II) and an erythematous-brownish halo (III)**.**

Histopathological examination from a nodule showed diffuse dermal inflammation rich in neutrophils, leukocytoclastic vasculitis (LCV) and dermal fibrosis.

A final diagnosis of vesiculobullous EED was made, and the patient was started on dapsone 100 mg/day. At 3-month follow-up, a significant improvement was observed with almost a clearance of all lesions.

Conclusion
EED represents a rare, chronic, and recurrent variant of cutaneous LCV. The vesiculobullous variant of EED is exceptionally rare. This unusual presentation has been reported most times in patients infected by human immunodeficiency virus. However, in the case described, the systemic evaluation did not reveal any association.

Chauhan et al. described distinct dermoscopic features of EED, with early lesions showing arborizing telangiectasia on a yellowish-red background, mature lesions revealing yellow-white streaks and multiple telangiectasias, and late lesions displaying fewer telangiectasias and more prominent yellow-white streaks. These features correspond to underlying histopathological changes: LCV in early stages and dermal fibrosis in later stages. Our case had similar dermoscopic findings with an erythematous-yellowish background due to extravasated erythrocytes, inflammation, and hemosiderin deposits. Vessels displayed different morphologies in our case, including dotted, arborizing, and curved vessels. This vascular pattern may reflect vascular dilatation observed histologically or the

vessel wall changes. The telangiectasic arborizing vessels can be also the result of the dermal plexus displacement by the underlying nodular lesion towards the skin. White structures were also seen in both cases as white shiny lines or streaks and white structureless areas. These white structures are more prominent in later stages as they reflect dermal fibrosis. In our patient, yellowish crusts were seen. They are due to serum extravasation resulting from the rupture of vesicles. Moreover, we described a “trizonal pattern” with three concentric areas of different aspects/colors in EED.

EADV CONGRESS
VIENNA
30 SEP - 3 OCT 2026

Abstract N°: 1401

Case series of different clinical variants of Porokeratosis diagnosed by dermoscopic examination.

Fida Anjum*[1]

[1] Yenepoya Medical College, Mangalore, India

Introduction
Porokeratosis is a rare, acquired or inherited disorder of keratinisation. It presents as a keratotic papule or plaque with an annular appearance due to its thread-like elevated border that expands centrifugally. We report a case series of porokeratosis confirmed by dermoscopy.

Case Presentation
We report four different clinical variants of porokeratosis confirmed by dermoscopy.

Case 1: 29 Y/F presented with itchy lesions over the face since 5 years. On examination two irregularly shaped erythematous plaques on either side of nose with areas of hyperpigmentation and hypopigmentation with elevated border was present.

Case 2: 23 Y/M presented with lesions with burning sensation over the nose since 2 months_.On examination discrete erthymatous papules distributed over left side of nose with raised keratotic border was present.

Case 3: 42 Y/F presented with asymmptomatic skin lesion over face since 6 month.On examination multiple hyperpigmented macules with hyperkeratotic borders was present.

Case 4: 20 Y/F presented with asymptomatic lesions over both palms and soles since 3months. On examination multiple hyperkeratotic papules was present over the creases both palms and soles was present.

Diagnosis was done by dermoscopy, which showed double marginated white track border, follicular plugging,whitish and brown coloured dots and globules confirming porokeratosis.

Conclusion
Porokeratosis is relatively uncommon and may show atypical presentation making the diagnosis difficult. The cases mentioned above had diagnostic dilemma and dermoscopy aided in confirming the diagnosis.

Porokeratosis has unique morphological presentation and it is essential to be familiar with its clinical and dermoscopic presentation. Dermatoscopy plays an important role in the differentiating it from other dermatoses.

EA DV CONGRESS
VIENNA
30 SEP - 3 OCT 2026

Abstract N°: 1469

The Danger of Super Smartphones in Dermoscopy Imaging: A Case Series Comparing Native Smartphone and Controlled Acquisition

Pedro Paulo Toshi Abe[1], Gustavo Longhi Bedin*[1], Ricardo Tadeu Villa[1], Carla de Marque Silva[1], Adriana Ramos Beltrão[1]

[1] Centro Universitário Ítalo Brasileiro Uniítalo, São Paulo, Brazil

Introduction

The increasing use of smartphones in dermoscopy has introduced advanced computational photography algorithms that may alter image characteristics. While these technologies enhance visual quality, their impact on diagnostic fidelity remains uncertain. This study aimed to evaluate the impact of smartphone computational photography on dermoscopic image fidelity across multiple clinical cases, as well as its influence on clinical perception.

Case Presentation

Four patients with pigmented skin lesions were evaluated. Patient 1: a 26-year-old female with a congenital lesion on the chest. Patient 2: a 57-year-old female with a pigmented lesion on the abdomen, present for approximately one year. Patient 3: a 32-year-old male with a previously stable lesion showing recent changes over the past two months. Patient 4: a 63-year-old patient with a pigmented lesion on the face of unknown duration.

Dermoscopic images were obtained using a iPhone 17 Pro Max coupled to a dermatoscope. Each lesion was photographed sequentially using the native camera application and Project Indigo (Adobe) under standardized conditions. Images were evaluated qualitatively, through quantitative analysis using ImageJ (assessing RGB distribution, contrast, and edge definition), and via a structured questionnaire completed by dermatologists in training.

Across all cases, images obtained with the native camera application demonstrated increased color saturation, reduced lesion-to-skin contrast, and smoothing effects that diminished the visibility of fine dermoscopic structures. In contrast, controlled acquisition consistently preserved color fidelity and enhanced visualization of subtle structures.

Quantitative analysis revealed differences in RGB distribution and edge intensity, supporting the presence of algorithm-induced alterations in native images.

A total of eight dermatologists in training participated in the evaluation. For structural visualization, 75% (6/8) preferred Image B, while 25% (2/8) preferred Image A. Regarding diagnostic confidence, 62.5% (5/8) selected Image B, 25% (2/8) selected Image A, and 12.5% (1/8) reported no difference. Importantly, 75% (6/8) indicated that image selection would not influence their clinical decision-making, while 25% (2/8) reported that it would.

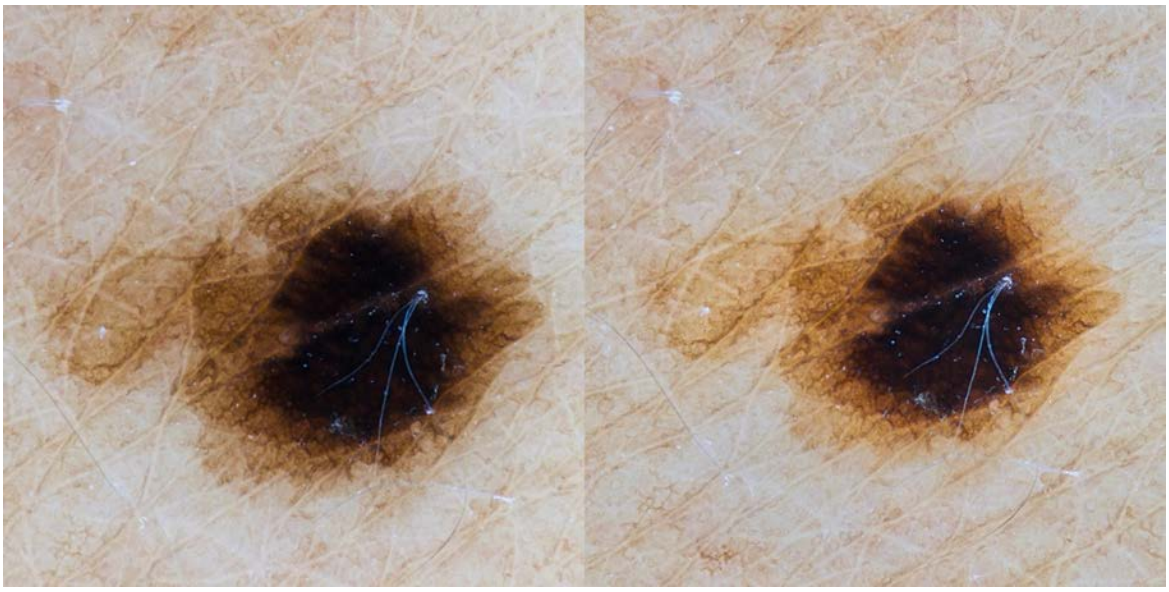

Dermoscopic images of the same lesion obtained using different acquisition methods. (Left - Image A) Native smartphone image demonstrating increased color saturation, reduced contrast, and smoothing effects with decreased visibility of fine dermoscopic structures. (Right - Image B) Image obtained using Project Indigo (Adobe) showing improved color fidelity and enhanced visualization of subtle structures, including pigmented network.

Conclusion

This case series demonstrates that computational photography may systematically alter dermoscopic features, both by artificially enhancing and by obscuring clinically relevant structures. Although these changes influenced image preference and perceived quality, their impact on clinical decision-making was limited in most cases. Controlled image acquisition methods may provide greater fidelity and should be considered in clinical and research settings.

EA DV CONGRESS
VIENNA
30 SEP - 3 OCT 2026

Abstract N°: 1474

Comparing Dermatologist and Artificial Intelligence Heat Maps in Dermoscopic Image Analysis via Eye Tracking

Noa Kremer*[1], Luísa Polo Silveira[2], Allan Halpern[2], Ashfaq Marghoob[2]

[1] Dermatology Service, Memorial Sloan Kettering Cancer Center, New York, United States

[2] Dermatology Service, Memorial Sloan Kettering Cancer Center, New York, NY., New York, United States

Introduction

AI-based predictive systems generate heat maps that highlight regions as proxy explanations for diagnostic predictions.
Comparing AI- and dermatologist-derived heat maps helps determine if AI allocation aligns with clinically relevant features—an essential step toward improving interpretability.
Our aim was to compare the areas of interest (AOI) between dermatologists and AI in dermoscopic images.

Materials and Methods

Four dermatologists inspected 120 diverse dermoscopic images of benign and malignant lesions, including 20 each of melanoma, BCC, SCC, nevi, benign keratoses (BK), and vascular lesions.
Their eye movements were tracked to generate heat maps. For the same images, class activation maps were produced using the DEXI algorithm (Canfield Scientific's Vectra software system).
Overlap was assessed using pixel-wise rank correlation. Inter-dermatologist correlation served as the upper reference, and the median null correlation between DEXI and dermatologist mismatched heat map image pairs served as the lower reference

Results

Median pixel-wise correlation was $\rho = 0.540$ for dermatologist–DEXI, $\rho = 0.591$ for inter-dermatologist, and $\rho = 0.434$ for null comparisons (Figure 1).
Melanoma and BK had higher correlations compared to basal cell carcinoma ($\rho = 0.555$, $\rho = 0.552$, and $\rho = 0.481$, respectively).
Incorrectly classified lesions showed higher correlations compared to correctly classified lesions ($\rho = 0.568$ vs. $\rho = 0.521$).

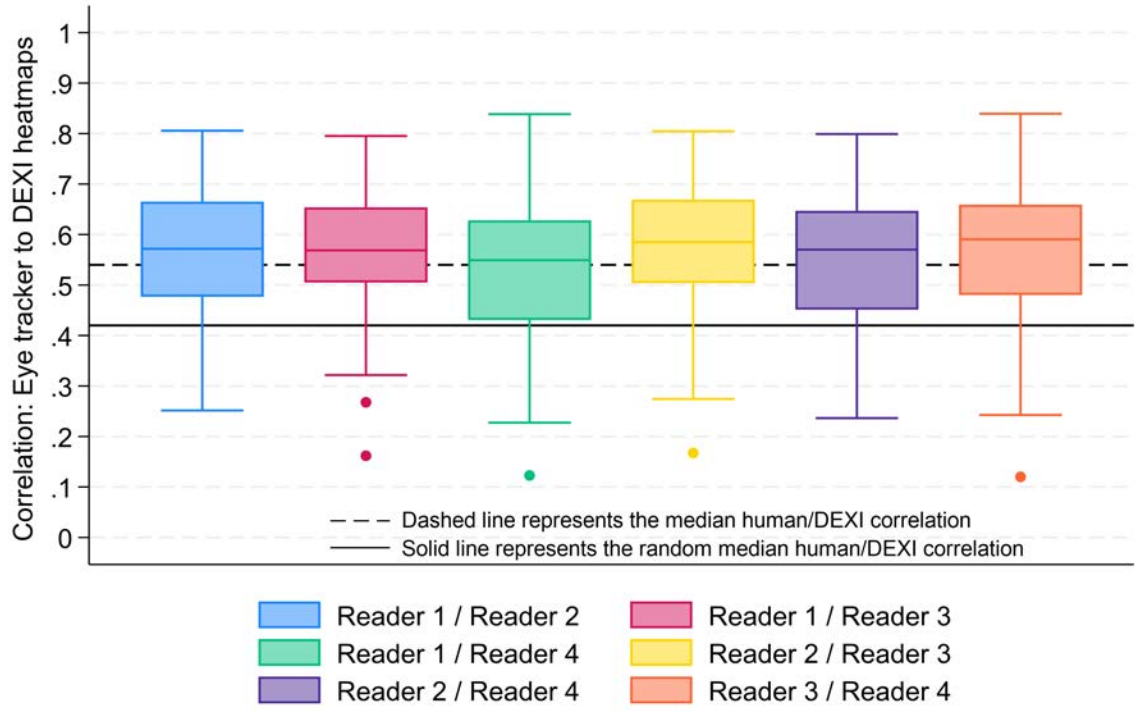

Boxplots of the pixel-wise rank correlations between dermatologists' eye-tracking heat maps and DEXI-generated heat maps.

Conclusions

Dermatologists and DEXI heat maps showed substantial overlap, suggesting shared diagnostic anchors, underscoring the model's potential for interpretability.

DEXI predictions are based on clinically relevant visual features.

Higher correlation for BK and melanoma, as well as for incorrect classified lesions, may reflect greater diagnostic difficulty, with longer visual inspection leading to greater overlap between dermatologist and DEXI heat maps.

EA DV CONGRESS
VIENNA
30 SEP - 3 OCT 2026

Abstract N°: 1481

Bridging the Gap Between Evidence and Practice: Dermoscopy Adoption Among Dermatology Residents in Saudi Arabia—A Cross-Sectional Study

Abdullah Almeziny*[1], Mohammed Al Mashali[1]

[1] College of Medicine, Imam Mohammad Ibn Saud Islamic University, Riyadh, Saudi Arabia, Riyadah, Saudi Arabia

Introduction
Dermoscopy is a key noninvasive diagnostic tool that enhances visualization of subsurface skin structures, improving early detection of skin malignancies and reducing unnecessary biopsies. Despite its incorporation into international dermatology guidelines, its integration into residency training programs remains inconsistent, particularly in emerging healthcare systems

Materials and Methods
A cross-sectional study was conducted using a validated questionnaire distributed to all dermatology residents enrolled in the Saudi Board of Dermatology and Venereology program in Saudi Arabia. Data collected included demographics, dermoscopy use patterns, training exposure, confidence levels, and perceived barriers. Statistical analysis was performed using descriptive statistics and chi-square testing to assess associations between variables, with significance set at $P<0.05$.

Results
A total of 63 residents participated (response rate 87.5%). Dermoscopy use was reported by 69.8% of participants, with 54% owning a dermoscope and 57.1% having received formal training. Frequent use was noted, with 34.1% utilizing dermoscopy daily. Clinical application was highest in pigmented lesions, where 34% reported use in more than 70% of cases, while use in inflammatory conditions remained limited. Most participants recognized its clinical value, with 93.2% reporting usefulness in melanoma diagnosis and 68.2% indicating increased diagnostic confidence. Dermoscopy was associated with reduced unnecessary biopsies (61.4%) and improved melanoma detection rates (68.2%). Significant associations were observed between dermoscopy use and age ($P=0.003$), residency level ($P=0.001$), and practice center ($P=0.004$). Key barriers included lack of equipment (42.1%) and insufficient training (31.6%).

Conclusions
Dermoscopy is widely adopted among dermatology residents in Riyadh and is strongly perceived as a valuable diagnostic tool. However, gaps in training and access continue to limit its full clinical integration. Strengthening structured dermoscopy education and improving resource availability may enhance diagnostic accuracy and optimize patient outcomes.

Abstract N°: 1582

Unilateral acral Sweet syndrome: expanding clinicodermoscopic insights in a rare presentation

Samantha Paulina Peña-Lozano*[1], Rosa Guevara-Castillo[1], Marissa Quintal-Ramirez[1], Erika Alvarado-Arana[1]

[1] Centro Médico Nacional La Raza "Dr. Antonio Fraga Mouret", Mexico City, Mexico

Introduction

Sweet syndrome is a prototypical neutrophilic dermatosis characterized by the abrupt onset of painful erythematous plaques or nodules accompanied by dense dermal neutrophilic infiltration. While the classic distribution involves the face, neck, and upper extremities, acral presentations are distinctly uncommon and often underrecognized. Dermoscopic features of acral Sweet syndrome remain poorly defined, with existing knowledge limited to isolated reports lacking consistent patterns.

Case Presentation

A 32-year-old woman with a history of immune thrombocytopenia presented with a 6-month history of recurrent, painful lesions localized to the right ring finger.

Dermatological examination revealed three well-demarcated erythematous pseudovesicular lesions on the palmar surface, raising a broad differential diagnosis that included inflammatory and autoimmune dermatoses.

Dermoscopy demonstrated a central yellowish-red area surrounded by a whitish peripheral ring over an erythematous-violaceous background with a white network and dotted vessels, suggesting an underlying inflammatory process with prominent dermal edema and vascular involvement.

Laboratory evaluation revealed positive antinuclear and antineutrophil cytoplasmic antibodies with hypocomplementemia; however, systemic autoimmune disease was excluded after rheumatologic assessment.

Histopathological examination showed a dense predominantly neutrophilic and histiocytic dermal infiltrate, with no evidence of infection on special stains.

Based on clinicodermoscopic and histopathological correlation, a diagnosis of unilateral acral Sweet syndrome was established. Treatment with topical clobetasol resulted in complete resolution, although localized recurrence was observed during follow-up.

Conclusion

Acral Sweet syndrome represents a diagnostically challenging and underreported presentation within the spectrum of neutrophilic dermatoses. Dermoscopic characterization remains limited, hindering pattern recognition in clinical practice.

The findings observed in this case partially overlap with previously reported features, such as pseudovesicular structures and dotted vessels, while also demonstrating distinctive peripheral morphology. These observations contribute to expanding the clinicodermoscopic spectrum of acral Sweet syndrome and reinforce the role of dermoscopy as a valuable adjunct in the evaluation of inflammatory dermatoses.

POWERED BY M-ANAGE.COM

EADV CONGRESS
VIENNA
30 SEP - 3 OCT 2026

Abstract N°: 1610

Dermoscopic features of angiolymphoid hyperplasia with eosinophilia: a report of 5 cases and a review of the literature

Kmar Turki*[1], Rim Chaabouni[1], Maissa Abid[1], Abderrahmen Masmoudi[1], Hamida Turki[1]

[1] Dermatology department, Hedi Chaker university hospital, Sfax, TUNISIA, Sfax, Tunisia

Introduction

Angiolymphoid hyperplasia with eosinophilia (ALHE) is a rare eosinophilic dermatosis. Diagnosing this condition clinically is challenging, particularly in atypical presentations. Dermoscopy may offer assistance in considering ALHE, but dermoscopic aspects have not yet been fully described in the literature.

Materials and Methods

All histopathologically confirmed ALHE cases of our department, with dermoscopic examination and available photos, were included.

Results

Five cases were included and each of them was confirmed by histopathology showing vascular proliferation with turgescent epithelioid endothelial cells.

Cases 1 and 2, featured two women, aged 60 and 56 respectively, both phototype IV, and both having erythematous-pigmented plaques of the face, evolving for 10 and 6 years respectively. Dermoscopy in both cases revealed a diffuse light pink background associated with a brown reticulate network, white circles, and white areas. The first case also featured white lines, circles within circles, brown dots, and rosettes.

Case 3 was of a 47-year-old man with dome-shaped papulonodules on the left ear, accompanied by pruritus and bleeding.

Case 4 involved a 30-year-old man (phototype III) with a 4-year-old erythematous-violaceous, alopecic nodule on the occipital region, with satellite papules.

Finally, Case 5 described a 64-year-old man with erythematous-squamous nodules on the right temple and ear for 4 months**.**

Dermosccopy in these 3 cases showed an erythematous or erythematous-violaceous background, white scales, radially arranged irregular linear vessels in case 3 and polymorphous vessels (dotted and linear) in cases 4 and 5. Short white lines were seen in cases 3 and 5. Flaky white areas were seen in cases 4 and 5. Case 4 features furthermore perifollicular scales in some areas with erosions and crusts and large sized red clods.

Conclusions

Dermoscopic characteristics of ALHE have been detailed in only 6 case reports, to our knowledge, including 13 patients in total.

The reddish-pink light background observed in most cases, and our own may be associated with the vascular proliferation in the dermis, typical of ALHE. The purplish background color (observed in our third case) may result from inflammatory infiltrates and hypertrophic endothelial cells visible on histopathology.

The polymorphous vascular pattern was also observed in most of the reported cases and three of our own. The monomorphous pattern was less prominent. Regular dotted vessels may reflect superficial, symmetrical vascular proliferation, while irregular linear vessels may correspond to deeper or dilated vessels in denser inflammatory zones.

Red clods were noticed in the 2 cases reported by Akay et al., and in 70% of the cases reported by Meena et al. Red clods were also seen in our fourth case. The presence of this structure might aid in distinguishing ALHE from other vascular lesions that might manifest with pink structureless areas and polymorphic vessels, such as amelanotic melanoma, Spitz nevus, and dermatofibroma.

White lines, observed in 88.2% of the cases reported by Meena et al., and all of our cases probably correlate with dermal fibrosis, often observed in advanced stages of ALHE.

Four new signs were found in our cases including rosettes, white flaky clods, reticulated brown dots and lines and circles within circles.

Flaky white clods and circles within circles may represent areas of pronounced desquamation, fibrosis, or vascular remodeling within affected tissues.

We are describing the hyperpigmented form of AHLE in 2 of our cases for the second time to our knowledge. We believe it may be linked to the prolonged duration of the disease and the dark phototypes in our region, leading to inflammatory pigmentary incontinence.

EA DV CONGRESS
VIENNA
30 SEP - 3 OCT 2026

Abstract N°: 1620

Diagnostic value of dermoscopy in facial pigmented dermatosis : a series of 38 cases

Kmar Turki*[1], Rim Chaabouni[1], Maissa Abid[1], Dora Zghal[1], Hamida Turki[1]

[1] Dermatology department, Hedi Chaker university hospital, Sfax, TUNISIA, Sfax, Tunisia

Introduction
Facial hyperpigmented dermatoses (FHDs) frequently pose diagnostic challenges because of their overlapping clinical presentations. The aim of this study was to evaluate the dermoscopic features of the 4 most common FHDs encountered in our practice and raising differential diagnostic issues: melanotic lupus (ML), lichen planus pigmentosus (LPP), pigmented demodicosis (PD), and actinic lichen (AL).

Materials and Methods
We conducted a retrospective study from January 2015 to June 2025. All patients diagnosed with one of these FHDs (ML, LPP, PD, or AL) and having good-quality clinical and dermoscopic photographs were included. The diagnosis was established on the basis of histopathological, immunological, and parasitological findings (for PD).

Results
Thirty-eight patients were included: 6 with ML, 19 with LPP, 11 with PD, and 2 with AL. The male-to-female ratio was 0.21 (8/38). Most patients (97.4%) had dark skin phototypes (≥ III). The mean age was 46.7 years. Dermoscopic analysis focused on pigmented, vascular, and follicular structures. A reticular pseudonetwork was observed in all cases. Perifollicular brown dots and globules were present in 100% of PD and AL cases, 83.3% of ML cases, and 52.6% of LPP cases. A linear arrangement of dots and/or globules in a “hem-like” pattern was observed in 31.5% of LPP cases and in none of the ML, PD, or AL cases. Pigmentation spared the skin folds in 50% of ML, LPP, and AL cases, whereas skin folds were always involved in PD ($p < 0.05$). Blue-gray blotches were observed in LPP and PD, with 1 case each. Demodex tails and Demodex follicular openings were found exclusively in PD. Keratotic plugs and horny pseudocysts were observed only in ML (66.6% and 16.6%, respectively; $p = 0.001$). Rosettes were noted in 33.3% of ML, 18.2% of PD, and 5% of LPP cases. An erythematous background was observed in 91% of PD and 66% of ML cases ($p = 0.31$). Telangiectatic vessels were found in 63.6% of PD cases ($p = 0.003$).

Conclusions
All FHDs shared a characteristic dermoscopic pseudonetwork, corresponding to pigmentation sparing the follicular openings. Pigmentary patterns varied according to the underlying etiology. Perifollicular accentuation appeared to be common across all FHDs. A linear arrangement of dots/globules associated with sparing of the skin folds was highly suggestive of LPP. Brown pigmentation suggested superficial epidermal pigmentation, whereas blue-gray globules were more likely correlated with dermal melanophages. Follicular structures, including keratotic plugs, horny pseudocysts, and rosettes, were suggestive of ML. Demodex tails and Demodex follicular openings were key features for the diagnosis of PD. Erythema and telangiectasias were more frequent in PD, probably because of the frequent association with rosacea.

EADV Congress 2026, VIENNA
30 SEPTEMBER - 03 OCTOBER 2026
POWERED BY M-ANAGE.COM

EA DV CONGRESS
VIENNA
30 SEP - 3 OCT 2026

Abstract N°: 1928

AI Improves Clinicians' Diagnostic Accuracy for Cutaneous Melanoma: A Prospective Teledermoscopy Study

Isabelle Krakowski*[1, 2], Philipp Tschandl[3, 4], Sebastian Krakowski[5], Karina Schultz[6, 7], Niki Radros[6], Christoph Rinner[8], Hanna Eriksson[6, 7], Jan Lapins[1, 2]

[1] Department of Dermatology, Theme Inflammation, Karolinska University Hospital, Department of Medicine Solna, Division of Dermatology and Venereology, Karolinska Institutet, Stockholm, Sweden

[2] Department of Medicine Solna, Division of Dermatology and Venereology, Karolinska Institutet, Stockholm, Sweden

[3] Comprehensive Center for AI in Medicine, Medical University of Vienna, Vienna, Austria

[4] Department of Dermatology, Medical University of Vienna, Vienna, Austria

[5] House of Innovation, Stockholm School of Economics, Stockholm, Sweden

[6] Theme Cancer, Unit of Head-Neck-, Lung- and Skin Cancer, Skin Cancer Center, Karolinska University Hospital, Stockholm, Sweden

[7] Department of Oncology and Pathology, Karolinska Institutet, Stockholm, Sweden

[8] Center for Medical Statistics, Informatics and Intelligent Systems, Medical University of Vienna, Vienna, Austria

Introduction

While artificial intelligence (AI) enhances skin cancer classification in experimental settings, its real-world clinical utility and optimal integration into workflows remain underexplored. We aimed to evaluate the behavioral impact of human-AI interaction and the timing of decision support on clinicians' diagnostic accuracy in a prospective study involving real-world teledermoscopy consultations for suspected cutaneous melanoma.

Materials and Methods

In this prospective study, 32 physicians of varying experience levels in dermatology from the Department of Dermatology, Karolinska University Hospital, Sweden, evaluated teledermoscopic images of skin lesions. Teledermoscopy consultations were prospectively collected from primary healthcare facilities in the Stockholm Region between May 22, 2023, and November 18, 2024, and subsequently evaluated by study participants between June 14, 2023, and February 20, 2025. Cases were randomized to three workflows: 1) Unaided assessment, 2) Immediate AI (AI support presented directly with the consultation), or 3) Sequential AI (presented after a preliminary independent decision without AI). The primary outcome, diagnostic accuracy, was analyzed using generalized linear mixed-effects models (GLMM) with random intercepts for both physician and case, adjusting for clinician and case characteristics.

Results

A total of 281 lesions were included, generating 7,364 diagnostic assessments. In the adjusted analysis, AI assistance significantly improved the odds of achieving a correct diagnosis (OR 1.23, 95% CI 1.05-1.44, p=0.01), with overall sensitivity increasing from 77.0% to 85.3% (p<0.001). Regarding workflow timing, the Immediate AI workflow significantly improved the odds of a correct diagnosis (OR 1.20, p=0.036), whereas the Sequential AI workflow did not reach overall statistical significance. However, dermatologists with less than 10 years of

experience, in contrast to residents and senior dermatologists, derived the highest benefit from AI assistance, which remained robust regardless of timing ($OR_{Immediate\ AI}$ 1.61, p=0.008; $OR_{Sequential\ AI}$ 1.63, p=0.006).

Conclusions

Interaction with AI decision support was associated with significantly improved diagnostic precision for suspected melanoma. Immediate AI presentation yielded the highest overall accuracy for the cohort. However, the benefit was not uniform, but appeared to be modulated by experience level, suggesting that a uniform approach to AI integration is suboptimal and that successful implementation should account for individual clinician factors.

EADV CONGRESS
VIENNA
30 SEP - 3 OCT 2026

Abstract N°: 1929

Umbilical Endometriosis Mimicking a Melanocytic Nevus: A Case Report with Dermoscopic Features

Vojtěch Tretera*[1], Marek Pásek[1], Veronika Veškrňová[2], Monika Arenbergerova[1]

[1] Third Faculty of Medicine, Charles University, Prague, Czech Republic

[2] Department of Dermatology and Venereology, Královské Vinohrady University Hospital, Prague, Czech Republic

Introduction

Cutaneous endometriosis is a rare entity defined by the presence of ectopic endometrial tissue in the skin. Umbilical involvement (Villar's nodule) is uncommon and may clinically resemble melanocytic or other pigmented lesions, posing a diagnostic challenge.

Case Presentation

A 24-year-old female patient with no significant comorbidities presented with a gradually enlarging pigmented lesion of the umbilicus, clinically suspected to be a melanocytic nevus. Dermoscopic examination revealed a predominantly structureless lesion with homogeneous brown to reddish-brown pigmentation, subtle violaceous areas, and scattered lacunae-like structures, without specific melanocytic criteria. In February 2025, a shave excision was performed. Histopathological examination revealed findings consistent with cutaneous endometriosis. Following diagnosis, the patient was referred to gynecology, where a radical excision of the umbilical endometriotic lesion was performed. No additional endometriotic foci were detected. Subsequent follow-up examinations have shown no evidence of recurrence or other pathological findings. The patient remains under regular gynecological surveillance and is asymptomatic.

Conclusion

Umbilical endometriosis should be considered in the differential diagnosis of atypical or changing umbilical lesions in women of reproductive age. Dermoscopy may show non-specific vascular–hemorrhagic features without melanocytic structures. Histopathology remains essential for definitive diagnosis, and complete surgical excision provides an excellent prognosis.

EADV CONGRESS
VIENNA
30 SEP - 3 OCT 2026

Abstract N°: 1968

When age and morphology mislead: flat vulvar melanoma in situ in a young woman

Maria Maddalena Nicoletti*[1], Vincenzo Pellegrino[1], Camila Araujo Scharf Pinto[1], Gabriella Brancaccio[1], Renato Franco[2], Giuseppe Argenziano[1]

[1] Dermatology Unit, University of Campania “L. Vanvitelli”, Naples, Italy, naples, Italy

[2] 2Pathology Unit, Department of Mental and Physical Health and Preventive Medicine, Università degli Studi della Campania "L. Vanvitelli", naples, Italy

Introduction

Pigmented vulvar lesions are common in clinical practice and encompass a broad spectrum of benign and malignant conditions. Epidemiological data indicate that pigmented vulvar lesions are reported in approximately 10–12% of women, with the vast majority being benign. Vulvar melanocytic neoplasms are rare (≈1% of melanomas in women) and predominantly affect postmenopausal patients. They typically present as raised or palpable lesions. Conversely, flat pigmented vulvar lesions in young women are usually benign, with vulvar melanosis and melanocytic nevi representing the most frequent diagnoses. However, reliance on age and clinical morphology alone may delay recognition of early or atypical presentations of vulvar melanocytic malignancies.

Case Presentation

A 28-year-old woman presented with a single, unilateral, flat pigmented lesion on the labia majora measuring approximately 7 mm in maximum diameter. The lesion was asymptomatic and appeared clinically low risk. Dermoscopy revealed irregular diffuse brown–black pigmentation, focal blue–white veil, irregularly distributed dots and globules, and marked structural asymmetry. No dermoscopic patterns typically associated with benign vulvar pigmentation—such as parallel, ring-like, homogeneous, regular globular, or reticular configurations—were identified. Despite the reassuring clinical context, clinic–dermoscopic discordance and multiple high-risk features prompted excisional biopsy. Histopathologic examination demonstrated a proliferation of atypical junctional melanocytes without evidence of dermal invasion or tumor formation. Immunohistochemical analysis revealed strong cytoplasmic positivity for HMB-45 within the atypical melanocytic component, supporting the diagnosis of melanoma in situ. In light of the typical clinical presentation of vulvar melanoma, which predominantly affects postmenopausal women and typically presents as a raised, nodular, or clinically palpable lesion, this case is noteworthy. Although young age and flat morphology are often perceived as reassuring clinical features, they should not be considered sufficient to exclude malignancy or defer histological evaluation.

In this case, dermoscopy played a key role in highlighting features not appreciable on clinical examination: the absence of recognizable benign dermoscopic structures, together with multiple high-risk features, supported the decision to perform histopathological evaluation despite the reassuring clinical context, including young age and flat morphology.



(A) Clinical image showing a unilateral flat pigmented macule on the labia majora. (B) Dermoscopic image demonstrating asymmetric multicomponent pigmentation with irregular brown–black areas, focal blue–white veil, and irregular dots and globules. (C) Hematoxylin–eosin–stained section showing an atypical junctional proliferation of melanocytes with enlarged hyperchromatic nuclei and architectural disorder, without dermal invasion, and a mild superficial lymphohistiocytic infiltrate. (D) Immunohistochemical staining for HMB-45 highlighting the atypical junctional melanocytic proliferation, confirming the intraepidermal nature of the lesion.

Conclusion

This case underscores the importance of integrating dermoscopic assessment into the evaluation of vulvar pigmented lesions. While clinical features such as young age and flat morphology are generally reassuring, dermoscopy may reveal malignant characteristics not evident on naked-eye examination. Early recognition of clinic-dermoscopic discordance may facilitate diagnosis at an intraepithelial stage, enabling timely surgical intervention and potentially improving outcomes in a malignancy known for its aggressive course. Dermoscopic evaluation should be systematically incorporated as a complementary tool in the assessment of vulvar pigmented lesions, enhancing clinical judgment.

EA DV CONGRESS
VIENNA
30 SEP - 3 OCT 2026

Abstract N°: 1993

Comparison of a Vision Transformer (ViT)-based Artificial Intelligence Model and a Large Cohort of Dermatologists in Dermoscopic Image Classification: A Multicenter Study

Arcan Kıvanç Çapçı*[1, 2], Yeşim Akpınar Kara[1]

[1] Ankara Eğitim ve Araştırma Hastanesi, Department of Dermatology and Venereology, Altındağ, Türkiye
[2] Sorgun Devlet Hastanesi, Department of Dermatology and Venereology, Yozgat, Türkiye

Introduction

The integration of advanced deep learning architectures in dermatology remains a critical frontier. This study aimed to compare the diagnostic performance of an artificial intelligence (AI) model based on the Vision Transformer (ViT) architecture against a large, representative group of dermatologists. To our knowledge, this is the first study evaluating a ViT-based model alongside such a substantial cohort (n = 223) in dermoscopic classification, comparing results across different levels of clinical experience.

Materials and Methods

A ViT-based AI model was developed using a publicly available dermoscopic dataset (ISIC 2019). The developed model architecture (Figure 1) employs a Vision Transformer (ViT) backbone. It utilizes patch embedding to vectorize input images, processed through Multi-Head Self-Attention (MHSA) and Efficient Channel Attention (ECA) modules for robust feature extraction. To enhance stability and decision-making, the model incorporates Layer Normalization (LN) and Average Pooling (AP), with final classification achieved through a Logistic Regression meta-model that concatenates multi-layered feature projections.

A total of 223 participants, including 71 dermatology specialists and 152 residents, were enrolled. A test set of 80 dermoscopic images was selected for classification by both the AI model and the human participants. Performance was evaluated using balanced accuracy (BACC), macro-F1 score (Macro-F1), sensitivity (SEN), and specificity (SPE). Subgroup analyses were performed based on years of clinical experience and the type of medical institution where the participants practice.

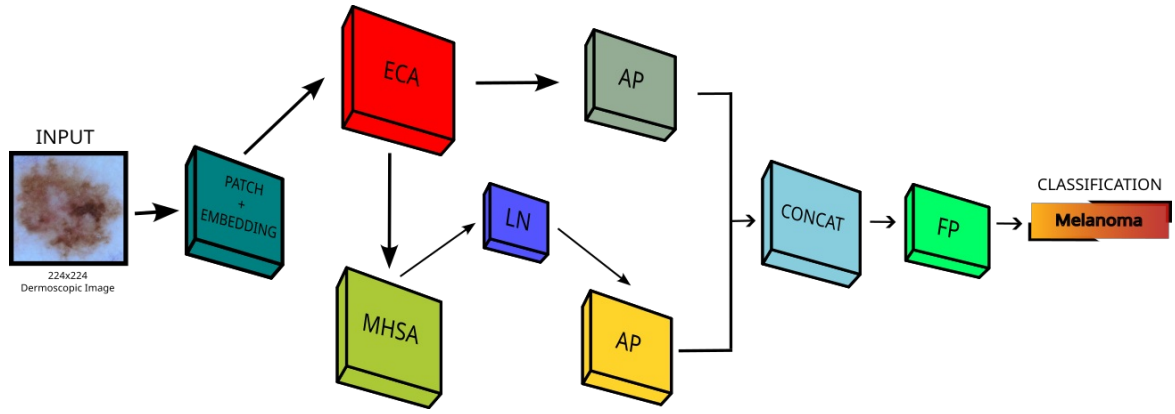

Figure 1. Schematic architecture and operational workflow of the proposed ViT-based model. The framework integrates patch embedding for spatial vectorization, followed by Multi-Head Self-Attention (MHSA) and Efficient Channel Attention (ECA) modules for relational and feature-wise optimization. Layer Normalization (LN) and Average Pooling (AP) ensure computational stability and dimensionality reduction. Final diagnostic output (e.g., Melanoma) is generated via a Logistic Regression meta-model that concatenates processed feature maps.

Results

The AI model demonstrated significantly higher diagnostic performance compared to human participants in both 8-class classification and malignant-benign differentiation. For the malignant-benign task, the model achieved consistent results across the test (n=1580) and quiz (n=80) datasets (BACC: 88.4%-85.3%, SEN: 83.9%-82.1%, SPE: 92.8%-88.5%, Macro-F1: 88.6%-85.0%, respectively). In contrast, the average performance of the 223 participants was substantially lower (BACC: 63.8% [range 49.7-81.5], SEN: 60.3% [21.4-89.3], SPE: 67.2% [36.5-94.2], Macro-F1: 62.9% [47.2-80.1]).

Subgroup analysis revealed that specialists with 1-2 years of experience achieved the highest BACC (68.3%) and Macro-F1 (67.4%), while specialists with <1 year experience had the highest SEN (65.7%). Among residents, the 4-5 year group showed the highest SPE (71.6%). While accuracy improved throughout training, performance peaked in early-career specialists and showed an inverse trend in those with over a decade of practice. Institution-based analysis showed that specialists at state hospitals excelled in 8-class classification, while those at university-affiliated centers performed better in malignant–benign differentiation. Notably, both the AI model and human participants demonstrated the lowest diagnostic accuracy in identifying actinic keratosis. Detailed metrics are provided in Table 1.

GROUP	Number of Participants (n)	BACC % (Min-Max)	SEN % (Min-Max)	SPE % (Min-Max)	Macro-F1 % (Min-Max)
Model - Test		88.4	83.9	92.8	88.6
Model - Quiz		85.3	82.1	88.5	85.0
All Participants	223	63.8 (49.7-81.5)	60.3 (21.4-89.3)	67.2 (36.5-94.2)	62.9 (47.2-80.1)
Institution Type					
University Hospital	110	64.1 (49.7-79.5)	59.7 (25.0-89.3)	68.4 (36.5-94.2)	63.3 (47.2-77.7)
State Hospital	85	64.0 (53.4-81.5)	62.1 (32.1-85.7)	65.9 (40.4-84.6)	62.9 (50.9-80.1)
Private Clinic	28	61.8 (53.0-71.6)	57.4 (21.4-78.6)	66.3 (42.3-92.3)	61.1 (51.2-71.4)
Title / Academic Rank					
Resident	152	63.7 (49.7-81.5)	60.3 (25.0-89.3)	67.1 (36.5-94.2)	62.8 (47.2-80.1)
Specialist	71	63.9 (53.0-78.7)	60.4 (21.4-78.6)	67.4 (42.3-92.3)	63.1 (50.9-77.5)
Workplace - Title					
Private Clinic - Specialist	28	61.8 (53.0-71.6)	57.4 (21.4-78.6)	66.3 (42.3-92.3)	61.1 (51.2-71.4)
State Hospital - Specialist	33	65.0 (53.4-78.7)	62.1 (42.9-78.6)	67.9 (42.3-84.6)	64.1 (50.9-77.5)
University Hospital - Specialist	10	66.0 (58.1-74.7)	62.9 (42.9-78.6)	69.2 (51.9-92.3)	65.2 (55.7-76.2)
State Hospital - Resident	52	63.4 (53.6-81.5)	62.2 (32.1-85.7)	64.6 (40.4-80.8)	62.2 (52.4-80.1)
University Hospital - Resident	100	63.9 (49.7-79.5)	59.4 (25.0-89.3)	68.4 (36.5-94.2)	63.2 (47.2-77.7)
Resident - Experience					
Resident - 1-2 years	62	63.5 (49.7-81.5)	61.2 (25.0-85.7)	65.9 (40.4-88.5)	62.5 (47.2-80.1)
Resident - 2-3 years	45	63.9 (53.7-74.7)	60.3 (28.6-89.3)	67.4 (36.5-94.2)	63.0 (52.4-71.9)
Resident - 3-4 years	41	63.8 (55.6-79.5)	59.5 (28.6-82.1)	68.0 (36.5-82.7)	63.0 (52.4-77.7)
Resident - 4-5 years	4	63.9 (58.7-72.3)	56.2 (50.0-71.4)	71.6 (67.3-78.8)	63.6 (58.4-71.0)
Specialist - Experience					
Specialist < 1 year	5	66.3 (64.0-68.4)	65.7 (57.1-71.4)	66.9 (63.5-73.1)	65.0 (63.1-66.5)
Specialist 1-2 years	3	68.3 (60.2-74.2)	65.5 (60.7-71.4)	71.2 (59.6-76.9)	67.4 (58.7-73.3)
Specialist 3-4 years	3	63.8 (61.0-65.2)	58.3 (53.6-64.3)	69.2 (57.7-76.9)	63.2 (59.1-65.4)
Specialist 4-5 years	14	65.6 (58.7-75.3)	64.3 (42.9-78.6)	66.9 (50.0-92.3)	64.4 (56.8-76.2)
Specialist 5-10 years	17	64.4 (53.4-73.6)	58.2 (42.9-78.6)	70.6 (46.2-86.5)	63.9 (50.9-74.4)
Specialist > 10 years	29	61.9 (53.0-78.7)	58.5 (21.4-78.6)	65.4 (42.3-92.3)	61.1 (51.2-77.5)

Table 1. Detailed Diagnostic Performance Metrics Abbreviations: BACC: Balanced Accuracy; SEN: Sensitivity; SPE: Specificity; Macro-F1: Macro-averaged F1-score; Min-Max: Minimum and Maximum values observed within the group; n: Number of participants. Notes: Data are presented as percentages (%). The "Model - Test" row refers to the performance on the ISIC 2019 validation set (n=1580), while "Model - Quiz" refers to the specific 80-image set evaluated by human participants. Participant experience for specialists is calculated from the date of obtaining the dermatology specialty degree.

Conclusions

ViT-based AI models can surpass dermatologists in dermoscopic image classification and hold significant potential as decision-support tools. Due to the large participant cohort and detailed subgroup analyses by experience level, this study provides unique insights into the comparative strengths of human versus machine intelligence in clinical dermatology.

EA DV CONGRESS
VIENNA
30 SEP - 3 OCT 2026

Abstract N°: 2039

Multiple Eruptive Dermatofibromas Mimicking Post-Acne Keloids in a Young Woman: A Case Report

Fatima Zahra Sassine*[1], Chourouq Mustapha Eid[1], Hyba Taounza[1], Yasmine Zekraoui[1], Kenza Benothmane[1], Syrine hamada[1], Laila Benzekri[1]

[1] Ibn Sina University Hospital, Dermatology Derpartment, Rabat, Morocco

Introduction

Dermatofibroma (histiocytofibroma) is a common benign fibrohistiocytic tumor typically presenting as a solitary, firm, hyperpigmented papule. Multiple eruptive dermatofibromas (MEDFs) are rare, defined by the rapid onset of numerous lesions, and have been associated with immunosuppressive conditions including systemic lupus erythematosus (19.8%), HIV infection (10.3%), hematologic malignancies (9.4%), and immunosuppressive therapies (23.4%). [2] However, a subset of cases remains idiopathic. The eruptive presentation may pose a diagnostic challenge, particularly when truncal lesions clinically mimic keloids or hypertrophic scars. Dermoscopy is a valuable non-invasive tool: the typical pattern of a peripheral delicate pigment network with a central white scar-like patch has a specificity approaching 100% for dermatofibroma.

Case Presentation

A 28-year-old woman with no significant medical history presented with multiple firm papular lesions predominantly involving the trunk, with a few additional lesions on the face, developing over a relatively short period. The lesions had been previously diagnosed as post-acne keloids and treated with multiple intralesional corticosteroid injections without clinical improvement.

On examination, multiple firm, skin-colored papules were noted on the back and trunk, with scattered facial lesions. Dermoscopic evaluation revealed a characteristic pattern consisting of a peripheral delicate pseudo-network with a central white scar-like area and a few vascular structures, findings highly suggestive of dermatofibroma. No features of keloidal or hypertrophic scarring were identified dermoscopically. A skin biopsy confirmed the diagnosis of dermatofibroma (histiocytofibroma).

Given the eruptive nature, a comprehensive workup was undertaken, including complete blood count, comprehensive metabolic panel, HIV serology, antinuclear antibodies, and autoimmune markers. All investigations returned within normal limits, classifying this case as idiopathic MEDFs.

Conclusion

This case illustrates several key clinical messages. First, the initial misdiagnosis as post-acne keloids highlights the clinical overlap between dermatofibromas and keloidal scars on the trunk, a pitfall further illustrated by the existence of keloidal dermatofibroma, a recognized histopathological variant bearing keloidal collagen. The failure of intralesional corticosteroid therapy should have prompted diagnostic reconsideration. Notably, corticosteroid therapy has itself been implicated as a potential trigger for MEDFs in immunosuppressed patients.

Second, dermoscopy proved essential in redirecting the diagnosis. The peripheral pigment network and central white scar-like patch pattern is highly specific for dermatofibroma and is absent in keloids, making dermoscopy a reliable tool for distinguishing these entities. Atypical dermoscopic patterns occur in up to 29.2% of dermatofibromas, reinforcing the need for biopsy in equivocal cases.

Third, the eruptive onset of multiple dermatofibromas warrants systematic investigation for associated conditions, as MEDFs show the most rapid disease onset among all multiple DF subtypes (mean 2.0 years) and are frequently linked to immune dysregulation. A proportion of cases, including ours, remain idiopathic after thorough evaluation.

Clinicians should maintain a high index of suspicion for dermatofibroma in patients with multiple firm papules unresponsive to keloid-directed therapies, and should systematically employ dermoscopy and histopathological confirmation.

EA DV CONGRESS
VIENNA
30 SEP - 3 OCT 2026

Abstract N°: 2048

Anatomical location shapes dermoscopic patterns and stage at diagnosis in lentigo maligna and lentigo maligna melanoma

Alejandra Méndez Valdés*[1], Reyes Gamo Villegas[1], Sara De Benito Mendieta[1], Irene Alonso Rodríguez[1], Lucía Martínez Rozas[1], Gemma María Jumilla Martínez[1], Soukaina Mellouk el Madroum[1]

[1] Hospital Universitario Fundación Alcorcón, Alcorcón, Spain

Introduction
Lentigo maligna (LM) and lentigo maligna melanoma (LMM) represent a continuous spectrum of melanoma arising on chronically sun-damaged skin. Dermoscopic features evolve progressively with tumor development, but their expression may vary according to anatomical location, potentially influencing early melanoma recognition and diagnostic accuracy. This study aimed to assess whether anatomical location is associated with differences in dermoscopic features of LM/LMM and whether these differences impact the stage at diagnosis.

Materials and Methods
Retrospective study including 233 histologically confirmed LM/LMM lesions. Dermoscopic features and predefined structural models were evaluated by experienced observers blinded to clinical and histopathological data. Lesions were categorized according to anatomical location (extrafacial, facial non-lateral, and facial lateral) and disease stage, and comparisons were performed across groups.

Results
Extrafacial lesions more frequently displayed melanocytic patterns characterized by relatively simple structures, including obliterated network (82.9% in extrafacial vs 23.3% in facial non-lateral, $p<0.001$) and irregular pigmentation foci (55.5% vs 21.9%, $p<0.001$). These findings suggest that reticular alterations represent highly sensitive dermoscopic markers for melanoma recognition, allowing identification of LM/LMM at very early stages, even before the development of more complex dermoscopic features.

In contrast, facial non-lateral lesions showed a predominance of follicle-dependent and structureless patterns, including blue-gray pigmentation (75.3% in facial non-lateral vs 54.1% in extrafacial, $p=0.002$) and structureless areas (65.8% vs 15.1%, $p<0.001$).

Importantly, facial non-lateral lesions were significantly larger at diagnosis (median 12.0 mm vs 9.0 mm in extrafacial lesions, $p=0.010$), and advanced lesions were more frequently observed in these locations compared with extrafacial sites ($p=0.002$).

Features reflecting structural complexity, such as pink coloration, white structures and atypical vessels, were significantly associated with advanced lesions (all $p\leq0.001$), whereas simpler patterns (parallel and/or radial lines, obliterated network) predominated in early lesions but were also observed in advanced stages, supporting a progression model in which early features may persist despite increasing structural complexity.

Conclusions
Dermoscopic expression of LM/LMM is strongly influenced by anatomical location. Extrafacial lesions tend to exhibit early reticular alterations that act as highly sensitive markers for melanoma recognition and may be present in both early and advanced lesions. In contrast, facial lesions display fewer reticular dermatoscopic features and a

predominance of alternative patterns, which may make early melanoma recognition more challenging.

These findings support a progressive dermoscopic model in which the lesion stage is reflected by the accumulation of structural complexity rather than the replacement of early features, highlighting the value of dermoscopy not only for early melanoma detection but also for assessing disease evolution.

EA DV CONGRESS
VIENNA
30 SEP - 3 OCT 2026

Abstract N°: 2117

Diagnostic and management concordance between dermatologists in an established secondary care teledermatology service in the United Kingdom

Pui Chi Lee*[1], Andre Khoo[1]

[1] Addenbrooke's Hospital, Cambridge, United Kingdom

Introduction
Teledermatology has emerged as a viable alternative to face-to-face review following the proliferation of high quality digital photography. However, the consistency of teledermatology assessments depends both on clinical experience and image quality. Our teledermatology service has been in operation since 2019 and complements our face-to-face skin lesion clinics in reviewing urgent referrals for suspected skin cancer. The aim of this study was to assess inter-clinician concordance in the diagnosis and management of skin lesions within our teledermatology service.

Materials and Methods
A retrospective random sample of 30 teledermatology cases referred under the two week wait skin cancer pathway (June - July 2024), was reviewed by five consultant dermatologists independently in an anonymised electronic survey. Each case included clinical vignette and photographs captured on a standardised protocol by medical photographers. All patient identifiers were removed, and clinicians were blinded to the outcome of the actual assessment. Patients with multiple skin lesions and ambiguous referral documentation were excluded from the selection process. Consultants recorded their diagnostic impression (benign, malignant, diagnostic uncertainty, or photographs non-diagnostic) and their recommended management. Inter-rater concordance was assessed using Fleiss' kappa coefficient and interpreted according to the Landis & Koch criteria.

Results
A total of 150 assessments across 30 cases were obtained from the 5 participating consultants. Diagnostic impressions were benign (43%), malignant (29%), diagnostic uncertainty (21%) or photographs non-diagnostic (4%) with kappa concordance of 0.38 (fair agreement). Management plan based on clinical impressions: benign (self-monitor/discharge 72%; topical treatment prescribed by GP 15%; clinic review 7%; biopsy 4%; excision 1%), malignant (excision 86%; biopsy 14%), diagnostic uncertainty (biopsy 56%; excision 25%; clinic review 13%; patient discharge with treatment recommendation to primary care 6%), and photographs non-diagnostic (clinic review 67%; biopsy 33%) - kappa concordance 0.42 (moderate agreement). Histological diagnosis was available for 13/30 cases who had gone on to have surgery during their original assessment. Comparing consultant diagnostic impression against histological outcome, the Cohen’s kappa concordance was 0.5 (moderate agreement).

Conclusions
In conclusion, the overall kappa concordance was fair for diagnosis and management with high consultant agreement for clearly benign and malignant lesions. Importantly, management variation

did not compromise clinical safety - no clinically ambiguous lesions were recommended for discharge and all such cases were directed towards biopsy, excision, or clinic review. A follow-up analysis incorporating an additional 30 cases reviewed by 9 consultants is currently underway, with results anticipated prior to the congress.

EADV CONGRESS
VIENNA
30 SEP - 3 OCT 2026

Abstract N°: 2164

Contribution of Dermoscopy to the Diagnosis of Temporal Triangular Alopecia

Ouissam BENMESSAOUD*[1], tarek MANSOUL[1], riadh BOUSSAID[1], amel GHERFI[1], Asma BOUHILA[1], Khadidja BOUARROUDJ[1], lilia Kaghouche[1], safa DJEBASS[1], Ahmed CHEHAD[1]

[1] Department of Dermatology, University of Constantine, Constantine, Algeria

Introduction

Temporal triangular alopecia (TTA), also known as congenital triangular alopecia, is a rare non-scarring alopecia first described in 1905 by Sabouraud. It presents as a localized and stable alopecic patch present from birth or early childhood. Its etiology is unknown, and most cases are sporadic. Often unrecognized and underdiagnosed, TTA may be confused with other causes of localized alopecia in children, leading to unnecessary investigations and inappropriate treatments. In this context, dermoscopy represents a simple and decisive tool to guide the diagnosis.

We report a new case highlighting the value of clinico-dermoscopic analysis in recognizing this entity

Case Presentation

A 6-year-old boy presented with a triangular alopecic patch present since birth, which had become a source of discomfort for the child and concern for his parents. Clinical examination revealed a single, well-demarcated, left-sided triangular patch, with a tuft of terminal hairs in the anterior third. Dermoscopy showed vellus hairs with normal follicular openings. No yellow dots, exclamation mark hairs, or dystrophic hairs were observed. The peripheral hair pull test was negative, confirming the stability of the lesion.

The clinical and dermoscopic findings, together with the congenital and stable course of the lesion, supported the diagnosis of temporal triangular alopecia. A conservative management approach with regular follow-up was adopted.

Conclusion

Temporal triangular alopecia is a benign, non-inflammatory, and non-scarring condition, whose diagnosis is based on characteristic clinical and dermoscopic features
Better recognition of this entity helps to avoid unnecessary investigations and treatments and ensures appropriate and reassuring management.

EA DV CONGRESS
VIENNA
30 SEP - 3 OCT 2026

Abstract N°: 2209

Magnified dermoscopy allows better differentiation between Dermal Nevi and Basal Cell Carcinoma.

Joanna Pogorzelska-Dyrbuś*[1], Maria Teresa Fernández-Figueras[2], Jacek C. Szepietowski[3]

[1] "Estevita" Specialist Medical Practice, Tychy, Poland

[2] Hospital Universitari General de Catalunya, Department of Pathology, Sant Cugat del Vallès, Barcelona, Spain

[3] Division of Dermatology, Venereology and Clinical Immunology, Faculty of Medicine, Wroclaw University of Science and Technology,, Wrocław, Poland

Introduction

Dermal nevi (DN) and Basal Cell Carcinoma (BCC) are among the most common nodular lesions on the face sometimes presenting with similar dermoscopic features. Magnified dermoscopy (MD), thanks to magnification up to 400x, can improve diagnostic accuracy of various lesions. So far, the literature on MD remains scarce, but the first observation published to date has shown that MD can reveal significant differences between DN and BCC. The purpose of our study was to find the characteristic MD features of both DN and BCC that could enable their better differential diagnosis.

Materials and Methods

A retrospective analysis of dermoscopic images from 73 histopathologically confirmed facial lesions (DN and BCC) was performed in standard dermoscopy (SD) (20x magnification) and MD (400x). All images were acquired using the Medicam 1000 (FotoFinder Systems, Bad Birnbach, Germany), and MD examination was performed with the D Scope III lens (FotoFinder Systems). Imaging data were jointly evaluated by two reviewers unaware of the results of histopathological examination. Image interpretation was performed in a consensus-based manner. Fifty-one (69.9%) of lesions were diagnosed as BCC and twenty-two (30.1%) as DN. Among SD features, morphology of the vessels and presence of pigmentation were evaluated, for MD, roundish and polygonal structures, structures with fading borders, granules and vessels according to the terminology criteria were analyzed. Patient characteristics and dermoscopic features were compared between DN and BCC.

Results

The SD and MD features of both types of lesions , and examples of features in both types of imaging in both BCC and DN are presented in Figure 1. Lesion localization differed ($p=0.001$), with DN more frequently located on the chin and nose, whereas BCC showed a higher proportion on the forehead and included eyelid involvement, which was absent in DN. Regarding SD features, coma vessels and pigment were significantly more common in DN (77.3% and 72.7%, respectively), while tree-like vessels were markedly more frequent in BCC (66.7%) (all $p<0.001$). Linear vessels in SD were common in both groups without significant differences, suggesting limited discriminatory value for this feature alone. Among MD features, the roundish structures were observed in 90.9% of DN and in none of the BCCs ($p<0.001$). Polygonal structures were present in 6 (27.2%) of DN and in 1 (1.9%) of BCC ($p=0.002$). MD allowed to observe vessels invisible in SD, with a statistically significantly higher prevalence of arborizing, irregular and looped vessels in BCC cases. Roundish structures observed in MD demonstrated the highest diagnostic performance, with very high sensitivity (91.0%) and perfect specificity (100%) for DN. Coma vessels in SD also showed strong discriminatory potential, with 77.0% sensitivity and 94.0% specificity. In contrast, the presence of arborizing or irregular vessels in MD strongly favored the diagnosis of BCC, with specificity of

both at respectively 80.0% and 76.0% for differentiation vs DN.

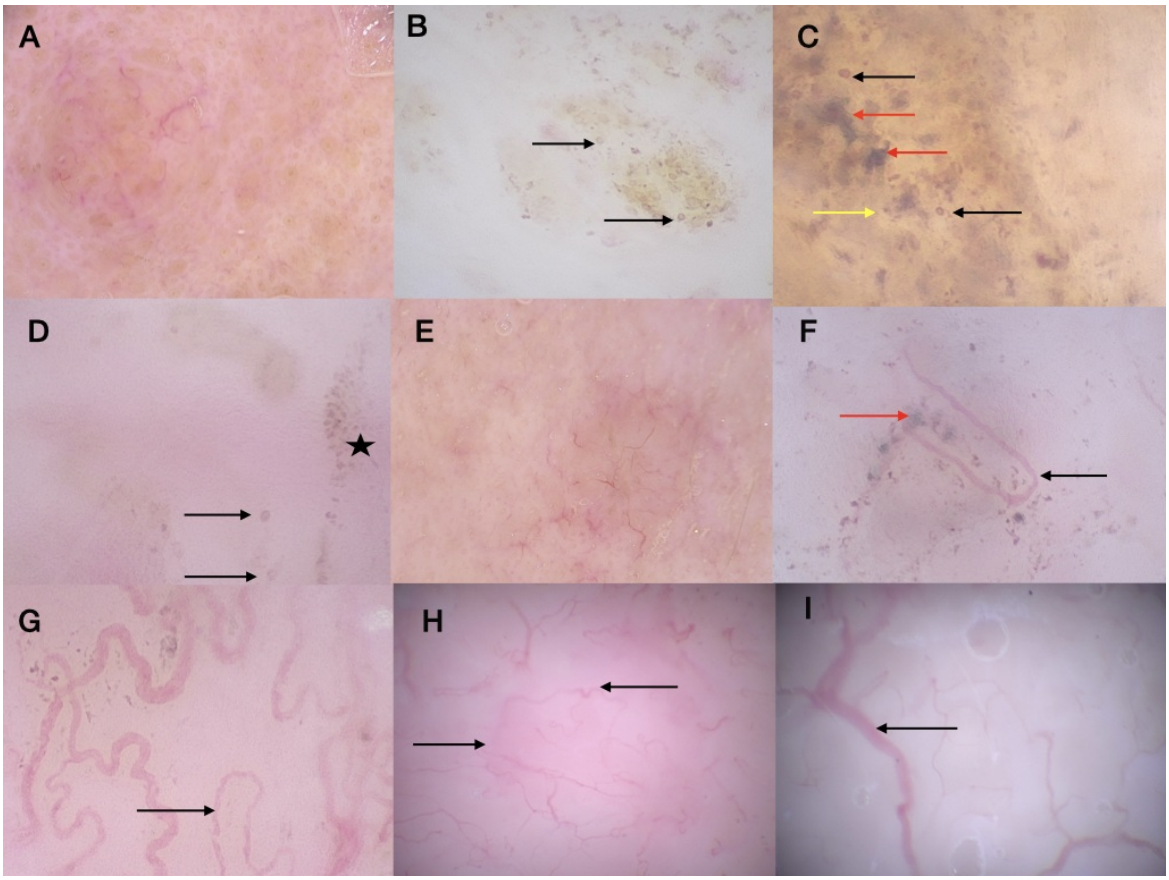

Dermoscopic and magnified dermoscopic features of dermal nevi and basal cell carcinoma. DN in standard magnification (A) and in MD (B-D). Brown roundish structures with a darker rim corresponding to melanocytes (black arrows). Structures with fading borders corresponding to melanophages indicated by red arrows, and granule corresponding to free melanin (yellow arrow). Polygonal structures corresponding to pigmented keratinocytes(asterisk). BCC in standard magnification (E), and in MD (F-I). Structures with fading borders (red arrow) and looped vessel (black arrow) (F). Looped vessels (G), irregualar (H), and arborizing(I) indicated by black arrows.

Conclusions

Our findings suggest that MD may be a useful adjunctive tool in the differential diagnosis between DN and BCC. Roundish structures appear to be a characteristic MD feature of DN and demonstrated the highest diagnostic performance, with very high sensitivity and perfect specificity. In contrast, the presence of arborizing or irregular vessels in MD strongly favors the diagnosis of BCC. Moreover, BCC lesions are characterized by the absence of roundish structures and by a higher number of irregular, linear, and looped vessels. Although these results highlight the potential diagnostic value of MD in distinguishing DN from BCC, further studies with larger cohorts are needed to validate these findings.

EA DV CONGRESS
VIENNA
30 SEP - 3 OCT 2026

Abstract N°: 2232

Ultraviolet-induced fluorescent dermoscopy: distinctive fluorescence patterns across dermatological disorders in skin of colour

Divya Madonna Dsouza*[1]

[1] Father Muller Medical College Hospital, Mangalore, India

Introduction

Ultraviolet-induced fluorescent dermoscopy (UVFD) is an emerging non-invasive imaging modality that complements conventional dermoscopy by exploiting fluorescence based on the Stokes shift phenomenon. It enables visualization of subsurface chromophore activity not appreciable under polarized or non-polarized light. While UVFD has demonstrated utility in selected neoplastic conditions, its broader applicability, particularly in patients with higher Fitzpatrick skin phototypes remains insufficiently characterized. This study aims to describe UVFD patterns across dermatological disorders and evaluate its diagnostic utility in comparison with polarized dermoscopy.

Materials and Methods

A cross-sectional observational study was conducted on 200 patients presenting with diverse dermatological conditions. Clinical diagnoses were supported by dermoscopic evaluation and histopathology where indicated. Each lesion was examined using non-polarized dermoscopy, polarized dermoscopy, and UVFD (365 nm). Images were independently assessed by two experienced dermatologists, with consensus resolution for discrepancies. UVFD features were categorized based on observed fluorescence patterns. Statistical analysis was performed using Fisher's exact test, with $p < 0.05$ considered significant.

Results

A total of 200 patients were included, encompassing inflammatory, infectious, pigmentary, adnexal, and neoplastic dermatoses. Ultraviolet-induced fluorescent dermoscopy (UVFD) revealed distinct, disease-specific fluorescence patterns. Among inflammatory disorders, psoriasis demonstrated characteristic pink-red fluorescence, while pityriasis rubra pilaris showed a "blue straggler star" appearance. Acne lesions exhibited orange-red follicular fluorescence in comedones along with follicular blackout areas in inflammatory lesions. Lichen planus showed absence of fluorescence with Wickham striae, and prurigo nodularis demonstrated no specific fluorescence. In infectious and infestational conditions, dermatophytosis showed absence of fluorescence, whereas scabies revealed burrows with bright blue-green fluorescence of the mite. Cutaneous larva migrans demonstrated linear bright green fluorescence corresponding to the larva, and pediculosis capitis showed viable ovoid nits attached to the hair shaft, enhanced under UVFD. Erythrasma displayed coral-red fluorescence, and onychomycosis showed yellow-orange fluorescence. Among pigmentary disorders, pityriasis versicolor had light green scaling accentuated within skin furrows, while vitiligo demonstrated accentuation of depigmented areas. Melasma showed enhanced epidermal pigmentation with well-defined borders, whereas café-au-lait macules exhibited ill-defined borders. Blue nevus (dermal pigmentation) appeared non-accentuated with blurred borders. In neoplastic and other conditions, verruca showed microhemorrhages, epidermodysplasia verruciformis demonstrated a cerebriform pattern, and cutaneous T-cell lymphoma exhibited yellowish-blue white clods. In hair disorders, presence of physiological cutibacterial orange–red coproporphyrin III fluorescence of the hair follicle ostia, a predictor of hair regrowth, Cutibacterium colonization -viable hair follicle units. In alopecia areata showed absence of orange-red follicular fluorescence with prominent yellow dots.

Conclusions

UVFD provides additional diagnostic information by revealing disease-specific fluorescence signatures across a broad range of dermatological conditions. It serves as a valuable adjunct to conventional dermoscopy, improving lesion characterization, diagnostic confidence, and potential treatment monitoring. Further standardization of UVFD criteria and validation in larger cohorts are warranted.

EA DV CONGRESS
VIENNA
30 SEP - 3 OCT 2026

Abstract N°: 2339

Hiding in Plain Sight: The Diagnostic Role of Dermoscopy in Hidradenitis Suppurativa

Alexandra Catrânescu*[1], Isabela Iancu[1], Maria Tiron[1], Alexandra-Irina Butacu[2]

[1] Spitalul Clinic Colentina, București, Romania

[2] 'Carol Davila' Faculty of Medicine, Spital Clinic Colentina Bucuresti, București, Romania

Introduction

Hidradenitis suppurativa (HS, hidradenitis suppurativa) is a chronic inflammatory disorder characterized by the appearance of nodules that may progress into extensive lesions with tunnel formation, potentially leading to suppuration and scarring, ultimately resulting in functional impairment and a dramatic reduction in quality of life.The pathogenesis of HS is centered on follicular occlusion, an altered immune response, and bacterial colonization, while hormonal factors and lifestyle habits may contribute to disease severity.

The diagnosis of HS is based on the recognition of typical lesions (nodules, abscesses, tunnels and scars) in characteristic anatomical sites (axillary, inguinal, inframammary regions); however, the spectrum of clinical presentations is highly heterogeneous. Dermoscopy represents a highly useful method for the diagnosis of HS and for differentiating it from other clinically similar conditions, especially in atypical cases. It also allows assessment of lesion activity, surrounding skin changes, lesion extent and treatment response. The most frequent dermoscopic features are summarized in Table 1.

Dermoscopy pattern	Characteristics of dermoscopic patterns
Double-ended Pseudocomedones	Deep-seated blackheads, often appearing in pairs or in close proximity, connected by a tunnel and surrounded by whitish fibrotic tissue
Whitish Fibrotic/Cicatricial Areas	Thick, white scar tissue surrounding active lesions
Vascular Structures	Perifollicular red dots and arborizing vessels
Open Comedones and Follicular Plugs	Widened hair follicle openings filled with keratin
Draining Tunnels and Sinus Openings	Dark-red or yellow-whitish openings that represent sinus tracts
Bluish Connections	Bluish lines connecting two openings and can indicate tunnels beneath the skin
Tombstone pattern	Linear scarring and multiple comedones give an appearance similar to a row of tombstones

Table 1: The most frequent dermoscopic features of HS

Materials and Methods

We present a case series of 5 patients (3 females and 2 males, age 29–50 years), diagnosed with HS, who underwent dermoscopic examination to evaluate the presence of the most common dermoscopic patterns associated with HS. At the time of assessment, all patients exhibited characteristic lesions, including painful nodules, cutaneous abscesses and fibrosing scars, located in typical anatomical sites (axillary and inguinal regions). Four patients were receiving anti-TNF- α biologic therapy (adalimumab), while one patient was undergoing systemic antibiotic treatment (clindamycin monotherapy).

Results

Dermoscopic evaluation revealed the presence of double-ended pseudocomedones, open comedones, follicular plugs, sinus openings, and whitish cicatricial areas in all 5 cases, representing highly characteristic signs of HS. Double-ended pseudocomedones, considered the hallmark dermoscopic feature of HS, appeared as paired or closely adjacent deep-seated blackheads connected by subcutaneous tunnels and surrounded by fibrotic tissue, typically developing in the context of chronic inflammation and scarring. Whitish cicatricial areas represented thick scar tissue secondary to longstanding inflammation and were consistently observed in chronic lesions. Dermoscopy also proved useful in distinguishing HS-related scars from atrophic acne scars, which generally display less sharply demarcated borders and a more homogeneous base. Sinus openings appear as small, often multiple holes on the skin surface, corresponding to underlying sinus tracts. Open comedones and follicular plugs

are key indicators of follicular occlusion and they are often associated with chronic inflammation and cicatricial changes.

Conclusions

Dermoscopy may significantly improve diagnostic accuracy by revealing features not visible to the naked eye and may contribute to a better understanding of the pathogenetic mechanisms underlying HS. Recognition of the most common dermoscopic patterns may facilitate accurate diagnosis in patients with minimal, atypical, or chronic inactive presentations.

EA DV CONGRESS
VIENNA
30 SEP - 3 OCT 2026

Abstract N°: 2344

Bilateral Nevoid Telangiectasia: Dermoscopic Findings and Differential Diagnosis

Yıldız Gürsel Ürün[1], Hülya Mürüvvet GÜVENDİ*[1], Mustafa Ürün[1]

[1] Trakya University Faculty of Medicine Department of Dermatology and Venereology, Edirne, Türkiye

Introduction
Unilateral nevoid telangiectasia (UNT) is typically confined to the upper trunk in a unilateral dermatomal distribution, particularly in the C3 and T3 dermatomes. Bilateral nevoid telangiectasia (BNT), a rare variant of UNT, presents with a bilateral distribution. The precise aetiology remains unknown; however, there is a recognised association with hyperestrogenic states. This case report aims to describe the dermoscopic features of BNT.

Case Presentation
A 48-year-old female patient presented to our clinic with a previously asymptomatic dermatological condition that had developed over time. The initial manifestation of the condition occurred on her breasts approximately 20 years ago following in vitro fertilisation treatment. Her medical history included fibromyalgia, which had been treated with duloxetine. A family history of breast and colon cancer was present, although no similar skin lesions were observed.

The dermatological examination revealed the presence of telangiectatic macules and patches on the bilateral breast, situated between the T3 and T5 dermatomes. No mucosal lesions were identified. A dermoscopic examination revealed thin (<2 mm) and thick (>2 mm) telangiectatic vascular structures, occasional spider-shaped telangiectasias, dot and blotch structures.

The following tests were conducted and the results were found to be within the normal range or negative: a complete blood cell count, biochemistry, thyroid function tests, antinuclear antibody, anti–extractable nuclear antigen antibody screening, c- perinuclear antineutrophil cytoplasmic antibody, cytoplasmic antineutrophil cytoplasmic antibody, rheumatoid factor test, coagulation profile, complement tests, and serology testing for human immunodeficiency virus, hepatitis C virus, hepatitis B virus, and syphilis.

The biopsy of the telangiectatic patch on the right breast revealed the presence of orthokeratosis, epidermal thinning, an increase in blood vessels in the mid-dermis, mild dilation in superficial vessels, and enlargement of endothelial cells. The patient was diagnosed with BNT based on clinical, dermoscopic and histopathological findings.

Conclusion
BNT is a rare condition, with a total of 26 cases described in the literature. Of these cases, eight were female and 18 were male. The age at diagnosis ranged from 27 to 65 years. The most common comorbidity was liver disease. Spider-shaped or punctate telangiectasia was observed in the majority of cases. In a case, both punctate and spider-shaped telangiectasia were observed.

Some authors proposed the term "acquired bilateral telangiectasia macules" (ABTM) as a replacement for "acquired BNT". Additionally, dermoscopic examination reveals the presence of brown pigmentation in ABTM. A

review of our case and other relevant literature reveals that erythematous background is a more prominent feature in BNT patients, rather than brown pigmentation, as observed clinically and dermoscopically.

Prior to diagnosing BNT, dermoscopy can also assist in this regard, in addition to the clinical features outlined in Table 1. In dermoscopic evaluation of our case, both spider-shaped and punctate telangiectasia were observed. It is important to note that both of these dermoscopic features can be seen in the differential diagnosis.

Although BNT is a rare condition, it is important to highlight the clinical, dermoscopic features of this entity and to emphasise that BNT should be considered as a differential diagnosis in cases of superficial telangiectasia.

Table 1. Differential diagnosis of primary telangiectatic disorders: Clinical and dermoscopic characteristics.

	Gender	Age of disease onset	Family History	Localisation	Other concomitant findings	Dermoscopy
Generalized Essential Telangiectasias	F>M	40s-50s	Positive	Lower legs, upper legs, abdomen, and arms	Only telangiectasies	Fine arborizing vascular dilations
Hereditary hemorrhagic telangiectasia	F=M	Middle age	Positive	Lips, palms, soles, nails, nasal mucosa	Epistaxis, gastrointestinal bleeding, pulmonary and central nervous system arteriovenous malformation	Thick serpentine and linear vessels, pinkish background
Telangiectasia macularis eruptiva perstans	F=M	Young adults	Negative	Trunk, proximal extremities	Mast cells in dermal tissue	Linear branching vessels, background of brownish discoloration
Unilateral nevoid telangiectasia	F>M	19-year-old	Negative	C3-T2 dermatomes	Increased level of estrogen or VEGF, HCV, cirrhosis	Red tortuous capillaries
Angioma serpiginosum	F>M	Childhood	Positive	Lower extremities	Asymmetrical distribution, typically arranged in a serpiginous pattern	Red oval lagoon
Acquired bilateral telangiectatic macules	M>F	Adults	Negative	Upper arms	Hyperpigmentation of basal layer of epidermis	Brown pigmentations, telangiectasia, angioid streak pattern

F: Female; M: Male; HCV: Hepatitis C virus; VEGF: Vascular endothelial growth factor.

EA DV CONGRESS
VIENNA
30 SEP - 3 OCT 2026

Abstract N°: 2405

Ultraviolet Dermoscopic Patterns in Pityriasis Versicolor: Clinical Significance and Diagnostic Value

Aimane Zaim*[1], Meryem Soughi[1], Ghita Gmira[1], Soraya Laraqui Houssaini[2], Ikrame Bejja[1], Saadia Boughaleb[1], Zakia Douhi[1], Sara Elloudi[1], Hanane Baybay[1], Fatima Zahra Mernissi[1]

[1] Department of Dermatology, Hassan II University Hospital, Sidi Mohamed Ben Abdellah University, Fez, Morocco
[2] Laboratory of Epidemiology, Clinical Research and Community Health, FMPDF, FEZ, Morocco Sidi Mohammed Ben Abdellah University, Fez, Morocco

Introduction

Pityriasis versicolor (PV) is a common superficial fungal infection caused by *Malassezia* species, leading to skin discoloration. Diagnosis is usually clinical and supported by Wood's lamp and potassium hydroxide examination, while dermoscopy may assist in doubtful cases. Although features observed with polarized dermoscopy have been described, data on ultraviolet fluorescence dermoscopy (UVFD) remain limited to isolated reports. These suggest greenish fluorescence related to pityrialactone, along with findings such as contrast halo, scaling, and interruption of cutibacterial fluorescence (blackout area). However, the diagnostic value of UV dermoscopy and its correlation with clinical patterns have not been systematically investigated.

Materials and Methods

We conducted a 12-month cross-sectional study including patients with clinically or mycologically confirmed PV. Each patient underwent polarized and UV dermoscopic examination of up to three lesions. Patients who had received antifungal treatment within the previous 4 weeks or had applied fluorescent products within 48 hours were excluded. We described UV dermoscopic patterns in PV and evaluate their diagnostic value by analyzing their association with clinical features, patient characteristics, disease-related factors, environmental factors, and their concordance with conventional dermoscopy.

Results

A total of 35 patients were included (77.8% male; mean age 28.3 years; 68.1% dark phototypes). Clinical forms were hypopigmented (18.1%), hyperpigmented (26.4%), erythematous (6.9%), bichrome (36.1%), and trichrome (18.1%). Pruritus was present in 61.1% of cases, and resistant/recurrent PV in 30.6%. Lesions were mainly located in seborrheic areas (79.2%). A total of 72 lesions were analyzed, predominantly macular (62.5%) versus papular/plaque (37.5%), with spontaneously visible scaling in 44.4%. Polarized dermoscopy supported the diagnosis of PV in 44.4% of cases. Under UV mode, greenish fluorescence was observed in 91.7% of lesions, with variable shades: light green (56.1%), dark green (25.8%), and blue-green (18.2%). Light green predominated in hypopigmented (84.6%), erythematous (75%), bichrome (50%), and trichrome forms (45.4%), whereas dark green was more frequent in hyperpigmented forms (42.1%) and blue-green in trichrome forms (45.4%). Fluorescence presence was only associated with pruritus and scaling. Fluorescence intensity was significantly associated with sex and lesion type, being stronger in females and in papular/plaque lesions. Interruption of cutibacterial fluorescence was observed in 22.2% of cases and was significantly associated with erythematous forms, longer disease duration (>6 months), and resistant/recurrent PV. Additional UV features included follicular/peripilar blue-white fluorescence (45.8%), green and blue fluorescence of scaling (72.2% and 31.9%, respectively). We also describe novel patterns, including cobblestone (8.3%), constellation (9.7%), and snowflake-like (2.8%) appearances.

Compared with conventional dermoscopy, UV dermoscopy improved lesion delineation (73.6%), highlighted the contrast halo sign (29.1%), enhanced detection of satellite lesions (starry sky pattern in 18%), and improved scaling visualization (visible only under UV in 25% and more prominent in 54.2%), with a “barbed-wire” scaling pattern in 15.3%. Concordance between UV and conventional dermoscopy was low (kappa = 0.085).

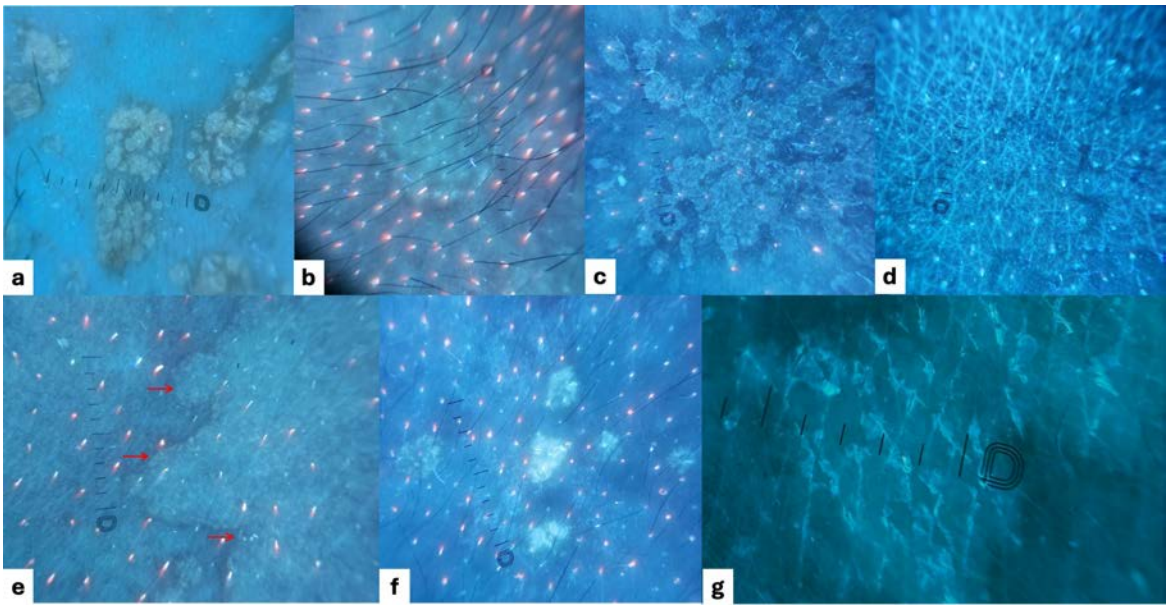

Figure: UV dermoscopic images (DermLite DL5, ×10) showing dark green fluorescence with a cobblestone pattern (a), light green fluorescence with interruption of cutibacterial fluorescence (b), blue–green fluorescence with a snowflake-like appearance (c), follicular/peripilar blue–white fluorescence with a constellation pattern (d), a contrast halo sign (red arrow, e), a starry sky pattern (f), and green fluorescence of scales with a “barbed-wire” scaling pattern (g).

Conclusions

This original study demonstrates that UV dermoscopy is a valuable, non-invasive diagnostic tool that enhances the detection and characterization of PV, outperforming conventional dermoscopy. It identifies distinct fluorescence patterns and introduces previously undescribed UV dermoscopic features. Importantly, fluorescence was not affected by recent washing, unlike in erythrasma. UV dermoscopy may also be useful for therapeutic monitoring, reflected by the disappearance of green fluorescence and scaling, and the reappearance of follicular cutibacterial fluorescence.

Parameter	Presence of fluorescence	Fluorescence intensity	Interruption of cutibacterial fluorescence
Clinical features			
Clinical forms	,230	1,000	**,001 (erythematous forms)**
Lesion type	,400	**,010 (papular/plaque lesions)**	,258
Lesion distribution	,189	,766	-
Scaling	**,022**	,327	-
Pruritus	**,001**	1,000	-
Patient characteristics			
Age	,459	,440	-
Sex	,119	**,029 (stronger in females)**	-
Phototype	,402	,304	-
Disease-related factors			
Duration	,459	,601	**,019 (longer disease duration >6 months)**
Resistant/recurrent forms	,440	,794	**,011**
Environmental factors			
Season	,459	1,000	-
Recent bathing/ scrubbing <48	,322	1,000	-

Table: Association between fluorescence characteristics and clinical features, patient characteristics, disease-related factors, and environmental factors.

EA DV CONGRESS
VIENNA
30 SEP - 3 OCT 2026

Abstract N°: 2431

Basaloid follicular hamartoma in Happle-Tinschert syndrome: dermoscopic findings in a rare entity

Carolina Cruz*[1], Amanda Tanaka Iasbeck Gonçalves[1], Ana Clara Maia Palhano[1], Luciana de Paula Samorano[1], Maria Cecília Rivitti-MacHado[1], Zilda Najjar Oliveira[1]

[1] Universidade de São Paulo, São Paulo, Brazil

Introduction

Basaloid follicular hamartoma (BFH) is a rare benign adnexal neoplasm derived from the hair follicle, histologically characterized by cords and trabeculae of basaloid cells associated with follicular structures. It can occur sporadically or in association with syndromes, including Hedgehog/PTCH pathway lesions, such as Happle-Tinschert syndrome. Clinically, it presents as papules, plaques, or linear lesions distributed along Blaschko lines, often raising suspicion of other adnexal neoplasms or basal cell carcinoma (BCC). Despite the increasing use of dermatoscopy in adnexal tumors, the dermoscopic findings of BFH remain poorly described.

Case Presentation

A 26-year-old woman presented with papules coalescing into plaques following Blaschko lines on the anterior chest, breast, and left upper and lower limbs since birth. Associated findings included syndactyly, forearm bone malformations, supernumerary and abnormally shaped teeth, and thoracolumbar levoconvex scoliosis. Histopathology of biopsies obtained from different site lesions revealed BCC-compatible findings in some samples, while others presented basaloid follicular hamartomas and trichoepitheliomas. Consistent with Happle-Tinschert syndrome.

Dermoscopy revealed multiple rounded whitish-yellow structures, some coalescent and multilobulated with a folliculocystic appearance, over a mildly erythematous pink background. Some structures had central keratotic content and partially ill-defined borders, forming aggregated whitish clods resembling "may globule-like structures." Fine linear telangiectasias, subtle brownish perifollicular pigmentation, and structureless whitish-yellow areas were also observed. No classic BCC criteria were identified, such as arborizing vessels, blue-gray ovoid nests, ulceration, or erosions.

Conclusion

Few reports have specifically addressed BFH dermoscopy. Choi et al. described a structureless blue lesion; Adya et al. reported whitish globules histologically corresponding to dilated follicles with brownish clods related to perifollicular basaloid proliferation; Muhammad et al. observed rounded structures with brown-gray globules, arc-like lines, and keratotic plugs; Rekik et al. described whitish-yellow areas, milia-like cysts, yellowish globules, and fine telangiectasias, including BCC transformation features. Our findings share previously described BFH characteristics, particularly milia-like cysts, though larger more confluent, and multilobulated, resembling "may globule-like structures," likely reflecting follicular dilation with perifollicular basaloid proliferation. The main differential is BCC, given their shared Hedgehog/PTCH molecular overlap. Recognizing BFH dermoscopic features is clinically relevant to avoid unnecessary excisions. Despite partial overlap with BCC within the adnexal follicular tumor spectrum, the absence of classic BCC criteria favors a benign follicular adnexal pattern. Finally, we compiled into a table the different dermoscopy findings between BCC and BFH.

Dermoscopic feature	Basaloid follicular hamartoma (BFH)	Basal cell carcinoma (BCC)
White structures	Whitish-yellow globules/clods, frequently follicular, may resemble milia-like cysts or "may globules-like"	Structureless whitish-red areas, white shiny streaks (may globules)
Brown/gray globules	Possible	Frequent
Blue-grey ovoid nests	Generally absent	Classic
Arborizing vessels	Absent or subtle	Frequent and typical
Fine short telangiectasias	May occur	Common in superficial BCC
Spoke-wheel structures	May occur, but without a typical dark central hub	Classic when converging toward a pigmented center
Ulceration/erosions	Absent in the benign form	Frequent
White streaks / chrysalis	Generally absent	Common
Maple leaf-like areas	Not classically described	Characteristic
Pink background	May occur	Frequent

EA DV CONGRESS
VIENNA
30 SEP - 3 OCT 2026

Abstract N°: 2496

Correlation Between Conventional Dermatoscopy and Ultraviolet Fluorescence in Cutaneous Circumscribed Lymphangioma

Carolina Droguett*[1], Paulina Naranjo Arce[1], Gabriel Aedo Inostroza[2], Ana María Martínez Afani[1]

[1] Universidad de Santiago de Chile, Santiago, Chile

[2] Hospital El Pino, Santiago, Chile

Introduction

Cutaneous lymphangiomas, or microcystic lymphatic malformations, are benign anomalies characterized by dilation of superficial lymphatic channels. Circumscribed lymphangioma (CL) is the most common superficial variant and presents clinically as clustered translucent or pinkish vesicles, with the classic "frog egg" appearance. Conventional dermatoscopy typically shows yellowish, whitish, or translucent lacunae, separated by pale septa, occasionally associated with hemorrhagic lacunae with the "hypopyon" sign, corresponding to a fluid-fluid level due to erythrocyte sedimentation at the bottom of the lacuna. Although these findings are well established, the behavior of these lesions under ultraviolet fluorescence dermatoscopy at 365 nm (UVFD) has been scarcely described, making the documentation of their optical patterns of particular interest.

Case Presentation

A female patient presented with grouped, asymptomatic, progressively growing papulovesicular lesions located on her right scapular region. These lesions had been previously excised in primary care under a diagnosis of molluscum contagiosum, without histopathological examination. Due to the recurrence of the lesions, the patient was referred for dermatology evaluation. Physical examination revealed multiple translucent papules and vesicles with a pinkish-white hue, some containing blood, and visible hemorrhagic areas. (Figure 1a)
Conventional dermatoscopy with polarized light showed: multiple rounded, whitish, translucent lacunae; pale septa delimiting the structures; homogeneous pink areas; reddish-purple hemorrhagic lacunae; and foci with a classic "hypopyon" appearance due to erythrocyte sedimentation. (Figure 1b)
UVFD showed marked accentuation of the whitish-yellow lacunar structures, with a significant increase in contrast to the surrounding skin. Pale septa were attenuated to a brownish-gray tone, and the translucent lacunae had an opaque, shiny appearance and intense bluish-white fluorescence. The hemorrhagic areas appeared dark (due to light absorption and the absence of hemoglobin fluorescence) and well-defined. UVFD also allowed for the identification of small satellite lacunae that were less evident under conventional dermatoscopy. (Figure 1c)
Given the suspected diagnosis, a histopathological study was requested, the findings of which were consistent with a microcystic lymphatic malformation (CL).

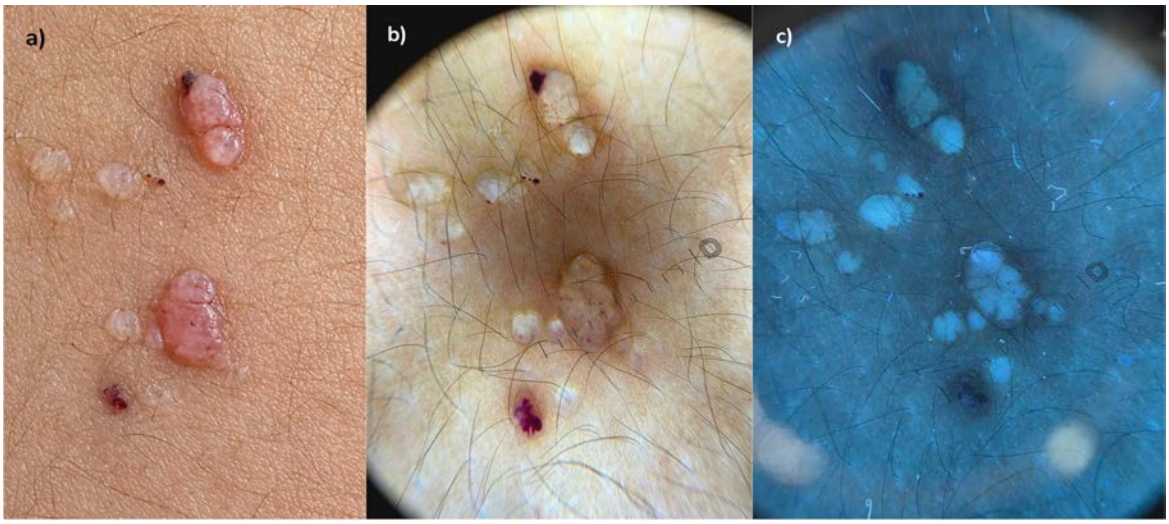

Figure 1. Clinical, conventional dermatoscopic, and ultraviolet fluorescence correlation in a circumscribed cutaneous lymphangioma. (a) Clinical photograph showing multiple grouped, translucent, pinkish-white papules and vesicles, some with blood content and punctate hemorrhagic foci, configuring the characteristic clinical appearance of superficial vesicular lesions of the "frog egg" type. (b) Conventional dermatoscopy under polarized light shows multiple whitish-translucent, rounded to multilobulated lacunae, corresponding to superficial lymphatic vesicles. Reddish-purple hemorrhagic foci and small intralesional hemorrhagic areas are also observed, consistent with bloody content secondary to microhemorrhage within dilated lymphatic spaces. (c) Dermoscopy under ultraviolet light shows that the vesicular structures acquire a pronounced fluorescent bluish-white hue, with better delineation of the cystic spaces and improved contrast with the surrounding tissue. The hemorrhagic foci retain a dark, non-fluorescent purplish coloration, facilitating their identification.

Conclusion

The dermatoscopic findings of the CL reflect dilated lymphatic channels in the superficial dermis. The hemorrhagic lacunae correspond to secondary accumulation of erythrocytes due to microtrauma or vascular anastomoses, which can mimic angiokeratomas or hemangiomas.

In this case, ultraviolet fluorescence dermatoscopy (UVFD) increased the structural contrast and improved the visualization of the lymphatic lacunae and satellite lesions. Under UV light, these structures showed intense bluish-white fluorescence, probably due to the interaction between surface keratin, lymphatic contents, and altered dermal collagen, consistent with recent reports of translucent bluish-white globules in lymphatic malformations evaluated with UVFD.

Compared to conventional dermatoscopy, where the lacunae appear whitish, yellowish, or translucent, UVFD at 365 nm accentuated them with an opaque-glossy appearance. The pale septa became more evident in a brownish-gray hue, while the hemorrhagic areas remained dark, well-defined, and non-fluorescent, likely due to light absorption by hemoglobin. Furthermore, it allowed for the detection of small satellite lacunae not visible with conventional dermatoscopy.

Overall, UVFD could be a useful complementary tool in cutaneous lymphangiomas, as it improves the contrast of lymphatic lacunae and the visualization of subtle structures. Larger studies are needed to standardize these findings and determine their differential predictive value compared to vascular or adnexal entities.

Structural finding	Conventional dermoscopy (polarized light)	Ultraviolet fluorescence dermoscopy (UVFD – 365 nm)
Lymphatic lacunae	Multiple rounded whitish, yellowish, or translucent lacunae.	Marked accentuation with intense bluish-white fluorescence, showing an opaque and shiny appearance.
Septa	Pale septa delimiting the structures.	Accentuated with a brownish tone.
Hemorrhagic content	Red-violaceous lacunae; presence of the "hypopyon" sign due to erythrocyte sedimentation.	Dark, well-demarcated areas due to light absorption by hemoglobin, without fluorescence.
Contrast and extent	Allows visualization of the main pinkish-white lesions.	Significant increase in contrast with the surrounding skin, enabling identification of additional small satellite lacunae.

Table 1. Correlation between conventional dermoscopic findings and ultraviolet fluorescence dermoscopy findings in cutaneous lymphangioma circumscriptum.

EA DV CONGRESS
VIENNA
30 SEP - 3 OCT 2026

Abstract N°: 2508

Scalp Juvenile Xanthogranuloma Mimicking a Cratered Lesion: The Diagnostic Value of Dermoscopy in a 4-Year-Old Child

Fatima Zahra Sassine*[1], Chourouq Mustapha Eid[1], Meria Saci[1, 2], Michele Sanchez[2]

[1] Ibn Sina University Hospital, Dermatology Derpartment, Rabat, Morocco

[2] Hopital Henri Duffaut, Dermatology Department, Avignon, France

Introduction

Juvenile Xanthogranuloma (JXG) is the most common form of , typically presenting in early childhood as asymptomatic yellow-red papulonodules, predominantly on the head and neck. While the diagnosis is often straightforward based on clinical examination, atypical morphological presentations, particularly on the scalp, may mimic other entities such as pyogenic granuloma, keratoacanthoma, or dermoid cyst, leading to diagnostic uncertainty. Dermoscopy has emerged as a valuable non-invasive tool in the evaluation of JXG, with the characteristic "setting sun" pattern, an orange-yellow background coloration, described as a hallmark dermoscopic feature. This pattern has been reported in up to 85–91% of early and developed-stage JXG lesions. Additionally, the association between JXG and (NF1) warrants systematic clinical screening, particularly in young children. We report the case of a 4-year-old girl with a scalp papulonodular lesion exhibiting a misleading cratered morphology, in whom dermoscopy was instrumental in establishing the correct diagnosis.

Case Presentation

A 4-year-old girl with no significant medical history presented with a progressively enlarging, asymptomatic papulonodular lesion of the scalp that had been evolving for 10 months. The consultation was prompted by bleeding triggered by a traumatic episode during hair grooming. Clinical examination revealed a firm, well-circumscribed nodule with a central crater-like depression, an appearance that was initially misleading and raised concern for other diagnoses. Dermoscopic evaluation, however, proved decisive: it revealed the characteristic "setting sun" pattern, consisting of an orange-yellow background coloration with a surrounding erythematous halo, consistent with juvenile xanthogranuloma. Additional dermoscopic features included vascular structures and yellow globules, further supporting the diagnosis. A thorough physical examination was performed to screen for signs of neurofibromatosis type 1, including café-au-lait macules, axillary or inguinal freckling, and cutaneous neurofibromas ; no stigmata of NF1 were identified. Given the benign and self-limiting nature of JXG, a conservative approach with clinical monitoring was adopted.

Conclusion

This case highlights the diagnostic challenge posed by atypical clinical presentations of juvenile xanthogranuloma, particularly when a central crater-like morphology may divert the clinician toward alternative diagnoses. Dermoscopy proved to be a pivotal non-invasive diagnostic tool, with the "setting sun" pattern enabling accurate identification of JXG and avoiding unnecessary biopsy in a pediatric patient. The "setting sun" pattern, described as an orange-yellow structureless area, has been reported in 35–91% of JXG cases depending on the series and the evolutionary stage of

the lesion. This case also underscores the importance of a comprehensive clinical examination to rule out NF1, given the well-documented association between JXG and this genodermatosis, particularly in children under 2 years of age. Clinicians should be aware that JXG can present with atypical morphologies on the scalp, and dermoscopy should be systematically employed in the evaluation of papulonodular lesions in children to improve diagnostic accuracy and reduce invasive procedures.

EA DV CONGRESS
VIENNA
30 SEP - 3 OCT 2026

Abstract N°: 2509

Erosive plantar lichen planus: the role of dermoscopy

Émélie Simone Okouango*[1], Hanane Rachadi[1], Soumiya Chiheb[1]

[1] Department of Dermatology, Ibn Rochd University Hospital, Casablanca, Morocco, Faculty of Medicine and Pharmacy of Casablanca, Hassan II University, Morocco, Casablanca, Morocco

Introduction
Erosive palmo-plantar lichen planus (EPPLP) is a rare localised variant of lichen planus (LP). On dermoscopy, it is characterised by rounded, yellowish areas, sometimes bordered by star-shaped peripheral projections on a purplish background. We report the case of a 60-year-old female patient being treated for LP, presenting with erosive plantar lichen planus (EPLP).

Case Presentation
A 60-year-old female patient with a history of congenital foot deformity treated surgically in 1993 and 2005, who had been treated for hypertrophic lichen planus since 2020 with topical corticosteroids but was subsequently lost to follow-up; there was no family history of similar cases. She presented with pruritic and painful plantar papules that had been present for 11 months, complicated by ulcerations that bled on contact. Dermatological examination revealed yellowish papules grouped into polycyclic plaques, hyperkeratotic in places, resting on an erythematous base with ulcerated areas. The palms, mucous membranes, and scalp were unaffected. Nail examination revealed partial anonychia and a ventral pterygium of the first left and right toes, respectively; brachyonychia of the last four left toes and the last three right toes; as well as micronychia of the second right toe. Dermoscopy revealed whitish Wickham's striae on a purplish background, punctate vessels at the sites of ulceration, a rainbow pattern on an erythematous-purplish background, yellow patches, irregular whitish scales, and serpiginous linear vessels on an erythematous background. Trichoscopy showed scales and peripilar pigmentation with absent pilary orifices. Onychoscopy revealed partial anonychia, incipient pterygium, black xanthonychia, and a fissure. Management consisted primarily of injectable and topical corticosteroids with close monitoring.

Conclusion
EPLP is a rare and severe form of LP, accounting for less than 5% of cases, predominantly affecting women and significantly impairing quality of life due to pruritus and pain. Its clinical polymorphism explains diagnostic delays, underscoring the value of dermoscopy.

Clinically, it manifests as erosions and plantar keratoderma consisting of yellowish, fissured hyperkeratotic plaques, often bilateral and localised on weight-bearing areas. The erythematous-squamous form is the most common, but vesicular or petechial forms have been described. Lesions tend to occur on the medial plantar arch without involvement of the palms or fingers.

Dermoscopy reveals concentric yellowish patches, sometimes bordered by star-shaped projections on a purplish background; a rainbow pattern on an erythematous-purplish background; irregular whitish scales; comma-shaped vessels; and punctate bleeding in the erosive areas. Our case illustrates a rarely reported condition, with no previous dermoscopic study described.

The rainbow dermoscopic pattern, initially associated with Kaposi’s sarcoma, has also been observed in other inflammatory and neoplastic skin conditions. It is thought to result from a combination of vascular proliferation and cellular hyperplasia. EPLP poses a significant diagnostic challenge due to its similarities with other palmoplantar dermatoses. Dermoscopy appears to be a valuable complementary diagnostic tool, although histology remains essential for diagnostic confirmation. Further studies are needed to clarify its prognostic value. The rarity of EPLP warrants the compilation of new cases and the development of dedicated dermoscopic studies.

EA DV CONGRESS
VIENNA
30 SEP - 3 OCT 2026

Abstract N°: 2819

Clinical and Dermoscopic Phenotype of Basal Cell Carcinoma in Skin of Color: Diagnostic Overlap with Mimicking Lesions

Ester Echeverry[1], Jonny Alejandro Garcia Luna[1], Melissa Isaza[1], Carolina Concha Arango[1], Sara Vanegas*[1]

[1] Universidad del Valle, Cali, Colombia

Introduction
Basal cell carcinoma (BCC) is the most prevalent skin cancer and can exhibit locally aggressive behavior. While dermoscopy has established classic diagnostic patterns, evidence in dark phototypes remains limited, particularly regarding clinical pigmentation. This study evaluated the clinical-dermoscopic characteristics of BCC, its association with histological subtypes, and its differentiation from mimickers in a predominantly dark phototype population.

Materials and Methods
A cross-sectional study was conducted with consecutive recruitment of patients with suspected BCC undergoing skin biopsy between January 2024 and January 2025 at Hospital Universitario del Valle. Sociodemographic, clinical, dermoscopic, and histopathological variables were collected. Descriptive and comparative analyses between BCC and clinical mimickers were performed using Fisher's exact test. Sensitivity (SN), specificity (SP), and 95% confidence intervals (95% CI) were calculated for the main dermoscopic structures. Lesions were independently evaluated by dermatology residents and dermoscopy experts, with final diagnosis confirmed by histopathology.

Results
The study included 100 patients with 141 lesions, of which 71.1% were confirmed as BCC. The median age was 73 years, and 53.8% were female. The most frequent histological subtype was nodular (56.6%). Clinically, 68.4% of BCCs were pigmented, and 82.9% were located on the face.

The most frequent dermoscopic structures in BCC were brown globules (85%), large blue-ovoid nests (74%), and fine-short telangiectasias (50%). Significant associations with BCC were found for ovoid nests ($p=0.045$), brown globules ($p=0.0128$), fine-short telangiectasias ($p=0.001$), ulceration ($p<0.001$), and erosions ($p=0.002$).

Diagnostic performance analysis revealed that brown globules had an SN of 66.7% (95%CI: 52.6–78.9) and an SP of 68.7% (95%CI: 41.3–89.0). Ulceration showed low SN but high SP (100%; 95%CI: 79.4–100), suggesting its utility as a confirmatory marker. Although arborizing vessels were frequent (~50%), they did not show a significant association or adequate diagnostic performance.

A mixed pigmented-vascular dermoscopic phenotype was identified. Ulceration predominated in the infiltrating subtype (100%), suggesting an association with higher aggressiveness. Common clinical mimickers (sebaceous hyperplasia and seborrheic keratosis) shared multiple dermoscopic structures with BCC, demonstrating significant diagnostic overlap, particularly in pigmented lesions. Notably, fine-short telangiectasias were also observed in mimickers, suggesting lower specificity of this vascular pattern in high-phototype patients.

Conclusions
In dark-phototype patients, BCC frequently presents with a pigmented phenotype and a mixed dermoscopic pattern, which reduces the specificity of classic criteria. Individual dermoscopic structures show moderate

diagnostic performance; thus, their isolated interpretation is limited. The presence of fine-short telangiectasias in mimicking lesions emphasizes the need for caution when interpreting vascular findings. Ulceration may serve as a marker for aggressive subtypes. These findings highlight the necessity of an integrated clinical, dermoscopic, and histopathological evaluation to optimize BCC diagnosis in this population.

EA DV CONGRESS
VIENNA
30 SEP - 3 OCT 2026

Abstract N°: 2884

When Dermoscopy Reveals Sebaceous Differentiation in a Linear Pediatric Facial Plaque: Clinicopathological Correlation in Nevus Sebaceus

Kenza Benothmane*[1], Nouha Touhami[1], Yasmine Zekraoui[1], Narjess Errachdy[1], Najoua Ammar[1], Syrine Hamada[1], Mariame Meziane[1], Laila Benzekri[1], Nadia Ismaili[1]

[1] Department of Dermatology, Ibn Sina University Hospital, Rabat, Morocco

Introduction

Nevus sebaceus is a congenital hamartoma involving epidermal, follicular, and sebaceous structures. It usually presents at birth or early childhood as a yellowish plaque on the scalp or face. In pediatric patients, clinical presentation may be subtle and overlap with other linear facial dermatoses, making diagnosis challenging. Dermoscopy may provide valuable non-invasive clues by revealing sebaceous differentiation patterns correlated with histopathology.

Case Presentation

A 10-year-old girl presented with a slowly progressive linear frontotemporal plaque present since early childhood. Clinical examination revealed a slightly elevated erythematous-yellowish plaque with mild papillomatous and scaly surface changes along the frontal hairline.

Dermoscopy demonstrated clustered yellow-white globules arranged in lobular structures over a pinkish erythematous background, associated with superficial papillomatous areas and absence of pigment network. These findings suggested a sebaceous hamartomatous proliferation.

Histopathological examination showed epidermal acanthosis associated with mature sebaceous gland hyperplasia, confirming the diagnosis of nevus sebaceus.

Conclusion

In children, nevus sebaceus may clinically mimic verrucous epidermal nevus, linear wart, or chronic inflammatory dermatoses.This case highlights the diagnostic value of dermoscopy in clinically nonspecific pediatric facial plaques. The recognition of yellow lobular structures may reveal sebaceous differentiation and strongly support the diagnosis of nevus sebaceus before histopathological confirmation.

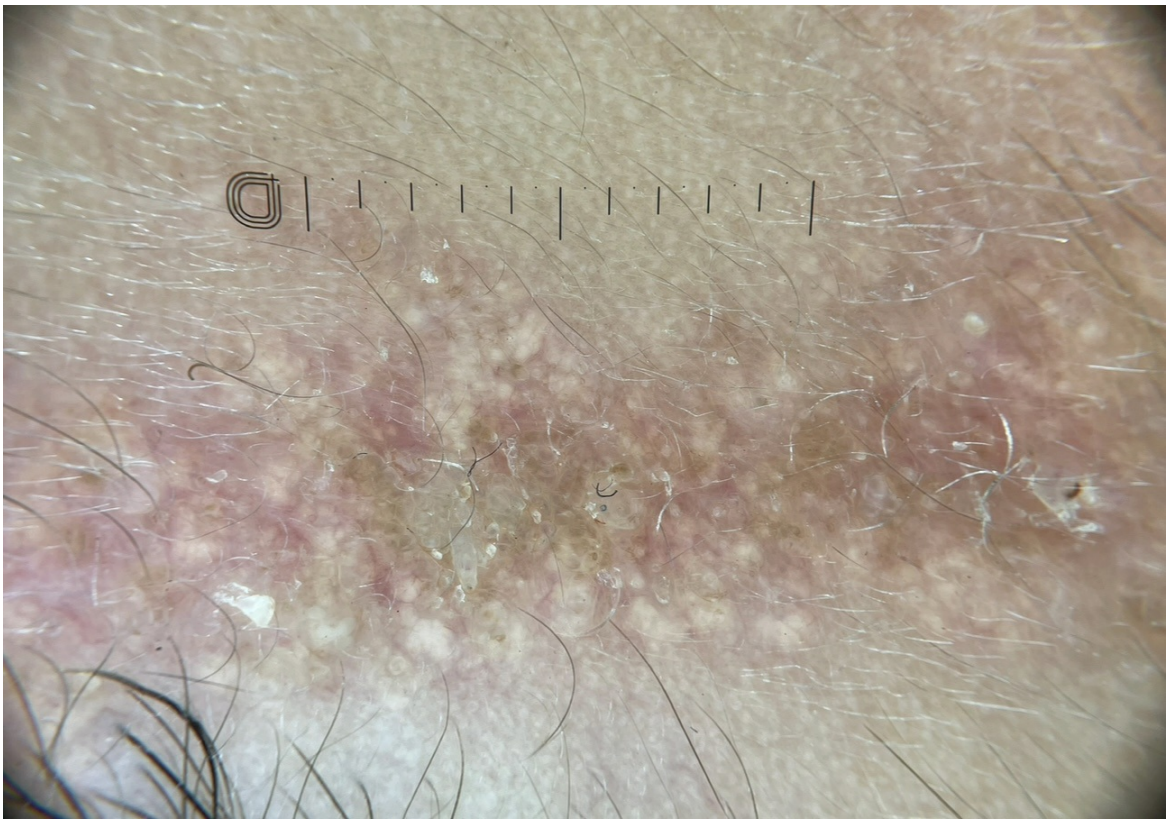

EA DV CONGRESS
VIENNA
30 SEP - 3 OCT 2026

Abstract N°: 2947

Diagnostic pitfalls in atypical seborrheic keratoses: a case series

Ana-Maria Toma*[1], Ioana-Roxana Nedelcu[2], Gabriela Turcu[3], Mihaela Antohe[4], Mihaela Balaban[5], Andreea Moroianu[6], Alice Brînzea[7]

[1] Elias Emergency University Hospital- Department of Oncologic Dermatology, Bucharest, Romania

[2] Derma 360 Clinic, "Carol Davila" University of Medicine and Pharmacy- Department of Pathophysiology II, Bucharest, Romania

[3] Colentina Clinical Hospital, Dermatology Clinic I, "Carol Davila" University of Medicine and Pharmacy - Department of Dermatology 3, Bucharest, Romania

[4] DermaBeauty Clinic, Bucharest, Romania

[5] M Hospital, Bucharest, Romania

[6] MedLife Clinic, Bucharest, Romania

[7] National Institute of Infectious Diseases 'Prof. Dr. Matei Balș', "Carol Davila" University of Medicine and Pharmacy- Department of Pathophysiology II, Bucharest, Romania

Introduction

Seborrheic keratoses are among the most common benign epidermal tumors and are typically diagnosed based on well-established clinical and dermoscopic criteria. However, certain atypical variants, particularly pigmented or irritated lesions, may present with features overlapping those of melanoma and other cutaneous malignancies, creating diagnostic uncertainty. This overlap has been recognized as a relevant dermoscopic pitfall, as both melanomas mimicking seborrheic keratoses and atypical seborrheic keratoses lacking classical features may challenge routine evaluation. In this context, we present a case series of atypical seborrheic keratoses highlighting their clinical and dermoscopic variability.

Case Presentation

Previous studies addressing clinically atypical seborrheic keratoses have consistently shown that these lesions are most frequently excised in the differential diagnosis with melanoma, followed by squamous cell carcinoma and, less commonly, basal cell carcinoma.

In addition, atypical seborrheic keratoses have been reported to exhibit a wide spectrum of dermoscopic appearances, with several recurring global patterns described, reflecting their marked variability.

Conversely, studies focusing on melanomas mimicking seborrheic keratoses have demonstrated that such lesions may combine seborrheic keratosis–like features with melanocytic criteria, leading to significant diagnostic ambiguity. In this setting, certain dermoscopic structures—including pigment network, blue-white structures, and pseudopods or streaks—have been identified as more suggestive of melanoma, while other features are more commonly associated with seborrheic keratosis.

Based on these observations, we conducted a retrospective case series including 22 patients presenting with clinically atypical seborrheic keratoses. All lesions underwent clinical and dermoscopic evaluation, with histopathological confirmation in excised cases.

The aim of this case series was to assess whether the dermoscopic criteria described in the literature are consistently encountered in real-life atypical seborrheic keratoses and to explore additional clinical, anamnestic, or

localization-related factors that may be associated with their atypical presentation and influence diagnostic decision-making.

Lesions were distributed across multiple anatomical sites, most commonly involving the trunk, face, and lower limbs.

In our series, atypical seborrheic keratoses most frequently entered the differential diagnosis with basal cell carcinoma, followed by melanoma and squamous cell carcinoma.

Dermoscopic evaluation revealed a high degree of variability, with lesions frequently displaying overlapping features. Classical seborrheic keratosis criteria-most commonly keratinization, crust, and fingerprint-like structures-were frequently identified. However, a substantial proportion of lesions also exhibited suspicious dermoscopic findings, including asymmetry, irregular pigmentation, multicomponent patterns, erosions, and polymorphous or irregular vessels.

Notably, more than one-third of lesions presented with multiple differential diagnoses and the coexistence of benign and malignant criteria within the same lesion contributed to more frequent indication for excision.

These findings suggest that atypical seborrheic keratoses may mimic not only melanocytic lesions but also a broad spectrum of keratinocytic malignancies, highlighting the complexity of their clinical evaluation.

Conclusion

Atypical seborrheic keratoses represent a frequent diagnostic challenge in daily practice, most often entering the differential diagnosis with melanoma and other cutaneous malignancies. The coexistence of benign and suspicious dermoscopic features within the same lesion highlights the limitations of individual criteria and explains the frequent need for excision.

Further analysis of clinical and dermoscopic patterns, as well as patient-related factors, may improve diagnostic accuracy in such challenging cases.

EADV CONGRESS
VIENNA
30 SEP - 3 OCT 2026

Abstract N°: 2956

Dermoscopy of vulvar hidradenoma papilliferum: A rare but challenging diagnosis

Joana Margarida Reis*[1], José Carlos Cardoso[2], André Laureano Oliveira[3]

[1] Serviço de Dermatovenereologia, Unidade Local de Saúde Almada-Seixal, Almada, Portugal
[2] Serviço de Dermatovenereologia, Unidade Local de Saúde de Coimbra, Coimbra, Portugal
[3] Skin Screening - Dermatology Unit, Champalimaud Clinical Centre - Champalimaud Foundation, Lisboa, Portugal

Introduction

Hidradenoma papilliferum is a rare benign adnexal neoplasm that predominantly affects the anogenital region of middle-aged women. Historically considered an apocrine tumor, current evidence suggests origin from anogenital mammary-like glands. Clinically, it usually presents as a solitary, slow-growing, asymptomatic nodule involving the vulvar or perianal region. Despite its benign nature, hidradenoma papilliferum may pose a significant diagnostic challenge, particularly in atypical or rapidly growing lesions, due to its resemblance to both benign and malignant tumors. Dermoscopic features remain poorly characterized, with only a limited number of reports available in the literature. Increasing recognition of its dermoscopic patterns may contribute to improved clinical suspicion and more accurate differential diagnosis in vulvar tumors.

Case Presentation

A 53-year-old woman was referred to the Dermatology Department due to a rapidly growing asymptomatic lesion on the left labium majus, with a three-month evolution. Physical examination revealed a well-circumscribed erythematous nodule with regular borders. Dermoscopic examination demonstrated white septal lines connected to a peripheral white collarette, surrounding homogeneous pink to milky-red areas containing elongated, blurred, linear-irregular vessels. No ulceration or pigmented structures were observed. Based on the clinical and dermoscopic findings, the main differential diagnoses included pyogenic granuloma, amelanotic melanoma, and poorly differentiated squamous cell carcinoma. Complete excision of the lesion was performed. Histopathological examination revealed a well-circumscribed dermal adnexal neoplasm composed of papillary structures lined by a double layer of epithelial cells with apocrine differentiation, confirming the diagnosis of vulvar hidradenoma papilliferum.

Conclusion

This case highlights the diagnostic difficulty of hidradenoma papilliferum, an uncommon benign vulvar adnexal tumor with nonspecific clinical presentation and dermoscopic overlap with malignant neoplasms. Recognition of characteristic dermoscopic clues, namely homogeneous pink to milky-red areas, white septal lines, peripheral white collarette, and irregular linear vessels, may assist in clinical suspicion and appropriate management. Nevertheless, histopathological examination remains mandatory for definitive diagnosis and exclusion of malignancy. Further reports are needed to better define the dermoscopic spectrum of this rare entity.

EA DV CONGRESS
VIENNA
30 SEP - 3 OCT 2026

Abstract N°: 2956

Trichoscopic features of eyebrow involvement in Frontal Fibrosing Alopecia: correlation with skin phototypes in a case series of 106 patients

Hajar El Hassani Taib*[1], Meryem El Moustaoui[1], Laila Benzekri[1], Mariame Meziane[1]

[1] Department of Dermatology and Venereology, Ibn Sina University Hospital, Mohammed V University, Rabat, Morocco

Introduction

Frontal fibrosing alopecia (FFA) is a lymphocytic cicatricial alopecia characterized by progressive frontotemporal hairline recession, frequently associated with early eyebrow loss, which can significantly impair quality of life. Trichoscopy is a rapid and non-invasive tool that aids in the early detection of follicular changes. However, trichoscopic features of eyebrow involvement in FFA remain poorly described, particularly across different skin phototypes. This study aims to analyze the trichoscopic characteristics of eyebrows in FFA and to assess their relationship with skin phototypes.

Materials and Methods

We conducted a single-center observational, descriptive and analytical study with both retrospective and prospective data collection over a 12-month period (November 2024 to November 2025). Trichoscopic examinations were performed using a DL5 dermoscope, and clinical images were captured using a smartphone. Data were analyzed using Excel and Jamovi (version 2.6).

Inclusion criteria comprised patients diagnosed with frontal fibrosing alopecia (FFA) based on clinical and trichoscopic findings, with or without histopathological confirmation. Exclusion criteria included patients with recent eyebrow epilation, a history of eyebrow tattooing or microblading, and other causes of eyebrow involvement.

Skin phototypes were classified according to the Fitzpatrick scale, and patients were grouped accordingly for comparative analysis of trichoscopic features.

Results

A total of 106 female patients with frontal fibrosing alopecia (FFA) were included, with a median age of 51 years; 52.8% were postmenopausal. The median age at disease onset was 45 years (range: 5–74), with a median disease duration of 7 years (range: 1–27). Phototypes III, IV, and V accounted for 24.5%, 58.5%, and 17% of cases, respectively. Eyebrow involvement preceded scalp hair loss in 62.3% of patients, whereas scalp involvement occurred first in 24.5%, highlighting the early involvement of eyebrows in FFA.

Pruritus was the most frequent symptom (77%), while trichodynia was reported in 15% of cases. According to the FFASI score, the majority of patients presented with moderate to advanced disease, predominantly stage 2 (51.9%) and stage 3 (29.2%).

Trichoscopic examination of the eyebrows revealed a wide spectrum of features. The most common findings were multidirectional hairs (83%), vellus hairs (64.2%), and broken hairs (35.8%), reflecting follicular miniaturization and

structural alteration. Inflammatory signs such as red dots (25.5%) and perifollicular hyperkeratosis (11.3%) were also observed, along with less frequent features including black dots (12.3%), yellow dots (10.4%), and dystrophic hairs (13.2%).

Comparative analysis according to skin phototype showed that multidirectional hairs, broken hairs, black dots, and yellow dots were significantly more frequent in phototypes IV–V compared to phototype III ($p = 0.003$, 0.001, 0.035, and <0.05, respectively). In contrast, red dots were significantly associated with phototype III ($p = 0.04$), suggesting potential differences in trichoscopic expression according to skin phototype.

Conclusions

Trichoscopy of eyebrow involvement in frontal fibrosing alopecia reveals a wide spectrum of features, with multidirectional hairs, vellus hairs, and broken hairs being the most frequent findings. Our study suggests a potential influence of skin phototype on trichoscopic patterns, with some features appearing more prevalent in phototypes IV and V. These results highlight the usefulness of eyebrow trichoscopy as an early, non-invasive diagnostic tool in FFA and may contribute to improving clinical recognition across different skin phototypes.

EA DV CONGRESS
VIENNA
30 SEP - 3 OCT 2026

Abstract N°: 2960

Dermoscopic Features Of Pigmented And Non Pigmented Eccrine Poromas : A Retrospective Observational Study Of 8 Cases

Hiba Essolaymany*[1], Meryem Soughi[1]

[1] CHU HASSAN II, FES, Morocco

Introduction

Eccrine poroma (EP) is an uncommon adnexal tumour originating from the the terminal portion of eccrine sweat ducts. This study underscores the significant clinical and dermoscopic diversity of this benign tumor making it a big mimicker. Based on dermoscopic features, we detected 2 main types of pigmented poroma in our study : one closely mimicking basal cell carcinoma (BCC) and the other mimicking nodular melanoma.

Materials and Methods

In this retrospective observational study, we included all patients admitted to our dermatology department between 2018 and 2025, who were diagnosed with EP through histopathological examination. Given the rarity of EP and the small sample size, a descriptive analysis was conducted to report the frequency of each dermoscopic feature. Each case was classified as pigmented or nonpigmented and each image was evaluated independently by 2 expert dermoscopists.

Results

8 patients with histopathologically proven EP were included in our study, their mean age at diagnosiswas 59 years. The majority occurred in males (62.5%). 5 patients were classified as phototype III, 2 as phototype IV, and 1 as phototype V. EP were most commonly located on non-acral sites : predominatly the legs (37.5%), face (25%), scalp (12.5%), trunk (12.5%), and the elbow (12.5%). Morphologically, 6 lesions presented as firm nodules and 2 lesions as plaques. 6 were non-pigmented, and 2 were pigmented. The pigmented poromas occurred in patients with Fitzpatrick skin phototypes IV or V and were located on the elbow and face. Dermoscopic features of EP included : polymorphic vessels (87,5%) including at least three types of vessels, with the most common types being : branched vessels with rounded endings (87,5%), glomerular vessels (87,5%), and clod vessels (75%). These vessels were surrounded by interlacing white cords in 87,5% of cases, that gave lesions a septate lobular appearance. 37.5% of EP exhibited ovoid nests mimicking a BCC. Additional dermoscopic features included structureless areas in various colors (blue, gray, pink, white, yellow), rainbow pattern (12.5%), and collarette (12.5%). Our cases had considerable heterogeneity in their clinical and dermoscopical appearance and main clinical differential diagnosis included BCC, malignant melanoma, squamous cell carcinoma, pyogenic granuloma and histiocytofibroma.

Conclusions

Pathogenesis of EP may be related to trauma, radiation, or scarring. In our study, the location on the head found in 3 patients suggested the implication of UV radiations. They are predominatly located on the soles and palms

due to higher density of eccrine sweat glands. Unexpectedly, this anatomical localization wasn’t found in any of our patients. Dermoscopy of nonpigmented EP is characterized by a polymorphous vascular pattern mainly composed of : Glomerular, hairpin and linear irregular vessels that are surrounded by white halo. Reddish–white globule-like structures are occasionally seen. Milky-red areas, commonly found in melanoma, may also be present. Despite having low prevalence, white interlacing cords surrounding vessels, branched vessels with rounded endings, and milky-red globules are specific for the diagnosis of poroma. Notably, branched vessels with rounded endings have been described in many publications as a specific clue in the diagnosis of EP, and were the most common vascular pattern observed in our study. The reddish-white globule-like structures are reminiscent of milky red globules seen in melanoma or red lacunae typical of vascular lesions and have been referred to as clod vessels, which were the second most common vascular pattern observed in our cases (75%). Pigmented eccrine poromas (PEP) are exceedingly rare, constituting only 17% of cases, they are seen more often in darker skin tones, and are usually found on non-acral sites. They are commonly confused with other pigmented tumors. Arborizing vessels and blue–grey ovoid nests observed in 3 of our cases, mimicked some typical dermoscopic features of pigmented BCC.

EADV CONGRESS
VIENNA
30 SEP - 3 OCT 2026

Abstract N°: 2987

Kyrle Disease: A Neglected Perforating Dermatosis in Diabetic Patient

Zouine Ikram*[1]

[1] Mohammed VI university hospital center of Agadir, agadir, Morocco

Introduction
Kyrle disease is an uncommon dermatological disorder characterized by hyperkeratotic papules containing central keratinous plugs, and is frequently linked to systemic conditions such as diabetes mellitus. Owing to its resemblance to other cutaneous disorders, it is often subject to diagnostic confusion.

Case Presentation
A 57-year-old female patient with a history of poorly controlled insulin-dependent diabetes mellitus for 18 years. She is currently managed in the cardiology department for global cardiac decompensation and was referred for dermatological evaluation due to intensely pruritic crusted lesions evolving over the past three months.

On physical examination, multiple hyperkeratotic papules with adherent and excoriated crusts were observed, predominantly involving the extensor surfaces of both upper and lower limbs. Dermoscopic examination revealed a central keratotic plug surrounded by a whitish peripheral halo.

A skin biopsy was performed, demonstrating characteristic histopathological features, including epidermal invagination filled with a compact keratin plug, associated with transepidermal elimination of basophilic keratinous debris. The surrounding epidermis showed acanthosis and hyperkeratosis, with a focal inflammatory infiltrate in the upper dermis. These findings were consistent with a diagnosis of Kyrle disease. The patient was treated with topical corticosteroids in combination with systemic antihistamines.



Clinical and dermoscopic features of Kyrle disease. Multiple hyperkeratotic papules and nodules with central keratotic plugs distributed on the lower limb (left). Dermoscopy reveals central yellow-brown keratotic/crusted plugs surrounded by a whitish hyperkeratotic rim on an erythematous background (right).

Conclusion

Due to its clinical resemblance to other perforating disorders and pruritic dermatoses, Kyrle disease is frequently underrecognized and may be misdiagnosed in routine practice.

The diagnosis is primarily established on histopathological examination, but dermoscopy can serve as a useful non-invasive adjunct, often demonstrating a central keratotic plug surrounded by a whitish or erythematous halo.

We report a case of Kyrle disease in a patient with diabetes mellitus, illustrating the diagnostic challenges and emphasizing the importance of clinicopathological correlation. This case highlights the need to consider Kyrle disease in the differential diagnosis of hyperkeratotic papular eruptions in patients with metabolic comorbidities. Although various therapeutic approaches—including topical keratolytics, retinoids, and systemic treatments—have been proposed, management remains challenging and no standardized treatment has been established.

EADV CONGRESS
VIENNA
30 SEP - 3 OCT 2026

Abstract N°: 2999

Atypical Spitz Tumor Initially Diagnosed as Nodular Melanoma in an Adult Patient: A Diagnostic Challenge

Rúbia Camargo dos Santos[1], Rafaella Bigotto e Silva Mexia[1], Rafaela Brito de Paula[1], Clovis Antonio Lopes Pinto[1], Raquel de Paula Ramos Castro*[1]

[1] AC Camargo Cancer Center, Sao Paulo, Brazil

Introduction

Spitz tumors are a heterogeneous group of melanocytic neoplasms that include Spitz nevi (SN), atypical Spitz tumors (AST), and Spitz melanoma (SM). Distinguishing among these entities is challenging because they share overlapping clinical, dermoscopic, histopathological and molecular features. AST represents an intermediate lesion with atypical characteristics that are insufficient for a definitive diagnosis of melanoma, resulting in uncertain malignant potential.

Recent advances in immunohistochemistry and molecular pathology have improved the diagnostic evaluation of spitzoid lesions however, accurate classification often requires careful clinicopathologic correlation. We report a case of an atypical Spitz tumor initially diagnosed as nodular melanoma highlighting the diagnostic difficulties associated with these lesions.

Case Presentation

A 43-year-old man with a personal history of two stage II melanomas and a family history of melanoma. At routine follow-up using total body mapping digital dermoscopy, a new lesion was detected on the left forearm. Clinically, the lesion presented as a normochromic papule with corkscrew vessels on dermoscopy, raising suspicion for nodular melanoma. The lesion was excised, and the initial histopathological diagnosis was nodular melanoma with a Breslow thickness of 1.0 mm. The lesion was subsequently underwent a histopathological review and was reclassified as an atypical Spitz tumor (AST). Histopathological examination demonstrated a classic spitzoid proliferation composed of epithelioid melanocytes with abundant eosinophilic cytoplasm and enlarged nuclei with prominent nucleoli. Immunohistochemical analysis revealed negative PRAME expression in melanocytes and preserved p16 expression. HMB-45 staining was weak, with evidence of progressive maturation. Ki-67 demonstrated a low proliferative index. BRAF mutation testing was negative, and BAP1 expression was preserved.

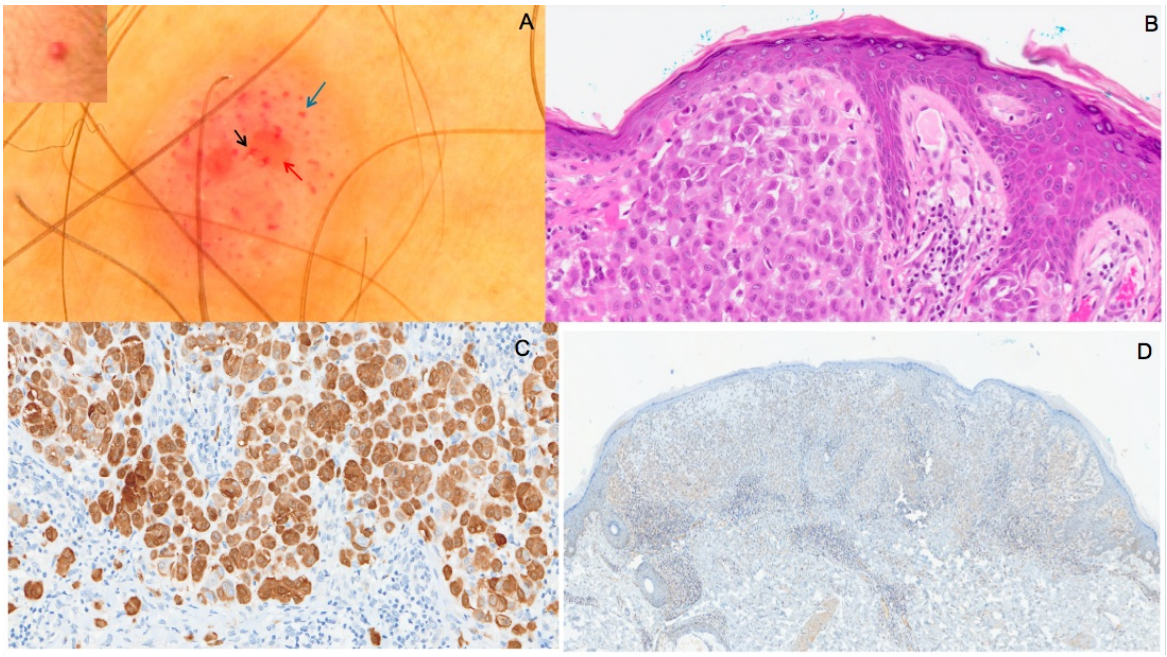

Figure. A. Clinical image of a nodular pink lesion. Dermatoscopy showing polymorphic vessels. Dotted vessels (blue arrow), corkscrew vessels (black arrow) and a milky red area (red arrow). B. H&E staining.100x magnification. Presence of junctional component, hypergranulosis and hyaline material compatible with Kamino bodies. C. Immunohistochemistry 200x magnification p16 marker with preserved expression. D. Immunohistochemistry 20x magnification BRAF marker negative also in appendages.

Conclusion

Spitz tumors is a distinct category of melanocytic neoplasms characterized by histopathological features that may overlap with those of melanoma. AST is characterized by epithelioid and spindle-shaped melanocytes demonstrating sufficient architectural and cytologic atypia to distinguish it from SN, but insufficient features to support a definitive diagnosis of melanoma. AST also presents morphological and genetic characteristics with both SN and SM and is therefore considered a diagnostically challenging lesion with uncertain malignant potential.

Clinically AST may occur at any anatomical sitenhowever, the lower extremities are the most common location. Dermoscopy of ASTs are more commonly associated with dotted vessels, whereas pigmented tend to exhibit multicomponent or nonspecific patterns.

Histopathological features significantly associated with AST include moderate mitotic activity (2–6/mm^2), lack of maturation, solid growth pattern, and asymmetry. Pagetoid spread in AST is typically peripheral rather than diffuse and usually involves the upper epidermis. Kamino bodies are less frequently observed and, when present, are often smaller in size. Molecular pathology and immunohistochemistry are increasingly used to support morphologic assessment. Immunohistochemical markers such as Ki-67, PHH3, Cyclin D1, and p16 may help evaluate cell cycle regulation and proliferative activity, while melanocytic markers including HMB-45, S100/S100A6, MITF, MART-1/Melan-A, and SOX10 assist in assessing tumor architecture and melanocytic differentiation. Typical Spitz tumors usually lack BRAF mutations. Spitz tumors are more commonly associated with kinase fusions and translocations involving ROS1, NTRK1, ALK, BRAF, and RET.

This case highlights the diagnostic challenges associated with atypical Spitz tumors and emphasizes the importance of clinicopathologic correlation, immunohistochemical analysis and expert pathologist to distinguishing AST from melanoma.

EA DV CONGRESS
VIENNA
30 SEP - 3 OCT 2026

Abstract N°: 3007

Branching Vessels and Yellow Globules in Nail Unit Melanoma In Situ: A Potentially Novel Intraoperative Dermoscopic Finding

Miguel Angel Nieto Bayona*[1], juan carlos hiromi lópez takegami[2], Isabela Dorado Caycedo[2]

[1] Universidad Nacional de Colombia, Bogotá, Colombia

[2] Fundación Universitaria Sanitas, Bogotá, Colombia

Introduction

Nail unit tumors are challenging entities. While each pathology presents with characteristic features, atypical presentations and mimickers are common. We present the case of a longitudinal melanonychia initially suspected to be benign, with unusual intraoperative dermoscopic findings raising concern for malignancy.

Case Presentation

A 42-year-old female with no significant medical history presented with a one-year asymptomatic lesion on the right thumbnail. She reported no growth or color changes and denied prior treatment. Examination revealed a longitudinal melanonychia with subtle background erythronychia. A small, triangular distal onycholysis with a notch and subungual hyperkeratosis was noted. Dermoscopy showed a 3 mm brown-gray band with proximal reddish hue and pigment granules. Given these features, onychopapilloma and reactive melanocytic activation were considered. A biopsy was planned.

Upon complete removal of the nail plate, intraoperative dermoscopy revealed longitudinal erythema in the nail bed with pigment arranged in parallel lines and striations with irregular brown-gray dots. In the proximal matrix, brown-gray dots were present over a light brown background. Notably, in the distal matrix, thick branching vessels and yellow globules were visualized. The presence of irregular pigmentation and prominent neovasculature raised concerns for malignancy, particularly melanoma and pigmented squamous cell carcinoma, thus warranting a longitudinal excisional biopsy.

Initial histology showed acanthosis, papillomatosis, and hyperkeratosis, consistent with onychopapilloma. Due to the atypical dermoscopic features, a re-evaluation was requested. This revealed intraepithelial melanocytic proliferation with solitary melanocytes at the dermoepidermal junction, focal pagetoid spread, and immunoreactivity for SOX10, MELAN A, MITF1, HMB45, and PRAME (+++), confirming a diagnosis of in situ nail unit melanoma.

Longitudinal melanonychia has variable prevalence by race: 1% in white individuals and 77–100% in individuals of African descent, main causes include melanocytic activation or racial melanonychia. Malignancy rates range from 6% in Hispanics to 40% in Asians. Nail unit melanoma is rare, accounting for 1.4–3% of all melanoma cases, typically presenting between ages 50–70, with mortality up to 50%, underscoring the importance of early diagnosis.

Longitudinal melanonychia red flags include band width >3 mm, irregular borders, temporal changes, and Hutchinson's sign. Dermoscopy shows longitudinal lines that are irregular in color, width, and alignment, granular and triangular pigmentation, and nail plate destruction. While these findings are useful (89% sensitivity, 62% specificity), intraoperative dermoscopy refines diagnostic accuracy and guides biopsy technique and site.

Melanoma is associated with “irregular pattern” —lines or globules of varying color and thickness—raising diagnostic performance (87% sensitivity, 100% specificity). However, thick branching vessels and yellow globules, as seen in this patient (graph 1), have not previously been reported in this context.

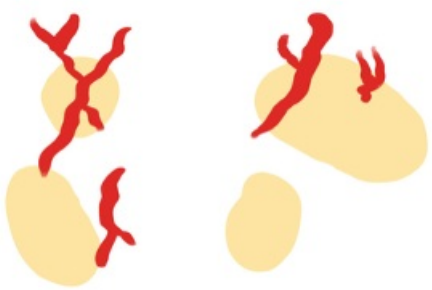

Schematic representation of the intraoperative dermoscopy.

Conclusion

This case highlights a nail lesion with initial benign suspicion, where intraoperative dermoscopy raised concern for melanoma, prompting histopathological reassessment and definitive diagnosis. Two potentially novel dermoscopic features are described.

EADV CONGRESS
VIENNA
30 SEP - 3 OCT 2026

Abstract N°: 3069

Dermoscopy of Cutaneous Leishmaniasis: Clinico-Dermoscopic Correlation: A Study of 29 Cases and 67 Lesions

Kawtar Diaa*[1]

[1] CHU IBN SINA Rabat, Rabat, Morocco

Introduction

Cutaneous leishmaniasis is an anthropozoonosis caused by flagellated protozoa of the *Leishmania* genus, transmitted by a vector: the sandfly. It is characterized by marked clinical polymorphism, which can lead to confusion with various infectious, inflammatory, or neoplastic conditions. Dermoscopy is a non-invasive diagnostic tool that has proven to be highly valuable in the evaluation and recognition of lesions in cutaneous leishmaniasis.

Materials and Methods

This is a prospective, descriptive, and analytical study including all patients who consulted at the Dermatology Department of Ibn Sina University Hospital in Rabat, with a diagnosis of cutaneous leishmaniasis confirmed by smear or skin biopsy, conducted over a period from September 2024 to March 2026. A dermoscopic examination was performed in all patients using a dermoscope (Dermlite DL4 or DL5).

Results

We included 29 patients with a total of 67 lesions, with a female predominance (21 women). The mean age was 40 years, ranging from 1 to 76 years. Sixty-three percent of patients were from rural areas or had a history of staying in rural settings prior to lesion onset. The diagnosis was confirmed by smear in 66% of cases, while a skin biopsy was required in 34%.

Lesions were located on the extremities in 60% of cases and on the face in 40%. Fifty-nine percent of patients had a single lesion, while 41% had multiple lesions. Clinical presentations included the ulcerocrusted form (35%), papulonodular form (27%), plaque form (21%), sporotrichoid form (7%, often with multiple lesions), verrucous form (2 cases), and erysipeloid form (1 case).

Dermoscopy revealed erythema in all lesions. Whitish scales were present in 79% of lesions. Central ulceration was observed in 58%. Yellow-orange areas or a lupoid appearance were seen in 55%. A white starburst-like pattern was noted in 40% of lesions. Yellow tears were present in 33%. Hemorrhagic crusts were observed in 48%, yellow crusts in 27%, whitish streaks in 24%, rosettes in 16.4%, and a rainbow pattern in only 2 cases. Vascular structures were present in 74.6% of lesions. The most frequent vessels were irregular linear vessels (57%), followed by hairpin vessels (36%), glomerular or dotted vessels (28.4%), arborizing vessels (21%), and comma vessels (6%).

Our study demonstrated statistically significant associations between dermoscopic features and lesion location. Yellow-orange areas ($p=0.013$), yellow tears ($p<0.001$), hemorrhagic crusts ($p=0.003$), central ulceration ($p=0.044$), white starburst-like pattern ($p<0.001$), and vascular structures—particularly irregular linear vessels ($p<0.001$), arborizing vessels ($p=0.002$), and comma vessels ($p=0.023$)—were correlated with facial involvement. In contrast, whitish streaks were more frequent on the extremities ($p<0.001$).

A statistically significant association was also found between clinical forms and dermoscopic features. Whitish scales ($p<0.001$), central ulceration ($p<0.001$), white starburst-like pattern ($p=0.001$), hemorrhagic crusts ($p=0.002$), yellow crusts ($p<0.001$), and the presence of irregular linear vessels ($p=0.001$), arborizing vessels ($p=0.002$), and comma vessels ($p=0.027$) were correlated with the ulcerocrusted form. Yellow tears ($p<0.001$) were associated with the papulonodular form. Rosettes ($p<0.001$) and whitish streaks ($p<0.001$) were strongly

associated with the sporotrichoid form.

Conclusions

Dermoscopy is a useful tool in the diagnostic approach to cutaneous leishmaniasis, allowing for rapid orientation of the diagnosis while awaiting parasitological confirmation. It can also help differentiate leishmaniasis from other inflammatory or tumoral dermatoses.

EADV CONGRESS
VIENNA
30 SEP - 3 OCT 2026

Abstract N°: 3076

Dermoscopic Features Differentiating Facial Atypical Intraepidermal and Junctional Melanocytic Proliferations from Lentigo Maligna

Noa Kremer*[1, 2], Luisa Polo Silveira[1], Alon Scope[2], Cristián Navarrete Dechent[3], Allan C. Halpern[1], Ashfaq Marghoob[1]

[1] Dermatology Service, Memorial Sloan Kettering Cancer Center, New York, United States
[2] The Gray Faculty of Medical and Health Sciences, Tel Aviv University, Tel-Aviv, Israel
[3] Department of Dermatology, Facultad de Medicina, Pontificia Universidad Católica de Chile, Santiago, Chile

Introduction
Atypical intraepidermal melanocytic proliferations (AIMP) and atypical junctional melanocytic proliferations (AJMP) frequently demonstrate clinical and dermoscopic overlap with lentigo maligna (LM), contributing to diagnostic uncertainty and management challenges.
Therefore, we aimed to identify dermoscopic features that differentiate facial LM from AIMP/AJMP.

Case Presentation
Methods: Dermoscopic images of biopsy-proven facial LM, AIMP, and AJMP were retrospectively reviewed. Invasive, recurrent, or amelanotic LM and AIMP/AJMP lesions reclassified as LM after excision were excluded. Two blinded dermatologists independently evaluated dermoscopic patterns, colors, borders, and previously described LM-associated and benign facial dermoscopic structures, with disagreements resolved by consensus or by a third expert. Multivariable logistic regression models adjusted for sex and lesion diameter were used to estimate odds ratios (ORs) with 95% confidence intervals (CIs).

Results: A total of 131 lesions were included, comprising 100 LM and 31 AIMP/AJMP lesions. Age, sex, lesion size, and anatomic location did not differ significantly between groups. Dermoscopic pattern, borders, and overall color distribution were similar, except for red color, which was more frequent in LM (59.0% vs 38.7%; p=0.048). LM demonstrated a higher number of dermoscopic structures compared with AIMP/AJMP (7.1 ± 2.1 vs 5.7 ± 2.2; p=0.003). Circle-in-circle structures (59.0% vs 38.7%; p=0.048), perifollicular granularity (35.0% vs 9.7%; p=0.007), and follicular size variability (50.0% vs 29.0%; p=0.040) were more frequently observed in LM. In contrast, parallel lines (19.4% vs 7.0%; p=0.044) and rhomboids (19.4% vs 8.0%; p=0.044) were more common in AIMP/AJMP. On multivariable analysis, perifollicular granularity (OR 3.9, 95% CI 1.1–14.6; p=0.041) and higher dermoscopic structure count (OR 1.3, 95% CI 1.0–1.7; p=0.041) remained independently associated with LM.

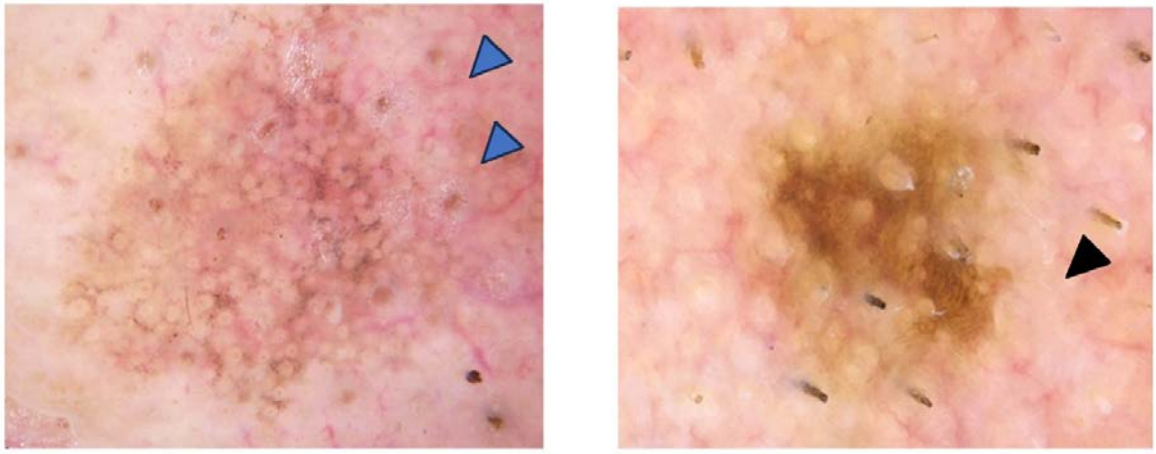

Figure 1. Facial lentigo maligna (LM) and atypical intraepidermal melanocytic proliferation (AIMP). (A) Dermoscopic image of LM showing follicular granularity (blue arrow). (polarized light dermoscopy, original magnification 10x) (B) Dermoscopic image of AIMP showing prominent parallel brown lines (black arrow). (polarized light dermoscopy, original magnification 10x)

Conclusion

Facial LM demonstrates more folliculocentric dermoscopic features and a higher number of dermoscopic structures compared with AIMP/AJMP. However, substantial morphologic overlap limits reliable bedside differentiation. Dermoscopic findings should therefore be interpreted alongside clinicopathologic correlation and longitudinal follow-up.

EADV CONGRESS
VIENNA
30 SEP - 3 OCT 2026

Abstract N°: 3094

Dermoscopic Features Differentiating Small-Diameter Lentigo Maligna and Lentigo Maligna Melanoma from Challenging Solar Lentigines

Noa Kremer*[1], Luisa Polo Silveira[1], Cristián Navarrete Dechent[2], Harold S. Rabinovitz[3], Ashfaq Marghoob[1]

[1] Dermatology Service, Memorial Sloan Kettering Cancer Center, New York, United States
[2] Department of Dermatology, Facultad de Medicina, Pontificia Universidad Católica de Chile, Santiago, Chile
[3] Dermatology Associates, Florida, Plantation, United States

Introduction

Although many solar lentigines (SLs) are readily recognized clinically, some demonstrate dermoscopic overlap with lentigo maligna/lentigo maligna melanoma (LM/LMM), creating diagnostic uncertainty. Misdiagnosis may result in unnecessary biopsies or inappropriate destructive treatment of melanoma.
Therefore, our objective was to identify dermoscopic features that differentiate small-diameter head and neck LM/LMM from challenging SLs.

Case Presentation

Methods:
This retrospective multicenter study included biopsy-proven head and neck lesions comprising small-diameter LM/LMM (≤1 cm) and challenging SLs biopsied to exclude melanoma. Recurrent LM/LMM and atypical intraepidermal melanocytic proliferations were excluded. Two blinded dermatologists independently evaluated dermoscopic patterns, colors, borders, and previously described LM/LMM- and SL-associated structures, with disagreements resolved by consensus or by a third expert. Least absolute shrinkage and selection operator (LASSO) regression identified the most informative predictors, and multivariable logistic regression models adjusted for age and sex estimated odds ratios (ORs) with 95% confidence intervals (CIs).

Results:
A total of 123 lesions were included, comprising 41 LM/LMM (85% in situ) and 82 SLs. Compared with SLs, LM/LMM more frequently demonstrated disorganized patterns (78.1% vs 39.0%), greater numbers of colors (3.20 vs 2.33), and greater numbers of dermoscopic structures (6.3 vs 3.2) (all $p<0.001$). LM/LMM also showed higher frequencies of hyperpigmented follicular openings (HFO), granularity, perifollicular linear projections, target-like structures, follicular size variability, non-follicular dots, angulated lines, rhomboids, red rhomboids, and dermoscopic darkening (all $p<0.05$). On multivariable analysis, angulated lines, granularity, gray color, and absence of scalloped borders remained independently associated with LM/LMM (OR range, 3.5–5.5; all $p<0.05$). The final model demonstrated excellent discrimination (AUC 0.88). Although HFO were common in SLs (56.1%), LM/LMM more frequently demonstrated >50% lesion involvement by HFO and mixed thick and thin pigmentation patterns.

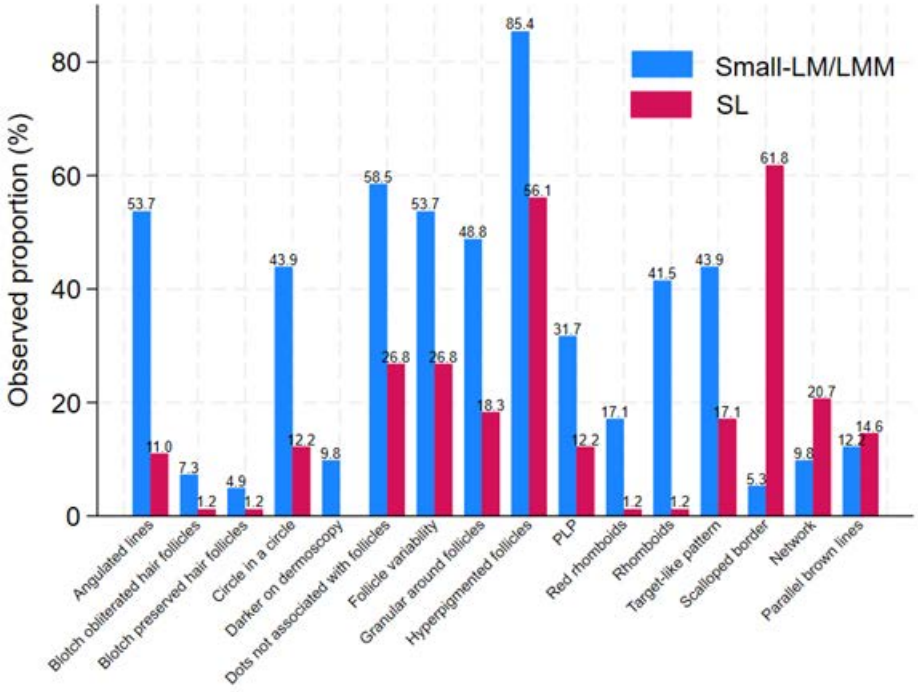

Figure 1. Barchart of the proportion of each of the dermoscopic structures as appears in the sample by lesion diagnosis.

Conclusion

disorganization, multiple dermoscopic structures, gray color, granularity, angulated lines, absence of scalloped borders, follicular size variability, and extensive HFO involvement should raise suspicion for LM/LMM.

EADV CONGRESS
VIENNA
30 SEP - 3 OCT 2026

Abstract N°: 3273

Chrysalis structures in dermoscopy: diagnostic insights from 350 cases

Ghita Gmira*[1], Meryem Soughi[1], Aimane Zaim[1], ikrame bejja[1], Saadia Boughaleb[1], Zakia Douhi[1], Sara Elloudi[1], hanane baybay[1], Fatima Zohra Mernissi[1]

[1] Department of Dermatology, Hassan II University Hospital, Fez, Morocco

Introduction
Chrysalis structures, also known as shiny white streaks visible under polarized dermoscopy, represent an important criterion in the analysis of skin lesions. However, their diagnostic value remains insufficiently defined.

Materials and Methods
A retrospective, descriptive, and analytical study was conducted from January 2019 to March 2026. A total of 350 patients with chrysalis structures were included and classified into six pathologies: Melanoma, squamous cell carcinoma (SCC), basal cell carcinoma (BCC), dermatofibroma, lichen sclerosus (LS), and actinic keratosis (AK), further grouped as malignant or benign. A comparative analysis of chrysalis morphology and orientation between melanoma and BCC was also performed. Clinical and dermoscopic features (morphology, orientation, distribution, brightness, and associated structures) were analyzed. All cases were histopathologically confirmed and independently assessed by two clinicians.

Results
A total of 350 patients with chrysalis structures were included. The mean age was 66 years, with a slight male predominance (180 males, 170 females). Most patients had Fitzpatrick phototype IV (258 cases), followed by III (82), II (7), and V (3). Facial localization was most frequent (51%), followed by limbs (15%), mucosal areas (13%), scalp (3.5%), and trunk (2.5%). Clinically, lesions were mainly plaques (48%), followed by nodules (17.3%), tumors (14.4%), and papules (5.6%), and were predominantly dyschromic (69.5%). Chrysalis morphology was bundle-like in 47% of cases, (lichen sclerosus 93%, BCC 68%, SCC 44%), star-shaped in 44% (AK 58%, dermatofibroma 87%, melanoma 65%), and fine linear in 5% without clear predominance. Morphology differed significantly between benign and malignant lesions, with bundle-like patterns more frequent in malignancies (61.8%) and star-shaped forms slightly more common in benign cases (52.3%) ($p = 0.004$). Orientation was heterogeneous in 66.5% of cases, followed by parallel (19.5%) and orthogonal (14%). Overall, orientation patterns were similar between benign and malignant cases, with no significant association with diagnosis ($p = 0.379$), despite minor variations in distribution. Differences in morphology and orientation of chrysalis structures between melanoma and BCC showed a predominantly organized parallel pattern in 50% of cases versus 17.1% in melanoma, while a disorganized star-shaped pattern predominated in melanoma. This difference was statistically significant ($p<0.055$). Diffuse distribution was the most frequent pattern (78.7%), followed by peripheral (17.0%) and central (4.3%), it was observed with comparable frequency in malignant (55%) and benign cases (45%), while peripheral and central distributions were slightly

more common in benign cases (52.5% and 73.3%, respectively), without a marked difference. However, no association between distribution and diagnosis, although a borderline trend may be noted($p=0.065$). Brightness was intense in 80.6% of cases, representing the most frequent intensity across all pathologies. Among associated white structures, rosettes were observed in 71% of AK, 30% of SCC, 6% of BCC, and 5.7% of melanomas, with a significant association with malignancy ($p < 0.001$). Structureless white areas were found in 97.7% of lichen sclerosus, 90% of melanomas, 83% of BCC, 27% of AK, and 26% of SCC, also significantly associated with malignancy ($p < 0.001$).

Conclusions

Chrysalis structures are common, polymorphic dermoscopic features with relevant diagnostic implications. In this study, only their morphology, particularly the distinction between bundle-like and star-shaped patterns, was associated with malignancy, whereas orientation and distribution showed no significant relationship. Therefore, the diagnostic value of chrysalis structures lies in their morphological assessment in combination with other dermoscopic criteria, which may provide useful guidance in distinguishing malignant from benign lesions.

EA DV CONGRESS
VIENNA
30 SEP - 3 OCT 2026

Abstract N°: 3305

Dermoscopic clues in steroid-induced rosacea and topical corticosteroid misuse: a practical review

Ana Beatriz Gomes Cordovil*[1]

[1] Universidade Estácio de Sá, Rio de Janeiro, Brazil

Introduction

Steroid-induced rosacea (SIR) is an increasingly recognized condition resulting from inappropriate or prolonged topical corticosteroid (TCS) use on facial skin. Clinically, SIR frequently overlaps with acneiform eruptions, seborrheic dermatitis, and erythematotelangiectatic rosacea, often leading to delayed diagnosis. Dermoscopy (inflamoscopy) has emerged as a pivotal non-invasive tool to enhance diagnostic precision. This review summarizes the key dermoscopic patterns of SIR and highlights their practical value in clinical differentiation.

Materials and Methods

A narrative literature review was conducted using PubMed, Scopus, and Embase databases (2010–2025). Search terms included “steroid-induced rosacea”, “topical corticosteroid misuse”, “inflamoscopy”, and “vascular patterns”. Studies focusing on dermoscopic-histopathological correlations and the differential diagnosis of inflammatory facial dermatoses were prioritized.

Results

The most characteristic dermoscopic findings in SIR included a diffuse erythematous background and a polygonal arrangement of linear vessels. In contrast to the relatively organized telangiectatic patterns observed in classical rosacea, SIR demonstrated prominent and disorganized vascular structures associated with epidermal atrophy. Additional findings included follicular pustules, perifollicular scaling, and “Demodex tails” or follicular plugs in cases with secondary infestation. Dermoscopy also showed utility in differentiating SIR from lupus erythematosus and seborrheic dermatitis through the recognition of distinct vascular and scaling patterns. Furthermore, inflamoscopy may assist in monitoring vascular recovery during the rebound phase following TCS withdrawal.

Conclusions

Dermoscopy is an accessible and valuable tool for the early recognition of corticosteroid misuse. Identification of characteristic vascular signatures, particularly polygonal vessels, may facilitate accurate diagnosis, reduce misclassification with other inflammatory facial dermatoses, and help prevent further iatrogenic skin damage. Incorporating inflamoscopy into routine facial assessment may improve diagnostic accuracy and support appropriate management during steroid withdrawal.

EADV CONGRESS
VIENNA
30 SEP - 3 OCT 2026

Abstract N°: 3306

The role of ochre fluorescence under ultraviolet-induced fluorescence dermatoscopy in melanoma

Pawel Piotr Pietkiewicz*[1], Marian Voloshynovych[2], Julien Anriot[3], Cristian Navarrete-Dechent[4]

[1] Zwierzyniecka Medical Center, Poznań, Poland

[2] Ivano-Frankivsk National Medical University, Ivano-Frankivsk, Ukraine

[3] Dermatology Department, Centre Léon Berard, Lyons, France

[4] Melanoma and Skin Cancer Unit, Escuela de Medicina, Pontificia Universidad Católica de Chile, Santiago, Chile

Introduction

Melanoma remains a challenge in dermatooncology, with high mortality rates tied closely to late-stage diagnosis. While conventional dermatoscopy revolutionized early detection and reduced unnecessary excisions, optimizing the assessment of tumor margins and Breslow thickness, the primary prognostic indicator, remains a clinical priority. Ultraviolet-induced fluorescence dermatoscopy (UVFD) has emerged as a novel modality complementary to conventional dermatoscopy. By utilizing UVA diodes at a 365nm wavelength, UVFD identifies specific substances, such as keratin, sebum, and porphyrins, through distinct fluorescent clues. Notably, preliminary observations have identified ochre fluorescence (OF) within certain melanomas; however, the diagnostic utility and prevalence of this phenomenon remain uncharacterized. This study aimed to determine whether OF could serve as a marker for melanoma detection in lesions suspicious for melanoma under conventional dermatoscopy. The secondary aim was to assess the potential link between OF and demographic, clinical, and pathology data.

Materials and Methods

This retrospective, international, cross-sectional cohort study was conducted across four centers (Poland, France, Ukraine, and Chile) with appropriate ethical approvals and informed consent. Between January 2024 and May 2025, consecutive UVFD images of equivocal pigmented lesions were captured using a DL5 dermatoscope paired with a smartphone and analyzed for OF independently by the two blinded dermatoscopy experts. Diagnostic categories included melanoma (in situ/invasive, with subtype specified or not otherwise specified); dysplastic nevus (low-, moderate-, and high-grade dysplasia; MELTUMP, including SAMPUS and IAMPUS); benign nevus (junctional, compound, and dermal, including blue nevus and Spitz nevus); and other pigmented lesions (pigmented basal cell carcinoma, pigmented intraepithelial carcinoma, pigmented actinic keratosis, seborrheic keratosis, lentigo, and dermatofibroma). Statistical analysis were utilized to evaluate the prevalence of OF and its association with melanoma diagnosis, clinicopathological data, and Breslow thickness. Interobserver agreement was assessed using Cohen's κ.

Results

A total of 234 lesions from 215 patients (mean age 49.57 ± 20.15 years) were analyzed, including 100 melanomas (50 invasive, 50 in situ) and 44 borderline lesions. OF was identified in 27 lesions, significantly favoring a melanoma diagnosis (23% vs. 3%; OR: 9.71; 95% CI: 3.24–29.12; $p = 0.009$). Within the melanoma cohort, OF was markedly more prevalent in invasive compared to *in situ* cases (40% vs. 6%; OR: 10.44; $p < 0.001$). Furthermore, OF-positive melanomas demonstrated a significantly higher mean Breslow thickness (1.03 ± 0.94 mm vs. 0.61 ± 1.70 mm; $p < 0.001$). No significant associations were observed between OF and age, sex, anatomical site, or specific melanoma subtypes. The diagnostic accuracy of OF for melanoma was 0.654, characterized by a low sensitivity (0.23) but very high specificity (0.97) and a PPV of 0.852. Interobserver agreement was almost perfect ($\kappa = 0.93$). These findings suggest that while OF is not a common feature, yet may server as a highly specific marker for melanoma among suspicious lesions, particularly invasive variants with greater tumor

thickness.

Conclusions

In conclusion, we have demonstrated a strong association between OF seen under UVFD and melanoma, particularly invasive disease and greater Breslow thickness. Although limited by sensitivity, the high specificity and very high interobserver agreement highlight OF as a reliable and reproducible clue. Given its specificity, the presence of OF may support immediate excision, especially in clinically ambiguous cases, rather than follow-up. These findings suggest that OF could complement melanoma detection. The prognostic value of OF and its potential influence on melanoma management require confirmation in future prospective studies with larger cohorts.

EADV CONGRESS
VIENNA
30 SEP - 3 OCT 2026

Abstract N°: 3363

Neglected Giant Basal Cell Carcinoma of the Scalp: The Diagnostic Power of Dermoscopy in Clinical Mimicry

Rihab Marzak*[1], Ilyass Anouar[1], Rachid Frikh[1], Naoufal Hjira[1]

[1] Military hospital of Rabat, Rabat, Morocco

Introduction

Basal cell carcinoma (BCC) is the most common skin malignancy and is generally characterized by slow growth and low metastatic potential. Nevertheless, neglected lesions may evolve into aggressive locally destructive tumors capable of invading deep structures such as muscle and bone. We report a giant scalp BCC with clinical features strongly mimicking Squamous cell carcinoma (SCC), in which dermoscopy played a decisive role in establishing the correct diagnosis and guiding surgical management.

Case Presentation

A 60-year-old man with no significant medical history presented with a massive ulcerated lesion involving the vertex of the scalp. The lesion had evolved progressively over five years, beginning as a small asymptomatic ulcer that was neglected by the patient and gradually enlarging to approximately 9 cm in diameter. Clinical examination revealed a deeply destructive tumor with a large central crater containing exuberant granulation tissue, fibrin deposits, hemorrhagic areas, and zones of necrosis. The peripheral margins were thickened, irregular, infiltrated, and partially crusted, giving the lesion a markedly inflammatory and “volcano-like” appearance. The rapid enlargement, ulceration, bleeding tendency, and destructive morphology strongly suggested an advanced SCC.

To refine the diagnosis, a systematic dermoscopic examination was performed on the less ulcerated peripheral areas of the lesion. Despite extensive surface erosion and hemorrhagic crusting, dermoscopy demonstrated several highly characteristic features of BCC, including large blue-gray ovoid nests, focal leaf-like structures, and prominent arborizing telangiectatic vessels. These findings redirected the diagnostic hypothesis toward an infiltrative and pigmented BCC rather than SCC. Based on these results, the patient was referred for specialized maxillofacial surgical management. During surgery, direct invasion of the underlying calvarial bone was identified, necessitating radical excision with removal of the outer cortical table to obtain adequate margins. Histopathological analysis confirmed a nodular and infiltrative BCC with cortical bone invasion, correlating closely with the dermoscopic findings.

Conclusion

This case highlights that giant BCCs can undergo significant clinical mimicry, losing their classic "pearly" appearance and adopting the inflammatory, crusted morphology typical of SCC. It demonstrates that dermoscopy remains a reliable and powerful diagnostic tool even in massive, neglected lesions. The early dermoscopic identification of BCC-specific structures allowed for an appropriate multidisciplinary orientation and ensured the necessary surgical radicality, proving that dermoscopy is vital regardless of the lesion's size or clinical stage.

EADV CONGRESS
VIENNA
30 SEP - 3 OCT 2026

Abstract N°: 3402

Multiple trichoblastoma: Clinical, Dermoscopic and Therapeutic Features

Afafe JEI*[1], fatimazahrae benhayoune[1], Hanane Rachadi[1], Soumiya Chiheb[1]

[1] Ibn Rochd University Center, casablanca, Morocco

Introduction

Trichoblastoma is a rare, benign adnexal tumor originating from the hair germ. It typically presents as a solitary nodule on the scalp or face of middle-aged adults. Multiple presentations are uncommon and can pose a diagnostic challenge, often mimicking other adnexal tumors or hamartomas. Herein, we aim to report an unusual case of multiple facial and scalp trichoblastomas and to discuss the clinical and dermoscopic features that distinguish this entity from other benign adnexal tumors.

Case Presentation

A 24-year-old patient with no significant medical history, presented with non-pruritic and non-painful skin lesions located on the central face and scalp, evolving since the age of 13. Clinical examination revealed firm, flesh-colored papular lesions of varying sizes, with regular borders and a smooth surface, located bilaterally and symmetrically on the face, predominantly on the forehead, glabella, perinasal area, as well as in the nasolabial folds and scalp, without any other mucocutaneous or nail lesions.

Dermoscopic examination revealed a pinkish background with milia-like cysts and whitish streaks, as well as fine, arborizing telangiectasias, with no signs of ovoid nests, ulceration, or maple leaf structures. Given this clinical picture, multiple trichoblastomas was the first diagnosis considered, but other benign adnexal tumors were also considered, including syringoma, sebaceous hyperplasia, fibrofolliculoma, and facial angiofibromas within the context of tuberous sclerosis complex (Bourneville disease). A skin biopsy was performed, which suggested a cribriform trichoblastoma. The treatment decision was ablative CO2 laser ablation.

Conclusion

Multiple facial trichoblastoma should be considered in the differential diagnosis of symmetric centrofacial papular eruptions, even in young patients without genetic syndromes. Dermoscopy and histopathology are key to accurate diagnosis, and laser ablation represents a valid treatment alternative.

EADV CONGRESS
VIENNA
30 SEP - 3 OCT 2026

Abstract N°: 3469

A Rarely Recognized Yet Diagnostically Simple Entity: Lipidized Fibrous Histiocytoma

Yasemin Dündar*[1], Esin Kaplan[1], Zeki Arıcı[1], Vildan Manav[1], Cem Leblebici[2], Ayşe Esra Koku Aksu[1]

[1] Istanbul Reasearch and Traning Hospital, Department of Dermatology and Venereology, Istanbul, Türkiye
[2] Istanbul Reasearch and Traning Hospital, Department of Pathology, Istanbul, Türkiye

Introduction

Lipidized fibrous histiocytoma, also known as lipidized dermatofibroma, is a rare histological variant of common fibrous histiocytoma, accounting for approximately 2% of all cases. It predominantly affects adults 30-60 years of age, with a slight female predominance (female: male ratio, 1.5:1). Lesions most commonly involve the lower extremities, particularly the ankle region, hence it has been termed "ankle-type dermatofibroma". It presents as a solitary, firm, well-circumscribed papule or nodule with color changing from yellowish-brown to reddish-blue, can be accompanied by pruritus and tenderness. Standart management involves simple surgical excision.

Case Presentation

A 36-year-old man presented with two slowly enlarging nodules on his left leg, present for approximately one year. Dermatological examination revealed two well-defined, reddish-purple nodules with peripheral pigmentation on the distal aspect of the left cruris, each measuring approximately 1 cm in diameter. The lesions were asymptomatic. Dermoscopic evaluation demonstrated homogenous areas of yellow globules, comma-shaped vessels, dotted vessels and a peripheral pigment network. Histopathologic examination confirmed the diagnosis of lipidized fibrous histiocytoma.

Lipidized fibrous histiocytoma is a benign cutaneous neoplasm with distinctive clinical and dermoscopic features. Dermoscopy typically reveals homogeneous yellow globules (reflecting lipid-laden histiocytes), a peripheral pigment network, and vascular structures such as comma-shaped and dotted vessels. A central white network may also be observed. Despite characteristic dermoscopic findings, diagnosis may be delayed or misdirected due to lack of familiarity among clinicians. As such, it is crucial to maintain awareness of this entity, particularly when encountering yellowish nodules on the lower extremities.

The differential diagnosis includes common dermatofibroma, xanthoma, juvenile xanthogranuloma, atypical fibroxanthoma, and pleomorphic dermal sarcoma. Recognition of key dermoscopic clues facilitates correct identification and prevents unnecessary concern or overtreatment.

Conclusion

Although lipidized fibrous histiocytoma is a benign and histologically well-defined lesion, its rarity may result in underrecognition. Characteristic dermoscopic features—such as yellow globules and peripheral pigmentation—can be diagnostically helpful, but may be overlooked. Recognizing this uncommon variant is key to ensuring accurate diagnosis and guiding conservative surgical management.

EADV CONGRESS
VIENNA
30 SEP - 3 OCT 2026

Abstract N°: 3489

Squamoid eccrine ductal carcinoma: dermoscopy of a rare adnexal malignancy

Joana Margarida Reis*[1], José Carlos Cardoso[2], André Laureano Oliveira[3]

[1] Serviço de Dermatovenereologia, Unidade Local de Saúde Almada-Seixal, Almada, Portugal
[2] Serviço de Dermatovenereologia, Unidade Local de Saúde de Coimbra, Coimbra, Portugal
[3] Skin Screening - Dermatology Unit, Champalimaud Clinical Centre - Champalimaud Foundation, Lisboa, Portugal

Introduction

Squamoid eccrine ductal carcinoma (SEDC) is an exceptionally rare malignant adnexal neoplasm that arises from the eccrine gland, typically affecting elderly patients and presenting as an erythematous or hyperkeratotic plaque or nodule on sun-exposed areas. Histopathologically, it is characterized by superficial squamous differentiation and deeper eccrine ductal differentiation. Dermoscopic descriptions of SEDC are exceedingly scarce in the literature. We report a case of SEDC with detailed dermoscopic-pathologic correlation, highlighting features that may aid in the recognition of this aggressive tumor.

Case Presentation

A 93-year-old patient presented with a rapidly growing amelanotic nodule on the presternal region, with a 3-month evolution. Dermoscopic examination revealed marked vascular polymorphism composed predominantly of well-focused, bright-red linear-irregular and bizarre vessels, associated with peripheral whitish globular structures and central homogeneous orange areas. Differential diagnoses included amelanotic melanoma, poorly differentiated squamous cell carcinoma, pyogenic granuloma, and adnexal carcinoma. Histopathological examination demonstrated a markedly infiltrative epithelial neoplasm replacing the epidermis and extending through the full thickness of the dermis with extensive hypodermal invasion. Superficially, the tumor consisted of keratinizing lobules and trabeculae connected to the epidermis and adnexal structures, while deeper areas showed angulated trabeculae and cords of eosinophilic cells with dyskeratosis and multiple foci of ductal differentiation embedded within a dense fibromyxoid stroma. The lesion exhibited deep infiltrative growth reaching the deep surgical margin. Based on histopathological findings, the diagnosis of squamoid eccrine ductal carcinoma was made.

Conclusion

Dermoscopic descriptions of squamoid eccrine ductal carcinoma remain exceedingly scarce in the literature. SEDC should nevertheless be considered in the differential diagnosis of rapidly growing pink nodules displaying polymorphous vascular patterns on dermoscopy. In this case, peripheral white globular structures likely reflected squamous differentiation, whereas central orange homogeneous areas may correspond to deeper eccrine ductal differentiation. The marked vascular polymorphism probably reflects the rapid growth dynamics and aggressive infiltrative behavior of the tumor. By highlighting these rarely reported dermoscopic findings, this case may contribute to the earlier recognition of this uncommon adnexal malignancy with locally aggressive and potentially metastatic behavior.

EADV CONGRESS
VIENNA
30 SEP - 3 OCT 2026

Abstract N°: 3514

Paederus dermatitis through the lens of the dermoscope

Kavita Poonia*[1, 1], parul chojer[1], Dr Shivani Bansal[1]

[1] All India Institute of Medical Sciences, Bathinda, India

Introduction
Paederus dermatitis is an irritant contact dermatitis caused by a beetle belonging to the genus Paederus. This study aims to comprehensively describe dermoscopic features in paederus dermatitis

Materials and Methods
Lesions of paederus dermatitis were classify into 3 phases on the basis of evolution – erythematous phase, followed by vesicular phase, and squamous phase. Dermoscopy was performed in all the lesions of paederus dermatitis using the Dermlite DL4 (10X magnification).

Results
We present a clinical series of 50 patients of blister beetle dermatitis (29 male, 21 female) patients. Their age ranged from 8-65 years**.** Mostly lesions were present over exposed part of the body. Most common pattern observed was localized. Three patients (n- 4, number of lesions) were present during erythematous phase, 31 Patients (n- 52) in vesicular phase and 16 patients (n- 25) in the squamous phase.

Dermoscopy of erythematous phase exhibited only bright erythema with normal reticular pigmentation. Dermoscopy of vesicular phase showed : translucent globules in 4/52(7.6%) lesions, multiple discrete to coalescing white and brown globules in 37/52(71.1%) lesions, white structureless area seen in 32/52(61.5%) lesions, and grey structureless area in22/52(42.3%) lesions, brown dots with white halo in 12/52(23%) lesions. Dermoscopy of squamous phase: exhibited multiple brown dots and craters in 24 lesions (96%) on white scales on the light pink background. White scales on a light pink background were observed in 19/25 (76%). Two lesions (8%) showed red dots/globules.

Conclusions
This study provide more methodical and detailed iteration of dermoscopy patterns based upon the severity classification and different phase of disease of paederus dermatitis.

EADV CONGRESS
VIENNA
30 SEP - 3 OCT 2026

Abstract N°: 3589

More Than Meets the Eye: Decoding the Dermoscopic Mystery of Kimura Disease

Hidaya Temsamani*[1], Mouna Korbi[1], Ben salem Wafa[2], Njima Manel[3], Youssef Monia[1], Belhadjali Hichem[1], Zili Jameleddine[1]

[1] Dermatology Department, Hôpital Fattouma Bourguiba, Monastir, Tunisia
[2] Internal Medicine Department, Hôpital Régional Docteur Mohamed Ben Salah de Moknine, Moknine, Tunisia
[3] Anatomopathology Department, Hôpital Fattouma Bourguiba, Monastir, Tunisia

Introduction

Kimura disease (eosinophilic lymphogranuloma) is a rare chronic inflammatory disorder of unknown etiology, predominantly affecting Asian men. Despite Kimura disease being well-characterized histologically, there is currently a significant lack of data regarding its dermoscopic presentation.

Case Presentation

A 52-year-old man presenting with a right retroauricular mass evolving since birth, with a progressive increase in size over the past four years, secondarily associated with pruritus.

Dermoscopic examination revealed a polymorphous pattern characterized by diffuse reddish-brown backgrounds associated with overlying whitish structureless areas. Notably, no distinct vascular patterns were identified in the observed fields.

An initial biopsy revealed nonspecific chronic inflammation, and initial imaging studies (CT scan and MRI) were unremarkable. Fifteen days after the biopsy, a rapid increase in tumor size was observed, reaching 7 cm, with extension to the preauricular region. Parotid MRI revealed a large protuberant and infiltrative soft-tissue mass associated with multiple parotid and right cervical jugulocarotid and spinal lymphadenopathies. A soft-tissue biopsy showed a cellular mesenchymal pseudo-tumor developed on an abundant fibro-edematous background, associated with numerous lymphoid aggregates and follicles with germinal centers, surrounded by eosinophils. The epidermis showed a regenerative appearance disrupted by an inflammatory infiltrate. Laboratory investigations revealed normal eosinophil counts with elevated total IgE levels (487 kIU/L). The patient was treated with complete surgical excision, and histopathological examination confirmed the previous findings.

Conclusion

Kimura disease is a rare chronic inflammatory disorder that often poses a diagnostic challenge due to its clinical similarity with other head and neck tumors. While histopathology remains the gold standard, the role of dermoscopy is increasingly recognized as a valuable non-invasive diagnostic aid. In our case, the observed reddish-brown (coppery) background provides a significant dermoscopic clue, correlating histologically with the dense dermal infiltration of lymphoid follicles and eosinophils—a common feature in granulomatous and lymphoproliferative processes. A striking finding

in this case is the prominence of whitish structureless areas, which reflect the underlying interstitial fibrosis and collagen hyalinization typical of chronic Kimura disease lesions. Interestingly, unlike most reports in the sparse literature—which often describe prominent arborizing or dotted vessels—our case presented an atypical avascular pattern. This discrepancy suggests that the dermoscopic signature of Kimura disease may be evolution-dependent: early inflammatory stages might showcase active neovascularization, whereas long-standing, chronic lesions are dominated by fibrotic remodeling that obscures surface vasculature. Thus, recognizing this 'fibro-coppery' pattern is essential to avoid misdiagnosis and to better understand the clinico-pathological progression of this rare entity.

EA DV CONGRESS
VIENNA
30 SEP - 3 OCT 2026

Abstract N°: 3661

Acrokeratoelastoidosis: Dermoscopic and histopathological clues in two cases of a rare marginal keratoderma

lalla safia echarif*[1], Intissar Kial[1], maryem aboudourib[1], layla bendaoud[1], ouafa hocar[1], said amal[1]

[1] Department of Dermatology and Venerology, Mohammed VI University Hospital, Biosciences and Health Laboratory, Faculty of Medicine and Pharmacy of Marrakesh, MARRAKECH, Morocco

Introduction

Acrokeratoelastoidosis (AKE), first described by Oswaldo Costa in 1952, is a rare form of marginal palmoplantar keratoderma. It is characterized by small, firm, flesh-colored to yellowish hyperkeratotic papules, typically distributed in a bilateral and symmetrical pattern along the lateral and medial borders of the hands and feet. Although most cases are hereditary with an autosomal dominant pattern linked to chromosome 2, sporadic cases are also well documented. Diagnosis relies on clinicopathological correlation to distinguish AKE from other acral keratodermas.



Figure 1 :Clinical image of case 1 showing yellowish hyperkeratotic plantar papules and plaques involving the lateral plantar surface.

Case Presentation

We report two cases of acrokeratoelastoidosis confirmed by clinicopathological correlation.

Case 1: A 14-year-old girl presented with a 7-year history of childhood-onset pruritic yellow hyperkeratotic marginal plantar papules. Clinical examination revealed characteristic yellowish hyperkeratotic plaques. Dermoscopy showed structureless yellow areas with central umbilication. There was no family history of similar lesions.

Case 2: A 22-year-old woman presented with asymptomatic flesh-colored papular lesions on the plantar surfaces, without associated systemic symptoms or family history.

Skin biopsies were performed in both patients. Histopathological examination demonstrated orthokeratotic hyperkeratosis, acanthosis, and hypergranulosis. Special staining with Orcein and Verhoeff–Van Gieson confirmed elastorrhexis, characterized by fragmentation and reduction of elastic fibers in the reticular dermis, a diagnostic hallmark of acrokeratoelastoidosis.

Both patients were treated with topical keratolytics, with partial improvement.

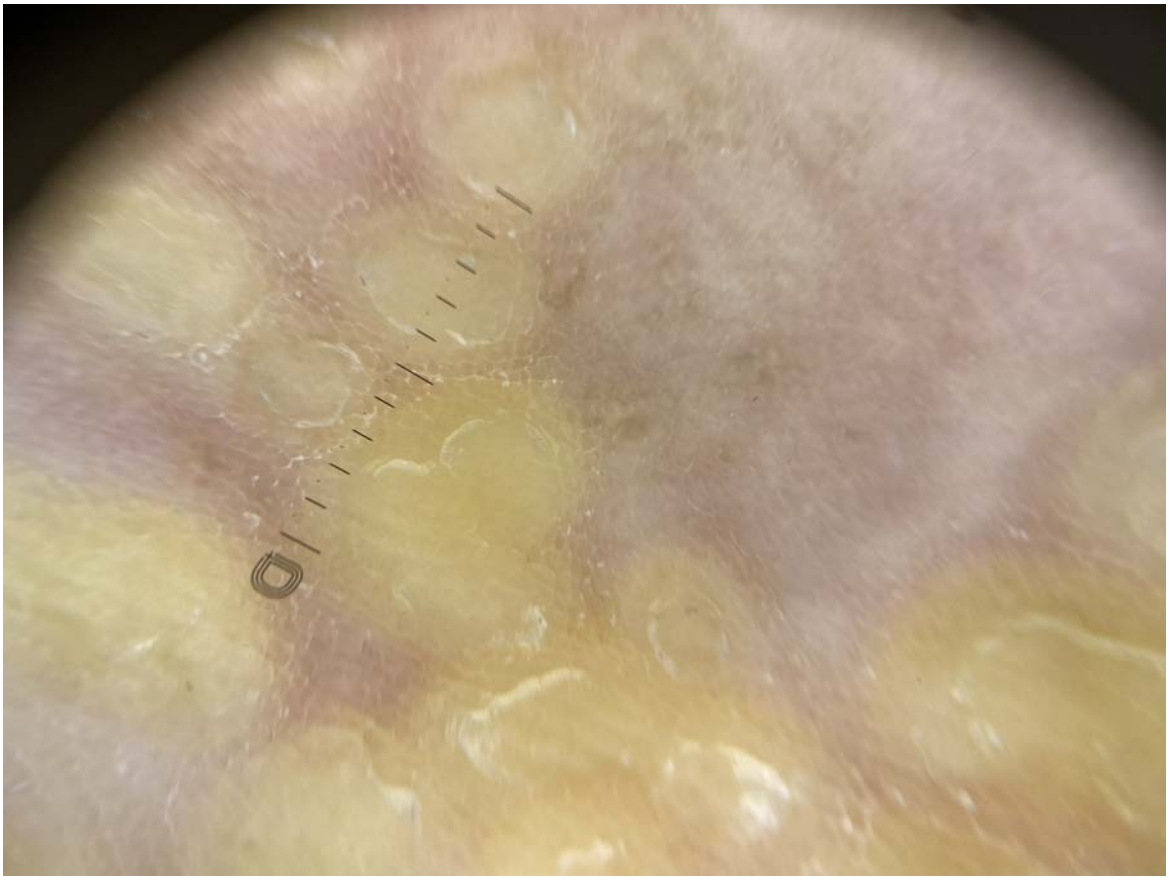

Figure 2: Dermoscopic image of case 1 demonstrating structureless yellow areas with central umbilication in places

Conclusion

Acrokeratoelastoidosis remains a diagnostic challenge due to its rarity and clinical overlap with other palmoplantar keratodermas, some of which may be associated with internal malignancy. These cases highlight the value of dermoscopy as a useful noninvasive tool that bridges clinical evaluation and the definitive histopathological finding of elastorrhexis. As currently available therapies, including topical keratolytics and systemic retinoids, provide only limited and often transient benefit, the main value of an accurate diagnosis lies in appropriate patient counseling rather than curative treatment. Establishing the diagnosis through clinicopathological correlation enables reassurance, reduces patient anxiety, and avoids unnecessary investigations for systemic disease.



Figure 3: Clinical image of case 2 showing multiple flesh-colored papular lesions on the plantar surface

EA DV CONGRESS
VIENNA
30 SEP - 3 OCT 2026

Abstract N°: 3676

Clinical and Dermoscopic Features of Melanonychia: Insights from 212 Patients and 682 Nails

Zineb Aqasbi Ouahi*[1], Meryem Soughi[1], ikrame bejja[1], Saadia Boughaleb[1], Zakia Douhi[1], Sara Elloudi[1], Hanane Baybay[1], Fatima Zohra Mernissi[1]

[1] Department of Dermatology, Hassan II University Hospital, Fez, Morocco

Introduction
Longitudinal melanonychia is a brown to black pigmentation of the nail plate, most commonly presenting as a longitudinal band. It may result from benign melanocytic activation, melanocytic proliferation, or non-melanocytic causes. It is a common finding in dermatology, highlighting its clinical relevance. However, the main diagnostic challenge remains the identification of subungual melanoma, as early diagnosis is crucial for improving prognosis. In this context, the present study aims to analyze the clinical and dermoscopic features of melanonychia in order to identify criteria that help differentiate benign from malignant causes.

Materials and Methods
This was a retrospective observational study conducted in the Dermatology Department over a one-year period, from March 2025 to March 2026. A total of 212 patients with 682 nails affected by melanonychia were included. Demographic, clinical, and dermoscopic data were collected from medical records, along with available histopathological and mycological findings. Statistical analyses were performed using standard methods, with a significance threshold set at $p < 0.05$.

Results
The mean age of patients was 51.45 years, with a female predominance (62.2%) and a majority of phototype IV. Longitudinal melanonychia accounted for 87% of cases, predominantly affecting the thumbs and big toes, with frequent involvement of multiple nails. Benign forms, mainly ethnic (34.7%), fungal (23.6%), and drug-induced (22.1%), were characterized by homogeneous gray or brown-gray bands, regularly parallel lines, absence of Hutchinson's sign, and pigment limited to the lower portion of the nail plate. Matrix nevi (3%) showed regular or irregular parallel lines, with congenital forms tending to be more irregular and less pigmented. In contrast, subungual melanomas ($n = 8$) were significantly associated with multicolored pigmentation, irregular longitudinal lines (variation in thickness and spacing), black lines, granular pigmentation, and the presence of Hutchinson's sign ($p < 0.001$), with diffuse pigment extending to the free edge. Statistical analysis revealed significant associations between etiology and several dermoscopic parameters, including band shape ($p = 0.015$), color ($p = 0.034$), pigment distribution at the free edge ($p < 0.001$), and the number of colors observed on dermoscopy ($p = 0.011$). Multicolored patterns were more frequently observed in melanomas, inflammatory lesions, and drug-induced cases. Moreover, discrepancies between clinical and dermoscopic colors were also significant ($p = 0.019$), particularly in exogenous and drug-induced pigmentation.

Conclusions
Our findings are consistent with the literature, showing that line irregularity, color heterogeneity, and pigment distribution are key dermoscopic features that help distinguish benign melanonychia from melanoma, while emphasizing that clinical examination remains essential for drug-induced or exogenous forms.

EADV Congress 2026, VIENNA
30 SEPTEMBER - 03 OCTOBER 2026
POWERED BY M-ANAGE.COM

EADV CONGRESS
VIENNA
30 SEP - 3 OCT 2026

Abstract N°: 3685

Trichoblastoma vs. Basal Cell Carcinoma: Dermoscopy as a Tool for Tissue-Sparing Surgery

BTISSAM JALLOUL*[1], Kenza BARBRI[1], FATIMA ZAHRA BENHAYOUN[1], BOUCHRA BAGHAD[1], HANANE RACHADI[2], SOUMIYA CHIHEB[1]

[1] Department of Dermatology, CHU Ibn Rochd, Casablanca, Morocco
[2] Department of Dermatology, CHU Ibn Rochd, casablanca, Morocco

Introduction

Trichoblastoma is a rare benign adnexal tumor derived from the germinative cells of the pilosebaceous follicle. Its primary clinical challenge lies in its striking mimicry of **Basal Cell Carcinoma (BCC)**, both clinically and dermoscopically. This diagnostic confusion often leads to unnecessarily aggressive surgical management. We illustrate the importance of meticulous dermoscopic analysis in guiding the diagnosis toward this benign entity prior to histological confirmation.

Case Presentation

A 52-year-old female patient presented with a nodular lesion located in the left infraorbital region, which had been evolving for one year. Dermatological examination revealed a well-circumscribed, rounded nodule approximately 1 cm in diameter, showing a pinkish-purple color and a translucent appearance. The surface of the lesion was smooth, featuring fine arborizing telangiectasias and a small central ulceration topped with a punctiform crust. This clinical presentation was immediately suggestive of a nodular basal cell carcinoma (BCC).

Although the examination revealed criteria classically associated with malignancy (blue-gray ovoid nests, arborizing vessels), the global morphological analysis allowed for trichoblastoma to be considered as the primary diagnostic hypothesis. Unlike a typical BCC, the arrangement of the nests and the regularity of the vascular structures suggested a benign basaloid tumor.

Surgical excision confirmed this hypothesis. Histology demonstrated architectural symmetry and the absence of retraction clefts (typical of BCC). Immunohistochemistry (positive for PHLDA1 and CK20) definitively validated the benign nature of the lesion.

Trichoblastoma is recognized as the "great mimicker" of BCC. Historically, distinguishing these entities based on clinical criteria alone was considered nearly impossible. However, our case demonstrates that a rigorous dermoscopic analysis now allows for the suspicion of benignity as the primary diagnosis. While BCC often presents with a disorganized and chaotic architecture, the regularity and symmetry of the basaloid structures observed here are valuable indicators of trichoblastoma. Although histology remains the gold standard—characterized by the characteristic absence of retraction clefts—the contribution of immunohistochemistry is decisive. This early diagnostic approach is fundamental: it allows for a simple excision to replace potentially disfiguring oncological surgery, thus preserving the aesthetics of the infraorbital area.



Conclusion

Trichoblastoma remains a diagnostic challenge, but this case highlights a paradigm shift. Modern dermoscopy now makes it possible to suspect benignity earlier through a fine morphological analysis of lesional symmetry. Identifying this entity during the initial examination is crucial to ensure healing through simple excision, thereby avoiding unnecessarily aggressive and mutilating treatments.

EADV CONGRESS
VIENNA
30 SEP - 3 OCT 2026

Abstract N°: 3742

Dermoscopic Features of Psoriatic Nails and Their Correlation to Disease Severity

Mohamed Zaky*[1]

[1] Al-Azhar University Hospital, Cairo, Egypt

Introduction

Nail psoriasis is a challenging chronic condition affecting patients functionally and psychologically. Nail involvement is observed in 15-80% of psoriatic patients with occasional presence of isolated nail psoriasis. The study aims to evaluate dermoscopic features of nail psoriasis and correlate them clinically.

Materials and Methods

The study included fifty subjects with nail psoriasis. Psoriasis skin and nail severity was evaluated using psoriasis area severity index (PASI) and nail psoriasis severity index (NAPSI). Dermoscopy of the nails (onychoscopy) was performed, and features were recorded and analyzed.



Various manifestations of nail psoriasis (NP). (a) Pitting; (b) onycholysis; (c) longitudinal striations; (d) pitting along with striations and subungual keratosis (e) splinter hemorrhages; (f) red lunula spotting; (g) subungual hyperkeratosis; (h) salmon patches; (i) onycholysis with distal plate crumbling.

Results

The most common clinical and dermoscopic findings were pitting (86%) and onycholysis (82%). Among all dermoscopic features of nail psoriasis, only longitudinal striations and subungual hyperkeratosis were significantly higher in patients with moderate to severe psoriasis than in patients with mild psoriasis (P=0.028; P=0.042, respectively). PASI scores correlated positively but none significantly with NAPSI scores (r = 0.132, P=0.360), and similarly, no significant correlation was observed between the duration of psoriasis and the dermoscopic NAPSI (r = 0.022, P=0.879).

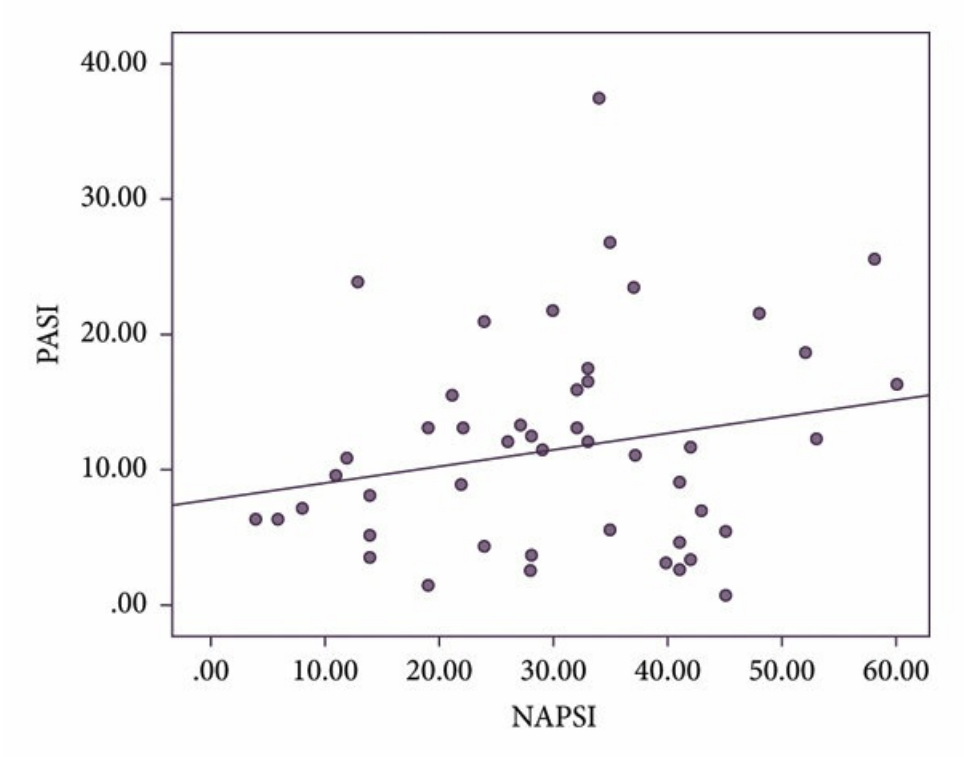

Correlation between NAPSI and PASI scores

Conclusions

Dermoscopy can serve as a useful tool for early diagnosis of psoriatic nail changes not always visible to the naked eye and is a non-invasive easy-to-use confirmatory tool for nail changes in psoriatic disease or in isolated nail involvement.

EADV CONGRESS
VIENNA
30 SEP - 3 OCT 2026

Abstract N°: 3759

Transient emergence of peripheral globules in melanocytic nevi under melanocyte-stimulating hormone drive: report of two cases — pregnancy and intense sun exposure

Thais Bello di Giacomo*[1], Natalia Scardua[2], Maria Messina[1]

[1] Private Practice, São Paulo, Brazil

[2] Private Practice, Sao Paulo, Brazil

Introduction

Peripheral globules are a dynamic dermoscopic feature commonly associated with growing melanocytic nevi. Although changes in dots and globules have been reported during pregnancy and following ultraviolet (UV) exposure, the de novo appearance of peripheral globules in previously documented nevi followed by their regression has been less well characterized. We report two such observations occurring during pregnancy and after intense sun exposure and discuss potential biological mechanisms underlying this transient dermoscopic phenotype.

Case Presentation

Case 1: A female patient, Fitzpatrick skin phototype II, under routine digital dermoscopic follow-up, developed peripheral dark-brown globules in a previously documented melanocytic nevus on the back during the second trimester of pregnancy. No additional melanoma-specific dermoscopic structures were identified. After delivery, progressive regression of the peripheral globules was documented, with the lesion returning toward its previous dermoscopic pattern.

Case 2: A male patient, Fitzpatrick skin phototype IV, presented after recent intense summer sun exposure with peripheral globules in a previously documented melanocytic nevus of the trunk in which this feature had not previously been present. No additional melanoma-specific dermoscopic structures were identified. At three-month follow-up, the peripheral globules had regressed, with the lesion returning toward its previous dermoscopic pattern.

Discussion

Pregnancy-associated dermoscopic changes in melanocytic nevi have been reported, although findings across studies are heterogeneous. In a prospective cohort of 703 nevi from 18 pregnant women, new dots or globules were documented in 12.4% of lesions. More recent controlled studies, however, have not demonstrated a consistent pregnancy-specific effect on dots or globules.

Experimental UV irradiation has also been shown to induce transient dermoscopic changes in melanocytic nevi. Following exposure to two minimal erythema doses, the number and intensity of brown-black globules increased at day 7, while most evaluated dermoscopic parameters subsequently returned toward baseline.

Melanocortin signaling represents one potential mechanism for reversible melanocytic changes. UV-induced activation of the p53–POMC–α-MSH pathway is well established, and pharmacological exposure to afamelanotide, an α-MSH analogue, has been associated with a transient increase in globule number in acquired melanocytic nevi. Supporting evidence is therefore stronger in the context of UV exposure, while the contribution of

melanocortin signaling to pregnancy-associated nevus changes remains to be determined.

Conclusion

These two cases document the transient emergence and subsequent regression of peripheral globules in previously monitored melanocytic nevi during pregnancy and following intense sun exposure. Together with previous reports of dynamic dermoscopic changes in these settings, these observations suggest that peripheral globules may represent a reversible dermoscopic phenotype under different melanogenic conditions. The potential contribution of melanocortin signaling, particularly in the context of UV exposure, provides a biologically plausible pathway deserving further investigation.

EA DV CONGRESS
VIENNA
30 SEP - 3 OCT 2026

Abstract N°: 3760

Exploring the Diagnostic Utility of Mucoscopy in Sjögren Syndrome: A Pilot Cross-Sectional Analytical Study

Rahul Nair*[1], Pankaj Das[1], Anuj Bhatnagar[1], Varghese Koshy[1], Varun Bajaj[1]

[1] Armed Forces Medical College, Pune, India

Introduction

Sjögren syndrome (SS) is a chronic autoimmune disorder characterized by lymphocytic infiltration and progressive dysfunction of exocrine glands, resulting primarily in xerostomia and keratoconjunctivitis sicca. Diagnosis is based on a combination of clinical, serological and histopathological findings. Minor salivary gland biopsy remains the diagnostic gold standard because of its high specificity and sensitivity; however, it is invasive and may be associated with postoperative pain, bleeding, infection and transient lower lip numbness. Mucoscopy is a non-invasive imaging modality that enables in vivo visualization of oral mucosal microvasculature and salivary gland duct openings. While mucoscopy has been explored in oral mucosal disorders, its role in xerostomia and SS has not been systematically evaluated. This study aimed to assess mucoscopic findings in SS and compare them with healthy controls to determine their potential diagnostic utility.

Materials and Methods

A pilot cross-sectional analytical study was conducted in 13 patients with primary or secondary SS and 13 age- and sex-matched healthy controls. Cases fulfilled established diagnostic criteria for SS, while controls had no autoimmune disease or xerostomia. Participants with active oral mucosal disorders, recent topical corticosteroid or immunomodulator use, drug- or nicotine-induced pigmentation, pregnancy or lactation were excluded. Standardized lower lip mucoscopy was performed using polarized and ultraviolet fluorescence dermoscopy. Images were obtained using a smartphone-attached dermoscope in maximum lower-lip eversion with a systematic zig-zag scanning technique covering the entire lower lip. Evaluated parameters included capillary loop morphology, vessel tortuosity, background vascularity, periductal vascularity, ductal fluorescence, mucinous secretions and pigmented or structureless areas. Frequencies of mucoscopic findings were compared between cases and controls.

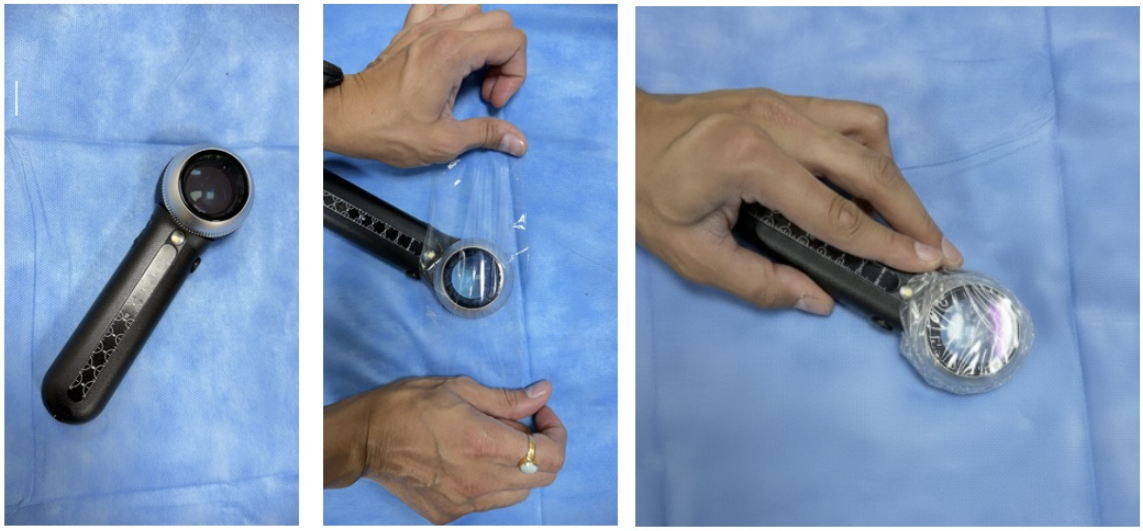

Methodology for preparing a DL5 Dermoscope for Mucoscopy by wrapping it with a clear film

Results

The study population demonstrated marked female predominance (female:male ratio 12:1) with a mean age of 39.9 years. Thin capillary loops were significantly more common in SS cases than controls (92.3% vs 23.1%; p=0.001). Short capillary loops were also significantly associated with SS (84.6% vs 15.4%; p=0.001). Periductal vascularity in a "necklace arrangement" was identified exclusively in SS cases and demonstrated statistical significance (38.5% vs 0%; p=0.039). Loss of background vascularity (61.5% vs 23.1%), decreased vessel tortuosity (53.8% vs 15.4%) and increased ductal fluorescence under ultraviolet fluorescence dermoscopy (46.2% vs 7.7%) were more frequently observed in SS, although these differences did not achieve statistical significance. Thick mucinous secretions at duct openings were observed only in SS cases. Structureless white areas and yellow gland-associated areas corresponding to minor salivary glands and adipose tissue were present in all participants and were non-discriminatory findings. Normal controls predominantly demonstrated thick, tortuous and elongated capillary loops with preserved background vascularity and regular duct openings.

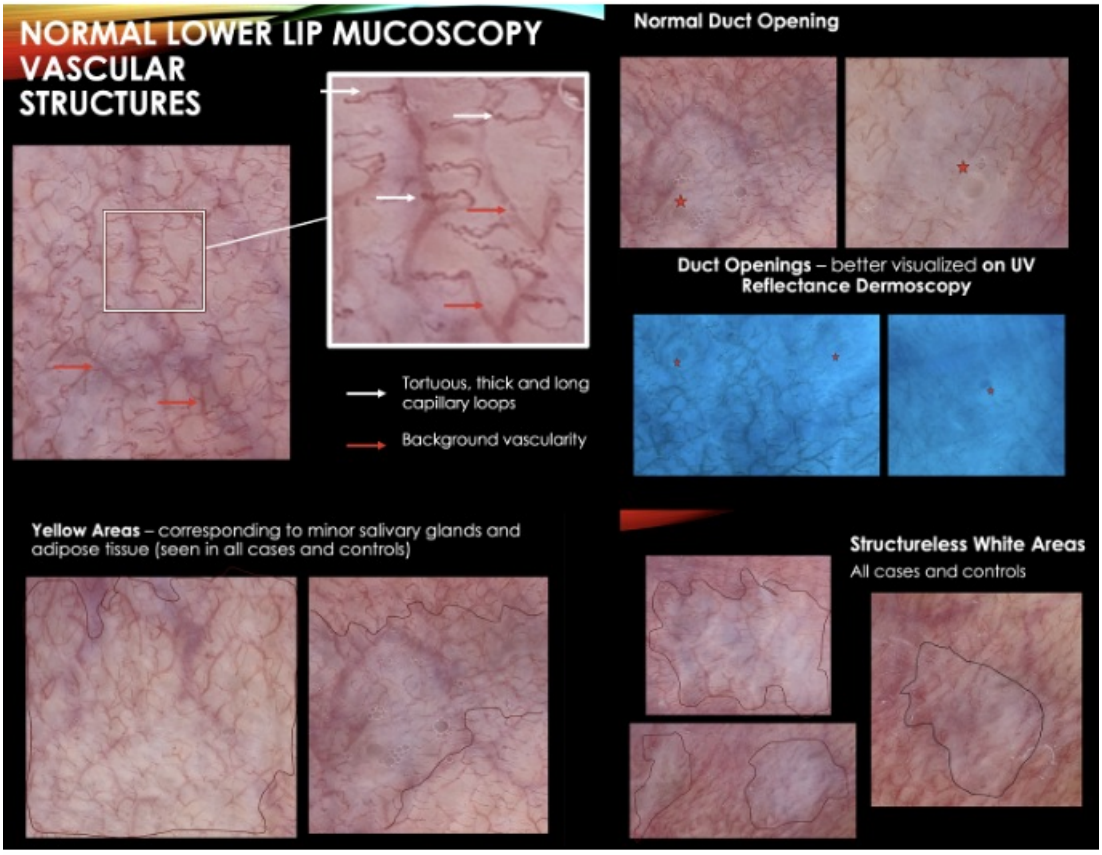

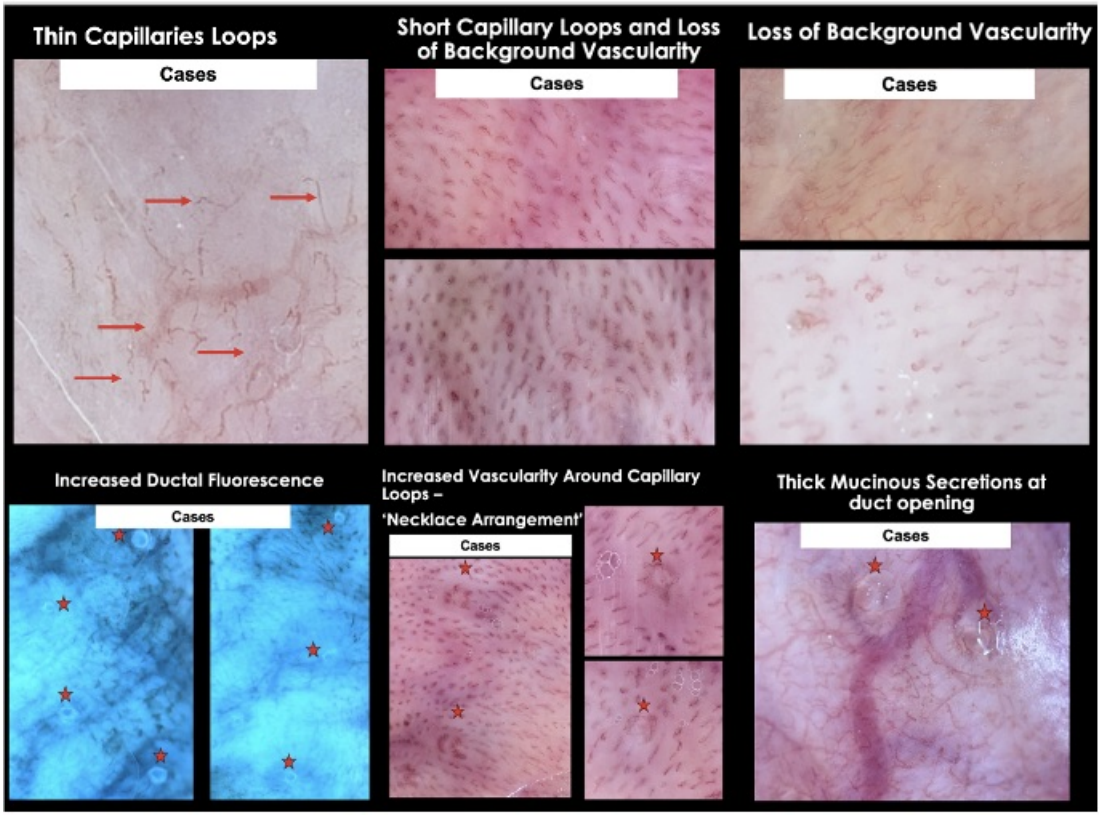

Normal versus Abnormal Mucoscopic features seen in Sjogren Syndrome

Conclusions

Mucoscopy demonstrated reproducible vascular and ductal alterations in Sjögren syndrome, particularly thinning and shortening of capillary loops and increased periductal vascularity, which showed significant association with disease status. These findings suggest that mucoscopy may serve as a rapid, inexpensive and non-invasive adjunctive tool for the evaluation of xerostomia and early identification of patients who may require further diagnostic workup. Visualization of oral microvascular and ductal changes may help bridge the diagnostic gap

between clinical suspicion and invasive biopsy. Larger multicentric studies with standardized mucoscopic criteria and quantitative vascular assessment are required to validate diagnostic accuracy, determine sensitivity and specificity and establish the role of mucoscopy within future diagnostic algorithms for SS.

EA DV CONGRESS
VIENNA
30 SEP - 3 OCT 2026

Abstract N°: 3832

Clinical and dermoscopic profile of psychodermatoses: a series of ten cases

Loubna Aitouarab*[1], Bendaoud Layla[1], Nada Naciri[1], Mariem Aboudourib[1], Said Amal[1], Ouafa Hocar[1]

[1] Department of Dermatology and Venereology,, Faculty of Medicine and Pharmacy of Marrakech, Mohammed VI University Hospital Center, Marrakech, Morocco

Introduction
Psychocutaneous disorders constitute a group of clinically polymorphic dermatoses. We report the clinical and dermoscopic features of ten cases of psychodermatoses collected in our department.

Case Presentation
The mean age of our patients was 17.6 years, with a male-to-female sex ratio of 0.11. The main psychodermatoses identified were trichotillomania (6 cases), dermatitis simulata (1 case), dermatitis artefacta (2 cases), and acne excoriée (1 case). Trichotillomania was the most frequent condition, involving the scalp in four cases and the eyelashes/eyebrows in two cases. The main trichoscopic findings included broken hairs at different lengths and black dots (95%), V-sign and trichoptilosis (66%), flame hairs (33%), hair powder (16%), and follicular microhemorrhages (16%).

The case of dermatitis simulata presented with periorbital erythematous plaques with exogenous dermoscopic pigment deposits that disappeared after alcohol cleaning. Cases of dermatitis artefacta showed bullous or ulcerated lesions with a suggestive triphasic dermoscopic pattern. In acne excoriée, dermoscopy revealed peripheral pigmentation associated with a central red area and punctate hemorrhages.

Conclusion
Our findings are consistent with the literature, confirming the major role of trichoscopy and dermoscopy in the diagnosis and differentiation of primary psychodermatoses.



dermatitis simulata

EADV CONGRESS
VIENNA
30 SEP - 3 OCT 2026

Abstract N°: 3857

Scleroderma-Associated Leukoderma in Diffuse Systemic Sclerosis: Dermoscopic Findings and Response to UVA-1 Phototherapy

Ana Carolina Salomão*[1], Mariana Diniz[1], Raphael Pereira[1]

[1] Universidade Estadual do Rio de Janeiro, Hospital Universitário Pedro Ernesto, Rio de Janeiro, Brazil

Introduction
Systemic sclerosis (SSc) is a chronic autoimmune connective tissue disease characterized by microvascular dysfunction and progressive fibrosis of the skin and internal organs. Diffuse cutaneous SSc may present with pigmentary alterations, including scleroderma-associated leukoderma, also known as the "salt-and-pepper" pattern, which can clinically mimic vitiligo. Early differentiation between these entities is essential, as diffuse SSc is associated with rapid progression and early visceral involvement.

Case Presentation
We report the case of a 43-year-old woman presenting with progressive skin tightening and hypopigmented lesions involving the trunk and extremities. Physical examination demonstrated marked microstomia, bilateral sclerodactyly, Raynaud phenomenon, and digital pitted scars. Dermatological evaluation revealed extensive hypochromic and achromic macules interspersed with islands of preserved pigmentation. Dermoscopic examination showed perifollicular pigment retention without confetti-like depigmentation or leukotrichia, findings consistent with scleroderma-associated leukoderma rather than vitiligo.

Further systemic investigation revealed positivity for anti-topoisomerase I antibodies (anti-Scl-70), and chest computed tomography demonstrated a nonspecific interstitial pneumonia pattern. The initial modified Rodnan skin score (mRSS) was 21, indicating severe cutaneous involvement. Treatment consisted of 11 cycles of systemic cyclophosphamide for interstitial lung disease associated with UVA-1 phototherapy administered three times weekly for a total of 30 sessions targeting cutaneous fibrosis.

Following treatment, the patient demonstrated clinical stabilization of leukoderma and significant improvement in skin thickening, with reduction of the mRSS from 21 to 14. Functional improvement and softening of fibrotic areas were also observed during follow-up.

Scleroderma-associated leukoderma results from dermal fibrosis with relative preservation of perifollicular melanocytes due to maintained periadnexal vascularization, explaining the characteristic dermoscopic pigment retention pattern. Dermoscopy therefore represents a valuable noninvasive diagnostic tool in distinguishing this manifestation from vitiligo. In addition, UVA-1 phototherapy has emerged as an important therapeutic modality in diffuse SSc because of its ability to penetrate deeply into the dermis, induce matrix metalloproteinases, and reduce collagen accumulation.



Figure. Multiple well-demarcated hypochromic and achromic punctate macules distributed over the upper chest and presternal region, consistent with a confetti-like leukoderma pattern on chronically photodamaged skin.

Conclusion

This case highlights the importance of dermoscopic evaluation in the differential diagnosis of pigmentary disorders in systemic sclerosis and supports the role of combined systemic immunosuppression and UVA-1 phototherapy in the management of severe diffuse cutaneous disease.

EADV CONGRESS
VIENNA
30 SEP - 3 OCT 2026

Abstract N°: 3972

The inflammoscopy code: Unlocking differential diagnosis of common plaque lesions – A prospective observational study

Ritjana Mala*[1], Monika Fida[1]

[1] University Hostpital Center " Mother Teresa", Tirana, Albania

Introduction
Recently, the utilization of dermoscopy has increasingly expanded beyond oncology to include the evaluation of various inflammatory skin conditions. Dermoscopy of inflammatory skin diseases (inflammoscopy) requires a structured approach to move beyond clinical suspicion. This study aims to validate a systematic "inflammoscopy code" by identifying specific micro-morphological markers across common plaque-like conditions.

Materials and Methods
A prospective observational study(February 2024-march 2026) was conducted involving a cohort of 104 patients presenting with various plaque lesions, including psoriasis, dermatitis (eczema), lichen planus, and pityriasis rosea. Exclusion criteria were strictly applied to ensure diagnostic clarity, excluding patients who had received topical corticosteroids or systemic immunomodulators within the preceding four weeks, as these treatments significantly alter vascular and scaling patterns. Statistical analysis was performed using SPSS, and a p-value of <0.05 was considered statistically significant.

Results
Distinctive dermoscopic signatures were identified for each primary pathology **($p < 0.001$)**. Psoriasis was characterized by a highly organized "code" of diffuse, regular dotted vessels on a bright red background with overlying silvery-white scales in 94% of cases. Conversely, eczema exhibited a non-specific distribution of dotted vessels associated with yellowish sero-crusts (the "yellow clod" sign) in 78% of cases. Lichen planus demonstrated high diagnostic specificity through the presence of Wickham striae in 92% of cases, while pityriasis rosea was uniquely identified by a peripheral collarette of scale in 88% of cases. Statistical significance was maintained across all comparative diagnostic patterns.

Conclusions
The results demonstrate that the "inflammoscopy code" provides a structured and reliable framework for the non-invasive differentiation of plaque lesions. Integrating these specific dermoscopic patterns into clinical practice allows for a more confident and accurate distinction from their clinical mimics, thereby potentially reducing the need for skin biopsies, facilitating timely management, and improving the monitoring of treatment response

EADV CONGRESS
VIENNA
30 SEP - 3 OCT 2026

Abstract N°: 4141

Evaluation of Psoriatic Lesional Activity Using UV Dermoscopy Within a Comprehensive Assessment Approach

Romaissaa Boufetama*[1], Zaineb Kettani[1], Kawtar Diaa[1], Meriem Chaouki[1], Narjess Er-Rachdy[1], Najoua Ammar[1], Syrine hamada[1], Nadia Ismaili[1], Laila Benzekri[1], Mariame Meziane[1]

[1] Centre Hospitalier Ibn Sina, Rabat, Morocco

Introduction
Psoriasis is a chronic inflammatory dermatosis characterized by heterogeneous lesional activity and fluctuating disease severity. Current assessment mainly relies on global clinical scores such as PASI and DLQI, which may insufficiently reflect local inflammatory changes and lesion-specific activity. Dermoscopy has improved the non-invasive evaluation of psoriatic plaques, while UV dermoscopy using 365-nm ultraviolet illumination enables visualization of endogenous autofluorescence associated with inflammatory and metabolic processes. However, the relationship between UV fluorescence and psoriasis severity remains insufficiently investigated. This study aimed to evaluate the association between UV dermoscopic fluorescence, lesion severity, dermoscopic vascular patterns, and clinical disease burden in plaque psoriasis.

Materials and Methods
A prospective observational study was conducted in 76 patients with plaque psoriasis. Overall disease severity was assessed using PASI and DLQI scores. One to three representative lesions per patient were clinically evaluated using a lesion-specific I-PASI score including erythema, infiltration, and scaling components. Conventional and UV dermoscopy were performed on the same lesions. Fluorescence intensity was graded on a semi-quantitative scale ranging from 0 to 3 according to visual intensity compared with adjacent uninvolved skin. Dermoscopic vascular and scaling features were analyzed and correlated with fluorescence intensity and lesion severity. Statistical analysis included Chi-square and Spearman correlation tests.

Results
A total of 161 lesions were analyzed. UV fluorescence was observed in 74.5% of lesions and increased significantly according to lesion severity, being detected in 22.4% of mild lesions, 96.6% of moderate lesions, and 100% of severe lesions ($p < 0.001$). Fluorescence intensity strongly correlated with I-PASI score ($\rho = 0.80$; $p < 0.001$), particularly with erythema and infiltration components, whereas scaling showed a limited contribution to fluorescence signal intensity. Higher fluorescence grades were associated with increased global PASI scores ($p < 0.001$) and the presence of pruritus ($p = 0.030$). Dermoscopic examination demonstrated significant correlations between lesion severity and the presence of ring vessels, hairpin vessels, and hemorrhagic dots ($p < 0.001$). Lesions with marked inflammatory vascular patterns also tended to exhibit stronger fluorescent signals under UV examination.

Conclusions
This integrated clinical, dermoscopic, and fluorescent assessment approach highlights a strong association between UV fluorescence and inflammatory activity in psoriasis. Observed in more than 70% of lesions, fluorescence appears to reflect increasing lesional activity and disease burden. The correlation between fluorescence intensity, vascular dermoscopic changes, and clinical severity supports the potential role of UV dermoscopy as a complementary non-invasive biomarker for lesion evaluation and therapeutic monitoring in

psoriasis.

EA DV CONGRESS
VIENNA
30 SEP - 3 OCT 2026

Abstract N°: 4193

Beyond white patches : Contribution of Dermoscopy in the Evaluation of Vitiligo Activity

Rehab Bellout*[1], Ouiame El Jouari[1], Sabrina Oujdi[1], Salim Gallouj[1]

[1] Dermatology Department, University Hospital Center Mohammed VI, Tangier, Morocco

Introduction
Vitiligo is a common acquired leukoderma caused by the destruction of melanocytes. It is a progressive and unpredictable depigmenting disorder whose assessment of activity mainly relies on clinical criteria that may sometimes be subjective and non-standardized. Dermoscopy is a promising non-invasive tool that can improve diagnosis, refine differential diagnosis, and especially contribute to the objective evaluation of disease activity.

Materials and Methods
This was a prospective, descriptive, and analytical study conducted between September 2020 and February 2026. A total of 184 patients with confirmed vitiligo were included. Dermoscopic examination was performed using a dermoscope coupled with a smartphone. The diagnosis was validated by two residents and one senior physician. Dermoscopic data were collected and statistically analyzed using the Chi-square test with a significance threshold of 5% ($p < 0.05$).

Results
Our population showed a marked female predominance, with a sex ratio of 2.03. The mean patient age was 32 years. Non-segmental vitiligo was by far the predominant form (80.99%), followed by segmental vitiligo (6.61%) and focal vitiligo (6.61%). The disease was considered active in 61% of patients. Patients reported active progression of lesions (evolution < 6 months) in 61.67% of cases, stability (no progression > 6 months) in 29.17%, while disease activity status was unspecified in 9.17% of cases.

Dermoscopy identified several patterns. The trichrome pattern was observed in 42.90% of cases, and the “starburst” pattern in 37.85%; both were correlated with disease activity. Perilesional pigmentation was present in 41.40% of examined lesions and was also associated with disease activity. In contrast, the altered pigment network (24.40%) showed no significant correlation with activity.

In addition, micro-Koebner phenomenon was noted in 33.97% of lesions, while telangiectasia or erythema were present in 29.14% of cases, both being associated with active disease. Two patterns were considered to have a possible or potential correlation with disease activity: the “Tapioca Sago” appearance (29.86%) and perifollicular pigmentation. Finally, leukotrichia (30.30%) and perifollicular depigmentation (29.75%) were more frequently associated with recently developed lesions.

Conclusions
Dermoscopy appears to be a promising tool for assessing vitiligo activity, revealing subtle morphological signatures of disease evolution. Certain patterns, such as trichrome, starburst, micro-Koebner phenomenon, and perifollicular and vascular abnormalities, seem to be relevant markers of disease progression. However, some

discrepancies remain in the literature, emphasizing the need for standardization of dermoscopic criteria and for prospective multicenter studies to better define their diagnostic and prognostic value.

EA DV CONGRESS
VIENNA
30 SEP - 3 OCT 2026

Abstract N°: 4306

Role of Nail Dermoscopy in the Diagnosis of Pediatric Nail Disorders: A Clinical Study

sbai khadija*[1], bouchra baghad[1], fatimazahra benhayoun[1], hanane rachadi[1], soumiya chiheb[1]

[1] Ibn Rochd University Hospital Center, casablanca, Morocco

Introduction

Nail disorders in children are a common reason for consultation in pediatric dermatology, although age-related physiological variations may complicate diagnosis. Nail abnormalities may reveal inflammatory dermatoses, infections, trauma, systemic diseases, or even genetic disorders.

In children, nail biopsy remains an invasive procedure, often difficult to perform and poorly tolerated.

Nail dermoscopy (onychoscopy) is a rapid, non-invasive, reproducible tool that is particularly useful in pediatric practice. It allows improved visualization of the nail matrix, nail bed, nail plate, and periungual folds.

The aim of our study was to evaluate the contribution of dermoscopy to the diagnosis of pediatric nail disorders and to identify the main dermoscopic criteria according to different etiologies.

Materials and Methods

This study was conducted in the Dermatology Department of Ibn Rochd University Hospital Center over a period of (study duration).

Children under 16 years of age consulting for nail disorders, regardless of the presenting complaint, were included.

All patients underwent:

1. A complete medical history
2. A full dermatological examination
3. Clinical examination of all 20 nails
4. Nail dermoscopic examination

Data collected included age, sex, medical history, lesion location, number of nails involved, clinical features, and dermoscopic characteristics. Dermoscopy was performed using a handheld polarized dermoscope (DermLite DL4), allowing analysis of the nail plate, nail bed, matrix, and periungual folds.

Nail disorders were classified into inflammatory, infectious, traumatic, tumoral, and pigmentary conditions.

Final diagnosis was based on clinical, dermoscopic, mycological, and/or histological findings.

Dermoscopic features assessed included:

- Subungual hyperkeratosis
- Nail plate color and structural changes
- Longitudinal pigmented bands

Results
Our study demonstrated that dermoscopy significantly improved the clinical assessment of nail disorders in children. It allowed better characterization of nail plate abnormalities, onycholysis, and periungual involvement.

In onychomycosis, the main dermoscopic features included longitudinal whitish or yellowish striations and areas of subungual hyperkeratosis.

In inflammatory conditions, particularly nail psoriasis, subungual hyperkeratosis was frequently observed.

In children presenting with longitudinal melanonychia, dermoscopy helped identify benign patterns, especially regular parallel lines on a homogeneous brown background, thereby avoiding unnecessary invasive biopsies.

Dermoscopy contributed to diagnostic confirmation in most cases and helped guide therapeutic management as well as biopsy indications.

The main conditions identified were:

- Longitudinal melanonychia
- Onychomycosis
- Nail psoriasis
- Nail lichen planus
- Paronychia

Conclusions
Nail dermoscopy is now considered an essential diagnostic tool in the evaluation of nail disorders in children. Its main advantage lies in its non-invasive nature, which is particularly suitable for the pediatric population.

In our study, dermoscopic findings were consistent with data from the literature, particularly in the assessment of longitudinal melanonychia and in the diagnosis of infectious and inflammatory conditions such as onychomycosis and nail psoriasis, where characteristic dermoscopic features can be identified.

A major advantage of dermoscopy is its ability to differentiate benign lesions from those requiring close follow-up or histological confirmation.

Thus, systematic integration of dermoscopy into routine pediatric dermatological examination could improve both diagnostic accuracy and therapeutic management of nail disorders in children.
Nail dermoscopy is a valuable complementary tool in the evaluation of pediatric nail disorders. It improves diagnostic orientation, facilitates differential diagnosis, and reduces the need for invasive procedures. Its routine use should be encouraged in pediatric dermatology practice.

EA DV CONGRESS
VIENNA
30 SEP - 3 OCT 2026

Abstract N°: 4383

Ultraviolet-Induced Fluorescence Dermoscopy in Nevus Sebaceous: A Descriptive Four-Case Series

Guillem Esteve-Boncompte*[1], Felip Vilardell Villellas[2], Pawel Pietkiewicz[3, 4], Veronica Sanmartín[1], Rosa M Martí[1]

[1] Department of Dermatology, Hospital Universitari Arnau de Vilanova, Lleida, Spain
[2] Department of Pathology, Hospital Universitari Arnau de Vilanova, Lleida, Spain
[3] Zwierzyniecka Medical Center, Poznań, Poland, Prisca Sapientia Institute, Zürich, Switzerland, Poznań, Poland
[4] Prisca Sapientia Institute, Zürich, Switzerland

Introduction

Ultraviolet-induced fluorescence dermoscopy (UVFD) is an emerging imaging technique that uses ultraviolet light, usually around 365 nm, to excite endogenous and microbial fluorophores in the skin, producing visible fluorescence patterns not seen with conventional dermoscopy. Nevus sebaceous is a congenital hamartoma involving sebaceous, follicular, and apocrine structures, typically presenting as a yellowish alopecic plaque on the scalp, face, or neck. Because of its adnexal composition, nevus sebaceous may show distinctive fluorescence related to follicular openings, sebaceous-rich areas, and porphyrin-producing microorganisms. We describe four cases of nevus sebaceous evaluated with conventional dermoscopy and UVFD to characterize recurrent fluorescence findings.

Materials and Methods

A descriptive case series was conducted, including four clinically and histopathologically diagnosed cases of nevus sebaceous evaluated in our dermatology department. Each lesion was examined using conventional polarized dermoscopy and ultraviolet-induced fluorescence dermoscopy (UVFD). UVFD images were obtained under standardized low-light conditions using dermatoscopes equipped with a 365-nm ultraviolet light source: IBOOLO DE-500, Shenzhen, China, or DermLite DL5, 3Gen, San Juan Capistrano, California, USA. Clinical, dermoscopic, and UVFD images were reviewed to identify recurrent fluorescence patterns, including color, distribution, relationship with follicular openings, and comparison with surrounding healthy skin. Available clinical data, lesion location, morphology, and histopathologic confirmation were recorded.



Figure 1. Clinical view of nevus sebaceous on the cheek of a 34-year-old woman, presenting as an irregular yellowish-brown plaque with lobulated borders and a slightly papillomatous surface.

Results

Four cases of nevus sebaceous were evaluated using conventional dermoscopy and UVFD. Clinically, lesions appeared as yellowish to brownish plaques with variable papillomatous surface changes and follicular prominence. Polarized dermoscopy showed yellow structureless areas, keratin-filled follicular openings, and sebaceous-looking clods. Under UVFD, the most relevant finding was the presence of red to orange-red fluorescence centered on follicular openings, appearing as small bright dots within the lesion. This pattern was more evident in some cases and may reflect follicular/sebaceous activity or porphyrin-related fluorescence. However, this finding was not consistently observed in all nevus sebaceous cases, suggesting variable UVFD expression.

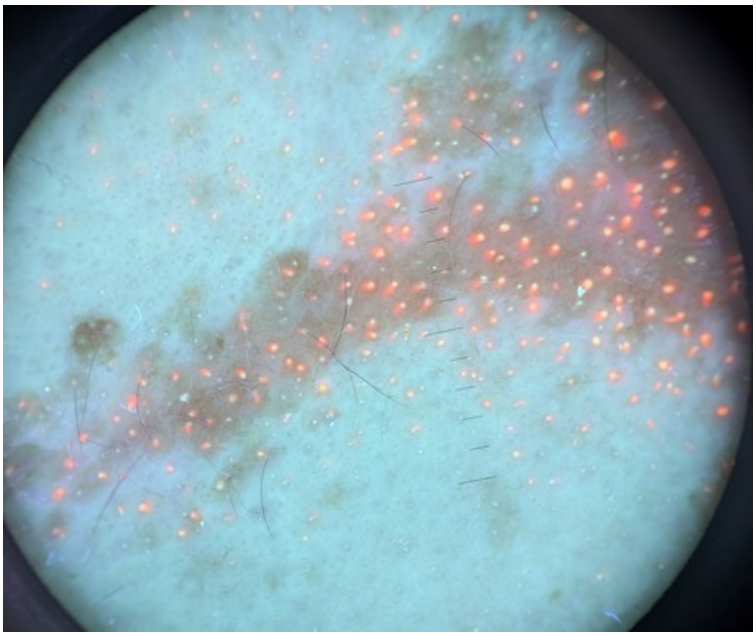

Figure 2. Ultraviolet-induced fluorescence dermoscopy (UVFD) of nevus sebaceous showing multiple bright red to orange-red fluorescent dots predominantly centered on follicular openings, more densely distributed within the lesion than in the surrounding skin, consistent with porphyrin-related follicular fluorescence.

Conclusions

UVFD may provide additional, non-invasive information in the evaluation of nevus sebaceous by revealing red to orange-red fluorescence centered on follicular openings. This fluorescence pattern is probably related to porphyrin production, particularly coproporphyrin III, by Cutibacterium acnes, a lipophilic bacterium that preferentially colonizes sebaceous follicles. Because nevus sebaceous is characterized by increased sebaceous gland density and adnexal involvement, its lipid-rich follicular environment may favor greater C. acnes colonization and enhanced porphyrin accumulation, resulting in brighter follicular fluorescence under 365-nm ultraviolet illumination. However, this finding was not observed in all cases, suggesting that fluorescence intensity may depend on variable factors such as sebaceous activity, microbial load, lesion maturation, anatomical site, or technical conditions. Larger studies with histopathologic and microbiological correlation are needed to determine whether this UVFD pattern represents a reproducible diagnostic clue in nevus sebaceous.

EADV CONGRESS
VIENNA
30 SEP - 3 OCT 2026

Abstract N°: 4521

Prospective and Retrospective Study of Dermoscopic Structures of Irritated Seborrheic Keratoses (iSKs): Descriptive Analysis

Faiza Boukhobza*[1], Meryem Soughi[1]

[1] Dermatology departement HASSAN II University Hospital, FES, Morocco

Introduction

Irritated seborrheic keratoses (iSKs) are a frequent diagnostic pitfall. Inflammation, crusting, erosion, haemorrhage, or vascularization can obscure the typical dermoscopic features of seborrheic keratosis (SK) and make iSKs resemble malignant tumours or benign lesions. Published data on iSK dermoscopy are limited, retrospective, and single-centre; none have studied the effect of consultation context, formalized a minimum diagnostic threshold to avoid biopsy, integrated reflectance confocal microscopy (RCM) as a second-line tool in an iSK-specific algorithm, or stratified findings by irritation mechanism or immune status.

Materials and Methods

Mixed-design observational descriptive study (retrospective and prospective) across multiple dermatological settings: general dermatology clinics, emergency departments, oncology follow-ups, xeroderma pigmentosum centres, and systematic skin exams. We included 153 iSKs (48 retrospective, 105 prospective). Clinical and dermoscopic photographs were taken for all lesions. Inclusion required clinical or dermoscopic signs of irritation plus at least one SK-specific structure; retrospective cases were included only when documentation allowed reliable dermoscopic re-evaluation. Diagnostic pathway: in less ambiguous cases, the presence of a single classic SK dermoscopic criterion (milia-like cysts, fissures and ridges, or cerebriform pattern) together with a consistent clinical history was considered sufficient to avoid biopsy. For challenging lesions, RCM was used as a second-line non-invasive test. Biopsy with histopathology was performed only when uncertainty remained. Dermoscopic analysis was performed independently by at least two dermatologists, blinded to final diagnosis. Recorded variables included epidemiology (age, sex, phototype, personal history of skin cancer, immune status), clinical data (location, size, morphology, Koebner phenomenon, mechanism of irritation), and dermoscopic features.

Results

153 iSKs were analysed. Mean patient age was 46 years; male:female ratio 1.3. The most frequent vascular feature was disorganized vascularisation (91.2%); adherent scales occurred in 54% of lesions. Hairpin vessels were seen in 22.6%; glomerular and dotted inhomogeneous vessels were observed in 43.7%. A whitish halo was present in 32% and erosion in 17%. Chrysalis (shiny white) structures appeared in a subset, more often in older lesions, consistent with progressive fibrosis. Classic SK dermoscopic criteria were identified in only 39% of lesions; milia-like cysts were rare and microcomedones were usually absent. Pattern distribution: SK-like 19.6%, SCC-like 38.2%, melanoma-like 9.3%, nevus-like 11.2%, unclassifiable 8.8%, BCC-like 7.3%, keratoacanthoma-like 7.2%, verruca vulgaris-like 1.6%. Biopsy was ultimately required for 64 lesions (41.8%). Pattern distribution differed significantly by consultation context (emergency, oncology, general

dermatology). Immune status and mechanism of irritation were significantly associated with specific dermoscopic features, particularly in patients with pruritic dermatoses (bullous diseases, psoriasis, eczema, atopic dermatitis, pruritus related to xerosis). Darker phototypes posed additional diagnostic challenges, as vascular structures were less consistently visible on dermoscopy. Pseudo-lacunae were identified as an additional mimic in selected cases.

Conclusions

Diagnosis of iSKs remains challenging because classic SK criteria are often absent or masked; irritated lesions can convincingly mimic malignant tumours. Dermoscopic pattern distribution varies with consultation context and patient immune status.

The presence of a single classic SK dermoscopic criterion combined with a coherent clinical history appears sufficient to confirm the diagnosis in selected cases; this minimum diagnostic threshold had not been formalized previously. These findings provide a practical, evidence-based framework for managing iSKs in routine dermatological practice.

EADV CONGRESS
VIENNA
30 SEP - 3 OCT 2026

Abstract N°: 4538

ARTIFICIAL INTELLIGENCE- ASSISTED DERMOSCOPIC EVALUATION OF ERYTHEMATOUS SKIN TUMOURS

Raquel Cardoso*[1], Maria Miguel Amaral[1]

[1] Instituto Português Oncologia De Coimbra Francisco Gentil, Coimbra, Portugal

Introduction

Erythematous skin tumours, benign and malignant, can be challenging both clinically and dermoscopically. Artificial Intelligence (AI) has shown encouraging results in dermatology, especially on the recognition of skin cancer. AI effectiveness and value in evaluating non or less pigmented lesions, namely rare tumor types, is still unclear and under investigation. The aim of this prospective study was to compare AI diagnostic accuracy with expert dermatologists and histopathological results.

Materials and Methods

Clinical and dermoscopic images of erythematous lesions (n=111) were collected from 100 patients observed in the Dermatology Department of the Portuguese Oncology Institute of Coimbra (IPO). It was used a dermatoscope attached to a mobile phone with AI to collect and analyse the images. Suspected malignant lesions were excised and a histopathological examination was disclosed. The uncertain lesions on dermoscopy or clinical examination were also excised or biopsied for diagnostic purposes. The undoubtful benign lesions identified by three expert dermatologists, after examining the clinical and dermoscopic images, were not excised. All images were confronted with AI evaluation.

Results

Concerning confirmed malignant lesions and AI, 96.6% of the dermoscopic images only were considered high risk. Regarding benign lesions and AI, 52% of dermoscopic images were classified as high risk. .The panel of dermatologists showed precision and agreement on their diagnosis. The diagnosis accuracy score of AI on dermoscopic images was 74%, the sensitivity was 96.6% and specificity was 48.1%.

Conclusions

AI was effective in identifying malignant erythematous lesions on dermoscopy images. It was responsible for high rates of false-positive findings respecting benign lesions. In this study AI demonstrated some weaknesses suggesting that there is still necessary improvement and validation of algorithms in real-world clinical scenarios.