EADV CONGRESS
VIENNA
30 SEP - 3 OCT 2026

Abstract N°: 33

A Rare Case of Lichen Planus Pemphigoides Highlighting Clinicopathological and Immunological Features

Abhishek Wilson Pallippattu*[1], Anu Gunavardhan[1], Alison Godwin[1]

[1] Glan Clwyd Hospital, Rhyl, United Kingdom

Introduction
Lichen planus pemphigoides (LPP) is a rare autoimmune immunobullous dermatosis characterized by lichenoid skin changes and bullous lesions. We present a rare case of LPP highlighting the correlation between its clinical, histological, and immunological features.

Case Presentation
A 20-year-old female presented with a one-month history of widespread, intensely pruritic, polygonal papules and plaques. Examination of the buccal mucosa revealed patterned white streaks. Two days prior to presentation, she acutely developed tense haemorrhagic blisters on the soles of both feet, areas previously unaffected by lichenoid lesions. Histopathological examination of a lichenoid lesion demonstrated features typical of lichen planus, including hyperkeratosis, saw-tooth acanthosis, and a lichenoid interface dermatitis with vacuolar change. Colloid (Civatte) bodies representing apoptotic keratinocytes were observed within the dermis, along with a dense, band-like inflammatory infiltrate composed predominantly of lymphocytes with occasional neutrophils. Direct immunofluorescence revealed linear deposition of IgG and complement factor C3 along the dermal–epidermal junction. The combination of lichenoid clinical features, bullous eruption on previously uninvolved skin, characteristic histopathology, and immunoreactant deposition at the basement membrane zone supported a diagnosis of LPP.

Conclusion
LPP is a rare autoimmune condition with an estimated prevalence of 1 per 1,000,000. Diagnosis of LPP relies on clinical observation followed by confirmatory direct immunofluorescence of IgG/C3 and/or serologic tests for autoantibodies against BP, BP180 and BP230, proteins found in type XVII collagen. Although usually idiopathic, LPP has been associated with medications such as ACE inhibitors and, rarely, with internal malignancies, suggesting a possible paraneoplastic variant. There is no current consensus on the optimal treatment regime for LPP. However, combinations of systemic with topical corticosteroids, potentially in combination with dapsone or acitretin are worth considering. Through this case, we aim to educate dermatologists to be vigilant and recognise LPP as a differential in patients presenting with lichen planus-like lesions with tense blisters or bullae.

EA DV CONGRESS
VIENNA
30 SEP - 3 OCT 2026

Abstract N°: 44

MULTIPLE CLONAL SEBORRHEIC KERATOSES IN A PATIENT WITH RED SCROTUM SYNDROME: CHALLENGES IN DIAGNOSIS

Semen Belozerov*[1], Irina Fedorova[2], Sofiia Tymchuk[2], Arina Kogadei[1], Kristina Khazhomiya[2], Polina Ptashnikova[2], Irina Smirnova[2]

[1] SZGMU imeni Mechnikova mediko-profilakticheskiy tsentr, Sankt-Peterburg, Russian Federation

[2] SPbGU, Sankt-Peterburg, Russian Federation

Introduction

Differential diagnosis of pigmented lesions in the anogenital area is challenging because of the anatomic and clinical features of this site. Additional difficulties arise in the presence of chronic dermatoses and long-term use of topical corticosteroids. We analyzed the clinicopathologic features of multiple clonal seborrheic keratoses in a patient with red scrotum syndrome and identified diagnostically relevant criteria.

Case Presentation

A 55-year-old man presented with persistent scrotal erythema, pruritus, and burning since 2010, with daily use of topical corticosteroids. Clinical examination showed persistent erythema and skin atrophy consistent with red scrotum syndrome, along with multiple verrucous pigmented lesions. Dermoscopy revealed cerebriform structures and milia-like cysts. Two biopsies were performed with histologic and immunohistochemical evaluation, including Ki-67, p16, carcinoembryonic antigen, and epithelial membrane antigen. Histology demonstrated horn pseudocysts and focal intraepidermal proliferation of monomorphic keratinocytes forming sharply demarcated nests consistent with the Borst-Jadassohn phenomenon. Ki-67 expression was predominantly confined to the basal layer. p16 showed a mosaic pattern within clonal nests without diffuse expression. There was no evidence supporting a virus-associated lesion or adnexal neoplasm. The final diagnosis was multiple clonal seborrheic keratoses arising in the setting of red scrotum syndrome.

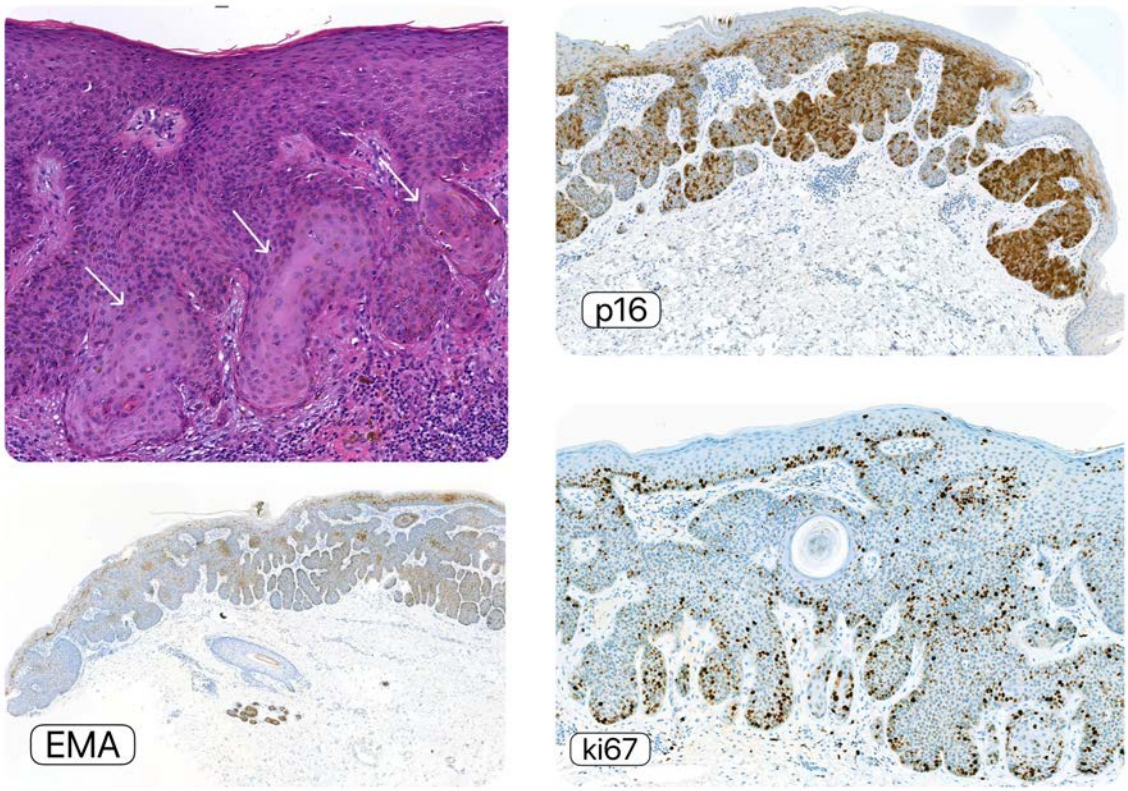

H&E - Borst–Jadassohn phenomenon (arrows)

Conclusion

Pigmented lesions of the anogenital region require integrated assessment with careful correlation of clinical findings, dermoscopy, and morphology. Immunohistochemical markers are supportive rather than decisive and should be interpreted in the context of histopathologic features. The combination of chronic steroid-induced dermatitis and multiple clonal seborrheic keratoses may obscure the clinical picture and lead to overdiagnosis of virus-associated or premalignant lesions.

EA DV CONGRESS
VIENNA
30 SEP - 3 OCT 2026

Abstract N°: 70

Melanocytic Acral Nevus with Intraepidermal Ascent of Cells (MANIAC): A Diagnostic Pitfall in Acral Pigmented Lesions.

Lula María Nieto Benito*[1], Loreto Carrasco-Santos[1]

[1] Hospital Central De La Defensa Gómez Ulla, Madrid, Spain

Introduction

Melanocytic lesions may pose a diagnostic challenge at the clinical, dermoscopic, and often also histopathological levels. Nevi of Special Sites (NOSS) are benign melanocytic lesions located in particular anatomical sites that display certain concerning histological features, including architectural and cytological changes that may raise suspicion and mimic atypical, dysplastic, or malignant lesions. Acral melanocytic nevi belong to this group of special-site nevi and, in some cases, the presence of a specific or low-grade pagetoid/intraepidermal ascent of melanocytes, although benign, may be alarming and has led to the introduction of the term MANIAC: Melanocytic Acral Nevus with Intraepidermal Ascent of Cells.

Case Presentation

A 66-year-old woman who consulted for the presence of two pigmented lesions on the left plantar region, of uncertain duration, noticed during a podiatric examination. Physical examination revealed two palpable pigmented lesions located on the lateral aspect of the left plantar region. The inferior lesion showed a dermoscopic pattern consistent with a compound melanocytic nevus, with a central intradermal component displaying homogeneous pigmentation and a peripheral flat, faintly pigmented area, with predominance of pigment within the furrows. The superior lesion also exhibited a dermoscopic pattern of a compound pigmented lesion but showed asymmetry in both pattern and distribution of structures. The central area displayed slate blue–gray pigmentation mixed with brown–black areas, whereas the peripheral area showed well-defined pigmented globules arranged asymmetrically. Based on these dermoscopic features, the second lesion was surgically excised.Histopathological examination revealed a melanocytic proliferation located at the dermoepidermal junction and within the superficial dermis, composed of nests and cords of nevic cells with uniform morphology and progressive maturation with depth, without cytological or architectural atypia. At the dermoepidermal junction, nests and thecae were observed within the epidermal ridges, occasionally fused, with the presence of melanocytes showing focal pagetoid ascent without atypia. PRAME staining did not demonstrate expression in melanocytic cells, and immunohistochemical (IHC) studies with Melan-A, HMB45, p16, and SOX10 showed findings consistent with a benign lesion. Surgical margins were free of lesion.

Conclusion

NOSS occur in particular anatomical sites that correspond to regions representative of the embryonic mammary line (breast, axilla, groin, umbilicus, and perineum), as well as in the genital, acral, cephalic, cervical, and flexural regions.Despite their benign behavior and lack of risk for melanoma development, these lesions present striking histopathological features, such as intense junctional melanocytic proliferation, clustering and cohesion of melanocytic nests at the dermoepidermal junction, elongation and fusion of rete ridges, large melanocytes with vesicular nuclei, small nucleoli, pale cytoplasm, or melanin pigment granules. As in the present case, pagetoid spread or intraepidermal ascent of melanocytes may be present; this is usually low-grade and accompanied by other features that help distinguish it from melanoma, including adequate circumscription, symmetry, absence of high-grade pagetoid spread, and lack of mitoses or necrosis. Regarding immunohistochemistry, recent studies characterize these lesions by strong HMB45 expression in the lentiginous component and in the nests, along with

maturation with depth, and a characteristically negative PRAME staining pattern.Therefore, NOSS—and particularly MANIAC lesions—may be difficult to diagnose due to their clinical features and the concerning nature of their histopathological findings. In such cases, clinicopathological correlation is essential, as well as the information provided by immunohistochemical studies and PRAME staining, which may be helpful in reaching a final diagnosis.

EADV CONGRESS
VIENNA
30 SEP - 3 OCT 2026

Abstract N°: 125

Preliminary Clinical Observations of Repigmentation in Vitiligo Patients Treated with a Novel Nutritional Phytotherapeutic Formulation

C.K. de Montaxel*[1]

[1] Green Fields R&D, Jos, Nigeria

Introduction

Introduction Vitiligo is a chronic depigmenting skin disorder characterized by the loss of melanocytes, resulting in white patches on the skin. The condition affects approximately 0.5–2% of the global population and often carries significant psychosocial burden. Current treatment options, including corticosteroids, calcineurin inhibitors, and phototherapy, show variable effectiveness and may require prolonged treatment. Nutritional and phytotherapeutic approaches targeting oxidative stress, immune modulation, and melanocyte support are increasingly explored as complementary strategies. This report presents preliminary observations from an ongoing clinical monitoring program evaluating a proprietary oral phytotherapeutic formulation in patients with vitiligo.

Case Presentation

Materials and Methods Patients with clinically diagnosed vitiligo were enrolled in an observational clinical monitoring program evaluating a proprietary oral phytotherapeutic formulation administered daily for 8 months. Participants underwent periodic clinical assessments to evaluate pigmentation changes within depigmented areas. Treatment response was categorized based on estimated repigmentation levels: no response, mild (<25%), moderate (25–50%), and marked (>50%). Safety observations were also recorded during the monitoring period.

Table 1. Baseline characteristics of vitiligo patients

Characteristic ValueTotal patients 20 Age range 35–90 years Sex distribution 13 Male (65%), 7 Female (35%)Duration of vitiligo 10–40 yearsTreatment duration 8 months

Results Preliminary observations revealed variable degrees of repigmentation among treated patients during the monitoring period. In several cases, early repigmentation appeared as small pigmented macules within depigmented areas, occasionally progressing gradually over time. No significant adverse effects were reported during the observation period.

Table 2. Clinical response observed after treatment

Response Category Definition of Repigmentation Patients (n) Percentage (%)No response No visible repigmentation 0 0% - Mild response <25% repigmentation 7 35% - Moderate response 25–50% repigmentation 10 50% - Marked response >50% repigmentation 3 15% - Total — 20 100%

Conclusion

Conclusions Preliminary observations from this ongoing clinical evaluation suggest that the investigated phytotherapeutic nutritional formulation may support repigmentation in a subset of vitiligo patients, including individuals with long-standing disease duration. The presence of mild to marked repigmentation in several participants indicates potential therapeutic potential. However, these findings remain observational and limited in scale. Larger controlled clinical studies with standardized outcome measures are required to confirm efficacy and further investigate possible mechanisms involved in melanocyte recovery.

EA DV CONGRESS
VIENNA
30 SEP - 3 OCT 2026

Abstract N°: 159

Immunohistochemistry as a Diagnostic Decisive Tool in a Cutaneous Spindle Cell Lesion: A Case of Cellular Dermatofibroma

Shama Naaz*[1]

[1] Ck Birla Hospital, Gurugram, India

Introduction

Dermatofibroma (DF) is a common benign fibrohistiocytic tumor clinically presenting as a solitary, firm, subcutaneous nodule. It is prevalent in patients of all ages but commonly seen in adults between the second and fifth decade of life. There are several variants of DF, distinguished by their distinct clinical and histological features. Cellular DF is a morphological variant of DF known for its deeper involvement and recurrences. Cellular DF may be confused with malignant spindle cell tumors such as dermatofibrosarcoma protuberans (DFSP), atypical fibroxanthoma, or spindle cell squamous cell carcinoma (SpSCC) as clinical and microscopic features can overlap. Therefore, immunohistochemistry (IHC) plays a significant role in distinguishing benign from aggressive entities. We present a diagnostically challenging spindle cell lesion where the role of IHC was essential in confirming a diagnosis of cellular dermatofibroma.

Case Presentation

A 56-year-old woman presented with a solitary brown nodule on the left forearm, gradually increasing in size over two years. During the last six months, the lesion had suddenly increased in size and became firmer. Examination revealed a well-defined, firm, dome-shaped dermal nodule with a central crater filled with keratin debris on the extensor aspect of the forearm. The firm adherence and resistance raised concern for a deeper pathology. Histopathological examination showed a well-circumscribed, non-encapsulated dermal spindle cell proliferation. The lesion consisted of densely packed spindle cells arranged in fascicles and short whorls. There were no significant atypia, necrosis, or atypical mitoses. Importantly, there was no honeycomb infiltration into subcutis which is a characteristic feature of DFSP. Immunohistochemistry revealed spindle cells showed focal S100 positivity. CD34, AE1/AE3, STAT6, SOX10, desmin, SMA, caldesmon, calponin, and ERG was negative. The overall findings supported a diagnosis of cellular dermatofibroma. Complete excision was recommended for cosmetic reasons and to prevent recurrence. The patient is under ongoing follow-up with no evidence of regrowth.

Conclusion

Cellular DF is a variant of benign fibrohistiocytic tumor, characterized by increased cellularity and a fascicular growth pattern. Histopathology of cellular DF can resemble certain malignant spindle cell tumors such as DFSP, SpSCC, solitary fibrous tumor, neural or smooth muscle tumors. DFSP typically shows diffuse CD34 positivity and infiltrates the subcutis in a honeycomb pattern. In contrast, cellular DF remains confined to the dermis and is CD34-negative. In the present case, the absence of subcutaneous infiltration and negative CD34 staining were key distinguishing features. The focal S100 positivity seen in some cases of DF may mimic neural tumours, however the lack of diffuse S100 positivity and SOX10 negativity can help to exclude these entities. SpSCC is an important differential due to its spindle-shaped tumor cells, but cytokeratin expression is essential for its diagnosis. The negative AE1/AE3 staining in this case helped exclude SpSCC. Solitary fibrous tumors show strong nuclear STAT6 positivity due to NAB2-STAT6 fusion, and this marker is invaluable in differentiation. Smooth muscle tumours display eosinophilic cytoplasm and are positive for SMA, desmin, and caldesmon, all of which were negative in this case. The diagnostic value of IHC lies not only in confirming the benign nature of the lesion but also in preventing over-treatment. DFSP requires wide local excision due to its infiltrative nature and high recurrence rate, whereas

cellular DF is benign and adequately treated with simple excision. This case highlights the importance of immunohistochemical approach when evaluating spindle cell lesions of the skin. Relying solely on the morphology of the lesion and histopathology may lead to misdiagnosis and unnecessary aggressive surgical intervention.

EA DV CONGRESS
VIENNA
30 SEP - 3 OCT 2026

Abstract N°: 163

Generalized Infantile Myofibromatosis in a Term Neonate With Severe Intrauterine Growth Restriction: A Diagnostic Challenge

Paulina Naranjo Arce[1], Nicole López Cerda[1], Ana María Martínez Afani[1], Diego Mendez-Villanueva*[1], María Fernanda Murúa Royo[2]

[1] Universidad de Santiago de Chile, Santiago, Chile
[2] Universidad del Desarrollo, Santiago, Chile

Introduction

Infantile myofibromatosis (IM) is a rare mesenchymal neoplasm of myofibroblastic origin and represents the most common fibrous tumor of infancy. The disease may present as solitary, multicentric, or generalized forms. While solitary lesions typically follow a benign course, the generalized variant with visceral involvement may be associated with significant morbidity and mortality. In neonates, multiple congenital cutaneous nodules may clinically mimic congenital infections, hematologic disorders, or vascular tumors, particularly in the context of "blueberry muffin" lesions. Accurate diagnosis therefore requires careful clinicopathological correlation and immunohistochemical confirmation. We report a case of generalized infantile myofibromatosis in a neonate with severe intrauterine growth restriction (IUGR), highlighting the diagnostic challenges and the role of dermatopathology.

Case Presentation

A female neonate born at 37 weeks of gestation with severe intrauterine growth restriction presented with multiple firm violaceous to red-brown nodules ranging from 0.5–2 cm located on the face, hard palate, trunk, and extremities since birth. At two months of age, the patient developed acute respiratory distress secondary to bronchopneumonia. Given the presence of congenital skin lesions and respiratory symptoms, congenital infection was initially suspected; however, an extensive infectious workup including TORCH serologies, cultures, and viral testing was negative. Imaging studies revealed numerous bilateral pulmonary nodules on chest computed tomography and nonspecific abdominal calcifications. A punch biopsy of a representative cutaneous lesion demonstrated a lobular dermal proliferation composed of ovoid and spindle cells arranged in fascicles around thin-walled vessels. Immunohistochemistry showed diffuse positivity for vimentin and caldesmon with patchy expression of smooth muscle actin (SMA). Tumor cells were negative for GLUT-1, S100, desmin, and other lineage markers. These findings confirmed the diagnosis of generalized infantile myofibromatosis. After stabilization of respiratory symptoms and anemia, the patient was discharged under multidisciplinary follow-up with a conservative management approach.



Figure 1. Cutaneous manifestations of generalized infantile myofibromatosis in a neonate (A) Well-defined erythematous-violaceous cutaneous nodule with firm consistency, located on the left plantar region, present since birth. (B) Nodular lesion on the right plantar region with an erythematous-violaceous halo. (C) Erythematous-violaceous cutaneous nodule on the first finger of the left hand, with a pearly appearance and a paler center (D) Dermoscopic image showing an erythematous-violaceous nodule with superficial telangiectasias (E) Rounded nodular lesion on the left lower extremity with brownish-violaceous coloration

Conclusion

Generalized infantile myofibromatosis should be considered in the differential diagnosis of neonates presenting with multiple congenital cutaneous nodules and systemic involvement. Dermatopathologic evaluation with targeted immunohistochemistry is essential for distinguishing this entity from vascular tumors and congenital infections. Early recognition allows appropriate management, prevents misdiagnosis, and supports careful monitoring given the potential for visceral disease and spontaneous regression.

EA DV CONGRESS
VIENNA
30 SEP - 3 OCT 2026

Abstract N°: 164

Diagnostic Dilemma in a Child: Hypopigmented Mycosis Fungoides versus Hypopigmented Pityriasis Lichenoides Chronica with CD8+ Predominance

Paulina Naranjo Arce[1], Ana María Martínez Afani[1], Catalina Montané Canales[1], Franco Javier Aguirre Serazzi[1], Nicole López Cerda[1], Diego Mendez-Villanueva*[1]

[1] Universidad de Santiago de Chile, Santiago, Chile

Introduction

Hypopigmented mycosis fungoides (HMF) is the most common variant of cutaneous T-cell lymphoma in children but often mimics inflammatory dermatoses such as pityriasis lichenoides chronica (PLC). The overlap of clinical and histopathologic features, particularly in hypopigmented lesions, can create significant diagnostic uncertainty. CD8+ predominance, which may occur in pediatric HMF, further complicates differentiation from PLC. We report a pediatric case illustrating the diagnostic challenge between these two entities.

Case Presentation

An 11-year-old boy presented with a 5-month history of progressive, asymptomatic hypopigmented macules involving the face, trunk, and extremities (Figure 1). Initial clinical differential diagnoses included Hansen's disease and hypopigmented mycosis fungoides. Skin biopsies from multiple sites showed a superficial lichenoid lymphocytic infiltrate with marked epidermotropism and focal basal vacuolar damage. Fite-Faraco staining was negative. Immunohistochemistry demonstrated a CD3+ T-cell infiltrate with CD8+ predominance and preserved pan-T-cell markers (CD2, CD5, CD7). While the preserved antigen profile favored pityriasis lichenoides chronica, the extensive distribution and prominent epidermotropism raised concern for early hypopigmented mycosis fungoides. The patient remains under close clinical surveillance.

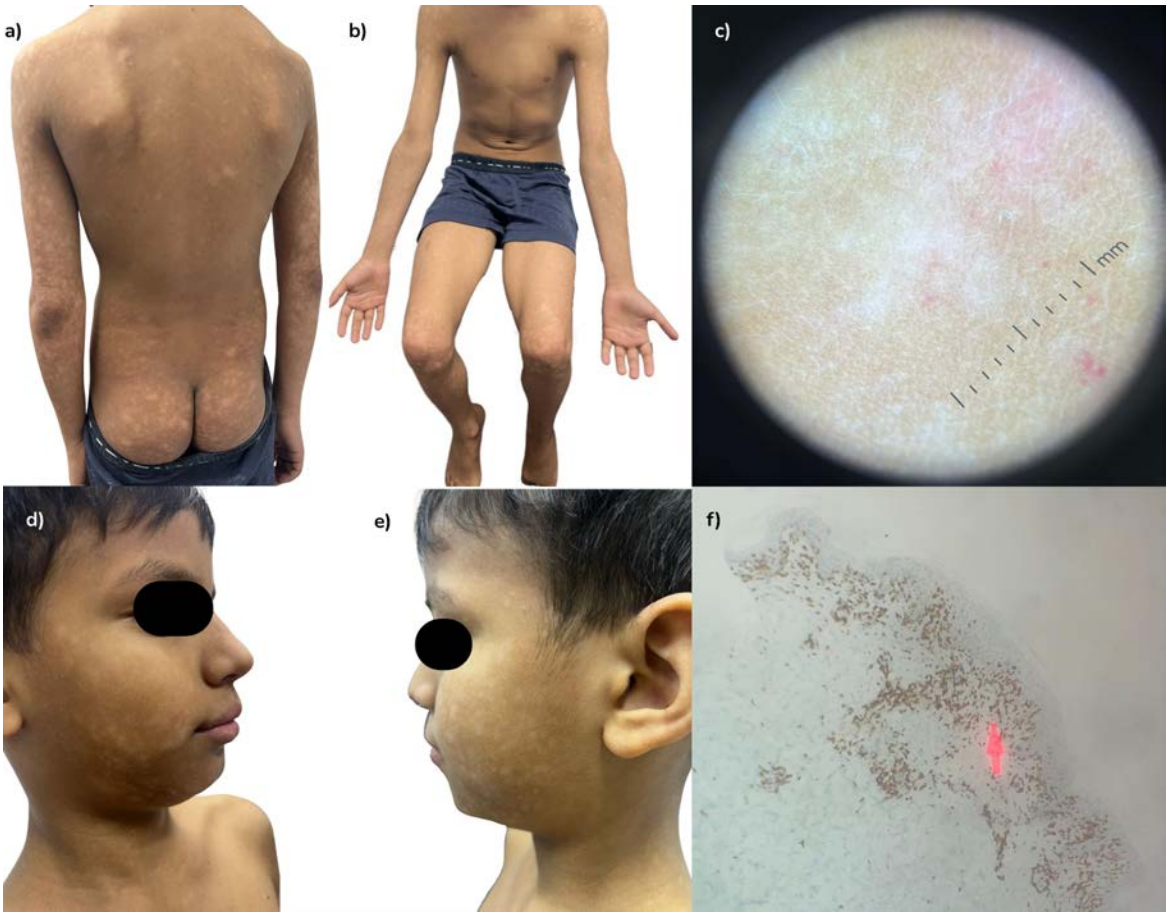

Figure 1. Clinical, dermoscopic, and histopathological findings in a pediatric hypopigmented dermatosis with lichenoid features. (A) Posterior view of the trunk and upper extremities showing multiple ill-defined hypopigmented macules diffusely distributed over the dorsal, lumbar, and flank regions, as well as the posterior aspects of the arms, with a tendency toward coalescence in the lumbar area. (B) Anterior view of the patient demonstrating extensive involvement of the trunk and extremities, including the lower limbs, with greater lesion density over the knees. Multiple hypopigmented macules with indistinct borders, non-scaly, and relatively symmetrically distributed are observed. (C) Dermoscopy of a hypopigmented lesion showing a whitish background with decreased pigment network, associated with mild, diffuse, non-homogeneous background erythema, without specific melanocytic structures. (D–E) Facial clinical details (right and left lateral views) showing subtle hypopigmented involvement with bilateral malar predominance, with slight extension to the perioral and submental regions, sparing the forehead and nasal dorsum. Lesions appear homogeneous, with ill-defined borders and no clinically evident scaling. (F) Immunohistochemistry for CD3 demonstrating a T-cell lymphocytic infiltrate with marked epidermotropism (arrow), highlighting intraepidermal lymphocytes. This is associated with a superficial lichenoid infiltrate showing mild cytologic atypia.

Conclusion

Distinguishing hypopigmented mycosis fungoides from pityriasis lichenoides chronica in pediatric patients can be challenging due to overlapping clinical and histopathologic findings. CD8+ predominance alone is not sufficient for diagnosis, and careful clinicopathologic correlation with longitudinal follow-up is essential to differentiate early cutaneous lymphoma from inflammatory dermatoses.

EADV CONGRESS
VIENNA
30 SEP - 3 OCT 2026

Abstract N°: 169

Twenty Years of Diagnostic Uncertainty: Verruciform Acrokeratosis Beyond Its Classical Presentation

Adina-Elena Micu*[1], Laura Solovastru[1]

[1] Emergency County Hospital "St. Spiridon" Iași, Iași, Romania

Introduction

Verruciform acrokeratosis of Hopf is a rare disorder of keratinization, traditionally described as a localized acral condition, but increasingly considered within the clinical spectrum of Darier disease. However, atypical presentations with widespread distribution may lead to significant diagnostic confusion, particularly with inherited or viral-associated verrucous dermatoses.

Case Presentation

We report the case of a 41-year-old female undergoing treatment with secukinumab for rheumatoid arthritis, who presented with a 20-year history of persistent, asymptomatic cutaneous lesions.Clinical examination revealed multiple, well-demarcated, flat-topped papules and plaques measuring 2-10 mm, with smooth to verrucous surfaces and a pink to brown-grey coloration. The lesions showed a tendency toward confluence and progressive extension over time and were distributed on the dorsal hands, forearms, abdomen, inguinal region, and oral mucosa, without a clear predilection for photo-exposed areas. Given the extensive distribution and mucosal involvement, epidermodysplasia verruciformis was initially considered. A skin biopsy was performed to clarify the diagnosis.

Histopathological examination demonstrated orthokeratotic hyperkeratosis, papillomatosis, hypergranulosis, and regular acanthosis, associated with mild spongiosis. The superficial dermis showed fibrosis, vascular congestion, and a sparse lymphoplasmacytic infiltrate.Importantly, no viral cytopathic changes, acantholysis, or dyskeratosis were identified. Based on these findings, the final diagnosis established by histopathology was verruciform acrokeratosis of Hopf.

Conclusion

This case highlights an unusual, generalized presentation of verruciform acrokeratosis with mucosal involvement, mimicking epidermodysplasia verruciformis and leading to initial diagnostic uncertainty. Although typically described as a localized acral disorder, verruciform acrokeratosis may present with broader distribution, emphasizing the key role of histopathological examination in establishing the correct diagnosis. Recognition of such atypical presentations is essential to avoid misdiagnosis and inappropriate management.

EA DV CONGRESS
VIENNA
30 SEP - 3 OCT 2026

Abstract N°: 200

Beyond Xanthomatosis: A case of perforating granuloma annulare on the dorsal hands and histopathological features

Chanilka Abegunawardana Pahalage*[1], Irina Smirnova[1]

[1] Saint Petersburg state university, Saint Petersburg, Russian Federation

Introduction

A 48-year-old female presented with a chronic, progressive dermatosis confined to the dorsal hands, marking a five-year diagnostic quandary. The initial presentation featured asymptomatic, static papules that were clinically diagnosed as Xanthomatosis. The patient's condition has since undergone a significant transformation, characterized by centrifugal expansion of the plaques and notable change of the color, signaling an active disease process that defies the initial diagnostic impression.

Case Presentation

Observation: The skin process is localized, chronic, and treatment-refractory, confined to the dorsal surfaces of both hands. The primary lesion is a solitary, well-demarcated plaque on each hand, approximately 6 cm in diameter. The plaques are composed of coalescing, firm, smooth-surfaced dermal papules, giving the area a raised, irregular topography. The color is a heterogeneous mix of erythematous, violaceous, and yellowish hues, clinically mimicking xanthomatosis. Upon close inspection, central umbilication and subtle crusting are observed in some papules, suggesting transepidermal elimination. The surrounding skin is unremarkable. The nail plates are unchanged. Dermographism is mixed. Turgor is preserved, and sweat and sebaceous gland functions are intact, with normal hair growth. Regional lymph nodes are not palpable. Based on the patient's complaints of a five-year history, the failure of prior topical corticosteroid therapy, and the distinctive clinical morphology with umbilication, a diagnosis of Perforating Granuloma Annulare is suspected. To confirm the diagnosis and definitively rule out Xanthomatosis and other granulomatous processes, a skin biopsy for histopathological examination was done.Materials & Methods:A 4mm punch biopsy was obtained from the plaque on the dorsal hand. Results: Histopathological examination revealed a slightly thickened epidermis with focal, predominantly follicular hyperkeratosis. Within the dermis, confluent areas of collagen degeneration were observed, surrounded by a palisaded infiltrate of large histiocytes and epithelioid cells, admixed with lymphocytes, fibroblasts, and multinucleated giant cells. Small vessels exhibited features of productive vasculitis.Further detailed dermatohistopathological analysis demonstrated a granular layer consisting of 2-3 cell rows, mild acanthosis, a distinct basal layer, and preserved rete ridges. Within the upper and mid-dermis, confluent foci of collagen necrobiosis were present, characterized by palisading histiocytes surrounding degenerated collagen bundles, with peripheral lymphocytes and scattered foreign body-type giant cells. While the differential diagnosis included elastolytic granuloma and necrobiosis lipoidica, the overall histological picture, in conjunction with the clinical presentation of umbilicated papules on the dorsal hands, was most consistent with a perforating variant of granuloma annulare.

Conclusion

This case highlights a rare and easily misdiagnosed variant of granuloma annulare. Perforating granuloma annulare should be considered in the differential diagnosis for any chronic, treatment-refractory plaque on the dorsal hands, particularly those with a yellowish hue mimicking xanthomatosis. The five-year delay in diagnosis in this patient underscores the importance of histopathological correlation when clinical presentations are atypical or fail to respond to standard therapy. The definitive diagnosis was achieved through biopsy, which revealed the

characteristic palisaded granulomatous inflammation with collagen necrobiosis and features suggestive of transepidermal elimination. This case serves as a reminder to clinicians to maintain a broad differential and to re-evaluate diagnoses when the clinical course defies expectations.

EADV CONGRESS
VIENNA
30 SEP - 3 OCT 2026

Abstract N°: 209

A rare case of Actinomycosis Canaliculitis

Madeleine Kelly*[1], Graeme Kelly[2]

[1] Townsville University Hospital, Townsville, Australia
[2] Townsville EyeCare, Townsville, Australia

Introduction

Lacrimal canaliculitis is a rare medical condition, commonly undiagnosed or misdiagnosed for long periods of time in up to 60% of patients. It is an infection of the canaliculus of the lacrimal drainage system, often symptomatic with chronic tearing of the eye and irritation in the medial portion of the infected eyelid. Examination reveals erythematous protrusion of the lacrimal punctum, erythema of the surrounding skin and mucopurulent discharge. Actinomyces, belonging to the phylum Actinobacteria, are gram-positive non-acid fast bacilli that can have a fungal mycelia-like appearance. Actinomyces, typically Actinomyces israelii, first described, are the most common aetiological causative organism of canaliculitis, although several organisms have been shown to cause the disease.

Case Presentation

An 88-year-old female presented with a four-year history of tender, injected conjunctiva associated with purulent discharge with episodes lasting for a period of two to three weeks. Previously diagnosed with blocked left nasolacrimal duct in 2014, the patient remained symptomatic after surgery and had multiple regimes of oral flucloxacillin and chloramphenicol ointment. A tender erythematous lump was present in the left medial canthus inferiorly, with exudate in the punctum. Canaliculitis was initially diagnosed and treated with canaliculotomy performed at the lid margin. The contents were sent for microbiological and histopathological examination. Microscopy showed gram positive bacilli resembling Actinomyces Species, displaying typical branching and filamentous organisms. Post-operatively the patient was treated with topical tobramycin drops four times daily for one month, with complete resolution at 6 weeks review and no recurrence at her annual review.

Conclusion

This case highlights the typical features reported in the literature with a long delay in diagnosis often leading to inappropriate investigations and treatment that ultimately fails to resolve the symptoms. Aids to diagnosing Actinomycosis canaliculitis include a high clinical suspicion in the presence of a chronic relapsing discharge, medial conjunctival injection and a pouting punctum with pus. Treatment should include canaliculotomy with curette to remove all concretions and breakdown loculations with lavage of penicillin drops and post-operative topical penicillin. Due to its rarity, Actinomycosis canaliculitis can present a diagnostic challenge, leading to unnecessary suffering to patients, making it essential to recognise the condition early.

EADV CONGRESS
VIENNA
30 SEP - 3 OCT 2026

Abstract N°: 243

An exceptionally rare case of EBV-positive Primary cutaneous Peripheral T-Cell Lymphoma, Not Otherwise Specified

Woo Jin Ahn*[1], Sun Gyu Kim[1], Hyun-MIn Seo[1], Joung Soo Kim[1]

[1] Hanyang university Guri hospital, Korean Dermatological Association, Guri, Korea, Rep. of South

Introduction

Primary cutaneous peripheral T-cell lymphoma, not otherwise specified (pcPTCL, NOS), is a rare and heterogeneous subgroup of cutaneous T-cell lymphomas characterized by clonal proliferation of mature T cells confined to the skin without evidence of extracutaneous disease at diagnosis. In the WHO 5th edition classification of hematolymphoid neoplasms, pcPTCL, NOS is recognized as a distinct entity within primary cutaneous T-cell lymphomas, defined largely by exclusion of other well-characterized subtypes. Clinically, it most often presents as solitary or multiple nodules on the extremities, and histologically demonstrates diffuse dermal to subcutaneous infiltration of pleomorphic atypical T lymphocytes with an aberrant immunophenotype. The disease generally carries an aggressive clinical course and poor prognosis compared to other cutaneous T-cell lymphomas. While Epstein–Barr virus (EBV) is commonly associated with certain T- and NK-cell lymphomas, including extranodal NK/T-cell lymphoma and systemic EBV-positive T-cell lymphoproliferative disorders, its role in pcPTCL, NOS remains unclear and is exceedingly rare. Herein, we report an unusual case of EBV-positive pcPTCL, NOS, highlighting its diagnostic challenges and potential implications for disease classification.

Case Presentation

A 79-year-old woman presented with a 10-day history of rapidly progressive erythematous, firm noduloplaque lesions on both lower extremities and the left forearm, accompanied by lower extremity swelling. The lesions showed marked progression over the preceding week without associated systemic symptoms. Histopathologic examination revealed a dense, diffuse infiltrate of atypical lymphoid cells extending from the upper dermis to the subcutaneous layer in a lobular growth pattern, without significant epidermotropism. The infiltrating cells were predominantly medium- to large-sized with marked pleomorphism, mitotic figures, and occasional multinucleated and bizarre forms. Immunohistochemical studies demonstrated a T-cell lineage with positivity for CD2 and cytoplasmic CD3, while CD4, CD5, CD7, and CD56 were negative, indicating an aberrant T-cell phenotype. Cytotoxic markers showed negativity for TIA-1, but positivity for granzyme B and focal positivity for perforin. Markers for T-follicular helper phenotype (CD10, CXCL13, CD21, PD-1) were negative or equivocal, and TCR-γ was negative. CD30 expression was positive, and in situ hybridization for Epstein–Barr virus–encoded RNA (EBER) revealed diffuse positivity. Comprehensive systemic evaluation, including PET-CT and bone marrow biopsy, showed no evidence of extracutaneous involvement.

Conclusion

Based on the clinicopathological correlation, a final diagnosis of EBV-positive pcPTCL, NOS was established. Importantly, pcPTCL, NOS is a diagnosis of exclusion, requiring thorough clinicopathologic and immunophenotypic evaluation to rule out other defined entities of cutaneous T-cell lymphoma, including CD30-positive lymphoproliferative disorders, extranodal NK/T-cell lymphoma, γδ T-cell lymphoma, and T-follicular helper–type lymphomas. In this case, the lack of CD56 expression, negative TCR-γ, absence of T-follicular helper markers (CD10, CXCL13, CD21), and no evidence of systemic disease supported exclusion of these entities. Notably, in the EORTC study by Werner Kempf et al., published in Journal of the European Academy of Dermatology and Venereology (2020), all reported cases of pcPTCL, NOS were negative for EBER, underscoring

the unusual nature of EBV association in this entity. Although a limited number of EBV-positive primary cutaneous T-cell lymphoma cases have been described, these were predominantly associated with a follicular helper T-cell phenotype rather than pcPTCL, NOS. Therefore, this case represents an exceptionally rare presentation of EBV-positive pcPTCL, NOS, expanding the clinicopathological spectrum of this already rare lymphoma subtype and highlighting the importance of a comprehensive diagnostic approach.

EA DV CONGRESS
VIENNA
30 SEP - 3 OCT 2026

Abstract N°: 267

Acantholytic squamous cell carcinoma of vulva: a rare case report.

Vinoo Sekhri*[1], Richa Nagpal[2], Rajiv Sekhri[3]

[1] Consultant Dermatopathologist, Fortis Hospital, Sector 62, Noida, India
[2] Consultant Dermatologist, Skin Clinic, 77, Niti Khand 3, Indirapuram, Ghaziabad, India
[3] Consultant Dermatologist, Fortis Hospital, Sector 62, Noida, India

Introduction

Acantholytic squamous cell carcinoma (ASCC) was first described by Lever in 1947 as adenoacanthoma of sweat glands, as it was earlier thought to be eccrine in origin. Later with more studies, it became evident that it is a distinct variant of squamous cell carcinoma (SCC). It is also known by other names like pseudo-glandular SCC or adenoid SCC, which imply the presence of gland-like structures within the tumour. Clinically, ASCC is shown to have predilection for sun exposed areas, especially head and neck of elderly patients. Very few reports have been reported in sun protected areas.

Case Presentation

A 62-year-old female presented to the dermatology clinic with an ulcer on the right side of vulva. The lesion started as a papule 5 months back but rapidly grew in size to from an ulcer. The ulcer was around 1.25 x 1 inch in size, with moist erythematous base and raised violaceous margins. A punch biopsy was taken from the margin of the lesion which showed an ulcerated tumour composed of nests and islands of atypical cells forming a pseudo-glandular tubular patten with central acantholysis (Image 1). Most of these structures were lined by more than a single layer of cells with few tubular structures lined by a single layer of cells resembling glands. Continuity with overlying squamous epithelium was seen. The presence of keratin pearls and abnormal keratinocytes was documented. There was no lympho-vascular invasion. A diagnosis of ASCC was made and the patient was referred to oncology department where she underwent right modified radical hemi-vulvectomy with bilateral robot-assisted video-endoscopic inguinal lymphadenectomy. Follow-up appointments are maintained, with the patient exhibiting good condition. A 5- month PET scan showed no evidence of disease.

Conclusion

ASCC is an uncommon histological variation of SCC, and its aggressiveness is still debated. Hopefully, more reports in the future will help determine the proper course of the disease.

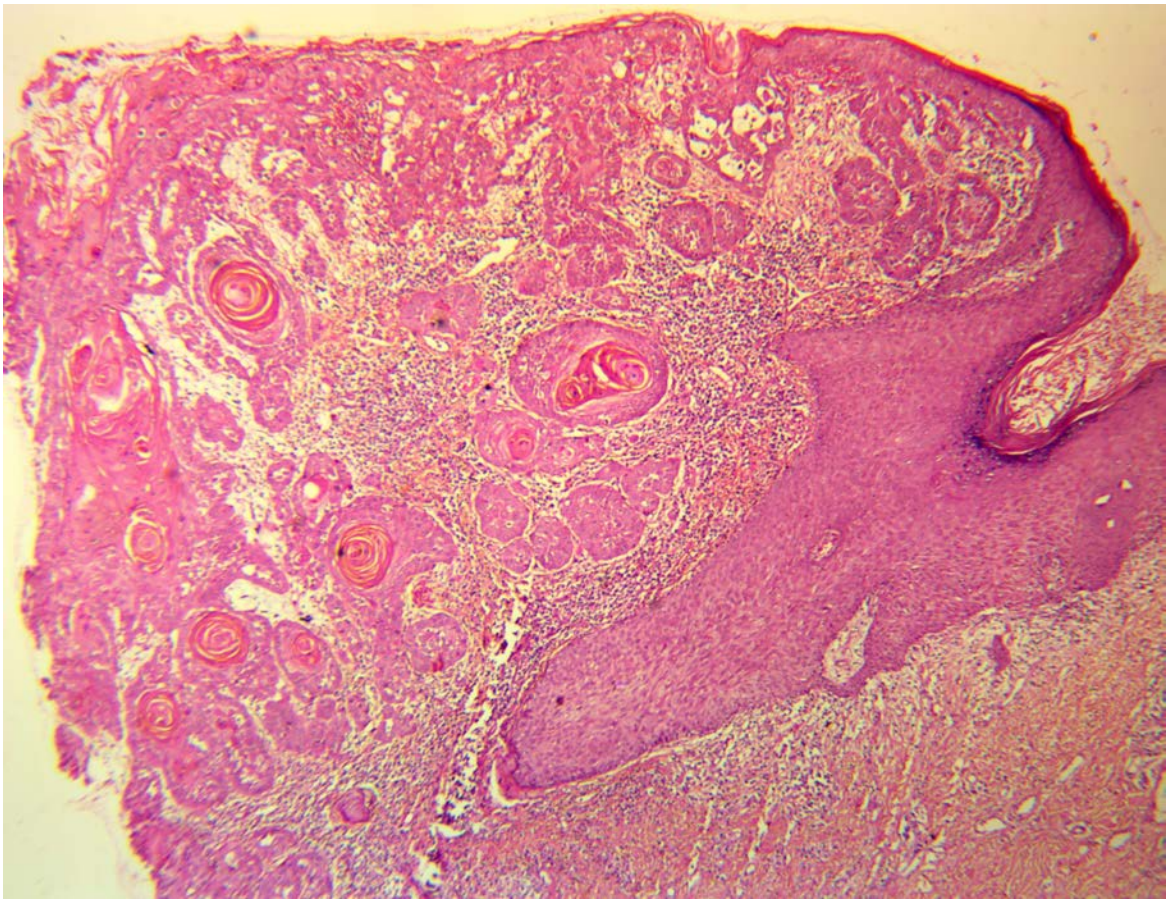

Image 1: Islands of atypical cells forming a pseudo-glandular tubular patten with presence of keratin pearls.

EADV CONGRESS
VIENNA
30 SEP - 3 OCT 2026

Abstract N°: 282

Breast Ulcers in a Hemodialysis Patient: A Diagnostic Challenge Between Pyoderma Gangrenosum and Calciphylaxis

Aya Awwad*[1, 2], Ali Hamieh[1, 2], Ali Fakih[1, 2], Fouad El-Sayed[1, 2]

[1] Lebanese University, Faculty of Medical Sciences, Hadath, Lebanon
[2] Baabda Governmental University Hospital, Baabda, Lebanon

Introduction

Pyoderma gangrenosum is a rare neutrophilic dermatosis characterized by rapidly progressive painful ulcers. In patients with End-Stage Renal Disease (ESRD), it may closely mimic calciphylaxis, a life-threatening condition requiring different management. Early differentiation between these two entities is therefore crucial to avoid inappropriate treatment and to stop rapid progression of skin ulcers.

Case Presentation

A 58-year-old woman with type 2 diabetes, hypertension, coronary artery disease, and long-standing hemodialysis-dependent ESRD presented with rapidly progressive, extremely painful necrotic ulcers involving both breasts since 4 months. Given this clinical context and medical history, calciphylaxis was strongly suspected. Despite appropriate antibiotic therapy for presumed superinfection, the ulcers worsened.
Laboratory studies revealed an elevated CRP, and there were no findings suggestive of significant calcium-phosphate imbalance. Breast ultrasound and mammography did not detect any breast pathology. Skin biopsy revealed ulceration, epidermal and dermal necrosis, a dense neutrophilic infiltrate, and mild vascular changes, without evidence of vascular calcification or thrombosis, thereby arguing against calciphylaxis and supporting the diagnosis of pyoderma gangrenosum.
Systemic corticosteroids, started prior to consultation, resulted in only limited improvement. Following a multidisciplinary discussion, cyclosporine (4 mg/kg/day) was subsequently initiated, leading to rapid pain relief and significant regression of the ulcers within 8 weeks.

Conclusion

This case highlights a diagnostic pitfall in ESRD patients, in which pyoderma gangrenosum may closely mimic calciphylaxis. Careful clinical and pathological correlation is essential, as misdiagnosis may delay appropriate immunosuppressive therapy. Recognition of atypical presentations, including breast involvement, is crucial for improving patient outcomes and quality of life.

EADV CONGRESS
VIENNA
30 SEP - 3 OCT 2026

Abstract N°: 331

Diagnostic Performance of PRAME IHC, p16 IHC, and 9p21 FISH Alone and in Combination for Ambiguous Melanocytic Lesions

weihong hu*[1]

[1] Department of Dermatology, The Second Affiliated Hospital of Xi'an Jiaotong University, Xi'an, Shaanxi, 710004, People's Republic of China, xi'an, China

Introduction
Distinguishing malignant melanoma from indeterminate melanocytic lesions remains a major challenge in routine dermatopathological diagnosis. Although advanced molecular tests are effective, their high cost, long turnaround time, and limited accessibility restrict widespread clinical application. p16 protein, encoded by the CDKN2A gene located on chromosome 9p21, can be assessed by immunohistochemistry and by 9p21 fluorescence in situ hybridization, together providing complementary information on p16 pathway integrity. This study aimed to evaluate the diagnostic performance of PRAME IHC, p16 IHC, and 9p21 FISH alone and in combination, and to explore a clinically actionable stratified diagnostic workflow.

Materials and Methods
This single-center retrospective study enrolled 26 patients with ambiguous melanocytic lesions (16 melanomas, 10 benign/indeterminate). Sensitivity, specificity, PPV, NPV, and diagnostic accuracy were calculated for each test. Parallel and serial combination strategies were analyzed. A stratified model integrating PRAME screening with p16 assessment (combining p16 IHC and 9p21 FISH) was proposed. ROC curves and AUC values compared diagnostic efficacy.

Results
Results: A total of 26 patients were enrolled, including 16 confirmed melanomas and 10 benign/indeterminate lesions. The two groups were comparable in sex, age, site, and Breslow thickness, but differed in Clark level (III–V: 37.5% vs. 0%, p=0.038) and mitotic figures (>1/mm^2: 42.3% vs. 20.0%, p=0.041), consistent with malignant histology. PRAME IHC was evaluable in 22 cases, showing positivity in 50.0% of melanomas and 33.3% of atypical lesions (p=0.208); p16 IHC in 25 cases showed complete/partial loss in 93.3% of melanomas and 80.0% of atypical lesions (p=0.400); 9p21 FISH in all 26 cases showed positivity (deletion) in 81.3% of melanomas and 60.0% of atypical lesions (p=0.369). For diagnostic performance, PRAME IHC demonstrated a sensitivity of 50.0%, specificity of 80.0%, and diagnostic accuracy of 61.5%; 9p21 FISH had a sensitivity of 81.3%, specificity of 40.0%, and accuracy of 65.4%; p16 IHC exhibited high sensitivity (93.3%) but low specificity (20.0%), with an accuracy of 65.4%. Since both p16 IHC and 9p21 FISH reflect p16 status, they were combined as a p16 integrity assessment, where p16 IHC negativity or 9p21 FISH positivity (deletion) was considered abnormal, yielding a sensitivity of 93.8% and specificity of 30.0%. For the combination of PRAME and p16 assessment, the parallel strategy (either positive) achieved a sensitivity of 100% and specificity of 20.0%; the serial strategy (both positive) showed a sensitivity of 43.8% and specificity of 90.0%. The stratified diagnostic workflow was defined as follows: cases with negative PRAME and intact p16 (p16 IHC positive and 9p21 FISH negative) were classified as low risk; cases with positive PRAME or p16 pathway abnormality required integrated clinicopathological correlation. ROC curve analysis showed that the combined assay (PRAME plus p16 assessment using a logistic regression model) had an AUC of 0.81, higher than that of PRAME IHC alone (0.65) and 9p21 FISH alone (0.61).

Conclusions

PRAME IHC and p16 assessment (combining p16 IHC and 9p21 FISH) provide complementary diagnostic value in ambiguous melanocytic lesions. Integrating p16 IHC and 9p21 FISH as protein-level and gene-level evaluation of the same molecular pathway allows a more comprehensive assessment of p16 integrity. The parallel combination improves sensitivity for malignancy screening to reduce missed diagnosis, while the serial combination enhances specificity for melanoma confirmation with a notable risk of underdiagnosis. The stratified diagnostic model (PRAME screening followed by p16 integrity verification) is clinically actionable and can be readily integrated into routine pathological practice, offering a low-cost, accessible evidence-based approach, particularly in settings with limited access to advanced molecular techniques.

EADV CONGRESS
VIENNA
30 SEP - 3 OCT 2026

Abstract N°: 470

Multiple asymptomatic papules on the trunk and upper limbs

Hui Sun*[1], Wei Shen[1], Qiying Zhang[2], Shun-Li Tang[1], Yuan Wu[1], Hua-Jie Zhong[1]

[1] Huzhou Central Hospital, Huzhou, China

[2] Jinhua Municipal Central Hospital, Jinhua, China

Introduction

Syringomas are benign adnexal tumors derived from eccrine sweat ducts. Generalized eruptive syringoma is a rare variant characterized by multiple small papules appearing over time, typically on the trunk and proximal extremities. The condition is often asymptomatic and primarily of cosmetic concern. Recognition through clinical and histopathological correlation is essential to differentiate it from other papular dermatoses.

Case Presentation

A 38-year-old male presented with multiple, asymptomatic papules on his trunk and upper limbs, which had developed over the past 20 years. The lesions began as millet-sized papules and gradually increased in number, without pruritus, ulceration, or discharge. There was no relevant family history or prior treatment.Physical examination revealed scattered, discrete, red-brown papules on the arms, chest, and abdomen, showing well-defined borders and no coalescence or exudation. The remainder of the examination was unremarkable (Figure 1).Histopathological examination of a biopsy from the anterior chest showed basal layer hyperpigmentation and proliferation of epithelial cells in the superficial dermis, forming small ducts, cysts, and nest-like structures. Some of these exhibited characteristic comma or tadpole shapes, consistent with a benign adnexal tumor of eccrine origin (Figure 2). These findings supported a diagnosis of generalized eruptive syringoma.Given the benign and asymptomatic nature of the condition, the patient was reassured and opted for observation without active intervention. No changes were observed at the six-month follow-up.

Conclusion

Generalized eruptive syringoma is a rare, benign eccrine tumor that can present with slowly progressive asymptomatic papules on the trunk and extremities. Diagnosis is confirmed by characteristic histopathology showing comma- and tadpole-shaped ductal structures. In asymptomatic cases, conservative management with reassurance and observation is appropriate, as the lesions are stable and do not require aggressive intervention.

EADV CONGRESS
VIENNA
30 SEP - 3 OCT 2026

Abstract N°: 473

A Rare Case of Male Mucinous Breast Carcinoma Presenting as an Isolated Cutaneous Nodule without a Palpable Breast Mass

Da Yeon Kim*[1], Ji Yeon Byun[1], You Won Choi[1], Joo Young Roh[1], Hae Young Choi[1], Heera Lee[1]

[1] Department of Dermatology, Ewha Womans University College of Medicine, Seoul, Korea, Rep. of South

Introduction

Mucinous breast carcinoma (MBC) is a rare variant of invasive breast cancer characterized by tumor nests floating in extracellular mucin pools. Distinguishing MBC from primary cutaneous mucinous carcinoma (PCMC) is challenging due to overlapping histological features, especially when primary breast lesion is clinically occult.

Case Presentation

A 61-year-old male presented with a long-standing, painless, clear nodule with superficial telangiectasia on the right anterior chest, accompanying ipsilateral axillary lymphadenopathy. PCMC was initially suspected in the absence of a palpable breast mass. Excisional biopsy of the nodule revealed tumor islands within mucin pools separated by fibrous septa. Immunohistochemistry demonstrated positivity for ER, PR, GATA-3, and GCDFP-15. Crucially, loss of p63 and CK5/6 expression, indicating absence of the myoepithelial layer, supported mammary adenocarcinoma lineage. Breast MRI and PET-CT failed to identify a distinct primary breast mass. Axillary lymph node excision confirmed metastasis, leading to a final diagnosis of occult MBC with skin and nodal metastases. The patient underwent breast-conserving surgery with axillary lymph node dissection, and adjuvant chemotherapy is ongoing.

Conclusion

This case highlights that an isolated skin nodule in a male patient may be the first clue to occult MBC. High suspicion, comprehensive IHC panel, and radiologic imaging are essential to avoid misdiagnosis of this systemic malignancy.

EADV CONGRESS
VIENNA
30 SEP - 3 OCT 2026

Abstract N°: 620

From Slide to Screen: Experience with Teledermatopathology from Nepal

Elisha Shrestha*[1]

[1] Dhulikhel Hospital Kathmandu University Hospital, Dhulikhel, Nepal

Introduction
Limited access to dermatopathology expertise remains a major challenge in many low- and middle-income countries. Teledermatopathology offers a potential solution by enabling remote expert consultation, yet real-world data on diagnostic concordance and clinical impact are scarce.
Objective is to evaluate the role and impact of teledermatopathology within virtual multidisciplinary diagnostic discussions on dermatopathologic diagnosis and patient management at Dhulikhel Hospital in collaboration with Stanford University.

Materials and Methods
A retrospective review was performed of difficult dermatologic biopsy cases evaluated through teledermatopathology between January, 2023 to December, 2024. Digital photomicrographs including case history were shared with dermatopathologists from Standford University for provisional diagnosis via a virtual platform (zoom meeting). Concordance was assessed between teledermatopathology diagnoses, clinical impressions, and final histopathological reports. Turnaround time and changes in patient management were analyzed.

Results
A total of 120 difficult dermatologic biopsy cases were included. Diagnostic concordance between teledermatopathology interpretation and final histopathology demonstrated a clinically meaningful level of agreement, with higher concordance observed in inflammatory dermatoses compared to neoplastic conditions. Importantly, no malignant cases were underdiagnosed during teledermatopathology review.
Teledermatopathology contributed to improved diagnostic confidence and facilitated earlier treatment initiation in a substantial proportion of cases. A reduction in diagnostic turnaround time was observed, particularly in settings where on-site dermatopathology services were unavailable.

Conclusions
Teledermatopathology is a feasible and effective adjunct for dermatologic diagnosis in resource-limited settings, demonstrating acceptable diagnostic concordance and meaningful clinical impact. Integration of teledermatopathology may help bridge diagnostic gaps and improve patient care where specialist access is limited.

EADV CONGRESS
VIENNA
30 SEP - 3 OCT 2026

Abstract N°: 719

Histopathologic clues to psoriasiform drug reactions: A single-center, comparative study with psoriasis vulgaris controls

Ivan Arni Preclaro*[1], Natsumi Hama[2], Riichiro Abe[2]

[1] DOH-Tondo Medical Center, Niigata University, St. Luke's College of Medicine, Manila, Philippines
[2] Niigata University, Niigata, Japan

Introduction

Psoriasiform drug reactions (PDR) are drug eruptions resembling psoriatic lesions. Oftentimes, histopathologic features of PDR overlap with those of psoriasis vulgaris (PV), which may delay diagnosis and management. Despite its limited diagnostic utility, histopathology may be helpful in clinically indistinguishable drug reactions from its idiopathic counterparts. The aims of this study are to review the clinical features and histopathologic patterns of PDRs, to compare the histopathologic findings seen in PV controls, and to identify histopathologic clues pertaining to PDRs

Materials and Methods

This single-center retrospective study included biopsies with diagnosis as “psoriasiform drug reaction” retrieved from the biopsy database for histopathological review. The final diagnosis of a psoriasiform drug reaction must be consistent with the following: (1) presence of cutaneous lesions with similar morphology as in psoriasis, (2) a pertinent drug history relative to onset of lesions, and (3) a skin biopsy finding of a psoriasiform dermatitis. We reviewed the charts of the patients, and excluded patients with personal or family history of psoriasis, underwent topical treatments and unidentified drug culprit. From the patients’ database, we checked the drug history of the patient and evaluated using Naranjo adverse drug reactions scale. A score of more than 4 (probable) from the scale was included in the study. To lessen the confounding risk, each PDR case was matched with 4 PV control specimens for comparison. Fisher’s exact test with Clopper-Pearson method was used to compare the histopathologic findings.

Study flow chart

Results

Seven patients were included (median age, 83 years; five males and two females). The culprit drugs identified were as follows: antihypertensive agents (amlodipine, candesartan, nifedipine; n= 3), immunomodulating therapies (pembrolizumab, imiquimod; n= 2), an antiepileptic drug (n = 1), and an antifungal agent (fluconazole; n = 1). The median onset of drug latency was 4 weeks (range: 4-52 weeks). The most striking histopathological features pointing to PDR diagnosis were necrotic keratinocytes (p=<0.0001), basal vacuolization (p=0.0001), pigment incontinence (p=0.0073), and presence of eosinophils(p=0.0017), while regular acanthosis (p=<0.0158), and increased number of capillaries (p=0.00007) point to PV. Shared features between PV and PDR include parakeratosis, hyperkeratosis, hypogranulosis, and neutrophils in the stratum corneum.Our findings suggest that careful assessment of interface change, combination of tissue reaction patterns, dermal infiltrate composition and absence of microangiopathies in the papillary dermis may significantly distinguish PDR from PV when clinical features overlap.

Conclusions

PDR can be distinguished from PV based on histological features. Interface changes, including necrotic keratinocytes, basal vacuolization and pigment incontinence, with eosinophil dermal infiltrate and absence of microangiopathies may improve diagnostic accuracy and facilitate prompt drug discontinuation.

EADV CONGRESS
VIENNA
30 SEP - 3 OCT 2026

Abstract N°: 720

A Unique Case of Undertreated Confluent and Reticulated Papillomatosis Persisting for 10 Years, Treated with Azithromycin

Laden Elkiran*[1], Tunahan İnan[1], Oğuz Kaan Yılmaz[1], Aysun Gökçe[2], Enes Kuloğlu[2], Selda Pelin Kartal[1]

[1] Etlik City Hospital, Department of Dermatology and Venereology, Ankara, Türkiye
[2] Etlik City Hospital, Department of Pathology, Ankara, Türkiye

Introduction

Confluent and reticulated papillomatosis (CARP) is an unusual, chronic, relapsing dermatological condition presenting as brownish papules with fine scales that coalesce to form plaques, which are confluent and reticular in nature. The lesions are predominantly located on the trunk, neck and axilla of young people. The lesions tend to persist for a few years before treatment or resolution. Herein, we report a case of CARP that had been ongoing for a decade, treated with azithromycin.

Materials and Methods

The patient's medical history and records were obtained, and a detailed review of literature was performed, using the keywords "confluent and reticulated papillomatosis", "CARP" and "macrolides".

Results

A 25-year-old, otherwise healthy, male patient presented with asymptomatic reddish-brown reticular plaques with thin scales distributed on the neck, back, and anterior trunk. The lesions had been present for 10 years and had not improved despite multiple topical corticosteroids. There was no family history of similar lesions. Wood's light examination revealed no fluorescence, and the potassium hydroxide assessment for spores and hyphae was negative. Furthermore, when the lesions were swabbed with 70% alcohol, they were not removed. A punch biopsy was performed, and the differential diagnoses were CARP, pityriasis versicolor, terra firma-forme, and reticular erythematous mucinosis. The biopsy demonstrated focal parakeratosis, bacterial colonisation, acanthosis, fusion of the rete ridges, slight papillomatosis, and minimal dermal perivascular infiltrates consisting of lymphocytes. PAS staining of the specimen was negative. Based on clinicopathologic correlation, a diagnosis of CARP was made. The patient was treated with azithromycin 500 mg for 3 consecutive days weekly for 3 weeks. After 3 weeks, all the lesions subsided, leaving only mild hyperpigmentation on the back.

Conclusions

First identified by Gougerot and Carteaud in 1927, CARP is an infrequent dermatologic disorder, primarily affecting adolescents and young adults. Hyperpigmented, reddish-brown papules merge, forming plaques with peripheral reticulation and central confluence, as the characteristics of the lesions. CARP is commonly asymptomatic, but pruritus has been reported in some patients. The lesions are preferentially distributed in areas subjected to friction and moisture, such as the trunk, shoulders and axillae. The pathogenesis of CARP is not fully elucidated, but keratinisation abnormalities and bacterial colonisation are thought to be the main contributing factors. In one study, the average duration of the disease was three years, but the duration varied from 3 months to 20 years. In this case, the patient had persisting lesions present for a decade in spite of previous treatment. The defining histological findings of the condition are rippled basket-weave hyperkeratosis, papillomatosis, increased basal melanin pigmentation, and focal acanthosis in the areas of elongated rete ridges. Based on clinical appearance, the main differential diagnoses to consider are pityriasis versicolor, terra firma-forme, acanthosis nigricans, and Darier disease. Both topical and systemic treatment modalities are available for the treatment. Therapeutic options

include retinoids, antifungal agents, and antibiotics, administered either topically or systemically. Although minocycline is the first-line treatment, it has a broad side effect profile and is also contraindicated in pregnancy. Hence, the use of macrolides, such as azithromycin, which are safer and are pregnancy category B, may be a superior alternative in the future. This case emphasises the need to select the correct modality of treatment, as CARP is a chronic disease which may continue for many years, causing cosmetic concerns for the patients. Furthermore, due to their favourable safety profiles and possible use in vulnerable patients, macrolides might be the preferred first-line treatment in the future.

EA DV CONGRESS
VIENNA
30 SEP - 3 OCT 2026

Abstract N°: 729

Pacinian Neurofibroma: A Rare Benign Neural Tumor

Ana Clara Maia Palhano*[1], Amanda Tanaka Iasbeck Gonçalves[1], Carolina Cruz[1], Bruna Polito Teixeira[1], nilceo michalany[2], Luciana de Paula Samorano[1], Maria Cecília Rivitti-MacHado[1], Zilda Najjar Oliveira[1]

[1] University of São Paulo, São Paulo, Brazil

[2] Federal University of São Paulo, São Paulo, Brazil

Introduction

Pacinian neurofibroma (PNF) is a very rare benign neural tumor characterized histopathologically by the presence of structures that mimic Pacinian corpuscles. 1 It is considered a variant of conventional neurofibroma because it demonstrates differentiation toward these specialized mechanoreceptors. Clinically, it occurs most frequently on the hands and feet, particularly on the fingers and palmar regions, where Pacinian corpuscles are more abundant, although it may involve other areas of the body. 1 Lesions may be solitary or multiple, are generally slow-growing, and may be painful, without associated sensory changes. 1 This tumor typically occurs as a solitary lesion; however, its coexistence with glomus tumor, Dupuytren's contracture, foreign body reaction, neurofibromatosis type 1, burns, and congenital macrodactyly has been described. 1 We report a case of pacinian neurofibroma with characteristic clinical and histopathologic findings in a 7-year-old child.

Case Presentation

A 7-year-old child presented with a history of cutaneous lesions first appearing at 2 years of age, followed by a slow and progressive increase in the number and size of the lesions over time. On examination, the patient exhibited skin-colored nodules distributed over the palms and fingers and soles, which were mobile and non-tender upon palpation. A biopsy of one of the lesions revealed a benign neural neoplasm formed by spindle cells with elongated, wavy nuclei and eosinophilic fibrillary cytoplasm arranged in concentric bundles, with transition from Pacinian corpuscle–like structures to neurofibromatous proliferation, consistent with pacinian neurofibroma and confirming the diagnosis of PNF.

Conclusion

The Vater–Pacinian corpuscles are pressure-sensitive tactile mechanoreceptors located at the sensory nerve terminals, found in the hypodermis. 1 Pacinian neurofibroma is a rare benign dermal tumor whose histology reproduces structures resembling these corpuscles. 2 Clinically, PNF typically presents as slow-growing, well-circumscribed, mobile, skin-colored nodules, solitary or multiple, and usually asymptomatic. 3,4 Additional morphological presentations include papular lesions, ulcerated tumors, pedunculated nodules, multiple soft plaques, and areas of surface pigmentation. 4 Although it is most commonly described on the hands, it may occur at other anatomical sites and is more frequently reported in children and young adults. The main differential diagnoses include post-traumatic neuroma, glomus tumor, plexiform neurofibroma, schwannoma, and malignant peripheral nerve sheath tumors. 1 Imaging studies may help to distinguish among these entities. 1 Histologically, there is an increased number of corpuscle-like structures of heterogeneous size and at different stages of maturation. 1 These structures are composed of spindle cells with variably shaped nuclei arranged in concentric layers and embedded within a myxoid or fibrous stroma. 1,2 The main histopathologic differential diagnosis is Pacinian hyperplasia, a hamartomatous overgrowth generally associated with prior trauma, in which the classic architecture of Pacinian corpuscles remains preserved. 2 Surgical excision is the treatment of choice and generally provides good local control, although recurrence has been reported in some cases. To date, no malignant transformation has been described, supporting the benign behavior of this entity and its favorable prognosis. 1,2

EA DV CONGRESS
VIENNA
30 SEP - 3 OCT 2026

Abstract N°: 775

Dermoscopic–Histopathological Correlations: Diagnostic Pitfalls in Common Skin Lesions – A Series of Four Clinical Cases

Aylin Kafelova*[1], Vali Mateeva[1], Grisha Mateev[1], Kossara Drenovska[1]

[1] Medical University of Sofia, Sofia, Bulgaria

Introduction

Dermoscopy significantly improves the diagnostic accuracy of skin tumors by enabling the visualization of subsurface structures with direct histopathological correlates. Nevertheless, overlapping dermoscopic features between lesions with different biological behavior remain a frequent source of diagnostic error. In routine clinical practice, this may result in both unnecessary excisions of benign lesions and delayed recognition of malignant tumors. Understanding the morphological substrate of dermoscopic patterns is therefore essential for accurate interpretation and clinical decision-making.

Case Presentation

We present a case series of four clinically common skin lesions, including melanocytic nevus, basal cell carcinoma, seborrheic keratosis, and fibroma molle, evaluated dermoscopically and correlated with histopathological findings.

Melanocytic nevi demonstrated a pigment network and globules, corresponding to melanocytic nests at the dermoepidermal junction and within the dermis (Fig. 1A). Basal cell carcinoma exhibited arborizing vessels and blue-gray structures, reflecting basaloid tumor nests and stromal alterations (Fig. 1B). Seborrheic keratosis showed milia-like cysts and comedo-like openings, correlating with intraepidermal keratin-filled structures, acanthosis, and papillomatosis (Fig. 1C). Fibromas appeared predominantly structureless, occasionally with fine vascular patterns, corresponding to dense fibrous stromal proliferation (Fig. 1D).

In selected cases, clinical impression differed from dermoscopic evaluation, emphasizing the role of dermoscopy in identifying subtle malignancy-associated features not visible on naked-eye examination. Despite distinct histopathological origins, several dermoscopic features overlapped across lesions, including homogeneous pigmentation, white structures, and vascular elements.

Importantly, these structures reflect different underlying morphological processes—melanin distribution, keratin accumulation, fibrosis, and vascular proliferation—highlighting that similar dermoscopic patterns may arise from fundamentally different histopathological substrates.

This underscores the importance of interpreting dermoscopic features within the global pattern of the lesion rather than in isolation, particularly in cases lacking classic diagnostic criteria.

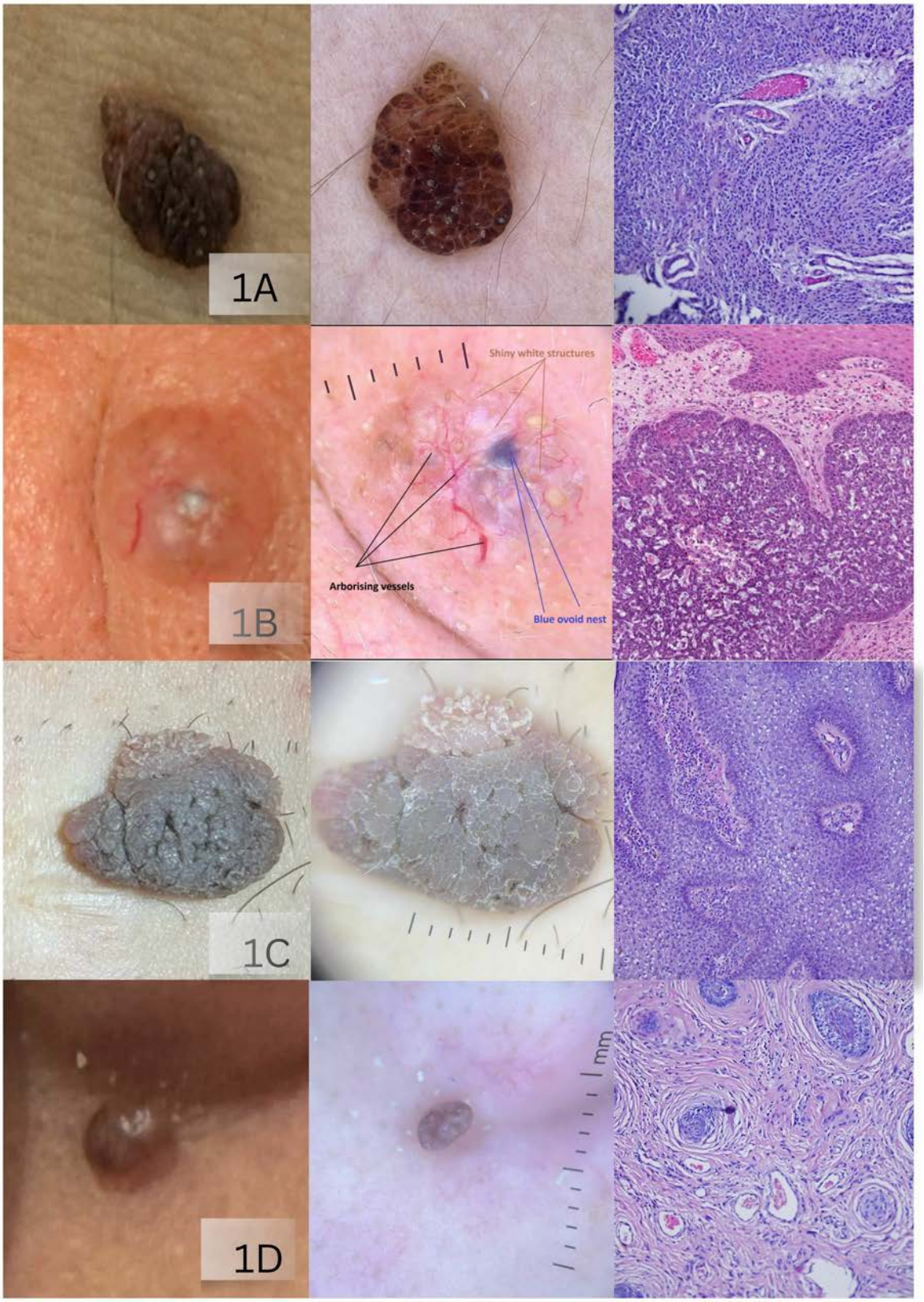

Figure 1. Dermoscopic–histopathological correlations illustrating diagnostic pitfalls in common skin lesions. A – Melanocytic nevus: pigment network and globules corresponding to melanocytic nests at the dermoepidermal junction and in the dermis. B – Basal cell carcinoma: arborizing vessels and blue-gray structures reflecting basaloid tumor nests and stromal alterations. C – Seborrheic keratosis: milia-like cysts and comedo-like openings corresponding to intraepidermal keratin-filled structures and acanthosis. D – Fibroma molle: structureless appearance with subtle vascular features corresponding to fibrous stromal proliferation.

Conclusion

Common skin lesions with different biological potential may share similar dermoscopic features, representing a potential source of diagnostic uncertainty. Accurate diagnosis relies on the integrated assessment of global dermoscopic pattern, distribution of structures, and clinicopathological correlation, rather than on isolated dermoscopic findings. Recognizing the histopathological basis of dermoscopic structures is essential for reducing diagnostic error and guiding appropriate clinical management.

EA DV CONGRESS
VIENNA
30 SEP - 3 OCT 2026

Abstract N°: 789

More Than 100 Lesions: Adult-Onset Xanthogranuloma in an Exceptional Presentation

Ece Barcinli*[1], Burhan Engin[1]

[1] Istanbul University-Cerrahpasa, Department of Dermatology, Istanbul, Türkiye

Introduction

Adult-onset xanthogranuloma is a benign, non-Langerhans cell histiocytosis that typically presents as a solitary lesion and is encountered far less frequently than its juvenile counterpart. The adult form is characterized by notable differences in clinical course and treatment response. Multiple and widespread lesions represent an exceptionally rare manifestation within this already uncommon entity. Here, we report a 39-year-old female patient presenting with more than 100 disseminated xanthogranulomatous lesions, detailing the clinical, histopathological, and immunohistochemical features of this extraordinary case.



Figure 1. Multiple yellowish-brown, smooth-surfaced, firm papules, widely distributed over the trunk. Lesions show no ulceration, crusting, or surface change, consistent with the clinical appearance of adult-onset xanthogranuloma.

Case Presentation

A 39-year-old female was referred to our dermatology outpatient clinic with a three-year history of asymptomatic, slowly progressive yellowish-brown papular lesions. Her personal and family medical histories were unremarkable, and systemic review revealed no significant findings.Dermatological examination demonstrated more than 100 well-defined, smooth-surfaced, firm papules measuring 1–3 mm in diameter with yellowish-brown coloration, widely distributed across the face, neck, chest, abdomen, and axillary regions. No ulceration, scaling, or peripheral lymphadenopathy was noted.A punch biopsy was obtained from the left forearm. Histopathological examination revealed orthokeratosis, loss of rete ridge prominence, and mild lymphocytic exocytosis in the epidermis. Within

the papillary and reticular dermis, a prominent infiltrate of vacuolated, spindle-shaped, and xanthomatized histiocytes was identified, accompanied by characteristic Touton giant cells, eosinophils, plasma cells, and lymphocytes. Collagen thickening and hyalinization were also observed.Special stains (PAS, Alcian blue, colloidal iron) were negative for mucin deposition. Immunohistochemical analysis demonstrated strong positivity for CD68 and CD163, with focal positivity for S100 and Factor XIIIa. CD1a, langerin, and ALK were negative. The Ki67 proliferation index was below 1%, consistent with a reactive, non-neoplastic process. Balanced kappa and lambda light chain expression was observed. These findings collectively confirmed the diagnosis of adult-onset xanthogranuloma.Given the extensive distribution and the known rarity of spontaneous regression in adult-onset cases, isotretinoin 20 mg/day was initiated as a conservative systemic approach. CO_2 laser ablation was additionally considered for the more prominent and cosmetically bothersome individual lesions.



Figure 2. Multiple yellowish-brown, smooth-surfaced, firm papules diffusely distributed over the back, face, and neck. The widespread distribution of lesions underscores the disseminated nature of the disease in this adult-onset case.

Conclusion

This case highlights the diagnostic importance of adult-onset xanthogranuloma in the workup of widespread papular eruptions in adults, a clinical scenario that can easily be overlooked or misdiagnosed. Unlike the juvenile form, spontaneous regression is considerably less frequent in adults, necessitating individualized treatment strategies. The histopathological hallmarks — particularly Touton giant cells and the characteristic immunohistochemical profile — remain essential for definitive diagnosis. Continued reporting of such rare presentations is crucial to better delineate the etiology, natural history, and optimal management of this condition.

EADV CONGRESS
VIENNA
30 SEP - 3 OCT 2026

Abstract N°: 814

An Unexpected Diagnosis and Atypical Localization in Resistant Scalp Plaques: Cutaneous Plasmacytosis

Adnan Semiz*[1], Selami Aykut Temiz[1], İlkay Özer[1], Munise Daye[1], Recep Dursun[1]

[1] NECMETTİN ERBAKAN UNIVERSITY DERMATOLOGY DEPARTMENT, Konya, Türkiye

Introduction

Cutaneous plasmacytosis (CP) is an exceedingly rare entity characterized by the benign polyclonal proliferation of plasma cells in the dermis, with an etiology that remains yet to be fully elucidated. The classic clinical presentation manifests as symmetrical, erythematous-brown papulonodules or plaques, typically localized on the trunk, face, and axillary regions. In this report, we present an atypical case of cutaneous plasmacytosis involving the scalp—an exceptionally rare localization in the literature—which had been monitored under a different preliminary diagnosis for two years. Our objective is to underscore that Cutaneous Plasmacytosis should be considered in the differential diagnosis of treatment-resistant scalp plaques.

Case Presentation

A 51-year-old male patient presented with a two-year history of non-healing lesions on the scalp. The patient had previously received topical corticosteroid therapy based on a clinical diagnosis of psoriasis vulgaris, which yielded no clinical response. Dermatological examination revealed indurated, infiltrative plaques covered with thick yellow-brown scales on an erythematous base, localized on the scalp. Systemic review was unremarkable, with no findings suggestive of fever, weight loss, or organomegaly. Complete blood count, routine biochemistry, serum protein electrophoresis, and serological screening (HIV, VDRL, ANA, Hepatitis) were within normal limits; systemic involvement was excluded through radiological imaging.A diagnostic punch biopsy was performed. Histopathological analysis revealed a dense inflammatory infiltrate rich in mature plasma cells, predominantly in the perivascular areas of the dermis. Immunohistochemical staining demonstrated CD38 positivity in plasma cells. Polyclonality was confirmed by kappa and lambda light chain expression, and the Ki-67 proliferation index was found to be remarkably low. Based on these findings, the case was diagnosed as cutaneous plasmacytosis.A combined protocol consisting of topical 0.05% clobetasol propionate, 0.1% tacrolimus, and monthly intralesional injections of 10 mg/mL triamcinolone acetonide was implemented. At the end of the three-month follow-up period, significant regression was observed in the lesions.

Conclusion

It should be noted that cutaneous plasmacytosis (CP) can present with scalp localization, extending beyond its classic involvement of the trunk. In cases of persistent plaques on the head and neck region that exhibit resistance to standard therapies, CP must be considered in the differential diagnosis. Particularly for scalp plaques unresponsive to conventional treatments, early tissue biopsy combined with immunohistochemical analysis is of critical importance in preventing misdiagnosis and determining the most appropriate therapeutic strategy.

EADV CONGRESS
VIENNA
30 SEP - 3 OCT 2026

Abstract N°: 836

Primary Cutaneous Mucinous Carcinoma of the Cheek: A Rare Mimicker of Benign Subcutaneous Lesions

Juan BAI*[1, 1], Xinyi CHEN[1], Jianjun QIAO[1]

[1] The first affiliated hospital of Zhejiang university school of medicine, Hangzhou, China

Introduction

Primary cutaneous mucinous carcinoma (PCMC) is an exceptionally rare, indolent sweat gland malignancy. Due to its slow growth and non-specific presentation, it frequently mimics common benign subcutaneous lesions such as epidermal cysts, lipomas, or pilomatricomas. Establishing a primary diagnosis is a significant clinical challenge, as PCMC is histologically identical to cutaneous metastases from internal mucinous adenocarcinomas.

Case Presentation

A 71-year-old male presented with a 3-year history of a slowly enlarging, painless nodule (1.2 cm) on his left cheek. His medical history was significant for squamous cell lung carcinoma, previously treated with radical surgery. Ultrasonography revealed a well-defined, solid-cystic subcutaneous nodule (1.1×1.0×1.2 cm) without internal vascular signals.Following surgical excision, histopathology demonstrated a well-circumscribed neoplasm comprising islands of basaloid epithelial tumor cells "floating" in large pools of basophilic mucin, compartmentalized by delicate fibrous septae. The tumor cells exhibited focal cribriform patterns with minimal atypia and no mitotic figures. Immunohistochemical analysis showed positivity for CK7, CEA, ER, and PR, but negativity for CK20 and CK5/6. Mucin pools stained positive with Alcian blue and PAS. Crucially, a total-body PET/CT examination was negative for any other primary malignancy or metastatic disease. Based on the clinico-pathological and imaging findings, a diagnosis of PCMC was established. No recurrence was observed during a 30-month follow-up.

Conclusion

PCMC is a rare, low-grade malignancy that frequently mimics benign subcutaneous lesions due to its slow-growing and asymptomatic nature. Because its histopathological and immunophenotypic features overlap significantly with metastatic mucinous carcinomas, a comprehensive systemic evaluation is mandatory. In this case, a negative PET-CT was instrumental in excluding occult internal primaries and confirming the primary cutaneous origin. Surgical excision remains the gold standard of treatment, offering an excellent long-term prognosis when identified early.

EADV CONGRESS
VIENNA
30 SEP - 3 OCT 2026

Abstract N°: 867

Histopathology of Vulva Lichen Planus

Xin Yan Cheng[1], Levina Ying Xin Ang*[1], Daniel Tang[1], Mark Koh[2]

[1] Lee Kong Chian School of Medicine, Singapore, Singapore
[2] KK Women's and Children's Hospital, Singapore, Singapore

Introduction
Lichen Planus (LP) is a chronic inflammatory condition affecting the skin, oral mucosa and genitalia. While the histopathology of cutaneous and oral LP is well established, few studies have evaluated the histopathology of vulva LP. As such, vulva LP may be under-recognised, partly due to overlapping clinical and histopathological features with other vulva dermatoses and pathologies. This case review aims to examine and characterise the histopathological features of vulva LP and compare them to those observed in cutaneous and oral LP.

Materials and Methods
We performed a retrospective review of the histopathological findings of skin biopsies in a cohort of women with vulva LP from 2016 to 2024.

Results
A total of 21 samples were identified. Most samples displayed features characteristic of LP at other sites, such as basal vacuolar degeneration and lichenoid bands. However, features more commonly seen in vulva LP were identified, such as parakeratosis, epidermal atrophy or erosion, and plasma cell infiltration. In contrast, hypergranulosis and saw-tooth rete ridge acanthosis were seen less commonly in vulva LP.

Conclusions
Our study demonstrates various differences in the histopathological features of vulva LP compared with oral LP and LP at other cutaneous sites. Therefore, close clinical-pathological correlation is important for accurate and prompt diagnosis of vulva LP.

EA DV CONGRESS
VIENNA
30 SEP - 3 OCT 2026

Abstract N°: 1040

Label-Free FTIR Spectroscopic Imaging and Whole-Spectrum Unsupervised Clustering Reveal Fungus-Associated Molecular Signatures in Human Skin Tissue Sections

Maximilian Lammer*[1], Paul Bellmann[1], Matthias Schmuth[1], Verena Moosbrugger-Martinz[1], Bettina Zelger[2], Birgit Moser[1], Roland Stalder[3], Christian Huck[4], Miranda Klosterhuber[5], Johannes Pallua[5]

[1] Department of Dermatology, Venereology and Allergy, Medical University Innsbruck, Innsbruck, Austria, Innsbruck, Austria

[2] Department of Pathology, Medical University Innsbruck, Innsbruck, Austria, Innsbruck, Austria

[3] Institute of Mineralogy and Petrography, Leopold-Franzens University Innsbruck, Innsbruck, Austria, Innsbruck, Austria

[4] Institute of Analytical Chemistry and Radiochemistry, University of Innsbruck, Innsbruck, Austria, Innsbruck, Austria

[5] Department of Orthopaedics and Traumatology, Medical University Innsbruck, Innsbruck, Austria, Innsbruck, Austria

Introduction

Background: Rapid and reliable diagnosis of fungal skin infections remains challenging, particularly when confirmation relies on histopathology and molecular methods. Fourier-transform infrared (FTIR) spectroscopic imaging enables label-free, spatially resolved molecular characterization of tissue and may provide a complementary approach for identifying mycotic lesions.

Objective: To evaluate the feasibility of FTIR spectroscopic imaging for detecting fungus-associated biochemical signatures in human skin tissue sections with confirmed mycosis.

Materials and Methods

Formalin-fixed, paraffin-embedded human tissue sections with histologically and molecularly confirmed fungal infection were analyzed by FTIR imaging. A total of 19 histologically confirmed cases were included in the study. Spectral assessment included carbohydrate-, phosphate-, protein-, and lipid-associated regions, with particular focus on the 900–1200 cm^{-1} fingerprint range, as well as whole-spectrum unsupervised segmentation in CytoSpec using k-means clustering (KMC), fuzzy c-means (FCM), and hierarchical cluster analysis (HCA). Chemical maps and clustering results were compared with visible morphology and Grocott methenamine silver (GMS) staining.

Results

FTIR imaging revealed a robust and spatially coherent lesion-associated molecular signature. The strongest and most biologically plausible fungus-associated contrast was observed in carbohydrate-sensitive bands within the 900 - 1200 cm^{-1} region, consistent with polysaccharide-rich fungal structures. Additional alterations in amide- and lipid-associated regions further delineated lesion architecture and surrounding host tissue changes. FTIR abnormalities co-localized with the morphologically abnormal lesion in the visible image and with fungus-containing structures

identified by GMS staining. Importantly, unsupervised whole-spectrum clustering reproducibly separated the lesion from adjacent tissue by KMC, FCM, and HCA, even without spectral preprocessing, and consistently resolved lesion rim, internal lesion compartments, and surrounding host tissue.

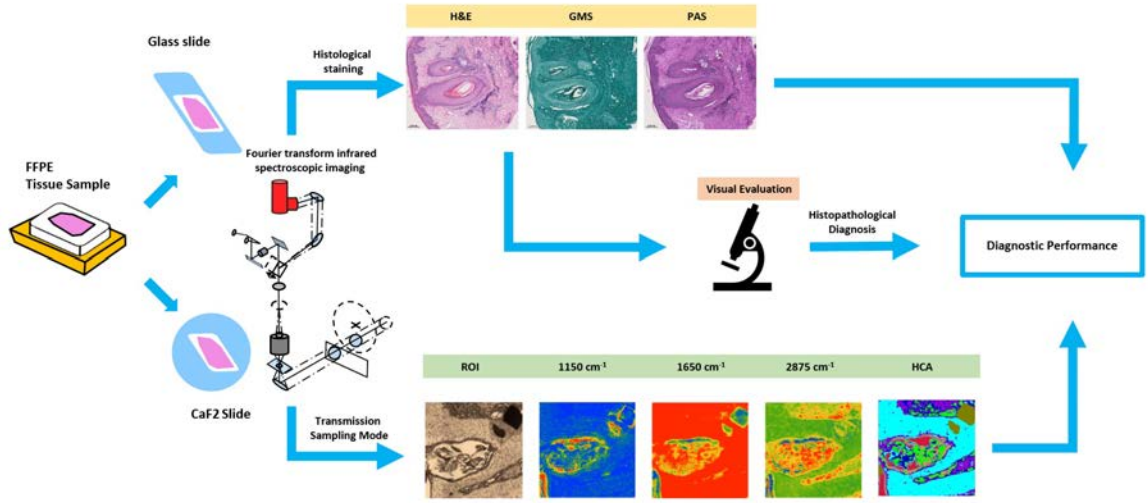

Workflow of FTIR microscopic imaging. Both stained (H&E, GMS, PAS) and unstained FFPE tissue sections were analyzed. Conventional histopathology relied on histological staining followed by visual evaluation to establish the histopathological diagnosis. In parallel, Fourier transform infrared (FTIR) spectroscopic imaging in transmission mode on CaF_2 slides enabled the extraction of characteristic spectra (e.g., at 1150, 1650, and 2875 cm^{-1}), the generation of spectral maps, and the application of hierarchical cluster analysis (HCA) for tissue classification. This combined workflow enables complementary morphological and spectral characterization of tissue and enhances diagnostic performance.

Conclusions

FTIR spectroscopic imaging demonstrates strong potential as a label-free, spatially resolved method for detecting and characterizing fungal skin lesions in human tissue sections. Carbohydrate-sensitive bands appear particularly promising for fungus-associated detection, while whole-spectrum clustering highlights robust global molecular differences between fungal lesion and surrounding tissue. These findings support further development of FTIR imaging as an adjunct tool for dermatopathological diagnostics.

EA DV CONGRESS
VIENNA
30 SEP - 3 OCT 2026

Abstract N°: 1059

Inflammation or Lymphoma? Early-Stage Inflammatory Morphea Mimicking Mycosis Fungoides: A Diagnostic Challenge

Aslıhan Çiçekli[1], Selami Aykut Temiz*[1], Naciye Hilal Büyükboyacı[2], Pembe Oltulu[2]

[1] Department of Dermatology, Faculty of Medicine, Necmettin Erbakan University, Konya, Türkiye
[2] Department of Pathology, Faculty of Medicine, Necmettin Erbakan University, Konya, Türkiye

Introduction

Early-stage inflammatory morphea is a rare but important diagnostic pitfall that may closely mimic the neoplastic process Mycosis Fungoides (MF) due to overlapping clinical, histopathological, and immunohistochemical features. We present a case initially suspected as MF but ultimately diagnosed as morphea through multiple biopsies and close clinical follow-up, and compare it with similar cases in the literature.

Case Presentation

A 58-year-old female presented with a 6-month history of progressive, asymptomatic skin eruptions on the trunk and extremities. Physical examination revealed ill-defined erythematous patches involving the breasts, abdomen, back, and thighs. A punch biopsy was performed with preliminary diagnoses of mycosis fungoides and generalized morphea. Histopathological examination demonstrated an epidermotropic infiltrate of atypical T lymphocytes with cerebriform nuclei and perinuclear halos, showing increased alignment along the basal layer. Immunohistochemical evaluation revealed strong CD3 (95%) and CD8 (99%) positivity in intraepidermal lymphocytes, with sparse CD4 expression (CD4/CD8: 1/10). Partial loss of CD2 and CD5 (10%) and marked reduction of CD7 expression (5%) were also observed. Dermal examination showed fibrosis, adnexal loss, perivascular lymphocytic infiltration, and thick-walled vessels, consistent with morphea. In addition, dermal mucin deposition and CD138-positive perivascular plasma cells were identified. Based on combined findings, the case was interpreted as early inflammatory-stage morphea mimicking MF. The patient was treated with topical corticosteroids and narrowband UVB phototherapy three times weekly. At 3-month follow-up, repeat biopsies demonstrated sclerosing dermatitis in the dermis. In two of three biopsy sites, epidermotropism was completely absent, while a biopsy from the right axilla showed persistent minimal epidermotropism with approximately 90% regression compared to baseline, involving no more than four atypical lymphocytes along the basal layer. These cells retained CD8 positivity with persistent CD4 and CD7 loss. At 9-month follow-up, the initial erythematous patches had evolved into firm, white-yellow sclerotic plaques and brown atrophic plaques consistent with morphea.

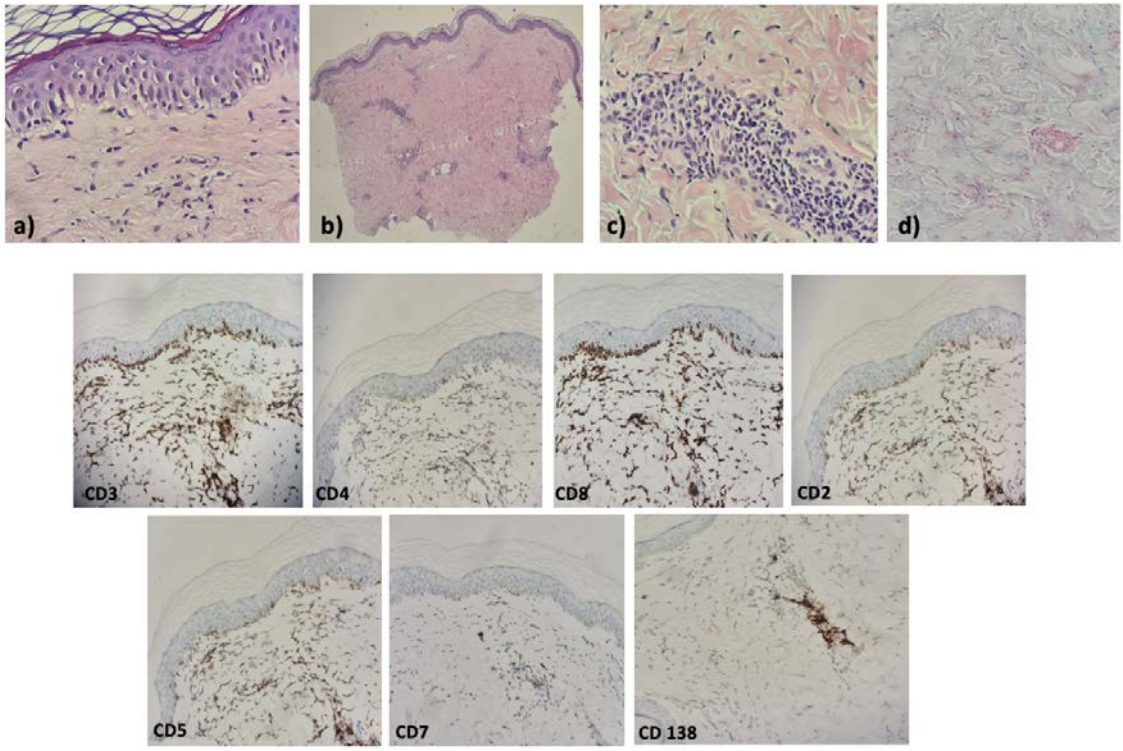

H&E staining: Atypical lymphocytes with cerebriform nuclei and perinuclear halos aligned along the basal layer of the epidermis (a). Dermal features consistent with morphea, including fibrosis, adnexal loss, perivascular lymphocytic infiltration, and thick-walled vessels (b, c). Alcian blue staining: Presence of dermal mucin (d). Immunohistochemical staining: Strong positivity for CD3 (95%) and CD8 (99%) in intraepidermal T lymphocytes, with sparse CD4 positivity (CD4/CD8 ratio: 1/10), partial loss of CD2 and CD5 expression (10%), markedly reduced CD7 expression (5%), and CD138-positive dermal perivascular plasma cells.

Conclusion

This case is consistent with reported early inflammatory morphea cases mimicking MF, typically seen in middle-aged women and initially presenting as patch-stage MF.Histopathological features such as epidermotropism, basal alignment, and cerebriform lymphocytes represent major diagnostic pitfalls leading to confusion with MF. Prominent CD8 positivity and low CD4/CD8 ratio further support this overlap. Marked CD7 loss is a well-recognized pseudolymphomatous feature that may strongly mimic cutaneous T-cell lymphoma. In contrast, CD138-positive plasma cells and dermal mucin deposition are important clues favoring morphea and are rarely observed in MF. Notably, while most reported cases show complete resolution of MF-like features on follow-up biopsies, our case demonstrated a heterogeneous pattern, with residual epidermotropism persisting in a single focus despite marked regression elsewhere. This finding suggests that morphea and MF-like features may coexist simultaneously at varying degrees, emphasizing the dynamic and multifocal nature of the diagnostic process.In conclusion, early inflammatory morphea may closely mimic MF both clinically and histopathologically. Accurate diagnosis requires careful clinicopathological correlation and serial biopsies with close follow-up.

EADV CONGRESS
VIENNA
30 SEP - 3 OCT 2026

Abstract N°: 1079

Skin Barrier Response to Rapid Environmental Shifts: Modulation of Filaggrin and Aquaporin-3 in an Ex Vivo Model

Ana Lucia Tabarini Alves Pinheiro*[1], Barbara Carli[1], Giovana Albigesi[1], Kelen Fabiola Arroteia[1], Samir Eberlin[2], Carla Lopes[1], Samara Eberlin[1]

[1] Kosmoscience Group, Valinhos, Brazil

[2] Sante D'Or Institute, Sumaré, Brazil

Introduction

Rapid and recurrent transitions between contrasting environmental conditions have become a hallmark of modern urban living. Daily exposure to temperature and humidity fluctuations, driven by climate variability and frequent indoor–outdoor shifts, poses a significant challenge to skin homeostasis. The epidermis, as the primary interface with the environment, is particularly vulnerable to these dynamic stressors, which may compromise barrier integrity and hydration. While the effects of isolated factors such as heat, cold, or low humidity have been extensively studied, the impact of abrupt and sequential environmental changes, which more closely reflect real-life exposure, remains poorly understood. Thermal stress is known to activate multiple cellular pathways, including heat-shock responses, thermosensitive transient receptor potential (TRP) channels, and inflammatory signaling cascades, which may ultimately impair epidermal differentiation and barrier function. Conversely, cold exposure and low humidity have been associated with reduced expression of structural proteins, increased transepidermal water loss (TEWL), and enhanced susceptibility to irritation. However, the combined and sequential effects of these stressors on key epidermal biomarkers remain unclear.

Materials and Methods

In this context, the present study aimed to evaluate the effects of acute sequential thermal and humidity fluctuations on the expression of two critical epidermal markers: filaggrin, a major structural protein essential for barrier integrity and natural moisturizing factor formation, and aquaporin-3 (AQP3), a membrane channel involved in water and glycerol transport and epidermal hydration. A controlled ex vivo human skin model was employed to mimic real-life environmental transitions. Skin explants were allocated into two groups: (1) basal control, maintained under standard culture conditions (37°C, 80 ± 5% relative humidity), and (2) environmental stress, consisting of sequential exposure to heat (42°C) followed by cold stress (0°C), both under low humidity (30 ± 5%). This protocol was designed to reproduce abrupt climatic variations experienced in daily life. Following exposure, samples were cryopreserved, sectioned, and processed for immunofluorescence analysis using specific antibodies against filaggrin and AQP3. Fluorescence intensity was quantified using digital image analysis, and statistical evaluation was performed using ANOVA with appropriate post-hoc testing.

Results

Sequential environmental stress induced significant alterations in epidermal homeostasis Filaggrin expression decreased by 50.63% compared to basal conditions ($P<0.01$), indicating disruption of keratinocyte differentiation and impairment of barrier protein organization. In contrast, AQP3 expression increased by 65.83% ($P<0.001$), suggesting the activation of a compensatory adaptive response aimed at maintaining epidermal hydration through enhanced water and glycerol transport.

Conclusions

These findings demonstrate a dual biological response to rapid environmental transitions: structural barrier

compromise accompanied by activation of acute adaptive hydration mechanisms. This imbalance may contribute to increased skin vulnerability under fluctuating environmental conditions, particularly in urban settings characterized by high thermal amplitude and low humidity exposure. Overall, this study provides novel insights into the effects of sequential climate-related stressors on epidermal physiology. Understanding these mechanisms is essential to anticipate the impact of environmental instability on skin health and supports the development of targeted dermatological and dermocosmetic strategies aimed at reinforcing barrier function, improving skin resilience, and mitigating damage induced by rapid environmental fluctuations.

EADV CONGRESS
VIENNA
30 SEP - 3 OCT 2026

Abstract N°: 1181

Immunohistochemical Markers of Recurrence in Basal Cell Carcinoma: A Narrative Review

Maria Płocka-Karpińska*[1], Katarzyna Napiórkowska-Baran[2]

[1] Academia Copernicana Interdisciplinary Doctoral School, Nicolaus Copernicus University in Toruń, Toruń, Poland
[2] Department of Allergology, Clinical Immunology and Internal Diseases, Collegium Medicum in Bydgoszcz, Nicolaus Copernicus University in Toruń, Toruń, Poland

Introduction

Basal cell carcinoma (BCC) is the most common skin cancer, characterized by limited metastatic potential but a significant risk of local recurrence, particularly in high-risk histological subtypes. Reliable biomarkers for predicting recurrence remain limited. Immunohistochemistry (IHC) provides insight into tumor biology, enabling evaluation of proliferation, apoptosis, adhesion, and invasiveness. This narrative review summarizes key immunohistochemical markers associated with BCC recurrence from a dermatopathological perspective.

Materials and Methods

A narrative literature review was conducted using the PubMed database to identify relevant studies published between 2000 and 2025. The search strategy combined the terms “basal cell carcinoma”, “recurrence”, “immunohistochemistry”, and “biomarkers”, along with terms related to tumor proliferation, apoptosis, differentiation, extracellular matrix remodeling, and cell adhesion.

Eligible studies were selected based on relevance and included original articles reporting immunohistochemical findings in BCC with correlation to clinical outcomes, particularly recurrence or aggressive behavior. Preference was given to studies providing clinicopathological correlation, including defined patient cohorts, histopathological characterization, and available clinical follow-up data.

Reference lists of selected articles were manually screened to identify additional relevant publications, and citation tracking of key studies was performed. Duplicate records were excluded. Reviews, case reports, and studies lacking correlation between immunohistochemical findings and clinical or histopathological parameters were assigned lower priority.

Results

Increased Ki-67 expression consistently correlates with higher proliferative activity and is more frequently observed in recurrent and aggressive BCC subtypes. Aberrant p53 expression reflects genomic instability and has been associated with recurrence, although with variable reproducibility across studies.
Bcl-2 expression is typically high in BCC; however, reduced or heterogeneous staining patterns may indicate a shift toward more aggressive tumor behavior. CK17 overexpression, together with altered expression of other cytokeratins, is associated with less differentiated phenotypes and infiltrative growth patterns.

MMP-9 expression correlates with extracellular matrix degradation and enhanced invasiveness, supporting its role in locally recurrent disease. Reduced E-cadherin expression reflects impaired cell–cell adhesion and is consistently linked to infiltrative growth and increased recurrence risk.

Importantly, available evidence suggests that no single marker reliably predicts recurrence; rather, recurrent BCCs

demonstrate a reproducible composite phenotype characterized by high proliferative index, altered differentiation, increased matrix remodeling, and loss of adhesion.

Conclusions

Immunohistochemical profiling provides valuable insight into the biological mechanisms underlying BCC recurrence. While individual markers such as Ki-67, p53, Bcl-2, CK17, MMP-9, and E-cadherin show limited standalone predictive value, their combined assessment may enable identification of high-risk tumors.

These findings support the development of composite biomarker panels integrating markers of proliferation, differentiation, adhesion, and invasion. Incorporating such panels into semi-quantitative scoring systems based on staining intensity, distribution, and proportion of positive tumor cells may improve standardization and reproducibility of risk stratification.

The development of integrated clinicopathological models combining IHC profiles with established histopathological risk factors may enhance prediction of recurrence and support personalized management strategies in BCC patients. Prospective validation and standardization of scoring criteria remain essential for clinical implementation.

EA DV CONGRESS
VIENNA
30 SEP - 3 OCT 2026

Abstract N°: 1266

Livedo racemosa after intra-articular hyaluronic acid injection confirmed by histopathology

Seungmin Ko*[1], Yeji Jang[1]

[1] Hallym Sacred Heart Hospital, Anyangsi, Gyeonggido, Korea, Rep. of South

Introduction

Livedo racemosa is a persistent, irregular, broken net-like violaceous discoloration that usually reflects cutaneous microvascular dysfunction. Although it is often associated with systemic disorders, iatrogenic causes should also be considered. We report a case of livedo racemosa that developed after intra-articular hyaluronic acid injection and resolved with conservative management including aspirin.

Case Presentation

A 68-year-old man presented with a painful reticulated violaceous-to-blue patch with focal necrosis on the left knee that had developed 3 hours after an intra-articular hyaluronic acid injection performed without ultrasound guidance. The lesion persisted for 2 weeks before presentation and was associated with decreased sensation and intermittent pruritus. Laboratory evaluation, including inflammatory, coagulation, and autoimmune studies, was unremarkable, and magnetic resonance imaging showed no specific vascular abnormality. A 5-mm punch biopsy demonstrated amorphous basophilic material within dermal vessels, with thickened vessel walls and endothelial swelling, consistent with hyaluronic acid embolization. Based on the temporal relationship and histopathologic findings, the patient was diagnosed with livedo racemosa secondary to intra-articular hyaluronic acid injection. He was managed conservatively with continuation of oral aspirin, daily saline dressings, and topical fusidic acid to necrotic areas. The lesion improved progressively and resolved within 3 weeks with post-inflammatory pigmentation.

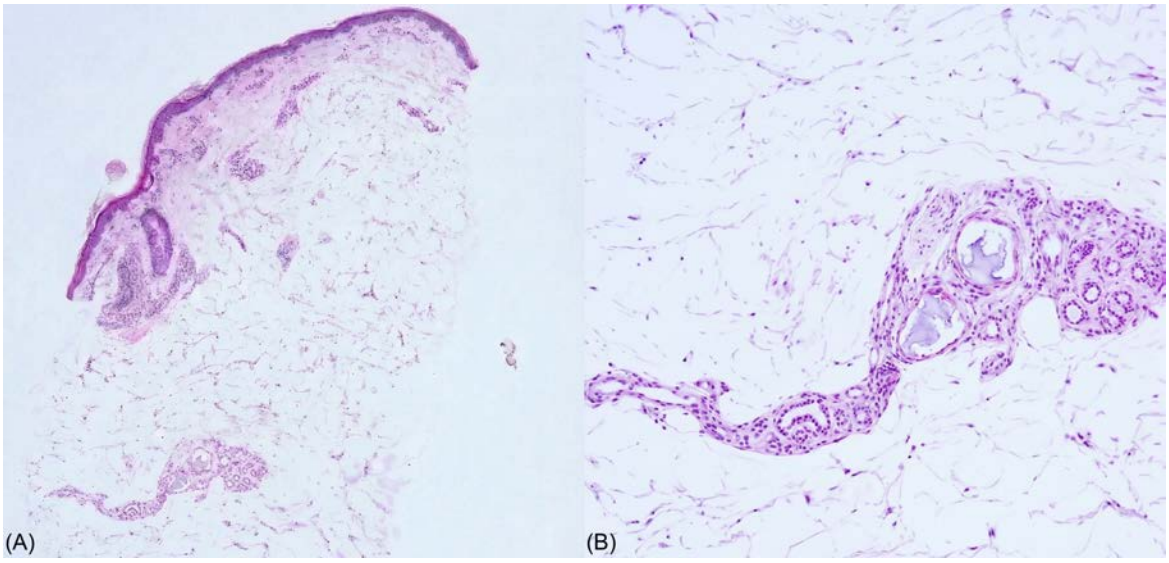

Figure 1. Histopathological findings of livedo racemosa secondary to intra-articular hyaluronic acid injection. (A) Low-power view showing dermal vascular involvement. (B) Higher-power view showing amorphous basophilic material within a dermal vessel, consistent with hyaluronic acid embolization (haematoxylin-eosin; A, low power; B, high power).

Conclusion

This case highlights that iatrogenic vascular injury should be considered in the differential diagnosis of a painful reticulated eruption arising shortly after intra-articular hyaluronic acid injection. Histopathologic examination was critical for confirming hyaluronic acid embolization, and conservative treatment including aspirin may be a reasonable option in selected localized cases.

EA DV CONGRESS
VIENNA
30 SEP - 3 OCT 2026

Abstract N°: 1378

Multiple desmoplastic trichoepithelioma: a major facial imitator

Yasmine Zekraoui*[1], siham alaoui[1], kenza benothmane[1], Narjess Errachdy[1], najoua ammar[1], syrine hamada[1], mariam meziane[1], Laila Benzekri[1], Nadia Ismaili[1]

[1] Department of Dermatology and Venereology, Ibn Sina University Hospital, Mohammed V University Souissi, Rabat, Morocco

Introduction

Desmoplastic trichoepithelioma is a rare benign follicular adnexal tumor, usually solitary and located on the face. Its importance lies in its clinicopathological overlap with more aggressive neoplasms, particularly morpheaform basal cell carcinoma and microcystic adnexal carcinoma.

Case Presentation

A 50-year-old woman with a history of pulmonary sarcoidosis presented with a two-year history of asymptomatic flesh-colored papules measuring about 3 mm in the perinasal and perioral regions. The unusual feature was the multiplicity of lesions. Dermoscopy showed horn cysts and a few linear vessels. Histopathology revealed a basaloid proliferation arranged in thin cords and small nests within a fibro-hyaline desmoplastic stroma, without marked atypia, consistent with desmoplastic trichoepithelioma.Desmoplastic trichoepithelioma is classically solitary and centrofacial. Multiple lesions are uncommon and may create therapeutic difficulties, since complete excision of each lesion is often impractical and cosmetically challenging. Dermoscopic findings may include an ivory-white background, shiny white structures, linear or arborizing vessels, and horn cysts. However, these signs are not specific and may overlap with basal cell carcinoma, making biopsy necessary in doubtful cases. Histologically, the main challenge is to distinguish this benign tumor from infiltrative mimickers, especially morpheaform basal cell carcinoma and microcystic adnexal carcinoma. In selected cases, immunohistochemistry may assist diagnosis. When lesions are multiple, management is often conservative and may include follow-up, ablative procedures or topical therapies.

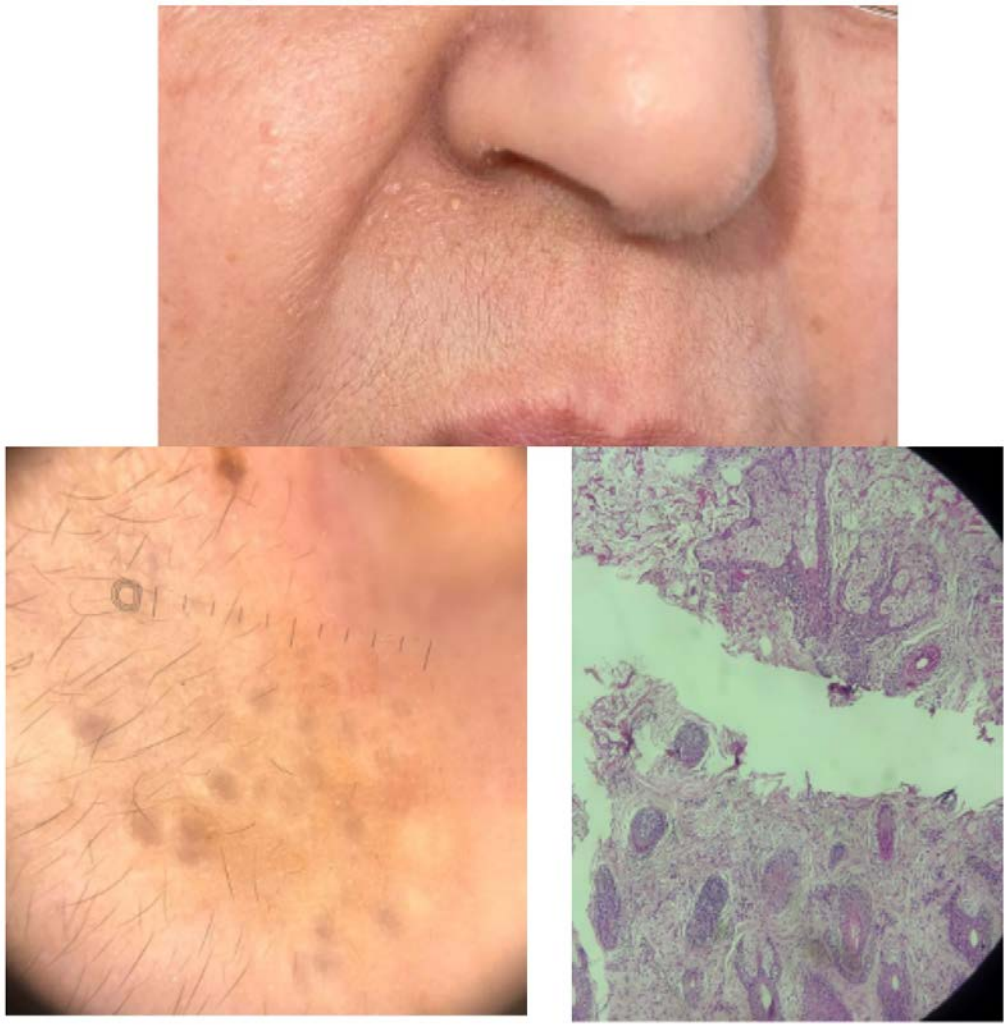

Clinical, dermoscopic and histopathological features of multiple desmoplastic trichoepithelioma.

Conclusion

This case highlights a rare multiple presentation of desmoplastic trichoepithelioma and emphasizes the importance of histological confirmation and careful differential diagnosis. In extensive forms, management should balance diagnostic certainty, cosmetic outcome and therapeutic burden.

EADV CONGRESS
VIENNA
30 SEP - 3 OCT 2026

Abstract N°: 1383

Granulomatous Pseudolymphoma of the Lower Eyelid in a Child Mimicking Leishmaniasis and Pilomatrixoma

Ela Gazal*[1], Güliz İkizoğlu [1], yasemin karabulut[2]

[1] Department of Dermatology, Mersin University Hospital, Mersin, Türkiye
[2] Department of Pathology, Mersin University Hospital, Mersin, Türkiye

Introduction

Cutaneous pseudolymphoma comprises a heterogeneous group of benign reactive lymphoproliferative infiltrates that clinically and histopathologically mimic cutaneous lymphoma. It may present as solitary papules, plaques, or nodules and can pose a substantial diagnostic challenge, particularly on the face, where a broad spectrum of inflammatory, infectious, and adnexal tumors enter the differential diagnosis. In children, eyelid lesions are especially problematic because subtle clinical clues may overlap among entities such as cutaneous leishmaniasis, pilomatrixoma, chalazion, juvenile xanthogranuloma, and other granulomatous or lymphoid infiltrates. Recognition of pseudolymphoma in this setting is important to avoid misclassification as infection or neoplasia.

Case Presentation

A 6-year-old girl presented with an asymptomatic erythematous-orange nodule on the left lower eyelid that had been present for 3–4 months. Because cutaneous leishmaniasis was initially suspected, a smear was obtained; however, abundant inflammatory cells obscured evaluation and no amastigotes were identified. Dermoscopy showed telangiectasias on a yellow-orange background with scattered white dots resembling microcalcifications. Based on the clinical and dermoscopic appearance, leishmaniasis, pilomatrixoma and juvenile xanthogranuloma were considered. Biopsy revealed orthokeratosis, focal hyperkeratosis, and mild spongiosis in the epidermis. The dermis showed dense nodular and diffuse lymphohistiocytic infiltration throughout the full dermal thickness with plasma cells, sparse eosinophils, and clusters of epithelioid histiocytes forming variably sized granulomatous aggregates. The infiltrate accentuated around hair follicles and eccrine structures. Serial sections demonstrated focal microcalcification within the cytoplasm of a multinucleated giant cell. Immunohistochemistry showed mixed lymphoid populations highlighted by CD3 and CD20, CD38-positive cells within the infiltrate, sparse CD30-positive cells, CD68 positivity in histiocytes/granulomatous aggregates, and sparse CD1a-positive Langerhans cells. These findings supported the diagnosis of pseudolymphoma.

Conclusion

This case was diagnostically challenging because both the clinical and dermoscopic findings overlapped with several more common pediatric eyelid lesions. Cutaneous leishmaniasis may present as a chronic painless erythematous papule or nodule on exposed sites, and orange-yellow areas with telangiectasias may reflect underlying granulomatous inflammation. Pilomatrixoma was also a strong consideration, as periocular lesions are common in children and white dermoscopic structures suggestive of calcification may closely resemble the scattered white dots seen in our case. Juvenile xanthogranuloma may likewise present as a yellow-orange facial papule or nodule in childhood, while chalazion and other benign inflammatory eyelid nodules may initially simulate a localized reactive process. In this setting, clinicodermoscopic findings alone may be misleading. Histopathologic and immunohistochemical evaluation was crucial for diagnosis, demonstrating a mixed reactive infiltrate composed of B and T lymphocytes, plasma cells, histiocytes, and granulomatous aggregates, supporting pseudolymphoma rather than a true lymphoid neoplasm. The absence of demonstrable parasites and the overall tissue architecture argued against leishmaniasis, whereas focal microcalcification further increased the

resemblance to pilomatrixoma. In our patient, a localized arthropod-bite reaction may represent the most plausible triggering factor for pseudolymphoma, although no definite history was documented. This case highlights that pseudolymphoma should be included in the differential diagnosis of persistent pediatric eyelid nodules, particularly when infectious, granulomatous, or adnexal tumors are clinically suspected.

EA DV CONGRESS
VIENNA
30 SEP - 3 OCT 2026

Abstract N°: 1590

Disseminated large plaque granuloma annulare mimicking IgG4-related disease: a diagnostic pitfall

Esmeraldito Ferreira*[1], Yaohan Xu[1], Zexi Mi[1], Tong Wu[1], Yongfeng Chen[1]

[1] Dermatology Hospital, Southern Medical University, Guangzhou, Guangdong, China, Guangdong, Guangzhou, China

Introduction

Disseminated granuloma annulare (DGA) is a chronic granulomatous dermatosis with heterogeneous clinical presentations. The large plaque variant is rare and may closely mimic fibroinflammatory conditions, posing a significant diagnostic challenge.

Case Presentation

A 55-year-old male presented with a 6-year history of progressively enlarging, asymptomatic annular plaques involving the trunk, back, and face. Clinical examination revealed multiple well-demarcated violaceous plaques with raised borders and central atrophy (Figure 1A, B). Histopathological examination demonstrated dermal granulomatous inflammation with palisading histiocytes surrounding areas of necrobiosis and central mucin deposition (Figure 1C, D). A prominent plasma cell-rich infiltrate raised suspicion for IgG4-related disease (Figure 1E).

Serological evaluation showed elevated total IgG levels, whereas IgG4 levels remained within the normal range. Immunohistochemical analysis revealed numerous IgG-positive plasma cells but only scattered IgG4-positive cells, resulting in a low IgG4/IgG ratio (Figure 1F, G). The absence of storiform fibrosis further excluded IgG4-related disease. A diagnosis of disseminated large plaque granuloma annulare was established. Treatment with systemic corticosteroids, hydroxychloroquine, and nicotinamide led to marked clinical improvement.

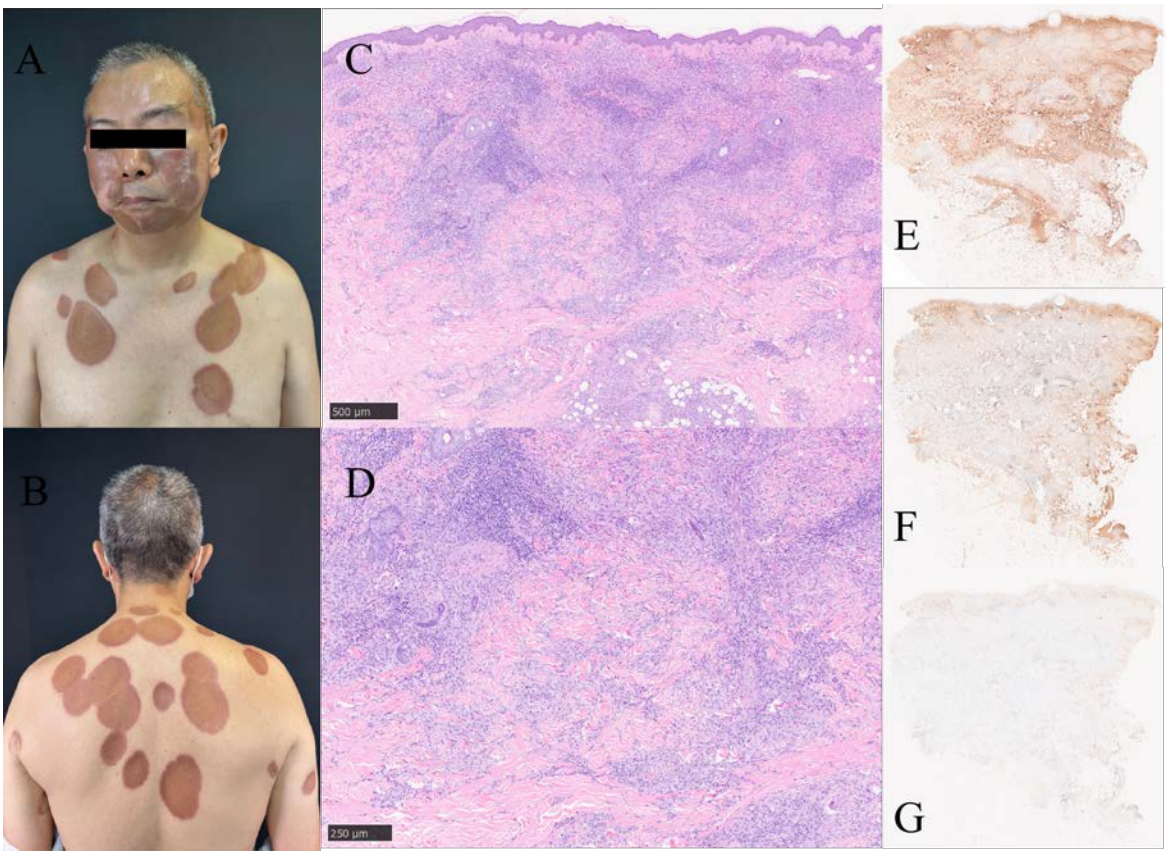

Figure 1. Clinical, histopathological, and immunohistochemical features of disseminated large plaque granuloma annulare. (A–B) Multiple well-demarcated annular plaques with violaceous raised borders and central atrophy involving the face, trunk, and back. (C) Low-power view showing dermal granulomatous inflammation (H&E; scale bar = 500 µm). (D) Higher magnification demonstrating palisading granulomas with central mucin deposition (H&E; scale bar = 250 µm). (E) CD38 immunostaining highlighting prominent plasma cell infiltration. (F) IgG immunostaining showing numerous IgG-positive plasma cells. (G) IgG4 immunostaining demonstrating only scattered IgG4-positive cells, resulting in a low IgG4/IgG ratio, arguing against IgG4-related disease.

Conclusion

This case highlights a rare presentation of disseminated granuloma annulare with prominent plasma cell infiltration mimicking IgG4-related disease. Careful clinicopathological correlation, particularly the identification of a low IgG4/IgG ratio and absence of storiform fibrosis, is essential to avoid misdiagnosis and guide appropriate management.

EA DV CONGRESS
VIENNA
30 SEP - 3 OCT 2026

Abstract N°: 1618

A wolf in sheep's clothing: syringotropic melanoma mimicking seborrheic keratosis

Maria Rojão Mouro*[1], Pola Marchewczyk[1], Cristina Claro[1], Rui Bajanca[1]

[1] Unidade Local de Saúde de Lisboa Ocidental - Hospital de Egas Moniz, Lisboa, Portugal

Introduction

Syringotropic melanoma is a rare histopathological pattern characterized by the extension of neoplastic melanocytes along the eccrine apparatus into the reticular dermis and/or subcutaneous tissue. This variant poses a unique diagnostic challenge, as the eccrine-associated invasion may be clinically unsuspected and raises unresolved questions regarding Breslow thickness measurement and staging.

Case Presentation

An 85-year-old female with controlled arterial hypertension (treated with perindopril and nebivolol) presented with a long-standing pigmented lesion on the lateral aspect of the left arm. Clinical examination revealed a 2 cm asymmetric macule with ill-defined and irregular borders, heterogeneous colour, ranging from light to dark brown, with a subtle keratotic surface.

The clinical appearance was suggestive of seborrheic keratosis; however, melanoma could not be excluded, mainly based on dermoscopic findings. An incisional biopsy was performed.

Initial histopathology revealed a superficial spreading malignant melanoma with a thickness of 0.4 mm. Subsequent wide excision and definitive histopathological analysis confirmed superficial spreading melanoma with a Breslow thickness of 0.6 mm, without ulceration (stage T1a). Tumour-infiltrating lymphocytes were brisk, and focal regression was present. No lymphovascular or perineural invasion was identified, and surgical margins were free. Notably, there was extension of atypical melanocytes along eccrine ducts and focally into the secretory portion, indicating deep adnexal involvement. However, this component remained confined to epithelial structures, with no evidence of syringocentric invasion into the surrounding dermis. In accordance with current recommendations, this adnexotropic extension was not included in the Breslow measurement.

This case highlights two key clinical challenges. First, the bland clinical presentation, a homogeneous brown macule with subtle asymmetry mimicking seborrheic keratosis, underscores that melanoma, including rare variants, can masquerade as benign lesions. The absence of classic clinical and dermoscopic red flags reinforces the importance of maintaining a low threshold for biopsy of clinically ambiguous pigmented lesions, particularly in elderly patients with long-standing lesions. Second, the syringotropic component raises important staging and prognostic questions. In the largest published series, 57% of cases showed syringocentric invasion deeper than the conventional component, and in one case deep dermal syringocentric invasion was the sole site of tumorigenic growth. It has been proposed that syringotropic melanomas affecting the secretory coil may behave differently from those limited to the duct, with secretory involvement associated with a higher rate of advanced disease. The myoepithelial cell layer surrounding the secretory portion has been hypothesized to act as a barrier to neoplastic melanocytes, and its breach may carry prognostic significance. In a study of 257 melanomas with periadnexal extension, sentinel lymph node positivity was significantly higher in tumors >1 mm with periadnexal spread (24% vs. 12.3%, p=0.01), though without worsened overall outcomes, supporting the current practice of excluding adnexal extension from Breslow measurement. In the present case, focal extension into the secretory portion was documented, which warrants careful clinical follow-up despite the thin Breslow measurement.

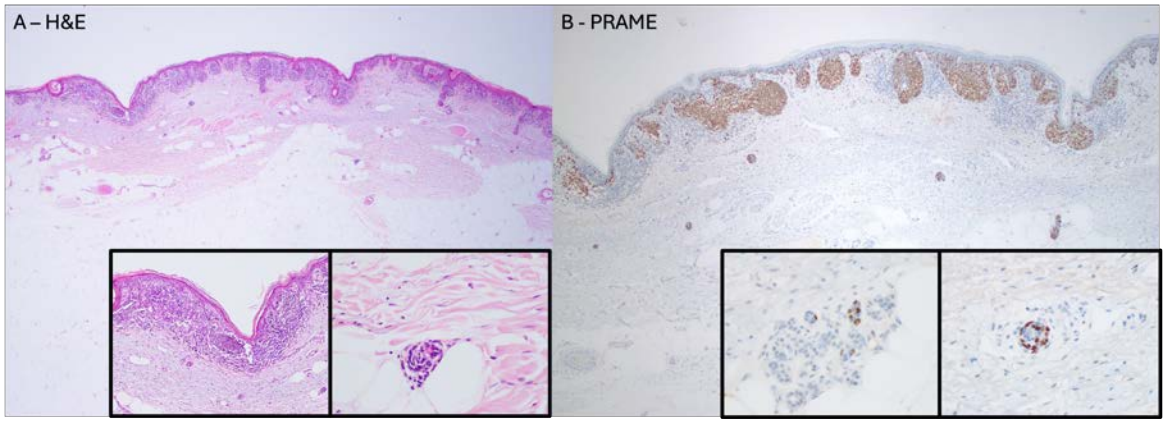

Figure 1. (A) Hematoxylin and eosin staining showing melanoma with syringotropic spread, characterized by atypical melanocytes involving the eccrine apparatus and extending into the dermis and subcutaneous tissue. (B) PRAME immunohistochemistry demonstrating nuclear positivity in neoplastic melanocytes, highlighting secretory coil and eccrine duct involvement.

Conclusion

Syringotropic melanoma is a rare but clinically significant variant that may be underdiagnosed. Meticulous histopathological evaluation of the eccrine apparatus is essential to avoid underestimation of tumor extent. Awareness of this entity among dermatologists and dermatopathologists is paramount, as further evidence is needed to determine whether the anatomical level of eccrine extension independently impacts prognosis and should influence staging or management decisions.

EADV CONGRESS
VIENNA
30 SEP - 3 OCT 2026

Abstract N°: 1633

Histopathological Features of Mechanic's Hands: A Comparative Histopathological Analysis of Dermatomyositis and Antisynthetase Syndrome

Daisuke Suzuki*[1]

[1] Sagamihara National Hospital, Kanagawa, Japan

Introduction

Mechanic's hands are a characteristic cutaneous manifestation observed in both dermatomyositis (DM) and antisynthetase syndrome (ASyS). Recent advances in clinicoserological classification have increasingly supported the recognition of ASyS as a distinct entity within the spectrum of idiopathic inflammatory myopathies rather than simply a subset of DM. However, the histopathological differences in mechanic's hands between DM and ASyS have not been fully characterized. Recognized histopathological findings of mechanic's hands include focal parakeratosis, psoriasiform acanthosis, vacuolar change, and necrotic keratinocytes. In addition, a pseudocheckerboard pattern in the corneal layer, characterized by alternating vertically arranged parakeratosis and orthokeratosis with intervening orthokeratotic areas (Figure 1), has been described, although it is not regarded as a specific finding. The purpose of this study is to investigate the frequency and histopathological significance of the pseudocheckerboard pattern in mechanic's hands in our case series, and to compare histopathological features between DM and ASyS cases.

Materials and Methods

We retrospectively analyzed 8 patients who underwent skin biopsy of lesions clinically diagnosed as mechanic's hands. Histopathological assessment focused on the presence or absence of a pseudocheckerboard pattern, together with other histopathological findings including focal parakeratosis, psoriasiform acanthosis, vacuolar change, and necrotic keratinocytes. These findings were then compared between ASyS and DM cases.

Results

A pseudocheckerboard pattern was identified in 5 of the 8 cases (Figure 2). All 3 patients with ASyS showed this pattern, whereas it was also observed in anti-MDA5 antibody-positive DM (Table). Among the recognized histopathological findings of mechanic's hands, focal parakeratosis, vacuolar change, and necrotic keratinocytes were present in all cases. This tendency was consistent with a previous report, in which 2 of 2 patients with ASyS showed a pseudocheckerboard pattern.

Conclusions

The pseudocheckerboard pattern in mechanic's hands is not a widely recognized histopathological finding and cannot be considered specific for ASyS, as it was also observed in DM. However, our findings suggest that, like other recognized histopathological findings of mechanic's hands, it may serve as a useful histopathological clue and may be particularly frequent in ASyS. Although serological testing for myositis-related autoantibodies has expanded considerably, some anti-ARS antibodies remain undetectable by standard serological testing. Histopathological assessment therefore continues to have important clinical value, and evaluation of mechanic's hands may provide adjunctive diagnostic information in suspected ASyS.

Figure 1

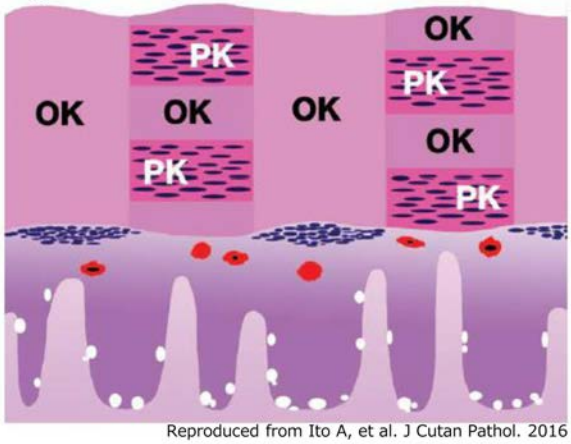

Reproduced from Ito A, et al. J Cutan Pathol. 2016

Figure 2

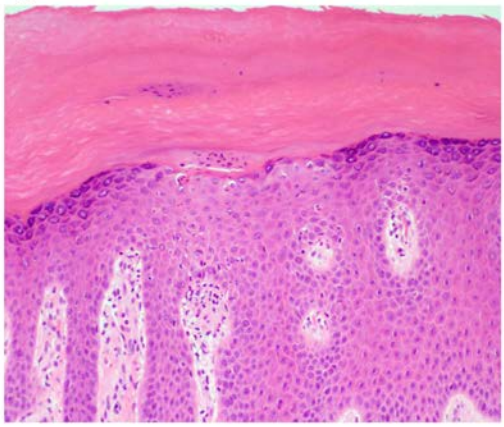

Talbe

	Case	Autoantibody	Pseudo-checkerboard pattern	Focal parakeratosis	Psoriasiform acanthosis	Vacuolar change	Necrotic keratinocytes
1	59/F	MDA5	-	+	-	+	+
2	53/F	ARS	+	+	+	+	+
3	67/F	ARS	+	+	+	+	+
4	47/M	MDA5	+	+	+	+	+
5	67/M	Mi-2	-	+	+	+	+
6	37/M	MDA5	+	+	+	+	+
7	63/F	MDA5	-	+	+	+	+
8	52/M	ARS	+	+	+	+	+

Figure 1: Pseudocheckerboard pattern of mechanic’s hands. In the hyperkeratotic corneal layer, there are areas of alternating parakeratosis (PK) and orthokeratosis (OK) in a vertical arrangement, and the former areas further showed alternating parakeratosis and orthokeratosis in a horizontal arrangement (reproduced from Ito A, et al. J Cutan Pathol. 2016). Figure 2: Histopathological findings of mechanic’ hands Case 4. A pseudocheckerboard pattern, focal parakeratosis, psoriasiform acanthosis, vacuolar change, and necrotic keratinocytes were present (hematoxylin and eosin, original magnification x200). Table: Autoantibody and pathological findings of patients with mechanic’s hand. Reference: Ito A, Yamada N, Yoshida Y, Yamamoto O. Pseudocheckerboard pattern: an interesting histopathological finding in mechanic's hands. J Cutan Pathol. 2016 :5-11

EADV CONGRESS
VIENNA
30 SEP - 3 OCT 2026

Abstract N°: 1689

Pilomatricoma Growing at the SARS-CoV-2 mRNA Vaccination Site

Melike Güven*[1, 2], Merve ERKAYMAN[3], Merve BİNGÖL[4], Numan BULUT[5], Rabia Demirtaş[5]

[1] Department of Dermatology and Venereology, Ataturk University, Erzurum, Türkiye., Department of Dermatology and Venereology, Hopa State Hospital, ERZURUM, Türkiye

[2] ARTVIN STATE HOSPITAL, ARTVIN, Türkiye

[3] Department of Dermatology and Venereology, Ataturk University, Erzurum, Türkiye., ERZURUM, Türkiye

[4] Private Practice, Dermatology, Department of Dermatology and Venereology, Kars Harakani State Hospital, Kars, Türkiye., ERZURUM, Türkiye

[5] Department of Pathology, Faculty of Medicine, Ataturk University, ERZURUM, Türkiye

Introduction

Pilomatricoma (PM) (also known as pilomatrixoma or Malherbe's calcified epithelioma) is a benign neoplasm that originates from hair follicle matrix cells. PMs are usually asymptomatic and often located on the head and neck region and upper extremities but can rarely occur on the chest, trunk or lower extremities. There have been several cases of pilomatricoma documented after various immunisations. Here, we present a case of pilomatricoma that grew at the vaccination site after BNT162b2 mRNA vaccine.



Solid nodular lesion with overlying erythematous soft skin on the lateral side of upper left arm

Case Presentation

A healthy 21-year-old woman was presented to our outpatient clinic with an asymptomatic swelling on her left arm. She had received two doses of BNT162b2 mRNA vaccination at the lesion site 1 year and 6 months before admission. Additionally, two to three weeks following the second dose of vaccine, she mentioned about an erythematous injection site reaction. Physical examination revealed a deeply palpable nodular lesion with overlying soft, erythematous skin in the deltoid region of the left shoulder. An excisional biopsy was performed with a preliminary diagnosis of pilomatricoma and foreign-body granuloma. Histopathological investigation disclosed a tumoral lesion with centrally positioned large ghost cells with diffuse eosinophilic cytoplasm, multinucleated giant cells and calcification in the deep dermis and subcutaneous tissue, supporting the diagnosis of PM. A Verhoeff–van Gieson stain showed normal elastic fibres (not shown). Following the total excision of the tumour, no recurrence was observed during a 10-month follow-up period.

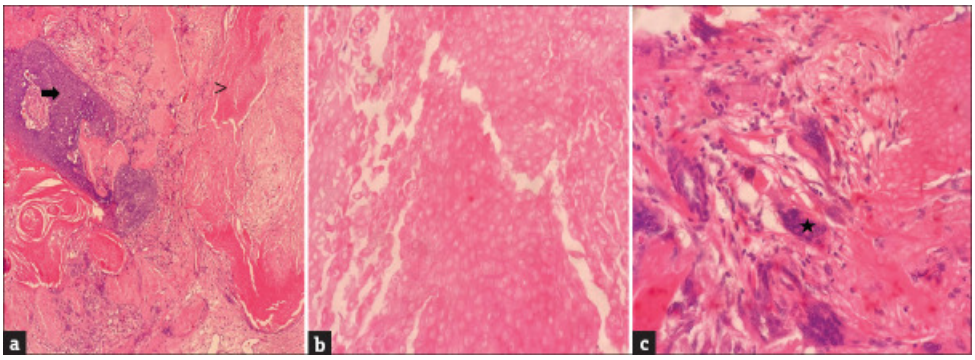

(a-c) Pilomatricoma. (a) (H and EX100); solid islands of basaloid cells, which are the characteristic feature of the tumour (arrow), ghost cells (arrowhead) (b) (H and EX400) and multinucleated giant cells (asterisk) (c) (H and EX400)

Conclusion

Following COVID-19 vaccination, various mucocutaneous adverse effects have been reported. We present a case of Pilomatricoma that may represent a rare local adverse effect of SARS-CoV-2 mRNA vaccination.

Pilomatricoma can occur at any age, often in children and young adults, and has been linked to trauma. Previous reports have described pilomatricoma following vaccines or injectable drugs, with a predominance in females (Table 1). Proposed mechanisms include injection-site trauma preventing apoptosis of damaged follicular epithelial cells, as well as persistent inflammation, wound healing, or effects related to the inoculated agent. Our patient also had delayed erythema at the injection site after immunization, supporting the possible role of continuous inflammation.

Pilomatricoma usually presents as a hard bluish papule or nodule, although several clinical variants have been described. Histopathologically, it is characterized by a well-defined nodular lesion composed of basaloid cells and ghost/shadow cells. Bullous pilomatricoma has rarely been reported following vaccination; however, no such histologic changes were present in our case despite a suggestive clinical appearance.

Although coincidental occurrence cannot be excluded, previous similar reports support a possible association. This case highlights that pilomatricoma should be considered in the differential diagnosis of nodular lesions developing at vaccination sites, and a history of injection-site reaction may provide a diagnostic clue.

Table 1.

Reported cases of pilomatricoma associated with vaccine or drug injection

Age/gender	Injection/vaccine type	Time to diagnosis	Injection site reaction	Clinical findings	Reference
13 yrs/F	BCG	3 years	Prolonged BCG reaction	Ulcerated nodule	Aquilina S. *et al.*
7 yrs/F	Methotrexate	4 years	-	Nodule	Perez E. *et al.*
7 yrs/F	Influenza	4 months	Redness, discharge, 1 month later	Nodule	Jeon H. *et al.*
7 yrs/F	Hepatitis A	1 month	Redness, 2 days later	Bullous	Tas B. *et al.*
21 yrs/M	MMR, conjugated pneumococcal, chickenpox	1 month	Redness, 1 week later	Nodule	Tuzlalı Z. *et al.*
15 yrs/M	Hepatitis B	9 months	Inflammation	Bullous	Zhang L. *et al.*
9 yrs/F	Influenza	9 months	-	Bullous	Zhang H. *et al.*
27 yrs/M	Diclofenac sodium	7 months	Ecchymoses	Giant nodule	Malpathak V. *et al.*
4 yrs/F	DTaP	2 months	-	Nodule	Jeong DS. *et al.*
43 yrs/F	SARS-CoV-2	5 months	Nodule, immediately	Nodule	Nakazano M. *et al.*
21 yrs/F	SARS-CoV-2	7 months	Redness, 2–3 weeks later	Nodule	Present case

MMR=mumps, measles, rubella; DTaP=diphtheria-tetanus-pertussis; SARS-CoV-2=severe acute respiratory syndrome coronavirus 2

EADV Congress 2026, VIENNA
30 SEPTEMBER - 03 OCTOBER 2026
POWERED BY M-ANAGE.COM

EADV CONGRESS
VIENNA
30 SEP - 3 OCT 2026

Abstract N°: 1704

Animal-type melanoma with amelanotic nodal metastasis mimicking plasma cell neoplasm

Jooyoung Roh*[1], Da Yeon Kim[2], Jeewoo Choi[2], Heera Lee[2], Ji Yeon Byun[2], You Won Choi[1], Sunho Kee[3]

[1] Department of Dermatology, Ewha Womans University College of Medicine, Seoul Hospital, Seoul, Korea, Rep. of South
[2] Department of Dermatology, Ewha Womans University College of Medicine, Mokdong Hospital,, Seoul, Korea, Rep. of South
[3] Department of Microbiology, Korea University College of Medicine, Seoul, Korea, Rep. of South

Introduction
Amelanotic melanoma is diagnostically challenging because the absence of pigment may obscure melanocytic differentiation. In metastatic lesions, unusual morphology and aberrant immunophenotypic features may further lead to misclassification as hematologic malignancy, particularly plasma cell neoplasm.

Case Presentation
A 61-year-old man presented with persistent lymphadenopathy. A previously biopsied supraclavicular lymph node had undergone serial diagnostic revisions, from cytomegalovirus lymphadenitis to chemotherapy-refractory multiple myeloma/plasmacytoma. He was referred for generalized vitiligo-like depigmented patches and an enlarging brown-black papule on the back. Histopathological examination of the cutaneous lesion revealed heavily pigmented epithelioid melanocytic proliferation, consistent with animal-type melanoma. Re-evaluation of the nodal specimen, previously diagnosed as plasmacytoma, demonstrated amelanotic plasmacytoid tumor cells. Although these cells expressed CD138 and cyclin D1, they were diffusely positive for S100, SOX10, and HMB45, confirming melanocytic differentiation. A BRAF mutation was also detected. Systemic imaging did not reveal another primary lesion, supporting the cutaneous animal-type melanoma as the most likely origin of the nodal metastasis.

Conclusion
This case highlights that melanoma should remain in the differential diagnosis of plasmacytoid or small round cell tumors, even when plasma cell markers are expressed. A comprehensive immunohistochemical panel including melanocytic markers is essential to avoid diagnostic delay. The accompanying vitiligo-like depigmentation may reflect anti-melanocytic immune activity and may be related to amelanotic transformation.

EADV CONGRESS
VIENNA
30 SEP - 3 OCT 2026

Abstract N°: 1736

Painful Cutaneous Tumor of the Ankle: Consider Leiomyoma

Ghita Gmira*[1], Meryem Soughi[1], ikram bejja[1], Saadia Boughaleb[1], douhi zakia[1], Sara Elloudi[1], Hanane Baybay[1], Fatima Zohra Mernissi[1]

[1] Department of Dermatology, Hassan II University Hospital, Fez, Morocco

Introduction

Leiomyoma is a benign tumor initially described by Virchow in 1854. It accounts for 3.8% of all soft tissue tumors. Cutaneous leiomyomas are benign neoplasms arising from the arrector pili muscle. They represent approximately 5% of all leiomyomas . Clinically, they present as papules, nodules, or plaques, either solitary or multiple, red or brown in color. They may be painful and sensitive to physical and mechanical stimuli such as touch, pressure, and cold. Due to their rarity and clinical polymorphism, cutaneous leiomyomas represent a real diagnostic challenge in dermatological practice.

Case Presentation

We report the case of a 37-year-old woman with no significant past medical history who presented with a lesion on the right leg evolving for six years. The slow and chronic progression of the lesion, without associated systemic symptoms, initially suggested a benign condition. Clinical examination revealed a skin-colored, roughly oval nodule, painful on palpation, located on the lateral aspect of the right lateral malleolus. Pain elicited on palpation was a significant clinical feature. Dermoscopy showed dotted vessels. Based on these findings, the differential diagnoses included a nerve sheath tumor such as schwannoma or neurinoma, as well as venous ectasia or cystic ectasia. Doppler ultrasound revealed a subcutaneous soft tissue lesion on the lateral aspect of the right ankle, primarily suggestive of an epidermoid cyst. Excisional biopsy revealed histological features consistent with a benign mesenchymal tumor. Immunohistochemical study was compatible with leiomyoma without signs of malignancy, consistent with piloleiomyoma.

Conclusion

Cutaneous leiomyoma is a rare benign tumor whose diagnosis may be challenging due to its polymorphic clinical presentation and broad differential diagnoses. Our observation illustrates the initial diagnostic difficulty, with several hypotheses considered before histological confirmation. Histological examination combined with immunohistochemistry confirms the diagnosis. Surgical excision remains the treatment of choice for solitary forms, with a generally favorable prognosis. Regular follow-up is nevertheless recommended, particularly in multiple forms, in order to detect early any associated systemic involvement.

EA DV CONGRESS
VIENNA
30 SEP - 3 OCT 2026

Abstract N°: 1747

Differential expression patterns of Bcl-2 and CD10 across histologic subtypes of basal cell carcinoma

Yeji Jang*[1], Dayeon Jung[1]

[1] Hallym Sacred Heart Hospital, Anyangsi, Gyeonggido, Korea, Rep. of South

Introduction
Basal cell carcinoma (BCC) comprises histologic subtypes with different biologic behaviors and recurrence risks. Although Bcl-2 and CD10 immunohistochemistry is widely used for diagnostic purposes, their expression patterns across BCC subtypes and their association with histologic aggressiveness remain incompletely defined. We evaluated Bcl-2 and CD10 expression patterns and expression grading scores according to BCC subtype and predefined risk category.

Materials and Methods
We retrospectively analyzed 57 BCC specimens diagnosed between November 2013 and November 2025 in patients who underwent both Bcl-2 and CD10 immunohistochemical staining. Tumors were classified as nodular, superficial, micronodular, or infiltrating subtype, and further categorized as low-risk (nodular and superficial) or high-risk (micronodular and infiltrating). Tumor staining patterns were recorded, and expression grading scores were calculated on a 0–7 scale by combining percentage positivity and staining intensity. Differences among subtypes were analyzed using the Kruskal-Wallis test, and monotonic trends were assessed using Spearman rank correlation and the Jonckheere-Terpstra test. Correlations between CD10 tumor and stromal expression were also evaluated.

Results
Among the 57 BCC specimens, Bcl-2 most commonly showed a diffuse tumor staining pattern (56.1%), whereas CD10 most commonly showed a peripheral tumor staining pattern (89.5%). The distribution patterns of Bcl-2 and CD10 did not differ significantly among subtypes. However, Bcl-2 tumor expression scores were significantly lower in high-risk subtypes than in low-risk subtypes and showed a significant monotonic decrease across the predefined aggressiveness gradient from nodular to superficial to micronodular to infiltrating BCC (Spearman rho = -0.574, $p < 0.001$; Jonckheere-Terpstra $p = 0.021$). In contrast, CD10 tumor expression scores differed significantly according to subtype, were higher in infiltrating BCC than in nodular BCC, and showed a significant monotonic increase across the same subtype order (Spearman rho = 0.481, $p < 0.001$; Jonckheere-Terpstra $p = 0.021$). CD10 tumor and stromal expression scores were inversely correlated ($r = -0.347$, $p < 0.05$), whereas stromal CD10 expression and retraction staining did not differ significantly among subtypes.

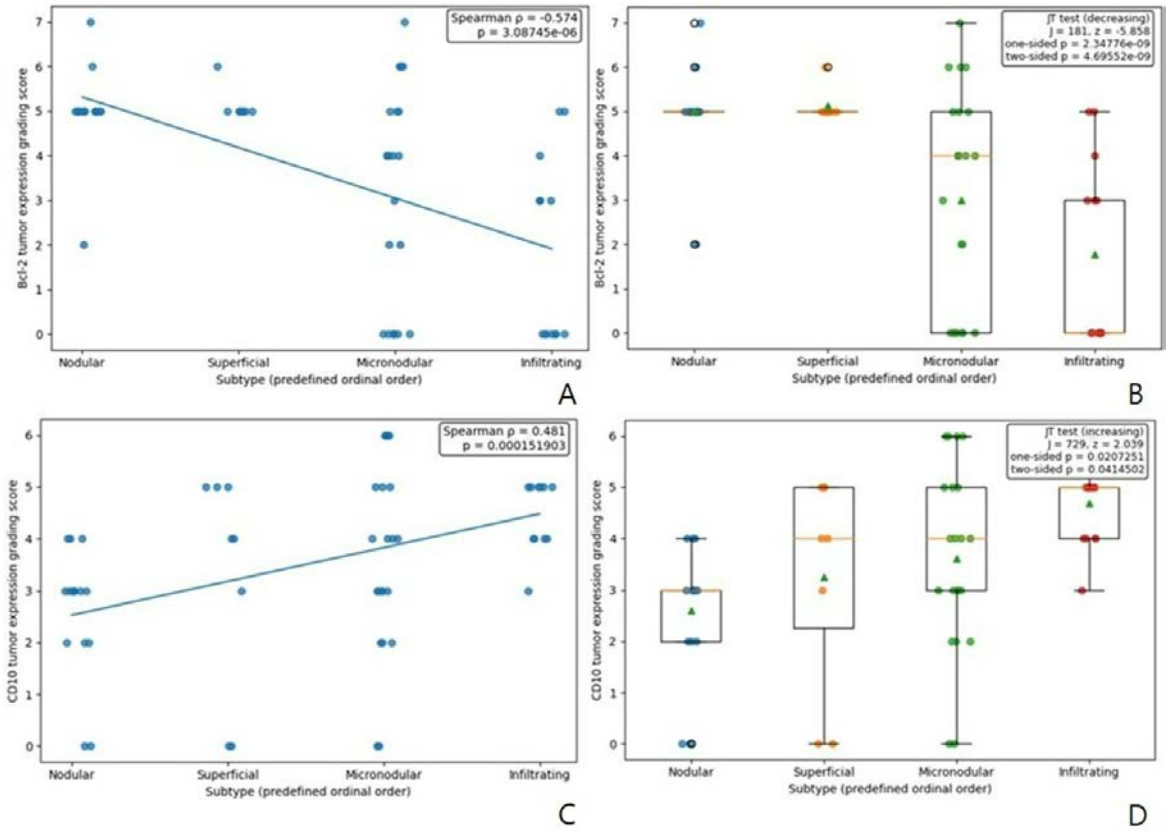

Figure. Trends in Bcl-2 and CD10 tumor expression according to basal cell carcinoma subtype. (A) Spearman correlation between subtype order and Bcl-2 tumor expression grading score. (B) Jonckheere-Terpstra trend test for Bcl-2 tumor expression grading score across subtypes. (C) Spearman correlation between subtype order and CD10 tumor expression grading score. (D) Jonckheere-Terpstra trend test for CD10 tumor expression grading score across subtypes.

Conclusions

Bcl-2 and CD10 tumor expression showed opposite trends across the histologic aggressiveness spectrum of BCC. These findings suggest that, beyond their diagnostic utility, Bcl-2 and CD10 may serve as adjunctive biomarkers reflecting biologic behavior in BCC.

EA DV CONGRESS
VIENNA
30 SEP - 3 OCT 2026

Abstract N°: 1880

Sweet's syndrome and episcleritis

Émélie Simone Okouango*[1], Hanane Rachadi[1], Fatimazahrae Benhayoun[1], Bouchra Baghad[1], Soumiya Chiheb[1]

[1] Department of Dermatology, Ibn Rochd University Hospital, Casablanca, Morocco, Faculty of Medicine and Pharmacy of Casablanca, Hassan II University, Morocco, Casablanca, Morocco

Introduction

Sweet's syndrome (SS), or acute febrile neutrophilic dermatosis, is a rare inflammatory skin condition characterised by dense infiltration of neutrophils in the dermis and sometimes the epidermis. Its aetiology is often unclear; it is generally considered a hypersensitivity reaction triggered by infections, autoimmune diseases, neoplasms, or medications. Ocular involvement, although clinically significant, is often underdiagnosed, with a reported frequency of 4% to 72%. In the classic form, its incidence varies. The most common ophthalmic symptoms are eye pain, blurred vision, and decreased visual acuity. The most common signs include conjunctivitis, red eye, and episcleritis. These manifestations may be initial. The average time to resolution is approximately two weeks with appropriate treatment. We report the case of a 46-year-old female patient presenting with classic bullous SS of idiopathic origin associated with episcleritis.

Case Presentation

This is a 46-year-old female patient with a history of cholecystectomy performed 9 years ago who presented with erythematous lesions that had been developing for five days. The lesions, initially localised to the hands, had spread to the neck, forearms, and legs, accompanied by an undetermined fever and a decline in general health. Physical examination revealed confluent erythematous-purplish papular plaques that were infiltrated and oedematous, sometimes with a bullous centre and a nodular surface in places, and were warm and painful. They were located on the neck, forearms, hands, legs, and palms. Pseudo-cocarde lesions were associated with left conjunctival hyperaemia. Laboratory findings revealed neutrophil-predominant leukocytosis with an inflammatory syndrome. Skin histology showed a perivascular neutrophilic infiltrate. After ruling out infectious, neoplastic, and drug-related causes, a diagnosis of classic idiopathic bullous pemphigoid associated with episcleritis was made. The patient was treated with systemic corticosteroids combined with local therapy (indomethacin eye drops), resulting in marked improvement of the episcleritis within two weeks.

Conclusion

SS belongs to the group of neutrophilic dermatoses and is the most common form, with a higher prevalence in women. It can be idiopathic, inflammatory, paraneoplastic, or drug-induced, with the classic idiopathic form being the most common. Ocular involvement is generally benign, unilateral, or bilateral. It presents as ocular redness, pain, visual disturbances, or periorbital oedema. The described manifestations include, in particular, blepharitis, conjunctivitis, episcleritis, scleritis, uveitis, iridocyclitis, and peripheral ulcerative keratitis; and retinal vasculitis, as well as, more rarely, glaucoma or choroidal involvement. Although relatively rare, this condition can be serious, particularly when associated with a neoplasm, an infection, or a drug-induced cause. In paraneoplastic forms, particularly those linked to certain cancers, severe complications such as choroidal infiltration or retinal detachment may occur, compromising visual prognosis. Similarly, certain drug-induced forms can lead to more extensive ocular inflammation, requiring close monitoring. Thus, early and systematic ophthalmological

examination is essential. This case report illustrates a rare form of SS with episcleritis. A rigorous clinical evaluation and patient education are necessary to ensure that these ocular manifestations which remain poorly characterised despite growing recognition are not overlooked.

EA DV CONGRESS
VIENNA
30 SEP - 3 OCT 2026

Abstract N°: 1888

Evaluation of Aggrecan Protein Expression in Morphea and Keloids Associated with Exaggerated Collagen Formation

Nilay Duman[1], Banu Yaman[2], Aslıhan Özel*[1], Mahdi Shekari[3], Taner Akalın[2], Özgür Çoğulu[4]

[1] Ege University Faculty of Medicine, Department of Dermatology and Venereology, İzmir, Türkiye
[2] Ege University Faculty of Medicine, Department of Medical Pathology, İzmir, Türkiye
[3] Ege University Faculty of Engineering, Department of Biotechnology, İzmir, Türkiye
[4] Ege University Faculty of Medicine, Department of Pediatrics, Division of Pediatric Genetics, İzmir, Türkiye

Introduction
Although aggrecan is a major proteoglycan in articular cartilage, it is a minor component of the skin and may accumulate in tissues when the activity of various aggrecanases, such as ADAMTS-5, is diminished. Several studies have demonstrated increased aggrecan expression at the margins of wound healing and keloidal scars. Additionally, previous research has shown that keloids aberrantly express extracellular matrix (ECM) proteins typically associated with cartilage, including aggrecan and type II collagen. While there is evidence indicating increased expression of a different cartilage-associated matrix protein in morphea, no study evaluating the role of aggrecan in morphea has been identified. The aim of this study was to immunohistochemically evaluate aggrecan expression in keloid and morphea tissues and to obtain evidence regarding its potential role in the sclerotic processes of these disorders.

Materials and Methods
This study included 15 cases of morphea, 13 cases of keloid, 3 hypertrophic scar tissues, 2 cartilage samples and 3 skin biopsy specimens with normal morphology diagnosed in the Medical Pathology Laboratory between 2010 and 2025. Clinical data including patient history, age, sex, and lesion location were obtained from archival records. Morphea cases were classified into three subgroups according to histopathological findings: early-phase, intermediate-phase, and late-phase. Cases of keloidal morphea (nodular scleroderma) were excluded. For immunohistochemical analysis, 4-µm sections were obtained from archival paraffin-embedded tissues and stained using an anti-aggrecan antibody (Santa Cruz Biotechnology, Clone 4F4). The presence, distribution pattern, and staining intensity of aggrecan expression were evaluated semi-quantitatively.

Results
Aggrecan expression was detected in all keloid cases included in the study. Expression intensity was moderate in 7 cases, mild in 3 cases, and strong in 3 cases. No aggrecan expression was observed in hypertrophic scar tissues. Strong aggrecan expression was identified in three late-phase morphea specimens, whereas no aggrecan expression was detected in five early-phase morphea cases. Focal/mild aggrecan expression was observed in seven morphea tissues. In the three morphea patients with strong aggrecan positivity, review of clinical history and lesion characteristics revealed that biopsies had been obtained from markedly sclerotic areas, which also demonstrated pronounced sclerosis histopathologically. Furthermore, strong aggrecan expression in both keloid and morphea cases was associated with increased collagen condensation observed histopathologically.

Conclusions
Strong aggrecan expression was observed in biopsy specimens obtained from long-standing, highly sclerotic morphea plaques, while moderate-to-strong aggrecan expression was present in the majority of keloid cases. In contrast, aggrecan expression was absent in early-phase morphea tissues and hypertrophic scars. Our findings

demonstrate that aggrecan expression increases in both morphea and keloidal tissues in parallel with the degree of sclerosis. These findings provide important evidence that may contribute to clarifying unresolved aspects of sclerosis pathogenesis.

EADV CONGRESS
VIENNA
30 SEP - 3 OCT 2026

Abstract N°: 1916

Syringocystadenoma Papilliferum Arising on Nevus Sebaceus: A Case Report

Gizem Kaya Efe*[1], Muhammet Ali Mergen[1], Tubanur Çetinarslan[1], Peyker Temiz[2], Aylin Türel Ermertcan[1]

[1] Manisa Celal Bayar University Faculty of Medicine, Department of Dermatology and Venereology, Manisa, Türkiye
[2] Manisa Celal Bayar University Faculty of Medicine, Department of Pathology, Manisa, Türkiye

Introduction

Nevus sebaceus, also known as Jadassohn's nevus or organoid nevus, is a rare congenital benign cutaneous hamartoma composed of epidermal, follicular, sebaceous, and apocrine components. These lesions are typically present at birth and tend to enlarge during puberty under hormonal influences. Over time, secondary neoplasms may develop within the lesion.

The majority of these neoplasms are benign adnexal tumors, including trichoblastoma, sebaceoma, and syringocystadenoma papilliferum (SP). However, malignant transformations have also been reported.

Syringocystadenoma papilliferum (SP) is a rare benign adnexal tumor of apocrine or eccrine origin, and approximately one-third of cases arise in association with nevus sebaceus. As it may clinically resemble malignant lesions, histopathological confirmation remains important. Herein, we present a case of syringocystadenoma papilliferum arising on a nevus sebaceus and discuss its clinical, dermoscopic, and histopathological features.

Case Presentation

A 17-year-old female patient presented to our dermatology clinic with a long-standing lesion located in the temporal region, present for approximately 15 years. Over the past year, the lesion had gradually increased in size.

Dermatological examination revealed a well-demarcated lesion measuring approximately 1 cm in diameter, located in the temporal region adjacent to the scalp. The lesion was yellowish-pink in color and exhibited a verrucous surface.

Dermoscopic evaluation demonstrated clustered yellow-white globules on a yellow-pink background, along with papillomatous yellow-white structures, yellow crusts, and focal areas of hemorrhagic crusting. The patient reported habitual trauma to the lesion.

The lesion was completely excised. Histopathological examination revealed a papillary lesion lined by cylindrical epithelium with prominent plasma cell infiltration, showing continuity with an acanthotic epidermis. Adjacent areas contained superficial sebaceous glands and deeper apocrine structures.

These findings were consistent with SP arising within a nevus sebaceus.

Conclusion

Nevus sebaceus is a congenital hamartoma that occurs in approximately 0.3% of newborns and shows no gender predilection. Clinically, it presents as a well-demarcated, yellow-orange plaque with a smooth surface during childhood, which becomes thicker, elevated, and more verrucous or papillomatous during adolescence under

hormonal influences.

The risk of secondary tumor development increases with age, with reported rates ranging from 10% to 30%. Most of these tumors are benign adnexal neoplasms, including trichoblastoma, trichoepithelioma, sebaceoma, and SP. Malignant transformation occurs in approximately 2.5% of cases, most commonly as basal cell carcinoma.

Syringocystadenoma papilliferum is a rare adnexal tumor with apocrine or eccrine differentiation. Approximately around one-third are associated with nevus sebaceus.

Clinically, SP typically presents as papillomatous or verrucous plaques or nodular lesions. Lesions may exhibit erythema, secretion, or ulceration, which can clinically resemble malignant conditions. As it may clinically resemble malignant lesions, histopathological confirmation is required.

Although SP is a benign tumor, it may be associated with malignant neoplasms such as basal cell carcinoma, metastatic adenocarcinoma, and ductal carcinoma.

Therefore, lesions arising on nevus sebaceus should be carefully evaluated. Histopathological examination after excision helps confirm the diagnosis and exclude malignancy.

Surgical excision remains the gold standard treatment, with a low recurrence rate. Considering the potential for secondary tumor development, elective excision of nevus sebaceus—particularly in adulthood—may be an appropriate approach.

In our case, syringocystadenoma papilliferum arising on a nevus sebaceus was identified based on characteristic clinical and histopathological findings, and the patient had an uneventful postoperative course with no evidence of recurrence.

EA DV CONGRESS
VIENNA
30 SEP - 3 OCT 2026

Abstract N°: 1933

Mycosis Fungoides and Lichen Planus: SimpleAssociation or Misleading Clinical Presentation

Mansouri Rayane*[1], Bounneche Houda[1], kaghouche lilia[1], Safa Djebbas[1], Amel Gherfi[1], khadidja bouarroudj[1], esma bouhila[1], Tarek Mansoul[1], RIADH BOUSSAID[1], Ahmed Samaouel Chehad[1]

[1] Department of Dermatology, CHU Benbadis, Constantine, Algeria, constantine, Algeria

Introduction

Mycosis fungoides (MF), the most frequent primary cutaneous T-cell lymphoma, may mimic lichenoid dermatoses such as lichen planus (LP). Clinical and histological overlap or coexistence between MF and LP represents a diagnostic challenge, requiring close clinicopathological and immunohistochemical correlation. We report a new case illustrating this diagnostic complexity and the importance of careful follow-up.

Case Presentation

A 57-year-old patient with no significant medical history presented with a 4-year history of intense pruritus associated with progressive violaceous erythematous-squamous plaques, hyperkeratotic verrucous lesions, and poikilodermatous patches involving the face, scalp, trunk, and limbs. Recent onset of ectropion and diffuse cicatricial alopecia affecting the scalp hair, eyelashes, and eyebrows was noted. Histological examination of multiple biopsies showed, depending on the lesion, epidermal hyperplasia with hypergranulosis; a dense band-like lichenoid lymphoid infiltrate with marked epidermotropism; or an atrophic epidermis with basal layer destruction, melanophages, and cytoid bodies. No pilotropism or mucin deposition was observed. Immunohistochemistry demonstrated a predominant intraepidermal CD3+ CD4+ T-cell phenotype. Staging work-up, including LDH levels, blood smear, lymph node ultrasound, and thoraco-abdomino-pelvic CT scan, was normal. Based on clinical, histological, and immunohistochemical findings, a diagnosis of MF with a lichenoid presentation or associated with true LP was established. Treatment with methotrexate 25 mg/week, antihistamines, and topical corticosteroids was initiated.

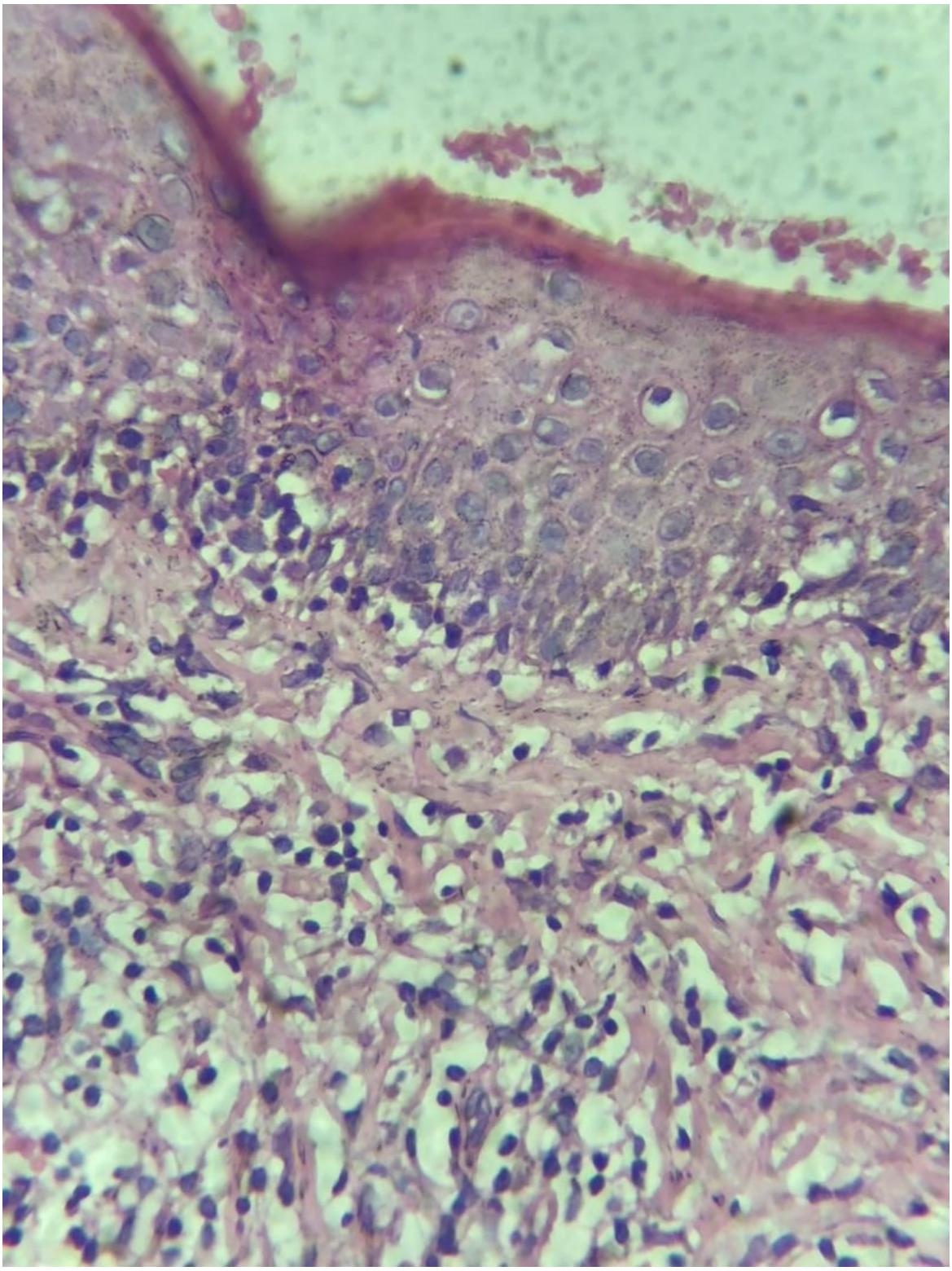

lichenoid infiltrate composed of lymphoid cells arranged along the basal layer; the cells are of medium size and form small aggregates, likely corresponding to microabscesses

Conclusion

Discussion:

The patient presented with a polymorphic dermatosis evolving over four years, with violaceous erythematous-squamous, verrucous, and poikilodermatous lesions associated with cicatricial alopecia. Such features may be observed in both LP and MF, complicating the diagnosis. Histology and especially immunohistochemistry allow differentiation: MF is characterized by a CD4+ epidermotropic lymphoid infiltrate, whereas LP typically shows a CD8+ lichenoid infiltrate at the dermoepidermal junction. Several reports describe patients with clinically and histologically proven LP who later developed MF, up to 17 years after the initial LP diagnosis. These observations raise

the question of MF mimicking LP, coexistence of both entities, or transformation of LP. Therapeutically, some treatments may be shared, but prognosis and follow-up differ: MF requires long-term surveillance with a more guarded prognosis, while LP generally follows a favorable course.

Conclusion

This case highlights the importance of close clinical, histological, and immunohistochemical correlation when facing atypical or evolving lichenoid lesions, in order to avoid missing a true mycosis fungoides.

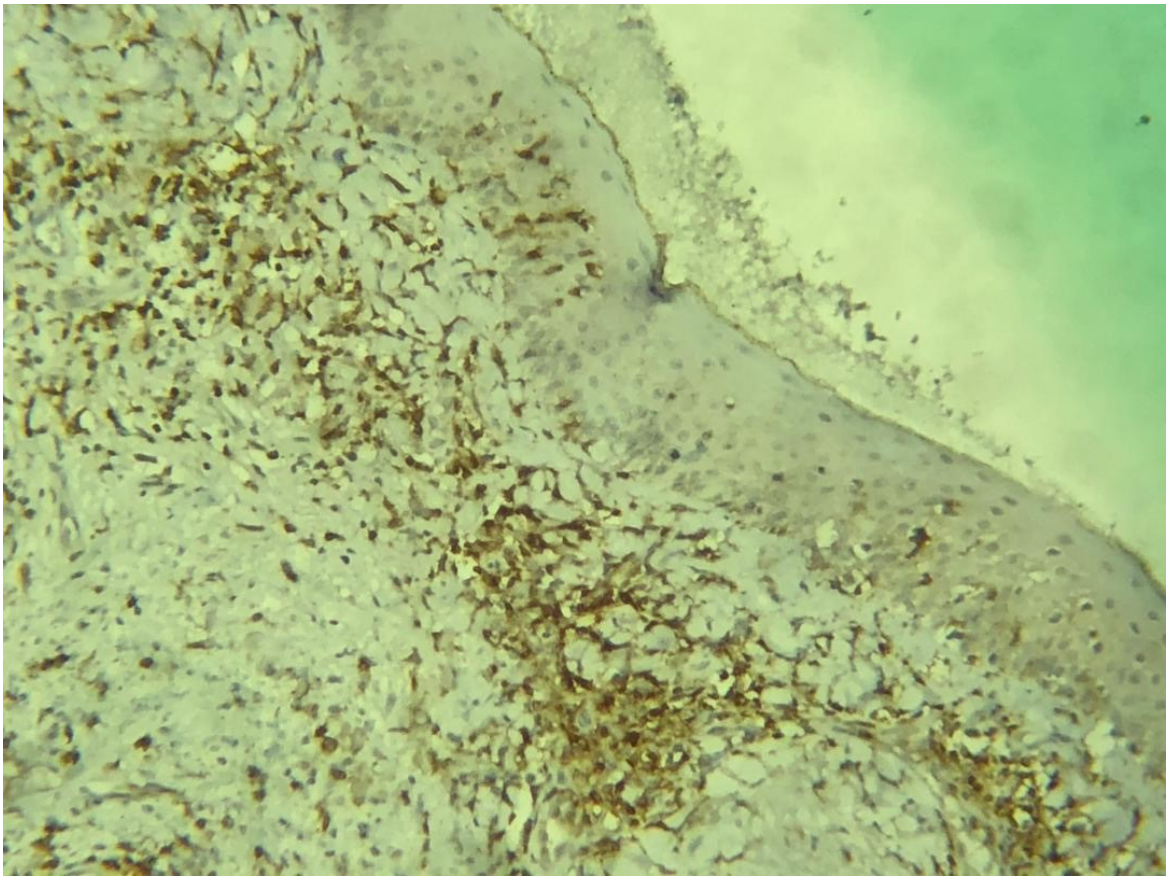

Immunohistochemical image demonstrating CD3 positivity.

EADV CONGRESS
VIENNA
30 SEP - 3 OCT 2026

Abstract N°: 1961

Sarcoidosis caused by eyebrow tattooing

Xinyi CHEN*[1], Juan Bai[1], Jianjun QIAO[1]

[1] Department of Dermatology, The First Affiliated Hospital, Zhejiang University School of Medicine, Hangzhou, China

Introduction

Sarcoidosis is a systemic granulomatous disorder characterized by non-caseating epithelioid granulomas. It commonly affects the lungs, lymph nodes, and skin. Tattoo-associated sarcoidosis is a rare presentation that can be misdiagnosed. We describe a 46-year-old woman with systemic sarcoidosis involving the skin, lungs, and lymph nodes, linked to a prior eyebrow tattoo.

Case Presentation

A 46-year-old female presented with multiple yellowish and pink plaques on the forehead, eyebrows, and back for several months, without pain, itching, or fever. She had a history of eyebrow tattooing and denied tuberculosis.

Physical Examination: Multiple pink plaques on the forehead and back; symmetric yellowish smooth plaques on both eyebrows.

Laboratory Tests: ANA, CCP, ANCA, T-SPOT, ESR, and infectious markers were negative. Serum ACE was elevated at 93 U/L (normal 10–55 U/L).

Chest HRCT: Multiple nodules in both lungs and pleura, with bilateral hilar and mediastinal lymphadenopathy.

Skin Biopsy: Epidermal atrophy, dermal histiocytic granulomas, sparse perigranulomatous inflammation; acid-fast staining negative. Consistent with sarcoidosis.

Diagnosis: Systemic sarcoidosis (cutaneous, pulmonary, lymph node involvement)

- **Treatment**: Hydroxychloroquine 200 mg bid, prednisone 10 mg qd, topical halometasone and tacrolimus, plus calcium, potassium, and gastric protection.

Conclusion

We report a case of systemic sarcoidosis manifesting as widespread cutaneous plaques, lung nodules, and lymphadenopathy in a woman with eyebrow tattooing. Diagnosis relied on clinical, laboratory, radiologic, and histopathologic findings. Sarcoidosis must be differentiated from infectious and foreign body granulomas. Early combined systemic and topical therapy achieves good control.

EA DV CONGRESS
VIENNA
30 SEP - 3 OCT 2026

Abstract N°: 1972

A pruritic and misleading presentation of fibroelastolytic papulosis

Oumaima Sbai*[1]

[1] Hôpital universitaire internationale Cheikh khalifa, casablanca, Morocco

Introduction
Fibroelastolytic papulosis is a rare acquired disorder of elastic tissue, typically presenting as multiple non-follicular, asymptomatic, white-to-yellow papules on the neck of elderly patients. However, atypical presentations may occur and lead to diagnostic challenges.

Case Presentation
A 73-year-old woman with diabetes presented with a 3-year history of progressively pruritic papules on the neck. There was no relevant family history. Clinical examination revealed multiple firm, non-follicular, white-to-yellow papules measuring 2–4 mm, symmetrically distributed over the lateral cervical and supraclavicular areas (Figure 1A). Dermoscopy showed homogeneous whitish-yellow areas without specific vascular or follicular structures (Figures 1B). Differential diagnoses included follicular mucinosis, cutaneous amyloidosis, and xanthogranuloma. Histopathological examination demonstrated a marked reduction and fragmentation of elastic fibers in the papillary dermis without calcification, mucin deposition, or histiocytic infiltration (Figures 1C). Systemic evaluation was unremarkable. A diagnosis of fibroelastolytic papulosis was established. Topical corticosteroids led to improvement of pruritus.

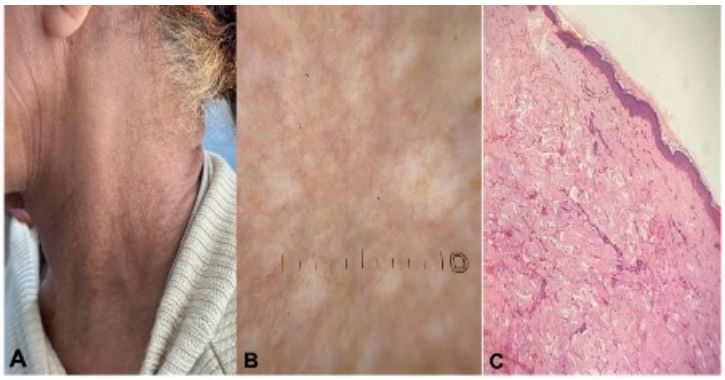

Figure 1: A. Clinical image showing multiple, non-follicular, white-to-yellow papules symmetrically distributed on the lateral neck. B. Dermoscopy revealing homogeneous whitish-yellow areas without specific vascular or pigmentary structures, consistent with dermal involvement. C. Histopathology (H&E) showing marked reduction and fragmentation of elastic fibers in the papillary dermis, without calcification or specific deposits.

Conclusion
Fibroelastolytic papulosis is a rare acquired disorder of elastic tissue, typically presenting as asymptomatic, non-

follicular papules on the neck of elderly individuals. However, atypical symptomatic forms have been rarely reported and may lead to diagnostic confusion. In our case, the presence of significant pruritus and the initial clinical suspicion of other infiltrative dermatoses highlight the misleading nature of this presentation. Dermoscopy, although non-specific, supported a dermal process, while histopathology remained essential for confirming the diagnosis by demonstrating loss and fragmentation of elastic fibers without associated deposits. This case underlines the importance of clinicopathological correlation in atypical presentations and raises awareness of pruritic variants of fibroelastolytic papulosis, which may be underrecognized in clinical practice.

EA DV CONGRESS
VIENNA
30 SEP - 3 OCT 2026

Abstract N°: 2025

Incidental finding of Cutaneous Amyloidosis : A Case Report

Hanane El Halla*[1], chaouche mohammed[1], Mortaji Zineb[1], ikram zouine[1], mhaimer soukaina[1], sokaina chhiti[1], Radia Chakiri[1]

[1] University hospital Mohammed 6, Agadir, Morocco

Introduction

Cutaneous amyloidosis represents a heterogeneous group of disorders characterized by the extracellular deposition of amyloid proteins within the skin, in the absence or presence of systemic involvement. It is traditionally classified into primary localized forms—such as macular, lichen, and nodular amyloidosis—and secondary forms associated with chronic inflammatory or neoplastic conditions. While localized cutaneous amyloidosis is generally considered benign and limited to the skin, its clinical presentation can be highly variable and occasionally misleading, posing a diagnostic challenge for clinicians.

Clinically, cutaneous amyloidosis most commonly manifests as pruritic, hyperpigmented macules or lichenoid papules, typically distributed on the trunk or extensor surfaces. However, atypical presentations have been reported, including dyschromic, atrophic, or purpuric variants, which may mimic other dermatological or systemic conditions. In particular, ecchymotic or bruise-like lesions are uncommon and may raise suspicion for vascular, hematological, or systemic amyloid disorders.

Dermoscopy and histopathological examination remain essential tools for diagnosis. The identification of amyloid deposits within the papillary dermis, highlighted by Congo red staining and characteristic birefringence under polarized light, confirms the diagnosis. Given the potential overlap with systemic amyloidosis, a thorough clinical and laboratory assessment is often warranted to exclude extracutaneous involvement.

We report a case of cutaneous amyloidosis incidentally discovered in a patient initially presenting with facial rosacea and extensive ecchymotic lesions, illustrating an unusual clinical presentation and emphasizing the importance of a comprehensive skin examination in dermatological practice.

Case Presentation

A 52-year-old woman with a history of hypertension, insulin-dependent diabetes mellitus for 5 years, a history of heart disease and nephropathy, presented with facial lesions evolving over one year, associated with a burning sensation after sun exposure and heat.

Clinical examination revealed a patient with Fitzpatrick skin phototype IV, presenting with erythematous patches over the cheeks, surmounted by telangiectasias. Dermoscopic examination showed diffuse erythema, telangiectasias, and the presence of *Demodex*, supporting the diagnosis of rosacea.

Further full-body examination disclosed extensive bluish patches involving the abdomen, thighs, and trunk, which did not blanch on diascopy, consistent with ecchymoses.

Cutaneous amyloidosis was suspected, and a skin biopsy was performed. Histopathological examination revealed mild chronic dermatitis associated with a subepidermal band suggestive of amyloid deposition. Congo red staining, examined under polarized light, demonstrated a subtle apple-green birefringence within the subepidermal band and in some perivascular dermal deposits, confirming the diagnosis of cutaneous amyloidosis.

A systemic evaluation for amyloidosis was initiated. The patient was treated with topical clobetasol propionate applied once daily, resulting in significant clinical improvement.

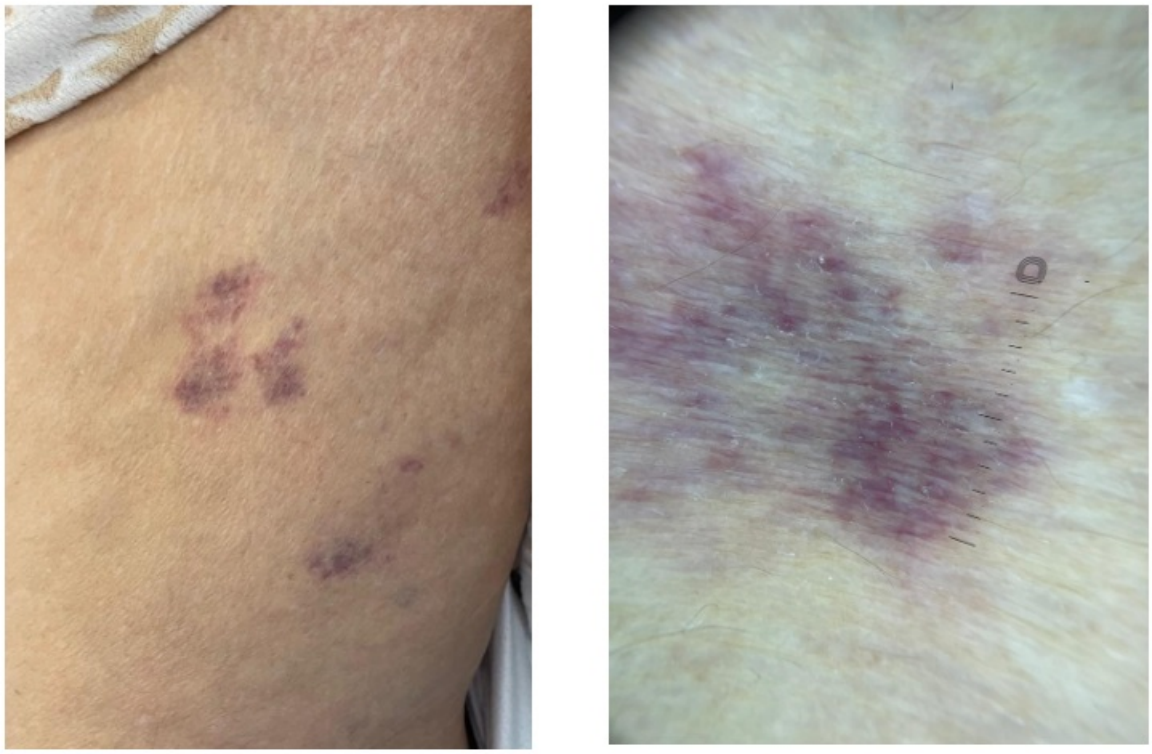

Clinical and dermoscopic images of the thigh lesions.

Conclusion

An atypical ecchymotic presentation of cutaneous amyloidosis may mimic other conditions, emphasizing the key role of clinicopathological correlation and systematic evaluation.

EADV CONGRESS
VIENNA
30 SEP - 3 OCT 2026

Abstract N°: 2040

Rapid Onset Followed by 8-Year Stability: Extensive Non-clustered Multiple Eruptive Dermatofibromas in an Apparently Immunocompetent Patient

Lu Gan*[1], Mengjie Zhao[1]

[1] Department of Dermatology, Zhongnan Hospital of Wuhan University, Wuhan, China

Introduction

Multiple eruptive dermatofibromas (MEDF) are rare and have been reported in diverse clinical and therapeutic settings, including autoimmune disease, HIV infection, hematologic malignancy or monoclonal gammopathy, pregnancy, and exposure to immunosuppressive, biologic, targeted, or antineoplastic therapies. Because underlying diseases and treatment exposures often coexist, we assessed systemic background and drug exposure together. Existing reports vary in terminology and in the reporting of eruption tempo, distribution pattern, systemic or therapeutic background, and follow-up. We reviewed MEDF-related literature and collected case-level data on non-clustered presentations, separating definite MEDF from chronic or tempo-indeterminate multiple dermatofibromas. Well-documented immunocompetent non-clustered MEDF with long-term stability appears uncommon.

Case Presentation

We report an otherwise healthy 41-year-old man who developed more than 60 disseminated, non-clustered papules and nodules within approximately one year, without segmental, linear, plaque-like, or clustered arrangement. Targeted systemic evaluation did not identify autoimmune disease, HIV infection, hematologic malignancy, monoclonal gammopathy, or relevant immunosuppressive, biologic, or antineoplastic exposure. Histopathologic examination of a representative back lesion showed a well-circumscribed hypocellular dermal lesion with prominent collagen hyalinization, mild epidermal acanthosis, and basal hyperpigmentation, without atypia, necrosis, increased mitotic activity, or subcutaneous infiltration. Immunohistochemistry was negative for CD34, S-100, α-SMA, and CD68 in lesional cells, helping exclude major spindle-cell, neural/melanocytic, and histiocytic-rich mimickers. The clinicopathologic findings were compatible with atrophic dermatofibroma. During 8 years of follow-up, the lesions remained stable, with no substantial increase in number and no systemic disease identified.

Conclusion

This case shows that non-clustered MEDF may rarely occur in an apparently immunocompetent patient and remain stable for many years after a rapid eruptive phase. Adult-onset non-clustered MEDF should prompt systemic evaluation, but rapid eruption does not necessarily indicate a continuously progressive disorder. MEDF should be reserved for cases with documented eruptive onset, adequate lesion number, and non-clustered distribution; slowly progressive or tempo-unclear cases are better described as multiple dermatofibromas.

POWERED BY M-ANAGE.COM

EA DV CONGRESS
VIENNA
30 SEP - 3 OCT 2026

Abstract N°: 2049

Clinicopathological Concordance Between Clinical and Histopathological Diagnoses in Skin Disorders: A Retrospective Study

Vatanyu Utamachant[1], Pat Pongwattanasuk[1], Phattarapol Watjumnong[1], Naruemon Tridangnoi[1], Songkran Kheawlek[1], Prateep Warnnissorn[2], Sakchai Chaiyamahapurk*[3], Chaiyaporn Virochsangaroon[4]

[1] Medical student, Faculty of Medicine, Naresuan university, Phitsanulok, Thailand
[2] Department of Medicine, Faculty of Medicine, Naresuan university, Phitsanulok, Thailand
[3] Department of Community Medicine, Naresuan university, Phitsanulok, Thailand
[4] Department of Pathology, Faculty of Medicine, Naresuan university, Phitsanulok, Thailand

Introduction
Skin biopsy is a key diagnostic tool for differentiating complex dermatological conditions. Evaluating clinicopathological concordance provides insight into the diagnostic performance of both clinicians and pathologists. Such evaluation can inform improvements in diagnostic strategies and optimize patient care in dermatology.

Materials and Methods
This retrospective cross-sectional study included patients with dermatological conditions who underwent skin biopsy at a university hospital between January 1, 2020, and August 31, 2024. Biopsies were performed by dermatologists and interpreted by pathologists. Clinicopathological agreement was categorized into four groups: (1) definite pathological diagnosis concordant with clinical diagnosis, (2) descriptive pathological diagnosis concordant with clinical diagnosis, (3) definite pathological diagnosis discordant with clinical diagnosis, and (4) descriptive pathological diagnosis discordant with clinical diagnosis. Descriptive statistical analyses were performed to assess agreement and associated factors.

Results
A total of 515 biopsy samples were analyzed. The most common clinical indications for biopsy were vasculitis/vasculopathy (13.2%), vesiculobullous diseases (11.1%), and connective tissue diseases (10.3%). The most frequent pathological diagnoses were non-specific descriptive diagnosis (12.6%), spongiotic dermatitis (8.74%), interface dermatitis (8.5%), and benign epithelial tumors (8.5%).

Overall clinicopathological concordance was 64.27%, comprising 48.35% definite agreement and 15.92% descriptive agreement. Discordance was observed in 34.17% of cases, including 11.26% definite disagreement and 22.91% descriptive disagreement. In 1.55% of cases, specimens were inadequate or lacked a clinical diagnosis.

Among 15 clinical diagnostic categories, malignant epithelial tumors, benign epithelial tumors, intraepidermal blistering diseases, and cysts showed high concordance, whereas eczema and connective tissue diseases demonstrated lower agreement.

Conclusions
Moderate clinicopathological concordance was observed, comparable to previous studies. Agreement may be

influenced by clinician expertise, disease category, and biopsy utilization patterns. Skin biopsy may have limited diagnostic value in certain conditions, such as eczema, where histopathological findings are often non-specific.

EADV CONGRESS
VIENNA
30 SEP - 3 OCT 2026

Abstract N°: 2129

Chronic annular erythematous plaques revealing isolated cutaneous sarcoidosis

ikrame bejja*[1], Sara Elloudi[1], Saadia Boughaleb[1], Zakia Douhi[1], Meryem Soughi[1], hanane baybay[1], Fatima Zohra Mernissi[1]

[1] department of dermatology, University Hospital Center Hassan II, fez, Morocco

Introduction

Cutaneous sarcoidosis is a granulomatous inflammatory disease with heterogeneous clinical manifestations, often mimicking other dermatological conditions. Annular presentations are uncommon and may lead to diagnostic difficulties, particularly in the absence of systemic involvement. Histopathological examination remains essential for diagnosis, supported by clinicodermoscopic features.

Case Presentation

A 75-year-old patient with no significant medical history was referred for diffuse, asymptomatic erythematous skin lesions evolving for approximately 10 years. Clinical examination revealed multiple annular plaques with erythematous to orange-colored borders, mildly scaly and infiltrated, with central areas of normal skin. On vitropressure, the lesions showed a lipoid (apple-jelly) appearance. There were no sensory disturbances, sudomotor abnormalities, hair loss, or peripheral nerve hypertrophy. Polarized dermoscopy revealed an erythematous background with yellow-orange areas and telangiectasias. Differential diagnoses included annular sarcoidosis, generalized granuloma annulare, granulomatous mycosis fungoides, subacute annular cutaneous lupus erythematosus, and lepromatous leprosy. Skin biopsy demonstrated an atrophic epidermis without interface changes and multiple well-formed, non-caseating granulomas in the superficial and deep dermis, surrounded by a sparse lymphocytic infiltrate, consistent with cutaneous sarcoidosis. Systemic evaluation showed no extracutaneous involvement. Treatment with hydroxychloroquine led to a favorable clinical outcome.

Conclusion

Annular cutaneous sarcoidosis is a rare clinical variant that may closely resemble other granulomatous or inflammatory dermatoses, making diagnosis challenging. Non-invasive findings such as apple-jelly appearance on vitropressure and yellow-orange areas on dermoscopy can suggest a granulomatous disorder but are not specific. Histopathology remains the cornerstone of diagnosis, and systematic assessment is required to exclude systemic involvement. Antimalarial therapy represents an effective and well-tolerated treatment option in isolated cutaneous sarcoidosis.

EA DV CONGRESS
VIENNA
30 SEP - 3 OCT 2026

Abstract N°: 2191

Angiolymphoid Hyperplasia with Eosinophilia (ALHE): A Challenging Case of Recurrent Parotid and Auricular Involvement Managed Conservatively

Sabina Tăpălagă*[1], Alexia Roberta Baia[1], Tania Maria Prainer[1], Tudor-Alex Rus[1], Maria Mirabela Fratila[2], Lavinia-Manuela Lenghel[3], Carmen Georgiu[4], Simona Corina Senila[5]

[1] University of Medicine and Pharmacy "Iuliu Haţieganu", General Medicine, Cluj-Napoca, Romania

[2] Cluj County Emergency Clinical Hospital, Department of Dermatology, Cluj-Napoca, Romania

[3] University of Medicine and Pharmacy "Iuliu Haţieganu", Radiology and Imaging, Cluj-Napoca, Romania

[4] University of Medicine and Pharmacy "Iuliu Haţieganu", Pathological Anatomy, Cluj-Napoca, Romania

[5] University of Medicine and Pharmacy "Iuliu Haţieganu", Department of Dermatology, Cluj-Napoca, Romania

Introduction

Angiolymphoid hyperplasia with eosinophilia (ALHE) is a rare, benign, vasculo-proliferative disorder of unknown etiology. Characterized by erythematous papules or nodules, it typically manifests in the head and neck region. Pathogenetically, it represents a reactive process involving CD4+ lymphoproliferation and vascular neoplasia, potentially triggered by hormonal imbalances like hyperestrogenism. Elevated estrogen and progesterone levels during pregnancy stimulate angiogenesis through VEGF and bFGF, while also promoting a Th2-polarized immune response, which favors the development of characteristic eosinophil-rich infiltrates.

Case Presentation

This case highlights an atypical parotid and lymph node involvement, its correlation with multiple pregnancies, and the differential diagnosis from Kimura disease and pyogenic granuloma.

A 30-year-old multiparous female (7 pregnancies) presented with papulo-nodular lesions on the left auricle, pre- and retro-auricular regions, accompanied by conductive hearing loss. Lesions debuted in 2017 during the third trimester of her first pregnancy, initially showing spontaneous remission, followed by progression (previous biopsies and CO2 laser vaporizations performed in 2021 and 2022).

Dermoscopy, cutaneous, and lymph node ultrasound revealed well-defined, hypo-echoic, hyper-vascular nodules (up to 9.4 x 8.1 mm) and reactive regional lymph nodes, including intraparotid (21/11 mm). Head and neck contrast-enhanced CT showed diffuse nodular thickening of the external auditory canal (EAC) soft tissues, causing near-complete stenosis, and an enlarged, heterogeneous parotid gland with multiple iodophilic conglomerate nodules (largest 21 x 13 mm) (Fig. 1A, B).

Histopathology identified dilated, non-muscular vascular spaces with "hobnail" endothelial cells and a lymphoplasmacytic and eosinophilic infiltrate (Fig. 1C-E). The diagnosis of ALHE was established by these pathognomonic features ,while Kimura disease was definitively excluded by the absence of follicular hyperplasia with germinal centers and eosinophilic microabscesses. Furthermore, systemic workup confirmed the absence of peripheral eosinophilia, elevated serum IgE, or signs of renal involvement.

Immunohistochemistry was negative for HHV-8, CK, and S100 (excluding Kaposi sarcoma, carcinoma, and melanoma) and positive for ERG, CD31, CD34, and D2-40 (Fig. 1F-H). A low Ki67 index supported the benign nature of the lesion. Following diagnosis, the patient was initiated on topical Tacrolimus and systemic Propranolol (40 mg/day). Significant clinical improvement was observed at 6 months. This therapeutic approach was selected to avoid high-risk surgery and to manage the patient's reproductive profile; for future pregnancies, the protocol includes

multidisciplinary monitoring for potential beta-blocker associated risks.

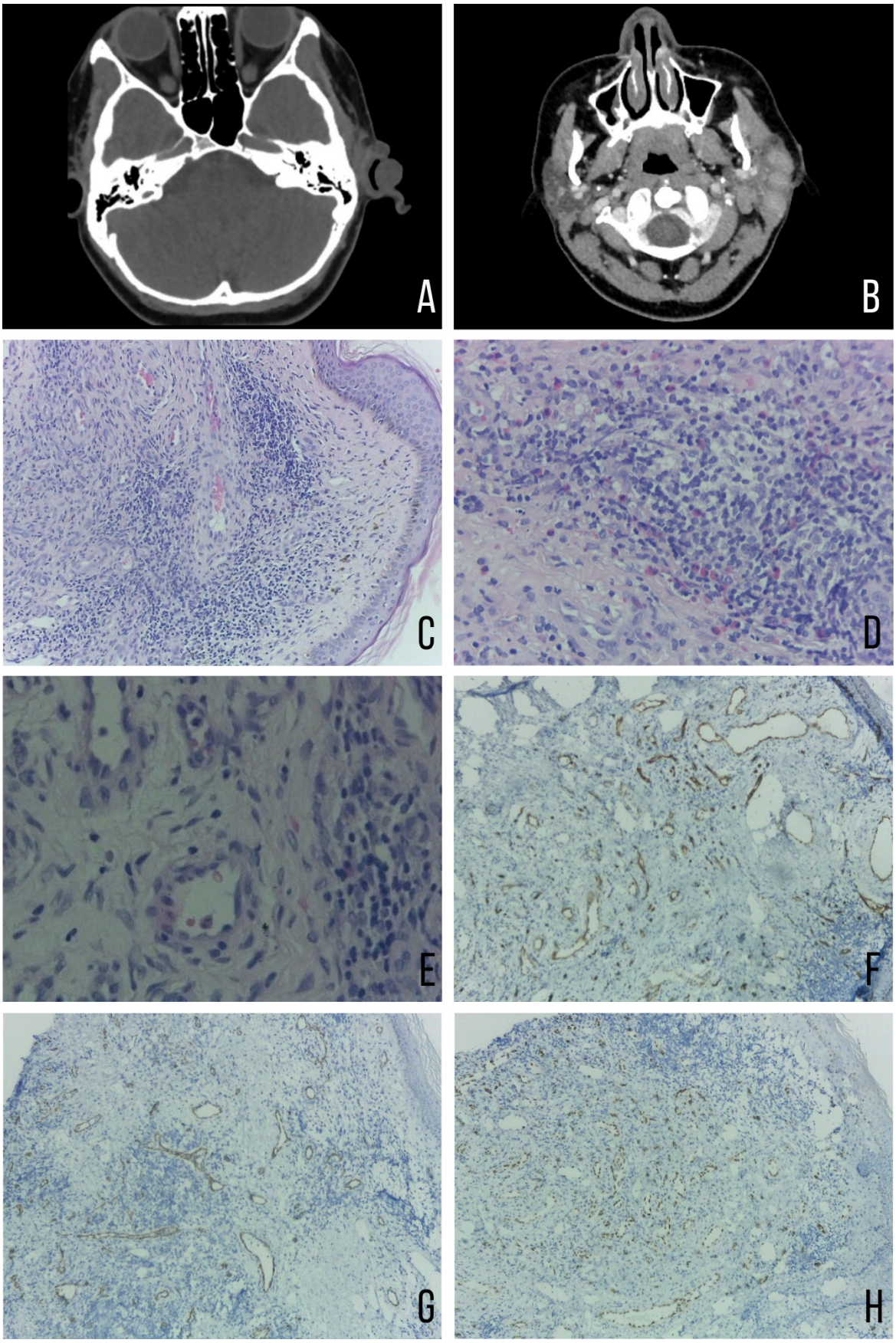

Figure 1. Radiologic, histopathological, and immunohistochemical features of the case. • A-B: CT scan shows a heterogeneous and enlarged parotid gland due to the presence of multiple iodophilic, conglomerate nodular formations in both the superficial and deep portions, the largest measuring 21/13 mm. C-E: Histopathological examination (Hematoxylin-Eosin staining) reveals vascular

proliferation with dilated vessels, lacking a muscular layer, lined by prominent "hobnail" endothelial cells. This is accompanied by a dense inflammatory infiltrate rich in lymphocytes and eosinophils, a pathognomonic finding for the diagnosis of ALHE. F-H: Immunohistochemical analysis demonstrates strong expression of CD31 (F) and CD34 (G) in endothelial cells, while ERG nuclear staining (H) further confirms their endothelial identity, validating the vascular origin of the proliferation.

Conclusion

We report a rare case of ALHE with parotid and lymph node involvement, suggesting a potential correlation with hormonal changes during pregnancy. This case reinforces the necessity of excluding clinical mimics through rigorous histopathology and demonstrates the efficacy of systemic propranolol in managing recurrent lesions, highlighting the importance of interdisciplinary collaboration.

EA DV CONGRESS
VIENNA
30 SEP - 3 OCT 2026

Abstract N°: 2240

Erythema Elevatum Diutinum and Ankylosing Spondylitis

Mansouri Rayane*[1], kaghouche lilia[1], Safa Djebbas[1], Amel Gherfi[1], esma bouhila[1], khadidja bouarroudj[1], Tarek Mansoul[1], RIADH BOUSSAID[1], Ahmed Samaouel Chehad[1]

[1] Department of Dermatology, CHU Benbadis, Constantine, Algeria, constantine, Algeria

Introduction
Erythema elevatum diutinum (EED) is a rare chronic neutrophilic dermatosis, often associated with systemic diseases.
The association between EED and ankylosing spondylitis (SpA) is exceptional and rarely reported.
We report a case illustrating this association.

Case Presentation
A 48-year-old patient with a history of SpA presented with multiple painful, red-violet nodules symmetrically located on the knees for several months.
Histological examination revealed a preserved epidermal architecture with underlying dermal collagen fibrosis infiltrated by aggregates of neutrophils, with perivascular and peri-adnexal accentuation.
Based on clinical and histopathological findings, the diagnosis of EED was established.
Treatment with colchicine at a dose of 1 mg/day was initiated, leading to a reduction in infiltration and number of lesions after two months.

Conclusion
Discussion
EED is a rare chronic neutrophilic dermatosis, classically considered a persistent form of leukocytoclastic small-vessel vasculitis.
It typically presents as erythematous-violaceous papules, plaques, or nodules with acral and periarticular predominance, evolving chronically.
Histology is characteristic, showing a perivascular and peri-adnexal neutrophilic infiltrate, progressive dermal fibrosis, and absence of granulomas, as observed in our patient.
EED is frequently associated with systemic diseases, suggesting an underlying immunological mechanism involving persistent neutrophil activation and immune complex deposition in small cutaneous vessels.
In this context, the association with SpA remains exceptional but physiopathologically plausible.
SpA is a chronic inflammatory disease characterized by systemic immune activation, with a central role of the IL-23/IL-17 axis and neutrophils in inflammation.
This chronic inflammation may promote the development of neutrophilic dermatoses such as EED, explaining this rare association.
Therapeutically, there is no consensus due to the rarity of EED. Dapsone is traditionally considered the treatment of choice; however, colchicine represents an effective and well-tolerated alternative, particularly in patients with contraindications or associated inflammatory conditions.
In our case, colchicine at 1 mg/day resulted in marked clinical improvement within two months.

Conclusion

EED is a rare chronic neutrophilic dermatosis requiring careful clinicopathological correlation for diagnosis.
Its association with SpA is exceptional but physiopathologically plausible.

EADV CONGRESS
VIENNA
30 SEP - 3 OCT 2026

Abstract N°: 2338

Adult multiple xanthogranulomas: diagnostic value of the dermoscopic ‘setting sun’ sign

salma larabi*[1]

[1] Department of dermatology, Ibn Sina University Hospital ,Rabat , Morocco, rabat, Morocco

Introduction

Xanthogranuloma is a benign non-Langerhans cell histiocytosis that predominantly occurs in children. Its occurrence in adults is rare, and multiple forms are even more uncommon, often posing a diagnostic challenge. We report a case of multiple adult xanthogranulomas in which dermoscopy played a key role in diagnostic orientation.

Case Presentation

A 64-year-old woman, with a medical history of type 2 diabetes treated with oral hypoglycemic agents and prior cholecystectomy, presented with pruritic cutaneous lesions evolving over approximately one year.

Clinical examination revealed multiple papulo-nodular lesions predominantly on the face, ranging from skin-colored to yellowish. Xanthelasma-like deposits were observed, particularly on the eyelids. The main differential diagnoses included xanthomatosis, histiocytosis, and infiltrative dermatoses.

Dermoscopy revealed the characteristic “setting sun” sign, consisting of a homogeneous yellow-orange central area surrounded by an erythematous halo, with sparse, nonspecific vascular structures, suggestive of non-Langerhans cell histiocytosis.

Histopathological examination demonstrated a dermal infiltrate composed of foamy histiocytes and Touton giant cells, without evidence of collagen necrobiosis or cholesterol clefts, thereby excluding necrobiotic xanthogranuloma.

Based on the correlation of clinical, dermoscopic, and histological findings, the diagnosis of multiple adult xanthogranulomas was established.

An etiological workup, including serum protein electrophoresis, was unremarkable. Ophthalmologic examination showed no evidence of extracutaneous involvement.

Given the multiplicity of lesions and their cosmetic impact, surgical excision of selected lesions was performed, resulting in satisfactory aesthetic improvement. No systemic therapy was indicated.

Conclusion

Multiple adult xanthogranulomas are a rare entity and may represent a diagnostic pitfall. Recognition of the dermoscopic “setting sun” sign is a key feature that allows early orientation toward non-Langerhans cell histiocytosis and helps avoid unnecessary investigations.

Management is not standardized and depends on the extent and impact of the lesions: observation is often sufficient, while localized treatments such as surgical excision may be considered for cosmetically or functionally

bothersome lesions, as illustrated in our case. The dermoscopic “setting sun” sign is a valuable clue for the diagnosis of adult multiple xanthogranulomas and helps distinguish them from other xanthomatous or infiltrative dermatoses.

EA DV CONGRESS
VIENNA
30 SEP - 3 OCT 2026

Abstract N°: 2407

Cutaneous Leiomyoma : an uncommon benign tumor

Chaima Ezzaki*[1], chaouche mohammed[1], Imane Mouabbir[1], mhaimer soukaina[1], sokaina chhiti[1], Radia Chakiri[1]

[1] Department of Dermatology, Faculty of Medicine and Pharmacy, Ibn Zohr University, Agadir, Morocco, agadir, Morocco

Introduction

Leiomyomas are benign tumors arising from smooth muscle. They can arise at any organ, the most common location is the uterus, other locations include the skin and the gastrointestinal tract.

Cutaneous leiomyoma is rare benign tumor of the dermis or subcutis. It may occasionally be present in the extremities and cause pain secondary to mass effect. It can develop sporadically or present as part of an autosomal dominant genetic syndrome. Clinically, it is often underrecognized due to its rarity; therefore, accurate diagnosis relies on histopathological examination.

Case Presentation

We report the case of a 31-year-old woman with no significant past medical history and no history of repetitive physical strain, who presented to the dermatology department with a small, painful, non-pruritic lesion evolving over 3 months on the dorsum of the left foot.

Clinical examination revealed a small, well-circumscribed, rounded, firm nodule that was highly tender on palpation, with no overlying inflammatory signs and fixed to the deep plane.

Ultrasound imaging demonstrated a subcutaneous cystic-appearing lesion, avascular on Doppler study, exerting a mass effect on a collateral vein.

An excisional biopsy was performed. Histopathological examination showed a well-circumscribed benign mesenchymal proliferation composed of interlacing bundles of elongated smooth muscle cells with elongated, cigar-shaped nuclei, consistent with a subcutaneous leiomyoma.

At the two-week post-excision follow-up, the surgical site showed good healing, with no evidence of infection, erythema, or discharge, and no residual nodule detected.

Conclusion

Cutaneous leiomyomas are rare, benign, smooth muscle tumors, that was initially described by Virchow in 1854. It account for approximately 3,8% of all soft tissue tumors.

According to the smooth muscle origin, cutaneous leiomyomas are classified into three subtypes ; angioleiomyomas, piloleiomyomas and genital leiomyomas. Angioleiomyoma is the most common type, it arises from the tunica media of venous blood vessels, it affects patients between the fourth and sixth decades of life in approximately two-thirds of cases, with a female predominance of about 2 :1. Piloleiomyoma arise from the arrector pili muscle of the hair follicle, it tend to occur more frequently in adults than children, with no apparent predilection for any particular race. Genital leiomyoma arise from the smooth muscle found in the scrotum, labia, or the nipple.

Cutaneous leiomyoma may be solitary or multiple. Typically, it presents as firm and painful dermal nodule, ranging from 2mm to 20mm in size, and may appear skin-colored, pink, or red-brown. The pain may arise spontaneously or be triggered by factors such as pressure, cold exposure, emotional stress, or light touch. The extremities, trunk, and laterofacial and laterocervical regions are the most commonly affected sites. The presence of multiple

cutaneous leiomyomas may be part of a rare autosomal dominant hereditary syndrome ; hereditary leiomyomatosis and renal cell carcinoma also known as Reed syndrome, which predisposes patients to an increased risk of renal malignancy.

Biopsy allows confirmation of the diagnosis. Histopathology shows bundles and fascicles of well-differentiated smooth muscle cells, characterized by eosinophilic cytoplasm, cigar-shaped nuclei, and an abundant extracellular matrix. Immunohistochemical staining for caldesmon, a smooth muscle–specific marker, supports the diagnosis of leiomyoma. The gold standard treatment is surgical excision ; however, there is a significant risk of local reccurence. Pharmacological therapy such as nitroglycerin and doxazosin may be indicated for patients with extensive widespread leiomyomas.

EA DV CONGRESS
VIENNA
30 SEP - 3 OCT 2026

Abstract N°: 2413

A Case of Forehead Linear Atrophoderma of Moulin Mimicking Linear Morphea

Shu Hui Leow*[1], Cheryl Ann Ma[1], Kong Bing Tan[2], Adeline Yong[1]

[1] Department of Dermatology, National University Hospital, Singapore, Singapore

[2] Department of Pathology, National University Hospital, Singapore, Singapore

Introduction

Linear atrophoderma of Moulin (LAM) is a rare condition characterized by unilateral hyperpigmented, depressed band-like skin lesions following Blaschko's lines, with under 40 cases described in the literature to date. Cases reported typically present during childhood or adolescence and mainly affects the trunk or limbs. Facial involvement and presentation in elderly patients are rare. Here we describe a case of linear atrophoderma in a 64-year-old Chinese female.

Case Presentation

A 64-year-old woman presented with a linear indentation on the forehead close to the hairline for 5 months, without underlying induration. There was no history of trauma, pain, redness, itch or any family history of a similar condition. There were no extracutaneous symptoms or neurological symptoms, nor similar lesions on the rest of her body. Histology revealed mild dermal oedema with mild focal increase in small blood vessels, reduced dermis thickness, and no increased dermal mucin or thickened dermal collagen (Figure 1). There was no significant inflammatory infiltrate, and the epidermis appeared normal (Figure 1). A diagnosis of LAM was made based on a normal epidermis and collagen, lack of evidence of inflammation, and reduced dermal thickness.

LAM is a rare disorder with few reports published in dermatologic literature. Cases described typically arise in childhood or adolescence and primarily affect the trunk and limbs. Lesions follow the lines of Blaschko and develop over a finite period, after which they neither progress nor remit, although new lesions may develop. They are benign and do not result in disability or systemic morbidity.

This case represents an unusual presentation of LAM in multiple aspects, such as the advanced age at presentation, and forehead involvement. The diagnosis was established based on characteristic clinical features of linear atrophy following Blaschko's lines, absence of preceding inflammation or induration, and supportive histopathological findings. The differential diagnosis included linear morphea (en coup de sabre variant), linear lupus erythematosus, and atrophoderma of Pasini and Pierini. Linear morphea was excluded in view of the absence of sclerosis, clinical progression, deep tissue involvement, and systemic or extracutaneous involvement. Lupus erythematosus was excluded in view of lack of inflammatory infiltrate and dermal mucin, as well as normal direct immunofluorescence.

The aetiology of LAM is still not known. It has been postulated to be caused by a somatic mutation that takes place early in embryogenesis, resulting in a genotypic and phenotypic mosaicism similar to other dermatoses following Blashkoid lines, although no causative gene has been identified to date. Given its rarity, there is inadequate evidence in the literature to suggest any effective treatment, with topical steroids and high dose benzylpenicillin reported to be ineffective, although in case reports there has been partial response to calcipotriol, methotrexate, and intralesional platelet-rich plasma injections. In this case, the patient declined treatment as she was not bothered by the appearance and was otherwise asymptomatic.

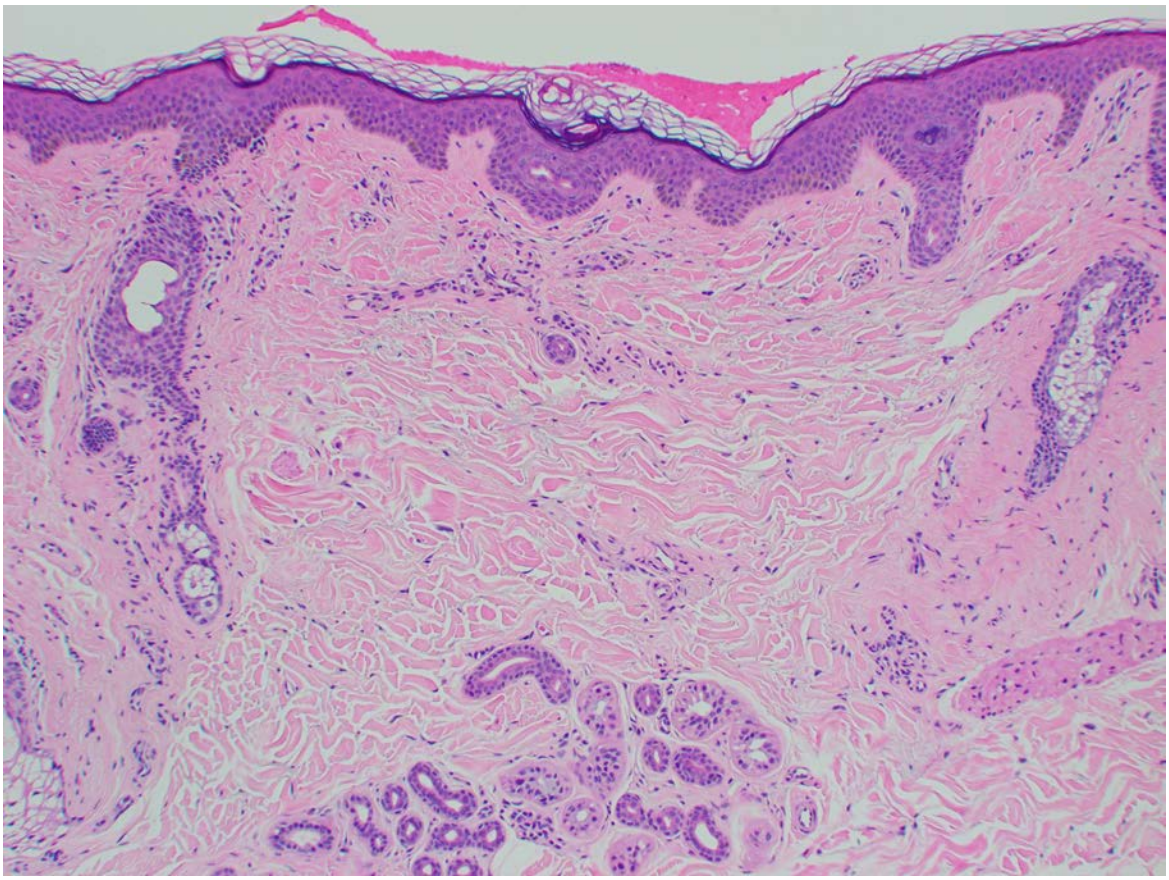

Figure 1 – Haematoxylin and Eosin stain x100 magnification with eccrine grands situated superficially, demonstrating reduced dermal thickness, normal epidermis and no inflammatory infiltrate.

Conclusion

This case expands the clinical spectrum of LAM to include elderly patients and facial involvement, and as a differential diagnosis of linear morphea. LAM may be suspected in linear atrophic lesions following Blaschko's lines, even in atypical age groups and anatomic locations.

EADV CONGRESS
VIENNA
30 SEP - 3 OCT 2026

Abstract N°: 2425

Adult-onset Truncal Inflammatory Linear Verrucous Epidermal Naevus Presenting in a Male Patient

Kate Price*[1], Danning Li[1], Ali Alsaeed[1], Ilona Blee[1], Amy Barrett[1], Louise Zuzarte[1], Domenico Mesiano[1], Bruce Gee[1]

[1] South Warwickshire NHS Foundation Trust, Warwick, United Kingdom

Introduction

Inflammatory linear verrucous epidermal naevus (ILVEN) is a rare subtype of epidermal naevus, typically presenting during early childhood as pruritic linear papules and plaques following the lines of Blaschko. There is a female predominance, with lesions most commonly affecting the lower extremities. Adult-onset truncal presentations in male patients are rare and may pose a diagnostic challenge because of overlap with other linear inflammatory dermatoses.

Case Presentation

A 25-year-old man with a background of ulcerative colitis was referred with an 18-month history of a persistent asymptomatic rash affecting the right anterolateral chest wall. Previous treatment with topical corticosteroids, emollients and miconazole/hydrocortisone cream had been ineffective. There was no personal or family history of skin disease.

Dermatological examination demonstrated a linear erythematous slightly scaly plaque extending from the right inframammary region to the right lateral chest wall in a blaschkoid distribution. No other significant cutaneous abnormalities were identified. Differential diagnoses initially considered included epidermal naevus, Hailey-Hailey disease and erythrasma.

Investigations included fungal microscopy and culture from skin scrapings, which were negative. A 4 mm punch biopsy was performed and demonstrated mild epidermal hyperplasia, papillomatosis, focal hypergranulosis within areas of orthokeratosis and a mild superficial perivascular lymphocytic infiltrate with occasional eosinophils. No acantholysis was identified on multiple deeper levels and periodic acid–Schiff staining was negative for fungal organisms. Histopathological review at a dermatopathology meeting supported a diagnosis of inflammatory linear verrucous epidermal naevus.

In view of the asymptomatic nature and stability of the eruption, the patient declined topical treatment with calcipotriol/betamethasone foam and was discharged from follow-up.

Conclusion

This case highlights a rare adult-onset truncal presentation of ILVEN in a male patient, contrasting with the typical childhood presentation and lower limb predominance described in the literature. ILVEN should be considered in the differential diagnosis of persistent linear blaschkoid eruptions in adults, particularly when histopathology demonstrates alternating orthokeratosis with hypergranulosis and parakeratosis with hypogranulosis. Management of ILVEN remains challenging, with variable responses reported to topical corticosteroids, vitamin D analogues, retinoids, cryotherapy, laser therapy and surgical excision.

EA DV CONGRESS
VIENNA
30 SEP - 3 OCT 2026

Abstract N°: 2463

Atrophoderma of Pasini and Pierini in a Bulgarian patient: unique (first) case of disease progression after infection with Covid-19

Simona Kordeva*[1], Valentina Broshtilova-Nikolova[2], Konstantin Tchernev Jr[3], Georgi Tchernev[1, 3]

[1] Medical Institute of Ministry of Interior - Department of Dermatology and Venereology, Sofia, Bulgaria
[2] Sofia University Saint Kliment Ohridski, Faculty of Medicine - Department of Internal Diseases, Pharmacology and Clinical Pharmacology, Pediatrics, Epidemiology, Infectious Diseases, and Skin Diseases, Sofia, Bulgaria
[3] Onkoderma- Clinic for Dermatology, Venereology and Dermatologic Surgery, Sofia, Bulgaria

Introduction

Atrophoderma of Pasini and Pierini is a rare, considered benign, skin disease characterized by single or multiple asymptomatic atrophic plaques. The lesions can occur everywhere on the body with the trunk being the most often reported affected site. It appears in the second or third decade of life and affects mostly the female population, with male to female ratio of 1:6, commonly of white European descent.

Different risk factors were described in the literature – genetic predisposition, infections with Epstein-Barr virus, varicella zoster and Borrelia burgdorferi, vaccinations, local trauma and more. Since the pandemic with COVID-19, skin manifestations after the viral infection with COVID-19 were reported. After a thorough search of the existing medical literature, we believe, we present the first case of a rapid progression of Atrophoderma of Pasini and Pierini after COVID-19 infection.

Due to its similarity to morphea in some aspects, the condition is often misdiagnosed and the proper treatment is delayed. Sometimes the dilemma “Is it atrophoderma Pasini-Pierini or is it in fact morphea?” stays, but the histopathological verification and the “diagnostic clues” which can be used during the examination stage, are usually enough to diagnose the condition.

Materials and Methods

We present a 63-year-old female with a rapid progression of atrophoderma of Pasini and Pierini (Figure 1a,b) after a COVID-19 infection. The lesion that she presented with was single, asymptomatic, with central hypopigmentation and slight atrophy, with a smooth, shiny surface and ivory color, and peripheral hyperpigmentation, measured 18x5cm, without the presence of erythema. The patient was initially diagnosed with localized scleroderma and treated with hydroxychloroquine 200 mg once daily for a 5 year period without improvement. IgM and IgG serology for Borrelia Burgdorferi was negative.

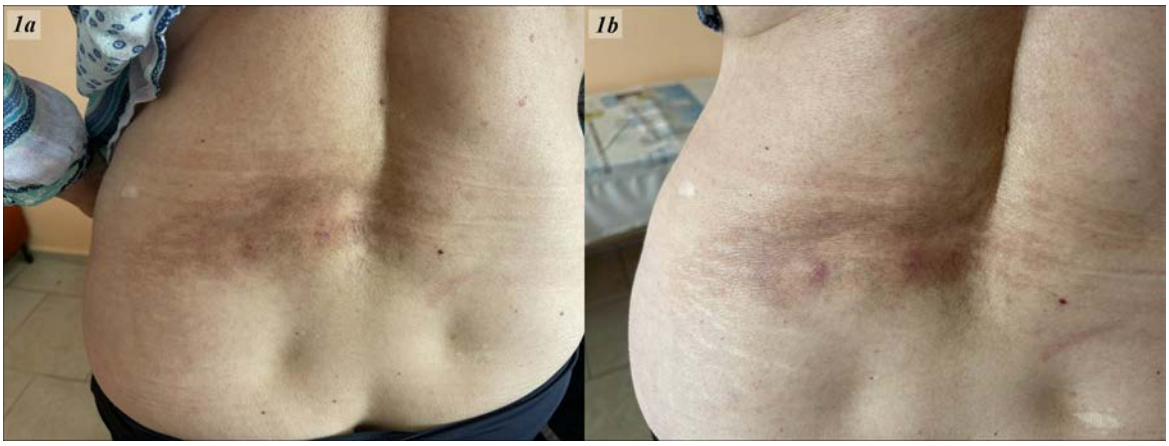

Fig.1a,b: A single, clearly demarcated from the surrounding skin, elliptical-striped plaque with 18 cm x 5 cm in size, central - with hypopigmentation and slight atrophy, with a smooth, shiny surface and ivory color, and peripheral hyperpigmentation, located in the left lumbar region.

Results

Two biopsies from different lesional sites were taken, resulting in absence of sclerosis and dermal atrophy with hyalinized, horizontally-oriented collagen bundles, confirming the diagnosis of atrophoderma Pasini-Pierini (Figure 2a,b). The patient's therapy was switched to methotrexate 2.5 mg 3x2 tablets at 12 o'clock every Thursday and folic acid 5 mg once weekly every Monday. Regular control follow-ups were recommended in order to supervise the disease and manage the dose regimen of the medications.

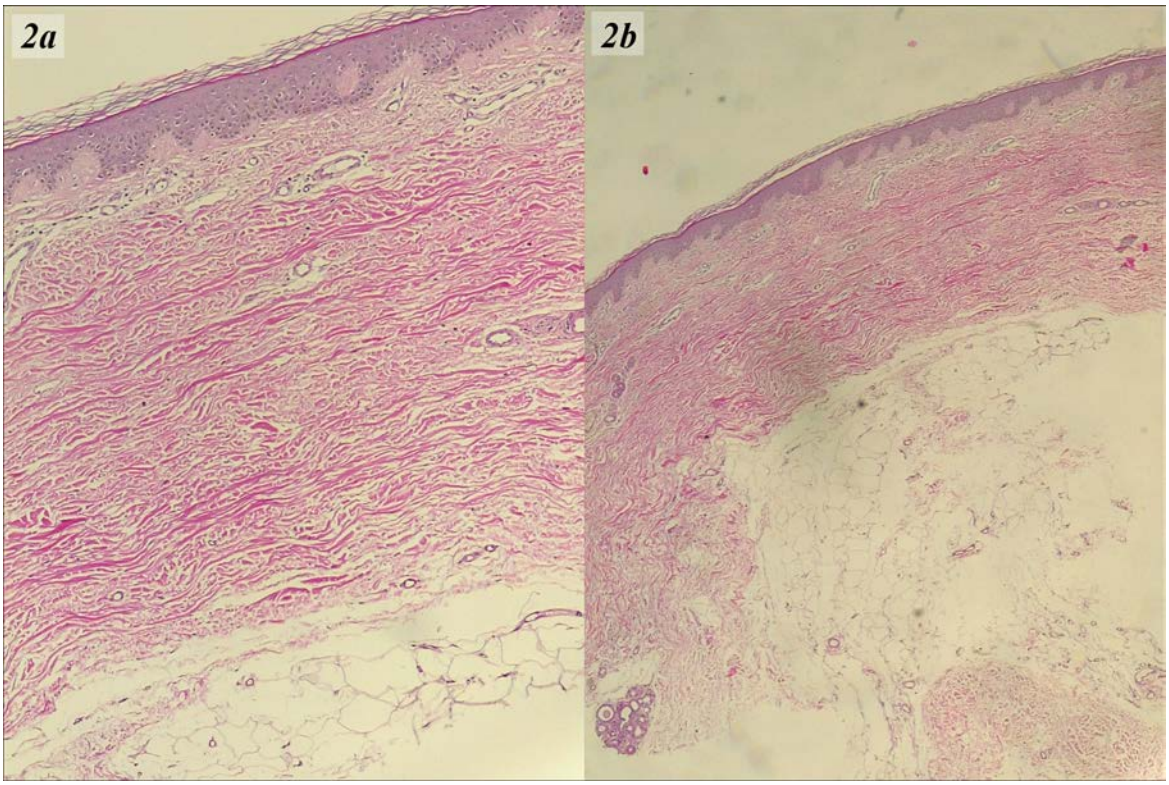

Fig.2a,b: Marked hyperkeratosis of "woven basket" type, intact epidermis, reduction in the thickness of the dermis with fragmentation and hyalinization of collagen fibers forming a parallel orientation, dilated vascular vessels of small caliber and reduced number of skin appendages 2a: Atrophic dermis with hyalinized collagen bundles and dilated small-to-medium sized vessels x HE x 100 2b: Dermal atrophy with hyalinized, horizontally-oriented collagen bundles x HE x 40

Conclusions

Often, the two conditions – morphea and atrophoderma of Pasini and Pierini can be mistaken due to its clinical similarity and sometimes coexistence.

Several key points in the case report were crucial for the diagnosis of atrophoderma of Pasini and Pierini:

- The patient presented with a single asymptomatic plaque characterized by central hypopigmentation and slight atrophy, with a smooth, shiny surface and ivory color, and peripheral hyperpigmentation.
- Surrounding inflammation in the form of erythema was not observed, unlike in morphea lesions. However, the absence of inflammation in our histology might be due to the years of local therapy with clobetasol propionate and immunosuppressive systemic therapy with hydroxychloroquine.
- Absence of sclerosis and dermal atrophy with hyalinized, horizontally-oriented collagen bundles, which are specific for atrophoderma of Pasini and Pierini.

It is important to differentiate the disease since the therapeutic approach may be different even for similar skin conditions.

EA DV CONGRESS
VIENNA
30 SEP - 3 OCT 2026

Abstract N°: 2489

A rare pigmented apocrine hidrocystoma of the scalp mimicking cutaneous malignancy

Irfana Pharveen*[1], Callum Verran[1], Nastassia Nardini[1], Erin Kamp[1]

[1] University Hospitals Sussex NHS Trust, UK, Brighton, United Kingdom

Introduction

Hidrocystomas are rare benign dermal cysts of eccrine or apocrine origin, typically arising in adults aged 30–70 years. They usually present as solitary or multiple lesions affecting the head and neck, while scalp involvement is uncommon. Although classically translucent, pigmented variants are rare. Pigmentation is thought to reflect lipofuscin or its oxidative derivatives, with the Tyndall effect contributing to the characteristic hue. We report a case of a pigmented apocrine hidrocystoma of the scalp in an elderly woman.

Case Presentation

An 84-year-old woman with Fitzpatrick skin type II was referred via the urgent skin cancer pathway with an enlarging pigmented lesion on the mid-scalp. The lesion had been present for over 30 years but had recently enlarged following minor trauma and initially bled. Examination demonstrated a 1.5-cm bluish-red crusted plaque with prominent vessels, raising suspicion for pigmented basal cell carcinoma or melanoma.

Histopathological examination demonstrated a dermal and subcutaneous cystic lesion lined by a double layer of epithelial cells with characteristic decapitation secretion, confirming apocrine differentiation (Figure 1a). Diffuse pigmentation within the lesion stained positive with Fontana–Masson stain and negative with Perls' stain, supporting pigment consistent with melanin or lipofuscin. Although specific melanin testing was not performed, the pigmentation was interpreted as most likely lipofuscin, accentuated by the Tyndall effect (Figure 1b). No cytological atypia was identified. Findings were consistent with a pigmented apocrine hidrocystoma. After diagnosis, no further follow-up or intervention was required.

Figure 1a.

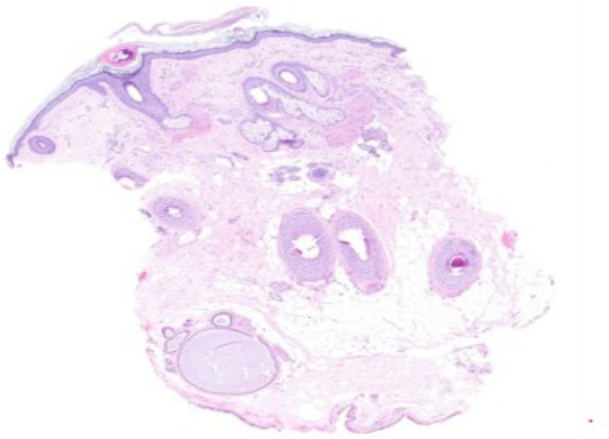

Figure 1b.

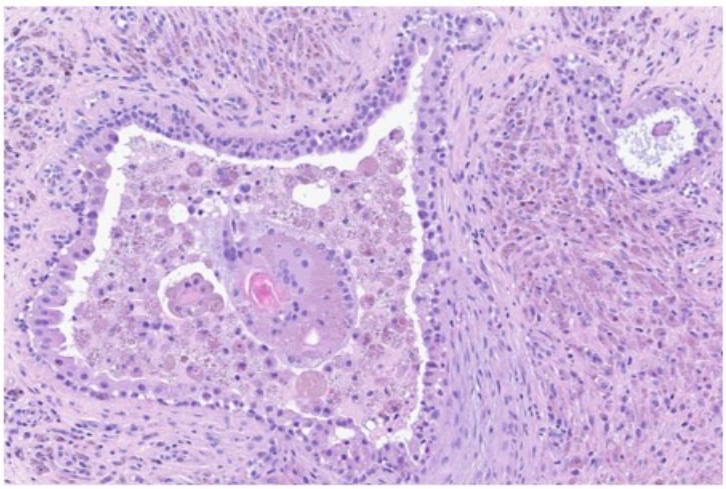

Figure 1a. Cystic lesion lined by epithelial cells with abundant eosinophilic cytoplasm and characteristic decapitation secretion. (H&E 4X) 279*329 mm (59*59 DPI) . Figure 1b. Pigmentation within the lesion and surrounding histiocytes (H&E 40X) 371*257 mm (59 *59 DPI)

Conclusion

Pigmented apocrine hidrocystomas may mimic a wide variety of melanocytic and non-melanocytic lesions, including basal cell carcinoma, melanoma, blue naevus, haemangioma, glomus tumour, nodular hidradenoma and seborrhoeic keratosis. This case highlights the need to consider pigmented apocrine hidrocystoma in the differential diagnosis of pigmented scalp lesions and underscores the crucial role of histopathological evaluation in establishing a definitive diagnosis, guiding management, and avoiding unnecessary patient anxiety or extensive surgical intervention. Surgical excision remains the treatment of choice for solitary lesions, providing both diagnostic clarity and therapeutic benefit.

POWERED BY M-ANAGE.COM

EADV CONGRESS
VIENNA
30 SEP - 3 OCT 2026

Abstract N°: 2508

Histopathological spectrum of mycetoma in Ethiopia: Findings from a community based study

Almut Böer-Auer[1], Dereje Bedane[2], Wendemagegn Enbiale*[3]

[1] Dermatologikum Hamburg GmbH, HAMBURG, Germany

[2] Bahar Dar Universsity, College of Medicine and Health Sciences, Bahir Dar, Ethiopia

[3] Arba Minch University, College of Medicine and Health Sciences, Bahir Dar University College of Medicine and Health Science, Arbaminch Zuriya, Ethiopia

Introduction

Mycetoma is a chronic, neglected tropical disease caused by fungal or bacterial pathogens, leading to progressive tissue destruction and disability. In endemic settings such as Ethiopia, histopathology remains a key diagnostic tool, particularly where advanced laboratory diagnostics are limited.

Objectives

To describe the histopathological characteristics of mycetoma and assess diagnostic patterns in an endemic setting in Ethiopia.

Materials and Methods

Within a large community-based survey conducted in four regions of Ethiopia in 2025, individuals with suspected mycetoma were referred for further evaluation. Tissue samples were obtained from 30 participants. Histopathological examination using hematoxylin and eosin (H&E) and selected special stains assessed grain morphology, inflammatory response, and tissue architecture. Analysis was descriptive, with categorical variables summarized as frequencies and percentages.

Results

All 30 specimens had adequate tissue for evaluation. Grains were identified in 23/30 cases (76.7%), while 6 (20.0%) showed no grains and 1 (3.3%) demonstrated coccoid aggregates. Mixed inflammatory infiltrates were observed in 26/29 cases (89.7%), with neutrophilic abscesses in 22/29 (75.9%) and suppurative granulomas in 18/28 (64.3%). Fibrosis was present in all cases, and giant cells in 16/29 (55.2%).

Grain morphology was heterogeneous, with predominantly large, irregular, brown-staining grains and frequent cement matrix (95.8%). Branching was common, while septation was less frequent. Special stains showed variable utility, with PAS and GMS highlighting fungal elements in a subset, while Gram and Ziehl–Neelsen stains were often negative.

Mycetoma was histologically confirmed in 26/30 cases (86.7%), including 15 (57.7%) likely eumycetoma, 9 (34.6%) likely actinomycetoma, and 2 not specified.

Conclusions

Histopathology remains a valuable and practical diagnostic tool for mycetoma in Ethiopia, despite limitations in species identification. Strengthening pathology capacity and integrating complementary diagnostic methods are essential to improve accurate diagnosis and guide appropriate management in endemic settings.

EADV CONGRESS
VIENNA
30 SEP - 3 OCT 2026

Abstract N°: 2510

Bullous pemphigoid and concomitant scabies: a diagnostic and therapeutic challenge

Émélie Simone Okouango*[1], Bouchra Baghad[1], Hanane Rachadi[1], Soumiya Chiheb[1]

[1] Department of Dermatology, Ibn Rochd University Hospital, Casablanca, Morocco, Faculty of Medicine and Pharmacy of Casablanca, Hassan II University, Morocco, Casablanca, Morocco

Introduction
Bullous pemphigoid (BP) is the most common autoimmune bullous dermatosis. It is associated with the presence of autoantibodies directed against basement membrane antigens, primarily BP180 and BP230, and occurs mainly in individuals over the age of 60. Scabies is a parasitic infestation caused by Sarcoptes scabiei, characterised by intense pruritus that worsens at night, often associated with excoriated papular lesions. More rarely, it can present in a bullous form mimicking an autoimmune bullous dermatosis. We report the case of a 62-year-old female patient presenting with a combination of bullous pemphigoid and scabies.

Case Presentation
The patient was a 62-year-old woman with hypertension who had been taking amlodipine for 5 years. For more than two years, she had presented with tense, diffuse, pruritic bullous lesions, occurring in the context of afebrile status and preserved general condition. Dermatological examination revealed small, diffuse post-bullous erosions, sometimes crusted, on otherwise healthy skin, associated with hyperpigmented, scarred papulomacular lesions on the trunk and limbs. The mucous membranes, palmar and plantar regions, and appendages were spared. Nikolsky's sign was negative, and the BPDAI score was 20. Dermoscopy revealed the hang-glider sign. Laboratory tests showed eosinophilia at 1,050/mm^3. Skin biopsy revealed subepidermal detachment with an inflammatory infiltrate. Direct immunofluorescence revealed linear deposits of IgG and C3 at the dermo-epidermal junction. Indirect immunofluorescence was positive at 60, with anti-BP180 antibodies positive at 65 IU/mL and anti-BP230 antibodies negative. Direct parasitological examination of skin samples from the hands and buttocks revealed the presence of numerous Sarcoptes scabiei mites and eggs. The patient was treated with ivermectin, with simultaneous treatment of household contacts, followed by systemic corticosteroid therapy at a dose of 0.5 mg/kg/day.

Conclusion
Bullous scabies is a rare form of scabies, observed primarily in the elderly. It can present as tense or flaccid blisters, sometimes haemorrhagic, mimicking bullous pemphigoid or bullous impetigo. The pathophysiology of this form remains poorly understood. Several immunological mechanisms have been proposed. Enzymes produced by the mites may induce damage to the basement membrane, leading to antigenic exposure and the production of anti-BP antibodies. These antibodies would then activate the complement system and recruit eosinophils, resulting in dermo-epidermal detachment.

Another hypothesis is based on antigenic mimicry, in which the parasite's antigens induce antibodies that cross-react with antigens on the basement membrane. Some studies have demonstrated the presence of anti-BP180 and anti-BP230 antibodies in patients with bullous scabies, suggesting that certain bullous lesions observed in scabies actually correspond to true bullous pemphigoid triggered by the infestation. A Koebner phenomenon has also

been suggested, particularly when the blisters are located exclusively on areas affected by scabies.

The diagnosis of bullous scabies should be considered in any pruritic bullous eruption, particularly in the presence of nocturnal pruritus, associated papular lesions, or resistance to corticosteroids. Detection of Sarcoptes scabiei mites or eggs confirms the diagnosis.

Our observation underscores the importance of systematically screening for parasitic infection before initiating immunosuppressive therapy in patients with bullous pemphigoid. Scabies can not only mimic BP but also coexist with it or serve as a potential trigger.

EADV CONGRESS
VIENNA
30 SEP - 3 OCT 2026

Abstract N°: 2522

Solitary Trichilemmoma on the Scrotum: A Rare Case Presentation

Soumya Nanda*[1], Sushantika Sushantika[2], Akash Dhiman[2]

[1] All India Institute of Medical Sciences, Bhubaneswar, India, Bhubaneswar, India
[2] All India Institute of Medical Sciences, Rishikesh, India, Rishikesh, India

Introduction
Trichilemmoma is a benign adnexal neoplasm arising from the outer root sheath of the hair follicle. It commonly presents as a solitary papule on the face or neck, whereas genital involvement is exceedingly uncommon. Scrotal trichilemmoma is particularly rare and may clinically mimic infectious or malignant lesions, posing a diagnostic challenge.

Case Presentation
A 26-year-old man presented with a solitary asymptomatic papule over the left hemiscrotum, progressively increasing in size over two months. Examination revealed a 1 × 1 cm firm, dome-shaped pink papule with central umbilication and focal erosion. Dermoscopy demonstrated red globules and dotted vessels on a pink background with surrounding shiny white structureless areas. Clinical differentials included verruca vulgaris, adnexal tumor, pyogenic granuloma, molluscum contagiosum, and basal cell carcinoma.

The lesion was completely excised under local anesthesia. Histopathology revealed a well-circumscribed lobulated epitheloid proliferation composed of glycogen-rich clear cells with peripheral palisading and surrounded by a eosinophilic PAS-positive basement membrane. Focal vacuolated clear-cell change was present without cytologic atypia, necrosis, or increased mitotic activity. CD34 immunostaining was negative. These findings established the diagnosis of trichilemmoma. Surgical margins were free of tumor. The postoperative course was uneventful, and no recurrence was observed at 6-month follow-up.

Conclusion
Trichilemmoma at non-facial sites is rare, with only isolated reports involving genital skin. Scrotal involvement is exceptionally uncommon. Clinically, these lesions may resemble viral warts or adnexal malignancies, while histopathologically they may overlap with basal cell carcinoma, particularly in desmoplastic variants. Recognition of characteristic features including clear glycogen-rich cells, peripheral palisading, and hyaline basement membrane is essential for accurate diagnosis.

Interestingly, although CD34 positivity is typically described in trichilemmoma, our case demonstrated negative staining, highlighting the importance of correlating immunohistochemistry with morphology. Complete surgical excision remains curative.

This case highlights the importance of considering trichilemmoma in the differential diagnosis of genital papules and emphasizes histopathology as the gold standard for diagnosis. Increased awareness of this uncommon presentation may help avoid misdiagnosis and unnecessary aggressive management.

EA DV CONGRESS
VIENNA
30 SEP - 3 OCT 2026

Abstract N°: 2527

Epidemiological, clinical, immunological, and histological profile of cutaneous vasculitides: a retrospective study of 129 cases

Émélie Simone Okouango*[1], Bouchra Baghad[1], Fatimazahrae Benhayoun[1], Hanane Rachadi[1], Soumiya Chiheb[1]

[1] Department of Dermatology, Ibn Rochd University Hospital, Casablanca, Morocco, Faculty of Medicine and Pharmacy of Casablanca, Hassan II University, Morocco, Casablanca, Morocco

Introduction

Cutaneous vasculitides constitute a heterogeneous group of inflammatory conditions affecting the dermal vessels, which may occur in isolation or be indicative of systemic vasculitis. Their clinical presentation and aetiologies are varied, making their diagnosis and management complex. The objective of our study was to describe the epidemiological, clinical, biological, histological, immunological, and etiological profile of cutaneous vasculitides managed at the Ibn Rochd University Hospital in Casablanca.

Materials and Methods

A retrospective descriptive and analytical study conducted in the Dermatology Department of the Ibn Rochd University Hospital in Casablanca from January 2020 to December 2025. The study included all patients with a diagnosis of cutaneous vasculitis confirmed by skin biopsy. Epidemiological, clinical, laboratory, histological (with direct immunofluorescence), and etiological data were collected. Statistical analyses used the chi-square test, Fisher's exact test, and Pearson's correlation coefficient ($p < 0.05$).

Results

A total of 129 patients were included, comprising 87 women (67.4%) and 42 men (32.6%), with a mean age of 43 years (range: 15–83 years). Petechial purpura of the lower extremities (55.0%) was the predominant cutaneous manifestation, and arthralgia (59.7%) was the main extracutaneous manifestation. An inflammatory syndrome was present in 75.2% of patients. ANCA was positive in 4.7%. Histology showed leukocytoclastic vasculitis in 70.5% of cases, and direct immunofluorescence was positive in 84.5% (predominantly IgA and C3 deposits). The aetiologies were dominated by primary systemic vasculitides (46.5%), with a predominance of rheumatoid purpura (23.2%) and drug-induced vasculitides (44.2%). The latter were significantly associated with age ≥ 65 years (92.3% of cases, $p = 0.013$). Infectious (5.4%) and paraneoplastic (3.9%) causes were less frequent but significant ($p = 0.024$).

Conclusions

Cutaneous vasculitides predominantly affect young women, with a clinical presentation dominated by purpura. The high proportion of drug-induced vasculitides in the elderly underscores the importance of a thorough medication history. Skin biopsy with direct immunofluorescence remains the key test for diagnosis and determining the aetiology.

EADV CONGRESS
VIENNA
30 SEP - 3 OCT 2026

Abstract N°: 2563

When histology reveals the unexpected: Melanotic neurofibroma, a case report

tinhinane benbrahim*[1]

[1] CHU Bab El Oued, ALGIERS, Algeria

Introduction
Melanotic neurofibroma is a rare tumor whose diagnosis is often challenging, both clinically and histologically. We report a case of extensive neurofibromas mimicking eruptive dermatofibromas.

Case Presentation
A 27-year-old woman with no significant past medical history consulted for widespread brownish papulonodular lesions located on the trunk, back, and labia majora, ranging from a few millimeters to one centimeter in diameter, with a firm consistency. The lesions appeared in the context of repeated microtrauma related to hair removal procedures. Clinical examination initially suggested eruptive dermatofibromas.

Dermoscopic examination was suggestive of neurofibroma.

Histopathological examination of the skin biopsy revealed hyperpigmentation of the basal epidermal cells and a benign mesenchymal tumor proliferation located within the dermis and hypodermis, composed of spindle-shaped cells without atypia or mitotic activity. Immunohistochemical staining showed negative CD34, HMB45, Melan-A, and CD68 markers, while PS100 was positive.

The diagnosis of diffuse melanotic neurofibroma was established. Investigation for other signs suggestive of neurofibromatosis, as well as similar familial cases, was negative.

Discussion:

Melanotic neurofibroma may occur as an isolated lesion or in association with neurofibromatosis. It should be distinguished from conventional neurofibroma, which may also present clinically with pigmentation. Melanotic neurofibroma most commonly occurs during the second or third decade of life and more rarely in children.

In adults, the main diagnostic challenge is distinguishing it from dermatofibroma or pigmented dermatofibrosarcoma, which may share both clinical and histological similarities with melanotic neurofibroma.

In our patient, immunohistochemical analysis helped rule out differential diagnoses and confirmed the diagnosis of melanotic neurofibroma.

Conclusion
We report a rare case of melanotic neurofibroma mimicking dermatofibroma, highlighting the importance of close collaboration between clinical dermatologists and pathologists.

EA DV CONGRESS
VIENNA
30 SEP - 3 OCT 2026

Abstract N°: 2566

Unique Trichoepithelioma-like Basaloid Proliferation in Intradermal Melanocytic Naevus

Khalid M. A. Ahmed*[1], Rishi Agrawal[2], Arif Aslam[1], Richard A Carr[2]

[1] Leeds Centre of Dermatology, Leeds Teaching Hospitals, Leeds, United Kingdom
[2] Cellular Pathology, South Warwickshire NHS Trust, Warwick, United Kingdom

Introduction

Trichoepithelioma (TE) may mimic basal cell carcinoma (BCC) clinically and histologically. Associations between melanocytic naevi and TE have rarely been described in the literature, most commonly the desmoplastic variant. We present an unusual case of a strikingly TE-like basaloid proliferation intimately admixed throughout an intradermal naevus.

Case Presentation

A 78-year-old women undergoing dermatological follow-up following excision of stage IA malignant melanoma developed a 5-mm pearly papule on the right cheek, clinically suspicious for nodular BCC, excised with 4-mm margins.

Histology showed a dermal organoid branching basaloid epithelial proliferation with TE-like features. The epithelial proliferation was intimately admixed with a second nested component comprising melanocytes without cytological atypia or mitoses in keeping with intradermal naevus. BerEP4 highlighted the epithelial population (negative for EMA) that was present throughout the naevus and negative for EMA. CD10 stain stromal cells focally around the basaloid component. Both components showed mosaic p16 and low expression of p53 and Ki67. MelanA highlighted the melanocytic population, which was PRAME negative.

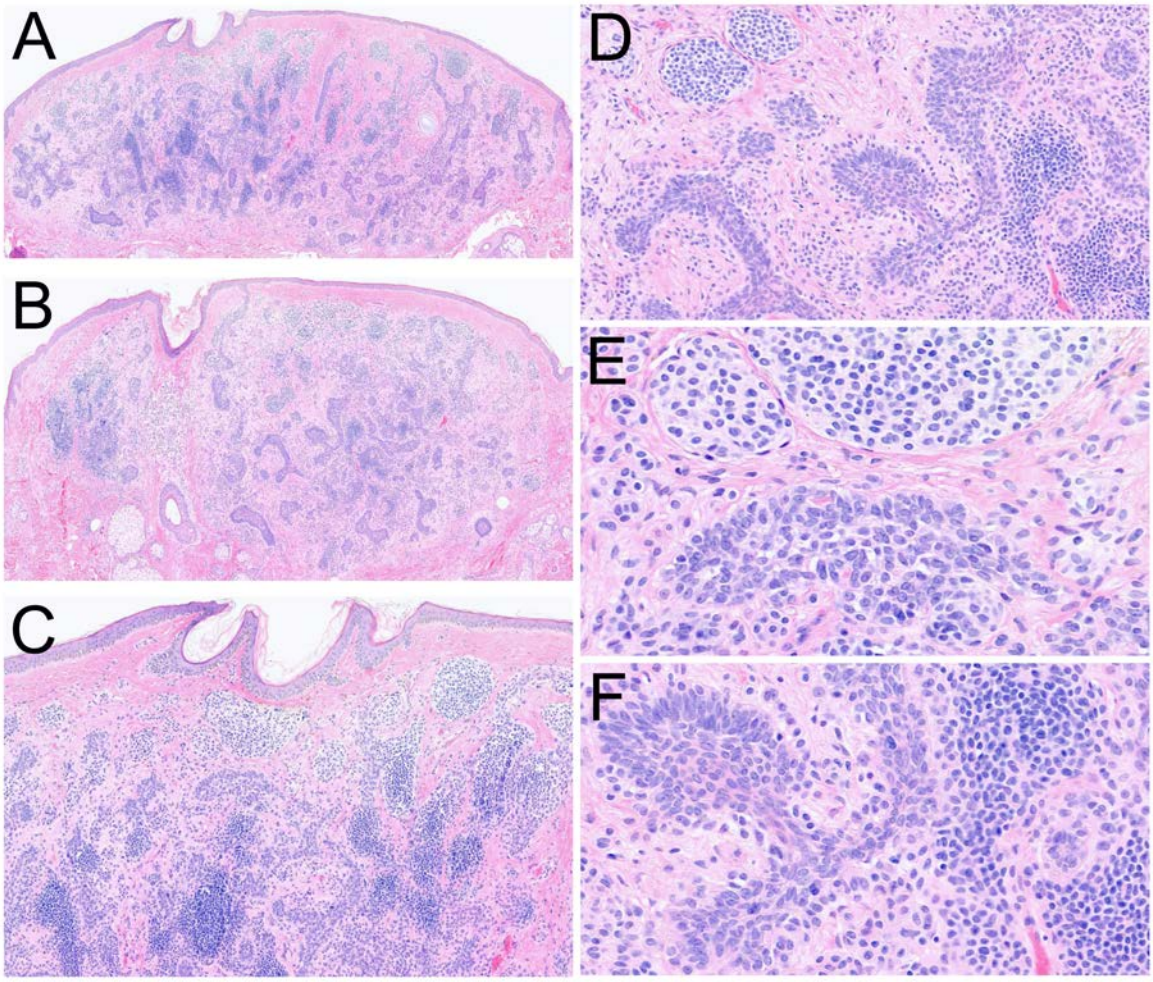

A. & B. Scanning view shows a branching basaloid proliferation, relatively circumscribed but unencapsulated in profile (H&E x50). C. On medium view there is a second nested population in the upper dermis which transitions to rounded balls of darkly hyperchromatic cells indicative of a high-nuclear cytoplasmic ratio. The branching basaloid epithelial proliferation can be appreciated throughout (H&E x100). D. The nested population of cells with high nuclear-cytoplasmic ratio can be distinguished from trichoepithelioma-like branching basaloid cords with peripheral rounded buds (H&E x 200); E. Upper dermis the nested population has moderately abundant pale cytoplasm. Nuclei are slightly larger with inconspicuous nucleoli and even chromatin and lack atypia (H&E x400). F. Branching basaloid epithelial component with second population of small hyperchromatic cells having inconspicuous cytoplasm hugging the epithelial cords and forming ill-defined nests in the corium (H&Ex400).

Conclusion

In our opinion this is a unique combined tumour comprising, benign or possibly more likely reactive, TE-like basaloid proliferation throughout a naevus. Immunohistochemistry highlighted the two components and helped to rule out BCC and melanoma.

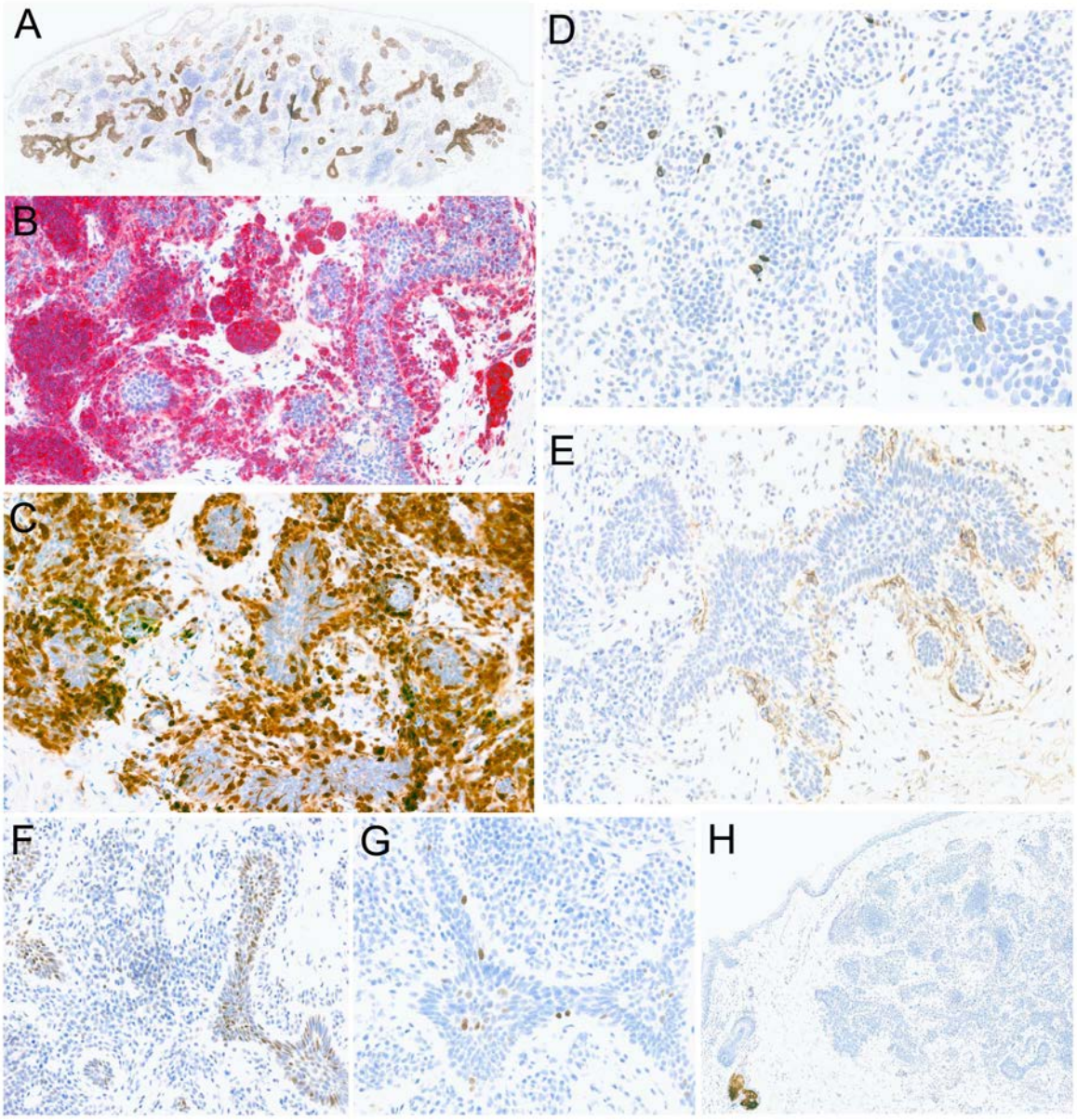

A. BerEP4 highlights the branching epithelial component, trichoepithelioma-like (x30) B. MelanA highlighting the melanocytic nested component with scattered cells also present within the basaloid cords (x100) C. p16 shows a mosaic pattern in the melanocytic nested component and the intra-epithelial melanocytes which have dendritic processes. The epithelium is also focally positive in a mosaic pattern (x260) D. CK20 highlights Merkel cells scattered within the corium and focally within the trichoepithelioma-like epidermal compent (x260, inset x400). E. CD10 showed only focal staining around the epithelial component. F. p53 weak to moderate staining in the epithelial component and minimal expression in the melanocytic component (x260). G. Ki67 proliferation is low in the epithelial component and minimal in the melanocytic (x260). H. PRAME negative in both components, strong cytoplasmic control staining in the sebaceous gland (x50).

EADV CONGRESS
VIENNA
30 SEP - 3 OCT 2026

Abstract N°: 2569

Tuberculous erythema nodosum: about two cases

tinhinane benbrahim*[1]

[1] CHU Bab El Oued, ALGIERS, Algeria

Introduction
Erythema nodosum (EN) is a common inflammatory panniculitis, often reactive to various infectious, inflammatory, or drug-related causes. Tuberculosis remains an important cause of EN in endemic countries and may reveal latent or active tuberculosis. We report two observations illustrating the diversity of clinical and histological presentations of tuberculous erythema nodosum.

Case Presentation
The first observation concerns a 32-year-old woman who consulted for painful nodular lesions on the anterior aspect of both legs, recurring mainly during winter, and evolving over the past three years. General physical examination was unremarkable. Laboratory investigations, including complete blood count, liver and renal function tests, were normal, with negative ASLO titers. Skin biopsy revealed septal panniculitis without vascular involvement.

The tuberculin skin test was strongly positive with a phlyctenular reaction measuring 21 mm. Thoraco-abdomino-pelvic CT scan demonstrated multiple deep lymphadenopathies (hilar, peripancreatic, retroperitoneal, and pararénal), suggestive of a tuberculous origin. Ultrasound-guided lymph node biopsy confirmed the presence of tuberculous granulomas.

The second observation concerns a 68-year-old woman presenting with recurrent erythema nodosum of both legs evolving in flares over one year. Skin biopsy was consistent with septal panniculitis without vascular involvement. Etiological investigations supported a tuberculous origin based on a positive QuantiFERON test. The patient was started on antituberculous therapy with marked clinical improvement.

Discussion

Erythema nodosum is a frequent reactive cutaneous manifestation of tuberculosis and may be associated with latent or systemic forms of the disease. The diversity of histological findings highlights the importance of a comprehensive diagnostic approach integrating epidemiological context, immunological tests, and imaging studies. Early diagnosis allows appropriate management and favorable outcomes under antituberculous treatment.

Conclusion
Erythema nodosum may represent a revealing manifestation of tuberculosis, particularly in endemic areas. A systematic etiological investigation is essential in all recurrent forms in order to initiate specific treatment early and improve prognosis.

EA DV CONGRESS
VIENNA
30 SEP - 3 OCT 2026

Abstract N°: 2569

Panniculitis: clinical polymorphism and diagnostic difficulties (interim results of a prospective study)

Alina Eroshenkova*[1], Olga Grabovskaya[1]

[1] First Moscow State Sechenov Medical University, Moscow, Russian Federation

Introduction
Panniculitis is a heterogeneous group of diseases characterized by inflammation of subcutaneous adipose tissue. Etiology includes infectious, drug-induced, traumatic, hormonal factors, associations with pancreatic pathology and rheumatic diseases. A unified classification is lacking; histology plays a key role in verification, differentiating lobular and septal types of inflammation, with or without vasculitis. The aim of the interim analysis (2025–2026) within a three-year prospective study (2025–2028) is to assess the structure of panniculitides and identify diagnostic difficulties.

Materials and Methods
The interim stage of the prospective study (2025–2028) included 15 patients with nodular subcutaneous lesions. All underwent skin biopsy histology. Clinical and laboratory parameters (CRP, cryoglobulins, Diaskintest, procalcitonin, CT, ultrasound) were evaluated before and after treatment.

Results
Among 15 patients (11 females, 4 males, mean age 64.5 years), the nosological structure was as follows:

Erythema nodosum – 8 cases (53.3%): 2 with cancer history, 1 with tuberculosis, 1 with CRP 133 mg/L, pulmonary infiltrates, cirrhosis.

Panniculitides associated with systemic diseases and rare forms – 4 cases (26.7%): lupus panniculitis, Weber-Christian panniculitis, mesenteric panniculitis (cryoglobulins+), cold panniculitis.

Necrobiosis lipoidica – 1 case (6.7%) with impaired glucose tolerance.

Lipodermatosclerosis – 1 case (6.7%).

Deep morphea – 1 case (6.7%).

The most informative markers were CRP, cryoglobulins, and Diaskintest. In 4 patients at risk of infection, procalcitonin was normal. In one case of erythema nodosum, elevated procalcitonin (0.7 ng/mL) was detected, requiring chest CT, soft tissue ultrasound, pulmonology consultation, and antibiotic therapy. Histology confirmed the diagnosis in 100% of cases. Positive dynamics were observed in 80% of patients.

Conclusions
At the interim stage of the three-year study, a predominance of erythema nodosum (53.3%) and a significant

proportion of rare forms (26.7%) were found. Main diagnostic difficulties are related to excluding infectious, oncological and systemic triggers. Elevated procalcitonin in one case highlights the importance of a comprehensive approach. Histological verification remains the key method. These data will serve as a basis for the final outcome assessment in 2028.

EA DV CONGRESS
VIENNA
30 SEP - 3 OCT 2026

Abstract N°: 2577

Painful Multiple Piloleiomyomas: Analgesic Efficacy of Doxazosin

FATIMA ZAYOUN*[1], Hanane Rachadi[1], Fatima Zahra Benhayoun[1], Bouchra Baghad[1], soumiya Chiheb[1]

[1] Ibn Rochd University Hospital Center, CASABLANCA, Morocco

Introduction

Cutaneous leiomyomas are rare benign tumors arising from smooth muscle fibers within the dermis. Among them, piloleiomyomas are the most common subtype and originate from the arrector pili muscle. Clinically, they typically present as firm flesh-colored to reddish-brown papules or nodules, often multiple and painful.

Pain, whether spontaneous or triggered by cold exposure, pressure, or emotional stress, represents a major functional symptom that may significantly impair patients' quality of life. Therapeutic management remains challenging because of the frequently multifocal nature of the lesions and the lack of standardized treatment guidelines.

We report the case of a patient with painful multiple piloleiomyomas who showed significant clinical improvement following treatment with doxazosin.

Case Presentation

A 42-year-old man with no significant past medical history presented with painful cutaneous lesions evolving over several years. Dermatological examination revealed multiple firm papulo-nodular lesions, flesh-colored to erythematous-brown in appearance, distributed over the trunk. The lesions were tender on palpation, with worsening pain upon exposure to cold. The remainder of the physical examination was unremarkable.

A skin biopsy was performed, and histopathological examination was consistent with piloleiomyoma. Given the multiple and painful nature of the lesions, symptomatic treatment with doxazosin was initiated, resulting in marked improvement of the painful symptoms during follow-up.



Conclusion

Multiple piloleiomyomas are rare benign cutaneous tumors accounting for approximately 5% of soft tissue leiomyomas. They most commonly occur between the second and fourth decades of life, without clear sex predominance. Clinically, pain is the hallmark symptom, reported in nearly 90% of cases in some series, and may occur spontaneously or be triggered by cold, pressure, or emotional stress.

Management of multiple forms remains challenging, as surgical excision is often unsuitable for extensive lesions. Several symptomatic therapies have been proposed for pain control, with variable outcomes. Alpha-adrenergic blockers, particularly doxazosin, are thought to reduce smooth muscle contraction, a mechanism implicated in the pathophysiology of leiomyoma-associated pain. In our patient, doxazosin led to significant pain relief with good clinical tolerance.

Moreover, the limited published data regarding the use of doxazosin in multiple piloleiomyomas further highlights the interest of our observation, suggesting that this drug may represent a promising therapeutic option in diffuse painful forms.

Finally, in the presence of multiple piloleiomyomas, it is important to consider Hereditary Leiomyomatosis and Renal Cell Cancer because of the associated risk of aggressive renal cell carcinoma, thus warranting appropriate clinical evaluation and follow-up.

EADV CONGRESS
VIENNA
30 SEP - 3 OCT 2026

Abstract N°: 2638

Pregnancy-Associated Eccrine Nodular Hidradenoma Mimicking a Pyogenic Granuloma: A Diagnostic Challenge

salma larabi*[1]

[1] Department of dermatology, Ibn Sina University Hospital ,Rabat , Morocco, rabat, Morocco

Introduction

Eccrine nodular hidradenoma is a rare benign adnexal neoplasm originating from eccrine sweat glands that may clinically and dermoscopically mimic vascular or malignant tumors. Pregnancy-related hormonal changes may further alter the presentation of cutaneous lesions and complicate the diagnostic approach. We report an unusual case of eccrine nodular hidradenoma arising during pregnancy and clinically simulating a pyogenic granuloma.

Case Presentation

A 33-year-old woman with no significant medical history presented with an 8-month history of a lesion located on the right cheek. The lesion first appeared during the first month of pregnancy as a small flesh-colored papule and progressively enlarged over time. The patient reported recurrent bleeding upon minor trauma, while the lesion remained otherwise asymptomatic. No preceding local trauma was noted.

Clinical examination revealed a solitary erythematous nodule with an eroded surface arising on an infiltrated erythematous base. The remainder of the physical examination was unremarkable.

Dermoscopy demonstrated polymorphous vascular structures, including arborizing and telangiectatic vessels on a whitish-pink background, associated with shiny white streaks, hemorrhagic crusts, and focal hemorrhages. Based on the clinical presentation and the pregnancy context, several differential diagnoses were considered, including pyogenic granuloma, pregnancy granuloma, amelanotic melanoma, basal cell carcinoma, and adnexal tumor.

Complete surgical excision was performed. Histopathological examination revealed a well-circumscribed dermal tumor composed of solid and cystic areas formed by polygonal eosinophilic and clear cells, consistent with benign eccrine nodular hidradenoma, without evidence of malignancy.

Conclusion

This case highlights the diagnostic challenge posed by eccrine nodular hidradenoma during pregnancy, particularly when presenting as a rapidly growing hemorrhagic facial nodule. Clinical and dermoscopic findings may closely mimic pyogenic granuloma or malignant tumors, making histopathological examination essential for definitive diagnosis. Complete surgical excision remains both diagnostic and curative, with an excellent prognosis in the absence of malignant transformation.

EA DV CONGRESS
VIENNA
30 SEP - 3 OCT 2026

Abstract N°: 2642

Hybrid open-top light-sheet microscopy for 3D dermatopathology of inflammatory and neoplastic skin diseases

Deborah Winkler*[1, 1], Brandy Olin[2], Alexandra Alvarsson[2], Julia Welzel[1], Sandra Schuh[1]

[1] University hospital of Augsburg, Augsburg, Germany

[2] Alpenglow Biosciences Inc., Seattle, United States

Introduction

Conventional dermatohistopathology relies on two-dimensional sections, which restrict the evaluation of complex tissue architecture. Hybrid open-top light-sheet microscopy (OTLS) offers three-dimensional visualization of intact, formalin-fixed paraffin-embedded (FFPE) specimens. This study aims to assess the utility of OTLS for three-dimensional characterization of both inflammatory and malignant skin conditions.

Case Presentation

Methods: In collaboration with Alpenglow Bioscience, FFPE skin specimens from two inflammatory dermatoses (psoriasis, atopic dermatitis) and two malignant skin tumors (basal cell carcinoma, malignant melanoma) were examined. Immunofluorescence staining targeted specific markers for immune cells, nerve structures, and vasculature. Concurrently, in vivo imaging of the same lesions was performed using line-field confocal optical coherence tomography (LC-OCT).

Results: In malignant tumors, volumetric reconstructions revealed intricate blood and lymphatic vessel networks and their spatial relationships with immune cell infiltrates. Tumor cell clusters not specifically labeled by OTLS were detected in vivo with LC-OCT. In inflammatory dermatoses, immune cell populations displayed characteristic distribution patterns, including perineural aggregates (Fig.1). Additionally, in malignant tumors, detailed vessel networks and their interactions with tumor cell clusters and immune infiltrates were clearly visualized.

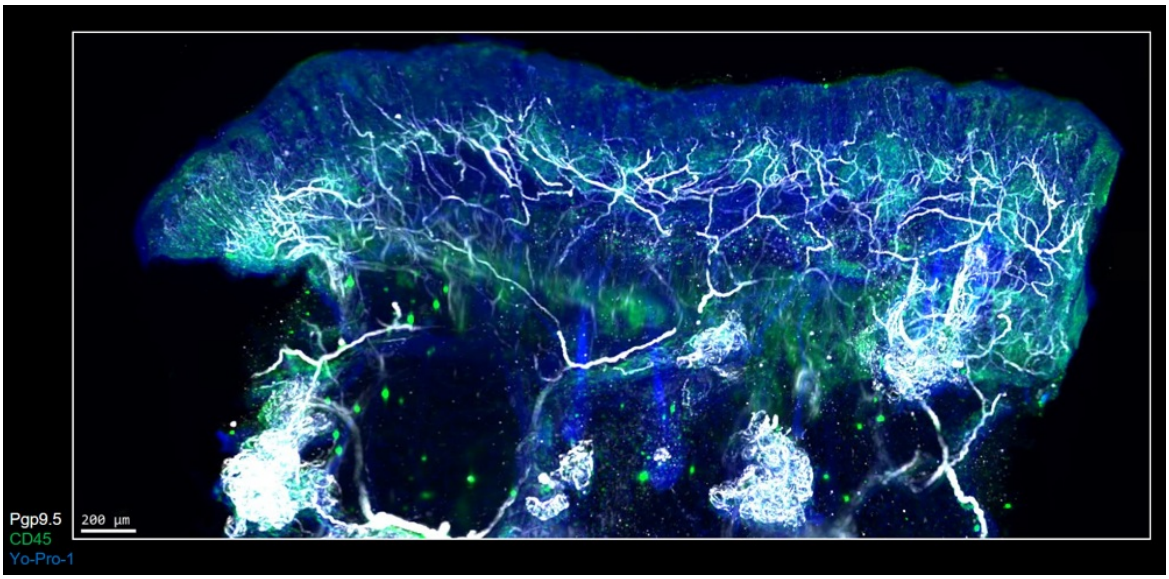

Figure 1: Biopsy specimen from a patient with atopic dermatitis visualized using hybrid open-top light-sheet microscopy. CD45 immunostaining (green) identifies immune cells, PGP9.5 staining (white) labels neuronal structures, and Yo-Pro-1 staining (blue) marks cells undergoing early apoptosis.

Conclusion

OTLS enables volumetric evaluation of intact skin specimens, offering insights into inflammatory microenvironments and tumor-vascular interactions that extend beyond the capabilities of conventional histology.

Literature:

1. Glaser et al. A hybrid open-top light-sheet microscope for versatile multi-scale imaging of cleared tissues.*Nat Methods*. 2022 May;19(5):613-61

EADV CONGRESS
VIENNA
30 SEP - 3 OCT 2026

Abstract N°: 2718

Solitary and linear multiple leiomyomas involving different dermatomes- A rare presentation

Dr. Smriti Venkatesh*[1], Dr. Riya Maheshwari[1], Dr. Meghana Phiske[1], Dr. Shylaja Someshwar[1, 2]

[1] Mgm Institute of Health Sciences, Panvel, India

[2] Kasturba Medical College, Mangaluru, India

Introduction

Cutaneous leiomyomas are rare, benign, soft-tissue tumors arising from smooth muscle, most commonly arrector pili muscle, presenting as firm, reddish-brown, papules/ nodules, painful on pressure/ exposure to cold. They account for 75% of extra-uterine leiomyomas, comprising 5% of all leiomyomas. All races are equally affected without sex predilection. Extensor surfaces of extremities are most commonly affected. Piloleiomyoma is commonest, presenting as solitary/multiple lesions. Linear, segmental, and zosteriform and lesions following Blaschko's lines are described. Causes of pain are local pressure by tumor on cutaneous nerves or muscle contraction. Differential diagnosis includes angiolipoma, glomus tumour, eccrine spiradenoma, neurofibroma, fibromyoma and lipoma. Histology shows poorly circumscribed proliferation of haphazardly arranged smooth muscle fibers in dermis. Positivity for smooth muscle actin and desmin is confirmatory. Surgical excision is curative, recurrences are reported in 50%. Nifedipine, nitroglycerine and doxazosin are for multiple lesions.

Case Presentation

A 28/M, had asymptomatic single, well-defined, round skin coloured smooth nodule on right anterior chest well, 2X2 cm since 5 years. There were multiple well-defined, round, smooth skin coloured/erythematous papules and nodules, 0.5x0.5- 2x2 cm with smooth surface over left lateral side of mid thigh. Dermoscopy (chest and left thigh) showed homogenous red-brown areas, whitish discoloration, arborising vessels and hyperpigmented periphery. Ultrasonography showed hypoechoic lesions in subcutaneous plane. Chest wall and thigh lesion measured 2.2 × 1.4 × 2 cm and 1.6 × 1.0 cm respectively, both showing posterior acoustic enhancement and mild internal vascularity, s/o benign soft tissue tumor. Excision biopsy of chest lesion was s/o cutaneous leiomyoma. Subsequently following increase in size and pain IN lesions ON left thigh, biopsy was done, which was s/o Leiomyoma. Final diagnosis was solitary and multiple leiomyoma involving different dermatomes.

Conclusion

Early detection, management and follow-up of cutaneous leiomyomas are crucial as they may be associated with underlying genetic mutations which increase susceptibility to develop renal cell carcinoma.

EA DV CONGRESS
VIENNA
30 SEP - 3 OCT 2026

Abstract N°: 2741

Longitudinal Melanonychia Evaluated by Ex Vivo Dermoscopy with Incidental Follicular Epithelial Inclusions in Nail Matrix Biopsy

Karine Domingues Tavares*[1], Carolina Vitória De Lucia[1], João Barreto[1], Anna Maria Andrade Barbosa[1], Carlos Baptista Barcaui[1], Juan Piñeiro-Maceira[1]

[1] Universidade Estadual do Rio de Janeiro, Hospital Universitário Pedro Ernesto, Rio de Janeiro, Brazil

Introduction

Melanonychia presents as a pigmented band in the nail plate and may result from several benign or malignant conditions. Because nail plate pigmentation originates in the nail matrix, matrix biopsy remains the gold standard when progressive clinical changes raise diagnostic concern. Histopathological findings vary according to the underlying cause; however, follicular inclusions within nail matrix specimens are an uncommon finding rarely described in the literature.

Case Presentation

A 48-year-old woman presented with a 2-year history of progressive longitudinal melanonychia of the left thumbnail. She denied trauma. Her medical history included hypertension, type 2 diabetes mellitus, anxiety, chronic venous insufficiency, and menopause. Chronic medications included atenolol, amlodipine, hydrochlorothiazide, spironolactone, hydralazine, diosmin, omeprazole, and fluoxetine.

Clinical evolution, characterized by progressive widening and darkening of the pigmented band confirmed by serial dermoscopic follow-up, adult onset, and involvement of a single nail, supported the indication for nail matrix biopsy. The surgical exposure od the matrix was performed to select the biopsy site. Ex vivo dermoscopy was then performed as an adjunctive tool. It demonstrated granular melanin distribution within the nail matrix, with linear and orderly extension toward the nail bed.

Histopathological examination revealed hyperpigmentation of the epidermal basal layer and dermal melanin deposition consistent with benign melanocytic activation. There were neither cytological atypia nor other features of malignancy. Besides, follicular epithelial inclusions were identified within the nail matrix.

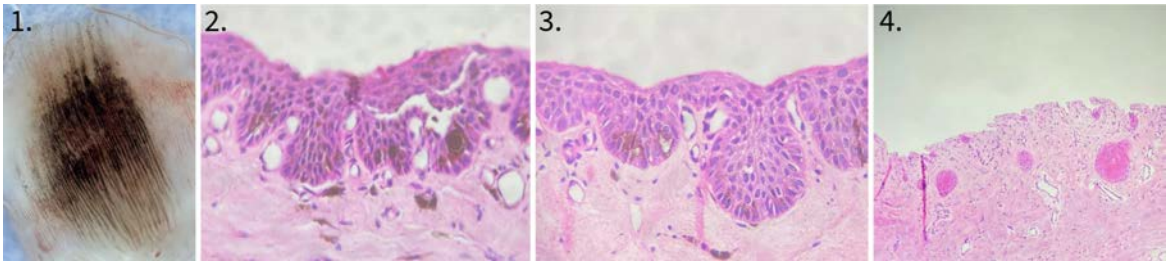

Figure 1: Ex vivo dermoscopy: brown granular pigment deposition in a regular pattern spreading throughout the nail matrix. Figure 2 and 3: H&E - Nail matrix biopsy: hyperpigmented dendritic and globular melanocytes distributed sparsely in the nail epithelium and melanophages. Figure 4: H&E - Nail matrix biopsy, follicular inclusions in the subungual connective tissue.

Conclusion

Melanonychia secondary to melanocytic activation remains the most common benign cause of longitudinal nail pigmentation.

Follicular inclusions within the nail matrix may act as a trigger for melanocytic activation. They are rare and may originate from persistent embryonic follicular units in the subungueal connective tissue. The incidental finding of these epithelial structures during the investigation of melanonychias may or not be associated with melanocytic nevi. Further case accumulation and correlative clinico-histopathological studies are required to determine whether these structures reflect a reactive process, a developmental remnant with latent proliferative potential, or an epiphenomenon associated with specific nail matrix microenvironmental changes.

EADV CONGRESS
VIENNA
30 SEP - 3 OCT 2026

Abstract N°: 2821

Histopathologic Evaluation of Collagen Staining Patterns in Chronic Wounds After Bilayered Skin Substitute Application: A Retrospective Study

Laura Dalla Rosa Prati*[1], Stephanie V Shimon[1, 2], Sammya Mufarrej[1], Rama Abdin[1, 3], Paolo Romanelli[1], Mariya Miteva[1], Ivan Jozic[1]

[1] Dr. Phillip Frost Department of Dermatology and Cutaneous Surgery, University of Miami Miller School of Medicine, Miami, United States
[2] Nova Southeastern University College of Allopathic Medicine, Fort Lauderdale, United States
[3] Charles E. Schmidt College of Medicine, Florida Atlantic University, Boca Raton, United States

Introduction
A bilayered living cellular skin substitute (BSS) is the only cellular construct currently approved for the treatment of chronic venous leg ulcers (VLU) and neuropathic diabetic foot ulcers (DFU). BSS is composed of a dual-layer structure: an epidermal layer containing keratinocytes and fibroblasts, and a dermal layer consisting of bovine type I collagen and human neonatal foreskin fibroblasts. Despite its established clinical efficacy, the duration of BSS persistence within the wound bed remains incompletely understood, with prior molecular studies yielding inconsistent results. This study aimed to evaluate histopathologic staining patterns consistent with BSS-associated collagen in chronic wounds using Gömöri Trichrome (GT) staining, a technique previously validated to detect bovine collagen.

Materials and Methods

We performed a single-center retrospective pilot study using archived formalin-fixed paraffin-embedded (FFPE) biopsy specimens from chronic wounds treated with BSS between 2014 and 2018. Ten wound specimens and ten matched healthy control samples (matched by two of three parameters: age, sex, ethnicity, and/or biopsy site location) were stained with GT. Wound etiologies included VLU (n=5), pyoderma gangrenosum (n=2), radiation ulcers (n=1), DFU (n=1), and squamous cell carcinoma ulcers (n=1). Biopsies were performed between 14 and 273 days (median 30 days) from initial BSS application. GT-stained sections were independently reviewed by two dermatopathologists using a semi-quantitative scoring system: no positivity (0), mild positivity (1+, focal weak staining), moderate positivity (2+, multifocal or moderate staining), and strong positivity (3+, diffuse strong staining). Differences between groups were analyzed using Fisher's exact test.

Results
GT staining positivity was observed in 9 of 10 (90%) BSS-treated wound specimens compared to 0 of 10 (0%) control samples (Fisher's exact test, $p < 0.001$). Among positive specimens, staining intensity was 1+ in 2 samples, 2+ in 5 samples, and 3+ in 2 samples; one BSS-treated specimen showed no staining (score 0). Staining distribution was predominantly diffuse (n=7), with focal staining in 2 cases, both from pyoderma gangrenosum wounds, where GT reactivity was most prominent in a perivascular distribution within the wound bed.

Conclusions

GT staining identified collagenous material in chronic wounds previously treated with BSS but not in healthy controls, with positivity observed at up to 273 days following application. These findings contrast with prior PCR-based studies, which reported absence of BSS-derived allogeneic DNA by 8-12 weeks, suggesting that BSS-associated matrix components may persist beyond cellular viability, or alternatively, that BSS promotes endogenous matrix remodeling within the wound bed. Notably, GT staining in pyoderma gangrenosum wounds showed only focal perivascular positivity, in contrast to the predominantly diffuse pattern observed in VLUs, possibly reflecting differences in the wound microenvironment and local inflammatory responses. These findings offer a novel histopathologic perspective on BSS longevity and highlight the need for larger controlled studies incorporating more specific molecular techniques to further characterize the persistence and functional role of BSS-associated matrix in chronic wound healing.

EADV CONGRESS
VIENNA
30 SEP - 3 OCT 2026

Abstract N°: 2821

Cutaneous Rosai–Dorfman Disease: Clinical and Histopathological Regression During Cryosurgical Treatment — A Case Report

Anna Tekielak*[1, 2], Jacek Pająk[3], Karina Polak[1], Wiktor Kruczek[2], Aleksandra Frątczak[1], Beata Bergler-Czop[1]

[1] Medical University of Silesia, Chair and Department of Dermatology, Katowice, Poland, Medical University of Silesia, Doctoral School, Katowice, Poland, Katowice, Poland

[2] Medical University of Silesia, Doctoral School, Katowice, Poland, Katowice, Poland

[3] Department of Pathomorphology and Molecular Diagnostics, Medical University of Silesia in Katowice, Katowice, Poland, Katowice, Poland

Introduction

Rosai–Dorfman disease is a rare non-Langerhans cell histiocytosis that may present with nodal or extranodal involvement. Cutaneous manifestations are uncommon and often pose a diagnostic challenge due to their heterogeneous clinical presentation. Histopathological examination remains crucial for establishing the diagnosis and monitoring disease evolution.

Case Presentation

We report the case of a 59-year-old male patient with disseminated nodular skin lesions present since 2022. The patient was admitted to the Department of Dermatology due to multiple pruritic nodules located over the entire body. Laboratory investigations, including complete blood count, revealed no abnormalities. Abdominal ultrasonography with spleen assessment showed no pathological findings. Due to the absence of systemic or haematological involvement, systemic haematological treatment was not initiated.

A skin nodule from the left antecubital fossa was excised for histopathological examination. The microscopic picture was consistent with cutaneous Rosai–Dorfman disease. The patient was treated with cryosurgery. This method involves local destruction of pathological tissue by rapid freezing, most commonly using liquid nitrogen, followed by tissue thawing and secondary necrosis. Cryosurgery is a minimally invasive therapeutic option that may be considered in selected localized or symptomatic cutaneous lesions.

During treatment, clinical regression of the nodular lesions was observed, accompanied by reduction of pruritus. Follow-up histopathological assessment demonstrated regression of the inflammatory-histiocytic infiltrate compared with the initial biopsy. The clinical and histopathological findings before and during treatment are presented in the figure, demonstrating parallel improvement in skin lesions and microscopic features of the disease.

Conclusion

This case highlights the importance of clinicopathological correlation in the diagnosis and follow-up of cutaneous Rosai–Dorfman disease. In patients without systemic involvement, local treatment modalities such as cryosurgery may represent a useful therapeutic approach. Serial histopathological evaluation may provide valuable insight into treatment response and disease regression.

EADV Congress 2026, VIENNA
30 SEPTEMBER - 03 OCTOBER 2026
POWERED BY M-ANAGE.COM

EADV CONGRESS
VIENNA
30 SEP - 3 OCT 2026

Abstract N°: 2830

Cytophagic histiocytic panniculitis associated with rectal adenocarcinoma: a case report

Zineb Aqasbi Ouahi*[1], Zakia Douhi[1], ikrame bejja[1], Saadia Boughaleb[1], Meryem Soughi[1, 1], Sara Elloudi[1], Hanane Baybay[1], Fatima Zohra Mernissi[1, 1]

[1] Department of Dermatology, Hassan II University Hospital, Fez, Morocco

Introduction

Cytophagic histiocytic panniculitis (CHP) is an exceptionally rare lobular panniculitis characterized by infiltration of benign histiocytes with hemophagocytic activity. It is mainly associated with hematologic malignancies, whereas its association with solid tumors remains exceptional. Clinical presentation ranges from isolated indolent nodules to severe forms associated with hemophagocytic lymphohistiocytosis. We report a rare case of CHP occurring in a patient treated for rectal adenocarcinoma, initially suspected to represent cutaneous metastasis, with a spontaneous favorable outcome.

Case Presentation

A 28-year-old woman, followed for rectal adenocarcinoma treated with neoadjuvant chemoradiotherapy followed by surgery, presented with firm, skin-colored subcutaneous nodules evolving over 20 days. Histological examination revealed a hypodermal histiocytic infiltrate, which was confirmed by immunohistochemistry showing CD68 and CD163 positivity. CD34 highlighted a vascular network without evidence of a fibrous tumor. Epithelial and Langerhans cell markers (CK AE1/AE3, CD1a, and langerin) were negative. Laboratory investigations showed no evidence of hemophagocytic lymphohistiocytosis. The lesions resolved spontaneously with a favorable outcome. Overall, the clinical, histological, and immunohistochemical findings were consistent with cytophagic histiocytic panniculitis, without evidence of malignancy. A conservative management approach with close clinical surveillance was adopted.

Conclusion

CHP is a rare and heterogeneous entity whose prognosis mainly depends on the occurrence of hemophagocytic lymphohistiocytosis. However, certain isolated and benign forms may resolve spontaneously, highlighting the importance of an individualized and patient-tailored management approach.

EA DV CONGRESS
VIENNA
30 SEP - 3 OCT 2026

Abstract N°: 2861

BAP1-Inactivated Melanocytic Tumor in an Adolescent Patient: Histopathological and Immunohistochemical Correlation in a Clinically Nonspecific Lesion

Camila Gouvea Facure*[1], Juliana Arêas de Souza Lima Beltrame Ferreira[1], Clovis Antonio Lopes Pinto[1], Célia Antonia Xavier de Moraes Alves[1], Mariana Careta[1], Glaucos Ricardo Paraluppi[1], Carolina Lourenço dos Santos Landini Freitas[1], JOÃO GARCIA DA ROCHA NETO[1], MARIA BEATRIZ LIRA DO O ESPOSITO[1], EDUARDA LUISA ROCHA CORTI[1], Carolina Siqueira Varotto Martins[1]

[1] Faculdade de Medicina de Jundiaí - FMJ, jundiai, Brazil

Introduction

BAP1-inactivated melanocytic tumors (BIMTs) are rare melanocytic neoplasms characterized by loss of nuclear BRCA1-associated protein 1 (BAP1) expression. Although generally considered biologically indolent, these lesions are clinically relevant because of their association with BAP1 tumor predisposition syndrome, linked to uveal melanoma, cutaneous melanoma, mesothelioma, and renal cell carcinoma. Clinically, BIMTs may resemble common nevi or atypical melanocytic lesions, making diagnosis challenging and highly dependent on histopathological and immunohistochemical evaluation.

Case Presentation

A 17-year-old female patient presented with a pigmented lesion in the submental region, clinically described as a brownish papule suggestive of an atypical melanocytic nevus. The patient reported that she had this lesion since childhood. She had no personal history of atypical melanocytic lesions or skin cancer and no family history of melanoma, skin cancer, or BAP1-associated malignancies.

Complete excision of the lesion was performed. Histopathological examination demonstrated a dermal melanocytic proliferation composed predominantly of large epithelioid melanocytes with abundant eosinophilic cytoplasm and vesicular nuclei. A biphasic architectural pattern was observed, consisting of peripheral conventional nevus cells and a central population of atypical epithelioid melanocytes. Despite marked cytologic atypia, no necrosis, significant mitotic activity, or unequivocal melanoma features were identified. Maturation in the deeper dermal component was preserved.

Immunohistochemistry revealed positivity for Melan-A, HMB-45, S100, P16, and SOX10, with a low Ki-67 proliferative index of approximately 2%. PRAME expression was negative. The key diagnostic finding was complete loss of nuclear BAP1 expression within the epithelioid melanocytic component, while surrounding keratinocytes and nonlesional melanocytes retained nuclear staining, serving as an internal positive control. Initial surgical margins were focally involved laterally and deeply, and complete surgical margin enlargement was subsequently performed.

Conclusion

BIMTs exemplify the growing importance of integrating dermatopathology, immunohistochemistry, and molecular biology in melanocytic tumor classification. Diagnosis relies mainly on recognizing characteristic epithelioid morphology associated with loss of BAP1 nuclear staining. Current molecular models suggest a “two-hit” mechanism involving biallelic BAP1 inactivation, frequently associated with concomitant BRAF V600E mutation.

This case is noteworthy because the lesion was clinically nonspecific and mimicked a common atypical nevus in a young patient without personal or familial cancer history. It also highlights the so-called “clinical iceberg” phenomenon of BIMTs, in which apparently benign cutaneous lesions may represent the visible manifestation of underlying molecular alterations with potential syndromic implications.Furthermore, the absence of significant mitotic activity, preservation of maturation, PRAME negativity, and low Ki-67 index reinforced the importance of immunohistochemistry in distinguishing BIMT from spitzoid melanoma and other malignant melanocytic neoplasms.

This case emphasizes the critical role of histopathological and immunohistochemical correlation in diagnosing BAP1-

inactivated melanocytic tumors, particularly in clinically nonspecific lesions affecting young patients. Recognition of this rare entity is essential for accurate diagnosis, adequate surgical management, and appropriate long-term follow-up.

EADV CONGRESS
VIENNA
30 SEP - 3 OCT 2026

Abstract N°: 2865

Sporadic Sclerotic Fibroma of the Hand: An Unusual Acral Presentation Mimicking Benign Soft Tissue Tumors

Juliana Pacheco*[1], Cecilia Lagalhard Victer[1], Felipe Nazareth de Matos Pinto de Carvalho[1], Tullia Cuzzi[2], Danielle Quintella[2]

[1] Sector of Dermatology and Post Graduation Course, School of Medicine and University Hospital, Federal University of Rio de Janeiro, Rio de Janeiro, Brazil
[2] Department of Pathology, School of Medicine, Federal University of Rio de Janeiro, Rio de Janeiro, Brazil

Introduction

Sclerotic fibroma (SF), or storiform collagenoma, is an uncommon benign fibrocollagenous neoplasm characterized by dense hyalinized collagen bundles and sparse spindle cell proliferation in a storiform architecture.

Clinically, SF presents as a slow-growing, asymptomatic firm papule or nodule, predominantly on the face and upper trunk. Palmar involvement is exceptionally rare, with only isolated cases reported, and may represent a diagnostic pitfall due to its clinical resemblance to other soft tissue tumors. Solitary lesions are usually sporadic, while multiple lesions may be associated with Cowden syndrome (PTEN hamartoma tumor syndrome).

Although classically regarded as a distinct neoplasm, similar storiform and sclerotic patterns may be observed as a nonspecific fibrosing response in other conditions, including dermatofibroma and inflammatory disorders such as erythema elevatum diutinum, highlighting the importance of clinicopathological correlation. Lesional cells typically express vimentin and CD34, while lacking epithelial and neural markers.

Case Presentation

A 59-year-old male presented with a solitary, slow-growing lesion on the hypothenar region of the left palm, associated with mild functional discomfort. The patient denied pain, pruritus, or bleeding. His medical history included systemic arterial hypertension, type 2 diabetes mellitus, and well-controlled HIV infection with undetectable viral load and preserved CD4 count. Dermatological examination revealed a firm, well-circumscribed hypochromic papule with a faint erythematous halo and no ulceration. Dermoscopy showed a homogeneous whitish structureless area.

A shave biopsy demonstrated a dermal lesion composed of spindle cells and hyalinized collagen bundles arranged in a storiform pattern with cleft-like spaces, consistent with sclerotic fibroma. The patient is currently under clinical follow-up.

Conclusion

Clinical differential diagnosis includes dermatofibroma, eccrine poroma, fibroma of tendon sheath, and, less frequently, amelanotic melanoma or basal cell carcinoma, as these entities may present with similar clinical features despite distinct histopathological findings.

This case highlights a rare palmar presentation of solitary sclerotic fibroma, expanding its known clinical spectrum.

Awareness of this atypical localization is important to avoid misdiagnosis of palmar papules and prevent unnecessary interventions.

EA DV CONGRESS
VIENNA
30 SEP - 3 OCT 2026

Abstract N°: 2878

A Case of Vulvar Verruciform Xanthoma Dermoscopically Mimicking Squamous Cell Carcinoma.

Ceyda Çaytemel*[1], Özgür Timurkaynak[1], Cuyan Demirkesen[2]

[1] Acıbadem University, School of Medicine, Department of Dermatology and Venereology, Istanbul, Türkiye
[2] Acıbadem University, School of Medicine, Department of Pathology, Istanbul, Türkiye

Introduction

Verruciform xanthoma (VX) is a rare benign lesion most commonly affecting the oral mucosa and anogenital region. Vulvar involvement is uncommon and may pose diagnostic challenges due to its clinical resemblance to malignant epithelial tumors. Dermoscopic descriptions of VX are scarce, and to date, dermoscopic features of vulvar VX have not been reported.

Case Presentation

A 23-year-old woman presented with a painless, slowly growing lesion in the genital region that had been present for approximately five years. She had no history of genital warts and was otherwise healthy. Dermatological examination revealed a 6-mm-sized flat pinkish-whitish papule with a hyperkeratotic yellowish surface localized on the left labium minora (Figure 1a).

Dermoscopy demonstrated a well-demarcated papular lesion with a yellow keratinous area involving the medial one-third of the lesion, surrounded by white irregular clods on a yellowish-pink homogeneous background, accompanied by a few dotted, short linear, and curved vessels (Figure 1b). Based on the clinical and dermoscopic findings, squamous cell carcinoma (SCC) was considered in the differential diagnosis, and a shave excision was performed.

Histopathological examination revealed marked epidermal hyperkeratosis and widespread parakeratosis with occasional enlarged nuclei forming invaginations into the epidermis. Bacterial aggregates were present within the keratin lamellae. Areas of papillary epidermal hyperplasia were observed, with neutrophilic clusters at the tips of the dermal papillae. The papillary dermis showed proliferating vessels and collections of xanthomatous cells (Figure 1c). These findings were consistent with a diagnosis of vulvar verruciform xanthoma.

Conclusion

VX may clinically and dermoscopically mimic SCC due to shared features such as hyperkeratosis, surface irregularity, and atypical vascular patterns. Dermoscopically, SCC often exhibits central keratin masses, white circles related to adnexal involvement, and polymorphous vessels.

There are only a limited number of publications addressing the dermoscopic features of scrotal VX. Reported dermoscopic findings include a papillary or mulberry-like surface pattern, whitish rims surrounding individual papillae, linear, hairpin, and occasionally glomerular vessels with relatively uniform distribution, as well as yellow dots, yellow plaques, or amorphous yellow areas that become more prominent under compression dermoscopy. Although a yellow–orange coloration may represent a useful diagnostic clue for xanthomatous lesions, this feature was not observed in our case.

To the best of our knowledge, no dermoscopic descriptions of vulvar verruciform xanthoma have been published previously in the literature. This case highlights the importance of considering VX in the differential diagnosis of vulvar keratotic lesions and underscores the role of dermoscopy as a noninvasive tool in guiding clinical decision-making, particularly in anatomically sensitive areas where tissue preservation is essential.

EADV CONGRESS
VIENNA
30 SEP - 3 OCT 2026

Abstract N°: 2979

Malignant Mimicry: A Retrospective Analysis of Skin Cancers Misidentified as Dermatofibroma and the Burden of Diagnostic Errors

Tania Maria Prainer*[1], Sabina Tăpălagă[1], Tudor-Alex Rus[1, 1], Vlad Rus[1], Nicholas Kormos[1]

[1] University of Medicine and Pharmacy "Iuliu Haţieganu", Cluj-Napoca, Romania

Introduction

Dermatofibroma (DF) is frequently regarded as a trivial benign lesion. However, its clinical and dermoscopic polymorphism often masks life-threatening malignancies. The benign appearance of a lesion can lead to a dangerous diagnostic bias, delaying the excision of melanomas or basal cell carcinomas (BCC). Furthermore, while multiple DFs are often perceived as signs of benignity, the literature suggests they can serve as cutaneous markers for hematologic malignancies or severe immunosuppression (HIV, SLE). This study investigates literature-based clinical indicators associated with the misdiagnosis of malignant tumors as DFs. Additionally, it quantifies the actual risk of malignancy in lesions initially classified as benign.

Materials and Methods

We conducted a retrospective analysis of 8,035 surgical excisions performed between 2016 and 2022. We specifically isolated cases where a malignant tumor was histopathologically confirmed despite a prior clinical suspicion of dermatofibroma. The study was organized into two distinct cohorts for analysis: a histopathological arm, comprising 50 cases confirmed as dermatofibroma through pathology, and a clinical arm, consisting of 33 cases where a malignant tumor was histopathologically confirmed despite an initial clinical suspicion of dermatofibroma. To identify variables contributing to diagnostic failure (patient age, anatomical site, and clinician experience) we conducted statistical analysis using Student's t-test and the Chi-square test ($p < 0.05$).

Results

The study revealed a significant rate of malignant mimicry. In the clinical arm (n=33 suspected DFs), the overall diagnostic accuracy was 63.6%. Notably, 12.1% of lesions clinically suspected as DF were histopathologically confirmed as Basal Cell Carcinoma (BCC), and 3.03% were identified as Melanoma.

The risk of missing a malignancy was significantly higher in older patients (mean age 59.0 years for misdiagnosed cases vs. 44.6 years for correct DF diagnosis, p=0.018, Cohen's d=1.08). The identified high-risk anatomical regions were:

- Head and Neck: 0% diagnostic accuracy; all suspected cases proved to be other entities.
- Trunk: Highest diagnostic difficulty (p=0.02).
- Lower Extremities: Produced the highest clinical uncertainty (86% of uncertain cases, p=0.03).

Our findings align with recent systematic reviews indicating that multiple DFs (n>1) are strongly associated with immune dysregulation. In our cohort, the presence of multiple lesions coincided with a higher clinical suspicion for occult systemic conditions or underlying hematologic malignancies.

Histopathologically, epidermal hyperplasia was the most common finding (87%), but diagnostic challenges arose

from rare variants, including aneurysmal and epithelioid DFs, which clinically mimicked vascular or melanocytic tumors. Dermoscopically, while the central white patch and peripheral network were typical, 12% of confirmed DFs displayed atypical patterns, contributing to clinician bias.

Conclusions

The clinical diagnosis of dermatofibroma is identified as a frequent pitfall that may mask skin cancers. Conventional clinical signs are considered insufficient to exclude malignancy, especially in the elderly. To avoid severe underdiagnosis, histopathological confirmation is strongly recommended for any clinically suspicious DF-like lesion located on the trunk or cephalic region in patients over 55. Histopathology remains the only safe gateway to rule out malignancy. Furthermore, multiple or eruptive DFs should be recognized as potential sentinels for systemic immune dysregulation, necessitating thorough clinical investigation.

EADV CONGRESS
VIENNA
30 SEP - 3 OCT 2026

Abstract N°: 3061

Skin aging characteristics in Chinese women: facial skin yellowness and associated determinants

Simin Lin[1], Jian Mu[1], Fuming Wang[1], Lingling Xuan[1], Jing Wang[1], Hu Huang[1], Lieve Declercq*[2]

[1] PROYA Cosmetics Co., Ltd., Hangzhou, China

[2] PROYA Europe, Courbevoie, France

Introduction

Skin darkness and yellowness represent one of the primary initial aging concerns for Chinese women. However, the specific characteristics and underlying drivers of this phenotype require further elucidation. This study aims to investigate the age-related distribution of facial skin yellowness, identify its key behavioral and biological determinants, and pinpoint specific advanced glycation end-products (AGEs) that serve as key biomarkers for skin yellowing.

Materials and Methods

A large-scale cohort study was conducted involving 1077 healthy Chinese women aged 18 to 65 by combining data from two distinct cohorts of 853 and 224 participants. The methodology incorporated questionnaire surveys to assess lifestyle factors and self-perceived skin concerns, alongside the objective measurement of facial skin yellowness using a Vplus and CM-26dG spectrophotometer. The correlation between lifestyle behaviors and skin yellowness was analyzed. For targeted biomarker screening, skin samples were collected from the upper eyelids of two subjects exhibiting different degrees of yellowness. An UPLC-ESI-MS/MS analytical method was employed to quantify the expression of 15 different AGEs and compare their levels between samples with varying degrees of skin yellowness.

Results

Self-perceived darkness and yellowness were identified as the most prominent skin concerns among the participants. Notably, individuals with clinically confirmed yellowness exhibited an approximately normal age distribution, with the highest prevalence concentrated between 36 and 55 years. Consistent with these observations, facial skin yellowness was found to significantly increase with age. Furthermore, higher skin yellowness values were significantly associated with specific lifestyle factors, including smoking, higher dairy intake, and insufficient sleep duration. In the biomarker analysis, skin tissue examination revealed that the top five most abundant AGEs were consistent across samples regardless of yellowness levels, namely N^{ε}-acetyl L-lysine, fructosyl-lysine, N^{ω}-carboxymethyl-L-arginine (CMA), N^{ε}-(carboxymethyl)-L-lysine (CML), glycolic acid-lysine-amide (GALA). However, the total content and profile of these AGEs differed significantly between high-yellowness and low-yellowness skin. Consequently, a significant positive correlation was established between the levels of specific AGEs and the degree of skin yellowness, identifying them as key molecular markers for this condition.

Conclusions

This study provides a comprehensive characterization of facial skin yellowness in Chinese women, delineating its distinct age distribution and identifying high-risk populations. Our findings demonstrate that skin yellowness is driven by a complex interplay between extrinsic lifestyle factors (smoking, dietary habits, and sleep patterns) and intrinsic biological processes (aging and endogenous AGEs). By validating specific AGEs associated with skin yellowness as key biomarkers, this research establishes a scientific foundation for targeted anti-glycation strategies, guiding functional ingredient screening and the development of products to improve sallow skin.

EADV CONGRESS
VIENNA
30 SEP - 3 OCT 2026

Abstract N°: 3256

Weber-Christian Disease Versus Necrobiotic Xanthogranuloma – Apropos a Case

Yana Turkowski*[1], Nellie Konnikov[1], Meera Mahalingam[1]

[1] VA Medical Center, Boston, United States

Introduction

Weber-Christian disease or relapsing, febrile, lobular non-suppurative panniculitis is a relatively uncommon entity of unknown etiopathogenesis. Clinical features include multiple, tender symmetrically distributed subcutaneous nodules with a predilection for the lower extremities. Systemic manifestations, although non-specific, are typically present. Initial reports claimed that the histopathological features varied with disease phase with purportedly 3 distinct phases: an early phase characterized by fat necrosis; a subsequent phase characterized by a non-specific inflammatory infiltrate and a late "fibrotic" phase. Given that these may be seen in any lobular panniculitis, from a histopathologic perspective Weber-Christian disease remains essentially non-diagnostic.

Case Presentation

Our patient is a 71-year-old Caucasian male who initially presented with a bilateral erythematous skin eruption over the thighs and systemic manifestations in the form of acute weight loss, weakness, malaise, night sweats, chills, and fever. Over a course of two weeks, the erythematous areas were replaced by subcutaneous nodules which progressively increased in size.

Histopathology of two biopsied nodules revealed similar histopathologic findings - a moderate, superficial and deep lymphohistiocytic infiltrate with numerous Touton-type giant cells, subtle foci of necrobiosis and scattered cholesterol clefts - features compatible with a histopathologic diagnosis of Touton cell panniculitis or necrobiotic xanthogranuloma. Clinically, however, diagnostic features of necrobiotic xanthogranuloma were not observed and given the clinical presentation appeared to be more compatible with of Weber-Christian disease.

Conclusion

Despite the similarity in histopathology, the clinical presentation of our patient and absence of paraproteinemia argued against a diagnosis of NXG. In conclusion and to the best of our knowledge, this is the first case of Weber-Christian disease with histopathologic features characteristics of necrobiotic xanthogranuloma.

EADV CONGRESS
VIENNA
30 SEP - 3 OCT 2026

Abstract N°: 3425

Atypical post-radiation vascular proliferation with a biphasic course and spontaneous involution

Mónica Gómez Manzanares*[1], Omar Al-Wattar Ceballos[1], Marina Montero García[1], Víctor Haro González-Vico[1], José Antonio Ortiz Serrano[1], Marta Tricio Navarro[1], Juan Luis Santiago Sánchez-Mateos[1], María Prado Sánchez Caminero[1]

[1] Hospital General Universitario de Ciudad Real, Ciudad Real, Spain

Introduction

Atypical vascular proliferations (AVPs) are rare vascular lesions arising after radiotherapy, most commonly following breast cancer treatment. They are currently considered part of a spectrum of radiation-induced vascular changes ranging from benign lymphangiectatic lesions to secondary angiosarcoma. Clinically, AVPs usually present as small papules confined to the irradiated field, with a latency period typically ranging from 2 to 10 years after radiotherapy.

Histologically, they are characterized by superficial vascular proliferations with minimal atypia and low proliferative activity, expressing endothelial markers such as CD31 and CD34, with frequent D2-40 positivity in lymphatic variants. Their main diagnostic challenge is differentiation from post-radiation angiosarcoma, which typically shows deep infiltration, marked cytologic atypia, and high proliferative activity. In addition, MYC amplification is commonly detected in angiosarcoma but is usually absent in AVPs.

Management is not standardized. While isolated lesions may be excised, conservative management with close follow-up is often preferred in multifocal cases because of their generally benign behavior.

Case Presentation

A 55-year-old woman with a history of left breast carcinoma treated in 2019 with surgery, chemotherapy, and adjuvant radiotherapy presented with cutaneous lesions confined to the previously irradiated breast.

Approximately one year after radiotherapy, she developed two or three asymptomatic papules on the left breast, strictly limited to the radiation field. Over the following years, the lesions evolved slowly, with a slight increase in number and no associated symptoms or extension beyond the treated area. Initially, they were interpreted as nonspecific yellowish dermal papules, and a skin biopsy was reported as compatible with dermatofibroma, leading to conservative management.

In January 2025, the patient experienced a rapid clinical change, with the sudden appearance of multiple new papules on the left breast over a short period of time. These lesions showed a more erythematous-vascular appearance, without ulceration or systemic symptoms.

A new skin biopsy revealed a superficial dermal vascular proliferation with predominant lymphatic differentiation, composed of small-caliber vessels, low proliferative activity (low Ki-67), and positivity for CD31, CD34, and D2-40, findings consistent with atypical post-radiation vascular proliferation. Additional biopsies confirmed a superficial atypical vascular proliferation with minimal cytologic atypia, absence of necrosis or deep invasion, and no histological evidence of malignancy.

During follow-up, the lesions underwent progressive spontaneous regression, with complete disappearance of the

vascular component within approximately six months, leaving only residual flat brownish-yellow macules. No extension outside the irradiated field, locoregional lymphadenopathy, or lymphedema was observed. Given the benign histopathological findings and favorable evolution, close clinical follow-up was maintained.

Conclusion

The present case is noteworthy because of its unusual biphasic evolution, with an initial indolent phase followed by an eruptive vascular outbreak and subsequent spontaneous involution. This pattern suggests that AVPs may represent a dynamic process within the spectrum of radiation-induced vascular injury, with potentially underrecognized evolutionary phases.

EA DV CONGRESS
VIENNA
30 SEP - 3 OCT 2026

Abstract N°: 3490

Post-traumatic Acantholytic Dyskeratotic Acanthoma: A Rare Presentation

Emre Burakhan Akay*[1], Özge Aydın[2], Huriye Aybüke Koç[3]

[1] Giresun Training and Research Hospital, Department of Dermatology, Giresun, Türkiye
[2] Giresun Training and Research Hospital, Department of Pathology, Giresun, Türkiye
[3] Giresun University, Faculty of Medicine, Department of Dermatology, Giresun, Türkiye

Introduction

Acantholytic dyskeratotic acanthoma (ADA) is a solitary, extragenital lesion characterized by prominent acantholysis and dyskeratosis in the absence of cup-shaped architecture or follicular involvement. The etiopathogenesis of ADA remains unclear. Physical trauma has been suggested as a possible triggering factor, particularly in some subungual presentations. Although benign, ADA is clinically relevant because of its rarity and its potential to mimic nonmelanoma skin cancer, which may lead to diagnostic uncertainty. Herein, we report a case of cutaneous ADA temporally associated with physical trauma and highlight trauma as a possible triggering factor.

Case Presentation

A 57-year-old man presented with a gradually enlarging lesion on the left lateral thigh that had developed over one year following local blunt trauma. According to the patient, the lesion arose after the area was struck and compressed while loading the bed of a truck. The injury initially resulted in persistent ecchymosis that failed to resolve and subsequently evolved into the present lesion. The patient had no known history of immunosuppression, organ transplantation, malignancy, or other significant systemic disease, and he was not receiving immunosuppressive therapy. Examination revealed a pedunculated, firm, skin-colored nodular lesion measuring 1.7 × 1.5 cm with a hemorrhagic crust and a slightly verrucous surface. Dermoscopy was not performed prior to excision because the lesion surface was largely obscured by hemorrhagic crust. Excisional biopsy was performed with a differential diagnosis including squamous cell carcinoma, verrucous carcinoma, verrucous trichoadenoma, tuberculosis verrucosa cutis, and chromoblastomycosis. Histopathological examination revealed acanthosis, papillomatosis, and hyperkeratosis. Prominent suprabasal acantholysis was noted within the epidermis. Dyskeratotic cells were identified in the upper epidermal layers, including corps ronds, which were round eosinophilic cells with pyknotic nuclei and perinuclear halos, as well as grains, which appeared as small, flattened dyskeratotic cells with basophilic nuclei in the stratum corneum. No cytological atypia or atypical mitotic figures were observed. Warty dyskeratoma was considered in the differential diagnosis but was excluded because of the absence of cup-shaped epidermal invagination and follicular involvement. Complete excision was curative, and no recurrence was observed during the 9-month follow-up period.

Conclusion

ADA is a rare benign epidermal tumor characterized histopathologically by prominent acantholysis and dyskeratosis without follicular involvement or cup-shaped architecture. Clinically, it usually presents as a solitary papule or plaque that may mimic nonmelanoma skin cancers and other benign lesions, making histopathological evaluation essential for diagnosis. Although its etiopathogenesis remains unclear, factors such as immunosuppression, ultraviolet exposure, smoking, hormones, and physical trauma have been proposed as

possible triggers. Our case was notable for an unusually large verrucous lesion measuring 1.7 cm and its clear temporal association with trauma, suggesting that physical trauma may also act as a triggering factor in cutaneous ADA. Histopathological findings, including suprabasal clefting, prominent dyskeratosis, and absence of cytologic atypia or follicular involvement, supported the diagnosis. Complete surgical excision was both diagnostic and curative, with no recurrence during follow-up. This case highlights the importance of considering ADA in the differential diagnosis of verrucous or keratotic lesions to avoid unnecessary aggressive treatment, and further suggests that cutaneous ADA may present with larger lesion sizes and may be triggered by physical trauma.

EADV CONGRESS
VIENNA
30 SEP - 3 OCT 2026

Abstract N°: 3509

Sporadic acrokeratosis verruciformis of Hopf in adulthood: A diagnostic challenge

Speranța-Cristina Andronic*[1], Carmen Comănescu[1], Alexandra-Ioana Cioroianu[2]

[1] Colentina Clinical Hospital, Dermatology II, Bucharest, Romania
[2] Colentina Clinical Hospital, Department of Pathology, Bucharest, Romania

Introduction

Acrokeratosis verruciformis of Hopf (AKV) is a rare disorder of keratinization classically inherited in an autosomal dominant manner and associated with mutations in the ATP2A2 gene, also implicated in Darier disease. Clinically, AKV presents with multiple flat-topped keratotic papules predominantly involving the dorsal aspects of the hands and feet and may be associated with nail abnormalities including nail plate thickening and leukonychia. Two clinicopathologic variants have been described: the classic familial form, usually arising in childhood, and the sporadic form, characterized by later adult onset, absence of family history, and occasionally atypical distribution. Because of its variable presentation, AKV may mimic seborrheic keratosis, verruca plana, Darier disease, lichen planus, and epidermodysplasia verruciformis. Histopathologic findings may be subtle or nonspecific, making clinicopathologic correlation essential for accurate diagnosis, particularly in sporadic adult-onset cases.

Case Presentation

We report the case of a 46-year-old woman with a 4-year history of rheumatoid arthritis, positive rheumatoid factor and anti-citrullinated protein antibodies, with minimal articular involvement controlled under methotrexate therapy. Her medical history also included Raynaud phenomenon, paresthesias, myalgias, iron deficiency anemia, and treated pulmonary tuberculosis.
She presented with a 6-month history of multiple asymptomatic flat-topped keratotic papules and verrucous skin-colored-to-brown lesions distributed predominantly on the dorsal forearms and thighs.
Dermoscopic examination revealed a whitish network with focal interruptions, central white homogeneous areas, and a cobblestone-like appearance, corresponding to hyperkeratosis, papillomatosis and acanthosis.
Histopathologic examination showed moderate lamellar hyperkeratosis, mild papillomatosis, regular acanthosis, minimal basal hyperpigmentation, and sparse superficial perivascular lymphoplasmacytic infiltrate without acantholysis, dyskeratosis, lichenoid inflammation, or viral cytopathic changes. The findings excluded epidermodysplasia verruciformis and lichen planus and were interpreted in the appropriate clinical setting as compatible with sporadic acrokeratosis verruciformis.
Given the benign nature of the condition, treatment was primarily aimed at cosmetic improvement. Topical keratolytics containing urea and topical retinoids were recommended, while cryotherapy or laser ablation may be considered in the future.

Conclusion

AKV remains a rare and probably underrecognized disorder, particularly in sporadic adult-onset presentations lacking a family history or classical acral distribution. In our case, the absence of acantholysis and dyskeratosis helped differentiate the condition from Darier disease, while the
lack of viral cytopathic changes excluded epidermodysplasia verruciformis. This case highlights the diagnostic

challenges posed by atypical keratotic papular eruptions and emphasizes the importance of clinicopathologic correlation in establishing the diagnosis of sporadic AKV. This case further underscores the crucial role of dermatopathology and adequate biopsy sampling, as histopathological examination was essential in excluding clinically similar entities and guiding the final diagnosis.

EA DV CONGRESS
VIENNA
30 SEP - 3 OCT 2026

Abstract N°: 3542

Untargeted MALDI imaging of photodamaged skin and actinic keratosis guided by transcriptomic findings

Teresa Torres*[1], Mercedes Abarquero[2], Gemma Tell-Martí[1], Josep Malvehy Guilera[1], Leonor Prieto[2], Susana Puig[1]

[1] Instituto de Investigaciones Biomédicas August Pi i Sunyer (IDIBAPS), Hospital Clinic de Barcelona, Barcelona, Spain
[2] Laboratorio Dermatológico La Roche-Posay, L'ORÉAL, MADRID, Spain

Introduction

Chronic ultraviolet (UV) exposure induces progressive molecular alterations leading to photodamage, field cancerization (FC), and actinic keratosis (AK). Previous RNA sequencing studies have identified key pathways involved in extracellular matrix remodeling and cancer-related processes. However, these approaches lack spatial resolution and do not capture protein-level heterogeneity within tissue. Main objectives are to perform an untargeted MALDI imaging mass spectrometry characterization of photodamaged skin, FC, and AK, and to explore spatially resolved peptide signals corresponding to transcriptomically-derived candidates.

Materials and Methods

Formalin-fixed paraffin-embedded (FFPE) skin sections from two paired patient cohorts were analyzed using matrix-assisted laser desorption/ionization imaging mass spectrometry (MALDI-IMS). The first cohort comprised 5 patients with photodamaged skin, contributing 15 paired sections (non-photodamaged skin, photodamaged skin pre- and post-treatment with a nicotinamide-containing sunscreen). The second cohort comprised 5 patients with AK and FC, contributing 20 paired sections (AK and FC, pre- and post-treatment). An untargeted approach was applied to detect and spatially map peptide features across tissue sections. Based on prior RNA-seq analyses, peptide features tentatively assigned to proteins involved in extracellular matrix remodeling and cancer-related pathways were selected for spatial annotation.

Results

Untargeted MALDI imaging is currently underway across all tissue types. Peptide features tentatively assigned to extracellular matrix and collagen-related proteins (COL16A1, COL1A1, COL1A2, COL21A1, COL3A1, COL4A5, COL4A6, COL6A1) are being evaluated across the photodamage cohort, and peptide features corresponding to cancer- and cell cycle–associated proteins (LAPTM4A, TMEM50A, SMYD3, MXD3, AKR1B15, BABAM2, CNRIP1, FAM149A, GTF2F2, APOD, CPB1, SERPINA5, CRTAP, MIA) across the AK/FC cohort. The paired within-patient design allows direct intra-individual comparison of peptide signals across tissue types and treatment conditions, minimizing inter-patient variability.

Conclusions

This study integrates transcriptomic discovery with spatially resolved MALDI imaging in paired human skin tissue samples, providing a robust framework to bridge gene expression findings with peptide-level spatial evidence across the photodamage-to-AK continuum.

EA DV CONGRESS
VIENNA
30 SEP - 3 OCT 2026

Abstract N°: 3609

A Case Series of Syringotropic Melanoma: An Under Recognised Variant of Melanoma

Charlotte Simms*[1], Niamh Pang[1], Dijon Millette[1], Nitin Khirwadkar[1]

[1] Liverpool University Hospitals NHS Foundation Trust, Liverpool, United Kingdom

Introduction

Syringotropic melanoma represents an uncommon pattern of melanoma growth in which malignant melanocytes extend along eccrine adnexal structures. This phenomenon may allow tumour cells to extend deeper than the conventional invasive component, potentially complicating histopathological assessment and tumour staging. Although described in small case series and isolated reports, the clinicopathological significance of this pattern remains incompletely understood.

The aim of this case series was to describe the clinicopathological features of syringotropic melanoma and highlight the implications of eccrine extension for assessment of tumour depth.

Materials and Methods

We retrospectively reviewed four cases of primary cutaneous melanoma demonstrating syringotropic growth identified in dermatopathology practice. Clinical features, histopathological findings and immunohistochemical results were evaluated, with particular attention to the relationship between conventional invasion and depth of adnexal extension.

Results

Clinical and histopathological features are summarised in table 1. Patient age ranged from 38 to 86 years; three patients were female and one male. Three lesions were clinically suspected to represent melanoma. Histologically, three cases were superficial spreading melanoma in vertical growth phase with Breslow thickness ranging from 1.3–2.7 mm, and one case represented lentigo maligna (melanoma in situ). Immunohistochemistry including Melan-A, PRAME and SOX10 supported the diagnosis and highlighted melanocytic proliferation within eccrine structures.

All cases demonstrated syringotropic extension of malignant melanocytes within eccrine ducts and coils reaching deeper levels than the invasive melanoma component, predominantly within the reticular dermis. The maximum additional depth of adnexal extension was 1.7 mm beyond the deepest invasive tumour nests. This syringotropic component was not included in Breslow thickness measurements. In some areas the adnexal involvement was subtle on routine haematoxylin and eosin sections and required careful examination of eccrine structures for identification.

None of the cases demonstrated ulceration, vascular invasion, perineural invasion, microsatellites or regression. Mitoses ranged from 1–5/mm^2 and tumour-infiltrating lymphocytes were non-brisk or absent.

Case	Age/Sex	Clinical Diagnosis	Biopsy	Histological subtype	Breslow thickness	Clarks level	Depth of Syringotropism	Staging (TNM 8)
1	79/F	Melanoma	Excision	Superficial spreading MM	2.70mm	II/III	3.7mm	pT3a
2	59/F	Atypical BCC/ GA	Punch	Lentigo maligna (melanoma in situ)	N/A	N/A	1.2mm	pTis
3	38/M	Melanoma	Excision	Superficial spreading MM	1.30mm	II/III	3.0mm	pT2a
4	86/F	Melanoma	Excision	Superficial spreading MM	1.56mm	III/IV	2.0mm	pT2a

Table 1: Clinical and Histopathological Features

Conclusions

Syringotropic melanoma is an uncommon but likely under-recognised growth pattern. The risk of local and regional metastasis is poorly understood. In addition, there are currently no established guidelines in the UK which provides a guidance of management and follow-up. In this case series, adnexal extension consistently exceeded the depth of the invasive component, highlighting a potential pitfall in tumour assessment. Recognition of syringotropic spread is important as eccrine structures may provide a pathway for deeper tumour extension not captured by conventional Breslow measurement. Careful evaluation of adnexal structures and appropriate use of immunohistochemistry are essential to ensure accurate diagnosis and avoid underestimation of tumour extent.

EA DV CONGRESS
VIENNA
30 SEP - 3 OCT 2026

Abstract N°: 3706

Secondary Osteoma Cutis Following Chronic High-Dose Vitamin D Supplementation

Milena Neves Sampaio*[1], Lara Pavlikoff Lopes[1], Cintia Mara Nakata[1], Rafael Pena[2], Juliana Cavalcante[3], Mariam Queiroz[1], Gabriela César de Barros Abrantes[4]

[1] University of Brasília, University Hospital of Brasília, Brasília, Brazil
[2] HRAN, Brasília, Brazil
[3] Faculdade De Medicina Da Universidade De São Paulo, São Paulo, Brazil
[4] Faculdade Nova Esperança, João Pessoa, Brazil

Introduction

Osteoma cutis is a rare disorder characterized by ectopic formation of mature bone within the dermis or subcutaneous tissue. Secondary osteoma cutis is most frequently associated with inflammatory dermatoses, trauma, neoplasms, or genetic syndromes. In contrast, metabolic disturbances related to vitamin D excess are classically associated with calcinosis cutis rather than true dermal ossification. The association between chronic hypervitaminosis D and osteoma cutis remains exceptionally uncommon and poorly characterized.

Case Presentation

A 77-year-old woman presented with multiple firm, skin-colored papules and nodules localized exclusively to the face. Lesions had progressively developed since the age of 71 years, with slow enlargement and gradual increase in number over time. No predisposing inflammatory, traumatic, infectious, or procedural factors were identified. The patient denied previous acne, chronic inflammatory dermatoses, cosmetic procedures, trauma, or surgical interventions involving the affected areas.

Dermatological examination revealed multiple indurated papules and nodules distributed symmetrically on the malar and perioral regions, without erythema, ulceration, transepidermal elimination, or associated calcium extrusion. Clinical differential diagnoses included calcinosis cutis, osteoma cutis, pilomatricoma, and ossified epidermal cysts.

Medical history was notable for daily high-dose vitamin D supplementation for approximately one year during the COVID-19 pandemic without medical supervision. Initial laboratory evaluation demonstrated serum 25-hydroxyvitamin D levels exceeding 150 ng/mL during the early clinical course. Despite marked hypervitaminosis D, the patient did not develop clinically significant manifestations of hypercalcemia, including nausea, vomiting, weakness, polyuria, polydipsia, neuropsychiatric symptoms, or nephrolithiasis.

Histopathological examination demonstrated mature lamellar bone with trabecular architecture and osteocytes within the dermis, without cytologic atypia, granulomatous inflammation, foreign-body reaction, or evidence of malignancy, confirming osteoma cutis. Current metabolic evaluation, including calcium profile assessment, showed no significant abnormalities. Following discontinuation of vitamin D supplementation, lesions remained clinically stable, without progression in size, number, or distribution during a two-year follow-up period.

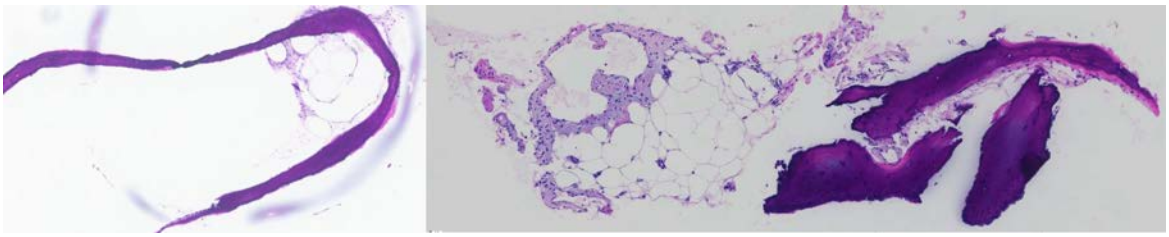

Histopathological examination (H&E stain) of the malar lesion. The section demonstrates a distinct fragment of mature lamellar bone tissue within the dermis, showing well-developed trabecular architecture and visible osteocytes. There is no evidence of cytological atypia or an associated skin appendage relationship. These findings are highly consistent with secondary osteoma cutis, supporting the diagnosis of ectopic dermal ossification in this clinical context.

Conclusion

This case broadens the spectrum of metabolic factors potentially associated with cutaneous ossification and suggests chronic hypervitaminosis D as a possible underrecognized trigger for secondary osteoma cutis in the absence of classical predisposing conditions. Distinction between calcinosis cutis and true dermal ossification is essential, particularly in patients with metabolic dysregulation and atypical facial calcified lesions. Given the increasing prevalence of unsupervised high-dose vitamin supplementation following the COVID-19 pandemic, clinicians should remain aware of uncommon dermatologic complications related to prolonged metabolic imbalance.

EA DV CONGRESS
VIENNA
30 SEP - 3 OCT 2026

Abstract N°: 3731

Not All Axillary Masses Are Breast Lesions: Think Pilomatricoma

ikram lahmouch*[1]

[1] Department of Dermatology, Ibn Sina University Hospital, Rabat, Morocco, rabat, Morocco

Introduction

Pilomatricoma is a benign adnexal tumor derived from hair matrix cells, most commonly occurring in children and young adults, with a predilection for the head and neck region.

In adults, extra-cephalic localizations are uncommon, and axillary involvement is particularly rare, constituting a true diagnostic pitfall as it may closely mimic breast lesions or lymphadenopathy. This misleading presentation can result in extensive and unnecessary imaging, thereby delaying definitive diagnosis and management.

We report a case of axillary pilomatricoma illustrating this diagnostic challenge and highlighting the pivotal role of clinical dermatological examination and histopathological confirmation.

Case Presentation

A 54-year-old woman with no significant past medical history was referred to the gynecology department for evaluation of a progressively enlarging left axillary swelling, evolving over several months. Given its anatomical location within the axillary tail of the breast, the initial clinical concern was a possible breast-related lesion or lymphadenopathy of suspicious origin.

First-line ultrasound imaging was inconclusive, failing to clearly characterize the lesion. This prompted further evaluation with breast MRI, which demonstrated normal breast parenchyma bilaterally (BI-RADS 1) with no detectable abnormalities. A subsequent second-look ultrasound reclassified the lesion as a superficial subcutaneous formation, favoring an epidermoid cyst.

Given the persistent diagnostic uncertainty, the patient was referred to dermatology for further management and surgical excision. Dermatological examination identified a well-circumscribed, ovoid subcutaneous nodule, firm to hard in consistency, suggesting a calcified component. The lesion was freely mobile over deep planes and notably lacked a central punctum. In this clinical context, these features were highly suggestive of pilomatricoma.

A complete surgical excision was performed without complication. Histopathological examination confirmed the diagnosis of a calcified pilomatricoma, showing characteristic basaloid cells, ghost cells, and areas of calcification.

Conclusion

Axillary pilomatricoma is an uncommon entity that may closely mimic breast or lymph node pathology, often leading to an extensive and unnecessary diagnostic workup. This case highlights that not all axillary masses originate from the breast: a firm, well-circumscribed subcutaneous lesion with possible calcified features should prompt consideration of a cutaneous adnexal tumor.

EADV CONGRESS
VIENNA
30 SEP - 3 OCT 2026

Abstract N°: 3799

Distinguishing Vulvar Melanoacanthoma from Vulvar Melanoma: A Case Series Highlighting Histopathological Diagnostic Challenges

Viviane Maria Maiolini*[1], Leonardo Cardili[2], Leidi Liliana Mosquera Mercado[3], Cynthia Tararam de Laurentys[4], Lilian Kelly Faria Licarião Rocha[3], Marie Line Chedid[5], Nancy Emmanuel[3], José Antonio Sanches Junior[3]

[1] Division of Surgical Dermatology, Instituto do Câncer do Estado de São Paulo, ICESP, São Paulo, Brazil

[2] Department of Pathology, Instituto do Câncer do Estado de São Paulo, ICESP, São Paulo, Brazil

[3] Department of Dermatology, Hospital das Clínicas da Faculdade de Medicina da Universidade de São Paulo, São Paulo, Brazil

[4] Department of Pathology, Hospital das Clínicas da Faculdade de Medicina da Universidade de São Paulo, São Paulo, Brazil

[5] Medical University of Łódź, Łódź, Poland

Introduction

Melanoacanthoma is a rare benign variant of seborrheic keratosis characterized by acanthotic epidermal proliferation with keratinocytes interspersed with dendritic melanocytes. While most commonly described in oral mucosa and cutaneous sites, vulvar localization is rare and may clinically and histopathologically mimic vulvar melanoma. This differential diagnosis is particularly challenging as vulvar melanoma carries a poor prognosis with 5-year survival rates of approximately 30-47%, significantly lower than cutaneous melanoma, and is often diagnosed at advanced stages. The aim of this case series is to describe three cases of vulvar melanoacanthoma and highlight the histopathological and immunohistochemical features essential for accurate diagnosis and exclusion of melanoma.

Case Presentation

Case 1 involved a 71-year-old female presenting with a 2 cm pigmented lesion on the left labia majora that, upon histopathological examination, revealed a unique nested arrangement of basaloid cells and dendritic melanocytes measuring 0.2–0.5 mm. Case 2 featured a 74-year-old female with a long-standing, 3 cm papillomatous plaque on the inner labia majora demonstrating characteristic basaloid cell proliferation, though immunohistochemical analysis of the sampled tissue notably lacked S100 or Melan-A expression. Case 3 presented in a 68-year-old female with a pigmented genital lesion where histopathology confirmed the presence of pigmented basaloid keratinocytes and dendritic melanocytes alongside a moderate population of CD1a-positive Langerhans cells. Collectively, these three cases involved elderly patients (aged 68–74 years) with pigmented, papillomatous lesions of the labia majora that clinically mimicked melanoma or seborrheic keratosis. Dermatopathological analysis consistently revealed acanthotic and papillomatous epidermal proliferation of basaloid keratinocytes interspersed with numerous pigmented dendritic melanocytes, all while lacking cytologic atypia, mitotic activity, or dermal invasion. While Case 1 exhibited a distinct nested growth pattern, all cases shared a benign architectural framework and a low Ki-67 proliferative index. Immunohistochemical profiles generally confirmed this dual cell population; specifically, Cases 1 and 3 demonstrated robust expression of S100, Melan-A, and HMB-45 within the dendritic melanocytes, whereas Case 2 showed predominantly keratinocytic markers, such as p63 and CK5, with negative melanocytic staining in

the evaluated sections. Furthermore, the identification of CD1a-positive Langerhans cells in Case 3 helped further delineate the complex intraepidermal cellular composition characteristic of these vulvar melanoacanthomas.

Conclusion

Awareness of melanoacanthoma's characteristic histopathologic features including evenly dispersed dendritic melanocytes throughout the epidermis without pagetoid spread, absence of cytologic atypia, lack of abnormal melanocytic nesting, and absence of dermal invasion, is essential. Immunohistochemical confirmation showing melanocytic markers (S-100, HMB-45, Melan-A) in dendritic cells and proliferative markers restricted to keratinocytes helps distinguish melanoacanthoma from melanoma. Recognition of this entity is critical to avoid overtreatment with potentially disfiguring surgical procedures in this anatomically sensitive location.

EADV CONGRESS
VIENNA
30 SEP - 3 OCT 2026

Abstract N°: 3844

BAP1-inactivated melanocytic tumours: germline mutation yield, clinicopathological features and clinical outcomes – a systematic review

Celia Ziane*[1], Akash Thumbe[2], Anirban Mandal[3], Hassan Jouni[4]

[1] Countess of Chester NHS Foundation Trust, Chester, United Kingdom

[2] University of Liverpool, Liverpool, United Kingdom

[3] The Mersey Regional Burns and Plastic Surgery Unit, Mersey and West Lancashire Teaching Hospitals NHS Trust, Knowsley, United Kingdom

[4] Liverpool University NHS Foundation Trust, Liverpool, UK, Liverpool, United Kingdom

Introduction

BAP1-inactivated melanocytic tumours (BIMTs) are important cutaneous markers of BAP1 tumour predisposition syndrome (BAP1-TPDS). However, reported rates of germline BAP1 mutation detection vary widely, and the clinicopathological characteristics and clinical outcomes of BIMTs remain incompletely defined. This systematic review evaluated germline mutation yield, clinicopathological features and reported clinical outcomes of BIMTs.

Materials and Methods

A systematic review was conducted in accordance with PRISMA 2020 guidelines. MEDLINE and Embase (via Ovid) were searched for studies reporting clinical, histopathological, molecular or outcome data on BIMTs. Observational studies reporting germline BAP1 testing, clinicopathological findings or clinical outcomes were included. Data regarding study characteristics, mutation detection, lesion features and outcomes were extracted and synthesised narratively.

Results

Ten studies published between 2011 and 2025 met inclusion criteria, including familial cohorts, retrospective case series, cohort studies and one case–control study. Germline BAP1 mutation detection varied substantially according to clinical context, exceeding 85% in individuals with BIMTs occurring alongside other BAP1-associated tumours, compared with approximately 12–35% in sporadic or unselected BIMT cohorts. Clinically, BIMTs most commonly presented as small pink or skin-coloured dome-shaped papules resembling benign melanocytic lesions. Histologically, lesions demonstrated dermal epithelioid melanocytic proliferations with loss of nuclear BAP1 expression, frequently associated with activating BRAF mutations. Reported recurrence and metastasis rates were low, although follow-up duration was heterogeneous and often limited.

Conclusions

BIMTs represent clinically important markers of BAP1-TPDS, and germline BAP1 mutation detection is strongly dependent on clinical presentation. These findings support selective germline testing and surveillance based on clinical context. Larger prospective studies with longer follow-up are required to better define the natural history and long-term outcomes of BIMTs.

EADV CONGRESS
VIENNA
30 SEP - 3 OCT 2026

Abstract N°: 3862

Juvenile pityriasis rubra pilaris associated with hypercarotenemia: a case report

fella laissaoui*[1], Houria Sahel[1]

[1] Department of Dermatology, Bab El Oued University Hospital, Algiers, Algiers, Algeria

Introduction
Pityriasis rubra pilaris (PRP) is a rare, chronic inflammatory dermatosis characterized by erythematous follicular papules and diffuse yellow–orange palmoplantar keratoderma (PPK). The juvenile form presents early, often within the first months of life, and may be aggravated by dietary or iatrogenic factors. Association with hypercarotenemia is exceptional but should be considered in cases of yellow–orange discoloration of the lesions, particularly when dietary diversification is inappropriate.

Materials and Methods
A 22-month-old infant with no significant past medical history presented with erythematous lesions tending toward a yellow–orange coloration, topped with diffuse follicular and non-follicular papules involving the entire integument with some islands of spared skin, affecting the face, trunk, back, and all four limbs.

Yellow–orange palmoplantar keratoderma was also noted. In addition, the patient had growth retardation associated with hypertrichosis, secondary to excessive application of topical corticosteroids.

Laboratory investigations were unremarkable. A skin biopsy was performed, and histopathological examination was consistent with juvenile pityriasis rubra pilaris.

Systemic treatment with acitretin was initiated at a dose of 0.3 mg/kg/day. Hypercarotenemia was suspected in view of excessive carrot consumption, leading to the recommendation of a low beta-carotene diet.

The clinical course was marked by significant improvement of the papular lesions and palmoplantar keratoderma, as well as a progressive fading of the yellow–orange discoloration of the erythema.

Results
PRP is a rare, chronic inflammatory dermatosis. Its pathophysiology involves keratinocyte hyperproliferation and abnormal differentiation mediated by innate and adaptive immune dysregulation, with local activation of pro-inflammatory cytokines such as TNF-α, IL-17, and IL-23, as well as defects in the skin barrier.

The juvenile form presents early, as in our case where the first symptoms appeared at 4 months of age. Dietary diversification was poorly conducted, with the infant consuming carrots exclusively, likely contributing to yellow–orange skin discoloration suggestive of hypercarotenemia. This pigmentation results from beta-carotene accumulation in the stratum corneum and subcutaneous tissue and may be accentuated by the hyperkeratosis and cutaneous inflammation characteristic of PRP, in which epidermal differentiation is disrupted and the skin barrier altered, favoring retention of liposoluble pigments within keratinocytes.

Systemic treatment with acitretin (0.3 mg/kg/day) led to marked clinical improvement, confirming the efficacy of retinoids in juvenile forms.

Conclusions

This case highlights the importance of a multidimensional approach combining systemic management, careful monitoring of topical therapies, and dietary correction in order to optimize cutaneous outcomes and growth development.

EA DV CONGRESS
VIENNA
30 SEP - 3 OCT 2026

Abstract N°: 3896

Rosai-Dorfman disease: the role of dermatological manifestations

Cheikh Elkadhi*[1], yosra bouattour[2], sahar mekki[2], Abderrahmen Masmoudi[1], sameh marzouk[2], Hamida Turki[1]

[1] Dermatology Department, Hedi Chaker University Hospital, Sfax, sfax, Tunisia
[2] Internal Medicine Department, Hedi Chaker, Sfax, sfax, Tunisia

Introduction
Rosai-Dorfman disease (RDD) is a rare non-Langerhans cell histiocytosis. The classic clinical presentation includes massive bilateral cervical lymphadenopathy. Extranodal involvement is reported in 40% of cases, with a predilection for the skin, central nervous system, liver, spleen, and bone. We aimed to study the clinical characteristics and disease course of RDD presenting with cutaneous involvement.

Materials and Methods
We report two cases of Rosai-Dorfman disease

Results
We report two cases of Rosai-Dorfman disease revealed by cutaneous involvement.
-The first case was a 53-year-old man presenting with a one-year history of an infiltrated erythematous lesion on the left shoulder, with a yellowish base and overlying vessels. He had no systemic symptoms, lymphadenopathy, or hepatosplenomegaly. Laboratory tests showed mild inflammation, renal impairment, and 24-hour proteinuria of 2 g. Skin biopsy confirmed Rosai-Dorfman disease, with S100 and CD68 positivity and CD1a negativity. Methotrexate was initiated at 10 mg/week. Further investigations revealed multisystemic involvement, including thickening of the aortic arch and left common iliac artery, a hypervascular right renal mass, and intracranial and cervical extradural lesions causing cerebellar edema, mass effect on the fourth ventricle, and triventricular hydrocephalus. High-dose corticosteroid therapy was started, and urgent neurosurgical management was indicated
-The second case was a 52-year-old woman with no medical history who presented with multiple infiltrated skin lesions evolving for one year, without systemic symptoms. Clinical examination showed indurated, violaceous, hyperpigmented plaques involving the face, thighs, chest, and abdomen. Laboratory tests were normal. Skin biopsies and surgical excision of facial lesions were performed. Histology revealed large histiocytes with emperipolesis, and immunohistochemistry showed positivity for S100 protein and CD68, with negative CD1a staining. The extension workup was negative, leading to the diagnosis of pure multifocal cutaneous Rosai-Dorfman disease. High-dose corticosteroids were started, but due to an unfavorable initial response, methotrexate was added at 15 mg/week. After 6 months, some lesions had decreased in size and no new lesions appeared.

Conclusions
Rosai-Dorfman disease is a rare condition with heterogeneous clinical presentations. Histological and immunohistochemical studies are the cornerstone of diagnosis. Dermatological manifestations are polymorphic and may present as erythematous, yellowish, or brownish nodules, plaques, or papules. A purely cutaneous form is rarely described in the literature. It occurs preferentially in women in their fifth decade of life, as in our patient. However, skin lesions may reveal a multisystemic form, highlighting the importance of performing an extension workup and ensuring regular follow-up.

EA DV CONGRESS
VIENNA
30 SEP - 3 OCT 2026

Abstract N°: 3987

Basal Proliferative Growth Patterns Correlate More Strongly with Epidermal Thickness Than KIN Grade in Actinic Keratosis

Afife Uğuz[1], Seda Koç Şahin[2], Gökhan Şahin*[3], Sibel Acat[1]

[1] Department of Pathology, Karamanoğlu Mehmetbey University Faculty of Medicine, Karaman, Türkiye
[2] Samsun University, Faculty of Medicine, Department of Pathology, Samsun, Türkiye
[3] Department of Dermatology, Ondokuz Mayıs University, Samsun, Türkiye

Introduction

Actinic keratosis (AK) is a common ultraviolet-associated keratinocytic neoplasm and a recognized precursor of cutaneous squamous cell carcinoma. Conventional keratinocytic intraepidermal neoplasia (KIN) grading evaluates the upward extent of atypical keratinocytes within the epidermis, whereas the PRO score reflects downward basal proliferative growth. The relationship between basal proliferative architecture, epidermal thickness and chronic ultraviolet-induced dermal damage remains incompletely characterized.
The aim of this study was to evaluate the histopathological relationships between PRO score, KIN grade, epidermal thickness, histological subtype and solar elastosis in actinic keratosis, and to determine whether epidermal architectural expansion is more closely associated with basal proliferative growth than with conventional upward dysplastic extension.

Materials and Methods

A retrospective histopathological study was performed on 89 AK cases with adequate hematoxylin–eosin-stained sections for re-evaluation. KIN grade, PRO score, solar elastosis grade, epidermal thickness, inflammatory infiltrate, histological subtype and adnexal involvement were assessed. Due to low case numbers, PRO 0, I and II lesions were grouped as low-PRO and compared with PRO III lesions. Histological subtype analysis was performed in cases with evaluable subtype classification. Categorical variables were analyzed using Pearson chi-square or Fisher–Freeman–Halton exact tests, as appropriate. Nonparametric comparisons were performed using Kruskal–Wallis tests, and ordinal associations were evaluated using Spearman correlation analysis. A p-value <0.05 was considered statistically significant.

Results

The mean age was 66.1±14.0 years, and 52 patients (58.4%) were male while 37 (41.6%) were female. Median epidermal thickness was 250 µm (IQR: 300). KIN I, II and III were observed in 39 (43.8%), 37 (41.6%) and 13 (14.6%) cases, respectively. Most lesions demonstrated a PRO III growth pattern (57/89, 64.0%). Epidermal thickness showed a moderate positive correlation with PRO score (rho=0.504, $p<0.001$), whereas its correlation with KIN grade was weaker (rho=0.260, $p=0.014$). Cases with PRO III demonstrated significantly greater epidermal thickness compared with low-PRO lesions ($p<0.001$). Histological subtype was significantly associated with PRO pattern ($p<0.001$); proliferative, hypertrophic and bowenoid AKs predominantly demonstrated PRO III growth, whereas atrophic AKs mainly exhibited low-PRO patterns. Solar elastosis grade was significantly associated with anatomical localization ($p=0.027$), being more prominent in chronically sun-exposed regions, but did not correlate significantly with PRO score, epidermal thickness or KIN grade.

Conclusions

These findings suggest that epidermal architectural expansion in AK is more closely related to basal proliferative growth patterns than to conventional upward dysplastic extension or cumulative dermal photodamage severity. The strong association between PRO score, epidermal thickness and histological subtype supports the complementary value of PRO-based assessment in the histopathological evaluation of AK.

EA DV CONGRESS
VIENNA
30 SEP - 3 OCT 2026

Abstract N°: 4015

To study Clinical, Histopathological features and complications of Erythroderma

Swagata Tambe*[1], PRIYA MOTE[1], Sakshi Nehete[2], Pratik Gajbe[2], Kirti Jangid [2]

[1] Seth V.C. Gandhi & M.A. Vora Municipal General Hospital Rajawadi, Innovation Skin Clinic, Mumbai, India
[2] Seth V.C. Gandhi & M.A. Vora Municipal General Hospital Rajawadi, Mumbai, India

Introduction

Erythroderma also known an exfoliative dermatitis is a clinical presentation caused by many dermatological diseases in their severe form. Early recognition of underlying etiology is most important for the treatment and prevention of complication like acute skin failure leading to systemic involvement and increased mortality.

Materials and Methods

Patients presenting with erythroderma were included in study with detailed evaluation of history, clinical presentation, duration, precipitating factors, histopathology, serological investigations, complications and treatment outcome.

Results

Total 56 patients were included over a period of 4 years. Maximum number of patients were in the 5th decade followed by 3rd and 4th decade. Male: Female ratio 1.24:1. Duration of erythroderma ranged from 4 days to 8 months. Precipitating factors included ingestion of systemic medication (37%), pre-existing dermatitis(21%), genetic diseases(8%).

Apart from skin, nail involvement was seen in 33% of patients, scalp involvement was seen in (30%) and palmoplantar involvement was seen in 21% of patients. Facial involvement was seen in 30% of patients. Facial edema was the prominent feature seen in patients of drug reaction. Drug induced erythroderma was the most common cause of erythroderma seen in 37% of patients followed by psoriasis (28% of patients). Other causes were dermatitis, ichthyosis and Immunodeficiency disorders. In Adults drug induced erythroderma was the commonest cause followed by psoriasis while pediatric age group dermatitis followed by Ichthyosis and immunodeficiency syndromes were common causes. Histopathology was very important in establishing the diagnosis. Associated common systemic features included fever, hypotension pre-renal failure, hypotension, pedal edema due to hypoproteinaemia, transaminitis, leucocytosis, eosinophilia. All patients of drug reactions recovered completely after treatment with systemic corticosteroids and cyclosporin. Patients of erythroderma secondary to psoriasis also responded well but recurrence was seen in few patients of pustular psoriasis. Atopic dermatitis, seborrheic dermatitis in pediatric erythroderma responded very well while patients of hyper IgE syndrome and ichthyosis required prolonged treatment and recurrences after discontinuation of therapy was common.

Mortality in our study was very low due to prompt diagnosis and treatment however 1 patient of hyperIgE syndrome who as diagnosed late and has already developed secondary adrenal failure succumbed.

Conclusions

Erythroderma should be considered as an emergency due to its potential systemic complication and adverse

prognosis. If the cause is not diagnoses and treated promptly systemic complications are inevitable.

EA DV CONGRESS
VIENNA
30 SEP - 3 OCT 2026

Abstract N°: 4098

Dermatologists are the leading providers of skin cancer care and screening in Germany

Matthias Augustin*[1], Leïla von Felbert[1], Katharina Müller[1], Theresa Klinger[1], Kristina Hagenström[1]

[1] Institute for Health Services Research in Dermatology and Nursing (IVDP), German Center for Health Services Research in Dermatology (CVderm), Hamburg, Germany

Introduction

Skin cancer is among the fastest increasing oncological conditions in Germany and poses growing challenges due to demographic ageing, cumulative ultraviolet exposure and rising treatment demand. Since 2008, statutory skin cancer screening (SCS) for persons aged ≥35 years has been covered by statutory health insurance (SHI), targeting malignant melanoma (MM) and non-melanoma skin cancer (NMSC). Screening may be performed by dermatologists and general practitioners (GPs), whereas diagnostics, surgery and long-term care are mainly provided by dermatologists. However, little is known about the distribution of SCS and skin cancer care across specialties and over time. This study quantified the contribution of dermatologists and other physician groups to SCS and skin cancer care in Germany.

Materials and Methods

A retrospective longitudinal analysis of SHI claims data and national dermatological health care data was conducted. Individuals undergoing statutory SCS between 2016 and 2022 were identified using billing codes. Participation rates were calculated for the eligible SHI-insured population, and screening services were analyzed by physician group. As patients could be seen sequentially by different providers, provider shares were not mutually exclusive.

Published nationwide analyses of inpatient dermatological care structures and hospital performance were integrated, including data from 95 of 105 dermatology hospitals on inpatient volumes, oncological care spectra, staffing and performance indicators.

Results

Biannual SCS participation ranged from approximately 24% to 34% between 2016 and 2022, indicating moderate uptake, a tendency towards lower participation over time and a slight decline during the COVID-19 pandemic. Dermatologists were the largest provider group for SCS in 2022, accounting for 55.6% of documented screening contacts (n=122,453), while GPs accounted for 48.4% (n=106,623). Other specialties contributed marginally (<0.1%). These proportions were not mutually exclusive because patients could receive sequential consultations from different physician groups.

In outpatient curative skin cancer treatment, dermatologists provide approximately 80% of treatments for melanocytic lesions and 75% for NMSC using surgical or pharmacological interventions. In hospitals, dermatology departments treat around 65% of NMSC and 80% of MM inpatients, making them the major pillar of inpatient skin cancer care in Germany. Surgical dermatology accounted for approximately one third of inpatient dermatology care, while dermato-oncology represented another major component; together, these fields accounted for more than 60% of dermatology hospital admissions. The analyses further indicated increasing inpatient demand driven by demographic ageing and rising oncological case loads. Nationwide integrated care is supported by approximately 80 certified regional skin cancer networks (Hauttumorzentren), combining diagnostic, surgical, medical and follow-up expertise and ensuring externally validated quality standards.

Conclusions

These analyses demonstrate a substantial and increasing burden of skin cancer screening and care in Germany, with dermatologists representing the leading provider group across the care pathway. In addition to diagnostic confirmation, dermatosurgery and longitudinal oncological management, dermatologists also perform the majority of documented SCS contacts in routine care.

At the same time, population-based screening participation remains moderate, indicating persistent coverage gaps despite nationwide availability. Given the rising skin cancer burden, future strategies should strengthen dermatological capacity across sectors while maintaining low-threshold access to specialized expertise.

EADV CONGRESS
VIENNA
30 SEP - 3 OCT 2026

Abstract N°: 4110

Volumes and effects of skin cancer screening in Germany: Current analyses indicate a shift towards earlier-stage detection

Matthias Augustin*[1], Leïla von Felbert[1], Katharina Müller[1], Theresa Klinger[1], Kristina Hagenström[1]

[1] Institute for Health Services Research in Dermatology and Nursing (IVDP), German Center for Health Services Research in Dermatology (CVderm), Hamburg, Germany

Introduction
A statutory skin cancer screening was introduced in Germany in 2008 to enhance earlier-stage detection of skin cancers and reduce advanced-stage disease. However, evidence on its effectiveness in large-scale routine care remains limited. This study aimed to quantify detection volumes associated with screening and to compare the stage distribution of skin cancer cases with and without prior screening.

Materials and Methods
A longitudinal analysis of statutory health insurance (SHI) claims data was conducted. New cases of skin cancer were identified between 2020 and 2022 based on ICD-10 diagnoses.
As clinical stage is not directly available in SHI claims data, stage was approximated using proxy definitions: Localized invasive disease was identified by C43 (melanoma; MM) or C44 (non-melanoma skin cancer (NMSC] (=keratinocyte skin cancer), including basal cell carcinoma, and squamous cell carcinoma) without metastatic codes, and advanced disease was defined by C43 or C44 in combination with metastasis-related codes (C71, C77, C78, C79) in the same or following quarter. In situ disease was defined by ICD-10 D03 and D04, respectively, when not associated with invasive skin cancer coding (C43 or C44) in the same quarter and without metastasis codes in the same or subsequent quarter.
A case was classified as incident if no previous skin cancer diagnosis had been recorded in the preceding eight quarters. Additionally, a tumor-related excision had to have occurred in the quarter of diagnosis or the preceding quarter. The cohort comprised incident cases with documented skin cancer screening in the quarter of diagnosis or the preceding quarter. The comparison cohort comprised incident cases fulfilling the same clinical criteria but had no documented skin cancer screening between 2018 and 2022. Screening rates were analyzed by age and sex.

Results
Screening-associated detections showed a shift towards markedly earlier tumor stages. For MM, the proportion of in situ lesions was approximately 10% higher among participants in skin cancer screenings (36.3% vs. 26.3%), while advanced-stage disease was markedly less frequent (stage IV: 1,7% vs. 16.9%) compared with cases without screening. Invasive localized stages accounted for the majority of MM cases in both groups, but the screened group showed a lower proportion of metastatic disease. For NMSC, the proportion of stage 0 tumors was higher in screening-associated detections (54,8% vs. 51.7%), whereas advanced-stage tumors were less frequent (stage IV: 0,5% vs. 2,7%).
Screening participation rates ranged between approximately 12% and 17% from 2016 to 2022, with a slight decline in the time of the COVID-19 pandemic. Participation rates increased with age and peaked among individuals aged 70–80 years. Women showed higher participation rates than men in middle-aged groups, whereas participation became more balanced in older age groups.

Conclusions

Skin cancer screening in Germany is associated with a shift towards earlier-stage detection in routine care. However, participation remains moderate, which may limit its population-level impact. Increased participation may further enhance the potential of screening to reduce advanced-stage disease and associated disease burden.

EA DV CONGRESS
VIENNA
30 SEP - 3 OCT 2026

Abstract N°: 4331

Virtual and Augmented Reality for Dermatologic Education: A Systematic Review of Current Evidence and Future Directions

Joy Xu*[1], Morayo Akintonde[2], Sara Ramezani[3], Sia Mehta[4], Divya Pushparajah[5], Imeth Illamperuma[5], Viktoriya Taran[6], Chelsea Nnajiofor[7]

[1] David Geffen School of Medicine at University of California, Los Angeles, Los Angeles, United States
[2] Howard University, Washington, United States
[3] University of Waterloo, Waterloo, Canada
[4] University of North Carolina at Chapel Hill, Chapel Hill, United States
[5] McMaster University, Hamilton, Canada
[6] John Carroll University, Cleveland, United States
[7] Uc Davis Health, Sacramento, United States

Introduction
Virtual and augmented reality (VR/AR) are increasingly acclaimed as transformative tools in medical education, however, their evidence-based efficacy within dermatology remains poorly characterized. Dermatologic education is an area where visual learning and patient understanding are especially important, yet many patients report insufficient knowledge about information relating to their condition. Skin cancer remains the most commonly diagnosed cancer in the United States, and prior evidence suggests that knowledge about non-melanoma skin cancer remains low even after treatment. This systematic review investigates the current landscape and pedagogical impact of immersive technologies on dermatological training, patient education, knowledge retention, and clinical usability.

Materials and Methods
A comprehensive search was conducted across PubMed, Ovid, Cochrane, Web of Science, and IEEE Xplore using terms related to virtual reality, augmented reality, immersive technology, patient education, knowledge retention, patient understanding, satisfaction, treatment adherence, and behavior change. Eligible studies included English-language human-subject research published within the last 10 years that used VR or AR to teach patients or medical students about a diagnosis, condition, treatment, procedure, or dermatology-related concept. Studies using traditional educational methods without VR/AR were excluded. Following PRISMA-aligned procedures, articles underwent independent, double-blind title and abstract screening followed by full-text review. Data extraction focused on population, intervention type, immersion level, interactivity, gamification, educational content, usability, satisfaction, adverse effects, and learning outcomes. Evidence certainty was quantified using GRADE.

Results
Five studies met the inclusion criteria, including narrative reviews, clinical commentaries, and empirical trials with a combined sample of 170 participants. Across studies, VR/AR interventions demonstrated high learner satisfaction, favorable usability, and promising knowledge retention. However, most outcomes relied on self-reported measures rather than standardized pre- and post-intervention assessments. One empirical study demonstrated a

statistically significant improvement in self-efficacy for skin self-examination following AR-based gamification, with mean scores increasing from 2.63 to 3.47 ($p = 0.011$). Technical usability was favorable across included studies, with low cybersickness scores (mean 2.0 ± 1.3 on a 5-point scale), suggesting that immersive dermatologic tools may be acceptable for learners and patients. Reported strengths included improved engagement, interactive visualization, and the ability to simplify complex dermatologic concepts such as disease progression, skin examination, or treatment processes. Despite these findings, certainty was low to very low due to small sample sizes, heterogeneous designs, inconsistent outcome measures, and limited long-term follow-up. Few studies directly compared VR/AR interventions with standard education, and few assessed behavior change, diagnostic accuracy, accessibility, or economic feasibility.

Conclusions

While VR shows early promise for dermatological education, the field lacks rigorous, standardized outcome measures necessary to establish its efficacy and guide broader implementation.Future research should use standardized outcome measures, larger controlled trials, longer retention periods, and direct comparison with traditional educational methods. These findings underscore the importance of developing high-fidelity, evidence-based simulation tools, including “tissue-to-slide” pathology models, that can enhance dermatologic curricula, diagnostic precision, patient education, and informed decision-making.

EADV CONGRESS
VIENNA
30 SEP - 3 OCT 2026

Abstract N°: 4448

Cutaneous Metastases: A Retrospective Single-Center Clinicopathological Study

Seda Koç Şahin[1], Gökhan Şahin*[2]

[1] Samsun University, Faculty of Medicine, Department of Pathology, Samsun, Türkiye
[2] Department of Dermatology, Ondokuz Mayıs University, Samsun, Türkiye

Introduction
Cutaneous metastases are uncommon manifestations of internal malignancies and may occasionally represent the first manifestation of an underlying cancer. Breast, lung, and gastrointestinal tumors are among the most common primary malignancies associated with cutaneous metastases. Metastatic patterns and anatomical distribution may vary according to tumor type and sex. In addition to distant spread, cutaneous involvement may also occur as locoregional extension or local recurrence. In this study, we retrospectively evaluated the demographic characteristics, primary tumor distribution, anatomical localization, and locoregional versus distant metastatic patterns of histopathologically confirmed cutaneous metastases diagnosed in a tertiary center.

Materials and Methods
We retrospectively evaluated cutaneous metastasis specimens from 83 patients diagnosed between January 1, 2015 and May 1, 2026 at our institution. In patients with repeated biopsies, only the first diagnostic specimen was included. Demographic data, primary tumor origin, anatomical localization of cutaneous metastases, and metastatic patterns were analyzed. Cases were classified as locoregional or distant cutaneous involvement according to the relationship between the primary tumor site and skin localization.

Results
Among the 83 patients, 44 (53.0%) were male and 39 (47.0%) were female. All patients were adults. The mean age was 62.3±15.1 years (range: 22–105). Gastrointestinal system carcinomas (31.3%), breast carcinomas (26.5%), and lung carcinomas (18.1%) were the most common primary tumors. In males, gastrointestinal system (36.4%) and lung carcinomas (34.1%) were the predominant primary tumors, whereas breast (56.4%) and gastrointestinal system carcinomas (25.6%) predominated in females. Forty patients (48.2%) were classified as having locoregional cutaneous involvement, while 43 patients (51.8%) had distant cutaneous metastases. The most frequent anatomical localizations were abdomen (19.3%), unspecified skin (16.9%), breast region (15.7%), and thorax/trunk (13.3%). At the time of biopsy, 65 patients (78.3%) had a known primary malignancy, while 15 patients (18.1%) were first diagnosed with a solid malignancy through skin biopsy. Three patients (3.6%) developed cutaneous metastases from a second distinct malignancy during follow-up. Survival data were available for all patients; 66 patients (79.5%) were deceased. Among deceased patients, gastrointestinal system (33.3%), breast (24.2%), and lung carcinomas (22.8%) were the most frequent primary tumors.

Conclusions
Although cutaneous metastases are infrequent, they may occasionally serve as an important clue to an underlying internal malignancy. Accurate and timely diagnosis requires careful clinicopathological correlation and detailed clinical history. In some cases, distinguishing cutaneous metastatic carcinoma from primary cutaneous adnexal carcinoma may be diagnostically challenging. Since prognosis and treatment strategies differ substantially

between these entities, this distinction should be made cautiously. Recognition of metastatic patterns and anatomical distribution may contribute to improved diagnostic awareness and clinical management.